ROSWELL P. FLOWER, LIBRARY. CORNELL UNIVERSITY.

CORNELL UNIVERSITY.

THE

Roswell P. Flower Library

THE GIFT OF

ROSWELL P. FLOWER

FOR THE USE OF

THE N. Y. STATE VETERINARY COLLEGE.

1897

Cornell University Library
SF 761.C51 1873
The comparative anatomy of the domestica
3 1924 000 012 389
vet

Cornell University Library

The original of this book is in
the Cornell University Library.

There are no known copyright restrictions in
the United States on the use of the text.

http://www.archive.org/details/cu31924000012389

THE

COMPARATIVE ANATOMY

OF THE

DOMESTICATED ANIMALS.

BY A. CHAUVEAU,

PROFESSOR AT THE LYONS VETERINARY SCHOOL.

ROSWELL P. FLOWER, LIBRARY. N.Y. STATE VET. COLL.

Second Edition, Revised and Enlarged, with the Co-operation of

S. ARLOING,

LATE PRINCIPAL OF ANATOMY AT THE LYONS VETERINARY SCHOOL;
PROFESSOR AT THE TOULOUSE VETERINARY SCHOOL.

TRANSLATED AND EDITED

BY

GEORGE FLEMING, F. R. G. S., M A. I.,

VETERINARY SURGEON, ROYAL ENGINEERS,
AUTHOR OF "TRAVELS ON HORSEBACK IN MANTCHU TARTARY," "HORSE-SHOES AND HORSE-SHOEING," "ANIMAL PLAGUES," "PRACTICAL HORSE-SHOEING," "RABIES AND HYDROPHOBIA," ETC.

WITH 450 ILLUSTRATIONS.

NEW YORK:
D. APPLETON AND COMPANY,
549 & 551 BROADWAY.
1873.

Dedicated

TO THE MEMORY OF

JOHN LAWSON, M.R.C.V.S.,

OF MANCHESTER,

WHO FIRST URGED THE DESIRABILITY OF UNDERTAKING THIS TASK,

AND WHOSE SINCERE AND INESTIMABLE FRIENDSHIP AND ENCOURAGEMENT FOR

MANY YEARS

THE EDITOR AND TRANSLATOR HEREBY ACKNOWLEDGES WITH SORROWFUL

AFFECTION AND GRATITUDE.

W. L. Hill, M. D.
Veterinarian,
1526 Race St., Phila.

PREFACE BY THE TRANSLATOR AND EDITOR.

In undertaking the arduous task of translating and editing the '*Traité d' Anatomie Comparée des Animaux Domestiques*' of M. Chauveau, I have been moved by a desire to fill a void in medical literature which has always existed, so far as the English language is concerned. There has been no complete treatise on the anatomy of the domesticated animals, and the absence of such a work has exerted a serious influence on the progress of veterinary science, and doubtless proved more or less of a loss to the community at large.

The only text book to which the student or practitioner of animal medicine could until recently refer, has been that on the anatomy of the Horse, written by the late distinguished army veterinary surgeon, William Percivall, more than forty years ago: a book which, though in every way creditable to its author, was notoriously incomplete, even as regards the anatomy of the only animal it treated of, and was without illustrations. No serious attempt has been made to teach the structure of the other useful creatures domesticated by man, valuable though many of them are; and the student who was anxious to acquire this knowledge had no guide to lead or instruct him. At college, this loss may not have been so severely felt as when, having graduated, he entered on the practice of his profession; and if the experience of veterinary surgeons in general has been like my own, they will be ready to testify to the almost daily regret they felt at the very meagre notions of anatomy they possessed, and the benefit a complete and trustworthy manual would confer.

My professional avocations in the army would not permit me to make the necessary dissections for the production of such a work · and indeed so many classical and standard treatises on the subject have appeared, during this century, on the Continent, and notably in France and Germany, that it would seem a mere waste of time and labour to attempt a task which

has been already so thoroughly accomplished by very zealous and proficient anatomists.

In selecting for translation the present treatise in preference to other works which are justly held in high estimation, I was influenced not only by the knowledge that it was written by one of the most talented comparative anatomists and physiologists of the day, but by the ability and originality which are so conspicuous in every page. I was also aware that, for more than a century, the French veterinary schools have been celebrated for the careful and thorough manner in which anatomy has been taught by most efficient teachers, who are all selected by open competition; and that Professor Chauveau's book was the approved dissection manual of these and other Continental schools.

Excellent as was the first edition of the work, the second is still more complete; indeed it may be said to be almost a new book, owing to the assistance afforded by M. Arloing, an anatomist who promises to assume a high rank in his profession.

The French treatise is illustrated by three hundred and sixty-eight woodcuts, but for several reasons it was deemed advisable to select only one hundred and seventy-three from this number: those rejected being chiefly human figures, and either far larger than was necessary or compatible with the space at disposal, or not so well suited for such a work as I was intent on producing. Nearly sixty original figures have been added to those selected; and through the courtesy and liberality of Messrs. J. and A. Churchill, the total number has been increased to four hundred and fifty. The profuseness and general excellence of these drawings, and their great accuracy, will, it is hoped, materially lessen the fatigue and time demanded for the study of this most important subject, and prove valuable for reference to the operator or busy practitioner.

No labour or pains have been spared to make the work the most complete and useful of any that has been produced. The best treatises in German, French, and Italian have been consulted in editing it, and when necessary, I have added to the descriptions. These additions are contained within brackets, thus ( ). As my task has been accomplished without any aid, I assume the entire responsibility for any errors of omission or commission that may exist; my aim being to furnish what has been an urgent desideratum for very many years—a complete dissection manual for the student of veterinary science, a book of reference for the veterinary surgeon, and a work that might be available for the zoologist, comparative anatomist, ethnologist, and medical practitioner. I have for a long time believed that the two branches of medicine—human and animal—should be more closely allied than they are at present, and that this alliance can only be effected by a mutual study and recognition of the facts which prove that the two are really one—wide apart though they have hitherto been kept in this country—and that each is capable of conferring on the other great and lasting benefits. Hence my retaining what constitutes a new feature

in the second edition of Chauveau's treatise—the comparison of the organs of MAN with those of ANIMALS.

I have omitted from the translation the references made to the Dromedary and Rabbit; these animals seldom, if ever, coming under the notice of the comparative pathologist in this country.

My grateful acknowledgments are due to my friend and colleague, Professor Chauveau, for the great courtesy with which he not only sanctioned the translation now before the public, but offered to supply me with the proof sheets of the new edition as it passed through the press.

To the numerous professional friends who pressed upon me the necessity of making such an extensive sacrifice of my few leisure hours, by undertaking a work of this magnitude, I have to express my deep regret at the delay which has occured in its appearance. The fault was not mine: but for the disturbance and abeyance of all business, save that of slaughter, in and around Paris while the book was in course of publication, my task must have been achieved nearly two years ago.

I may assure them, however,. that the delay has been rather beneficial than otherwise; as it has allowed me to give more time to perfect what might, under other circumstances, have been less complete and satisfactory.

GEORGE FLEMING.

BROMPTON BARRACKS, CHATHAM.
February, 1873.

PREFACE TO THE FIRST EDITION.

To present in a concise and complete form an exact description of the anatomical machinery of which the bodies of our domesticated animals are composed, has been our aim in writing the book now offered for public appreciation.

We have sought for concision, not only in language, but also in the choice of facts and ideas, with a kind of stubbornness. In imposing on ourselves this condition, we believe we have rendered a service to those who may have recourse to the book, in economising their time. In an age of progress like the present, when the sciences are becoming multiplied and developed, and when the human mind, seized by the fever of production, gives forth every day books consecrated to the study of these sciences, there is scarcely leisure to read and to learn. It is, therefore, the duty of a writer to be brief. If he loads his book with puerile details; if he says that which may easily be divined by his reader; and if he describes facts and ideas too redundantly; will he have attained the wished-for perfection —in a word, will he be complete? No, he will be tedious: a serious inconvenience, which neither elegance, warmth, nor brilliancy of style will always excuse when met with in a didactic work, and especially in an elementary treatise.

No effort has been spared to achieve exactitude—the primary desideratum in such a work as this; neither have evenings spent in bibliographic researches, nor fatigue in the dissecting-room been considered. All published writings on animal organisation, general treatises, special manuals, monographs, and articles in periodicals have been read and interrogated. But we have more particularly sought for information from Nature—that certain and infallible guide, always wise, even in her diversities; we have consulted her, scalpel in hand, with a perseverance that nothing could repel. Animals of every kind were had recourse to, and we have largely profited by the immense resources which our position as principal of anatomical teaching in the Imperial Veterinary School has placed at our disposal.

It was not enough that we should be correct, that we should faithfully describe the organs of the animal economy. It was desirable that the truth might be presented from a high philosophical point of view—one that should rise above details. It is necessary in a book, and especially in one on anatomy, that there should be a salient idea which might indicate its purpose and originality, and distinguish it as something more than a mere arid catalogue, by unifying the thousand different objects of which it treats. In support of this, we would ask permission to explain, in a few words, the idea that presided in the construction of our work.

Among the beings or objects composing the natural world, animals are distinguished by diversity in size and external conformation. Is this diversity repeated in their internal structure? When order and simplicity prevail everywhere else in nature, should we expect to find disorder and complication there, or look for as many different organisations as there are particular species? To state these questions, and to resolve them in the affirmative, would be to insult the wisdom of the Creator. The early naturalists, guided by instinct rather than knowledge, admired a certain uniformity in the composition of animals.

It was a good inspiration, which threatened to become effaced at the period when anatomical science, diffused and cultivated everywhere with the most laudable eagerness, daily discovered the secrets of the organisation of new species. Without a guide in the search for analogies, struck with the apparent differences their scalpel exposed every moment, the anatomists of that epoch neglected to compare the diverse animals. In presence of a new form of organs, they believed in the existence of a new instrument, and created a new name to designate it. Then was human anatomy, and that of the Horse, Ox, etc., established; monographs became multiplied; as the different opinions increased, so there was the greater need for a bond to unite these incongruous materials; confusion commenced, and chaos was about to appear; and the principle of analogies was on the point of being buried beneath the ruins of science.

Happily, two men appeared, men of genius, who were the glory of France—G. Cuvier and Etienne Geoffroy Saint-Hilaire; two names which will be for ever illustrious, and which we love to unite as the expression of one and the same symbol.

The first, after immense researches, ventured to compare the innumerable species in the animal kingdom with each other; he seized their general characters—the analogies which allied them to one another; he weighed these analogies, contrasted them with the dissimilarities, and established among them different kinds and different degrees; and in this way was he able to form natural groups, themselves subdivided into several categories in which individuals were gathered together according to their analogies and affinities. Then the chaos was swept away, light appeared, and the field of science was no longer obscured; *comparative anatomy* was created in all its branches, and the structure of the animal kingdom was

brought within those laws of uniformity which shine throughout the other parts of creation.

Geoffroy Saint-Hilaire followed Cuvier over the same ground. More exclusive than Cuvier, he entirely neglected the differential characters, and allowed himself to be governed by the consideration of resemblances. He especially pursued the discovery of a fixed rule for guidance in the search after these resemblances—a difficult task, and a dangerous reef, upon which the sagacity of his illustrious rival was stranded. To be more certain than Cuvier, and the better to grasp his subject, he restricted the scope of his observations, confining himself more particularly to the class of vertebrata in order to solve the enigma whose answer he sought. At last he found it, and made it known to us in those memorable, though abstruse pages, in which the meaning is often obscure and hidden, but which contain, nevertheless, magnificent hymns chanted to the honour of the Creator. The shape and functions of organs, he says, do not offer any stability, only their relations are invariable; these alone cannot give deceptive indications in the comparison of the vital instruments. He thus founded his great *principle of connections*, firmly established its value, fortified it by accessory principles, and held it up to the generations to come as a compass, a succourable beacon-light, under whose protection they might proceed to the conquest of analogies with confidence and security. Then was the philosophical sentiment decidedly introduced into the researches in organisation, and anatomy became a veritable science.

Enthusiastically admiring these two great masters, we glory in belonging to their school; it is, therefore, enough to say that the prevailing idea in our work has been inspired by their labours. Thus, in describing the organs in the somewhat numerous species of animals treated of, and noting their differential characters, we have always endeavoured to demonstrate their analogies.

The hopes that Geoffroy Saint-Hilaire entertained for the future of philosophical anatomy have not been entirely realised. Naturalists, it is true, have always cultivated this admirable science; Lecoq has preserved its traditions at the Lyons Veterinary School, in his simple, lucid, and elevated teaching; and at Toulouse, an able and learned professor, Lavocat, has courageously hoisted his flag. But everywhere else, and particularly in the Medical Schools, has not anatomy remained essentially monographic and purely surgical? And many medical men and veterinary surgeons, only looking at the practical side of this science, and full of defiance with respect to speculative theories, will perhaps give us no credit for our efforts in bringing the anatomy of animals into philosophical courses. To these we have nothing to say; if they do not see how much science is developed and becomes comprehensible with such elements; if they cannot understand all that is noble and useful in these generalising views; and if they do not feel elevated sentiments revolve in their mind in presence of the simplicity of Nature's laws, it is because their thoughts are not in unison

with ours, and we carefully abstain from engaging in a sterile discussion with them.

Such is our plan: have we executed it in a satisfactory manner? We have not deluded ourselves with regard to our strength, and willingly acknowledge that many resources and many qualities have failed us in carrying the enterprise to a favourable termination; therefore we hope to be indulgently judged.

If we have succeeded in facilitating the study of so important a subject as anatomy for the pupils of the veterinary schools; if our book becomes, in the hands of practitioners, a useful surgical guide; if, lastly, medical men and naturalists find that it will assist them in their researches in comparative anatomy, our object will have been attained, and we shall have received the best recompense which the honest writer can hope to obtain.

Before terminating, a sentiment of justice and recognition again brings the honourable name of M. Lecoq to our pen; the idea of this book was conceived at his lectures, and it is from these lectures that we have derived the major part of our materials; it was to satisfy the most imperious desire of our heart and conscience that we offered to dedicate this first attempt to him. Could it be better placed than under his patronage?

We have also willingly joined to his name that of M. H. Bouley, that eminent and devoted master, to whose advice we owe so much, and who has evinced the liveliest solicitude for us in circumstances which we can never forget. May he deign to accept this homage as the expression of our sincere recognition.

We have found in the obligingness and intelligence of M. Rodet a very efficacious aid; he will permit us to tender all our gratitude.

We have frequently put the complaisance of the students around us to a severe test; but they have never failed, and we are gratified in being able to thank them most cordially. We especially mention the name of M. Violet, whose intelligent zeal has spared us much toil in the difficult task imposed upon us.

A. Chauveau.

Lyons,
September 30, 1854.

TABLE OF CONTENTS.

PAGE

Translator and Editor's Preface vii
Preface to the First Edition xi
Preface to the Second Edition xv
Table of Contents xvii
Table of Illustrations xxxvi

GENERAL CONSIDERATIONS.

Definition and Division of Anatomy 1
Enumeration and Classification of the Domesticated Animals 2
General Idea of the Organisation of Animals, and the order followed in studying their apparatus 3

BOOK I.

LOCOMOTORY APPARATUS.

First Section.—The Bones 6
Chapter I.—The Bones in General 6
Article I.—The Skeleton 7
Article II.—General Principles applicable to the Study of all the Bones . 10
Name, Situation, Direction, and Configuration of the Bones . . 10
Internal Conformation of the Bones. Structure of the Bones . . 13
Development of the Bones 16
Chapter II.—The Bones of Mammalia in Particular 18
Article I.—Vertebral Column 18
Characters Common to all the Vertebræ . . . 19
Characters Proper to the Vertebræ in each region 21
1. Cervical Vertebræ 21
2. Dorsal Vertebræ 24
3. Lumbar Vertebræ 25
4. Sacrum 26
5. Coccygeal Vertebræ 27
Of the Spine in General 28
Differential Characters in the Vertebral Column of other than Soliped Animals 29
Comparison of the Vertebral Column of Man with that of Animals . 32
Article II.—The Head 33
The Bones of the Cranium 33
1. Occipital 33
2. Parietal 35
3. Frontal 36

PAGE
4. Ethmoid 37
5. Sphenoid 39
6. Temporal 41
The Bones of the Face 44
1. Superior Maxillary or Great Supermaxillary 44
2. Intermaxilla, Incisive Bone, Small Supermaxilla, or Premaxilla . 45
3. Palate 46
4. Pterygoid 47
5. Zygomatic 47
6. Lachrymal 48
7. Bones proper to the Nose, or Supernasal 48
8. Turbinated Bones 49
9. Vomer 51
10. Inferior Maxillary 51
11. Hyoid 53
Of the Head in General 54
Differential Characters in the Head of other than Soliped Animals . 55
Comparison of the Head of Man with that of Animals . . . 63
Article III.—The Thorax 66
The Bones of the Thorax in Particular 66
1. Sternum of the Horse 66
2. Ribs 67
Of the Thorax in General 70
Differential Characters in the Thorax of other than Soliped Animals . 70
1. Sternum 70
2. Ribs 71
Comparison of the Thorax of Man with that of Animals . . 71
1. Sternum 71
2. Ribs 71
Article IV.—Anterior Limbs 71
Shoulder 72
Scapula 72
Arm 73
Humerus 73
Fore-arm 75
1. Radius 75
2. Ulna 76
Anterior Foot 77
1. Bones of the Carpus 78
2. Bones of the Metacarpus 81
3. Bones of the Digit, or Phalangeal Region 82
Differential Characters in the Anterior Limb of other than Soliped Animals 86
Comparison of the Thoracic Limb of Man with that of the Domesticated Animals 89
Article V.—Posterior Limbs 91
Pelvis 91
A. Coxæ 91
B. The Pelvis in General 95
Thigh 98
Femur 98
Leg 100
1. Tibia 100
2. Fibula 101
3. Patella 102

PAGE
Posterior Foot 102
1. Bones of the Tarsus 102
2. Bones of the Metatarsus 105
3. Bones of the Digital Region 105
Differential Characters in the Posterior Limb of other than Soliped Animals 105
Comparison of the Abdominal Limb of Man with that of the Domesticated Animals 107
Article VI.—The Limbs in General, and their Parallelism . 109
CHAPTER III.—The Bones in Birds 112
CHAPTER IV.—Theory of the Vertebral Constitution of the Skeleton . 118
SECOND SECTION.—The Articulations 121
CHAPTER I.—The Articulations in General 121
General Characters of Diarthroses 123
General Characters of Synarthroses 128
General Characters of Amphiarthroses or Symphyses . . . 129
CHAPTER II.—The Articulations of Mammalia in Particular . 129
Article I.—Articulations of the Spine 130
Articulations between the Vertebræ, or Intervertebral Articulations . 130
Article II.—Articulations of the Head 135
1. Atlo-axoid Articulation 135
2. Occipito-atloid Articulation 137
3. Articulations between the Bones of the Head . . . 137
4. Temporo-maxillary Articulation 138
5. Hyoideal Articulations 139
Article III.—Articulations of the Thorax 140
1. Costo-vertebral, or Articulations of the Ribs with the Vertebral Column 140
2. Costo-sternal Articulations 141
3. Chondro-costal Articulations, or Articulations between the Ribs . 142
4. Articulations between the Costal Cartilages . . . 142
5. Sternal Articulation peculiar to the Ox and Pig . . 142
6. The Articulations of the Thorax considered in a general manner, with respect to their Movements 142
Article IV.—Articulations of the Anterior Limbs . . . 143
1. Scapulo-humeral Articulation. 143
2. Humero-radial Articulation . . . 144
3. Radio-ulnar Articulation . . . 147
4. Articulations of the Carpus . . . 148
5. Intermetacarpal Articulations. . . 152
6. Metacarpo-phalangeal Articulations 153
7. Articulation of the First Phalanx with the Second, or first Interphalangeal Articulation 156
8. Articulation of the Second Phalanx with the Third, Second Interphalangeal Articulation, or Articulation of the Foot . 157
Article V.—Articulations of the Posterior Limbs 159
1. Articulations of the Pelvis 159
2. Coxo-femoral Articulation 161
3. Femoro-tibial Articulation . . . 163
4. Tibio-fibular Articulation 167
5. Articulations of the Tarsus, or Hock . . . 168
CHAPTER III.—The Articulations in Birds 172
THIRD SECTION.—The Muscles. 173
CHAPTER I.—General Considerations on the Striped Muscles . . 174
The Striped Muscles in General 174

PAGE
Structure of the Striped Muscles 178
Physico-chemical Properties of the Striped Muscles . . . 180
Physiological Properties of the Striped Muscles 181
Annexes of the Muscles 183
Manner of Studying the Muscles 183
CHAPTER II.—The Muscles of Mammalia in Particular . . . 186
Article I.—The Muscles of the Trunk 186
Subcutaneous Region 186
Fleshy Panniculus 186
Cervical Region 187
A. Superior Cervical or Spinal Region of the Neck . . . 187
1. Rhomboideus 188
2. Angularis Muscle of the Scapula 189
3. Splenius 189
4. Great Complexus 191
5. Small Complexus (Trachelo-mastoideus) 191
6. Transverse Spinous Muscle of the Neck (Spinalis Colli) . . 193
7. Intertransversal Muscle of the Neck 193
8. Great Oblique Muscle of the Head (Obliquus Capitis Inferior) . 193
9. Small Oblique Muscle of the Head (Obliquus Capitis Superior) . 194
10. Great Posterior Straight Muscle of the Head . . . 195
11. Small Posterior Straight Muscle (Rectus Capitis Posticus Minor) 195
B. Inferior Cervical or Trachelian Region 195
1. Subcutaneous Muscle of the Neck (Panniculus Carnosus) . 196
2. Mastoido-humeralis (Levator Humeri). 196
3. Sterno-maxillaris 198
4. Sterno-hyoideus 198
5. Sterno-thyroideus. 198
6. Omo-hyoideus, or Subscapulo-hyoideus 198
7. Great Anterior Straight Muscle of the Head (Rectus Capitis Anticus Major) 199
8. Small Anterior Straight Muscle of the Head (Rectus Capitis Anticus Minor) 199
9. Small Lateral Straight Muscle (Obliquus Capitis Anticus) . 199
10. Scalenus 200
11. Long Muscle of the Neck (Longus Colli) 200
Differential Characters in the Muscles of the Cervical Region of other than Soliped Animals 201
A. Superior Cervical Region 201
B. Inferior Cervical or Trachelian Region 201
Spinal Region of the Back and Loins 203
1. Trapezius 203
2. Great Dorsal (Latissimus Dorsi) 203
3. Small Anterior Serrated Muscle (Superficialis Costarum) . 205
4. Small Posterior Serrated Muscle (Superficialis Costarum) . . 205
5. Ilio-spinalis Muscle (Longissimus Dorsi) . . . 206
6. Common Intercostal Muscle (Transversalis Costarum) . . 208
7. Transverse Spinous Muscle of the Back and Loins (Spinalis and Semispinalis Dorsi 209
Differential Characters in the Muscles of the Spinal Region of the Back and Loins of other than Soliped Animals 209
Comparison of the Muscles of the Back, Neck, and Cervix in Man with the analogous Muscles in the Domesticated Animals . . . 209
A. Muscles of the Back and Cervix 210

PAGE
B. Muscles of the Neck 211
Sublumbar or Inferior Lumbar Region 211
1. Iliac Fascia or Lumbo-iliac Aponeurosis 212
2. Great Psoas Muscle 212
3. Iliac Psoas Muscle (Iliacus). 212
4. Small Psoas Muscle 214
5. Square Muscle of the Loins (Sacro-lumbalis) . . . 214
6. Intertransverse Muscles of the Loins (Intertransversales Lumborum) 215
Differential Characters in the Muscles of the Sublumbar Region of other than Soliped Animals 215
Comparison of the Sublumbar Muscles of Man with those of Animals . 215
Coccygeal Region. 215
1. Sacro-coccygeal Muscles 215
2. Ischio-coccygeus (Compressor Coccygeus) . . . 217
Region of the Head 217
A. Facial Region 217
1. Labialis (Orbicularis Oris) 217
2. Alveolo-labialis (Buccinator) 218
3. Zygomatico-labialis (Zygomaticus) 219
4. Lachrymo-labial, or Lachrymal Muscle . . . 220
5. Supernaso-labialis (Levator Labii Superioris) . . 220
6. Supermaxillo-labialis (Nasalis Longus Labii Superioris) . . 220
7. Great Supermaxillo Nasalis (Dilatator Naris Lateralis) . 221
8. Small Supermaxillo-nasalis (Nasalis Brevis Labii Superioris) . 221
9. Transversalis Nasi (Dilatator Naris Anterior). . 221
10. Middle Anterior Muscle (Depressor Labii Superiori) . 222
11. Maxillo-labialis (Depressor Labii Inferioris) . . . 222
12. Mento-labialis, or Muscle of the Chin 222
13. Middle Posterior Muscle (Levator Menti) . . 222
B. Masseterine or Temporo-maxillary Region . . 223
1. Masseter 223
2. Temporal or Crotaphitic Muscle 223
3. Internal Pterygoid (Pterygoideus Internus) . . . 224
4. External Pterygoid 224
5. Digastricus 225
C. Hyoideal Region 225
1. Mylo-hyoideus 225
2. Genio-hyoideus 226
3. Stylo-hyoideus (Hyoideus Magnus) 227
4. Kerato-hyoideus (Hyoideus Parvus) 227
5. Occipito-styloideus 227
6. Tranversalis Hyoidei 228
Differential Characters in the Muscles of the Head of other than Soliped Animals 228
A. Facial Region 228
B. Masseterine or Temporo-maxillary Region . . . 229
C. Hyoid Region 230
Comparison of the Muscles of the Human Head with those of the Domesticated Animals 230
A. Epicranial Muscles 230
B. Muscles of the Face 230
C. Muscles of the Lower Jaw 231
D. Hyoid Muscles 231
Axillary Region 231

PAGE
1. Superficial Pectoral (Pectoralis Transversus) 231
2. Deep Pectoral 233
Differential Characters in the Muscles of the Axillary Region of other than Soliped Animals 235
Costal Region 235
1. Great Serratus 236
2. Transverse Muscle of the Ribs (Lateralis Sterni) . . 236
3. External Intercostals 237
4. Internal Intercostals 237
5. Supercostals (Levatores Costarum) 237
6. Triangularis of the Sternum (Sterno-costales) . . . 237
Differential Characters in the Muscles of the Costal Region of other than Soliped Animals 238
Comparison of the Thoracic Muscles of Man with those of the Domesticated Animals 238
Inferior Abdominal Region 238
1. Abdominal Tunic 239
2. White Line. 240
3. Great or External Oblique of the Abdomen . . . 240
4. Small or Internal Oblique of the Abdomen . . . 242
5. Great Rectus Muscle of the Abdomen 243
6. Transverse Muscle of the Abdomen 244
Differential Characters in the Muscles of the Abdominal Region of other than Soliped Animals 245
Comparison of the Abdominal Muscles of Man with those of Animals . 245
Diaphragmatic Region 246
Diaphragm 246
Differential Characters in the Diaphragm of other than Soliped Animals 248
Comparison of the Diaphragm of Man with that of Animals . . 248
Article II.—Muscles of the Anterior Limbs 248
Muscles of the Shoulder 249
A. External Scapular Region 249
1. External Scapular Aponeurosis 249
2. Long Abductor of the Arm, or Scapular portion of the Deltoid (Teres Major) 249
3. Short Abductor of the Arm, or Teres Minor . . . 250
4. Superspinatus (Antea Spinatus) 251
5. Subspinatus (Postea Spinatus) 251
B. Internal Scapular Region 252
1. Subscapularis 252
2. Adductor of the Arm, or Teres Major 253
3. Coraco-humeralis, Coraco-brachialis, or Omo-brachialis . . 254
4. Small Scapulo-humeralis 254
Differential Characters in the Muscles of the Shoulder of other than Soliped Animals 254
Comparison of the Muscles of the Shoulder of Man with those of Animals . 255
Muscles of the Arm 255
A. Anterior Brachial Region 255
1. Long Flexor of the Fore-arm, or Brachial Biceps (Flexor Brachii) 255
2. Short Flexor of the Fore-arm (Humeralis Externus) . . 256
B. Posterior Brachial Region 258
1. Long Extensor of the Fore-arm (Caput Magnum) . . 258
2. Large Extensor of the Fore-arm (Caput Magnum) . . 258
3. Short Extensor of the Fore arm (Caput Medium) . . 259

PAGE
4. Middle Extensor of the Fore-arm (Caput Parvum) . . 259
5. Small Extensor of the Fore-arm, or Anconeus 260
Differential Characters in the Muscles of the Arm of other than Soliped Animals 260
Comparison of the Muscles of the Arm of Man with those of Animals 260
Muscles of the Fore-arm 261
Antibrachial Aponeurosis 261
A. Anterior Antibrachial Region 262
1. Anterior Extensor of the Metacarpus (Extensor Metacarpi Magnus) 262
2. Oblique Extensor of the Metacarpus (Extensor Metacarpi Obliquus) 263
3. Anterior Extensor of the Phalanges (Extensor Pedis) . . 263
4. Lateral Extensor of the Phalanges (Extensor Suffraginis) . 264
B. Posterior Antibrachial Region 265
1. External Flexor of the Metacarpus, or Posterior Ulnaris. . 265
2. Oblique Flexor of the Metacarpus, or Anterior Ulnaris (Flexor Metacarpi Medius) 266
3. Internal Flexor of the Metacarpus, or Palmaris Magnus (Flexor Metacarpi Internus) 266
4. Superficial Flexor, Sublimis of the Phalanges, or Perforatus . 267
5. Deep Flexor of the Phalanges, or Perforans . . . 268
Differential Characters in the Muscles of the Fore-arm of other than Soliped Animals 270
Muscles proper to the Fore-arm in Carnivora 272
1. Proper Extensor of the Thumb and Index 272
2. Long Supinator. 272
3. Short Supinator 274
4. Round Pronator 274
5. Square Pronator 274
Comparison of the Muscles of the Fore-arm of Man with those of Animals 274
A. Anterior Region 274
B. External Region 276
C. Posterior Region 276
Muscles of the Anterior Foot or Hand 276
A. Muscles of the Anterior Foot in Carnivora 276
1. Short Abductor of the Thumb 276
2. Opponens of the Thumb 277
3. Short Flexor of the Thumb 277
4. Adductor of the Index 277
5. Cutaneous Palmar (Palmaris Brevis) 277
6. Adductor of the Small Digit 277
7. Short Flexor of the Small Digit 277
8. Opponens of the Small Digit 277
9. Lumbrici 278
10. Metacarpal Interosseous Muscles 278
B. Muscles of the Anterior Foot in the Pig 278
C. Muscles of the Anterior Foot in Solipeds 278
D. Muscles of the Anterior Foot in Ruminants . . . 279
Comparison of the Hand of Man with that of Animals . . 279
A. Muscles of the Thenar Eminence 279
B. Muscles of the Hypothenar Eminence. 279
C. Interosseous Muscles 279
Article III.—Muscles of the Posterior Limbs 280
Muscles of the Gluteal Region, or Croup 280
1. Superficial Gluteus (Gluteus Externus) . . . 280

PAGE
2. Middle Gluteus (Gluteus Maximus) 281
3. Deep Gluteus (Gluteus Internus) 282
Differential Characters in the Muscles of the Gluteal Region of other than Soliped Animals 283
Comparison of the Gluteal Muscles of Man with those of Animals . . 283
Muscles of the Thigh 283
A. Anterior Crural, or Femoral Region 283
1. Muscle of the Fascia Lata (Tensor Vaginæ) 284
2. Crural Triceps 284
3. Anterior Gracilis (Crureus vel Cruralis). 285
B. Posterior Crural Region 286
1. Long Vastus (Biceps Abductor Femoris) 286
2. Semitendinosus Muscle (Adductor Tibialis) . . . 287
3. Semimembranosus (Adductor Tibialis) 288
C. Internal Crural Region 288
1. Long Adductor of the Leg (Sartorius) 288
2. Short Adductor of the Leg (Gracilis) 289
3. Pectineus 289
4. Small Adductor of the Thigh (Adductor Femoris) . . . 291
5. Great Adductor of the Thigh (Adductor Longus) . 291
6. Square Crural (Quadratus Femoris). 292
7. External Obturator 292
8. Internal Obturator 292
9. Gemelli of the Pelvis (Gemini) 293
Differential Characters in the Muscles of the Thigh of other than Soliped Animals 294
A. Anterior Crural Region 294
B. Posterior Crural Region 294
C. Internal Crural Region 295
Comparison of the Muscles of Man's Thigh with those of the Thigh of Animals 295
A. Anterior Muscles 295
B. Muscles of the Posterior Region 295
C. Muscles of the Internal Region 296
Muscles of the Leg 297
Tibial Aponeurosis 297
A. Anterior Tibial Region 298
1. Anterior Extensor of the Phalanges (Extensor Pedis) . . 298
2 Lateral Extensor of the Phalanges (Peroneus) . . 298
3. Flexor of the Metatarsus 300
B. Posterior Tibial Region 302
1. Gastrocnemii, or Gemelli of the Tibia (Gastrocnemius Externus) 302
2. Soleus, or Solearis (Plantaris) 304
3. Superficial Flexor of the Phalanges, or Perforatus (Gastrocnemius Internus) 304
4. Popliteus 304
5. Deep Flexor of the Phalanges, or Perforans (Flexor Pedis) . . 305
6. Oblique Flexor of the Phalanges (Flexor Pedis Accessorius) . 306
Differential Characters in the Muscles of the Leg of other than Soliped Animals 306
A. Anterior Tibial Region 306
B. Posterior Tibial Region 309
Comparison of the Muscles of the Leg of Man with those of Animals . 309
A. Anterior Region 309

PAGE
B. External Region . . . 309
C. Posterior Region 309
Muscles of the Posterior Foot 311
Comparison of the Muscles of the Foot of Man with those of Animals 311
A. Dorsal Region 311
B. Plantar Region 312
C. Interosseous Muscles 313
CHAPTER III.—The Muscles in Birds 313
CHAPTER IV.—General Table of the insertions of the Muscles in Solipeds . 315

BOOK II.

THE DIGESTIVE APPARATUS.

CHAPTER I.—General Considerations on the Digestive Apparatus . . 325
CHAPTER II.—The Digestive Apparatus in Mammalia 330
Article I.—Preparatory Organs of the Digestive Apparatus . . 330
The Mouth 330
1. Lips 330
2. Cheeks 332
3. Palate 332
4. Tongue 334
5. Soft Palate 340
6. Teeth 344
7. The Mouth in General 355
Differential Characters in the Mouth of other than Soliped Animals . 356
Comparison of the Mouth of Man with that of Animals . . 362
The Salivary Glands 364
1. Parotid Gland 365
2. Maxillary, or Submaxillary Gland 367
3. Sublingual Gland 369
4. Molar Glands 369
5. Labial, Lingual, and Palatine Glands 370
Differential Characters in the Salivary Glands of other than Soliped Animals 370
Comparison of the Salivary Glands of Man with those of Animals . 372
The Pharynx 372
Differential Characters in the Pharynx of other than Soliped Animals . 376
Comparison of the Pharynx of Man with that of Animals . . . 377
The Œsophagus 377
Differential Characters in the Œsophagus of other than Soliped Animals 380
Comparison of the Œsophagus of Man with that of Animals . . 380
Article II.—The Essential Organs of Digestion . 380
The Abdominal Cavity 380
Differential Characters in the Abdominal Cavity of other than Soliped Animals 384
Comparison of the Abdominal Cavity of Man with that of Animals . 385
The Stomach 385
1. The Stomach of Solipeds 385
Differential Characters in the Stomach of other than Soliped Animals 393
1. The Stomach of the Pig 393
2. The Stomach of Carnivora 393
3. The Stomach of Ruminants 393
Comparison of the Stomach of Man with that of Animals . . . 400

PAGE
The Intestines 400
1. The Small Intestine 400
2. The Large Intestine 407
A. Cæcum 407
B. Colon 410
C. Rectum 413
Differential Characters in the Intestines of other than Soliped Animals . 414
1. The Intestines of Ruminants 414
2. The Intestines of the Pig 416
3. The Intestines of Carnivora 416
Comparison of the Intestines of Man with those of Animals . . 417
General and Comparative Survey of the Abdominal or Essential Portion of the Digestive Canal 418
Organs Annexed to the Abdominal Portion of the Digestive Canal . 419
1. Liver 419
2. Pancreas 427
3. Spleen 428
Differential Characters in the Organs Annexed to the Abdominal Portion of the Digestive Canal in other than Soliped Animals . . 432
Comparison of the Organs Annexed to the Abdominal Portion of the Digestive Canal of Man with those of Animals 434
CHAPTER III.—The Digestive Apparatus of Birds 435

BOOK III.

RESPIRATORY APPARATUS.

CHAPTER I.—Respiratory Apparatus in Mammalia 439
The Nasal Cavities 439
1. The Nostrils 440
2. The Nasal Fossæ 441
3. The Sinuses 446
Differential Characters in the Nasal Cavities of other than Soliped Animals 448
Comparison of the Nasal Cavities of Man with those of Animals . 449
The Air-tube succeeding the Nasal Cavities 449
1. The Larynx 449
2. The Trachea 457
3. The Bronchi 460
Differential Characters in the Air-tube succeeding the Nasal Fossæ of other than Soliped Animals 461
Comparison of the Larynx and Trachea of Man with these Organs in the Domesticated Animals 462
The Thorax 462
Differential Characters in the Thorax of other than Soliped Animals 466
The Lungs 466
Differential Characters in the Lungs of other than Soliped Animals . 470
Comparison of the Larynx, Trachea, and Lungs of Man with the same Organs in Animals 471
The Glandiform Bodies connected with the Respiratory Apparatus . 472
1. The Thyroid Body 472
2. The Thymus Gland 473
Differential Characters in the Glandiform Bodies annexed to the Respiratory Apparatus of other than Soliped Animals 474

PAGE
Comparison of the Glandiform Bodies annexed to the Respiratory Apparatus in Man with those of Animals 475
CHAPTER II.—The Respiratory Apparatus of Birds 475

BOOK IV.

URINARY APPARATUS.

1. The Kidneys 484
2. The Ureters 490
3. The Bladder 491
4. The Urethra 493
5. The Suprarenal Capsules 494
Differential Characters of the Urinary Apparatus in other than Soliped Animals 495
Comparison of the Urinary Apparatus of Man with that of Animals . 496

BOOK V.

CIRCULATORY APPARATUS.

FIRST SECTION.—The Heart 499
1. The Heart as a Whole 499
2. External Conformation of the Heart 500
3. Internal Conformation of the Heart 503
4. Structure of the Heart 507
5. The Pericardium 512
6. The Action of the Heart. 513
Differential Characters in the Heart of other than Soliped Animals . 513
Comparison of the Heart of Man with that of Animals . . . 514
SECOND SECTION.—The Arteries 515
CHAPTER I.—General Considerations 515
CHAPTER II.—Pulmonary Artery 521
CHAPTER III.—Aorta 522
Article I.—Common Aorta, or Aortic Trunk 522
Cardiac, or Coronary Arteries 523
Article II.—Posterior Aorta 523
Parietal Branches of the Posterior Aorta 525
1. Intercostal Arteries 525
2. Lumbar Arteries 526
3. Diaphragmatic Arteries 526
4. Middle Sacral Artery 526
Visceral Branches of the Posterior Aorta 526
1. Broncho-Œsophageal Trunk . . . 526
2. Cœliac Artery 527
3. Great Mesenteric Artery 529
4. Small Mesenteric Artery 532
5. Renal, or Emulgent Arteries 534
6. Spermatic Arteries 534
7. Small Testicular Arteries (Male), Uterine Arteries (Female) . 535
Differential Characters in the Posterior Aorta and its Collateral Branches of other than Soliped Animals 535
1. Posterior Aorta in Ruminants 535
2. Posterior Aorta in the Pig 537
3. Posterior Aorta in Carnivora 537
Comparison of the Aorta of Man with that of Animals . . . 538

PAGE
Article III.—Internal Iliac Arteries, or Pelvic Trunks 538
1. Umbilical Artery 538
2. Internal Pudic, or Bulbous Artery 540
3. Subsacral, or Lateral Sacral Artery 540
4. Iliaco-muscular, or Ilio-lumbar Artery 541
5. Gluteal Artery 542
6. Obturator Artery 542
7. Iliaco-femoral Artery 543
Differential Characters in the Internal Iliac Arteries of other than Soliped Animals 543
1. Internal Iliac Arteries of Ruminants 543
2. Internal Iliac Arteries of the Pig 544
3. Internal Iliac Arteries of the Carnivora 544
Comparison of the Internal Iliac Arteries of Man with those of Animals . 545
Article IV.—External Iliac Arteries, or Crural Trunks 545
Femoral Artery 547
1. Prepubic Artery 547
2. Deep Femoral, Deep Muscular, or Great Posterior Muscular Artery of the Thigh 548
3. Superficial Muscular, or Great Anterior Muscular Artery . 548
4. Innominate Muscular, or Small Muscular Arteries 549
5. Saphena Artery 549
Popliteal Artery 549
Terminal Branches of the Popliteal Artery 550
1. Posterior Tibial Artery 550
2. Anterior Tibial Artery 551
3. Pedal Artery 551
Differential Characters in the External Iliac Arteries of other than Soliped Animals 555
1. External Iliac Arteries of Ruminants . . . 555
2. External Iliac Arteries of the Pig 556
3. External Iliac Arteries of Carnivora 556
Comparison of the External Iliac Arteries of Man with those of Animals 557
Article V.—Anterior Aorta 559
Article VI.—Axillary Arteries, or Brachial Trunks 559
Collateral Branches of the Axillary Arteries 560
1. Dorsal, Dorso-muscular, or Transverse Cervical Artery . . 560
2. Superior Cervical, Cervico-muscular, or Deep Cervical Artery 561
3. Vertebral Artery 561
4. Internal Thoracic, or Internal Mammary Artery . . . 563
5. External Thoracic, External Mammary, or Inferior Thoracic Artery 563
6. Inferior Cervical Artery 564
7. Superscapular Artery 564
8. Subscapular Artery 564
Terminal Branch of the Brachial Trunk, or Humeral Artery . . 565
1. Anterior Radial Artery 566
2. Posterior Radial Artery 567
1. First Terminal Branch of the Posterior Radial Artery, or Common Trunk of the Interosseous Metacarpals . . . 568
2. Second Terminal Branch of the Posterior Radial Artery, or Collateral Artery of the Canon 569
Differential Characters in the Axillary Arteries of Non-soliped Animals 570
1. Axillary Arteries of Ruminants 570
2. Axillary Arteries of the Pig 572

PAGE
3. Axillary Arteries of Carnivora 572
Comparison of the Axillary Arteries of Man with those of Animals . 574
Article VII.—Common Carotid Arteries 575
Occipital Artery 577
Internal Carotid Artery 579
External Carotid Artery 581
1. External Maxillary, Facial, or Glosso-Facial Artery . . 581
2. Maxillo-Muscular Artery 585
3. Posterior Auricular Artery 585
4. Superficial Temporal Artery, or Temporal Trunk . . 585
5. Internal Maxillary, or Gutturo-maxillary Artery . . 586
Differential Characters in the Carotid Arteries of Non-soliped Animals . 590
1. Carotid Arteries of Carnivora 590
2. Carotid Arteries of the Pig 591
3. Carotid Arteries of Ruminants 592
Comparison of the Carotid Arteries of Man with those of Animals . . 595
THIRD SECTION.—The Veins 596
CHAPTER I.—General Considerations 596
CHAPTER II.—Veins of the Lesser Circulation, or Pulmonary Veins . 599
CHAPTER III.—Veins of the General Circulation 599
Article I.—Cardiac, or Coronary Veins 599
Article II.—Anterior Vena Cava 600
Jugular Veins 601
Roots of the Jugular 603
1. Superficial Temporal Vein 603
2. Internal Maxillary Vein 605
3. The Sinuses of the Dura Mater 605
Axillary Veins 609
1. Subscapular Vein 610
2. Humeral Vein 610
3. Spur, or Subcutaneous Thoracic Vein 610
4. Deep Veins of the Fore-arm 610
5. Superficial Veins of the Fore-arm 611
6. Metacarpal Veins 611
7. Digital Veins 612
8. Veins of the Foot, or Ungual Region 612
a. External Venous Apparatus 612
b. Internal, or Intra-osseous Venous Apparatus . . . 616
Article III.—Posterior Vena Cava 617
Diaphragmatic Veins 617
Vena Portæ 617
1. Roots of the Vena Portæ 620
2. Lateral Affluents of the Vena Portæ 621
Renal Veins 621
Spermatic Veins 621
Lumbar Veins 622
Common Iliac Veins, or Pelvi-crural Trunks 622
1. Internal Iliac Vein 622
2. External Iliac Vein 623
3. Femoral Vein 623
4. Popliteal Vein 623
5. Deep Veins of the Leg 623
6. Superficial Veins of the Leg 624
7. Metatarsal Veins 624
8. Veins of the Digital Region 625

PAGE
Differential Characters in the Veins of other than Soliped Animals . . 625
Comparison of the Veins of Man with those of Animals . . 626
FOURTH SECTION.—The Lymphatics 627
CHAPTER I.—General Considerations 627
Lymphatic Vessels 627
Lymphatic Glands, or Ganglia 632
CHAPTER II.—The Lymphatics in Particular 634
Article I.—The Thoracic Duct 634
Article II.—The Lymphatics which constitute the Affluents of the Thoracic Duct 637
Lymphatics of the Abdominal Limb, Pelvis, Abdominal Parietes, and Pelvi-inguinal Organs 638
1. Sublumbar Glands 638
2. Deep Inguinal Glands 638
3. Superficial Inguinal Glands 638
4. Popliteal Glands 640
5. Iliac Glands 640
6. Precrural Glands 640
Lymphatics of the Abdominal Viscera 640
1. Glands and Lymphatic Vessels of the Rectum and Floating Colon 640
2. Glands and Lymphatic Vessels of the Large Colon . . 641
3. Glands and Lymphatic Vessels of the Cæcum . . 641
4. Glands and Lymphatic Vessels of the Small Intestine . 641
5. Glands and Lymphatic Vessels of the Stomach . . 641
6. Glands and Lymphatic Vessels of the Spleen and Liver . . 642
Glands and Lymphatic Vessels of the Organs contained in the Thoracic Cavity 642
Glands and Lymphatic Vessels of the Thoracic Parietes . . 642
Lymphatic Vessels of the Head, Neck, and Anterior Limb . . 643
1. Prepectoral Glands 643
2. Pharyngeal Glands 643
3. Submaxillary, or Subglossal Glands 644
4. Prescapular Glands 644
5. Brachial Glands 644
Article III.—Great Lymphatic Vein 644
Differential Characters in the Lymphatics of Non-soliped Animals . 645
CHAPTER III.—The Circulatory Apparatus in Birds 647
Article I.—The Heart 647
Article II.—The Arteries 648
Article III.—The Veins 649
Article IV.—The Lymphatics 649

BOOK VI.

APPARATUS OF INNERVATION.

FIRST SECTION.—The Nervous System in General 650
General Conformation of the Nervous System 651
Structure of the Nervous System 652
Properties and Functions of the Nervous Systems 655
SECOND SECTION.—The Central Axis of the Nervous System . . . 659
CHAPTER I.—Protective and Enveloping Parts of the Cerebro-spinal Axis 659
The Bony Case which lodges the Central Cerebro-spinal Axis . 659
1. The Spinal Canal 659
2. The Cranial Cavity 660

PAGE
The Envelopes of the Cerebro-spinal Axis . . 660
1. The Dura Mater . . . 661
2. The Arachnoid 663
3. The Pia Mater 665
Differential Characters in the Protecting and Enveloping Parts of the Cerebro-spinal Axis in other than Soliped Animals . . 666
Comparison of the Protective and Enveloping Parts of the Cerebro-spinal Axis of Man with those of Animals . . . 666
CHAPTER II.—The Spinal Cord 666
External Conformation of the Spinal Cord . . 666
Internal Conformation and Structure of the Spinal Cord . . 668
Differential Characters in the Spinal Cord of the Domesticated Mammals other than Solipeds 672
Comparison of the Spinal Cord of Man with that of Animals . . 672
CHAPTER III.—The Encephalon 672
Article I.—The Encephalon as a Whole 672
Article II.—The Isthmus 675
External Conformation of the Isthmus 675
1. The Medulla Oblongata 676
2. The Pons Varolii 677
3. The Crura Cerebri 677
4. The Crura Cerebelli 678
5. The Valve of Vieussens 679
6. The Corpora Quadrigemina, or Bigemina 679
7. The Optic Thalami 679
8. The Pineal Gland 680
9. The Pituitary Gland 681
Internal Conformation of the Isthmus 682
1. The Middle Ventricle, or Ventricle of the Optic Thalami . 682
2. The Aqueduct of Sylvius 683
3. The Posterior, or Cerebellar Ventricle 683
Structure of the Isthmus 683
Differential Characters in the Isthmus of other than Soliped Animals . 685
Comparison of the Isthmus of Man with that of Animals . . . 685
Article III.—The Cerebellum 686
1. External Conformation of the Cerebellum . . 686
2. Internal Conformation of the Cerebellum . . . 688
Differential Characters of the Cerebellum in other than Soliped Animals . 689
Comparison of the Cerebellum of Man with that of Animals . . 689
Article IV.—The Cerebrum 689
External Conformation of the Cerebrum . . 690
1. The Longitudinal Fissure . . 690
2. The Cerebral Hemispheres . . . 691
Internal Conformation of the Brain . . 692
1. The Corpus Callosum 693
2. The Lateral, or Cerebral Ventricles . 693
3. The Septum Lucidum . . . 694
4. The Cerebral Trigonum (or Fornix) . . 694
5. The Hippocampi 695
6. The Corpora Striata 695
7. The Cerebral Choroid Plexus, and Velum Interpositum . 696
Structure of the Cerebrum 697
Differential Characters in the Brain of other than Soliped Animals . 698
Comparison of the Brain of Man with that of Animals . . . 698

PAGE

THIRD SECTION.—The Nerves 700
CHAPTER I.—The Cranial, or Encephalic Nerves 703
1. First Pair, or Olfactory Nerves 705
2. Second Pair, or Optic Nerves 706
3. Third Pair, or Common Motor Ocular Nerves 708
4. Fourth Pair, or Pathetici Nerves 709
5. Fifth Pair or Trigeminal Nerves 710
6. Sixth Pair, or External Motor Ocular Nerves . . . 721
7. Seventh Pair, or Facial Nerves 721
8. Eighth Pair, or Auditory, or Acoustic Nerves 727
9. Ninth Pair, or Glosso-Pharyngeal Nerves 727
10. Tenth Pair, Vagus, or Pneumogastric Nerves 728
11. Eleventh Pair, Spinal, or Accessory Nerves of the Pneumogastrics 736
12. Twelfth Pair, or Great Hypoglossal Nerves 738
Differential Characters in the Cranial Nerves of other than Soliped Animals 739
Comparison of the Cranial Nerves of Man with those of Animals . . 744
CHAPTER II.—Spinal Nerves 747
Article I.—Cervical Nerves (Eight Pairs) 748
Article II.—Dorsal Nerves (Seventeen Pairs) . . . 750
Article III.—Lumbar Nerves (Six Pairs) 751
Article IV.—Sacral Nerves (Five Pairs) 752
Article V.—Coccygeal Nerves (Six to Seven Pairs) 753
Article VI.—Composite Nerves formed by the Inferior Ramuscules of the Spinal Branches 753
Diaphragmatic Nerves 754
Brachial Plexus 754
1. Diaphragmatic Branches 755
2. Branch to the Angularis and Rhomboideus 755
3. Branch to the Serratus Magnus, or Superior Thoracic . 756
4. Branches to the Pectoral Muscles, or Inferior Thoracic . . 756
5. Subcutaneous Thoracic Branch 756
6. Branch to the Great Dorsal 758
7. Axillary, or Circumflex Nerve 758
8. Nerve of Adductor of the Arm, or Teres Major 758
9. Subscapular Branches 758
10. Superscapular Nerve 758
11. Anterior Brachial Nerve 758
12. Radial Nerve 759
13. Ulnar, or Cubito-cutaneous Nerve 760
14. Median, or Cubito-plantar Nerve 760
Differential Characters in the Brachial Plexus of other than Soliped Animals 763
Comparison of the Brachial Plexus of Man with that of Animals . 767
Sacro-lumbar Plexus 770
1. Iliaco-muscular Nerves 772
2. Crural, or Anterior Femoral Nerve 772
3. Obturator Nerve 772
4. Small Sciatic, or Anterior and Posterior Gluteal Nerves . . 773
5. Great Sciatic, or Great Femoro-popliteal Nerve . . 774
Collateral Branches 775
Terminal Branches 777
Differential Characters in the Sacro-lumbar Plexus of other than Soliped Animals 777
Comparison of the Sacro-lumbar Plexus of Man with that of Animals . 778

PAGE
CHAPTER III.—The Great Sympathetic 781
1. Cephalic Portion of the Sympathetic Chain 782
2. Cervical Portion of the Sympathetic Chain 783
3. Dorsal Portion of the Sympathetic Chain 786
4. Lumbar Portion of the Sympathetic Chain 788
5. Sacral Portion of the Sympathetic Chain 788
Differential Characters in the Great Sympathetic of other than Soliped Animals 789
Comparison of the Great Sympathetic of Man with that of Animals 789
CHAPTER IV.—The Nervous System of Birds 790

BOOK VII.

APPARATUS OF SENSE.

CHAPTER I.—Apparatus of Touch 792
Article I.—Of the Skin Proper 792
Article II.—The Integumentary Appendages 797
The Hair 797
Horny Productions 799
1. The Hoof of Solipeds 800
a. The Parts contained in the Hoof 800
b. Description of the Hoof 805
2. The Claws of Ruminants and Pachyderms 812
3. The Claws of Carnivora 812
4. The Frontal Horns 813
5. The Chesnuts 813
(6. The Ergots . . . . . 813)
CHAPTER II.—Apparatus of Taste 813
Differential Characters in the Apparatus of Taste of other than Soliped Animals 815
Comparison of the Apparatus of Taste in Man with that of Animals . 815
CHAPTER III.—Apparatus of Smell 815
CHAPTER IV.—Apparatus of Vision 816
Article I.—Essential Organ of Vision, or Globe of the Eye . 817
Membranes of the Eye 817
1. The Sclerotica 817
2. The Transparent Cornea 819
3. The Choroid Membrane 820
4. The Iris 822
5. The Retina 824
The Humours of the Eye 826
1. Crystalline Lens 826
2. Vitreous Humour 827
3. Aqueous Humour 827
Article II.—Accessory Organs of the Apparatus of Vision . 828
Orbital Cavity 828
Motor Muscles of the Globe of the Eye 828
Protective Organs of the Eye 830
1. Eyelids 830
2. Membrana Nictitans 833
Lachrymal Apparatus 834
Differential Characters in the Visual Apparatus of other than Soliped Animals 835
Comparison of the Visual Apparatus of Man with that of Animals . . 836

PAGE

CHAPTER V.—Apparatus of Hearing 837
Article I.—Internal Ear, or Labyrinth 837
Bony Labyrinth 837
1. The Vestibule 837
2. The Semicircular Canals 837
3. The Cochlea 837
The Membranous Labyrinth 838
1. The Membranous Vestibule . . . 838
2. The Membranous Semicircular Canals . . 839
3. The Membranous Cochlea 839
Liquids of the Labyrinth 840
Distribution and Termination of the Auditory Nerve in the Membranous Labyrinth 840
Article II.—Middle Ear, or Case of the Tympanum . . . 840
1. Membrane of the Tympanum 841
2. The Promontory, Fenestra Ovalis, Fenestra Rotunda . 842
3. The Mastoid Cells 842
4. Chain of Bones of the Middle Ear 842
5. Mucous Membrane of the Tympanic Case 844
6. Eustachian Tube 844
7. Guttural Pouches 844
Article III.—The External Ear 846
External Auditory Canal 846
The Concha, or Pavilion 846
1. Cartilaginous Basis of the Concha 846
2. Muscles of the External Ear 847
3. Adipose Cushion of the External Ear 850
4. Integuments of the External Ear 850
Differential Characters in the Auditory Apparatus of other than Soliped Animals 850
Comparison of the Auditory Apparatus of Man with that of Animals . 850

BOOK VIII.

GENERATIVE APPARATUS.

CHAPTER I.—Genital Organs of the Male 851
The Testicles, or Secretory Organs of the Semen . . . 851
1. Description of the Vaginal Sheath . . . 852
2. Description of the Testicles 853
Excretory Apparatus for the Semen 858
1. The Epididymis and Deferent Duct 858
2. The Vesiculæ Seminales and Ejaculatory Ducts . 860
3. The Urethra 861
4. The Glands Annexed to the Urethral Canal . . . 864
5. The Corpus Cavernosum 864
6. The Penis 865
Differential Characters in the Male Genital Organs of other than Soliped Mammals 867
Comparison of the Genital Organs of Man with those of Animals . 871
CHAPTER II.—Genital Organs of the Female 872
1. The Ovaries 872
2. The Uterine Cornua, Fallopian Tubes, or Oviducts . . . 876
3. The Uterus 877

PAGE
4. The Vagina 880
5. The Vulva 882
6. The Mammæ 884
Differential Characters in the Female Genital Organs of other than Soliped Mammals 886
Comparison of the Genital Organs of Woman with those of Domesticated Female Animals 888
CHAPTER III.—Generative Apparatus of Birds 889
1. Male Genital Organs 889
2. Female Genital Organs 889

BOOK IX.

EMBRYOLOGY.

CHAPTER I.—The Ovum and its Modifications after Impregnation . . 890
Article I.—The Ovum 890
Article II.—Modifications in the Ovum until the Appearance of the Embryo . 890
Article III.—Development of the Blastodermic Laminæ . . 892
External Lamina 893
Middle Lamina 893
Internal Lamina 894
CHAPTER II.—The Fœtal Envelopes of Solipeds 895
1. The Chorion 895
2. The Amnion 896
3. The Allantois 896
4. The Umbilical Vesicle 899
5. The Placenta 899
6. The Umbilical Cord 900
Differential Characters in the Annexes of the Fœtus of other Domesticated Animals than Solipeds 901
Comparison of the Annexes of the Human Fœtus with those of the Fœtus of Animals 904
CHAPTER III.—Development of the Fœtus 905
Article I.—Formation of the Embryo 905
Development of the Chorda Dorsalis and Vertebral Laminæ . . 905
Development of the Lateral and Cephalic Laminæ . . . 905
Article II.—Development of the Various Organs of the Animal Economy . 907
Development of the Nervous System 907
Development of the Organs of Sense 908
Development of the Locomotory Apparatus 911
Development of the Circulatory Apparatus . . . 914
Development of the Respiratory Apparatus . . . 918
Development of the Digestive Apparatus 919
Development of the Genito-urinary Apparatus 922
CHAPTER IV.—The Ovum of Birds 925
Index 927

TABLE OF ILLUSTRATIONS.

FIGS.			PAGE
1.	Skeleton of the Dog	*Chauveau*	7
2.	Skeleton of the Pig	*Chauveau*	7
3.	Skeleton of the Horse	*Original*	8
4.	Skeleton of the Cow	*Original*	9
5.	Skeleton of the Sheep	*Chauveau*	9
6.	Vertical section of bone	*Carpenter*	13
7.	Minute structure of bone	*Carpenter*	14
8.	Lacunæ, or osteoplasts of osseous substance	*Carpenter*	14
9.	Cartilage at the seat of ossification	*Carpenter*	17
10.	Elements of a vertebra	*After Owen*	19
11.	Atlas, inferior surface	*Original*	22
12.	A cervical vertebra	*Original*	22
13.	The axis or dentata, lateral view	*Original*	23
14.	Type of a dorsal vertebra, the fourth	*Original*	24
15.	Upper surface of lumbar vertebræ	*Chauveau*	26
16.	Lumbar vertebra, front view	*Original*	26
17.	Lateral view of sacrum	*Original*	27
18.	Horse's head, front view	*Original*	33
19.	Anterior bones of the head of a fœtus at birth	*Chauveau*	38
20.	Posterior bones of the head of a fœtus at birth	*Chauveau*	41
21.	Posterior aspect of Horse's skull	*Original*	46
22.	Antero-posterior and vertical section of the Horse's head	*Chauveau*	49
23.	Longitudinal and transverse section of the Horse's head	*Chauveau*	50
24.	Inferior maxilla	*Chauveau*	51
25.	Hyoid bone	*Chauveau*	53
26.	Lateral view of the Horse's skull	*Original*	55
27.	Ox's head, anterior aspect	*Chauveau*	56
28.	Ram's head, anterior aspect	*Chauveau*	57
29.	Ox's head, posterior aspect	*Chauveau*	58
30.	Median and vertical section of the Ox's head	*Chauveau*	59
31.	Head of the Pig, anterior aspect	*Chauveau*	60
32.	Head of the Pig, posterior aspect	*Chauveau*	61
33.	Head of Dog, anterior aspect	*Chauveau*	62
34.	Dog's head, posterior aspect	*Chauveau*	63
35.	Front view of the human cranium	*Wilson*	64
36.	External or basilar surface of human skull	*Wilson*	65
37.	The sternum	*Chauveau*	66
38.	Typical ribs of the Horse	*Chauveau*	68
39.	Thorax of Man, anterior face	*Wilson*	71
40.	Right scapula, outer surface	*Original*	72

FIGS.			PAGE
41.	Antero-external view of right humerus	*Original*	73
42.	Posterior view of right humerus	*Original*	74
43.	External face of the radius and ulna	*Original*	76
44.	Right fore-foot of a Horse	*Original*	77
45.	Posterior view of the right carpus	*Original*	80
46.	Front view of right carpus	*Original*	80
47.	Posterior view of right metacarpus	*Original*	81
48.	Lateral view of the digital region: outside of right limb	*Original*	83
49.	Posterior view of front digital region	*Original*	83
50.	Plantar surface of third phalanx	*Original*	84
51.	Navicular bone	*Original*	86
52.	Fore-arm and foot of the Ox, front view	*Chauveau*	87
53.	Fore-arm and foot of the Dog, anterior face	*Chauveau*	88
54.	Human scapula, external aspect	*Wilson*	89
55.	Right human humerus, anterior surface	*Wilson*	90
56.	Human arm bones, front view	*Wilson*	90
57.	Palmar surface of left human hand	*Wilson*	91
58.	The Coxæ, seen from below	*Chauveau*	92
59.	Pelvis, front view	*Original*	93
60.	Pelvis, lateral view	*Original*	94
61.	Left femur, anterior view	*Original*	99
62.	Left femur, posterior view	*Original*	99
63.	Section of left femur, showing its structure	*Original*	100
64.	Posterior view of right tibia	*Original*	101
65.	Left hind foot, external aspect	*Original*	103
66.	Left hock, front view	*Original*	104
67.	Left hock, internal aspect	*Original*	104
68.	Posterior aspect of left metatarsus	*Original*	105
69.	Human pelvis, female	*Wilson*	108
70.	Right human femur, anterior aspect	*Wilson*	109
71.	Human tibia and fibula of right leg, anterior aspect	*Wilson*	109
72.	Dorsal surface of left human foot	*Wilson*	109
73.	Skeleton of a Fowl	*Chauveau*	113
74.	Cephalic vertebræ of the Dog	*Lavocat*	120
75.	Plans of the different classes of articulations	*Beaunis and Bouchard*	122
76.	Section of branchial cartilage of Tadpole	*Carpenter*	124
77.	Fibro-cartilage	*Wilson*	124
78.	White or non-elastic fibrous tissue	*Carpenter*	125
79.	Yellow or elastic fibrous tissue	*Carpenter*	125
80.	Intervertebral articulations	*Chauveau*	133
81.	Atlo-axoid and occipito-atloid articulations	*Chauveau*	137
82.	Temporo-maxillary articulation	*Chauveau*	138
83.	Articulations of the ribs with the vertebræ, upper plane	*Chauveau*	140
84.	Articulations of the ribs with the vertebræ, inferior plane	*Chauveau*	140
85.	Scapulo-humeral and humero-radial articulations, external face	*Chauveau*	145
86.	Carpal articulations, front view	*Chauveau*	150
87.	Lateral view of the carpal articulations	*Chauveau*	151
88.	Section of inferior row of carpal bones, and metacarpal and suspensory ligament	*Chauveau*	155
89.	Posterior view of metacarpo-phalangeal and interphalangeal articulations	*Original*	156
90.	Sacro-iliac and coxo-femoral articulations	*Chauveau*	161
91.	Femoro-tibial articulation	*Chauveau*	164
92.	Ligaments attaching the three bones of the leg	*Chauveau*	167

FIGS.			PAGE
93.	Tarsal articulations, front view	*Chauveau*	169
94.	Articulations of the tarsus, lateral view	*Chauveau*	171
95.	Ultimate fibril of muscle	*Bowman*	178
96.	Striated muscular tissue fibre	*Bowman*	178
97.	Termination of nerves in muscular fibre	*Kühne*	179
98.	Distribution of capillaries in muscle	*Berres*	180
99.	Termination of nerves in an elementary muscular fibre	*Beale*	180
100.	Striated fibre of muscle during contraction	*Bowman*	181
101.	Lateral view of the neck, superficial muscles	*Original*	188
102.	Superficial muscles of the neck and spinal region of the back and loins	*Chauveau*	190
103.	Lateral view of the neck, middle layer of muscles	*Original*	192
104.	Cervical ligament and deep muscles of the neck	*Chauveau*	194
105.	Muscles of the spinal region of the neck, back, and loins	*Chauveau*	204
106.	Deep ditto	*Chauveau*	207
107.	Muscles of the back and cervix of Man	*Wilson*	210
108.	Muscles of the sublumbar, patellar, and internal crural regions	*Chauveau*	213
109.	Deep muscles of the sublumbar region	*Chauveau*	214
110.	Superficial muscles of the face and head	*Original*	218
111.	Hyoideal and pharyngeal regions	*Original*	226
112.	Superficial muscles of the Ox's head	*Chauveau*	228
113.	Muscles of the human head	*Wilson*	231
114.	Muscles of the axillary and cervical regions	*Chauveau*	232
115.	Axillary and thoracic muscles	*Original*	234
116.	Muscles of the inferior abdominal region	*Chauveau*	243
117.	Muscles of the anterior aspect of the body of Man	*Wilson*	245
118.	Diaphragm, posterior face	*Chauveau*	247
119.	External muscles of the anterior limb	*Chauveau*	250
120.	Muscles of anterior aspect of Man's upper arm	*Wilson*	255
121.	Internal aspect of left anterior limb	*Original*	257
122.	Deep muscles on external aspect of right anterior limb	*Original*	260
123.	Muscles of the fore-arm of the Ox	*Chauveau*	270
124.	Tendinous and ligamentous apparatus in the digital region of the Ox	*Chauveau*	271
125.	Muscles of the fore-arm and paw of the Dog	*Chauveau*	273
126.	Superficial muscles of human fore-arm	*Wilson*	275
127.	Deep layer of superficial muscles of human fore-arm	*Wilson*	275
128.	Muscles of human hand	*Wilson*	279
129.	Superficial muscles of the croup and thigh	*Original*	282
130.	Muscles of the sublumbar, patellar, and internal crural regions	*Chauveau*	290
131.	Coccygeal and deep muscles surrounding the coxo-femoral articulation	*Chauveau*	293
132.	Superficial muscles of the croup and thigh in the Cow	*Chauveau*	294
133.	Muscles of the anterior femoral region in Man	*Wilson*	296
134.	Muscles of the posterior femoral and gluteal region in Man	*Wilson*	296
135.	External deep muscles of right posterior limb	*Original*	299
136.	Flexor muscle of metatarsus	*Chauveau*	300
137.	Muscles on inner aspect of left posterior limb	*Original*	303
138.	External muscles of the leg of the Ox	*Chauveau*	307
139.	Muscles of the human leg, anterior tibial region	*Wilson*	310
140.	Superficial posterior muscles of the human leg	*Wilson*	310
141.	First layer of plantar muscles of human foot	*Wilson*	312
142.	Third, and part of second layer of plantar muscles of human foot	*Wilson*	312

FIGS.			PAGE
143.	Squamous epithelium from the mouth	*Wilson*	327
144.	Columnar epithelium	*Kölliker*	327
145.	Columnar ciliated epithelium	*Carpenter*	327
146.	Conical villi on mucous membrane of small intestine	*Wilson*	328
147.	Fusiform cells of smooth muscular fibre	*Bowman*	328
148.	Hard and soft palate	*Chauveau*	333
149.	Muscles of the tongue, soft palate, and pharynx	*Chauveau*	338
150.	Lobe of racemose gland from the floor of the mouth	*Kölliker*	339
151.	Follicular gland	*Kölliker*	339
152.	Median longitudinal section of the head and upper part of neck	*Original*	341
153.	Section through the fang of a molar tooth	*Carpenter*	345
154.	Transverse section of enamel	*Carpenter*	346
155.	Magnified section of a canine tooth	*Wilson*	347
156.	Theoretical section of dental sac of permanent incisor	*Chauveau*	348
157.	Section of dentine and pulp of an incisor tooth	*Carpenter*	349
158.	Dentition of inferior jaw of Horse	*Chauveau*	350
159.	Incisor teeth of Horse, details of structure	*Chauveau*	351
160.	Profile of upper teeth of the Horse	*Chauveau*	353
161.	Transverse section of Horse's upper molar	*Chauveau*	354
162.	The teeth of the Ox	*Chauveau*	357
163.	Ox's incisor tooth	*Chauveau*	358
164.	Incisor teeth of a Sheep two years old	*Chauveau*	359
165.	Teeth of the Pig	*Chauveau*	360
166.	General and lateral view of the Dog's teeth	*Chauveau*	361
167.	Anterior view of the incisors and canine teeth of Dog	*Chauveau*	361
168.	Section of the human face	*Quain*	362
169.	Lobule of parotid gland	*Wagner*	365
170.	Capillary network of follicles of parotid gland	*Berres*	365
171.	Termination of the nerves in the salivary glands	*Pflüger*	366
172.	Inferior aspect of head and neck	*Original*	367
173.	Maxillary and sublingual glands	*Chauveau*	368
174	Pharyngeal and laryngeal region	*Original*	372
175.	Median longitudinal section of head and upper part of neck	*Original*	373
176.	Muscles of the pharyngeal and hyoideal regions	*Original*	375
177.	Human pharynx	*Wilson*	377
178.	Transverse vertical section of head and neck	*Original*	378
179.	Pectoral cavity and mediastinum	*Chauveau*	379
180.	Theoretical transverse section of abdominal cavity	*Chauveau*	382
181.	Theoretical, longitudinal, and median section of abdominal cavity	*Chauveau*	383
182.	The abdominal cavity, with the stomach and other organs.	*Original*	386
183.	Stomach of the Horse	*Chauveau*	387
184.	Interior of the Horse's stomach	*Chauveau*	388
185.	Muscular fibres of stomach, external and middle layers	*Chauveau*	390
186.	Deep and middle muscular fibres of stomach	*Chauveau*	390
187.	Peptic gastric gland	*Kölliker*	391
188.	Portion of a peptic cæcum	*Kölliker*	391
189.	Mucous gastric gland	*Kölliker*	392
190.	Capillaries of mucous membrane of stomach	*Carpenter*	392
191.	Stomach of the Dog	*Chauveau*	393
192.	Stomach of the Ox	*Chauveau*	394
193.	Interior of the stomach of Ruminants	*Chauveau*	395
194.	Section of the wall of the omasum of Sheep	*Chauveau*	398
195.	Section of a leaf of the omasum	*After Chauveau*	399

FIGS.			PAGE
196.	Longitudinal section of a large papilla from the omasum	*Chauveau*	399
197.	Villi of human and Sheep's intestine	*Teichmann*	403
198.	Portion of Brunner's gland	*Thomson*	403
199.	Section of mucous membrane of small intestine	*Teichmann*	404
200.	Section of mucous membrane of large intestine	*Teichmann*	405
201.	Injected villi of intestine	*Kölliker*	405
202.	Blood-vessels in Peyerian glandulæ	*Kölliker*	406
203.	Diagram of origin of lacteals in villi	*Funke*	406
204.	General view of the intestines of the Horse, right side	*After Chauveau*	408
205.	General view of the Horse's intestines, inferior aspect	*Chauveau*	409
206.	The colon of the Horse	*Original*	410
207.	Plan of the colon	*Chauveau*	411
208.	General view of the intestines of the Ox	*Chauveau*	415
209.	Intestines of the Dog	*Chauveau*	416
210.	Human intestines	*Wilson*	417
211.	Abdominal cavity, with the liver and other organs	*Original*	421
212.	Portion of a hepatic column, with secreting cells	*Leidy*	423
213.	Biliary capillaries and ducts	*Irminger and Frey*	423
214.	Blood-vessels in lobules of liver	*Kiernan*	424
215.	Section of lobules of liver, with intralobular veins	*Kiernan*	424
216.	Excretory apparatus of the Horse's liver	*Chauveau*	425
217.	Malpighian corpuscles attached to splenic artery	*Kölliker*	430
218.	Splenic corpuscle from the spleen of Ox	*Kölliker*	430
219.	Liver of the Dog, with its excretory apparatus	*Chauveau*	433
220.	Under surface of the human liver	*Wilson*	434
221.	General view of the digestive apparatus of a fowl	*Chauveau*	436
222.	Cartilages of the nose	*Chauveau*	440
223.	Transverse section of the head of Horse	*Chauveau*	442
224.	Longitudinal section of the head, and upper part of neck	*Original*	443
225.	Cells of the olfactory mucous membrane	*Clarke and Schultze*	445
226.	Fibres of olfactory nerve	*Ecker*	446
227.	Superior face of larynx	*After Chauveau*	452
228.	Inferior face of larynx	*After Chauveau*	452
229.	Postero-lateral view of larynx	*Original*	454
230.	The respiratory organs, inferior aspect	*Original*	458
231.	Ciliated epithelium from the trachea	*Kölliker*	459
232.	Bronchial tube, with its bronchules	*Heale*	460
233.	Mucous membrane of a bronchial tube	*Heale*	461
234.	The pectoral cavity and mediastinum	*Chauveau*	463
235.	Theoretical section of thoracic cavity, behind the heart	*Chauveau*	465
236.	Theoretical section of thoracic cavity, at root of lungs	*Chauveau*	465
237.	Theoretical section of thoracic cavity, in front of right ventricle	*Chauveau*	465
238.	Plan of a pulmonary lobule	*Waters*	468
239.	Air-cells of lung	*Kölliker*	469
240.	Capillaries and air-cells of lung	*Carpenter*	469
241.	Lung of the Sheep, inferior view	*Chauveau*	471
242.	Human lungs and heart	*Wilson*	471
243.	Gland vesicles of thyroid	*Kölliker*	472
244.	Portion of thymus of calf	*Kölliker*	474
245.	Course and termination of ducts in thymus gland of calf	*Wilson*	474
246.	General view of the air-sacs in the duck	*Chauveau*	480
247.	General view of the genito-urinary apparatus in the male	*Chauveau*	485
248.	Horizontal longitudinal section of the Horse's kidney	*Chauveau*	487
249.	Section of the cortical substance of the kidney	*Ecker*	488

FIGS.			PAGE
250.	Course of the uriniferous tubuli	*Hertz*	488
251.	Diagram of the circulation in the kidney	*Bowman*	489
252.	Transverse horizontal section of kidney	*Original*	489
253.	The kidneys and bladder in the fœtus of Solipeds	*Chauveau*	492
254.	Right kidney of Ox, upper and external face	*Chauveau*	496
255.	Left kidney of Ox, internal and inferior face	*Chauveau*	496
256.	The calices in left kidney of Ox	*Chauveau*	496
257.	Theoretical plan of the circulatory system	*Colin*	498
258.	The heart and principal vessels, left face	*Chauveau*	501
259.	The heart and principal vessels, right face	*Chauveau*	502
260.	Right side of the heart laid open	*Wilson*	504
261.	Section of the heart at the level of the valves	*Sibson*	505
262.	Left cavities of the heart laid open	*Wilson*	507
263.	Anastomosing muscular fibres of heart	*Kölliker*	509
264.	Epithelium of the endocardium	*Kölliker*	511
265.	Human lungs and heart, front view	*Wilson*	514
266.	Web of Frog's foot, showing blood-vessels and their anastomoses	*Wagner*	518
267.	Epithelial cells of blood-vessels	*Kölliker*	518
268.	Fenestrated membrane from the carotid artery of the Horse	*Kölliker*	519
269.	Coarse elastic tissue from pulmonary artery of the Horse	*Kölliker*	519
270.	Transition of a minute artery of the brain into capillary vessels	*Kölliker*	519
271.	Distribution of the great mesenteric artery	*Chauveau*	530
272.	Distribution of the small mesenteric artery	*Chauveau*	533
273.	Arteries of the stomach in Ruminants	*Chauveau*	536
274.	Upper and general view of the genito-urinary apparatus and arteries in the male	*Chauveau*	539
275.	Lateral view of the genito-urinary organs in the male	*Chauveau*	542
276.	Abdominal aorta, with its branches, in Man	*Wilson*	544
277.	The external and internal iliac arteries in the Mare	*Chauveau*	546
278.	Principal arteries and veins of the posterior foot	*Chauveau*	552
279.	Anterior aspect of human leg and foot	*Wilson*	558
280.	Posterior aspect of human leg	*Wilson*	558
281.	Arteries of sole of human foot	*Wilson*	559
282.	Distribution of the anterior aorta	*Chauveau*	562
283.	Arteries of the fore-foot, seen from behind	*Chauveau*	568
284.	Arteries of the human fore-arm and hand	*Wilson*	574
285.	Arteries of the brain	*Chauveau*	580
286.	Arteries of the head	*Chauveau*	583
287.	Réseau admirable of the Sheep, seen in profile	*Chauveau*	593
288.	Réseau admirable of the Ox, posterior face	*Chauveau*	594
289.	Arteries of the face and head of Man	*Heath*	595
290.	Roots of the superior jugular vein, with its collateral affluents	*Chauveau*	604
291.	Section of the cranial cavity and spinal canal	*Chauveau*	607
292.	Veins of the foot	*After Bouley*	614
293.	General view of the veins in the Horse	*Chauveau*	618
294.	The vena portæ and its roots	*Chauveau*	620
295.	Section of a lymphatic rete mirabile	*Teichmann*	631
296.	Section of lymphatic gland	*Kölliker*	632
297.	Section of simple lymphatic gland	*Teichmann*	632
298.	Section of the medullary substance of lymphatic gland of Ox	*Kölliker*	633
299.	Ordinary disposition of the thoracic duct	*Colin*	636
300.	Double variety of the thoracic duct	*Colin*	636
301.	Triple variety of the thoracic duct	*Colin*	636
302.	Lymphatic system of the Horse	*Colin*	639

FIGS.			PAGE
303.	Great lymphatic vein and entrance of the thoracic duct	*Colin*	645
304.	Great lymphatic duct, another variety	*Colin*	645
305.	Thoracic duct in the Ox	*Colin*	645
306.	A variety of the thoracic duct in the Ox	*Colin*	646
307.	Another variety of the thoracic duct	*Colin*	646
308.	A fourth variety of the thoracic duct	*Colin*	646
309.	Thoracic duct of small Ruminants	*Colin*	647
310.	Diagram of structure of nerve-fibre	*Carpenter*	652
311.	Multipolar, or stellate nerve-cell	*Ecker*	653
312.	Ganglion from heart of Frog	*Ecker*	654
313.	Bipolar ganglionic cells and nerve-fibres	*Ecker*	654
314.	Stellate nerve-cell	*Beale*	654
315.	Structure of ganglionic cells	*Beale and Arnold*	654
316.	General view of the spinal cord	*Colin*	667
317.	Segment of the spinal cord at the cervical bulb	*Colin*	667
318.	Section of the spinal cord of the Horse at the lumbar region	*Chauveau*	669
319.	Transverse section of spinal cord of Man at the middle of the lumbar region	*I. L. Clarke*	670
320.	Longitudinal section through cervical bulb of spinal cord of the Cat	*I. L. Clarke*	671
321.	General view of the brain, upper surface	*Chauveau*	673
322.	General view of the brain, lower surface	*Original*	676
323.	Superior view of the encephalic isthmus	*Chauveau*	678
324.	Lateral view of the isthmus	*Chauveau*	680
325.	Transverse section of the encephalon	*Chauveau*	682
326.	Dissection of the medulla oblongata	*Solly and Carpenter*	684
327.	Median and vertical section of the encephalon	*Chauveau*	687
328.	Section of the cortical substance of the cerebellum	*Kölliker*	689
329.	Antero-posterior and vertical section of the encephalon	*Chauveau*	690
330.	Corpus callosum	*Chauveau*	693
331.	Anterior portion of the lateral ventricles	*Chauveau*	696
332.	Corticle substance of the cerebral hemispheres	*Kölliker*	697
333.	Base of the human brain	*Hirschfeld and Leveillé*	699
334.	Muscular fibres, with termination of motor nerve	*Cohnhein*	702
335.	Nerves of the eye	*Chauveau*	708
336.	General view of the superior and inferior maxillary nerves	*Chauveau*	714
337.	Section through the summit of the medulla oblongata	*Carpenter*	721
338.	Origin of the nerves arising from the medulla oblongata	*Toussaint*	730
339.	Pneumogastric nerve, with its branches in the neck	*Toussaint*	731
340.	Origin and distribution of the eighth pair of nerves in Man	*Wilson*	732
341.	Distribution of the nerves in the larynx of the Horse	*Toussaint*	734
342.	Deep nerves of the head	*Chauveau*	738
343.	Nerves of the guttural region in the Ox	*Toussaint*	740
344.	Nerves of the face and scalp of Man	*Hirschfeld and Leveillé*	745
345.	Distribution of eighth pair of nerves on left side	*Hirschfeld and Leveillé*	746
346.	Ganglion of a spinal nerve from the spinal region	*Kölliker*	748
347.	Nerves of the brachial plexus	*Chauveau*	757
348.	External nerves of anterior limb	*Chauveau*	759
349.	Nerves of the digit of Horse	*Bouley*	762
350.	Nerves of the digital region of Ruminants	*Chauveau*	764
351.	Nerves of the palmar face of Dog's foot	*Chauveau*	766
352.	Nerves of the palmar face of Cat's foot	*Chauveau*	767
353.	Nerves of the axilla of Man	*Hirschfeld and Leveillé*	768
354.	Nerves of the front of fore-arm and hand of Man	*Hirschfeld and Leveillé*	769

FIGS.			PAGE
355.	Lumbo-sacral plexus and internal nerves of posterior limb	*Chauveau*	771
356.	Posterior portion of the lumbo-sacral plexus	*Chauveau*	773
357.	External nerves of posterior limb	*Chauveau*	776
358.	Lumbar plexus of Man	*Hirschfeld and Leveillé*	779
359.	Nerves at the posterior aspect of human leg	*Hirschfeld and Leveillé*	780
360.	Nerves at the front aspect of human leg	*Hirschfeld and Leveillé*	780
361.	Sympathetic ganglion from a Puppy	*Kölliker*	782
362.	Sympathetic system of the Horse	*Chauveau*	784
363.	Section of Horse's skin	*Chauveau*	793
364.	Capillary loops in cutaneous papillæ	*Berres*	793
365.	Tactile papillæ from the skin	*Ecker*	794
366.	Interungulate gland of Sheep	*Owen*	794
367.	Branches of cutaneous nerves in skin	*Ecker*	795
368.	Sudoriparous gland	*Wagner*	795
369.	Oblique section of epidermis	*Carpenter*	796
370.	Longitudinal median section of Horse's foot	*Original*	800
371.	Horizontal section of Horse's foot	*Original*	801
372.	Lower surface of the Horse's foot	*Original*	802
373.	Lateral view of the Horse's foot	*Original*	803
374.	Hoof removed from the foot	*Leisering*	806
375.	Hoof with outer portion of wall removed	*Leisering*	806
376.	Plantar surface of hoof	*Leisering*	807
377.	Horn-cells from the sole of hoof	*Leisering*	809
378.	Constituent elements of the wall	*Leisering*	810
379.	Horizontal section of the junction of the wall with the sole of hoof	*Leisering*	811
380.	Horizontal section of wall, and horny and vascular laminæ	*Leisering*	811
381.	Fibres of ultimate ramifications of olfactory nerves	*Ecker*	816
382.	Cells of olfactory mucous membrane	*Clarke and Shultze*	816
383.	Theoretical section of the Horse's eye	*Chauveau*	818
384.	Anterior segment of a transverse section of the globe of the eye (human)	*Wilson*	821
385.	Cells from pigmentum nigrum	*Carpenter*	822
386.	The eye (human) with the sclerotic coat removed	*Holden*	823
387.	Muscular structure of the iris	*Kölliker*	823
388.	Vertical section of retina	*Müller*	825
389.	Diagram of the structure of the retina	*Krause*	826
390.	Capillaries in the vascular layer of the retina	*Berres*	826
391.	Muscles of the eye-ball, viewed from above	*Original*	829
392.	Section of lamina spiralis of the cochlea	*Carpenter*	838
393.	Section of the cochlea parallel to its axis	*Breschet*	838
394.	Right tympanic cavity of Horse's ear	*Chauveau*	841
395.	Bones of the middle ear of the Horse	*Lavocat*	843
396.	Muscles of the ear	*Original*	848
397.	Human testis, injected with mercury	*Lauth*	854
398.	Vertical section of the Horse's testis	*Chauveau*	855
399.	Internal genito-urinary organs of the fœtus of a Mare	*Chauveau*	857
400.	Spermatozoa of various animals	*Carpenter*	858
401.	Diagram of the testicle	*Holden*	859
402.	Superior view of the genito-urinary organs	*Chauveau*	860
403.	Longitudinal section of the free extremity of the Horse's penis	*Chauveau*	866
404.	Sections of the urethra of the Ox at different points	*Chauveau*	868
405.	Penis and muscles of the sheath of the Bull	*Chauveau*	869
406.	Section of human pelvis	*Gray*	871

FIGS.			PAGE
407.	Ovarium of the Rabbit	*Pouchet*	874
408.	Constituent parts of mammalian ovum, entire	*Coste*	875
409.	Constituent parts of mammalian ovum, ruptured	*Coste*	875
410.	Formation of the corpus luteum	*Pouchet*	875
411.	Generative organs of the Mare, isolated	*Chauveau*	878
412.	Generative organs of the Mare, *in situ*	*Chauveau*	881
413.	Termination of milk-duct in cluster of follicles	*Sir A. Cooper*	885
414.	Ultimate follicles of mammary gland, with secreting cells	*Lebert*	885
415.	Microscopic appearance of milk	*Funke*	885
416.	Human uterus, with its appendages	*Wilson*	888
417.	First stages in segmentation of mammalian ovum	*Coste*	891
418.	Later stages in segmentation	*Coste*	891
419.	Section through embryo of the Chick, first day of incubation	*Kölliker*	893
420.	Plan of early uterine ovum	*Wagner*	894
421.	Diagram of ovum at formation of the amnion	*Wagner*	894
422.	Exterior of the chorial sac, Mare	*Chauveau*	895
423.	Fecundated egg, showing formation of amnion and allantois	*Dalton*	896
424.	Fecundated egg, with amnion nearly completed	*Dalton*	896
425.	Fœtus of the Mare, with its envelopes.	*Chauveau*	898
426.	Portion of ultimate ramifications of umbilical vessels	*Carpenter*	899
427.	Portion of one of the fœtal villi	*Ecker*	900
428.	Equine fœtus, opened on left side to show umbilical vessels	*Chauveau*	901
429.	Blood-vessels in liver of an equine fœtus at mid-term	*Colin*	902
430.	Liver of a Lamb at birth	*Colin*	902
431.	Diagram of an early human ovum	*Wagner*	904
432.	Diagram of a human ovum in second month	*Wagner*	904
433.	Early stages in the development of a Fowl	*Huxley*	906
434.	Transverse section of embryo of Chick on third day	*Kölliker*	908
435.	Plan of development of eye	*Kölliker*	909
436.	Origin of encephalic centres in human embryo of sixth week	*Wagner*	910
437.	Plan of chorda dorsalis at period of formation of embryo	*Kölliker*	912
438.	Plan of vertebra at an early period of development	*Kölliker*	912
439.	Head of a fœtal Lamb, showing Meckel's cartilage	*Huxley*	913
440.	Plan of first system of vessels, embryo	*Kölliker*	914
441.	Embryonic heart at an early period, anterior view	*Kölliker*	915
442.	Ditto, seen from behind	*Kölliker*	915
443.	Heart of an equine fœtus	*Chauveau*	916
444.	Plan of the aorta and its arches at an early period	*Kölliker*	917
445.	Plan of the circulation in the human embryo, side view	*Coste*	918
446.	First appearance of the lungs	*Wagner*	919
447.	Embryo of Dog at twenty-five days	*Bischoff*	919
448.	Origin of liver from intestinal wall of embryo Chick	*Müller*	922
449.	Urinary and genital apparatus in embryo Chick	*Müller*	922
450.	Section of Fowl's egg	*Allen Thomson*	925

THE COMPARATIVE ANATOMY

OF THE

DOMESTICATED ANIMALS.

GENERAL CONSIDERATIONS.

DEFINITION AND DIVISIONS OF ANATOMY.

Anatomy is the science of organisation; it studies the structure of animated beings when these have been deprived of life. It comprises two grand divisions: *physiological anatomy*, which describes healthy organs, and *pathological anatomy*, whose object is the description of diseased organs.

Physiological anatomy, in its turn, embraces:—

1. *General anatomy*, which is occupied with the analogous matters or tissues of the animal body, with regard to their texture, and their physical, chemical, and physiological properties, irrespective of the organs in which these tissues exist. The particular study of the anatomical elements entering into the composition of the tissues is named *histology*.

2. *Descriptive anatomy*, which studies the situation, form, and relation of organs, as well as the relative arrangement of the various tissues composing them, with the exception of the structure and properties of these tissues.

If this study be devoted to a single species, it is designated *special anatomy*. Example: human anatomy, or *anthropotomy;* the anatomy of the Horse, or *hippotomy*.

When descriptive anatomy embraces the study of the organisation of the entire animal kingdom, and examines the *differences* which characterise the same organ or the same series of organs in each class, family, genus, or species, it is named *comparative anatomy*. Restricted to the domesticated animals, this study constitutes *veterinary anatomy*.

Philosophical or *transcendental* anatomy differs from comparative anatomy, inasmuch as it indicates the *analogies* of organs or apparatus, in order to exhibit the simplicity of Nature's plan in the general laws of organisation.

Finally, if descriptive anatomy is limited to denoting the relations existing between the various organs of a region, particularly with a view to the performance of operations and the diagnosis of external diseases, it takes the names of *topographical*, *regional*, or *surgical anatomy*.

ENUMERATION AND CLASSIFICATION OF THE SPECIES OF DOMESTICATED ANIMALS.

The object of this book is the study of veterinary anatomy. The animals of which it treats belong to the mammiferous class and to that of birds.

The domesticated mammals of our regions have their representatives in a large number of orders. Thus, we find among them :—

1. Of the carnivora, the *Dog* and *Cat;*
2. A rodent, the *Rabbit;*
3. A pachyderm, the *Pig;*
4. Of solipeds, the *Horse* and *Ass;* the produce of the male ass with the mare, *i.e.*, the *Mule*, and that of the horse with the female ass, known by the name of *Hinny;*
5. Of ruminants, the *Ox*, *Sheep*, and *Goat.*

With regard to poultry, they range themselves:—

1. In the gallinaceous order, the genera to which the *common fowl*, *guinea fowl*, *turkey*, and *pigeon* belong;
2. In the order of palmipeds, the *geese* and *ducks.*

Girard has proposed a special classification for the domesticated mammals, based upon the number of digits terminating each of their limbs, and has defined four categories: the first comprises the horse, ass, mule, and hinny, which take the name of *monodactyles*, because their digital region is composed of a single digit; in the second, under the denomination of *didactyles* or *bisulcate* animals, those with two digits, such as the ox, sheep, and goat; in the third, or *regular tetradactyles*, is found ranged the pig, each of whose limbs shows four digits; lastly, the dog and cat, which most frequently have four digits on the posterior members and five on the anterior ones, and form the class of *irregular tetradactyles.*

This nomenclature will not be followed here, as it is opposed to the general laws of organisation; philosophical anatomy has, in fact, demonstrated that there are really no veritable monodactyles, didactyles, etc., all are materially or virtually pentadactyles. It is therefore considered better to keep to the classification established by zoologists, because it prevents confusion in scientific language, which should always be the same for everyone engaged in the study of anatomy.

The regimen and habits of the domesticated animals bring about differences in their organisation which appear very great at first sight, though in reality they are not so profound as they seem.

In order to study the descriptive anatomy of all these animals, we will not pass them in review, one after another, giving for each the description of every organ; but shall take a type, which will most frequently be the Horse, and briefly compare all the others with it. In the majority of cases, we will describe, without leaving the Horse, all the organs of an apparatus; afterwards the same organs in the other species will be studied in the same order. In this comparison, the animals will be generally classed according to their domestic value; though exceptions will be made to the rule which has been instituted by our predecessors, whenever any advantage in point of concision or perspicuity is likely to be obtained.

GENERAL IDEA OF THE ORGANISATION OF ANIMALS.

Order followed in studying the Various Apparatus.

The bodies of animals, formed of organised matter, contain fluids and solids.

The fluids are very abundant in the animal economy; not only do they fill certain vessels constructed for them, but they also impregnate all the solid parts of the body. Their importance is very great, for without them the organic solids would perish; an element deprived of humidity is an element deprived of life.

Fluids vary in their nature and composition. Apart from those that the solids imbibe, there is not one which is completely amorphous. In the midst of a liquid holding organised matter in solution there are always elements which will be referred to hereafter. Examples: the blood and lymph.

In studying the organic solids, we will proceed from the simple to the complicated.

ELEMENTS.—Solid organised matter presents itself in the form of more or less voluminous particles, in every instance invisible to the naked eye, and named the *anatomical elements*. They may be reduced to three principal: the granule, cell, and fibre.

Granules.—These are the smallest known elements. They may be held in suspension in animal fluids, remain free among the other elements, or be enclosed in the interior of cells. Their nature is not always the same: they are *proteic* or *fatty*. They are called *pigmentary* when they exhibit a brown colour.

Cells.—The cell is pre-eminently the anatomical element.

It may be represented to the mind as a microscopic collection of a nitrogenous substance, viscid or slightly granular, and endowed with extreme vitality. Frequently in the midst of this *protoplasm* (for so it has been called), there is perceived a nucleus provided with a nucleolus, and at its periphery an enveloping membrane is discovered. It must not be forgotten that this membrane, and even the nucleus, is necessarily a constituent portion of the cell.

The cell lives like an entire organism: it feeds, grows, multiplies, absorbs, secretes, moves, etc. It behaves like a complete animal, though it be a microscopic one.

The form of the cell varies greatly, as does its volume and its nature. It has therefore received various names.

There are round, polyhedral, fusiform, stellate, and other shaped cells. Some have a diameter of 1-12000th part of an inch, while others are 1-2000th part. Cells multiply in various ways: 1st, by the division of the nucleus and segmentation of the protoplasm in the interior of the enveloping membrane (*endogenous multiplication*); 2nd, by constriction, the division of the nucleus, protoplasm, and enveloping membrane (*fissiparous multiplication*); 3rd, by a kind of bulging or swelling of the enveloping membrane, and strangulation and separation of the enlargement thus formed (*gemmation*).

A large number of cells only temporarily remain in this condition. In consequence of modifications that cannot be referred to here, they are converted into fibrillæ or other elements, in which it is difficult to recognise them.

Others maintain the cellular form: then they are developed, live, and die in several ways. Sometimes they are worn by the contact of foreign

bodies, as on the surface of the skin; at other times they become dissolved, as in some glands; finally, at other periods they submit to fatty degeneration, which gradually brings about their complete destruction.

The permanent cells have been arranged according to the following denominations:—

1. *Hæmaties* or *red globules*, which are found in a state of suspension in the blood; they are round or elliptical.
2. *Leucocytes*, or *white globules*, which float in the blood, lymph, and chyle.
3. *Connective cells*, comprising the connective cell properly so-called, the plasmatic cell, and the adipose cell.
4. *Medullary cells*, forming the principal elements of the marrow of bones (myeloplaxes and medullo-cells).
5. *Contractile cells*, which constitute the basis of muscular tissue.
6. *Nerve cells*, met with in the cerebro-spinal centres and the ganglia of the cerebro-spinal and sympathetic systems.
7. *Epithelial cells*, comprising the epithelial cells properly called, situated on the surface of the skin and mucous membranes, and the glandular cells.

Fibres.—A fibre is an elongated anatomical element, of variable dimensions and composition. It may be very fine and represented by a single line, or thicker and marked by two lines more or less apart from one another. It is homogeneous throughout, or the contents are distinct from the envelope.

The vitality of fibres is not to be compared with that of cells; after they are formed, they can only be nourished, and cannot multiply of themselves. In the animal economy four kinds of fibres are distinguished:—the *connective fibre*, *elastic fibre*, *muscular fibre*, and *nervous* (or *nerve*) *fibre*.

Tissues.—The elements that have now been rapidly described, in becoming united and grouped in different fashions, form the tissues.

Some tissues are composed of one kind of element; these are the simple tissues. Example:—The epithelium.

The majority, however, are formed by the union of several different elements: these are the composite tissues. Example:—Nervous tissue.

It is also remarked that there are tissues in which exists a fundamental intercellular substance, and others in which this is absent. The latter are few in number, for the vessels and nerves may, in certain tissues, be considered as intercellular substance.

The anatomical, physico-chemical, and physiological characters of the tissues repeat, as might easily be inferred, the anatomical, physico-chemical, and physiological properties of the elements entering into their formation.

Only four fundamental tissues are recognised, basing them on the morphological, chemical, and physiological characters of the elements.

In the first place, the *tissue of the conjunctival* substance should be noticed; this, in consequence of some differential characters, may be divided into:—*gelatinous tissue*, *conjunctival* (or *connective*) *tissue*, *cartilaginous tissue*, and *bony tissue*.

Then comes the *cellular tissue*, formed entirely of persistent cells. It comprises the *epithelial tissue* and the *glandular tissue*.

The cells of the epithelial tissue may affect different arrangements. If they are disposed in a single row, there results a *simple epithelium*; if they are superposed it is a *stratified epithelium*. According to the form of the cells of the superficial layer, the epithelium is *polyhedral*, *pavement*, *cylindrical*, or *spherical*. In certain points, these superficial cells are furnished with vibratile filaments; they are then designated *vibratile* (or *ciliated*) *epithelium*.

In the third place, is the *muscular tissue*, which may be divided into *striated* and *non-striated* (or *striped*, and *non-striped* or *smooth*) *fibres*.

Lastly comes the *nervous tissue*, which offers two aspects: the white and grey substance. The first is entirely formed by nerve fibres, and the second by fibres and nerve cells.

ORGANS.—The term *organ* is given to an agglomeration of tissues possessing a determinate form, and having a function to fulfil. Organs are therefore composed of tissues, as the tissues themselves are constituted by anatomical elements.

All animal organs are enclosed between two membranes named *limitary* or *tegumentary membranes*, which are continuous with one another at the margin of the natural openings. These are the skin and the mucous membranes, in whose composition is included a layer of connective tissue covered by an epithelium.

Organs are distinguished into those which are solid, and those which are hollow.

Among the first, a certain number act as supports: such are the organs formed by the connective tissue, and particularly the cartilages and bones.

Others are destined to produce movements: these are the two kinds of muscles. The action of the muscles is communicated directly to the organs that are to be moved, or it is transmitted through the medium of other organs, such as the tendons and aponeuroses.

The central nervous organs, nerves properly so called, and the vascular glands, belong to this group of solid organs.

With regard to the hollow organs, they are everywhere covered by the internal, tegumentary, or mucous membrane. Examples:—the lungs and stomach. There must also be included the vessels formed by elastic and contractile membranes arranged as canals, in which the blood and lymph circulate; and, lastly, the serous membranes, which line the interior of the splanchnic cavities, and cover the surface of the organs contained in them.

APPARATUS.—Organs are very numerous in the animal economy, and in order to study them profitably it is necessary to classify them in a methodical manner, according to their physiological affinities. Consequently, there have been collected into a single category all those organs which are destined to achieve the same physiological finality, and to such a group has been given the name of *apparatus*.

An apparatus is, then, an assemblage of all those organs of an animal which concur to the same end, and which serve for the accomplishment of the same function.

We will successively describe, in the following order, the different apparatus of which the organism is composed:—

1. *Locomotory Apparatus;*
2. *Digestive Apparatus;*
3. *Respiratory Apparatus;*
4. *Urinary Depurative Apparatus;*
5. *Circulatory Apparatus;*
6. *Innervatory Apparatus;*
7. *Sensory Apparatus;*
8. *Generative Apparatus;*

This description will be terminated by a brief exposition of the *evolution of the fœtus and its appendages.*

BOOK I.

Locomotory Apparatus.

The *locomotory apparatus* is composed of all those organs which minister to the movements an animal may execute. It is certainly one of the most important in the economy, from the number and volume of the pieces which enter into its formation, and by the necessary co-operation that it affords the other apparatus in the performance of the physiological acts which are allotted to them.

It is constituted of two kinds of organs; the *bones* and *muscles*. The *bones*, hard and resisting, stony in appearance, are real inert levers, joined to each other by firm and movable *articulations*, which permit their playing upon each other with the greatest facility, at the same time maintaining them in their relative positions. The *muscles*, grouped around the bones and attached to them, are soft organs which possess the property of contraction, under certain determinate conditions and of involving in that movement the bones to which they are fixed by their extremities. The first are altogether passive in their motion, while the second are really the active organs of locomotion—the powers intended to move the bony levers.

We will treat successively of:—

1. The study of the bones, a particular branch of descriptive anatomy which has received the name of *osteology;*
2. The study of the articulations, or *arthrology*,
3. The study of the muscles, or *myology*.

FIRST SECTION.

The Bones.

CHAPTER I.

THE BONES IN GENERAL.

Bones, properly speaking, are only to be found in vertebrate animals, and constitute their principal zoological character. In the animal body they form an internal framework which consolidates the entire edifice, and gives it its general form and dimensions. It is advantageous, before commencing a particular description of each bone, to survey them in a general manner. This study comprises: 1, The description of the *skeleton;* 2, The summary indication of the *general principles* which should be known in order to comprehend the details of the special descriptions.

Article I.—The Skeleton.

The whole of the bones, considered in their natural relations to each other, constitute the *skeleton*. In order to prepare the skeleton of any animal, it is sufficient to free it from the soft parts surrounding it. The skeleton should be designated *natural*, if in this operation the ligaments

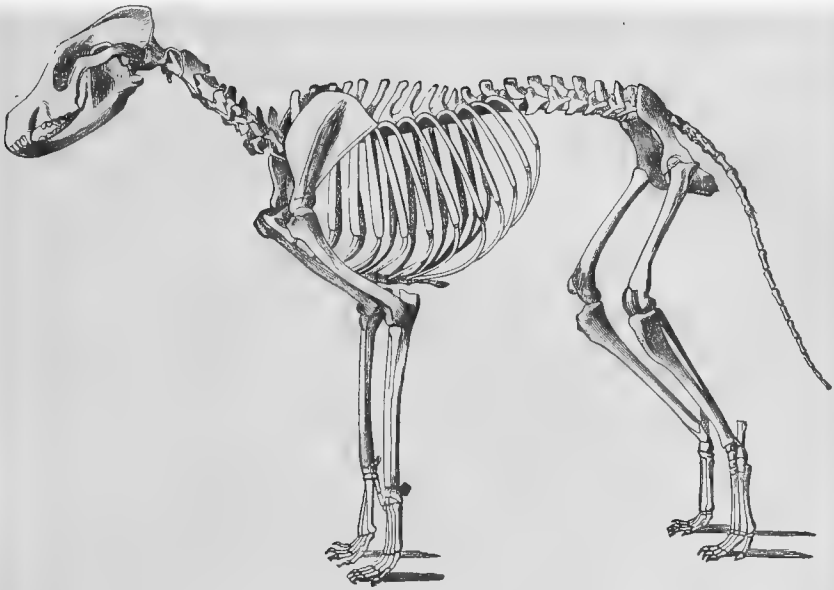

SKELETON OF THE DOG.

Fig. 2.

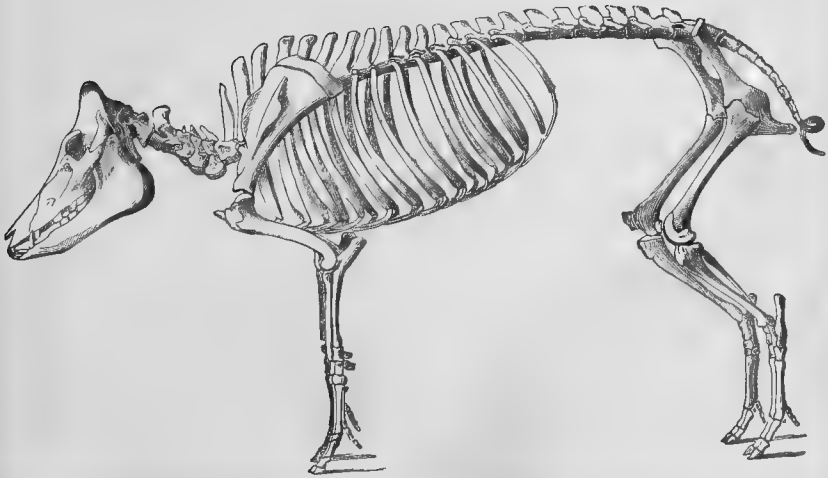

SKELETON OF THE PIG.

that naturally join the various pieces together are allowed to remain; and *artificial* if, after these ligaments have been destroyed, it is necessary to replace them by materials foreign to organisation, such as iron or brass wire.

The skeleton is divided into *trunk* and *limbs*.

The trunk offers for consideration, in the median line, the *spine* or *vertebral column*, a flexible stalk measuring the entire length of the animal, and composed of a series of distinct pieces articulated one behind the other. Anteriorly, this stalk supports the *head*, a pyramidal protuberance which itself results from the assemblage of a large number of bones. On each side of the middle portion of the spine, there are detached bony

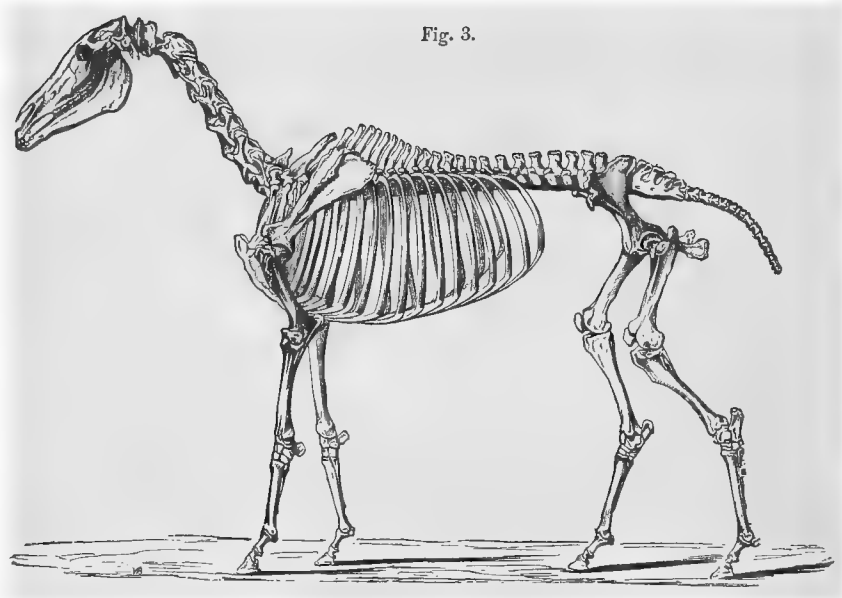

SKELETON OF THE HORSE.

arches which have received the name of *ribs*, and which rest, directly or indirectly, by their inferior extremities, on a single bone called the *sternum*. These bony arches in this way circumscribe the *thorax*, a spacious cavity destined for the reception of the principal organs of respiration and circulation.

The *limbs*, four in number, two *anterior* and two *posterior*, are the appendages which support the trunk. Each represents a column divided into several rays resting upon one another, and generally forming more or less acute angles. The *anterior limbs* are each divisible into four principal regions: the *shoulder*, applied against the front part of the thorax; the *arm*, which succeeds the shoulder; and the *fore-arm* and *foot*. The *posterior limbs* also comprise four regions: the *haunch* or *pelvis*, which articulates with the posterior part of the spine; and the *thigh*, *leg*, and *posterior foot*.

In birds, the posterior limbs alone assume the function of columns of support. The anterior limbs, formed for flight, constitute the *wings*.

Fig. 4.

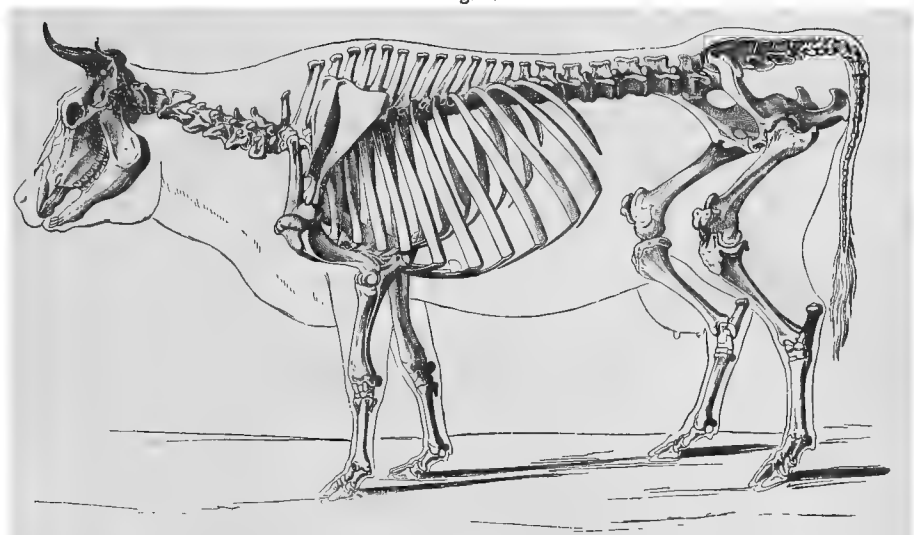

SKELETON OF THE COW.

Fig. 5.

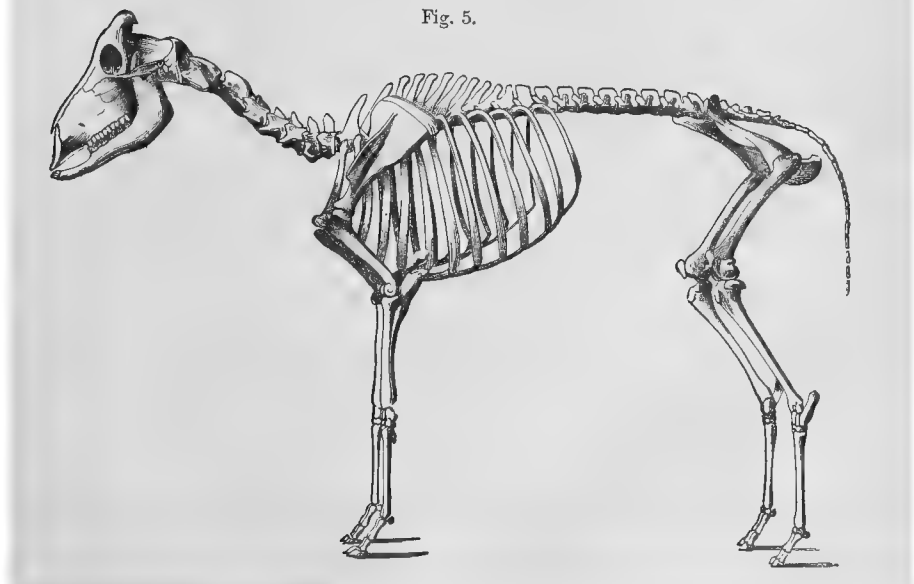

SKELETON OF THE SHEEP.

The number of bones entering into the composition of the skeleton of the domesticated animals, arrived at the adult period of life varies according

to the species. They are apportioned to the regions of the trunk and limbs just mentioned, in the manner indicated in the following table:

DESIGNATION.		Solipeds.[1]	Ruminants.	Pig.	Dog.[2]
Vertebral Column[3]		44	43	42	43
Head[4]		28	28	29	28
Thorax		37	27	29	27
Shoulder	Double regions	1–2	1–2	1–2	1–2
Arm		1–2	1–2	1–2	1–2
Fore-arm		2–4	2–4	2–4	2–4
Fore-foot		16–32	20–40	36–72	36–72
Pelvis		1–2	1–2	1–2	1–2
Thigh		1–2	1–2	1–2	1–2
Leg		3–6	3–6	3–6	3–6
Hind-foot		15–30	19–38	36–72	32–64
		189	194	262	252

Article II.—General Principles Applicable to the Study of all the Bones.

The description of any bone comprises its *name, situation, direction, conformation, structure,* and mode of *development.*

Name.

The nomenclature of osteology does not rest on any basis capable of conferring upon it a methodic form. Consequently, we find bones which derive their name from their shape, (example: the fibula); others from their resemblance to known objects (the tibia and vomer). Some owe it to their position (*côtes*, sides or ribs), or their uses (the axis and parietal bones). Several attempts have been made to submit the nomenclature of the bones to more precise and uniform rules, but the new designations proposed have not been sanctioned by custom.

Situation.

The situation of a bone should be viewed in two ways: 1st, *Relative to the median plane of the body;* 2nd, *Relative to the other portions of the skeleton.*

A. *Situation relative to the median plane of the body.* The designation of *median plane,* or improperly *median line,* is given to an imaginary vertical plane, passing through the middle of the skeleton which it divides, from before to behind, into two equal portions. The bones may be situated on the median plane, in which case there is only one of each kind, and they are called *single;* they are also named *symmetrical bones,* because the median plane divides them into two equal lateral halves exactly alike. The bones disposed in a double and regular manner on the sides of the median plane bear, for this reason, the name of pairs; they are also called *asymmetrical bones,* because their form does not admit of their being separated in any sense into two similar portions. On the contrary, a bone of this kind always offers the most perfect symmetry with its fellow on the opposite side.

[1] One lumbar vertebra less is found in the ass, and sometimes also in the mule.
[2] The *os penis* has not been included.
[3] The sacrum is reckoned as a single bone, and the number of coccygeal vertebræ at an average of 12 for the Horse, 16 for the Ox, 14 for the Pig, and 15 for the Dog.
[4] The os hyoïdes comprises, and is reckoned as, a single bone.

B. *Relative situation to the other parts of the skeleton.*—To indicate the situation of a bone, considered from this point of view, is to make known the place it occupies in the region to which it belongs, and the connections it may have with adjoining regions. Thus the radius is situated in front of the ulna between the arm-bone and the carpus.

Direction.

This is absolute or relative. The direction of a bone may be vertical, horizontal, or oblique. Example: the scapula is placed in an oblique direction from above to below, and from behind to before.

Configuration of the Bones.

FORM.—This is also absolute or relative.

A. *Absolute Form.*—The absolute form of a bone is that which it owes to the relations existing between its three dimensions—length, width, and thickness. *a.* A bone in which one of its dimensions much exceeds those of the other two is a *long bone.* Example:—the femur. All the long bones are hollowed out internally by an elongated space—the *medullary cavity.* Long bones belong exclusively to the limbs. In the animal economy, there are found bones which resemble them in their dimensions, but they have no medullary canal. Example:—the ribs. These differ essentially from the true long bones, and are sometimes distinguished from them by the appellation of *elongated bones.* *b.* A bone that offers two dimensions much more developed than the third, is a *flat* or *wide bone.* Example:—the parietal bone. The bones of this category, destitute of a medullary cavity, are met with in the head and the upper regions of the limbs. *c.* A bone which offers nearly the same development in all its dimensions, is called a *short-bone.* Example:—the astragalus. Destitute, like the preceding, of a medullary cavity, the short bones are found in the spine and some regions of the limbs.

B. *Relative Form.*—To make known the relative form of a bone is to indicate the greater or less exact resemblance it may bear to geometrical figures, or to familiar objects. Thus the scapula is a bone of a triangular form.

EXTERNAL PECULIARITIES OF BONES.—These markedly attract the attention, because they modify the general shape of bones, and singularly assist us in distinguishing one bone from another. These peculiarities, which are real distinctive features that permit their description to be precisely established, are always either eminences (*processes*) or depressions.

Eminences.—The eminences that stand out in relief from the surfaces of bones are divided into two different categories. One class concurs in the formation of the articulations which join the bones to each other; they are named *articular eminences*, in which, again, are distinguished *diarthrodial* and *synarthrodial eminences*, according as they belong to movable or immovable articulations. The others, usually destined for the insertion of ligaments and muscles, are called *non-articular*, or *eminences of insertion.*

(The term *imprint* is also used in anatomy, and signifies a collection of small rugged eminences which make the surface of the bone uneven and rough. There are muscular, tendinous, ligamentous, and aponeurotic imprints, according as they give attachment to muscles, tendons, ligaments, or aponeuroses.)

The *synarthrodial eminences* are always indentations more or less deep and finely cut.

The *diarthrodial eminences* are voluminous and smooth, and in a fresh state are covered with cartilage. They are named heads and condyles: *heads*, when they describe the segment of a sphere (head of the femur, head of the humerus); *condyles*, when they represent the segment of an oval figure, cut parallel to its large axis (condyles of the femur.)

The *non-articular eminences* receive various names. If they are voluminous and much detached from the bone, they are called *processes* or *apophyses*. Apophyses receive qualificatives derived from the analogies perceived between them and known objects. (Examples:—the styloid, clinoid, coronoid and coracoid processes.) The appellations of *protuberances* and *tuberosities* are given to non-articular eminences when they are large and round, and but slightly prominent. Lastly, they are named *lines*, *crests*, and *ridges*, when they are narrow and very long.

Cavities.—The cavities of bones have also been divided into *articular* and *non-articular cavities*.

The first correspond to the eminences of the same name in the bony joints. They take the designation of *cotyloid cavities* when they are deeply excavated, like a basin or the cup of an acorn (the glenoid cavity of the scapula, and the cotyloid cavity of the coxa).

The non-articular cavities serve either for ligamentous or muscular implantation, or for the passage of vessels, nerves, tendons, etc.

They are termed *channels* or *furrows*, when they are wide, deep, and smooth; *grooves*, when they are long, narrow, and even at the bottom; *fissures*, when they are narrow and rough. *Digital impressions* is the name given to those excavations in bones which look as if produced by the pressure of the finger. The *fossæ*, *sinuses*, *cells*, and *notches* are also non-articular cavities of bones. The sinuses and cells are formed by open spaces in the interior of bones; notches, by cavities excavated on their margins.

When a cavity passes quite through a bone it is termed a *foramen*. If this foramen offers a certain length, it is then designated a *conduit* or *canal*. *Fissures* are long, narrow foramina; *hiatus* is the term applied to wide openings with irregular outlines.

Regions of the Bones.—When it is desired to describe the eminences and external cavities of a bone, it is essential not to notice them, as it were, by chance—passing indifferently from one to another. In order to avoid the difficulties which would result from the application of such an irrational system, it is convenient to divide the bone to be described into several regions, in which are examined, one after another, all the external peculiarities that may offer.

The following is the course to pursue in order to establish the regions of a long, a flat, and a short bone.

(*a*) A long bone is always divided into three parts: a body and two extremities. The *body*, *middle part*, or *diaphysis*, is the narrowest portion of the bone. It represents a geometrical solid, approaching more or less the figure of a very elongated prism. In a long bone, therefore, it is necessary to study as many faces, angles, or borders, as the prism it represents may offer.

With regard to the *extremities*, or *epiphyses*, these are more or less considerable enlargements, showing articular surfaces, as well as surfaces intended for muscular or ligamentous insertion.

(*b*) A flat bone must necessarily have two *faces*, as well as *borders* and *angles*.

(*c*) A short bone offers for description a variable number of faces, and plane or salient angles, which are often neglected because of their trifling importance.

Internal Conformation of Bones.

Sections made in various directions through the substance of bones show that their internal conformation varies, according as they belong to the category of long, flat, or short bones. The diaphysis of long bones is hollowed out into a large fusiform cavity; this is the medullary canal. This canal is absent in the flat and short bones. Its walls are formed by a very dense bony tissue, whose pores are scarcely visible to the naked eye, and which is called the *compact substance*. The extremities of long bones are surrounded by a thin layer of compact substance, while the remainder of their mass is constituted by the *spongy substance*—bony tissue channeled into cells, or very large areolæ, which freely communicate with each other. (*Reticulated* bony tissue is but another form of spongy substance, the only difference between the two consisting in the cells or meshes of the first being formed of intercrossed osseous *fibres*, while those of the second are formed of *lamellæ*.) The medullary canal, and areolæ of the spongy tissue, are filled by a cellulo-fatty substance, the *marrow* (or *medulla*). The flat bones are constituted by a layer of spongy tissue placed between two laminæ of compact substance. In the flat bones of the cranium, the two layers of compact tissue are termed the *vitreous tables*, while the cells of the spongy tissue are designated *diploë*. In certain points of their extent, the spongy substance disappears, and then the bone is found to be composed of a single lamina of compact tissue. The short bones have a nucleus of spongy substance, enveloped in a layer, more or less thick, of compact tissue.

The compact substance of the bones being very resisting, is found in all those situations which have to sustain violent efforts. The spongy substance is very light and bulky, and is met with in the widened portions of the bones, to which it affords increased size without adding sensibly to their weight.

Structure of Bones.

Bones are formed of a *proper tissue*, covered externally by a particular membrane, the *periosteum*, and occupied internally by the *medulla*, *vessels*, and *nerves*.

Fig. 6.

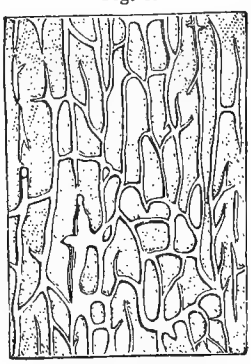

VERTICAL SECTION OF BONE, showing the network of Haversian canals.

Proper tissue.—The texture of the proper tissue of bones varies slightly in the compact and spongy substance.

The compact tissue is composed of a fundamental substance, which is amorphous, or slightly granular, white, and more or less opaque, according to the thickness it offers.

This fundamental substance is penetrated by an infinite number of vascular canaliculi, known as the *Haversian canals*. These canals, which measure from 1-2500th to 1-200th of an inch in diameter, are parallel to each other and to the larger axis of the bone; they frequently communicate by transverse branches. The most superficial open on the surface of the bone, beneath the periosteum, and the deepest into the

medullary canal; while a certain number terminate in the areolæ of the spongy substance.

The walls of these canals are constituted by several concentric lamellæ of fundamental substance, and in the body of these are lodged the essential elements of the bony tissue, or osteoplasts (*corpuscles* or *lacunæ*). These are minute cavities lined by a cellular membrane, and furnished, at their circumference, with a great number of canaliculated prolongations, which communicate with the adjacent osteoplasts, or with the Haversian canals. In a thin dried section of bone, the osteoplasts appear black by transmitted light, and white and brilliant by direct light; this appearance has led some observers to suppose that they were formed of small masses of calcareous matter. It is now well known that they are minute ramifying cavities, lodging a cell impregnated with liquid.

Fig. 7.

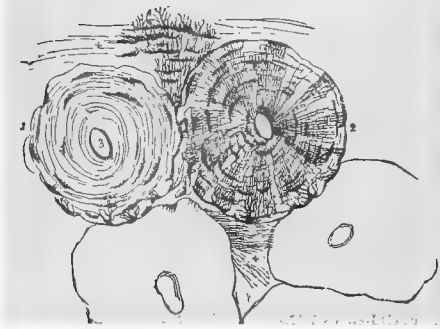

MINUTE STRUCTURE OF BONE, as shown in a thin section cut transversely to the direction of the Haversian canals.

1, A Haversian canal surrounded by its concentric lamellæ; the lacunæ are seen between the lamellæ, but the radiating tubuli are omitted; 2, *Ibid*, with its concentric laminæ, lacunæ, and radiating tubuli; 3, The area of one of the canals; 4, 4, Intervening lamellæ, and between them, at the upper part, several very long lacunæ with their tubuli.

Fig. 8.

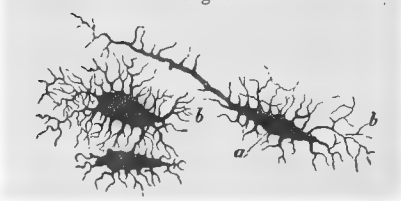

LACUNÆ, OR OSTEOPLASTS OF OSSEOUS SUBSTANCE, magnified 500 diameters.

a, Central cavity; *b*, Its ramifications.

In the spongy texture no Haversian canals can be seen, the osteoplasts are irregularly disposed in the thickness of the fundamental substance, which constitutes the septa of the areolæ of this tissue.

As a rule, the proper tissue of the bones is composed of a framework of organic matter which has gelatine for its base, and in which are deposited the calcareous phosphates and carbonates, which give to this tissue its characteristic hardness. This is easily rendered evident by immersing any bone in dilute nitric or hydrochloric acid; acids dissolve the calcareous salts, but do not act upon the organic framework. So it is that, after some days' maceration, the bone becomes flexible, like cartilage, and loses part of its weight, although it preserves its volume. The counterpart of this experiment may be made by submitting it to the action of fire. It is then rendered quite friable, because its organic skeleton has been destroyed without the earthy salts it contained being affected.

Periosteum.—This is a very vascular and nervous fibrous membrane that covers the entire bone, with the exception of the articular surfaces. Its thickness and adherence are not the same everywhere. By its inner face it corresponds to the surface of the bone; by its external face, it is confounded with the insertion of the tendons and ligaments, or with the surrounding connective tissue.

The periosteum may be resolved into two layers, though these are not very distinct. The superficial layer is essentially fibrous, and is formed by a mixture of connective and elastic fibres and plasmatic cells. The deep layer also contains a loose connective tissue, but more especially elastic fibres, and more or less voluminous spherical or fusiform cells. This is called the *osteogenous layer*.

Medulla.—The medulla, or marrow, is a pulpy, fatty substance, which fills the medullary canal and the areolæ of the spongy tissue of the bones. Somewhat consistent, and of a rose tint in the bones of the young animal, the marrow becomes diffluent and yellow in the bones of those advanced in age. In the first instance, it only contains traces of fat; while in the second it has 96 per cent. of this substance. The medulla of bones is composed of: 1st, Some trabeculæ of delicate connective tissue, which serves to support the vessels and nerves; 2nd, Fat either free or inclosed in vesicles; 3rd, Particular cells, named by M. Robin *medullo-cells* and *myeloplaxes.*

The *medullo cells*, abundant in the red or fœtal marrow, are small cells with a spherical nucleus; while the *myeloplaxes* are large, flattened, or polyhedral elements of an irregular outline, containing a great number of nuclei. Rare in the yellow marrow, they are more particularly found adhering to the walls of the medullary canal, or the alveoli of the spongy tissue.

Blood-vessels.—The arteries of bones belong to three orders; a distinction founded on their volume and the extent of their distribution.

The arteries of the first order penetrate to the interior of the medullary canal of long bones by a particular orifice, the *nutritious foramen.* They soon divide into two branches, which break up into a network that lines the walls of the canal and enters the tissue of the medulla. This network communicates with the arteries of the second order, which are destined to the spongy tissue of the extremities of the long bones, penetrating them by the numerous nutritious foramina that surround the epiphyses. Lastly, the arteries of the third order are branches of the periostic network which enter the superficial Haversian canals. These canals which open in this manner on the surface of the bones may be considered, strictly speaking, as a third category of nutritious conduits. In the flat and short bones there are no arteries of the first order.

Veins accompany the arteries, and are always more voluminous than these; they frequently make their exit by special and very large openings at those points where the spongy tissue is abundant. The veins of bones sometimes exhibit saccular dilatations on their course. Certain veins in the cranial bones have their parietes entirely composed of osseous tissue.

Lymphatic vessels.—The existence of these in the interior of bones cannot be affirmed.

Nerves.—These belong to the cerebro-spinal and ganglionic system of nerves; the latter are always vaso-motory nerves.

Almost constantly a somewhat voluminous nerve enters the medullary canal by passing through the nutritious foramen, and is distributed to the medulla. The compact tissue receives few nervous filaments; while, on the contrary, the spongy tissue at the extremities of the long bones, as well as the short bones, obtains an abundant supply. Certain short bones, such as the vertebræ, are especially remarkable for the numerous nerves they receive.

DEVELOPMENT OF BONES.

Bones, before arriving at the state in which they present themselves in the adult animal, pass through several successive phases, whose study constitutes what is termed *osteogeny*.

In the embryo, at a very early period, the bones are composed of a mucous material analogous to that which enters into the composition of all the other organs; this matter is constituted by a mass of what are called embryonic cells. At a later period they are impregnated with gelatine, and nearly all become harder, white, and elastic, passing into the cartilaginous state. Exception must be made, however, to the lateral and anterior parietes of the cranium and the face, the bones of which are at first fibrous but never cartilaginous. The cartilaginous bones show a fundamental amorphous substance, in which are disseminated spherical cells containing one or more nuclei. This condition is transitory; the cartilaginous tissue soon submits to modifications which result in conferring on the pieces that it composes the hardness and structure of perfect osseous tissue. These modifications constitute the process of ossification. There are several portions of the skeleton which do not undergo this osseous transformation, and which most frequently remain in the cartilaginous condition during the entire life of the animal. These permanent cartilages are met with at those points where the bony skeleton must preserve a certain degree of flexibility, and on the articular surfaces. During the process of ossification, the cartilages become vascular, are impregnated with calcareous salts, and excavated with Haversian canaliculi and medullary cavities. The saline molecules are deposited in the amorphous substance, which grows more hard and opaque; at the same time the cartilaginous cells become the point of departure of a new embryonic proliferation, from which results the neoplasts.

Ossification begins at the same time in several parts of the skeleton, and in each of the bones in particular; though it does not appear over the whole extent of the latter at once; on the contrary, in certain determinate points of the cartilaginous mass, bony tissue can be perceived developing itself and extending gradually until it finishes by completely invading it. These points are called *centres of ossification.*

These centres are *primary* or *complementary;* the latter are in some way added to the bone, and form, wholly or in part, certain processes. Although these centres of ossification enlarge from day to day, yet for a somewhat long period they remain completely independent of one another, and are only connected by cartilaginous tissue.

The term *epiphyses* is given to the osseous centres which are placed at the extremities of the principal centre. When the skeleton is completely developed, the various centres of ossification are fused into each other, and then there are no longer epiphyses; this fusion always takes place at an almost determinate epoch. It has been remarked that, of two epiphyses, it is constantly the one near which the nutritious foramen is directed that is first united to the body of the bone.

Growth.—Bones grow in width and thickness by the apposition of new elements. In the long bones, the growth in length takes place by the ossification of the cartilage uniting the epiphyses to the body of the bone. Consequently, elongation should cease as soon as the epiphyses are incorporated with the diaphysis. With regard to the long bones of the limbs, Duhamel, Flourens, and particularly MM. Ollier and Humphry, have remarked that, in the thoracic limb, the extremity furthest removed from

the humero-radial articulation grows fastest; while in the abdominal limb, the extremity most distant from the femoro-tibial articulation grows the least. Concerning the growth of the bones in thickness, this occurs by the ossification of the deep layer of the periosteum called the *osteogenetic layer*. The experiments of the above-named authors have irrefutably demonstrated this fact. The formation of bony tissue in the deep layer of the periosteum is very active during the youth of animals; but it soon slackens, and in advanced age ceases completely. In the first period of life, in proportion as the new layers are added to the surface of the bone, the old layers, those nearest the medullary canal, disappear by resorption. Later, the process of resorption exceeds that of formation, which is, in old age, completely annihilated. It has also been observed that the formation of a certain quantity of the osseous elements takes place on the inner face of the medullary canal, at the expense of the medullary tissue. In the flat bones, the primitive centre of ossification is developed nearly in the middle, and the calcareous salts are afterwards deposited in radiating lines from this spot towards the periphery. These bones are augmented in thickness by the formation of subperiostic layers, and by the development of the spongy tissue between their two compact laminæ; they increase in width by the ossification of what are termed the *marginal epiphyses*.

The short bones grow from the periosteum and the epiphysery cartilages, when they possess complementary centres.

Nutrition.—The experiments which consisted in feeding young animals with madder, and afterwards examining their osseous system, have for a long period demonstrated the nutrition of bones. When bones cease to grow, their nutrition becomes less active; but it is evident that it does go on, in order to maintain the organic matter of the osseous tissue in a proper condition.

(Professor Owen has explicitly and concisely stated the development of bone to occur as follows:—"The primitive basis, or 'blastema' of bone is a transparent glairy matter containing numerous minute corpuscles. It progressively acquires increased firmness; sometimes assuming a membranous or ligamentous state, usually a gristly consistence, before its conversion into bone. The change into cartilage is noted by the appearance of minute nucleated cells, which increase in number and size, and are aggregated in rows, with intercellular tracts, where the ossification is about to begin, as in fig. 9.

Fig. 9.

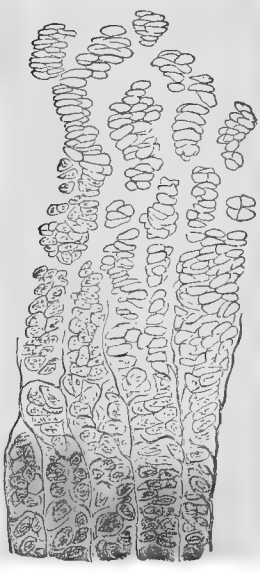

CARTILAGE AT THE SEAT OF OSSIFICATION, showing at its lower portions the clusters of cells arranged in columns, each of which is inclosed in a sheath of calcified intercellular substance.

These rows, in the cartilaginous basis of long bones, are vertical to its ends; in that of flat bones they are vertical to the margin. The cells furthest from the seat of ossification are flattened and in close contact; nearest that seat they become enlarged and separated.

The first appearance of bone is that of minute granules in the intercolumnar and intercellular tissue. Canals are next formed in the bone by

absorption, which ultimately receive bloodvessels, and become the 'vascular canals.' The immediate nutrition of bone is provided for by the production of minute 'plasmatic canals' from the vascular ones. When these canals become dilated, so as to offer definite forms, they are termed 'lacunæ' or 'bone-cells,' and to some extent characterise, by their shape and size, the osseous tissue of the respective vertebrate classes. In the concentric laminæ surrounding the vascular canal, the bone-cells or osteoplasts are arranged concentrically, between the laminæ, with the long axis in the direction of the circular line of the plate. Most of the plasmatic tubes continued from the bone-cells pierce the plates at right angles in their course to the vascular canal, with which they communicate; and they form the essential vehicle of the material for future growth. Extension of parts, however, is not the sole process which takes place in the growth of bone; to adapt it to its destined offices, changes are wrought in it by the removal of parts previously formed. In marine creatures, the bones usually remain solid; but in the active land quadrupeds, the shaft of the long bones is hollow, the first-formed osseous substance being absorbed, as new bone is being deposited without. The strength and lightness of the limb-bones are thus increased after the well-known principle of the hollow column. The bones of birds present this quality in the highest degree, particularly those of powerful flight. In these the medullary cavity of beasts is transformed into a capacious cavity containing rarified air instead of marrow. In the mammalian class, the air-cells of bone are confined to the head, and are filled from the cavities of the nose or ear, not from the lungs, as in birds. Such cells are called 'frontal sinuses,' 'antrum,' 'sphenoidal,' and 'ethmoidal.' The frontal sinuses extend backward over the top of the skull in the ruminant and some other quadrupeds, and penetrate the cores of the horns in oxen, sheep, and certain antelopes. The most remarkable development of cranial air-cells is presented by the elephant, the intellectual physiognomy of this large quadruped being caused, as in the owl, not by the actual capacity of the brain-case, but by the vast extent of the pneumatic cellular structure between the outer and inner plates of the skull-wall. All these varied changes in the osseous tissue, from mere cancelli to large medullary or pneumatic cavities, are the result of secondary changes by absorption, and not of the primitive constitution of bones, which were at first solid.")

CHAPTER II.

THE BONES OF MAMMALIA IN PARTICULAR.

ARTICLE I.—VERTEBRAL COLUMN.

THE vertebral column, or spine, is a solid and flexible stalk situated in the middle and upper part of the trunk, of which it forms the essential portion. It protects the spinal cord and sustains the thorax, as well as the principal organs of the circulation, respiration, and digestion. Articulated anteriorly with the head, and terminating in a point at its posterior extremity, this piece is formed by a somewhat considerable assemblage of short, single, tuberous bones, to which has been given the name of *vertebræ*. These

bones, though all constructed on an uniform type, yet do not offer the same configuration throughout the whole rachidean stalk. The differences they present into this respect, have allowed of their being formed into five principal groups; whence the division of the vertebral column in five regions, which are, enumerating them from before to behind: 1, *Cervical region;* 2, *Dorsal region;* 3, *Lumbar region;* 4, *Sacral region;* 5, *Coccygeal region.* The first comprises seven vertebræ, which serve as a base for the animal's neck: the second has eighteen, against which the ribs are placed; the third has only six, which correspond to the loins; in the fourth there are five, constantly solidified into one mass in the adult, to constitute a single bone—the *sacrum;* while the fifth possesses a variable number of small degenerate vertebræ, gradually decreasing in size to form the tail. The pieces constituting the first three regions are called *true vertebræ;* those of the last two are designated *false vertebræ.*

The characters belonging to all these vertebræ will be first studied; then a particular description of the vertebræ of each region will be given; and, finally, an examination will be made of the spine as a whole.

CHARACTERS COMMON TO ALL THE VERTEBRÆ.

Each of these small bones is pierced from before to behind by a wide

Fig. 10.

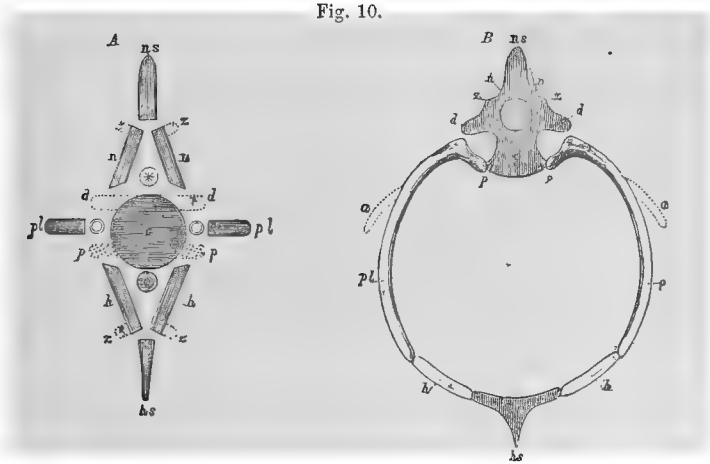

ELEMENTS OF A VERTEBRA: AFTER OWEN.

A, Ideal typical vertebra; B, Actual thoracic vertebra of a bird; *c*, Centrum (or *body*), giving off, *d*, *d*, the diapophyses, and *p*, *p*, the parapophyses (*transverse* and *articular processes*); the neural arch, inclosing the spinal cord, is formed by *n*, *n*, the neurapophyses (*laminæ*), and *n*, *s*, the neural spine (*spinous process*); the hæmal arch, inclosing the great centres of the circulation, is formed by *h*, *h*, the hæmapophyses (*costal cartilages*), and *h*, *s*, the hæmal spine (*sternum*). From both the neurapophyses and hæmapophyses may be given off the zygapophyses, *z*, *z*. The lateral arches, which may inclose the vertebral arteries, *o*, *o*, are completed by the pleurapophyses (*ribs*), *pl.*; these in B are bent downwards, so as to form part of the hæmal arch, and give off the diverging appendages, *a*, *a*.

opening, the spinal foramen; whence results, for the entire spine, a long canal traversing its whole length, and which lodges a very important

portion of the nervous centres—the spinal marrow. This canal, which traverses the vertebra from one end to the other, transforms it into a veritable ring in which we recognise, for facility of description, two parts—the one inferior, the other superior. The first, or *body*, is very thick, and forms the base of the vertebra; the second, which is thin, has been designated *spinous* or *spinal*, from one of the peculiarities it presents, or *annular*, because it circumscribes the major portion of the spinal foramen. This division is not altogether an arbitrary one, for the body and the annular portion constitute, in the fœtus, two distinct pieces, which do not become united for a long time after birth.

Body.—The shape of the body of a vertebra is that of a prism with four faces, of which two only—the *superior* and *inferior*—are free, and can be studied in the adult; the two lateral faces being united and confounded with the annular portion. This prism also presents two *extremities*—an *anterior* and *posterior*.

Faces.—The *superior face*, limited in extent, forms part of the spinal foramen, constituting its floor. It exhibits: 1, On the median line, two roughened, prominent surfaces, representing two triangles, whose summits are opposed; 2, On the sides, two depressed smooth surfaces, perforated by one or more openings that lead to the interior of the bone. The *inferior face* is divided into two lateral portions by a median crest.

Extremities.—The *anterior* has a prominent convex head, more or less detached. The *posterior* offers a cavity for the reception of the head of the next vertebra. These two planes, the one convex, the other concave, do not come into immediate contact; an elastic, flexible fibro-cartilage, firmly attached to each, being interposed between them.

Annular Portion.—This is formed by an osseous plate that curves suddenly downwards, in the shape of an arch, the two extremities of which approach each other, inclose the body, and become united to it. It offers for study: 1, An *internal* and an *external* surface; 2, An *anterior* and a *posterior* border.

Surfaces.—The *internal* surface, concave and smooth, forms, with the superior face of the body, the spinal foramen. The *external*, convex and irregular, presents: 1, A single prominence, raised in the middle of the superior portion, and named the *spinous process*; 2, The *transverse processes* are a double pair of eminences, one on each side, and projected transversely outwards.

Borders.—The *anterior border* has two articular facets looking upwards: these are the *anterior articular processes*, right and left. In each is a notch which, when placed in opposition to a similar excavation in the preceding vertebra, forms the *intervertebral foramen*. The *posterior border* presents the same peculiarities, with this difference, that the articular faces of the *posterior articular processes* are inclined downwards, to correspond with the anterior facets of the succeeding vertebra.

Structure of the vertebræ.—The compact substance, which is abundant in the spinous portion, forms, in the body, an extremely thin layer, inclosing a voluminous nucleus of spongy tissue. The latter is traversed by numerous venous canals, which open on the surface of the bone.

Development.—It has been already shown that the body and spinous portion of a vertebra constitute, in young animals, two distinct pieces. Each was primarily formed from two lateral centres, which met on the median line. In the body, the fusion of these centres is so prompt, that it is generally believed, perhaps justly, that the development of this part of the vertebra

proceeds from a single centre of ossification. The union of the two centres in the annular portion, usually designated the *vertebral laminæ*, is slower. It commences in the most anterior vertebræ, and is latest in the sacral and coccygeal regions. To the two principal pieces of the vertebra in process of ossification, is added, at a subsequent period, complementary points of ossification, five or six in number: one or two for the spinous process, one for the summit of each transverse process, another for the head, and the last for the posterior cavity of the body.

CHARACTERS PROPER TO THE VERTEBRÆ OF EACH REGION.

A casual inspection of a vertebra might suffice, strictly speaking, to distinguish the region of the spine to which it belonged. For instance, a cervical vertebra is recognised by its volume, the absence of a spinous process, and the foramen which traverses the base of its transverse processes. The dorsal vertebra is conspicuous by its tubercular transverse processes, and by being furnished, outwardly, with an articular surface, as well as by the depression on its body destined to receive the heads of the ribs. The lumbar vertebra has its long flattened transverse processes; while the coccygeal vertebra offers rudimentary laminæ and processes. There is no necessity for noticing the sacrum, whose five pieces form one bone: a feature which markedly distinguishes it from the other regions of the vertebral column. But these few distinctive characteristics do not satisfy the requirements of descriptive anatomy; so that it is necessary to undertake a more extensive study of each of these regions.

1. *Cervical Vertebræ.*

General Characters.—These vertebræ, the longest and thickest in the spine, present generally a cubic form. They are usually distinguished from the vertebræ of the other regions by the following characters:—The *inferior spine* of the body is strongly marked, especially behind, where it terminates in a small tubercle. The *head* is well detached from the remainder of the bone, and describes a very short curve. The *posterior cavity*, wide and deep, represents a veritable cotyloid depression, which is too large to fit the head exactly; the intermediate fibro-cartilage on these two surfaces is also of a great thickness. The *spinous process* forms a simple roughened, and but slightly prominent, ridge. The *transverse processes*, very developed, are elongated in an antero-posterior direction, and inclined downwards. In this region they are designated the *trachelian processes*, because of their relations with the trachea; a foramen that traverses them from before to behind at their base has been, for the same reason, named the *trachelian foramen* (*vertebral foramen*). The *articular processes*, large and prominent, are inclined downwards and inwards. The *notches* are wide and deep.

Specific Characters.—The seven cervical vertebræ are reckoned from before to behind, and receive numerical names indicating their place in the region.

First.—The first vertebra of the neck, which has been named the *atlas*,[1] deserves a very careful description. At first sight there is recognised the

[1] So named from the mythological personage who was supposed to support the earth, as the first vertebra (human) supports the head. (For this bone in the domesticated animals the name is not appropriate.)

great development of its transversal diameter, the considerable dimensions of the spinal foramen, and the thinness of its body. The intra-rachidian face of the latter is divided into two portions by a transverse ridge: one anterior, furnished with ligamentous imprints, exhibits, laterally, two deep excavations, which lodge the venous sinuses; the other, posterior, is smooth and concave from side to side, and forms an articular surface into which is received the odontoid process of the axis; this surface resembles the cotyloid cavity. The inferior spine of the body appears as a large tubercle. The head is absent, and is replaced by two concave facets. The anterior articular processes have their gliding surfaces looking downwards; they are joined to the two preceding facets to constitute two large diarthrodial cavities, which correspond to the occipital condyles. There is no spinous process, but a roughened surface instead. The transverse processes are large, flattened above and below, incline forwards and downwards, and are provided with a thick rugged lip. Posteriorly, quite at their base, and on each side of the spinal foramen, they show two large vertical facets which represent the posterior articular processes; these facets are uneven, are confounded with the articular cavity of the upper face of the body, and correspond to the two analogous facets of the axis. Each transverse process is pierced at its base by two foramina, which traverse it from below upwards. The posterior represents the vertebral foramen of the other vertebræ; while the anterior is continued to the external surface of the process by a wide, deep, but very short channel, running from without to within, and joins a third foramen, which enters the spinal canal. These last two openings, with the demi-canal which unites them, replace the anterior notch; the posterior is altogether absent. Lastly, an inflected venous canal, whose position varies, and whose presence is not constant, crosses the laminæ of the atlas, and opens, on one side, into the spinal canal, and on the other, beneath the transverse process. The atlas contains much compact tissue, and is generally developed from six centres of ossification: two for the body, which at an early period becomes a solid piece, and two for the annular part; the other two are complementary centres, each of which forms one of the two posterior undulated facets, and the lip of the corresponding transverse process.

Fig. 11.

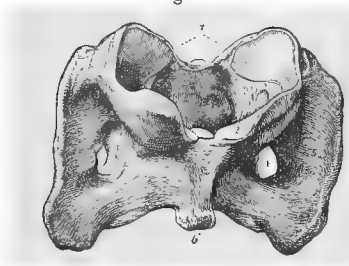

ATLAS; INFERIOR SURFACE.

1, Articular processes for condyles of the occipital bone; 2, ibidem; 3, Vertebral or antero-internal foramen; 4, Posterior, or cervical foramen; 5, Transverse process; 6, Tubercle representing the inferior spinous process; 7, Superior arch, forming the roof of the spinal foramen.

Fig. 12.

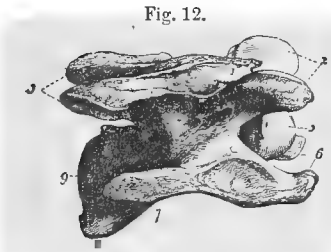

A CERVICAL VERTEBRA.

1, Superior spinous process; 2, Anterior articular processes; 3, Posterior articular processes; 5, Anterior convex face of body; 6, 7, Transverse processes, with their tubercles or rudimentary ribs; 8, Inferior crest, or spine; 9, Concave posterior face.

Second.—This is named the *axis* (or *dentata*). It is the longest of all the cervical vertebræ; those which succeed it gradually diminish in length and augment in thickness. The body of the axis has not any head anteriorly,

but a conical process termed the *odontoid*, which is flattened above and below, concave and rough from one side to the other on its superior face; convex in the same direction, and perfectly smooth on its inferior face. The latter represents an articular half-hinge, around which glides the concave articular surface on the superior face of the body of the atlas. The anterior articular processes are carried to the base and to each side of the odontoidian pivot, in the shape of two undulated facets, which are confounded with the gliding surface of the latter, whose destination has been already noted. The spinous process, very powerful and elongated antero-posteriorly, is divided behind into two roughened lips. The transverse processes are slightly developed, and terminate posteriorly in a single tubercle, directed backwards. The anterior notches are very deep, and are most frequently converted into foramina. This vertebra, although voluminous, is light, in consequence of its containing much spongy substance. In the young animal, the odontoid process and the articular surfaces on each side, constitute two centres, distinct from each other and from the body of the vertebra. After the axis, the cervical vertebræ diminish in length and increase in thickness; while the obliquity of their articular processes becomes the more pronounced the more distant they are from that vertebra.

Fig. 13.

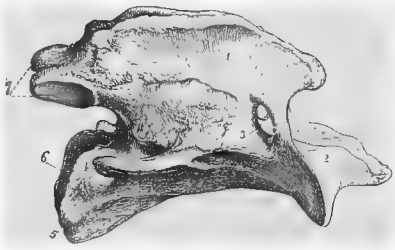

THE AXIS, OR DENTATA; LATERAL VIEW. 1, Superior spinous process; 2, Odontoid process; 3, Intervertebral foramen, or hole of conjugation; 4, Body; 5, Inferior spinous process; 6, 7, Inferior and superior articulating processes.

Third, fourth, and fifth.—Each of these has, at its transverse processes, two prolongations, one anterior, the other posterior. The inferior face of their bodies exhibits a median spine terminated posteriorly by a tubercle, which gradually increases in volume from the third to the fifth vertebra.

The third presents, between its anterior and posterior articular processes an almost complete gap; if its anterior extremity be placed on a horizontal plane, it will touch that plane by its articular and transverse processes and its head. In the fourth, the articular processes are united by a thin, sharp osseous plate, notched only in front. Laid on a horizontal plane, the head remains some distance from it. The fifth is known by the continuous, thick, and rugged lamina which unites the articular processes, and by the tubercle of the inferior spine on the body, which is in shape like the heart on a playing-card.

Sixth.—This is distinguished by the slight prominence of the spinous process, but particularly by the almost total disappearance of the inferior spine, and the presence of a third prolongation, very strong and inclining downwards at its transverse process, a circumstance to which this vertebra owes its designation of *tricuspid*.

Seventh.—This has received the name of *prominens*, because its spinous process, terminating in a point, is more distinct than in the preceding vertebræ, the axis excepted. It exhibits, besides deep imprints, which replace the inferior spine, a concave demi-facet on each side of the posterior cavity for the articulation of the head of the first rib; a particular disposition of its transverse processes, which are unituberculous; the complete absence of the vertebral foramen; and, lastly, the depth and width of its notches.

The spinal foramen, which has already assumed a somewhat considerable diameter in the sixth cervical vertebra, is still larger in the seventh.[1]

2.—*Dorsal Vertebræ.*

General Characters.—In the dorsal vertebræ the *body* is very short, and in front has a large slightly projecting head; behind, it has a shallow cavity. Laterally, these vertebræ present, at the base of the transverse processes, four concave *articular facets*, the two anterior of which are situated near the head, while the posterior two are hollowed out of the border of the articular cavity of the body. Each of these facets is joined to an analogous facet on the neighbouring vertebra to form a small excavation, into which is received the head of the corresponding rib. The *spinous process* is very high, is compressed on both sides, inclines backwards, and its summit is terminated by a tubercle. The *transverse processes* are unitubercular, and directed obliquely outwards and upwards; on their external aspect they have a diarthrodial plane facet which corresponds to the tuberosity of the rib. The *articular processes* are narrow, and constitute simple unrelieved facets cut on the base of the spinous process. The *posterior notches* are deep, and sometimes converted into foramina.

Fig. 14.

TYPE OF A DORSAL VERTEBRA; THE FOURTH.

1, Body; 2, 2, Articular facets for the head of rib; 3, Articular facet for tuberosity of the rib; 4, Articular processes; 5, Spinal foramen; 6, Tuberous base of spinous process; 7, Posterior articular face of body; 8, 8, Transverse processes; 9, Superior spinous process; 10, Anterior articulation of body.

Specific Characters.—None of the eighteen dorsal vertebræ differ much from the type just described; and it is difficult to establish special characters for each. It is, nevertheless, possible to assign to a dorsal vertebra, approximately, the rank it should occupy, in accepting the following facts as a guide:—1. The vertical diameter of the *vertebral bodies* augments progressively from before to behind. Their lateral diameter, which determines that of the spinal canal, becomes, on the contrary, less from the first to the tenth vertebra; after which it assumes increasing proportions to the last one. The articular surfaces, which serve for the mutual contact of head and cavity, become larger and shallower in proportion as the vertebræ are more posterior. The inferior spine on the body is very salient and tuberculous in the two first vertebræ, very acute in the third and fourth; it disappears in the sixth and ninth, to re-appear and become more marked from the tenth to the last. 2. The *intervertebral cavities*, intended for the reception of the heads of the ribs, diminish in depth and extent from the first to the last. 3. The longest *spinous process* belongs to the third, fourth, and fifth vertebræ; those which follow gradually decrease to the eighteenth. Their width diminishes from the second to the eighth; it afterwards increases in a progressive manner in the succeeding vertebræ;

[1] M. Goubaux has sometimes met with asymmetrical cervical vertebræ; certain vertebræ, tricuspid on one side, are only bicuspid or unicuspid on the opposite side.

from the second to the tenth vertebra, the summit of the spinous process is large and tuberculous; in the last seven it is flattened laterally. Their obliquity is less marked as they proceed backwards; in the sixteenth and seventeenth vertebræ, the spinous process is nearly vertical; it inclines slightly forward in the eighteenth. Those of the tenth, eleventh, and twelfth vertebræ are slightly curved like an S. 4. The *articular processes*, from the first to the tenth vertebra, gradually contract and approach the median line; in the succeeding vertebræ they, on the contrary, increase, and become concave and wider apart from those of the opposite side. 5. The volume of the *transverse processes* and the size of their diarthrodial facets diminish from before to behind. In the three first vertebræ this facet is concave; in the first nine the articular facet looks outwards and backwards, while the facet on the body looks forwards; in the last the two facets are directed forwards. These two facets are generally confounded in the seventeenth and eighteenth vertebræ. The first dorsal vertebra much resembles the prominens; it is distinguished from it, however, by the presence of four diarthrodial facets on its extremities. It also differs from the other vertebræ by the shortness of its spinous process, which terminates in a point; by the size and prominence of its articular processes; and by the depth of its notches. The last vertebra never has facets on the contour of its posterior cavity.[1]

3. *Lumbar Vertebræ.*

General Characters.—A little longer and wider than the dorsal vertebræ, which they resemble in the arrangement of their bodies, these vertebræ are characterised: 1, By their short, thin, and wide *spinous processes*, which are slightly inclined forwards, and are provided at their summits with a scabrous tubercle; 2, By their largely developed *transverse processes*, flattened above and below, and directed horizontally outwards;[2] 3, By the salient *anterior articular processes*, hollowed out on each side, and provided externally with a tubercle for insertion; 4, By their equally prominent *posterior articular processes*, rounded in the form of a half-hinge.

Specific Characters.—The characteristics which may serve to distinguish these vertebræ from one another are derived from the body, and the spinous and tranverse processes. 1. From the first to the last there is a progressive diminution in the vertical diameter of the bodies, and an increase in their transverse diameter. The inferior spine on the body becomes shorter and wider from the first to the last vertebra; in the six vertebræ it resembles an elongated triangle whose summit is directed forwards. 2. The spinous processes decrease in width from before to behind, and their anterior border becomes more and more concave; their summits are thickened and tuberculous in the three first, and thin and sloping forward in the three last. 3. The transverse processes are longer in the middle vertebræ than in those placed before and behind. The processes in the first and

[1] In well-formed horses, it is not uncommon to find nineteen dorsal vertebræ, with an equal number of ribs; though in these instances there are most frequently only five lumbar vertebræ. Husson and Goubaux have sometimes met with nineteen, and the normal number in the other regions. Sometimes there are only seventeen dorsal vertebræ.

[2] It has been correctly stated that these processes are the representatives of rudimentary ribs which have become united to the vertebræ. Therefore it is that they are frequently designated *costiform processes.*

second vertebræ incline slightly backward; in the third they are more upright; and in the succeeding ones are directed a little forward. In the last two they are remarkable for their thickness; in the fifth an oval-shaped articular facet is observed on their posterior border; in the sixth, two are present—one in front, corresponding to the preceding, and one behind, slightly concave, meeting a similar facet on the sacrum. The fourth and fifth vertebræ very often correspond, at their transverse processes, by means of analogous facets.[1]

Fig. 15.

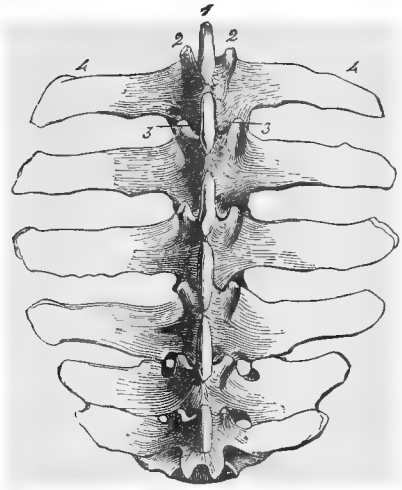

UPPER SURFACE OF LUMBAR VERTEBRÆ.
1, Summit of spinous process; 2, 2, Anterior articular processes; 3, 3, Posterior articular processes; 4, 4, Transverse processes.

In the *Ass*, and sometimes in the *Mule*, only five lumbar vertebræ are found. According to M. Sanson, this is the natural number in the Arab Horse.[2]

4. *Sacrum.*

The sacrum results, as already stated, from the consolidation of five vertebræ. This single bone articulates, in front, with the last lumbar vertebra; behind, with the first coccygeal bone, and on the sides with the ossa innominata. It is triangular, flattened above and below, and from before to behind describes a slight curve upwards. It offers for study a *superior* and an *inferior face*, two *borders*, a *base*, a *summit*, and a *central canal*, the extension of the spinal canal.

Fig. 16.

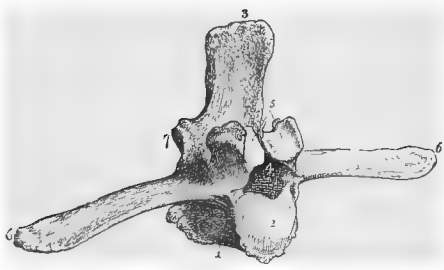

LUMBAR VERTEBRA; FRONT VIEW.
1, Body; 2, Its articular face; 3, Superior spinous process; 4, Spinal foramen; 5, Anterior articular processes; 6, 6, Transverse, or costiform processes; 7, Posterior articular process.

Faces.—The *superior face* presents, on its middle, the spinous processes of the sacral vertebræ, which together constitute what is called the *sacral* or *supersacral spine.* These processes are united at their base only, and remain isolated for the remainder of their extent; they all incline backwards

[1] We possess the skeleton of a horse which has seven lumbar vertebræ, with the normal complement in the other regions. The seventh is no doubt the first sacral, as it has all its characters. The fifth sacral vertebra is evidently derived from the coccygeal region.

[2] (This statement is scarcely correct. M. Sanson has established the fact that there is in reality no Arab horse; and asserts that the specific type with five lumbar vertebræ, is very probably of African origin, and that these vertebræ, independently of their number, offer individual characteristics different from those observed in the vertebræ of the type which has six.)

and terminate, with the exception of the first, by a tuberous summit, which is often bifid; their length diminishes from the second to the fifth bone. On each side of the sacral spine exists a groove, at the bottom of which are four openings—the *supersacral foramina*. These orifices open into the spinal canal, and communicate with four analogous, but wider apertures, pierced at the inferior face of the bone, and for this reason named the *subsacral foramina*. The *inferior face* is smooth, and shows traces of the primitive separation of the vertebral bodies; the subsacral foramina, which represent, with the corresponding supersacral openings, the intervertebral foramina of the other regions of the spine, are observed on this surface.

Fig. 17.

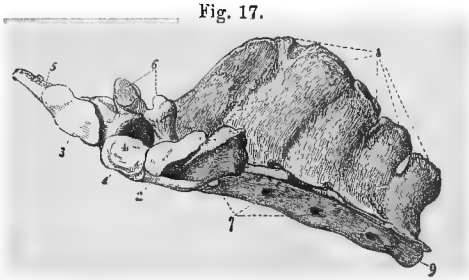

LATERAL VIEW OF SACRUM.

1, Articular surface of body; 2, 3, Articular surfaces corresponding to those on the transverse processes of last lumbar vertebra; 4, Spinal foramen; 5, Auricular facet; 6, Anterior articular processes; 7, Inferior or subsacral foramina; 8, Superior spinous processes; 9, Summit or coccygeal extremity.

Borders.—The *two borders*, thick and concave, form, posteriorly, a rugged lip; in front, they present an irregular surface inclining obliquely from above to below, from within outwards, and from before to behind. This surface, which is intended for the articulation of the sacrum with the ossa innominata, is divided into two parts: one, the inferior, named in man the *auricular facet*, is slightly undulated and diarthrodial; the other, the superior, serves for ligamentous insertions.

Base.—This offers: 1, On the median line, the anterior orifice of the sacral canal, and the anterior articular surface of the body of the first sacral vertebra, which is oval and slightly convex; 2, On the borders, the articular processes and anterior notches of this vertebra, as well as the elliptical and somewhat convex facets which bring it into contact with the transverse processes of the last lumbar vertebra.

Summit.—The summit, thrown back, presents: 1, The posterior orifice of the sacral canal; 2, The posterior articular surface of the body of the last sacral vertebra; 3, The vestiges of the articular processes and posterior notches of that vertebra.

Sacral canal.—This is the portion of the spinal canal which is channeled out of the sacrum; it is triangular, and diminishes in width from before to behind.

5. *Coccygeal Vertebræ.*

The *coccygeal region*, or *coccyx*, comprises from fifteen to eighteen degenerate vertebræ, which gradually diminish from the first to the last. In the first three or four, nearly all the characteristics of true vertebræ are found; they show a spinal foramen, a body, a spinous process, and transverse processes, looking backwards; the articular processes only are altogether absent. In the succeeding vertebræ, these characters become effaced; the vertebral laminæ do not join completely, and the spinal canal is only a simple groove, which, gradually decreasing in depth, at last

entirely disappears. The insertion eminences also become less salient, and the coccygeal vertebræ are soon reduced to small bony cylinders, narrow in the middle and wider at both extremities, with a convex articular surface at each end (except the last, which has only one articular surface). These small cylinders, the last traces of the vertebral bodies, are each developed from three centres of ossification; they are very spongy and light. The first coccygeal vertebra is frequently consolidated with the sacrum in aged animals.

THE SPINE IN GENERAL.

The vertebral column has now to be considered in its entirety, and examined successively in its *superior face*, its *inferior face*, its *lateral faces*, and its *spinal canal*. Afterwards its direction and mobility will be noticed.

Superior face.—This presents, on its median line, the series of spinous processes. But little salient in the cervical region, these eminences are much developed in the dorsal and lumbar, where they constitute a long crest, the *dorso-lumbar spine*, as well as in the sacrum, where they form the *sacral spine*. They soon disappear in the coccygeal vertebræ. Outwards, and on each side of these processes, is seen a succession of tubercles of insertion, represented in the cervical and lumbar vertebræ by articular processes, and in the dorsal vertebræ by the superior or rugose portion of the transverse processes. These tubercles are disposed in line, and separated from the spinous processes by a channel designated the *vertebral groove*, which is more or less deep and wide. It is on these, and on the spinous processes, that the extensor muscular fasciculi of the spine receive the greater portion of their fixed or moveable insertions.

Inferior surface.—Wide at the neck, this face becomes narrow in the dorsal region, to be again widened at the lumbo-sacral region, and once more contracted at the coccyx. Crests more or less developed, which divide the vertebral bodies into two lateral portions, right and left, are remarked.

Lateral surfaces.—These offer for study the thirty-six intervertebral foramina, through which the spinal nerves pass. They exhibit besides, on the neck, the transverse processes; in the back, the external facets of these processes, and the intervertebral facets, all destined to sustain the heads of the ribs; on the loins, the transverse or costiform processes. It may be remarked that the ribs and the transverse processes of the neck and loins furnish points of insertion to the powerful muscles which produce the lateral movements of the spine. In the sacrum, the lateral faces are formed for the articulation of the spine with the *ossa innominata*.

Spinal canal.—This canal communicates, in front, with the cranial cavity. Very wide in the atlas, for the reception of the odontoid process and to permit the rotatory movements of the head without injury to the spinal cord, this canal suddenly diminishes in the axis. It again dilates at the termination of the cervical region and the commencement of the dorsal; there the spinal cord presents a greater volume, and the movements of the spine are very extensive. Towards the middle of the back, the spinal canal offers its smallest diameter; it widens from this part to the lumbo-sacral articulation; after which it contracts rapidly, and disappears altogether near the fourth or fifth coccygeal vertebra. The lumbo-sacral dilatation coincides with the enlargement of the cord in this region, and with the enormous quantity of nerves lying beside it.

Direction of the vertebral column.—The spine does not extend in a straight line from the head to the posterior extremity of the body. If it is followed from the caudal termination, which is free and looks downwards, to the anterior extremity, it will be seen that it rises upwards and forwards, forming a convex inflexion corresponding to the roof of the pelvis. In the lumbar and the posterior half of the dorsal region it is nearly horizontal and rectilinear; from thence it descends to the cervical region, when it again rises and forms two curves, the one posterior, bending upwards, the other anterior, turned down. This disposition of the cervical spine gives it the shape of a console.

Mobility of the vertebral column.—In the cervical region, the almost total absence of spinous processes, the great development of the articular processes, and the very short curve described by the surfaces of contact of the vertebral bodies, allows the spine very extensive and very diverse movements. In the dorsal region, however, these movements are very limited, the spinous processes and the costal arches preventing the play of the vertebræ on each other. In the lumbar region, the spine can be flexed or extended more than in the dorsal; but its lateral movements are quite as restricted, owing to the presence of the transverse processes and the reciprocal joining or dovetailing of the articular processes. Lateral motion is even rendered impossible in the posterior half of this region, from the manner in which the transverse processes are adapted to each other. It may be remarked, however, that this disposition singularly favours the integral transmission of the propulsive efforts thrown upon the trunk by the posterior extremities.

The sacral vertebræ, having to afford the ossa innominata a solid fixed point, could not preserve their independence and mobility, and are consequently consolidated into a single piece which fulfils all its requirements in this respect. In the coccyx the rachidean stalk again recovers its mobility, and to a degree more marked than elsewhere; the coccygeal bones, articulated with each other by means of convex surfaces, and deprived of long processes at their extremities, are placed in the best possible conditions for variety and extent of movement.

DIFFERENTIAL CHARACTERS IN THE VERTEBRAL COLUMN OF OTHER THAN SOLIPED ANIMALS.

The NUMBER of PIECES composing the SPINE slightly varies in the Domesticated Animals, as will be seen in the following TABLE.

ANIMALS.	VERTEBRÆ.				
	Cervical.	Dorsal.	Lumbar.	Sacral.	Coccygeal.
Ox . .	7	13	6	5	16 to 20
Sheep .	7	13	6 or 7	4	16 to 24
Goat .	7	13	6	4	11 to 12
Pig . .	7	14	6 or 7	4	21 to 23
Dog .	7	13	7	3	16 to 21
Cat . .	7	13	7	3	21

A. VERTEBRÆ OF THE OX, SHEEP, AND GOAT.—1. *Cervical Vertebræ.*—The cervical vertebræ of the *Ox* differ from those of solipeds by their shortness and the greater development of their insertion eminences. In the *Sheep* and *Goat* they are relatively longer than in the Ox. The transverse processes of the *atlas* are less inclined than in the Horse,

and have no vertebral foramina; the posterior facets for articulation with the axis are nearly flat and join each other. The *axis* has a semicylindrical, not a conical, odontoid process, which is so concave on its upper surface that it looks like a groove. Its spinous process is not so thick as in the Horse, and is not bifid posteriorly.

In the *five succeeding vertebræ*, a rugged continuous lamina unites the anterior articular processes to the posterior. The spinous process inclines forward and is flattened transversely at its summit, which is sometimes bifid; it augments progressively in height from the third to the fifth vertebra.

In the *sixth*, the transverse processes have only two prolongations—a superior and inferior; the latter, large and flattened on both sides, is bent abruptly downwards. The spinous process has already attained the height of $1\frac{1}{2}$ to 2 inches in this vertebra, and is flattened laterally.

The *seventh* well deserves the name of *prominens:* its spinous process being no less than from 4 to $4\frac{3}{4}$ inches.

2. *Dorsal vertebræ.*—In the *Ox* these bones are longer and thicker than in the Horse. Their spinous processes are larger and incline more backward; their transverse processes are very voluminous, and are provided with a convex facet from above to below; while their posterior notches are nearly always converted into foramina.

Considered individually, they are more slender in the middle than at the extremities. Their spinous processes diminish in width, especially at their summits, from the first to the eleventh vertebra, and widen again in the two last; they progressively increase in slope to the tenth, after which they become more and more upright; the first four are the longest, and are nearly the same in height; the others gradually decrease.

In the first four or five vertebræ, the articular facet of the transverse processes, while retaining its vertical convexity, is concave in an antero-posterior direction. This facet is always absent in the last vertebra, and sometimes even in the preceding one. The two bones terminating the dorsal region show, in addition, the articular processes disposed like those of the lumbar vertebræ.

The dorsal vertebræ of the *Sheep* and *Goat* are relatively less strong than those of the Ox; their spinous processes are not so wide, and their posterior notches are never converted into foramina.

3. *Lumbar vertebræ.*—The lumbar vertebræ of the *Ox* are longer and thicker than in the Horse. The transverse processes are also generally more developed, are concave on the anterior border, convex on the posterior, and incline slightly downward, with the exception of the two first, which remain nearly horizontal. They increase in length from the first to the fourth vertebra; in the latter and the fifth, they are nearly of the same dimensions; in the last they suddenly become shorter. Their width gradually decreases from before to behind. In the fifth and sixth vertebra, these processes have no articular facets between them and the sacrum, these being only met with in solipeds. The articular processes are prominent, and further removed from the median line as they belong to posterior vertebræ.

In the *Goat* the transverse processes are more inclined downwards.

In the *Sheep*, on the contrary, the processes rise up towards their extremities.

4. *Sacrum.*—The sacrum of the *Ox* is more voluminous and curved than that of the Horse. The spinous processes are entirely consolidated, and are surmounted by a thick rugged lip; they are lengthened at their base and on each side by a ridge that represents the rudiments of the articular processes. The lateral borders are sharp and bent downwards. The surfaces that serve to unite the sacrum to the ossa innominata have a somewhat vertical direction. There are no lateral facets on the base of the bone for the union of the sacrum with the transverse processes of the last lumbar vertebra. In the *Sheep* and *Goat*, the sacrum is shorter; sometimes the consolidation of the spinous processes is late, or never occurs.

5. *Coccygeal vertebræ.*—In proportion, the coccygeal vertebræ of ruminants are stronger and more tuberous than those of the Horse. The anterior articular processes exist in a rudimentary condition.

B. Vertebræ of the Pig.—1. *Cervical vertebræ.*—Of all the domesticated animals, this has the shortest, the widest, the most tuberous, and consequently the strongest cervical vertebræ. The body of these bones is deprived of its crest on the inferior face; its head, but little detached, is scarcely round, and looks as if driven back on itself; consequently, its posterior cavity is not deep.

The vertebral laminæ are very narrow, and scarcely extend from one part of the vertebra to the other in the superior portion; so that the spinal canal appears at this point to be incomplete.

In the *atlas*, the transverse processes are yet less inclined than in ruminants; the vertebral foramen is not constant, and when it exists, opens on one side, under the

transverse process, and on the other, on its posterior margin, after pursuing a certain track in the substance of the bone.

The odontoid process of the *axis* is constricted at its base. This vertebra is distinguished by its high and thin spinous process inclining slightly back, by its transverse processes being but slightly prominent and perforated by an enormous vertebral foramen.

In the *four succeeding vertebræ*, the spinous process terminates in a blunt point, and inclines forward; slightly salient in the first, it gradually rises in the others. The transverse processes form two prolongations: one, the superior, is tuberculous, and is joined to the anterior articular process by a plate of bone, which is pierced by a foramen; the other, the inferior, flattened on both sides, bent downwards, and large, as it belongs to the posterior vertebræ, transforms the inferior face of these vertebral bodies into a large groove. The *seventh* is provided with a spinous process as long as those of the dorsal region. A perforated bony plate, as in the preceding vertebræ, unites the anterior articular process to the single tubercle composing the transverse process; the latter is continued back nearly to the posterior notch by a second plate, also perforated with a foramen (see Fig. 2).

2. *Dorsal vertebræ.*—The *Pig* has fourteen dorsal vertebræ, which, in their general disposition, are not unlike those of the *Ox*. As with that animal, the intervertebral foramina are double, each vertebral lamina being perforated laterally by an opening situated in front of the posterior notch. In addition, the vertebræ of the *Pig* present this peculiarity, that their transverse processes are generally traversed at the base by a single or multiple foramen which communicates with the preceding.

With regard to the special characters proper to some of the vertebræ, these are, as with the other animals, very few, and may be described as follows: 1. The transverse processes of the four vertebræ preceding the last project but slightly; 2. In the fourteenth this process resembles those of the lumbar vertebræ; 3. The articular facet of the transverse process in the four last vertebræ is confounded with the anterior lateral facet corresponding to the head of the rib, 4. The articular processes of the last five vertebræ are arranged like those of the lumbar vertebræ; and the prominence formed by the tubercle on the outside of the anterior articular process replaces, to a certain degree, the transverse process of these vertebræ.

3. *Lumbar vertebræ.*—These bones in the *Pig* greatly resemble those of ruminant animals. It commonly happens that seven are met with; but in this case the supplementary vertebra is generally a sacral one. It is not denied, however, that seven lumbar vertebræ may exist in the Pig, along with the normal number of sacral vertebræ.

4. *Sacrum.*—This is formed by four vertebræ, which are a long time in becoming fused together, and it is often difficult to discover where the sacrum ends and the coccyx begins.[1] The spinous processes are entirely absent. The vertebral laminæ are not consolidated; so that the spinal canal is half cut through in its upper portion, as in the cervical region; this canal is also much compressed above and below.

5. *Coccygeal vertebræ.*—These vertebræ in the *Pig* are more particularly distinguished by the presence of articular processes, by means of which the foremost bones correspond with each other.

C. Vertebræ of the Dog and Cat.—1. *Cervical Vertebræ.*—In these animals, the cervical vertebræ are long and thick, and much resemble those of solipeds. Nevertheless, besides their smaller volume, they are distinguished: 1, By the disposition of their corresponding articular surfaces; the anterior, or head, is nearly flat, and is even slightly excavated in its centre; the posterior, or cavity, is but little hollowed to receive the head of the next vertebra; 2, By the width of the vertebral laminæ, which exactly cover one another; 3, By the height of their spinous processes, which increases as the vertebræ extend back; 4, By the great extent of the anterior and posterior articular processes, which are united by means of a continuous and very salient bony plate, that considerably augments the transversal diameter of each vertebra.

In the *atlas*, the articular surface for the odontoid pivot is confounded in front with the cavities which correspond to the occipital condyles. The two facets which are annexed posteriorly to this articular surface, instead of being plane or gently undulated, as in the

---

[1] This can always be made out, however, by consulting the disposition of the articular processes. Thus, in the sacral vertebræ these eminences—if we except the anterior ones of the first and the posterior of the last—never exist except in a rudimentary state; while in the other five coccygeal vertebræ they re-appear with all their characters.

other domesticated animals, are transformed into real glenoid cavities.[1] The transverse processes are carried directly outwards and a little backward; the lip which borders each is slightly raised; of the two foramina which replace the anterior notch, one only exists, and this penetrates to the interior of the spinal canal; the other is merely a simple notch.

In the *axis*, the odontoid process is cylindrical, narrow at its base, and bent a little upwards; the lateral facets of this eminence represent true condyles.[2] The spinous process is very thin and undivided, and is curved forward above the laminæ of the atlas. The anterior notches are never converted into foramina.

The third cervical vertebra is the largest, and the succeeding ones gradually diminish in thickness to the last, contrary to what occurs in the other species. The seventh does not show the spinous process so developed as in ruminants and pachyderms (*see* Fig. 1).

2. *Dorsal vertebræ.*—In the *Dog* the dorsal vertebræ are formed on the same model as those of the Horse; but their spinous processes are in general narrower and thicker. The tenth always has its spinous process vertical, triangular, and terminated in a sharp point. The last three have no posterior facets for the articulation of the heads of the ribs, and exhibit, in the conformation of their articular processes, the same disposition as the lumbar vertebræ. In the *Cat*, the transverse processes of the three last dorsal vertebræ are thin, sharp, and turned backwards, they never possess facets for the tuberosity of the ribs.

3. *Lumbar vertebræ.*—In the *Dog* and *Cat*, the lumbar vertebræ are remarkable for their strength, due to their length, thickness, and the development of the eminences of insertion. The spinous process is low, and becomes acute in the last vertebra. The transverse processes incline very much forward and downward; they become longer from the first to the second-last bone, in the latter they become contracted, and in the seventh vertebra they are still more diminished, and terminate in an obtuse point. The tubercle of the anterior articular process is extremely prominent, and the posterior notches are surmounted by a small, very acute prolongation, directed backwards, which becomes more developed towards the anterior vertebræ. This small prolongation exactly represents the transverse process of the dorsal vertebræ.

4. *Sacrum.*—The three vertebræ which form the sacrum of carnivora are early consolidated. The supersacral spine constitutes a thin sharp ridge; while the lateral surfaces for articulation with the ossa innominata are turned quite outwards and are nearly vertical.

5. *Coccygeal vertebræ.*—The vertebræ of the coccyx are very strong and tuberous. The first five or six are as perfect as the true vertebræ, and comport themselves in every respect like them. The last are small V-shaped bones, which M. Goubaux has described by the name of *hypsiloid bones.*

COMPARISON OF THE VERTEBRAL COLUMN OF MAN WITH THAT OF THE DOMESTICATED ANIMALS.

The vertebral column of *Man* is composed of twenty-nine bones . twenty-four vertebræ, the sacrum, and four pieces constituting the coccyx. The twenty-four vertebræ are thus distributed:

Cervical vertebræ	7
Dorsal „	12
Lumbar „	5

In all these vertebræ, the bodies are slightly excavated at the two extremities, while in the domesticated animals, the superior or anterior is convex, and the inferior or posterior concave.

1. *Cervical vertebræ.*—These are wide and short. The spinous processes are moderately developed and bifid at their summits; the transverse processes are also divided into two branches—a posterior and an anterior.

2. *Dorsal vertebræ.*—In these vertebræ, the bodies increase in thickness from the first to the last. In the first as well as in the last dorsal vertebræ, the spinous process is almost immediately directed backwards; in the middle portion of this region these processes are very obliquely directed downwards and backwards.

---

[1] (A *glenoid cavity* is a shallow, oval, articular depression.)

[2] (A *condyle* is an articular eminence representing an ovoid segment. Condyles always correspond to the glenoid cavities in the articulations.)

3. *Lumbar vertebræ.*—The lumbar vertebræ are the strongest bones in the spine, and their bodies are nearly as thick as those of the larger domesticated animals. This enormous development of the lumbar vertebræ in Man is related to his position as a biped. In the fifth, the lower face of the body is cut very obliquely backwards and upwards, and the transverse processes are more voluminous than those of the other lumbar vertebræ.

4. *Sacrum.*—The sacrum is formed by the union of five pieces. It is very concave from above to below and before to behind. In becoming united to the lumbar region, it forms a salient angle in front, to which has been given the name of *promontory* or *sacro-vertebral angle.* The sacral spine is continuous or interrupted, according to the subject; it is alway bifid inferiorly.

5. *Coccygeal vertebræ.*—These are little bones or flattened tubercles, four in number, rarely five, and usually consolidated. The coccyx is conical in shape. Its base shows two processes directed upwards, which are called the cornua of the coccyx. Its summit is often deviated to the right or left.

Fig. 18.

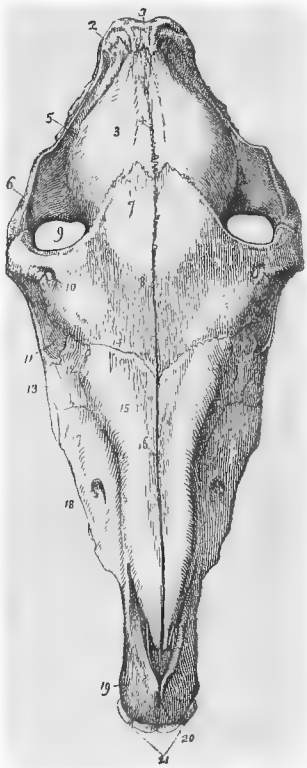

HORSE'S HEAD; FRONT VIEW.

1, Occipital protuberance; 2, Origin of the mastoid crest; 3, Parietal bone; 4, Saggital suture; 5, Junction of the parietal and temporal bones; 6, Zygomatic arch; 7, Frontal bone; 8, Frontal suture; 9, Temporal fossa; 10, Supraorbital foramen; 11, 12, Lachrymal bone; 13, Malar bone; 14, Nasal border of frontal bone; 15, Nasal bone; 16, Suture of nasal bones; 17, Superior maxillary bone; 18, Infraorbital foramen; 19, Anterior, or pre-maxillary bone; 20, Foramen incisivum; 21, Incisor teeth—young mouth.

Article II.—The Head.

The head is a large bony pyramid, elongated from above to below, and quadrangular, suspended to the anterior extremity of the spine; it is in a direction varying with the attitudes of the animal, but which we will suppose, for convenience of description, to be nearly vertical. It is formed of a great number of particular bones, which are only distinct from one another in very young animals; for well before the adult period is reached the majority of the bones are united and cannot be separated.

The head is divided into two parts: the *cranium* and the *face.*

BONES OF THE CRANIUM.

The *cranium*, or upper part of the head, is composed of seven flat bones, five of which are single: the *occipital*, *parietal*, *frontal*, *sphenoid*, and *ethmoid*; one only, the *temporal*, is double. These bones circumscribe a central cavity, the *cranial*, which communicates behind with the spinal canal, and lodges the principal portion of the nervous centres—the encephalon.

1. *Occipital Bone.*

The *occipital* bone occupies the superior extremity of the head, which it supports from the anterior extremity of the spine. This bone is very irregular in its form, and is bent at a right angle in front and behind. It has an *external* and an *internal face*, and a *circumference* which brings it into contact with the adjoining cranial bones; the latter is subdivided into two *anterior*

lateral borders, two *posterior lateral borders*, an *anterior* and *posterior salient angle*, and two *lateral re-entering angles*.

Faces.—The *external face* is divided into three portions by the double flexure of the bone: one looks forward, another upward, and the third backward. It exhibits:—1. On the median line, and from before to behind: *a*, an antero-posterior ridge which constitutes the origin of the parietal ridges, to be mentioned hereafter; *b*, a transverse, voluminous, and very prominent eminence, marked posteriorly by deep imprints, with a medium projection named the *cervical tuberosity;* this is the *external occipital protuberance* which, in the Horse, corresponds at the same time to the *superior curved lines* of the occipital bone of Man. This protuberance forms the culminating point of the head, and divides the anterior and superior parts of the external face of the bone; *c*, the *occipital foramen* (*foramen magnum*), a large orifice that passes through the bone at the posterior flexure, and establishes a communication between the cranial cavity and spinal canal; *d*, the external surface of the *basilar process*, a narrow and thick prolongation formed by the bone as it passes to meet the sphenoid: this surface is convex laterally. 2. On the sides: *a*, A sharp crest which prolongs, laterally, the superior curved lines, and descends on the middle of the lateral anterior border to be continued with the superior root of the zygomatic process and the mastoid crest of the temporal bone; *b*, Linear imprints, parallel to the latter, and prolonged on the base of the styloid process: they are destined for the insertion of the small oblique muscle of the head, and represent the *inferior curved lines* of the occipital bone of Man; *c*, Within these imprints is a slightly-roughened cavity for the insertion of the posterior recti muscles; *d*, The two *condyles*, articular eminences with a double convexity, one superior, the other inferior: these eminences are situated on each side of the occipital foramen (*foramen magnum*), and correspond to the anterior cavities of the atlas; *e*, More outwards are the two *styloid processes*, or *jugular eminences*, long projections flattened on each side, terminated in blunt points, directed backwards, and separated from the condyles by a deep space, the *stylo-condyloid notch;* *f*, Under the condyles is the *condyloid fossa*, a smooth depression, pierced at the bottom by the *condyloid foramen*, which penetrates the cranium.

The *internal face* of the occipital bone is concave, and shows: behind, the foramen magnum; above, an uneven surface, which forms the roof of the cerebral cavity; below, the superior face of the basilar process, slightly hollowed into a groove; on the sides, the internal orifice of the condyloid foramen.

Circumference.—The *anterior lateral borders* are thick, and are united by suture with the parietal bone, and with the tuberous portion of the temporal bone by the harmonia[1] suture. The posterior lateral borders are sharp, and constitute the sides of the basilar process; each concurs in the formation of the *occipito-spheno-temporal* hiatus, also termed the *lacerated foramen*, a vast irregular opening, extending from above downwards, penetrating the cranium, and divided by a ligament, in the fresh state, into two portions, one inferior, the *anterior lacerated foramen*, the other superior,[2] the *posterior lacerated foramen*. The *anterior angle*, which is dentated, is dovetailed into the parietal bone. The *posterior angle* is very thick, and forms the summit of the basilar process; it is united by suture with the body of the sphenoid. The *lateral re-entering angles*, or *jugular notches*, correspond to the

[1] (The *harmonia suture* (ἁρεῖν, to adapt) is the simple apposition of contiguous borders, which are roughened to facilitate retention.)

[2] (The *anterior and posterior lacerated foramen* of Man.)

point where the bone is bent posteriorly; they separate the anterior lateral from the corresponding posterior lateral border, and are occupied by the tuberous portion of the temporal bone.

Structure.—The occipital bone contains much spongy substance.

Development.—It is developed from four centres of ossification: one, the anterior, is single, and forms the occipital protuberance; another, the posterior, also single, forms the basilar process; the other two are pairs, and comprise each a condyle, with the styloid process and the corresponding condyloid foramen.

2. *The Parietal Bone.*

The *parietal* is a wide and thin bone, very much arched to form the roof of the cranial cavity. It is bounded above by the occipital bone, below by the frontal, and laterally by the two temporal bones. It offers for study an *external* and *internal face*, and a *circumference* divided into four regions or *borders*.

Faces.—The *external face* is convex. It exhibits two curved ridges whose concavity is directed outwards; these two crests, which are termed the *parietal ridges*, approach each other and unite superiorly, to be continued with the antero-posterior ridge of the occipital bone; below they diverge and proceed, one on each side, to join the supraorbital process. They divide the surface of the bone into three portions: two lateral, which are rough and traversed by vascular channels, forming part of the temporal fossæ; the third, or middle, is plane, smooth, and of a triangular form, and covered by the skin. The *internal face* is concave, covered by digital impressions, and grooved by small vascular canals; it offers, on the median line, and altogether above, the *parietal eminence.*[1] This trifacial and very salient projection presents at its base, on each side, an excavation elongated transversely, into which opens the parieto-temporal canal, and which is destined to lodge a venous sinus. It is continued, in front, by a median crest, which is often replaced by a slight groove, the *saggital furrow*, bordered by linear imprints. Two other ridges, resulting from the abutment of the lateral border of the bone against the anterior face of the petrous bone, rise from the sides of this eminence and descend to the sphenoid bone; they separate the cerebral from the cerebellar cavity.

Borders.—The *superior border* is notched, thick, and slightly dentated; it articulates with the occipital bone. The *inferior border*, slightly concave, and deeply dentated, offers an external bevel in its middle portion, and an internal bevel on its sides; it corresponds with the frontal bone. The *lateral borders* are very thin, and are cut at the expense of the external plate into a wide, sloping edge, which shows a groove destined to form the parieto-temporal canal. A very prominent angle separates each into two portions, an inferior, that articulates by suture with the squamous portion of the temporal bone; and a superior, curved inwards towards the centre of the cranial cavity; the latter portion of the lateral border is in contact with the anterior face of the petrous portion of the temporal bone, with which it concurs to form the lateral crest that descends to the parietal eminence.

Structure.—This bone contains much compact tissue, the spongy substance existing only in its middle.

Development.—It is developed from two large centres of ossification, to

[1] The *internal occipital eminence* of Man.

which is added a single centre to form the parietal eminence.[1] In early life the parietal ridges are absent.

3. *Frontal Bone.*

The *frontal* is a flat quadrilateral bone, whose sides are bent in the middle at an acute angle, and are carried back, and a little inwards, to meet the wings of the sphenoid bone. It assists in forming the cranial roof and part of the face. It is bordered: above, by the parietal bone; below, by the nasal and lachrymal bones; and on each side, by the temporal bones. It offers for study an *external* and an *internal face*, and *four borders.*

Faces.—The *external face* is divided, by the double flexure of the bone, into three regions: a middle and two lateral. The first, nearly plane, is lozenge-shaped, is covered by the skin, and constitutes the base of the forehead. It gives rise on each side, at the point where it is inflected, to a long *process*, flattened above and below, which curves backward, forming the *orbital arch.* The superior or external face of this process is convex and slightly roughened; the internal face is smooth and concave, and forms part of the orbital fossa. Its posterior border, thick and concave, is continued, inwardly, with the corresponding parietal ridge, and outwardly with the superior border of the zygomatic process. It limits, in front, the temporal fossa. The anterior border, also concave, but thin, concurs in the formation of the orbital margin; the summit, thickened and denticulated, rests upon, and is united to, the zygomatic process of the temporal bone; the base is wide, and is traversed by an opening termed the *supraorbital*, or *superciliary foramen.* The two lateral regions of the external face of the frontal bone are slightly excavated, and assist, for the greater portion of their extent, to form the orbits. They often show, near the base of the orbital arch, a small depression corresponding to the flexure described by the great oblique muscle of the eye in passing through its pulley.

The *internal face* of the frontal bone is concave, and divided into two unequal parts by a transverse ridge, corresponding to the anterior border of the cribriform plate of the ethmoid bone. The superior, the most extensive, is covered with digital impressions, and belongs to the cranial cavity. It exhibits: 1, On the median line, a slight furrow, or a crest which is continuous, above, with the median ridge of the parietal bone, and below, with the *crista-galli* process; 2, On the sides, and in the re-entering angle formed by the flexure of the bone, there is a narrow slit, or mortice, which receives the wing of the sphenoid bone. The inferior part is united, on the median line, to the perpendicular plate of the ethmoid. It assists in forming the bottom of the nasal cavities, and presents laterally two large openings which lead to the frontal sinuses—vast anfractuous spaces excavated between the two plates of the bone.

Borders.—The *superior border* is denticulated, and cut obliquely, in its middle portion, at the expense of the internal plate, and on the lateral parts at the expense of the external table; it is in contact with the parietal and

[1] This centre is described as the *interparietal bone* by those anatomists who consider the two lateral centres as two distinct parietals. (Leyh is one of the veterinary anatomists who describe this nucleus as a separate bone, designating it the *falciform* or *interparietal* bone. He also describes the parietal as a *pair* or double bone; whereas the majority of French anatomists include the interparietal bone as the median protuberance of the parietal, which they look upon as a single or impair bone. Percivall names it a pair bone, but follows the example of the French hippotomists with regard to the interparietal.)

squamous portion of the temporal bone. The *inferior*, prolonged to a point in the middle, is in apposition with the nasal bones through the medium of a wide external bevel; laterally, it is very thin, faintly serrated, and articulates with the lachrymal bone. The *lateral borders*, thin and irregular, present two notches: one, the superior, is wide and deep, and occupied by the wing of the sphenoid bone; the other, inferior, is very narrow, and uniting with a similar notch in the sphenoid bone, forms the *orbital foramen*, which opens into the cranium, very near, but external to, the ethmoid fossa. Each of these borders, also, is adapted, for a limited extent, to the corresponding palate bone.

Structure.—The two compact plates of the frontal bone are separated by spongy texture towards the middle and in the upper part; they separate below to form the frontal sinuses. Laterally, they are very thin and consolidated with each other.

Development.—The frontal bone is developed from two lateral centres of ossification, which only coalesce at a late period. In youth the cranial portion of the bone forms, in front of the head, a large rounded protuberance standing beyond the facial portion. This prominence disappears when the frontal sinuses begin to be developed. These cavities do not exist at an early period of fœtal life; but commence to form about the fourth month of conception, by a process of resorption, which removes the spongy substance interposed between the two compact tables of bone, and may even cause the destruction of the internal table. The sinuses enlarge with age, and remain during life separated from one another by a vertical septum.

4. *Ethmoid Bone.*

The *ethmoid bone*, deeply situated in the limit between the cranium and the face, is inclosed between the frontal, the sphenoid, the vomer, the palate, and the supermaxillary bones. It is composed of three portions: a *perpendicular plate*, and *two lateral masses.*

The Perpendicular Lamina of the Ethmoid Bone.—Situated in the median plane, and flattened on both sides, this bone presents *two faces*, a left and right, and *four borders.*

Faces.—The *faces*, covered by the pituitary membrane, present, posteriorly, small sinuous crests; elsewhere they are smooth. A very narrow interval, constituting the bottom of the nasal cavities, separates them from the lateral masses.

Borders.—The *superior border* looks towards the centre of the cranial cavity, and constitutes what is called the *ethmoidal ridge*, or *crista-galli process.* It is free, concave, and sharp, prolonged in front and above by the median crest of the frontal bone, and confounded behind with the middle portion of the inferior sphenoid. The *inferior border* is continuous with the cartilaginous plate which separates the nasal cavities. When this plate becomes ossified, which is not unfrequent, it is impossible to discover the point where it begins or the ethmoid bone terminates. The middle septum of the nose has been considered, and justly, as a prolongation of the perpendicular plate (or *lamina*) of this bone. The *anterior border* is consolidated with the vertical septum which separates the frontal sinuses. The *posterior border* is joined, above, to the median plate which divides the sphenoidal sinuses into two compartments. Below, it is fixed in the groove of the vomer, and soon becomes confounded with that bone, which is itself consolidated with the inferior sphenoid.

Lateral Masses of the Ethmoid Bone.—These are two large pyriform

tuberosities placed on each side of the perpendicular lamina, and offering for study a *middle portion*, a *base*, and a *summit*. Each of these is formed by an assemblage of numerous, extremely thin, osseous plates, curved into small and very fragile convolutions. These, elongated from above to below, become longer as they are more anterior; they are attached by their superior extremities to the transverse plate which separates the cranium from the nasal cavities, and by one of their borders to a thin leaf of bone which envelops the lateral masses outwardly. They have received the name of the *ethmoidal volutes* (or *cells*).

Fig. 19.

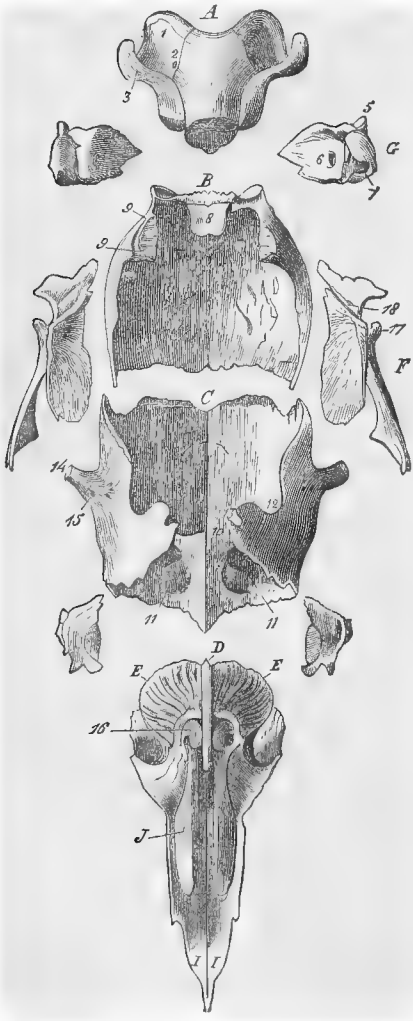

ANTERIOR BONES OF THE HEAD OF A FŒTUS (HORSE) AT BIRTH; DISARTICULATED, AND VIEWED FROM BEHIND.

Middle portion.—This should be studied externally and internally.

The *external surface* of each ethmoidal mass is divided into two sections: an internal, making part of the nasal cavities; the other, external, concurs in forming the walls of the frontal and maxillary sinuses. The first, the least extensive, is almost plane; parallel to the perpendicular lamina, it is isolated from it by the narrow space which forms the bottom of the nasal cavities; it presents several openings which separate the most superficial cells, and join the internal canals to be hereafter noticed. The second,

A, Occipital bone.—1, Condyle; 2, Condyloid foramen; 3, Styloid process; 4, Summit of basilar process.—B, Parietal bone.—8, Parietal protuberance; 9, Channel which concurs to form the parieto-temporal canal.—C, Frontal bone.—10, Transverse crests separating the cranial from the facial portion of the bone; 11, Frontal sinuses; 12, Notch on the lateral border occupied by the wing of the sphenoid bone; 13, Notch for the formation of the orbital foramen; 14, Summit of the orbital process; 15, Supraorbital foramen.—D, Perpendicular lamina of the ethmoid bone.—E, E, Lateral masses of the ethmoid bone.—16, The great ethmoid cell.—F, Squamous portion of the temporal bone.—17, Supercondyloid process; 18, Channel for the formation of the parieto-temporal canal.—G, Tuberous portion of the temporal bone.—5, Mastoid process; 6, Internal auditory hiatus; 7, Opening for the eustachian tube into the tympanum.—H, Lachrymal bone.—I, Nasal bone.—J, Superior turbinated bone.

very extensive and convex, looks outwards in front and behind, and is covered by an osseous plate traced with shallow furrows, which correspond internally with the small crests to which the cells are attached. This lamella is prolonged, inferiorly, a little beneath the inferior extremity of these latter, and turns outwards to articulate with the palate and superior maxillary bones; superiorly, it coalesces with the sphenoid and the orbital portion of the frontal bone.

Internally, the lateral masses are hollowed from above to below by extremely diverging canals, which open inferiorly into the nasal cavities, and separate the cells from one another. The latter are so incurvated that the internal cells communicate with each other. There are some, however, which are completely closed; the anterior, or great cell, is frequently so.[1]

Base.—The *base* of each lateral mass looks upwards, and is formed by the transverse septum between the cranium and the nasal cavities. This septum is perforated by openings which give passage to the ethmoidal nerves; it is named the *cribriform plate* of the ethmoid bone. It is concave on the superior surface, which constitutes the *ethmoidal fossa*, and convex on the opposite face, where attachment is given to the superior extremities of the cells. It is consolidated internally with the perpendicular plate; the other points of its circumference are attached to the sphenoid bone, and to the transverse ridge on the internal face of the frontal bone.

Summit.—The *summit* of each lateral mass is formed by the inferior extremity of the ethmoidal cells, which is directed downwards towards the nasal cavities. One, more voluminous than the others, is carried much lower, and terminates by a rounded protuberance. It corresponds to the middle cornu (*concha media*) of Man.

Structure of the ethmoid bone.—Very little spongy tissue enters into the composition of this bone, and this is only found near the anterior border of the perpendicular plate.

Development.—The ethmoid bone is late in attaining its development, and the adjoining bones are nearly completely ossified when it is yet entirely cartilaginous. The bony transformation commences in it at the inferior extremity of the cells, and advances progressively from below upwards. The perpendicular plate is only ossified in part when the cells have passed through the first half of the process; at the same time it coalesces with the inferior sphenoid. The cribriform plate is the last to become ossified; this transformation having scarcely been achieved when the animal is six or eight months old.

5. *Sphenoid Bone.*

The *sphenoid* bone is situated behind the cranium, between the occipital, ethmoidal, palate, vomer, pterygoid, frontal, and temporal bones. It is flattened from before to behind, curved from one side to the other, thick in its middle part, named the *body*, and thin on the sides, which, in their inferior half, are prolonged in the form of *alæ* or *wings*. It has *two surfaces* and *four borders*.

Surfaces.—The *external surface* is convex, and presents: 1, On the median line, the external surface of the body, rounded from one side to the other, is continued with that of the basilar process, and has marked muscular imprints superiorly; 2, On the sides and from within outwards: *a*, the *vidian* (or *pterygoid*) *fissure*, directed from above downwards, and continued by the *vidian canal*, a very small foramen which opens into the

[1] It is not rare to find it opening into the frontal sinus.

orbital hiatus; *b*, the *subsphenoidal*, or *pterygoid process*, a long eminence, flattened on both sides, inclining downwards, articulating with the palate and pterygoid bones, and traversed at its base by the vidian canal; *c*, a little behind and above this eminence, the superior orifice of the *subsphenoidal foramen*, a large canal which bifurcates inferiorly; *d*, more in front, the *orbital hiatus*, a kind of vestibule into which open in common the principal branch of the subsphenoidal canal, the three supersphenoidal canals, the vidian and optic canals, and the orbital opening: this hiatus is surmounted by a thin and sharp bony plate, above which opens the smallest branch of the subsphenoidal foramen; *e*, altogether without the hiatus is remarked a smooth surface belonging to the wing of the sphenoid, and which concurs to form the orbital cavity.

The *internal face* is concave from side to side. It shows: 1, On the median line, and from before to behind, a small projection united to the *crista-galli;* the *optic fossa*, elongated transversely in the form of a shuttle, and presenting at the bottom, and on each side, the superior orifice of the optic foramen, a cylindrical canal directed obliquely downwards, forwards, and outwards, to reach the orbital hiatus; the *supersphenoidal* or *pituitary fossa*, also named the *sella turcica*, a slight depression, limited behind by a scarcely noticeable transverse projection separating it from the superior channel of the basilar process; 2, On the sides, and in front, the internal surface of the wings, depressed by very superficial digital impressions; more behind and outwards, a fossa, elongated from before to behind, which lodges the mastoid lobule of the brain; between this fossa and the sella turcica, two vertical fissures: an internal, named the *cavernous sinus*, and an external, wider and deeper, for the passage of a large nervous branch. These two fissures open below, near the junction of the three supersphenoidal canals. Two of these, which are very wide, are placed one before the other, and separated only by a slight partition. The superior of these constitutes the *great sphenoidal fissure;* the other, the lower, is the *foramen rotundum*, and opens into the orbital hiatus. The third, very small, is situated outside the great anterior canal, opens above the optic foramen, within the bony mass surmounting the hiatus, and sometimes on the free margin of this lamina.

Borders.—The *superior* is a little concave, and shows, in its middle, the superior extremity of the body, mammillated and articulated with the summit of the basilar process; on each side, two notches which circumscribe below the occipito-spheno-temporal hiatus (*foramina lacera basis cranii*). The internal notch is the narrowest, and from its affording a passage for the internal carotid artery, is called the *carotid notch;* it is continued on the external face of the bone by a smooth excavation to which Rigot has given the name of *carotid fossa.* The external is also prolonged on the exterior surface of the sphenoid by a short and wide fissure; it lodges the inferior maxillary nerve. Outside this is another very narrow notch, intended for the passage of the middle meningeal artery. The fibro-cartilaginous substance that partly fills the occipito-spheno-temporal hiatus, transforms these notches into foramina, the first of which is named the *carotid canal*, the second, the *foramen ovale*, and the third, the *foramen spinosum.* The *inferior border*, also concave, is likewise divided into three portions, a middle and two lateral. The first is thick, and formed by the inferior extremity of the body; it is excavated by two large cavities belonging to the sphenoidal sinus. These cavities are separated from one another by a vertical osseous plate, often perforated, which, at an early period, is fused with the perpendicular

lamina of the ethmoid bone. The very thin lateral portions form part of the circumference of the wings; they are notched near their union with the middle piece to assist in the formation of the orbital foramen. The *two lateral borders* are thin and convex in their anterior half, as is also the contour of the wings, which are mortised in the frontal bone. For the remainder of their extent they are thick, denticulated, and bevelled at the expense of the external plate, to articulate with the squamous portion of the temporal bone.

Structure.—This bone is compact on its sides, and spongy in its middle part; inferiorly, it is excavated by the sphenoidal sinuses.

Development.—It is developed from two principal nuclei of ossification; a superior forms the subsphenoidal process and the canal of the same name, the vidian fissure, pituitary fossa, fissures of the internal face, and the most posterior of the great supersphenoidal canals; the other, the inferior, forms that portion of the body hollowed by the sinuses, the lateral alæ,[1] and the optic fossa and canals. In meeting each other, these centres form the vidian canal and the two anterior supersphenoidal canals. They are not consolidated with each other until a very late period; for which reason they are sometimes described as two distinct bones. M. Tabourin has even proposed to attach the description of the inferior sphenoid to that of the ethmoid, because it is united with this bone a long time before it is joined to the superior portion.

Fig. 20.

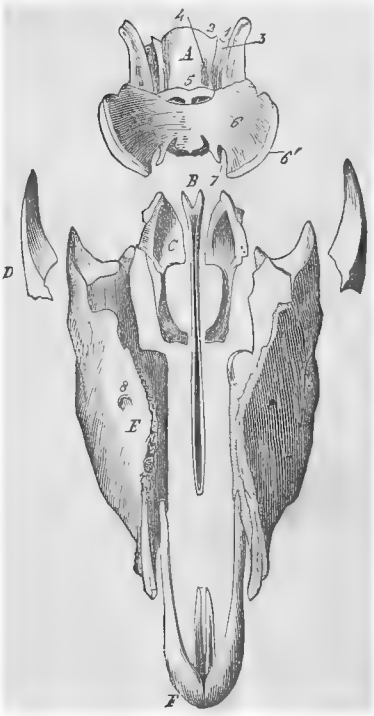

POSTERIOR BONES OF THE HEAD OF A FŒTUS (HORSE) AT BIRTH; DISARTICULATED AND VIEWED IN FRONT.

A, Sphenoid bone,—1, Maxillary notch; 2, Carotid notch; 3, Groove for the passage of the maxillary nerve; 4, Cavernous sinus; 5, Optic fossa; 6, Great wing; 6', Unossified portion of the great wing; 7, Notch for the formation of the orbital foramen.—B, Vomer.—C, Palate bone.—D, Zygoma.—E, Superior maxilla.—8, Inferior orifice of the maxillo-dental canal.—F, Premaxillary bone.

6. *Temporal Bone.*

The *temporal bones* inclose the cranial cavity laterally, and articulate with the occipital, parietal, frontal, sphenoidal, and the zygomatic bones; also with the inferior maxilla and the hyoid bone. Each is divided into two pieces, which are never consolidated in the horse; one forms the *squamous portion of the temporal bone;* the other, the *tuberous portion.* They will be described separately.

Squamous Portion.—This is flattened on both sides, oval, and slightly incurvated like a shell, a shape to which it owes its name. It offers for study an *external* and an *internal face*, and a *circumference.*

[1] These wings are not analogous to those portions of the sphenoid bone in Man bearing the same name. They are the processes *of Ingrassias* enormously developed.

Faces.—The *external face* is convex, and marked by some muscular imprints, vascular fissures, and openings which penetrate the parieto-temporal canal. It forms part of the temporal fossa, and gives origin near its middle to the *zygomatic process*, a long eminence which at first runs outwards, and soon curves forwards and downwards to terminate in a thin summit. The *base* of this eminence forms, in front, a concave surface belonging to the temporal fossa; behind, it offers the articular surface which corresponds with the maxillary bone. The latter is composed of: 1, A *condyle* transversely elongated, convex above and below, and slightly concave from side to side; 2, A *glenoid cavity*, limited below by the condyle, above by a mammiform eminence, the *supercondyloid*,[1] against which rests the maxillary condyle when this bone is drawn backwards; it is immediately above this eminence that the inferior orifice of the parieto-temporal canal opens. The *external face* of the zygomatic process is smooth and convex; the *internal*, concave, is also smooth, and bordered outwards by the temporal fossa. Its *anterior border* is sharp and convex; the *posterior*, very short, is thick and roughened. Its *summit* is flattened from before to behind, and marked by notches on its two faces; it somewhat resembles a wedge, fixed as it is between the orbital process of the frontal bone and the zygoma; it comes in contact with the maxillary bone, and by a small portion of its anterior face, which is deprived of notches, it concurs in circumscribing the orbital cavity. In the domesticated animals, as in Man, the zygomatic process appears to arise from the surface of the bone by two roots: one, the *inferior* or *transverse*, is represented by the condyle; the other, the *superior*, forms a sharp crest which is continuous with the anterior border of the process, and above, joins the lateral crest of the occipital protuberance.

The *internal* or *cerebral* face of the squamous portion is divided into two parts by an almost vertical channel which terminates above the supercondyloid eminence, and which, meeting a similar furrow on the parietal bone, forms the *parieto-temporal canal*. The superior portion is but of small extent, and of a triangular form; it articulates by a simple harmonia suture with the external face of the petrous portion. The inferior part, the widest, presents in its middle some cerebral impressions. For the remainder of its extent or circumference, it is cut into a wide, dentated, and lamellar bevel, which brings it in contact with the surrounding bones.

Circumference.—This may be divided into *two borders:* one, *anterior*, is convex and united with the parietal and frontal bones; the other, *posterior*, articulates with the sphenoid in its inferior moiety, and is provided, above the level of the supra-condyloid eminence, with a deep notch which receives the external auditory canal. Superiorly, the two borders unite at the summit in a thin point which rests on the occipital bone.

Structure.—The squamous portion of the temporal bone is formed of two very thin compact plates which have but little spongy tissue between them; the latter, however, is very abundant in the body of the zygomatic process.

Development.—It is developed from a single nucleus of ossification.

Tuberous Portion.—This is one of the most interesting parts of the skeleton for study, in consequence of its containing two systems of cavities which inclose the essential organs of hearing. One of these systems is named the *cavity of the tympanum* or *middle ear;* the other forms the *internal ear*. These cavities will be studied when we come to speak of the auditory

[1] In Man this is represented by the inferior or vertical ramus of the upper root of the zygomatic process.

apparatus. In the meantime, only the exterior surface and the structure and development of this portion of the temporal bone will be noticed.

It is wedged between the antero-lateral border of the occipital bone, the lateral border of the parietal, and the superior part of the internal face of the temporal shell. It represents a quadrangular pyramid whose base is turned downwards and a little backwards. It will be studied successively in its *four faces*, a *summit*, and *base*.

Faces.—The *anterior face* is united by harmonia suture to the parietal bone. The *posterior face* articulates in the same manner with the occipital bone. The *external face* lies against the squamous portion of the bone. The *internal face*, slightly concave and marked by very superficial digital impressions, forms a part of the lateral wall of the cerebellar cavity. It presents the *canal* or *internal auditory hiatus* (*meatus auditorius internus*), a small fossa, the bottom of which is pierced by several foramina for the transmission of nerves; the largest of these is the internal orifice of the *aquæductus Fallopii*, a flexuous canal which passes through the bone and opens at the external surface of its base; the other foramina penetrate the cavities of the internal ear.

These faces are separated from each other by so many *borders* or *plane angles*, two of which more particularly merit attention; one of these isolates the external from the posterior face, and the other separates the anterior from the internal face. The *first* is thick and rugged, and constitutes the *mastoid crest;* it is continuous above with the lateral ridge of the occipital bone, after being united to the superior root of the zygomatic process, and terminates, near the base of the bone, by a tuberosity for muscular insertion, to which has been given the name of *mastoid process.* This border is traversed by a slit, the *mastoid fissure*,[1] which passes under the squamous portion and enters the parieto-temporal canal. The *second* is thin, and, with the superior part of the lateral border of the parietal bone, forms the crest which establishes the line of demarcation between the cerebral and cerebellar cavities of the cranium; it gives attachment to the tentorium cerebelli.

Summit.—This is slightly denticulated, and articulates with the occipital bone.

Base.—This is very irregular, and offers: outwardly, the *external auditory canal* which penetrates the middle ear, and the external orifice of which has been named in veterinary anatomy the *external auditory hiatus;* inwardly, a sharp crest which circumscribes the external contour of the lacerated foramen; above, and under the mastoid process, the *stylo-mastoid* or *pre-mastoid foramen*, the external orifice of the aqueduct of Fallopius; below, the *subuliform* (or *styloid*) *process* for the attachment of the stylo-staphyleus (tensor palati) muscle and the Eustachian tube: this is a long, thin, and pointed process presenting, at its base and within, a canal which enters the cavity of the tympanum, and which is incompletely partitioned by a small bony plate into two parallel portions; in the centre, the *hyoid prolongation* or *vaginal process*,[2] a little cylindrical eminence surrounded by a bony sheath, and the *mastoid protuberance* or *process*, a slightly salient, smooth, and round eminence hollowed internally by numerous cells, which form part of the middle ear.

The several small and very remarkable canals which pass through the tuberous portion of the temporal bone, will be noticed when the nervous and arterial branches they lodge are described.

[1] This is the analogue of the *mastoid canal* in Man.

[2] This process is prolonged by a cartilage that unites it to the *styloid bone.*

Development.—The tuberous portion of the temporal bone is developed from two principal centres of ossification which are consolidated at birth, and which are often described as two distinct portions: the one as the *petrous* or *stony portion*, the other as the *mastoid portion.*

The faces, borders, summit and inner side of the base of the bone are formed by the *petrous* part, which contains the cavities of the internal ear and furnishes the inner wall of the middle ear.

The *mastoid portion* constitutes almost entirely the base of the temporal pyramid; to it belongs the external auditory canal, the mastoid process, the sheath of the hyoid prolongation, and the styloid process; it forms the external wall and circumference of the case of the tympanum.

For the tuberous portion of the temporal bone there are also two small complementary nuclei: one for the vaginal process, whose base is united to the petrous portion, and another forming the ring of the tympanum.

Structure.—The petrous portion is the hardest mass of bone in the skeleton, and scarcely contains any spongy tissue, except at the centre of the mastoid process; in the mastoid portion it may be said not to exist.

In the other domesticated animals, the tuberous portion of the temporal bone is always consolidated with the squamous, and the summit of the zygomatic process only articulates with the malar bone.

BONES OF THE FACE.

The face is much more extensive than the cranium in the majority of the domesticated animals, and is composed of *two jaws*, a bony apparatus that serves as a support to the passive organs of mastication—the teeth. The *superior* or *anterior jaw*, traversed in its entire length by the nasal cavities, is formed by nineteen wide bones, only one of which, the *vomer*, is a single bone; the pairs are: the *superior* and *intermaxillaries* (or *premaxillaries*), the *palate*, *pterygoid*, *zygomatic*, *lachrymal*, *nasal*, and *superior* and *inferior turbinated bones.* Of these only four, the maxillaries, are intended for the implantation of the teeth; the others form the union between the cranium and the superior maxilla, or concur in the formation of the nasal cavities. The *lower jaw* has for its base a single bone, the *inferior maxilla* or *maxillary bone.*

1. *Great Supermaxilla, or Superior Maxillary Bone.*

This bone, the most extensive in the upper jaw, is situated on the side of the face, and is bordered above by the frontal, palate, zygomatic, and lachrymal bones; below, by the premaxillary bones; in front, by the nasal bone; behind and within, by that of the opposite side. It is elongated vertically, is irregularly triangular, and exhibits *two faces, two borders*, and *two extremities.*

Faces.—The *external face*, which is more convex in the young than the old animal, presents: 1, On the level of the fourth and fifth molar teeth, a vertically elongated ridge which is continued above with the inferior border of the zygomatic bone; this is the *supermaxillary spine;* 2, The inferior orifice of the *supermaxillo-dental canal*, or *infra-orbital foramen.*

The *internal face* concurs in forming the external parietes of the nasal cavities. We observe, above and in front, a deep, wide, and diverticulated excavation, forming part of the maxillary sinus; above and behind, a surface roughened by fine lamellæ and dentations to correspond with the palate bone, and traversed from above to below by a fissure which forms, in uniting with a similar fissure in the latter bone, the *palatine canal.* For the remainder of its extent it is unequally smooth, covered by the membrane

of the nose, and divided into two surfaces by a slightly vertical and sinuous crest that affords attachment to the maxillary turbinated bone: the anterior surface, which responds to the middle meatus of the nasal fossa, shows the lower orifice of the osseous lachrymal canal continued by a fissure to the lower extremity of the bone; the posterior surface belongs to the inferior meatus. This face presents, near its inferior border, a large vertical apophysis, the *palatine process*, which offers an anterior slightly concave face, forming the floor of the nasal fossæ; a posterior face, furrowed by small fissures, perforated by fine openings, and traversed along its length by a somewhat wide groove, the *palatine fissure*, which commences above at the lower orifice of the palatine canal. The internal border of this process articulates with the analogue of the palatine process of the opposite side.

Borders.—The *anterior*, thin and convex, is divided into two parts: an inferior, which is mortised to receive the external border of the nasal bone and the external process of the premaxillary; and a superior, cut in a wide bevel at the expense of the external plate, to respond to the lachrymal and zygomatic bones. The *external* border is very thick and hollowed into six large quadrilateral cavities, named *alveoli*, in which are implanted the molar teeth. Above the last alveolus it forms a rugged eminence designated the *alveolar tuberosity;* below the first it becomes thin and sharp, and constitutes part of the interdental space which separates the molar from the incisor teeth.

Extremities.—The *superior* is the thickest, and represents a smooth rounded protuberance, into the interior of which the maxillary sinus is prolonged. Above and within this eminence, is a wide and deep excavation, in the formation of which the palate bones participate. This is the *maxillary hiatus*, situated directly opposite the orbital hiatus. At the bottom of this cavity is seen the nasal foramen, as well as the upper orifice of the supermaxillo-dental and the palatine canals. The *nasal foramen* belongs to the palate bone and enters the nasal cavity. The *supermaxillo-dental* or *infra-orbital canal* traverses the maxillary sinus in passing above the roots of the molar teeth, and terminates by two branches: one, short and wide, which opens on the external surface of the bone, on a level with the third molar; the other, very narrow, continues the course of the canal in the thickness of the bone, and is prolonged by several small very fine branches into the premaxillary bone. The *palatine canal*, channeled between the supermaxillary and the palate bone, extends from the maxillary hiatus to the palatine fissure.

The *inferior extremity* presents a cavity which forms the alveolus of the tusk by uniting with a similar space in the premaxillary bone.

Structure and development.—This bone is developed from a single nucleus, and is the more spongy, particularly towards the alveolar border and the superior extremity, as the animal is young.

2. *Premaxillary, Intermaxillary, Anterior Maxillary or Incisive Bone.*

This bone occupies the inferior extremity of the head, and is composed of a *thick prismatic portion*, lengthened superiorly by two long *processes*.

Thick portion or base.—This presents a solid mass with *three faces:* an *external* or *labial*, smooth and convex; an *internal*, denticulated for union with the opposite bone, and traversed from before to behind by an inflexed fissure, which forms, with an analogous one in the other premaxillary, the *incisive canal* or *foramen;* the third or *posterior*, also called the *buccal*, is slighty concave, and shows the continuation of the palatine fissure, which

opens into the incisive foramen. These three faces are separated by as many *borders*: *two internal*, limiting before and behind the corresponding face; and *an external*, separating the labial from the buccal face. The latter only merits notice; it is very thick, and is divided into two parts: an inferior, which describes a curved line with the concavity upwards, and is hollowed by three alveoli to receive the incisor teeth; another, the superior, is straight, vertical, and somewhat sharp, and forms a part of the dental interspace. It is limited above, near the base of the external process, by a cavity for the formation of the alveolus of the tusk.

Fig. 21.

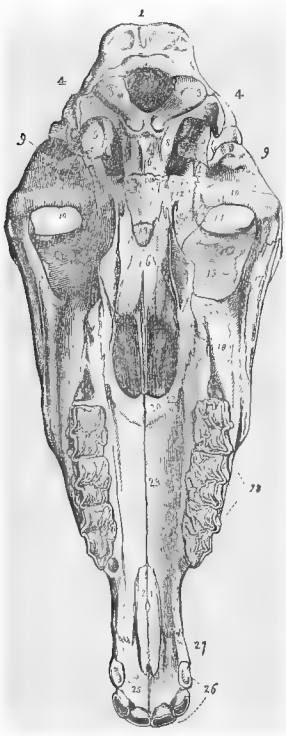

POSTERIOR ASPECT OF HORSE'S SKULL.

1, Occipital protuberance; 2, Foramen magnum; 3, 3, Occipital condyles; 4, 4, Styloid processes; 5, 5, Petrous bone; 6, Basilar process; 7, Pterygoid fissure of the sphenoid bone; 8, Foramen lacerum; 9, 9, Supra-condyloid, or anterior mastoid process; 10, 10, Articular eminence, or temporal condyle; 11, Body of sphenoid bone; 12, Pterygoid process; 13, Ethmoid bone; 14, Temporal bone and sphenoidal suture; 15, Lachrymal bone; 16, Vomer; 17, Malar bone; 18, Maxillary tuberosity; 19, Posterior, or guttural opening of the nose; 20, Palate bone; 21, Palatine styloid process; 22, Palato-maxillary foramen; 23, Palatine process of superior maxillary bone with suture; 24, Ditto of premaxillary bone; 25, Premaxillary bone; 26, Upper incisor teeth; 27, Point of junction of the premaxillary with the superior maxillary bone; 28, Upper molar teeth—young mouth.

Processes.—These are distinguished as *external* and *internal*. The first, the longest and strongest, is flattened on both sides; its external face is smooth and continued with that of the thick portion of the bone; its internal face is covered by the mucous membrane of the nose; the anterior border is smooth and rounded; the posterior, denticulated to respond to the supermaxillary bone, is in contact with the external border of the base; its summit is thin, and is insinuated between the latter and the nasal bone. The *internal process*, the smallest, is flattened from before to behind, and forms a very thin tongue of bone, separated from the other portions by a narrow and very deep notch named the *incisive opening* or *cleft*. Its inferior face constitutes a small portion of the floor of the nasal fossæ; the posterior, continuous with the same face of the principal mass of the bone, forms part of the palatine roof; its external border circumscribes, inwardly, the incisive opening; the internal is united by dentated suture with the opposite bone.

Structure and development.—It is a spongy bone, developed from a single nucleus.

3. *Palate Bones.*

The *palate bones* are situated between the supermaxillaries, at the margin of the guttural opening of the nasal cavities, and are articulated with the sphenoid, ethmoid, vomer, frontal, and pterygoid bones. Elongated from above to below, flattened laterally, and curved

towards each other at their inferior extremity, which is flattened from before to behind, these bones, though irregular in shape, offer for study *two faces, two borders*, and *two extremities*.

Faces.—The *external face* of the palate bone is divided into three fractions, a superior, or *orbital*, an inferior, or *palatine*, and a middle, or *articular*. The first is smooth and slightly excavated, and participates in the formation of the maxillary hiatus; it shows a small fissure, the *staphyloid*, which reaches the palatine fraction in passing between the posterior border of the bone and the alveolar tuberosity. The second is not extensive, and looks backwards in consequence of the antero-posterior flattening which the bone presents at its inferior extremity; it forms part of the roof of the palate. The third presents a lamellar and denticulated surface which corresponds to a similar face on the supermaxillary bone, and is channeled from above to below by the internal fissure of the palatine canal.

The *internal face*, smooth and concave, forms part of the external wall and the floor of the nasal fossa.

Borders.—The *anterior* is indented, near its superior third, by a deep notch, which is often converted into a foramen, the *nasal*. Below this notch the bone is thin and denticulated for union with the supermaxillary bone; above, its two plates separate widely from one another, giving rise to a very spacious cavity which forms part of the sphenoid sinus. The *posterior border* presents, above, a rugged crest called the *palatine*, flattened from side to side, bent outwards, and bordered at its base and inwards by a very narrow synarthrodial surface which responds to the pterygoid bone. It is smooth and concave in its inferior half, and forms, with that of the opposite side, a parabolic arch which circumscribes, below and at the side, the double guttural orifice of the nasal cavities.

Extremities.—The *superior*, flattened on both sides, is bevelled on the external side to articulate with the subsphenoidal process. The *inferior*, flattened from before to behind, is curved inwards and united by simple suture with that of the opposite bone.

Structure and development.—This is a very compact bone, developed from a single centre of ossification.

4. *Pterygoid Bone.*[1]

A small and very narrow bone, elongated from above to below, flattened on both sides, and situated on the inner aspect of the subsphenoidal process, but external to the vomer.

Its *external face* is in contact with the palate and sphenoid bones; the *internal* is smooth and covered by the pharyngeal mucous membrane. Its *superior extremity* is tapering, and concurs in forming the vidian canal; the *inferior* is thickened into a small pointed process (the *hamular process*), whose apex, directed backwards, offers outwardly a groove which serves as a pulley to the tendon of the tensor palati. This bone is composed entirely of compact tissue, and is developed from a single centre of ossification.

5. *Zygomatic Bone.*

This bone, also designated the malar and jugal bone, is elongated from above to below, flattened on both sides, and irregularly triangular in shape; it is situated on the side of the face, and articulates with the supermaxillary,

[1] This bone is the representative of the *internal wing* of the pterygoid process in Man.

lachrymal, and temporal bones. It is described as having *two faces*, *two borders*, a *base*, and a *summit*.

Faces.—The *external face* comprises two portions separated from each other by a semicircular ledge that extends from the summit to the middle of the anterior border of the bone, and concurs to form the outer margin of the orbit. The anterior portion, smooth and concave, belongs to the orbital cavity. The posterior, more extensive, is also smooth and slightly convex. The *internal face* is excavated in its central part, which corresponds to the maxillary sinus. On its margin it shows dentations and lamellæ for articulation with the supermaxillary bone.

Borders.—The *anterior*, thin and denticulated, is joined to the lachrymal bone. The *posterior*, or *masseteric border*, is thicker, and constitutes a roughened crest, the *zygomatic* ridge, which is continued above with the posterior border of the process of the same name, and below with the maxillary spine.[1]

Base and summit.—The *base*, very thin, is united to the supermaxillary bone. The summit, flattened from before to behind and bevelled on its anterior face, joins the zygomatic process, and forms with it the *jugal bridge* or *zygomatic arch*.

Structure and development.—This bone is rather spongy in its upper part, and is developed from a single nucleus of ossification.

6. *Lachrymal Bone.*

A small, thin, and very light bone, bent on itself at a right angle, it is situated beneath the orbit, which it aids in forming, and is wedged between the frontal, nasal, supermaxillary, and zygomatic bones. It is studied on its *external* and *internal faces* and *circumference*.

Faces.—The *external* is divided into two regions, superior and inferior, by a curved crest which forms part of the orbital margin, and is provided with notches, which are variable in their form and number. The superior region, named the *orbital*, because of its situation in the orbit, is slightly concave and smooth. It presents, near the orbital margin, the orifice of the *lachrymal duct*, which traverses the maxillary sinus and opens on the internal face of the supermaxillary bone, where it is continued by a fissure; behind this is the lachrymal fossa. The inferior or *facial* region is slightly bulging, and provided sometimes with a tubercle of insertion, the *lachrymal tubercle*. The *internal face* is employed, for the whole of its extent, in the formation of the walls of the maxillary and frontal sinuses; it exhibits a cylindrical prominence produced by the bony tube of the lachrymal duct.

Circumference.—This is very irregular and denticulated to respond to the neighbouring bones.

Structure and development.—This bone is entirely compact, and is developed from a single nucleus of ossification.

7. *Nasal Bones.*

Situated on the anterior aspect of the head, these bones articulate with each other in the median line, and are fixed between the frontal, lachrymal, and supermaxillary bones; they are triangular in shape, elongated from above to below, flattened from before to behind, and offer for study *two faces*, *two borders*, a *base*, and a *summit*.

Faces.—The *external* or *anterior face*, larger above than below, is convex

[1] The designation of *zygomatic crest* is often given to these three parts collectively.

from side to side and almost smooth. The *posterior, internal,* or *nasal face* exhibits a vertical crest passing along the external border of the bone, which gives attachment to the nated portion of the ethmoid; at its superior extremity this crest bifurcates, and between its two branches shows a concave surface which forms part of the frontal sinus. For the remainder of its extent the internal face is smooth, and covered by the mucous membrane of the nasal fossa; it is also excavated into a channel to form the superior meatus of this cavity.

Borders.—The *external border* is very thin in its upper two-thirds, and articulates with the lachrymal bone, the anterior border of the supermaxillary, and the upper extremity of the premaxillary bones. In its lower third it becomes isolated from the latter bone, in forming with the anterior border of its large process a very acute re-entering angle whose opening looks downwards. The *internal border* is denticulated to correspond with the opposite bone.

Base and Summit.—The *base* occupies the superior extremity of the bone; it describes a curved line with the convexity above, and in uniting on the median line with that of the opposite bone, forms a notch similar to that of the heart figured on playing cards; it is bevelled at the expense of the internal plate to articulate with the frontal bone. The *summit* of the two nasal bones, which is pointed, constitutes the *nasal prolongation:* the name given to a single triangular process which comprises all that portion of the nasal bones separated from the premaxillaries by the re-entering angle before mentioned.

Structure and development.—Almost entirely compact in structure, it is developed from a single centre.

8. *Turbinated Bones.*

The *turbinated bones*, two on each side, represent two irregular bony columns, wider above than below, compressed laterally, hollowed internally, and lying vertically side by side on the external wall of the nasal fossa, which they divide into three *meatuses* or passages.

They are distinguished into *anterior* and *posterior turbinated bones.*

The *anterior* or *superior,* also named the

Fig. 22.

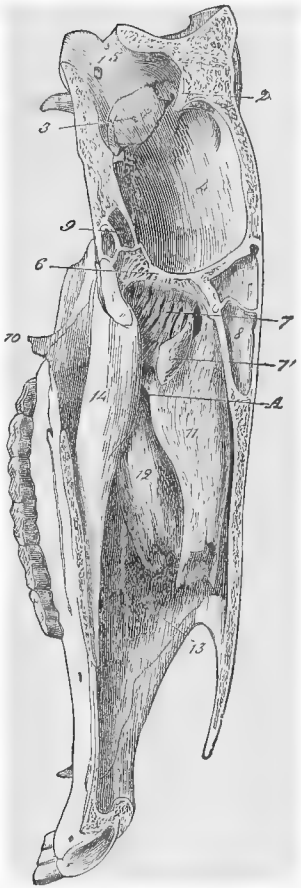

ANTERO-POSTERIOR AND VERTICAL SECTION OF THE HORSE'S HEAD.

1, Condyloid foramen; 2, Parietal protuberance; 3, Internal auditory hiatus; 4, Cerebral cavity; 5, Cerebellar cavity; 6, Superior border of the perpendicular plate of the ethmoid bone (crista-galli process); 7, Ethmoidal volutes—nasal face; 8, Vestiges of the right frontal sinus; 9, Ditto of the sphenoidal sinus; 10, Pterygoid process; 11, Ethmoidal turbinated bone; 12, Maxillary turbinated bone; 13, Crest of the supermaxillary bone to which the latter is fixed; 14, Vomer.—A, Orifice of communication between the nasal cavity and the sinus.

Fig. 23.

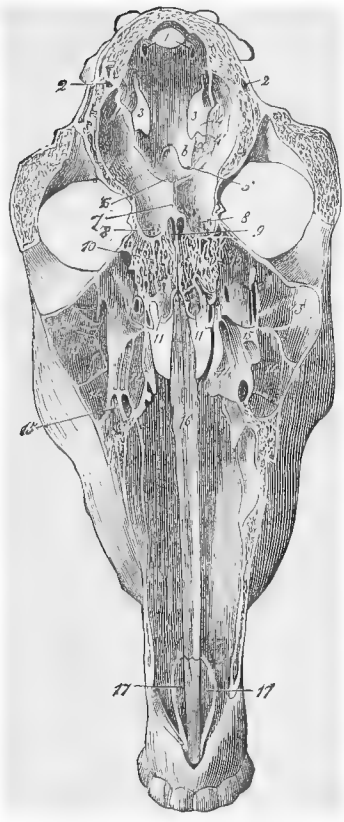

LONGITUDINAL AND TRANSVERSE SECTION OF THE HORSE'S HEAD, SHOWING THE FLOOR OF THE CRANIAL AND NASAL CAVITIES, WITH THE MAXILLARY SINUSES.

Condyloid foramen; 2, Section of the parieto-temporal canal; 3, Occipito-spheno-temporal hiatus; 4, Carotid notch; 4′, Maxillary notch.—*a*, Supermaxillary fissure; *b*, Cavernous fissure; 5, Origin of the supersphenoidal canals.—*c*, Sella turcica; 6, Optic fossa; 7, Portion of the crista-galli process; 8, Cribriform plate of the ethmoid bone; 9, Perpendicular plate of the same bone; 10, 10, Its lateral masses; 11, Interior of the great ethmoidal cell; 12, 12, Bottom of the maxillary sinuses communicating with the sphenoidal sinuses; 13, Superior maxillary sinus; 14, Inferior maxillary sinus; 14′, Superior compartment of the maxillary turbinated bone, forming part of the latter sinus; 15, Section of the supermaxillo-dental canal; 16, Channel of the vomer; 17, Internal process, or point of the premaxillary bone.

ethmoidal, is formed by a very thin plate of compact tissue, fragile and like papyrus, fixed by its anterior border to the internal crest of the nasal bone, and rolled on itself, from before to behind, in the same manner as the cells of the ethmoid bone. Above, it is confounded with the last-named bone, of which it is only, properly speaking, the most anterior volute. At its inferior extremity, it is prolonged by a fibro-cartilaginous framework to the external orifice of the nose.

Its internal cavity is partitioned by a transverse plate into two portions: the superior compartment forms part of the frontal sinus; the inferior is subdivided by other small lamellæ into a variable number of cells which communicate with the nasal cavity. This bone, developed from a single nucleus, is ossified at the same time, and in the same manner, as the ethmoidal cells. Before birth, it is already intimately consolidated with the nasal bone.

The *posterior*, *inferior*, or *maxillary turbinated bone* resembles the first, except in some particulars. Thus, its bony or proper portion is not so long or voluminous, while its cartilaginous part is, on the contrary, more developed. It is attached, by its posterior border, to the vertical and sinuous crest of the supermaxillary bone, and is rolled from behind to before, or in an inverse direction to the other. It has no connection with the ethmoid, and its superior cavity forms part of the inferior maxillary sinus. It is late in becoming ossified, and is scarcely united in a definite manner to the maxillary bone until the horse is about a year old.

The *meatuses* are distinguished into *anterior* or *superior*, *middle*, and *posterior* or *inferior*. The first passes along the front of the ethmoidal turbinated bone; the second separates the two turbinated bones, and presents, near its superior extremity, the opening communicating between the sinuses and the nasal cavi-

ties.[1] The third is situated behind the maxillary turbinated bone, and is confounded with the floor of the nasal fossa.

The turbinated bones are essentially destined to furnish the membrane of the nose with a vast surface of development. This membrane, indeed, covers their entire superficies, and even penetrates the anfractuous cells of their lower compartment.

9. *Vomer.*

This, a single bone, elongated from above to below, flattened on both sides, and extending on the median line from the body of the sphenoid to the premaxillary bone, offers for study *two lateral faces, two borders,* and *two extremities.*

The *faces* are smooth, plane, and covered by the nasal membrane. The *anterior border* is channeled for the whole of its length by a deep groove which receives the posterior border of the cartilaginous septum of the nose. The *posterior border* is sharp and smooth in its upper half, which separates the two guttural openings of the nasal cavities: it is thick and slightly denticulated for the remainder of its extent, and rests on the median suture resulting from the union of the two supermaxillary bones. The *superior extremity* is provided, in its middle, with a notch which divides it into two lateral prolongations shaped like a cat's ears; it articulates with the inferior sphenoid, ethmoid, palate, and pterygoid bones. The *inferior* extremity rests on the prolongations of the incisive bones.

This bone is entirely compact, and is developed from one centre of ossification.

10. *Inferior Maxillary Bone.*

The *maxillary bone* is not consolidated with any of the preceding bones, and is only united to two of them, the temporals, by diarthrodial articulation. It is a considerable bone, situated behind the upper jaw, and composed of two symmetrical branches, which are flattened on both sides, wider above than below, curved forwards in their upper third, joined at their lower extremities, and separated superiorly so as to leave a wide gap between them, like the letter V in shape, called the *intramaxillary space.* Each offers for study *two faces, two borders,* and *two extremities.*

Faces.—The *external face* of the maxillary branches is smooth and rounded in its inferior two-thirds, and transformed superiorly into a rugged surface, in which is implanted the fibres of the masseter muscle. The *internal face* presents, in the corresponding point, an excavated surface on which is remarked the superior orifice of the *maxillo-dental canal,* a long channel which descends between the two plates of the branch, passing under the roots of the molar teeth, and insensibly disappearing in the body of the bone after being widely opened externally by the *mental* (or *anterior maxillary*) *foramen.* In its inferior two-thirds, the internal face is smooth, nearly plane, and shows nothing very remarkable. Near the alveolar border there is a slightly-projecting line—the *myloid ridge;* and quite below, or rather at the very summit of the re-entering angle formed by the separation of the branches, there is a slight rugged excavation confounded with that of the opposite branch, and named the *genial surface.*

Borders.—The *anterior,* also named the *alveolar border,* exhibits for study a straight or inferior, and a curved or superior portion. The first is hollowed by six alveoli to receive the inferior molar teeth.

[1] The two turbinated bones, in being applied against the excavation on the inner face of the supermaxillary, almost entirely close it, only leaving between them a vertical slit which constitutes the opening mentioned above.

The second, thinner, concave, and rugged, serves for muscular insertion. The *posterior border* is also divided into straight and curved portions. The latter is convex, thick, rugged, and margined on each side by an uneven lip; the first is regularly rectilinear, so that all its points rest at the same time on a horizontal plane; it is thick and rounded in the young animal, but becomes sharp with age; an oblique and transverse fissure—the *maxillary*—separates it from the curved part. The union of these two portions forms the *angle* of the jaw.

Extremities.—The *superior extremity* has two eminences: a *condyle*, and a long non-articular process named the *coronoid process*. The condyle is elongated transversely, and convex in its two diameters; it responds, through the medium of a fibro-cartilaginous disc, to the articular surface of the zygomatic process. The coronoid process is situated in front of the condyle, from which it is separated by a division called the *sigmoid* or *corono-condyloid notch*; it is flattened on both sides, and curved backwards and slightly inwards.

Fig. 24.

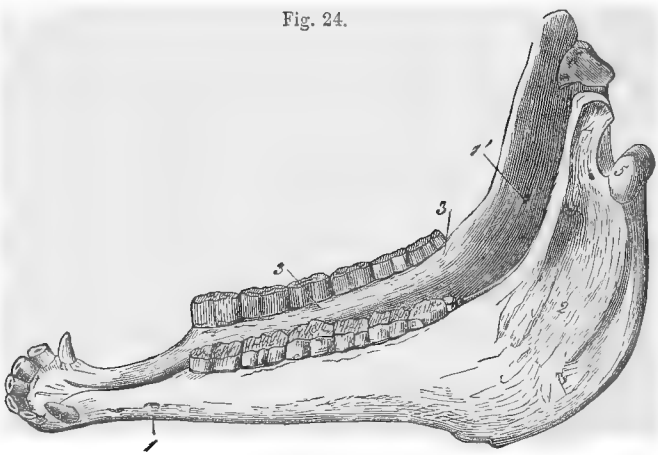

INFERIOR MAXILLA.

1, Mental foramen; 1′, Superior orifice of the maxillo-dental canal; 2, Surface of implantation for the masseter muscle; 3, Myloid ridge; 4, Coronoid process; 5, Condyle.

From the union of the branches of the maxillary bone at their *inferior extremity* results a single piece, flattened before and behind, and widened like a spatula, which has been designated the *body* of the bone. This merits a special description.

Its form allows us to divide it into an *anterior* or *buccal face*, a *posterior* or *labial face*, and a *circumference*. The *anterior face* is smooth and concave, is lined by the buccal mucous membrane, and supports the free extremity of the tongue. The *posterior face* is convex, more extensive than the preceding, and continuous with the external face of the branches; it presents: 1, On the median line, a slight crest or small groove, traces of its being originally separated into two pieces; 2, On the sides and above, the *mental foramen*, the inferior orifice of the maxillo-dental canal. On a level with this foramen, the bone very markedly contracts to form the *neck*. The *circumference* describes a parabolic curve, the concavity being uppermost, and joins, by its extremities, the anterior border of each branch. It is excavated in its middle part by the six alveoli for the lodgment of the

inferior incisors, and behind these, in male animals only, there is an additional alveolus for the tusk. The portion included on each side between the last incisor and first molar, forms a more or less sharp ridge, which constitutes the *inferior interdental space* or *bars*.

Structure and development.—Formed, like all the flat bones, by two compact plates separated by spongy tissue, the inferior maxilla is developed from two centres of ossification, which correspond to each branch, and which coalesce some time after birth.

11.—*The Hyoid Bone.*

The *hyoid bone* constitutes a small and special bony apparatus which serves to support the tongue, as well as the larynx and pharynx; its description is placed immediately after that of the bones of the head because of its connection with that region, it being situated between the two branches of the supermaxillary bone, and suspended to the base of the cranium in an oblique direction from above to below, and from before to behind.

This apparatus is composed of seven distinct pieces, arranged in three series: a middle, constituted by a single bone, and named the *body;* two lateral, forming two quasi-parallel *branches*, to the extremities of which the body is articulated.

Body.—The body of the hyoid resembles a fork with two prongs. It presents: 1, A middle part flattened above and below, and consequently provided with a superior and an inferior face; 2, A single and long prolongation flattened on both sides, which is detached from the middle part, and directed forward and downward to plunge into the muscular tissue of the tongue: this is the *anterior appendix of the hyoideal body;* 3, *Two lateral cornua, thyroid cornua*, or *great cornua*, projecting backwards and upwards, articulating by their extremities with the thyroid cartilage of the larynx, and offering, at their point of union with the middle part, two convex diarthrodial facets looking upwards, and corresponding with the *styloid cornua.* The body of the hyoid bone is developed by three centres of ossification, a middle, and two lateral for the cornua.

Fig. 25.

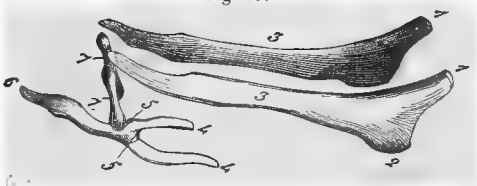

HYOID BONE.

1, 1, Superior extremity of the styloid bones, 2, Angle described by their posterior border; 3, 3, Styloid bones; 4, 4, Extremities of the thyroid cornua; 5, Articular surface of the body corresponding with the small branches; 6, Anterior appendix of the body; 7, 7, Small branches, or styloid cornua.

Branches.—The three pieces composing these are articulated end to end, by means of a cartilaginous substance that joins them together; they are of very unequal dimensions. The first, which is in relation with the body, is of medium size, and is named the *styloid cornu, small cornu*, or *small branch.* The second, termed the *styloid nucleus*, is the smallest. The third, the largest, constitutes the *styloid process*, or *bone*, or *great branch.*

1. The *styloid cornu* is a small cylindrical piece bearing a concave diarthrodial surface on its inferior extremity to unite it to the body; it is very spongy, and is developed from two ossifying centres, one of which, the epiphysary, is for the inferior extremity.

2. The *styloid nucleus*, which is often absent, is imbedded in the uniting cartilaginous substance.

3. The *styloid bone*, or *great hyoideal branch*, is long, thin, flattened on both sides, and directed obliquely from above to below, and before to behind; it presents two faces, two borders, and two extremities. The faces —an external and internal—are marked by some few imprints. The anterior border is sharp and slightly concave in its upper third. The posterior border is thicker, and is divided into two portions: a superior or horizontal, which is very short, and an inferior or vertical, much more extensive. The angle they form at their point of junction presents a salient, and more or less roughened, tuberosity. The superior extremity is united to the hyoideal prolongation of the temporal bone by means of a cylindrical fibro-cartilage. By its inferior extremity, the *styloid bone* is united either to the styloid nucleus or the styloid cornu, forming a sharp elbow directed forwards. The styloid bone, developed from a single centre of ossification, is almost entirely formed of compact tissue.

OF THE HEAD IN GENERAL.

From the union of all the bones which constitute the cranium and face results a quadrangular pyramid, whose summit is inverted, which it is necessary to study as a whole. We will pass in review, successively, its *four faces*, its *base*, and its *summit*.

Anterior Face.—The anterior aspect of the head has the parietal, frontal, and nasal bones for its base. Superiorly, it inclines backwards and offers, on each side of the parietal ridges, two bulging surfaces which form part of the temporal fossæ. For the remainder of its extent, it presents a plane surface which forms the base of the forehead and the middle portion of the face. Wide above, this surface gradually tapers to the extremity of the nasal spine. In well-formed animals, it is as straight and wide as possible.

Posterior Face.—This face, which is extremely irregular, presents: above, the basilar process, the lacerated foramina, and the base of the tuberous portion of the temporal bones; then the intramaxillary space, and, at the bottom of this, the body of the sphenoid bone, vidian fissure, superior orifice of the subsphenoidal canal, sphenoidal process, palatine ridges, pterygoid bones, guttural openings of the nasal cavities separated from one another by the posterior border of the vomer, roof of the palate, incisive openings, and the incisive foramen.

Lateral Faces.—These exhibit: behind, the external face of the maxillary branches; before, a surface more or less convex, though sometimes hollow in old animals, presenting at its middle the inferior orifice of the maxillo-dental canal, and forming the base of the lateral parts of the face; above, the zygomatic ridge and arch, the *orbit*, and the *temporal fossa*. These two cavities, in the formation of which many bones participate, have been hitherto merely indicated; this is the place for giving them a more detailed description.

The *orbit* or *orbital cavity* is irregularly circular in outline, and circumscribed by the orbital process of the frontal bone, the lachrymal and malar bones, and the summit of the zygomatic process. At the bottom, which shows the maxillary and orbital hiatus, it is confounded, in the skeleton, with the temporal fossa.[1] It lodges the globe of the eye and the muscles which move it. Some organs, accessory to the visual apparatus,

[1] A fibrous membrane, the *ocular sheath*, isolates it from the temporal fossa in the majority of mammiferous animals. Only in Man and the quadrumana has the orbital cavity complete bony walls.

such as the lachrymal gland and the membrana nictitans, are also contained in this cavity.

The *temporal fossa* surmounts the orbit, and is incompletely separated from it by the orbital arch (or process). Oval in shape, lying obliquely from above to below, and from within outwards, on the sides of the cranium, the temporal fossa is limited, within, by the parietal ridge, and outwardly by the anterior border of the longitudinal root of the zygomatic process. It lodges the temporal muscle.

Base or superior extremity of the head.—This presents the occipital protuberance, cervical tuberosity, occipital foramen, mastoidean ridge and fissures, styloid processes of the occipital bone, stylo-condyloid notches, and the condyles. On a lower plane, and behind, the curved portion of the posterior border of the maxillary bone is remarked.

Summit.—Formed by the premaxillary bones and the body of the super-

Fig. 26.

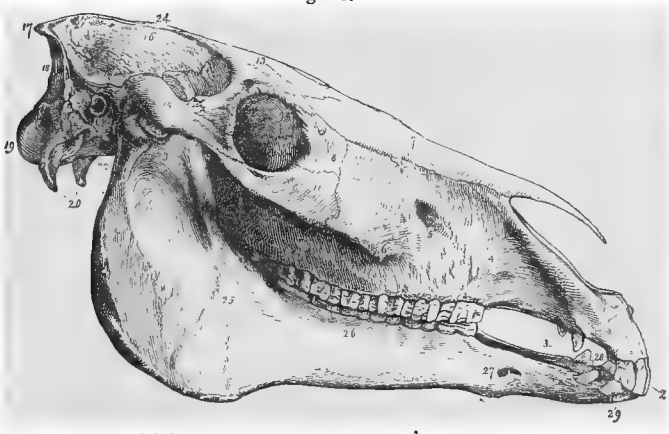

LATERAL VIEW OF THE HORSE'S SKULL.

1, Premaxillary bone; 2, Upper incisors; 3, Upper canine teeth; 4, Superior maxillary bone; 5, Infraorbital foramen; 6, Superior maxillary spine; 7, Nasal bones; 8, Lachrymal bone; 9, Orbital cavity; 10, Lachrymal fossa; 11, Malar bone; 12, Upper molar teeth; 13, Frontal bone; 15, Zygomatic process, or arch; 16, Parietal bone; 17, Occipital protuberance; 18, Occipital crest; 19, Occipital condyles; 20, Styloid processes; 21, Petrous bone; 22, Basilar process; 23, Condyle of inferior maxilla; 24, Parietal crest; 25, Inferior maxilla; 26, Inferior molars; 27, Anterior maxillary foramen; 28, Inferior canine teeth; 29, Inferior incisor teeth.

maxilla, the summit supports the incisor teeth, and presents a tuberosity more or less rounded, according to the age of the animal. In front, it is surmounted by the external opening of the nasal cavities; this opening, which is comprised between the external process of the premaxillary bones and the nasal spine, is divided in the fresh state into two orifices which constitute the nostrils.

Internally, the head contains the *nasal fossæ* and the *cranial cavity.* These will be described when the apparatus belonging to them is noticed. (See the *respiratory and nervous apparatus*).

DIFFERENTIAL CHARACTERS OF THE HEAD IN OTHER THAN SOLIPED ANIMALS.

A. HEAD OF THE OX, SHEEP, AND GOAT.—1. *Occipital bone.*—The occipital bone in these animals does not show any anterior elbow. The cervical tuberosity, or occipital

protuberance is obtuse, and gives rise on each side to the superior curved lines; in the Sheep, these curved lines are very salient and occupy the summit of the head.

The styloid processes are short and much bent inwards. The basilar process, wide, short, and thick, has a groove in the middle of its external face; this groove is sometimes absent in the Sheep and Goat.

The condyloid foramina are double, sometimes triple; the superior foramen does not pass directly into the cranium, but goes to a vast conduit that opens behind on the lateral margin of the occipital foramen, and which terminates in front by two orifices, one entering the parieto-temporal canal, the other opening on the external surface of the bone. The foramen lacerum is divided into an anterior and posterior foramen by the mastoid portion of the temporal bone.

Parietal bone.—The parietal bone in the *Ox* does not occupy the anterior aspect

Fig. 27.

OX'S HEAD; ANTERIOR FACE.

1, Mastoid process; 2, Superciliary, or supra-orbital foramen; 3, Zygoma; 4, Lachrymal bone; 5, Maxillary spine; 6, Inferior orifice of the supermaxillo-dental canal.

of the head, but concurs with the occipital to form the base of the neck. It represents a very narrow osseous plate, elongated transversely, and curved at its two extremities, which descends into the temporal fossæ to rest upon the sphenoid bone. There are no parietal ridges. The internal protuberance is only marked by a slight elevation of the internal plate: for the most part it belongs to the occipital bone.

The parietal bone of the Ox is developed from three centres of ossification, and the middle nucleus is even primarily divided into lateral halves; but these centres are consolidated with each other at an early period, as well as with the anterior portion of the occipital. It does not aid in the formation of the parieto-temporal canal, and is excavated internally by cavities which communicate with the frontal sinuses.

The parietal bone of the *Sheep* and *Goat* is relatively much larger than that of the Ox. It participates in the formation of the parieto-temporal canal, and has no sinuses.

3. *Frontal bone.*—In ruminants, the frontal bone does not respond to the temporal and palate bones.

In the *Ox*, this bone is extremely developed, by itself occupying the anterior half of the

face. It is particularly distinguished by:—1, Its great thickness. 2, The osseous conical cores which support the horns. These eminences, more or less long and curved, very rugged, perforated by foramina, and grooved by small vascular channels, are detached outwards from each side of the bone, near the summit of the head. The processes which form the orbital arches rest by their summits on the zygomatic bone. The supra-orbital foramen is transformed into a veritable and frequently multiple canal; its anterior orifice opens into a vasculo-nervous groove, which ascends towards the base of the horns, and descends to near the lower border of the bone. Between this groove and the base of the orbital arch is the frontal boss. The orbital foramen entirely belongs to this bone. The inferior border is deeply notched in its middle to receive the nasal bones, the frontal sinuses are prolonged into the horn-cores, the parietal bone, and even into the occipital bone.

In the *Sheep* and *Goat*, the frontal bone is relatively less extensive and strong than in the Ox; it does not ascend to the summit of the head, and the frontal sinuses are not prolonged beyond its superior border.

4. *Ethmoid bone.*—In *ruminants*, the great ethmoidal cell is enormously developed, and looks like a third turbinated bone prolonged between the usual two; it has been named the *olfactory antrum*.

The ethmoid bone is closely imprisoned between the adjacent bones, in consequence of the slight development of the sinuses around it. This character otherwise belongs to all the domesticated animals, except solipeds.

5. *Sphenoid bone.*—In the *Ox*, the subsphenoidal or pterygoid processes are large and thin. The subsphenoidal canal is absent. The sella turcica is deep, and the bony projection separating it from the basilar process is very high. The three suprasphenoidal canals are converted into a single, but wide one. There are no notches in the superior border for the passage of the internal carotid and sphenospinous arteries. That for the inferior maxillary nerve is converted into a canal—the oval foramen.

In the *Sheep*, the osseous prominence that limits the pituitary fossa posteriorly forms a lamina curving forwards and prolonged at its extremities into two points, which constitute the *posterior clinoid processes*.

6. *Temporal bone.*—In the *Ox*, *Sheep*, and *Goat*, the tuberous portion of the temporal bone is always consolidated with the squamous portion, and the summit of the zygomatic process only articulates with the malar bone.

Fig. 28.

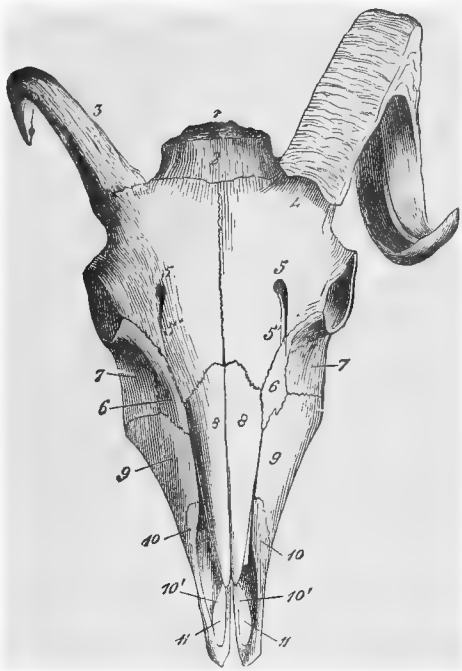

RAM'S HEAD; ANTERIOR FACE.

1, Occipital bone; 2, Parietal bone; 3, Core of right frontal bone; 4, The left core covered by its horn; 5, Superciliary foramen; 5', Channel descending from it; 6, Lachrymal bone; 7, Zygoma; 8, Nasal bone; 9, Supermaxillary bone; 10, Premaxillary bone; 10', Its internal process; 11, Incisive opening.

In the *Ox*, the condyle of the zygomatic process is very wide and convex in every sense. The parieto-temporal canal is very large and entirely excavated in the temporal bone; its superior or internal extremity opens above the petrous portion in an excavation which represents the lateral cavity of the parietal protuberance in the Horse; at its inferior extremity it always shows several orifices.

The mastoid process is very salient, and belongs to the squamous portion. The mastoid crest is confounded with the upper root of the zygomatic process; inferiorly, it

surpasses the mastoid process, and is prolonged to the mastoid protuberance. The latter is very voluminous. The subuliform process is larger and stronger than in the Horse; and there is no mastoid fissure.

In the *Sheep* and *Goat*, the mastoid process is scarcely distinct from the crest; and the mastoid portion of the bone is only at a late period consolidated with the petrous portion.

Fig. 29.

OX'S HEAD; POSTERIOR FACE.

A, Parietal bone.—1, Occipital foramen; 2, Occipital condyle; 3, Styloid process of that bone; 4, Condyloid foramina; 5, Mastoid process; 6, Mastoid protuberance; 7, Subuliform (temporal) process; 8, Hyoideal sheath; 9, Stylo-mastoid foramen; 10, External auditory hiatus; 11, Inferior orifice of the parieto-temporal canal; 12, Temporal condyle; 13, Posterior foramen lacerum; 14, Oval foramen; 17, Subsphenoidal process; 18, Orbital hiatus; 19, Optic foramen.—B, Frontal bone.—20, Superciliary foramen; 21, Orbital foramen; 22, Lachrymal protuberance.—C, Zygoma.—23, Pterygoid bone.—D, Palate bone.—24, Nasal foramen; 25, Inferior orifice of the palatine canal.—E, Supermaxillary bone.—26, Maxillary spine.—G, Premaxillary bone.—27, Its internal process; 28, External process; 29, Incisive openings.

7. *Supermaxillary bone.*—In the *Ox*, *Sheep*, and *Goat*, the maxillary spine does not directly join the zygomatic crest a curved line, whose concavity is posterior, effects the union between these two parts. The inferior orifice of the supermaxillo-dental canal or infraorbital foramen is pierced above the first molar tooth. There is no fissure for the formation of the palatine canal. The cavity of the sinus is more spacious than in the Horse, and is prolonged (in the Ox only) between the two laminæ of the palatine roof. There is no alveolus for the tusk.

8. *Premaxillary bone.*—The inferior or principal portion of this bone is flattened before

and behind, and deprived of aveoli in its external border; neither is there any incisive foramen. It is rarely consolidated with the adjacent bones, and is never, in the smaller ruminants, articulated with the nasal bone.

9. *Palate bone.*—This bone is very developed in the *Ox*, and noticeable for the considerable extent of the palatine portion of its external surface. The palatine canal is entirely channeled out in its substance. The palatine crest, very thin and elevated, is formed altogether by the posterior border of the palate bone, the pterygoid, and the subsphenoidal process. There is no excavation for the sphenoidal sinuses; but, instead, all that part of the bone which enters into the roof of the palate is hollowed by irregular cavities which communicate with the maxillary sinus of the same side. The nasal foramen is very wide. In the *Sheep* and *Goat*, the maxillary sinuses do not extend to them.

10. *Pterygoid bone.*—The pterygoid of the *Ox*, *Sheep*, and *Goat* is very large, and closes an aperture left between the sphenoid and palate bones.

11. *Zygoma.*—The jugal bone of *Ruminants* is very developed. The zygomatic crest is no longer formed by the posterior border of the bone, but is carried to the posterior part of the external face, and runs parallel with the eyebrow. The summit is bifurcated, the anterior branch forming a buttress against the summit of the orbital process of the frontal bone, while the posterior articulates with the temporal.

12. *Lachrymal bone.*—The lachrymal bone, much more extensive than that of the Horse, forms in the bottom of the orbit an enormous protuberance, hollowed internally by the maxillary sinus, and whose walls are so thin and fragile that the slightest jar is sufficient to cause their fracture (in the skeleton). It would be convenient to designate it the *lachrymal protuberance.*[1] In the smaller ruminants, the inferior region of the external face shows a depression, the *lachrymal fossa.*

13. *Nasal bones.*—The nasal bones of the *Ox* are never consolidated with each other, nor yet with the neighbouring bones. The external border only comes in contact to a small extent with the supermaxillary bone; the superior extremity is fixed in the notch of the inferior border of the frontal bone. At their inferior extremity, they each present a notch which divides them into two points.

In the *Sheep* and *Goat* the nasal spine is unifid, as in the Horse.

14. *Turbinated bones.*—In the *Ox*, the ethmoidal turbinated bone is very small, and united to the nasal bone by the two borders of its osseous plate; its internal cavity entirely belongs to the frontal sinus. The maxillary turbinated bone is very developed, and is joined to the bone which sustains it at a later period than in the Horse. The bony lamina of which it is composed is curved

[1] Girard, who named this eminence the *orbital protuberance*, wrongly described it as belonging to the supermaxillary bone.

Fig. 30.

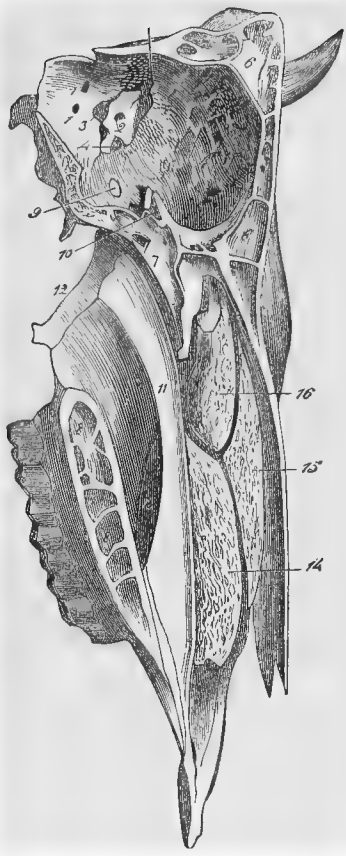

MEDIAN AND VERTICAL SECTION OF THE OX'S HEAD.

1, Condyloid foramen; 1', Posterior orifice of the occipital lateral canal joining the parieto-temporal canal in front; 2, Internal auditory hiatus; 3, Anterior foramen lacerum; 4, Posterior ditto; 5, Intra-cranial orifice of the parieto-temporal canal; 6, 6, Median bony plate separating the frontal sinuses; 7, Lamina which isolates the sphenoidal sinus; 8, Lamina partitioning the palatine portion of the maxillary sinuses; 9, Oval foramen; 10, Optic fossa; 11, Vomer; 12, Pterygoid bone; 13, Large opening leading into the maxillary sinus, and which, in the fresh state, is closed by the pituitary membrane; 14, Maxillary turbinated bone, 15, Ethmoidal turbinated bone; 16, Great ethmoidal cell.

on itself in two different directions: from before to behind by its posterior border, and behind to before by its anterior border. It is fixed to the supermaxillary bone by its middle part, through the medium of a particular bony lamina, and it very incompletely closes the excavation which concurs to form the maxillary sinus. In the skeleton there is also found behind, and at the base of this turbinated bone, a vast opening which is totally closed in the fresh condition by the pituitary membrane. The maxillary sinus is not prolonged in its interior. In the smaller ruminants, the cavity of the sinus is closed by the maxillary turbinated bone in a more complete manner than in the Ox.

15. *Vomer.*—This is a very large thin bone, resting only on the inferior half of the median suture of the premaxillaries.

Fig. 31.

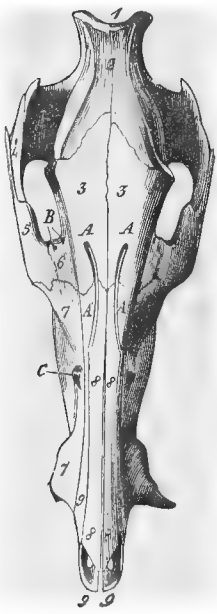

HEAD OF THE PIG; ANTERIOR FACE.

1, Summit of occipital protuberance; 2, Parietal bone; 3, Frontal bone. —A, Superciliary foramen; A′ Channel descending from it.—4, Zygomatic process; 5, Zygoma; 6, Lachrymal bone.—B, Lachrymal canals.—7, Supermaxillary bone.—C, Inferior orifice of the supermaxillo-dental canal; 8, Nasal bone; 9, Premaxillary bone.

16. *Premaxillary bone.*—In the *Ox*, the inferior part of the posterior border is convex, and cannot rest on a horizontal plane by all its points at the same time. The condyle is convex in its small diameter, and slightly concave laterally. The coronoid process is bent backwards and outwards. The body does not show any alveolus for the tusk, because this tooth is absent in these animals; but it is hollowed by eight alveoli for the incisor teeth. The two branches of the bone are never consolidated, but remain movable on each other during life.

17. *Hyoid bone.*—The hyoid bone of *Ruminants* is always composed of seven pieces; the styloid nucleus, whose presence is not constant in solipeds, is never absent in these, and assumes the proportions of a second small branch. The anterior appendix is very short and thick.

B. Head of the Pig.—1. *Occipital bone.*—The occipital bone in this animal is not bent anteriorly; but the transverse protuberance representing the curved lines forms, nevertheless, as in the Horse, the summit of the head. This eminence, which is excavated on both sides on the posterior face, unites in front with the parietal bone, which abuts on the occipital at an acute angle. There is no external occipital protuberance, properly speaking, and the styloid processes are very long and directed downwards.

2. *Parietal bone.*—This bone is very thick, and deprived of an internal protuberance. The process concurring to circumscribe the orbit is short, and joins neither the zygomatic or temporal bones; the orbital arch is completed by a ligament. The superciliary foramen, disposed as in the Ox, opens in front into a channel that descends to the nasal bones. The orbital foramen is formed by the frontal bone only. There is no mortice for the union of the frontal with the sphenoid bone, and the maxillary sinus is prolonged into the parietal bone. The frontal bone of the pig articulates with the supermaxillaries.

3. *Frontal bone.*—The frontal bone of the Pig is very thick and short, and does not join the temporal or zygomatic bone; the orbital arch is completed by a ligament. The superciliary foramen, disposed as in the Ox, abuts in a channel that descends on the nasal bones. The orbital foramen is formed by the frontal bone only. There is no mortice for the union of the frontal with the sphenoid bone; and the frontal sinuses are prolonged into the parietal. The frontal bone of the Pig articulates with the supermaxillaries.

4. *Sphenoid bone.*—The sphenoid of the Pig is very short, but the subsphenoidal processes are extraordinarily developed and flattened before and behind. There is no subsphenoidal canal, and the sella turcica is deep, and limited behind by a very salient crest. A single canal replaces the foramen rotundum and the great sphenoidal fissure, as in the Ox. The wings, slightly salient, are articulated by suture with the frontal bone.

5. *Temporal bone.*—The articular surface of this bone resembles that of rodents; it is not limited posteriorly by a subcondyloid eminence, and, in addition, offers a wider transverse surface. The zygomatic process articulates with the jugal bone by the whole extent of its posterior border. A crest leading from the external auditory hiatus to the

mastoid protuberance replaces the mastoid process. The mastoid crest is, as in the Ox, confounded with the superior root of the zygomatic process.

The projection formed by the mastoid protuberance is enormous. The subuliform process is little marked, and there is no hyoideal prolongation or parieto-temporal canal.

6. *Supermaxillary bone.*—In the Pig, the external surface of this bone is hollowed in its middle, and presents in front a voluminous relief formed by the alveolus of the canine tooth. The cavity is entirely formed in the supermaxilla. There is no alveolar tuberosity, and the interdental space is very short, while the cavity for the sinus is little developed. The lower orifice of the palatine canal is even pierced in the substance of the supermaxilla.

7. *Premaxillary bone.*—The external process of the premaxillary bone is very long and wide at its base, and consolidated with the nasal bone for about the upper two-thirds of its length. There is no incisive foramen or cavity for the tusk. The incisive openings are oval.

8. *Palate bone.*—The palatine portion of the external face is more developed than in the Ox, but the orbital portion is very limited. The palatine crest is replaced by a tuberosity, against which rests, outwardly, the subsphenoidal process, and inwardly, the pterygoid bone. The union of these three parts constitutes, on the posterior surface of the head, a thick and very remarkable trifid projection or mamelon.

9. *Pterygoid bone.*—See the description of the palate bone.

10. *Zygomatic bone.*—The summit of this bone in the Pig is flattened on each side, and divided into two branches, between which is wedged the summit of the zygomatic process; the anterior branch is very short, and does not join the frontal bone.

11. *Lachrymal bone.*—In the Pig there are observed a lachrymal fossa and two lachrymal canals, which are pierced outside the orbital cavity, and soon coalesce in the substance of the bone to constitute a single canal. The fossa is very deep.

12. *Nasal bones.*—These bones are long and narrow, and traversed on their external face by the fissure that descends from the superciliary foramen. The nasal prolongation is short.

13. *Turbinated bones.*—The same arrangement as in the Sheep and Goat, except that they are much longer and less fragile.

14. *Inferior Maxilla.*—A straight line leading from the greater axis of the alveoli of the molar would not traverse the posterior border of the maxillary branches; the bottom of these alveoli corresponds to the relief on the inner face. The condyle is compressed on both sides, and elongated from before to behind; while the coronoid process is short and wide. There is no neck; the interdental spaces are very short; and the maxillo-dental canal opens inferiorly by multiple orifices.

15. *Hyoid bone.*—The body is voluminous and deprived of an appendix; the small branches are short and consolidated with the body; while the large branches, curved like an S, are very thin, and are united to the small branches and the temporal bone no longer by fibro-cartilage, but by veritable yellow elastic ligaments.

Fig. 32.

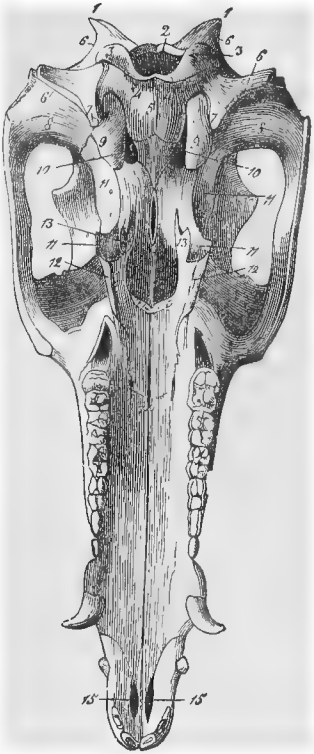

HEAD OF THE PIG; POSTERIOR FACE

1, Occipital protuberance; 2, Occipital foramen; 3, Occipital condyle; 4, Condyloid foramen; 5, Basilar process; 6, 6, Mastoid crest; 7, Styloid process of the occipital bone; 8, Articular surface of the temporal bone; 9, Mastoid protuberance; 10, Foramen lacerum; 11, Subsphenoidal process — external wing of pterygoid process; 12, Palatine crest; 13, Pterygoid bone —internal wing of the pterygoid process; 14, Inferior orifice of the palatine canal; 15, 15, Incisive openings.

C. Head of Carnivora.—1. *Occipital bone.*—The eminence which constitutes the

origin of the superior curved lines is very elevated and strong. The cervical tuberosity of the external occipital protuberance is absent or little marked; the styloid processes are short, and well deserve the name of jugular eminences. The foramen lacerum is divided into two portions by the mastoid protuberance, and the basilar process is wide, long, and thick, and hollowed on the side by a channel that joins a similar one in the temporal bone to form a large venous canal. This last communicates, behind, with the posterior foramen lacerum, and opens, in front, in the cranium, where it is continuous with the cavernous groove of the sphenoid. The anterior angle forms a very marked prominence, which is deeply fixed into the parietal bone, and partly constitutes the internal protuberance of that bone.

2. *Parietal bone.*—In the *Dog* the parietal bone, formed by two ossific centres only, is distinguished by the great development of the ridges and the parietal protuberance. This last, constituted in part by the occipital bone, does not show any lateral excavations at its base; they are carried lower, near the summit of the petrous process, on the sides of the occipital bone. The parieto-temporal canals are continued, notwithstanding, to the base of the protuberance, which they traverse, to open into each other in its interior.

Fig. 33.

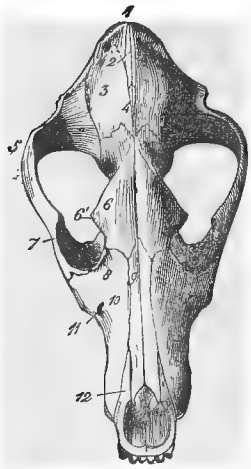

HEAD OF DOG; ANTERIOR FACE.

1, Occipital protuberance; 2, Median spur of the occipital bone; 3, Parietal bone; 4, Origin of the parietal crests; 5, Zygomatic process of the temporal bone; 6, Frontal bone; 6', Orbital process; 7, Zygoma; 8, Lachrymal bone; 9, Nasal bone; 10, Supermaxilla; 11, Inferior orifice of the supermaxillo-dental canal; 12, Premaxillary bone.

In the *Cat* there are scarcely any parietal crests, and the internal protuberance is replaced by two great transverse bony plates which separate the cavity of the cerebrum from that of the cerebellum.

3. *Frontal bone.*—In carnivora, the external face of this bone presents in its middle a more or less marked depression. The orbital arch is incomplete, and there is no superciliary foramen, or mortice on the inner face. The bone is united with the supermaxillaries.

4. *Ethmoid bone.*—The ethmoidal fossa is very deep, and the cells very developed and diverticulated. The perpendicular lamina is at a late period consolidated with the sphenoid bone.

5. *Sphenoid bone.*—The superior sphenoid of the *Dog* is very short, and bears, laterally, two wide wings which ascend to the temporal fossa; they correspond to those of the sphenoid bone in Man. The inferior sphenoid is, on the contrary, very narrow, and its lateral prolongations, or processes of Ingrassias, are reduced to very small proportions. The sub-sphenoidal or pterygoid process is very short, and the canal is single, and communicates with the foramen rotundum. The pituitary fossa is shallow, limited behind and before by the *posterior clinoid* and *anterior clinoid processes*, so named because of their being compared to the four posts of an ancient bed. The supersphenoidal canals are only two in number: one represents the great sphenoidal fissure, the other the round foramen. The carotid notch, joining a similar one in the temporal bone, forms an opening which may be designated the *carotid foramen*, because it gives passage to an extremely remarkable loop the internal carotid artery describes after passing through the carotid canal. The oval foramen is the same as in the Ox.

In the *Cat* there is the same disposition, with the exception of no sphenoidal canal or carotid notch being present.

6. *Temporal bone.*—In the carnivora, the articular surface of the zygomatic process merely forms a glenoid cavity, into which the condyle of the maxillary bone exactly fits. The temporal bone in these animals is also distinguished by the width of the external auditory canal, the absence of a hyoid prolongment, the small development of the mastoid and styloid processes, the enormous volume of the mastoid protuberance, and the presence of two particular canals which cannot be traced in the other animals. One of them, the *carotid canal*, traverses the mastoid portion, and joins, superiorly, the venous canal which passes between the basilar process and the temporal bone; by its inferior extremity it joins the carotid foramen which itself penetrates the cranium, a little beyond the venous canal just mentioned. The other conduit is pierced in the petrous portion immediately above the carotid canal; it affords a passage to the fifth pair of encephalic nerves.

7. *Supermaxillary bone.*—In carnivora, this bone is very short; its anterior border offers a long process analogous to the nasal spine of Man. It alone furnishes the alveolus of the tusk. The palatine canal, pierced entirely in the bone of that name, nevertheless opens, by its inferior extremity, at the junction of the supermaxillary with the palate bone. The maxillary sinus is not very spacious, and there is no maxillary spin

8. *Premaxillary bone.*—Of little size, the premaxillary of carnivora has no incisive foramen or alveolar cavity for the canine tooth. The incisive openings are the same as in the Pig.

Fig. 34

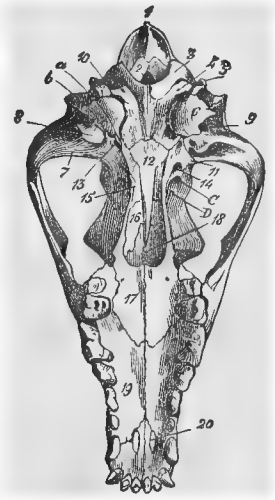

DOG'S HEAD; POSTERIOR FACE.

1, Occipital protuberance; 2, Occipital foramen; 3, Occipital condyle; 4, Condyloid foramen; 5, Styloid process of the occipital; 6, Mastoid protuberance; 7, Concave temporo-maxillary articular surface; 8, Supercondyloid eminence; 9, Inferior orifice of the parieto-temporal canal; 10, Lacerated foramen, posterior; 11, Ditto, anterior.—On the opposite side at *a* is shown the orifice communicating with the Eustachian tube and the tympanum; at *b* the passage for the carotid convolution.—12, Body of the sphenoid; 13, Oval foramen; 14, Inferior orifice of the subsphenoidal canal; 15, Pterygoid bone; 16, Nasal surface of the palate bone; 17, Palatine surface of the same; 18, Vomer; 19, Supermaxillary bone; 20, Incisive opening.

9. *Palate bone.*—In the carnivora, the palate bones are of great extent in their proper palatine portion. They have no share in the formation of the sphenoidal sinuses, but furnish a small excavation to the maxillary sinuses.

10. *Pterygoid bone.*—This bone is very strong in carnivora, and quadrilateral in shape.

11. *Zygoma.*—The zygoma of the *Dog* and *Cat* only articulates with the supermaxillary bone by its base. The crest describes a curve backwards, and the summit comports itself as in the Pig.

12. *Lachrymal bone.*—This bone in carnivora is extremely small. Its external face entirely belongs to the orbit, and does not descend beneath the margin of that cavity; it has no lachrymal fossa.

13. *Nasal bone.*—The two bones of the nose are little developed, and are wider below than above; they have no nasal prolongation, but offer instead a semicircular notch.

14. *Turbinated bones.*—These bones in the *Dog* and *Cat* are particularly distinguished for their numerous convolutions. Neither participate in the formation of the frontal or maxillary sinuses; the latter is not in any way closed by the maxillary turbinated bone, but opens into the nasal cavity by a large gaping aperture.

15. *Inferior maxillary bone.*—In carnivora, this is hollowed at the point corresponding to the insertion of the masseter muscle into a somewhat deep fossa. The posterior border is disposed as in ruminants, and below the condyle has a very marked tuberosity. The condyle represents an ovoid segment, and fits exactly into the temporal cavity. The coronoid process is very strong, elevated, and wide. The mental foramina are double or treble. There are no interdental spaces, nor excavated surface on the inner face of the branches; and the latter are never consolidated.

16. *Hyoid bone.*—The three pieces composing the body of the hyoid in early life are never consolidated in the adult animal, but always remain isolated, as in Man. The middle piece has no anterior appendix; the fibro-cartilages uniting the styloid portions to each other and to the temporal bone are very long and flexible.

COMPARISON OF THE HEAD OF MAN WITH THAT OF THE DOMESTICATED ANIMALS.

1. *Occipital bone.*—The occipital of Man is large, flat, incurvated like a shell, and the external protuberance is slightly developed, and united by a ridge to the occipital foramen, which is relatively very wide. Two series of ridges arise from the external protuberance and pass towards the circumference of the bone; these are the superior and inferior curved or semicircular lines. There is an anterior and a posterior condyloid fossa pierced by a foramen at the bottom; and the jugular eminences, wide and slightly prominent, replace the styloid processes of the domesticated animals.

The internal face of the occipital of Man corresponds with the cerebrum and

cerebellum; and for this purpose it shows four fossæ, distinguished into superior or cerebral, and inferior or cerebellar. These fossæ are separated by a crucial projection whose most developed portion forms the internal occipital protuberance.

The union of the occipital with the parietal bones constitutes the lambdoidal suture. At the point where this bone meets the parietal and the squamous portion of the temporal, is found, in the infant, the lateral posterior fontanella.

2. *Parietal bones.*—The parietals are always isolated in early life, and sometimes consolidated with each other at the adult age. They are very large, quadrilateral, and occupy the summit and sides of the cranium.

Fig. 35.

FRONT VIEW OF THE HUMAN CRANIUM.

1, Frontal bone; 2, Nasal tuberosity; 3, Supra-orbital ridge; 4, Optic foramen; 5, Sphenoidal fissure; 6, Spheno-maxillary fissure; 7, Lachrymal fossa; 8, Opening of the nose divided by the vomer; 9, Infra-orbital foramen; 10, Malar bone; 11, Symphysis of the lower jaw; 12, Mental foramen; 13, Ramus of the lower jaw; 14, Parietal bone; 15, Coronal suture; 16, Temporal bone; 17, Squamous suture; 18, Upper part of the great ala of the sphenoid bone; 19, Commencement of the temporal ridge; 20, Zygoma of the temporal bone, concurring to form the temporal arch; 21, Mastoid process.

The parietal crests are absent, but are replaced, in certain individuals, by two faintly-marked curved lines situated a little above the inferior border of the bone. The middle portion of the external face is very convex.

On the internal face there is no parietal protuberance, but in its stead the internal occipital protuberance. It also exhibits ramous channels, which in disposition are analogous to the ribs of a fig-leaf; as well as the parietal fossa which corresponds to the parietal eminence.

3. *Frontal bone.*—The frontal bone of Man forms the upper part of the face and the anterior portion of the cranium. Convex from behind forward, then vertical in its upper three-fourths, the bone suddenly bends at the orbits, so as to become horizontal in its lower fourth.

The external face offers, above the forehead, two lateral frontal eminences, and above the nose, a middle frontal boss. To the right and left of the latter are two salient arches, the supraorbital ridges. The internal face entirely belongs to the cranial cavity. It offers on the median line, the saggital groove terminated by a frontal crest; and on each side of this line the frontal fossæ, corresponding to the eminences of that name, and orbital bosses to match the orbital roofs. There is no mortice for the articulation of the sphenoid bone.

On the middle portion of the superior frontal border, in young persons, is the anterior angle of the anterior fontanella. The anterior border exhibits three superciliary foramina and the orbital arches.

4. *Ethmoid bone.*—In Man, the external face of the lateral masses, formed by a very thin lamina, termed the *os planum* or *lamina papyracæ*, belongs to the internal wall of the orbit.

5. *Sphenoid bone.*—This is distinguished, in Man, into a body and four wings, two large and two small.

The inferior surface of the body offers nothing remarkable, except the presence of a conical prolongation named the beak (*rostrum*) of the sphenoid. The external face of the greater wings forms part of the temporal fossa, as also the external wall of the orbit At the union of the wings with the body are detached two bifid pterygoid processes; their internal branch represents the pterygoid bones of animals. There is no subsphenoidal canal.

The two lesser wings are very thin and triangular, and visible only on the superior surface of the bone; they constitute the processes of Ingrassias.

On the internal face of the bone are found :—1, A deep pituitary fossa, limited by four clinoid processes: 2, An optic fossa, shallow, showing very short optic canals transformed into foramina: 3, The sphenoidal fissure, which replaces the great supersphenoidal canal in the Horse; 4, The great foramen rotundum: 5, The internal face of the wings, much excavated; 6, The foramen ovale, which transmits the inferior maxillary nerve; 7, The small foramen rotundum that lodges the spheno-spinous artery.

6. *Temporal bone.*—In the squamous portion of the temporal bone of Man, the zygomatic process only rests on the malar bone, as in ruminants. The glenoid cavity is concave in every sense, and divided into two parts by an opening named the *fissura Glaseri;* the anterior portion only is articular, the posterior lying against the external auditory canal, does not belong to the articulation; it corresponds to the supracondyloid eminence of the Horse. The tuberous portion is consolidated with the squamous. It is divided into a mastoid and a pyramidal portion; the latter comprises, in its turn, the petrous and tympanic portions. The mastoid portion corresponds to the mastoid process, mastoid protuberance, and superior border of the petrous bone in the Horse. It presents a rugged mastoid process; above this is the mastoid canal; and above and behind it, the digastric groove; the pyramid forming a considerable projection in the interior of the cranium. The styloid process or bone is altogether separate from the other pieces of the hyoid, and in the adult is consolidated with the temporal bone.

7. *Supermaxilla.*—In Man the premaxilla is no longer found independent, the centre which forms it coalescing with the supermaxillary bone.

The supermaxilla of Man concurs, for the greater part of its extent, to form the floor of the orbit; it is also divided into three faces: an external or facial, a superior or orbital, and an internal or naso-palatine. The external face presents, from before to behind: 1, A small fossa, into which is inserted the myrtiform muscle; 2, The infraorbital, or canine fossa, showing the inferior orifice of the infraorbital canal; 3, A crest corresponding to the maxillary spine of solipeds; 4, The alveolar tuberosity. This face carries, in front, a prolongation that forms the ascending process, also named, because of its relation, the fronto-nasal process. The superior or orbital face offers a fissure which precedes the infraorbital canal, and, outwards, the malar process. The internal face is divided by the palatine process. It shows, in front, the half of the anterior nasal spine and a groove which participates in the formation of the incisive canal.

Fig. 36.

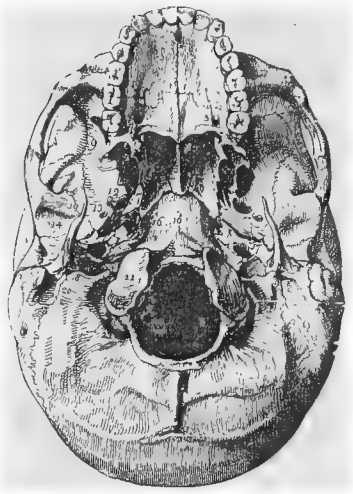

EXTERNAL OR BASILAR SURFACE OF THE BASE OF THE HUMAN SKULL.

1, 1, The bony palate; 2, Incisive, or anterior palatine foramen; 3, Palatine process of palate bone, with the posterior palatine foramen; 4, Palate spine with transverse ridge; 5, Vomer; 6, Internal pterygoid palate; 7, Scaphoid fossa; 8, External pterygoid plate, with fossa; 9, Zygomatic fossa; 10, Basilar process of occipital bone; 11, Foramen magnum; 14, Glenoid fossa; 15, Meatus auditorius externus; 16, Foramen lacerum anterius; 17, Carotid foramen of left side; 18, Foramen lacerum posterius, or jugular foramen; 19, Styloid process; 20, Stylo-mastoid foramen, with jugular tubercle and digastric fossa; 21, Mastoid process; 22, Occipital bone; 23, Posterior condyloid fossa.

8. *Palate bone.*—The palate bone of Man is formed of two osseous laminæ: one horizontal, the other vertical, which are joined at a right angle. The first part presents one-half of the posterior nasal spine, which is altogether rudimentary, or even null in animals; the orifice of the posterior palatine canal, which belongs entirely to the palate bone; the pterygo-palatine foramen; lastly, the pterygoid process, which represents the pterygoid bone of animals. The vertical portion forms the external wall of the nasal cavities by its internal face, and by its external face concurs in the formation of the zygomatic or temporal fossa.

9. *Zygoma.*—This offers three faces. The external, or cutaneous, serves as a base for the most salient part of the cheek. The superior, or orbital, forms part of the external wall and floor of the orbit; it belongs to a long apophysis, the *orbital process,* which rests on the sphenoid and frontal bones. The posterior face is smooth and concave behind, where it aids to form the temporal fossa; in front it is uneven, and articulates with the supermaxilla. The posterior, or masseteric border, unites with the zygomatic process of the temporal bone.

10. *Lachrymal bone.*—This bone is also called the *os unguis* in Man, because of its likeness to the nail in shape and tenuity. It is entirely lodged in the orbit, and its

external face is divided into two portions by a vertical crest; the portion situated in front of this crest forms part of the lachrymal channel. By its internal face, the lachrymal bone limits, outwardly, the bottom of the nasal cavities, and covers the anterior cells of the ethmoid; by its posterior border, within the orbit, it articulates with the os planum of the ethmoid.

11. *Nasal bone.*—The proper bones of the nose of Man exhibit a great analogy to those of the Dog. They do not possess a nasal prolongation, and they articulate with the lateral cartilage of the nose.

12. *Vomer.*—The same general form and relations as in solipeds.

13. *Inferior maxillary bone.*—This bone in Man is in shape somewhat like a horse-shoe. It is nearly of the same width throughout its whole extent. The symphysis is vertical—a character peculiar to Man. Below this symphysis is a triangular projection, the mental eminence The genial surface of the Horse is replaced by four little tubercles termed the genial processes. The alveoli of the molar teeth form a great projection on the inner face of the bone. The mylo-hyoid ridge is very developed. The superior orifice of the dental canal is covered by a little sharp lamina. From this orifice begins the mylo-hyoidean groove. The coronoid process is short; the condyle is bent towards the median line, and the sigmoid notch is wide and shallow. The superior border contains fourteen or sixteen alveoli.

Article III.—The Thorax.

The *thorax* represents a conoid cage, elongated from before to behind, suspended under the vertebræ of the dorsal region, and destined to contain the principal organs of respiration and circulation. It is composed of bony arches named *ribs*, thirty-six in number—eighteen on each side—and a single piece, the sternum, which serves for the direct or indirect support of the inferior extremities of the ribs.

THE BONES OF THE THORAX IN PARTICULAR.

1. *Sternum of the Horse.*

This is an osteo-cartilaginous body, elongated from before backwards, flattened on each side in two-thirds of its anterior extent, and from above to below in its posterior third, slightly curved on itself, and situated beneath the thorax in an oblique direction from above to below, and before to behind. It offers for study, a *superior face*, *two lateral faces*, *three borders*, and *two extremities*.

Fig. 37.

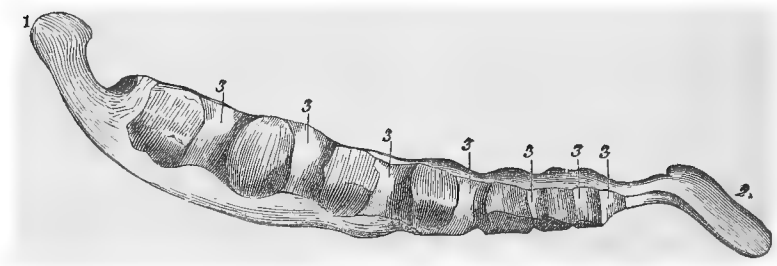

THE STERNUM.

1. The cervical prolongation (or cariniform cartilage); 2, The xiphoid appendage (or *ensiform cartilage*; 3, 3, Cavities for the articulation of the sternal cartilages; 4, Inferior border.

Faces.—The *superior face*, slightly concave longitudinally, represents an isoscelated, lengthened triangle, the summit of which is directed forwards; it constitutes the floor of the thoracic cavity. Each *lateral face* comprises two parts—a *superior* and an *inferior*. The first shows eight diarthrodial

cavities, which receive the inferior extremity of the cartilages of the true ribs. These cavities are elongated vertically, and draw closer to each other as they extend backwards. The inferior part, which is more extensive before than behind, offers to the powerful pectoral muscles a large surface for insertion.

Borders.—The *two lateral borders* separate the superior from the lateral faces; they are situated above the diarthrodial cavities, are united anteriorly, and each gives attachment to a fibrous band. The *inferior border* is opposite the superior face; convex, thin, and very prominent in its anterior two-thirds, it somewhat resembles the keel of a ship.

Extremities.—The *anterior* flattened on each side and curved upwards, exceeds to some extent the first articular cavity of the lateral faces, and in this way constitutes the *cervical* prolongation of the sternum. The *posterior* extremity is flattened superiorly and inferiorly, and forms a large cartilaginous plate, very thin, concave above, convex below, which has received the name of the *abdominal prolongation* (*ensiform cartilage*) or *xiphoid appendage.*

Structure and development.—The sternum is one of the parts of the skeleton which do not submit to complete osseous transformation. It is developed, in solipeds, from six single centres of spongy substance, ranged one behind the other, like beads on a string. These centres never coalesce to form a solid piece, but remain separated, during the life of the animal, by the primitive cartilaginous mass. The latter constitutes the entire anterior prolongation of the bone and its carina, as well as the xiphoid appendage. When these parts of the sternum become ossified, which is rare, it is only partially.

2. *The Ribs.*

As has been already noticed, on each side of the thorax eignteen ribs are counted. These are nearly parallel to each other, and separated by the intervals termed the *intercostal spaces.* Attached by their superior extremity to the vertebræ of the dorsal region, these bones terminate at their inferior extremity by an elastic and flexible prolongation, named the *costal cartilage,* by means of which they are brought into direct or indirect relations with the sternum. The characters common to all the ribs will be first noticed, then the special features which serve to distinguish them from each other, and, lastly, the differences they exhibit in other than soliped animals.

A. Characters common to all the Ribs.—These will be studied from a typical point of view, first in the rib itself, and then in its cartilage.

1. *Description of a typical rib.*—A rib is an elongated symmetrical bone, oblique from above to below, and from before to behind, flattened on both sides, curved like a bow, and twisted on itself in such a fashion that its two extremities cannot rest on the same horizontal plane. It is divided into a *middle portion* and *two extremities.*

Middle portion.—This offers two faces and two borders. The external face is convex, and hollowed by a wide groove in its anterior half; it shows superiorly, towards the point corresponding to the angle of the rib in Man, some tubercles and muscular imprints. The internal face is concave and smooth, and covered by the pleura, which separates it from the lungs. The anterior border is concave, thin, and sharp; the posterior, convex, thick, and covered with rugged eminences, is channeled inwardly by a vasculo-nervous fissure, which disappears near the middle of the rib.

Extremities.—The superior has two eminences, a *head* and a *tuberosity,* which serve for the support of the rib against the spine. The first is formed by two articular demi-facets, placed one before the other, and separated by a

groove for ligamentous insertion; it is isolated from the tuberosity by a narrow part, named the *neck*, which exhibits a rugged fossa for the implantation of a ligament. The second, situated behind the head, and smaller than it, is provided with imprints on its margin, and presents an almost flat diarthrodial facet at the summit. Each rib articulates by its head and tuberosity with two dorsal vertebræ; the head is received into the inter-

Fig. 38.

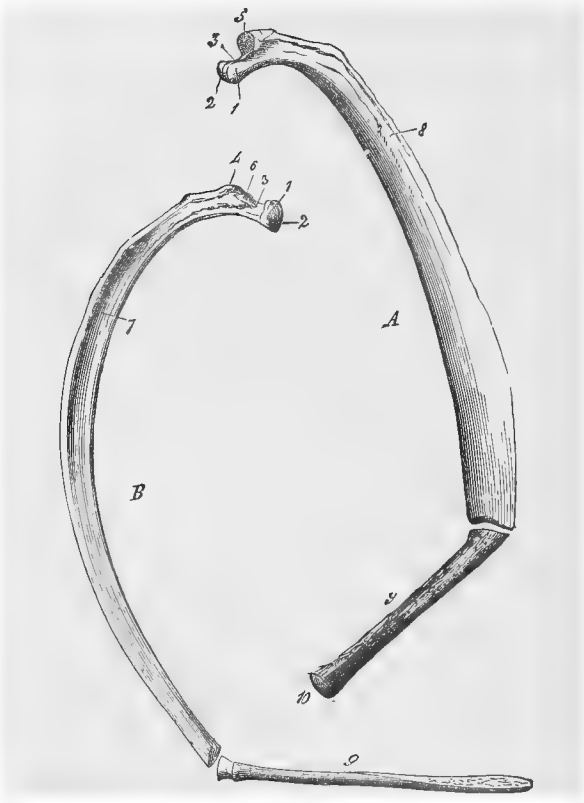

TYPICAL RIBS OF THE HORSE.

A, Inner face of the fifth sternal rib; B, External face of the first asternal rib.—1, Head of the rib; 2, Its fissure; 3, Neck; 4, Tuberosity; 5, Articular facet; 6, Scabrous fossa for the insertion of the interosseous costo-transverse ligament; 7, Groove on the external face; 8, Vasculo-nervous groove of the posterior border; 9, Prolonging cartilage; 10, A, Articular tuberosity for union with the sternum.

vertebral articular cavity; the tuberosity corresponds, by its facet, to the transverse process of the posterior vertebra.

The inferior extremity is tuberous and excavated by a shallow cavity, irregular at the bottom, for the reception of the upper end of the costal cartilage.

Structure and development.—The ribs are very spongy bones, especially

in their inferior moiety, and are developed at a very early period by three centres of ossification: a principal for the middle portion and inferior extremity, and two complementary for the head and tuberosity.

2. *Description of a typical costal cartilage.*—The costal cartilage very evidently represents the inferior rib in birds; it is a cylindrical piece, slightly compressed at the sides, and round and smooth on its faces and borders. By its superior extremity, it is united to the rib it serves to lengthen, and forms with it an angle more or less obtuse, opening in front. At its inferior extremity, it is terminated by an articular enlargement, or by a blunt point. In youth, the costal prolongations are entirely composed of cartilaginous matter, but they are soon invaded by ossification; so that in the adult animal they are already transformed into a spongy substance, with large areolæ which remain during life surrounded by a thin layer of cartilage.

B. Specific Characters of the Ribs.—The ribs, like the vertebræ of each region of the spine, have received numerical designations of first, second, third, etc., computing them from before to behind. (See Fig. 1.) Owing to the presence of an altogether essential characteristic, they are naturally divided into two great categories: the *sternal* or *true ribs*, and the *asternal* or *false ribs*. The *sternal ribs*, numbering eight (the first eight), have their cartilages terminating inferiorly by an articular enlargement, which corresponds to one of the lateral cavities of the sternum, and brings the true ribs into direct contact with this portion of the skeleton. The *asternal ribs*, ten in number, rest on each other—the last on the seventeenth, this on the sixteenth, and so on—by the inferior extremity of their cartilage, which ends in a blunt point. The cartilage of the first false rib is united somewhat closely to the last sternal rib, and it is through the medium of this that all the asternal ribs lie indirectly on the sternum.

If, however, the ribs are considered altogether, with regard to the differential characters presented by them in their length, width, and degree of incurvation, it will be noted: 1, That their length increases from the first to the ninth, and from this diminishes progressively to the last: 2, That the same progressive increase and decrease exists in the cartilages; 3, That they become gradually wider from the first to the sixth inclusive, and then contract by degrees until the eighteenth is reached; 4, That the curve described by each is shorter and more marked as the rib is situated more behind. It may be added that the channel on the external face is less conspicuous in proportion as the rib is narrow.

The first rib, considered individually, is always distinguished by the absence of the groove on its outer surface, the vasculo-nervous fissure on its posterior border, and the groove or notch intermediate to the two facets of its articular head. It is also recognised by the deep muscular imprints on its external face, the shortness and thickness of its cartilage. and particularly by the articular facet which this cartilage exhibits inwardly, to correspond to that of the opposite rib. The last rib has no channel on its external surface; the facet of its tuberosity is confounded with the posterior facet of the head. This last character is also nearly always remarked in the seventeenth rib, and sometimes even in the sixteenth.

In the *Ass* and *Mule*, all the ribs in general, but particularly those most posterior, are less curved than in the Horse. (In the Horse, a nineteenth pair of ribs is sometimes found, and this even with five, and at other times with six lumbar vertebræ; it happens that the nineteenth rib is formed by the transverse process of the first lumbar vertebra, and at times a ligament

is given off from this process, which joins it to a pointed bone or a cartilage in its vicinity. If the hymn on the "Sacrifice of the Horse," in the most ancient collection of Aryan poems, is to be credited, the horses of antiquity in Central Asia had only seventeen pairs of ribs. The mobility of the ribs is scarcely perceptible in the first, but increases until the ninth or tenth is reached, after which it gradually diminishes.)

THE THORAX IN GENERAL.

The description of the interior of the thoracic cavity will be referred to when treating of the respiratory apparatus. It is only necessary here to examine the external surface of this bony cage; for this purpose it is divided into six regions:—*a superior plane, an inferior plane, two lateral planes, a base*, and *a summit.*

Planes.—The *superior plane* is separated into two portions by the spinous processes of the dorsal vertebræ; each forms, with these spinous processes, the *costo-vertebral* furrow, intended to lodge the majority of the muscles belonging to the spinal region of the back and loins. The *inferior plane*, less extensive than the preceding, offers: 1, On the median line, the cariniform and xiphoid cartilages of the sternum; 2, On the sides, the chondro-sternal articulations, and the cartilages of prolongment of the true ribs. The *lateral planes* are convex and wider at their middle part than in front or behind, and exhibit the intercostal spaces. They serve to give support, anteriorly, to the superior rays of the two fore-limbs.

Base.—This is circumscribed by the posterior border of the last rib, and by the cartilages of all the asternal ribs; it is cut obliquely from above to below, and from before to behind. It gives attachment, by its internal circumference, to the diaphragm, a muscle which separates the thoracic from the abdominal cavity.

Summit.—It occupies the anterior portion of the thorax, and presents an oval opening, elongated vertically, situated between the two first ribs. This opening constitutes the entrance to the chest, and gives admission to the trachea, the œsophagus, and important vessels and nerves.

DIFFERENTIAL CHARACTERS OF THE THORAX IN OTHER THAN SOLIPED ANIMALS.

1. *Sternum.*

In all the domesticated animals except solipeds, the sternum is flattened above and below, instead of from side to side.

Ruminants.—In ruminants, each piece is developed from two lateral centres of ossification. The bones which compose it are seven in number; they are much more compact than those in the sternum of the horse, and at an early period are united to each other, with the exception of the first, which is joined to the second by a diarthrodial articulation that permits it to execute lateral movements. There is no cervical prolongation, and the xiphoid cartilage is feebly developed and well detached from the body of the bone. In the sternum of the *Goat* and *Sheep*, the two first pieces have no diarthrodial joint, but are simply united by a layer of cartilage which, in old animals, becomes completely ossified.

Pig.—The sternum of this animal presents in its general conformation the essential features of that of large ruminants. It is provided with a well-defined cervical prolongation, and is composed of six pieces which, at least in the four or five last, are each divided into two lateral centres.

Carnivora.—The sternum of the *Dog* and *Cat* is formed of eight pieces elongated from before to behind, hollowed in their middle part, and thick at their ends—formed, indeed, like the last coccygeal vertebræ of the Horse. They are never ossified to each other.

2. *Ribs.*

The number of ribs varies like that of the dorsal vertebræ. The following table indicates the number of these bones in the different domesticated animals.

Pig	14
Ox	13
Sheep	13
Goat	13
Dog	13

RUMINANTS.—These animals have eight sternal and five asternal ribs.

In the *Ox*, they are longer, wider, and less arched than in solipeds. The articular eminences of the superior extremity are voluminous and well detached; the neck especially is very long. The sternal ribs are joined to their cartilage of prolongment by a real diarthrodial articulation. In the last rib, and sometimes in the one before it, the tuberosity is scarcely perceptible, and has no articular facet. In the *Sheep* and *Goat*, the sternal ribs are consolidated with the cartilages (see fig. 5.)

PIG.—In this animal there are fourteen pairs of ribs, seven of which are sternal and seven asternal. The first are provided with cartilages of prolongment flattened on both sides, extremely wide and sharp, and convex on their superior border. In the four last asternal ribs, the facet of their tuberosity is confounded with the posterior facet of the head. (Otherwise, the ribs of the Pig resemble, in their general conformation, those of the Sheep or Goat; though more incurvated and wider.)

CARNIVORA.—They possess thirteen ribs on each side—nine sternal and four asternal. These are very much arched, narrow, and thick, and their cartilages rarely ossify. In the *Dog*, the articular facet of the tuberosity remains isolated from the posterior facet of the head in all the ribs. It is absent in the three last ribs of the *Cat*.

Fig. 39.

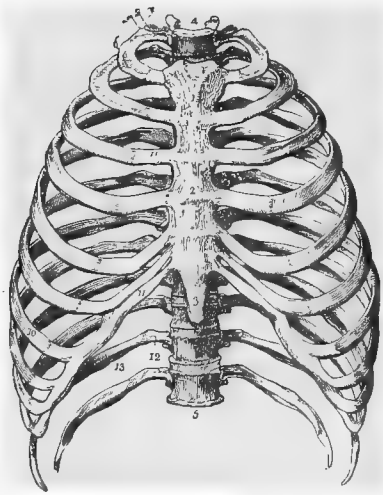

THORAX OF MAN; ANTERIOR FACE.

1, Superior piece of the sternum; 2, Middle piece, or body; 3, Inferior piece, or ensiform cartilage; 4, First dorsal vertebra; 5, Last dorsal vertebra; 6, First rib; 7, Its head; 8, Its neck, resting against the transverse process of the first dorsal vertebra; 9, Its tubercle; 10, Seventh, or last true rib; 11, Costal cartilages of the true ribs; 12, The last two false or floating ribs; 13, The groove along the lower border of the rib.

COMPARISON OF THE THORAX OF MAN WITH THAT OF THE DOMESTICATED ANIMALS.

1. *Sternum.*

The sternum of Man is flattened before and behind, and diminishes in width from above to below. The xiphoid appendage is narrow, and single or bifid. Besides the articular surfaces for the ribs, there are found on the upper end two lateral notches for articulation with the clavicles.

2. *Ribs.*

Of the twelve ribs in Man, seven are sternals and five asternals. They are short, narrow, and much incurvated, especially the first ones. In each rib the curvature is more marked in the posterior fourth or fifth than in the anterior three-fourths or four-fifths; this sudden change of curvature is indicated in the external face by a kind of inflexion and thickening called the angle of the ribs. The prolonging cartilages of the eleventh and twelfth ribs are short, and are lost in the texture of the abdominal parietes; for this reason they are termed the *floating* (or *false*) *ribs* (see fig. 39).

ARTICLE IV.—ANTERIOR LIMBS.

The *anterior* (or *thoracic*) limb is divided into four secondary regions: the shoulder, arm, fore-arm, and fore-foot or hand.

SHOULDER.

In solipeds, this region has for its base a single bone, the *scapula* or *omoplat.*

Scapula.

This is a flat, triangular, and asymmetrical bone, prolonged at its superior border by a flexible cartilage, articulated inferiorly with the humerus only, and applied against the lateral plane of the thorax in an oblique direction downwards and forwards. It has *two faces, three borders,* and *three angles.*

Fig. 40.

THE RIGHT SCAPULA; OUTER SURFACE.

1, Anterior border; 2, Superior margin for insertion of cartilage; 3, Tuberosity of the spine; 4, Antea-spinatus fossa; 5, Postea-spinatus fossa; 6, Neck of the scapula; 7, Coracoid process; 8, Glenoid cavity.

Faces.—The *external face* is divided by the *scapular* or *acromian spine,* into two cavities of unequal width—the *supra* and *infraspinous* (or *antea* and *postea spinatus*) *fossæ.* The *spine* is a very salient crest which runs the whole length of the external scapular surface; very elevated in its middle part, which shows an irregular enlargement—the *tuberosity* of the spine—it insensibly decreases towards its two extremities. The *supraspinous fossa,* the narrowest, is situated above, or rather in front of the spine; it is regularly concave from side to side, and perfectly smooth. The *infraspinous fossa* is twice the width of the preceding, and occupies all the surface behind the spine. It exhibits: 1, Below, and near the posterior border, several rows of roughened lines for muscular insertion; 2, Near the neck, the nutritious foramen of the bone, and some vascular grooves.

The *internal face* is excavated in its centre to form a hollow called the *subscapular fossa,* which is prolonged superiorly by three diverging points. The median point extends to the superior border of the bone, and separates two roughened triangular surfaces destined for muscular implantation.

Borders.—The *superior* is indented by an irregular groove to receive the inferior margin of the *cartilage of prolongment.* The latter is convex on its superior border, extends beyond the posterior angle of the bone, and gradually diminishes in thickness as it leaves its point of attachment. In old horses it is nearly always found partially ossified. The *anterior border,* thin and sharp, is convex in its superior two-thirds, and slightly concave for the remainder of its extent. The *posterior* is thicker and a little concave.

Angles.—The *anterior* or *cervical angle* is the thinnest of the three. The *posterior* or *dorsal angle* is thick and tuberous. The *inferior* or *humeral angle* is the most voluminous, and is separated from the remainder of the bone by a slight constriction, which constitutes the *neck* of the scapula. It exhibits: 1, The *glenoid cavity*, an oval diarthrodial surface, excavated to a slight extent to receive the head of the humerus, notched on the inner side, and bearing on the external margin of the ridge which surrounds it a small tubercle of insertion; 2, The *coracoid process*, situated in front, and at a certain distance from the glenoid cavity. This is a large eminence in which may be distinguished two parts: the *base*, a thick rugged process; and the *summit*, a kind of beak curved inwards.

Structure and development.—Like all the wide bones, the scapula is formed of two compact lamellæ separated by spongy tissue. The latter is very scanty towards the centres of the supra and infraspinous fossæ, where it is often altogether wanting; it is most abundant in the angles. The scapula is developed from two centres of ossification, one of which forms the coracoid process.

Fig. 41.

ANTERO-EXTERNAL VIEW OF RIGHT HUMERUS.

1, Trochlear or bicipita ridges; 2, External deltoid tuberosity; Head or articular face; 4, External cle; 5, Sh its Art cor W

ARM.

This region has only one bone, the *humerus*.

Humerus.

The *humerus* is a long single bone, situated between the scapula and the bone of the fore-arm, in an oblique direction downwards and backwards. Like all the long bones, it offers for study a *body* and *two extremities*.

Body.—The body of the humerus looks as if it had been twisted on itself from within to without in its superior extremity, and from without to within at the opposite end. It is irregularly prismatic, and is divided into *four faces*. The *anterior face*, wider above than below, has in its middle and inferior portions some muscular imprints. The *posterior*, smooth and rounded from one side to the other, becomes insensibly confounded with the neighbouring faces. The *external* is excavated by a wide furrow, which entirely occupies it, and turns round the bone obliquely from above to below and behind to before; it is to the presence of this channel that the humerus owes its apparent twist, a pro is in consequence designated the *furrow of tor* the body of the humerus.

This furrow is separat the anterior face by a salient border, the *a st of the furrow of torsion*, which ends inf the coronoid fossa, and superiorly, tow third of the bone, by the *imprint*. This is a roughened, very pr hafce and behind, and torsion; by its a curved li base

outwards, is seen the *posterior crest of the furrow of torsion*, which separates the latter from the posterior face of the bone. The *internal face* of the body of the humerus, rounded from side to side, is not separated from the anterior and posterior faces by any marked line of demarcation. It offers, near its middle, a depressed scabrous process for the insertion of the adductor muscles—teres major and great dorsal—of the arm. Towards its inferior third it shows the nutritive foramen of the bone.

Extremities.—These are distinguished into *superior* and *inferior*. Both are slightly curved, the first backwards, the second forwards, a disposition which tends to give to the humerus the form of an S.

The *superior extremity* is the most voluminous, and has three thick eminences; a posterior, external, and internal. The first constitutes the *head* of the humerus; it is a very slightly-detached articular eminence, rounded like the segment of a sphere, and corresponding to the glenoid cavity of the scapula, which is too small to receive it entirely. The external eminence, named the *trochiter*, *large trochanter*, and *great tuberosity*, comprises three portions, named the *summit*, *convexity*, and *crest* of the great tuberosity. The internal eminence, the *trochin*, *little trochanter*, or *small tuberosity*, also presents three distinct portions, which, by their position, correspond exactly with the three regions of the large trochanter: these are so many muscular facets.

Fig. 42.

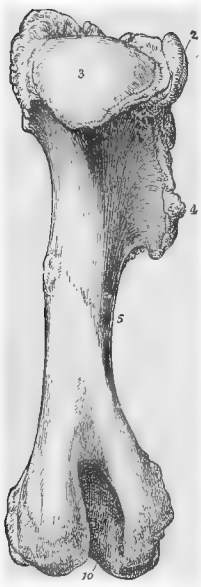

POSTERIOR VIEW OF THE RIGHT HUMERUS.

2, External tuberosity; 3, Articular head of the bone; 4, External tubercle and ridge; 5, Body or shaft of the bone; 10, Condyloid fossa.

The great and small trochanters are separated from one another in front by a channel called the *bicipital groove*, because the superior tendon of the biceps muscle glides over it; it consists of two vertical grooves with a median ridge between them.

The *inferior extremity* of the humerus has an articular surface corresponding to the radius and ulna. This surface, elongated transversely, convex from before backwards, and of greater extent within than without, exhibits two trochlea separated by an antero-posterior relief.

The *median* or *internal trochlea*, the deepest, is limited internally by a kind of voluminous condyle, which corresponds to the inner lip of the humeral trochlea of Man. *external trochlea* is bordered outwardly by a sli salient lip, which corresponds to the condyle of umerus of Man. Above and behind this articul face is a wide deep fossa, the *olecranian* (or *con* n named because it lodges the f the olecranon in the exten nts of the fore-arm. It is eminences, the ex is less elevated than the irst represents and the second the epi- umerus of Mar ove the inner trochlea, s the coronoid pro- r this reason, it Lastly, at the rface is

remarked: outwardly, an excavation for ligamentous insertion; inwardly, a small tuberosity intended for the same purpose.[1]

Structure and development.—The humerus, like all the long bones, is only spongy at its extremities. It is developed from six points of ossification; one of which alone forms the body, one the head and the small trochanter, another the large trochanter, a fourth the inferior articular surface, a fifth the epicondyle, and the last for the epitrochlea. The latter is sometimes absent.

FORE-ARM.

This region has for its base two bones, the *radius* and *cubitus* (or *ulna*) united into a single piece at an early period in most of the domesticated animals.

1. *Radius.*

This is a long bone, placed in a vertical direction between the humerus and the first row of carpal bones, and divided into a *body* and *two extremities.*

Body.—Slightly arched and depressed from before to behind, the body presents for study *two faces* and *two borders.* The *anterior face* is convex and perfectly smooth. The *posterior*, a little concave from one extremity to the other, offers: 1, Near the external border, a triangular surface, covered with asperities, elongated vertically, very narrow, commencing near the upper fourth of the bone and terminating in a fine point towards the lower fourth: this surface is brought into contact with the anterior face of the ulna by an interosseous ligament, which is completely ossified before the animal reaches adult age; 2, Above, there is a wide, transverse, but shallow groove, which aids in forming the radio-ulnar arch and shows, near the point where it touches the preceding surface, the nutrient foramen of the bone; 3, Near the internal border, and towards the inferior third, there is a vertically elongated and slightly salient eminence of insertion. The *two borders, external* and *internal,* are thick and rounded; they establish an insensible transition between the faces.

Extremities.—The *superior* is larger than the inferior. It has: 1, An articular surface elongated from one side to the other, concave from before to behind, wider within than without, and moulded to the articular surface of the inferior extremity of the humerus; there is also seen, outwardly, a double gorge which receives the two lips of the external trochlea; in the middle, an antero-posterior ridge which is received into the internal trochlea; within, an oval cavity corresponding to the internal border of the former; 2, The *external tuberosity*, placed at the extremity of the great diameter of the articular surface; it is prominent and well detached; 3, The *internal* or *bicipital tuberosity*, a large, very rugged, and depressed process, situated within and in front of the glenoid cavity; 4, A little lower, and on the same side, there is a strong muscular and ligamentous imprint, separated from the preceding tuberosity by a transverse groove intended for the passage of a tendinous branch; 5, The *coronoid process*,[2] a small conical eminence, at the summit of which terminates, anteriorly, the median ridge of the articular

[1] The articular surfaces which, in veterinary anatomy, have received the names of *trochlea* and *condyle*, not being the same as in human anatomy, there results an annoying inversion of the situation of the *epitrochlean* and *epicondyloid* eminences, so named. It has therefore been our endeavour to remedy the improper employment of these denominations, which has been a cause of error in comparative anatomy.

[2] In Man this belongs to the ulna.

surface; 6, Two diarthrodial facets elongated transversely, cut on the posterior outline of the large articular surface, with which they are confounded by their superior border; they correspond to similar facets on the ulna; 7, Below these, a roughened surface which extends to the radio-ulnar arch, and is in contact with an analogous surface of the same bone through the medium of an interosseous ligament; in the Horse this ligament rarely ossifies.

Fig. 43.

EXTERNAL FACE OF THE RADIUS AND ULNA.

1, Ulna; 2, Point of the olecranon; 3, Beak of the olecranon; 4, Radio-ulnar arch; Supero-external tuberosity; 6, Radio-ulnar articular surfaces for the humerus; 7, Bicipital tuberosity; 8, Shaft or body of the radius; 9, Grooves for tendons.

The *inferior extremity*, flattened from before to behind, presents: 1, Below, an articular surface elongated transversely and somewhat irregular, responding to the four bones in the upper row of the carpus; 2, On the sides, two tuberosities for ligamentous insertion, the *internal* salient and well circumscribed, the other *external* and excavated by a vertical fissure, in which passes a tendon; 3, In front, ~~three~~ four grooves for the gliding of tendons; the external is the largest, and vertical like the median; the internal, the narrowest, is oblique downwards and inwards; 4, Posteriorly, a strong transverse ridge which surmounts the articular surface and serves for the insertion of ligaments.

Structure and development. The radius is a very compact bone, and is developed from three centres of ossification: one for the body and two for the extremities.

2. *Ulna.*

This is an elongated, asymmetrical bone, in the form of an inverted triangular pyramid, applied against the posterior face of the radius, to which it is united in adult solipeds. It offers for description a *middle portion* and *two extremities.*

Middle portion.—This has *three faces* wider above than below, and *three borders* which become joined at the inferior extremity of the bone. The *external face* is smooth and nearly plane. The internal is also smooth and slightly hollowed. The *anterior* is formed to correspond to the radius, and presents peculiarities analogous to those of the posterior face of that bone. Thus there is found in proceeding from above to below: 1, Two small diarthrodial facets;[1] 2, A rough surface; 3, A transverse groove for the formation of the radio-ulnar arch; 4, A triangular surface, studded with rugosities, which occupies the remainder of the bone to its lower extremity. The lateral borders, *external and internal*, are sharp, and, like the anterior face, are in contact with the radius. The *posterior border* is concave, rounded, and thicker than the other two.

Extremities.—The *superior extremity* comprises all that portion which exceeds the articular surface of the radius. It constitutes an enormous

[1] It is represented in Man by the *smaller sigmoid notch.*

process—the *olecranon*—flattened on both sides, and presenting: 1, An external face, slightly convex; 2, An internal excavated face; 3, An anterior border, thin and sharp superiorly, notched below to for mthe *sigmoid cavity*:[1] an articular surface concave from above downwards, rounded from one side to the other, which corresponds with the humeral cavity, and is surmounted by a salient prolongation named the *beak of the olecranon*; 4, A concave and smooth posterior border; 5, The *summit*, a kind of thick roughened tuberosity which terminates the olecranon above, and into which are inserted the extensor muscles of the fore-arm.

At its *inferior extremity*, the ulna ends, towards the lower fourth of the principal portion of the fore-arm, in an acute point, and sometimes by a small knob (*capitulum ulnæ*). It is not rare to see it prolonged, especially in the Ass and Mule, to the inferior external tuberosity of the radius. This tuberosity then appears to belong to it, at least in part; and all that portion which is situated behind its vertical groove might be justly considered as belonging to the ulna.

Structure and development.—The ulna contains much compact tissue, even in the region of the olecranon; it is also very solid. It is an imperfect bone, developed from two centres of ossification only, one of these being for the apex of the olecranon.

Fig. 44.

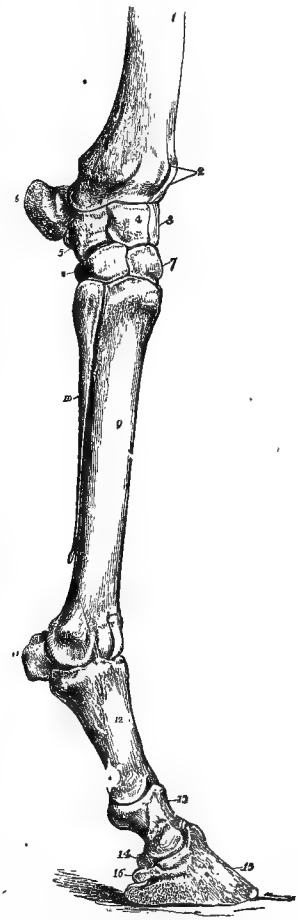

RIGHT FORE-FOOT OF A HORSE.

1, Radius; 2, Groove for the anterior extensor of the phalanges; 3, Scaphöides; 4, Lunare; 5, Cuneiform; 6, Trapezium; 7, Magnum; 8, Unciform; 9, Metacarpal; 10, Small metacarpal; 11, Sesamoid bone; 12, Suffraginis; 13, Coronary; 14, Navicular; 15, Pedal; 16, Its ala.

FORE-FOOT OR HAND.

The anterior foot, or hand, is the region which presents the greatest differences when it is inspected in the various individuals of the animal series. Nevertheless, in all the mammalia the constitution of the hand is fundamentally the same, and may be divided into three sections: the *carpus*, *metacarpus*, and *phalangeal region*.

The hand is formed by five parallel or quasi-parallel rays that constitute the digits, each of which is effectively or virtually composed of *two superposed carpal*, a *metacarpal*, and *three phalangeal bones*, forming altogether the *digit*, *properly so called*. But this typical composition, established through the labours of MM. Joly and Lavocat, is rarely found to be realised in a complete manner.

The following is what is presented in the hand of *Man*, who is the most

[1] The *greater sigmoid cavity* of Man.

perfect pentadactylous type. The *carpus* is composed of eight bones, the *metacarpus* of five small, parallel, bony columns; the *phalangeal region* of five digits—*thumb*, *index*, *medius*, *annularis*, and *auricularis*, formed each of three phalanges, with the exception of the thumb, which has only two.

In the domesticated animals, the constitution of the hand is more or less removed from this type, in consequence of abortive development, which diminishes either the number of rays, or the number of pieces composing these.

Thus, in the *Cat* and *Pig* there are eight bones in the carpus; but in the *Dog* and *Horse* there are no more than seven; in the *Ox* and *Sheep* there are only six, for in them two or three bones are fused together.

The metacarpus of the *Dog* and *Cat* has certainly five metacarpal bones, but the metacarpus of the *Pig* has no more than four, that of the *Horse* three, and that of *Ruminants* only two. In the metacarpus of the *Pig* the fifth bone is not developed. In the *Horse* it is entirely absent; the fourth and first are independent, and the third and second are confounded to form a voluminous bone which has been named the principal (or large) metacarpal. In *Ruminants*, the fourth and fifth metacarpals are quite imperfect, the first being arrested in its development, and the second and third becoming consolidated as in the horse.

Lastly, it is noted that the digital region of *Carnivora* has five digits, the *Pig* four, *Ruminants* two, and *Solipeds* only one. In the Pig, the thumb is undeveloped; in ruminants it is completely absent, and the first and fourth are represented by two small bones situated behind the metacarpo-phalangeal articulation; while in solipeds the single digit already mentioned results from the fusion of the auricularis and medius.

From this preliminary synthetical exposition, it will be easy to understand the description of the bones composing the hand in solipeds.

1. *Carpal Bones.*

The carpus forms the base of the hand. Situated between the inferior extremity of the radius and the superior extremity of the metacarpal bones, it is composed of several small bones joined to each other in the fresh state by extremely solid articular bands. Collectively, they form an almost quadrilateral mass in which may be distinguished two faces and four borders.

The *anterior face* is slightly convex from side to side and irregular; it corresponds to the tendons of the extensor muscles of the metacarpus and phalanges.

The *posterior face* is very unequal and converted, especially outwardly, into a groove in which the tendons of the flexor muscles of the phalanges glide.

The *superior border* articulates with the radius; the *inferior border* with the metacarpal bones.

The *lateral borders* are nearly level; above and behind the external border is remarked a considerable eminence, formed by the bone which will be hereafter studied as the supercarpal bone (or trapezium).

In the carpus of the Horse are seven bones, which are disposed in two superposed rows. The superior row comprises four bones placed side by side, and designated by the numerical names of *first*, *second*, *third*, and *fourth*, viewing them from without to within. The inferior row has only three, which are named in the same manner.

In applying to them the names proposed by Liser, we have, in the upper row:

1. The pisiform, or supercarpal bone (trapezium);
2. The pyramidal (or cuneiform) bone;
3. The semilunar (or lunare) bone
4. The scaphoid bone;

In the inferior row:

1. The hook or unciform bone;
2. The great bone or capitatum (magnum);
3. The trapezoid bone.[1]

The description of these bones is most simple, and may be made in a general manner for all. Thus, with the exception of the supercarpal bone, they are solids, nearly cubical in form, and exhibit on their periphery: 1, *Articular surfaces*; 2, *Surfaces of insertion.*

The *articular surfaces* represent small, flat, or slightly-undulating facets, distributed on the superior, inferior, and lateral surfaces; none are found in front or behind. The superior and inferior faces are entirely occupied by a single facet which responds either to the radius, the metacarpal, or to the bone of the other row. The lateral facets are always multiple and in contact with the bones of the same tier; they do not exist, of course, on the eccentric side of the first and third bones of the superior or inferior rows.

The *surfaces of insertion* are absent on the superior and inferior faces; they separate, in the form of roughened fossæ, the lateral articular facets. Before and behind they are covered by more or less marked rugosities.

Bones of the Upper or Antibrachial Row.—The *first*, or *os pisiforme*, is without the row; it is situated above and behind the carpus, from whence its name of *supercarpal bone*, by which it is usually known in veterinary anatomy. This bone, which merits a special description, represents a disc flattened on both sides, offering for study two faces and a circumference. The external face is convex, roughened, and channeled anteriorly by a groove that traverses it from above to below, and in which glides the inferior tendon of the external flexor of the metacarpus. Its internal face, smooth and concave, concurs to form the external wall of the carpal sheath. The circumference presents, in front, two articular facets: the superior, concave, corresponds to the radius; the inferior, convex, is in contact with the second bone of the upper row.

The other three bones of this row increase in volume from without to within.

The *second*, or *os pyramidalis* (or *cuneiform*), responds to the radius, the first bone of the lower row, the third of the upper, and the supercarpal bone; it has in all five articular facets.

The *third*, or *os semilunare (lunare)*, has six facets, and is united below to the first and second bones of the second row.

[1] The analogue of the trapezium of Man is not found in the Horse. According to M. Lavocat, we ought to regard as such a small supernumerary bone sometimes seen articulating behind the third bone. We are entirely of his opinion. (Leyh is also of this opinion, and states that this supernumerary bone is more frequently found in large common-bred horses. Stubbs, in his old, but fine 'Anatomy of the Horse,' does not refer to it, but describes the seventh bone as the pisiform. Percivall says the supernumerary bone is not invariably present, and that sometimes two are found. He designates Stubbs' and Chauveau's pisiform bone as the trapezium. Girard names the supernumerary bone the "pisiform" or pea-shaped. When one or more of these osseous nodules are present, they represent the pollex and fifth digit of the human hand.)

The *fourth*, or *os scaphoides*, the most voluminous of the row, has only four facets, and articulates by its inferior face with the *os magnum* and *trapezoides*.

Collectively, the second, third, and fourth bones of the upper row form two articular surfaces.

The superior, or radial articular surface, is very irregular; but in examining it from without to within there may be observed: 1, A glenoid cavity on the pyramidal bone; 2, In front, a transversely-elongated condyle

Fig. 45.

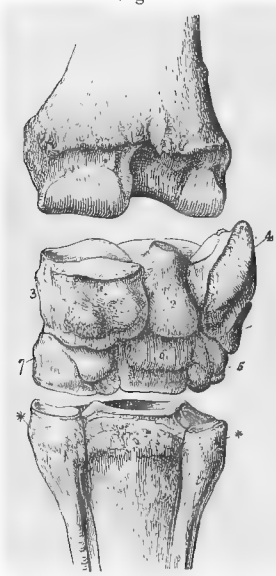

POSTERIOR VIEW OF THE RIGHT CARPUS.

1, Second cuneiform, or pyramidalis; 2, Third, or lunare; 3, Fourth, or scaphöides; 4, First, supercarpal, pisiform, or trapezium; 5, First of lower row, or unciform; 6, Second, or magnum; 7, Third, or trapezoides; *, *, Small metacarpal bones.

Fig. 46.

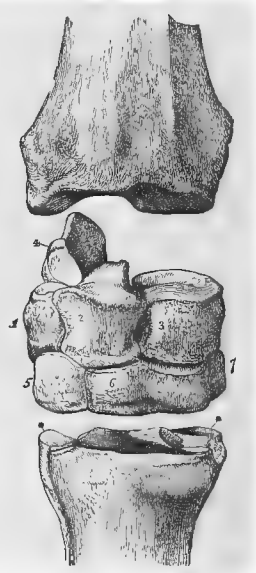

FRONT VIEW OF RIGHT CARPUS.

1, Second of upper row, or cuneiform; 2, Third, or lunare; 3, Fourth, or scaphöides; 4, First, supercarpal, or trapezium; 5, First of second row, or unciform; 6, Second, or magnum; 7, Third, or trapezoides.

on the semilunar and scaphoid bones; 3, A groove placed behind the preceding condyle.

The inferior articulating surface, which corresponds to the second row, is constituted by several undulated facets; it is convex outwardly and in front, concave posteriorly and inwardly.

Bones of the Inferior or Metacarpal Row.—The thickness of these bones decreases from without to within.

The *first*, *unciform*, or *hookbone* (*os hamatum*), has four diarthrodial facets, and responds, above, to the two first bones of the superior row; below, to the first and second metacarpals.

The *second*, *os magnum*, or *os capitatum*, the largest, has seven articular facets, three of which are on the interno-lateral face. It articulates, above,

with the semilunar and scaphoides; below, with the principal metacarpal and the internal rudimentary metacarpal.

The *third*, or *trapezoides*, the smallest, is provided with five facets, and is in contact with the scaphoides above, and the middle and internal metacarpals below.

Collectively, these bones of the lower row form two large diarthrodial surfaces. The upper surface responds to the bones of the upper row, and is constituted in front, and from without to within, by a small condyle and two glenoid cavities; behind, by two isolated condyles, formed by the os magnum and the trapezoides. The inferior articular surface is only formed by more or less long and plane facets, which incline towards each other. It corresponds to the three portions of the metacarpus.

Structure and development.—Each carpal bone is formed by a nucleus of close spongy substance enveloped in a layer of compact tissue. Each is developed from a single centre of ossification.

Fig. 47.

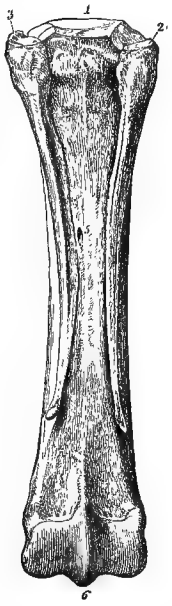

POSTERIOR VIEW OF RIGHT METACARPUS.

1, Head of large metacarpal bone for articulation with the trapezoides, magnum, and unciform; 2, Inner splint, or small metacarpal bone, for articulation with the trapezoides; 4, Scabrous surface for the attachment of the suspensory ligament; 5, Nutrient foramen; 6, Median ridge separating the two inferior condyles.

2. *Metacarpal Bones.*

In Solipeds, the *metacarpus* is composed of three bones, named the "metacarpals," standing parallel to each other. These are the *principal metacarpal* and the *two rudimentary metacarpals*, an *external* and *internal*.

Principal Metacarpal.—This is a long cylindrical bone, situated vertically between the carpus and the digital region.

Body.—The body is a little depressed before and behind, a disposition which permits it to be described as having *two faces* and *two borders*. The *anterior face* is perfectly smooth and rounded from side to side. The *posterior face* is flat, and exhibits: 1, Towards the upper third, the nutritive foramen of the bone; 2, On the sides, two narrow, roughened surfaces, parallel and elongated vertically, commencing near the superior extremity to disappear a little below the middle of the bone; these surfaces are held in apposition with the rudimentary metacarpals by means of an interosseous ligament which is often ossified in old horses. The *borders*, *external* and *internal*, are very thick, round, and smooth, like the anterior face.

Extremities.—The *superior* is flattened before and behind, and presents: 1, Above, an undulating articulatory surface, formed by the union of several flat facets more or less inclined on one another: they respond to all the lower row of carpal bones; 2, Anteriorly and inwardly, a tuberosity for muscular insertion; 3, Posteriorly, and directly above the roughened surfaces of the posterior face, four small diarthrodial facets in pairs, and running into the larger articular surface by their superior border: they are adapted to similar facets on the rudimentary metacarpals. The *inferior extremity*, elongated transversely, corresponds to the first phalanx and the large sesamoids by an articular surface, convex from before to behind, which

is composed of *two lateral condyles* separated by a median spine. The two condyles would be exactly alike, if the antero-posterior diameter of the external condyle was not less extensive than that of the opposite condyle. Both are hollowed on the sides by an excavation for the attachment of ligamentous fasciculi.

Structure and development.—The principal metacarpal is one of the most compact bones in the body. It is developed from two centres of ossification, one of which is for the inferior extremity.

Rudimentary Metacarpals.—The two rudimentary (*small*) metacarpal (or *splint*) bones are elongated, and placed against the posterior face of the principal bone, one without, the other within. Each is in the form of an inverted pyramid, and exhibits a *middle part* and *two extremities*.

Middle portion.—Prismatic and triangular, this offers: 1, *Three faces*,—an *external*, smooth and rounded from one border to the other; an *internal*, plane, and equally smooth; an *anterior*, covered with asperities to give attachment to the interosseous ligament uniting the lateral metacarpal bone to the median; 2, *Three salient borders* which markedly separate the faces from each other.

Extremities.—The *superior*, the largest, is named the *head*, and shows: above, a diarthrodial facet which corresponds to one or two bones of the inferior row of the carpus; in front, other two small facets continuous with the preceding, and in contact with similar facets on the median metacarpal bone; on the other points of its periphery are rugosities for the attachment of ligamentous and tendinous fibres. The *inferior extremity* only reaches to about the lower fourth of the large metacarpal bone, and terminates in a small enlargement or button, which is never consolidated with the latter.

The two lateral metacarpals, although very much alike, may yet be easily distinguished from each other. For instance, the internal bone is always the thickest and often the longest; besides, the superior articular surface of its head results from the union of the two facets corresponding to the two last carpal bones of the lower tier.

Structure and development.—Of a somewhat compact texture, like all the long bones, these have no medullary canal, and are developed from only one ossific centre. Not unfrequently, however, the tubercle is formed from a special centre.

3. *Bones of the Phalangeal Region or Digit.*

Solipeds have only one digit, supported by the principal metacarpal bone, and composed of three pieces placed end to end, one upon another. The first comprises three bones: a principal, the *first phalanx*, and two complementary ones, the *sesamoids*. The second is formed by the *second phalanx*, and the last, which terminates the limb, is constituted by the *third phalanx* and an accessory bone which has received the name of the *small sesamoid* (*navicular bone*).

First (proximal) or Metacarpal Phalanx.—The first phalanx (or *pastern bone*), the smallest of all the long bones, is situated in an oblique direction from above downwards, and behind to before, between the principal metacarpal and the second phalanx.

Body.—Depressed in front and behind, this bone exhibits: an *anterior face*, round from one side to the other, and slightly roughened above and below; a *posterior face*, flat, covered with ligamentous imprints in the form of a triangle with the base reversed; *two lateral borders*, thick, rounded, and provided with some imprints.

Extremities.—The *superior*, the largest, presents: Above, an articular surface adapted to the inferior metacarpal surface, and consequently composed of two glenoid cavities separated by a groove running from front to back; laterally, and a little posteriorly, a well-defined tubercle of insertion. The *inferior extremity* has a transversely elongated articular surface to correspond to the second phalanx; this surface is formed by *two condyles* separated by a middle groove, and surmounted laterally by a small tuberosity for ligamentous insertions. The external condyle is smaller

Fig. 48.

LATERAL VIEW OF THE DIGITAL REGION; OUTSIDE OF RIGHT LIMB.

1, Large metacarpal bone; 2, 3, Outer and inner sesamoids; 4, First, proximal, suffraginis or metacarpal phalanx, 5, Its posterior surface; 6, Tuberosity for ligamentous insertion; 7, Inner condyle of ditto; 8, Eminences on second phalanx for attachment of lateral ligament; 9, Smooth surface for passage of deep flexor tendon on second phalanx; 10, Imprint for the insertion of the terminal branch of the perforatus tendon; 11, Navicular bone; 12, Third phalanx, pedal, or coffin bone; 13, Its basilar process.

Fig. 49.

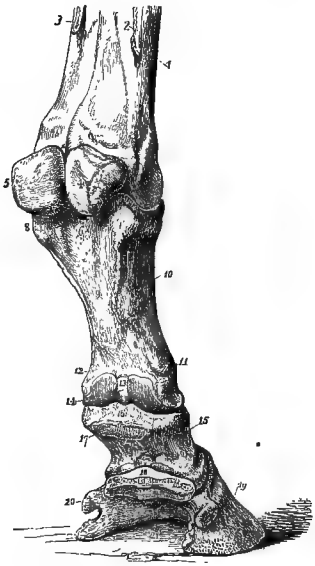

POSTERIOR VIEW OF FRONT DIGITAL REGION.

1, Large metacarpal bone; 2, 3, Outer and inner splint bones; 4, 5, Sesamoid bones; 6, Suffraginis; 7, 8, Tuberosities for insertion of crucial ligaments; 9, Triangular space for insertion of short sesamoid ligament; 10, Anterior face of suffraginis; 11, 12, Tuberosities for ligamentory insertion; 13, Articular depression separating condyles; 14, 15, Second phalanx; 16, Scabrous surface for ligamentous attachment; 17, Smooth surface for gliding of deep flexor tendon; 18, Navicular bone; 19, Pedal bone; 20, Basilar process; 21, Plantar foramen.

than the internal, and when the bone is placed upon a horizontal plane, the anterior face turned upwards, it only touches by three points—the two tubercles of the upper extremity and the internal condyle; by pressing on the external condyle, it is easy to make the bone rock.

The first phalanx is a very compact bone, and is developed from two points, one of which is for the superior extremity alone.

Sesamoids.—These are two small short bones placed side by side behind the superior extremity of the first phalanx, whose articular surface it completes, as it has not extent enough to be exactly adapted to the metacarpal surface. Each of these bones represents a small, irregularly-shaped polyhedron, or rather, a short trifacial pyramid. It offers: an *anterior face*, which is articular, and corresponding to the inferior extremity of the principal metacarpal bone, moulded, as it were, on one of the condyles and one of the sides of the median ridge; a *posterior face*, covered with cartilage in the fresh state, and forming, with that of the opposite bone, a gliding concave surface for the flexor tendons of the phalanges; a *lateral face*, studded with ligamentous imprints; a *summit*, directed upwards; and a *base*, turned downwards, and serving for the attachment of several ligaments.

Second (or Middle) Phalanx (Os Coronæ, Small Pastern Bone).—This is a short bone, situated in the same oblique direction as the first phalanx, and between it and the third. Its general form is that of a cube flattened before and behind, and offering the following features: an *anterior face*, covered with some slight imprints; a *posterior face*, provided, above, with a transversely elongated gliding surface; a *superior face*, channeled by two glenoid cavities, to match the inferior articulating surface of the first phalanx; an *inferior face*, formed on the same plan as the last, being occupied by two unequal condyles which articulate with the third phalanx and the navicular bone; *two lateral faces* exhibiting a very marked imprint. In the interior of this bone is found a nucleus of very condensed spongy substance, enveloped in a layer of compact tissue. It is usually developed from a single centre of ossification; though in many subjects there is a complementary nucleus for the superior articular surface and the posterior gliding surface.

Third (Distal) Phalanx, Os Pedis (or Pedal Bone).—This is a short bone which terminates the digit, and sustains the hoof that incloses it and the navicular bone. When completed by a special *fibro-cartilaginous apparatus*, it represents the segment of a very short cone, obliquely truncated behind, from the summit to the base. It offers for study: *three faces*, *three borders*, and *two lateral angles*

Faces.—The *anterior*, convex from side to side, and cribbled by porosities and vascular openings, shows on each side: 1, The *preplantar fissure*, a horizontal groove more or less ramified, which commences behind, between the retrossal and basilar processes, terminating in front in one of the foramina which penetrate the bone; 2, The *patilobe eminence*, a roughened projecting surface, situated between the preceding fissure and the inferior border of the bone. The *superior face* is occupied by an articular surface formed by two glenoid cavities and a slight median ridge; it comes in apposition with the inferior face of the second phalanx. The *inferior* (or *solar*) *face*, hollowed out like an arch, is divided into two regions by the *semilunar crest*, a salient line which describes a curve forwards. The anterior region is perforated with very fine porosities, and corresponds to that part of the hoof named the *sole*. The posterior region shows, immediately behind the semilunar crest, a median imprint, and two lateral channels designated the

Fig. 50.

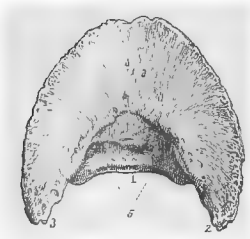

PLANTAR SURFACE OF THIRD PHALANX.

1, Lower face, or sole; 2, 3, Wings, or retrossal processes; 4, Internal border; 5, Plantar foramina.

plantar fissures. These originate at the root of the basilar process, are directed obliquely downwards and inwards, and open into the *plantar foramina*, the external orifices of two large canals which enter the bone and unite in its interior to form the semilunar sinus.

Borders.—The superior describes a curve, with the convexity forward, and presents: 1, In its middle, the *pyramidal eminence* of the os pedis, a single triangular process, flat before and behind, roughened on its anterior aspect, and concurring, by its posterior surface, to form the articular surface which responds to that of the second phalanx, 2, Laterally, two facets of insertion which encroach on the anterior surface, and even advance, posteriorly, nearly to the preplantar fissure. The *inferior border* is thin, dentated, convex, and semicircular; it is perforated by from five to ten large foramina which pass into the bone. The *posterior border* is slightly concave; on it is observed a very narrow, transversely elongated, diarthrodial facet, which becomes confounded with the superior large articular surface, and is adapted to a similar facet on the navicular bone.

Lateral angles.—These are two projections directed backwards, on whose summit the three borders of the bone unite, and which gives attachment to the lateral fibro-cartilages. A deep notch, the origin of the preplantar fissure, separates each into two particular eminences: one, the superior, named by M. Bouley the *basilar process;* the other, the inferior, prolonged behind, and designated by Bracy Clark the *retrossal process*, from *retro*, behind, and *ossa*, bone.

Structure.—The os pedis exhibits in its interior the *semilunar sinus*, a cylindrical, transversely elongated, and semicircular cavity resulting from the arching anastomoses of the two plantar canals. From this cavity pass off numerous channels, which anastomose frequently with each other, and open externally by the foramina on the anterior face of the bone, or by those on its inferior border. The os pedis has for its base a nucleus of spongy substance, surrounded by a layer of compact tissue. The latter is thicker towards the pyramidal eminence than elsewhere, and sends into the interior numerous prolongations which form the walls of the semilunar sinus, as well as the bony channels which spring from it.

Development.—The third phalanx, formed from a single nucleus of ossification, undergoes numerous changes in its configuration during life. Thus, in the young animal the lateral angles are thick, obtuse, and but little prolonged posteriorly; but as it grows older, they increase in length and become salient. The development they then assume is due to the progressive ossification of the lateral cartilages implanted on their surface. It often happens, in very old horses, that this ossifying process is carried to an extreme degree, and nearly the whole substance of these complementary organs is invaded. From the commencement, its inevitable result is to convert the notch which separates the basilar from the retrossal process into a foramen.

The complementary fibro-cartilaginous apparatus of the os pedis.—To understand properly the disposition of this portion of the foot, it is necessary that a previous knowledge of the ligaments and tendons attached to the os pedis should have been obtained; therefore a detailed description will only be given when the Horse's foot is studied as a whole. It will be sufficient here to state that this apparatus consists of two lateral pieces, the *fibro-cartilages* of the os pedis, united behind and below by the *plantar cushion*, a fibrous and elastic mass on which rests the navicular bone through the medium of the perforans tendon.

THE SMALL SESAMOID (OR NAVICULAR) BONE.—This short bone is annexed to the third phalanx, behind which it is situated; it is elongated transversely, flattened above and below, and narrowed at its extremities. It offers: 1, A *superior face*, on which are prolonged the glenoid cavities and the median ridge of the articular surface of the os pedis; it responds to the second phalanx; 2, An *inferior face*, divided by a slight relief into two undulated facets, and covered with cartilage to form a gliding surface; 3, An *anterior border*, channeled lengthways by a groove of insertion, above which is remarked a diarthrodial facet that brings the small sesamoid into contact with the posterior border of the third phalanx; 4, A *posterior border* and *two extremities*, for ligamentous insertion. This bone, as well as the sesamoids, originates from a single centre of ossification. It is formed of a layer of compact tissue enveloping a nucleus of very condensed spongy substance.

Fig. 51

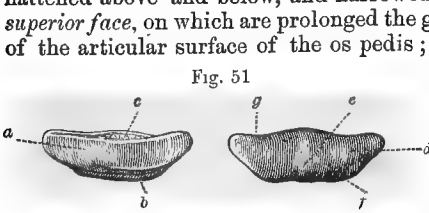

NAVICULAR BONE.

a, Upper, or articular surface; *b*, Inferior border; *c*, Superior border; *d*, Inferior, or posterior surface; *e*, The median transverse ridge; *f*, Inferior margin; *g*, Superior margin.

DIFFERENTIAL CHARACTERS OF THE ANTERIOR LIMB IN OTHER THAN SOLIPED ANIMALS.

A. SHOULDER.—In *Carnivora* the shoulder is composed of two bones, these creatures being furnished with a clavicle. This bone in the *Dog* is a little osseous shell imbedded among the muscles situated in front of the scapulo-humeral angle. That of the *Cat* constitutes a small styloid bone, which is joined to the acromion and sternum by two ligamentous cords.

In all the domesticated animals except Solipeds, the coracoid process is immediately applied against the glenoid cavity. In all, also, with the exception of the *Pig*, the scapular spine gradually rises from above to below, and terminates in a sharp salient point, the *acromion*.

The spine partitions the external face of the bone into two equal fossæ in the *Dog*, and in Ruminants into two fossæ, which, for extent, are as one to three to each other. The scapular spine of the *Pig* is much elevated towards the middle part, and bends more or less backwards,

In the *Carnivora* the prolonging cartilage is entirely absent; the anterior border of the scapula is very convex, as if the bone had been curved downwards. In the other domesticated mammals the scapula is somewhat regularly triangular.

B. ARM.—Proportionately, the humerus is longer, and more inflected like an S, as the number of apparent digits is increased. Therefore it is that in the Carnivora the characters of length and inflexion are most marked.

In the *Ox*, *Sheep*, *Pig*, and *Dog*, the furrow of torsion is not so deep as in the Horse, and the deltoid imprint is less salient. In the *Dog* this imprint is represented by a large roughened surface; in the *Pig* by some asperities only. The nutrient foramen is on the posterior face. It has been stated that the medullary canal in the *Ox* is traversed by an osseous band; but the presence of this is not constant.

The summit of the trochiter is very elevated, particularly in Ruminants, and is thrown back on the bicipital groove, which is single; in the *Dog* and *Pig*, this groove is carried inwards above the internal face of the humerus.

The external trochlea in the *Ox* and *Pig* is well marked. In Carnivora, the inner lip of this trochlea is very high, and the external lip incomplete; a foramen establishes communication between the olecranian and coronoid fossæ. In the *Cat* there is found, on the inner side of the lower extremity, a particular foramen that forms a vascular arch.

C. FORE-ARM.—The fore-arm is short in the *Ox*, *Sheep*, and *Pig*; very long in the *Carnivora*. The principal differential characters that it presents are connected with the relative dimensions of the two bones and their mode of union. Regarding these, and as generally applicable, the following principles may be laid down:—

1. *The development of the ulna is in direct relation to the division of the foot.*—Monodactylous animal, such as the Horse, Ass, and Mule, have in fact only a rudimentary

ulna. In the pentadactylous animals, as Man, the Cat, etc., on the contrary, this is a veritable long bone which equals, or even exceeds, the radius in volume.

2. *The closeness of union between the radius and ulna is in increased proportion as the animal exclusively employs its inferior extremity for standing or walking.*—Thus, in Solipeds and Ruminants, and Pachyderms in general, the two bones are consolidated, or at least united, by an interosseous ligament, and in so firm a manner that they can only execute very obscure movements on each other. The anterior limb of these animals is indeed only used to support the body on the ground. In those, on the contrary, which may employ it to dig up the soil, climb on trees, etc., or as an organ of prehension, the radius and ulna are merely joined at their extremities by an articulation, which permits them to move upon one another with the greatest facility. Rodents, the majority of the Carnivora, and the quadrumana, are so provided; but it is in Man that the relative independence of the two bones is carried to the highest degree. No animal can so easily execute the movements of pronation and supination of the hand, which are determined by the play of the two bones of the fore-arm on each other.

To the indication of these fundamental characters may be added some details on a few particular and important points.

In all the domesticated animals other than Solipeds, the ulna is developed from three ossifying centres, extends the whole length of the radius, and concurs to form the articular surface corresponding to the carpal bones. It is an elongated bone in *Ruminants*, and a long bone, hollowed by a medullary canal, in the *Pig* and *Carnivora*.

The inferior articular surface of the bone of the fore-arm in *Ruminants* is cut obliquely from above to below, and from without to within. In these animals we find the radius very flat from before to behind, the bicipital tuberosity scarcely noticeable, and two radio-ulnar arcades united externally by a deep fissure. The union of the two bones is more intimate than in the Horse, for the ossification always finishes by invading that portion of the interosseous ligament placed above the superior vascular arcade.

In the *Pig*, the ulna is flattened from before to behind, and spread out on the posterior face of the radius, which it almost completely covers. Its olecranon is very prominent. In the *Dog* and *Cat*, the two bones of the fore-arm are nearly equal in volume, and are slightly crossed in an X fashion. The superior extremity of the ulna is thicker than its lower extremity; it is nearly the opposite of this in the radius. Movable on one another, these bones only touch by their extremities, and to this effect offer: 1, Above, on the ulna, a concave articular surface, the small sigmoid cavity, and on the radius a rounded hinge-like facet; 2, Below, on the radius, a concave surface, and on the ulna a convex one.

D. Fore-foot, or hand.—1. *Carpal bones.*—The carpus of the *Pig*, like that of Man, contains eight bones—four in each of the rows. The *second* bone of the upper row corresponds with the ulna, and to a small extent with the radius. In the bones of the lower row, it is observed that the first corresponds with the two external metacarpals, the second with the great internal metacarpal, the third with the preceding and the small internal metacarpal. The fourth, or trapezium, terminates inferiorly by a blunt point, and has no relations with the metacarpal bones, because the thumb is entirely undeveloped in this animal.

Fig. 52.

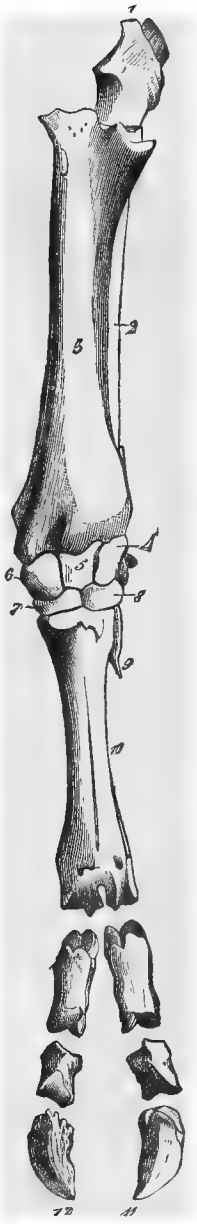

FORE-ARM AND FOOT OF THE OX; FRONT VIEW.

1, Olecranon; 2, Body of the ulna; 3, Body of the radius; 4, 5, 6, First, second, and third bones of the upper row of the carpus; 7, 8, First and second bones of the lower row; 9, Rudimentary metacarpals; 10, Principal metacarpals; 11, External digit; 12, Internal digit.

In the *Cat* there are also eight bones. The *second*, or pyramidalis, of the upper row is very developed; it occupies all the external border of the carpus, and articulates with the ulna, the first bone of the second row, and the first metacarpal. The *supercarpal* bone, elongated, prismatic, and thickened at its extremities, offers in front two coalescing articular facets, one to correspond with the ulna, the other to join the *pyramidalis*. The bones of the inferior row decrease in thickness from the first to the fourth, and correspond: the first, to the first and second metacarpals; the second, to the metacarpal of the third digit; the third, to that of the fourth digit; the fourth, to the metacarpal of the thumb.

Fig. 53.

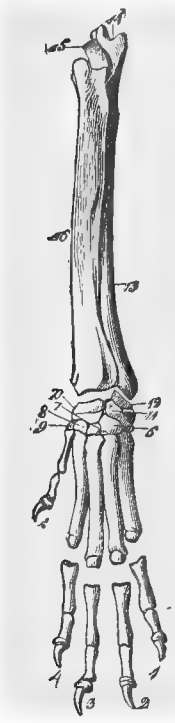

FORE-ARM AND FOOT OF THE DOG; ANTERIOR FACE.

1, First digit; 2, Second digit; 3, Third digit; 4, Fourth digit; 5, Thumb; 6, 7, 8, 9, First second, third, and fourth bones of the lower row of carpal bones; 10, 11, First and second bones of the upper row; 12, Supercarpal bone; 13, Body of the ulna; 14, Apex of the olecranon; 15, Beak of the olecranon; 16, Body of the radius.

In the *Dog* there are only seven bones, as the scaphoid and semilunar bones are united, but the general disposition is the same as that in the Cat.

Lastly, in the *Ox* and *Sheep* the carpus is only composed of six bones: four in the upper row, and only two in the lower, where the os magnum and trapezoides are consolidated. The supercarpal bone has no groove for gliding, and the pyramidalis articulates with the radius and cubitus. The bones of the lower row only articulate with the principal metacarpal bone. (Professor Gobaux, in 1865, exhibited specimens which go to prove that of the two bones of the lower row in the carpus of Ruminants, the internal really represents two; so that these animals actually have seven carpal bones like the Horse.)

2. *Metacarpal bones.*—The number of metacarpal bones varies much in the domesticated animals:—

In the Carnivora there are	5
In the Pig there are	4
In Ruminants there are.	2

The five metacarpals of the *Dog* and *Cat* articulate with each other, at their superior extremities, by lateral facets; they offer, at their inferior extremity, a condyle prolonged backwards by an articular surface resembling that of the Horse. The middle two are always longer than the two lateral. The smallest belongs to the fifth digit, or thumb, and is terminated inferiorly by a trochlea.

The four metacarpals of the *Pig* articulate with each other, as in the Carnivora. The second and third are larger than the first and fourth. The fifth metacarpal is not developed.

In *Ruminants* the metacarpal bones are two in number: a principal, which itself results from the consolidation of the second and third metacarpals, and another altogether rudimentary.

The principal metacarpal is channeled on its anterior face, and for its whole length, by a deep vascular fissure—a trace of the primitive separation of the bone in two pieces. This fissure presents, inferiorly, the anterior orifice of a canal that completely traverses the bone. The posterior face is also marked by a very slight longitudinal groove. The superior extremity exhibits, externally and posteriorly, a single diarthrodial facet for the articulation of the rudimentary metacarpal. The inferior extremity is divided by a deep notch into two articular surfaces, which together resemble the single surface in the Horse; each corresponds to one of the digits; the external is always smaller than the internal. In the fœtus, the two long bones that form the great metacarpal are simply laid together, and their medullary canals are separated from each other by the double partition which results from this apposition; after their coalescence, however, the partitions are completely destroyed by resorption, and in a short time there is only a single medullary canal for the entire bone.

The rudimentary metacarpal is only a small osseous stylet, articulating, by a diarthrodial facet, behind and to the outside of the superior extremity of the principal metacarpal; it is sometimes absent in the *Sheep* and *Goat*.

3. *Digital Region.*—In the domesticated animals the number of complete digits is as follows:—

Carnivora	5
Pig	4
Ruminants	2

The five digits of the *Dog* and *Cat* are exactly analogous to those of Man. Thus, the external corresponds to the auricularis, the second to the annularis, the third to the medius, the fourth to the index, and the internal to the thumb.—The latter, very small, has only two phalanges and does not come into contact with the ground. Each of the first four is composed: 1, Of a first phalanx, to which are annexed two sesamoids; 2, A second phalanx, which yet represents a veritable long bone; 3, A conical phalangette, pointed, bent downwards, and hollowed at its base by a circular groove, in which is lodged the matrix of the claw. The small sesamoid (or navicular bone) is absent, but is replaced by a prominence of the ungual phalanx. The auricularis and index are alike, and not so long as the annularis and medius, which are the same in length.

The *Pig* has four complete digits articulating from the metacarpals; the thumb is absent. The index and auricularis, or fourth and fifth digits, are short, and do not usually rest on the ground.

Ruminants certainly possess four digits, but only two are perfect—the medius and annularis—and these articulate with the inferior extremity of the principal metacarpal. The two others—the index and auricularis - are in a rudimentary condition, and are represented by two small bones situated above and behind the metacarpo-phalangeal articulation.

In the *Ox*, *Sheep*, and *Goat*, each of the perfect digits comprises three phalanges and three sesamoids.

The *first phalanx* fairly represents the moiety of the phalanx in the Horse. It has no posterior imprints, but shows them on its inner surface for the attachment of several ligaments. This internal face is plane, and the external convex; these characters are repeated in the other two phalanges. It is also remarked in all the phalangeal bones, that the external articular facet of the extremities is always larger than the internal. Of the two *sesamoids*, the external is larger and less elongated than the internal. first particulate with each other, and with the They halanx by small diarthrodial facets.

The *second phalanx* is hollowed internally by a small medullary cavity.

The *ungual phalanx*, as a whole, resembles one of the lateral moieties of the os pedis of solipeds. This phalanx has no complementary fibro-cartilage, basilar process, or retrossal eminence, nor yet a cavity of insertion on the sides of the pyramidal eminence. The semilunar crest is replaced by an obtuse, thick, and rugged relief, which occupies quite the posterior limit of the inferior face of the bone. Three large canals penetrate the third phalanx, two to the base of the pyramidal eminence, and one towards the origin of the preplantar fissure. They form, in the interior of the bone, a vast sinus, giving rise to several vascular canals which open on the surface. There is only one foramen at the base of the pyramidal eminence in the *smaller Ruminants.*

Fig. 54.

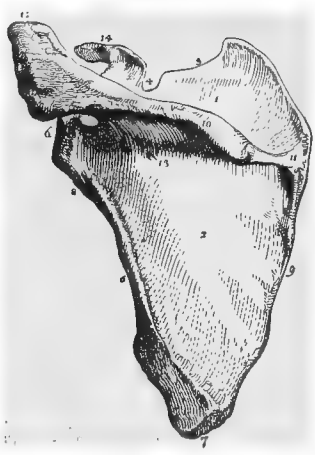

HUMAN SCAPULA; EXTERNAL ASPECT.

1, Supraspinous fossa; 2, Infraspinous fossa; 3, Superior border; 4, Suprascapular notch; 5, Anterior or axillary border; 6, Head of the scapular and glenoid cavity; 7, Inferior angle; 8, Neck of the scapula; 9, Posterior border; 10, Spine; 11, Triangular smooth surface, over which the tendon of the trapezius glides, with the tuberculum spinæ scapulæ between it and 10; 12, Acromion process; 13, Nutrient foramen, 14, Coracoid process.

COMPARISON OF THE THORACIC LIMB OF MAN WITH THAT OF THE DOMESTICATED ANIMALS.

A. SHOULDER.—The shoulder of man (fig. 54) has for its base two well-developed bones, the scapula and clavicle. The scapula is more distinctly triangular than that of all the domesticated animals; its vertebral border is also more extensive. The scapular spine, very

elevated, is followed by an acromion whose extremity reaches to above the scapulo-humeral articulation. The latter is separated from the remainder of the spine by a constriction called the pedicle of the acromion. The coracoid process is voluminous, and resembles a semi-flexed finger. The clavicle extends from the acromion to the sternum; it is flattened above and below, and flexed like an italic *S*. This inflexion of the clavicle is more pronounced in the male than the female.

B. Arm.—The humerus of Man is much longer than that of animals. Its diaphysis is prismatic and divisible into three faces: the deltoid imprint has the form of a V with its point directed downwards. The voluminous articular head is turned inwards; the

Fig. 55.

RIGHT HUMAN HUMERUS; ANTERIOR SURFACE.

1, Shaft; 2, Head; 3, Neck; 4, Greater tuberosity; 5, Lesser tuberosity; 6, Bicipital groove; 7, Interior bicipital groove; 8, Posterior bicipital ridge; 9, Rough surface for insertion of deltoid; 10, Nutrient foramen; 11, Eminentia capitata; 12, Trochlea; 13, External condyle; 14, Internal condyle; 15, External condyloid ridge; 16, Internal condyloid ridge; 17, Fossa for the coronoid process of ulna.

Fig. 56.

HUMAN ARM-BONES; FRONT VIEW.

1, Shaft of ulna; 2, Greater sigmoid notch; 3, Lesser sigmoid notch; 4 Olecranon process; 5, Coronoid process; 6, Nutrient foramen; 7, Ridges for insertion of interosseous membrane; 8, Capitalum ulnæ; 9, Styloid process; 10, Shaft of radius; 11, Its head; 12, Its neck; 13, Its tuberosity; 14, Oblique line; 15, Lower end of bone; 16, Styloid process.

bicipital groove is single, and looks outwards. The inferior articular surface resembles that of animals, except that the condyle is more distinct.

C. Fore-arm.—The two bones of the fore-arm, as we have already seen, only articulate by their extremities; they are separated from one another in their middle part. The superior extremity of the radius corresponds to the condyle of the humerus; that of the ulna articulates with the humeral trochlea. The coronoid process belongs to the ulna. At the lower extremity of the fore-arm it is remarked: 1, That the radius corresponds to the greater portion of the carpus, while the ulna only articulates with the pyramidalis; 2, That the radio-carpal articulation is protected outwardly and inwardly by two small osseous prolongations, the styloid processes of the ulna and radius.

D. Hand.—1. *Carpus.*—The carpus of Man is composed of eight bones—four in each

row. The three first of the upper row articulate with the radius; the fourth responds to the ulna. In the bones of the lower row, the *trapezium* responds to the metacarpal of the thumb and that of the index the *trapezoides* to the latter only, the *os magnum* and *unciform* to the metacarpals of the medius, annularis, and little finger. The pisiform bone and the cuneiform process of the unciform convert the posterior face of the carpus into a channel.

2. *Metacarpus.*—The five metacarpals of Man are parallel to each other, and articulate by their superior extremities with the bones of the carpus; by their inferior extremities with the phalanges. They are all concave in their middle portion, and thickened at their ends. The metacarpal of the thumb is the shortest and strongest. The others diminish in volume from the fourth to the first.

3. *Digital Region.*—Here we find five digits, each composed of three bony columnettes, with the exception of the thumb, in which only the second and third phalanges are present. They decrease in length from the third to the first, and the third to the fifth. The first and second phalanges are small semicylindrical bones, slightly thickened at their extremities. The ungueal phalanges are constricted in their middle, and widened like a horse-shoe at their inferior extremity; the palmar face is roughened, the dorsal face smooth.

Fig. 57.

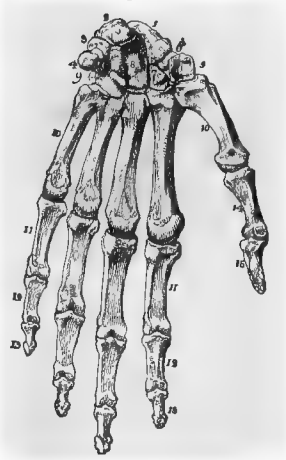

PALMAR SURFACE OF LEFT HUMAN HAND.

1, Scaphoid bone; 2, Semilunare; 3, Cuneiform; 4, Pisiform; 5, Trapezium; 6, Groove in trapezium for tendon of flexor carpi radialis; 7, Trapezoides; 8, Magnum; 9, Unciform; 10, 10, The five metacarpal bones; 11, 11, First row of phalanges; 12, 12, Second row; 13, 13, Third row; 14, First phalanx of the thumb; 15, Second and last phalanx.

Article V.—Posterior Limbs.

Each of these is divided, as already noted, into four secondary regions: the *pelvis*, *thigh*, *leg*, and *foot*.

PELVIS.

The pelvis is a kind of bony cavity formed by the union of the sacrum with two lateral pieces, the coxæ, which are consolidated with each other in the inferior median line. The description of the sacrum having been already given, it now remains to speak of the coxa.

A. Coxa.

The *coxa*, also designated *os iliacum*, *os innominatum*, is a very irregularly-shaped flat bone, double (with its fellow on the opposite side), and directed obliquely from above to below and before to behind. It is contracted in its middle part, which presents externally an articular cavity, the *cotyloid;* anteriorly, where it rests on the sacrum, it becomes widened, as it also does in its posterior portion, which is inflected inwards to be united, on the median line, with the bone of the opposite side.

It is divided, in the fœtus, into three distinct pieces, joined by cartilage in the centre of the cotyloid cavity, which the three concur in forming. Although they soon become consolidated into a single piece, it is customary to describe them as so many separate bones by the names of *ilium*, *pubis*, and *ischium*.

Ilium.—The *ilium*, a flat and triangular bone, curved on itself, directed obliquely from above to below, before to behind, and within outwards, forms the anterior portion of the coxa which corresponds with the sacrum. It is the most considerable of the three divisions, and has *two faces*, *three borders*, and *three angles*.

Faces.—The *external* or *superior face*, studded with some muscular imprints, is excavated on both sides, and is named the *external iliac fosssa.* The *internal* or *inferior face* offers for study: 1, An external portion, smooth, and crossed by some vascular grooves; this is the *iliac surface*, which is replaced in Man by an excavation called the *internal iliac fossa;* 2, An internal portion, roughened and uneven, presents, posteriorly, the *auricular facet*, an irregular diarthrodial surface, elongated from side to side, a little oblique in front and inwards, and responding to an analogous surface on the sacrum.

Borders.—The *anterior border*, or *crest of the ilium*, is slightly concave,

Fig. 58.

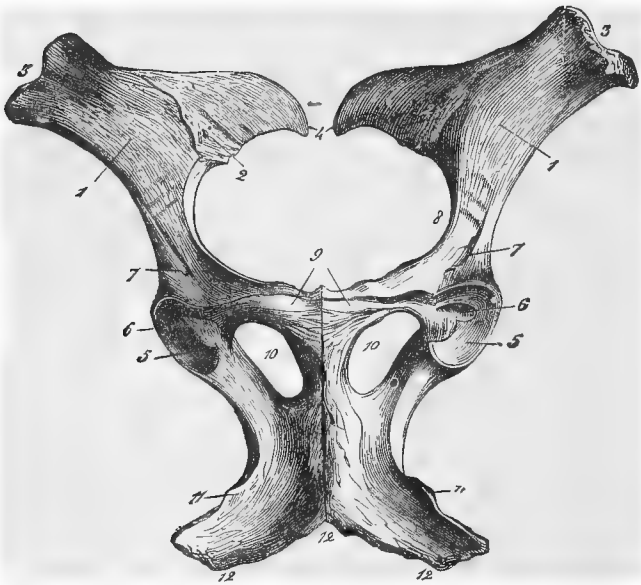

THE COXÆ; SEEN FROM BELOW.

1, Iliac surface; 2, Auricular facet; 3, Angle or crest of the ilium; 4, Angle of the haunch; 5, Cotyloid cavity; 6, Its bottom; 7, One of the imprints for the insertion of the anterior straight muscle of the thigh (rectus femoris); 8, Ilio-pectineal ridge; 9, Channel on the external face of the pubes; 10, Oval (or obturator) foramen; 11, Ischial spine; 12, 12, Ischial arch.

and bears a roughened lip for muscular insertion. The *external border* is thick, concave, and furrowed by vascular fissures; it presents, inferiorly, the nutrient foramen The *internal border* is thin and concave, particularly in its posterior part, which constitutes the *great ischiatic notch.*

Angles.—The *external angle*, or *anterior and superior spinous process*, is thick, wide, and flat, and bears four tuberosities: two superior and two inferior. The *internal angle*, or *posterior and superior spinous process*, represents a rugged tuberosity curved backwards and upwards.[1] The

([1] At the external angle of the ilium, there is sometimes found in the horse a process—often a very marked one—directed downwards, and completely enveloped by the external ilio-femoral muscle.)

posterior or *cotyloid* angle is prismatic and very voluminous. It exhibits: 1, Behind, a wide concave articular facet, which forms part of the cotyloid cavity; 2, Above this cavity, the supracotyloid crest, represented in Man by the *ischiatic spine.* This is an eminence elongated from before to behind, sharp on its summit, smooth inwardly, roughened outwardly, and continuous by its anterior extremity with the internal border of the bone; 3, Outwardly, two deep imprints for the insertion of the rectus muscle; 4, In front and inwards, the *ilio-pectineal eminence*, a small elongated prominence forming the most salient point of a kind of ridge (*linea ilio-pectinea*) that insensibly subsides above on the inner face of the ilium, and is continued below by the anterior border of the pubis.

Of the three angles of the ilium, the first is also termed the *angle of the haunch*, and the second the *angle of the croup.*

PUBIS.—Situated between the ilium and ischium, elongated from side to

Fig. 59.

PELVIS; FRONT VIEW.

1, Crest and anterior spinous process of the ilium; 2, Angle of the croup, with the auricular facets proceeding from it; 3, Shaft of the ilium, with the ilio-pectineal crest; 4, Cotyloid cavity; 5, Symphysis pubis; 6, Ischiatic tuberosity.

side, flattened above and below, and irregularly triangular, the pubis, the smallest of the three divisions, is divided for convenience of description into *two faces, three borders*, and *three angles.*

Faces.—The superior, smooth and concave, concurs in forming the floor of the pelvis. It shows one or two nutrient foramina. The *inferior* is roughened, and marked throughout its length by a wide channel which reaches the bottom of the cotyloid cavity. This fissure lodges the pubio-femoral ligament and a very large vein.

Borders.—The *anterior* is constituted by a thin rugged lip, which is curved upwards. The *posterior*, thick and concave, circumscribes anteriorly a wide opening, the *oval, subpubic*, or *obturator foramen;* it is channeled near the cotyloid angle by a fissure which runs obliquely inwards and downwards. The *internal* is united with that of the opposite pubis to form the pubic portion of the pelvic symphysis.

Angles.—The *external*, also named the *cotyloid angle*, is the thickest of the three. To it chiefly belongs the rugged depressed surface that constitutes the bottom of the cotyloid cavity. The *internal* unites with the analogous angle of the opposite pubis. The *posterior* is consolidated at an early period with the antero-internal angle of the ischium, to inclose, inwardly, the oval foramen.

Ischium.—This is the mean, in volume, of the three pieces of the coxa. Situated behind the pubis and ilium, it is flattened above and below, and of a quadrilateral form. It offers for study: *two faces, four borders*, and *four angles*.

Faces.—The *superior* is smooth and nearly plane, and forms part of the floor of the pelvic cavity. It has a small nutritious foramen directed outwards. The *inferior* presents some rugosities clustered particularly about the symphysis.

Fig. 60.

PELVIS; LATERAL VIEW.
1, Crest of the ilium; 2, Angle of the croup; 3, Shaft of the ilium; 4, Cotyloid cavity, or acetabulum; 6, Ischial spine.

Borders.—The *anterior*, thick and concave, circumscribes the oval foramen posteriorly. The *posterior*, straight and directed obliquely forwards and inwards, forms, with the analogous border of the opposite bone, a large notch named the *ischiatic arch*. It exhibits, throughout its extent, a rugged depressed lip (the *spine*), arising from the side of the inferior face. The *external*, thick and concave, constitutes the *lesser ischiatic notch*. The *internal* is joined to the ischium of the other side to constitute a portion of the pelvic symphysis.

Angles.—The *antero-external* or *cotyloidean* is the most voluminous of the four, and affords for study: 1, An excavated diarthrodial facet, making part of the cotyloid cavity; 2, The posterior extremity of the super-cotyloidean crest, limited by a small transverse fissure which separates it from the external border of the bone. The *antero-internal angle* is consolidated with the posterior angle of the pubis. The *postero-external angle* forms the *ischiatic tuberosity*. This is a large prismatic process which looks upwards, and is prolonged by a salient ridge, elongated from before to behind, with its sharp border turned outwards and downwards. The *postero-internal angle*

forms, with that of the other ischium, the summit of the triangular space which constitutes the ischiatic arch, or pubic arch of some species.

THE COXA IN GENERAL.—The bone whose three constituent parts we have just been studying, presents for consideration, as a whole, a middle portion and two extremities. The middle, very much contracted, offers, outwards and downwards, the *cotyloid cavity* (or *acetabulum*), which has not yet been described, because its study does not properly pertain to either of the three regions of the coxa. This cavity is intended to receive the articulating head of the femur, and represents the segment of a hollow sphere; it is circumscribed by a very salient rim which is thin at its free margin and widely notched on the inner side. The deeper portion is occupied by the roughened and depressed surface already designated as the *bottom* of the cotyloid cavity (*fundus acetabuli*), and which communicates by the internal notch of the rim with the inferior groove of the pubis. The anterior extremity, flattened on both sides, and formed by the ilium, rests, as has been shown, on the sacrum. The posterior extremity, flattened in an inverse sense to the preceding, is constituted by the pubis and the ischium, and traversed, from above to below, by the sub-pubic (or *obturator*) foramen, the large oval aperture which separates these two bones from one another, and perforates the floor of the pelvis; this opening is closed in the fresh state by muscles.

The two coxæ, by uniting in their posterior part, form the articulation to which has been given the name of *ischio-pubic* or *pelvic symphysis;* thus united, the two bones represent something like a V with the opening in front; a circumstance which makes the lateral diameter of the pelvis greater in front than behind.

STRUCTURE AND DEVELOPMENT OF THE COXA.—To the three centres of ossification which constitute the coxa, are added two complementary centres: one for the anterior spinous process and spine of the ilium, another for the ischiatic tuberosity.

In youth, the different parts of the coxa are very thick, and the spongy tissue is abundant, while the compact is rare. The pubis is always convex on its two faces, and the middle part of the coxa—that adjoining the cotyloid cavity—is of considerable thickness, a feature which much diminishes the extent of the pelvic reservoir. As the animal advances in age, however, the layers of compact tissue increase in thickness, approaching each other as the spongy substance is lessened. The pubis becomes thinnest, and at an advanced period of life is sometimes even translucid.

The compact tissue is always abundant in the neighbourhood of the cotyloid cavity, as this is the centre on which converge all the impulsive efforts communicated to the trunk by the posterior limbs. It is also in this cavity that ossification commences.

B. The Pelvis in General.

1. EXTERNAL AND INTERNAL CONFORMATION OF THE PELVIS.—The pelvis is a kind of rear cavity in the form of a cone, which prolongs the abdominal cavity.

It occupies the posterior part of the trunk, and with regard to its conformation, presents for study an external and an internal surface.

External surface.—This may be resolved into four regions or faces.

The *superior region* is slightly oblique from above to below, and before to behind; its degree of obliquity varies. It is contracted from before to behind, and shows: 1, On the median line, the spinous processes of the sacral and the first coccygeal vertebræ; 2, On each side the sacral grooves, at the bottom of which open the supersacral canals.

The *inferior region* is nearly horizontal. Formed by the pubes and ischia, it presents from before to behind: 1, In the middle, the ischio-pubic symphysis; 2, On each side the subpubic groove, the oval foramina, and the inferior face of the ischia; 3, Quite externally, the cotyloid cavities, by which the pelvis rests on the posterior limbs.

The *lateral regions* are oblique from above to below and within to without, and wider in front than behind. They exhibit: 1, The spine of the ilium and the two anterior spinous processes; 2, The external iliac fossa; 3, The ischiatic arch; 4, The supercotyloid crest or ischiatic spine, which presents outwardly the surface of insertion for the internal or deep gluteus muscles; 5, The lesser ischiatic notch; 6, The ischiatic tuberosity.

Internal surface.—The internal surface of the Horse's pelvis cannot be divided into two portions as in Man, because the inner aspect of the iliac bones is not hollowed out to form an anterior cavity.

The pelvis of Solipeds is, therefore, a simple conoid cavity, in which are distinguished four regions or faces, and two apertures called the *inlet* and *outlet.*

The *anterior opening* or *inlet* is nearly circular, especially in the Mare, and a little oblique downwards and backwards. It is limited above by the inferior face of the base of the sacrum; inferiorly, by the anterior border of the pubis; and on the sides by a portion of the inner face of the iliac bones, and also the internal aspect of the pectineal crests.

The inlet presents four diameters: a vertical, horizontal, and two oblique. The first extends from the inferior face of the sacrum to the anterior border of the pubic symphysis; its mean length is $8\frac{1}{4}$ inches. The second is measured from one pectineal crest or eminence to another; the mean of this is $8\frac{6}{10}$ inches. The two last diameters are estimated from the inferior face of the sacro-iliac articulation of one side to the ilio-pectineal eminence of the other; this is on an average $8\frac{7}{10}$ inches. These measurements irrefutably demonstrate that the inlet is not elliptical in the vertical direction.

The *posterior aperture* or *outlet*, situated at the posterior end of the pelvic cavity, gives exit to the rectum and genital organs. As the pelvis of the horse is horizontal, the outlet should be considered as limited, we think, by the inferior face of the summit of the sacrum, the superior face of the ischia, the supercotyloid crest or ischiatic spine, and the internal face of the sacro-ischiatic ligaments. At the outlet only two diameters are recognised: a vertical and a horizontal. The vertical measures on an average $6\frac{7}{10}$ inches; it extends from the inferior face of the sacrum to the superior face of the ischial symphysis. The horizontal diameter, comprised between the two supercotyloid crests, is $7\frac{7}{10}$ inches.

The *superior region* of the pelvic cavity is a little concave from before to behind; it has for base the sacrum, which presents on each side of the median line the subsacral foramina. This part is also called the sacral plane or roof of the pelvis.

The *inferior region*, or ischio-pubic plane, is formed by the pubis and the ischia. It is concave from side to side; its anterior border is nearly straight, and its posterior border is scooped out by a wide notch to form the *arch of the ischium.*

It has been remarked by M. Gobaux, that the portion of this plane corresponding to the pubis presents numerous varieties. The superior face of the pubis may be convex in its anterior moiety and concave in its posterior; or it may be concave before and convex behind, the concavity being separated from the convexity by a transverse ridge. This ridge is sometimes represented by a series of small conical eminences; at other times this upper face is

disposed as a smooth inclined plane, directed backwards and upwards, and a kind of rim surmounts the anterior contour of the oval foramen.

With regard to the *lateral regions*, they are formed by a small portion of the inner face of the ilia, and in great part by the sacro-sciatic ligaments.

2. Differences in the Pelvis of the Sexes.—The pelvis of the Mare exceeds that of the Horse in all its dimensions, but the difference is most marked in the transverse diameters.

The anterior inlet forms a vast circumference when compared with that of the male; the pectineal crests are widely apart, and the distance separating the anterior border of the pubis from the lower face of the sacrum is considerable.

If the pelvis be viewed in its superior plane, it is found that in the Mare the ischiatic notches are very deep; that the internal border of the ilium forms a regularly curved and very concave line; and that the supracotyloid crests, or ischiatic spines, are widely separated from each other. It is also noticed that the floor of the pelvis is wide, and that the bones composing it tend towards the same horizontal plane.

In the male, the ischiatic border is only represented by a very curved line; this line is composed of two almost straight portions, which join at an obtuse angle at the origin of the neck of the ilium; the supracotyloid crests are relatively near each other, and bent towards the longitudinal axis; while the two moieties of the pelvic floor are directed very obliquely downwards and inwards.

In the Mare, the ischial arch is larger than in the male, and forms a regular curve uniting the two tuberosities of the same name. In the Horse, the two ischiatic tuberosities are but little apart from each other, and the ischial arch forms a somewhat acute angle whose borders are nearly straight.

Lastly, when the pelvis is examined in its inferior plane, in addition to the features already indicated in the ischiatic arch, it is found that in the Mare the obturator foramina are large and nearly circular, while in the Horse they are elliptical; the cotyloid cavities are also further removed from the ischio-pubic symphysis in the female than the male.

The sacrum of the Mare has appeared to us, in some individuals, to be a little more arched from before to behind than that of the Horse; but this character is not constant.

The following figures relating to the capacity of the pelvis in the Mare and Horse confirm what has just been enunciated.

MARE. Horizontal Diameters.		HORSE. Horizontal Diameters.	
Between the Pectineal Crests.	Between the Supercotyloid Crests.	Between the Pectineal Crests.	Between the Supercotyloid Crests.
Inches. $9\frac{1}{5}$	Inches. $7\frac{1}{2}$	Inches. $8\frac{1}{14}$	Inches. $6\frac{4}{10}$
MARE. Vertical Diameters.		**HORSE. Vertical Diameters.**	
Between the Sacrum and Pubis.	Between the Sacrum and Ischium.	Between the Sacrum and Pubis.	Between the Sacrum and Ischium.
Inches. $8\frac{9}{10}$	Inches. $6\frac{9}{10}$	Inches. 8	Inches. $6\frac{3}{10}$

To recapitulate, there is observed in the pelvis of the Mare:

1. A great increase in the transverse diameters;
2. A deep and regularly concave ischiatic notch;
3. A wide and concave ischial arch;
4. Circular obturator foramina;
5. The cotyloid cavities distant from the pubic symphysis.

THIGH.

This has for its base one bone, the *femur*.

Femur.

The *femur* is a long, pair bone, situated in an oblique direction downwards and forwards, between the coxa and the principal bone of the leg; it is divided into a *body* and *two extremities*.

Body.—It is irregularly cylindrical, and presents for study *four faces*. The *external*, *internal*, and *anterior*, confounded with one another, are regularly rounded and almost smooth, showing only some slight imprints and vascular grooves. The *posterior*, nearly plane, and wider above than below, offers: 1, Outwardly and towards the superior third, an uneven circular surface; 2, On the same level, and inwardly, a slight crest, oblique downwards and outwards; 3, In the middle, a very extensive roughened surface, having the form of an obliquely angular parallelogram, for the attachment of the great adductor muscle of the thigh; 4, Below this surface, a large vascular groove running obliquely outwards and downwards.

On the limit of the posterior and external faces are found, towards the upper third, a large rugged, flattened eminence, curved in front, and termed the *subtrochanterian crest*,[1] because of its position under the trochanter; below, a deep fossa, named the ~~*sub*~~*condyloid*, garnished at its bottom with asperities and bordered in front by an uneven lip. On the limit of the posterior and internal face, there is observed from above to below: 1, The *small trochanter*, a large scabrous tuberosity, elongated in conformity with the bone, and situated near its upper fourth; 2, A marked longitudinal imprint for the attachment of the pectineus; behind, it is confounded with the surface for the insertion of the great adductor muscle of the thigh, and presents, in front, the nutrient foramen of the bone; 3, The origin of the great posterior fissure; 4, Quite below, a collection of large tubercles which form the *supracondyloid crest*.

Extremities.—The *superior extremity* is sensibly flattened before and behind, and shows: 1, Inwardly, an articular head which is received into the cavity of the acetabulum. This head is separated from the other portion of the body by a neck, which is, however, not well marked in the Horse, and forms two-thirds of a sphere, excavated in its internal part by a very deep cavity for ligamentous insertion, 2, Outwardly, a very large eminence, the *trochanter*, or *great* (*external*) *trochanter*, in which is recognised, as in the trochlea of the humerus: a *summit*, much more elevated than the articular head and slightly bent inwards; a *convexity*, incrusted with cartilage and anterior to the summit, from which it is separated by a narrow and deep notch; a *crest* situated under the convexity, and formed by a tuberculous surface on which one of the tendons of the middle gluteus muscle becomes

[1] This is the third trochanter of Cuvier, and takes the place of the external and superior branch of the *linea aspera* of Man. (It is the *external small trochanter* of Percivall and the *middle trochanter* of Leyh.)

inserted, after gliding over the convexity; 3, Posteriorly, the *fossa of the trochanter*, or *digital fossa*, a deep cavity studded with imprints and circumscribed, outwardly, by a salient lip which descends vertically from the summit of the trochanter to the posterior face of the bone, where it gradually subsides.

The *inferior extremity* is flattened on both sides; consequently, its larger axis crosses at a right angle that of the upper extremity. It is distinguished

Fig. 61.

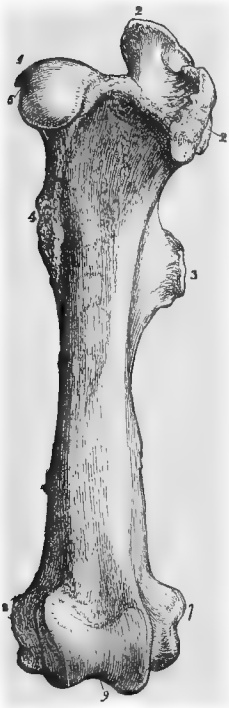

LEFT FEMUR; ANTERIOR VIEW.

1, Head; 2, 2, Trochanter major, with its crest; 3, Trochanter minor externus, subtrochanterian crest, or third trochanter; 4, Lesser, or internal trochanter; 5, Notch for insertion of ligamentum teres; 7, 8, Tuberosities for tendinous and ligamentous insertion; 9, Trochlea.

Fig. 62.

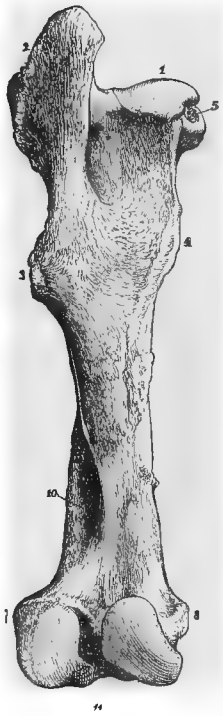

LEFT FEMUR; POSTERIOR VIEW.

1, Head; 2, Great trochanter; 3, Third, or trochanter minor externus; 4, Lesser, or internal trochanter; 5, Fossa for insertion of ligamentum teres; 6, Trochanterian fossa; 7, 8, Tuberosities; 9, Fossa for the insertion of the external meniscus; 10, Supracondyloid fossa; 11, Condyles.

by the presence of *two condyles* and *a trochlea*. The *two condyles*, placed one beside, the other behind, correspond to the superior extremity of the tibia. They are separated by a deep depression designated the *intercondyloid fossa*, which lodges the spine of the tibia and the interosseous ligaments of the femoro-tibial articulation. The *external condyle* bears outwardly two fossæ: one superior, for ligamentous insertion; the other, inferior, for muscular

attachment. The *internal condyle* presents, posteriorly and inwardly, near the posterior extremity of the intercondyloid notch, a roughened depression for the insertion of the fibro-cartilaginous meniscus interposed between the external condyle and the corresponding articular plane of the tibia. It is surmounted outwardly, i.e., on the side opposite to the intercondyloid notch, by a large tubercle of insertion. The *trochlea*, a wide pulley on which the patella glides, is situated in front of the condyles. It is slightly oblique downwards and inwards, and appears to continue in front the intercondyloid notch. Of the two lips which border its cavity laterally, the internal is the thickest and the most prominent. Between the external and the corresponding condyle is seen a digital fossa for muscular insertion.

Fig. 63.

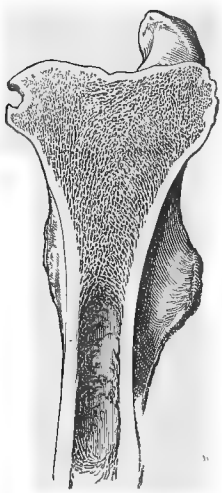

SECTION OF LEFT FEMUR, SHOWING ITS STRUCTURE.

Structure and development.—The femur, very spongy at its extremities, is developed from four principal centres of ossification: one for the body, another for the articular head, the third for the trochanter, and the last for the inferior extremity alone.

LEG.

This has for its base three bones: the *tibia*, *peroneus* (or *fibula*), and the *rotula* (or *patella*).

1. *Tibia.*

The *tibia* is a long, prismatic bone, thicker at the superior than the opposite extremity, and situated between the femur and the astragalus, in an oblique direction downwards and backwards, constituting the principal portion of the leg.

Body.—This offers for study *three faces* and *three borders*. The *faces* are wider above than below. The *external* is almost smooth, and is concave in its superior part and convex below, where it deviates to become the anterior. The *internal*, slightly convex on both sides, presents, superiorly, deep imprints for the attachment of the adductor muscles of the thigh and the semitendinosus. The *posterior*, nearly plane, is divided into two triangular surfaces: one, superior, slightly roughened, serves for the attachment of the popliteus muscle; the other, inferior, much more extensive, is furrowed into numerous longitudinal crests which give attachment to the perforans muscle. On the limit of these two surfaces is remarked the nutrient foramen of the bone. The *borders* are distinguished as *anterior*, *external*, and *internal*. The *first* is rounded, and not very salient in its inferior two-thirds; it forms in its superior third, a curved crest, with the concavity external, which joins the anterior and superior tuberosity of the bone; this has received the name of the *tibial crest*. The *external border* is very thick and concave above, where it constitutes, in common with the fibula, the *tibial arch*. The *internal* is also very thick straight, and provided superiorly with some salient tubercles to which the popliteus is attached.

Extremities.—The *superior extremity*, the most voluminous, is formed by three tuberosities, an anterior and two lateral, which are external and internal. The *first*, the smallest, is a rugged process continuous with the tibial crest, and separated from the external tuberosity by a wide and

deep groove in which passes a tendinous cord; it is excavated, in front, by a vertically elongated fossa which lodges the middle ligament of the patella. The *external tuberosity*, medium in size and the most detached, has outwardly an articular facet for the head of the fibula. The *internal tuberosity*, the largest and least detached, presents: on the sides, ligamentous imprints; behind, a small tubercle which gives attachment to the posterior crucial ligament of the femoro-tibial articulation. The superior face of the two lateral tuberosities is occupied by two large irregular and undulated articular surfaces, which respond to the condyles of the femur through the medium of the two meniscus-shaped fibro-cartilages interposed between the two bones. Of these two surfaces the external is always the widest, because it serves, by its posterior part, for the gliding movements of the popliteal tendon. They are separated from each other by the *tibial spine*, a conical articular eminence divided into two lateral parts by a groove of insertion excavated at its base, and in front by two lateral facets for the insertion, anteriorly, of the two inter-articular cartilages; it is bordered behind by another fossa which receives the posterior insertion of the internal meniscus.

Fig. 64.

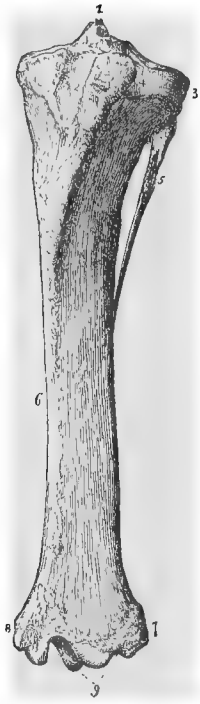

POSTERIOR VIEW OF RIGHT TIBIA.

1, Tibial spine; 2, Fossa for the insertion of the internal meniscus; 3, External tuberosity with articulation for the fibula; 4, Fossa for the insertion of external meniscus; 5, Fibula, forming with the tibia the tibial arch; 6, Shaft, or body of the tibia; 7, 8, External and internal malleoli, inferior tuberosities, or lateral processes of the tibia; 9, Articular trochleæ with a median ridge, for articulation with the astragalus.

The *inferior extremity*, flattened behind and before, exhibits an articular surface moulded on the pulley of the astragalus, and two lateral tuberosities. The *articular surface* is formed by two deep cavities oblique from behind to before and within outwards, and separated by a median tenon which terminates posteriorly by a very prominent projection on which the bone rests when it is made to stand vertically on a horizontal plane. The *external tuberosity*[1] projects but little, and is traversed in its middle by a vertical fissure. The *internal tuberosity*,[2] better defined, is margined posteriorly by an oblique channel.

Structure and development.—The tibia is very compact in its inferior portion, and is developed from four chief centres of ossification. The body is formed by one and the superior extremity by two, the anterior tuberosity taking one of these; the last develops the whole of the inferior extremity. It is rare to see the external tuberosity of this extremity formed from a separate nucleus.

2. *Fibula* (*or Peroneus*).

A small, undeveloped bone, elongated and styloid in shape, situated outside the tibia, and extending from the superior extremity of that bone to the middle or lower third of its body.

The *middle portion* of the fibula is thin and cylindrical, and forms above, in common with the external border of the larger

[1] The *external malleolus* of Man. [2] The *internal malleolus*.

bone, the tibial arch. Its *superior extremity*, wide and flattened on both sides, has received the name of *head;* it offers, on its internal face, a diarthrodial facet to articulate with the external and superior tuberosity of the tibia; on its external face it shows ligamentous imprints. The *inferior extremity* of the fibula terminates in a blunt point, and gives attachment to the ligamentous fibres that unite it to the tibia.

The fibula is sometimes continued to the external inferior tuberosity of the latter bone, with which it is confounded; and as it is particularly under such circumstances that this tuberosity has been noticed to be developed from a special nucleus, it seems quite natural, having regard to the disposition observed in pachyderms and carnivores, to consider it as the inferior extremity of the fibula joined to the tibia. With these animals, indeed, the tuberosity or external malleolus is formed by the inferior extremity of the fibula.

Structure and development.—This bone is very compact, and developed from a single nucleus of ossification.

3. *Patella.*

A small, short, and very compact bone, situated in front of the femoral trochlea, and annexed to the tibia, to which it is attached by three extremely solid ligamentous bands.

The small polyhedron which it represents only offers for observation three faces: the *superior*, roughened, and serving for the insertion of the triceps cruralis and rectus muscles; the *anterior*, convex and irregular; and the third, the *posterior*, moulded on the femoral trochlea, to which it is but imperfectly adapted. In the fresh state, however, the articular surface formed by the latter face is completed by a fibro-cartilaginous apparatus, which will be noticed when describing the femoro-tibial articulation. This articular surface is composed: 1, Of a median ridge, which occupies the bottom of the trochlear cavity; 2, Of two depressed, gliding, lateral facets on the sides of this cavity; the internal facet is always larger than the external, a disposition which permits the patella of one limb to be distinguished from that of the other.

POSTERIOR FOOT.

This region, which bears the greatest resemblance to the same region in the anterior limb, comprises three subdivisions: the *tarsus*, *metatarsus*, and the *digital region*.

1. *Bones of the Tarsus.*

These are short, very compact bones, six or seven in number, and situated between the inferior extremity of the tibia and the superior extremity of the metatarsal bones; they are arranged, like the bones of the carpus, in two tiers—a superior and an inferior.

The superior row only comprises two bones, the largest; these are the *astragalus* and the *calcaneus* (or *calcis*). The inferior row is formed, outwardly, by the cuboides alone; inwardly and anteriorly, it is subdivided into two secondary rows, the superior of which is constituted by the *scaphoides*, and the inferior by the *large* and *small cuneiform* bones. The last is sometimes divided into two, in which case there are three cuneiforms; then the total number of the bones is seven.

Astragalus.—An irregular cubical bone, situated in front of the

calcaneus, between the tibia and the scaphoid, and divided into *five faces*:—

Fig. 65.

LEFT HIND FOOT; EXTERNAL ASPECT.

1, Tibia; 2, Summit of calcis or calcaneus; 3, Astragalus; 4, Cuboid; 5, Scaphoid; 6, Cuneiform magnum; 7, Large metatarsal bone; 8, Small metatarsal bone; 9, Suffraginis, proximal, or first phalanx; 10, Sesamoid bones; 11, Coronary, second, or middle phalanx; 12, Pedal bone, or third or distal phalanx; 14, Navicular bone; 15, Basilar process of pedal bone.

1, A *superior* and *anterior*, formed as an articular pulley to correspond to the inferior extremity of the tibia; this pulley, oblique from above downwards, forwards, and outwards, may be considered as the type of the most perfect trochlea in the organism; its groove receives the median tenon of the tibia, and its two ridges or lips fit into the lateral furrows of that bone. 2, An *inferior face*, occupied by a slightly convex articular surface responding to the scaphoid; this surface is notched outwardly by an excavation for ligamentous insertion. 3, A *posterior face*, irregular, cut into three or four diarthrodial facets adapted for similar facets on the calcaneus, and which are separated by a wide, rugged excavation. 4, An *external face*, covered with imprints. 5, An *internal face*, provided below with a small tubercle of insertion.

Calcaneus.—A bone vertically elongated, flattened on both sides, and presenting *two faces*, *two borders*, and *two extremities*.

The *external face* is smooth and nearly plane. The *internal face* is excavated into a gliding groove to form the *tarsal arch*, in which passes the tendon of the perforans. The *anterior border* is slightly concave. The *posterior border* is thicker, straight, and rugged. The *superior extremity*, slightly tuberous, constitutes the summit of the calcaneus, and is divided into three parts: a middle, which gives attachment to the tendon of the gastrocnemius; the other, the anterior, is a smooth surface on which this tendon rests when the foot is much flexed; the third, altogether posterior, also constitutes a gliding surface for the tendon of the perforatus. The *inferior extremity*, wide and voluminous, shows in front three or four articular facets which correspond to the astragalus, and are separated, like those of the last bone, by an irregular and slightly excavated surface of insertion. Below, it shows for articulation with the cuboid a fifth facet, continuous with one of the preceding.

Development.—The calcaneus is developed from two nuclei of ossification, one of which is for the summit.

Cuboid bone.—This little bone, situated at the external side of the scaphoid and the

large cuneiform bone, between the calcaneus and two of the metatarsals, does not resemble a cube, but a parellelopiped elongated from before to behind. It offers *six faces:* a *superior*, an articular face, and in contact with the calcaneus; an *inferior*, also articular, responding to the principal and external rudimentary metatarsal bones; an *internal*, furnished with three facets for contact with the scaphoid and great cuneiform, and crossed from before to behind by a fissure, which forms with these two bones a vascular canal; an *external*, an *anterior*, and a *posterior*, covered with imprints.

Scaphoid bone (the *large cuneiform* of Percivall).—Flattened above and below, it is described as having *two faces* and a *circumference.* The *faces*, both articular, are furrowed by a channel of insertion, and are distinguished as *superior* and *inferior.* The first is concave, and responds to the astragalus; the second is convex and in contact with the two cuneiform bones. The *circumference* offers, outwardly, two small facets which are adapted to similar facets on the cuboid bone. For the remainder of its extent, it is covered with imprints.

Great Cuneiform bone (the *middle cuneiform* of Percivall).—Flattened above and below, and triangular in shape, this bone is much smaller than the scaphoid, though resembling it in a striking manner. Its *superior face* is in contact with the latter bone, and its *inferior face* articulates with the middle and internal lateral metatarsal bones. Its *external border* is provided with one or two facets to correspond with the cuboid bone; and its *internal border* also offers one, which is in contact with another on the small cuneiform. Its *anterior border* is roughened throughout its extent.

Fig. 66.

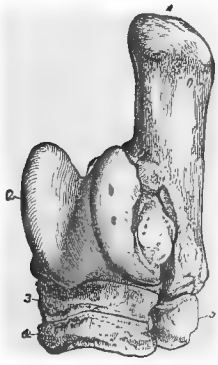

LEFT HOCK; FRONT VIEW.

1, Apex of calcaneus; 2, Astragalus, inner ridge; 3, Scaphoid; 4, Cuneiform magnum; 5, Cuboides.

Fig. 67.

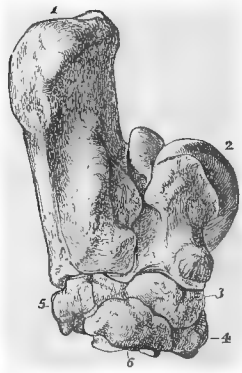

LEFT HOCK; INTERNAL ASPECT.

1, Apex of calcaneus; 2, Inner articular ridge of astragalus; 3, Navicular, scaphoid, or cuneiform medium; 4, Cuneiform magnum; 5, Cuboides; 6, Cuneiform parvum.

Small Cuneiform bone.—Situated at the inner side of the tarsus, this bone, the smallest of any yet examined, is elongated from before to behind, flattened on both sides, and wedged in between the os scaphoides, the large cuneiform bone, and the large and internal small rudimentary metatarsal bones, with which it corresponds by four articular facets: a superior, two inferior, and one internal. When this bone is in two portions, there are then three cuneiforms, which may be distinguished, as in Man, by naming them *first*, *second*, and *third.*

2. *Bones of the Metatarsus.*

These bones are three in number, a median and two lateral, and offer the greatest analogy to the metacarpal bones. This enables us to dispense with a general description of them, and to confine ourselves only to indicating the differential characters which distinguish them from the corresponding bones in the anterior limb.

The *principal*, or *median* metatarsal bone, is longer than the same metacarpal, and its body, instead of being slightly compressed before and behind, is nearly a regular cylinder. It presents outwardly a fissure which is directed at first obliquely backwards and downwards, and afterwards descends vertically along the lateral external metatarsal bone. The articular surface of the superior extremity is excavated in its centre by a large fossa of insertion. The inferior extremity is at the same time wider and thicker than that of the metacarpus.

Fig. 68.

POSTERIOR ASPECT OF LEFT METATARSUS.

1, Head of principal metatarsal bone; 2, 3, External and internal splint bones, or metatarsals of the rudimentary digits; 4, Rough surface for insertion of suspensory ligament; 5, Nutrient foramen; 6, Middle ridge of inferior articular surface.

Of the *two rudimentary (digital) or lateral metatarsal bones*, the external is always longest and thickest. The internal bears on the superior face of its head three articular facets, two of which respond to the small cuneiform, and the third to the large bone of that name.

3. *Bones of the Digital Region.*

The digital region of the posterior closely resembles that of the anterior limb. The analogy in the conformation of these bones is even pushed so far, that it becomes very difficult to distinguish them from one another.

It is remarked, nevertheless: 1, That the first phalanx is not so long as in the anterior limb, and less wide and thick at its inferior extremity, but is, on the contrary, wider and thicker at its superior extremity; 2, That the lateral diameter of the second phalanx is shorter; 3, That the third phalanx, less spread out towards its inferior border, has more the shape of a V, and that its inferior face is more concave; 4, That the sesamoids are less voluminous; 5, That the navicular bone is shorter and narrower.

DIFFERENTIAL CHARACTERS OF THE POSTERIOR LIMB IN OTHER THAN SOLIPED ANIMALS.

A. Pelvis.—It is remarked: 1, That in all the domesticated animals, with the exception of Solipeds, the direction of the coxæ is nearly horizontal; 2, That in all, except Solipeds, the ilium tends to assume a vertical direction; 3, That in all the transverse diameter of the pelvis is relatively less extensive.

In the *Ox*, *Sheep*, and *Goat*, the space between the two coxæ is scarcely so great in front as behind; the ilium is not voluminous, and has only three processes on the superexternal iliac spine. There is no furrow on the lower face of the pubis, and its upper face, like that of the ischium, is very concave. Three eminences are seen on the postero-external angle of the ischium. In early life, the ischio-pubic symphysis shows an epiphysary nucleus in the middle of its inferior face. (The epiphysis on the inner border of the ischium has been considered by some anatomists as an independent bone, and described by them as the *interischial bone.*)

The rim of the cotyloid cavity has also three notches, and the supracotyloid crest, or ischiatic spine, is very elevated and sharp, and but little roughened outwardly.

The external iliac fossa of the *Sheep* and *Goat* is separated into two portions by a small longitudinal crest.

The pelvis of the *Pig* closely resembles that of the smaller ruminants; though the crest of the ilium is convex, and there is no protuberance outside the ischio-pubic symphysis.

In *Carnivora* the lateral diameter of the pelvis is greater behind than in front. The ilium is nearly vertical, and its external face is much depressed. The notch forming the ischial arch occupies no more than the internal moiety of the posterior border of the ischium; between this arch and the ischiatic tuberosity is a rugged lip directed downwards. There is no furrow on the lower face of the pubis.

B. THIGH.—In all the domesticated animals except Solipeds, the *femur* tends to become curved, prismatic, and triangular; the posterior face contracts, and the surfaces of insertion that it presents gradually approach each other until they become confounded and form the *linea aspera* in certain species. The head is more distinct; the small trochanter is a rough tubercle, and is joined to the large trochanter by an oblique osseous lip; the latter trochanter subsides and forms a single mass whose summit and convexity are confounded; the third trochanter, the fossa, and the supracondyloid crest are more or less effaced.

In the *Ox*, there is no subtrochanterian crest; the supracondyloid fossa is shallow, and the crest little noticeable. The head is well detached and has its centre excavated by a shallow fossa of insertion. The trochlea is narrow, and its inner border ascends much higher on the anterior face of the bone than the external.

In the *Sheep* and *Goat*, the general form of the femur resembles that of the Ox. It is observed, however, that the body is slightly curved backwards; that the supracondyloid fossa is nearly obliterated; that the trochanter has subsided nearly to a level with the articular head, and that the trochlea is circumscribed by two equal-sized lips.

In the femur of the *Pig* there is also noticed a supracondyloid fossa, but it is wide and shallow; the rugosities of the posterior face are replaced by some salient lines; the trochanter is on a level with the head; the latter is supported by a somewhat constricted neck, and is situated within and in front of the great trochanter. This latter disposition changes the direction of the great axis of the superior extremity, which obliquely crosses that of the inferior extremity.

In the *Dog* and *Cat*, the femur is long and curved like a bow. The rugged surfaces of the posterior face are confounded, and form two crests representing the linea aspera of the human femur. These crests do not lie against each other in the middle portion of the bone; they are merely parallel, then they diverge above and below, to terminate beneath the great and small trochanters, and above the two condyles. The great trochanter is not so high as the articular head. The femur of Carnivora is also distinguished: 1, By the complete absence of the third trochanter and the supracondyloid fossa—this last being replaced by a small tubercle which terminates below the external branch of the linea aspera; 2, By the marked constriction and length of the neck supporting the articular head; 3, By the depth of the digital fossa, which is bordered by an oblique lip extending from the great to the small trochanter.

C. LEG.—In the leg-bone there is observed, in the various domesticated animals, differences analogous to those mentioned as existing in the *fore-arm* of the thoracic limb. More particularly is this the case with regard to the development of the *fibula;* in Ruminants this bone is reduced to its inferior nucleus. In these animals the patella is also very narrow; and in all the domesticated species except Solipeds, the articular grooves in the lower end of the tibia are directed immediately from before to behind.

In the *Ox*, the tibia is short; it is longer in the *Goat* and the *Sheep*. The *tibia* of these animals is remarkable for: 1, The absence of the lateral facet on the supero-external tuberosity; 2, The absence of a vertical fossa on the anterior tuberosity; 3, The absence of roughened lines on the posterior face; the obliquity downwards and inwards of the inferior articular surface. The most salient point of this surface is the anterior extremity of the middle tenon.

The body of the *fibula* and its upper extremity are replaced by a fibrous cord which is sometimes ossified wholly or in part.

In the *Pig*, the fibula is flattened on both sides, extends the whole length of the leg, and is united to the tibia by its two extremities: above, by a diarthrodial facet; below, by an interosseous ligament. It is developed from three ossific centres: the inferior articulates with the calcaneus and astragalus, and forms a prominence resembling the external malleolus.

In *Carnivora*, the tibia is long and slender, and presents a salient anterior crest. The

fibula is also as long as the tibia, and is united to that bone at three points: at the two extremities by articular surfaces, in the inferior third and middle by an interosseous ligament.

D. Posterior Foot.—1. *Bones of the tarsus.*—The number of tarsal bones varies a little in the domesticated animals, as the following list will show:

Carnivora and Pig	7
Ox, Sheep, and Goat	5

In the *Dog*, *Cat*, and *Pig*, there are three cuneiform bones, and in the *Ox* and *Sheep*, in addition to there being only two cuneiforms, the scaphoid and cuboid bones are consolidated into one piece.

The astragalus of the *carnivora* articulates with the scaphoid by means of a veritable head, separated from the rest of the bone by a constriction termed the neck of the astragalus. The cuboid and the cuneiform bones respond to all the metatarsals.

In the *Pig*, the astragalus and calcaneus are very long. The cuneiforms and cuboid respond to the four perfect digits.

The tarsus of the domesticated *Ruminants* is slender above. The astragalus is elongated from above to below, and is united to the scaphoid by an antero-posterior groove, and to the calcaneus by a more superficial vertical groove. The calcaneus is long and thin; the posterior gliding surface on the summit is excavated into a channel; the small cuneiform is pisiform and but slightly developed.

2. *Bones of the metatarsus.*—The metatarsus is also a region in which the number of bones varies in the domesticated animals. Thus in the *Carnivora* and *Pig* there are five, and only two in Ruminants.

The metatarsals of the *Carnivora* and *Pig* are exactly like the same bones in the anterior limb. Those of *Ruminants* are slightly different.

In the *Dog* and *Cat* are one rudimentary and four perfect metatarsals. The former is articulated with the internal cuneiform, and represents the vestige of the thumb.

The *Pig* has four perfect metatarsals, and an internal rudimentary one. The latter is a small bone flattened on both sides, articulating by means of a diarthrodial facet, and sometimes consolidated behind the upper end of the fourth metatarsal.

In the *Ox*, *Sheep*, and *Goat*, is found a principal and a rudimentary metatarsal bone. The latter is like the rudimentary metacarpal bone, but the former differs from the principal metacarpal bone in being longer, quadrilateral in form, and having a vascular canal traversing the posterior face of its upper extremity.

3. *Bones of the digital region.*—In all the domesticated animals, the posterior digits comport themselves exactly like the anterior. The Carnivora alone offer a notable difference; in them, in reality, the thumb does not exist, or rather, it is only represented by the rudimentary metatarsal bone alluded to above. Nevertheless, it frequently occurs that a completely developed thumb is found in this animal; and in this case the rudimentary metatarsal is ordinarily followed by a ligamentous cord, to which is suspended a bony stylet that represents either the inferior extremity of the metatarsal, or the first phalanx; it is to this stylet that are found articulated in succession the second and third phalanges.

(Professor Fuchs, of Carlsruhe, found, in a Newfoundland dog, four true claws and two false: the internal of the latter corresponded to a well-developed, small metatarsal bone, while the external was only rudimentary, terminating in a point, and bound to the tarsus by a simple ligament.)

COMPARISON OF THE ABDOMINAL LIMB OF MAN WITH THAT OF ANIMALS.

A. Pelvis.—The longitudinal axis of the pelvis of *Man* forms, with the horizon, an angle of about 40°.

The bones which compose it are proportionately larger and stronger than in all the domesticated animals.

The two faces of the ilium, and especially the inner face, are much hollowed; the iliac crest has the form of an italic *S*.

The pubis alone participates in the formation of the pelvic symphysis, and the concavity which, in the domesticated animals, is called the ischial arch, is designated in Man the pubic arch.

In consequence of the excavation on the inner face of the ilium, the pelvic cavity may be divided into the great and lesser pelvis In the latter are lodged the genital and urinary organs, as well as the extremity of the digestive tube.

B. Thigh.—The femur of Man is nearly vertical, and situated in a direction slightly

oblique downwards and inwards; it presents a curvature forwards. The body of the bone is prismatic and triangular in its middle part; the posterior border of this prism forms a somewhat salient crest, which takes the place of all the insertion eminences on the posterior aspect of the femur in animals, and is designated the *linea aspera*. This line bifurcates above and below; below, the branches margin a triangular or *popliteal space*.

Fig. 69.

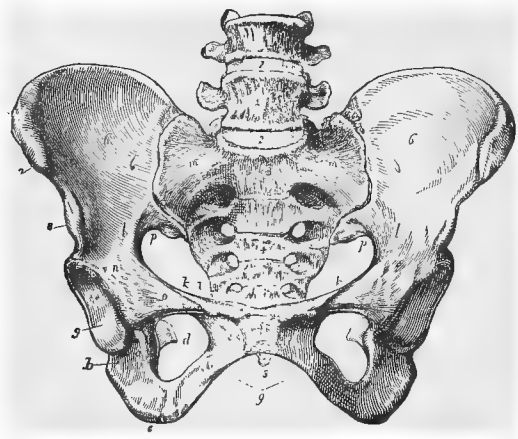

HUMAN PELVIS; FEMALE.

1, Last lumbar vertebra; 2, 2, Intervertebral substance; 3, Promontory of the sacrum; 4, Anterior surface of the sacrum; 5, Coccyx; 6, Iliac fossæ; 7, Antero-superior spinous process; 8, Antero-inferior spinous process; 9, Acetabulum.—*a*. Its notch; *b*, Body of ischium; *c*, Its tuberosity; *d*, Its spine; *e*, Pubis; *f*, Symphysis pubis; *g*, Arch of the pubes; *h*, Angle of os pubis; *i*, Spine of pubes, with crest between it and *h*; *k*, *k*, Pectineal line; *l*, *l*, Ilio-pectineal line, with its prolongation, *m*, *m*; *n*, Ilio-pectineal eminence; *o*, Smooth surface for femoral vessels; *p*, *p*, Great sacro-ischiatic notch.

The head is supported by a long neck, inserted obliquely into the superior extremity. The two condyles are joined together in front by the trochlea, which is wide and shallow.

C. Leg.—Three bones: the tibia, fibula, and patella.

The *tibia* is very long; its crest (or spinous process) is much more developed than in any of the domesticated animals, and describes a kind of curve like an italic *S*. On the inner aspect of the inferior extremity is seen a voluminous process which occupies, inwardly, a portion of the tibio tarsal articulation: this is the internal malleolus. The articular surface is not exactly formed to correspond with the whole articular surface of the astragalus.

The *fibula* is as long as the tibia. It is prismatic, and slightly twisted on itself. It articulates above and below with the tibia. The lower extremity responds to the astragalus, and forms a prominence named the external malleolus.

There is nothing particular to note in the patella.

D. Foot.—The *foot* of Man is situated in a horizontal direction. Its upper aspect is convex; its inferior face is excavated, and it rests on the ground by its two extremities.

1. *Tarsus*.—In the *tarsus* there are seven bones, three of which are cuneiform The astragalus articulates with the tibia and fibula; it responds to the scaphoid by a well detached convex articular surface, named the head.

In the bones of the lower row, it is remarked that the cuboid responds to the fifth and fourth metatarsals: the first cuneiform to the third; the second cuneiform to the second metatarsal, and the third to the first.

2. *Metatarsus*.—The metatarsus is composed of five bony columns, nearly parallel to each other. They are enumerated from without to within, and increase in length from the first to the fourth; the fifth is the shortest and most voluminous.

3. *Digital region.*—This comprises five digits or toes. The phalanges of these toes are analogous to those of the fingers, from which they are distinguished by their small size. They increase in volume from the first to the fifth digit.

Fig. 70. Fig. 71. Fig. 72.

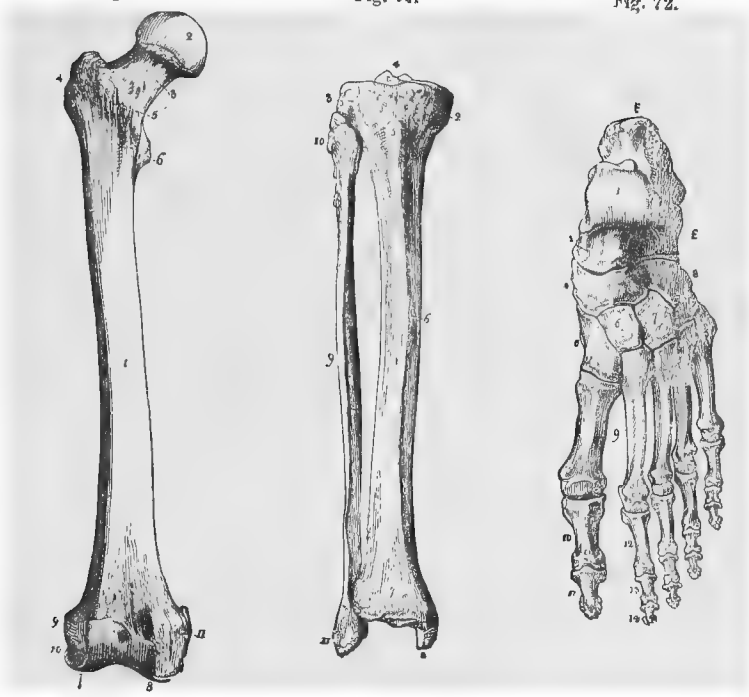

RIGHT HUMAN FEMUR; ANTERIOR ASPECT.

1, Shaft; 2, Head; 3, Neck; 4, Great trochanter; 5, Anterior intertrochanteric line; 6, Lesser trochanter; 7, External condyle; 8, Internal condyle; 9, Tuberosity for attachment of external lateral ligament; 10, Fossa for tendon of origin of popliteus muscle; 11, Tuberosity for attachment of internal lateral ligament.

HUMAN TIBIA AND FIBULA OF RIGHT LEG; ANTERIOR ASPECT.

1, Shaft of tibia; 2, Inner tuberosity; 3, Outer tuberosity; 4, Spinous process; 5, Tubercle; 6, Internal surface of shaft; 7, Lower extremity of tibia; 8, Internal malleolus; 9, Shaft of fibula; 10, Its upper extremity; 11, Its lower extremity; between 1 and 6 is the sharp crest of the tibia.

DORSAL SURFACE OF LEFT HUMAN FOOT.

1, Astragalus; 2, Its Anterior extremity articulating with the cuboid bone, 4; 3, 3, Calcis; 4, Scaphoid; 5, Internal cuneiform bone; 6, Middle cuneiform bone; 7, External cuneiform bone; 8, Cuboid bone; 9, Metatarsal bones of first and second toes; 10, First phalanx of great toe; 11, Second ditto; 12, 13, 14, Phalanges of second toe.

Article VI.—The Limbs in General and their Parallelism.

A. The Limbs in General.—The interrupted columns which compose the limbs are destined not only to support the trunk in a stationary attitude, but also to transport it during progression. This double destination gives rise to a difference between the anterior and posterior members. The front limbs,

being nearer the centre of gravity than those behind, have to sustain the largest share of the weight. They ought, consequently, to be specially organised as organs of support. Therefore it is that the four principal rays composing each of them—shoulder, arm, fore-arm, and foot—although flexed, or disposed to be flexed, in an inverse sense to one another, oppose to the pressure of the weight of the trunk, which tends incessantly to throw them down, obstacles purely mechanical, and of such energy that we may still understand how the body can be sustained on the anterior limbs, if we suppose all the muscular masses surrounding these bony rays removed except one.

Thus, the weight of the body is at first transmitted to the scapula through the muscles that attach that bone to the trunk. It then passes to the humerus, and from thence to the radius, to be thrown, finally, on the different pieces composing the foot. Now the humerus forming with the scapula an angle which is open behind, and with the bones of the fore-arm another angle open in front, the weight of the body pressing continually on these angles tends to close them, and thus cause the flexion of the bony rays. But this result is prevented by the combined action of two muscular powers—the biceps and the extensors of the fore-arm. With regard to the radius, carpus, and metacarpus, owing to their vertical direction they themselves support the pressure of the weight of the body without requiring any muscular aid. But the digital region, being directed obliquely forward and downward, forms, with the principal metacarpal, a third angle open in front, for the sustenance of which nature has given solid, inert, or contractile mechanical bands.

The anterior limbs are also agents of transport, for they can elevate the trunk by the spring of their bony rays, and fix themselves on the ground by their free extremity.

The posterior limbs are less favourably disposed than those in front to assume the function of columns of support, as their rays are for the most part in a state of permanent flexion, and joined in an angular manner to one another, as may be seen by glancing at the skeleton (See Figs. 1, 2, 3, 4, 5). It is therefore necessary that muscular agency should prevent the breaking-down of these rays. Though defective as supporting columns, they are nevertheless admirably designed to serve as agents of locomotion. The slightest erection of these inclined rays propels the mass of the body forward, and this impulsion is almost wholly transmitted to the trunk in consequence of the very intimate union of the pelvis with the vertebral column.

B. Parallel between the Anterior and Posterior Limbs.—After what has just been said, it will be seen that the anterior limbs are more particularly destined for the support of the body, while the posterior ones more especially play the part of impulsive agents in the locomotory acts.

Notwithstanding this difference in the functions assigned them, these two columns offer in their conformation such striking resemblances to each other, that some authors have been inclined to consider the posterior as an exact repetition of the anterior limb. The following is a brief analysis of the analogies existing between them.

At the end of the last century, Winslow and Vicq-d'Azyr, and nearer our own time, Cuvier, Flourens, Paul Gervais, Martins, Gegenbaur, and Lavocat, have occupied themselves with the parallelism existing between the anterior and the posterior members. All these anatomists did not absolutely arrive at the same conclusion; for several of them, forgetting that the question should be examined in the whole animal series, made Man alone the subject of their

meditations. In such a matter, it must not be forgotten that the limbs are constructed with a view to their physiological functions, and that the differences remarked in examining them in several species are dictated by the kind of life the animals are intended to lead.

Vicq-d'Azyr and Cuvier recommend that the anterior and posterior limbs of opposite sides should be compared. Martins and Gegenbaur, allowing a torsion of the humerus of 180°, advise that the two members of the same side should be collated, care being taken to make allowance for the untwisting of the 180° contortion at the lower end of the humerus. Lastly, Flourens and Lavocat contrast the two members of the same pair with each other, after placing the hand in a position of natural pronation by rotation of the radius on the ulna, and without turning either limb or ray, or even a portion of a ray, no matter what kind of animal may be under examination. We will adopt the latter proceeding, as it is the simplest and most natural.

Parallel between the coxa and scapula.—The analogies existing between these two bones are but little striking at first sight; nevertheless, with attention there is no difficulty in finding in the coxa the three pieces that enter into the composition of the shoulder.

The ilium represents the scapula. The external iliac fossa reminds one of the supra- and subspinous fossæ. Occasionally, there is met with in the Horse a rudiment of the crest dividing the iliac fossa into two parts, and, in some animals—the Pig, Sheep, and Goat—this crest, which is the trace of the scapular spine, becomes constant and very evident.

With regard to the cotyloid cavity, it repeats in the posterior limb the glenoid cavity of the scapula. There remains to determine in the latter bone the portions analogous to the ischium and pubis. If we rely upon the evidence afforded by the muscular insertions, we come to the conclusion that the ischium corresponds to the coracoid process, and the pubis to the clavicle of animals which are provided with one. It will also be remarked that the coxa is directed backwards, while the scapula inclines obliquely forwards; this opposition in the direction of the bones in no way alters their analogies; the functions of the members to which they correspond require this inverse position.

Parallel between the femur and humerus.—The resemblance between these two bones is remarkable. Thus there is found in the first: 1, An articular head, better detached than that of the humerus, but shaped in the same manner; 2, A trochanter analogous to the great tuberosity, and also like it decomposable into three distinct parts—summit, crest, and convexity; 3, A lesser trochanter, representing the smaller tuberosity; 4, An eminence for the insertion of the superficial gluteus muscle, which takes the place of the deltoid imprint; 5, An inferior articular pulley continued between the two condyles by a non-articular groove; this trochlea certainly corresponds to the median groove of the inferior humeral face.

There are, no doubt, differences between the two bones, but they have no bearing upon the result just indicated. Thus the linea aspera of the femur is situated behind; that of the humerus in front. In the femur the two condyles of the inferior extremity are placed behind the trochlea; the contrary holds in the humerus. These modifications are necessary in order to give the movements of the limbs a convenient direction. The leg is flexed backward on the thigh, while the fore-arm is flexed in front on the humerus.

Parallel between the bones of the leg and those of the fore-arm.—It is

more particularly in these two regions that the question of analogies has been resolved in a contradictory manner by anatomists. It would have appeared less complicated had it been studied in a large number of species.

It has been pretended that the patella and the upper part of the tibia represent the superior extremity of the ulna and radius; and that the inferior portion of the ulna is represented by the fibula, and the lower part of the radius by that of the tibia. This opinion is erroneous. It is true that in Man the tibia and patella articulate with the femur, as the superior extremity of the ulna and radius responds to the humerus. But in quadrupeds, whose thoracic members are destined to sustain the weight of the body, this disposition is no longer observed; the radius is seen to give support to all the humeral surface, just as the tibia receives the femoral surface; and, besides, the ulna becomes only a simple complement to the elbow articulation, as the fibula does to the femoro-tibial articulation.

The tibia, therefore, corresponds to the radius, and the fibula to the ulna.

The olecranon is represented by the superior nucleus of the fibula, and not by the patella. The latter bone is nothing more than a kind of sesamoid, intended to facilitate the action of the extensor muscles of the leg. It might be objected to this comparison that, in the anterior limb, the extensor muscles are attached to the olecranon. But we reply that it matters little where the muscles which move the leg or arm are fixed on one or other of the two bones of these regions, because these bones act conjointly in the movements of flexion and extension.

Parallel between the bones of the posterior and those of the anterior foot.—The analogy becomes so marked when these two regions are compared, that it is scarcely necessary to allude to it. The tarsal bones are to the posterior limb what the carpals are to the anterior one; it is even possible to compare, one by one, the several pieces in these regions. The metatarsals are but a repetition of the metacarpals; while the digital bones are so much alike that it is difficult to distinguish the anterior from the posterior phalanges.

CHAPTER III.

THE BONES IN BIRDS.

These animals, destined for the most part to sustain themselves in the air, should exhibit in the conformation of their skeleton all the conditions which may favour ærial locomotion; from this arise the differences which distinguish their skeleton from that of mammalia,—differences which will now be rapidly traced.

Vertebral Column.—*Cervical vertebræ.*—The cervical stalk represents in the bird, as in the mammal, a kind of balancing pole curved like an S, which supports the head, and by its changes of form and direction varies the centre of gravity. When a bird rises in the air and flies rapidly, it lengthens the neck and stretches out the head to carry the centre of gravity forwards. But when it rests on the ground, it makes the balancing-pole assume the natural and more or less graceful inflection, by throwing the head backwards, and transferring the greater portion of the weight of its body to the columns of support formed by the posterior members. These displacements of the centre of gravity are executed in birds on a more extensive scale than in mammalia; the vertebral stalk in the former is also longer, lighter, and enjoys an excessive mobility.

The vertebræ composing it number fourteen in *fowls*, twelve in the *pigeon*, fifteen in the *duck*, and eighteen in the *goose;* in the *swan* twenty-three have been counted:—a curious variety which singularly contrasts with the numerical unity noticed as one of the most remarkable characters in mammalia! These vertebræ are generally longer than in the latter class, and are particularly distinguished by the configuration of the

articular surfaces of the inferior part or body. These are diarthrodial facets convex in one sense and concave in the other, articulating the vertebral bodies by a veritable and

Fig. 73.

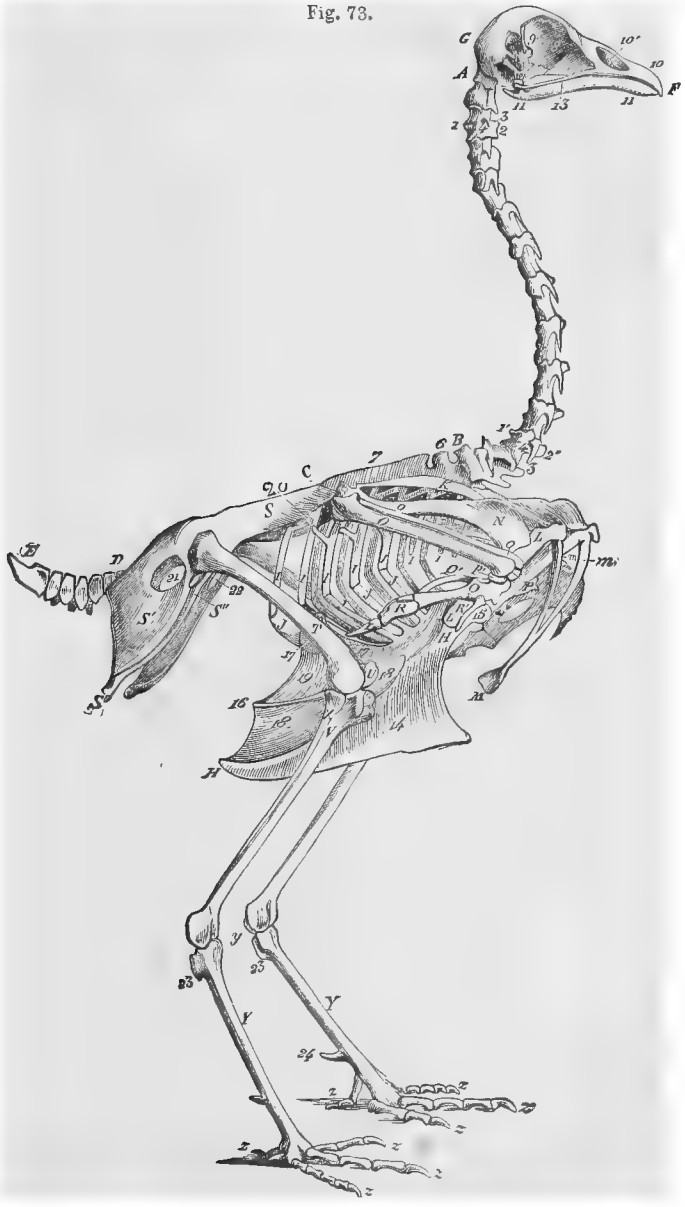

SKELETON OF A FOWL.

From A to B, Cervical Vertebræ.—1, Spinous process of the third vertebra; 2, Inferior ridge on body of the same; 3, Styloid prolongation of the transverse process of

reciprocal clamping. In this manner, the anterior head of the body of each vertebra is replaced by a facet concave from one side to the other, and convex vertically; while the posterior extremity of the bone bears, instead of a concavity, a facet convex in the lateral sense, and concave from above to below. The inferior crest of the body (fig. 73, 2, 2′) only exists in the first and last vertebræ; but it forms a veritable spine, analogous to that observed in the lumbar vertebræ of the rabbit. The spinous process (fig. 73, 1, 1′) only forms a simple crest in the middle part of the neck, it becomes more salient in the vertebræ which occupy the two extremities of this region. The transverse process represents on the side of the vertebra a thick, obtuse, and irregular tubercle, situated under the anterior articular process, and pierced at its base by a large vertebral foramen (fig. 73, 4, 4′). It is most frequently furnished with a small styloid prolongation (fig. 73, 3, 3′) directed backwards and downwards, forming an epiphysis at an early period, and representing a real undeveloped rib.

The atlas has no transverse processes. This vertebra is shaped like a thin ring, and is excavated on its anterior contour by a small cavity into which is received the single condyle of the occipital bone.

The axis shows a very marked odontoid process with a single facet under that eminence.

Dorsal vertebræ (Fig. 73, B, C.).—These are seven in the *Fowl* and *Pigeon*, and nine in the *Goose* and *Duck*, they are nearly always consolidated into a single piece to which the trunk is fixed, and which gives the wings a solid support in the violent efforts that flight demands. The two or three last are often even covered by the wing-bones, and joined to them. The inferior crest of the body forms a very long spine, especially in the first vertebræ. The spinous processes, flat, wide, short, and consolidated with each other by their opposite borders, constitute a long crest extending from the last cervical vertebra to the bones of the wings (fig. 73, 7). The transverse processes widen to their summit; in the *fowl* they are nearly constantly fused with each other.

Lumbar and sacral vertebræ.—All these vertebræ are formed exactly on the same type; so that it becomes difficult, if not impossible, to fix the point where the lumbar region ends or the sacral begins. At first independent of each other, these vertebræ, numbering fourteen, soon become consolidated with one another and with the ribs; but their primitive separation is always indicated by the lateral septa which form, on their inferior face, the vestiges of the transverse processes. The former are closely united to the latter in the dorsal region.

Coccygeal vertebræ.—In the coccygeal region, the spine recovers its mobility. The tail of the bird, indeed, fulfils the office of a rudder to direct it during flight; and it is absolutely necessary that the vertebræ which serve as a base for the steering feathers should preserve their independence, so as to allow these to be carried to the right, left, downwards, or upwards. These vertebræ, seven in number, present spinous processes which are often bifurcated, transverse processes very developed, and sometimes even spines more or less long on the inferior surface of their bodies. The last vertebra is always the most voluminous; it is flattened on both sides, and terminates in a curved-up point.

HEAD (Fig. 73, F. G.).—The head of the bird is small, and of a conical form. The anterior extremity is elongated, and terminated by a pointed or flattened beak, which allows the animal to cut the air with more facility.

---

the same; 4, Vertebral foramen of the same; 1′, 2′, 3′, 4′, The same parts in the twelfth vertebra.—From B to C, Dorsal Vertebræ.—6, Spinous process of the first; 7, Crest formed by the union of the other spinous processes.—From D to E, Coccygeal Vertebræ.—F, G, Head.—8, Interorbital septum; 9, Foramen of communication between the two orbits; 10, Premaxillary bone; 10′, External openings of the nose; 11, Maxilla; 12, Square bone; 13, Jugal bone.—H, Sternum.—14, Brisket or keel; 15, Episternal process; 16, Internal lateral process; 17, Lateral external process; 18, Membrane which closes the internal notch; 19, Membrane of the external notch.—I, etc., Superior ribs.—20, Posterior process of the fifth.—J, Inferior ribs; K, Scapula; L, Coracoid bone; M, Furculum.—*m*, *m*, Its two branches.—N, Humerus; O, Ulna.—*o*, Radius.—P, P′, Bones of carpus; Q, Q′, Bones of metacarpus; R, First phalanx of the large digit of the wing.—*r*, Second phalanx of the same.—R′, Phalanx of thumb; S, Ilium; S′, Ischium; S″, Pubis.—21, Sciatic foramen; 22, Foramen ovale.—T, Femur; U, Patella; V, Tibia; X, Fibula.—*y*, Single bone of tarsus.—Y, Metatarsus.—23, Superior process representing a united metatarsal bone; 24, Process supporting the claw.—*z*, etc., Digits.

Bones of the cranium.—The bones which compose the cranium are, as in mammalia, an occipital, parietal, frontal, ethmoid, sphenoid, and two temporals. These bones are not isolated from each other, excepting during early life in the shell; and the ossifying process which unites them is so rapid, that the cranium, shortly after hatching, is already a single piece. No detailed description of the separate bones will be given here, but only a few brief observations which may be of some utility.

Thus, the *occipital* bone shows for articulation with the spine only a single condyle, situated under the occipital foramen, and excavated by a slight groove. In palmipedes, this bone is pierced, behind the crests which give attachment to the extensor muscles, by two foramina which penetrate the cranium, and represent permanent fontanella. The *parietal* bone is feebly developed, and formed from only two primary nuclei. The *frontal* is the largest bone of the cranium; its orbital process is supported by a particular piece which is generally considered as belonging to the large wing of the sphenoid. The perpendicular lamina of the *ethmoid* is considerable, and forms between the two orbits a thin vertical septum (fig. 73, 8). Its posterior border is notched opposite to the optic foramen, and thus constitutes an opening which communicates between the two orbital cavities (fig. 73, 9). It is also channeled, near its upper border, by a fissure which terminates by two openings at its extremities, one entering the cranium, the other the nasal cavities. This fissure and these foramina permit the passage of the ethmoidal nerve, which in this way traverses the orbit before arriving at its destination. The *ethmoidal cells* are more membranous than bony; their base is attached to a very delicate transverse plate, which is often membranous and not cribbled, and forms part of the anterior orbital wall. These cells replace, at the same time, the lateral masses of the ethmoid and turbinated bones of mammalia. The *sphenoid* appears to be formed of a single piece, and shows on its sides two diarthrodial facets corresponding to the pterygoids. It is pierced by one foramen for the passage of the optic nerves; but this foramen opens on the outer and opposite side of the posterior notch of the interorbital septum, and thus allows each of the nerves passing through it to reach the eye for which it was intended.

It is worthy of remark, that an analogous disposition is also noticed in the rabbit.[1] The *temporal* bones present at their base an articular surface corresponding to the square bone. In the *fowl* species, the zygomatic process forms a small flattened tongue, directed forwards, sometimes free, and at other times united by its superior border to the summit of the orbital process. These two eminences are exceedingly short in *pigeons*. In *palmipedes* they are consolidated and confounded so intimately, that it becomes impossible to distinguish them from one another. From this union results a long and strong process, which inclines forward and meets a particular prolongation of the os unguis, forming with it areal bony arch. This arch limits, below and outwardly, the orbital cavity.

Bones of the face.—The supermaxilla comprises: a premaxilla, two nasal, two lachrymal, two palate, two pterygoid, two zygomatic bones, and a vomer. The inferior jaw has for its base a maxillary bone, which articulates with the cranium by means of two supplementary pieces named the *square bones*. The *premaxillary bone* is found, before hatching is completed, of two lateral pieces, which represent the two small premaxillaries of mammals. This bone is very considerable, and of itself forms the base of the upper beak, whose form it determines; it is pointed and conical in the *gallinacea*, and wide and flattened above and below in *palmipedes*. In front it circumscribes the external openings of the nose, and is prolonged superiorly into two lengthy processes which dovetail between the nasal bones. Two inferior processes belonging also to this bone concur in the formation of the palatine roof. The *supermaxillaries*, analogues of the supermaxillaries of mammals, are two rudimentary bones situated on the sides and at the base of the beak. They form a part of the palatine roof and the walls of the nasal cavities. The *nasal bones* circumscribe above, inwardly, and even outwardly, the external orifices of these cavities. The *palate bones* encircle, as in mammals, the guttural openings of the nose, and constitute in great part the roof of the palate; their posterior extremity lies against the pterygoids; the anterior joins the supermaxillaries and the inferior process of the premaxillary bone. The *pterygoids* extend obliquely from the sphenoid to the square bones, and are united to the sphenoid by diarthrodial articulation.

---

[1] This analogy is really striking, and might, in our opinion, serve as a basis for a new determination of the interorbital septum. We are tempted, indeed, to consider this bony lamina as the inferior sphenoid and the middle portion of the ethmoid of birds. This manner of viewing it tends to confirm the ideas of M. Tabourin on the inferior sphenoid and the ethmoid of mammals.

The *zygomatic bones* have the form of two very thin stylets, and are united to the square bone by their posterior, and consolidated with the supermaxillary by their anterior extremity. The *vomer* separates the guttural openings of the nose from one another.

The bones of the upper jaw are not fused with each other so rapidly as the bones of the cranium. The ascending processes of the premaxillary and nasal bones even remain for a long time united to the frontal bone by a simple synarthrodial articulation. This arrangement allows the upper beak to execute a certain elevating movement, of which we will speak when describing the articulations.

The *inferior maxillary bone* is originally formed of a great number of distinct segments which are soon united into a solid piece. The *square, petrous,* or *bone of the tympanum* ought to be considered as detached from the temporal. It is prismatic in shape, and provided on its upper surface with a diarthrodial facet which unites it to the temporal, and on its lower face with another facet articulating with the branch of the maxilla. Outwards it joins the zygomatic bone, and inwards with the pterygoid. Behind, it gives attachment to the membrane of the tympanum; and in front it presents a small eminence of insertion which Meckel considered a second zygomatic process.

THORAX.—*Sternum* (fig. 73, H).—The *sternum* of birds, serving as a basis of support to the muscles moving the wings, should offer, and does in fact show, a remarkable degree of strength, because of the extraordinary volume of these muscles. And these being more powerful and energetic as the bird exhibits a greater degree of aptitude for flight, it results that the structure of the sternum is solid in proportion as the bird is strong on the wing. For this reason we may infallibly pronounce as to the extent and power of a bird's flight by an inspection of the sternum of individuals of its species. In this respect, however, we only announce what is well known to be a particular application of the rules established by the great law of concordance between the anatomical disposition of organs and their physiological finality.

Studied in *Palmipedes*, which will serve as a type for description, the sternum presents itself in the form of a large rectangular cuirass, elongated from before to behind, of itself constituting the inferior wall of the thoracic cavity, and also largely protecting the abdominal cavity. Its superior face is concave, while the inferior is convex, and entirely occupied by the insertion of the pectoral muscles. It presents, on the median line, a thin and very salient ridge, named the *brisket* (or *keel*), which in a remarkable manner multiplies the points of attachment of these muscles. The anterior border offers in its middle a small eminence of insertion, the *episternal*. Laterally, two articular grooves are seen which correspond to the coracoids. The posterior border is cut by two notches which are often converted into foramina. On the lateral borders are observed small double articular facets answering to the inferior ribs. The angles which separate these two borders from the anterior are both prolonged into a little eminence, named by some authors the *costal process*.

In the *Fowl*, the sternum is not so strong as in the *Goose* or *Duck*. On each side of the brisket it shows two wide notches, which greatly reduce its substance. These notches, closed in the fresh state by membranes, are distinguished as external and internal. The latter, of greater size than the former, extends nearly to the extremity of the bone. From this division of the lateral plates of the sternum result two long and slender processes directed backwards. The external terminates by becoming widened, and forming a kind of bony plate, which covers the last inferior ribs.

The sternum of *Pigeons* is distinguished by the enormous development of the brisket. The two notches of the fowl are also met with in these birds, but the internal is nearly always converted into a narrow foramen.

This comparative study of the sternum in the chief domesticated birds leads us to appreciate the correctness of the principles just enunciated, with regard to the form and extent this bone may exhibit. The *Gallinaceous Birds*, properly so called, which fly little and badly, have the sternum singularly weakened by the deep notches cut in its lateral parts. With *Palmipedes*, the sternum is wide and but slightly notched, so that the goose and duck, which waddle along so awkwardly in our poultry yards, are capable of sustaining long and rapid flight, like that of the wild individuals of the same species. With regard to *Pigeons*, which are well known to be swift and powerful flyers, may this advantage not be due to the extraordinary development of the keel which constitutes the brisket?

Ribs.—In the *Fowl* and *Pigeon* there are seven pairs of ribs; and in the *Duck* nine pairs. Articulated superiorly with the dorsal vertebræ, as in mammals, these bones are provided near their middle with a flat eminence which commences at the posterior border, and is directed backwards and upwards to rest by its free extremity on the external face of the next rib. These eminences (Fig. 73, 20) form an epiphysis at an

early period, and are usually absent in the first and last ribs. They concur in an efficacious manner to increase the solidity of the thorax.

The costal cartilages in mammalia are in birds often transformed into veritable inferior ribs, joined to the superior ribs by a diarthrodial articulation (Fig. 73, I). These pieces are long and strong, and all terminate at their lower extremity by a double facet which articulates with the lateral border of the sternum; they are nearly always absent in the two first ribs. It is not rare to see the last united to the one before it, instead of passing directly to the sternum; in which case it comports itself like the asternal ribs of the mammalia.

Anterior Members.—*Shoulder-bone.*—The shoulder comprises: a *scapula*, a particular bone named the *coracoid* by Cuvier; and a *clavicle*, which forms, in coalescing with that of the opposite side, a single bone called the *fork* (*furculum*), or *os furculare*. The *scapula* is narrow, elongated, and falciform, and shows no trace of a spine. Its anterior extremity only forms a portion of the glenoid cavity, and is united by means of a fibro-cartilage with the *fork* of the coracoid bone. The latter is so named because it represents the coracoid process of mammals, and is a long prismatic bone, directed obliquely from above downwards, and before to behind. Its superior extremity is often fused with the scapula, and united at an acute angle with that bone to form a portion of the articular cavity which receives the head of the humerus. Its inferior extremity is flattened from before to behind, and responds by a diarthrodial articulation to the anterior border of the sternum. The *coracoid* is long in birds which fly slowly; it is, on the contrary, short, thick, and therefore very solid in quick flyers. The *fork* is a single bone, shaped like a V or U, situated at the base of the two wings, in front of the trunk, and in an oblique direction downwards and backwards. The two branches which form it represent the clavicles; they meet and are united at their inferior extremities, where they describe a curvilinear angle more or less open, attached to the brisket by means of a membranous ligament. Their superior extremity rests within, and opposite to the glenoid cavity, against the scapula and coracoid, forming with these bones a remarkable foramen, through which passes the tendon of the elevator muscle of the wing (Fig. 73, A, 4, B, 6). The fork plays the part of an elastic spring, whose office it is to prevent the wings coming towards each other during contraction of the depressor muscles. The conformation of this bone is, therefore, like the sternum, related to the extent and power of flight; and for this reason it is that, in swift flyers, the two branches of the furculum are thick, solid, widely separated, and curved like a U; while in those which fly heavily and with difficulty, these branches are thin and weak, and joined at an acute angle. The latter formation greatly diminishes its strength, and lessens, in a singular manner, the reactionary power of the bony arch it represents.

Bone of the arm.—The *humerus* offers an articular oval-shaped head, and an air-opening placed beneath this eminence. It is long in *Palmipedes*, ordinarily so in the *Gallinacæ proper*, and very short in *Pigeons*.

Bones of the fore-arm.—The radius is much less voluminous than the ulna. The latter has an extremely short olecranon; and the two bones are separated from one another in their middle part to meet again at their extremities, where they are united by ligamentous bands in such a way as to render the movements of pronation and supination impossible. This mode of fastening, which nevertheless does not prevent the two bones from gliding slightly on each other in the direction of their length, has been wisely adopted by nature in order that the wing might strike the air, like an oar, by its inferior face; otherwise, the resistance of the aerial medium would make these two bones pivot, and cause the wing to present itself to the air in a wrong direction.

Bones of the carpus.—These are only two, and are distinguished by the names of *radius* and *ulna*, in consequence of their corresponding more particularly to these bones in other animals.

Bones of the metacarpus.—These also number only two, and are separated at their middle portion, to be consolidated at their extremities.

Bones of the digital region.—The wing of a bird is composed of three digits. One of them, which resembles the thumb and forms the basis of the false wing, is composed of a single styloid-shaped phalanx, articulated at the base of a small particular process belonging to the superior extremity of the largest metacarpal bone. The largest digit comprises two phalanges which succeed the last bone. The third digit is represented by a small rudimentary phalanx, which corresponds to the inferior extremity of the small metacarpal bone, and lies beside the first phalanx of the large digit in the closest manner.

It is well to remark that the hand and the fore-arm are longer in proportion to the quality of flight; those two regions of the wing, for example, are very short in *Gallinaceous Birds*.

Posterior Members.—*Coxa* or *os iliac.*—This is a voluminous and very solid piece,

particularly in walking birds, and composed, as in the mammalia, of an ilium, ischium, and pubis. The *ilium* is consolidated with the last dorsal, the lumbar, and the sacral vertebræ; it is excavated on its internal face. The *ischium* partly incloses the side of the pelvic cavity; between its internal border and the external border of the ilium is an orifice which replaces the great ischiatic notch. Its inferior border is united to the *pubis*. The latter is thin and elongated, and follows the direction of the inferior border of the ischium, with it circumscribing an *oval opening* more or less spacious. Its inferior extremity extends beyond the ischium to curve inwards towards that of the opposite side, but without uniting with it. We do not, therefore, find the pelvic symphysis in birds, and the pelvis is widely open below, a circumstance which favours the passage of the egg through the cavity and out of the cloaca. The *cotyloid cavity* is perforated by an opening at the bottom which traverses the bone.

Thigh bone.—The *femur* is articulated inferiorly with the patella, tibia, and fibula. In all walking birds, like the gallinacæ, it is long and strong, as well as the rays below it.

Leg bones.—The *patella* is wide and thin. The *tibia* terminates, below, by two condyles separated by a groove which becomes articular behind. The fibula articulates by its head with the external condyle of the femur, and is consolidated with the tibia; it never descends to the inferior extremity of that bone.

Tarsal bones.—The tarsus appears to be altogether absent in birds. Nevertheless we may venture to consider, as a vestige of the bones of this region, a small bony nucleus buried in a fibro-cartilaginous mass which glides on the posterior pulley of the tibia. This nucleus represents the calcaneus of mammals.

Metatarsal bone.—A single metatarsal bone is found in birds, articulating superiorly with the inferior extremity of the tibia, and terminating inferiorly by three pulleys which support the three principal digits. This bone shows in the *Fowl*, near its inferior third, a conical process turned backwards, which serves as a base for the spur. Behind its superior extremity, it exhibits another which may be considered as a consolidated metatarsal bone.

Bones of the digital region.—All the domesticated birds have four digits on the inferior members: three principal, directed forwards, and one rudimentary, carried backwards. The first, designated as internal, median, and external, articulate with the inferior pulleys of the metatarsal bones. The internal is formed by three phalanges, the second has four, and the third five. These phalanges are formed something like those of the carnivora: the last is pointed, conical, and enveloped in a horny sheath. The fourth digit, or thumb, is composed of three pieces; one of these, the first, is generally considered as a rudimentary metatarsal bone. It is attached by fibro-cartilaginous tissue to the inner and posterior aspect of the inferior extremity of the principal metatarsal bone.

CHAPTER IV.

THEORY OF THE VERTEBRAL CONSTITUTION OF THE SKELETON.

In the series of vertebrated animals the bony pieces of the trunk bearing the name of vertebræ are those which offer the highest degree of fixity, and to which the existence or the arrangement of the others appears to be subordinate. This feature in organisation, recognised by E. Geoffroy Saint-Hilaire and Professor Owen, has caused these men of science to assert that the type of construction of vertebrated animals is the vertebra.

After E. Geoffroy Saint-Hilaire and Professor Owen, several German, English, and French anatomists have studied the vertebral composition of the skeleton; and among the works published in France on this subject must be specially noticed those of M. Lavocat.[1] In principle, all the writers have arrived at the same conclusions, and only differ in some few details.

It is certain that the base of the vertebral column is formed by a series of bony segments. Each of these segments is called an *osteodesm*, and each osteodesm represents the *body* or *centrum* of a vertebra.

([1] The distinguished anatomist and Director of the Imperial Veterinary School of Toulouse.)

In examining the dorsal region, it is evident that to the body or centrum of a vertebra are added two complete osseous arches, a superior and an inferior. The superior arch is formed by the vertebral lamina; the inferior by the ribs, the cartilages, and a portion of the sternum. The first is designated the *neural arch*, because it furnishes a protecting sheath for the nervous centres; and the second, which more particularly protects the vascular system, is called the *hæmal arch* (see Fig. 10).

The hæmal arch may have prolongations or *appendices* more or less developed, and comparable to the apophysary prolongations of the ribs in birds and some fishes.

Such is the general composition of a typical vertebra; but there are also to be distinguished in the neural and hæmal arches the following parts:—

NEURAL ARCH.

1. Neural parapophysis = the posterior costal cupola.
2. Neural metapophysis = the anterior costal cupola.
3. Neural diapophysis = the summit of the transverse process.
4. Neurapophysis = the vertebral lamina.
5. Neural spine = the summit of the spinous process.

HÆMAL ARCH.

1. Hæmal parapophysis = the tuberosity of the rib.
2. Hæmal metapophysis = the head of the rib.
3. Hæmal diapophysis = the rib proper.
4. Heumapophysis = the costal cartilage.
5. Hæmal spine = the corresponding sternal portion.

The vertebræ sometimes depart more or less from the model just described. They may vary not only from one species to another, but also in the same animal, and even in the same region. Thus the neural arch may be absent, as has been observed in certain coccygeal vertebræ; or the hæmal arch is incomplete or null, as in the cervical or lumbar vertebræ; or, lastly, the arches are often unequal; though this inequality is of no importance, since their size is in relation to the volume of the parts they should protect.

Notwitstanding these differences and variations, or the transformations experienced by certain parts, there is not a bone in the skeleton which cannot be included in the vertebral type.

The vertebra being admitted as the type of construction of the skeleton, it is easy to find it in all the regions of the bony framework. In the thoraco-abdominal region, the centrum, neural arch, and hæmal arch are readily perceived; in the lumbar vertebræ, the enormously developed transverse process indicates the existence of an infravertebral arch.

In the sacral region, the bony girdle of the pelvis represents the hæmal arch. The posterior limbs, articulating with the bones of the pelvis, belong to the hæmal arch, and should be considered as appendices of this arch, analogous to the costal appendices of birds.

The cervical region may be compared to the sacral region; as in it the inferior hæmal arch is represented by the osseous ring supporting the anterior limbs—the scapulo-clavicular cincture. The limbs themselves are appendices of the cervical hæmal arch.

Difficulties begin to appear when the extremities of the trunk—the head and coccyx—come to be examined. Nevertheless, the composition of the coccyx is revealed when the caudal vertebræ of certain fishes, especially those of the pleuronectidæ, in which the neural and hæmal arches are complete, are examined. But the vertebral constitution of the head remained for a long time an insoluble question, or was solved in a contradictory

manner by the naturalists who attempted it. Some admitted a single cephalic vertebra; others admitted three or four; while others again arrived at six or seven.

These difficulties and contradictory results may be understood, when it is

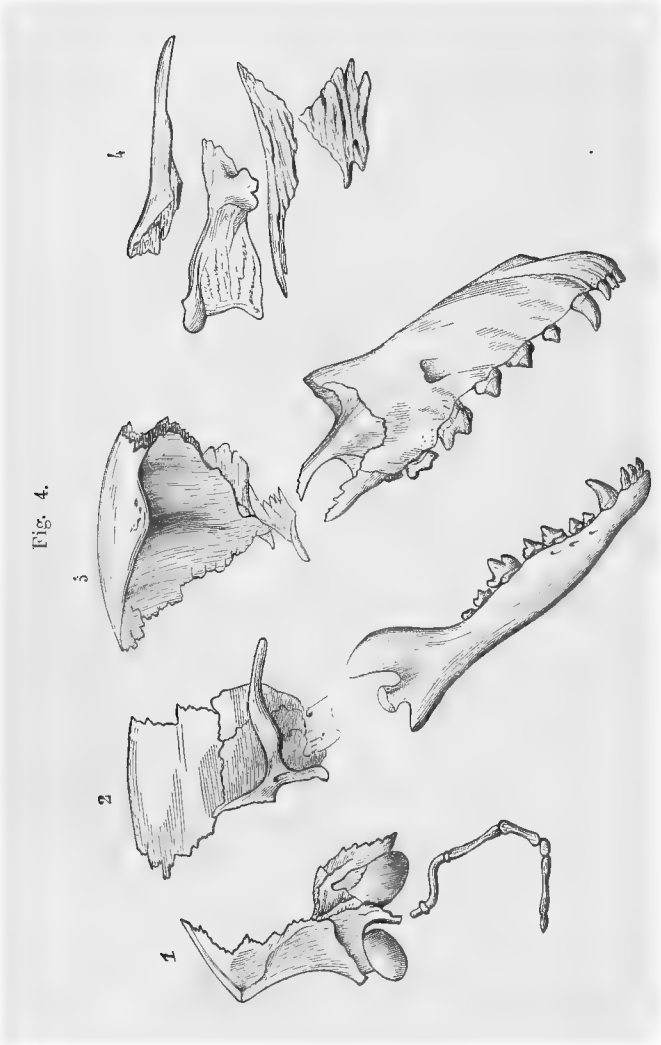

CEPHALIC VERTEBRÆ OF THE DOG.—*After Lavocat.*
1, Occipito-hyoideal vertebra; 2, Parieto-maxillary vertebra; 3, Fronto-mandibular vertebra; 4, Naso-turbinal vertebra.

borne in mind what profound modifications the vertebræ must have experienced to constitute the bones of the head

At present the problem appears solved. The head is composed of four vertebræ, in which are found the various parts enumerated in the description of the typical vertebra.

In the four classes of vertebrata, the head is constantly formed of four vertebræ, which are determined as follows:"[1]

VERTEBRÆ.	CENTRUM.	NEURAL ARCH.	HÆMAL ARCH.
Occipito-hyoideal.	Basilar process of the Occipital.	Occipital (3 pieces). Mastoid walls of the Tympanum.	Hyoideal apparatus (5 pieces).
Parieto-maxillary.	Body of the posterior Sphenoid.	Wing and pterygoid process of the posterior Sphenoid. Squamous portion and zygomatic process of the Temporal. Parietal.	Inferior Maxilla 5 pieces).
Fronto-mandibular.	Body of the Anterior Sphenoid.	Wing and pterygoid process of the anterior Sphenoid. Posterior Frontal and its orbital process. Frontal.	Jugal. Lachrymal. Palatine. Supermaxillary. Premaxillary.
Naso-turbinal.	Vomer.	Ethmoid. Nasal.	Turbinated Subethmoidal.

The number of cephalic vertebræ is invariable, as each is destined to lodge the organs of one of the four senses. The occipito-hyoideal lodges the principal organs of hearing; the parieto-maxillary osteodesm protects the sense of taste; finally, the organs of vision are sustained by the fronto-mandibular vertebra, while the naso-turbinal contains the sense of smell.

It was therefore with reason that Geoffroy Saint-Hilaire and Professor Owen proclaimed that the type of construction of the vertebrated animals is the vertebra.

SECOND SECTION.

The Articulations.

CHAPTER I.

THE ARTICULATIONS IN GENERAL.

The different pieces constituting the solid framework of the animal body are, as has been said, united in such a manner that they can move one upon the other From this union results the *articulations* or *articular joints*, whose construction will now be referred to in a general manner, before commencing a particular description of each

To form articulations, the bones correspond to each other by certain points of their periphery, which are named *articular surfaces*. Every articu-

[1] *Lavocat*, 'Nouvelles études sur le système vertébral,' 1860.

lation is, therefore, essentially constituted by two opposite osseous surfaces, which are moulded to each other. These are either contiguous, independent, and very movable—continuous with each other by means of a cartilaginous substance which condemns them, if not to total immobility, at least to very

Fig. 75.

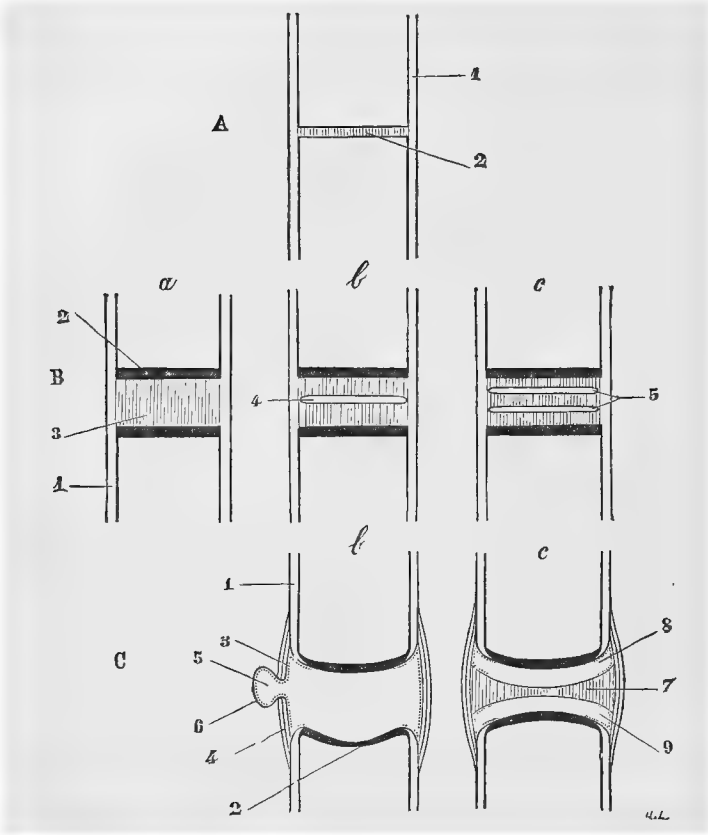

PLANS OF THE DIFFERENT CLASSES OF ARTICULATIONS.

A, Suture.—1, Periosteum; 2, Sutural ligament.—B, Amphiarthrosis; *a*, First degree.—1, Periosteum; 2, Articular cartilage; 3, Interarticular ligament.—*b*, Second degree; 4, Single cavity in the interarticular ligament.—*c*, Third degree; 5, Double cavity in the interarticular ligament.—C, Diarthrosis; *b*, Simple diarthrosis.—1, Periosteum; 2, Articular cartilage; 3, Epithelial layer of the synovial membrane—dotted line; 4, Fibrous capsule; 5, Cul-de-sac of the synovial membrane; 6, Fibrous layer of the synovial membrane.—*c*, Double diarthrosis; 7, Interarticular meniscus; 8, 9, Cavities of the two synovial membranes.

limited movements: or united by a fibro-cartilage whose elasticity permits a certain degree of displacement between the bones which are in contact.

In the first case, the articulations are classed as *diarthroses*, or *movable articulations.*

In the second, they are designated *synarthroses*, *sutures*, or *immovable articulations.*

In the third, they are *amphiarthroses*, or *mixed articulations;* so termed because they participate in the movements of the other two classes; synarthroses, by the continuity established between the articular surfaces; and diarthroses, by the extensive motion they permit.

The general characters that distinguish each of these three great classes of articulations will be successively studied.

(The study of the articulations, or rather of the ligaments, is termed *syndesmology*—from σὺν, together, and δεσμὸς, bond; or *arthrology*—from ἄρθρον, a joint, and λόγος, a description.)

GENERAL CHARACTERS OF DIARTHROSES.

We ought to consider in the diarthrodial articulations: 1, The contiguous *bony surfaces* which form them; 2, The cartilaginous layer (*cartilages of incrustation*) which cover these; 3, The fibro-cartilaginous tissue (*articular fibro-cartilages*) which complete them, when they are not shaped so as to be reciprocally adapted to each other; 4, The *ligaments* which maintain them in contact; 5, The serous membranes (*synovial capsules*) that cover the internal face of the latter, and which secrete the *synovia*, a kind of animal oil that facilitates the gliding of the articular surfaces; 6, The *movements* of which these articulations may be the seat; 7, Their *methodical classification;* 8, Their *nomenclature.*

Articular Surfaces.—These surfaces have the common character of being destitute of asperities, so that they can glide with the greatest facility on each other. They are designated, according to their form, by the names of *facets, heads, condyles, cotyles, glenes, pulleys, etc.* There is no need to revert to their general description, as they have already been sufficiently studied in the osteology; so we will confine ourselves to repeating that they are found at the extremities of long bones, on the faces of short bones, and on the angles of wide bones. We may mention also that they are often excavated by one or several hollows named *synovial fossæ*, a sort of natural reservoirs which receive the unctuous fluid secreted by the interarticular serous membranes.

Cartilages of Incrustation.—This designation is given to the layers of cartilaginous matter which, as it were, varnish the articular surfaces they adhere to by their inner face; their free surface is distinguished by a remarkable polish and brilliancy Thicker towards the centre than at the circumference when they cover bony eminences, these cartilages show an inverse disposition when they line cavities. They are elastic, of a pearly whiteness, and resisting, though they are soft enough to be cut by a sharp instrument; in a word, they possess all the physical characteristics of the primary cartilage of bones They appear to be formed of parallel fibres placed perpendicular to the bony surfaces, and implanted in these by one of their extremities: the opposite extremity corresponding to the free surface of the cartilage. Viewed by the microscope, they are found to consist of a fundamental substance excavated by small cavities The cartilage of incrustation therefore belongs to the group of true or hyaline cartilages.

The fundamental matter is amorphous and homogeneous, and more or less transparent, according to its thickness. It is transformed into chondrine by boiling in water.

The cavities are irregular, and more or less wide. They contain from one to five cells whose walls are very thin, and their contents slightly granular; in the centre of each cell is a nucleus with a nucleolus. These

cavities are elongated and directed almost perpendicularly towards the articular surface in the deep layer; in the middle layer they are oblique, and are parallel to the surface of friction in the superficial layer.

Fig. 76.

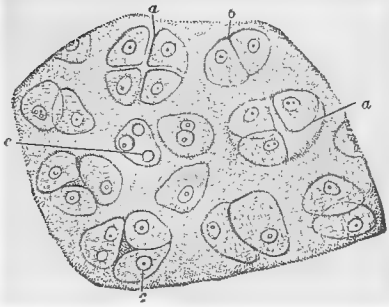

SECTION OF BRANCHIAL CARTILAGE OF TADPOLE.

a, Group of four cells separating from each other; *b*, Pair of cells in apposition; *c*, *c*, Nuclei of cartilage-cells; *d*, Cavity containing three cells. These cells are imbedded in the finely-granular matrix, or fundamental substance.

(Under a high magnifying power the fundamental substance, or matrix, loses its homogeneous and amorphous character, and appears to be granular or faintly striated. In the midst of this granular matrix, the lacunæ or cavities are observed to contain from one to six different-sized cells. It has been stated that a membrane lines these spaces. In addition to the granular matter observed in the cells, it is not rare to find fat globules. The nuclei of the cells vary from $\frac{1}{4000}$ to $\frac{1}{2400}$ of an inch in diameter. The cells multiply endogenously.)

The cartilage cells are insoluble in boiling water; consequently, so far as their chemical composition is concerned, they are distinct from the fundamental substance.

The diarthrodial cartilages receive neither vessels nor nerves. The presence of cartilages of incrustation in the articulations is of the greatest importance. When they are worn, absorbed, or transformed into bone in consequence of certain articular maladies, the movements become painful and very difficult. With regard to the part they play in the economy, it may be said that: 1, They favour, by their smoothness, the gliding and displacement of the bones, 2, They attenuate, by their suppleness and elasticity, the violent shocks to which the articulations are exposed; 3, They resist the wear and deformation of the articular surfaces.

Complementary Fibro-cartilages.—There are several kinds of complementary fibro-cartilages:—Some (*interosseous*) represent circular cushions which bolster the margins of certain cavities, filling up the notches which might render them imperfect. They increase the depth of these cavities

Fig. 77.

FIBRO-CARTILAGE; MAGNIFIED 155 TIMES. Showing interlacement of fibrous fasciculi, with scattered groups of cartilage-cells.

and protect their borders from injury. Others (*interarticular*) are interposed between articular surfaces when these do not exactly fit each other, as

when two opposing extremities are convex. It may be remembered that the lateral tuberosities of each tibial surface present, for articulation with the condyles of the femur, two convex diarthrodial faces whose coaptation is rendered perfect by the interposition between each condyle and corresponding tibial surface of a crescent-shaped fibro-cartilage, which for this reason has been named a *meniscus*. In other joints these interarticular fibro-cartilages are shaped like discs or biconcave lenses. There then result double diarthroses:—example, the temporo-maxillary articulation. (Fibro-cartilage also covers bony surfaces over which tendons play, as on the trochlear surface of the humerus, postero-inferior face of the navicular bone, and elsewhere. In these situations it is named *stratiform fibro-cartilage.*) These organs are formed, as their name indicates, by fibrous and cartilaginous tissue; their mode of association need not be referred to here, though it may be observed that the cartilage is more particularly found in all those points where there is most articular friction. They receive vessels, and sometimes nerves.

Ligaments.—These are bands which unite contiguous diarthrodial surfaces. They are sometimes formed of white fibrous tissue, and sometimes of yellow; from whence their division into two great classes of *white* and *yellow ligaments.*

a. The *white ligaments* are distinguished by the pearly whiteness of their tissue and want of elasticity. Those which are found on the outer

Fig 78



WHITE OR NON-ELASTIC FIBROUS TISSUE.

Fig 79

YELLOW OR ELASTIC FIBROUS TISSUE, FROM THE LIGAMENTUM NUCHÆ.

aspect of the articulations are termed *peripheral*, and those in their interior are designated *interosseous* or *interarticular ligaments.*

The *peripheral ligaments* are generally composed of parallel fibres collected in fasciculi, or spread out as membranes. In the first they are called *funicular*, or *ribbon-shaped;* in the second, they are termed *membraniform*, or *capsular*. The *funicular ligaments* constitute short, round, or flattened bands, attached by their extremities to the two bones they unite; they are lined on their inner aspect by the synovial capsule, and covered externally by tendons, aponeuroses, muscles, vessels, or nerves. The *capsular ligaments* are often complete—that is to say, they envelope the whole articulation like a sack. At other times they are incomplete, and

then they are simple membranes, binding together the different funicular bands of a joint.

The *interosseous ligaments*, less numerous than the preceding, are often formed of interlacing fibres; they are always *funicular*, and fixed by their extremities into excavations in the centre of articular surfaces.

b. The *yellow ligaments* are all *peripheral*, *funicular*, or *membranous*, and enjoy a marked degree of elasticity, which permits them mechanically to bring back to their usual position the bony levers which have been momentarily displaced. These ligaments, which are powerful auxiliaries to the muscular forces, are destined to give equilibrium in a permanent manner to the weight of certain parts of the body which incessantly tend to fall to the ground.

Synovial Capsules.—These are very thin membranes of a serous nature, intended to secrete the *synovia*. They are composed of two layers: a deep, formed by fasciculi of the connective tissue; the other, superficial, is of an epithelial character. The first sometimes adheres intimately to the inner face of the funicular or membranous ligaments of the articulation; at other times it is loosely attached to them by an abundance of connective tissue. The second layer is constituted by a single row of flattened polygonal cells.

It is generally admitted that the synovial membranes comport themselves like the other serous membranes, by forming sacs which are everywhere closed. According to this admission, a synovial membrane, after covering the internal face of the peripheral ligaments of a diarthrodial articulation, ought to be prolonged on the free surface of the cartilages of incrustation, and should give them their brilliancy and polish. But it is necessary to state that this is a pure hypothesis, against which rises a multitude of carefully-observed facts. The discussion of these belongs to general anatomy, but they will be referred to here as briefly as possible.

1. If direct observation be consulted, it gives on this debated subject the most precise information; the cartilages are uncovered, and there is no synovial membrane on their face. The anatomists who have mistaken for this membrane the thin pellicle which it is possible to render evident on the cartilages in obliquely cutting their substance and separating morsels by tearing it off, were evidently deceived. This pellicle has nothing of a serous nature in its texture; it is not vascular, for it has never been possible to inject vessels on the surface of cartilages, nor yet in their thickness; it is not covered by epithelium; and submitted to microscopical examination, it exhibits all the characters of the amorphous matter of cartilage. It ought, then, to be considered as a cartilaginous pellicle, detached from the superficial layers of the articular surface—a pellicle which it has always been impossible to find on cartilages which are quite fresh; and it has never been possible to observe it without giving, by a preliminary desiccation, a certain degree of tenacity to the cartilaginous substance about to be examined.

2. Pathological facts prove nothing in favour of the existence of a synovial membrane on the cartilages. Hypertrophy of this pretended membrane has never been witnessed; the fungosities looked upon as a result of this hypertrophy are derived from another source. It has been demonstrated that they extend, in certain cases, from the articular margins of the cartilaginous surface, whence their successive invasions may often be followed. In other cases, the vegetating membrane which constitutes them appears in the centre of the articular surfaces, at points deprived of cartilage; they afterwards extend to a certain distance on the remaining cartilage.

3. It may be asked of the partisans of the opinion now combated, how they can believe in the existence of a serous membrane between two articular surfaces, without its being exposed to bruises and destruction a thousand times in the day? Do they take into account the amount of pressure sustained by certain articulations, and the intense friction to which their surfaces are submitted? Have they compared the intensity of these destructive influences, with the delicate texture of the serous membranes, and their great inflammatory susceptibility? It is sufficient to lightly touch in this way the weak side of our adversaries' argument, and to conclude the third portion of this discussion: There is friction between the cartilages of the two opposed articular surfaces, therefore there must be wear, this is a physical law which no body escapes, let it be as hard as the diamond, or as soft as caoutchouc. And if there is wear between these rubbing surfaces, there cannot be an irritable and sensitive membrane lying on the inert and insensible strata which constitute them. In fine, a synovial membrane, after being fixed to the margin of the articular cartilage of a diarthrodial joint, is reflected in every direction to cover the inner aspect of the ligaments, and becomes attached to the periphery of the diarthrodial surface corresponding to the first.

There are generally found within articulations little masses of fat which push the synovial membrane enveloping them inwards. Erroneously considered by Clopton Havers as glands for the secretion of synovia, these accumulations of fat have been named *synovial fringes*. They are more particularly numerous in the neighbourhood of the articular margins: that is, on the edges of diarthrodial surfaces.

The *synovia* is a viscid, colourless, or slightly yellow fluid, in its physical characters somewhat resembling oil; it does not possess them, however, so far as its composition is concerned, for chemical analysis has not demonstrated the presence of fatty principles. It is the albumen it contains which gives it its viscidity, and which fits it for lubricating the articular surfaces over which it is spread. Its use in the animal economy is absolutely identical with that of the greasy substances employed to lubricate the axles of carriages.

Movements.—The movements peculiar to diarthrodial articulations are divided into seven principal classes:

1. *Simple gliding*, the only movement possible between two plane or undulating facets.
2. *Flexion*, which brings two bony pieces nearer each other by closing more or less their angle of union.
3. *Extension*, the inverse movement, during which the bones are straightened on each other.
4. *Adduction*, which brings the inferior extremity of the movable bone towards the median line.
5. *Abduction*, the contrary movement to the preceding
6. *Circumduction*, or the sling movement, during which the bone passes successively through the last four positions.
7. *Rotation*, in which one bone pivots on another

Classification of the Diarthroses.—The basis of this classification is founded on the configuration of the articular surfaces and the nature of the movements they permit. This double base serves to establish five kinds of diarthrodial articulation:

1. *Enarthrosis*, characterised by the reception of an articular head within

a cavity of appropriate form. This articulation may be the seat of the most extensive and varied movements: flexion, extension, abduction, adduction, circumduction, and rotation. Example: the coxo-femoral articulation.

2. The *trochlean, angular ginglymoid*, or *perfect hinge articulation*, when the articular surfaces are formed into trochlea, reciprocally fitting into each other, and whose movements—flexion and extension only—are executed with the precision of a hinge. Example: the tibio-tarsal articulation.

3. The *condyloid*, or *imperfect hinge articulation*, which permits, like the preceding, the two principal movements of extension and flexion, and the accessory movements of rotation or lateral inclination. The articular surfaces, though very diversely shaped, nevertheless exhibit in all the articulations one or more condyles opposed to an equal number of oval excavations. Example: the femoro-tibial articulation.

4. The *pivot, trochoid*, or *lateral ginglymoid articulation*, is a diarthrosis formed by a pivot which turns in a semi-cylindrical cavity. Rotation is the only movement. Example: the atlo-axoid articulation.

5. *Arthrodia*, or *planiform diarthrosis*, is constituted by plane, or nearly plane facets. Gliding is the only possible movement. Example: the carpo-metacarpal articulation.

Nomenclature.—The names of the articulations are usually those of the bones which form them. For instance, the *scapulo-humeral* articulation is the joint between the scapula and humerus; the *intervertebral* articulations join to each other the various pieces constituting the spine. When the qualifying name of an articulation is composed of two elements, as in the first instance, it is well to place first the word which indicates the bone usually most fixed.

GENERAL CHARACTERS OF THE SYNARTHROSES.

Sutures are the temporary articulations which exist only at an early period of life. They nearly all disappear in the adult animal, in consequence of the bones forming them becoming consolidated. They belong almost exclusively to the bones of the head.

Articular Surfaces.—The bones forming these come in contact by their borders or angles, which, for this purpose, generally present very anfractuous surfaces.

Sometimes they are cut perpendicularly and simply roughened; at other times they are bevelled and joined by means of fine laminæ or trifling inequalities; again, they are notched into deep and sinuous dentations; and lastly, one bone is fixed into a groove cut in the other. It will be understood that such conformations of the articular surfaces ought to limit their movements and assure the solidity of their union.

Modes of Union.—Cartilage interposed between these synarthrodial surfaces directly unites them to each other. It absolutely possesses the same texture as the primary cartilage of the bones, and like it, has the property of becoming ossified after having been vascularised. This ossification, which causes the disappearance of the sutures, occurs earlier inwards than outwards. The periosteum, in passing from one bone to another, adheres intimately to the sutural cartilage, and also aids in bringing about a more complete synarthroses. It should, therefore, be included in their means of union.

Movements.—These are very obscure, and only noticeable in young

animals by the elasticity they communicate to the bony walls of the cranium or face. In the adult, they may be said to be null.

CLASSIFICATION.—There are four principal descriptions of *sutures:*

1. When two wide bones correspond by means of denticulations fitting into each other, the suture is named *true* or *dentated.* Example: the articulations uniting the three portions of the parietal bone. 2. If the opposed borders of two bones in contact are widely bevelled, one inwards, the other outwards, it forms a *scaly* or *squamous suture.* Example: the parieto-temporal articulations. 3. When the union of bones takes place by plane or roughened surfaces, cut perpendicularly on their borders or angles, this constitutes the *harmonia suture*, or *suture by juxtaposition* (or *apposition*). Example: the occipito-temporal articulations. 4. The *schindylesis*, or *mortised suture*, results from the reception of a bony plate into a groove more or less deep in another bone. Example: the spheno-frontal and supermaxillo-nasal articulations.

GENERAL CHARACTERS OF THE AMPHIARTHROSES OR SYMPHYSES.

ARTICULAR SURFACES.—They are frequently smooth, and formed almost on the same model as the diarthrodial surfaces. They are covered by a thin layer of cartilage, but instead of being smooth and polished, they are more or less rugged, without, however, presenting the anfractuous disposition of the majority of synarthrodial surfaces.

MODES OF UNION.—The organs which perform this office are: 1, The fibro-cartilage which establishes continuity between the articular surfaces; 2, Ribbon-shaped or peripheral ligaments. These latter do not differ from the analogous bands attaching the diarthrodial articulations. With regard to the fibro-cartilage, it is distinguished from the complementary discs of these same articulations by a less intimate mixture of the cartilaginous and fibrous elements entering into its composition. The last may be sometimes absent, as well as the peripheral bands; and then the articulation only differs from the synarthroses by the extent of motion it permits Occasionally the interarticular fibro-cartilages are excavated by one or two little narrow cavities; but these are never lined by a synovial membrane like the diarthrodial cavities.

MOVEMENTS.—The amphiarthroses only permit of a see-saw or swinging movement. the extent of which depends on the thickness of the intermediate fibro-cartilage.

CLASSIFICATION.—Only one kind of amphiarthrosis is recognised, the most remarkable example of which is found in the articulations between the bodies of the vertebræ.

CHAPTER II.

ARTICULATIONS OF MAMMALIA IN PARTICULAR.

IN the special study of the articulations, the same order will be followed as for the bones; the articulations of the spine will be first noticed, then those of the head, thorax, and anterior and posterior limbs.

Preparation.—The preparation of the bones which have been described has not been made the subject of any particular recommendation, because it suffices, in order to study them, to remove the soft parts by which they

are surrounded either by boiling, maceration, or scraping. But when we come to examine the soft textures, in order to do so profitably it is necessary to learn beforehand the rules which should be followed in their preparation. The following are laid down with regard to the study of the articulations:

1. To prepare the articulations, young subjects are chosen in preference to those advanced in years, because the density of the cellular tissue in them is not so great, and this tissue is easily removed from around the ligaments. As these are prepared with difficulty when the external surface is in a dry state, care should be taken before dissecting them to have them excluded from the air by covering them with damp cloths, or with the skin of the animal.

2. It is convenient to separate the articulation we wish to dissect by sawing through the bones at a certain distance from the articular surfaces. The manipulation of the part is then rendered easier, and its dissection can be made under the most favourable conditions.

3. It is necessary to preserve as carefully as possible the muscles surrounding the articulations, in order to be able to study their relations with the ligaments which bind these. If it be absolutely necessary to remove them, their insertions corresponding to the articulation should always be retained.

4. The capsular ligaments should be the first studied, as these have soon to be removed the better to show the funicular ligaments. These, in their turn, must be sacrificed in order to display, by different sections, the interosseous cords, when these exist. Lastly, the two articular surfaces should be completely separated, so as to examine their conformation.

5. The synovial membranes, with their different *culs-de-sac*, being a very important study, with reference to the diagnosis and treatment of articular tumours, it is convenient to devote a special piece to the examination of these serous membranes. It is very useful to inject their interior with plaster or tallow coloured black, in order to distend their cavities, and thus aid the study of their relations with ligaments, tendons, or muscles.

For the preparation of each articulation it is not necessary to give any directions; a glance at the figures accompanying the description will suffice to dispel any embarassment the student may experience, while he always requires particular indications.

(Notwithstanding the above remarks with regard to the preparation of the ligaments, I have thought it advisable to follow the example given in the last edition of 'Leyh's Anatomy' by Zundel, and briefly indicate the readiest method of demonstrating these organs, for the special benefit of the student.)

Article I.—Articulations of the Spine.

(*Preparation.*—Remove all the soft parts surrounding the vertebral column, taking care not to injure the inferior longitudinal ligament in cutting away the pillars of the diaphragm and the psoas muscles; nor the ligaments uniting the articular processes to each other and the transverse processes of the dorsal vertebræ to the ribs, in removing the supercostal and transverse spinal muscles. To expose the common superior longitudinal ligament, separate the bodies of the vertebræ from their annular portions by the saw or chisel, and remove the spinal cord and dura mater; in doing this the inferior face of the interannular ligaments will be also removed. Examine an intervertebral fibro-cartilage by two sections—a transverse at an equal distance from the two vertebræ, and a longitudinal through the middle line of the bodies.)

These articulations are *intrinsic* and *extrinsic*. The first comprises all the articulations of the vertebræ with each other; the second those of the spine with the head, the ribs, and the coxæ.

Intervertebral Articulations.

The vertebræ correspond: 1, By their bodies; 2, By their spinal or annular portion. There results from this union two kinds of articulation, which must be studied separately, as they do not belong to the same class. It is well to mention, however, that the general details into which this study leads us apply only to the articulations uniting the last six

cervical vertebræ, all the dorsal and lumbar vertebræ, and the first sacral vertebra.

UNION OF THE VERTEBRÆ BY THEIR BODIES.—The articulations forming this union are so many amphiarthroses.

Articular surfaces.—The vertebral bodies come into contact by the surfaces which terminate them before and behind. In the cervical region these surfaces represent, anteriorly, a veritable head, posteriorly, a cotyloid cavity which receives the head of the next vertebra. Beginning from the first dorsal vertebra and passing on to the sacrum, these tend to become effaced and more and more plane, though they still preserve their convexity and concavity.

Modes of union.—1, By fibro-cartilages interposed between the articular surfaces; 2, By a common superior vertebral ligament; 3, By a common inferior vertebral ligament.

a. Intervertebral fibro-cartilages (Fig. 80, 1, 1).—These are circular or elliptical discs, convex in front, concave behind, and solidly fixed by their faces to the articular planes which they separate. The fibro-cartilaginous substance composing them consists of concentric layers, which become denser and closer to each other as they near the circumference; they even disappear towards the centre of the disc, where this substance becomes pulpy and assumes the histological characters of pure cartilage. It may be remarked, that each of these layers is made up of a collection of thick parallel filaments, which cross with those of other layers like an X, and are attached by their extremities to the articular surfaces. From this arrangement results so intimate an adherence between the vertebral bodies and their intermediate fibro-cartilages, that an attempt to disunite them is more likely to determine a fracture of the former. The fibro-cartilages, thicker in the cervical and lumbar regions than in the dorsal, respond by their circumference to the two common ligaments. Those which separate the vertebræ of the back concur to form the intervertebral cavities, which are destined for the reception of the heads of the ribs, and give attachment to the interosseous costo-vertebral ligaments.

(Leyh designates the superficial fibres of the excentric layer of these fibro-cartilages as *intervertebral* ligaments. Luschka has shown that the cartilages are in reality articular capsules.)

b. Common superior vertebral ligament (Fig 83, 1).—This ligament extends from the axis to the sacrum, and is lodged in the spinal canal; it represents a long fibrous band cut on its borders into wide festoons. (The wide portions correspond to the discs.)

By its inferior face, it is attached to the intervertebral discs and the triangular imprints on the upper faces of the bodies of the vertebræ. Its superior face is in contact with the dura mater through the medium of an abundant cellulo-adipose tissue. Its borders are margined by the intra-vertebral venous sinuses (*venæ basium vertebrarium*).

c. Common inferior vertebral ligament (Fig. 84, 5).—Situated under the spine, this ligament is absent in the cervical and the anterior third of the dorsal region. It only really begins about the sixth or eighth vertebra of the latter region, and is prolonged in the form of a cord, at first narrow, then gradually widening until it reaches the sacrum, on the inferior surface of which it terminates by a decreasing expansion. From its commencement, it is attached to the inferior crest of the bodies of the vertebræ and the intervertebral discs. By its inferior face, it responds to the posterior aorta.

(Leyh commences this ligament at the seventh cervical vertebra, and says

that it adheres to the crests on the bodies of the dorsal and lumbar vertebræ, as well as to the lower face of the sacrum and coccyx. At the fifth dorsal vertebra it widens and thickens, and in the lumbar region is bound up with the pillars of the diaphragm and confounded on each side with the large ligaments of the pelvis.)

Union of the Vertebræ by their Spinal Portions.—Each vertebra, in uniting by its annular portion with that which follows or precedes it, forms a double arthrodial joint.

Articular surfaces.—These are the facets cut on the anterior or posterior articular processes, and which have been described when speaking of the vertebræ themselves. They are covered by a thin layer of cartilage.

Modes of union.—1, A common superspinous ligament; 2, Interspinous ligaments; 3, Interlamellar ligaments; 4, Ligamentous capsules, proper to the articular processes.

a. Common superspinous ligament.—This ligament, whose name sufficiently indicates its situation, extends from the sacrum to the occipital bone and is divided into two portions : one posterior, or *superspinous dorso-lumbar ligament;* the other anterior, or *superspinous cervical ligament.* These two ligaments, although continuous with one another, yet differ so strikingly in form and structure that they are best described separately.

1. *Superdorso-lumbar ligament* (Fig. 80, 2).—This is a cord of white fibrous tissue, which commences behind on the sacral spine and ceases in front about the inferior third of the dorsal region by insensibly assuming the texture and elasticity of the cervical ligament, with which it is continuous. It is attached in its course to the summits of all the lumbar spinous processes and to the ten or twelve last dorsal. On the sacral spine, it is confounded with the superior ilio-sacral ligaments. In the lumbar region, it is united on each side to the aponeuroses of the common mass of muscles.

2. *Superspinous cervical,* or simply *cervical ligament* (Fig. 104, 1, 2).—This ligament is entirely formed of yellow fibrous tissue, and constitutes, in the median plane of the body, a very remarkable elastic apparatus which separates the superior cervical muscles of the right side from those of the left, and plays the part not entirely of an articular band, but rather of a permanent stay charged to balance the weight of the head.

In the cervical ligament there is distinguished a *funicular* and a *lamellar portion.* The first, usually called the *cord* of the cervical ligament, is a wide funiculus which extends directly from the first dorsal spinous processes to the summit of the head. Divided into two lateral lips by a median groove, this cord is continued posteriorly with the dorso-lumbar ligament, and is inserted forwards into the cervical tuberosity of the occipital bone. It is covered above by a mass of fibro-adipose tissue which, in certain common-bred horses, is very abundant. Below, it gives rise, in its posterior two-thirds, to the majority of the fibres belonging to the lamellar portion. On the sides, it receives the insertions of several cervical muscles. The *lamellar portion,* comprised between the funicular portion, the spinous processes of the second dorsal vertebra, and the cervical stalk, constitutes a vast triangular and vertical septum, which itself results from the apposition of the two laminæ which lie back to back, and are united by cellular tissue; they are bordered above by the two lateral lips of the cord. The elastic fibres which enter into their composition are given off either from the latter, or from the spinous processes of the second and third dorsal vertebræ; they are directed downwards or forwards, and reach the spinous processes of the last six cervical vertebræ, into which they are inserted by so many digitations,

becoming confounded with the interspinous ligaments of the neck. The fibres of the two last digitations are few in number, widely separated from one another, and united by many anastomosing branches, which make them appear as a kind of wide network. The laminæ of the cervical ligament are in relation, outwardly, with the superior branch of the ilio-spinal ligament, the transverse spinous muscle of the neck, and the great complexus.

(This important structure, which is in reality the mechanical stay and support of the heavy head and neck of quadrupeds, and is usually termed the *ligamentum nuchæ*, is all but absent in Man, being represented in him by a thin narrow band, or rather two thin planes of fibres, the *ligamenta subflava*. It is described by Leyh as if there were not two portions, and that excellent anatomist does not appear to insist sufficiently on the difference between the dorso-nuchal and the dorso-lumbar divisions. Percivall, who almost entirely neglects the ligaments, also makes no distinction. The difference in structure, elasticity, and situation, warrants the distinction made by Chauveau. As already indicated, the function of this ligament, and more particularly of its nuchal division, is to maintain the head and neck in their natural position during repose, and to allow the most extensive movements at other times.)

b. Interspinous ligaments (Fig. 80, 3).—Fibrous laminæ fill the interspinous spaces, and are attached, before and behind, to the opposite borders of the spinous processes which they unite; they are continued below by the interlamellar ligaments, forming two lateral planes which are applied against each other, like the laminæ of the cervical ligament, and covered outwardly by the transverse spinous (*dorsalis colli*) muscle.

Fig. 80.

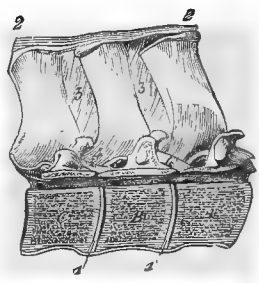

INTERVERTEBRAL ARTICULATIONS.

A, B, C, Bodies of three dorsal vertebræ divided longitudinally and vertically to show (1, 1) a section of the intervertebral discs; 2, Superspinous dorso-lumbar ligament; 3, Interspinous ligament; 4, Fibrous fascia, constituting the proper capsule to the articular processes in the dorsal region.

In the region of the neck, the interspinous ligaments are yellow and elastic. In the dorso-lumbar region, they are formed by fasciculi of white fibrous tissue, loosely united to each other at their extremities, and directed very obliquely backwards and downwards. In consequence of this disposition, and notwithstanding their inextensibility, they permit the separation of the spinous processes. Their lateral surfaces are divided by a layer of grey elastic fibres, which cross like an X the direction of the preceding fasciculi. Very abundant in the anterior moiety of the dorsal region, these fibres operate, by their proper elasticity, in bringing the spinous processes towards each other.

c. Interlamellar, or *interannular ligaments.*—Situated, as their name indicates, between the vertebral laminæ, and divided into two lateral moieties, these ligaments appear to be produced by the two fibrous planes of the preceding ligaments, which, on arriving at the base of the spinous processes, separate from one another to be carried outwards. Their anterior border is inserted into the posterior margin of the vertebral lamina in front. Their posterior border is fixed to the anterior border and inferior face of the lamina behind. Their superior face is in relation with some spinal muscles, and their inferior face is in contact with the dura mater. Outwardly, they are confounded with the capsules proper

to the articular processes. Yellow and elastic in the cervical region, these ligaments are white and inelastic in the dorso-lumbar region.

d. Capsules proper to the articular processes (Fig. 81, 5).—Each anterior articular process is maintained against the corresponding posterior process by a direct band: this is a peripheric capsule attached around the diarthrodial facets, doubled internally by a synovial membrane which facilitates their gliding, and covered, outwardly, by the insertions of some spinal muscles. These capsules, yellow and elastic in the cervical, are composed of white fibrous tissue in the dorso-lumbar region. Very developed at the neck, in consequence of the thickness of the articular tubercles they envelope, they become reduced, near the middle of the back, to some fibres which cover, outwardly, the diarthrodial facets in contact.

Characters proper to some Intervertebral Articulations.—1. *Intercoccygeal and sacro-coccygeal articulations.*—These are constructed after the same type as the other spinal articulations, except that they are appropriate to the rudimentary state of the vertebræ they unite. The coccygeal bones only come in contact by their bodies, their spinal laminæ being reduced to the merest traces, or are altogether absent. The anterior and posterior articular surfaces of each vertebra are convex, and the interarticular fibro-cartilages, hollow on both faces, resemble a biconcave lense. With regard to the peripheral bands, they are represented by a bundle of longitudinal fibres spread over the surface of the bones, which they envelope in a common sheath.

2. *Intersacral articulations.*—The sacral vertebræ being fused into one piece—the os sacrum—there is no occasion to study the true articulations in this region. It may be remarked, however, that the superspinous dorso-lumbar ligament is continued on the sacral spine, and that there exist between the processes formed by this spine veritable interspinous ligaments.

3. *Sacro-lumbar articulation.*—In this articulation, the great thickness of the fibro-cartilage is to be remarked; and, in addition, that the last lumbar vertebra corresponds with the sacrum not only by its body and articular processes, but also by the oval and slightly concave facets shown on the posterior border of its transverse processes, which are adapted to analogous slightly-convex facets on the sides of the base of the sacrum. The bundles of fibres thrown from one bone to another from around these *sacro-transversals* (real planiform diarthroses) maintain the articular surfaces in contact, and cover, outwardly, the synovial membrane which facilitates their gliding.

4. *Articulation of the two last lumbar vertebræ.*—This is distinguished by the presence, between the transverse processes, of a planiform diarthrosis like that of the sacro-transversal just noticed. These two articulations are only found in Solipeds.

5. *Atlo-axoid articulation.*—This is so far removed by its conformation and special uses from the other intervertebral articulations, that it will be described as an extrinsic articulation of the head and spine. (See the *Articulations of the Head.*)

The Movements of the Spine in general.—Each intervertebral articulation is the seat of very obscure movements, whose separate study offers little interest. But these movements, when conjoined with those of the other articulations, result in bending the whole spinal stalk in a somewhat marked manner, and producing either the *flexion*, *extension*, or *lateral inclination* of this flexuous column.

When *flexion* takes place, the spine is arched upwards, the common inferior ligament is relaxed, the spinous processes separate from one

another, and the superspinous ligament, becoming very tense, soon imposes limits to this movement.

Extension is effected by an inverse mechanism, and is checked by the tension of the common inferior ligament and the meeting of the spinous processes.

Lateral inclination takes place when the spine bends to one side. This movement is very easily executed in the cervical and coccygeal regions, but is arrested by the ribs and the costiform processes in the dorso-lumbar region.

A *circumflex movement* is possible at the two extremities of the vertebral column—neck and tail; for they pass easily from extension to lateral inclination, and from this to flexion, etc.

Owing to the elasticity of the intervertebral fibro-cartilages, the spine is endowed with a very limited amount of *rotation*, or rather of *torsion*.

For the special study of the movements of each spinal region, reference must be made to what has been already said (page 29) regarding the mobility of this column.

In the *Ox* the intervertebral discs are much thicker than in the Horse. The common inferior vertebral ligament is very strong in the lumbar region. The superspinous dorso-lumbar ligament is composed of yellow elastic tissue. The cervical ligament is much more developed than in Solipeds, in consequence of the greater weight of the head; and it presents a conformation altogether special, which M. Lecoq has made known in the following terms: "On leaving the withers, the superspinous ligament ceases to cover the head of the spinous processes, and extends from each side in a wide and strong band, taking points of attachment on the sides of the processes, and becoming separated, on leaving that of the first dorsal vertebra, into two parts—a superior and inferior. The first reaches the cervical tuberosity in the form of a thick cord united to the cord of the opposite; the other thins off into a band which is attached to the posterior half of the spinous process of the axis and to that of the third and fourth vertebræ. A production of the same nature, an auxiliary to the principal portion, leaves the anterior border of the spinous process of the first dorsal vertebra, and is attached to that of the fourth, fifth, sixth, and seventh vertebræ. The superior border of this auxiliary ligamentous production is concealed between the two lamina of the principal ligament."[1]

The *Pig*, remarkable for the shortness of its neck and the limited movements of this region, does not show any cervical ligament, properly so called. It is replaced by a superficial fibrous raphé extending from the occipital bone to the spinous process of the first dorsal vertebra.

The *Cat* has no cervical ligament, and shows, instead, a raphé like the Pig. In the *Dog* the ligament is reduced to a simple cord, continued from the dorso-lumbar ligament, and which goes no further than behind the spinous process of the axis. In the *Cat* the interspinous ligaments are replaced by small muscular fasciculi; with the *Dog* this substitution only takes place in the cervical region. The laminæ of the first coccygeal vertebræ possess the principal characters which distinguish perfect vertebræ, and are united by vestiges of the articular bands which exist in the other regions of the spine.

Article II.—Articulations of the Head.

We will first study the two extrinsic articulations which are the centre of the movements of the head on the spine—the *atlo-axoid* and *occipito-atloid articulations*. Afterwards, we will pass to the examination of the joints which unite the different bones of the head.

1. *Atlo-axoid Articulation.*

(*Preparation.*—It suffices to remove the soft parts from around the articulation to expose the interannular, the interspinous, and the inferior odontoid ligament. To examine

---

[1] 'Journal de Médecine Vétérinaire' (Lyons, 1848), p. 122.

the superior odontoid ligament and the synovial membrane, one half the atlas and axis must be separated by sawing longitudinally through them from one side to the other.)

This may be considered as the type of the trochoides.

Articular surfaces.—To form this articulation, the axis offers its odontoid pivot and the undulated diarthrodial facets at its base. The atlas opposes to the pivot the concave semicylindrical surface hollowed on the superior face of its body; and for the lateral undulated facets it has analogous facets which are cut on the transverse processes, on each side of the vertebral canal.

Mode of union.—1. An odontoid, or odonto-atloid ligament; 2. An inferior atlo-axoid ligament; 3. A superior ditto; 4. A fibrous capsule.

a. Odontoid ligament (Fig. 81, 3).—Continued to the common superior vertebral ligament, very short and strong, flattened from above to below, and triangular in shape, the odontoid ligament is composed of glistening white fibres, fixed behind in the superior channel of the odontoid process, and inserted in front on the transverse ridge which separates the superior face from the inferior arch of the atlas, as well as on the imprints situated in front of this ridge. This ligament is covered, on its lower face, by the synovial membrane of the articulation; and by its upper surface is in contact with the spinal dura mater. It sends some bands within the condyles of the occipital bone.

b. Inferior atlo-axoid ligament.—This is a wide, thin, and nacrous-looking band, extending from the inferior face of the axis to the inferior tubercle of the atlas, and covered by the long muscle of the neck; it is united to the synovial membrane by its deep face, and confounded on its borders with the fibrous capsule to be immediately described.

c. Superior atlo-axoid ligament.—This exactly represents the inter-spinous ligaments of the other cervical articulations. Yellow, elastic, and formed like the two lateral bands, it is continuous, laterally, with the capsular ligament.

d. Capsular ligament.—This, it may be said, is only the interlamellar ligament proper to the atlo-axoid articulation. It commences from the sides of the preceding ligament, and becomes united to the inferior atlo-axoid one, after contracting adhesions with the borders of the odontoid ligament. In this way it encloses the articulation and the spinal canal. Before and behind, it is attached to the anterior or posterior margin of the bones it unites. Its external face is in contact with the great oblique muscle of the head; its internal responds, in its inferior half, to the articular synovial membrane, and its superior moiety to the spinal dura mater. (Leyh describes this ligament as the interannular.)

Synovial membrane.—This lines the odontoid ligament, the atlo-axoid ligament, and the articular portion of the peripheral capsule.

Movements.—*Rotation*, the only movement possible in the atlo-axoid articulation, is effected in the following manner: the axis remains fixed, and the first vertebra, drawn to one side chiefly by the great oblique muscle, rotates on the odontoid pivot, carrying the head with it.

In the *Dog* and *Cat* the odontoid ligament is replaced by three particular ligaments: 1, Two *lateral cords*, rising in common from the summit of the odontoid process, and inserted, each on its own side, within the condyles of the occipital bone; 2, A *transverse ligament*, passing over the odontoid process, which it maintains in its place against the inferior arch of the atlas, and is attached by its extremities to the superior face of the latter. A small synovial capsule facilitates the gliding of the odontoid process beneath this ligament. The articular synovial membrane always communicates with that of the occipito-atloid articulation.

In the *Pig* the disposition is nearly the same as in the Carnivora

2. *Occipito-atloid Articulation.*

(*Preparation.*—Dissect away all the soft parts that pass from the neck to the head and cover the articulation, and more particularly the flexor, the recti, and the small oblique muscles of the head. To expose the synovial membranes, open the sides of the capsular ligament.)

This is a condyloid articulation.

Articular surfaces.—In the atlas, the two cavities which replace the anterior articular processes and the heads of the other vertebræ; in the occipital bone, the two condyles flanking the sides of the occipital foramen.

Mode of union.—A single capsular ligament envelopes the entire articulation; it is attached by its anterior border to the margin of the occipital condyles, and by its posterior to the anterior contour of the atlas. Thin and slightly elastic in its inferior half, this ligament presents, superiorly, four reinforcing fasciculi: two middle, which intercross in X—from whence the name "cruciform," sometimes given to this ligament (Fig. 81, 1, 1); and two lateral, which pass from the sides of the atlas to the base of the styloid processes (Fig. 81, 2, 2). It is lined within by the synovial membranes, and is enveloped externally by a large number of muscles, which protect the articulation and greatly strengthen it everywhere. Among these may be particularly noticed the straight muscles of the head, the small oblique, and the great complexus. There is also the cord of the cervical ligament.

Synovial membranes.—These membranes are two in number, one for each condyle and corresponding atloid cavity. Sustained above, below, and outwardly by the capsular ligament, they are related inwardly to the dura mater and to the fibrous tractus which, from the odontoid ligament, is carried to the internal face of the occipital condyles.

Movements.—*Extension, flexion, lateral inclination,* and *circumduction,* are the possible movements of the occipito-atloid articulation.

In the *Pig, Dog,* and *Cat* this articulation, strengthened as it is by the capsular and odontoido-occipital ligaments already mentioned, has only one synovial capsule.

Fig. 81.

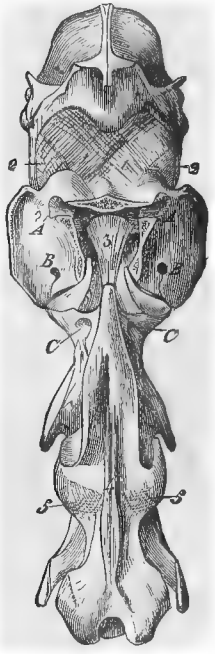

ATLO-OXOID AND OCCIPITO-ATLOID ARTICULATIONS. The upper arch of the atlas has been removed to show the odontoid ligament.

1, 1, Middle accessory fasciculi; 2, 2, Lateral fasciculi of the capsular ligament of the occipito-atloid articulation; 3, Odontoid ligament; 4, Interspinous ligament uniting the second and third vertebræ of the neck; 5, Fibrous capsule uniting the articular processes of these vertebræ.—A, Anterior internal foramen of the atlas converted into a groove by the section of the bone; B, B, Vertebral foramina of the atlas; C, C, Foramina replacing the anterior notches of the axis.

3. *Articulations of the Bones of the Head.*

If we except the articulation which unites the inferior jaw to the cranium—the temporo-maxillary—and the hyoideal articulations, it will be found that all the bones of the cranium and face are united to each other by synarthrosis, forming the different kinds of sutures already generally described (page 128). Nothing is to be gained by entering into more detail

with regard to these articulations, as it will be found sufficient to call to mind the topographical description of each piece entering into their formation.

4. *Temporo-maxillary Articulation.*

(*Preparation.*—Remove the masseter muscle and the parotid gland. Saw through the head about the middle line. Open the articulation externally to exhibit the interarticular meniscus.)

The lower jaw, in its union with the cranium, constitutes a double condyloid articulation.

Articular surfaces.—With the temporal bone, these are the condyle, the glenoid cavity, and the supracondyloid process which exists at the base of the zygomatic process. The glenoid cavity is not lined by cartilage, and appears to be merely covered by synovial membrane. With the maxillary bone there is the oblong condyle situated in front of the coronoid process.

Interarticular fibro-cartilage.—The articular surfaces just named are far from fitting each other accurately; this is only accomplished by the interposition of a fibro-cartilaginous disc between the temporal and maxillary bones. This disc is a kind of irregular plate, flattened above and below, thicker before than behind, and moulded on each of the diarthrodial surfaces it separates. Its superior face, therefore, presents: in front, a cavity to receive the condyle of the temporal bone; behind, a boss which is lodged in the glenoid cavity. The inferior face is hollowed by an oblong fossa in which the maxillary condyle is lodged.

Fig. 82.

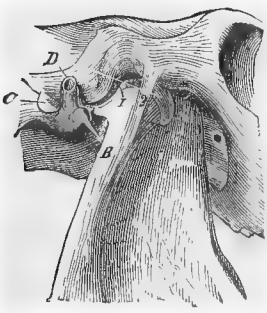

TEMPORO-MAXILLARY ARTICULATION.

1, Interarticular fibro-cartilage; 2, External fasciculus of the capsular ligament.—A, Base of the coronoid process; B, Neck of the maxillary condyle; C, Mastoid process; D, External auditory hiatus.

Mode of union.—A fibrous envelope—a true *capsular ligament*—surrounds the articulation, and is attached by its borders to the margin of the articular surfaces it unites. Formed, outwardly, by a thick fasciculus of white vertical fibres (Fig. 82, 2), this ligament becomes greyish-coloured and elastic for the remainder of its extent, and greatly diminishes in thickness, especially in front. Its inner face is lined by the synovial capsules, and adheres to the circumference of the interarticular fibro-cartilage. Its external face responds, in front, to the temporal and masseter muscles; behind, to the parotid gland; inwardly, to the external pterygoid muscle; and outwardly, to a fibrous expansion which separates it from the skin. (Leyh mentions a lateral external and a posterior ligament for this articulation, but Chauveau and Rigot evidently look upon these as portions of the capsular.)

Synovial membranes.—This articulation has two synovial sacs, one above the other, which are separated by the fibro-cartilaginous disc.

Movements.—The temporo-maxillary articulation is the centre of all the movements performed by the lower jaw. These are: *depression*, *elevation*, *lateral motion*, and *horizontal gliding*.

The lower jaw is *depressed* when it separates from the superior one, and is *elevated* when it approaches this. These two opposite movements are executed by a mechanism of such great simplicity that it need not be

described here. *Lateral movements* take place when the inferior extremity of the jaw is carried alternately to the right and left. It then happens that one of the maxillary condyles, taking with it the fibro-cartilage, is brought into contact with the temporal condyle, while the other is imbedded in the glenoid cavity of the opposite side. The *horizontal gliding* is effected from behind to before, or *vice versâ*. In the first case, the two maxillary condyles are carried at the same time under the temporal condyles, bearing with them the fibro-cartilages. In the second case, they are drawn into the glenoid cavities, and rest against the supracondyloid eminence, which prevents their going further. It will be understood, after this brief description, that the presence of the fibro-cartilages singularly favours the lateral movements and horizontal gliding of the lower jaw.

In the *Pig* the temporo-maxillary articulation is formed after the same type as that of rodents, and allows very extensive movements from before to behind; a circumstance due to the complete absence of the supracondyloid eminence.

In the *Dog* and *Cat* the maxillary condyle is exactly fitted into the temporal cavity. This disposition, in giving great precision to the movements of depression and elevation, restrains in a singular manner the lateral and horizontal gliding motions. The inter-articular fibro-cartilage is extremely thin in these animals.

5. *Hyoideal Articulations.*

(*Preparation.*—Disarticulate the lower jaw, and dissect away from the right of each articulation the muscles that may conceal the view.)

These are of two kinds: *extrinsic* and *intrinsic*. The first comprise the two *temporohyoideal* articulations; to the second belong the joints which unite the different pieces of the hyoid bone—the *interhyoideal articulations*.

Temporo-hyoideal Articulations.—These are two amphiarthrodial joints, in the formation of which each great branch of the hyoid bone opposes its upper extremity to the hyoideal prolongation lodged in the vaginal sheath of the temporal bone. An elastic cartilage, from 4-10ths to 6-10ths of an inch in length, unites the two bones in a solid manner; and it is owing to the flexibility of this cartilage that the hyoid bone can move entirely on the temporal bones.

Interhyoideal Articulations.—*A.* The great branch articulates with the small one by an amphiarthrosis analogous to the preceding. To form this articulation, these two pieces of bone are joined at an acute angle through the medium of a more or less thick cartilaginous band, in the centre of which there is often a little bony nucleus. This cartilage is elastic and flexible, and permits the opening and closing of the articular angle at the summit of which it is placed.

B. Each small branch is united to the body of the hyoid bone by an arthrodial articulation. The articular surfaces are: for the hyoideal branch, the small cavity terminating its inferior extremity; for the body, the rounded lateral facet situated at the origin of the cornu. These surfaces are covered by cartilage, and enveloped by a small synovial sac and a peripheral fibrous capsule. They can glide on each other in nearly every direction. (Median and superior hyoideal capsular ligaments are described by Leyh as sometimes present. The latter unites the upper and middle branches, and the former the middle with the inferior branches. They are absent when these branches are confounded with the superior ones.)

Article III.—Articulations of the Thorax.

These are also divided into *extrinsic* and *intrinsic*. The first, named costo-vertebral, unite the ribs to the spine. The second join the different pieces of the thorax together; they comprise: 1, The chondro-sternal articulations; 2, Chondro-costal articulations; 3, The articulations of the costal cartilages with each other; 4, The sternal articulation peculiar to the larger Ruminants and the Pig. All these joints will be first studied in a particular manner, then examined in a general way as to their movements.

1. *Articulations of the Ribs with the Vertebral Column, or Costo-vertebral Articulations.*

Each rib responds to the vertebral column by two points—its head and its tuberosity. The first is received into one of the intervertebral cavities hollowed out on the sides of the spine, and is therefore in contact with two dorsal vertebræ; the second rests against the transverse process of the posterior vertebra. From this arrangement arises two particular articulations belonging to the arthrodial class, which are named *costo-vertebral* and *costo-transverse*.

Costo-vertebral Articulations.—*Articular surfaces.*—Pertaining to the rib, we have the two convex facets of the head, separated from each other by a groove of insertion and covered by a thin layer of cartilage. On the vertebræ, the concave facets which by their union form the intervertebral cavity; these facets are also covered with cartilage, and separated, at the bottom of the cavity by the corresponding intervertebral disc.

Mode of union.—1. An *interarticular ligament* (Figs. 83, 2; 84, 1), implanted in the groove of insertion of the head of the rib, and attached to

Fig. 83.

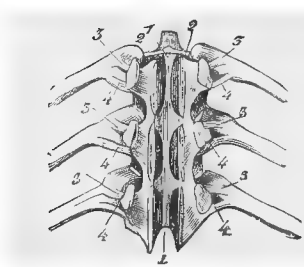

ARTICULATIONS OF THE RIBS WITH THE VERTEBRÆ, AND OF THESE WITH EACH OTHER (UPPER PLANE).

1, Spinal canal, upper face, showing the common superior ligament; 2, Interarticular costo-vertebral ligament; 3, Interosseous costo-transverse ligament; 4, Posterior costo-transverse ligament.

Fig. 84.

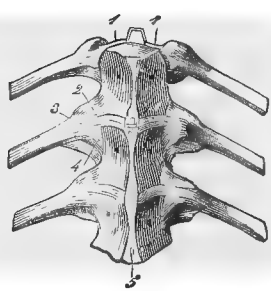

ARTICULATIONS OF THE RIBS WITH THE VERTEBRÆ, AND OF THESE WITH EACH OTHER (INFERIOR PLANE).

1, Interarticular costo-vertebral ligament; 2, 3, 4, Fasciculi of the stellate, or inferior costo-vertebral ligament; 5, Common inferior vertebral ligament.

the superior border of the intervertebral disc, which it encircles upwards and inwards, to unite on the median line with the ligament of the opposite side. 2. An *inferior peripheral ligament* (Fig. 84, 2, 3, 4), flat above and below, thin and radiating (whence it is often named the *stellate* ligament), formed of three fasciculi which are fixed in common on the inferior face of

the head of the rib, and in diverging are carried over the bodies of the two vertebræ and the intervertebral disc. Lined above by the synovial membranes, this ligament is covered below by the pleura. (Leyh includes a capsular ligament for the head of the rib and another for the costal tuberosity. He probably viewed the synovial membrane of these articulations as such.)

Synovial membranes.—Two in number, these are distinguished into anterior and posterior, lying against each other, and separated in part by the interarticular ligament they cover. Supported below by the stellate ligament, above they are directly in contact with the small supercostal muscles, and with vessels and nerves.

Costo-transverse Articulations.—*Articular surfaces.*—In the rib, the diarthrodial facet cut on the tuberosity. In the vertebra, the analogous facet on the outside of the transverse process.

Mode of union.—Two ligaments bind this articulation: 1, The *posterior costo-transverse ligament* (Fig. 83, 4), a white fibrous band attached by its extremities behind the tranverse process and the costal tuberosity, lined by synovial membrane, and covered by the transverse insertions of several spinal muscles; 2, The *anterior costo-transverse*, or *interosseous ligament* (Fig. 83, 3), a fasciculus of short, thick, white fibres, fixed on the anterior surface of the transverse process near its base, and in the rugged excavation on the neck of the rib. This ligament is invested, posteriorly, by the synovial membrane, and covered in front by pads of adipose tissue which separate it from the costo-vertebral articulation.

Synovial membrane.—This is a small particula. capsule kept apart from the posterior synovial membrane of the costo-vertebral articulation by the costo-transverse interosseous ligament.

Characters peculiar to some Costo-vertebral Articulations.—1. The first, and sometimes the second, costo-vertebral articulation has no interosseous ligament, and only exhibits one synovial membrane. The intervertebral cavity which concurs in forming the first is often excavated between the last cervical and first dorsal vertebræ.

2. The two or three last costo-transverse articulations are confounded with the corresponding costo-vertebral joints. They have no proper serous membrane, but the posterior synovial membrane of the latter is prolonged around their articular surfaces.

2. *The Chondro-sternal or Costo-sternal Articulations.*

(*Preparation.*—To show the articulation of the ribs with the cartilages, these with the sternum, and the cartilages with each other, carefully remove the pleura, the triangular muscle of the sternum, the diaphragm, the transverse muscle of the abdomen, then the pectorals, the great oblique, the transversalis of the ribs, and the intercostal muscles.)

The first eight ribs, in resting upon the sternum by the inferior extremity of their cartilages, form eight similar arthrodial articulations.

Articular surfaces.—Each sternal cartilage opposes to one of the lateral cavities of the sternum the convex and oblong facet at its lower extremity.

Mode of union.—The diarthrosis resulting from the union of these two surfaces is enveloped everywhere by bundles of white, radiating, fibrous tissue, which constitute a veritable ligamentous capsule. The superior part of this capsule, known as the *stellate* or *superior costo-sternal ligament*, is covered by the triangular (sterno-costalis internus) muscle; it is joined to a fibrous cord lying on the superior face of the sternum, and which

is confounded in front with that of the opposite side. The inferior portion, the *inferior stellate* or *costo-sternal ligament*, is in relation with the pectoral muscles.

Synovial capsule.—There is one for each articulation.

Characters proper to the first costo-sternal articulation.—The first costo-sternal articulation is not separated from its fellow of the opposite side; so that these two joints are, in reality, only one, and the two cartilages lying close to each other correspond by a small diarthrodial facet, continuous with that for the sternum. The two sternal facets are inclined upwards, and confounded with one another. Only one synovial cavity exists for this complex articulation, which unites the two first ribs to each other and to the sternum.

3. *Chrondo-costal Articulations uniting the Ribs to their Cartilages.*

These are synarthrodial articulations whose movements are very obscure. They are formed by the implantation of the cartilages in the rugged cavities the ribs present at their inferior extremities. The solidity of these articulations is assured by the adherence of the fibro-cartilage to the proper substance of the ribs, and by the periosteum which, in passing from the bone to the cartilage, plays the part of a powerful peripheral band.

In the *Ox*, the sternal ribs, in uniting with their cartilages, form a veritable ginglymoid diarthrosis, whose movement is facilitated by a small synovial capsule.

4. *Articulations of the Costal Cartilages with each other.*

The ribs, attached to each other by means of the intercostal muscles, are not united by real articulations; neither are their cartilages of prolongment. But the asternal cartilages are bound together by a small yellow elastic ligament, which is carried from the free extremity of each to the posterior border of the preceding cartilage; the anterior border of the first asternal cartilage is directly united to the posterior border of the last sternal cartilage, through the medium of the perichondrium and very short ligamentous bands. This same asternal cartilage is also bound to the inferior face of the xiphoid appendage by a small white ligament (the *chondro-xiphoid*), under which passes the anterior abdominal artery.

5. *Sternal Articulation peculiar to the Ox and Pig.*

It has been already shown that in these animals the anterior piece of the sternum is not consolidated with the second portion. The two are united by a diarthrodial articulation; and for this purpose the anterior presents a concave surface, the posterior a convex one. Bundles of peripheral fibres firmly bind them to each other, and a special small synovial capsule facilitates their movements, which are very limited.

6. *The Articulations of the Thorax considered in a general manner in regard to Movements.*

The thorax can increase or diminish in diameter in an antero-posterior and a transverse direction; whence arises the dilatation and contraction of this cavity: the *inspiratory movements* accompanying the entrance of the external air into the lungs, and the *expiratory movements* expelling the air contained in these organs.

The variations in the antero-posterior diameter of the chest being due to changes in the figure of the diaphragm, need not be noticed here. But the transverse variations being the result of the play of the costal arches on the

spine and sternum, it is advantageous to study the mechanism which presides in the execution of their movements.

The costal arches being inclined backwards on the middle plane, the space they inclose in their concavity is not nearly so extensive as if they had been perpendicular to this plane. Owing to their double arthrodial joints, the ribs are movable on the spine, and their inferior extremity, also movable, rests either directly or indirectly on the sternum. Therefore it is that, when they are drawn forward by their middle portions, they pivot on their extremities, and tend to assume a perpendicular direction, which is the most favourable for the largest increase of the space they limit; then there is enlargement of the lateral diameter of the thorax, which signifies dilatation of its cavity. The inverse movement, by an opposite mechanism, causes the contraction of the chest.

The ribs are said to be *elevated* during the forward movement, and *depressed* when they fall backwards. These expressions, though perfectly applicable to Man, who stands in a vertical position, are not correct when employed in veterinary anatomy.

Article IV.—Articulations of the Anterior Limbs.

1. *Scapulo-humeral Articulation.*

(*Preparation.*—Detach the limb from the trunk. Remove from the upper extremity those muscles which are inserted in the vicinity of the glenoid cavity of the scapula; turn down from its lower extremity those which are inserted into the superior end of the humerus or a little below, preserving the attachments of their tendons with the capsular ligament. The thin scapulo-humeralis muscle may be allowed to remain in order to show its relations.)

To constitute this enarthrodial articulation, the scapula is united to the humerus, and forms an obtuse angle which is open behind.

Articular surfaces.—In the scapula there is the glenoid cavity, the shallow, oval fossa, elongated in an antero-posterior direction, notched inwardly, and excavated at its centre or near the internal notch by a small synovial fossette. A ligamentous band, attached to the brim of the cavity, fills up this notch, and is the vestige of the glenoid ligament of man. In the humerus, the articular head, fixed between the large and small tuberosities, is often excavated by a shallow synovial fossette.

Mode of union.—One *capsular ligament* (Fig. 85, 1), a kind of sac having two openings: one inferior, embracing the head of the humerus; the superior, inserted into the margin of the glenoid cavity. This capsule presents in front two supporting fasciculi, which diverge as they descend from the coracoid process to the great and small tuberosities. The aponeurotic expansion thus formed is very thin and loose, so as to allow the two bones to separate to the extent of from $\frac{4}{10}$ to $\frac{8}{10}$ of an inch; but it is far from being sufficiently strong to bind them firmly together. The articulation is, therefore, consolidated by the powerful muscles which surround it, among which may be noticed: 1, In front, the coraco-radial (flexor brachii), separated from the fibrous capsule by an adipose cushion; 2, Behind, the large extensor of the fore-arm and thin scapulo-humeral (teres minor) muscles, whose office appears to be to pull up this capsule during the movements of flexion, so as to prevent its being pinched between the articular surfaces; 3, Outwards, the short abductor of the arm and the subspinous (postea spinatus) tendon; 4, Inwards, the wide and strong tendon of the subscapular muscle. In addition to these powerful retaining apparatus,

there is the atmospheric pressure, whose influence is of a certain importance. This may be proved by removing all the surrounding muscles, when it will be found that the capsule is not relaxed, nor are the articular surfaces separated; to effect this, it is necessary to make an opening in the capsule, so as to allow the air to enter its cavity, when the surfaces immediately separate.

Synovial capsule.—This is very loose, and entirely enveloped by the peripheral capsule, whose internal surface it lines.

Movements.—Like all the enarthrodial articulations, the scapulo-humeral permits *extension*, *flexion*, *abduction*, *adduction*, *circumduction*, and *rotation*. These various movements, however, are far from being so extensive as in Man, the arm in the domesticated animals not being detached from the trunk, but being, on the contrary, fixed with the shoulder against the lateral parietes of the thorax. *Flexion* and *extension* are the least limited and the most frequently repeated movements; their execution always demands a displacement of the two bones, which are almost equally movable. In *flexion*, the scapulo-humeral angle is closed, not only because the inferior extremity of the humerus is carried backwards and upwards, but also because the scapula pivots on its superior attachments in such a manner as to throw its glenoid angle forward and upward. *Extension* is produced by an inverse mechanism. During the execution of the other movements, the scapula remains fixed, and the humerus alone is displaced, bringing with it the inferior rays of the limbs. If it is carried outwards, we have *abduction*, or inwards, *adduction;* if the member passes successively from flexion to abduction, and from that to extension, etc., in describing a circle by its lower extremity, then there is *circumduction;* if it pivots from left to right, or right to left, we have *rotation*.

In the *Pig*, *Dog*, and *Cat*, the synovial membrane is not exactly inclosed by the fibrous capsule, but forms in front a *cul-de-sac*, which descends in the bicipital groove to favour the gliding of the coraco-radial tendon.

In *Man*, the scapulo-humeral articulation is disposed as in animals, but it is also protected above by the coraco-acromion roof. For the reasons noted above, this articulation allows of more extensive motion than in animals. As remarked by Cruveilhier, of all the joints in the human body, the scapulo-humeral is that which has the most extensive motion; in movements forward and outward, the humerus can become horizontal; in those of circumduction it describes a complete cone, which is more extensive in front and laterally than behind and inwardly.

2. *Humero-radial, or Elbow Articulation.*

(*Preparation.*—Turn down the inferior extremity of the flexors of the fore-arm, remove the olecranian, epicondyloid, and epitrochlean muscles, taking care not to damage the ligaments to which they somewhat closely adhere.)

Three bones concur to form this articulation, which presents a remarkable example of an angular ginglymus: the humerus, by its inferior extremity, and the two bones of the arm by their upper extremities.

Articular surfaces.—The *humeral surface*, already described at page 74, is transversely elongated, and convex from before to behind. It presents: 1, A median groove excavated by a synovial fossette; 2, An external groove (humeral trochlea) not so deep as the preceding; 3, A kind of voluminous condyle which borders, inwardly, the internal pulley, and whose antero-posterior diameter is much greater than that of the external lip of the trochlea of the opposite side. The *antibrachial* surface, divided into two portions, is moulded to the humeral surface; it is, therefore, concave before and behind, and is composed: 1, Of a double external groove; 2, Of an

internal glenoid cavity, both excavated, on the superior extremity of the radius; 3, A middle ridge responding to the middle groove of the humerus, separating the two preceding surfaces, and prolonged on the ulnar beak, where it forms the sygmoid notch. This ridge shows a small synovial fossette hollowed out on the radius and ulna.

Mode of union.—Three ligaments: two lateral and an anterior.

a. The *external lateral ligament* (Fig. 85, 8) is a thick, short, and strong funicle, attached above to the crest limiting outwardly and posteriorly the furrow of torsion, and in the small cavity placed at the external side of the humeral articular surface. Below, it is inserted into the supero-external tuberosity of the radius. Its anterior border is confounded with the capsular ligament, and is margined by the principal extensor of the phalanges, which derives from it numerous points of attachment. By its posterior border it is in contact with the external flexor of the metacarpus. Its internal face is lined by synovial membrane, and its external face is only separated from the skin by the antibrachial aponeurosis and some of the fasciculi from the origin of the lateral extensor muscle of the phalanges. Its superficial fibres are vertical, and are continuous, behind, with the arciform ligamentous bands which stretch from the ulna to the radius. Its deep fibres are slightly oblique downwards and forwards.

Fig. 85.

SCAPULO-HUMERAL AND HUMERO-RADIAL ARTICULATIONS, WITH THE MUSCLES SURROUNDING THEM (EXTERNAL FACE).

1, Scapulo-humeral capsular ligament; 2, Short abductor muscle of the arm; 3, Its insertion in the humerus; 4, Insertion of the subspinous muscle on the crest of the great tuberosity; 5, Coraco-radial muscle; 6, Its tendon of origin attached to the coracoid process; 7, Its radial insertion confounded with the anterior ligament of the ulnar articulation; 8, 8, External lateral ligament of that articulation; 9, Anterior ligament; 10, Aconeus, or small extensor of the fore-arm; 11, Origin of the external flexor muscle of the metacarpus; 12, Short flexor muscle of the fore-arm.—A, Tuberosity of the scapular spine.—B, Superspinous fossa.—C, Subspinous fossa.—D, Convexity of the small trochanter.—E, Summit of the trochanter.

b. The *lateral internal ligament*, also funicular, is longer, but not so strong as the preceding. It arises from the small tuberosity on the inner side of the

superior articular face of the humerus and, widening as it descends, reaches the radius. Its median fibres, which are the longest, are directed vertically downwards to reach the imprints situated below the bicipital tuberosity; its anterior fibres, curved forwards, are united to the tendon of the coraco-radial muscle, or are confounded with the anterior ligament; the posterior are turned backwards, near their inferior extremities, to join the arciform fibrous fasciculi which inwardly unite the ulna to the radius. The middle fibres of this ligament cover the inferior insertion of the short flexor of the fore-arm and, in part only, that of the long flexor. It is covered by the ulna-plantar nerve and the posterior radial artery and vein.

c. The *anterior* or *capsular ligament* (Fig. 85, 9) is a membraniform band, attached by its superior border above the humeral articular surface, and by its inferior to the anterior margin of the radial surface. By its lateral borders, it is confounded with the funicular ligaments. Its internal half is formed of vertical fibres which descend from the humerus and expand over the radius, where they become united with the inferior tendon of the coraco-radial muscle. In its external moiety it is extremely thin, and composed of fibres crossed in various directions. Lined internally by synovial membrane, this ligament is in contact, by its external surface, with the anterior radial vessels and nerves, the two flexor muscles of the fore-arm, the anterior extensor of the metacarpus, and anterior extensor of the phalanges. The two latter muscles are even attached to it in a very evident manner. The elbow articulation, closed in front and on the sides by the three ligaments just described, has no particular ligaments posteriorly; but it is powerfully consolidated there by the olecranian insertion of the extensor muscles of the fore-arm, and by the tendons of origin of the five flexor muscles of the metacarpus or phalanges.

Synovial membrane.—This membrane is very extensive and, stretched out on the internal face of the before-mentioned ligaments, forms behind three great *culs-de-sac* of prolongment: a superior, occupying the olecranian fossa, and covered by a fatty cushion, as well as by the small extensor muscle of the fore-arm;[1] two lateral, which descend from each side of the ulnar beak, and are distinguished as internal and external; the first lin the tendon of the external flexor of the metacarpus; the second facilitates the play on the upper radial extremity of the four flexor muscles of the foot or digits, and which are attached in common to the epitrochlea. This synovial sac also furnishes the radio-ulnar articulation with a diverticulum which descends between the bones of the fore-arm to below the adjacent diarthrodial facets.

Movements.—Flexion and *extension.*

In *flexion*, the two bones do not approach each other directly, the inferior extremity of the radius deviating a little outwards. This is due more to the slight obliquity of the articular grooves than to the difference in thickness existing between the external and internal extremities of the humeral surface.

Extension is limited by the reception of the beak of the olecranon in its fossa, and by the tension of the lateral ligaments; so that the two rays cannot be straightened on one another in a complete manner, or placed on the same line.

In the *Dog* and *Cat*, the external lateral ligament is very thick, and forms in its

[1] Some grey elastic fibres which cover this cul-de-sac externally, have been wrongly described as a posterior membraniform ligament.

inferior moiety a fibro-cartilaginous cap which is fixed on the ulna and radius, and united in front to the annular ligament of the superior radio-ulnar joint. This cap, with the last-named ligament, completes the osteo-fibrous ring in which the superior extremity of the radius turns. The internal lateral ligament is inserted by two very short fasciculi into the ulna and inner side of the head of the radius. A third fasciculus, deeper and median, much more developed than the first, and covered by the inferior insertion of the flexors of the fore-arm, descends between the radius and ulna to the posterior face of the former, and is there inserted near the inferior attachment of the external ligament, which it appears as if about to join.

In *Man*, the elbow articulation is formed nearly on the same plan as that of the Dog and Cat. The radius and ulna move together when the fore-arm is flexed and extended on the humerus.

3. *Radio-ulnar Articulation.*

Articular surfaces.—The two bones of the fore-arm correspond by diarthrodial and synarthrodial surfaces.

a. The *diarthrodial surfaces* consist of four undulated, transversely elongated facets, two of which are *radial* and two *ulnar*. The first border, posteriorly, the great articular surface forming the elbow joint; the second are situated beneath the sigmoid notch.

b. The *synarthrodial surfaces* are plane and roughened, and are also two on each bone: one, superior, extends below the diarthrodial facets to the radio-ulnar arch; the other, inferior, more extensive, occupies all the anterior face of the ulna from this arch; on the radius it forms a very elongated triangular imprint which descends to the lower fourth of the bone. See pages 75, 76.

Mode of union.—Two interosseous and two peripheral ligaments.

a. The *interosseous ligaments*, interposed between the synarthrodial surfaces, are composed of extremely short white fibres passing from one to the other surface, and which are endowed with a very remarkable power of resistance. The inferior always ossifies a long time before the animal is full grown: a circumstance which caused the older veterinary anatomists to describe, and with some show of reason, the radius and ulna as a single bone. Ossification of the superior ligament is very rare.

b. The *peripheral bands* are bundles of arciform fibres which, from the back of the olecranon to the radio-ulnar arch, leave the lateral faces of the ulna to pass, some inwards, others outwards, to the posterior face of the radius. The fibres of the external ligament are confounded with the external humero-radial ligament. The internal fibres are united to the internal humero-radial ligament, and to the small ulnar tendon belonging to the short flexor of the fore-arm. Analogous fibres are found beneath the radio-ulnar arch; but they are much shorter and less apparent. (This is the *external transverse radio-ulnar ligament* of Leyh.)

Movements.—Very obscure in youth; nearly null when consolidation of the two bones takes place.

In the *Ox*, ossification of the superior interosseous ligament is constant at adult age.

In the *Dog* and *Cat*, we have already seen (p. 87) that the radius and ulna are not fused to each other, but remain independent during life. They are united in their middle portion by an interosseous ligament, and join by diarthrosis at their two extremities. These animals therefore exhibit: 1, An *interosseous ligament*; 2, A *superior radio-ulnar articulation*; 3, An *inferior radio-ulnar articulation.*

Interosseous ligament.—It is composed of very resisting white fibres, attached by their extremities to the bodies of the bones. Notwithstanding their shortness, they are loose enough to allow movements taking place between the radio-ulnar articulations.

Superior radio-ulnar articulation.—This is a trochoid articulation, which only allows movements of rotation or pivoting.

The *articular surfaces* which form this articulation are: in the ulna, the small sigmoid cavity, a surface excavated in the lateral sense, and semicircular; in the radius, a cylindrical half-hinge received into the preceding cavity.

To unite these there is an *annular ligament*, a kind of fibrous web thrown around the superior extremity of the radius, fixed inwardly on the ulna near the inner extremity of the small sigmoid cavity, attached outwardly to the external lateral ligament of the elbow articulation, and confounded superiorly with the anterior ligament of the same articulation. This fibrous web, in uniting with the fibro-cartilaginous cap of the external humero-radial ligament, and joining the small sigmoid cavity by its internal extremity, transforms this last into a complete ring, covered with cartilage in its bony portion, and lined by synovial membrane—that of the elbow articulation—in its ligamentous portion. The head or superior extremity of the radius is also incrusted over its entire contour with a layer of cartilage: a disposition which permits it to glide not only in the concave face of the small sigmoid cavity, but also on the internal face of the two ligaments which complete this cavity.

Inferior radio-ulnar articulation.—This is also a trochoid articulation analogous to the preceding, but inversely disposed. Thus, the concave articular surface is hollowed on the radius, outside the inferior extremity; the convex surface lies within the ulna. These two facets are very small, and are maintained in contact by a diminutive peripheral fibrous capsule. A strong interosseous ligament, situated under the articular facets, also consolidates this diarthrosis, and concurs by its inferior border to form the antibrachial surface of the radio-carpal articulation. A small synovial capsule is specially devoted to this articulation.

Mechanism of the radio-ulnar joints.—The play of these two articulations is simultaneous, and tends to the same end; that is, to the execution of the double rotatory movement which constitutes *supination* and *pronation*.

Supination is when the ulna remains fixed, and the radius pivots on it in such a manner as to carry its anterior face outwards. Its superior extremity then turns from within forwards, and even from before outwards if the movement is exaggerated, in the articular girdle formed by the small sigmoid cavity of the ulna and the ligaments which complete it. The inferior extremity also rolls on the ulnar facet in describing a similar movement, and the internal tuberosity of this extremity is carried forwards.

In the movement of *pronation*, this tuberosity is brought inwards, and the anterior face of the radius comes forward by an opposite mechanism.

The inferior ray of the anterior member being articulated in a hinge-like manner with the radius, it follows that bone in its rotatory movements, the anterior face of the metacarpus looking outwards during supination and forwards in pronation.

The radio-ulnar articulation in *Man* resembles that of the Dog and Cat, the articular surfaces only being larger and the movements more extensive. In supination, the palmar face is turned forward, and the radius, situated on the outer side of the ulna, is in the same direction as the latter. In pronation, on the contrary, the palmar face of the hand looks backwards, and the radius, remaining outwards in its upper part, crosses the ulna in front in such a manner that its lower extremity is placed within the ulna.

4. *Articulations of the Carpus.*

(*Preparation.*—Remove the tendons from around the articulation, detaching their sheaths, but taking care of the ligaments.)

These comprise: 1, The articulations uniting the carpal bones of the first row to each other; 2, The analogous articulations of the second row; 3, The radio-carpal articulation; 4, The articulation of the two rows with each other; 5, The carpo-metacarpal articulation.

Articulations which unite the Bones of the First Row to each other.—These bones, four in number, are joined by the diarthrodial facets on their lateral faces and form small arthrodial articulations.[1] They are maintained in contact by six ligaments, *three anterior*, and *three interosseous*. The *anterior ligaments* are small flattened bands carried from the fourth bone to the first, from the first to the second, and from that to the third. The first, placed outside rather than in front of the carpus, is covered by the

[1] The facet uniting the supercarpal to the first bone is not situated on one of its faces, but rather on the anterior part of its circumference.

external lateral ligament and the inferior tendon of the external flexor of the metacarpus; the others adhere to the capsular ligament. The *interosseous ligaments* are implanted in the grooves of insertion which separate the diarthrodial facets. One of them, derived from the common superior ligament, unites the first to the second bone. The two others, situated between the three last carpal bones, are confounded with the corresponding anterior ligaments.

Articulations uniting the Carpal Bones of the Second Row.—These are arthrodial articulations, like the preceding, but numbering only two. They are fixed by *two anterior* and *two interosseous ligaments*. One of the *anterior ligaments* joins the first bone to the second, and strongly adheres to the capsular ligament; the other is entirely covered by the lateral internal ligament, and attaches the two last bones to each other. Of the two *interosseous ligaments*, the second alone is confounded with the corresponding anterior ligament. That which is situated between the two first bones is separated from the anterior ligament by one of the diarthrodial facets between these bones.

Radio-carpal Articulation.—The inferior extremity of the radius, in becoming united to the upper row of carpal bones, constitutes a diarthrosis which, from the nature of the movements it permits, may be considered as an imperfect hinge joint.

Articular surfaces.—The radial surface, elongated transversely and very irregular, presents: 1, Outwardly, a wide groove, limited in front by a small glenoid cavity, and bounded, posteriorly, by a non-articular excavation which receives a prolongation of the second bone in the movement of flexion, 2, Inwardly, a condyle, with a more extensive curvature than that of the preceding groove and, like it, completed by a small anterior glenoid cavity. The carpal surface, moulded exactly on the radial, offers depressions corresponding to the projections on it, and *vice versâ*.

Mode of union.—The radio-carpal articulation is bound by three ligaments which entirely belong to it, and by four strong ligaments that are common to it and articulations which will be studied hereafter.

Of the *three ligaments proper* belonging to the radio-carpal articulation, one forms a thick, rounded funicle, extending from the radius to the fourth bone in an oblique direction downwards and inwards, and concealed by the common posterior ligament. The second (Fig. 87. 5), much smaller, is carried from the supercarpal bone to the external side of the inferior extremity of the radius, and is partly covered by the common external ligament. When the synovial capsule is distended by dropsy, it may form a hernia at the outer side of the carpus, by passing between this small ligament and the common posterior ligament. The third, very delicate, but always present, is deeply situated beneath the last; it is inserted, for one part, into the radius near the first proper ligament, and for the other, into the second bone and the interosseous ligament which unites the supercarpal to the second bone.

Synovial membrane.—After lining these three ligaments and the four great ligaments yet to be described, this membrane is prolonged between the three first carpal bones to cover the superior face of the interosseous ligaments which unite them. It even more frequently descends into the articulation which joins the supercarpal to the first bone; though it also sometimes happens that this has a particular synovial capsule of its own.

Articulation of the Two Rows between Each Other.—Like the preceding, this is an imperfect hinge articulation.

Articular surfaces.—These are two, and are both transversely elongated, very irregular in their configuration, and divided into three portions. The inferior shows: behind, three small condyles placed side by side; in front, two slightly concave facets. The superior corresponds to the first by three glenoid cavities and two convex facets.

Mode of union.—For this articulation, besides the common great ligaments, there are *three particular ligaments.* Two of these are very short, and are situated behind the carpus, underneath the great common posterior ligament. They are readily perceived by removing the capsular ligament, and strongly flexing the carpus. "The strongest extends vertically from the internal bone of the superior row to the second and third bones of the metacarpal row; the other descends obliquely from the first bone of the antibrachial row to the second of the inferior row."—*Rigot.* The third ligament proper, much stronger than the other two, reaches from the supercarpal to the first bone of the inferior row and the head of the external metacarpal bone. It is confounded, outwardly, with the great external lateral ligament; inwardly, with the common posterior ligament. Its posterior border gives attachment to the fibrous arch which completes the carpal sheath. This ligament has also a branch which is fixed on the second bone of the upper row (Fig. 87, 4).

Synovial membrane.—This lines all the ligaments, and is prolonged above and below, between the carpal bones, to facilitate the gliding of their articular facets. Two upper prolongations ascend between the three first bones of the antibrachial row to cover the inferior face of the interosseous ligaments uniting them. Two other prolongations descend between the carpal bones of the second row; the external, after covering the first interosseous ligament, passes between it and the corresponding anterior ligament, and communicates with the synovial capsule of the carpo-metacarpal articulation. The internal forms a *cul-de-sac* which rests on the interosseous ligament

Fig. 86.

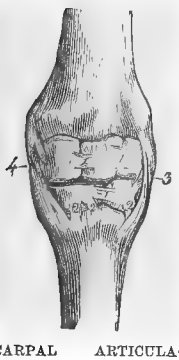

CARPAL ARTICULATIONS; FRONT VIEW. 1, 1, Anterior ligaments uniting the carpal bones of each row; 2, 2, Anterior ligaments proper to the carpo-metacarpal articulation; 3, Common external ligament; 4, Common internal ligament.

CARPO-METACARPAL ARTICULATION.—The carpal bones of the second row articulate with the superior extremity of the metacarpal bones, constituting a planiform diarthrosis.

Articular surfaces.—These are, on each side, plane facets more or less inclined one on the another, and continued between each other The largest is in the middle, and is generally hollowed by a small, shallow, synovial fossette

Mode of union.—There are the four great common ligaments, and also *six special ligaments: two anterior, two posterior,* and *two interosseous.*

Of the *two anterior ligaments* (Fig. 86, 2, 2), one is divided into two distinct bands, and unites the second bone to the principal metacarpal; the other, concealed by the external lateral ligament, attaches the first bone to the head of the external metacarpal bone.

The two posterior ligaments described by Rigot do not appear to us to be sufficiently distinct from the great ligament to merit a special description.

The *two interosseous ligaments,* completely overlooked by that able

anatomist, start from the interstices which separate the median metacarpal bone from the lateral metacarpals, and join the interosseous ligaments of the second row; they are thick and short. We have sometimes noted one or other of them to be absent.

Synovial membrane.—This communicates, as indicated above, with the synovial capsule of the preceding articulation. It furnishes a superior *cul-de-sac* which rests on the interosseous ligament interposed between the two last carpal bones of the second row. Two inferior *culs-de-sac* descend into the intermetacarpal arthrodial articulations.

LIGAMENTS COMMON TO THE THREE PRECEDING ARTICULATIONS. — As before mentioned, these are four in number two lateral, one anterior, and one posterior.

Fig. 87.

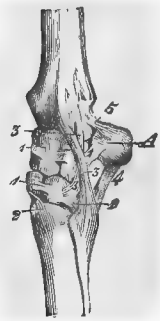

LATERAL VIEW OF THE CARPAL ARTICULATIONS.

1, 1, Anterior ligaments uniting the two rows of carpal bones; 2, 2, Anterior ligaments proper to the carpo-metacarpal articulation; 3, Common external ligament; 4, One of the ligaments proper to the articulation of the two rows (metacarpo - supracarpal); 5, One of the ligaments proper to the radio-carpal articulation (radio supracarpal).—A, Groove on the external surface of the supracarpal bone for the passage of the external flexor of the metacarpus.

a. The external lateral ligament (Figs. 86 and 87, 3) is a thick funicular cord composed of two orders of fibres—a deep-seated and a superficial order, slightly crossed. It leaves the external and inferior tuberosity of the radius, descends vertically to the side of the carpus, transmits a fasciculus to the first bone of the upper row, gives off another fasciculus which stops at the external bone of the second row, and terminates on the head of the corresponding metacarpal bone. Traversed obliquely by the lateral extensor of the phalanges, this ligament covers the external carpal bones. In front, it is united to the capsular ligament; near its inferior extremity, it is confounded with the strong ligament which joins the supercarpal bone to the first bone of the inferior row and to the head of the external metacarpal bone.

b. The *internal lateral ligament* (Fig. 86, 4), analogous to the preceding and situated on the opposite side, is wider and thicker than it. It commences on the internal tuberosity of the radius, and terminates on the upper extremity of the middle and internal metacarpal bones, after being attached, by two distinct fasciculi, to the third carpal bone of the upper row, and the two last of the metacarpal row. In contact by its external face with the tendon of the oblique extensor muscle of the metacarpus, this ligament responds, by its deep face, to the synovial membranes of the carpus and to the bones to which it is attached. By its anterior border it is united to the capsular ligament, the opposite border is intimately confounded with the posterior ligament, from which it is impossible to distinguish it.

c. The *anterior*, or *capsular ligament*, is a membranous band covering the anterior face of the carpal articulations. Its superior border is attached to the radius, the inferior is inserted into the superior extremity of the principal metacarpal bone. The two right and left borders are united with the lateral ligaments. Its external face is in contact with the tendons of the anterior extensor muscles of the metacarpus and phalanges. The internal face is lined at certain points by synovial membrane, and adheres in others to the carpal bones and the anterior ligaments binding these to one another. This ligament is composed of transverse

fibres more or less oblique, and arranged crosswise; by its amplitude it can adapt itself to the movements of flexion of the knee.

d. The *posterior ligament*, one of the strongest in the animal economy, covers the posterior face of the carpus, filling up the asperities which roughen it. It is inserted: above, on the transverse crest surmounting the articular surface of the radius; by its middle portion into all the carpal bones; below, into the head of the principal metacarpal bone. Confounded inwardly with the internal lateral ligament, united outwardly to the band which attaches the supercarpal to the external metacarpal and the second carpal bone of the upper row, this ligament is continued, by its inferior extremity, with the carpal stay (or check ligament) which sustains the perforans tendon. Its posterior face is perfectly smooth, and is covered by the synovial membrane of the carpal sheath.

Movements of the Carpal Articulations.—The carpus is the seat of two very extensive and opposite movements—*flexion* and *extension;* to which are added three very limited accessory movements—*adduction, abduction,* and *circumduction.*

All the carpal articulations do not take an equal part in the execution of these movements, for it is easy to discover that they are chiefly performed in the radio-carpal diarthrosis, and in the imperfect hinge articulation uniting the two rows of carpal bones. Each of these articulations participates in the movements of the carpus in nearly the same proportions, and; both act in an identical manner. Their mechanism is most simple.

In *flexion*, the first tier of bones rolls backwards on the radius, the inferior row moves in the same sense on the upper, the metacarpus is carried backwards and upwards, the common posterior ligament is relaxed, the capsular ligament becomes tense, and the articular surfaces, particularly those of the second joint, separate from each other in front. In *extension*, the metacarpus is carried downwards and forwards by an inverse mechanism. This movement stops when the ray of the fore-arm and that of the metacarpus are in the same vertical line. In flexion, these rays never directly approach each other; the inferior extremity of the metacarpus being always carried outwards. It may also be remarked, that the slight movements of *abduction, adduction,* and *circumduction* of the carpus are only possible at the moment when the foot is flexed on the fore-arm.

With regard to the planiform diarthrosis articulating the carpal bones of the same row, they only allow a simple gliding between the surfaces in contact; and with the carpo-metacarpal arthrodia it is absolutely the same. The restricted mobility of these various articulations has but a very secondary influence on the general movements of the carpus; but it nevertheless favours them by permitting the carpal bones to change their reciprocal relations, and adapt themselves, during the play of the radio-carpal and intercarpal hinges, to a more exact coaptation of the articular planes which they form.

In the other animals, the carpal articulations have the same essential characteristics we have noticed in Solipeds. The four principal peripheral bands differ but little in them; though in the *Dog* and *Cat* they are lax enough to allow somewhat extensive lateral movements.

5. *Intermetacarpal Articulations.*

Each lateral metacarpal bone articulates with the middle one by means of diarthrodial and synarthrodial surfaces, for the description of which refer to page 82. An interosseous ligament, composed of very short and strong

fasciculi, is interposed between the synarthrodial surfaces, and binds them firmly together. Its ossification is not rare. The diarthrodial facets are maintained in contact by the preceding ligament, and by the carpal ligaments inserted into the head of the lateral metacarpal bones. The intermetacarpal articulations only allow a very obscure, vertical, gliding movement.

In the *Ox*, there is only one intermetacarpal articulation, which is much simpler than those in the Horse.

In the *Pig*, the four metacarpal bones correspond, at their upper extremity, by means of small diarthrodial facets on their sides. Fibrous fasciculi, derived from the great anterior and posterior ligaments of the carpus, protect these intermetacarpal articulations before and behind. Other fibres, situated between the adjacent faces of the metacarpal bones, are real interosseous ligaments.

In the *Dog* and *Cat*, the four great metacarpal bones articulate with each other in almost the same manner as in the Pig, but their mobility is greater.

6. *Metacarpo-phalangeal Articulation.*

(*Preparation.*—Turn down the anterior and lateral extensor tendons of the phalanges, after carefully cutting through their attachment with the capsular ligament. Lay open the metacarpo-phalangeal sheath from above to below, and turn down the flexor tendons.)

This is a perfect hinge-joint, formed by the inferior extremity of the median metacarpal bone on the one part, and the superior extremity of the upper phalanx and sesamoids on the other.

Articular surfaces.—For the metacarpal bone, there are two lateral condyles and a median antero-posterior eminence; for the first phalanx, two glenoid cavities and an intermediate groove prolonged posteriorly on the anterior face of the two sesamoids. Divided in this manner into three portions, the digital surface is well constituted for solidity, because the pressure transmitted to this region is diminished and diffused by the natural elasticity of the bands which unite these three pieces to each other.

Mode of union. The means of union may be divided into two categories: 1, Those which join together the several bones of the inferior surface; 2, Those which maintain in contact the two opposed articular surfaces.

A. The first have received the generic name of *sesamoid ligaments*, and are six in number: an *intersesamoid ligament*, which keeps together the two complementary bones of the digital surface; *three inferior* and *two lateral sesamoid ligaments*, which unite these bones to the first phalanx.

a. The *intersesamoid ligament* is composed of fibro-cartilaginous substance which appears to be the matrix in which the two sesamoids were developed, as it is spread around these bones, after being solidly fixed on their internal face. Behind, this ligament, in common with the posterior face of the sesamoids, forms the channel (Fig. 89, 5) in which the flexor tendons glide. In front, it occupies the bottom of the intersesamoid articular groove.

b. The *inferior sesamoid ligaments*, situated at the posterior face of the first phalanx, are distinguished as superficial, middle, and deep.

The superficial ligament (Fig. 89, 8), the longest of the three, is a narrow band flattened before and behind. It arises from the middle of the fibro-cartilaginous mass which completes, posteriorly, the superior articular surface of the second phalanx, and slightly widening, ascends to the base of the sesamoids, into which it is inserted by becoming confounded with the intersesamoid ligament. Its posterior face, lined by the synovial membrane of the so-called sesamoid sheath, is covered by the flexor tendons; it partly covers the middle ligament.

The *middle ligament*, triangular and radiating, is composed of three

particular fasciculi: two lateral (seen on each side of the superficial ligament in Fig. 89, 8), and a median which has been generally confounded with the superficial ligament, although it is clearly distinguished from it by its inferior insertion. Fixed in common to the posterior imprints of the first phalanx, these three fasciculi diverge in ascending to the base of the sesamoids, where they have their upper insertion.

The *deep ligament* is constituted by two small bands concealed beneath the middle ligament. Thin, short, flattened before and behind, and intercrossed, these bands are fixed to the base of the sesamoids in one direction, and in the other to the superior extremity of the first phalanx, near the margin of its articular surface. This ligament is lined on its anterior face by the synovial membrane of the articulation.[1]

c. The *lateral sesamoid ligaments* are two thin layers extending from the external face of each sesamoid to the tubercle of insertion on the side of the superior extremity of the first phalanx. They are covered by the digital vessels and nerves, by the fibrous stay detached from the suspensory ligament to the anterior extensor tendon of the phalanges, and by the superficial fasciculus of the lateral metacarpo-phalangeal ligament; they are covered by synovial membrane on their internal face.

B. The ligaments destined to unite the two articular surfaces of the metacarpo-phalangeal joint are four: *two lateral*, *one anterior*, and *one posterior*.

a. Each *lateral ligament* comprises two fasciculi, a superficial and a deep, firmly united by their adjacent faces. The superficial fasciculus commences on the button of the lateral metacarpal bone, attaches itself to the median metacarpal, and descends vertically to terminate at the superior extremity of the first phalanx. It covers the phalangeal insertion of the lateral sesamoid ligament and the deep fasciculus. The latter, attached superiorly in the lateral excavation of the inferior extremity of the principal metacarpal, radiates as it reaches the sesamoid and the superior extremity of the first phalanx, where it is fixed by mixing its fibres with those of the lateral sesamoid ligament. The inner face of this fasciculus is lined by the articular synovial membrane.

b. The anterior ligament belongs to the class of capsular ligaments. It is a very resisting membraniform expansion which envelops the anterior face of the articulation. Attached by its upper border to the anterior margin of the metacarpal surface, and by its inferior border to the first phalanx, this expansion is confounded at its sides with the lateral ligaments. It is covered by the extensor tendons of the phalanges, which glide on its surface by means of small serous sacs. Its internal face adheres throughout its whole extent to the synovial capsule.

c. The *posterior ligament*,[2] very appropiately named the *suspensory ligament of the fetlock* (Figs. 88; 89, 4), is a long and powerful brace, composed of white fibrous tissue, and often containing fasciculi of fleshy fibres in its texture. Lodged behind the median metacarpal, and between the two lateral metacarpal bones, this brace is quite thin at its origin, but it soon becomes enlarged, and preserves its great thickness to the extent of its upper fourth. Examined in section, it appears to be formed of two superposed portions which are closely adherent to each other. The superficial portion, the thinnest, commences by three small branches, which are fixed to the first and second

[1] The two bands described by Rigot as forming part of this ligament, belong to the lateral fasciculi of the middle ligament.

[2] It corresponds to the two muscles which, in MAN, lie alongside the interosseous metacarpal muscles. *See* the *Muscles of the foot.*

bones of the lower carpal row; the deep portion, much thicker, is attached to the posterior face of the principal metacarpal for about 8–10ths of an inch. It has been wrongly asserted that the suspensory ligament of the fetlock is continuous with the common posterior ligament of the carpus; it is, on the contrary, quite distinct from it. The carpal stay or deep palmar aponeurosis of Man, is alone in direct continuity with the common posterior ligament of the carpus. The suspensory ligament of the fetlock is bifid at its inferior extremity; its two branches, after being fixed into the summits of the sesamoid bones, give origin to two fibrous bands which pass downwards and forwards to become united on each side to the anterior extensor tendon of the phalanges. It is in relation, by its posterior face, with the perforans tendon and its carpal stay; by its anterior face, with the median metacarpal bone, and arteries and veins; by its borders, with two small interosseous muscles, the lateral metacarpal bones, and the digital vessels and nerves.

Fig. 88.

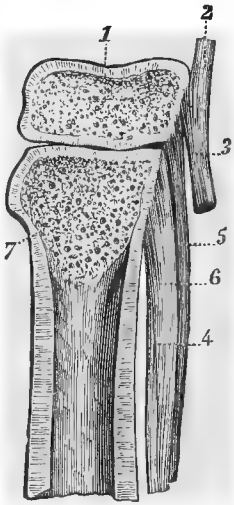

SECTION OF THE INFERIOR ROW OF CARPAL BONES, THE METACARPAL, AND THE SUSPENSORY LIGAMENT OF THE FETLOCK.

1, Os magnum; 2, Common posterior ligament of the carpus; 3, Stay, or band for the perforans tendon; 4, Suspensory ligament of the fetlock; 5, Its superficial layer; 6, Its deep fasciculus, 7, Principal metacarpal bone.

Synovial membrane.—This membrane is prolonged as a *cul-de-sac* between the terminal branches of the preceding ligament. It is the distention of this sac which causes the articular swellings vulgarly designated "windgalls."

Movements.—The metacarpo-phalangeal articulation permits the *extension* and *flexion* of the digit, and some slight lateral motion when the movable osseous ray is carried to the limits of flexion.

In the *Ox*, *Sheep*, and *Goat*, this articulation constitutes a double hinge which resembles the simple ginglymus of monodactyles.

They have *three intersesamoid ligaments* two lateral to unite the large sesamoids of each digit, and a median which unites the internal sesamoids. The *inferior sesamoidean ligamentous apparatus* is far from showing the same degree of development as in the Horse; it is reduced for each digit to four small bands, which remind one very much of the deep ligament of the latter animal, as it has been described by Rigot: two lateral bands pass directly from the sesamoids to the upper extremity of the first phalanx; the other two, situated between the first, intercross and are confounded with the latter by their extremities.—A *lateral sesamoid ligament* unites the first phalanx to the external sesamoid.

For each digit there are *two lateral metacarpo-phalangeal ligaments* an external, analogous to that of the Horse, but less complicated, is attached by its inferior extremity to the first phalanx only; the other, internal, fixed superiorly in the bottom of the inter-articular notch of the metacarpal bone, is inserted into the inner face of the first phalanx in mixing its fibres with those of the *superior interdigital ligament.* This latter is situated between the two first phalanges, and is composed of short, intercrossed fibres, attached to the imprints which in part cover the internal face of the two first phalangeal bones. In the *Sheep* there are only traces of this interdigital ligament, and each internal metacarpo-phalangeal ligament gives rise, near its phalangeal insertion, to a fibrous branch which is directed backwards from the interdigital space, and is terminated in the bone of the ergot (or posterior rudimentary digit), which it sustains. The *anterior* or *capsular ligament*, single as in Solipeds, unites the two external lateral ligaments. The *suspensory ligament*, single superiorly, is divided inferiorly into eight branches, two of which are joined to the perforatus tendon to form with it the double ring through which the two branches of the perforans pass. Four other branches, in

pairs, extend to the summits of the sesamoids. That which is sent to each external sesamoid gives off, on the side of the first phalanx, a reinforcing band to the proper extensor of the digit. The two last, profound and median, descend into the interarticular notch of the metacarpal bone, after becoming a single fasciculus, afterwards, they pass between the two internal metacarpo-phalangeal ligaments, and separate from each other in passing downwards and forwards on the inner side of the first phalanx, to join the proper extensor tendon of each digit.

Fig. 89.

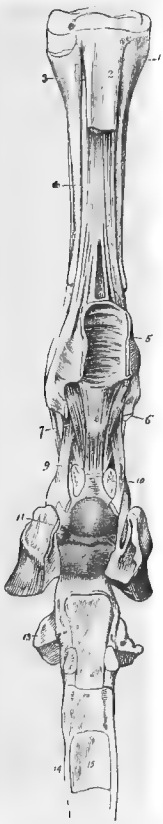

POSTERIOR VIEW OF THE METACARPO-PHALANGEAL AND INTER-PHALANGEAL ARTICULATIONS; RIGHT LIMB.

1, 3, Outer and inner rudimentary metatarsal bones; 2, Perforans tendon and its check ligament; 4, Suspensory ligament; 5, Gliding surface, or sheath for the flexor tendons, formed by the posterior face of the sesamoid bones, and intersesamoid, transverse, and annular ligaments; 6, Section of lateral sesamoid ligament; 7, Lateral fasciculus of the middle inferior sesamoid ligament; 8, Inferior superficial sesamoid ligament; 9, Lateral ligament of the first interphalangeal articulation; 10, Section of the terminal branch of the perforatus tendon; 11, Section of the lateral cartilage of the foot; 12, Postero-inferior surface of navicular bone; 13, Section of lateral cartilage, plantar cushion, and wing of pedal bone; 14, Perforatus tendon; 15, Perforans tendon.

In the *Pig*, *Dog*, and *Cat*, for each metacarpo-phalangeal there is: a proper synovial membrane; an intersesamoid ligament; an inferior sesamoid ligament composed of two cross-bands; two small lateral sesamoid ligaments; two lateral metacarpo-phalangeal ligaments, attached inferiorly to the first phalanx and the sesamoids; an anterior capsular ligament, in the centre of which is found a small bony nucleus, a kind of anterior sesamoid, over which glides one of the branches of the common extensor of the digits. The suspensory ligament is replaced by real palmar interosseous muscles (see the *Muscles of the fore-foot*). Some fibres situated between the first phalanges of the great digits in the Pig, remind one of the superior interdigital ligament of the Ox.

In *Man*, the cavity in the upper extremity of the first phalanx is completed by a glenoid ligament. The glenoid ligaments of the four first digits are united to each other by a transverse ligament of the metacarpus. The articulations are consolidated by two lateral ligaments. The metacarpo-phalangeal articulations allow flexion and extension movements, as well as those of abduction and adduction; but the latter are limited by the lateral ligaments.

7. *Articulation of the First with the Second Phalanx, or First Interphalangeal Articulation.*

(*Preparation.*—Remove the extensor tendon; throw open the metacarpo-phalangeal sheath, and turn down the flexor tendons.)

This is an imperfect hinge-joint.

Articular surfaces.—On the inferior extremity of the first phalanx, there are two lateral condyles separated by a groove. On the superior surface of the second phalanx, there are two glenoid cavities and an antero-posterior ridge.

The latter surface is completed behind by a *glenoidal fibro-cartilage*, very dense and thick, which also acts as a ligament. It is attached, in one direction, to the second phalanx, between the superior articular surface and the kind of fixed sesamoid which margins it behind; in the other, it is inserted into the first phalanx by means of six fibrous bands: two superior, which embrace the inferior, middle, and superficial sesamoid ligaments; two middle and two inferior, which extend to the sides of the inferior extremity of the first phalanx. This fibro-cartilage is moulded, in front, to the articular surface of the latter bone, and forms, by its posterior face, a gliding

surface for the perforans tendon (Fig. 89, 5). It is confounded, laterally, with the two branches of the perforatus, and receives in the middle of its superior border the insertion of the inferior superficial sesamoid ligament.

Mode of union.—*Two lateral ligaments*, to which are added, behind, the fibro-cartilage just described, and in front the tendon of the anterior extensor of the phalanges. These ligaments are large and thick, and passing obliquely downwards and backwards, are inserted, superiorly, into the lateral tubercles on the inferior extremity of the first phalanx. They are attached, beneath, to the sides of the second phalanx. Their most inferior fibres are even prolonged below that point to reach the extremities of the navicular bone, and constitute the posterior lateral ligaments of the pedal articulation.

Synovial membrane.—This covers the tendon of the anterior extensor of the phalanges, the lateral ligaments, and the glenoid fibro-cartilage. Behind, it forms a *cul-de-sac* which extends between the latter and the posterior face of the first phalanx.

Movements. This imperfect hinge is the seat of two principal movements: *extension* and *flexion*. It also allows the second phalanx to *pivot* on the first, and permits some *lateral movements*.

In the *Ox*, *Sheep*, and *Goat*, the glenoid fibro-cartilage is confounded with the perforatus tendon, and is only attached to the first phalanx by two lateral bands. The internal lateral ligament comprises two fasciculi: one, very short, which terminates in the second phalanx; and another, very long, descending to the internal face of the third phalanx. The external is very thin, and is also prolonged to the terminal phalanx; so that the two last interphalangeal articulations of each digit are fixed by two common lateral ligaments which correspond exactly, by their position and inferior attachments, to the anterior lateral ligaments of the pedal joint of Solipeds.

In the *Dog* and *Cat*, the glenoid cartilage, also confounded by its posterior face with the perforatus tendon, only adheres to the first phalanx by some cellular bands. The two lateral ligaments pass from the inferior extremity of the first phalanx to the superior extremity of the second.

In the *Pig*, there is somewhat the same arrangement as in Carnivora. The external lateral ligament is, nevertheless, more like that of the Horse, in its most anterior fasciculi being prolonged to the external extremity of the navicular bone.

8. *Articulation of the Second Phalanx with the Third, Second Interphalangeal Articulation, or Articulation of the Foot.*

To form this imperfect hinge-joint, the second phalanx is opposed to the third, and to the navicular bone.

Articular surfaces.—On the inferior face of the second phalanx there are two lateral condyles and a median groove. On the superior face of the third phalanx and the navicular bone, are two glenoid cavities separated by an antero-posterior ridge. The two bones which form this last surface articulate with each other by an arthrodia; the navicular bone presents for this purpose an elongated facet on its anterior border; the os pedis also offers an analogous facet on the posterior contour of the principal articular surface.

Mode of union.—Five ligaments: a single interosseous one which joins the navicular to the pedal bone; and four lateral pairs, distinguished as anterior and posterior.

a. Interosseous ligament.—This is formed of very short fibres which are inserted, behind, into the anterior groove of the navicular bone; and in front, into the posterior border and inferior face of the third phalanx. This ligament is lined, on its superior surface, by the synovial membrane, and on its inferior face is covered by the navicular sheath.

b. Anterior lateral ligaments.—These are two thick, short, and wide

fasciculi, attached by their superior extremities to the lateral imprints of the second phalanx, and by their inferior extremities into the two cavities at the base of the pyramidal eminence of the os pedis. Each ligament is partly covered by the complementary fibro-cartilage of that bone, and appears to form a portion of it. Its anterior border is continuous with the common extensor tendon of the phalanges; its internal face is covered by the synovial membrane, which adheres closely to it.

c. Posterior lateral ligaments.—These have been already noticed. Each is composed of the lowermost fibres of the lateral ligament of the first interphalangeal articulation; these fibres, after being attached to the second phalanx, unite into a sensibly elastic fibrous cord, which is chiefly fixed into the extremity and superior border of the navicular bone, where the ligaments join each other, and in this way form a kind of complementary cushion which increases the navicular articular surface. It also sends off a short fasciculus to the retrossal process, and a small band to the internal face of the lateral fibro-cartilage. Partly concealed by the latter and the plantar cushion, this ligament is covered inwardly by the articular synovial membrane.

(For full details as to the manner in which the navicular is attached to the pedal bone, the student is referred to the series of papers on the Horse's Foot, published by me in the '*Veterinarian*' for 1870. It is only necessary to refer here to the intimate connection there exists between the lateral and interosseous ligaments, and the stratiform fibro-cartilage covering the posterior face of this sesamoid: a connection, or rather unification, which has been strangely overlooked by hippotomists and hippo-pathologists, but which has undoubtedly a most important bearing on the genesis of that very prevalent and formidable malady of the anterior foot of the Horse —navicularthritis.)

Synovial membrane.—This descends below the facets which unite the navicular to the pedal bone. It offers, posteriorly, a vast *cul-de-sac* which reaches the posterior face of the second phalanx, and lies against the two navicular sheaths. It also forms another much smaller, by being prolonged between the two lateral ligaments of the same side. This is very often distended, and it is liable to be opened in the operation for diseased cartilages.

Movements.—The same as those of the first interphalangeal articulation.

In the *Sheep* are found: 1, An interosseous ligament to unite the navicular bone to the third phalanx; 2, Two anterior lateral ligaments commencing, as already stated, at the first phalanx; 3, Two lateral posterior ligaments, passing to the posterior face of the second phalanx and the navicular bone (the internal is yellow and elastic); 4, A single, anterior, elastic ligament, attached above to the superior extremity of the second phalanx, and fixed below into the third, between the insertion of the common extensor of the digits and that of the internal anterior lateral ligament; an inferior interdigital ligament, situated between the ungueal phalanges, whose separation from each other it limits. This ligament is composed of parallel fibres, which extend transversely from the one navicular bone to the other, and is covered on its inferior face by the skin of the interdigital space. Its upper face is in contact with an adipose cushion.

In the *Ox*, the external anterior lateral ligament, wide and expanding, is almost entirely covered by the long branch of the proper extensor of the digit, to which it is intimately adherent. The interdigital ligament has a much more complicated character than that of the Sheep. It is formed of fibres intercrossed on the median line, and divided at its extremities into two fasciculi: a superior passes over the perforans tendon, to which it serves as a restraining band, and is fixed to the outside of the inferior extremity of the first phalanx, after contracting very close adhesions with a strong fibrous web which descends from the posterior metacarpal region, and which will be more fully noticed when describing the muscles; an inferior, shorter than the preceding, attached to the internal extremity of the navicular bone and the internal face of the third phalanx,

becoming confounded with the perforans tendon, the plantar cushion, and the keratogenous membrane.

In the *Pig*, for the maintenance of the second interphalangeal articulation there are: 1, Two lateral ligaments, carried from the lateral faces of the second phalanx to the external and internal faces of the third; 2, A third ligament, exactly resembling one of the posterior lateral ligaments of the pedal articulation of the Horse; this ligament descends from the inferior extremity of the first phalanx to the internal extremity of the navicular bone. Its analogue of the inner side appears to be altogether absent; but in the large digits there is an anterior yellow elastic ligament like that of Ruminants.

In the *Dog*, the two last phalanges are united by two lateral ligaments, very simply arranged. A third ligament, formed of elastic tissue, divided into two lateral portions, and situated in front of the articulation, plays the part of a spring, which mechanically produces the retraction of the claw when the flexor muscles cease to contract. In the *Cat*, this yellow ligament is very strong; and this animal also exhibits a very striking obliquity of the articular pulleys by which the two phalanges correspond: an arrangement which permits the claw to be lodged between two digits when they are raised, and thus favour its retraction.

The second interphalangeal articulation of the *Dog* and *Cat* is also distinguished by another essential arrangement. The articular surface of the third phalanx is completed by a glenoid fibro-cartilage analogous to that of the first articulation, but much thicker. This fibro-cartilage (*see* MUSCLES OF THE HAND) is fixed into the posterior projection of the third phalanx, and serves, by its inferior face, as a pulley for the perforans tendon and, with the projection just named, plays the part of the navicular bone in other animals.

The interphalangeal articulations of *Man* are formed on the same plan as the metacarpo-phalangeal articulations. They are consolidated by a glenoid and lateral ligaments, and possess only the two movements of *flexion* and *extension*.

ARTICLE V.—ARTICULATIONS OF THE POSTERIOR LIMBS.

1. *Articulations of the Pelvis.*

(*Preparation.*—These ligaments are all exposed to view by carefully removing the soft parts connected with the sacrum and coxæ.)

A. SACRO-ILIAC ARTICULATION (Fig. 90).—This is a pair articulation which establishes the union of the posterior limb with the spine, and is formed by the sacrum and coxa. It belongs to the arthrodial class.

Articular surfaces.—On the sacrum, the irregular diarthrodial facet named the "auricular," cut on the sides and near the base of the bone. For the coxa, the analogous facet on the internal face of the ilium.

Mode of union.—By four ligaments, which, after the example of Rigot, we will name *sacro-iliac*, *superior ilio-sacral*, *inferior ilio-sacral*, and the *sacro-ischiatic*.

a. Sacro-iliac ligament.—This is composed of thick fibrous fasciculi, which envelope the whole articulation in being firmly attached by their extremities to the imprints around the diarthrodial facets. The inferior moiety of this ligament is covered by the psoas-iliacus (iliacus) muscle. Its posterior half[1] is much stronger, is hidden by the ilium, and gives attachment to the ilio-spinalis (longissimus dorsi) muscle.

b. Superior ilio-sacral ligament.—A thick and short funicle which, rising from the internal angle of the ilium, is carried backwards to be fixed to the sacral spine, where its fibres are confounded with those of the superspinous dorso-lumbar ligament.

c. Inferior ilio-sacral ligament.—This is a very resisting, triangular, membranous band, formed of parallel fibres passing obliquely downwards and backwards. It is attached, by its anterior margin, to the upper half of

[1] It represents the *interosseous sacro-iliac ligament* of Man. The inferior half corresponds to the *anterior sacro-iliac ligament.*

the ischiatic border and the internal angle of the ilium, in becoming confounded with the preceding ligament. Its inferior margin is inserted into the rugged lip which borders the sacrum laterally. Its posterior border is united to the aponeurosis covering the coccygeal muscles, and its external face is in contact with the principal gluteal and the long vastus muscles; while the internal corresponds to the lateral sacro-coccygeal muscle.

d. Sacro-sciatic or *ischiatic ligament* (Fig. 90, 2).—This is a vast membranous expansion situated on the side of the pelvis, between the sacrum and the coxa, and serves more as a means for inclosing this portion of the pelvic cavity than to assure the solidity of the sacro-iliac articulation. Its form is irregularly quadrilateral, and permits its circumference to be divided into four borders: a superior, attached to the rugged lateral ridge of the sacrum; an inferior, fixed to the supercotyloid ridge, as well as the ischial tuberosity, and forming by the portion comprised between these two insertions, with the small ischiatic notch, the opening by which the internal obturator and pyramidal muscles leave the pelvis; an anterior, imperfectly limited, along with the great ischiatic notch, circumscribes the opening through which the gluteal vessels and nerves, and the sciatic nerves pass; a posterior, doubled in the form of two laminæ which embrace the semimembranosus muscle, and is confounded superiorly with the aponeurosis enveloping the coccygeal muscles. The external face of this ligament is traversed by the sciatic nerves, and is covered by the long vastus and the semitendinosus muscles, which derive numerous insertions from it. Its internal face is covered, in front, by the peritoneum, and posteriorly is in contact with the ischio-coccygeal and ischio-anal muscles, to which it gives attachment.

Synovial membrane.—This lines the sacro-iliac ligament, but only furnishes a small quantity of synovia.

Movements.—The two sacro-iliac articulations being the centres towards which all the impulsive efforts communicated to the trunk by the posterior limbs converge, they do not offer much mobility, as that would oppose the integral transmission of the quantity of movement. So that they permit only a very restricted gliding of the articular surfaces; and the union of the sacrum and coxa by diarthrosis appears to be exclusively designed to prevent the fractures to which these bones would be incessantly exposed if they were fixed together in a more intimate manner.

B. Articulation of the Two Coxæ, or Ischio-pubic Symphysis.—The two coxæ are united to each other throughout the whole extent of the inner border of the pubis and the ischial bones. In youth, this is a veritable amphiarthrosis, fixed by an interosseous cartilage and bundles of peripheral fibres.

The cartilage is solidly fixed to the small rugged eminences which cover the adjacent articular surfaces, and becomes ossified, like the sutural cartilages, as the animal advances in age. In adult Solipeds the coxæ are always fused with each other.

The peripheral fibrous fasciculi extend tranversely from one bone to the other, above and below the symphysis; those on the inferior face are incomparably stronger and more abundant than the others.

The movements of this articulation are most restricted, and depend solely upon the elasticity of the interosseous cartilage. They cease after its ossification.

The fusion of the two coxæ proceeds very slowly in the *female* of the *Cat*, *Dog*, *Pig*, *Ox*, *Sheep*, and *Goat* species.

2. *Coxo-femoral Articulation.*

(*Preparation.*—Remove the muscles surrounding the articulation. To view the interior, divide the capsular ligament by a circular incision.)

This is an enarthrosis, formed by the reception of the head of the femur into the cotyloid cavity of the coxa.

Articular surfaces.—As already shown, the cotyloid cavity represents the segment of a hollow sphere, deeply notched on the inner side, and

Fig. 90.

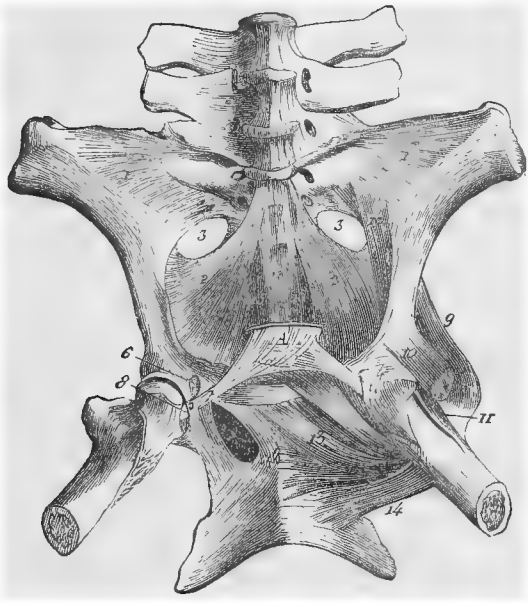

SACRO-ILIAC AND COXO-FEMORAL ARTICULATIONS, WITH THE SMALL DEEP MUSCLES SURROUNDING THE LATTER.

1, Sacro-iliac ligament; 2, Sacro-ischiatic ligament; 3, Great ischiatic notch; 4, Anterior portion of the capsular ligament of the coxo-femoral articulation; 5, Internal band of cotyloid ligament; 6, Coxo-femoral ligament; 7, Pubio-femoral ligament; 8, Its insertion into the femur; 9, Small gluteal muscle; 10, Origin of the straight anterior muscle of the thigh (rectus); 11, Anterior thin muscle (rectus parvus); 12, Pyramidal muscle of the pelvis; 13, External obturator muscle; 14, Square crural muscle (quadratus femoris); 15, Inferior sacro-coccygeal muscle.

provided at the bottom with a wide depression, the internal moiety of which is destined for the insertion of one of the interosseous ligaments, while the external half plays the part of a synovial fossa. This depression is not covered by cartilage, and communicates by the internal notch with the inferior furrow on the pubis. The lip of the cotyloid cavity is covered by a complementary fibro-cartilage—the *cotyloid ligament.* This fibro-cartilage is not interrupted at the notch just mentioned, but passes over it, forming a remarkable band (Fig. 90, 5) that converts it into a foramen, through which pass the pubio- or ilio-femoral ligament and the vessels of the articulation.

Fixed by its adherent border to the margin of the cotyloid cavity, this ligament is lined by synovial membrane on its faces and free border. It is thickest in front and within.

With regard to the head of the femur, it will be remembered that it is exactly moulded to the cavity, and, like it, is excavated by a rugged fossa which is entirely occupied by the insertion of the interarticular ligaments.

Mode of union.—This joint is maintained by a peripheral capsule, and by two interarticular bands constituting the coxo-femoral and pubio-femoral ligaments.

a. Capsular ligament (Fig 90, 4).—This is a membranous sac, like that of the scapulo-humeral articulation, embracing the head of the femur by its inferior opening, and attached by its opposite aperture to the margin of the cotyloid cavity and its protecting fibro-cartilage. This ligament is composed of intercrossed fibres, and is strengthened in front by an oblique fasciculus which descends to the body of the femur, along with the anterior thin muscle, near which it is fixed. Its internal face is covered by the articular synovial membrane, and its external face is in contact, through the medium of adipose cushions, with: in front, the anterior thin muscle (*crureus*) and the straight muscle (*rectus*) of the thigh; behind, to the gemini, the internal obturator, and the pyramidal muscles; outwards and upwards, to the small gluteal muscle; within and below, to the external obturator.

b. Coxo-femoral ligament (*ligamentum teres*, Fig. 90, 6).—A thick and short funicle of a triangular shape, deeply situated between the two bony surfaces, which it cannot, notwithstanding its shortness, maintain exactly in contact without the other muscular or ligamentous structures enveloping the articulation. Its upper insertion occupies the internal moiety of the bottom of the cotyloid cavity; and its inferior extremity is confounded with the pubio-femoral ligament, being fixed with it into the rough fossa in the head of the femur. It is enveloped by the synovial membrane.

c. Pubio-femoral ligament (Fig. 90, 7, 8).—This ligament, longer and stronger than the last, originates from the pubic tendon of the abdominal muscles and the anterior border of the pubis. Lodged in the inferior channel of that bone, it passes outwards, enters the internal notch of the cotyloid cavity, is inflected downwards on the fibrous band which converts that notch into a foramen, and goes with the preceding ligament to be inserted into the fossa in the head of the femur. Its pubic portion lies between the two branches of the pectineus, while its interarticular surface is covered by synovial membrane.

Synovial membrane.—This membrane is very extensive; it lines the internal face of the capsular and cotyloid ligaments, and is reflected on the interarticular ligaments to form around them a serous vaginal covering. It is even prolonged into the synovial fossa occupying the centre of the cotyloid cavity.

Movements.—The coxo-femoral articulation is one of the joints which is endowed with the most varied and extensive movements. It permits the *flexion, extension, abduction, adduction, circumduction*, and *rotation* of the thigh on the pelvis. The mechanism of these movements is so simple, that they need no particular consideration.

The domesticated animals other than Solipeds, are distinguished by the complete absence of the pubio-femoral ligament; so that in them the movements of abduction, which are limited in Solipeds by the tension of this ligament, are much more extensive; and it is the absence of the ligament in question, which explains the facility with which the larger Ruminants are enabled to strike sideways, a movement known as a "cow's kick."

In *Man*, the head of the femur is more detached than in the domesticated animals, and the cotyloid cavity, encircled by the cotyloid ligament, is deeper. The femur is united to the coxa: 1, By a capsular ligament; 2, By a triangular ligament, fixed above, to the cotyloid ligament at the notch, and below, into the depression in the head of the femur. Also, as the brothers Weber have shown, the atmospheric pressure is a powerful adjunct to these means of union.

The coxo-femoral articulation of Man permits more extensive movements than that of animals, and especially abduction and adduction, which can be carried to 90 degrees.

3. *Femoro-tibial Articulation.*[1]

(*Preparation.*—Remove the soft parts surrounding the articulation, taking care not to wound the synovial membrane. To expose the crucial ligaments, make an antero-posterior vertical section of the femur in such a way as to separate the condyles.)

This is the most complicated joint in the body, and is formed by the union of the femur with two of the thigh bones—the tibia and patella. It represents an imperfect hinge-joint.

Articular surfaces.—To form this articulation, the femur opposes its two condyles to the wide, convex, and undulated facets on the superior face of the lateral tuberosities of the tibia, and its articular pulley to the posterior face of the patella.

The *femoral faces* have already been described in detail at page 98; but it may be repeated that the two condyles, placed side by side, are elongated in an antero-posterior direction, and are separated by a non-articular notch called the intercondyloid; also, that the femoral trochlea situated in front of these two condyles appears to continue the preceding notch, and that its internal border is much more elevated than the external; an arrangement which explains why it is so difficult, if not impossible, for the patella to be dislocated inwards.

The *tibial facets* ascend on each side to the lateral faces of the tibial spine. They are separated from one another by the antero-posterior groove cut on the summit of that bone, and by the fossæ of insertion situated at its base before and behind. The external facet, wider than the internal, is devoted in part to the gliding of the originating tendon of the popliteal muscle. (See page 100.)

The *patellar surface*, moulded on the femoral pulley, fits it in an imperfect manner. It is bordered, outwardly, by a small fibro-cartilaginous ring, which is united to the fibrous capsule of the femoro-patellar articulation (Fig. 92, 1). Inwardly, it is completed by the insertion of the internal patellar ligament, to be noticed immediately.

Interarticular meniscii (*semilunar fibro-cartilages*)—(Figs. 91, No. 1, 2, 3, 4; and 92, 5, 6, 7, 8).—By this designation is known the two fibro-cartilages interposed between the condyles of the femur and the tibial facets, to assure their coaptation. They are crescent-shaped bodies, and present: an internal, concave, thin and sharp border, embracing the tibial spine; an external, thick, and convex border; a superior face, excavated and moulded to one of the condyles; an inferior face, nearly plane, gliding on the tibia; and two extremities terminated by ligaments, and fixed to the bones in apposition. The articular surfaces are not entirely separated throughout their extent by

[1] By this name is understood the joint uniting the femur to the tibia, and that which articulates it with the patella. Following the example of anthropotomists, it has not been deemed necessary to describe a femoro-patellar articulation distinct from the femoro-tibial, properly so called. This innovation appears to be justified by the community of the principal articular bands which bind these two joints, and by the reciprocal dependence of their movements.

these complementary meniscii, for the tibial spine rubs directly against the inner sides of the femoral condyles. The *internal semilunar fibro-cartilage*, the widest and thickest, is inserted by its anterior extremity into one of the excavations situated in front of the spine; its posterior extremity is attached in the fossa behind that eminence. The *external semilunar fibro-cartilage* is fixed, in front, near the anterior insertion of the opposite fibro-cartilage; its posterior extremity gives origin to two slips or cords, one superior, the other inferior. The first, the strongest and longest, terminates in the fossa near the posterior extremity of the intercondyloid notch. The second, thin and flat, is inserted on the posterior outline of the external tibial facet.

Fig. 91.

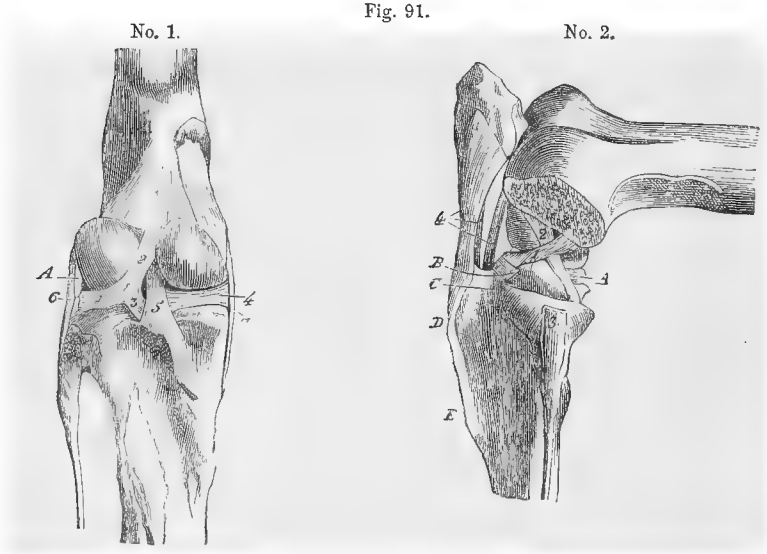

FEMORO-TIBIAL ARTICULATION.

No. 1. Posterior face: the posterior ligament has been removed.—1, External meniscus; 2, Fibrous fasciculi fixing it to the femur; 3, Fibrous fascia which attaches it to the posterior contour of the tibial surface; 4, Internal meniscus; 5, Tibial insertion of the posterior crucial ligament; 6, External lateral ligament; 7, Internal lateral ligament.

No. 2. External face: the external condyle of the femur and the meniscus have been removed to show the crucial ligaments.—1, Anterior crucial ligament; 2, Posterior ditto; 3, Fibular insertion of the external lateral ligament; 4, Anterior patellar ligaments.—A, Internal meniscus; B, Anterior insertion of the external meniscus; C, Passage for the tendinous cord common to the flexor of the metatarsus and the anterior extensor of the phalanges; D, Anterior and superior tuberosity of the tibia; E, Tibial crest.

The external border of this meniscus is separated from the external lateral ligament by the tendon of the popliteus muscle, and acts, with regard to this tendon, as a pulley.

Mode of union.—The bands which bind this complicated articulation are very numerous. They will be successively described as: 1, Those which attach the patella to the tibia; 2, Those which unite the femur with the tibia.

A. *Ligaments attaching the patella to the tibia.*—The patella is bound to the tibia by three funicular ligaments, designated by the generic epithet of "patellar." They are situated in front of the articulation, and are charged

with the duty of transmitting to the leg the action of the muscles which are attached to the patella. They are distinguished according to their position, as external, internal, and middle. (Fig. 92, 2, 3, 4.)

a. The *external patellar ligament*, the largest and most powerful, is a flattened band, attached, by its lower extremity, to the culminating point of the anterior tuberosity of the tibia. Its upper extremity is fixed to the anterior face of the patella, and is confounded with the patellar insertion of the long vastus muscle. It is joined to the internal ligament by a very resisting aponeurotic expansion, a dependency of the *fascia lata.*

b. The *internal patellar ligament* also forms a flattened band, longer, but not so wide or thick as the preceding. Its inferior extremity is attached to the inner side of the anterior tuberosity of the tibia. Its superior extremity becomes much thickened and fibro-cartilaginous, and is inserted into a prominence inside the patella. This fibro-cartilaginous portion (Fig. 92, 3′) of the ligament glides on the internal border of the femoral trochlea, and may justly be considered as a complementary apparatus of the patellar surface. The ligament, joined to the preceding by the fibrous fascia already mentioned, is mixed up, inwardly, with the aponeurosis of the adductor muscles of the leg.

c. The *middle patellar ligament* is a round cord, situated, as its name indicates, between the other two, concealed beneath the aponeurosis which unites these, and in the middle of the adipose tissue protecting the synovial capsules in front. It leaves the anterior face of the patella, and descends vertically to the tibia, to be lodged in the fossa in the middle of the anterior tuberosity, where a small synovial bursa facilitates its movements. Its inferior extremity is inserted into the most declivitous part of this excavation.

B. *Ligaments which attach the thigh and leg bones.*—These are six in number: 1, A femoro-patellar capsule maintaining the patella against the femoral trochlea; 2, Five femoro-tibial ligaments, as follows: two lateral, external and internal; a posterior; and two interarticular, distinguished with reference to their inferior insertion into anterior and posterior.

a. The *femoro-patellar capsule* is a membranous expansion which covers, above and laterally, the superior synovial membrane. This capsule is attached by its borders around the femoral trochlea and the periphery of the patellar surface. It is extremely thin in its superior part; but laterally it is thicker, and constitutes two wide fibrous fasciculi which bind the patella to the eccentric sides of the two condyles, and is described in several works as two special ligaments. Its external face is covered by the insertion of the long vastus and the crural triceps.

b. The *lateral ligaments* are two ribbon-shaped cords situated at the extremities of the transversal axis of the articulation, more behind than before; they are relaxed during flexion, and very tense in extension.

The *external*, the shortest and strongest, proceeds from one of the hollow facets on the external condyle of the femur, and is inserted into the head of the fibula by its inferior extremity, after gliding over the external tuberosity of the tibia by means of a special synovial bursa. It is covered by the crural or tibial aponeurosis, and covers the tendon of the popliteus, from which it is sometimes separated by a vesicular synovial membrane.

The *internal* is attached, superiorly, to the eminence of insertion that surmounts the eccentric face of the internal condyle, and descends vertically to the tibia, gliding over the margin of its articular surface by means of a small facet covered with cartilage, and a *cul-de-sac* prolongation of the

internal synovial membrane. It is fixed by its inferior extremity to the imprints which cover the internal tibial tuberosity.

Its fibres are disposed in two layers, which slightly intercross in X fashion; those passing downwards and forwards adhere to the border of the internal meniscus. Covered by the aponeurosis of the adductor muscles of the leg, this ligament adheres by its deep face to the internal meniscus.

c. The *posterior ligament* belongs to the class of membranous or capsular ligaments. It is formed of two aponeurotic laminæ separated superiorly, but confounded inferiorly. The superficial lamina is composed of strong, fibrous, intercrossed fasciculi, perforated with vascular openings. It is fixed, above, to the posterior face of the femur, below the external gastrocnemius muscle. The deep lamina envelopes, like a cap, the femoral condyles. After becoming united, these two laminæ are attached to the posterior face of the tibia, close to the superior articular face of that bone. Its external face is in contact with the popliteal vessels, and the external gastrocnemius muscle. Its internal face is covered throughout nearly the whole of its extent by the lateral synovial membranes, embraces the condyles of the femur, and adheres to the posterior crucial ligament, as well as to the interarticular meniscii.

d. The *interosseous ligaments* are two funicular bands lodged in the intercondyloid notch. They are more commonly designated *crucial ligaments*, because they cross each other at their middle part, like the letter X. (Fig. 91.)

The *anterior*, oblique downwards and forwards, is attached by its superior extremity to the bottom of the intercondyloid notch, and inwardly to the external condyle. Its inferior extremity is fixed in the groove on the summit of the tibial spine. The fibres entering into its formation are not parallel, but slightly twisted in a spiral manner.

The *posterior*, longer than the preceding, and oblique in the opposite direction, is inserted, inferiorly, into the little eminence behind the internal tibial facet; whence it goes to the bottom of the intercondyloid notch, to be attached by its superior extremity within the internal condyle.

Synovial membranes.—For this articulation there are three synovial membranes: a superior and two lateral. The first, very large and sustained by the femoro-patellar capsule, facilitates the gliding of the patella on the femoral pulley; it is prolonged in a *cul-de-sac* below the insertion of the crural triceps. The other two, which lubricate the articular surfaces of the proper femoro-tibial joint, include the crucial ligaments between them, and cover the posterior ligament, the lateral ligaments, and the fibrous fasciculi for the attachment of the meniscii. The external covers, in addition, the tendon of the popliteus muscle, and furnishes a vast *cul-de-sac* which descends in the anterior groove of the tibia to envelop the tendon common to the anterior extensor of the phalanges and the flexor of the metatarsus. These two femoro-tibial synovial membranes lie against that of the femoro-patellar articulation, in front of the condyles and the notch which separates them, and if not always, at least not unfrequently, they communicate with it. The three are separated from the ligaments of the patella by a considerable mass of adipose tissue which is prolonged into the intercondyloid notch, at the bottom of which it appears to be fixed.

Movements.—This imperfect hinge joint can execute the two principal and opposite movements of *flexion* and *extension*, and a somewhat limited accessory movement of *rotation*. The mechanism of these movements being simple enough to be readily understood without any preliminary explanation,

they will not be detailed here; but some remarks will be made with regard to the displacement the fibro-cartilages undergo when the articulation is in motion.

During *flexion* and *extension*, these bodies, fixed on the tibial facets, which they transform into glenoid cavities, move with them on the condyles of the femur, from before to behind, or behind to before, according to the movement executed. But at the same time they also glide in an inverse direction, and to a very appreciable degree, on the superior extremity of the tibia. Therefore, during flexion, they pass from behind forward on this extremity, and are drawn backwards during extension.

In *rotation*, which may take place from within to without, or from without to within, the movement is produced not only by the pivoting of the condyles in their glenoid cavities, but also by a sensible displacement of the meniscii on the tibial surfaces.

In the *Dog* and *Cat*, the meniscii are joined together near their anterior insertion by a transverse fibrous band. There is only one patellar ligament, and the posterior ligament shows in its thickness two small sesamoid bones against which the condyles of the femur play inwardly, and which give attachment, outwardly, to the originating branches of the external gastrocnemius muscle. There is no femoro-patellar capsule, and only one synovial membrane for the whole articulation.

In the *Pig* and *Sheep*, there is also only one ligament and one synovial capsule.

Fig. 92.

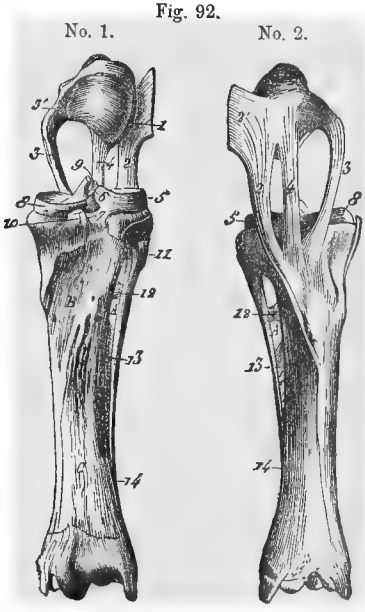

LIGAMENTS ATTACHING THE THREE BONES OF THE LEG.

No. 1. Posterior face.—No. 2. Anterior face. —1, Complementary fibro-cartilaginous pad of the patellar surface; 2, External patellar ligament; 2′, Insertion of the long vastus into this ligament; 3, Internal patellar ligament; 3′, Its upper insertion transformed into a complementary apparatus of the patellar surface; 4, Middle patellar ligament; 5, External meniscus of the tibia; 6, Its branch of insertion into the femur cut off at its origin: 7, Its posterior tibial insertion; 8, External meniscus; 9, Insertion of the anterior crucial ligament into the fossa of the tibial spine; 10, Tibial insertion of the posterior crucial ligament; 11, Inferior insertion of the external femoro-tibial ligament; 12, 13, 14, Tibio-fibular ligaments.—A, Tibial arch; B, Surface of insertion of the popliteus muscle; C, Surface of insertion for the perforans muscle.

4. *Tibio-fibular Articulation.*

This articulation represents a small planiform diarthrosis, whose movements are very limited and obscure. It is formed by the union of the irregular diarthrodial facet which occupies the internal face of the head of the fibula, with the analogous facet on the external superior tuberosity of the tibia. Short and strong interosseous or peripheral fibres envelop these facets on every side, and maintain them firmly in contact.

The fibula is also attached to the tibia: "1, Above, by two small ligamentous fasciculi crossed like the letter X, which form the superior part of the great arch through which pass the anterior tibial artery and vein (Fig. 92, 12); 2, In the middle, by a kind of aponeurotic membrane, whose width

diminishes from above to below, like that of the space it fills (Fig. 92, 13); 3, Below, by a ligamentous cord (Fig. 92, 14) which prolongs the fibula to the external tuberosity of the inferior extremity of the tibia, where this cord bifurcates, and is united to the two external lateral ligaments of the tibio-tarsal articulation."—*Rigot.*

In the *Ox*, *Sheep*, and *Goat*, the fibula being replaced by a ligament, there is no proper tibio-fibular articulation.

In the *Dog* and *Cat*, the two principal bones of the leg are united at their extremities and middle part:

1. At their superior extremity, by means of a small arthrodial articulation, analogous to that of the Horse, and, like it, provided with a particular synovial bursa;

2. At their inferior extremity, by means of a second arthrodial articulation, whose action is facilitated by a prolongation of the tibio-tarsal synovial membrane;

3. By their middle part, through the interposition, between the two bones, of an interosseous ligament, which is wide and membranous in its upper two-thirds, and formed of extremely short and strong fibres at its lower third.

In the *Pig*, the arrangement is somewhat the same as in Carnivora. It may be noted, however, that the facet of the upper extremity of the fibula is joined to the tibia by a small interosseous ligament, and that the articulation which results should be looked upon as a small amphiarthrosis.

In *Man*, as in the Dog there are two *peroneo-tibial arthrodiæ:* a superior and inferior.

5. *Articulations of the Tarsus or Hock.*

(*Preparation.*—Remove the tendons from around the articulation, and incise, layer after layer, the superficial fibres of the lateral ligaments.)

These comprise: 1, The tibio-tarsal articulation; 2, The articulation of the first row of bones—the astragalus and calcis; 3, Those which unite the bones of the lower row; 4, The articulation of the two rows with each other; 5, The tarso-metatarsal articulation. The first is a perfect ginglymoid, and the only joint really movable; all the others are arthrodial, and their action is so restricted that they appear to be condemned to almost absolute immobility. This intimate union of the tarsal and metatarsal bones is evidently chiefly intended to guarantee precision in the movements of the tibio-tarsal articulation.

Tibio-tarsal Articulation.—Two bones alone concur in the formation of this angular ginglymoid joint: these are the tibia and astragalus.

Articular surfaces.—For the tibia: 1, The two deep grooves, oblique forwards and outwards, channeled in the inferior extremity of the bone; 2, The salient tenon which separates these grooves, and on which there is often a small synovial fossette.—For the astragalus, the pulley occupying its anterior face (*see* page 103).

Mode of union.—Seven ligaments bind these articulations: two external lateral, three internal lateral, an anterior and a posterior.

a. External lateral ligaments.—These are distinguished, according to their relative position, into superficial and deep.

The *external superficial ligament* (Figs. 93, 2; 94, 2), is a thick funicular cord, flattened in its inferior half. It commences above on the external tuberosity of the tibia, behind the groove which divides this tuberosity into two parts; from thence it descends almost vertically, fixing itself successively to the astragalus, calcaneus, cuboides, middle metatarsal bone, and the external rudimentary metatarsal bone. Passing in front with, and partly covered by, the lateral extensor of the phalanges, to which it supplies a retaining band (Fig. 94, 2), this ligament is confounded behind, and near its inferior extremity, with the calcaneo-metatarsal ligament. It

covers the external and deep ligament, the short band which constitutes the external calcaneo-astragaloid ligament, the insertion of one of the branches of the flexor of the metatarsus, and the small cuboido-cunean (cuneiform) ligament.

The *external deep ligament* (Figs. 93; 94, 1), much shorter than the preceding, is attached, superiorly, to the anterior part of the external tuberosity of the tibia, and is directed obliquely backwards and downwards, to be fixed by two fasciculi at the external side of the astragalus and calcis. This ligament, covered by the preceding, which crosses it like an X, is lined on its inner face by the synovial membrane of the articulation.

Fig. 93.

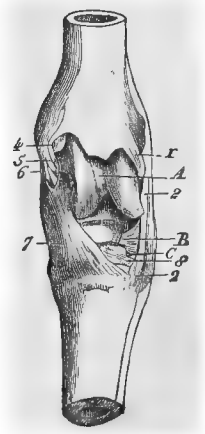

TARSAL ARTICULATIONS; RONT VIEW.

1, External deep ligament of the tibio-tarsal articulation; 2, 2, External superficial ligament; 4, Internal deep ligament; 5, Internal middle ligament; 6, Internal superficial ligament; 7, Astragalo-metatarsal ligament; 8, Small cuboido-cunean ligament.—A, Pulley of the astragalus; B, Cuboidal insertion belonging to the tendinous cord of the flexor of the metatarsus; C, Vascular canal of the tarsus.

b. Internal lateral ligaments.—These are also three funicular bands superposed on one another, and are consequently designated as superficial, middle, and deep.

The *internal superficial ligament* (Fig. 93, 6), the strongest and longest of the three, proceeds from the internal and inferior tuberosity of the tibia, diminishing as it descends on the inner side of the tarsus. It is fixed, in mixing with the astragalo-metatarsal ligament and with the posterior tarso-metatarsal ligamentous arrangement, to the tuberosity of the astragalus, the scaphoid, the two cuneiform, the superior extremity of the principal metatarsal, and that of the internal rudimentary metatarsal bones.

The *internal middle ligament* (Fig. 93, 5) is composed of two funicular cords, attached in common beneath the preceding ligament to the internal tibial tuberosity. These two fasciculi, exactly resembling those of the external deep ligament, are directed downward and backward, and terminate, one at the astragalus, the other at the calcis.

The *internal deep ligament* (Fig. 93, 4) is an extremely slender fasciculus, enveloped by the synovial membrane; it is often reduced to a thin shred, scarcely distinct from the serous covering surrounding it. It is attached, in one direction, to the tibia below the middle ligament; in the other to the astragalus, and nearly at the same point as the superior fasciculus of the middle ligament.

c. Anterior ligament.—This is a membraniform band formed of intercrossed fibres, stronger outwards than inwards, attached by its upper border above and in front of the tibial surface, fixed by its inferior border to the astragalus, the scaphoid and great cuneiform bones, and the astragalo-metatarsal ligament; it is confounded at its sides with the two superficial lateral ligaments. Its internal face is lined by articular synovial membrane, while the external is covered by the flexor of the metatarsus, the anterior extensor of the phalanges, the anterior tibial artery, and several large anastomosing veins from whose junction arises the anterior tibial vein.

d. Posterior ligament.—This is the second membraniform or capsular band which protects the articulation posteriorly. It presents, in its centre,

a fibro-cartilaginous thickening, on which glides the perforans tendon. It is attached, above, to the tibia, below, to the astragalus and calcis; at its sides it is mixed with the two superficial lateral ligaments, and the astragalian fasciculus of the middle internal ligament. Its internal face is lined by articular synovial membrane; the external is covered and lubricated by the vaginal serous membrane which facilitates the gliding of the perforans tendon in the tarsal sheath.

Synovial membrane.—This membrane is developed at the internal face of the two capsular ligaments, nearly covers the three internal ligaments, and lines the external deep ligament. It communicates, in front and below, with the synovial membrane proper to the articulation of the two rows of tarsal bones. When it becomes the seat of dropsical effusion, it is always distended forwards and inwards, because it is only sustained at that place by the anterior capsular ligament. But the effusion may also raise the posterior ligament and produce hernia in the hollow of the hock, behind the lateral ligaments. It is not, therefore, absolutely correct to attribute all the synovial tumours in the hollow of the hock to dilatation of the tarsal tendinous sheath.

Movements.—Nothing can be less complicated than the mechanism of the tibio-tarsal articulation; this joint only permitting two opposite movements, those of *flexion* and *extension*, which are so simple and precise that we may dispense with a description of the manner in which they are executed. It may only be remarked that, in order to prevent contact between the leg and foot during flexion, the latter fraction of the limb deviates a little outwards, owing to the marked obliquity of the articular grooves.

Articulation of the Bones of the First Row, or Calcaneo-astragaloid Articulation.—This is a compound arthrodial joint, resulting from the coaptation of the three or four articular facets of the posterior face of the astragalus with the analogous facets of the calcis.

This joint is maintained by the lateral ligaments of the tibio-tarsal articulation, and by four *calcaneo-astragaloid ligaments*—a *superior*, *external*, *internal*, and the last *interosseous*.

The *superior calcaneo-astragaloid* ligament is formed of short parallel fibres thrown across from one bone to the other, and is situated towards the superior extremity of the pulley of the astragalus; it is lined superiorly by the synovial membrane of the tibio-tarsal articulation.

The *lateral* ligaments are two very thin fasciculi concealed by the ligaments which bind, laterally, the tibia to the tarsal bone.

The *interosseous* ligament is very strong, and occupies a great portion of the rugged excavation which separates the articular facets.

This articulation does not usually possess proper synovial capsules. Two prolongations of the synovial membrane of the two rows, in ascending between the calcis and astragalus, facilitate the gliding of the two inferior facets. An analogous prolongation of the tibio-tarsal synovial membrane is effected for the superior facets, and it is not rare to find this prolongation form a distinct capsule.

Movements nearly null

Articulation of the Bones of the Second Row with each other.—These bones, four in number, are brought into contact in the following manner:—The cuboides responds to the scaphoid by two facets, one anterior, the other posterior; it articulates with the great cuneiform by two similar facets, the posterior of which is not always present. The scaphoid is united to the two cuneiforms by the large convex facet occupying its entire lower

face. The two cuneiforms are joined by means of a small articular surface.

The fibrous fasciculi which maintain the diarthrodial surfaces in contact are somewhat numerous. They are as follows:

1. The astragalo-metatarsal ligament and tarso-metatarsal apparatus, which will be described hereafter; these two bands do not properly belong to the articulations of the second row of bones.

2. Two anterior ligaments, named *cuboido-scaphoid* and *cuboido-cunean* (Figs. 93, 8; 94, 5), which are carried from the cuboid to the scaphoid and to the great cuneiform bone, one above, the other below the vascular channel formed between these three bones.

3. Two interosseous ligaments analogous to the preceding two, forming the superior and inferior walls of the aforesaid channel.

4. An interosseous *scaphoido-cunean* ligament, passing from the scaphoid to the two cuneiform bones.

5. An interosseous ligament, named the *intercunean*, is directed from one cuneiform bone to the other, and is confounded with the preceding ligament.

The disposition of the lubricating membranes varies with that of the articular facets. The following is what is most generally observed:—A proper synovial membrane is specially destined for the facets by which the scaphoid and great cuneiform bones correspond; this synovial membrane belongs also to the two cuboido-scaphoid and posterior cuboido-cunean arthrodiæ. The anterior cuboido-scaphoid diarthrosis receives a prolongation from the synovial membrane of the two rows. The play of the anterior cuboido-cunean and intercunean facets is facilitated by two prolongations of the tarso-metatarsal synovial membrane.

Movements almost null.

Fig. 94.

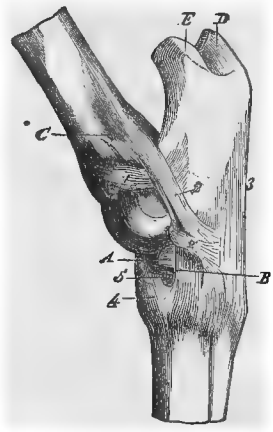

ARTICULATIONS OF THE TARSUS; LATERAL VIEW.

1, External deep ligament; 2, External superficial ligament; 2', Ring furnished by the latter ligament for the passage of the lateral extensor tendon of the phalanges; 3, Calcaneo-metatarsal ligament; 4, Astragalo-metatarsal ligament; 5, Small cuboido-cunean ligament.—A, Cuboidal insertion of the flexor muscle of the metatarsus; B, Anterior orifice of the vascular conduit of the tarsus; C, Groove on the external tuberosity of the tibia for the gliding of the lateral extensor of the phalanges; D, Insertion of the gastrocnemius tendon of the leg into the os calcis; E, Gliding surface for that tendon.

Articulation of the two Rows with each other.—This arthrodial joint is formed by the union of the calcis and the astragalus, on the one side, with the scaphoid and cuboid bones on the other. Its solidity is assured by six principal bands:

1. The two lateral superficial ligaments of the tibio-tarsal articulation.

2. The *calcaneo-metatarsal* ligament (Fig. 94, 3), a strong fibrous brace which unites the posterior border of the calcis to the cuboides, and to the head of the external rudimentary metatarsal bone. It is confounded, outwardly, with the external and superficial tibio-tarsal ligament; inwardly, with the posterior tarso-metatarsal band.

3. The *astragalo-metatarsal* ligament (Fig. 93, 7), a radiating fasciculus whose fibres leave the internal tuberosity of the astragalus, become mixed

up with the internal and superficial tibio-tarsal ligaments in diverging downwards to the scaphoides, the great cuneiform bone, and the upper extremity of the principal metatarsal bone.

4. The *posterior tarso-metatarsal* ligament is a vast, very strong, and very complicated fibrous arrangement, which binds, posteriorly, all the tarsal bones, and also fixes them to the three portions of the metatarsus. This band, which is crossed by several tendons and by the artery and vein lodged in the cuboido-scaphoido-cunean canal, is continued below by the tarsal stay of the perforans tendon. It therefore closely resembles the posterior carpal ligament. Its posterior face is covered by the tendinous synovial membrane lining the tarsal sheath for the passage of the perforans tendons. It is confounded, on its sides, with the calcaneo-metatarsal, and the internal and superficial tibio-tarsal ligaments.

5. An *interosseous ligament*, attached to the four bones composing this articulation.

It is provided with a particular synovial membrane which always communicates, in front, with the tibio-tarsal capsule. This membrane is prolonged, superiorly, between the calcis and astragalus, to lubrify two of the facets by which these bones come into contact; and, in addition, it descends between the cuboid and scaphoid bones to form a third prolongation for the anterior cuboido-scaphoid arthrodia.

Movements almost null.

Tarso-metatarsal Articulation.—This joint, formed by the meeting of the three tarsal bones—the cuboid and the two cuneiforms—with the three bones of the metatarsus, is fixed by the lateral superficial ligaments of the tibio-tarsal articulation, the calcaneo-metatarsal ligament, those which have been named the astragalo-metatarsal and tarso-metatarsal, and by a strong interosseous ligament which naturally forms three fasciculi.

The synovial membrane proper to this joint ascends into the small anterior cuboido-cunean arthrodia, and into that which unites the two cuneiform bones; it descends to the intermetatarsal articulations.

Movements nearly null.

In all the domesticated animals except Solipeds, the tarsal articulations offer some differential peculiarities whose study is without interest, as it is without utility. It is only necessary to remark that the immobility of the tarsal joints, properly called, is less absolute than in Solipeds, owing to the peculiar configuration of the articular surfaces of some of the bones composing them. Thus, in the *Ox*, *Sheep*, *Goat*, and *Pig*, the calcis is joined to the astragalus by a real trochlear articulation, and the latter bone is united to the scaphoid by a diarthrodial joint of the same kind; a mode of articulation much more favourable to motion than that of the planiform diarthrodial joint. In the *Dog* and *Cat*, the same result is obtained by the reception of the head of the astragalus into the superior cavity of the scaphoids.

In *Ruminants* and the *Pig*, it is also observed that the tibio-tarsal articulation is formed by the tibia and fibula in the one direction, and by the astragalus and os calcis in the other.

CHAPTER III.

OF THE ARTICULATIONS IN BIRDS.

The study of the articulations in birds will only arrest us for a few moments, as it will be confined to some remarks on the intervertebral occipito-atloid and temporo-maxillary joints, the only ones exhibiting a special conformation worthy of attention.

Intervertebral articulations.—The great mobility of the neck of birds is not only due to the fact of its length, relatively considered, but also to the peculiar manner in which the vertebræ of this portion of the spinal stalk are articulated. It will be remarked that

these do not unite by their bodies in the form of a continuous series of amphiarthroses, as in the domesticated mammals; but that instead of these mixed articulations there are veritable diarthroses, which may be included in the class created by Cruveilhier under the title of *articulation by reciprocal ball and socket*, each vertebra becoming connected with the adjacent vertebræ by means of facets convex in one sense and concave in the sense perpendicular to the first. These facets are manifestly covered by cartilage of incrustation; and it appears that, instead of their being applied directly against the opposite facets, which present a precisely inverse conformation, they are separated by an extremely thin fibro-cartilaginous disc, which resembles the interosseous meniscus of the temporo-maxillary articulation in the Carnivora of the *Cat* species. Two loose synovial capsules, separated by this interarticular lamina, complete the framework of each articulation, and favour the play of the vertebræ on one another. This arrangement has only, so far as we are aware, been observed in the swan, and that very imperfectly; but it probably belongs to the entire class of birds, for until now we have met with it in all the individuals submitted to examination.

In its dorso-lumbar and sacral portion, the spine is a single piece, in consequence of the consolidation of the vertebræ, and does not show any proper articulations.

In the coccygeal region, the mobility of the spine re-appears; but it is far from being so marked as in the cervical region; the vertebræ here are united by amphiarthrosis, and not by reciprocal ball and socket.

Occipito-atloid articulation.—It has been shown that there is only one more or less spheroidal condyle of the occipital bone, and a single cavity on the anterior margin of the spinal canal of the atlas. The occipito-atloid articulation is therefore a true enarthrosis, with varied and very extensive movements; a disposition which accounts for the facility with which birds can pivot their heads on the superior extremity of the vertebral stalk.

Temporo-maxillary articulation.—The play of this articulation offers one peculiarity in that it causes, during the separation of the mandibles, not only the depression of the inferior, but also the elevation of the superior mandible. The arrangement which permits this movement has been already made known; but yet it is difficult to understand, because there is no active agent, no proper muscle to directly effect it. Nevertheless, the mechanism which executes it is most simple, and may be given in a few words: Thus, we know that the square bone, interposed between the temporal and maxillary bones, like the interarticular meniscus of mammals, is united outwardly with the jugal bone, and inwardly with the pterygoid. We know also that the latter rests, by means of a diarthrodial facet, on the body of the sphenoid, and that it abuts against the posterior extremity of the palate bones; while the first, the zygomaticus, is joined directly to the supermaxillary bone. The superior jaw, it is also known, is movable on the cranium, because of the flexibility of the cartilages or bony plates uniting these two portions of the head. It may then be added, that the square bone receives on its anterior process one or two small muscles which are attached to the base of the cranium, and that these bones may be pushed, or rather drawn forward, by the contraction of these muscular fasciculi. It is this projecting, or pushing, transmitted to the upper mandible through the medium of the jugal bone on the one side, and the pterygoid bone on the other, that produces the elevation of that mandible.

Nothing is easier than to prove it; it is only necessary to take the head of a bird, denude it of all its soft parts, and press with the fingers behind the two square bones, to imitate the action of the elevator muscles; we then see the internal extremity of the pterygoid bone glide on the facet of the sphenoid, and push before it the palatine bone, during which the zygomatic bone acts in the same manner on the maxillary; and in this way is produced, through the influence of this postero-anterior propulsion, the ascending movement we undertook to explain.

THIRD SECTION.

The Muscles.

After the study of the bony levers and their articulations, comes the description of the agents whose function it is to move them. These are the *muscles*, fibrous organs possessing the property of contracting under the influence of a stimulus.

They are distinguished as *striated* (or *striped*) and *non-striated* (or *unstriped*) *muscles*, according to the character of the anatomical element composing them.

The *non-striated* (or *unstriped*) *muscles* are removed from the influence of the will, and belong to the organs of vegetative life. They are also designated as *internal muscles*, or *muscles of organic life.*

The *striated* (or *striped*) *muscles*, differ from the first in that, with the exception of the fleshy tissue of the heart, their contractile power is immediately placed under the influence of the will. They are more particularly concerned in the execution of the functions of relation, which causes them to be named the *external muscles*, or *muscles of animal life.* These muscles are nearly all attached to the skeleton, and represent the active agents in the movements of the osseous framework; they will, therefore, be the only ones referred to in this place, in studying the locomotory apparatus.

But before entering upon the particular description of each muscle, we will allude to the general considerations relative to their history.

CHAPTER I.

GENERAL CONSIDERATIONS ON THE STRIATED MUSCLES.

THE STRIATED MUSCLES IN GENERAL.

In this first paragraph, we will survey in a general manner the volume, situation, form, direction, attachments, relations, and names of the muscles belonging to the locomotory apparatus.

A. Volume.—Nothing is more variable than the respective volume of the external muscles. What a difference there is, for example, between the small scapulo-humeral muscle and the long vastus or ilio-spinalis (longissimus dorsi)! and what a number of intermediate sizes between these three points of comparison! There are consequently very great, great, medium, small, and very small muscles.

The weight of the total mass of these organs varies according to the species, age, sex, and state of health; but taking a general average, it will be found that it represents nearly one-half the entire weight of the body.

B. Situation.—There is no need to insist upon the fact, that a knowledge of the situation of the muscles is one of the first objects to be acquired with regard to their disposition.

They may, like the bones, be described in two ways.

1. *In relation to the median plane of the body*, from whence their division into pairs and single muscles. The last, very few in number, are far from exhibiting the symmetry which exists in the bones of this division, as may be seen in the diaphragm.

2. *In relation to the other organs*, such as the bones and surrounding muscles.

C. Form.—With regard to their absolute form, the muscles, again, like the bones, are classed as long, wide, and short.

Long muscles.—These muscles are more particularly met with in the limbs. Provided with a principal axis, to which we may ascribe the effect of their contraction, they present a *middle portion*—usually protuberant, and

two extremities of unequal thickness; the most voluminous, always turned upwards, is metaphorically designated the *head*, the other the *tail*. They are most frequently *fusiform*, sometimes *conical*, but rarely *cylindrical*, *prismatic* or *flattened* into thin bands.

"There is a particular kind of long muscles which have no analogy with those of the extremities, except in their external appearance. They are those which lie below, but more particularly above, the spine. Although at the first glance they appear simple, yet they present as many distinct fasciculi as there are vertebræ. The transverse spinous (*spinalis dorsi*), etc., is no doubt an elongated fasciculus like the sartorious, etc., but the structure of this fasciculus has nothing in common with that of the latter muscle: it is a series of small fasciculi which have each their distinct origin and termination, and only appear as a single muscle because they are in juxtaposition."—*Bichat*, '*Anatomie Générale*.'

Wide muscles.—Wide muscles are those which have two principal axes, and are stretched beneath the skin, or around the great cavities of the trunk, which they concur in inclosing and separating from one another. They are *elliptical*, *quadrilateral*, *triangular*, *trapezoid*, etc.

Short muscles.—These are found chiefly around the short bones, or at the periphery of the articulations which are deeply buried under enormous muscular masses. Although their name indicates that their three axes offer nearly the same dimensions, yet there is most frequently one, and even two, which predominate. They may therefore be assimilated, in this respect, to the long or wide muscles.

D. Direction.—Cruveilhier has justly remarked, that the direction of a muscle is one of the most important features in its history; for it allows the determination of the angle of incidence of the muscle on its arm of the lever, the power of its action, and the nature of its uses.

With regard to the direction of the muscles, we may observe: 1, The form of their principal axis; 2, The relation of this axis to the plumb-line; 3, Its comparison with the axis of the bony levers which the muscles surround or move.

a. A muscle is termed *rectilinear* when its principal axis is straight; it is *curvilinear*, or *circular*, if this axis describes a curve more or less marked; it becomes *inflected* when it proceeds in a certain direction, and afterwards turns on a bony or cartilaginous pulley in another direction: that is to say, when its principal axis is broken into several lines. If the muscle offers two axes, it will be *flat* or *concave*, these being one or the other, or straight or curvilinear.

b. With regard to the direction of the muscles to that of the plumb-line, it is either *vertical*, *horizontal*, or *oblique*, expressions which carry their own definition and require no explanation.

c. If the direction of the muscles be compared with that of the bony levers they surround and move, it will be found that they are either parallel to these levers, or form with them angles more or less acute. The proper direction of the bones being known, it is sufficient to indicate that of the muscles to clearly establish this comparison. For instance, in saying that the majority of the muscles of the shoulder are oblique from above to below, and from before to behind, it is understood that these muscles are parallel to the scapula, and that their incidence on the humerus takes place at a right angle.

E. Attachments or Insertions.—This is undoubtedly the most essential part of the study of the muscles; for with the knowledge of their insertions

we may determine their extent and direction, and even their relations and uses.

By the term *attachment, fixed insertion*, or *origin*, is meant the point of the muscle which most usually remains fixed while that organ contracts; the *attachment, movable insertion*, or *termination* is the name given to that portion which corresponds to the lever displaced by the muscular contraction. Muscles are frequently met with whose two insertions are alternately fixed or movable; and in such cases care is taken not to give these insertions one or other of the designations.

The fixed insertion is often confounded with that of other muscles; the movable insertion is generally free and independent.

The muscles are sometimes directly attached to the bones by the extremities of their fleshy fibres; but most frequently they are fixed to these inert levers through the medium of a tendon or an aponeurosis, whose volume is less considerable than that of the fibres. Without this latter disposition, the surface of the skeleton would not have been sufficiently extensive to give insertion to all the external muscles.

The attachment of the muscles to the bony levers is effected by a kind of fusion between the fleshy or tendinous fibres, and the periosteum.

F. Relations.—The indication of the relations of the muscles completes the idea of their situation, and is of great importance in a surgical point of view. They should, therefore, be studied with all the precision possible.

The muscles entertain relations either with the skin, the bones, other muscles, or with vessels and nerves.

a. It is only, properly speaking, the subcutaneous muscles, such as the panniculus carnosus and the muscles of the face, which are really in immediate contact with the skin. The others are separated from it by the aponeurotic fascia which will be described as the appendices of the muscular system.

b. The superficial muscles are only related to the bones by their extremities. Those which are deeply situated are immediately applied by their bodies against the bones of the skeleton.

c. The muscles are related to each other in a more or less intimate manner. Sometimes they adhere closely to one another; and at other times they are separated by interstices filled with fat or cellular tissue, and generally traversed by vessels and nerves.

d. The connections of the muscles with the latter organs sometimes assume a remarkable character; this is when one of them accompanies, like a *satellite*, the vascular and nervous trunks concealed beneath its deep face. There is in this circumstance an important fact with regard to surgical anatomy.

G. Nomenclature.—Before the time of Sylvius, the muscles had not received particular names. Since the days of Galen they had been distinguished by the numerical epithets of *first, second, third*, etc., to indicate their place and their order of superposition in the regions to which they belonged. It is in this fashion that they are designated in the Italian work on the Anatomy of the Horse by Ruini.

Sylvius was the first to give the muscles real names; and his example being followed by succeeding anthropotomists, the nomenclature of these organs was soon completed. But no general view, no methodic spirit guided Sylvius and his successors; it was sometimes their form, and sometimes their direction, position, uses, etc. to which the muscles owed their names.

Bourgelat applied this nomenclature to the horse, but modified it in many points.

Chaussier, struck by the imperfections of the nomenclature introduced into science by Sylvius, sought to substitute for it another much more philosophical. This anatomist gave to each muscle a name formed by two words indicating the insertions of the organ. Girard imported this ingenious idea into veterinary anatomy.

Nevertheless, notwithstanding its advantages, this new nomenclature did not supersede the old one; because it ceased to be correct when applied to comparative anatomy, the same muscles not having the same insertions in all the species.[1]

[1] It is not, however, that the ancient nomenclature has more advantages in this respect than the new. What can be more improper, for example, than the names of deltoid, splenius, soleus, digastricus, etc.? Do the muscles which receive these designations, considered in mammals only, offer in all species the form or the structure which justifies the employment of these names in the human species? Are the distinctive epithets of great, medium, little, etc., given to many of them, reasonably applicable in every case? May not the same objection be urged against the majority of the names derived from their uses, complications, etc.?

No system of myological nomenclature is really philosophical, and we are of those who believe it to be indispensably necessary to create one; indeed, we are inclined to think that it would be simple and easy to attain this result in starting from a basis whose fixity and invariability should be well defined. And this basis is, in our opinion, already discovered; it is the *principle of connections* founded by E. Geoffroy Saint-Hilaire in his immortal '*Philosophie Anatomique*,' a principle to which modern science certainly owes its finest conquests.

This is a subject which it is our intention to treat in a special work; but we may, nevertheless, indicate here the manner in which it presents itself to us.

We are desirous that *the myological nomenclature should rest entirely, in the first place, on the relations of the muscles with the pieces of the skeleton, or with other organs equally fixed and very important; in the second place, on the reciprocal connections of the muscles.*

Such is our plan; and it is not precisely new, for the old anatomists were often inspired with it, though unwittingly, as the principle on which it is founded was to them entirely unknown; this circumstance, however, immediately leads us to an appreciation of its value. For instance, what could be happier than the name of intercostals given to the muscles situated between the ribs, and their distinction into external and internal? Here we have names which indicate the *relations of the muscles* they designate *with the portions of the skeleton and the reciprocal connections of these muscles.* It can also be applied in an equally rigorous manner to every species. We may also cite the supracostals, the intertransverse, the transverse spinous, the subscapularis, the supraspinous, the subspinous, etc., as they are found in a greater or less marked degree in identical conditions.

Other muscles have received names derived in part from their situation, and in part from their volume. These names are far from being as convenient as the first; as may be judged from the following examples:

In the majority of vertebrate animals, there are three important muscles situated above and behind the pelvis, and forming the basis of the buttock; they have been designated *gluteals*, and this name is convenient, because it designates their situation. But to distinguish them from each other, regard has been had to their volume; so that there is a great, a medium, and a small gluteus. This is an error, however, for the volume of the muscles is subject to the greatest variations, and a voluminous muscle in one species may be a very small one in another, and *vice versâ*. The muscle analogous to the gluteus maximus in Man has been described by Bourgelat as the minimus, and by Lafosse and Rigot as the medius. With regard to the gluteus medius of Man, its representative in the lower animals has been designated as the maximus by the majority of veterinary anatomists. What confusion! And how easy it was to evade it by distinguishing these muscles, not by their volume, but by their reciprocal connections, which are the same in every species! Is it not, indeed, more natural to substitute the names of superficial, middle, and deep gluteals, for those of great, etc?

The same remark is applicable to the muscles which, in Man, cover the anterior aspect of the chest. Designated in common, and justly so, as *pectorals*, these muscles are wrongly distinguished into great and little; for the last, which is already an

In this work we will follow the nomenclature of Bourgelat, which will however, be submitted to some change. But as the names given by Girard are, in our opinion, of some assistance to students, care will be taken to include them in the synonymy.

(It only remains for me to add that Chauveau's nomenclature will be followed as closely as possible. It possesses advantages which are greatly superior to that adopted by Percivall; and as, in my opinion, the names and terms imported into science should be as nearly alike in all languages as may be compatible with circumstances, in order to facilitate study, comparison, and reference, I the more readily venture to take this step. Percivall's nomenclature will, however, be added in brackets to the synonyms, as well as that of Leyh and Gurlt when occasion appears to demand it.)

STRUCTURE OF THE STRIPED MUSCLES.

There enter into the structure of muscles: 1, Muscular tissue, properly so-called; 2, Conjunctival tissue in the form of delicate lamellæ, aponeuroses, or tendons; 3, Vessels and nerves.

Fig. 95.

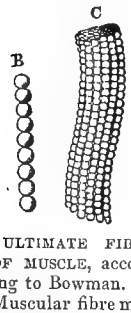

B, ULTIMATE FIBRIL OF MUSCLE, according to Bowman.
C, Muscular fibre more highly magnified, its myolemma being so thin and transparent as to allow the ultimate fibrillæ to be seen.

A. MUSCULAR TISSUE.—This tissue is composed of prismatic fasciculi, which it is possible to divide and subdivide into several smaller and smaller fasciculi, until the *muscular fibre* or *primitive fasciculus* is reached.

The *muscular fibre* is a kind of irregular polyhedron, with rounded angles, and extremities terminating in a blunt point. It is sometimes straight, sometimes wrinkled, but always striped either in a longitudinal or transversal direction, or both at once.

This fibre is formed by an *envelope* and *contents*.

The *envelope* is a very delicate, structureless membrane of an elastic nature, named the *sarcolemma* or *myolemma*. Nuclei in greater or less number can be seen on its inner face.

The *contents* are resolved into *contractile fibrillæ* and an *interstitial substance*.

The *contractile fibrilla* constitutes the primary element of striped muscle. It is a minute column whose surface, according to Rouget, exhibits the alternate prominences and depressions of the turns of a more or less fine screw; and which, according to Bowman, is formed by a mass of small discs, named by him the *sarcous elements*.

Fig. 96.



MUSCULAR FIBRE BROKEN ACROSS, SHOWING THE UNTORN SARCOLEMMA CONNECTING THE FRAGMENTS.

The *interstitial substance*, granular and nucleated, unites the fibrillæ in the interior of the sarcolemma and, in addition, according to Bowman's hypothesis, the discs entering into the composition of each fibrilla.

The aggregation of the fibrillæ produces the longitudinal striation: the transverse striation is the result

---

enormous muscle in the smaller Ruminants, is represented in Solipeds by two considerable muscles, much more voluminous than the muscle analogous to the great pectoral. It is only necessary, in this case, to change their names into superficial and deep pectorals.

either of the helicoid disposition of the fibrillæ, or of the fusion of the sarcous elements which compose the latter, according to the admitted opinion as to the structure of the contractile element.

The muscular fibres are united parallel to each other to form secondary fasciculi, which are surrounded by a conjunctival sheath—the *perimysium*. The secondary fasciculi are laid together to constitute more voluminous fasciculi which, in their turn, form the entire muscle. The conjunctival sheath enveloping the muscle is named the *external perimysium*.

Fig. 97.

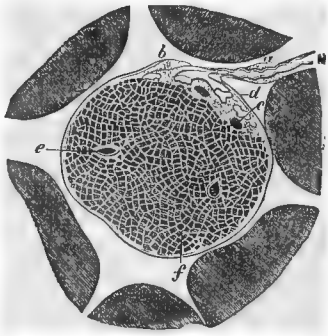

TRANSVERSE SECTION OF FROZEN MUSCLE, MAGNIFIED 400 DIAMETERS.

N, Nerve; M, Muscular fibre, surrounded by portions of six others.—*a*, Nucleus of the nerve sheath; *b*, Nucleus of the sarcolemma; *c*, Section of nucleus of terminal plate of nerve; *d*, Transverse section of terminal plate, surrounded by granular material; *e*, Transverse section of muscle nuclei; *f*, Fine fat drops. The angular dark particles are sections of sarcous elements: the clear intervening spaces represent the fluid isotropal part of the muscle substance.

B. Tendons and Aponeuroses.—The *tendons* are white, nacreous, round, or flattened cords fixed to the extremities of the long muscles. They are composed of fasciculi of condensed conjunctival tissue, affecting a parallel direction, and united to one another by connective sheaths.

The *aponeuroses* belong almost exclusively to the wide muscles; they are formed of several planes of parallel fibres which are not intercrossed in their middle part; at their superficies, however, the fibrous fasciculi are matted together in a more or less inextricable manner.

It is very interesting to study the mode of union of the muscular fibres with the tissue of the aponeuroses and tendons, as well as the reciprocal relations of these two parts.

The muscular fibre may be found passing in the same direction as the tendon, or it may fall upon the latter obliquely. In both cases there is no insensible transition between the muscular fibre and the fasciculus of the fibrous tissue; on the contrary, the contractile fibre terminates by a rounded extremity, which is buried in a corresponding depression in the tendon or aponeurosis. The union of the muscular with the fibrous tissue is very intimate; when the muscles are submitted to a degree of traction sufficient to cause a rupture, this never happens at the point of union.

The tendons commence sometimes by a hollow cone, which receives on its internal face the insertions of its muscular fibres; and sometimes by a thin point, often divided, which is plunged into the substance of the muscle. It is worthy of remark that a muscle provided with two tendons shows the first-named arrangement at one of its extremities, and the other at its opposite extremity; so that all the fibres which compose the muscle offer nearly the same length, those which leave the summit of the internal tendon being fixed to the bottom of the hollow cone formed by the second tendon, and so on reciprocally.

The muscular fibres which are continued by the fibrous fasciculi may be divergent or parallel. In the first case—the diaphragm, for example—the connective fibres run in the same direction as the muscular fibres. In the second case, several arrangements may be observed:

1. Tendons may pass in the same direction as the muscular fibres. This is the most simple manner. But the muscle may be divided into two bodies or bellies by a middle tendon; it is then called a *digastric* muscle.

2. Muscular fasciculi, passing altogether from the same side to become united into a tendinous cord, constitute a *semi-penniform* muscle.

3. Muscular fasciculi may be implanted to right and left of the tendon, and form a *pennated* or *penniform* muscle.

"This arrangement of fibres demonstrates that the length of the muscle, the length of its belly, and the length of its muscular fibres, should be carefully distinguished. The first term is applicable to the whole of the muscle, the tendon included; the second, to the fleshy body of the muscle, with the exception of the tendon; the third, to the muscular fasciculi constituting this fleshy body: the latter idea is the most important, for it alone indicates the amount of contraction a muscle is susceptible of, and consequently the possible extent of movement it is capable of effecting."—*Beaunis and Bouchard.*

Fig. 98.

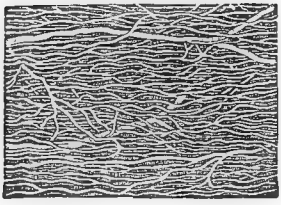

DISTRIBUTION OF CAPILLARIES IN MUSCLE.

C. Vessels and Nerves.—The muscular *tissue* receives much blood; the fibrous tissue very little. The *arteries* are large, numerous, and each is acccompanied by two veins. The capillary vessels anastomose in such a manner as to form rectangular meshes, whose greatest diameter is directed towards the length of the muscle.

The *lymphatic vessels* of the muscles are few; they sometimes penetrate their interior in following the capillaries; at other times they remain on the surface, in the external perimysium. The existence of lymphatics has not yet been demonstrated in tendons, aponeuroses, or synovial membranes.

Fig. 99.

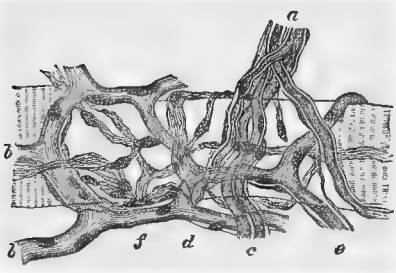

PORTION OF AN ELEMENTARY MUSCULAR FIBRE, WITH FOUR DARK-BORDERED FIBRES (*a*) CROSSING ITS SURFACE; *after Beale.*

b, Capillary blood-vessel, with fine nerve-fibres; a few only of the transverse markings of the muscle are represented; *c*, Two of the dark-bordered nerve-fibres passing over the elementary fibre to be distributed to adjacent fibres. This arrangement, in which a dark-bordered nerve-fibre, distributed to muscle, divides into branches, one of which passes to a vessel, while the other ramifies upon a muscle, is frequent. Magnified 700 diameters.

The *nerves* emanate from the cerebro-spinal centre. At their terminal extremity they offer a small enlargement, called by Rouget the *terminal motor plate*, and by Doyère and Kühne the *nervous colline* (hillock). It is admitted that the motor tube traverses the sarcolemma, losing its envelope; and that the substance of the cylinder is spread over the surface of the muscular fibrillæ to form the motor plate or nervous colline.

PHYSICO-CHEMICAL PROPERTIES OF STRIPED MUSCLES.

Muscles are soft organs, remarkable for their more or less deep-red colour, which varies with the species, and even in these with the age and health of the animals.

By desiccation, muscles become hard and brown; by repeated washing they assume a straw-yellow tint.

Muscles are extensible and elastic; they are also tenacious, and their tenacity is more marked during life than after death.

It has been remarked that the juice impregnating the muscular tissue is distinguished from the serum of the blood by an acid reaction. (The fluid or "muscle plasma" obtained by pressing flesh, is either neutral or slightly alkaline. It soon coagulates and separates into two portions—a semi-solid portion, "myosin," and the fluid serum that at ordinary temperatures quickly acquires an acid reaction.) It holds in solution a variable quantity of albumen, casein, fat, a little creatine, creatinine, and a somewhat large proportion of lactic acid. The solid substance of the muscle may be partly transformed into gelatine by boiling in water; but its largest portion is a nitrogenous substance, soluble in dilute hydrochloric acid, called "syntonine," or muscular fibrine; it differs but little from the fibrine of the blood.

PHYSIOLOGICAL PROPERTIES OF THE STRIPED MUSCLES.

In this paragraph will only be discussed the development of the muscles, muscular contractility, and the part the muscles assume in locomotion.

A. Development of the Muscles.—A muscle is derived from a mass of embryonic cells. Each cell becomes considerably elongated, and its nucleus becomes multiple, to constitute a muscular fibre. The membrane of the cell, enormously developed, forms the sarcolemma, while the contents of the cell, becoming more dense, divide longitudinally and give rise to the contractile fibrillæ. Lastly, when the muscles are formed, they grow by the augmentation in length and thickness of the primary fasciculi or muscular fibres.

B. Muscular Contractibility.—Muscles possess the property of contracting under the influence of a natural or artificial stimulus. *Muscular contraction* is the phenomenon resulting from the operation of this property. Muscles in a state of contraction are the seat of physical and chemical phenomena; they change their form and consistency, and become the theatre of a relatively abundant production of carbonic acid. creatinine, and inosinic acid. During contraction, it has been remarked that the muscular fibres contract by increasing in volume, like an india-rubber tube left to itself after being extended: the zig-zag doubling mentioned by Prevost and Dumas has not been observed.

But these physical and chemical modifications, important as they are in

Fig. 100.

MUSCULAR FIBRE IN A STATE OF CONTRACTION IN THE CENTRE; THE STRIÆ APPROXIMATED; THE BREADTH OF THE FIBRE INCREASED; AND THE MYOLEMMA RAISED IN VESICLES ON ITS SURFACE.

a physiological point of view, cannot longer be dwelt upon here. It is particularly important to speak of muscular contraction.

A muscle that contracts becomes shortened; its two extremities approach each other if they are free; or one draws near the other if the latter is fixed

to an immovable point. If the extremities of a muscle are attached to two movable levers, its contraction will bring about the displacement of one or other of these; from this a movement is produced.

The degree of shortening of a muscle varies, according to its being entirely free, or having a resistance to overcome. The mean limit of this shortening is about one-fourth the length of the muscular fibres; from this it will be understood that the movement produced by the contraction will be in proportion to the length of the fibres; though in this appreciation it will be necessary to keep in mind the density and energy of the fibre, as well as the intensity of the contractile stimulant.

As each fibre represents a force independent in its action, it results that we may judge of the power of a muscle by the number of its fibres, or its volume.

Muscles are often aided in their action by mechanical conditions: such as the disposition of the levers on which they act, the direction of the muscular fibres in connection with these levers, and, lastly, by the presence of lamellæ or elastic cords.

C. Uses of Muscles.—There are *flexor*, *extensor*, *abductor*, *adductor*, *rotator*, and other muscles, for all the movements of which the articulations are the centre.

To determine the functions or uses of the muscle, it is sufficient to know their insertions, and the mode in which the bones furnishing these insertions articulate with each other.

The result of muscular contraction being influenced by the form of their principal axis, and the length and direction of their levers, it is necessary to briefly examine these two points:

1. The immediate effect of the contraction of *rectilinear* muscles is the approximation of the bones to which they are attached. This approximation is usually brought about by the displacement of a single ray: that which receives the movable insertion of the muscle. Sometimes, however, the two rays move simultaneously, or they are alternately fixed and movable.

The first result produced by a *curvilinear* muscle is the straightening of its component fibres; after which it may act on the bony levers as do the rectilinear muscles, if its contractile power be not entirely expended. When a muscle is quite *circular*, its only action is to contract the opening it circumscribes.

With regard to the *inflected* muscles, their action can only be estimated from their point of inflexion; they operate as if this point represented their origin or fixed insertion.

2. The muscular powers are submitted to the statical and dynamical laws which govern the theory of levers; for the bony rays are only levers moved by the muscles.

In the locomotory apparatus we find the three kinds of lever recognised by physicists. Thus the head, extended by the great complexus muscle, represents an *interfixed*, or lever of the first class; the foot, extended by the gastrocnemii muscles, offers an example of the *interresisting*, or second kind, when this member remains fixed on the ground; lastly, the lower jaw raised towards the upper by the masseter muscle, forms an *interpuissant* or third kind.

It is worthy of remark that the arm of resistance in the bony levers is always extremely long; a circumstance which favours speed and the extent of movement at the expense of power.

On the other hand, muscles are rarely perpendicular to the arm of their

levers, at least at the commencement of their action; another circumstance which again diminishes their energy.

APPENDAGES OF THE MUSCLES.

These are: 1, The enveloping or contentive aponeuroses; 2, The serous or mucous bursæ; 3, The tendinous and synovial sheaths.

A. Contentive Aponeuroses.—These are layers of white fibrous tissue, which envelop, in common, all the muscles of one or several adjoining regions, principally those of the inferior rays of the limbs, where they constitute a kind of hollow cylinder.

These aponeuroses are formed by very resisting interwoven fibres, which are attached to the bones at numerous points. At their periphery they receive the insertion of one or several muscles, which keep them more or less tense. Their external face responds to a thin fibro-cellular layer that separates them from the skin. The internal face sends lamellar prolongations between the muscles, which are destined to isolate these organs in special sheaths.

The aponeuroses maintain the muscles in their position, and sustain them during their contraction.

B. Serous Bursæ.—The serous or mucous bursæ are small cavities, filled with a serous fluid, which are met with at those points where the muscles glide over resisting surfaces. They are generally orbicular or rounded, and their interior is often divided by fibrous bands.

Their walls are formed by slightly condensed conjunctival tissue, and may be lined by a pavement epithelium; in which case it is believed that the serous bursa is produced by the simple dilatation of one of the conjunctival meshes.

C. Tendinous Sheaths and Synovial Membranes.—*Tendinous sheaths* is the name given to the half-bony, half-fibrous, sometimes exclusively fibrous, gliding grooves into which the tendons pass when they are inflected to change their direction.

The *tendinous synovial membranes* are serous membranes lining the tendinous sheaths and covering the tendons at the points where these two parts correspond. They secrete a synovial fluid quite like that of the articulations.

When they almost completely envelop the tendon, and are afterwards carried to the walls of the sheath, they are termed *vaginal.*

Their walls are composed of: 1, A very fine conjunctival membrane, confounded by its external face with the tendinous sheath, by the other face with the tendon; 2, A simple layer composed of pavement epithelium, extended over the whole or a part of the internal face of the conjunctival membrane.

MANNER OF STUDYING THE MUSCLES.

A. Classification.—To facilitate the study of the muscles, two methods may be employed in grouping them. The first consists in classifying them according to their uses; describing, for example, all the flexors, extensors, etc., of the same region. In the second method, the uses of the muscles are not taken into account, their relations only being considered; and they are divided into groups or *regions,* which comprise all the muscles situated around a bony ray. The latter is the method now adopted, because it is the most convenient, useful, and rational.

(Leyh describes the muscles by layers, or according to their situation,

which, he asserts, facilitates the study of anatomy in a surgical point of view).

B. Preparation.—We will limit ourselves to some general remarks on the following points:

Choice of a subject.—If there is for disposal a certain number of subjects from among which it is possible to make a selection, the preference should be given to those that have the muscular system best developed; not that large, soft, lymphatic horses with enormous masses of muscle should be chosen, for these animals are always less convenient than small or middle-sized, well-bred horses. Asses and mules, when very emaciated, answer well for the preparation of the muscles.

Position of the subject.—It is necessary to place the subject, immediately after death, in a convenient position, in order that the cadaveric rigidity may set in while it is in that attitude. Without this precaution, the various parts of the body may assume an inconvenient shape or direction, and all attempts to amend them will prove almost unavailing, particularly in the larger animals.

Three principal positions may be given to subjects:

1. The animal is in the *first position* when it is placed on its back, the four extremities in the air, and maintained in that posture by means of long cords passed round the pasterns and fixed to the movable rings which terminate the extremity of the four bars of the wheeled-table on which the subject is laid. The head should be beyond the end of the table and rest upon a stool. The animal should always be placed in such a manner that the head be opposite the fore-part of the table, so that the movements of the pole or shaft be not impeded during the displacement of the apparatus. In order that the neck be not twisted to the right or left, in attaching the fore-limbs the subject should be raised so that the withers rest lightly on the table. According to the bulk of the animal and the length of the bars, the ropes should be passed around either the pasterns, above the fetlocks, or even above the knees.

2. To place the animal in the *second position*, it is turned on the belly, the two thighs flexed, the extremities carried beyond the table, and the head fixed between two bars by means of a rope passed under the zygomatic arches.

3. The subject is in the *third position* when it rests on its side.

Rules to be observed during the preparation.—1. By no means, if possible, remove the skin from the regions to be dissected until quite ready to begin the dissection. If this is impossible, then take the precaution of enveloping these regions in damp cloths, or in the animal's skin, to prevent desiccation of the aponeuroses and the superficial muscles.

2. To dissect a muscle, it is necessary to remove the aponeuroses or the other muscles which cover it, the cellular tissue enveloping it, and the fat, glands, vessels, and nerves lodged in the neighbouring interstices. The aponeuroses should be removed in shreds by making them very tense with the forceps, but without raising them, and causing the blade of the scalpel to glide between the fibrous and muscular surfaces, keeping it always parallel to these two planes. The covering muscles should not be entirely excised, but ought to be cut through the middle, across their fibres, and the ends thrown back; in this way it is always possible to replace a muscle by bringing the two portions together; the study of its relations is then much more easy. The cellular tissue is got rid of by removing it with the forceps, and carrying the edge of the scalpel in the re-entering angle formed by the cellular layer and the surface of the muscle. This method also suffices for removing aponeuroses when they are slightly adherent to the muscular fibres. But when they give attachment to these by their under face, as may be noticed in the external scapular aponeurosis, it is necessary to have recourse to the method indicated above. To remove fat, glands, etc., scissors will be found very advantageous.

Order to follow in preparing all the muscles of the same subject, and to derive most advantage therefrom.—1. Place the subject in the first position, and commence by studying the muscles of the inferior abdominal region. Then excise them, leaving the posterior extremity of the great pectoral muscle, the prepubic tendon, and the crural arch intact. The abdominal cavity having been emptied of the viscera it contains, dissect and study successively the diaphragm, the internal crural region, except the deep muscles, the sublumbar region, the femoral and posterior crural regions, the superficial muscles of the inferior cervical region, and the pectoral region.

2. After detaching for future use one of the anterior limbs, the animal is placed in the second position, and one after another may be dissected the muscles of the ear, those of the superior cervical region, the croup and costal regions, except the triangular muscle, and the spinal region of the back and loins.

3. The regions of the anterior limb may be prepared at the same time, or immediately afterwards.

4. Separate the two posterior limbs by sawing the femurs through their middle, and proceed to the dissection of the muscles of the posterior leg and foot.

5. By means of another application of the saw across the middle of the loins, the pelvis is completely isolated for the preparation of the coccygeal muscles, and the deep muscles of the internal crural region, nearly as they are represented in figures 90 and 131.

6. The animal being placed on its side. the pectoral cavity is opened by sawing through the ribs near their extremities; on the two particular portions thus obtained may be studied, in one part, the triangularis of the sternum, and in the other the deep muscles of the inferior cervical region, including the long muscle of the neck and the anterior and lateral straight muscles of the head.

7. Lastly, the head is disarticulated and the muscles of this region are prepared

The subject may afterwards serve for the study of nearly all the articulations.

Preservation of the muscles.—The muscles may be preserved by immersing them in appropriate fluids, and the muscular preparations by drying them.

A large number of liquids preserve muscles from putrefaction. We may mention alcohol; a mixture of alcohol and spirits of turpentine; alcohol, water, and chloroform; a solution of sulphate of iron, bichloride of mercury, or arsenious acid. The best preservative fluid, however, is nitric acid diluted with water, in the proportion of one of the former to three of the latter. The acid hardens the muscles and softens the conjunctival tissue; this allows all the interstices to be completely cleared out, and even permits the primitive muscular fasciculi which have been concealed by the white tissues to be exposed.

Desiccation, after immersion in a bath of arsenious acid or sulphate of iron, causes the muscles to become hardened and deformed. It is therefore a bad procedure.

(A careful dissection of the muscles, with regard to their origin, insertion, action, and relations, is of infinite importance to the student of human anatomy; to the Veterinary Student it is no less important, and more particularly with reference to the muscles of the limbs. A correct knowledge of their situation, attachments, and functions is often the only guide the Veterinary Surgeon can rely upon in the diagnosis of those apparently obscure cases of lameness which are of such comparatively frequent occurence. In the words of Mr. Henry Gray, we may repeat that "an accurate knowledge of the points of attachment of the muscles is of great importance in the determination of their action. By a knowledge of the action of the muscles, the surgeon is able at once to explain the causes of displacement in the various forms of fracture, or the causes which produce distortion in the various forms of deformities, and, consequently, to adopt appropriate treatment in each case. The relations also of some of the muscles, especially those in immediate apposition with the larger bloodvessels, and the surface markings they produce, should be especially remembered, as they form most useful guides to the surgeon in the application of a ligature to these vessels."—'*Anatomy, Descriptive and Surgical.*'

An accurate knowledge of the muscular system is also of great service to the Veterinary Surgeon in estimating the value to be placed upon the external conformation presented by animals intended for different kinds of labour.

"In dissecting," says Mr. Holden, "there are four principal objects to be constantly borne in mind by the student: 1st, The impression on the memory of those facts of general anatomy taught in the lectures. 2nd, The study of those parts of the body more especially concerned in surgical affections and operations. 3rd, The education of the sense of touch, and of the hand in the use of instruments; and 4th, The education of the eye in the knowledge of the several tissues of the body, in various positions, and varying circumstances. . . . The education of the eye is a gradual and tedious process, but one which is pretty certain to be satisfactorily accomplished if the student do but use his hands properly, and therefore a few words on the manual part of dissection may not be out of place.

"First, as to the instruments requisite for dissection. A case, containing six or eight scalpels, two pairs of scissors, a pair of dissecting forceps, a set of chain-hooks, a blowpipe, and a probe, will enable the student to make all requisite dissections, supposing that he is allowed the use of a saw and chisel in the dissecting-room. Great variety exists in dissecting-cases, both as to form and expense, but so long as the instruments themselves are strong and good, the simpler the case the better. Scalpels for dissection are made of two principal shapes; in one, the edge is bevelled to the point, the back being straight; in the other, both back and edge are bevelled to a point midway between the two. The latter form is preferable for most purposes. The blade should not be more than an inch and a half long, and never double edged; but the material of which the handle is constructed is a matter of indifference.

"For all ordinary dissection, it will be found most convenient to hold the scalpel like a pen; but for cleaning the fascia off muscles, and following out small nerves, it is better to hold it reversed, so that the *back* of the knife may be against the tissue which is to be preserved. In making the first incision through the skin of a limb, or in any other position where a long incision is required, the knife may, with advantage, be held *under* the hand, by which the wrist has more play, and the student has the opportunity of practising a mode of holding the knife, which he will find very useful when operating on the living body.

"The forceps should be broad at the extremities and coarsely serrated, so that it may retain a firm hold on small portions of tissue. It is very important that the forceps should not be too strong in the spring, for in that case it becomes so fatiguing to the hand that it is impossible to continue its use for any length of time. The forceps should be held lightly between the thumb and the first and second fingers of the left hand, which may be steadied by resting the little finger on a neighbouring part.

"The chain-hooks should be strong, and bent in the direction of the thickness and not of the breadth of the steel, as is sometimes done. These latter are very inferior, being liable to be unbent under any considerable strain. Care should be taken that the chains are firmly linked, and that the central ring is sufficiently stout to bear any force that may be applied. The scissors should be large and strong, and it will be found advantageous to have one curved pair, which is very useful in preparing the ligaments.

"The student will do well to bear in mind that he will probably be called upon in after life to operate on the living body, the only true preparation for which is careful dissection; he should therefore, as far as possible, conduct all his dissections as methodically, and with as much care, as if operating on the living body.

"The student should bear in mind that his manual labour is only a part of his duty, and will be thrown away, unless he at the same time study the description of the part upon which he is engaged; he should not, therefore, carry the dissection further than he can learn the description on the same day, *and at the subject*, and should, if possible, re-peruse the description in the evening, and always on the next morning, before carrying the dissection any further.")

CHAPTER II.

THE MUSCLES OF MAMMALIA.

Article I.—Muscles of the Trunk.

SUBCUTANEOUS REGION.

This only comprises a single muscle, the *fleshy panniculus (panniculus carnosus)*, destined to move the skin covering the trunk. Strictly speaking, however, we may describe as dermal muscles all those which are attached to the inner surface of the superficial integument—the muscles of the face, for example.

Fleshy Panniculus.

Preparation.—Place the animal on its side, and carefully remove the skin, allowing the cuticular muscle to remain on the subjacent muscles.

Situation—Form—Extent.—Situated on the inner surface of the skin covering the sides of the thorax and abdomen, the fleshy panniculus is an immense broad muscle, irregularly triangular in shape, thin at its borders, and thicker in the middle than elsewhere.

The upper border corresponds to a curved line, convex superiorly, and extending obliquely from the flank to the withers. The inferior border is carried horizontally from the flank to the posterior border of the olecranian mass of muscles, passing along the upper margin of the great pectoral muscle, which it covers, and to which it adheres somewhat closely. The

anterior border descends from the superior extremity of the shoulder on to the muscles of the fore-arm.

Structure—Attachments.—The fleshy fibres entering into the composition of this muscle are directed forward for its posterior two-thirds; but on arriving on the shoulder they gradually straighten and become vertical. They are continued, on the margins of the muscle, by aponeuroses which attach it either to the internal surface of the skin or to the fibrous fasciæ of the superficial muscles.

This muscle has, besides, a very remarkable insertion into the humerus, which was noticed by G. Cuvier, in his 'Leçons d'Anatomie Comparée,' and which appears to have been omitted, at least so far as Solipeds are concerned, in every treatise on Veterinary Anatomy. The following is what we have often observed in this respect:—On reaching the posterior border of the ulnar mass of muscles, the panniculus divides into two superposed layers: one, superficial, is carried to the muscles of the anterior member; the other, deep, soon terminates by an aponeurosis which is united to the great pectoral muscle, and is bordered at its upper margin by a nacrous aponeurotic band, which penetrates between the thorax and the muscles of the arm to be fixed to the small trochanter.

Relations.—By its superficial face, with the skin, to which it closely adheres; by its deep face, with the great dorsal, the dorsal portion of the trapezius, the abdominal tunic, the great oblique muscle of the abdomen, the great serratus, some external intercostals, the spur vein, and the superficial muscles of the shoulder and arm.

Action.—The animal, in contracting this muscle, shakes the whole of the cutaneous integument which covers it; thus preventing insects from alighting on the surface of the body, or tormenting by their bites or stings.

In the *Dog*, the panniculus carnosus is prolonged over the croup, and is united along the dorso-lumbar spine to that of the opposite side. It is very developed in the *Cat*.

CERVICAL REGION.

This region comprises all the muscles grouped around the cervical vertebræ—muscles which are conspicuous by their volume and the important part they play in the animal economy. There are described a *superior* and an *inferior cervical*.

A. Superior Cervical, or Spinal Region of the Neck.

This includes seventeen pairs of muscles, which are: the *cervical portion of the trapezius,*[1] *rhomboideus, angularis of the scapula, splenius, great complexus, small complexus, transverse spinous of the neck, the six intertransverse muscles of the neck, great oblique muscle of the head, great posterior rectus, and small posterior rectus.* These form four superposed layers on each side of the cervical ligament, and occupy the triangular space circumscribed by the upper border of that ligament, the transverse processes of the vertebræ of the neck, and the spinous process of the second dorsal vertebra.

Preparation.—Place the subject in the second position and dissect in succession the four layers of the region. To study the first layer, which is formed by the cervical portion of the trapezius, remove the skin, cellular tissue, and the fibrous fascia covering that muscle (*See* fig. 102). The preparation and study of the second layer, composed of the rhomboideus, angularis, and splenius, is carried out in two stages. In the first, the trapezium and the mastoido-humeralis is removed, leaving only the cervical insertions

---

[1] For the description of this muscle, see the SPINAL REGION of the back and loins.

of the latter muscle; then the limb is removed by sawing through the scapula beneath the insertions of the angularis and great serrated muscles, as in figure 105. But as neither the cervical or dorsal insertions of the splenius are exposed, it is necessary to proceed to the second part of the operation by removing the rhomboideus, angularis, and the superior extremity of the shoulder. To prepare the third layer, which comprises the great and small complexus, it is sufficient to excise the splenius, in following the direction of the neck, and to turn upwards and downwards the two portions of the muscle (*See* fig. 106). Lastly, the deep layer—the transverse spinous, intertransverse, oblique, and posterior straight muscles, as well as the cervical ligament—is exposed by removing the two complexus and the ilio-spinalis muscles (*See* fig. 104).

1. *Rhomboideus.* (Figs. 101, 6; 104, 1, 2.)

Synonyms.—Described by Bourgelat as two muscles, the *proper elevator of the shoulder* and the *rhomboideus*, these were termed by Girard the cervico-subscapularis and dorso-subscapularis. (This is the *rhomboideus longus* and *brevis* of Percivall, and the *dorso-scapularis* and *cervico-subscapularis* of Leyh.)

Form—Situation—Direction.—This muscle has the form of a very elongated triangle, and is situated at the inner aspect of the cervical trapezius and the scapular cartilage, beneath the cervical ligament, whose direction it follows.

Fig. 101.

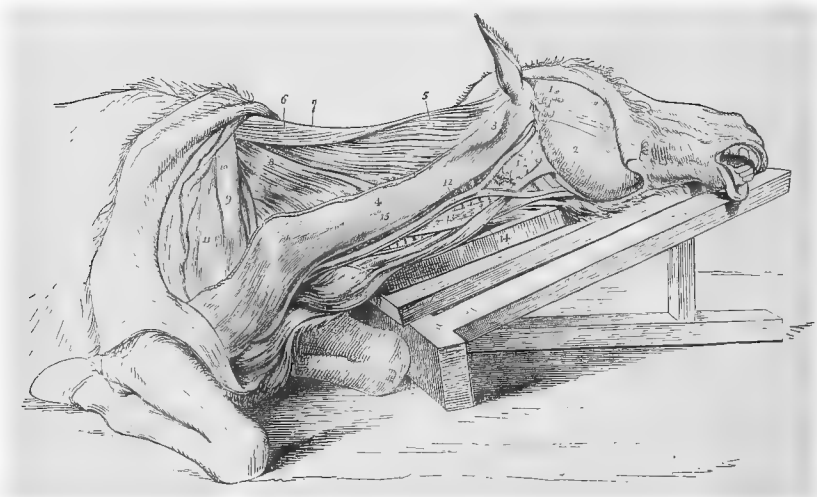

LATERAL VIEW OF THE NECK; SUPERFICIAL MUSCLES.

1, 1, Parotid gland; 2, Sterno-maxillaris and, 14, Its junction with its fellow of the opposite side; 3, 4, Mastoido-humeralis, or levator humeri; 5, Splenius; 6, Rhomboideus; 7, Funicular portion of the cervical ligament, or ligamentum colli; 8, Angularis of the scapula; 9, Supra-, or antea-spinatus; 10, Trapezius; 11, Infra-, or postea-spinatus; 12, Jugular vein; 13, Subscapulo-hyoideus; 15, Trachea.

Structure—Attachments.—It is composed of thick, fleshy fasciculi, the anterior of which are oblique downwards and backwards, the posterior passing directly downwards. These fasciculi are fixed by their superior extremity to the funicular portion of the cervical ligament and the summits of the spinous processes of the four or five dorsal vertebræ succeeding the

first—*fixed insertion;* by their inferior extremity, to the inner aspect of the scapular cartilage, where the anterior fasciculi are confounded with those of the angularis.

Relations.—Covered by the cervical portion of the trapezius, the scapular cartilage, and the aponeurosis of the great dorsal muscle, the rhomboideus covers the sphenius, which is excavated near its superior border for its reception, as well as the aponeurosis of the anterior small serrated muscle through the medium of a yellow elastic lamina.

Action.—It draws the shoulder upwards and forwards.

2. *Angularis Muscle of the Scapula.* (Figs. 102, 4; 105, 3.)

Synonyms.—Trachelo-subscapularis—*Girard.* Portion of the serratus magnus—*Bourgelat.* Elevator of the scapula—*Cuvier.* (Anterior portion of the *serratus magnus* of Percivall. The *levator anguli scapulæ* of Man.)

Situation—Form—Structure.—This is a very strong muscle, situated in front of the shoulder, triangular, flattened on both sides, thin at its superior border, thick behind and below, and almost entirely fleshy.

Attachments.—It takes its origin from the transverse processes of the five last cervical vertebræ by five distinct portions, which are directed towards the scapula in converging towards each other, and soon join to form a single muscular body, which is inserted into the internal face of the scapula, on its anterior triangular surface.

Relations.—This muscle is confounded at its inferior border with the serratus magnus. It is covered by the cervical trapezius, the mastoido-humeralis, and the small pectoral muscle. It covers the splenius, the inferior branch of the ilio-spinalis, and the common intercostal muscle. Near its junction with the serratus magnus, its internal face adheres very closely to the transverse processes of the three first dorsal vertebræ.

Action.—It draws forward the superior extremity of the scapula, while the humeral angle is carried backwards. If the shoulder becomes the fixed point, it can act in the extension or lateral inclination of the neck.

3. *Splenius.* (Figs. 105, 4, 5; 106, 5.)

Synonyms.—Cervico-trachelian—*Girard.*

Form—Situation.—A considerable muscle, flattened on both sides, triangular, and comprised between the cord of the cervical ligament, the inferior branch of the ilio-spinalis muscle, and the transverse processes of the four first cervical [redacted] vertebrae

Structure.—The splenius, aponeurotic only at its periphery, is composed of thick fleshy fasciculi which are all directed forwards and upwards, to reach the head and the first cervical vertebræ.

Attachments.—It is fixed, by its posterior border, to the lip of the cervical ligament and the summits of the spinous processes of the first dorsal vertebræ, by means of an aponeurosis which is continuous behind with that of the small anterior serratus, and confounded, by its inner surface, with that of the great complexus. Its anterior border is cut into four or five digitations which constitute the movable insertions of the muscle: *a.* The superior digitation is the widest and thinnest, and terminates in an aponeurosis (Fig. 105, 5), which unites it to the mastoid tendon of the small complexus, and passes to the mastoid crest. *b.* The second joins a very strong tendon common to the splenius, the small complexus, and the mastoido-humeralis, which tendon is attached to the transverse process of

the atlas (Fig. 105, 9). *c, d.* The two or three others are directly inserted into the transverse processes of the third, fourth, and fifth cervical vertebræ.

Relations.—The splenius is related, outwardly, to the rhomboideus, the angularis, cervical trapezius, and mastoido-humeralis; inwardly, to the two complexus and two oblique muscles of the head; by its inferior border, to the superior margin of the inferior branch of the ilio-spinalis (longissimus dorsi).

Action.—It extends the head and neck in inclining them to one side. If the two act in concert, the extension is direct.

Fig. 102.

SUPERFICIAL MUSCLES OF THE NECK AND SPINAL REGION OF THE BACK AND LOINS.

1, Dorsal trapezius; 2, Great dorsal; 3, Cervical trapezius; 4, Levator anguli scapulæ; 5, Splenius; 6, Anterior, or superficial portion of the mastoido-humeralis; 7, Its humeral insertion; 7′ Its mastoid insertion; 8, The thin aponeurosis uniting this insertion to the sterno-maxillary muscle; 8′, Posterior portion of the mastoido-humeralis; 9, Its inferior aponeurosis inserted into the interstice of the long abductor of the arm; 10, Sterno-maxillaris; 11, Subscapulo-hyoideus; 12, Portion of the dermal muscle of the neck; 13, Portion of the great extensor of the fore-arm; 14, Posterior belly of the long abductor of the arm; 15, Great pectoral muscle.

4. *The Great Complexus.* (Fig. 106, 6, 7.)

Synonyms.—Dorso-occipitalis—*Girard.* (*Complexus major—Percivall.*)

Situation—Direction—Form.—A powerful muscle, included between the internal surface of the splenius and the cervical ligament, whose oblique direction forwards and upwards it follows; it is triangular, flattened on both sides, elongated from before to behind, and divided longitudinally into two unequal portions—a posterior and anterior.

Structure.—The posterior portion (Fig. 106, 6), the most considerable, is aponeurotic at its origin, intersected by linear fibrous bands which obliquely cross its direction, and is formed of fleshy fibres directed forwards. Those which compose the anterior portion (Fig. 106, 7), intermixed with some tendinous fasciculi, are directed upwards, and appear to be inserted into the preceding. It is this difference in the direction of the fibres of the two portions of the great complexus which allows them to be distinguished from one another; the two being only really separated by an interstice near their inferior extremity. Superiorly, the muscle is constricted to form the summit of the elongated triangle it represents, and terminates by a strong tendon.

Fixed insertions.—The posterior portion derives its origin: 1, From the summit of the spinous processes of the first dorsal vertebræ, by a strong aponeurosis which is confounded with that of the splenius and the anterior small serratus; 2, From the transverse processes of the four or five dorsal vertebræ which follow the second, by as many aponeurotic digitations united by their margins. The anterior portion is fixed: 1, To the transverse processes of the two first dorsal vertebræ, by two tendinous digitations analogous to those of the posterior portion; 2, To the articular tubercles of the cervical vertebræ, by the inferior extremity of its fleshy fasciculi.

Movable insertion.—The movable insertion of the great complexus is effected through its superior tendon, which is fixed to the posterior face of the occipital protuberance, beside the cervical tuberosity.

Relations.—It is covered by the splenius and the small complexus. It covers the cervical ligament, the upper branch of the ilio-spinalis, the transverse spinous of the neck, and the oblique and posterior straight muscles of the head. The aponeurotic digitations which attach it to the dorsal transverse processes are comprised between the two branches of the ilio-spinalis. The interstice which separates, inferiorly, the two portions of the muscle affords a passage to the superior cervical artery.

Action.—It is a powerful extensor of the head.

5. *Small Complexus.* (Figs. 105, 6, 7; 106, 8, 9.)

Synonyms.—Dorso-mastoideus—*Girard.* (*Trachelo-mastoideus—Percivall.*)

Situation—Direction.—Situated at the internal face of the splenius, in an oblique direction upwards and forwards, this muscle lies along the anterior border of the great complexus, and follows the inferior branch of the ilio-spinalis, which it appears to continue to the head.

Form—Structure.—The small complexus is a long muscle, divided into two fleshy, fusiform, and parallel portions—anterior and posterior—which we might strictly consider as two distinct muscles. Both are composed of successive fasciculi, which become longer as they are superficial, and terminate by a tendon at their superior extremity. The tendon of the posterior muscle is flattened, and joins the mastoid aponeurosis of the

splenius. That of the anterior muscle is funicular, and receives, before its insertion, a digitation from the splenius (fig. 106, 10), and another from the mastoido-humeralis (fig. 106).

Fixed attachments.—The two fleshy portions of the small complexus have their fixed insertion in common with the anterior portion of the great complexus: 1, On the transverse processes of the two first dorsal vertebræ, through the medium of aponeurotic digitations which serve as an origin to the last-named muscle; 2, On the articular tubercles of the cervical vertebræ, by the inferior extremity of their component fasciculi.

Movable attachments.—The terminal tendon of the posterior muscle passes to the mastoid process of the temporal bone. The anterior passes to the transverse process of the atlas.

Fig. 103.

LATERAL VIEW OF THE NECK; MIDDLE LAYER OF MUSCLES.

1, Funicular portion of the cervical ligament; 2, Complexus major; 3, Complexus minor; 4, Rectus capitis posticus major; 5, Rectus capitis posticus minor; 6, Stylo-maxillaris; 7, Carotid artery; 8, Pneumogastric nerve and branch of sympathetic; 9, Longus colli; 10, Recurrent nerve; 11, Inferior scalenus; 12, Spinalis, or transversalis colli; 13, Incision through rhomboideus and trapezius; 14, Trachea.

Relations.—Outwardly, with the splenius; inwardly, with the great complexus and the oblique muscles of the head. The tendon of the posterior fleshy portion is covered by the mastoid aponeurosis of the mastoido-humeralis.

Action.—The small complexus inclines to its side the head and upper part of the neck. It also acts as an extensor of the head.[1]

[1] Bourgelat has described, by the name of *long transversal*, the anterior portion of this muscle, and attached it to the posterior portion of the splenius. We do not know where to find one or other of these in the crude description of Lafosse and Vitet. Girard considered them, like ourselves, as a single muscle, which he designates the *dorso-mastoideus.* Rigot has united them with the anterior portion of the great complexus and the foremost fasciculi of the short transverse muscle (inferior branch of the ilio-spinalis), to make his *long transversal;* in doing so he has only complicated their description. These two muscular fasciculi, being, to our view, exactly represented, the posterior, at

6. *Transverse Spinous Muscle of the Neck.* (Fig. 104, 4.)

Synonyms.—Short spinous—*Bourgelat.* Dorso-spinalis—*Girard.* (*Spinalis colli*—*Percivall.* *Transversalis colli* of Man.)

Situation.—Between the great complexus and the cervical ligament, on the laminæ of the last five vertebræ of the neck.

Form—Structure—Attachments.—This muscle, a continuation in the cervical region of that of the back and loins, is generally formed of five thick and short fasciculi, strongly aponeurotic, directed forwards, upwards, and inwards.

These fasciculi, attached by their posterior extremities—*fixed insertion*—to the five last articular tubercles of the cervical region, are fixed by their anterior or superior extremities—*movable insertion*—into the sixth, fifth, fourth, third, and second spinous processes of that region.

Relations.—Outwards, with the great complexus; inwards, with the superior branch of the ilio-spinalis and the cervical ligament. By its anterior face, with the laminæ of the cervical vertebræ and the interlamellar ligaments.

Action.—An extensor and flexor of the cervical spine.

7. *Intertransversal Muscles of the Neck.* (Fig. 104, 9.)

Synonyms.—Intercervicals—*Girard.* (The *intertransversales* of Man. Not mentioned by Percivall.)

These are six small, short, and very tendinous fasciculi, each of which is doubled into two secondary fasciculi, a superior and inferior. They are lodged in the lateral excavations comprised within the transverse and articular processes of the cervical vertebræ, and are carried from one vertebra to another, except from the first to the second. Covered by the cervical attachments of the majority of the muscles of the neck, they cover the vertebræ to which they are attached, as well as the vertebral arteries and veins, and the intervertebral foramen. They incline the neck to the side.

8. *Great Oblique Muscle of the Head.* (Fig. 104, 7.)

Synonyms.—Axoido-atloideus—*Girard.* (*Obliquus capitis inferior*—*Percivall.*)

Form—Direction—Situation.—A short, thick, and broad muscle, oblique forwards and outwardly, and applied to the superior face of the two first vertebræ of the neck.

Structure and Attachments.—Its fibres are nearly all fleshy, parallel to each other, and longer as they become superficial; they are attached by their posterior extremity—*fixed insertion*—to the external face of the spinous process of the axis, and by their anterior extremity—*movable insertion*—to the superior surface of the transverse process of the atlas.

Relations.—Outwards, with the splenius, the great and little complexus; inwards, with the atlas, the axis, and the atlo-axoid articulation; above,

---

least, by the *small complexus* of anthropotomists, we have thought it proper to give it that name. With regard to the muscle generally termed the *small complexus* by veterinary anatomists, following the example of Meckel we will describe it as a portion of the great posterior straight muscle of the head.

(Percivall names Girard's *axoido-occipitalis longus* the "complexus minor," and his *dorso-mastoideus* the "trachelo-mastoideus." Leyh, following Girard, designates the latter muscle the *dorso-mastoideus.*)

with the posterior straight muscles of the head; below, with the anterior great straight muscle.

Action.—It pivots the atlas on the odontoid process of the axis; it is, therefore, the special rotator of the head.

Fig. 104.

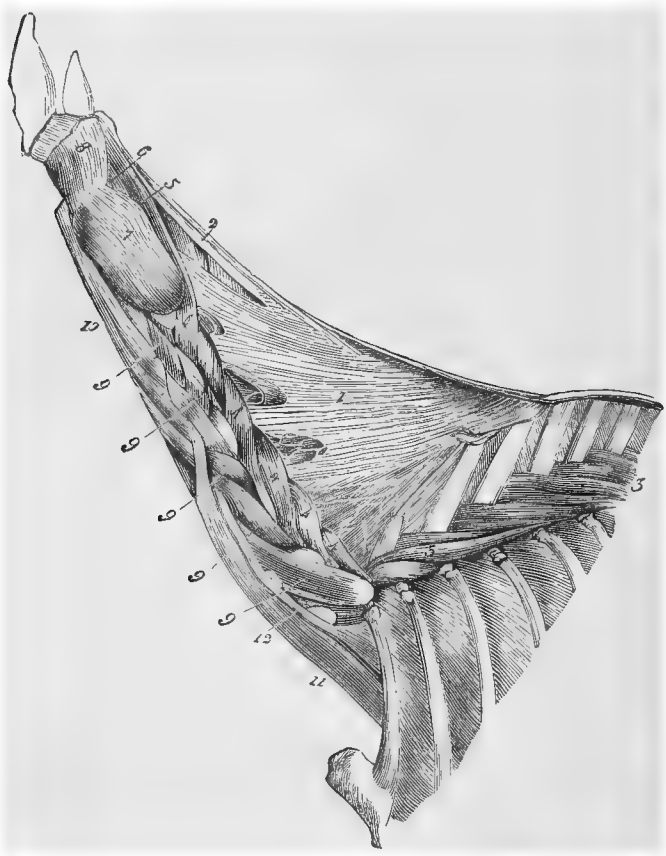

CERVICAL LIGAMENT AND DEEP MUSCLES OF THE NECK.

1, Lamellar portion of the cervical ligament; 2, Funicular portion; 3, 3, The transversales muscle of the back and loins; 4, 4, Transversales of the neck; 5, Posterior great straight muscle of the head; 6, Small ditto; 7, Great oblique muscle of the head; 8, Small ditto; 9, 9, Intertransversales of the neck; 10, Anterior great straight muscle of the head; 11, Inferior scalenus muscle; 12, Superior ditto.

9. *Small Oblique.* (Fig. 104, 8.)

Synonyms.—Atloido-mastoideus—*Girard.* (*Obliquus capitis superior—Percivall. Lateral atloido-occipitalis* of Leyh. *Obliquus superior* of Man.)

A short, thick, quadrilateral, and strongly aponeurotic muscle. Its fibres are fixed posteriorly—*origin*—to the lip bordering the transverse process

of the atlas; they are carried from thence forward, upward, and inward, to to be attached—*termination*—1, To the styloid process of the occipital bones; 2, To the external surface of that bone, on the imprints which border the mastoid crest posteriorly; 3, To the mastoid crest itself. This muscle is covered by the mastoid tendon of the small complexus, by the superior aponeurosis of the splenius, and that of the mastoido-humeralis. It covers the occipito-atloid articulation, the occipital insertion of the posterior straight muscles of the head, and the origin of the occipito-styloid and digastric muscles. It inclines the head on the atlas, and slightly extends it.

10. *Posterior Great Straight Muscle of the Head.* (Fig. 104, 5.)

Synonyms.—Small complexus and great posterior straight muscle—*Bourgelat.* Long and short axoido-occipitalis—*Girard.* (*Complexus minor* and *rectus capitis posticus major.*—*Percivall.* Leyh gives this muscle the same designations as Girard. It is the *rectus capitis posticus major* and *medius* of Man.)

Form—Structure—Situation.—Elongated, prismatic, easily divisible into two fasciculi—one superficial, the *complexus minor* of Bourgelat (and Percivall); the other deep, the *great posterior straight* muscle of Bourgelat (and the *rectus capitis posticus major* of Percivall)—entirely fleshy, and formed of parallel fibres, this muscle is lodged, with the small posterior straight muscle, in a triangular space circumscribed by the cord of the cervical ligament and the internal border of the oblique muscles.

Attachments.—It is attached, by its superior extremity, to the whole extent of the uneven lip which terminates the spinous process of the axis—*fixed insertion.* Its anterior extremity is insinuated beneath the small oblique muscle, and is fixed to the occipital bone, behind the superior insertion of the great complexus, whose tendon receives some of the fibres of the superficial fasciculus—*movable insertion.*

Relations.—Above, with the great complexus; below, with the small straight muscle; inwards, with the cord of the cervical ligament and the analogous muscle of the opposite side; outwards, with the oblique muscles.

Action.—This muscle, a congener of the great complexus, aids in extending the head.

11. *Small Posterior Straight Muscle.* (Fig. 104, 6.)

Synonyms.—Atloido-occipitalis—*Girard.* (*Rectus capitis posticus minor*—*Percivall.* The *Atloido-occipitalis superior* of Leyh. *The rectus capitis posticus minor* of Man.)

A very small, wide, and triangular muscle, flat above and below, and lying immediately upon the fibrous capsule of the occipito-atloid articulation. It is attached, posteriorly, to the superior face of the atlas—*origin;* in front, to the external surface of the occipital bone, below the preceding muscle, whose action it shares.

B. *Inferior Cervical or Trachelian Region.*

The muscles composing this region are situated in front of the cervical vertebræ, and are, for the most part, grouped around the trachea, which they envelop as in a kind of sheath. They are eleven in number: the *cuticular muscle of the neck*, the *mastoido-humeralis*, *sterno-maxillaris*, *sterno-hyoideus*, *sterno-thyroideus*, *omo-* or *subscapulo-hyoideus*, the *great* and *small anterior straight muscles of the head*, the *small straight lateral muscle*, the *scalenus*, and the *long muscle of the neck.*

Preparation.—1. Place the animal in the first position. 2. Remove the skin of this region, in order to expose and study the cuticular muscle. 3. Remove that muscle and the parotid gland to prepare the mastoido-humeralis,[1] the stylo-maxillaris, sterno-hyoideus, and sterno-thyroideus. 4. Transversely cut through the mastoido-humeralis near the angle of the shoulder, and isolate it from the subscapulo-hyoideus to expose this muscle; taking care to preserve the jugular vein and parotid gland, in order to study their relations with it. 5. Remove the fore limbs; open the thoracic cavity by sawing through the eight first ribs near their superior extremity; take out the viscera contained in this cavity, as well as the trachea, œsophagus, pharynx, and larynx, to expose the long muscle of the neck, the scalenus, and the straight muscles of the head.

1. *Subcutaneous Muscle of the Neck.* (Figs. 102, 12; 114, 1.)

Synonyms.—It has been described by Bourgelat, and the majority of veterinary anatomists who have followed him, as two muscles: the cuticularis of the neck and the face. (Percivall includes this muscle in his description of the *panniculus carnosus.*)

This is a membraniform expansion, partly fleshy, partly aponeurotic, which covers the muscles of the neck, the intermaxillary space, and the face.

The fleshy fibres form, in front of the neck, a thin band, which is united, through the medium of a fibrous raphé, to that of the opposite side. This band is in contact with the sterno-maxillary, sterno-hyoid, subscapulo-hyoid, and sterno-thyroid muscles, as well as the jugular vein: enveloping them all as in a sort of gutter. It gradually thins from below upwards, in such a manner that around the upper part of the throat it is only composed of some scattered fibres. In the intermaxillary space, and on the expanding borders of the maxillary branches, the fleshy fibres appear again of a certain thickness, but only to become attenuated on the external surface of the cheeks.

These fleshy fibres leave the anterior prolongment of the sternum[2] and intermediate middle raphé of the two muscles, and directing their course outwards and upwards, soon become confounded with the aponeurosis. The latter, extremely thin, is spread over the mastoido-humeralis, the superior cervical muscles, parotid region, and the cheeks, and is finally attached to the zygomatic crest. On arriving near the commissure of the lips, the cuticular muscle is united to the alveolo-labialis (or buccinator muscle) by a fleshy fasciculus named, in Man, the *risorius santorini* (Fig. 110, 24).

The cuticularis colli braces the muscles it covers during their contraction and pulls backwards the commissures of the lips. We doubt very much whether it has, in the cervical region at least, any action on the skin, for it adheres but very slightly to its inner surface.

2. *Mastoido-humeralis.* (Figs. 102, 105, 106, 114.)

Synonyms.—The muscle common to the arm, neck, and head—*Bourgelat.* Representing the cleido-mastoid, and the clavicular portions of the trapezius and deltoid of

---

[1] The mastoido-humeralis may be dissected at the same time as the trapezius, the subject being placed in the second position. This conveniently permits the superior insertions of the muscle to be studied. (*See* fig. 102).

[2] It will be seen, on referring to figure 114 and its legend, that we restore to the cuticular muscle of the neck the sternal band attributed until now to the mastoido-humeralis. These are the considerations which induce us to make this modification: 1, This band is not distinct from the cuticularis of the neck; a separation between the two muscles can only be artificially obtained. 2, In dissecting this band with care, we can see that its fibres, like those of the cuticularis, are not mixed with those of the mastoido-humeralis (superficial portion); they pass along the external surface of that muscle, to which they intimately adhere, it is true, but they can easily be separated, and are continuous with the aponeurosis of the first.

Man, and the trachelo-acromialis peculiar to quadruped mammals[1]—*G. Cuvier*, 'Leçons d'Anatomie Comparée,' 2nd edition. (This is the muscle which Percivall names the *levator humeri*. The above is the designation given to it by Girard and Chauveau. Leyh gives it the same designation as Bourgelat.)

Extent—Situation—Direction—Composition.—This muscle extends from the summit of the head to the inferior part of the arm, and is applied to the scapulo-humeral angle at the side of the neck, in an oblique direction downwards and backwards. It is composed of two portions lying longitudinally and somewhat intimately united, and distinguished into *anterior* and *posterior*.

Form—Structure—Attachments.—A. The *anterior* or *superficial* portion (Fig. 106, 6) constitutes a long fleshy band, which appears to be united, by its anterior border, to the cuticular muscle of the neck. Its superior extremity, thin and wide, is attached to the mastoid process and crest by an aponeurosis (Fig. 102, 7), which is united, in front, to the tendon of the sterno-maxillaris by a very thin cellulo-aponeurotic fascia. Its inferior extremity, thicker than the superior, is inserted by means of a very short aponeurosis into the humerus, on the salient border descending from the deltoid imprint, and which limits, in front, the furrow of torsion on the body of that bone (Fig. 102, 7).

B. The *posterior* or *deep portion* (Fig. 102, 9) is a second muscular band, shorter and stronger than the preceding. It is attached, above, to the transverse processes of the first four cervical vertebræ by as many fleshy bands (Fig. 102, 8′), which cover the superficial portion. The upper digitation, given off to the atlas, is united to the tendon common to the small complexus and splenius (Figs. 105, 9; 106, 9′, 10, 11). The inferior extremity of this portion of the muscle widens on the scapulo-humeral angle, which it envelops in becoming closely united to the anterior portion, terminating with it on the humerus. An aponeurosis, which is confounded with that of the trapezius, and sends off a septum into the interstice between the two portions of the long abductor of the arm, concurs to fix this extremity by spreading over the muscles of the arm.

Relations.—It is covered, near its mastoid insertion, by the parotid gland and the cervico-auricularis muscles; for the remainder of its extent, by the aponeurosis of the cuticularis colli, from which it is separated by a thin fascia continuous with that which extends over the trapezius. It covers the splenius, the small complexus, the oblique muscles of the head, subscapulo-hyoideus (to which it adheres intimately), the digastricus, long flexor of the head, the angularis, scalenus, small pectoral, supra- and infraspinatus, the long abductor of the arm, and the coraco-radialis.

[1] At first sight we might hesitate to admit that this muscle is formed of such varied and complicated elements as are enumerated above. Nevertheless, it is a scientific fact; and we will give a demonstration, as simple as it is clear, that such is the case—the idea we owe to J. F. Meckel. If we take the Dog, for example, and suppose it to be possessed of a clavicle extending from the anterior extremity of the sternum to the acromion; this clavicle would cut, transversely, the inferior portion of the mastoido-humeralis, which would thus be divided into two portions, a superior and an inferior. The first, extending from the clavicle to the mastoid process, on this side, and on the other to the mastoid crest, as well as to the cervical ligament, where it is confounded with the trapezius, would exactly represent the *clavicular portion* of the latter muscle, and the *cleido-mastoideus*. With respect to the inferior portion, it perfectly resembles, by its attachments, the *clavicular portion* of the deltoid. But, on the contrary, if we suppose Man deprived of a clavicle, the three muscular fasciculi indicated, in becoming confounded with each other, would form the mastoido-humeralis of the Dog, *minus* the posterior portion, or the trachelo-acromialis, which is not represented in Man.

Action.—When the superior is the fixed point, it carries the entire anterior limb forward. This muscle, therefore, plays a very important part in locomotion; as it is called into action when the animal raises the fore-limb in getting over the ground. If the fixed point of the muscle is the limb, it inclines the head and neck to one side.

3. *Sterno-maxillaris.* (Figs. 102, 10; 114, 4.)

Synonym.—The *sterno-mastoideus* of Man and a large number of the lower animals.

Form—Structure—Situation—Direction—Attachments.—A long narrow muscle, almost entirely fleshy, and terminated at its upper extremity by a flattened tendon; situated in front of the neck, beneath the cuticularis, and parallel to the anterior border of the superficial portion of the mastoido-humeralis, from which it is separated by a space that lodges the jugular vein; attached, inferiorly, to the cariniform cartilage of the sternum—*fixed insertion;* and superiorly—*movable insertion*—to the curved portion of the posterior border of the maxillary bone by its terminal tendon.

Relations.—The muscle is covered by the cuticularis colli, and the parotid gland. It covers the trachea, the subscapulo-hyoideus, sterno-hyoideus, sterno-thyroideus, and the maxillary gland. Its external border, parallel to the anterior border of the mastoido-humeralis, forms with it a longitudinal depression termed the *jugular furrow*, because it lodges the vein of that name. Its inner border is intimately united, in its lower third, to that of the opposite muscle.

Action.—It directly flexes the head, when acting in concert with its congener; but alone it turns it to one side. Lafosse and Rigot have wrongly considered this muscle as a depressor of the lower jaw. Bourgelat has correctly stated that it cannot move this jaw independently. (Percivall says that the pair will assist in opening the mouth; and Leyh asserts that when the mouth is closed, each muscle will act as a flexor to the head.)

4. *Sterno-hyoideus.*—5. *Sterno-thyroideus.* (Fig. 114, 6, 7.)

(*Synonym.*—The *sterno-thyro-hyoideus* of *Percivall.*)

Form—Structure—Situation—Attachments.—Small, ribbon-shaped, long, and slender muscles; digastric; situated in front of the trachea; confounded at their inferior extremity and united to those of the opposite side, so as to form a single fasciculus which is attached to the cariniform cartilage of the sternum—*fixed insertion;* isolated from each other above the tendon which makes them digastric, and terminating by their superior extremity—*movable insertion:* the first, on the inferior surface of the body of the hyoid bone in common with the subscapulo-hyoideus; the second, on the posterior border of the thyroid cartilage.

Relations.—Covered by the sterno-maxillaris and the cuticularis muscle, they cover the anterior face of the trachea.

Action.—Depressors of the hyoid bone and larynx.

6. *Omo-hyoideus or Subscapulo-hyoideus.* (Figs. 102, 11; 114, 5.)

Synonyms.—Hyoideus—*Bourgelat.* (*Subscapulo-hyoideus—Percivall.*)

Form—Structure—Situation—Direction.—This muscle forms a thin and wide band, almost entirely fleshy, oblique forwards and upwards, extending from the scapulo-humeral angle to the intermaxillary space, and applied to the side of the trachea, whose direction it slightly crosses.

Attachments.—It derives its fixed insertion from the inner surface of the subscapularis, by an aponeurosis which is detached from that covering the latter muscle. Its movable insertion is into the body of the hyoid bone, in becoming confounded with the sterno-hyoideus, and in being intimately united to the muscles of the opposite side.

Relations.—Outwardly, with the subscapularis, supraspinatus, small pectoral, mastoido-humeralis—which closely adheres to it, the jugular vein, the sterno-maxillaris, and the cuticularis. Inwardly, with the scalenus, the large anterior straight muscle of the head, the main trunk of the carotid artery and the nerves accompanying it, the trachea, thyroid gland, and the inferior face of the larynx. The jugular vein is entirely separated from the carotid artery by this muscle in the upper half of the neck.

Action.—It is a depressor of the hyoid bone and its appendages.

7. *Great Anterior Straight Muscle of the Head.* (Figs. 104 and 105, 10; 106, 13.)

Synonyms.—Long flexor of the head—*Bourgelat.* Trachelo-suboccipitalis—*Girard.* (*Rectus capitis anticis major—Percivall. Trachelo-occipitalis—Leyh.*)

Form—Structure—Situation—Direction.—A long, flat muscle, fasciculated in its posterior half, terminated in a tendinous cone at its anterior extremity, and passing along the first cervical vertebræ in front.

Attachments.—Behind, to the transverse processes of the third, fourth, and fifth cervical vertebræ by as many fleshy digitations, the most inferior of which are the longest—*fixed insertion.* In front, into the imprints on the body of the sphenoid bone and the basilar process, by its terminal tendon—*movable insertion.*

Relations.—Outwardly, with the mastoido-humeralis, the subscapulo-hyoideus, and the small anterior straight muscle. Inwardly, with the long muscle of the neck and the muscle of the opposite side. In front, with the common carotid, the nerves accompanying this artery, and the guttural pouch, which lines it near its movable insertion. Behind, with the great oblique muscle of the head and the occipito-atloid articulation.

Action.—It either directly flexes the head or carries it to one side, according as it acts alone or with its fellow of the opposite side.

8. *Small Anterior Straight Muscle of the Head.*

Synonyms.—Flexor capitis brevis—*Bourgelat.* Atloido-suboccipitalis—*Girard.* (*Rectus capitis anticus minor—Percivall. Atloido-occipitalis inferior—Leyh.*)

A small, entirely fleshy, prismatic fasciculus, lying to the external side of the preceding muscle; attached, posteriorly, to the inferior face of the body of the atlas; in front, to the body of the sphenoid bone and the basilar process, beside the great anterior straight muscle. It is covered by the guttural pouch, and covers the occipito-atloid articulation. It concurs in flexing the head.

9. *Small Lateral Straight Muscle.*

Synonyms.—Flexor capitis parvus—*Bourgelat.* Atloido-styloideus—*Girard.* (*Obliquus capitis anticus—Percivall.* The *rectus capitis lateralis* of Man.)

Yet smaller than the preceding, and prismatic and entirely fleshy, like it this muscle lies on the side of the occipito-atloid articulation; it is attached to the atlas, outside the small anterior straight muscle—*fixed insertion;* and to the inner face of the styloid process of the occipital bone—*movable insertion.* It is the congener of the two anterior straight muscles of the head.

10. *Scalenus.* (Figs. 104, 105, 106.)

Synonyms.—Costo-tracheleus—*Girard.* (*Scalenus anticus* and *posticus* of Man.)

Situation—Direction—Composition.—Deeply situated at the inferior part of the neck, in an oblique direction downwards and backwards, this muscle comprises two portions of unequal dimensions, placed one above another.

Form—Structure—Attachments.—A. The *superior portion* (*scalenus posticus* of Man), the smallest, is composed of three or four fleshy fasciculi, attached by their extremities to the transverse processes of the last three or four cervical vertebræ. The last terminates at the superior extremity of the first rib.

B. The *inferior* (*scalenus anticus* of Man), the most considerable, is flattened on both sides, thick and wide posteriorly, thin and narrow anteriorly, and is composed almost entirely of fleshy fibres which are longest as they are inferior. It is attached: 1, To the transverse processes of the last four cervical vertebræ by short fasciculi scarcely distinct from one another, the first of which is crossed by the last digitation of the great anterior straight muscle; 2, To the anterior border and external face of the first rib, where all its fibres end.

Relations.—The scalenus responds: by its external face, to the sub-scapulo-hyoideus, mastoido-humeralis, and the sterno-prescapularis; by its internal face, to the longus colli, trachea, common carotid artery and its accompanying nerves, and—on the left side only—to the œsophagus; by its inferior border, to the jugular vein. The two portions of the scalenus are separated from one another, in front of the first rib, by an interspace traversed by the nerves of the brachial plexus.

Action.—When the first rib is the fixed point, this muscle either directly flexes the neck or inclines it to one side. When the neck is the fixed point, it draws forward the first rib and fixes it in this position during the dilatation of the chest, in order to aid the inspiratory action of the external intercostal muscles.

11. *Long Muscle of the Neck.*

Synonyms.—Flexor longus colli—*Bourgelat.* Subdorso-atloideus—*Girard.* (*Longus colli*—*Percivall.* *Dorso-atloideus*—*Leyh.*)

Situation—Composition.—A single and considerable muscle, immediately covering the inferior aspect of all the cervical and the first six dorsal vertebræ, and composed of two lateral portions which are united on the median line, and constitute, in certain animals, two distinct muscles.

Structure—Attachments.—Each lateral portion of the longus colli is composed of a succession of very tendinous fasciculi. The most posterior of these is attached to the inferior face of the bodies of the first six dorsal vertebræ, and proceeds directly forward to reach the inferior tubercle of the sixth cervical vertebra, into which it is inserted by a strong tendon. The other fasciculi, less considerable, and confounded outwardly with the inter-transversales of the neck, are carried from one cervical vertebra to another, and are directed forwards, upwards, and inwards, in converging towards those of the opposite side. They are attached successively: outwardly, to the transverse processes of the last six cervical vertebræ; inwardly, to the inferior ridge on the bodies of the first six. The most anterior fasciculus passes to the inferior tubercle of the atlas, into which it is inserted by a

tendon common to it and the fasciculus of the opposite side, and which receives the most superficial fibres of the three or four preceding fasciculi.

Relations.—Above and behind, with the vertebræ which it covers, as well as their intervertebral discs; below and in front, with the trachea and œsophagus, and the vessels and nerves accompanying these two tubes; on the sides, with the great anterior straight and the scalenus muscles in its cervical portion, and in its intrathoracic portion, with the pleuræ, and important vessels and nerves.

Action.—It flexes the whole neck, and the cervical vertebræ on one another.

DIFFERENTIAL CHARACTERS OF THE MUSCLES OF THE CERVICAL REGION IN OTHER THAN SOLIPED ANIMALS.

A. Superior Cervical Region.

1. Ruminants.—In the *Ox*, the *angularis* arises by six digitations from all the cervical vertebræ except the first; the *splenius* is little developed, and is not attached to either the third or fourth cervical vertebra.

2. Pig.—The muscles of the superior cervical region in this animal are generally very developed. The *rhomboideus* is divided into two fleshy bodies, one of which proceeds to the occipital protuberance, and the other to the rudimentary cervical ligament and the first dorsal vertebræ. The *angularis* is attached, as in Ruminants, to the six cervical vertebræ; sometimes it even shows a digitation that descends to the atlas. The *splenius* only terminates anteriorly by three fleshy bodies; but they are voluminous, and are inserted, one into the atlas, another into the mastoid crest, and the third into the occipital protuberance. In the *great complexus*, the two portions are completely separated from each other, except at their upper extremity, by the interspace lodging the superior cervical artery. The aponeurosis attaching the muscle to the spinous processes of the first dorsal vertebræ is not confounded with that of the splenius or the small anterior serrated respiratory muscle. The atloidean fleshy body of the *small complexus* is scarcely distinct from the superior branch of the ilio-spinalis and the intertransversales. Lastly, it is difficult to distinguish the *small posterior straight* muscle from the deep fasciculus of the great straight muscle.

3. Carnivora.—In these animals the muscles of the superior cervical region are nearly all voluminous, as in the Pig. The *rhomboideus* is bifid at its origin, and its anterior branch arises from the mastoid crest. The *angularis* is also attached to the last six cervical vertebræ. Very thick and broad, the *splenius* only passes to the atlas and mastoid crest. The *oblique* and *straight posterior muscles of the head* are also remarkably thick.

B. Inferior Cervical or Trachelian Region.

1. Ruminants—In the *Ox* and *Sheep*, the disposition of the *cuticularis colli* offers a very considerable difference from that observed in Solipeds. The fleshy portion is absent, or appears to be absent, in the cervical region; the anterior muscles of the neck are only covered by a thin fascia developed on the sides of the neck. When this fascia reaches the face, it becomes continuous with the fleshy fibres; a fasciculus of these fibres comports itself as in the Horse, and goes to join the alveo-labialis; another is intercrossed in the maxillary space by the analogous fasciculus of the opposite side.

The *cervical cuticularis* muscle of the *Ox* is also distinguished by an extremely remarkable peculiarity which it is necessary to allude to here:—The fleshy cervical band, altogether absent in the Sheep, is not so in the Ox; we have found it forming, beneath the above-mentioned aponeurotic fascia, the long, thick strip which has been described by veterinary anatomists as the analogue of the sterno-maxillaris in the Horse. This strip is attached, like the muscular band which represents it in Solipeds, to the anterior point of the sternum. But its fibres, instead of being spread outwards over the mastoido-humeralis, ascend, perfectly isolated from that muscle, to the posterior border of the maxillaris. There it terminates (Fig. 112, 18) by a flattened tendon which, after reaching the anterior border of the masseter, is confounded with the aponeurosis of that muscle, and sends some fibrous bands over the muscles of the face.

The two portions of the *mastoido-humeralis* of Ruminants are better defined, and more oblique on one another, than in the Horse. The *superficial portion* receives on its inner

face a small, bright-red, funicular fasciculus, which proceeds from the cartilage of the first rib, and which Meckel is inclined to consider as the vestige of the subclavius. It is divided, superiorly, into two branches: one, the *clavicular portion of the trapezius*, very wide, passes to the mastoid process, the curved line of the occipital bone, and to the cervical ligament, in becoming confounded with the trapezium (Fig. 112, 22); the other, the *cleido-mastoideus*, terminates in a tendon that joins the sterno-suboccipitalis, and is inserted into the basilar process, after receiving the fibres of the long flexor of the head (Fig. 112, 21). The upper extremity of the *deep portion* of the mastoido-humeralis is inserted into the atlas by a flattened tendon alone, which is quite distinct from the atloid insertions of the splenius and the small complexus.

In the *Sheep* and *Goat*, the costal band that joins the superficial portion is absent. The latter is divided at its inferior extremity into two branches, between which pass the biceps. The upper branch passes to the epitrochlea.

The *sterno-maxillary* muscle, instead of being inserted into the inferior maxilla, is united to the suboccipital branch of the mastoido-humeralis, to be attached to the basilar process. At another time we will discuss the determination of this muscle, and that of the fleshy band here considered as belonging to the first (*see* Spinal Nerve).

The *sterno-hyoid* and *sterno-thyroid* muscles are thicker than in the Horse, and not digastric.

The *subscapulo-hyoideus* of Ruminants is but slightly developed, and might be termed the *trachelo-hyoideus;* as it proceeds to the transverse process of the third or fourth cervical vertebra. In its passage beneath the basilar branch of the mastoido-humeralis and sterno-suboccipitalis (sterno-maxillaris), it contracts adhesions with the fibres of these two muscles.

The *great anterior straight muscle of the head* descends to the sixth cervical vertebra. Its cervical insertions are covered by a very strong muscular fasciculus, which is annexed to it. Like it, this fasciculus leaves the sixth cervical vertebra, and is attached to the transverse processes of the four vertebræ preceding the last, by becoming confounded with the intertransversales, and finally terminating at the tracheal process of the atlas by fleshy and aponeurotic fibres. This muscular fasciculus singularly strengthens the neck when it is inclined to one side. In consequence of its attachments, it might be named the *trachelo-atloideus* (Fig. 112, 24).

Lastly, in Ruminants the *superior scalenus* is very developed, being a flattened band which, gradually expanding, is prolonged to the surface of the serratus magnus.

2. Pig.—In this animal, the *cuticularis colli* is in two portions: an inferior, which comes from the point of the sternum; and a superior, from the external scapular region. They unite in front, and are prolonged in common on the muscles of the face, contracting adhesions with the external aspect of the body and the branches of the maxillary bone.

The other muscles of the inferior cervical region are not unlike those of Ruminants.

Of the two portions of the *mastoido-humeralis*, the superficial is bifid at its superior extremity. The posterior branch, the *clavicular portion of the trapezius*, is attached to the side of the occipital protuberance; the anterior branch, the *cleido-mastoideus*, goes beneath the external auditory hiatus, to the crest that replaces the mastoid process; the deep portion is attached above to the atlas only.

In the Pig, the *sterno-maxillaris* exactly represents the sterno-mastoideus, as its tendon passes directly to the mastoid process.

The *sterno-thyroideus* is double; the supplementary branch going to the inferior face of the thyroideus.

The *subscapulo-hyoideus* and *great anterior straight muscle of the head*, resemble those of the Ox. The *small straight lateral* muscle is scarcely distinct from the small oblique. The *superior scalenus* extends to the third rib. The two lateral portions of the *long muscle of the neck* are separate, and form two distinct muscles.

3. Carnivora.—In the *Dog*, each *cuticularis* is doubled into two portions, as in the Pig. The fibres from the breast are directed in a diverging manner over the face, the submaxillary space, and the parotid gland, where they form the parotido-auricularis muscle. The portion coming from the external scapular region is thicker and wider; it covers the lateral parts of the neck, the parotid gland, the parotido-auricularis, passes above the preceding, and terminates on the face and in the submaxillary space, where its fibres join those of the opposite side.

The *mastoido-humeralis* comports itself somewhat as in Ruminants and the Pig. The *superficial portion* is bifid superiorly; one of its branches is fixed into the mastoid process—the *cleido-mastoideus;* the other into the mastoid crest and cervical ligament, in uniting by aponeurosis with the trapezius—the *clavicular portion of the trapezius*. The deep portion passes from the atlas to the scapular spine.

The tendon of the *sterno-maxillaris* goes to the mastoid process. The *sterno-hyoideus* and *thyroideus* are thick and not digastric, and commence from the cartilage of the first rib.

The Carnivora have no *subscapulo-hyoideus;* but they possess a very long *scalenus*, which passes to the eighth rib, and a *long muscle of the neck*, which tends to become divided into two lateral portions.

SPINAL REGION OF THE BACK AND LOINS.

This offers for study eight pairs of muscles, nearly all of which have their insertions extended over the dorso-lumbar spine, and are disposed in several layers on each side of this long multifidious crest. These muscles are, enumerating them according to their order of superposition: 1, The *trapezius;* 2, *Great dorsal;* 3, *Small anterior respiratory serratus;* 4, *Small posterior serratus;* 5, *Ilio-spinalis* (*longissimus dorsi*); 6, *Common intercostal;* 7, *Transversales of the back and loins* (*semispinalis dorsi* and *lumborum*).

Preparation.—1. Place the animal in the second position. 2. Remove the skin with the panniculus and the mass of olecranian muscles, to show, in a first operation, the trapezius and great dorsal muscles (Fig. 102). 3. In a second operation, remove the entire fore-limb, with the great dorsal muscle, whose mode of termination may then be studied; then prepare the two small serrated muscles. 4. Remove these two muscles, as well as the angularis of the scapula and the splenius, to expose the common intercostal and ilio-spinalis (Fig. 106). The superior branch of the latter remaining covered by the great complexus, excise this muscle, leaving only its insertions into the transverse processes of the dorsal vertebræ, to show how they are fixed between the two branches of the ilio-spinalis (longissimus dorsi). 5. Dissect the transversales (semispinalis) by removing the ilio-spinalis and the internal angle of the ilium.

1. *Trapezius.* (Fig. 102, 1, 3.)

Synonym.—Dorso- and cervico-acromialis—*Girard.*

Situation—Form—Structure.—This is a superficial membranous muscle, situated on the sides of the neck and withers. Its shape is that of a triangle whose base is upwards. It is aponeurotic at its upper border and in its centre, which allows it to be distinguished, especially in emaciated subjects, into a cervical and a dorsal portion. The fleshy fibres of the first are directed downwards and backwards; those of the second are oblique forwards.

Attachments.—By its superior aponeurosis, it is fixed to the cervical cord and to the summits of the [redacted] processes of the first dorsal vertebræ, where it adheres to the external face of the great dorsal muscle. By its central aponeurosis and that of its summit, it is attached to the tuberosity of the [redacted] spine and the external scapular aponeurosis.

Relations.—This muscle is covered by two aponeurotic planes, whose fibres cross its own at a right angle. Inwardly, it responds to the rhomboideus, splenius, angularis, sterno-prescapularis, the supra- and infra-spinatus, and the great dorsal.

Action.—It raises the shoulder, and carries it forward or backward, according as one or other of its muscular portions contract.

2. *Great Dorsal.* (Fig. 102, 2.)

Synonyms.—Dorso-humeralis—*Girard.* (*Latissimus dorsi—Percivall.*)

Form—Situation—Structure—Attachments.—A very broad triangular muscle, extended over the loins, back, and side of the thorax, and formed of an aponeurotic and a muscular portion.

The aponeurosis is attached, by its superior border, to the summits

of the spinous processes of all the lumbar and the last fourteen or fifteen dorsal vertebræ—*fixed insertion of the muscle.*

The fibres of the fleshy portion are detached from the inferior border of the aponeurosis, at the twelth or thirteenth ribs, to the cartilage of the scapula. They are directed forwards and downwards, and all converge into a flat tendon which is inserted into the internal tuberosity on the body of the humerus—*movable insertion.* This tendon is remarkable, at its termination, for being placed at the external face of the teres magnus or adductor of the arm, from which it receives fibres, and between it and the long extensor of the fore-arm; it then turns inwards, on the inferior extremity of the first, in such a manner that this extremity is comprised

Fig. 105.

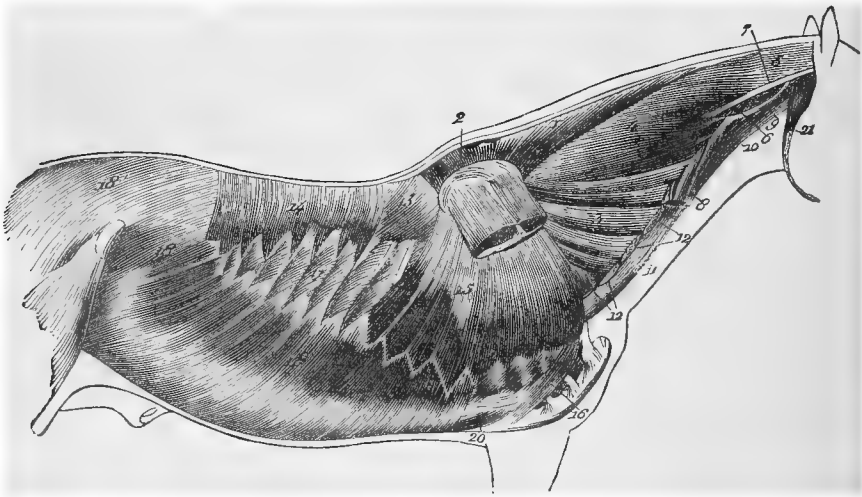

MUSCLES OF THE SPINAL REGION OF THE NECK, BACK, AND LOINS, MIDDLE LAYER; AND OF THE COSTAL AND ABDOMINAL REGION, SUPERFICIAL LAYER.

1, 2, Rhomboideus; 3, Angular muscle of the scapula; 4, Splenius; 5, Its mastoid aponeurosis; 6, Mastoid portion of the small complexus; 7, Its tendon; 8, Cervical insertions of the mastoido-humeralis; 9, Atloidean tendon common to the mastoido-humeralis, splenius, and small complexus; 10, Great anterior straight muscle of the head; 11, Inferior scalenus; 12, Superior scalenus; 13, Small anterior serratus; 14, Posterior ditto; 15, Great serratus; 16, Transverse muscle of the ribs; 17, One of the external intercostals; 18, Great oblique muscle of the abdomen; 20, Straight muscle of the abdomen; 21, Stylo-maxillary portion of the digastric muscle.

within a duplicature of the membranous tendon of the latissimus dorsi (Fig. 121).

Relations.—This muscle is covered by the skin, panniculus carnosus, dorsal portion of the trapezius, and the mass of olecranian muscles. It covers the infraspinatus; the cartilage of the scapula; the rhomboideus; the small anterior and posterior serrated muscles, whose aponeurosis is directly joined to its own; the ilio-spinalis; the principal gluteal; a portion of the external surface of the last ribs, to which its aponeurosis strongly adheres; as well as the corresponding external intercostals, and the great serrated muscle. Between the last rib and the external angle of the ilium,

the aponeurosis unites with the small oblique, but more particularly with the great oblique, muscle of the abdomen; it is prolonged, posteriorly, on the muscles of the croup to constitute the gluteal aponeurosis.

Action.—It carries the arm backwards and upwards; and it may, according to a great number of authors, serve as an auxiliary in inspiration when its fixed point is the humerus. According to others, but in whose opinion we do not share, it is an expiratory muscle.

3. *Small Anterior Serrated Muscle.* (Fig. 105, 13.)

Synonyms.—Dorso-costalis—*Girard.* Anterior portion of the long serrated muscle —*Bourgelat.* (*Superficialis costarum—Percivall.* *Anterior serrated muscle* of Leyh. *Serratus posticus superior* of Man.)

Form—Situation.—This is a flat, thin, and quadrilateral muscle, situated beneath the rhomboideus and the great dorsal muscle.

Structure.—It is composed of an aponeurotic and a fleshy portion. The first is confounded, in front, with the aponeurosis of the splenius, and is insinuated, behind, underneath that of the posterior small serratus, with which it soon becomes united. Its inferior border gives origin to the muscular portion, a little above the interval which separates the common intercostal and the ilio-spinalis. Narrow and elongated antero-posteriorly, the muscular portion is composed of bright-red fibres directed obliquely backwards and downwards, and which form at the inferior border irregular, and sometimes but faintly marked, festoons.

Attachments.—It takes its fixed insertion, by the superior border of its aponeurosis, from the summits of the anterior dorsal spines, with the exception of the first, to the thirteenth inclusive. The movable insertion takes place on the external surface and anterior border of the nine ribs succeeding the fourth, by means of the digitations of the fleshy portion. This muscle is also attached to the external surface of these ribs by a short fibrous band, which is detached from the internal face of the aponeurosis, near its inferior border, and penetrates the space between the ilio-spinalis and the common intercostal muscle.

Relations.—Outwards, with the rhomboideus, great serratus, great dorsal, and the posterior small serratus, which covers its three last festoons; inwards, with the ilio-spinalis, the common intercostal, and the external intercostals.

Action.—This is an inspiratory muscle, and it also serves as a check to the deep spinal muscles.

4. *Small Posterior Serrated Muscle.* (Fig 105, 14.)

Synonyms.—Lumbo-costalis—*Girard.* Posterior portion of the long serrated muscle —*Bourgelat.* (*Superficialis costarum—Percivall.* The *posterior serrated* muscle of Leyh. The *serratus posticus inferior* of Man.)

Situation.—Situated behind the preceding, which it follows, and presenting the same form and arrangement, this muscle also offers the following particular features for study:

1. *Structure.*—Its muscular portion, which is thicker and of a deep-red colour, is cut into nine well-defined digitations.[1] The fibres which compose it run in an almost vertical direction.

2. *Attachments.*—Its aponeurosis, closely united to that of the great dorsal muscle, which covers it, is attached to the spinous processes of the dorsal

[1] It frequently happens that only eight digitations are found.

vertebræ after the tenth, and to some lumbar vertebræ. Its digitations are fixed to the posterior border and external face of the nine last ribs.

3. *Relations.*—Outwards, with the great dorsal; inwards, with the small anterior serratus, the ilio-spinalis, common intercostal, and the external intercostals. Some of its posterior digitations are partly concealed by those of the great oblique muscle of the abdomen; the last, indeed, is entirely covered by that muscle.

4. *Action.*—This is an expiratory muscle, in consequence of its drawing the ribs backwards and upwards.

5. *The Ilio-spinalis Muscle.* (Fig. 106.)

Synonyms.—It represents the long dorsal, short transversal, and long spinous of Bourgelat. Cuvier and others have described it as consisting generally, in mammalia, of five particular muscles, designated as longissimus dorsi, transversalis cervicis, semispinalis dorsi, and semispinalis colli. It corresponds to the longissimus dorsi, and transversalis cervicis of Man.

(Percivall designates this important muscle the *longissimus-dorsi*—the name given to its analogue in Man. By Girard, Leyh, and Chauveau, it is styled the *ilio-spinalis.*)

Extent—Situation.—This, the most powerful and complex of all the muscles in the body, extends along the dorso-lumbar spine, above the costal arches, from the anterior border of the ilium to the middle of the cervical stalk.

Form.—It is elongated from before to behind, and flattened above and below in its posterior half, which represents the *common mass* in Man; this mass is prismatic in form, thick inwards, and thin outwards. Anteriorly, it is flat on both sides, and bifurcates into two voluminous branches, a superior and inferior, between which pass the insertions of the complexus to be fixed into the transverse processes of the first dorsal vertebræ.

Attachments.—1, Upon the lumbar border, the external angle and internal surface of the ilium, the sacro-iliac ligament, and the sacrum; 2, To the spinous processes of all the lumbar and dorsal, and last four cervical vertebræ; 3, To the articular tubercles of the lumbar vertebræ and the transverse processes of all the dorsal, and the last four cervical vertebræ; 4, To the costiform processes of the lumbar vertebræ, and the external surface of the fifteen or sixteen last ribs.

Structure.—If this muscle is examined posteriorly, in the part which forms the *common mass*, it will be found to be composed of very compact fleshy fibres, covered in common by a thick aponeurosis. These fibres commence at the posterior extremity of the muscle, and all proceed forward, stopping to take successive insertions on the various bony eminences in its track, and forming three different orders of fasciculi, which are more or less tendinous at their anterior or terminal extremity. These fasciculi are *internal* and *superficial*, *internal* and *deep*, and *external.*

The *internal* and *superficial*, or *spinal* fasciculi, pass to the summits of the spinous processes already noticed when speaking of the attachments. These fasciculi are little, if at all distinct posteriorly; but they become more so anteriorly. About the sixth dorsal vertebra, they separate from the other fasciculi to form the superior branch of the muscle (Fig. 106, 3).

The *internal* and *profound*, or *transverse* fasciculi, are those which attach the muscle to the articular tubercles of the lumbar vertebræ and transverse processes of the back and neck. They are well detached from each other, even posteriorly, and are very tendinous. Anteriorly, they pass into the inferior branch of the ilio-spinalis, which they, in common with

Fig. 106.

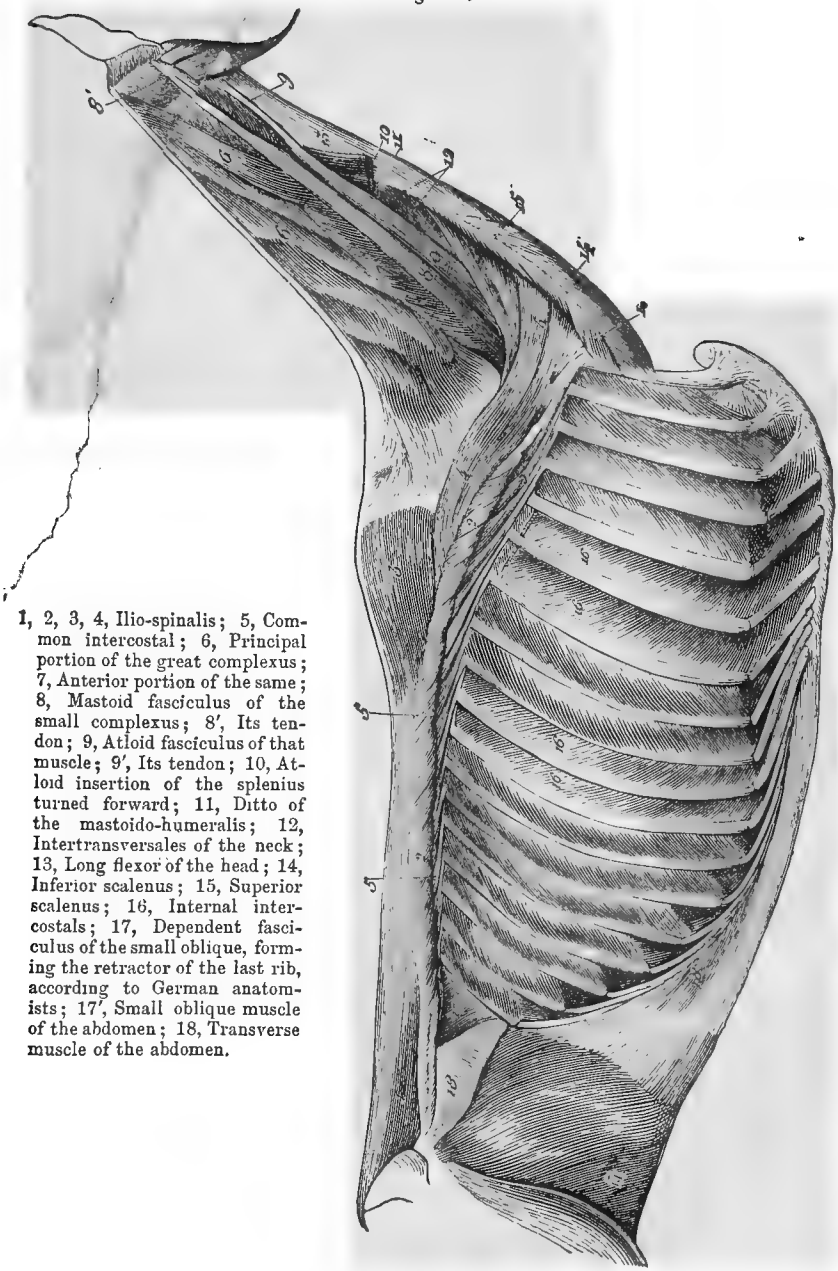

1, 2, 3, 4, Ilio-spinalis; 5, Common intercostal; 6, Principal portion of the great complexus; 7, Anterior portion of the same; 8, Mastoid fasciculus of the small complexus; 8′, Its tendon; 9, Atloid fasciculus of that muscle; 9′, Its tendon; 10, Atloid insertion of the splenius turned forward; 11, Ditto of the mastoido-humeralis; 12, Intertransversales of the neck; 13, Long flexor of the head; 14, Inferior scalenus; 15, Superior scalenus; 16, Internal intercostals; 17, Dependent fasciculus of the small oblique, forming the retractor of the last rib, according to German anatomists; 17′, Small oblique muscle of the abdomen; 18, Transverse muscle of the abdomen.

DEEP MUSCLES OF THE SPINAL REGION OF THE NECK, BACK, AND LOINS, AND THE COSTAL AND INFERIOR ABDOMINAL REGIONS.

the external fasciculi, go to form. From profound, they now become superficial; and they are seen springing up between the others, which appear to separate to allow them to pass (Fig. 106, 4, 4).

The *external*, or *costal* fasciculi, turn a little outwards to reach the ribs and costiform processes of the lumbar region; they are not very apparent in this direction (Fig 106, 2, 2).

It will be easily understood that all these fasciculi do not come from the common mass, which would be expended long before its termination at the neck, in consequence of the successive emissions of the fasciculi composing it. To prevent this expenditure, there are continually added to it numerous reinforcing bundles of fibres, which arise either from its aponeurotic envelope, or from the bones on which the primary fasciculi terminate, and comport themselves absolutely like these, which they are charged to continue to the neck.

Relations.—The ilio-spinalis is covered by the pyramidal point of the principal gluteal muscle, which it receives in a particular excavation, and by the aponeurosis of the great dorsal and the small serrated muscles. It covers the intertransversales of the lumbar region, the transversales of the back and loins, the supercostals (*levatores costarum*) and the external intercostals. Outwards, it is bordered by the common intercostal.

The superior branch is covered by the great complexus and the transversales colli. Inwardly, it responds to the cervical ligament and the analogous branch of the opposite muscle.

The inferior branch responds, outwardly, to the angularis of the scapula it covers some intertransversales colli, and the aponeurotic digitations which attach the great complexus to the transverse processes of the first dorsal vertebræ. From these digitations it even detaches a number of muscular fasciculi, which go to strengthen this branch of the ilio-spinalis.

Action.—It is a powerful extensor of the vertebral column, which, when it acts singly, it inclines to one side. It may also take part in expiration.

6. *Common Intercostal Muscle.* (Fig. 106, 5.)

Synonyms.—Trachelo-costalis—*Girard.* The *sacro-lumbalis* of Man. (*Transversalis costarum—Percivall.*)

Form—Situation.—A long, narrow, and thin muscle—particularly at its extremities—situated along the external border of the preceding muscle, with which it is confounded behind the last rib.

Structure—Attachments.—This muscle, whose structure has been complicated at will by so many anatomists, is yet extremely simple. It is formed of a series of fasciculi, directed obliquely forwards, downwards, and outwards, tendinous at their extremities, and originating and terminating successively on the external surface of the ribs. The most posterior leave the external border and inferior face of the common mass. The tendinous digitation of the anterior fasciculus is inserted into the transverse process of the last cervical vertebra, in common with the inferior branch of the ilio-spinalis.

Relations.—Outwards, with the great and small serratus; inwards, with the external intercostals.

Action.—It depresses the ribs, and may extend the dorsal portion of the spine.

7. *Transverse Spinous Muscle of the Back and Loins.* (Fig. 106, 3.)

Synonyms.—Transverso-spinous—*Girard. Dorso-lumbar portion* of the semispinalis of Man. (The *spinalis* and *semispinalis dorsi*—*Percivall.*)

Situation—Extent.—This is a very long muscle, directly applied to the supersacral and dorso-lumbar spine, and continuous, in front, with the transversales colli; these two muscles, therefore, measure nearly the whole length of the spine.

Structure.—It is formed of an assemblage of short fasciculi, which are flattened on both sides, tendinous at their extremities, directed obliquely forwards and downwards, and a little inwards, thus crossing at a right angle the spinous processes they cover.

Attachments.—These fasciculi are attached, below, to the lateral lip of the sacrum, the articular tubercles of the lumbar vertebræ, and the transverse processes of the dorsal vertebræ—*origin.* They are fixed, above, to the spinous processes of the sacral, lumbar, and dorsal vertebræ, and into that of the last cervical vertebra—*termination.* It is to be remarked that they do not attain the summits of these spinous processes in the first half of the dorsal region.

Relations.—Outwards, with the lateral sacro-coccygeal and ilio-spinalis muscles, which are confounded with it near its posterior extremity; inwards, with the sacral spine and the spines of the lumbar and dorsal vertebræ, and with the interspinous ligaments of these three regions.

Action.—It is an extensor of the spine.

DIFFERENTIAL CHARACTERS OF THE MUSCLES IN THE SPINAL REGION OF THE BACK AND LOINS IN OTHER THAN SOLIPED ANIMALS.

1. Ruminants.—In the *Ox*, *Sheep*, and *Goat*, the *trapezius* is thick and very broad. The *anterior small serrated muscle* is inserted, by its last digitation, into the ninth rib. The *posterior serrated* is fixed into the four last ribs.

2. Pig.—Its *trapezius* is well developed. The *great dorsal* is voluminous, and is attached to the surface of the ribs, which it covers by digitations from its fleshy portion. It is fixed near the small trochanter to the lip of the bicipital groove. The inferior branch of the *ilio-spinalis* of this animal is easily divided into two portions, traces of which are found in the Horse: one is formed by the costal fasciculi, the other by the transversal fasciculi. The latter constitutes the muscle to which Bourgelat has given the name of short transversal.

3. Carnivora.—Several of the spinal muscles in the *Dog* resemble those of the Pig; such are the *trapezium*, the *great dorsal*, and the *ilio-spinalis.* In animals of this group, it is remarked that the anterior serrated is very thick and very developed, and that it is attached to the eight ribs succeeding the second by as many well-marked festoons. The *posterior* has only three digitations, which are attached to the three last ribs. The *common intercostal* exactly resembles the sacro-lumbalis of Man; behind the last rib, it constitutes a thick fleshy body, separated by a fissure from the ilio-spinalis, with which it is attached to the coxa. Lastly, the *transverse spinal muscle of the back and loins* is very strong in the lumbar region, and is prolonged on the coccygeal vertebræ.

(According to Leyh, the interspinales muscles are absent in the Horse and Ruminants; they are found in the Pig between the spinous processes of the dorsal and lumbar vertebræ, and in Carnivora between the spinous processes of the cervical vertebræ.)

COMPARISON OF THE MUSCLES OF THE BACK AND NECK IN MAN WITH THE ANALOGOUS MUSCLES IN THE DOMESTICATED ANIMALS.

It is usual, in human anatomy, to describe by the name of muscles of the back and neck those which correspond to the superior cervical region, and those of the spinal region of the back and loins of the domesticated animals. The muscles of the inferior cervical region are described in Man as muscles of the neck, with the hyoid muscles and the scalenus.

A. Muscles of the Back and Cervix.

In the *trapezius* of Man, a cervical and a dorsal portion can no longer be distinguished. Above, it is attached to the superior occipital curved line; below, it is fixed to the external third of the upper border of the clavicle, and to the acromion and scapular spine.

Fig. 107.

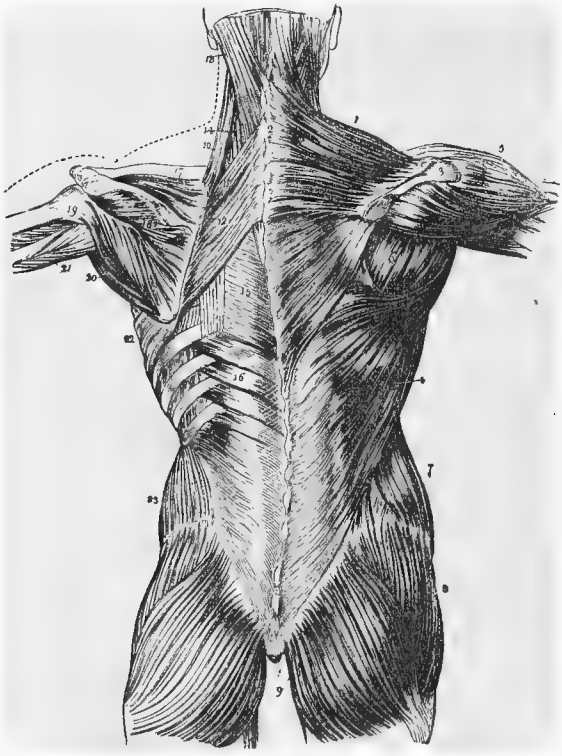

FIRST, SECOND, AND PART OF THIRD LAYER OF MUSCLES OF THE BACK OF MAN; THE FIRST LAYER OCCUPIES THE RIGHT, THE SECOND THE LEFT SIDE.

1, Trapezius; 2, Tendinous portion, forming, with a corresponding part of the opposite muscle, the tendinous ellipse on the back of the neck; 3, Acromion process and spine of scapula; 4, Latissimus dorsi; 5, Deltoid; 6, Muscles of dorsum of the scapula: infraspinatus, teres minor, and teres major; 7, Obliquus externus; 8, Gluteus medius; 9, Glutei maximi; 10, Levator anguli scapulæ; 11, Rhomboideus minor; 12, Rhomboideus major; 13, Splenius capitis, overlying the splenius, above; 14, Splenius colli, partially seen: the common origin of the splenius is attached to the spinous processes below the origin of the rhomboideus major; 15, Vertebral aponeurosis; 16, Serratus posticus inferior; 17, Supraspinatus; 18, Infraspinatus; 19, Teres minor; 20, Teres major; 21, Long head of triceps, passing between teres minor and maior to the arm; 22, Serratus magnus, proceeding forwards from its origin at the base of the scapula; 23, Obliquus internus abdominis.

The fibres of the trapezius which are fixed into the clavicle, represent a portion of the mastoido-humeralis of quadrupeds.

The *great dorsal* resembles that of the Dog and Pig, its fleshy portion being very developed; it is attached to the external face of the four last ribs by muscular digitations, and terminates on the border of the bicipital groove.

The *rhomboideus* is bifid, as in the smaller quadrupeds. Less developed than in these animals, the *angularis* is only fixed in front to the four first cervical vertebræ.

In Man, the *splenius* is large, but by its insertions it resembles that of Solipeds. The *great complexus*, thick and broad above, is incompletely divided into two fleshy bodies, which are attached, superiorly, to the sides of the external occipital crest. The *small complexus* is not fixed into the axis and atlas, its superior extremity passing directly to the mastoid process.

There is nothing particular to note regarding the *straight posterior* and *oblique muscles of the head;* the differences they offer in their form are allied to the conformation of the bones in this region.

Of the two *small serrated* muscles, that which corresponds to the anterior serrated of animals rises very high; for it is attached by an aponeurosis to the spinous processes of the three first dorsal vertebræ, the seventh cervical, and the cervical ligament.

There are found in Man, lying along the vertebral furrows, several muscles which represent the *ilio-spinalis* and the *common intercostal* of Solipeds. Thus the *common mass* covering the lumbar vertebræ behind, is prolonged by two series of fleshy and tendinous fasciculi: one forms the *sacro-lumbalis*, which resembles the *common intercostal* of animals; the other, the *long dorsal*, represents the inferior branch of the ilio-spinalis. The superior branch of the latter is found in the *transversalis colli.*

Lastly, there are also seen in Man a *transverse spinal* and *intertransverse muscles*, which correspond: the first, to the *transverse spinous of the back and loins* and *transverse spinous of the neck;* the second, to the *intertransversales of the loins* of the domesticated species.

B. Muscles of the Neck.

The *mastoido-humeralis* is not present in Man, being peculiar to quadrupeds; but we should see a portion of its fasciculi in the *cleido-mastoideus muscle*, and in the *clavicular portions of the trapezius* and *deltoid.*

The *sterno-mastoideus* corresponds to the *sterno-maxillaris* of animals; as in the Dog, it is inserted into the external face of the mastoid process and the external two-thirds of the superior occipital curved line. Below, it commences by two fasciculi—one from the sternum, the other from the clavicle. We have already alluded to this clavicular fasciculus.

The *sterno-hyoideus* and *sterno-thyroideus* are large and well developed, resembling in their disposition those of the smaller animals. It is to be noted that the *sterno-hyoideus* leaves the sternum, the first costal cartilage, and the internal extremity of the clavicle. The *scapulo-hyoideus* is digastric. The *anterior great straight muscle of the head* is attached to four cervical vertebræ, as in Ruminants and the Pig. The *anterior small straight*, the *lateral small straight*, and the *long muscle of the neck*, comport themselves as in the smaller animals. The *anterior scalenus* is very developed, for it is attached to the six last cervical vertebræ.

SUBLUMBAR, OR INFERIOR LUMBAR REGION.

The muscles of this region are deeply situated at the inferior face of the lumbar vertebræ and the ilium, concurring to form the roof of the abdominal cavity, and are in more or less direct contact with the viscera contained in that cavity. They are nine pairs. Three have received the generic name of *psoas*, and are of large volume; they are maintained by a strong aponeurosis. the *iliac fascia*, and are distinguished as the *great psoas, iliac psoas*, and *small psoas.* A fourth is named the *square muscle of the loins* (*quadratus lumborum*), The other five, placed between the transverse processes of the lumbar vertebræ, represent, in consequence of their connection with these kind of fixed ribs, veritable intercostal muscles; these are the *intertransverse muscles of the loins.*

Preparation.—1. Place the subject in the first position; open the abdominal cavity by completely removing its inferior walls; empty the cavity of the viscera it contains, and excise the diaphragm, as that muscle prevents the anterior extremity of the great and small psoas muscles being seen. 2. First study the iliac fascia, its form, relations with the long abductor of the leg, its attachments, its continuity with the tendon of the small psoas, and the expansion reflected from the aponeurosis of the great abdominal oblique muscle. 3. Expose the three psoas muscles by removing the iliac fascia, the two adductors of the leg, and the three adductors of the thigh. 4. Remove the psoas muscles for the dissection of the quadratus and intertransversales.

1. *Iliac Fascia or Lumbo-iliac Aponeurosis.* (Fig. 108, A.)

This is a very resisting fibrous expansion, covering the great and iliac psoas muscles. Attached, inwardly, to the tendon of the small psoas, outwardly to the angle and external border of the ilium, this aponeurosis, as it extends forwards over the great psoas, degenerates into cellular tissue. Behind, it also becomes attenuated in accompanying the two muscles it covers until near their insertion into the internal trochanter of the femur. Its external or inferior face receives, posteriorly, the insertion of the crural arch, and gives attachment to the long adductor of the leg; for the remainder of its extent, it is covered by the peritoneum.

2. *Great Psoas Muscle.* (Fig. 108, 1.)

Synonyms.—Sublumbo-trochantineus—*Girard.* Psoas—*Bourgelat.* (*Lumbo-femoral-Leyh. Psoas magnus—Percivall.*)

Form—Situation.—This is a long muscle, flattened above and below at its anterior extremity, prismatic in its middle, and terminated in a cone at its posterior extremity. It lies beneath the transverse processes of the lumbar vertebræ.

Structure.—Almost entirely fleshy, this muscle is formed of fasciculi, very delicate in texture, directed backwards, and long in proportion to their superficial and deep situation. They all converge to a tendon which is enveloped by the iliac muscle, and is confounded with it.

Attachments.—The great psoas is attached: 1, By the anterior extremity of its fleshy fasciculi to the bodies of the last two dorsal and the lumbar vertebræ, except the hindermost, and to the inferior face of the two last ribs and the transverse processes of the lumbar vertebræ; 2, By its posterior tendon to the internal trochanter, in common with the psoas iliacus.

Relations.—Below, with the pleura, the superior border of the diaphragm, the lumbo-iliac aponeurosis, which separates it from the peritoneum and the abdominal viscera situated in the sublumbar region; above, with the two last internal intercostals, the quadratus, and the intertransversales muscles; inwardly, with the small psoas and the internal branch of the iliac psoas; outwardly, for its posterior third, with the principal branch of the latter muscle.

Action.—A flexor and rotator of the thigh outwards when its fixed point is the loins, this muscle also flexes the lumbar region when the thigh is a fixed point. It is, therefore, one of the agents which determine the arching of the loins, and which operate, during exaggerated rearing or prancing, in bringing the animal into a quadrupedal position again.

3. *Iliac Psoas Muscle.* (Fig. 108, 3, 4.)

Synonyms.—Ilio-trochantineus—*Girard.* (Leyh divides this muscle into two portions, which he describes as the *great* and *middle ilio-femoralis.* *Iliacus—Percivall.*)

Form—Situation—Direction.—This is a very strong, thick, and prismatic muscle, incompletely divided into two unequal portions by the groove for the reception of the tendon of the great psoas: an external portion, somewhat considerable in size; and an internal, small. These two muscular portions lie at the entrance to the pelvis, on the inner face of the ilium, in an oblique direction downwards, backwards, and inwards.

Structure.—It is almost entirely fleshy. The fasciculi forming it are

spread out in front, and collected behind, where they become slightly fibrous, and unite with the tendon of the great psoas.

Attachments.—It has its fixed insertion on the whole of the iliac surface, on the external angle of the ilium, the sacro-iliac ligament, and the ilio-

Fig. 108.

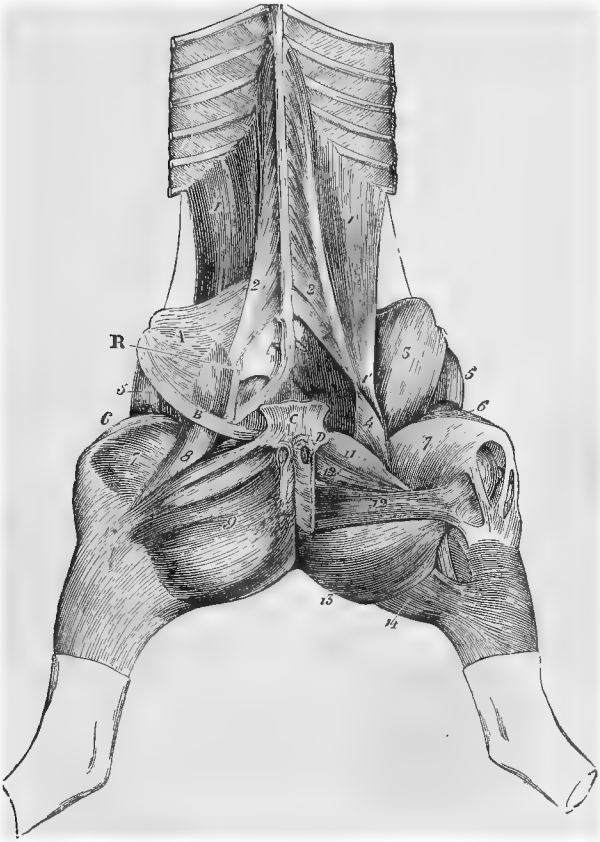

MUSCLES OF THE SUBLUMBAR, PATELLAR, AND INTERNAL CRURAL REGIONS

1, Psoas magnus; 1', Its terminal tendon; 2, Psoas parvus; 3, Iliac psoas; 4, Its small internal portion; 5, Muscle of the *fascia lata;* 6, Anterior straight muscle of the thigh; 7, Vastus internus; 8, Long adductor of the leg; 9, Short adductor of the leg; 11, Pectineus; 12, Great adductor of the thigh; 12', Small adductor of the thigh; 13, Semimembranosis; 14, Semitendinosis.—A, Portion of the *fascia iliaca;* B, Portion of the membrane reflected from the aponeurosis of the abdominal great oblique muscle, forming the crural arch (Poupart's ligament); C, Pubic tendon of the abdominal muscles; D, Origin of the pubio-femoral ligament.

pectineal crest. Its movable insertion is into the small internal trochanter, in common with the great psoas.

Relations.—Above, with the ilium; below, with the iliac fascia and the long adductor of the leg; outwardly, with the muscle of the fascia lata and

the origin of the anterior straight muscle of the thigh, from which it is separated by a space filled with fat; inwardly, with the crural vessels. It passes between the vastus internus and the pectineus, to reach the trochanter.

Actions.—It is a flexor and rotator outwards of the thigh.

4. *Small Psoas Muscle.* (Fig. 108, 2.)

Synonyms.—Psoas of the loins—*Bourgelat.* Sublumbo-pubialis, or sublumbo-iliacus, according to Girard. (*Psoas parvus—Percivall.* The *lombo-iliacus* of Leyh.)

Situation—Form—Structure.—Placed at the inner side of the great psoas, very much elongated, and semipenniform in shape, this muscle is terminated behind by a flattened tendon, and is composed of fleshy fibres, the longest of which are anterior. These fasciculi are all directed backwards and outwards to gain the tendon.

Attachments.—1, To the bodies of the three or four last dorsal, and to all the lumbar vertebræ, by the anterior extremity of its fleshy fibres; 2, To the ilio-pectineal eminence and the lumbo-iliac aponeurosis, by the posterior extremity of its tendon.

Relations.—By its inferior face with the pleura, the superior border of the diaphragm, the aorta or posterior vena cava, and the great sympathetic nerve; by its upper face, with the psoas magnus. It is traversed, near its vertebral insertions, by numerous vascular and nervous branches.

Actions.—It flexes the pelvis on the spine, when the loins are the fixed point; but should the pelvis be fixed, it arches or laterally inclines the lumbar region. It is also the tensor muscle of the lumbo-iliac aponeurosis.

Fig. 109.

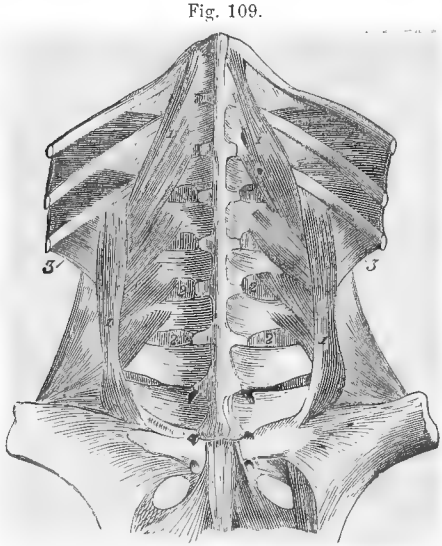

DEEP MUSCLES OF THE SUBLUMBAR REGION.
Quadratus lumborum; 2, 2, Intertransversales; 3, Small retractor muscle of the last rib—a dependent of the small oblique of the abdomen.

5. *Square Muscle of the Loins.* (Fig. 109, 1.)

Synonyms. — Sacro-costalis — *Girard.* (*Sacro-lumbalis—Percivall. Quadratus lumborum* of Man.)

Situation—Form—Structure—Attachments.—This muscle is comprised between the transverse processes of the lumbar region and the great psoas, and is elongated from before to behind, flattened above and below, and divided into several very tendinous fasciculi. The principal fasciculus, situated outwardly, takes its origin from the sacro-iliac ligament, near the angle of the sacrum, and extends directly forward to gain the posterior border of the last rib, after being attached by its upper face to the summits of the transverse processes of the lumbar vertebræ. The other fasciculi are longer as they are anterior; they leave the internal border of the first, and are directed obliquely forward and inward, to be

fixed into the transverse processes of the majority of the lumbar vertebræ, and the inner face of the two or three last ribs.

Relations.—By its upper face, with the intertransversales, the small retractor of the last rib, and the fibrous fascia which unites that muscle to the small oblique of the abdomen. By its inferior face, to the great psoas.

Actions.—It draws the last ribs backwards, and inclines the lumbar spine to one side.

6. *Intertransverse Muscles of the Loins.* (Fig. 109, 2, 2.)

(*Synonym—Intertransversales lumborum—Percivall.*)

These are very small flat muscles which fill the intervals between the transverse processes of the lumbar vertebræ. The muscular fibres entering into their composition are mixed with tendinous fibres, and are carried from the anterior border of one transverse process to the posterior border of the other.

They respond, by their superior face, to the ilio-spinalis (longissimus dorsi), and by their inferior face to the quadratus, as well as the psoas magnus. They act by inclining the lumbar region to one side.

DIFFERENTIAL CHARACTERS OF THE MUSCLES OF THE SUBLUMBAR REGION IN OTHER THAN SOLIPED ANIMALS.

In *Ruminants* and the *Pig*, the muscles of this region so closely resemble those of Solipeds, that a special description is unnecessary.

In the *Dog*, the *great psoas* is little developed, and only commences at the third, or even the fourth lumbar vertebra; the *iliac psoas* is very slender, particularly in its external portion; otherwise it is scarcely distinct from the great psoas, with which it may be said to form one muscle; the *small psoas* is relatively larger than the great; it is not prolonged into the pectoral cavity, and its anterior extremity is confounded with the *quadratus lumborum*, which is longer and stronger than in all the other animals.

COMPARISON OF THE SUBLUMBAR MUSCLES OF MAN WITH THOSE OF ANIMALS.

In human anatomy, by the names of *psoas* and *iliacus* are described the *great psoas* and *iliac psoas* of animals. The *psoas magnus* of MAN is distinguished from that of Solipeds by its superior insertions, which do not go beyond the last dorsal vertebræ.

The *small psoas* is often absent; when present, it is attached, above, to the bodies of the twelve dorsal vertebræ, below, to the ilio-pectineal crest.

The *intertransversales* have been studied with the muscles of the back. The *quadratus of the loins*, classed by anthropotomists with the abdominal muscles, is distinctly divided into three series of fasciculi: *ilio-costal* fasciculi, which pass from the upper border of the ilium to the twelfth rib; *lumbo-costal* fasciculi, passing from the transverse processes of the three or four last lumbar vertebræ to the twelfth rib, and *ilio-lumbar* fasciculi, going from the iliac crest to the posterior face of the transverse processes of all the lumbar vertebræ.

COCCYGEAL REGION.

This region is composed of four pairs of muscles destined for the movements of the tail: three, named the *sacro-coccygeal*, are disposed longitudinally around the coccygeal vertebræ, which they completely envelop; the fourth is designated the *ischio-coccygeus*.

1. *Sacro-coccygeal Muscles.* (Fig. 131, 1, 2, 3.)

These three muscles are inclosed, with those of the opposite side, in a common aponeurotic sheath which is continuous with the inferior ilio-sacral and sacro-ischiatic ligaments. They commence on the sacrum, are directed backwards and parallel with the coccyx, gradually diminishing in thickness, and are decomposed into several successive fasciculi terminated by small

tendons, which are inserted into each of the coccygeal bones. With regard to their situation, these muscles are distinguished as *sacro-coccygeus superior*, *sacro-coccygeus inferior*, and *sacro-coccygeus lateralis*.

a. Sacro-coccygeus Superior.

(*Synonym.—Erector coccygis—Percivall.*)

The fasciculi which form this muscle take their fixed insertion either from the summits and sides of the three or four last processes of the super-sacral spine, or from the coccygeal vertebræ themselves. The tendons through which they effect their movable insertion into these vertebræ are always very short.

This muscle, covered by the coccygeal aponeurosis, in turn covers the vertebræ it is designed to move. It responds: inwardly, to the analogous muscle of the opposite side; outwardly, to the lateral sacra-coccygeus, and, near its anterior extremity, to a very strong aponeurotic expansion which separates it from the transverse spinous muscle. It directly elevates the tail, or pulls it to one side, according as it acts in concert with its fellow or singly.

b. Sacro-coccygeus Inferior.

(*Synonym.—Depressor coccygis—Percivall.*)

This muscle is thicker than the preceding; its constituent fasciculi take their origin from the inferior surface of the sacrum, towards the third vertebra, and from the internal face of the sacro-ischiatic ligament and the coccygeal bones. It readily divides into two parallel portions, which Bourgelat has described as two separate muscles. The fasciculi of the internal portion are inserted, by their posterior extremity, into the inferior face of the first coccygeal vertebræ. Those of the external portion are all furnished with strong superficial tendons, nearly all of which are for the bones of the tail.

This muscle responds: outwardly, to the ischiatic ligament, the ischio-coccygeus and coccygeal aponeurosis; inwardly, to the muscle of the opposite side, and to the coccygeal attachment of the rectum; above, to the sacrum, the bones of the tail, and the lateral muscle; below, to the rectum and the coccygeal aponeurosis.

It either directly depresses the tail or inclines it to one side.

c. Sacro-coccygeus Lateralis.

(*Synonym.—Curvator coccygis—Percivall.*)

This muscle may be considered as the transverse spinous of the coccygeal region; indeed, it is confounded with that muscle of the back and loins by its anterior extremity, and appears to continue it to the inferior extremity of the tail.

The fasciculi composing it have their origin from the spinous processes of the last lumbar vertebræ, through the medium of the transverse spinous, and from the coccygeal bones. The tendons terminating these fasciculi are deep and not very distinct.

It responds; outwardly, at the posterior extremity of the ilio-spinalis, to the inferior ilio-sacral ligament and the coccygeal aponeurosis; inwardly, to the transverse spinous and the coccygeal vertebræ; above, to the superior muscle; below to the inferior muscle, from which it is nevertheless

separated by several small independent muscular fasciculi, which are carried from one coccygeal vertebra to another. (Leyh designates these the *inter-transversales of the tail.*) It inclines the tail to one side.

2. *Ischio-coccygeus.* (Fig 131, 41.)

(*Synonym.—Compressor coccygis—Percivall.*)

A small, thin, wide, and triangular muscle, situated against the lateral wall of the pelvis, at the internal face of the sacro-ischiatic ligament.

It is attached, by an aponeurosis, to that ligament and to the ischiatic crest; it is then directed upwards to be fixed, by its muscular fibres, to the side of the last sacral vertebra and the first two coccygeal bones.

It is related, outwardly, with the sacro-ischiatic ligament, and inwardly to the lateral sacro-coccygeus and the rectum.

It depresses the entire caudal appendage.

REGION OF THE HEAD.

The head comprises a large number of muscles, of which only those covering the bones of the face, and those which move the lower jaw and os hyoides, will be described. The others will be studied with the apparatus to which they belong.

A. *Facial Region.*

This region includes those muscles of the head which form a part of the framework of the lips, cheeks, and nostrils: that is, all those which are grouped around the face, properly called. Authors are far from being unanimous with regard to the nomenclature and description of these muscles. Girard recognised eleven, to which he gave the following names: *labialis, alveolo-labialis, zygomatico-labialis, lachrymo-labialis, supernaso-labialis, supermaxillo-labialis, supermaxillo-nasalis magnus, supermaxillo-nasalis parvus, transversalis nasi, maxillo-labialis, mento-labialis.* To these eleven muscles, three of which are single, two others are added; these were described by Bourgelat as the *middle (intermediate) anterior* and *middle (intermediate) posterior* muscles, which Girard wrongly considered as belonging to the labial.

1. *Labialis, or Orbicularis of the Lips.* (Fig. 110, 27.)

(*Synonym.—Orbicularis oris—Percivall.*)

Preparation.—Remove with scissors the skin covering the two portions of this muscle; afterwards the buccal mucous membrane and subjacent glands within the lips, to expose its internal face.

The labialis, disposed as a sphincter around the anterior opening of the mouth, is regarded as the intrinsic muscle of the lips, and is composed of two portions or fasciculi, one for the upper, the other for the lower lip. United to each other at the commissures of the mouth, and confounded with the superficial layer of the alveolo-labialis, which they appear to continue, these two muscular portions also receive a large portion of the fibres belonging to the majority of the extrinsic muscles, such as the supermaxillo-nasalis magnus and supernaso-labialis.

The orbicularis is not attached to the neighbouring bone; its component fibres affecting a circular form, have, consequently, neither beginning nor ending, except in being continuous with other fibres.

The internal face of the superior fasciculus responds to a layer of salivary

glands, which in part separate it from the buccal mucous membrane. The external, covered by the skin, adheres to it in the most intimate manner, and is found isolated from it only on the median line, at first by the aponeurotic expansion of the supermaxillo-labialis, then by a musculo-fibrous layer analogous to that which forms the mento-labialis.

By its internal face, the inferior fasciculus likewise responds to the buccal mucous membrane, and to some salivary glands. By its external face, it

Fig. 110.

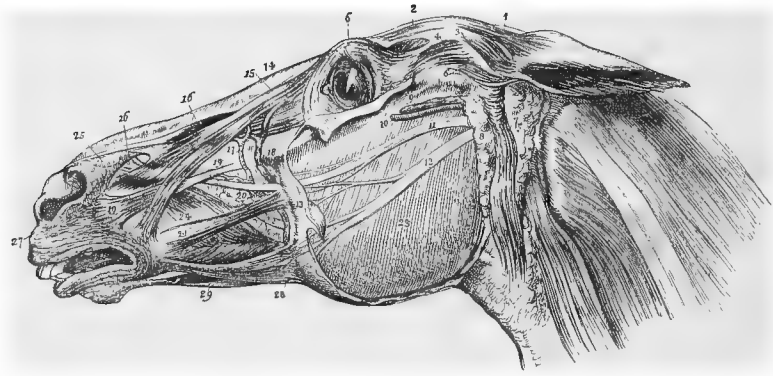

SUPERFICIAL MUSCLES OF THE FACE AND HEAD.

1, Temporo-auricularis externus, or attollens maximus; 2, Levator palpebræ, or corrugator supercilii; 3, Temporo-auricularis internus, or attollens posterior; 4, 5, Zygomatico-auricularis, or attollens anterior; 6, Orbicularis palpebrarum; 7, Parotido-auricularis, or deprimens aurem; 8, Parotid gland; 9, Temporal, or subzygomatic vein; 10, Ditto, artery; 11, 12, Superior and inferior maxillary nerves; 13, Fascia of the masseter muscle; 14, Nasal bones; 15, Supernaso-labialis, or levator labii superioris alæque nasi; 16, Supermaxillo-labialis, or nasalis longus labii superioris; 17, External maxillary or facial artery; 18, Facial vein; 19, Supermaxillo-nasalis magnus, or dilatator naris lateralis; 20, Superior maxillary nerve; 21, Zygomatico-labialis, or zygomaticus; 22, Parotid, or Stenon's duct; 23, Masseter; 24, Alveolo-labialis, or buccinator; 25, Supermaxillo-nasalis parvus, or nasalis brevis labii superioris; 27, Labialis, or orbicularis oris; 28, Maxillo-labialis, or depressor labii inferioris; 29, Mento-labialis, or levator menti.

forms an intimate union with the cutaneous integument, like the superior fasciculus.

This muscle plays the part of a constrictor of the anterior opening of the mouth, and has complex functions to perform in suction, the prehension of food, and in mastication.

2. *Alveolo-labialis.* (Fig. 110, 24.)

Synonyms.—Molaris externus et internus—*Bourgelat.* (*Buccinator—Percivall.* Leyh divides this muscle into two portions; its superficial plane he designates the *buccinator*, and the deep plane the *molaris.*)

Preparation.—Proceed to the ablation of the masseter; dissect the external surface of the muscle, taking care of the risorius Santorini and zygomaticus, which are confounded with it. Then divide it in the middle, as far as the commissure of the lips; turn down each strip on the jaws, and remove the mucous membrane, in order to study the inner face of the muscle and the attachments of the superficial plane to the maxillary bones.

Situation—Form.—Situated on the sides of the face, partly concealed by the masseter muscle, and applied to the mucous membrane of the cheeks, the alveolo-labialis is a flat, thin muscle, elongated in the direction of the head, and formed of two superposed planes.

Extent—Structure—Attachments.—The *deep plane*, the longest and least wide, is narrower at its extremities than its middle, and is formed of strongly aponeurotic muscular fasciculi, which are attached, posteriorly: 1, To the alveolar tuberosity; 2, To the external surface of the superior maxillary bone, above the last three molar teeth; 3, To the anterior border of the inferior maxillary bone, behind the sixth molar, in common with the maxillo-labialis. On reaching the commissure of the lips, this muscular layer appears to be continued by small tendons with the fibres of the orbicularis.

The *superficial plane* only begins about the middle of the deep one, whose anterior half it entirely covers. Its fibres, less tendinous than those of the latter, extend from a median raphé which also divides the deep layer in its length, and are directed, some forwards, some backwards, to terminate in the following manner: the first are inserted into the external face of the supermaxillary bone, above the first molar tooth and the superior interdental space; the second are attached to the inferior interdental space alone.

Relations.—Externally, with the masseter, zygomatico-labialis, cuticularis, great supermaxillo-nasalis, supernaso-labialis, the parotid duct, which crosses it to enter the mouth, and the facial artery and veins; internally, with the buccal mucous membrane. The deep plane is accompanied and covered at its anterior border by the upper molar glands; its posterior border is margined by the inferior molar teeth, which it partially covers. The superficial layer is distinctly separated from the deep one in its anterior part, which is attached to the superior maxillary bone. Behind, these two planes adhere more intimately to one another, though they are found completely isolated by an interstice in which one or two large veins pass.

Actions.—The function of the alveolo-labialis is particularly related to mastication: this muscle, in fact, pushes between the molar teeth the portions of food which fall outside the alveolar arches; but it cannot aid in bringing the two jaws together, as M. Lecoq has correctly observed.

3. *Zygomatico-labialis.* (Fig. 110, 21.)

Synonyms.—Portion of the cuticularis of *Bourgelat.* The *zygomaticus major* of Man. (*Zygomaticus—Percivall.*)

A very small, pale, and thin ribbon-like muscle, arising from the surface of the masseter, near the maxillary spine, by an aponeurosis which is confounded with the cuticularis; it terminates on the surface of the alveolo-labialis, at a short distance from the commissure of the lips. Covered by the skin, it covers the alveolo-labialis muscle, and some of the superior molar glands, vessels, and nerves.

This muscle pulls backwards the commissure of the lips when it is in a state of contraction.

In *Solipeds* there is also sometimes found a muscle resembling the *zygomaticus minor* of Man. It is a very small fasciculus situated under the preceding muscle, near its superior extremity. It appears that this fasciculus is continued, above, by the fibres of the lachrymo-labialis, and is lost, below, on the alveolo-labial surface, a little beneath the carotid canal.

4. *Lachrymo-labial, or Lachrymal Muscle.*

(*Synonym.*—Not mentioned by Percivall. It is the *inferior palpebral* muscle of Leyh.)

A wide and very thin muscle, situated superficially below the eye: it is continuous, in front, with the supernaso-labialis; behind, with the cuticularis; above, with the orbicularis of the eyelids. Its fibres, partly muscular and partly aponeurotic, leave the external surface of the lachrymal and zygomatic bones, are directed downwards, and become lost in a cellular fascia which covers the alveolo-labialis; some pass beneath the zygomatico-labialis and form the zygomaticus minor, when this is present.

This muscle is supposed to corrugate and twitch the skin below the eye.

5. *Supernaso-labialis.* (Fig. 110, 15.)

Synonyms.—The maxillaris of *Bourgelat.* The *levator labii superioris alæque nasi* of Man. (*Levator labii superioris alæque nasi—Percivall. Fronto-labialis—Leyh.*)

Situation—Direction—Form—Structure.—Situated on the side of the face, in an oblique direction downwards and backwards,[1] the supernaso-labialis is a wide muscle, flattened on both sides, elongated from below to above, aponeurotic at its superior extremity, and divided inferiorly into two unequal branches, between which passes the great supermaxillo-nasalis.

Attachments.—It has its origin, by its superior aponeurosis, from the frontal and nasal bones, and unites on the median line with the muscle of the opposite side. Its anterior branch, the widest and thickest, goes to the external ala of the nose and to the upper lip, where its fibres are confounded with those of the orbicularis. The posterior branch terminates at the commissure of the lips.

Relations.—Outwards, with the skin; inwards, with the supermaxillo-labialis, the posterior portion of the small supermaxillo-nasalis, and vessels and nerves. Its posterior branch covers the great supermaxillo-nasalis, and the anterior is covered by that muscle.

Actions.—It elevates the external ala of the nose, the upper lip, and the commissure of the lips.

6. *Supermaxillo-labialis.* (Fig. 110, 16.)

Synonyms.—Levator labii superioris of *Bourgelat.* The *levator labii superioris proprii* of Man. (*Nasalis longus labii superioris—Percivall.*)

Situation—Direction—Form—Structure.—Lying vertically on the side of the face, below the supernaso-labialis, this muscle is a thick and conical fleshy mass, terminated inferiorly by a tendon.

Attachments.—It is attached, by the upper extremity of its fleshy body, to the external surface of the supermaxillary and zygomatic bones—*origin.* Its terminal tendon passes over the transverse muscle of the nose, to unite with that of the opposite side, and with it to form a single aponeurotic expansion, which dips by small fibres into the subcutaneous musculo-fibrous tissue of the upper lip.

Relations.—Covered by the lachrymal and supernaso-labialis muscles, this muscle in turn covers the supermaxillary bone, the bottom of the false nostril, the small supermaxillo-nasalis, and the transversalis nasi.

Actions.—It raises the upper lip, either directly or to one side, as it acts singly or in concert with its congener.

[1] It is to be remembered that we suppose the head maintained in a vertical position.

7. *Great Supermaxillo-nasalis.* (Fig. 110, 19.)

Synonyms.—The pyramidalis-nasi of Bourgelat. The *caninus* of Man. (*Dilatator naris lateralis—Percivall.*)

Situation—Direction—Form—Structure.—This muscle, situated on the side of the face, between the two branches of the supernaso-labialis, in an almost vertical direction, is of a triangular form, and slightly tendinous at its summit.

Attachments.—It has its origin, by the aponeurotic fibres of its summit, from the external face of the supermaxillary bone, below its ridge.—It terminates, by its base, on the skin covering the external wing of the nostril, its most posterior fibres being confounded with those of the orbicularis of the lips.

Relations.—Outwardly, with the skin and the inferior branch of the supernaso-labialis; inwardly, with the anterior branch of that muscle, and with vessels and nerves.

Actions.—It dilates the external orifice of the nasal cavity, by pulling outwards the external wing of the nostril.

8. *Small Supermaxillo-nasalis.* (Fig. 110, 25.)

Synonyms.—The nasalis brevis, and portion of the subcutaneous muscle of Bourgelat. (*Nasalis brevis labii superioris—Percivall.*)

Girard has described, by the above name, a small, thick, and short muscular fasciculus which covers the external process of the premaxillary bone, and whose fibres, either originating from that, the supermaxillary bone, or the internal face of the supernaso-labialis muscle, terminate in the skin of the false nostril, and the appendix of the inferior turbinated bone.

Rigot has attached to this muscle that described by Bourgelat as the short muscle. The latter is composed of short, transverse fibres, applied to the expansion of the cartilaginous septum of the nose which projects laterally beyond the nasal spine. These fibres abut, by their most eccentric extremities, against the skin of the false nostril and the appendix of the superior turbinated bone.

In adopting Rigot's description, it is found that the small supermaxillo-nasalis is composed of two portions, which border the re-entering angle formed by the large process of the premaxillary bone and the nasal spine. These two portions, *posterior* and *anterior*, unite at their upper extremities. The first appears to be confounded, below, with the middle anterior (depressor alæ nasi), the second is continuous with the transversalis nasi. When they contract, they concur in the dilatation of the false nostril and the proper nasal cavity.

9. *Transversalis Nasi.*

Synonym.—(*Dilatator naris anterior—Percivall.*)

A single, short, and quadrilateral muscle, flattened before and behind, applied to the widened portion of the nasal cartilages, and composed of transverse fibres proceeding from one cartilage to the other. Covered by the skin and the aponeurotic expansion of the two elevator muscles of the upper lip, the transverse muscle of the nose covers the cartilages to which it is attached, and is confounded below with the orbicularis of the lips.

Designed to bring together the internal alæ of the nose, this muscle ought to be considered more particularly as the dilator of the nostrils.

10. *The Middle (Intermediate) Anterior Muscle.*

Synonyms.—Medius anterior—*Bourgelat.* Myrtiformis of Man. (*Depressor labii superiori—Percivall. Incisive muscle of the upper lip—Leyh.* A portion of the *orbicularis*, according to Rigot.)

Bourgelat thus names a deeply-situated muscle which is fixed to the inner face of the premaxillary bone, above the incisor teeth, and whose fibres ascend to meet those of the posterior portion of the small supermaxillo-nasalis muscle, to terminate with them on the anterior appendix of the inferior turbinated bone; some fibres become lost in the lip. It is regarded as a dilator of the entrance to the nasal fossa.

To study this muscle, it is necessary to raise the upper lip and remove the mucous membrane covering it. It may be dissected at the same time as the bony attachments of the superficial plane of the alveolo-labialis muscle.

11. *Maxillo-labialis.* (Fig. 110, 28.)

Synonyms.—Depressor labii inferioris—*Rigot.* A dependency of the buccinator of Man. (*Depressor labii inferioris—Percivall. Inferior maxillo-labialis—Leyh. Depressor anguli oris* of Man.)

Situation—Direction—Form—Structure.—Situated along the inferior border of the alveolo-labialis, whose direction it follows, this muscle forms a long narrow fasciculus, terminating inferiorly by an expanded tendon.

Attachments.—1, By its superior extremity, to the anterior border of the lower jaw, in common with the deep plane of the alveolo-labialis—*fixed origin;* 2, By its terminal tendon, to the skin of the lower lip—*movable insertion.*

Relations.—Outwardly, with the masseter and the facial portion of cuticularis of the neck; inwardly, with the maxillary bone; in front, with the alveolo-labialis muscle, with which it is directly united in its upper two-thirds.

Actions.—It separates the lower from the upper lip, and pulls it to the side if one alone acts.

12. *Mento-labialis or Muscle of the Chin.* (Fig. 110, 29.)

(*Synonyms.*—Percivall appears to describe this and the next muscle as one. It is the *quadratus menti* of Man.)

This name is given to a musculo-fibrous nucleus, forming the base of the rounded protuberance beneath the lower lip in front of the beard. This single nucleus is confounded, in front, with the orbicularis of the lips, and receives into its upper face the insertion of the two posterior middle muscles (levatores menti).

13. *Middle (Intermediate) Posterior Muscle.*

Synonyms.—Medius posterior—*Bourgelat.* (*Levator menti—Percivall. Incisive muscle of the lower lip—Leyh.*)

Bourgelat describes, by this name, a small muscular fasciculus, analogous in every respect to the medius anterior. This little muscle takes its origin from the external surface of the body of the lower jaw, beneath the intermediate and corner incisors; from thence it descends into the texture of the lip, to unite with that of the opposite side on the upper face of the mento-labialis. Several authors have described it as a dependent of the last muscle.

It is an energetic elevator of the lower lip.

To dissect this muscle, the directions given for the preparation of the anterior medius will suffice.

B. *Masseteric or Temporo-maxillary Region.*

This pair region comprises five muscles for the movement of the lower jaw. These are: the *masseter*, *temporal*, *internal pterygoid*, *external pterygoid*, and *digastricus*.

Preparation.—1. First study the digastricus and its stylo maxillary portion, with the internal pterygoid, in preparing the hyoid muscles as they are represented in fig. 111. 2. Expose the pterygoideus externus, by removing in this preparation the hyoid bone and its dependencies, as well as the two preceding muscles. 3. To dissect the temporalis, excise the external pterygoideus from its inferior border, an operation which exposes the orbital fasciculus of the temporalis; then turn over the piece, saw off the orbital process at each end, and remove the eye and auricular muscles. 4. Dissect the masseter in clearing away from its external surface the cuticularis and the vessels and nerves which cover it.

1. *Masseter.* (Fig. 110, 23.)

Synonyms.—Zygomatico-maxillaris—*Girard.* (The *zygomatico maxillaris* of Leyh.)

Situation—Form—Structure.—Applied against the external face of the lower jaw, the masseter is a short, wide, and very thick muscle, flattened on both sides, irregularly quadrilateral, and formed of several superposed planes, two of which are perfectly distinct towards the temporo-maxillary articulation, by the somewhat different direction of their fibres. These are divided by a considerable number of intersections, and are covered by a strong aponeurotic layer, which becomes gradually thinner backwards and downwards.

Attachments.—The fasciculi of the masseter have their fixed insertion on the zygomatic crest.—Their movable insertion is on the imprints which cover the upper half of the inferior maxillary branch.

Relations.—It responds, by its superficial face, to the facial portion of cuticularis colli, to the nerves of the zygomatic plexus, and several venous and arterial vessels; by its deep face, to the inferior maxillary bone, the alveolo-labialis and maxillo-labialis muscles, the superior molar glands, and two large venous branches; by its inferior border, with the parotid canal, and the glosso-facial artery and vein; by its superior and posterior border, to the parotid gland. Its deep plane responds, anteriorly, with the temporo-maxillary articulation, and is so intimately confounded with the temporalis, that it is impossible to define the respective limits of the two muscles.

Action.—This muscle, the special elevator of the lower jaw, plays an important part in mastication. It always acts as a lever of the third class, the middle line, which represents the resultant of all its constituent fibres, passing behind the last molar.

2. *Temporal or Crotaphitic Muscle.*

Synonyms.—Temporo-maxillaris—*Girard.* (The *temporo-maxillaris* of Leyh.)

Situation—Form—Structure.—Situated in the temporal fossa, to which it is moulded, and which it fills, this muscle is flattened from above to below, divided by strong tendinous intersections, and covered by a nacrous aponeurotic layer.

Attachments.—It takes its origin: 1, In the temporal fossa and on the

bony crests which margin it; 2, By a wide fasciculus, paler than the other portion of the muscle, but not unconnected with it, from the imprints situated behind the crest surmounting the orbital hiatus. It terminates on the coronoid process and the anterior border of the branch of the lower jaw.

Relations.—This muscle covers the temporal fossa, and is covered by the temporo-auricularis muscles, scutiform cartilage, internal scuto-auricularis, the fatty cushion at the base of the ear, and by another adipose mass which separates it from the ocular sheath. Its deep fasciculus responds, by its internal face, to the two pterygoid muscles.

Action.—It brings the lower jaw in contact with the upper, by acting as a lever of the first kind; but the orbital portion of the muscle elevates the inferior maxilla and moves it laterally by a lever of the third class.

3. *Internal Pterygoid.*

Synonyms.—Portion of the spheno-maxillaris of Bourgelat. (The *pterygoideus internus* of Percivall. Leyh designates the *pterygoideus internus* and *externus* as one muscle, the *spheno-maxillaris* or *internal masseter.*)

Situation—Form—Structure.—Situated in the intermaxillary space, opposite the masseter, the pterygoideus internus, although not so strong as that muscle, yet so closely resembles it in form and structure as to be named by Winslow the *internal masseter.*

Attachments.—1. To the palatine crest and subsphenoidal process—*fixed insertion*: 2. In the hollow excavated on the inner face of the branch of the lower jaw—*movable insertion.*

Relations.—Outwardly, with the pterygoideus-externus, the orbital fasciculus of the temporal, the maxillo-dental nerves, mylo-hyoideal, and lingual muscles, arteries and veins, and the inner surface of the bone which receives its movable insertion. Inwardly, with the tensors palati—external and internal, the guttural pouch, the hyoideus magnus, hyoid bone, digastricus, the hypoglossal and glosso-pharyngeal nerves, glosso-facial artery and vein, the hyoglossus longus and brevis muscles, the laryngo-pharyngeal apparatus, the Stenonian duct, and the submaxillary glands.

Action.—It is an elevator of the lower jaw, and also gives it a very marked lateral or deductive motion. If the left muscle acts, this movement carries the inferior extremity of the lower jaw to the right; and if it be the right muscle, then in the contrary direction.

4. *External Pterygoid.*

Synonym.—Portion of the spheno-maxillaris of Bourgelat.

Form—Situation—Structure—Attachments.—A small, short, and very thick muscle, situated within and in front of the temporo-maxillary articulation, formed of slightly tendinous fasciculi which leave the inferior face of the sphenoid bone and the subsphenoidal process, and are directed backwards and upwards to be fixed to the neck of the inferior maxillary condyle.

Relations.—Outwardly, with the orbital fasciculus of the temporal muscle, and the temporo-maxillary articulation. Inwardly, with the numerous nerves emanating from the inferior maxillary branch, and with the internal pterygoid and tensors palati.

Action.—When the two external pterygoids act in concert, the inferior maxilla is pulled forward; but if only one contract, the propulsion is

accompanied by a lateral movement, during which the extremity of the jaw is carried to the opposite side.

5. *Digastricus.*

Synonyms.—Bourgelat has made two distinct muscles of this—the digastricus and stylo-maxillaris. Girard has described it as the stylo-maxillaris. (Percivall has evidently followed Bourgelat's example, and divided the muscle into *digastricus* and *stylo-maxillaris*. Leyh adopts the same course.)

Form—Structure—Situation—Direction.—Composed of two fleshy bodies more or less divided by intersections, and united at their extremities by a median tendon, this muscle is situated in the intermaxillary space, and extends from the occiput to near the symphysis of the chin, describing a curve upwards.

Attachments.—It takes its origin from the styloid process of the occipital bone, by its superior fleshy body. It terminates: 1, On the curved portion of the posterior border of the lower jaw by a considerable fasciculus, which is detached from the superior fleshy body;[1] 2, On the internal face of the same bone and the straight portion of its posterior border, by aponeurotic digitations which succeed the muscular fibres of the inferior fleshy body.

Relations.—The superior belly of the muscle responds, superficially, to the parotid gland and the tendon of insertion of the sterno-maxillaris; deeply, to the guttural pouch, the submaxillary gland, and the larynx and pharynx. The median tendon passes through the ring of the hyoideus magnus. The lower belly is in contact, outwards, with the ramus of the inferior maxilla; inwards, with the mylo-hyoideus muscle.

Action.—When this muscle contracts, it acts at the same time on the hyoid bone, which it raises in becoming straight, and on the lower jaw, which it pulls backwards and depresses at the same time.

C. *Hyoideal Region.*

This region includes six muscles grouped around the os hyoides, which they move. Five of these are pairs: the *mylo-hyoideus*, *genio-hyoideus*, *stylo-hyoideus*, *kerato-hyoideus*, and the *occipito-styloideus*. The single one is the *transversalis hyoidei*.

Preparation.—Separate the head from the trunk, and remove the muscles of the cheeks on one side, with the parotid gland. 2. The branch of the inferior maxilla being thus exposed, it is sawn through in two places; at first behind the last molar, then in front of the first. 3. After having separated the pterygoids and the stylo-maxillaris from the upper fragment or condyle, and the coronoid process, it is torn off by pulling it backwards; then the pterygoids and the digastricus are excised. 4. The inferior fragment of the jaw bearing the molar teeth is turned down by isolating the mylo-hyoideus from the mucous membrane. 5. Carefully remove the tongue by separating its extrinsic muscles from the genio-hyoideus, the anterior appendix of the hyoid bone, the transverse muscle, and the small hyoideus.

The dissection having been performed in this manner, the large hyoideal branch may be separated from the small, by sawing through the head longitudinally, leaving the symphysis menti intact, and turning down the corresponding half to the side already dissected, as well as the great hyoid branch, the pharynx, larynx, and soft palate.

1. *Mylo-hyoideus.*

Form—Situation—Structure.—A membranous muscle situated in the intermaxillary space, flattened from side to side, elongated in the direction

---

[1] This is the fasciculus which Bourgelat has described as a distinct muscle, and named the *stylo-maxillaris*.

of the head, thinner and narrower below than above, and formed entirely of fleshy fibres which extend transversely from its anterior to its posterior border. Inferiorly, it is composed of a small fasciculus, which is distinguished from the principal portion by the slightly different direction of its fibres, and which covers in part the external surface of the muscle.

Fig. 111

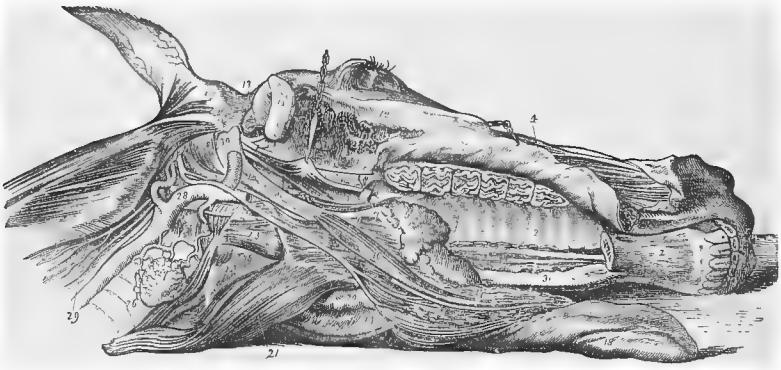

HYOIDEAL AND PHARYNGEAL REGIONS.

1, Neck of inferior maxilla; 2, Hard palate; 3, Molar teeth; 4, Buccal membrane; 5, Submaxillary glands; 6, Soft palate; 7, Tendon of hyoideus magnus through which the tendon, 8, of the digastricus passes; 9, Lower portion of digastricus; 10, Stylo-hyoideus; 11, Buccal nerve; 12, Zygomatic arch; 13, Orbital branch of fifth pair of nerves; 14, Articular process of temporal bone; 15, Right cornu of hyoid bone; 16, Hyo-glossus longus, or Kerato-glossus; 17, Lingual nerve; 18, 18, Tongue; 19, Angle of left branch of inferior maxilla; 20, Submaxillary gland, left side; 21, Subscapulo-hyoideus; 22, Great hypoglossal nerve; 23, Hyo-thyroideus; 24, Sterno-hyoideus; 25, Sterno-thyroideus; 26, Subscapulo hyoideus; 27, Thyroid gland; 28, External carotid artery; 29, Pneumogastric nerve; 30, Stylo-hyoideus; 31, Genio-hyoideus.

Attachments.—It originates from the mylo-hyoid line by the anterior extremities of its fibres. Its movable insertion takes place on the inferior face of the hyoid body, on its anterior appendix, and on a fibrous raphé which extends from the free extremity of this appendix to near the genial surface, and which unites, on the median line, the two mylo-hyoidean muscles.

Relations.—By its external face, with the inferior maxilla, the digastric muscle, and the submaxillary lymphatic glands. By its internal face, with the sublingual gland, the Whartonian duct, the hypoglossal and lingual nerves, the genio-glossus, hyo-glossus longus and brevis, and genio-hyoideus. Its superior border responds to the internal pterygoid.

Action.—In uniting on the median line with that of the opposite side, this muscle forms a kind of wide band or brace on which the tongue rests. When it contracts, it elevates this organ, or rather applies it against the palate.

2. *Genio-hyoideus.*

Form—Structure—Situation.—A fleshy, elongated, and fusiform body, tendinous at its extremities, but especially at the inferior one, and applied, with its fellow of the opposite side, to the mylo-hyoidean brace.

Attachments.—By its inferior extremity it is fixed to the genial surface—*origin;* by its superior, it reaches the free extremity of the anterior appendix of the hyoid body—*termination.*

Relations.—Outwards and downwards, with the mylo-hyoideus; inwards, with its fellow, which is parallel to it; above, with the genio-glossus.

Action.—It draws the hyoid bone towards the anterior and inferior part of the intermaxillary space.

3. *Stylo-hyoideus.*

(*Synonyms.*—The *hyoideus magnus of* Percivall. The *kerato-hyoideus magnus* of Leyh.)

Form — Structure — Situation — Direction — Thin and fusiform, this muscle, smaller than the preceding, and, like it, tendinous at both its extremities, is situated on the side of the laryngo-pharyngeal apparatus and the guttural pouch, behind the large branch of the hyoid bone, whose direction it follows.

Attachments.—Above, to the superior and posterior angle of the styloid bone—*fixed insertion;* below, to the base of the cornu of the os hyoides—*movable insertion.*

Relations.—Outwards, with the pterygoideus internus; inwards, with the guttural pouch, the pharynx, and hypoglossal nerve. Its anterior border is separated from the posterior border of the styloid bone by the glosso-facial artery and glosso-pharyngeal nerve; along the posterior border lies the upper belly of the digastricus. Its inferior tendon is perforated by a ring for the passage of the cord intermediate to the two portions of the latter muscle.

Action.—It is antagonistic to the preceding muscle, drawing the body of the hyoid bone backwards and upwards.

4. *Kerato-hyoideus.*

(*Synonyms.*—This is the *hyoideus parvus* of Percivall, and the *small kerato-hyoideus* of Leyh.)

A very small fasciculus, triangular in shape, and flattened on both sides. Inserted, *on one side,* into the posterior border of the styloid cornu and the inferior extremity of the styloid bone; and *on the other,* to the superior border of the thyroid cornu. It responds, outwardly, to the basio-glossus and the lingual artery; inwardly, to the buccal mucous membrane.

It approximates the cornua of the os hyoides to each other.

5. *Occipito-styloideus.*

Synonyms.—This is the muscle which, up to the present time, has been described by veterinary anatomists as the *stylo-hyoideus.* This name has been given to the muscle named by Girard the *kerato-hyoideus magnus.*

A small, flat, and triangular muscle like the preceding, yet thicker and more spread, filling the space comprised between the styloid process of the occipital and the horizontal portion of the posterior border of the styloid bone. Its fasciculi become longer as they are situated posteriorly, are rather tendinous, and are carried from one of these bones to the other. Outwardly, it responds to the parotid gland; inwardly, to the guttural pouch, which it covers for its whole extent; its posterior border is largely confounded with the superior insertion of the digastricus. When this muscle acts, it causes the os hyoides to swing, carrying its inferior extremity backwards and downwards.

6. *Transversalis Hyoidei.*

By this name Bourgelat has described a short riband of parallel muscular fibres, which unites the superior extremities of the styloid cornua, and approximates them to each other.

DIFFERENTIAL CHARACTERS OF THE MUSCLES OF THE HEAD IN OTHER THAN SOLIPED ANIMALS.

A. *Facial Region.*

RUMINANTS.—There are found in the *Ox*.

1. An *orbicular muscle of the lips*, analogous to that in the Horse.
2. An *alveolo-labialis* of the same kind (fig. 112, 5).
3. A *zygomaticus* or *zygomatico-labialis*, stronger and redder than in Solipeds. Its aponeurosis of origin, covered by the cuticularis muscle of the face, extends upon the surface of the masseter muscle as far back as the zygomatic arch, to which it is attached (fig. 112, 7).

Fig. 112.

SUPERFICIAL MUSCLES OF THE OX'S HEAD.

1, Supermaxillo-labialis; 1, 1′, Accessory fasciculi of the supermaxillo-labialis; 2, Supermaxillo-nasalis magnus; 3, Supernaso-labialis; 4 Lachrymalis; 5, Alveolo-labialis; 6, Maxillo-labialis confounded with the preceding; 7, Zygomatico-labialis; 8, Frontal, or cuticularis muscle of the forehead; 9, Orbicular muscle of the eyelids; 10, Zygomatico-auricularis; 11, External temporo-auricularis; 12, Scutiform cartilage; 13, External scuto-auricularis; 14, Mastoid process; 15, Masseter; 16, Stylo-hyoideus; 17, Digastricus; 18, Sterno-maxillary fasciculus belonging to the cuticularis muscle of the neck; 19, Trachelo-hyoideus (subscapulo-hyoideus); 20, Sterno-suboccipitalis (sterno-maxillaris, or mastoideus); 21, Anterior branch of the superficial portion of the mastoido-humeralis (levator humeri); 22, Superior branch of ditto; 23, Deep portion of same muscle; 24, Trachelo-atloideus, peculiar to Ruminants and Pachyderms; 25, Great anterior straight muscle of the head.

4. A *lachrymalis*, thicker and more developed than in the Horse. Its most anterior fibres glide beneath the zygomaticus, and are lost on the alveolo-labialis surface; the most posterior pass over the aponeurotic tendon of the zygomatico-labialis, and are confounded with those of the cuticularis. Above, it joins the orbicularis of the eyelids in a still more intimate manner than in the Horse; so that it is almost impossible to distinguish the limits of the two muscles (fig. 112, 4).

5. A *supernaso-labialis* continued, above, with the inferior border of the frontal or fronto-cuticularis muscle; and divided, inferiorly, into two branches, which comprise between them the supermaxillo-labialis and the pyramidalis-nasalis. These two branches, however, are not disposed as in Solipeds, the anterior covering the preceding muscles, and the posterior, of but little importance, passing beneath them to lose itself in the substance of the upper lip (fig. 112, 3).

6. A *supermaxillo-labialis*, which gains the middle of the muzzle by passing along the inner side of the nostrils (fig. 112, 1).

7. Two additional *supermaxillo-labialis* muscles, considered as accessories to the first, and which originate with it. Each terminates by a ramifying tendon that passes under the nostril to mix in the tissue of the upper lip (fig. 112, 1′,1′).

8. A *pyramidalis* or *great supermaxillo-nasalis*, situated between the supermaxillo-labialis and its two accessory muscles, and deriving its origin, in common with these three muscles, in front of the maxillary spine (fig. 112, 2).

9. A *maxillo-labialis*, confounded with the alveolo-labialis, and having no terminal tendon.

10. A *mento-labialis*, attached to the body of the inferior maxillary bone, as in the Horse, by two *middle posterior* muscles. No anterior middle muscle has been found by us; and it is certain that there is no *naso-transversalis* or *small supermaxillo-nasalis* present.

In the *Sheep*, the *supernaso-labialis* does not exist; apart from this peculiarity, there is no difference between the facial muscles of this animal and the Ox.

Pig.—This animal has neither the *lachrymalis*, *supernaso-labialis*, or *naso-transversalis* muscles. The *small supermaxillo-nasalis* is present; it is short, very thick, and situated near the margin of the nostrils. The *supermaxillo-labialis* and the *great supermaxillo-nasalis* are replaced by three fleshy bodies, nearly parallel, lying on the side of the face. The superior originates in the lachrymal fossa, and terminates by a tendon in the middle of the snout. The inferior, with the middle, leaves the imprints in front of the zygomatic ridge, and is continued at its inferior extremity by a tendon divided into several fibrillæ, which pass below the nostril to be united to the tendon of the superior portion: this is done in such a manner that the external opening of the nose is encircled on the inner side by a kind of fibrous cravat which, when these two muscles contract, carries this opening outwards. It will also be understood that the superior fleshy body, acting alone, ought to elevate the snout, while the inferior depresses it in drawing it to one side. With regard to the intermediate fleshy mass, it is the representative of the pyramidalis of the Ox, and terminates in a great quantity of tendinous fibrillæ at the internal ala of the nose.

Carnivora.—In the *Dog* and *Cat* the following peculiarities are found:—

The *labialis* (or orbicularis) is quite rudimentary.

The *buccinator* is very thin and formed of only one muscular plane.

The *zygomatico-labialis* is continued, superiorly, with the zygomato-auricularis.

The *supernaso-labialis* represents a wide, undivided, muscular expansion, united superiorly to the cuticularis of the forehead, and terminating inferiorly on the upper lip.

The *supermaxillo-labialis* and the *supermaxillo-nasalis magnus* constitute a single fleshy body formed of several parallel fasciculi, which take their origin above the supra-orbital foramen, and terminate together at the external wing of the nose and in the upper lip.

There is no *supermaxillo-nasalis parvus*, or *naso-transversalis*.

The *middle anterior* (*depressor alæ nasi*) is perfectly developed.

The *mento-labialis* and its suspensory muscle, the *middle posterior*, are scarcely apparent.

B. *Masseteric or Temporo-maxillary Region.*

In *Ruminants*, the *masseter* and *temporal* are not so large as in Solipeds. In the *Carnivora*, however, they offer a remarkable development. The origin of the *pterygoideus internus* in *Ruminants* is nearer the middle line than in the Horse. Its obliquity si also greater, and the movements of diduction it gives the lower jaw are more

extensive. In all the animals, the *stylo-maxillaris* fasciculus of the *digastricus* is entirely absent, and the muscle has only a single belly extending directly from the occipital to the maxillary bone. In the *Ox* is found a small square muscle, formed of transverse fibres, which unites the two digastric muscles by passing beneath the base of the tongue. This muscle, in contracting, may raise the hyoideal apparatus, and in this way supplements the tendon of the digastricus and the inferior ring of the stylo-hyoideus.

C. *Hyoid Region.*

The two fleshy planes composing the *mylo-hyoideus* are more distinct in *Ruminants* than in the Horse. The *stylo-hyoideus* of these animals commences by a long thin tendon. The muscle has no ring for the passage of the digastricus, a feature observed in all the domesticated animals except Solipeds.

In the *Carnivora*, the *stylo-hyoideus*, formed by a narrow, very thin, and pale fleshy band, commences on the mastoid portion of the temporal bone by a small tendon; the *kerato-hyoideus* is remarkable for its relatively considerable volume; the *occipito-styloideus* and the *transversalis hyoideus* are absent.

COMPARISON OF THE MUSCLES OF THE HUMAN HEAD WITH THOSE OF THE DOMESTICATED ANIMALS.

In *Man*, there are described as *muscles of the head*, the *epicranial muscles*, *muscles of the face*, and those of the *lower jaw*. The *hyoid* and *digastric muscles* are reckoned in the region of the neck. Here they will be placed in the region of the head.

A. *Epicranial Muscles.*

The middle portion of the human cranium is covered by an aponeurosis that adheres closely to the hairy scalp, but glides easily on the surface of the bones. To the circumference of this epicranial aponeurosis are attached four muscles which move it. One of them, attached behind to the superior occipital curved line, is named the *occipital muscle;* another, fixed in front of the forehead, is called the *frontal muscle;* the other two, double and lateral, are inserted on the face of the temporal bone or the external ear, and are designated *auricular muscles*. These epicranial muscles move the scalp forwards, backwards, and sideways.

B. *Muscles of the Face.*

These are fourteen in number, ten of which are found in the domesticated animals. We commence by describing these common muscles (fig. 113).

1. The *orbicularis of the lips*, which has a fasciculus that passes to the skin from the columna of the nose; this fasciculus is termed the depressor of the columna, or moustache muscle (*naso labialis*).
2. The *buccinator*, corresponding to the alveolo-labialis of animals. Besides its office in mastication, it takes an important part in the blowing of wind instruments.
3. The *superficial elevator of the wing of the nose and the upper lip*. It resembles the supernaso-labialis, descends from the orbital margin of the supermaxilla, passes along the wing of the nose, and is lost in the upper lip.
4. The *deep elevator of the wing of the nose and the upper lip*, whose analogue is found in the supermaxillo-labialis of animals.
5. The *great zygomaticus*, whose presence is constant in all species.
6. The *small zygomaticus*. represented in the Horse by only the small oblique fasciculus sometimes found beneath the great zygomaticus.

The small zygomaticus and the two elevators of the lips are lachrymal muscles; by their simultaneous contraction they express discontent and melancholy. The great zygomaticus, on the contrary, is the muscle of laughter; it draws the commissures of the lips outwards.

7. The *canine*, or great supermaxillo-nasal of animals, is attached beneath the infra-orbital foramen, and terminates in the skin of the upper lip.
8. The *risorius of Santorini*.
9. The *muscle of the chin* (*mento-labialis*).
10. The *myrtiformis*, or middle anterior of Bourgelat.

The other facial muscles of Man, whose analogues it is difficult or impossible to find in animals, are:—

11. The *triangularis of the lips*, which is inserted into the anterior face of the inferior maxilla, and is carried upwards to the commissure of the lips. By its contraction it gives the face an expression of melancholy or contempt.

12. The *quadratus menti*, which, after being attached to the maxilla within the mental foramen, passes upwards on the skin of the lower lip, which it depresses, and thus contributes to the expression of fear or dismay.

13. The *transversalis nasi* (*compressor nasi*), a muscle which is fixed into the supermaxilla and on the bridge of the nose, where it is confounded with the opposite muscle.

14. The *dilator of the ala of the nostril*, a very small triangular fasciculus applied to the external part of the nostril, which, by contracting, it elevates.

C. *Muscles of the Lower Jaw.*

There is nothing remarkable to be noted in the *masseter*, *temporal*, or *pterygoid* muscles. The upper belly of the *digastricus* is not attached directly to the inferior maxilla.

D. *Hyoid Muscles.*

These are only three in number:—

1. The *mylo-hyoideus.*
2. The *stylo-hyoideus*, which commences at the styloid process of the temporal bone, and shows a ring for the tendon of the digastricus.
3. The *genio-hyoideus.*

We do not find in Man the occipito-styloideus, kerato-hyoideus, or the transversalis-hyoideus.

Fig. 113.

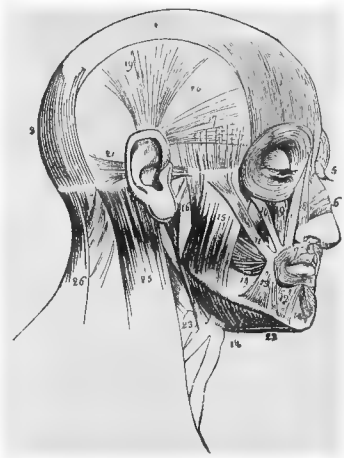

MUSCLES OF THE HUMAN HEAD; SUPERFICIAL LAYER.

1, Frontal portion of the occipito-frontalis; 2, Its occipital portion; 3, Its aponeurosis; 4, Orbicularis palpebrarum; 5, Pyramidalis nasi; 6, Compressor nasi; 7, Orbicularis oris; 8, Levator labii superioris alæque nasi; 9, Levator labii superioris proprius; 10, Zygomaticus minor; 11, Zygomaticus major; 12, Depressor labii inferioris; 13, Depressor anguli oris; 14, Levator labii inferioris; 15, Superficial portion of masseter; 16, Its deep portion; 17, Attrahens aurem; 18, Buccinator; 19, Attollens aurem; 20, Temporal fascia covering temporal muscle; 21, Retrahens aurem; 22, Anterior belly of the digastricus, with tendon passing through pulley; 23, Stylo-hyoid muscle; 24, Mylo-hyoideus; 25, Upper part of sterno-mastoid; 26, Upper part of trapezius—the muscle between 25 and 26 is the splenius.

Axillary Region.

This comprises two muscles, pairs, placed beneath the sternum, in the armpit, which terminate on the anterior limb. These are the *superficial* and *deep pectorals.*[1]

Preparation.—1. Place the animal in the first position. 2. Unfasten one of the fore-limbs, and allow it to hang, so as to separate it from the opposite one. 3. Remove the skin with care, and dissect, on the side corresponding to the detached limb, the two muscles which form the superficial pectoral. 4. Prepare the deep pectoral on the opposite side. To do this, remove the panniculus cautiously, so as not to injure the muscle about to be examined; divide the superficial pectoral transversely, and turn back the cut portions to the right and left; divide also the mastoido-humeralis (levator humeri) and cervical trapezius near their insertion into the limb, and reflect them upon the neck.

1. *Superficial Pectoral.* (Fig. 114, 9, 10.)

Synonyms.—Muscle common to the arm and fore-arm—*Bourgelat.* Pectoralis magnus of Man. (*Pectoralis transversus—Percivall.* Leyh divides this muscle into two portions, which he designates the *sterno-radialis* and *small sterno humeralis*).

---

[1] For a justification of the employment of these new denominations, see the note at p. 177.

Fig. 114.

MUSCLES OF THE AXILLARY AND CERVICAL REGIONS.

1, Portion of the cuticularis colli; 2, Anterior portion of the mastoido-humeralis; 3, Posterior portion of ditto; 4, Sterno-maxillaris; 5, Subscapulo-hyoideus; 6, Sterno-hyoideus; 7, Sterno-thyroideus; 8, Scalenus; 9, Sterno-humeralis; 10, Sterno-aponeuroticus; 11, Sterno-trochineus (pectoralis magnus); 12, Portion of the fascia enveloping the coraco-radialis, receiving part of the fibres of the sterno-trochineus; 13, Sterno-prescapularis; 14, Its terminal aponeurosis.

Situation—Composition.—This muscle is situated between the two anterior limbs, occupies the inferior surface of the chest, and is formed by two portions which adhere closely to each other, but are yet perfectly distinct. Following the example of Girard, we will describe these as two particular muscles by the names of *sterno-humeralis*, and *sterno-aponeuroticus*.

A. Sterno-humeralis. — *Form — Structure.*—This is a short, bulky muscle, flattened above and below, contracted at its termination, and composed almost entirely of thick parallel fibres.

Direction and Attachments.—It commences on the anterior appendage and the inferior border of the sternum, and is directed obliquely backwards, downwards, and inwards, to reach the anterior ridge of the humerus, where it terminates by an aponeurosis common to it, the mastoido humeralis, and the sterno-aponeuroticus.

Relations.—It responds, by its external face, to the skin, from which it is separated by a cellular layer, and to the inferior extremity of the cuticularis colli; by its internal face, to the sterno-aponeuroticus and sterno-prescapularis. Its anterior border forms, with the mastoido-humeralis, a triangular space occupied by the subcutaneous, or "plate," vein of the arm.

Action.—It acts principally as an adductor of the anterior limb.

B. Sterno-aponeuroticus.—*Form—Structure — Direction — Attachments.*—A very wide, thin, and pale quadrilateral muscle formed of parallel fleshy fibres, which arise from the entire inferior border of the sternum, to pass at first outwards, then downwards, and terminate in the following manner: the anterior fibres go to the aponeurosis which attaches the mastoido-humeralis and sterno-humeralis to the anterior ridge of the humerus; the posterior fibres are also continued by a very thin fascia, which is spread inside the limb to the external face of the antibrachial aponeurosis.

Relations.—By its superficial face,

with the skin, which adheres intimately to it by means of a dense cellular tissue, and with the sterno-humeralis, which covers its anterior border. By its deep face, with the two portions of the deep pectoral, the coraco-radialis (flexor brachii), and the long extensor of the fore-arm; it also responds, by this face, to the antibrachial aponeurosis and the subcutaneous vein of the fore-arm, which it maintains applied against that aponeurosis.

Action.—It is an adductor of the anterior limb, and a tensor of the antibrachial aponeurosis.

2. *Deep Pectoral.* (Figs. 114, 11, 13; 115, 1.)

Synonym.—The pectoralis parvus of Man.

Volume—Situation—Composition.—An enormous muscle, situated beneath the thorax, and composed, like the preceding, of two perfectly distinct portions, described by Girard as two muscles, and designated by him as the *sterno-trochineus* and *sterno-prescapularis.*

A. Sterno-trochineus.—Pectoralis magnus of (Percivall, Rigot, and) Bourgelat. (The *great sterno-humeralis* of Leyh.)

Volume—Extent.—This muscle, the largest of the two, offers a considerable volume. Extending from the ninth or tenth rib to the upper extremity of the arm, it at first lies beneath and against the abdomen, then beneath the chest, and at last is comprised between the walls of the latter cavity, and the internal face of the anterior limb.

Form.—It is thin and flat above and below in its posterior third, thicker and depressed from side to side in its middle third, and narrow and prismatic in its anterior third. Its general form may be compared to that of a somewhat irregular triangle, elongated from before to behind, which would have a very short posterior border, a longer internal or inferior border, and an external or superior still more extensive.

Structure.—It is entirely composed of thick, parallel, fleshy fasciculi, all of which leave the posterior or internal border of the muscle to gain its narrow or anterior extremity. These fasciculi, as they approach the superior border, become longer, and those which proceed from the posterior border commence by aponeurotic fibres. Unfrequent intersections of fibrous tissue exist towards the anterior extremity of the muscle.

Attachments.—It originates: 1, From the tunica abdominalis by the aponeurotic fasciculi of its posterior border; 2, By its internal border, from the posterior two-thirds of the inferior border of the sternum. It terminates, by its anterior extremity, on the internal tubercle at the head of the humerus, the tendon of origin of the coraco-humeralis, and the fascia enveloping the coraco-radialis. Through the medium of this fascia, it is inserted into the external lip of the bicipital groove formed by the great trochanter, and is united to the two terminal branches of the supraspinatus muscles. (*See* Fig. 114, 12.)

Relations.—Its deep face, which is successively superior and internal, covers the external oblique and the straight muscle of the abdomen, the serratus magnus, costo-sternalis, and sterno-prescapularis, as well as some thoraco-muscular nerves; all these relations are maintained by means of a loose and abundant cellular tissue. Its superior face, which alternately looks downwards and outwards, responds: to the skin, from which it is separated by a slight cellulo-fibrous fascia; to the sterno-aponeuroticus; and to the muscles, vessels, and nerves of the inner aspect of the arm, through

the medium of the subbrachial aponeurosis of the panniculus and a considerable quantity of cellular tissue. Its upper border adheres in an intimate manner to the last-named muscle, and is bordered by the spur (external thoracic) vein. The large vascular trunks which leave the chest to reach

Fig. 115.

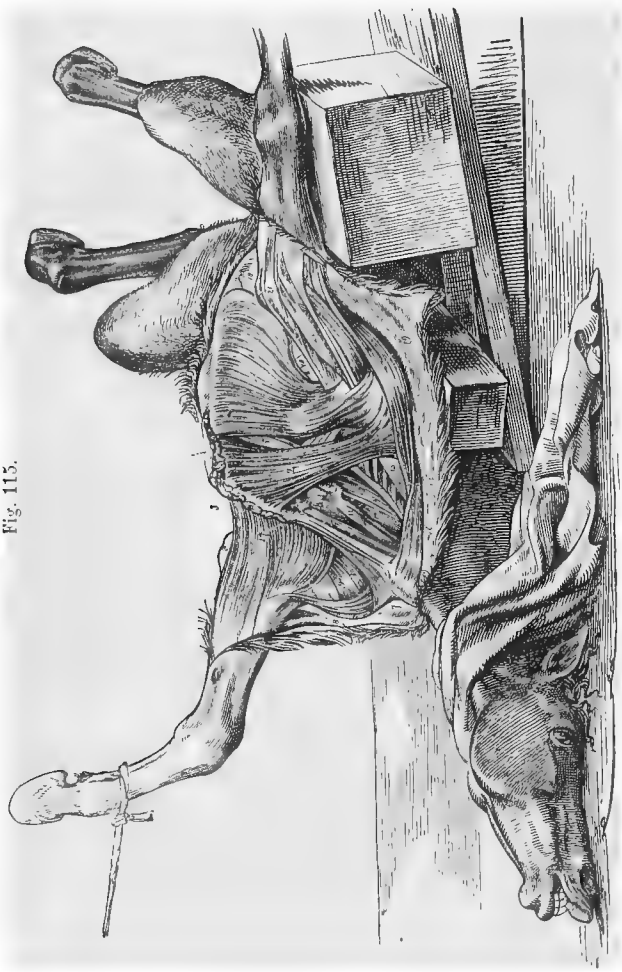

AXILLARY AND THORACIC MUSCLES.

1, Deep pectoral, or pectoralis major, with 2, The pectoralis parvus; 3, Superficial pectoral, or pectoralis transversus, including the sterno-aponeuroticus and sterno-humeralis; 4, Their attachment to the sternum; 5, Lateralis sterni, or transversalis of the ribs; 6, Sterno-maxillaris; 7, 16, Panniculus; 8, 19, Levator humeri, or mastoido-humeralis; 9, 10, Outer attachments of the deep pectoral muscle; 11, Sterno-thyroideus; 12, Sterno-hyoideus; 13, Inferior scalenus; 14, Superior scalenus; 15, Rhomboideus; 17, Point of sternum; 18, Intercostal muscle; 18′, Abdomen; 20, Subscapularis; 21, Ulna.

the anterior limb, pass above its anterior extremity, by crossing its direction.

Action.—It pulls the whole limb backwards, in pressing on the angle of the shoulder.

B. Sterno-prescapularis.—(The *pectoralis parvus* of Percivall and Bourgelat.)—*Form—Situation—Direction.*—A long prismatic muscle, con-

tracted at its two extremities, situated in front of the preceding, arising from the sternum, directed forwards and outwards towards the scapulo-humeral angle, and afterwards reflected upwards and backwards on the anterior border of the shoulder, which it follows to near the cervical angle of the scapula.

Structure and Attachments.—It is formed of very large fleshy fasciculi, analogous to those of the sterno-trochineus, which originate, by their inferior extremities, from the sides of the sternal keel and the cartilages of the first three or four ribs. They follow the direction of the muscle, and terminate, one above the other, on a short aponeurosis which covers the supraspinatus, and is confounded with the external aponeurosis of the scapula (Fig. 114, 14).

Relations.—In its axillary portion, this muscle responds, inwardly, to the costo-sternalis, the first sternal cartilages, and the corresponding intercostal muscles: outwards, to the sterno-trochineus and sterno-aponeuroticus. In its prescapular portion, it is in relation, outwardly, with the mastoido-humeralis and trapezius; inwardly, with the subscapulo-hyoideus, the scalenus, and the angularis of the scapula; behind, with the supraspinatus which is separated from it by the external scapular aponeurosis.

Action.—This muscle is a congener of the sterno-trochineus, and pulls the scapula backwards and downwards. It is also a tensor of the scapular aponeurosis.

DIFFERENTIAL CHARACTERS OF THE MUSCLES OF THE AXILLARY REGION IN OTHER THAN SOLIPED ANIMALS.

With regard to the *superficial pectoral*, it is remarked that in the *Ox*, *Sheep*, and *Pig*, the sterno-humeralis is small and less distinct from the sterno-aponeuroticus than in Solipeds; and that in the *Dog* and *Cat*, the sterno-aponeuroticus is very thin and narrow.

In the *deep pectoral* there is found, in the *Ox*, a sterno-prescapularis scarcely distinct from the sterno-trochineus, and which does not extend beyond the inferior extremity of the supraspinatus. In the *Sheep*, this muscle is quite confounded with the sterno-trochineus. In the *Pig*, the sterno-prescapularis somewhat resembles that of the Horse. Its inferior extremity only covers the first chondro-sternal articulation; the superior extremity is more voluminous. With regard to the sterno-trochineus, it terminates on the summit of the great trochanter, after detaching a short branch to the tendon of the coraco-humeralis. The sterno-prescapularis of the *Dog* is very feeble, and terminates with the principal muscle on the humerus.

COSTAL REGION.

In each costal region we find fifty-four muscles, which concur, more or less directly, in the respiratory movements. These muscles are: 1, The *great serratus;* 2, The *costo-transversalis;* 3, Seventeen *external intercostals;* 4, Seventeen *internal intercostals;* 5, Seventeen *supercostals;* 6, The *triangularis sterni.*

Preparation.—1. Place the subject in the second position. 2. Remove the fore-limb and all the muscles attaching it to the trunk, by sawing through the scapula as shown in figure 105, in order to expose the great serratus and costo-transversalis muscles; finish the dissection of the former by taking away all the yellow fibrous tissue which covers its posterior dentations. 3. Study the external intercostals and the supercostals, after removing the great oblique muscle of the abdomen, the serrati muscles, the common intercostal (ilio-costalis), and the ilio-spinalis. 4. Excise some external intercostals in order to show the corresponding internal ones. 5. The triangularis is dissected on another portion, which is obtained in separating the sternum from the thorax by sawing through the sternal ribs a little above their inferior extremity.

1. *Great Serratus.* (Fig. 105, 15.)

Synonyms.—Costo-subscapularis—*Girard.* Posterior portion of the serratus magnus of Bourgelat. (A portion of Percivall's *serratus magnus.*)

Form—Situation.—A very wide muscle, disposed like a fan, split up into digitations at its inferior border, applied against the thoracic walls, and partly concealed by the shoulder.

Structure.—It is composed of divergent fleshy fibres, all of which converge towards the superior extremity of the scapula, and are covered by a very strong aponeurosis that gradually diminishes from above to below, and only adheres to the muscle in its inferior part.

Attachments.—1, To the external face of the eight sternal ribs; 2, To the anterior triangular surface of the internal face of the scapula, behind the angularis, with which it is confounded; 3, To the whole extent of the posterior triangular surface of that bone.

On reaching the scapula, the aponeurosis separates from the fleshy fibres, and is inserted alone into the fibrous plane which covers the muscular fasciculi of the subscapularis.

Relations.—The great serratus responds: outwardly, and through the medium of an abundant supply of cellular tissue, which facilitates the play of the limb against the lateral wall of the thorax, to the subscapularis, supraspinatus, the adductor of the arm, great dorsal (latissimus dorsi), and the mass of olecranian muscles; inwardly, to the first seven external intercostals, to the sides of the sternum, and the anterior small serratus. Its four posterior digitations cross the first five of the great oblique muscle of the abdomen, and are covered by a prolongation of the abdominal tunic.

Action.—With that of the opposite side, this muscle constitutes a vast brace or girth on which the thorax rests when the animal is supported on its limbs; it therefore acts, in relation to the trunk, like a suspensory ligament. When it contracts, its fixed point being the thoracic walls, it pulls the superior extremity of the scapula downward and backward, and causes this portion of the limb to perform a swinging movement which carries the inferior angle upwards and forwards. If the limb is the fixed point, then it raises the thorax between the two anterior members, and assists in the respiratory movements by elevating the ribs.

2. *Transverse Muscle of the Ribs.* (Fig. 105, 16.)

Synonyms.—Costo-sternalis—*Girard.* (*Lateralis sterni—Percivall.*)

Form — Structure — Direction — Situation. — This is a flattened band, aponeurotic at its extremities, oblique from upwards and forwards, and situated under the preceding muscle, at the inner aspect of the deep pectoral.

Attachments.—Its posterior extremity is fixed to the sternum and the fourth sternal cartilage; the anterior to the external face of the first rib.

Relations.—Inwardly, with the second and third ribs, into which are often inserted some of its fasciculi, and with the three first intercostal muscles. Outwardly, with the two portions of the deep pectoral muscle.

Action.—This is an auxiliary to the expiratory muscles. (Leyh says its action is to raise the ribs and their cartilages, and thus to enlarge the anterior portion of the thorax during inspiration.)

3. *External Intercostals.* (Fig. 104, 68.)

Situation—Form.—These muscles fill the spaces between the ribs, but do not descend beyond their inferior extremities; they, therefore, do not occupy the intervals between the cartilages. They are flattened, fleshy bands, gradually diminishing in thickness from above to below.

Structure—Attachments.—Each intercostal muscle is composed of a series of muscular fasciculi, intermixed with numerous aponeurotic fibres, both of which pass obliquely backwards and downwards, from the posterior border of the preceding to the external face of the succeeding rib.

Relations.—They respond, outwardly, to the different muscles applied against the thoracic walls; inwardly, to the internal intercostals.

4. *Internal Intercostals.* (Fig. 106, 16.)

These are placed at the internal face of the preceding, which they exactly repeat with regard to their general form, but from which they differ in the following points:

1. Very thick between the costal cartilages, these muscles are reduced at the upper part of the intercostal spaces to a thin aponeurotic layer, supported only by some fleshy fibres. They therefore gradually diminish in thickness from below upwards.

2. Their fasciculi are less tendinous than those of the external intercostals, and are carried obliquely forward and downward, from the anterior border of the posterior rib to the posterior border and internal face of the rib in front; so that the fibres of the external and internal intercostals cross each other like the letter X.

3. Outwardly, they respond to the external intercostals; inwardly, to the costal pleura.

Action of the intercostal muscles.—The function of these muscles has been for a long time, and is even now, much discussed; and it may be said that there were never, perhaps, more diverse or contrary opinions given on any subject than on this. M. Bérard, who has summed up the elements of the discussion with the greatest judgment, considers the external intercostals as inspiratory muscles, and the internal ones also as inspiratory by those fasciculi which occupy the spaces between the costal cartilages; the remainder, the majority, are expiratory.

5. *Supercostals.*

Synonyms.—Transverso-costales—*Girard.* (*Levatores costarum—Percivall.*)

Small, flat, triangular, muscular and tendinous fasciculi, constituting, it might be said, the heads of the external intercostals, from which they are scarcely distinguishable in the first and last costal intervals.

They arise from the transverse processes of the dorsal vertebræ, and are directed backwards and outwards, gradually expanding, to terminate on the external face of the one or two ribs which succeed their fixed insertion. Outwardly, they respond to the ilio-spinalis; inwardly, to the external intercostals.

The supercostals draw the ribs forward, and are consequently inspiratory muscles.

6. *Triangularis of the Sternum.*

Synonyms.—Sternalis—*Bourgelat.* Sterno-costalis—*Girard.* (The *sterno-costales* of Percivall, and *sterno-costalis* of *Leyh.*)

Form—Situation.—This muscle, flattened above and below, elongated from before to behind, and dentated at its external or superior border, is situated in the thoracic cavity, above the sternum and the cartilages of the true ribs.

Attachments.—It is fixed, by its internal border, on the superior face of the sternum, to the ligamentous cord which circumscribes it outwardly. It has its movable insertion on the cartilages of the sternal ribs, the first excepted, by means of digitations from its external border.

Structure.—It is formed of strongly aponeurotic muscular fasciculi, which are directed from the internal to the external border.

Relations.—Inwardly, with the pleura; outwardly, with the cartilages to which it is attached, the internal intercostals, and the internal thoracic vein and artery.

Action.—The triangularis of the sternum concurs in expiration by depressing the costal cartilages. (Leyh asserts that if the fixed point be the sternum, this muscle pulls the ribs forwards, and so widens the thoracic cage; but if the fixed point is the ribs, the sternum will be raised and the thoracic space diminished.)

DIFFERENTIAL CHARACTERS IN THE MUSCLES OF THE COSTAL REGION IN OTHER THAN SOLIPED ANIMALS.

The muscles of the costal region cannot be the same in number in all the domesticated animals; the intercostals and supercostals, for instance, must vary in number with that of the ribs. Beyond this, the differences are slight. In the *Ox*, the *great serratus* is very extensive, and the portion which passes to the posterior triangular surface of the scapula is readily distinguished from the anterior by its diminished thickness, the larger proportion of aponeurotic fibres it contains, and the flattened tendon by means of which it is inserted. In the *Pig*, it is remarked that the internal intercostals are prolonged, maintaining a certain thickness, to near the vertebral column.

COMPARISON OF THE THORACIC MUSCLES OF MAN WITH THOSE OF THE DOMESTICATED ANIMALS.

The muscles of the axillary region, the costal region, and the diaphragm are designated in Man as the *thoracic muscles.*

The *pectoral muscles* are distinguished into great and small. The *great pectoral* corresponds to the superficial pectoral of the Horse. It is attached, on one side, to the inner two-thirds of the clavicle, the anterior face of the sternum, and the cartilages of the first six ribs; on the other, to the anterior border of the bicipital groove and, by a fibrous expansion, to the aponeurosis of the arm. The costal fasciculi are distinctly separated from the clavicular and sternal fasciculi.

The *small pectoral*, which corresponds to the deep pectoral of animals, is inserted, on the one part, into the external face of the third, fourth, and fifth ribs, on the other part by a tendon to the anterior border of the coracoid process.

In Man, there is found a muscle which does not exist in animals; this is the *subclavius*, a very slender fasciculus situated beneath the clavicle, and attached to the cartilage of the first rib and the external portion of the lower face of the clavicle (see Fig. 117, 5).

The *great serratus* does not show any distinct aponeurosis on its surface; it arises from the eight first ribs, and its digitations are grouped into three principal fasciculi.

Lastly, in Man the *internal intercostals* are prolonged to the vertebral column by small muscles, named the *subcostals* (or *intracostals*).

INFERIOR ABDOMINAL REGION.

The lateral and inferior walls of the abdominal cavity are formed by a wide musculo-aponeurotic envelope, which rests, by its periphery, on the sternum, ribs, lumbar vertebræ, ilium, lumbo-iliac aponeurosis, and the pubis. This envelope is concave on its superior surface, and results from the assemblage of four pairs of large membranous muscles arranged in

superposed layers. Reckoning them from without inwards, these are designated the *great*, or *external oblique*, the *small*, or *internal oblique*, the *great straight*, and the *transverse* muscle. Covered outwardly by an expansion of yellow fibrous tissue, the *tunica abdominalis*, and separated from those of the opposite side by the *white line* (*linea alba*), a medium raphé extending from the sternum to the pubis, these muscles support the intestinal mass, and by their relaxation or contraction adapt themselves to the variations in volume these viscera may experience.

Preparation.—After placing the animal in the first position, a wide opening is to be made in the pectoral cavity by the ablation of a certain number of ribs, which should be divided inferiorly, above the costal attachments of the great oblique muscle. The heart and lungs are removed; then an incision is made in the diaphragm, to allow the digestive viscera contained in the abdominal cavity to be taken away. It is not absolutely necessary, however, to empty that cavity, and if its contents be allowed to remain, several punctures should be made in the large intestine to prevent the accumulation of gas, and the too great distention of the abdominal parietes.

These preliminary precautions having been adopted, then proceed in the following manner:

1. Remove the skin from this region, and with it the panniculus carnosus, in order to study the external surface of the abdominal tunic. 2. The dissection of the great oblique muscle is accomplished by removing the yellow fibrous envelope from the fleshy portion of the muscle, together with the sterno-trochineus. The inguinal ring should be exposed by the ablation of the dartos muscle, the sheath and penis, or the mammæ. 3. On the opposite side, the small oblique is uncovered by excising the great oblique, leaving, however, that portion of the aponeurosis which is mixed up with that of the first muscle. 4. The latter having been studied, dissect the great straight muscle of the abdomen on the same side, in separating from the white line, by a longitudinal incision, the aponeurosis common to the two oblique muscles, dividing this aponeurosis and the fleshy portion of the internal oblique by another incision extending transversely from the umbilicus to the middle of the lumbar region, and laying back one of the musculo-aponeurotic sections on the thigh, the other on the ribs. 5. The transverse muscle is dissected on the same side as the external oblique has been. To expose it, nothing more is necessary than to make two incisions similar to the foregoing, but including the two oblique and the straight muscle, throwing back the two portions as above. 6. Lastly, open the entire abdominal cavity by cutting through the transverse muscle in the same way; then study the muscular digitations of that muscle, the internal orifice of the inguinal canal, and the leaf reflected from the aponeurosis of the great oblique muscle.

1. *Abdominal Tunic.*

The vast expansion of yellow elastic fibrous tissue spread over the two external oblique muscles of the abdomen is so named.

Very thick towards the prepubic tendon of the abdominal muscles and in the vicinity of the linea alba, this expansion gradually thins as it approaches the sternum, and disappears near the abdominal insertion of the sterno-trochineus muscles. It also diminishes in thickness as it extends from the linea alba; and when it reaches the fleshy portion of the great oblique muscle it becomes reduced to an extremely thin leaf, whose fasciculi separate more and more from one another, until they completely disappear. Anteriorly, however, it is seen to be prolonged on each side to the posterior digitations of the serratus magnus. Posteriorly, it furnishes some bundles of fibres, which are detached from the surface of the common tendon, and are carried between the thighs to be lost on the internal crural muscles.

The abdominal tunic is covered by the skin and the panniculus carnosus, from which it is separated by an abundance of cellular tissue. In the male, its external surface gives attachment to the suspensory ligaments of the sheath, and to the dartos; and in the female, to the elastic capsule which envelops each mammary gland. By its internal face, it closely adheres to the aponeurosis of the great oblique muscle; though it is easily

separated from the fleshy portion. It is traversed by several openings which afford passage to the subcutaneous vessels and nerves of the abdominal region.

The abdominal tunic acts as an immense elastic girth or bandage, which aids the muscles in sustaining the weight of the intestines. As the digestive organs increase in volume this tunic increases in thickness.

In the *Pig*, *Dog*, and *Cat*, it is reduced to a simple cellulo-aponeurotic lamina, owing to the stomach and intestines in these animals exercising but a small amount of pressure on the abdominal parietes.

2. *White Line.*

The white line (*linea alba*) is a fibrous cord comprised between the internal border of the two great straight muscles, and is considered as being formed by the intercrossing, on the median-line, of the aponeuroses belonging to the oblique and transverse muscles. Attached, in front, to the inferior surface of the xiphoid appendage, this cord is confounded, behind, with a large tendon, the *prepubic* or *common tendon of the abdominal muscles*, which is fixed to the anterior border of the pubes (Figs. 90, A; 108, C; 116, 4). This tendon, covered by the abdominal tunic, contributes to form the internal commissure of the inguinal ring, and gives origin to the pubio-femoral ligament.

Towards the union of its posterior third with its two anterior thirds, the white line widens, so as to form a lozenge-shaped space, in the centre of which is found the remains of the umbilicus and the umbilical cord (Fig. 116, 14).

3. *Great Oblique, or External Oblique of the Abdomen.* (Figs. 105, 18; 116, 5.)

Synonyms.—Costo-abdominalis—*Girard.* (*Obliquus externus abdominis—Percivall.*)

Situation—Composition.—This muscle, the largest and the most superficial of the four, is composed of a fleshy and an aponeurotic portion.

Form, Structure and Attachments of the fleshy portion.—This is composed of fibres directed obliquely downwards and backwards, and presents itself as a wide muscular band, narrower before than behind, applied to the inferior surface of the last thirteen or fourteen ribs. Its superior border is concave, and attached: 1, To the external surface of the ribs just mentioned by as many slightly aponeurotic digitations, the first four of which cross the dentations of the great serratus; 2, To the aponeurosis of the great dorsal muscle, from the last rib to the external angle of the ilium (Fig. 105, 18). Its inferior border, convex and sinuous, is continuous with the aponeurosis; it descends, in front, to the cartilaginous circle of the false ribs, which it projects beyond posteriorly, increasing in this as it nears the lumbar region.

Form, Structure, and Attachments of the aponeurosis.—This is narrow and thin in front, wide and thick behind, of a triangular form, and composed of white, nacrous-looking fibres passing in the same direction as the fibres of the fleshy portion, with whose inferior border it is continuous by its external border. Its internal border is inserted into the white line and the prepubic tendon; and its posterior border, extending from the external angle of the ilium to the anterior border of the pubis, responds to the plicature of the flank, embraces the corresponding crural muscles, and establishes the line of demarcation between the trunk and the abdominal limb (Fig. 116, 10).

The aponeurosis of the great oblique gives rise, at its posterior border, to two very remarkable fibrous leaves which appear to be produced by the

doubling of this aponeurosis into two layers. One of these leaves descends on the internal muscles of the thigh to constitute the *crural aponeurosis* (Fig. 116, 11); while the other is reflected upwards and forwards, to enter the abdominal cavity; this reflected leaf of the great oblique aponeurosis is named the *crural arch (ligament of Poupart* or *Fallopius*). (Fig. 108, B.)

Near the prepubic tendon of the abdominal muscles, and immediately before its division into two leaves, the aponeurosis of the external oblique is pierced by a large oval aperture (Fig. 116, 5), the inferior orifice of the canal through which passes the cord of the testicle in the male, and the mammary vessels in the female. This channel has been named the *inguinal canal.*

The description of the femoral aponeurosis, the crural arch, and the inguinal ring—a necessary complement of the great oblique muscle—will be given hereafter.

Relations of the Great Oblique Muscle.—By its superficial face, the external oblique responds to the sterno-trochineus and the abdominal tunic, which latter separates it from the skin and the panniculus. By its deep face, it is related to the ribs, into which it is inserted, as well as with their cartilages, the corresponding intercostal muscles, the small oblique, and the great straight muscle. The latter even appears to be attached, through the anterior moiety of its external border, to the fleshy portion of the great oblique, by means of a slight lamina of yellow elastic tissue, which covers, to a small extent, the deep face of the two muscles.

Action.—The external oblique, in contracting, compresses the abdominal viscera, flexes the vertebral column, and acts as an expiratory muscle. (By its compression on the abdominal viscera it concurs in the acts of defecation, micturation, and parturition.)

Internal Crural Aponeurosis.—This fibrous lamina descends from the plicature of the flank on the patella and the inner surface of the leg. Outwardly, it is confounded with the aponeurosis of the fascia lata; inwardly, it degenerates into cellular tissue. It covers the long adductor of the leg, part of the short adductor, the vastus internus, and the crural vessels at their exit from the abdominal cavity.

Crural Arch.—As already mentioned, this is the reflected leaf of the great oblique aponeurosis, and is also named the *ligament of Fallopius* and *Poupart's ligament.* It is a wide, flat band, attached by its extremities to the external angle of the ilium and the anterior border of the pubis. Its anterior face (Fig. 108, B) forms, inwardly, the posterior wall of the inguinal canal; it gives attachment, outwardly, to the posterior fibres of the small oblique muscle. Its posterior face, applied against the superior extremity of the patellar muscles, the long adductor of the leg, the pectineus, and the crural vessels on their leaving the abdomen, embraces all these parts as in a vast arch, and from this peculiarity it derives its name. Its superior border is inserted, for its external half, into the lumbo-iliac aponeurosis. In its middle part it is much thinner, and is prolonged to the external surface of the long adductor muscle of the leg and the iliac fascia, to be at last mixed up with the latter. Within the pectineal insertion of the small psoas muscle, it forms the anterior margin of the *crural ring:* a triangular orifice circumscribed on the other side by the anterior border of the pubis, the iliacus, and the long adductor of the leg, and through which pass the crural vessels as they leave the abdomen by the crural arch.[1] The inferior border

[1] This orifice is covered by a very thin aponeurotic layer, which is prolonged, above, on the crural vessels, behind, into the pelvic cavity, and which appears to be continuous,

is continuous with the femoral aponeurosis and that of the great oblique muscle.

Inguinal Canal.—This is an infundibuliform canal compressed on each side, through which the spermatic cord and scrotal artery pass from the abdomen in the male, and the external mammary vessels in the female.

Situated on the side of the prepubic region, in an oblique direction downwards, backwards, and inwards, and measuring from two to two-and-a-half inches in length, this canal lies between the crural arch, which constitutes its posterior wall, and the fleshy portion of the small oblique muscle, which forms the anterior wall.

Its *inferior* (*external*) or *cutaneous orifice*, also named the *inguinal ring*, is much larger than the superior (*internal*). Pierced in the aponeurosis of the great oblique, in the angle formed by the union of the internal border with the posterior border of the aponeurosis, this opening is of an oval form, directed obliquely backwards and inwards, which permits it to be described as having *two lips* or *pillars*, and *two extremities* or *commissures*.

The *pillars*, distinguished into *anterior* and *posterior*, are composed of the arciform fibres from the aponeurosis of the great oblique muscle.

The *commissures*, *internal* and *external*, result from the union of the two pillars at their extremities. The internal is limited by the prepubic tendon of the abdominal muscles.

The *superior* (*internal*) or *peritoneal orifice* of the inguinal canal is situated in front of, and directly opposite to, the crural ring. It is a simple dilatable slit, comprised, like the canal itself, between the crural arch and the small oblique muscle. Not well defined at its extremities, this opening includes the neck of the vaginal sheath.

4. *Small or Internal Oblique Muscle of the Abdomen.*
(Figs. 106, 17'; 116, 2.)

Synonyms.—Ilio-abdominalis—*Girard.* (*Obliquus internus abdominis—Percivall.*)

Situation—Composition.—Situated beneath the preceding, which exactly covers it, this muscle is, like it, composed of a fleshy and aponeurotic portion.

Form, Structure, Position, and Attachments of the muscular portion.—The muscular portion is very thick, triangular, and flabelliform, and occupies the region of the flank. Its superior border is united, by a thick, yellow, elastic production, to the aponeurosis of the great dorsal (latissimus dorsi), and a peculiar small muscle, named by the Germans the *retractor costæ (retractor of the last rib)*, which we consider as a dependency of the small oblique muscle. Its posterior border is slightly raised and lies against the crural arch, from which it separates, inwardly, to form the inguinal canal. Its anterior and inferior border is convex, irregular, and thinner than the other portions of the muscle, and is continuous with the aponeurosis. All the fibres entering into the composition of this muscular portion are spread like a fan, and leave the external angle of the ilium and the external fourth of the crural arch to be directed, the posterior fibres backwards and inwards, the middle fibres downwards, and the anterior fibres forwards to reach the antero-inferior border of the muscle.

---

inferiorly, with the upper border of Poupart's ligament. This lamina is perhaps only a dependency of the subperitoneal aponeurosis; and if so, it represents the only vestige of the *fascia transversalis* it has been p ssible to discover in Solipeds.

Form, Structure, and Attachments of the aponeurosis.—The aponeurosis is irregularly triangular, and formed of nacrous-looking fibres, which are directed like the muscular fibres, and cross in X fashion the aponeurotic fibres of the external oblique. It succeeds the antero-inferior border of the muscular portion, and is separated, superiorly, into several digitations which reach the internal face of the last asternal cartilages. Throughout the whole extent of its internal border it is fixed to the white line.

Relations.—This muscle is covered by the external oblique. The aponeuroses of the two muscles, which are merely superposed outwardly, are blended inwardly in so intimate a manner that it might be thought their respective fasciculi were woven into each other. The small oblique covers the great straight and the transverse muscles.

Action.—This muscle, a congener of the preceding, compresses the abdominal viscera, depresses the last ribs, and causes the flexion, either direct or lateral, of the vertebral column.

The retractor muscle of the last rib.—This small muscle, flattened on each side, and triangular in form, originates by aponeurotic fibres from the summits of the first two or three transverse processes of the lumbar region. It terminates on the posterior border of the last rib. Covered by the last digitation of the posterior serratus and by the great oblique, it covers in turn the transverse muscle of the abdomen. In contracting, it draws the last rib backwards, and fixes it in that position, in order to permit the expiratory action of the internal intercostal muscles. It therefore plays the same part, in regard to these muscles, that the scalenus does to the external intercostal muscles (Fig. 106, 17).

Fig. 116.

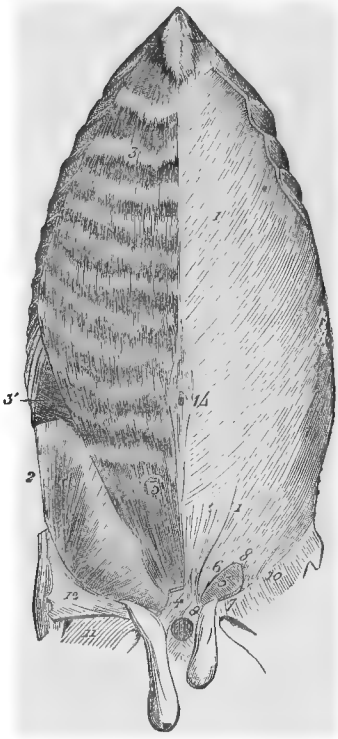

MUSCLES OF THE INFERIOR ABDOMINAL REGION.

1, Aponeurosis of the great oblique; 2, Muscular portion of the small oblique; 3, Rectus abdominis; 3′, Transverse muscle; 4, Flat tendon by which the four abdominal muscles are inserted into the pubis; 5, Inguinal ring; 6, Its anterior pillar; 7, Its posterior pillar; 8, Its external commissure; 9, Internal commissure; 10, Posterior border of the great oblique aponeurosis; 11, Internal crural aponeurosis; 12, Strip of the great oblique aponeurosis turned downwards to show the origin of Poupart's ligament, 14, Traces of the umbilicus.

5. *Great Rectus Muscle of the Abdomen.* (Figs. 105, 20; 116, 3.)

Synonyms.—Sterno-pubialis—*Girard.* (*Rectus abdominis—Percivall.*)

Situation—Extent—Form—Structure.—This is a wide and powerful muscular band, extending from the sternum to the pubis, included between the aponeurosis of the internal oblique and that of the transverse muscle, narrower at its extremities than in its middle portion, and divided by numerous transverse and zig-zag fibrous inter-

sections. These strongly adhere to the aponeurosis of the small oblique muscle, are nearer to each other, and more distinct, in front than behind, and are produced by small tendons which are placed at certain distances on the track of the muscular fasciculi, making it somewhat of a polygastric muscle.

Attachments.—In front: 1, To the prolonging cartilages of the last four sternal, and the first asternal ribs; 2, To the inferior face of the sternum. Outwardly, by the anterior moiety of its external border, to the internal face of the great oblique.

Behind, to the anterior border of the pubis through the medium of the common tendon, which is a direct continuation of the great straight muscle.

Relations.—By its inferior face, and in front, with the sterno-trochineus and great oblique; for the remainder of its extent, with the aponeurosis of the small oblique. By its superior face, with the transverse muscle and the cartilages of several ribs. By its internal border, with the white line, which separates it from the opposite muscle.

Action.—It draws the thorax backwards, and compresses the abdominal viscera. It is also the principal flexor of the spine. (Leyh, remarking that it shares in the functions of the preceding muscles, adds that it draws the pelvis forwards during copulation.)

6. *Transverse Muscle of the Abdomen.* (Figs. 106, 18; 116, 3′.)

Synonyms. — Lumbo-abdominalis — *Girard.* (*Transversalis abdominis* — *Percivall.* The *costo-abdominalis internus* of Leyh.)

Situation—Composition.— This muscle is situated immediately without the peritoneum, and forms the deep layer of the abdominal parietes. It is muscular outwardly, and aponeurotic for the remainder of its extent.

Form, Structure, and Attachments of the muscular portion.—It presents a band elongated from before to behind, extending from the sternum to the transverse processes of the last lumbar vertebræ, following in its course the direction of the cartilages of the ribs, and formed of parallel fibres passing from one border to the other.

Its superior border, concave, is attached: 1, To the internal surface of the asternal ribs by digitations placed opposite those of the diaphragm, but the majority of which do not mix with them; 2, To the extremity of the transverse processes of the lumbar region by a thin fibrous lamina. Its inferior border is convex and continuous with the aponeurosis.

Form, Structure, and Attachments of the aponeurosis.—This is triangular-shaped, with the base behind, and with its fibres running in a transverse direction to the median line. Closely laid one against another in front, these fibres separate behind, and form only a very thin and incomplete lamina.

By its external border, the aponeurosis is joined to the inferior margin of the muscular portion. Its internal border is fixed to the xiphoid cartilage and the white line. Its posterior border, badly defined, appears to join the crural arch only on its outer aspect.

Relations.—Outwards, with the inferior extremity of the asternal ribs and their cartilages, with the rectus abdominalis, the small oblique, and the depressor muscle of the last rib; inwardly, with the peritoneum, from which it is separated by the subperitoneal aponeurosis: an extremely fibrous layer which, in Man and some animals, becomes much thickened towards the crural

arch, where it forms adhesions. It has been described, in human anatomy, as the *fascia transversalis.*

Action.—It compresses the abdominal viscera when it contracts, and presses them against the vertebral column.

DIFFERENTIAL CHARACTERS OF THE MUSCLES OF THE ABDOMINAL REGION IN OTHER THAN SOLIPED ANIMALS.

As has been already said, the development of the *abdominal tunic* is in proportion to the volume of the digestive viscera. This membrane is, therefore, very wide and thick in *Ruminants*, while it is reduced to an insignificant leaf in the *Pig* and *Carnivora.* In these animals the internal crural aponeurosis does not exist, and is replaced by a cellular layer. The aponeurosis of the *great oblique*, instead of being doubled into two laminæ at its posterior border, is entirely reflected to form the crural arch. In the latter animals, the great oblique is also distinguished by the extensive development of its muscular part, and the narrowness of its aponeurosis.

The muscular portion of the *small oblique* of *Ruminants* occupies the entire space comprised between the posterior border of the last rib, the extremity of the transverse processes of the lumbar vertebræ, and the external angle of the ilium. The small retractor of the last rib is not distinct from the principal muscle. This arrangement is likewise present in the smaller domesticated animals. It is also to be remarked that, in *Ruminants*, the tendinous intersections of the *great rectus muscle of the abdomen* are more marked at its superior than its inferior face; and that the aponeurosis of the *transverse* is much thicker and more resisting than in Solipeds.

Fig. 117.

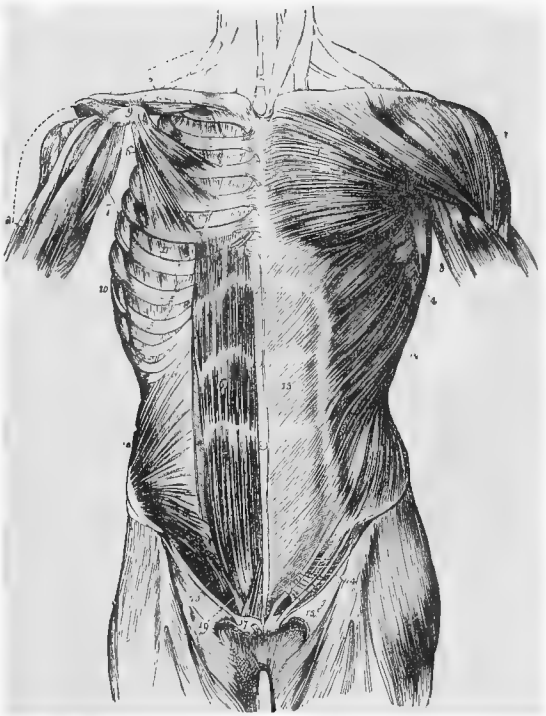

MUSCLES OF THE ANTERIOR ASPECT OF THE BODY OF MAN; ON THE LEFT SIDE THE SUPERFICIAL LAYER IS SEEN, ON THE RIGHT THE DEEPER LAYER.

1, Pectoralis major; 2, Deltoid; 3, Anterior border of the latissimus dorsi; 4, Serratus magnus; 5, Subclavius, right side; 6, Pectoralis minor; 7, Coraco-brachialis; 8, Biceps, with its two heads; 9, Coracoid process of the scapula; 10, Serratus magnus, right side; 11, External intercostal muscle of the fifth intercostal space; 12, External oblique; 13, Its aponeurosis with the linea alba; 14, Poupart's ligament; 15, External abdominal ring; 16, Rectus muscle of right side; 17, Pyramidalis muscle; 18, Internal oblique; 19, Conjoined tendon of internal oblique muscle and Poupart's ligament.

COMPARISON OF THE ABDOMINAL MUSCLES OF MAN WITH THOSE OF ANIMALS.

With the exception of some slight differences, the abdominal muscles of Man present the same disposition as those of the smaller animals.

The abdominal tunic is not present, but is replaced by a cellular layer which

separates the skin from the aponeurosis of the *great oblique.* The muscular portion of this muscle has no attachment to the aponeurosis of the great dorsal.

The aponeurosis of the *small oblique* is divided into two lamellæ at the external border of the great straight muscle; the anterior is consolidated with the great oblique, and passes in front of the great straight; the posterior is united to the transverse, and passes behind that muscle.

The aponeurosis of the *transverse* is divided into two leaves, only one of which remains behind the great straight muscle; this is named the *semilunar fold of Douglas.*

The *great rectus muscle of the abdomen* offers three transverse fibrous intersections in its length (*lineæ transversæ*). At its upper extremity, it divides into three branches: the internal is attached to the xiphoid appendage and the cartilage of the seventh rib; the middle, to that of the sixth rib; the external, to the cartilage of the fifth rib.

"To the great rectus is annexed a small triangular muscle, the *pyramidal*, which is not found in animals. This muscle is about 2⅓ inches long; is sometimes absent; most developed in children; is attached by its base to the pubis, between the spine and the symphysis; and by its summit is continuous with a tendon which is lost in the white line, and constitutes, with that of the opposite side, a fibrous cord which may be followed to the umbilicus."—*Beaunis and Bouchard.*

Lastly, at the inner aspect of all the abdominal muscles, beneath the peritoneum, is a fibrous lamella—the *fascia transversalis.* This fascia is not distinctly limited upwards or outwards; below, it is fixed to the crural arch, in the vicinity of the inguinal canal, and sends a layer to the surface of the cord spermatic.

DIAPHRAGMATIC REGION.

This is composed of a single muscle, the *diaphragm.*

Diaphragm.

Preparation.—Place the subject in the first position; open the abdomen and remove the viscera it contains, as well as the large vascular trunks lying upon the sublumbar region; detach the peritoneum from the fleshy portion of the muscle, in order to show the digitations of the latter more distinctly, taking care not to allow the air to enter the thoracic cavity, as it would destroy the tense and concave form of the diaphragm.

Situation—Direction.—The diaphragm is a vast musculo-aponeurotic partition separating the thoracic from the abdominal cavity, between which it is placed in an oblique direction downwards and forwards.

Form.—It is flattened before and behind, elliptical, wider above than below, concave posteriorly, and convex anteriorly.

Structure.—This muscle comprises: 1, A central aponeurotic portion designated the *phrenic centre*, which is incompletely divided into two *folioles* (*leaflets*) by the *pillars*—fleshy columns which descend from the sublumbar region; 2, A peripheral (or circumferential) portion forming a wide muscular band around the phrenic centre.

The *phrenic centre* (also named the *speculum Helmontii* or mirror of Helmont) is composed of white, glistening, radiating fibres which, originating from the pillars, extend in every direction to join the muscular fibres of the peripheral portion. It is pierced, in its right leaflet, by a large opening for the posterior vena cava.

The *pillars* are two in number, a *right* and *left.* The *right pillar*, the most considerable, is a very thick, fleshy fasciculus which commences under the loins by a strong tendon, united to the inferior common vertebral ligament. It descends to the phrenic centre, to which it gives a heart-shaped appearance. Near its inferior extremity, it presents an opening for the passage of the œsophagus into the abdominal cavity.—The *left pillar* is a small triangular fasciculus, partly separated from the preceding by an orifice for the transmission of the posterior aorta and the thoracic duct. It also arises

from the sublumbar region by a tendon, which is confounded with that of its congener.

The *peripheral muscular portion* is continuous, by its concentric border,

Fig. 118.

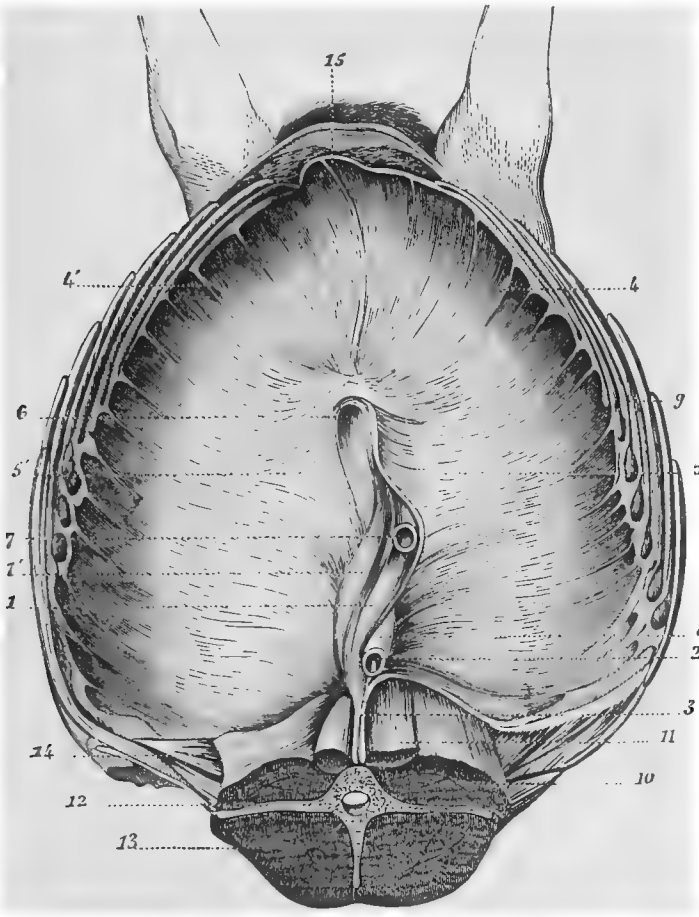

DIAPHRAGM OF THE HORSE; POSTERIOR FACE.

1, 1', The two portions of the right pillar; 2, Left pillar; 3, Tendons of the pillars; 4, 4', Peripheral muscular portion; 5, Left leaflet of the aponeurotic portion; 5, 5', Right leaflet of the same; 6, Posterior vena cava; 7, Œsophagus passing through the opening in the right pillar; 8, Posterior aorta between the two pillars; 9, Cartilaginous circle of the ribs; 10, 11, Section of the psoas muscle; 12, Section of a lumbar vertebra; 13, Section of the common mass; 14, Retractor muscle of the last rib; 15, Xiphoid appendage of the sternum.

with the central aponeurosis. Its excentric border is divided into dentations. Above, and on the left side, it nearly always joins the left pillar; but on the right side it stops at a certain distance from the corresponding pillar,

so that towards this point the phrenic centre is not enveloped by the peripheral portion, and is in contact with the sublumbar region.

Attachments.—1, To the bodies of the lumbar vertebræ by the tendons of its two pillars, which tendons are confounded with the inferior common vertebral ligament; 2, By the external contour of its muscular portion, to the superior face of the xiphoid appendage and the inner face of the last twelve ribs, near their inferior extremities or cartilages. The digitations forming the last insertions do not intercross, in Solipeds, with those of the transverse muscle of the abdomen, being separated by an interval which is wider behind than before.

Relations.—The anterior face of the diaphragm is covered by the pleura, and responds, mediately, to the base of the lung. The posterior aspect, covered by the peritoneum, is in contact with the greater part of the viscera contained in the abdominal cavity—the stomach, colon, spleen, and liver; the latter is even attached to this surface for a portion of its extent.

On each side of the pillars, the circumference of the muscle forms an arch which passes over the great and small psoas muscles.

Action.—The diaphragm, in contracting, tends to become an inclined plane; its central portion is carried backwards, and the antero-posterior diameter of the chest is increased. It is, therefore, essentially an inspiratory muscle. It may also raise the ribs by making the mass of abdominal viscera its fixed point; it then acts as a reflected muscle, to which these viscera serve as a pulley. (The diaphragm also aids the other abdominal muscles in expulsive efforts and, when affected with irregular spasmodic contractions, produces the peculiar phenomenon in Man and some of the lower animals, known as hiccough.)

DIFFERENTIAL CHARACTERS OF THE DIAPHRAGM IN OTHER THAN SOLIPED ANIMALS.

In the *Ox*, the pillars of the diaphragm are very long and voluminous. "The attachments of the muscular portion are much farther distant from the cartilaginous circle than in the Horse, particularly at the superior part; this disposition explains the innocuousness of puncture of the paunch in the middle of the *last intercostal space;* for with the Horse, when the instrument is passed through this part, it penetrates the thorax.—*Communicated to M. Lecoq by M. Tabourin.*

In the *Sheep* we have not remarked that the costal attachments were more forward than in the Horse.

Rigot erroneously states that, in the *Pig* and *Dog*, the œsophagus passes between the two pillars of the diaphragm; on several occasions we have convinced ourselves that this conduit traverses the right pillar, as in the other animals.

COMPARISON OF THE DIAPHRAGM OF MAN WITH THAT OF ANIMALS.

In the human diaphragm, the aponeurotic portion is divided into three leaflets, which has caused it to be termed the *aponeurotic trefoil.* Between the middle and right leaflet is the orifice through which the inferior vena cava passes. The openings for the passage of the œsophagus and the aorta are situated between the two pillars. There are frequently met with in Man one or two small accessory pillars, separated from the large pillars by an aperture that affords a passage, on the right side, to the vena azygos and the sympathetic nerve, and on the left side, to one of the lumbar veins and the other sympathetic nerve.

The peripheric muscular portion always joins, posteriorly, the central muscular portion.

Article II.—Muscles of the Anterior Limbs.

These are divided into four principal groups: the muscles of the shoulder, arm, fore-arm, and foot.

MUSCLES OF THE SHOULDER.

These muscles are grouped around the scapula, and all act upon the arm, which they extend, flex, abduct, adduct, etc. They form two regions: an *external* or *suprascapular*, and an *internal* or *subscapular*.

A. *External Scapular Region.*

This comprises four muscles: the *long abductor of the arm*, the *short abductor*, the *super-* (or *supra-*) *spinatus*, and *sub-* (or *infra-*) *spinatus*. These muscles are applied to the external surface of the scapula, and are covered by an aponeurotic lamella.

Preparation of the external scapular region.—Separate the limb from the trunk; remove the trapezius and mastoido-humeralis, to expose the external surface of the aponeurosis; take away, also, the small pectoral muscle, after studying its mode of insertion into this fascia.

This being accomplished, next remove the latter muscle to show the supraspinatus, the subspinatus, and long abductor muscle of the arm; leaving only the strip which attaches the anterior portion of the latter to the tuberosity of the scapular spine.

To study the short abductor muscle, it is only necessary to cut the long abductor and superspinatus across, and to throw back the sections: an operation requiring some care, because of the intimate adherence of the short abductor to the infraspinatus.

1. *External Scapular Aponeurosis.*

This aponeurosis, to which the sterno-prescapularis and long adductor of the arm act as tensors, gives origin, by its internal face, to several septa which penetrate between the scapular muscles, and form around them more or less complete contentive sheaths. Its external face is separated from the skin by the panniculus carnosus, trapezius, mastoido-humeralis, and the aponeurotic fascia which unites the last two muscles. It is continuous, in front, with the thin fibrous expansion extended over the internal scapular muscles; behind and downwards, it is prolonged over the muscles of the arm and insensibly degenerates into conjunctival tissue; above, it is attached to the fibro-cartilaginous prolongation of the scapula.

2. *Long Abductor of the Arm, or Scapular Portion of the Deltoid.* (Fig. 119, 1, 1.)

Synonyms.—Scapulo-humeralis magnus—*Girard.* (*Teres major—Percivall. Great scapulo-trochiterius—Leyh.*)

Situation—Composition—Form—Direction.—This muscle is situated beneath the scapular aponeurosis, behind the subspinatus, and is composed of two portions placed one above the other, separated by a superficial interspace. The posterior portion, the most considerable, is elongated from above to below, bulging in its middle, narrow at its extremities, plane on its external, and convex on its internal surface. It accompanies the posterior border of the subspinatus, and is lodged in a depression in the thick extensor muscle of the fore-arm.

The anterior portion, much shorter than the preceding, extends over the subspinatus and short abductor, by slightly crossing the direction of these two muscles. Thick inferiorly, this portion diminishes considerably towards its superior extremity.

Fig. 119.

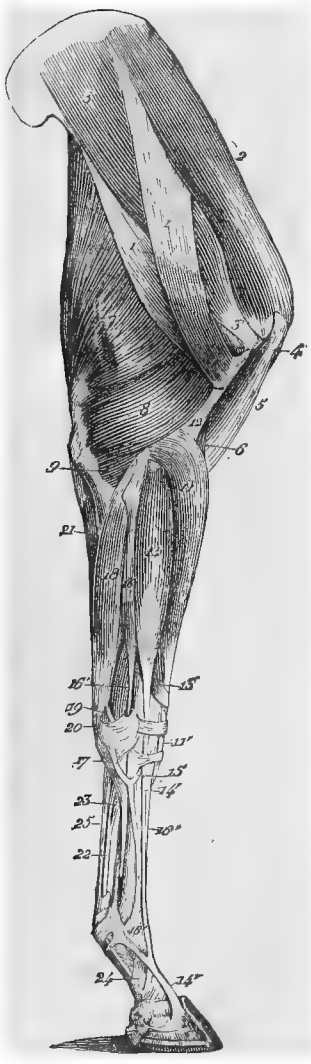

EXTERNAL MUSCLES OF THE RIGHT ANTERIOR LIMB.

Structure and Attachments.—The first portion is generally paler than the second, and is composed of longitudinal fleshy fibres deeply intersected by tendinous strips. It takes its origin, by its superior extremity, from the dorsal angle of the scapula. The anterior portion is deeper-coloured and more tendinous than the other. Its superior extremity, included within two fibrous folds resulting from the duplicature of the scapular aponeurosis, is fixed, through the medium of these, to the tuberosity of the scapular spine.

These two muscular bodies unite inferiorly, and terminate together on the deltoid imprint or subtrochiterian crest by tendinous and muscular fasciculi.

Relations.—This muscle responds: outwardly, to the scapular aponeurosis, with which it may be said to form one body; inwardly, to the subspinatus, the short abductor of the arm, and the large and short extensors of the fore-arm.

Action.—It gives a very marked abduction movement to the humerus, and also makes it pivot outwards. It acts, besides, as a flexor of that bone, when its action is combined with that of the adductor of the arm. It should also be considered as a powerful tensor of the scapular aponeurosis.

3. *Short Abductor of the Arm, or Teres Minor.* (Fig. 85, 2, 3.)

Synonyms.—Scapulo-humeralis minor—*Girard.* (*Teres minor — Percivall. Scapulo-trochiterius, medium and parvum—Leyh.*)

Volume—Situation—Direction.—A small elongated muscle, situated below the preceding and the subspinatus, along the posterior border of the scapula, whose direction it follows.

Form—Structure.—In its inferior half it

1, 1, Long abductor of the arm; 1′, Its humeral insertion; 2, Superspinatus; 3, Subspinatus; 3′, Its tendon of insertion; 4, Short abductor of the arm; 5, Biceps; 6, Anterior brachialis; 7, Large extensor of the fore-arm; 8, Short extensor of the fore-arm; 9, Anconeus; 11, Anterior extensor of the metacarpus; 11′, Its tendon; 12, Aponeurosis separating that muscle from the anterior brachialis; 13, Oblique extensor of the metacarpus; 14, Anterior extensor of the phalanges; 14′, Its principal tendon; 15, The small tendinous branch it furnishes to the lateral extensor; 16, Lateral extensor of the phalanges; 16′, Its tendon; 17, The fibrous band it receives from the carpus; 18, External flexor of the metacarpus; 19, Its metacarpal tendon; 20, Its supracarpal tendon; 21, Ulnar portion of the perforans; 22, Tendon of the perforans; 23, Its carpa lligament; 24, Its reinforcing phalangeal sheath; 25, Tendon of the perforatus.

is prismatic, muscular, divided by fibrous intersections, and easily separated into several irregular fasciculi. In its superior half it is flattened, entirely tendinous, and split into several digitations, the longest of which are behind.

Attachments.—It originates 1, Through the medium of its tendinous digitations, from the posterior border of the scapula and the linear imprints in the posterior spinous fossa; 2, From the small tubercle situated on the external side of the margin of the glenoid cavity, by a short tendon. It terminates on the humerus, between the crest of the external tubercle and the deltoid imprint.

Relations.—Outwardly, with the subspinatus and the long abductor; inwardly, with the large extensor of the fore-arm, the short extensor, and the capsule of the scapulo-humeral articulation.

Action.—Like the preceding, this muscle is an abductor and outward rotator of the humerus.

4. *Superspinatus.* (Figs. 119, 2; 121, 5.)

Synonyms.—Superacromio-trochiterius—*Girard.* (*Antea spinatus—Percivall. Anterior spinatus—Leyh.*)

Form—Situation.—This muscle is thick and prismatic, stronger below than above, representing a very elongated pyramid, and completely filling, and even projecting beyond, the super-scapular fossa.

Structure—Attachments.—It is almost entirely formed of fleshy fibres, which are attached, by their superior extremities, to the cartilage of prolongment of the scapula, the inner face of the scapular aponeurosis, the super-scapular fossa, and the anterior border and cervical angle of the scapula—*fixed insertion.* These fibres, on reaching the inferior extremity of the muscle, form two very thick, short, and slightly tendinous branches, united to each other by the enveloping coraco-radial or biceps aponeurosis. The external branch reaches the summit of the external tubercle: the internal is inserted into the corresponding part of the internal tuberosity—*movable insertion.*

Relations.—Outwards, with the scapular aponeurosis, to which its fibres adhere in the most intimate manner; inwards, with the scapula and the subscapularis muscle; forwards, with the small pectoral; and behind, with the acromion spine and the subspinatus. The two terminal branches cover and embrace the coraco-radialis tendon, and the capsule of the scapulo-humeral articulation.

Action.—This muscle is an extensor of the humerus, and a tensor of the enveloping coraco-radial aponeurosis. With regard to the articulation of the shoulder, it plays the part of a powerful ligament: a function it shares with the majority of the other scapular muscles.

5. *Subspinatus.* (Fig. 119, 3, 3′.)

Synonyms.—Sub-acromio-trochiterius—*Girard.* (*Postea spinatus—Percivall. Posterior spinatus—Leyh.*)

Situation—Form.—Situated, as its name indicates, in the subspinatus fossa, this muscle is wide, thin, and flattened on both sides at its superior extremity, thick and prismatic in its middle, and conoid at its inferior extremity, which is terminated by two short branches—an external and internal.

Structure.—The muscular fibres entering into its composition are directed, like the muscle itself, forward and downward; they are deeply mixed with strong aponeurotic lamellæ. Of the two branches which terminate it inferiorly the external is the strongest, and is entirely constituted by a powerful tendon; the internal is both muscular and aponeurotic.

Attachments.—All the fleshy fasciculi of this muscle are fixed, either directly, or through the medium of the internal aponeurotic lamellæ: 1, To the whole extent of the subspinatus fossa; 2, To the acromion spine and its tuberosity; 3, To the cartilage of prolongment of the scapula; 4, To the internal face of the scapular aponeurosis—*fixed insertion.* The movable insertion of the muscle takes place, on the external tuberosity, by its two terminal branches, the internal passing within the convexity: and the strong tendon constituting the external branch (Fig. 119, 3′) gliding, by means of a synovial bursa, over the surface of this convexity, and attaching itself to the roughened facet which forms the crest of the external tubercle.

Relations.—This muscle is covered by the anterior portion of the long abductor of the arm, and by the scapular aponeurosis. It covers the scapula, its cartilage, the fixed insertion of the large extensor of the fore-arm, and the short abductor, which adheres to it in the most intimate manner at its superior or aponeurotic portion. Its anterior border responds to the acromion spine and superspinatus; the posterior is bordered by the long abductor of the arm. Its inferior extremity protects, outwardly, the capsule of the scapulo-humeral articulation, and is concealed beneath the mastoido-humeralis.

Action.—The subspinatus acts on the humerus as an abductor and outward rotator.

B. *Internal Scapular Region.*

This is composed of four muscles: three principal, the *subscapularis, adductor of the arm* or *teres major*, and the *coraco-brachialis*, are situated at the internal face of the scapula, and are covered by a very small fibrous fascia which is formed of some scattered parallel fibres that run in a transverse direction. The last, named the *small scapulo-humeralis*, is a very slender fasciculus deeply lodged behind the articulation of the shoulder.

Preparation.—Turn over the limb which has served for the dissection of the preceding region, and take away the slight internal scapular fascia. Be careful to preserve the termination of the great dorsal muscle, in order that its relations and adhesions with the adductor of the arm may be studied; leave also the humeral insertion of the sterno-trochineus, so that its union with the tendon of the coraco humeralis may be noted; in a word, prepare the region as it is represented in figure 121. With regard to the small scapulo-humeral muscle, which is not shown in this preparation, it ought to be dissected at the same time as the short flexor of the fore-arm.

Subscapularis. (Fig. 121, 3).

Synonym—Subscapulo-trochineus—*Girard.*

Situation—Direction—Form.—This muscle, lodged in the subscapular fossa whose name it bears, affects the same oblique direction as the scapula. It is wider above than below, and divides superiorly into three portions; so that its form exactly repeats that of the excavated surface it covers.

Structure.—The muscular fibres of the subscapularis slightly converge towards its inferior extremity, and all end in a very strong, wide, and short tendon. They are intermixed with deep and superficial tendinous fibres,

which singularly augment the tenacity of the muscle; the superficial fibres are spread over the internal surface in glistening, nacrous layers.

Attachments.—The subscapularis takes its origin from the whole extent of the fossa whose name it bears. Its movable insertion takes place on the internal tubercle, by means of a voluminous tendon it offers at its inferior extremity. A particular small synovial bursa facilitates the gliding of this tendon over the eminence into which it is inserted.

Relations.—The external face of the muscle is in contact with the scapula. Its internal face is applied against the great serratus, from which it is separated by a thick layer of cellular tissue, as well as by the rudimentary fascia covering the three muscles of the internal scapular region in common. Its anterior border, margined by the superspinatus, adheres closely to that muscle in its upper two-thirds, and forms with it, by its inferior third, the intermuscular space that lodges the subscapular vessels and nerves. Its posterior border responds to the adductor of the arm, with which it also unites for the greater part of its extent; it is isolated from this muscle, in its inferior third, by the interspace lodging the subscapular vessels and nerves. Its terminal tendon covers the capsule of the scapulo-humeral articulation, which it powerfully binds; it is in part covered by the tendon of origin of the coraco-humeralis muscle, which glides over its surface as on a pulley, by means of a synovial bursa.

Action.—This muscle is principally, and perhaps exclusively, an adductor of the arm. It may be admitted, however, that it rotates the humerus inwards.

Adductor of the Arm, or Teres Major. (Fig. 121, 4.)

Synonyms.—Subscapulo-humeralis—*Girard.* (*Teres major*—*Percivall.* *Great scapulo-humeralis*—*Leyh.*).

Form—Situation—Direction.—A long muscle, flattened on both sides, bulging in its middle, contracted at its extremities, thick at its anterior, and thin at its posterior border. It is situated behind the preceding, in the same oblique direction, and is parallel with the posterior portion of the long abductor, which it appears to repeat in the internal scapular region.

Structure.—It is almost entirely muscular, showing only some tendinous fibres at its external surface and upper extremity. Its inferior extremity is terminated by a flat tendon, which also belongs to the great dorsal, and which has been already described (see page 203).

Attachments.—It arises from the dorsal angle of the scapula, and the posterior border of the subscapular muscle—*origin;* it passes to the circular imprint on the body of the humerus, to be attached by its inferior tendon—*termination.*

Relations.—Outwards, with the aponeurosis of the great dorsal and that of the long extensor of the fore-arm, which isolates it from the large extensor muscle; inwards, with the great serratus, from which it is separated by the fibrous and cellular layers mentioned in the description of the subscapularis. Its inferior extremity covers the short flexor and middle extensor of the fore-arm; it is covered by the long branch of the coraco-humeralis, and by the vascular and nervous trunks which send their ramifications to the arm, fore-arm, and foot.

Action.—This muscle adducts the arm, and causes it to rotate inwards. If it contracts at the same time as the long abductor, it directly flexes the humerus.

3. *Coraco-humeralis, Coraco-brachialis, or Omo-brachialis.* (Fig. 121, 10.)

(*Synonyms.—Coraco-humeralis—Percivall. Middle scapulo-humeralis—Leyh.,*

Volume—Situation—Direction.—A small elongated muscle, which appears to belong to the arm rather than the shoulder, as it is situated at the internal face of the humerus, whose direction it slightly crosses. If it is described as in the subscapular region, it is because of its attachments and action, which are, in every respect, analogous to those of the other muscles of the shoulder.

Attachments—Form—Structure.—It commences on the beak of the coracoid process by a small flat tendon, which is at first included between the supraspinatus and subscapularis, but afterwards leaves the interstice formed by these two muscles, to glide and be inflected over the terminal tendon of the latter. This small tendon is succeeded by two muscular branches, one deep, the other superficial. The first is a wide, thin, and short band, almost entirely muscular, attached to the body of the humerus above the internal tuberosity. The second forms a fleshy body of a certain thickness, flattened on both sides, and strongly aponeurotic; the fasciculi composing it are longer as they are more posterior, and are inserted, by their inferior extremities, into the imprints on the anterior face of the humerus.

Relations.—This muscle is covered by the coraco-radialis, and by the sterno-trochineus, which is partly attached to its tendon. It covers the internal insertion of the subscapularis, the humerus, the common tendon of the great dorsal, and the adductor of the arm, and a small portion of the short flexor and middle extensor of the fore-arm. Its posterior border is margined by the vascular and nervous trunks on the inner aspect of the arm. The anterior humeral nerve passes between its two branches, along with an arterial and venous ramification.

Action.—It is an adductor of the arm, and makes it also pivot inwards. Its direction and the disposition of its attachments do not permit it to produce rotation outwards, though it has been stated to do so by several authors.

4. *Small Scapulo-humeralis.*

(*Synonyms.*—Not mentioned by Percivall. Leyh, in addition to the above designation, names it the *tensor of the capsular ligament.*)

The scapulo-humeralis gracilis is a very small cylindrical fasciculus, comprised between the large extensor of the fore-arm and the capsule of the scapulo-humeral articulation; deriving its origin above the margin of the glenoid cavity of the scapula, and terminating below the head of the humerus by a thin tendon, which insinuates itself between the fibres of the short flexor of the fore-arm. This muscle appears to be peculiar to Solipeds, and has been regarded by Rigot as intended to raise the capsule of the scapulo-humeral articulation during flexion, so as to prevent its being pinched between the articular surfaces.

DIFFERENTIAL CHARACTERS OF THE MUSCLES OF THE SHOULDER IN OTHER THAN SOLIPED ANIMALS.

The *Carnivora* are the only animals which offer somewhat notable differences in the muscles of the shoulder.

Thus, the *long abductor of the arm*, very developed, has an anterior portion arising directly from the acromion, and a posterior portion which springs from the whole extent

of the scapular spine, by a short aponeurosis. The *superspinatus* is considerable, and terminates in a single branch that goes to the great trochanter.

The *subspinatus* is not so large as the preceding, and is also undivided at its inferior extremity: it is the inferior branch which is absent.

The *coraco-brachialis* is very short, and composed of a single fasciculus, which terminates above the humeral insertion of the adductor of the arm.

In the *Pig*, the disposition of this muscle is the same; it is, besides, very tendinous.

COMPARISON OF THE MUSCLES OF THE SHOULDER OF MAN WITH THOSE OF ANIMALS.

As muscles of the shoulder, there are only described the *deltoid*, *subspinatus*, *teres minor* and *major*, and the *subscapularis*; the *coraco-brachialis* being included in the region of the arm, and the *small scapulo-humeralis* is absent (*see* Fig. 120).

The *deltoid*, represented in part by the long abductor of the arm of Solipeds, is a large, triangular, flat muscle, that covers the articulation of the shoulder. Its fibres are inserted into the external third of the anterior border of the clavicle, the external border of the acromion, and the inferior border of the scapular spine for the whole of its width; below, it is attached, through the medium of a tendon, to the deltoid imprint.

By their disposition, the *superspinatus*, *subspinatus*, and *subscapularis* resemble the muscles of Carnivora. The *teres major*, after establishing relations with the great dorsal, as in Solipeds, is fixed into the inner lip of the bicipital groove.

Fig. 120.



MUSCLES OF ANTERIOR ASPECT OF MAN'S UPPER ARM.

1, Coracoid process of scapula; 2, Coraco-clavicular ligament (trapezoid) passing upward to clavicle; 3, Coraco acromial ligament, passing to acromion; 4, Subscapularis; 5, Teres major; 6, Coraco-brachialis; 7, Biceps; 8, Upper end of radius; 9, Brachialis anticus; 10, Internal head of triceps.

MUSCLES OF THE ARM.

These muscles, grouped around the humerus, are attached to the fore-arm by their inferior extremities. Those situated in front flex this portion of the limb, while those behind extend it. The first form the *anterior brachial region*, the second the *posterior brachial region*.

A. *Anterior Brachial Region.*

This region is composed of only two muscles, the *long* and *short flexors of the fore-arm.*

1. *Long Flexor of the Fore-arm or Brachial Biceps.* (Figs. 85, 119, 121.)

Synonyms.—Coraco-cubitalis, or coraco-radialis, according to *Girard*. (*Flexor brachii—Percivall. Scapulo-* or *coraco-radialis—Leyh.*)

Preparation.—Place the limb on its internal face, throw back the brachial insertion of the mastoido-humeralis, sterno-humeralis, and sterno-aponeuroticus, over the external muscles of the fore-arm; excise, lengthways, the inferior extremity of the superspinatus, to show the originating tendon of the muscle. The inferior insertion may be studied with that of the short flexor muscle.

Form — Situation — Direction — Structure.—A long, cylindrical muscle, thick in its middle portion, bifid inferiorly, situated in front of the humerus, in an oblique direction downwards and backwards, tendinous at its two extremities, divided by a great number of strong fibrous intersections, one of which, nearly central and much more considerable than the others, is a very resisting cord that traverses the muscle throughout its length, and becomes continuous with the tendons at its extremities.

Attachments.—This muscle has its origin at the base of the coracoid

process by a superior, round, and thick tendon (Fig. 85, 6) that reaches the bicipital groove, on which it is moulded in becoming fibro-cartilaginous, and over which it glides by means of a synovial sac, to be inflected backwards and confounded with the body of the muscle. Its inferior tendon, extremely short and strong, terminates on the superior and internal tuberosity of the radius—the *bicipital tuberosity*—in uniting itself to the capsular ligament of the elbow joint, and insinuating itself beneath the internal ligament of this articulation. At its origin, this tendon gives off a somewhat resisting fibrous band, which is spread over the surface of the anterior extensor of the metacarpus, and is confounded with the antibrachial aponeurosis.

Relations.—The coraco-radialis covers an adipose cushion which separates it from the capsule of the scapulo-humeral articulation, the anterior face of the humerus, the coraco-humeralis, and the articulation of the elbow. It is covered: 1, By the superspinatus, between the two branches of which it passes; 2, By a special aponeurotic sheath, whose tensor is the above-named muscle, with the sterno-trochineus (*see* Fig. 114, 12, in which this aponeurosis has been partly preserved). This sheath separates the coraco-radialis from the mastoido-humeralis, the sterno-aponeuroticus, and from its congener, the short flexor.

Action.—This muscle is a flexor of the fore-arm, and a tensor of the antibrachial aponeurosis. It acts, besides, through the cord which traverses its entire length, as an inextensible band that mechanically opposes the flexion of the scapulo-humeral angle while the animal is standing, and when the fore-arm is maintained fixed by the contraction of the humero-olecranian muscles.

2. *Short Flexor of the Fore-arm.* (Fig. 85, 12.)

Synonyms.—Humero-cubitalis obliquus, or humero-radialis—*Girard.* (*Humeralis externus—Percivall. Humero-radialis—Leyh.*)

Preparation.—Lay the limb on its internal face, and remove the abductors of the arm, the subspinatus, and the large and short extensors of the fore-arm, in order to expose the middle and upper extremity of this muscle. Then turn the limb on its external face to dissect the inferior extremity. To study it in all its details, it is a good plan to cut through the internal ligament of the ulnar articulation, and those muscles of the fore-arm which are attached to the epicondyle.

Form—Structure—Situation—Direction.—This is a very thick muscle, almost entirely fleshy, voluminous in its superior part, and constricted inferiorly. It is lodged in the twisted furrow of the humerus, the direction of which it exactly follows as it turns round the bone to cover, successively, its posterior face, external face, anterior face, and the capsule belonging to the elbow articulation, until it finally reaches the inner side of the radius.

Attachments.—The muscular fibres entering into its composition have their fixed insertion on the posterior face of the humerus, below the articular head. They terminate, inferiorly, on a flat tendon, which they almost entirely cover. This tendon glides in a transverse groove situated on the inner face of the radius, below the bicipital tuberosity, and afterwards passing under the internal ligament of the elbow joint, it divides into two very short fasciculi; one of these goes to the radius, and the other to the ulna, where it is mixed up with the bundles of arciform fibres, which unite, on the inner side, the two bones of the fore-arm.

Relations.—We already know the parts this muscle covers. It is covered, inwardly, by the adductor of the arm and the middle extensor of the fore-arm; posteriorly and externally, by the large and short extensors of that ray. Its inferior extremity, comprised between the anterior extensor of the

metacarpus and the coraco-radialis, passes below the antibrachial band of the latter, as under a fibrous bridge.

Action.—It is simply a flexor of the fore-arm.

Fig. 121.

INTERNAL ASPECT OF LEFT ANTERIOR LIMB.

1, Prolonging cartilage of scapula; 2, Inner surface of scapula; 3, Subscapularis; 4, Adductor of the arm, or teres major; 5, Supra- or antea-spinatus; 6, Long extensor of the fore-arm, or portion of the caput magnum; 7, Large extensor of the fore-arm, the other portion of the caput magnum; 8, Middle extensor, or caput medium; 9, Humeralis externus, or short flexor of the fore-arm; 10, Coraco-humeralis; 11, Upper extremity of humerus; 12, Coraco-radialis, or flexor brachii; 13, Lower extremity of humerus; 14, Brachial fascia; 15, Anterior extensor of the metacarpus, or extensor metacarpi magnus; 16, Belly and aponeurotic termination of the flexor brachii; 17, Ulna; 18, Ulnaris accessorius, or oblique flexor of the metacarpeus; 19, Internal flexor of the metacarpus, or epicondylo-metacarpeus; 20, Radius; 21, Tendon of the oblique extensor; 22, Large metacarpal bone; 23, Flexor tendons of the foot; 24, Suspensory ligament; 25, Internal rudimentary metacarpal bone; 26, Extensor tendon of the foot; 27, Metacarpo-phalangeal sheath; 28, Lateral cartilages of the foot; 29, Podophyllæ.

B. *Posterior Brachial Region.*

This is composed of five muscles, which have their movable insertion in common on the summit of the olecranon, and are consequently designated *olecranian muscles.* With reference to their action, they are also designated *extensors of the fore-arm,* and are distinguished into *long, short, middle,* and *small.*

Preparation.—The muscles of this region ought to be studied before those of the preceding region. To dissect the large and short extensors, it is necessary to lay the limb on its inner face, remove the slight fibrous layer which covers these two muscles, and raise the abductors of the arm, which in great part conceal their origin. The limb is kept in the same position for the dissection of the small extensor, which is not easily accomplished, as it is almost entirely concealed by the short extensors which, besides, closely adhere to it. To dissect the long and middle extensors, it suffices to turn the limb on its external surface and cut away the vessels, nerves, and lymphatics which partly cover the latter. The first, lying closely to the internal face of the large extensor, requires some care in order to free it from its aponeurosis.

1. *Long Extensor of the Fore-arm.* (Fig. 121, 6.)

Synonyms.—Scapulo-olecranius—*Girard.* (A portion of the *caput magnum* of the *triceps extensor brachii—Percivall. Long scapulo-olecranius—Leyh.*)

Form—Situation.—This is a wide muscle, flattened within and without, and applied against the inner face of the large extensor, to which it closely adheres.

Structure and Attachments.—It is composed of an aponeurosis, attached to the posterior border of the scapula—*fixed insertion*; and a muscular portion, easily divisible into two fasciculi, one anterior, the other posterior. These two fasciculi are formed of vertical fibres, the longest of which are posterior, and terminate at the posterior border of the ulna, as well as on the antibrachial aponeurosis—*movable insertion.*

Relations.—Outwards, with the large and middle extensors; inwards, with the sterno-trochineus, the adductor of the arm, and the great dorsal. Its aponeurosis adheres closely to the tendinous portion which terminates the last-named muscle, and its anterior border is united to the aponeurotic sheath of the coraco-radialis by a particular fibrous fascia, which covers the vessels and nerves on the inner aspect of the arm.

Action.—It extends the fore-arm, and renders the antibrachial aponeurosis tense.

2. *Large Extensor of the Fore-arm.* (Figs. 119, 7; 121, 7.)

Synonyms.—Scapulo-olecranius major—*Girard.* The long portion of the triceps brachialis of Man. (Portion of the *caput magnum* of the *triceps extensor brachii—Percivall.*)

Volume—Form—Situation.—An enormous, short, and triangular muscle, occupying, with the short extensor, the space comprised between the posterior border of the scapula and the humerus.

Structure and Attachments.—The fleshy mass constituting this muscle is formed of very thick fasciculi, among which are found some aponeurotic bands. These fasciculi have their origin on the dorsal angle and the axillary border of the scapula, either directly, or through the medium of two strong fibrous layers, between which they are at first included. They are afterwards directed backwards and downwards, and converge towards a thick tendon which occupies the posterior and inferior angle of the triangle represented by this muscle. The tendon terminates by attaching itself to the summit of

the olecranon, after receiving a great number of fibres from the short extensor, and after gliding, by means of a synovial capsule, over the eminence which serves for its insertion.

Relations.—The external surface is covered by a thin, fibrous, white-and-yellow elastic layer, which separates it from the panniculus; it is hollowed, near the upper border of the muscle, by an excavation into which is received the posterior portion of the long abductor. Its internal face responds to the great dorsal, the adductor of the arm, and to the long extensor. Its posterior border is margined by the latter muscle; the superior follows the axillary border of the scapula, and is attached to it to constitute the fixed insertion of the muscle; the inferior responds to the short and middle extensors.

Action.—It is an extensor of the fore-arm.

3. *Short Extensor of the Fore-arm.* (Fig. 119, 8.)

Synonyms.—Humero-olecranius externus—*Girard.* The vastus externus of the triceps brachialis of Man. (*Caput medium—Percivall.*)

Situation — Direction — Form — Structure. — This muscle is situated between the humerus and the inferior border of the preceding, and is directed obliquely downwards and backwards. It is thick and short, flattened and aponeurotic at its upper extremity, prismatic, and entirely formed of thick parallel muscular fasciculi for the remainder of its extent.

Attachments.—One of its attachments is on the humerus, to the curved line extending from the deltoid imprint to the base of the articular head (*see for this line* Fig. 41, *above* 4), by the short aponeurosis of its superior extremity—*fixed insertion;* the other is to the olecranon, either directly, or through the tendon of the large extensor—*movable insertion.*

Relations.—The prismatic shape of this muscle offers three faces, which respond: externally, to the two abductors of the arm and to a slight fibrous layer continuous, above, with that which covers the large extensor, and below, with the antibrachial aponeurosis; internally, to the small extensor, from which it is difficult to separate it, to the short flexor of the fore-arm, and to the anterior extensor of the metacarpus; superiorly, to the large extensor, which closely adheres to it.

Action.—An extensor of the fore-arm.

4. *Middle Extensor of the Fore-arm.* (Figs. 119, 17; 121, 8.)

Synonyms.—Humero-olecranius internus—*Girard.* The vastus internus of the triceps brachialis of Man. (*Caput parvum—Percivall.*)

Situation—Direction—Form—Structure.—This muscle is situated at the internal face of the humerus, along the inferior border of the large extensor. It is oblique downwards and backwards, pyriform, bulging at its superior extremity, contracted inferiorly, where it terminates by two small flat tendons.

Attachments.—It originates, by its superior extremity, from the inner aspect of the humerus, behind and above the tuberosity on its body. One of its terminal tendons is attached to the summit of the olecranon; the other glides over a small convexity on the inner side of that eminence, and goes to be inserted a little lower than the first.

Relations.—Above, with the inferior border of the large extensor; outwards, with the humerus, the short flexor, and short extensor of the fore-arm; inwards, with the humeral insertion of the great dorsal and the adductor of the arm, the long branch of the coraco-brachialis, the vessels

Fig. 122.

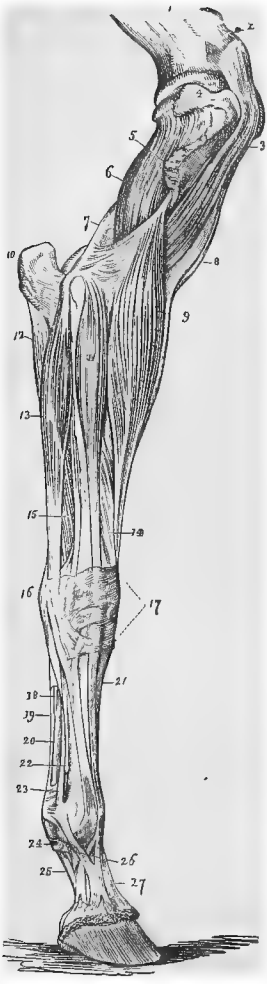

DEEP MUSCLES ON EXTERNAL ASPECT OF RIGHT ANTERIOR LIMB.

1, Scapula; 2, Coracoid process of scapula; 3, Flexor brachii; 4, Superior extremity of humerus; 5, External tuberosity of humerus; 6, Humeralis externus; 7, Body of humerus; 8, Biceps; 9, Anterior, or great extensor of the metacarpus; 10, Ulna, 11, Extensor pedis, or anterior extensor of the phalanges; 12, Ulnaris accessorius, or ulnar portion of the perforans; 13, Lateral extensor of the metacarpus, or extensor suffraginis; 14, Oblique extensor of the metacarpus; 15, Flexors of the foot; 16, Trapezium, 17, Annular ligament; 18, Carpal ligament of perforans tendon, 20; 19, Perforatus; 21, Tendon of anterior extensor of metacarpus; 22, Small metacarpal bone; 23, Suspensory ligament; 24, Lateral band of metacarpo-phalangeal sheath, 25, Perforans tendon; 26, Branch of the suspensory ligament joining the extensor pedis, 27.

and nerves on the inner side of the arm, and the long extensor of the fore-arm.

Action.—An extensor of the fore-arm.

5. *Small Extensor of the Fore-arm or Anconeus.* (Fig. 85, 10.)

Synonym.—Humero-olecranius minor—*Girard.*

Form — Structure — Situation—Relations.—This is a small, thick, and prismatic muscle, almost entirely fleshy, situated behind the elbow articulation. It is applied against the synovial cul-de-sac which ascends into the olecranian fossa, and to which it is strongly attached; it is hidden by the short extensor, from which it is not easily distinguished.

Attachments.—It originates from the margin of the olecranian fossa, chiefly above and outwards. It terminates by being inserted into the anterior and external part of the olecranon.

Action.—This little muscle, a congener of the preceding, raises the articular capsule it covers, and prevents its being pinched between the bony surfaces.

DIFFERENTIAL CHARACTERS OF THE MUSCLES OF THE ARM IN OTHER THAN SOLIPED ANIMALS.

In all animals, the *long flexor of the fore-arm*, or *coraco-radialis*, is less thick and tendinous than in Solipeds.

In the *Pig*, *Dog*, and *Cat*, it comports itself in a special manner at its inferior extremity; it is attached at first to the bicipital tuberosity, and also furnishes a small tendinous branch which glides over the inner side of the radius by means of a synovial bursa, and is fixed within the ulna, towards the base of the olecranon.

The *short flexor of the fore-arm*, or *anterior brachial*, is terminated, in the *Pig*, *Dog*, and *Cat*, by a small tendon which is fixed in the ulna, below the ulnar branch of the coraco-radialis.

The *long extensor of the fore-arm*, which is found in all the domesticated animals, arises from the external face of the great dorsal in the *Pig* and *Dog*. The *middle extensor of the fore-arm* and *anconeus* of these animals are remarkable for their volume.

COMPARISON OF THE MUSCLES OF THE ARM OF MAN WITH THOSE OF ANIMALS.

In *Man*, three muscles are situated in front of the

humerus: the *biceps*, *coraco-brachialis*, and the *anterior brachialis;* behind are found the *triceps brachialis* and the *anconeus*.

The *biceps*, which corresponds to the coraco-radialis of animals, commences on the capula by two heads, which unite towards the upper part of the humerus. The long or tion is detached from the upper part of the rim of the glenoid cavity; the shortest commences from the summit of the coracoid process. The inferior tendon of the biceps gives off, before fixing itself on the bicipital tuberosity, a fibrous lamella which is confounded with the antibrachial aponeurosis.

The *coraco-brachialis* has only one fleshy body.

As in the Carnivora and Pig, the *anterior brachialis* terminates on the ulna, below the coronoid process.

The *triceps brachialis* exactly represents, by its three heads, the large, middle, and short extensors of the fore-arm of animals (See Fig. 120)

There is nothing particular with regard to the *anconeus*. The long extensor of the fore-arm of the Horse has no representative in Man.

MUSCLES OF THE FORE-ARM.

These muscles, nine in number, distributed in two regions—anterior and posterior—envelop the bones of the fore-arm on every side except the internal, where the radius is in mediate contact with the skin. They all terminate on the different sections of the foot, which they flex or extend, and are contained in a common fibrous sheath, which constitutes the *antibrachial aponeurosis.*

Antibrachial Aponeurosis.

This retaining fascia forms a very strong and resisting envelope, which is firmly fixed around the antibrachial muscles by the insertions it has on the bones of the fore-arm, being attached to the olecranon, the internal aspect of the radius, and to the inferior extremity of that bone, both inwards and outwards.

Its external face is covered by superficial vessels and nerves, that are separated from the skin by a very thin fibrous layer, which is more particularly observable on the inner side, where it covers the antibrachial aponeurosis in a very evident manner; it is rendered tense by the sterno-aponeuroticus. Up to the present time, this fibrous layer has not been distinguished from the aponeurosis it covers. The inner face of the latter gives rise to several septa, which penetrate the interstices of the muscles to form around some of them special retentive sheaths; it adheres to several of them very intimately. At its upper border, this aponeurosis receives, inwardly, the insertion of the long extensor of the fore-arm; in front, the accessory band of the coraco-radialis; outwardly, it is continuous with the fibrous fascia covering the external face of the olecranian muscles. Inferiorly, it is prolonged around the knee to form the tendinous sheaths in that region.

The antibrachial aponeurosis is made tense by the contraction of the long extensor of the fore-arm and the coraco-radialis. With reference to the sterno-aponeuroticus, which has hitherto been regarded as intended to play the same part, it can only act on the fibrous fascia which covers, externally, the antibrachial aponeurosis.

Preparation of the muscles of the fore-arm.—The preparation of these muscles is extremely simple, as it suffices to remove the antibrachial aponeurosis and the interstitial cellulo-adipose tissue, to expose and to isolate them from each other. No special recommendations need, therefore, be given, as a glance at figures 89, 119, 121, and 122 will guide the student in his dissection, and supplement the manual details which would be superfluous here.

Nevertheless, as the terminal insertions of some of these muscles are inclosed within the hoof, and as it is indispensable, in order to expose them, to remove this horny case, some explanation will be given as to the manner in which this should be effected,

particularly as the apparent difficulty and labour too frequently cause this part to be omitted in the dissecting rooms.

1. The instruments necessary to remove the hoof are: a scalpel, toe-knife, hammer, and a pair of pincers.

2. The limb should be in a vertical position, held by one or two assistants, and the foot placed on a table, stool, or very solid block of wood.

3. Pass the scalpel as deeply as possible around the coronet, to separate the wall of the hoof from the organised tissues.

4. With the knife and hammer, split the wall into four or five pieces by vertical incisions.

5. When the wall is thus divided, it is sufficient to insert the knife under the fragments, and making it serve as a lever, tear them off; pincers may also be used for this purpose, each of the pieces being twisted from the sole.

6. To remove the sole, the blade of the scalpel should be passed between its upper face and the plantar surface of the third phalanx; afterwards the toe-knife may be inserted in the interval at the bulbs of the frog, so as to slightly raise the external border of the sole. This is then seized by the pincers and pulled off, along with the frog, in a single piece, by a powerful twisting movement, aided by the assistants, who press on the limb in a contrary direction.

A. *Anterior Antibrachial Region.*

In Solipeds, this region includes four extensor muscles. Two act on the entire foot; these are the *anterior extensor* and the *oblique extensor of the metacarpus.* Two others, the *anterior* and *lateral extensor of the phalanges,* terminate in the digital region.

1. *Anterior Extensor of the Metacarpus.* (Figs. 119, 11; 121, 15; 122, 9.)

Synonyms.—Epicondylo-premetacarpeus—*Girard.* It represents the two external radials of Man. (*Extensor metacarpi magnus—Percivall. Humero-metacarpeus—Leyh.*)

Situation—Direction—Form—Structure.—The anterior extensor of the metacarpus, situated in front of the radius, in an almost vertical direction, is composed of a muscular body and a tendon. The first has the form of an inverted cone, is intersected by some aponeurotic lamellæ, and is composed of muscular fibres slightly arciform at their superior extremities. The second, at first rounded, then flattened, commences below the middle third of the radius, and succeeds the inferior extremity of the muscular portion.

Attachments.—This muscle has its fixed insertion: 1, By the upper extremity of its fleshy fibres, on the crest that limits, behind and below, the furrow of torsion of the humerus; 2, Above and in front of the inferior articular surface of the humerus, by means of a strong fibrous band common to it and the anterior extensor of the phalanges, and which expands on the deep face of these two muscles in becoming intimately united with the capsular ligament of the elbow articulation. Its movable insertion takes place on the anterior and superior tuberosity of the large metacarpal bone, by the inferior extremity of its tendon.

Relations.—The muscular portion is covered by the antibrachial aponeurosis and the short extensor of the fore-arm. It covers the anterior face of the radius, as well as the elbow articulation; outwards and behind, it is in contact with the inferior extremity of the short flexor of the fore-arm or brachialis anticus, whose aponeurosis adheres intimately to the arciform portion of the fibres of the anterior extensor of the metacarpus, and appears to attach this muscle to the deltoid imprint. Its tendon covers a small portion of the anterior aspect of the radius, and enters the internal vertical groove channeled in front of the inferior extremity of that bone; afterwards it passes over the capsular ligament of the carpus, and is

maintained against that membranous expansion by a wide fibrous sheath, through which it glides by the aid of two synovial membranes. This tendon is crossed above the knee by that of the oblique extensor, which passes to its surface.

Action.—The name of this muscle indicates its function; it extends the metacarpus on the fore-arm.

2. *Oblique Extensor of the Metacarpus.* (Figs. 119, 13; 121, 21; 122, 14.)

Synonyms.—Cubito-premetacarpeus, or radio-premetacarpeus—*Girard.* It is the representative of the long abductor and short extensor of the thumb in Man. (*Extensor metacarpi obliquus vel parvus—Percivall. Radio-metacarpeus—Leyh.*)

Situation—Form—Structure—Direction.—A small muscle situated at the internal side of the radius, beneath the anterior extensor of the phalanges, penniform in shape, strongly aponeurotic, and terminated by a tendon which turns obliquely round the anterior aspect of the radius in passing downwards and inwards, to reach the oblique channel on the inferior extremity of that bone, and to pass from thence to the inside of the knee.

Attachments.—It has its origin on the external side of the radius; its terminal tendon is fixed into the head of the internal metacarpal bone, by its fibres becoming confounded with those of the internal ligament of the carpus.

Relations.—This muscle is covered by the anterior extensor of the phalanges and the antibrachial aponeurosis. It successively covers the anterior face of the radius, the tendon of the anterior extensor of the metacarpus, the radial groove lodging its tendon, and in which it glides by means of a small synovial bursa, as well as the internal ligament of the carpus.

Action.—It extends the metacarpus, and may make it pivot from within forwards.

3. *Anterior Extensor of the Phalanges.* (Figs. 119, 14; 121, 15; 122, 9.)

Synonyms.—Epicondylo-prephalangeus—*Girard.* The extensor communis digitorum of Man. (*Extensor pedis—Percivall. Humero-prephalangeus—Leyh.*)

Situation—Direction—Extent—Form—Structure.—This is a long vertical muscle, situated external to, and behind the anterior extensor of the metacarpus, which it resembles in being composed of a fleshy and a tendinous portion. The muscular portion extends from the inferior extremity of the humerus to above the lower third of the radius; it is fusiform in shape, intersected by aponeurotic lamellæ, and bifid at its superior extremity.[1] The tendinous portion forms two unequal cords, which succeed the two terminal branches of the muscular part, and lie close to each other. These two cords enter the most external of the three grooves in front of the inferior extremity of the radius, and reach the anterior face of the carpal capsular ligament, against which they are maintained by an annular ligamentous apparatus. After passing from beneath this ring, the smallest, which is the most external, joins the tendon of the lateral extensor (Fig. 119, 15). The principal branch (Fig. 119, 14′) continues its course on the anterior aspect of the middle metacarpal bone and articulation of the fetlock, until it arrives in front of the digit; here it terminates on the os pedis, after widening in a remarkable manner, and after receiving, laterally, at the middle of the first phalanx, a

[1] This division, which has been noticed by several writers, has not been shown in figure 119. This is a mistake, as it is constantly present.

reinforcing band which appears to be given off from the inferior extremity of the suspensory ligament of the fetlock.

Attachments.—The anterior extensor of the phalanges has its fixed attachment by the superior extremity of its muscular body: 1, Below the crest that limits, posteriorly, the furrow of torsion of the humerus; 2, In front of the inferior extremity of the humerus; 3, To the anterior border of the external ligament of the elbow joint; 4, To the external and superior tuberosity of the radius; 5, To the external border of that bone. Its principal tendon is inserted into the pyramidal eminence of the third phalanx, after being successively attached to the capsular ligament of the fetlock joint and the anterior surfaces of the first two phalanges.

Relations.—The muscular portion, covered by the antibrachial aponeurosis, covers the articulation of the elbow, the anterior face of the radius, and the oblique extensor of the metacarpus; it responds, in front, to the anterior extensor of the same ray, to which it is intimately attached by its upper half; behind, to the lateral extensor of the phalanges. The tendinous cords cover the different parts already enumerated in describing the course of the muscle—that is, the anterior face of the radius, the carpal joints, the principal metacarpal bone, the articulation of the fetlock, and the first two phalanges. A vaginal synovial membrane envelops them at the knee, to facilitate their gliding in the radial groove and on the anterior aspect of the capsular ligament of the carpus; while the inner surface of the principal tendon is covered, in front of the fetlock, by a small vesicular capsule, and still lower by the synovial membranes of the two interphalangeal articulations.

Action.—This muscle extends the third phalanx on the second, that on the first, and this again on the metacarpal bone. It may also concur in the extension of the entire foot on the fore-arm.

(Two small muscles, which should be only considered as heads of this anterior extensor, have been particularly described by Thiernesse and Phillips, and named after these authors.

The *muscle of Phillips*, according to Leyh, is long and thin; it commences on the lateral external ligament of the ulnar articulation and the external superior tuberosity of the radius; it is directed obliquely downwards and forwards, lying beside the muscular portion of the common extensor. Towards the middle and outer aspect of the radius, it gives off a small tendon, which passes in the same sheath as the preceding, in front of the carpus, and continues its course between the two tendons of the extensors of the phalanges to near the fetlock, where it becomes confounded with that of the lateral extensor, a little above the first phalanx.

The *muscle of Thiernesse* is smaller than that of Phillips, and situated at its inner side. It arises in front of the transverse ligament of the ulna by a muscular portion, becomes thinner as it descends, and terminates by a fine tendon which is confounded with that of the common extensor, towards the lower third of the fore-arm.)

4. *Lateral Extensor of the Phalanges.* (Figs. 119, 16; 122, 13.)

Synonyms.—Cubito or radialis-prephalangeus, according to Girard. The extensor minimi digiti of Man. (*Extensor suffraginis—Percivall.*)

Direction—Situation—Extent—Form—Structure.—A small vertical muscle, situated at the external side of the fore-arm, between the preceding and the external flexor of the metacarpus, and formed of a fleshy body and a

tendon. The fleshy body, not very considerable, and flattened from before backwards, extends from the upper extremity of the radius to the lower fourth of the same bone. The tendon (Fig. 119, 16′), at first rounded, then flattened, reaches the gliding groove which divides the external inferior tuberosity of the radius into two portions, passes to the external side of the carpus, crossing the lateral ligament common to the articulations of this region, and arrives at the anterior surface of the principal metacarpal bone, where it receives the small tendinous branch detached from the anterior extensor, as well as a strong fibrous band coming from the external side of the carpus (Fig. 119, 17). Afterwards, descending alongside the external border of the principal tendon of its congener, and united to it by a fibrous fascia, it gains the articulation of the fetlock, and expanding, terminates at the upper extremity of the first phalanx.

Attachments.—1, By its muscular body, to the external tuberosity of the radius, the external ligament of the elbow articulation, and to the bodies of the two bones of the fore-arm—*origin;* 2, By the inferior extremity of its tendon, to the capsule of the metacarpo-phalangeal articulation, and in front of the superior extremity of the first phalanx—*termination.*

Relations.—Its muscular portion, enveloped in a special aponeurotic sheath, responds: in front, to the anterior extensor of the phalanges; behind, to the external flexor of the metacarpus and the perforatus and perforans muscles; outwards, to the antibrachial aponeurosis. The tendon, surrounded by a vaginal synovial sheath, in passing over the carpus, covers, beyond the knee, the anterior aspect of the metacarpus, and the anterior ligament of the metacarpo-phalangeal articulation, over which it glides by means of a small vesicular synovial bursa. It is covered by a slight fibrous fascia, which separates it from the skin, and which is also spread over the tendon of the anterior extensor.

Action.—This muscle is an extensor of the digit, and also concurs in the extension of the entire foot on the fore-arm.

B. *Posterior Antibrachial Region.*

This is composed of five flexor muscles grouped vertically behind the bones of the fore-arm. Three are situated superficially, and act on the whole foot; these are the *external flexor*, *oblique flexor*, and the *internal flexor of the metacarpus.* The other two, fixed to the digit by their inferior extremity, and covered by the preceding, are designated the *superficial* and *deep flexors of the phalanges.*

1. *External Flexor of the Metacarpus, or Posterior Ulnaris.*[1] (Fig. 119, 18.)

Synonyms.—Epicondylo-supercarpeus—Girard. (*Flexor metacarpi externus—Percivall. Humero-supercarpeus externus—Leyh.*)

Situation.—The external flexor of the metacarpus is situated at the external side of the fore-arm, between the lateral extensor of the phalanges and the oblique flexor.

Form—Structure—Attachments.—This muscle is elongated from above to below, flattened from one side to the other, thick in its middle part, and intersected by very strong aponeurotic bands. It commences on the summit

[1] It is known that the bony eminences, hitherto termed in veterinary anatomy "epitrochlea" and "epicondyle," correspond: the first, to the epicondyle of Man, the second, to the epitrochlea. It need excite no surprise, therefore, to see the denominations given by Girard to the muscles of the posterior antibrachial region changed as above.

of the epicondyle by a very powerful, but extremely short tendon. Inferiorly, it terminates by a second tendon longer than the preceding, and divides into two branches, an anterior and a posterior. The latter (Fig. 119, 20), short and wide, is inserted into the supercarpal bone in becoming mixed up with the oblique flexor. The former (Fig. 119, 19), rounded and funicular in shape, glides by means of a synovial bursa in the channel excavated on the external aspect of the supercarpal bone, and which is converted into a canal by a little fibrous apparatus; this branch is afterwards fixed on the head of the external metacarpal bone by being confounded with the external ligament of the carpus.

Relations.—Covered by the antibrachial aponeurosis, this muscle covers the two flexors of the digit. Its anterior border responds to the lateral extensor of the phalanges; the posterior to the oblique flexor. Its superior tendon lies behind the external ligament of the elbow joint, and is covered deeply by the external *cul-de-sac* of the synovial capsule belonging to that articulation.

Action.—It flexes the foot on the fore-arm. (Leyh observes that it is more particularly concerned in what is known as "high action.")

2. *Oblique Flexor of the Metacarpus, or Anterior Ulnaris.* (Fig. 121, 19.)

Synonyms.—Epitrochlea supercarpeus—*Girard.* (*Flexor metacarpi medius—Percivall. Humero-metacarpeus internus—Leyh.*)

Situation—Form—Structure.—This muscle, situated behind and within the fore-arm, is an exact counterpart of the preceding in form and structure.

Direction.—Bourgelat has improperly named it an oblique flexor, for its direction is vertical like that of the other muscles of this region.

Attachments.—It has its origin: 1, On the base of the epitrochlea by the tendinous fibres of its superior extremity; 2, On the olecranon, by a small, very thin, and very pale fleshy band, which is annexed to the principal muscular body, and soon unites with its posterior border. Its inferior tendon is undivided, and terminates on the supercarpal bone, along with the external flexor, to which it is intimately attached.

Relations.—By its superficial face, with the antibrachial aponeurosis, which strongly adheres to its tendon; by its deep face, with the flexors of the phalanges. Its anterior border is covered by the internal flexor; the posterior responds to the external flexor.

Action.—It is a congener of the preceding.

3. *Internal Flexor of the Metacarpus, or Palmaris Magnus.* (Fig. 121, 19.)

Synonyms.—Epitrochlea metacarpeus—*Girard.* (*Flexor metacarpi internus—Percivall. Humero-metacarpeus internus—Leyh.*)

Situation—Form—Structure—Attachments.—This muscle is situated within the fore-arm, against the posterior face of the radius, and in its general features resembles its congeners, the two preceding muscles. It is, however, not so wide, is thinner, and less aponeurotic. Its upper extremity is fixed, by tendinous fibres, to the base of the epitrochlea at the same point as the oblique flexor, with which it is confounded—*origin.* Its inferior extremity terminates in a long, thin, funicular tendon which passes through a fibrous sheath at the inner side of the knee, and is inserted into the head of the internal metacarpal bone—*movable insertion.*

Relations.—It is covered by the antibrachial aponeurosis, and covers the oblique flexor, the perforatus and perforans, as well as important blood-

vessels and nerves. Its anterior border responds to the radius. A synovial sheath envelops its terminal tendon, and facilitates its movements in the fibrous canal through which it passes.

Action.—It is a congener of the preceding.

4. *Superficial Flexor, Sublimis of the Phalanges, or Perforatus.* (Figs. 89, 119, 121, 122.)

Synonyms.—Epitrochlo-phalangeus—*Girard.* (*Flexor pedis perforatus—Percivall Humero-coronaris* or *humero-phalangeus—Leyh.*)

Situation.—The superficial flexor of the phalanges is situated, with its fellow, the perforans, beneath the flexors of the metacarpus, which form around them a kind of muscular envelope.

Form—Structure—Extent.—It is composed of a muscular and tendinous portion. The first, long, thin, prismatic, and divided by a great number of aponeurotic intersections, extends from the inferior extremity of the arm nearly to the carpus. The tendon, continuous with the inferior extremity of the muscular portion, receives at its origin an enormous fibrous production that arises from the eminence of insertion situated at the posterior face of the end of the radius, and which contracts somewhat intimate adhesions with the antibrachial aponeurosis, as well as with the perforans.

After being thus reinforced, this tendon passes through the carpal sheath and arrives behind the fetlock, where it forms a ring (Fig. 89, 14) for the passage of the tendon of the deep flexor. To this peculiarity is owing the designations of *perforatus* and *perforans*, given to the two flexors of the phalanges. Afterwards it is inflected forwards over the sesamoid groove, and terminates by two branches towards the middle of the digital region.

Attachments.—It takes its origin, in common with the perforans, at the summit of the epitrochlea, and is inserted, by the bifurcations of its tendon, into the extremities of the pulley formed behind the superior extremity of the second phalanx.

Relations.—The muscular portion, covered by the external and the oblique flexors of the metacarpus, may be said to be incrusted in the perforans, to which it adheres in the most intimate manner. The tendon covers that of the latter muscle, and is in turn covered by the fibrous expansions of the two metacarpal and metacarpo-phalangeal sheaths which are now to be described.

The *Carpal sheath* is the name given to a very remarkable annular apparatus, formed by the superficial face of the common posterior ligament of the carpus, and by a thick expansion of inelastic white fibrous tissue, together constituting a perfect arch thrown across like a bridge, from the supercarpal bone to the inner side of the carpus. This arch is continuous, above, with the antibrachial aponeurosis, and is prolonged, below, over the metacarpal portion of the flexor tendons. An extensive synovial membrane covers the internal aspect of the carpal sheath, envelops the perforatus and perforans in their passage through this canal, ascends above the carpus, and descends as far as the lower third of the metacarpal region.

The *Metacarpo-phalangeal sheath* is formed by the sesamoid groove, the posterior face of the principal navicular ligaments, that of the glenoid fibro-cartilage of the first interphalangeal articulation, and by the posterior pulley of the second phalanx. It is completed by a very wide membranous expansion applied against the flexor tendons, closely adherent to the perforatus on the median line of the digit, and fixed, laterally, to the phalangeal bones by the

aid of three special fibrous bands. A very extensive vaginal synovial membrane covers the internal walls of this passage, and is reflected on the flexor tendons; it ascends along these tendons to the inferior extremities of the lateral metacarpals, and forms, inferiorly, a somewhat large *cul-de-sac* which, behind the second phalanx, lies against the posterior *cul-de-sac* of the articular synovial membrane of the foot, and also against the superior *cul-de-sac* of the navicular sheath. The metacarpo-phalangeal sheath is also named the *great sesamoid sheath;* but this designation is more frequently applied to the synovial membrane lining its walls.

Action.—This muscle flexes the second phalanx on the first, that on the metacarpus, and the entire foot on the fore-arm. Its tendon, through the influence of the fibrous band which attaches it to the posterior face of the radius, acts mechanically as a stay while the animal is standing, by maintaining the metacarpo-phalangeal angle.

5. *Deep Flexor of the Phalanges or Perforans.* (Figs. 119, 121, 122.)

Synonyms.—Cubito-phalangeus, or radio-phalangeus—*Girard.* (*Flexor pedis perforans—Percivall. Humero-radio-phalangeus—Leyh.*)

Situation—Composition—Extent.—This muscle is situated immediately behind the radius, and is composed of three portions which unite at the carpus, to be continued to the inferior extremity of the digit by a long powerful tendon.

Form, Structure, and Attachments of the muscular portion of the perforans.—The three muscular portions may be distinguished, in regard to their origin, into ~~*epitrochlean*~~, *ulnar*, and *radial.*

The ~~*epitrochlean*~~ *portion* is the most considerable, and lies beside the perforatus; being three or four times the volume of that muscle, it is easily divided into several very tendinous fasciculi, which leave the summit of the epitrochlea along with the superficial flexor. The *ulnar portion*, situated between the external flexor and the oblique flexor of the metacarpus, is very short and conoid, thick at its superior extremity, contracted at its inferior, to which succeeds a long flat tendon, united below to the principal tendon; it has its origin on the summit and the posterior border of the olecranon. The *radial portion*, representing the flexor longus pollicis of Man, is the smallest, and is deeply concealed beneath the epitrochlean muscular portion. The fibres composing it are fixed to the posterior surface of the radius, where they are slightly divergent, and collect upon a small particular tendon, which is confounded with the common tendon after contracting adhesions with the radial band of the perforatus.

Course and Attachments of the tendon.—The tendon which succeeds these three portions enters the carpal sheath with that of the superficial flexor. Towards the middle of the metacarpal region, it receives a strong fibrous band from the great posterior ligament of the carpus (Figs. 119, 23; 122, 18), traverses the sesamoid annular apparatus of the perforatus tendon, passes between the two terminal branches of that tendon, over the pulley on the posterior face of the second phalanx, and afterwards widens to form a large expansion designated the *plantar aponeurosis.*

This aponeurosis glides, by its anterior face, over the inferior surface of the navicular bone, by means of a particular synovial membrane, the *small navicular sheath*, and is covered, posteriorly, by a fibrous layer, noticed for the first time by M H. Bouley, who considers it as a *reinforcing sheath* for the perforans tendon. It is finally inserted into the semilunar

crest of the os pedis, and the median imprints situated behind this crest, in becoming confounded at its sides with the tissue of the lateral fibro-cartilages.

The *navicular sheath* is vesicular in form; it covers the navicular bone and the single ligament of the pedal articulation, becomes reflected on the plantar aponeurosis in front of this ligament, and ascends to the inferior *cul-de-sac* of the sesamoid sheath, where it is again reflected and continued by itself. It therefore forms two *culs-de-sac*, one superior, the other inferior, which are readily perceived in a longitudinal and vertical section of the digital region. The first is in contact with the posterior *cul-de-sac* of the synovial membrane of the pedal articulation, and is separated from the inferior sac of the sesamoid sheath by a transverse layer of yellow fibrous tissue which attaches the perforans tendon to the posterior face of the second phalanx. The second is situated beneath the interosseous ligament which unites the navicular bone to the third phalanx.

The *reinforcing sheath* of the perforans tendon is formed by a fibrous membrane applied against the posterior face of the plantar aponeurosis. This membrane adheres intimately below, to the expansion it covers, and ends in becoming entirely confounded with it. It is fixed, at its borders, to the inferior extremity of the first phalanx, by means of two lateral bands.

Relations.—The epitrochlean muscular portion is covered, at its origin, by the external *cul-de-sac* of the elbow joint, which sac also covers the other muscles attached to the epitrochlea—the external and oblique flexors of the metacarpus. It responds, anteriorly, with the radius and radial portion of the muscle; posteriorly, with the perforatus; externally, with the external flexor of the metacarpus; inwardly, with the internal and oblique flexors of the same ray.

The ulnar portion, covered by the antibrachial aponeurosis, covers the epitrochlean portion.

The radial division is comprised between the latter and the posterior face of the radius.

The tendon is in contact, posteriorly, with that of the perforatus; anteriorly, with the posterior ligament of the carpus, the suspensory ligament of the fetlock, and the sesamoid groove; by its sides, with the vessels and nerves of the digit. Its terminal expansion is covered by the plantar cushion, which adheres to it, in front, in the most intimate manner; it covers the navicular bone.

Action.—This muscle flexes the phalanges on one another and on the metacarpus. It also concurs in the flexion of the entire foot on the fore-arm. The band which attaches its tendon behind the carpus, as well as its phalangeal reinforcing sheath, gives it the mechanical power necessary to support the angle of the metacarpo-phalangeal articulation and the digital region, while the animal is in a standing posture.

(In the "Deep Flexor," of M. Chauveau's description, we find included two portions which are separately named and described by Mr. Percivall and Professor Gurlt. These are the *ulnaris accessorius* and *radialis accessorius* of the former, and the *cubito-ulnar* and *radial branches* of the latter. These, in reality, are portions of the perforans, and have been so designated in this treatise. Though arising independently, they terminate in the perforans tendon before it leaves the carpal sheath, and join with it in flexing the metacarpus and phalanges.)

Fig. 123.

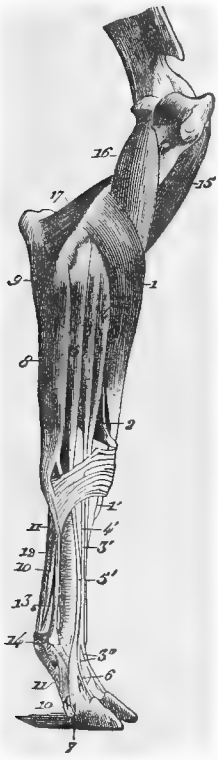

MUSCLES OF THE FORE-ARM OF THE OX; EXTERNAL FACE.

1, Anterior extensor of the metacarpus; 1', Insertion of its tendon; 2, Oblique extensor; 3, Common extensor of the digits; 3', Its tendon; 3'', Terminal bifurcation of that tendon; 4, Proper extensor of the internal digit; 4', Its tendon; 5, Proper extensor of the external digit; 5', Its tendon; 6, Its branch of insertion into the second phalanx; 7, Branch to the third phalanx; 8, External flexor of the metacarpus; 9, Olecranian portion of the perforans; 10, Tendon of the perforans; 11, Tendon of the perforatus; 12, Suspensory ligament of the fetlock; 13, The band it furnishes to the perforatus to form the ring through which the perforans passes; 14, The external band it gives off to the proper extensor of the external digit; 15, Coraco-radialis; 16, Anterior brachial; 17, Anconeus.

DIFFERENTIAL CHARACTERS OF THE MUSCLES OF THE FORE-ARM IN OTHER THAN SOLIPED ANIMALS.

RUMINANTS.—In the *Ox* and *Sheep*, the *anterior extensor of the metacarpus* comports itself as in Solipeds.

The *oblique extensor of the metacarpus* of the same region terminates inside the upper extremity of the principal metacarpus.

The *anterior extensor of the phalanges* offers a remarkable disposition. This muscle is divided throughout its length into two parallel portions: an external, which forms the *common extensor of the digits;* and an internal, the *proper extensor of the internal digit.*

a. The fleshy body of the *common extensor* (fig. 123, 3) is a little more voluminous than that of the second muscle. Its tendon (3') commences near the inferior third of the radius, passes over the knee, the metacarpal bone, and the metacarpo-phalangeal articulation. On arriving at the origin of the digits it bifurcates, and each of its branches goes to be inserted into the pyramidal eminence of the third phalanx (3''). This muscle, in extending the digits, brings them together, as M. Lecoq has judiciously remarked.

b. The *proper extensor of the internal digit* (fig. 123, 4) much resembles the common extensor in volume, form, and direction. Its tendon (4') passes, with that terminating the latter muscle, into one of the inferior grooves of the radius and over the capsular ligament of the carpus, where the two cords are enveloped by a common synovial sheath. Arrived at the metacarpo-phalangeal articulation, this tendon is placed at the excentric side of the internal digit, and descends, gradually expanding, until it reaches the inferior extremity of this bone; towards the middle of the first phalanx, it receives from the suspensory ligament of the fetlock two constraining bands similar to those which, in Solipeds, bind the anterior extensor of the phalanges on the same bone. This tendon bifurcates inferiorly; one of its branches is attached to the anterior face of the second phalanx; the other, much wider than the first, covers the common external lateral ligament of the two inter-phalangeal articulations, and terminates on the whole external side of the third phalanx. In the *Sheep,* this second branch is feeble, and is directed towards the heel, which it envelopes by uniting its fibres with the perforans tendon and the plantar cushion.

The *lateral extensor of the phalanges* of Ruminants is thicker than in the Horse, and constitutes the proper extensor of the external digit (fig. 123, 5). Its terminal tendon (4', 6, 7) comports itself exactly the same as that of the proper extensor of the internal digit, and consequently does not merit a special description. We may remark, with M. Lecoq, that these two muscles separate the digits from each other in extending them; they are, therefore, to a certain point, antagonists of the common extensor.

The *perforatus* of the *Ox* and *Sheep* is composed of two portions, whose tendons unite towards the middle of the metacarpal region. The single tendon (fig. 124, 1, 2, 3) which results from this union afterwards divides into two branches, each of which comports itself, in regard to the

digits, as the single perforatus tendon does in the Horse, except that they receive from the suspensory ligament a fibrous band analogous to that which, in Solipeds, goes to the perforans tendon. This band (fig. 123, 13) concurs in the formation of the annular ligament through which the latter tendon passes.

In the *Ox*, the terminal tendon of the perforans does not receive any carpal band; this goes to the perforatus. Above the fetlock, it divides into two branches, one for each digit, which, after traversing the perforatus, terminates behind the inferior face of the third phalanx. There it is blended with the plantar cushion, the inferior interdigital ligament, and a fibrous fascia already noticed in the description of that ligament. This layer arises from the aponeurosis covering the flexor tendons in the metacarpal region; it descends on the heels, behind and outside the digits, remains united to that of the other digit by an intermediate fibrous fascia, and is attached to the enveloping sheaths of the flexor tendons, as well as to the superior interdigital ligament. Each terminates inferiorly, in becoming united to the proper extensor of the digit, the plantar cushion, the inferior digital ligament, and the deep flexor of the phalanges.

There is not, properly speaking, a phalangeal reinforcing sheath; though we may consider as such the superior fasciculi of the inferior interdigital ligament (fig. 124, 6).

Pig.—In this animal, the *anterior extensor tendon of the phalanges* passes to the superior extremity of the inner large metacarpal bone, and that of the oblique extensor to the small internal metacarpal.

Instead of the *anterior extensor of the phalanges*, two muscles are found analogous to those described as existing in Ruminants. The external, or *common extensor of the digits*, is easily divided into several fasciculi, and is terminated by four tendinous branches which reach the pyramidal eminence of the third phalanx of the four digits. The tendon of the small external digit often gives off a thin bifid ramification, destined to supplement the tendons of the two large digits. The internal muscle, or *proper extensor of the two internal digits*, possesses a bifurcated tendon; each branch goes to the excentric side of the third phalanx of the digit it is charged to move.

Fig. 124.

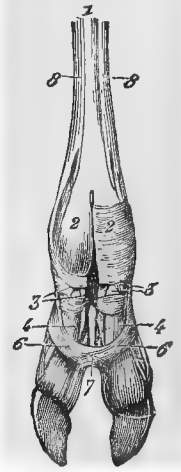

TENDINOUS AND LIGAMENTOUS APPARATUS OF THE POSTERIOR FACE OF THE DIGITAL REGION IN THE OX; POSTERIOR LIMB.

1, Perforatus tendon; 2, 2, Its terminal branches; 3, 3, Their bifurcation; 4, 4, Perforans; 6, 6, Superior bands of the inferior digital ligament attached to the first phalanx; 7, Inferior interdigital ligament; 8, 8, Suspensory ligament of the fetlock.

With regard to the muscles of the posterior antibrachial region, it is remarked: 1, That the anterior branch of the terminal tendon of the *external flexor* of the metacarpus passes to the head of the outer metacarpal bone; 2, That the *internal flexor* terminates on the metacarpal of the great external digit; 3, That the *perforatus* is formed by two muscular bodies, each terminated by a tendon inserted, inferiorly, into the second phalanx of one of the great digits. 4, That the perforans is divided into four terminal branches which arrive at the large phalanx of the digits.

Carnivora.—In the *Dog* and *Cat*, the *anterior extensor* of the metacarpus divides, at its lower extremity, into two branches, which resemble those of the two external radial muscles of Man: one is inserted into the metacarpus of the index, the other into the metacarpus of the medius (fig. 125, A, 5, 6, 7).

The *oblique extensor* passes to the metacarpus of the thumb; it furnishes, besides, a small particular branch that glides, by means of a sesamoid, over the third bone of the inferior row of the carpus, and is blended with the posterior ligament of the carpus (fig. 125, A, 8; B, 4; D, 8); it separates the thumb from the other digits, but we think it scarcely adapted for the function of extensor.

The anterior extensor of the phalanges of solipeds is replaced by a single muscle, the *common extensor of the digits*, terminated by a quadrifurcated tendon, whose branches are distributed to the four great digits (fig. 125, A, 9, 9').

The tendon of the *lateral extensor* is divided into three branches, which are inserted on the anterior face of the three outer digits, and are blended with the tendons of the common extensor, or with the fibrous bands furnished to these tendons by the interosseous metacarpal muscles.

The *external flexor of the metacarpus* comports itself as in the Pig. But the *oblique*

flexor is covered by the perforatus, and its olecranian portion, thicker than in the other animals, is only united to the principal fleshy body altogether inferiorly. The *internal flexor* is feeble and conoid; its tendon, thin and long, reaches the metacarpus of the index.

The *perforatus* of the *Dog* and *Cat* offers a long, wide, and superficial body, separated from the perforans by the oblique flexor of the metacarpus. Its tendon passes outside the carpal sheath, and is divided into four branches, attached by their inferior extremity to the second phalanx of the four principal digits.

For the perforans, it is noted:

1. That the radial portion of the muscle (the *long flexor of the thumb* in Man) commences towards the superior extremity of the radius (fig. 125, C, 4).

2. That the ulnar division is a semi-penniform muscle, attached by the superior extremities of its fibres to nearly the whole extent of the posterior face of the ulnar (fig. 125, C, 3).

3. That the epitrochlean portion sends off, above the knee, a small particular fasciculus terminating in a very thin tendon, which becomes lost in the fibrous arch of the carpal sheath (fig. 125, C, 6). This small muscle represents the palmaris brevis of Man.

The terminal tendon divides into five branches, one for each digit (fig. 125, D, 4, &c.).

There have been already described in these animals:

1. Two *external radial muscles*, only distinct at their terminal extremity, and confounded for the remainder of their extent. This is the anterior extensor of the metacarpus in Solipeds (fig. 125, A, 5, 6, 7).

2. A *long abductor of the thumb*, which appears to be the representative of the analogous muscle, and the short extensor of the same digit in Man. It is the oblique extensor of the metacarpus in the Horse (fig. 125, A, 8).

3. A *common extensor of the digits;* the anterior extensor of the phalanges in the Horse (fig. 125, A, 10).

4. A *proper extensor of the three external digits*, the proper extensor of the little finger in Man, or lateral extensor of the phalanges in the Horse (fig. 125, A, 10).

5. A *posterior ulnar*, or external flexor of the metacarpus in the Horse (fig. 125, A, 14).

6. An *anterior ulnar*, or oblique flexor of the metacarpus in the Horse (fig. 125, D, 6).

7. A *great palmar*, corresponding to the internal flexor of the metacarpus in the Horse (fig. 125, B, 8).

8. A *small palmar*, a dependency of the deep flexor of the phalanges (fig. 125, C, 6).

9. A *flexor sublimis of the phalanges* (fig. 125, D, 1).

10. A *deep flexor of the phalanges* (fig. 125, C, 5, D, 3).

11. A *long flexor of the thumb*, united to the preceding muscle, the radial portion of the perforans (fig. 125, C, 4).

But in *Carnivora* there are five additional muscles, which are not generally found in the other animals. These are: the *proper extensor of the thumb and index*, *long supinator*, *short supinator*, *round pronator*, and the *square pronator*. A special description will be given of these.

MUSCLES PROPER TO THE FORE-ARM OF CARNIVORA.

1. *Proper Extensor of the Thumb and Index.* (Fig. 125, A, 11; B, 3.)

Synonyms.—The *extensor secundi internodii pollicis* and *extensor indicis* of Man.

This is a very small muscle, composed of a fleshy body and a tendon. The first is thin and fusiform, and is situated under the lateral extensor; it has its origin with the oblique extensor of the metacarpus at the external side of the radius. The tendon crosses the anterior aspect of the knee, enveloped by the synovial sheath of the common extensor of the digits, under which it passes. It divides into two branches, one of which goes to the thumb, the other to the index.[1]

2. *Long Supinator.* (Fig. 125, A, 12; C, 8.)

This muscle only exists in the rudimentary state in *Carnivora.* Its existence in the Dog has even been denied, but this is an error; our researches have demonstrated that it is present, in a more or less evident manner, in all breeds.

---

[1] In very powerful Horses, and more frequently in the Ox, we have met with traces of this muscle in the form of a deep fasciculus situated in front of the lateral extensor.

Fig. 125.

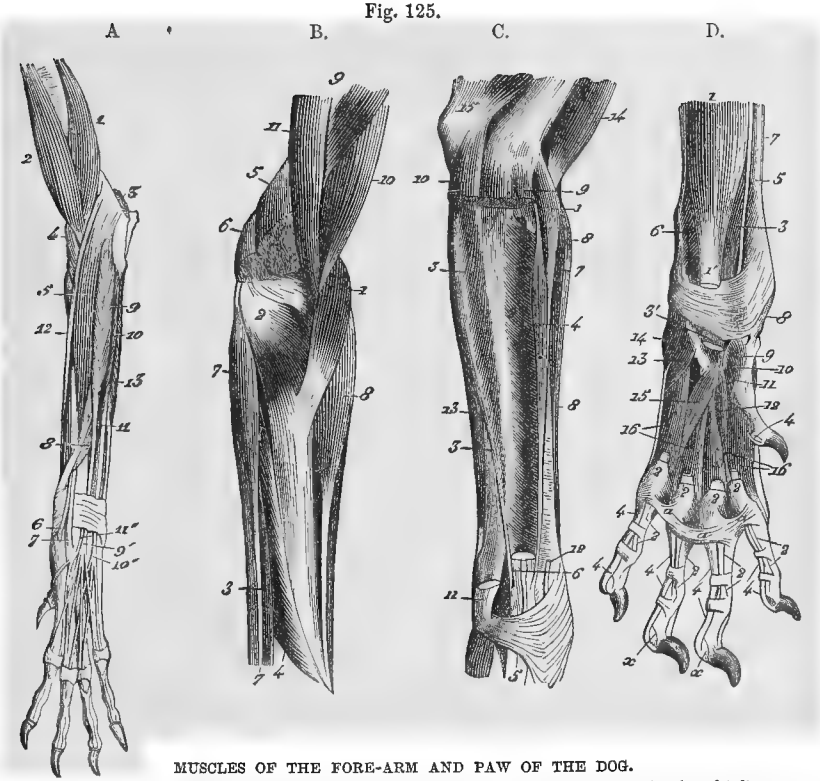

MUSCLES OF THE FORE-ARM AND PAW OF THE DOG.

A. *Anterior superficial region.*—1, Short flexor of the fore-arm (anterior brachial); 2, Long flexor of the fore-arm (brachial biceps); 3, Anconeus; 4, Round pronator; 5, Anterior extensor of the metacarpus (external radial); 6, Its tendon of insertion, destined for the fourth metacarpal bone; 7, That which goes to the third; 8, External oblique of the metacarpus (long abductor and short extensor of the thumb); 9, Common extensor of the digits; 9′, Its terminal tendon at the point where it divides into four branches; 10, Proper extensor of the three external digits, or lateral extensor of the phalanges in the Horse; 10′, Its terminal tendon at the commencement of its trifurcation; 11, Proper extensor of the thumb and index; 11′, Its terminal tendon; 12, 12, Long supinator; 13, External flexor of the metacarpus (posterior ulnar).

B. *Deep anterior region.*—1, Round pronator; 2, Short supinator; 3, Proper extensor of the thumb and index; 4, Oblique extensor of the metacarpus; 5, Superior insertion of the anterior extensor of the metacarpus; 6, Ditto of the anterior extensor of the phalanges; 7, Proper extensor of the three external digits; 8, Internal flexor of the metacarpus (great palmar); 9, Levator humeri; 10, 11, Long and short flexors of the fore-arm.

C. *Deep posterior region.*—1, Round pronator; 2, Square pronator; 3, Ulnar portion of the perforans; 4, Radial portion of the same (long flexor of the thumb); 5, Terminal tendon of the same; 6, Tendon of the small palmar (division of the perforans); 7, Anterior extensor of the metacarpus; 8, Long supinator; 9, Epicondyloid insertion of the perforatus, perforans, and oblique and internal flexors of the metacarpus; 10, Olecranian insertion of the oblique flexor; 11, Supercarpal insertion of the same; 12, Terminal tendon of the internal flexor; 13, Proper extensor of the external digits; 14, Coraco-radialis; 15, Tendon of the extensors of the fore-arm.

D. *Superficial posterior region, and the special muscles of the foot or hand.*—1, Perfo-

It is a very delicate band, situated in front, and on the inner side of the anterior extensor of the metacarpus, taking its origin, along with that muscle, from the crest limiting the furrow of torsion of the humerus, behind the ridge; and terminating within the inferior extremity of the radius by fleshy and aponeurotic fibres. This small muscle can have but a very limited influence on the movements of the bones of the fore-arm, because of its trifling volume. As its name indicates, it acts in supination.

3. *Short Supinator* (Fig. 125, B, 2.)

A triangular and slightly divergent muscle, covered by the anterior extensor of the metacarpus and the common extensor of the digits. It has its origin in the small fossa situated outside the humeral trochlea, by a flat tendon which is confounded with the external lateral ligament of the elbow joint. It terminates above the anterior face and the inner side of the radius, by the inferior extremities of its fleshy fibres. Covered by the two preceding muscles, it covers the elbow articulation and the bone receiving its insertion. It ought to be considered, in Carnivora, as the principal supinator; it pivots the radius on the ulna, so as to turn the anterior face of the first bone outwards.

4. *Round Pronator.* (Fig. 125, B, 1; C, 1.)

Situated on the inner and upper part of the fore-arm, between the great palmar or internal flexor of the metacarpus and the interior extensor of the same ray, the round pronator is a thick and short muscle, which originates on the small epicondyloid tuberosity of the humerus, and terminates at the internal side of the radius by aponeurotic fibres.

5. *Square Pronator.* (Fig. 125, C, 2.)

This muscle is situated immediately behind the bones of the fore-arm, beneath the muscular masses of the posterior antibrachial region. It extends from the insertion of the flexors of the fore-arm to near the carpus, and is formed of transverse fibres which pass directly from the ulna to the radius. It is, then, no longer, as in Man, a square muscle attached only to the lower fourth of these two bones. The two pronators are antagonists of the short supinator, turning forwards the anterior face of the radius and metacarpus.

COMPARISON OF THE MUSCLES OF THE FORE-ARM OF MAN WITH THOSE OF ANIMALS.

All the muscles of the fore-arm of *Man* are more or less perfectly represented in the fore-arm of Carnivora.

In Man, these muscles are described in placing the fore-arm in a state of supination, and are divided into three regions: anterior, external, and posterior.

A. *Anterior Region.*

This comprises eight muscles:—

1. The *round pronator*, absent in animals except the Carnivora. This muscle forms the internal oblique prominence in the bend of the elbow. It leaves the epitrochlea and the coronoid process of the ulna, terminating on the middle third of the external face of the radius.

2. The *great palmaris*, which corresponds to the internal flexor of the metacarpus of the Horse. Situated within the preceding, it is attached, above, to the epitrochlea; below, to the base of the second metacarpal. It is more especially a flexor of the hand.

3. The *small palmaris*, whose presence is not constant, and which is represented in the Dog by a portion of the deep flexor of the phalanges.

---

ratus; 1′, Its tendon divided at its passage behind the carpal sheath; 2, *Do.*, Its terminal branches; 3, Perforans; 3′, Its tendon divided after its exit from the carpal sheath; 4, *Do.*, Its terminal branches; 5, Tendon of the internal flexor of the metacarpus; 6, Oblique flexor (anterior ulnar); 7, Inferior extremity of the long supinator; 8, Terminal tendon of the oblique extensor of the metacarpus; 9, Short abductor of the thumb; 10, Opponent of the thumb; 11, Short flexor of the thumb; 12, Adductor of the thumb, transformed, in the Dog, into the adductor of the index; 13, Short flexor of the small digit; 14, Adductor of the small digit; 15, Opponent of the small digit; 16, 16, Metacarpal interosseous muscles; *a*, *a*, *a*, Bands which maintain the flexor tendons on the metacarpo-phalangean articulations, and limit the separation of the digits; collectively, they represent, in a rudimentary state, the palmar aponeurosis of Man.

4. The *superficial flexor* or *perforatus* has two planes of muscular fibres. The superficial plane is destined to the tendons of the medius and annularis; the deep plane to the tendons of the index and little finger. These tendons are fixed into the secondary phalanges of the above-named digits.

5. The *anterior ulnar* resembles the oblique flexor of the metacarpus of the Horse. It is inserted, above, into the epitrochlea and the olecranon; below, in the pisiform bone. Its action is transmitted, by a fibrous band, from this bone to the fifth metacarpal. It flexes the hand by inclining it inwards.

Fig. 126.

SUPERFICIAL MUSCLES OF HUMAN FORE-ARM.

1, Biceps, with its tendon; 2, Brachialis anticus; 3, Triceps; 4, Pronator radii teres; 5, Flexor carpi radialis; 6, Palmaris longus; 7, A fasciculus of flexor sublimis digitorum; 8, Flexor carpi ulnaris; 9, Palmar fascia; 10, Palmaris brevis; 11, Abductor pollicis; 12, Flexor brevis pollicis; 13, Supinator longus; 14, Extensor ossis metacarpi, and extensor primi internodii pollicis.

Fig. 127.

DEEP LAYER OF SUPERFICIAL MUSCLES OF HUMAN FORE-ARM.

1, Internal lateral ligament of elbow joint; 2, Anterior ligament; 3, Orbicular ligament of radius; 4, Flexor profundus digitorum; 5, Flexor longus pollicis; 6, Pronator quadratus; 7, Adductor pollicis; 8, Dorsal interosseous of middle, and palmar interosseous of ring finger; 9, Dorsal interosseous muscle of ring-finger, and palmar interosseous of little finger.

6. The *deep flexor* or *perforans* is resolved into two fasciculi: one, the internal, for the little finger, the annularis, and the medius the other, the external, for the index. The three first tendons are at first united to each other by fibrous bands, and together pass through a sheath formed by the perforatus.

7. The *proper flexor of the thumb*, represented in the Dog by the radial portion of the perforans. It is attached, for one part, to the upper three-fourths of the anterior face of

the radius, the interosseous aponeurosis, and the coronoid process of the ulna; on the other part, to the second phalanx of the thumb.

8. The *square pronator*, a thick, quadrilateral muscle with transverse fibres, situated at the deep and inferior portion of the fore-arm. This muscle in the Dog is much more extensive in length.

B. *External Region.*

The muscles of this region are four in number, two of which, the *supinators*, are only represented in Carnivorous animals:—

1. The *long supinator* forms a prominent mass at the bend of the elbow. It is attached to the inferior third of the external border of the humerus, and to the base of the styloid process of the radius. It is a flexor of the fore-arm, not a supinator, as its name indicates.

2. The *first external radial* is represented by a portion of the anterior extensor of the metacarpus of animals. It commences at the inferior part of the external border of the humerus, and terminates at the posterior part of the base of the second metacarpal.

3. The *second external radial*, also represented by a portion of the anterior extensor of the metacarpus, terminates at the base of the third metacarpal.

4. The *short supinator*, a muscle bending round the upper third of the radius, is the essential agent in supination.

C. *Posterior Region.*

The muscles of this region, divisible into two layers, are:—

1. The *common extensor of the digits*—anterior extensor of the phalanges of the Horse—divided into four tendinous branches which pass to all the fingers, except the thumb.

2. The *proper extensor of the little finger*, whose tendon is joined to the branch of the common extensor that passes to the auricularis—the lateral extensor of animals.

3. The *posterior ulnar*, corresponding to the external flexor of the metacarpus of the Horse. It goes to the epicondyle at the upper extremity of the fifth metacarpal.

4. The *long abductor of the thumb*, resembling a portion of the oblique extensor of the metacarpus of animals. This muscle is attached to the posterior face of the ulna and radius, and the upper extremity of the first metacarpal.

5. The *short extensor of the thumb*, which is also represented in animals by a portion of the oblique extensor of the metacarpus.

6. The *long extensor of the thumb*, arising from the ulna, and inserted into the second phalanx of the thumb. This muscle limits, inwardly, the excavation termed the *anatomical snuff-box.*

7. The *proper extensor of the index*, whose tendon is confounded with the branch of the common extensor passing to this digit.

These two latter muscles, blended in the Dog, exist only in a rudimentary state in the other animals.

We say nothing of the *anconeus*, placed in the antibrachial region by anthropotomists, and which has been described in the posterior brachial region.

MUSCLES OF THE ANTERIOR FOOT OR HAND.

These will be studied successively in Carnivora, the Pig, Solipeds, and Ruminants.

A. *Muscles of the Anterior Foot or Hand of Carnivora.*

All the muscles of the human hand are found in that of Carnivora, some perfectly developed, others quite rudimentary. These muscles are: 1, The *short abductor of the thumb*; 2, The *opponent of the thumb*; 3, The *short flexor of the thumb*; 4, An *adductor of the index—adductor of the thumb in Man*; 5, The *cutaneous palmar*; 6, The *adductor of the small digit*; 7, The *short flexor of the small digit*; 8, The *opponent of the small digit*; 9, The three *lumbrici*; 10, Four *interosseous metacarpals.*

1. *Short Abductor of the Thumb.* (Fig. 125, D, 9.)

This is rudimentary, like the digit it is intended to move, and is situated behind the metacarpal bone of the thumb; it is composed of very pale fleshy fasciculi, which are continued inferiorly by some tendinous fibres. It has its origin at the carpal arch, and terminates on the metacarpal bone of the thumb, as well as at the external side of the superior extremity[1] of the first phalanx. It is a flexor and abductor of the thumb.

---

[1] It is necessary to remember that the position of the digits is considered in relation to the axis of the hand—that is, the median line separating the medius from the annularis

2. *Opponent of the Thumb.* (Fig. 125, D, 10.)

This vestige of the thick short muscle which bears the same name in Man is situated beneath and within the preceding, in a slightly oblique direction downwards and outwards. Pale and almost entirely muscular, it is attached to the posterior ligament of the carpus and the metacarpal bone of the thumb. Owing to the conformation of this digit in Carnivora, this muscle cannot act as it does in Man in producing the opposition of the thumb; it only draws it towards the axis of the hand, and is therefore merely an adductor of the thumb.

3. *Short Flexor of the Thumb.* (Fig. 125, D, 11.)

A very small muscle, deeper in colour than the other two, and situated between them, the adductor of the index, and the fourth interosseous muscle. It is fixed, by its superior extremity, in the mass of the posterior carpal ligament, and attached, below, to the internal side of the first phalanx. It is a somewhat extensive flexor of the thumb.

4. *Adductor of the Index.* (Fig. 125, D, 12.)

Synonym.—The adductor of the thumb in Man.

Elongated, prismatic, compressed on each side, included between the third and fourth interosseous muscles, and concealed by the tendinous portion of the common flexor of the digits, this muscle is attached, superiorly, to the posterior carpal ligament with the third interosseous muscle. It is fixed, inferiorly, by means of a small flattened tendon, along the superior and internal side of the first phalanx of the index. It is regarded as the adductor of the thumb in Man transformed into an adductor of the index, in consequence of the atrophy of the fifth digit.

5. *Cutaneous Palmar* (*Palmaris Brevis*).

A thick, hemispherical, musculo-adipose body, forming the base of the exterior tubercle placed behind the carpus. It adheres intimately to the skin by its superficial face, and deeply to the aponeurosis covering the muscles of the hand.

6. *Adductor of the Small Digit.* (Fig. 125, D, 14.)

This muscle is superficially situated, external to, and behind the outer metacarpal bone, and is composed of a thick, conical fleshy body, concave on its anterior surface, convex posteriorly, and of a long, thin, and flat tendon, which succeeds the inferior extremity of the muscular portion.

It is attached, by the superior extremity of the latter, to the pisiform bone; the tendon terminates outside the superior extremity of the first phalanx of the small digit.

This muscle separates that digit from the axis of the hand, and is therefore an abductor and not an adductor, as its name would indicate. That name has been given to it in Man, because the hand has been considered in a state of supination, a position in which it is effectively an adductor in regard to the median plane of the body. If this name has been preserved here, it is owing to a desire not to import any new element of confusion into a nomenclature already too complicated.

7. *Short Flexor of the Small Digit.* (Fig. 125, D, 13.)

Situated within the preceding, in a slightly oblique direction downwards and outwards, flattened before and behind, triangular, and almost entirely muscular, this muscle derives its origin from a ligament which unites the pisiform bone to the metacarpal region, and terminates inferiorly on the tendon of the adductor, whose congener it is. It may also concur in the flexion of the small digit, though to a very limited degree.

8. *Opponent of the Small Digit.* (Fig. 125, D, 15.)

A muscle elongated from above downwards, flattened before and behind, situated under the perforans tendons, behind the second interosseous muscle, in a direction slightly downwards and outwards. It originates from the posterior ligament of the carpus, and terminates within the superior extremity of the first phalanx of the external digit by a small tendon. It acts as an adductor by drawing the small digit towards the axis of the hand.

9. *Lumbrici.*

These small muscles, which owe their name to the resemblance they bear to the lumbricales or earthworms, are only three in number in Carnivora. They occupy the interval between the four chief branches of the perforans tendon, from which they have their origin; they terminate, by a small fibrous digitation, on the extensor tendons of the three external digits. It is often impossible to trace them so far; for they are frequently observed to stop within and above the first phalanx of the digits for which they are destined. Their functions cannot be rigorously defined in Carnivora.

10. *Metacarpal Interosseous Muscles.* (Fig. 125, D, 16, 16.)

These are four thick and prismatic muscular fasciculi, elongated from above to below, bifid at their inferior extremity, placed parallel to one another, in front of the flexor tendons, from which they are separated by a thin aponeurotic layer, and behind the four large metacarpals.

They have their origin on the posterior and lateral faces of these bones, as well as on the posterior carpal and intermetacarpal ligaments. Each terminates, by the two branches of its inferior extremity, on the great sesamoids of the digit to which it corresponds. There they are continued by a small tendon, which joins the chief extensor of the digit. These muscles oppose undue extension of the digits while the animal is standing, flex them on the metacarpal bones, and maintain the extensor tendons on the anterior aspect of the phalanges.

B. *Muscles of the Anterior Foot in the Pig.*

In our notes on the myology of this animal, we find:

1. A muscle which originates in the substance of the metacarpo-supercarpal ligament, and terminates on the proper extensor of the small external digit by a fibrous strip joined to the external fasciculus of the first interosseous muscle; it is also attached to the external sesamoid. This is, no doubt, the representative of the *short flexor of the small digit* in Man and the Carnivora.

2. A single, but very voluminous *lumbricus*, fixed, at the one part, to the perforans tendon, and at the other, to the proper extensor tendon of the small internal digit (index), as in the preceding muscle.

3 Four *interosseous metacarpal muscles*, similar to those in the Dog, and whose terminal digitations join the proper extensor tendons. The interosseous muscles of the two small digits are not only divided at their inferior extremity, but throughout their whole length are observed to be two very distinct fasciculi, one superficial and external, the other deep and internal. The fibrous membrane covering these muscles, and which separates them from the perforans tendons, is much thicker than in the Carnivora.

C. *Muscles of the Anterior Foot in Solipeds.*

In Solipeds only two *lumbrici* and two *interosseous metacarpal* muscles have to be described.

1. The *lumbrici* originate at the right and the left of the perforans tendon, above the sesamoid annular band of the perforatus. They each terminate by a thin tendon, which is lost in the fibrous lamina enveloping the elastic cushion of the ergot of the fetlock.

2. The *interosseous* muscles (*anterior lumbrici—Percivall*) have been wrongly considered by French veterinary anatomists as lumbrici muscles, and are described by them as the *superior*, or *great lumbrici.* Situated within the rudimentary metacarpal bones, these two little muscles are formed of a very delicate fleshy mass imbedded in the fibrous tissue surrounding the head of the metacarpal bones, and of a long tendon which descends to the metacarpo-phalangeal articulation, to be confounded with the band furnished to the anterior extensor of the phalanges by the suspensory ligament. Sometimes this tendon is directly united to one of the extensors of the phalanges.

These two muscles represent the interossei of the lateral digits. With regard to those of the median digit, they are transformed, as we have already seen, into a fibrous brace which constitutes the suspensory ligament of the fetlock.

D. *Muscles of the Anterior Foot in Ruminants.*

These animals have no muscles, properly speaking, in the region of the foot; in fact, we only find in them the supensory ligament of the fetlock, which is the interosseous of the two complete digits.

COMPARISON OF THE HAND OF MAN WITH THAT OF ANIMALS.

The muscles of Man's hand are numerous and well-developed, in consequence of the extent and variety of the movements of its various parts. They are divided into three groups: the external, or group of the *thenar eminence*, induce the movements of the thumb; the internal, or group of the *hypothenar eminence*, those of the little finger; and the middle group, occupying the metacarpal spaces, comprising the *interosseous muscles*. In addition, there is found in the hand a cuticularis muscle, the cutaneous palmaris (*palmaris brevis*).

The *cutaneous palmaris* occupies two-thirds of the hypothenar eminence; its fibres are directed downwards and inwards. It corrugates the skin on the ulnar border of the hand.

A. Muscles of the Thenar Eminence.

These muscles, nearly all present in the Dog, are:

1. The *short adductor of the thumb*, whose fibres, leaving the lower portion of the antibrachial aponeurosis, the process of the trapezius and the scaphoides, are succeeded by a tendon which is inserted into the upper extremity of the first phalanx of the thumb.

2. The *opponent* (*opponens*) *of the thumb*, which passes from the anterior part of the trapezium to the external border, and near the anterior face of the first metacarpal.

3. The *short flexor of the thumb*, a muscle adjoining the preceding, and which is resolved into two series of fibres—a deep and a superficial.

4. The *short adductor of the thumb*, a triangular muscle, occupying the outer half of the hollow of the palm. It is attached to the os magnum, along the entire length of the third metacarpal bone and, by a tendon, to the sesamoid and supero-internal tuberosity of the first phalanx of the thumb.

Fig. 128.

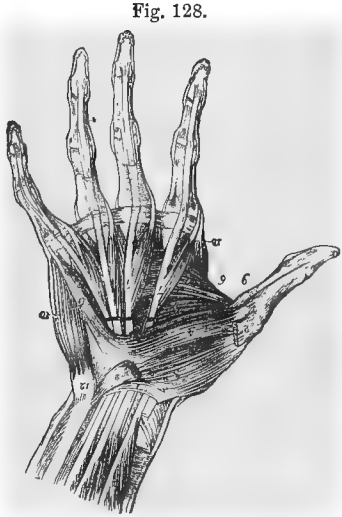

MUSCLES OF HUMAN HAND.

1, Annular ligament; 2, 2, Origin and insertion of the abductor pollicis muscle; 3, Flexor ossis metacarpi, or opponens pollicis; 5, Deep portion of flexor brevis pollicis; 6, Adductor pollicis; 7, 7, Lumbricales muscles arising from the deep flexor tendons, upon which the figures are placed; 8, A tendon of deep flexor; 9, Tendon of flexor longus pollicis; 10, Abductor minimi digitii; 11, Flexor brevis minimi digitii; 12, Pisiform bone; 13, First dorsal interosseous muscle, the abductor indicis.

B. Muscles of the Hypothenar Eminence.

These muscles are: 1. The *abductor of the little finger*, a small fusiform muscular body, which is attached, above, to the pisiform bone, and below to the supero-internal part of the first phalanx.

2. The *short flexor of the little finger*, situated without the preceding, fixed in one part to the process of the unciform bone, and in the other to the inner part of the first phalanx.

3. The *opponent* (*opponens*) *of the little finger*, a triangular muscle, situated below the preceding. It is inserted into the process of the unciform bone, then into the inner border of the fifth metacarpal and the adjacent portion of its anterior face.

C. Interosseous Muscles.

"The interosseous muscles are situated in each interosseous space, two for each space, and are divided into *dorsal* and *palmar*. As there are four interosseous spaces, there ought to be eight muscles; but it is usual to exclude the short adductor of the thumb, because

of its special insertions; this reduces the total number of interosseous muscles to seven—four dorsal and three palmar.

"These small muscles arise from the lateral faces of the metacarpals to the lateral and upper portions of the first phalanges. By their contraction, they incline these phalanges laterally, and consequently carry the corresponding digit inwards and outwards."

It may be added that the *lumbrici* muscles are small muscular and tendinous fasciculi annexed to the tendons of the deep flexor of the phalanges, and whose tendons terminate on the external side of the four last digits in becoming blended with the interossei.

Article III.—Muscles of the Posterior Limbs.

These form four principal groups: the muscles of the croup, thigh, leg, and foot.

MUSCLES OF THE GLUTEAL REGION OR CROUP.

This region is composed of three superposed muscles, which are applied to the ilium, and are distinguished according to their relative situation as the *superficial*, *median*, and *deep gluteus*.[1]

They are covered by a thick fibrous fascia, a prolongation of the aponeurosis of the great dorsal, and which is continued backwards over the muscles of the posterior crural region, where it is confounded with the superficial lamella of the fascia lata. This *gluteal aponeurosis* is fixed to the external angle of the ilium and the supersacral spine. By its deep face it gives attachment to several fasciculi of the superficial and middle glutei.

Preparation.—1. Place the animal on its side, or, better, in the second position. 2. Remove the skin from this region in order to show the gluteal aponeurosis, and to study its extent, attachments, and relations. 3. Cut away this aponeurosis to expose the anterior point of the middle gluteus and the muscular portion of the superficial. To prepare the aponeurotic portion of the latter muscle, the sacro-sciatic insertion of the long vastus must be detached by the scalpel and thrown downwards. 4. Incise the superficial gluteus near its femoral insertion, and reverse it on the sacral spine, so as to lay bare the external face of the middle or principal gluteus. 5. Divide this muscle near its femoral insertions, taking care not to injure these, and remove the whole of its mass, studying meanwhile the nature of its relations to the parts it covers; the deep or small gluteus then becomes apparent, and may be conveniently examined.

1. *Superficial Gluteus.* (Fig. 129, 4.)

Synonyms.—Ilio-trochanterius medius—*Girard.* Gluteus minor—*Bourgelat.* Gluteus medius—*Rigot* and *Lafosse.* The gluteus magnus of Man. (*Gluteus externus—Percivall. Ilio-trochanterius externus—Leyh.*)

Composition—Situation.—This muscle is composed of a fleshy portion, situated beneath the gluteal aponeurosis, and an aponeurotic portion entirely concealed by the anterior portion of the long vastus (*abductor magnus—Percivall*).

Form and Structure.—The muscular portion is triangular, and most frequently divided into two branches, an external and internal, by an excavation which deeply indents its superior border. Its constituent fasciculi are very thick, loosely attached to each other, and are all directed backwards and downwards to converge into a flat tendon, which terminates the inferior angle of the muscle. The aponeurosis likewise terminates the inferior angle of the muscle. This aponeurosis, also triangular, is con-

[1] For the justification of the employment of these new denominations *see* note, page 177

founded, anteriorly, with the posterior border of the muscular portion of its terminal tendon; at its inner and superior border it degenerates into cellular tissue.

Attachments.—This muscle has its fixed insertion: 1, On the internal aspect of the gluteal aponeurosis, by the superior extremity of its muscular fasciculi;[1] 2, On the postero-external angle of the ischium, and the ischiatic ligament, by the internal border of its aponeurotic portion. It has its movable insertion, by means of its terminal tendon, on the small external or third trochanter of the femur.

Relations.—Outwardly, with the gluteal aponeurosis and the anterior portion of the long vastus. Inwardly, with the middle gluteus; by its anterior border, with the fascia lata, to which it is closely united.

Action.—This muscle has been justly considered by Lafosse as an abductor of the thigh. Bourgelat wrongly regarded it as an extensor, and Girard and Rigot have repeated his error. Lecoq has proved that it rather produces flexion than extension. (Leyh states that it is an extensor and a rotator of the thigh outwards.)

2. *Middle Gluteus.* (Fig. 129, 1.)

Synonyms.—Ilio-trochanterius magnus—*Girard.* Gluteus maximus—*Bourgelat, Lafosse, Rigot*, etc. Gluteus medius of Man. (*Gluteus maximus—Percivall. Superior portion of the great ilio-trochanterius—Leyh.*)

Volume—Situation.—This muscle, the largest of the glutei, presents a considerable volume, and is applied against the iliac fossa, the sacro-ischiatic ligament, and the ilio-spinalis muscle.

Form and Structure.—It is elongated from before to behind, wide and very thick in its middle, prolonged forward by a thin point, and terminated behind by three branches of insertion—two tendinous and one muscular. The muscular fasciculi entering into its composition are generally very thick and more or less long; all converge towards the posterior insertions of the muscle.

Attachments.—1, By the superior or anterior extremities of the muscular fasciculi, on the internal aspect of the gluteal aponeurosis, the aponeurosis of the common mass, the superior face and the two anterior angles of the ilium, the two sacro-iliac ligaments, and a small portion of the sacro-ischiatic ligament. 2, On the trochanter (major) by its three posterior branches: the first, or median, is a thick, round tendon fixed on the summit; the anterior is formed by a second wide, thin, and flat tendon, which is inserted into the crest, after gliding over the convexity; the posterior is a small, triangular, fleshy slip, aponeurotic at its anterior border, by means of which it is attached behind the trochanter. This slip corresponds to the *pyramidal* muscle of Man.

Relations.—Covered by the gluteal aponeurosis and the superficial gluteal muscle, it covers the ilio-spinalis, which receives its anterior point, the iliac fossa, the small gluteal, the ilio-sacral, and sacro-ischiatic ligaments, the sciatic nerves, and the gluteal nerves and vessels. Near the external angle of the ilium it is bordered by the fascia lata and the iliacus, which are closely united to it.

Action.—When its fixed point is superior, this muscle extends and abducts the thigh; but when the femur is fixed, it causes the pelvis to rock on the

[1] We have been frequently able to convince ourselves that none of the fasciculi of the superficial gluteus proceed direct from the ilium or the sacral spine.

superior extremity of that bone, and assists in *rearing*. In the first instance it acts as a lever of the first order; in the second, as one of the third order.

Fig. 129.

SUPERFICIAL MUSCLES OF THE CROUP AND THIGH.

1, Middle gluteus, or gluteus maximus; 2, Anterior spinous process of ilium; 3, Muscle of the fascia lata, or tensor vaginæ; 4, Superficial gluteus, or gluteus externus; *, Great trochanter of femur; 5, Fascia lata; 6, Patella, with insertion of rectus; 7, Long vastus, or adductor magnus; 8, Superior and, 9, lateral coccygeal muscles; 10, Semitendinosus and semimembranosus; 11, 12, Inferior portions of long vastus; 13, Fascia of the thigh; 14, Vastus externus.

3. *Deep Gluteus.* (Fig. 131, 5.)

Synonyms.—Ilio-trochanterius parvus—*Girard.* Gluteus medius—*Bourgelat.* Gluteus minimus—*Lafosse* and *Rigot.* The gluteus minimus of anthropotomists. (*Gluteus internus—Percivall.*)

Form—Situation.—A small, short, thick, and quadilateral muscle, flattened above and below, situated beneath the preceding, and above the coxo-femoral articulation.

Structure and Attachments.—It is composed of voluminous muscular and

tendinous fasciculi, which arise from the neck of the ilium and the supra-cotyloid ridge, to be directed outwards and backwards, and terminate within the convexity of the trochanter.

Relations—Its upper face responds to the middle gluteus; the inferior covers the coxo-femoral articulation, and strongly adheres to the fibrous capsule of that joint; this face is also separated from the anterior gracilis (ilio-femoralis) of the thigh and the origin of the anterior rectus (rectus femoris), by a very strong fibrous layer, which extends from the external border of the ilium to the base of the trochanter. Its posterior border is in relation with the anterior gemellus of the pelvis.

Action.—It is the special abductor of the thigh, and is also an accessory rotator of the femur inwards. (Leyh says it is a congener of the preceding muscle, and therefore an extensor of the thigh. It may also maintain the capsular ligament tense.)

DIFFERENTIAL CHARACTERS OF THE MUSCLES OF THE GLUTEAL REGION IN OTHER THAN SOLIPED ANIMALS.

In *Ruminants* and the *Pig*, the gluteal muscles much resemble, though they sensibly differ from, those of Solipeds. In fact, the *superficial gluteus* and the long vastus form but one and the same muscle: the *middle gluteus*, thinner than in the Horse, is not so much prolonged in front on the ilio-spinalis; and, on the contrary, the *deep gluteus*, more developed than in the Horse, is easily divided into two portions, which Rigot has designated as two distinct gluteals.

In *Carnivora*, the *superficial gluteus* is voluminous; it proceeds from the sacrum, and terminates by an aponeurosis below and behind the trochanter. This aponeurosis receives, in front, a small muscular band which arises by tendinous fibres from the surface of the middle gluteus, near the external angle of the ilium, and which resembles the external branch of the superficial gluteus of the Horse. In these animals, also, the *middle gluteus* does not extend beyond the lumbar border of the ilium in front, and terminates behind by a single branch.

COMPARISON OF THE GLUTEAL MUSCLES OF MAN WITH THOSE OF ANIMALS.

The gluteal muscles are distinguished, in regard to their volume, into great, medium, and small (*see* note, p. 177).

The *great gluteus* (*gluteus maximus*) corresponds to the superficial gluteal of animals.

The *medium gluteus* (*gluteus medius*) to the middle gluteus of Solipeds.

The *small gluteus* (*gluteus minimus*) to the deep gluteus.

The *medium gluteus* does not extend beyond the crest of the ilium in front (*see* Figs. 133, 134).

With regard to the *great gluteus*, it is inserted inwardly into the sacrum and the coccyx; below, into the external bifurcation of the linea aspera, from the trochanter to the middle third of the femur.

MUSCLES OF THE THIGH.

These have been divided into three secondary regions, which are: the *anterior crural* (or *femoral*) or *patellar*, the *posterior crural* (or *femoral*), and the *internal crural* (or *femoral*) *region*.

A. Anterior Crural or Femoral Region.

This region comprises three muscles situated in front of the femur: the *muscle of the fascia lata*, the *crural triceps*, and the *anterior gracilis of the thigh*.

Preparation.—1. Place the subject in the first position. 2. Study the fascia lata muscle immediately after removing the skin from this region. 3. Take away this muscle and the superficial gluteus, the long vastus, the semitendinosis and semimembranosis, the two adductors of the leg, the pectineus, and the two adductors of the thigh, to expose the three portions of the triceps. Separate these three muscular divisions from one another, commencing above where they are scarcely adherent. Dissect the anterior gracilis at the same time.

1. *Muscle of the Fascia Lata.* (Fig. 129, 3.)

Synonyms.—Ilio-aponeuroticus—*Girard.* (*Tensor vaginæ—Percivall. Ischio rotuleus externus—Leyh.*)

Form—Situation.—A flat and triangular muscle, situated in front of the superficial gluteus, and outside the external vastus.

Structure—Attachments.—It comprises: 1, A flabelliform muscular portion covered on its faces by tendinous fibres, and attached, superiorly, to the external angle of the ilium; 2, An aponeurosis named the *fascia lata*, continuous with the inferior border of the muscular portion, and soon divided into two superposed layers, one superficial, the other deep. The latter is insinuated between the long vastus and the external vastus, joins the terminal tendon of the superficial gluteus, and is inserted into the external border of the femur. The first, which also appears to divide into two layers, is spread outwardly over the long vastus, where it is confounded with the gluteal aponeurosis; and inwardly, over the internal crural muscles, to become united to the femoral aponeurosis. Below, it is prolonged to the patella, into which it is fixed; it is even continued below that bone, to join the terminal aponeurosis of the posterior branch of the long vastus.

Relations.—Outwards, with the skin; inwards, with the external vastus, the anterior rectus, and the iliacus; behind, with the superficial and middle glutei. In front, it responds to a cluster of lymphatic glands, and receives on its aponeurosis the insertion of the panniculus carnosus.

Action.—It flexes the femur by raising the entire limb, and renders tense its own terminal aponeurosis.

(In speaking of the uses of this muscle, Leyh states that, in addition to its being a flexor of the thigh and an extensor of the leg through its action on its aponeurosis, it maintains the position of the limb while the animal is standing, and allows the other muscles to become relaxed.)

2. *Crural Triceps.*[1]

An enormous muscle lying against the anterior and lateral aspects of the femur, composed of three portions which are not very distinct from each other for the greater part of their extent, and which are separately described as the *anterior rectus* or *straight muscle*, and the *vastus externus* and *internus.*

A. Anterior Straight Muscle of the Thigh, or Middle Portion of the Triceps.

The ilio-rotuleus of *Girard.* (*Rectus—Percivall. Anterior ilio-rotuleus—Leyh.*) (Fig. 137, 16.)

This muscle is imbedded between the two lateral portions of the triceps, and extends from the cotyloid angle of the ilium to the patella, in a direction slightly oblique forwards and downwards.

Form—Structure.—Elongated, thick, and fusiform, the anterior rectus offers, at its superior extremity, two short and flattened tendinous branches; its middle portion is formed of pale-red muscular fibres lying close to each other, and marked by tendinous intersections; its inferior extremity is enveloped by a vast aponeurotic cone.

Attachments.—It originates, by its two superior branches, from the imprints which surmount, forwards and outwards, the lip of the cotyloid

[1] Following the example of M. Cruveilhier, we will describe by this name the triceps cruris of the older anatomists, and the anterior rectus of the thigh.

cavity. It terminates, by its inferior extremity, on the anterior face of the patella.

Relations.—Externally, internally, and posteriorly, with the two other portions of the triceps; anteriorly, with the muscle of the fascia lata. Its superior extremity, included between the iliacus and the deep gluteus, is separated from the coxo-femoral capsule by a little adipose cushion which is insinuated between its two branches.

Action.—An extensor of the leg and flexor of the thigh.

B. External Vastus (Fig. 129, 4).—*Form—Extent—Situation.*—This is a thick and wide muscular mass, flattened on each side, extending from the superior extremity of the femur to the patella, and situated to the outer side of the anterior rectus.

Structure and Attachments.—The fasciculi composing this muscle are intermixed with strong aponeurotic layers, and originate from the whole outer surface of the femur and the external half of its anterior face; they are directed forwards and downwards, to terminate either on the anterior rectus, or on the superior face and external side of the patella.

Relations.—Outwardly, with the fascia lata and superficial gluteus; inwardly, with the anterior rectus and the vastus internus, which is intimately confounded with it except towards the superior extremity of the femur, where the two muscles are distinctly separate; behind, with the femur and the long vastus.

Action.—It is an extensor of the leg.

C. Vastus Internus (Figs. 131, 7; 137, 17).—This muscle is not very distinct from the preceding for the greater part of its extent, and forms with it a deep and wide channel, in which the anterior rectus is lodged. It is a repetition of the vastus externus in so far as its form, structure, extent, attachments, and action are concerned; but it possesses the following peculiarities:

The fibres entering into its composition arise from the whole internal face and the inner half of the anterior face of the femur, and go to be inserted, some on the aponeurosis of the rectus, others on the internal patellar ligament, the corresponding side of the patella, and on the superior face of the same bone, in common with the vastus externus.

Relations.—By its external face, it responds to the latter muscle and the rectus; by its internal face, to the internal crural aponeurosis, the long adductor of the leg, the iliacus, pectineus, and to the long branch of the great adductor of the thigh.

3. *Anterior Gracilis.* (Figs. 90, 11; 131, 6.)

Synonyms.—Gracilis anterius—*Rigot.* Ilio-femoral gracilis—*Girard.* (*Crureus vel cruralis—Percivall.*)

A small cylindrical muscle, situated in front of the capsule of the coxo-femoral articulation, alongside the fibrous fasciculus that strengthens the anterior portion of this membranous ligament.

Attachments.—It originates from the ilium, very near, and to the outside of, the external branch of the anterior rectus; it afterwards insinuates itself between the two vasti, and terminates on the anterior aspect of the femur by aponeurotic fasciculi.

Relations.—This muscle is included between the three portions of the triceps and the capsular ligament of the coxo-femoral articulation, to which it strongly adheres.

Action.—It appears to raise (or render tense) the capsular ligament during flexion of the femur.

B. Posterior Crural Region.

This region is constituted by three muscles situated behind the thigh. These are the *long vastus*, the *semitendinosus*, and the *semimembranosus.*

Preparation.—Place the subject in the first position, allow one hind leg to lie unfastened, and incline the body to the corresponding side, leaving the other limb attached to the supporting bar, with the thigh slightly flexed to make these muscles tense. These preliminary arrangements being adopted, proceed in the following manner: 1. Make a transverse incision through the short adductor of the thigh, and turn back the two portions to the right and left, so as to expose the whole of the semimembranosus, which is to be afterwards dissected from the semitendinosus and the great adductor of the thigh. 2. After removing the aponeurosis covering the long vastus and semitendinosus, the latter is to be dissected by circumscribing as carefully as possible its two superior insertions. 3. The long vastus is then to be prepared by isolating the two component portions, whose sacro-sciatic insertion is revealed by dividing the analogous insertion of the semitendinosus; after which, reflect the entire muscle in order to study its deep face, its femoral insertion, and its relations with the subjacent organs.

1. *Long Vastus.* (Fig. 129, 7.)

Synonyms.—Ischio-tibialis externus—*Girard.* The biceps femoris and part of the gluteus maximus of Man. (The *biceps abductor femoris* of Percivall. *Anterior pubio-ischio-tibialis—Leyh.*)

Volume—Situation—Extent—Direction.—This muscle offers an enormous volume, as its name indicates; it is situated behind the thigh and the glutei muscles, and forming a curve with its concavity forwards, it extends from the sacral spine to the superior extremity of the leg.

Form and Structure.—It is composed of two prismatic portions perfectly distinct from each other for nearly the whole of their extent, lying side by side, and designated as *anterior* and *posterior.*

The *anterior portion*, the most considerable of the two, is very wide at its upper extremity, and singularly contracted below. It is covered, on the inferior half of its deep face, by a broad and strong tendinous band, which becomes aponeurotic in ascending towards the superior extremity of the muscle. Its component fibres are longest posteriorly, and all arise from the superior extremity to be inserted into the tendinous layer.

The *posterior portion*, much shorter than the preceding, presents an inverse disposition, being contracted at its upper extremity and very wide below. Its muscular fibres are partly attached, by their superior extremities, to a longitudinal aponeurotic layer, which gives the muscle a penniform appearance; they terminate, inferiorly, in a strong aponeurosis united to that of the fascia lata.

Attachments.—The *anterior portion* arises, by its superior extremity, from the sacral spine, the sacro-ischiatic ligament, the aponeurosis enveloping the coccygeal muscles, and the ischial tuberosity. It terminates: 1, On the circular imprint situated behind the subtrochanterian crest, by a fibrous branch detached from the deep tendon; 2, On the anterior face of the patella, by the inferior extremity of that tendon.

The *posterior portion* commences on the spine and tuberosity of the ischium, where it joins the anterior division. Its terminal aponeurosis is spread over the tibial muscles to constitute the fascia of the leg, and is inserted into the tibial crest.

Relations.—The gluteal aponeurosis is prolonged over the external surface of the long vastus, becomes increased in thickness, and is more or less elastic; it strongly adheres to this muscle, and superiorly gives attachment to a great number of its muscular fasciculi, Inwards, the long vastus responds: To the aponeurosis of the superficial gluteus, which separates it, for the most part, from the principal gluteus and the trochanter; to the deep layer of the fascia lata, which isolates it from the external vastus; to the anterior face of the patella, over which it glides by means of a small synovial bursa, before becoming inserted; to the external muscles of the leg; to the sciatic nerves; to the great adductor of the thigh, and to the semimembranosus. Inferiorly, the semitendinosus is related to its internal face, and more superiorly, it is in contact with the posterior border of this muscle, whose sacro-ischiatic insertions it covers by its upper extremity.

Action.—The two portions of the long vastus do not act in the same manner, and in this respect they are essentially distinct. The principal division, pulling the patella outwards and the femur backwards, is an abductor of the entire limb, and an extensor of the thigh; while the posterior portion merely determines the flexion of the leg and the tension of the tibial aponeurosis.[1]

If the leg be the fixed point, this muscle, in contracting, causes the pelvis to swing on the head of the femur, and in this way it plays an important part in *rearing.*

2. *Semitendinosus.* (Figs. 129, 10; 130, 14.)

Synonyms.—Ischio-tibialis medius or posticus—*Girard.* (*Posterior sacro-ischio-tibialis—Leyh.* Percivall describes this and the next muscle by the name of *adductor tibialis.*)

Situation—Extent—Direction.—This muscle is situated behind the preceding, and, like it, extends from the sacral spine to the leg, describing a curve whose convexity is posterior.

Volume—Form—Structure.—Less considerable than the long vastus, it is elongated from above to below, bifid at its superior extremity, thick and prismatic, but nevertheless compressed on both sides. Its muscular fibres are of a pale-red colour, are parallel to each other, and follow the general direction of the muscle; they terminate, inferiorly, on an aponeurosis and on a flattened tendon.

Attachments.—This muscle arises, above, by one of its branches from the sacral spine and the sacro-ischiatic ligament, in common with the long vastus; by the other branch, which is the shortest, from the ischiatic tuberosity. Its inferior aponeurosis is confounded with that of the tibia; the tendon glides over the internal surface of the tibia, and is inserted into its anterior crest.

Relations.—Its sacro-ischiatic branch is covered by the gluteal aponeurosis, and covers the long vastus. For the remainder of its extent, it responds: posteriorly, to that aponeurosis; anteriorly, to the sciatic nerves; externally, to the long vastus and gastrocnemius; internally, to the semimembranosus and the long adductor of the thigh.

Action.—It is a flexor of the leg, and tensor of the tibial aponeurosis,

[1] If it were wished to establish a comparison between the nature of the action of the two portions of the long vastus, and their relations and attachments, their analogues in Man could be easily determined. The anterior is undoubtedly a considerable portion of the gluteus maximus, prolonged to the patella; the posterior represents the biceps femoralis.

when its fixed point is above; when the leg is fixed, it becomes one of the active agents in *rearing*

3. *Semimembranosus.* (Figs. 129, 10; 130, 13.)

Synonyms.—Ischio-tibialis internus—*Girard.* (*Great ischio-femoralis—Leyh.*)

Situation—Volume—Extent—Direction.—Situated within the semitendinosus, and shorter and thinner than it, the semimembranosus extends from the ischium to the inferior extremity of the femur, and follows an oblique direction downwards and forwards.

Form—Structure.—Elongated vertically, depressed on each side, prismatic, thick at its anterior, and very thin at its posterior borders. It is also voluminous at its upper extremity, which has a small prolongation whose point ascends to the base of the tail; contracted, and terminated by a short tendon at its inferior extremity. It is formed of thick muscular fasciculi, which all terminate, below, on the tendon.

Attachments.—Above: 1, To the aponeurosis of the coccygeal muscles, by the thin prolongation from its superior extremity; 2, To the ischiatic tuberosity, and on the inferior face of the ischium. Below, to the small eminence situated within the internal condyle of the femur.

Relations.—Inwards, with a very thin prolongation from the gluteal aponeurosis, and with the ischio-cavernous muscle and short adductor of the leg; outwards, with the semitendinosus, the long vastus, and the sciatic nerves; in front, with the great adductor of the thigh, which is so intimately united to it that some difficulty is experienced in separating their fibres.

Action.—It is an adductor of the limb and an extensor of the thigh, when its fixed point is above; but when the femur is fixed, it is an auxiliary in *rearing*.

C. *Internal Crural Region.*

This region comprises nine muscles, applied in three superposed layers against the inner aspect of the thigh. These are: the *long* and *short adductor of the leg*, forming the superficial layer; the *pectineus* and the *small* and *great adductors of the thigh*, forming the middle layer. Those of the deep layer—that is, the *square crureus*, *external obturator*, *internal obturator*, and *gemini of the pelvis*, are not all situated on the inner face of the femur, one of them being contained within the pelvic cavity. With these muscles, which do not present a very considerable volume, another region might be formed and designated the *deep pelvi-crural*, or *coxo-femoral* region.

Preparation.—1. Place the subject in the first position. 2. Prepare on one side the two muscles of the superficial layer, by removing the slight fibrous layer covering them, the internal crural aponeurosis, and the inferior parietes of the abdomen. 3. To expose, on the opposite side, the three muscles of the middle layer, cut through the two adductors of the leg, and turn them back to the right and left; separate the semimembranosus from the great adductor of the thigh; it may be even useful, in order to study the latter muscle, to remove the entire mass of the three ischio-tibial muscles. 4. Dissect the small deep muscles on a separate piece, as shown in figures 90 and 131.

1. *Long Adductor of the Leg.* (Fig. 130, 8.)

Synonyms.—Sublumbo-tibialis—*Girard.* (*Sartorius—Percivall. Internal ilio-rotuleus—Leyh.*)

Form—Situation—Direction.—This muscle is long, thin, and flattened, narrow at its inferior extremity, and situated at first within the abdominal

cavity, at the entrance to the pelvis; afterwards, inside the thigh; it is oblique from above to below, behind to before, and within to without.

Structure.—It is formed of parallel muscular fibres, and terminates, inferiorly, by an aponeurosis which is confounded with that of the short adductor.

Attachments.—It originates, superiorly, from the inferior face of the iliac fascia near the tendon of the psoas parvus, and is inserted, by means of its terminal aponeurosis, not on the supero-internal tuberosity of the tibia, but on the internal patellar ligament, in common with the short adductor.

Relations.—It is covered by the crural aponeurosis and Poupart's ligament, and covers the iliacus, psoas magnus, the anterior femoral nerve, and the internal vastus. Superiorly, its inner border forms the limit, with the pectineus and the anterior border of the short adductor, to a triangular space occupied by the crural vessels; below this space the two adductors of the leg are closely adherent to each other.

Action.—It adducts the leg, and flexes the femur.

2. *Short Adductor of the Leg.* (Fig. 130, 9.)

Synonyms.—Subpubio-tibialis—*Girard.* (*Gracilis—Percivall. Pubio-tibialis—Leyh.*)

Form—Situation—Direction.—A large quadrilateral muscle, thin at its borders, situated inside the thigh in an oblique direction downwards and outwards. It forms the base of what is called the *flat of the thigh.*

Structure.—Formed of parallel muscular fibres, which extend from its superior to its inferior border, this muscle is tendinous at its origin, is covered by an albugineous layer, and terminates inferiorly in a wide aponeurosis.

Attachments.—It originates, by the whole extent of its superior border, from the ischio-pubic symphysis, and is confounded with the muscle of the opposite side—*origin.* Its terminal aponeurosis, united with that of the long adductor, is inserted on the internal patellar ligament and the internal face of the tibia—*movable insertion;* posteriorly, it is confounded with the aponeurosis of the semitendinosus, and with it forms the tibial aponeurosis enveloping the tibial muscles.

Relations.—Its superficial face is covered by a cellulo-fibrous layer, and by the saphena vessels and nerves. It covers, by its deep face, the pectineus, the adductors of the thigh, the semimembranosus and semitendinosus, and the internal femoro-tibial ligament. It is traversed at its origin, and altogether in front, by a very large venous branch.

Action.—An adductor of the limb and a tensor of the tibial aponeurosis.

3. *Pectineus.* (Fig. 130, 11.)

Synonyms.—Superpubio-femoralis—*Girard.* Its anterior branch corresponds to the pectineus, and the posterior to the middle adductor in Man. (*Anterior pubio-femoralis—Leyh.*)

Situation—Direction—Form.—Situated beneath the preceding, in an oblique direction downwards, forwards, and outwards, this muscle is conoid, thick, and bifid at its superior extremity, contracted at its inferior extremity.

Structure and Attachments.—Its fasciculi arise either from the anterior border and inferior surface of the pubis, or from the surface of the pubio-femoral ligament, which passes between its two branches—*fixed insertion.* They are enveloped, at their inferior extremity, by a tendinous cone, which

is attached, on the inner aspect of the femur, to the imprints surrounding the nutrient foramen—*movable insertion.*

Action.—The pectineus is an adductor and flexor of the thigh, and also rotates it inwardly.

Fig. 130.

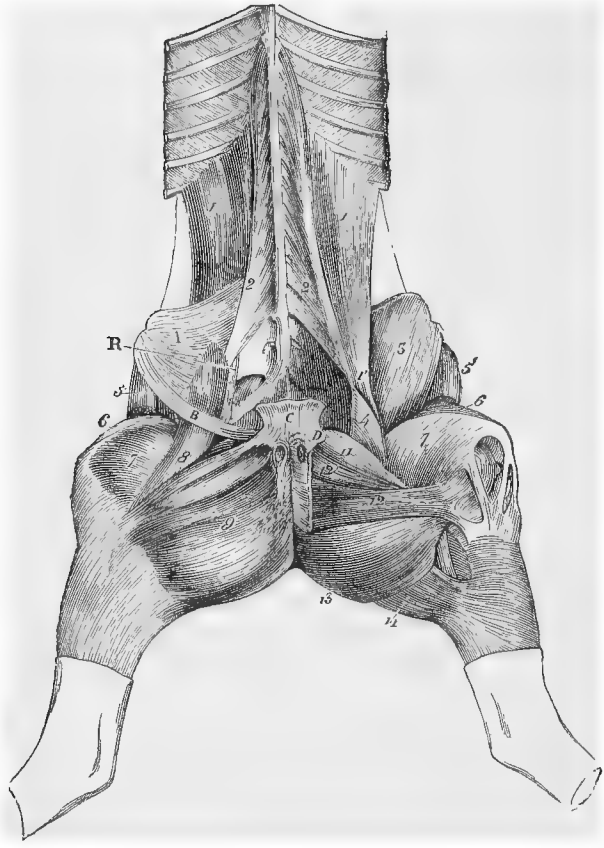

MUSCLES OF THE SUBLUMBAR, PATELLAR, AND INTERNAL CRURAL REGIONS.

1, Psoas magnus; 1′, Its terminal tendon; 2, Psoas parvus; 3, Iliacus; 4, Its small internal portion; 5, Muscle of the fascia lata; 6, Rectus of the thigh; 7, Vastus internus; 8, Long adductor of the leg; 9, Short adductor of the leg; 11, Pectineus; 12, Great adductor of the thigh; 12′, Small adductor of the thigh; 13, Semimembranosus; 14, Semitendinosus.—A, Portion of the iliac fascia; B, Portion of the layer reflected from the aponeurosis of the abdominal great oblique, forming Poupart's ligament; C, Pubic tendon of the abdominal muscles; D, Origin of the pubio-femoral ligament.

Relations.—Inwards, with the short adductor of the leg; outwards and forwards, with the femoral insertion of the psoas magnus and iliacus, the vastus internus, the crural vessels, and the long adductor of the leg; behind, with the small adductor of the thigh, and, near its superior extremity, with the external obturator.

Action.—This muscle is an adductor and flexor of the thigh, and more particularly a rotator inwards of the same ray.

4. *Small Adductor of the Thigh.* (Figs. 130, 12; 137, 14.)

Synonyms.—The anterior portion of the biceps femoralis of *Bourgelat*, and of the subpubio-femoralis of *Girard.*[1] (*Middle pubio-femoralis* of Leyh. A portion of the *adductores femoris* of Percivall, and which he has named the *adductor brevis.*)

Situation—Direction.—This muscle is situated beneath the short adductor of the leg, between the pectineus and the great adductor of the thigh, in an oblique direction downwards and outwards.

Form—Structure.—It is flat from before backwards, thick and narrow at its upper extremity, thin and wide inferiorly. Its muscular fibres are of a pale-red colour, nearly parallel to each other, and sometimes very indistinct —superficially, at least—from those belonging to the great adductor; inferiorly, they become aponeurotic.

Attachments.—Above, to the inferior face of the pubis—*origin;* below, to the roughened quadrilateral surface on the posterior aspect of the femur, in common with the short branch of the great adductor—*termination.*

Relations.—Inwards, with the short adductor of the leg; outwards, with the obturator externus: in front, with the pectineus; behind, with the great adductor of the thigh.

5. *Great Adductor of the Thigh.* (Figs. 130, 12.)

Synonyms.—Posterior portion of the biceps femoralis of Bourgelat, and of the subpubio-femoralis of Girard. (The *adductor longus*, of Percivall. *Posterior pubio-femoralis —Leyh.*)

Situation—Direction.—The great adductor is situated beneath the preceding muscle, between the small adductor and the semimembranosus, proceeding obliquely downwards and outwards.

Form—Structure.—It is a long, thick, prismatic muscle, depressed from before to behind, terminating, inferiorly, by two branches of unequal length, and almost entirely composed of parallel muscular fibres, which are generally distinguished from the fasciculi of the small adductor by their deeper colour.

Attachments.—Above, to the lower face of the ischium and to the single tendinous band which attaches the two muscles of the flat of the thigh to the pelvic symphysis—*origin.* Below: 1, By its external branch, the thickest and shortest, to the quadrilateral scabrous surface on the posterior face of the femur, outside the small adductor; 2, By its internal branch, the longest and thinnest, to the supero-internal condyle of the femur, in common with the semimembranosus and the internal femoro-tibial ligament —*termination.*

Relations.—Inwards, with the short adductor of the leg; behind, with the semimembranosus; in front, with the small adductor, the external obturator, and the inferior extremity of the square crural muscle. Its external border, thinner than the internal, partly covers the superior

[1] After mature deliberation, we have decided on describing as two muscles the biceps femoralis of Bourgelat, and to give to them the names of small and great adductors of the thigh, by which Bichat has designated the corresponding muscles in the lower extremity of Man. We have thought it our duty, in this instance, to follow the example given us by several German authors.

extremity of the latter muscle, and is separated from the sciatic nerves and the long vastus by an aponeurotic lamina. The crural vessels pass between its two branches, one of which, the internal, responds anteriorly and near its insertion to the internal vastus muscle.

Action.—This muscle is an adductor and extensor, as well as a rotator outwards of the femoral ray.

6. *Square Crural.* (Figs. 90, 14; 131, 10.)

Synonyms.—The gracilis internus of *Bourgelat*, and the ischio-femoral gracilis of *Girard.* (Not described by Percivall. *Small ischio-femoralis* of Leyh. The *quadratus femoris* of Man.)

Situation—Direction—Form—Structure.—Situated on the posterior face of the femur, between the great adductor and external obturator, and oblique downwards and outwards, the quadratus cruralis is a small band flattened from before to behind, and formed of parallel muscular fibres, slightly tendinous at their inferior extremity.

Attachments.—Above, to the inferior surface of the ischium, in front of the ischiatic tuberosity—*origin; terminating*, below, on the linear imprint on the posterior face of the femur, a little below the trochanter.

Relations.—In front with the posterior face of the femur and external obturator. Behind, and inwardly, with the great adductor of the thigh. Outwards, with the sciatic nerves and the posterior gemellus of the pelvis.

Action.—It is an extensor and adductor of the femur. In our opinion, its mode of attachment will not permit it to rotate this bone either inwards or outwards—at least in Solipeds.

7. *External Obturator.* (Fig. 90, 13.)

Synonym.—Subpubio-trochanterius externus—*Girard.*

Form — Structure — Situation — Direction. — A short, thick muscle, flattened on both sides, triangular, fasciculated, fleshy and aponeurotic, very delicate in texture, and placed almost horizontally beneath the pelvis, at the margin of the oval foramen, which it appears destined to close, and from which it derives its name of *obturator.*

Attachments.—1. To the inferior surface of the pubis and ischium, by the internal extremities of its fasciculi—*fixed insertion*; 2. To the trochanterian fossa, by the external extremities of these fasciculi—*movable insertion.*

Relations.—Its inferior face is covered by the pectineus, the two adductors of the thigh, and the square crural; the superior covers the capsule of the hip-joint, and is related to the internal obturator.

Action.—An adductor and rotator outwards of the thigh.

8. *Internal Obturator.* (Figs. 90; 131.)

Synonym.—Subpubio-trochanterius internus—*Girard.*

Situation.—This muscle is situated in the pelvic cavity, above the oval foramen, and is, consequently, opposite the external obturator.

Form—Structure—Attachments.— It is formed of two portions. One is very thin, and composed of slightly tendinous divergent muscular fasciculi, which arise from around the oval foramen, are directed outwards, and terminate in a tendon belonging to the other portion. The latter, elongated and penniform, is situated in the pelvis, and extends from the anterior angle

of the sacrum to the inferior extremity of the femur, following the direction of the ischiatic border of the ilium, into which it is inserted. The tendon to which it owes its penniform shape is inflected outwards, behind the supra-cotyloid crest or sciatic ridge, joins the gemelli, and terminates in the bottom of the trochanterian fossa.

Relations.—In its intrapelvic portion, this muscle responds: outwards

Fig. 131.

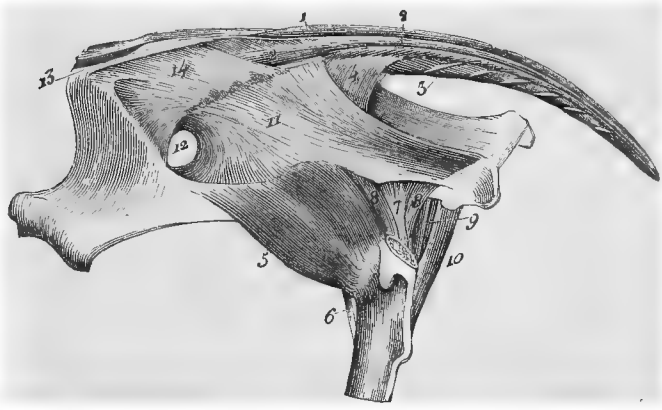

COCCYGEAL AND DEEP MUSCLES SURROUNDING THE COXO-FEMORAL ARTICULATION.

1, Superior sacro-coccygeus; 2, Lateral sacro-coccygeus; 3, Inferior sacro-coccygeus; 4, Ischio-coccygeus; 5, Small gluteus; 6, Anterior gracilis; 7, Tendon of the internal obturator; 8, 8, Gemelli of the pelvis; 9, Accessory fasciculus of the gemelli; 10, Quadratus cruralis; 11, Sacro-sciatic ligament; 12, Great sciatic notch; 13, Superior ilio-sacral ligament; 14, Inferior ilio-sacral ligament.

and downwards, to the ilium, pubis, ischium, and external obturator; inwards and upwards, to the peritoneum, important vessels and nerves, and to a fibrous lamina that separates it from the bladder. In its extra-pelvic portion, it is in relation with: behind, the middle gluteal muscle and the sciatic nerves; in front, with the gemelli. A synovial sheath facilitates the gliding of its tendon in the groove in which it turns.

Action.—It is a rotator of the thigh outwards, and, contrary to the opinion of the majority of authors, we believe it to produce abduction rather than adduction, if at any time its position allows it to execute either of these two movements.

9. *Gemelli of the Pelvis* (Fig. 131, 8, 8, 9).

Synonyms.—Ischio-trochanterius—*Girard.* (*Gemini—Percivall. Bifemoro-calcaneus—Leyh.*)

The two small muscles which receive this name are far from presenting the same disposition in every subject; but we will describe that which appears to be the most frequent. Two little elongated muscular fasciculi are usually found, one above, the other below the tendon common to the two portions of the internal obturator. These two fasciculi (Fig. 131, 8, 8), arise from the external border of the ischium, follow the direction of the above-mentioned tendon, and are inserted into it by the external extremities of their fibres, exactly representing the gemelli of Man. But there is also

a third (Fig. 131, 9), wide, flat, and often very voluminous, situated between the preceding and the external obturator; it is attached, by its inner border, to the external border of the ischium, contracting intimate adhesions with the other two and with the tendon of the internal obturator, and becoming inserted by the whole extent of its external border into the digital fossa.

Relations.—The gemelli respond posteriorly, to the sciatic nerves; anteriorly, to the capsule of the hip-joint and the external obturator, through the medium of an adipose cushion.

Action.—Like the preceding muscle, these rotate the thigh outwards, and perhaps tend to produce the abduction of this ray.

DIFFERENTIAL CHARACTERS OF THE MUSCLES OF THE THIGH IN OTHER THAN SOLIPED ANIMALS.

A. Anterior Crural Region.

In the *Ox*, *Sheep*, and *Goat*, the muscle of the *fascia lata* is much wider than in Solipeds. In the *Dog* and *Cat*, this muscle offers in front a supernumerary fasciculus—a long thick band, confounded inwardly with the long abductor of the leg, and extending vertically from the external angle of the ilium to the patella, into which it is inserted by a short aponeurosis.

The *anterior rectus of the thigh* in the *Dog* and *Sheep* has only one originating branch.

The *anterior gracilis*, the very small muscular fasciculus, is only present in Solipeds and Carnivores.

B. Posterior Crural Region.

Ruminants.—In the *Ox*, *Sheep*, and *Goat*, the two portions of the long vastus are but little distinct from each other, and the anterior is reinforced superiorly by the superficial gluteus, which, with the long vastus, forms but one remarkably developed muscle.

Fig. 132.

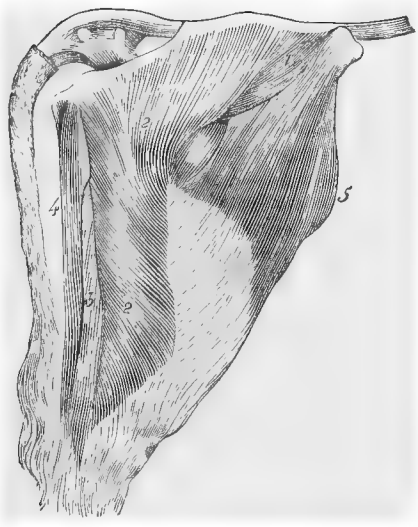

SUPERFICIAL MUSCLES OF THE CROUP AND THIGH IN THE COW.

1, Middle gluteal; 2, 2, Long vastus; anterior portion; 3, Ditto, posterior portion; 4, Semitendinosus; 5, Muscle of the fascia lata.

The internal face of this muscle has no point of attachment on the femur; it glides behind the trochanter by means of a vast mucous bursa, which is often the seat of pathological alterations—synovial tumours which constitute the *swellings* or *gout* of the larger Ruminants. Another synovial bursa, liable to the same maladies, covers the patellar tendon of the muscle on its passage over the external condyle of the femur, and facilitates its gliding on that bony eminence. Before joining the external patellar ligament, this tendon shows a very thick, fibro-cartilaginous enlargement, and receives some of the fibres of the external vastus.

Another arrangement in this muscle, which it is essential to recognise in a surgical point of view, is the union of the anterior border of the *long vastus* of the Ox with the *fascia lata*, whose two lamellæ comprise that muscle between them, and closely adhere to each of its faces. It very frequently happens that in emaciated beasts, this fascia is ruptured at the trochanter, and the latter, instead of gliding on the inner face of the long vastus, slips before its anterior border to pass through the solution of continuity, where it is fixed so firmly that it is sometimes necessary to cut across the fibres of the long vastus in order to give the limb liberty of movement.

The *semitendinosus* has no sacral prolongation; it arises only from the ischium.

The *semimembranosus* is divided, inferiorly, into two branches: one, very thick, passes to the femur; the other, much smaller, terminates by a tendon which is insinuated beneath the internal lateral ligament of the femoro-tibial articulation, to gain the superior extremity of the tibia.

CARNIVORA.—In these animals it is somewhat difficult to isolate the two portions of the *long vastus* from each other. The anterior only proceeds from the ischium. Inferiorly, they terminate in common by an aponeurosis which passes to the tibial crest and the external patellar ligament.

The *semitendinosus* and *semimembranosus* comport themselves as in the smaller Ruminants.

C. Internal Crural Region.

RUMINANTS.—The *long adductor of the leg* in the *Ox* and *Sheep* is traversed, near its origin, by the femoral artery. The *pectineus* of the *Ox*, single at its upper extremity, is divided into two branches at its inferior extremity. One of these branches, thin and pale, is prolonged to near the internal condyle of the femur, while the principal stops, as in the Horse, on the posterior face of the bone.

The *small adductor of the thigh* is scarcely distinct from the *great adductor*. The latter is undivided at its inferior extremity, which stops at the posterior face of the femur without going to the inner condyle of that bone.

The *internal obturator* has no upper portion; it is united to the external obturator in passing through the oval foramen.

PIG.—In this animal, the internal crural muscles offer somewhat the same disposition as in the Ox.

CARNIVORA.—In the *Dog* and *Cat*, the *long adductor of the leg* arises from the external angle of the ilium, and by its muscular portion is prolonged to the inner face of the tibia. The *short adductor* is much thinner and narrower than in the other animals. The *small adductor of the thigh* is a little, distinctly-isolated, muscle, which begins on the inferior face of the pubis, and terminates at the posterior face of the femur, below the square crural. The *great adductor* is, on the contrary, a wide, thick, undivided muscle, attached to nearly the whole extent of the linea aspera of the femur.

There is nothing particular to note with regard to the *square crural* and the *obturators*; the *gemelli of the pelvis* are always composed of two small, distinctly-isolated, fasciculi, which comport themselves as in Man.

COMPARISON OF THE MUSCLES OF MAN'S THIGH WITH THOSE OF THE THIGH OF ANIMALS.

A. Anterior Muscles.

The *anterior gracilis* is not found in *Man*; nevertheless, there are reckoned three anterior muscles of the thigh, as the *sartorius*, which corresponds to the long adductor of the leg of animals, is included in this region.

The *sartorius* is a very long muscle, whose width at most is about two fingers' breadth. It is attached above, not to the lumbo-iliac aponeurosis, but to the anterior and superior iliac spine: it is afterwards directed downwards and inwards, to pass round the internal condyle of the femur, and terminate by an expanding tendon at the crest of the tibia.

The *tensor of the fascia lata* (*tensor vaginæ femoris*) shows the same general disposition observed in animals. It is the same with the *femoral triceps*. The *anterior rectus* arises by two tendinous branches: one is detached from the anterior and inferior iliac spine; the other from the brim of the cotyloid cavity.

B. Muscles of the Posterior Region.

These are three in number: the femoral or crural biceps, semitendinosus, and semimembranosus.

The *femoral biceps* is represented in Solipeds by the posterior portion of the long vastus. It is an elongated muscle arising by two heads: the long head comes from the ischiatic tuberosity; the shortest from the middle of the linea aspera. After their union, these two heads give rise to a tendon which is fixed into the head of the fibula, and sends an expansion over the tibial aponeurosis.

The *semitendinosus* arises in common with the long head of the biceps; its inferior tendon is reflected beneath the internal tuberosity of the tibia, to be fixed into the crest

of that bone. This tendon, with that of the sartorius, forms the aponeurotic expansion called the *goose's foot.*

The *semimembranosus* is voluminous in its lower portion, and arises, like the other two, from the tuberosity of the ischium; its fibres pass to a tendon which, on reaching the inner side of the knee, terminates in the three pieces composing that articulation (*see* fig. 134).

Fig. 133.

MUSCLES OF THE ANTERIOR FEMORAL REGION IN MAN.

1, Crest of the ilium; 2, Its antero-superior spinous process; 3, Gluteus medius; 4, Tensor vaginæ femoris; 5, Sartorius; 6, Rectus; 7, Vastus externus; 8, Vastus internus; 9, Patella; 10, Iliacus internus; 11, Psoas magnus; 12, Pectineus; 13, Adductor longus; 14, Portion of adductor magnus; 15, Gracilis.

Fig. 134.

MUSCLES OF THE POSTERIOR FEMORAL AND GLUTEAL REGION IN MAN.

1, Gluteus medius; 2, Gluteus maximus; 3, Vastus externus, covered by fascia lata; 4, Long head of biceps; 5, Short head; 6, Semitendinosus; 7, 7, Semimembranosus; 8, Gracilis; 9, Portion of inner border of adductor magnus; 10, Edge of sartorius; 11, Popliteal space; 12, Gastrocnemius, with its two heads.

C. Muscles of the Internal Region.

In books on human anatomy, these muscles are sometimes designated, from their action, by the generic name of *adductors.* They comprise: the internal rectus, pectineus, first or middle adductor, second or small adductor, and third or great adductor. The square crural, the obturators, and the gemelli are described among the posterior muscles of the pelvis. They will, however, be briefly alluded to here.

The *internal rectus* corresponds to the short adductor of the leg of animals. It is a thin muscle, bordering the inner side of the thigh. It is attached, above, to the symphysis pubis; below, to the crest of the tibia, in common with the sartorius tendon.

The *pectineus* repeats the anterior branch of the pectineus of the Horse. It is inserted, below, into the internal bifurcation of the linea aspera of the femur.

The *first adductor* corresponds to the posterior branch of the pectineus of Solipeds. It is represented by a voluminous muscular mass, which arises from the spine of the pubis and terminates on the middle third of the linea aspera.

The *second* or *small adductor* corresponds to the muscle of the same name in animals. It is inserted into the same points as the preceding.

The *third* or *great adductor* is attached, above, to the ischiatic tuberosity and to the whole of the lower branch of the ischium by aponeurotic fibres. It afterwards divides into two branches: the external branch, entirely muscular, is fixed into the entire interspace of the linea aspera; the internal branch gives rise to a tendon which goes to the inner condyle of the femur. Between these two branches is found, as in the Horse, the *ring of the adductors*, in which pass the large vessels of the thigh.

The *square crural* of Man is nearly horizontal, as it is attached, inwardly, to the external border of the ischium, and outwardly, between the great and small trochanters.

The *internal obturator* and *gemelli* resemble those of the Dog.

MUSCLES OF THE LEG.

These muscles, nine in number, are grouped around the two principal bones of the leg, so as almost to completely envelop them, leaving only the internal face of the tibia uncovered. Like those of the fore-arm, they form two particular regions: an *anterior* and a *posterior*; and they are sheathed in common by the *tibial aponeurosis*, a very solid fibrous covering which in every respect corresponds to the antibrachial aponeurosis.

TIBIAL APONEUROSIS.

This aponeurosis is formed of several superposed layers which are intimately united, and receives, superiorly, the insertion of the long vastus, the semitendinosus, and the short adductor of the leg, which may be considered as its tensor muscles.

It is continued, inferiorly, over the tarsus and the metatarsal region, in becoming singularly attenuated, and in covering the fibrous bands which bind and retain the anterior tibial muscles in the bend of the hock. Its external surface is separated from the skin by a very thin cellulo-fibrous expansion; its internal face furnishes special and very firm sheaths around the majority of the tibial muscles.

The tibial aponeurosis is attached to the internal surface and crest of the tibia, as well as to the summit of the calcis. The latter attachment takes place by a thick fibrous band, whose singular and complicated disposition has not yet been exactly described. It is situated in front of the tendon of the hock, or between that tendon and the deep layer of the posterior tibial muscles. By its borders, it is continuous with the tibial aponeurosis or fascia. Superiorly, it adheres most intimately to the perforatus tendon, near the point where the latter originates; there it sends off a thick fasciculus which descends to the gastrocnemius tendon. Below this, it appears to divide into two branches, an external and internal, which are united to the calcanean cap of the perforatus tendon, and are attached to the sides of the calcis in such a manner, that near its insertion the gastrocnemius tendon is found to be enveloped by a complete fibrous sheath, formed partly by the perforatus tendon and partly by the band just described. This latter, therefore, constitutes a strengthening apparatus for the tendon of the hock: a structure noticed by Girard, who made it a branch of insertion of the semitendinosus; and not without reason, perhaps, because it arises from the tibial aponeurosis, which, in part at least, is itself derived from the semitendinosus muscle.

Preparation of the Muscles of the Leg.—Separate the limb from the trunk by sawing

through the femur at its middle. Dissect the insertions of the long vastus, the short adductor of the leg, and the semitendinosus, to observe the continuity of these muscles with the tibial aponeurosis; study the insertions of this aponeurosis, particularly that which it has on the summit of the calcis. To expose the muscles, remove their aponeurotic envelope, leaving, however, the band it forms in front of the tendon of the hock, as well as the bands which retain the tendons. Remove the hoof in the manner already indicated for the anterior extremity, and, finally, separate the muscles from one another—an operation so very simple as not to require any special directions.

A. *Anterior Tibial Region.*

This is composed of three muscles: the *flexor of the metatarsus*, the *anterior extensor*, and the *lateral extensor of the phalanges.* The first is deep-seated, the other two are superficial.

1. *Anterior Extensor of the Phalanges.* (Fig. 135, 20.)

Synonyms.—Femoro-prephalangeus—*Girard.* The extensor longus digitorum pedis of Man. (*Extensor pedis—Percivall.*)

Situation—Direction—Extent.—This muscle, situated in front of the leg and foot, follows the direction of these two rays for their whole extent.

Form—Structure.—It is formed of a muscular body and a tendon. The first is fusiform, depressed from before to behind, aponeurotic at its superficies in its superior moiety, and tendinous internally in its inferior moiety. The tendon, at first round, then flat, commences a little above the inferior fourth of the tibia, and reaches the anterior face of the principal metatarsus, where it receives the pedal (extensor brevis digitorum) muscle, the tendon of the lateral extensor, and a funicular prolongation of the tibial aponeurosis. It afterwards descends on the fetlock, where it comports itself exactly as the corresponding tendon in the anterior extremity. (*See* the anterior extensor of the phalanges in the fore-limb, page 262.)

Attachments.—Above, in the digital fossa placed between the trochlea and external condyle of the femur, through the medium of the tendinous portion of the flexor of the metatarsus—*fixed insertion.* Below, on the capsular ligament of the metatarso-phalangeal articulation, the anterior face of the two first phalanges, and the pyramidal eminence of the os pedis.

Relations.—The muscular portion responds: outwardly, with the tibial aponeurosis; inwardly, to the flexor of the metatarsus; posteriorly, to the lateral extensor of the phalanges. The tendon successively covers: the anterior aspect of the tibia, the anterior capsular ligament of the tarsus, the pedal muscle, the anterior face of the principal metatarsal, the articulation of the fetlock, and the two first phalanges. It is covered by the tibial aponeurosis, and by three annular fibrous bands destined to maintain the tendon in the bend of the hock. One of these bands, the superior, is fixed by its extremities to the tibia, a little above the tibio-tarsal articulation; it is common to the muscle we are describing, and to the flexor of the metatarsus. The middle band, attached to the cuboid branch of the latter muscle and the inferior extremity of the calcis, is exclusively intended for the anterior extensor of the phalanges. The inferior maintains the two extensors against the superior extremity of the principal metatarsal.

Action.—This muscle extends the digit and flexes the entire foot.

2. *Lateral Extensor of the Phalanges.* (Fig. 135, 28.)

Synonyms.—Peroneo-prephalangeus—*Girard.* The peroneus brevis of Man. (*Peroneus Percivall. Tibio-prephalangeus—Leyh.*)

Situation—Form—Structure—Extent—Direction.—This muscle, situated

on the external side of the leg, between the preceding and the deep flexor of the phalanges, is composed of a muscular portion and a tendon. The first,

Fig. 135.

EXTERNAL DEEP MUSCLES OF RIGHT POSTERIOR LIMB.

1, Crest of the ilium; 2, Inferior sacro-sciatic ligament; 3, Sacro-ischiatic ligament; 4, Obturator ligament; 5, Tuberosity of the ischium; 6, Anterior tuberosity of the ilium; 7, Small gluteus, or gluteus internus; 8, Its insertion into the great trochanter, 9; 10, Iliacus, or iliac psoas; 11, Vastus externus; 12, Rectus; 13, Great sciatic nerve; 14, Gracilis; 15, Sartorius; 16, Patella; 17, Lateral ligament; 18, Oblique flexor of the phalanges, or flexor pedis accessorius; 19, Peroneus; 20, Extensor pedis; 21, Solearis, or plantaris; 22, Gastrocnemius externus; 23, Flexor pedis; 24, Tendon of oblique flexor of the phalanges; 25, Perforatus tendon; 26, Lateral ligament of gastrocnemius; 27, 28, Annular ligament; 29, Tendon of lateral extensor of the phalanges, or peroneus; 30, External rudimentary metatarsal bone.

elongated, prismatic, and slightly penniform, extends in the direction of the leg, from the superior extremity of that region to beyond its inferior extremity. The tendon succeeds the lower end of the muscular portion, and traverses the groove on the middle of the infero-external tuberosity of the

tibia, passing to the external side of the tarsus, where it is enclosed in a very firm sheath, and is inflected forwards to become united to the tendon of the anterior extensor, near the middle of the metatarsal region.

Attachments.—The lateral extensor is attached, by the superior extremity of its muscular fibres, to the external femoro-tibial ligament, to the whole extent of the fibula, and to the fibrous partition which separates this muscle from the perforans—*origin.* It terminates in the tendon of the anterior extensor.

Relations.—Its muscular body is enveloped in a special containing aponeurosis, which separates it, in front, from the anterior extensor, and behind from the perforans. The tendon covers the tibia, and margins the external and superficial ligament of the tibio-tarsal articulation; which ligament supplies a fibrous ring destined for the formation of its reflected sheath. A vaginal synovial membrane facilitates its motion in the interior of this sheath.

Action.—It acts like the preceding.

3. *Flexor of the Metatarsus.* (Fig. 136.)

Synonyms.—Tibio-premetatarsus—*Girard.* Its muscular portion represents the tibialis anticus of anthropotomists. (*Flexor Metatarsi—Percivall.*)

This muscle is situated beneath the anterior extensor of the phalanges, on the external surface of the tibia, and is composed of two distinct portions: one muscular, the other aponeurotic, not united from end to end, but placed parallel one before the other.

Fig. 136.

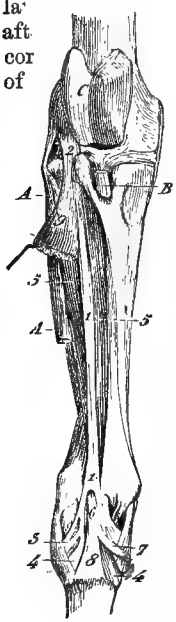

FLEXOR MUSCLE OF THE METATARSUS.

A. Tendinous Portion (Fig. 136, 1).—*Course—Attachments.*—This is a strong, pearly-white cord, comprised between the *muscular portion* and the anterior extensor of the phalanges. It commences at the inferior extremity of the femur, in the fossa excavated between the trochlea and the external condyle; it afterwards passes through the superior groove of the tibia, where it is enveloped by a prolongation from one of the synovial membranes of the femoro-tibial articulation, giving origin, below this groove, to the muscular fibres of the anterior extensor of the phalanges. Lower, it receives some of the fasciculi from the muscular portion, to which it sends in exchange several aponeurotic layers; it passes under the superior annular band in front of the hock, in company with the anterior extensor, and reaches the level of the trochlea of the astragalus, where it is perforated to form a ring for the passage of the inferior extremity of the muscular portion. It finally terminates in two branches: a large one, inserted in front of the superior extremity of the principal metatarsus (Fig. 136, 4); the other, narrower, deviates outwards to reach the anterior surface of the cuboid bone (Fig. 136, 3).

1, Tendinous portion; 2, Its attachment to the femur; 3, Its cuboid branch; 4, Its metatarsal branch; 5, Muscular portion; 6, Its succeeding tendon passing through the ring of the tendinous portion; 7, Cuneiform portion of this tendon; 8, Its metatarsal branch; 9, Anterior extensor of the phalanges drawn outwards by a hook.—A, Lateral extensor; B, Tibial insertion of the middle patellar ligament; C, Femoral trochlea.

Relations.—In front, with the anterior extensor of the phalanges; behind, with the muscular portion, and the anterior capsular ligament of the tarsus.

Action.—This tendon enjoys the curious property of bending the hock by an action altogether mechanical, whenever flexion of the superior bones of the limb takes place. It is, therefore, a conducting cord, whose office it is to regulate the movements of flexion in the hock, and conform them to those taking place in the other joints, without requiring the intervention of an active agency for the execution of these movements.

Another function has also been attributed to it: that of passively opposing the flexion of the femur on the tibia while the animal is standing, and in this way serving as an adjunct to the muscular powers which support the weight of the body. But, in our opinion, this is incorrect; as in order that it may perform this task, it would be necessary for the foot to be maintained in a fixed position by the contraction of its extensor muscles. But these muscles are really the gastrocnemii, which have their origin behind the femur, and which undoubtedly tend to flex that bone on the tibia—that is, to determine the movement it is supposed to prevent. And experiment clearly shows that we are justified in this opinion; for division of this tendinous cord in the living animal does not interfere in the slightest degree with its natural attitude, either when standing at liberty or when forced to stand.[1]

B. Muscular Portion.—*Situation—Form—Structure.*—Situated between the tendinous cord and the tibia, this portion is elongated from above to below, very wide at its superior part and narrow inferiorly, where it terminates in a bifid tendon.

Attachments.—It originates, by the upper extremity of its muscular fibres, from the tibia, below and on the sides of the groove through which the tendinous cord passes; its most superficial fibres are even attached to the aponeurotic sheath which envelops the lateral extensor. Its terminal tendon (Fig. 136, 6) traverses the annular ligament which the tendinous portion forms at its inferior extremity, and becomes inserted, by one of its branches,

[1] J. F. Meckel rightly considers this tendinous cord, not as a portion of the anterior tibial, but as a dependency of the extensor longus digitorum. It would be wrong, however, to describe it apart from the anterior tibial, properly so-called—that is, the muscular portion of our flexor of the metatarsus, the two being, in their action, essentially one.

Is there anything in the human species analogous to this fibrous cord? After much hesitation, we answer in the affirmative, and give it as our opinion that this tendon represents the anterior peroneus (*peroneus tertius*) in Man. These are our reasons for making this assertion, hazardous as it certainly is at first sight: In Man, the peroneus tertius cannot always be easily distinguished from the extensor longus digitorum; so that these two muscles may be regarded as a single one until reaching the instep, where it extends to the phalanges of the toes on the one part, and the metatarsus on the other. Precisely the same arrangement is found in Solipeds; the single muscle divides into two fasciculi, one for the digital region (*anterior extensor of the phalanges*), the other to the metatarsal region (*tendinous cord* of our *flexor metatarsi*). This tendinous cord, then, exactly represents the fasciculus of the long common extensor of the toes (in Man), which goes to the metatarsus, and is designated the peroneus tertius.

But to this it may be said: your peroneus tertius in the Horse has no relation whatever to the peroneus, and does not this prove that you are in error? No; for if this muscle is attached to the fibula in Man, it is because the principal muscle on which it depends is inserted there itself. But as the anterior extensor of the phalanges of the Horse—that is, the common extensor of the toes—is not inserted into the fibula, and has no connection with it in any way, its metatarsal fasciculus, or rather its tendinous cord or peroneus tertius, ought to be absolutely in the same condition. We repeat, however, that this opinion may be, perhaps, a little hazardous; and we give it with reserve, though we have some reasons for considering it to be correct.

in front of the superior extremity of the principal metatarsal bone, along with the analogous branch of the tendinous division (Fig. 136, 8). The other ramification is directed to the inside of the tarsus, to be attached to the second cuneiform bone (Fig. 136, 7).

Relations.—In front, with the tendinous portion of the muscle and the anterior extensor of the phalanges; behind, with the external face of the tibia. The tendon, after traversing the annular ligament of the cord, covers the metatarsal branch of the latter, and is in turn covered by the anterior extensor.

Action.—It is an active agent in flexing the foot on the leg.

B. *Posterior Tibial Region.*

This region comprises six muscles, which are arranged in two superposed layers behind the tibia. The superficial layer is formed by the *gastrocnemii*, *soleus*, and the *superficial flexor of the phalanges*. The deep layer is composed of the *popliteus*, the *deep flexor*, and the *oblique flexor of the phalanges*.

1. *Gastrocnemii, or Gemelli of the Tibia.* (Figs. 135, 22; 137, 20.)

Synonyms.—Bifemoro-calcaneus—*Girard.* (*Gastrocnemius externus—Percivall.*)

Situation—Composition—Extent.—The gemelli of the leg, situated behind the femoro-tibial articulation, below the ischio-tibial muscles, constitute two thick fleshy fasciculi distinct from one another only at their superior extremity, being confounded for the remainder of their extent, and continued inferiorly by a single tendon which extends to the point of the calcis.

Form—Structure.—Both of these muscular masses are flattened on both sides, thick in the middle, narrow at the extremities, and intersected by strong tendinous bands. By their union they form a wide channel, open in front, which embraces the femoro-tibial articulation and the muscles of the deep layer.

The tendon, at first fasciculated, then single and funicular, receives that of the soleus, and is reinforced by a fasciculus from the fibrous band annexed in front to the tendon of the perforatus (*see* the *description of the tibial aponeurosis*, p. 297). An aponeurotic lamina which covers the external gemellus, is continued downwards, partly with this fibrous band, and partly with the tendon of the muscle itself.

Attachments.—The external gemellus arises on the femur, from the rugged lip which margins in front the supracondyloid fossa; the internal, from the collection of tubercles which constitutes the crest of the same name. The terminal tendon of the two bellies is fixed on the summit of the calcis, not at its anterior part, but posteriorly, this being lubricated by a vesicular synovial membrane forming a gliding surface on which the tendon rests during extreme flexion of the foot (Fig. 67, 1).

Relations.—The gemelli respond: by their superficial face, to the three ischio-tibial muscles, and the tibial aponeurosis; by their deep face, to the perforatus, which contracts intimate adhesions with the vastus externus, to the posterior ligament of the femoro-tibial articulation, the popliteal muscle and vessels, the great sciatic nerve, and the oblique and deep flexor muscles of the phalanges. The tendon lies beside that of the perforatus, which is twisted around and completely envelopes it at its inferior extremity, in common with the fibrous band from the tibial aponeurosis. The two tendons form what is usually termed the *tendon of the hock*, or *tendon of Achilles.*

Action.—The gastrocnemii extend the foot upon the tibia. They act as a lever of the first order when the limb is raised from the ground, and as

Fig. 137.

MUSCLES ON INNER ASPECT OF LEFT POSTERIOR LIMB.

1, Crest of the ilium; 2, Section through it; 3, Sacro-ischiatic ligament; 4, Pyriformis; 5, Posterior portion of sacro-ischiatic ligament; 6, Tuberosity of ischium; 7, Anterior portion of ischium, sawn through; 8, Pubis; 9, Obturator foramen; 10, External iliac artery and vein, 11; 12, Obturator artery and vein; the figures are placed on the internal obturator muscle; 13, Long adductor of the leg, or sartorius; 14, Small adductor of the thigh, or adductor brevis; 15, Short adductor of the leg, or gracilis; 16, Rectus of the thigh; 17, Vastus internus; 18, Patella, with insertion of rectus; 19, Upper extremity of tibia; 20, Gastrocnemius; 21, Popliteus; 22, Oblique flexor of the phalanges, or flexor pedis accessorius, with its tendon, 34; 23, Perforans muscle, with its tendon, 35; 24, Flexor metatarsi; 25, Anterior extensor of the phalanges, or extensor pedis; 26, Annular ligament; 27, Tendon of flexor metatarsi, and its cunean branch, 28; 29, Tendon of superficial flexor or internal gastrocnemius; 30, Tendon of gemelli or external gastrocnemius; 31, Os calcis; 32, Astragalus; 33, Perforatus tendon; 34, Tendon of oblique flexor joining the perforans tendon, 35; 36, Large metatarsal bone; 37, Extensor pedis tendon; 38, Terminal knob of small metatarsal bone.

one of the second order when the hoof is placed on the ground. They maintain the tibio-tarsal angle while the animal is standing, and in progression give to the hock that spring which carries the body forward.

2. *Soleus* (*or Solearis*). (Fig. 135, 21.)

Synonyms.—Bourgelat and his successors have erroneously assimilated it to the plantaris of Man. In regarding this little muscle as the soleus, we conform to the well-founded opinion of Cuvier. It is the peroneo-calcaneus of *Girard.* (*Plantaris—Percivall.*)

Form—Situation.—This is a thin, long, and riband-shaped rudimentary muscle, situated at the external side of the leg, between the tibial aponeurosis and the muscular portion of the perforans.

Attachments.—It is fixed, by its superior extremity, behind the supero-external tuberosity of the tibia; and terminates, inferiorly, by a small tendon, which joins that of the gastrocnemii.

Action.—It is a feeble auxiliary of the last-named muscles.

3. *Superficial Flexor of the Phalanges, or Perforatus.* (Figs. 135, 25; 137, 30.)

Synonyms.—Femoro-phalangeus—*Girard.* It is represented in Man by the plantaris and flexor brevis digitorum, or perforatus. These two, in the majority of mammalia, are united from end to end to form a single muscle. (The *gastrocnemius internus* of *Percivall.*)

Form—Structure.—The perforatus of the posterior limb is only represented, in reality, by a long tendinous cord, that is somewhat muscular, slightly thickened, and fusiform in its upper fifth, which forms the body of the muscle.

Origin—Direction and Relations—Termination.—It originates, by its upper extremity, in the supercondyloid fossa, descends between the two portions of the gastrocnemii, to the external of which it is intimately related, on the posterior face of the femoro-tibial articulation and the three posterior deep tibial muscles. On reaching the inferior extremities of the muscular bellies of the gastrocnemii, it becomes exclusively tendinous, and is directly united to the fibrous band which reinforces the tendon of the hock. It afterwards disengages itself below the gastrocnemius, and is placed at the internal side of its tendon, then on its posterior surface, and in this position gains the summit of the os calcis. There it becomes widened to form a fibrous cap, which is covered by a large vesicular synovial membrane; it is moulded to the posterior region of this bony eminence, which it completely envelops in order to be fixed on its lateral portions, and is united to the calcanean band from the tibial aponeurosis. From this point the tendon of the perforatus is prolonged behind that of the perforans to the posterior face of the second phalanx, where it terminates in exactly the same manner as the analogous muscle of the anterior limb.

Action.—It flexes the second phalanx on the first, and this on the metacarpus. It also concurs in the extension of the foot. Its principal office, however, is that of a mechanical stay, destined to sustain the equilibrium of the body while the animal is in a standing posture, by preventing the diminution of the angle of the hock and that of the fetlock, the femur being fixed by the contraction of the crural triceps and the gluteal muscles.

4. *Popliteus.* (Fig. 137, 21.)

Synonyms.—The abductor tibialis of *Bourgelat*, and femoro-tibialis obliquus of *Girard.*

Situation—Direction—Form—Structure.—Situated behind the tibia, below the femoro-tibial articulation, this muscle is oblique downwards and inwards, short and triangular, tendinous at its supero-external angle, and formed, for the remainder of its extent, of divergent fleshy fibres, the longest of which are the most inferior.

Attachments.—1. In the lowest of the two fossæ excavated on the outside of the external condyle of the femur, by its tendon—*origin.* 2. On the supero-posterior triangular surface of the body of the tibia, by the inferior extremity of its muscular fibres—*termination.*

Relations.—Posteriorly, with the gastrocnemii and the perforatus. In front, with the posterior ligament of the femoro-tibial articulation, and the popliteal vessels. Outwards, with the oblique and deep flexors of the phalanges. Inwards, with the semitendinosus and tibial aponeurosis. The tendon, concealed at its origin beneath the external femoro-tibial ligament, glides, by its deep face, over the contour of the external semilunar cartilage and the posterior portion of the external facet on the tibia.

Action.—It flexes the tibia, and gives it a slight rotatory movement outwards.

5. *Deep Flexor of the Phalanges or Perforans.* (Figs. 135, 23; 137, 23.)

Synonyms.—Tibio-phalangeus—*Girard.* The flexor perforans and flexor longus pollicis pedis of Man. (*Flexor pedis—Percivall. Great tibio-phalangeus—Leyh.*)

Extent—Situation—Direction—Composition.—Extending from the superior extremity of the leg to the third phalanx, and situated behind the tibia and foot, whose direction it follows, this muscle is composed of a muscular body and a tendon.

Form, Structure, and Attachments of the muscular portion.—This is thick and prismatic, and incompletely divided into two portions—an internal,[1] and an external,[2] which is the most voluminous. It is attached: 1, To the posterior face of the tibia, on the linear imprints which occupy the inferior triangular surface; 2, To the supero-external tuberosity of the same bone; 3, To the peroneus; 4, To the interosseous ligament uniting that bone to the tibia.

Direction and Attachments of the tendon.—The tendon commences above the inferior extremity of the tibia, where it is most usually double, each muscular portion being succeeded by a tendinous cord whose volume is in harmony with the size of the muscle from which it proceeds. The single tendon resulting from the union of these two primary ones enters the groove formed by the inner face of the os calcis, where it is retained by a fibrous arch which transforms this channel into a perfect sheath, designated the *tarsal sheath;* it glides in the interior of this canal by means of a very extensive vaginal synovial membrane, which extends upwards on the posterior ligament of the tibio-tarsal articulation, and is prolonged inferiorly to the middle third of the metatarsal region. The tendon of the perforans afterwards descends vertically behind the suspensory ligament, receiving from it a strong fibrous band analogous to that of the fore-limb, but less voluminous; it then passes through the annular portion of the perforatus, is inflected with that muscle over the great sesamoid groove, glides on the posterior articulating surface of the second phalanx and that on the small sesamoid bone, thinning out into a *plantar aponeurosis* which is provided with

[1] The tibialis posticus of Man. [2] The flexor longus pollicis of Man.

a phalangeal reinforcing sheath, and finally terminates on the semilunar crest of the os pedis. This tendon, therefore, on leaving the tarsus, comports itself exactly like that of the anterior limb.

Relations.—Outwards, with the lateral extensor of the phalanges, the soleus, and the tibial aponeurosis. Inwards, with this aponeurosis and the oblique flexor Behind, with the gastrocnemii, the perforatus, and the fibrous band of the tendon of the hock. In front, with the tibia.

Action.—This muscle flexes the phalanges on one another and on the metatarsus. It may also extend the foot in pressing, during its contraction, behind the tibio-tarsal articulation. In addition to this, its tendon acts, while the animal is standing, as a mechanical support to the phalanges and the articular angle of the fetlock.

6. *Oblique Flexor of the Phalanges.* (Fig. 137, 22.)

Synonyms.—Peroneo-phalangeus—*Girard.* The tibialis posticus of Man. (*Flexor pedis accessorius—Percivall. Small tibio-phalangeus—Leyh.*)

Situation—Direction.—A muscle situated behind the tibia, between the popliteus and the perforans, in a direction slightly oblique downwards and inwards.

Form—Structure.—It is composed of a fleshy fusiform body, intersected by numerous fibrous bands, and provided with a funicular tendon inferiorly.

Attachments.—The superior extremity is fixed behind the external tuberosity of the tibia—*origin.* The tendon is united, by its inferior extremity, to that of the perforans towards the upper third of the metatarsal region—*termination.*

Relations.—The muscular portion responds: in front, to the perforans, the popliteus, and the posterior tibial artery; behind, to the gastrocnemii and the perforatus. The tendon, at first lodged in a muscular channel in the perforans and covered by the tibial aponeurosis, afterwards enters a tortuous sheath at the inner side of the tarsus, and which is formed by the groove that bends behind the infero-internal tuberosity of the tibia.

Action.—It is a congener of the deep flexor.

DIFFERENTIAL CHARACTERS OF THE MUSCLES OF THE LEG IN OTHER THAN SOLIPED ANIMALS.

A. Anterior Tibial Region.

RUMINANTS.—Among these animals, the *Ox* presents:

1. A complex muscle, which is represented in the Horse by the anterior extensor of the phalanges, and the tendinous cord of the flexor metatarsi. Single at its superior extremity, which begins by a tendon arising from the digital fossa situated between the trochlea and the external condyle of the femur (Fig. 138, 1), this muscle comprises in its middle part three fleshy divisions which are terminated inferiorly by tendons.

One of these divisions, situated in front of, and within the other two, has its tendon prolonged to the superior extremity of the principal metatarsal bone, and is also inserted into the cuneiform bones. It is a flexor of the metatarsal region, and replaces the tendinous cord which performs this function in Solipeds (Fig. 138, 2).

The second, placed without the preceding, constitutes a *common extensor of the digits*, whose tendon comports itself exactly like that of the anterior limb (Fig. 138, 5, 5′, 6) (*see* p. 270).

The third, concealed by the other two, forms the *proper extensor of the internal digit*, and resembles its fellow in the fore extremity (*see* p. 270).

2. An *anterior tibial* muscle (muscular portion of the flexor of the metatarsal of the Horse). It is a triangular, muscular body, lodged in the antero-external fossa of the tibia, into the upper part of which it is inserted, and is succeeded by a tendon that

commences towards the middle of the tibia. This tendon passes through a ring pierced in the tendon of the muscle that represents the tendinous portion of the flexor of the metatarsus; it then deviates inwards, and is fixed into the cuneiforms and the superior extremity of the principal metatarsal bone (Fig. 138, 4).

3. A *proper extensor of the external digit* (lateral extensor of the phalanges in Solipeds, the peroneus brevis lateralis in Man), whose fleshy body is altogether similar to that of the analogous muscle in the Horse, and is terminated by a long tendon which resembles that of the proper extensor of the internal digit (Fig. 138, 7, 8, 9, 10).

4. A muscle which represents the peroneous longus in Man, and of which in Solipeds there is not a trace. This muscle commences by a short, conical, muscular body in front of the supero-external tuberosity of the tibia; and it terminates by a long tendon whose direction is as follows: included at first, like the muscular portion, between the proper extensor of the external digit and the triple muscular fasciculus already described, it arrives on the outside of the tarsus, passes through the fibrous groove of the proper extensor, where it is enveloped by a special synovial membrane, passes over the latter in slightly crossing its direction, and is inflected at first backwards, then outwards, in insinuating itself underneath the external tibio-tarsal ligament, and the calcaneo-metatarsal and the posterior tarso-metatarsal ligaments, which retain it in a channel on the inferior face of the cuboido-scaphoid bone. It is finally inserted into the deep face of the second cuneiform bone, and the external side of the superior extremity of the metatarsus, by a small branch detached from the outer side of the principal tendon.

All these muscles are similarly disposed in the *Sheep* and *Goat*.

Pig.—The anterior tibial muscles of this animal resemble those of Ruminants, with the exception of some peculiarities of secondary importance, among which the following may be cited:

The muscular fasciculus which replaces the *cord of the flexor metatarsi* in the Horse terminates on the scaphoid and the second cuneiform bone. The *common extensor of the digits* has four tendons, one for each digit. The *proper extensors* have two each, one for the small digit, the other for the great. The *anterior tibial* passes to the second cuneiform bone. The *peroneus longus lateralis* is inserted by its tendon into the upper extremity of the internal metatarsus.

Carnivora.—Four muscles are described in these animals: 1, An anterior tibial; 2, A

Fig. 138.

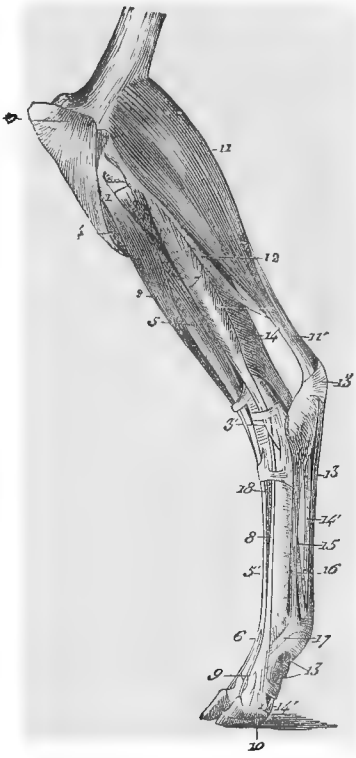

EXTERNAL MUSCLES OF THE LEG OF THE OX.

1, Originating tendon of the muscle which represents the anterior extensor of the phalanges and the tendinous cord of the flexor metatarsi in the Horse; 2, Its flexor fasciculus; 5, That which forms the common extensor of the digits; 5′, The tendon of this fasciculus; 6, Its terminal bifurcation; 3, The long lateral peroneus; 3′, Its tendon; 4, Origin of the anterior tibial (the muscular portion of the flexor metatarsi in the Horse); 7, Proper extensor of the external digit (short lateral peroneus); 8, Its tendon; 9, Its insertion into the second phalanx; 10, Its insertion into the third phalanx; 11, External belly of the gastrocnemii; 11′, Their tendon; 12, Solearis; 13, Tendon of the perforatus; 14, Perforans; 14′, Its tendon; 15, Suspensory ligament of the fetlock; 16, The band it gives off to the perforatus tendon; 17, That which it sends to the proper extensor of the external digit; 18, The pedal muscle· 19, The insertion of the long vastus on the patella and its external ligament.

long common extensor of the digits; 3, A long lateral peroneus; 4, A short lateral peroneus.

1. *Anterior tibial.*—Situated in front of the tibia, and more voluminous than the common extensor of the digits, whose superior extremity it covers, this muscle has its origin on the crest and external tuberosity of the tibia. It receives, near the inferior third of this bone, an extremely thin muscular band which proceeds from the fibula, and which we may with justice compare to the *proper extensor of the big toe* in Man. Then it terminates by a tendon on the metatarsal bone of the internal digit; when this bone is connected with a digital region, the third phalanx receives a particular branch from this tendon, which represents the tendinous portion of the small proper extensor fasciculus annexed to the anterior tibial. This muscle responds: in front to the tibial aponeurosis; inwards and backwards, to the tibia; outwards, to the common extensor of the digits. Its tendon is fixed in the bend of the hock by a fibrous band, whose arrangement is singular enough to deserve mention here. Attached in front of the inferior extremity of the tibia, this band gives origin, by its internal extremity, to a strong ligamentous cord which passes under the tendon of the anterior tibial muscle to reach the anterior face of the tarsus, where it contracts intimate adhesions with the capsular ligament of this region, and terminates on the superior extremity of the metatarsal bone of the middle digit. This cord binds the inferior extremity of the tibia to the metatarsus, and prevents undue extension of the tibio-tarsal articulation. It is, perhaps, the representative of the tendinous cord of the anterior tibial region in the Horse.

2. *Long common extensor of the digits.*—This muscle is composed of a fusiform fleshy body, and a quadrifurcated tendon. The fleshy body, situated beneath the tibial aponeurosis, between the anterior tibial and the lateral peroneal muscles, covers the external face of the tibia and the small fasciculus of the proper extensor of the thumb; it originates by a short and strong tendinous cord, from the inferior extremity of the femur, between the external condyle and the trochlea. The tendon is continuous with the inferior extremity of the fleshy portion, passes beneath the band of the anterior tibial, through another fibrous ring at the cuboid bone, and is inserted, by its four terminal branches into the four large digits, in the same manner as the analogous tendon in the fore-limb.

3. *Long lateral peroneus.*—This muscle is composed of a very short conical fleshy portion, succeeded by a long tendon. The former originates in front of the tuberosity of the supero-external tuberosity of the tibia, and does not appear to have any connection with the fibula. Included between the common extensor of the digits and the short lateral peroneus, it is covered by the tibial aponeurosis, and covers the anterior tibial vessels. The tendon descends parallel with the fibula to its inferior extremity, over which it glides in becoming inflected. On reaching the cuboides, it enters a groove excavated on its external surface, gives off a short isolated branch to the superior extremity of the first metatarsal bone, afterwards crosses transversely the direction of the tarsus in passing behind the inferior row of bones, and terminates on the metatarsus of the thumb. On its way behind the cuboides, this tendon gives off another branch which we have every reason to believe is constantly present; it is a short, interosseous fasciculus, which at first penetrates between the cuboides and the external metatarsal bone, then between the latter and the second metatarsal.

This muscle carries the inferior extremity of the limb outwards, and when the foot is much extended it may act as a flexor.

4. *Short lateral peroneus.*—In Carnivora, this muscle is formed of two fasciculi, a superior and inferior, which may be described as two distinct muscles.

The superior fasciculus comprises a very weak muscular portion attached to the upper third of the anterior border of the fibula, and a funicular tendon succeeding its inferior extremity about the middle of the tibia. This tendon glides over the inferior extremity of the fibula, behind the long lateral peroneus, which it passes under and crosses in descending to the phalanges of the external digit, where it is united to the tendinous branch of the common extensor belonging to this digit.

The inferior fasciculus has its origin on the anterior border and external aspect of the peroneus, by penniform fibres which join a short, but more voluminous tendon than that of the preceding fasciculus. This tendon, with the last, enters the posterior groove in the fibula, and is attached, by its inferior extremity, to the upper end of the external metatarsus, outside the branch furnished by the long lateral peroneus to that bone.

The superior fasciculus acts as a proper extensor of the external digit. The inferior is an abductor of the foot.

B. Posterior Tibial Region.

RUMINANTS.—In the *Ox*, *Sheep*, and *Goat*, the muscular portion of the *perforatus* is thicker than in Solipeds. The portion of the *perforans* is better defined than in Solipeds, and is lodged in a depression on the principal portion; it can easily be traced from the supero-external surface of the tibia, where it originates. The tendon does not differ from that in the fore-limb; but the bands which descend from the metatarsus to the heels, to be united with the two terminal branches of this tendon, are much smaller than those in the metacarpal region.

CARNIVORA.—The *soleus* is absent in the *Dog* and *Cat*. The muscular body of the perforatus is prismatic, voluminous, and entirely blended, in its upper two-thirds at least, with the external gastrocnemius; these two muscles have therefore a common origin. The tendon is quadrifurcated, as in the anterior limb; it offers on its surface, shortly before its division, several thin muscular bands, traces of the fleshy portion of the common short muscle of Man. Several of these bands come from the perforans tendon, and all pass to the four terminal branches of the muscle. The terminal tendon of the perforans is divided into four or five branches, one for each digit.

The *posterior tibial* is not united inferiorly to this tendon, but constitutes a perfectly distinct muscle situated between the deep and oblique flexors of the phalanges. Formed by a very small fleshy body and a long thin tendon, this muscle originates above the peroneus, from the posterior surface of the tibia. Its tendon lies beside that of the oblique flexor, and with it enters the groove behind and within the inferior extremity of the tibia. Enveloped by a synovial membrane proper to its passage through this groove, this tendon soon leaves it to pass to the free surface of the posterior tarso-metatarsal ligament, with which it is blended towards the middle of the tarsus.

COMPARISON OF THE MUSCLES OF THE LEG OF MAN WITH THOSE OF ANIMALS.

In *Man*, the muscles of the leg are divided into three regions: an anterior, external, and posterior

A. Anterior Region.

This includes three muscles:

1. The *anterior tibial*, which corresponds to the fleshy portion of the flexor of the metatarsus, and whose imperforate tendon is fixed into the first cuneiform.
2. The *common long extensor of the toes*, which represents the anterior extensor o the phalanges of the Horse. This muscle is attached, above, to the external tuberosity of the tibia and the upper three-fourths of the inner face of the fibula; its tendon divides into two fasciculi, the internal of which furnishes a branch to the second, third, and fourth toes, and the external goes to the fifth.
3. The *proper extensor of the large toe*, represented in the Dog by a small fasciculus blended with the anterior tibial, is an elongated semi-penniform muscle which arises from the inner face of the fibula and the interosseous ligament, and terminates on the second phalanx of the great toe, after receiving the *pedal* tendon (*extensor brevis digitorum*).

B. External Region.

This region is only composed of two muscles: the *long* and *short peroneus*.

The first, which does not exist in Solipeds, is a penniform muscle attached to the upper third of the fibula, the external tuberosity of the tibia, and the internal face of the tibial aponeurosis, by the superior extremities of its muscular fibres. The flat tendon which terminates it is fixed to the outer portion of the base of the first metatarsal.

The second corresponds to the lateral extensor of the phalanges of the Horse, and is found in all animals. It is penniform, and is attached above, by its fleshy fibres, to the lower two-thirds of the external face of the fibula; below, by its tendon, to the upper extremity of the fifth metatarsal.

These two muscles determine very complicated movements in the region of the foot.

C. Posterior Region.

The posterior tibial muscles form two layers: a superficial and a deep

The first comprises the *crural triceps* and the *plantaris*. The triceps itself is

composed of the *gastrocnemii*, of which we will say nothing, and the *soleus*. The latter is flattened from before to behind, attached to the upper third of the fibula, the oblique line of the tibia, and the middle third of the inner border of this bone, and terminated by an aponeurotic lamina which is blended with the tendo-Achilles. The *plantaris* is formed by a small fusiform muscular body, situated beneath the external gemellus, then

Fig. 139.

MUSCLES OF THE HUMAN LEG; ANTERIOR TIBIAL REGION.

1, Quadriceps extensor inserted into the patella—the figure is on the tendon of the rectus, the vastus internus and externus being on each side; 2, Subcutaneous surface of the tibia; 3, Tibialis anticus; 4, Extensor longus digitorum; 5, Extensor proprius pollicis; 6, Peroneus tertius; 7, Peroneus longus; 8, Peroneus brevis; 9, 9, Borders of the soleus muscle; 10, Part of the inner belly of the gastrocnemius; 11, Extensor brevis digitorum—the tendon in front of the cipher is that of the peroneus tertius, that behind it the peroneus brevis.

Fig. 140.

SUPERFICIAL POSTERIOR MUSCLES OF THE HUMAN LEG.

1, Biceps forming outer ham-string; 2, Tendons forming inner ham-string; 3, Popliteal space; 4, Gastrocnemius; 5, 5, Soleus; 6, Tendo-Achilles; 7, Posterior tuberosity of os calcis; 8, Tendons of peroneus longus and brevis passing behind the outer ankle; 9, Tendons of tibialis posticus and flexor longus digitorum passing into the foot behind the inner ankle.

by a long slender tendon, which is confounded with the inner border of the tendo-Achilles, or is inserted into the os calcis.

The deep layer is composed of four muscles:

1. The *popliteus*, which in its attachments and position resembles that of animals.
2. The *common long flexor of the toes*, corresponding to the oblique flexor of animals.

It is an elongated penniform muscle, fixed above to the oblique line and middle third of the posterior face of the tibia. Its tendon is inflected beneath the external malleolus, passes in front below the astragalus, receives the accessory of the long flexor, and then divides into four branches for the four lesser toes.

3. The *posterior tibial*, represented by a portion of the perforans of animals; its tendon is reflected beneath the internal malleolus of the tibia, and is attached to the scaphoid process.

4. The *proper long flexor of the great toe*, also represented by a portion of the perforans. This muscle is voluminous and prismatic, and is attached above to the lower two-thirds of the posterior face of the fibula. Its tendon is reflected inwards on the astragalus and the groove in the os calcis, crosses the tendon of the common long flexor, and terminates on the posterior extremity of the third phalanx of the great toe.

MUSCLES OF THE POSTERIOR FOOT.

SOLIPEDS.—In these animals are found: 1, *Two lumbrici* and *two interosseous* muscles, corresponding to those of the anterior limb; 2, A *pedal* muscle.

Pedal muscle.—The *tarso-prephalangeus* of *Girard.* (The *flexor metatarsi parvus.* Not mentioned by Percivall.) This is a small riband-shaped fasciculus, situated in front of the principal metatarsal bone, beneath the extensors of the phalanges. It is attached, by its inferior extremity, to the internal surface of the tendon common to these two muscles, and by its upper extremity to the lower end of the os calcis (and astragalus). It aids in extending the digit (flexing the hock, and probably keeping the tendons tense.)

RUMINANTS.—The *pedal* is the only muscle in the region of the foot met with in Ruminants. It is attached, inferiorly, to the tendon of the common extensor and that of the proper extensor of the internal digit.

PIG.—This animal possesses: 1, A *pedal* muscle attached, below, to the two branches of the common extensor of the large digits: 2, Four *interosseous metatarsal muscles*, which do not appear to differ in their general arrangement from the metacarpal interosseous muscles.

CARNIVORA.—In the *Dog* and *Cat* there exist in the region of the posterior foot:

1. A *pedal* muscle, composed of three fasciculi which have their origin either from the inferior extremity of the os calcis, or from the tendinous sheaths in the bend of the hock; they terminate on the second, third, and fourth digits by small tendons joined to the branches of the common extensor.

2. The muscular digitations annexed to the tendon of the perforatus, traces of the fleshy portion of the *flexor brevis digitorum* of Man.

3. A *flexor pedis accessorius*, or *perforans*, a small undeveloped muscle commencing outside the tarsus, and terminating by a very delicate aponeurosis on the posterior face of the perforans tendon.

4. Two or three pale and rudimentary bands, situated inside the tarsus and near the internal digit. These are the vestiges of the *muscles proper to the great toe* in Man.

5. An *adductor of the little toe* (abductor minimi digit) is a thin, elongated muscle, carried obliquely from the posterior tarso-metatarsal ligament to the internal side of the first phalanx of that digit.

6. Four *interosseous metatarsal* muscles, resembling the analogous muscles of the metacarpal region.

7. *Lumbrici*, similar to those of the anterior limb.

COMPARISON OF THE MUSCLES OF THE FOOT IN MAN WITH THOSE OF ANIMALS.

In *Man*, there are distinguished the muscles of the dorsal region, the plantar region, and the interosseous muscles.

A. Dorsal Region.

This only contains one muscle, the *pedal* (*extensor brevis digitorum*). It is attached, behind, to the antero-external part of the upper face of the os calcis by several aponeurotic laminæ; its fleshy fasciculi, four in number, are prolonged by as many tendons destined to the first four toes; three of them pass along with the tendons of the common extensor.

B. Plantar Region.

This is subdivided into three regions: a middle, internal, and external.

The first comprises: 1. The *common short flexor of the toes* which is represented in Solipeds by a portion of the perforatus. It is attached to the infero-internal tuberosity of the os calcis, and to the upper face of the middle plantar aponeurosis. It is followed by four tendons, which are inserted into the second phalanges of the first four toes, after forming rings through which pass the tendons of the common long flexor.

2. The *accessory of the long flexor*, whose fibres pass to the tendons of the common flexor.

3. The *lumbrici*, four in number, and analogous to those of the hand.

The internal plantar region is composed of three muscles, which are found in a rudimentary condition in the Dog.

Fig. 141.

FIRST LAYER OF PLANTAR MUSCLES OF HUMAN FOOT.

1, Os calcis; 2, Posterior part of plantar fascia divided transversely; 3, Abductor pollicis; 4, Abductor minimi digitii; 5, Flexor brevis digitorum; 6, Tendon of flexor longus pollicis; 7, 7, Lumbricales.

Fig. 142.

THIRD AND PART OF SECOND LAYER OF PLANTAR MUSCLES OF HUMAN FOOT.

1, Incised plantar fascia; 2, Musculus accessorius; 3, Tendon of flexor longus digitorum; 4, Tendon of flexor longus pollicis; 5, Flexor brevis pollicis; 6, Adductor pollicis; 7, Flexor brevis minimi digitii; 8, Transversus pedis; 9, Interossei muscles, plantar and dorsal; 10, Convex ridge formed by tendon of peroneus longus in its oblique course across the foot.

1. The *short adductor of the great toe*, which extends from the internal tuberosity of the os calcis to the internal sesamoid and the first phalanx of the great toe.

2. The *short flexor of the great toe*, which arises from the third cuneiform and the tendon of the posterior tibial, and terminates by two branches on the external sesamoid and the internal sesamoid of the great toe.

3. The *short adductor of the great toe*, a muscle formed by two fasciculi, and having a common termination on the external sesamoid. One of these fasciculi arises from the inferior face of the cuboides, the third cuneiform, and the base of the third and fourth metatarsal; it has been formerly described as the *oblique adductor*. The other has its origin from the inferior face of the three last metatarso-phalangeal articulations: this has also been called the *transverse adductor*.

The external plantar region likewise comprises three muscles, which are:

1. The *short abductor of the little toe*, which is detached from the internal tuberosity of the os calcis, and is inserted into the external portion of the first phalanx of the little toe.

2. The *short flexor of the little toe* is attached, behind, to the sheath of the long peroneus and to the process of the fifth metatarsal; in front, to the external part of the first phalanx of the little toe.

3. The *opponens of the little toe*, concealed beneath the preceding, is inserted at one end to the sheath of the long peroneus, and at the other to the external border of the fifth metatarsal.

C. Interosseous Muscles.

These are divided into *dorsal* and *plantar interossei.* Their disposition is nearly the same as in the hand.

CHAPTER III.

THE MUSCLES IN BIRDS.

In birds we find the majority of the muscles already described; though they are appropriate by their form, volume, arrangement, etc., to the particular conformation of the skeleton in these animals.

To undertake, in this essentially practical work, a special description of all these organs, would be [illegible] from the object aimed at: and we therefore confine ourselves to those points [illegible] present most interest in an animal mechanic point of view.

1. *Tendons.*—The tendons in birds present in the inferior limbs and at the extremity of the wings [illegible] amount of ossification more or less extensive along their course. This transformation [illegible] fibrous tissue of the muscles is not the effect of senility, for it is noticed in very young animals.

The tendons, in [illegible] the greater part of their elasticity, doubtless gain in tenacity; and this allows them to transmit to the bony levers the muscular efforts in a more integral manner.

It is also observed that the partial ossification of the tendons does not exclusively belong to the limbs; for it is not rare to meet with this change in other regions, as in the neck of wading birds. In the museum of the Veterinary School at Lyons is the skeleton of a heron which shows this peculiarity in the highest degree; the cervical vertebræ are roughened by a multitude of filiform bony stylets, all directed backwards, and which have originated from the ossification of the tendinous fibrillæ annexed to the muscles of the cervical region.

2. *The Pectoral Muscles.*—The two alternative movements which produce flight—the elevation and depression of the wings—being due to the action of the pectoral muscles, these merit special notice.

The *superficial* or *great pectoral*, "which alone weighs heavier than all the other muscles of the bird put together, is attached to the furculum, to the great ridge of the sternum, and to the last ribs; it is inserted into the very salient rugged outline of the humerus. It is by this muscle that birds are able to give those powerful strokes of the wings which are necessary in flight."

The *deep* or *small pectoral* is "placed in the angle formed by the body of the sternum and its crest, and in the interval between the furculum and the coracoid bone. Its tendon passes through the foramen formed by the union of the furculum, the coracoid bone, and the scapula, as over a pulley; it is inserted above the head of the humerus, which it raises. It is by means of this arrangement that nature has been able to place an elevator and depressor at the inferior surface of the trunk so far from the centre of gravity, without which the bird would have been liable to lose its equilibrium and tumble over head foremost in the air.[1]

Cuvier, adopting the nomenclature of Vicq-d'Azyr, called this muscle the *middle pectoral*, and he gave the name of *small pectoral* to a triangular fasciculus which leaves the lateral angle of the sternum and the base of the coracoid bone, to be inserted under

---

[1] *Cuvier*, 'Leçons d'Anatomie Comparée.'

the head of the humerus. In our opinion, this tendon does not belong to the pectoral region, but to that of the shoulder; and with J. F. Meckel we are inclined to consider it as the coraco-humeralis, which has followed the coracoid process in its development.[1]

3. *The Diaphragm.*—"In birds, the diaphragm is so differently disposed from what it is in the higher vertebrata, that its existence has been successively described and misunderstood, admitted and refuted, and is still looked upon as problematical by a large number of anatomists. Nevertheless, this muscle exists, and its development is in perfect harmony with the importance of its functions. It is composed of two planes, which at their origin are confounded with each other, but soon become separated and pursue, one a transverse, the other an oblique direction. The transverse plane is triangular in form, and is carried horizontally from the right to the left ribs against the inferior surface of the lungs. The oblique plane is convex in front, concave behind, and extends from the dorsal aspect of the spine to the sternum, dividing the cavity of the trunk into two secondary cavities—the thorax and abdomen.

"In birds, as in mammals, the diaphragm is therefore intended to perform two principal functions; but to do this perfectly in the former, it is doubled. So far, then, from this inspiratory muscle being absent in birds, or from its existing in a rudimentary degree, they are really provided with two diaphragms: 1, A *pulmonary diaphragm*, which presides in the dilatation of the lungs; 2, A *thoracic abdominal diaphragm*, which partitions the great cavity of the trunk, and concurs in the inspiration of the air by dilating the large ærial reservoirs lying at its posterior surface. Of these two muscular planes, the first is analogous to that portion of the diaphragm which, in Man and the mammalia, is inserted into the sternum and the ribs; the second manifestly represents the pillars of the diaphragm."

This description, taken from the work of M. Sappey, an observer who is as conscientious as he is talented, gives a perfectly exact idea of this muscle.

[1] E. Geoffroy Saint-Hilaire, in his memoir on the bones of the sternum ('Philosophie Anatomique,' vol. i. p. 89), in comparing the pectoral muscles of fish to those of birds, also employs the nomenclature of Vicq-d'Azyr, and recognises three pectorals as well. We are, however, obliged to confess ourselves as in opposition to the great master who has established rules to follow in the classification of organs, in consequence of his having limited his comparisons to the two classes of vertebrata he had principally in view. If he had extended his observations to the mammalia, and, in them sought for the analogue of the pectoralis parvus, he would have discovered it, as we have done, in the region of the shoulder, and not in that of the sternum.

CHAPTER IV.

GENERAL TABLE OF THE INSERTIONS OF THE MUSCLES IN SOLIPEDS.

1. Vertebral Column.

A. CERVICAL VERTEBRÆ.

I. *Atlas.*

The atlas gives insertion to nine pairs of muscles :—

a. By the surface representing the spinous process, to the—

Small posterior recti muscles of the head.

b. By its transverse processes, to the—

1. Splenius muscles.
2. Small complexus muscles.
3. Great oblique muscles of the head.
4. Small oblique muscles of the head.
5. Mastoido-humeralis muscles.

c. By its body, to the—

1. Small anterior recti muscles of the head.
2. Small lateral recti muscles.
3. Long muscle of the neck.

II. *Axis.*

The axis gives insertion to six pairs of muscles :—

a. By its spinous process, to the—

1. Transverse spinous muscles of the neck.
2. Great oblique muscles of the head.
3. Great posterior recti muscles of the head.

b. By its transverse processes, to the—

1. Intertransverse muscles of the neck.
2. Mastoido-humeralis muscles.

And by the inferior face of its body, to the—

3. Long muscle of the neck.

III. *Third, Fourth, Fifth, Sixth, and Seventh Cervical Vertebræ.*

These vertebræ give insertion to the following muscles :—

a. By their spinous processes, to the—

1. Transverse spinous muscles of the neck.
2. Ilio-spinalis muscles (4th to the 7th).

b. By their articular tubercles, to the—

1. Great complexus muscles.
2. Small complexus muscles.
3. Transverse spinous muscles of the neck.
4. Intertransverse muscles of the neck.

c. By their transverse processes, to he—

1. Angular muscles of the scapula.
2. Splenius muscles (3rd and 4th).
3. Mastoido-humeralis muscles (3rd and 4th).
4. Common intercostal muscles (7th).
5. Intertransverse muscles of the neck.
6. Ilio-spinalis muscles (inferior branch).

And by the inferior faces of their bodies, to the—

1. Great anterior recti muscles of the head.
2. Long muscle of the neck.

B. DORSAL VERTEBRÆ.

The dorsal vertebræ give insertion:—

a. By their spinous processes, to the—

1. Splenius muscles (1st to 5th or 6th).
2. Great complexus muscles (1st to 6th).
3. Small complexus muscles (1st and 2nd).
4. Trapezius muscles.
5. Great dorsal muscles (4th to 18th).
6. Rhomboid muscles (2nd to 7th).
7. Small anterior serrated muscles (2nd to 13th).
8. Small posterior serrated muscles (10th to 18th).
9. Ilio-spinalis muscles.
10. Transverse spinous muscles of the back and loins.

b. By their transverse processes, to the—

1. Great complexus muscles.
2. Small complexus muscles.
3. Ilio-spinalis muscles.
4. Transverse spinous muscles of the back and loins.
5. Supercostal muscles.

c. By their bodies, to the—

1. Long muscle of the neck (1st to 6th).
2. Great psoas muscles (17th to 18th).
3. Small psoas muscles (16th to 18th).

C. LUMBAR VERTEBRÆ.

The lumbar vertebræ give insertion:—

a. By their spinous processes, to the—

1. Great dorsal muscles.
2. Small posterior serrated muscles (1st to 3rd).
3. Ilio-spinalis muscles.
4. Transverse spinous muscles of the back and loins.

b. By their articular tubercles, to the—

1. Ilio-spinal muscles.
2. Transverse spinous muscles of the back and loins.

c. By their transverse processes, to the—

1. Great psoas muscles.
2. Square muscles of the loins.
3. Intertransverse muscles of the loins.
4. Transverse muscles of the abdomen.
5. Ilio-spinalis muscles.

d. By their bodies, to the—

1. Great psoas muscles.
2. Small psoas muscles.
3. Pillars of the diaphragm.

D. SACRUM.

The sacrum gives insertion to the—

1. Ilio-spinalis muscles.
2. Transverse spinous muscles of the back and loins.
3. Superior sacro-coccygeal muscles.
4. Lateral sacro-coccygeal muscles.
5. Inferior sacro-coccygeal muscles.

6. Ischio-coccygeal muscles.
7. Long vasti muscles.
8. Semitendinosus muscles.
9. Internal obturator muscles.

E. COCCYX.

The coccyx gives insertion to the—

1. Superior sacro-coccygeal muscles.
2. Inferior sacro-coccygeal muscles.
3. Lateral sacro-coccygeal muscles.
4. Ischio-coccygeal muscles (1st and 2nd coccygeal vertebræ).

2. Head.

A. BONES OF THE CRANIUM.

I. *Occipital.*

The occipital gives insertion to nine pairs of muscles:—

1. Great complexus muscles.
2. Small oblique muscles of the head.
3. Great posterior recti muscles of the head.
4. Small posterior recti muscles of the head.
5. Great anterior recti muscles of the head.
6. Small anterior recti muscles of the head.
7. Small lateral recti muscles.
8. Digastric muscles.
9. Occipito-styloid muscles.

II. *Parietal.*

The parietal gives attachment to one muscle:—

The temporal.

III. *Frontal.*

The frontal gives insertion to the—

Supernaso-labialis.

IV. *Sphenoid.*

The sphenoid gives attachment to four muscles:—

1. Great anterior recti muscles of the head.
2. Small anterior recti muscles of the head.
3. Internal pterygoid muscles.
4. External pterygoid muscles.

V. *Temporal.*

The temporal gives insertion to five muscles:—

1. Splenius.
2. Small complexus.
3. Small oblique muscle of the head.
4. Mastoido-humeralis.
5. Temporal.

B. BONES OF THE FACE.

I. *Superior Maxillary.*

The supermaxillary gives insertion to the following muscles:—

1. Cuticularis of the neck.
2. Alveoli-labialis.

3. Supermaxillo-nasalis.
4. Great supermaxillo-nasalis.
5. Masseter.

II. *Premaxillary Bone.*

The premaxillary bone gives insertion to the—

1. Small supermaxillo-nasalis.
2. Anterior middle or intermediate muscle.

III. *Palatine Bone.*

The palatine bone gives insertion to the—

Internal pterygoid muscle.

IV. *Zygomatic.*

The zygomatic bone gives insertion to one muscle, the—

Supermaxillo-labialis.

V. *Lachrymal.*

The lachrymal bone gives insertion to one muscle, the—

Lachrymo-labialis.

VI. *Nasal Bone.*

The nasal bone gives insertion to one muscle, the—

Supernaso-labialis.

VII. *Inferior Maxilla.*

The inferior maxilla gives insertion to the following muscles:—

1. Sterno-maxillaris.
2. Alveolo-labialis.
3. Maxillo-labialis.
4. Posterior middle or intermediate muscles.
5. Masseter muscles.
6. Temporal muscles.
7. Internal pterygoid muscles.
8. External pterygoid muscles.
9. Digastric muscles.
10. Mylo-hyoid muscle.
11. Genio-hyoid muscles.

C. HYOID BONE.

The hyoid bone gives insertion to the following muscles:—

a. By its body and its thyroid cornua—

1. Sterno-hyoid muscles.
2. Scapulo-hyoid muscles.
3. Mylo-hyoid muscles.
4. Genio-hyoid muscles.
5. Stylo-hyoid muscles.
6. Kerato-hyoid muscles.
7. Transverse muscle of the hyoid bone.

b. By its branches (styloid cornua and styloid bones)—

1. Stylo-hyoid muscles.
2. Kerato-hyoid muscles.
3. Occipito-styloid muscles.

3. Bones of the Thorax.

A. THE RIBS AND THEIR CARTILAGES.

The ribs and costal cartilages give insertion to the—

1. Scalenus (1st).
2. Small anterior serrated muscle (5th to 9th).
3. Small posterior serrated muscle (9th to 18th).
4. Ilio-spinalis muscle (3rd to 18th).
5. Common intercostal muscle.
6. Great psoas (17th to 18th).
7. Square muscle of the loins (16th to 18th).
8. Great serrated muscle (1st to 8th).
9. Transverse muscle of the ribs (1st).
10. External intercostal muscles.
11. Internal intercostal muscles.
12. Supercostal muscles.
13. Triangular muscle of the sternum (2nd to 8th)
14. Great oblique muscle of the abdomen (5th to 18th).
15. Small oblique muscle of the abdomen (asternal cartilages).
16. Great rectus muscle of the abdomen (asternal cartilages).
17. Transverse muscle of the abdomen.
18. Diaphragm (7th to 18th).

STERNUM.

The sternum gives insertion to the—

1. Cuticularis of the neck.
2. Sterno-maxillary muscles.
3. Sterno-thyroid muscles.
4. Sterno-hyoid muscles.
5. Superficial pectoral muscles.
6. Deep pectoral muscles.
7. Transverse muscles of the ribs.
8. Triangular muscle of the sternum.
9. Great recti muscles of the abdomen.
10. Transverse muscles of the abdomen.
11. Diaphragm.

4. Thoracic Limb.

A. BONES OF THE SHOULDER.

Scapula.

The scapula gives insertion to seventeen muscles:—

a. By its external face to the—

1. Supraspinatus.
2. Subspinatus.
3. Short abductor of the arm, or teres minor.
4. Long abductor of the arm.
5. Trapezius.
6. Mastoido-humeralis.

b. By its internal face, to the—

1. Rhomboid muscle.
2. Angular muscle of the scapula.
3. Great serrated muscle.
4. Subscapularis.
5. Small scapulo-humeral muscle.

c. By its anterior border, comprised between the cervical angle and the coracoid process, to the—

1. Sterno-prescapularis, or small pectoral muscle.

2. Long flexor of the fore-arm, or brachial biceps.
3. Coraco-brachial muscle.
4. Supraspinatus muscle.

d. By its posterior border, comprised between the dorsal angle and the corresponding portion of the humeral angle, to the—

1. Long extensor of the fore-arm.
2. Large extensor of the fore-arm.
3. Adductor of the arm, or teres major.
4. Long abductor of the arm.
5. Short abductor of the arm.

B. BONES OF THE ARM.

Humerus.

The humerus gives insertion to twenty-four muscles:—

a. By its superior extremity, to the—

1. Supraspinatus.
2. Subspinatus.
3. Subscapularis.
4. Small scapulo-humeralis.
5. Sterno-trochineus, or deep pectoral.
6. Panniculus carnosus.

b. By its body, to the—

1. Long abductor of the arm.
2. Short abductor of the arm.
3. Coraco-brachial muscle by two points.
4. Adductor of the arm, or teres major.
5. Short flexor of the fore-arm, or anterior brachial muscle.
6. Short extensor of the fore-arm.
7. Middle extensor of the fore-arm.
8. Small extensor of the fore-arm, or anconeus muscle.
9. Anterior extensor of the metacarpus.
10. Anterior extensor of the phalanges.
11. Great dorsal muscle.
12. Mastoido-humeralis muscle.
13. Sterno-humeralis, or superficial pectoral muscle.

c. By its inferior extremity, to the—

1. Anterior extensor of the phalanges.
2. External flexor of the metacarpus.
3. Oblique flexor of the metacarpus.
4. Internal flexor of the metacarpus.
5. Superficial flexor of the phalanges, or perforatus.
6. Deep flexor of the phalanges, or perforans.

C. BONES OF THE FORE-ARM.

I. *Radius.*

The radius gives insertion :—

a. By its upper extremity, to the—

1. Long flexor of the fore-arm, or brachial biceps.
2. Anterior extensor of the phalanges.
3. Lateral extensor of the phalanges.

b. By its body, to the—

1. Short flexor of the fore-arm. or anterior brachial muscle.
2. Oblique extensor of the metacarpus
3. Anterior extensor of the phalanges.
4. Lateral extensor of the phalanges.
5. Deep flexor of the phalanges, or perforans.

II. *Ulna.*

The ulna gives insertion :—

a. By its upper extremity (olecranon) to the—

1. Long extensor of the fore-arm.
2. Large extensor of the fore-arm.
3. Short extensor of the fore-arm.
4. Middle extensor of the fore-arm.
5. Small extensor of the fore-arm, or anconeus muscle.
6. Oblique flexor of the metacarpus.
7. Deep flexor of the phalanges, or perforans.

b. By its body, to the—

1. Short flexor of the fore-arm, or anterior brachial muscle.
2. Lateral extensor of the phalanges.

D. BONES OF THE CARPUS.

Supercarpal Bone.

The supercarpal bone, the only bone of the carpus which has muscular attachments, gives insertion to two muscles :—

1. External flexor of the metacarpus, or posterior ulnar.
2. Oblique flexor of the metacarpus.

E. BONES OF THE METACARPUS.

I. *Principal Metacarpal.*

The principal metacarpal gives insertion to a single muscle :—

By its superior extremity, to the—

Anterior extensor of the metacarpus.

II. *External Rudimentary Metacarpal.*

This gives insertion to a single muscle :—

External flexor of the metacarpus, or posterior ulnar.

III. *Internal Rudimentary Metacarpal.*

This gives insertion to two muscles :—

1. Oblique extensor of the metacarpus.
2. Internal flexor of the metacarpus, or great palmar muscle.

F. BONES OF THE DIGITAL REGION.

I. *First Phalanx.*

This gives insertion to two muscles :—

1. Anterior extensor of the phalanges.
2. Lateral extensor of the phalanges.

II. *Second Phalanx.*

This gives insertion to two muscles :—

1. Anterior extensor of the phalanges.
2. Superficial flexor of the phalanges.

III. *Third Phalanx.*

The third phalanx, or os pedis, gives insertion to two muscles :—

1. Anterior extensor of the phalanges.
2. Deep flexor of the phalanges.

5. Abdominal Limb.

A. BONES OF THE HAUNCH.

Coxa.

The coxa gives insertion :—

a. By the ilium, to the—

1. Ilio-spinalis muscle.
2. Iliac (psoas) muscle.
3. Small psoas muscle.
4. Square muscle of the loins.
5. Ischio-coccygeal muscle.
6. Great oblique muscle of the abdomen.
7. Small oblique muscle of the abdomen.
8. Transverse muscle of the abdomen (through the medium of the crural arch).
9. Middle gluteal muscle.
10. Deep gluteal muscle.
11. Muscle of the fascia lata.
12. Anterior rectus muscle of the thigh.
13. Anterior gracilis muscle.
14. Internal obturator.

b. By the pubis, to the—

1. Great oblique muscle of the abdomen.
2. Small oblique muscle of the abdomen.
3. Great rectus muscle of the abdomen.
4. Transverse muscle of the abdomen (through the medium of the crural arch).
5. Short adductor of the leg.
6. Pectineus muscle.
7. Small adductor of the thigh.
8. External obturator muscle.
9. Internal obturator muscle.

c. By the ischium, to the—

1. Superficial gluteus muscle.
2. Long vastus muscle.
3. Semitendinous muscle.
4. Semimembranous muscle.
5. Short adductor of the leg.
6. Great adductor of the thigh.
7. Square crural muscle.
8. External obturator muscle.
9. Internal obturator muscle.
10. Gemelli muscles of the pelvis.

B. BONES OF THE THIGH.

Femur.

The femur gives insertion :—

a. By its upper extremity, to the—

1. Great psoas muscle.
2. Iliac psoas muscle.
3. Middle gluteus muscle.
4. Deep gluteus muscle.
5. External obturator muscle.
6. Internal obturator muscle.
7. Gemelli muscles of the pelvis.

b. By its body, to the—

1. Superficial gluteus muscle.
2. Fascia lata.

3. External vastus muscle (crural triceps).
4. Internal vastus muscle (crural triceps).
5. Anterior gracilis muscle.
6. Long vastus muscle.
7. Pectineus muscle.
8. Small adductor of the thigh.
9. Great adductor of the thigh.
10. Square crural muscle.
11. Gastrocnemii muscles.
12. Superficial flexor of the phalanges, or perforatus.

c. By its inferior extremity, to the—

1. Semimembranous muscle.
2. Great adductor of the thigh.
3. Anterior extensor of the phalanges.
4. Flexor of the metatarsus.
5. Popliteus muscle.

C. BONES OF THE LEG.

I. *Tibia.*

The tibia gives insertion :—

a. By its upper extremity, to the—

1. Flexor of the metatarsus.
2. Soleus muscle.
3. Deep flexor of the phalanges, or perforans.
4. Oblique flexor of the phalanges.
5. Long adductor of the leg (through the medium of the internal patellar ligament).

b. By its body, to the—

1. Long vastus muscle.
2. Semitendinous muscle.
3. Short adductor of the leg (in common with the long adductor)
4. Flexor of the metatarsus.
5. Popliteus muscle.
6. Deep flexor of the phalanges or perforans.

II. *Fibula.*

The fibula gives insertion to two muscles :—

1. Lateral extensor of the phalanges.
2. Deep flexor of the phalanges or perforans.

III. *Patella.*

The patella gives insertion to five muscles :—

1. Fascia lata muscle (or tensor vaginæ).
2. Anterior rectus of the thigh.
3. External vastus (crural triceps).
4. Internal vastus (crural triceps).
5. Long vastus muscle.

D. BONES OF THE TARSUS.

Calcis.

The calcis gives insertion to the :—

Gastrocnemii muscles.

Cuboides.

The cuboides gives insertion to the—

Flexor of the metatarsus.

Second Cuneiform.

This gives attachment to the—

Flexor of the metatarsus.

E. BONES OF THE METATARSUS.

The principal metatarsal gives insertion to the—

Flexor of the metatarsus.

F. BONES OF THE FOOT.

I. *First Phalanx.*

The first phalanx gives insertion to one muscle, the—

Anterior extensor of the phalanges.

II. *Second Phalanx.*

The second phalanx gives insertion to two muscles:—

1. Anterior extensor of the phalanges.
2. Superficial flexor of the phalanges, or perforatus.

III. *Third Phalanx.*

The third phalanx gives insertion to two muscles:—

1. Anterior extensor of the phalanges.
2. Deep flexor of the phalanges, or perforans.

BOOK II.

THE DIGESTIVE APPARATUS.

CHAPTER I.

GENERAL CONSIDERATIONS ON THE DIGESTIVE APPARATUS.

WE have considered the animal as a machine composed of various levers and susceptible of various movements; but it will be easily understood that the working of this machine will cause the wear or decomposition of the molecules which enter into the construction of its organs, and that these springs or animated wheels demand for their maintenance an incessant supply of new materials, destined to repair their continual losses. Animals, therefore, are under the necessity of taking *aliment*, from which they extract those reparative principles which, distributed to all the organs, are assimilated into their proper substance.

The organs in which this work of preparation and absorption of the organisable material is carried on are collectively named the *digestive apparatus:* one of the most important of those which, as we will see, successively complicate and perfect the animal machine. This apparatus does not, properly speaking, constitute an essentially distinctive characteristic of animality, as there are animals without a digestive cavity; but it is yet one of the most salient attributes, for the exceptions just mentioned are extremely rare. Considered in the vertebrata, this apparatus appears as a long tube, most frequently doubled on itself many times, bulging at intervals, and provided along its course with several supplementary organs, the majority of which are of a glandular nature. This tube extends the whole length of the animal's body, and opens externally by two orifices, one of these serving for the introduction of aliment, the other for the expulsion of the residue of digestion. These openings are at the extremities of the alimentary canal.

The conformation of this apparatus is not identically the same in all the individuals composing the sub-kingdom of vertebrata; on the contrary, it presents very numerous varieties, according to the habits and mode of life of these individuals, and this makes its study interesting from two points of view: in relation to the science of zoology, and to that of veterinary hygiene, which derives from this study valuable indications concerning the *régime* of the domesticated animals.

But this diversity of characters does not suffice to establish sharply-defined limits between the conformations that are distinguished by it. There is, in reality, but one typical form for the digestive apparatus, and the same principle prevails in its construction throughout the entire series. Thus, whichever of the vertebrata we may be studying, its alimentary tube will be found composed of a collection of bulging or tubuliform cavities, which succeed each other from before to behind in the following order: the *mouth*, *pharynx*, *œsophagus*, *stomach*, and *intestine*.

This system of cavities is divided, physiologically, into two principal sections: the first comprises the mouth, pharynx, and œsophagus, or the compartments in which are carried on those digestive operations termed "preparatory," because they prepare the aliment for the subsequent modifications which constitute the essential phenomena of digestion; the second section is formed by the stomach and intestine, where these phenomena take place.

Each of these two sections is furnished in its course with annexed organs, which are present in the majority of vertebrata; these are the *salivary glands* for the cavities of the first category, and the *liver*, *pancreas*, and *spleen* for those of the second.

In considering the general position of these various parts, principally in mammals and birds, it is found that the first section of the digestive canal and its appended organs is lodged beneath the upper jaw and the base of the cranium, and under the cervico-thoracic portion of the vertebral column. The second section, with its annexes, occupies the great abdominal cavity.

In Man, these two sections are divided into *supra-diaphragmatic* and *infra-diaphragmatic*, because of their relations to the diaphragm.

The constituent parts of the first category might be termed, by reason of their functions, the *preparatory organs of the digestive apparatus;* and those of the second, or abdominal portion, the *essential organs of digestion.*

These various organs, with those composing the respiratory and genito-urinary apparatus, have received the name of viscera, and the term *splanchnology* is often given to that branch of anatomy devoted to their study.[1]

These new organs differ so notably from those already described, that it is necessary to enter into some generalities as to their nomenclature, disposition, form, structure, and physical or chemical characteristics.

Nomenclature in splanchnology does not rest on any scientific basis; the name of organs being sometimes derived from their form—as the *amygdalæ;* sometimes from their direction—*rectum;* sometimes also from their uses—the *œsophagus*, *salivary glands;* their length—*duodenum;* the names of the anatomists who have described them—the *duct of Stenon*, *Fallopian tube;* and at times these names are purely conventional, as the *spleen.*

They are distinguished as *hollow* and *solid organs.*

1. The *hollow organs* have a more or less considerable cavity, capable of being increased or diminished, but they are not of a definite shape or volume. Their consistency varies with their state of plenitude or vacuity, and they are single or double, symmetrical or asymmetrical.

In all cases, the walls of the hollow organs are composed of two or more membranes which we will now describe in a general manner.

a. The innermost is called the MUCOUS MEMBRANE, because of the mucus with which its free surface is always covered. It is made continuous with the skin at the natural openings; and from its similarity of organisation it has been named the *internal* or *re-entering skin*, or *internal tegumentary membrane.*

[1] The name of *viscera* (from *vescor*, I nourish) has been given to the organs which aid in nutrition, and the term *Splanchnology* (from σπλάγχνον, a viscus or intestine) has been bestowed on that division of anatomy which treats of these organs. Splanchnology, thus understood, comprises the study of the digestive, respiratory, urinary, and circulatory apparatus. But the description of the latter forms a separate category, designated in the language of the schools by the name of *Angiology.* On the other hand, however, several authorities include in Splanchnology the organs of generation, and others even add the organs of sense. There is, therefore, no accord in the limits given to the definition of Splanchnology; and this being the case, we have thought it best to omit this expression and the distinction it seeks to establish.

A mucous membrane comprises a superficial or *epithelial layer* and a deep portion which constitutes the *derm* or *chorion* (*corium*).

The *epithelium* is a very thin, inert pellicle, entirely composed of epithelial cells united by an almost insignificant quantity of amorphous matter (*blastema*). The cells are flat or polygonal, round or cylindrical, polyhedral, or very irregular in shape. In consequence of these diverse forms, there is *pavement* (or *squamous*), *spherical* (or *spheroidal*), and *cylindrical* or *conical* (or *columnar*) *epithelium*. If the cells are furnished with small filiform appendages, named *vibratile cilia*, the epithelium is then designated *ciliated*. When the cells are arranged in a single layer on the surface of the corium, the epithelium is said to be *simple;* it is *stratified* when the cells are arranged in strata upon each other. In stratified epithelium, the shape of the cells is not the same on the surface and beneath it, and it is named after the form of the superficial layer.

Fig. 143.

SQUAMOUS EPITHELIUM FROM THE MOUTH.

The large scale is magnified 310 diameters, and exhibits a nucleus with nucleolus in the centre, and secondary nucleated cells forming the body of the scale.

The *mucous derm* or *corium* corresponds to that of the skin, as the epithelium corresponds to the epidermis. It is composed of connective (or areolar) tissue, whose thickness, elasticity, vascularity, and sensibility varies with the situation and the function of organs. The corium is thin and almost destitute of elastic fibres when applied to the bony walls of a cavity; on the contrary, it is thick, elastic, and slightly adherent when it lines organs which, like the stomach, œsophagus, and intestines, are capable of increasing or diminishing in capacity. The fasciculi of the connective tissue in the deeper layers of the corium are loosely united, but nearer the surface they lie closer; sometimes they form, under the epithelium, an amorphous surface-layer, the *basement* (or *limitary*) membrane. The sub-epithelial face of the corium is scarcely ever smooth, but offers minute prolongations named *villosities* or *papillæ*, which are very varied in their form and volume, and is more or less marked by depressions designated *follicles*. The villi are observed on the deep-seated mucous membranes; they are more particularly the vascular and absorbent organs. The papillæ are found towards the natural apertures, and are rich in nerves; they are more especially the organs of sensibility. The follicles, lined by one or other form of cell, are exclusively organs of secretion.

Fig. 144.

COLUMNAR EPITHELIUM.

1, Nucleus of the cell; 2, Membrane of the cell raised from its contents by the absorption of water.

Fig. 145.

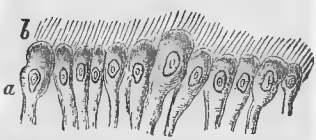

COLUMNAR CILIATED EPITHELIUM; MAGNIFIED 310 DIAMETERS.

a, Nucleated cells resting on their smaller extremities; *b*, Cilia.

b. The second membrane met with in the walls of the hollow organs is of a *muscular*, and sometimes of a *cartilaginous* nature. The muscular membrane is formed of unstriped fibres whose slow contraction is involuntary. In certain organs—those adjoining the natural apertures—the unstriped fibres are replaced by striped, which are under the influence of the will, or have the same physiological properties as the smooth fibres, as in the œsophagus.

(*Unstriped* or *smooth* bands of muscles are composed of long fusiform cells with staff-shaped, elongated nuclei, the cells varying from 1–1125th to 1–50th of an inch in length, and from 1–5625th to 1–1125th of an inch in breadth.)

Fig. 146.

CONICAL VILLI ON MUCOUS MEMBRANE OF SMALL INTESTINE; MAGNIFIED 19 DIAMETERS.

a, Zone of follicles surrounding a solitary gland; *b*, Apertures of simple follicles.

Fig. 147.

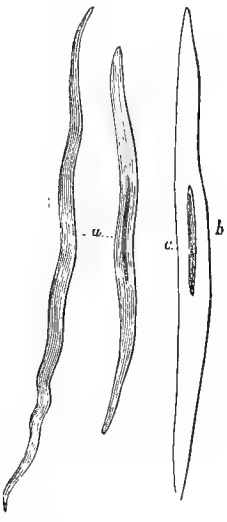

FUSIFORM CELLS OF SMOOTH MUSCULAR FIBRE.

a, Two cells in their natural state, one showing the staff-shaped nucleus; *b*, A cell with its nucleus, *c*, brought distinctly into view by acetic acid.

c. When the organs are lodged in one of the great splanchnic cavities, such as the chest or abdomen, they have a third membrane—a serous layer, which lines the cavity, and is reflected around the viscera contained in it, so as to envelop them more or less completely. This layer has, therefore, an adherent face, applied either against the walls of the cavity or the external surface of the splanchnic organs; and a free face always in contact with itself.

A serous membrane is composed of two layers: a deep, connective portion, analogous to the mucous corium; and a superficial, which is only pavement epithelium. The free surface of this epithelium is perfectly smooth, and lubricated by a limpid *serosity* to facilitate the gliding of the parts the membrane covers. (The epithelium is a simple tesselated layer of flattened and polygonal nucleated cells, about 1–1200th of an inch in diameter).

2. The *solid organs* are either contained in the splanchnic cavities or situated outside them, in the midst of connective tissue, which, in condensing around them, often forms a fibrous covering.

Like the hollow organs, they are single—*spleen*, *liver*; or in pairs—*kidneys*; and symmetrical or asymmetrical. They are retained in their *situation* by their vessels and nerves, by adherence to the neighbouring organs, or by particular serous attachments.

With the exception of the lungs of animals that have respired, all the solid organs have a *density* greater than water. Their *weight* and *volume* offer numerous differences, which are individual or relating to the species to which they belong. Nevertheless, each organ possesses a certain volume and weight which might be termed physiologic; when the organ is above or below this average, we are authorized in saying that it is in a pathological condition.

Organs are more or less round in *form*, and their surface is traversed by a variable number of furrows which indicate their division into lobes or lobules.

Their *colour* is diverse; they may be very pale—*parotid gland;* or very dark—*liver, spleen;* or uniform, or of different shades: varieties which are most frequently due to the mode of distribution of the vessels, or to the presence of certain anatomical elements. The colour of organs is not always the same in the deeper parts and at the surface, especially when they are enveloped by a thick, opaque membrane; for instance, the *testicle.* Lastly, the coloration is less intense after death than during life, and particularly if the animal to which the organs belonged has been killed by effusion of blood.

The *consistence* of organs depends on their internal formation and the nature of their constituent elements; there are soft organs, such as the *lungs*, and resisting organs, as the *testicles.* As a general rule, the consistence of organs diminishes after putrefaction has set in.

Cohesion is the resistance that organs offer to the forces which tend to tear them; it depends upon the texture of the organs, and the more or less abundance in their interior of fibrous and elastic tissue. Cohesion is very different from consistency; thus, such an organ as the lung may be easily compressed, but may be very difficult to tear.

If organs are examined with regard to their *structure*, it will be observed that all have a thin or thick fibrous casing which throws septa into their interior, and which support their proper tissue; this tissue varies with the nature of the organs. It will also be found that they are traversed by a more or less considerable number of *blood-vessels*—arteries and veins. These vessels expand into a capillary network, whose meshes have a shape closely allied to that of the elements of the proper tissue. The number and volume of the vessels of an organ give an exact idea of its importance, and of the activity of the physiological phenomena taking place in it. Finally, into the composition of organs enter superficial and deep *lymphatic vessels* and *nerves*, which generally follow the arteries. The nerves show in their course small ganglionic enlargements; their mode of termination is most frequently unknown.

Glands are organs of a particular construction, whose function it is to eliminate certain fluid or solid products of the economy.

The very *simple* (or *tubular*) *glands* consist of a straight or convoluted tube, or of a small vesicular cavity opening on a tegumentary membrane, and are lined on their inner face by one or more layers of cells. As examples, there may be cited the tubular glands of the intestines and stomach, the racemose (or lobulated) glands of Brünner, and the solitary follicles of the intestine.

But there are also *conglomerate glands*, organs more complex, though belonging to the same groups as the simple glands. These are glands composed of tubes, like the *kidneys* and *testicles;* racemose glands, such as the *salivary glands* and *pancreas;* a network of glands, like the *liver;* or glands with closed follicles, such as the *thyroid.* In these the essential anatomical element—the polygonal, cylindrical, or spherical gland-cell—is situated on the inner face of a tube, as in the *kidney*, or a demi-vesicle, as is seen in the *pancreas*, or deposited without any order in the meshes of a plexus of canaliculi, as occurs in the *liver.*

The conglomerate glands are provided with a common excretory canal, that commences in their mass by a great number of arborescent ramifications.

The walls of this canal are composed of an elastic, and sometimes contractile, conjunctival membrane, covered on its inner face by an epithelium, which may or may not be of the same character as that of the gland.

For a long time there have been classed as glands certain organs—such as the spleen and thymus body—without excretory ducts, and having only remote analogies to glands. The function of these organs is but little known; though as they are always abundantly supplied with blood-vessels, and as they are therefore believed to have connections with the vascular system, they have been named *vascular blood-glands.*

This is the limit to which the generalities relating to the viscera that form the object of splanchnology must be confined. We will now pass to the description of the digestive apparatus in mammals, and which consists, as mentioned above, of a series of enlarged or tubuliform cavities, to which are annexed the glandular organs designated the liver pancreas, and spleen.

CHAPTER II.

THE DIGESTIVE APPARATUS IN MAMMALIA.

We will study, successively: 1, The *preparatory organs*, which include the *mouth*, the *salivary glands* annexed to that cavity, the *pharynx*, and the *œsophagus;* 2, The *essential organs*, comprising the *stomach* and *intestine*, and their *annexes*—the *liver*, *pancreas*, and *spleen;* with the *abdominal cavity*, which contains and protects these organs.

Article I.—Preparatory Organs of the Digestive Apparatus.

THE MOUTH.

The mouth, the first vestibule of the alimentary canal, is a cavity situated between the two jaws, elongated in the direction of the larger axis of the head, and pierced by two openings: an anterior, for the introduction of food, and a posterior, by which the aliment passes into the pharynx.

The mouth should be studied in six principal regions: 1, The *lips*, which circumscribe its anterior opening; 2, The *cheeks*, forming its lateral walls; 3, The *palate*, which constitutes its roof or superior wall; 4, The *tongue*, a muscular appendage, occupying its inferior wall; 5, The *soft palate* (*velum pendulum palati*), a membranous partition situated at the posterior extremity of the buccal cavity, which it separates from the pharynx, and concurs in the formation, by its inferior border, of the *isthmus of the fauces*, or posterior opening of the mouth; 6, The *dental arches* fixed on each jaw.

We will study each of these regions in particular, before passing to the examination of the mouth in general.

Preparation.—The whole of the mouth ought to be examined in an antero-posterior and vertical section of the head, as in figure 152.

1. *The Lips.* (Fig. 110.)

These are two membranous movable folds, placed one above, the other below, the anterior opening of the mouth, which they circumscribe. There is, consequently, a SUPERIOR and an INFERIOR LIP, united at each side by a *commissure.*

Each lip offers for study an external and internal face, and a free and an adherent border.

The *external face* is convex, and presents, on the median line: in the upper lip, a slight projection which divides it into two lateral lobes; in the

inferior lip, and altogether posteriorly, the single prominence named the *tuft of the chin*. This face, formed by the skin, is garnished with fine, short hairs, amongst which may be remarked long, coarse bristles, whose bulbs are implanted perpendicularly in the integument, and pass beyond its deep surface, to be lodged in the subjacent muscular tissue. These pilous tentacles ought to be considered as veritable tactile organs, as several sensitive nervous twigs penetrate to the bottom of their follicles.

The *internal face*, constituted by the buccal mucous membrane, and moulded on the incisor teeth, is concave, smooth, rose-coloured, and often stained with black spots. In the superior lip, particularly, may be remarked numerous orifices opening on the summits of three small papillæ; these are the openings of the excretory canals by which the labial glands discharge their fluid into the interior of the mouth.

The *free border*, thin and sharp, bears the line of demarcation, which separates the two teguments.

The *adherent border* is limited, in the buccal cavity, by a groove formed by the mucous membrane in its passage from the dental arches to the inner side of the lips. Beyond the mouth it is not indicated by any peculiarity of structure or arrangement, the skin being continued directly from the neighbouring parts on the lips.

The *commissures* mark, on each side, the point of reunion between the free border of the two lips. They are rounded in Solipeds, and offer nothing remarkable otherwise.

Structure.—Each lip is composed of two tegumentary layers: one *cutaneous*, the other *mucous*, between which is found *muscular tissue* and *glands*, and the general elements of every organisation—*vessels* and *nerves*.

1. *Tegumentary layers.*—The *skin* adheres closely to the subjacent tissues, and apart from the characters already indicated, there is nothing more to be said at present, with regard to its disposition, as it will be studied more completely with the organs of sense. With regard to the *mucous membrane*, it may be remarked that its derm is thick and dense, and lies on a layer of salivary glands; that it is provided with simple conical papillæ, and is covered by stratified pavement epithelium. (It is sometimes streaked with pigment.)

2. *Muscles.*—These are: the *labial* or *orbicularis*, the sphincter of the buccal aperture, and common to the two lips; in the upper lip, the aponeurotic expansion of the *supermaxillo-labialis*, the musculo-fibrous tissue which separates this expansion from the cutaneous integument, and the terminal insertion of the *supernasalis-labialis* and the great *supermaxillo-nasalis*; in the inferior lip, the *tuft of the chin* and its suspensory muscles—the *posterior intermediates* (*levatores menti*). All these muscles having been studied in detail in the *Myology* (page 217), there is no necessity for their being again described.

3. *Labial glandules.*—These form an almost continuous layer between the mucous membrane and the labial muscle. They are little secretory organs, similar in their structure and uses to the salivary glands, and will be described when these come under notice.

4. *Vessels and nerves.*—The blood is carried to the lips by the *palato-labial*, and the *superior* and *inferior coronary arteries*. It is returned to the heart by the satellite *veins* of the two last vessels. The *lymphatics* are very numerous, and pass to the glands between the branches of the lower jaw. The *nerves* are of two kinds: the motor, which are given off from the facial nerve, and are distributed in the muscular tissue of the lips to cause its

contraction; the sensitive nerves, which are furnished by the maxillary branches of the fifth encephalic pair, are distinguished by their number and considerable volume, and are nearly all buried in the cutaneous integument, to which they communicate an exquisite sensibility.

FUNCTIONS.—The lips serve for the prehension of solid and liquid food; they retain it in the mouth after its introduction thereto, and likewise prevent the escape of the saliva. They ought also to be regarded, especially the upper lip, as very delicate organs of touch.

2. *The Cheeks.* (Fig. 110.)

These are two membranous walls, which inclose the mouth laterally. In the interior of the buccal cavity they are limited: behind, by the posterior pillars of the tongue; in front, by the lips, with which they are confounded around the commissures; above and below, by the groove formed by the gingival mucous membrane, where it is reflected from the molar arches on to the cheeks.

The greatest diameter of the cheeks is antero-posterior, like that of the cavity it incloses. Their vertical diameter is very narrow, especially behind; in the anterior region, however, it can assume a certain amplitude by the separation of the jaws.

STRUCTURE.—The cheeks are formed by the *buccal mucous membrane*, external to which we find *muscular tissue* and *glands*. *Vessels* and *nerves* pass through these parts for the conveyance of nutritive fluids, sensibility, or the stimulus to contractility.

1. *Mucous membrane.*—The external face of this membrane is united in an intimate manner to the buccinator muscle, and to the inferior molar glands. Its free face presents, at the level of the third superior molar tooth, the buccal opening of the parotid duct, pierced at the summit of a variable-sized tuber On the face of each dental arcade there is also remarked a linear series of little salient points, analogous in their constitution to the large parotideal tubercle; these are the excretory orifices of the molar glands. Its structure is the same as the mucous membrane of the lips. (It is of a pale colour, and sometimes stained in patches with pigment.)

2. *Muscular tissue.*—This is the buccinator or alveolo-labialis muscle already described. It may be remembered that the external face of this muscle is covered by the masseter, the superior molar glands, and the skin; while the internal responds to the mucous membrane and the inferior molar glands.

3. *Glands.*—These are two masses of glandular lobules, known as the *molar glands*. They will be described with the salivary glands.

Vessels and nerves.—The *external maxillary*, *coronary*, and *buccal arteries* carry blood to the cheeks. The *veins* empty themselves into the satellite branches of these arteries.

The *lymphatics* proceed to the submaxillary glands. The *nerves* are of the same kind, and proceed from the same source, as those supplying the lips: being the seventh pair of encephalic or facial nerves for the muscular layer, and the fifth pair for the integuments (with filaments of the sympathetic for the circulation and the labial glandules).

FUNCTIONS.—The cheeks are very active agents in mastication, by constantly pushing the aliment, through the action of the buccinator, between the dental grinding surfaces.

3. *The Palate.* (Fig. 148.)

Preparation.—Separate the head from the trunk; saw through the branches of the

maxilla above the angle of the jaw, and from the crown of the last molar tooth, so as to pass between the curtain of the soft palate on the one part, and the base of the tongue on the other, leaving the latter organ adherent to the lower jaw. This last should be removed from the upper jaw by cutting through the masseter and alveolo-labial muscles, and so exposing the hard and soft palates in such a manner as to render easy the special dissections necessary for their study. These dissections are limited to the removal of the mucous layer covering the deep venous network, and to the partial excision of this, which allows the artery and palatine nerves to be seen. (*See* figure 148.)

Fig. 148.

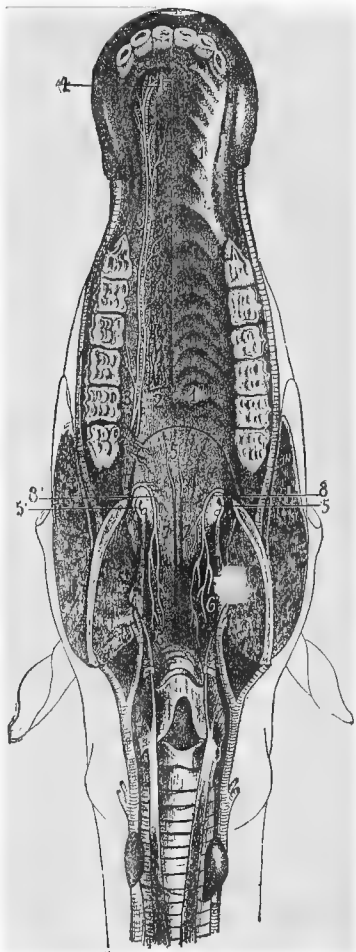

THE HARD AND SOFT PALATE.

The mucous membrane has been removed from the right side, and, with the glandular layer, from the soft palate.—1, The ridges of the palatine mucous membrane; 2, Venous network of the deep layer, which is cut through at the external side to show the palatine artery, 3, accompanied by the filaments of the palatine nerve; 4, Cartilaginous digitation, over which passes and is inflected the palatine artery; 5, Aponeurosis of the soft palate; 5′, Terminal extremity of the tendon of the external tensor palati, forming by its expansion the staphylin aponeurosis; 6, The palato-pharyngeus; 7, Circumflexus palati; 8, Staphylin nerves.

The *palate* (*hard palate*), *palatine arch*, or *upper wall of the mouth*, is circumscribed, in front and on the sides, by the superior dental arcade, and limited, behind, by the anterior border of the soft palate. It is a parabolic surface, exactly representing, in its configuration, the bony palate (Fig. 21).

On its face is remarked a median groove, which partitions it into two equal divisions, and which commences quite in front, at the base of a small tubercle. Curved transverse furrows, twenty in number (Leyh gives from sixteen to eighteen), divide each of these halves into an equal number of salient arches, whose concavities are turned backwards, and which become narrower and less marked as they are more posterior. (These arches and furrows aid in retaining the aliment which the tongue carries towards the palate during deglutition).

Structure.—The palatine lies on the bony vault formed by the palatine and supermaxillary bones. It includes in its structure:

1. A fibrous membrane, applied to the bone just mentioned, which sustains a remarkably-developed venous network constituting a veritable erectile tissue, and gives to the palate a greater or less degree of thickness, according to its state of turgescence (Fig. 148, 1).

2. A mucous layer, extremely adherent, by its deep face, to the preceding tissue, and of a whitish aspect in the horse. The corium, formed entirely of connective

tissue, shows numerous conical papillæ, especially at the posterior part of the palate. The epithelium fills up the depressions between the papillæ; it is stratified and squamous, and remarkable for the great thickness of its horny layer.

3. Two voluminous *arteries*—the *palatine* or *palato-labials*—lodged in the bony fissures of the palatine roof. These arteries proceed parallel to one another, and unite in front by anastomosing to form a single trunk, which enters the incisive foramen. It is of importance to know their disposition in a surgical point of view, as care ought to be taken not to wound them when abstracting blood from the palate. The blood carried by these arteries arrives in the deep-seated erectile membrane, and is finally removed by two very short *venous trunks*, which do not pass with the palato-labial arteries into the palatine canal, but only into the palatine fissure.

4. Sensory *nerves* which accompany the arteries, and are derived from the superior maxillary branch of the fifth pair of cranial nerves.

Functions.—The palate has a passive, but important, share in mastication and deglutition; furnishing the tongue, as it does, with a firm basis in the movements it executes when passing the food between the molar teeth, and in carrying the alimentary mass backwards to the pharynx.

4. *The Tongue.* (Figs. 149, 152.)

Preparation.—1. By means of a strong saw without a back, make an antero-posterior and vertical section of the head, in order to study the general disposition of the tongue. 2. From another head remove the lower jaw, leaving the tongue in the intermaxillary space, to examine the external conformation of the organ (*see* the dissection of the palate). On a third head, kept for the study of the muscles, these parts are exposed in the following manner: The masseter is entirely removed, and the cheek is detached from the lower jaw and folded back on the upper jaw; then the branch of the inferior maxilla is sawn through transversely, at first behind, next in front of the molar teeth: the upper piece of bone should be detached by luxating it behind the temporo-maxillary articulation, after destroying the capsular ligament and dividing the insertions of the pterygoid muscles. With regard to the inferior piece, it is reversed in such a way as to put the line of the molars downwards, and the inferior border of the bone upwards in the bottom of the intermaxillary space. To do this it is sufficient to separate the buccal mucous membrane from the mylo-hyoideus muscle, proceeding from above to below. The dissection thus prepared, serves not only for the study of the muscles of the tongue, but also for those of the deep salivary glands, the pharynx, larynx, guttural pouches, the nerves and arteries of the head, etc. It is always better, in order to facilitate this dissection, to keep the jaws apart by fixing a piece of wood or bone between the incisor teeth immediately after the death of the animal.

The lingual canal.—The inferior wall of the mouth (or floor), circumscribed by the lower alveolar arches, forms an elongated cavity named the *lingual canal* (or *space*), which lodges the organ designated the tongue. This canal occupies, in its anterior third, the superior face of the body of the lower maxilla. For the remainder of its extent, it is formed by a double groove, which is directed to the bottom of the mouth, at the sides of the tongue. It exhibits the *sublingual crest* and the *barbs*, of which we will speak when describing the sublingual and maxillary glands.

Situation of the tongue.—The tongue occupies the whole length of this elongated cavity, and thus extends from the back part of the mouth to the incisor teeth, lying in the intermaxillary space, where it rests on a species of wide sling formed by the union of the two mylo-hyoidean muscles.

External conformation.—It is a fleshy organ, movable in the interior of the buccal cavity, and almost entirely enveloped by the mucous membrane which lines that cavity. In Solipeds, it forms a kind of triangular pyramid,

depressed from side to side, fixed to the os hyoides and the inferior maxilla by the muscles which form the basis of its structure, or by the tegumentary membrane which covers the organ.

Its form permits it to be divided, for the study of its external disposition, into *three faces*, *three borders*, and *two extremities*.

The *superior face* or *dorsum* of the tongue, narrower in front than behind, is roughened by numerous papillæ which give it a downy aspect. Two of these papillæ are remarkable for their enormous volume, their lobulated appearance, and the situation they occupy at the bottom of two excavations placed side by side, near the base of the organ; they are named the *lingual lacunæ*, or *foramen cæcum* of *Morgagni*. This face responds to the palatine arch or roof, when the jaws are together. The *lateral faces*, wider in the middle of the tongue than at its extremities, are limited by the internal surfaces of the maxillary branches. Onthem are seen several large papillæ, and the orifices of some *lingual glandulæ*.

These two faces are separated from the former by *two lateral borders*, which correspond to the superior alveolar arches when the mouth is exactly closed. With regard to the third or *inferior border*, its existence may be said to be fictitious; by it enter the muscles which constitute the substance of the tongue, and it is by it, also, that the organ is fixed at the bottom of the intermaxillary space.

The *posterior extremity*, or *base* of the tongue, is limited, in the interior of the mouth, by a furrow which borders the base of the epiglottis. It presents a thick, median, mucous fold, plaited in different ways, and carried over the anterior aspect of the epiglottic cartilage. Two other folds, more anterior, also formed by the buccal membrane, unite with the soft palate on each side the base of the tongue; these are the *posterior pillars* of the organ (or the *glosso-epiglottic ligaments* of Man), and comprise in their thickness a voluminous collection of glands. Behind these pillars are two triangular spaces, included between the velum pendulum palati and the base of the tongue, each of which has an excavation perforated with openings, a veritable *amygdaloid cavity*, which represents the *amygdalæ* (*tonsils*) of Man and the Carnivora; it is a kind of common confluent for the numerous glandulæ accumulated outside the mucous membrane which lines this excavation.

The *anterior extremity* of the tongue is quite independent from the middle of the interdental space, and moves freely in the interior of the buccal cavity: it is also termed the *free portion* of the tongue, in opposition to the remainder of the organ, which is named the *fixed portion*. This free portion is flattened above and below, and slightly widened or spatulated. Its superior face is plane, or nearly so, and prolongs that of the fixed portion. The inferior, slightly convex, and perfectly smooth, is continuous with the lateral faces of the organ, and rests on the body of the maxillary bone; it is fixed to that bone by a median fold of mucous membrane, the *anterior pillar*, or *frænum linguæ*. The borders, in joining each other in front, describe a parabolic curve which is in contact with the incisive arches.

Structure.—The tongue offers for study, in regard to its structure: 1, The *mucous membrane* enveloping the organ; 2, The *muscular tissue* which, in reality, forms its mass; 3, The *vessels* and *nerves* distributed to it.

1. *Mucous membrane.*—This membrane, a continuation of that lining the mouth, is folded at the bottom of the canal on the sides of the tongue, covers the upper surface of the organ, and envelops the whole of its free portion. Its derm or corium has not the same thickness throughout, but is incom-

parably thinner and less dense on the sides of the fixed portion and the inferior plane of the free part; on the dorsum of the tongue it is difficult to cut it. Its deep face receives the insertion of a large number of the muscular fibres of the organ, and for the greater part of its extent it adheres in the most intimate manner to these fibres; though its adherence is not so close at those points where it is in contact with the labial glandules.

Its superficial face is not smooth, but shows a prodigious quantity of minute prolongations or *papillæ*, which, according to their shape, are distinguished as *filiform*, *fungiform*, and *calyciform papillæ*.

The *filiform papillæ* are formed by thin prolongations terminating in a point, each being covered by an epithelial sheath which greatly increases its dimensions. They are simple or composite, having at their summit secondary prolongations, much smaller, and provided also with an epithelial covering. These filiform papillæ are largest on the middle part of the dorsum of the tongue, where they present a tufty appearance; towards the point of the organ they are imbedded in epithelium, and are scarcely apparent in the minute elevations on its surface.

The *fungiform papillæ* (*p. capitatæ*) are club or sponge-shaped elevations of the derm, attached to the membrane by a short pedicle. Their surface is convex and smooth, or studded with filiform papillæ. They are scattered irregularly over the dorsum of the tongue, among the filiform papillæ, and are most numerous on the posterior third of its surface.

The *calyciform papillæ* (*fossulate*, *circumvallate*, or *lenticular papillæ*) are really fungiform, but instead of projecting above the free surface of the derm, they are placed in a depression of this membrane. They are surrounded by a slightly-elevated ring, within which is a narrow fossa around the pedicle of the papilla; several papillæ may be contained within one cup-shaped cavity. They only exist at the base of the tongue, where two of their number, very developed and composite, correspond to the *blind holes of Morgagni* (*foramen cæcum*). At the base of a certain number of the fungiform and calyciform papillæ is a band of adenoid tissue.

It is generally believed that these three kinds of papillæ have each a distinct function; the filiform are to retain the alimentary and sapid substances on the surface of the tongue; the fungiform are tactile organs, and the calyciform are gustatory.

2. *Muscles.*—Beneath the mucous membrane, on the dorsal surface of the tongue, is a cylindrical fibrous cord which sometimes attains the thickness of a large goose-quill. This cord is situated in the median plane, near the middle part of the organ, and is from 2 to 3 inches long. It may be considered as a fibrous support to the muscular tissue, and it sometimes directly adheres to the deep surface of the tegument. At other times, it is only connected with that membrane by a very short lamellar prolongation, and is then buried a little deeper among the fibres of the superior muscular layer.

(The German hippotomists designate this the *cartilage of the tongue.* It is only found in Solipeds, and was first described by Brühl, who gave it this designation. Leyh states that it is composed of dense fibro-cartilage, surrounded by cellular and adipose tissue; that it is from 4 to 7 inches long, and $\frac{3}{4}$ths to 1 inch in thickness; and that it commences about an inch from the anterior appendix of the hyoid bone.)

A similar cord, but not so strong or well defined, is sometimes found at the inferior surface of the free portion of the tongue.

Intrinsic muscles.—In studying the proper substance of the tongue in

two sections, one vertical and longitudinal, the other transverse, there is seen, under the dorsal mucous membrane, a layer of red fibres, very close in their texture, and very adherent to that membrane. Amongst these fibres, there are some which affect a longitudinal direction, but the majority are vertical or transverse, and all are interlaced in the most intimate manner. It appears as if this layer (the *lingualis superficialis* of Man) was perfectly independent of the other muscular fibres, whose insertion it receives. It also forms a portion of those which writers have named the intrinsic muscles of the tongue, and which comprise a *superior* and *inferior*, a *transverse* and a *vertical lingualis* muscle. An attentive examination, however, readily shows that the fibres proper to this submucous layer are continuous with those which, coming from a point situated beyond the tongue, form the muscles named, in consequence, *extrinsic*, and that they are only the prolongations of these. This division of the tongue into two orders of muscular fasciculi does not, for this reason, possess the importance generally accorded to it.

Extrinsic muscles.—If the muscular fibres of the tongue appear to be one mass in the superior layer just referred to, it is not so when they are followed beyond this layer; on the contrary, we see them separate from one another, and even admit between them—at least in the fixed portion—a certain amount of adipose tissue, which is particularly abundant towards the base, where it forms a mass called the *fatty nucleus of Baur;* then they collect into fasciculi, or perfectly distinct muscles.

In Solipeds, these muscles number five pairs; 1, The *stylo-* or *Kérato-glossus;* 2, The *great hyo-* or *basio-glossus;* 3, The *genio-glossus;* 4, The *small hyo-glossus* (the *superior lingual* of some authorities); 5, The *pharyngo-glossus*

STYLO-GLOSSUS.

(*Synonyms.*—The *hyo-glossus longus* of *Percivall. Kerato-glossus externus—Leyh.* The *stylo-glossus* of Man.)

This is a very long riband-shaped band, formed of bright-red parallel fibres, and extending from the styloid bone, or large branch of the os hyoides, to each side of the free extremity of the tongue.

It originates on the external surface of the large hyoideal branch, near its inferior extremity, by a very thin aponeurosis; and terminates near the tip of the tongue in expanding over the inferior surface and borders of the organ, and confounding its fibres with those of the opposite muscle.

In the fixed portion of the tongue, this muscle responds: outwardly, to the mylo-hyoideus, sublingual gland, lingual nerve, and the Whartonian duct; inwardly, to the genio-glossus and great hyo-glossus muscles. The whole of its free portion is covered by the buccal membrane.

In contracting, this muscle pulls the tongue towards the back of the mouth, and inclines it to one side when acting independently of its fellow on the opposite side (Fig. 149, 1.)

GREAT HYO-GLOSSUS OF BASIO-GLOSSUS.

(*Synonyms.—Hyo-glossus brevis—Percivall. Hyo-glossus—Leyh.*)

A wide muscle, flattened on both sides, thicker than the preceding, and composed of fibres passing obliquely forward and upward, the longest of which are anterior.

Its origin occupies the whole side of the body of the os hyoides, from the extremity of the cornu to that of the anterior appendix. Its fibres, after

becoming detached from this point of insertion, are insinuated beneath the preceding muscle, spread out under the mucous membrane covering the lateral aspect of the tongue, and for the most part are reflected inwards, nearly to the superior face, to constitute the transverse fibres of the organ.

It is in relation, outwardly, with the mylo-hyoideus, stylo-glossus, the great hypo-glossal nerve, Wharton's duct, and the lingual mucous membrane; inwardly, with the small hyo-glossus, the small branch of the os hyoides, the pharyngo-glossus, genio-glossus, lingual artery, the terminal divisions of the glosso-pharyngeal nerves, and great and small hypo-glossals. (Fig. 149, 2.)

It retracts the tongue in depressing its base, according as it acts singly or simultaneously with its fellow.

(In 1850, Brühl described as the *middle descending stylo-glossus*, a long, narrow muscle arising from the lower extremity of the inner face of the styloid bone, or large branch of the os hyoides, and terminating near the tip of the tongue, where it is covered by the hyo-glossus. It has since been described as the internal or small Kérato-glossus. Its action is the same as the stylo-glossus.)

GENIO-GLOSSUS.

(*Synonym.—Genio-hyo-glossus—Percivall.*)

This is a beautiful muscle, whose fibres are disposed like a fan in the vertical and median plane of the tongue.

It originates from the inner surface of the lower jaw, near the symphysis, by a tendon parallel to that of the genio-hyoidous. From this tendon are detached a multitude of divergent fibres which pass backwards, upwards, and forwards, to reach the upper surface of the tongue and become continuous with the vertical fibres of the submucous layer.

Fig. 149.

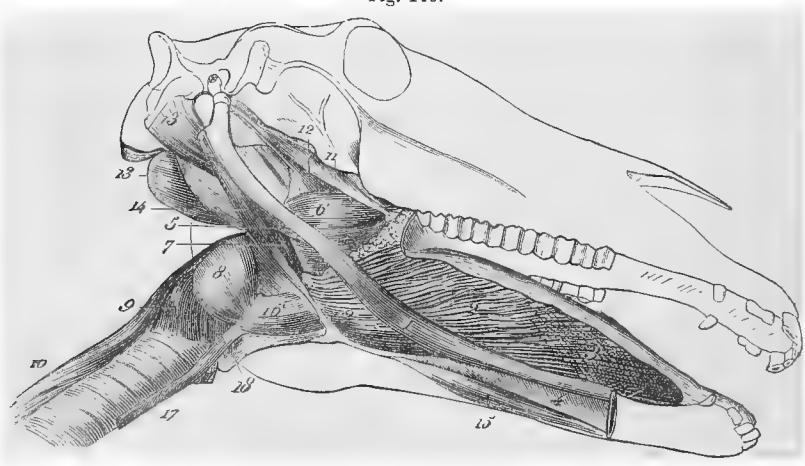

MUSCLES OF THE TONGUE, SOFT PALATE, AND PHARYNX.

1, Stylo-glossus; 2, Great hyo-glossus; 3, The same, covered by the submucous layer formed by the expansion of the small hyo-glossus; 4, Genio-glossus; 5, Pharyngo-glossus; 6, Pterygo-pharyngeus; 7, Hyo-pharyngeus; 8, Thyro-pharyngeus; 9, Crico-pharyngeus; 10, Œsophagus; 11, 12, Tensors palati; 13, Stylo-hyoideus; 14, Hyoideus magnus; 15, Genio-hyoideus; 16, Hyo-thyroideus; 17, Sterno-thyroideus; 18, Crico-thyroideus.

The two genio-glossi lie together on the median plane of the tongue, except towards their origin, where they are constantly kept apart by adipose tissue. Their inferior border responds to the genio-hyoid muscles, and their anterior fibres are partly included between the two mucous layers of the frænum linguæ. They are related, by their external face, to the basio- or great hyo-glossus, the stylo-glossus, the sublingual gland, the lingual artery, and the terminal branches of the three lingual nerves.

The action of the genio-glossus is complex; according to the portion of its fibres which contract, it will carry the tongue forwards, pull it into the buccal cavity, or draw it downwards into the floor of the mouth. (Fig. 149, 4.)

Fig. 150.

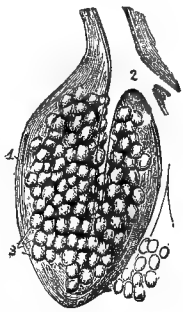

ONE LOBE OF A RACEMOSE GLAND.

1, Casing of connective tissue; 2, Excretory duct; 3, Glandular vesicle, or acini.

SMALL HYO-GLOSSUS.

Synonym.—Lingualis superior of Man. (*Lingualis* of *Percivall.*)

Under this name is described a thin band, formed of parallel fibres, which is exposed immediately on removing the mucous membrane, with the subjacent glands, from the base of the tongue. This band arises from the inner side of the articulation uniting the body of the os hyoides to its small branch. It passes above the transverse muscle of that bone, which it crosses perpendicularly, is surrounded at this point by a great mass of adipose tissue, and is prolonged directly forward, beneath the lingual mucous membrane. Its fibres then vanish, either on the superior aspect of the tongue or on its sides, or they descend obliquely in crossing the direction of the hyo-glossus, to join the superior border of the stylo-glossus (Fig. 149, 3).

(This muscle contracts and retracts the tongue.)

Fig. 151.

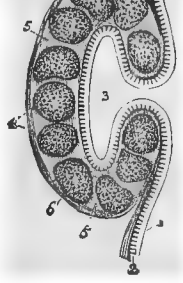

FOLLICULAR GLAND FROM THE ROOT OF THE TONGUE.

1, Epithelium; 2, Papillæ of mucous membrane; 3, Cavity of the follicle; 4, Investing coat of the gland composed of connective tissue; 5, Fibro-vascular matrix, forming its parenchyma, and containing, 6, 6, the closed capsules or follicles.

PHARYNGO-GLOSSUS.

(*Synonym.*—The *palato-glossus* of Man.)

A rudimentary muscle formed of parallel fibres, which, from their origin on the lateral wall of the pharynx, pass outside the articular angle of the branches of the os hyoides, and between the hyo-glossus and genio-glossus, mixing with, and intercrossing their fibres.

3. *Labial glands.*—The numerous glands of the tongue may be divided into racemose (or lobulated) glands, and closed follicles (or follicular glands.)

The *racemose glands* are spread on the sides and base of the tongue. Near its upper border they form two rows, which are rendered visible by the presence of a small tubercle placed beside each of them. At the base of the tongue they are found beneath the fungiform and calyciform papillæ, as well as beneath the layer of inclosed follicles which lines the isthmus of the fauces.

At the entrance to this passage, the lingual mucous membrane is mammillated, and each elevation has an

orifice. This arrangement is connected with the presence, at this part of the tongue, of the *closed follicles*, which are more or less voluminous and aggregated, and separated from the muscles by a continuous layer of racemose glands. They are composed of a casing of condensed connective, and a mass of adenoid tissue, which has in its centre a cavity that communicates with the orifice above the follicle, and is lined by the lingual epithelium *minus* its horny layer.

4. *Vessels and nerves.*—The tongue is supplied with blood by two arteries, the *lingual* and *sublingual;* the blood is removed by three large veins, two of which enter the *external maxillary*, and the third the *internal maxillary vein.* The *lymphatics* constitute a very fine superficial network, whose emergent branches pass to the submaxillary glands. The *nerves* are the lingual, the glosso-pharyngeal, and the great hypo-glossal; the latter is a motor nerve, and consequently supplies the muscles; the others are exclusively sensitive, and are distributed more particularly to the mucous membrane.

Functions.—The tongue serves for the prehension of liquids in all animals, and for solid aliment in the Ox. It concurs, with the jaws, in propelling the substances to be crushed between the molar teeth during mastication; and it is, besides, one of the essential organs of deglutition. It is able to play this important and complex part through the varied movements it can execute in the interior of the mouth; and the extent of these movements demands a moment's notice. They are of two kinds: those which influence only the form of the organ, and those which cause it to submit to various displacements. They result in either compressing it from side to side, above to below, or curving it longitudinally, and even transversely. These movements are principally, but not exclusively, due to the action of the intrinsic fibres; they are perfectly independent of the movements which, as a whole, produce the total displacement of the tongue. With regard to these latter, they may result in carrying the tongue beyond the mouth, or withdrawing it into that cavity, inclining it to one side, raising it against the palate, depressing it on the floor of the intermaxillary space or, finally, lifting it towards the pharynx. It is worthy of remark that these movements do not alone result from the action of the proper lingual muscles above described; those belonging to the os hyoides, to which is attached the lingual appendix, concur also in producing them. But this appendix is not the only organ thus attached to the hyoideal apparatus; the larynx and, through its intermediation, the pharynx, are placed in the same conditions, and are obliged to follow, like the tongue, the movements of the bony framework supporting them.

There consequently results between these three organs a remarkable unity of action, which is readily explained by the part they all take in the one common act of deglutition.

5. *Soft Palate.* (Figs. 148, 152.)

Preparation.—The soft palate is studied: 1, On the antero-posterior and vertical section of the head (fig. 152); 2, On the portion intended to show the interior of the pharynx (see the preparation of this region); 3, On the portion represented in fig. 148, the mode of dissecting which has been indicated at page 333; in removing the mucous membrane and glandular layer, the fibrous membrane and the two intrinsic muscles are exposed. The extrinsic muscles should be studied with those of the pharynx.

Situation—Form.—The soft palate (*palatum molle, velum pendulum palati*) is suspended like a partition between the mouth and the pharynx, and by its

posterior border circumscribes the orifice which establishes a communication between these two cavities.

This partition, which continues the palate posteriorly, represents in its external form a membranous valve, oblique from above to below and before to behind, much longer than it is wide, and exhibiting for study *two faces* and *four borders*.

The *inferior* or *anterior face*, turned towards the mouth, shows longitudinal folds and transverse ridges, with multitudes of orifices belonging to the submucous glandulæ. On its sides it is united to the base of the tongue by means of two thick mucous columns, designated the posterior pillars of the tongue. The *superior* or *posterior face* constitutes the anterior wall of the pharynx; it only exhibits some very slight longitudinal ridges.

Fig. 152.

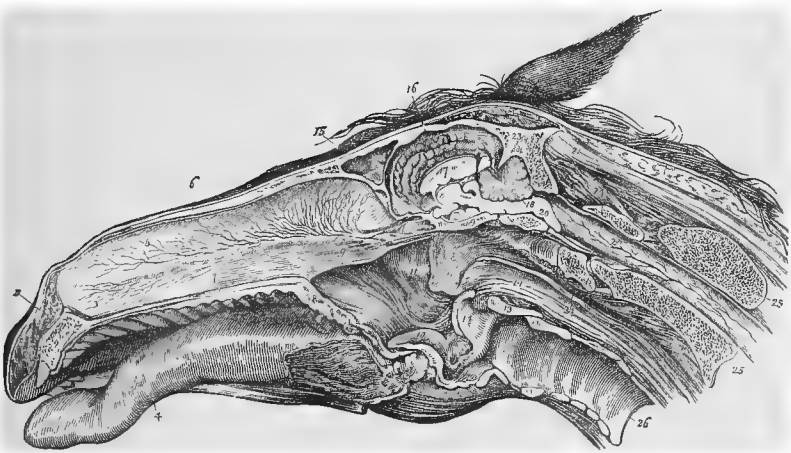

MEDIAN LONGITUDINAL SECTION OF THE HEAD AND UPPER PART OF NECK.

1, Upper lip; 2, Premaxilla; 3, Hard palate; 4, Tongue; 5, Septum nasi; 6, Nasal bone; 7, Palatine arch; 9, Pterygoid bone; 10, Epiglottis; 11, Entrance to the Eustachian tube; 12, Arytenoid cartilage, 13, Cricoid cartilage; 14, Œsophagus; 15, Frontal bone and sinus; 16, Cerebrum; 17, Corpus callosum; 18, Cerebellum; 19, Sphenoid bone; 20, Medulla oblongata; 21, Cervical ligament; 22, Spinal cord; 23, Occipital bone; 24, 24, Atlas; 25, 25, Dentata; 26, Trachea.

The two *lateral borders* are inserted into the walls of the two cavities which the soft palate separates. The *anterior border*, continuous with the palate, is attached to the palatine arch, and follows the curve described by it. The *posterior border*, the only free one, has a concave form, and closely embraces the base of the epiglottis, which is most usually found reversed on the posterior surface of this curtain. This border is continued at its extremites by two thin prolongations, which can be followed on the lateral walls of the pharynx to the œsophageal infundibulum, above which they unite in the form of an arch. These prolongments are named the *posterior pillars of the soft palate*, in contradistinction to the two mucous folds at the base of the tongue, which constitute, by their relation to this partition, veritable *anterior pillars*. This posterior border concurs to cir-

cumscribe what is named the *isthmus of the fauces*, an aperture constantly closed, in consequence of the great development of the soft palate; it is only dilated for the passage of the alimentary substances passing into the pharynx. The isthmus of the fauces is, therefore, not merely an opening; it is a passage which has for its inferior wall the base of the tongue as far as the epiglottis; for its upper wall the anterior face of the soft palate; and for its sides the posterior pillars of the latter.

Structure.—To give the most simple idea of the structure of the soft palate, it might be said that the mucous membrane of the palate and that of the floor of the nasal cavities are prolonged behind the palatine arch, parallel to one another, and become joined towards the free border of this curtain; and it might be further shown that, in the space between these two mucous membranes, there is a fibrous membrane, muscles, a glandular layer, vessels, and nerves; besides these, there are no other elements in the organisation of the soft palate. They may be studied in the following order: 1, *Fibrous membrane;* 2, *Muscles;* 3, *Mucous membranes;* 4, *Vessels and nerves.*

1. *Fibrous membrane* (Fig. 148, 5).—This membrane, remarkable for its power of resistance, forms a real framework for the soft palate, of which it only occupies the anterior moiety. It is attached in front of the palatine arch, and is prolonged posteriorly by a particular muscle, the palato-pharyngeus.

2. *Muscles.*—Of these muscles, which are all pairs, there are those which constitute a layer situated in the middle of the soft palate itself, and representing the *intrinsic muscles;* these are the *pharyngo-staphyleus* (*palato-pharyngeus*) and the *palato-staphyleus* (*circumflexus palati*). The others, the *peristaphyleus*,—external and internal (*tensors palati, external and internal*), are only inserted into the organ by their terminal extremities and therefore act as *extrinsic muscles.*

PHARYNGO-STAPHYLEUS. (Fig. 148, 6).

(*Synonym.—Palato-pharyngeus.—Percivall.*)

In removing the mucous and glandular layers which cover the anterior face of the soft palate, there is exposed a wide and thin muscular fasciculus succeeding the fibrous layer behind, and occupying the posterior half of the entire organ. The fibres of which this muscle is composed, confounded on the median line with those of the muscle on the opposite side, are directed backwards and outwards, the most posterior following the curve of the free border of the curtain. Arriving near the lateral border, they are reflected upwards, passing between the pharyngeal mucous membrane and the middle constrictor of the pharynx, with which it appears to be confounded posteriorly; but with a little attention it can be followed to the superior border of the thyroid cartilage, into which it is inserted after making a somewhat long track under the mucous membrane of the pharynx.

This muscle stretches the curtain, and draws its free border from the œsophageal infundibulum during pharyngeal deglutition.

PALATO-STAPHYLEUS.

(*Synonyms.*—Staphyleus—*Girard. Circumflexus palati—Percivall.* The *azygos uvulæ* of Man.)

A small, elongated, cylindrical, bright-red muscle, in opposition, on the median line, to that of the other side, and extending over the inferior surface of the preceding, from the palatine arch to the free border of the soft palate, which it pulls forward and upward to dilate the isthmus of the fauces. It

originates by a small glistening tendon, not from the palatine, but from the uvular aponeurosis (Fig. 148, 7). The fascia which the two muscles form is for the most part covered, in its middle portion, by the fibres of the tensores palati.

PERISTAPHYLEUS EXTERNUS.

(*Synonyms.—Tensor palati—Percivall.* The *circumflexus* of Man.)

This is a small, elongated muscle, depressed on both sides, bulging in its middle, thin and tendinous at its extremities, and extending obliquely forward and downward from the styloid process of the temporal bone, where it has its origin, to the pterygoid trochlea. Its terminal tendon glides and is inflected inwards on this pulley, to be afterwards spread out and confounded with the fibrous framework of the soft palate, which causes this framework to represent an expansion of the tendon.

The muscle is covered outwardly by the pterygoidei muscles; it responds, internally, to the next muscle, which separates it from the Eustachian tube.

It is a tensor and depressor of the aponeurosis of the soft palate (Fig. 149, 11).

PERISTAPHYLEUS INTERNUS.

(*Synonyms.—Stylo-pharyngeus—Percivall.* The *levator palati* of Man.)

This is formed by a pale and thin band, which originates with the preceding muscle, descends between it and the Eustachian tube, passes beneath the superior constrictor of the pharynx, then below the mucous membrane of the pharynx to reach the soft palate, where it expands on the anterior or posterior surface of the palato-pharyngeus, beneath the glandular layer, its fibres becoming mixed, on the median line, with those of its fellow.

This is an elevator of the soft palate (Fig. 149, 12).

3. *Glandular layer.*—This layer is comprised between the fibrous membrane and the anterior mucous layer, becoming thinner as it is prolonged over the intrinsic muscles; it does not extend to the free border of the organ. It is thickest on each side of the median plane, where it forms two lobes which appear on the anterior aspect of the soft palate as an elongated ridge, much more marked in the Ass than the Horse. It is worthy of notice, that the glandular granulations composing this layer throw all their secretion into the mouth—that is, on the anterior face of the septum.

4. *Mucous membranes.*—The soft palate is covered on both its surfaces by two mucous layers, one anterior, the other posterior, united, as has been remarked, at the free border of the organ. The anterior is continuous, above, with the mucous membrane of the hard palate; on its sides, with that which covers the base of the tongue. In structure it is the same as the buccal membrane; its epithelium is stratified pavement. The other layer is nothing more than the pituitary membrane extended over the posterior surface of the septum, and thence to the lateral surfaces of the pharynx. It will be more fully described with the latter.

5. *Vessels and nerves.*—The soft palate is supplied with blood by the *ascending pharyngeal* and *internal maxillary arteries.* The nervous filaments this partition receives emanate from the fifth pair of cranial nerves (superior maxillary branch), and from Meckel's ganglion; they form the *posterior palatine nerve* (Fig. 148, 8).

Functions.—During the act of deglutition, the soft palate is raised to

enlarge the isthmus and allow solids or liquids to pass through. The description given of this septum permits us to understand how it plays the part of a valve in rising freely while the alimentary bolus or mouthful of fluid passes from the mouth into the œsophagus, across the pharyngeal vestibule, but never allows the matters which have once entered the œsophageal canal to return into the buccal cavity. Also why, when any obstacle is opposed to the descent of aliment into the œsophagus, after it has cleared the isthmus of the fauces, or even when the animal vomits, the matters arrested in their passage or expelled from the stomach are ejected by the nasal cavities, after flowing over the posterior surface of the soft palate. This disposition of the pendulous curtain, in forming a complete partition which hermetically seals the orifice of communication between the mouth and pharynx, likewise sufficiently explains why, in normal circumstances, Solipeds respire exclusively by the nostrils.

6. *The Teeth.*

Passive agents in mastication, the *teeth* are hard organs, bony in appearance, implanted in the jaws, and projecting into the interior of the mouth to bruise or lacerate the solid alimentary substances.

Identical in all our domesticated animals, by their general disposition, their mode of development, and their structure, in their external conformation these organs present notable differences, the study of which offers the greatest interest to the naturalist. For it is on the form of its teeth that an animal depends for its mode of alimentation; it is the régime, in its turn, which dominates the instincts, and commands the diverse modifications in the apparatus of the economy; and there results from this law of harmony so striking a correlation between the arrangement of the teeth and the conformation of the other organs, that an anatomist may truly say, "Give me the tooth of an animal, and I will tell you its habits and structure."

Compelled by the limits of our task to confine ourselves to the purely descriptive part of the dental apparatus, we cannot stop to notice the interesting physiological considerations on which this principle is founded; but will begin at once the anatomical study of the teeth by indicating their general characters, before examining them successively in all the domesticated species.

A. General Characters of the Teeth.—General Disposition.—The teeth are fixed in the jaws, and ranged one against the other in such a way as to form two parabolic arches opening behind, and interrupted on each side by what is called the interdental space. Distinguished into superior and inferior, like the jaws to which they belong, these arches come in contact with one another in a more or less exact manner when the mouth is perfectly closed.

Those teeth which are placed altogether in front, at the middle of the dental arches, are named *incisors* or *incisive teeth;* the others, situated behind these, and always numbering two for each jaw, are called the *canine teeth* or *tusks;* while the designation of *molars* is given to those which occupy, in the more retired portion of the buccal cavity, the lateral parts and extremities of the dental arches.

External Conformation.—Each tooth represents, when completely developed, an elongated polyhedron, which has sometimes a pyramidal form, and at others that of a cone or a parallelopiped.

A portion of the tooth is buried and solidly implanted in one of the alveolar cavities of the maxillary bones; this is the *root* or *imbedded portion*, (or *fang*). The other portion, circumscribed at its base by the gum, leaves the alveolus to project into the interior of the mouth, forming the *crown* or *free portion*. The narrow constriction between the crown and root is named the *neck*.

The *fang* is perforated at its inferior extremity by one or more excavations (*cavitas pulpæ*) which penetrate deeply into the substance of the tooth, and admit into their interior the vasculo-nervous papilla, simple or ramified, known by the name of the *bulb* or *dental pulp*.

The *crown*, the portion submitted to friction during mastication and, consequently, to wear, offers the most varied forms: sometimes it is shaped like a very acute cone; at others, it is divided into several tubercles more or less salient; and sometimes, again, it carries at the extremity of the tooth a wearing surface more or less plane and regular.

STRUCTURE.—Three essentially different substances enter into the structure of all the teeth: the *ivory*, *enamel*, and *cement*; to which ought to be added the soft parts. the *pulp*, *gum*, and *alveolo-dental periosteum*.

IVORY.—The *ivory*, or *dentine*, has the hardness of bone, is of a whitish-yellow colour, and is rendered brilliant in places by its nacrous reflection. It forms the principal mass of the tooth, enveloping everywhere the pulp cavity.

Examined by aid of the microscope, this substance is found to be channeled by a multitude of minute, undulating, and branching canals (*dental tubuli*) imbedded in amorphous matter—the *fundamental substance*.

Fig. 153.

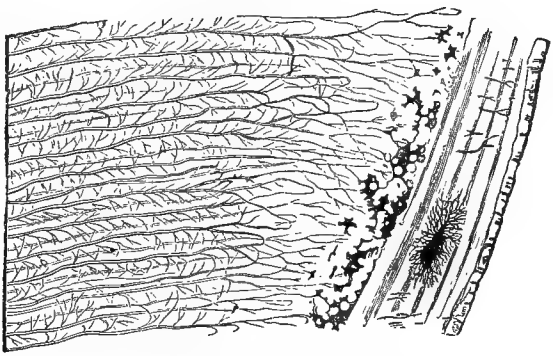

SECTION THROUGH THE FANG OF A MOLAR TOOTH.

a, *a*, Dentine traversed by its tubuli; *b*, *b*, Interglobular, or nodular layer; *c*, *c*, Cementum.

The *tubuli*, or *canaliculi*, extend from the dental cavity to the inner face of the enamel; single at their origin. they soon bifurcate, and again anastomose several times during their slightly-undulating course. They terminate in a *cul-de-sac*, or in irregular cavities situated beneath the enamel, and named the *interglobular spaces of Czermak* (forming the *interglobular* or *nodular layer*). These canals have a thin proper wall, and contain a dental fibre, which very probably is a continuation of the pulp-cells. The *fundamental substance* (or *matrix*) is amorphous, and not very abundant; in

its mass are deposited the saline molecules which give the dentine its bony consistency. (These molecules are deposited in lamellæ, concentric with the pulp cavity. Nasmyth considers the fibres to be rows of minute opaque points arranged in a linear series (baccated fibres), and to be merely the nuclei of the ivory cells, the interfibrous substance being the remainder of the cell filled with calcareous matter.)

Its chemical composition much resembles that of bones. After remaining in dilute hydrochloric acid for several weeks, it comports itself like them, by giving up the calcareous salts with which it is impregnated to the acid solution, and becoming soft like cartilage; submitted to the action of boiling water it yields gelatine.

Enamel.—The *enamel* extends in a layer over the bony substance of the free portion of the tooth, whose exterior it entirely envelops; it is prolonged over the fang in some animals, and in several kinds of teeth it dips by the crown into the interior of the organ to a very great depth. It is brilliantly white, and so hard that it strikes fire like steel.

Its microscopic structure is very interesting, the enamel being composed of small prismatic hexagonal rods, 1-5000th of an inch in diameter, and notched on their faces. Owing to this notching, the prisms are intimately united to each other. They form several layers which cross each other at

Fig. 154.

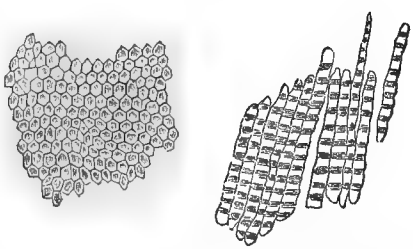

A. TRANSVERSE SECTION OF ENAMEL, SHOWING ITS HEXAGONAL PRISMS; B. SEPARATED PRISMS.

an acute angle, though in each layer they are exactly parallel to one another. By immersing the enamel in dilute hydrochloric acid, there is detached from its surface a fine amorphous membrane or *cuticle of the enamel.*

(The chemical composition of enamel appears to be 96·5 per cent. of earthy matter, and 3·5 of animal substance. The first consists of phosphate of lime, with traces of fluoride of calcium, carbonate of lime, phosphate of magnesia, and other salts. The rods are directed vertically on the summit of the crown of the tooth, and horizontally at the sides.)

Cement.—(*Cementum, substantia ostoidea, cortical substance*, or *crusta petrosa*).—The *cement* is spread in a non-continuous layer over the external surface of the enamel and dentine. It is accumulated in large quantity in the substance of some teeth, as will be noticed when speaking of the incisors in the Horse and the molars of the Herbivora.

The structure and properties of this substance differ in nothing from the structure and properties of the spongy tissue of bone. In a physiological state, the cement does not contain any *Haversian canals.* (It

contains, sparingly, the lacunæ and canaliculi which characterise true bone: those placed near the surface have the canaliculi radiating from the side of the lacunæ towards the periodontal membrane; and those more deeply placed join with the adjacent dental tubuli. In the thicker portions of the crusta petrosa, the lamellæ and Haversian canals peculiar to bone are also found. As age advances, the cementum increases in thickness, and gives rise to those bony growths, or exostoses, so common in the teeth of the aged; the pulp cavity also becomes partially filled up by a hard substance, intermediate between dentine and bone (*osteo-dentine—Owen; secondary dentine—Tomes*). It appears to be formed by a slow conversion of the dental pulp, which shrinks or even disappears—*Gray.*)

Dental pulp.—The *pulp*, or *papilla*, is formed by a fibrillar and nuclear mass that fills the internal dental cavity. It receives blood-vessels and nerves, and is enveloped in a very thin membrane which is entirely composed of several layers of beautiful cylindrical or prismatic cells, the most superficial of which send fibrillar prolongations into the dental tubuli. Towards the base of the papilla, this membrane assumes the texture of connective tissue, and is reflected upwards on the fang of the tooth to line the alveolus, and join the gum at the origin of the crown.

Fig. 155.

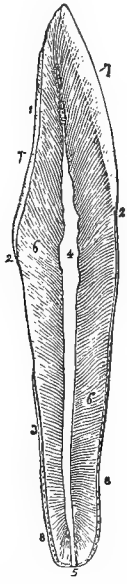

MAGNIFIED SECTION OF A CANINE TOOTH, SHOWING ITS INTIMATE STRUCTURE.

1, Crown; 2, 2, Neck; 3, Fang, or root; 4, Cavitas pulpæ; 5, Opening by which the vessels and nerves communicate with the pulp; 6, 6, Ivory, showing fibrous structure; 7, 7, Enamel; 8, 8, Cement.

Gum.—The *gum* is a portion of the buccal mucous membrane surrounding the neck of the tooth, and concurs in consolidating it in the alveolar cavity. Its structure is that of the membrane to which it belongs, being a thick dermis furnished with papillæ and tesselated epithelium. It does not contain any glands.

Alveolo-dental periosteum.—This scarcely differs from the ordinary periosteum except in being a little softer. It lines the alveolus and covers the cementum of the fang.

Development.—Each tooth is developed in the interior of a closed sac named the *dental follicle*, and lodged in an excavation in the maxillary bones. The sac presents, according to the species of animal and kind of teeth, numerous variations, which we cannot stay to consider here; but must confine ourselves merely to a brief sketch of the general and constant characteristics of its organisation.

The *dental follicle* is constituted by an external enveloping membrane of a cellulo-vascular nature (Fig. 156, A). It shows at bottom the simple or compound papilla which at a later period is termed the *dental pulp* (B); this organ, destined for the secretion of the dentine, then fills nearly the whole of the follicle. In its upper part is observed the *enamel organ*, or *germ* (*enamel membrane*), formed by a prolongation of the gingival epithelium, and connected with the latter by a small mass of cells named the *gubernaculum dentis.* Most frequently there is, opposite the bottom of the follicle, one or more papillæ which, in some cases, adhere by their whole length to one of the lateral walls of the follicular sac, and the free extremities of which cross those of the dentine papillæ, or are buried in

a kind of cup hollowed on the summit of the latter appendages (C). These are covered by the membrane of cylindrical cells mentioned above (D).

With regard to the enamel organ, its internal face also presents a layer of cylindrical cells.

It is in the interval between these two papillary systems, that the dental substance is deposited as in a mould, consequent on a process of secretion and transformation, the mechanism and progress of which are somewhat complicated. The *dentine* is produced by the metamorphosis of the superficial cells of the *dental germ*. These cells send out ramifying prolongations which constitute the tubuli of the dentine, and those of the middle layer secrete an intertubular amorphous substance in which the earthy salts are deposited from without inwards. The *enamel* is deposited on the dentine, and results from the transformation of the cylindrical cells of the germ into enamel prisms. The *cement* is, in its turn, deposited either on the enamel or the dentine after their formation, and is produced, like the bony tissue, by the internal face of this (periodontal) sac, which has become alveolar periosteum. This development will be alluded to in the chapter on the fœtus.

Fig. 156.

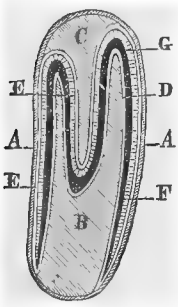

THEORETICAL SECTION OF THE DENTAL SAC OF A PERMANENT INCISOR IN THE HORSE.

A, Proper membrane of the sac; B, Dental pulp; C, Papilla of the external cavity (*pit*) of the tooth, a dependency of the enamel membrane; D, Epithelial layer of the dentine membrane; E, Cylindrical cells of the enamel membrane; F, Dentine; G, Enamel. The secretion of the cement is not supposed to have commenced.

When formed by the process above indicated, the tooth pierces its follicle and appears in the interior of the mouth, after having traversed the table of the maxillary bones, if there is any, and the gingival membrane. (When the calcification of the different tissues of the tooth is sufficiently advanced to enable it to bear the pressure to which it will be afterwards subjected, its eruption takes place, the tooth making its way through the gum. The gum is absorbed by the pressure of the crown of the tooth against it, which is itself pressed up by the increasing size of the fang. Concurrent with this, the septa between the dental sacs, at first fibrous in structure, soon ossify, and constitute the alveoli; these firmly embrace the necks of the teeth, and afford them a solid basis of support—*Gray*.) Though it has so far become established in its functions, the process of growth in the tooth has not yet ceased. The pulp lodged in the internal dental cavity, and charged with the formation of the ivory or dentine, continues its functions: incessantly depositing new layers on those which were originally secreted. The dental cavity gradually diminishes in extent; the papilla becomes atrophied, and finishes by disappearing altogether at a period of life more or less advanced, according to the kind of teeth and species of the animal.

In considering the entire dental apparatus, with regard to its development, very interesting differences are remarked in the progress and period of evolution; differences which have been made available for ascertaining the age of animals, but the details of which would be out of place here. It may only be noted, that all animals have two successive dentitions: the first, composed of a certain number of teeth designated the *caducous* (*temporary, deciduous*, or *milk-teeth—caduques*, decaying or frail), because they are soon shed and give place to others which are stronger and more solid

(and also because they appear while the animal is yet sucking); the second, comprising the latter, are named *replacing teeth* (*remplaçantes*), with new, non-deciduous teeth which are not replaced, and are therefore named *persistent* teeth. (The *replacing* and *persistent teeth* are generally included by us in the term *permanent.*)

B. Teeth of Solipeds.—The dentition of adult Solipeds is composed of from 36 to 40 teeth, thus distributed in each jaw: male, 6 incisors, 2 canines, 12 molars; female, 6 incisors, 12 molars. With regard to the first dentition, it comprises the incisors and three anterior molars only, the canine teeth and the three posterior molars being persistent.

The latter teeth—those of the second dentition—offer in their development a common, but very remarkable character, rarely met with in the other animals. They are thrust up from the alveoli during the entire life of the animal, to replace the surfaces worn off by friction; so that the crown is formed successively by the various portions of the fang, each of which issues in its turn from the alveolar cavity.

Incisors.—These are so named because they serve, particularly in the

Fig. 157.

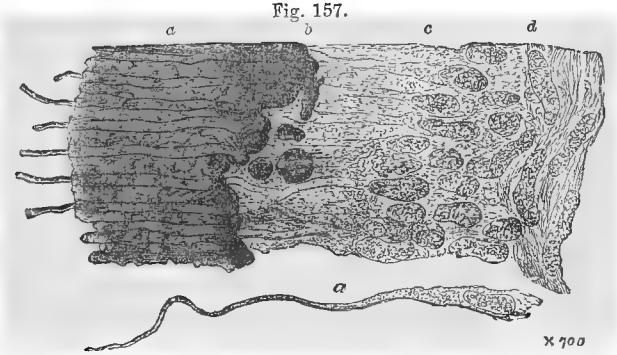

THIN SECTION OF THE INNER PORTION OF THE DENTINE AND OF THE SURFACE OF THE PULP OF AN INCISOR TOOTH.

Portion in which calcification is complete, showing separate globular masses at the line of junction with the uncalcified substance, *b*; at *c* are seen oval masses of germinal matter (cells), with formed material on their outer surface; *d*, Terminal portions of nerve fibres.

Herbivora, for the incision (*incido*, to cut) of the food. They are arranged in the segment of a circle, at the extremity of the jaw, and are distinguished by the names of *pincer*, *intermediate* or *lateral* (*mitoyennes*), and *corner* teeth. The *pincers* are the two middle teeth, the *intermediates* the next, and the *corners* occupy the extremities of the incisive semicircle.

The general form of these teeth is that of a trifacial pyramid, presenting an incurvation whose concavity is towards the mouth. The base of this pyramid, formed by the crown, is flattened before and behind; the summit, or extremity of the fang, is, on the contrary, depressed on both sides; the shaft of the pyramid offers, at different points of its height, a series of intermediate conformations which are utilised as characteristics of age, the continual pushing outwards of the teeth bringing each of them in succession to the frictional surface of the crown (Fig. 159, 1).

Examined in a young tooth which has completed its evolution, the *free portion* exhibits: an anterior face, indented by a slight longitudinal groove, which is prolonged to the root; a posterior face, rounded from side to side;

two borders, of which the internal is always thicker than the external; lastly, the surface of friction (*table*). The latter does not exist in the tooth which has not been used; but in its stead is found two sharp margins circumscribing a cavity named the *external dental cavity* (or better, *infundibulum*). This cavity terminates by a conical *cul-de-sac*, which descends more or less deeply into the substance of the tooth. The margins are distinguished into anterior and posterior; the last, less elevated than the first, is cut by one or more notches which are always deepest in the corner teeth. It is by the wear of these margins that the surface of friction is formed, and in the centre of which the infundibulum persists during a certain period of time (Fig. 159, 2).

Fig. 158.

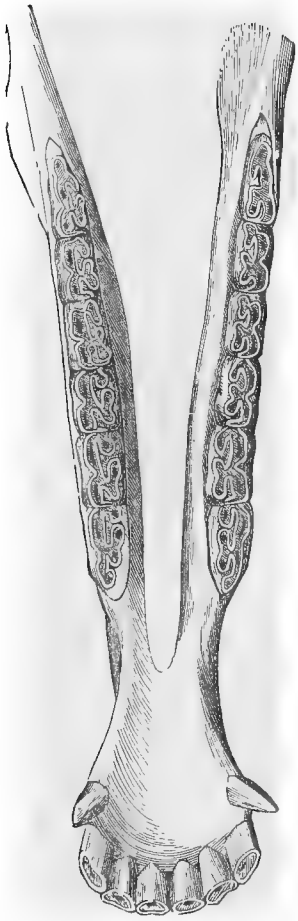

THE DENTITION OF THE INFERIOR JAW OF THE HORSE, THE TEETH SEEN ON THEIR TABLES.

Consult figure 21 for the dentition of the upper jaw.

The *fang* is perforated by a single aperture, through which the pulp of the tooth penetrates into the internal cavity (Fig. 159, 3, *c*).

In the composition of the incisor teeth is found the three fundamental substances of the dental organ. The *dentine* (Fig. 159, 3, *b*) envelops, as has been shown, the pulp cavity. That which is deposited in this cavity after the complete evolution of the tooth, to replace the atrophied pulp, has always a yellower tint than the dentine of the first formation; it forms on the table of the tooth the mark designated by Girard the *dental star* (Fig. 159, 4, *c*). The *enamel* covers the dentine, not only on its free portion, but also on the roots of the incisors; it is not prolonged, however, to their extremities. It is doubled into the external dental cavity, lining it throughout (Fig. 159, 3, *a*); and when the surface of friction is established, there can be perceived a ring of enamel surrounding that surface, and an internal ring circumscribing the infundibulum: the first circle forms what is called the *encircling enamel;* the second, the *central enamel* (Fig. 159, 4, *a*, *b*).

In the virgin tooth, the latter is continuous with the external enamel, and passes over the border which circumscribes the entrance to the infundibulum. The *cement* is applied over the enamel like a protecting varnish; but it does not exhibit the same thickness everywhere: on the salient portions it is extremely thin, and does not even exist when the tooth has been submitted for some time to the friction arising from the contact of the aliment, the lips, and the tongue. It is more abundant in depressed situations, as in the longitudinal groove on the anterior face, and particularly

at the bottom of the infundibulum. Nevertheless, the quantity accumulated in this *cul-de-sac* is not always the same; we have seen it sometimes almost null, and on the other hand we possess incisors unworn, or nearly so, in which the cavity is almost entirely obstructed by the crusta petrosa. We are not aware that, up to the present time, any account has been taken of these differences when calculating the progress of *wear;* but it may be imagined that they ought to influence in a sensible manner the period at which effacement of the external dental cavity takes place.

Fig. 159.

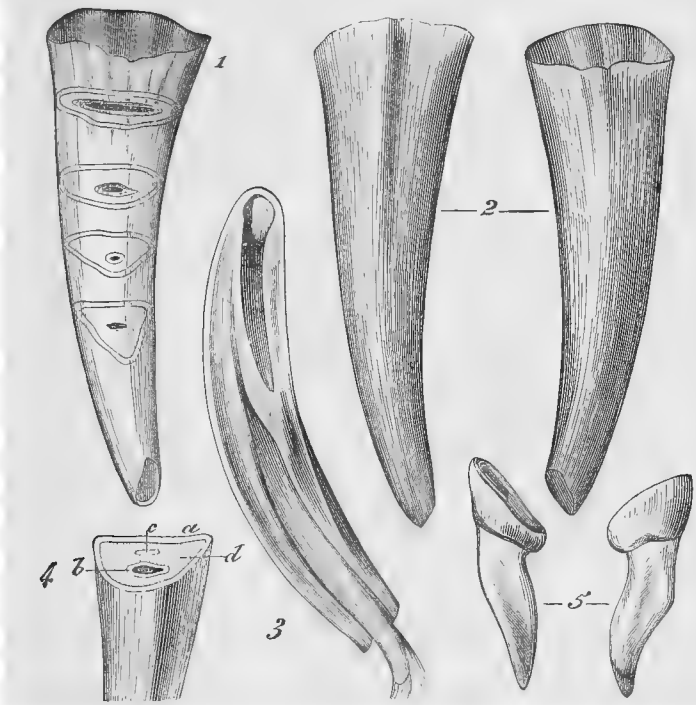

INCISOR TEETH OF THE HORSE. DETAILS OF STRUCTURE.

1, A tooth in which is indicated the general shape of a permanent incisor, and the particular forms successively assumed by the dental table in consequence of friction, and the continued pushing outwards of these teeth; 2, A virgin tooth, anterior and posterior faces; 3, Longitudinal section of a virgin tooth, intended to show the internal conformation and structure. Not to complicate the figure, the external cement, and that amassed in the infundibulum, has not been exhibited. 4, Transverse section for the same purpose; *a*, Encircling enamel; *b*, Central enamel; *c*, Dental star; *d*, Dentine; 5, Deciduous tooth.

All the characteristics just indicated belong to the *deciduous teeth* (Fig. 159, 5), except that they are smaller than the permanent; that they are of a shining milky-white colour, due to the thinness or absence of the crusta petrosa; that they show at the point of union between the free portion and the root, a constriction named the *neck;* that their crown is finely striated, and not cannular, on the anterior face; that the external *cul-de-sac*

(infundibulum) is shallow; and that they are not constantly pushed outwards from their cavities, their growth ceasing when they begin to be used. When the replacing teeth appear, they do so a little behind the temporary ones, whose shedding they cause by gradually destroying their roots, which at last become only a long and very thin shell of dentine.

The follicle in which the incisor teeth are developed shows only two papillæ; one for the secretion of the dentine, lodged in the internal cavity of the tooth, and hollowed into a cup-shape at its free extremity; the other is contained in the external *cul-de-sac* (Fig. 156, A. B. C).

Tusks, Fangs, or Canine Teeth.[1]—"The tusks of Solipeds only exist in the male; it being quite exceptional to meet with them in the female, and even then they are rarely so strong as in the male.

"These teeth are four in number, and are placed one at each side of the jaws, a little behind the incisors, to which the lower canines are much nearer than the upper. Between them and the first molar there is left a considerable space, which constitutes the *bar* of the inferior jaw.

"The free portion of the tusk, slightly curved and thrown outwards, particularly in the lower jaw, offers two faces: an external and an internal, separated from one another by two sharp borders inclined to the inner side, and meeting in a point at the extremity of the tooth. The external face, slightly rounded, presents a series of fine striæ, longitudinal and parallel.

"The internal face has a conical eminence in its middle, whose point is directed towards that of the tooth, and is separated from each border by a deep groove.

"The fang of the tusk, more curved than the free portion, bears internally a cavity analogous to that of the root of the incisors, and like it, this diminishes and finally disappears as it advances in age; but it is always relatively larger, because of the absence of the infundibulum in the canine teeth.

"The form we have described for the tusks is that which they present while still young. As the Horse grows older they lose their whiteness, and become worn in an irregular manner, and this most frequently by the action of the bit or snaffle; for the difference in position of these teeth in the two jaws does not allow of friction between them.

"The canine teeth are not shed, and grow but once. Some veterinarians, and among them Forthomme and Rigot, have witnessed instances in which they were replaced; but the very rare exceptions cannot make us look upon these teeth as liable to be renewed. We must not, however, confound with these exceptional cases the shedding of a small spicula or point, which, in the majority of Horses, precedes the eruption of the real tusks."

"The structure of these teeth is much simpler than that of the incisors; consisting, as they do, of a central mass of dentine hollowed by the pulp cavity, and covered by an external layer of enamel, on which is deposited a little cement.

"The disposition of the developing follicle is in harmony with the simplicity of structure of the tusks; at the bottom there is a simple and conical papilla for the internal cavity; on the inner wall, a double longitudinal ridge, on which are moulded the ridge and grooves on the internal face of the tooth."

Molar Teeth.—"The molars are twenty-four in number—six in each side of each jaw. There are also sometimes supplementary molars met with

[1] The quotations included within inverted commas are from M. Lecoq's 'Traité de l'Extérieur du Cheval et des Principaux Animaux Domestiques.'

in front of the true ones, and which may be four in number; but these are small teeth, having but little resemblance to the others, are most frequently shed with the first deciduous molar, and are not replaced.

"Generally considered, the molar arcades have not the same disposition in both jaws. Wider apart in the superior one, they form a slight curve, whose convexity is outwards. In the inferior jaw, on the contrary, the two arcades separate in the form of a V towards the back of the mouth. Instead of coming in contact by level surfaces, the molars meet by inclined planes, and in such a way that the internal border is higher than the external in the inferior molars, while the opposite takes place in the superior.

"Like the incisors, each molar presents for study a free and a fixed portion.

"The free portion, nearly square in the upper molars, longer than wide in the lower, shows at the external surface of the former two longitudinal grooves, the anterior of which is the deepest, and which are continued on the encased portion. This is not the case with the inferior molars, which have but one narrow, and frequently an indistinct, groove.

Fig. 160.

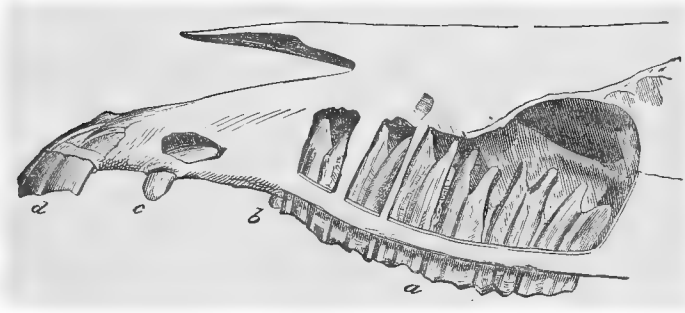

PROFILE OF THE UPPER TEETH OF THE HORSE, MORE ESPECIALLY INTENDED TO SHOW THE MOLARS; THE FANGS HAVE BEEN EXPOSED.

a, Molar teeth; *b*, Supplementary molar; *c*, Tusk; *d*, Incisors.

"The internal face in both jaws only shows one groove, and that but little marked; it is placed backwards in the upper molars, and is most apparent towards the root.

"The anterior and posterior faces are in contact with the corresponding faces of the adjoining molars, except at the extremities of the arcades, where the isolated face is converted into a narrow border.

"With regard to the table of the tooth, it inclines, as we have already mentioned, outwards in the lower jaw, and inwards in the upper; a circumstance which prevents the lateral movements of the jaws taking place without separation of the incisors, which separation removes them from friction." In the virgin molar this face is completely covered with enamel, and irregularly undulated. In it may be recognised the entrance to the two infundibular openings, which are prolonged in the interior of the organ to the extremity of the root, and which are almost entirely filled with cement at the period when the tooth has completed its evolution; they are only vacant before the secretion of this crusta petrosa. In the tooth which has

been worn, this frictional surface assumes a particular aspect, which will be indicated with most advantage to the student by examining the structure of the molar.

"The root, if examined a short time after the eruption of the free portion, looks only like the shaft of the latter, without any appearance of fangs, and has internally a wide cavity. It is not until the tooth begins to be pushed from the alveolus and its crown to become worn, that its fangs are formed; these are at first hollow, and afterwards filled, as well as the cavity of the tooth, by the formation of a new quantity of dentine. From this time the fangs cease to grow; but the tooth, constantly projected beyond the alveolar cavity, allows the walls which inclose it to contract; so that, in extreme old age, it happens that the shaft, completely worn away, instead of the tooth, leaves several stumps formed by the fangs.

"The molars of the two jaws exhibit a variety of roots. In the molars terminating the arcades, either above or below, or at the extremities of these, there are three; while the intermediate molars have four fangs in the upper jaw, and only two in the lower.

"The molars are separated from each other by their imbedded portion, particularly at the two extremities of the arcade; an arrangement which strengthens them by throwing the strain put upon the terminal teeth towards the middle of the line."

The structure of the molars resembles that of the incisors, though it is much more complicated. The internal cavity is extremely diverticulated, and enveloped by the *dentine.* The *enamel* is applied in a layer over it, and is doubled in its external *culs-de-sac* exactly as in the incisors. There is also on the table of the tooth which has been worn, an external covering of enamel, and two circles, or rather two irregular polygons, of central enamel circumscribing the two cavities. In the superior molars, these bands of enamel represent a Gothic B, having a small appendix on the loop nearest the entrance to the mouth. This figure is modified in the teeth of the lower jaw, the enamel of the infundibuli being continuous, on the inner side, with the external enamel. The *cement* is extremely abundant, and in the upper molars its total quantity nearly equals that of the dentine; it accumulates in the *culs-de-sac* and on the external covering of enamel, where it partially fills up the flutings on the faces of the crown. Prolonged steeping of a molar tooth in hydrochloric acid easily permits the isolation of these elements.

Fig. 161.

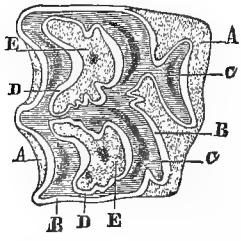

TRANSVERSE SECTION OF A HORSE'S UPPER MOLAR TOOTH.

A, External cement; B, External enamel; C, Dentine; D, Internal enamel; E, Internal crusta petrosa.

Owing to the arrangement above described, the section of an adult molar tooth, naturally represented by the surface of friction (Fig. 161), exhibits, outwardly, a layer of cement; next, the external enamel; between this and the central enamel, the dentine, always yellower, and sometimes even black in the middle; lastly, the enamel bands of the infundibuli, and the crusta petrosa filling them. As these enamel bands are much harder than the other substances, they are worn more slowly and stand out in relief on them. The table of the tooth has also, for this reason, the appearance of a veritable mill-stone, and is admirably disposed for the trituration of those fibrous substances on which the animal usually feeds.

The follicle which develops these three elements of the molar tooth, offers at the bottom an enormous papilla divided into several lobes, which lie together for their whole length; lodged in the internal dental cavity, it gradually decreases, like the papilla in the other kinds of teeth, as the cavity becomes diminished by the formation of new dentine. Opposite to it are two long papillæ, which occupy the enamelled infundibuli.

"It was believed for a long time that the molars of Solipeds were all persistent teeth. This error, founded on the authority of Aristotle, was so deeply rooted, that although Ruini, towards the end of the sixteenth century, had discovered the existence of two temporary molars, Bourgelat did not believe it when he founded the French Veterinary Schools, and was only convinced when Tenon had proved by specimens, in 1770, that the first three of each arcade are deciduous.

"The replacement of these twelve molars is not at all like what happens with the incisors. The molar of the adult grows immediately beneath the temporary one, and divides its two fangs into four, until its body is reduced to a simple plate and falls off, allowing the contracted summit of the permanent to appear; and this grows up until it is soon on a level with the others in the row.

"The first replacing molar is always a little more elongated than that which it succeeds, and it most frequently expels at the same time the supplementary molar; so that if forty-four teeth be developed in the male Horse, it is very rare that they are all present at the same time."

7. *The Mouth in General.*

We will now consider, as a whole, the cavity whose various parts have been studied in detail, and examine, successively, its *general disposition, capacity*, and *mucous membrane.*

General disposition and capacity of the mouth.—The mouth being elongated in the direction of the head, offers a great antero-posterior diameter, and two small diameters—one vertical, the other transverse. The first extends from the base of the epiglottis to the anterior opening of the mouth; the second, from the palate to the floor of the mouth; and the third, from one jaw to the other. When the jaws are in contact, the space included between these limits is divided into two regions: one central, the other peripheral. The first is circumscribed by the dental arches; the second is comprised between these arches on the one side, and the cheeks and inner aspect of the lips on the other. It may, therefore, be remarked, that the capacity of the mouth is almost null in these regions. The cheeks and lips, in reality, lie almost exactly against the alveolar arches, and the tongue, in contact with the palate by its superior surface, almost entirely fills the central region. If the jaws separate from one another, and the cheeks recede from the dental arcades, the cavity of the mouth becomes enlarged in proportion as these movements are extensive. It must be remembered that the separation of the jaws is effected in an angular manner, and that the dilatation produced in the mouth by this movement is greater before than behind, the opening of the angle comprised between the two jaws being directed towards the entrance of the cavity.

Mucous membrane.—The walls of the buccal cavity are covered by a tegumentary membrane, which we have hitherto only examined in parts in the different regions it covers, but which, it is to be noted, forms here a single and continuous layer, the *mucous membrane of the mouth.*

This membrane is continuous with the external skin at the margin of the

buccal opening; followed from this point into the interior of the cavity it lines, it is seen to spread itself at first over the internal surface of the lips, then to be prolonged backwards on the cheeks as far as the posterior pillars of the tongue. If it is examined above and below, to the bottom of the groove which corresponds to the point of insertion of the lips and cheeks, it is seen to cover the maxillary bones and envelop the base of the teeth, where it constitutes the *gums*. From the superior dental arcade, it extends over the palatine arch and the soft palate. And from the inferior arcade, it descends to the floor of the mouth, and is reflected over the tongue to form a covering for that organ. At the isthmus of the fauces it is continuous with the pharyngeal mucous membrane.

The organisation of the mucous membrane of the mouth is perfectly in harmony with the digestive acts performed in that cavity. It is there where the alimentary substances, which are sometimes very hard, very resisting, and covered with asperities, are crushed; and to escape inevitable injury, this membrane is protected by a very thick epidermis in those places which are most particularly exposed to the contact of these substances, such as the upper surface of the tongue, the palate, and the cheeks; even the corium or sub-epidermic layer, is also greatly thickened. But nature has not made this provision for the parts which are removed from the direct contact of alimentary matters; as, for example, on the lateral aspects of the tongue, where the buccal membrane is delicately organised.

This membrane also shows, in its lingual portion, small organs for the gustation of savours, the perception of which is one of the most important preparatory acts of the digestive functions; as the sensation resulting from this appreciation constitutes an excitant to the desire for food, and also informs the animal of the good or bad properties of the substance introduced into the mouth.

DIFFERENTIAL CHARACTERS IN THE MOUTH OF OTHER THAN SOLIPED ANIMALS.

That the different regions of the mouth in the domesticated animals should offer some diversities will be readily conceived, as all are not submitted to the same régime, nor do they all live in the same manner.

RUMINANTS. 1. *Lips.*—The lips of the *Ox* are remarkably thick and rigid, and possessed of but little mobility, notwithstanding the great development of the muscles that move them; so that they only concur indirectly in the prehension of food, the tongue being charged with the largest share in this important task. The upper lip offers in the middle of its external surface a large patch destitute of hair, variously coloured in different animals, always humid in health, covered by small depressed eminences, and perforated by minute apertures, through which the secretion of numerous thick, yellow, subcutaneous glandules passes to the surface. This space, situated between the two nostrils, constitutes the *muffle*. (Around the muffle are a few hairs sometimes, of the nature of tentaculæ.)

In the *Sheep* and *Goat* the lips are thin and very mobile, and take an active part in the prehension of food. The upper lip does not show any muffle, and is divided into two portions by a median groove. In the Sheep this groove is in reality a fissure; so that each half of the lip can be readily moved independently of the other. (The upper lip is covered with hair in both animals. The *Goat* has a long tuft of hair appended to its lower lip, the *beard*.)

2. *Cheeks.*—On the inner surface of the cheeks in the *Ox*, *Sheep*, and *Goat*, from the commissure of the lips to the first molar tooth, is a multitude of long, thick, conical papillæ directed backwards. Beyond, there are only small round elevations and a single row of large papillæ similar to the preceding, in a line with the upper molars. In the *Sheep* the mucous membrane is sometimes spotted black.

3. *Palate.*—In the *Ox*, the palate is most extensive. Its posterior third is quite smooth, and the transverse ridges (*bars*) only occupy the anterior two-thirds. (They are usually sixteen in number.) They are not curved, but are cut into notches on their summit, which is inclined backwards. In the *Sheep* and *Goat*, as also in the *Ox*, is

remarked, in front and in the middle, near the pad that replaces the upper incisor teeth a kind of T, the stem of which is directed forwards, and at the extremity of whose branches is a very narrow aperture, the buccal opening of *Jacobson's canal.* This will be described with the nasal cavities.

4. *Tongue.*—The tongue of the *Ox* is distinguished by the enormous development of the muscles composing it, It is garnished with conical papillæ which have a horny sheath, and whose summits, inclining backwards, give the tongue a very rough feel. In this animal it serves for the prehension of food; its mobility is very great, and it can be carried into the nostrils with ease. (The body of the organ is rounder, and the point finer than in the Horse The calicyform papillæ are spread over the whole of its dorsal surface; and at the root, on the middle line, is a somewhat deep groove.)

The tongue of the *Sheep* and *Goat* is smaller, proportionally, than that of Solipeds.

5. *Soft Palate.*—It may be said, in a general manner, that the palatine prolongment is shorter than in Solipeds. (The isthmus of the fauces is wider, however, and the amygdalæ, very developed, are situated in the two large depressions formed on the sides of the soft palate by the folding of the mucous membrane.)

6. *Teeth.*—The teeth of the *Ox* are thirty-two in number, twenty-four of which are molars, arranged as in the Horse, and eight incisors belonging to the lower jaw. The latter are replaced in the upper jaw by a thick cartilaginous pad, covered by the mucous membrane of the mouth; this pad forms the gum, and furnishes a bearing for the incisors of the lower jaw. Sometimes, as in the Horse, there are found supplementary molars, which, if four in number, will make up the whole to thirty-six; though they are never all present at one time, as the supplementary ones are shed before the molar dentition is completed.

The composition of the Ox's teeth is the same as those of the Horse, the only difference being in the arrangement of the several substances.

Fig. 162.

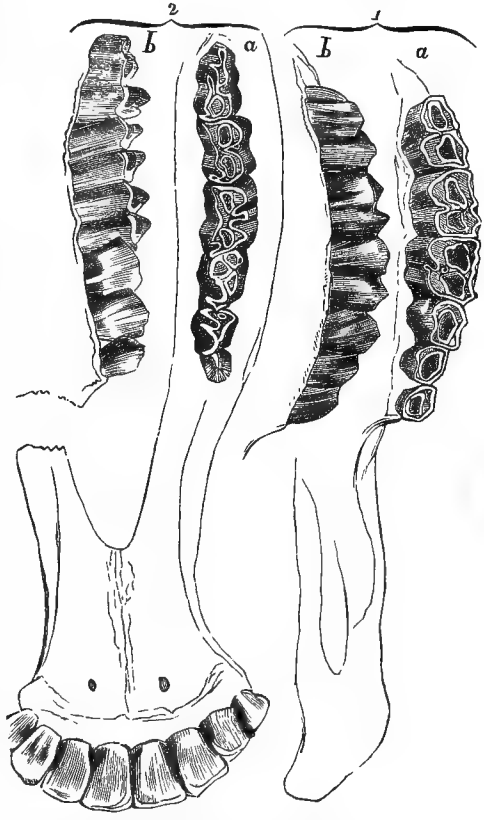

THE TEETH OF THE OX.

1, Upper jaw, with *a*, the friction surface, and *b*, the external surface; 2, Lower jaw, with *a*, the dental tables, and, *b*, the external face.

Incisors. — "The incisors, eight in number, are placed *en clavier* (like a key-board) at the extremity of the kind of rounded shoulder-bone by which the maxillary bone terminates, forming around this point a perfect circle when they have acquired their full development.

"Instead of being fixed in the alveoli, as in Solipeds, they possess a certain degree of mobility, sometimes mistaken for a diseased condition; this is necessary in order to prevent their wounding the cartilaginous pad of the upper jaw against which they press. They are divided, according to their position, into two *pincers*, two *first intermediates*, two *second intermediates*, and two *corner* incisors.

"Each incisor offers for consideration two parts: one free, the other encased, con-

stituting the root, and separated from one another by a very marked constriction—the neck. This arrangement gives to the tooth the form of a shovel, the root representing the handle (fig. 163).

"The free portion, flattened above and below, and thinnest and widest towards its anterior extremity, presents two faces—an inferior or external, the other superior or internal; with three borders, an anterior and two lateral.

"The external face, slightly convex, and milk-white in colour, is covered with fine, undulating, longitudinal striæ, which disappear with age, and leave the surface beautifully polished (fig. 163, *a*).

Fig. 163.

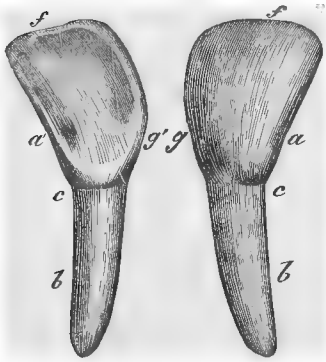

OX'S INCISOR TOOTH.

a, Free portion, external face, outer border; *a'*, *Ibid*, internal face, outer border; *b*, Root; *c*, Neck; *f*, Anterior border; *g*, *g'* Inner border.

"The internal face, flatter than the preceding, presents in its middle a slight conical eminence, whose base widens and is terminated near the free extremity of the tooth, while its sides are circumscribed towards each border by a well-defined groove (fig. 163, *a'*).

"The two lateral borders (the internal slightly convex in its length, the external slightly concave in the same direction) make the free portion appear as if thrown outwards. The anterior border is sharp, and slightly convex from one side to the other; it is the first part of the tooth destroyed by wear.

"The root is rounded, slightly conical, and implanted in an alveolus of the same form; in youth, it shows at its extremity an opening communicating with an internal cavity analogous to that in the teeth of Solipeds, and prolonged into the interior of the free portion (fig. 163, *b*).

"In the virgin tooth, the enamel forms around the free portion a continuous layer, thinnest on the internal surface, and extending very scantily over a part of the root.

"The dentine composes the remainder of the organ, and the (pulp) cavity, which is originally a large space of the same form as the tooth, is filled, as the animal grows old, by new dentine, which, as in the Horse, has a yellower tint than the primitive ivory.

"When the cavity is completely filled, the tooth ceases to grow, and is not pushed beyond the alveolus during wear, like the teeth of the Horse.

"The incisor tooth has scarcely arrived at its perfect development before it begins to be worn. Its horizontal position, and its coming in contact with the pad on the upper jaw, exposes the anterior border and superior face to friction, and consequent wear from before to behind. The wear, therefore, chiefly affects this upper face, which really forms the table of the tooth, and which Girard designated the *avale*. When use has worn away the conical eminence and the grooves bordering it, the tooth is *levelled*.

"As wear goes on, there appears at first, and at the extremity of the tooth, a yellow band, which is the dentine denuded of its enamel; and later, in this ivory a yellower transverse band shows itself. With increase of wear, this contracts, then widens, and finishes by forming a mark nearly square, and then round, which is nothing else than the recently-formed dentine that fills the pulp cavity of the tooth. It is a veritable dental star, analogous to that in the Horse's tooth, and varying in form according to the incisor in which it appears.

"In proportion as the teeth are used, they seem to separate from one another, although they still remain in the same places. This is because these teeth, in youth, only touched each other by their extremities, and as they became worn they decreased in width, and necessarily became separated to an extent varying with their degree of wear.

"Finally, when the tooth has reached its last stage of wear, there only remains the root, the upper portion of which, becoming apparent by the retreat of the gum, stands as a yellow stump, very distant from those which form with it the remains of the incisive arcade.

"The first incisors (or *milk-teeth*) of the Ox, like those of the Horse, are all deciduous, and differ from those which replace them by their smaller volume, less width, the transparency of their enamel, and their being more curved outwards. Their roots are much shorter, and are destroyed by the succeeding teeth. The two temporary pincers are always separated by a marked interval, depending on the thickness of the fibro-cartilage in the maxillary symphysis during youth."

MOLARS.—"As in Solipeds, the molars are six in each side of the jaws, but they are much smaller, and form a much shorter arcade. Their reciprocal volume is far from being as uniform as in the Horse, but goes on augmenting from the first to the sixth; and to such a degree, that the space occupied by the three anterior molars is only about one-half of that required for the three posterior ones; the last molar alone occupies nearly four times as much space, lengthwise, as the first.

"Their wearing surface, constructed on the same system as that of the Horse's molars presents eminences a little more acute."

The arrangement of their three constituents is in principle the same as in the latter animal.

"As in the Horse, the three front molars are deciduous.

"The teeth of the *Sheep* and *Goat* are, like those of the Ox, thirty-two in number, divided into eight incisors and twenty-four molars, to which are sometimes added supplementary molars.

"The incisors of the smaller Ruminants are not disposed like a key-board, as in the Ox, but stand up to form a grip, resting against the pad on the upper jaw much more by their extremity than by their inner surface.

"They are, besides, narrow, have scarcely any neck, and are fixed more solidly in the alveoli (fig. 164).

"Their external face is white and polished, and is encased towards the gum in a kind of black cement.

"The internal face has two wide, longitudinal grooves, separated towards the middle of the table by a simple ridge, which replaces the conical eminence of the Ox's incisor. These grooves are nearly always lined with the black cement-like substance.

"The incisors of the Sheep are, like the Ox's, distinguished into temporary and replacing teeth; the first are known from the others by their smallness, and particularly by their narrowness.

"The wear of the incisors in the Sheep, from their position, ought to take place nearer the anterior border than in the Ox; the dental star is observed more promptly, and always forms a narrower line from before to behind.

"The absence of a neck in these teeth is the reason why they never appear to separate with wear, as has been remarked in the Ox.

"The molars have the greatest resemblance, in their general form and relative proportions, to those of the Ox."

Fig. 164.

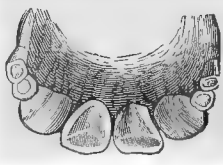

INCISOR TEETH OF A SHEEP TWO YEARS OLD.

The second intermediates and the corner incisors have not yet been replaced.

PIG.—"1. *Lips.*—In this animal the lips are widely cleft. The lower is pointed and little developed; the upper is confounded with the *snout*, which will be described with the nostrils." (The upper lip has but little mobility.)

"2. *Cheeks.*—These are small and thin, and the mucous membrane smooth.

"3. *Palate.*—Narrow and elongated, it is disposed as in the Horse. In front is seen the orifices of Jacobson's canals." (The transverse ridges are twenty to twenty-two in number, the anterior being larger than the posterior, and their free borders are united).

"4. *Tongue.*—5. *Soft Palate.*—These two organs are the same as in the smaller Ruminants, except that the filiform papillæ are perhaps less developed." (The isthmus of the fauces is circular, and the posterior pillars are confounded with the mucous membrane at the upper part of the œsophagus. Its anterior surface has several conical eminences in the middle, and the amygdalæ are little rounded elevations.)

"6. *Teeth.*—The Pig has forty-four teeth, which are divided into twelve incisors, four canines and twenty-eight molars" (fig. 165).

"The incisors, six in each jaw, exhibit very remarkable differences between each other. The pincers and the intermediates of the upper jaw offer, by their form and the cavity they show on their table, some analogy to those of the Horse. In the lower jaw, these teeth are straight, directed forwards, and bear some resemblance to the incisors of rodent animals. The corner incisors of both jaws are isolated between the intermediate and canine teeth, and are not nearly so voluminous as the other incisors.

"The tusks are very developed, particularly in the male, and cross each other during the life of the animal; they project from the mouth, and form a very dangerous weapon in the wild boar. The primary canines are deciduous like the incisors.

"The molars, seven in each row, increase in volume from the first to the last, which is very strong. Their tables hold a middle place, with regard to disposition, between that of the Carnivora and Herbivora.

"CARNIVORA.—1. *Lips.*—The Carnivora, like the Pig, do not use their lips to grasp

their food, and they are therefore thin, though movable. The upper lip of the *Dog* has a groove in the middle line, and it covers the lower lip more or less at the sides according to the breed. The lower lip is always scalloped on its free border near the commissures, which are very high. In the *Cat*, the hairy tentaculæ are collected on the upper lip into two long lateral tufts, the *moustaches;* they are very sensitive and movable.

"2. *Cheeks.*—3. *Palate.*—The cheeks resemble those of the Pig; the palate that of Ruminants. The mucous membrane is often stained by patches of pigment, especially on the palate." (The latter is frequently quite black. The number of ridges varies from seven to nine. Jacobson's canal opens behind the incisors.)

"4. *Tongue.*—This is thin and very movable. The papillæ on its upper face vary somewhat in the *Cat* and *Dog*. In the former, the filiform papillæ on the anterior two-

Fig. 165.

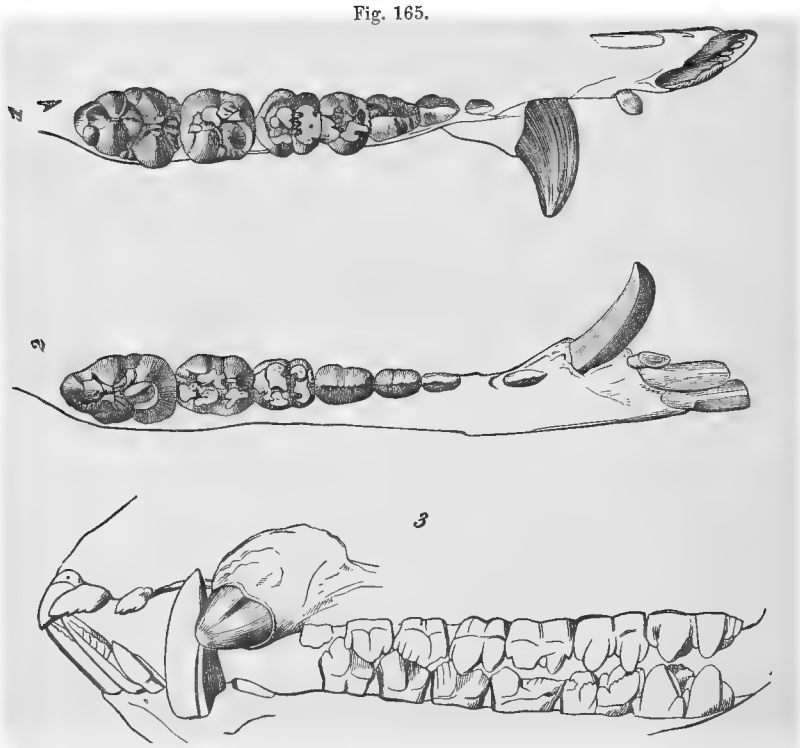

THE TEETH OF THE PIG.

1, Upper teeth, table surface; 2, Lower teeth, table aspect; 3, Lateral view of the jaws.

thirds of the tongue are covered by a very strong horny sheath, whose point is directed backwards. In the *Dog* these papillæ are less developed, and there are observed, more particularly, a number of composite filiform papillæ whose divisions are very flexible. There also are found regularly disposed among these, white shining epithelial particles which correspond to the fungiform papillæ.

"At the base of the tongue of Carnivora, and within the anterior pillars of the soft palate, are two elongated bodies with rounded extremities and a bosselated slippery surface; these are veritable *amygdalæ*, formed by an agglomeration of closed follicles.

"5. *Soft Palate.*—In the *Dog* and *Cat*, the soft palate is very short, and the isthmus of the fauces wide. Consequently, these creatures breathe easily by the mouth, and expel matters by it from the stomach during vomiting. At its free border the soft palate shows a small prolongation, something like the uvula.

"6. *Teeth.*—The teeth of the *Dog* are forty-two in number: twelve incisors, four canines, and twenty-six molars.

"The incisors, six in each side of the jaws, are more developed in the superior than in the inferior maxilla, and are divided, as in the Horse, into pincers, intermediates, and corner incisors; the last being much stronger than the preceding, and these again stronger than the pincers.

"Their free part presents, in the virgin tooth, three tubercles: a middle, which is the strongest, and two lateral; these, together, are not unlike a trefoil or the upper part of a *fleur-de-lis*, especially those in the upper jaw. On the internal face is remarked a table or slope, somewhat resembling that of the Ox and Sheep, and separated from the root by a very distinct border whose extremities mark the lateral lobes. This table is of no advantage in ascertaining the age.

"The root, very developed, flattened on both sides, and separated from the free

Fig. 166.

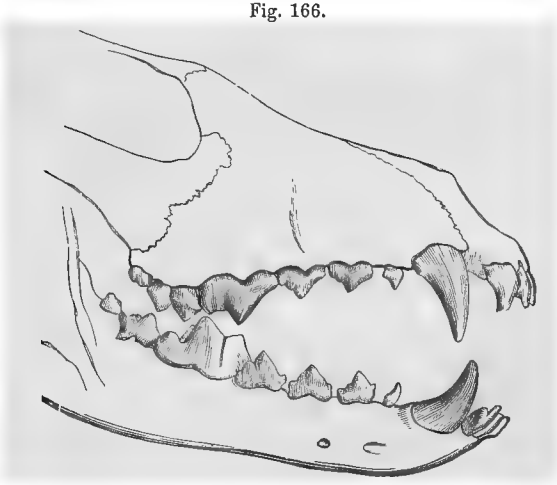

GENERAL AND LATERAL VIEW OF THE DOG'S TEETH.

portion by a well-defined neck, is solidly encased in a deep alveolus. Its internal cavity is very promptly obliterated.

"When the tooth is submitted to wear, the middle lobe is the first to disappear; so that it no longer resembles a trefoil (fig. 167).

"The caducous incisors are much smaller and more pointed than the permanent ones; yet, like them, they show lateral lobes. At the period of their eruption these teeth are somewhat widely apart.

"The fangs, or canine teeth, two in each jaw, are very strong, elongated organs, conical in form, curved backwards and outwards, and placed immediately after the incisors.

"The upper fangs are the thickest, and have a small space between them and the corner incisors, in which the inferior canines are lodged.

"These teeth are deciduous, like the incisors, and are distinguished from the replacing ones by their being thinner and more elongated.

"They are worn more or less quickly, according to the kind of food the animal obtains, and are sometimes broken in fighting.

Fig. 167.

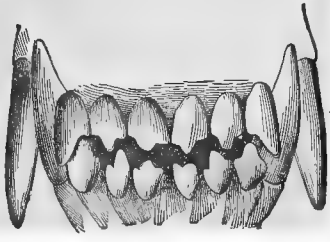

ANTERIOR VIEW OF THE INCISORS AND CANINE TEETH IN A YEAR-OLD DOG.

"The molars are distributed in the two jaws, twelve being fixed in the upper and fourteen in the lower. Nearly all of them are terminated by somewhat acute lobes, proper for tearing animal food. The strongest in each jaw is, for the upper, the first back-molar or fourth in the row, and in the lower, the fifth. All in front of these are deciduous."

After their complete eruption from the alveolar cavities, the Dog's teeth are no longer pushed outwards. They are remarkable for their brilliant whiteness, which they owe to the absence of cement on their covering of enamel.

The *Cat* has thirty teeth: twelve incisors, four tusks, and fourteen molars, eight of which are in the upper, and six in the lower jaw.

All these teeth are constructed on the same type as those of the Dog. The tusks are deeply striated on their external surface, instead of being smooth.

(The importance of a correct knowledge of the period of eruption, shedding, replacing, and general wear of the teeth of the domesticated animals, as a guide to their age, induces me to give the table on page 363 (from Leyh), as indicating at a glance the age at which the teeth appear, are shed, and replaced in the different creatures:

Baumeister divides the successive evolutions in the wear of the tables of the Horse's incisor teeth into four periods—from six years to extreme old age. The first, the transversely-oval period, extends from six to twelve years; the round, from twelve to eighteen years; the triangular, from eighteen to twenty-four years, and the antero-posterior oval or triangular, from twenty-four years and upwards. Girard and other French authorities shorten these periods somewhat. The triangular period, for instance, only lasts from fourteen to seventeen years.)

COMPARISON OF THE MOUTH OF MAN WITH THAT OF ANIMALS.

The brevity of *Man's* face influences the shape of the mouth; therefore it is proportionally shorter and wider than in the domesticated mammals.

Fig. 168.

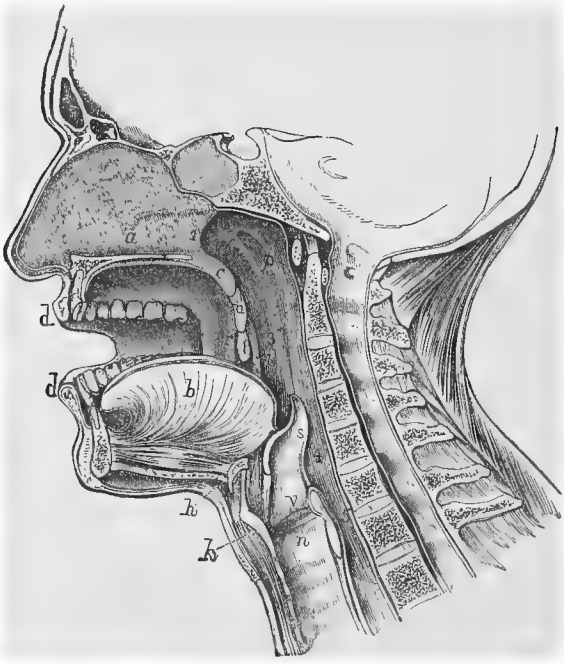

MEDIAN ANTERO-POSTERIOR SECTION OF THE HUMAN FACE.

a, Septum of nose, with section of hard palate below it; *b*, Tongue; *c*, Section of soft palate; *d*, *d*, Lips; *u*, Uvula; *r*, Anterior arch, or pillar of fauces; *i*, Posterior arch; *t*, Tonsil; *p*, Pharynx; *h*, Hyoid bone; *k*, Thyroid cartilage, *n*, Cricoid cartilage; *s*, Epiglottis; *v*, Glottis; 1, Posterior opening of nares; 3, Isthmus faucium; 4, Superior opening of larynx; 5, Passage into œsophagus; 6, Orifice of right Eustachian tube.

Teeth.	Horse.		Ruminants.		Pig.		Dog.	
	Eruption.	Replacement.	Eruption.	Replacement.	Eruption.	Replacement.	Eruption.	Replacement.
I. INCISOR TEETH.								
Pincers . . .	Before, or some days after birth	2½ years .	Before, or some days after birth	1½ years .	3 to 4 months	2½ to 3 years	4 to 6 weeks .	3 to 4 months.
First Intermediates	4 to 6 weeks .	3½ years .	*Idem* . .	2½ years .	*Idem* . . .	*Idem* . . .	*Idem* . .	*Idem.*
Second Intermediates	. .	. .	14 days . .	3½ years	. .	. .	.	. .
Corners . . .	6 to 9 months	4½ years .	2 to 3 weeks .	4½ years .	Before, or some days after birth	6 months . .	*Idem* . .	5 months.
II. CANINE TEETH.								
Canine Teeth .	6 months . .	4 to 5 years	. .	. .	*Idem* . . .	1 year . .	*Idem* . . .	5 to 6 months.
III. MOLAR TEETH.								
First	Before, or some days after birth	2½ years .	Before, or some days after birth	1½ years .	Before, or some days after birth	. .	3 to 4 months	. .
Second . . .	*Idem* . . .	*Idem* . .	*Idem* . . .	2½ years .	*Idem* . . .	2 years . .	4 to 5 weeks .	5 to 6 months.
Third . . .	*Idem* . . .	3½ years .	*Idem* . . .	3½ years .	*Idem* . . .	2 years .	*Idem* . . .	*Idem.*
Fourth . .	10 to 12 months	. .	6 to 9 months	. .	5 to 6 months	*Idem* . . .	*Idem* . . .	*Idem.*
Fifth	2 to 2½ years.	. .	2½ years . .	. .	1 year . .	. .	4 to 5 months	. .
Sixth. . .	4 to 5 years .	. .	4 to 5 years .	. .	1½ to 2 years.		5 to 6 months	. .
Seventh . . .	. .	.	. .	. .	3 years .	. .	5½ to 6½ months	. .
NUMBER OF TEETH.								
Males . . .	40		. .		. .		(Dog	42)
Females . . .	36		32		44		(Cat	30)

1. *Lips.*—The lips have a thick, free, everted border. They are lined by a rosy mucous membrane, which is insensibly continued inwards by the buccal membrane. The upper lip is limited by the nose and the naso-labial furrow; the lower is limited by the mento-labial groove. The first has in its middle the *subnasal furrow.* Their structure is analogous to those of animals.

2. *Cheeks.*—The cheeks are limited by the inferior border of the maxilla, the root of the ear, the prominence of the chin, and the naso-labial furrow. Between the skin and the mucous membrane, there is found, as in brutes, a glandular layer and muscles, chiefly the buccinator. An adipose ball is always found near the anterior border of the masseter.

3. *Palate.*—It does not possess a vascular membrane, as in the Horse, and its mucous membrane shows a longitudinal and transverse furrows in its anterior two-thirds. It is pale and resisting.

4. *Tongue.*—This is thick, short, and broad; its base is almost vertical, and in the middle is a perpendicular, fibrous, and semilunar lamina, the *lingual septum* which gives insertion to muscular fibres.

Anthropotomists distinguish intrinsic and extrinsic muscles. The first are: the lingualis superior and inferior, transversus, and longitudinalis. The second are, as in Solipeds, the stylo-glossus, genio-glossus, hyo-glossus, and pharyngo-glossus. There is also described a palato-glossus, which partly belongs to the soft palate.

The mucous membrane shows the different characters recognised in that of animals. That of the dorsal face is divided into two portions by two A-shaped rows of papillæ, whose summit abuts on the deep mucous follicle named the *foramen cæcum.* The posterior portion presents depressions which correspond to the closed follicles, and the fungiform and calyciform papillæ; the anterior portion has a villous aspect, due to the great number of filiform papillæ covering it.

5. *Soft Palate.*—In Man, the soft palate is short and divided into two portions: an *anterior*, horizontal, attached to the base of the tongue by the anterior pillars of the curtain; a *posterior*, movable and oblique, having a free portion, the *uvula*, and fixed to the lateral walls of the pharynx by the posterior pillars. The *amygdalæ*, or mass of closed follicles, are lodged in the triangular space between the anterior and posterior pillars. The fibrous structure is not present, unless the small expansion of the external tensor of the palate represents it. The muscles are the same as in animals, and, in addition, there are described two palato-glossal muscles, included between the mucous folds that form the anterior pillars. The palato-pharyngeus extends to the posterior nasal spine. The isthmus of the fauces is wider than in the Carnivora.

6. *Teeth.*—The teeth are thirty-two in number, sixteen in each jaw. They are distributed in the following manner: four incisors, two canines, two small molars (*bicuspidati*), and three large molars (*multi-cuspidati*).

The incisors, when viewed in profile or longitudinal section, have a wedge-shape, and their free border is more or less sharp. The canines are irregularly conical; the molars have a multiple fang, and the crown is studded with a variable number of tubercles: two on each small molar and four on the large. In youth, there are only twenty teeth, ten in each jaw.

THE SALIVARY GLANDS.

The *salivary glands* are secretory organs annexed to the buccal cavity, into which they pour saliva: a recrementitious fluid that softens the food, favours its mastication and deglutition, and has a chemical action upon it after its arrival in the abdominal portion of the digestive canal.

Though very diversified in form, yet they present in their structure such common characters, that, to obviate a recurrence to their organisation when speaking of each gland, we will describe it here.

The *salivary glands* are constituted by a red or yellow spongy tissue, which is divided into small, rounded, or polyhedral masses, called *salivary lobules.* These extend in a layer beneath the adherent face of the mucous membrane, and remain isolated from each other, or are agglomerated in a body to form a single gland. In the latter case they are united by condensed connective tissue, which is disposed over the surface of the organ as a very thin enveloping membrane, and into the lobular interstices in lamellar prolongations.

In studying the organisation of one of these lobules, it will be observed that it is made up of many very small secondary lobules or *acini*, which are themselves due to the agglomeration of minute elementary vesicles or follicles, whose average diameter is from 1–500th to 1–1200th of an inch; these open into the little canal belonging to each of the secondary lobules, and which again joins those of the other acini of the primary lobule, to form a single duct.

The minute elementary vesicles or follicles, the *glandular culs-de-sac* (or *ultimate follicles*) consist of a thin amorphous membrane (*membrana propria*), lined by a layer of polygonal epithelium cells. (They are closely surrounded by a plexus of capillary blood-vessels).

When the salivary lobules remain isolated, this canal, which is designated as *excretory*, because it carries from the lobule the saliva secreted within the elementary follicles, opens directly into the mouth. But when, on the contrary, they all unite and form a single gland, their excretory canals finally converge into one or more principal ducts, whose termination in every case takes place in the same manner—by opening into the mouth from the summit of a more or less salient tubercle, an arrangement which

Fig. 169.

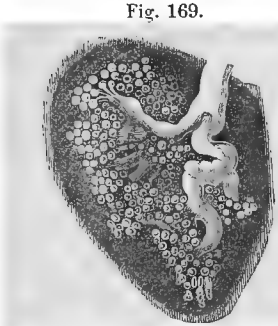

LOBULE OF PAROTID GLAND, INJECTED WITH MERCURY, AND MAGNIFIED 50 DIAMETERS.

Fig. 170.

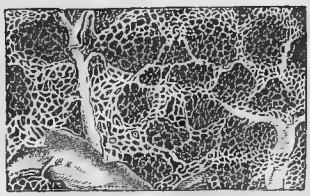

CAPILLARY NETWORK AROUND THE FOLLICLES OF THE PAROTID GLAND.

renders the introduction of particles of food into these excretory orifices somewhat difficult. The fibrous and elastic walls of these ducts are lined internally by columnar epithelium.

If to the fundamental tissue just described, be added *arteries*, *veins*, and *lymphatics*, which convey the materials of secretion and nutrition, as well as the *nerves* which regulate the secretory and nutritive acts, all the elements entering into the organisation of the salivary glands are made known.

The most voluminous of these glands—or those which comprise a very great number of agglomerated lobules, will be first noticed. They are the *parotid*, *maxillary*, *sublingual*, and *molar glands*, which are all pairs, and are placed in proximity to the mouth when they do not lie immediately beneath the adherent face of its mucous membrane. Secondly, the less important glands—those which are spread in layers under that membrane, and including the *labial*, *lingual*, and *palatine glands*, will be examined.

1. *Parotid Gland.* (Figs. 110; 172, 8).

Preparation.—This gland, with its excretory canal, is seen after the removal of the cervico-facial subcutaneous and parotido-auricularis muscles.

The *parotid gland* is situated in the space included between the posterior

border of the inferior maxilla and the transverse process of the atlas. It is elongated from above to below, flattened on both sides, and divided into two faces, two borders, and two extremities.

The *external face*, nearly plane, is hollowed in its inferior part into a longitudinal channel, which is sometimes transformed into a complete canal, and lodges the jugular vein after it has traversed the gland from below to its superficies. This *external face* responds to the parotido-auricularis muscle, the subcutaneous muscle, the atloidean loop, a cervical ramification of the facial nerve, and the posterior auricular vein. The *internal face* is very uneven and moulded on the subjacent parts. It covers the guttural pouch, the mastoid insertion of the small oblique muscle of the head, levator humeri, stylo-hyoideus, the tuberosity on the posterior border of the os hyoides, the digastricus, the tendon of the sterno-maxillaris, and the submaxillary gland, which is separated from it by the thin cellulo-aponeurotic layer uniting the latter muscle to the levator humeri; also to

Fig. 171

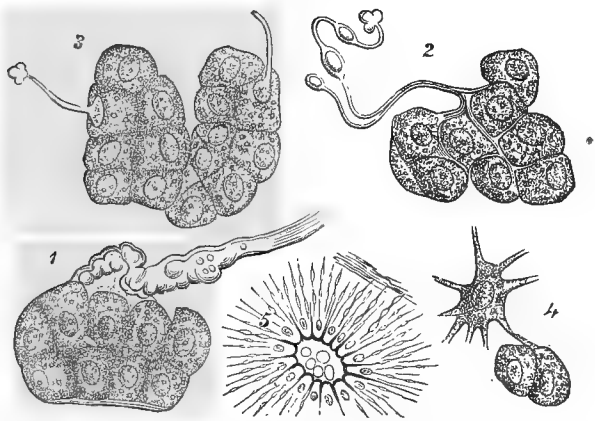

MODES OF TERMINATION OF THE NERVES IN THE SALIVARY GLANDS.

1, 2, Branching of the nerves between the salivary cells; 3, Termination of the nerve in the nucleus; 4, Union of a ganglion cell with a salivary cell; 5, Varicose nerve-fibres entering the cylindrical cells of the excretory ducts.

the external carotid artery and its two terminal branches, the posterior auricularis, the muscles of the jaw, and, lastly, the facial nerve, which often passes through the substance of the gland.

The *anterior border* of the gland is intimately united to the posterior border of the maxilla; it is related to the temporo-maxillary articulation, the subzygomatic vessels and nerves, and the maxillo-muscular vessels. The *posterior border* is thicker than the preceding, and is separated from the transverse process of the atlas by the terminal aponeurosis of the levator humeri, to which it is only feebly adherent: it can also be easily separated from it, in order to raise the parotid and pass through the stylo-hyoideus muscle, in the operation of hyo-vertebrotomy.

The *superior extremity* is bifurcated, and embraces the base of the concha of the ear. The *inferior extremity* is comprised in the angle formed by the union of the jugular and glosso-facial veins.

Vessels and nerves of the parotid gland.—This gland receives its blood by a multitude of *arterial* branches from the large vessels it covers. Its *nerves* are very numerous, and are derived from the facial and inferior maxillary nerves, and the carotid plexus.

Excretory canal.—The parotid gland is provided with a single excretory canal, the *duct of Stenon,* so named from the anatomist who gave the first good description of it. It is detached from the anterior border of the gland, near its inferior extremity, where the eye may readily follow it between the lobules to the three or four principal branches from which it originates (Fig. 172). At first in contact with the terminal tendon of the sterno-maxillaris, it afterwards turns round the posterior border of the digastric muscle (stylo-maxillaris portion), advances into the submaxillary space, creeps over the internal masseter muscle (pterygoid), beneath the glosso-facial vein, and arrives at the maxillary fissure, into which it enters with the aforesaid vein and corresponding artery, but behind both. It then ascends externally along the anterior border of the masseter muscle to the level of the inferior molars, when it passes beneath its two satellite vessels, obliquely crosses their direction, and pierces the cheek towards the third upper molar tooth, opening into the mouth by a large tubercle.

Fig. 172

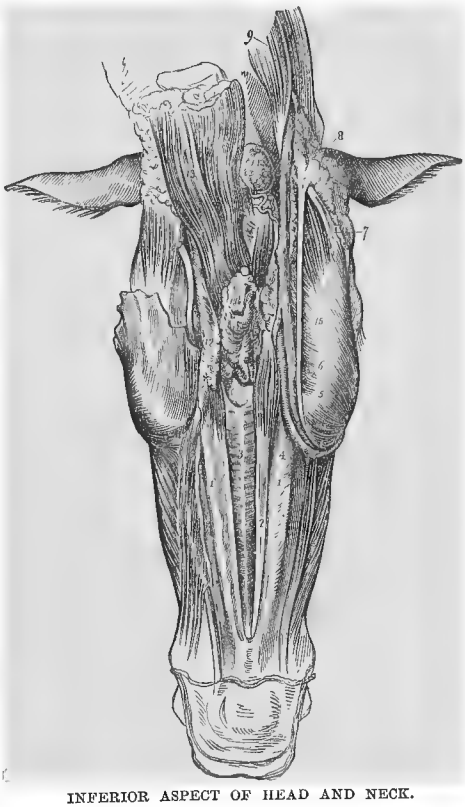

INFERIOR ASPECT OF HEAD AND NECK.

1, Inferior border of lower jaw; 2, Genio-hyoideus; 3, Mylo-hyoideus; 4, Submaxillary artery; 5, Ditto vein; 6, Parotid duct; 7, Sterno-maxillaris tendon; 8, Parotid gland; 9, Sterno-maxillaris muscle; 10, 11, 12, Submaxillary glands; 13, Sterno-thyro-hyoideus and subscapulo-hyoideus muscles; 14, Thyroid gland; 15, Pterygoideus internus.

The parotid duct is composed of two membranes: the internal, mucous, with columnar epithelium; and the external, made up of connective tissue, and circular and longitudinal elastic fibres.

2. *Maxillary or Submaxillary Gland.* (Figs. 172, 173.)

Preparation.—To expose this gland, as well as the sublingual, divide the maxilla, as in preparing the muscles of the tongue for dissection (see p. 334).

This gland, smaller than the preceding, is situated in the intermaxillary space, on the lateral plane of the larynx, and within the parotid gland.

It is long and narrow, flattened on both sides, and describes a slight curve with the concavity turned upwards: a form which allows it to be studied, with regard to relations, on two faces, two borders, and two extremities.

By its *external face*, it responds to the internal pterygoid muscle, the digastricus, the sterno-maxillaris tendon, and the cellulo-aponeurotic layer separating it from the parotid. Its internal face, applied to the side of the larynx, responds, superiorly, to the guttural pouch, to the carotid artery, and to the nerves which accompany that vessel in the upper part of the neck.

The *superior border*, thin and concave, is margined by the middle part of the digastricus. The *inferior*, thick and concave, is in contact with the glosso-facial vein.

The *posterior extremity* is maintained beneath the transverse process of

Fig. 173.

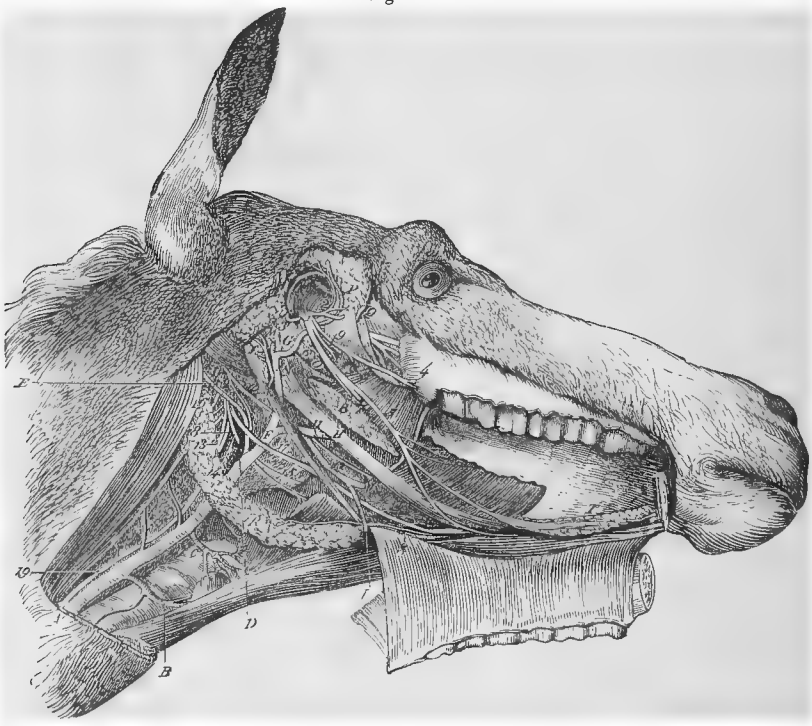

MAXILLARY AND SUBLINGUAL GLANDS.
R, Maxillary gland; S, Wharton's duct; T, Sublingual gland.

the atlas, by an extremely loose and abundant cellular tissue; the *anterior* is insinuated between the internal pterygoid and the thyro-hyoideus muscle.

Vessels and nerves.—The blood is distributed to the maxillary gland by various small innominate *arteries*, like those of the parotid gland, and which are most frequently derived from the external carotid and the glosso-facial. The *nerves* are principally furnished by the *carotid plexus*.

Excretory Canal.—Wharton's duct, as it is termed, is long and narrow; has very attenuated walls, and exists for nearly the whole length of the superior border of the gland: sometimes on its internal face, where it receives the ramifications from various lobules. At the anterior extremity of the organ it becomes free, and passes forward between the mylo-hyoideus and basio- (hyo-) glossus muscles. After crossing, outwardly, the glosso-facial artery and great hypoglossal nerve, and, inwardly, the tendon of the digastricus and the lingual nerve, it passes between the hyo-glossus longus and the sublingual gland, lying closely to the inner side of the latter; thus it extends parallel to the lateral groove (or channel) of the lingual canal (on the floor of the mouth). It finally arrives near the frænum of the tongue, but underneath the buccal membrane, and opens into the mouth by a small, but very salient, floating tubercle, situated a little in advance of the frænum, and vulgarly named the *barb* (*barbillon*).

The structure of Wharton's duct is identical with that of Stenon, but its external tunic is extremely thin, and has not any circular elastic fibres.

3. *Sublingual Gland.* (Fig. 173.)

This is less in volume than the preceding, and is situated under the tongue, in the intermaxillary space.

Elongated from before to behind, and very flat laterally, it has, like the submaxillary gland, two faces, two borders, and two extremities, whose relations we will briefly indicate.

The *external face* is covered by the mylo-hyoideus muscle; the *internal* responds to Wharton's duct and the genio-glossus and hyo-glossus longus muscles. The *upper border* projects beneath the mucous membrane on the floor of the mouth, where it forms the *sublingual ridge;* the *inferior*, thin and sharp, is comprised between the mylo-hyoideus and the genio-glossus muscles. The *two extremities* are thin and tapering; the *posterior* contains a branch of the lingual nerve; the *anterior* extends to the bottom of the angle formed by the union of the two branches of the inferior maxilla.

Vessels and nerves.—This gland possesses a special, but small *artery*—the *sublingual*. Its nerves come from the *lingual* nerve, and even from the *carotid plexus.*

Excretory canals.—These number fifteen or twenty, and are named the *ductus Riviniani.* Flexuous and very slender, they are detached from the superior border or internal face of the gland, ascend perpendicularly, and open into the mouth on the sublingual crest or ridge by a linear series of small orifices pierced, as usual, in the centre of a tubercle.

4. *Molar Glands.*

These are so named because they are disposed parallel to the molar arches. There are two on each side.

The *superior molar gland*, the most considerable, represents a narrow line of salivary lobules placed outside, and along the upper border of, the alveolo-labialis muscle. In its posterior part, where it is concealed beneath the masseter muscle, this gland is thicker and more compact than in front, where the few lobules which compose it scarcely come in contact with each other.

The *inferior molar gland*, less lobulated and voluminous, and not so wide as the preceding, is placed at the inferior border of the buccinator, immediately beneath the mucous membrane of the mouth, and near the

point where it is reflected from the side of the cheek on to the inferior maxillary bone. It is bordered, for the whole of its extent, by the buccal nerve.

Both glands pour their secretion into the mouth by numerous salient orifices, which can be seen arranged in line on the buccal membrane, parallel to each molar arcade.

It may be remarked that these glands establish a transition between the preceding and those yet to be mentioned. Their lobules are far from representing so compact an agglomeration as that formed by the parotid or sublingual lobules; and they tend to separate from each other to become more independent. Therefore it is that many writers regard them as distinct, and describe them as *superior* and *inferior molar glands.*

5. *Labial, Lingual, and Palatine Glands.*

The lobules composing these glands are spread in layers more or less thick on the inner face of the mucous membrane, instead of being agglomerated in masses, as in the previous glands. Sometimes they are scattered, in consequence of their small number. In general, the excretory duct of each glandule opens independently into the mouth, without communicating with those of the neighbouring lobules.

Labial Glandulæ.—These are more abundant in the upper than in the lower lip, and pass beyond the commissures to be spread for a short distance over the inner aspect of the cheeks. It is easy, in the living Horse, after turning up the lip and carefully wiping it, to see the salivary fluid secreted by these small organs escape by their excretory ducts.

Lingual Glandulæ.—They form a layer under the mucous membrane at the base of the tongue, and adhere very closely to the fibres of the small hyo-glossus muscle, and, laterally, are continuous with the layer which covers the external face of the amygdaloid mucous membrane. They are also found on the side of the tongue, above the superior border of the hyo-glossus longus muscle; though these are few and scattered, and look as if incrusted in the substance of the hyo-glossus muscle.

Staphyline (or Palatine) glandulæ.—The thick layer these form under the anterior mucous covering of the soft palate has been described with that organ. We have only to observe here, that it is continuous, laterally, with the glands at the base of the tongue, through the medium of the glandulæ of the amygdaloid cavity; and in such a manner, that the part of the mouth immediately in front of the isthmus of the fauces, and which might be justly considered as the isthmus itself, is enveloped in a complete glandular zone. In the dead body, we always find in this compartment a greater or less quantity of viscid fluid, which is certainly secreted by this zone. It is here, then, that the alimentary bolus is enveloped in the glutinous matters intended to favour its passage in the pharynx and œsophagus; and it is worthy of notice that the constricted passage where this secretion is poured out in the living animal, immediately precedes the canal traversed by the bolus of food in the act of deglutition.

DIFFERENTIAL CHARACTERS IN THE SALIVARY GLANDS OF OTHER THAN SOLIPED ANIMALS.

The salivary system of the Herbivora is more extensive than that of the Omnivora, and especially the Carnivora.

RUMINANTS.—1. *Parotid gland.*—The parotid glands of the *Ox* are distinguished by

their meagre development and red colour, which contrasts markedly with the pale yellow hue of the maxillary glands. In the *Sheep* and *Goat*, Stenon's duct passes through the masseter muscle. (In the *Ox*, this gland offers, at the upper part of its anterior border, a round lobe lying on the masseter. Stenon's duct opens into the mouth at the fifth molar. It terminates in the *Sheep* and *Goat* at the fourth molar.)

2. *Maxillary gland.*—In the *Ox* this gland is much thicker than in Solipeds, its volume being in inverse relation to that of the parotid. In its posterior moiety it enlarges into an oval lobe which, below the larynx, lies against that of the opposite side. Wharton's duct follows the same course as in the Horse; the papilla through which it opens is hard, resisting, and notched, and is lodged in an elliptical fossette near the incisors.

3. *Sublingual gland.*—In the *Ox*, *Sheep*, and *Goat*, this gland comprises two portions: a posterior, somewhat voluminous and lobulated, provided with a special excretory duct which follows and opens near Wharton's duct (by the *ductus Bartholinianus*); and an anterior, pouring out its secretion by many canals, and representing the gland proper. This arrangement allows the saliva to be collected separately from this gland.

4. *Molar glands.*—These are more developed in *Ruminants* than in Solipeds. The upper one is enlarged at its posterior extremity.

Pig.—*The parotid gland* of this animal is little developed, as in Ruminants, and Stenon's duct follows the posterior border of the lower jaw. (Leyh says that it is, proportionately, largely developed; that its upper end does not reach the conch of the ear, and that Stenon's duct opens at the sixth molar.)

The *sublingual gland* is analogous in its disposition to that of the Ox. Cuvier, in his 'Leçons d'Anatomie Comparée,' indicates this:—"The *Pig* has two sublingual glands. One, very long and narrow, accompanies, outwardly, the excretory canal of the submaxillary gland, from the angle of the jaw to the second sublingual. It is composed of small lobules of a pale red colour. Its excretory duct arises near the posterior third, and passes along with, but to the outside of, the submaxillary duct. It terminates near the orifice of the latter by a small opening; its diameter is equally small. The second sublingual gland is placed before the first; its form is square and flattened, and the lobes of which it is composed are larger and redder. It has from eight to ten excretory ducts." (In this animal the duct of Wharton does not open into the mouth by a papilla; consequently there is no *barb.*)

Carnivora.—The parotid of the *Dog* and *Cat* is small, and Stenon's duct always passes through the masseter. (It opens at the fourth molar in the Dog, and the third in the Cat.)

In the *Dog* the *submaxillary* glands are larger than the parotids. "They even have in front, along Wharton's duct, a small accessory gland, with a distinct excretory canal opening into the same papilla as Wharton's." (Leyh states that the submaxillary duct does not project into the mouth). The supplementary gland is absent in the *Cat.*

The *sublingual gland* is not present in the *Dog*; it is very small in the *Cat*, and carried further back than in the other animals. (Leyh describes a sublingual gland as present in the Carnivora, and which is divided into two portions, as in the Pig: the anterior being formed of detached lobules that open into the mouth by several ducts; and the posterior, larger above than below, with two ducts, the smaller opening into Wharton's duct, and the larger a little in front of it.)

The *upper molar gland* of the *Dog*, scarcely noticeable for the greater part of its extent, forms posteriorly, under the zygomatic arch, near the eye, an independent lobe, remarkable for its large size and its single excretory duct. Duvernoy who first described it, proposed to name itthe *subzygomatic gland.* It is not present in the *Cat.* (This is doubtless the organ described by Leyh as the *orbital gland*, which, he says, is only found in the Dog; the superior molar gland, according to him, not existing in that animal. This orbital gland is external to the ocular muscles, has three or four excretory canals (the *ductus Nuckiani*) which converge into one duct that opens into the mouth above the last molar.)

The *labial*, *lingual*, and *palatine glandulæ* are much less developed in the Carnivora than the Herbivora. This predominance of the salivary system in the latter is sufficiently accounted for, when we consider the hard, fibrous, and coriaceous food these animals live upon, and which must be ingested in large quantity, because of the small amount of nutrition it contains. For its mastication and deglutition a great amount of saliva is absolutely necessary.

COMPARISON OF THE SALIVARY GLANDS OF MAN WITH THOSE OF ANIMALS.

As in animals, the *parotid* is the most voluminous of the salivary glands. Its tissue is reddish-grey and lobulated, the lobules adhering closely to each other. Its shape is irregular, and it is moulded to the excavation behind the angle of the jaw. Stenon's duct passes across the masseter, and shows on its course some salivary lobules, forming what is named the *accessory parotid* (or *socia parotidis*); it opens opposite the third upper molar.

The *submaxillary gland* weighs about half-an-ounce. It is partly situated beneath the deep cervical fascia, and partly within the body of the lower jaw, between the mylo-hyoideus and hyo-glossus muscles. Its lobules are more loosely united than those of the parotid. *Wharton's duct* opens on the sides of the frænum linguæ by a small opening at the apex of a round papilla (*caruncula sublingualis*).

The *sublingual gland* is analogous to that of the Ox and Pig. There are, in fact, two sublinguals; an anterior about the size of an almond, and furnished with a single excretory canal—the *ductus Bartholini*, that terminates near Wharton's duct; the other, posterior, formed by several isolated lobules with multiple excretory ducts, the *ductus Riviniani*.

There are also labial, palatine, and lingual glands; with, besides, near the frænum, a small conglomerate gland, the *gland of Nuhn*, which has a special duct.

Fig. 174.

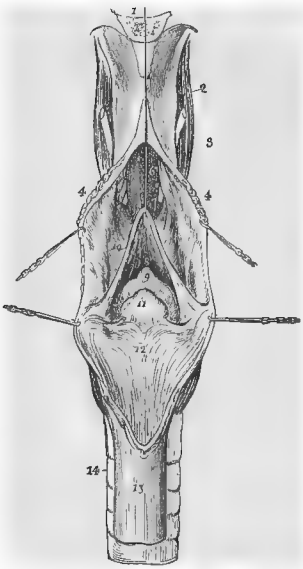

PHARYNGEAL AND LARYNGEAL REGION; THE POSTERIOR PART OF THE HEAD INCISED AND THROWN FORWARD.

1, Base of the cranium; 2, Roof of the pharynx; 3, Muscles of the cheek; 4, 4, Walls of the pharynx; 6, Septum nasi; 7, Posterior openings of nostrils; 8, Entrance to the mouth; 9, Epiglottis; 10, Posterior pillars of soft palate; 11, Arytenoid cartilages; 12, Opening of the œsophagus; 13, Œsophagus; 14, Trachea.

THE PHARYNX. (Figs. 174, 175.)

Preparation.—1. Study the general disposition and situation of this vestibule in the antero-posterior vertical section of the head (fig. 175). 2. In order to examine the interior conveniently, the head should be separated from the neck, leaving attached to it a certain portion of the trachea and œsophagus; then by sawing across, either through or behind the temporo-maxillary articulations, all that portion of the cranium is removed, and the posterior parietes of the pharynx is exposed, and may be dissected to study the muscles (Fig. 178), or opened in the middle line to reach the interior of the cavity (Fig. 174). 3. The muscles should be dissected with those of the tongue, and in the same manner.

The *pharynx* is a membranous vestibule common to the digestive and air passages, and situated behind the soft palate, which separates it from the mouth; above, it is attached to the base of the cranium, and, below, to the laryngeal apparatus.

Form and internal disposition.—In consequence of the conformation of the soft palate, which, in the domesticated animals, and particularly in Solipeds, is prolonged to the base of the epiglottis, the pharynx forms a cylindrical cavity elongated from before to behind, enclosed laterally and posteriorly by wide thin muscles, and with the soft palate for an anterior wall. At the two extremities of this cavity are openings which allow the pharynx to communicate with the other passages or cavities, and whose disposition we will at once begin to study.

At the upper extremity of the large axis of the pharyngeal cavity is to be remarked: 1, In front, the two posterior

openings of the nasal cavities; 2, Behind, and directly opposite the preceding, the two pharyngeal openings of the Eustachian tubes, which are closed by a cartilaginous kind of clap-valve.[1]

At the inferior extremity of this axis is found: 1, In the centre, a vast gaping orifice projecting into the anterior of the pharyngeal cavity, like a tap into a cask: this is the *entrance to the larynx*, the salient portions of which form, on the walls of the pharynx, two lateral gutters limited superiorly by the posterior pillars of the soft palate; 2, In front of, and beneath this, is the *isthmus of the fauces;* Behind and above, the *œsophageal opening* at the bottom of an infundibulum, which may be considered as a special region of the pharynx.

These seven openings of the pharyngeal cavity give it the appearance of a cross road, into which abut different thoroughfares. It is necessary to note that the air and digestive passages intersect each other here, and in such a way that, during deglutition, the bolus of food passes over the entrance of the larynx to reach the œsophageal opening. This peculiarity is easily seen by referring to figure 175.

Fig. 175.

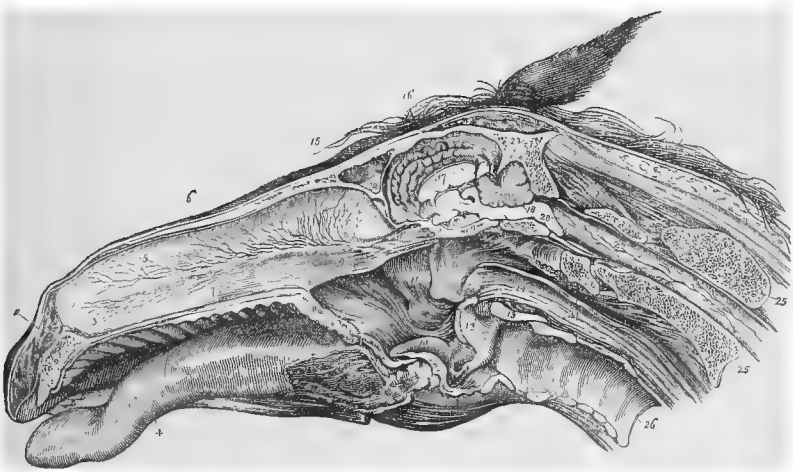

MEDIAN LONGITUDINAL SECTION OF HEAD AND UPPER PART OF NECK.

1, Upper lip; 2, Premaxilla; 3, Hard palate; 4, Tongue; 5, Septum nasi; 6, Nasal bone; 7, Palate bone; 8, Soft palate; 9, Pterygoid bone; 10, Epiglottis; 11, Entrance to Eustachian tube; 12, Arytenoid cartilage; 13, Cricoid cartilage; 14, Œsophagus; 15, Frontal bone and sinus; 16, Cerebrum; 17, Corpus callosum; 18, Cerebellum; 19, Sphenoid bone; 20, Medulla oblongata; 21, Cervical ligament; 22, Spinal cord; 23, Occipital bone; 24, 24, Atlas; 25, 25, Dentata; 26, Trachea.

Relations.—Viewed externally, for the study of its connections, it will be found that the pharynx responds, posteriorly, to the guttural pouches and guttural lymphatics; laterally, to the large branch of the os hyoides, the

[1] This region corresponds to the posterior nares (*arrière fond*) of Man, a diverticulum which cannot be distinguished from the pharynx in the domesticated animals. Under the designation of the *posterior nares of the nasal fossæ*, it will be understood that we mean the posterior extremities of these cavities.

(In the '*Annales de Médecine Vétérinaire*,' of Brussels, for 1871 (p. 244), M. Lorge describes a pharyngeal cæcum as existing in Solipeds, which he states corresponds to the naso-pharyngeal region, or posterior nares, of Man.)

internal pterygoid and stylo-hyoid muscles, the glosso-pharyngeal, great hypoglossal, and superior laryngeal nerves, and the glosso-facial artery.

STRUCTURE.—The walls of the pharynx are composed of a *mucous membrane*, external to which is a *muscular layer*.

1. *Mucous membrane.*—This membrane is covered, externally, by a thin layer of yellow elastic fibres, and is much more delicate and less protected by its epidermis than the buccal mucous membrane, of which it is a continuation; it also communicates with that of the œsophagus, the larynx, the nasal fossæ, and the Eustachian tubes.

Its *epithelium* is stratified throughout; but it is thin and *ciliated* in the upper part, thicker and tesselated on the inferior moiety, which more particularly belongs to the digestive apparatus.

Everywhere there are *racemose glands*, though they are most numerous towards the roof of the pharynx. There are also some *follicular glands* beneath the mucous membrane, in the neighbourhood of the guttural opening, the nasal cavities, and the Eustachian tubes.

2. *Muscular layer.*—This is composed of seven pairs of muscles, indicated in the following enumeration: the *palato-pharyngeus, pterygo-pharyngeus, hyo-pharyngeus, thyro-pharyngeus, crico-pharyngeus, aryteno-pharyngeus, stylo-pharyngeus.*

PALATO-PHARYNGEUS (*Pharyngo-staphylinus*).—This muscle, which has already been described as belonging to the soft palate, is prolonged backwards on the lateral wall of the pharynx, where its fibres are mixed with those of the pterygo-pharyngeus, and go to be attached to the superior border of the thyroid cartilage by passing beneath the hyo-pharyngeal and thyro-pharyngeal muscles. It therefore also belongs to the pharynx.

PTERYGO-PHARYNGEUS, OR SUPERIOR CONSTRICTOR (the *palato-pharyngeus* of *Percivall*).—This muscle is thin, wide, flat, and triangular. It originates from the pterygoid process, whence its fibres diverge, some posteriorly, others inwardly. The former mix with those of the palato-pharyngeus, and comport themselves like that muscle; and the latter are united, on the median line, with the analogous fibres of the opposite muscle, forming a kind of zone around the origin of the Eustachian tube. This muscle is covered, externally, by a layer of yellow elastic tissue, which is attached with it to the pterygoid bone; afterwards it is fixed to the superior border of the great branch of the os hyoides, and is even prolonged on the external surface of the muscle it covers to the thyroid cartilage.

The elasticity of this fibrous covering plays a certain part in the movements of the hyo-laryngeal apparatus, in acting as a passive antagonist of its depressors.

This muscle is, and can only be, a perfect constrictor of the pharynx, as it diminishes the diameter of that cavity in every direction: the longitudinal diameter, by means of its posterior fibres, which draw the thyroid cartilage forward; and its transverse diameter, by the circle thrown around the orifice of the Eustachian tubes (Figs. 149; 176, 8).

HYO-PHARYNGEUS, OR FIRST MIDDLE CONSTRICTOR; THYRO-PHARYNGEUS, OR SECOND MIDDLE CONSTRICTOR; AND CRICO-PHARYNGEUS, OR INFERIOR CONSTRICTOR.—The two first of these muscles only form one in Man, the *middle constrictor* of the pharynx. They are three muscular bands which terminate above the pharynx, on a median fibrous fold sometimes wide enough to look like an aponeurosis. The first band arises from the cornu of the os hyoides; the second, from the external surface of the thyroid cartilage; the third, from the superficial face of the cricoid cartilage.

These are universally regarded as constrictors.

Sometimes two fasciculi are observed in the crico-pharyngeus. The supplementary fasciculus is somewhat thin, and arises from the posterior border of the bezil of the cricoid cartilage, ascending parallel to the œsophagus to terminate with the principal fasciculus.

ARYTENO-PHARYNGEUS.—By this name has been described a small fasciculus, extremely thin in Solipeds, which extends from the posterior border of the arytenoid cartilage to the origin of the œsophagus. To expose this muscle, which we do not look upon as constant, it is necessary to turn the œsophagus forward on the superior surface of the pharynx.

STYLO-PHARYNGEUS.—A narrow band which descends from the great hyoideal branch to the side of the pharynx, where it is confounded with the pterygo-pharyngeus. It elevates the pharynx in contracting, and it is also regarded as a dilator; though the disposition of the parietes of the pharynx, and the feeble volume of this muscle, scarcely allows it to play any efficacious part in the dilatation of that cavity. It may only produce a very slight infundibulum where it is inserted. The real dilating agent of the pharyngeal cavity is the alimentary bolus, which is pushed into it by the action of the tongue (Fig. 149, 5).

Fig. 176.

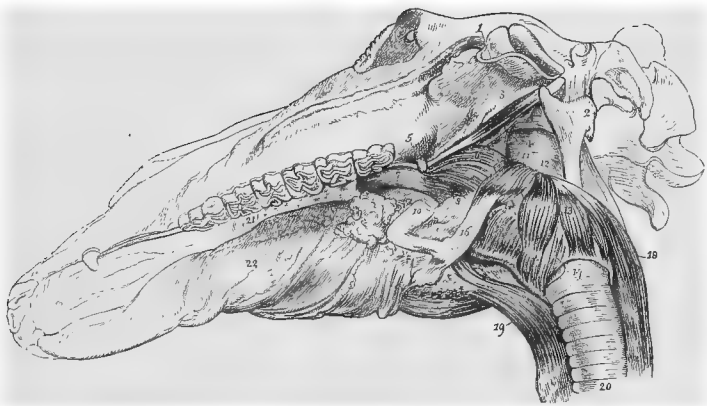

MUSCLES OF THE PHARYNGEAL AND HYOIDEAL REGIONS.

1, Glenoid cavity of temporal bone; 2, Superior extremity of styloid bone; 3, Tensor palati with its pulley, 5; 4, Stylo-pharyngeus; 6, Palato-pharyngeus; 7, Circumflexus palati; 8, Pterygo-pharyngeus; 9, Sublingual gland; 10, Portion of hyoid bone; 11, Hyo-pharyngeus; 12, Thyro-pharyngeus; 13, Crico-pharyngeus; 14, Portion of stylo-pharyngeus; 15, Hyo-thyroideus; 16, Styloid bone; 17, Crico-arytenoideus lateralis; 18, Œsophagus; 19, Sterno-maxillaris and hyoideus, and subscapulo hyoideus; 20, Trachea; 21, Hard palate; 22, Tongue.

It is not rare to meet a second *stylo-pharyngeus* muscle terminating on the same point as the first, but proceeding from the inferior extremity of the large branch of the os hyoides, instead of its upper part.

Certain anatomists designate it the inferior kerato-pharyngeus, and consider it as a constrictor of the pharynx. It sometimes exists only on one side.

3. *Vessels and nerves.*—The blood sent to the pharynx comes from the

pharyngeal and *thyroideal arteries.* The *nerves* are supplied by the *glosso-pharyngeus, pneumogastric,* and *great sympathetic.*

FUNCTIONS.—The pharynx plays a passive part in respiration, by serving as an intermediate canal between the nasal passages and the larynx.

Its principal function, however, is connected with the digestive phenomena, by its being an active agent in the first stage of deglutition—a complex and rapid movement, which is executed in the following manner: The bolus of food, propelled by the tongue into the pharynx, is seized by the constrictor muscles, which come into action successively from before to behind, in a peristaltic and involuntary manner, to carry the mass to the entrance of the œsophagus. The food thus passes over the opening of the larynx during pharyngeal deglutition, but it cannot enter it, because the bolus forces back the epiglottis on this aperture, which it almost exactly closes; because, also, the passage of the food prevents pulmonary inspiration, which might, if allowed to take place, divert it from its natural course, and throw it into the nasal air-passages; the application of the walls of the pharynx to the pellet of food during its momentary passage over the larynx, intercepts all communication between the external air and the lungs, and only permits the elevation of the ribs with the utmost difficulty. The extreme rapidity of the act of deglutition is another reason for the food escaping the larynx.

(Gray concisely remarks: When deglutition is about to be performed, the pharynx is drawn upwards and dilated in different directions to receive the morsel propelled into it from the mouth. The stylo-pharyngei, which are much further removed from one another at their origin than at their insertion, draw upwards and outwards the sides of this cavity, the breadth of the pharynx, in the antero-posterior direction, being increased by the larynx and tongue being carried forwards in their ascent. As soon as the morsel is received in the pharynx, the elevator muscles relax, the bag descends, and the constrictors contract upon the morsel and convey it gradually downwards into the œsophagus.)

The deglutition of liquids is carried on in a similar manner.

It is curious to remark that, in Solipeds, the food does not come into direct contact with the greater portion of the superior wall of the pharynx during its passage through that cavity. When the alimentary mass is carried back by the tongue, it raises the soft palate and bears its posterior border backwards to the entrance of the œsophagus. The extreme development of this palatine curtain, therefore, quite prevents this surface of the pharynx from being directly applied to the food, and it is through the medium of this partition that the constrictors exercise their peristaltic action on the morsel of aliment until it reaches the œsophageal infundibulum.

DIFFERENTIAL CHARACTERS OF THE PHARYNX IN OTHER THAN SOLIPED ANIMALS.

The pharynx of *Ruminants* is long and very spacious. The hyo-, thyro-, and crico-pharyngeal muscles—the first and second of the two middle constrictors, and the inferior constrictor—are less distinct from each other than in the Horse; the last-named muscle is very small, and the fibrous raphé on which the constrictors unite is little developed. In the pharynx of the *Sheep* is noticed a mucous duplicature that descends to the middle of the posterior wall, and appears to be a continuation, posteriorly and inferiorly, of the nasal septum.

In the *Pig*, the posterior part of the pharynx is narrow, and has a pouch immediately above the glottis, between the thyro- and crico-pharyngeal muscles.

In the *Dog*, the infundibulum is very spacious, and the pharyngeal mucous membrane, much finer than that of the œsophagus, is distinguished from it by a well-marked line of demarcation. The crico-pharyngeal is not very distinct from the thyro-pharyngeal muscle; so that, in reality, only three constrictors can be distinguished.

COMPARISON OF THE PHARYNX OF MAN WITH THAT OF ANIMALS.

In consequence of the smallness of the soft palate, the pharynx of *Man* is only a kind of channel between the mouth and the larynx and œsophagus. It is usually divided into three portions: a superior, the *posterior nares*, covered by ciliated epithelium; a middle, or *guttural*, and an inferior, or *œsophageal*; the two latter are covered with tesselated epithelium.

The muscles are almost the same as in the Dog, being a portion of the palato-pharyngeus, the superior, middle, and inferior constrictors, and a stylo-pharyngeal muscle.

Below the sides of the pharynx, and between the pillars of the soft palate, are the *amygdalæ*: almond-shaped organs, whose surface shows the openings of the follicles that, with the vessels and a little connective tissue, compose their substance.

THE ŒSOPHAGUS. (Figs. 178, 179.)

Preparation.—Place the subject in the first or second position; remove the subcutaneous cervical muscle from the left side; take away the corresponding anterior limb, and proceed to the excision of the ribs of this side, with the exception of the first. Afterwards dissect the vessels and nerves in the neighbourhood of the œsophageal canal, taking care to preserve their relations to each other.

Fig. 177.

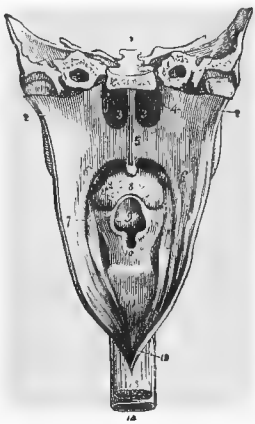

HUMAN PHARYNX LAID OPEN FROM BEHIND.

1, Section through base of skull; 2, 2, Walls of pharynx drawn aside; 3, 3, Posterior nares, separated by the vomer; 4, Extremity of one Eustachian tube; 5, Soft palate; 6, Posterior pillar of soft palate; 7, Anterior pillar; 8, Root of the tongue, partly concealed by the uvula; 9, Epiglottis overhanging (10) the cordiform opening of the larynx; 11, Posterior part of larynx; 12, Opening of œsophagus, 13; 14, Trachea.

Form.—The œsophagus is a long, cylindrical, narrow, membranous canal, easily dilated for the greater part of its extent, and destined to convey the food from the pharynx to the stomach, and to complete the act of deglutition.

Course.—This canal begins at the pharynx, and communicates with it by means of the posterior opening situated above the glottis. It afterwards descends behind the trachea to the middle of the neck, where it commences to deviate towards the left side of that tube, and enters the thoracic cavity by inclining towards the inner aspect of the first left rib. It soon after regains its situation above the trachea, passes over the base of the heart, and reaches the opening of the right pillar of the diaphragm, in passing between the two layers of the posterior mediastinum. Traversing this opening, it penetrates the abdominal cavity, and immediately afterwards is inserted into the smaller curvature of the stomach by an orifice designated the *cardiac*, which will be studied at the same time as that viscus.

Relations.—The œsophagus in its course has the following numerous relations:

At its origin, it is comprised between the guttural pouch and the posterior crico-arytenoid muscles.

In the cervical region, it is enveloped in a thick layer of cellular tissue, which unites it in a loose manner to the surrounding organs, its relations with these varying as we consider them superiorly or inferiorly. *Superiorly*, and in the median plane, it occupies the space included between the trachea and the longus-colli, being bordered on each side by the common carotid artery, with its satellite nerves—the

trunk common to the great sympathetic and pneumogastric, and the inferior laryngeal.

Inferiorly, it is related to the trachea internally; and, externally, to the inferior scalenus muscle, and the vessels and nerves of the left cervical channel, which also includes the jugular vein.[1]

At its entrance into the thoracic cavity, the œsophagus, still deviating to the left, and lying on the side of the trachea, responds, externally, to the inferior cervical ganglion, the afferent and emergent nervous branches of that ganglion, the vertebral arteries and veins, and the superior cervical and dorso-muscular vessels, which obliquely cross its direction. *Beyond this*

Fig. 178.

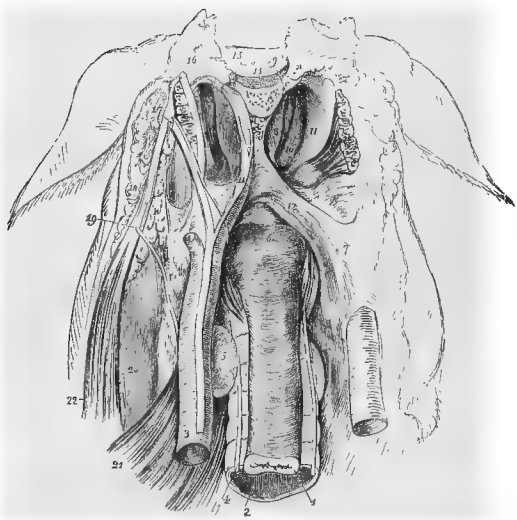

TRANSVERSE VERTICAL SECTION OF HEAD AND NECK IMMEDIATELY IN FRONT OF THE STYLOID PROCESSES, AND BEHIND THE ŒSOPHAGUS.

1, Œsophagus; 2, Inner surface of trachea; 3, Common carotid artery; 4, Recurrent nerve; 5, Thyroid gland; 6, Exterior of pharynx; 7, Crico-pharyngeal muscle; 8, 9, 10, 11, Guttural pouch and objects in its interior; 12, Stylo-pharyngeus muscle; 13, Sphenoid bone; 14, Jugular ganglia; 15, Internal carotid; 16, 17, Pneumogastric nerve; 18, Parotid gland; 19, Great hypoglossal nerve; 20, Jugular vein; 21, Subscapulo-hyoideus; 22, Stylo-maxillaris.

it regains its position between the trachea and the longus colli, passes above the left bronchus, to the right of the thoracic aorta, until it reaches between the layers of the posterior mediastinum, which bring it into relation with the internal face of the lungs; these are channeled for its reception, and here it is accompanied by the œsophageal artery, and the œsophageal branches of the pneumogastric nerve.

The *very short portion* lodged in the abdominal cavity responds, on the

[1] It is not rare to find the œsophagus deviate to the right below the neck; in this case its relations will be inverted. We have never seen this canal enter the thorax in the median plane of the body.

right, to a fissure in the superior border of the liver, and is enveloped by the peritoneum.

Interior.—Internally, the canal whose course and relations we have just studied presents nothing of interest; and it only requires to be remarked, that its walls are always shrunken and in contact when food is not passing between them.

STRUCTURE.—The œsophagus has two tunics: a *mucous* and a *muscular*.

The *mucous membrane* is continuous with that of the pharynx and the stomach; it is white, and shows numerous longitudinal folds which allow the canal to dilate. It adheres but loosely to the muscular coat, on which it can glide with the greatest facility. It has a thick, resisting, stratified, tesselated epithelium, an unstriped muscular layer, and some racemose glands.

Fig. 179.

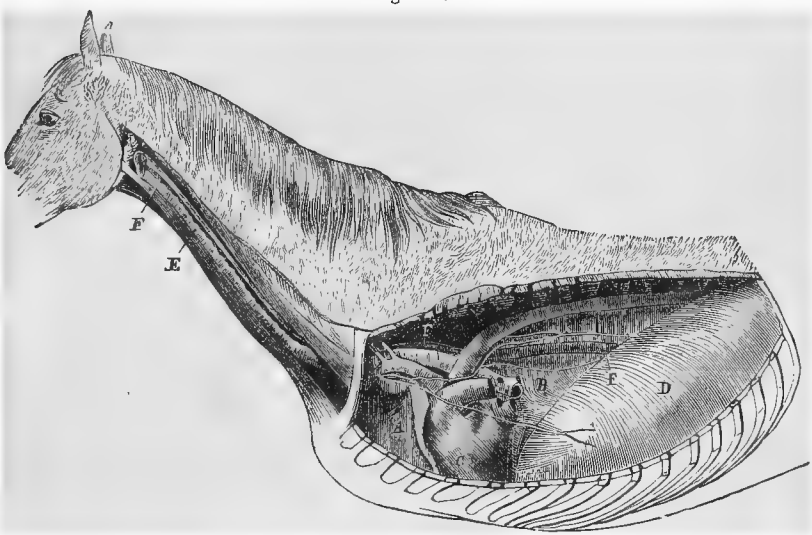

PECTORAL CAVITY AND MEDIASTINUM, SHOWING THE COURSE OF THE TRACHEÆ AND ŒSOPHAGUS.

(A *third* or *middle* coat is sometimes mentioned by anatomists; it is composed of the tissue connecting the latter tunic with the one to be next described.)

The *muscular coat* commences at the posterior part of the pharynx by the aryteno-pharyngei muscles, and by two small superficial bands which are detached from the posterior portion of the crico-pharyngei muscles. This tunic is formed of superficial longitudinal fibres, often assembled in fasciculi; and of a deeper series of spiral or circular fibres, which, towards the inferior extremity of the canal, intercross in an almost inextricable manner. This muscular layer in the cervical, and for a great part of the thoracic portion of the œsophagus, has the red colour of voluntary muscles; but it becomes white, like the involuntary fibres, after the conduit enters the mediastinum, and acquires considerable thickness and marked rigidity. It is to be noted that this arrangement of the muscular tunic is especially

evident towards the insertion of the œsophagus into the stomach, and that the muscular tube is at this point so narrow, that it is almost exactly filled by the folds of mucous membrane it contains. For this reason it is that we may inflate a stomach by the pylorus, without applying a ligature to the œsophagus; the aperture of the canal being so perfectly closed that it does not allow a bubble of air to escape. In describing the interior of the stomach, we will refer to the consequences resulting from this interesting anatomical fact.

Vessels and nerves.—The œsophagus is supplied with blood by the divisions given off by the common carotid artery, as well as the bronchial and œsophageal arteries. The nerves are almost exclusively derived from the pneumogastric; the motor nerves are the superior œsophageal filaments, branches of the external pharyngeal and laryngeal; the sensitive filaments are derived from the recurrent.

Functions.—This canal conveys nutriment from the pharynx to the stomach; it has no other uses.

DIFFERENTIAL CHARACTERS OF THE ŒSOPHAGUS IN OTHER THAN SOLIPED ANIMALS.

In all the other domesticated animals, the muscular coat is red-coloured throughout its whole extent, and everywhere offers the same degree of thickness and the same flaccidity, The canal is also as wide towards the stomach as at the pharynx. In *Ruminants* and the *Carnivora*, it enters the stomach as a funnel-shaped (infundibuliform) tube.

The dilatability of the œsophagus is very remarkable in these animals: Dogs swallow large pieces of flesh; and Cows and Oxen are able to injest large turnips, or such voluminous foreign bodies as shoes.

(In *Ruminants* and the *Carnivora* the œsophagus is, proportionally, wider than in the Horse and Pig.)

COMPARISON OF THE ŒSOPHAGUS OF MAN WITH THAT OF ANIMALS.

The œsophagus of *Man* resembles that of Carnivora; its diameter is almost uniform. It also inclines to the left below the neck, but in the thorax is in the median line, though it again deviates to the left as it joins the stomach. As the thyroid in Man is very voluminous, it is related to the œsophagus in the upper part of the neck. Two small accessory fasciculi, belonging to the muscular tunic of the œsophagus, have been described: one is the *broncho-œsophageal muscle*, which is detached from the left bronchus; and the other the *pleuro-œsophageal muscle*, detached from the left layer of the posterior mediastinum.

Article II.—The Essential Organs of Digestion.

These organs being all contained in the *abdominal cavity*, this common receptacle will first be studied; afterwards the *stomach*, *intestines*, and their *annexed organs*—the *liver*, *pancreas*, and *spleen*—will be described.

THE ABDOMINAL CAVITY.

In mammalia, the interior of the trunk is partitioned by the diaphragm into two great cavities, that lodge the majority of the organs so vaguely termed the viscera. The anterior, the smallest, is the *pectoral* or *thoracic cavity;* the posterior is named the *abdomen*, or *abdominal cavity*. The latter, the only one we have now to study, is a vast oval-shaped reservoir, elongated from before to behind, having for its upper wall the muscles of the sublumbar region, inclosed below and laterally by the muscles of the inferior abdominal region, bounded in front by the diaphragm, and prolonged behind between the bones and membranous ligaments of the pelvis.

The elements composing the parietes of this cavity having been already described, we will confine ourselves to an examination of its interior, in

order to determine the various regions into which it is possible to divide it: a matter of some importance, as it singularly facilitates the topographical study of the contained viscera; for to say that an organ is situated in the abdomen, is a very vague reference to its precise situation, in consequence of the great extent of this cavity. It is necessary, therefore, to divide the abdomen into a certain number of peripheral regions which correspond to the different parts of its wall, with a view to define the situation of the organs lodged therein, yet without complicating anatomical description. Six principal regions are recognised in the abdominal cavity.

A. The *superior*, or *sublumbar region*, corresponds to the superior wall of the abdomen: that is, to the psoas muscles and the bodies of the lumbar vertebræ. It extends from the opening between the two pillars of the diaphragm to the entrance to the pelvis.

B. The *inferior region*, limited, laterally, by the hypochondriacs and the flanks, commences, in front, at the xiphoid cartilage, and is prolonged to the pubis; it comprises all that portion of the abdomen which corresponds to the linea alba and the two recti muscles. Its great extent necessitates its subdivision into five secondary regions: The *suprasternal region*, named the *epigastric* in Man, placed above the xiphoid cartilage of the sternum; the *umbilical region*, situated behind the preceding, and so named in consequence of its including that part of the wall which is pierced by the umbilicus; the *prepubic region*—the *hypogastric or pubic* of Man—occupies the space in front of the anterior border of the pubis; the *two inguinal regions*, diverticuli of the abdominal cavity, located in the inguinal tracts, where they form the special reservoirs to be hereafter described as the *vaginal sheaths* (or *canals*).

C. The *lateral regions* (*right* and *left lumbar* of Man) are limited: in front, by the costal attachments of the diaphragm; behind, by the entrance to the pelvic cavity; above, by the superior border of the small oblique muscle; below, by the interval comprised between the inferior border of that muscle and the external border of the great rectus muscle. The designation of *hypochondriac* is given to the subregion which corresponds to the cartilaginous circle of the false ribs. The *flank* is that section covered by the muscular portion of the small oblique muscle.

D. The *anterior*, or *diaphragmatic region*, comprises the cavity formed by the posterior face of the diaphragm. Like that muscle, it is divided into two regions, a *central* and *peripheral*.

E. The *posterior*, or *pelvic region*, is a special diverticulum of the abdomen described as the *pelvic cavity*. It is bounded, above, by the sacrum; below, by the superior face of the pubes, the ischia, and the internal obturator muscle; on the sides, by the constricted portions of the ossa innominata and the sacro-ischiatic ligaments. The entrance to this diverticulum is situated above the pubes, and is of an oval form. Posteriorly, it is narrower, and is traversed by the rectum and the genito-urinary organs, which open externally.

THE PERITONEUM.—The abdominal cavity is covered, internally, by a serous membrane, the *peritoneum*, which will now be briefly described.

Like all the splanchnic serous membranes, the peritoneum is composed of a parietal and a visceral layer, which together form a closed sac, so arranged that the organs contained in the abdomen are situated external to this sac. The adjoining theoretical figure (180), representing a transverse section of the abdominal cavity, will show at a glance this arrangement. Let A represent the section of the small intestines floating at liberty in the interior of the

cavity, B that of the aorta, at the level of the great mesenteric artery: the peritoneal membrane, CC, covers the walls of the abdomen, and at the points DD (not inserted, but intended to be placed *within the cavity* below, and on each side of B, the aorta) is folded around the great mesenteric artery in such a manner as to form two layers, FF, which come in contact by their adherent face, reach the intestine, and then separate to envelop it. We then see in this figure the parietal layer of the peritoneum, CC, the visceral layer, GG, and the two layers, FF, which establish the continuity of the parietal and visceral portions; the complete sac formed by these is apparent, and it could be rendered more so by the further separation and development of the layers FF; so that there is no difficulty in understanding how the small intestine may be at the same time *in the interior* of the abdominal cavity, and *outside* the sac formed by the serous membrane which lines that cavity.

Fig. 180.

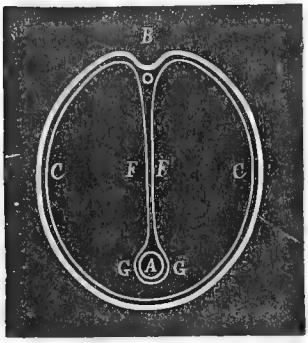

THEORETICAL TRANSVERSE SECTION OF THE ABDOMINAL CAVITY, TO SHOW THE DISPOSITION OF THE PERITONEUM.

This arrangement is common to all the organs freely suspended in the abdomen. The serous folds which suspend them, in joining their peritoneal layer to that which covers the parietes of the cavity, will be studied under the names of *ligaments*, *mesenteries*, and *omenta*. Some organs—the kidneys, for example—have no proper visceral layer, being comprised between the abdominal wall and the external face of the parietal peritoneum, and are invested with none of the duplicatures just mentioned.

We will briefly study the duplicatures, ligaments, mesenteries, and omenta that the peritoneum forms, starting from the umbilicus and passing forwards and backwards (Fig. 181).

On reaching the suprasternal region, the peritoneum forms a *falciform* duplicature, extending from the umbilicus to the middle lobe of the liver, and which is even prolonged between that lobe and the posterior face of the diaphragm; at the free border of this fold is a thickening which is regarded as the remains of the obliterated umbilical vein. In becoming doubled over the neighbouring organs, the diaphragmatic portion constitutes: 1, The *ligaments of the right* and *left lobes of the liver;* 2, The *common ligament* of that gland, which surrounds the posterior vena cava: 3, The *cardiac ligament* that envelops the termination of the œsophagus. Behind the liver is found the *hepato gastric ligament*, which fixes the stomach in the posterior fissure of the liver and is, to the right and backwards, attached to the duodenum at the lower face of the right kidney; it is then directed from right to left, and becomes continuous with the parietal peritoneum of the sublumbar region and the *mesentery* proper.

The two laminæ of the hepato-gastric ligament separate at the lesser curvature of the stomach to cover that viscus; then join at its greater curvature, and pass to the interior of the abdominal cavity. This fold receives the name of the *great* or *gastro-colic omentum;* it leaves the left tuberosity of the ventriculus, which it suspends to the sublumbar region from the whole extent of the great curvature; to the right it goes beyond the pylorus,

to be continued on the concave curvature of the duodenum as far as the cæcum. By its posterior border, the great omentum is spread around the termination of the large colon and the origin of the floating colon, where it is confounded with the visceral peritoneum of these organs, as well as with the parietal peritoneum. It results from this arrangement that the great omentum forms behind the stomach, and in front of the adherent portion of the large colon, a space that communicates with the great peritoneal cavity by a very narrow opening, the *foramen of Winslow*. This aperture is included between the vena portæ, posterior vena cava, anterior extremity of the pancreas, and the lesser curvature of the stomach. To the left of the latter viscus, on the external face of the great omentum, the spleen is suspended; consequently, that portion extending from the spleen to the ventriculus is named the *gastro-splenic omentum.*

The two layers composing the great omentum are very thin for the greater part of their extent, and include the blood-vessels between them. In emaciated animals these vessels are distinctly seen, owing to the transparency of the membranes, and they give the omentum a lace-work appearance; but in fat subjects they are concealed by the adipose tissue deposited along their course, and which may accumulate in considerable quantity.

In the sublumbar region, the parietal peritoneum forms several folds; these are: the *hepatico-renal ligament*, extending from the right lobe of the liver to the anterior border of the right kidney; the *ligament of the lobus Spigelii*, the *mesentery* proper, the *colic mesentery;* lastly, the greatly developed laminæ surrounding the cæcum and the second flexure of the colon, which constitute the *meso-cæcum* and *meso-colon.*

Fig. 181.

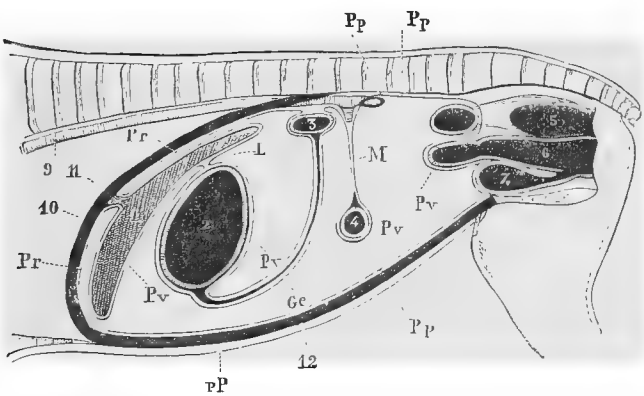

THEORETICAL LONGITUDINAL AND MEDIAN SECTION OF THE ABDOMINAL CAVITY, TO SHOW THE REFLEXIONS OF THE PERITONEUM.

1, Liver; 2, Stomach; 3, Small intestine; 4, Origin of the floating colon; 5, Rectum; 6, Vagina and uterus; 7, Bladder; 9, Posterior aorta; 10, Diaphragm; 11, Posterior vena cava; 12, Inferior abdominal wall.—Pp, Pp, Parietal peritoneum; Pv, Pv, Visceral peritoneum.—L, Hepato-gastric ligament; M, Mesentery. —Ge, Great omentum.

The *great mesentery* is detached from the border of the large mesenteric artery, and projects into the abdominal cavity to reach the small intestine at its lesser curvature, and envelop that viscus.

Its shape is that of an irregular triangle, whose summit corresponds to the mesenteric artery, the very short anterior border being continuous with the duodenal frænum, and the posterior border, the longest, with the meso-colon, its convex festooned base being as long as the intestine itself. Between the two laminæ that compose it are the blood-vessels and lymphatics, as well as the nerves, of the small intestine.

The *colic mesentery* is constituted like the great mesentery. Its inferior border, plane or plicated, is fixed to the small curvature of the floating colon and the commencement of the rectum; its upper border extends from the great mesenteric artery as far as the entrance to the pelvic cavity.

Around the cross of the cæcum, from the origin and the termination of the great colon, the peritoneum is reflected to cover these viscera; a layer passes from the anterior border of the cæcum on to the ileum and the second flexure of the colon: this is the *meso-cæcum;* another layer, comprised between the second and third portion of the colon, and whose shape is that of a battledore, is named the *meso-colon.*

If, again, the peritoneum is taken at the umbilical region and followed backwards, it will be found to insinuate itself into the inguinal canals, cover the organs contained in the pelvis, and become reflected at the bottom of that cavity, to be continued either with the peritoneum of the sublumbar region, or with that on the abdominal walls.

This serous membrane covers the anterior *cul-de-sac* of the bladder, and at this point has three ligaments. The *middle ligament*, falciform in shape, leaves the large extremity of the bladder, is attached to the anterior border of the pubis, and insensibly disappears on the inferior abdominal wall; on its free border is a small fibrous cord, which is supposed to be the remains of the urachus. The *two lateral ligaments* are more developed, and extend from the entrance to the pelvic cavity to the vesical *cul-de-sac;* they have on their free border the obliterated umbilical arteries. In the male, the peritoneum is prolonged from the upper face of the bladder to the enlargement of the deferent ducts, between which it sends a transverse fold to the anterior extremity of the vesiculæ seminales, and is then reflected around the rectum.

In the female, it is carried from the bladder to the terminal portion of the vagina, to the uterus, and to the cornua of that organ, where it forms three folds named the *broad ligaments, ligaments of the ovary,* and the *round ligament;* then it re-descends on the upper face of the vagina, and thence envelops the rectum, around which it is reflected from behind forwards.

According to this arrangement, we see that the termination of the digestive canal, and the parts of the genito-urinary organs situated altogether at the posterior portion of the pelvic cavity, are placed outside the peritoneal serous membrane.

Structure.—Like all the serous membranes, the peritoneum is formed by a membrane of connective tissue, rich in elastic fibres, and covered on its free face by a simple tesselated layer of epithelium (the cells of which are flat and polygonal, and about $\frac{1}{1200}$ of an inch in diameter). Many *blood-vessels* are found on the adherent surface, while *lymphatics* are abundant in the visceral layer. Its *nerves* come from the diaphragmatic, lumbar, and intercostal branches, and the great sympathetic.

DIFFERENTIAL CHARACTERS IN THE ABDOMINAL CAVITY OF OTHER THAN SOLIPED ANIMALS.

In the *Carnivora*, the abdominal cavity is very narrow; while in *Ruminants* it is very vast, its capacity being in direct relation to the volume of the viscera it contains.

The general disposition of the peritoneum varies but little in the different species, the only notable diversities being remarked in the great omentum. In the *Ox*, *Sheep*, and *Goat*, this is detached from the middle of the lower face of the rumen, and envelops the right sac of that organ, fixing the fourth compartment to its great curvature, and then passing upwards to become continuous with the mesentery. In the *Dog* and *Pig*, this fold descends in front of the intestinal mass until near the pelvis; then it ascends in gathering on itself, and ultimately spreads over the colon: in the middle portion of the great omentum there are, consequently, four layers placed against each other.

COMPARISON OF THE ABDOMINAL CAVITY OF MAN WITH THAT OF ANIMALS.

The abdominal cavity of *Man* is elongated vertically, and has an inferior cavity occupying the entrance to the pelvis. There is nothing particular to note in its disposition, the differences observed in it being allied to the external shape of the body. The peritoneum is spread over its parietes nearly in the same manner as in the Carnivora; the great omentum is constituted by four layers, and covers the intestines like an apron: between its two laminæ is the *lesser cavity* of the omentum, virtually in the adult.

THE STOMACH.

The *stomach* is a membranous sac comprised between the œsophagus and intestines, and in which are commenced the essential phenomena of digestion.

1. *The Stomach in Solipeds.* (Figs. 182, 183, 184, 185, 186.)

Preparation.—In order to study the relations of this organ, it suffices to open the abdomen and remove the intestinal mass in the following manner:—Place the animal in the first position, and very slightly inclined to the left side; make an incision through the inferior abdominal wall, or, still better, carry it away entirely by a circular incision, taking care not to wound any part of the intestine. The entire viscera should then be withdrawn from the abdominal cavity, and laid on the table which supports the subject; for this mass cannot be allowed to fall on the ground without risk of being pulled and torn, either in the intestine itself, or those parts which it is desired to preserve intact in the abdomen. Incise the floating colon where it joins the rectum, and the duodenum where it passes behind the great mesenteric artery; the base of the cæcum should now be detached from the sublumbar surface by the rupture of the cellular tissue which connects it to the right kidney and the pancreas; the cellular connection between the latter gland and the terminal extremity of the fourth portion of the large colon should also be broken; after this, it is only necessary to divide the attachment of the mesenteric bands to the sublumbar region, with the vessels contained between them. The intestinal mass is then definitively expelled from the abdominal cavity. In this way it is possible to expose, and conveniently prepare, not only the stomach, but also the spleen, liver, pancreas, kidneys, ureters, etc. Nothing more remains than to make known the procedure to be adopted in everting the stomach, in order to study its internal surface, or dissect its deep muscular layer. It is recommended, first, to excise the stomach with at least three inches of the œsophagus, and eight inches of the duodenum, and cleanse the interior of the organ. This may be done in several ways, but the following is the simplest:—a certain quantity of water is introduced into the stomach by fixing the duodenum to a water-tap, the right hand manipulating the organ while the left closes the duodenum to prevent the escape of the liquid. The alimentary substances contained in it are in this way mixed with the water, and may be expelled from the duodenum by pressing the stomach; this operation being repeated four or five times, thoroughly cleanses the cavity of the organ. To evert the inner surface, it is only necessary to introduce by the duodenum a loop of wire, and make it pass through the œsophagus; a strong waxed thread is fastened in the loop and firmly fixed around the œsophagus, when, in pulling back the wire, this extremity is drawn towards the pylorus, and by careful traction the latter is so dilated as to allow the passage of the cardiac end, and complete eversion of the stomach. Inflation will then give it its normal form and disposition; with this difference, that the mucous membrane is external, and the serous tunic internal.

Lastly, to render the muscular layers of the stomach more evident, it is advisable to plunge the organ into boiling water for some minutes, after which it should be put into cold water. If it is desired to study the external and middle layers, the stomach should be inflated, and its serous covering removed by strips with forceps and the fingers; if the deep layer is to be examined, the mucous membrane must be removed by means of the forceps and scalpel from a stomach previously everted.

Situation.—The *stomack*, also designated the *ventriculus*, is situated in the diaphragmatic region of the abdomen, where it affects a direction transverse to the median plane of the body.

Dimensions.—Its average capacity, in an ordinary-sized Horse, is from 3 to 3½ gallons; but it varies greatly according to the bulk of the animal, its breed, and the nature of its food. Relatively, it is more considerable

Fig. 182.

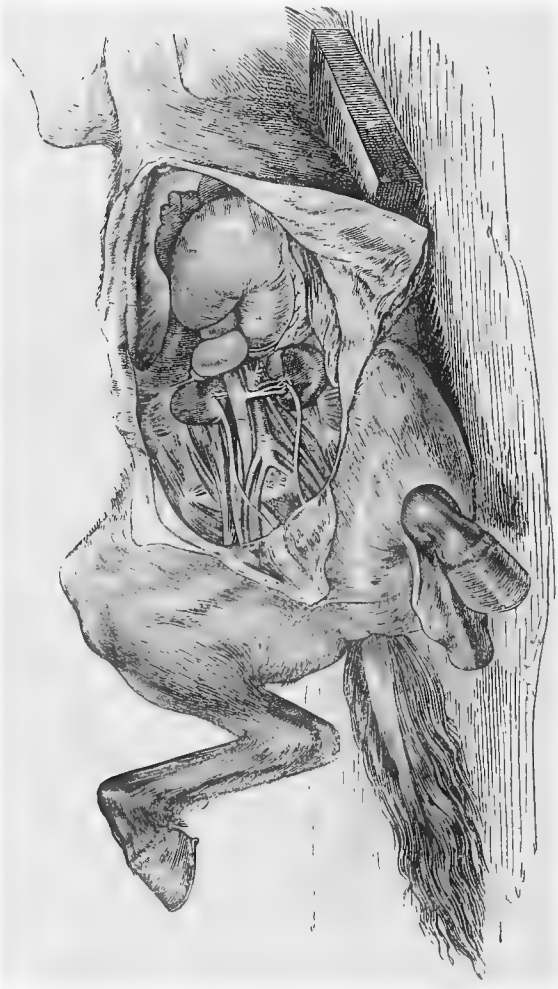

THE ABDOMINAL CAVITY WITH THE STOMACH AND OTHER ORGANS.

1, Right lobe of liver; 2, Middle lobe; 3, Right extremity, or ventriculus of stomach; 4, Left extremity; 6, Left kidney; 7, Supra-renal capsule; 8, Ureter; 9, Posterior vena cava; 10, Posterior aorta; 11, 12, Psoas parvus and magnus; 13, Iliac psoas; 14, Tensor vaginæ; 15, External iliac artery; 16, Internal iliac artery.

in common-bred Horses, and in the Ass and Mule. When empty, its average weight is between 3 and 4 pounds.

Form.—Elongated laterally, curved on itself, often constricted in its middle, and slightly depressed from before to behind, this reservoir presents, externally: 1, *Two faces*—an *anterior* and *posterior*, smooth and rounded; 2, A *great* or *convex curvature*, forming the inferior border of the

organ, and giving attachment, throughout its extent, to the great omentum—a membranous fold which has been described as a dependency of the serous membrane; a *lesser* or *concave curvature*, into which the œsophagus is inserted, and which is united, to the right of that canal, to the liver, by means of a frænum known as the hepato-gastric ligament; 4, A *left extremity*, dilated in the form of a large conical tuberosity, and constituting the *left cul-de-sac* (or *fundus*) of the stomach; 5, A *right extremity*, narrower, curved upwards, and continued by the duodenum, from which it is separated by a marked constriction: this is named the *right cul-de-sac* of the stomach.

Relations.—Studied in its connections with the neighbouring organs, the stomach is related: by its anterior face, with the diaphragm and liver; by

Fig. 183.

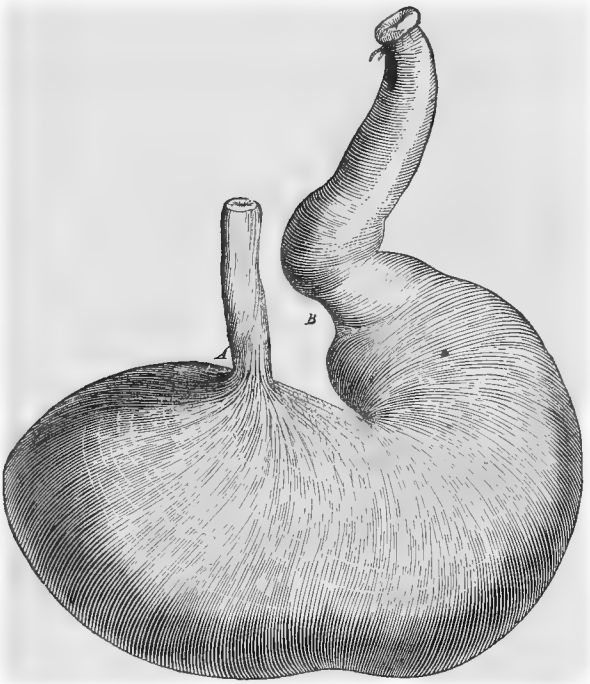

STOMACH OF THE HORSE.
A, Cardiac extremity of the œsophagus; B, Pyloric ring.

its posterior face, with the diaphragmatic curvature of the colon. Its inferior border, margined to the left by the spleen, which is suspended from it by means of the great omentum, is separated from the inferior abdominal wall by the large anterior curvatures of the colon; its distance from this wall depends upon the fulness of the organ. The left extremity, suspended to the sublumbar region by the aid of a very short serous ligament, a portion of the great omentum, responds to the base of the spleen, the left extremity of the pancreas and, less directly, to the anterior border of the left kidney.

The right extremity, lower than the left, touches the right lobe of the liver and the above-mentioned intestinal curvatures.

Interior.—When a stomach is opened to study its interior, one is at first struck by the different aspect its internal membrane presents, according as it is examined to the right or left. To the left, it has all the characters of the œsophageal mucous membrane, in being white, harsh, and even resisting; it is covered by a thick layer of epithelium. To the right, it is thick, wrinkled, spongy, very vascular and follicular, has a reddish-brown tint which is speckled by darker patches, loses its consistency, and is deprived of the remarkable epidermis it exhibits on the left side, to be covered by a very thin epithelial pellicle. It is not by an insensible, but a sudden transition that the mucous membrane of the stomach is thus divided into two portions; and their separation is indicated by a salient, more or less sinuous, and sharply-marked ridge. This crest, then, divides the stomach into two compartments: a division already indicated externally by the circular depression observed in the majority of subjects. The *left sac* or *compartment* is considered as a dilatation of the œsophagus. The *right sac* constitutes the true stomach of Solipeds; as on it alone devolves the secretory function which elaborates the gastric juice, the essential agent of digestion in this organ.

Fig. 184.

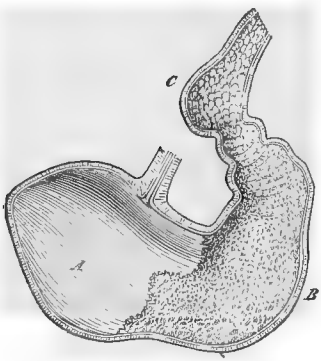

INTERIOR OF THE HORSE'S STOMACH, A, Left sac; B, Right sac; C, Duodenal dilatation.

The interior of the stomach (Fig. 184) offers for study two apertures: the *cardiac* and *pyloric*. The *cardiac*, or *œsophageal orifice*, is in the lesser curvature of the left sac of the stomach. Its disposition has given rise to numerous discussions, as in it has generally been sought the reason why Solipeds vomit with such extreme difficulty. At one time there has been described a semilunar or spiroidal valve, which is opposed to the retrograde movement of the food; and at another time it was the oblique insertion of the œsophageal canal, resembling that of the ureters into the bladder, and which, by a mechanism analogous to these, proved an obstacle to the return of aliment into the œsophagus. Both suppositions are wrong. When we attentively observe the manner in which the œsophagus comports itself at its termination, it will be noticed that it is inflected downwards, after traversing the right pillar of the diaphragm, and is inserted almost perpendicularly into the lesser curvature of the stomach. In opening into this viscus, the œsophagus does not widen into an infundibulum, as in other animals; on the contrary, its calibre is here narrower than elsewhere, and its cardiac or stomachal orifice, completely obstructed by the folds of mucous membrane, only occupies an infinitely small portion of the internal surface of the stomach.

With regard to the *pylorus*, it represents a large aperture formed at the bottom of the right sac, and furnished with a thick circular ring; this opening can be completely closed through the action of the powerful sphincter surrounding it.

Structure.—The parietes of the stomach are composed of three

membranes: an external, or *serous;* a middle, or *muscular;* and an internal, or *mucous.*

1. *Serous membrane.*—This membrane, derived from the peritoneum, adheres closely to the muscular layer, except towards the lesser curvature, where it is constantly covered by an expansion of yellow elastic tissue, whose use appears to be to maintain the two extremities of the stomach near each other; for when this is destroyed the lesser curvature becomes considerably elongated. Along the whole of the greater curvature is a triangular space occupied by connective tissue; this space disappears more or less completely as the organ becomes distended.

It has three folds, which are detached from the stomach and carried on to the adjacent parts, and which are formed in the manner indicated in the general description of the peritoneum. These folds constitute the *cardiac ligament*, the *gastro-hepatic ligament* or *omentum*, and the *great omentum.*

The *cardiac ligament* is a short, serous band developed around the terminal extremity of the œsophagus, and strengthened by fibres of yellow fibrous tissue. It attaches the stomach to the posterior face of the diaphragm, and is continuous, on each side, with the two folds about to be described.

The *gastro-hepatic* (or *lesser*) *ligament* is a band composed of two layers, which leave the lesser curvature of the stomach, and are inserted into the posterior fissure of the liver. It is prolonged posteriorly, and to the right, along the duodenum, where it constitutes a peculiar serous frænum which will be studied with the small intestine.

The *great*, or *gastro-colic omentum*, is detached from the whole extent of the great curvature, from the cardia to the pylorus, beyond which it extends to the duodenum. The portion surrounding the left *cul-de-sac* is excessively short, and is carried to the sublumbar wall of the abdomen, to which the stomach is fixed. For the remainder of its extent, this omentum is greatly developed, and hangs freely in the abdominal cavity, among the intestinal convolutions. The border opposed to the stomach is attached to the terminal portion of the large colon, and to the origin of the lesser colon. For further details, see the description of the peritoneum. These three ligaments fix the stomach in the abdominal cavity, in addition to the œsophagus and duodenum, which are continuous with it.

2. *Muscular membrane.*—This tunic, comprised between the serous and mucous layers, is lined internally by a *covering* of condensed connective tissue which adheres intimately to it, and which may be regarded as the *fibrous membrane* of the stomach. Dissection shows this muscular tunic to be composed of three superposed planes.

The *superficial plane* envelops all the right sac, and the majority of the fibres composing it are spread in loops around the left *cul-de-sac*, their extremities being lost on the surfaces of the organ. Some of them even extend over the great curvature, to the surface of the right sac; while others are evidently continuous with the superficial fibres of the œsophagus (Fig. 185, A).

The *middle plane* (Fig. 185, B) is formed of circular fibres spread over the whole of the organ. In the right sac, they are placed immediately below the serous membrane; in the left sac, they pass beneath the fibres of the superficial plane, and finish by becoming confounded so intimately with these, that towards the tuberosity formed by the left extremity it is impossible to distinguish them. By their aggregation around the pylorus,

they constitute the sphincter (or pyloric valve) which envelops that orifice.

The *deep plane* (Fig. 186, A), like the first, is specially destined for the left sac, and cannot be properly studied except in an everted stomach deprived of its mucous membrane. Much thicker than the superficial plane, it yet, in its general arrangement, much resembles it. Thus, its fasciculi present loops which embrace the left *cul-de-sac*, and whose extremities are lost on the faces of the organ, where some of them become continuous with

Fig. 185.

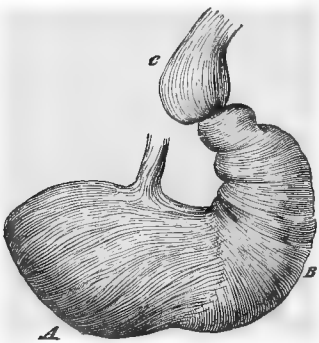

MUSCULAR FIBRES OF THE STOMACH; EXTERNAL AND MIDDLE LAYERS.

A, Fibres of the external layer enveloping the left sac; B, Fibres of the middle plane in the right sac; C, Fibres of the œsophagus.

Fig. 186.

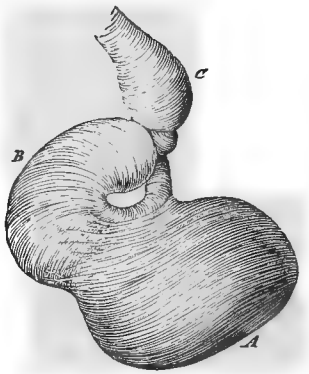

DEEP AND MIDDLE MUSCULAR LAYERS EXPOSED BY REMOVING THE MUCOUS MEMBRANE FROM AN EVERTED STOMACH.

A, Deep layer of fibres enveloping the left sac; B, Fibres of the middle plane which alone form the muscular layer of the right sac; C, Fibres of the œsophagus.

the circular fibres. The loops nearest the œsophagus embrace the stomachal opening of that canal like a cravat. It is to be remarked that the fibres of this deep layer intersect those of the superficial plane; the former passing from the left to the right sac, in inclining downwards towards the great curvature, while the latter are directed to the right and slightly upwards.

From this arrangement it results, as a glance at Figs. 185, 186 will show: 1, That the right sac has only a single muscular plane; 2, That, on the contrary, the left sac has three, all of which concur in propelling the aliment that has accumulated in the left or œsophageal compartment into the right, or true stomach.

3. *Mucous membrane.*—Independently of the general characters notified in the interior of the stomach, it has to be remarked that the gastric mucous membrane is united to the preceding tunic by an expansion of connective tissue; though it adheres but feebly throughout the right sac, especially towards the greater curvature, where it is thickest; and that it has no ridges in the left sac, though in the right they are always present, even when the organ is inflated.

On the surface of this membrane are seen microscopical apertures (*alveoli*), the orifices of the excretory ducts of glands; these are rare in the left sac,

but extremely numerous in the right. In this region they are separated from each other by minute processes resembling papillæ; but the latter are only met in the vicinity of the pylorus.

The gastric mucous membrane is composed of an *epithelial layer* and a *corium*, in which is distinguished a *glandular* and a *muscular layer*. The epithelium is stratified and tesselated in the left compartment, simple and cylindrical in the right sac, where it covers the little mucous processes that separate the glandulæ, and penetrates more or less deeply into the interior of these.

In the left side there are found some glandular organs analogous to those of the œsophagus, but the real *glandular layer* belongs only to the

Fig. 187.

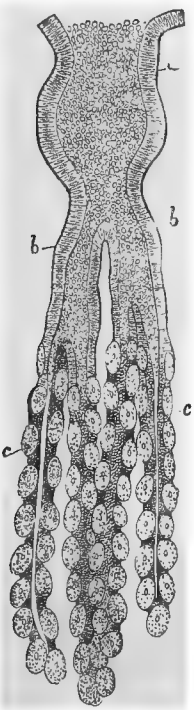

PEPTIC GASTRIC GLAND.

a, Common trunk; *b*, *b*, Its chief branches; *c*, *c*, Terminal cæca, with spheroidal gland-cells.

Fig. 188.

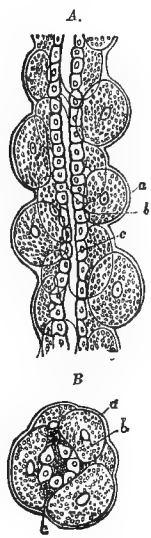

PORTIONS OF ONE OF THE CÆCA MORE HIGHLY MAGNIFIED, AS SEEN LONGITUDINALLY (A), AND IN TRANSVERSE SECTION (B).

a, Basement membrane; *b*, Large glandular cell; *c*, Small epithelial cells surrounding the cavity

right side. There are found multitudes of parallel tubular glands, united by a small quantity of delicate connective tissue which is very rich in nuclei. They secrete the gastric fluid, or furnish the mucus that covers the surface of the epithelium: they are consequently distinguished as *pepsine* (or *peptic*), and *mucous glands*, the former being much more numerous than the latter.

They are composed of a simple straight tube at their origin (excretory duct), which frequently divides into two or more flexuous tubes that

terminate in *culs-de-sac* (or *glandular cæca*). The epithelium is not the same in the two kinds of glands: the mucous glands (Fig. 189, *a*, *b*) are lined with cylinder-epithelium throughout their extent; the peptic glands (Figs. 187, 188) are lined with cylinder-epithelium at their origin (Fig. 187, *a*), but the secretory tubes contain round peptic cells. (Each cæca, when highly magnified, is found to consist of a delicate basement membrane (Fig. 188, *a*) inflected over a series of nearly globular cells (*b*), which occupy almost the whole cavity of the tube, and contain a finely-granular matter; the narrow passage left vacant in the centre is, however, still surrounded by a layer of epithelial cells (*c*), whose small size is in striking contrast to the large dimensions of the gland cells.)

Fig. 189.

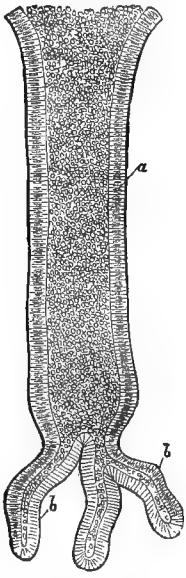

MUCOUS GASTRIC GLAND WITH CYLINDER EPITHELIUM.

a, Wide trunk; *b*, *b*, Its cæcal appendage.

The *muscular layer* (of the mucous membrane) is immediately beneath the glandular structure, and contains two planes of intersecting fibres. Lastly, the connective layer of the corium is thick and loose, sustains the vessels (and nerves), and unites the mucous to the muscular tunic of the stomach.

4. *Vessels and nerves.*—The stomach receives its blood by the two branches of the *gastric artery*, the *splenic* and its terminal branch—the *left epiploic artery*, and by the *pyloric* and *right epiploic arteries*. The principal arterial ramifications extend between the mucous and muscular layers, where they furnish two capillary reticulations to the glandular layer: a deep network that surrounds the secretory tubes, and a superficial placed between the alveoli. The blood is carried from the organ to the vena portæ by the satellite *venous branches*. The *lymphatics*

Fig. 190.

APPEARANCE OF THE PROPER GASTRIC MEMBRANE OF THE STOMACH IN AN INJECTED PREPARATION (HUMAN).

A, From the convex surface of the folds or *rugæ*; B, From the neighbourhood of the pylorus, where the orifices of the gastric follicles occupy the interspaces of the deepest portions of the vascular network.

form a subserous and two deep networks at the base of the glandular layer and in the fibrous membrane. They enter small ganglia (or glands) situated along the curvatures, and from these to Pecquet's reservoir. The

nerves are derived from the pneumogastrics and solar plexus, and in accompanying the vessels show microscopic ganglia in their course; their mode of termination is not known.

FUNCTIONS.—In the stomach is begun those transformations by which alimentary matters are rendered capable of being assimilated. There the food comes into contact with the gastric fluid, by whose action its principal elements, and particularly the albuminoid substances, become soluble and absorbable, after undergoing some isomeric changes.

DIFFERENTIAL CHARACTERS IN THE STOMACH OF OTHER THAN SOLIPED ANIMALS.

The stomach is an organ that exhibits great differences in the various domesticated animals. In the study of these differences, we will proceed from the simple to the complex.

1. *The Stomach of the Pig.*

The *Pig's* stomach is simple, like that of the Horse, but it is less curved on itself, and the cardia is nearer the left extremity; the latter has also a small conical dilatation, which has been compared to a cowl curved backwards. The œsophagus opens into the stomach by a wide infundibulum, and the mucous membrane of that conduit is prolonged over the gastric surface in a radius of from two to three inches around the cardia. Here again we find a "trace of the division into two sacs," common to Solipeds.

The capacity of the PIG's stomach averages from one and a half to two gallons. (The muscular tunic is thicker in the right than the left extremity; near the œsophagus the serous tunic shows some transverse folds.)

2. *The Stomach of Carnivora.* (Fig. 191.)

In the *Dog* and *Cat* the ventriculus is but little curved, and is pear-shaped, the small extremity corresponding to the pylorus. The cardia is dilated like a funnel, and is nearer the left extremity of the organ than in other animals. The œsophageal mucous membrane is not continued beyond the margin of that orifice. The simple stomach of Carnivora forms only a single sac, whose internal mucous membrane presents, throughout its whole extent, the same organisation as the membrane lining the right sac of Solipeds. This membrane is remarkable for the regular and undulated folds it forms when the stomach is empty. Nothing is more variable than the capacity of the Dog's stomach, because of the great differences in the size of this animal, according to breed. M. Colin has found the minimum to be $1\frac{1}{4}$ pints, and the maximum $1\frac{3}{4}$ gallons; he calculates the average to be about $2\frac{1}{2}$ quarts. In the Cat, the average is from 2 to $2\frac{1}{4}$ gills.

Fig. 191.

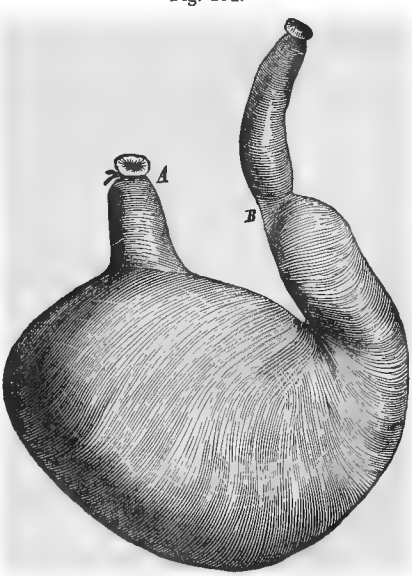

STOMACH OF THE DOG.
A, Œsophagus; B, Pylorus.

3. *The Stomach of Ruminants.*

These animals are distinguised from the others by the faculty they possess of swallowing their food after imperfect comminution, and causing it to return again into the mouth to submit it to a second mastication, previous to final deglutition. The gastric apparatus is admirably arranged to effect this physiological finality, and is remarkable for its enormous development, as well as its division into four separate pouches, which are regarded as so many stomachs.

These cavities represent a considerable mass that fills the greater part of the abdominal cavity, and the medium capacity of which is not less than fifty-five gallons! One of them, the *rumen*, into which the œsophagus is inserted, constitutes nine-tenths of the total mass. The other three, the *reticulum*, *omasum*, and *abomasum*, form a short chain, continuous with the left and anterior portion of the rumen. The abomasum alone should be considered as a true stomach, analogous to that of the Dog, or the right sac of the ventriculum of Solipeds. The other three compartments only represent, like the left sac in the latter animals, œsophageal dilatations.

The description about to be given of each of these divisions more particularly applies to the *Ox*; care will be taken, in the proper place, to note the special peculiarities in the stomach of the *Sheep* and *Goat*.

Rumen (Fig. 192).—This reservoir, vulgarly designated the *paunch*, alone occupies three-fourths of the abdominal cavity, in which it affects a direction inclined from above to below, and from left to right.

Fig. 19

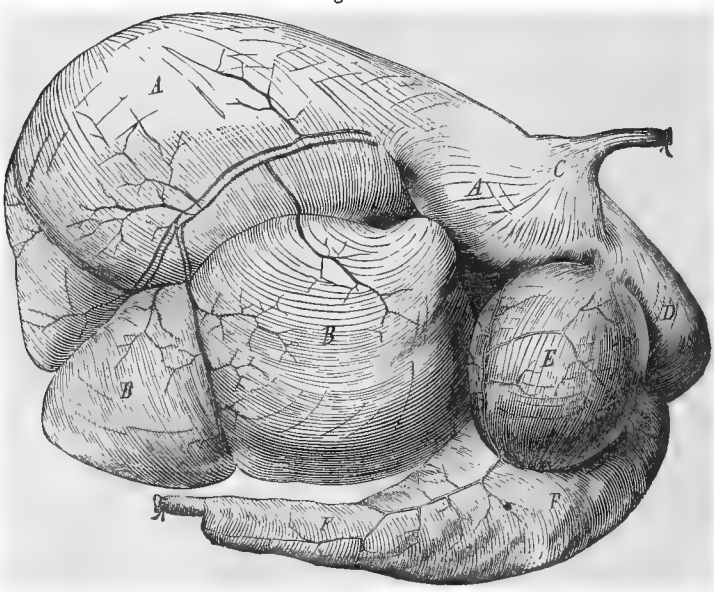

STOMACH OF THE OX, SEEN ON ITS RIGHT UPPER FACE, THE ABOMASUM BEING DEPRESSED.

A, Rumen, left hemisphere; B, Rumen, right hemisphere; C, Termination of the œsophagus; D, Reticulum; E, Omasum; F, Abomasum.

External conformation.—Elongated from before to behind, and depressed from above to below, it offers for study: 1, An *inferior* and a *superior* face, nearly plane, smooth, and divided into two lateral regions by traces of fissures, which are only sensible at the extremities of the organ; 2, A *left* and *right border*, smooth, thick, and rounded; 3, A *posterior extremity*, divided by a deep notch into two lobes, described by Chabert by the name of *conical cysts*; 4, An *anterior extremity*, offering an analogous arrangement, and concealed, at first sight, by the stomachs (or compartments) superadded to the rumen; the notch on the right of this extremity divides it into two unequal pouches, which will be referred to presently.

It is to be remarked that these two notches, which are prolonged on the surface by furrows that separate these into two lateral regions, divide the rumen into *two sacs*, a *right* and *left*; this division we will find more manifest in the interior of the viscus. The *right sac*, the shortest, is in great part enveloped by the serous covering which constitutes the great omentum. The *left sac* surpasses the other by its two extremities, except in the Sheep and Goat, in which the right conical cyst is longer than the left. The anterior extremity of this left sac is thrown backwards on the corresponding

lobe of the right sac; above, it receives the insertion of the œsophagus, and is continuous, in front, with the reticulum.

Relations.—The external form of the rumen being determined, the study of its relations becomes easy. By its superior surface, it is in contact with the intestinal mass; its opposite face rests on the inferior abdominal wall. Its left border, supporting the spleen, touches the most elevated part of the flank and the sublumbar region, to which it adheres by cellular tissue, as well as the vicinity of the cœliac trunk and the great mesenteric artery; the right border, margined by the abomasum, responds to the most declivitous portion of the right hypochondriac and flank, as well as to the intestinal circumvolutions. The anterior extremity, bounded by the reticulum and omasum, advances close to the diaphragm; the posterior occupies the entrance to the pelvic cavity, where it is more or less in contact with the genito-urinary organs lodged there. In the pregnant female, the uterus is prolonged forwards on the upper face of the viscus just described.

Interior (Fig. 193).—In the interior of the rumen are found incomplete septa, which repeat the division into two sacs already so marked externally. These septa are two in

Fig. 193.

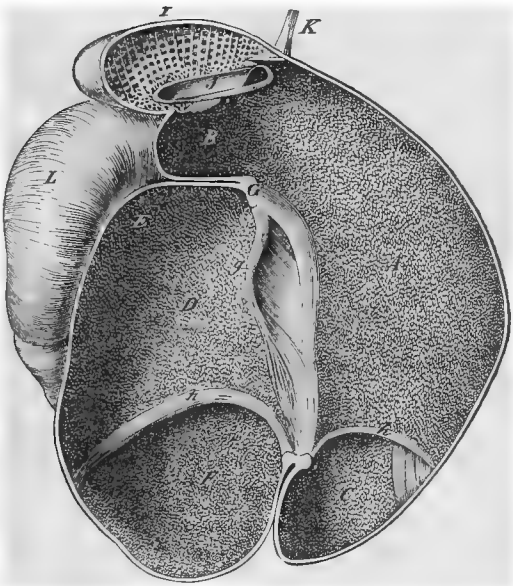

INTERIOR OF THE STOMACH IN RUMINANTS; THE UPPER PLANE OF THE RUMEN AND RETICULUM, WITH THE ŒSOPHAGEAL FURROW.

A, Left sac of the rumen; B, Anterior extremity of that sac turned back on the right sac; C, Its posterior extremity, or left conical cyst; G, Section of the anterior pillar of the rumen; *g*, *g*, Its two superior branches; H, Posterior pillar of the same; *h*, *h*, *h*, Its three inferior branches; I, Cells of the reticulum; J, Œsophageal furrow; K, Œsophagus; L, Abomasum.

number, and represent large muscular pillars, which correspond inferiorly to the notches described at the extremities of the organ. The *anterior pillar* (Fig. 193, G) sends to the inferior wall of the rumen a strong prolongation, directed backwards, and to the left; it is continued on the superior wall by two branches, which separate at an acute angle. The *posterior pillar* (Fig. 193, H), more voluminous than the preceding, has three branches at each of its extremities—a middle and two lateral. The middle branches are carried forwards on the limit of the two sacs, which they separate from one another; that from above meets the corresponding branch from the anterior pillar The

lateral branches diverge to the right and left in describing a curve, and in circumscribing the entrance to the conical cysts, which they transform into two compartments distinct from the middle portion of the sacs of the rumen; the inferior go to meet the superior branches, but do not altogether join them.

The internal surface of the rumen is covered by a multitude of papillary prolongations, dependencies of the mucous membrane. To the right, and in the *culs-de-sac*, these papillæ are remarkable for their number, their enormous development, and their general foliated shape. On the left side they are more rare, particularly on the superior wall, and only form very small mammiform tubercles; they are absent on the muscular columns. This papillary arrangement is still more developed in certain wild Ruminants, and it is scarcely possible to give an idea of their richness in the stomach of the Gazelle.

The interior of the rumen offers for study two openings, situated at the anterior extremity of the left sac: one is the œsophageal orifice, pierced in the superior wall, dilated into an infundibulum, and prolonged into the small curvature of the reticulum by a particular furrow (or channel), which will be described after the latter compartment; the other, placed below, and opposite the preceding, traverses the bottom of the *cul-de-sac* from before to behind, and forms the communication between the paunch and reticulum: it is a very large opening, circumscribed below and on the sides by a septum or semilunar valve, resulting from the junction of the parietes of the rumen with those of the reticulum.

Structure.—Like all the hollow organs in the abdomen, the rumen has three tunics: a *serous*, a *muscular*, and a *mucous*.

The *serous* envelops the organ throughout, except above, in front, and to the left, the point which touches the sublumbar region, and the pillars of the diaphragm, as well as the bottom of the notches which separate the *culs-de-sac* from the extremities. This membrane gives origin, like that of the stomach of the Horse, to a vast duplicature—the great omentum. The arrangement of this, which is somewhat difficult to observe in the Ox, in consequence of the enormous weight of the gastric mass, is readily seen in the smaller Ruminants. It begins at the middle of the faces of the paunch and the fissure intermediate to the two conical cysts, forming a wide envelope that contains the right sac and the abomasum; it becomes attached in passing over the great curvature of the last-named cavity, and is confounded, superiorly and posteriorly, with the great mesentery.

The *muscular coat* is very thick, and forms the internal columns of the viscus. Its fibres are disposed in several layers, whose arrangement is simple, and offers nothing really interesting to study, except in the points where the serous tunic passes from one *cul-de-sac* to another, or from the rumen to the reticulum; there it is often accompanied by thin and wide muscular fasciculi which, like the latter membrane, stretch over the intermediate fissures, and thus become real unitive or common fibres.

The muscular fibres of the rumen present an unmistakable transverse striation—a very rare physical characteristic in the muscular tissue of organic life.

The *mucous membrane* offers some peculiarities, which deserve a few words. The *corium* is very thick, and probably contains some glands, but they must be extremely few. The free face of the membrane is excessively uneven, in consequence of the papillary apparatus mentioned above.

The *papillæ* of the rumen are foliaceous, conical, or fungiform. Those of the first description are much more numerous than the others; they have the shape of an oval, elongated leaf, their summit is wide and rounded, and the base narrow and apparently implanted in the corium. On one face is a little rib that springs from the base and disappears on the widened portion, resembling the principal vein or nervule of a leaf. On the other face, opposite the vein, is a faint longitudinal groove.

These papillæ are constituted by a layer of nucleated connective tissue, covered by epithelium; the former, in the principal papillæ, has on its faces and extremities minute prolongations, resembling on a small scale the secondary papillæ described as existing on the lingual mucous membrane. In the centre of the papillæ are one or two main arteries, derived from the network of the corium. These pass, in a slightly flexuous manner, to the summit, and break up into several branchlets, succeeded by veins, that descend along the surface of the papilla into each of its secondary prolongations.

The conical and fungiform papillæ are few in the left sac, and resemble the papillæ of the same name described on the tongue.

The *epithelium* of the mucous membrane of the rumen is remarkable for its strength and cohesiveness. It belongs to the category of stratified tesselated epithelium, and forms a sheath to each papilla, covering the corium in the interpapillary spaces.

There are frequently found, in opening the rumen of animals just killed, large

exfoliated patches on the surface of this layer. This is a sufficient indication of the activity of the secretion of the epithelium, and the rapidity of its renovation.

RETICULUM (HONEYCOMB) (Figs. 192, 193).—*Situation—Form—Relations.*—This, the smallest compartment, is elongated from one side to the other, slightly curved on itself, and placed transversely between the posterior face of the diaphragm, in one direction, and the anterior extremity of the left sac of the rumen in the other; the latter only appearing, externally, to be a prolongation, or a diverticulum of the rumen.

It has *two faces, two curvatures*, and *two extremities.* The anterior face adheres to the phrenic centre of the diaphragm by cellular tissue. The *posterior face* lies against the anterior extremity of the rumen. The *great inferior* or *convex curvature* occupies the suprasternal region. The *lesser, superior*, or *concave curvature* partly responds to the lesser curvature of the omasum. The *left extremity* is only separated from the rumen by a fissure, which lodges the inferior artery of the reticulum. The *right extremity* forms a globular *cul-de-sac*, in relation with the base of the abomasum.

Interior (Fig. 193).—The internal surface of the reticulum is divided by ridges of the mucous membrane into polyhedral cells, which, in their regular arrangement, look like a honeycomb; they are widest and deepest in the *cul-de-sac*, and become gradually smaller in approaching the superior curvature. The interior of these cells is divided into smaller spaces, included one within the other, by secondary and successively-decreasing septa. The principal septa offer on their free border a series of conical prolongations, with a rough hard summit; while their faces are studded with minute, blunt, or pointed papillæ. The secondary septa also show similar prolongations; and those on their free margin are even more developed than on the chief septa. Lastly, from the bottom of the cells spring up a crowd of long, conical, and very pointed papillæ, resembling stalagmites in their arrangement.

It may be noted that the foreign bodies so frequently swallowed by Ruminants, are usually lodged in the reticulum; therefore it is that at the bottom of the cells are found either small stones, and needles or pins, often fixed in the intermediate septa, or nails, scraps of iron, etc. The interior of the reticulum communicates with the left sac of the rumen by the orifice already described, and with the omasum by a particular opening, placed near the middle of the small curvature, though a little more to the right than the left. This opening, eight or ten times smaller than the preceding, is connected with the infundibulum of the cardia by a remarkable groove (or channel), the *œsophageal*, which will be described separately, as it does not properly belong to the reticulum.

Structure.—The *serous membrane* does not cover all the anterior surface of the organ, as the latter adheres to the posterior face of the diaphragm. The *muscular tunic* is much thinner than that of the paunch, and more fasciculated. The fibres pass in the same direction. The *corium* of the *mucous membrane* sends a prolongation into each of the septa of the alveoli, and into each of the conical papillæ on these septa, or to the bottom of these alveoli. The stratified pavement epithelium is very thick, and its horny layer is very developed at the summit of the papillæ.

ŒSOPHAGEAL GROOVE (Fig. 193).—This gutter is so named because it appears to continue the œsophagus to the interior of the stomach. It extends on the lesser curvature of the reticulum from the cardia to the entrance of the omasum; commencing in the rumen, it belongs to the reticulum for the remainder of its extent. Measuring from six to eight inches in length, this demi-canal is directed from above downwards, and from left to right, between two movable lips, which are fixed by their adherent border to the superior wall of the reticulum. These two lips are thickened at their free margins, which look downwards and to the left. At their origin at the œsophageal infundibulum, they are thin and but slightly elevated; but they become thick and salient on arriving near the orifice of the omasum, which orifice they surround, though they neither meet nor become confounded with each other.

The mucous membrane covering these two lips is much corrugated outwardly and on the free border; but in the interior of the groove it possesses all the characters of the œsophageal mucous membrane in being smooth, white, and ridged longitudinally; near the orifice of the omasum it has some large conical papillæ

If this membrane be removed to study the subjacent tissue, the following arrangement is observed: At the bottom of the channel, and in the space comprised between its two lips, are transverse muscular fibres, which belong to the rumen or reticulum. The lips themselves are entirely composed of longitudinal muscular fasciculi, particularly abundant towards the free border; these fasciculi are confounded with the proper fibres of the stomach towards the extremities of the canal, and are carried from one lip to the other in forming loops around the orifices which communicate by this canal.

OMASUM (*Psalterium*, MANY-PLIES, MANY-LEAVES, or MANYPLUS. Fig. 192).—In the

Ox, this compartment is larger than the reticulum, but in the *Sheep* and *Goat* it is smaller.

Situation—Form—Relations.—Situated above the *cul-de-sac* of the reticulum and the anterior extremity of the right sac of the rumen, this compartment, when distended, has an oval form, is slightly curved in an opposite direction to the honeycomb division, and depressed from before to behind. It has, therefore, an *anterior face*, applied against the diaphragm, to which it is sometimes attached by connective tissue; a *posterior face* lying towards the paunch: a *great curvature*, turned upwards, and fixed in the posterior fissure of the liver by an omental frænum which is continued on the lesser curvature of the abomasum and duodenum; a *lesser curvature*, which looks downwards and responds to the reticulum; a *left extremity*, exhibiting the *neck*, which corresponds to the orifice of communication between the reticulum and many-plies; a *right extremity*, continuous with the base of the abomasum, from which it is separated by a constriction analogous to that of the anterior extremity, but much less marked.

Interior.—This compartment shows in its interior the two apertures placed at its extremities. The right orifice, opening into the abomasum, is much wider than the left, which

Fig. 193

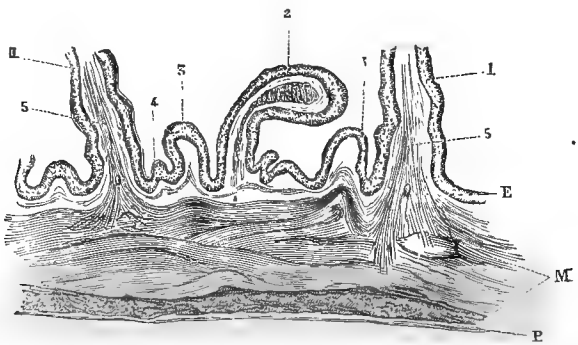

SECTION OF THE WALL OF THE OMASUM OF THE SHEEP: FROM THE GREAT CURVATURE, SHOWING THE ORIGIN OF THE LEAVES.

P, Peritoneum; M, The two muscular layers; E, Epithelium; 1, 1, Principal leaves at their origin; 2, Secondary leaf; 3, 3, Leaves of the third order; 4, Denticulated lamina; 5, 5, Two planes of muscular fibres ascending into the principal leaves, some issuing from the muscular layer of the organ.

communicates with the reticulum. The cavity which these orifices bring into communication with the adjoining compartments, offers one of the most curious arrangements met with in the viscera; it being filled by unequally-developed leaves of mucous membrane, which follow the length of the cavity. These laminæ have an adherent border attached either to the great curvature or to the faces of the organ, and a free concave border turned towards the lesser curvature. They commence at the side of the orifice of the reticulum by denticulated ridges, between which are furrows, and which are prolonged from the base of the leaves to the entrance of the abomasum. At the latter aperture they disappear altogether, after rapidly diminishing in height. Their faces are studded by a multitude of very hard mamillary papillæ, resembling grains of millet, which are more developed and conical on some of the leaves than others. All these lamellar prolongations are far from being of the same extent: twelve to fifteen are so wide that their free border nearly reaches the lesser curvature of the viscus, and between these principal leaves are others which, though regularly enough arranged, are more or less narrower. At first there is remarked a secondary leaf, half the width of the chief ones, between which it is placed; then, on each of its sides, another, one-half narrower; and, lastly, at the base of these, two denticulated laminæ more or less salient. In a general way, the laminæ which are inserted into the great curvature are the longest and widest; and those attached to the faces of the viscus become shorter and narrower as they draw nearer the lesser curvature. The space comprised between these prolongations is always filled by very attenuated alimentary matters, which are usually impregnated by a very small quantity of fluid, but are also often dry, and sometimes even hardened into compact flakes.

Structure.—The *serous layer* is a dependency of the peritoneum, and offers nothing particular; it does not completely cover the anterior face.

The *muscular tunic* is much fasciculated, and thin.

The *mucous membrane* is remarkable for the thickness of its stratified pavement epithelium; all the leaves are formed by two layers of this membrane, laid one against the other; and as their structure is interesting, we will notice it.

The principal leaves are composed of this duplicature of mucous membrane, and two layers of muscular fibres between; these layers are opposite each other at the commencement of the leaf, and separated by a transverse vessel; in the remainder of their extent they are kept apart by the vessels that pass towards the border of the leaf. Their fibres are detached from the surface of the muscular tunic and, at certain points, from its deep layer. In the smaller leaves there appears to be only one layer of muscular fibres; on all the leaves are various-sized papillæ, the smallest of which are like a grain of millet,

Fig. 195.

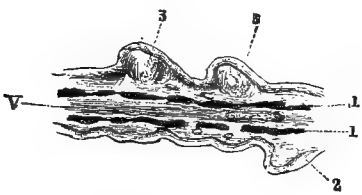

SECTION OF A LEAF OF THE OMASUM.

1, 1, Muscular planes; *v*, vessel; 2, Epithelium; 3, 3, Small-sized papillæ, round and hard.

Fig. 196.

LONGITUDINAL SECTION OF A LARGE PAPILLA FROM THE OMASUM, SHOWING NERVE-CELLS IN ITS INTERIOR.

and have for base a mass of condensed connective tissue, whose superficial fibres form a kind of shell (Fig. 195); the largest are club-shaped. They receive blood-vessels, and we have found in the connective tissue, elements with a somewhat irregular outline, provided with nuclei, which we considered to be nerve-cells (Fig. 196.)

Abomasum (Reed or Rennet. Figs. 192, 193).—*Situation—Form—Relations.*—The abomasum stands next to the rumen for capacity. It is a pyriform reservoir, curved on itself, elongated from before to behind, and situated behind the omasum, above the right sac of the rumen. On the right it touches the diaphragm and the hypochondriac; on the left it is related to the rumen. The *greater curvature*, turned downwards, receives the insertion of the great omentum. The *lesser curvature*, inclined upwards, gives attachment to the serous band already noticed when speaking of the great curvature of the omasum. Its *base* is in contact with the *cul-de-sac* of the reticulum, and is separated from the omasum by the constriction in the form of a thick neck, which corresponds to the communicating orifice of the two stomachs. Its *point*, directed upwards and backwards, is continued by the duodenum.

Interior.—This being the true stomach of Ruminants, the mucous membrane lining its interior acquires all the characters which distinguish that of the stomach of the Carnivora, or that of the right sac of the Horse's stomach. It is soft, spongy, smooth to the touch, vascular, red-coloured, covered by a thin epithelium, and provided with numerous glands for the secretion of the gastric juice. Thinner than in monogastric animals, this tenuity is compensated for by a much greater extent of surface, which is still further increased by numerous lamellar folds. These latter are analogous in constitution to those of the omasum, cross in a very oblique manner the great axis of the abomasum, and altogether affect a kind of spiral arrangement.

The abomasum has two apertures: one, situated at its base, opens into the omasum; the other, placed opposite to the first, and much narrower, is the pylorus, which is circumscribed, as in the other animals, by a muscular ring.

Structure.—The *serous membrane* is continuous with the omenta which abut on the great and lesser curvatures of the viscus. The *muscular layer* is of the same thickness as in the omasum. The *internal tunic* has already been noticed.

Functions of the Stomach in Ruminants.—We cannot pretend to give here a complete history of the phenomena of rumination, but must confine ourselves to describe in a few words what are the principal attributes of each gastric dilatation.

The *rumen* is a sac where the aliment taken during feeding-time is kept in reserve, and whence it is again carried into the mouth during rumination, after having been more or less softened.

The *reticulum* participates in the functions of the rumen, to which it is only a kind of diverticulum. But it is particularly with regard to liquids that it plays the part of a reservoir; the solid substances contained in it being always diluted by a larger quantity of water.

The *œsophageal groove* carries into the omasum the substances swallowed a second time after rumination, or even those which the animal ingests in very small quantity for the first time.

The *omasum* completes the trituration and attenuation of the food, by pressing it between its leaves.

The *abomasum* acts as a true stomach charged with the secretion of the gastric juice; in this reservoir occur the essential phenomena of gastric digestion.

COMPARISON OF THE STOMACH OF MAN WITH THAT OF ANIMALS.

In its form, the stomach of *Man* much resembles that of the Carnivora.

The insertion of the œsophagus, however, does not offer so large an infundibulum. The organ is situated in the left hypochondriac, and is nearly horizontal.

Everywhere the mucous membrane is red and glandular; the muscular fibres are disposed in three planes, as in Solipeds; but the superficial and deep are particularly directed towards the left sac.

THE INTESTINES. (Figs. 204, 205, 206.)

The alimentary canal is continued from the stomach, in the abdominal cavity, by a long tube doubled on itself a great number of times, and which terminates at the posterior opening of the digestive apparatus. This tube is the *intestine.* Narrow and uniform in diameter in its anterior portion, which is named the *small intestine,* it is irregularly dilated and sacculated in its posterior part, the *large intestine.* These two portions, so markedly defined in all the domesticated mammals, are but imperfectly distinguished from one another with regard to the digestive phenomena occurring in their anterior. We will study them in all the animals which interest us, and conclude by a general and comparative examination of the entire abdominal portion of the digestive canal.

Preparation.—The study of the intestines does not demand, properly speaking, any special preparation; it being sufficient to incise the inferior wall of the abdomen to expose these viscera. As their mass, however, is heavy and unmanageable, it is advisable to expel their contents in a manner similar to that recommended for the preparation of the stomach; a puncture at the point of the cæcum allows the escape of the substances accumulated in that reservoir—those which fill the large colon may be removed by an incision made toward the pelvic curvature, and those in the floating colon by the rectum. The small intestine may be evacuated by three or four openings at about equal distances in the length of the viscus. Having done this, inflate the intestines to somewhat of their natural volume; this preparation then permits the general arrangement of the intestinal mass in the interior of the abdomen to be easily studied.

It would be well to remove the entire mass altogether from the body, and lay it out on a table, so as to isolate the various parts, study them in succession, and note their form.

1. *The Small Intestine.* (Figs. 204, 205, 206.)

Length—Diameter.—The small intestine is a long tube, which, in a horse of ordinary height, may average about 24 yards in length, and from 1 to $1\frac{3}{4}$ inches in diameter. This diameter is susceptible of variation, according to the state of contraction of the muscular tunic of the viscus.

Form.—This tube is cylindrical, doubled on itself, presenting two curvatures: one *convex,* perfectly free; the other *concave,* called the *small curvature,* which serves as a point of insertion to the mesentery that sustains

the organ. Removed from the abdominal cavity, freed from the serous folds which suspend it, and distended by air or water, this disposition of the small intestine naturally causes it to twist in a spiral manner.

Course and Relations.—The small intestine commences at the right *cul-de-sac* of the stomach, from which it is separated by the pyloric constriction. At its origin it presents a dilatation which, in form, closely simulates a small stomach, whose curvatures are the inverse of those of the proper stomach. Placed at the posterior face of the liver, this expansion, or head, of the small intestine begins the narrower portion, which at first is directed forward, then bends suddenly backward: thus forming a loop investing the base of the cæcum on the right side; then it is carried to the left in crossing, transversely, the sublumbar region, behind the great mesenteric artery; here it is joined to the origin of the floating colon by a very short serous frænum. It then reaches the left flank, where it is lodged, and where it forms numerous folds that are freely suspended in the abdominal cavity among the convolutions of the small colon. The terminal portion of this conduit, which is easily recognised by the greater thickness of its walls and its smaller diameter, disengages itself from these convolutions to return to the right, and opens into the concavity of the cæcum, below, and a little to the inside of, the point where the large colon has its commencement.

In the language of the schools, this terminal portion is named the *ileum* (εἱλεῖν, *to twist*); the part which is suspended in the left flank, and which forms the principal mass of the intestine, is designated the *jejunum* (*jejunus*, empty); and the curvature formed by this viscera at its origin, from the pylorus to the great mesenteric artery, is termed the *duodenum* (twelve fingers' breadth).

This classical division is, however, altogether arbitrary, and scarcely deserves to be retained, It would be better to divide the intestine into a *fixed* or *duodenal*, and a *free* or *floating portion*.

Mode of attachment.—The small intestine is maintained in its position, at its extremities, by the stomach and the cæcum. But its principal means of fixation consists in a vast peritoneal fold, which, from its use, is named the *mesentery* (μέσον, ἔντερον).

This serous layer presents a very narrow anterior part which sustains the duodenum, and fixes it in such a manner as to prevent its experiencing any considerable displacement. Continuous, in front, with the gastro-hepatic omentum, this portion of the mesentery is successively detached from the base of the liver, the inferior aspect of the right kidney, or even from the external contour of the base of the cæcum, and, lastly, from the sublumbar region, to be soon confounded with the principal mesentery. This becomes wider as it approaches the cæcal extremity, and arises, as from a centre, from the outline of the great mesenteric artery, to spread in every direction, and is inserted into the small curvature of the floating portion of the viscus. The great length of this insertion causes it to become extended in a spiral or screw-like manner, around its point of origin. It may be remarked that the terminal extremity of the intestine is retained between the two serous layers of the mesentery, to a certain distance from its free border. This peritoneal fold consequently forms at this point, at the side opposite to its insertion into the intestinal tube, a particular frænum, which is observed to be carried to the anterior face of the cæcum.

Interior.—The interior of the cylindrical tube formed by the small intestine offers longitudinal folds, which are effaced by distention, except towards the origin of the duodenal portion. Those met with in this situation

possess all the characters of the *valvulæ conniventes* (*valves of Kerkring*) of Man; they resist the effects of traction exercised on the intestinal membranes, and are formed by two mucous layers laid together, with a plentiful supply of connective tissue between them.

The internal surface of the small intestine also offers for study a multitude of villosities and glandular orifices, or follicles, which will be noticed hereafter. It communicates with the inner surface of the stomach by the pyloric orifice, and with that of the cæcum by means of an opening which projects into the interior of that reservoir, like a tap into a barrel. This projection, which is not very marked, is formed by a circular mucous fold, strengthened externally by muscular fibres, and is named the *ilio-cæcal valve* or *valvula Bauhini*. Two additional orifices open on the surface of the small intestine in its duodenal portion, from 5 to 8 inches from the pylorus: one is the orifice common to the biliary and principal pancreatic duct, the other that of the accessory pancreatic duct.

Structure.—The wall of the small intestine, like that of the other hollow viscera in the abdominal cavity, is composed of three tunics:

1. *Serous membrane.*—This envelops the organ everywhere, except at its small curvature, which receives the insertion of the mesentery.

2. *Muscular coat.*—Covered internally by a layer of condensed connective tissue (which is sometimes designated as a fourth tunic) this middle membrane has two planes of fibres: one, superficial, is formed of longitudinal fibres uniformly spread over the whole surface of the viscus; the other, deep-seated, is composed of circular fibres, which are a continuation of those of the pyloric ring.

3. *Mucous membrane.*—This tunic, extremely interesting to study, is soft, spongy, highly vascular, very delicate, and of a reddish-yellow colour. Its external face is loosely adherent to the muscular layer, and its free aspect exhibits the villi, and the glandular or follicular orifices already noticed.

It comprises, in its structure, an epithelial covering, and a mucous derm or corium.

The *epithelial layer* is formed by a single row of cylindrical (or columnar) cells, implanted, by their summit, on the surface of the derm, and lining the interior of the orifices which open on the inner face of the membrane. The base of these cells has an amorphous cushion, which, when they are all united, appears like a thin layer spread on the inner surface of the intestine.

The *mucous derm* is thick and loose in its deeper portion, and is constituted by fasciculi of connective tissue mixed with elastic fibres, and lymphoid elements. On its free surface it exhibits *villosities* and *depressions*, which correspond to the *glands*. It has a *muscular layer*, whose unstriped fibres are arranged in a similar manner to those of the muscular coat of the intestine. Lastly, it contains follicles, and vascular and nervous reticulations. We will study each of these.

The *villi* are the foliated or conical appendages which are found to be most developed in the shortest portions of the intestine. In Birds and the Carnivora they attain their maximum length; while in Ruminants they are in a rudimentary state, though, whatever may be their dimensions, they are always visible to the naked eye. Their number is considerable, and they have been justly compared to the pile of velvet. In structure, they are formed of a small spongy mass of embryonic connective tissue, in the centre of which are one or more lymphatic (or lacteal) vessels, with a

magnificent network of peripheral capillary blood-vessels; the whole being inclosed in a complete epithelial sheath.

Fig. 197.



A. VILLI OF MAN, SHOWING THE BLOOD-VESSELS AND LACTEALS.—B. VILLUS OF A SHEEP.

The *orifices* opening on the intestinal mucous membrane belong either to Brunner's (*duodenal*) glands, or to those of Lieberkühn (*simple follicles*).

Brunner's glands form a continuous layer beneath the duodenal mucous membrane. In their organisation, these small granular bodies are exactly like the *acini* of the salivary glands; each acinus possesses an extremely short excretory duct, that passes through the mucous membrane. (These racemose glands secrete a clear alkaline mucus, which contains no formed elements, such as cells or nuclei.)

Fig. 198.

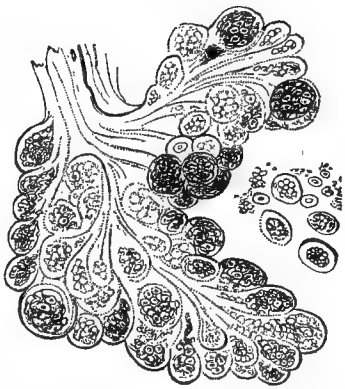

PORTION OF ONE OF BRUNNER'S GLANDS.

The *glands* (or *cryptæ mucosæ*) *of Lieberkühn* or *Galeati* are placed in the substance of the mucous membrane, and are distinguished by their microscopical dimensions, their considerable number, and their tubular form, which has caused each of them to be compared to the finger of a glove; they are implanted perpen-

dicularly in the mucous membrane, and open on its free surface. They are found throughout the whole extent of the intestine, and are lined with columnar epithelium.

The *solitary glands* (*glandulæ solitariæ*, or *lenticular glands*) are round, salient bodies, visible to the naked eye. They are somewhat rare in the small intestine, but are more abundant at the posterior portion of the large intestine. They are formed by a mass of lymphoid elements enveloped by some condensed fasciculi of connective tissue. Above them the mucous membrane is slightly umbilicated, and is destitute of villi and tubular glands, though these are arranged in a circle around the follicles, to form the *coronæ tubulorum*. (The solitary glands usually contain a cream-like secretion, which covers the villi on their free surface.)

Fig. 199

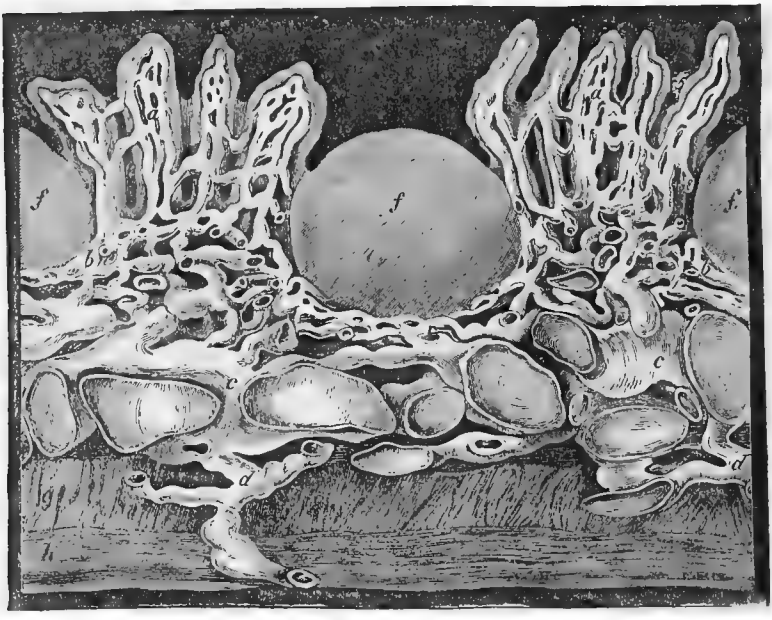

PERPENDICULAR SECTION THROUGH ONE OF PEYER'S PATCHES IN THE LOWER PART OF THE ILEUM OF THE SHEEP

a, *a*, Lacteal vessels in the villi: *b*. *b*. Superficial layer of the lacteal vessels (*rete angustum*); *c*, *c*, Deep layer of the lacteals (*rete amplum*); *d*, *d*, Efferent vessels provided with valves; *e*, Lieberkühn's glands; *f*, Peyer's glands; *g*, Circular muscular layer of the wall of intestine; *h*, Longitudinal layer; *i*, Peritoneal layer.

The *aggregated follicles* (*glandulæ agminatæ*) are nothing more than solitary glands collected together in a limited space, where they constitute what are known as the *glands of Peyer* or of *Pecklin*, or the *honeycomb glands*. Absent in the duodenum, and even at the commencement of the jejunum, these glands, about a hundred in number, are very irregularly placed on the internal surface of the intestine at its great curvature, on the side opposite to the mesentery. Their form is oval or circular, and the

smallest scarcely measure more than some few hundredths of an inch square; while the diameter of the largest increases to $1\frac{1}{2}$ inch.

(Each of these patches is composed of a group of small, round, whitish vesicles, covered with mucous membrane; these vesicles consist of a

Fig. 200.

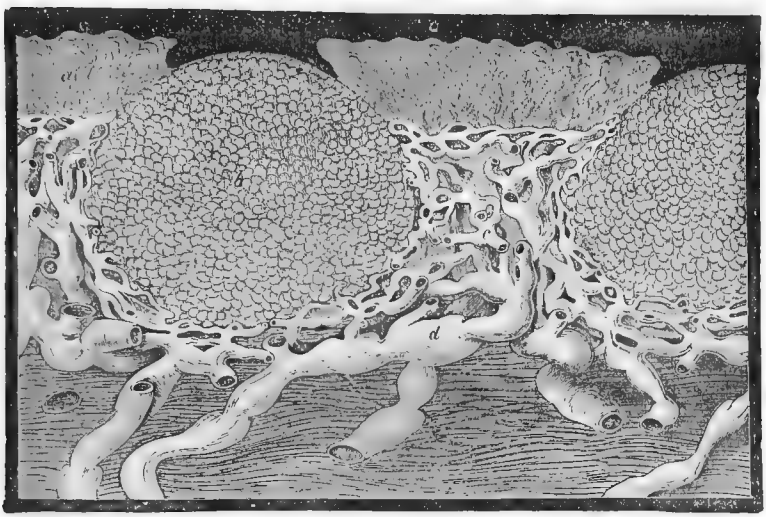

PERPENDICULAR SECTION THROUGH THE INTESTINAL WALL TO SHOW A SOLITARY FOLLICLE.

a, Lieberkühnian glands; *b*, Solitary follicle; *c*, Lacteal vessels surrounding, but not penetrating, the follicles; *d*, Large efferent vessels, provided with valves.

moderately-thick external capsule, having no excretory canal, and containing a similar secretion to that in the solitary follicles. They are surrounded by a zone or band of simple follicles, and the spaces between them are covered with villi. The vesicles are usually closed; though it is supposed they open at intervals to discharge their secretion. The mucous and submucous coats of the intestine are intimately adherent and highly vascular, opposite the Peyerian glands.)

Fig. 201.

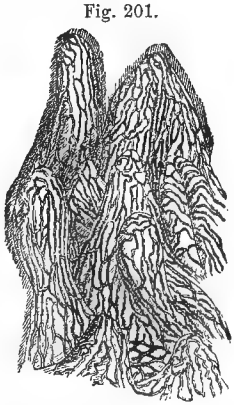

VILLI OF INTESTINE, WITH THEIR CAPILLARY PLEXUS INJECTED.

4. *Vessels and nerves.*—The small intestine receives its arteries almost exclusively from the *great mesenteric artery.* One, which goes to the duodenum, comes from the cœliac trunk. These arteries form a submucous network, from which branches pass inwards and outwards, the first to the muscular and serous tunics, the second to the glands and the villi. A tubular network surrounds each Lieberkühnian gland, and is observed in each villus; while a spherical reticulation surrounds each solitary follicle, loops being given off which penetrate nearly to the centre of the follicle.

The *veins* have the same arrangement, and finally enter the vena portæ.

The *lymphatics* constitute three superposed networks in the mucous membrane. The first is situated around the glandular orifices; it receives

Fig. 202.

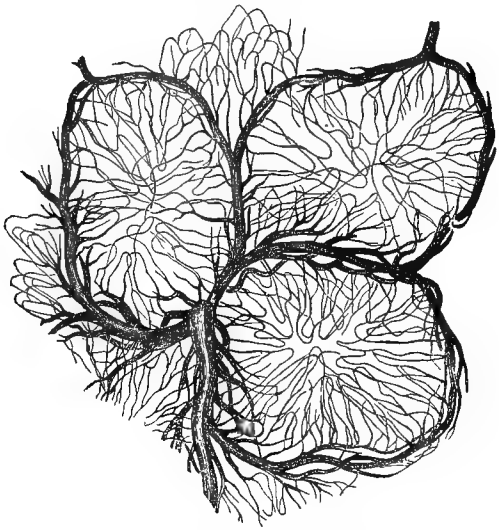

HORIZONTAL SECTION THROUGH THE MIDDLE PLANE OF THREE PEYERIAN GLANDS, SHOWING THE DISTRIBUTION OF THE BLOOD-VESSELS IN THEIR INTERIOR.

the central lacteal from each villus; the second is placed between the glandular and the muscular layer of the mucous membrane; finally, the third exists in the deep portion of the membrane, and communicates with the meshes encircling the closed follicles. The most voluminous emergent vessels pass through the wall of the intestine and accompany the blood-vessels between the layers of the mesentery, entering the mesenteric glands, and terminating in the reservoir of Pecquet (receptaculum chyli).

Fig. 203

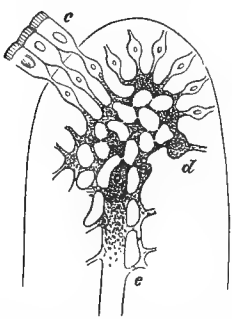

DIAGRAMMATIC REPRESENTATION OF THE ORIGIN OF THE LACTEALS IN A VILLUS.

e, Central lacteal; *d*, Connective-tissue corpuscles with communicating branches; *c*, Ciliated columnar epithelial cells, the attached extremities of which are directly contiguous with the connective tissue corpuscles.

The *nerves* are from the solar plexus; they form a submucous reticulation and a *myenteric plexus*, comprised between the two planes of the muscular tunic.

Microscopic ganglia are found on their course.

Development.—The small intestine shows itself at an early period in the fœtus, and during the fœtal existence of Ruminants preserves a very remarkable predominance over the large intestine: a predominance equally marked in the vessels it receives, for, in a fœtus of five months, we have found the collective arteries of the small intestine equivalent to about ten times the volume of those of the cæcum and colon.

Functions.—It is in this tube, and under the

influence of the hepatic, pancreatic, and intestinal secretions, that are carried on those molecular transformations which properly constitute the digestive function. It is also in this intestine that the absorption of the nutritive principles and fluids commences, and in which the villi are the essential organs.

2. *The Large Intestine.*

The large intestine commences by a vast reservoir in the form of a *cul-de-sac*, named the *cœcum*. It is continued by the *colon*, whose posterior extremity is succeeded by the *rectum*. It is separated from the small intestine by the *ileo-cœcal valve*.

A. *Cœcum.* (Figs. 204, 205, 206.)

Situation—Direction.—This is a very wide and elongated sac, occupying the right hypochondriac, where it affects an oblique direction downwards and ~~backwards~~. forwards

Dimensions—Capacity.—Its length is ordinarily a little over three feet, and it will contain, on an average, about $7\frac{1}{2}$ gallons of fluid.

Form—External surface.—The elongated sac formed by the cæcum is conical in shape, terminating in a point inferiorly, and bulging and curved like a crook superiorly. Externally, it exhibits a great number of circular furrows, interrupted by longitudinal muscular bands, four of which are observed in the middle portion of the organ; they disappear towards its extremities. The bottom of these furrows necessarily corresponds to the internal ridges, and these can be made to disappear by destroying the longitudinal bands, which considerably lengthens the cæcum; thus showing that these transverse puckerings are due to the presence of the riband-like cords, and have for their object the shortening of the intestine without diminishing the extent of its surface.

Relations.—To study its relations, the cæcum is divided into three regions:

1. The *superior extremity, base, arch,* or still better, the *crook,* presents in the concavity of its curvature, which is turned forwards, the insertion of the small intestine and origin of the colon. Placed in the sublumbar region, it responds, superiorly, to the right kidney and to the pancreas, through the medium of an abundant supply of connective tissue. Outwardly, it touches the parietes of the right flank, and is encircled by the duodenum. On the inner side, it adheres by cellular tissue to the termination of the large colon, and is in contact with the convolutions of the small intestine.

2. The *middle portion* (*meso-cœcum*) is in contact, inwardly, with the same convolutions and the large colon; outwardly, with the cartilages of the false ribs, whose curvature it follows.

3. The *inferior extremity,* or *point,* usually rests on the abdominal prolongation of the sternum; but as it is free and can move about in every direction, it often happens that it is displaced from this situation.

Mode of attachment.—The cæcum is fixed to the sublumbar region and the terminal extremity of the large colon by a wide adherent surface. All around this surface the peritoneum, which constitutes the serous covering of the cæcum, is gathered into folds, and in passing from the cæcum to the origin of the colon, this tunic forms a particular short and narrow frænum designated the *meso-cœcum.*

Interior.—Viewed internally, the cæcum offers for study the *valvulæ* or transverse ridges corresponding to the external furrows. We have already seen that these are due to simple circular folds, comprising in their thickness the three tunics of the organ, and that they are susceptible of being effaced by distention, to re-appear afterwards in varying number and position; differing widely, in this respect, from the valvulæ conniventes of the small intestine.

Two orifices, placed one above the other, open on the internal surface of the cæcum, at the point corresponding to the concavity of the crook. The

Fig. 204

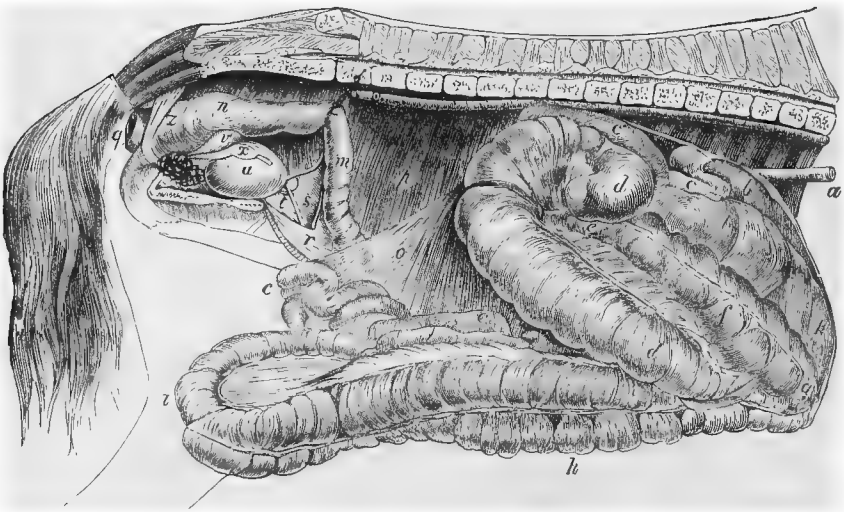

GENERAL VIEW OF THE INTESTINES OF THE HORSE; SEEN FROM THE RIGHT SIDE, WITH THE PELVIC CURVATURE AND A PORTION OF THE SMALL INTESTINE CARRIED BEYOND THE ABDOMINAL CAVITY.

a, Œsophagus; *b*, Right sac of the stomach; *c*, Small intestine, showing its origin, or duodenal portion encircling the base of the cæcum; *d*, Cæcum; *e*, Origin of the large colon; *f*, First portion of the large colon; *g*, Suprasternal flexure; *h*, Second portion of the large colon; *i*, Pelvic flexure; *j*, Third portion of the large colon; *k*, Diaphragmatic flexure; *l*, Fourth portion of the large colon; *m*, Termination of the free colon; *n*, Rectum; *o*, Mesentery proper; *p*, Colic mesentery (meso-colon); *r*, Neck of the vaginal canal; *s*, Spermatic vessels; *t*, Deferent canal; *u*, Bladder; *v*, Vesiculæ seminales; *x*, Pelvic enlargement of the deferen canal; *y*, Prostate; *z*, Suspensory ligament of the penis.

most inferior represents the terminal opening of the small intestine at the centre of the *ilio-cœcal valve*, whose presence in the domesticated animals has, in consequence of a wrong appreciation of analogies, been denied; it is nothing more than the projection described as being made by the end of the small intestine. The second opening, placed about 1½ or 2 inches above the preceding, and puckered around its margin, establishes a communication between this viscus and the colon. If this opening be compared with the capacity of the canal which begins from it, it will be remarked that it could scarcely be narrower.

Fig. 205.

A, The duodenum as it passes behind the great mesentric artery; B, Free portion of the small intestine; C, Ileocæcal portion; D, Cæcum; E, F, G, Loop formed by the large colon; G, Pelvic flexure; F, F, Point where the colic loop is doubled to constitute the suprasternal and diaphragmatic flexures.

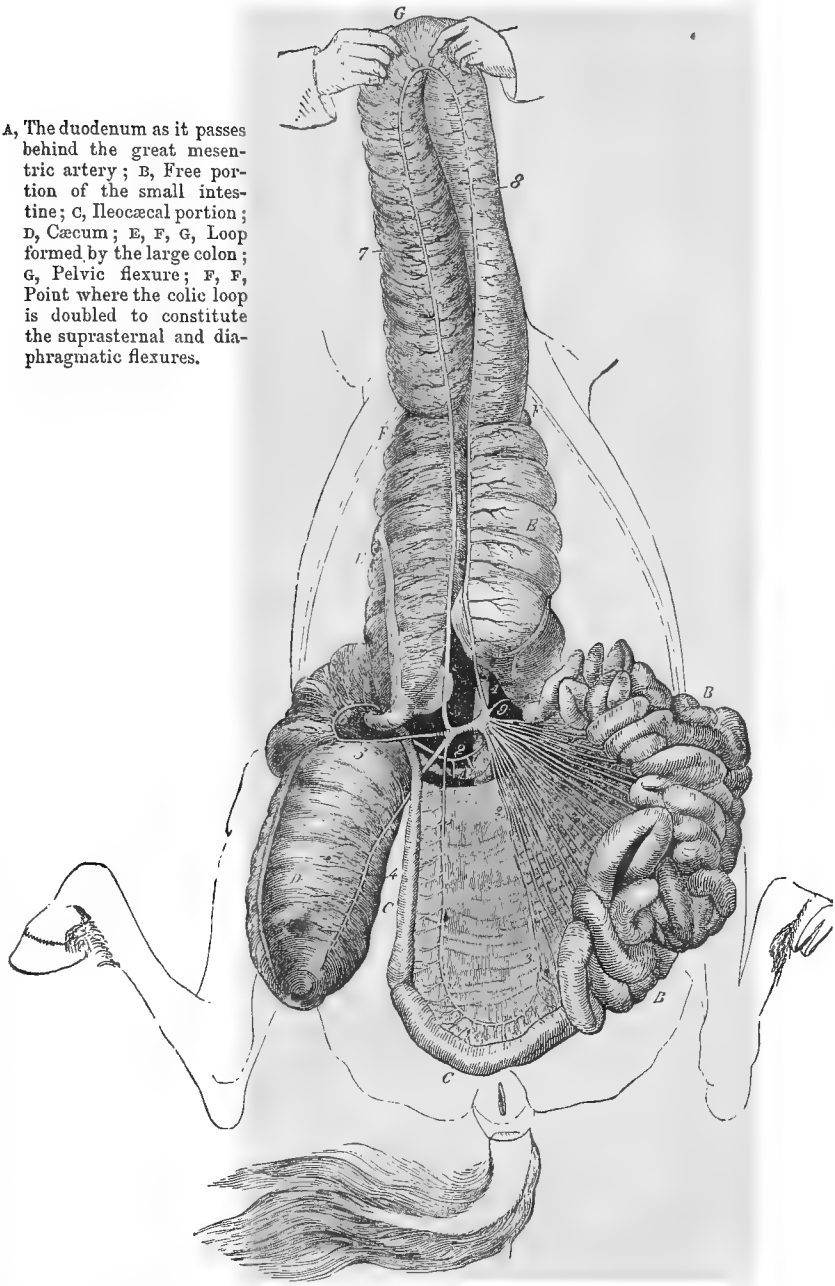

GENERAL VIEW OF THE HORSE'S INTESTINES; THE ANIMAL IS PLACED ON ITS BACK, AND THE INTESTINAL MASS SPREAD OUT.

Structure.—The *serous tunic* does not call for any notice beyond that already given when speaking of the attachments proper to the cæcum. The *muscular tunic* is formed of circular fibres, crossed externally by longitudinal bands, which maintain the organ in transverse folds. The *mucous membrane* is thicker than that of the small intestine, and is also distinguished from it by the absence of the *Brunnerian* and *aggregated glands*. It has, however, the solitary follicles and crypts of Lieberkühn, as well as some few intestinal villi. The *blood-vessels* are the *cæcal arteries* and *veins*. The *lymphatics* pass to the sublumbar receptacle; and the *nerves* are derived from the great mesenteric plexus.

Functions.—The cæcum serves as a reservoir for the enormous quantities of fluid ingested by herbivorous animals. The greater part of this fluid, in its rapid passage through the stomach and small intestine, escapes the absorbent action of the villi and accumulates in the cæcum, where it may be said to wash the alimentary mass with which it comes in contact; thus dissolving the soluble and assimilable matters this mass may yet contain, and favouring their entrance into the circulation through the immense absorbing surface formed by the mucous membrane of the large intestine.

It does not appear that the aliment is submitted in the cæcum to any transformation, all the molecular changes of the digestive process, properly speaking, having been accomplished when the mass reached the interior of this viscus.

B. *Colon.*

The colon is divided into two portions, which differ from each other in

Fig 206.

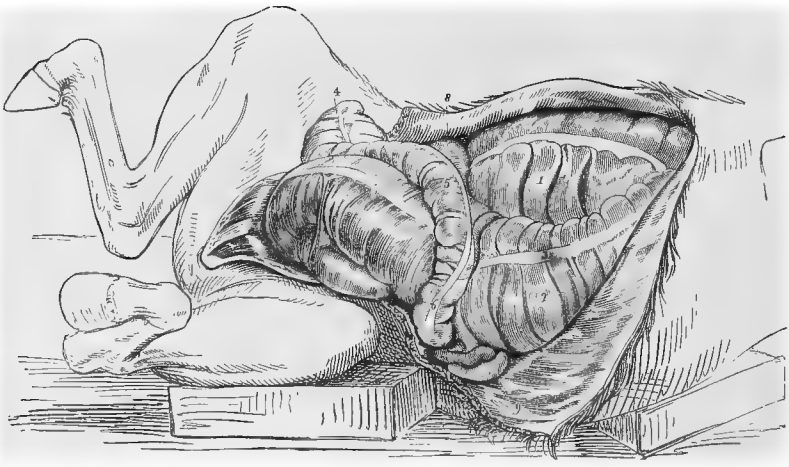

THE COLON OF THE HORSE.

1, First portion ascending to form the suprasternal flexure; 2, Second portion descending to form the pelvic flexure, 7; 3, 6, Longitudinal muscular bands; 4, Point of the cæcum, 5; 8, Duodenum; 9, Small intestine.

volume, and in the disposition they affect in the abdominal cavity. The first is the *large* or *double colon;* the second, the *small* or *floating colon.*

The Large or Double Colon (Figs. 204, 205, 206).—This intestine

begins at the cæcum, and terminates by suddenly contracting at the origin of the small colon.

Length—Capacity.—It is from about 10 to 13 feet in length, and has a medium capacity equal to 18 gallons.

Form—General disposition.—Removed from the abdominal cavity, and extended on a table or on the ground, this portion of the intestine appears as a voluminous canal, offering a succession of dilatations and contractions; its surface being traversed by longitudinal bands, and sacculated and furrowed transversely for a great part of its extent, exactly like the cæcum. It is also doubled in such a manner as to form a loop, whose two branches are of equal length and are held together by the peritoneum, which is carried from one to the other; so that the terminal extremity of the large colon returns towards the point of its origin.

But this colic flexure, owing to its length, could not be contained in the abdomen; and it is therefore doubled in its turn from above to below and from right to left (at the points F, F, in Fig. 20) and forms curvatures which will be noticed presently. From this circumstance, it happens that the large colon, studied in the abdominal cavity, is divided into four portions lying beside each other in pairs; so that a transverse section of that cavity, made in front of the base of the cæcum, would give for this intestine the results indicated in the annexed figure.

Fig. 207.



PLAN OF THE COLON.

Course and Relations.—In following the course of the large colon from its origin to its termination, in order to study its four portions in their normal relations, the following is observed:

Commencing from the arch of the cæcum, the colon is directed forwards, above the middle portion of that reservoir, which it follows to its point. Arrived at the posterior face of the diaphragm at its most declivitous part, it bends downwards and to the left, forming its first or *suprasternal flexure*, because it rests on the xiphoid cartilage of the sternum (Fig. 204, *g*). Here begins the second portion of the viscus, which is in immediate contact with the inferior abdominal wall, and extends backwards into the pelvic cavity, where it is inflected to the left to constitute the *pelvic flexure*. This curvature, the centre of the colic loop, responds to the rectum and bladder, as well as to the deferent canals, or the uterus and ovaries, according to the sex. It is succeeded by the third portion of the colon, which is carried forward, above, and to the left of the preceding. Bound to the second division by peritoneum and connective tissue, this new section reaches the phrenic centre, and is then doubled upwards and to the right. The flexure arising from this third duplicature is called the *diaphragmatic*, because of its relations with the musculo-aponeurotic membrane which partitions the great cavity of the trunk, or the *gastro-hepatic curvature*, in consequence of its lying equally against the liver and stomach (it is also designated the *sigmoid flexure*) (Fig. 204, *k*). To this flexure succeeds the fourth and last portion of the large colon, bound to the first portion, as the second is to the third. This extends, posteriorly, to the base of the cæcum, where it terminates in a sudden contraction, and is continued by the small colon; it occupies the sublumbar region, and through the medium of a cellular layer is applied against the inferior face of the pancreas and the inner side of the cæcal arch.

Mode of attachment.—The large colon can be easily displaced in the

abdominal cavity. It is nevertheless fixed: 1, By its origin, to the cæcum and to the serous frænum which attaches it to that receptacle; 2, By the adherence of its terminal portion to the pancreas and the cross of the cæcum; 3, By the mesocolon. The latter ligament forms, in the concavity of the pelvic flexure a kind of racket, the handle of which is prolonged to a short distance between the two branches of the colic flexure. Beyond this, these two branches are directly placed side by side.

External surface.—We have seen that the large colon does not offer the same diameter everywhere, and that it is bosselated, plicated, and traversed by longitudinal bands; it is, however, important to study in detail this disposition of its external surface in each of the regions already named.

At its origin, the large colon is extremely narrow, and scarcely equal to the small intestine. But it soon dilates and assumes a considerable volume, which it preserves beyond the pelvic flexure. It then becomes progressively constricted to the middle of its third portion, where the diameter, reduced to its minimum, is yet much greater than at the origin of the first portion. Near the diaphragmatic flexure, the large colon is again gradually dilated, and finishes by acquiring, near its termination, the greatest volume it has yet exhibited. The muscular bands which maintain its transverse folds throughout the whole extent of its first dilated portion, are four in number. Three disappear in arriving towards the pelvic curvature, and the only one remaining is that which is placed in the concavity of that curvature. At the second dilatation there are three bands, two of which are prolonged to the floating colon. The transverse folds formed by these flat bands are but faintly marked towards the pelvic curvature, and are altogether absent in the narrow portion succeeding it; it is only in the whole extent of the first dilatation that they are deepest and most numerous.

Internal surface.—This is exactly like that of the cæcum.

Structure.—The *serous membrane* envelops the whole organ, except in those places where it comes in contact with itself or with other viscera. So it happens that the peritoneum, in passing from the sublumbar region to the last portion of the colon, does not cover the surface which adheres by cellular tissue to the inferior aspect of the pancreas and cæcum; neither, in being carried from one branch of the colic flexure to the other, does it envelop their opposed sides, except at the pelvic flexure, where it forms the *mesocolon.*

The *muscular tunic* does not differ in its arrangement from that of the cæcum; neither does the *mucous membrane.* The *arteries* emanate from the great mesenteric; they are the *two colic arteries.* The two satellite *veins* soon form a single trunk, which enters the vena portæ. The *lymphatics* empty themselves into Pecquet's reservoir. The *nerves* emerge from the great mesenteric plexus.

The Small, or Floating Colon (Fig. 204).—This is a bosselated tube, which succeeds the large colon, and is terminated in the pelvic cavity by the rectum.

Length—Form—Course—Relations.—This tube is about 10 feet in length, and offers a disposition analogous to that of the small intestine, except that it is double the size of that viscus, is regularly bosselated on its surface, and is provided with two wide and thick longitudinal bands, one on the side of its great, the other on its small, flexure. Arising from the terminal extremity of the large colon, to the left of the cæcum, where it responds to the termination of the duodenum, and where it receives the insertion of the great omentum, this intestine is lodged in the left flank, forming folds which

are mixed with the convolutions of the small intestine. It afterwards passes into the pelvic cavity, to be directly continued by the rectum.

Mode of attachment.—Floating like the small intestine, the small colon is suspended by a serous layer, exactly similar to the mesentery proper, though wider, and named the *colic mesentery*. This mesentery is detached from the sublumbar region, not from around a central point, but from a line extending from the great mesenteric artery to the bottom of the pelvic cavity. It is narrower at its extremities than in its central portion.

Interior.—The internal surface of the floating colon shows valvular folds, analogous to those of the cæcum and large colon. It is in the intervals between these that the fæcal matters are moulded into balls.

Structure.—The *serous membrane* is without special interest, and the *muscular tunic* is similar to that of the large colon. The *mucous membrane* is also the same. These membranes receive their blood by the *small*, and a branch of the *great, mesenteric artery*. A venous trunk, passing between the layers of peritoneum composing the mesentery, carries back the blood to the vena portæ. The *lymphatics* are nearly as fine and as numerous as those of the small intestine; they enter the same confluent, the reservoir of Pecquet.

Functions of the Colon.—In this intestine is accomplished the absorption of fluids, and of soluble alible matters. When the alimentary mass arrives in the small colon, deprived of its assimilable principles and charged with excretory substances thrown out on the surface of the intestinal tube, it loses its name and receives that of *excrement* or *fæces*. These excrements, compressed by the peristaltic contractions of the muscular tunic, are divided into little rounded or oval masses, which find their way to the rectum, where they accumulate, and whence, in due course, they are expelled.

C. *Rectum.* (Fig. 204.)

The rectum extends, in a straight line, from the entrance to the pelvic cavity to the posterior opening of the digestive canal, or *anus*. It is nothing more, properly speaking, than the extremity of the small colon, the limit which separates them being somewhat arbitrary; it differs from that viscus, however, in having no ridges, and in its walls being thicker and more dilatable, so that it can be distended into an elongated pouch, and form a reservoir or receptacle for the excrementitious matters until they are expelled.

Relations.—It responds, superiorly, to the roof formed by the os sacrum; inferiorly, to the bladder, the deferent canals, vesiculæ seminales, prostate gland, Cowper's glands, or to the vagina and uterus; laterally, to the sides of the pelvis.

Mode of attachment.—There ought to be considered as such: 1, The posterior extremity of the colic mesentery, representing the *mesorectum;* 2, An orbicular fold, constituted by the peritoneum in its circular reflection around this viscera at the extremity of the pelvic cavity; 3, The suspensory ligaments of the penis, which, joining under the rectum, form a ring encircling the posterior extremity of the intestine (*see* Fig. 204 and the description of the penis); 4, A thick, triangular fasciculus, comprising two lateral parts, and composed of white muscular fibres; this fasciculus, which is really a prolongation of the muscular tunic of the viscera, is detached from the rectum above the anus, and is attached to the inferior aspect of the coccygeal bones, between the inferior sacro-coccygeal muscles, where its outline can be seen beneath the skin when the tail is elevated.

STRUCTURE.—The *serous membrane* does not envelop the whole of the organ; that portion which traverses the bottom of the pelvic cavity being left uncovered by it. The *muscular layer* is very thick, and composed of large, longitudinal, and slightly spiral fasciculi, beneath which are annular fibres. The *mucous membrane*, loosely attached to the muscular tunic, shows longitudinal and transverse rugæ. The *small mesenteric* and the *internal pudic artery* (*artery of the bulb*) supply these membranes with blood. The nerves are derived from the *pelvic* or *hypogastric plexus.*

ANUS.—The anus, or posterior opening of the digestive tube, is situated at the posterior extremity of the rectum, under the base of the tail, where, in Solipeds, it can be seen forming a rounded prominence which diminishes with age. It is the border or margin of this orifice, which is corrugated like the mouth of a draw-purse, where the intestinal mucous membrane meets with, and is continued by, the external skin.

In proceeding from within outwards, there are found the following elements entering into the structure of the anus: 1, The mucous membrane of the rectum; 2, The prolongation of the circular and longitudinal fibres of the muscular layer, forming what is named the *internal sphincter;* 3, A *sphincter muscle*, composed of red fibres, which receives the insertion of a *retractor;* 4, The fine, hairless, and closely-attached skin, which covers the sphincter; though destitute of hair, it is rich in sebaceous follicles. We will only notice the muscles.

The SPHINCTER OF THE ANUS, (*sphincter ani*) is formed of circular fibres, some of which are fixed above, under the base of the tail, and are confounded, below, with the muscles of the perineal region. Comprised between the skin and the prolongation of the muscular layer of the rectum, this muscle is (during life) in a state of almost permanent contraction to keep the anal aperture closed, it being only relaxed during the expulsion of fæcal matters.

The RETRACTOR OF THE ANUS, or ISCHIO-ANAL muscle (*retractor ani*), is a wide band attached to the internal surface of the ischiatic ligament (sacro-ischiatic), and even to the supercotyloid crest, by aponeurotic fibres. The fasciculi composing this band are all parallel to each other, while their posterior extremities are insinuated beneath the sphincter, and are confounded with its fibres. This arrangement of the retractor ani clearly indicates that it pulls the anus forwards, re-establishing it in its normal position after expulsion of the fæces: an act which always results in carrying the posterior extremity of the rectum backwards.

These two muscles are of a red colour, and belong to those of animal life. Their vessels are derived from the same sources as those of the rectum. The hæmorrhoidal nerve supplies them both with filament

DIFFERENTIAL CHARACTERS OF THE INTESTINES IN OTHER THAN SOLIPED ANIMALS.

In the domesticated animals, the intestines vary as much in their dimensions, length, and diameter, as in their general disposition.

1. *The Intestines of Ruminants.* (Fig. 208.)

The small intestine of the *Ox* floats at the extremity of a broad mesenteric lamina, which is narrower in front than behind, plane throughout, except at its intestinal border, which is of considerable length, and is folded into a multitude of festoons. Twice the length of the small intestine of the Horse—averaging about 49 yards—it is about one-half its diameter. The duodenum, at first sustained by the omentum, which attaches the small curvature of the fourth compartment of the stomach to the posterior fissure of the liver, forms a particular loop, which is in contact with the sublumbar region before it goes to be suspended by the large mesentery, and to be continued by the convolutions of the floating portion. The ileum terminates as in the Horse. The

Peyerian glands are less numerous on the internal surface of the small intestine than in Solipeds, though they are larger in size. In the *Sheep* and *Goat*, they are often more than eight inches in length, and extend to Bauhin's (ileo- cæcal) valve.

The *cæcum* is nearly cylindrical in form, without bulges or longitudinal bands. The extremity of the *cul-de-sac*, rounded and globular, floats freely in the abdominal cavity, and is directed backwards. At its opposite extremity, the cæcum is continued directly with the colon, without forming a crook, after having received the insertion of the small intestine.

In the *Ox*, in the vicinity of this insertion, there are traces of one of Peyer's patches. In the *Sheep* and *Goat*, these patches are very numerous.

The *colon*, sustained between the layers of the great mesentery, on the margin of which is suspended the small intestine, is rolled upon itself in such a way as to form a certain number of elliptical convolutions, by at first making several concentric spiral turns, which leave a certain interval between them for the reception of the excentric convolutions. The last spiral turn is a little distant from the others; in the smaller Ruminants,

Fig. 208.

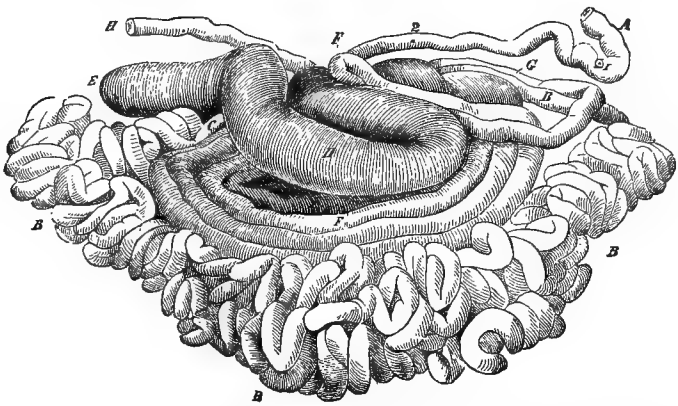

GENERAL VIEW OF THE INTESTINES OF THE OX; RIGHT FACE.

A, Origin of the duodenum; B, Floating portion of the small intestine; C, Termination of the small intestine; D, Cæcum; E, Its point directed backwards; F, Flexure of the large colon at its termination; G, H, Terminal portion of the intestine.—1, Insertion of the ductus choledochus; 2, Insertion of the pancreatic duct.

it is close to the insertion of the mesentery in the small intestine, which it follows to near the duodenum in describing regular festoons. On reaching the trunk of the great mesenteric artery, this convolution passes to the right, and is directed backwards, then forwards, thus forming a flexure, and turns back in company with the duodenal flexure. The colon then continues in a direct line to the rectum, attached to a short mesenteric layer, which, by its position, resembles the large suspensory band of the floating colon in Solipeds.

The calibre of this intestine is at first equal to that of the cæcum; but it soon becomes constricted, and maintains a uniform diameter, which scarcely exceeds that of the small intestine of the Horse. The muscular layer has the same arrangement as in the latter, although it is not covered in all its points by the serous tunic, in consequence of the situation of the colon between the two layers of the mesentery. In emaciated animals, however, it may be remarked that the serous covering furnished by these layers to the muscular coat of the colon is more extensive than at first we might be led to think; on the left side, the prominences of the spiral convolutions are found to stand in relief on the surface of the mesentery, and it is therefore more completely enveloped in the corresponding peritoneal layer.

From this description, it will be seen that in the large intestine of Ruminants the *cæcal* division is well defined, but that the division of the *colon* into a *large* or *double*, and a *small* or *floating portion* can scarcely be made; unless we regard as the large or flexured colon the spiral folds contained between the layers of mesentery, and see the floating portion in the posterior extremity of the tube lying at first against the sublumbar wall

of the abdomen, and afterwards suspended by the short mesenteric frænum which resembles the great colic mesentery of Solipeds. It is worthy of remark that the great mesenteric artery goes to the first, and the small mesenteric to the second portion, as in the Horse.

Fig. 209.

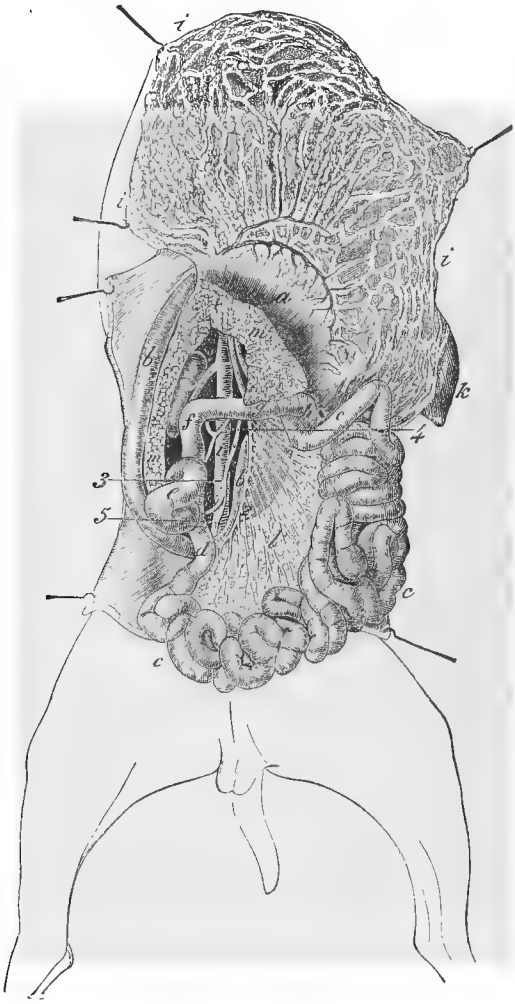

INTESTINES OF THE DOG.

a, Stomach; *b*, Duodenum; *c*, Jejunum; *d*, Ileum; *e*, Cæcum; *f*, Ascending colon; *g*, Transverse colon; *h*, Origin of descending colon; *i*, Great omentum; *k*, Spleen; *l*, Mesentery; *m*, Pancreas.—1, Aorta; 2, Great mesenteric artery; 3, Artery of the duodenum; 4, Artery of the large intestine; 5, Small mesenteric artery.

Measured throughout its whole extent, from the cæcal *cul-de-sac* to the anus, the large intestine of the *Ox* is from 33 to 39½ feet. It is, therefore, longer than that of the Horse; but its capacity is much less, for it does not exceed from 6½ to 7½ gallons.

2. *The Intestines of the Pig.*

The average length of the *Pig's* intestines is about 72 feet, of which 56 go to the small, and 16 to the large intestine.

In their general disposition they bear some resemblance to those of the Ox; though only the last portion of the colon is included between the layers of the mesentery, it being, for the remainder of its extent, outside that membrane, where it forms a distinct mass.

Among the peculiarities of the *small intestine*, may be cited the presence of an immense Peyerian gland, which occupies the latter portion of the canal, where it figures as a band measuring from 5 to 6½ feet in length.

The *cæcum* shows, on its internal surface, some Peyerian patches, it is bosselated, as in the Horse, and is furnished with three longitudinal bands. The *colon* has two of these muscular bands in a portion of its track, and even three towards the cæcum; as well as some transverse folds. It is doubled exactly as in the Ox

3. *The Intestines in Carnivora.* (Fig. 209.)

The intestines of the Carnivora are remarkable for their shortness and small volume. In a *Dog* of ordinary size, they scarcely measure more than 14 feet in length, of which only 24 to 28 inches are for the large intestine. In the *Cat*, the latter is about one-half this length, and the entire extent of the viscus is equal to about 6 or 7 feet. With regard to

capacity, M. Colin gives the following averages: for the Dog's small intestine, 1 quart; that of the Cat, 1-4th of a pint; the large intestine in the Dog, nearly 1 quart, and in the Cat, a trifle more than 1-4th of a pint.

The *small intestine*, suspended at the extremity of a mesentery similar to that of Solipeds, rests on the inferior abdominal wall. It is distinguished by the thickness of its parietes, the length and number of its villosities, which cover its inner surface, and which are even found accumulated on Peyer's patches. These latter number about 20 in the *Dog*, and 5 or 6 in the *Cat*. The *cæcum* forms only a small, spirally-twisted appendix, lined by a plicated and very follicular mucous membrane, particularly in the *Cat*, which shows at the bottom of the *cul-de-sac* a true Peyer's gland.

The *colon* is scarcely larger than the small intestine, and is neither sacculated nor furnished with longitudinal bands. In its short course, it is disposed somewhat like the same intestine in Man; and, as in him, it may be divided into the *ascending* (Fig. 209, *f*), *transverse* (*g*), and *descending colon* (*h*), which is continued directly with the rectum.

Near the anus, this latter viscus presents on its sides two narrow apertures leading to two glandular pouches, which are filled with a brownish matter, that has a strong and fetid odour, and which is secreted by the glands covering the internal wall of these diverticuli.

(Measurements of the intestines, always a subject of interest to comparative anatomists, have been frequently made by different authorities. Leyh gives the length of the *Horse's* intestines as from 10 to 12 times that of its body; those of the *Ox* as from 20 to 22 times; the *Sheep* and *Goat* from 26 to 28 times; the *Pig* from 15 to 17 times; the *Dog* from 4½ to 5½ times; and the *Cat* from 4 to 5 times.

According to Hering, the entire length of the intestines of the *Horse* averages 100 Wurtemburg feet, 70 of which are for the small intestine, and 30 for the large. In the *Ox* they are 150 feet, 120 being for the small intestine, and 30 for the large; in the *Sheep* they average 90 feet, 65 to 70 being allowed for the small intestine; those of the *Goat* measure 95, the small intestine being 70; in the *Pig* they are 90 feet, 72 of which are for the small intestine, and 18 for the large; large-sized *Dogs* averaged from 23 to 27 feet, 20 to 22 of which were for the small intestine; small dogs had only 6 feet in many instances. The *Cat* has from 4 to 5 feet.)

Fig. 210.

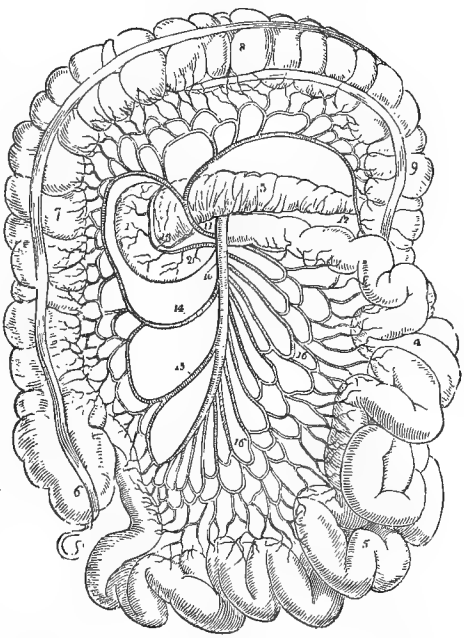

THE HUMAN INTESTINES AND SUPERIOR MESENTERIC ARTERY.

1, Descending portion of the duodenum; 2, Transverse portion; 3, Pancreas; 4, Jejunum; 5, Ileum; 6, Cæcum and appendix vermiformis; 7, Ascending colon; 8, Transverse colon; 9, Descending colon; 10, Superior mesenteric artery; 11, Colica media; 12, The branch that inosculates with the colica sinistra; 13, Pancreatico-duodenalis inferior; 14, Colica dextra; 15, Ileo-colica; 16, 16, Vasa intestinis tenuis.

COMPARISON OF THE INTESTINES OF MAN WITH THOSE OF ANIMALS.

Not unfrequently the *small intestine* of Man is divided into *duodenum* and *small intestine proper*. The *duodenum* is from 9 to 11 inches; is dilated at its origin, and firmly attached to the posterior face of the liver by a peritoneal fold, and to the right of the sublumbar region by connective tissue. It describes the arc of a circle, in the concavity of which is lodged the right extremity of the pancreas, and not the cæcum as in Solipeds.

The *small intestine proper* is suspended by a mesentery somewhat similar to that of the Horse. Its length varies much—from 13 to 26 feet. Its internal face has a large number of transverse rugæ, the *valvulæ conniventes*. It also shows from 20 to 25 Peyer's patches, particularly in the ileo-cæcal portion. Its structure is like that already described.

In the *large intestine* is recognised the cæcum, colon, and rectum.

The cæcum is a small reservoir placed in the right iliac fossa, a little obliquely downwards and to the left. It commences at the ileo-cæcal valve, has an average length of about 2½ inches, and terminates by a rounded extremity with a small hollow prolongation, averaging 3 inches in length, the *cæcal* or *vermiform appendix*. The mucous membrane is like that of animals, and the muscular tunic is the same.

The human *colon* is regularly sacculated, like the small colon of the Horse; it begins in the right iliac fossa, above the valvula Bauhini; it ascends to the lower face of the liver, passes abruptly across from right to left, and, arriving at the spleen, again changes its direction downwards to the iliac fossa; it then again describes the iliac S, to reach the mesial line, where it is continued by the rectum. From this course, the colon has been divided into three portions: the *ascending colon, transverse colon*, and *descending colon*. In the ascending and transverse colon are observed three series of sacculi, separated by three muscular longitudinal bands; the descending colon has only two.

There is scarcely anything special to note in the *rectum* and *anus*, except that they, and especially the latter, are very rich in arteries and varicose veins, and that the anus is separated from the rectum by small cavities open in front, and which are found in the Dog; these are the *sinuses of Morgagni*.

GENERAL AND COMPARATIVE SURVEY OF THE ABDOMINAL OR ESSENTIAL PORTION OF THE DIGESTIVE TUBE.

We have terminated the description of the anatomical characters which distinguish the essential portion of the alimentary canal in all the domesticated animals, and what gradations has this study revealed! Let us recapitulate and compare them, before showing the admirable harmony which pervades these diverse arrangements, and adapts them to the variations in general organisation, habits, and instincts.

In the Carnivora which subsist on flesh (*Dog* and *Cat*), we have seen a very ample stomach, secreting a gastric fluid throughout the whole extent of its mucous membrane, and intestines, (relatively) extremely short.

In the Omnivora, or mammalia which live on a mixed diet (*Pig*), we have found a small portion of the internal surface of the stomach occupied by a mucous membrane unfitted to secrete gastric juice, and the intestines relatively of much more considerable capacity than in Carnivora.

With the Herbivora, which derive their nourishment exclusively from the vegetable kingdom (*Ruminants* and *Solipeds*), the surface destined for the production of the gastric juice also singularly diminishes in extent, although the stomach in some of these animals is remarkable for its extraordinary development. But to compensate for this, the capacity of the intestinal canal assumes considerable proportions, and in the various species is in directly inverse relation to the area of the gastric surface. This surface being relatively more extensive in Ruminants than in Solipeds, all these animals ought to be classed in an inverse order with regard to the development of the intestinal surface.

Finally, in considering as the internal surface of the stomach (a point of view quite rational) only those portions of the mucous membrane organised for the secretion of the gastric juice, we are led to recognise that this surface is in inverse proportion to that of the intestine; that it reaches its highest degree of development in Carnivorous animals; and that it is reduced to the smallest dimensions in Solipeds, animals which, on the contrary, present a very great development of the intestinal surface.

The nature of the aliment readily accounts for these remarkable differences. The Carnivora, living on substantial food, take it in very large quantity, because they are exposed to frequent fastings; it is, therefore, necessary that they should have a stomach large enough to contain the ingested substances, and to secrete the amount of gastric juice needed to transform them into assimilable materials. If these animals have a short and narrow intestine, it is because a small surface only is required to absorb the products of digestion, these being mixed with but a minimum quantity of non-nutritive substances, and readily come in contact with the absorbing membrane.

With regard to the Herbivora, their food contains a trifling proportion of nutritive elements inclosed in an extremely abundant matrix, and being compelled to ingest great

quantities at short intervals, the stomach, properly called, can only be a temporary receptacle for the aliment, which passes rapidly through it after being impregnated by the gastric juice. The surface which secretes that fluid is also singularly reduced, because if it has to perform its functions more frequently than in Carnivora, it is not required to display so much activity in a given time. If, on leaving the stomach, the alimentary matters encounter a vast intestinal surface, it is in order that the reparative materials dispersed in the alimentary mass may not escape the absorbent action of that surface, and may be the more effectually brought into contact with it. We have this exemplified in Ruminants; owing to their double mastication and the triturating action of the *many-plies*, their food arrives in the stomach proper more comminuted and better attenuated than in the Horse; the mass, more finely broken up, retains less of the assimilable and reparative matters, and these are more easily seized by the absorbing surface; and, as a necessary consequence, the intestinal tube, although longer than in Solipeds, is far from offering the same capacity.

Analogous considerations explain the reason for the intermediate conformation of the digestive canal in Omnivorous animals.

There is, then, an admirable correlation between the conformation of the digestive tube and the nature of the substances which form the base of the alimentation of animals; and this harmony is equally apparent when the stomach and intestines are compared with the other apparatus of the economy, and with the natural habits and instincts of creatures. So it is that a creature furnished with an ample stomach and narrow intestine, will have sharp teeth and claws to tear its prey, strength and agility to capture it, and will also possess sanguinary instincts, while another, with its gastric surface greatly diminished, will have intestines as developed in their length as in their capacity, and be distinguished by its peaceful habits, the absence of aggressive claws, and the crushing and grinding form of the principal pieces of its dental apparatus, etc.

ORGANS ANNEXED TO THE ABDOMINAL PORTION OF THE DIGESTIVE CANAL.

These organs are three in number: two glands—the *liver* and *pancreas*, which pour into the small intestine two particular fluids, the *bile* and *pancreatic juice;* and a glandiform organ, the *spleen*, remarkable for its numerous vascular connections with different organs of the digestive apparatus, and which for this reason deserves to be studied with it, although it is doubtful, if not improbable, that it has anything to do with digestion.

Preparation.—These three organs can readily be studied after removing the intestinal mass, as indicated at page 385. In order to examine the details of their organisation with more facility, it would be well to detach them altogether with the diaphragm and kidneys, and to lay out the whole on a table. (To study the relations of these three organs with those of the abdominal cavity, it is advisable to place the subject on its sternum after removing the intestines, and to detach the posterior part of the body at the loins.)

The Liver. (Figs. 182, 211, 216.)

Situation—Direction.—This organ is situated in the abdominal cavity, to the right of the diaphragmatic region, and in an oblique direction downwards and to the left.

Weight.—The weight of the healthy liver, in a middle-sized Horse, is eleven pounds.

Form and External Surface.—Released from all its connections with the neighbouring organs, and viewed externally, it is seen to be flattened before and behind, irregularly elongated in an elliptical form, thick in its centre, and thin towards its borders, which are notched in such a manner as to divide the organ into three principal lobes. This configuration permits it to be studied in *two faces* and a *circumference.*

The *anterior face* is convex, perfectly smooth, and channeled by a wide

and deep notch formed for the passage of the posterior vena cava. This fissure extends directly from behind to before, and consequently slightly crosses the general direction of the liver; near the point where the vena cava leaves the gland to traverse the diaphragm are seen the openings of the principal suprahepatic veins. The *posterior face* is equally smooth and convex, and has also a fissure by which the vena portæ and the hepatic artery and nerves enter, and by which the biliary ducts emerge from the liver. This groove is slightly concave towards the left, and follows the direction of the liver in proceeding obliquely downwards, backwards, and to the left.

The circumference may be divided into a *superior* or *left*, and an *inferior* or *right border*, united at both extremities by the ellipsis formed by the liver. The *superior border* presents, in proceeding from right to left: 1, The insertion of the ligament of the right lobe; 2, The origin of the fissure for the vena cava; 3, A notch for the œsophagus; 4, The insertion of the left ligament. The *inferior border* is sharp, and offers two deep notches, which divide the liver into three lobes: a superior or right, an inferior or left, and an intermediate one. The *right lobe* is usually of medium volume, and has above, on its posterior face, an appendix in the shape of a small secondary lobule of a triangular form, whose base responds to the commencement of the portal fissures: this is the *lobus Spigelii*. The *left lobe* is nearly always the largest. The *middle lobe*, the smallest of the three, is itself divided by secondary notches into several digitations or lobules.

Relations.—Viewing the organ in position, in order to study its general relations, it is found that the anterior face is applied against the diaphragm—a disposition which augments its convexity in diminishing that of its posterior face; and that the latter is in contiguity with the stomach, the duodenum, and the diaphragmatic curvature of the colon.

The connections proper to each lobe are observed to be as follows: 1, The middle lobe responds to the centre of the aponeurotic portion of the diaphragm; 2, The left lobe touches the left and inferior part of this aponeurosis, and is prolonged to the corresponding point of the fleshy peripheral band of that muscle; 3, The right lobe is in contact with the right and superior part of the muscle; its upper border touches the right kidney; the pancreas rests against its base, on the posterior face.

Mode of attachment.—The liver is suspended to the sublumbar wall of the abdomen by the large blood-vessels which enter its fissures, and it is also fixed to the posterior face of the diaphragm by four particular bands. One of these is carried from the anterior face of the liver to the phrenic centre, and appears intended to oppose total displacement of the organ; the other three belong to each particular lobe.

A. The *ligament of the anterior face of the liver* (or *coronary ligament*) comprises two series of very short aponeurotic fibres, which, arising from the two borders of the vena cava fissure, go to be fixed to the posterior face of the phrenic centre. The peritoneum is folded over it on each side in passing from the diaphragm to the liver. The adherence of these fibres to the walls of the vena cava is extremely close; and the vena cava itself, being thus in a manner united to the tissue of the liver, it happens that the union of the anterior face of the viscus with the phrenic centre could not be more solidly established.

B. The *ligament of the left lobe* is a wide peritoneal fold, between the two layers of which are some fasciculi of white fibrous tissue. It is detached

from the aponeurotic centre, to the left of the œsophageal orifice, and is inserted into the left part of the superior border of the liver.

C. The *ligament of the right lobe* is a fold analogous to the preceding, but much shorter, and whose origin, placed very high and near the sub-lumbar parietes, is partly covered by the right kidney. It is inserted into the

Fig. 211.

THE ABDOMINAL CAVITY, WITH THE LIVER AND OTHER ORGANS.
1, Right lobe of the liver; 2, Middle lobe; 3, Right extremity, or ventriculus of stomach; 4, Right extremity; Left abdominal wall.

superior border of the viscus, and sends a small layer to the lobus Spigelii; most frequently, however, this lobule is sustained by a special peritoneal frænum, given off from the anterior border of the kidney.

D. The *ligament of the middle lobe* (the *longitudinal, broad, falciform*, or *suspensory ligament*) is a falciform and vertical serous layer, whose adherent

border is attached, almost in the median plane, to the posterior face of the diaphragm, and even to the inferior abdominal parietes. At its free border is a fibrous cord (the *round ligament*), formed by the obliteration of the fœtal umbilical vein. By its upper part, it penetrates a secondary notch in the middle lobe, and is prolonged on the anterior face of this to the point where the vena cava traverses the diaphragm.

STRUCTURE.—As elements in its structure, the liver offers for study: 1, A *serous membrane;* 2, A *fibrous capsule;* 3, The *proper and fundamental tissue* of the organ.

1. SEROUS MEMBRANE.—This membrane is only an expansion of the peritoneal bands or ligaments already described, and of which the two, on arriving at the organ, separate to become developed on its surfaces, and to completely cover it, except in the anterior and posterior fissures.

2. FIBROUS, OR GLISSON'S CAPSULE.—This, the proper envelope of the liver, is formed by a very fine fibrous membrane, closely adherent to the preceding layer on the one side, and to the tissue of the liver on the other. It penetrates the substance of that tissue in passing around the vessels lodged in the posterior fissure, and from its inner face it sends a multitude of lamellar partitions, which separate the hepatic granulations, and form a veritable framework in the interior of the organ. The presence of this capsule has been denied, but its existence is not to be doubted in all the domesticated animals; it is particularly well developed in Ruminants.

3. PROPER TISSUE OF THE LIVER.—The proper substance of the liver is distinguished by its bluish-brown or violet hue, the shades of which vary much according to the subjects. It is heavy, compact, and so friable that it is crushed by the most moderate pressure. It is composed of polyhedric granulations from 1–20th to 1–10th of an inch in diameter, which are readily enough distinguished from one another through the peritoneum on the surface of the organ, particularly when the septa thrown in between them from Glisson's capsule are hypertrophied from some slight chronic irritation.

Sometimes the *hepatic lobule* is uniform in colour throughout; often it shows a red central point, with a yellow circle around it, and an interrupted red ring circumscribing this again, and which communicates with a similar circle belonging to the adjoining lobules, so as to compose a network at the surface of the gland; at other times the lobules are yellow at the centre and red at the circumference. All these appearances, the study of which at one time was considered of much importance, are uncertain, and may vary in a thousand ways, in combining with one another; so that they really demand but little attention, due as they are to the greater or less degree of plenitude of the different vessels entering the lobule.

As the liver is composed of lobules placed beside each other, we will describe one; as when its structure is well known, we will be familiar with the organisation of the entire organ.

In a *hepatic lobule* we find: 1, *Hepatic* (or *biliary*) *cells;* 2, *Biliary canaliculi* (or *ducts*); 3, *Afferent vessels;* 4, An *efferent vessel;* 5, *Lymphatics;* 6, *Connective tissue.*

Hepatic cells.—These are polygonal or round, and much resemble squamous epithelium; their diameter varies from 1–500th to 1–200th of an inch. They are composed of a thin enveloping membrane and yellow-coloured contents. The latter comprise one or two nuclei with nucleoli, coloured granules, biliary matter, a small mass of a substance which has been

studied by Bernard and Schiff, and named "animal amidon;" and, lastly, adipose granules, whose volume and quantity vary with the condition of the animals, or the period of digestion at which the liver has been removed. The hepatic cells are situated in the network formed by the vessels of the lobule, and constitute its principal portion.

Hepatic Ducts.—Destined to carry away the bile secreted in the interior of the hepatic lobule, the biliary ducts form around it a kind of girdle that accompanies the interlobular branches of the vena portæ. Within and without, this girdle sends off small prolongments: the first bring it into communication with the ducts of the neighbouring lobules; the second enter the substance of the lobule and are soon lost.

Fig. 212.

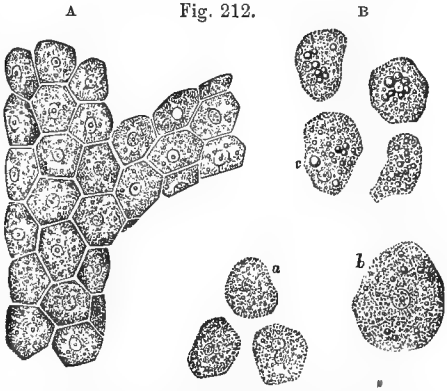

A. Portion of a hepatic column, showing its component secreting cells; B, Secreting cells detached; *a*, In their normal state; *b*, A cell more highly magnified, showing the nucleus and distinct oil-particles; *c*, In various stages of fatty degeneration.

The wall of the biliary ducts is a thin amorphous membrane, lined by polygonal cells, smaller than the hepatic cells.

The *origin of the biliary* or *hepatic ducts* in the interior of the lobules is still a vexed question in histology. It was believed, and some authorities still believe, that the ducts terminate in pouches, at a short distance from the periphery of the lobule. But it has been remarked that an injection introduced by the ductus choledochus does not remain near the periphery of the lobule, but, on the contrary, penetrates to its centre by passing between the hepatic cells; and from this it is admitted that the hepatic ducts furnish a very fine network around each of the cellular elements of the liver (Fig. 213). Nevertheless, there are histologists who do not share in this opinion, who assert that these terminal ducts have no proper walls, and that the supposed networks they form is only a simple system of *intercellular spaces* distended by the injection.

Fig. 213.

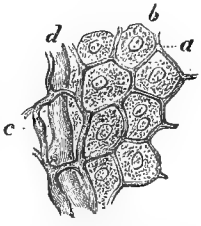

BILIARY CAPILLARIES OF THE RABBIT'S LIVER. PART OF A LOBULE, SHOWING THE ARRANGEMENT OF THE BILIARY DUCTS IN RELATION TO THE HEPATIC CELLS.

a, Capillaries of the biliary ducts; *b*, Hepatic cells; *c*, Biliary ducts; *d*, Capillary blood-vessels.

Afferent vessels.—These are the branches of the portal vein and hepatic artery. The portal vein, after reaching the interior of the liver, divides into gradually decreasing vessels, until it terminates by forming the *interlobular* or *subhepatic veins.* These vessels surround the lobule, communicate with the neighbouring interlobular veins, and give off a large number of twigs to the interior of the lobule, where they anastomose, and constitute the hepatic capillary plexus. The hepatic artery furnishes ramuscules, which mix with the ramifications of the portal vein in the (vaginal) plexus. The principal branches of the latter are all

directed from the periphery towards the centre of the lobule, where they unite to form the afferent vessel. It results from this arrangement that the hepatic cells which fill the spaces between the vessels are placed in radiating series.

Fig. 214.

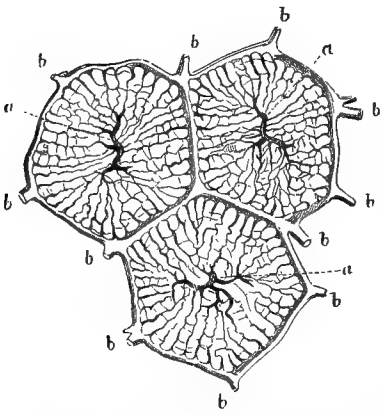

HORIZONTAL SECTION OF THREE SUPERFICIAL LOBULES, SHOWING THE TWO PRINCIPAL SYSTEMS OF BLOOD-VESSELS.

a, *a*, Intralobular veins, terminating in the hepatic veins; *b*, *b*, Interlobular plexus, formed by branches of the portal vein.

Efferent series.—Situated in the centre of the lobules, this vessel receives all the ramifications of the capillary plexus, and is named the *intralobular* or *central supra-hepatic vein.* It is voluminous, and communicates with the other intralobular veins. (These intralobular veins terminate in the larger trunks that run along the bases of the lobules, and are named the *sublobular veins.*)

Lymphatics.—In a hepatic lobule are found very fine lymphatic vessels that surround the branches of the hepatic plexus, where they form the lymphatic vaginæ, or canals which contain the blood-vessels.

Connective tissue.—The intralobular connective tissue is scanty, the lobule being almost entirely composed of cells or capillaries; so that only some trabeculæ exist around the lymphatic sheaths. There is, however, a larger quantity in the interlobular spaces; and in some animals—especially the Pig—Glisson's capsule sends somewhat thick lamellæ of connective tissue between these lobules.

Fig. 215.

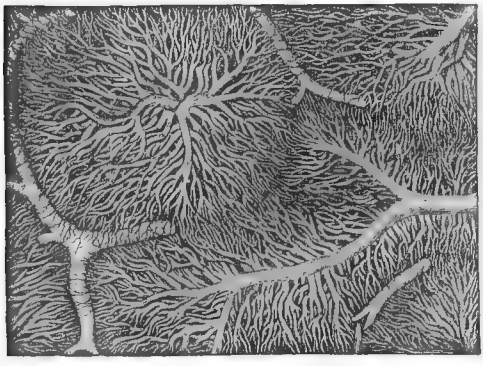

SECTION OF A SMALL PORTION OF THE LIVER OF A RABBIT, WITH THE HEPATIC OR INTRALOBULAR VEINS INJECTED.

Excretory Apparatus.—This is very simple in Solipeds, and is composed of a vessel named the *ductus choledochus*, resulting from the union of several trunks lodged in the posterior fissure of the liver, and which come from the three lobes. Traced in the substance of the hepatic tissue, these branches divide into more and more attenuated ramuscules that arise from the periphery of the lobules, and are continuous with the biliary ducts that envelop and penetrate these.

Course.—At its exit from the liver, the ductus choledochus is placed between the layers of the gastro-hepatic omentum, and ascends to the wall of the duodenum, which it passes through at about six inches from the pylorus,

along with the principal pancreatic duct. The orifices of these two canals are surrounded by a circular mucous fold (*ampulla of Vater*), which is usually very prominent, and acts as a valve in preventing the entrance of alimentary substances into the apertures it encircles; this office it fills so well, that it will not even allow the air with which the duodenum is inflated to pass into the ducts.

Fig. 216.

EXCRETORY APPARATUS OF THE HORSE'S LIVER.

1, Left lobe of the liver; 2, Middle lobe; 3, Right lobe; 4, Lobule of Spigel; 6, Posterior vena cava at its entrance into the liver; 7, Vena portæ; 8, Ductus choledochus; 9, Pancreatic duct; 10, Common entrance of these two ducts into the small intestine.

There enter into the structure of the ductus choledochus: 1, A *fibrous membrane*, which some anatomists believe contains unstriped muscular fibres; 2, *Cylindrical epithelium;* 3, Numerous *racemose glands*, opening on its inner surface by very small orifices.

Vessels and Nerves of the Liver.—The *blood-vessels* are the hepatic artery, portal vein, and suprahepatic veins.

The *hepatic artery* is a branch of the cœliac, and enters the gland by the posterior fissure, in company with the portal vein and ductus choledochus. In the liver it divides into very fine ramifications which join the intralobular plexus, anastomose on the surface of the biliary ducts, or expand either on the serous membrane, or in the walls of the portal vein.

The *portal vein* is the functional vessel of the liver. It reaches that organ by the posterior fissure, and Glisson's capsule accompanies its ramifications as far as the hepatic lobules, where they form the plexus of subhepatic veins.

The *suprahepatic* (or *sublobular*) *veins* are so named because they gain the antero-superior face of the viscus to open into the posterior vena cava. They carry away the blood that has been brought by the portal vein and hepatic artery. Their origin is due to the union of the intralobular veins, which make a passage through the hepatic tissue with which their walls are immediately in contact, gradually join each other, and enter the posterior vena cava on its way through the anterior fissure of the liver. The number of trunks (*hepatic*) entering this vessel is considerable, but the majority are very small; the principal confluent is placed at the anterior extremity of the fissure.

The *lymphatics* form a fine superficial plexus, easy to inject; with deeper

networks placed around the vessels that penetrate by the posterior fissure. In the lobules they are disposed as described above. Joined to the lymphatics of the stomach, they constitute a single trunk that goes to the sublumbar receptacle.

The *nerves* are more particularly derived from the solar plexus, although the pneumogastric and diaphragmatic also supply filaments to the liver. They interlace around the hepatic artery and portal vein; their mode of termination is unknown.

Functions.—The most important considerations are attached to the study of the functions of the liver; but we cannot enter into them in detail without going beyond our subject. Besides, there is yet much to be learned respecting them.

The liver is a biliary and glycogenetic gland. It secretes the bile at the expense of the blood of the portal vein, which comes from the intestinal tunics charged with the assimilable substances absorbed by the veins from the villi. This fluid is submitted to modifications in the interior of the liver, by which it is relieved of certain matters, while at the same time it furnishes the biliary secretion.

The bile is, therefore, in this respect an excrementitious secretion; though all its elements are not thrown off, some of them acting on the alimentary substances, and others being absorbed. From the most recent researches, it would appear that it has a share in the purification of the blood, in digestion, and in calorification; in the latter especially, as its absorbed elements are very rich in carbon and hydrogen, bodies eminently adapted for the production of animal heat.

The liver is also a glycogenetic gland, this function having been demonstrated to pertain to it by Bernard. The sugar formed in the liver finds its way into the blood, and leaves the organ by the suprahepatic veins. It is elaborated in the hepatic cells by the transformation of the substance known as "animal amidon," which is brought into contact with a kind of diastase that exists with it in their interior.

Lastly, it is also believed that the liver is a *hæmatogenetic* organ, the red globules being formed in its mass at the expense of the fibrine of the blood that passes through it.

It will thus be seen that the liver furnishes two very different products—bile and sugar. The knowledge of this fact, combined with the internal arrangement of the organ, has led some anatomists to consider the organ as two glands reciprocally contained within each other. But this hypothesis loses its value if it be admitted that the hepatic ducts pass between the cells to the centre of the lobule, and that in this portion they are destitute of epithelium. It is therefore probable that the sugar and bile are produced in the large hepatic cells, and that the first passes into the veins, while the second is poured into the biliary ducts.

In Solipeds, the secretion of bile, though most active during the digestive period, yet goes on in a continuous manner.

(Certain deductions of a pathological kind are based upon the foregoing anatomical facts, and have an important bearing with regard to comparative pathology. They have been pointed out by Wilson, and are as follows:—Each lobule is a perfect gland; its structure and colour are uniform, and it has the same degree of vascularity throughout. It is the seat of a double venous circulation; the vessels of the one (*hepatic*) being situated in the centre of the lobule, and those of the other (*portal*) in the circumference. Now the colour of the lobule, as of the entire liver, depends chiefly on the

proportion of blood contained within these two sets of vessels; and so long as the circulation is natural, the colour will be uniform. But the instant that any cause is developed which shall interfere with the free circulation of either, there will be an immediate diversity in the colour of the lobule.

Thus, if there be any impediment to the free circulation of the venous blood through the heart or lungs, the circulation in the hepatic veins will be retarded, and the sublobular (or supralobular) and intralobular veins will become congested, giving rise to a more or less extensive redness in the centre of each of the lobules; while the marginal or non-congested portion presents a distinct border of a yellowish white, yellow, or green colour, according to the quantity or quality of the bile it may contain. "This is '*passive congestion*' of the liver, the usual and natural state of the organ after death;" and, as it commences with the hepatic vein, it may be called the first stage of hepatic venous congestion.

But if the causes which produced this state of congestion continue, or be from the beginning of a more active kind, the congestion will extend through the lobular venous plexuses "into those branches of the portal vein situated in the *interlobular fissures*, but not to those in the *spaces*, which being larger, and giving origin to those in the fissures, are the last to be congested." In this second stage the liver has a mottled appearance, the non-congested substance is arranged in isolated, circular, and ramose patches, in the centres of which the spaces and parts of the fissure are seen. This is an extended degree of *hepatic venous congestion;* it is "*active congestion*" of the liver, and very commonly attends disease of the heart and lungs.

These are instances of *partial congestion;* but there is sometimes *general congestion* of the organ. "In general congestion the whole liver is of a red colour, but the central portions of the lobules are usually of a deeper hue than the marginal portions.")

Development.—The liver of the fœtus is remarkable for its enormous development. Its function commences early, for at birth the intestines are filled with *meconium*, a product of the biliary secretion. A more detailed description will be given when the general development of the fœtus comes to be studied.

2. *The Pancreas.*

This organ has the greatest resemblance to the salivary glands in its structure and physical properties; and for this reason it has been named the *abdominal salivary gland.*

Situation.—It is situated in the sublumbar region, across the aorta and posterior vena cava, in front of the kidneys, and behind the liver and stomach. Its weight is seventeen ounces.

Form and Relations.—The pancreas is rather irregular and variable in form, according to the kind of animal. Flattened from above to below, traversed obliquely from its inferior to its superior face by an opening for the passage of the portal vein, and which is named the *pancreatic ring*, this gland is sometimes triangular, sometimes oblong, and curved on itself; it is under the latter form that we will notice it.

Its *faces* present the lobulated aspect of salivary glands. The *superior* adheres by cellular tissue to the aorta, posterior vena cava, cœliac trunk, solar plexus, splenic vessels, and the right kidney and supra-renal capsule; it is covered by the peritoneum for a certain portion of its extent. The *inferior* responds to the base of the cæcum and the fourth portion of the

colon, through the medium of a thick layer of cellular tissue. The *anterior border*, concave and undulating, is in contact with the duodenum and the left extremity of the stomach. The *posterior* is very convex, especially to the right, and near its middle presents a notch for the reception of the portal vein before its entrance into the ring. The *right extremity* (or *head*), the thinnest, adheres to the duodenum, and shows the excretory ducts of the gland. The *left* is carried towards the base of the spleen, in passing between the left extremity of the stomach and the kidney of the same side.

Structure.—It resembles the salivary glands, except in its epithelium. This, instead of being simple polygonal cells lining the thin, structureless membrane of the ultimate follicles, is very granular, and fills these cavities. The gland receives its blood by the hepatic and great mesenteric arteries; the nerves come from the solar plexus.

Excretory apparatus.—The pancreas has two excretory ducts: a principal, described by Wirsung, whose name it bears, and an accessory. The *duct of Wirsung*, lodged in the substance of the gland, but nearer the superior than the inferior face, at first comprises two or three thick branches, which soon unite to form a single trunk that emerges from the pancreas by the left extremity of the organ. Larger than the ductus choledochus, it opens, as already stated, at the same part of the duodenal surface. The *accessory duct* (*ductus pancreaticus minor*) is much smaller; it leaves the principal trunk, receives some branches in its passage, and opens alone into the small intestine, directly opposite the duct of Wirsung.

The ductus choledochus and the duct of Wirsung do not pass directly through the wall of the intestine, but obliquely, like the entrance of the ureters into the bladder. They open in the middle of a circular valve—the *ampulla of Vater*. This ampulla is limited by a thick primary mucous fold, and within this is a second, thinner, beneath which the ductus choledochus opens; at the bottom of the space circumscribed by this second fold, beneath a free mucous lip, is seen the duct of Wirsung.

Functions.—From the researches of Bernard, it appears established that the fluid secreted by the pancreas emulsifies fatty matters and renders them absorbable.

3. *The Spleen.*

The spleen differs from glands not only in the absence of an excretory duct, but also in the other details of its organisation. It has been considered as a vascular gland, whose uses are not yet determined in a precise manner.

Situation.—It is situated in the diaphragmatic region, close to the left hypochondriac, and appears as if suspended in the sublumbar region, as well as at the great curvature of the stomach.

Form—Direction—Relations.—The spleen is falciform, and directed obliquely downwards and backwards. It has *two faces, two borders*, and a *point.*

The *external face* is in relation with the muscular portion of the diaphragm, and is moulded to it. The *internal*, slightly concave, touches the large colon; it has sometimes a small lobule, or offers traces of lobulation. The *posterior border* is convex, thin and sharp. The *anterior*, thicker, concave, and bevelled at the expense of the internal face, is channeled by a slight longitudinal fissure which lodges the splenic vessels and nerves; it

receives the insertion of the great mesentery, by which it is held to the greater curvature of the stomach. The *base*, or *superior extremity*, is thick and wide, and responds to the left kidney and the corresponding extremity of the pancreas; it shows the insertion of the suspensory ligament. The *point*, or *inferior extremity*, is smooth and thin.

Weight.—The average weight is 32 ounces; but it is sometimes of enormous dimensions—as much as three or four times its normal volume.

Mode of attachment.—The spleen is a floating organ, whose displacements are limited by a *suspensory ligament*, and the *great* (or *gastro-splenic*) *omentum*. The first is a peritoneal fold which proceeds from the anterior border of the left kidney and the sublumbar wall, and is strengthened by the elastic fibrous tissue comprised between its two layers. It is fixed to the base of the spleen, and is confounded, inwardly, with the great omentum. The latter is already known as proceeding to the colon, and in its passage becoming attached to the splenic fissure, whence it extends over the surface of the organ to form its serous covering.

Structure.—The tissue of the spleen has a violet-blue colour, sometimes approaching to a red hue; it is elastic, tenacious, and soft, yields to the pressure of the finger, and retains the imprint. Enveloped externally by the *peritoneum*, its substance includes a *fibrous framework*, *splenic pulp*, *Malpighian corpuscles*, *vessels*, and *nerves*.

Serous membrane.—This is developed over the whole surface of the organ, except in the fissure of the anterior border. Its internal face adheres most intimately to the proper tunic of the spleen. It is only an expansion of the serous bands which limit the movements of the viscus.

Fibrous framework.—Under the peritoneal membrane is a thick, resisting, fibrous tunic, roughened and granular on its exterior, and sending from its deep face into the interior of the mass a multitude of prolongations called *trabeculæ*, which cross in all directions, forming a cellular network whose numerous narrow meshes contain the other elements of the organ. In washing a morsel of spleen in a jet of water, the latter are removed, and the outlines of this fibrous structure are fully exposed. If a stream of water is passed through the splenic artery, the same result will be arrived at. Kölliker has found in the proper tunic of the spleen, and in its trabeculæ, a particular contractile tissue, the *muscular cell-fibres*, mixed with fasciculi of elastic or inelastic fibrous tissue. (The proper coat, the sheaths of the vessels, and the trabeculæ consist of a dense mesh of white and yellow elastic fibrous tissues, the latter considerably predominating. It is owing to the presence of this tissue that the spleen possesses a considerable amount of elasticity, admirably adapted for the very great variations in size that it presents under certain circumstances. In some of the mammalia, in addition to the usual constituents of this tunic, are found numerous pale, flattened, spindle-shaped nucleated fibres, like unstriped muscular fibre. It is probably owing to this structure, that the spleen possesses, when acted upon by the galvanic current, faint traces of contractility.)

Splenic pulp.—This name is given to a reddish pultaceous material, which partly occupies the aveolar framework formed by the intersections of the trabeculæ. It is sustained by a very delicate reticulum of connective tissue, and is composed of numerous elements, such as pigment granules, free nuclei, large cells with several nuclei, lymphoid elements, and blood-globules in a state of decomposition or transformation. These globules are free or enveloped in an albuminoid membrane. (The proper substance of the spleen consists of coloured and colourless elements. The coloured

are composed of red blood-globules and coloured corpuscles, either free or included in cells. Sometimes unchanged blood-discs are seen included in a cell; but more frequently the included blood-discs are altered both in form and colour. Besides these, numerous deep-red, or reddish-yellow, or black corpuscles and crystals, either single or aggregated in masses, are seen diffused throughout the pulp substance; these, in chemical composition, are closely allied to the hæmatine of the blood. The colourless elements consist of granular matter; nuclei, about the size of the red blood-discs, homogeneous or granular in structure; and nucleated vesicles in small numbers. These elements form a large proportion of the entire bulk of the spleen in well-nourished animals; whilst they diminish in number, and occasionally are not found at all, in starved animals. The application of chemical tests shows that they are essentially a proteine compound.)

Fig. 217.

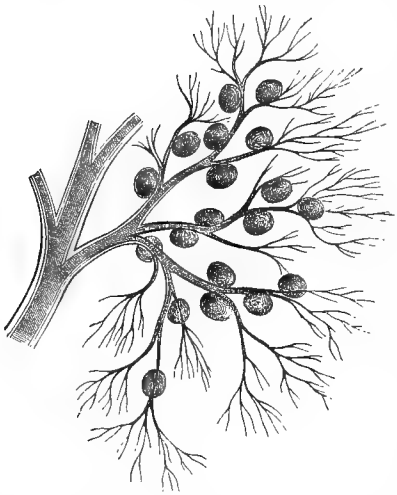

BRANCH OF SPLENIC ARTERY WITH ITS RAMIFICATIONS STUDDED WITH MALPIGHIAN CORPUSCLES.

Malpighian corpuscles.—These are contained, like the pulp, in the meshes of the fibrous framework, and are enveloped by this pulp. Scattered along the track of the small arteries, these corpuscles are visible to the naked eye, and appear as whitish closed sacs, cells, and nuclei floating in a plasma. The Malpighian corpuscles are constituted by the adventitious tunic of the arteries, in which lymphoid elements are accumulated at certain points. They are therefore allied to the closed follicles of the intestines. (These splenic or Malpighian corpuscles, are round, whitish, semi-opaque bodies, glutinous in consistence, and disseminated throughout the substance of the organ. They are more distinct in early than in adult life or old age, and vary considerably in size and number. From the manner in which they are appended to the sheaths of the smaller arteries and their branches, they resemble the buds of the moss-rose. Each consists of a membranous capsule, composed of fine pale fibres interlacing in all directions. The blood-vessels ramifying on the surface of the corpuscles, are the larger ramifications of the arteries to which the sacculus is connected, and also of a delicate capillary plexus, similar to that surrounding the vesicles of other glands. These vesicles have also a close relation with the veins, and the vessels begin on the surface of each vesicle throughout the whole of its circumference, forming a dense venous mesh in which

Fig. 218.

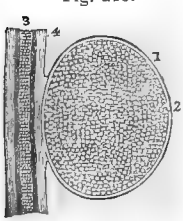

A SINGLE SPLENIC CORPUSCLE, FROM THE SPLEEN OF THE OX.

1, External tunic, or membrana propria, 2, Granular contents; 3, Part of a small artery; 4, Its sheath, derived from the external tunic of the spleen, with which the corpuscle is closely connected.

each of these bodies is inclosed. It is probable that, from the blood contained in the capillary network, the material is separated which is occasionally stored up in their cavity; the veins being so placed as to carry off, under certain conditions, those contents that are again to be discharged into the circulation. Each capsule contains a soft, white, semi-fluid substance, consisting of granular matter, nuclei similar to those found in the pulp, and a few nucleated cells, the composition of which is apparently albuminous. These bodies are very large, after the early periods of digestion, in well-fed animals, and especially those fed upon albuminous diet. In starved animals, they disappear altogether.)

Arteries.—These emanate from the splenic artery at different elevations, and plunge into the tissue of the spleen, preserving their reciprocal independence. Their terminal ramifications do not open, as has been said, into venous sinuses, but into minute tufts of capillaries, which traverse the splenic pulp, to be continued by the venous network.

Veins.—All the venous branches of the spleen open into the splenic vein, and are lodged with the corresponding artery in the fissure of the organ. Traced from their commmencement, they are seen to gradually lose their constituent membranes, and to open into sinuses which are only lined by the epithelium of the vessels. It is in these sinuses that the network of venous capillaries which succeed the arterial capillaries, originates.

Lymphatic vessels.—These are found on the external surface of the organ, and along the track of the blood-vessels. (They invest these with a distinct sheath, between which and the parietes of the vessels numerous lymph corpuscles may be found.)

Nerves.—They are derived from the solar plexus, and enveloping the splenic artery, with it enter the spleen. (They appear to be very large, but this appearance is due to the great proportion of ordinary fibrous tissue investing them.)

From what has been said above respecting the arrangement of the splenic arteries and veins, it will be perceived that the areolæ formed by the trabeculæ of the fibrous framework contain the pulp, and are not in direct communication with the arterial capillaries. Such an organisation belongs to erectile tissues. The arteries communicate with the veins proper by venous canals channeled in the splenic pulp, and are lined only by elliptical cells. These venous canals are extremely dilatable, especially in the Horse. When the splenic vein is inflated, their walls separate and press back the pulp, they become considerably enlarged, and distend the cells of the fibrous structure, but the air does not reach the interior of these cells.

Functions.—Nothing precise is known regarding the functions of the spleen; though they must be of very secondary importance, because animals in which the organ has been extirpated, and which have recovered from the consequences of the operation, have continued to live in apparent good health. Numerous hypotheses have been formed on this subject; two of which, founded on the study of the anatomical peculiarities of the spleen tissue, and on exact physiological observations, are as follows: 1, *The spleen is a diverticulum for the portal vein;* 2, *The red globules are destroyed in the spleen.*

With regard to the first hypothesis, it is evident that, owing to the presence of the venous sinuses already mentioned, and their great dilatability, as well as to the elasticity and contractility of the spleen tissue, the organ is favourably constructed to act as a blood reservoir. M. Goubaux,

on the other hand, has demonstrated that there is always an augmentation in the spleen's volume when an animal has ingested large quantities of water, the consecutive absorption of which determines a certain tension in the portal venous system.

The second opinion, emitted by Kölliker, is founded on the existence in the splenic pulp of blood-globules in a state of decomposition, and in the analyses made by J. Beclard of the blood in the splenic vein, which have proved that there is a notable diminution in the proportion of globules.

It is to be remarked that, in the researches undertaken to discover the functions of the spleen, account has not been taken of the connections existing between this organ and the great omentum in the majority of mammals, and which testify that the spleen is only, properly speaking, a vascular appendage placed on the track of this omentum. But the uses of this vast peritoneal fold are themselves little understood. Might they not be included with those which are presumed to belong to its appended organ?

DIFFERENTIAL CHARACTERS IN THE ANNEXED ORGANS IN THE ABDOMINAL PORTION OF THE DIGESTIVE CANAL IN OTHER THAN SOLIPED ANIMALS.

The important differences these organs offer in the domesticated mammals belong more particularly to the liver.

1. *Liver.*—In the domesticated mammals other than Solipeds, the liver exhibits variations in form, volume, and position, which have no influence on its organisation: so that the study of these possesses but a mediocre attraction. This is not so, however, with regard to the excretory apparatus, the arrangement of which is complicated, and becomes very interesting. The biliary duct, in fact, on leaving the fissure of the portal vein, and before reaching the intestine, gives rise to a particular conduit which is detached at an acute angle, and which, after a course of variable length, according to the size of the animal, becomes dilated into a vast sac, the so-called *gall-bladder.*

In all treatises on anatomy, the special conduit is designated the *cystic duct*, that portion which precedes its origin being named the *hepatic duct;* while the appellation of *ductus communis choledochus* is reserved for the section which goes to the intestine. But these distinctions are vicious, and we limit ourselves to the recognition of: (*a*) A ductus choledochus exactly like that of Solipeds, and like it extending from the posterior fissure, where it originates by the union of several branches, to the duodenum; and (*b*) a *cystic duct*, which branches suddenly into the choledic duct, and terminates in the *gall-bladder.*

a. The *gall-bladder* is a reservoir with membranous walls, in which the bile accumulates during the intervals of digestion. This sac, lodged wholly, or in part, in a fossa on the posterior face of the liver, is oval or pyriform, and presents a *fundus* and *neck.* Its parietes comprise three *tunics:* an *external*, of peritoneum: a *middle*, formed of dartoid tissue; and an *internal*, or mucous, continuous with that of the various biliary ducts.

b. The *cystic duct* extends in a straight line from the neck of the gall-bladder to the choledic duct. It adheres intimately to the tissue of the liver, and does not exhibit, internally, the spiral valves which have been described in Man. In opening it longitudinally, there are discovered, at least in Ruminants and the Carnivora, very small orifices which pierce the wall adherent to the tissue of the liver: these are the openings of several minute but particular biliary canals, named the *hepatico-cystic ducts.*

c. The *ductus communis choledochus* comports itself exactly as in Solipeds. It is much wider than the cystic duct, and opens sometimes alone, sometimes with the pancreatic canal, into the duodenum in a manner which, up to a certain point, reminds one of the mode of termination of the ureters. Instead of passing perpendicularly across the intestinal parietes, it first pierces the muscular layer, follows for a short distance between it and the mucous membrane, and then opens on the internal face of the latter by an orifice which is encircled by a valvular fold, as in the Horse.

Such is the excretory apparatus belonging to the liver in animals provided with a gall-bladder. In these animals the biliary secretion is certainly continuous, as in the Horse; but in the intervals of digestion the bile, instead of flowing directly on to the intestinal surface, passes into the gall-bladder by the cystic duct, and there

accumulates. When digestion commences again, this reserve of bile is thrown into the ductus choledochus by the contraction of the muscular fibres of the cyst, and by the pressure of the abdominal viscera; it meets that which comes directly from the liver, and with it is carried to the duodenum.

We will now glance at the particular arrangement of this viscus in each species.

In the *Ox*, the liver is entirely confined to the right diaphragmatic region. It is thick, voluminous, and scarcely notched at its periphery; so that it is difficult, if not impossible, to distinguish three lobes in it, the lobus Spigelii alone being detached from the mass of the organ. The gall-bladder, fixed towards the superior extremity, is nearly always floating; near its neck it receives the insertion of several large conduits, which come directly from the upper part of the liver. The ductus choledochus opens alone at

Fig. 219.

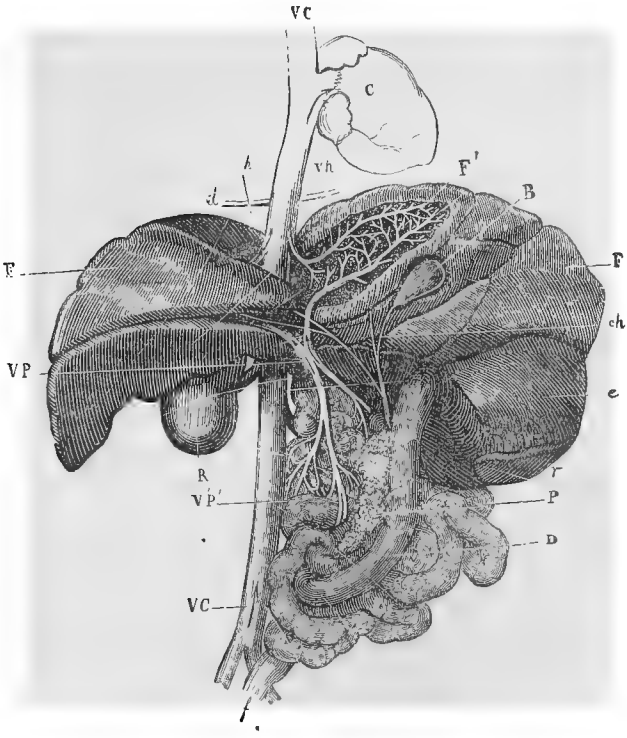

LIVER OF THE DOG, WITH ITS EXCRETORY APPARATUS.

D, Duodenum and the intestinal mass; P, Pancreas; *r*, Spleen; *e*, Stomach; *f*, Rectum; R, Right kidney; B, Gall-bladder; *ch*, Cystic duct; FF, Liver; F', Lobe of the liver, prepared to show the distribution of the vena portæ and hepatic vein; VP, Vena portæ; V*h*, Hepatic vein; *d*, Diaphragm; VC, Vena cava. C, Heart.

a great distance from the pylorus; M. Colin has found it to be 24½ inches in one cow, and 29½ inches in another. In the *Sheep* and *Goat*, the form and position of the liver differs but little from that of the Ox. The ductus choledochus, however, unites with that of the pancreas, and terminates at 12 to 16 inches from the pylorus.

In the *Pig*, the liver has three well-marked lobes; the middle carries the gall-bladder. The ductus choledochus opens alone at 1 or 1½ inches only from the pylorus.

In the *Dog* and *Cat*, the liver is very voluminous, is deeply notched, and is divided into five principal lobes. The middle lobe has the gall-bladder attached to it, and gives it complete lodgment in a fossa.

In the *Dog*, the ductus choledochus, joined to a small branch from the pancreatic duct, enters the intestine at a variable distance from the pylorus, depending upon the size of the animal, but usually between $1\frac{1}{2}$ and $4\frac{3}{4}$ inches. In the portion comprised between the intestine and the origin of the cystic duct, it receives several biliary canals of somewhat considerable diameter. In the *Cat*, the ductus choledochus is most frequently inserted from about 1 to $1\frac{1}{2}$ inches from the pyloric orifice; it opens immediately alongside the pancreatic duct when it does not join it.

2. *Pancreas.*—In the *Ox*, the pancreas is not placed across the sublumbar parietes, but is comprised between the layers of the mesentery, to the right of the great mesenteric artery. The excretory duct is single, and opens into the small intestine at from 14 to 16 inches beyond the ductus choledochus.

In the *Sheep* and *Goat*, there is the same general arrangement, but the excretory duct opens with that of the liver.

In the *Pig*, this duct is inserted at from 4 to 6 inches behind the ductus choledochus.

The pancreas of the *Dog* is extremely elongated, and included between the layers of the mesentery which sustain the duodenum. It is curved at its anterior extremity, behind the stomach, to one side of the median line. Its excretory duct, usually single, pierces the intestinal membranes 2 inches beyond the hepatic duct (Fig. 219, *m*). Except in the mode of insertion of the excretory duct, which has been described in noticing the ductus choledochus, the pancreas of the *Cat* comports itself exactly like that of the Dog.

3. *Spleen.*—In *Ruminants*, the spleen is not supported by the great omentum, but adheres to the left side of the rumen and diaphragm. It is not falciform, and its breadth is the same throughout its extent. In the *Carnivora*, it is suspended to the great omentum at a certain distance from the left sac of the stomach. It is irregularly falciform, its point is less acute than in Solipeds, and is directed upwards.

COMPARISON BETWEEN THE ANNEXED ORGANS OF THE ABDOMINAL PORTION OF THE DIGESTIVE CANAL IN MAN AND THOSE OF ANIMALS.

1. *Liver.*—Like that of Ruminants, the human liver is situated in the right excavation of the lower face of the diaphragm. Its direction is nearly horizontal; its shape is oval, and its average weight from forty-nine to fifty-three ounces. The posterior border is thick and round; the anterior border and extremities thin and sharp. The upper face, which in expiration ascends to the fourth rib, is divided into two portions or lobes—right and left, by the falciform ligament; it is smooth and convex. The inferior face has three furrows, or fossæ: two longitudinal, united by a transverse, resembling altogether the letter H. The transverse furrow represents that on the posterior aspect of the liver of animals, and its destination is the same. The right longitudinal furrow lodges the obliterated umbilical vein; the left, well marked before and behind, lodges the gall-bladder in front, and the inferior vena cava behind. This face has four lobes, the right and left, and two middle lobes. In front of the transverse furrow is the lobus quadratus, and behind the same fissure is the lobus Spigelii.

Fig. 220.

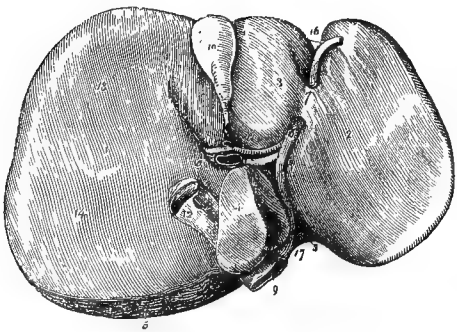

UNDER SURFACE OF THE HUMAN LIVER.

1, Right lobe; 2, Left lobe; 3, Lobus quadratus; 4, Lobus Spigelii: 5, Lobus caudatus; 6, Longitudinal fossa; 7, Pons hepatis; 8, Fossa of ductus venosus; 9, Inferior vena cava; 10, Gall-bladder; 11, Transverse fossa; 12, Vena cava; 13, Depression corresponding to the curve of the colon; 14, Double depression produced by right kidney and supra-renal capsule.

On the lower face of the right lobe are three depressions: an anterior or *impressio colica;* a deep middle one, *impressio vesicæ;* and a small posterior one, which receives the supra-renal capsules, *impressio renalis.*

2. *Pancreas.*—This organ is very elongated transversely, like that of the Dog and Cat. It is closely applied against the lumbar vertebræ, as in the Horse, but its anterior face is much more enveloped by the peritoneum Its right extremity rests on the duodenum, while the left corresponds to

the spleen and left kidney. Its texture is consistent, and of a greyish-white colour. The duct of Wirsung terminates along with the ductus choledochus in the ampulla of Vater.

3. *Spleen.*—This is not falciform, but quadrangular; its inferior extremity is larger than the superior. It is attached to the stomach by the great omentum, and its inner face is divided into two portions by a salient ridge; a little in front of this is a fissure, the *hilum lienis*, by which vessels enter it.

CHAPTER III.

THE DIGESTIVE APPARATUS OF BIRDS.

CONSTRUCTED on the same plan as that of Mammals, the digestive apparatus of *Birds* nevertheless offers in its arrangement several important peculiarities, which will be hurriedly noticed in reviewing, from the mouth to the anus, its different sections.

Mouth.—The essentially distinctive character of the mouth of birds consists in the absence of *lips* and *teeth*, these organs being replaced by a horny production fixed to each jaw, and forming the salient part termed the *beak*. In the *Gallinaceæ*, the beak is short, pointed, thick, and strong, the upper mandible being curved over the lower. In *Palmipeds*, it is longer, weaker, flattened above and below, widened at its free extremity, and furnished within the mouth, on the borders of each mandible, with a series of thin and sharp transverse laminæ to cut the herbage.

The muscular appendage, or *tongue*, lodged in the buccal cavity, is suspended to a remarkably mobile hyoidean apparatus. Covered by a horny epithelium, and provided at its base with several papillæ directed backwards, this organ always affects the form of the lower jaw: in *Poultry* it is like the barbed head of an arrow, the point being directed forwards; in *Pigeons* this saggital form is still more marked; in *Geese* and *Ducks*, on the contrary, and in consequence of the wide shape of the beak, it has not this disposition, and is softer and more flexible than in the Gallinaceæ.

With regard to the *salivary glands* annexed to the mouth, they are imperfectly developed, the presence of the fluids they secrete being less necessary in birds than in Mammals, as the food is nearly always swallowed without undergoing mastication; consequently insalivation is all but useless.

Gurlt[1] speaks of a *parotid gland* situated beneath the zygomatic arch, whose duct opens into the mouth behind the commissure of the jaws. Meckel names this organ the *angular gland of the mouth*, and says that it is difficult to regard it as representing the parotids, any morethan the glands of the cheeks and lips. Duvernoy[2] categorically assimilates it to the latter.

The *sublingual glands* lie in the median line throughout nearly their whole extent, and form an apparently single and conical mass, whose apex occupies the re-entering angle formed by the union of the two branches of the lower maxilla.

According to Duvernoy, the submaxillary glands are represented by two very small organs situated behind the preceding. Their existence, however, is far from being general; for among common poultry, the *Turkey* was the only bird in which Duvernoy observed these submaxillary glands.

PHARYNX (Fig. 221, 2).—This cavity is not distinct from the mouth, the soft palate being entirely absent in birds. On its superior wall may be remarked the guttural orifice of the nasal cavities: a longitudinal slit divided into two by the inferior border of the vomer. Below is another less extensive slit, the entrance to the larynx, and which is remarkable for the complete absence of the epiglottidean operculum.

ŒSOPHAGUS.—This canal is distinguished by its enormous calibre and great expansibility. Its walls are very thin, and contain in their substance lenticular glands, easily seen in an inflated œsophagus, in consequence of the tenuity and transparency of its textures.

At its origin, the œsophageal canal is not separated from the pharynx by any constriction; in its course it lies alongside the long muscle of the neck, and the trachea; its terminal extremity is inserted into the first compartment of the stomach, or succentric ventricle, after entering the thorax and passing above the origin of the bronchi, between their two branches.

In *Palmipeds*, the œsophagus is dilated in its cervical portion in such a manner as to form, when its walls are distended, a long fusiform cavity.

---

[1] 'Anatomie der Hausvogel.' Berlin, 1849.
[2] *Cuvier.* 'Anatomie Comparée.' 2nd Edition. Paris, 1836.

Fig. 221.

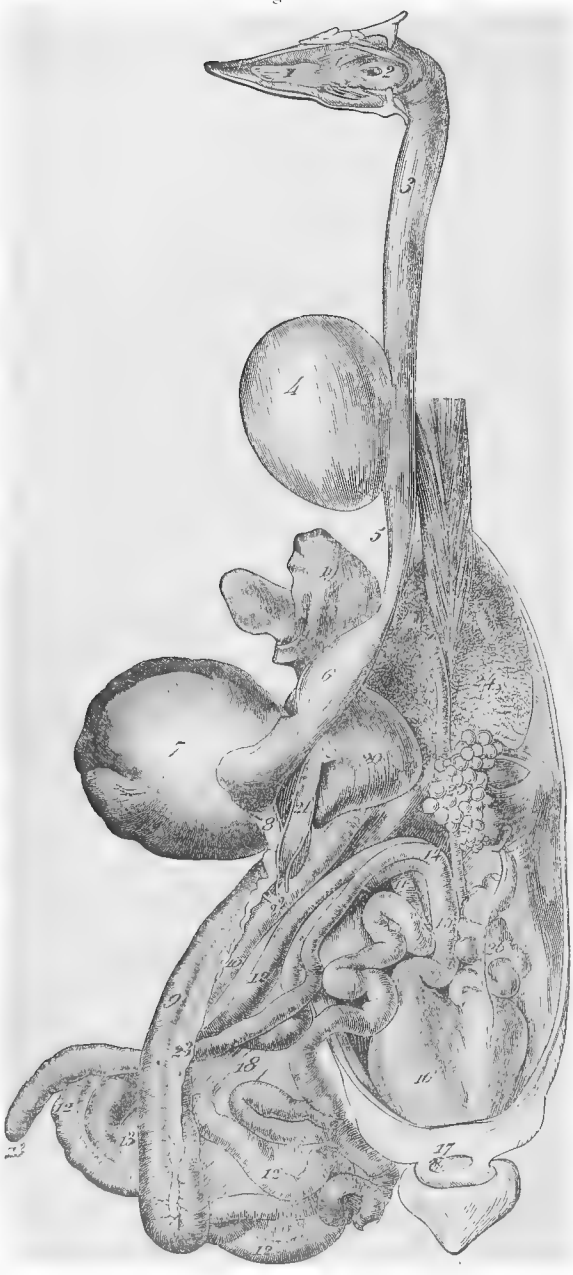

GENERAL VIEW OF THE DIGESTIVE APPARATUS OF A FOWL.

The abdominal muscles have been removed, as well as the sternum, heart, trachea, the greater portion of the neck, and all the head except the lower jaw, which has been turned back to show the tongue, the pharynx, and the entrance to the larynx. The left lobe of the liver, succentric ventricle, gizzard, and intestinal mass, have been pushed to the right to exhibit the different portions of the alimentary canal, and to expose the ovary and oviduct.

1, Tongue; 2, Pharynx; 3, First portion of the œsophagus; 4, Crop; 5, Second portion of the œsophagus; 6, Succentric ventricle; 7, Gizzard; 8, Origin of the duodenum; 9, First branch of the duodenal flexure; 10, Second branch of the same; 11, Origin of the floating portion of the small intestine; 12, Small intestine; 12′, Terminal portion of this intestine, flanked on each side by the two cæca (regarded as the analogue of the colon of mammals); 13, 13, Free extremities of the cæcums; 14, Insertion of these two culs-de-sac into the intestinal tube; 15, Rectum; 16, Cloaca; 17, Anus; 18, Mesentery; 19, Left lobe of the liver; 20, Right lobe; 21, Gall-bladder; 22, Insertion of the pancreatic and biliary ducts; the two pancreatic ducts are the anteriormost, the choledic or hepatic is in the middle, and the cystic duct is posterior; 23, Pancreas; 24, Diaphragmatic aspect of the lung; 25, Ovary (in a state of atrophy); 26, Oviduct.

In *Gallinacæ* (Fig. 221, 3, 4, 5), this dilatation does not exist; but the œsophagus presents in its course, and immediately before entering the chest, an ovoid membranous pouch named the *crop* (or *ingluvies*.) In the œsophagus of these birds, then, we find two distinct sections, joined end to end—one superior or cervical, the other inferior or thoracic, on the limit of which is the *crop*. The latter does not differ in its structure from the œsophagus, and is a temporary reservoir for the food swallowed by the animal during its meal, and where it is softened by being impregnated with a certain quantity of fluid; after which it is passed into the succentric ventricle by the contractions of the external membrane of the crop, aided by a wide subcutaneous cervical muscle which covers that reservoir.

In *Pigeons*, the crop is also present; but it is divided into two lateral pouches, and exhibits glandular eminences towards the common inferior opening of these sacs into the œsophagus. "Otherwise, singular changes are observed in the apparent structure of its walls in the male as well as in the female, during incubation, or during the first weeks after hatching." (Hunter was the first to observe this:—'Observations on Certain Parts of the Animal Economy,' London, 1792). "At this period, the membranes of the crop become thickened; the vessels, more numerous and more apparent, are redder, and the glands more developed. The internal surface is divided by folds or ridges, which cross each other, and form triangular meshes; while an apparently milky fluid is poured out from the secretory pores into the cavity of the crop. Pigeons exclusively nourish their young with this fluid during the first three days of their existence."[1]

Stomach.—The stomach presents numerous variations in birds. Its simplest form is seen in the heron, pelican, petrels, etc., where it is a single sac provided with a thick zone of glands around the entrance of the œsophagus, which secrete the gastric juice. But in the majority of the other species, and particularly in our domesticated birds, the disposition of the stomach is modified and complicated; the glandular zone destined for the gastric secretion forms a special compartment—the *succentric ventricle*, and this is followed by a second reservoir—the *gizzard*, which is remarkable for the strong muscular constitution of its walls. The first is also named the *glandular stomach*, and the second the *muscular stomach*.

Glandular stomach, or *succentric ventricle* (*proventriculus*) (Fig. 221, 6).—This is an ovoid sac placed in the median plane of the body, between the two lobes of the liver, and beneath the aorta. Its anterior extremity receives the insertion of the œsophagus; the posterior is continued by the gizzard. The volume of this stomach is inconsiderable, and its cavity is very narrow; the aliment does not accumulate in it, but merely passes through, carrying with it the acid juice which afterwards dissolves its protein elements. Its walls have three tunics: an external or peritoneal; a middle, formed of white muscular fibres, continuous with those of the œsophagus; and an internal, of a mucous nature, perforated by orifices for the passage of the gastric juice. These are small cylinders placed perpendicularly to the surface of the stomach, closely laid against one another, like the microscopic glands of Lieberkühn, and contained in the cellular layer uniting the inner to the middle tunic. The glandular structure of this receptacle sufficiently demonstrates that it should be assimilated to the right sac of the stomach in Solipeds, and therefore must be regarded as the true stomach.

Gizzard, or *muscular stomach* (*ventriculus bulbosus*) (Fig. 221, 7).—Much more voluminous than the preceding, this stomach is oval in form, depressed on each side, and situated behind the liver, being partly covered by the lateral lobes of that gland. Above, and to the right, and at a short distance from each other, are seen the insertion of the succentric ventricle and the origin of the duodenum. The cavity of the gizzard always contains food mixed with a large quantity of silicious pebbles, whose use will be indicated hereafter.

This viscera is composed of the three tunics which form the walls of all the abdominal reservoirs. The internal, or mucous, is distinguished by the thickness and extraordinary induration of its epidermic layer, which presents nearly all the characters of horny tissue, and is so easily detached from the mucous chorium that it is often regarded as a special membrane. On the adherent face of this corium are applied two powerful red muscles—a superior and inferior, occupying the borders of the organ, and whose fibres, disposed in flexures, pass from side to side, and are inserted into a strong, nacrous aponeurosis on the lateral surfaces of the organ. Outside this contractile apparatus is a thin peritoneal envelope.

The gizzard is the triturating apparatus of birds. When the aliment reaches its cavity it has not yet submitted to any disaggregation, but here it meets with all the conditions

[1] *Duvernoy*. 'Leçons d'Anatomie Comparée de G. Cuvier.' 2nd Edition.

indispensable to the accomplishment of this act: two energetic compressor muscles, a corneous layer spread over the internal surface of the viscera, giving to it the rigidity necessary to resist the enormous pressure exercised on its contents; and silicious pebbles—veritable artificial teeth—which an admirable instinct causes birds to swallow, and between which, by the efforts of the triturating muscles, the food is bruised. This triturating action of the gizzard is only effected in birds fed on hard coriaceous aliment, such as the various kind of grain. It would be useless in birds of prey, in which the two gizzard muscles are replaced by a thin fleshy membrane of uniform thickness; showing that the presence of these muscles is subordinate to the kind of alimentation.

INTESTINE.—The length of the intestine varies, as in Mammals, according to the nature of the food: very short in birds of prey, it is notably elongated in omnivorous and granivorous birds. Its diameter is nearly uniform throughout its whole extent, and it is difficult to establish in birds the various distinctions recognised in the intestine of Mammalia. It begins by a portion curved in a loop, which represents the *duodenum*, and whose two branches, lying side by side, are parallel to each other like the colic flexure of Solipeds. Fixed by a short mesenteric frænum to the colon, this part of the intestine includes the pancreas between its two branches. Its curvature floats freely in the pelvic portion of the abdominal cavity (fig. 221, 8, 9, 10).

To the *duodenal loop* succeed convolutions suspended to the sublumbar parietes by a long mesentery, and which are rolled up into a single mass, elongated from before to behind, occupying a middle position between the air sacs of the abdominal cavity. The analogy existing between this mass of convolutions, and the *floating portion of the small intestine* of Mammals, does not require demonstration (fig. 221, 11, 12).

The terminal part of this floating intestine lies beside the duodenal loop, and is flanked by the two appendages disposed like *cæca*. These, scarcely marked in the *Pigeon* by two small tubercles placed on the track of the intestinal tube, do not measure less than from six to ten inches in the other domesticated birds; they are two narrow *culs-de-sac*, slightly club-shaped at their closed extremities, which are free and directed towards the origin of the intestine, while the other extremity opens into the intestinal canal near the anus. There are always alimentary matters in these sacs, these becoming introduced, in following a retrograde course, by the same almost unknown mechanism which presides over the accumulation of spermatic fluid in the vesiculæ seminales. According to the majority of naturalists, these two appendages, although described as *cæca*, do not represent the reservoir bearing that designation in Mammals. This reservoir is nothing more than a small particular appendix placed on the track of the intestine, in front of the free extremity of the above-mentioned *culs-de-sac*, and which is only to be found in a small number of birds, and among these sometimes, as Guilt affirms, is the *Goose*. According to this view, which appears to be a very rational one, the portion of intestine comprised between the two blind tubes annexed to the viscera (fig 221, 12') corresponds to the *colon*, and these tubes themselves are only dependencies of this intestine.

The *rectum* (fig. 221, 15) terminates the digestive canal; it is the brief portion of intestine which follows the opening of the cæca. Placed in the sublumbar region, this viscus is terminated by a dilatation, the cloaca (fig. 221, 16), a vestibule common to the digestive and genito-urinary passages, which opens externally at the anus, lodges the penis when it exists, and serves as a confluent for the ureters, oviduct, bursa of Fabricius, and the deferent canals.

ABDOMINAL APPENDAGES OF THE DIGESTIVE CANAL.—*Liver* (Fig. 221, 19, 20).—This is a voluminous gland, divided into two principal lobes—a right and left, the former always larger than the latter; these incompletely include, on each side, the gizzard and succentric ventricle. In the *Pigeon*, this gland is provided with a gall-bladder (fig. 221, 21) attached to the internal face of the right lobe. But the arrangement of the excretory apparatus is not altogether identical with that observed in Mammals which possess this receptacle; as two biliary ducts open separately into the intestine towards the extremity of the second branch of the duodenal loop. One proceeding directly from the two lobes of the liver, is the *hepatic* or *choledic duct;* the other, the *cystic duct*, remains independent of the latter, and opens behind it. It carries into the digestive canal the bile accumulated in the gall-bladder, and which arrives there by a particular duct belonging exclusively to the right lobe; the cystic canal is a branch of this duct (fig. 221, 22).

Pancreas (Fig. 221, 23).—In the *Gallinacæ*, this gland is very developed, long, and narrow, and is comprised in the duodenal loop or flexure; at the extremity next the gizzard it has two principal excretory ducts, which separately pierce the intestinal membranes, a little in front of the hepatic canal.

Spleen.—This is a small, red-coloured, disc-shaped body, placed to the right of the stomachs, on the limit of the gizzard and succentric ventricle.

BOOK III.

Respiratory Apparatus.

The maintenance of life in animals not only requires the absorption of the organisable and nutritive matters conveyed to the internal surface of the digestive canal, but demands that another principle, the *oxygen* of the atmosphere, should enter with these materials into the circulation. In animals with red blood, this element, in mixing with the nutritive fluid, commences by expelling an excrementitial gas, *carbonic acid*, and communicating a bright red colour to that fluid, with which it circulates; it is brought into contact, in the general capillary system, with the minute structures of the various apparatus, exercising on the organic matter composing them a special excitory influence, without which the tissues could not manifest their properties, as well as inducing a combustible action which evolves the heat proper to the animal body.

This new absorption constitutes the phenomenon of respiration. In the Mammalia, this is effected in the *lungs:* parenchymatous organs hollowed out into a multitude of vesicular spaces which receive the atmospheric air and expel it, after depriving it of a certain quantity of oxygen, and giving, in return, a proportionate quantity of carbonic acid. These organs are lodged in the *thoracic cavity*, whose alternate movements of dilatation and contraction they follow. They communicate with the external air by two series of canals placed end to end: 1, A *cartilaginous tube* originating in the pharyngeal vestibule, and ramifying in the lungs; 2, The *nasal cavities*, two fossæ opening into that vestibule, and commencing by two openings formed at the anterior extremity of the head.

CHAPTER I.

RESPIRATORY APPARATUS OF MAMMIFERS.

In this apparatus we will first study the organs external to the thoracic cavity: the *nasal* cavities, and *larynx* and *trachea;* then the chest and the organs it contains—the *lungs.*

To this study will be added that of the two glandiform organs whose uses are unknown, but which, by their anatomical connections, belong to the respiratory apparatus. These are the *thyroid bodies* and the *thymas gland.*

THE NASAL CAVITIES.

These cavities are two in number, right and left, and offer for study: their entrance, or *nostrils*—the *fossæ* properly called, which constitute these cavities; and the diverticuli named *sinuses.*

Preparation.—Remove the lower jaw from three heads. On the first of these make two transverse sections, one passing between the second and third molar tooth, the other behind the dental arcade. Saw through the second head longitudinally and vertically, a little to one side of the median line. On the third make a horizontal section in such a manner as to obtain an inferior portion analogous to that shown in figure 23.

1. *The Nostrils.*

The *nostrils* are two oblong, lateral openings, situated at the extremity of the nose, circumscribed by *lips* or movable *wings* (*alæ*) disposed in an oblique direction downwards and inwards, and slightly curved on themselves, so as to present their concavity to the external side.

The *lips* or *alæ* of the nostril are enveloped, inwardly and outwardly, by a thin, delicate skin, covered by fine, short hairs. The *external* is concave on its free margin; the *internal* is convex. The *commissure* which unites these two wings superiorly, forms a slight cross curved inwards. When the finger is introduced into this commissure it does not enter the nasal cavity, but the *false nostril:* a conical pouch formed by the skin, extending to the angle comprised between the nasal spine and the elevated process of the premaxillary bone.

In the Ass, according to Goubaux, the false nostril is areolated at the posterior extremity, which ascends beyond the summit of the re-entering angle formed by the nasal and premaxillary prolongation.

The *inferior commissure* is round and wide, and, towards the bottom, presents an opening, sometimes double, which looks as if punched out; this is the inferior orifice of the lachrymal duct, which, in the Ass and Mule, is carried to the inner face of the external wing, near the superior commissure.

Structure.—The nostril is composed of a *cartilaginous framework, muscles* to move it, and *integuments, vessels,* and *nerves.*

Cartilaginous framework (Fig. 222).—This framework is formed by a cartilage, bent like a comma, and which, in its middle part, lies against that of the opposite side, the two making a kind of figure X. Fixed in a movable manner to the inferior extremity of the middle septum of the nose, by means of short interposed fibres, this cartilage offers: a wide upper part, situated in the substance of the inner wing of the nostril, and covered by the transverse muscle of the nose (Fig. 222, 1); and an inferior portion, which, after passing into the lower commissure, is prolonged, in a blunt point, to the external wing, where it receives the insertion of several fasciculi belonging to the orbicularis muscle of the lips, the pyramidal muscle of the nose, and the supernaso-labialis (Fig. 222, 2). Each wing, therefore, possesses a cartilaginous skeleton; but that of the external wing is very incomplete, in consequence of its being only formed by the inferior extremity of the common cartilage.

Fig. 222.

CARTILAGES OF THE NOSE.
1, 1, Wide portion, forming the base of the internal wing of the nostril, 2, 2, Narrow extremity prolonged into the external wing; 3, Superior or anterior border of the septum.

This cartilage, it will be understood, sustains the alæ of the nose, prevents their falling inwards, and always keeps open the external orifices of the respiratory apparatus.

Muscles.—The motor muscles of the alæ are all dilators in the domesticated animals. They are: the *transversalis nasi* (*dilatator naris anterior*—Percivall), or *transversalis of the*

nose, a single muscle placed on the widened portion of the cartilaginous pieces; the *supermaxillo-nasalis magnus* (*dilatator naris lateralis*—Percivall), *or pyramidal muscle of the nose*, whose insertion occupies the whole extent of the external wing; the *supermaxillo-nasalis parvus* (*nasalis brevis labii superioris*—Percivall), fixed, by its two portions, to the skin of the false nostril; the *middle anterior* (*depressor alæ nasi*—Percivall) which is confounded, superiorly, with the external fasciculus of the preceding muscle, it being attached to the inferior branch of the cartilaginous appendix of the maxillary turbinated bone; and, lastly, the *supernaso-labialis* (*levator labii superioris alæque nasi*—Percivall), whose anterior branch is inserted, in part, into the external wing. All these muscles having been described in the Myology (page 220), need not be further alluded to here.

Integuments of the nose.—The skin covering the alæ of the nose, externally, is doubled over their free margin to line their internal face, being prolonged over the entire extent of the false nostril, and is continued, in the nasal fossæ, properly called, by the pituitary membrane. This skin is fine, thin, charged with colouring pigment, often marked by leprous spots, and adheres closely to the muscles included between its duplicatures, through the medium of a very dense and resisting fibro-cellular tissue.

Vessels and nerves.—The nostrils are supplied with blood by the *superior coronary*, the *external nasal*, and the *palato-labial arteries*; it is returned by the *glosso-facial veins*, and partly by the venous network of the nasal mucous membrane. The *lymphatics*, large and abundant, receive those of the pituitary membrane, and join the submaxillary glands by passing over the cheeks. The *nerves* are very numerous, the sensory being derived from the maxillary branch of the fifth pair, and the motors from the facial nerve.

Functions.—The nostrils permit the entrance to the nasal cavities, of the air which is to pass to the lungs. Their dilatability allows the admission of a greater or less volume, according to the demands of respiration. It is to be remarked that, in Solipeds, the nostrils constitute the only channel by which the ærial column can be introduced to the trachea, in consequence of the great development of the soft palate, which is opposed to the entrance of air by the mouth; these orifices are also, for the same reason, relatively larger than in the other domesticated animals, in which the passage of air, by the buccal cavity, is easily accomplished.

2. *The Nasal Fossæ.* (Figs 223, 224.)

Channeled in the substance of the head, above and in front of the palate, and separated from one another, in the median plane, by a cartilaginous septum which does not exist in the skeleton, the nasal fossæ extend from the nostrils to the cribriform plate of the ethmoid bone, in a direction parallel to the larger axis of the head. Their length is, therefore, exactly measured by that of the face. *See* Fig. 223 for the whole of these cavities.

The nasal fossæ are formed by *two lateral walls*, a *roof* or *arch*, a *floor*, and *two extremities*.

Walls.—The two walls are very close to each other, and the more so as they are examined towards the ethmoid bone and the roof of the cavity. The space separating them varies, in proportion as it is measured at the level of the turbinated bones or at the meatuses.

Inner wall.—This is formed by the nasal septum, and is perfectly smooth.

Outer wall.—This is chiefly constituted by the supermaxillary bone, is very rugged, and is divided into three *meatuses*, or passages, by the turbinated bones—the irregular columns applied against the inner face of the before-mentioned bone.

The *turbinated bones* have already been described, and we will only now refer to the principal features of their organisation. Each is formed of a bony plate rolled upon itself (Fig. 223, 2, 3), and is divided, internally, into two sections, the superior of which forms part of the sinus, and the inferior belongs to the nasal fossæ; they are continued, inferiorly, by a fibro-cartilaginous framework, which prolongs their nasal section to the external orifice of the nose. The flexible appendix of the ethmoidal turbinated bone is usually single, sometimes double, and disappears before reaching the alæ of the nose. That of the maxillary turbinated bone is always bifurcated,

Fig. 223.

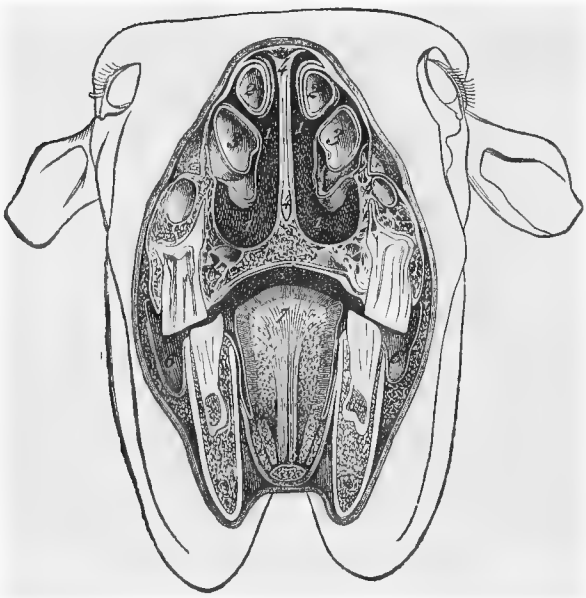

TRANSVERSE SECTION OF THE HEAD OF AN OLD HORSE, SHOWING THE ARRANGEMENT OF THE NASAL CAVITIES AND MOUTH.

1, Nasal fossa; 2, Superior turbinated bone; 3, Inferior ditto; 4, Median septum of the nose; 5, Central part of the buccal cavity (drawn more spacious than it really is when the two jaws are brought together); 6, 6, Lateral portions of the same; 7, Section of the tongue.

and its antero-superior branch is directly continued by the superior extremity of the internal wing of the nostril.

The *meatuses* are distinguished into *superior*, *middle*, and *inferior*, or into *anterior*, *middle*, and *posterior*, as the head is inspected in a vertical or horizontal position. The *superior* passes along the corresponding border of the ethmoidal turbinated bone, and is confounded with the roof of the nasal cavity; it is prolonged, behind, to near the cribriform plate of the ethmoid

bone: it is the narrowest. The *middle*, comprised between the two turbinated bones, presents, on arriving near the ethmoidal cells, the orifice which brings all the sinuses into communication with the nasal fossa. This orifice is ordinarily narrow and curved; but we have seen it sometimes converted into a foramen sufficiently wide to permit the introduction of a finger end. It is also by this meatus that the inferior compartment of the turbinated bones opens into the nasal fossa, these two bones being each rolled in a contrary direction. The *inferior meatus*, situated under the maxillary turbinated bone, is not distinct from the floor of the nasal cavity. *See* figure 224 for the arrangement of the turbinated bones and the meatuses on the external wall of the nose.

Roof or arch.—This is formed by the nasal bone, and is only a narrow channel, confounded, as has been said, with the superior meatus.

Floor.—Wider, but not so long as the roof, which is opposite to it, but from which it is distant by the height of the cartilaginous septum, the floor is concave from side to side, and rests on the palatine arch, which separates the mouth from the nasal cavities.

In front of this nasal region is remarked the *canal* or *organ of Jacobson:* a short duct terminating in a *cul-de-sac* in the middle of the cartilaginous

Fig. 224.

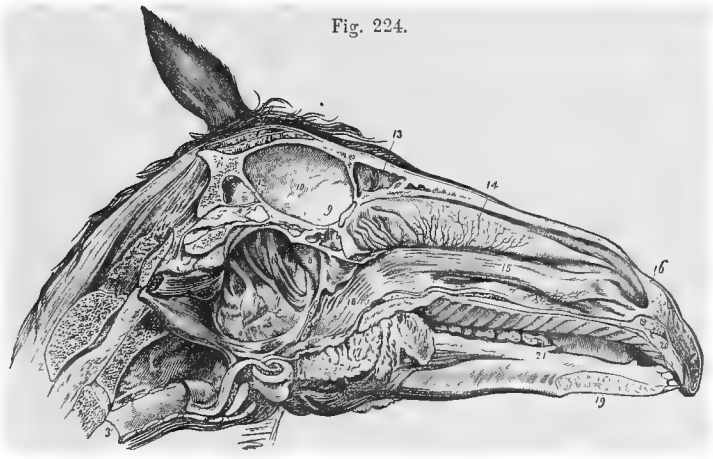

LONGITUDINAL MEDIAN SECTION OF THE HEAD AND UPPER PART OF NECK.

1, 1, Atlas; 2, 2, Dentata; 3, Trachea; 4, Right stylo-thyroideus; 5, Guttural pouch; 6, Stylo-pharyngeus; 8, Palato-pharyngeus; 9, Sphenoidal sinus; 10, Cranial cavity; 11, Occiput; 12, Parietal protuberance; 13, Frontal sinus; 14, Ethmoidal turbinated bone; 15, Maxillary turbinated bone; 16, Entrance to nostril, 18, Pharyngeal cavity; 19, Inferior maxilla; 20, Premaxilla; 21, Hard palate.

substance which closes the incisive foramen. At the bottom of this *cul-de-sac* opens a second canal, longer, wider, and more remarkable, but which has not yet been described. (It has been described by Stenson, and is named "Stenson's duct.") It has sometimes the diameter of a writing quill, commences by a *cul-de-sac* on a level with the second molar tooth, accompanies the inferior border of the vomer from behind to before, where it is enveloped in a kind of cartilaginous sheath—a dependency of the nasal septum; it terminates, as we have said, after a course of about 5 inches.

The structure of this duct resembles that of the excretory ducts of glands; its walls are evidently composed of two tunics—an internal or mucous, very rich in follicles, and having longitudinal folds, and an external, of a fibrous nature. These membranes receive numerous vessels, as well as nervous divisions emanating from a long filament of the spheno-palatine ganglion, and which may be traced from the external side of the canal to near the incisive foramen, where it is lost. Such is the organ of Jacobson; its uses are quite unknown.

Extremities.—The *anterior* or *inferior extremity* of the nasal fossa is formed by the nostril already described. The *posterior* or *superior extremity* presents, above, a space occupied by the ethmoidal cells. Below and behind, this extremity communicates with the pharyngeal cavity by a wide oval opening, which is circumscribed by the vomer and palate bones: this is the guttural opening of the nasal fossa.

Structure.—The nasal fossæ offer for study in their organisation: 1, The *bony framework* by which these cavities are formed; 2, The *cartilaginous septum* separating them; 3, The *pituitary membrane*—the mucous layer covering their walls.

1. Bony Framework of the Nasal Fossæ.—This comprises: 1, The *nasal, maxillary, frontal*, and *palate bones*, which together form a vast irregular tube circumscribing the nasal fossæ; 2, The *ethmoid bone*, occupying the bottom of this tubular cavity and the *turbinated bones* applied against the lateral walls; 3, The *vomer*, placed in the median plane, and serving as a support for the cartilaginous partition dividing this single cavity into two compartments. All these bones having been already studied in detail, we confine ourselves to their simple enumeration.

2. Middle Septum of the Nose (Fig. 223, 4).—Formed of cartilage susceptible of ossification, this partition is nothing more than the perpendicular lamina of the ethmoid bone prolonged to the extremity of the nose. Its elongated form permits us to recognise in it *two faces, two borders*, and *two extremities*. The *faces* are channeled by a multitude of furrows, which lodge the anastomosing divisions of the magnificent venous plexus of the pituitary membrane.

The *superior border*, united to the frontal bone and median suture of the nasal bones, expands to the right and left on the inner faces of these, in forming two laminæ, thin at their free margin, the section of which is represented in Fig. 223. These laminæ are wide enough in front to project beyond the nasal spine. The *inferior border* is received into the mortice of the vomer.

The *posterior extremity* is continued without any precise limitation, by the perpendicular lamina of the ethmoid bone.

The *anterior extremity*, a little wider, supports the cartilages of the nostrils. It is joined, below, to the premaxillary bones, and is spread out on the incisive openings in a thick layer which exactly closes them.

This septum is covered by a thick perichondrium, which adheres intimately to the pituitary membrane.

3. Pituitary Membrane.—This membrane, also designated the *olfactory mucous membrane*, and *Schneiderian membrane*, is continuous with the cutaneous integument covering the inner face of the alæ of the nose. Considered at first on the internal wall of the nasal fossæ, the pituitary membrane is seen to cover the cartilaginous septum forming this wall, then to be spread over the floor as well as the roof of the cavity, reaching the outer wall, which it also covers in enveloping the external surface of the turbinated bones,

and is insinuated, by the middle meatus, into the cells of the inferior or anterior compartment of these osteo-cartilaginous columns. It also penetrates, by the semicircular opening of this meatus, into the sinus, to give it its mucous covering, and is likewise prolonged into the apparatus of Jacobson. Behind, it is confounded with the lining membrane of the pharyngeal cavity.

Its deep face is separated by the periosteum or perichondrium, from the bony or cartilaginous walls on which it is spread; and it is united to the two precited layers, this union being closest where it is thinnest, although it can always be easily distinguished from these two fibrous layers throughout the whole extent of the nasal fossa. The free, or superficial face, presents numerous glandular orifices, and is constantly covered by an abundance of mucus, that prevents the desiccation to which this surface is exposed by the incessant movement of air over it.

Structure.—The organisation of the pituitary membrane resembles that of other mucous membranes, but it also presents some differences according as to whether it is examined near the nostrils or deeper in the cavities. It is also usual to divide it into two portions: the *olfactory mucous membrane*, which covers the upper part of the ethmoidal turbinated bone and cells; and the *Schneiderian membrane* covering the inferior two-thirds of the nasal cavities.

The *corium* of the *Schneiderian membrane* is thick, soft, spongy, and rose-coloured, and contains a large number of vessels and *glands*. The latter are mucous or racemose glands, and are extremely abundant in the layer covering the septum of the nose, as well as at the inner face of the cartilaginous appendices of the turbinated bones; though they are rare or altogether absent on the external face of the latter. The *epithelium* is *ciliated* and *stratified*, the deeper cells being round, those on the surface columnar.

Fig. 225.

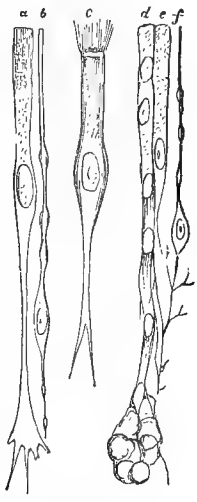

CELLS OF THE OLFACTORY MUCOUS MEMBRANE.

a, *b*, *c*, After Schultze, *d*, *e*, *f*, After Lockhart Clarke.

The *olfactory mucous membrane* differs from the preceding by its greater thinness, its delicateness, its slightly yellow tint, and the character of its epithelium. The *corium* contains straight or slightly-contorted *tubular glands*—the glands of Bowman. The *epithelium* is *columnar* and *stratified*, and readily changes; in animals it is destitute of cilia. The deeper cells contain some yellowish pigment granules. Schultze describes as *olfactory cells*, certain fusiform elements which he considers as concerned in olfaction. These cells have two prolongations a deep one, which is connected with the fibres of the olfactory nerve; and a superficial, that enters between the epithelial cells and tends to approach the free surface of the membrane.

(The "olfactory cells" are thin, rod-like bodies (Fig. 225, *b*), presenting varicose enlargements which are connected with processes of deeper-seated nerve-cells. The epithelial cylinders proper (*d*, *e*) are related at their bases with the septa of connective tissue belonging to the sub-epithelial glandular layer, and are probably in communication with the olfactory cell. Schultze describes another set of epithelial cells (*a*) as terminating externally by truncated flat surfaces, and to all

appearance not covered by any membrane, apart from the contents of the cell, which are a yellow, granular proto-plasma surrounding an oval nucleus lying in colourless proto-plasma. The extremity of these cells is thin, and they can be traced inwards until they expand into a flat portion that sends off processes which appear to be continuous with the fibres of the submucous connective tissue. Similar cells (*c*) are found towards the margin of the true olfactory region, but these have a band at their free extremity, which is also provided with a circle of cilia.)

The pituitary membrane receives its blood by the *ophthalmic* and *nasal arteries;* it is returned by the large anastomosing *veins* which form, in the deep layer, a long, close, and magnificent plexus that terminates in the satellite vein of the nasal artery. This plexuous arrangement is so marked at certain points—as at the appendices of the turbinated bones, that it gives the mucous membrane somewhat the appearance of erectile tissue. It will be understood that in favouring the stagnation of the blood, this arrangement predisposes to hæmorrhage.

The *lymphatics* of the pituitary membrane could not be injected for a long time, neither in man nor animals; and this led several anatomists to deny their existence. Nevertheless, they do exist, and form a fine superficial network on the septum of the nose, the turbinated bones, and the meatuses. The trunks passing from it go to the submaxillary glands.

The *nerves* of this membrane are numerous, and are derived from the first and fifth pairs, and from Meckel's ganglion. The ramifications of the olfactory nerve, on emerging from the apertures of the cribriform plate of the ethmoid bone, pass to the inner and outer walls of the nasal cavities; being destined for the olfactory mucous membrane, they do not descend below the upper third of these cavities. They form at first a close plexus, and afterwards terminate in a manner not quite understood. Schultze admits that they terminate on the olfactory cells mentioned above.

The branches derived from Meckel's ganglion and the fifth pair are specially destined for the Schneiderian membrane, and are named the ethmoidal branches of the palpebro-nasal and spheno-palatine nerves. They endow the nose with an acute degree of sensibility, and it is believed that they render olfaction more perfect.

Fig. 226.

FIBRES OF ULTIMATE RAMIFICATIONS OF OLFACTORY NERVE OF DOG.

(It is to be remarked that the filaments composing the olfactory plexus differ from ordinary cephalic nerves in containing no white substance of Schwann, and are nucleated and finely granular in texture, resembling the gelatinous form of nerve-fibres. The surface to which they are limited is that covered with the yellowish-brown epithelium.)

3. *Sinuses.*

The *sinuses* are very anfractuous cavities, excavated in the substance of the bones of the head, on the limits of the cranium and face, and around the ethmoidal masses, which they envelop.

These cavities, diverticuli of the nasal fossæ, are pairs, and are five on each side: the *frontal, supermaxillary, sphenoidal, ethmoidal,* and *inferior maxillary sinuses.* The first four communicate; the last is usually perfectly isolated.

FRONTAL SINUS.—This cavity, situated at the inner side of the orbit,

presents very irregular walls, which are formed by the frontal, nasal, lachrymal, and ethmoidal bones, and the superior portion of the ethmoidal turbinated bone. It communicates with the superior maxillary sinus by a vast opening made in a very thin bony partition. A thick vertical plate, often bent to the right or left, but always imperforate, separates this sinus from that of the opposite side.

Superior Maxillary Sinus.—Channeled beneath the orbit, between the maxillary, zygomatic, ethmoid, and lachrymal bones, this diverticulum is the largest of all, and is divided into two compartments by the maxillo-dental canal, which traverses it. The internal compartment constitutes a kind of shallow cavity, continuous with the sphenoidal sinus, and presents a narrow slit, which penetrates to the ethmoidal sinus. The external compartment is separated, in front, from the maxillary sinus by a partition which M. Goubaux has, contrary to the generally-received opinion, demonstrated to be imperforate at all periods of life; though he has sometimes found it so thin as only to consist of two mucous layers laid against each other. This compartment is prolonged backwards into the maxillary protuberance, and the roots of the two last molars project into its anterior.

Sphenoidal Sinus.—This is the smallest, after that of the great ethmoidal cell. Formed by the sphenoid and palate bones, this cavity is very irregular, and is subdivided by incomplete septa into several compartments, which may be always reduced to two: an anterior, comprised between the palatine laminæ; the other posterior, hollowed in the body of the sphenoid bone. In contact, on the median line, with the sinus of the opposite side, it is separated from it by a twisted plate, which is constantly perforated, even in young animals.

Ethmoidal Sinus.—By this name is designated the internal cavity of the large ethmoidal cell, which constitutes a real sinus, and which a narrow slit brings into communication with the superior maxillary sinus.

Inferior Maxillary Sinus.—This last diverticulum is remarkable because of its not communicating with the others. Excavated in the supermaxillary bone, and separated from the superior sinus by the imperforate septum previously mentioned, it is divided, like the latter cavity, into twe compartments: an internal, prolonged into the superior cavity of the maxillary turbinated bones; and an external, the smallest, showing the roots of the fourth molar, rarely those of the third. It does not descend, as Rigot has asserted, above the three front molars; but supposing the head to be vertical, it does not extend, in the adult Horse, beyond the extremity of the maxillary ridge, in front of which it would be necessary to trepan, in order to arrive at its interior.

Communicating Orifice of the Sinuses with the Nasal Fossa.—All the sinuses of one side communicate with the corresponding nasal fossa by the curved slit which has been observed at the bottom of the middle meatus. This slit penetrates the superior maxillary sinus, under the septum that separates it from the frontal sinus; it also enters the inferior maxillary sinus, which thus communicates solely with the nasal cavity, while the other diverticuli open in common into this cavity through the medium of the superior maxillary sinus.

Mucous Membrane of the Sinuses.—In entering the sinuses to cover their walls, the pituitary membrane becomes extremely thin, and loses its great vascularity; it is applied immediately to the bones, and serves as a periosteum.

Development of the Sinuses.—These cavities begin to be developed in

the fœtus, and are gradually hollowed in the thickness of the bones which concur to form them. They increase during the animal's lifetime, by the thinning of the bony plates inclosing or partitioning them, and particularly by the growth of the superior molar teeth, whose roots project into these cavities. The formation of the inferior maxillary sinus is more tardy than the others; though it is not so late as seven or eight years, as the majority of Veterinary Anatomists have asserted. M. Goubaux has proved that the sinus is already present at six months old; and in a head which has been for several years in the museum of the Lyons School, and which belonged to a foal of very small stature, about a year old, this sinus is seen, in its external part, to be already 1½ inches in depth, and 8-10ths of an inch in width.

Functions of the Sinuses.—Have the sinuses or diverticuli of the nasal cavities the same uses as these cavities? It is probable, although not absolutely certain. There is nothing to prove that they have anything to do with respiration or olfaction; and it would seem that their exclusive function is to give increased volume to the head without increasing its weight, and in this way to furnish wide surfaces of insertion for the muscles attached to this bony region—these cavities being all the more ample as the muscles are large and numerous.

DIFFERENTIAL CHARACTERS OF THE NASAL CAVITIES IN OTHER THAN SOLIPED ANIMALS.

1. *Nostrils*—In the *Ox*, the nostrils, placed on each side of the muffle, are narrower and less movable than in the Horse. (The superior extremity of the ala is not horizontal; the inferior is divided into two branches.)

In the *Pig*, the end of the nose constitutes the snout (*rostrum suis*), whose anterior surface, plane and orbicular, shows the external orifices of the nostrils. This *snout*, a veritable tactile organ employed by the animal to dig up the ground, is covered by a dark-coloured skin, kept damp by a humid secretion, like the muffle of the Ox. It has for a base the *scooping-bone*, a particular piece situated at the extremity of the nasal septum, and enveloped by a layer of cartilage which extends around the nostrils. It is easy to distinguish two symmetrical halves in this bone, which evidently represent the two cartilaginous pieces in the nose of Solipeds.

In the *Dog*, the end of the nose forms a salient region, which is roughened, naked, usually dark-coloured, damp, and sometimes divided by a median groove; in this region the nostrils are pierced, their form resembling two commas opposed to each other by their convexities. The cartilaginous framework sustaining these orifices is not composed of separate pieces, but is only a dependance of the median septum and the appendages of the turbinated bones.

The same considerations apply to the nostrils of the *Cat* with the exception of the colour of the integument, which is nearly always of a rosy hue, like the mucous surfaces.

2. *Nasal Cavities.*—The nasal fossæ of the *Ox*, *Sheep*, and *Goat* are distinguished by the presence of a third turbinated bone—the *olfactory antrum*, and by the communication existing between them, posteriorly, above the inferior border of the vomer. We have already seen that in these animals, as in those yet to be mentioned, the canal of Jacobson completely traverses the palatine arch.

In the *Pig*, the nasal fossæ are long and narrow. They are, on the contrary, very short in the *Dog* and *Cat*, and the internal cells of the turbinated bones, remarkable for their number and complexity, all communicate with the proper nasal fossæ, without concurring in the formation of the sinuses.

3. *Sinuses.*—In the *Ox*, the *frontal sinuses* are prolonged into the bony cores which support the horns, and into the parietal and occipital bones; they therefore envelop, in a most complete manner, the anterior and superior part of the cranium, and form a double wall to this bony receptacle. They are extremely diverticulated, and do not communicate with those of the great maxillary bones. They usually open, on each side, into the nasal cavities by four apertures pierced at the base of the great ethmoidal cell. According to Girard, three of these orifices lead to special compartments, isolated from one another, and grouped around the orbit; in consequence of which these diverticuli of the frontal sinuses are designated the *orbital sinuses*.

This author has denied the presence of *sphenoidal sinuses;* but they exist, although small, and are in communication with the preceding.

The *sinus of the great ethmoidal cell* comports itself as in the Horse.

There is only one pair of *maxillary sinuses*, which are very large, and partitioned into two compartments by a plate of bone, that bears at its superior border the supermaxillo-dental canal, like the superior maxillary sinus of Solipeds. The external or maxillary compartment is prolonged into the lachrymal protuberance; the internal occupies the thickness of the palatine arch. A wide orifice at the base of the maxillary turbinated bone affords a communication between this sinus and the nasal fossa.

In the *Sheep* and *Goat*, there exists a similar arrangement of the sinuses of the head; but these cavities are much less spacious than in the Ox; the frontal sinus, in particular, does not extend beyond the superior border of the frontal bone.

In the *Pig*, these latter sinuses are prolonged into the parietal bones; though they are far from offering the same extent as in the smaller Ruminants. It is the same with the others; they present an arrangement analogous to those of the *Sheep* and *Goat*.

In the *Dog* and *Cat*, there are only, on each side, a maxillary and a frontal sinus. The first scarcely merits notice; and the second, a little more developed, opens into the nasal cavity by means of a small aperture situated near the middle septum of the two frontal sinuses.

(Leyh states that the Carnivora have no maxillary sinus; consequently, the *sphenoidal sinus* communicates below with the nasal fossæ.)

COMPARISON OF THE NASAL CAVITIES IN MAN WITH THOSE OF ANIMALS.

The external orifices of the nasal cavities of *Man* are called *nostrils*; these are flattened transversely, and prolonged in front of the lobule of the nose; their external face or ala is concave and movable. They are lined internally by a membrane that holds a middle place between the skin and mucous membranes; it has a number of little hairs, called *vibrissæ*.

The *cavities* or *nasal fossæ* offer nothing particular; as in animals, they show a superior, middle, and inferior meatus. On their floor, in front, is seen the superior orifice of the incisive foramen, which corresponds to the commencement of Jacobson's canal. The *pituitary membrane* has a squamous epithelium in its olfactory, as on its Schneiderian portion. At the bottom of the nasal cavities and the upper part of the pharynx, is a kind of diverticulum named the *posterior nares;* it has been already alluded to when speaking of the pharynx.

The *sinuses* are: 1, The sphenoidal sinus and the posterior ethmoidal cells, that open beneath the roof of the nasal fossæ; 2, The middle ethmoidal cells, opening into the superior meatus; 3, The anterior ethmoidal cells, and frontal and maxillary sinuses, communicating with the middle meatus. All these sinuses have a proper communicating orifice with the nasal cavities.

THE AIR TUBE SUCCEEDING THE NASAL CAVITIES.

This single tube comprises: the *larynx*, which commences the *trachea;* the latter forms the body or middle portion, the *bronchiæ* terminating it.

. *Larynx.* (Figs. 227, 228, 229.)

Preparation.—1. Make a longitudinal section of the head, in order to study the general disposition of the larynx (Fig. 224). 2. Isolate the cartilages, to examine their external conformation. 3. Remove the muscles from a third larynx, to show the mode of articulation of the various cartilages (Figs. 227, 228). 4. Prepare the muscles in conformity with the indications furnished by a glance at figure 229. 5. Remove a larynx as carefully as possible, so as not to injure the walls of the pharynx, in order to study the interior of the organ, and especially its pharyngeal opening.

Form—Situation.—The *larynx* forms a very short canal, which gives passage to the air during respiration, and is at the same time the organ of the voice.

It is a cartilaginous box, depressed on each side, and open from one end to the other: the anterior orifice being situated at the bottom of the pharyngeal cavity, and the posterior continuous with the trachea.

This apparatus, situated in the intermaxillary space, is suspended between the two cornua of the os hyoides, and fixed to the extremities of these appendages by one of its constituent pieces. It serves to support the

pharynx, and by means of the walls of the latter is attached to the circumference of the posterior openings of the nasal cavities.

In order to facilitate description, this brief notice of its form, situation, general relations, and mode of attachment will be followed by a notice of its structure; afterwards, the study of its external and internal surfaces will receive attention.

STRUCTURE OF THE LARYNX.—It comprises in its structure: 1, A *cartilaginous framework*, composed of five pieces; 2, *Muscles* which move these pieces; 3, A *mucous membrane* spread over the inner surface of the organ; 4, *Vessels* and *nerves*.

1. *Cartilaginous framework of the larynx.*—In this we find: three single median cartilages, the *cricoid*, *thyroid*, and *epiglottis;* and two lateral cartilages, the *arytenoid*. All are movable one upon the other.

CRICOID CARTILAGE.—This cartilage, as its name indicates (κρίκος, εἶδος, *like a ring*), is exactly like a ring with a bezel looking upwards. Depressed on each side, but all the less as the animal has its respiratory apparatus well developed, this ring offers *two faces*, and *two borders* or *circumferences*. The *internal face* is smooth and covered by mucous membrane. The *external face* is provided, in the middle of the widened portion forming the bezel with a little eminence more or less prominent, elongated in the form of a crest, and separating the two posterior crico-arytenoid muscles, to which it gives attachment, from each other. On the sides of this bezel are two small, articular, concave facets, which correspond to the branches of the thyroid cartilage. Nothing remarkable is to be noted for the remainder of the extent of this face. The *superior circumference*, comprised laterally between the two branches of the thyroid cartilage, is hollowed out in the narrow part opposite the bezel, where its shows two lateral convex articular facets for articulation with the arytenoid cartilages. The *inferior circumference* responds to the first ring of the trachea; it offers a small notch, often double, on the middle of the bezel.

THYROID CARTILAGE (θυρεός, εἶδος, *like a shield*).—This is composed of two lateral plates, which have the form of an obliquangular parallelogram, and are united at their anterior extremity to form a thick constricted part which, in Veterinary Anatomy, is named the *body of the thyroid*. This *body* is smooth on its *inferior face*, where it is covered by the terminal extremity of the subscapulo-hyoideii muscles. On its *superior face* is an obtuse, rounded, and irregular protuberance, on which the epiglottis articulates.

The *plates, lateral branches*, or *alæ* of the thyroid present *two faces*, *two borders*, and *two extremities*. The *external* face, slightly convex, is covered by the hyo-thyroideus and thyro-pharyngeus muscles. The *internal face*, slightly concave, is covered, near the superior border, by the pharyngeal mucous membrane; for the remainder of its extent it responds to the thyro-arytenoid and lateral crico-arytenoid muscles.

The *superior border* is divided by a small prolongation into two parts: an anterior, giving attachment to the thyro-hyoid membrane; the other posterior, into which is inserted the pharyngo-staphyleus (palato-pharyngeus) muscle. This appendix, the *great thyroid cornu* of Man, forms one of the obtuse angles of the parallelogram represented by each lateral plate of the thyroid cartilage; it is united to the extremity of the hyoid cornu; and at its base is an opening, or deep notch, through which passes the superior laryngeal nerve. The *inferior border* is also divided into two parts by the second obtuse angle of the cartilage: the anterior part forms, with that of

the opposite plate, a receding angle occupied by the crico-thyroid membrane; the posterior gives attachment to the crico-thyroid muscle. The *extremities* constitute the acute angles of the thyroid plate. The *anterior* is confounded with that of the opposite branch, to form the body of the cartilage. The *posterior*, slightly curved downwards, is terminated by a small, convex diarthrodial facet, which articulates with the concave facets of the external face of the cricoid cartilage.

The thyroid cartilage is frequently partially, or even entirely, ossified.

Epiglottis.—This piece forms a soft and flexible appendix, shaped like a sage-leaf; inferiorly, it circumscribes the entrance to the larynx, and is bent over it, so as to close it hermetically when the alimentary bolus is traversing the pharyngeal vestibule.

This cartilage has *two faces*, *two lateral borders*, a *base*, and a *summit*. The *anterior face* is convex from side to side, concave from above to below, and covered by the mucous membrane of the pharynx; it gives attachment to the hyo-epiglottidean muscle.

The *posterior face* shows an inverse configuration, and is covered by the lining membrane of the larynx, which is perforated by glandular orifices. The *borders* offer a free portion, which aids in circumscribing the entrance to the larynx; as well as an adherent part fixed to the arytenoid cartilage by means of a mucous fold, and made irregular by the little cartilaginous bodies which are superadded to it. (These are the *cuneiform cartilages*, or *cartilages of Wrisberg*, placed in the aryteno-epiglottidean fold of mucous membrane which extends from the apex of the arytenoid cartilage to the side of the epiglottis.) The *base* is thick, and articulated with the middle part of the thyroid; it gives origin, posteriorly, to two lateral prolongations, which pass to the inferior border of the arytenoids, but usually without joining these.

The *summit* unites the free portion of both borders, and is thrown forwards on the upper face of the soft palate (Fig. 174, 9).

Arytenoid Cartilages.—These two pieces have been so designated from their resemblance, when approximated, to the mouth of a pitcher (ἀρύταινα, εἶδος, *like a pitcher*). They are situated in front of the cricoid, above the entrance to the larynx; each affects an irregular quadrilateral form, and presents for study *two faces* and *four borders*. The *internal face* is smooth, almost flat, and lined by the laryngeal mucous membrane. The *external* face is divided by a ridge into two portions: a superior, covered by the arytenoid muscle; and an inferior, giving attachment to the thyro-arytenoid and lateral crico-arytenoid muscles. The *superior border* is concave, and joined to that of the opposite cartilage. The *inferior border* gives attachment, posteriorly, to the vocal cord. The *anterior border*, thick and convex, and covered by the mucous membrane, circumscribes, superiorly and laterally, the entrance to the larynx; it is in joining above, with the homologous border of the other arytenoid cartilage, that the pitcher-beak already mentioned is formed. The *posterior border* projects into the larynx by its inferior portion; superiorly, this border is very thick, and is hollowed by a small articular facet, which responds to the anterior facet of the bezel of the cricoid. Above, and to the outside of this facet, is a very prominent tubercle which terminates behind the crest of the external face, and gives attachment to the posterior crico-arytenoid muscle.

Articulations of the Laryngeal Cartilages (Figs. 227, 228).—These articulations are of the simplest kind. They are as follows:

A. The thyroid cartilage is joined to the os hyoides: 1, At the

extremities of the cornua, by means of a short ligament interposed between that extremity and the appendix of the superior border of the thyroid; 2, To the whole extent of the hyoid concavity, by an elastic membrane—the *thyro-hyoid membrane*, attached to the body of the thyroid cartilage and the superior border of the lateral plates of that cartilage (Fig. 228, 4).

Fig. 227.

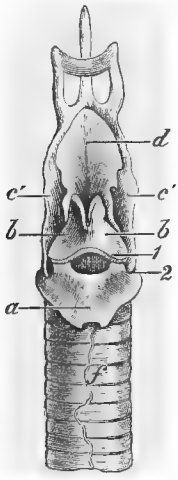

SUPERIOR FACE.

Fig 228.

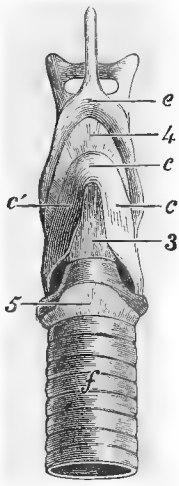

INFERIOR FACE.

CARTILAGINOUS PIECES OF THE LARYNX, MAINTAINED IN THEIR NATURAL POSITION BY THE ARTICULAR LIGAMENTS.

a, Cricoid cartilage; *b*, *b*, Arytenoid cartilages; *c*, Body of the thyroid; *c′*, *c′*, Lateral plates of the thyroid; *d*, Epiglottis; *e*, Body of the hyoid; *f*, Trachea.—1, Crico-arytenoid articulation; 2, Capsule of the crico-thyroid articulation; 3, Crico-thyroid membrane; 4, Thyro-hyoid membrane; 5, Crico-trachealis ligament.

B. The thyroid cartilage articulates with the cricoid by two small arthrodiæ, which unite the posterior extremities of the branches of the first cartilage with the facets on the external face of the second. A thin external capsule incloses this articulation (Fig. 227, 2). These two cartilages are also held together by means of a membranous elastic ligament—the *crico-thyroid membrane*, which passes from the angle comprised between the two branches of the thyroid to the anterior notch of the cricoid (Fig. 228, 3).

C. The two arytenoid cartilages are united, at their superior border, by the arytenoid muscle and laryngeal mucous membrane.

D. The latter cartilages are brought into contact with the anterior facets of the cricoid bezel, by means of the concave articular surface of their posterior border; the result is a small, but very movable, arthrodial joint, inclosed by a thin external capsule and by the surrounding muscles (Fig. 227, 1).

E. These cartilages are also united to the thyroid through the medium of the *vocal cords*. These are two elastic bands which project within the larynx, and between them include the triangular space termed the *glottis*; their internal face is covered by the mucous membrane of the larynx; the thyro-hyoid muscles envelop their external face; their inferior extremity is fixed into the crico-thyroid membrane, and the angle of the thyroid cartilage;

the superior is attached to the inferior border of the arytenoid cartilage, towards the angle which separates this from the posterior border. The articulation of sounds is principally due to the vibration of these cords.

F. The epiglottis is fixed by amphiarthrosis to the body of the thyroid cartilage, by means of elastic fasciculi mixed with fat, which pass from the base of the first to the upper face of the second. It is not rare to find among these fasciculi small synovial bursæ.

G. The epiglottis is united, laterally, to the inferior border of the arytenoids, through the medium of the two mucous folds already noticed, in the substance of which are the cartilaginous prolongations annexed to the base of this fibro-cartilage. These prolongations circumscribe, anteriorly, the ventricles of the larynx, and are sometimes designated the *superior vocal cords:* a name we rarely give them, as they do not merit it.

H. Finally, the first ring of the trachea is attached to the cricoid cartilage by a circular elastic membrane.

All of these articulations have neither the same importance nor mobility. The kind of movements they permit is easily understood, and they are sufficiently indicated in the description of the muscles which execute them.

It is sufficient here to state, that these movements may either produce the shortening or elongation of the larynx, its dilatation or contraction in a transverse direction, or the occlusion of its anterior opening.

2. *Muscles of the larynx.*—The laryngeal apparatus is elevated or depressed with the hyoid bone, which it follows in all its movements. It is also moved by proper muscles, which either produceits total displacement, or cause the several pieces of its cartilaginous framework to play upon each other. Among these muscles there are three extrinsic: the *sterno-thyroideus, hyo-thyroideus,* and the *hyo-epiglottideus.* The others are intrinsic, or attached in their origin and termination to the different pieces of the larynx; they are: the *crico-thyroid, posterior crico-arytenoid, lateral crico-arytenoid, thyro-arytenoid,* and the *arytenoideus* muscles. All are pairs, except the last and the hyo-epiglottideus.

Sterno-thyroideus.—(See page 198.)

Hyo-thyroideus.—This is a wide, triangular muscle formed entirely of muscular fasciculi, which originate from the whole extent of the hyoid cornu, and terminate on the external face of the thyroid ala; the most inferior are longest. This muscle covers the thyroid cartilage and the thyro-hyoid membrane. It is covered by the maxillary gland.

In contracting, this muscle brings the thyroid cartilage within the branches of the hyoid bone, and in this way carries the larynx forward and upward.

Hyo-epiglottideus.—By this name is designated a small cylindrical fasciculus, whose fibres are buried in the middle of a mass of adipose tissue, and which extend from the superior face of the body of the hyoid bone to the antero-inferior face of the epiglottis. Partly covered by the mucous membrane of the pharynx, this muscle concurs in restoring the epiglottis to its normal position after the passage of the alimentary bolus. But it is also necessary to state that the epiglottis is carried forward more particularly by its own proper elasticity, as well as that of the ligamentous fasciculi which attach it to the thyroid cartilage.

Crico-thyroideus (Fig. 229, 8).—This small muscle, applied to the external side of the cricoid cartilage, is elongated from above to below, and composed of strongly tendinous fibres which cross, more or less, the general direction of the muscle. They arise from the above-named cartilage, and pass to the posterior border of the thyroid plate.

The crico-thyroideus shortens the larynx, in bringing together the two cartilages into which it is inserted.

Fig. 229

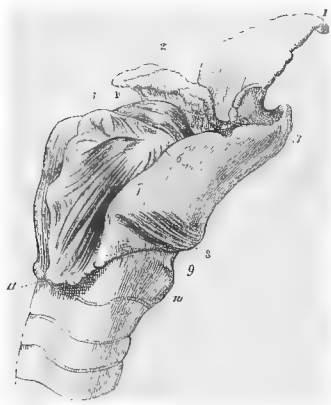

POSTERO-LATERAL VIEW OF THE LARYNX

1, Epiglottis; 2, Arytenoid cartilages; 3, Thyroid cartilage; 4, Arytenoideus muscle; 5, Crico-arytenoideus lateralis; 6, Thyro-arytenoideus; 7, Crico-arytenoideus posticus; 8, Crico-thyroideus; 9, Ligament between the cricoid cartilage and first ring of trachea, 10; 11, Infero-posterior extremities of crico-thyroid cartilages.

Posterior Crico-arytenoideus (Fig. 229, 7) —This is the most powerful muscle in this region. Its fibres are directed forwards and outwards, and originate from the bezel of the cricoid, which they cover, and from the median crest of that part. They all converge, in becoming more or less tendinous, towards the posterior tubercle of the arytenoid cartilage, on which they terminate. Covered by the œsophagus and the crico-pharyngeal muscular band, this muscle is separated from that of the opposite side by the median crest of the cricoid bezel.

The posterior crico-arytenoid muscles dilate the entrance to the larynx, as well as the glottis, in causing the arytenoid cartilages to rotate or swing on the cricoid cartilage. and in separating them from one another by their anterior and inferior borders. They act as a lever of the first order.

Lateral Crico-arytenoideus (Fig. 229, 5). — A triangular muscle, smaller than the preceding, situated between the thyroid and arytenoid cartilages, and formed of fasciculi longer in front than behind; these originate on the side of the anterior border of the cricoid cartilage, and are directed upwards to terminate outside the posterior crico-arytenoideus, on the tubercle of the arytenoid cartilage.

It is a direct antagonist of the last muscle, and, consequently, a constrictor of the larynx.

Thyro arytenoideus (Fig. 229, 6).—Lodged at the inner face of the thyroid ala, this muscle comprises two fasciculi, separated by the ventricle of the glottis.

The anterior fasciculus is a long and pale band, originating on the internal surface of the ala of the thyroid cartilage, near its receding angle, and ascending to the arytenoid cartilage, bending round its external face to join, on the median line, the analogous fasciculus from the opposite side, mixing its fibres with those of the arytenoideus. By its inner face it covers the superior vocal cord and the laryngeal mucous membrane.

The *posterior fasciculus*, wider than the anterior, comports itself in a somewhat similar manner. It commences from behind the same point, and terminates on the external crest of the arytenoid cartilage; but its most anterior fibres pass over this crest and join the arytenoid muscle. Its internal face corresponds to the vocal cord, and its posterior border is confounded with the fibres of the lateral crico-arytenoideus.

Sometimes it happens that these fasciculi are not distinct from each other, and exist only as a wide muscular band applied against the ventricle of the glottis.

It is surmised that this muscle is a constrictor of the larynx. Its

function is particularly marked in phonation, when it modifies the length, separation, and tension of the vocal cords.

ARYTENOIDEUS.—Situated beneath the pharyngeal mucous membrane, above the arytenoid cartilages, this, the smallest of the laryngeal muscles, is composed of two lateral portions whose fibres arise from a median raphé and, diverging, pass to the superior part of the external face of the before-mentioned cartilages, where they terminate by becoming inserted into the crest dividing that face, and uniting with the thyro-arytenoid muscle.

The French works on Veterinary Anatomy cite this muscle—we do not know why—as a dilator of the larynx. Its position in front of the crico-arytenoid cartilages sufficiently indicates that it cannot act otherwise than in bringing the two arytenoid cartilages together. And the continuity of a large number of its fibres with those of the thyro-arytenoideus, does not allow it to have any other action than that of this muscle.

3. *Mucous membrane of the larynx.*—This membrane is only a continuation of the pharyngeal mucous membrane, which, after covering the prominence formed by the opening of the larynx, is folded over the circumference of that opening, to be spread on the posterior face of the epiglottis and the internal face of the arytenoid cartilages, to dip into the ventricles, pass above the vocal cords, line the inner face of the cricoid cartilage, and, finally, to be prolonged into the tracheal tube. Its deep face adheres closely to the parts it covers, except in the lateral ventricles. The free face is perfectly tense, and is covered with stratified tesselated epithelium at the epiglottis and vocal cords, but only with ciliated epithelium elsewhere.

The *glandulæ* of the larynx are racemose, and are numerous on the posterior face of the epiglottis, where they are lodged in the minute depressions of the cartilage; they are also found on the arytenoid cartilages and the aryteno-epiglottidean folds. The mucous membrane of the larynx possesses an exquisite sensibility, owing to which admission to the air-passage is denied to the solid or liquid alimentary particles, which, during deglutition, might deviate from their normal course and pass into this opening. The slightest touch brings into play this sensibility, and determines an energetic reflex excitation of the constrictor muscles of the larynx and chest; from this results the almost complete occlusion of the laryngeal tube, and a violent cough which expels the substances whose contact has occasioned the irritation of the membrane. Everyone has experienced the effects of this reflex action, and knows by experience the great sensibility of the larynx.

4. *Vessels and nerves.*—Blood is carried to the larynx by the *laryngeal arteries*, which pass between the cricoid and the posterior border of the thyroid cartilages. Their branches spread over the ventrical of the glottis and the thyro-arytenoid muscle, to be expended in the substance of the muscles and mucous membrane. The terminal ramifications form red plexuses on certain parts of the larynx. The *veins* are satellites of the arteries. The *lymphatics* form a superficial and a submucous network.

The *pneumogastric* furnishes the larynx with its principal nerves—the *superior* and *inferior laryngeal.* The first is distributed to the upper part of the organ and to the entrance to the glottis, endowing the mucous membrane with that high degree of sensibility that distinguishes it. The second is more especially a motor nerve, and supplies all the muscles, except the crico-thyroid muscle. A filament of the recurrent nerve is distributed in the mucous membrane of the subglottal portion, and to the

inferior border and inner face of the vocal cords. The presence of nervous filaments, analogous to those of the trachea, in the sub-glottal part of the larynx may explain the difference, well known to physiologists, that exists between the sensibility of the entrance to the glottis and that of the inferior border of the vocal cords.

External Surface of the Larynx.—It is divided into four planes: a *superior*, *inferior*, and *two lateral*. The *superior plane*, formed by the arytenoid and posterior crico-arytenoid muscles, is covered by the pharynx and œsophagus; in its anterior moiety, it is directly covered by the pharyngeal mucous membrane.

The *inferior plane* presents, from before to behind, the thyro-hyoid membrane, the body of the thyroid cartilage, the crico-thyroid membrane, the inferior part of the cricoid cartilage, and the crico-trachealis ligament. There is remarked, laterally, the inferior border of the thyro-hyoid muscle. This plane corresponds to the scapulo-hyoideal muscles, which entirely cover it.

The *lateral planes* exhibit the external faces of the thyro-hyoid and crico-thyroid muscles, that of the cricoid cartilage, and the alæ of the thyroid. They also show the opening through which passes the superior laryngeal nerve; they are related to the crico- and thyro-pharyngeal muscles, as well as the maxillary gland.

Internal Surface of the Larynx.—This surface is divided into three perfectly distinct regions: a middle one, named the *glottis*; a superior, called the *supraglottic portion*; and an inferior, designated the *subglottic portion*.

The *glottis* (*rima glottidis*) is a narrow space which affects the figure of a very elongated isoscelated triangle, its base being uppermost. This irregular fissure is comprised between the elastic structures known as the vocal cords. It is the narrowest part of the larynx.

The *supraglottic portion*, wider than the glottis, but always greatly depressed on each side, particularly in the region comprised between the arytenoids, presents: 1, The *two ventricles of the larynx*, lateral excavations, dilated at the bottom, and which penetrate between the anterior border of the vocal cords and the prolongations of the base of the epiglottis, insinuating themselves even between the fasciculi of the thyro-arytenoid muscle (in the Ass and Mule the ventricles are proportionately larger than in the Horse, and open close to the base of the epiglottis); 2, The *subepiglottic sinus*, a deep depression at the base of the epiglottis, which is provided, in the Ass and Mule, with a thin membrane, capable of vibrating; 3, The *entrance of the larynx*, or pharyngeal opening of the cavity, a vast, gaping aperture of an oval form, circumscribed by the anterior border of the arytenoids and the lateral border of the epiglottis, and making a remarkable projection at the bottom of the pharyngeal space.

The *subglottic portion* of the larynx is the widest of the three; it is directly continuous with the internal canal of the trachea. In front is seen the prominence formed by the posterior border of the vocal cords: above, a diffused and shallow excavation, placed at the point of junction of the arytenoid and cricoid cartilages, and which is named the *subarytenoid sinus*.

Functions.—As a tube intended for the passage of a column of air during the act of respiration, the larynx does not give rise to any very interesting physiological considerations. It is, nevertheless, worthy of remark that this organ, in imitation of the nostrils, dilates or contracts, according to the volume of the column of air introduced into, or expelled from, the lungs, and that its paralysis, during rapid movements, causes an embarrassment in the respiration which betrays itself in "roaring." But a physio-

logical study of the larynx acquires a real interest when it is examined with regard to the articulation of sounds, or as an organ of phonation. This study, however, does not come within our province; though what has been said concerning the vocal cords will give a summary, but satisfactory, idea of the mechanism which presides over this function, and the part the larynx plays.

It may also be added, that nearly all the muscles of the larynx are concerned in phonation; by modifying the tension and the separation of the vocal cords they determine differences in the sounds. One only is concerned in respiration; this is the posterior crico-arytenoideus, which is a dilator of the glottis.

2. *The Trachea.* (Figs. 230, 234.)

Preparation.—Follow the same procedure as for the dissection of the œsophagus.

The *trachea* is a flexible and elastic tube, formed of a series of incomplete cartilaginous rings, which succeed the larynx, and terminate above the base of the heart by two divisions, which constitute the *bronchi.*

Form.—This tube is cylindrical, and (slightly) flattened on both sides. Its inferior face and two borders are regularly rounded, and offer transverse grooves, which correspond to the intervals between the constituent pieces of the trachea. The superior face, nearly plane, shows the thin and widened extremities of these cartilaginous arcs.

Course.—Leaving the posterior extremity of the larynx, the trachea descends backwards to the entrance of the chest, by following the inferior border of the neck below the longus colli muscle. It afterwards becomes inflected, superiorly, to pass between the two first ribs, enters the chest in traversing the anterior mediastinum, proceeds directly backwards, and finally arrives above the left auricle of the heart, to the right of the posterior aorta, where the tube presents its terminal bifurcation.

Relations.—*In its cervical portion,* the trachea, surrounded by a loose and abundant cellular tissue, lies in a kind of muscular envelope which the majority of the muscles of this region form around it, and which are: the sterno-hyoid and sterno-thyroid, placed in front; the sterno-maxillaries, situated at first in front, and afterwards on the sides towards their termination; the subscapulo-hyoideii, above and in the middle of the lateral parts; the scalenii, altogether below and at the sides; the longus colli, behind; and outside all these muscles, the superficial expansion of the subcutaneous muscle of the neck. This envelope is thinnest in front of the middle portion of the neck; and this is the place where the operation of tracheotomy should be performed.

The trachea is also in relation, *in its cervical portion:* 1, With the œsophagus, which descends, as we know, at first in the middle of the posterior face, then to the left side of the air-tube; 2, With the carotid arteries, which pass along both sides of the tube, accompanied by their satellite nerves—the pneumogastric, great sympathetic, and recurrent nerves.

After clearing the two first ribs, where it reaches *its thoracic portion,* the trachea responds, superiorly, to the longus colli and the œsophagus; below to the brachial trunks, to the anterior aorta which furnishes them, to the anterior vena cava, the cardiac and recurrent nerves, and to the base of the heart; laterally, to the inferior cervical ganglia of the great sympathetic, the vertebral vessels—cervical and dorso-muscular—and to the two layers of the anterior mediastinum; to the right, the vena azygos; to the

left, the arch of the aorta and the thoracic duct. The latter is sometimes carried to the opposite side.

Structure.—The trachea comprises in its structure: the *cartilaginous rings* which form its base; the *ligaments* which unite these rings; the *mucous membrane* spread over its inner face; a *muscular layer*, which only lines that membrane superiorly; and *vessels* and *nerves*.

Fig. 230.

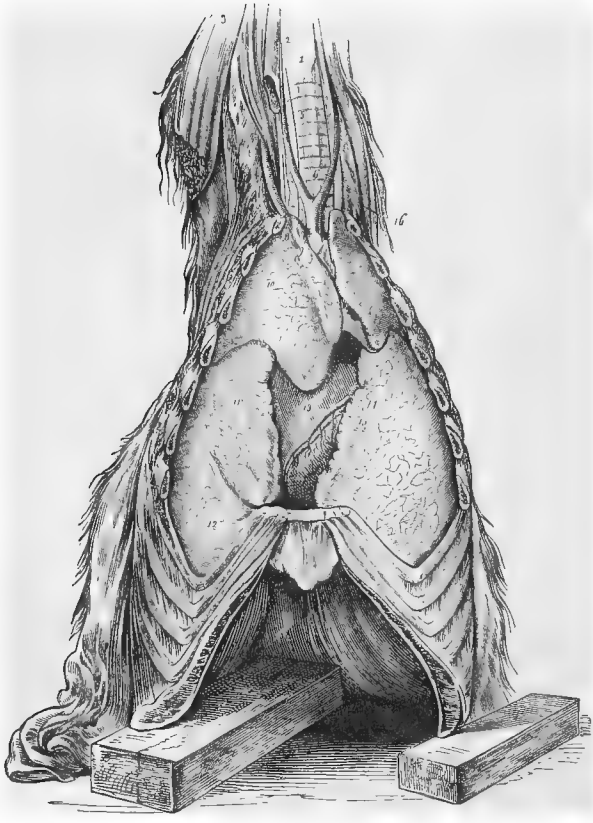

THE RESPIRATORY ORGANS; INFERIOR, OR FRONT VIEW.

1, Trachea; 2, Jugular vein; 3, Great rectus anticus muscle; 4, Carotid artery; 5, Longus colli muscle; 6, Origin of the common carotids; 7, Vertebral artery; 8, Section of first rib; 9, Cephalic trunk of right axillary artery; 10, Anterior lobe of right lung; 11, Middle, or supplementary lobe of ditto; 12, Posterior portion or lobe of ditto; 13, Heart; 14, Cardiac artery; 15, Ventricular branch of cardiac vein; 16, Œsophagus.

Cartilaginous rings of the trachea.—These are about fifty in number, and do not form perfect rings, being incomplete on the upper side of the trachea. Each is a kind of arc, composed of a cartilaginous plate flattened and curved on itself, whose extremities are turned towards each other, and

joined in the majority of the rings; they even overlap in some. These extremities are thin and wide, and sometimes bifurcate and unite with the adjoining rings.

In the middle part of the trachea, these rings are generally larger than at the origin or termination of the tube. The last ring, in serving as a transition between the trachea and bronchi, presents a more complicated arrangement; being frequently completed by isolated cartilaginous plates, and is always divided by a median spur or bifurcation—directed towards the interior of the trachea, into two lateral segments, each of which corresponds to a bronchus.

Ligaments.—The rings of the trachea are united at their borders by intermediate ligaments, which are composed of elastic tissue, and permit the lengthening or shortening of the tube they concur to form.

Towards the extremities of the arcs, they are confounded with a thin cellular layer that unites these extremities. The first cartilage is received by its anterior border into the cricoid ring, and joined to it by the wide annular ligament mentioned at page 452. Owing to the elasticity of this ligament, the two cartilages it binds together can move one within the other, like two segments of a telescope, and in this way vary the length of the tube.

Muscular layer.—This layer only covers the superior face of the trachea; it is formed of pale, rose-coloured, transverse fasciculi, attached by their extremities to the internal face of the cartilages. Its action undoubtedly diminishes the diameter of the trachea, by contracting the arcs composing this cartilaginous tube. (Kölliker has found some longitudinal fibres passing across the transverse ones at the posterior part of the trachea. Leyh describes longitudinal fibres in the anterior wall of the trachea, between the mucous membrane and the cartilaginous rings, and which, he states, diminish the length of the tube.)

Mucous membrane.—Continuous with that of the larynx, this membrane is prolonged, through the medium of the bronchi, and in becoming modified in character, into the air-cells. Its free or superficial surface is perforated by glandular orifices, and exhibits longitudinal ridges which are ineffacable by distension; it is lined with ciliated epithelium. Its deep face is covered with yellow elastic tissue disposed in longitudinal fasciculi, and adheres intimately either to the face of the cartilages and their intermediate ligaments, or to the posterior muscular layer.

Fig. 231.

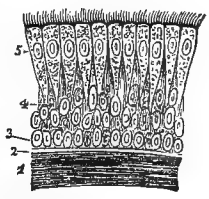

CILIATED EPITHELIUM FROM THE TRACHEA.

1, External layer of longitudinal elastic fibres; 2, Homogeneous surface layer of the mucous membrane; 3, Round cells; 4, Oval and oblong cells; 5, Ciliated cells.

An essential characteristic which distinguishes this membrane from that lining the larynx, is its slight sensibility.

(The tracheal glands, whose orifices are so numerous in the mucous membrane, abound towards the posterior part of the tube; they are small, ovoid bodies, lying between the muscular and fibrous coats. Other glands, less in size, are placed between the layers of fibrous tissue uniting the cartilages at the sides of the trachea. Their secretion is poured out upon the free surface of the mucous membrane, to lubricate and protect it.)

Vessels and nerves.—The *small arteries* emanating from the vessels in the vicinity of the trachea—as the carotid and the collateral branches

of the brachial arteries—supply it with blood. Its *nerves* come from the recurrent; they show small ganglia on their track.

Functions.—Except as a tube for the passage of the inspired and expired air, the trachea performs no other function.

3. *The Bronchi.* (Fig. 232.)

Preparation.—After removing the lung from the thoracic cavity, it is filled with water by fixing the trachea to a water-tap. The bronchi may then be dissected by tearing and triturating the pulmonary tissue.

Each of the two bronchi—the terminal branches of the trachea—resembles a tree imbedded in the substance of the lung, and sending out a multitude of branches.

Fig. 232.

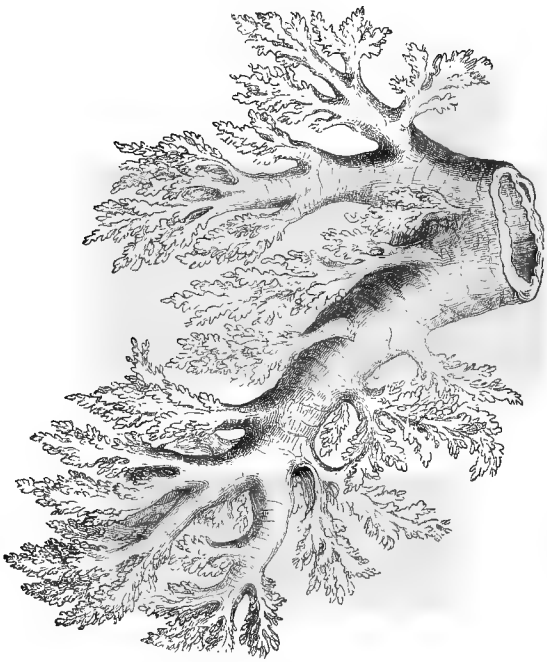

BRONCHIAL TUBE, with its Bronchules and Ultimate Ramifications (natural size).

Disposition.—At a short distance from their origin, the bronchi enter the lobes of the lung, and pass backwards and outwards towards the superior part of the base of the organ, giving off in their course large collateral branches until they themselves are expended. These branches originate alternately above, within, below, and outwards; and thus extend in every direction. The first forms an obtuse angle with the principal trunk, and is directed forwards, to ramify in the anterior lobule of the lung; the others are detached at an angle more or less acute. All are subdivided into gradually-decreasing branches, which soon become of a capillary diameter, and finally open into the pulmonary air-cells. (*See* STRUCTURE OF THE LUNGS.)

Form.—The bronchial tubes are not flattened like the trachea; a transverse section shows them to be regularly cylindrical.

Volume.—The left bronchus is always smaller than the right, and both are much inferior in volume to the aggregate of their respective branches.

Relations.—Each bronchus enters the pulmonary lobe along with the blood-vessels, which with it forms what is called the *root of the lung.* The divisions of this arborescent trunk are accompanied by the bronchial artery, vein, and nerves, which ramify in the same manner.

Near their origin, the bronchi are related to the bronchial glands, above which, and to the left side, passes the œsophagus.

STRUCTURE.—The structure of the bronchial tubes resembles that of the trachea; their walls being formed by a *cartilaginous framework*, a *muscular layer*, *mucous membrane*, and *vessels* and *nerves.*

Cartilages of the bronchi.—These only exist in tubes of a certain calibre, the minute passages being deprived of them, and having only membranous walls. As in the trachea, this framework includes, for each tube, a series of transverse rings joined border to border; though these are no longer formed of a single arciform piece, but each results from the union of several lozenge-shaped pieces whose extremities overlap, and which are united to each other, like the cartilaginous segments of the neighbouring rings, by means of cellular layers, and also by the membranes spread over their internal surface.

Muscular layer.—Extended in a very thin continuous layer over the entire inner surface of the cartilaginous rings, this layer disappears in the smallest bronchial tubes.

Mucous membrane.—This membrane is distinguished from that of the trachea by its great sensibility; it alone constitutes the walls of the terminal bronchial divisions. (When the cartilages terminate, the tubes are wholly membranous, and the fibrous coat and longitudinal elastic fibres are continued into the ultimate ramifications of the bronchiæ. The muscular coat is disposed in the form of a continuous layer of annular fibres, and may be traced upon the smallest tubes; it is composed of the unstriped variety of muscular fibre.)

Fig. 233.

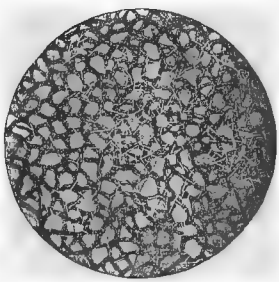

MUCOUS MEMBRANE OF A BRONCHIAL TUBE, WITH THE CAPILLARIES INJECTED.

Vessels and nerves.—The vascular and nervous branches distributed in the tissue of the bronchial tubes come from the satellite vessels and nerves of these tubes—the *bronchial arteries*, *veins*, and *nerves.* The *lymphatics* pass to the bronchial glands.

DIFFERENTIAL CHARACTERS IN THE AIR-TUBE SUCCEEDING THE NASAL CAVITIES IN OTHER THAN SOLIPED ANIMALS.

RUMINANTS.—In the *Ox*, *Sheep*, and *Goat*, the interior of the *larynx* is simpler than in the Horse, and the lateral ventricles and vocal cords are almost effaced. The most important differences in its various pieces are as follows: 1, The thyroid cartilage has no anterior appendices, but is provided, posteriorly, with two considerable prolongations that articulate with the cricoid cartilage (it has no excavation between the two wings, and is formed by a single piece; its inner face, in the middle, near the lower border, has a small fossette to which a round and very salient tuberosity on the external face corresponds); 2, The upper border of the cricoid is not notched in front (neither is the bezel on its lower border); 3, The epiglottis is wider, but less acute, than in Solipeds (Leyh says it

is less extensive, but thicker); 4, A hyo-epiglottidean muscle bifid at its origin. (There is no aryteno-epiglottidean ligament.)

The *trachea* of these animals does not offer any important differences. The last ring is not so developed as in the Horse, and the tube detaches a supplementary bronchus to a lobe of the lung which does not exist in Solipeds. (The rings of the middle portion are proportionally narrow, and their extremities meet behind and form a salient ridge.)

PIG.—The *larynx* of the *Pig* is remarkable for its great mobility, suspended as it is to the hyoid cornua by the base of a very developed epiglottis, rather than by the wings of the thyroid cartilage. "There are wide, shallow, lateral ventricles, which have a small oblong sinus that ascends between the thyroid cartilage and the mucous membrane. These ventricles are not surrounded by the thyro-arytenoideus muscle, which is small and undivided; above and outwardly, they are margined by a thick cord—a kind of superior vocal cord, considered by Duges as acting with the ventricles to modify the deep grunting sounds."[1] (Instead of a tuberosity on the external face of the thyroid cartilage, there is a median crest, and its inferior border has a small point. The cricoid appears to be drawn downwards and backwards, and its lower border is very prominent in the middle, and articulates with one or two small cartilaginous plates which have been sometimes wrongly described as belonging to the proper cartilages of the larynx. The antero-superior angles of the arytenoid cartilages are united to a small cartilaginous piece which prolongs them; their external face has a spine, and the internal angles are separated by a small pisiform body called the "interarticular cartilage.")

The *trachea* of this animal resembles that of Ruminants. (It has about thirty rings, and has three bronchi.)

CARNIVORA.—The larynx of the *Dog* and *Cat* is very like that of the Horse. In proportion, the epiglottis is shorter, wider at the base, and more triangular than in the other species; the lateral ventricles are shallow. (There is an interarticular cartilage as in the Pig; there is no sub-epiglottidean ventricle, and the vocal cords appear to be nearer each other. The trachea has about forty-two rings, whose extremities do not meet; the space between them is less in the Cat than the Dog.)

The larynx and trachea of *Man* will be compared with that of animals when we come to describe the lungs.

THE THORAX. (Figs. 230, 234.)

The *thorax*, also called the *thoracic* or *pectoral cavity*, lodges not only the lungs, but also the heart and the large vessels that spring from or pass to that organ, with a portion of the œsophagus and trachea, as well as nerves, which are as remarkable for their number as their physiological importance.

Situation.—We have seen that the thorax has for its base the bony cage formed by the ribs, sternum, and bodies of the dorsal vertebræ. Suspended beneath the middle portion of the spine, this cage is transformed into a closed cavity by the intercostal muscles, which fill the spaces between the ribs; and by the diaphragm, that vast oblique partition which separates the thorax from the abdomen.

Internal conformation.—Considered as a whole, the thoracic cavity represents a hollow cone placed horizontally, depressed on each side, and particularly in front towards the summit; with its base, formed by the diaphragm, cut very obliquely, in consequence of the direction taken by that muscle. This obliquity of the diaphragm renders the antero-posterior diameter of the cavity much greater above than below; the difference is more than double.

The internal surface of this conical cavity may be divided into six regions: a *superior*, *inferior*, and *two lateral planes*, a *base*, a *posterior plane*, and a *summit*.

The *superior plane* presents, on the middle line, a large projection resulting from the union of the vertebral bodies; and, laterally, two deep channels—furrows—the *vertebro-costal channels*. These latter, wider behind than before, are formed by the superior extremities of the costal arches;

[1] *Lavocat*, 'Anatomie des Animaux Domestiques.'

they lodge the superior border of the pulmonary lobes. The middle projection, or ridge, is comprised between these two lobes. Covered in front by the posterior extremity of the longus colli, this ridge responds, for the remainder of its extent, to the posterior aorta, the thoracic canal, and the vena azygos; on its sides are seen the subdorsal branches of the great sympathetic nerve.

The *inferior plane*, much shorter than the preceding, is, like it, narrower in front than behind; it has for a base the superior face of the sternum, the sternal cartilages, and the triangularis sterni muscle. Posteriorly, it gives attachment to the fibrous sac containing the heart.

Fig. 234.

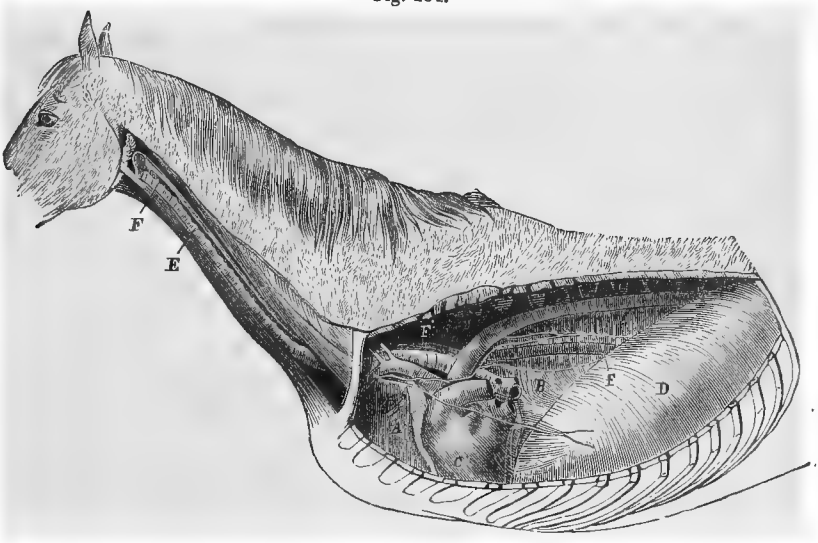

THE PECTORAL CAVITY AND MEDIASTINUM, WITH THE COURSE OF THE TRACHEA AND ŒSOPHAGUS.

A, Anterior mediastinum; B, Posterior mediastinum; C, The heart and pericardium in the middle part of the mediastinum; D, Diaphragm; E, Trachea; F, Œsophagus.

The *lateral planes*, more extensive than the other two, are concave in both their diameters. Formed by the internal face of the ribs and the deep intercostal muscles, they are in contact with the external face of the lung.

The *base*, or *posterior plane*, formed by the convex face of the diaphragm, is circumscribed on its exterior contour by the circle of asternal cartilages, and by the last rib. In it we see the three openings which traverse the diaphragmatic septum.

The *summit*, or *entrance of the thorax*, is an oval opening, elongated vertically, comprised between the two first ribs and the longus colli muscle, and which is partly obstructed by an enormous collection of lymphatic glands; through this opening passes the trachea, œsophagus, the axillary and carotid arteries, the anterior vena cava, and the pneumogastric, great sympathetic, inferior laryngeal, and diaphragmatic nerves.

Such is the thoracic cavity. Like the abdomen, it is provided with a serous lining, which remains to be examined.

THE PLEURÆ.—The serous lining of the thorax comprises two distinct membranes, designated as the *pleuræ*, constituting two sacs placed one against the other in the median plane, and forming a septum named the *mediastinum*, which divides the thoracic cavity into two lateral compartments. Each pleura, therefore, covers one of the external or costal walls of the thorax, and the corresponding moiety of the diaphragm; it is afterwards reflected in the vertical and antero-posterior plane of the cavity, to concur in the formation of the mediastinum, whence it is carried over the lung. This arrangement exhibits the pleura in four portions: a *costal*, *diaphragmatic*, *mediastinal*, together representing the *parietal layer* of the membrane, and a *pulmonary* or *visceral* portion.

The *costal pleura* is applied to the inner face of the ribs and the internal intercostal muscles. Strengthened on its adherent face, at each intercostal space, by a lamina of yellow elastic tissue, this membrane responds, by its free face, to the external plane of the lung, with which it does not, in a normal condition, contract any adhesions. It is continued, posteriorly, with the diaphragmatic layer; in front, above, and below, with the mediastinal pleura.

The *diaphragmatic pleura* adheres somewhat loosely to the fleshy portion of the muscle, but the union is more intimate on the aponeurotic portion. This layer is contiguous, by its free face, with the base of the lung; it is confounded with the mediastinum by the internal part of its periphery.

The *mediastinal pleura* is placed, by its adherent face, against that of the opposite side, and in this way produces the middle septum which divides the thoracic cavity into two portions. Several organs are comprised between the two layers of this partition, but most important of all is the heart. In Veterinary Anatomy, that part of the septum in front of this organ is named the *anterior mediastinum;* the appellation of *posterior mediastinum* being reserved for the portion situated behind it. These terms have not the same signification as in human anatomy, though they are retained here to prevent misunderstanding.

The *anterior mediastinum*, thicker than the posterior, but much less extensive, contains, superiorly, the trachea, œsophagus, the anterior aorta and its divisions, the anterior vena cava, thoracic duct, the cardiac, pneumogastric, recurrent, and diaphragmatic nerves; it also includes the thymus gland in the fœtus and young animal. The *posterior mediastinum* is incomparably narrower below than above, in consequence of the oblique position of the diaphragm. Its inferior part, always deviated to the left, is extremely thin, and perforated by small openings, which give it the appearance of fine lace-work. Traversed altogether superiorly by the posterior aorta, the vena azygos, and the thoracic duct, this mediastinum gives passage, a little lower between its layers, to the œsophagus, the œsophageal branches of the pneumogastric nerves, and to the left diaphragmatic nerve. It is these layers of this mediastinum which pass to the lung to constitute the pulmonary pleura, in becoming reflected above and below, in a horizontal line extending from the root of the pulmonary lobe to the anterior face of the diaphragm.

The *pulmonary* or *visceral pleura*, a continuation, as has been said, of the mediastinal pleura, is in contact, by its free face, with the parietal layer of the membrane. Its deep face adheres intimately, in Solipeds, to the proper tissue of the lungs.

Independently of these four serous layers, the right pleura furnishes a special membranous fold, which arises from the inferior wall of the thoracic cavity, and ascends to envelop the posterior vena cava. This fold also sustains the right diaphragmatic nerve.

In order to study the various portions of the pleuræ collectively, with their reciprocal relations, and their connections with the organs contained in the thoracic cavity, we will suppose three transverse sections of this cavity: one passing behind the heart; the other at the roots of the lungs, and dividing the left ventricle of the heart, the third traversing the anterior mediastinum, a little in front of the right ventricle.

If, in the first section (Fig. 235), we take the costal pleura at the point *a*, and follow it up to *b*, we will see it folded downwards to form the

Fig. 235. Fig. 236. Fig. 237



THEORETICAL SECTIONS OF THE THORACIC CAVITY; INTENDED TO SHOW THE DISPOSITION OF THE PLEURÆ.

mediastinal layer, to be applied to the aorta, *c*, and the œsophagus, *d*; then reflected at *e* on the lung, *f*, enveloping every part of the organ; returning to the point *e*, it leaves the lung, is again reflected to achieve the formation of the mediastinal septum, *b g*, and finally regains the point it started from. On the right side, with only a slight variation, it has the same arrangement. After being carried from the point *a'* to *b'*, then to *e'*, and after enveloping the lung, returning to *e'*, and being reflected in the median plane to the point *g'*, the right pleura leaves the inferior thoracic wall to pass around the posterior vena cava, and come back to *a'*, its point of departure.

The second section, (represented by Fig. 236) shows the pleura arrived at the point *b*, descending on the root of the lung, *c*, covering that organ and returning to *c*, and reflected on the pericardium, *d*, to gain the point *a*.

In the third section (Fig. 237), we see the parietal pleura, *a b*, without any points of continuity with the visceral pleura, *c*. It is at the level of this section that the lung forms two perfectly free lobes, which are not attached to the anterior mediastinum.

Structure.—Like all the serous membranes, the pleuræ have a free face covered by a simple tesselated epithelium; it is perfectly smooth, always in contact with itself, and constantly lubricated by a serous fluid which facilitates the gliding of the lung on the parietes of the thoracic cavity.

The deep face is united to the subjacent parts by connective tissue destitute of fat; the adherence of the visceral pleuræ is most intimate.

The pleura has plexuses of *vessels*: one, the subserous, has large meshes; but a second, the subepithelial, has a closer network.

The *nerves* are from the sympathetic and pneumogastric for the pulmonary pleura: from the diaphragmatic and intercostal nerves for the parietal pleura.

FUNCTIONS.—The thorax is not a mere receptacle, but, on the contrary, performs a very important part in the act of respiration. We know, in fact, that it is dilated and contracted by the movements of the diaphragm and the ribs (see pp. 142, 248). The lung being applied immediately against the thoracic walls, and never at any time separate from them, follows this cavity in its movements, dilating in inspiration and contracting in expiration, after a certain quantity of the oxygen of the inspired air has been removed and replaced by an equivalent amount of carbonic acid.

The movements of the thorax are, therefore, of capital importance, constituting, as they do, the initial phenomenon of respiration, and having dependent on them all the other acts of this function.

DIFFERENTIAL CHARACTERS IN THE THORAX OF OTHER THAN SOLIPED ANIMALS.

In the *Ox*, the thorax is not so long, particularly in its superior part, as in Solipeds, by reason of the slight obliquity of the diaphragm, and of its mode of attachment to the ribs.

The total capacity of this cavity is also certainly inferior to that of the Horse's chest. It is the same, though relatively more extensive, in the *Sheep*, *Goat*, and *Pig*; while the *Dog* possesses in this respect an incontestable superiority over Solipeds. It is to be noted that all these animals, without exception, are distinguished from the Horse, Ass, and Mule by the conformation of the posterior mediastinum. In them it is not open in its lower part, but as solid, thick, and complete there as elsewhere. Therefore it is that the consecutive effusion of pleuritis is readily localised in one of the pleural sacs in the first-named animals, while this localisation is impossible in the second. (This is an important observation, in a pathological point of view.)

THE LUNG (OR LUNGS). (Figs. 230, 234.)

Preparation.—The disposition of the lung in the thoracic cavity is best studied by placing the subject in the second position, opening the chest by excision of the ribs, as in Fig. 234, and inflating the organ by the trachea. To study its external conformation, it should be removed from the cavity, with the heart and large vessels, and inflated as before.

Situation—General disposition.—This essential organ of respiration is a spongy viscus, lodged in the thoracic cavity, and divided into two lateral, but independent, moieties, each of which occupies one of the two serous sacs formed by the pluræ. It is also described as *two pulmonary lobes*, or *two lungs*—a *right* and *left*, the latter a little less voluminous than the former.

Form and Relations.—Together, the lungs affect the outline of the thoracic cavity; each represents the moiety of a cone, and offers for study: an *external* and *internal face*, a *base* and *summit*, and a *superior*, *inferior*, and *posterior border*.

The *external* or *costal* face is convex (and smooth), and moulded to the external wall of the thorax.

The *internal*, or *mediastinal face*, forms a vertical plane, separated from the opposite lung by the mediastinum. It shows: 1, An inextensive anterior part, in contact with the anterior mediastinum; 2, At the level of the heart, an excavation in which that organ is lodged; 3, Immediately behind this excavation, and a little above it, the *root of the lung* (*hilum-pulmonis*), a fasci-

culus formed by the air-tubes and pulmnary vessels in entering the viscus; 4, A posterior portion, more extensive than the other two put together, corresponding to the posterior mediastinum, and attached to that septum by means of a fold developed around the organ, to form the pulmonary pleura; this fold constitutes, posteriorly, a small serous ligament (*ligamentum latum pulmonis*), attached at once to the mediastinum and the posterior face of the diaphragm. On this portion of the lung are remarked two antero-posterior fissures: one, hollowed near the upper border of the organ, to receive the thoracic aorta; the other situated lower, but not so deep, more marked in the left than the right, and lodging the œsophagus. In the right lung this mediastinal face offers a small particular lobule, which is absent in the left.

The *base*, or *diaphragmatic face* of the lung, cut obliquely from above to below, and before to behind, is concave, and moulded to the anterior face of the diaphragm. On the right lung is seen the posterior face of the small lobule noticed on the inner side, and a deep fissure excavated between it and the principal lobe, for the passage of the posterior vena cava.

The *summit* of the viscus, situated behind the first rib, presents a kind of detached appendix, designated the *anterior lobule* of the lung.

The *superior border*, thick, convex, and rounded, is lodged in the vertebro-costal channel or concavity. The *inferior*, much shorter and thinner, is deeply notched at the level of the heart, and more so at the left than the right side. The *posterior* is elliptical, and everywhere circumscribed by the face of the diaphragm, which it separates from the costal and mediastinal faces.

Structure.—An *external serous envelope, proper fundamental tissue, functional* and *nutrient vessels, lymphatics*, and *nerves:* such are the elements which enter into the organisation of the lung.

Serous Envelope.—This is the pleura pulmonalis already described. (There has also been described a *subserous connective tissue*, containing a large proportion of elastic fibres; it invests the entire surface of the lung, and extends between the lobules.)

Fundamental Tissue.—*Physical characters.*—The pulmonary tissue in the adult is of a bright rose-colour; it has a deeper hue in the fœtus which has not respired. Although soft, it is yet very strong and resisting, and can with difficulty be torn. Its elasticity is remarkable; it concurs in the collapse the lung experiences when air is admitted to the pleural sacs. It is very light: plunged in water, if healthy, it floats: this specific lightness ought to be attributed to the air imprisoned in the pulmonary vesicles. This may be proved by what takes place when the lung of a fœtus is inflated: heavier than water before that operation, it then becomes lighter, because, notwithstanding all the manipulation that may be employed to expel the air introduced into the pulmonary vesicles, a certain quantity always remains. On the other hand, the absolute weight of the lung is relatively more considerable in the adult than in the fœtus, the first representing 1–30th of the total mass of the body, while it is only 1–60th in the second.

A knowledge of these facts may be utilised in determining whether a given lung has belonged to an animal which has respired or has died before birth. If the tissue is plunged in water, this test is called hydrostatic pulmonary docimacy; if its relative weight is to be ascertained, it is designated pulmonary docimacy by weight.

These are the physical characters of the fundamental tissue of the lung; we will now study its anatomical characters.

Anatomical characters.—The pulmonary tissue is partitioned into a great

number of small polyhedral lobules by septa of connective tissue, which appear to be prolongations of the *corium* of the external serous membrane. This segmentation into lobules is a common feature in the organisation of the lungs in the mammalia, but it is more readily demonstrated in some than others: not very evident in Solipeds, and less so in the Carnivora, it is well defined in Ruminants and Pachyderms.

The organisation of these lobules resembles, in a striking manner, that of the salivary lobules. Each receives a small bronchial tube (lobular bronchial tube), which is prolonged into the lobule by several short terminal branches, in which open a certain number of elementary vesicles. In comparing, for the moment, the lung to a gland, it will be seen that this organ should be ranged in the category of racemose glands.

To demonstrate the vesicular structure of the lung, it may be inflated and dried, and sections afterwards made to show the pulmonary vesicles. But this procedure has the inconvenience of unduly extending the vesicles, and thinning, and even destroying, their walls. A better method is the following: leave the lung in the intact thoracic cavity; by the jugular vein, pour into the right side of the heart an injection of very hot tallow, employing a certain amount of force to propel it from the pulmonary artery into the veins; when this injection has cooled, open the thoracic cavity, and take out the lungs. These, being impregnated with solidified fat, do not collapse on contact with the air, and sections made in different directions then exhibit innumerable perfectly-circular porosities, which are the open pulmonary vesicles.

In this way it is easy to demonstrate the presence of the air-cells; but, in order to conveniently study their arrangement, it is necessary to take a cast of them by means of a solidifiable material introduced by the bronchii, and afterwards destroyed by the maceration of the pulmonary tissue. The Darcet alloy, employed in this manner, often gives very good results. It is then found that the pulmonary vesicles form, in each lobule, saccular dilatations or *culs-de-sac*, from 1–70th to 1–200th of an inch in diameter, grouped around the *infundibuli*, of which they are only diverticuli; these infundibuli communicate with the terminal bronchule of the lobule through the medium of a narrow central cavity, into which they all open. Such are the principal histologic details relative to this important point in the history of the lungs; and it must necessarily be followed by a notice of the structure of the pulmonary vesicles (or air-cells).

Fig. 238.

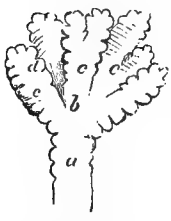

PLAN OF A PULMONARY LOBULE.

a, Bronchule terminating in a slight dilatation, *b*; *c*, Air-sacs, or infundibuli; *d*, Air or pulmonary vesicles.

The *pulmonary vesicles* comprise, in the organisation of their walls: a proper membrane; epithelium; and capillary vessels.

1. The *proper membrane* is thin and homogeneous: it contains the nuclei of connective tissue and elastic fibres, and its external face is applied to that of the neighbouring vesicles; its internal face is lined by epithelium.

2. The epithelium is simply tesselated, and is composed of extremely thin cells. It is continuous throughout the vesicles, and with that of the terminal bronchule. In a properly-prepared section, the polyhedral cells lining the latter can be seen changing gradually and rapidly into squamous epithelium in the cavity of the lobule, at the entrance to the *infundibuli*.

(The minute polygonal cells lining the air or pulmonary vesicles measure from 1–1600th to 1–2250th of an inch in diameter, and from 1–2800th to 1–3800th of an inch in thickness. Between the vesicles is a trabecular tissue, mainly composed of yellow elastic with a few muscular fibres, some of which are united with the lining membrane to strengthen it, especially around the apertures of communication between the adjoining air-cells.)

Fig. 239.

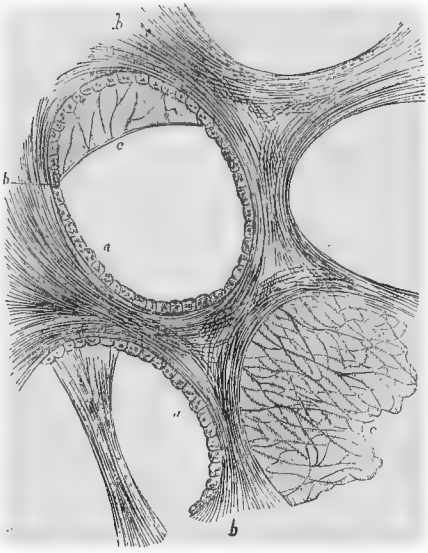

AIR-CELLS OF LUNG, WITH INTERVENING TISSUES. *a*, Epithelium; *b*, Elastic trabeculæ; *c*, Membranous wall, with fine elastic fibres.

3. *Capillary vessels* ramify in the walls of the vesicles, and even project on their inner face.

(The capillary plexuses are so arranged between the two layers forming the walls of two adjacent cells, as to expose one of their surfaces to each, in order to secure the influence of the air upon them. These networks are so close, that the diameter of the meshes is scarcely so great as that of the capillaries which inclose them.)

Vessels.—The lung is a very vascular organ. The numerous ramifications it receives divide into two orders—the functional and the nutritive vessels.

Functional vessels of the lung.—We know that the blood returns from all parts of the body by the veins, after losing, along with its bright red colour, the properties which render it fit to maintain the vitality of the tissues. It thus arrives at the right side of the heart, whence it is propelled into the lung, there to be regenerated by mediate contact with the air. It is the *pulmonary artery* which conveys this fluid into the parenchyma of the organ, and by the *pulmonary veins* it is carried back to the heart. The artery is at first divided into two branches, which ramify and finally terminate in dense capillary plexuses upon the walls of the air-cells. The veins, innumerable and attenuated at their origin, like the arterial capillaries, terminate in from four to eight principal trunks, which open into the left auricle of the heart.

Fig. 240.

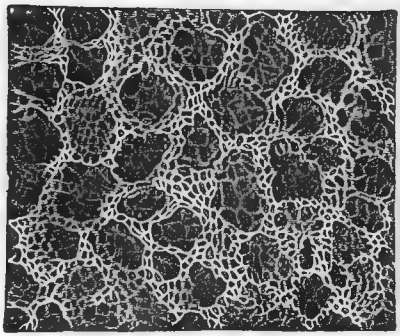

ARRANGEMENT OF THE CAPILLARIES AROUND THE AIR-CELLS.

These two orders of vessels, which necessarily participate in the physiolo-

gical functions of the lung, like the vena portæ with the liver, are very properly distinguished from the other arteries or veins of the organ by the designation of *functional vessels*. But though they are so named, it must not be inferred that they are excluded from all participation in the acts of nutrition. It is now admitted by competent authorities that the blood of these vessels concurs to sustain vitality in the tissue of the lung, in common with the nutritive fluid carried by the arteries and veins now to be described.

Nutrient vessels.—By this name is designated the divisions of the *bronchial arteries* and *veins*, whose terminal ramifications anastomose with the capillaries of the pulmonary vessels at the ultimate bronchules.

Lymphatics.—These vessels are divided into *superficial* and *deep*. The first form a network beneath the pleura, the second exist in large numbers around the lobules. They mix together, and terminate in the bronchial glands. (Lymphatics of very small size have been described as commencing in the alveolar spaces, on leaving which they gain a proper coat or internal tunic, and are subsequently supplied with valves.)

Nerves.—The nervous branches supplied to the tissue of the lung come from the same source as those of the bronchial tubes—the *pneumogastric* and *great sympathetic nerves*. Their ramifications accompany the pulmonary vessels and bronchiæ, and they show small ganglia on their course.

Functions.—To know that the lung is the seat of the absorption of oxygen and the expulsion of carbonic acid from the nutritive fluid—phenomena accompanied by the transformation of the dark into red-coloured blood, and probably of several other metamorphoses yet doubtful or unknown—is the only authentic fact necessary to remember with regard to the functions of this organ. It must be added that the subtle molecular operations from which all these phenomena result, take place in the lung by the mediate contact of the atmosphere introduced into the air-cells during inspiration, with the blood traversing the walls of these cells. With the intimate mechanism of these molecular actions we have nothing to do here, however

Development.—Although the lung is in a state of inactivity in the fœtus, yet it is one of the organs early developed. During the whole period of fœtal existence, its lobular texture is much better defined than in the adult, and it then appears to be formed exactly like a racemose gland. Sections of it prepared for microscopical examination distinctly show the vesicles and their arrangement. We have already made known the differences in colour and density which distinguish the pulmonary tissue of the fœtus and that of the adult. It only remains to repeat what has been said as to the slight vascularity of the first, and to note that the blood of the pulmonary artery passes almost entirely into the posterior aorta by the arterial canal (or *ductus arteriosus*).

DIFFERENTIAL CHARACTERS IN THE LUNGS OF OTHER THAN SOLIPED ANIMALS.

The lungs of the *Ox*, *Sheep*, and *Goat* are remarkable for the distinctness with which the lobules are defined. They are, in fact, separated by thick layers of cellular tissue, continuous with the internal face of the visceral pleura. (These thick septa are rather the interlobular ramifications sent off from the *subserous* envelope.) Dietrichs, who was the first to draw attention to this peculiarity in the larger Ruminants, has justly remarked that it perfectly explains the altogether special characters of the lesions of pneumonia in these animals.

The general figure of the lungs of Ruminants does not differ from that observed in the Horse; the left lung, however, is divided into two lobes, and the right into four,

of which one, an anterior, is curved in front of the heart. The annexed figure shows this peculiarity.

In the *Pig*, the lungs comport themselves like those of Ruminants.

In the *Dog* and *Cat*, there is no well-marked fissure in either lung towards the heart, which causes that organ to be almost completely enveloped by pulmonary tissue. The left lung has three lobes, and the right four, separated from one another by deep furrows, which are generally prolonged to the root. The lobules are small, very close, and the pulmonary tissue is exceedingly compact. (The pulmonary vesicles are proportionately larger than in Ruminants.)

Fig. 241.

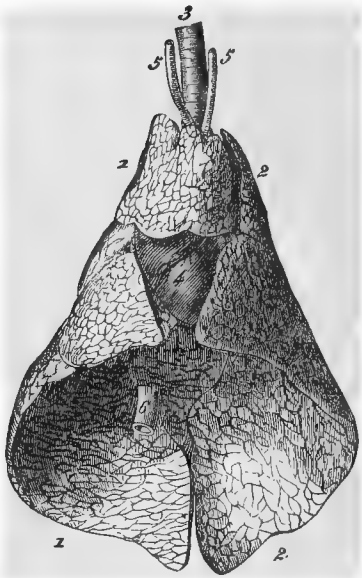

LUNG OF THE SHEEP; INFERIOR VIEW.

1, Right lung; 2, Left lung; 3, Trachea; 4, Heart; 5, Carotid arteries; 6, Posterior vena cava.

COMPARISON OF THE LARYNX, TRACHEA, AND LUNGS OF MAN WITH THOSE OF ANIMALS.

1. *Larynx.*—The human larynx is proportionally shorter and wider than that of animals. The principal *cartilages* are those which have been already studied; but there are, besides, small cartilaginous bodies, to which special names have been given: these are the cartilages of Santorini and of Wrisberg. The facets on the cricoid for articulation with the thyroid are placed on the small cornua detached from the external face of the cartilage. The thyroid is wide, and protects the anterior face of the larynx; the angle formed by the alæ, which is more marked in the male than the female, is very prominent, and is named the pomum Adami. The epiglottis is short, broad in its middle, and rounded at its summit, something like that of the Carnivora. The muscles are the same in number and disposition as in these animals; but there is distinguished an oblique arytenoideus—a fasciculus of the arytenoid, which crosses its fellow to form an X in passing from the upper border of one arytenoid cartilage to the lower border of the other.

Fig. 242.

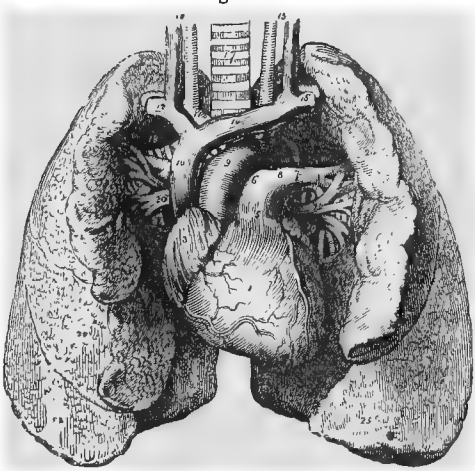

HUMAN LUNGS AND HEART; FRONT VIEW.

1, Right ventricle; 2, Left ventricle; 3, Right auricle; 4, Left auricle; 5, Pulmonary artery; 6, Right pulmonary artery; 7, Left pulmonary artery; 8, Ligament of ductus arteriosus; 9, Arch of aorta; 10, Superior vena cava; 11, Arteria innominata; 12, Right subclavian vein, with the artery behind it; 13, Right common carotid artery and vein; 14, Left vena innominata; 15, Left carotid artery and vein; 16, Left subclavian vein and artery; 17, Trachea; 18, Right bronchus; 19, Left bronchus; 20, 20, Pulmonary veins; 21, Superior lobe of right lung; 22, Middle lobe; 23, Inferior lobe; 24, Superior lobe of left lung; 25, Inferior lobe.

Internally, the human larynx has no subepiglottic or subarytenoid sinus like that of Solipeds, though it has lateral, or Morgagni's, ventricles that ascend a little to the outside of the superior vocal cords.

2. *Trachea.*—3. *Bronchi.*—There is little difference to be remarked in these. The trachea is about four inches long and about one inch wide, and is composed of about twenty C-shaped rings, which are closely united, as in animals. It is situated in the median plane, in the upper part of the neck, where it is embraced by the lobes of the thyroid gland; at its entrance into the chest it deviates slightly to the right. The two short canals between its lower extremity and the lungs are the *bronchi;* the right bronchus is the shortest and widest, and has an almost horizontal direction, entering the right lung at the fourth dorsal vertebra; the left is longer and less voluminous, and reaches the corresponding lung at the fifth vertebra.

4. *Lungs.*—The lungs weigh about forty ounces. As in all animals, the right is more voluminous than the left, and is divided into three lobes; the latter has only two. The inferior vena cava is not surrounded by pulmonary tissue; the principal lobes are partitioned into lobules, which are visible on the surface, and on the limits of which are deposited, only in the adult, a notable quantity of pigmentary matter, that gives the lungs the appearance of a chess-board. There is nothing to be said respecting their internal conformation and structure.

THE GLANDIFORM BODIES CONNECTED WITH THE RESPIRATORY APPARATUS.

1. *Thyroid Body (or Gland).*

The *thyroid gland*, or *body*, is composed of two oval lobes of a reddish-brown colour, and is situated close to, and behind, the larynx, beside the two first rings of the trachea.

These two lobes, distinguished as right and left, appear at first sight to be perfectly independent; but a less superficial examination shows them to be united by an intermediate portion (the *isthmus*), which passes across the anterior face of the trachea.

Each lobe of the thyroid body corresponds, inwardly, to that tube; outwardly, it is covered by the subscapulo-hyoid muscle.

Fig. 243.

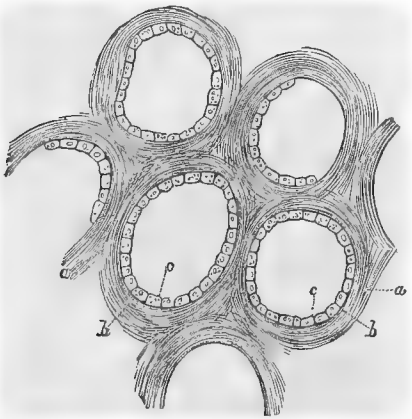

GROUP OF GLAND VESICLES FROM THE THYROID BODY OF A YOUNG SUBJECT.

a, Connective tissue; *b*, Basement membrane of the vesicles; *c*, Epithelial cells.

STRUCTURE.—The thyroid body is composed of a fibrous envelope, and a proper tissue or parenchyma.

The *fibrous envelope* is composed of slender, but strong connective tissue; it sends from its inner face a large number of thin nucleated laminæ that intersect each other, forming spaces in which the proper tissue is contained.

The *parenchyma* is divided into lobules, whose presence is manifested on the surface of the organ. They are composed of vesicles, the shape and contents of which vary considerably with age and situation. In the fœtus, or very young animal, they are round or elliptical, and constituted by a thin amorphous membrane, lined by polygonal cells with a large nucleus, and containing a granular fluid. In the adult, these vesicles are deformed, and, after being distended, several are confounded together;

the epithelium is less evident and uniform, the contents have become brown, and hold granules and nuclei in suspension, and, finally, often assume the character of colloid matter in becoming viscous and of a yellow tint.

Vessels and nerves.—The thyroid body is remarkable for the relatively enormous volume of its blood-vessels; the *arteries* chiefly come from the thyro-laryngeal branch—a collateral of the primitive (or common) carotid (they form plexuses on the vesicle walls); the *veins* pass to the jugular. Its *nervous* filaments are from the first and second cervical pairs, with twigs from the sympathetic. It has an abundance of *lymphatics.*

Functions.—The thyroid is one of the organs classed, in a somewhat arbitrary manner, in the ill-defined category of ductless or blood-vascular glands. Our knowledge of its use is as uncertain at present as in the infancy of anatomical science. So that we can say nothing more on this subject, except that the successive or simultaneous excision of the two lobes in the Horse do not appear to cause any derangement in the animal's health.

Neither does the study of its development throw any light on its functions. It is certainly relatively larger in the fœtus and young animals than in adults; but the difference is not sufficiently marked to authorize us in drawing any physiological inductions therefrom.

2. *Thymus Gland.*

The *thymus gland* is a transitory organ, only present in the fœtus and very young animals, and in its nature closely resembling the thyroid gland. Like it, it is divided into two lateral lobes placed close together in the middle line, under the lower face of the trachea, partly without and partly within the chest, between the two layers of the anterior mediastinum. It is elongated from before to behind, of a whitish colour, and uneven or lobulated on its surface like a salivary gland.

Structure.—It owes its uneven aspect to its lobular structure, for it is effectively reduced by dissection into a multitude of granular lobules, in the centre of which are found vesicular cavities containing a lactescent fluid. The vesicles are larger than those of the thyroid gland, and have for their walls a very thin layer of delicate connective tissue; they are filled by a mass of nuclei. A wide, irregular cavity has been described as existing in the middle of each lobe (*reservoir of the thymus*), and evidently communicating with the vesicles of the lobules, as it contains a notable quantity of the same milky fluid. This cavity is certainly not present at all periods; for I have not met with it in two young fœtuses now lying before me as I write. But without dwelling on this particular point, we may notice enormous blood-vessels, lymphatics, and nerves, as complementary elements in the organisation of the gland, whose structure is very similar to that of the proper glands, though differing from them in an important feature—the absence of an excretory duct.

Nothing positive is known as to the functions of the thymus gland; it is only certain that they are exclusively related to the development of the young animal, as it generally disappears some months after birth, though it is sometimes found in adult, and even in very aged animals.

(Its functions are supposed to be the same as, or analogous to, those of the thyroid. Structurally, the organ may be said to consist of an assemblage of hollow glandular lobules joined together by connective tissue, each having a cavity which opens into a central canal that has no duct, and being lined

externally by an almost amorphous membrane which divides it into "acini," or gland-granules. Separate acini are often observed on the main canal. Each lobule is made up of its greyish-white, soft parenchyma composed of free nuclei and small cells, and has a minutely-distributed capillary plexus.

Fig. 244.

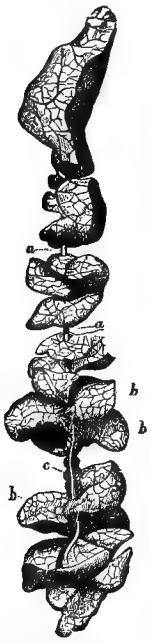

PORTION OF THYMUS GLAND OF CALF, UNFOLDED.

a, Main canal; *b*, Glandular lobules; *c*, Isolated gland granules seated on the main canal.

Fig. 245.

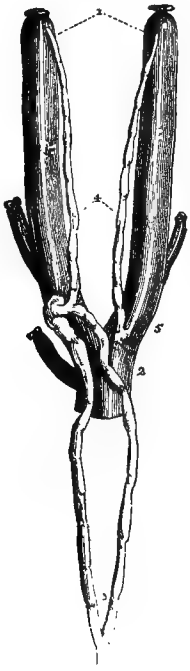

COURSE AND TERMINATION OF THE ABSORBENT DUCTS OF THE THYMUS GLAND OF A CALF.

1, Internal jugular veins; 2, Superior vena cava; 3, Thoracic duct, dividing into two branches, that again unite before terminating in the root of the left jugular vein; 4, The two thymic ducts: that on the left side opening into the thoracic duct, and the right into the root of the corresponding jugular vein.

The lymphatics terminate in two large ducts that commence at the upper extremities of the lobes of the gland, the *thymic ducts*, and pass downward to terminate at the junction of the jugular and axillary veins at each side.)

DIFFERENTIAL CHARACTERS IN THE GLANDIFORM BODIES ANNEXED TO THE RESPIRATORY APPARATUS IN OTHER THAN SOLIPED ANIMALS.

The *thyroid body*, peculiar to Mammals, is more developed in *Ruminants*, *Pachyderms*, and the *Carnivora*, than in Solipeds. The two lobes are closer together, and often joined by the thyroid isthmus. In the *Pig* this is very marked, and the gland well merits its name, as it forms a veritable shield in front of the trachea, towards the lower part of the neck.

The *thymus gland* in young Ruminants is more voluminous than in the Foal, and is situated higher up in the cervical region. (In the Carnivora, it is divided into two branches; but it is small, and completely lodged between the layers of the anterior mediastinum. It persists for some time after birth, and seldom disappears in less than a year.)

COMPARISON OF THE GLANDIFORM BODIES ANNEXED TO THE RESPIRATORY APPARATUS IN MAN WITH THOSE OF ANIMALS.

In *Man* the two lobes of the *thyroid body* are connected by an isthmus, and the upper extremity of the lobe is carried up to the side of the thyroid cartilage. The isthmus often gives origin to a process of variable length and size, called the *pyramid* or third lobe, which is generally situated to the left A muscle is sometimes found connected with the isthmus or pyramid, and is attached above to the body of the os hyoides or to the thyroid cartilage; it has been named the *levator glandulæ thyroidæ*.

The *thymus gland* is composed of two lobes, a right and left, only joined by connective tissue, and having no structural communication. There is a cervical and a thoracic portion, the whole extending from the fourth rib as high as the thyroid gland. After birth it continues to enlarge until the end of the second year, and begins to diminish between the eighth and twelfth years.)

CHAPTER II.

THE RESPIRATORY APPARATUS IN BIRDS.

THE organs composing the respiratory apparatus of birds, offer conditions altogether special, and which have a remarkable influence on the mechanism of respiration. The modifications imposed upon the performance of this function will be indicated after an examination of the *tubular apparatus*, which carries the air into the *lung*, and the characters of that organ, as well as the *air reservoirs* (or *sacs*) annexed to it.

THE TUBULAR APPARATUS.—When this apparatus is compared with that of Mammals, no very sensible differences are observed—at least in domesticated birds.

The nostrils, pierced through the upper mandible of the beak, have no membranous and movable wings, and the nasal fossæ open into the pharynx by a long, narrow slit behind the bony palate. A transverse row of small, horny papillæ, placed at the anterior extremity of this aperture, represents the soft palate.

The *larynx* has no epiglottis: a defect which does not prevent the complete occlusion of the glottis during the passage of food, as the laryngeal orifice is circumscribed by two lateral lips which then meet in the most exact manner.

The *trachea* is composed of complete cartilaginous rings, and not simple arcs. In song-birds, the last ring is a second larynx, the real organ which produces the modulated voice of these creatures; it only exists in a rudimentary condition in poultry, however, the last tracheal piece in them being slightly dilated, and showing at the origin of the bronchi a membranous layer, from whose vibration results cries or crowing. Other singular peculiarities belonging to the trachea deserve to be described here, if they were not the exclusive appanage of some wild fowl. We are content to mention the presence of the bony drum found at the terminal extremity of the trachea in the whistling duck, and the remarkable convolutions that tube forms in the breast-bone of Cranes and male Swans.

The *bronchi* only show incomplete rings in their structure. They pass into the lung by its inferior face, towards the union of its anterior and two posterior thirds. When describing this organ, their mode of ramification, and the nature of the relations they bear to its proper tissue will be considered.

THE LUNGS.—M. Sappey, in the remarkable memoir published by him in 1847, has described them as follows: "The lungs of birds are situated on the lateral parts of the vertebræ of the back—which separate them, and lying against the arch of the thoracic cavity, to which they adhere. Their rosy colour resembles that presented by these organs in Man and the Mammalia during uterine life, and for some time after birth; they are especially remarkable for their restricted volume, which scarcely represents an eighth part of the thoracic capacity. Their configuration is far removed from the conical form of the lungs in Mammals, and the oval form of the same organs in reptiles; they are semi-elliptical, and if the two lungs of a Mammal were opposed base to base,

their likeness would be produced; to obtain the same results with the lungs of a reptile, it is necessary to divide them in the direction of their great axis.

"This shape enables us to distinguish in the lungs of a bird, *two faces*—a convex and concave; *two borders*—an external and internal; and *two extremities*—an anterior and posterior.

"The *convex face*, also named the *dorsal*, *costal*, or *superior face*, corresponds inwardly to the dorsal vertebræ, and outwardly to the ribs and the intercostal muscles; it is exactly moulded on the walls of the thorax, and as the ribs protrude on the internal face of these walls, it results that this surface of the lungs is marked by transverse furrows which give it a lobulated aspect; but these lobes or lobules show nothing common with those composing the same organ in Mammalia. In that class, the existence of lobes and lobules is an established fact, and is caused by the dichotomous division of the bronchi; in birds, it is only apparent, and depends on the diminished thickness of the lung at each rib. This face, quite imperforate, is covered by a thin layer of cellular tissue, which unites it to the sides of the thorax.

"The *plane* or *concave* face looks downwards; it is in relation with the diaphragm, which separates it from the viscera of the thorax, and from the abdomen; from this arises its other names of *inferior*, *diaphragmatic*, or *visceral face*. Like the preceding, it is covered by a very fine layer of cellular tissue, which forms adhesions with the diaphragm; but it differs from it by the orifices it presents, which are five in number, and constitute veritable canals, through which the air passes and repasses incessantly to and from the sacs, and from them to the lungs.

"The *borders* are parallel to the axis of the body; the internal is rectilinear, thick, and rounded; the external, convex, thin, and sharp.

"Of the two extremities, the *anterior*, which is very acute, occupies the receding angle formed by the spine within and the first rib without; the *posterior*, more considerable, has a rounded form."

In regard to structure, that which distinguishes the lung of birds from that of Mammals is the mode of distribution and termination of the air-passages. In Mammals, the large bronchial tubes, placed in the centre of the lung, send their divisions towards the surface of the organ, or in a centrifugal manner; in birds they are disposed at the periphery of the lung, and direct their different ramifications towards the centre, or in a centripetal fashion. On the other hand, the arboreal division of the bronchi in Mammals is replaced in birds by penniform ramification. Lastly, the terminal bronchial tubes instead of opening into a series of closed vesicles, as in Mammals, anastomose with one another in birds, so as to form an inextricable ærial network.

M. Sappey has further developed the knowledge acquired on this interesting subject in the following terms: "Arrived in the pulmonary tissue, it (the bronchial trunk) dilates, divides, gradually contracts in following its primary direction, and in this way gains the posterior extremity of the organ, where it terminates by opening into the abdominal reservoir.

"This ærifying trunk, therefore presents two very distinct portions, the one extra-pulmonary, the other intra-pulmonary. The first offers the greatest analogy to the bronchi of Mammalia; it is membranous internally, elastic and fibrous elsewhere, provided outwardly with cartilaginous rings, which embrace three-fourths of its circumference, and is lined by mucous membrane characterised by its pale rose-colour, and its marked adherence.

"The second differs from the preceding in its dimensions, form, and structure. Owing to its dilatation at its entrance to the lung, its dimensions are more considerable, and may be stated as three to two of the extra-pulmonary portion. Beyond this enlargement, it diminishes in capacity by the emission of branches, losing its cylindrical form to assume that of a cone with a truncated summit. Its walls are almost entirely destitute of cartilaginous rings, so that the origin of the principal conduits is constantly membranous.

"The air-passages arising from this common trunk to constitute the framework of the lung, are remarkable for their uniformity in number, form, and the direction they offer in all classes of birds. They are generally twelve, and their origin is thus distributed: four arise from the internal wall of the trunk by a series of orifices placed one after the other; seven are detached from its external wall by a second series of orifices also disposed in rows; the twelfth springs from its inferior wall, and immediately bends downwards and outwards to open into the posterior diaphragmatic reservoir, which may be considered as a terminal branch of the principal trunk.

"All the canals which have their origin from these linear series of openings on the internal and external walls of the generating trunk, show this common disposition: that from their commencement they pass towards the periphery of the lung, that they divide

and subdivide at this periphery, that they cover it with their ramifications, and do not leave it to enter the pulmonary parenchyma until their volume has been considerably reduced.

"The conduits leaving the orifices situated on the inner wall of the ærial trunk ramify on the inferior face of the lung; those proceeding from the echeloned orifices on the outer wall are distributed on the opposite face. The first constitute the diaphragmatic, and the second the costal bronchial tubes.

"The *diaphragmatic bronchial tubes*, four in number, like the orifices from which they originate, may be distinguished by the numerical names of first, second, third, and fourth, in proceeding from before to behind; the first bronchus is carried forward horizontally, the second transversely inwards, the third obliquely inwards and backwards, and the fourth directly backwards. In view of their divergent direction, which resembles a fan, they might be designated as the anterior, internal, and posterior diaphragmatic bronchial tubes; and to distinguish the last two, the more voluminous one, which is directed backwards and inwards, might be named the great posterior diaphragmatic bronchus, and the one passing directly backwards the small posterior diaphragmatic bronchus.

"The *costal bronchial tubes*, seven in number, may be also designated as first, second, third, etc., in proceeding from before to behind; parallel at their origin, and in juxtaposition, like the pipes of an organ, they separate after following a certain course, and affect, by their divergence, the fan-shape already observed in the disposition of the diaphragmatic bronchiæ. Like the latter, they become peripheral from their origin, and spread out from centre to circumference. The first is carried very obliquely upwards and inwards, to attain the anterior extremity of the lung; all the branches it furnishes arise from its anterior wall, and those which are nearest its origin are inflected to gain the external border of the organ; the succeeding tubes are directed forwards, the others forwards and inwards; while all proceed to meet those coming from the anterior diaphragmatic bronchus, though they do not anastomose with them. Coming in contact, they plunge into the pulmonary tissue in such a way, that, when a lung is inflated, we observe between these two orders of ramifications a very manifest groove, which is perfectly distinct from those due to the protrusion of the ribs; this groove evidently represents, though in a rudimentary state, the interlobular fissures in the lungs of quadrupeds.

"The second, third, and fourth costal bronchiæ follow a transverse course, and ramify on the inner border of the lung; the fifth and sixth incline towards the posterior extremity of the organ; the seventh, very small, reaches this extremity and disappears.

"The first costal bronchus is the most voluminous: those succeeding it gradually diminish in calibre. At their point of emergence they adhere closely to the ribs; all are imperforate, and this feature essentially distinguishes them from those occupying the opposite face.

"The *canaliculi* furnished by these principal tubes do not sensibly differ in calibre in the various bronchi: all offer an equal diameter, and their dimensions are only in relation to the total volume of the lung. All are detached at a right angle from the pulmonary wall of each bronchus, and descend perpendicularly into the lung; and all, from their origin to their termination, preserve the same diameter, and consequently the same cylindrical form. If this mode of ramification be compared with that observed in Mammals, it will be seen to differ considerably. In the latter class, the air-passages affect the dichotomous division proper to the arteries and veins, the result of which is a series of arboreal canals decreasing in capacity. In birds only two kinds of conduits are observed, the primitive and peripheral, disposed around a generating axis like the barbs of a feather on their stalk; and the secondary and parenchymatous, implanted on the pulmonary walls of the first, like the hairs of a brush on their common base. These two arrangements are evidently similar, except that the peripheral canals, which are few, only form a single row on each side; while the canaliculi, very numerous, form several. Consequently, it may be said that the mode of ramification proper to Mammalia is essentially dichotomous, and that observed in birds essentially penniform.

"Independently of the canaliculi arising from the pulmonary walls of the diaphragmatic and costal bronchiæ, there are others which spring directly from the generative trunk; but in their dimensions, direction, form, and general disposition, they do not differ from the preceding.

"How do these canals terminate? Notwithstanding the importance of this question, it has been generally neglected; though its solution alone may furnish the analogies and differences necessary for the parallel which has always been attempted to be established between the lungs of birds and those of other vertebrates. Our special researches on this

point have led us to the conclusion that all the canaliculi open into one another, and by this anastomosis constitute an extricable plexus whose various parts communicate with each other."

Finally, it may be mentioned that "the walls of the pulmonary canaliculi, examined microscopically, appear to be covered internally with irregular septa which circumscribe the areolæ, and give them a cellular aspect."

THE AIR-SACS.[1]—"In birds, the pulmonary mucous membrane is continued, at the level of the orifices in the lung, into the utriculiform cavities which are developed between the walls of the thorax and the abdomen on the one side, and the thoracic and abdominal viscera on the other. These air-reservoirs exist in all the vertebrata of the second class. In all, they are situated at the periphery of the viscera in the trunk, in such a manner that Carus has justly observed that the lungs of birds inclose all the other viscera; so that when they are distended by the entrance of air, they generally depress these viscera by pushing them towards the median plane. In all, they are independent of each other, and freely communicate either with the lung by a single aperture, or with the bones by one or more openings. Lastly, in all they are nine in number.

"These reservoirs are: the *thoracic sac*, situated at the anterior part of the thorax: two *cervical reservoirs*, situated at the base of the neck; *two anterior diaphragmatic reservoirs*, placed between the two diaphragms; *two posterior diaphragmatic reservoirs*, also between these two diaphragms, but behind the preceding and, lastly, *two abdominal reservoirs*, placed against the superior wall of the abdomen. Of these nine reservoirs, the first only is single and symmetrical; the others are pairs, and similarly arranged on each side of the median plane.

"The thoracic and cervical reservoirs are situated beneath, and in front of, the lungs; the abdominal reservoirs lie behind these organs, and the four diaphragmatic sacs at their inferior part and between the preceding; hence the denomination of middle reservoirs sometimes applied to the latter, in opposition to the first, which are named the anterior reservoirs, and to the second, called the posterior reservoirs."

EXTERNAL CONFORMATION OF THE RESERVOIRS.—1. *Thoracic reservoir* (Fig. 246, 2).—"It is situated above the clavicles and the inter-clavicular space, in the cavity of the thorax, which it extends beyond on each side to the roots of the wings, around the articulation of the shoulder. It is related with: above, the trachea and œsophagus on the middle plane, the lungs and the origin of the cervical reservoirs on the lateral parts; below, with the sternum, the clavicles, and the interclavicular aponeurosis; behind, with the heart and anterior diaphragmatic reservoirs, beneath which it is prolonged by forming on each a long point; in front, with the integuments of the neck, which it raises into a hemisphere in Palmipeds, but which is angularly depressed in other classes; on the sides, with the sternal ribs, the two clavicles, and the membrane uniting them.

"The prolongations which arise from the lateral parts of these reservoirs, and cross the walls of the thorax to pass around the articulation of the shoulder, are three in number, and may be distinguished into inferior or subpectoral, superior or subscapular, and middle or humeral.

"The *subpectoral prolongation* (Fig. 246, *d*) issues from the thoracic reservoir by an orifice situated behind the posterior clavicle, and passes beneath the tendon of the great pectoral muscle, where it spreads out as a lenticular cavity. The relations it contracts with that muscle are remarkable: in birds, still more than in Man and a great number of quadrupeds, the tendon of the great pectoral is formed of two parts, one direct, the other reflected; it is between thes two portions that this small air-sac is insinuated, and where it forms a very firm connection with them; the effect of which is, that at the moment the great pectoral muscle contracts, it dilates the subjacent cell and draws into it a greater quantity of air.

"The *subscapular* and *humeral prolongation* communicate with the principal reservoir by a common opening placed behind the small adductor muscle of the humerus. After leaving this orifice, the subscapular sac spreads under the scapular and subscapular muscle, which it separates from the ribs and corresponding intercostal muscles, it is developed more particularly in a longitudinal direction.

"The humeral prolongation occupies the axilla; it is smaller than the preceding, of a pyramidal form, and opens by its summit into an infundibular fossa, which leads to the canal of the humerus.

"The thoracic reservoir differs from all the others by the extremely numerous

---

[1] What is said relating to these air-sacs is taken from the Memoir of M. Sappey—'Recherches Sur l'Appareil Respiratoire des Oiseaux,' Paris, 1847.

membranous folds which partition its cavity. The membrane forming it being continued on itself, every organ traversing the thorax becomes the cause of a fold in which it is imprisoned; and as the thoracic cavity is traversed by the trachea and the œsophagus, the muscles which move the inferior larynx, and the arteries and veins, it will be understood how this reservoir should become irregular in consequence of these various partitions, and also why the other ærial sacs situated between the viscera and the walls of the thorax, or the simple contiguous surfaces, should preserve their regular and proper form.

"The thoracic reservoir communicates with the lungs by an infundibular orifice, situated on the external side of the embouchure of each bronchus. This orifice is dilated during inspiration, by the contraction of the two first fasciculi of the pulmonary diaphragm."

2. *Cervical reservoirs* (Fig. 246, 1, 1).—"They are situated above the preceding, and the inferior part of the neck and anterior part of the lung; inflated after removal from the neighbouring parts, they resemble two cones, whose rounded base looks forwards, and whose pediculated summit is directed backwards.

"Superiorly, these reservoirs lie against the cervical muscles; inferiorly, they correspond to the air-sac of the thorax, from which they are separated by the trachea, the œsophagus, the pneumogastric nerves, and the jugular veins. Inwardly, they are in juxtaposition, and consequently form a median septum which includes in its substance the two common carotid arteries. Outwardly, they are related to the origin of the cervical nerves, to each of which they furnish a small sheath, and with the vertebral artery which they surround, but do not contain in their cavity, as well as with a subcutaneous muscle and the skin. By their summits, they communicate with the anterior diaphragmatic bronchus; and by their base they send out a prolongation which conducts the air into all the vertebræ of the neck and back, into all the vertebral ribs, and, finally, into the spinal canal.

"In their cervical portion, these prolongations present themselves in the form of two canals extending from the base of the cervical reservoirs to the base of the cranium, where they terminate; parallel and contiguous to the vertebral arteries, like them they are lodged in the canals excavated in the substance of the transverse processes.

"From their external part arises, at the six last cervical vertebræ, as many diverticuli, which, lying against each other, pass from each side in the muscles of the neck, surrounded by a common fibrous envelope, and apparently form a kind of canal at the inferior part of this region; when, however, this fibrous membrane is removed, it becomes easy to isolate them, and it is then seen that they are completely independent, and resemble small cornua. Highly developed in Palmipeds, they are only present in a rudimentary state in the other classes.

"On the internal side of these conduits, we see, at the level of each vertebra, one or more orifices by which the air enters their interior; and at the intervertebral foramina another orifice, which allows it to pass into the spinal canal. From the communication established by these orifices between the respiratory apparatus and the spinal canal, it follows that in birds the cervical region is traversed by three atmospherical currents—two lateral or intertransverse, parallel to the vertebral arteries; the third median or interspinal, parallel to the spinal cord.

"Just as the medullary tissue is replaced by air in the bones of birds, so might it be imagined that the sub-arachnoidean fluid was also replaced by air around their spinal cord; and observation justifies the correctness of this prevision. The dura mater, whose capacity is so superior to the volume of the marrow in Mammals, exactly measures the volume of that organ in birds; so that there does not exist between the fibrous and nervous surfaces any space for an accumulation of liquid; this anatomical fact is sufficient to demonstrate the absence of sub-arachnoidean fluid in birds. In denying the existence of this fluid, it ought to be added that in this class of vertebrata, as in the preceding, the spinal prolongation is covered by a triple envelope; that in each, between the pia mater and dura mater, is found a thin transparent membrane, which is lubricated by a serous fluid; but here this fluid does not collect, it only moistens the arachnoid membrane.

"Considered in their dorsal portion, the prolongations springing from the cervical reservoirs offer an entirely different arrangement to that already noticed. The interspinal current, having entered the thorax, terminates by passing into the first dorsal vertebra; after coursing through every part of this vertebra, it escapes by a lateral orifice into a small sac situated between the two first ribs, at the origin of the first dorsal nerve; from this sac, it passes into the second vertebra by an opening placed on its antero-lateral part, then it flows back from this into a new air-sac developed between the second and third ribs; and passing in the same manner into the third vertebra to

sweep through a third intercostal sac, it arrives nearer and nearer the last dorsal vertebra. In their dorsal portion, the prolongations emanating from the cervical reservoirs thus form two currents, though these are constituted alternately by the vertebræ and the small air-sacs placed on their lateral aspect. At the same time that these sacs receive the air from the vertebræ preceding them, and transmit it to those which follow, they communicate it to all the vertebral ribs.

Fig. 246.

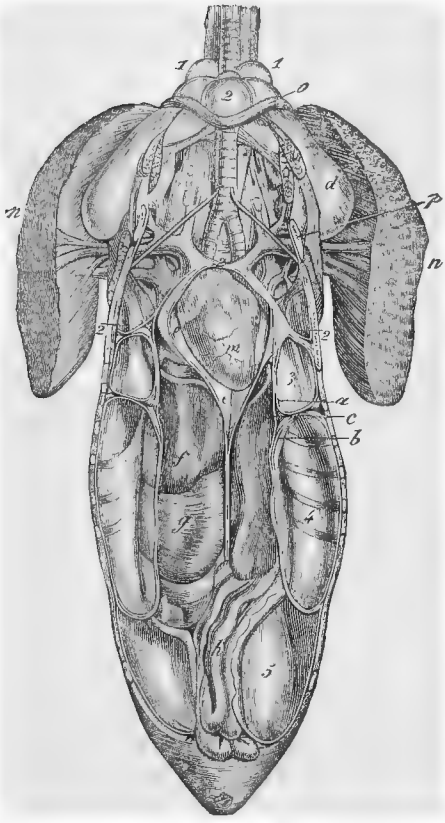

GENERAL VIEW OF THE AIR RESERVOIRS OF THE DUCK, OPENED INFERIORLY; ALSO THEIR RELATIONS WITH THE PRINCIPAL VISCERA OF THE TRUNK.

1, 1, Anterior extremity of the cervical reservoirs; 2, Thoracic reservoir; 3, Anterior diaphragmatic reservoir; 4, Posterior ditto; 5, Abdominal reservoir.—*a*, Membrane forming the anterior diaphragmatic reservoir; *b*, Membrane forming the posterior ditto.—6, Section of the thoraco-abdominal diaphragm.—*d*, Subpectoral prolongation of the thoracic reservoir; *e*, Pericardium; *f*, *f*, Liver; *g*, Gizzard; *h*, Intestines; *m*, Heart; *n*, *n*, Section of the great pectoral muscle above its insertion into the humerus; *o*, Anterior clavicle; *p*, Posterior clavicle of the right side cut and turned outwards.—*From M. Sappey's work.*

"In no order of birds do the ærial currents leaving the cervical reservoirs communicate with those which circulate in the cranium. Liquids injected either by the ærial portion of the vertebral canal or the lateral prolongations of the neck, never enter the bones of that cavity. Thinking that the injection might perhaps penetrate if passed in the opposite direction, we have perforated the bones of the cranium, and to the aperture have adapted the extremity of a steel syringe filled with mercury; but the metal did not reach the ærial prolongations of the neck. From this double experiment, we concluded that the cranial bones have no communication with the respiratory apparatus."

3. *Anterior diaphragmatic reservoirs* (Fig. 246, 3).—"Placed between the two diaphragms, they correspond: in front, to the thoracic reservoirs, against which they stand; behind, to the posterior diaphragmatic reservoirs; outwardly, to the ribs and intercostal muscles; inwardly, to the thoraco-abdominal diaphragm and œsophagus; below, to the most distant part of the thoracic reservoir; above, to the pulmonary diaphragm, which separates them from the corresponding lung. These air-sacs communicate with the lungs by a circular opening, which originates from the great posterior diaphragmatic bronchus; there is often a second opening of communication beyond the embouchure of the trunk; this reservoir is the only one which receives air from the lung by a double orifice."

4. *Posterior diaphragmatic reservoirs* (Fig. 246, 4).—"Oval-shaped like the preceding, and situated like them in the interval which separates the two diaphragms, these air-sacs are in contact, by their anterior part, with the anterior diaphragmatic reservoirs, with which they form a vertical and transverse septum. Sometimes this septum is carried a little more forward, and then the anterior reservoir is smaller; this is most frequent in

Palmipeds. At other times it inclines backwards, and the anterior reservoir is larger; this arrangement is peculiar to the Gallinacæ. And, lastly, this partition divides the intercepted space between the diaphragms into two equal cavities; rapacious birds offer numerous examples of this.

"Behind, these reservoirs stand against the abdominal sacs, from which they are separated by the thoraco-abdominal diaphragm; below, they respond to the sternal ribs and the lateral parts of the sternum; above, to the pulmonary diaphragm; inwards, to the thoraco-abdominal diaphragm; outwards, to the vertebral ribs and intercostal muscles.

"A parabolic opening, situated in the middle part of the external border of the lung, or a little more behind, establishes their communication with that organ This orifice, which is remarkable for its great dimensions, occupies the extremity of a voluminous bronchial tube which follows the direction of the generating trunk, and in such a manner that this trunk appears to pass directly towards the posterior diaphragmatic reservoir, and to open as a canal."

5. *Abdominal reservoirs* (Fig. 246, 5).—"The two air-sacs situated in the abdomen present themselves, when inflated, as two enormous bladders, the capacity of each differing but little from the volume of the trunk. Situated between the superior and lateral parietes of the abdomen on one side, and the abdominal viscera on the other, they cannot be dilated without driving the intestinal mass downwards and inwards.

"Their anterior extremity, continuous with the lung, is somewhat inflected to pass under the fibrous arch extending from the spine to the pelvis.

"Their posterior extremity, dilated and voluminous, responds to the cloaca. Outwardly, they adhere by cellular tissue to the thoraco-abdominal diaphragm, the parietes of the abdomen, and those of the pelvis. Inwardly, they are in contact with the intestinal mass and the testicles or ovaries. Below and in front, they rest on a fibrous septum, which in all birds divides the abdominal cavity into two smaller cavities: one anterior, which represents the abdomen and lodges the liver, the other posterior, which represents the pelvis and contains the stomach and intestines. This fibrous septum is extremely remarkable in large birds, particularly the Ostrich, in which it has been described by Perrault as a transverse diaphragm; it is inserted into the entire circumference of the pelvic bones, and sustains the stomach as well as the intestinal tube. Below and behind, the abdominal reservoirs lie on the intestines. Above, these sacs cover the inferior face of the kidneys, and there furnish three prolongations: 1, A suprarenal prolongation; 2, Two femoral prolongations.

"The suprarenal prolongation leaves the principal reservoir at the postero-external part of the kidneys; from thence it passes obliquely upwards and forwards, to spread over the superior surface of the kidney, which it depresses when the abdominal sac is inflated. Arrived at the internal border of the kidneys, these prolongations are introduced between the transverse processes of the sacral vertebræ, and ascend from behind forwards to the height of the two first dorsal vertebræ, forming two triangular canals situated above the sacrum, in the sacral channels, and separated from one another by a series of corresponding spinous processes. The suprarenal prolongations are not present in all birds; they are particularly observed in the Gallinacæ and diurnal rapacious birds. In some Palmipeds, the Swan for example, they are equally developed; in the Ostrich, they are replaced by the supraspinal canals.

"The femoral prolongations are two in number—an anterior small and a posterior large; they arise from the abdominal reservoir at the cotyloid cavities, and leave the pelvis in traversing the bony opening through which the crural vessels pass; after clearing the limits of these cavities, they spread around the coxo-femoral articulation, and terminate in a cæcum in the majority of birds. In diurnal birds of prey, they communicate with the femoral canal by an orifice situated at the anterior part of the great trochanter. These prolongations, very developed in the Ostrich, also open in it into the femoral cavity; it is not without surprise that we see this arrangement, which is peculiar to birds remarkable for their rapidity and power of flight, also present in those to which ærial locomotion has been entirely denied. The abdominal reservoirs communicate with the lung by an orifice situated beneath the fibrous arch of the diaphragm, and disposed like the rose of a watering-can."

Communication of the Reservoirs with the Bones.—"The communications of the respiratory apparatus with the skeleton in birds are extremely numerous. We will successively examine those belonging to each reservoir.

"The bones which receive air from the thoracic reservoir are: 1, The anterior clavicle, which is perforated at its two extremities; 2, The posterior clavicles, which are also perforated a little below their scapular extremity 3, The sternum which presents two

series of openings—the middle ones that conduct the air into the sternal ridge, and the lateral ones, very small, six to eight in number, corresponding to the intercostal spaces; 4, The scapulæ, which offer one or more apertures at their anterior extremity, and receive the air for the subscapular prolongation; 5, The humerus, which obtains the air for the humeral prolongation by a fossa situated at the inferior and internal part of its articular head; 6, The sternal ribs, which allow the atmosphere to penetrate by small openings at their inferior extremities. To sum up, eight bones, without reckoning the sternal ribs, whose number varies, receive the air which fills them from the thoracic reservoir.

"The cervical reservoirs conduct the air: 1, To all the cervical vertebræ; 2, To all the dorsal vertebræ; 3, To all the vertebral ribs. The vertebræ of the neck are ærated in their anterior part by the currents which accompany the vertebral artery, and in their posterior part by the interspinal current. The first obtain entrance to the anterior segment by one or more orifices made in the inner wall of the intertransverse canals; the median current penetrates the posterior segment by two orifices, a right and left, situated on the inner and medullary wall of that segment. The first vertebra of the back is provided with air in the same manner, by the middle and lateral currents of the neck. This air, after passing through the first vertebra, leaves by its lateral parts, to enter a small sac; from this it goes into the superior part of the second vertebra, escapes from this by its lower portion, to be received into a lateral sac, and so on to the last dorsal vertebra. These sacs also supply the vertebral ribs with air, which enters them by very small apertures situated at their spinal extremity.

"The diaphragmatic reservoirs have no bony communications. The abdominal reservoirs supply: 1, The sacrum; 2, The coccygeal vertebræ; 3, The iliac bones; 4, The femurs. The air traversing the sacrum, coccyx, and ileum, comes directly from the suprarenal prolongations, and that filling the femoral cavity from the femoral prolongations. In this enumeration of the communications between the skeleton and the respiratory apparatus, we have taken as a type the most ærated skeleton: that of diurnal birds of prey, like the eagle, kite, hawk, etc.; the bones which communicate with the air-sacs are not so numerous in the other classes. In this respect, they may be ranged in three categories: 1, Those which are æriferous in all classes; 2, Those in certain classes only; 3, And those which are not so in any class. The bones always ærated are the cervical and dorsal vertebræ, the sternum, and we may add the humerus, though it is not so in the Ostrich. Those ærated in some classes only are: the furculum, clavicles, scapulæ, vertebral and sternal ribs, the sacrum, coccyx, and femurs. And the bones which are never ærated are those of the fore-arm and hand, the leg and foot."

Structure of the Reservoirs.—The walls of these cavities are essentially formed by a thin cellulo-serous membrane, strengthened in some places by an external envelope of elastic fibrous tissue. Long, thin blood-vessels are distributed to the substance of these walls; they do not belong to the pulmonary, but to the general circulation, the arteries being derived from the aorta, and the veins opening directly or indirectly into the venæ cava. No lymphatics have been found in the air-sacs.

Mechanism of Respiration in Birds.—The anatomical arrangement described above differs in so many respects from that existing in Mammals, that it ought to bring about important modifications in the mechanism of respiration. It does not come within our scope to write the history of these modifications; but we cannot dispense with indicating, in a summary way, their principal characters, in order to make known in a general manner the signification of the special organisation this apparatus offers in birds.

We remark, in the first place, that the slight mobility of the vertebral ribs, and the adhesion of the lung to their inner face, only allows of a very slight dilatation of that viscus during inspiration. And the entrance of air into the pulmonary tissue is not due to this dilatation; it is due to the dilatation of the diaphragmatic reservoirs; the position of these effectively admits of their expansion, by the play of the inferior on the superior ribs. The air is then drawn into their cavity after traversing the larger bronchial tubes which open into them, and also after passing across a certain region of the capillary network formed by the canaliculi, where it comes into mediate contact with the blood, and is submitted to the necessary transformations. The atmosphere, therefore, arrives in the diaphragmatic sacs partly pure and partly altered by its contact with the blood. During expiration, it again resumes the course it followed on its introduction, traverses a second time the lung, and is thus respired once more before being expelled from the body. It is, therefore, obvious that the hæmatosic transformations accomplished in the lung take place during the two acts of respiration—inspiration and expiration.

In studying the part that the other reservoirs play in this function, M. Sappey has

been able to prove that they act as antagonists to the first, by contracting during inspiration and expanding in expiration. No doubt, at the time of the contraction of the middle reservoirs, a small quantity of the air they contain is driven back into the anterior and posterior sacs in passing across the lung; and without doubt, also, these latter give a part of their contents to the diaphragmatic sacs at the moment of the expansion which draws the air into these reservoirs. M. Sappey has also noted that these contents are always formed of entirely vitiated air, while the air of the middle reservoirs has only been partially respired.

It is necessary to add that the functions of the air-sacs do not cease here; for it has been demonstrated that they exercise a very marked influence: 1, On locomotion, by diminishing the weight of the body, and, by their position, rendering equilibrium more stable; 2, On the voice, the extent and power of which they augment.

BOOK IV.

Urinary Apparatus.

This apparatus, though simple, yet plays a very important part in the animal economy, as it is charged with the duty of eliminating from the blood, along with the superfluous water and other accessory substances, the excrementitial azotised products resulting from the exercise of the vital functions. These products we find in the urine—the liquid secreted by the *kidneys*, and which is carried by the *ureters* into a special reservoir, the *bladder*, where it accumulates, and whence it is expelled from the body by the *urethral canal*, at periods more or less distant, according to the requirements of the animal.

The *kidneys*, the essential organs of urinary depuration, will be first studied; then the *excretory apparatus;* and, finally, a brief notice will be given of the *suprarenal capsules*—small appendicular bodies annexed to the kidneys, and whose function is not yet determined.

Preparation.—Place the animal in the first position, and remove one of the posterior limbs. Take out the intestines, adopting the precautions indicated at page 385. Saw through the pelvic symphysis, as well as the neck of the ilium on the side opposite the remaining abdominal member, removing the coxal portion between these sections. The pelvic cavity being now opened, the urinary apparatus is exposed, and to complete the preparation it is necessary to: 1, Remove the peritoneum, to show that the urinary apparatus is situated external to that membrane; 2, Free the ureters and kidneys from the cellulo-adipose tissue surrounding them, but retaining the vessels of the latter, and leaving undisturbed their relations with the pancreas and suprarenal capsules; 3, Inflate the bladder, and dissect its neck, taking care to preserve the orbicular peritoneal fold which envelops its anterior cul-de-sac.

In the male, the inflation of the bladder is very simple, and requires no directions. In the female, however, it is requisite first to close the meatus urinarius, which is accomplished by drawing its two lips towards the entrance to the vulva, by means of two chain-hooks, passing two pins through their mucous membrane, and tying a ligature behind these; the bladder is then inflated by the ureter.

Independently of this dissection *in situ*, it is advisable to examine the urinary apparatus when isolated, and laid arranged upon a table, as in Fig. 247. We can then study: 1. By dissection, the structure of the kidneys and arrangement of the pelvis renalis; 2, The mode of termination of the ureters; 3, The interior of the bladder.

1. *The Kidneys.* (Figs. 182, 247.)

Situation.—These are two glandular organs situated in the abdominal cavity, to the right and left of the sublumbar region, lying against the great psoas muscles, and maintained in that position: 1, By an envelope of cellulo-adipose tissue; 2, By the peritoneum, which passes beneath them; 3, By the pressure of the digestive organs contained in the abdominal cavity.

Their *situation* is not absolutely alike, for the *right* comes forward to beneath the two last ribs, while the *left* scarcely reaches beyond the eighteenth rib. The latter is therefore more posterior than the former.

External conformation.—Studied *externally*, the kidneys present a special form, which often serves as a term of comparison, and resembles more or less that of a haricot bean, or the heart on a playing card. The latter configuration is most frequently noticed in the right kidney, the left being generally like the first.

Flattened on both sides, the kidneys show two perfectly smooth faces, the inferior of which always exhibits a variable number of furrows which

Fig. 247.

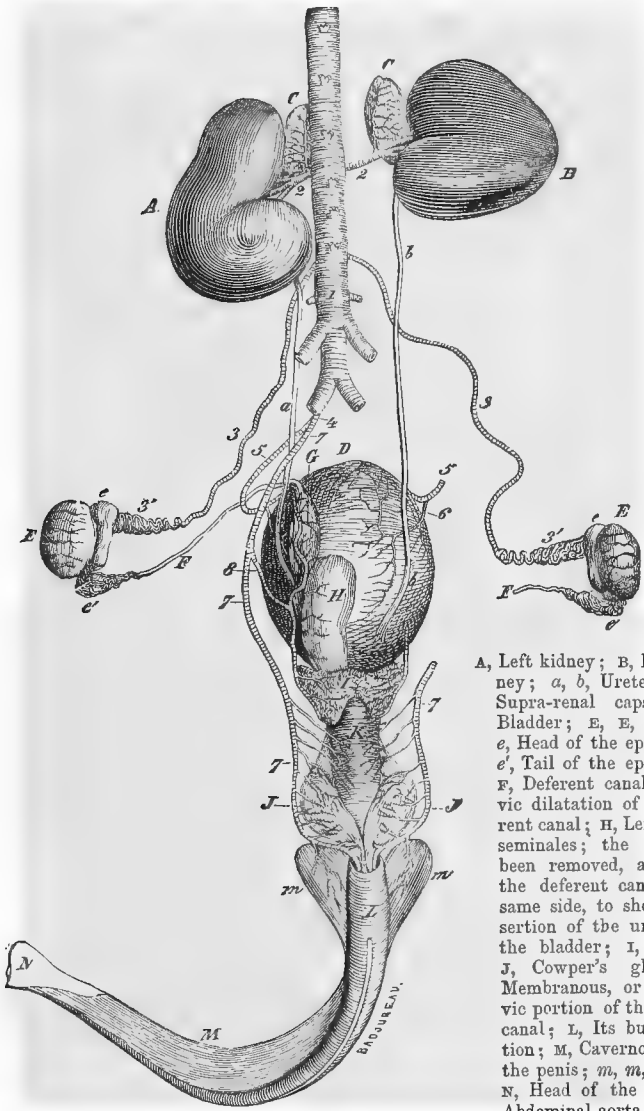

SUPERIOR AND GENERAL VIEW OF THE GENITO-URINARY APPARATUS IN THE MALE, WITH THE ARTERIES.

A, Left kidney; B, Right kidney; *a*, *b*, Ureters; C, C, Supra-renal capsules; D, Bladder; E, E, Testicles; *e*, Head of the epididymus; *e'*, Tail of the epididymus; F, Deferent canal; G, Pelvic dilatation of the deferent canal; H, Left vesicula seminales; the right has been removed, along with the deferent canal of the same side, to show the insertion of the ureters into the bladder; I, Prostate; J, Cowper's glands; K, Membranous, or intra-pelvic portion of the urethral canal; L, Its bulbous portion; M, Cavernous body of the penis; *m*, *m*, Its roots; N, Head of the penis.—1, Abdominal aorta; 2, 2, Arteries (renal) giving off the principal capsular artery, 3, Spermatic artery, 4, Common origin of the umbilical and arteries of the bulb; 5, Umbilical artery 6, Its vesical branch; 7, Internal artery of the bulb; 8, Its vesico-prostatic branch.

lodge the arteries; the right kidney has always a special furrow for the ureter. Each kidney has a circumference divisible into three borders, only the internal of which offers a certain interest. This is deeply notched, to form the *fissure* or *hilus* of the kidney, which lodges the vessels and nerves of the organ, as well as the origin of its excretory canal.

Weight.—The kidneys vary much in weight in individuals. The right is always more voluminous and heavy than the left, its average weight being 27 ounces, while that of the last is 25 ounces.

Relations.—The *relations* of these two glands with the neighbouring parts ought to be particularly examined. The right kidney corresponds, by its upper face, to the great psoas muscle, the muscular portion of the diaphragm, and to the last, or even the second-last rib. Its inferior face, incompletely covered by peritoneum, adheres, for the greater part of its extent, either to the pancreas and supra-renal capsule, or to the base of the cæcum, by means of a loose and abundant cellular tissue. The internal border is in contact with the posterior vena cava and the small psoas muscle; the anterior, with the base of the right lobe of the liver and the lobule of Spigel (*lobus Spigelii*), through the medium of the peritoneum; the posterior border is enveloped in peritoneum. The *left kidney* affects, by its superior face, the same connections as the right, except in its relation with the second last rib. Its inferior face is almost entirely covered by peritoneum, and responds, in front and inwardly, to the supra-renal capsule. The internal border is margined by the aorta; the anterior touches the base of the spleen and the left extremity of the pancreas; the posterior is, like the inferior face, in contact with the serous membrane of the abdominal cavity.

Internal conformation.—If a horizontal section is made of the kidney, it will be found to possess a cavity called the *renal pelvis*, into which the urine secreted by the gland flows, and at which the ureter commences. Placed in the middle of the kidney, near the hilus, the pelvis is elongated from before to behind, and depressed from above to below. Within it is remarked a wide infundibulum, the origin of the ureter (the *sinus-renalis*). Opposite to this funnel-shaped space is a very prominent *crest* that runs along the whole length of the external side of the pelvis, and on which are noticed the orifices of the uriniferous tubes; these, by pressing the tissue of the kidney with the fingers, can be made to pour out the urine accumulated in them. The renal cavity forms some very small diverticuli opposite the infundibulum, the largest of which, situated before and behind the latter, are named the *arms of the pelvis.*

This cavity is lined by a transversely plicated mucous membrane, continuous with that of the ureter, and is covered with the epithelium of the uriniferous tubes which open on the border of the crest.

Structure.—The kidneys present for study in their structure: 1, An *enveloping tunic;* 2, Their *proper tissue;* 3, A cavity named the *renal pelvis*, into which the urine secreted in the glandular tissue flows, and which serves as the origin of the ureter.

1. Enveloping Tunic.—This is a fibrous membrane, intimately united to the proper substance of the kidney, into which it sends a multitude of prolongations, and is folded around the blood-vessels in such a manner as to form sheaths, which enter with them into the organ. (Some authors—among them Leyh—describe, in addition to this capsula propria, a thin layer formed by the condensed areolar matrix of the kidney, from which it can be easily torn.)

Proper Tissue.—The glandular tissue of the kidneys (*areola parenchyma* or *matrix*) has, externally, a reddish-brown colour, more or less deep in different individuals. It is dense and friable, and easily torn when deprived of its fibrous capsule. Its substance is not everywhere homogeneous: very dark-coloured externally, where it forms the *cortical layer*, it becomes whiter around the pelvis, where it consitutes the *medullary layer;* where the latter comes in contact with the former, and sometimes even near the pelvis, it assumes a tint like that of wine.

These two portions are not well defined, but penetrate each other reciprocally, so as to compose, at their point of junction, irregular festoons, very readily perceived in a horizontal section of the kidney (Fig. 248).

The cortical is also distinguished from the medullary substance by its granular aspect, and the presence of minute, reddish spheres, readily visible to the naked eye, and named *Malpighian corpuscles;* while the medullary substance appears composed of radiating fibres.

Fig. 248.

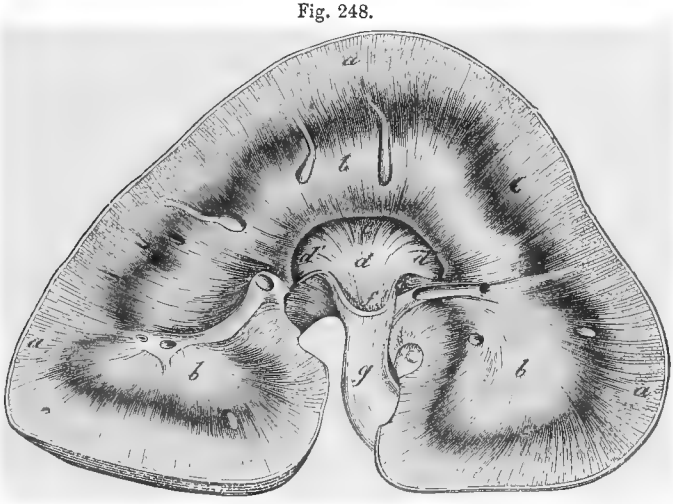

HORIZONTAL LONGITUDINAL SECTION OF THE HORSE'S KIDNEY.

a, Cortical (or vascular) portion; *b*, Medullary (or tubular) portion; *c*, Peripheral portion of the latter; *d*, Interior of the pelvis; *d'*, *d'*, Arms of the pelvis; *e* Border of the crest; *f*, Infundibulum; *g*, Ureter.

In the Horse, the tissue of the kidney cannot be divided into lobules or pyramids; to the naked eye it appears to be composed of fibres that start from every part of its exterior, and converge towards the crest of the pelvis. A microscopical examination demonstrates these fibres to be canals or tubes; hence they are designated *tubuli uriniferi* or *Bellini's tubes.* A delicate connective tissue, a kind of *stroma*, which is very rare in the cortical, but more abundant in the medullary substance, especially in the vicinity of the pelvis, sustains the vessels and nerves, and unites the tubuli uriniferi to each other.

The *tubuli uriniferi* are constituted by a proper amorphous membrane, very thin and elastic, whose internal face is lined by simple epithelium that readily alters; the cells are polygonal in certain points, polyhedral in others, and transparent or granular

The uriniferous tube has not everywhere the same direction or diameter Taking it at its termination on the crest of the pelvis, and following it to its

Fig. 249.

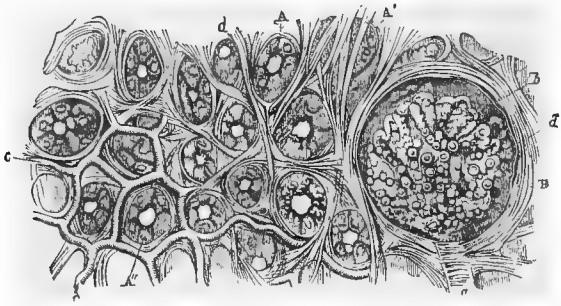

SECTION OF THE CORTICAL SUBSTANCE OF THE KIDNEY

A, A, Tubuli uriniferi divided transversely, showing the spheroidal epithelium in their interior; B, Malpighian capsule; *a*, Its afferent branch of the renal artery; *b*, Its glomerulus of capillaries; *c*, *c*, Secreting plexus formed by its efferent vessels; *d*, *d*, Fibrous stroma.

Fig. 250.



DIAGRAM OF THE COURSE OF THE URINIFEROUS TUBULE.

a, Orifice of tubule at pelvic crest; *b*, Recurrent branches which form loops, *c*, in the medullary portion of the kidney, and terminate in the Malpighian capsules in the cortical portion.

origin in the Malpighian body, it is found that the tubule is at first single, straight, and voluminous, but that during its course across the medullary substance it divides into three or four tubes, which, in their turn, subdivide in a dichotomous manner. These divisions are less voluminous and *straight*, and their diameter is uniform until they reach the cortical substance; here they bifurcate, each branch becomes flexuous, and is designated the *uniting tube*, and is continued in a kind of elongated U shape, the *ansiform tube of Henle*, which descends towards the centre of the kidney. The ascending branch of this ansiform tube, whose diameter is very small, suddenly dilates on entering the cortical substance, describes several bends, contracts into a narrow neck, and then opens into a Malpighian body, after having taken the name of *convoluted tube*.

The *corpora Malpighiana* (or *capsules*) are minute vesicles, whose walls possess the same structure as the uriniferous tubes; each lodges a cluster of arterial capillaries or *renal glomerulus*, and has two opposite openings: one communicating

between the corpora and convoluted tubes, the other affording a passage to the afferent and efferent vessels of the glomerule.

3. Vessels and Nerves.—*a.* The kidney possesses a special *artery* and *vein*, remarkable for their enormous volume.

The *artery* forms several branches which reach the kidney by its inner border and inferior face, and divide into a certain number of principal vessels, which are disposed in a wavy manner on the limits of the cortical and medullary substances. From them are given off branches to each of these substances, and among those distributed to the cortical are some regularly disposed, which furnish, on each side, the glomerule ramifications; these are the *afferent vessels* or *Malpighian glomerules* (or *tufts*); the others form a polyhedral plexus around the convoluted tubes and corpora Malpighiana. The *afferent vessels* of the renal glomerules enter this plexus.

Fig. 251.

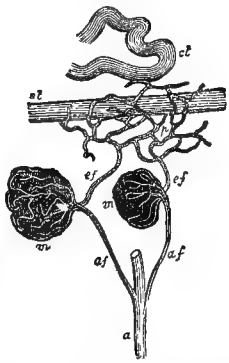

DISTRIBUTION OF THE RENAL VESSELS IN THE HORSE'S KIDNEY.

a, Branch of renal artery; *af*, Afferent vessel; *m*, *m*, Malpighian tufts; *ef*, *ef*, Efferent vessels; *p*, Vascular plexus surrounding the tubes; *st*, Straight tube; *ct*, Convoluted tube.

The arterial branches of the medullary substance descend parallel to the straight tubes, and anastomose by transverse branches, so as to form a network with elongated meshes.

The vein issues from the kidney by the hilus, and succeeds the arterial capillaries. In the medullary substance, there are straight veins as there are straight arteries. On the surface of the organ, beneath the fibrous envelope, are the *stars of Verheyen:* the junction of five or six venules which converge towards a central vein. The veinlets of the two substances collect into more voluminous vessels, which form complete arches at their limits; it is to the presence of these vascular canals, that the dark colour observed at this point of the renal tissue must be attributed.

Fig. 252.

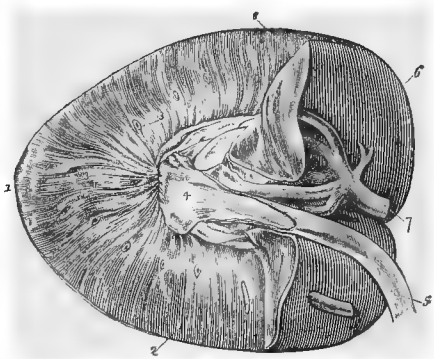

TRANSVERSE SECTION OF THE KIDNEY.

1, Inferior border; 2, Cortical tissue; 3, Section of blood-vessels; 4, Pelvis; 5, Ureter; 6, Superior border; 7, Renal artery; 8, Proper capsule.

b. The *lymphatics* are abundant at the superficies and in the mass of the organ, forming plexuses, whose ultimate branches pass to the sublumbar glands.

c. The *nerves* emanate from the *solar plexus*, and compose a particular network around the arteries, exhibiting, on their course, some microscopic ganglia. It is not known how they terminate.

Development.—The kidneys appear very early in the fœtus, above and a little behind the Wolffian bodies. They are then very distinctly lobulated, but the lobes gradually become fused, and have entirely disappeared at birth; the

small irregularities on the surface being the only indications of their having existed in Solipeds.

FUNCTIONS.—The kidneys are the organs which secrete the urine; but this secretion does not take place to the same extent in all parts of their tissue. The abundance of vessels in the cortical substance, the presence of the Malpighian corpuscles, and the flexuosities described by the uriniferous tubes, sufficiently indicate that this substance should be the principal, if not the exclusive, seat of the secretory function. But in what manner does this secretion take place? At present it is generally agreed that the urinary secretion is simply an infiltration of the elements of the urine contained in the blood, through the walls of the vessels and the uriniferous tubes. A knowledge of the phenomenon of dialysis, discovered by Graham; and the difference existing between the diameter of the afferent and efferent vessels of the Malpighian glomerules—a fact whose importance was pointed out by Ludwig—sufficiently explains this filtration of the urine through the tissue of the kidneys.

2. *The Ureters.* (Fig. 247.)

Form.—The *ureter* is a membranous canal, having the diameter of a thick goose quill, which conveys the urine from the pelvis of the kidney into the bladder. Its origin, course, termination, and structure, will be successively considered.

Origin.—It has been already shown that the origin of the ureter is at the infundibulum of the pelvis; it leaves the kidney by the internal fissure or hilus, curves outwards, passes along its lower face, and is inflected backwards in quitting the organ.

Direction.—The course it afterwards follows is almost in a straight line towards the pelvic cavity, along with the aorta or posterior vena cava, according to the side to which it belongs; it is in contact with the small psoas muscles, and proceeds above the peritoneum. After passing beyond the terminal branches of the aorta, which it crosses very obliquely, it becomes enveloped in a short peritoneal fold that maintains it against the lateral wall of the pelvis; it afterwards emerges from this fold, and reaches the posterior and superior part of the bladder.

Termination.—Having reached that viscus, its termination takes place as follows: instead of opening directly into the bladder by traversing at once, and perpendicularly, the two membranes composing the organ, the ureter at first pierces the muscular coat, between which and the mucous membrane it passes for about an inch, and then opens on the surface of the latter. This arrangement prevents the flowing back of the urine into the ureter during its expulsion, the intermembranous portion of that canal being strongly compressed by the external pressure then exerted by the muscular coat, and by the internal resistance which the accumulation of urine in the bladder opposes to this pressure. So well are Nature's intentions fulfilled in this respect, that we may inflate the bladder by the ureter, after tying the canal of the urethra, and press vigorously on the distended organ, without being able to make a single bubble of air pass through the perfectly pervious canal.

STRUCTURE.—The excretory canal of the kidney is composed of three tunics:

1. An internal *mucous* tunic, continuous, in front, with that lining the pelvis of the kidney, and behind, with that of the bladder. It is very thin, pale, ridged longitudinally, and has a stratified tesselated epithelium. (It has some mucous follicles, but no villi.)

2. A middle *muscular* layer arranged in two orders: a superficial, whose fibres are circular, and a deep, passing in a longitudinal direction. (Leyh and other authorities describe the arrangement of the muscular planes, which are composed of smooth fibres, to be the reverse of this, the longitudinal being superficial, and the deep circular.)

3. An external tunic, composed of connective tissue and elastic fibres.

The muscular tissue of the ureter, by contracting, accelerates the flow of the urine.

3. *The Bladder.* (Fig. 247.)

Position.—This is a membranous reservoir, lodged in the pelvic cavity, where it occupies more or less space, according to the quantity of urine it contains; it may extend beyond the pubis, into the abdominal cavity.

Form.—Considered in a moderate state of plenitude, the bladder is ovoid in figure; its large extremity being turned forward, forms a rounded *cul-de-sac* (*fundus*), at the bottom of which is remarked a kind of cicatrice, caused by the obliteration of the urachus. The other extremity terminates, posteriorly, by a well-marked constriction, *the neck of the bladder*, which gives rise to the urethral canal.

Weight.—The average weight of the empty bladder is about sixteen ounces.

Relations and mode of attachment.—The bladder responds: above, to the vesiculæ seminales, to the pelvic dilatations of the deferent ducts, as well as to the rectum; below, to the inferior wall of the pelvis, on which it rests (by its *base*); on the sides, to the lateral walls of that cavity. In the female, the superior face of the bladder is in relation with the uterus and vagina, which entirely separate it from the rectum. The posterior extremity or *neck* (*cervix*), flanked on each side by the lobes of the prostate, is fixed below to the ischio-pubic symphysis, by means of a particular ligament or fasciculus of elastic and contractile fibres, which are detached from the muscular layer, and expanded over the lower face of Wilson's muscle, to be carried backwards and downwards, and terminate on the surface of the internal obturator muscle. The anterior extremity, or *fundus*, usually responds to the pelvic curvature of the large colon.

It is remarked that this extremity is covered by a serous cap, which is prolonged backwards on its body, but further above than below. This covering is continuous with the parietal layer of peritoneum, and adheres closely to the muscular tunic of the bladder, so that it constitutes its chief attachment; its disposition is precisely similar, in principle, to that of the other serous visceral membranes.

Thus the peritoneum, after covering the walls of the pelvis, is reflected on the organs contained in that cavity, and in particular on the bladder, around which it forms an orbicular fold. This again gives rise to three secondary folds, a kind of serous layers, which are usually termed the *ligaments of the bladder.* One of these layers is single and vertical, and is fixed to the inferior part of the fundus; it is not rare to see it prolonged forward on the lower wall of the abdomen, as far as the umbilicus; on its free border it is said to have a thin hem or cord, the last vestige of the urachus. If this cord exists, which appears doubtful to us, it cannot possess the signification given to it; for the urachus has not, like the umbilical arteries, an abdominal portion; it only commences at the umbilicus to be prolonged in the cord to the allantois. The other two serous layers (umbilical ligaments), pairs and horizontal, are attached to the sides of the

fundus, and present, on their free border, a thick cord, the obliterated umbilical artery.

Owing to this disposition of the peritoneum, the bladder is divided into two perfectly distinct regions: an anterior, enveloped by a serous layer; the other, posterior, is brought in contact with the surrounding organs through the medium of the loose and abundant cellular tissue of the pelvic

Fig. 253.

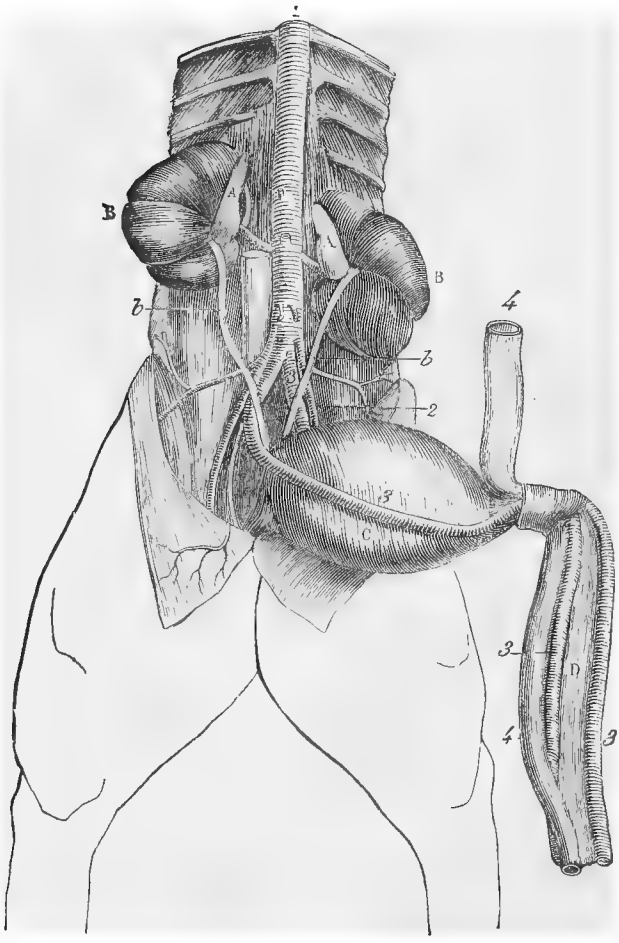

THE KIDNEYS AND BLADDER IN THE FŒTUS OF SOLIPEDS.

A, Supra-renal capsules; B, Kidney; b, Ureter; C, Bladder; D, Urachus.—1, Abdominal aorta; 2, External iliac artery; 3, Umbilical artery; 4, Umbilical vein.

region. This tissue, constantly mixed with adipose masses around the neck of the bladder, submits, with the serous membrane of the anterior region, to the changes in form and continual displacements of the urinary sac.

Interior.—This pouch, studied internally, exhibits folds and ridges more or less marked, according to its state of plenitude. It also shows, posteriorly, the opening of the neck, which communicates with the urethral canal, and a little higher, the orifices of the ureters. These three apertures circumscribe a triangular space, the *trigonum vesicæ.*

Structure.—The structure of the bladder is very simple. Two membranes compose its walls, the internal of which is mucous, and the external muscular. Anteriorly, the latter is covered by the serous investment described above.

The *mucous membrane* is pale and thin, and is continuous with that lining the ureters and the urethra. It shows some papillæ and some simple tubular glands towards the neck. Its epithelium is stratified and tesselated, the superficial cells being very irregular.

The *muscular layer* is composed of white fibres, the arrangement of which is very complicated. Certain authorities describe three superposed planes, whose fibres pass in different directions. In the Horse, the walls of whose bladder are very thin, these planes are difficult to demonstrate. The fibres are longitudinal, circular, oblique, spiral, and even twisted towards the fundus of the bladder; the deep fibres are reticulated. In the posterior region they do not form a sphincter around the neck of the organ, as is generally believed; the real sphincter is Wilson's muscle, which encircles the membranous portion of the urethral canal.

Vessels and nerves.—The parietes of the bladder receive their blood from several sources. The principal *arteries* come from the vesico-prostatic branch of the internal pudic; the umbilical artery also furnishes ramifications that reach the fundus of the organ. The *lymphatics* pass to the sublumbar glands. The *nerves* are furnished by the pelvic or hypogastric plexus, and the inferior branches of the two last sacral pairs; their twigs are spread more especially between the muscular and mucous layers.

Development.—The study of the development of the urinary reservoir is very interesting. It is narrower and more elongated in the fœtus than the adult, and is relatively more capacious during the whole period of intra-uterine life. It then occupies the abdominal cavity as far as the umbilical opening, and is flanked by the two umbilical arteries. Its posterior extremity alone enters the pelvis; the anterior extremity, forming a veritable neck, is continuous with the urachus, just as the neck, properly so called, is continuous with the urethral canal (Fig. 253). At birth, this anterior neck separates from the urachus, and is transformed into a free *cul-de-sac;* while the bladder is gradually withdrawn into the pelvic cavity, carrying with it the umbilical arteries, and finishes by acquiring the position it definitively preserves in the adult.

Functions.—The part played by the bladder is one of incontestible utility. In permitting the accumulation of the urine and the intermittent expulsion of that excrementitial fluid, it spares animals the disagreeable condition in which they would be placed if the liquid secreted by the kidneys was continually being discharged as it was produced.

4. *Urethra.*

The description of this organ will be given with that of the genital organs; as in the male it is common to the urinary and generative apparatus; even in the female it is intimately connected with the latter

5. *The Supra-renal Capsules.* (Fig. 247.)

Situation—Form.—The supra-renal capsules (or *adrenals*) are two small bodies applied to the lower face of the kidneys, in front of the hilus, and close to their inner border.

They are elongated from before to behind, flattened on both sides, and irregularly lobulated on their surface. Their length is from 2 to $2\frac{1}{3}$ inches, and width from $1\frac{1}{4}$ to $1\frac{1}{2}$ inches. They have not the same volume, the right being larger than the left.

Relations.—A large amount of connective tissue, vessels, and nervous filaments attach these bodies to the neighbouring organs. The right is related, in front, to the liver; above, to the right kidney; and inwardly, to the posterior vena cava and the ramifications of the solar plexus. The left does not touch the liver or spleen, but, by its inner border, is applied against the posterior aorta and great mesenteric artery.

Structure.—At present, anatomists are not agreed as to the structure of the supra-renal capsules. The following is what is probably most reliable in this difficult point in normal histology.

These organs offer an enveloping membrane and parenchyma.

The *enveloping membrane* is fibrous, and sends off, from its inner face, prolongations which pass into the parenchyma and form cylindrical spaces, subdivided by transverse lamellæ. These spaces are named glandular cavities; but the septa soon become thin, and disappear almost completely, leaving nothing but some very few trabeculæ of connective tissue.

The *parenchyma* is divisible into two layers: the *cortical* and *medullary substance.* The first is of a dark-brown colour; the second is yellow and soft, and does not show any cavity in its centre; that which has been described is the result of the destruction of its proper elements, which soon change after death.

The glandular cavities of the *cortical substance* are filled with nucleated, granular, and often fat cells in the adult animal; near the central substance these cavities only contain a single cell.

The *medullary substance* has, for its basis, a very delicate reticulum, supporting cells analogous to those of the cortical substance, and stellate elements which Luschka considered were nerve cells.

Vessels and nerves.—Like the kidneys, which are contiguous to them, the supra-renal capsules receive a large quantity of blood, compared with their small volume. The *arteries* are branches of the neighbouring vessels: the mesenteric and renal. They form a very delicate plexus in the parenchyma. (They keep to the stroma of the trabeculæ; consequently, their finest ramifications are found in the secondary septa of the cortical substance, where they form elongated plexuses, which are rounder in the medullary portion. In the middle of the latter, the venous ramuscules unite, and give rise to a considerable trunk, the *vena supra-renalis*, on which the organ is placed as on a pedicle. It is this vein which constitutes the debated cavity.)

The *veins* are satellites of the arteries in the tissue of the organ, and pass into the renal vein or posterior vena cava. The *lymphatics* are scarce.

The supra-renal bodies receive many *ganglionic nerves* derived from the solar plexus, and whose mode of termination is unknown. (As mentioned by Chauveau, the nerves of these organs are extremely numerous, they being more abundantly supplied than any other structure of the kind in the body; a large number of small branches enter the cortical portion, to become

developed in the medullary tissue. As these nerves do not leave the medullary substance, and as, besides, its cellular elements appear to be of the same nature as the multipolar ganglionic cells, it is presumed that the nervous fibres emerge from these globules, and that the medulla acts as a ganglionic nervous centre. Though Leydig fully believed the internal portion to be of a nervous character, he thought another function might be attributed to the cortical, in consequence of its being most frequently of a fatty nature. Bergmann was the first, in 1839, to class these organs with the nervous system, and Remak, in 1847, by his researches in embryology, was led to group them with the sympathetic ganglia, and named them *nervous glands.* Injury to the dorsal portion of the spinal cord causes congestion and hypertrophy of the supra-renal capsules. In a watery solution of the cortical portion, a rose-tinted substance has been discovered, which changes to green with persalts of iron.)

Development.—These bodies are relatively larger in the fœtus than the adult, though this difference does not influence their structure.

FUNCTIONS.—Their uses are still unknown; they are ranked in the category of blood-vascular glands, along with the spleen and thyroid body, whose functions are also not yet ascertained. (Leydig is of opinion that these bodies should be regarded as belonging to the nervous system.)

DIFFERENTIAL CHARACTERS IN THE URINARY APPARATUS OF OTHER THAN SOLIPED ANIMALS

1. *Kidneys.*—In other than Soliped animals, the renal glands are simple or multiple, or in other words, simple or lobulated. In the *Ox*, the kidneys have an elongated shape from before to behind, which is altogether characteristic; and, in addition, they preserve during life the lobulated form only seen in the other animals during intra-uterine existence. Each agglomeration is composed of from fifteen to twenty secondary kidneys; but the pelvis is not formed in the centre of this agglomeration, being carried altogether outwards, and occupying an excavation in the inferior face of the organ, which represents the hilus. This cavity is divided into as many short, wide prolongations—the *calices*, as there are principal lobules; the uriniferous tubes from each lobule open on a small papilla, which projects into the bottom of the calyx. This papilla is, therefore, nothing more than the crest of the simple pelvis in the kidney of Solipeds (Fig. 256).

In the *Sheep*, the kidneys are not lobulated, and the pelvis is carried to the inner border, as in the Horse.

The kidneys of the *Pig* are simple and voluminous, and their pelvis is disposed as in the Horse. (There are 10 or 12 papillæ, and as many calices.)

In the *Dog* and *Cat*, there are no calices absolutely comparable with those of Ruminants. The pelvis is simple, and presents at the bottom a single, large, elongated tubercle, that has at its base some very short projections or pillars.

2. *Bladder.*—The most important difference in the bladder of the domesticated animals consists in the extent of the development of its peritoneal envelope. In non-soliped animals this covers all the organ to the neck; the ligaments are also very short, and the viscus may be easily projected into the abdominal cavity. The bladder is thin, and of a considerable capacity in *Ruminants* and the *Pig;* in the *Dog*, on the contrary, it has a very thick muscular layer, its fibres forming distinct fasciculi, especially when in a state of retraction. (In Ruminants, the orifices of the ureters are near each other; at the fundus the mucous membrane shows a small fossa which is continued by a narrow canal that terminates in a *cul-de-sac*, and constitutes a free appendix about half an inch long, and of the thickness of a goose-quill.)

3. *Supra-renal capsules.*—These small organs are discoid in the *Sheep* and *Pig*, reniform in the *Dog*. In the *Ox*, they are situated at a certain distance in front of the kidneys, and their shape is like that of these bodies in the Horse; though they are a little constricted in the middle, and slightly curved.

In *Birds*, the kidneys "are lodged at the same height, behind the peritoneum, immediately posterior to the lungs, and in the lumbar and pelvic regions, where they occupy several fossæ excavated in the upper face of the pelvis. Their form is irregular and more or less elongated, depending upon the bones and other parts to which they are

applied, and on which they are moulded. In many birds, nevertheless, three portions, more or less separated by fissures, may be recognised. The ileo-lumbar portion (so named because of its constant position in this region) is the most advanced; it is often the largest. The middle is the narrowest; it is turned towards the ileo-sacral region, to enter the pelvis. The posterior is contained in that cavity, and is again larger. These two latter portions are designated as the anterior or superior pelvic, and the inferior or deep pelvic portions. Their internal and superior border is often notched by a series of trans-

Fig. 254. Fig. 255. Fig. 256.

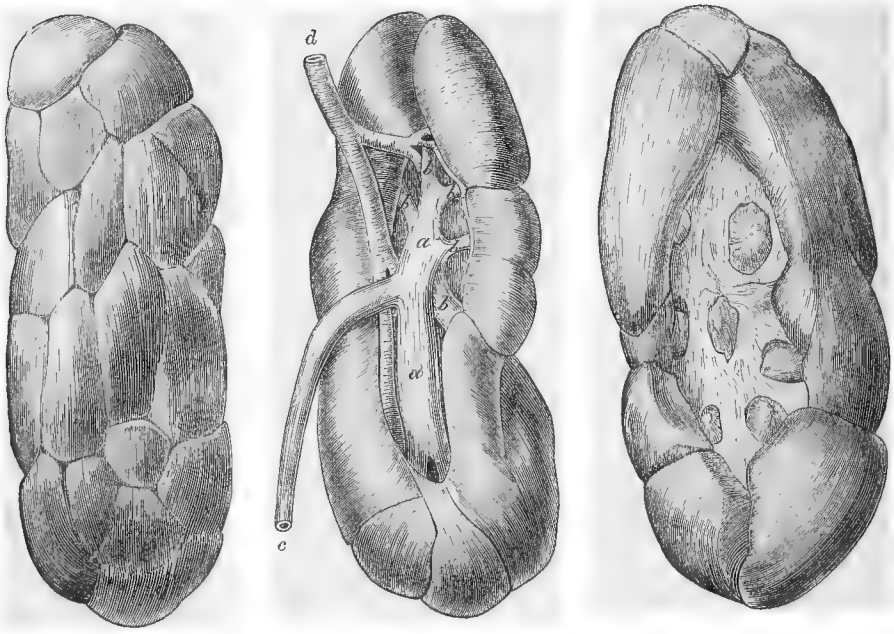

KIDNEYS OF THE OX.

Fig. 254.—Right kidney, viewed on its upper and external face. Fig. 255.—Left kidney, from its internal and inferior face; *a*, Pelvis; *b*, *b*, *b*, Branches of the pelvis terminating in calices; *c*, Ureter; *d*, Renal artery. Fig. 256.—The calices in the left kidney. The contents of the hilus, including the branches of the pelvis, have been removed to show the tubercles at the bottom of these calices. Only seven are visible, the others being beneath the borders of the renal fissure.

verse fissures produced by the protrusion of the transverse processes of the sacral vertebræ, as the lungs are furrowed by the projection of the ribs."[1]

The excretory apparatus is incomplete, and is only formed by the ureters, which open into the cloaca, where the urine is mixed with the fæces. Only one bird, the Ostrich, possesses a bladder, which is disposed in a particular manner.

COMPARISON OF THE URINARY APPARATUS OF MAN WITH THAT OF ANIMALS.

1. *Kidneys.*—The two kidneys of *Man* have, like those of the smaller domesticated animals, the same shape—that of a haricot bean. The average weight is about from three to five ounces. Contrary to what is observed in the Horse, the left kidney is more voluminous than the right, and is higher.

The kidneys are simple externally, though their tissue is disposed in distinct lobes, which number from eight to fifteen, and are composed of a Malpighian pyramid and a

[1] *Cuvier*, '*Anatomie Comparée*,' 2nd edition. Paris, 1836–46.

superposed pyramid of Ferrein; they terminate, towards the hilus, by a cone or renal papilla, each surrounded by a calyx, and are separated by small prolongations of the cortical substance—the columnæ Bertini.

2. *Ureters.*—The canals are disposed at their origin as in the Ox; they terminate as in the other animals. In the hilus of the kidney are from eight to fifteen prolongations or *calices*, which unite into a larger cavity or *great calyx*, that finally opens into the renal pelvis; this is immediately followed by the ureter.

3. *Bladder.*—The large extremity of this organ is directed downwards in the bottom of the pelvis, where it is continuous with the urethral canal; its summit is directed upwards, and is frequently pointed. Its mode of attachment and internal conformation are the same as in animals; and, as in the Horse, the peritoneum envelops it very incompletely. The muscular fibres are arranged into three planes: a superficial, which forms a band that is carried from the anterior to the posterior face in passing over the summit; a middle plane whose fibres are circular; and a deep plane with reticulated fibres.

Supra-renal capsules.—This name is quite appropriate to these bodies, as in Man, or at least in the fœtus, they form a kind of helmet that covers the upper part of the kidney.

There is nothing to add respecting their structure.

BOOK V.

Circulatory Apparatus.

The animal economy is incessantly traversed by two fluids—*blood* and *lymph*.

The blood is a liquid, coloured bright-red or brown by particular globules, from which the tissues derive not only the materials for nutrition and secretion, but also the exciting principle which vivifies the organic matter. It is named *red* or *dark-coloured* blood, according to its tint.

The *lymph* or *white blood* is a transparent, citrine-coloured fluid, which can be obtained from the majority of the organs. That which comes from the abdominal portion of the alimentary canal is charged, during digestion, with a portion of the reparative materials elaborated in that apparatus, and is distinguished by its lactescent aspect; it is designated the *chyle*.

Fig. 257.



THEORETICAL PLAN OF THE CIRCULATORY SYSTEM.

(H, D, C, E, The canal for red blood; E, B, A, G, Canal for black blood. The arrows indicate the course of the blood. The two canals are represented in their middle portion, AB, CD, as isolated; but in nature they are enveloped at this point in a common sac that concurs to form the heart.)

These fluids are carried by *vessels*—tubes which are continuous with one another. When joined together, end to end, these tubes give rise to three principal canals:

"One of these canals extends from the lungs to all parts of the body, and is traversed by red blood.

"The second extends from all parts of the body to the lungs, and carries dark blood.

"The third passes from the majority of the organs towards the canal carrying dark blood, in which it terminates; it conveys the white blood or lymph.

"The red-blood and dark-blood canals bear the greatest analogy to each other. Both are simple in their middle portion, which alternately dilates and contracts to impress upon the blood the movement necessary to life. Both present at their extremities innumerable ramifications, which ultimately join each other; so that the fluid they carry passes from one to the other in a constant and circular direction. Both are composed, at their origin, of vessels in which the blood moves in confluent columns: *these are the veins;* and in their terminal part, of vessels in which the same liquid is spread in divergent columns: *these are the arteries.*

"The *canal for white blood* is composed of a single order of vessels, the *lymphatics:* converging tubes, whose common trunk opens into the circulatory canal that results from the abouchement of the red and dark blood canals; the relation it affects with these latter is that of a tangent with its circumference."—*Sappey.*

These three canals constitute the *circulatory apparatus.*

This apparatus therefore comprises: 1, The *heart*, a central organ, charged to propel the blood; 2, A system of centrifugal vessels, the *arteries*, which carry the blood from the heart into the different organs; 3, A system of centripetal vessels, the *veins*, which bring the nutritive fluid to the heart; 4. The *lymphatics*, an accessory centripetal system, destined to convey the lymph into the blood-vascular circle.

In many anatomical works, the study of this apparatus—the heart, arteries, veins, and lymphatics, is designated "angiology."

FIRST SECTION.

THE HEART.

THE history of the heart comprises: 1, A general view of the organ; 2, The study of its external conformation; 3, Its interior; 4, Its structure; 5. A description of the pericardium, the serous cavity containing it; 6, A glance at its physiology.

1. *The Heart as a Whole.* (Figs. 230, 234, 258, 259.)

General sketch.—The heart, the central portion of the circulatory apparatus, is a hollow muscle, whose cavity is divided by a thick vertical septum into two perfectly independent pouches. Of these two contractile pouches, one placed on the track of the dark blood, propels it into the lungs; the other, situated on the course of the red blood, distributes it to all parts of the body.

Each of these is subdivided into two superposed compartments by a circular constriction, at which is a membranous valve that at certain fixed periods is elevated, and then forms a complete horizontal partition extended between the two compartments.

The superior compartment receives the convergent or centripetal portion

of the blood canal—that is the veins: it is named the *auricle*. The inferior gives origin to the divergent or centrifugal part of the same canal, and is designated the *ventricle*.

The cavities of the heart are distinguished into *right* or *anterior*, and *left* or *posterior*, because of their relative positions. There are, then: a *right auricle* and *ventricle*, the two dark-blood pouches; and a *left auricle* and *ventricle*, situated on the track of the red-blood canal.

Situation.—The heart, enclosed as it is in a fibro-serous sac, named the *pericardium*, is placed in the chest between the two layers of the mediastinum, opposite the third, fourth, fifth, and sixth ribs; in front of the diaphragm, which separates it from the abdominal viscera; above the sternum, which appears to support it; and beneath the vertebral column, to which it is suspended by means of the large vessels. (Between the middle of the anterior border of the heart, in front, and the entrance to the chest, is an interval of about four inches; and behind, at the same level, this organ is at a similar distance from the diaphragm. It is distant from the fifth and sixth dorsal vertebræ, from which it is suspended, about 4½ to 5 inches in an average-sized Horse.)

Form and direction.—The heart presents the form of an inverted cone, slightly depressed on each side, and whose axis, directed obliquely downwards and backwards, deviates a little to the right at its superior extremity.

Volume.—In a middle-sized Horse, the greater axis of the heart is about 10¼ inches in length; its antero-posterior diameter, measured near the base, is equivalent to about 7½ inches. Its lateral diameter does not exceed from 5 to 5½ inches.

Capacity.—It is very difficult, if not impossible, to obtain the exact capacity of the heart's cavities. From reasoning, one is led to think that the two hearts have exactly the same capacity, and that this capacity is equivalent to an average of 1 to 1¼ pints. The amount obtained by measurement is much more considerable; but then the heart is distended to a greater degree than in its physiological state.

Weight.—The weight of the heart varies with the size of animals, and that to a considerable degree. Its average is about 6¾ pounds. (The volume and weight of the heart are very much greater in well-bred than in under-bred Horses. Its dimensions and capacity are greater in the living than the dead animal; as, after death, its cavities contract, particularly the aortic ventricle, whose walls are the thickest. This ventricle will then scarcely contain more than 3–4ths to 1¼th gills; the pulmonary ventricle, which is not so thick, and consequently less contracted, may usually receive double that quantity; while in animals experimented on when expiring, it was observed that these two ventricles were much more capacious, and that each contained at least from 1¼ to 1½ pints.)

External Conformation of the Heart. (Figs. 258, 259.)

The cone represented by the heart is divided by a horizontal groove into two unequal portions: the one superior, comprising the *auricles* or *auricular mass;* the other inferior or principal, formed by the *ventricles* or *ventricular mass.*

A. Ventricular Mass.—It is this which determines the conical shape of the heart, and constitues its largest portion. Owing to the slight flattening which depresses the organ in a lateral sense, it may be considered as

having a *right* and *left face*, an *anterior* and *posterior border*, an *apex*, and a *base*.

The *right face*, smooth and rounded, is traversed by a vascular furrow parallel to the axis of the heart, and which divides this face into two sections: an anterior, belonging to the right ventricle; and a posterior, less extensive, forming part of the left ventricle (Fig. 259).

The *left face*, disposed in the same manner, also shows a groove on the limit of the two ventricles. whose direction slightly crosses the great

Fig. 258.

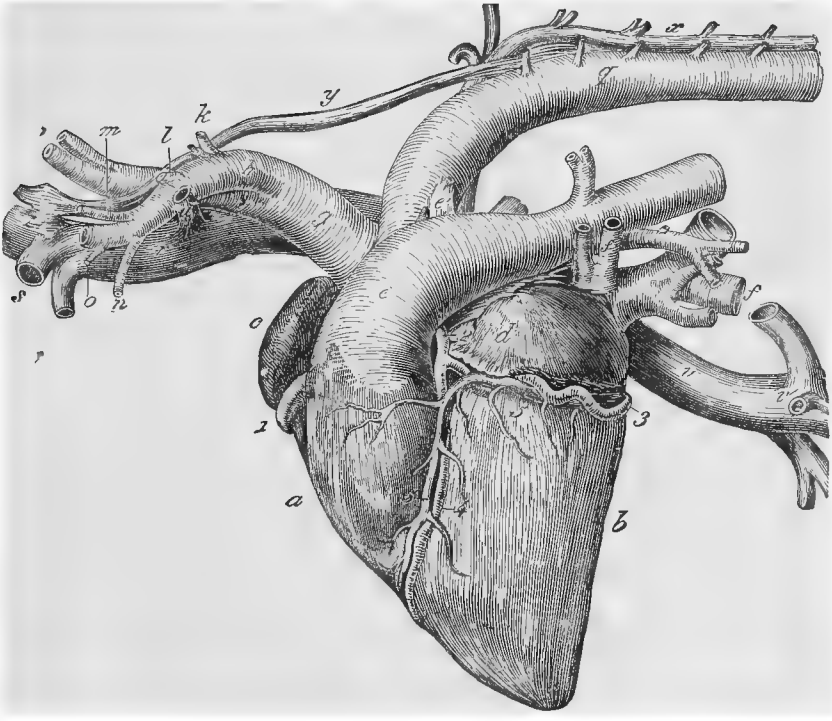

THE HEART AND PRINCIPAL VESSELS; LEFT FACE.

a, Right ventricle; *b*, Left ventricle; *c*, Right auricle; *d*, Left auricle; *e*, Pulmonary artery; *e'*, Obliterated arterial canal; *f*, Pulmonary veins; *g*, Anterior aorta; *h*, Left axillary artery; *i*, Right axillary artery, or brachio-cephalic trunk; *j*, Origin of the dorsal artery; *k*, Origin of the superior cervical artery; *l*, Origin of the vertebral artery; *m*, Origin of the inferior cervical artery; *n*, Origin of the internal thoracic artery; *o*, Origin of the external ditto; *p*, Carotid arteries; *q*, Posterior aorta; *r*, Anterior vena cava; *s*, Trunk of the axillary vein; *t*, Trunk of the internal thoracic vein; *u*, Trunk of the dorso-cervical vein; *v*, Posterior vena cava; *v'*, Embouchure of the hepatic and diaphragmatic veins; *x*, Vena azygos; *y*, Thoracic duct; *z*, Embouchure of that vessel, placed near the origin of the anterior vena cava.—1, Right cardiac artery; 2, Left cardiac artery; 3, Auriculo-ventricular branch of the latter; 4, Its ventricular branch; 5, Cardiac vein.

diameter of the heart from behind to before, and above to below, and which is much nearer the anterior than the posterior border (Fig. 258).

These two faces respond, through the medium of the pericardium, to the pluræ and the pulmonary lobes; the latter separate them from the thorax, except towards the middle and apex of the organ, where these faces come directly in contact with the thoracic parietes through the notch at the inferior border of the lung, and which we know is more marked in the left than the right.

The *borders* are thick, smooth, and rounded. The *anterior*, formed by the right ventricle, is very oblique from above to below, and before to behind; it then inclines on the sternum more or less, according to the subjects.

Fig. 259.

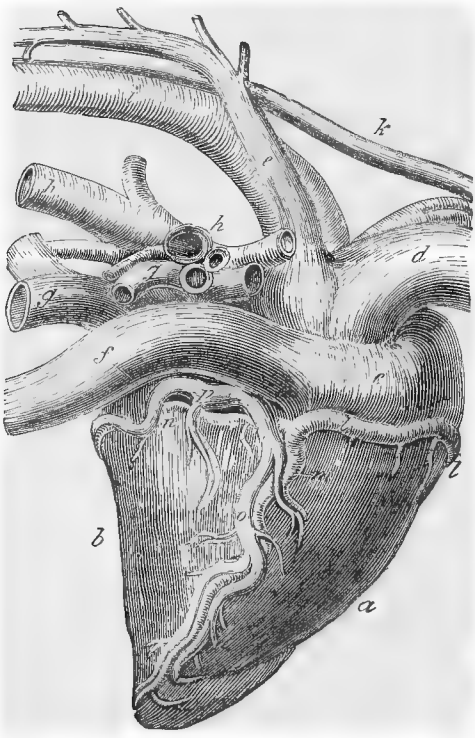

THE HEART AND PRINCIPAL VESSELS; RIGHT FACE.

a, Right ventricle; *b*, Left ventricle; *c*, Right auricle; *d*, Anterior vena cava; *e*, Vena azygos; *f*, Posterior vena cava; *g*, *g*, Pulmonary veins; *h*, *h*, Divisions of the pulmonary artery; *i*, Posterior aorta; *j*, Anterior aorta; *k*, Thoracic duct; *l*, Right cardiac artery; *m*, Its vertical or ventricular branch; *n*, Its horizontal or auriculo-ventricular branch; *o*, Ventricular branch of the cardiac vein; *p*, Auriculo-ventricular branch of the same.

The *posterior border*, much shorter than the anterior, is nearly vertical. Superiorly, it is separated from the diaphragm by the lung; but, below, it is quite close to that muscular septum.

The *apex*, or point of the ventricular cone, is blunt, slightly rounded, turned to the left, and formed entirely by the left ventricle.

The *base* responds on the right, in front, and behind, to the auricular mass; it gives exit on the left, and a little in front, to the two arterial aortic and pulmonary trunks.

B. Auricular Mass.—Elongated from before to behind, disposed like a crescent above the right side of the base of the ventricles, constricted in its middle part, on the limit of the two auricles, the auricular mass presents for study *three faces*, *two extremities*, and *a base*.

The *superior face* is divided by a middle constriction into two convex sections, each of which corresponds to an auricle. The anterior, or right section, shows the insertion of the anterior vena cava and vena azygos; the posterior, or left, that of the pulmonary veins. The trachea, bronchi, and pulmonary artery pass above this face (Figs. 258, 259).

The *right face*, the most extensive in the antero-posterior direction, is divided like the preceding, and disposed in a similar manner. The right, or anterior part, receives, behind and below, the insertion of the posterior vena cava, and the coronary and bronchial veins (Fig. 259).

The *left face*, concave from before to behind, includes the arterial trunks which leave the base of the heart.

Each of the extremities, *anterior* and *posterior*, constitutes a detached portion, named the *appendix auricularis;* these appendages are curved towards each other in being flattened from above to below. Their convex border is more or less crenelated, like the margin of a cock's comb, and their culminating portion advances nearly to the pulmonary artery, above the trunk of the cardiac vessels (Fig. 258).

The *base* of the auricular mass, opposed to the base of the ventricles, is separated from it at its periphery by the horizontal groove of the heart.

3. *Internal Conformation of the Heart.*

Preparation.—It suffices to make a longitudinal incision before and behind the organ, in order to expose its cavities. (I have followed Wilson's directions for many years when examining the interior of the heart, and as a careful inspection of it is often necessary in the course of an autopsy, I think the student should practise the best method of laying open these cavities. The right auricle is prepared by making a transverse incision along its ventricular margin, from the appendix to its right border, and crossed by a perpendicular incision, carried from the side of the anterior to the posterior cava. The right ventricle is laid open by making an incision parallel with, and a little to the right of, the middle line, from the pulmonary artery in front, to the apex of the heart, and thence by the side of the middle line behind to the auriculo-ventricular opening. The interior of the left auricle is exposed by a ⊥-shaped incision, the horizontal section being made along the border which is attached to the base of the ventricle. The latter is opened by making an incision a little to the left of the septum ventriculorum, and continuing it around the apex of the heart to the auriculo-ventricular opening behind.)

If the heart, when viewed externally, appears to be a single organ, it is not so when examined internally. The vertical septum which divides it into two bilocular pouches, in reality makes two hearts of it—one for the dark, the other for the red blood. We will successively study these two cavites by commencing with the partition that separates them.

A. Cardiac Septum.—The superior part of this septum, placed between the two auricles, is named the *interauricular partition* (*septum auricularum*). The inferior portion constitutes the *interventricular partition* (*septum ventriculorum*). The first, thin and not extensive, is perforated in the fœtus by the *foramen of Botal* (*foramen ovale*). The second, thick in its centre, thins a little towards its borders.

B. Dark-blood (or Pulmonary) Heart.—The two superposed cavities forming this pouch are situated in front and to the right. They are indifferently named the *anterior* or *right cavities* of the heart: the latter term being in most general use, though the first is much more convenient in Veterinary Anatomy.

Right Ventricle.—The right ventricle represents a hollow cone, the horizontal section of which resembles a crescent, its posterior plane being pushed into the cavity by the left ventricle.

It offers *two walls, an apex,* and *a base.*

Walls.—The *anterior wall* is concave; its thickness is more considerable above than below, and averages 6–10ths of an inch. The *posterior wall* is convex, and formed by the septum ventriculorum.

Both walls are uneven, from the presence of fleshy columns (*columnæ carneæ*), which we will commence examining in a general manner, as they are found in the four compartments of the heart. They are of three kinds: one kind, named the *pillars of the heart* (*columnæ* or *musculi papillares*), thick and short, and fixed by their base to the walls of the ventricles, have a free

summit, into which are implanted the tendinous cords (*chordæ tendinæ*) proceeding from the auriculo-ventricular valve; those of the second order are free in their middle part, and attached by their extremities to the walls of the heart; while the third description adhere throughout their length to the cardiac tissue, on which they stand as if sculptured in relief.

In the right ventricle, two columns of the first order, rarely three, are met with: one on the anterior wall, the other on the posterior. The columns of the second order number two or three principal ones, extending from one wall to the other, or attached to two different points of the same wall. There also exist a considerable number of small ones intermixed with those of the third order. The latter are particularly abundant in the angles formed by the union of the two faces, where they interlace and give rise to more or less complicated areolæ.

Fig. 260.

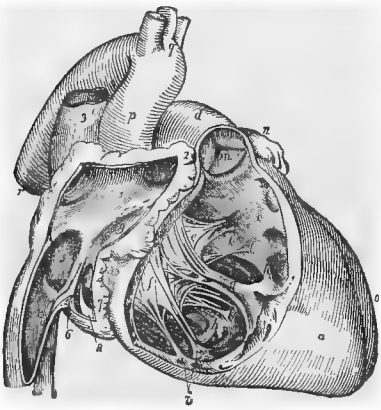

RIGHT SIDE OF THE HEART LAID OPEN.

1, Cavity of right auricle; 2, Appendix auriculæ, with musculi pectinati; 3, Anterior vena cava opening into the upper part of the right auricle; 4, Posterior vena cava; 5, Fossa ovalis, surrounded by the annulus ovalis; 6, Eustachian valve; 7, Opening of the coronary sinus; 8, Coronary valve; 9, Entrance of auricular-ventricular opening.—*a*, Right ventricle; *b*, Its cavity; *c*, Conus arteriosus, or infundibulum; *d*, Pulmonary artery; *e*, *f*, Tricuspid valve; *g*, One of the musculi papillares to which the curtains of the tricuspid valve are attached by chordæ tendinæ; *h*, Columnæ carneæ; *i*, Two musculi papillares of valvular curtain; *l*, *l*, Chordæ tendineæ; *m*, Semilunar valves of pulmonary artery; *n*, Apex of left appendix auriculæ; *o*, Left ventricle.

Apex.—The *apex* of the right ventricle does not descend to the point of the heart, being distant from it about $1\frac{1}{2}$ inches.

Base.—This is pierced by two large orifices—the *auriculo-ventricular opening* and the *pulmonary opening*.

Auriculo-ventricular opening.—Placed on a level with the constriction which divides the right heart into two superposed compartments, this orifice, widely open and almost a regular circle, forms the communication between the auricle and ventricle. It is provided with a valvular fold that exactly closes the orifice when the ventricle contracts to propel the blood into the lungs, and which is termed the *tricuspid* (having three points) valve, in consequence of its form. This valve offers: 1, A superior border, attached to the entire margin of the auriculo-ventricular opening; 2, An inferior opening, free, cut into three festoons by three deep notches, and fixed to the ventricular walls, principally on the summits of the fleshy columns, by means of tendinous cords which ramify on reaching the valve. One of these festoons, more developed than the others, is placed on the limit of the auriculo-ventricular and pulmonary openings; thereby constituting a kind of vertical partition which divides the ventricular cavity at its base into two compartments: a right or auricular, and a left or arterial. The other festoons are applied to the anterior and posterior walls of the ventricle; 3, An external face, which receives the insertion of a great number of

tendinous cords; 4, An internal face, which becomes superior when the valve is raised to close the opening, at which period it constitutes the floor of the auricular cavity.

Pulmonary opening.—This orifice represents the embouchure of the pulmonary artery. Situated in front and to the left of the preceding, and a little higher, it occupies the summit of a kind of infundibulum formed by the left compartment of the ventricle being prolonged upwards. It is perfectly circular, smaller than the artery to which it gives origin, as well as the auriculo-ventricular opening, from which it is separated by a species of muscular spur, to which is attached the principal festoon of the tricuspid valve.

Fig. 261.

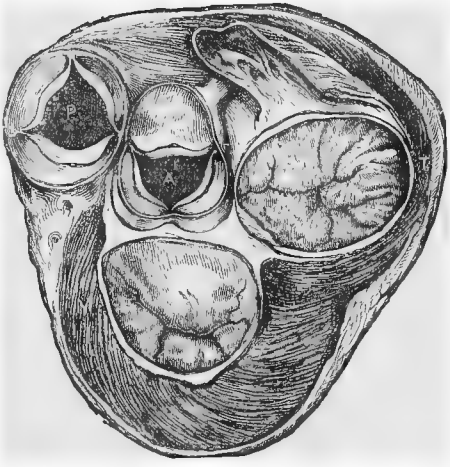

SECTION OF THE HEART AT THE LEVEL OF THE VALVES.

P, Pulmonary artery; A, Aorta; M, Mitral valve; T, Tricuspid valve.

The pulmonary opening is furnished with *three valves:* the *sigmoid* (or *semicircular*), suspended over the entrance to the pulmonary artery, and, as has been ingeniously remarked (by Winslow), like three pigeon's nests joined in a triangle. These valves are remarkable for their thinness; a circumstance which does not interfere with their solidity. They present: an external, convex border, attached to the margin of the orifice and to the walls of the pulmonary artery; a free border, straight when pulled tense, concave when left to itself, and sometimes provided in its middle with a small, though very hard, tubercle, the *nodule of Arantius* (*noduli Arantii*); a superior, concave face; and an inferior, convex one. The sigmoid valves are raised and applied to the walls of the vessel whose entrance they garnish, when the ventricle contracts and sends the venous blood into the lung. When this contraction ceases, they fall back one against the other by that part of their inferior face next to their free border, so as to oppose the reflux of the blood into the ventricular cavity.[1]

Right Auricle.—The cavity of the right auricle represents a very concave lid or cover surmounting the auriculo-ventricular opening, and is prolonged, anteriorly, by a curved *cul-de-sac.* It offers for study this *anterior cul-de-sac*, a *posterior*, *external*, and *internal wall*, as well as a *superior*

[1] It has been repeated, *ad nauseam*, that the occlusion of the arterial openings results from the juxtaposition of the *free border* of the sigmoid valves; even the small tubercle in the middle of this border has been considered to play its part in closing the triangular central space left when these valves meet. In passing the finger into the pulmonary artery of a living animal, to explore the function of these membranous folds, it is readily perceived that they come in contact by a large portion of their convex face, and not alone by their free border. This arrangement is such, that we have with much difficulty tried to produce an insufficiency of contact by keeping one of the valves up against the walls of the vessel with the finger; but the others came down against the finger and applied themselves around it so as to exactly close the orifice.

wall or *roof*, and the *auriculo-ventricular opening*, which occupies the whole floor of the cavity. This orifice has been already described.

The *anterior cul-de-sac* is in the appendix auriculæ; it is divided by a great number of muscular columns of the second and third orders (*musculi pectinati*), into deep and complex areolæ.

The *posterior wall* responds to the interauricular septum; it is smooth, and usually marked by an oblique and more or less deep *cul-de-sac* (or depression), the remains of Botal's foramen. This depression is surrounded by the *ring of Vieussens* (*annulus ovalis*) and is named the *fossa ovalis;* it is only separated from the left auricular cavity by a thin membrane, a vestige of the valve circumscribing the interauricular opening in the fœtus.

The *external wall* is areolated, and perforated behind and below by two orifices, the largest of which is the embouchure of the posterior vena cava, the other the opening of the large coronary vein. Both are destitute of valves, though these are found at a short distance in the coronary vein. The bronchial vein sometimes opens separately beside the latter.

The *internal wall* is smooth.

The *superior wall*, or *roof* of the auricle, shows the openings of the anterior vena cava and vena azygos; the latter only is provided with valves, which are, however, not always present. On this wall are also remarked, in front, areolæ separated by muscular columns.

The thickness of the right auricular walls is very irregular, in consequence of the reliefs sculptured on the inner face of that cavity. In some points it is about the third of an inch, and in others, particularly in the small *culs-de-sac* formed by the reticulations, it is sometimes so thin as to appear exclusively formed by the union of the external and internal serous membrane.

(When the vena azygos opens behind, there is between it and the orifice of the anterior vena cava, a muscular lamella with a free concave border, which forms a kind of valve whose extent is very variable. Behind this vena cava is a thick eminence, the *tuberculum Loweri;* this has the form of a crescent, open in front, and elongated from right to left at the superior border of the septum. The anterior, or left border of the fossa ovalis, is thin and prominent, and constitutes the Eustachian valve: a muscular membranous fold of a semilunar shape, with a concave free border directed to the right and behind. It is of little use in animals, because of their horizontal position. Immediately beneath the posterior vena cava, and between it and the coronary vein, is a small membranous crescent—the *valve of Thebesius.*)

C. Red-blood (or Aortic) Heart.—This is also called the *posterior heart*, and more frequently the *left heart*, because it is situated behind and to the left of the dark-blood heart. Its general disposition otherwise exactly resembles that of the latter receptacle.

Left Ventricle.—This is a cylindro-conical cavity, whose transverse section gives an irregularly circular figure. Its walls attain a thickness of from $1\frac{1}{5}$ to $1\frac{5}{8}$ inches, except towards the apex of the heart, where they are extremely thin. They are less reticulated than those of the right ventricle, and exhibit several columns of the second order, as well as two enormous muscular pillars—an external and internal, for the attachment of the tendons of the auriculo-ventricular valve. The *apex* of the cavity forms a reticulated *cul-de sac*, which occupies the point of the heart. The *base* is perforated by the auriculo-ventricular and the aortic openings. The *auriculo-ventricular opening*, precisely similar to that of the right ventricle, is

provided with a circular membrane, the *mitral* (or *bicuspid*) *valve*, because it is cut into several festoons, of which two are the principal: the one anterior, the other posterior, simulating in their outline the two faces of a bishop's mitre. The anterior festoon is the largest, and is attached to the limit of the two orifices, isolating from the ventricular cavity a diverticulum which corresponds, in every respect, to the pulmonary infundibulum. The posterior festoon is applied to the walls of the ventricle. Between these two there are usually two secondary festoons, making up the total number to four; frequently there is an accessory fold, situated on the right side, and fairly developed; the valve is then tricuspid, like that of the right ventricle. Sometimes two of these rudimentary folds are found on the left side—making five festoons in all. The *aortic opening*, so named because it constitutes the origin of the aorta, is placed in front and to the left of the auriculo-ventricular opening, from which it is only separated by a thin muscular spur, to which is attached the adherent border of the great festoon or curtain of the mitral valve. It does not differ in anything from the pulmonary opening, and like it, is provided with *three sigmoid valves.*

Fig. 262.

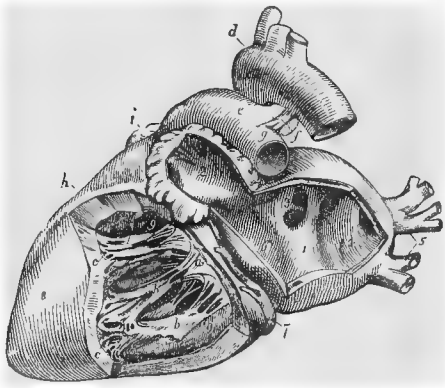

LEFT CAVITIES OF HEART LAID OPEN.

1, Cavity of left auricle; 2, Cavity of appendix auriculæ; 3, Opening of two right pulmonary veins; 4, Sinus into which left pulmonary veins open; 5, Left pulmonary veins; 6, Auriculo-ventricular opening; 7, Coronary vein lying in auriculo-ventricular groove; 8, Left ventricle; 9, 9, Cavity of left ventricle.—*a*, Mitral valve, its curtains connected by chordæ tendinæ to *b*, *b*, Columnæ carneæ; *c*, *c*, Fixed columnæ carnæ on inner surface of ventricle; *i*, Point of appendix of right auricle.

Left Auricle.—As in the right auricle, this forms a kind of cover above the auriculo-ventricular opening. Smooth behind, in front, inwards and outwards, its cavity presents a reticulated cul-de-sac, which occupies the appendix auriculæ; and a superior wall, also reticular, having from four to eight orifices, the openings of the pulmonary veins. These orifices have no valves. (Carneæ columnæ of the third kind are also present, but chiefly between the two posterior pillars; small ones are very numerous on the borders and summit of the ventricle. The columns of the second order are simple or ramous, and pass from the angles of union of the walls and the point of the cavity; others on the posterior wall go to the borders and the interval between the two pillars. The most remarkable are bands extending from one wall to the other, the two principal of which are long, strong, and ramous; they are fixed, on the one side, to the centre of the great posterior reliefs, and ascend to be implanted, on the other side, into the middle of the anterior wall.)

4. *Structure of the Heart.*

Preparation.—Before proceeding to dissect the muscular fibres of the heart, it is indispensable to keep that viscus in boiling water for half or three-quarters of an hour. It should then be immediately immersed in cold water, to prevent the desiccation of the

serous membrane covering it, and which must be at once removed. The furrows should then be cleared of their vessels and fat; this renders the superficial muscular fibres very apparent. The same result may be attained by immersing the heart in vinegar or dilute hydrochloric acid. To isolate the ventricles and unitive fibres from each other, the following procedure may be adopted: After removing the auricular mass and dissecting the fibrous rings, the unitive fibres around these are divided with the point of the scalpel, care being taken not to injure the proper fibres. Then, with the aid of the finger-nail or handle of the scalpel, follow the more or less artificial limit of these two series of muscular planes in a spiral manner; the vessels passing through the walls of the heart must be cut through. The same course is followed in the substance of the interventricular septum, in order to separate the two sacs formed by the proper fibres.

(It will be found that the simplest and best way to prepare the heart for an examination of its fibres, is to steep it in a very weak dilution of hydrochloric acid. Remove the serous membrane, and the fibres can then be traced, layer by layer, from their origin to their termination.)

The muscular tissue composing the heart rests on a fibrous framework, disposed in rings around the auriculo-ventricular and arterial openings; it receives vessels and nerves, and while covered in the internal cavities by two independent serous membranes, it is enveloped, externally, by another membrane of the same kind. An *annular framework, muscular tissue proper, vessels and nerves*, and *serous tunics*—such are the elements entering into the organisation of the heart.

A. Fibrous Rings.—These are also named the *fibrous zones* of the heart, and are four in number: one for each of the openings at the base of the ventricles.

The two *arterial zones* (the *pulmonary* and *aortic*) constitute two complete rings, which are not disposed in a circular manner around the pulmonary aortic openings, but are divided into three regular festoons with their concavities superior and internal, and which correspond to the insertions of the three sigmoid valves. These zones are continuous, by their superior and external contour, with the walls of the arteries, from which they are only distinguished by their whitish-grey colour and slight elasticity, the arterial tissue being yellow and very elastic. Their internal and inferior outline sends three thin prolongations into the serous duplicatures of the sigmoid valves.

The *auriculo-ventricular zones* do not completely surround the openings they circumscribe. They are flattened, brilliant-white tendons, laid one against the other at the level of the ventricular septum, and against the aortic ring; they turn to the right and left around the auriculo-ventricular openings, but without joining at their extremities, which are dispersed as fibrillæ in the muscular tissue of the ventricles. Above, these zones give attachment to the muscular fibres of the auricles; below, to the ventricular fasciculi. Their internal and inferior border is prolonged into the mitral and tricuspid valves, and is continuous, through these valves, with the tendinous cords fixed to the walls of the ventricles. Some of these cords, generally the strongest, are even directly inserted into the auriculo-ventricular zones.

It must be noted that, in Solipeds, there is constantly found, at the point where the aortic and auriculo-ventricular zones lie against each other, a more or less developed cartilaginous body, which, in the larger Ruminants, is transformed into true bone. (Lavocat speaks of two cartilaginous points, one to the right, at the junction of the aortic with the left auriculo-ventricular ring and the cardiac septum; the other, less developed, on the left, at the origin of the left ventricular groove.)

B. Muscular Tissue.—The muscular tissue composing the mass of the

heart belongs to the system of organic life, as it contracts without the participation of the will. Nevertheless, it is formed of red striated fibres, which only differ from the muscular fibres of animal life in being less in diameter. As in the tongue, these fibres also possess ramifications that unite them to each other; they are likewise very granular. (They are more friable than those of the muscular system generally; the sarcolemma is more delicate, and the longitudinal markings and nuclei are more apparent, the latter being placed in the axis of the fibre along with rows of minute fatty granules, which are extremely numerous in fatty degeneration of the heart. The connective tissue is scanty; so that the fibres lie closer together while forming innumerable anastomosing networks and interlacings—a character peculiar to the muscular organisation of the heart. It has been asserted that there is no sarcolemma.)

The striation of the muscular fibres of the heart, which constitutes an exception in the laws of organisation, may be explained to a certain point by the nature of the functions imposed on the muscular tissue of the organ. Charged to propel the blood into the arterial ramifications by successive, instantaneous, and vigorous contractions, the heart, probably, would not have been capable of executing such movements if it had been composed of organic fibres, as these come into action in a steady, slow, and prolonged manner. The ramifications that unite the fibres, and establish a kind of solidarity between them, afford a clue to the simultaneousness in the movements of the auricles and ventricles.

Fig. 263.

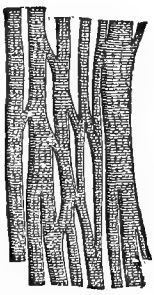

ANASTOMOSING MUSCULAR FIBRES OF HEART.

It is also worthy of remark, that between these fibres there is so little connective tissue that the majority of anatomists absolutely deny its existence.

The arrangement of the muscular fasciculi of the heart has been the object of numerous recent investigations, which have only complicated what was already known on the subject. We will endeavour to sum up, as simply as possible, this arrangement, in examining it in the different compartments of the organ. The following is the disposition of the fasciculi, considered successively in the ventricles and auricles:

1. Fibres of the Ventricles.—According to the remark of Winslow, we may compare the ventricles, in regard to the arrangement of the fibres essentially composing them, to "two muscular sacs included in a third:" that is to say, each ventricle is formed of *proper muscular fibres*, covered externally by a layer of *unitive fibres*, which envelop the two ventricles in common.

a. Proper fibres of the ventricles.—Taken altogether, these fibres represent, for each cavity, a hollow cone, open at both its extremities: at the superior extremity by the auriculo-ventricular and arterial orifices; and at the inferior extremity, by an aperture which admits the reflected fibres of the common layer. All form loops attached, by their extremities, to the outline of the superior orifices, on the fibrous zones, and are rolled, more or less obliquely, around the axis of the ventricles. It is from the apposition of the right and left systems that the ventricular septum is formed.

b. Unitive fibres of the ventricles.—These are disposed as an external shell enveloping the proper fibres. They leave the fibrous zones at the base of the heart, and descend towards its apex: those of the right side, by inclining forward; the anterior, in following the direction of the great axis of the

ventricles; those of the left face, by directing their course from above to below, and before to behind; and the posterior, in rolling themselves from left to right around the left ventricle. On arriving near the point of the heart, they turn from left to right, and before to behind, in-forming a twisted spire; then they are reflected from below upwards, to enter the inferior extremity of the ventricles, on the internal face of whose proper fibres they spread and ascend to the fibrous zones at the base of the heart, where they terminate. Some of these reflected fibres are disposed in relief to constitute the columnæ carneæ, and reach the auriculo-ventricular zones through the medium of the tendinous cords which directly connect these fibrous rings with the summits of the muscular pillars.

Such is the general disposition of the unitive fibres of the ventricles; and it will be seen that they form a superficial and a deep or reflected plane, between which are comprised the fasciculi proper to each ventricular pouch.

The unitive fibres of the ventricles, therefore, form collectively a kind of figure 8, the smallest loop of which is at the point of the heart; there the fibres are heaped together, leaving in the centre of the loop a very small space, through which it is possible to pass a probe into the ventricle, without piercing anything but the external and internal serous membranes of the organ.

2. Fibres of the Auricles.—The fibres of the auricles are either common to the two cavities, or proper to each. The *unitive fibres* constitute two thin bands—a right and left, carried from one auricle to the other.

The *proper fibres* are divided into several fasciculi, some of which are arranged in rings around the auriculo-ventricular opening; others in interwoven loops, and others, again, in sphincters, which surround the embouchures of the veins. These fibres are arranged in such a manner that, in contracting, they diminish the auricles by their superior and lateral planes and extremities, and propel the blood towards the auriculo-ventricular openings.

(The arrangement of the muscular fibres constitutes the most remarkable feature in the anatomy of the heart. We have seen that the auricles, as well as the ventricles, possess not only fibres proper to each compartment, but also unitive or common fibres which assure the simultaneousness in action of the similar or homologous cavities. Besides, the fibres of the auricles and those of the ventricles are distinct. and not continuous; so that, from their independence of each other, it results that these two sections of the heart may act separately, and contract, not simultaneously, but alternately, a condition indispensable to the free course of the blood. The extremely fine and close connective tissue uniting the muscular fibres, is another peculiarity of structure that must be favourable to the solidarity of their action, which ought to be simultaneous. Adipose tissue is only found in the grooves on the surface of the organ, around the vessels lodged in them, and particularly at its base, between the large arterial trunks.)

C. Vessels and Nerves of the Heart.—Blood is carried to the muscular tissue of the heart by two large vessels, the *coronary arteries.* They emanate from the trunk of the aorta, at the sigmoid valves, and each divides into two principal branches: one passing along the horizontal, the other in the vertical furrow of the heart. Collectively, these arteries form two circles, which surround the heart in intersecting it at a right angle in the auriculo-ventricular groove.

The blood is carried from the walls of the heart by a single but important *vein,* which empties itself into the right auricle.

The *lymphatics* follow the arteries, passing along the visceral layer of the pericardium, and entering the cluster of glands situated near the base of the heart. (The endocardium, especially in the ventricles, has a network of fine lymphatics, the walls of which consist of only a single layer of intimately-adhering cells. None have been traced upon the chordæ tendineæ, and very few upon the auriculo-ventricular and semilunar valves.)

The *nerves* of the heart, furnished by the cardiac plexus, come from the pneumogastric and sympathetic. The tubes are small, and show some cells in their course. In addition to these, the heart is provided with a particular ganglionic system, to which Remak has called attention. It is believed that there exist three ganglia in different points of the cardiac parietes, and that on these depend the movements of the organ. (According to Carpenter, the nerves of the heart are: 1, Minute ganglia and fibres of the sympathetic, situated in the walls of the cavities, and especially in the auriculo-ventricular furrow; 2, Fibres derived from the cervical portion of the sympathetic, and passing to the cardiac plexus, between the aorta and pulmonary artery; 3, Cerebro-spinal fibres entering the inferior cervical or stellate ganglion, and proceeding to the same plexus, and probably derived from a centre situated in the brain and spinal cord; and, 4, Fibres coursing in the vagus, and originating in a centre situated in the medulla oblongata. The first three of these ganglia and fibres probably collectively constitute the excito-motor system of the heart, the fourth is an inhibitory, restraining, or regulo-motor centre.)

D. Serous Membranes of the Heart.—These are three in number: two internal, or *endocardial*, one of which occupies the right, the other the left cavity; and an external, a dependency of the fibro-serous sac which contains the heart.

1. *Internal serous membranes, or endocardia.*—These two membranes, independent, like the cavities they line, are spread over the auricular and ventricular walls, covering the tendinous or muscular columns attached to these walls, and are prolonged into the veins and arteries, to form the internal tunic of these vessels. At the auriculo-ventricular and arterial openings, they constitute a duplicature for the valves situated there. These valves are, therefore, due to the projection of a circular fold of the endocardia, between the two layers of which a thin prolongation of the fibrous zones from the base of the heart is insinuated. In the auriculo-ventricular valves there is also found, beneath the internal or superior layer, muscular fibres furnished by the auricles.

Fig. 264.

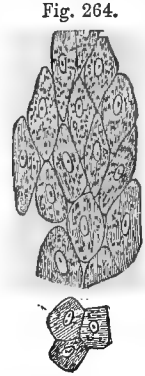

EPITHELIUM OF THE ENDOCARDIUM.
1, Nucleated cells assuming the fusiform figure; 2, Polygonal nucleated cells.

The endocardium of the right heart has a red tint, which is deepest in the ventricle. In the left heart, this tint is slightly yellow, especially in the walls of the auricular appendix, which may be attributed to the presence of a thin layer of yellow elastic tissue that covers the adherent face of the membrane.

(The endocardium consists of three layers: 1, A thin bed of white fibrous tissue, connecting it to the muscular structure; 2, A middle layer, composed of elastic tissue which is very abundant in the auricles; and 3, An epithelium, consisting of a single or double layer of somewhat elongated, polygonal, pavement nucleated cells.)

2. *External serous membrane.*—This is the visceral lining membrane of the pericardium, the description of which follows.

5. *The Pericardium.* (Fig. 234, c.)

Preparation.—Place the animal in the second position, and remove the sternal ribs by separating the cartilages and luxating their costo-vertebral articulations. This procedure permits the study of the situation and general disposition of the heart and pericardium. But in order more easily to examine the reciprocal arrangement of these two parts, it is necessary to extract them from the thoracic cavity by tearing through the sternal insertion of the pericardium.

The *pericardium*, or proper serous membrane of the heart, is a membranous sac inclosing that organ, fixing it in the thoracic cavity, and favouring its movements by its polished surface.

This sac is formed by a fibrous layer, within which is spread a serous membrane, divided into two parts—one parietal, the other visceral.

The *fibrous layer* of the pericardium presents somewhat the general form of the heart Its internal surface is covered by the parietal portion of the serous membrane. The external surface corresponds to the two laminæ of the mediastinum. Its *summit* (or *apex*), depressed on each side, and elongated from before to behind, is firmly attached to the superior face of the sternum, from the fourth rib to the origin of the xiphoid cartilage. By its *base*, it is fixed to the large vessels going to and leaving the heart, where it is continuous with their cellular sheath, and where it sends some fibres to the longus colli.

The *serous membrane of the pericardium* has been well compared by Bichat to a cotton night-cap, the external part of which would represent the parietal layer, and the inverted part the visceral division of that membrane. The *parietal layer* adheres in the most intimate manner to the internal face of the fibrous tunic, and is seen to be reflected, to form the visceral portion, around the pulmonary arteries and the aorta to a certain distance from their origin, and on the pulmonary veins. The *visceral layer* envelops in common the two arterial trunks, covers a small part of the venæ cavæ, particularly the anterior, spreads over the insertion of the pulmonary veins, and then descends on the auricles and ventricles. The free face of this layer is in contact with that of the parietal layer; the adherent face is applied to the tissue of the heart or that of the large vascular trunks, except at the horizontal and vertical grooves, where it rests on the coronary vessels, and on the mass of adipose tissue constantly accumulated on their track.

In the living animal, the cavity of the pericardium is never entirely filled by the heart, whose movements are, therefore, allowed much more liberty. Otherwise, as it does not contain any gas, nor a sensible proportion of fluid,[1] its walls are immediately applied to the surface of the heart.

Blood reaches the pericardium by the mediastinal arteries. Its walls receive some sympathetic nerve-fibres.

(The pericardium is composed of a fine network of elastic fibres adhering to the muscular structure of the heart by one surface, and covered by a single or double layer of tesselated epithelium on the other. Gurlt, in 1867,

[1] With horses in health, the fluid exhaled into the pericardium is barely sufficient to moisten and lubrify the free surface of its serous membrane. But in those worn out and enfeebled by age, privations, or disease, it is not rare to see it accumulated in greater or less quantity. To verify this, however, an examination ought to take place *immediately* after death, as the accumulation of fluid in the serous cavities by cadaveric exhalation is common in all animals.

described a thin muscle, nine inches long, situated between the pericardium and the diaphragm of the Horse.)

6. *Action of the Heart.*

The function of the heart is to maintain the circulation of the blood, by the rhythmical contractions of its two pouches. The right pouch sends that fluid to the lungs, whence it returns to the left pouch, and from this it is thrown into all parts of the body, and is brought back again to the right heart. These contractions take place simultaneously in the two cardiac compartments.

In taking the heart at the moment when it is in a state of repose: that is, in the intervals between the two contractions, we find that its two pouches are being rapidly filled with the blood brought to it by the venous openings. When sufficiently replete, the auricles slightly contract and push a portion of the fluid they contain into the ventricles: these contracting immediately after, to propel the blood into the arterial ramifications. This passage of the blood into the arteries is a necessary consequence of the contraction of the ventricles, as at the moment of this contraction the auriculo-ventricular valves are raised, and so prevent the reflux of the blood into the auricles. This fluid is then forced to enter the arterial orifices, whose valves are separated under the impulsive effort communicated to the column of blood. When the heart returns to a state of repose, these valves fall down, preventing the return of the blood into the ventricular cavities; while the mitral and tricuspid valves subside against the walls of these cavities, and thus again allow the passage of blood through the auriculo-ventricular openings.

By the term *systole* is designated the contraction of the heart's cavities, and by *diastole*, the repose or relaxation of its tissue. For each revolution of the heart there is, therefore: 1, The *general diastole* of the organ, during which the two cardiac cavities are filled by the afflux of venous blood; 2, The *systole of the auricles*, the effect of which is the repletion of the ventricles; 3, The *systole of the ventricles*, propelling the blood into the arterial systems; after which comes another period of general diastole.

DIFFERENTIAL CHARACTERS IN THE HEART OF OTHER THAN SOLIPED ANIMALS.

In the *Ox*, *Sheep*, and *Goat*, the ventricular mass of the heart is more regularly conical than in Solipeds; it has three longitudinal furrows, one of which is accessory and passes behind the (left) ventricle.

In the *Ox* two small bones, named *bones of the heart*, are found in the substance of the aortic zone. The largest is in the right side, at the point where the arterial ring is approximated to the auriculo-ventricular zones: the other, situated in the left, is perhaps not constantly present. The first is triangular in shape, curved to the right and its base directed upwards. The right face lies against the auriculo-ventricular opening; the left is covered by the walls of the aorta at its commencement. It is about an inch in length. (The Ox's heart averages from about $3\frac{1}{2}$ to $4\frac{1}{2}$ lbs., that of the Sheep from $5\frac{1}{2}$ to 7 oz. It is more elongated and pointed in Ruminants than in the Horse or Pig. The *large* bone in the Ox's heart is elongated from before to behind, flattened laterally and curved to the left; its surface is roughened, and its length is sometimes about 2 inches. The left, or *small* bone, is usually flattened on each side and triangular, one of its points is directed forwards, another backward, and a third inferiorly; its length is about three-quarters of an inch when fully developed. Besides the Ox, a small cross-shaped bone is found in the heart of the Sheep, Pig, Camel, Deer, Giraffe, and sometimes in the Horse. Remak found in the pericardium of the *Ox*, at the border of the left auricle, a row of villi similar to those discovered in the border of the chicken's heart.)

The heart of the *Pig* resembles that of the Horse; its direction is a little more oblique,

and the pericardium is fixed to the sternum from the third rib to the xiphoid appendix, as well as to the diaphragm. (The cartilage is not ossified until a late period.)

In the *Dog* and *Cat*, the heart is oval or nearly globular. It is almost entirely resting on the upper face of the sternum; its anterior face has become the inferior, and its point, directed backwards, touches the anterior surface of the diaphragm. The pericardium is attached to the aponeurotic centre of the diaphragm.

COMPARISON OF THE HEART OF MAN WITH THAT OF ANIMALS.

The human heart is ovoid, and similar to that of the Carnivora; the ventricular mass is not acute at its apex, as in Solipeds and Ruminants. Its direction is modified in consequence of the antero-posterior flattening of the chest. It is situated across the median plane of the thorax, its right face in animals has become the anterior face in Man, and is applied to the sternum; the anterior border is in him the right border, and the posterior the left border.

Fig. 265.

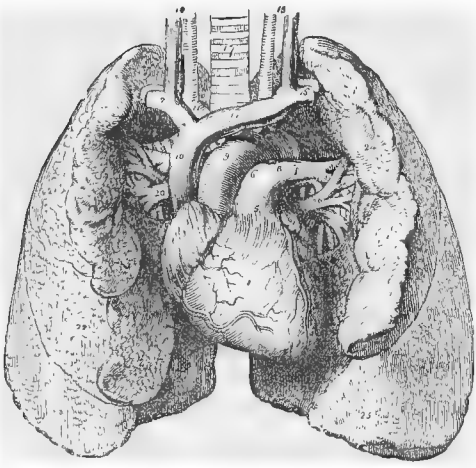

HUMAN LUNGS AND HEART; FRONT VIEW.

1, Right ventricle 2, Left ventricle; 3, Right auricle; 4, Left auricle; 5, Pulmonary artery; 6, Right pulmonary artery; 7, Left pulmonary artery; 8, Ligament of ductus arteriosus; 9, Arch of aorta; 10, Superior vena cava; 11, Arteria innominata; 12, Right subclavian vein, with the artery behind it; 13, Right common carotid artery and vein, 14, Left vena innominata, 15, Left carotid artery and vein; 16, Left subclavian vein and artery; 17, Trachea; 18, Right bronchus; 19, Left bronchus; 20, 20, Pulmonary veins; 21, Superior lobe of right lung; 22, Middle lobe; 23, Inferior lobe; 24, Superior lobe of left lung; 25, Inferior lobe.

The organ is suspended obliquely downwards, forwards, and to the left; consequently, the right auricle is to the right of the sternum, between the third and fourth ribs, and the point on a level with the sixth left intercostal space. The auricular appendages, particularly the right, are more rounded and bulging than in animals. The pulmonary veins, four in number, open on the upper face of the left auricle.

There are no essential differences to be noted in its internal conformation. We may indicate the presence of a fold that passes from the ring of Vieussens to the opening of the inferior vena cava: this is the *Eustachian valve*. We may also mention the Thebesian valve at the entrance of the coronary vein.

The fibrous rings and muscular fasciculi are disposed as in the Horse.

The *pericardium* is a conical sac; but instead of its base being presented upwards, it rests against the aponeurotic centre of the diaphragm: its summit is lost among the large vessels, and it adheres to the posterior face of the sternum.

SECOND SECTION.

The Arteries.

CHAPTER I.

GENERAL CONSIDERATIONS.

The name of *arteries* is given to the centrifugal vessels, which carry the blood from the heart to the various organs. These vessels proceed from the heart by two trunks, which are perfectly independent in the adult animal; they originate, one in the right ventricle, the other in the left.

The first of these trunks, destined to carry the dark blood, is the *pulmonary artery*. The second conveys the red blood, and is named the *aorta*. There exist, therefore, two groups of arteries; the *pulmonary system*, and the *aortic system*.

General Form.—Single at their origin, the two arterial systems soon divide into less voluminous trunks, which again subdivide into successively decreasing canals, until at last their diameter becomes reduced to an extreme degree of tenuity. In a word, the arterial trunks present the ramous disposition of dicotyledonous plants. The total volume of the secondary trunks exceeds that of the primary trunk, and the same relation exists between the respective dimensions of the branches and their ramifications, to the ultimate divisions of the artery. In tracing all the ramifications of one of these systems to a single canal, it will then be found that this canal is incessantly increasing from its origin to its termination, and that it represents a hollow cone whose apex corresponds to the heart.

Form of the Arteries.—Each arterial tube affects a regularly cylindrical form, whatever its volume may be. When the diameter of these vessels is measured at their origin and their termination, between two collateral branches, no sensible difference is perceived.

Mode of Origin.—The arterial ramifications are detached in an angular manner from the parent branches which give them origin. Sometimes the angle of separation is more or less acute—this is most frequently the case; sometimes it is at a right angle, and at other times it is obtuse. It will be readily understood that the opening of this angle exercises a somewhat marked influence on the course of the blood; for example, the blood from a principal vessel, in passing into the canal of a secondary one which springs from it at an obtuse angle, must experience a notable check in its impetus, because of the change in direction it has to encounter, on the contrary, the rapidity of the current is not modified to any appreciable degree in those vessels which separate from their trunk of origin at a very acute angle. Towards the point of separation, there is always remarked, in the interior of the vessel, a kind of spur whose sharp border is towards the heart, thus dividing the current of blood and diminishing the resistance. This spur resembles in its disposition the pier of a bridge, against which the waters are divided to pass on each side. (When a short trunk divides abruptly into several branches, proceeding in different directions, it is termed an *axis*. A very peculiar feature in the division of arteries, however, and one which will be

made amply conspicuous in the following description, is their bifurcation or dichotomous arrangement, which prevails so largely.)

Course.—In the course pursued by an artery, it is necessary to consider the *situation* occupied by the vessel, its *direction*, *relations*, and the *anastomoses* which establish communication between it and the neighbouring vessels.

Situation.—The arteries tend constantly to recede from the superficial parts: to become lodged in the deep-seated regions, and in this way to be removed from the hurtful action of external causes, a tendency all the more marked as the arteries are more considerable in volume, and which ceases to be manifested in the less important ramuscules. These vessels, therefore, occupy either the great cavities of the trunk, or the deep interstices on the internal face of the members; when they pass over an articulation, it is always on the side at which flexion occurs. But in the limbs, for instance, the joints are flexed alternately in opposite directions, and it then happens that the arteries in these regions have a slightly helicoid (or spiral) disposition. This is evident in the case of the femoral artery, which passes round the inner face of the femur to become the popliteal artery; and also in the humeral artery, which is at first situated to the inner side of the scapulo-humeral articulation, then turns around the humerus to be placed in front of the elbow joint.

Direction.—The arteries are sometimes rectilinear, and at other times more or less flexous. The latter disposition is evidently intended to prevent the dilaceration of the vessels in organs susceptible of elongation and contraction, as may be remarked in the tongue or to moderate the impetus of the blood, as in the internal carotid arteries.

Relations.—In their course, the arteries may be in contact with the viscera, nerves, muscles, bones, skin, and connective tissue.

a. In nearly every part of the body, the arteries maintain the most intimate relations with the veins: sometimes with two of these vessels, when the artery is placed between them; sometimes with only one, which is always more superficial.

b. The arteries are usually accompanied by nerves belonging to the cerebro-spinal or ganglionic systems. Those of the latter category are distinguished by the reticular interlacing they form around the visceral arteries; their structure will be alluded to presently.

c. Lodged for the most part in the interstices of the muscles, the arteries contract relations with these organs which it is very important to know in a surgical point of view. Some of these muscles lie parallel with important arteries, and for this reason have been designated *satellite muscles;* they serve to guide the surgeon in searching for the arteries, by the more or less salient relief their presence affords beneath the skin.

It is worthy of remark that the arteries are not included in the fibrous sheaths enveloping the muscles; these vessels nearly always occupy, with the nerves which accompany them, special lodgments resulting from the approximation of several aponeurotic sheaths. When they pass through the substance of a muscle, which sometimes happens, they are covered by an arch or fibrous ring, which protects them from compression during muscular contraction: the arch or ring receiving on its convexity the insertion of fibres from the muscle.

d. Nothing is more common than to see the arteries in direct contact with the bones: as, for instance, the aorta, intercostals, &c. Neither is it very rare to find a more or less thick muscular layer between the arteries and portions of the skeleton. In every case, a knowledge of the connections

of the arteries with the bones is important to the surgeon; as it enables him, temporarily, to interrupt the circulation in these vessels by exercising external pressure on the points of their course which correspond to the several bones, and thus diminish their calibre by flattening them.

e. By virtue of their deep situation, the arteries are, in general, distant from the skin; there are, nevertheless, some which course immediately beneath the inner face of that membrane; these are only found about the head and in the extremities.

f. Lastly, all the arteries are enveloped by a layer of connective tissue, which forms around them a kind of sheath, generally difficult to tear with the fingers alone, and which isolates from the neighbouring parts, but chiefly the veins. This connective tissue, more or less abundant according to the regions, is always loose enough to allow the arteries to roll and be displaced with the greatest facility, and thus to glide away from incisive bodies accidentally introduced into the tissues.

Anastomoses.—Very often the arterial branches are united to each other by communications, which have received the name of *anastomoses*, and which assure the distribution of the blood in regulating its flow. There are distinguished:

1. *Anastomoses by convergence:* formed by two vessels joining at their terminal extremity in an angular manner, to form a third and more voluminous trunk.

2. *Anastomoses by arches* or *by inosculation:* due to the junction of two principal branches, which are inflected towards each other, meet, and unite to form a single and curvilinear canal.

3. *Anastomoses by transverse communication:* represented by ramifications thrown transversely between two parallel arteries.

4. *Mixed* or *composite anastomoses:* in which are found a combination of the different types enumerated above.

A knowledge of the anastomoses of vessels is of the highest practical interest; as these communications permit the surgeon, in extreme cases, to tie the principal artery of a region without the latter experiencing any considerable nutritive disturbance; the blood continuing to arrive by the collateral vessels which, at first very small, gradually dilate from the excentric pressure to which their walls are submitted. But these anastomoses, if they offer this immense advantage, have also their inconveniences: we allude to the difficulties experienced in arresting hæmorrhage in wounds of certain organs, owing to the relations of the principal vessel with its communicating collaterals.

Mode of Distribution.—The branches an artery distributes in the neighbouring organs are distinguished as *terminal* and *collateral.* The arterial trunks, after finishing a certain course, divide into several branches—nearly always two, which, as new arteries, continue the primary vessel and take the name of *terminal branches*, because they really begin at the terminal extremity of that vessel.

The *collateral vessels* originate at various distances along the course of the arteries, and proceed in a lateral direction: these collateral branches increase in number as the arteries become more superficial, the ramifications being particularly abundant around the articulations, and in the organs which are prominent on the surface of the body. This abundance of vessels is intended to maintain a moderate temperature in those parts which, by their structure or situation, are exposed to sudden chills.

The distinction between the terminal and collateral branches of arteries

is not always easy to establish, and is far from having an absolute value; it possesses, nevertheless, some importance, as it greatly facilitates description.

TERMINATION.—The arteries terminate in the substance of the tissues by extremely fine and numerous ramuscules, which so frequently anastomose with each other as to form a plexus or microscopical network, whose meshes

Fig. 266.

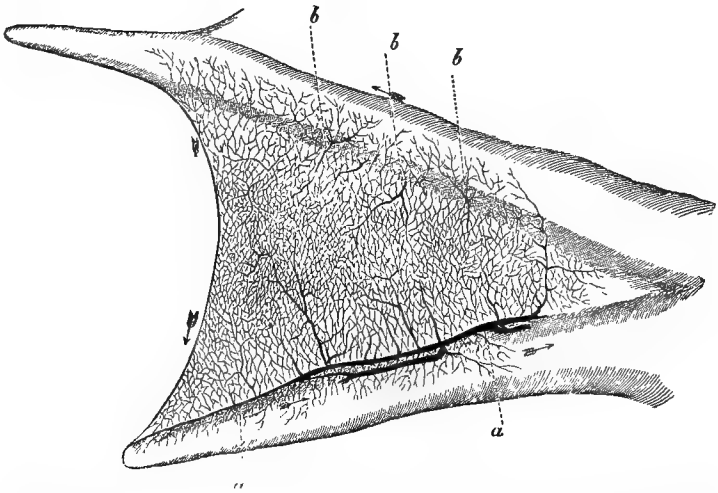

WEB OF FROG'S FOOT STRETCHING BETWEEN TWO TOES, SHOWING THE BLOOD-VESSELS AND THEIR ANASTOMOSES.

a, *a*, Veins; *b*, *b*, *b*, Arteries, the capillaries being between.

are very close. These ramuscules constitute the *capillary system*, which again gives rise to ramifications of gradually increasing size, the *veins*. The capillary system is, therefore, nothing more than a network of microscopical canals intermediate to the arteries and veins.

Fig. 267.

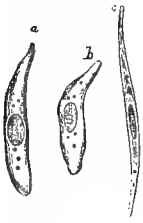

EPITHELIAL CELLS OF BLOOD-VESSELS.

a, *b*, From a vein; *c*, From an artery, Magnified 350 diameters.

In the erectile tissues, the mode of termination is different: the small arteries sometimes opening directly into the cells placed at the origin of the veins, without passing through a capillary plexus. In describing the genital organs we shall notice, in detail, the termination of the arteries in the cavernous tissues.

STRUCTURE.—The walls of arteries offer a certain rigidity, which permits these vessels to remain open when they are emptied of blood. The ancients believed this was their normal condition, and that they were filled with air during life. This was a grave error, as a perfect vacuum exists throughout the entire circulatory system. The gaping of the arteries must be attributed solely to the physical properties of their walls.

These walls comprise three superposed tunics: an *internal*, *middle*, and *external*.

The *internal tunic* is continuous with the endocardium of the left heart

on the one part, and on the other with the capillaries and veins. For a long time it has been assimilated to a serous membrane, but it has not absolutely the same texture. It is composed of a simple epithelial layer which is in contact with the blood, and is formed by fusiform cells that slightly bulge in the situation of their nucleus. These cells sometimes become detached, and are carried about in the nutritive fluid, in which, after a certain period, they resemble more or less mis-shapen blood-globules. The epithelium lies upon a layer of amorphous elastic tissue, perforated by openings, and named the *fenestrated membrane;* on its external face are proper elastic fibres passing in a longitudinal direction.

Fig. 268.



FENESTRATED MEMBRANE FROM THE CAROTID ARTERY OF THE HORSE. Magnified 350 diameters.

The *middle tunic* is remarkable for its thickness, its elasticity, and the yellow colour it offers in the principal vessels. It is composed of a mixture of elastic fibres, as well as smooth muscular fibres, the first constituting a kind of network, in the meshes of which the contractile fibres are disposed in a circular manner around the vessels. The proportion of these two elements varies with the size and situation of the artery. In the large trunks, such as the aorta, the elastic is more abundant than the contractile; in the middle-sized vessels they are about equal; but in the small arteries, in which the contractile force of the heart is lost because of their distance from it, the muscular fibres almost exclusively compose the middle tunic.

Fig. 269.

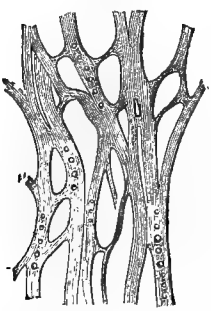

NETWORK OF COARSE ELASTIC TISSUE FROM MIDDLE COAT OF PULMONARY ARTERY OF THE HORSE, THE FIBRES BEING PIERCED WITH CIRCULAR OPENINGS. Magnified 350 diameters.

The *external tunic* is only a layer of connective tissue, with some longitudinal reticulated elastic fibres in its deeper part. Though this tunic is very thin, yet it is strong; as a ligature tied tightly around an artery will rupture the other tunics, but not this.

Fig. 270.

TRANSITION OF A MINUTE ARTERY OF THE BRAIN INTO CAPILLARY VESSELS.

1, Minute artery; 2, Transitional capillary; 3, Coarse capillary with thick coat, represented by *a* double contour line; 4, Fine capillary, with single contour. The nuclei are seen widely scattered in 4 and 3; more closely congregated in 2; and still more so in 1, where they form an epithelium.—*a*, Transverse elongated nuclei of muscular cells, the incipient muscular coat of the artery.

The structure of the *capillaries* is not the same as that just described, but is modified in proportion as they are fine. In the smallest capillaries, the walls are formed by a thin amorphous membrane, in which (oblong) nuclei are somewhat regularly disseminated; in medium-sized vessels, another layer containing transverse nuclei is observed; and in the largest capillaries—those immediately succeeding the small

arteries, these two nucleated layers are enveloped by a thin tunic of connective tissue.

(Some authorities state that the walls of the very finest capillaries are merely composed of closely-adhering cells, without any basement membrane, which only becomes apparent in tubes of a large diameter.)

Vessels and nerves—The arteries are provided with vessels termed *vasa vasorum*, which are furnished either by the arteries themselves, or by neighbouring vessels. These vasa vasorum form a superficial network with quadrilateral meshes, and a deep plexus whose principal branches are helicoidal. The majority of anatomists believe that this plexus does not extend beyond the external tunic.

The lymphatic vessels maintain intimate relations, in certain regions, with the capillaries. In the brain and spleen there has been discovered, around the arterial capillaries, a vessel that completely envelops them, and which has been named the *lymphatic sheath.*

The *nerves*, designated *vasa motors*, accompany the vessels and penetrate the muscular tunic, for which they are naturally destined. These vasomotor filaments join the branches of the capillary plexuses, and form, at the points where they meet each other, ganglionic enlargements, from which arise the fibres of Remak, the termination of which is unknown.

Anomalies in the Arteries.—In their arrangement, the arteries very often present anomalies which the surgeon should be guarded against. These usually belong to their number, their point of origin, and their volume. In a purely anatomical and physiological point of view, however, these anomalies are of no moment; as it matters little whether the blood comes from one source rather than another, or that a collateral vessel becomes the principal at the expense of the parent trunk, provided its relations are not altered, and the principle of immutability of connections is maintained.

Preparation of the Arteries.—This requires two successive operations: 1, Injection; 2, Dissection.

Injection of the arteries.—The object to be attained in injecting these vessels, is to introduce into their interior a solidifiable substance which will cause them to assume the volume and conformation they presented during life, when they are filled with blood.

Tallow, coloured by lamp-black, is the most convenient and general injecting material. Sometimes a solution of gelatine, with the addition of a certain quantity of plaster of Paris, is used; but this is seldom employed in the French schools. A copper or brass syringe, and a canula with a stop-cock to fit on its extremity, are the only instruments necessary to propel these matters into the arteries.

The following are the details of the operation, when it is desired to make a general injection:—The animal being placed on a table, the carotid artery is exposed by an incision in the jugular channel, and opened longitudinally.[4] A ligature is applied above the opening, and the tube, with the stop-cock, is firmly fixed in the cavity of the artery towards the heart by a second ligature. The injection, previously prepared, is taken up by the syringe, which is fitted into the tube, and the piston pushed, in order to drive the contents of the instrument into the arterial canals.

To perform the operation successfully, the following precautions are to be attended to: 1. Inject the vessels of an animal killed by effusion of blood, and yet warm. 2. If suet is employed, and which is always to be recommended, make it so hot that the finger can scarcely endure it. When it is colder than this it solidifies too quickly, and when hotter it shrivels up the sigmoid valves, passes into the left ventricle, and from thence into the auricle and pulmonary veins; an accident generally attributed to the too powerful force applied to the piston of the syringe. 3. Do not make any undue pressure on the piston, though this does not strain the sigmoid valves so frequently as is believed. 4. Cease injecting when the arteries react, by their elasticity, on the piston, so as to drive it back in the syringe.

In order to insure the retention of the injected matter in the arteries, and prevent the sigmoid valves being forced a cork may be introduced into the aorta through the

left ventricle, and firmly tied there by a strong ligature; the cork should have a transverse notch for the reception of the ligature.

Instead of injecting by the carotid, a long curved canula may be fixed to the aorta itself, after making an opening in the left side of the chest, on a level with the heart, by the ablation of two segments of the ribs, and incising the pericardium and left auricle to introduce it. This mode allows the tallow to be injected at a very high temperature, and gives the best results, for it can then penetrate to the capillaries, if we only know how to manage it; in certain organs the injected matter may even be made to return by the veins.

But no matter what procedure may be adopted, there are several parts into which the tallow can never be made to enter by a general injection: these are the four extremities. So that a special operation must be resorted to, in order to fill their vessels. After separating them from the trunk, by sawing them through above the knees and hocks, they should be allowed to steep for two hours in water, constantly kept up to a temperature of 140° to 160° Fahr. at most; it is then easy to inject them, either by the posterior radial artery, or the anterior tibial, after tying those branches which may be open at the cut extremity of the limbs.

If it is desired to make partial injections in other parts of the body, it will be better not to separate them from the trunk; but only to tie those vessels which anastomose between the arteries to be filled and those which are not. For example, to inject the arteries of the head, it suffices to push the mixture into one of the common carotids, after ligaturing the other in the middle of the neck, and both vertebrals in the space between the two portions of the scalenus muscle.

We may give the tallow more fluidity, and a higher degree of penetration, by mixing with it a little spirits of turpentine; or more consistence, in adding to it a small proportion of beeswax.

The two following mixtures are borrowed from Cruveilhier's Anatomy:—

Tallow	9 parts
Turpentine	1 „
Ivory Black, mixed with spirits of turpentine .	2 „

For preservative injections:—

Beeswax	1 part
Tallow	3 „
Vermilion, indigo, or Prussian blue, previously mixed in spirits of turpentine	A sufficient quantity.

Of course it is well understood that these instructions are only intended for the dissecting-room injections necessary for the study of descriptive anatomy. To inject the capillaries, it is requisite to have recourse to other substances and other procedures. Suffice it to say that these injections are made with cold fluids, such as varnish, alcohol, or spirits of turpentine, holding in suspension extremely fine colouring matter, gum arabic dissolved and coloured by a substance also in solution, etc., or, better still, colours rubbed up in oil, and mixed with spirits of turpentine.

Dissection of the arteries.—There are no general rules to be given for the dissection of arteries.

CHAPTER II.

PULMONARY ARTERY (Fig. 258, *e*).

Preparation.—The pulmonary artery is not filled by the general injection mentioned above. It is directly injected by propelling the tallow into the right heart by the anterior vena cava, after tying the posterior vena cava.

The *pulmonary artery* springs from the infundibulum of the right ventricle, is directed upwards and then backwards, describing a curve whose concavity is infero-posterior, and arrives above the left auricle, where it divides into two secondary arteries, one for each lung. These arteries enter the pulmonary tissue with the bronchi, and exclusively ramify in it.

The pulmonary artery accompanies the trunk of the aorta on the right side, and is enveloped with it in a serous sheath, a dependency of the visceral layer of the pericardium. At its origin, it is flanked before and behind by

the appendages of the auricles and the cardiac vessels. About the middle of its course, it is united to the posterior aorta by means of a yellow elastic fibrous cord (the *ligamentum arteriosum*), the remains of the ductus arteriosus which, in the fœtus, establishes a large communication between these two vessels (Fig. 258, *e*).

The walls of the pulmonary artery are much thinner than those of the aorta, and are yellow and elastic, as in the other canals of the same order. We remember, however, having seen them in an Ass, formed almost entirely of red muscular fibres, analogous to the fasciculi of the heart.

It may be repeated that the pulmonary artery conveys into the lungs the dark blood carried to the right heart by the veins of the general circulation.

CHAPTER III.

THE AORTA.

If we take a general survey of the aortic trunk, we will find that it arises from the base of the left ventricle, ascends to beneath the dorso-lumbar column, curving backwards and downwards, and reaches the entrance to the pelvis, where it terminates by four branches. It furnishes, besides, about 2 to 2½ inches from its origin, a secondary trunk, which soon divides into two new arteries, the right and largest of which gives off a particular trunk, the common origin of the two long vessels destined for the head.

This disposition permits us to recognise in the aorta seven principal sections:

1. The *aortic trunk* or *common aorta:* the source of all the arteries belonging to the red-blood system, and giving rise to the anterior and posterior aorta. It only furnishes blood directly to the heart itself.

2. The *posterior aorta:* the veritable continuation of the common aorta, is distributed to the posterior moiety of the trunk and to the abdominal limbs; it terminates by a double bifurcation.

3. The *internal* and, 4, *external iliac arteries:* branches of this bifurcation which are almost entirely expended in the posterior limbs.

5. The *anterior aorta:* the smallest of the two trunks furnished by the common aorta, is chiefly destined to the anterior moiety of the trunk and the thoracic limbs.

6. The *axillary arteries*, or *brachial trunks:* these come from the bifurcation of the preceding artery, and are continued by their terminal extremity into the fore-limbs.

7. The *carotid arteries*, or arteries of the head: these emanate by a common trunk from the right brachial bifurcation.

Article I.—Aortic Trunk or Common Aorta.

The point of departure for all the arteries carrying red blood, the aortic trunk proceeds from the left ventricle by becoming continuous with the festooned fibrous zone which circumscribes the arterial orifice of that cavity. It passes upwards and a little forwards, bifurcating, after a course of 2 or 2½ inches, into the *anterior* and *posterior aortæ*.

Its volume, inferior to that of its two terminal branches, is not uniform; as at its origin, and opposite the sigmoid valves, it presents (an enlargement —the *bulbus aortæ*—caused by) three dilatations described as the *sinus of* the *aorta* (*sinus aortici*, *sinus Valsalvæ*).

Included, on the right side, in the crescent formed by the auricular mass; in relation, on the left side, with the pulmonary artery, which is joined to it by means of cellulo-adipose tissue traversed by the cardiac nerves, the common aorta forms, with the latter artery, a fasciculus enveloped by the visceral layer of the pericardium, which is reflected as a sheath around these two vessels.

Two collateral arteries are given off directly from the aortic trunk: these are the *cardiac* or *coronary arteries.*

Cardiac or Coronary Arteries. (Figs. 258, 259.)

There are two *cardiac arteries*, a right and left, exclusively destined for the tissue of the heart.

Right Cardiac Artery (Figs. 258, 259, L).—This originates from the front and to the right of the aorta, at the free margin of the sigmoid valves, and proceeds perpendicularly, or at a right angle, from the trunk, passing forwards to the right of the pulmonary artery, beneath the anterior auricle; then to the right and backwards, to reach the auriculo-ventricular groove, which it follows till near the origin of the right ventricular furrow. Here it divides into two branches: one vertical, descending in this furrow to the apex of the heart, which it bends round to the front, and anastomoses with an analogous branch of the left coronary artery; the other is horizontal, is smaller than the first, and follows the primitive course of the artery in the auriculo-ventricular groove, also inosculating with the artery of the left side.

Left Cardiac Artery (Fig. 258, 2).—This arises opposite the preceding, at the same angle of incidence, passes behind the pulmonary artery, and divides, under the left or posterior auricle, into two branches similar in every respect to those of the right artery. The vertical branch descends in the left perpendicular furrow; the horizontal is lodged in the coronary groove; and both anastomose with the analogous branches of the opposite vessel.

From this arrangement, it results that the heart is surrounded by two arterial circles: a vertical, or ventricular, which has been compared to a meridian; and a horizontal, or auriculo-ventricular, analogous to an equatorial circle.

In their course, which is more or less tortuous, the coronary arteries throw out a considerable number of ramuscules, which enter the muscular tissue of the heart. The vertical circle gives off branches which are entirely ventricular; while from the horizontal circle come the superior or auricular, and inferior or ventricular branches. Among the latter there is one which, rising from the right artery where it bends at an angle beneath the auricle, enters the substance of the right ventricle by passing round the pulmonary infundibulum; its ramifications anastomose with those of a similar branch from the left artery, and in this way establish another communication between the two vessels.

Article II.—Posterior Aorta.

Course.—This artery is a continuation of the aortic trunk, which it nearly equals in volume, and from which it passes upwards and backwards, describing a curve whose convexity is antero-superior, and which is known as the *arch of the aorta.* It thus reaches the left side of the inferior face of the spine, about the seventh dorsal vertebra, behind the posterior extremity of the longus colli muscle, and is then carried directly backwards, following

the vertebral bodies, though a little to the left at first; it gradually inclines to the right, however, and reaches the median plane at the pillars of the diaphragm. Here it passes through the opening circumscribed by these two pillars, enters the abdominal cavity, and extends to the entrance of the pelvis, under the spine, still preserving its median position. On reaching the last intervertebral articulation, the posterior aorta terminates by a double bifurcation, from which arises the *external and internal iliac arteries.*

Relations.—To facilitate the study of its connections, the posterior aorta may be divided into two sections: one *thoracic*, the other *abdominal.*

a. At its origin or arch, the *thoracic aorta* is crossed to the right by the trachea and œsophagus; on the opposite side, it responds to the pulmonary artery and the left lung. For the remainder of its extent, it is comprised between the two layers of the posterior mediastinum, and through these is in relation with the pulmonary lobes, which are fissured for its reception; this fissure is much deeper in the left than the right lung. Above, it is in contact with the bodies of the last twelve dorsal vertebræ, and is accompanied on the right by the large vena azygos and the thoracic duct; the latter is often carried to the left for the whole or a portion of its extent.

(Remak observed muscular fibres on the external face of the aortic arch and thoracic aorta in the Horse, Sheep, and Pig; the fasciculi they form are so large as to be visible to the naked eye.)

b. The *abdominal aorta*, enlaced by the abdominal nerves of the great sympathetic, corresponds, above, with the bodies of the lumbar vertebræ, the originating tendon of the diaphragmatic pillars, Pecquet's reservoir, and the common inferior vertebral ligament; it passes above the pancreas and the peritoneum, the latter by its sublumbar layer covering the posterior two-thirds of the vessel. On the right, it is accompanied by the posterior vena cava, which perhaps it slightly pushes to the left of the median plane.

Collateral branches.—The arteries emanating from the posterior aorta during its long course, very naturally form two classes; some are designated *parietal*, because they are distributed to the parietes of the great splanchnic cavities; the others are the *visceral branches*, destined for the organs lodged in these cavities.

Among the *parietal branches*, may be noticed:

1. The *intercostal arteries*, furnished by the thoracic aorta.

2. The *diaghragmatic arteries*, whose origin is placed on the limits of the two portions of the vessel.

3. The *lumbar arteries*, and the *middle sacral artery*, springing from the abdominal aorta.

The *visceral branches* are:

1. The *broncho-œsophageal trunk*, emitted by the thoracic portion of the aorta.

2. The *cœliac trunk*, *great mesenteric artery*, *small mesenteric artery*, *renal arteries*, *spermatic arteries*, and *small testicular* or *uterine arteries*, which emerge from the abdominal portion.

Preparation of the posterior aorta and its collateral branches.—Immediately after injecting according to one of the modes recommended at p. 519, place the subject in the first position, the two posterior members being well extended backwards. Open the abdominal cavity, and remove from it the intestines in the manner already indicated. The tallow having become perfectly solidified during these necessary manipulations, dissection may be proceeded with at once. It is requisite, however, to remove the right and left walls of the thoracic cavity beforehand, by sawing through the last fourteen or fifteen ribs at six or seven inches from their superior extremity, and afterwards separating them from the sternum by the saw, taking the precaution of detaching the peri-

pheral insertion of the diaphragm. It is recommended to prepare, from before to behind, the various visceral branches of the vessel; first, the broncho-œsophageal trunk, then the cœliac trunk, next, the great mesenteric artery and the renal arteries, after spreading out the intestinal mass as in figure 271; and, lastly, the small mesenteric and testicular arteries, after arranging the intestines as in figure 272.

PARIETAL BRANCHES OF THE POSTERIOR AORTA.

1. *Intercostal Arteries.* (Fig. 237.)

The *intercostal arteries*, placed, as their name indicates, in the intervals of the ribs, number seventeen pairs.

Origin, Course, and Distribution.—The last thirteen emanate from the thoracic aorta only; the first comes from the cervical artery; and the next three are furnished by a special branch of the dorsal artery.

The aortic intercostals escape at a right angle from the superior plane of the trunk, on a level with the bodies of the dorsal vertebræ, and at regular intervals. Their origin is nearer that of the arteries on the opposite side as they are more anterior, the first two or three arising in pairs from a common trunk.

These aortic intercostals ascend to the vertebral bodies, beneath the pleura, in crossing the direction of the sympathetic nervous chain and (the arteries of the right side only), in addition, that of the vena azygos and the thoracic duct, to the superior extremity of the intercostal spaces, where those of both sides divide into two branches: the one *inferior*, or *proper intercostal;* the other *superior*, or *dorso-spinal.*

The inferior and superior branches of the first four intercostal arteries emanate solely from the trunk which furnishes them, and which is the superior cervical artery for the first intercostal, and the subcostal branch of the dorsal artery for the succeeding three.

Inferior or intercostal branch.—This branch, the most considerable of the two, placed at first beneath the pleura, then between the two intercostal muscles, is lodged, along with a satellite vein and nerve, in the furrow on the posterior face of the rib, and descends to the inferior extremity of the intercostal space, where it terminates in the following manner: the first twelve or thirteen branches anastomose with the intercostal ramifications of the internal thoracic artery and its asternal branch; the others are prolonged into the abdominal muscles, where their divisions communicate with those of the anterior and posterior abdominal arteries, as well as with the circumflex iliac.

In their course, these intercostal branches give arterioles to the pleuræ, the ribs, and the thoracic muscles, with the perforating ramuscules which cross these muscles to ramify in the skin and the panniculus carnosus, but which, of course, are absent where the pectoral wall is covered by the thoracic limb.

Superior or dorso-spinal branch.—This passes directly upwards to be distributed to the spinal muscles of the dorsal region and the integument covering them, after giving off, when passing the intervertebral foramen, a branch which enters the spinal canal by that opening, and is destined for the spinal cord and its envelopes. An auxiliary of the middle spinal artery, this branch will be studied at greater length when the cerebro-spinal artery comes to be described.

Variations in origin.—Not unfrequently the first two pairs of aortic intercostal arteries proceed from a single trunk, which thus gives rise to four branches; and this trunk is also often the common source of these four

intercostals and the bronchial and œsophageal arteries, when its volume is very considerable. It is much smaller when it only gives off the second pair of intercostals, which is sometimes the case.

2. *Lumbar Arteries.*

These are five or six in number, and do not differ in their general arrangement from the intercostal arteries; they having the same mode of origin, the same division into two branches, and the same distribution. The *superior*, or *lumbo-spinal* branch, is much larger than the inferior, and goes to the muscles and integuments of the lumbar region; it also furnishes a branch to the spinal cord. The *inferior branch* passes above the large and small psoas muscles, giving them numerous twigs, and extending to the muscular portions of the transverse and small oblique abdominal muscles, where their ramifications anastomose with those of the circumflex iliac artery.

The last, and sometimes also the second-last lumbar artery, arises from the internal iliac trunk; the others emerge directly from the abdominal aorta.

3. *Diaphragmatic (or Phrenic) Arteries.*

These are two or three small vessels which spring from the aorta as it passes between the two pillars of the diaphragm, and are destined for that muscle. The left pillar receives a very insignificant branch; but the right has two, the most considerable of which is alone constant; it sometimes sends subpleural ramuscules to the right lung.

4. *Middle Sacral (Sacra Media) Artery.*

This vessel is often absent, and when it exists is very variable in size, though always extremely slender. It arises from the terminal extremity of the aorta, in the re-entering angle comprised between the two internal iliac arteries, and is carried to the inferior face of the sacrum, where it is expended in lateral ramifications which go to the periosteum. It has been thought necessary to notice this artery, as it attains a considerable volume in Man and some animals, and continues the aortic tree beneath the sacral portion of the vertebral column.

VISCERAL BRANCHES OF THE POSTERIOR AORTA.

1. *Broncho-œsophageal Trunk.*

Destined for the lung, the visceral pleura, the mediastinum, and the œsophagus, this artery arises, not, as is generally said, in the concavity of the arch of the aorta, but opposite to it, and very near, but to the right of, the first pair of intercostals; often even in common with these arteries and with the second pair.[1] After leaving the aorta, it insinuates itself between that trunk and the œsophagus, and above the bifurcation of the trachea divides into branches, the *bronchial arteries.* In its short course, it gives off the two *œsophageal arteries* and a certain number of *innominate ramuscules.*

Bronchial Arteries.—The disposition of these two vessels is extremely simple; they enter the lung with the bronchi, one to the right, the other to the left, and there break up into arborescent ramifications which follow the air-tubes to the pulmonary lobules.

Œsophageal Arteries.—These two arteries are placed in the posterior

[1] *See* Intercostals.

mediastinum, one above, the other below the œsophagus, which they accompany for a short distance, from before to behind, to the extremity of that canal.

The *superior œsophageal artery*, much more voluminous than the inferior, inosculates with a branch of the gastric artery. In its course it gives descending branches to the œsophagus, and ascending ones to the mediastinum.

The *inferior œsophageal artery* also anastomoses with a branch of the gastric; most frequently with that noticed above. It likewise furnishes ascending and descending divisions; the latter, however, going to the mediastinum, and the former to the œsophagus.

Innominate Ramuscules.—The innominate ramuscules of the broncho-œsophageal trunk do not all come directly from it; there being always a certain number which emerge from the bronchial or œsophageal arteries. They are more particularly distributed to the trachea, to that portion of the œsophagus which is in contact with the posterior extremity of this cartilaginous tube, to the bronchial glands, the mediastinum, and the pulmonary pleura. Those destined for the latter form on the surface of the lung, along with the divisions of the pleural branch furnished by the gastric artery, a beautiful plexus.

2. *Cœliac Artery or Trunk (or Axis).*

This artery arises at a right angle from the inferior face of the aorta, immediately on the entrance of that vessel into the abdominal cavity. After a course of from half to three-fourths of an inch at most, in the middle of the solar plexus, and beneath the superior face of the pancreas, this trunk separates into three branches: a middle, the *gastric artery;* a right, the *hepatic artery;* and a left, the *splenic artery.*

1. Gastric Artery (the *coronaria ventriculi* of Man.)—This artery descends on the large tuberosity of the stomach, extends to near the insertion of the œsophagus, and then divides into two branches: the *anterior* and *posterior gastric.* The first passes behind and to the right of the œsophagus, and crossing the small curvature of the stomach, gains the anterior face of that viscus, where it separates into flexuous and divergent branches which run beneath the serous membrane, and are carried more particularly towards the left *cul-de-sac* and around the cardia. The second vessel is distributed in the same manner to the posterior wall of the organ, but chiefly to the right sac.

Independently of these two arteries, the gastric trunk gives off a third and constant branch, which often comes from one of the two branches of this trunk, and sometimes also from the cœliac artery itself, or from the splenic. This branch accompanies the œsophagus, along with the right pneumogastric, crosses the opening of the right pillar of the diaphragm to enter the pectoral cavity, and then divides into two branches, each of which anastomoses with one of the œsophageal arteries, and is then thrown over the posterior extremity of pulmonary lobe, which it covers with a magnificent subpleural reticular arborisation. This gastro-pulmonary artery often anastomoses with the superior œsophageal branch only, and goes exclusively to the right lung; for the left lung and the inferior œsophageal artery, in this case there is a special branch which emanates from the anterior gastric. It is not rare to meet with varieties of another kind, but of which it is not necessary to speak; inasmuch as in these pleural ramifications we find a disposition common to the whole arterial system: distribution almost invariable, origin very inconstant.

2. Splenic Artery.—The largest of the three branches of the cœliac

axis, this artery is directed downwards and to the left, lying beside its satellite vein and the superior face of the left extremity of the pancreas. It reaches the anterior fissure of the spleen in turning round the large tuberosity of the stomach, passes along the entire length of that fissure, and leaving it only near the point of the organ to throw itself into the great omentum, where it is named the *left gastro-omental artery* (or *gastro-epiploica sinistra*).

The splenic artery gives off, during its course, very numerous collateral branches. These are:

1. External or *splenic* ramifications, which immediately enter the substance of the spleen.

2. Internal or *gastric* ramifications, also called the *short vessels* (*vasa brevia*) in Man, which are comprised between the two layers of the gastro-splenic omentum, and go to the great curvature of the stomach, where they nearly always divide into two branches: one which ramifies on the anterior wall of the viscus, the other on its posterior wall. These vessels inosculate with those sent to the membranes of the stomach by the proper gastric artery.

3. Posterior or *omental* twigs of little importance, destined for the great omentum.

Left gastro-omental artery.—This artery follows the great curvature of the stomach to a distance varying with the state of repletion of that viscus, passing between the two layers of the omentum, and inosculating with the right gastro-omental artery. The branches it sends off on its track are descending or *omental*, and ascending or *gastric;* the latter being disposed exactly like the analogous branches emanating directly from the splenic artery.

3. Hepatic Artery.—Applied to the superior face of the pancreas, and incrusted, as it were, in the tissue of that gland, whose anterior border it follows, the hepatic artery is directed from left to right, passes under the posterior vena cava, which it crosses obliquely, reaches the posterior fissure of the liver, and enters it with the vena portæ to become broken up into several branches, whose ultimate divisions carry nutritive blood to the lobules of the liver.

Before reaching that organ, however, the hepatic artery furnishes the *pancreatic branches*, the *pyloric artery*, and the *right gastro-omental artery*.

Pancreatic arteries.—Irregular and very numerous, these branches are detached from the hepatic artery on its passage over the superior face of the pancreas, and plunge into the tissue of that gland, whose arterial blood is chiefly derived from this source.

Pyloric artery.—This vessel arises at the dilatation towards the origin of the duodenum, before the hepatic artery enters the posterior fissure of the liver, and most frequently by a trunk common to it and the right gastro-omental artery. It passes towards the small curvature of the stomach, and sends off branches around the pylorus, which anastomose with the posterior gastric arteries and the right gastro-omental artery.

Right gastro-omental artery (*gastro-epiploica dextra*).—This artery crosses the duodenal dilatation inferiorly and posteriorly, to place itself in the substance of the great omentum; in doing which it passes along the great curvature of the stomach, and anastomoses by inosculation with the left gastro-omental artery. In its course, it throws off omental and gastric branches, which are analogous to those emanating from the latter vessel. Before crossing the duodenum, it also emits a particular branch, designated in treatises on Veterinary Anatomy the *duodenal artery*; this is a somewhat considerable division, which follows the small curvature of the duodenum in

the substance of the mesentery, and joins the first artery belonging to the left fasciculus of the great mesenteric, after furnishing some twigs to the pancreas, and numerous branches to the duodenum.

In terminating the description of the right gastro-omental artery, it may be remarked that the stomach, owing to the anastomoses uniting that vessel with the artery of the left side, is suspended, as it were, in a vertical arterial circle, formed by the splenic and left gastro-omental arteries on the one part, and the hepatic and right gastro-omental arteries on the other—a circle whose concavity sends out on the stomach a great number of divisions, which communicate with the arterial ramuscules proper to that viscus.

3. *Great Mesenteric Artery.* (Fig. 271.)

The great mesenteric artery, which almost entirely supplies the intestinal mass with blood, is as remarkable for its volume as for its complicated distribution. This complexity, together with that of the intestine itself, gives rise to some difficulty in the study of this vessel; but this may be averted by adopting the mode of description, as simple as it is methodical, resorted to in his lectures by M. Lecoq.

The great mesenteric arises at a right angle from the abdominal aorta, at the renal arteries, and at 2 or $2\frac{1}{2}$ inches behind the cœliac trunk, from which it is separated by the pancreas; it is directed immediately downwards, enlaced by the anastomosing nervous branches of the solar plexus, and divides, after a course of from 1 to $1\frac{1}{2}$[1] inches, into *three fasciculi* of branches, which are distinguished as *left*, *right*, and *anterior*. The *left fasciculus* goes to the small intestine; the *right* is distributed to the terminal portion of that intestine, to the cæcum, and to the first portion of the loop or flexure formed by the large colon; the *anterior* is carried to the second portion of that flexure, and to the origin of the small colon. The order in which these three fasciculi have been indicated will also be that followed in their description; it has, as will be observed, the advantage of recalling to the memory the regular succession of the various parts of the intestine, and consequently the passage of the food in this important portion of the digestive canal.

A. Arteries of the Left Fasciculus (Fig. 271, 2).—These arteries number from fifteen to twenty, and are named the arteries of the small intestine (*vasa intestini tenuis*), because of their destination. All spring at once from the great mesenteric artery, either separately, or several in common, and pass between the two layers of the mesentery to gain the intestine. Before reaching the small curvature of that viscus, each divides into two branches, which go to meet corresponding branches from the neighbouring arteries, and to anastomose with them by inosculation; from this arrangement results a series of uninterrupted arterial arches, whose convexity is downwards, and which exist for the whole length of the intestine opposite, and in proximity to, its concavity. From the convexity of these arches emanate a multitude of branches that arrive at the inner curvature of the intestine, and whose divisions pass to each of the faces of that viscus to rejoin and anastomose on its great curvature. These divisions are situated beneath the peritoneum or in the muscular layer, and send the majority of their ramuscules to the mucous tunic, which is therefore distinguished by its great vascularity: a feature common to all the hollow organs in the abdominal cavity.

[1] This trunk of the great mesenteric is usually, in the old horses killed for dissection, the seat of a more or less voluminous aneurism, which sometimes extends to the arterial tube placed at the origin of the branches of the right fasciculus, and it is not unfrequently met with in one or the other section of the great mesenteric artery.

Fig. 271.

Abdominal aorta; 2, 2, 2, Arteries of the left fasciculus, destined for the small intestine; 3, Ileo-cæcal artery; 4, Superior cæcal artery; 5, Inferior cæcal artery; 6, Artery of the arch of the cæcum; 7, Right colic artery; 8, Left colic artery; 9, First artery of the small colon.

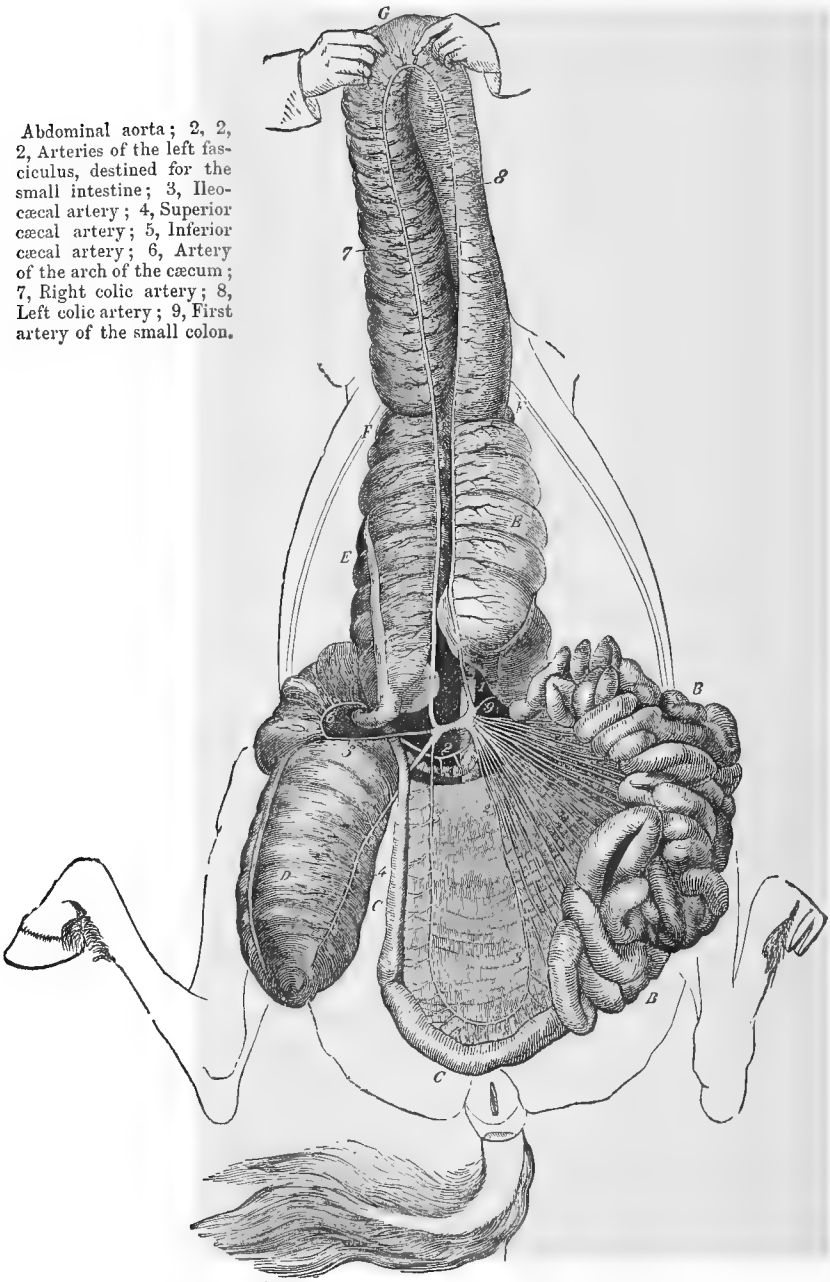

DISTRIBUTION OF THE GREAT MESENTERIC ARTERY.

Such is the general arrangement of the arteries of the small intestine; and it remains to indicate some of their special characters, which are as follows: 1, The longest arteries of the small intestine are the most posterior, as they follow the development of the mesentery, by which they are sustained; 2, The anterior arteries generally form two series of superposed arches, before sending their divisions to the intestine; 3, The first reaches the duodenum and anastomoses with the duodenal artery—a branch given off by the cœliac axis; 4, The last communicates with the ileo-cæcal artery—one of the branches of the right fasciculus.

B. Arteries of the Right Fasciculus.—The right fasciculus of the great mesenteric artery constitutes, at first, a single trunk some inches in length, which soon divides into four branches; these are as follows: the *ileo-cæcal artery*, the *two cæcal arteries*, and the *right* or *direct colic artery*.

Ileo-Cæcal Artery (Fig. 271, 3).—This vessel often has its origin from the internal cæcal artery. It is placed between the two layers of the mesentery, follows for a short distance, and in a retrogade manner, the ileo-cæcal portion of the small intestine, and wholly anastomoses with the last artery of the left fasciculus, after emitting a series of branches, which are distributed to the intestinal membranes.

Cæcal Arteries.—Distinguished into *internal* or *superior*, and *external* or *inferior*, these two arteries pass downward and a little to the right, towards the concavity of the cæcal flexure, embracing between them the terminal extremity of the small intestine, and lying at the middle part of the cæcal sac, whose direction they follow.

The *superior*, or *internal cæcal artery*, is lodged in the most anterior of the fissures formed by the longitudinal bands of the cæcum, and extends beneath the serous tunic to nearly the point of the viscus, where it terminates by anastomosing with the external cæcal artery. The branches furnished by this artery during its course escape in a perpendicular direction, and distribute their ramifications on the walls of the cæcum (Fig. 271, 4).

The *external*, or *inferior cæcal artery*, passes between the cæcum and the origin of the colon, to descend along the first-named receptable by placing itself in one of the external fissures, which is situated outwardly and posteriorly. Arriving at the point of the organ, this artery bends over it to anastomose with the vessel just described (Fig. 271, 7). It gives off on its track a series of transverse ramifications, similar to those of the latter artery; and besides these, a remarkable branch which may be named the *artery of the cæcal arch*. This branch is detached from the principal vessel near the origin of the colon, and ascends to the cæcal arch, whose concavity it follows outwardly to pass forwards and downwards to the initial portion of the large colon, where it disappears after following a certain course. The numerous collateral branches detached by this artery are sent to the walls of the latter portion of intestine, and the arch of the cæcum (Fig. 271, 6).

Right or Direct Colic Artery (Fig. 271, 7).—This is the largest of the branches composing the right fasciculus of the great mesenteric artery. Destined for the right portion of the flexure formed by the large colon, it lies immediately beside that viscus, beneath the peritoneal membrane, following it from its origin to its pelvic curvature, where the artery anastomoses by inosculation with the left colic or retrograde artery.

C. Arteries of the Anterior Fasciculus.—These are only two in number: the *left colic* or *retrograde*, and the *first artery of the small colon*, joined at their origin to an extremely short trunk.

Left Colic or Retrograde Artery (Fig. 271, 8).—This is carried

to the left portion of the colic flexure, which it passes over, beneath the peritoneum, from the terminal extremity of the viscus to the pelvic curvature, where it meets the right artery; in this manner it follows a course the inverse of that pursued by the aliment, and whence its name of *retrograde colic artery*.

Considered collectively, the *two colic arteries* represent a loop or flexure exactly like that formed by the large colon itself. They proceed parallel to each other, and finish, after being slightly separated, by uniting to form a parabolic curve. This arterial loop occupies a deep position on the intestinal loop, being found on the inferior face of the first and fourth sections of the large colon, in the concavity of the flexure which gives rise to the suprasternal and diaphragmatic curvatures, and on the superior plane of the second and third portions of the viscus.

A considerable number of collateral branches escape perpendicularly from this arterial loop, and pass into the membranes of the intestine; some of them establish a transverse communication between the two vessels.

First Artery of the Small Colon (Figs. 271, 9; 272, 4).—This branch, whose calibre is often considerable, is inflected to the left, downwards and backwards, to be placed in the substance of the colic mesentery, very near the lesser curvature of the floating or small colon. It soon meets a branch of the small mesenteric artery, with which it anastomoses by inosculation.

D. Innominate Branches of the Great Mesentery.—These are the twigs sent to the lymphatic glands, supra-renal capsules, mesentery, and pancreas, and whose existence it is sufficient merely to mention. Among those supplied to the pancreas, there is one of somewhat considerable volume.

E. The Anastomoses of the Great Mesenteric Artery.—The multiplicity and calibre of these anastomoses assure, in the most favourable manner, the circulation of the blood in the intestinal mass, which, by reason of its great mobility, is exposed to displacements capable of inducing more or less extensive compression. Not only do these anastomoses unite the different branches destined to the same portion of the viscera, be it the small intestine, the cæcum, or the large colon; but they also establish communications between the great mesenteric artery and the neighbouring trunks, which in case of need can maintain the circulation: as, for example, when the two intestinal arteries are completely obstructed. The blood from the cœliac trunk can really pass from the duodenal artery into the branches of the left fasciculus of the great mesenteric artery: then by the ileo-cæcal artery into the branches of the right fasciculus, and thence into the left colic artery, which, finally, transmits it to the first artery of the small colon, as well as to the arches of the small mesenteric artery. The communication existing between the broncho-œsophageal and the cœliac trunks, through the medium of the œsophageal and gastric arteries, even allows a collateral circulation to be formed, and which would be capable of supplementing the posterior aorta, supposing that vessel tied behind the trunk that distributes blood to the bronchi and œsophagus.

4. *Small Mesenteric Artery.* (Fig. 272.)

This artery carries blood to the small colon and rectum, and arises at a right angle from the inferior face of the abdominal artery, from 4½ to 6 inches behind the great mesenteric. It descends between the two layers of the colic mesentery, and is soon inflected back in describing a curve

upwards, to pass above the rectum; when near the anus, its terminal divisions enter the walls of that intestine.

In its course this artery gives off, at pretty regular intervals, thirteen or fourteen branches, the foremost of which are the largest and longest; they originate from the convexity of the artery—that is from below, and either

Fig. 272.

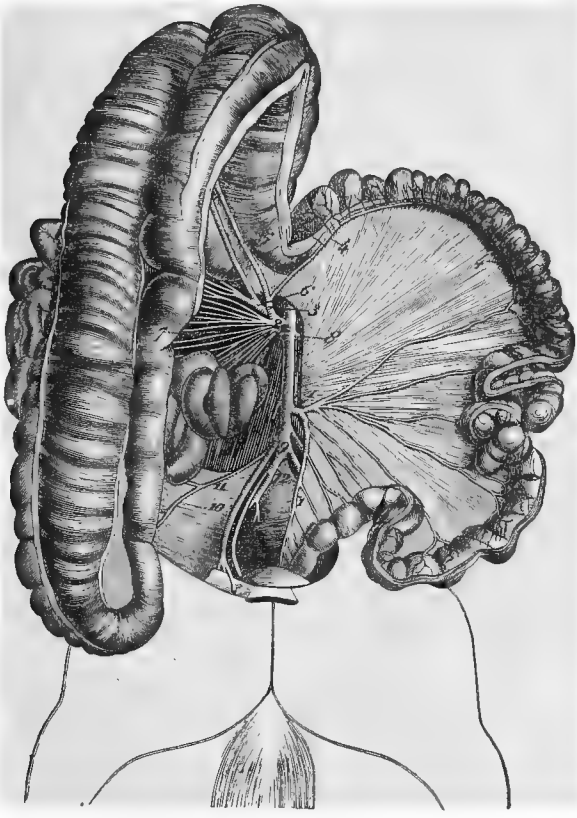

DISTRIBUTION OF THE SMALL MESENTERIC ARTERY; THE SMALL COLON WITH ITS MESENTERY IS SPREAD OUT, AND THE SMALL INTESTINE THROWN BACK TO THE RIGHT UNDER THE LARGE COLON.

1, Trunk of the small mesenteric artery; 2, Great mesenteric artery; 3, Its anterior fasciculus; 4, First artery of the small colon, forming part of that fasciculus; 5, Retrograde colic artery; 6, Right fasciculus of the great mesenteric; 7, Branches of the left fasciculus; 8, Renal artery; 9, Terminal extremity of the aorta; 10, External iliac artery; 11, Circumflex iliac artery; 12, Internal iliac artery.

singly or in clusters; the latter disposition is the most common for the first four or five. They descend into the mesentery and arrive near the superior curvature of the intestine, where they are disposed in the following manner: The first seven or eight bifurcate, and form arches like those of the arteries supplying the small intestine, differing from them only in being nearer the

small curvature of the colon; the other branches, which are destined for the terminal part of that viscus and the rectum, ramify in the intestinal membranes without having previously formed any arches.

The anterior ramuscule of the first branch anastomoses directly with the artery sent to the small colon by the great mesenteric, and from this anastomosis results the first colic arterial arch.

5. *Renal or Emulgent Arteries.* (Fig. 275, 2.)

These are two arteries, one for each kidney, detached laterally, and at a right angle, from the abdominal aorta, near the great mesenteric artery; passing outwards to the internal border of these organs, each divides into several branches, which enter the gland either by its notch or by its inferior face. Reaching the interior of the kidney, these branches subdivide, and form a network of large vessels placed on the limit between the cortical and medullary substances, from which a multitude of ramuscules are given off, and pass almost exclusively into the tissue of the cortical portion. (See the description of the kidneys.)

The right renal artery, longer than the left, passes between the small psoas muscle and the posterior vena cava, to reach the right kidney. Both arteries are in relation with the posterior extremity of the supra-renal capsules.

Remarkable for their relatively enormous volume, when compared with that of the glands receiving them, these arteries do not, before penetrating the proper tissue of the kidneys, give off any but a few unimportant ramuscules, the principal of which proceed to the supra-renal capsules (Fig. 275). Other twigs from the great mesenteric artery, or even from the aorta itself, also supply these small bodies. It is not unusual to find the kidneys receiving vessels from the arteries in their vicinity. Thus, we have seen an artery from the external iliac pass into a kidney by its lower face; and we have also observed an artery, detached from the aorta along with the great mesenteric, enter the kidney by its anterior border.

6. *Spermatic Arteries.*

These arteries differ in the male and female; in the male they are also named the *great testicular arteries;* in the female they are exclusively designated as the *utero-ovarian arteries.*

Great Testicular Artery (Fig. 275, 3).—This arises close to the small mesenteric artery, either before, behind, or to one side of it, but rarely on the same level as the artery of the opposite side; it is then directed backwards and downwards, sustained, with its satellite vein, in a particular fold of peritoneum, and reaches the entrance to the vaginal sheath (internal abdominal ring), into which it is seen to pass with the other constituent portions of the spermatic cord, and to descend on the testicle by forming remarkable flexuosities united in an elongated mass. Arrived within the head of the epididymis, this artery insinuates itself under the tunica albuginea, becomes incrusted, as it were, in its substance, and successively passes round the superior border, posterior extremity, and the inferior border and anterior extremity of the testicle. In this course it is very sinuous, and detaches at a right angle a large number of equally flexuous branches, which creep over the faces of the organ while sending numerous ramuscules into its structure. The epididymis also receives its blood by this artery.

Utero-ovarian Artery.—The origin of this vessel is conformable with that of the preceding artery. It is placed between the two laminæ of the broad ligament, and soon bifurcates into the *ovarian* and *uterine arteries*. The *ovarian* branch describes numerous flexuosities, like the corresponding artery in the male, and comports itself on the ovary in the same manner as the latter vessel does on the testicule. The *uterine* branch passes to the cornu of the uterus, where its divisions anastomose with the proper uterine artery.

7. *Small Testicular Arteries: Male. Uterine Arteries: Female.*

Small Testicular Artery (Cremasteric Artery, Artery of the Cord).—A pair, like the great testicular artery, this vessel is very slender, and originates either from the aorta between the internal and external iliacs, or from the latter, near its commencement. The last being the most common, it is usual to describe it as a collateral branch of the crural (external iliac) trunk. We have regarded it as an artery emanating directly from the posterior aorta, in order to include its description with that of the great testicular and the utero-ovarian arteries.

Whatever may be its mode of origin, it gains the entrance to the vaginal sheath, and enters it with the spermatic vessels, to be distributed to the various parts constituting the cord. Before penetrating the substance of this cord, it gives off several ramuscules destined for the peritoneum, iliac glands, ureter, and deferent canal.

Uterine Artery.—This has the same point of origin as the preceding, its analogue, but differs from it in its larger volume. It is placed between the two layers of the lumbar ligament, and is divided into two branches on arriving at the small curvature of the uterine cornu: the anterior branch anastomoses by its divisions with the utero-ovarian artery; the posterior passes to the body of the matrix, where it communicates with the vaginal artery.

DIFFERENTIAL CHARACTERS OF THE POSTERIOR AORTA AND ITS COLLATERAL BRANCHES IN OTHER THAN SOLIPED ANIMALS.

1. *Posterior Aorta in Ruminants.*

The artery pursues the same course as in Solipeds, and also terminates by four branches, towards the entrance to the pelvic cavity.

Parietal Branches.—The *intercostal arteries* only differ from those of the Horse in their number; as but twelve are met with, of which eight or nine alone are furnished by the posterior aorta.

The *lumbar* and *diaphragmatic branches* are absolutely identical, in their disposition, with the analogous arteries of Solipeds.

The *middle sacral artery* is more considerable in volume, particularly in the *Sheep* and *Goat*. This will be referred to hereafter (see *internal iliac artery* of Ruminants).

Visceral Branches.—*Broncho-œsophageal trunk.*—This offers nothing particular.

Cœliac trunk (Fig. 273, 1).—This artery descends on the rumen, a little behind the insertion of the œsophagus, is directed to the right, and divides near the omasum into two terminal branches—the *superior* and *inferior arteries of the omasum and abomasum.*

The collateral branches escaping from this trunk are:

1. Several *diaphragmatic arteries.*
2. The *splenic artery*, almost exclusively destined for the spleen (Fig. 273, 8).
3. The *superior artery of the rumen*, always arising from a very short trunk common to it and the preceding vessel, is carried backward to the superior face of the rumen, and from this descends between the two conical vesicæ to anastomose with the artery of the inferior face of the viscus (Fig. 273, 2).
4. The *inferior artery of the rumen*, which is insinuated between the two anterior *culs-de-sac*, and afterwards runs along the inferior face of the organ, passing towards the notch separating the two conical vesicæ, to meet the superior vessel (Fig. 273, 3).

5. The *artery of the reticulum*, having usually a common origin with the inferior artery of the rumen, and passing forward on the left of the œsophagus, to be divided, near the insertion of that conduit, into two branches: one, the *superior*, inclines to the right to the small curvature of the viscus (Fig. 273, 5); the other, the *inferior*, occupying the fissure separating the great curvature of the reticulum from the right sac of the paunch, and giving to the latter organ a great number of branches (Fig. 273, 4).

6. The *hepatic artery*, which is not only distributed to the liver, but also furnishes a branch for the gall-bladder, and a duodenal artery breaking up into two branches: the posterior branch forming with the first artery of the small intestine an arching anastomosis; the anterior communicating with the superior artery of the omasum and abomasum. This hepatic artery always originates between the trunk common to the splenic artery and the superior branch of the rumen, and that which gives rise to the superior branch of the same viscus and the artery of the reticulum.

The terminal branches of the cœliac artery comport themselves as follows:

1. The *superior artery of the omasum and abomasum* passes successively to the great curvature of the first of these reservoirs, and to the concave curvature of the second; then it goes beyond the pylorus to unite with the duodenal branch of the hepatic artery by inosculation (Fig. 273, 6).

Fig. 273.

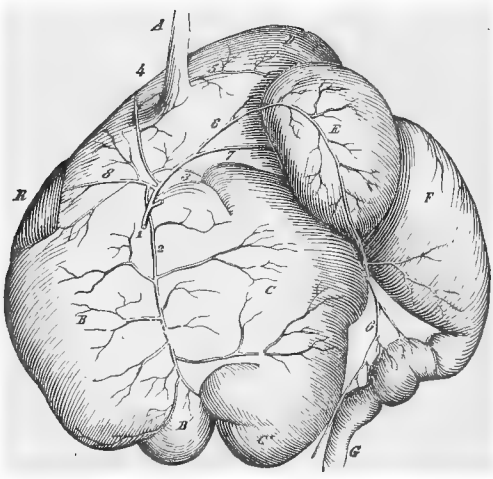

ARTERIES OF THE STOMACH IN RUMINANTS.

1, Cœliac trunk; 2, Superior artery of the rumen; 3, Inferior artery of the rumen; 4, Inferior artery of the reticulum; 5, Superior artery of the reticulum; 6, Superior artery of the omasum and abomasum; 7, Inferior artery of ditto; 8, Splenic artery; A, Œsophagus; B, Left sac of the rumen; B′, Left conical vesica; C, Right sac of the rumen; C′, Right conical vesica; D, Reticulum; E, Omasum; F, Abomasum; G, Duodenum; R, Spleen

2. The *inferior artery of the omasum and abomasum*, on the contrary, passes at first over the small curvature of the omasum, afterwards the great curvature of the abomasum, and disappears in the omentum, to which on its course it furnishes a great number of branches (Fig. 273, 7).

In small Ruminants, the distribution of the arteries of the cœliac trunk presents some modifications. We will cite the principal, which belong to the mode of origin of the two branches destined for the reticulum: these branches form two particular vessels which arise singly from the cœliac trunk; the inferior artery at the same point as the superior artery of the rumen, the superior towards the terminal bifurcation of the trunk.

Great mesenteric artery.—Its origin approaches very closely that of the cœliac trunk. After a course of from 6 to 8 inches, it divides into two branches—an anterior and a

posterior. The first, destined for the small intestine, creeps above it, between the two layers of the mesentery, and passes backward by describing a curve which gives off from its convexity—that is, below, a great number of branches, analogous in their mode of termination to the arteries of the small intestine in the Horse. The posterior branch goes to the large intestine, where it separates into two principal branches: one which passes to the colon, and whose divisions cross to the right, from before to behind and from above to below, the convolutions described by that viscus; another which reaches the concave curvature of the cæcum, and anastomoses by an arch with the terminal extremity of the parent-branch of the arteries supplying the small intestine.

Small mesenteric artery.—Very short and narrow.

Renal, spermatic, and small testicular arteries.—These do not differ in their essential disposition from the analogous vessels in Solipeds.

2. *Posterior Aorta in the Pig.*

With the exception of the mesenteric vessels, whose distribution resembles that already indicated for Ruminants, and with the exception, also, of the middle sacral artery, which will be alluded to when describing the internal iliac arteries, all the branches given off by the posterior aorta comport themselves almost as in the Horse.

3. *Posterior Aorta in Carnivora.*

In these animals, as well as in the Pig, the denomination of posterior aorta is not justifiable, because the arteries of the head and thoracic limbs spring directly from the aortic arch.

The branches of the aorta are distinguished as parietal and visceral.

A. Parietal Branches.—Beyond the fourth space, the *intercostal arteries* are furnished by the aorta: the first is voluminous, and throws off some considerable filaments to the muscles of the withers. The first two *lumbar arteries* arise from the thoracic portion of the aorta, because of the very backward insertion of the diaphragm; the third is detached between the two pillars of that partition. In the abdominal cavity, close to the great mesenteric, the aorta gives off a branch that soon divides into two: one is *diaphragmatic*, and descends on the posterior face of that muscle; the other reaches the sublumbar region, passes over the psoas muscle, and traverses the abdominal wall in the vicinity of the transverse processes of the lumbar vertebræ. We will speak presently of the *middle sacral.*

B. Visceral Branches.—I have not found in the *Dog* any special *bronchial arteries;* but there are four or five *œsophageal arteries* that arise from different points of the thoracic aorta; they descend into the mediastinum, to the right and left of the œsophagus, to which they are distributed. They furnish branches that accompany the bronchi and enter the lungs.

The *cœliac trunk* is again divided into three branches, whose disposition is as follows: The *gastric*, or *stomachic coronary artery*, does not divide into two branches (anterior and posterior gastric) as in Solipeds. Near its origin it furnishes a pancreatic branch; then it expends itself in a great number of filaments that are spread over the posterior face and great tuberosity of the stomach, or over its anterior face after crossing the small curvature.

The *splenic artery* reaches the spleen at the middle of its upper border. It gives on its course: 1, A splenic branch that enters the upper extremity of that organ; 2, The left gastro-omental. The *hepatic artery* provides the principal hepatic vessel at the posterior fissure of the liver; it is then continued by the right gastro-omental artery. On the duodenum, the latter gives origin to the pyloric and the pancreatico-duodenal branches; the latter is voluminous, is lodged in the substance of the pancreas, and anastomoses by its last filaments with the great mesenteric.

The *great mesenteric artery* arises in the vicinity of the cœliac artery; it forms a curve whose convexity is backward, and anastomoses by its extremity with the pancreatico-duodenal branch of the hepatic. From its convexity are detached several filaments (filaments to the small intestine), that form arches towards the smaller curvature of that viscus. Behind, and at a short distance from its origin, it gives a branch to the cæcum and branches to the colon; the latter are sometimes large.

The *small mesenteric* commences near the termination of the aorta, and divides into two branches: one passing forward, and the other backward; they form the hæmorrhoidal vessels (see Fig. 209).

There is nothing special to note with regard to the renal and spermatic arteries.

COMPARISON OF THE AORTA OF MAN WITH THAT OF ANIMALS.

The aorta in *Man* offers the same general disposition as in the Carnivora, the trunk being inflected across, to be placed along the body of the dorsal and first lumbar vertebræ, where it terminates in the iliac vessels.

It furnishes the *coronary arteries*, the arteries of the head and thoracic members—which will be noticed hereafter; and the parietal and visceral branches to the chest and abdomen. At first these are the *intercostals*, beyond the third space; the *diaphragmatic arteries*, superior and inferior according as they occupy one or other face of the diaphragm; and, lastly, the *lumbar arteries*.

Among the visceral branches are distinguished: 1, The *bronchial arteries*, two in number; the left arises from the concavity of the aortic arch, and enters the lungs with the left bronchus; the right originates alone or in common with the preceding, and enters on the right bronchus; 2, The *œsophageal arteries* disposed somewhat as in the Dog; 3, The *cœliac trunk*, whose distribution is nearly identical with that of the Carnivora; 4, The *superior* or *great mesenteric*, disposed in arches as in the Dog (see Fig. 276, 9). Its last branches pass to the cæcum, and the ascending and origin of the transverse portion of the colon; 5, The *inferior* or *small mesenteric*, which arises 1½ to 2 inches from the bifurcation of the aorta; this artery descends into the meso-colon, and terminates on the sides of the rectum by the hæmorrhoidal vessels; to the left, they emit branches to the large intestine; the first ascend along the descending colon, and anastomose on the transverse colon with the right colic branch of the superior mesenteric; 6, The *renal* and *capsular arteries*, which do not offer important differences; 7, Lastly, the *spermatic arteries*, which are remarkable for the length of their course, commencing, as they do, at the aorta, a short distance below the renal vessels

Article III.—Internal Iliac Arteries or Pelvic Trunks. (Fig. 277, 2.)

The two internal iliac arteries represent the middle or internal branches of the quadrifurcation formed by the posterior aorta at its terminal extremity.

Extending from the body of the last lumbar vertebræ, to near the terminal insertion of the small psoas muscle, in an oblique direction downwards, outwards, and backwards, these arteries correspond: in front, with the trunks of the common iliac veins, which separate them from the external iliacs; inwards, to the peritoneum; above and outwards, to the sacro-iliac articulation and to the ilium.

In its course, the internal iliac artery emits the following branches: the *umbilical artery*, *artery of the bulb*, *ileo-lumbar*, *gluteal*, and *subsacral arteries*. At its terminal extremity, it is divided into two branches which ride on the superior border of the tendon belonging to the small psoas muscle: the one within, the other without that tendon. The first is the *obturator artery*, the second the *ileo-femoral artery*. All these branches will be studied in the order of their enumeration.

Preparation of the internal iliac artery.—Place the subject in the first position; remove one of the posterior limbs, leaving the rectum and bladder in the pelvis, and slightly inflating the latter organ. Dissect, on the side from which the limb has been removed, the origin and visceral ramifications of the branches furnished by the trunk of the artery. Follow, on the opposite side, the ramifications given off by these branches to the muscles. To conveniently prepare the coccygeal arteries, it is necessary, after removing the great sciatic ligament and dissecting the internal artery of the bulb along with the subsacral trunk, to raise up the rectum and bladder by means of the chain-hooks.

Umbilical Artery. (Figs. 274, 5; 277, 3.)

This artery forms a considerable vessel during fœtal life, and carries the blood of the fœtus to the placenta; it will be described in detail in the anatomy of the fœtus.

In the adult it is almost entirely obliterated, appearing only as a fibrous cord extending from the internal iliac artery to the fundus of the bladder, and placed at the free margin of the lateral serous fold detached from the

cul-de-sac of that organ. This cord throws off on its track, one or more *vesical branches*, beyond which its canal altogether disappears. These

Fig. 274.

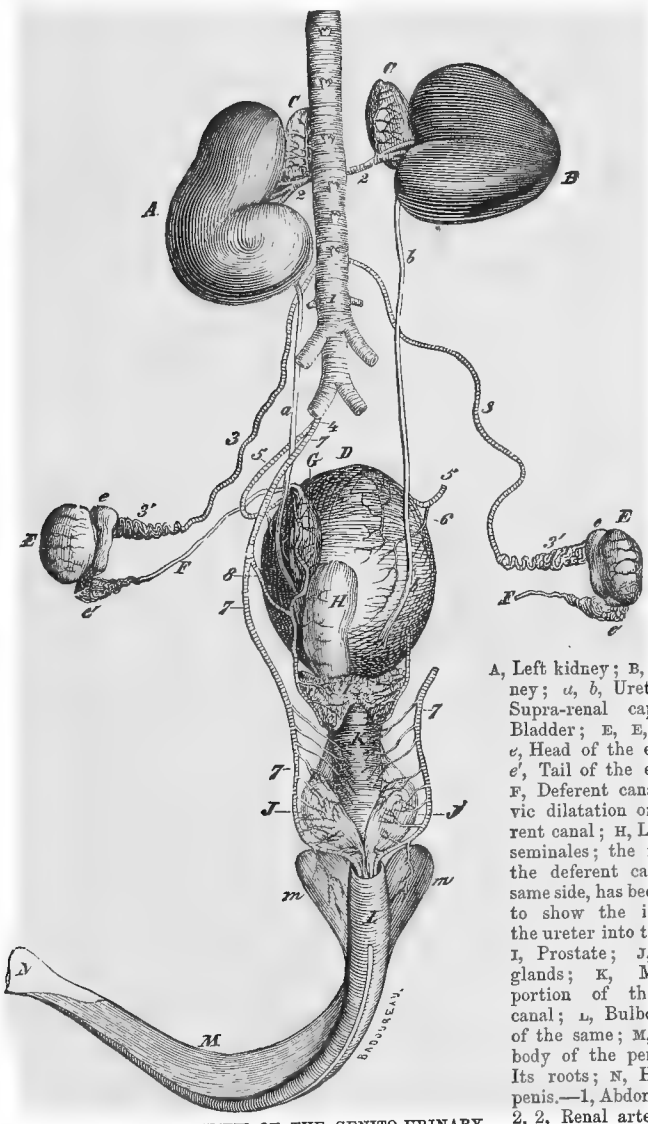

UPPER AND GENERAL VIEW OF THE GENITO-URINARY APPARATUS AND ARTERIES IN THE MALE.

A, Left kidney; B, Right kidney; *a*, *b*, Ureters; C, C, Supra-renal capsules; D, Bladder; E, E, Testicles; *e*, Head of the epididymis; *e'*, Tail of the epididymis; F, Deferent canal; G, Pelvic dilatation of the deferent canal; H, Left vesicula seminales; the right, with the deferent canal of the same side, has been removed, to show the insertion of the ureter into the bladder; I, Prostate; J, Cowper's glands; K, Membranous portion of the urethral canal; L, Bulbous portion of the same; M, Cavernous body of the penis; *m*, *m*, Its roots; N, Head of the penis.—1, Abdominal aorta; 2, 2, Renal arteries giving off the principal capsular artery; 3, Spermatic, or great testicular artery; 4, Common origin of the internal pudic and umbilical arteries; 5, Umbilical artery; 6, Its vesical branch; 7, Internal pudic artery; 8, Its vesico-prostatic branch.

vesical branches also, though very rarely, come from the internal artery of the bulb; in which case the obliteration of the umbilical artery is complete.

2. *Internal Pudic Artery, or Artery of the Bulb.* (Figs. 274, 7; 275, 16; 277, 4.)

This vessel differs in its distribution in the male and female.

Internal Pudic Artery in the Male.—It proceeds from the internal iliac, near the origin of that vessel, by a trunk common to it and the umbilical artery; it is then directed backwards, following the superior border of the internal obturator (pyriformis) muscle, and placed either without or within the texture of the great ischiatic ligament. Arrived at the neck of the bladder, it enters the pelvic cavity, lying beside the prostate and Cowper's glands, and is finally inflected downwards, passing round the ischial arch to reach the bulb of the urethra.

In its progress it furnishes:

1. Insignificant ramuscules to the muscle adjoining the sacro-ischiatic ligament.

2. *The vesico-prostatic artery* (Figs. 274, 8; 275, 17). This is a branch constant in its distribution, but variable in its origin. Destined to supply the prostate gland, vesiculæ seminales, the pelvic dilatation of the deferent canal and the canal itself, as well as the bladder, it usually commences near the prostate gland, and passes from behind to before, in a flexuous manner, on the vesiculæ seminales and the deferent canal.

3. Slender ramifications for the pelvic portion of the urethral canal, Cowper's glands, the anus, and the ischio-cavernous muscle (erector penis).

The terminal extremity of the vessel is insinuated beneath the accelerator muscle, and immediately divides into a multitude of ramuscules which enter the erectile tissue of the urethral bulb, where they comport themselves as in all tissues of this kind.

Varieties.—It is not rare to see the artery of the bulb detach, before attaining Cowper's gland, the *cavernous artery*, which then passes round the ischial arch along with the nerve of the penis. Sometimes it only gives off the *posterior dorsal artery of the penis*, a branch of the cavernous.

Distribution of the Internal Pudic Artery in the Female. (Fig. 277, 4.)—This artery terminates, towards the vagina, by rectal, vulvular, vaginal, and bulbous branches; the latter are for the bulb of the vagina. As in the male, it does not give off more than one important branch on its course; this, the *vaginal artery* (Fig. 277, 5) is analogous in every respect to the vesico-prostatic artery; its terminal divisions go, not only to the middle portion of the vagina, but also to the body of the uterus, where they anastomose largely with the branches of the uterine artery, and even pass to the bladder and rectum.

The internal pudic artery of the female, as in the male, is liable to numerous variations. It may furnish the cavernous artery, or only the dorsal artery of the clitoris. We have seen the vaginal artery come from the umbilical.

3. *Subsacral or Lateral Sacral Artery.* (Figs. 275, 2; 277, 6.)

Rising within the internal iliac artery, at, or a little behind the lumbo-sacral articulation, lying above the peritoneum, and beneath the sacral foramina and the large nerves passing through them, this vessel is directed backwards and arrives near the posterior extremity of the sacrum, where

it ends in two branches: the *ischiatic* and *lateral coccygeal arteries*, to which must be added the *middle coccygeal artery*, usually emitted by the subsacral vessel of the right side.

Collateral Branches.—The lateral sacral artery distributes on its course several insignificant ramuscules destined for the neighbouring parts, and four spinal branches which enter the vertebral canal by the inferior sacral foramina, and leave it again by the superior, after throwing off some divisions to the posterior extremity of the spinal cord and the nerves of the tail; these branches ramify in the muscles lying on the sacral spine.

Terminal Branches.—1. Ischiatic Artery.—It crosses the ligament of the same name to place itself under the superior extremity of the anterior portion of the long vastus, passes backwards and downwards, and divides into several branches which descend into the substance of the ischio-tibial muscles (semimembranosis and semitendinosis), to beneath the ischial tuberosity. These branches anastomose, by their extremities, with the ascending branches from the the femoro-popliteal as well as with the divisions of the obturator and deep femoral arteries.

2. Lateral Coccygeal Artery.—This vessel represents the continuation of the lateral sacral artery, though not by its volume, which is much less than the ischiatic artery, but in its direction. It proceeds from before to behind, for the whole length of the coccyx, between the rudimentary vertebræ of that region and the depressor muscles of the tail, gradually diminishing in volume, and detaching on its course a series of collateral ramuscules which are expended in the muscles and integuments of the tail.

There has been described a superior lateral artery, a branch of the preceding, and which passes between the elevator muscle of the tail and the superior face of the coccygeal vertebræ; but this artery never exists: the superior coccygeal muscle receives its blood by branches analogous to the spinal branches of the intercostal, lumbar, and sacral arteries, and which emanate from the lateral coccygeal artery at each of the vertebral bodies.

3. Middle Coccygeal Artery.—The origin of this vessel is liable to numerous variations. Ordinarily, it is detached from the right subsacral artery, in common with the lateral coccygeal of the same side. At other times, it escapes from the lateral at 5 or 6 inches from its origin. In a specimen now before us, it arises nearly from the middle of the subsacral artery. And it may also proceed from either the left sacral or the corresponding lateral coccygeal artery.

Whatever may be its point of emergence, this vessel is placed beneath the inferior face of the caudal vertebræ, between the two depressor muscles of the tail, crosses the suspensory ligament of the rectum, and extends to the extremity of the coccyx, distributing ramuscules to right and left, and even below.

4. *Ilio-muscular or Ilio-lumbar Artery.* (Figs. 275, 14; 277, 8.)

Immediately after clearing the inferior face of the lateral angle of the sacrum, and even often before, the pelvic trunk gives off from its external side, and at a right angle, the ilio-lumbar artery, which passes directly outwards, behind the sacro-iliac articulation, between the iliacus muscle and the bony surface covered by it, and emits divisions that proceed to the above-named articulation, as well as to the muscles of the sublumbar region. Near the angle of the haunch, it terminates in several branches, which bend upwards on the external border of the ilium, to penetrate the principal gluteal muscle, or the muscle of the fascia lata (tensor vaginæ femoris.)

5. *Gluteal Artery.* (Figs. 275, 13; 277, 7.)

This, the most voluminous of the branches emanating from the pelvic trunk, arises opposite the preceding, and from 8-10ths of an inch to $1\frac{1}{5}$ inches behind the subsacral. It is immediately reflected on the internal

Fig. 275.

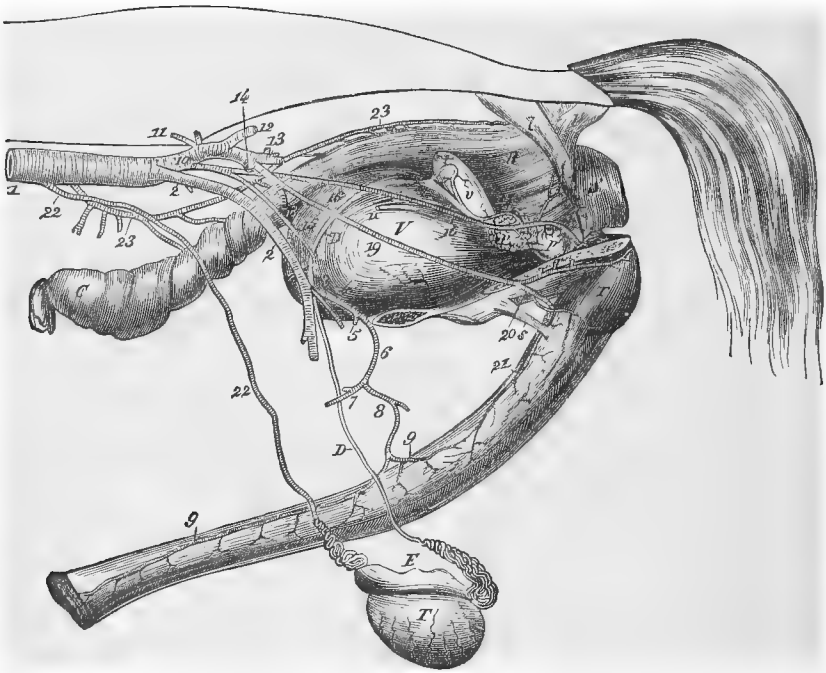

LATERAL VIEW OF THE GENITO-URINARY ORGANS IN THE MALE.

1, Abdominal aorta; 2, External iliac artery; 3, Common origin of the prepubic and deep femoral arteries; 4, Prepubic artery; 5, Posterior abdominal artery; 6, External pudic artery; 7, Subcutaneous abdominal artery; 8, Anterior dorsal artery of the penis; 9, 9, Anterior and posterior branches of that artery; 10, Internal iliac artery; 11, Last lumbar artery; 12, Subsacral artery; 13, Gluteal artery; 14, Iliaco-muscular artery; 15, Umbilical artery; 16, Internal pudic artery; 17, Its vesico-prostatic branch; 18, Iliaco-femoral artery; 19, Obturator artery; 20, Artery of the corpus cavernosum; 21, Posterior dorsal artery of the penis—a branch of the preceding; 22, Spermatic artery; 23, Posterior mesenteric artery; C, Termination of the small colon; R, Rectum; S, Sphincter of the anus; *l*, Suspensory ligament of the penis; *l'*, Suspensory ligament of the rectum; V, Bladder; *u*, Ureter; T, Testicle; E, Epididymis; D, Deferent canal; *v*, Vesiculæ seminales; P, Prostate; *p*, Cowper's gland; *r*, Crus penis; *s*, Ligament of the corpus cavernosum.

border of the ilium, and emerges from the pelvis by the great sciatic notch, along with the anterior gluteal nerves, dividing into several branches which ramify in the texture of the great and small gluteal muscles.

6. *Obturator Artery.* (Figs. 275, 19; 232, 10.)

This vessel, the origin of which has been already indicated, directs its

course backward and downward, accompanied by a satellite vein and nerve, passes beween the peritoneum and ilium in following the inferior border of the internal obturator muscle, and finally insinuates itself beneath that muscle to make its exit from the pelvis by creeping through the oval (obturator) foramen, after furnishing a constant vesical twig. Placed between the external obturator muscle and the inferior face of the ischium, it separates into several branches, the majority of which descend into the internal crural and ischio-tibial muscles (long or external vastus, and the semimembranosis and semitendinosis), anastomosing with the ultimate divisions of the ischiatic and deep femoral arteries. Among these branches there are two or three which go to the roots of the penis, and enter the erectile tissue of the cavernous body; one of them, more important than the others by its volume, is designated the *artery of the corpus cavernosum.*

Artery of the Corpus Cavernosum (Fig. 275, 20).—This vessel creeps on the inferior face of the ischium, backwards and inwards, reaches the crus penis, and pierces it by several branches, after supplying some muscular divisions and the *posterior dorsal artery of the penis.*

The latter is situated on the dorsal margin of the penis, passes forward between the two ligaments attaching that organ to the symphysis pubis, and proceeds to anastomose with the posterior branch of the anterior dorsal artery (Fig. 275, 21.)

7. *Iliaco-femoral Artery* (Figs. 275, 18; 277, 9.)

Noticed as one of the terminal branches of the pelvic trunk, the iliaco-femoral artery only exists as a vessel of a certain volume in Solipeds. In other animals, as in Man, it is merely an insignificant and innominate branch of the obturator artery. It proceeds outside the tendon of the small psoas muscle, between the iliacus and the neck of the ilium, which it passes round obliquely, above the origin of the anterior rectus muscle, to descend on the external side of the latter, and plunge into the mass of the patellar muscles, entering them between the anterior rectus and vastus externus, after sending out some branches to the psoas, gluteal, and muscles of the fascia lata.

DIFFERENTIAL CHARACTERS OF THE INTERNAL ILIAC ARTERIES IN OTHER THAN SOLIPED ANIMALS.

1. *Internal Iliac Arteries of Ruminants.*

The terminal extremity of the aorta, after giving off the external iliac arteries, bifurcates to constitute the pelvic trunks, and in the angle of bifurcation throws out a very large branch—the *sacra media*—from which emanate the arteries of the tail. This, however, is not the only important peculiarity to be noted in the disposition of the pelvic arteries. The internal iliac artery emits at its origin a very short, but very large branch, which divides to form the *umbilical artery*, and an enormous *uterine artery*, that supplants, to a great extent, the utero-ovarian artery; it is then directed backwards, on the internal face of the great ischiatic ligament, crossing the direction of the lumbo-sacral plexus. In its course it furnishes branches resembling the *iliaco-muscular*, the *gluteal*, and the *ischiatic*, and is continued about the middle of the pelvis by the *internal pudic artery*, which terminates by forming the *dorsal artery of the clitoris*, after distributing branches to the rectum and the genito-urinary organs lodged in the pelvic cavity.

It will be seen from this description—which refers only to female animals, but is easily applicable to males—that no mention is made of an *iliaco-femoral* or *obturator artery*. This is because these two vessels are entirely absent in the *Sheep*, and the last, though present in the larger Ruminants, is yet in a very rudimentary state, both being supplemented by the deep femoral, whose dimensions are considerable. Neither is the *lateral sacral* or *subsacral artery* described, as it is also wanting, its *ischiatic branch* coming directly from the pelvic trunk, and its *coccygeal divisions* being supplied by the middle sacral artery.

2. *Internal Iliac Arteries of the Pig.*

Two single branches, originating one above the other, arise from the extremity of the aorta, between the two internal iliac arteries; one divides almost at once into two lateral branches, which go to right and left beneath the iliacus, and are the representatives of the *iliaco-muscular arteries* of the Horse; the other, or *sacra media*, placed in the middle line, proceeds backwards on the inferior face of the os sacrum, and constitutes the *coccygeal arteries*, after giving off, at about 1½ inches from its origin, two lateral branches, traces of the *lateral sacral arteries*, which furnish the spinal ramuscules of the sacral region.

Fig. 276.

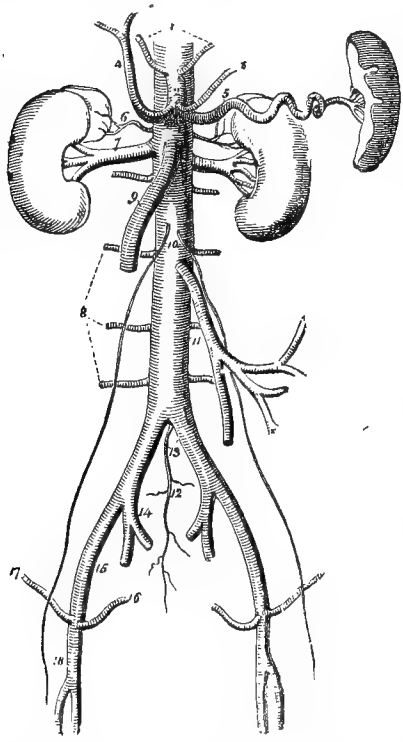

ABDOMINAL AORTA, WITH ITS BRANCHES, IN MAN.

1, Phrenic arteries; 2, Cœliac axis; 3, Gastric artery; 4, Hepatic artery, dividing into right and left hepatic branches; 5, Splenic artery, passing outwards to the spleen; 6, Suprarenal artery of right side; 7, Right renal artery longer than the left, passing outward to right kidney; 8, Lumbar arteries; 9, Superior mesenteric artery; 10, The two spermatic arteries; 11, Inferior mesenteric artery; 12, Sacra media; 13, Common iliacs; 14, Right internal iliac; 15, External iliac; 16, Epigastric artery; 17, Circumflexa ilii; 18, Common femoral artery, dividing into superficial and deep femoral.

The *iliac trunk* near its origin sends off the *umbilical artery*, is directed back towards the great sciatic notch, there detaches gluteal branches, and is prolonged beyond the notch to the external surface of the great ischiatic ligament in forming the *internal pudic artery*.

The latter emits, before leaving the pelvic cavity, a long *hæmorrhoidal artery*, that creeps back by the side of the rectum, to be distributed to the posterior extremity of that intestine and the adjoining genito-urinary organs. Without the pelvis, it abandons some gluteal branches, the most considerable and posterior of which represent the *ischiatic artery* of Solipeds. It then re-enters the cavity of the pelvis, and terminates at the base of the penis by forming the *cavernous* and *dorsal arteries* of that organ.

3. *Internal Iliac Arteries of Carnivora.*

The internal iliac arteries in the Carnivora result from the bifurcation of an arterial trunk, that prolongs the aorta beyond the origin of the external iliacs, as far as the first intersacral articulation.

The pelvic trunk of the *Dog* at first transmits the *umbilical artery*, which is remarkable for its small calibre, and the flexuosities it describes before reaching the bladder.

Then the internal iliac courses for 1 or 1½ inches behind, and to the inside of, the pelvi-crural venous trunk, dividing into two branches at the entrance to the pelvis.

One of these branches goes towards the viscera contained in the pelvic cavity; this is the *internal pudic artery*. It passes backwards, turns the ischial arch, and terminates in the *cavernous* and *dorsal arteries of the penis*, after furnishing vesical, hæmorrhoidal, and urethral branches, as well as the *uterine artery* of the female. The latter is very voluminous, and is placed in the substance of the broad ligament, above the small curvature of the uterine cornu, whence it is directed forward to the ovary, where it meets the utero-ovarian artery, after emitting numerous collateral branches, remarkable for the richness of the vascular network they form in the walls of the uterus.

The second branch of the internal iliac artery resembles the *subsacral artery* and its

ischiatic branch in Solipeds; it escapes from the pelvic cavity with the great sciatic nerve, which it accompanies to behind the thigh, where it is expended, after giving off on its course spinal and gluteal twigs. It is not this branch which supplies the *coccygeal arteries;* these come, as in the Pig and Ruminants, from the *middle sacral artery.*

COMPARISON OF THE INTERNAL ILIAC ARTERIES IN MAN WITH THOSE OF ANIMALS.

The aorta in *Man* bifurcates at the fourth lumbar vertebra to form the *primitive* (or *common*) *iliac arteries*, which descend to each side of the margin of the pelvis, where they divide into two branches, the *internal* and *external iliacs.*

The *internal iliac*, or *hypogastric artery*, passes beneath the sacro-iliac articulation, and breaks up into nine or eleven branches that go to the walls of the pelvic cavity, or to the organs contained in it. Their disposition somewhat resembles that of Carnivora; in their distribution they represent the various branches of the internal iliac of Solipeds. Thus we find: 1, An *umbilical artery;* 2, The *vesico-prostatic artery*, resembling the branch of the same name given off in the Horse by the internal pudic; 3, The *middle hæmorrhoidal artery*, that passes to the rectum like the branch of the internal pudic; 4, The *ileo-lumbar artery*, the iliaco-muscular of Solipeds; 5, The *lateral sacral artery*, which, behind, joins the middle sacral instead of dividing, as in the Horse, into ischiatic and lateral coccygeal; 6, The *obturator artery;* 7, *Gluteal artery;* 8, *Ischiatic;* 9, *Internal pudic*, that terminates, as in animals, by the cavernous, dorsalis penis, and the transversa perinei arteries. The arterial branches of the rectum, or *inferior hæmorrhoidal*, are furnished by the internal pudic artery.

Article IV.—External Iliac Arteries or Crural Trunks. (Fig. 277, 11.)

The external branches of the terminal quadrifurcations of the posterior aorta, the crural trunks descend on the sides of the entrance to the pelvic cavity, in describing a curve downwards and forwards, and a direction oblique from above to below, before to behind, and within outwards. Maintained within the small psoas and iliacus muscles by the peritoneum covering them, they are bordered posteriorly, and to the inner side, by the iliac vein, which isolates them from the pelvic trunk. When they arrive at the anterior border of the pubis, in the interstice which separates the pectineus from the long adductor of the leg, each is prolonged to the thigh, and takes the name of *femoral artery;* and thence into the angle of the femoro-tibial articulation, where it receives the denomination of *popliteal artery.*

Before passing to the description of these two vessels—continuations of the external iliac artery, we will indicate the collateral branches which emanate from this trunk itself. These are two principal: the *small testicular* or *uterine* (*cremasteric*), and the *circumflexa ilii.* The first having been already described (p. 534), we have only to notice the second.

Circumflex Iliac Artery (Fig. 272, 11).—This artery commences at an acute angle near the origin, and in front of, the external iliac; it sometimes emerges directly from the abdominal aorta. It is directed outwards, passes between the peritoneum and the lumbo-iliac aponeurosis, and arriving at the external border of the great psoas muscle, or even beyond that, it bifurcates. The *anterior branch* sends its ramifications into the transverse and small oblique muscles of the abdomen, where they anastomose with the abdominal ramuscules of the lumbar and intercostal branches; the *posterior bifurcation*, after giving some vessels to the same muscles, traverses the abdominal wall a little below the external angle of the ilium, in passing between the small oblique and iliacus muscles, to descend within the anterior border of the ilio-aponeuroticus (tensor vaginæ) muscle, and expend itself in front of the thigh by subcutaneous divisions.

Fig. 277.

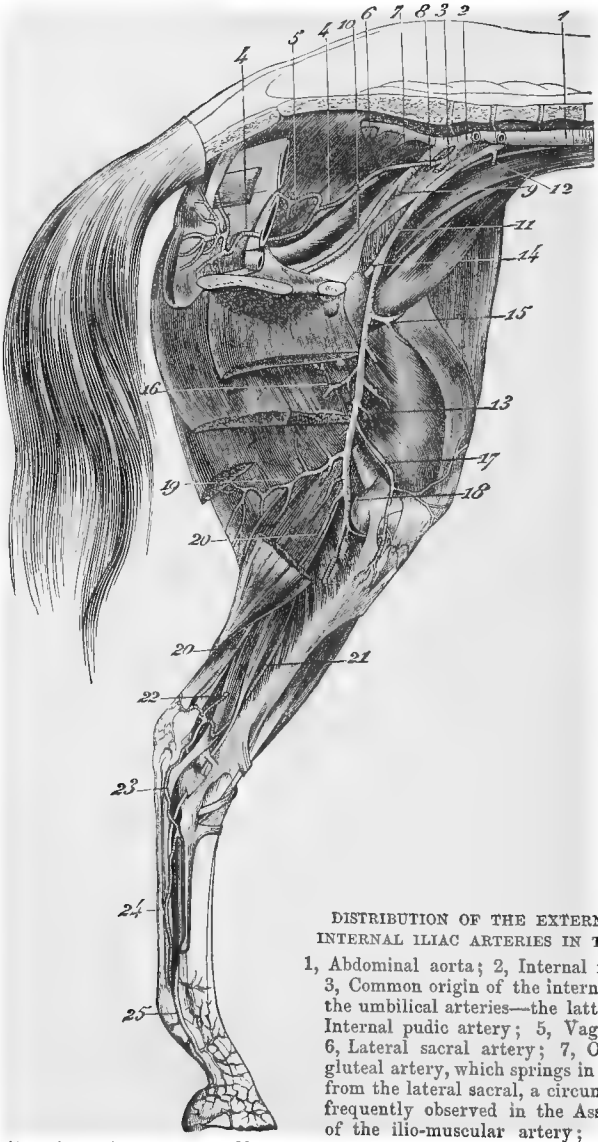

DISTRIBUTION OF THE EXTERNAL AND INTERNAL ILIAC ARTERIES IN THE MARE.

1, Abdominal aorta; 2, Internal iliac artery; 3, Common origin of the internal pudic and the umbilical arteries—the latter is cut; 4, Internal pudic artery; 5, Vaginal artery; 6, Lateral sacral artery; 7, Origin of the gluteal artery, which springs in this instance from the lateral sacral, a circumstance most frequently observed in the Ass; 8, Origin of the ilio-muscular artery; 9, Origin of the iliaco-femoral artery; 10, Obturator artery; 11, External iliac artery; 12, Circumflex iliac artery, cut; 13, Femoral artery; 14, Common origin of the deep femoral and prepubic arteries; 15, Origin of the anterior great muscular artery; 16, Origin of the saphena artery, cut; 17, Innominate branch; 18, Popliteal artery; 19, Femoro-popliteal; 20, Satellite artery of the great femoro-popliteal nerve; 21, Posterior tibial artery; 22, Its communicating branch with the saphena; 23, External plantar artery; 24, Satellite artery of the internal plantar nerve; 25, Digital artery.

FEMORAL ARTERY. (Fig. 277, 13).

The femoral artery, a prolongation of the external iliac, which changes its name on leaving the anterior border of the pubis, at first lies beneath the crural arch, beside a cluster of lymphatic glands, in the space comprised between the pectineal muscles, the long adductor of the leg, and the iliacus. From this interstice it descends, accompanied by its satellite vein, which lies behind it, and the internal saphena nerve, along the pectineus and vastus internus, at the posterior border of the long adductor of the leg. It soon leaves that muscle, however, to traverse the ring formed by the two branches of the great adductor of the thigh and the oblique concavity on the posterior face of the femur, and reaches the superior extremity of the gastrocnemii, between which it is continued, and assumes the name of *popliteal artery.*

On its course the femoral artery distributes a certain number of collateral branches to the adjacent parts. These are: the *prepubic, deep muscular, superficial muscular*, the *small muscular*, and *saphena arteries.*

Preparation.—The animal being placed in the first position, and the limb raised, the skin is carefully removed from the inner aspect of the thigh, the external generative organs in the inguinal region, and the inferior abdominal wall. The saphena vein is first to be exposed, and the branches of the artery of that name dissected; next, the prepubic artery, which is to be sought for in the inguinal canal, and its branches prepared by dissecting from their origin to their termination. The excision of a portion of the adductors of the leg, and the great adductor of the thigh will sufficiently expose the femoral artery and its other collateral branches.

1. *Prepubic Artery.* (Fig. 275, 4.)

This artery originates at the artificial line of demarcation which separates the external iliac from the femoral artery, at the superior extremity of the latter. It therefore emerges from that vessel at the anterior border of the pubis, and never alone, but always with the deep muscular branch, by means of a common and generally very short trunk, which springs at an acute angle from the inner side of the femoral artery.

The prepubic artery traverses the crural ring, opposite which it arises; it lies on the anterior face of Poupart's ligament, behind the neck of the vaginal sheath, and after a very short course separates into two branches—the *posterior abdominal* and *external pudic arteries.*

Posterior Abdominal Artery (*Epigastric* of Man)—(Fig. 275, 5).—This leaves the external pudic artery at an acute angle, enters the femoral ring by crossing the direction of the spermatic cord, places itself between the small oblique and transverse muscles of the abdomen, passes forward along the external border of the great rectus muscle, and finally enters the substance of that muscle, where its terminal divisions anastomose with those of the anterior abdominal artery. The numerous collateral branches this artery throws off on its track principally go to the rectus muscle, or the other parts composing the inferior abdominal wall, the skin included; the superior branches communicate with the circumflexa ilii.

The position this artery occupies at its origin, and with reference to the abdominal ring, is worthy of remark; indicating, as it does, that in strangulated inguinal hernia division of the ring should be made outwards, to avoid wounding the vessel.

External Pudic Artery (Fig. 275, 6).—This artery descends at first on the posterior wall of the inguinal canal, behind, and a little to the inside of, the spermatic cord; then, having passed the inferior ring of the canal, it

bifurcates into the *subcutaneous abdominal artery*, and the *anterior dorsal artery of the penis.*

The *subcutaneous abdominal artery* is directed forward on the superficial face of the abdominal tunic, bordering in its course the insertion of the suspensory ligament of the sheath. Arriving at the anterior extremity of that ligament, it terminates in several subcutaneous divisions, one of which is inflected beyond the umbilicus to anastomose *en arcade* with a similar branch from the opposite artery. It gives off twigs to the scrotum, sheath, superficial inguinal glands, skin, &c. (Fig. 275, 7).

The anterior dorsal artery of the penis gains the superior border of that organ, after supplying one or two scrotal branches, and separates into two portions; one, *posterior*, meets the dorsal cavernous artery of the penis and anastomoses with it; the other, anterior, longer, more voluminous, and very flexuous during retraction of the penis, follows the dorsal border of the organ to its anterior extremity, where it enters the erectile tissue that forms this part. From the two branches of this anterior dorsal artery, there are given off, as in the posterior one, ramuscules which penetrate the corpus cavernosum, and the walls of the urethra; they give, besides, some præputial twigs (Fig. 275, 8).

In the FEMALE, the external pudic artery offers a disposition which, if not similar, is yet analogous to that just indicated. As in the male, this vessel traverses the inguinal canal, and after leaving it divides into two branches: one, the *anterior*, or *subcutaneous abdominal artery*, the other the *posterior*, or *mammary artery*. The last, the most voluminous, represents the dorsal artery of the penis. It distributes several branches to the mammary tissue, and is prolonged between the thighs by a perineal branch, which terminates in the inferior commissure of the vulva, after giving off glandular and cutaneous branches.

2. *Profunda Femoris, Great Posterior Muscular Artery of the Thigh, or Deep Muscular Artery.* (Fig. 277, 14).

Arising in common with the prepubic artery, the profunda femoris passes backward, penetrates between the iliacus and the pectineus muscles, afterwards between the latter and the external obturator muscle. In this way it arrives beneath the deep face of the adductors of the thigh, when it becomes inflected behind the femur, and disappears in the substance of the internal and posterior crural muscles by ascending branches, which anastomose with the ischiatic artery, and descending and internal branches, whose terminal ramifications open into those of the obturator artery.

The principal twigs of the coxo-femoral articulation are derived from this vessel.

3. *Superficial Muscular, or Great Anterior Muscular Artery.* (Fig. 277, 15.)

Smaller than the preceding, and commencing opposite to it, but a little lower, this artery passes downwards, outwards, and forwards, runs between the long adductor of the leg and the musculo-tendinous cone which terminates in common the psoas magnus and iliacus, furnishes some ramuscules to these muscles, dips into the interstice separating the vastus internus from the anterior rectus of the thigh, and is lost in the mass of the triceps cruris.

This vessel, therefore, resembles the iliaco-femoral artery, which we observed to enter this triceps by penetrating between the anterior rectus and the vastus externus.

4. *Innominate or Small Muscular Arteries.*

The femoral artery gives off on its course numerous small branches destined for the neighbouring muscles, though too diminutive to merit particular description. One of these furnishes the *nutritive artery of the femur*, the largest, perhaps, of all the arteries supplying bones. Another (Fig. 277, 17) sends to the stifle a long articular branch, analogous to the *great anastomoticus* of Man, which descends along the vastus internus, beneath the adductors of the leg, at the interstice which separates these two muscles.

5. *Saphena Artery.* (Fig. 277, 16.)

This artery, remarkable for its small volume, the length of its course, and its connections with the vein whose name it bears, is destined for the skin on the inner side of the thigh and leg.

It takes its origin at an acute angle, from nearly the middle of the femoral artery, either alone or in common with one of the principal innominate muscular branches, and becomes superficial in passing into the interstice of the two adductors of the leg, or in traversing one of these, usually the short one or gracilis. It lies on the surface of this muscle, beside the saphena vein, and bifurcates at the angle of union of the two roots which constitute that vessel. One of the branches accompanies the anterior vein to nearly the lower third of the leg; the other follows the posterior vein, and usually anastomoses in the hollow of the hock, above the calcaneus, with a branch from the posterior tibial artery, and which also communicates with one of the branches of the femoro-popliteal artery.

Popliteal Artery. (Fig. 277, 18.)

Preparation.—The preparation which has served for the study of the femoral artery being nearly arranged as in figure 277, remove from it the internal gastrocnemius and popliteus muscles.

The above name is given to the continuation of the femoral artery. This vessel follows a descending direction behind the femoro-tibial articulation, between the two gastrocnemii muscles, insinuates itself beneath the popliteus, and bifurcates at the peroneal arch after a course of from 6 to 8 inches, to form the *posterior* and *anterior tibial arteries.*

The popliteal artery emits on its track: 1, The *femoro-popliteal artery;* 2, Articular branches; 3, Muscular branches chiefly destined to the gastrocnemii muscles, of which it is necessary to particularise one long division that descends within the perforatus, in company with the great femoro-popliteal nerve, to terminate superficially near the tendo-Achillis, where it anastomoses with a recurrent branch of the posterior tibial artery (Fig. 277, 20).

The *femoro-popliteal artery* is the only one of these collateral branches deserving particular mention. Its origin indicates the limit of the femoral and popliteal arteries, as it is detached at a right angle below the ring of the great abductor of the thigh, at the intermediate point of these two vessels. Placed between the semimembranosis and semitendinosis muscles on the one part, and the long vastus on the other, this vessel is directed from before to behind, and arrives at nearly the posterior border of the buttock, where it terminates in subcutaneous branches, after emitting descending and ascending branches. Among the first of these, which are principally destined to the gastrocnemii muscles, sometimes exists the

satellite branch of the sciatic nerve, and a thin twig which descends with the external saphena nerve into the hollow of the hock, where it meets, like the preceding, a branch of the posterior tibial artery. Several of the ascending branches pass along the great femoro-popliteal nerve, and all anastomose either with the deep femoral, or with the ischiatic arteries in the substance or interstices of the ischio-tibial muscles (Fig. 277, 19).

TERMINAL BRANCHES OF THE POPLITEAL ARTERY.

1. *Posterior Tibial Artery.* (Fig. 277, 21.)

Preparation.—Follow the indications furnished by figure 277.

At first situated deeply behind the tibia, beneath the popliteal muscles and the oblique and deep flexors of the phalanges, this artery descends towards the hollow of the hock, becoming gradually more and more superficial, and lying below the tibial fascia, behind the tendon of the oblique flexor muscle, along with its satellite vein. Arriving at the apex of the os calcis, it crosses the precited fascia, describes an S curve, and, along with the sciatic nerve, passes beneath the tarsal arch; at the astragalus it separates into two terminal branches—the *plantar arteries.*

Collateral branches.—We cite: 1, Numerous branches destined to the posterior deep tibial muscles; 2, The medullary artery of the tibia; 3, The tarsal articular arteries, a principal of which, with a large venous arch, passes under the perforans, near the inferior extremity of the tibia, to be distributed outside the tarsus by descending ramuscules and ascending twigs, which extend as far as the gastrocnemii tendons; 4, A superficial ascending branch, arising ordinarily from the second inflexion of the S curvature formed by the artery at its lower extremity, situated in the hollow of the hock, anastomosing with the saphena artery, as well as with the satellite popliteal branch of the sciatic nerve, and whose ramifications, nearly all subcutaneous, are scattered, within and without, on the sides of the hock and the inferior extremity of the thigh.

Terminal branches.—The two terminal branches of the posterior tibial artery are slender vessels, vestiges of the *plantar arteries* in Man. Lying on the outer side of the synovial tendinous sheath lining the tarsal groove, they are placed, one within, the other without, the perforans tendon, and descend along with the plantar nerves to the upper extremity of the metatarsus, where they leave the nerves, each to anastomose with the perforating pedal artery, and form a kind of deep arcade across the upper extremity of the suspensory ligament of the fetlock: that is, from the post-metatarsal fibrous band which represents the interosseous plantar muscles of tetradactylous or pentadactylous animals.

In their course, these *plantar arteries* only distribute some insignificant ramuscules to the tarsal articulations.

From the convexity of the arch they form in uniting with the perforating pedal artery, arise four long descending branches: 1, Two superficial, innominate and very fine twigs accompanying the plantar nerves, and creeping by the side of the flexor tendons to the sesamoid groove, where they inosculate with the collaterals of the digit (Figs. 277, 24; 278, 8); 2, Two deep branches constituting the *plantar interosseous arteries*, distinguished into *external* and *internal.* The first is only an extremely fine vascular thread, very uncertain in its disposition, and possesses no other importance in Solipeds than representing, in a rudimentary state, an

artery which is of considerable size in other animals. Placed within the external metatarsal bone, it anastomoses, by its inferior extremity, with a branch of the metatarsal pedal artery. The *internal interosseous plantar artery* may be considered, if we would neglect the study of analogies, as the continuation of the perforating pedal artery, which it rivals in volume. It descends to the external side of the internal metatarsal bone, beneath the margin of the suspensory ligament of the fetlock, and terminates a little above the tubercle of the external metatarsal bone, in uniting at a very acute angle with the metatarso-pedal artery. It gives off on its tract: the medullary branch of the principal metatarsal bone; a small branch to the external interosseous artery; several ramuscules which transversely cross the posterior border of the internal metatarsal bone to supply the cellular tissue, the skin, and the tendons applied to the median metatarsal bone.

2. *Anterior Tibial Artery.* (Fig. 278, 1.)

Preparation.—Expose the artery by removing the anterior muscles of the leg.

The anterior tibial artery is the largest of the two branches terminating the popliteal trunk. It traverses the tibial or tibio-peroneal arch, and, with its satellite veins, places itself on the anterior aspect of the tibia, down which it passes by following the deep face of the flexor muscle of the metatarsus. On reaching the front of the tibio-tarsal articulation, it loses its name and takes that of the *pedal artery.*

The anterior tibial artery gives off a great number of collateral branches, which are principally distributed among the tibial muscles. One of them, descending along the fibula, beneath the lateral extensor muscle of the phalanges, clearly represents a trace of the *peroneal artery* of Man.

3. *Pedal Artery.* (Fig. 278, 1′.)

A continuation of the anterior tibial artery, whose name changes on its arrival in the region of the foot, the pedal artery courses downward over the anterior face of the tibio-tarsal articulation, by bending slightly outwards, and passing beneath the cuboid branch of the flexor muscle of the metatarsus. At the second row of tarsal bones it divides into two branches, which we will designate *the perforating pedal*, and the *metatarso-pedal arteries*,[1] the latter continued inferiorly by the *digital arteries*, or *collaterals of the digit.*

The collateral branches emanating from this vessel are all articular cutaneous, and of no importance.[2]

Perforating Pedal Artery.—It crosses the tarsus from before to behind, by passing, with a venous branch, into the canal between the cuboid, scaphoid, and great cuneiform bones; it then joins the arch formed by the anastomoses of the two plantar arteries—terminal divisions of the posterior tibial (Fig. 278, 2).

Metatarso-pedal or Collateral Artery of the Cannon.[3]—Much

[1] The vessel we have here named the *perforating pedal artery* is only the like termination of the same artery in Man. The *metatarso-pedal artery* ought to be regarded as the representative of one of the dorsal interossei arteries, because of its position in the interstice of the middle and external lateral metatarsal bones. The dorsal interstice of the inner side also lodges an interosseous branch, usually supplied by the external plantar artery; but its diameter is so diminished that, in order to avoid complexity by introducing an almost useless element into the didactic description of the posterior tibial artery, we have thought it our duty to neglect its indication.

[2] One of these may be regarded as the analogue of the *dorsalis pedis* of Man.

[3] Rigot has designated this artery—we do not know why—the *superficial plantar artery.*

larger than the preceding, this vessel (Fig. 278, 3) may be considered as a continuation of the primitive pedal artery. It is lodged at first in the fissure situated outside the middle metatarsal bone, in front of the external metatarsal bone, and afterwards passes between these two bones, above the tubercle terminating the latter, reaching the posterior face of the first, between the two inferior branches of the suspensory ligament, above the sesamoid groove, where the vessel bifurcates to form the *collateral arteries of the digit.*

Fig. 278.

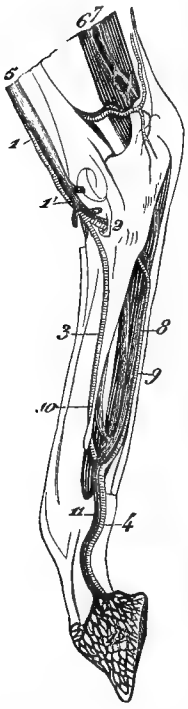

PRINCIPAL ARTERIES AND VEINS OF THE POSTERIOR FOOT.

1, Anterior tibial artery; 1′, Pedal artery; 2, Perforating pedal artery; 3, Metatarso-pedal, or collateral artery of the cannon; 4, Digital artery; 5, Anterior tibial artery; 6, Posterior root of the internal saphena vein; 7, Origin of the external saphena vein; 8, 9, 10, Metatarsal veins; 11, Digital vein; 12, Venous plexus of the foot.

The collateral artery of the cannon receives, a short distance above this terminal bifurcation, the internal plantar interosseous artery.

On its course it gives off: 1, Numerous anterior ramuscules for the cellular tissue, tendons, ligaments, and the skin on the anterior face of the metatarsus and fetlock; 2, Some thin posterior divisions, one of which ascends within the external metatarsal bone to anastomose with the external plantar interosseous artery, after furnishing several ligamentous, tendinous, and cutaneous ramuscules in the posterior metatarsal region.

Digital Arteries, or Collateral Arteries of the Digit (Figs. 277, 25; 278, 4; 283, 11).—Remarkable for their volume, these arteries carry blood to the keratogenous apparatus enveloping the ungual phalanx, and from this destination derive such importance that they deserve a detailed study.

Origin.—The digital arteries succeed the terminal extremity of the collateral of the cannon, and separate from one another in forming an acute angle below the sesamoid venous arch, above the fetlock joint, between the two branches of the suspensory ligament, behind the inferior extremity of the principal metatarsal bone, and in front of the flexor tendons of the phalanges.

Course and Relations.—These vessels descend, one to the right, the other to the left, from the lateral parts of the metacarpo-phalangeal (and *metatarso-phalangeal*) articulation to the internal face of the basilar process, where they bifurcate to form the *plantar* and *preplantar ungueal arteries.*

"In the whole of this course, it (the *digital artery*) follows the track of the flexor tendons, on whose margin it rests, and where it is maintained by loose connective tissue. Behind, it is flanked by the plantar nerve, which

---

It would have been better to have allowed it to retain the name given to it by Girard—the *lateral artery of the cannon.* This is not the only instance in which the attempts of Rigot to conform the nomenclature of the arteries to that of anthropotomists has proved unfortunate, as he has not always succeeded in finding in the Horse the real representatives of arteries in Man. The aim of this work does not allow us to discuss the vicious determinations and denominations of Rigot every time we meet them. We are content to change them, purely and simply, leaving to the judgment of the reader, should this matter interest him, the task of deciding if we are right.

covers a portion of its surface, enlaces it with numerous filaments, and is so closely associated with it in all its flexuosities as to form but a single cord with it.

"In front, it is margined, though for a short distance, by its satellite vein, which for the whole of its track rests on the lateral faces of the two first phalanges.

"At its upper part, near its origin, and on the lateral portions of the metacarpo-phalangeal articulation, the digital artery is crossed from behind to before by the anterior branch of the plantar nerve, and it is covered for the whole of its extent by the fascia which continues the proper tunic of the plantar cushion, whose lateral ligamentous band cuts its direction obliquely from above to below and behind to before, at the middle portion of the first phalanx.[1]"

Collateral divisions.—These are: 1. At the fetlock, numerous fine branches distributed to the metacarpo-phalangeal articulation, but particularly to the sesamoid sheath, and the tendons lodged in it.

2. To the environs of the upper extremity of the first phalanx, a slightly ascending and sometimes voluminous twig, for the tissue of the ergot (the horny tubercle behind the fetlock).

3. Towards the middle of the same bone, the vessel named by Percivall the *perpendicular artery*, and correctly so, for it arises at a right angle from the digital artery to divide almost immediately afterwards into two series of ramifications—anterior and posterior. The anterior branches are in nearly every instance two principal: one ascending, passing beneath the check band of the extensor tendon, and climbing to the capsular ligament of the fetlock joint to meet the arterial divisions furnished directly to that ligament by the collateral artery of the cannon; the other descending, which reaches the side of the second phalanx, where its ramuscules anastomose with the coronary circle and the circumflex artery of the coronary substance (cushion). The posterior ramifications consist most frequently of two principal branches, —one ascending, the other descending; these insinuate themselves between the flexor tendons and the sesamoid ligaments, to be distributed to these organs, but especially to the synovial membrane lining the large sesamoidean sheath. Sometimes it is seen to arise alone from the digital artery. It must here be noted, that the divisions furnished by the anterior branches of this perpendicular artery communicate with those of the opposite side in front of the first phalanx, either above or below the principal extensor of the digit; and that the posterior branches exhibit a series of analogous anastomoses. The body of the first phalanx is therefore enveloped on every side by an arterial plexus.

4. At different elevations on the first and second phalanges, several tendinous and cutaneous twigs, which are of no importance.

5. The *artery of the plantar cushion*, which arises at the superior border of the lateral cartilage, is directed obliquely backward and downward, and placed within the posterior border of that cartilage, to be distributed to the middle portion of the complementary apparatus of the third phalanx, as well as to the villous tissue and the coronet. The branch expended in the latter sometimes proceeds directly from the digital artery; it is a very remarkable vesssel, is inflected from before to behind, crossing the posterior border of the pedal cartilage, creeping on the internal face or in the texture of the skin, a little above the coronet, parallel with that portion of the

[1] *H. Bouley.*—'Traité de l'Organisation du Pied du Cheval.' Paris, 1851.

keratogenous apparatus, and terminates by anastomosing with a branch of the artery now to be noticed.

6. The *coronary circle*,[1] formed by two transverse branches—one anterior, the other posterior, springing at a right angle from the digital artery, under the cartilaginous plate of the os pedis—passes around the coronary bone to meet the analogous branches of the opposite artery, to anastomose with them directly and by inosculation. The coronary circle therefore presents two distinct portions: one posterior, placed above the superior border of the small sesamoid, beneath the perforans tendon; the other anterior, more extensive and voluminous, covered on the sides by the lateral cartilages of the foot, and in its front or middle part by the expansion of the anterior extensor tendon of the phalanges.

The collateral ramuscules furnished by the posterior part of the circle are small, few, and of no interest.

Among the branches arising from the anterior portion, there is only a single pair of arteries to be noted, which are remarkable for their mode of distribution and their volume. They originate near the border of the extensor tendon, and immediately divide into two divergent branches: one the internal, which passes across that tendon to anastomose with the homologous branch of the opposite side; the other, external, passes backward to meet the cutigeral branch furnished by the artery of the plantar cushion, and joins that vessel. From this disposition results a very fine superficial vascular arch around the coronet, which is well named the *circumflex artery of the coronary cushion;* it is situated a little above the cutidural artery, beneath the skin of the coronet, and looks as if incrusted in that membrane; by its two extremities it rests on the arteries of the plantar cushion, and is fed by the two principal vessels of the coronary circle; while it furnishes ascending anastomosing ramuscules to the inferior divisions of the perpendicular artery, as well as numerous descending branches passing into the coronary cushion and the laminal tissue of the foot.

Such is the ordinary disposition of the coronary circle and its superficial arch—the circumflex artery of the coronary substance; though it varies much in different animals, and even in the feet of the same animal. To attempt to describe here the variations we have seen would be supererogatory, and we may limit ourselves to saying that these varieties were almost exclusively confined to the origin of the branches composing these two circular vessels and their manner of arrangement, without modifying in any way the general disposition of the circles.[2]

Terminal divisions.—These are, as has been already mentioned, the *plantar* and *preplantar ungual arteries.*[3]

a. The *preplantar ungual artery* is the smallest of these two terminal branches. Situated at first inside the basilar process of the third phalanx, it turns round this to traverse the notch which separates this process from the retrossal eminence, is lodged with a satellite nerve in the preplantar

[1] So named because it ncircles the coronet.

[2] We may notice here one of these variations, which is somewhat frequently met with in the anterior limb. This consists in the anterior descending branch of the perpendicular artery uniting at its terminal extremity with the circumflex artery of the coronary substance, which it concurs to form.

[3] In all treatises on anatomy these vessels are simply designated the *plantar* and *preplantar arteries.* We have added the epithet *ungueal* to distinguish these arteries from the properly so-called *plantar* branches—the terminal divisions of the posterior tibial artery.

fissure, which it crosses from before to behind, and terminates near its anterior extremity by several divisions that bury themselves in the os pedis. In its course, it distributes: 1, Before passing into the sub-basilar notch, a deep retrograde branch destined to the bulb of the heel and the villous tissue; 2, Immediately after leaving that notch, a second retrograde branch, whose divisions pass backward, behind the great circumflex artery of the pedal bone; 3, During its passage in the preplantar fissure, several ascending and descending branches which ramify in the laminal tissue; the first anastomose with the descending divisions of the coronary circle and the circumflex artery of the coronary cushion.

b. The *plantar ungual artery* ought to be regarded as a continuation of the digital artery, because of its volume and direction. Lodged at first, with a fine nervous branch, in the plantar fissure, it afterwards enters the canal of the same name, and thus penetrates into the semilunar sinus of the os pedis, where it anastomoses by inosculation with the opposite artery, forming a deep vascular arcade which we designate the *plantar arcade* or *circle*, or, after M. H. Bouley, the *semilunar anastomosis* (Fig. 283, 12).

Two orders of branches emanate from the convexity formed by this anastomotic loop. The *ascending* order "irradiate in the spongy framework of the third phalanx, and like so many hair-roots, escape by numerous openings from its anterior face, where they form a very intricate plexus by anastomosing, in the texture of the laminal tissue, with the extreme divisions of the anterior branch of the digital artery and those of the coronary circle. . . . . It is to these divisions that Spooner has given the name of *anterior laminal arteries*."—H. Bouley.

The *descending* order, much more considerable, named by Spooner (W. C., of Southampton) the *inferior communicating arteries*, arise at a right angle from the anterior circumference of the semilunar anastomosis, traverse in a divergent manner the tissue of the phalanx, and make their exit by the large foramina situated a little above the inferior border of the bone, where they furnish a multitude of ascending ramuscules which concur to form the arterial network of the laminal tissue. "Then they anastomose transversely by a succession of little arcades which are thrown from one to the other, and in this way give rise to a great circumflex canal which follows the contour of the parabolic curve exhibited by the thin border of the os pedis, on its inferior face."—H. Bouley. This vascular arcade, which we purpose naming the *inferior circumflex artery of the foot*, to distinguish it from the circumflex of the coronary cushion, is joined by its extremities to the preplantar artery, in the same manner that the latter circumflex is united to the artery of the plantar cushion. From its concavity it throws off some fourteen or fifteen convergent branches, which are destined to the villous tissue of the sole.

DIFFERENTIAL CHARACTERS OF THE EXTERNAL ILIACS IN OTHER THAN SOLIPED ANIMALS.

1. *External Iliac Arteries of Ruminants.*

In the *Ox*, apart from the considerable volume of the great muscular arteries of the thigh, the crural trunk, as well as the femoral and popliteal arteries continuing it, comport themselves almost the same as in the Horse. It is only when we reach the *posterior* and *anterior tibial arteries* that we find some peculiarities worthy of notice.

Posterior tibial artery.—Much more voluminous than that of Solipeds, this artery follows the same track, and terminates in an analogous manner: forming at its lower extremity two plantar branches, which anastomose with the perforating pedal artery behind the superior extremity of the principal metatarsal bone, and beneath the suspensory ligament. But these two branches are far from possessing the same volume; the internal is incomparably the largest, and appears to be the direct continuation of the posterior tibial artery.

From this anastomosis results, as in the Horse, two series of *metatarsal branches*—a *profound* and a *superficial*.

The *profound branches*, two or three in number, form on the posterior face of the metatarsal bone, below the suspensory ligament, the posterior interosseæ, mixed with two or three reticulated venous branches, and anastomose by their inferior extremity with a perforating branch of the collateral of the cannon.

The *superficial branches*, similar to those which accompany the plantar nerves in the Horse, are of very unequal calibre: the external is so rudimentary that it often escapes dissection; the internal in reality continues the plantar artery of the same side. Both are united to the perforating branch already noticed.

Anterior tibial artery.—After passing down along the leg on its antero-external face, as in Solipeds, this vessel arrives on the hock, where it takes the name of *pedal artery*, and furnishes the *perforating-pedal artery;* it is continued by the *metatarso-pedal* or *collateral artery of the cannon.*

a. The *perforating-pedal artery* does not differ from that of the Horse.

b. The *metatarso-pedal*, or *collateral of the cannon*, descends, flanked by two satellite veins, in the channel on the anterior face of the metatarsal bone, giving off towards the inferior extremity of that channel the *perforating branch* already spoken of, and is continued into the digital region as the *common digital artery.*

The *perforating branch* of the collateral of the cannon passes into the foramen pierced from before to behind, across the inferior extremity of the metatarsal bone, arriving beneath the suspensory ligament, and then divides into several *ascending* and *descending branches.* The first join the deep and superficial posterior metatarsal arteries furnished by the plantar and pedal perforating arteries. Among the second, we notice three digital arteries, *fac-similes* in miniature of those which will be described in the anterior limb: two lateral, descending on the excentric side of the phalanges; a median, turning within the flexor tendons to place itself behind them on the middle line of the digital region, and prolonged into the interdigital space, where it anastomoses with a branch of the principal artery of the digits.

The latter artery, the *common digital*, descends into the space between the digits, after passing beneath the capsular ligament of the metatarso-phalangeal articulations, in the notch comprised between the two articular surfaces of the metatarsal bone, and terminates above the inferior extremity of the first phalanx by two *ungueal arteries*, whose description will be reserved until describing the arteries of the anterior limb. In the number of collateral branches emanating from this vessel, there may be particularly remarked a large off-shoot which arises a little before the separation of the two ungueal arteries, and is directed from before to behind, dividing at the posterior part of the interdigital space into several divisions, the principal of which are: 1, Two transverse branches passing between the flexor tendons and the phalanges, to be joined to the lateral digital arteries; 2, A single ascending branch, joining with the posterior median digital artery; 3, A descending branch, also single, dividing into two portions which reach the heels, to be distributed to the plantar cushion and the villous tissue. These branches represent the arteries of the plantar cushion in the Horse, and will be noticed more in detail in the description of the arteries of the anterior limb, where in principle they are found to be exactly like these.

2. *External Iliac Arteries of the Pig.*

The distribution of these vessels in the *Pig* is remarkably like that we have described as existing in Ruminants, even in the terminal portions of the limbs, notwithstanding the complete development of the two lateral digits. It may be noted, however, that the posterior tibial artery is somewhat slender, and that it is singularly reinforced by its anastomosis with the saphena artery, whose dimensions are relatively considerable.[1]

3. *External Iliac Arteries of Carnivora.*

The crural trunk is divided in the Carnivora, as in the other animals, into three sections: the *proper iliac artery*, the *femoral artery*, and the *popliteal artery*, terminated by the *tibial branches.*

Proper iliac artery.—This vessel does not give rise to any branch, as the *circumflexa ilii* comes directly from the abdominal aorta.

---

[1] In small Ruminants, the posterior tibial artery, properly speaking, is equally rudimentary; the saphena artery constitutes the principal vessel. From a note which we made a long time ago, it appears the first vessel is altogether absent sometimes, and that the plantar divisions come exclusively from the saphena, as in the Carnivora.

Femoral artery.—As in the Horse, this gives off: 1, Several *muscular innominate branches;* 2, Two *great muscular arteries,* the posterior of which furnishes the *prepubic artery;* 3, A *saphenal branch.*

In the *Bitch,* the *external pudic artery,* emanating from the *prepubic* division, presents some peculiarities in its distribution: it gives off a long branch which is placed in the texture of the mammæ, and passes forward to meet and unite with the mammary branch furnished by the internal thoracic artery; it then runs between the two thighs in a flexuous manner, and reaches the lips of the vulva, where it ends in numerous ramuscules that anastomose with the vulvular divisions of the internal pudic artery.

The *saphena artery* is as remarkable for its large volume as for its destination. It descends on the internal face of the leg, furnishing numerous subcutaneous divisions, and terminates at the hock by several slender *plantar twigs,* which accompany the flexor tendons. Among the branches given off by this vessel in its course, it is necessary to distinguish two: one which follows the anterior branch of the saphena vein to the hock, where it communicates by its terminal divisions with the tarsal artery; the other arises a little lower, passes beneath the phalangeal flexor muscles, and is expended on the hock in articular and malleolar branches. In the latter branch we see a trace of the *peroneal artery* of Man. The saphena itself, considered as a whole, and particularly towards its inferior moiety, supplements the posterior tibial artery.

Popliteal artery.—This artery gives an important *femoro-popliteal branch,* and enters the tibio-peroneal arcade to constitute the *anterior tibial artery,* after distributing on its course muscular ramuscules—rudiments of the posterior tibial artery of other animals.

The *anterior tibial artery,* arriving in front of the hock, detaches the *tarsal artery:* a voluminous branch divided near its origin into several superficial superior and inferior branches. It continues to descend, traverses from before to behind the superior part of the third intermetatarsal space, and terminates by an arterial arcade situated beneath the flexor tendons; from this arcade emanate ascending divisions, which anastomose with the plantar arteries, and three large descending or *digital branches,* which affect the same disposition as three analogous principal arteries emanating from the superficial palmar arcade of the anterior limb.

COMPARISON OF THE EXTERNAL ILIACS OF MAN WITH THOSE OF ANIMALS.

In *Man,* the *external iliac* forms the external branch of the bifurcation of the common iliac; it extends to the crural arch, where it takes the name of *femoral artery.* It furnishes the *circumflexa ilii* and *epigastric:* the latter resembling, in its distribution, the posterior abdominal branch given off by the prepubic artery in the Horse.

The *femoral artery* has the same general disposition as in animals, and almost the same collateral branches. There is no prepubic artery; the divisions furnished by this trunk in Solipeds originate separately from the femoral artery; these are: the *abdominal tegumental artery* (*superficial epigastric*), and the *external pudic arteries*—the one resembling the subcutaneous abdominal artery, and the others the branches of the external pudic artery of animals.

The *popliteal artery* is a superficial vessel situated at the posterior face of the knee-joint, in a lozenge-shaped space limited by the muscles of the region and named the *popliteal space.* At the tibio-peroneal arch it bifurcates, and constitutes the anterior tibial and the tibio-peroneal trunks.

The *tibio-peroneal trunk* does not exist in animals in which the peroneal artery is in a rudimentary state, in consequence of the feeble development of the peroneus. This trunk is short, and furnishes the nutrient artery of the tibia, then divides into the *peroneal* and *posterior tibial arteries.* The first descends to the external malleolus, along the inner face of the tibia, and terminates in two branches, one of which, the anterior peroneal, communicates with the dorsal artery of the tarsus—a branch of the pedal. The *posterior tibial,* on reaching the concavity of the calcis, constitutes the *internal* and *external plantar arteries.* The *internal plantar* is directed forwards, beneath the sole of the foot, and is lost in the muscles of the great toe, or forms the collateral of the latter vessel. Beneath the tarsal articulations, the *external plantar* describes a curve, having its concavity backwards, and anastomoses, at the fourth intermetatarsal space, with the termination of the dorsalis pedis; from this results a plantar arch, which gives off, from without to within: 1, The external collateral of the little toe; 2, 3, 4, 5, the *interosseous plantar* (or *digital*) *arteries* of the first, second, third and fourth intermetatarsal spaces; these arteries, at the root of the toes, bifurcate to furnish collaterals to these organs.

The *anterior tibial artery,* situated on the anterior face of the interosseous ligament that unites the tibia to the peroneus, extends to the annular ligament of the tarsus,

where it is continued by the *dorsalis pedis*, which descends along the dorsum of the foot to gain the summit of the fourth interosseous space.

The *dorsal artery of the metatarsus* (*metatarsea*) is almost *nil* in Solipeds. In Man it

Fig. 279.

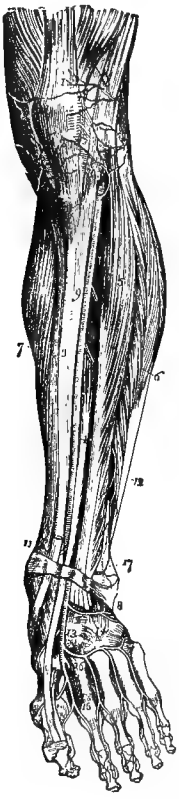

ANTERIOR ASPECT OF HUMAN LEG AND FOOT.

1, Tendon of insertion of the quadriceps extensor muscle; 2, Insertion of the ligamentum patellæ; 3, Tibia; 4, Extensor longus digitorum; 6, Peronei; 7, Inner belly of gastrocnemius and soleus; 8, Annular ligament; 9, Anterior tibial artery; 10, Its recurrent branch inosculating with (2) inferior articular and (1) superior articular arteries, branches of the popliteal; 11, Internal malleolar artery; 17, External ditto, inosculating with anterior peroneal artery, 12; 13, Dorsalis pedis artery; 14, Tarsea and metatarsea; 15, Dorsalis hallucis artery; 16, Continuation of dorsalis pedis into sole of foot.

Fig. 280.

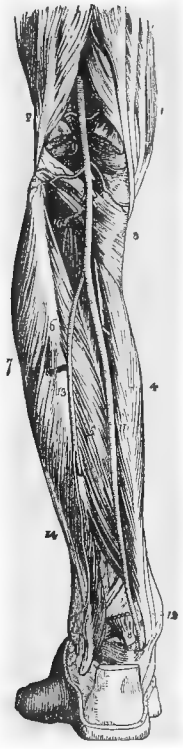

POSTERIOR ASPECT OF HUMAN LEG.

1, Tendons of inner ham-string; 2, Ditto of biceps; 3, Popliteus muscle; 4, Flexor longus digitorum; 5, Tibialis posticus; 6, Fibula; 7, Peronei muscles; 8, Lower portion of flexor longus pollicis, with its tendon; 9, Popliteal artery, giving off articular and muscular branches; 10, Anterior tibial artery; 11, Posterior tibial artery; 12, Relative position of tendons and artery; 13, Peroneal artery; 14, Posterior peroneal.

is directed transversely to the tarsus, from within to without; its terminal branches unite on the dorsum of the tarsus, and the arch it forms gives off the dorsal interosseous arteries of the three first spaces. These communicate above and below in the inter-

metatarsal spaces, with the plantar interosseous arteries by the *anterior* and *posterior perforating arteries;* finally, at the base of the toes they bifurcate to form the *collateral arteries of the toes.*

The *dorsal collateral artery of the fourth space* represents the vessel described in the Horse by the name of metatarso-pedal artery, or collateral of the cannon; it forms the internal collateral dorsal of the fourth toe, and external collateral of the great toe.

The *dorsalis pedis*, after giving off the last-named vessel, dips into the fourth space and reaches the lower surface of the foot, where it anastomoses with the internal plantar artery. In this last portion of its course it resembles the vessel we have named the perforating pedal in Solipeds.

Fig. 281.

ARTERIES OF SOLE OF HUMAN FOOT.

1, Under surface of os calcis; 2, Musculus accessorius; 3, Long flexor tendons; 4, Tendon of peroneus longus; 5, Termination of posterior tibial artery; 6, Internal plantar; 7, External plantar; 8, Plantar arch giving off four digital branches, three of which are seen dividing into collaterals for adjoining toes.

Article V.—Anterior Aorta. (Fig. 282, 1.)

This vessel, the smallest of the two trunks succeeding the common aorta, is no more than 2 or 2½ inches in length at the most. It leaves the pericardium to pass between the two layers of the mediastinum in an oblique direction from below upwards and behind forwards, above the right auricle, below the trachea, and to the left of the anterior vena cava. After furnishing some insignificant twigs to the pericardium and mediastinum, it divides into two branches which constitute the *brachial trunks* or *axillary arteries.*

In the Pachyderms and Carnivora, the anterior aorta does not exist, and the axillary arteries arise directly from the aortic trunk, towards the point from which the anterior aorta springs in other animals.

Article VI.—Brachial Trunks or Axillary Arteries. (Fig. 282, 2, 3.)

The brachial trunks, terminal branches of the anterior aorta, are distinguished into left and right. The latter is much larger than the former, because it furnishes the arteries of the head. It is also named the *brachio-cephalic trunk* (or *arteria innominata*).

Origin.—They separate from one another at an acute angle, the left being a little more elevated than the right.

Course and direction.—Both branches are directed forwards, between the laminæ of the anterior mediastinum and beneath the trachea; gaining the entrance to the chest, and leaving it by turning round the anterior border of the first rib, under the insertion of the scalenus, they become inflected backwards and downwards, to be placed, one to the right, the other to the left, at the internal face of the anterior limb, in the middle of the nervous branches of the brachial plexus, and continue within the arm, assuming the name of *humeral artery* on leaving the interstice which separates the subscapularis muscle from the adductor of the arm.

In its thoracic course, the left trunk describes a curve whose convexity is upwards, the right taking a rectilinear direction.

Relations.—In studying the relations of the brachial trunks, we recognise two principal portions: one thoracic, placed in the chest; the other axillary,

situated beneath the limb. In their thoracic portion, the brachial trunks, at first lying beside each other, separate slightly in front to reach the internal face of each of the two first ribs. They are accompanied by the cardiac, pneumogastric, inferior laryngeal, and diaphragmatic nerves, and are included, as already noticed, between the two layers of the anterior mediastinum. The right occupies nearly the median line beneath the inferior face of the trachea, to the left and above the anterior vena cava. The left slightly rises on the side of the trachea, and generally corresponds inwardly to the thoracic duct.

In their axillary portion, these vessels accompany the corresponding venous trunks, cross the terminal tendon of the subscapularis muscle in passing below the humeral insertion of the pectoralis magnus, and among the branches of the brachial plexus, but embraced more particularly by the median, anterior humeral, and ulnar nerves.

Distribution.—The axillary arteries give off, on their course, eight collateral branches. Four arise from the thoracic portion: three upper, the *dorsal*, *superior cervical*, and *vertebral arteries*; and an inferior, the *internal thoracic*. Two are detached at the first rib: one downwards, the other forwards; these are the *external thoracic* and *superior cervical arteries*. Two originate from the axillary portion of the trunk and pass upwards: they are the *super-* and *subscapular arteries*. After furnishing the latter vessel, the brachial trunk is continued by the *humeral artery*.

Independently of all these branches, the right axillary artery gives off, near its origin, the common trunk of the two *carotid arteries*, which will be studied in a separate article.

Preparation.—The subject being placed on the right side, remove the skin and the left anterior limb, in order to make the dissection at two periods.

First period.—Dissect all the intra-thoracic portion of the left axillary artery and its collateral branches, as in figure 282, taking care to leave the inferior cervical artery (which has been cut in the figure to render the drawing more distinct) attached by its superior extremity to the middle portion of the mastoido-humeralis, which has not been disturbed.

Second period.—Prepare, on the separated limb, the extra-thoracic portion of the vessel and all the arteries it furnishes, in taking as guides figures 283, 290, and 291.

COLLATERAL BRANCHES OF THE AXILLARY ARTERIES.

1. *Dorsal, Dorso-muscular or Transverse Cervical Artery.* (Fig. 282, 4.)

Chiefly destined to the muscles of the withers, this artery, the first given off by the brachial trunk, crosses outwardly the trachea, thoracic duct, œsophagus, great sympathetic nerve, and the long muscle of the neck, in proceeding beneath the mediastinal layer; it reaches and passes over the second intercostal space, bends slightly backwards, and places itself in the interstice which separates the angular muscle of the scapula and great serratus muscle from the inferior branch of the ilio-spinal muscle (longissimus dorsi), where it separates into several divergent branches. The majority of these ascend towards the superior border of the withers, neck, and shoulders, by gliding between the latter muscles, the splenius, and the small anterior serratus on the one part, and the great serratus, rhomboideus, and proper elevator of the shoulder on the other, to be distributed to those muscles and the integuments covering them. The most anterior of these branches passes between the splenius and the great complexus muscles, parallel with the superior cervical artery, which is in front of it, and communicates by its ramuscules with the latter vessel, as well as with the vertebral and occipito-muscular arteries. The last-named branch is some-

times long and voluminous, and partly supplements the superior cervical, as is exemplified in the specimen which served for Fig. 282.

Before leaving the thorax, the dorsal artery gives off some unimportant ramuscules and the *subcostal artery* (*superior intercostal* of Man). This branch (Fig. 282, 5) curves backwards and, with the sympathetic chain, places itself beneath the costo-vertebral articulations, against the long muscle of the neck, furnishing the second, third and fourth intercostal arteries and the corresponding spinal branches, and terminating at the fifth intercostal space by either forming the artery which descends into that space, in anastomosing by inosculation with a branch emanating from the first posterior intercostal artery, or by expending itself in the spinal muscles. Frequently the second intercostal and its spinal branch come directly from the dorsal artery; the fifth also often arises from the posterior aorta.[1]

On the right side, the dorsal artery always proceeds from a trunk common to it and the superior cervical artery: a circumstance sometimes observed in the left. This trunk has no relation with the œsophagus.

2. *Superior Cervical, Cervico-muscular, or Deep Cervical Artery.* (Fig. 282, 6.)

This vessel arises in front of the preceding artery, affects the same relations in the thoracic cavity, which it leaves by passing between the two first ribs, behind the last costo-transverse articulation;[2] it is then directed upwards and forwards, passing beneath the inferior branch of the ilio-spinal and great complexus muscles, courses in a flexuous manner through the space comprised between the latter muscle on one side, and the superior branch of the ilio-spinalis and cervical ligament on the other, and arrives at the second vertebra of the neck, where its terminal divisions anastomose with the branches of the occipito-muscular, vertebral, and even the dorsal, arteries.

The superior cervical artery distributes in its course: 1, The first intercostal artery and the first spinal branch; 2, Very numerous branches which are expended in the muscles and integuments of the cervical region, as well as in the large ligament occupying the middle plane of that region; among these branches, one longer than the others traverses the great complexus muscle to place itself between it and the splenius, and which is sometimes supplemented in great part by the dorsal artery.

3. *Vertebral Artery.* (Fig. 282, 7.)

Arising at an acute angle from the axillary artery at the first intercostal space, and covered at its origin by the mediastinal layer, the vertebral artery proceeds forward and upward, within the first rib, outside the œsophagus,[3] the trachea, and the inferior cervical ganglion, and is situated at the bottom of the interstice separating the two portions of the scalenus, with the fasciculus of branches originating from the brachial plexus, which is a little above the vessel. It then passes beneath the transverse process of the seventh cervical vertebra, and traverses the series of cervical foramina, hidden beneath the intertransverse muscles, to anastomose in

[1] For the description of these arteries, see page 524.

[2] We have seen it escape, along with the dorsal artery, by the second intercostal space.

[3] On the right, these relations with the œsophagus are not present.

Fig. 282.

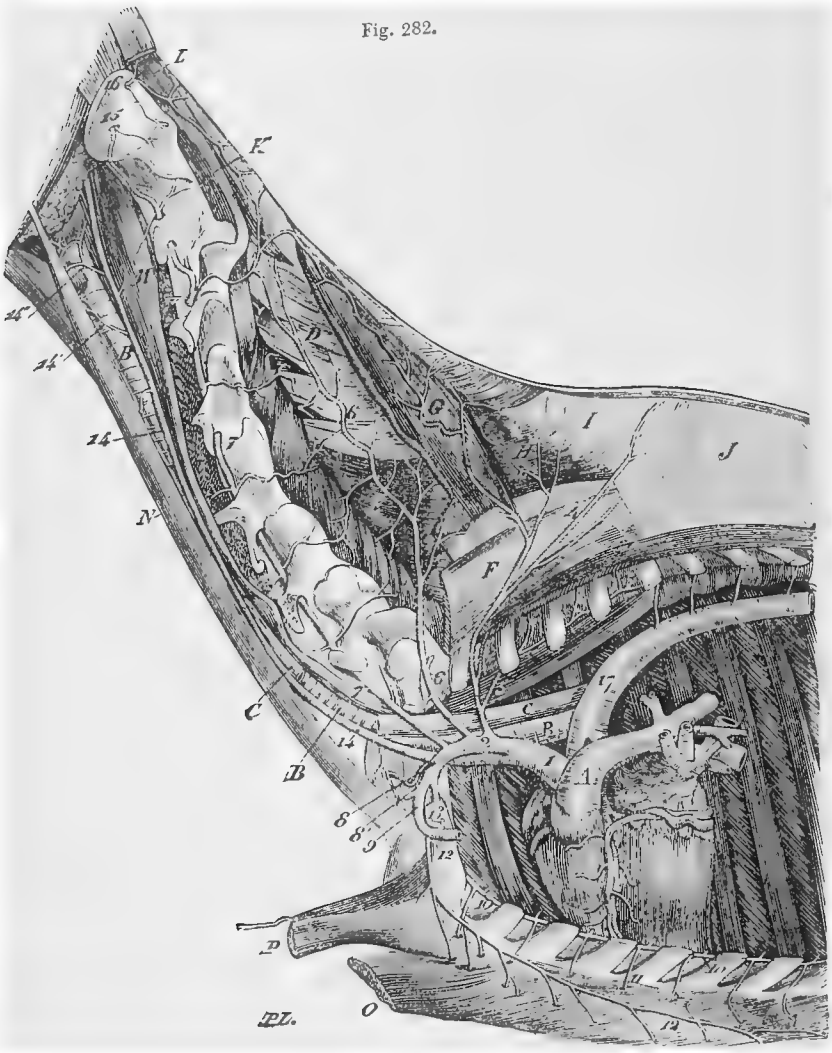

DISTRIBUTION OF THE ANTERIOR AORTA.

1, Anterior aorta; 2, Left axillary artery; 3, Right axillary artery; 4, Dorsal artery; 5, Subcostal artery; 6, Superior cervical artery; 7, Vertebral artery; 8, 8′, Inferior cervical artery; 9, Origin of the internal thoracic artery; 10, Origin of one of the external or intercostal branches of this artery; 11, One of its inferior ramuscules; 12, External thoracic artery; 13, Origin of the superscapular artery; 14, Primitive, or common carotid artery; 14′, Accessory thyroid artery; 14″ Thyro-laryngeal artery; 15, Atloido-muscular artery; 16, Occipito-muscular artery; 17, Posterior aorta.—A, Pulmonary aorta; B, Trachea; C, Œsophagus; D, Cervical ligament; E, Superior branch of the ilio-spinal muscle; F, Inferior branch of the same; G, Great complexus muscle; H, Splenius muscle; I, I, Originating aponeurosis of the splenius and the small anterior serratus muscles; K, Section of the great oblique muscle of the head; L, Great posterior rectus muscle of the head; M, Great anterior ditto; N, Sterno-maxillaris muscle; O, P, Great pectoral and sterno-prescapularis muscles turned downwards.

full canal with the retrograde branch of the occipital artery, at the atlo-axoid articulation, underneath the great oblique muscle of the head.

In its track, it detaches at each intervertebral space numerous branches, which may be divided into inferior, superior, external, and internal. The first chiefly pass to the scalenus, longus colli, and the great anterior rectus muscle of the head. The second, which are incomparably larger and more numerous than all the others, are destined to the two complex muscles, the transverse-spinous (semispinalis) muscles of the neck, and to the ilio-spinal muscle; they anastomose with the divisions of the superior cervical and occipito-muscular arteries. The external branches, are very small, and pass to the intertransverse muscles. The internal branches enter the intervertebral foramina to join the middle spinal artery.

4. *Internal Thoracic, or Internal Mammary Artery.* (Fig. 282, 9.)

The internal thoracic artery emerges from the brachial trunk at the first rib, and immediately descends along the inner face of that bone to the sternum, remaining covered by the pleura. It then bends backwards, passes under the triangular muscle and above the sternal cartilages, which it crosses near the chondro-sternal articulation, and reaches the base of the xiphoid appendix, where it ends in two branches: one *abdominal*, the other *thoracic*, and which have been named the *anterior abdominal* and *asternal arteries.*

In its course, the internal thoracic artery sends off collateral branches which may be distinguished into superior, inferior, and external. The *superior* are always very slender. and proceed to the pericardium and mediastinum. The *inferior* (Fig. 282, 11) are very large, and traverse the intercostal spaces to enter the pectoral muscles, where they meet the ramifications of the external thoracic artery. The *external branches* (Fig. 282, 10) follow the intercostal spaces; each generally divides into two branches, which finally anastomose by inosculation with the terminal divisions of the first seven intercostal arteries.

Terminal branches of the internal thoracic artery.—1. *Anterior abdominal artery.*—This vessel separates from the asternal artery at an acute angle, and passes directly backward to escape from the chest by coursing beneath the xiphoid appendix; it then places itself on the superior face of the rectus muscle of the abdomen, which it enters, after detaching lateral branches to the abdominal walls, and anastomoses by its terminal ramifications with the posterior abdominal artery.

2. *Asternal artery.*—This vessel glides within the cartilaginous circle formed by the false ribs, in crossing the digitations of the transverse muscle of the abdomen, and terminates at the thirteenth intercostal space, in which it ascends to anastomose with the corresponding intercostal artery. It supplies in its track: intercostal branches, which comport themselves like the analogous branches of the internal thoracic artery; fine diaphragmatic twigs; and abdominal divisions, which particularly ramify in the tranverse muscle.

5. *External or Inferior Thoracic, or External Mammary Artery.* (Fig. 282, 12.)

Principally destined to the deep pectoral muscles, this artery commences at an acute angle in front of, but close to, the preceding, turns the anterior border of the first rib, and then passes back against the internal face of the great pectoral and sterno-prescapular muscles, in which are expended its

collateral and terminal divisions. It gives off a fine branch which accompanies the spur vein, and ramifies in the panniculus carnosus.

This artery sometimes rises from the suprasternal vessel; its volume is subject to great variations, and we have seen it entirely absent.

6. *Inferior Cervical, or Trachelo-muscular Artery.* (Fig. 282, 8, 8′.)

Originating opposite the two preceding vessels, sometimes near the external, and at other times near the internal mammary arteries, this vessel is at first situated in the gulf between the jugulars, within the sterno-prescapular muscle, and above the glands at the entrance to the chest; it divides after a short course into two branches, which separate at a very acute angle. One of these, the *superior* (*ascending cervical* of Man), rises between the mastoido-humeralis and subscapulo-hyoideus muscles, to which it is distributed, as well as to the glands at the point of the shoulder, and the sterno-prescapularis and triangularis scapulæ muscles.

The *inferior branch* (*thoracica acromialis* of Man) descends in the interstice comprised between the mastoido-humeralis and the sterno-humeralis (pectoralis parvus) muscles, accompanying the cephalic vein; it is distributed to these two muscles, the sterno-aponeuroticus (pectoralis transversus), and the sterno-prescapularis.

7. *Superscapular, or Superior Scapular Artery.* (Fig. 282, 13.)

A small and slightly tortuous vessel, which arises from the axillary artery, a little before it reaches the tendon of the subscapularis muscle. It is directed upwards, and enters the space included between that muscle and the super- (antea-) spinatus, after sending off some divisions to the sterno-prescapularis muscle. Its terminal branches are expanded in the inferior extremity of the super- and subspinati muscles, the tendon of the coraco-radialis, and in the articulation of the shoulder.

8. *Inferior, or Subscapular Artery.* (Fig. 347.)

This artery is remarkable for its considerable volume; it arises at a right angle from the axillary artery, at the space separating the subscapularis from the adductor of the arm. Its origin indicates the limit artificially fixed between the brachial trunk and the humeral artery. It is seen to proceed upwards and backwards in this interstice, within the large extensor of the fore-arm, until near the dorsal angle of the scapula, where it terminates.

It gives off on its track:

1. An artery which, following the inferior border of the great dorsal muscle, ascends to its inner face, throwing off twigs into the substance of the muscle as well as into the panniculus carnosus.

2. The *scapulo-humeral*, or *posterior circumflex artery of the shoulder*, which passes from within that articulation, beneath the great extensor muscle of the shoulder, to reach its external face; after giving off some collateral branches, it arrives, with the circumflex nerves, underneath the abductors of the arm, where it breaks up, like its satellite nerve, into several divergent branches destined to the three muscles above named, the oblique flexor and short extensor of the fore-arm, and to the mastoido-humeralis and panniculus carnosus.

3. *Muscular branches*, which escape at intervals during the course of the vessel, and are sent forwards and backwards. The *anterior* pass either to the internal or external side of the scapula, or to both sides of that bone, whose posterior border they embrace in their bifurcation. The internal divisions creep in the fissures on the deep face of the bone, throwing their ramuscules into the subscapularis muscle, and even reaching the super- (antea-) spinatus, as well as the insertion of the angularis and great serratus muscles. The external divisions traverse the large extensor of the fore-arm, to be distributed to the super- and subspinati and the abductor muscles of the arm, one furnishing the nutrient artery of the scapula. The *posterior branches* supply the abductor of the arm, and the large extensor of the fore-arm.

HUMERAL ARTERY, OR TERMINAL ARTERY OF THE BRACHIAL TRUNK.
(Fig. 347, A.)

Course.—This, a continuation of the axillary artery, which changes its name after giving off the subscapular branch, at first describes a slight curve forwards to descend almost vertically within the thoracic limb by crossing obliquely the direction of the humerus, and terminates above the inferior extremity of that bone by two branches which constitute the *anterior* and *posterior radial arteries.*

Relations.—In its course, the humeral artery corresponds: in front, to the median or ulno-plantar nerve, and to the posterior border of the coraco-humeralis muscle, which it closely follows; behind, to the vein of the arm, and through it to the ulnar nerve; outwardly, to the common tendon of the great dorsal muscle and the adductor muscle of the arm, to the middle extensor of the fore-arm, and to the humerus; inwardly, to the sheath of the coraco-radialis muscle, which separates the pectoralis magnus from the artery of the arm, and in which this vessel is inclosed, in common with its satellite vein, the lymphatic glands and vessels of the arm, as well as with the nerves of the fore-limb.

Collateral branches.—Among these may be distinguished four, which merit particular mention. They are the *prehumeral, external* and *internal collateral arteries of the elbow*, and the *principal artery of the coraco-radialis muscle.* We need only indicate, besides these, several irregular ramuscules which go to the latter muscle, to the coraco-humeralis, and to the middle extensor of the fore-arm.

1. *Prehumeral, or anterior circumflex artery of the shoulder.*—This arises at a right angle, is directed forward, passes between the two branches of the coraco-humeralis, turns round the anterior face of the humerus, beneath the bicipital groove, and terminates in the mastoido-humeralis muscle. During its progess it gives off branches to the scapulo-brachial and biceps muscles, as well as to the articulation of the shoulder. Among the articular ramifications, there is one which ascends outwardly on the tendon of the subspinatus, and whose ultimate divisions anastomose with the ramuscules of the posterior circumflex artery.

2. *Deep humeral, or external collateral artery of the elbow.*—A very large branch which emerges from the humeral trunk, by forming with that artery an almost right angle at the common terminal tendon of the great dorsal muscle and the adductor of the arm. After a very short course, it divides into two principal branches; one of these sends its ramuscules into the body of the large extensor muscle; the other passes under that muscle in

turning round the oblique flexor of the fore-arm, along with the radial nerve, and reaching beneath the short extensor, to descend, still with its satellite nerve, in front of the articulation of the elbow, where this branch anastomoses with the anterior radial artery; it supplies all the olecranian muscles, except the long extensor, as well as the oblique flexor of the fore-arm and the anterior extensor of the metacarpus.

3. *Epicondyloid, internal collateral of the elbow, or ulnar artery.*—Smaller than the external collateral, this artery arises at the nutrient foramen of the humerus, and proceeds backwards on the internal face of that bone, to pass beneath the long extensor of the fore-arm, by following in a more or less flexous manner the inferior border of the middle extensor; it then descends, at first behind the epicondyle, then on the fore-arm, which it passes along for its whole length, underneath the aponeurotic sheath of this region, between the oblique and the external flexor of the metacarpus, accompanied by the ulnar vein and nerve of the same name, and the tendon of the ulnar portion of the perforans muscle. Arriving near the carpus, this long branch anastomoses by inosculation with a branch from the posterior radial artery.

In its antibrachial course, this artery only gives off very attenuated branches, whose study is of little importance. But before attaining the fore-arm, it furnishes: 1, The nutrient artery of the humerus; 2, Articular ramuscules; 3, More or less voluminous muscular branches, particularly for the long extensor of the fore-arm, the middle extensor, and the sterno-aponeuroticus: those which arrive in the latter muscle traverse it only to become subcutaneous alternately; one of them accompanies the principal superficial vein of the fore-arm, and sends ramuscules into the bend of the elbow. Regular in their distribution, these different arteries present numerous varieties of origin, among which it is difficult to distinguish the most constant disposition. The last-mentioned vessel and the nutrient artery of the humerus, often emanate directly from the humeral trunk.

4. *Principal artery of the biceps, or coraco-radialis artery.*—This originates a little below or above the preceding; opposite to, or in front of it, it usually divides into two branches: one ascending, the other descending, which enter the substance of the muscle.

1. *Anterior Radial Artery.* (Fig. 348, A.)

The anterior radial artery,[1] the smallest of the two terminal branches of the humeral, separates itself at an acute angle from the posterior artery, above the articular condyle of the humerus. It descends on the anterior face of the ulnar articulation, passing beneath the inferior extremity of the flexor muscles of the fore-arm and the superior extremity of the principal extensor of the metacarpus, where it meets the radial nerve; in company with this nerve it extends on the anterior face of the radius, below the anterior extensor muscle of the phalanges, to the knee, where it becomes very thin and breaks up into several ramuscules, which are continued on the capsular ligament of the carpal articulations, after anastomosing on the inner side with the divisions of a branch furnished by the posterior radial artery, and on the outside with the ramifications from the interosseous artery of the fore-arm.

[1] In Man this artery is absent, or rather it is represented by an insignificant muscular twig.

These terminal ramuscules of the anterior radial artery are distributed to the carpal articulation, or the sheaths of the extensor tendons, and communicate with the dorsal interosseous metacarpal arteries.

The collateral branches given off by this artery are very numerous, the majority of them being detached from the superior portion of the vessel near the elbow; they are intended to supply that articulation, but more especially the muscular masses lying in its neighbourhood, or covering it.

Such is the usual disposition of the anterior radial artery; though it is liable to numerous variations: principally in the manner in which it comports itself with the interosseous artery of the fore-arm, which may even supplement it for the whole of the middle and lower part of its course. This will be noted in describing the next artery.

2. *Posterior Radial Artery.* (Figs. 283, 1; 347, B.)

This vessel, in its volume and direction, represents the continuation of the humeral artery. It descends, along with the ulno-plantar nerve, on the internal ligament of the humero-radial articulation, behind the terminal extremity of the coraco-radialis; then under the internal flexor of the metacarpus, its satellite muscle. Arriving at the inferior extremity of the radius, it divides into two terminal branches; which are, the *common trunk of the interosseous metacarpal arteries* and the *collateral artery of the cannon.*

The following are the principal collateral branches furnished by the posterior radial artery:

1. At the superior extremity of the radius, articular ramuscules which anastomose with analogous branches from the epicondyloid artery.

2. A little lower, large divisions destined for the muscles of the posterior antibrachial region, some of them arising from the next artery.

3. The *interosseous artery of the fore-arm*, a considerable vessel which originates at the same point as the preceding—the radio-ulnar arch, and which crosses this from within to without, after traversing the posterior face of the radius, beneath the perforans muscle, to descend along the lateral extensor muscle of the phalanges, in the channel formed outwardly by the union of the two bones of the fore-arm. This interosseous artery furnishes, immediately after its exit from the radio-ulnar arch, several branches to the articulation of the elbow and the antibrachial muscles. At its terminal extremity it usually divides into a number of branches, the majority of which join the branches sent to the carpus by the anterior radial artery. It is rare that it does show some fine anastomoses with one of the divisions of the latter artery in front of, or outside the articulation of the elbow; sometimes it directly joins that vessel; and I have seen it, on the contrary, receive the anterior radial artery, which it in part supplanted.

4. Several muscular and musculo-cutaneous ramuscules without any fixed arrangement, arising from different points of the course of the parent artery, below the preceding divisions.

5. A deep branch, also liable to very numerous variations, having its origin at the radial insertion of the perforatus muscle, descending on the posterior face of the radius, chiefly destined to the carpus, and remarkable for the anastomoses that its internal divisions contract with the anterior radial artery, and for those which occasionally unite its external ramifications to the ultimate branches of the interosseous artery of the fore-arm or the epicondyloid artery (Fig. 283, 2).

Fig. 283.

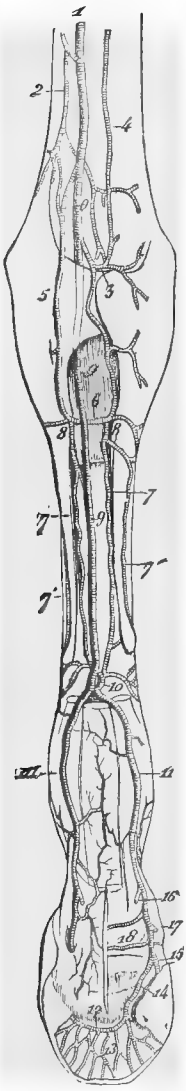

ARTERIES OF THE FORE-FOOT, SEEN FROM BEHIND.

1. *First Terminal Branch of the Posterior Radial Artery, or Common Trunk of the Interosseous Metacarpal Arteries.*[1] (Fig. 283, 5.)

This arterial branch separates at a very acute angle from the collateral artery of the cannon. It descends inside and behind the carpus, accompanied by the principal subcutaneous vein of the limb, and with it is included underneath a superficial fascia, which maintains them in a channel hollowed on the external face of the carpal fibrous sheath. It thus arrives within the head of the inner metacarpal bone, where it is inflected to the outer side by crossing the superior extremity of the suspensory ligament, and between it and the metacarpal ligament the latter furnishes to the perforans tendon; it anastomoses by inosculation with a descending branch which emanates from the superficial arch that, above the carpus, unites the epicondyloid or ulnar artery to the origin of the collateral artery of the cannon (Fig. 283, 6). The loop-like anastomosis thus formed by the radio-palmar artery, exactly corresponds to the *deep palmar arch* of pentadactylous animals, particularly to that of Man. We propose to name it also the *subcarpal arch*, by reason of the position it occupies in regard to the carpus, reserving the appellation of *supracarpal arch* for the *superficial palmar arch*, which is represented by the anastomosis established between the collateral artery of the cannon and the epicondyloid artery.

Four principal branches emanate from this subcarpal arch: these are the *metacarpal interosseous arteries*, distinguished into *posterior* or *palmar*, and *anterior* or *dorsal*.

a. The *posterior interosseous* arise, one on the right, the other on the left, at the head of the lateral metacarpal bones, each descending on its own side, and in a flexuous manner, along these rudimentary bones, in the angular groove formed by their inner face and the posterior face of the principal metacarpal bone, terminating

The muscles and tendons have been removed, only a small portion of the perforans tendon being left; the os pedis has been chiselled away on its plantar face to expose the semilunar anastomosis.

1, Posterior radial artery; 2, Innominate carpal branch; 3, Supracarpal arch; 4, Epicondyloid (ulnar) artery; 5, Radio-palmar artery, or common trunk of the interosseous metacarpal arteries; 6, Subcarpal arch; 7, 7, Posterior interosseous metacarpal arteries; 7′, 7′, Anterior interosseous metacarpal arteries; 8, 8, Their origin; 9, Collateral artery of the cannon; 10, Its communicating branch with the interosseous arteries; 11, 11, Digital arteries, 12, Semilunar anastomosis in the os pedis; 13, Emergent branches of this anastomosis; 14, Plantar ungueal artery, forming this anastomotic arch; 15, Origin of the preplantar ungueal artery; 16, Origin of the plantar-cushion artery; 17, Origin of the anterior branch of the coronary circle; 18, Posterior branch of the same.

[1] This vessel corresponds to the *radio-palmar artery* of Man, by which name it is sometimes designated. Rigot has improperly named it the *deep plantar artery*.

at the inferior extremity of the lateral bones by anastomosing in full canal with a branch of the collateral of the cannon. They furnish some ramifications to the suspensory ligament which covers them, and several tendinous and cellulo-cutaneous twigs; one supplies the medullary artery of the principal cannon bone (Fig. 283, 7).

b. The *anterior interosseous arteries* arise from nearly the same point as the preceding, one outwards, the other inwards, turning back round the head of the lateral metacarpals to place themselves in the groove which separates these from the principal metacarpal bone, on their external or dorsal face, after having thrown off several anastomosing ramuscules which communicate between the two arteries in front of the upper extremity of the median metacarpal bone, or with the terminal branches of the anterior radial and the interosseous arteries of the fore-arm. By their terminal extremity, these two arteries anastomose with a branch of the collateral of the cannon—that which receives the posterior interosseous arteries (Fig. 282, 7′, 8).

The dorsal interosseous arteries, although much finer than the palmar (in Solipeds these arteries are quite rudimentary), nevertheless furnish collateral divisions destined for the anterior tendons of the metacarpus, the periosteum, the connective tissue, and the skin. They often communicate with the posterior arteries by deep branches, which cross the intermetacarpal ligaments.

Variations.—The existence of the interosseous metacarpal arteries, their position, and their anastomoses with the inferior extremity of the collateral of the cannon, are constant; though this is not the case with regard to their origin, or the source from which they arise. In the typical description we have given, we have considered them all as being furnished by the radio-palmar artery; but it is necessary to add that one of the four, the external dorsal, often comes directly from the arterial branch that, from the *supra-carpal arch*, descends along the carpus to concur in forming the *subcarpal arch*, by anastomosing with the radio-palmar, or rather with a branch of the interosseous of the fore-arm. It is also necessary to add that these metacarpal arteries sometimes arise together from one large branch furnished by the collateral of the cannon, at the superior extremity of the metacarpus, and which receives the now rudimentary radio-palmar artery, as well as that given off by the supracarpal arch; so that we may have two superposed supracarpal arches. We have met other anomalies which need not be noticed here, as they are without interest.

2. *Second Terminal Branch of the Posterior Radial, or Collateral Artery of the Cannon.*[1] (Fig. 283, 9.)

The collateral artery of the cannon continues, in its volume and direction, the posterior radial artery. It passes, with the flexor tendons, under the carpal arch, and descends on the inner side of these tendons, accompanied by the internal plantar nerve, to above the fetlock and near the great sesamoid bones, where it bifurcates into the *digital arteries.*

Collateral branches.—We observe:

1. Near the origin of the artery, and very often from the posterior radial artery itself, a branch which anastomoses above the pisiform bone with the epicondyloid artery, forming an arch whose convexity is inferior (Fig. 283, 3), and which has been already noticed as the *supracarpal* or *superficial palmar*

[1] This artery, the *superficial plantar* of Rigot, represents one of the *metacarpal palmar branches* furnished by the superficial palmar arch in Man and other pentadactylous animals.

arch, in contradistinction to the *subcarpal* or *deep palmar arch*, the source of the interosseous arteries of the metacarpus. This ramification furnishes one or more muscular twigs that usually anastomose with the other branches of the posterior radial artery; and an inferior division,[1] which descends in the carpal arch, within the pisiform bone, to the superior extremity of the metacarpus, where it inosculates with the radio-palmar artery, after detaching several carpal ramuscules, the principal of which turns round the inferior border of the pisiform bone.

2. On its course, numerous and fine synovial tendinous and cutaneous divisions.

3. A trunk springing from the terminal extremity of the vessel, between the two digital arteries, sometimes even from one of these, which is placed at the posterior face of the principal metacarpal bone, within the two branches of the suspensory ligament, and, passing upwards, soon divides into two branches; these anastomose by inosculation with the posterior interosseous arteries of the metacarpus, after giving off on each side two other ramuscules which wind round the borders of the middle metacarpal bone, receiving the dorsal interosseous arteries, and ramify in front of the fetlock, on the anterior face of the cannon bone, and in the texture of the capsular ligament of the metacarpo-phalangeal articulation (Fig. 283, 10).

Terminal branches.—These are, as we said, the *digital arteries*, whose disposition almost exactly repeats that of these vessels in the posterior limb, and which have been described at page 551.

DIFFERENTIAL CHARACTERS IN THE AXILLARY ARTERIES OF OTHER THAN SOLIPED ANIMALS.

1. *Axillary Arteries of Ruminants.*

These vessels comport themselves in their origin, course, and relations, as in Solipeds. The special characters they present in their distribution are as follows:

1. *Dorsal artery.*—This arises from a trunk common to it and the vertebral artery, and usually leaves the thorax by passing above the first costo-vertebral articulation. Its *subcostal branch* proceeds directly from the above-named trunk.

2. *Superior cervical artery.*—This is absent, and is replaced by a branch of the dorsal artery, but particularly by the superior muscular divisions of the vertebral artery.

3. *Vertebral artery.*—Extremely voluminous, and terminates in the muscles of the neck, after passing through the foramen of the axis; it is remarkable for the considerable size of its spinal branches.

4. *Inferior cervical, internal and external thoracic arteries.*—These do not present anything worthy of special consideration, except that the last is very voluminous in the *Ox* and very slender in the *Sheep*, and supplies the satellite arterial branch of the cephalic vein, which, in Solipeds, arises from the inferior cervical artery.

5. *Superscapular artery.*—This vessel appears to us to be absent in the *Sheep*, and its place supplied by the divisions of the inferior cervical artery.

6. *Subscapular artery.*—The *scapulo-humeral* branch gives off the majority of the branches destined to the posterior brachial muscles.

7. *Humeral artery.*—The muscular arteries are of small size, particularly the deep humeral, which is largely replaced by the scapulo-humeral branch.

8. *Anterior radial artery.*—This comports itself similarly to that of the Horse, and is liable to as frequent anomalies.

9. *Posterior radial artery.*—This artery follows the same course as in Solipeds; only instead of furnishing the *radio-palmar artery* near the carpus, at the point where it becomes the *collateral artery of the cannon*, it gives off that vessel much higher, and near the upper third or middle of the fore-arm. Its *interosseous branch*, lodged in the deep channel on the outside of the bones of this region, where the radius and ulna join, is separated into two branches near the inferior extremity of that groove. The anterior of these ramifies on the dorsal face of the carpus, and anastomoses with the divisions of the

[1] Analogous to the *radio-ulnar artery* of Man.

anterior radial artery; the posterior traverses the inferior radio-ulnar arch, to distribute the majority of its branches behind the carpal articulations.

10. *Radio-palmar artery.*—Arising, as we have already seen, from the posterior radial artery, towards the upper third of the fore-arm, this branch descends to the superior extremity of the metacarpus in following, as in the Horse, a superficial course, and ends in four *metacarpal interosseous arteries three posterior* or *palmar*, and *one anterior* or *dorsal*. The *posterior interosseous* arteries are very irregular and inconstant in their disposition; they communicate with each other by several branches, and anastomose, inferiorly, either with the lateral digital arteries, the collateral of the cannon, or, as is most commonly the case, with a branch of the latter vessel. These interosseous arteries are distinguished into external, middle, and internal; the first two are comprised between the posterior face of the metacarpus and the suspensory ligament; the third, placed at the inner border of that ligament, is more considerable than the others, and by its volume and direction represents the continuation of the radio-palmar artery. The *anterior interosseous* artery passes through the foramen at the superior extremity of the metacarpus, and arriving at the dorsal face of the bone, it bifurcates, its ascending branch reaching the capsular ligament of the carpal articulations, where it anastomoses with the divisions of the anterior radial and interosseous arteries of the fore-arm; the descending is lodged in the anterior groove of the metacarpal bone, and joins a perforating branch of the collateral artery of the cannon—a branch which crosses the foramen pierced towards the inferior extremity of the bony diaphysis. If it is desired to ascertain the signification of these interosseous arteries in their relation to the elements composing the foot of Ruminants, we readily recognise: in the posterior median artery, the interosseous palmar of the two great digits; in the posterior lateral arteries, the interosseous palmar, intermediates to these middle digits, and the rudimentary lateral digits represented by the ergots or dew claws; and in the single anterior artery, the dorsal interosseous of the two great digits. We may even prove, by a more minute examination, the existence of dorsal interosseous arteries corresponding to the lateral palmar interosseous vessels.

11. *Collateral artery of the cannon.*—This artery follows the same track as in the Horse, as far as the lower third or fourth of the metacarpus. Arrived at this point, it abandons, as in the Horse, a branch whose divisions communicate with the interosseous arteries, and are continued by the digital arteries, three in number: a middle and two lateral (Fig. 349).

a. The *communicating branch with the metacarpal interosseous arteries* very often arises from the internal digital artery.

It is insinuated between the divisions of the suspensory ligament, and ascends on the posterior face of the metacarpus, breaking up into a number of branches which nearly all join the precited arteries, or even the lateral digital, in affecting a variable and complicated disposition which it is needless to notice here. One of these branches—a true *perforating artery*, traverses the inferior extremity of the cannon bone, and ascends in its anterior groove to join the anterior interosseous artery, after detaching ramuscules to the metacarpo-phalangeal articulation.

b. The *middle digital artery* represents, by its dimensions, the continuation of the collateral artery of the cannon, and is a very voluminous vessel. It is at first inflected backwards and outwards to be placed on the posterior face of the perforatus tendon; then it descends into the interdigital space by passing behind the great sesamoid sheath, beneath the ligament uniting the two claws. Reaching the inferior extremity of the first phalanx, it divides into two *ungueal arteries*, one for each digit, which are inflected forwards, pass beneath the internal ligament common to the two interphalangeal articulations, and enter by the foramen pierced at the inner side of the pyramidal eminence into the internal sinus of the third phalanx, where each ramifies in the same manner as the plantar ungueal arteries of the Horse.

Several collateral branches, remarkable for the richness of their arborisations, escape from this median artery of the digits and its terminal divisions. The most important of these are: 1, At the middle of the first phalanx, two short transverse branches—a right and left, passing beneath the flexor tendons and going from the median digital artery to the lateral arteries of the digits; 2, Nearly at the same point, a single artery which traverses the interdigital space from behind to before, to pass between the two tendons of the common extensor of the phalanges, whence it ramifies on the anterior face of the digits by ascending along the anterior median vein, and anastomosing with a descending branch of the perforating artery which crosses the inferior extremity of the metacarpus; 3, A double branch analogous to the artery of the plantar cushion of the Horse, having its origin at the terminal extremity of the digital artery, often arising from the ungueal artery, either on one side or both, and communicating, by a transverse branch,

with its homologue; it is directed backward and downward on the bulb of the heel, where it forms an anastomotic arch with the lateral digital artery; from the convexity of this arch, which is turned downwards, there escape a large number of reticulating ramuscules, destined for the keratogenous membrane and the plantar cushion.

c. The *lateral digital arteries* are distinguished into *internal* and *external.* The first has its origin at the bend formed by the collateral of the cannon, when that vessel is inflected on the posterior face of the perforatus tendon to become the median digital artery, most frequently in common with the branch whose divisions join the metacarpal interosseous arteries. The second commences a little further off, after having received a branch from either this communicating artery, or from the external interosseous palmar; it is not rare to see it entirely formed by one of these branches, or by the two together. Whatever may be their point of origin, the lateral digital arteries descend on the excentric side of the digits, without the flexor tendons, and terminate in anastomosing by inosculation with the artery of the plantar cushion. Among the collateral branches emanating from these arteries, there ought to be distinguished that which goes to the ergot, and the transverse branch thrown across between each, as well as the median digital artery.[1]

2. *Axillary Arteries of the Pig.*

Both spring separately from the arch of the aorta; consequently, there is no anterior aorta. The *right artery*, or *brachio-cephalic trunk*, first arises; the *left* comes immediately after.

a. The *brachio-cephalic trunk* is directed forwards, under the inferior face of the trachea, and leaves the thorax to reach the inner face of the anterior limb, as in other animals.

It furnishes successively:—

1. At the first rib, and below, the two *carotid arteries*, rising singly from nearly the same point.

2. Directly opposite to these vessels, a trunk remarkable for the complication attending its mode of distribution; it is directed upwards and backwards, on the side of the trachea and longus colli, crosses the interval between the second and third ribs, and elevates itself into the deep cervical muscles, to terminate in the vicinity of the nape of the neck. It evidently represents the *deep* or *superior cervical artery.* Near its origin it gives off the *vertebral artery*, whose mode of termination is exactly the same as in the Horse. Beyond this, it detaches the *dorsal artery*, which ascends into the muscles of the withers, after passing into the first intercostal space. Lastly, it supplies, before leaving the thorax, the *subcostal* or *superior intercostal artery*, placed across the superior extremities of the third, fourth, and fifth ribs.

3. Always within, but a little more forward than the first rib, a voluminous *inferior cervical artery*, divided into several ascending branches; and the *two thoracic arteries*, which offer nothing particular for description.

4. Without the thorax, on the internal face of the scapulo-humeral articulation, the *humeral* or *subscapular arteries;* the first, less voluminous than the other, presents, from its origin to the distribution of its branches in the foot, a disposition essentially resembling that observed in this vessel in Ruminants; the second courses upwards in the space between the subscapular muscle and the teres major, and soon divides into two terminal branches, one of which continues the primitive track of the vessel, while the other passes beneath the subscapular muscle to carry its ramifications into the antero-external muscles of the shoulder, furnishing in its course: 1, The great dorsal artery, throwing a part of its ramifications into the olecranian muscles: 2, A voluminous branch which provides the greater number of the divisions given off, in the Horse, by the deep humeral and prehumeral arteries; 3, Two articular branches, one of which closely represents the superscapular artery.

b. The *left brachial trunk* only differs from the right in the disposition of the *superior cervical, dorsal,* and *vertebral* arteries, which have distinct origins; the two last are very close to each other, and the first furnishes the *subcostal branch.*

3. *Axillary Arteries of Carnivora.*

These arise separately from the convexity of the arch of the aorta, as in the Pig, and furnish successively, apart from the carotids, special branches of the brachio-cephalic trunk:—

1. A voluminous trunk, the common origin of the *dorsal, superior cervical,* and *sub-*

---

[1] In several instances, we have seen the lateral digital arteries stop at this transverse anastomosis, which then received them entirely.

costal or *superior intercostal* arteries the first passes between the two anterior ribs; the second in front of the first; the third across the internal face of the first, second, and third ribs near their cartilages, where it emits ascending and descending intercostal branches.

2. The *vertebral artery*, anastomosing, as in Solipeds, with a retrograde branch from the occipital artery; it supplements, in very great part, the superior cervical, whose volume is diminutive, and which is only distributed to the posterior part of the neck.

3. The *inferior cervical artery*, giving off the pectoral branches.

4. The *internal thoracic artery*, remarkable for its large volume, and for a superficial division chiefly destined to the mammæ, which joins an analogous branch from the external pudic artery.

5. An *external thoracic* branch, whose origin more resembles that of the *superscapular artery*, which appears to be absent.

6. The *subscapular artery*. After furnishing this vessel, the brachial trunk is prolonged by the humeral artery, which we will now examine in detail.

Humeral Artery.—Placed at first immediately behind the coraco-radial or biceps muscle, this vessel descends beneath the round pronator, and divides at the superior extremity of the radius into two terminal branches; these are the *ulnar* and *radial arteries*.

It detaches on its course collateral branches, analogous to those which have been described for Solipeds, and among which is a thin vessel, a vestige of the *anterior radial artery*, that passes beneath the terminal extremity of the biceps to supply the muscles covering, anteriorly, the articulation of the elbow.

Ulnar artery.—Much smaller than the radial, this vessel transmits, near its origin, the *interosseous artery*, which sometimes proceeds directly from the humeral artery, and whose calibre always exceeds, in animals, that of the ulnar artery. The latter is directed obliquely outwards and downwards, passing under the perforans, and gains the internal face of the anterior ulnar or oblique flexor of the metacarpus, where it lies beside the ulnar nerve, to descend with it inside the unciform bone, and join the posterior interosseous artery, or one of its terminal branches. On its track it gives off a number of muscular or cutaneous branches, several of which anastomose with the internal collateral artery of the elbow, as well as with divisions of the radial artery.

Interosseous artery.—This artery is placed between the cubitus and radius, underneath the square pronator, and is prolonged to the lower third of the fore-arm, where it separates into two branches—the *anterior* and *posterior interosseous arteries*, after abandoning on its way several branches, mostly anterior, which enter the antibrachial muscles by traversing the space comprised between the two bones of the fore-arm, the principal escaping by the radio-ulnar arch.

The *anterior interosseous artery*, after passing between the radius and ulna, descends on the anterior face of the carpus, where its divisions meet, inwardly, the collateral ramuscules of the radio-palmar artery, and outwardly, the arborisations of a branch from the posterior interosseous artery, forming with these vessels a wide-meshed plexus, from which definitively proceed several filaments that join the dorsal interosseous metacarpal arteries.

The *posterior interosseous artery* may be regarded, by its volume and direction, as the continuation of the interosseous trunk. After emerging from beneath the square pronator, it detaches an internal flexuous branch anastomosing with the radio-palmar artery, then several external musculo-cutaneous branches; after which it is placed within the pisiform bone, where it divides into two branches, after receiving the ulnar artery. The smallest of these branches anastomoses by inosculation with the superficial palmar arch; the other, larger and deeper-seated, is carried in front of the flexor tendons, beneath the aponeurosis covering the interosseous muscles, across the superior extremity of these, and so forming the *deep palmar arch*, which unites with a thin filament from the radio-palmar artery. This arch supplies, with some ramuscules destined to the muscles of the hand (or paw), *eight interosseous metacarpal arteries: four posterior* or *palmar*, which are united by their inferior extremity with the collaterals of the digits, after giving several divisions to the muscles of the hand; and *four anterior* or *dorsal*, traversing the superior extremity of the intermetacarpal spaces, like the *perforating arteries* in Man, joining the anterior interosseous branches of the fore-arm, and descending afterwards into the intermetacarpal spaces, to unite with the collateral arteries of the digits at the metacarpo-phalangeal articulations.

Radial artery: the *posterior radial* of the other animals. Lying alongside the long flexor of the thumb and the perforans muscle, this artery follows the inner face of the perforatus muscle, and curving outwards to be united to a branch from the posterior antibrachial interosseous artery, forms the *superficial palmar arcade*, from which escape

Fig. 284.

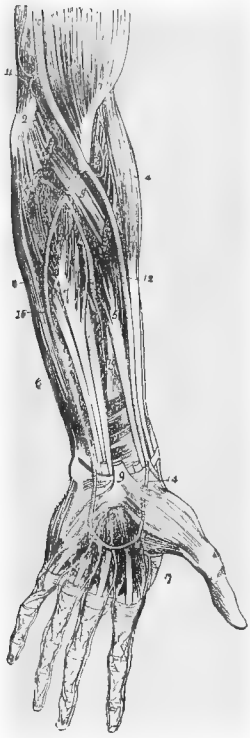

ARTERIES OF THE HUMAN FORE-ARM.

1, Lower part of biceps; 2, Inner condyle of humerus; 3, Deep portion of pronator radii teres; 4, Supinator longus; 5, Flexor longus pollicis; 6, Pronator quadratus; 7, Flexor profundus digitorum; 8, Flexor carpi ulnaris; 9, Annular ligament; 10, Brachial artery; 11, Anastomotica longus magna, inosculating above with the inferior profunda, and below with the anterior ulnar recurrent; 12, Radial artery; 13, Radial recurrent inosculating with the superior profunda; 14, Superficialis volæ; 15, Ulnar artery; 16, Superficial palmar arch, giving off digital branches to three fingers and a half; 17, Magna pollicis and radialis indicis; 18, Posterior ulnar recurrent; 19, Anterior interosseous; 20, Posterior interosseous.

four branches—the *palmar* or *collateral of the digits.* These are at first situated between the perforatus and perforans tendons, and reach the superior extremity of the interdigital spaces, where they receive the metacarpal interosseous arteries, and comport themselves in the following manner: the *internal* goes to the thumb; the *second*—counting from within outwards—gains the concentric side of the index; the *third*, the largest, divides into two branches which lie alongside the great digits; the *last* goes to the external digit.

COMPARISON OF THE AXILLARY ARTERIES IN MAN WITH THOSE OF ANIMALS.

The arteries of the thoracic limbs and head arise separately from the arch of the aorta; consequently, in *Man* there is no anterior aorta.

The vessel of the limb that represents the axillary of animals is here resolved into two portions: the *subclavian artery* and *axillary artery.*

The SUBCLAVIAN ARTERY has not the same origin on both sides; on the right it arises from the aorta by a trunk common to it and the carotid of that side—the *brachio-cephalic trunk* (*arteria innominata*); while the left is detached separately from the most distant part of the aortic arch. The subclavian vessels extend to the inferior border of the clavicles, and furnish seven important collateral branches, which are present in the domesticated animals. They are:—

1. The *vertebral artery*, situated in the vertebral foramina of the cervical vertebræ, as far as the axis; there it anastomoses, as in Solipeds, with a branch of the carotid, enters the spinal canal by the foramen magnum, and unites with its fellow at the lower border of the pons Varolii to form the basilar artery which, in the Horse, comes from the cerebro-spinal artery of the occipital.

2. The *inferior thyroid*, whose origin and some branches we find in the ascending branch (ascending cervical) of the inferior cervical artery in the *Horse.*

3. The *internal mammary* artery divides into two branches at the xiphoid appendix of the sternum.

4. The *superior intercostal artery*, whose analogue we see in Solipeds, in the subcostal branch of the dorsal.

5. The *superscapular artery*, present in all animals and disposed in the same manner.

6. The *transverse cervical* (*transversa colli*), represented by the extra-thoracic branches of the dorsal artery.

7. The *deep cervical* (*cervicalis profunda*) corresponds to the superior cervical in the Horse.

The AXILLARY ARTERY, or extra-thoracic portion of the subclavian trunk, extends to the external border of the pectoral muscle, where it is continued by the humeral artery. The axillary gives off: the *thoracica acromialis*, resembling the descending branch of the inferior cervical artery of large quadrupeds; the *external mammary*, *subscapular*; and *posterior* and *anterior circumflex*, branches of the preceding in Solipeds.

HUMERAL (BRACHIAL) ARTERY.—This artery extends from the external border of the pectoral muscle to the bend of the elbow: here it divides into two terminal branches—the ulnar and radial.

In its course it gives off several muscular branches,

and an *external* and *internal collateral of the elbow* (*collateralis ulnaris superior* and *inferior*). In the lower third of the arm, the brachial artery is comprised between the brachialis anticus and inner border of the biceps; so that, during flexion, and especially active and forced flexion, of the fore-arm on the arm, in vigorous subjects, the circulation is arrested in the vessels of the hand.

The *radial artery* of Man is represented in the Horse by the posterior radial artery. It is directed downward and a little inward, supposing the hand to be in a state of pronation; it crosses the carpus in front of the trapezium and scaphoides, at the bottom of the anatomical snuff-box, and beneath the flexor tendons of the phalanges forms the *deep palmar arch*, finally anastomosing with a branch of the ulnar at the hypothenar eminence. Along its course it furnishes muscular branches: the *carpea anterior; radio-palmar*, which passes outwards, and unites with a branch of the ulnar artery to form the *superficial palmar artery;* the *dorsalis pollicis;* the *carpea posterior*, which concurs in the formation of the *dorsal arch of the carpus* that gives origin to the *dorsal interosseous branches.*

The *ulnar artery*, formed, in Solipeds, by the anterior radial, passes downward and outward; it is at first covered by the great pronator muscles, great and small palmar, and superficial flexor; lower, it is only protected by the antibrachial aponeurosis and the skin. On the anterior face of the carpus, it passes within the pisiform bone, and anastomoses with the radio-palmar artery, whence results the superficial palmar arch. It gives rise to two *recurrent* arteries that ascend to receive the collateral vessels of the elbow, then to a trunk seen in animals, and which divides into the *anterior* and *posterior interosseæ.*

The three arches that exist in the vicinity of the carpus, the constitution of which has been already given, are distributed in the following manner

The *superficial palmar arch* is situated at the surface of the flexor tendons; from its convexity it emits four or five metacarpal branches: the first reaches the external border of the little finger as the *external collateral* of that organ the other four are lodged in the interosseous spaces, and when they reach the roots of the fingers they bifurcate and constitute the *external or internal collateral arteries* of the five fingers. The *deep palmar arch* furnishes: articular branches to the wrist, the *perforating branches* which cross the interosseous spaces to unite with the dorsal interosseæ; the *palmar interosseæ*, which join the superficial interosseæ before their division into collateral branches. Lastly, the *carpal dorsal arch* gives off the *dorsal interosseæ*, which receive perforating filaments above and below the metacarpus, and are expended in the articulations and skin of the fingers.

Article VII.—Primitive (or Common) Carotid Arteries.
(Figs. 282, 14; 286, 1.)

Origin.—These two vessels (named from κάρα, the head) arise from the right axillary artery, at a short distance from its origin, by a common trunk, the *cephalic*, which is detached at a very acute angle, and is directed forward beneath the inferior face of the trachea, and above the anterior vena cava, to terminate near the entrance to the chest by a bifurcation that commences the two common carotids.

Course.—Each of these arteries afterwards ascends in the midst of an abundant, though dense, connective tissue, along the trachea, at first beneath that tube, then at its side, and finally a little behind its lateral plane. Each carotid arrives in this way at the larynx and guttural pouch, where it divides into three branches.

Relations.—In its course, this vessel, independently of the connection between it and the trachea, affects the following relations:—

Throughout its entire length, it is accompanied by the cord that results from the union of the pneumogastric nerve with the cervical portion of the sympathetic, and by the recurrent nerve; the latter is placed below or in front of the vessel, from which it is somewhat distant in the lower part of the neck; the first is situated above or behind the artery, and lies close to it.

It also corresponds: behind, in its upper two thirds, to the longus colli

and the rectus anticus major; outwardly, to the scalenus, towards the inferior extremity of the neck, and to the subscapulo-hyoideus, which separates the artery and jugular vein in the middle and superior part. But near the entrance to the chest, these two vessels are in direct relationship, the vein below and the artery above.

It is also to be noted, that the glands at the entrance of the chest are in contact with the carotids, and that the left artery corresponds, besides, to the œsophagus.

Collateral Branches.—The branches furnished by the common carotid on its course are somewhat numerous, but they are of such inconsiderable diameter that their successive emission does not sensibly vary the calibre of the vessel from which they emanate; so that the carotids represent, from their origin to their termination, two somewhat regular cylindrical tubes. These collateral branches are destined either to the muscles of the cervical region, or to the œsophagus and trachea. Two of them, the *thyro-laryngeal* and *accessory thyroid arteries*, will occupy us in a special manner.

Thyro-laryngeal Artery (Fig. 282, 14″).—This vessel, which corresponds exactly to the *superior thyroid artery* of Man,[1] arises from the common carotid at a short distance from its termination, a little behind the larynx or above the thyroid body; it passes on that organ, into which it enters by two principal branches that turn round its superior extremity and anterior border, after sending two branches to the larynx—a superior, destined also to the pharyngeal walls; and an inferior, much more considerable, which is exclusively distributed to the laryngeal apparatus.

It sometimes happens that the thyro-laryngeal artery is found divided from its origin into two quite distinct branches, each furnishing a laryngeal and a thyroid division, as in figure 286, 3.[2]

We have already remarked the disproportion that exists between the considerable calibre of the branches sent by this artery to the thyroid body, and the slender volume of that organ; so that it will at present suffice to remind the student of this peculiarity.

Accessory Thyroid Artery (Figs. 282 14′; 286, 2).—The origin of this vessel precedes that of the first; it is much smaller, and enters the thyroid body by the posterior or inferior extremity of this glandiform lobe.

This artery often sends only some excessively fine ramuscules to the thyroid gland, and expends itself almost entirely in the cervical muscles.[3]

Terminal Branches.—The three branches which terminate the common carotid are the *occipital, and internal* and *external carotid arteries*; the latter is incomparably larger than the other two, which only appear to be collateral twigs from the principal vessel. It is these branches which distribute the blood to the various parts of the head. We will devote three special paragraphs to their study; but their preparation will previously demand some notice.

[1] We would have given it the same name if we could have found the true representative of the *inferior thyroid artery*.

[2] It was doubtless a case of this kind that Rigot had before him when he described the above vessel, and made two arteries of it—the *thyroid* and *laryngeal*. But, we repeat, this example is only exceptionally met with, and does not authorize its being supposed to be the rule, and cause the creation of a distinct thyroid and laryngeal artery; since each branch of the vessel is distributed to the larynx and thyroid body at the same time.

[3] We regard it as the analogue of the *middle thyroid* of Man.

Preparation of the arteries of the head.—After carefully removing the skin, dissect the superficial arteries of one side—that is, the external maxillary, maxillo-muscular, the temporal trunk, and the posterior auricular arteries, excising the parotid to expose the origin of the three last-named vessels. On the opposite side, the deep arteries are prepared, after disposing of the branch of the maxilla, as in the preparation of the muscles of the tongue; the orbital and zygomatic processes being removed in three sections with the saw, as in figure 286, which will serve as a guide in the dissection of all these arteries.

OCCIPITAL ARTERY. (Fig. 286, 6.)

The occipital artery is a slightly flexuous vessel, lying beside the upper third of the internal carotid. It ascends beneath the transverse process of the atlas in passing behind the guttural pouch, between the maxillary gland and the straight anterior muscles of the head. It then insinuates itself between the small lateral straight muscle and the inferior arch of the above vertebra, to pass through its anterior foramen, and terminate by two branches, after coursing along the short fissure which unites this foramen with the superior. In its track, this artery is crossed, outwardly, by the pneumogastric and spinal nerves, and the occipital nerve of the great sympathetic, and is accompanied by the divisions of the inferior branch of the first pair of cervical nerves.

The two terminal branches of the vessel are the *occipito-muscular* and *cerebro-spinal arteries.*

The collateral branches are three in number, and in the order of their emission are named: 1, The *prevertebral artery;* 2, The *mastoid artery;* 3, The *atloido-muscular artery.*

Collateral Branches.—1. Prevertebral Artery (Fig. 286, 9).—The smallest of all the branches emanating from the occipital, this artery is detached at a very acute angle, and immediately divides into several filaments, some *muscular*, the others *meningeal.* The majority of the first pass between the occipito-atloid articulation and the small anterior rectus muscle of the head, and expend themselves either in that muscle, or the great rectus; the second, generally two in number, are always very slender, and reach the dura mater by entering, one through the posterior foramen lacerum, the other by the condyloid foramen.

2. Mastoid Artery (Fig. 286, 8).—This vessel arises at an acute angle above the preceding, and goes towards the mastoid foramen by creeping on the external surface of the styloid process of the occipital bone, beneath the small oblique muscle of the head. It enters the parieto-temporal canal by this foramen, to anastomose by inosculation with the spheno-spinous artery.

In its course it describes a curve downwards, and throws off a large number of collateral branches. Among these are some which originate before the artery enters its bony canal, and which are destined for the muscles of the nape of the neck. Others arise in the interior of this canal, and escape from it by the orifices that cribble the temporal fossa, to expend themselves in the temporal muscle. Some ramuscules reach the dura mater.

We have seen the mastoid artery arise directly from the common carotid, and furnish a parotideal branch.

3. Atloido-muscular or Retrograde Artery (Fig. 286, 7).—This branch is not constant, and when it does exist it presents a variable volume. It is detached from the occipital, underneath the transverse process of the atlas, by forming with the parent branch a right, or even an obtuse angle; it is directed backwards, traverses the inferior foramen of the process of the

atlas, places itself beneath the atlo-axoid muscle, and in a flexuous manner advances to meet the vertebral artery, which it directly joins, after giving off some branches to the great oblique and neighbouring muscles. This anastomosis is the means of establishing a collateral communication between the vertebral artery, and the divisions furnished by the common carotid; so that these two arteries can mutually assist or supplant each other.

Terminal Branches.—1. Occipito-muscular Artery (Fig. 286, 10).—Covered at its origin by the great oblique muscle, the occipito-muscular artery is directed transversely inwards to the surface of the posterior straight (recti) muscles, and soon separates into several branches—ascending and descending—mixed with the nervous divisions of the first superior cervical branch, all of which are destined to the muscles and integuments of the occipital region. The descending branches anastomose with the terminal divisions of the superior cervical artery.

2. Cerebro-spinal Artery.—This vessel enters the spinal canal by the anterior foramen of the atlas, traverses the dura mater, and divides into two branches on the inferior face of the spinal cord. Of these two branches, the anterior is united, by convergence, with the analogous branch of the opposite artery on its arrival at the middle of the length of the bulb (medulla oblongata), and so forms the *basilar trunk;* the other passes backwards, and constitutes the origin of the *median spinal artery*, by anastomosing, after a short course, with the corresponding branch of the other cerebro-spinal artery. There results from this distribution a kind of vascular lozenge, situated at the lower face of the medulla oblongata, which receives in its middle the two cerebro-spinal arteries. This regular arrangement is not, however, always observed; these arteries may unite at the posterior extremity of this lozenge, as is shown in figure 285.

Basilar trunk.—This is a single vessel which creeps in a somewhat flexuous manner on the inferior face of the medulla oblongata, beneath the visceral arachnoid membrane, and passing over the annular protuberance (pons Varolii), terminates at the anterior border of this portion of the encephalic isthmus, by anastomosing with the two posterior cerebral arteries (Fig. 285, 11, 11).

On its course it gives off:

1. A multitude of plexuous ramuscules, which enter the substance of the medulla oblongata and the pons Varolii, or are distributed to the roots of the nerves emanating from the medulla oblongata.

2. The *posterior cerebellar arteries*, vessels liable to numerous anomalies in their origin; they usually arise from the basilar trunk at a right angle, behind the posterior border of the pons Varolii, and bend outwards, one to the right, the other to the left, by gliding along the surface of the bulb (medulla oblongata), whose external border it thus reaches, and is then inflected backwards beneath the cerebellar plexus choroïdes, whence they spread their ramifications on the lateral and posterior parts of the cerebellum.

3. The *anterior cerebellar arteries*, two or three on each side, only one of which is constant. These vessels are very variable in their disposition, and arise from the terminal extremity of the basilar trunk, in front of the pons Varolii, and sometimes even from the posterior cerebral arteries. Usually united in fasciculi, they are directed outwards and a little backwards in turning round the cerebral pedunculi, and plunge into the anterior part of the cerebellum.

4. Two branches anastomosing with the internal carotid artery; these

branches are not constant, and are most frequently met with in the Ass. They begin at the basilar trunk, in front of the posterior border of the annular protuberance, traverse the dura mater to enter the cavernous sinus, and join the carotid arteries at their second curvature.

Posterior Cerebral Arteries.—These terminate the basilar trunk, and separate into right and left of it, behind the pisiform tubercle (Fig. 285, 11). They first proceed forward, receiving posterior communications, then pass outward and upward, to turn round the cerebral peduncles and reach Bichat's fissure. On their course, they furnish a multitude of hair-like twigs that enter the substance of the peduncles; but the principal branches they give off are flexuous, and directed either towards the great cerebral fissure, where they terminate, to the posterior extremity of the hemisphere of the cerebrum, or its interior, to the plexus chorides more particularly, or even to the cerebellum. The disposition and number of these branches are very variable.

Median Spinal Artery.—A very long vessel, lodged in the inferior fissure of the spinal cord, and measuring the whole extent of that organ, which it follows from before to behind. It is from this artery that are given off the branches which cover with their arborisations the medullary tissue, or penetrate its substance. This emission, which ought soon to exhaust the artery, does not sensibly diminish its diameter, as it receives on both sides, during its course, numerous additional filaments. Two series of ramuscules, in fact, emanate either from the vertebral, intercostal, lumbar, or sacral arteries, and enter the spinal canal by the intervertebral foramina, and go to join this artery. Generally, however, they do not pass to the spinal cord until they have anastomosed with each other outside the dura mater, so as to form on the floor of the vertebral canal two lateral conduits placed beside the venous sinus, and united by transverse anastomoses; this disposition is most evident in the cervical region of the Ox (Fig. 288).

INTERNAL CAROTID ARTERY. (Figs. 285, 8; 286, 5.)

One of the terminal branches of the common carotid, the internal carotid ascends at first to beneath the base of the cranium, outside the anterior rectus muscles of the head, and bends forward to reach the lacerated foramen. In this primary portion of its course, it is suspended in a particular fold of the guttural pouch, margined by the superior cervical ganglion, accompanied by the cavernous branch of the sympathetic nerve, and crossed in various directions by the nerves which form the guttural plexus. On arriving at the middle of the occipito-spheno-temporal hiatus, it enters the cavernous sinus, and in the interior of that cavity, where it is bathed in venous blood, describes two successive and opposite curvatures; the first looking forwards, occupies the carotid fossa of the sphenoid bone: the second, with its convexity posterior, at which the internal carotid receives an anastomosing branch from the basilar trunk: which branch is voluminous and nearly constant in the Ass; but is rare and, when present, very slender in the Horse. After the last inflexion, the two internal carotids communicate by a very large transverse branch, which is always flexuous, often reticulated, and leave the cavernous sinus in crossing the dura mater, to gain the cranial cavity.

These arteries are then placed at the sides of the pituitary gland, within the superior maxillary nerve, proceed from behind forward, and terminate in two branches before reaching the optic nerve. One of these branches

constitutes the *posterior communicating artery*; the other soon bifurcates to form the *middle* and *anterior cerebral arteries*.

Fig. 285.

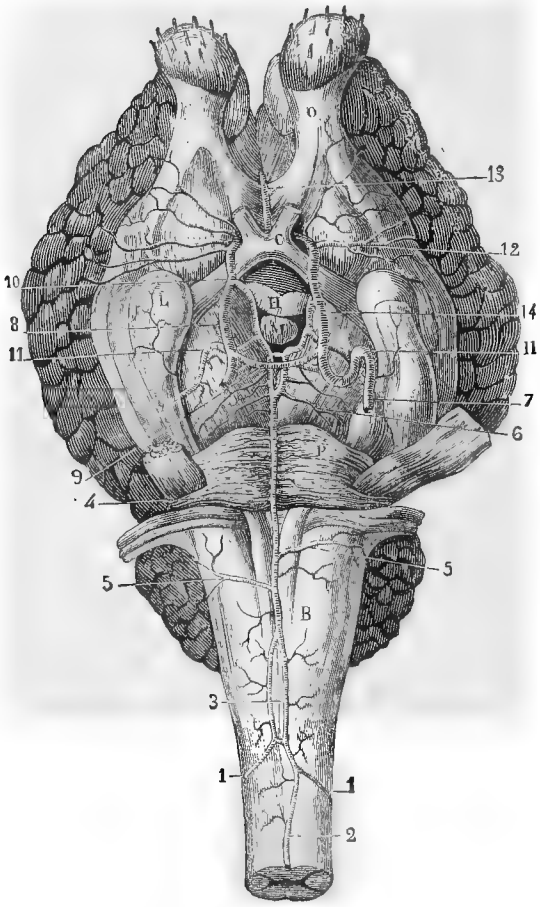

ARTERIES OF THE BRAIN.

B, Medulla oblongata; P, Pons Varolii; L, Mastoid lobule; O, Olfactory lobule; C, Chiasma of the optic nerves; M, Mamillary, or pisiform tubercle; H, Pituitary gland; three-fourths have been excised.—1, 1, Cerebro-spinal arteries; 2, Median spinal artery; 3, Lozenge-shaped anastomosis of the two cerebro-spinal arteries, from which result, in front:—4, The basilar trunk (usually the cerebro-spinal arteries arrive in the middle of the lozenge); 5, 5, Posterior cerebellar arteries; 6, Anterior ditto; 7, Internal carotid artery, with the two curves it makes in the cavernous sinus; 8, Internal carotid on the sides of the pituitary gland; 9, Transverse reticulated anastomosis thrown between the two internal carotids behind the pituitary gland; 10, Bifurcation of the internal carotid; 11, 11, Posterior cerebral arteries anastomosing behind the pisiform tubercle, receiving in the middle of this anastomosis the two terminal branches of the basilar trunk; 12, Middle cerebral artery; 13, Anterior cerebral artery; 14, Posterior communicating artery.

Posterior Communicating Artery.—This vessel is inflected backward on the side of the pituitary gland, and anastomoses behind it with the posterior cerebral artery.

Middle Cerebral Artery.—This vessel separates itself from the anterior cerebral artery, external to the chiasma of the optic nerves, is lodged in the fissure of Sylvius, passing through it in a flexuous manner, and at its extremity separates into several branches which ramify on the lateral and superior faces of the brain, and anastomose by their terminal divisions with the posterior and anterior cerebral arteries.

Anterior Cerebral Artery.—This enters immediately above the commissure of the optic nerves, and proceeds inwards to unite, in the middle line, with the opposite artery, forming with it a single vessel. This median artery (or *arteria corporis callosi*) enters the longitudinal fissure of the brain by bending round the anterior extremity of the corpus callosum, and, after a short course, divides into two branches which pass from before to behind, one to the right, the other to the left, on the internal face of the hemispheres, a short distance from the corpus callosum, and near the posterior extremity of that great commissure. The branches emitted by these arteries, either in their track or at their termination, anastomose with those of the posterior and middle cerebral arteries, as well as with the lobular branch of the ophthalmic.

Before uniting in a common trunk, the two anterior cerebral arteries receive the meningeal branch of the ophthalmic, the calibre of which often even surpasses that of these vessels.

EXTERNAL CAROTID ARTERY. (Fig. 286, 12.)

This artery ought to be considered, because of its volume and direction, as the continuation of the common carotid. It is directed forward, arrives at the posterior border of the great branch of the os hyoides, passes between it and the great hyoid muscle, and is inflected so as to form an elbow which is turned forward, and afterwards ascends vertically to near the neck of the condyle of the inferior maxilla, at the posterior angle of the hyoid branch. There it bifurcates to give rise to the *superficial temporal* and *internal maxillary arteries.*

In the first part of its course—that is, from its origin to the hyoid bone, the external carotid artery responds: inwardly, to the guttural pouch and the glosso-pharyngeal and superior laryngeal nerves; outwardly, to the outer belly of the digastric muscle, and the hypoglossal nerve.

In its second portion, it is comprised between the guttural pouch, the parotid gland, the great branch of the os hyoides, and the inner side of the posterior border of the inferior maxilla.

The collateral branches this artery furnishes are three principal: the *glosso-facial, maxillo-muscular*, and *posterior auricular*. But it also gives off others of less importance, which are distributed to the guttural pouch, the guttural glands, and the parotid gland.

1. *External Maxillary, Facial, or Glosso-facial Artery.* (Fig. 286, 13.)

It originates from the external carotid, at the point where that vessel passes beneath the great hyoid muscle, and is immediately inflected downwards on the side of the pharynx, between the posterior border of the large branch of the hyoid bone and the above muscle. It passes in proximity to the anterior extremity of the maxillary gland, crossing Wharton's duct outwardly,

and leaves the deep situation it at first occupied, to become more superficial in the submaxillary space, where it rises on the surface of the internal pterygoid muscle, and is directed forwards to the maxillary fissure. Turning round this fissure, it climbs on the face, in front of the masseter muscle, to above the maxillary spine, where it terminates in two small branches.

In its long and complicated course, the glosso-facial artery describes a semicircle upwards, and is very naturally divided, for the study of its relations, into three portions: a deep, an intermaxillary, and a facial. The first, or deep portion, accompanied in its superior moiety by the glosso-pharyngeal nerve, responds, outwardly, to the internal masseter (internal pterygoid) muscle; inwardly, to the guttural pouch, the hyo-pharyngeal muscle, hypoglossal nerve, middle tendon of the digastricus, the basio-glossus, canal of Wharton, and the subscapulo-hyoideus. The inter-maxillary, or middle portion, is bordered by the glosso-facial vein, lies against the pterygoideus internus, and is in contact with the submaxillary glands. The facial, or terminal part, is lodged, at its commencement, in the maxillary fissure, in front of the glosso-facial vein and the parotid duct; it ascends with these two vessels along the anterior border of the masseter. on the maxillo-labial and buccinator muscles, beneath the subcutaneous and zygomatico-labial muscles and the ramifications of the facial nerve, which perpendicularly crosses the direction of the artery.

Terminal Branches.—The external maxillary artery terminates in two small branches which separate from each other at an obtuse angle, one being directed upwards, the other downwards. The *ascending* branch passes to the surface of the elevator muscle of the upper lip, below the lachrymal muscle. and anastomoses with the divisions of a palpebral branch emanating from the supermaxillo-dental artery (Fig. 286, 19). The *descending* branch goes to the false nostril and the entrance to the nasal cavities, by creeping beneath the supernasalis-labialis muscle (Fig. 286, 20).

Collateral Branches.—These are five principal branches: 1, The *pharyngeal;* 2, *lingual;* 3, *sublingual;* all of which arise from the first portion of the glosso-facial artery; 4, The *inferior* and *superior coronary arteries*, emanating from the facial portion. Besides these, there are a great number of innominate branches of secondary importance, which proceed to the neighbouring parts, and principally to the maxillary gland, sub-maxillary glands, the masseter muscle, and the muscles and integuments of the face. We will content ourselves with merely noting the existence of these latter branches.

1. Pharyngeal Artery (Fig. 286, 14).—This arises from the glosso-facial, at a variable distance from its origin, and sometimes even in the angle formed by that vessel and the external carotid artery. Whatever may be its commencement, it is always directed forwards, passes between the hyo-pharyngeus muscle and the great branch of the hyoid bone, and describing some flexuosities, goes towards the pterygoid process, beneath the elastic layer which covers the pterygo-pharyngeus muscle (anterior constrictor of the pharynx). It terminates in the soft palate, after giving off on its course ascending and descending branches, which expend themselves in the walls of the pharynx.

2. Lingual Artery (Fig. 286, 15).—As considerable in volume as the parent branch, this artery is detached at an acute angle from it, at the extremity of the hyoid cornu. With the glosso-pharyngeal nerve, it passes beneath the basio-glossal muscle, crossing the small branch of the os hyoides, and extends to the extremity of the tongue by gliding in the

Fig. 286.

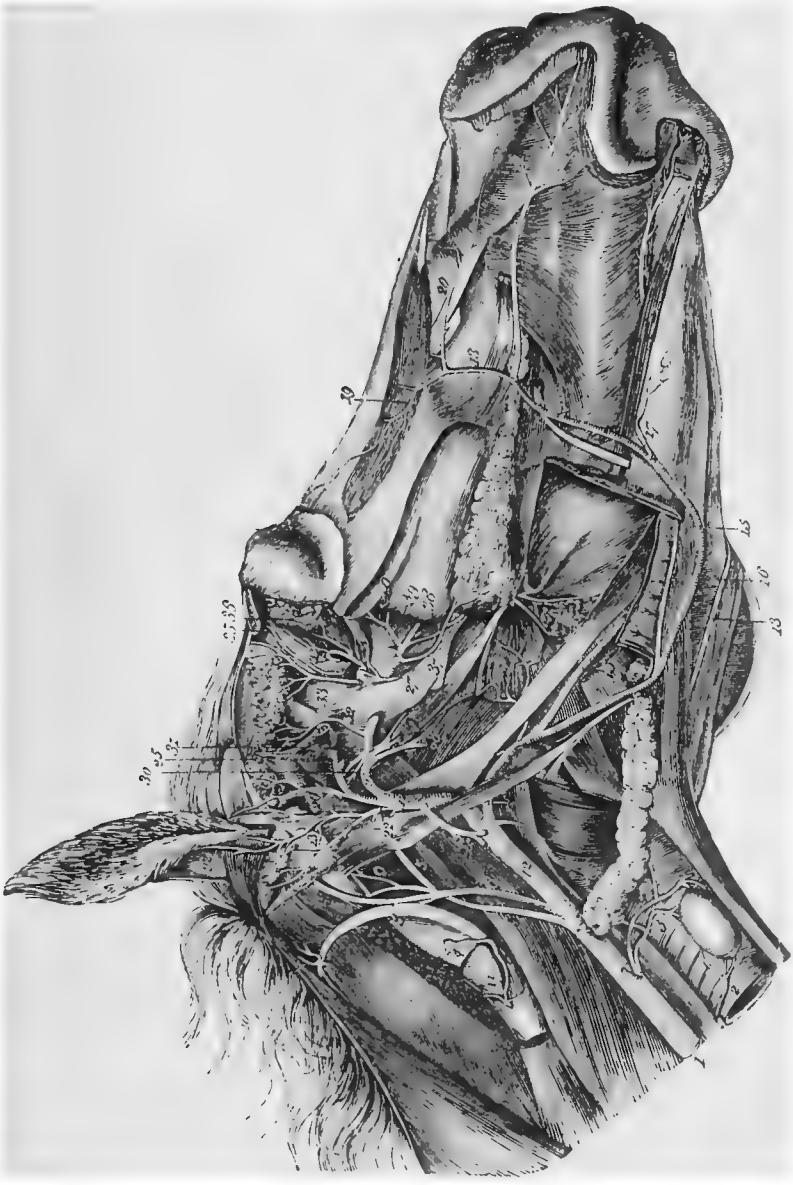

ARTERIES OF THE HEAD.

1, Common carotid artery; 2, Accessory thyroid artery, 3, 4, Thyro-laryngeal artery, divided into two branches; 5, Internal carotid artery; 6, Occipital artery; 7, Atloido-muscular artery at its exit from the inferior foramen of the atlas; 8, Mastoid artery; 9, Prevertebral artery; 10, Occipito-muscular artery;

interstice between the genio-glossus and basio-glossus muscles, where it meets the branches of the lingual and hypoglossal nerves.

Flexuous in its course, in order to adapt itself to the elongation of the tongue, the lingual artery emits a very great number of collateral branches, which escape perpendicularly from the entire periphery of the vessel; but chiefly above, below, and on the inner side, to ramify in the muscles and integuments of the tongue.

Running parallel to each other, the two lingual communicate by five transverse ramuscules, and join at their terminal extremity, which becomes very slender.

3. Sublingual Artery (Fig. 286, 16).—This artery has its origin at the anterior extremity of the maxillary gland, and runs forward along the external surface of the mylo-hyoideus muscle, which it afterwards crosses towards the posterior extremity of the sublingual gland. It then follows the inferior border of this gland, sending into it numerous branches, and after giving some filaments to the genio-glossus and genio-hyoideus muscles, is prolonged on the sides of the frænum linguæ, where it ends by fine ramuscules in the buccal mucous membrane.

Among the branches this artery detaches before attaining the sublingual gland, it is necessary to distinguish those which are destined to the mylo-hyoideus muscle, some of which, the descending, are thin and irregular; and others, ascending, being long, thick, and parallel to each other.

Sometimes this artery does not reach the sublingual gland; it then remains, for the whole of its extent, external to the mylo-hyoideus muscle, and sends its terminal divisions to the vicinity of the symphysis of the chin. In this case, the gland receives a special branch from the lingual artery, a circumstance which is usual in Man, in whom this artery is named the *submental*.

4. Coronary or Inferior Labial (Fig. 286, 17).—Springing from the glosso-facial artery at an acute angle, shortly before that vessel arrives at the maxillo-labial muscle, the inferior coronary artery passes under that muscle, and following its direction, descends into the texture of the lower lip, where it is mixed up with the ramifications of the mental nerve, and where it terminates by forming a very fine anastomotic arch with the vessel of the opposite side.

In its track, it gives branches to the buccinator and maxillo-labial muscles, and to the tissues of the lower lip, to which it is chiefly destined. In its passage near the mental foramen, it receives the inferior dental artery as it leaves that opening.

5. Coronary or Superior Labial Artery (Fig. 286, 18).—Smaller than the preceding vessel, and often altogether rudimentary, this artery is detached from the principal trunk at nearly a right angle, above the

---

11, Terminal extremity of the vertebral artery joining the atloido-muscular branch; 12, External carotid artery; 13, External maxillary artery; 14, Pharyngeal artery; 15, Lingual artery; 16, Sublingual artery; 17, Coronary, or inferior labial artery; 18, Coronary, or superior labial artery; 19, Superior terminal branch of the external maxillary artery; 20, Inferior terminal branch of ditto; 21, Maxillo-muscular artery; 22, 23, Posterior auricular artery; 24, Superficial temporal trunk; 25, Subzygomatic artery; 26, Inferior auricular artery; 27, Internal maxillary artery; 28, Inferior dental artery; 29, Fasciculi of pterygoid arteries; 30, Tympanic artery; 31, Spheno-spinous artery, 32, Deep posterior temporal artery; 33, Deep anterior temporal artery; 34, Ophthalmic artery; 35, Supra-orbital artery; 36, Lachrymal artery; 37, Buccal-artery; 38, Palatine artery; 39, Superior dental artery; 40, Orbital branch of that vessel.

origin of the pyramidal muscle of the nose, (supermaxillo-nasalis magnus), and sometimes below that muscle. It subsequently gains the upper lip, along with the infra-orbital branches of the superior maxillary nerve, by passing between the supernasalis-labialis and the pyramidal muscle of the nose; it then terminates in forming an arch by inosculation with the palato-labialis artery.

The branches it gives off pass to the external ala of the nose and the textures of the upper lip. Some are expended in the muscles just named, and in the alveolo-labialis.

2. *Maxillo-muscular Artery.* (Fig. 286, 21.)

The maxillo-muscular artery is a vessel that does not appear to have its representative in Man. It emerges from the external carotid, above the point where it is included between the large branch of the os hyoides and the stylo-hyoid muscle. Remarkable for the very obtuse angle it forms at its origin with the principal vessel, it descends behind the posterior border of the inferior maxilla, covered by the parotid gland. It then divides into two branches: a deep one, which goes to the internal pterygoid muscle, after furnishing some ramuscules to the neighbouring organs; and a superficial one, which turns round the posterior border of the maxilla, and emerging from beneath the parotid gland, above the insertion of the sterno-maxillaris muscle, plunges into the masseter, and expends itself in the body of that muscle by several branches which anastomose with the divisions of the subzygomatic artery.

3. *Posterior Auricular Artery.* (Fig. 286, 22.)

Third collateral branch of the external carotid, the posterior auricular artery arises at a very acute angle above, and a little behind, the preceding vessel. It ascends beneath the parotid gland, behind the base of the concha of the ear, crosses the cervico-auricular muscles, and reaches the extremity of the cartilage by passing underneath the skin which covers its posterior plane.

In its course, it emits several ascending auricular branches, which arise at different elevations and cover the concha with their divisions. Among these we ought to distinguish the first (Fig. 286, 23); this has its origin at the temporal trunk, and soon divides into two branches: one, profound, after sending a very thin filament into the middle ear by the stylo-mastoid foramen, passes between the external auditory canal and the mastoid process to enter the subconchal adipose tissue and the internal scuto-auricular muscle; the other, superficial, imbedded in the parotid tissue, proceeds to the external side of the concha, and buries itself in the interior of that cartilage, along with the middle auricular nerve, after abandoning some external ramuscules.

From these auricular branches there also escape a multitude of parotideal twigs.

4. *Superficial Temporal Artery or Temporal Trunk.* (Fig. 286, 25.)

This is the smallest of the two terminal branches of the external carotid. After a short ascending course between the parotid gland, the guttural pouch, and the neck of the maxillary condyle, behind which it is situated, this artery is divided into two branches: the *anterior auricular* and the *subzygomatic.*

Anterior Auricular Artery (Fig. 286, 26).—This vessel appears to be, not only by its volume, but also by its direction, the continuation of the temporal trunk. Embraced, near its origin, by the facial nerve and subzygomatic branch of the inferior maxillary nerve, it rises behind the temporo-maxillary articulation and supercondyloid process, beneath the parotid gland, to the temporal muscle, into which it passes after emitting parotideal twigs and auricular branches, one of which penetrates to the interior of the concha, while the others are expended in the anterior muscles of the ear and the integuments covering these muscles.

Subzygomatic Artery (Fig. 286, 25.)—More considerable than the anterior auricular, this artery disengages itself from beneath the parotid gland by turning round the posterior border of the maxilla, along with the nervous anastomosis which gives rise to the subzygomatic plexus, and is placed above that anastomosis, beneath, and to the outside of, the afore-mentioned condyle. There it ends in two branches of equal volume: a superior or superficial, and an inferior or deep, both of which ramify in the substance of the masseter muscle, and anastomose with the divisions of the maxillo-muscular, or with the masseter branches of the external maxillary arteries.

The *superior branch*, or *transverse artery of the face*, goes towards the anterior border of the masseter muscle in a flexuous manner, close to the zygomatic ridge. At first lying on the superficies of the masseter, it afterwards buries itself in that muscle.

The *inferior branch*, or *masseteric artery*, dips in among the deep fasciculi of the masseter muscle, to which it is distributed, along with the masseteric nerve. Near its origin, it communicates with the deep posterior temporal artery by a fine ramuscule, which passes into the sigmoid notch. In Man and some animals, this artery comes from the internal maxillary.

5. *Internal maxillary or Gutturo-maxillary Artery.* (Fig. 286, 27.)

Situated at first immediately within the maxillary condyle, below the articulation of the jaw, this artery passes to the inner side, towards the entrance of the subsphenoidal (or pterygo-palatine) canal, by describing two successive curvatures: the first backwards, the other forwards. After being thus shaped like an S, it travels forward along the subsphenoidal canal to the orbital hiatus, and then reaches the maxillary hiatus to enter the palatine canal, where it is designated the *palato-labial artery*.

In order to study its relations, the course of this artery may be divided into three portions: a posterior or guttural, a middle or sphenoidal, and an anterior or infra-orbital. The posterior portion lies on the internal face of the external pterygoid muscle, covered inwardly by the guttural pouch, and crossed outwardly by the inferior maxillary nerve and some of its branches. The middle division is enveloped by the bony walls of the subsphenoidal canal. The anterior portion, alone with the superior maxillary nerve, passes across the space separating the orbital from the maxillary hiatus, by creeping along the palate bone, beneath a considerable mass of fat.

Collateral Branches.—The arteries given off by the internal maxillary on its course are eleven principal. Five arise from the first portion of the vessel: two below, the *inferior dental* and the group of pterygoid arteries; three above, the *tympanic*, *spheno-spinous*, and *deep posterior temporal*.

Two escape from the superior portion of the interosseous or sphenoidal division. These are the *deep anterior temporal* and *ophthalmic arteries*. Four

commence from the third section of the artery: two inferior, the *buccal* and *palatine;* and two upper, the *superior dental* and the *nasal.*

1. Inferior Dental Artery (Fig. 286, 28).—This vessel, also named the *maxillo-dental artery*, is detached at a right angle from about the middle of the first curvature described by the internal maxillary. It travels forward and downward between the two pterygoid muscles, afterwards between the internal one and the maxillary bone, entering with the inferior maxillary nerve into the dental canal, through the whole extent of which it passes. Arrived at the mental foramen, it separates into two branches: a deep one, which continues the interosseous course of the vessel, to be distributed to the roots of the tusk or tush, and the three adjoining incisor teeth; the other superficial, generally very slender and even capillary, issuing by the mental foramen with the terminal branches of the maxillary nerve, and anastomosing with the inferior coronary artery.

Before penetrating the maxilla, this artery furnishes divisions to the internal pterygoid and mylo-hyoid muscles.

In the interior of the maxillo-dental canal, it gives off diploïc branches as well as twigs, destined to the roots of the molar teeth and the alveolar membrane.

2. Pterygoid Arteries (Fig. 286, 29).—It may be said, in a general manner, that the two pterygoid muscles borrow their arteries from all the vessels passing near them, though there are two, and sometimes three, branches more especially intended for them. These branches, or, properly speaking, *pterygoid arteries*, arise from the middle of the second curvature of the internal maxillary, either at an acute or right angle, and enter the pterygoid muscles, after a short course forward and downward on the external tensor palati muscle; this and its fellow, the internal muscle, also receiving some branches.

3. Tympanic Artery (Fig. 286, 30).—A very thin and small, but constant artery, gliding along the surface of the guttural pouch, accompanying the tympano-lingual nerve, and penetrating the tympanic cavity by a foramen situated at the base of the styloid process of the temporal bone (the *fissura Glaseri*). It throws off ramuscules to the wall of the guttural pouch and the trigeminal nerve; these often arise directly from the trunk of the internal maxillary artery, besides the tympanic branch.

4. Spheno-spinous or Great Meningeal Artery (Fig. 286, 31).—Commencing at an obtuse angle, opposite the pterygoideal vessels, this artery lies against the sphenoid bone, near the temporal insertion of the tensor palati muscles, is directed backwards and upwards, enters the cranium by the anterior lacerated foramen, outside the inferior maxillary nerve, passes beneath the dura mater, and soon after engages itself in a particular foramen in the parieto-temporal canal, where it anastomoses by inosculation with the mastoid artery.

Before penetrating this canal, the spheno-spinous artery gives off a meningeal branch, whose ramifications, destined to the dura mater, stand in relief on that membrane, and creep along in the small grooves channeled on the inner surface of the cranium.

The volume of this vessel is subject to the greatest variations, and is always in an inverse proportion to that of the mastoid artery.

5. Deep Posterior Temporal Artery (Fig. 286, 32).—This arises at a right angle, immediately before the entrance of the internal maxillary artery into the subsphenoidal canal. Then it ascends on the temporal bone, in the temporal muscle, passing in front of the temporo maxillary articula-

tion, which it turns round to be inflected backwards. This vessel communicates with the masseteric artery by a fine division, which traverses the sigmoid notch of the maxillary bone.

6. Deep Anterior Temporal Artery (Fig. 286, 33).—Springing at a right angle, like the preceding, in the interior of the subsphenoidal canal, this artery escapes by the superior branch of that conduit, ascends against the bony wall of the temporal fossa, along the anterior border of the temporal muscle, in which it is almost entirely expended. It gives some ramuscules to the adipose tissue of the temporal fossa. Its terminal extremity arrives beneath the internal parieto-auricular muscle, ramifies in it, and in the skin of the forehead.

7. Ophthalmic Artery (Fig. 286, 34).—This vessel has a somewhat singular arrangement. After being detached from the internal maxillary in the subsphenoidal canal, in front of the deep anterior temporal artery, with which it is sometimes united, it penetrates by the orbital hiatus to the bottom of the ocular sheath; it then enters the cranium by the orbital foramen, after describing a loop opening backwards and downwards, which passes between the muscles of the eye, beneath the superior rectus, and above the optic nerve and the sheath formed round it by the posterior rectus (or retractor).

Entering the cranium, the ophthalmic artery passes inwards along a groove in the ethmoidal fossa, and terminates by two branches: a *meningeal* and *nasal.*

Collateral branches.—In its orbital track, the ophthalmic artery emits numerous collateral branches, which arise from the convex side of the loop described by this vessel. These are: the muscular arteries of the eye, the *ciliary*, *central artery of the retina*, *supra-orbital*, and *lachrymal arteries.*

In its cranial portion, it furnishes the *cerebral branches.*

The *muscular arteries of the eye* have a destination sufficiently indicated by their name. Their number and mode of origin vary. They are usually two principal, which arise directly from the ophthalmic artery, and others of a smaller size furnished by the lachrymal and supra-orbital branches.

The *ciliary arteries*, destined to the constituent parts of the globe of the eye, but chiefly to the choroid coat, the ciliary processes, and the iris, are long thin branches, emanating, for the most part, from the muscular arteries.

We only mention the *centralis retinæ artery* here; as it and the ciliary arteries will be described when we come to study the visual apparatus.

The *supra-orbital artery* ascends, with the nerve of the same name, against the inner wall of the ocular sheath, to gain the supra-orbital foramen; passing through that orifice, it is distributed to the frontal and supra-orbital muscles, the orbicularis of the eyelids, external temporo-auricularis muscle, as well as to the integument of the frontal region (Fig. 286, 35).

The *lachrymal artery* creeps upwards and forwards, between the muscles of the globe of the eye and the superior wall of the ocular sheath, to terminate in the lachrymal gland and the upper eyelid (Fig. 286, 36.)

The *cerebral branches* of the ophthalmic artery vary in number, and frequently there is only one, of somewhat considerable volume. They pass to the anterior extremity of the cerebral lobe, and anastomose with the divisions of the anterior cerebral artery.

Terminal branches.—The *meningeal branch*, after detaching ramuscules

to the dura mater, and particularly to the falx cerebri, anastomoses on the median line, below the process of the crista galli, with that of the opposite side, and afterwards joins the anterior cerebral artery.

The *nasal branch* traverses the cribriform plate of the ethmoid bone, and divides into a number of ramuscules, which descend either on the ethmoidal cells, or on the middle septum of the nose, where their ramifications form arterial tufts of a pleasing aspect.

8. Buccal Artery (Fig. 286, 37).—The buccal artery emerges at an acute angle from the internal maxillary, a short distance in front of the orbital hiatus, and descends obliquely between the maxillary bone and the superior insertion of the internal pterygoid muscle, terminating in the posterior part of the molar glands, and in the alveo-labial and maxillo-labial muscles.

In its course it gives some insignificant ramuscules to the pterygoid muscles, as well as the masseter, and a long adipose branch to the cushion in the temporal fossa. The latter sometimes comes directly from the internal maxillary artery.

9. Staphylin Artery (Fig. 286, 38).—A very thin filament, which accompanies the posterior palatine nerve in the groove of the same name, and is distributed to the soft palate.

10. Superior Dental Artery (Fig. 286, 39).—This vessel, which is also named the *supermaxillo-dental* artery, enters the superior dental canal, arrives near its inferior or infra-orbital opening, and then divides into two thin branches. One of these continues in the same course in the supermaxillary bone, to supply arterial blood to the alveoli of the foremost molars, the tusk, and the incisor teeth; the other passes out of the canal with the terminal divisions of the superior maxillary nerve, and communicates on the forehead with a ramuscule from the external maxillary artery.

On its way, the superior dental artery emits several collateral branches, the majority of which commence in the interior of the dental canal, and pass either to the alveoli of the posterior molars, the tissue of the bone, or the membrane lining the sinuses. One of these branches—the *orbital*, and the largest—escapes from the principal artery before its entrance into the supermaxillary canal, creeps along the floor of the orbit towards the nasal angle of the eye, whence it descends on the forehead, after giving off some divisions to the caruncle of the eye, the lachrymal sac, and the lower eyelid.

11. Nasal or Spheno-palatine Artery.—Situated, at first, at the bottom of the maxillary hiatus, this artery, springing at a right angle from the parent trunk, traverses the nasal foramen, and separates into two terminal branches—an external and an internal—in ramifying on the walls of the nasal cavity.

Terminal Branch of the Internal Maxillary Artery. Palato-Labial or Palatine Artery. (Fig. 148, 3.)—A continuation of the internal maxillary, this vessel at first traverses the palatine canal, follows the palatine groove to near the superior incisors, is then inflected inwards above a small cartilaginous process (Fig. 148, 4), and unites on the median line with the artery of the opposite side, forming an arch whose convexity is forwards, and from which proceeds a single trunk that passes into the incisive foramen.

The palatine arteries, in their advance, furnish a series of branches destined to the anterior part of the soft palate, the membranes on the roof of the mouth, and the gums and upper teeth.

The single trunk which results from their anastomoses is placed, immediately after its exit from the incisive foramen, directly beneath the buccal mucous membrane, and at once divides into two principal branches —a right and left; these are lodged in the tissue of the upper lip, and pass back to meet the coronary arteries, with which they anastomose by inosculation, after throwing off on their track a great number of branches destined to the muscles and integuments of the lip and nostrils.

DIFFERENTIAL CHARACTERS IN THE CAROTID ARTERIES OF OTHER THAN SOLIPED ANIMALS.

1. *The Carotid Arteries in Carnivora.*

In the *Dog*, the carotids arise singly from the brachio-cephalic trunk, and ascend beneath the transverse process of the atlas, along the trachea, following a course exactly like that pursued by these vessels in the Horse.

Among the collateral branches furnished by them, may be distinguished the *thyro-laryngeal artery*, remarkable for its enormous calibre, its descending in front of the lateral lobe of the thyroid gland, and its termination in the median isthmus of that gland.

The terminal branches of the carotid are, as in Solipeds: 1, The *occipital;* 2, The *internal carotid;* 3, The *external carotid*, the continuation of the primitive vessel.

Occipital Artery.—Inconsiderable in volume, this vessel arises in front of the anterior border of the transverse process of the atlas, passes into the notch on its border, and divides into two branches—the *occipito-muscular* and the *cerebro-spinal arteries.*

In its course, it gives off branches analogous to those which emanate from the *prevertebral* artery of the Horse. It also gives a *mastoid artery*, which only sends one very small branch into the parieto-temporal canal, and is destined almost exclusively to the deep muscles of the neck. In addition, the occipital throws off a *retrograde artery*, which directly joins the vertebral.

The arrangement of the occipital artery in Carnivora is, therefore, almost identical with what has been described in Solipeds.

Internal Carotid Artery.—This vessel reaches the posterior opening of the carotid canal, along which it passes forward, then describes a very curious flexure which leaves the cranium by the carotid foramen (see page 62), then re-enters that cavity after receiving a particular branch from the external carotid. It afterwards anastomoses on the side of the pituitary fossa, with the divisions of the spheno-spinous artery and the returning branches of the ophthalmic artery, forming a kind of plexus, which appears to be a trace of the *réseau admirable* of Ruminants and Pachyderms, and from which proceed the cerebral arteries.

External Carotid Artery.—This arterial branch terminates, as in Solipeds, by the *superficial temporal* and the *internal maxillary arteries.*

It gives off on its course: 1. An artery representing the meningeal branch of the *prevertebral* of the Horse, and which ascends in a flexuous manner on the side of the pharynx to join the carotid flexure.

2. A *laryngeal artery*, entering the larynx with the superior nerve of that organ, after giving ramuscules to the maxillary gland.

3. The *lingual artery*, a very large tortuous branch, whose course resembles that of the same vessel in the Horse.

4. A *facial* or *external maxillary artery*, divided into two branches above the inferior insertion of the digastricus. One of these branches, analogous perhaps to the *submental* of Man, passes within this insertion, and is prolonged to the chin, after furnishing ramuscules to the parts lodged in the intermaxillary space. The other branch winds round the inferior border of the maxilla, in front of the masseter muscle, and is expended on the face by ascending and descending branches, among which we can readily perceive the two *coronary arteries*, and the two twigs which we have noticed in Solipeds as terminal branches of the vessel.

5. The *posterior auricular artery*, after detaching parotideal and musculo-cutaneous vessels, is situated on the middle of the external face of the concha, and is directed towards the terminal extremity of the cartilage, where it separates into two branches, which are inflected *en arcade*, and return, in following the borders of the concha, towards the base of the latter, where they anastomose with other branches, either from the posterior or anterior auricular, and which come to meet them.

Superficial temporal artery.—After a brief course behind the temporo-maxillary articulation, this vessel bifurcates: its posterior or *auricular* branch anastomosing with a division of the posterior auricular, but not before it has sent ramuscules to the interior of the concha, and furnished some musculo-cutaneous twigs. The other, the anterior or *temporal* branch, glides beneath the aponeurosis of the temporal muscle, above the upper margin of the zygomatic arch, and winds upwards and inwards around the outline of the orbit, to terminate on the face by anastomosing ramuscules, either with the infra-orbital branch of the superior dental artery, or with the facial. In its subaponeurotic course, it gives divisions to the temporal muscle. Above the orbital arch, it emits several superficial ascending and internal twigs, one of the principal of which communicates by ramuscules with the posterior auricular artery, the auricular branch of the superficial temporal, and with the homologous ramuscules from the opposite side.

Internal maxillary artery.—The course pursued by this vessel is similar to that it follows in the Horse. After describing an S curvature between the condyle of the maxillary bone and external pterygoid muscle, it traverses the subsphenoidal canal, and passes outside the internal pterygoid towards the maxillary hiatus, where it is continued by the *superior dental artery.*

a. The following are the principal collateral branches emitted by this vessel:

1. The *inferior dental artery.*

2. The *deep posterior temporal artery*, which furnishes a *masseteric branch* that traverses the sigmoid notch of the maxillary bone to enter the masseter muscle.

3. A fine *tympanic twig.*

4. The *spheno-spinous artery*, almost entirely destined to the formation of the plexus of the cerebral arteries.

5. Several *pteryyoid arteries.*

6. The *ophthalmic artery*, which, before entering the ethmoidal fossa by the orbital foramen, gives, independently of the branches noted in Solipeds—except the *supra-orbital*, which is absent—a fasciculus of particular branches. These penetrate the cranium by the great sphenoidal fissure, accompanying the motor and sensory nerves of the eye, to join the internal carotid and spheno-spinous arteries.

7. The *deep anterior temporal artery.*

8. A *staphylin artery*, more voluminous than that in the Horse.

9. The *palatine artery.*

10. A *buccal* and an *alveolar artery*, whose principal divisions enter Duvernoy's gland.

b. The *superior dental artery*, which terminates the internal maxillary, and furnishes an *orbital* and an *infra-orbital branch*, as in Solipeds. The latter, remarkable for its volume, emerges from the supermaxillary canal with the infra-orbital nerves, to join the divisions of the external maxillary artery on the face, and in the tissue of the upper lip.

2. *Carotid Arteries in the Pig.*

There is nothing particular to notice regarding the course of these vessels, which we know arise separately from the brachio-cephalic trunk.

Occipital artery.—In its distribution, it greatly resembles the same vessel in the Horse and Dog. Its most important branches are the following: 1, A very small *retrograde artery*, anastomosing with the vertebral; 2, A branch which mounts into the muscles of the neck, representing the *mastoid artery*; 3, Several occipital twigs, which pass, with the principal artery, by the anterior foramen of the atlas. This artery is expended in a complete manner in the muscles of the neck, and without sending a cerebro-spinal branch to the interior of the spinal canal.

Internal carotid artery.—After furnishing a large meningeal artery, this vessel enters the cranium by the posterior lacerated foramen, and there divides to form a *réseau admirable*, analogous to that of Ruminants, and of which a description will be given hereafter. The cerebral arteries arising from this *réseau* differ but little from those of Solipeds; these are the posterior cerebral arteries, which give rise to the basilar trunk, and originate the median spinal artery.

External carotid artery.—This artery is seen to pass between the pterygoid muscles and the branch of the maxillary, in describing several inflexions, and arrives in the maxillary hiatus, without exhibiting in its course any sensible distinction between the external carotid, properly called, and its continuation, the internal maxillary artery.

Among the branches it supplies, we notice:

1. The *lingual artery*, more voluminous, perhaps, than in the other animals.

2. A branch analogous, in its origin at least, to the glosso-facial artery of the Horse, and which distributes its ramuscules in the intermaxillary space, and particularly to the salivary and lymphatic gland

3. The *posterior auricular artery*, noticeable for its great length and considerable volume.

4. The *transverse artery of the face* and the *anterior auricular artery*, arising separately beside each other, and extremely slender.

5. Several *deep temporal* and *masseteric arteries.*

6. *Pterygoid branches.*

7. An enormous *buccal branch.*

8. The *ophthalmic artery*, concurring to form the *réseau admirable.*

9. A small *orbital branch*, coming from the superior dental artery in Solipeds and Carnivora.

10. The *nasal, palatine,* and *superior dental arteries.*

3. *Carotid Arteries of Ruminants.*

A. In the *Sheep*, which will serve as a type for this description, the carotid arteries arise by a common trunk from the right axillary artery, as in Solipeds. Arriving in the cephalic region, towards the upper part of the neck, they furnish a *thyroid* and a *laryngeal branch*, then give off a very slender *occipital artery*, and are continued from this point by the *external carotid.*

The *internal carotid*, properly called, is absent, and we will see immediately how it is compensated for.

Occipital artery.—Having given some ramuscules to the anterior recti muscles of the head, and a small meningeal branch which enters the cranium by the posterior lacerated foramen, this vessel passes into the condyloid foramen, which also affords a passage to the hypoglossal nerve, places itself beneath the dura mater, and is inflected backward to open into the anterior extremity of the collateral artery of the spine, at the superior foramen of the atlas. The branch resulting from this junction emerges by that foramen, to be distributed in the muscles of the neck, where its divisions resemble those of the occipito-muscular and atloido-muscular branches in the Horse.

In traversing the condyloid foramen, the occipital artery sends into the parieto-temporal canal, by a peculiar bony conduit (*see* page 56), a very small filament which is distributed to the dura mater, in anastomosing with a branch of the posterior auricular.

It communicates, after its entrance into the cranial cavity, with the *réseau admirable.*

External carotid artery.—Terminated, as in the Horse, by the *superficial temporal* and *internal maxillary arteries*, this vessel sends off on its course:

1. A *pharyngeal artery*, whose origin is nearly confounded with that of the occipital artery.

2. The *lingual artery*, furnishing a collateral branch which exactly represents the *submental* of Man, and is divided into two branches, which resemble the *sublingual* and *ranine* arteries.

3. A large division for the maxillary gland.

4. The *posterior auricular artery*, from which proceeds: 1, The *stylo-mastoid* twig, which penetrates the aqueduct of Fallopius; 2, *Concho-muscular* branches; 3, A large branch, resembling the *mastoid artery* of the Horse. This enters the temporo-parietal canal by a small foramen between the occipital and petrous portion of the temporal bone, and forms two branches: an external, emerging from this canal by the wide orifice in the temporal fossa, and expending itself in the temporal muscle, after anastomosing with the two deep temporal arteries; and an internal, a considerable meningeal artery, destined principally to the falx cerebri and the tentorium cerebelli.

5. A small *maxillo-muscular* artery, ramifying entirely in the internal pterygoid and the subcutaneous muscles.

Superficial temporal artery.—This vessel divides, almost at its origin, into three branches:

1. A posterior, supplying the *anterior arteries* of the ear.

2. An anterior, forming the transversal faciei, and terminating by the *coronary* or *labial arteries,* after giving some ramuscules to the masseter and the muscles of the forehead.

3. A median artery, representing the *middle temporal* of Man. This vessel detaches some divisions to the temporal muscle, gives off the *lachrymal artery*, as well as a palpebral branch rising from the same point, and terminates near the base of the cranium by two particular arteries which are developed around the base of the horn, and form a real arterial circle from which inferior and superior divisions are given off. The latter are the most considerable, and glide on the bony core of the frontal appendage, where they are distributed almost exclusively to the generating membrane of the horny tissue, only throwing some filaments into the sinuses.

Internal maxillary artery.—It does not traverse the subsphenoidal canal, as that bony passage does not exist.

The following are its principal branches:

1. The *inferior dental artery*, which emits some pterygoid ramuscules.
2. The *spheno-spinous artery*, arising from the same point as the preceding, often in common with it, giving also some *pterygoid branches*, and entering the cranium by the oval foramen to aid in the formation of the *réseau admirable*, in a way to be indicated hereafter.
3. The *deep posterior temporal artery*, which detaches a *masseteric* artery.
4. The *deep anterior temporal artery*.
5. The *buccal*, principally destined to the masseter muscle.
6. The *ophthalmic artery*, longer than in the other animals, forming a loop before traversing the orbital foramen, and giving a *supra-orbital branch* and a fasciculus of *muscular* and *ciliary arteries*. Near the point where the originating trunk of this

Fig. 287.



THE RÉSEAU ADMIRABLE OF THE SHEEP, SEEN IN PROFILE.

1, Carotid artery; 2, Occipital artery; 3, Lingual artery; 4, Maxillo-muscular artery; 5, Posterior auricular artery; 6, Superficial temporal artery; 7, Anterior auricular artery; 8, Middle temporal artery; 9, Transverse artery of the face; 10, Internal maxillary artery; 11, Inferior dental artery; 12, Spheno-spinous artery; 13, Deep posterior temporal artery; 14, Deep anterior temporal artery; 15, Commencement of the originating arteries of the *réseau admirable;* 16, Encephalic *réseau admirable;* 17, Trunk of the encephalic arteries arising from the *réseau admirable;* 18, Ophthalmic artery; 19, Ophthalmic *réseau admirable;* 20, Common origin of the arteries of the eye; 21, Supra-orbital artery; 22, Buccal artery; 23, Superior dental artery; 24, Orbital branch of the latter; 25, Palatine artery; 26, Nasal artery

fasciculus is detached, the ophthalmic artery shows on its course a very curious arrangement which has not yet been noticed, we believe: this is a veritable arterial plexus in a ganglionic form, in principle exactly disposed as that about to be described (Fig. 287, 19).

7. The *originating arteries of the réseau admirable*, usually consisting of two principal vessels, arising with the ophthalmic. passing backward through the suprasphenoidal canal, and ramifying in a special manner to form a mass of reticular twigs, designated the *réseau admirable* (Fig. 287, 16).

This network is a small ovoid mass, elongated from before to behind, placed beneath the dura mater, on the side of the sella turcica, within the superior maxillary nerve, and composed of a multitude of fine arterial divisions which anastomose with each other

in an extremely complicated manner. Its inferior extremity, passing into the supra-sphenoidal canal, receives the generating arteries. The posterior extremity, covered by the clinoid process, is in communication with the spheno-spinous artery, which there expends itself. Towards its middle part, and above, the twigs forming it reconstitute themselves into a single trunk analogous to the intercranial portion of the *internal carotid* of Solipeds (Fig. 287, 17), and which traverses the dura mater, dividing into three branches. These are the *anterior, middle,* and *posterior cerebral arteries;* the latter anastomoses, by convergence, with the homologous artery of the opposite side, behind the pituitary gland, to form the basilar trunk and the median spinal artery, which continues it.

This singular disposition of the arteries of the encephalon well deserves the name of *réseau admirable* (admirable network), by which it is known. If we were desirous of giving a summary idea of this network, we might compare it to a lymphatic gland, whose efferent vessels would be represented by the *originating arteries* with the *spheno-spinous,* and the efferents by the originating trunk of the encephalic arteries.

8. Next comes the *superior dental,* whose *orbital branch* presents a considerable volume, and terminates on the anterior surface of the head by long superficial divisions. Some of these, the ascending, anastomose with the inferior branches of the arterial circle situated around the base of the horn; while others, the descending, communicate with the *infra-orbital branch* of the same vessel, and with the superior coronary artery.

9. The last to be given off are the *nasal* and *palatine arteries,* which terminate the internal maxillary: the *nasal artery* is disposed as in the Horse; the *palatine* goes entirely to the palate.

Fig. 288.

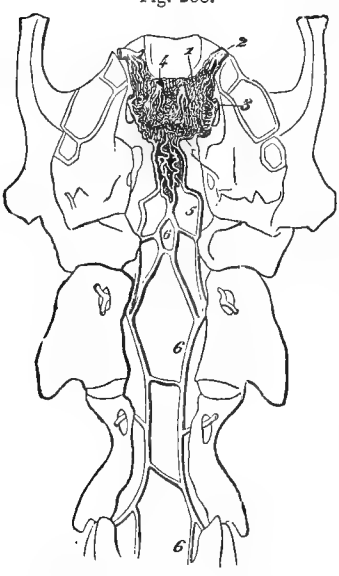

THE RÉSEAU ADMIRABLE OF THE OX; POSTERIOR FACE.

1, *Réseau admirable;* 2, Trunk of the originating arteries of the *réseau admirable;* 3, Spheno-spinous artery; 4, Trunk of the encephalic, or internal carotid arteries; 5, Branches of the occipital passing to the *réseau admirable;* 6, Interspinal arterial canal, formed by the intervertebral spinal branches.

B. In the *Ox,* we find all the peculiarities just enumerated, save with the following differences:

1. A little above the origin of the lingual artery, the external carotid gives rise to an *external maxillary* artery, which turns round the inferior border of the maxillary bone, in company with its satellite vein, and terminates on the forehead, as in the Horse, after supplying the coronary arteries.

2. The *maxillo-muscular artery* is distributed to the two masseters—to the external as well as the internal.

3. The *transverse artery of the face* does not form the coronary arteries, as these come from the external maxillary; it is altogether expended in the masseter muscle.

4. The *anterior auricular artery* sends an enormous branch into the temporo-parietal canal, by the orifice situated behind the supercondyloid process.

5. The *ophthalmic artery* and the *generating arteries* of the *réseau admirable* proceed from a common trunk.

6. The *réseau* itself shows some differences. We do not find, as in the *Sheep,* two lateral elongated lobes, almost independent of each other, but a circular mass surrounding the sella turcica. Besides, the occipital arteries concur in its formation, and pass into its posterior part (Fig. 288).

(This *réseau admirable* is the "*rete mirabile*" of Galen, and would appear to be formed on the carotid and vertebral arteries of animals, which, in a state of nature, feed from the ground; the object being to furnish an equable and prolonged supply of blood without the risk of check or hindrance, and thus to obviate the tendency to congestion of the brain during the dependent position of the head. This minute subdivision and subsequent reconstitution of an artery, with a like intention, is also observed in other creatures besides grazing

animals. The vessels in the arm of the sloth are so disposed that the animal can remain suspended by it for long periods, and a similar arrangement is noted in the legs of birds, such as the swan, goose, &c., which stand for a long time. Around the Horse's foot the arteries break up into numerous divisions, and we know that this animal can remain in a standing attitude for months, and even years. The *rete ophthalmicum* of birds is arranged like the *rete mirabile*. The same object is sometimes attained by great tortuosity, as we have already seen in the description of several of the arteries. Perhaps the most marked example, however, is to be found in the carotid artery of the Seal, which is nearly forty times longer than the space it has to traverse.)

COMPARISON OF THE CAROTID ARTERIES OF MAN WITH THOSE OF ANIMALS.

The *common carotids* of Man have a separate origin, the right arising from the arteria innominata, the left from the arch of the aorta. At the inferior border of the thyroid cartilage, they terminate by only two branches: the external and internal carotids; the occipital artery is but a division of the former.

Fig. 289.

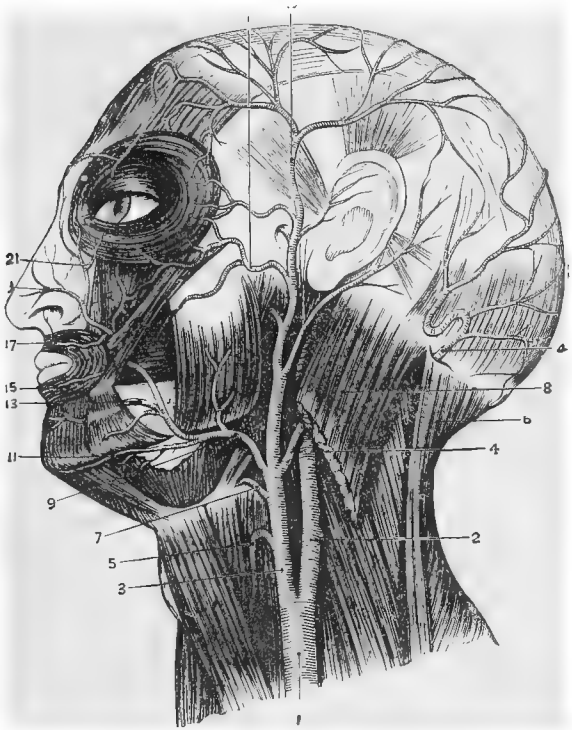

ARTERIES OF THE FACE AND HEAD OF MAN.

1, Common carotid; 2, Internal carotid; 3, External carotid; 4, 4, Occipital artery; 5, Superior thyroid artery; 6, Trapezius; 7, Lingual artery; 8, Sternomastoid; 9, Facial artery; 10, Temporal artery, dividing into anterior and posterior branches; 11, Submental branch; 12, Transverse facial artery; 13, Inferior labial branch; 15, Inferior coronary, and, 17, Superior coronary branch; 19, Lateral nasal branch; 21, Angular branch.

Internal Carotid Artery.—Contrary to what is observed in animals, the internal carotid is a little larger than the external, a difference which is explained in Man by

the predominance of the cranium over the face. This vessel describes a flexuous course until it reaches the carotid foramen in the petrous bone; it forms two curves in the cavernous sinus, penetrates the dura mater, and divides at the fissure of Sylvius into four branches, which are, as in Solipeds: the *posterior communicating, anterior cerebral, middle cerebral*, and *artery of the choroid plexus*. The internal carotid has an important collateral branch, the *ophthalmic artery*, that arises from the convexity of the curve the carotid makes inside the anterior clinoid process, at the bottom of the orbit. If it differs at its origin, yet this vessel has a distribution analogous to that already described.

External Carotid Artery.—In its origin, course, and termination, the external comports itself as in animals. It gives rise to six branches:

1. The *superior thyroid*, resembling in its distribution the thyro-laryngeal of Solipeds.
2. The *lingual artery*, which furnishes a sublingual, and takes the name of *ranine* at its termination.
3. The *facial artery*, which gives off the palatina ascendens analogous to our pharyngeal, and the submental.
4. The *posterior auricular artery*.
5. The *inferior pharyngeal artery*.
6. The *occipital*.—This vessel represents the occipital of the Horse *minus* its cerebro-spinal branch. It gives off a mastoid artery, and terminates in the muscles of the neck and on the posterior aspect of the cranium. The cerebro-spinal branch is replaced by the termination of the vertebral artery, which forms on the inferior face of the medulla oblongata the *basilar trunk*, whose disposition is identical with that already described.

The *superficial temporal artery*, and the *internal maxillary artery*, constitute the termination of the external carotid.

The *internal maxillary* is directed towards the spheno-palatine or nasal foramen, into which it passes and terminates as the spheno-spinous artery. It does not give off the ophthalmic artery, that vessel coming from the internal carotid; but it furnishes all the other branches we have studied in animals. There are, therefore: a *tympanic artery*; a *meningeal, middle*, or *spheno-spinous*; an *anterior* and *posterior deep temporal*; an *inferior dental*; a *buccal*; a *masseteric*; *pterygoideans*; and a *descending palatine* or palato-labial artery.

THIRD SECTION.

The Veins.

CHAPTER I.

GENERAL CONSIDERATIONS.

Definition.—The veins are the centripetal vessels of the circulatory system. They bring back to the heart the blood which had been carried from that viscus to the organs. Some proceed from the lungs, carrying red blood, and converge towards the left auricle of the heart: these are the *pulmonary veins*, or *veins of the lesser circulation*. Others emerge from the mass of all the organs, transport the dark blood, and open into the right auricle: these are the *veins of the general circulation*.

There are, therefore, two venous systems commencing by a capillary network, opposite an arterial network. Sometimes a third system of veins has been described for the intestines; indeed, the vena portæ offers a certain independence in the midst of the veins of the general circulation, as it terminates in a capillary plexus in the interior of the liver, and by this plexus it communicates with the posterior vena cava.

External Conformation.—The veins, after succeeding the capillary network which terminates the arteries, or the cells of the erectile tissues,

form a series of convergent ramifications which repeat, in a general manner, but in an inverse sense, the arterial ramifications whose course they for the most part follow. A certain number, nevertheless, are placed at some distance from the arterial trunks, beneath the external tegumentary membrane, where they are disposed in a vast network which constitutes the *superficial veins* of the body. Apart from this peculiarity, we have nothing more to say with regard to the *situation*, *direction*, *relations*, and *anastomoses* of the veins than has been already made known in studying the arteries. It is only to be remarked, that the anastomoses of the venous system are more numerous, larger, and more complicated, than those of the arterial system; that they also communicate with more voluminous trunks; and that they very often join the deep to the superficial veins. At certain points (external genital organs, bladder, rectum), the anastomoses are so numerous as to constitute veritable *venous plexuses*. These are more especially met with in regions where the circulation is exposed to be more or less hindered, either from the displacement of organs or variations in their volume.

With regard to *form*, we also find a close analogy between the veins and arteries. The majority of the first, at least, represent—as do the second—cylindrical tubes, slightly knotted, it is true, on those parts of their track which correspond to their valves; the only exceptions are found in the venous dilatations of the dura mater—polyhedral spaces which are designated sinuses. On the other hand, veins offer the same collective form as the arteries; the general volume of the venous ramifications being as much more developed as they are distant from the heart, all the branches collected at last into an imaginary single canal would form a hollow cone whose apex would correspond to the auricles.

It is only in comparing the two orders of vessels with reference to their *number* and *capacity*, that we can discover any sensible difference. The veins are more numerous than the arteries, as a great number of the latter are accompanied by two of the former, and the subcutaneous veins have no representatives in the arterial system. All the veins being, besides, much more voluminous than the corresponding arteries, it follows that the total capacity of the venous system much surpasses that of the arterial tree, and that we may boldly consider the relation of two to one as being the approximative expression of this difference.

When the veins are compared with the arteries, it is remarked that the relations between the length of the trunks and branches are reversed. In the arteries, the trunks are large and the branches short; in the veins, on the contrary, the branches are relatively much longer than the trunks. This disposition favours the flow of the blood in the veins, at whose commencement we do not find, as in the arteries, a propelling organ.

Another arrangement to answer the same end, in opposing the influence that atmospheric pressure might have on the veins, is the attachment of these vessels to the walls of the cavities they pass through; this is observed, for instance, at the entrance to the thorax.

This disposition, so favourable to the circulation of the blood, becomes a constant source of danger to the surgeon, by its permitting the introduction of air into the circulatory system when a vein is opened.

Internal Conformation.—The interior of the veins is remarkable for the presence of valvular folds, whose disposition resembles, in principle, that of the sigmoid valves of the heart. These veins offer: an adherent border attached to the walls of the vessel; a free, semilunar border; a concave

face turned towards the heart when the valves are tense; and a convex face which, on the contrary, looks towards the roots of the veins.

These valves are often isolated, and sometimes joined in twos or threes; according to some authorities, they are even found four or five together, arranged in a circular manner. All the veins are not provided with them, however, and where they exist they may be more or less numerous. They are absent in the pulmonary system, and in the trunk of the vena cava; absent or quite rudimentary throughout the extent of the vena portæ; rare and slightly developed in the vena azygos, the veins of the testicle, uterus, and ovary; and very numerous, very large, and very complete in the veins of the limbs.

The function of these valves is to favour the course of the blood, and to oppose its reflux from the heart towards the organs. Applied, as they are, to the walls of the veins by their concave face during the regular and normal circulation, they are disposed as a transverse valve to sustain the column of blood when any strain or pressure gives that column a retrograde movement.

Structure.—The walls of the veins are thin, semi-transparent, and elastic, and collapse when the vessels are empty. Like the arteries, they have three tunics.

The *internal tunic* is composed of an epithelial layer of elongated cells, lying on an elastic membrane made up of longitudinal fibres. In the small veins, besides the epithelium and elastic fibres, are striped layers with elongated nuclei. This tunic is the most important; it is persistent, while the other two may be absent in certain veins.

The *middle tunic* is much thinner than that of arteries, and has fewer muscular and elastic fibres, while its tint is rather red than yellow. The proportion of smooth fibres, disposed in a circular manner in the midst of the connective tissue, varies with the volume and situation of the veins; being more considerable in the small than the large vessels, and also in those through which the blood circulates with difficulty.

The *external*, or *adventitious tunic*, is formed by connective tissue and some longitudinal fasciculi of elastic and muscular fibres.

In the veins of the bones, and in the sinuses of the dura mater, the two latter tunics may be absent, and the walls of the vessels only consist of epithelium.

The veins have very numerous *vasa vasorum*, which form a complete network around them. The vena portæ alone is accompanied by *nervous filaments* of the great sympathetic.

(As remarked, the superficial veins are generally unaccompanied by arteries; they usually pass between layers of superficial fascia, and at the most convenient situations—generally those best protected—pass through the underlying fascia to terminate in the deep veins. These are most frequently accompanied by arteries, being often inclosed in the same sheath with them, particularly in the extremities. With a large number of arteries there are two veins, one on each side, the *venæ comites*, though the largest arteries have only one venous trunk. The large and frequently repeated communications are undoubtedly intended to compensate for the thinness of their parietes, which exposes to obstruction and dilatation; this they cannot overcome, because of the slowness with which the blood passes through them. The valves are accessory to these inosculations; upon the cardiac face of each valve the vein is expanded into two sinuses, which correspond with the extent of the valve; these pouches give the distended vessel its

nodulated appearance. Remak found longitudinal muscular fibres in the *adventitia* of the large veins of the *Ox* and *Sheep*, but chiefly in the hepatic portion of the posterior vena cava and the veins of the liver.)

INJECTION OF THE VEINS.—To render the dissection and study of the veins more easy, they ought to be filled with tallow or any other solidifiable matter, like the arteries. But to attain this result the same mode of procedure cannot be employed as for them. Instead of causing the injecting material to flow from the trunk into the branches, it is necessary to propel it from the branches towards the trunk, because of the presence of the valves; this is to be done by successively fixing the canula into several venous branches.

Four injections generally suffice to fill the whole venous system in a satisfactory manner. The first is made from the alveolar vein, beneath the masseter muscle; the second from a digital vein of one or both anterior limbs, or from the side of the foot, after having destroyed by a stylet the few valves which are sometimes found towards the point of union in this vein; or from the side of the heart. The third, from the posterior digital veins, in the same way; the fourth, by an intestinal vein. If any important veins are empty after these four injections, a case of frequent occurence, they can be directly injected.

CHAPTER II.

VEINS OF THE LESSER CIRCULATION, OR PULMONARY VEINS.

THE pulmonary veins comport themselves in the same manner as the corresponding arteries. They are lodged in the substance of the lung (commencing in the capillaries, upon the walls of the intercellular spaces and air-cells, joining to form a single trunk for each lobe), and collect in from four to eight trunks, which open into the roof of the left auricle, after emerging from the pulmonary organ immediately above the origin of the bronchi. As they are destitute of valves, they readily allow the blood to flow towards their roots. It is they which carry to the left heart the fluid thrown into the lung by the right ventricle, to be submitted to the revivifying influence of the atmosphere.

CHAPTER III.

VEINS OF THE GENERAL OR SYSTEMIC CIRCULATION.

THESE vessels bring to the right auricle the blood which has been dispersed in the texture of organs, by the ramifications of the great arterial tree.

They open into the auricle by forming three groups: the group of *coronary or cardiac veins;* the *anterior vena cava*, and the *posterior vena cava.*

ARTICLE I.—CARDIAC OR CORONARY VEINS.

There are several *small*, and one *large* or *great coronary vein.*

SMALL CARDIAC VEINS.—These are the almost insignificant vessels, undetermined in number, which come from the walls of the right ventricle and open directly into the corresponding auricle at the coronary groove. (Among these may be included the debatable *venæ Thebesii*, a multitude of minute venules said to arise in the structure of the heart and open directly into its cavities.)

GREAT CORONARY VEIN (Figs. 258, 5; 259, *o*, *p*).—This vein is formed by two roots: one is lodged in the right ventricular groove, and accompanies

the cardiac artery of the same side; the other follows at first the left ventricular groove, ascends nearly to the pulmonary artery, and is then inflected backwards by placing itself in the coronary groove, along with the horizontal branch of the left cardiac artery. Turning round the base of the posterior ventricle, it joins the right root, near the upper extremity of its groove. The common trunk resulting from this junction, after a short course, opens into the right auricle, below and within the embouchure of the posterior vena cava.

In their track, the two branches of the coronary vein receive branches which escape from the auricular and ventricular walls.

The *bronchial veins*, ramifying on the bronchi like the arteries, whose satellites they are, also open into the great coronary vein, very near its embouchure, after becoming a single vessel, which is sometimes thrown directly into the auricular cavity.

Article II.—Anterior Vena Cava. (Figs. 258, *r*; 259, *d*; 293.)

This is a voluminous trunk, which ought to be considered as the corresponding vein of the anterior aorta. It extends from the entrance of the chest to the right auricle, into the roof of which it is inserted. It is comprised between the two layers of the anterior mediastinum, and lies below the trachea, to the right of the anterior aorta.

Four large vessels—the *two jugular* and *two axillary veins*—opening in common in the space comprised between the two first ribs, constitute the roots of this vessel.

Collateral Affluents.—The affluent vessels which the anterior vena cava receives in its course are: the *internal thoracic*, *vertebral*, *superior cervical*, and *dorsal veins*, and the *great vena azygos*.

Internal Thoracic (or Internal Mammary) Vein.—A satellite of the artery of the same name, this vein opens into the anterior vena cava, at its origin (Fig. 293).

Vertebral Vein.—It accompanies the corresponding artery in the canal formed by the foramina in the transverse processes of the cervical vertebra, and joins the vena cava at the origin of that artery (Fig. 293).

Superior Cervical Vein.—Exactly resembles the artery whose name it bears.

Dorsal Vein.—This vessel follows the dorso-muscular artery, and, like it, presents a *subcostal* branch. On the left side, this branch is designated the *small vena azygos*, and is often prolonged to the eleventh or twelfth rib; it receives the intercostal veins of the spaces it crosses.

It may be remarked that the vertebral, superior cervical, and dorsal veins of the right side, are nearly always thrown separately into the vena cava, while on the left side they constantly unite to form a single trunk (Figs. 258, *u*; 293).

Great Vena Azygos (Figs. 258, *x*; 259, *e*; 293).—This is a long single vein, which commences at the first lumbar vertebra, and extends forward on the right of the thoracic aorta, beneath the bodies of the dorsal vertebræ to about the sixth, when it is inflected downward to terminate in the anterior vena cava, near the embouchure of that vessel, or even directly into the right auricle.

In its course, the great vena azygos is maintained against the bodies of the dorsal vertebræ by means of the parietal pleura; it runs alongside the outer border of the thoracic duct, which separates it from the

aorta.[1] The terminal extremity of its inflection crosses the œsophagus and trachea to the right, and is included between these two tubes on the one side, and the right layer of the mediastinum on the other.

Its roots are some branches emerging from the spinal and psoas muscles, and which are not usually in direct communication with the posterior vena cava, as in Man and the other animals.

During its progress, it receives the first lumbar and the satellite veins of all the aortic intercostal arteries, right and left. But when the small vena azygos is prolonged backwards beyond the posterior extremity of the subcostal artery, that vessel, as we have already seen, forms the confluent of a certain number of left posterior intercostals

JUGULAR VEINS.

The jugular is a satellite vein of the carotid artery.

Origin.—It commences behind the inferior maxilla, below the articulation of the jaw, by two large roots: the *superficial temporal trunk* and the *internal maxillary vein*, which correspond to the two terminal branches of the external carotid artery (Fig. 290).

Situation—Direction.—This vessel passes downward and backward, lodged at first in the substance of the parotid gland, afterwards in the muscular interstice designated the *jugular channel*, and which is comprised between the adjacent borders of the levator humeri (mastoido-humeralis) and sterno-maxillaris muscles. Reaching the inferior extremity of the neck, it terminates in the following manner (Fig. 290):

Termination.—On arriving near the entrance to the chest, the two jugulars unite in forming a vessel named the *confluent of the jugulars*. This confluent, into the sides of which open the two axillary veins, is comprised between the two first ribs, and situated below the trachea, in the middle of the lymphatic glands at the opening of the chest. Fixed by fibrous bands to the neighbouring parts, and particularly to the two first ribs, the walls of the jugular confluent do not collapse when the venous system is in a state of vacuity: an anatomical peculiarity which it is necessary to understand, in order to explain the manner in which air obtains an entrance into the circulatory system when the jugular or axillary veins are opened, as well as affording an indication how to prevent this serious accident.

Relations.—At its upper extremity, the jugular vein is surrounded by the parotideal tissue. For the remainder of its extent, it is covered externally by the subcutaneous muscle of the neck, and by the branches of the cervical plexus which creep on the external surface of that muscle. Inwardly, its relations vary as we consider its situation, above or below: above, it responds to the subscapulo-hyoideus muscle, which separates it from the common carotid and its satellite nerves; in its inferior moiety, it is in direct relation with that vessel, which is above it, as well as with the trachea, and even, though only on the left side, with the œsophagus.

Collateral Affluent Vessels.—The collateral veins which go to the jugular from its origin to its termination, are: 1, *Maxillo-muscular veins;* 2, *Posterior auricular vein;* 3, *Occipital vein;* 4, *External maxillary*, or *glosso-facial vein;* 5, *Thyroid vein;* 6, *Cephalic vein;* 7, *Parotideal* and *innominate muscular branches.*

A. Maxillo-muscular Veins.—Two in number, corresponding to the

[1] Sometimes the azygos is situated between the aorta and the thoracic duct. When the latter lies to the left side, it is in direct contact with the posterior aorta.

branches of the artery of the same name, and entering the jugular close to its origin, either separately, or after forming a common trunk (Fig. 290).

B. Posterior Auricular Vein.—A voluminous vessel which commences on the concha, and descends on the external face of the parotid gland, near its posterior border, where it is joined by numerous divisions from the parotid lobules. It opens into the jugular vein, generally a little below, and opposite to, the maxillo-muscular vessels, though it is sometimes lower, and even beyond the occipital vein (Fig. 290).

C. Occipital Vein.—The occipital vein corresponds, in every respect, to its fellow artery. It offers two roots: an anterior, which originates at the posterior extremity of the subsphenoidal confluent; and a posterior, commencing beneath the transverse process of the atlas, and formed by three principal branches.

Among the branches of the latter root, one passes with the retrograde artery through the posterior foramen of the atlas, and constitutes, as it were, the origin of the vertebral vein; the second communicates with the occipito-atloid sinuses, by traversing the atlas near its middle; the third, satellite of the cerebro-spinal artery, comes also from these sinuses, and receives the venules which accompany the ramifications of the occipito-muscular artery.

D. External Maxillary or Glosso-facial Vein.—A satellite of the artery of the same name, this vessel begins on the forehead by two roots: a superior and inferior, analogous in every point to the terminal branches of the artery. It descends along the anterior border of the masseter muscle, gains the maxillary fissure, into which it is inflected, placing itself between the artery and Stenon's duct; then proceeds backwards and downwards on the internal pterygoid muscle, always accompanied by the glosso-facial artery until near the anterior extremity of the maxillary gland, when it leaves it to follow the inferior border of that gland, and enters the jugular, after crossing the sterno-maxillaris muscle outwardly, and forming with the latter vein an angle which is occupied by the inferior extremity of the parotid gland (Fig. 290).

Branches of origin.—Of the two branches which, by their union, constitute the origin of the external maxillary vein, the inferior, a satellite of the nasal branch of the corresponding artery, possesses no interest. The superior, or *angular vein of the eye*, merits particular notice, as venesection is sometimes practised on it. It arises near the nasal angle of the eye, and creeps to the external face of the elevator muscle of the upper lip, below the lachrymal muscle.

Collateral branches.—In its progress, the external maxillary vein receives a great number of affluents, the principal of which are the *alveolar vein*, the *labial* or *coronary veins*, the *buccal vein*, and the *sublingual vein*.

a. Alveolar vein.—This is a considerable vessel lodged beneath the masseter, and lying against the great supermaxillary bone, between the zygomatic crest and the line of the molar teeth (Fig. 291).

The disposition of this vessel is most singular; its anterior extremity opens into the external maxillary vein, and its posterior extremity traverses the ocular sheath, receives the ophthalmic veins, and passes, with the ophthalmic nerve of the fifth pair, into one of the supra-sphenoidal canals, to open into the cavernous sinus in the interior of the cranium.[1]

[1] We have also seen it send into the subsphenoidal canal, to the the inner side of the internal maxillary artery, a slender branch that joined the anterior extremity of the subsphenoidal confluent. But we cannot say that this disposition is constant.

Before traversing the ocular sheath, and towards the maxillary hiatus, this vein receives the *superior dental* and the confluent of the *nasal veins:* vessels which emerge from the bony orifices traversed by the arteries of the same name—that is, the maxillo-dental canal and the nasal foramen. It also receives the confluent of the *palatine veins*, which pass by the palatine groove, instead of coursing along the palatine canal with the corresponding artery. In general, these three branches do not join the alveolar separately, but rather by a common trunk.

The alveolar vein does not present a uniform volume. It increases from before to behind to the maxillary protuberance, where it forms a kind of large reservoir; but in traversing the ocular sheath it suddenly becomes constricted, and maintains a small diameter until its entrance into the cavernous sinus.

This vein may be considered as an affluent of the sinuses of the dura mater, as well as of the external maxillary vein.

b. Labial or *coronary veins.*—Satellites of the labial arteries. The *superior* is often rudimentary. The *inferior*, always voluminous, is constituted by the union of several anastomotic branches lying against the external face of the mucous membrane of the cheek.

c. Buccal vein.—Among the affluents of the external maxillary vein, we cite this, because it opens into the latter by its anterior extremity, opposite the inferior coronary vein, with which it sometimes communicates by a particular branch. But the buccal vein, properly speaking, constitutes the root of the internal maxillary, and we will describe it as such.

d. Sublingual vein.—A large vessel, formed of two branches, which arise in the substance of the tongue, and are sometimes thrown separately into the internal maxillary vein. This sublingual vein passes through the mylo-hyoideus muscle, from within to without, and joins the principal vessel at the lymphatic glands lodged in the intermaxillary space.

E. Thyroid Vein.—This is a voluminous trunk, resulting from the union of the venous divisions which accompany the laryngeal and thyroid branches of the thyroid or thyro-largyngeal artery. It joins the jugular beside the external maxillary vein, and most frequently above it.

F. Cephalic or Plat Vein.—A superficial vessel, which represents one of the terminal branches of the principal subcutaneous vein of the fore-arm. It is lodged in the interstice of the levator humeri and small pectoral muscles, and enters the inferior extremity of the jugular vein (Fig. 293).

G. Innominate Veins.—A certain number come from the parotid gland, but the principal arise in the muscles of the neck and withers. One of the latter accompanies the superior branch of the cervico-muscular artery.

ROOTS OF THE JUGULAR VEIN.

These are constituted by the *superficial temporal* and *internal maxillary veins*, which are chiefly fed by the *sinuses* of the encephalic dura mater.

1. *Superficial Temporal Vein.*

Corresponding in the most exact manner to the temporal trunk, this vessel is lodged behind the posterior border of the maxilla, near the articulation of the jaw, beneath the parotid gland, and is, as it were, incrusted in its tissue.

From the union of these two roots, there results:

1. The *anterior auricular vein*, a very large, often multiple, and reticulated branch, anastomosing with the pterygoid branches of the

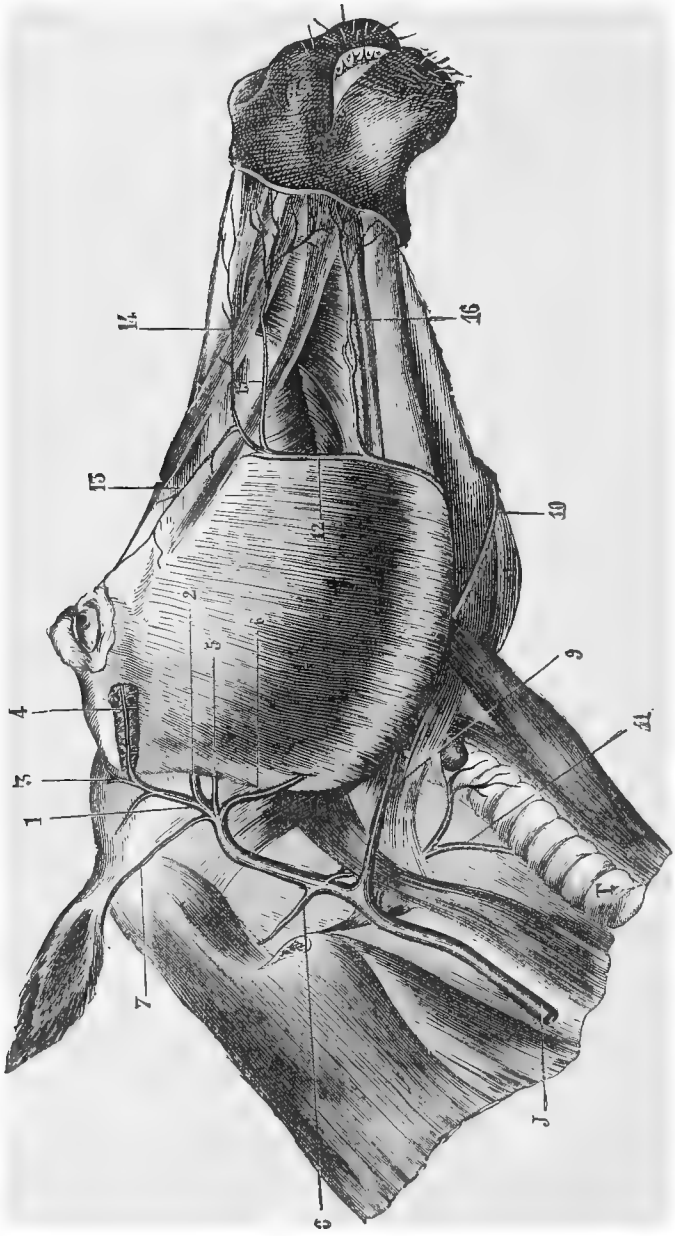

ROOTS OF THE JUGULAR VEIN, WITH ITS SUPERIOR COLLATERAL AFFLUENTS.

J, Jugular vein; T, Trachea.—1, Superficial temporal vein; 2, Internal maxillary vein; 3, Anterior auricular vein; 4, Subzygomatic vein; 5, 6, Maxillo-muscular branches; 7, Posterior auricular vein; 8, Occipital vein; 9, 10, Glosso-facial vein; 11, Thyroid vein; 12, Facial vein; 13, Angular vein of the eye; 14, Nasal branch; 15, Superior coronary vein; 16, Inferior coronary vein.

internal maxillary artery. This vein issues from the parieto-temporal conduit, behind the supercondyloid eminence; it receives one or two branches which escape from this conduit by the foramina in the temporal fossa, crosses the temporal muscle, and is charged with venules which arise in the interior of that muscle, as well as in the textures of the external ear.

2. The *subzygomatic vein*, a satellite of the homonymous artery, and like it, divided into two branches: one accompanying the transverse artery of the face, the other the masseteric artery. The latter branch communicates by its inferior extremity with the external maxillo-muscular vein; it joins, by its other extremity, an enormous branch which comes from the temporal muscle, and which passes into the corono-condyloid notch, after being largely anastomosed with the deep temporal branches of the internal maxillary vein.

2. *Internal Maxillary Vein.*

Remarkable for its enormous volume, this vein creeps between the internal masseter muscle and the maxilla, in an oblique direction upwards and backwards. Arriving within the articulation of the jaw, a little below the maxillary condyle and the external pterygoid muscle, it joins the temporal trunk after being slightly inflected downwards. It, therefore, runs its course at a certain distance from the corresponding artery (Fig. 290).

The internal maxillary has for its root the *buccal vein*, which it succeeds near the superior extremity of the alveolo-labialis muscle.

Satellite of the artery and nerve of the same name, this buccal vein, remarkable for its volume, is situated beneath the masseter muscle, near the inferior border of the alveo-labialis muscle; by its anterior extremity it communicates directly with the internal maxillary vein, nearly opposite to the embouchure of the inferior coronary vein; its posterior extremity is continued directly with the internal maxillary. The collateral branches it receives in its course come from the masseter muscle and the parietes of the cheek.

On its way it receives a great number of affluents; these are:

1. A large *lingual vein*, accompanying the small hypoglossal nerve.
2. The *inferior dental vein*.
3. The *trunk of the deep temporal veins*, a large vessel situated in front and to the inside of the temporo-maxillary articulation, where it communicates with the masseteric. This vessel arises in the texture of the temporal muscle, but particularly in the parieto-temporal confluent, with which it joins by the foramina in the temporal fossa.
4. The *pterygoid veins* (Fig. 291), numerous branches, only a portion of which come from the pterygoid muscles. The others, springing from the subsphenoidal confluent of the sinuses of the dura mater, form, on the superficial face of the external pterygoid muscle, a wide-meshed network which communicates posteriorly with the temporal trunk, and anteriorly with the confluent of the deep temporal veins. But as these two vessels are bound together, outside the temporo-maxillary articulation, by means of the masseteric artery, it results that this articulation is enlaced on every side by one of the richest venous plexuses in the whole economy.

3. *Sinuses of the Dura Mater.*

We will here describe not only the sinuses of the encephalic dura mater which supply the roots of the jugular vein, but also those of the spinal dura

mater, although these empty themselves into other veins; in order that we may be able to consider, in their entirety, all the vessels of the nervous centres which carry dark blood.

THE SINUSES OF THE DURA MATER IN GENERAL.—These are vascular spaces comprised in the texture of the external meninge, or situated between that membrane and the bones which form the walls of the cerebro-spinal sheath, or even excavated on the inner surface of these bones. These spaces differ more particularly from the veins, by their being generally of a prismatic form, by being continually open, by the absence of valves in their interior, and the presence, in some of them, of lamellæ (*trabeculæ*), or intersecting filaments (*chordæ Willisii*) which stud their inner surface, and make them look reticulated.

Their walls are reduced to an epithelial layer that lies either on the dura mater, or on the osseous tissue.

It is into these sinuses that the veins of the encephalon and the spinal cord disgorge themselves.

THE SINUSES OF THE CRANIAL DURA MATER IN PARTICULAR.—Four principal will be described: the *sinus of the falx cerebri* or *median sinus*, the *two cavernous or sphenoidal sinuses*, and the group of *occipito-atloid sinuses*.

1. SINUS OF THE FALX CEREBRI, OR MEDIAN SINUS.—Channeled in the substance of the falx cerebri, and becoming wider as it extends backwards, this sinus commences near the crista galli, and terminates on the internal parietal protuberance by bifurcating. The two branches resulting from this division form the origin of the parieto-temporal confluent, or *winepress of Hérophilus* (*torcular Herophili*).

2. CAVERNOUS OR SUPRA-SPHENOIDAL SINUSES.—These are two in number—a right and a left. They occupy, on the internal face of the sphenoid bone, at each side of the sella turcica, the so-called cavernous fissures. Bordered outwardly by the superior maxillary nerve, they receive at their anterior extremity the insertion of the alveolar vein. Posteriorly, they join each other, and in doing so form a kind of arch, open in front, around the pituitary gland. Each opens widely at the lacerated foramen, into the subsphenoidal confluent.

3. OCCIPITO-ATLOID SINUSES.—By this name is designated a network of large irregular veins, situated beneath the external face of the dura mater, on the sides of the occipital foramen, and on the entire internal surface of the atloidean ring. Anteriorly, these venous reservoirs communicate, through the condyloid foramen, with the posterior extremity of the subsphenoidal confluent. Posteriorly they are continuous with the spinal sinuses, of which we may consider them to be the origin.

4. RUDIMENTARY SINUSES OF THE CRANIAL DURA MATER.—Independently of the above-described reservoirs, there exist, on the inner wall of the cranium, some rudimentary venous sinuses which should be indicated; these are: 1, One or two veins lodged in the structure of the tentorium, designated the *petrosal* or *transverse sinuses*, communicating, below, with the cavernous sinuses, and entering, above, into the parieto-temporal confluent;[1] 2, Some small, irregular, and reticulated cavities, very variable in their disposition, situated beneath the dura mater, on the sides of the cerebellar cavity, and which generally empty themselves into the subsphenoidal confluent, by

[1] More frequently, perhaps, these veins arise directly from the substance of the brain, and do not communicate, below, with the cavernous sinuses.

traversing the posterior part of the lacerated foramen, and also opening sometimes into the petrosal sinus; these cavities may be regarded as the representatives of the *lateral sinuses* in Man; 3, In some instances, an *inferior*

Fig. 291

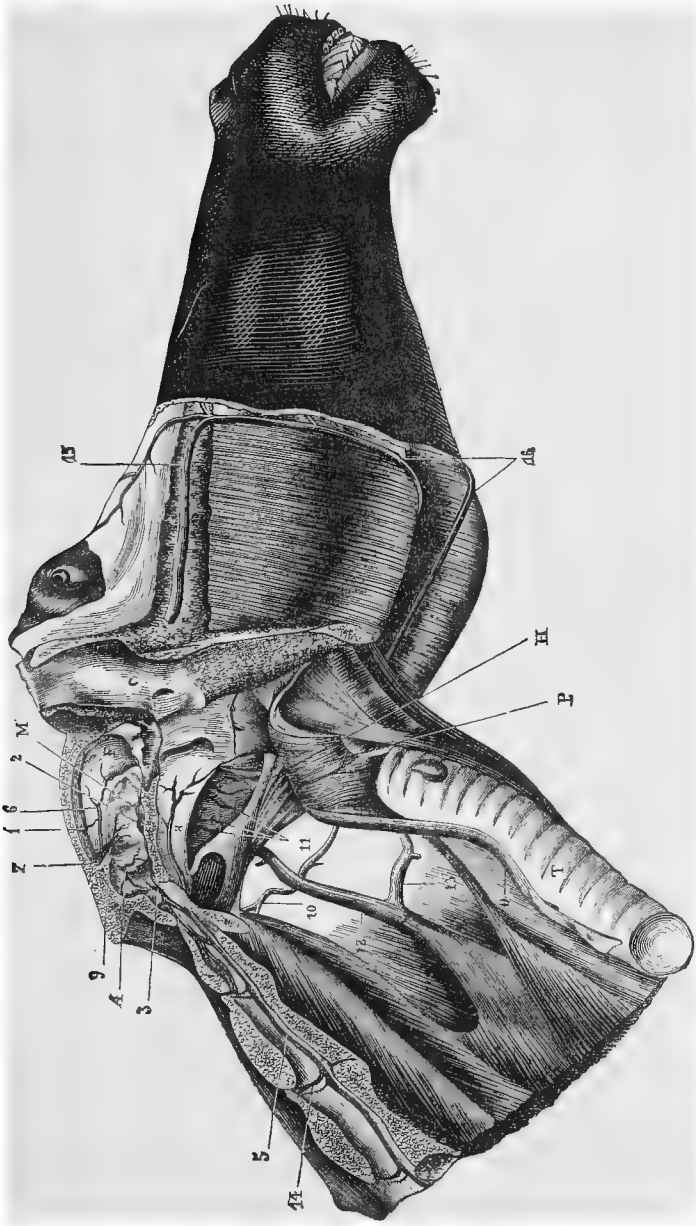

SECTION OF THE CRANIAL CAVITY AND SPINAL CANAL, SHOWING THEIR VENOUS SINUSES.

T, Trachea; O, Œsophagus; P, Pharynx; H, Hyoid bone; F, Falx cerebri; M, Pituitary gland.—1, Median sinus; 2, Cavernous sinus; 3, Occipito-atloid sinus; 4, Petrous sinus; 5, Spinal sinus; 6, Inferior median sinus; 7, Parieto-temporal confluent; 8, Subsphenoidal confluent; 9, Great cerebral vein, or vena Galeni; 10, Root of the occipital vein, carrying the blood from the subsphenoidal sinus; 11, Pterygoid veins; 12, Jugular vein; 13, Glosso-facial vein; 14, Emergent vein of the spinal sinuses; 15, Alveolar vein; 16, Facial vein.

median sinus, channeled near the free border of the face of the brain, passes behind into the torcular Herophili.

The Spinal Sinuses in Particular.—We thus designate in Veterinary Anatomy, and with good reason, two series of venous reservoirs which are found throughout the whole extent of the vertebral column, on the sides of the roof of the spinal canal. Lodged in the lateral depressions of the superior face of the vertebral bodies, at the side of the common superior vertebral ligament, and covered by the dura mater, these reservoirs, continued from one vertebra to the other, are like two large, irregular, parallel veins, which commence at the atlo-axoid articulation, terminate on the first coccygeal vertebræ, where their presence is yet well defined, and communicate with one another during their course by transversal anastomoses.

Affluent Veins that open into the Sinuses of the Dura Mater.—These are the vessels which carry blood either from the dura mater itself, or from the substance of the nervous centres: those of the first category are rare, but the second are numerous. Although we are unwilling to make a detailed study of the latter, we must nevertheless notice what is most remarkable in their disposition.

a. On the encephalon, the veins form a much richer and closer network than that of the arterial ramifications; from this network proceed a certain number of principal branches, which throw themselves into the sinuses of the cranial dura mater. The veins of the cerebrum, for the most part, gain the median and transverse sinuses; a few only pass into the cavernous sinuses. Those of the isthmus and cerebellum go to the petrosal and occipito-atloid sinuses.

With regard to the internal veins of the brain—those which, by their interlacing, constitute the choroid plexus—we see them unite into a large trunk—the *great vein of the brain*, or *vena Galeni*, which bends round the superior extremity of the corpus callosum, reaches the interlobular fissure, and throws itself into the falciform or middle sinus, near its posterior extremity, after receiving the superficial veins from the inner face of the hemispheres.

b. The venules arising from the spinal cord are also very remarkable for the fine network they form on the surface of the organ. They collect into a common trunk—the *median spinal vein*, which runs from before to behind, throughout the whole extent of the superior groove in the spinal cord; thus occupying an analogous, though opposite, position to that of the artery of the same name. From this vein escape, at intervals, emergent branches which open into the spinal reservoirs.

Effluent Canals of the Dura Mater Sinuses.—We have to notice, under this designation, the veins which transport the blood from the sinuses, and we will consider in succession those which commence at the encephalic reservoirs, as well as those that emerge from the interspinal canals.

a. To be carried from the encephalic sinuses, the blood flows into two kinds of double gulfs, known as the *parieto-temporal* and *subsphenoidal confluents*.

The *parieto-temporal confluents* are lodged in the canals of the same name, along with the mastoid artery. Each commences at the base of the internal parietal protuberance, and terminates behind the supercondyloid eminence. The median and transverse sinuses are confounded with the superior extremity of these reservoirs, and empty into them the blood coming from the encephalic mass. This fluid is subsequently taken away by the super-

ficial and deep temporal veins, which have their principal roots in these confluents.

The *subsphenoidal confluents* extend on the sides of the body of the sphenoid bone and the basilar process, from the base of the subsphenoidal process to the condyloid fossa, by concurring in the obturation or closing of the occipito-spheno-temporal hiatus. They open at their middle portion into the corresponding cavernous sinus, by an oval aperture which the internal carotid artery traverses in penetrating into the cranium. The anterior extremity terminates in a *cul-de-sac*. Posteriorly, they communicate through the condyloid foramina with the occipito-atloid sinuses. The vessels which carry off the blood from these confluents are the pterygoid veins, and the anterior root of the occipital vein. We already know that the posterior branch of the latter vessel removes the blood directly into the occipito-atloid sinuses.

b. The emergent veins of the spinal sinuses present a more simple disposition. At each intervertebral space arise several branches, which more particularly make their exit by the intervertebral foramina to join the neighbouring veins; in the cervical region, the vertebral veins serve as a receptacle in this way for the venous branches emanating from the spinal sinuses; in the dorsal region, it is the spinal branches of the intercostals; in the loins, the analogous branches of the lumbar veins; and in the sacral region, the lateral sacral vein.

AXILLARY VEINS.

A general confluent of all the veins of the thoracic limb, and of some from the trunk, the axillary vein commences beneath the scapulo-humeral articulation, towards the terminal extremity of the corresponding arterial trunk, accompanying the latter to the entrance of the chest, and joining the confluent of the jugulars to constitute, with these two vessels, the inferior vena cava (293, 18).

In studying, from their origin to their termination, the numerous branches which concur in the formation of this venous trunk, we recognise:

1. That they form in the foot a very rich network, from which proceed the *digital veins*, satellite vessels of the homonymous arteries.

2. That to these digital veins, which are united in an arch above the large sesamoids, succeed three *metacarpal branches* or *collaterals of the cannon*: two *superficials*, placed on each side of the flexor tendons, and a *profound* (or *deep*) vein, situated underneath the suspensory ligament, along with the interosseous arteries.

3. That the metacarpal veins also open into each other, in the superior and posterior region of the carpus, to form, on again separating, two groups of *antibrachial veins*: one group comprising the *ulnar* and the *posterior* or *internal radials*, which accompany the arteries of the same name; the other, constituted by a single subcutaneous branch, the *median vein*, which receives at its superior extremity the *anterior superficial radial vein*.

4. That at the ulnar articulation, these two groups of antibrachial veins join the satellite vessel of the *anterior radial artery*, and communicate by a very complicated system of anastomoses, from which results a principal trunk, the *humeral vein*.

5. That the *humeral vein*, after receiving on its course several muscular

branches and the *subcutaneous thoracic vein*, unites near the shoulder-joint with the *subscapular* trunk, to form the axillary vein.

We will study all these branches in the inverse order of their enumeration.

1. *Subscapular Vein.*

A very considerable vessel, whose disposition resembles that of the subscapular artery, though presenting some special peculiarities whose study does not deserve a moment's delay; for example, it most frequently receives the satellite vein of the prehumeral artery.

2. *Humeral Vein.*

Placed behind and within the humeral artery, this vessel commences above the articulation of the elbow, being formed at this point by the anastomosing system of veins from the fore-arm, and terminates below the shoulder-joint in opening into the subscapular vein.

Independently of the subcutaneous thoracic vein, which will be studied in a special manner, the humeral vein receives on its way several collateral satellites of the branches emanating from the humeral artery. One of these, the *epicondyloid*, is only a continuation of the ulnar vein.

Very often we find a second humeral vein in the deep region of the arm; this is an accessory vessel, parallel to the preceding, and situated opposite it in front of the artery.

3. *Subcutaneous Thoracic or Spur Vein.*

This vein, which is important to know, as bleeding is sometimes practised from it, commences on the flank and belly by numerous superficial divisions, which unite in two principal roots, and afterwards become a single trunk, placed in the substance, or on the external surface of the panniculus carnosus, where it is directed forwards in following the superior border of the large pectoral muscle, accompanied by an arterial ramuscule and a thick nerve. It insinuates itself beneath the olecranian muscles, and finally terminates in the humeral vein by opening into the branch that follows the deep muscular artery.

4. *Deep Veins of the Fore-arm.*

A. Anterior Radial Vein.—This follows the same track, and affects the same variations, as the corresponding artery.

B. Posterior Radial Veins.—The posterior radial artery is always accompanied, and, as it were, enveloped, by a fasciculus of three or four venous branches, which frequently anastomose with each other, and are reinforced by collateral branches, among which the *interosseous vein* must be noted.

These radial branches commence above the carpus, by continuing the metacarpal veins. They concur to form the humeral vein, in joining the other antibrachial veins at the inferior extremity of the arm.

C. Ulnar Vein.—This vessel is lodged, with the nerve and small artery of the same name, in the interstice of the oblique and internal flexors of the

metacarpus. A number of muscular and subcutaneous branches enter this vein.

It has the same origin as the posterior radial veins. Its superior or terminal extremity bends forward, close to the trunk of the epicondyloid artery, and goes to the inferior extremity of the humeral vein. Frequently the ulnar vein is double in the latter portion of its track, and between the two branches lies the artery. It always communicates at this point, by one or more branches, with the deep muscular vein.

5. *Superficial Veins of the Fore-arm.*

Placed outside the fibrous sheath formed by the antibrachial aponeurosis, these veins, which are principally two in number, are maintained against the external face of that membrane by a thin fascia which separates them from the skin.

A. Median, or Internal Subcutaneous Vein (Fig. 293, 31).—This is also one of the vessels selected for the operation of phlebotomy. It is the continuation of the internal metacarpal vein, ascends from the inner face of the carpus to the superior extremity of the fore-arm, by crossing the radius in a very oblique manner, and terminates in two very large branches, the posterior of which is the *basilic vein*, and the anterior the *cephalic vein*.

The *basilic vein* traverses the sterno-aponeurotic (transverse pectoral) muscle, to aid in forming the humeral trunk (Fig. 293, 34).

The *cephalic*, or *plat vein*, crosses the superficial band of the biceps or coraco-radial muscle, is lodged in the space comprised between the levator-humeri and small pectoral muscles, and afterwards opens into the jugular vein (Fig. 293, 35).

B. Subcutaneous, or Anterior Radial Vein (Fig. 293, 32).—Less considerable than the preceding, this vein arises at the carpal region, in its course occupies the anterior face of the fore-arm, and terminates in uniting its superior extremity either to the subcutaneous median or the cephalic vein; the last is most frequently the case.

6. *Metacarpal Veins.*

Three in number, as we know, these veins are distinguished into *internal* and *external collateral of the cannon*, and *deep* or *interosseous collateral*.

A. Internal Collateral of the Cannon.—More voluminous than the others, this vein passes from the vicinity of the fetlock along the flexor tendons, accompanied by the principal artery of the cannon and the external plantar nerve, places itself in the special sheath which envelops the common trunk of the interosseous arteries to the inside of, and behind the carpus, to be continued in the antibrachial region by the median subcutaneous vein, after communicating with the other metarcarpal veins (Fig. 293, 30).

B. External Collateral of the Cannon.—Situated opposite the preceding—to the external side of the flexor tendons, in company with the corresponding plantar nerve—the external collateral of the cannon follows that nerve to near the trapezium, and then separates into several reticulated branches which anastomose with the internal collateral, from which proceed the ulnar and internal or posterior radial veins.

C. Interosseous Vein.—A tortuous, irregular, and sometimes multiple vessel, lodged with the plantar interosseous arteries between the suspensory ligament and the posterior face of the principal metacarpal bone. Reaching the superior extremity of that bone, it unites largely to the right and left with the external and internal collaterals, sending upwards one or two small branches which traverse the carpal sheath along with the collateral artery of the cannon, and open into the posterior radial branches above the knee.

7. *Digital Veins.*

These veins occupy, on the sides of the digital region, the same position as the homonymous arteries in front of which they are placed. They arise from the network formed on the lateral cartilages by the veins of the foot, and terminate in uniting above the fetlock, between the flexor tendons of the phalanges and the superior sesamoid ligament, so as to form an arch from which proceed the three metacarpal veins (Fig. 293, 37).

8. *Veins of the Foot or Ungual Region.*

The importance of the region to which these vessels belong, requires that they should be described more fully than the other veins, and as has been already done with the arteries of this part of the body. We will, therefore, borrow the exact and minute description given by M. H. Bouley.[1]

This venous apparatus may be divided into *external* and *internal* or *intra-osseous.*

a. External Venous Apparatus.

"The external venous apparatus of the digital region is very remarkable for the number, development, superficial distribution, and reticulated disposition of the canals composing it. To give an idea of this, we cannot do better than compare its general form to a net whose irregular meshes are extended over, and moulded on, the two last phalanges which are contained in it.

"This intricate reticulation of the venous apparatus of the foot is marvellously displayed in specimens injected after maceration, and then dried.

"To facilitate its description, we recognise in it three parts distinct by their situation, though they only form a continuous one. They are:

"1. The *solar plexus.*

"2. The *podophyllous plexus.*

"3. The *coronary plexus.*

"A. Solar Plexus.—The veins of the solar plexus are remarkable for the equality of their calibre throughout the whole extent of the plantar surface, and by the almost absolute absence of anastomotic communications with the deep parts.

"Sustained in a special fibrous web (plantar reticulum), which replaces the periosteum at the lower surface of the phalanx, and is a continuation of the corium of the villous tissue, these veins appear indeed to have so little communication, except with each other, that it is possible to detach the *plantar reticulum* from the superior face of the third phalanx without disturbing them.

[1] 'Traité de 'Organisation du Pied du Cheval,' p. 65.

"The general disposition of the venous canals in the texture of the reticulum supporting them, closely resembles that of the secondary ribs of the limb (or *laminar merithal*) of certain asymmetrical leaves. In their course they follow an irregularly-broken line, intercepting each other by joining at short intervals, so as to form unequal-sized, unsymmetric, polygonal spaces.

"These venous conduits have a double canal for discharging themselves: a *central*, the least considerable and least constant; the other *peripheral* or *circumflex*, corresponding to the artery of the same name,[1] and whose satellite vein it is.

"*Central canal.*—The central canal is formed by the simultaneous anastomoses of a crowd of venous ramifications converging towards the centre of the digit. It is of a parabolic shape, and embraces in the concavity of its curvature the point of the pyramidal body, whence it throws its two branches in a parallel manner on the sides of that body, into the bottom of the lateral lacunæ as far as the cartilaginous bulbs, where it proceeds to the external coronary plexus. This disposition is not constant, however, as specimens are frequently met with in which this central canal is replaced by multiple veins, which are more considerable than those forming the whole of the plexus, and which serve them as overfalls towards the superficial coronary plexus.

Circumflex vein, or peripheral venous canal.—"This vein is of large calibre, and formed by divergent ramifications from the solar plexus, as well as the descending veins of the podophyllous plexus; it margins the external limb of the villous tissue in following a slightly undulous line within the circumflex artery, whose satellite it is. It is sometimes broken up, at certain points of its course, into several smaller canals which are continuous with its trunks.

"In its circular route, all the divergent solar and descending podophyllous veins are discharged into it, and it terminates, at the extremities of the crescent formed by the third phalanx, in several large branches which pass beneath the podophyllous tissue to the lateral cartilage, where they concur to form the superficial coronary plexus.

"B. Podophyllous Venous Plexus or Network.—The veins of the podophyllous plexus exhibit a disposition analogous to those of the solar plexus; like them, they are sustained in the meshes of a fibrous texture (the *reticulum processigerum* of Bracy Clark, the *subpodophyllous reticulum* of French Veterinarians) spread on the anterior surface of the bone, in the same way as the periosteum is on other bones, and continuous with the corium of the laminal tissue. Communicating largely between each other by multiple anastomoses, like the solar plexus, they appear to be completely isolated from the deeper parts, from which it is commonly believed they emanate.

"Tortuous and split up into branches in their course, the podophyllous veins wind in a serpentine manner along the length of the laminæ they cover, very close to each other, and forming narrow elongated meshes. Their confluence is such, that at certain points they appear bound together by their external walls.

"The calibre of these vessels is tolerably uniform throughout the extent of the podophyllous plexus, except towards the posterior parts, where their principal canals empty themselves into the coronary plexus.

"The podophyllous veins are in anastomotic communication, below, with

[1] The *inferior circumflex artery of the foot.*

the circumflex vein of the solar plexus, which they concur to form, and above, with the coronary plexus, which is only a continuation of them.

"C. Coronary Venous Plexus.—The coronary venous plexus (Fig 292, 2, 4) is arranged like a ramose garland around the second phalanx to the origin of the third, and on the surface of the cartilaginous apparatus which completes the latter.

Fig. 292.

THE VEINS OF THE FOOT.

"It is supported, like the other venous networks of the digit, by a fibrous texture immediately subjacent to, and continuous with, the corium of the coronary substance, and is juxtaposed, as well as adherent, to the expansion of the extensor tendon, the lateral cartilages, and to the bulbous enlargements of the plantar cushion.

"This plexus proceeds from the intra-osseous, podophyllous, and solar networks. To facilitate its description, we recognise in it three parts: one *central and anterior*, situated between the two cartilaginous plates, and *two lateral*, corresponding to these cartilages.

"Central Part of the Coronary Plexus.—The central part of the coronary plexus (Fig. 292, 2), immediately subjacent to the substance or cushion of that name, constitutes a very close network formed by innumerable venous radicles, which rise in a tortuous manner from, and are continuations of, the podophyllous plexus, until they reach a large anastomotic vein thrown across from one cartilaginous plexus to the other, and into which they open by ten to twelve principal mouths (Fig. 292, 3').

"These veins of the central part of the coronary plexus gradually increase in calibre, and diminish in number, from the podophyllus plexus, where they take their origin, to their superior and terminating canal, which itself only appears to be the result of their successive anastomoses.

"Cartilaginous Plexus, or Lateral Parts of the Coronary Plexus.—The cartilaginous plates serve to support, by their two faces and the canaliculi by which they are traversed, a mass of very close, anastomosing, and converging veins, which, from its situation, may be designated the *cartilaginous plexus.*

"This cartilaginous plexus is formed by two layers of vessels—a *superficial* and *deep.*

"*Superficial cartilaginous layer or plexus.*—The superficial layer (Fig. 292, 3, 4), extended over the external surface of the cartilaginous plates and bulbs, has its origin by innumerable roots from the veins of that part of the podophyllous plexus corresponding to the superficies it occupies. These

roots, massed in a very dense network, converge towards the superior portions by diminishing in number and augmenting in volume, and terminate in forming themselves, by the aid of successive anastomoses, into ten or twelve principal branches which again unite into two considerable vessels (Fig. 292, 6), situated at the superior limit of the plexus. These vessels, finally, by their last fusion at the inferior extremity of the first phalanx, constitute the digital vein, the satellite of the artery of the same name (Fig. 292, 5).

"Considered from below upwards, in a foot previously prepared by injection, the digital vein, divided into two branches, subdivides itself into secondary branches and ramuscules which diverge and spread over the convex surface of the cartilage and coronary cushion, resembling somewhat the disposition of trees trained on espaliers, whose spreading branches are fixed to the walls on which they ramify.

"The two peripheral branches of the superficial cartilaginous plexus establish communications with the opposite cartilaginous plexus, in contracting direct anastomoses with the branches of the plexus which are symmetrical to them.

"The anterior anastomosing canals are double and superposed.

"The most inferior and superficial is constituted by the large vein (Fig. 292, 3′) thrown slantingly across from one plexus to the other in the median plane, and on the external surface of the extensor tendon; this receives a considerable multitude of venous ramuscles, which emerge from the anterior part of the podophyllous plexus.

"This first *communicating* vein joins the anterior branches of the cartilaginous plexus.

"The second *communicating* vein, situated three-quarters of an inch above the first, and beneath the tendon, is thrown transversely from one anterior branch of the plexus to the other. They open into each other on each side, at the same point where the first communicating vein enters.

"Sinuous in the whole of its track, sometimes double, and sometimes formed of several confluent veins, as in Fig. 292, this anastomosing canal serves as an outlet for several deep veins.

"The anastomosis between the posterior peripheral branches of the cartilaginous plexus is formed by an irregularly curved and long vein of large calibre, sinuous or broken in its course, but always considerably longer than the distance from the two cartilaginous plates between which it is extended.

"This *posterior communicating* vein acts as a confluent to the canals emerging from the cartilaginous bulbs, and to the posterior part of the solar plexus, which throws into it five or six well-developed afferent veins.

"*Deep cartilaginous layer or plexus.*—The deep layer of the cartilaginous plexus is formed:

"1. By somewhat large ascending branches from the posterior part of the podophyllous and solar plexuses.

"2. By the deep internal venous apparatus of the third phalanx.

"3. By the deep veins arising from the coronary bone and the ligaments and tendons surrounding it.

"The ascending branches of the podophyllous tissue are introduced by the numerous foramina which traverse the base of the cartilaginous plate and the inferior fibrous covering of the plantar cushion; they follow the canals which continue those foramina in the substance of the cartilage, and reach its internal face, along with the branches proceeding from the intra-osseous

venous system and those coming from the tendons and ligaments, forming a fasciculus of five or six thick converging veins which unite in two large ascending branches. These anastomose with each other before their definitive junction with the two peripheral branches resulting from the superficial cartilaginous plexus, with which they concur in constituting the digital vein."

b. Internal, or Intra-osseous Venous Apparatus.

"Girard, the younger, and Rigot have denied that the plantar artery had, in the interior of the phalanx, a satellite venous system. These two able anatomists committed an error.

"The disposition of the venous apparatus in the interior of the phalanx is absolutely identical with that of the arterial.

"The satellite radicular venules of the terminal arteries converge, by forming successive anastomoses, towards the semilunar sinus, into which they enter by the anterior interosseous canals, ascending and descending, and by which the emergent arteries from the semilunar anastomosis pass outwards. There they join into a semicircular canal, the satellite of that anastomosis, which is continued backwards by two efferent veins that follow the posterior canals of the semilunar sinus, emerge by the plantar foramina, pass into the fissure of the same name, ascend within the basilar process, lie at the internal face of the cartilaginous plate, in one of the infractuosities with which it is sculptured, and concur in the formation of the deep layer of the cartilaginous plexus.

"Beside these veins converging towards the cartilaginous plexus, there is a small number of divergent ones which follow the track of the arteries, and pass into the podophyllous plexus through the anterior porosities of the phalanx.

"The dissection of specimens injected by the veins puts this arrangement of the venous apparatus in the interior of the os pedis beyond a doubt.

"But is this internal venous system limited to the group of vessels which are satellites of the arteries, or is it not rather extended over a vaster surface, and may not all the areolæ of the spongy tissue of the bone be considered as a dependency of it?

"This way of viewing it would seem to be supported by the result of certain injections, in which the material introduced by the neighbouring veins has filled all the internal spongiolæ of the bony tissue; though this was probably due to an accident in the operation, and it is presumable that the direct passage of the venous injection into the areolæ of the spongy tissue arose from a rupture in the vascular walls. If the tissue of the phalanx formed a kind of diverticulum for the venous system, as the opinion just given would admit, operations performed on this part during life, when the texture of the bone is deeply involved, ought to be followed by hæmorrhage from the open orifices of these aerolæ—a circumstance which does not take place.

"It does not appear, therefore, that there is in the structure of the third phalanx any departure from the general plan on which bones are constructed, and we think that its internal veinous system is limited to the vessels, very numerous as they are, which accompany the arterial divisions."

ARTICLE III.—POSTERIOR VENA CAVA. (Figs. 258, *v*; 259, *f*; 293.)

This vein, whose volume is not equalled by that of any other vessel in the body, commences at the entrance to the pelvis by two large roots, the *pelvi-crural trunks.*

From this point it is directed forward, beneath the bodies of the lumbar vertebræ, soon reaches the superior border of the liver, where it leaves the lumbar region to lodge itself in the fissure excavated on the anterior face of that gland; passing through this, it traverses the aponeurotic centre of the diaphragm, and opens into the postero-external part of the right auricle of the heart.

In this course, the posterior vena cava is naturally divided into three portions—a *sublumbar*, *hepatic*, and *thoracic.*

The *sublumbar portion*, placed to the right of the abdominal aorta and to the left of the right kidney and suprarenal capsule, is maintained against the common inferior vertebral ligament and the left small psoas muscle by the peritoneum and the pancreas. It responds, besides, to the right renal artery, which crosses its face perpendicularly, as well as the corresponding great splanchnic nerve and the nervous divisions of the right renal and lumbo-aortic plexuses.

In its *hepatic portion*, the posterior vena cava is only related to the liver and diaphragm, which form a complete canal around it.

The *thoracic portion* is lodged between the right lung and its internal accessory lobule, and enveloped by a particular serous fold—a dependency from the right pleura, and which has been already described (page 465).

Collateral afferents.—Those vessels which, as considerable as they are numerous, open into the posterior vena cava, are, enumerating them from before to behind:

1. The *diaphragmatic veins.*
2. The *vena portæ*, a trunk into which are collected the majority of the visceral abdominal veins, and which, instead of opening directly into the vena cava, is divided in the liver like an artery, reconstituting itself into a certain number of thick branches—the *suprahepatic vessels*, which enter the vena cava on its way through the anterior fissure of the liver.
3. *Renal veins.*
4. *Spermatic veins.*
5. *Lumbar veins.*

All these vessels will be studied, in the order above indicated, before the roots or *pelvi-crural trunks* of the vena cava.

DIAPHRAGMATIC VEINS.

These are two, sometimes three, enormous vessels lodged in the texture of the aponeurotic centre, commencing by several branches in the fleshy portion of the muscle, and entering the vena cava at the moment when it traverses the diaphragm.

VENA PORTÆ. (Figs. 293; 294.)

The manner in which this vessel comports itself gives it an altogether peculiar physiognomy, and has caused it to be considered as a separate vascular system. After what has been already said concerning the structure of the liver, it cannot be ignored that the vena portæ is distributed in that gland exactly like an artery.

Fig. 293.

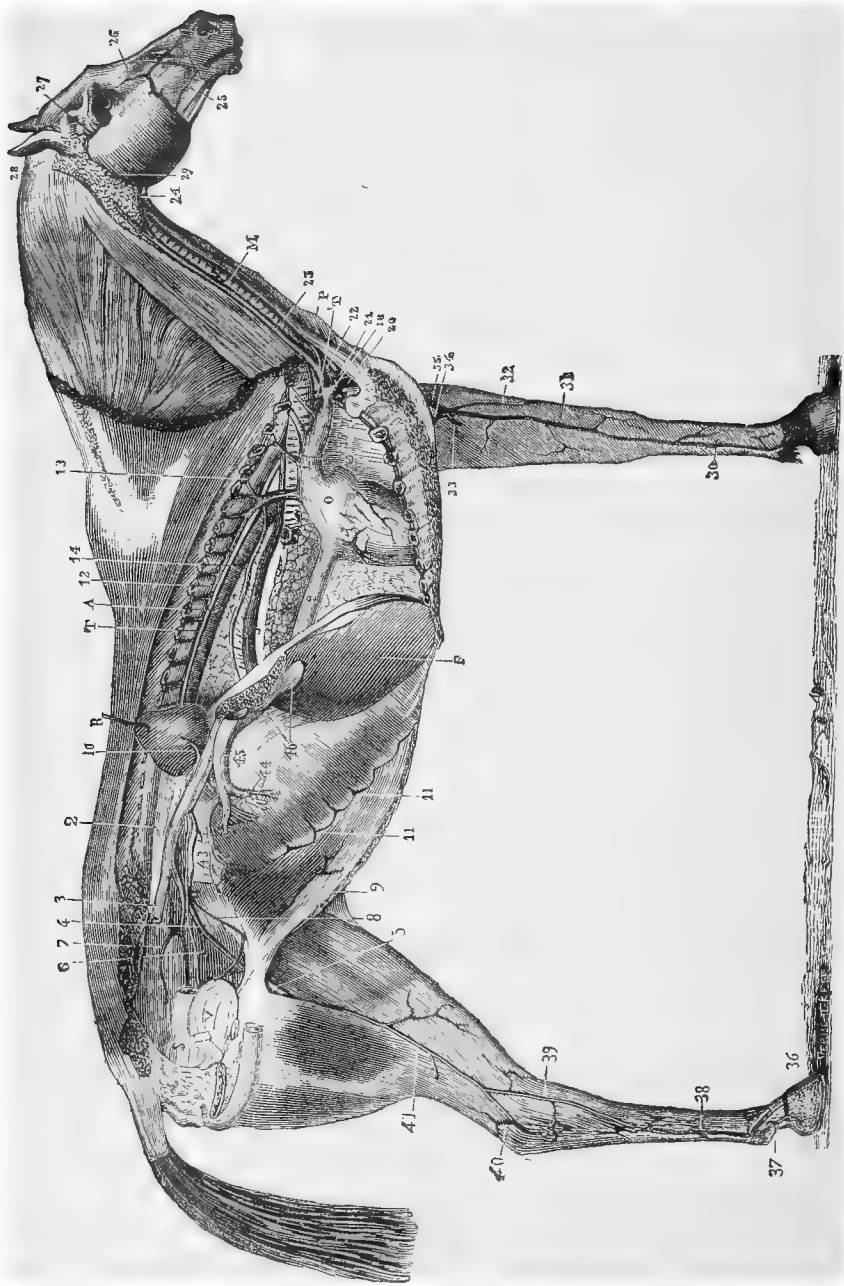

GENERAL VIEW OF THE VEINS IN THE HORSE.

It begins in the sublumbar region, at the great mesenteric artery, by the union of three large roots; it is then directed forwards and a little to the right, traversing the pancreatic ring, below the vena cava, and is afterwards lodged in the great posterior fissure of the liver, where it ramifies by forming the *subhepatic veins*, whose capillary divisions themselves give rise to the *suprahepatic vessels.*

Suprahepatic and *subhepatic veins* (Fig. 219, VP, V*h*).—These vessels having been already studied in the description of the liver, we need not again occupy ourselves with them, but refer only to a peculiarity incompletely noticed in that description, with reference to the suprahepatic veins.

We know that these vessels are divided into two categories, according to the arrangement of their openings. The majority enter the vena cava in forming a single confluent placed at the anterior extremity of the fissure in the liver, at the diaphragmatic veins; the others open separately over the whole extent of the hepatic portion of the venous trunk. In carefully examining the confluent towards which all the veins of the first group converge, we recognise the *embouchures* of three principal veins, one coming from each of the hepatic lobes, and furnished with three very thick, incomplete valves. With regard to the vessels of the second group, M. Claude Bernard[1] considers them to come, for the most part, directly from the subhepatic veins, and not from the capillary network formed by the arborisation of these veins in the lobules of the liver. It is true that injections readily penetrate from the vena portæ into the vena cava, but they do this quite as much by passing along the large suprahepatic vessels as the canals of which we now speak; and, besides, if the material forced into the vena portæ is mixed with some imperfectly-powdered colouring matter, the injection will arrive colourless, or but slightly tinged, in the suprahepatic vessels and the vena cava. These facts, we see, do not militate in favour of M. Bernard's

[1] '*Leçons de Physiologie Experimentale.*' Paris, 1856.

Anterior vena cava; 2, 2, Posterior vena cava; 3, Right pelvi-crural trunk, divided at the ilio-sacral articulation; 4, Left pelvi-crural trunk; 5, Femoral vein; 6, Obturator vein; 7, Subsacral vein; 8, Left testicular vein; 9, Posterior abdominal vein; 10, Renal vein; 11, 11, Ascending branches of the asternal vein; 12, Vena azygos, with its intercostal branches, and in front the subdorsal venous branch, 13; 14, Œsophageal vein; 15, Dorsal, or dorso-muscular vein; 16, Cervical, or cervico-muscular vein; 17, Vertebral vein; 18, Right axillary vein, cut at the anterior border of the first rib; 19, Substernal, or internal mammary vein; 20, Left axillary artery; 21, Termination of the left cephalic vein; 22, Left jugular; 23, Right jugular; 24, External maxillary, or glosso-facial vein; 25, Coronary vein; 26, Angular vein of the eye; 27, Subzygomatic vein; 28, Posterior auricular vein; 29, Maxillo-muscular vein; 30, Internal metacarpal vein; 31, Median subcutaneous vein; 32, Radial subcutaneous vein; 33, Posterior radial vein; 34, Basilic vein; 35, Plat, or cephalic vein; 36, Coronary venous plexus; 37, Digital vein; 38, Internal metatarsal vein; 39, Anterior root of the internal saphena vein; 40, Posterior root of ditto; 41, Internal saphena; 42, Great coronary vein; 43, Small mesaraic vein; 44, Different branches of the great mesaraic vein; 45, Trunk of the vena portæ in its sublumbar portion, lodged in the pancreas; 46, The same in the posterior fissure of the liver; below it is seen entering the substance of the gland.—M, Subscapular hyoideus muscle cut obliquely in the direction of the trachea; P, Cervical panniculus turned down to expose the jugular channel; O, Right auricle of the heart; A, Posterior aorta; G, Section of the right lung; F, Left lobe of the liver behind the section of the diaphragm; R, Right kidney carried up and forward; L, Œsophagus; V, Bladder; S, Rectum; T, Thoracic duct; T′, Termination of that duct in the confluent of the jugulars.

opinion; and there is every reason to believe that the system of the vena portæ and that of the vena cava do not communicate, in the adult, otherwise than by the capillary network which is intermediate to the subhepatic and suprahepatic vessels. If any other means of communication exist, they must be extremely small.

Fig. 294.

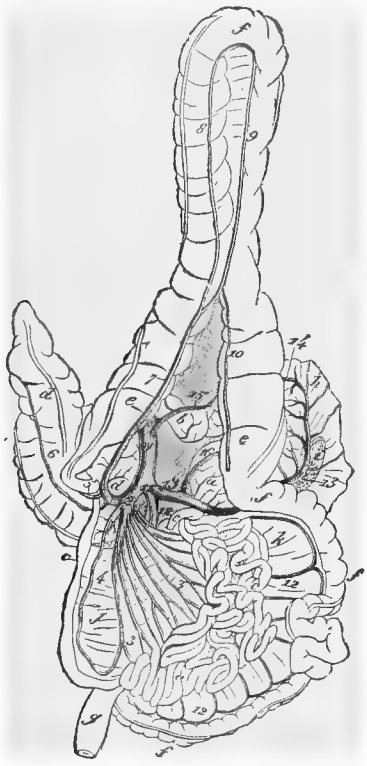

THE VENA PORTÆ AND ITS ROOTS; PARTLY THEORETICAL.

1, Trunk of the vena portæ; 2, Its origin; 3, Veins of the small intestine; 4, Ilio-cæcal vein; 5, External cæcal vein; 6, Internal cæcal vein; 7, Great mesaraic vein; 8, 9, Colic veins forming the roots of that vessel; 10, Collateral vein sometimes continuing the left colic, and joining the great mesaraic vein near its origin; 11, Common confluent of the small mesaraic and splenic veins; 12, Small mesaraic vein and its collateral branches; 13, Splenic vein; 14, Left gastro-epiploic vein; 15, Right ditto; 16, Posterior gastric vein.—*a*, Stomach; *b*, Duodenum; *c*, Small intestine; *d*, Cæcum; *e*, Large colon; *f*, Floating colon; *g*, Rectum; *h*, Portion of the great omentum; *i*, Spleen; *j*, Mesentery; *k*, Colic mesentery.

Constituent vessels of the vena portæ.—The three roots of this vein are the *great* and *small mesenterics* and the *splenic vein.*

The collateral affluents it receives on its course are principally two: the *right gastro-epiploic veins* and *anterior gastric.*

We will make a rapid survey of all these vessels.

1. *Roots of the Vena Portæ.*

A. Great Mesenteric or Anterior Mesaraic Vein (Fig. 293, 44; 294, 2, 7).—This is an enormous venous canal into which flows the blood that has passed through the walls of the small intestine, cæcum, large colon, and the origin of the small colon, and whose divisions correspond exactly to the different branches furnished by the great mesenteric artery.

When traced from its opening to its origin, in an inverse direction to the course of the blood, it is observed to lie between the two colic arteries, and proceed beyond the fold formed by the suprasternal and diaphragmatic curvatures, beyond which it divides into two satellite branches for the colic arteries, which anastomose in arcade towards the pelvic curvature, like the arteries they accompany.

It is therefore by the union of two *colic veins* (Fig. 294, 8, 9) that the great mesaraic vein is constituted, and in whose formation numerous collateral affluents concur; among these may be noticed the two *cœcal veins* (Fig. 294, 5, 6), the *ilio-cœcal vein* (Fig. 294, 4) coming from the origin of the floating colon, and the *veins of the small intestine:* vessels arranged so exactly like the corresponding arteries that we may dispense with any further description of them.

B. Small Mesenteric or Posterior Mesaraic Vein (Figs. 293, 43; 294, 12).—This vessel commences above the rectum, near the anus, by large *hæmorrhoidal* branches which communicate with the homonymous ramuscles of the internal pudic. It is directed forwards, between the two layers of the second mesentery, along the small mesenteric artery, which it passes, and extends to the great mesenteric artery, on the left side of which it unites with the splenic vein, before opening into the anterior mesaraic to form the vena portæ. In its course it receives all the satellite venous branches of the divisions of the artery of the same name, and whose arrangement is similar to that of the arterial ramifications.

C. Splenic Vein (Fig. 294, 13).—This is an enormous canal which follows the splenic artery, and comports itself exactly like it. It begins by the *left gastro-epiploic vein* (Fig. 294, 14) anastomosing in arcade with the right gastro-epiploic, receiving on its track *gastric*, *splenic*, and *epiploic branches*, and joining the small mesaraic after passing above the left extremity of the pancreas, and obtaining the *posterior gastric vein* (Fig. 294, 16).

2. *Collateral Affluents of the Vena Portæ.*

A. Right Gastro-epiploic Vein (Fig. 294, 15).—We already know that the hepatic artery, before entering the liver, gives off pancreatic branches, a pyloric branch, and a gastro-epiploic division, which in turn detaches a small duodenal artery; the vessel described as the *right gastro-epiploic* vein corresponds, in every respect, to all these collateral ramifications of the hepatic artery.

This vein, then, has its origin from around the great curvature of the stomach, but at an undetermined point, as it forms an anastomotic arch with the left gastro-epiploic vein. Posteriorly, it crosses the dilatation at the origin of the duodenum, receives the *pyloric*, *duodenal*, and *pancreatic veins*, and opens into the vena portæ after traversing the pancreas.

B. Anterior Gastric Vein.—Satellite of the homonymous artery, this vein joins the vena portæ separately, after the entrance of that vessel into the great posterior fissure of the liver, and when very near the terminal extremity of that fissure.

RENAL VEINS.

Two in number, like the arteries they accompany, these veins are distinguished by their enormous volume and the tenuity of their walls. The left, having to cross the abdominal aorta before entering the vena cava, is longer than the right. They receive the majority of the veins from the suprarenal capsules (293, 10).

SPERMATIC VEINS.

These vessels correspond to the great spermatic arteries of the male, and the utero-ovarian arteries of the female.

Testicular vein.—The radicles which constitute this vein present, at their emergence from the superior border of the testicle, a flexiform and very complicated arrangement, enlacing, turning, and inflecting themselves in a thousand ways around the convolutions of the great spermatic artery, and ascending in this manner towards the neck of the vaginal sheath (abdominal ring), which they pass through usually after joining to form two trunks. These rise towards the sublumbar region, beneath the peritoneum, in a fold of which they are at first included; they communicate with one another in

their course by anastomosing branches, and are generally confounded into a single spermatic vein, which opens into the vena cava near the renal vein (Fig. 293, 8).

Utero-ovarian vein.—This vein, which is very voluminous, enters the vena cava at the same point as the corresponding vessel in the male, and proceeds, as its name indicates, from the ovaries and uterus by flexuous and reticular branches, whose fusion into a single trunk only takes place near the vena cava.

LUMBAR VEINS.

Satellites of the arteries of the same name, these vessels enter the vena cava separately. The most anterior often open into the vena azygos.

PELVI-CRURAL TRUNKS OR COMMON ILIAC VEINS.

These appellations are given to two enormous vessels, into which are collected all the veins of the abdominal limb and the posterior part of the trunk—very short vessels, which, by their junction, form the posterior vena cava (Fig. 293, 3, 4).

The common iliac vein is lodged in the angle of separation comprised between the external and internal iliac arteries, and is a continuation of the two satellite veins of these arterial canals. The right, shorter than the other, passes above the external iliac artery to join the vena cava at its origin. The left, longer, insinuates itself between the body of the second last lumbar vertebra and the terminal extremity of the posterior aorta, to open into the other.

If we trace, as was done with the veins of the anterior extremity, from the ungueal region to the pelvis, all the branches which concur in the formation of these two trunks, we will find, as the common point of departure for each, a rich *subungueal plexus*, from which spring two *digital veins*. To these succeed three *metatarsal veins*, the common origin of all the vessels of the leg. These latter are distinguished as *superficial* and *deep*, and are four in number—two *saphena veins* in the first group, and *two tibial veins* in the second—continued by the *popliteal vein*. This vessel is itself continued by the *femoral* and *external iliac* veins, which finally form the pelvi-crural trunk by opening into the *internal iliac vein*.

All these vessels will be studied in an inverse order to that in which they have been enumerated, and as follows:

1. *Internal iliac vein.*
2. *External iliac vein.*
3. *Femoral vein.*
4. *Popliteal vein.*
5. *Deep veins of the leg.*
6. *Superficial veins of the leg.*
7. *Metatarsal veins.*
8. *Veins of the digital region.*

1. *Internal Iliac Vein.*

This vessel is formed by the satellite veins of the branches furnished by the homonymous artery: these are the *iliaco-femoral*, *obturator*, *iliaco-muscular*, *gluteal*, *lateral sacral*, and *internal pudic*, whose distribution does not differ from that of the corresponding arterial divisions.

The trunk resulting from the union of these different branches is usually very short; it may even be altogether absent, and we then see its constituent veins open into the common iliac vein by forming two or three separate groups situated very close to each other.

2. *External Iliac Vein.*

This vein constitutes the principal root of the pelvi-crural trunk, which is but a continuation of it, the internal iliac being only, properly speaking, a collateral affluent of the single canal represented by the external and common iliac veins.

Situated behind the crural arterial trunk, this external iliac vein commences at the anterior border of the pubis, where it is directly continued, without any line of demarcation, by the femoral vein.

The only important vessel it receives on its course is the *iliac circumflex vein*, which, however, opens more frequently into the common than the external iliac.

3. *Femoral Vein.*

Continuous by its superior extremity with the external iliac vein, and inferiorly with the popliteal, this femoral vein is remarkable for its large volume, and closely follows the artery of the same name throughout its extent (Fig. 293, 5).

The collateral affluents it receives in its course are distinguished by their number and considerable volume. They are:—

1. The *satellite veins of the muscular arteries.*
2. The *internal saphena vein*, which will be again referred to in describing the superficial veins of the leg.
3. The *prepubic vein*, formed by the *posterior abdominal* and the branches of the *internal pudic.* The latter are very numerous and large, and anastomose with each other, forming between the thighs, in the texture of the scrotum and sheath, and above the penis, a very rich network which communicates behind with the cavernous veins. This network only sends a small trunk into the inguinal ring, along the external pudic artery; in its middle part it opens into an enormous branch which traverses the ring in the sartorius muscle, and is lodged in the inferior groove of the pubis to join the femoral vein.

One of these external pudic veins represents the subcutaneous abdominal vein, and communicates with the subcutaneous thoracic vessel.

All these branches in the female show an analogous disposition,

4. *Popliteal Vein.*

Satellite of the popliteal artery, this vein is formed by the union of the anterior and posterior tibial veins.

Among the branches it receives on its course, the *femoro-popliteal vein* may be particularly noted; this accompanies the artery of the same name, and joins the external saphena before opening into the popliteal vein.

5. *Deep Veins of the Leg.*

These are two in number: the *anterior* and *posterior tibial.*

A. Anterior Tibial Vein (Fig. 278, 5).—Placed beside the homonymous artery, often double, always very ample, this vein originates on the

anterior face of the tarsal articulations by means of several anastomosing roots, the principal of which is formed by the deep metatarsal vein, that passes through the cuboido-cuneo-scaphoid canal from behind to before. After crossing the fibular arch with the artery, it joins the posterior tibial to constitute the popliteal vein.

B. Posterior Tibial Vein.—This commences near the hollow of the hock, within the calcis, by radicular branches which principally come from the two saphena veins. It then ascends along its satellite artery, to open into the anterior vein beneath the popliteal muscle.

6. *Superficial Veins of the Leg.*

These are the *internal* and *external saphena.*

A. Internal Saphena Vein.—This vessel shows two roots—an anterior and posterior (Fig. 293, 39, 40).

The first proceeds from the internal metatarsal vein, the second from the external. Both ascend, in converging towards each other, on the internal face of the tibia, uniting into a single branch before reaching the thigh.

This single branch, always very voluminous, glides upwards on the sartorius muscle, and terminates in a variable manner on reaching the groin: sometimes it is insinuated into the interstice of the two adductors of the leg, to join the femoral vein, and at other times it ascends to the ring of the short adductor, and opens into the external pudic veins.

B. External Saphena Vein.—It rises, by a short branch, outside the os calcis, communicates, even at its origin, with the posterior root of the internal saphena by means of a large reticular anastomosis thrown transversely in front of the apex of the calcis; and with the posterior tibial, by a large branch which passes between the tibia and the perforans muscle. It follows the external saphena nerve outside the gastrocnemii tendons, behind the external gastrocnemius muscle, and enters the popliteal vein, after joining the femoro-popliteal vessel.

7. *Metatarsal Veins.*

These veins are three in number, and are distinguished as *internal, external,* and *deep;* they proceed from the sesamoid arch, which is formed by the anastomosis of the two digital veins.

A. Internal Metatarsal Vein (Fig. 278, 9).—This vessel, the most considerable of the three, appears more particularly to continue the digital vein of the same side. For the greater part of its extent it is placed with the internal plantar nerve, along, and a little in advance of, the flexor tendons. Arriving near the tarsus, it deviates slightly to reach the anterior face of the tarsal articulations, and there communicates, by a very large transverse branch, with the origin of the anterior tibial vein; afterwards it rises on the internal face of the leg, where it constitutes the anterior root of the internal saphena vein.

B. External Metatarsal Vein (Fig. 278, 8).—It occupies, outside the flexor tendons, a position analogous to the preceding. Towards the superior extremity of the metatarsus, it communicates, by a short thick branch, with the deep vein. It then continues its ascending course by entering the tarsal sheath along with the plantar arteries, and is prolonged in the hollow of the hock, along the great femoro-popliteal nerve, in constituting the posterior root of the internal saphena.

C. Deep Metatarsal Vein (Fig. 278, 10).—This is placed beneath

the suspensory ligament, at the inner side of the principal interosseous plantar artery. Near the tarsus, it receives a very large branch from the external vein, and then traverses the cuboido-cuneo-scaphoid canal, to form the largest root of the anterior tibial vein.

8. *Veins of the Digital Region.*

As these resemble, in every respect, those belonging to the anterior limb, the same description will suffice for both (*see* page 613).

DIFFERENTIAL CHARACTERS IN THE VEINS OF OTHER THAN SOLIPED ANIMALS.

It does not come within our plan to give a complete history of the venous system of these animals, because of the small utility of such a study. To remain faithful to the object in view, we confine ourselves to the indication of the special characters of the veins on which bleeding is usually practised, and those which may be interesting in a surgical point of view, as the digital veins of Ruminants.

A. Angular Vein of the Eye.—This vessel is remarkable for its large volume in the *Sheep;* and as it is well defined beneath the skin, in consequence of the fineness of that membrane, it is more frequently selected for phlebotomy than in other animals.

B. Jugular Vein.—Very large in all animals, and particularly in the *Ox*, this vein deserves the preference given to it when it is proposed to abstract a certain quantity of blood from the system.

In all non-soliped animals there is found an accessory jugular, which sometimes exists in the Horse, but is much less in size, alongside the common carotid artery. It arises from the occipital vein, and, therefore, measures the whole length of the neck. Sometimes its diameter is small; but it is often so large as to receive a very notable quantity of blood from the principal jugular, when compression is applied to the latter to favour the flow of blood after opening it: a circumstance which explains the difficulty sometimes experienced in obtaining a voluminous jet of blood.

C. Abdominal Subcutaneous Vein.—In the Bovine species, this vessel has an enormous volume, especially in the milch-cow, in contradistinction to the subcutaneous thoracic vein, which is always very narrow.

This vein is prolonged forward on the wall of the abdomen, to nearly the xiphoid cartilage, where it passes through to join the internal thoracic vein.[1] Behind, it is formed by multiple branches, which anastomose with each other, or with those of the opposite vein, and are in communication with the proper external pudic veins.

D. Internal Saphena Vein.—This is alway smaller than in Solipeds, and is rarely selected to bleed from.

E. External Saphena Vein.—This vessel is, on the contrary, more voluminous than in the Horse, and at the same time more superficial; consequently, it is more favourably situated for phlebotomy, as well in *Pigs* and the *Carnivora*, as in *Ruminants*. It arises from the union, in the hollow of the hock, of the two principal roots furnished by the metatarsal veins.

F. Veins of the Posterior Foot in the Ox.—As in the Horse, they commence in the *subungueal network* of the digital region, which is double, like the region itself.

a. Three *digital veins* leave this reticulum: 1, A *median* or *anterior* one, arising by two roots from the anterior part of each network, passing between the two digits, and joining the anterior superficial metatarsal vein above the fetlock; 2, Two *laterals*, communicating with one another, behind, by a transverse anastomosis which receives several venules from the ungueal plexus, and with the anterior vein by an interdigital branch, united by an arch in front of the flexor tendons, above the sesamoid groove.

b. These digital veins are continued by five *metatarsal veins:* two *deep* and one *superficial anterior*, and two *posterior*.

The two *deep anterior veins* are small vessels which accompany the collateral artery of the cannon, which is placed between them. They arise in the interdigital space from the anterior digital vein, communicating, by the inferior metatarsal foramen, with the sesamoid arch, sending off on their way transverse anastomoses, and being continued above the tarsus by the two anterior tibial veins, whose roots they constitute.

The *anterior superficial* vein is very voluminous. It proceeds from the sesamoid arch,

---

[1] The openings through which these vessels pass in the abdominal parietes, are commonly named the *milk fountains* or *doors*.

receives near its origin the median digital vein, rises in front of, and a little to the outside of, the tarsus, communicating at this point with the anterior tibial veins; it divides above the tibio-tarsal articulation into two branches: a posterior, forming the anterior root of the external saphena; the other anterior, joining the anterior tibial vein of the external side.

The two *posterior veins* spring from the sesamoid arch. Situated at first between the suspensory ligament of the fetlock and the posterior face of the metatarsus, and communicating there by several anastomoses, these two veins are continued along the tarsus, the one within, the other without. The *internal* follows the corresponding plantar artery, and is prolonged in the tibial region by the posterior tibial and internal saphena veins. The external ascends within the calcis, and is united to a branch of the anterior superficial metatarsal, to form the external saphena vein. Before leaving the deep situation it occupies below the suspensory ligament of the fetlock, these two vessels concur, but especially the internal, to form a perforating branch which traverses the cuboido-scaphoid canal to join the anterior tibial veins.

G. Veins of the Anterior Foot in the Ox.—Four *digital veins* escape from the two subungueal plexuses: an *anterior*, *posterior*, and two *lateral*.

a. The *anterior digital vein*, which is very slender, is lodged superficially between the two digits, and comports itself at its origin like the analogous vein of the posterior limb, in rising by two roots. In being prolonged above the fetlock, it constitutes a subcutaneous metacarpal branch, which occupies the anterior and internal plane of the cannon, and is united above the knee to the principal cutaneous vein of the fore-arm.

b. The *posterior digital vein*, often doubled by a small accessory branch, accompanies the common digital artery, and extends along the collateral artery of the cannon, to constitute one of the posterior radial veins.

c. The *internal digital vein*, after passing the digital region, is lodged between the cannon bone and the internal border of the suspensory ligament, proceeds outside the carpal sheath with the radio-palmar artery, and divides above the knee into two branches: an anterior, the origin of the internal subcutaneous vein of the fore-arm; the other posterior, forming one of the posterior radial veins.

d. The *external digital vein* occupies, on the outer side of the external digit and the cannon bone, a position analogous to the internal vein. It gives rise to several deep metacarpal veins which anastomose, and are mixed with the interosseous palmar arteries; the principal vein and its accessory branches are joined, below the carpus, to the internal vein.

It is to be remarked that these four digital veins communicate, in the interdigital space, by anastomoses resembling those of the posterior limb; and that the last three, or principal veins, anastomose above the fetlock in forming a complicated and variably-arranged sesamoid arch, on leaving which these digital veins become metacarpal vessels.

COMPARISON OF THE VEINS IN MAN WITH THOSE OF ANIMALS.

In *Man*, as in animals, the veins are grouped into those of the lesser circulation, or *pulmonary veins*, and those of the greater circulation. The latter open into the heart by three trunks: the *cardiac veins*, and *superior* and *inferior vena cava*.

The *superior vena cava* represents the anterior vena cava of animals, and receives the blood from the veins of the head, thoracic limbs, and a portion of the chest. It extends from the first costal cartilage to the heart, and commences after the junction of the two brachio-cephalic trunks (innominate veins).

The superficial veins of the thoracic limb at first form, on the back of the hand, a plexus of elongated meshes from which the *median*, *radial*, and *ulnar veins* spring. Near the bend of the elbow, the median bifurcates and gives rise to the *median cephalic* and *median basilic*. Blood is abstracted from one or other of these branches. At the arm, all the superficial veins constitute but two trunks: the *cephalic* and *basilic veins*. The deep vessels join these to form the *axillary vein*, which becomes the *subclavian* below the clavicle, then the *brachio-cephalic trunk* (*vena innominata*) when it receives the internal jugular

The *venous sinuses of the cranial dura mater* are proportionately more developed than in Solipeds, though they have the same disposition. There is constantly present a median or inferior longitudinal sinus.

The jugulars which carry the blood from the cranium and face to the heart, are four in number. The *anterior jugular*, the smallest, descends beneath the superficial cervical aponeurosis, in front of the sterno-mastoideus muscle, and enters the subclavian vein. The *external jugular* commences by the union of the facial and temporal vein; in its disposition it resembles the jugular of the Horse, and would be a complete representative

if deprived of the branches from the cranial sinuses. The *internal jugular* arises at the posterior foramen lacerum, at a dilatation of the lateral sinus named the *bulbus venæ jugularis*, and passes to the subclavian vein. Lastly, the *posterior jugular* (or *vertebral vein*) situated beneath the great complexus, and in relation with the cervical vertebræ, carries the blood from the spinal sinuses in this region, and which, in Solipeds, is received by the occipital and vertebral veins.

The *inferior vena cava* corresponds to the posterior vena cava of animals, and receives the blood from all the subdiaphragmatic veins. It originates from the union of the two *common iliac veins*, at the third lumbar articulation, and terminates in the right auricle. In its course it receives the *median sacral*, *lumbar*, *renal*, *suprarenal*, *inferior phrenic*, and *right spermatic veins*. The latter forms on the surface of the testicle, and at the origin of the cord, a rich network—the *spermatic plexus;* on the abdominal portion of the cord it constitutes the *pampiniform plexus*.

The vena cava also receives the *vena portæ*, which has the same disposition as in animals. It begins by three branches: the *great* and *small mesaraic* and *splenic veins*. For affluents, it has the pancreatic and duodenal venules, and the right gastro-omental vein. It passes behind the pancreas, and not through that gland, as in the Horse.

The veins of the abdominal limb are divided into deep and superficial. The first terminate by forming the *femoral vein*, which, in joining the vessels of the pelvis, constitutes the *common iliac vein*. The *superficial veins* commence by a network on the dorsum of the foot, which gives origin to the two *saphenas: external* and *internal*.

FOURTH SECTION.

The Lymphatics.

CHAPTER I.

GENERAL CONSIDERATIONS.

Charged with the absorption and transport of the chyle and lymph, the *lymphatic* or *absorbent vessels* are convergent canals with thin and transparent walls, which originate in the texture of organs by fine reticulated radiculæ; and which, after traversing one or more *ganglia* (or *glands*)—glandiform bodies placed on their course—enter the venous system by two trunks: the *thoracic duct* and the *great lymphatic vein*.

LYMPHATIC VESSELS.

These canals resemble veins in so many points, as to merit the name of *white-blood veins*. Like these vessels, the lymphatics are directed from the periphery to the centre of the circulatory apparatus; like them, they are nodulated cylindrical tubes; internally, and at those points where they outwardly appear to be constricted, they show numerous valves which look towards the heart; like the veins, again, they separate into two orders of canals: the ones deep-seated, lodged in the vasculo-nervous intermuscular sheaths; the others superficial, situated on the surface of containing aponeuroses; like the veins, also, the lymphatics terminate in two principal trunks resembling the venæ cavæ; and, finally, as the veins have three tunics, so have the lymphatics, these not differing in any respect, except in being very much thinner.

In carrying this parallel still farther, we will find other analogies whose existence was but little suspected until recently: the glands—those organs which are apparently glandular, and seem to be proper to the lymphatic system—are they not represented in the venous system by the liver—

that enormous gland placed on the track of the abdominal veins—as the glands are on parts of the lymphatics?

It may be added that, if we pass into the domain of physiology, it is also easy to observe characters which are common to the two anatomical systems under comparison. They, in fact, almost equally divide the absorbent function between them: a function which is accomplished in the radicular network of each; and the dynamical process which gives impulsion to the fluids they carry, if it is not quite identical in both, is at any rate very similar in many points.

We may, nevertheless, observe numerous differences between the veins and the lymphatics, and chiefly in their form, number, capacity, and structure.

The *form* of the lymphatic canals is, as we have said, nodulated and cylindrical; but their external nodosities are much less marked, and are closer together than in the veins, owing to the larger number and greater development of the valves. Besides, as these canals travel for considerable distances, and preserve their regularly-cylindrical form with undiminished capacity, if we mentally bring all the divisions of the lymphatic system to a single canal, we no longer obtain a hollow cone whose apex corresponds with the heart, although the capacity of the lymphatic vessels augments from the trunk towards the branches; this conduit only represents a series of cylinders joined end to end, and successively decreasing from its origin to its termination.

The *number* of lymphatic vessels in a certain region is always much greater than that of the veins. But as the lymphatics are much smaller than the veins, there is not, as might at first be supposed, a proportional increase in their total capacity. Observation, indeed, demonstrates that the relation between the capacity of the lymphatics, and the corresponding veins of a region does not exceed one to two.

The *structure* of the lymphatics differs from that of veins in that there exists, in those of average dimensions, smooth muscular fibres in the adventitious tunic. The presence of muscular fibres in the external tunic of these vessels is rendered necessary by the absence of an impelling organ at the origin of the lymphatic system: this organ being, in reality, disseminated throughout the extent of the canals, and aids the *vis a tergo* that causes the lymph to circulate in their interior.

We terminate this short parallel, to dwell in detail on several points connected with the general history of the lymphatics, and which merit particular attention; we allude to the *origin*, *course*, and *termination* of these vessels.

Origin.—For a long period after the discovery of the lymphatic vessels, a state of profound ignorance existed as to their origin. Nevertheless, the importance of the solution of the problem was well appreciated, as it was really the key to the theory of absorption; numerous hypotheses, therefore, sprang into existence. The anatomists who occupied themselves with the question were hindered in their investigation by the imperfect means of research at their disposal. Beyond the larger branches, the lymphatics escaped attention, owing to their transparency and tenuity. Thanks, however, to the patient and minute researches of Hunter, Cruikshank, Mascagni, Fohmann, Panizza, Cruveilhier, and Sappey, the lymphatics were injected by colouring matters or by mercury, and thus rendered visible to their finest ramifications.

It is now known that the lymphatics arise from *capillaries*, which form networks or terminal *culs-de-sac*.

These terminal *culs-de-sac* exist in the intestinal villi; and it is no longer maintained that the ends of these small appendices have an opening by which the lymphatic receives the chyle that bathes the mucous membrane of the intestine.

The *plexuses* are composed of more or less irregular meshes, and their form and volume often vary with the disposition of the tissues or organs in which they are studied. They may be superficial or deep, and exist together or separately. In many membranes the two networks are found, but then the superficial is thinner than the deep. They are mixed with, or placed above, the blood-vessel plexuses, but never communicate with them.

Do these lymphatic plexuses exist in all the tissues, properly speaking? Here is another question of incontestible importance, and whose solution is even now occupying the attention of anatomists. Judging by analogies, one is tempted to reply in the affirmative: why, in fact, should the lymphatics not be spread everywhere throughout the organism, when the sanguine capillaries are constituent parts in the framework of each tissue? It is true we may ask if lymphatic absorption is a necessary act in the vital movement; and although science is far from being satisfied on this point, we know some facts which at least authorize the doubt. On the other hand, direct observation has not revealed lymphatic plexuses in all organs; there are even tissues in which their existence has been denied: though prematurely, it is well to say, because we may always attribute the non-success of a lymphatic injection either to the imperfection of the instruments employed, the insufficiency of the measures adopted, or certain peculiar conditions as yet unknown attaching to the species of animals selected for the demonstration of the lymphatic networks in a certain region. As bearing out this last assertion, we may observe that M. Sappey has not yet been able to inject the pituitary plexuses in Man or the Calf, and that he looks upon their existence as being at least doubtful; while in the Horse, this lymphatic apparatus is as remarkable for its richness, as for the facility with which it may be filled with mercury.

The following are the most trustworthy notions available on this subject.

The lymphatic vessels of the *skin* are very numerous, and form two networks: one, with extremely fine meshes, occupies the most superficial layer of the dermis; the other, placed beneath the deep face of the integument, includes vessels more voluminous than the first, and communicates with it by multiplied ramuscules. These lymphatic plexuses are far from being equally developed in every region: though it is unanimously agreed that no part is entirely destitute of them.

In the internal tegument, or *mucous membranes*, an analogous disposition of these vessels is met with. It is more than probable that they exist throughout the whole extent of these membranes, though their positive demonstration has yet to be made in some regions. In other regions, the injection of these networks is, on the contrary, very easy, and gives the most magnificent results; we particularly mention the lingual, intestinal, and pituitary mucous membranes. The lymphatics belonging to the latter membrane assume so beautiful an aspect in the Horse, that we would advise anatomists who desire to inject lymphatics always to choose that animal. The operation is simple and constantly performed, and we are astonished that in the hands of some individuals it should fail. Not only can the two networks of the membrane be filled, but also the trunks arising from them, and which are directed towards the entrance of the nasal cavities, collect in several thick branches around the nostril, and bend up towards the face

to reach the submaxillary cavity, where they enter the ganglia situated to the right and left of that space.

The majority of anatomists admit the presence of lymphatic plexuses in the splanchnic or synovial *serous* membranes. M. Sappey, however, denies this; he considers the vessels that can be so easily injected by pricking the external surface of a viscus, as belonging to its proper tissue, and not to the serous membrane covering it. Those on the inner face of the walls of the splanchinc or synovial cavities, and which are sometimes filled with mercury, do not, according to him, come from the serous tunic, but from the subjacent tissues.

The lymphatics do not exist in *vessels*, although some modern anatomists have admitted them to be present in the inner layer of the circulatory apparatus. The *lymphatic sheaths* discovered by His, Robin, and Tomaso, around the blood-capillaries of the frog, and those of the brain and spleen of Man, ought not to be considered as the lymphatics of vessels, as they merely surround the ultimate vascular ramifications, and do not arise in the substance of their walls.

In the *nervous tissue* lymphatics have not been discovered, though they are present in the meninges.

Their existence is doubtful in *bone tissue* and in the *muscles;* but they are abundant in the glands and glandiform organs of the animal economy, forming the finest, richest, and most easily demonstrated plexuses.

It has been stated above that the lymphatics commence by capillaries arranged in networks. *Are these networks the real, or only the apparent, origin of the lymphatics?* This is a question that has been, and is still, warmly discussed. It is, however, believed that the plexuses are fed by very minute radicles lodged in the substance of the tissues.

But how do these radicles originate? In the epithelium, says Küss; in the plasmatic cells of the connective tissue, asserts Virchow; in the serous membranes, states Recklinghausen, since he observed fatty matters penetrate the lymphatics by the abdominal face of the diaphragm. The opinion of Virchow is overthrown at present by the researches of Ranvier, which have modified the descriptions given of the connective tissue. According to this authority, plasmatic cells do not exist in that tissue; what have been described as such by Virchow have been only radiating spaces limited by the fasciculi of connective fibres, in which elements analogous to lymph globules circulate. It may be added that these fasciculi are covered by large flat cells, which give these spaces the appearance of a serous cavity with septa at close intervals. These conclusions of Ranvier, then, should affirm the hypothesis of the Würzbourg professor, and tend to prove that in the connective tissue of the economy there is an infinite number of minute serous cavities into which the lymphatic vessels open, in which the lymph circulates, and which are in communication, on the other hand, with the great splanchnic cavities. It must be mentioned, however, that these deductions are only hypothetical, particularly at the period of scientific evolution through which we are now passing.

Course of the Lymphatic Vessels.—The lymphatics follow the track of the veins, and are divided, exactly like them, into superficial and deep vessels. The latter, running parallel to each other, are grouped immediately around the corresponding veins, on which they are generally superposed. The first, although situated in proximity to the superficial veins, are widely spread on each side and on the surface of the superficial aponeuroses, by forming parallel fasciculi, like the deep lymphatics.

The direction followed by the lymphatics in their course is nearly always somewhat rectilinear; they never show the flexuosities which are so developed on the track of certain arteries, and even some veins. Neither do they communicate with one another by transverse or arching anastomoses, like those so commonly met with in the other two orders of canals belonging to the circulatory apparatus. They frequently, however, in their parallel course, bifurcate and join the neighbouring vessels. (At certain situations, as at some of the articulations, and in other parts, the larger stems suddenly break-up into a close interlacing plexus of small vessels or capillaries (Fig. 295), which in their disposition, greatly resemble the *rete mirabile* of the blood-vessels. This plexus is surrounded by condensed connective tissue, and is penetrated by blood-vessels, though no communication takes place between them and these, the only points at which communication occurs being where the great lymphatic trunks empty themselves into the vena cava. This *rete* would appear to be the first step towards the formation of a lymphatic gland.)

Fig. 295.

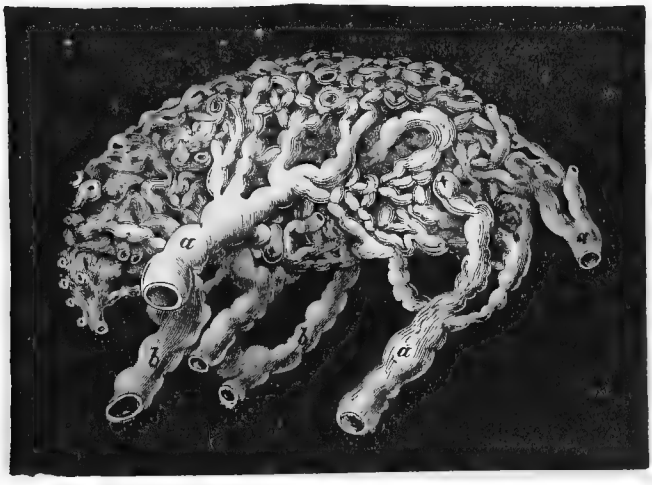

A SECTION OF A SIMPLE RETE MIRABILE, VIEWED FROM THE SURFACE.
a, *a*, Afferent vessels; *b*, *b*, Efferent vessels only partially visible; from the popliteal space.

But of all the considerations relative to the course of these canals, the most interesting are those which belong to the glandiform bodies placed along their track, and whose abridged history we shall give immediately.

Termination.—We have already mentioned the thoracic duct and the right great lymphatic vein as being the receptacles of all the absorbent vessels of the body, and we have also stated that these two trunks enter the general venous system; this union of the sanguine with the lymphatic system takes place at the origin of the anterior vena cava, and this vessel may be considered as the general confluent for all the absorbents. The researches of Haller, Cruikshank, and Mascagni first threw light on this important fact; and it is to those of Fohmann, Panizza, Rossi, &c., that we owe the dedication of this discovery.

LYMPHATIC GLANDS.

The lymphatic glands are ovoid, spherical, or discoid bodies of medium consistency, grey, rosy, or red-coloured, and sometimes quite black, and which at several points intercept the course of the lymphatic vessels.

Their number is considerable, and they are rarely isolated; most frequently they are collected in groups along the blood-vessels. They are always larger in youth than in old age.

All the canals of the lymphatic system are provided with at least one gland on their course, and some even traverse two or three before opening into the thoracic duct or great lymphatic vein. On reaching these glands, they plunge into their structure in ramifications, appearing on the opposite point after being reconstituted into several principal canals, which are generally larger and less numerous than the primitive vessels. The latter take the name of *afferents* (*vasa inferentia* or *afferentia*); the others are named *efferents* (*vasa efferentia*), because they leave the gland to reach the central canal.

Structure.—The structure of the glands is extremely complicated, and difficult to make out, in consequence of the delicateness of their tissue. The following is what is positively known in reference to this subject.

The glands have an *envelope* of connective tissue (continuous with the tunics of the afferent and efferent vessels), which surrounds a *substance* that is readily perceived to be composed of two layers of a different aspect: one *cortical*, the other *medullary*.

The first appears to be granular, the second somewhat fibrous. This proper tissue is sustained by connective laminæ (or septa—continuations of the capsule) which contain smooth muscular fibres. The laminæ form alveoli in the cortical layer, and a sort of minute tubes in the central layer. These *alveoli* are in their turn divided by reticular tissue into secondary spaces, which become smaller as they lie near the centre; at the periphery, where

Fig. 296.

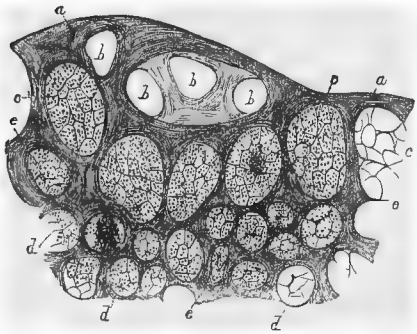

SECTION OF A LYMPHATIC GLAND.

a, *a*, The fibrous tissue that forms its exterior; *b*, *b*, Superficial vasa inferentia; *c*, *c*, Larger alveoli, near the surface; *d*, *d*, Smaller alveoli of the interior; *e*, *e*, Fibrous walls of the alveoli.

Fig. 297.

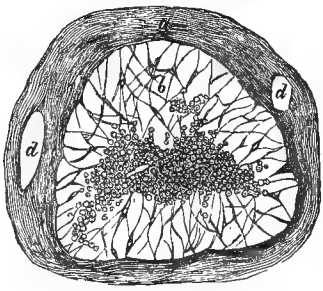

SIMPLE LYMPHATIC GLAND.

a, The capsule with sections of lymphatics, *d*, *d*, passing through it; *b*, Lacunar and intercommunicating passages, permeated by the lymph, and forming the superficial lymph path of Frey; *c*, Nucleus, or medullary portion, with section of blood-vessel in the centre.

they are most voluminous, they are named *lymphatic sinuses*. Everywhere these sinuses are filled with lymph globules. The arrangement is identical

in the medullary substance; in the interior are seen a great number of arterial capillaries. The nerves are derived from the sympathetic system.

The afferent lymphatics, where they enter the gland, communicate with the alveoli which correspond to the cortical substance; these alveoli are connected by the cords of the central layer, and the latter are united, in their turn, to the alveoli of the opposite side of the cortical substance, from which the efferent ramuscules spring. The lymph, therefore, traverses every part of the gland, and during this very tortuous course becomes charged with solid particles.

Fig. 298.

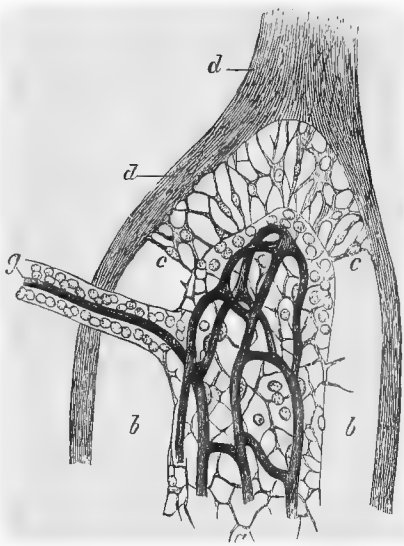

PORTION OF THE MEDULLARY SUBSTANCE OF THE MESENTERIC GLAND OF AN OX, THE ARTERY OF WHICH IS INJECTED WITH CHROMATE OF LEAD; MAGNIFIED 300 DIAMETERS.

a, Medullary substance with capillary network, fine reticulum of connective tissue, and a few lymph corpuscles; *b*, *b*, Superficial lymph-path, traversed by a reticulum of nucleated cells (*c c*), with numerous anastomosing prolongations. The lymph corpuscles have for the most part been removed; *d*, *d*, Trabeculæ composed almost exclusively of unstriped muscular tissue; *g*, A small medullary cord, or bridge, containing a blood-vessel and numerous lymph corpuscles.

Certain glands have a much more simple structure, being entirely composed of lymphatic capillaries rolled up on themselves in clusters, and anastomosing in networks. These capillaries arise from the divergent arborisation of the afferent vessels, and are continuous with the convergent branches which, by their union, form the efferent lymphatics. The organs have received the name of *false glands*, though they are really lymphatic glands. In support of this assertion, it may be said that "in descending the animal series, we see the glands becoming more and more simplified, and transformed at a great number of points into an interlacing of vessels. In birds, they only occupy the base of the neck and the entrance to the chest, forming in all the other regions simple plexuses; in reptiles and fishes, the lymphatic glands disappear altogether, and the plexuses that replace them are themselves not at all complicated."—*Sappey.*

PREPARATION OF THE LYMPHATIC VESSELS.—The lymphatic networks can only be studied after having been filled with mercury by means of injection; but as this operation is not usually practised by the pupils for whom this book is written, the mode of performing it will only be traced in a few words.

The apparatus in use consists of a glass tube continued by a flexible one, which carries at its inferior extremity an iron tap and a fine canula, also of iron, or (better) glass. To apply this apparatus, the tube ought to be suspended and then filled with mercury; the canula is then seized by the right hand, keeping it parallel to the membrane we wish to inject, and burying it in the most superficial layer of that membrane. The extremity of the canula is thus introduced into the midst of the meshes of the lymphatic network, and necessarily wounds some of the capillaries which compose it. In opening the tap, the mercury is allowed to flow into the capillaries by the solutions of continuity they present, and fills them in the most perfect manner. The lymphatic plexuses being

always superposed on the capillary blood-vessels, one is always certain of injecting them only, in taking the precaution to penetrate the membrane as superficially as possible. If the point of the canula enters too deeply, the mercury will pass into the veins, and the operation will be unsuccessful, and must be commenced again.

To study the branches and lymphatic trunks, it will suffice to inflate them from their origin towards their termination. This procedure, properly conducted—and it was almost exclusively the only one adopted by the older anatomists—gives the most satisfactory results, and is even sufficient to demonstrate the texture of the glands.

The latter do not require any particular precautions in their preparation.

CHAPTER II.

THE LYMPHATICS IN PARTICULAR.

We will commence with the examination of the *thoracic duct* and all its affluents, and terminate by studying the *great lymphatic vein.*

In this description the glands and principal lymphatic vessels will be only referred to, the disposition of the networks being already noticed in speaking of the different organs, and they will be further mentioned when speaking of the nervous system, the organs of sense, and those of generation

Article I.—The Thoracic Duct. (Fig. 293, t t.)

Preparation.—Tie the jugulars and axillary veins near their termination, as well as the anterior vena cava about the middle of its length; expose the thoracic duct by removing the ribs on the right side; open that canal near the pillars of the diaphragm, and throw into its interior two injections of tallow, one forward, the other backward from the incision. The first injection will fill the canal and the venous reservoir which is intersected between the ligatures applied to the above-named vessels; the second, although directed in opposition to the valves, overcomes the resistance offered by them, and passes into Pecquet's cistern and the principal branches which open into that confluent. Or we may select one of these branches in the abdominal cavity—for example, one of those which lie beside the colic arteries near their origin—and inject the entire thoracic duct from its origin to its termination.

But this proceeding requires more practical ability than the first, in order to find the vessel which is to receive the canula; and if the animal is very fat, it is impossible.

The thoracic duct is the general confluent for all the lymphatics of the body, with the exception of those which come from the right anterior limb and the right moiety of the head, neck, and thorax.

Extent.—It extends beneath the vertebral column, from the first lumbar vertebra to beyond the entrance to the thorax.

Origin.—Its origin is marked by a very irregular dilatation described as the *sublumbar reservoir*, or *cistern* of Pecquet (*receptaculum* or *cyster nachyli*), into which open the principal affluents of the canal.

This reservoir is divided, internally, by lamellæ into several incomplete compartments, and may be more or less voluminous and circumscribed, and present very variable forms.

It is placed above the abdominal aorta and the posterior vena cava, at the great mesenteric artery, or more frequently a little behind it. In the Dog it is of an enormous size, oval in shape, and prolonged between the pillars of the diaphragm into the thoracic cavity.

Course.—To this reservoir succeeds a tube whose calibre is very irregular, and appears singularly slender when compared with the diameter of the

initial dilatation, or that of the affluent vessels composing it. This is the thoracic duct. We see it enter between the two pillars of the diaphragm, along with the aorta, deviating more or less to the right side of that vessel, and follow it thus to about the sixth dorsal vertebra, in passing to the outside of the right intercostal arteries, which it crosses, and beneath the great vena azygos, beside which it lies. Sometimes, however, we find it carried in this first part of its course directly above the thoracic aorta, between the double series of intercostal arteries, and to the left of the vena azygos, which is then found immediately in contact with the right side of the aorta; or it may even creep to the right of that vein, concealing the greater part of it from sight. Leaving the above-mentioned dorsal vertebra, the thoracic duct abandons the aorta and crosses the flexure of the vena azygos to the left, to extend itself forward on the left side of the trachea, but often also on the right side. It afterwards places itself between the two axillary arteries, crosses the interval comprised between the prepectoral glands, emerges from the chest, and terminates in a manner to be indicated hereafter.

Termination.—The terminal extremity of the thoracic duct is always provided with a dilatation analogous to that which exists at its origin, though much smaller, better circumscribed, and less irregular—a dilatation which opens into the anterior vena cava sometimes by a single orifice furnished with valves, at other times by two very short branches, whose length we cannot estimate at more than the fifth part of an inch, and which are also valvular at their entrance. The point where this entrance takes place is nearly always at the summit of the vena cava, and precisely at the point of junction of the two jugulars. The thoracic duct rarely opens elsewhere; though the fact that it does so at times is exemplified in a specimen in the museum of the Lyons School, in which the embouchure of the duct is placed between the termination of the left jugular and that of the corresponding axillary vein.

Varieties in Solipeds.—"The thoracic duct is far from always showing itself in Solipeds as I have described it, but in its course and insertion presents a great number of variations which we will now pass in review.

"The single canal is separated sometimes, at a part of its length, into two branches, which, after proceeding parallel to each other, soon unite to form a single vessel. This division usually takes place at the base of the heart, at the place where the lymphatics of the bronchial and œsophageal glands enter; it forms a ring whose diameter is often not more than four-tenths of an inch, or an ellipse whose larger axis is from four to eight-tenths of an inch. We see this produced once, twice, and even thrice on the anterior half of the canal, which becomes simple at its termination as it was at its origin. The spaces circumscribed by the bifurcations constitute what have been termed the *insulæ.*

"The canal, instead of remaining single, very often becomes double from its commencement (Fig. 300). Then the two canals are sensibly equal, or one is larger than the other. If they are unequal, it is usually the right which has the advantage, though the contrary sometimes occurs. In any case, the two canals are isolated, one being to the right, the other to the left of the aorta. In advancing towards the entrance to the thorax, they remain completely separated, or communicate with each other by one or two, more or less voluminous, transverse anastomosing branches. Reaching to ten, eight, and sometimes even to two inches from their opening into the jugular gulf, the two canals approach each other, and become confounded into a single

Fig. 299.

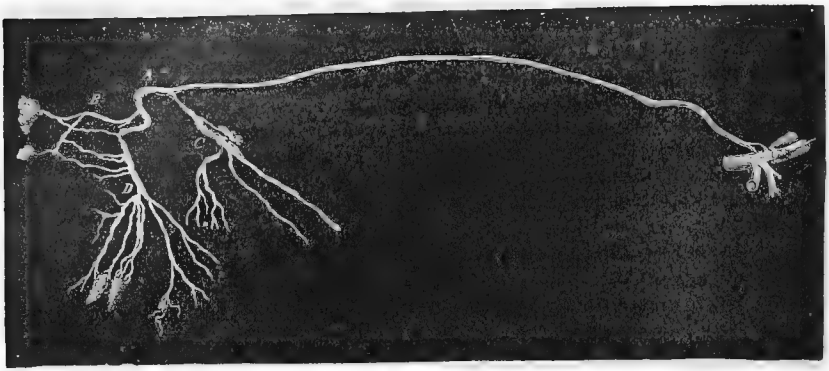

Fig. 300.



Fig. 301.

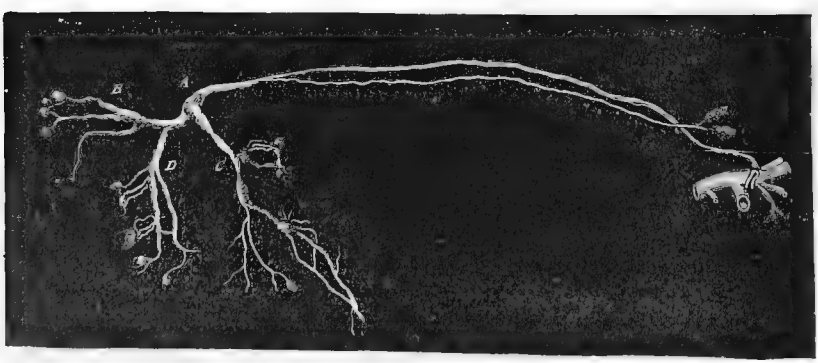

DIFFERENT VARIETIES OF THE THORACIC DUCT IN THE HORSE.

A, Receptaculum chyli; B, Sublumbar branches; C, Anterior mesenteric branch; D, Posterior mesenteric branch. In figure 299 the duct is single, the usual condition, and enters the

vessel. Their fusion generally takes place at the base of the heart, and I have never seen them remain distinct throughout their whole extent, to enter the vena cava separately.

"Sometimes (Fig. 301) there emanates from the gland, at the entrance to the thorax, a long canal which proceeds parallel to the first, and joins it, after a retrograde course, near the pillars of the diaphragm.

"The thoracic duct, double for the greater part of its extent, from the time it leaves the sublumbar reservoir, occasionally ends by becoming triple. In this case, the largest of the two canals is divided into two branches; then the three canals, after pursuing a certain course, all join at the same point, or two are first united into a single conduit, into which the third opens at a variable distance from the confluent of the first."[1]

The affluents of the thoracic duct.—The lymphatic branches which enter the thoracic duct are as remarkable for their number as their volume. Some empty themselves into the sublumbar reservoir; a few vessels open into the great lymphatic vein of the thorax, and the others terminate in that conduit, near its insertion into the venous system.

The first, variable in their number, particularly the largest, are more especially regarded as the roots of the thoracic duct.

Ordinarily three are found, with a certain number of small accessory trunks. One of the largest branches enters the posterior part of the cistern; very often double, and even multiple, it arises from an enormous group of ganglia placed in the sublumbar region, around the posterior extremity of the abdominal aorta and vena cava, and into which are collected all the vessels of the posterior limbs, the pelvis, abdominal walls, and the pelvi-inguinal viscera. The other two trunks reach the left side of the cistern, and result from the union of the lymphatics which have their source in the abdominal digestive organs; among these lymphatics, however, there are some belonging to the parietes of the stomach and the parenchyma of the liver and spleen, and which approach the right side of the sublumbar receptacle, to open singly into that cavity.

The affluents the thoracic duct receives on its course, proceed from the viscera contained in the thoracic cavity, and from the walls of that cavity.

Those which terminate at the anterior extremity of the duct are formed by the lymphatics of the left anterior limb, and the left half of the thorax, diaphragm, neck, and head.

We will now examine rapidly all the radicular branches of these affluents.

Article II.—The Lymphatics which form the Affluents of the Thoracic Duct.

These lymphatic vessels are divided into five groups. 1, Those of the abdominal limb, the pelvis, abdominal parietes, and the pelvi-inguinal organs; 2, Those of the abdominal digestive viscera; 3, Those of the organs contained in the chest; 4, Those of the thorax; 5, Those of the head, neck, and anterior limb.

[1] *G Colin.* 'Traite de Physiologie Comparée des Animaux Domestiques,' vol. ii.

---

summit of the anterior vena cava by two short branches. It is double in Figure 300; and in Figure 301 it has a long branch that arises at the entrance to the thorax and joins the duct, by a retrograde course, near the pillars of the diaphragm.

LYMPHATICS OF THE ABDOMINAL LIMB, PELVIS, ABDOMINAL PARIETES, AND THE PELVI-INGUINAL ORGANS.

All these vessels converge towards an immense group of ganglia, named the *sublumbar glands*. Besides these, there are other groups on different parts of their track, constituting the *deep inguinal*, *superficial inguinal*, *popliteal*, *iliac*, and *precrural glands*. The successive description of these ganglia, and their afferent and efferent vessels, will conveniently make known the lymphatic apparatus, whose study we have in view in this paragraph.

1. *Sublumbar Glands.*

This group, which occupies, as its name indicates, the sublumbar region, comprises: 1, A small single mass situated in the sinus of the angle formed between the two internal iliac arteries, and is often formed by a single large ganglion; 2, Another mass lodged between the two iliac arteries, and a third placed without, and to the front of, the crural trunk: these two are double; 3, A single agglomeration of glandular lobules dispersed around the origin of the small mesenteric and spermatic arteries: these are isolated from one another.

These different masses receive the lymphatics of the pelvis, the emergent branches of the deep inguinal ganglia, those which come from the iliac ganglia, some ramuscules from the rectum and large colon, and those from the spermatic cord.

They are bound to each other by communicating branches, and give rise to several series of emergent branches, which soon collect into one or more trunks that enter Pecquet's reservoir.

2. *Deep Inguinal Glands.*

This is a considerable mass of glandular lobules lodged beneath the aponeurosis and the crural arches, in the interstice of the adductor muscles of the leg, along with the crural vessels, within which they are placed.

The form of this group is elongated, and its length may be six to eight inches, or even more; its superior extremity extends as high as the anterior border of the pubis. It is composed of from fifteen to twenty lobules, which rarely have an uniform colour, some being grey and others brown, or nearly black.

The afferents are formed by the superficial lymphatics which accompany the internal saphena vein, whose roots may be traced beyond the fetlock, and by the deep satellite vessels of the crural artery and vein. The efferents proceed to the sublumbar glands, by ascending in the abdomen along the external iliac artery and vein.

3. *Superficial Inguinal Glands.*

These are placed in front of the inguinal ring, at the side of the sheath, on the track of the subcutaneous abdominal artery, where they form a small elongated mass from two and a-half to three inches in length, and are composed of a dozen principal lobules.

Their afferents, which are very numerous, come from the inner aspect of the thighs, the sheath, scrotum, and the inferior abdominal wall. The efferent vessels, much larger, but less numerous—there are only five or six—ascend in the inguinal canal, accompanying the external pudic artery and

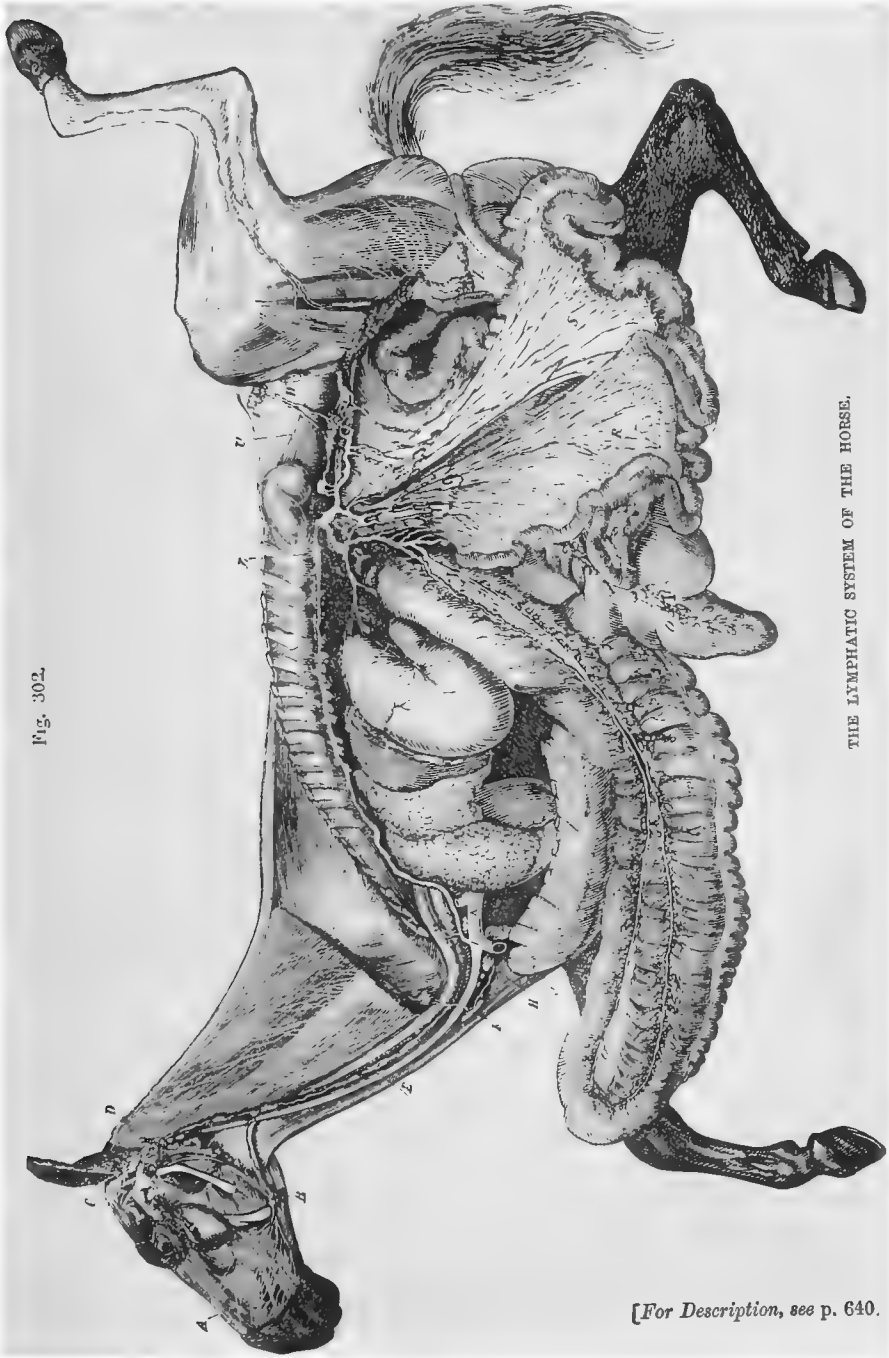

Fig. 302.

THE LYMPHATIC SYSTEM OF THE HORSE.

[*For Description, see* p. 640.

the inguinal nervous branches. They enter the deep inguinal glands, after traversing the crural ring, in company with the prepubic artery.

4. *Popliteal Glands.*

These glands represent a very small mass composed of from three to five independent lobules, situated behind the great sciatic nerve and gastrocnemii muscles, between the long vastus and semitendinous muscles, and near the femoro-popliteal artery.

They receive some of the lymphatics which arise from the environs of the hock, and those coming from the posterior and inferior part of the gluteal region. Their efferents join the deep inguinal glands, by following the muscular interstices of the thigh.

5. *Iliac Glands.*

Slightly yellow in colour, and of a soft consistence, these glands are five or six in number, and form a group which is situated in the triangular interval comprised between the two branches of the circumflex iliac artery. They receive the emergent branches of the anterior crural glands, and a great number of deep lymphatics from the abdominal wall. Their efferent branches, four or five in number, follow the circumflex iliac artery to pass to the sublumbar glands.

6. *Precrural Glands.*

Placed within the anterior border of the fascia lata, on the track of the circumflex iliac artery, these glands form a small elongated mass, composed of a dozen lobules lying close to each other. To this group come afferent vessels from the anterior and internal part of the thigh. It gives rise to three or four large efferent vessels, which ascend the internal face of the muscle of the fascia lata, accompanying the circumflex iliac artery, and entering the abdominal cavity near the angle of the haunch, to join the iliac glands.

LYMPHATICS OF THE ABDOMINAL VISCERA.

1. *Glands and Lymphatic Vessels of the Rectum and Small Colon.*

The glands in this portion of the intestinal tube are: at first, two or three lobules placed at the base of the tail and on each side of the sphincter ani; in the second place, a very numerous series of small glandular bodies situated along the small curvature of the viscus; thirdly, some rounded

---

A, Facial and nasal plexus whose branches pass to the subglossal glands; B, C, Parotid lymphatic gland, sending vessels to the pharyngeal gland; D, E, Large trunks passing towards the thorax; F, G, H, Glands receiving the superficial lymphatics of the neck, a portion of those of the limbs, and those of the pectoral parietes; I, Junction of the jugulars; J, Axillary veins; K, Summit of anterior vena cava; L, Thoracic duct; M, Lymphatics of spleen—N, of stomach—O, of large colon—S, of small colon; R, Lacteals of small intestine—all joining to form the two trunks, P, Q, which open directly into the receptaculum chyli; T, Trunk which receives the branches of the sublumbar glands, U, to which the vessels of the internal iliac glands, V, the receptacles of the lymphatics of the abdominal parietes, pass; W, Precrural glands receiving the lymphatics of the posterior limb, and which arrive independently in the abdomen; X, Superficial inguinal glands into which the lymphatics of the mammæ, external generative organs, some superficial trunks of the posterior limb, etc., pass; Z, Deep inguinal glands receiving the superficial lymphatics, Z, of the posterior limbs.

lobules comprised within the two layers of the mesentery, and placed on the track of the arterial and venous divisions.

Originating in the texture of the mucous and muscular tunics, the lymphatic radicles gain the glands of the small curvature of the colon, and escape from them as efferent branches, which pass in great numbers into the mesentery. These efferents, or at least some of them, traverse the lymphatic glands placed on the course of the blood-vessels, and collect, near the origin of the posterior mesenteric artery, into several somewhat voluminous branches, which join the divisions of the sublumbar glands, or those of the large colon.

2. *Glands and Lymphatic Vessels of the Large Colon.*

There is seen on this enormous viscus a double chain of glands, lying beside the colic arteries, and numerous small lobules disseminated at a short distance from the principal glands, and on the track of the collateral branches furnished by these two vessels.

Received at first, for the most part, by these lobular bodies, the lymphatics which have emanated from the tunics of the viscus afterwards join the principal glands, from which they emerge in forming several large satellite branches for the colic vessels. Only two or three in number at the pelvic curvature, these branches are increased to ten or twelve on arriving near the origin of the colic arteries. It is from the union of these vessels with those of the small intestine, that the two large mesenteric trunks (Fig. 299, A, C) arise, which, with the branches emanating from the sublumbar glands (Fig. 299, B), form Pecquet's reservoir.

3. *Glands and Lymphatic Vessels of the Cœcum.*

There exists, on the track of each cæcal artery, a moniliform series of glands, farther apart from one another than those of the double colic chain, to which the vessels coming from the cæcal membranes are directed, and from which several long satellite branches of the blood-vessels, that proceed to the same trunk as those of the small intestine, depart.

4. *Glands and Lymphatic Vessels of the Small Intestine.*

The glands which receive the lymphatic vessels from the small intestine are very large and abundant. About thirty in number, of a grey colour, very compact, fusiform, often bifurcated at their superior extremity, these glands are placed in the texture of the mesentery, near the origin of the great mesenteric artery, from which those belonging to the portion of intestine nearest the end of the viscus are most distant. The latter also possess, in addition, fifteen special small glandular lobules, dispersed on the track of the ileo-cæcal artery.

We have already noted the richness of the vascular apparatus which rises from the wall of the small intestine, towards the mesenteric glands It must be added that these glands give rise, at their superior extremity, to large emergent branches, two or three for each, which soon coalesce to make more voluminous branches that concur in the formation of the two intestinal roots of Pecquet's reservoir.

5. *Glands and Lymphatic Vessels of the Stomach.*

There are two classes of lymphatic glands for the stomach 1, Several large glands situated on the small curvature of the organ; 2, A series of

small lobules disseminated along the great curvature to the attachment of the great omentum.

The vessels which emerge from them "gather on the track of the gastric arteries and veins, and ascend to the great tuberosity, near the trunk of the cœliac artery; there they anastomose with the lymphatics derived from the spleen and liver, and unite into several flexuous branches, some of which open directly into the thoracic duct, to which the others pass, after being confounded with the anterior trunk of the intestinal lymphatics."—*Colin.*

6. *Glands and Lymphatic Vessels of the Spleen and Liver.*

"The lymphatic vessels of the spleen, rising some from the interior of the viscus, others from its surface, pass towards the splenic artery and vein; they traverse several groups of glands disposed on the track of these vessels, commencing from the middle of the length of the fissure, ascend, five or six in number, towards the origin of the artery in forming a sinuous mass whose divisions, anastomosing with those of the stomach and liver, open, on the one hand, with the latter in the anterior trunk of the intestinal lymphatics, and, on the other, into a magnificent plexus communicating directly with the thoracic duct.

"Finally, the lymphatics of the liver form a very close network on the surface, and another in the interior of the parenchyma. They collect towards the posterior fissure, and first dip into a primary and very small glandular group, then into a second group of voluminous round glands, which are concealed between the trunk of the vena portæ and the pancreas. They open in common with the vessels of the stomach and spleen."—*Colin.*

GLANDS AND LYMPHATIC VESSELS OF THE ORGANS CONTAINED IN THE THORACIC CAVITY.

We find annexed to these organs three groups of lymphatic glands: 1, A series of small granulations placed in the posterior mediastinum, on the course of the œsophagus; 2, The *bronchial glands*, situated in the angle of bifurcation of the trachea, around the origin of the bronchi, which they follow for a short distance into the pulmonary parenchyma; 3, Two long strings of lobules extended on the sides of the inferior face of the trachea, from the base of the heart to near the first rib.

The first group receives the posterior lymphatics of the œsophagus, the second those of the lung, and the third those of the pericardium, heart, and a portion of the trachea and œsophagus. Their efferents, uniting into some large trunks, enter the thoracic duct at different distances.

GLANDS AND LYMPHATIC VESSELS OF THE THORACIC WALLS.

These glands form three series: 1, A double chain of rounded grains, situated on each side of the dorsal column, above the intercostal spaces, and beneath the costal pleura; 2, A frequently voluminous mass, lodged at the base of the xiphoid appendix, behind the heart, and in front of the inferior part of the diaphragm; 3, Some rudimentary granulations lying beside the internal thoracic vessels.

The lymphatics of the diaphragm, after receiving those from the convex face of the liver, pass to the glands placed at the base of the muscle, from which they escape in the form of several canals that accompany the internal thoracic vessels, and open into the anterior extremity of the thoracic

duct or the great lymphatic vein, the majority of them through the medium of the prepectoral glands. These vessels receive, on their course, those which are brought from the inferior part of the intercostal spaces into the suprasternal granulations.

The other lymphatic vessels of the costal wall ascend between the two muscles which close these spaces, and go to the subdorsal glands, which afterwards eject them, near the origin of the thoracic duct, in the form of one or two long vessels proceeding in a retrograde manner on each side of the dorsal column.

LYMPHATIC VESSELS OF THE HEAD, NECK, AND ANTERIOR LIMB.

These vessels are all directed towards the entrance to the chest, and are gathered into a group of glands, called the *prepectoral*, which, with regard to the lymphatics of the anterior part of the body, play the same part as the sublumbar glands do to the vessels of the posterior region.

Before arriving at this common point of convergence, they are intercepted on their course by other glands, which form four principal groups: 1, The *guttural* or *pharyngeal glands;* 2, The *submaxillary glands;* 3, The *prescapular glands;* 4, The *brachial glands.*

In studying these different glandular groups in succession, with their afferent and efferent vessels, we will give a sufficient idea of the entire lymphatic apparatus in the region which remains for us to examine.

1. *Prepectoral Glands.*[1]

They form, on each side of the terminal extremity of the jugular, within the inferior border of the scalenus muscle, a very large mass which extends into the chest by passing beneath the axillary vessels, and ascends to the inner face of the first rib.

Into these glands pass the lymphatic vessels emerging from the prescapular and axillary glands, those which descend along the trachea with the common carotid, and which come from the pharyngeal glands, as well as the majority of those which follow the internal thoracic vessels.

They give rise to several short and voluminous branches: those from the glands of the right side form, by their junction, the great lymphatic vein; and those from the left side join the thoracic duct, or are inserted separately beside the latter, at the summit of the anterior vena cava.

2. *Pharyngeal Glands.*

Very numerous, soft, and loosely united to one another, these glands are disposed in an elongated mass that occupies the lateral plane of the pharynx, below the guttural pouch, and which is prolonged backwards even beyond the thyroid body.

They receive all the lymphatics from the head: some come directly from the base of the tongue, the soft palate, the pharyngeal walls, and the larynx; the others are derived from the submaxillary glands, and from a lobule lodged in the substance of the parotid gland.

The efferent branches which leave it are four or five in number. Always voluminous, they descend along the trachea, some separately, but the majority are united in a fasciculus which follows the carotid artery;

[1] These are glands, we believe, which ought to be regarded as the representatives of the axillary glands of Man.

they are provided on their course with several elongated glands, to which the lymphatic radicles that arise from the cervical portion of the trachea and œsophagus pass. On arriving near the entrance to the chest, they are lost in the prepectoral glands. Some of them, however, traverse these without dividing, and directly enter, on the left, the thoracic duct, and on the right, the great lymphatic vein. It has been even possible for us to inject the latter vessel by one of these canals exposed on the right side.

3. *Submaxillary or Subglossal Glands.*

They represent a fusiform mass situated at the bottom of the intermaxillary space, in the receding angle comprised between the digastricus on the one side, and the mylo-hyoideus and subscapulo-hyoideus muscles on the other, above and near to the external maxillary artery. The lymphatics of the tongue, cheeks, lips, nostrils, and nasal cavities join these glands. Their efferents reach the pharyngeal or guttural glands.

4. *Prescapular Glands.*

By their union they form a species of chain, at least twelve inches in length, placed on the course of the ascending branch of the inferior cervical artery, beneath the internal face of the levator humeri muscle, and descending close by the fixed insertion of the sterno-maxillaris muscle.

The majority of the lymphatics of the neck, and those of the breast and shoulder, open into these glands. Their efferents, short and voluminous, enter the prepectoral glands.

5. *Brachial Glands.*

Situated beneath the anterior limb, within the arm, these vessels are divided into two groups: one placed near the ulnar articulation, within the inferior extremity of the humerus; the other disposed in a discoid mass behind the brachial vessels, near the common insertion of the adductor muscle of the arm and the great dorsal muscle.

The first group receives the vessels from the foot and the fore-arm, which accompany the superficial veins, or pass with the deep arteries and veins into the muscular interstices. It sends nine or ten flexuous branches to the second group, into which open directly the lymphatics of the arm and shoulder, and from which emerge a certain number of efferents that pass, in company with the axillary vessels, to the prepectoral glands.

Article III.—Great Lymphatic Vein.

The second large receptive trunk of the lymphatic vessels, this great vein (the *ductus lymphaticus dexter*) leaves the prepectoral glands of the right side, and therefore becomes the general confluent of the lymphatics from the right anterior limb, the right axillary and superficial costal regions, as well as the right half of the head, neck, and diaphragm.

This trunk is only from three-fourths of an inch to two inches in length. "It usually opens at the junction of the jugulars, at the side of the canal, by an orifice furnished with a double semilunar valve. Sometimes one or two of the branches which concur to form it describe circumvolutions around the corresponding brachial trunks or some of its divisions, before joining the others. Lastly, it is not rare to see this lymphatic trunk anastomose

with the thoracic duct by voluminous collateral branches, then unite with it in such a way as to be inserted together by a single orifice above the gulf of the jugulars."—*Colin.*

Fig. 303.

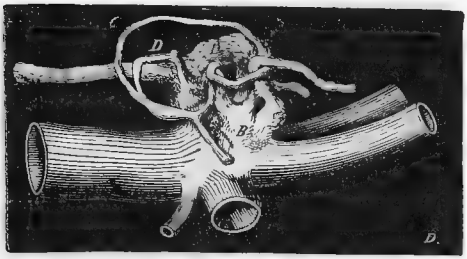

Fig. 304



THE GREAT LYMPHATIC VEIN AND ENTRANCE OF THE THORACIC DUCT.

A, Thoracic duct; B, Great lymphatic vein, or right lymphatic trunk; C, D, Anastomoses established between them near their insertion.

DIFFERENTIAL CHARACTERS IN THE LYMPHATIC SYSTEM OF OTHER THAN SOLIPED ANIMALS.

The lymphatic system, glands and vessels, is more developed in Ruminants and the Pig than in the Carnivora.

In this respect the domesticated animals may be classified in the following order: *Ox, Sheep, Horse, Pig, Dog, Cat.*

RUMINANTS.—"The *thoracic duct* of large Ruminants, when it has entered the thorax by a special opening in the diaphragm, almost distinct from that of the aortic arch, is placed above and to the right of the aorta, between it and the spine. There, although outside the corresponding intercostal arteries, it is completely concealed by a thick layer of adipose tissue, in which are numerous subdorsal glands. Towards the fifth dorsal vertebra, it receives a large lymphatic vessel coming from the enormous gland that exists on the track of the œsophagus in the posterior mediastinum; it then crosses the direction of the aorta and the œsophagus, passes to the left, gains the entrance to the thorax, and opens in front of the first rib, above the junction of the left jugular with the anterior vena cava.[1]

"The varieties it presents in the *Ox* are numerous and very common. The rarest disposition is that of a canal, single throughout its entire length, such as it has been described, and such as it is usually found to be in small ruminants (Fig. 309). This canal (Fig. 306), single at its origin and for the greater part of its extent, often bifurcates towards the base of the heart, or at a short distance from its insertion. Of these two branches, one passes to the right of the œsophagus and trachea, the other to the left of these, in following the ordinary direction; and, at the entrance to the thorax, they either terminate separately, each in the angle of union of the jugular and corresponding axillary vein, or together at the same point—the gulf of the two jugular veins.

Fig 305.



ENTRANCE OF THE THORACIC DUCT IN THE OX.

"It happens that one of the branches of the bifurcated canal is in its turn subdivided into two smaller branches, and that the other experiences at the same time a similar

(1 Zundel has pointed out the curious fact, that in Ruminants, the long, special, lymphatic gland situated between the layers of the mediastinum and above the œsophagus, sometimes becomes so voluminous that its weight impedes rumination, especially when the animal is lying. The bolus of food is prevented from ascending into the œsophagus, and this may become a frequent and periodic cause of indigestion.)

subdivision : in such a way that the trunk of the canal, at first single, becomes double, then quadruple, and consequently opens into the venous system by four distinct orifices.

Fig. 306



Fig. 307.

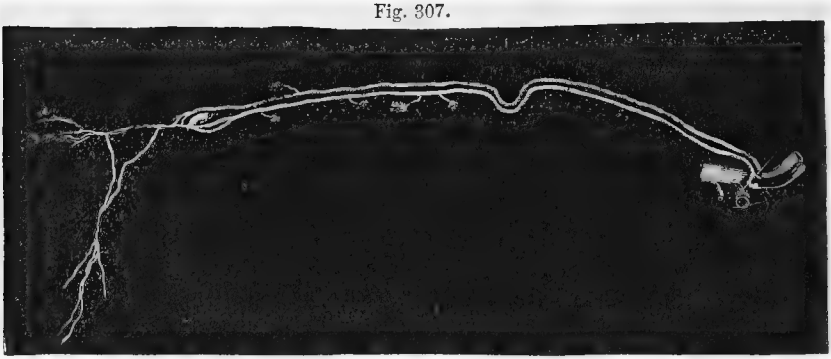

Fig. 308.

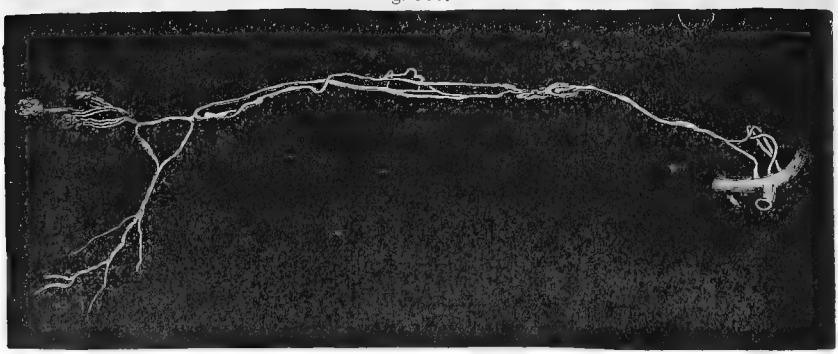

VARIETIES OF THE THORACIC DUCT IN THE OX.

If the branches of the canal, instead of remaining isolated. send off transverse anastomoses, there results a complication of which Solipeds do not offer an example (Fig. 305).

The thoracic duct is often double throughout its extent. The two canals are then

detached separately from the cistern, one follows the right side, the other the left side of the aorta, describing an arch whose concavity is downward at the base of the heart, on the lateral parts of the trachea, terminating either very near one another, and on the same transversal line, at the junction of the two jugulars, or one to the right, the other to the left, in each of these two veins, and not far from their junction with the axillaries (Fig. 307.)

"When the two canals arise from the sublumbar reservoir, they sometimes repeatedly anastomose with each other by sinuous and curved branches, as shown in figure 308.

Fig. 309

THORACIC DUCT OF SMALL RUMINANTS.

"Then all the branches collect in the anterior mediastinum, and constitute a single canal which, near its termination, again subdivides into four vessels that open separately, two to the right and two to the left, in the usual place.

"This variety is the most remarkable and complicated of all those observed in the domesticated animals.

Pig.—"The thoracic duct of the *Pig*, usually single throughout its whole extent, is sometimes divided, at one to one and a-half inches from its insertion, into two branches which soon reunite in an oval dilatation; this, after receiving the vessels from the head, neck, and limbs, opens towards the extremity of the left jugular.

Carnivora.—"In the *Dog*, Pecquet's reservoir is enormous; in shape it is ovoid, and is prolonged between the pillars of the diaphragm into the thoracic cavity. The thoracic duct of this animal generally resembles that of the Pig. Yet it sometimes offers in its course and termination very numerous variations: Rudbecky has noticed a bifurcation above the heart, and another bifurcation whose branches anastomose with each other several times. Swammerdam and Stenon have figured numerous irregular anastomotic divisions towards the middle of a single canal, to its point of departure. These old authors have indicated and represented double and triple insertions of different forms. Lastly, Bilsius has shown an arch, or rather a very remarkable ring, at the entrance of the conduit, and at its junction with the lymphatic vessels of the neck and anterior limbs, and which is more or less analogous to that which I have observed on several occasions in the Horse, Pig, and Cat."[1]

CHAPTER III.

THE CIRCULATORY APPARATUS OF BIRDS.

We will briefly examine the characteristics of the different portions of the circulatory apparatus—the heart, blood-vessels, and lymphatic vessels—of birds.

Article I.—The Heart.

The heart, in birds, is situated quite at the entrance to the chest, in the median line, and is contained in a *pericardium* that adheres to the posterior diaphragmatic septum

---

[1] *G. Colin*, op. cit.

and the cervical reservoir. In the domesticated species, it has the form of an acute cone, whose base is surmounted by a less distinct auricular mass than in the Mammalia.

Internally it has four cavities. The *right ventricle* is more crescent-shaped than in Solipeds, and in a manner envelops the left ventricle in front and to the right; it does not reach the point of the heart. The auricular valve is not tricuspid, and offers a very remarkable arrangement. "This valve, in fact, instead of being formed as usual by membranous curtains whose margin is retained by cords fixed to the walls of the ventricles, is composed of a wide muscular leaf which appears to be a portion of the inner wall of the ventricle detached from the interventricular septum. This septum is convex, and the auriculo-ventricular orifice is situated in the space comprised between it and the muscular valve in question; so that when the latter contracts at the systole, it is applied against this septum and closes the passage."[1]

There is nothing particular to note with regard to the *left ventricle*, whose walls are likewise thicker than those of the right.

The *auricles* have a kind of diverticulum or sinus, in which the veins that open into each of these cavities unite.

Article II.—The Arteries.

The *aorta* of Gallinaceous birds ascends beneath the lower face of the right lung, then turns abruptly backwards and a little to the left. It attains the median line towards the anterior extremity of the kidneys, and in this situation it reaches the sacral vertebræ, where it divides into three branches—the arteries of the pelvic limbs, and the middle sacral artery.

Close to its origin, the aorta gives off the *brachio-cephalic* (*or innominate*) *trunks*. With the *Fowl* this name is perfectly correct, as they both furnish vessels to the wings and head. The right passes upwards and forwards, is inflected backwards at the first rib, and continued on the lower face of the wing by the *humeral artery*. It throws off a *thoracic artery*, whose volume is in relation with that of the pectoral muscles; this artery emits superficial branches that form in the skin of the abdomen, with other vessels, a very rich plexus named by Barkow the *rete mirabile* of incubation. It afterwards gives off a cephalic trunk, from which arise the *ascending cervical*, *vertebral*, and *right carotid artery*. The left brachio-cephalic trunk has the same distribution as the right, a slight difference only being observed in its direction; on leaving the thoracic cavity it describes a small S curvature.

The *carotid arteries* exhibit a somewhat curious arrangement. Each springs from a corresponding brachial trunk; and placed at first on the sides of the neck they make a curve, whose convexity is anterior, and gain the median line by passing, the right above the œsophagus, the left above the trachea. They remain beside each other, beneath the longus colli, from the second last to the second cervical vertebræ, where they separate at an acute angle and reach the border of the jaw, terminating there in two branches—the *internal* and *external carotid* arteries.

The other collateral branches furnished by it, are: 1, The *intercostal arteries*. These may arise from the subcostal branches which are parallel to the aorta; thus, in the *Fowl*, there is a *common descending intercostal* which proceeds from the vertebral, and a *common ascending intercostal* that leaves the aorta as it passes into the abdomen; 2, The *cœliac trunk*, which commences at the middle of the lower face of the lung, and descending obliquely backward, reaches the posterior aspect of the liver. It divides into several ramuscules, of which there are three principal vessels: a very fine one goes to the spleen; a left or middle one passes to the gizzard along the proventriculus; the third, more voluminous, is directed to the right side, gives a twig to the liver, and is continued by a long *pancreatico-duodenal* branch that joins the extremity of the loop which the intestine forms at its origin; 3, The *anterior* or *superior mesenteric*, which arises at a short distance behind the cœliac trunk, enters the mesentery, and is directed backwards, describing a curve whose convexity is antero-inferior, and which emits twigs to the intestine; 4, The *spermatic* or *ovarian arteries*. The *inferior* or *posterior mesenteric* leaves the subsacral artery, and, by some ramuscules, reaches the rectum and cloaca.

Shortly before its termination in three branches, the aorta gives off an artery that crosses the middle portion of the kidneys, leaves the abdominal cavity, and becomes distributed to the anterior muscles of the thigh, after detaching the *epigastric artery*. The latter proceeds forward, beneath the skin of the abdomen, and anastomoses with the ramifications of the thoracic artery.

---

[1] *Milne Edwards*—'Leçons sur la Physiologie et l'Anatomie Comparée de l'Homme et des Animaux.' Vol. iii.

The arteries of the pelvic limbs—the *femoral* or *crural*, in passing above the kidneys, furnish the *renal arteries;* they then leave the pelvis by the great ischiatic notch, immediately behind the coxo-femoral articulation. Placed beneath the muscles on the posterior face of the thigh, in following the branches of the lumbo-sacral plexus as far as the femoro-tibial articulation, they are then continued by the *popliteal* vessels. These arteries throw off articular ramuscules, the medullary artery of the tibia, and a long branch to the muscles on the posterior aspect of the leg; they are placed in the groove resulting from the junction of the tibia and fibula, and pass through the osseous interspace to form the *anterior tibial arteries.*

The *middle sacral* continues the aorta to the bottom of the pelvis; when it arrives below the last coccygeal vertebra, it forms a kind of arch whose ramifications are distributed among the muscles and quills of the tail.

Article III.—The Veins.

As in Mammals, the veins are distinguished as belonging to the great and lesser circulation.

The veins of the great circulation are collected into three trunks that open into the right auricle of the heart; there are two *anterior venæ cavæ* and one *posterior vena cava.* They enter a particular compartment, a kind of sinus, in the auricle.

The *anterior venæ cavæ* collect the blood from the subclavian arteries and those of the head. The *jugular veins*, which are their principal branches, are not the satellites of the carotid arteries, as in the larger domesticated animals; they are superficial and placed on the sides of the trachea; while the carotids are placed in the median line, beneath the long flexor muscle of the neck. They are not of the same calibre in all species, the right jugular being more voluminous than the left; there is always, however, a transverse anastomosis between the two jugulars, below the base of the cranium.

The *posterior* or *inferior vena cava* commences at the anterior extremity of the kidneys, and passes forwards, traversing the right portion of the liver, receiving the hepatic veins, and enters the right auricle.

Among the branches forming it, there may be cited the *femoral* or *crural veins.* These vessels do not accompany the corresponding arteries; not entering the pelvic cavity by the great ischiatic notch, they pursue a course analogous to that described for these vessels in Solipeds, in passing beneath the crural arch.

In birds furnished with a crest and mandibles, the skin of the head is provided with an excessively rich vascular plexus.

Article IV.—The Lymphatics.

Birds possess *lymphatic vessels* and *glands.* The latter are few, and are scarcely met with elsewhere than in the cervical region; the former are abundant in the viscera, and unite in such a manner as to form *two thoracic ducts.* These ducts commence at the cœliac trunk, and pass along the lower face of the lung, receiving the lymphatics of that organ and those of the wings, and finally open into the jugular veins, a little in front of their union with the axillary veins. A transverse branch forms a communication between the two thoracic ducts, towards their termination.

BOOK VI.

Apparatus of Innervation.

FIRST SECTION.

THE NERVOUS SYSTEM IN GENERAL.

The functions whose instruments we have just described, suffice in themselves to maintain *nutrition*—that mysterious molecular movement which is the ultimate object of the activity of organs, and the essence even of life: locomotory acts which permit the animal to seek its food and to introduce it into its organism, lead to the elaboration and absorption of the assimilable materials of the alimentary mass in the interior of the digestive cavity, the circulation of the reparative fluids in the economy, and the depuration and revivification of these fluids by the action of the lungs and the kidneys: in brief, could anything more be required to constitute the conditions necessary for the manifestation of the nutritive phenomena?

And yet, while the anatomist conceives in his mind a vertebrate animal exclusively endowed with the apparatus destined to execute these functions; while he supposes the breath of life and the dependent properties of that animating principle to be due to these apparatus, he could not succeed in creating an imaginary being capable of moving, digesting, keeping in circulation the nutritive fluids, reviving these fluids by respiration and urinary depuration—in a word, of executing all those acts whose concurrence is indispensable to the maintenance of nutrition, the supreme vital act. It is because the tissues of that animal, though possessing the organic properties inherent in their structure, require an excitant capable of bringing these properties into play. Their inertia is due to the absence of this excitant; for all motion, no matter what kind it may be, demands for its realisation, not only the motor faculty in the organ which executes it, but also an excitatory cause.

But give to this mutilated organism, this creation of our fancy, white cords, ramifying by extremely slender divisions in the depth of these instruments of life, and commencing from a central axis lodged in the cranium and spinal canal; or, in other words, add to our incomplete animal an *apparatus of innervation*, and, as if by enchantment, there will appear the first signs of life. Owing to the peculiar properties which distinguish the tissues of this apparatus, and concerning which we will have more to say hereafter, it plays the part of an excitor and regulator with regard to the properties of the other tissues. Stimulated by the nervous system, these properties no longer remain in a latent state, but manifest themselves by their usual results—such as contraction in the muscles, and exhalation and secretion in the membranes and glands; then the imperfect being at once begins to digest, respire, etc.—in a word, to live, and is worthy of taking rank in the animated world.

But the effects of this radical transformation do not cease here. The animal thus rendered apt to the nutritive movement acquires, beyond this *vegetative life*, the common appanage of all organised beings, all the attributes of what it has become habitual, after Bichat, to term *animal life*,—that is, sensibility, volition, instinct, and intelligence.

The perceptive centre which receives the excitations developed at the periphery of organs, or in their structure; the excitatory centre which induces motion in all the other tissues; the seat of the instinctive and intellectual faculties; in short, does not the apparatus of innervation, thus charged with the grandest physiological finality, present itself as a most attractive study? We will commence by giving a general and succinct idea of its conformation, structure, properties, and functions, before undertaking the special description of the different parts composing it.

GENERAL CONFORMATION OF THE NERVOUS SYSTEM.

The apparatus of innervation comprises a central and a peripheral portion.

The first represents a very elongated stalk lodged in the spinal canal, and bulging at its anterior extremity, which occupies the cranial cavity. This is named the *cerebro-spinal axis* or *centre*.

The second consists of a double series of ramescent branches, which are given off laterally from the central stalk, to be distributed to all parts of the body; these branches are the *nerves*.

THE CEREBRO-SPINAL AXIS.—The stalk, or *axis* properly so called, lodged in the spinal canal, forms the *spinal marrow* (or *cord*). It is a large white cord, terminating in a point at its posterior extremity, and giving rise, at each intervertebral foramen, to one of those nervous branches which, collectively, represent the peripheral portion of the apparatus of innervation.

The bulging extremity inclosed in the cranium, is named the *encephalon* (or *brain*). More complicated in its conformation than the spinal cord, this portion is divided, as we will see, into four parts: 1, A white peduncle, the continuation of the spinal cord; 2, Three grey-coloured ovoid masses, one of which is posterior, the other two being anterior, and placed symmetrically side by side. This medullary prolongation emits, right and left, like the cord itself, nervous branches destined almost exclusively for the head.

THE NERVES.—The nerves are in the form of fasciculated cords, and make their exit from the orifices at the base of the cranium, or through the intervertebral foramina, passing into all the organs by ramifying like arteries, which they generally accompany.

All the nerves have their origin from the medullary axis, or from its encephalic prolongation, by radicles more or less apparent. They are divided, according to the relative position of their point of emergence, into two great categories; the *superior*, arising from the corresponding face of the spinal axis; the others, *inferior*, escaping from the lower face: a distinction which is perfectly appreciable with regard to the cord itself, but which is more difficult to establish in the encephalic peduncle, as it is less distinct.

At their emergence from the bony canals which give them passage, the radicles of each nerve always unite into a thick common trunk.

In the majority of cases, there enters into the composition of this trunk the nerves or fibres of the two orders; only a few nerves are composed of fibres of the one kind, and these all belong to the brain.

At the origin of the trunk into which the nerve roots are collected, there is a greyish enlargement termed a *ganglion;* but this peculiarity belongs exclusively to the superior fibres.

After a variable course, which is generally short, this trunk divides into branches, the point of departure for all the nerves of the body. Among these branches, those which are expended in the apparatus of animal life are pairs, and perfectly alike on both sides of the body. Those of the organs of nutrition are composed at first of an almost symmetrical double chain, placed beneath the spinal column, and whose elements are borrowed from nearly all the nervous trunks emanating from the cerebro-spinal axis; in proceeding to their destination, their distribution is most irregularly complicated. As they offer on their course a great number of ganglia similar to those we have already mentioned, they are called *ganglionic nerves;* they are also designated the *nerves of organic* or *vegetative life*, while the others are named the *nerves of animal life* or *of relation.*

STRUCTURE OF THE NERVOUS SYSTEM.

Two particular substances, one *grey*, the other *white*, enter into the organisation of the nervous apparatus. These two substances are formed, the first by nerve-tubes and united nerve-cells; the second by tubes alone.

The *nerve-tubes* are microscopic elements, composed of a proper wall and contents. The wall, named the *nervous sheath* (*sheath of Schwann*), is a thin, homogeneous, elastic membrane that contains in its substance or its inner face some nuclei of cells. It is not visible in quite fresh tubes. The contents comprise, in the centre, a solid core, the *axis-cylinder* (or *primitive band* of Remak), which becomes very apparent after the addition of certain reagents; between the axis-cylinder and the wall is found a viscid substance, the *nervous medulla* or *white substance of Schwann*, which coagulates very quickly under the influence of cold.

Fig. 310.

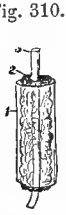

DIAGRAM OF STRUCTURE OF NERVE FIBRE.

1, Sheath; 2, Medullary substance of Schwann; 3, Axis-cylinder, or primitive band.

When the medulla is solidified, it is seen to be bordered by two dark lines, parallel to the walls of the nerve-tubes; this aspect has caused the latter to be named "double-contoured tubes (or nerve-fibres)."

All the nerve-tubes do not possess, at the same time, these three parts, for the medulla may be absent; so that there are distinguished *medullated* and *non-medullated nerve-fibres.* The first, more or less thick, are met with in the nervous centres, and at the origin, and in the middle portion of the nerves; the second are found at the termination of nerves, and in the great sympathetic.

There are also observed in the nerves of organic life, elongated elements, designated *fibres of Remak*, *grey fibres*, and *nucleated nervous fibres.* These are pale, flattened fibres, with parallel borders, and furnished with elliptical nuclei. Some authorities consider these to be bands of connective tissue, and not nerve elements.

The *nerve-cells*, or *corpuscles*, are voluminous, and are formed by a mass of granular protoplasm without any enveloping membrane. In the ganglia they are covered by a layer of fibrous connective tissue, provided with nuclei, which appear to furnish them with a very thick enveloping membrane. The nucleus, with one or two nucleoli, is often surrounded by granulations, whose dark colour gives rise to the supposition that they are pigment cells.

The nerve-cells have prolongations or poles, whose number varies from one to five. Cells with only one prolongation are named unipolar; those which have two are bipolar; and those which have a greater number are designated multipolar. These poles establish relations with the nerve-tubes, and constitute the origin of the nerves.

Fig. 311.

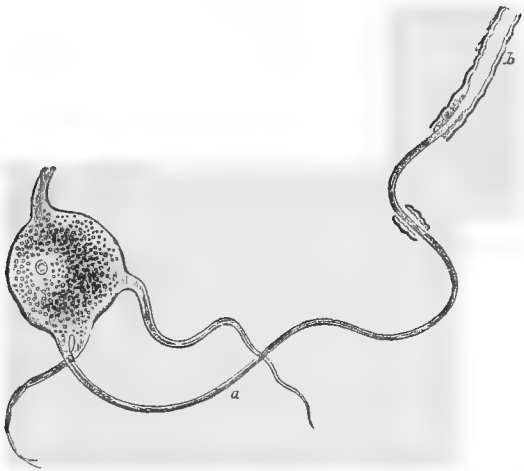

MULTIPOLAR OR STELLATE GANGLIONIC NERVE-CELL, WITH ONE OF ITS PROLONGATIONS—

a, Becoming continuous with the axis-cylinder of a double-contoured nerve-fibre, *b*.

Such are the anatomical elements that enter into the structure of the nervous system.

In the white substance of the cerebro-spinal axis, only medullated nerve-tubes of every size are found; in the grey substance are tubes, and a more or less considerable number of nerve-cells are situated along their course.

To these two elements is added a large quantity of *blood-vessels*, which are incomparably more abundant in the grey than in the white substance.

In the *nervous cords*, the elementary tubes are alone met with; they are disposed in long bundles, which are collected into successively increasing fasciculi. A cellulo-vascular envelope, the *neurilemma* (or *perineurium*), binds all these fasciculi into a single cord, and forms a special sheath around each of them. The details of their organisation will be referred to hereafter.

It is admitted that the ganglionic, or nerves of organic life, possess a greater quantity of slender tubes than the others. These tubes are commonly designated as the *organic nerve fibres*. They also contain fibres of Remak.

In the *ganglia*, the cells are joined to the nerve-tubes. It has been shown, by dissection and microscopical observation, that the corpuscles composing the ganglia at the origin of the trunks are all attached to the superior fibres. The other tubes have none.

In the *cerebro-spinal axis*, the two substances are equally associated with each other, but in a variable manner, according to the region. In the cord

and its prolongation into the encephalon, the grey substance occupies the interior, while it is spread over the exterior of the encephalic lobes and envelops the white substance.

Fig. 312

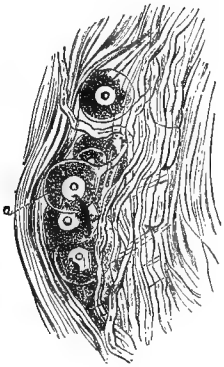

MICROSCOPIC GANGLION FROM HEART OF FROG.

Fig. 313.

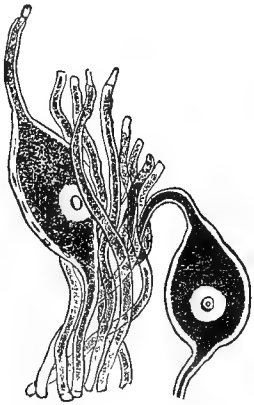

BIPOLAR GANGLIONIC CELLS AND NERVE-FIBRES, FROM GANGLION OF FIFTH PAIR IN LAMPREY.

(In some instances, as in the cells of various parts of the spinal cord, the prolongations subdivide and ramify in a curious manner, and form a close network that penetrates the surrounding nervous tissue. In addition to these. there are other very complex nerve-cells whose structure has only

Fig. 314.

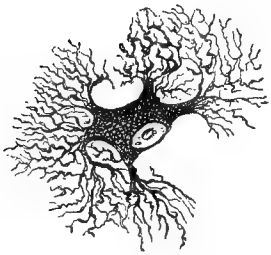

STELLATE NERVE-CELL, FROM THE NUCLEUS CERVICIS CORNU (POSTERIOR VESICULAR COLUMN) OF A FŒTUS OF SIX MONTHS. MAGNIFIED 420 DIAMETERS.

Fig. 315.

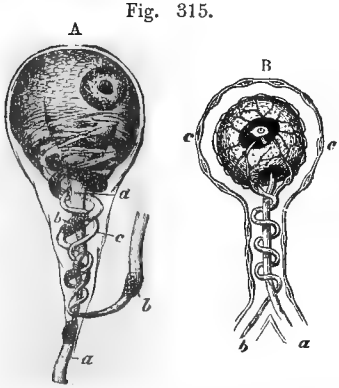

STRUCTURE OF GANGLIONIC NERVE-CELL.

A, According to Beale; B, According to Arnold.—*a*, Straight fibre; *b*, Double spiral fibre; *c*, Capsule of connective tissue.

recently been clearly established. These have been found in the sympathetic ganglia, and each is invested in a capsule of connective tissue. In shape, the cell is pyriform, and it contains a nucleus; from the narrow end spring two fibres, that pass in opposite directions when they reach the nervous

bundle to which they are distributed. This disposition has given rise to the opinion that every nerve-fibre, no matter how long its course may be, is a loop that originates in, and returns to, the same cell. One of the fibres that enters the cell, and looks like a stalk to it, is usually straight; the other seems to arise from the outside of the cell, is sometimes double, and circles round the other in a spiral manner two or three times. Both fibres at first resemble the cylinder-axis of ordinary nerve-fibres, and may subsequently become dark-bordered, or remain pale fibres. The spiral fibres bear large oblong nuclei in their course. Some observers state that they have traced the straight fibre into the nucleus, and the spiral fibre into a plexus on the exterior of the cell, but which may be ultimately traced into the nucleolus; so that the two fibres are continuous through the nucleus and nucleolus).

PROPERTIES AND FUNCTIONS OF THE NERVOUS SYSTEM.

It would require a long chapter to do justice to this subject, and we could not venture on it here without going beyond our domain. We will, however, offer some remarks on those notions connected with the properties and functions of the nervous system which are strictly necessary for the comprehension of the anatomical facts to be hereafter dealt with.

And first as to the properties of the nerves.

We will suppose the spinal canal to be opened in the lumbar region, and the cord laid bare in a living animal. If we cut across the inferior roots of one of the spinal nerves, and if we compress with a pair of forceps one or more of these roots, by the end remaining attached to the cord, nothing results to denote that this irritation has had any influence on the organism. But if, instead of operating on the central or attached end of these divided roots, we excite the peripheral end which is continued by the trunk of the nerve, contraction of the muscles of the limb which receives the fibres coming from the irritated roots is produced.

The muscular tissue comports itself as if the irritation were directly applied to it; so that the nerve has served as the medium of communication. It has *received* the excitation, it has been *impressioned* by it, and it has conducted this to the muscles to which the nerve is distributed. This double reaction produced by the nervous tubes is their special attribute, their essential property. With M. Vulpian we might designate it as a whole by the name of *neurility;* but it is necessary to distinguish the two modes it affects by naming the property of being impressed by excitations as the *excitability of the nerve*, and *nervous conductibility* its aptitude to convey the excitations which have impressed it.

The same experiment may be repeated on the upper roots. It is then perceived that the pinching, which produces no effect at the peripheral extremity, causes pain when applied to the central end. The animal testifies immediately, by cries and movements, that it feels the touch of the forceps. But, as will be mentioned in a moment, the impression resulting from this touch has only been perceived by the brain; it has therefore been conducted to the spinal cord by the excited nervous fibres, and then to the brain by the fibres of this medullary axis.

In putting to one side, for the moment, the part played by the latter in the phenomenon now analysed, it will be seen that the superior fibres of the spinal nerves enjoy the same attributes as the inferior; *neurility* is their appanage, and this property is apparent in its two qualities—*excitability* and *conductibility*. Only here the latter property is exercised in a *centripetal*

sense; while in the first instance it acted in a centrifugal sense. But it must not be assumed that these two conductibilities are essentially distinct. The physiological differences by which they appear to be distinguished seem to belong to the difference in the relations of the nerve-fibres with the organs to which they are distributed. In one case, that of the *centrifugal nerves*, the organs of reaction—the muscles—are placed at the peripheral extremity of the nerves; in the case of the *centripetal nerves*, the organs of reaction—the brain and spinal cord—are found at the central extremity of the nervous fibres. This theory of the unity of nervous conductibility has, moreover, been proved to be correct by the researches of Philipeaux and Vulpian, who have utilised the experiment of Gluge and Thiernesse on the union of the central end of the lingual (centripetal) with the peripheral end of the hypoglossal nerve (centrifugal), to demonstrate that the fibres of the former then acquire centrifugal conductibility.

It is easy to demonstrate that this double property of conduction belongs to all the nerve-fibres springing from the cerebro-spinal axis, *centripetal conductibility* being peculiar to the superior fibres, and *centrifugal conductibility* to the inferior ones. It is also demonstrated that this conduction acts in either one sense or the other, whatever may be the point on the course of the nerves so stimulated; as the nerve-tubes possess, throughout their whole length, the property of excitability and conductibility.

The fibres with centrifugal conductibility constitute the *motor nerves;* those whose conductibility is centripetal are the *sensitive nerves.* But sensibility does not exist only in the filaments of the superior roots; it has also been remarked in the lower roots, and they owe it to the filaments which are given off from the roots whose conductibility is centripetal, and which return to the nervous centres by the motor roots. The sensitiveness evinced by these motor roots is named *recurrent sensibility.*

The anatomical and physiological characters of the nerves persist as long as they communicate with the centres. If they are divided at any part of their course, the portion attached to the spinal axis still preserves its properties; but that situated beyond the section—the peripheral end, as it is named—degenerates, and becomes incapable of conducting the sensitive impressions, or of transmitting the voluntary motor excitations.

Now as to the spinal cord.

Does the medullary axis, which has apparently, in great part, the structure of a nerve, possess, like the latter, *excitability* and *conductibility*, those two essential properties of the peripheral nervous system?

Excitability is entirely absent in the grey substance. On the surface of a section of the cord, the slightest, or even the most intense irritation of this portion produces no reaction. In the white substance, this excitability can only be easily rendered evident on the surface of the upper bundles or fasciculi, where it is exquisite. With regard to the always limited reactions observed when the excitations are made on the deep part of the fasciculi, it is difficult to say if they result from the excitability of the spinal cord, or that of the nerve roots that traverse the white substance.

Nervous conductibility is certainly one of the attributes of the spinal cord; the transmission of excitations of the sensitive nerves to the brain, and the voluntary movements that result from stimulation of the motor nerves, demonstrate that the necessary medium between the nerves and brain—the spinal cord—possesses conductibility. But does this portion of the nervous system possess no other property? Yes; it may act as a nervous centre, and the following experiment irrefutably demonstrates it:

I will suppose that an animal has had its spinal cord cut across in the lumbar region, and I excite, by pinching, one of the superior roots remaining intact on the caudal portion. The stimulus cannot be conducted to the brain, as this part is isolated from it; and yet movements take place in the muscles of the posterior members. Does it happen that, after section of the medulla, the conductive property of the nervous fibres which originate superiorly is interverted and changed into centrifugal conductibility? No; for after the transverse section of these roots, the irritation of their central end produces exactly the same effects. It must be, therefore, that the excitation had first reached the medulla, and was then transmitted by it to the muscles by means of the centrifugal current fibres. And this is really what occurred; the section of the whole of these fibres on the trunk of the cord hindered the manifestation of all movement in the muscles when the superior roots were touched. There is, as has been said, *reflexion* in the substance of the cord, on to the inferior roots, from the irritation due to this pinching, and the property which permits the medullary axis to act in this manner is named the *reflex power*. It may be remarked that, if we suppose for a moment the superior and inferior nervous roots to be united in an arch in the substance of the spinal cord, this reflex property would be nothing more than the nervous conductibility itself operating precisely in the direction special to each kind of nerves.

This union really takes place; only the nerve-roots are not in communication, except through the medium of the cells in the grey substance, in which the sensitive is changed into motor excitation.

The reflex power is extinct immediately after death occurs in Mammals, but it may last for several hours, or even for a day, in a decapitated animal in which asphyxia has been averted by pulmonary insufflation. The extent of the movements it determines is in relation to the intensity of the stimulus which is the primary cause of it; merely localised when they result from a slight irritation, these movements may take place in all the muscles of the body after an energetic stimulation.

Let us now inquire into the attributes of the encephalon.

Excitability is not remarked in all parts of the brain; it exists in several points of the medulla oblongata, and in the deep substance of the cerebellum; but it cannot be rendered evident on the surface of the latter, nor yet in the cerebral hemispheres. The brain possesses conductibility, because the grey substance composing it is the receiver of, and the point of departure for, all the excitations. In fine, the encephalic mass should possess neurility like the nerves, but this general property is more or less modified. What more particularly distinguishes the encephalon is its action as a *sensitivo-motor centre;* in it arrive the excitations from the sensitive nerves, and there they are felt and judged. In the brain arise the motor excitations which result in *spontaneous voluntary movements.*

In an animal paralysed by division of the cord at the occipito-atloid articulation, and in which death has been prevented by artificial respiration, observation demonstrates that sensibility and spontaneous motricity are preserved in the head, whose nerves are in direct communication with the encephalon. Pinch the upper lip, and the patient testifies by the movements of this organ that it feels pain. Pass the finger towards the eye, and the eyelids are twinkled and closed: a proof that the animal sees objects, appreciates the distance which separates it from them, and tries to remove the eye from their contact. More striking still, the animal feels hungry, and endeavours to satisfy this craving by seizing the food within its reach, and

masticating and swallowing it. After this demonstration, it is no longer possible to doubt that, if an animal *feels*, it is by the brain, and if it *wills*, it is also by the brain.

But *sensibility* and *volition* do not constitute the only attributes of the brain tissue; for it is the seat of other manifestations not less interesting—those of the *instincts* and *intelligence*.

If the encephalon is to be considered as the immediate instrument of all these phenomena, it would be impossible—it is impossible—to attribute the cause, properly speaking, to the activity of its physical matter; above this hovers a mysterious power that can only be demonstrated by a methodical analysis of the manifestations produced by that activity. But we dare not venture to touch upon the nature of this power; the first word would be useless without the last, and this would carry us too far.

To sum up, the nerves possess a single vital property—*neurility*, which is manifested by *excitability* and by *centripetal conductibility* in the nerves whose roots are uppermost, *centrifugal conductibility* in the nerves whose roots are inferior.

The spinal cord is *inexcitable* in its grey substance, but is *excitable* on the surface of its superior fasciculi, though scarcely so in the remainder of its white substance. It serves as the *organ of transmission* between the brain and the nerve-roots; and is, in addition, endowed with the *reflex property* or *power*.

The brain has for its appanage a special activity, to which is due *sensibility*, *volition*, and the manifestations of *instinct* and *intelligence*.

It remains to make known the nature of the influence the nervous system exercises on the other apparatus through the properties we know it to possess. But here again we must limit ourselves to principles.

Since Bichat's time, it has been agreed to divide into two great classes those functions whose operation maintains the life proper of the individual: *those of animal life* or *relation*, and *those of organic* or *vegetative life*.

The first, which are exercised with consciousness, comprise the *sensorial functions* and *voluntary movements;* the latter are provoked by the spontaneous excitation originating in the brain, and transmitted to the muscles by the nerve-fibres whose conductibility is centrifugal; the former have for their object the appreciation, by the brain, of tactile sensations—of heat, light, taste, and smell, by means, or through the instrumentality, of the nerve-fibres possessed of centripetal conductibility, which transmits to the encephalic mass the stimulus developed at their terminal extremity by these diverse physical agents.

The functions of vegetative life—those which are executed unconsciously, we may say, in animals, and which are not the result of physico-chemical forces—are placed under the influence of the reflex power of the spinal cord. For example, the stomach is empty and its mucous and muscular membranes remain altogether passive; there being no contractions in the first, nor secretion of gastric fluid in the second. Food arrives in its interior, and immediately its activity is developed; the muscular tunic executes movements which cause the mixture of the food, and propel it towards the pyloric orifice; while the free surface of the internal membrane pours out an abundant solvent secretion. This change is due to the stimulus exercised by the presence of the alimentary particles on the extremity of the centripetal nerve-fibres, and which has been transmitted by them to the medullary axis, there reflected on the centrifugal fibres, and carried by these to the tunics of the stomach, whose special functions are thus brought into play.

It is worthy of remark that the properties of the nervous system, which act in so important a manner on the organs of vegetative life, have no direct influence on nutrition itself. Destruction of the nerves in a certain region will certainly derange the nutrition of its tissues, in consequence of the paralysis of the vessels, but it is not destroyed. There is an immense category of organised beings—vegetables, for instance—in which nutrition is very active, and in which there is no nervous system. So that the property which determines the essential phenomena of nutrition is independent of nervous action: it is an attribute of living matter.

SECOND SECTION.

The Central Axis of the Nervous System.

The *cerebro-spinal axis* is resolved, as we have said, into two principal sections—the *spinal cord* and the *encephalon.* We will study these two portions in succession, the spinal cord first, in order to facilitate our description, although that organ only holds the second place in a physiological point of view. The *protective parts* of these two apparatus will, however, be examined before we proceed further.

CHAPTER I.

THE ENVELOPING AND PROTECTING PARTS OF THE CEREBRO-SPINAL AXIS.

The cerebro-spinal apparatus is lodged, as we already know, in a bony case —the *spinal canal*—which is prolonged anteriorly by the *cranial cavity;* but it is protected more immediately by three *envelopes*, which have received the names of *dura mater*, *arachnoid*, and *pia mater.*

THE BONY CASE THAT CONTAINS THE CEREBRO-SPINAL AXIS.

A knowledge of the bones which enter into the composition of this protective case, cannot be acquired without also knowing the case itself; so that we dispense with its special study here. We will allude, however, to the succinct terms already employed in describing the *spinal canal*, and in the same spirit of concision will also describe what has hitherto been deferred—the *cranial cavity.*

1. *The Spinal Canal.*

This canal communicates, anteriorly, with the cavity of the cranium. Very wide at the atlas to receive the odontoid process, and allow those rotatory movements of the head which prevent the medulla being injured, the spinal canal suddenly contracts at the axis; it expands again at the end of the cervical, and the commencement of the dorsal region, where the medulla presents a greater volume, and the movements of the spine are very extensive. Towards the middle of the back, the spinal canal offers its smallest diameter, but on leaving this portion, and as far as the lumbo-sacral

articulation, it widens again; after which it rapidly lessens, and altogether disappears towards the fourth or fifth coccygeal vertebra. The lumbo-sacral dilatation coincides with the expansion the cord shows at this point, and with the enormous volume of the nerves lying beside it.

2. *The Cranial Cavity.* (Figs. 22, 23, 175.)

This is a very irregular oval box, whose walls are formed by the frontal, parietal, occipital, ethmoidal, and temporal bones.

It presents for consideration four planes and two extremities.

The *superior plane* offers on the middle line, and towards its superior third, the parietal protuberance, the two lateral crests of which concur with that eminence in dividing the cranial cavity into two compartments: one posterior, destined to contain the cerebellum; the other anterior, incomparably larger, lodging the cerebral hemispheres, and divided by the single rudimentary crest which begins at the falciform eminence, and joins the crista galli, into two lateral sections—one for each hemisphere. Hereafter we will see that the folds of the dura mater are attached to this parietal protuberance, and to the ridges detached from it, thus rendering much more perfect the partitioning of the cranial cavity.

On the *lateral planes* there is also noticed the division into a cerebellar and cerebral compartment, due to the lateral crests of the falciform process, which are prolonged obliquely to near the sphenoid bone: the first section is formed by the occipital and the inner face of the petrous bone; the second by the squamous portion of the temporal, the frontal, and the great ala of the sphenoid bone. Both are concave, and marked by digital impressions, as they also are on the superior plane.

The *inferior plane*, very irregular, offers from behind forward: 1, On the median line, the basilar channel, into which the greater portion of the encephalic isthmus is received; the pituitary fossa, made deeper by a circular fold of the dura mater, and lodging the gland of that name; the optic fossa, where the chiasma of the optic nerves is situated; 2, On the sides, the foramen lacerum, partly closed by cartilaginous substance, and by the dura mater; the cavernous sinuses and maxillary fissures, outside which is remarked a deep and wide digital impression for the reception of the mastoid lobule, or inferior lobe of the brain.

The *posterior extremity* of the cranial cavity presents the occipital foramen, by means of which this cavity communicates with the spinal canal.

The *anterior extremity* offers, in the median plane, the crista galli process, or superior border of the perpendicular plate of the ethmoid bone; on the sides, the two ethmoidal fossæ—deep depressions containing the olfactory lobes, and at the bottom of which is observed the cribriform aspect of the transverse plate of that bone.

THE ENVELOPES OF THE CEREBRO-SPINAL AXIS.

The three membranes which cover the cerebro-spinal axis, and separate it from the walls of the bony cavity inclosing it, are thus designated. Generally termed *meninges*, and distinguished as *external*, *middle*, and *internal meninge*, these membranes are better known as the *dura mater*, *arachnoid*, and *pia mater*—names which will be employed in our description.

The *dura mater*, or *external meninge*, is a strong fibrous membrane in contact with the walls of the cranium and the spinal canal.

The *arachnoid*, or *middle meninge*, is a tunic of a serous nature, which

resolves itself into two layers: an external, applied to the inner face of the dura mater; and an internal, spread, through the medium of the pia mater, over the cerebro-spinal axis, from which it is again separated in a great number of points by a particular fluid, the *subarachnoid.*

The *pia mater*, or *internal meninge*, is the proper envelope of the central nervous stalk; it is cellulo-vascular, closely adherent to the external surface of the cord, united to the visceral layer of the arachnoid by more or less dense connective tissue, between the meshes of which is deposited the subarachnoid fluid.

This arrangement of the cerebro-spinal envelopes permits the cerebro-spinal axis to be assimilated, to a certain extent, to a viscus, and the bony sheath containing them to a splanchnic cavity, whose serous membrane, the *arachnoid*, is covered outside its parietal layer by a fibrous expansion, the *dura mater*, and within its visceral layer by a cellulo-vascular tunic, the *pia mater*, or *internal meninge.*

This collective view of the envelopes belonging to the nervous centres will now be followed by a special description of each, in which their spinal and cranial portions will be successively considered, after glancing at them in a general manner.

1. *The Dura Mater.*

This membrane is the most external and the strongest of the cerebro-spinal envelopes, and covers the walls of the cerebro-spinal cavity, whose form it exactly repeats. It is, therefore, a second protective sheath, which is dilated at its anterior extremity into an ovoid cavity that lodges the encephalon, and terminates in a prolonged point in the coccygeal vertebræ.

It offers two faces: an external, in contact with the walls of the bony case; and an internal, adhering in the most intimate manner to the external layer of the arachnoid.

In several points of its extent it is traversed by the nerves which escape from the cerebro-spinal axis, and by the vessels destined to this portion of the nervous system.

Structure.—The dura mater possesses the texture of all white fibrous membranes. It is composed of parallel longitudinal fasciculi of connective tissue, mixed with some fine elastic fibres. Bourgelat thought they formed two distinct layers—an external and internal; but nowhere is it possible to demonstrate this. It receives *blood-vessels;* the arteries are derived, for the spinal portion, from the vertebral, the intercostals, lumbar, and lateral sacrals; for the cranial portion, meningeal ramuscules, such as the ethmoidal branch of the nasal, the spheno-spinous, and tympanic, mastoideal, and cerebro-spinal arteries. *Nerves* have been seen passing to its cranial portion; these have been divided into anterior, middle, and posterior. The first are furnished by the ethmoidal filament of the nasal nerve; the second from the Gasserian ganglion; and the third, by the ophthalmic branch of Willis. The existence of *lymphatic vessels* has not yet been demonstrated.

Spinal Dura Mater (Theca Vertebralis).—This is a very elongated sheath, continuous at the occipital foramen with the encephalic dura mater, and terminated behind by an attenuated point lodged in the narrow channel which, in the middle coccygeal vertebræ, represents a trace of the spinal canal. As it is in shape exactly like the latter, its largest diameter is at the atlas, and at the brachial and lumbo-sacral enlargements of the spinal cord. Its capacity depends greatly on the volume of the latter, and in some of its parts it can allow the accumulation of the cerebro-spinal fluid; this

accumulation is impossible for nearly the whole extent of the cranial region.

The *external face* of the dura mater is very slightly adherent, especially above, to the walls of the spinal canal; and it is even separated from them, at the intervertebral spaces, by a certain quantity of adipose tissue which is never absent, though the animals be ever so emaciated. This face covers, inferiorly, the common superior ligament, and the veins we have described as spinal sinuses.

The *internal face* gives attachment, between each pair of nerves, to the festoons of the dentated membrane, a dependency of the pia mater. It is rendered smooth and polished by the external layer of the arachnoid, to which it is so firmly united, that it is needless to attempt their separation. Here the external layer of the arachnoid is reduced to a simple layer formed by a row of cells with flattened nuclei.

On each side, the *substance* of this meninge is completely traversed by a double series of orifices for the passage of the spinal nerves, around which it sends small special sheaths as far as the intervertebral foramina.

Cranial or Encephalic Dura Mater.—This membrane forms a sac which is exactly moulded by its external face to the cranial parietes, and by its internal face to the superficial surface of the encephalon. The latter, therefore, completely fills the cavity of the cranium, a circumstance that explains why an accumulation of fluid is impossible in this region.

External surface.—It adheres strongly, by cellulo-vascular bands, to the cranial walls, whose undulations it follows; this adhesion is not, however, equally marked everywhere, for on the sides of the roof of the cerebral compartment it is least intimate, and it is closest on the middle plane of this roof, on the crista galli, around the parietal protuberance, on its crests, and towards the lateral faces of the cerebellar compartment at the petrous bones, where the membrane is very thin.

This face gives rise to a number of prolonged sheaths, corresponding to the nerves leaving the base of the cranium. The principal are found around the ethmoidal filaments, the optic nerves, and the two thick branches furnished by the Gasserian ganglion.

Internal surface.—The internal surface of the cranial dura mater is covered by the parietal layer of the arachnoid, which is firmly attached to it only in the spinal region. It sends into the cranial cavity three prolongations, which are distinguished as the *falx cerebri* (*falx*, a sickle), *tentorium cerebelli* (*tentorium*, a tent), and the *pituitary fold*. These processes complete the partitioning of the cranial cavity, isolate the various external bulgings of the encephalic mass, and protect them from the compression they might exercise on each other.

a. The *falx cerebri* is a vertical lamina comprised between the two cerebral hemispheres, and owes its name to its sickle-like form.

Its antero-superior border is adherent and very convex, and corresponds to the crista galli process, as well as to the median ridge on the inner face of the frontal and parietal bones. This border is very thick, and hollowed internally by a prismatic and triangular venous canal, which constitutes the median sinus.

Towards its inferior border, which is free and concave, and corresponds to the corpus callosum, the falciform process is extremely thin, and cribbled like lace-work.

The posterior extremity, or base of the falx, rests on the parietal protuberance,

The anterior extremity advances in a curve to near the optic fossa.

In aged animals, there are sometimes found on the faces of the falx cerebri, especially towards its posterior extremity, small yellow granules, known as the *Pacchionian glands*. They are little nuclei of connective tissue that arise from the subarachnoideal tissue; *meningeal granulations* would be a better designation for them than that of glands.

b. The *tentorium cerebelli* is composed of two lateral laminæ, which form a transverse partition between the cerebellum and the posterior extremities of the cerebral lobes.

Each lamina, coursed internally by one of the transverse sinuses, offers: an adherent convex border, attached to the parieto-temporal crest; a free concave border, turned inwards and a little forwards, remarkable for its thickness and solidity, and, with the second lamina, circumscribing an oval opening through which the encephalic isthmus passes; a superior extremity, attached to the parietal protuberance; an inferior extremity, which disappears above the Gasserian ganglion, near the fold that surrounds the pituitary gland.

Of the two faces of these laminæ, the anterior corresponds to the cerebral lobes, the posterior to the cerebellum.

c. The *suprasphenoidal*, or *pituitary fold*, is a thick, slightly salient, and almost circular pad, channeled internally by the cavernous sinus, and circumscribing the sella turcica by enveloping the pituitary gland laterally and posteriorly.

2. *The Arachnoid Membrane.*

The *arachnoid* presents the same disposition as all the splanchnic serous membranes, in being resolved into two layers—a *parietal* and a *visceral*, both constituting a perfectly closed sac, outside which the cerebro-spinal axis is contained. The cavity of this sac is traversed by the roots of nerves, the vessels of the brain and cord, and filaments and cellular lamellæ which pass from the pia mater to the dura mater; around all these its layers form sheaths by becoming continuous with one another.

Each of these layers exhibits an adherent and a free face. The *adherent face* of the parietal layer is united, as we have already seen, to the dura mater. That of the visceral layer covers the nervous axis in spreading itself over the pia mater, but without accompanying it into the anfractuosities of the central mass; it is beneath this face of the visceral layer that the cerebro-spinal (or *subarachnoid*) fluid is confined in spaces which will be studied hereafter. By their *free face*, which is smooth and moist, like that of all serous membranes, the arachnoid layers are in contact with each other.

Structure.—The structure of this membrane resembles that of all others of the same nature. The meshes of elastic fibres are most abundant in the cranial portion. Everywhere the parietal layer is only composed of a simple layer of epithelium. The arachnoid has no proper vessels or nerves; those which pass through it only accompany each other.

Spinal Arachnoid Membrane.—The *parietal layer* presents nothing of interest. The *visceral layer* is separated from the spinal cord, throughout its extent, by a somewhat considerable space (the *subarachnoid*), in which the subarachnoid fluid is collected; this space is greatest posteriorly, around the terminal extremity of the cord and the nerves of the cauda equina.

The adherent face of this membrane is only connected with the external

surface of the spinal cord by thin cellular filaments detached from the pia mater.

Cranial or Encephalic Arachnoid.—There is nothing special to note in the *parietal layer*.

If the *visceral layer* be traced from the occipital foramen, where it is continuous with the spinal arachnoid, to the anterior extremity of the cerebral lobes, it is seen to be prolonged inferiorly on the lower face of the isthmus, as far as the pituitary stalk, to which it furnishes a sheath: the pituitary gland itself is not covered by the arachnoid, except on a portion of the superior or deep face; from the isthmus it is carried forward, and extends on each side of the cerebellum and cerebral lobes. Superiorly, this internal layer spreads over the surface of the cerebellum, and is reflected at the bottom of the fissure between that organ and the cerebral hemispheres, over the posterior extremity of the latter, enveloping them separately by descending into the interlobular fissure as far as the corpus callosum. Reaching the anterior extremity of the cerebrum, it gains the olfactory lobes, is principally prolonged on their supero-posterior face, and doubles around the ganglion of grey substance on their inferior face, to be continued with the parietal layer.

In covering the external surface of the encephalon, the cranial arachnoid does not adhere everywhere to the nervous substance, but is only slightly connected with it, through the medium of the pia mater, at such salient portions as the summits of the cerebral convolutions. Neither does it dip down to enter the sulci existing between these parts, but passes over them, and in this way forms a large number of subarachnoid spaces analogous to that developed over the whole extent of the spinal cord.

These spaces, which are filled by the subarachnoid fluid, differ widely in form and dimensions. In Man, three principal have been described, and these are also found in animals; Magendie has named them the *confluents of the subarachnoid fluid*. Of these three confluents, the *anterior* is situated in advance of the chiasma of the optic nerves, between the two cerebral lobes; the *inferior*, the largest, is comprised between the pituitary stalk and the annular protuberance to the surface of the pedunculi of the cerebrum; while the third, or *posterior confluent*, lies behind the cerebellum, at the calamus scriptorius.

None of these spaces communicate with the internal cavities of the encephalon, and, consequently, the subarachnoid fluid cannot enter them. Magendie has nevertheless described a communication between the posterior confluent and the ventricle of the cerebellum; though the opening he described towards the calamus scriptorius has not been found in the Horse by M. Renault, and we believe we may affirm, with M. Lavocat, that it does not exist in the other animals.

The Subarachnoid Fluid.—The fluid contained in the subarachnoid spaces is slightly yellow or colourless, and perfectly limpid and transparent. Some authorities admit that it is secreted by the visceral layer of the arachnoid, and others by the pia mater. According to the remark made by Cruveilhier, the nervous centres are immersed in it, like a fœtus in the liquor amnii; and this remark, which is particularly applicable to the spinal cord, gives the key to the use of this fluid, which keeps the organ away from the walls of the spinal canal, deprives it of the greater part of its weight (Foltz), and thus diminishes every kind of concussion to which it might be exposed.

(This fluid, so necessary for the support and protection of the cord and

brain, is alkaline, and contains but a small quantity of albumen; it varies in quantity according to the relative size of the cerebro-spinal axis and its containing cavity, or with the amount of blood sent to this region. By affording, under all circumstances, an equable pressure on the brain and spinal cord, and the nerves emanating from these, its importance as a hydrostatic agent is greatly enhanced.)

3. *The Pia Mater.*

The *pia mater*, the proper envelope of the cerebro-spinal axis, is a thin membrane whose framework, essentially connective, sustains on its external face a very abundant network of blood-vessels and nerves.

Applied immediately to the surface of the encephalon and spinal cord, it adheres firmly to that surface and follows all its inequalities, penetrating between the cerebral or cerebellar convolutions, and forming in each intermediate sulcus two layers that lie against each other.

The *external face* of the pia mater, bathed in part of its extent by the subarachnoid fluid, adheres to the visceral layer of the arachnoid by means of a more or less dense and close filamentous connective tissue. From it arise the cellular coverings that constitute the neurilemma of the nerves. It detaches a multitude of filamentous or lamellar prolongations to the internal face of the dura mater, which traverse the arachnoid cavity in the same manner as the nerves and vessels, by being enveloped, like these, in a sheath furnished by the arachnoid membrane. Always very short, these prolongations simulate the adhesions established between the two layers of that membrane.

The *internal face* is united to the nervous substance by multitudes of arterial and venous radicles or connective filaments, which leave the pia mater to plunge into this substance.

The *vessels* of the pia mater form a very close network, from which are detached branches that reach the medulla and encephalon. They are accompanied by *nervous filaments*, and surrounded by *perivascular canals*, which are now believed to be *lymphatics*. Certainly, in their interior a colourless fluid circulates, and which contains globules very like those of lymph.

Spinal Pia Mater.—Less vascular than the cranial pia mater, with which it is continuous towards the medulla oblongata, this membrane is remarkable for the arrangement of the prolongations that arise from its two faces.

The *internal prolongations* form longitudinal laminæ at the fissures of the cord, and enter these fissures.

The *external prolongations* attach, as we have said, the pia mater to the external meninge. A very large number are filamentous in form, and are dispersed over the superior and inferior surfaces of the cord. Others constitute, on each side of the organ, a festooned band named the *dentated ligament* (*ligamentum dentata*, or *denticulatum*). These ligaments exist throughout the entire length of the medullary axis, between the superior and inferior nerve-roots: their inner border is confounded for its whole length with the pia mater; and their outer margin, cut into festoons, attaches itself to the dura mater by the summit of the angles separating these festoons.

To complete this description of the spinal pia mater, there may be noticed a *posterior* or *coccygeal prolongation* (*filum terminale*): a very narrow process formed by this membrane at the posterior extremity of the cord, situated in the midst of the cauda equina nerves, and attached to the bottom of the conical *cul-de-sac* at the termination of the dura mater.

(This ligament, or *membrana dentata*, serves to maintain the position of the spinal cord in its hydrostatic bed, and to prevent the nerves proceeding from it being dragged during flexion of the spine.)

Cranial, or Encephalic Pia Mater.—The vascular element predominates in this portion of the internal meninge.

This membrane sends scarcely any prolongations to the dura mater, except at the medulla oblongata, though it projects remarkably large ones into the cerebral mass and the sides of the cerebellum. The description of the *velum interpositum*, and the *cerebral* and *cerebellar plexus choroides*, belongs to the encephalon.

(The pia mater is extremely vascular on the surface of the cerebrum, and forms remarkable anastomosing loops in the intermediate spaces of the convolutions, which chiefly supply the grey substance. It is the nutrient membrane of the brain and spinal cord. Its nerves accompany its arterial branches, and are minute filaments from the sympathetic.)

DIFFERENTIAL CHARACTERS IN THE ENVELOPING AND PROTECTIVE PARTS OF THE CEREBRO-SPINAL AXIS IN OTHER THAN SOLIPED ANIMALS.

The oony canal that protects the spinal cord and brain does not present any noteworthy differences in the domesticated animals, and the subject has been already sufficiently studied in the osteology of the head and vertebral column.

With regard to the meninges, their number and general disposition are the same in all the species.

COMPARISON OF THE ENVELOPING AND PROTECTIVE PARTS OF THE CEREBRO-SPINAL AXIS OF MAN WITH THOSE OF ANIMALS.

There is nothing particular to be said respecting the cranial cavity and spinal canal, nor yet the arachnoid and pia mater. The dura mater offers the folds described in Solipeds, and, in addition, a *falx cerebellum*, that extends from the tentorium of the same name to near the foramen magnum. The meningeal granulations, or Pacchionian glands, are nearly constant in aged individuals, and their volume is sometimes so considerable, that by compression they thin away, and even perforate, the cranium at corresponding points.

CHAPTER II.

THE SPINAL CORD.

Preparation.—Isolate the cranium and vertebral column from all the other parts of the body; open the spinal canal and the cranial cavity by their superior surface, as in figure 316, by raising with a chisel (or *rogne-pied*, the farrier's "toe-knife") and hammer, the roof of the skull and annular portion of all the vertebræ. The organ may then be studied *in situ* in its bony case, and surrounded by its membranes; afterwards extract the whole cerebro-spinal axis inclosed in the dura mater, and open up the latter along the course of the cord, so as to completely expose that portion of the nervous system.

(The saw and farrier's pincers, or spine ratchet, will be found useful auxiliaries in the tedious and delicate operation of exposing the brain and cord; and particularly in laying open the cranial cavity. An easy mode of obtaining access to the spinal canal and its contents, is to saw through the laminæ of the vertebræ on each side, at the roots of the transverse processes, and raise the arches with the chisel or toe-knife.)

EXTERNAL CONFORMATION OF THE SPINAL CORD.

General view.—The *spinal cord* is that portion of the nervous centres which occupies the spinal canal. It is a thick, white, and irregularly cylindrical cord, commencing at the occipital foramen, where it continues the medulla oblongata, terminating in a point at the upper third of the sacral canal, or a

Fig. 316.

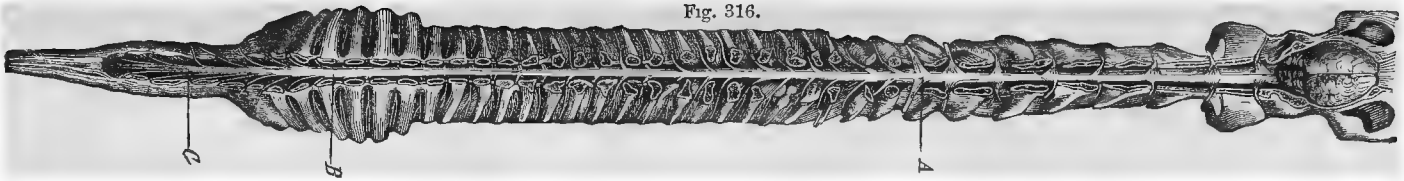

GENERAL VIEW OF THE SPINAL CORD. A, Cervical bulb; B, Lumbar bulb; C, Cauda equina.

Fig. 317.

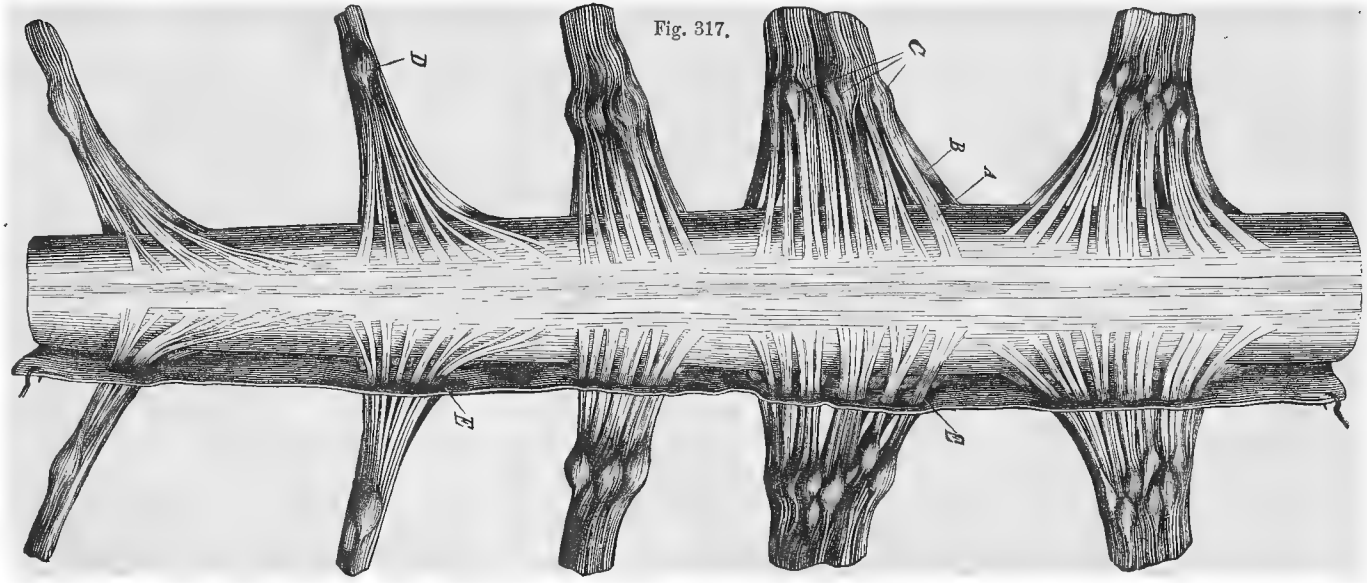

SEGMENT OF THE SPINAL CORD AT THE CERVICAL BULB, OR BRACHIAL PLEXUS, SHOWING ITS UPPER FACE AND THE ROOTS OF THE SPINAL NERVES. A, Superior roots; B, Inferior roots; C, Multiple ganglia of the superior roots; D, Single ganglion on an exceptional pair; E, E, Upper roots passing through the envelopes.

little beyond that, and giving rise at each side, during its course, to the superior and inferior roots of the spinal nerves.

Weight.—In medium-sized animals the weight of the cord is represented by the following approximate numbers: for the Horse, $10\frac{1}{2}$ ounces; the Ass, $5\frac{1}{4}$ ounces; Cow, $7\frac{3}{4}$ ounces; Sheep and Goat, $1\frac{3}{4}$ ounce; Pig, $2\frac{1}{2}$ ounces; Dog, $1\frac{1}{4}$ ounces; Cat, $4\frac{1}{2}$ drams.

Figure and volume.—The medullary cord is slightly depressed above and below, throughout its whole length; in whatever part we examine a transverse section of it, we will always find the lateral diameter greater than the vertical, and that this section appears regularly elliptical.

Its volume is far from being uniform. In following it from before to behind, we at first remark that it presents the same dimensions to the fifth cervical vertebra, and that between this point and the second dorsal vertebra it forms an oblong enlargement, designated the *brachial* (*brachio-rachidian*) *bulb* or *enlargement*. Beyond this, it assumes its primitive volume, and becomes gradually smaller even than in the cervical region. Towards the middle of the loins, it again augments to constitute the *crural* (*lumbo-rachidian*) *bulb* or *enlargement*, which extends to the entrance of the sacral canal. After this dilatation comes a conical prolongation, whose point represents the terminal extremity of the cord.

If we compare the diameter of this medullary axis with that of the spinal canal, we will observe, as has been already said, that the capacity of the containing cavity is generally related to the volume of its contents, and that the former is, as a rule, most capacious at the cervical and lumbar enlargements. It will even be noticed that the dilatation the spinal canal offers at these two points, is relatively more considerable than the excess in volume of the cord. This is because the mobility of the spine, which is justly very great in these two regions, requires this difference to secure the spinal axis from contusions during the movements executed by the vertebral column. This protective combination is also found elsewhere: at the atlas, for example, where we know the motion is considerable; and in the entire extent of the cervical region, which in this respect greatly exceeds the dorsal region.

External surface of the cord.—Covered by the pia mater, this surface presents an extremely simple disposition. On its superior and inferior planes, at each side, we remark the double series of sensitive and motor roots of the spinal nerves, which are implanted in the same longitudinal line to right and left of the median plane, and are collected in fasciculi opposite the intervertebral foramina.

In the middle line, and throughout the entire length of the organ, there are two deep and narrow fissures: one *superior* (*fissura longitudinalis superior*), the other inferior (*fissura longitudinalis inferior*), into which the pia mater enters. Four other fissures have been described at the point of emergence of the nerve roots, under the names of *superior* and *inferior collateral fissures* (or *sulci*); but the two superior alone exist, and even these are often scarcely noticeable.

INTERNAL CONFORMATION AND STRUCTURE OF THE SPINAL CORD.

In making a transverse section of any portion of the cord, we may convince ourselves that it has an internal cavity. This *central canal* is elliptical, and lined by cylindrical ciliated epithelium, resting on a thin connective membrane, the *ependymis* of Virchow. This section also shows

the two median fissures mentioned in describing the exterior of the cord, the inferior of which is wider and deeper than that of the superior, whose situation is scarcely perceptible.

These two fissures advance one before the other, and do not meet so as to completely divide the cord into two lateral halves, but remain separated by two thin horizontal and superposed bands of nervous matter, that pass from one end to the other of the medullary axis. The inferior, formed of white substance, corresponds to the bottom of the inferior fissure; while the superior, composed of grey matter, meets the superior fissure.

These bands are named the *white* and *grey commissures* of the spinal cord (Fig. 318).

Fig. 318.

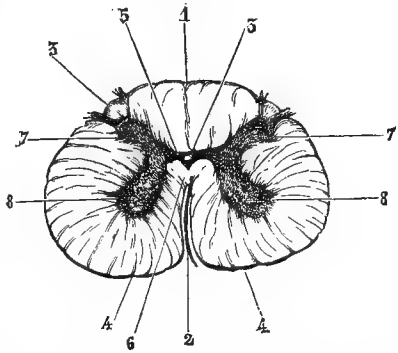

SECTION OF THE SPINAL CORD OF THE HORSE AT THE LUMBAR REGION; MAGNIFIED TWO DIAMETERS.

1, Superior median fissure; 2, Inferior median fissure; 3, 3, Superior collateral fissures; 4, 4, Inferior ditto; 5, Grey commissure; 6, White commissure; 7, 7, Superior grey cornua; 8, 8, Inferior grey cornua; 9, Central canal.

Notwithstanding the presence of these two commissures between the lateral halves of the spinal axis, these latter do not the less constitute two symmetrical systems, whose structure will now be studied.

Each medullary cord represents a semi-cylinder of white substance, in the centre of which is a mass of grey matter, that varies somewhat in quantity in different regions, but the arrangement of which is everywhere the same. Thus, inwardly, this grey matter joins the grey commissure; above, it sends off a thin prolongation which traverses the thickness of the medullary cord (superior grey cornu), to reach the bottom of the superior collateral fissure; below, it gives rise to an analogous, though a thicker and a more irregular, prolongation (inferior grey cornu), which is directed well in front of the inferior roots, but does not reach the surface of the cord. In consequence of this arrangement, the grey substance of the medulla forms altogether a kind of capital H, whose horizontal branch is perforated in the middle by the central canal.

This disposition of the grey substance causes the white matter to be divided, in each lateral moiety of the spinal axis, into three *cords* or *secondary columns;* the *superior* of these is perfectly isolated, and is comprised between the middle superior fissure and the origin of the sensitive roots; another, the *inferior*, united to that of the opposite side by the white commissure, is limited, inwardly, by the inferior median fissure, and outwardly by the line of origin of the motor nerve-roots; while a third, the *lateral* or *intermediate*, thicker than the others, is confounded superficially with the inferior, and formed by all that portion of the medulla situated between the lines of origin of the superior and inferior roots. Of these three columns of the medullary axis, the first is sensitive; the other two, which in reality are only one, are motor.

STRUCTURE.—Independently of the epithelium mentioned when describing

the ependymis, connective tissue, nerve tubes, nerve cells, and vessels enter into the structure of the medulla.

The connective tissue of the spinal cord is very delicate, rich in nuclei, and belongs to the variety that histologists have named "reticular" or "adenoid."

It appears to arise from the pia mater, and forms lamellæ that penetrate the nerve-substance to meet and anastomose with each other, and finally become confounded with the ependymis around the central canal. This tissue, which is also named *neuroglia*, has been compared to a sponge, in whose spaces are deposited the other elements of the cord. This neuroglia exists in the white and grey substances, but is more abundant in the superior than in the inferior grey cornua. It surrounds the upper extremity of the former in becoming softer and more transparent, and is here designated the *gelatinous substance of Rolando* (*substantia gelatinosa*). It constitutes, in great part, the grey commissure, and can be deeply stained by the carminate of ammonia.

Fig. 319.

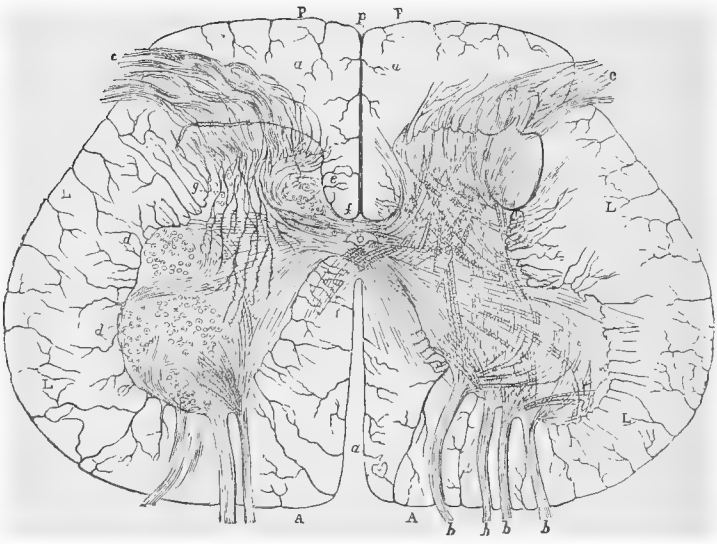

TRANSVERSE SECTION OF SPINAL CORD OF MAN THROUGH THE MIDDLE OF THE LUMBAR REGION, SHOWING ON THE RIGHT SIDE THE COURSE OF THE NERVE-ROOTS, AND ON THE LEFT THE POSITION OF THE PRINCIPAL TRACTS OF VESICULAR MATTER.

A, A, Anterior or inferior columns; P, P, Posterior or superior columns; L, L, Lateral columns.—*a*, Anterior or inferior median fissure; *p*, Posterior or superior median fissure; *b*, *b*, *b*, *b*, Anterior or inferior roots of spinal nerves; *c*, *c*, Posterior or superior roots; *d*, *d*, Tracts of vesicular matter in anterior column; *e*, Tracts of vesicular matter in posterior column; *f*, Central canal; *g*, Substantia gelatinosa.

The tubes and cells form, with the neuroglia, the whole of the grey substance. The cells have at least five prolongations, and the tubes are reduced either to the axis-cylinder (*axis-fibre*), or to this and a very thin layer of medullary substance.

The cells are not uniformly distributed in the grey substance, but are arranged in small masses that constitute three longitudinal columns: two

in the inferior, and one in the superior grey cornu. The columns correspond to what Stilling has named the *nuclei of the nerves.* A fourth mass of cells, the *superior vesicular column of Clarke*, or *dorsal nucleus of Stilling*, is observed at the point where the grey commissure joins the cornua. The nerve-tubes (or tubules) affect longitudinal, transversal, oblique, and vertical directions.

They bring the cells of one lateral moiety of the medulla into communication with: 1, The tubes of the white substance; 2, Each other; 3, The cells of the opposite moiety, by passing into the commissures; 4, The tubes of the white substance of the opposite moiety, by following the same course.

The neuroglia and nerve-tubes constitute the white substance, which is decomposed, as we know, into three cords. All the tubes of this substance do not ascend to the brain, as was believed for a long time; the opinion that the tubes of the spinal nerves formed the medulla and extended to the brain, has been abandoned since Volkmann measured, comparatively, the section of all these nerves and that of the nervous spinal-axis.

(Volkmann has established the fact, that the size of the medulla corresponds with the number of nerve-tubes given off at any point. He gives the weight of four segments, each $2\frac{8}{10}$ inches in length, from the spinal cord of the Horse, and the relative extent of the grey matter in square lines; these are as follows

	Grains.	Area of Grey Matter.	Area of White Matter.
From below 2nd Spinal Nerve,	219	13	109
" " 8th " "	293	28	142
" " 19th " "	163	11	89
" " 30th " "	281	25	121)

In the white substance the tubes are longitudinal, oblique, or transversal; the latter arise from the cells of the grey substance, and represent the roots of the nerves emerging either by the superior or inferior collateral fissure.

The tubes of the anterior cords pass to

Fig. 320.

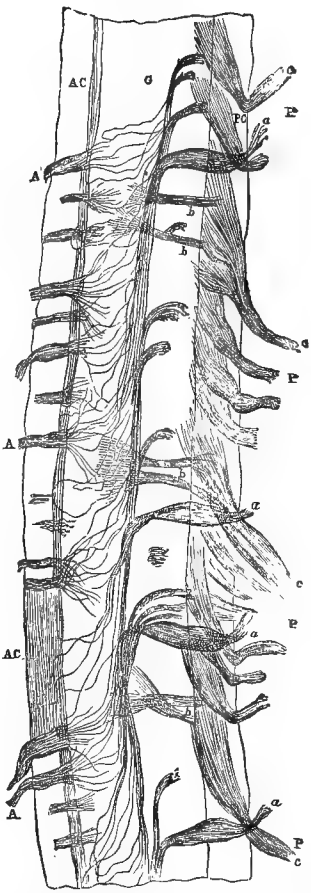

LONGITUDINAL SECTION THROUGH CERVICAL ENLARGEMENT OF SPINAL CORD OF CAT.

AC, Inferior white columns; AC′, Portion showing the arrangement of the longitudinal fibres; PC, Posterior white columns; G, Grey substance between them (the vesicles being omitted to avoid obscuring the course of the fibres); A, Anterior roots of the nerves, P, Posterior roots, consisting of three kinds: the first, *a*, crossing the posterior columns horizontally, and then passing obliquely downwards, across the grey substance, into the anterior columns; the second, *b*, traversing the posterior columns horizontally, and then losing themselves in the grey substance; the third, *c*, for the most part becoming continuous with the longitudinal fibres of the posterior column; all, or nearly all, ultimately entering the grey substance.

the cells of the grey substance, or reach the encephalon by remaining in the corresponding moiety of the medulla; for instance, the fibres of the right half of the medulla gain the brain without passing into the left half. Those of the lateral cords decussate, each cord sending to, and receiving from, the other, tubes which cross in the white commissures. The posterior cords contain fibres that extend directly to the brain: these are sensorial; there are also found transverse fibres that enter the cells of the superior grey cornua, and others that pass into the cells of the inferior or motor cornua.

Such is, in a few words, the disposition of the nerve-elements in the medulla. The subject is a very long and complicated one, which cannot be dealt with in a more detailed manner in a work on descriptive anatomy.

Vessels.—The medulla receives arteries from the ramifications of the pia mater. The grey is richer in vessels than the white substance; the latter is penetrated everywhere by a large number of minute arteries; while the first is traversed by the divisions of an artery that is thrown off by the median spinal, and ascends towards the bottom of the inferior fissure. The veins follow the arteries, and constitute two somewhat voluminous vessels that pass along the grey commissure, to the right and left of the central canal.

DIFFERENTIAL CHARACTERS IN THE SPINAL CORD OF OTHER THAN SOLIPED ANIMALS.

In all the species, the white and grey substances affect the disposition above described; only some slight differences in the reciprocal volume of each have been remarked. As in the Horse, the spinal medulla does not extend beyond the sacral region; its length has no relation to that of the coccygeal region, as certain anatomists would, in principle, establish; in the rabbit, for example, the tail of which is very short, the spinal cord is prolonged into the coccygeal vertebræ.

COMPARISON OF THE SPINAL CORD OF MAN WITH THAT OF ANIMALS.

The spinal medulla of the adult *Man* does not reach beyond the first lumbar vertebra, though in the fœtus it is in the coccyx. It is rounder than in the Horse, and the grey substance is, relative to the white, more abundant than in the spinal cord of the domesticated animals. The posterior grey cornua are also larger and less elongated than the superior cornua in the Horse; and the roots of the nerves are also more voluminous.

CHAPTER III.

THE ENCEPHALON.

ARTICLE I.—THE ENCEPHALON AS A WHOLE.

THE *encephalon* is that portion of the nervous system which is lodged in the cranial cavity. It succeeds, without any line of demarcation, the spinal cord, of which it may be considered, with regard to its figure, as a kind of efflorescence.

General form and constitution.—In shape it is an ovoid mass, elongated from before to behind, and very slightly depressed from above to below.

When it is viewed on its superior face (Fig. 321), we first see, behind, a white pedicle, the prolongation of the spinal cord, and a single lobe of a grey colour designated the *cerebellum.* In front of this is remarked two other lobes, separated from the first by a deep transverse fissure, into which

the tentorium of the cerebellum passes. Isolated from one another on the middle line by a shallower fissure, these two lobes constitute the *brain*, and are usually named the *cerebral hemispheres*.

In turning over the encephalon to examine its inferior face, we see that the posterior peduncle of the organ—a continuation of the spinal cord—is prolonged beneath the cerebellum, which is joined to the lateral parts of its superior face; this portion then enters the cerebral hemispheres by their inferior face, behind two thick white cords—the optic nerves, which mark the anterior limit of this prolongation (Fig. 322). This is the *isthmus of the encephalon:* a name given to it because it actually forms an intermediate bond between the three enlargements which form the principal mass of the encephalon.

Fig. 321.

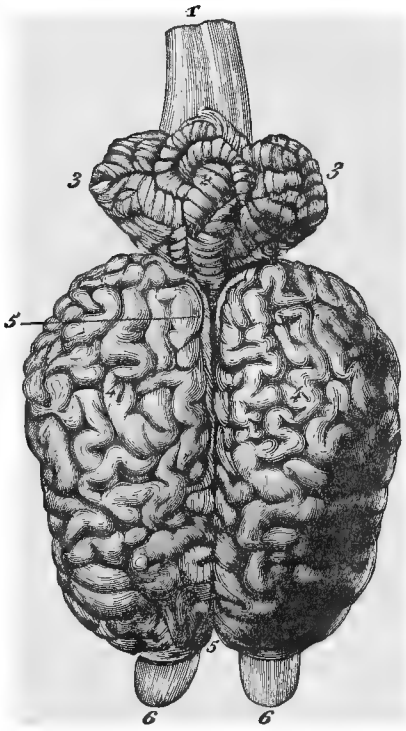

GENERAL VIEW OF THE BRAIN; UPPER SURFACE. 1, Medulla oblongata; 2, Middle lobe of the cerebellum; 3, 3, Lateral lobes of ditto; 4, 4, Cerebral hemispheres; 5, Interlobular fissure; 6, 6, Ethmoidal lobules.

The cranial portion of the central nervous mass is, then, composed of three apparatus: the *isthmus of the encephalon*, a prolongation of the spinal cord; and the *cerebellum* and *cerebrum*, bulbous lobes grafted on the superior face and anterior extremity of this peduncle. These three divisions are very well seen in their entirety and reciprocal relations in Figure 329. We will study them separately and in succession.

Volume of the encephalon.—Contrary to what is found in the spinal cord, the dimensions of the encephalon closely represent those of the cavity containing them: the visceral layer of the arachnoid lying everywhere immediately on the proper envelope of the nervous mass, the pia mater, except at the subarachnoid spaces; and, on the other hand, the arachnoid cavity can scarcely be said to exist while the dura mater is, as it were, glued to the cranial walls, and in reality constitutes their internal periosteum.

The encephalon has, therefore, no room to move in its receptacle, but is maintained in it in an almost absolutely immovable condition, which coincides exactly with that of the sutures or cranial articulations.

Weight.—The total weight of the encephalon, in average-sized animals, may be inferred from the following figures: Horse, 22 oz. 15 drams; Ass, 12 oz. 11 drams; Ox, 16 oz. 15 drams; Sheep and Goat, 4 oz. 9⅓ drams; Pig, 5 oz. 10 drams; Dog, 6 oz, 5½ drams; Cat, 1 oz. 1 dram.

In comparing these figures with those of the spinal cord, it will be seen that the relative weight of the medullary axis to that of the encephalic mass

differs notably in the several animals, being highest in the Dog. The relations in each species, between the two divisions, are the following: Dog, 1 : 5,14; Cat, 1 : 3,75; Sheep and Goat, 1 : 2,60; Ass 1 : 2,40; Pig, 1 : 2,30; Horse 1 : 2,27; Ox, 1 : 2,18. We give these numbers, as it has always been attempted to establish in the predominance of the encephalon the cause of the development of intelligence, and that the best measure of this predominance is really the relation of the spinal axis to the encephalic mass. It has also been attempted to measure this predominance of the encephalon by comparing its weight with that of the entire body; but it is sufficient to cast one's eye over the tables drawn up with this view in several anatomical and physiological works, to be convinced that this basis does not possess all the value desirable.

Preparation of the encephalon.—To study the encephalon, it is necessary to extract it from its bony receptacle; a result achieved in two ways. The first consists in opening the roof of the cranium by hammer and chisel, after removing from its exterior all the parts covering it, or which are in its vicinity. The dura mater is then excised with scissors, and the encephalon, which is thus directly reached, is completely isolated by raising its posterior extremity, and cutting from behind to before all the nerves passing through the foramina at the base of the cranium, with the pituitary stalk, as well as the extremity of the olfactory lobes. This method is very expeditious, but it sacrifices the pituitary gland, which remains firmly incrusted in the sella turcica: an inconvenience we obviate by resorting to the second procedure. In this, the cranium is opened by its base or floor, after separating the head from the trunk, cutting away the lower jaw, tongue, and os hyoides, and excising all the soft parts so as to expose the bony surfaces. The head, thus prepared, is held by an assistant, the roof of the cranium resting on a table or block. Armed with a chisel and hammer, the operator first removes the zygomatic arches and styloid processes of the occipital bone, then the condyles of this bone, the basilar processes, and the sphenoid, palate, and ethmoid bones, returning to the lateral portions of the cranium, which are chiselled away in succession from the occipital to the ethmoid bones. The encephalon being sufficiently exposed, is relieved from its dura mater as in the first method, and raised in the left hand to destroy, by means of scissors held in the right hand, the attachments which yet fix it to the cranial roof, and which are chiefly the veins that open into the sinuses of the dura mater. In afterwards excavating the ethmoidal fossæ with the point of a scalpel, the olfactory lobes are detached, and the nervous mass is free. This procedure is more difficult than the first, but possesses several advantages over it; for not only do we preserve the pituitary gland, but have the ethmoidal lobes more intact, and may also have, if desired, the ganglia of the cranial nerves, with a more or less considerable portion of the nerves themselves.

After indicating the methods for extracting the encephalon from its bony case, we ought to say some words as to the course to be pursued in order to study it successfully. To do this it is advantageous to have two brains; one of these should be hardened by steeping it for some weeks in alcohol (or methylated spirit), or in water to which has been added a tenth part of nitric acid. This hardening contracts the nervous substance, and causes the cavities and reliefs to appear more manifest. (It is a good plan to place the brain, base uppermost, in a suitable vessel, and if a piece of cloth be spread beneath it, its removal therefrom will be greatly facilitated.)

We commence by examining rapidly the whole apparatus, and pass immediately to the study of the isthmus, of which it is necessary to have at first a well-defined idea. We therefore take a hardened specimen, and isolate this portion of the encephalon in the manner represented in figure 323; to do this, it suffices to cut through the peduncles of the cerebellum, and excise the cerebral hemispheres upwards and backwards; the remains of these and the cerebellum should be preserved for an analysis of their structure. The isthmus thus isolated is fitted for an examination of its external conformation and its internal cavities: the ventricle of the optic layers and the aqueduct of Sylvius, into which we may penetrate by a superior longitudinal incision.

After the isthmus, the cerebellum is to be studied: in its external conformation, on an intact specimen; and in its internal conformation and structure on the incised piece.

We terminate with the cerebrum, whose superficies is soon examined, and whose interior should be studied in the following manner:—It is necessary to begin by demonstrating the existence of ventricles in the olfactory lobes, and their communication with all the other internal cavities of the brain, which can easily be done by the inflation of one of these organs by means of a straw (or dissecting-case tube) which

raises the pituitary gland, the cerebral lobes, and the cerebellum. Then we pass to the corpus callosum, which is exposed, as in figure 330, by a horizontal section of the hemispheres across the centrum ovale. The corpus callosum of each side is afterwards excised on the median line to reach the interior of the lateral ventricles, and this great commissure of the brain ought, after studying the septum lucidum, to be cut across in the middle and turned over, as in figure 331, so as to show the cerebral trigonal (fornix). The foramen of Monro is next examined, then the corpus striatum, hippocampi, tænia semicircularis, choroid plexus, and velum interpositum, which are exposed by the ablation of the hippocampi and trigonal. Lastly, we return to the foramen of Monro to study its communication with the ventricle of the optic layers; it will be well, also, to again examine the latter, as well as the aqueduct of Sylvius and the ventricle of the cerebellum, which we arrive at in dividing the organ through the middle and separating the halves.

Two longitudinal and vertical sections, one median (Fig. 327), the other at the side (Fig. 329), will not be without utility in the study of these particulars. They may be made by means of a saw, the brain remaining inclosed in the cranial cavity.

(A long-useful implement for removing the bony casing of the brain without risk of injuring it, is a chisel whose thin cutting edge is slightly concave, the corners being smooth and rounded, and projecting beyond the cutting edge.)

Article II.—The Isthmus.

We will study in succession the external and internal conformation of this organ, and its structure.

EXTERNAL CONFORMATION OF THE ISTHMUS.

The *isthmus* is a prismatic prolongation of the spinal cord supporting the cerebellum, and terminating in the cerebral hemispheres; it increases in size from behind to before, and may be considered as having four *faces* and *two* extremities.

The *inferior face* (Fig. 322), on which we can distinctly, and without any preparation, perceive the natural limits of the isthmus, is crossed nearly in its middle by a thick fasciculus of arciform fibres, which constitute the *annular protuberance* (*protuberantia annularis*), *pons Varolii*, or *mesocephalon* (or *nodus encephali*). All the portion lying behind this fasciculus belongs to the *rachidian bulb* (*bulbus rachidicus* or *medulla oblongata*). That in front forms the *cerebral peduncles* (*crura cerebri*).

The *superior face* (Fig. 323), covered by the cerebellum and the posterior extremity of the cerebral lobes, is more mammillated than the preceding. Passing from behind to before, on the superior face of the medulla oblongata, there is remarked the section of the *peduncles of the cerebellum*, the *valve of Vieussens*, the *corpora quadrigemina*, and the *optic layers* (*thalami optici*).

The *lateral faces* (Fig. 324), concealed in their anterior part by the hemispheres of the brain, exhibit the profile of the medulla oblongata, pons Varolii, peduncles of the cerebellum (*crura cerebelli*), cerebral peduncles (*crura cerebri*), corpora quadrigemina, and thalami optici.

The *posterior extremity* of the isthmus belongs to the medulla oblongata, and continues the spinal cord, from which it is only distinguished artificially.

The *anterior extremity* is enveloped, below and on each side, by the oblique fasciculi which form the two optic nerves, and beneath which are insinuated the fibres of the isthmus before they pass into that part of the cerebral hemispheres which bears the name of *corpora striata*.

After this enumeration of all the organs whose aggregation constitutes the isthmus of the encephalon, we will examine them in detail, and in the following order: 1, *Medulla oblongata*; 2, *Pons Varolii*; 3, *Crura cerebri*; 4, *Crura cerebelli*; 5, *Valve of Vieussens*; 6, *Corpora quadrigemina*; 7, *Thalami optici*. After these, we will describe the *pineal* and *pituitary*

glands: small appended lobes placed one on the superior, the other on the inferior face of the isthmus.[1]

Fig. 322.

GENERAL VIEW OF THE BRAIN; LOWER SURFACE.

1, Olfactory lobe; 2, Cavity of the olfactory lobe; 3, External root of olfactory lobe; 4, 5, Cerebral hemispheres; 6, Cerebellum; 7, Optic chiasma, or commissure; 8, Pituitary gland; 9, Optic nerves; 10, Tuber cinereum; 11, Crus cerebri; 12, Third cranial nerve; 13, Fourth nerve; 14, Pons Varolii; 15, Fifth nerve; 16, Sixth nerve; 17, Seventh and eighth nerves; 18, Medulla oblongata, the number being placed on the olivary body; 19, Anterior pyramid; 20, Roots of ninth, tenth, and eleventh nerves; 21, Twelfth nerve.

Medulla Oblongata. (Figs. 323, 324, 329.)

The *medulla oblongata* constitutes the posterior portion of the encephalic isthmus; it succeeds the spinal cord, and extends forward as far as the pons Varolii. It is a thick peduncle of a white colour, wider before than behind, flattened above and below, and having four *faces*—an *inferior*, *superior*, and two *lateral*.

Inferior face (Fig. 322).—This face rests in the channel of the basilar process. Convex from side to side, and limited anteriorly by a transverse fissure which separates it from the pons Varolii, posteriorly it does not offer anything to distinguish it from the medullary axis.

On the middle line there is a well-marked fissure, a continuation of the inferior fissure of the cord, which lies between two very elongated prominences that are sometimes but little apparent, and from their form are named the *pyramids of the bulb* (*corpora pyramidalia*) (Figs. 322, 19; 338, *b*). The base of these pyramids touches the pons Varolii, and their apex is insensibly lost, posteriorly, on reaching the spinal cord.

Outwardly is an almost plane surface, bordered anteriorly by a transverse band which lies immediately behind the pons Varolii; sometimes it is covered for the greater part of its extent by a very thin expansion of arciform fibres, between the anterior border of which and the transverse

[1] There is far from being any agreement as to the number of parts which ought to compose the encephalic isthmus, some authorities making more, some less. The limits of this small apparatus will, nevertheless, be found perfectly circumscribed if it be examined in the lower animals, and particularly in the Horse. An antero-posterior section of the encephalon made to one side of the median plane appears to us all that is needed to definitely settle the point. This section, seen in figure 329, shows in the plainest manner that the encephalic prolongation of the spinal axis extends to the corpora striata, and that it comprises the medulla oblongata, pons Varolii, cerebral and cerebellar peduncles (or crura), the corpora quadrigemina, and the thalami optici. All these, then, belong to one and the same system—the medullary peduncle, which serves as a bond of union between the three principal masses of the encephalon, and which we have designated the *isthmus*. It may be added that this manner of considering the encephalic isthmus perfectly agrees with the teachings of physiology.

band, and particularly in pieces that have been hardened by alcohol or acidulated water, is seen a slight oblong prominence which corresponds to what in Man is designated the *olive*[1] (*corpus olivare*); it is isolated from the pyramid by a longitudinal groove, whence emerge, in front, the roots of the sixth cranial pair, behind, those of the twelfth; outwardly, it is limited and separated from the restiform body by the origin of the majority of the roots belonging to the glosso-pharyngeal and pneumogastric nerves.

Superior face.—Covered by the cerebellum, it is channeled in its middle by an excavation (Fig. 323, 5), which constitutes the floor of the fourth ventricle. This cavity is prolonged forward above the pons Varolii, between the cerebellar peduncles, and from its forming behind an angle resembling the point of a pen, it has been named the *calamus scriptorius.*

Two thick cords, prolongations of the superior fasciculi of the medulla spinalis, border the calamus scriptorius on each side; these are designated the *corpora restiformia.* Lying together at their posterior extremities, they separate anteriorly, so as to represent the branches of a V (Fig. 323, 1).

Lateral faces.—Much narrower than the other two, and showing two thick borders, these faces give the profile of the corpora restiformia (Fig. 324, 2), corpora pyramidalia (4), and the fasciculus between these two.

2. *The Pons Varolii.* (Figs. 322, 14; 324, 5.)

The *pons Varolii*, also named the *tuber annulare* or *mesocephalon*, is that part of the brain which stands out prominently across the isthmus, between the medulla oblongata and the crura cerebri, and which is lodged in the anterior depression of the basilar process.

It is a semicircular band of white transverse fibres thrown across, like a bridge, from one side to the other of the cerebellum. In every sense it is convex, wider in its middle than in its lateral portions, and crossed from behind to before by a shallow median groove for the basilar artery. On its free surface, whose principal features we have just described, it offers for consideration two *borders* and two *extremities.*

The *posterior border*, slightly convex, is separated from the medulla oblongata by a faint groove.

The *anterior border*, also convex, but indented in its middle, largely overhangs the crura cerebri, which are limited on this side by a well-marked fissure.

The *extremities* are bent upwards to enter the substance of the cerebellum, in the form of two thick cords, which constitute the middle crura cerebelli (Fig. 324, 6). They exhibit the apparent origin of the trifacial nerves.

The pons Varolii does not exist in birds.

3. *The Pedunculi or Crura Cerebri.* (Figs. 322, 11; 324, 7.)

These are two very large white fasciculi, visible at the inferior surface and sides of the isthmus, covered superiorly by the corpora quadrigemina and thalami optici, and continuous, above the pons Varolii, with the fibres of the medulla oblongata; while their anterior extremities enter the cerebral hemispheres.

These peduncles (or crura) are separated from each other by a middle

[1] This prominence corresponds to the *corpus olivare* of Man only in its position, for it has not its structure.

fissure—the *interpeduncular*, which bifurcates in front to circumscribe the *mammillary* or *pisiform tubercle* (*corpus albicans, bulbi fornicis*) (Fig. 327, 18): a small, single, and rounded elevation of a white colour, like the peduncles, covered by the pituitary gland, whose root is represented by the tuber cinereum, and is situated in front of this body.

Behind, the crura cerebri are limited by the anterior border of the pons Varolii. In front, they are circumscribed by the optic nerves, which pass obliquely around their anterior extremity and join on the middle line before the tuber cinereum, to form a commissure called the *chiasma of the optic nerves* (Fig. 322, 7). On the sides, their tissue is confounded with that of the corpora quadrigemina and thalami optici, which are superposed on the cerebral peduncles. It may be remarked that the part of their lateral face situated below the tubercula testes, forms a well-defined triangular space, designated the *band of Reil, lateral triangular fasciculus*, and *lateral oblique fasciculus of the isthmus.*

Fig. 323.

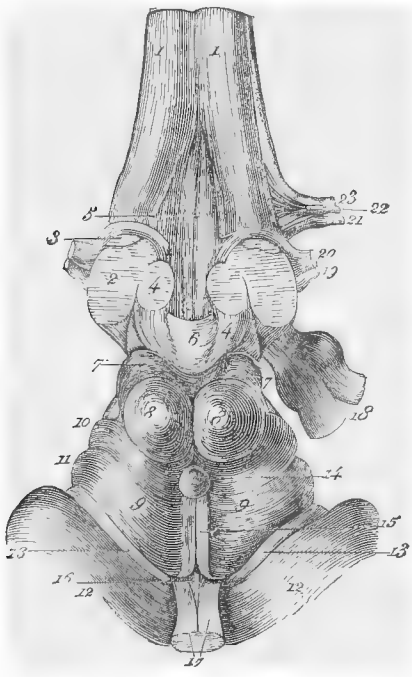

SUPERIOR VIEW OF THE ENCEPHALIC ISTHMUS.

1, 1, Corpora restiformia; 2, Section of the middle cerebellar peduncles; 3, Section of the posterior cerebellar peduncle; 4, Anterior cerebellar peduncle; 5, Floor of the posterior ventricle; 6, Valve of Vieussens; 7, 7, Tubercula testes; 8, 8, Tubercula nates; 9, 9, Thalami optici; 10, Corpus geniculatum internum; 11, Corpus geniculatum externum; 12, Corpus striatum; 13, Tænia semicircularis; 14, Pineal gland; 15, Its peduncle; 16, Common anterior opening; 17, 17, Anterior pillars of the trigonal; 18, Trifacial nerve; 19, Facial nerve; 20, Auditory nerve; 21, Glosso-pharyngeal nerve; 22, Pneumogastric nerve; 23, Spinal nerve.

4. *The Crura Cerebelli.*

The cerebellum is attached to the upper face of the isthmus by two short and thick lateral funiculi of white substance, between which is comprised the posterior ventricle; these constitute the *cerebellar crura.*

Three distinct fasciculi enter into the composition of each of these cords: an *anterior*, a *posterior*, and a *middle.*

The latter, or *middle cerebellar peduncle* (*crus cerebelli ad pontem*), is the largest of the three. It is formed by the prolongation of the extremities of the pons Varolii (Figs. 323, 2; 324, 6).

The *posterior cerebellar peduncle* (*crus ad medullam oblongatum*), the most slender, is formed by the restiform body, one portion of which is reflected below the posterior root of the auditory nerve to reach the substance of the cerebellum. It is closely united to the preceding, from which it is with difficulty distinguished (Fig. 323, 3).

The *anterior cerebellar peduncle* (*processus e cerebello ad testes*) is a fasciculus very distinct from the other two, related by its inner border to the middle peduncle, which it

obliquely crosses, loses itself in the cerebellum by its supero-posterior extremity, arriving behind the testes, and passing beneath these small organs by its antero-inferior extremity, along with the band of Reil or supero-lateral fasciculus of the cerebral peduncles.

In studying the structure of the cerebellum, we will see how these peduncles comport themselves in its interior.

5. *Valve of Vieussens.* (Fig. 323, 6.)

This designation is given to a very thin, white lamella which unites, on each side, the two anterior cerebellar peduncles. In shape it is nearly a parallelogram. Its *superior face* is covered by the cerebellum; the inferior concurs in forming the floor of the cerebellar (*fourth*) ventricle. The two *lateral borders* are joined to the peduncles this valve unites; the *anterior* is attached behind the *testes;* while the *posterior* adheres to the anterior vermiform eminence (*linguetta laminosa*) of the cerebellum.

Gall has considered this lamella as a commissure of the anterior cerebellar peduncles, and we think rightly; for we see it formed almost exclusively of transverse fibres which run from one of these peduncles to the other. These fibres are most apparent in front, where the membrane is much thicker; behind, they are mixed with some longitudinal fasciculi.

6. *Corpora Quadrigemina or Bigemina.* (Fig. 323, 7, 8.)

These are four round eminences, placed in pairs, which surmount the cerebral peduncles behind. The two posterior, the smallest, are also named the *tubercula testes*, and the anterior pair the *tubercula nates.*

The *posterior corpora quadrigemina*, or *tubercula testes*, are related, in front, with the anterior eminences: behind, with the anterior cerebellar peduncles and the valve of Vieussens, from which they are separated by a transverse groove, from the bottom of which arise the pathetici nerves. An oblique band unites them, outwardly, to that portion of the optic layer designated the *corpus geniculatum internum.*

The *anterior corpora quadrigemina*, or *tubercula nates*, are distinguished from the preceding not only by their larger volume, but by their colour, which is grey, that of the testes being white. They are also rounder, nearer each other, and covered by the cerebral hemispheres; while the posterior rather lie beneath the cerebellum. A curved groove isolates them, in front, from the thalami optici.

7. *Thalami Optici.* (Fig. 323, 9.)

This name is given to that part of the upper face of the isthmus which is situated in front of the corpora quadrigemina. These thalami are therefore placed above the anterior part of the cerebral peduncles.

Larger altogether than the corpora quadrigemina, and more so before than behind, each exhibits a grey, slightly convex, and very irregularly quadrilateral surface, covered by the velum interpositum, which separates it from the cornu Ammonis (*pes hippocampi*), and from the posterior pillars of the cerebral trigonal (fornix).

Inwardly, they incline towards each other in forming on the median line a somewhat deep fissure, in which runs, from before to behind, two white longitudinal bands that will be noticed hereafter as the *anterior peduncles* of the pineal gland. This fissure enters, behind, into the *common*

posterior opening (*foramen commune posterius*); in front, into the *common anterior opening* (*foramen commune anterius*): orifices which will be described with the interior of the isthmus.

Outwardly, the thalamus optici shows two prominences called the *corpora geniculata*, from which arise the second pair of nerves; placed one before the other, the posterior nearer the middle line than the anterior, these two projections are distinguished as *external* and *internal*. The *corpus geniculatum externum* is always more voluminous, better defined, and situated on a

Fig. 324.

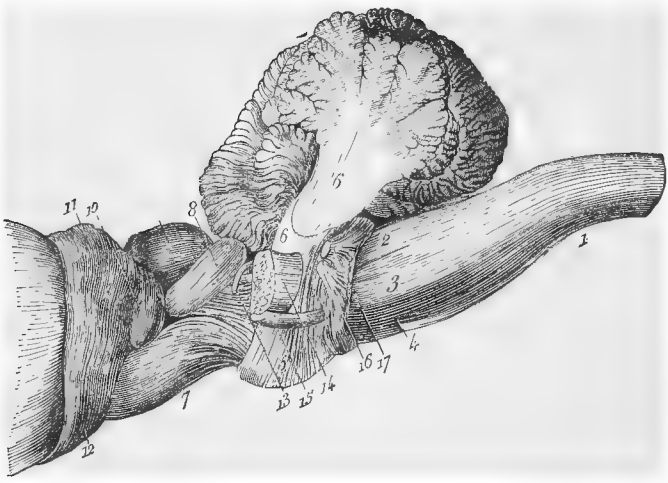

LATERAL VIEW OF THE ISTHMUS.

1, Medulla oblongata; 2, Corpus restiforme; 3, Lateral fasciculi of the medulla oblongata; 4, Inferior fasciculus, or corpus pyramidale; 5, Pons Varolii; 6, Middle peduncle of the cerebellum; 7, Cerebral peduncle; 8, Testis; 9, Natis; 10, Corpus geniculatum internum; 11, Corpus geniculatum externum; 12, Optic nerve; 13, Fourth nerve resting on the band of Reil; 14, Sensitive root of the trigeminal nerve; 15, Its motor root; 16, Facial nerve; 17, Auditory nerve.

more elevated plane than the *internal corpus geniculatum*, which is united to the posterior corpora quadrigemina by an oblique band (Figs. 323, 10; 324, 11).

Behind, the thalami optici appear to be notched to receive the nates, which they slightly inclose.

In *front*, they are separated from the corpus striatum by a groove, at the bottom of which is a narrow strip named the *semicircular band* (*tænia semicircularis*).

Pineal Gland or Conarium. (Fig. 323, 14.)

This name has been given to a small tubercle of a reddish-brown colour, in the form of a pine-cone, enveloped by a duplicature of pia mater from the velum interpositum, with its apex upwards, and its base resting on the common posterior opening, which it closes, and around which it is attached by a circular lamella.

From this lamella is detached, in front, two fibrous cords—the *anterior*

peduncles of the conarium (or *habenæ*). These (Fig. 323, 15) are two narrow white bands, which commence at the base of the pineal gland, and are directed forward parallel to each other, in the bottom of the fissure of the thalami optici, to which they firmly adhere. On arriving at the anterior common opening, they become attached to the anterior pillars of the cerebral trigonal (or crura of the fornix). Sometimes they are very narrow and separated by an interval; but more frequently they are relatively wide, and immediately in contact on the median line.

The conarium is far from always offering the same volume; it has been exhibited in its usual dimensions in Figure 323, and in Figure 327 it is shown as incomparably larger.

The structure of the pineal gland appears to be very simple, and only comprises one substance of a brownish-grey colour, apparently amorphous, and sometimes studded with calcareous granulations (*acervulus*), but without any internal cavities.

This organ and that whose description follows, do not belong, properly speaking, to the system of the encephalic isthmus; but are rather, as we have already said, appended glands, which merit to be described apart, the same as the three immense cerebellar and cerebral ganglia. If we have studied them in this place, it was only for the sake of simplification.

9. *Pituitary Gland.* (Figs. 322, 8; 327, 19.)

The *pituitary gland*, also named the *hypophysis cerebri* and *suprasphenoidal appendage*, is a small disc-shaped tubercle, fixed to the anterior extremity of the interpeduncular fissure by the *pituitary stem* (*infundibulum*) and the *tuber cinereum.*

a. The *tuber cinereum* is a little ominence of a grey colour, situated in the middle line, between the corpus albicans and the chiasma of the optic nerves, at the anterior limit of the encephalic isthmus. This eminence is hollow, and its cavity is nothing more than a diverticulum of the middle ventricle.

b. The *infundibulum* is only a short conical prolongation, whose base is attached to the tuber cinereum, and its apex to the superior face of the pituitary gland. The cavity of the tuber cinereum is continued into the infundibulum, and terminates in a *cul-de-sac* towards its summit. This prolongation, also formed of grey substance, is distinguished by its great fragility; so that it requires some care to preserve it intact when opening the cranium at its base.

c. The *pituitary gland* is lodged in the sella turcica, where it is enveloped by the suprasphenoidal duplicature of dura mater; it is a small, nearly circular body, flattened above and below, and more or less thick, according to the subjects.

Its *inferior face* rests on the sphenoid bone through the medium of the dura mater, to which it is strongly adherent; the *superior* covers the corpus albicans, with a portion of the cerebral peduncles, and in front receives the insertion of the pituitary stem. Its *circumference* responds to the suprasphenoidal duplicature, whose interior forms the cavernous sinus.

There is no cavity in the pituitary gland. The matter composing it appears to be almost amorphous; it is yellow in the anterior half of the organ, and brown in its posterior portion.

INTERNAL CONFORMATION OF THE ISTHMUS. (Fig. 327.)

The encephalic isthmus is hollowed at the thalami optici by a central cavity, named the *middle* (or *third*) *ventricle*, which is extended backwards beneath the corpora quadrigemina by a canal—the *aqueduct of Sylvius;* this opens, below the valve of Vieussens, into the *posterior* (or *fourth*) *ventricle*—another cavity comprised between the cerebellum and medulla oblongata. These three diverticuli will be studied in succession.

1. *Middle Ventricle, or Ventricle of the Thalami Optici.* (Fig. 327, 13.)

The *middle ventricle* is an irregular cavity, elongated from behind to before, depressed on each side, and offering for study two *walls*, a *floor*, a *roof*, and two *extremities*.

The two *walls* are smooth, nearly plane, or very slightly concave from above to below.

The *floor* is extremely narrow, and only forms a channel whose bottom corresponds to the interpeduncular fissure, which is nearer in front than behind, and to the corpus albicans and tuber cinereum. The cavity of the latter (Fig. 327, 20), prolonged into the pituitary stem, communicates with the middle ventricle, and assists in its formation.

The *roof*, as narrow as the floor, and, like it, nothing but a channel, is constituted by the two thalami optici which are joined to one another above the ventricle, forming a thick grey commissure (Fig. 327, 16). It is terminated at its extremities by the two orifices already noted as the *posterior* and *anterior common foramina*. The *posterior common foramen* (Fig. 327, 15) commences behind the grey commissure, and terminates at the base of the pineal gland by an irregularly expanded *cul-de-sac*. It is limited behind by the *posterior white commissure*, a thin fasciculus of transverse fibres placed in advance of the corpora quadrigemina, above the entrance to the aqueduct of Sylvius, (or *iter a tertio ad quartum ventriculum*), and whose extremities are lost in the substance of the thalami optici (Fig. 325, 9). The *anterior common foramen*, also designated the *foramen of Monro* (and *iter ad infundibulum*) (Fig. 327, 14), is the medium of communication between the middle and lateral ventricles, and affords a passage to the vascular cord which unites the two choroid plexuses. It is

Fig. 325

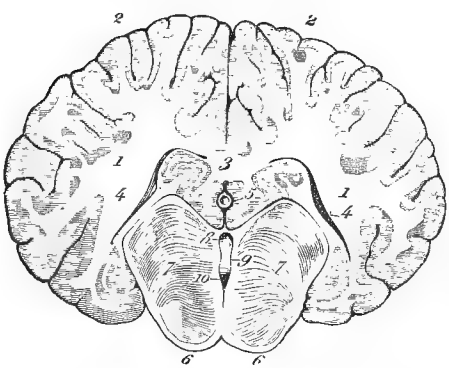

TRANSVERSE SECTION OF THE ENCEPHALON AT THE POSTERIOR COMMON FORAMEN.

1, White substance of the hemisphere, or centrum ovale of Vieussens; 2, 2, Grey substance forming the external layer of the convolutions; 3, Section of the corpus callosum; 4, 4, Interior of the lateral ventricles; 5, Section of the great vena Galeni; 6, 6, Cerebral peduncles; 7, 7, Section of the isthmus; 8, Posterior common foramen; 9, Posterior white commissure; 10, Entrance to the aqueduct of Sylvius.

pierced in front of the grey commissure, beneath the summit of the fornix, whose two pillars concur to circumscribe it, and between which is seen the *anterior white commissure*. This is a small band of white transverse fibres, analogous to that which constitutes the posterior commissure, but stronger, and passing in front of the anterior pillars of the fornix, its extremities entering and becoming lost in the corpus striatum on each side.

The *posterior extremity* of the middle ventricle, narrower than the anterior, and placed on a more elevated plane, is continuous with the aqueduct of Sylvius, whose entrance (Fig. 325, 10) is beneath the posterior commissure, towards the common foramen.

The *anterior extremity*, more dilated than the posterior, is situated immediately above the optic chiasma, and is only separated from the bottom of the great interlobular fissure of the brain by a small and very thin grey lamina attached to that chiasma, and for this reason named by writers the *grey root of the optic nerves*. This lamina (*lamina cinerea*) is readily seen when the optic commissure is turned down on the pituitary gland; it is sufficient to traverse this to enter the middle ventricle.

The *ependymis*, which lines the central canal of the medulla spinalis, also covers the walls of this cavity; through the aqueduct of Sylvius, it is prolonged into the posterior (or fourth) ventricle; by the anterior common foramen into the lateral ventricles, and thence into the spaces in the middle of the olfactory lobes.

2. *Aqueduct of Sylvius.* (Fig. 327, 6.)

This is a longitudinal median canal passing beneath the corpora quadrigemina, and above the peduncles of the brain.

Its anterior extremity communicates with the middle ventricle, and the posterior opens below the valve of Vieussens into the cerebellar (or fourth) ventricle.

3. *The Posterior or Cerebellar Ventricle.* (Fig. 327, 5.)

This ventricle[1] (or *sinus rhomboidalis*), situated beneath the cerebellum, between its peduncles, and above the medulla oblongata and pons Varolii, is a cavity elongated from before to behind, and almost entirely occupied by the vermiform processes.

Its *superior wall* is formed by these two processes, the valve of Vieussens, and that of Renault. The *inferior*, or *floor* of the cavity, is represented by the excavation on the superior face of the medulla oblongata, and which is prolonged in front, above the pons Varolii, to near the testes.

The *anterior extremity* communicates with the aqueduct of Sylvius. The *posterior* occupies the summit of the calamus scriptorius.

STRUCTURE OF THE ISTHMUS.

The encephalic isthmus being only a prolongation of the spinal cord, ought to resemble it in its structure; and this is, in fact, what is observed, particularly in its posterior part, the common features of their organisation disappearing as we approach its anterior extremity.

After what has been said as to the external conformation of the medulla oblongata, we know that this organ presents, on each of its lateral halves, traces of a division into three principal fasciculi: a superior, formed by

[1] As the cerebellum concurs in the formation of this cavity it would perhaps be better to defer its study until that organ has been described.

the *corpus restiforme;* an inferior, represented by the *corpus pyramidale;* and the third, or *intermediate* of the other two. These three fasciculi are only the continuation of those we have recognised in the cord itself, and whose properties they share—the first being sensitive, and the others motor.

Fig. 326.

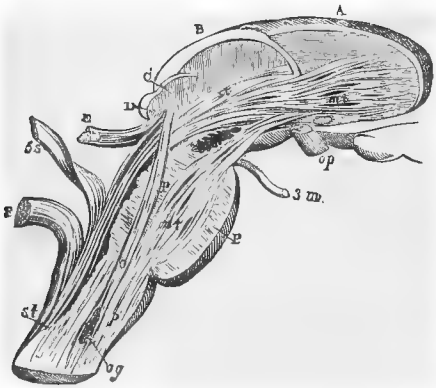

DISSECTION OF THE MEDULLA OBLONGATA, SHOWING THE CONNECTION OF ITS SEVERAL FASCICULI, OR STRANDS.

A, Corpus striatum; B, Thalamus opticus; C, D, Corpora quadrigemina; E, Commissure connecting them with the cerebellum; F, Corpora restiformia; P, P, Pons Varolii; *st*, *st*, Sensory tract; *mt*, *mt*, Motor tract; *g*, Olivary tract; *p*, Pyramidal tract; *og*, Olivary ganglion; *op*, Optic nerve; 3*m*, Root of third pair (motor); 5*s*, Sensory root of the fifth pair.

The *superior fasciculus*, or *corpus restiforme*, lying, at its posterior extremity, beside its fellow of the opposite side, is separated from it for the greater part of its extent by the excavation that constitutes the floor of the fourth ventricle. It rests on the external part of the lateral fasciculus. At the extremity of the pons Varolii is given off a small branch that forms the posterior cerebellar peduncle; it then continues its course on the side of the posterior ventricle, soon joins the anterior cerebellar peduncle, which is above it, and with it passes beneath the corpora quadrigemina.

The *inferior fasciculus*, the thinnest of the three, comprises, as has been said, all that portion of the bulb which constitutes the *pyramid*. But when this eminence is null, or but slightly marked, we ought to recognise the limits which separate it from the lateral fasciculus by the line of insertion of the roots of the great hypoglossal nerve, supposed to be prolonged to the pons Varolii, near the point of emergence of the external motores oculorum nerve. Its fibres partly intercross with those of the opposite fasciculus, in the bottom of the middle fissure. They all pass above or across the transverse fasciculi of the pons, to constitute the inferior plane of fibres of the cerebral peduncles.

The *lateral* or *intermediate fasciculus* of the bulb, comprised between the line of insertion of the hypoglossal nerve-roots, and those of the motor roots proper to the glosso-pharyngeal, pneumogastric, and spinal nerves, differs but little from the inferior cord. By a portion of its upper face it forms the floor of the fourth ventricle. After leaving the pons Varolii, like the pyramidal fasciculus, it goes to assist in the formation of the cerebral peduncles, and particularly of their triangular oblique fasciculus.

In examining, collectively, at these peduncles, the medullary fasciculi prolonged into the isthmus, we observe nearly the same order of superposition as in the bulb; but it is no longer possible to distinguish them clearly from each other, they being confounded with those of the opposite side. Their fibres can be seen prolonged in a mass beneath the corpora quadrigemina, across the proper substance of the thalami optici, and passing into the corpora striata, to disappear on each side, like a fine expanding sheath, in the middle of the cerebral hemispheres.

To this important system of *white longitudinal fibres*—a prolongation of those of the spinal cord—is found annexed as complementary elements in the organisation of the encephalic isthmus, several systems of transverse fibres—also white—and masses of grey substance. The following is a summary exposition of the arrangement of these new elements. In proceeding from behind to before, we notice, among the *white transverse fibres:*

1. The expansion of arciform fibres which sometimes covers the inferior face of the bulb (Fig. 338, *j*): their superior extremity is lost in the corpus restiforme; the inferior is buried in the intermediate fissure of the pyramid and the lateral fasciculus.

2. The proper fibres of the pons Varolii: they constitute a very thick semicircular fasciculus whose extremities form the middle cerebellar peduncles and enter the cerebellum; this fasciculus envelops, inferiorly and laterally, the longitudinal fibres of the isthmus; it is crossed by several superposed planes of transverse fibres.

3. The transverse fibres of the valve of Vieussens and those of the white commissures, which have been already noticed.

The *grey substance* of the isthmus, which now remains to be mentioned, is far from being so abundant as the white substance, and, as in the spinal cord, it is principally deeply buried in the texture of the organ. In the medulla oblongata none is found on the track of the superior and inferior fasciculi of fibres; but the lateral fasciculi are intermingled with it, and there is a layer on the floor of the fourth ventricle. It is also found in the cerebral peduncles, and particularly in the prolongation of the lateral fasciculi of the bulb.

Each of the corpora quadrigemina is composed of a small mass of this grey substance, and is covered by a thin pellicle of white matter which is scarcely perceptible in the anterior eminences. The optic thalamus is a similar mass, though more voluminous, darker coloured, and without a layer of white substance on its superficial face.

Lastly, nerve cells also exist between the various layers of transverse fibres of the pons Varolii, and between the tubes which constitute the valve of Vieussens.

DIFFERENTIAL CHARACTERS IN THE ISTHMUS OF OTHER THAN SOLIPED ANIMALS.

Apart from its volume, the isthmus does not present any sensible differences in *Ruminants* and the *Pig*. In the *Ox*, it is remarked that: 1, The *inferior pyramids of the medulla oblongata* are more prominent, and the transverse cords parallel to the pons Varolii more voluminous than in Solipeds; 2, The *crura cerebri* are short; 3, The *optic nerves* are larger than in Solipeds; 4, There is a largely developed *pituitary gland*, excavated by a wide cavity, and flattened from above to below; 5, Lastly, the *testes* are more conical and less distinct from the *nates* than in the animals already studied.

In the *Carnivora*, the *fourth ventricle* is very large and deep, and bordered by salient and detached *corpora restiformia*. Its floor is marked by some white transverse striæ. The *pons Varolii* is large; the *cords* (or *columns*) of the *medulla* oblongata, parallel to its posterior border, are as developed as in the Horse, without taking into consideration the difference in size of the two species. The *pyramids* are voluminous, and the *olivary bodies* well defined. The *testes* are larger than the *nates*.

COMPARISON OF THE ISTHMUS OF MAN WITH THAT OF ANIMALS.

In human anatomy, the *medulla oblongata* and *encephalic isthmus* are described separately.

The first shows on its lower face a well-marked groove, a continuation of that of the spinal medulla; it terminates anteriorly in a deep fossa named the *foramen cæcum of Vicq-d'Azyr*. The *pyramids* are well marked, The *olivary bodies* are much more

prominent than in animals, and are also distinguished by the presence of a grey nucleus in their interior. The medulla oblongata of Man has not the transverse band, behind the pons Varolii, which we described in the Horse (Fig. 333).

With regard to the isthmus proper, it contains the parts in front of the medulla oblongata already studied in the domesticated animals. The *pons Varolii* is very large; the *crura cerebri* are separated from each other by a groove, at the bottom of which are several small openings. The *fourth ventricle* is deep, is bordered by well-developed *corpora restiformia*, and inclosed posteriorly and laterally by the *valves of Tarin* (*velum medullare posterius*). On its floor are remarked transverse striæ (*lineæ transversæ*) named the *barbs of the calamus scriptorius*, which are also found in the Dog. The *testes* are smaller than the *nates;* but the difference in their volume is less considerable than exists between Solipeds and Ruminants. Their structure is already known.

Article III.—The Cerebellum.

The cerebellum, or posterior enlargement of the encephalon, is the single mass supported by the isthmus, separated from the cerebrum by the transverse partition constituting the tentorium cerebelli, and lodged in the posterior compartment of the cranial cavity, which almost exactly gives the measure of its volume.

1. *External Conformation of the Cerebellum.*

The cerebellum, isolated by dividing its lateral peduncles from the medullary prolongation on which it is fixed, presents the form of an almost globular mass, slightly elliptical, elongated transversely: while its external surface is furrowed by a great number of sulci, the two principal of which (*sulci horizontalis*) pass in a circular manner on each side of the middle line around the organ, dividing it into three *lobes*—a *middle* and two *lateral.*

The *three lobes* of the cerebellum are not always readily distinguished from each other, in consequence of the shallowness and irregularity of the two sulci separating them. We will, nevertheless, study them in succession, and afterwards examine, in a general manner, the furrows on their superficies.

Middle lobe (Fig. 321, 2).—This has been compared to a silk-worm rolled in a circular manner around the middle portion of the cerebellum, and whose two extremities are joined, without being confounded, below the inferior face of the organ.

This vermicular disposition is not well defined in the middle and superior portion of the cerebellum, where this lobe is always more or less subdivided into large multiple and irregular lobules; but it is better observed before and behind, in those points which correspond to the two extremities of the animal selected as a term of comparison. There may be remarked two longitudinal eminences transversely annulated on their surface, and curved beneath the cerebellum in such a way as to come in contact with each other. These eminences constitute the *anterior* and *posterior vermiform processes.* Their extremities are lodged in the fourth ventricle, whose roof they concur in forming.

On the *anterior vermiform process* the posterior border of the valve of Vieussens is inserted.

The *posterior vermicular process* also receives the insertion of a valve already mentioned, and which must be again briefly referred to. This valve, described for the first time by M. Renault,[1] forms a lamina of a certain thickness stretched above the calamus scriptorius. It has exactly the triangular form of this space, and presents a superior face covered by the

([1] The late eminent veterinary teacher and director of the Alfort School.)

posterior vermiform process; an inferior face, studded in some points with small vascular loops; a base fixed to the *vermis*, near the free extremity of that prominence, and to its lateral parts; two lateral borders, attached to the corpora restiformia on each side of the calamus scriptorius; and a summit corresponding to the receding angle of the excavation. This lamina is, doubtless, nothing more than a septum formed by the external pia mater, and on which is extended the internal membrane that covers the walls of the cerebellar ventricle. Otherwise, it is in direct continuity, towards its base, with an evident dependency of the pia mater—the *plexus choroides*.[1]

Fig. 327.

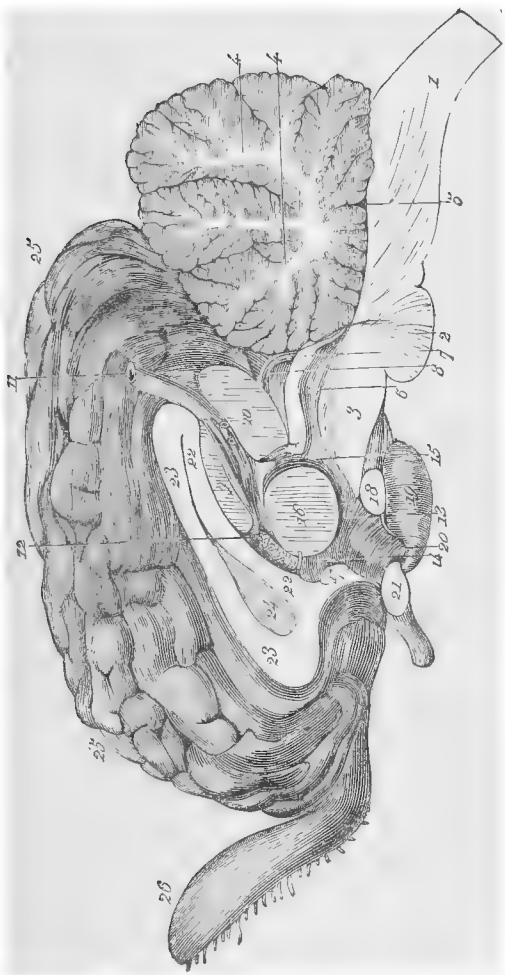

MEDIAN AND VERTICAL SECTION OF THE ENCEPHALON.

1, Section of the medulla oblongata; 2, Ditto of the pons Varolii; 3, Ditto of the crura cerebri; 4, Ditto of the cerebellum, showing the arbor vitæ; 5, Posterior ventricle covered by the cerebellum; 6, Aqueduct of Sylvius; 7, Section of the valve of Vieussens—the figure and the line proceeding from it are too much forward; 8, Natis; 9, Internal extremity of the hippocampus; 10, Section of the pineal gland; it is as voluminous as it was in the specimen from which this drawing was taken; 11, Great vena Galeni, proceeding from the velum interpositum and choroid plexus, 12; 13, Middle ventricle; 14, Foramen of Monro; 15, Common posterior foramen; 16, Grey commissure; 17, Anterior white commissure; 18, Section of the corpus albicans; 19, Ditto of the pituitary gland; 20, Interior of the pituitary stem communicating with the middle ventricle; 21, Section of the optic chiasma; 22, Ditto of the fornix; 23, Ditto of the corpus callosum; 24, Septum lucidum; 25, Cerebral convolutions; 26, Olfactory lobule.

Lateral lobes (Fig. 321, 3, 3).—These are shaped like two irregular segments of a sphere. Their surface, fissured and lobulated in every direction, presents nothing interesting externally, superiorly, or posteriorly. It is by

[1] This septum is represented in the rudimentary state in Man, by the *vavulæ Tarini*.

their inferior part that the peduncles enter the substance of the cerebellum; and behind this point, beneath their lateral parts, the *cerebellar plexus choroides* is applied.

The *cerebellar choroid plexuses.*—This name is given to two small reddish granular masses, formed of vascular loops, elongated from before to behind, depressed above and below, and comprised at their internal borders between the corpora restiformia and the inferior face of the lateral lobes of the cerebellum, to which they are strongly adherent by their superior face. These two plexuses are joined together by means of Renault's valve, which is united to them towards its base.

Sulci and lobules of the cerebellum.—On examining, in a general manner, all the sulci which intersect the external surface of the cerebellum, we see that they penetrate to very unequal depths in the substance of the organ, and that they divide it into successively decreasing segments, of which Figs. 324 and 327 may furnish a sufficient idea.

There is at first a certain number of principal lobules, which are divided into secondary lobules; and these, again, are in their turn separated into short lamellæ, representing the extreme limits of cerebellar lobulation.

2. *Internal Conformation and Structure of the Cerebellum.*

The cerebellum concurs, by its inferior plane and the internal face of its peduncles, to form the cavity already described as the *posterior* or *cerebellar ventricle;* but in the mass of the organ itself there is no trace of excavation or other peculiarity. This is demonstrated in the most evident manner by sections of its substance made either in an antero-posterior or in a transverse direction. We only see in these traces of the sulci which divide the organ into lobules; and they also afford evidence as to the structure of the cerebellum, showing that, like all the other parts of the cerebro-spinal axis, it is formed of *white* and *grey substance.*

The latter, spread over the entire surface of the organ, constitutes the cortical layer of the different segments of which it is composed. It is even prolonged into the convolutions which increase the surface-extent of the cerebellum; in each lobule it may be decomposed into superposed layers, parallel to the lamina of white substance that forms the nucleus of the lobule; between these layers of grey substance is a very thin mass of white matter.

The *white substance,* enveloped on every side by the grey, forms two thick nuclei occupying the centre of the lateral lobes, and which are united and confounded on the median line in the texture of the middle lobe.

These two nuclei, in continuity on each side with the cerebellar peduncles, are only their prolongations or intercerebellar portions. They send into the middle of each principal lobule a long and thick branch, which gives off smaller divisions that ramify in the secondary lobules, and from which escape a new series of ramuscules that enter the smallest segments; this gives to the cerebellum a beautiful arboreal aspect, justly designated by the older anatomists the *arbor vitæ.* (See Figs. 324, 327, 329, for representations of the *arbor vitæ cerebelli.*)

In the interior of these nuclei, a little in front, there sometimes exists a small, slightly-grey spot; this is the trace of the *corpus rhomboideum* (or *dentatum* of Man).

The nuclei of the white substance of the cerebellum are constituted, like the matter of the medulla, by nerve-tubes which are continuous on one side

with the crura cerebelli, and on the other terminate in the cells of the grey substance.

In the grey spot that forms the corpus rhomboideum, is a great number of large nerve-cells.

With regard to structure, the grey matter of the cerebellum may be decomposed into two layers; the superficial is very rich in blood-vessels, has a greyish tint, and is composed of large nerve-cells and smaller rounded elements; the deep layer is of a yellow colour, and also contains nerve-cells and round elements, though the latter are smaller than in the other layer, and have been sometimes mistaken for simple nuclei.

Fig. 328

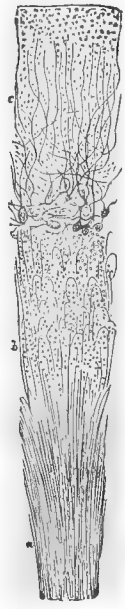

SECTION OF THE CORTICAL SUBSTANCE OF THE CEREBELLUM.

a, Meduliary substance, showing its fibres; *b*, Substantia ferruginea, composed of fibres and cell-nuclei; *c*, Grey surface, granular at the surface, and containing large multipolar branching cells near the substantia ferruginea.

DIFFERENTIAL CHARACTERS OF THE CEREBELLUM IN OTHER THAN SOLIPED ANIMALS.

The external and internal conformation of the cerebellum offers the closest analogies in the domesticated mammifers. In all, its volume, compared with that of the other encephalic lobes, is not invariable. Thus, while the relation between the weight of the cerebellum and that of the brain of the Horse is as 1 to 7; with the Ox it is as 1 to 9; with the Dog 1 to 8; with the Cat 1 to 6; and with the Sheep 1 to 3. These are the only differences to be noted

COMPARISON OF THE CEREBELLUM OF MAN WITH THAT OF ANIMALS.

In *Man*, the encephalic mass being enormous, the cerebellum is absolutely more considerable in volume than in the larger domesticated animals; though, in proportion to the cerebral hemispheres, it is smaller than in the Ox, its relation to the latter lobes being as 1 to 8.

It is wider than it is long, and projects much beyond the medulla oblongata. It has three lobes; but these are only visible on its lower aspect; on the opposite face, the median lobe is depressed and concealed beneath the lateral lobes, which are so large that they have been named the *cerebellar hemispheres*. The inferior vermis forms a free projection in which is the fourth ventricle; this is termed the *uvula of the cerebellum*. The uvula is connected at each side with the *valves of Tarin:* laminæ of nerve-substance lodged for the most part in the fourth ventricle, and hidden by the lower face of the cerebellar hemispheres. The latter constitute, on the sides of the medulla oblongata, two prominences situated one below the other, above the crura cerebelli; the first is designated the *amygdala* or *tonsil*, the second the *pneumogastric lobule* (or *flocculus*).

Article IV.—The Cerebrum.

The *cerebrum*, the principal portion of the encephalon, comprises the two anterior lobes or *hemispheres* of that apparatus: enlargements which are elongated in the direction of the great diameter of the head and cranial cavity, lie beside each other on the middle line, and are united at their central part by a transverse commissure, and by the encephalic isthmus, whose anterior extremity penetrates, inferiorly, into their substance. (See Fig. 329 for a good idea of this penetration.)

These two lobes together represent an ovoid mass, having its thick extremity adjacent to the cerebellum; it is depressed from above to below, deeply divided above, in front, and behind by a median antero-posterior

fissure, and receiving in the middle of its inferior face the insertion of the cerebral peduncles.

This mass, seven to nine times more voluminous than the cerebellum, fills the anterior compartment of the cranial cavity, and thus occupies the greater portion of that space.

It exhibits for study its *external conformation*, its *internal conformation*, and its *structure*.

Fig. 329.

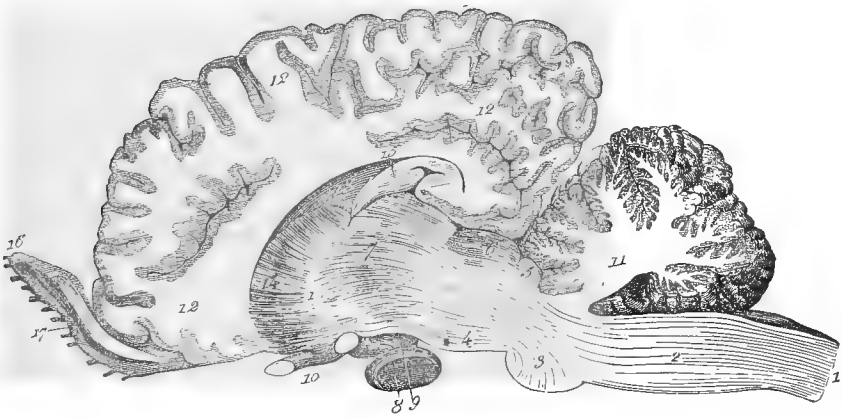

ANTERO-POSTERIOR AND VERTICAL SECTION OF THE ENCEPHALON TO ONE SIDE OF THE MEDIAN LINE.

1, 1, Isthmus of the encephalon; 2, Medulla oblongata; 3, Pons Varolii; 4, Cerebral peduncle; 5, 6, Corpora bigemina; 7, Optic thalamus; 8, Pituitary gland; 9, Pituitary stem; 10, Optic nerve; 11, Cerebellum; 12, 12, Cerebral hemisphere; 13, Ventricle of the hemisphere; 14, Corpus striatum· 15, Cornu Ammonis; 16, Olfactory lobe; 17, Ventricle of the olfactory lobe.

EXTERNAL CONFORMATION OF THE CEREBRUM.

Instead of examining the organ in mass, with regard to its external conformation, we will first consider the great *interlobular* (or *longitudinal*) *fissure* which divides it lengthways; and afterwards study its two lateral halves, or *cerebral hemispheres*, which in reality constitute two symmetrical organs.

1. *The Longitudinal Fissure.*

This fissure exists throughout the vertical and antero-posterior circumference of the cerebrum, but does not everywhere offer the same disposition. On the superior aspect of the organ it is very deep, and when the two hemispheres are separated to discover its extent, we see that it reaches to the upper face of the great commissure—the corpus callosum. Behind, it curves between the posterior lobes of the hemispheres, but without corresponding directly with the posterior thick rounded margin of the corpus callosum, above which there is a feeble adhesion established between the two halves of the cerebrum, forming a kind of bridge. But in front it passes to the anterior margin of this commissure, and is prolonged in the interval of the anterior lobes of the hemispheres to reach the inferior face of the organ.

Examined inferiorly, the interlobular fissure is well defined in front,

where it attains the anterior border of the corpus callosum; but behind, on leaving the chiasma of the optic nerves, and which marks the anterior limit of the isthmus, this fissure appears suddenly to stop. This is because it becomes considerably enlarged, and is changed into a vast notch which admits the anterior extremity of the isthmus: or rather, it bifurcates to pass on each side between the hemisphere and the anterior extremity of the medullary prolongation, at first crossing the optic nerve, then turning round the cerebral peduncles and corpora bigemina, above which its branches unite, and are confounded with the undivided part of the fissure, which separates the posterior lobes of the hemispheres.

There exists, then, around the point of immergence of the isthmus in the cerebrum a well-marked line of demarcation, which constitutes, above and laterally, a very deep fissure in which is imbedded the vascular expansion known as the *velum interpositum;* this aperture is designated the *fissure of Bichât*, or *great* (*transverse*) *cerebral fissure.*

The interlobular fissure receives the longitudinal septum of the dura mater—or falx cerebri. It also lodges arteries and veins, among which it is necessary to distinguish the *great vena Galeni*, which ascends from the bottom of the fissure, after passing round the posterior border of the corpus callosum.

2. *The Cerebral Hemispheres.*

Each hemisphere or lateral moiety of the cerebrum, represents an ovoid segment, in which we may consider four *faces* and two *extremities.*

The *superior face* is convex, and is covered by the roof of the cranium, which is formed by the frontal and parietal bones.

The *external*, equally convex and insensibly confounded with the adjacent faces, responds to the lateral walls of this cavity: that is, with the squamous portion of the temporal bone, the parietal and frontal bones, and the ala of the sphenoid.

The *inferior*, irregularly mammillated, rests on the sphenoid bone. The *internal* is plane, and for the greater part of its extent is related to the other hemisphere through the medium of the falx cerebri; it is in its central and inferior portion that the union of the two halves of the cerebrum takes place, by means of the great cerebral commissure and the anterior extremity of the isthmus.

The *posterior extremity* of the hemisphere corresponds to the cerebellum, which slightly depresses it, and from which it is separated by the transverse septum of the dura mater (tentorium).

The *anterior extremity* or *lobe* is lodged in the fossa formed on each side of the crista galli by the frontal and sphenoid bones.

The anatomical peculiarities to be found in these different regions of the external surface of the hemisphere are: 1, On the inferior face, and from before to behind, a detached appendage constituting the *olfactory* or *ethmoidal lobule*, a transverse groove named the *fissure of Sylvius*, and an elongated eminence called the *mastoid lobule;* 2, Everywhere else, the *cerebral convolutions*—depressed elevations curved about in a thousand ways, and separated by sulci of varying depth.

We will study these peculiarities in an inverse order to that of their enumeration.

1. Cerebral Convolutions (Figs. 321, 322, 327).—The cerebral convolutions are constituted by the folding of the external surface of the brain, apparently with the intention of considerably augmenting the extent of that

surface. These folds, which are very deep, are extremely irregular; on the surface of the hemispheres their disposition somewhat resembles the convolutions of the intestines, a circumstance to which they owe their designation. In Solipeds their number is considerable, and not inferior in this respect to those on the human brain.

Notwithstanding their great irregularity, the cerebral convolutions offer a somewhat constant arrangement; so that it is possible to describe them one by one. This has been done in human anatomy; but it would be needless to repeat the task in the case of the domesticated animals.

2. Mastoid or Sphenoid Lobule (Fig. 285, L).—This is a large pyriform eminence, corresponding to what has been described in Man as the *inferior* (or *middle*) *lobe of the hemisphere*, and occupies the posterior part of the inferior face of the hemisphere. This eminence is curved upon itself, and shows its convexity outwards. Its internal border, which corresponds to the cerebral peduncle, concurs in the formation of the *great transverse fissure*. Its large extremity is turned forward, and margined by the fissure of Sylvius. The posterior extremity insensibly disappears on the inner side of the posterior lobe of the hemisphere.

This eminence ought to be considered as a large projecting convolution. It is excavated internally by a cæcal cavity, which constitutes the bottom of the posterior or reflected portion of the lateral ventricles.

3. Fissure of Sylvius.—Thus is designated a transverse depression situated in front of the optic nerve and mastoid lobule, in which is lodged the middle cerebral artery.

4. Olfactory or Ethmoid Lobule (Figs. 321, 6; 322, 1; 327, 26; 329, 16).—The appendage to which this name is given is detached from the inferior face of the hemisphere, where it arises by two white-coloured roots; the *external* of these is continuous with a long convolution that borders the outside of the mastoid lobule, while the *internal*, the shortest, originates on the inner face of the hemisphere, in advance of the optic chiasma. Between these roots appears a prominent surface of a triangular form, constituting the *extra-ventricular nucleus of the corpus striatum* (*substantia perforata*). The appendage thus formed passes forward, terminating in an oval enlargement (*bulbus olfactorius*) extending much beyond the anterior extremity of the brain, to be lodged in the ethmoid fossa.

The olfactory lobe possesses an internal cavity, a diverticulum of the lateral ventricle (Fig. 322, 2). Both lobes being regarded as the first pair of cranial nerves, we will return to their description when studying the encephalic nerves.

INTERNAL CONFORMATION OF THE BRAIN.

In separatingt he cerebral hemispheres by their upper face, we discover the great commissure known as the *corpus callosum:* the first object that presents itself for study in the internal conformation of the brain.

If we afterwards remove, by a horizontal section, and with a sharp instrument, all that portion of the hemispheres which covers this commissure, and also if the latter be excised to a certain extent to the right and left of the median line, we will penetrate two symmetrically disposed cavities in the centre of each hemisphere. These cavities are the *lateral* or *cerebral ventricles*.

They are separated on the middle plane by a thin partition—the *septum lucidum*, which is attached to the corpus callosum by its upper border, and fixed by its inferior border into the *fornix*, a kind of median arch beneath

which is the *foramen of Monro*, or orifice communicating with the two ventricles. On the floor of these cavities is observed two large eminences, the *corpus striatum* and the *hippocampus ;* with a vascular and apparently granulated cord forming the *cerebral choroid plexus*, a dependency of the *velum interpositum.*

It now remains to enter into some detail with regard to the anatomical characteristics of all these parts.

1. *The Corpus Callosum.* (Figs. 327, 330.)

The *corpus callosum* is a kind of arch thrown over the two lateral ventricles, while at the same time it is a commissure uniting the two hemispheres. It belongs exclusively to mammalia.

Composed entirely of white substance, it affects a quadrilateral form, being elongated in an antero-posterior direction, and thus presents for study two *faces*, two *borders*, and two *extremities.*

The *superior face*, free in the middle, and corresponding to the bottom of the interlobular fissure, is covered right and left by the substance of the hemispheres. It is traversed from before to behind by two white, and generally very delicate, cords, the *tractus longitudinalis* (the *chordæ longitudinalis* of Lancisii) of the corpus callosum, which lie together on the middle line. The *inferior face* is divided by the insertion of the septum lucidum into two lateral portions, each of which forms the roof of one of the cerebral ventricles.

Fig. 330

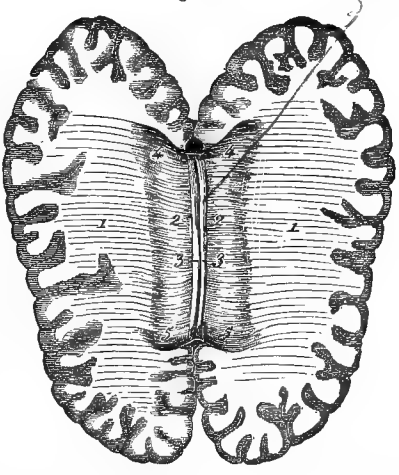

THE CORPUS CALLOSUM, AFTER REMOVAL OF THE UPPER PORTION OF THE CEREBRAL HEMISPHERES.

1, Centrum ovale of Vieussens; 2, 2, Chordæ longitudinales; 4, 4, Cornua, or angles of the posterior extremity; 5, 5, Ditto of anterior extremity.

The two *lateral borders* of the corpus callosum disappear in the central substance of the hemispheres, where it is almost impossible to distinguish their limits.

The *posterior extremity* appears at the bottom of the interlobular fissure, after the destruction of the adhesion usually established above it between the two hemispheres, in the form of a thick, rounded enlargement (splenium) folded in *genu*, below, and confounded with the middle part of the fornix. It is prolonged, laterally, above the ventricular cavities, by forming two angles (*lineæ transversæ*) which are soon lost in the white central substance of the cerebrum.

The *anterior extremity* comports itself in a similar manner between the anterior lobes of the hemispheres.

2. *The Lateral or Cerebral Ventricles.* (Figs. 325, 331.)

The *lateral ventricles* are two large elongated cavities excavated in the hemispheres, lying against each other in their anterior moiety, and divergent in their posterior part, which is very much curved backwards, outwards, and downwards, to open into the substance of the mastoid lobule.

This disposition permits the division of the cerebral ventricles into two regions: an *anterior*, and a *posterior* or *reflected*.

The anterior region is separated in the median plane from the opposite ventricle, by the septum lucidum and the summit of the fornix, beneath which is the foramen of Monro establishing a communication between the middle and the two lateral ventricles, and between these latter. Above, it offers a smooth wall formed by the corpus callosum. Below, on its floor, there is first remarked, in front, the corpus striatum; behind, the internal portion of the hippocampus; in the middle, an oblique groove running from behind to before, and without inwards, at the bottom of which floats the choroid plexus. The anterior extremity of this region, occupied by the base of the corpus striatum, is continued by a narrow opening into the interior of the olfactory lobe. The posterior is prolonged, without any line of demarcation, by the *reflected portion* of the ventricular cavity.

The latter region occupies the most declivitous portion of the posterior lobe of the hemisphere, and presents a strongly curved canal whose concavity looks forward; this canal terminates in a *cul-de-sac* in the substance of the mastoid lobule. On the floor of this canal is delineated the posterior portion of the hippocampus and the choroid plexus.

A very fine membrane—the *ventricular arachnoid*—plays the part of a serous membrane and covers the walls of these cavities, being spread everywhere over a layer of white substance, prolonged into the ethmoidal diverticulum, and continuous, through the foramen of Monro, with that of the middle ventricle. This membrane secretes a limpid and transparent liquid, analogous to the cerebro-spinal fluid, though in health it is always in small quantity.

3. *The Septum Lucidum.* (Fig. 327, 24.)

This appellation is given to a thin median lamella, standing vertically between the two lateral ventricles, elongated from before to behind, widened considerably at its anterior extremity, terminating in a point at its posterior extremity, and inserted above into the corpus callosum, below into the back of the fornix.

On the faces of this lamella, which is formed of white substance, is spread the proper membrane of the lateral ventricles. In the human species, a narrow ventricular cavity has been described as found in its substance; but this does not appear to exist in our domesticated animals.

4. *The Fornix* (*or Trigonum*). (Fig. 31~~3~~1, 3.)

Also named the *vault of three* or *four arches*, the fornix (*arch*) is a single and median body in the interior of the brain, concurring to separate the two ventricles, and serving to support the septum lucidum. It is depressed from below to above, and is of a triangular form; its apex, looking downward, stands in the median plane above the foramen of Monro and the thalami optici, though separated from the latter by the velum interpositum and the hippocampi, and receives on its upper face the insertion of the septum lucidum. Behind, towards its base, and on the median plane, the fornix is confounded with the corpus callosum, which it supports; it is prolonged on each side by a lamina extending to the surface of the hippocampus, forming the cortical layer of this deep convolution of the brain, and with its congener constituting the *posterior pillars* (*posterior crura*, or *corpora fimbriata*) *of the fornix.*

In front, at its apex, the fornix is also attached to the corpus callosum,

and divides into two cords or *anterior pillars* (*crura*) (Fig. 323, 17), which pass in front of the anterior cerebral commissure, are inflected downwards and backwards, in traversing the optic thalamus, on the sides of the middle ventricle, and, finally, have their extremities confounded with the mammillary process (*corpus albicans*).

These two crura limit, in front, the *foramen commune anterius* or *foramen of Monro*, over which the apex of the fornix is thrown across like an arch.

The fornix is white throughout its whole extent, with a greyish tint towards its summit.

5. *The Hippocampi.* (Fig. 331, 4.)

The *hippocampus* or *cornu Ammonis* (from its resemblance to a ram's horn, the crest of Jupiter Ammon), is an elongated projection, a veritable internal convolution of the brain (is, in fact, the internal surface of the *gyrus fornicatus* or convolution lying upon the corpus callosum, and which terminates at the fissure of Sylvius); it occupies the floor of the anterior region of the lateral ventricle, and is prolonged throughout its reflected portion, whose curvature it exactly follows. Considered together, the two hippocampi somewhat closely resemble the uterine cornua of the Cow.

By their internal extremity, they are in contact with each other beneath the middle portion of the fornix, and above the optic thalamus, which is separated from them by the velum interpositum (Fig. 327, 9). Their external extremity occupies, in the mastoid lobule, the *cul-de-sac* of the reflected portion of the lateral ventricle.

The central mass of this projection is formed by a nucleus of grey substance, covered superficially by a cortical layer of white—a prolongation of the posterior crura of the fornix.

Towards the concave border of the hippocampus, this white lamina offers a kind of wide hem, beneath which the choroid plexus passes; this hem constitutes a small curved band, like the cornu Ammonis, wider at its middle part than at its extremities, and is named the *corpus fimbriatum*, or *tænia hippocampus*.

6. *The Corpora Striata.* (Fig. 331, 7.)

The *corpus striatum* is another projection on the floor of the cerebral ventricle, occupying the anterior region of that cavity.

This eminence is pyriform in shape, and obliquely elongated from behind to before, and without to within. Its surface is smooth, and regularly convex. Its base, or anterior extremity, corresponds to the anterior cæcum of the ventricle. The summit, or posterior extremity, disappears at the commencement of the reflected portion of the ventricular cavity. Outwardly, the corpus striatum is limited by a groove that forms the angle of union between the floor and roof of the ventricle. Inwardly, it is separated from the optic thalamus and cornu Ammonis by another sulcus, in which the choroid plexus floats, and which is oblique inwards and forwards, and shows at the bottom the *tænia semicircularis* (Fig. 323, 13). This is a flattened white cord, which disappears inwardly towards the foramen of Monro, and bends outwards along the optic nerve to within about 3-8ths of an inch from the chiasma; in this way forming a sort of circular band around the anterior extremity of the isthmus, beneath which all the fibres of the latter pass to reach the cerebral hemispheres.

The corpus striatum owes its name to its structure, being composed of a

thick nucleus of grey substance that crosses the longitudinal fibres of the encephalic isthmus in passing into the hemispheres; these fibres appear in several points of this nucleus as very distinct white streaks.

Fig. 331.

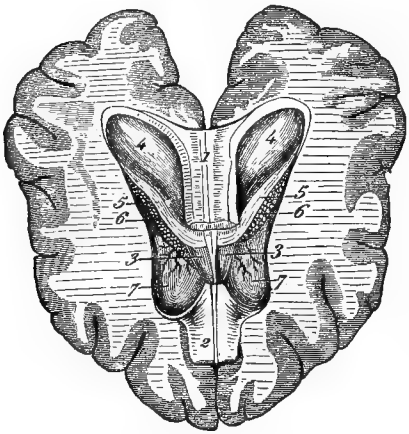

ANTERIOR PORTION OF THE LATERAL VENTRICLES OF THE DOG, EXPOSED BY REMOVAL OF THE ROOF.

1, Corpus callosum; 2, Anterior part of the corpus callosum, turned forward after destruction of the septum lucidum, to show the fornix, 3, 3; 4, 4, Hippocampi; 5, 5, Tænia semicircularis; 6, 6, Choroid plexus; 7, 7, Corpora striata.

This deep nucleus, which is intermediate to the superior extremity of the isthmus and the principal mass of the hemisphere, comprises the entire thickness of the floor of the lateral ventricle, and projects outwards, beneath the inferior face of the hemisphere, between the two roots of the olfactory lobe, where it constitutes the *extra-ventricular nucleus of the corpus striatum:* so named in contradistinction to the oblong eminence in the interior of the ventricle, which is often designated the *intra-ventricular nucleus of the corpus striatum.*

7. *The Velum Interpositum and Choroid Plexus.* (Fig. 331, 6.)

The *velum interpositum* (*velum vasculosum, tela choroidea*) is a vascular expansion dependent from the pia mater, which penetrates the brain by the transverse fissure, and insinuates itself between the thalamus opticus and the convolution of the cornu Ammonis. The velum, on arriving beneath the tænia hippocampus, terminates in the *choroid plexus:* a red, granular-looking cord, which is suspended by its antero-external border, and projects into the interior of the lateral ventricle.

The *choroid plexuses of the brain* extend from the anterior extremity of the corpus striatum to the bottom of the *cœcum* in the mastoid eminence or lobule. In the anterior region of the ventricle, they occupy the oblique sulcus which traverses that part, to the inner side of the corpus striatum. In the posterior region, they float in front of the cornu Ammonis. Their anterior or internal extremity, more voluminous than the external, always forms a small appendage which remains quite free. They are united to each other, near this extremity, by an intermediate cord, which traverses the foramen of Monro in passing beneath the fornix.

Like the velum interpositum, the choroid plexuses are formed by a network of arteries and veins. They are often incrusted in calcareous matter, and may be the seat of more or less voluminous cysts.

The veins proceeding from this vascular apparatus are very voluminous, and by their union form the great *vena Galeni*, which bends round the splenium of the corpus callosum to reach the interlobular fissure, and proceeds to the sinus of the falx cerebri.

STRUCTURE OF THE CEREBRUM.

The structure of the brain is certainly one of the most interesting points in the study of the nervous centres; for on a perfect knowledge of it depends the solution of the most difficult problems in the physiology of the nervous system. Numerous attempts have been made to elucidate its intimate organisation; but we must here omit the multitude of secondary details revealed by these researches, and limit ourselves to the essential and fundamental facts.

The *two substances* enter into the texture of the cerebral hemispheres, and both are exactly disposed as in the cerebellum.

The *grey substance* extends over the entire external surface of the brain, and dips into the sulci; thereby augmenting the extent of that surface, and forming the cortical layer of the cerebral convolutions. This layer, it is necessary to remark, though perfectly similar to that of the cerebellar lobules, is not homogeneous throughout its thickness, but may be decomposed into several secondary stratified layers, between which are extremely thin lamellæ of white substance; one of these lamellæ nearly everywhere forms the most superficial pellicle of the convolutions.

According to Kölliker, there are six layers in the cortical substance of the brain, and these are disposed as follows: 1, A superficial white layer; 2, Grey layer; 3, First white streak; 4, Yellowish-red layer, external portion; 5, Second white streak; 6, Yellowish-red layer—internal portion. In all these layers are nerve-cells, but in proportion as they are pale, these cells are few and small; the cells themselves contain colouring matter in the reddish-yellow layers. Everywhere they are furnished with from one to five fine prolongations, which bring them into communication with the very fine nerve-tubes of the cerebral hemispheres. (Lockhart Clarke gives seven layers for this cortical substance.)

Fig. 332.

CORTICAL SUBSTANCE OF THE CEREBRAL HEMISPHERES.

a, Medullary substance; *b*, Reddish-grey layer; *c*, Clear white streak, composed of horizontal fibres; *d*, Grey layer; *e*, External white layer.

In the middle of each hemisphere, the *white substance* constitutes a considerable nucleus, which, from its form, is named the *centrum ovale of Vieussens* (Figs. 325, 1; 330, 1), and which is united to that of the opposite side by the great cerebral commissure, or corpus callosum, sending a prolongation into each convolution; thus exhibiting the exact disposition of the lateral white masses of the cerebellum, with which the nuclei of the hemispheres have also another point of resemblance, in that they are attached to the cerebral peduncles, as the first are to the cerebellar. But the latter peculiarity is less evident than the others—which are at once obvious in horizontal and transverse sections of the brain—and can only be clearly demonstrated by the manipulations necessary to unravel the intimate texture of the white substance.

In studying this texture in brains hardened by nitric acid, washed in pure water, and exposed to dry air for a day or two, we perceive that the white cerebral substance is entirely composed of fine fibrous lamellæ, diverging in every direction, corresponding by their concentric extremity to the centre of the hemisphere, and abutting, by their

peripheral extremity, on the inner face of the grey covering of the convolutions.

The fibres of the white substance of the hemispheres are connected with those of the encephalic isthmus, through the latter being prolonged into the texture of the corpus striatum, where they appear either in the form of striæ, or as an elongated nucleus, known as the *double semicircular centre of Vieussens;* they then pass to the outside of the ventricular cavity, and plunge into the *centrum ovale* of the hemisphere, where they are manifestly continued by a portion of the fibres constituting it. It has been said that these fibres, instead of thus disappearing in the hemisphere, ascend at first to the right and left on the external side of the lateral ventricle, and are afterwards inflected inwards above that cavity, to join on the median line; and in this way form the corpus callosum. I have searched for this arrangement in our domesticated animals, and particularly in the Dog, whose brain is well adapted for studying the corpus callosum, but without success. It has always appeared to me that the extremities of the transverse fibres which form this great commissure are lost in the white substance of the hemispheres, some passing above, the others below; and I believe I have also seen some of the peduncular fibres radiating in the centrum ovale becoming insinuated between the extremities of the fasciculi of the corpus callosum, to gain the superior part of the hemisphere, without being continuous in any way with these fasciculi.

Some of the nerve-tubes certainly terminate in the corpus callosum; but in this there is nothing extraordinary, as in that layer there are nuclei and some nerve-cells.

DIFFERENTIAL CHARACTERS OF THE CEREBRUM IN OTHER THAN SOLIPED ANIMALS.

The brain, in the animals now referred to, offers some differences in volume, as might be inferred from what has been said regarding its relations with the cerebellum. In all, its development posteriorly is not so considerable that it covers the latter, which always remains exposed.

Its general form varies a little. In the *Ox*, the hemispheres are proportionately larger posteriorly than in the Horse, but contract suddenly at the fissure of Sylvius, preserving their reduced dimensions in the anterior lobes; the latter are therefore more conical than in Solipeds. The cerebrum of the *Dog* is regularly ovoid, except at the extremity of the anterior lobes; there the hemispheres become much flattened from one side to the other, and form a kind of spur that enters the ethmoidal fossæ.

The *cerebral convolutions* are a little larger in the *Ox* than in the Horse, but they are also less numerous; they are still fewer in the *Pig*, and yet less in the *Carnivora;* we will see hereafter that they are absent in *Birds*. The particular features of the lower face of the hemispheres are the same in all the species; except that the *olfactory lobes* are more detached than in Solipeds; they are remarkably developed in the *Dog*.

The *ventricles* are the same in all; the floor is always formed by the corpus striatum, hippocampus, and thalami optici, the roof by the corpus callosum. In the *Ox*, the band of the hippocampus is remarkable for its width; in the *Dog*, the corpus striatum, proportionately voluminous, is of a deep grey colour on its surface.

COMPARISON OF THE CEREBRUM OF MAN WITH THAT OF ANIMALS.

The cerebrum of *Man* (Fig. 333) is distinguished by its regularly ovoid shape, and its great development, particulary behind, where it covers the cerebellum—a feature never observed in animals.

Viewed superiorly, a cerebral hemisphere is clearly divided into three lobes: an *anterior* or *frontal*; a *middle* or *sphenoidal*, corresponding to the mastoid lobule of the Horse; and a *posterior* or *occipital*, covering the cerebellum. The two first are separated by a narrow, deep, and sinuous *fissure of Sylvius*.

The *convolutions* are larger, and separated by deeper furrows, than those of the Horse, but they are not more numerous. The *olfactory lobes* arise, as in animals, from two orders of roots, but they are small and entirely hidden beneath the inferior face of the frontal lobes.

The *corpus callosum* is very developed, and, above the ventricle, forms, from before to behind, a salient angular prolongation named the *frontal cornu* and *occipital prolongation*, or *forceps major*.

There is nothing to note concerning the *fornix* and *septum lucidum*, except that there is a ventricle in the latter which communicates with the middle ventricle by a small aperture, the *vulva*.

The *lateral ventricles* offer remarkable differences. They are not prolonged into the olfactory lobes, but possess a diverticulum that enters the occipital lobe, below the forceps major. This space is more or less developed, and terminates in a point; it is named the *ancyroid* or *digital cavity*, and shows on its floor a small convolution which

Fig. 333.

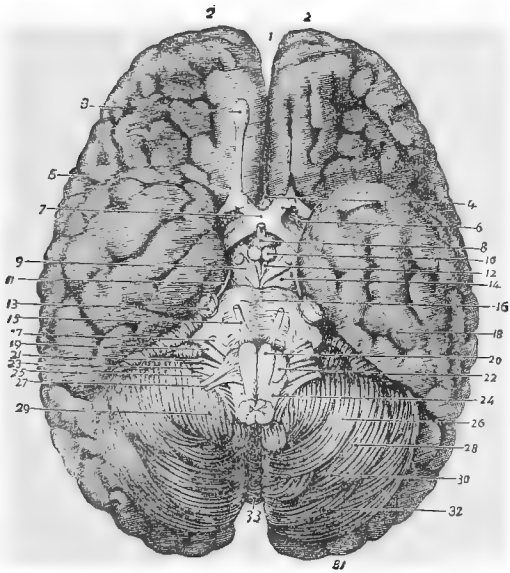

THE BASE OF THE HUMAN BRAIN.

1, Longitudinal fissure; 2, Anterior lobes of cerebrum; 3, Olfactory bulb; 4, Lamina cinerea; 5, Fissure of Sylvius; 6, Locus perforatus anticus; 7, Optic commissure; 8, Tuber cinereum; 9, Third nerve; 10, Corpus albicantium; 11, Fourth nerve; 12, Locus perforatus posticus; 13, Fifth nerve; 14, Crus cerebri; 15, Sixth nerve; 16, Pons Varolii; 17, Portio dura of seventh nerve; 18, Middle lobe of cerebrum; 19, Portio molliss of seventh nerve; 20, Anterior pyramid; 21, Glosso-pharyngeal nerve; 22, Olivary body; 23, Pneumogastric nerve; 24, Lateral tract; 25, Spinal accessory nerve; 26, Digastric lobe; 27, Hypoglossal nerve; 28, Cerebellum; 29, Amygdala; 30, Slender lobe; 32, Posterior inferior lobe.

has been designated the *ergot of Morand* (*pes hippocampi*). The diverticulum and convolution do not exist in animals. The *cornu Ammonis* is slightly bosselated on its surface; it is limited, inwardly, by a band, and below this by a grey denticulated lamina, the *gyrus fornicatus*.

The other portions of the human brain resemble those of animals; so that it is needless to allude to them.

THIRD SECTION.

The Nerves.

The *nerves* represent the peripheral portions of the nervous system, and are cords ramifying in every part of the body, having their origin in the medullary axis or its encephalic prolongation. Before commencing their special study, it is necessary to possess a summary notion of the principal distinctions of which they are susceptible, with regard to their origin, distribution and termination.

Structure.—The nerves are formed by an aggregation of the nerve-tubes already described. These are grouped in primary fasciculi, which are rectilinear or slightly undulating, and enveloped in a sheath of delicate connective tissue—the *perineurium*. These primary fasciculi are again assembled in bundles to compose secondary fasciculi, which are maintained by a layer of fibrous connective tissue thicker than the perineurium. Finally, these secondary bundles by their union constitute the nerve, around which the connective tissue becomes condensed, and found the *neurilemma*.

Vessels traverse the connective tissue separating the fasciculi from each other; they anastomose in a network whose elongated meshes are parallel with the nerve-tubes, and they are also surrounded by the *nervi nervorum*.

On the track of certain nerves is observed a greyish enlargement, or *ganglion*. This is composed of a mass of nerve-cells, which are generally bipolar, and are situated on the course of the tubes. It is not quite known whether some of these tubes are not merely placed alongside the ganglion.

Division.—Nerves are divided, with reference to their destination, into two principal groups: 1, The *cerebro-spinal* or *nerves of animal life;* 2, The *ganglionic* or *nerves of organic life*.

Cerebro-spinal Nerves.—These emanate directly from the cerebro-spinal axis, and are divided into two secondary groups: 1, The *cranial* or *encephalic nerves*, which originate in the encephalon, and make their exit by the foramina at the base of the cranium, to be distributed almost exclusively in the head; 2, The *spinal* or *rachidian nerves*, arising in the spinal cord, and passing to the muscular or tegumentary parts of the trunk and limbs, through the intervertebral foramina.

After what has been said in regard to the apparatus of innervation, we know that the fibres composing these cords are distinguished, by their point of origin and their properties, into *fibres of superior origin* or of *centripetal conductibility*, and *fibres of inferior origin* or of *centrifugal conductibility*. The first have a ganglion on their course.

The cerebro-spinal nerves are exclusively formed of the first description of fibres, and are named *sensitive nerves*, as they conduct the stimulus which brings into play the sensibility of the brain. They are distinguished as *nerves of general sensibility* and *nerves* of *special sensations* (or *sense*). The first are destined to convey all stimuli except those determined by light, sounds, or odoriferous particles; the second exclusively conduct the latter.

The nerves which are composed only of fibres of the second kind are called *motor nerves*, because it is they which carry to the muscles the spontaneous stimulus to motion originated by the will.

Those which are composed at once of motor fibres and fibres of general sensibility constitute the *mixed nerves;* these form the largest category.

Ganglionic Nerves.—These nerves, collectively representing the *great sympathetic system*, form below and on the sides of the spine, two long cords, rendered moniliform by the presence of ganglionic enlargements, and in the constitution of which nearly all the cerebro-spinal nerves concur; their ramifications, frequently ganglionic also, are destined to the viscera of the neck, the thorax, and the abdomen.

In these nerves of organic life are found the two kinds of nerve-tubes, or fibres of centripetal and centrifugal conductibility.

But these tubes appear to have only very indirect relations with the brain, for the will has no influence over the organs which receive their nervous fibres from the great sympathetic; and, besides this, in health, the excitations developed in these organs are all reflected by the spinal cord, and do not provoke in any way the special activity of the encephalon—they are not felt.

As the nerves of the great sympathetic system are principally formed of fine tubes, we ought perhaps to seek in this anatomical condition the cause of the special properties of these nerves; what tends to make this appear likely is the fact, that the cerebro-spinal nerves contain some of these tubes in their elements, and that they share, with the ganglionic ramuscules, the faculty of bringing into play the reflex power of the spinal cord. But this is only a probability, and is unsupported by any direct proof.

However this may be, it must be remarked that the special anatomical and physiological characteristics of the sympathetic nerves should not cause them to be considered as a system independent of the first, or cerebro-spinal nerves. The fibres composing both have, in fact, a common origin in the medullary axis, or rather those of the ganglionic nerves emanate from the nerves of animal life. In the considerations which follow, we will therefore omit this distinction of the nerves into two groups.

Origin of the Nerves.—We ought to distinguish in these cords their *real* or *deep origin*, and their *superficial* or *apparent origin*. The latter is represented by the point of emergence of the roots of the nerves, which are ordinarily spread in a fan shape, then united, generally after a very brief course, into a single trunk, which offers at its commencement a ganglionic enlargement, if fibres of general sensibility enter into its constitution. Their *real origin* is the point of departure of these roots in the depth of the cerebro-spinal axis. This is not well known, perhaps, of any nerve, even of those whose radicles are easily followed into the substance of the nervous centres.

Distribution of Nerves.—The nervous trunks, formed by the radicles of which we have just spoken, issue in pairs from the foramina at the base of the cranium or in the walls of the spine, to be distributed to all parts of the body by dividing into successively decreasing branches. Those among these branches which ramify in the organs of animal life, generally follow the track of the deep vessels or the subcutaneous veins, and are always found most superficial. Their ramescence is effected in a very simple manner, by the successive emission of the fasciculi composing the principal trunks, until they are completely expended. These branches pursue their course nearly always in a direct line; only some, as the ramifications of the two principal nerves of the tongue, describe very marked flexuosities, with the same protective intention as the arteries of that organ. *Anastomoses* sometimes join these branches to one another; and anastomoses, often enough complicated, unite many nerves together, and form what are called *plexuses*. But in these anastomoses, no matter how complicated they may

be, there is never any fusion of the nervous ramuscules, but simple aggregation of their fibres, which always preserve their independence, characters, and special properties. These anastomoses, then, differ essentially from those of arteries, and never permit two trunks to mutually supplement each other when the course of one is interrupted.

The nerves destined to the organs of vegetative life, and which arise from the two subspinal chains in whose formation nearly every pair of nerves concurs, comport themselves in their distribution in a slightly different manner. They are enlaced around arteries, forming on these vessels very complicated plexiform networks, and yet the fibres composing them are as absolutely independent as in the anastomoses above described.

Termination of the Nerves.—This point should be examined separately in the case of the motor and the sensitive nerves: that is, in the muscles and the integumentary membranes. The distinction, however, is not quite so absolute as this, for the muscles always receive some sensitive tubes with their motor filaments.

In entering the muscles the *motor* nerves divide their branches, still appearing as double-contoured tubes. It was at one time believed that these fibres formed loops (Valentin) in the interior of the muscle, and returned to their starting point. This opinion has become obsolete since the ultimate termination of the nerves has been studied by Rouget, Krause,

Fig. 334.

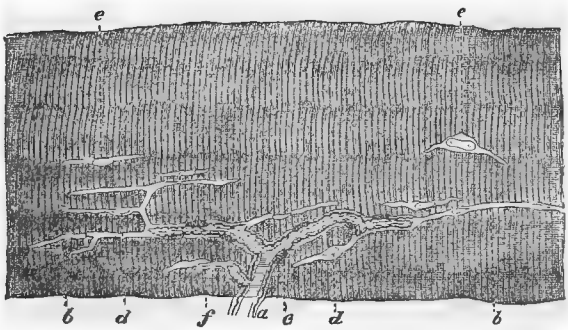

MUSCULAR FIBRES, WITH TERMINATION OF MOTOR NERVE; FROM THE GASTROCNEMIUS OF THE RANA ESCULENTA.

a, Terminal pencil of a dark-bordered nerve-fibre; *b*, Intramuscular naked axis-cylinder; *c*, Nucleus of the neurilemma; *d*, Clavate extremities of the nerve; *e*, Spaces of the muscle-nuclei; *f*, Terminal knob of nerve, with central fibres and vesicular dilatations of the nerve

Kühne. Kölliker, Engelmann, Conheim (Beale), and others. What is known of this subject is as follows:—The voluminous, double-contoured nerve-tubes which, more or less, cross the direction of the muscular fibres, soon divide and form pale tubes on whose track are disseminated the nuclei. These tubes contain an axis-cylinder and a medullary layer. They pass on to a muscular fibre in the following manner: the nucleated sheath of the nerve-tube spreads, and is confounded with the sarcolemma; the medulla suddenly stops, and the axis-cylinder expands to form a minute granular mass named the *terminal motor-plate*. Is this plate situated without or within the sarcolemma? This question is differently answered by histologists; but,

however this may be, this plate, which was discovered by Rouget, at first in reptiles, then in birds and mammals, has been studied by several micrographs, who are agreed as to its existence. There can, therefore, be no doubt that it is the ultimate termination of the motor-nerves.

The mode of termination of the *sensitive* nerves varies as they are sensorial or general sensibility nerves. It appears to be demonstrated that the tubes of the sensorial nerves have at their extremity an elongated cell, analogous to that from which they started. An idea has been given of this arrangement in describing the olfactive portion of the pituitary mucous membrane.

The other sensitive nerves have been supposed to terminate by peripheral loops, and again by free extremities passing into kind of cell elements. It is certain that these two modes exist simultaneously; recurrent sensibility, which Claude Bernard demonstrated in some cranial nerves, proves that certain nerves terminate by loops. Our own experiments have shown: 1, That this recurrent sensibility is a general phenomenon belonging to the *sensitive* nerves of the limbs, and even to all the *sensitive* ramifications of the spinal nerves; 2, That the recurrent anastomotic loops are formed at different parts along the course of the nerves, either beneath the integument or in its texture. It is, then, proved that the peripheral loops constitute a mode of termination of the sensitive nerves. But this is not the only mode of termination observed. In the papillæ of the skin, in certain regions—hand, foot, lips, tongue, glands, clitoris—the *corpuscles of Meissner*, or tactile corpuscles, are found; these are composed of condensed connective tissue, and are conical, like a pine-cone, the summit towards the periphery. By their base enters one or more nerve-tubes, that ascend toward the apex in a spiral manner. In the conjunctiva, lips, etc., are also found rounded bodies analogous in their structure to the tact corpuscles, and which are named the *corpuscles of Krause*. Lastly, on the course of the collateral nerves of the fingers and in the mesentery of the Cat, are the *Pacinian corpuscles:* small globular or ovoid bodies formed of several concentric layers of connective tissue, and with a central canal into which penetrates and terminates, by one or more enlargements, a filament from the nerve-trunk (reduced to the axis-cylinder only).[1]

CHAPTER I.

THE CRANIAL OR ENCEPHALIC NERVES.

THE *cranial nerves* leave the encephalon in pairs, regularly disposed to the right and left, and designated by the numerical epithets of first, second, etc., counting from before backwards.

Willis, taking for a basis the number of cranial openings through which the nerves passed, divided them into nine pairs, with which he described the first spinal pair, making it the tenth in the series of encephalic nerves. This division being faulty in some respects, it was sought to perfect it. Haller commenced by removing the first spinal or suboccipital pair of nerves to their proper region; then followed Sœmmering and Vicq-d'Azyr,

[1] *Arloing and Tripier.* 'Recherches sur la Sensibilité des Téguments et des Nerfs de la Main.' (Archives de Physiologie, 1869.)

who doubled the seventh pair of Willis, and reduced his eighth into three distinct pairs, according to considerations derived from the destination and uses of these nerves. The number of pairs of cranial nerves, their order of succession, and their nomenclature was then established in the following manner:

1st pair or olfactory nerves	corresponding to the	1st pair of Willis.
2nd pair or optic nerves		2nd pair —
3rd pair or common motores oculorum nerves		3rd pair —
4th pair or pathetici nerves		4th pair —
5th pair or trigeminal nerves		5th pair —
6th pair or abducentes nerves		6th pair —
7th pair or facial nerves		7th pair —
8th pair or auditory nerves		
9th pair or glosso-pharyngeal nerves		8th pair —
10th pair or pneumogastric nerves		
11th pair or accessory or spinal nerves		
12th pair or great hypo-glossal nerves		9th pair —

In the following table, these nerves are classed according to their properties:

1. Nerves of special sense	olfactory nerves	or 1st pair.
	optic nerves	2nd —
	auditory nerves	8th —
2. Mixed nerves with double roots	trigeminal nerves	5th —
	glosso-pharyngeal nerves	9th —
	pneumogastric nerves	10th —
3. Motor nerves with single roots	common motores oculorum nerves	3rd —
	pathetici nerves	4th —
	abducentes nerves	6th —
	facial nerves	7th —
	accessory or spinal nerves	11th —
	great hypo-glossal nerves	12th —

(Sir Charles Bell considered the fourth, seventh, and eighth nerves as forming a separate system, and to be allied in the functions of expression and respiration. In consonance with this view, he termed them *respiratory nerves*, and named that portion of the medulla oblongata from which they arise the *respiratory tract.*)

One of the characteristics of the cranial nerves being their diversity, it is scarcely possible to study them as a whole, and it is only in their *origin* that they resemble each other in some points. We therefore confine ourselves to those general considerations which alone touch this part of their description.

Do the cranial nerves proceed from the three principal apparatus composing the encephalon, or are they furnished by two, or even one of these? This is the question that should first be discussed. If it is evident to everyone that the isthmus gives rise to the majority of the encephalic nerves, and that the cerebellum has nothing whatever to do with their emission, it is not agreed among anatomists as to the part the brain-proper takes in this emission. Two pairs of cranial nerves are indeed considered by several authors as emanating from the latter organ, while others regard them as derived from the isthmus. According to the first, only ten encephalic pairs of nerves belong to this prolongation of the spinal cord, the other two—the olfactory and optic nerves—proceed from the brain; while the second aver that all the cranial nerves without exception arise from the medulla oblongata. Let us endeavour to discover the truth.

It is certain that this difference of opinion on a point apparently easy of

solution, has its source in a misunderstanding, and is really not founded on facts, which are the same for everyone, their appreciation only varying. Nothing is more easy to prove. Look, in the first instance, at the optic nerve. This, according to some, proceeds from the corpora quadrigemina and thalami optici; it therefore arises from the brain. No doubt, if these two parts of the encephalon be considered as a portion of the hemispheres; but this is far from proved, and in an anatomical and physiological point of view it is not so. As the corpora quadrigemina and thalami optici form part of the isthmus, it is natural to look upon it as the source from which the second pair of nerves arise. With regard to the first pair, their fibres are also connected with those of the isthmus, across the corpus striatum, as will be proved hereafter. But we are far from denying their connections with the hemispheres (*see the description of the first pair*), and which are very intimate; though this proves nothing against our opinion. Therefore it is, that, in recognising in the disposition of the roots of the olfactory nerve conditions altogether special, we admit that the isthmus of the encephalon is the common point of departure for all the cranial nerves—an important and capital fact, and which constitutes, for the great category of encephalic nerves, a true family character.

Among the other points relative to the origin of these pairs of nerves, are the following: All the encephalic nerves appear to be connected at their origin with the fasciculi of the isthmus, whose properties they share. All are equally connected with a centre of grey substance placed in the texture of the isthmus, and named by Stilling the *nucleus of the nerves*. The majority originate by converging filaments, the anterior of which come from the brain, and the posterior from the side of the spinal cord.

Preparation of the cranial nerves.—Four preparations are necessary to study the cranial nerves:

1. An encephalon extracted after opening the cranium by its base, and hardened by prolonged immersion in alcohol or very diluted acetic acid. This piece permits the origin of the nerves to be studied (Fig. 322).

2. The superficial nerves of the head; these are the auricular nerves, and the divisions of the subzygomatic plexus, with the suborbital and mental branches, as well as the superficial ramuscules of the three nerves of the ophthalmic branch of the fifth pair (Fig. 110).

3. A piece disposed as in figure 336. for the study of the maxillary nerves. To prepare it, the greater part of the masseter muscle should be removed in dissecting the masseteric nerve; the globe of the eye must be extirpated, the orbital and zygomatic processes excised, the two maxillary sinuses opened, and the branch of the inferior maxillary bone chiselled off as in the figure. Lastly, the anastomosis of the facial with the subzygomatic nerve is dissected by cutting away the parotid gland.

4. The deep nerves, including those of the globe of the eye; this preparation should be made by following exactly the instructions given for dissecting the arteries of the head. Figure 335 will serve as a guide for details.

The pneumogastric and spinal nerves, which are not included in these considerations, should be prepared and studied at the same time as the great sympathetic. When treating of the latter, we will refer to them.

1. *First Pair, or Olfactory Nerves.* (Figs. 327, 329.)

The first cranial pair is constituted by the olfactory lobes, whose anterior extremities give off a great number of nervous filaments, which pass through the cribriform foramina to ramify in that part of the pituitary membrane lining the bottom of the nasal fossæ.

Each olfactory lobe is connected with the encephalon by two roots, an external and an internal, both composed of white substance (Fig. 322).

The external commences by a grey-coloured convolution which borders, externally, the mastoid lobule or inferior lobe of the hemisphere. The internal, followed from before backwards, turns round in the interlobular fissure, in front of the chiasma of the optic nerves, to mix with the cerebral convolutions. These two roots circumscribe a triangular space occupied by the extra-ventricular nucleus of the corpus striatum, which they embrace. In brains which have been macerated for a long time in alcohol, it is easy to see that the fibres of these roots are continuous, in great part, with those of the corpus striatum, and commence with the fasciculi of the isthmus, which radiate and spread across the grey matter of that body.

After the union of its two roots, the olfactory lobe is constituted by a wide white band that passes forward on the inferior face of the hemisphere, and soon terminates in a very elongated oval dilatation lodged in the ethmoidal fossa. This bulb is formed by grey substance on its inferior face and white substance on the superior. It is said to be a flattened ganglion applied to a band of white substance, which at first represents in itself the olfactory lobe.

We have already seen that this lobe is hollow internally, and that it communicates with the lateral ventricles of the brain. This peculiarity, added to the special features of its external physiognomy, might, it appears to us, give rise to doubts as to the real nature of the lobes in question. It is evident that these are not nerves, but rather dependencies of the encephalon; and it is only conformable to custom that we describe them here as the first pair of encephalic nerves.

The real olfactory nerves are the filaments which arise from the inferior face of the ethmoidal bulb or ganglion, and which traverse the cribriform lamella to gain the mucous membrane of the nose. Their number corresponds with the ethmoidal foramina. At first very soft, delicate, and easily torn, they are enveloped on their passage through these apertures by a very strong neurilemma, which gives them great solidity. Some, in ramifying, descend on the septum nasi; others—and these are the most numerous—divide on the ethmoidal cells, where they form fine and more or less plexuous pencils, mixed up with the no less interesting divisions of the ethmoidal branch of the ophthalmic artery. Their terminal extremities do not descend below the upper third of the nasal fossæ, but remain confined to the bottom of these cavities.

These are the special nerves of smell. They receive the impression of odours and transmit them to the encephalon; and this function, which has been accorded and refused them time after time, has only been decided within the last thirty years.

2. *Second Pair, or Optic Nerves.* (Fig. 329.)

The nerves of vision present for consideration in their interesting study, their *origin*, *course*, *termination*, and *properties*.

There has been much dispute, and there will probably be much more, with regard to the origin of the second pair. But without confining ourselves to an appreciation of the opinions which have pervaded science on this matter, we will describe what we have observed in the domesticated animals.

When the encephalic isthmus is isolated from the brain (Fig. 324, 12) and examined laterally, we recognise on its anterior limit the white band that constitutes the optic nerve. Studied at its origin, this band is continued, in the most evident manner, with the external side of the thalamus

opticus, where it forms the two enlargements known as the *corpora geniculata*. This thalamus ought, therefore, to be regarded as the point of departure of the nerve that bears its name. But as the external corpus geniculatum is in contact with the natis, and as the internal is united to the testis by a band of white fibres, it is almost certain, according to several authorities, that the corpora quadrigemina concur in furnishing the constituent fibres of the optic nerves.

At first wide and thin, the optic band (*tractus opticus*) is rolled round the cerebral peduncle from above to below and behind to before, and gradually narrows. Arrived at the inferior surface of the encephalon, it is changed into a funicular cord, which unites with that of the opposite side to form the *commissure* or *chiasma of the optic nerves;* this is only a temporary fusion, as beyond it the two nerves reappear, and pass into the optic foramen, to reach the interior of the ocular sheath and the bottom of the globe of the eye.

We will enter into some details on the relations of the optic nerves in the different points of the *course* we have indicated.

In their flat portion, or origin, they are comprised between the cerebral peduncles and the hemispheres. From the point where they become free, at the inferior face of the encephalon, to the chiasma, they are covered by the pia mater, and adhere by their deep face to the superior extremity of the peduncles.

The *chiasma* is lodged in the optic fossa, and receives on its deep face the insertion of the small grey lamina which bounds the third ventricle in front; for which reason this is generally described as the *grey root* of the optic nerves. But of all the proper connections of the chiasma, the most important are certainly those which each nerve maintains with its congener at their junction. What becomes of the fibres of each nerve in this anastomosis? Do they cross one another to reach the opposite eye; or do they merely lie together, and afterwards separate, in order to go to the eye on their own side? Anatomy demonstrates that the fibres of the chiasma do not exclusively affect either of these arrangements; for in studying them in a specimen that has been macerated for some days, it is found that the majority cross each other in a very evident manner, but that a part regain the nerve corresponding to the side from which they came. It is therefore seen that the nerves of the second pair are composed of one kind of fibres on this side of the chiasma, while beyond it they show two sorts—the fibres from the right and left sides. The majority, we have said, cross each other; and the proof of this is afforded in certain facts observed in pathological anatomy, which are of sufficient interest to be mentioned here. In the cases so frequently occurring in the Horse, where an eye is lost from the ravages of specific ophthalmia (fluxion périodique), the consecutive atrophy of the optic nerve nearly always stops at the chiasma, though it sometimes happens that it gets beyond this; and it is observed that it is usually the nerve opposite to the diseased eye which suffers the most. Otherwise, the arrangement just described is only a degree less advanced than that remarked in certain species—in the osseous fishes for instance—in which the optic nerves entirely cross each other without confounding or mixing their fibres.

Beyond their commissure, the nerves of the second pair are in relation with the walls of the optic foramina, then with the posterior rectus muscle (*retractor oculi*), which envelops each nerve as in a sheath. In the orbits they are also related to some other nerves and vessels.

With regard to its *ermination*, the optic nerve enters the globe of the eye by piercing the sclerotic and choroid coats, towards the most declivitous part of its posterior surface, and in the form of a membrane which is described in the apparatus of vision as the *retina*. Before traversing the bottom of the eye, this nerve always becomes markedly constricted.

The study of the *structure* of the optic nerve reveals some peculiar facts which it is well to know, though they are more curious than interesting. The upper part is entirely destitute of envelope, while the inferior—that in front of the chiasma—has a double neurilemma. The external layer of this is only a dependency of the dura mater: a kind of fibrous sheath attached at one end to the margin of the optic foramen, and at the other to the sclerotica. The internal, which is analogous to the neurilemma of the other nerves, emanates from the pia mater, and presents a multitude of septa (forming the *lamina cribrosa*), which keep the fibres of this nerve apart from each other. To make this organisation manifest, the latter should be steeped in an alkaline solution for some days, and then washed in a stream of water to remove the softened nervous matter; the nerve is to be afterwards tied at one of its extremities, inflated, tied at the opposite end, and dried. By means of some sections all the canals that lodge the fasciculi of nervous tubules, and which are formed by the internal neurilemma, are then shown.

Fig. 335.

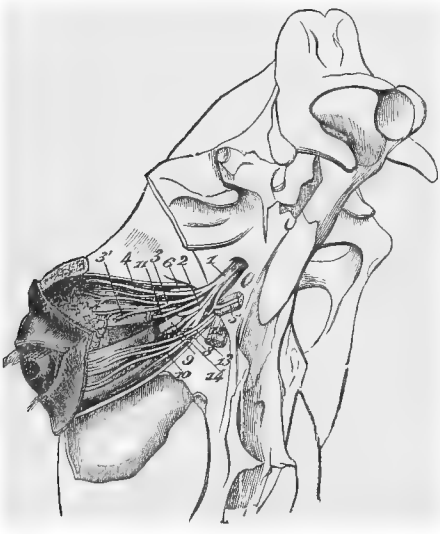

NERVES OF THE EYE.

1, Ophthalmic branch of the fifth pair; 2, Palpebro-nasal branch; 3, Lachrymal nerve; 3′, Temporal branch of that nerve, 4, Frontal nerve, 5, External oculo-motor nerve, 6, Trochlear nerve, 8, 9, 10, 11, Branches of the common oculo-moter nerve; 12, Superior maxillary nerve; 13, Its orbital branches.

Concerning the *properties* of the optic nerve, we will say nothing; though they are analogous to those of the other nerves of special sense; it is destined to transmit to the encephalon the impressions furnished by the sense of sight, and mechanical irritation of it does not cause pain.

3. *Third Pair, or Common Oculo-motor Nerves.* (Figs. 326, 335.)

The nerves of the third pair emanate from the cerebral peduncles, near the interpeduncular fissure, and at an almost equal distance between the corpus albicans and the pons Varolii. Their roots, seven or eight in each, penetrate the texture of these peduncles, pass backwards, and may be traced to their nucleus, which Stilling has placed above the anterior border of the pons Varolii, and which is united to that of the opposite side by fibres intercrossing on the median line.

From the union of these roots results a flattened trunk, which is at first carried outward, and is almost immediately inflected forward to enter, along

with the sixth pair and the ophthalmic branch of the trigeminal nerve, into the smallest of the great suprasphenoidal foramina. The common oculo-motor nerve afterwards arrives, by the orbital hiatus, at the bottom of the ocular sheath, where it separates into several branches destined to the following muscles of the eye: the elevator of the upper eyelid, superior rectus, internal rectus, inferior rectus, posterior rectus—except its internal fasciculus—and the small oblique. The branch to the latter is remarkable for its great length; it reaches its destination in passing to the outside of, and then below the inferior rectus. The motor roots of the ophthalmic ganglion furnished by this nerve, are given off from the same point as the branch for the small oblique muscle.

The nerves of the third pair are purely motor, as is shown by their connections with the inferior plane of the cerebral peduncles, and their exclusive distribution to contractile organs. They incite all the muscles lodged in the ocular sheath, except the external rectus, the great oblique, and posterior rectus.

(It also sends a motor filament to the lenticular ganglion, supplies the circular muscular fibres of the iris and ciliary muscle, and presides over contraction of the pupil.)

4. *Fourth Pair, or Pathetici.* (Fig. 335, 6.)

The *pathetic* or *internal oculo-motor* (or *trochlearis*) nerve is the smallest of all the cranial nerves. Its description is extremely simple. It arises from the band of Reil, immediately behind the corpora quadrigemina, by two short roots, which it has been impossible for me to follow very deeply in the substance of the isthmus.

It is directed outwards, downwards, and forwards, to disengage itself from the deep position it at first occupies, and lies beside the superior branch of the trigemini, accompanying it to the suprasphenoidal foramina, the smallest of which it enters. This opening is exclusively intended for it, and carries it to the bottom of the ocular sheath, when it gains the deep face of the great oblique muscle, in which it ramifies, supplying that organ with the stimulant principle of muscular contractility.

The physiological study of this nerve gives rise to some very interesting remarks, which we will sum up here in a few words. The two oblique muscles of the eye pivot the ocular globe in the orbit, without causing the slightest deviation either upwards, downwards, or otherwise, of the pupillary opening. But this rotatory movement is altogether involuntary, and is only accomplished in certain determinate conditions. "Guerin, Szokalski, Hueck, and Hélie have remarked, that when the head is alternately inclined to the right or left, while the vision is fixed on any object, the ocular globes describe around their antero-posterior axis an inverse rotatory movement that has the effect of preserving a constant relationship between the object from which the luminous rays proceed and the two retinæ. In this rotatory motion the great oblique muscle of one side has for its congener the small oblique of the other side: thus, when the head is inclined on the right shoulder, the right eye revolves inwards and downwards on its axis, under the influence of the superior oblique muscle, while the left eye turns on itself outwards and downwards, through the action of the inferior oblique; when the head is inclined on the left shoulder, an inverse movement takes place in the two eyes. This simultaneous rotation of the ocular globes around their antero-posterior diameter, when the head is inclined to

one side or the other, is necessary for the unity of perception of visual objects; if one of the two eyes remained fixed while the other turned on its axis, we would perceive two images, a superior corresponding to the healthy eye, and an inferior to the diseased one. These two images are visible when the head is vertical, and particularly when it is inclined to the affected side, they are confounded into a single one when the head is carried to the healthy side."[1]

The involuntary action of the oblique muscles of the eye in this rotatory movement strongly attracts atttention to the nerves which these muscles receive, and stimulates a desire to learn the particular conditions which permit them to act as excito-motors independently of the will; although they as well as the muscles to which they are destined, belong to those of animal life. In the present state of science, nothing positive can be affirmed on so delicate a subject. There are, nevertheless, two interesting remarks to make the pathetic nerve is *exclusively* destined to the superior oblique muscle, and the long branch sent by the common oculo-motor nerve to the inferior oblique does not give any filament to the neighbouring parts. This branch is, therefore, also the *exclusive* nerve of the inferior oblique, and may be considered as a second *pathetic.*

(Sir Charles Bell designated the fourth nerve the "respiratory nerve of the eye," and asserted that it was large in all animals capable of much expression.)

5. *Fifth Pair, or Trigeminii.* (Figs. 110, 322, 335, 336, 337, 338, 342.)

The nerve we are about to describe has also been named by Chaussier the *trifacial nerve.* It is distinguished among all the cranial nerves by its enormous volume, the multiplicity of its branches, the variety of its uses, and its connections with the great sympathetic system. It therefore requires to be described as completely as possible; and in this description we will include the study of the cephalic ganglia of the great sympathetic system, which ought to be regarded as annexes of the fifth pair.

Origin.—The trigeminus belongs to the category of mixed nerves, as it possesses two roots—one sensitive, the other motor.

Sensitive Root (Figs. 337, 338, *i*).—This is the largest root. It emanates from the outside of the pons Varolii, near the middle cerebellar peduncle, and is directed forward and downward to gain the anterior portion of the foramen lacerum, where it terminates in a very great semilunar enlargement constituting the *Gasserian ganglion.* Flattened from above to below, and wider in front than behind, this root on the outer side is about 6-10ths of an inch in length, but the inner side is double that measurement because of the oblique position of the ganglion which continues it.

If it be traced into the substance of the pons, it will be found that the fibres of the latter separate for its passage from the deep plane it at first occupies. The following is the manner in which it comports itself in this plane:—This root is separated into two orders of fibres, posterior and anterior. The first pass beneath the arciform fasciculi of the pons Varolii, to be continued with the restiform body, and consequently with the posterior columns of the spinal cord; the second separate from each other, and soon become confounded with the cells amassed in the interior of the isthmus, at the anterior cerebellar peduncles, and above the intermediate fasciculus of the medulla oblongata. The fibres of the trigeminus, or the cells

[1] *Sappey.* 'Anatomie Descriptive.'

which receive these fibres, are in communication with several cranial nerves, particularly the pneumogastric, glosso-pharyngeal, facial, and auditory.

Semilunar or Gasserian ganglion.—This ganglion, which receives the sensitive root of the trigeminus, is crescent shaped, its concavity being turned backwards and inwards. It may be said to be imbedded in the fibro-cartilaginous substance which in part closes the occipito-spheno-temporal hiatus, and divides it into several particular foramina. Its superior face is covered by the dura mater, and sends a number of filaments to that membrane.

The Gasserian ganglion is not continued by a single trunk, but immediately gives rise to two thick branches, one of which leaves the cranium by the foramen ovale—an opening formed by the above-named hiatus; while the other is lodged in the external fissure in the intercranial face of the sphenoid bone, and passing along it as far as the entrance to the supra-sphenoidal foramina, bifurcates.

Hence it results that the trigeminus is divided, even at its origin, into three branches: two superior—the *ophthalmic branch of Willis*, and the *superior maxillary nerve*, commencing by the same trunk; and an inferior, which constitutes the *inferior maxillary nerve.*

Motor or small root (Figs. 337, 338).—This is a flattened band which emerges from the pons Varolii, at the inner side of the principal root. Its fibres may be easily followed to the interior of the pons Varolii, and in their direction they comport themselves like those of the large root, by becoming confounded with the substance of the antero-lateral fasciculus of the medulla oblongata. Leaving the pons, this root passes forwards on the inferior face of the Gasserian ganglion, which it crosses in a diagonal manner outwards, and beyond which it intimately unites with the fibres of the inferior maxillary nerve. The superior maxillary nerve and the ophthalmic branch do not receive any fibres from it. In the fifth pair, then, it is only the inferior maxillary nerves which are at the same time sensitive and motor, and are real mixed nerves.

A. Ophthalmic Branch (Fig. 335, 1).—This is the smallest of the three divisions furnished by the Gasserian ganglion, and proceeds by a trunk common to it and the maxillary nerve, which will be described hereafter. This branch enters the smallest of the large suprasphenoidal foramina, along with the common and external oculo-motor nerves, and in the interior of this bony canal divides into three ramuscules, which reach the bottom of the ocular sheath by the orbital hiatus.

These ramuscules are:

1. The *frontal* or *supra-orbital* (*supratrochlear*) *nerve.*
2. The *lachrymal nerve.*
3. The *nasal* or *palpebro-nasal nerve.*

1. Frontal Nerve (Fig. 335, 4).—This is a flat, voluminous branch placed on the inner wall of the ocular sheath, and proceeding nearly parallel with the great oblique muscle of the eye to the supra-orbital foramen, into which it passes along with the artery of the same name. Undivided before its entrance into this orifice, immediately after its exit from it, it separates into several ramuscules, which meet the anterior auricular nerve, and are expended in the skin of the forehead and upper eyelid.

2. Lachrymal Nerve (Fig. 335, 3).—This is composed of several filaments, which ascend between the ocular sheath and the elevator muscles of the eyelid and superior rectus, to enter the lachrymal gland. One of

these (Fig. 335, 3′) traverses the ocular sheath behind the orbital process, and places itself, from before to behind, on the external surface of the zygomatic process, where it divides into a number of ramuscules, some of which mix with those of the anterior auricular nerve to form the plexus of that name, while the others pass directly into the anterior muscles and integuments of the ear.

Palpebro-nasal Nerve (Fig. 335, 2).—This describes a curve, like the ophthalmic artery, and passes with that vessel into the cranium by the orbital foramen. After coursing through the ethmoidal fissure that lodges the artery, it traverses the cribriform plate, and divides into two filaments—an internal and external, which ramify in the pituitary membrane on both sides of the nasal fossa. Before entering the orbital foramen, this nerve gives off a long branch (*infratrochlear*) that glides over the floor of the orbit to reach the nasal angle of the eye, where it is distributed to the lachrymal apparatus lodged there, as well as to the lower eyelid; it also detaches a long filament to the membrana nictitans and the sensitive roots of the ophthalmic ganglion, which will be noticed hereafter.

B. Superior Maxillary Nerve (Fig. 336, 15).—This nerve is the real continuation of the superior trunk given off by the Gasserian ganglion, where we will begin to follow it to its termination, examining briefly the ophthalmic branch already described as a collateral division of this trunk.

Remarkable for its volume, and its prismatic and funicular shape, the superior maxillary nerve proceeds from the inner and upper section of the semilunar ganglion, and at first occupies the fissure on the internal face of the sphenoid bone, without the cavernous sinus, and is covered at this point by the dura mater. After sending the ophthalmic branch into the smallest of the great suprasphenoidal conduits—the *great sphenoidal fissure*, it enters the most spacious of these openings—the *foramen rotundum*, arrives in the orbital hiatus beneath the sheath of the eye, and, with the internal maxillary artery, passes along the space filled with fat which separates that hiatus from the origin of the supramaxillo-dental (infra-orbital) canal, which it follows to its external orifice on the face. There it terminates in a number of branches named the *infra-orbital ramuscules* (or *pes anserinus*, from their resemblance to the claws of a goose's foot).

In its course, this nerve gives off a large number of collateral divisions, among which may be more particularly distinguished:

1. An *orbital branch.*
2. The *great* or anterior *palatine nerve.*
3. The *staphylin* or *posterior palatine nerve.*
4. The *nasal* or *spheno-palatine nerve.*
5. The *dental nerves.*

In addition to which are described:

6. The *infra-orbital*, or *terminal branches* of the superior maxillary nerve.

1. Orbital Branch (Fig. 335, 13).—This ramuscule arises in the interior of the suprasphenoidal canal, and enters the ocular sheath with the divisions of the ophthalmic branch. It almost immediately breaks up into two or three very slender filaments, which ascend to the temporal angle of the eye, passing between the fibrous lining of the orbit and the outer surface of the motor muscles of the eye, and are distributed to the eyelids and neighbouring integuments.

2. Great or Anterior Palatine Nerve (Fig. 148, 3).—It arises

from the superior maxillary nerve at the orbital hiatus, from a trunk common to it and the nasal and staphylin branches; it passes into the palatine canal with the palato-labial artery, which it follows to the foramen incisivum, where it stops.

During its course in the palatine canal, this nerve throws off two or three small filaments, which escape by particular foramina to the anterior part of the soft palate—*median palatine nerve.* Frequently they arise from a common trunk before the great palatine nerve enters its canal, and pass to their destination by particular openings. For the remainder of its extent on the roof of the palate, this nerve forms, around the artery it accompanies, a plexiform network similar to that of the ganglionic nerves; the filaments escaping laterally from it are sent to the soft parts of the palate, as well as to the gums.

3. Staphylin or Posterior Palatine Nerve (Fig. 148, 8).—The filaments composing this nerve are very easily separated, and frequently anastomose with those of the preceding nerve. They accompany the palatine artery in the canal of that name, bend in front of the pterygoid process to penetrate the soft palate between the glandular layer and the tunica albuginea. They then become inflected backwards, and ramify either in the mucous and glandular tissues of the velum pendulum, or the palato-pharyngeal and circumflexus-palati muscles. This destination, therefore, indicates in this nerve the presence of motor fibres; we will see hereafter whence they come.

4. Nasal or Spheno-palatine Nerve.—Springing from the same trunk as the two preceding nerves, thicker than the staphylin, and nearly of the same volume as the anterior palatine, the nasal nerve passes with its artery into the nasal or spheno-palatine foramen, to penetrate the cavity of the nose, where it separates into two branches—external and internal, which are distributed to the pituitary membrane.

5. Dental Branches.—These are destined to the roots of the upper teeth, and proceed from the superior maxillary nerve during its intermaxillary course; some even arise before the entrance of that nerve into the bony conduit, which it passes through to reach the face. These latter, analogous to the *posterior dental nerve* of Man, enter the canal with the parent branch, and throw their divisions into the roots of the last molar tooth, and sometimes also into the second last. One portion of them plunges directly into the maxillary protuberance, to be expended in the mucous membrane lining that protuberance, after furnishing some filaments to the periosteum.

Among the dental branches given off from the maxillary nerve during its interosseous course, some pass to the molars, and others to the canine and incisor teeth. The first, or *middle dental nerves,* separate in groups from the maxillary trunk on its passage above the roots of the grinding-teeth; they penetrate these roots after a brief forward course, and give some thin filaments to the membrane lining the maxillary sinuses.

The second are only at first a single branch—the *anterior dental nerve,* which rises from the maxillary trunk shortly before it leaves its bony canal. After a somewhat long track in the substance of the maxillary bones, this branch becomes expended in furnishing the ramuscules for the canine tooth and the incisors; it is always accompanied by a very slender arterial twig.

6. Infra-orbital or Terminal Branches of the Superior Maxillary Nerve.—These ramuscules spread on the side of the face in a magni-

ficent expansion, which may be looked upon as one of the richest nervous apparatus in the animal economy. Covered at its emergence from the infra-orbital foramen by the supermaxillo-labialis muscle, this fasciculus descends beneath the supernasalis-labialis and pyramidal muscle of the nose (supermaxillo-nasalis magnus) towards the nostrils and upper lip, which receive the terminal extremities of its constituent branches in the substance of their muscular and tegumentary tissues; these branches are slightly divergent and flexuous, and for the most part anastomose with a large motor trunk furnished by the facial nerve (Figs. 336, 15′).

C. Inferior Maxillary Nerve (Figs. 336, 11; 110, 12).—At its exit from

Fig. 336.

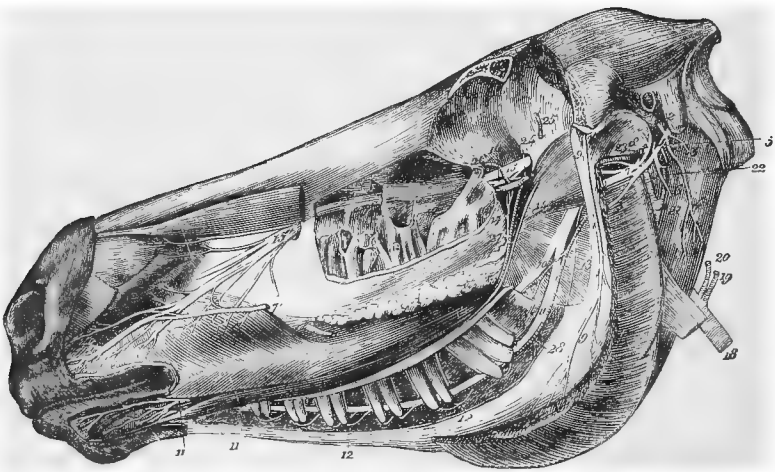

GENERAL VIEW OF THE SUPERIOR AND INFERIOR MAXILLARY NERVES.

The eye has been excised, after sawing through and removing the orbital and zygomatic processes. The maxillary sinuses have been exposed by means of a gouge or chisel, the masseter muscle removed, and the inferior maxilla opened to show the nerve in its interosseous course.

1, *Facial nerve;* 2, Origin of the posterior auricular nerve; 3, Filament distributed to the stylo-hyoid muscle; 4, Digastric branch; 5, Trunk of the anterior auricular nerve; 6, Origin of the cervical filament; 7, Plexus formed by the union of the facial and superficial temporal nerve; 7′, Branch of that plexus united to the infra-orbital nerves, 15′; 11, *Inferior maxillary nerve;* 8, Superficial temporal nerve; 9, Masseteric nerve; 10, Gustatory nerve; 12, 12, Dental branches; 13, Mylo-hyoid nerve; 14, Buccal nerve; 15, *Superior maxillary nerve;* 16, Spheno-palatine ganglion; 17, Staphylin (or palatine) nerve; 18, *Common carotid artery;* 19, Trunk of the occipital; 20, Trunk of the internal carotid; 21, External carotid; 22, Trunk of the posterior auricular artery embraced by a loop of the facial; 23, Trunk of the superficial temporal; 24, Internal maxillary artery; 25, Trunk of the deep anterior temporal artery; 26, Orbital branch of the superior dental; 27, Buccal artery; 28, Inferior dental artery.

the cranium, this branch is situated immediately within the temporo-maxillary articulation, and from thence is directed forward and downward, passing at first between the two pterygoid muscles, then between the inner and deep face of the maxilla, arriving at the maxillo-dental foramen, through which it passes and runs along the whole course of the canal, escaping at last by the mental foramen to form an expansion of terminal branches

similar to those of the superior maxillary nerve, and named the *mental nerves.*

For the first third of its extent, the inferior maxillary nerve is a flattened band; but beyond this it becomes thicker, and acquires a funicular shape.

At its origin it gives rise to four branches:

1. The *masseteric nerve.*
2. The *buccal nerve.*
3. The *nerve of the internal pterygoid muscle.*
4. The *superficial temporal or subzygomatic nerve.*

After its emergence from between the two pterygoid muscles, it furnishes:

5. The *gustatory nerve.*
6. The *mylo-hyoid nerve.*

In its intermaxillary course, it detaches:

7. The *dental branches.*

Also a triple series of collateral nerves which we will study before describing the terminal branches; these are:

8. The *mental nerves.*

The trunk of the inferior division of the fifth pair represents a mixed nerve, because it is formed of sensitive and motor fibres. Is it the same for each of the branches just enumerated; that is, do they all contain fibres of the two orders? This is a question on which the dissection of the two roots has taught us very little, for their fibres soon become confounded so intimately that it has always been found impossible to follow them separately into each nerve. But the study of the distribution of these branches, corroborated by physiological experiments, has greatly enlightened us in this inquiry. We see among them nerves destined to the muscles, and others to glandular or integumental structures; the first are therefore chiefly composed of motor fibres, like all other muscular nerves; and the second exclusively contain sensitive fibres, or at least are deprived of voluntary motor fibres. In describing each branch in particular we will notice their special properties.

1. Masseteric Nerve (Figs. 336, 9; 342, 2).—It is detached from the principal trunk, in front, though close to, the base of the cranium, bends round the anterior face of the temporo-maxillary articulation, and passes through the sigmoid notch of the inferior maxilla to descend into the texture of the masseter muscle and there ramify.

At its origin, this nerve furnishes two filaments which often proceed from one very short trunk, and ascend into and expend themselves in the temporal muscle; this trunk is then the *deep posterior temporal nerve.*

Before crossing the corono-condyloid notch, it detaches to this same temporal muscle a small branch which represents the *deep middle temporal nerve.*

The destination of all these branches sufficiently proves that they are motor.

2. Buccal Nerve (Figs. 336, 14; 342, 4).—This nerve, which is twice the size of the preceding, arises from the same point, though slightly below it. It is directed forwards, traverses the external pterygoid muscle, and reaches the posterior extremity of the superior great molar gland; leaving which, it is placed beneath the buccal mucous membrane, and descends to the commissure of the lips, along the inferior molar gland and the inferior border of the alveolo-labialis muscle.

It gives some very fine filaments to the external pterygoid, in its passage across that muscle. Beyond this, it furnishes a very slender ramuscule to the orbital portion of the temporal muscle—the analogue of the *anterior deep temporal* of Man.

On the superior molar gland, it emits a fasciculus of branches to this organ and the alveolo-labialis muscle. In its submucous track it throws off, at certain distances, ramuscules of various sizes which go to the inferior molar gland and the buccal membrane; while its terminal filaments are expended in the lining membrane and glands of the lips, near the commissure.

The majority of the filaments given off by this nerve to the external pterygoid and temporal muscles are doubtless motor, but the other ramuscules are sensitive; even those distributed to the alveolo-labialis muscle are no exception, for its submasseteric portion is supplied by the facial, as well as the superficial or anterior part.

3. Internal Pterygoid Nerve.—It forms, with the preceding nerves, a single fasciculus, which leaves the anterior part of the inferior maxillary nerve. After crossing, outwardly, the internal maxillary artery, it descends between the nervous trunk from which it emanated, and the external layer of the tensor palati muscle, to go to the inner side of, and become expended in, the internal pterygoid muscle.

This nerve is the smallest branch of the inferior maxillary trunk, after the mylo-hyoid, and excites the contraction of the muscle receiving it.

4. Superficial Temporal or Subzygomatic Nerve (Figs. 336, 8; 342, 3). —This arises from the inferior maxillary nerve, at the opposite side of the fasciculus formed by the three preceding branches, or posteriorly. Placed at first at the inner side of the temporo-maxillary articulation, and between it and the guttural pouch, it is afterwards directed downwards and outwards, passes between the parotid gland and the posterior border of the inferior maxilla, and below the condyle; it then bends round the neck of that bony eminence to arrive beneath, and to the outside of, the precited articulation, where it terminates by anastomosing with the facial nerve.

In its course it sends off numerous fine filaments to the guttural pouch, the parotid gland, and the integuments of the temporal region. Among the latter, it is necessary to notice more particularly those which accompany the superficial temporal artery.

The superficial temporal nerve appears to be exclusively sensitive. Section of it, before it anastomoses with the facial nerve, does not really prevent contraction of the muscles which receive the divisions of the plexus formed by this anastomosis.

5. Gustatory Nerve[1] (Figs. 111, 17; 336, 10; 342, 5).—The gustatory nerve, the principal branch of the inferior maxillary trunk, which it almost equals in volume, is detached at an acute angle from the anterior border of that nerve shortly after its exit from the pterygoid muscles. To accomplish its course, which it effects in describing a slight curve whose concavity is antero-posterior, it is directed forwards and downwards, passing between the internal pterygoid muscle and the branch of the inferior maxillary bone, and gaining the base of the tongue, where it is situated beneath the buccal mucous membrane. It afterwards descends more deeply, between the mylo-hyoid and hyo-glossus longus muscles, turns round the inferior

[1] (Professor Chauveau designates this the *lingual*, or *small hypoglossal nerve*. To prevent confusion I have, in preference, retained the usual designation given to it in this country.)

border of the latter—including also Wharton's duct, to enter the interstice separating the genio-glossus from the hyo-glossus longus and brevis muscles. From this point it continues to near the free extremity of the tongue, proceeding in a very flexuous manner, and giving off, on its course, divisions equally tortuous and which traverse the organ, but without detaching any ramuscules to the lingual muscles; these divisions terminate in the middle and anterior portions of the lingual mucous membrane.

Before penetrating the mass of the tongue, this nerve furnishes: 1, At, and in front of, the posterior pillars of that organ, some small ramuscules which are sometimes plexiform, and are distributed to the mucous membrane at the base of the tongue; 2, Lower, and behind, one or two thin filaments which are carried to Wharton's duct, and ascend with it to the maxillary gland; 3, A *sublingual* branch, whose divisions enter the gland of that name, as well as the mucous membrane covering the sides of the tongue.

The gustatory nerve receives, near its origin, the *tympano-lingual* filament or *chorda tympani*—a branch of the facial nerve soon to be described. Its terminal divisions mix and anastomose with those of the great hypoglossal nerve, in the deep muscular interstice which lodges both.

Physiology teaches us that the gustatory nerve gives to the anterior two-thirds of the lingual mucous membrane ordinary sensation, and, in addition, that special sensibility (or gustatory power) by virtue of which that membrane enjoys the property of appreciating savours. This is its exclusive function. With regard to the tympanic filament from the facial nerve, and which is joined to the gustatory, M. Bernard is of opinion that it participates in the exercise of this sense of taste. Its radiating fibres extend to the submucous muscular layer of which we have spoken, and on which the lingual papillæ rest, and endow it with the property of acting on these papillæ by adapting them, we may say, to the sapid substances brought into contact with them. Lussana goes further than this, and, basing his statement on observations made on Man and on experiments, asserts that the nerve of the tympanum passes to the mucous membrane, and endows it with the sense of taste. Vulpian, however, does not agree to either of these opinions, because, according to his experience, this nerve does not go to the tongue, but stops at the submaxillary ganglion.

6. Mylo-hyoid Nerve (Fig. 336, 13).—The designation of this nerve indicates its destination and uses. It goes to the muscle bearing its name, and excites its contractility; it arises opposite to the preceding, and, like it, descends between the internal pterygoid muscle and the inferior maxillary bone, adhering somewhat closely to the latter. But arriving at the posterior border of the mylo-hyoideus, it passes to the outside of it, and meeting with the sublingual artery, ramifies on the external face of that muscle.

7. Dental Branches (Fig. 336, 12).—These are of two orders: some passing to the molar, the others to the canine and incisor teeth. Their description does not merit any special indication.

8. Mental Nerves, or Terminal Branches of the Inferior Maxillary Nerve.—Perfectly analogous to the infra-orbital ramuscules, these nerves form a fasciculus by diverging and flexuous branches, which leave the mental foramen to be distributed to the textures of the lower lip, after receiving a branch from the facial nerve (Fig. 336, 11′).

D. The Sympathetic Ganglia annexed to the Fifth Pair.—These ganglia, joined by filaments of communication to the anterior extremity

of the great sympathetic nerve, in reality belong to the special system formed by that nervous chain, as they possess the formation and properties of the other ganglia composing it. It is therefore necessary that we should have a motive sufficiently powerful to induce us to move them from their natural category, and mix up their description with a nerve so different to them in its nature and functions. This motive we find in the intimate relations of contiguity and continuity which these ganglia manifest towards the branches of the trigemini; in the fact that we sometimes find them united to these branches, and deeply mixed up with their fibres; and also because, in certain cases, they seem to disappear entirely, and then their filaments of emission or reception are directly received or emitted by the fifth pair.

The study we are about to undertake of each of the ganglia will fully justify what we have advanced. We will precede it by a few words of introduction as to the general facts relating to these small organs.

The number of sympathetic ganglia annexed to the fifth pair is susceptible of variation, not only in different species, but also with individuals of the same species.

In the domesticated mammifers, we somewhat constantly, though not invariably, find three principal, placed on the course of the branches emanating from the Gasserian ganglion. These are: 1, The *ophthalmic ganglion*, belonging to the nerve of the same name; 2, The *spheno-palatine ganglion*, annexed to the superior maxillary branch; 3, The *otic ganglion*, which lies beside the inferior maxillary nerve. Anatomists describe other two, the *submaxillary ganglion* and the *naso-palatine* (or *Cloquet's*) *ganglion*; but their presence is not always constant in Solipeds, and their existence in the other domesticated animals is at least problematical.

These small bodies possess those common characters which have been so clearly indicated by Longet, and to which we will briefly refer. All are in communication with the superior cervical ganglion by one or more generally very slender filaments, and all receive one or more ramuscules from a sensitive and a motor nerve: these ramuscules—the *afferent branches* of the ganglia—are considered as their *roots*. All, finally, emit from their periphery a more or less considerable number of *emergent branches* or *ramifications* which share the properties, more or less modified, of the two orders of roots. The description of each ganglion therefore includes, independently of its form, situation, etc., an indication of all these ramuscules: *ramuscules of communication* with the superior cervical ganglion; *afferent ramuscules* or *roots*; and *emergent ramuscules*. This rule can be applied to all the ganglia, and renders their study perfectly methodical.

1. Ophthalmic (Ciliary or Lenticular) Ganglion.—This ganglion is readily discovered, as it is always in contact with the common oculomotor nerve, and united to it near the point where the branch passing to the inferior oblique muscle arises. It rarely exceeds the volume of a grain of millet, and is sometimes so minute that it would altogether escape observation, did we not know exactly where to look for it.

Its *motor root* is generally formed of two very short ramuscules coming from the third pair. Its *sensitive root*, much longer, proceeds from the palpebro-nasal nerve; it is usually through the medium of this root that the ophthalmic ganglion communicates with the superior cervical ganglion, by means of a thin filament it receives from the cavernous plexus.

The *emergent filaments* leave the anterior part of the ganglion, and arrange themselves in a flexuous manner around the optic nerve to reach the sclerotica, bearing the name of *ciliary nerves*. Some emanate directly

from the palpebro-nasal nerve, especially when the ganglion is rudimentary. Their number is uncertain, though it is usually from 5 to 8.

Reaching the sclerotica at the bottom of the eye, they traverse that membrane, and pass between its inner surface and choroid coat to the ciliary circle (or ligament), where each divides into two or three ramuscules that anastomose with those of the adjacent ciliary nerves, and in this manner form a circular plexus. From the concavity of this nervous circle arises a series of plexuous divisions, which are spread over the iris, whose contractile property is submitted to their influence.

2. Spheno-palatine, or Meckel's Ganglion.—The largest of the cephalic ganglia, nothing is more variable than the disposition of this small body. The following appears to be the most constant: in raising the superior maxillary nerve in its course across the space separating the orbital from the maxillary hiatus, we discover, lying on the upper border of the spheno-palatine nerve, a long, grey-coloured enlargement; this constitutes the ganglion we are about to describe.

It is elongated and slender, irregularly fusiform, constricted at different points of its extent and dilated in others; it is not attached to the spheno-palatine nerve by simple cellular adhesions or by some branches thrown from one cord to the other, but is intimately united to it by means of a most complicated intercrossing of fibres, in such a way that the spheno-palatine ganglion really forms part of the nerve of that name.

Afferent branches.—It receives, posteriorly, the *Vidian nerve*, a composite ramuscule which constitutes its *motor root*, and connects it with the superior cervical ganglion. This nerve will be described with the facial, as that trunk furnishes its principal portion. Its *sensitive roots* naturally come from the spheno-palatine nerve; they are as remarkable for their number as their volume, and also enter the posterior part of the ganglion.

Emergent branches.—Four series of these are recognised:

1. A very numerous series which is detached at a right angle from the superior border of the ganglion, and proceeds towards the ocular sheath. The majority appear to be lost in that fibrous membrane, but we have seen some pass through it, creep on the lower and inner wall of the orbit, and arrive at the margin of the orbital foramen. There they were manifestly united to the other filaments coming from the palpebro-nasal nerve, and formed a small plexus whose divisions seemed destined to the ophthalmic vessels, and even to some of the muscles of the eye, more especially the oblique ones. Among these divisions we have observed some which went to join the nerve of the membrana nictitans.

2. A second series proceeding from the opposite border, and establishing a union between the ganglion and the spheno-palatine nerve, or passing to the palatine nerves in a more or less complicated plexiform manner, to reinforce them.

3. A group arising from the anterior extremity and immediately passing to the spheno-palatine nerve.

4. A last fasciculus detached from the posterior extremity to enter the two great suprasphenoidal canals.

Such is the most usual arrangement of the spheno-palatine ganglion. We have found it divided into three small masses connected with each other by numerous filaments of a deep grey colour, and free from all adherences with the spheno-palatine nerve. The small posterior mass in this case received the Vidian nerve and the sensitive roots from the fifth pair. The distribution of the emergent branches was unaltered.

Among the anatomo-physiological facts pertaining to the study of this ganglion, we may remark that the staphylin, or posterior palatine, nerve derives from it the motor property which permits it to excite the contraction of the muscles in the soft palate.

3. Otic (or Arnold's) Ganglion.—It appears to us that the presence of this ganglion is not constant, for we have sometimes found it replaced by a small plexus provided with some almost microscopic ganglionic granulations.

When it does exist, it presents itself as a small fusiform enlargement placed within the origin of the inferior maxillary nerve, beneath the insertion of the Eustachian tube. To discover it, we have only to look for the commencement of the buccal nerve, to which it is joined by some filaments which are so short and thick, that we might imagine it to be fixed on that trunk.

Its *sensitive roots* are represented by the preceding filaments. The small superficial petrous nerve, coming from the facial, constitutes its *motor root.* From the sympathetic ramuscule accompanying the internal maxillary artery, it receives its *filament of communication* with the superior cervical ganglion.

Among its *emergent ramuscules* must be cited a superior filament, which enters the petrous portion of the temporal bone to disappear in the internal muscle of the malleus (tensor tympani), and two inferior filaments of a more considerable volume which separate in numerous ramuscules destined to the pterygoid muscles, the Eustachian tube, and the tensor palati muscle.

Physiological Resumé of the Fifth Pair.—The trigemini convey sensation to the skin covering the head, into the eyelids, the soft and hard palate, the nasal fossæ and sinuses, the nostrils, the greater portion of the tongue, and into the salivary glands and cheeks, and the upper and lower lips. The enormous tuft formed by the terminal branches of the superior maxillary nerve, endow the upper lip with the attributes of an organ of very exquisite tact.

The gustatory branch is, for the anterior two-thirds of the tongue, the essential instrument of the sense of taste.

By its motor root, the inferior maxillary nerve provokes the contraction of the muscles that bring the jaws into apposition—all those composing the masseteric region, except the digastricus. This root is often designated, in consequence of its function, the *masticatory nerve.*

The fifth pair also influences, as is demonstrated by vivisections and the observation of pathological facts, the secretion of the mucous membranes and glands receiving its filaments: undoubtedly by a reflex action which proceeds from the isthmus, and perhaps from the Gasserian ganglion.

Finally, it is admitted that the nutrition of the tissues in which the trigeminus ramifies depends upon that nerve. But here there is an exaggeration; for if nutrition be modified in these tissues, consequent on the section of the fifth pair, this effect is certainly due to paralysis of the capillaries, whose contractility is probably excited by the organic motor fibres mixed with the sensitive filaments of the fifth pair.

The ramuscules sent by the sympathetic chain to the Gasserian ganglion, are perhaps not foreign to the part the fifth pair seems to play in the secretory and nutritive functions.

6. *Sixth Pair* (*Abducentes*), *or External Oculo-motor Nerves.* (Fig. 335, 5.)

The *external oculo-motor* originates from the medulla oblongata, immediately behind the pons Varolii, by from five to eight converging roots, which appear to issue from between the inferior corpus pyramidale and the lateral fasciculus of the medulla (Figs. 337, 338, *h*).

It is directed immediately forward, leaves the pons Varolii in lying close to the inner side of the superior maxillary nerve, and traverses the sphenoidal canal, which already lodges the ophthalmic branch of the fifth pair and the common oculo-motor nerve, to pierce the bottom of the orbit. It is entirely expended in the external rectus (or abductor) muscle of the eye, after giving off a small ramuscule to the external portion of the posterior rectus.

7. *Seventh Pair, or Facial Nerves.* (Figs. 110, 336, 337, 338.)

The *facial* (*portio dura*) is a nerve exclusively motor at its orgin, but which becomes mixed, during its course, by the addition of several sensitive branches.

Origin.—It emanates from the medulla oblongata, immediately behind the pons Varolii, and appears to originate at the external extremity of the transverse band that margins the posterior border of that protuberance. But if we attempt to trace its origin in the substance of the medulla oblongata, we see the single fasciculus it constitutes, at its point of emergence, descend into the groove of separation between the pons Varolii and the above-mentioned band; it then traverses nearly the whole thickness of the medulla, passing between the lateral cord or column, and that portion of the restiform body which is continuous with the large root of the fifth pair. Arrived near the bottom of the fourth ventricle, the facial nerve separates into several roots—some anterior, others posterior—which are soon lost in the cells forming the corresponding nucleus. Among these fibres are some which remain isolated from the preceding, and, passing the median line, enter the facial nucleus of the opposite side (Fig. 337).

Fig. 337.

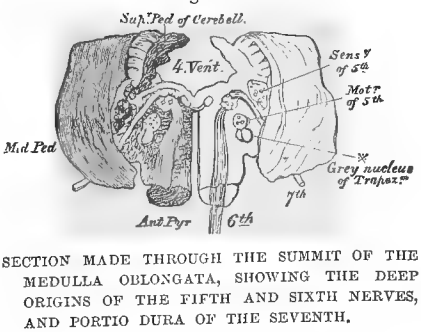

SECTION MADE THROUGH THE SUMMIT OF THE MEDULLA OBLONGATA, SHOWING THE DEEP ORIGINS OF THE FIFTH AND SIXTH NERVES, AND PORTIO DURA OF THE SEVENTH.

Course.—Scarcely has the facial nerve left the medulla oblongata, before it is directed outwards, to pass into the internal auditory meatus, along with the auditory nerve, which lies in contact with it behind. It afterwards enters the aqueduct of Fallopius, courses along it, and follows its inflexions, which results in its forming a bend forward at a short distance from the internal opening of the canal, and a curve whose concavity is anterior, on its passage behind the cavity of the tympanum. On leaving the aqueductus Fallopii by the stylo-mastoid foramen, it is hidden beneath the deep face of the parotid gland, and continues to be inflected forward, passing between that gland and the guttural pouch, and reaches the posterior border of the inferior maxilla, where it issues from beneath the anterior margin of the parotid to become superficial, and place itself on the masseter muscle.

immediately beneath the temporo-maxillary articulation. There it terminates in two or three branches, which anastomose with those of the superficial temporal nerve from the fifth pair, thus forming the *subzygomatic plexus* (*pes anserinus*, Fig. 110).

Distribution.—a. In its interosseous course, the facial nerve successively furnishes:

1. The *great superficial petrous nerve* (*nervus petrosus superficialis major*).
2. The *small superficial petrous nerve* (*nervus petrosus superficialis minor*).
3. The *filament of the stapedius muscle* (*tympanic branch*).
4. The *chorda tympani.*

It communicates, besides, with the pneumogastric nerve, by means of a voluminous filament described as:

5. The *anastomotic branch of the pneumogastric.*

b. The branches it emits on its course beneath the parotid gland arise either from its superior or inferior border; they are:

6. The *occipito-styloid nerve.*
7. The *stylo-hyoid nerve.*
8. The *digastric nerve.*
9. The *cervical ramuscule.*
10. *Filaments to the guttural pouch and parotid gland.*

The superior branches comprise:

11. The *posterior auricular nerve.*
12. The *middle auricular nerve.*
13. The *anterior auricular nerve.*

c. To this collection of collateral ramuscules are added the terminal branches, formed by their anastomoses with the superficial temporal nerve:

14. The *subzygomatic plexus.*

A. Collateral Branches.—1. Great Superficial Petrous Nerve.—This is a very remarkable ramuscule, which is detached from the bend of the facial nerve to proceed to Meckel's ganglion. The importance of the peculiarities attaching to the study of this nerve requires us to call special attention to its origin, course, and termination; though the details into which we are about to enter may be omitted by the student.

Origin.—Ganglion geniculare.—The manner in which the great superficial petrous nerve comports itself at its origin is yet an obscure and controverted fact, on which however light is beginning to be thrown. The following is the most general opinion: This nerve arises from a small grey enlargement, the *genicular ganglion* (or *intumescentia gangliformis*), placed on the course of the facial nerve, at the summit of the angle which that nervous trunk describes after its entrance into the aqueduct of Fallopius; and the presence of this small ganglion on the seventh pair should assimilate the facial to a mixed nerve, whose sensitive root would be represented by the *portio intermedia of Wrisberg*—a thin filament comprised between the seventh and eighth pair, and which emanates directly from the medulla oblongata to pass into the posterior part of the ganglion geniculare.

We have constantly found this ganglion in the domesticated animals. There exists, in fact, on this angle or elbow of the facial nerve, a very slight, grey, conical prominence, composed of ganglionic corpuscles which a microscopical examination readily reveals, and giving origin on its apex to the great superficial petrous nerve. This prominence, which, we repeat, is very

small, forms part of the facial nerve, on which it only presents a kind of intumescence. We have never seen the sharp and precise limitation of its base that is figured in the majority of iconographies of human anatomy.

On the other hand, when, on portions steeped for several weeks in water acidulated by nitric acid, we have studied the constitution of the great petrous nerve, even at its origin, we have found it formed of two fasciculi very easily separated—one internal, the other external: the latter alone is continuous with the geniculated ganglion; the other traverses the facial nerve from before to behind, then it is suddenly inflected inwards to ascend to the origin of the nerve, and mix with its fibres; but this fasciculus very often maintains its independence to the medulla oblongata, into which its fibres penetrate separately; they then appear as a small particular trunk beside that of the principal nerve, and comprised between it and the auditory. The great petrous nerve does not, therefore, proceed exclusively from the ganglion geniculare, as considerable portions of its fibres, entirely destitute of ganglionic corpuscles, emerge directly from the facial nerve. With regard to the external fasciculus, the separation of its fibres by the action of the acid shows very plainly that the grey substance of the ganglion is found almost exclusively on their track; and if we trace these fibres, like those of the preceding fasciculus, into the substance of the facial nerve, we will find that, instead of proceeding towards its origin, they appear to be directed to its termination: a remarkable circumstance, which we believe may be explained by admitting that they come from the anastomosing branch of the pneumogastric nerve, of which we will speak hereafter.

From this arrangement, it results that the great petrous nerve arises from the facial by two real, though intimately connected, roots: the internal is evidently motor; the internal possesses the ganglionic corpuscles of a sensitive root; and the trunk they both form may be regarded as a mixed nerve.

As will be observed, our view of the ganglion geniculare differs from the general opinion with regard to it, inasmuch as we make it belong exclusively to the great petrous nerve, and not to the whole of the facial fasciculi. On the other hand, the *portio intermedia of Wrisberg* is not, in our opinion, the sensitive root of the facial, whose fibres we only look upon as motor; it is not even that of the great superficial petrous nerve, of which it might at the most be considered as only an accessory filament. In the Horse, this ramuscule is extremely attenuated, and can scarcely, if at all, be distinguished at its origin from the filaments of the lateral root of the auditory nerve; it is seen to enter the aqueduct of Fallopius, and divide on the bend (or gangliform enlargement) of the facial nerve into several gradually diminishing filaments, which are confounded with the proper fibres of this nerve, or the ganglion geniculare.

What a difference there is between this arrangement and that of the veritable sensitive roots opposite the ganglia placed on their track! Why hesitate to admit that this *nerve of Wrisberg* is on y an anastomosing twig passing from the auditory nerve to the facial? Is it because of the radical difference in the properties of the two nerves? Nature, in bringing them so closely together, does not appear to have taken into account this difference; and the reason for this anastomosis might be explained by the connections the seventh pair maintains with the active portions of the auditory apparatus.

Is it not the facial nerve that animates the stapedius muscle, and, in an indirect manner, that of the malleus? Are all the muscles of the external ear not under its influence? In the present state of science it would be difficult

to discover the functional relationship that may exist between the connections of the ear with the facial, and those of the latter nerve with the auditory: but the mind perceives this relationship, and that ought to suffice.

The opinion which regards the nerve of Wrisberg as the sensitive root of the facial has, we believe, been more particulary accredited by the apparent impossibility of otherwise accounting for the sensibility this nerve possesses, even at its exit from the stylo-mastoid foramen—that is, before contracting any anastomosis with the fifth pair; but this sensibility belongs exclusively to the fibres of the communicating branch sent by the pneumogastric nerve, and not to the fasciculi of the facial, as is proved by stimulating the latter outside the aqueduct of Fallopius, after destroying the pneumogastric at its origin. If it is sought to regard the intermediate nerve absolutely as a branch distinct from the original filaments of the auditory, and if it be determined to make it a sensitive nerve, then it must at least be admitted that it does not carry its sensibility beyond the stylo-mastoid foramen, and that all its filaments disappear in the ramuscules furnished by the facial in its interosseous course. Otherwise, it is known that M. Longet considers this nerve as forming the small superficial petrous branch and the nervous filament of the stapedius muscle; but he makes it a motor branch destined to supply the muscles of the middle ear. His idea is very ingenious, and would assuredly be feasible if it were possible to follow the intermediate nerve from its origin to the lateral column of the medulla oblongata; but, unfortunately, this is not the case, as the small ramuscule only appears to be an offshoot of the fibres proper to the auditory nerve.

To sum up, the great superficial petrous nerve proceeds from the facial by two roots: one motor, the other sensitive, assimilable, to a certain point, to the roots of the spinal nerves. The first is furnished by the filaments of the seventh pair; while the second probably comes from the pneumogastric nerve, and has annexed to it on its course the ganglion geniculare. The nerve of Wrisberg perhaps concurs in the formation of this ganglion, but it is certainly not its principal source.

Course and Termination.—The great petrous nerve, after being detached from the facial, and forming with it an obtuse angle opening outwards, enters the hiatus (or aqueduct) of Fallopius—a small passage running from behind forward, in the substance of the petrous bone, above the fenestra, rotunda, and cochlea. Arriving at the interior of the cavernous sinus, which it traverses, immersed in the blood that sinus contains, it receives a branch from the ganglionic plexus there, is lodged in the Videan fissure, then in the Videan canal, and in this manner gains the orbital hiatus, where it separates into several branches—most frequently two—which join the posterior part of Meckel's ganglion. It constitutes the motor root and sympathetic filament of that ganglion.

2. Small Superficial Petrous Nerve.—A very thin filament detached from the facial to the outside of the preceding, and likewise traversing the petrous bone from behind to before to enter the otic ganglion, whose motor root it is.

3. Filament of the Stapedius Muscle (Tympanic).—The facial nerve, in its passage above and in front of the stapedius muscle, closely adheres to it, and gives it one, perhaps several, extremely short filaments.

4. Chorda Tympani (Fig. 342, 6).—This filament, also named the *tympano-lingual nerve*, arises at a very obtuse angle from the facial, near the external orifice of the aqueductus Fallopii. It penetrates the cavity of the tympanum by a particular opening, courses from its posterior to its

anterior wall in describing a curve downwards, and passes among the chain of auditory bones, between the handle of the malleus and long branch of the incus. Escaping from the middle ear by a canal (*fissura Glaseri*) on the limits of the mastoid and petrous portions of the temporal bone, it proceeds forwards and downwards, and finally joins the gustatory nerve aftet a short course beneath the external pterygoid muscle, outside the guttural pouch.

5. Anastomosing Branch of the Pneumogastric Nerve.—(*See the description of the tenth pair.*)

6. Occipito-Styloid Nerve. (Fig. 336, 3.)

7. Stylo-hyoid Nerve.

8. Digastric Nerve (Fig. 336, 4). — These three spring from a common fasciculus at the stylo-mastoid foramen, and ramify in their respective muscles, after a certain course beneath the parotid gland.

9. Cervical Branch (Figs. 336, 6).—This nerve has its origin almost in the middle of the subparotideal portion of the facial, near a particular loop thrown by that nerve around the posterior auricular artery, and often from this loop itself.

It afterwards traverses the parotid gland from within to without, and above to below, to descend at first on its external face, beneath the parotido-auricularis muscle, then into the jugular channel, where it is lodged below the deep face, or in the substance of the subcutaneous muscle of the neck, which receives its terminal divisions near the anterior appendix of the sternum.

In its course this nerve communicates with the inferior branches of the second, third, fourth, fifth, and sixth cervical pairs by branches from them; it sends numerous collateral filaments into the texture of the subcutaneous muscle.

10. Filaments of the Guttural Pouch and Parotid Gland.—Remarkable for their number and tenuity, these filaments do not otherwise deserve particular mention.

11. Posterior Auricular Nerve (Fig. 336, 2).—It commences at the stylo-mastoid foramen, is directed upwards beneath the parotid gland, accompanying the posterior auricular artery, and is distributed to the posterior muscles of the external ear. It sometimes offers at its origin a loop analogous to that embracing the posterior auricular artery.

12. Middle Auricular Nerve.—Most frequently this arise from the same point as the preceding nerve—it might be said in common with it—ascends towards the base of the concha in traversing the parotid gland, and pierces the cartilage to supply the interconchal integument and the contractile fibres which cover its adherent face in some parts.

13. Anterior Auricular Nerve (Fig. 336, 5).—This is the largest of the three auricular nerves. After being detached from the facial nerve, opposite the cervical branch, and after ascending across the parotideal tissue, it gains the external face of the zygomatic process, where it meets the superficial divisions of the lachrymal nerve; it continues forward beneath the external parieto-auricular muscle, reaches the base of the orbital process at the supra-orbital foramen, there crossing the terminal branches of the nerve of that name; it then descends vertically within the orbit to below the nasal angle of the eye, where it mixes with the superficial divisions of the palpebro-nasal nerve, and finally terminates on the face in the lachrymal and supernaso-labialis muscles.

In its progress, it gives off numerous ramuscules to the anterior muscles of the ear, the fronto-supra-orbital, and the orbicularis of the eyelids, whose contractibility it excites.

This nerve is remarkable for the relations it maintains with the terminal ramuscules of the three branches of the ophthalmic nerve, or fifth pair. Although there do not exist any real anastomoses between it and these various branches, it is customary to designate the reticular mass they form in front of the ear and on the side of the face, as the *anterior auricular plexus.*

Terminal Branches of the Facial Nerve or Subzygomatic Plexus (Fig. 110, 11, 12).—The facial nerve, as we have seen, terminates in several branches, usually two, on arriving beneath the temporo-maxillary articulation, where they join the superficial temporal nerve. After becoming sensory-motor, they are continued on the external face of the masseter, covered by the subcutaneous muscle of the head, to which they give some ramuscules, and are united to each other by anastomosing branches of variable disposition, which we need not stay to examine. It is always observed with regard to this arrangement, that the branches of the subzygomatic plexus, on arriving near the anterior border of the masseter, are divided into a series of divergent ramuscules which pass to the surface of the vascular or glandular canals situated in front of the masseter, to enter the tissues of the lips, cheeks, and nostrils.

Among these ramuscules, the superior is remarkable for its great volume; it passes beneath the zygomato-labialis muscle, lies close to the inferior border of the supermaxillo-nasalis magnus, beside the superior coronary artery, and afterwards runs below the supernaso-labialis muscle, where it joins the terminal ramuscules of the superior maxillary nerve, with which it is distributed to the textures of the upper lip and alæ of the nose (Fig. 336, 7′).

A second ramuscule—the inferior, smaller than the preceding—follows the inner aspect of the maxillo-labialis muscle, to mix by its anterior extremity with the terminal fasciculus of the inferior maxillary nerve, and ramify, with the proper filaments of that fasciculus, in the tissue of the lower lip.

Between these two principal branches is a series of smaller ramifications destined to the alveolo-labialis muscle. Among these are some which become inflected on the inner face of the masseter, and reach the deep portion of the buccinator, where they anastomose with the filaments of the buccal nerve. Other ramuscules, situated below the principal inferior branch, are expended in the subcutaneous muscle of the face; one of them, after bending round the lower border of the inferior maxilla, reaches the intermaxillary space.

Functions of the Facial Nerve.—This nerve excites the contractility of the muscles of the middle ear, external ear, the cheeks, lips, nostrils, orbicularis of the eyelids, and the cervico-facial subcutaneous muscle. By its great superficial petrous filament, it influences the movements of the muscles of the soft palate, and it is admitted, as already noticed when speaking of the gustatory nerve, that its tympano-lingual ramuscule acts as an excitant to the submucous muscular layer of the tongue. The facial nerve, also, without doubt, exercises its influence on the parotid gland; thus its action in this respect is not well determined; perhaps it is limited to producing the contractions of the excretory canaliculi which escape from the lobes of the gland.

It is to be remarked that the facial nerve has no influence over the masseter muscle; notwithstanding their intimate relations, it does not detach the smallest filament to it.

It is necessary to say, that its anastomoses with the various branches of the trigeminus and pneumogastric nerves, while endowing its distributive ramuscules with great sensibility, in no respect modify its mode of action

or its properties, because, notwithstanding these anastomoses, its proper fibres preserve their complete independence.

8. *Eighth Pair, or Auditory Nerves.* (Figs. 324, 338.)

This is the nerve of hearing, and affects a very simple disposition, which we will sum up in a few words.

Origin.—The auditory nerve (*portio mollis*) proceeds from the medulla oblongata by two roots, an anterior or lateral, and a posterior. The latter (Fig. 323, 20) commences on the floor of the fourth ventricle by some convergent striæ (*lineæ transversæ, striæ medullares*), as is admitted in the majority of treatises on human anatomy, though we have never been able to discover these striæ in the domesticated animals; it is afterwards directed outwards in winding round the posterior cerebellar peduncle, and unites with the anterior root on the side of the medulla oblongata. The latter root (Fig. 338, *g*), consists of a single fasciculus joined with that of the facial, and escapes from between the fibres of the corpus restiforme. The nucleus of the auditory nerve has been discovered by Schrœder Van der Kolk, a little below that of the facial nerve.

Course and Termination.—These two roots immediately unite into a single soft cord situated behind that of the seventh pair, with which it is directed outwards to reach the internal auditory hiatus (or meatus.) There it divides into two branches—an anterior and posterior, whose fasciculi traverse the foramina at the bottom of that hiatus: the former to gain the axis of the cochlea (the *cochlear* branch), and the latter the semicircular canals (*vestibular* branch.) The description of these two branches will be deferred till we come to the sense of hearing.

9. *Ninth Pair, or Glosso-Pharyngeal Nerves.* (Figs. 338, 3; 342, 10.)

The glosso-pharyngeal is a mixed nerve, which carries general sensation, with gustative sensibility, into the posterior third of the tongue, and excites contraction of the pharyngeal muscles.

Origin.—This nerve originates on the side of the medulla oblongata, behind the eighth pair, by eight or ten fine roots, some of which are implanted in the corpus restiforme, while the others, the smallest number, escape, like the filaments of the facial nerve, from the interstice between that body and the lateral column of the medulla oblongata.[1] These roots soon unite in a single cord, which issues from the cranium by a particular orifice in the posterior foramen lacerum, and at this point exhibits a grey oval-shaped enlargement—the *ganglion petrosum* or *ganglion of Andersch*, in which it is somewhat difficult to distinguish the motor filaments of the nerve from those which arise between the lateral and superior columns of the medulla oblongata (Fig. 338, 2).

Course and Termination.—Scarcely has the glosso-pharyngeal nerve escaped from the cranium, before it descends, in describing a curve whose concavity looks forward, behind the large branch of the os hyoides, included at first between a fold of the guttural pouch, then between the latter and

[1] This disposition, which is readily exposed in the Horse, appears to us sufficient to remove all the doubts existing in the minds of a large number of anatomists, as to the nature of the glosso-pharyngeal nerve. It evidently possesses at its origin, as motor filaments, those arising from the same part as the facial nerve, and as sensitive filaments those from the corpus restiforme. Besides, we may object to the opinion which would also attribute the motor property of the glosso-pharyngeal nerve to the anastomosing branches passing between it and the seventh pair, on the ground that these anastomoses are far from being constant, and that in some species they are always totally absent.

the internal pterygoid muscle. Lying beside the external maxillary artery in the latter part of its course, it passes with it along the posterior border of the large branch of the hyoid bone, and gains the base of the tongue with the lingual artery, by coursing beneath the hyo-glossus brevis muscle. The papillæ on the posterior portion of the lingual mucus membrane receive the terminal ramuscules of this nerve. (*See the Sense of Taste.*)

Collateral Branches.—On its course it furnishes:

1. *Jacobson's nerve* (*tympanic branch*), a very thin filament springing from Andersch's ganglion, proceeding upwards, and entering a particular foramen in the tuberous portion of the temporal bone, to be distributed more especially to the tympanum, sending also to the superficial petrous nerves two branches which are designated the *deep great* and *small petrous nerves.*

2. *Filaments of communication with the superior cervical ganglion,* two or three in number, though sometimes replaced by a single ramuscule.

3. A *branch to the carotid plexus,* which passes back on the guttural pouch to reach the terminal extremity of the common carotid, whence its filaments are sent, with those of the sympathetic nerve, either to the external carotid, occipital, or even to the common carotid artery itself. This branch communicates, by several anastomoses, with the numerous sympathetic branches which pass from the superior cervical ganglion to the surface of the guttural pouch, and which are either expended in that membrane, or join the posterior border of the great hypoglossal nerve.

4. A *pharyngeal branch* (Fig. 342, 11), which is generally detached close to the pharyngeal artery, and forms, along with the pharyngeal filaments of the pneumogastric nerve, a remarkably intricate plexus (*pharyngeal*) on the upper wall of the pharynx, below the guttural pouch. This plexus receives a filament from the hypoglossal nerve.

10. *Tenth Pair, Vagus, or Pneumogastric Nerves.* (Figs. 338, 342, 362.)

The pneumogastric nerve is as remarkable for its extent, as for the multiplicity of physiological uses imposed upon it.

It is prolonged to beyond the stomach, after distributing to that viscus, the œsophagus, pharynx, lung, bronchi, trachea, and larynx a large number of filaments on which depend the movements, secretory functions, and purely sensory phenomena of which all these organs are the seat.

Origin.—The pneumogastric is a mixed nerve, and consequently arises from two kinds of roots; these we will successively describe before passing to its distribution, though it must be remarked that this subject has not yet been fully determined.

Sensitive roots.—These arise from a nucleus of grey substance situated near the floor of the fourth ventricle, a little behind the glosso-pharyngeal nucleus, and in which the fibres of the antero-lateral columns of the medulla oblongata, or respiratory track of Bell, seem to be lost. In leaving the medulla, they form from four to ten bundles, which describe a slight curve whose convexity is upwards; the highest median fibres correspond to the groove that limits, superiorly, the respiratory tract, the posterior and anterior fibres bending down to the pyramids—the second more than the first.

These roots proceed transversely outwards, mixed with connective tissue and some fine muscular ramifications, and leave the cranium by one of the openings (jugular foramen) in the posterior foramen lacerum, uniting in their passage through that aperture in a somewhat voluminous ganglion, called in Man the *jugular ganglion.*

Motor roots.—Several anatomists and physiologists consider these as a portion of the accessory nerve of Willis, and give them the name of *internal* or *bulbous root of the spinal nerve.* They are situated a little behind the preceding, and emanate from the respiratory tract; consequently they are not so elevated as the whole of the sensitive fibres. They are separated from the sensitive roots by a comparatively large vein, and are distinguished from them by their anastomotic tendency. Becoming longer as they are more posterior, and frequently anastomosing with each other, the filaments forming these motor roots converge, and gain the posterior foramen lacerum; this they pass through by one or two special openings to join the jugular ganglion, beneath and behind which we find them applied. A certain number of the most posterior of these filaments lie beside the medullary root of the spinal nerve; but they are soon detached to pass with the others to the jugular ganglion.

Jugular or Ehrenritter's ganglion.— Elongated from before to behind, and flattened on both sides, the jugular ganglion is embedded in the cartilaginous substance that fills the foramen lacerum. When it has been macerated for some time in dilute nitric acid, it may be resolved into two portions: one corresponding to the sensitive, the other to the motor roots. Some white nervous filaments appear to pass to its surface without becoming confounded with it. It is in relation, in front, with the ganglion of Andersch; behind, it crosses somewhat obliquely the medullary root of the spinal nerve.

The jugular ganglion is also in relation with the spinal, glosso-pharyngeal, and facial nerve. It communicates with the *external root of the spinal nerve* by the few radicular filaments indicated above. With the *glosso-pharyngeal* it is connected by: 1, An afferent filament coming from the highest roots of the ninth pair, and which meets it at its antero-internal angle; 2, By an efferent branch it sends to the ganglion of Andersch. Lastly, it is united to the *facial* by a branch we have named the *anastomosing branch extending from the pneumogastric to the facial nerve.*

This anastomotic branch, on leaving the jugular ganglion, is somewhat considerable in volume, and it has appeared to us that, at times, among its radicles there were some in direct continuity with the sensitive roots of the pneumogastric nerve. This branch is directed forward, above the ganglion of Andersch, crosses Jacobson's branch, traverses the tuberous portion of the temporal bone, and arrives in the aqueduct of Fallopius; here it meets the facial nerve, at the point where the latter gives off the chorda tympani. A small number of its fibres then lie beside the nerve of the seventh pair in ascending towards the origin of that nerve, where, in our opinion, they constitute a large portion of the great petrous nerve—that which has at its origin the geniculated ganglion. Other fibres descend, on the contrary, in following the proper fibres of the facial nerve, and are lost among these; but the largest number cross that nerve and continue their course in the substance of the temporal muscle, to be chiefly distributed to the membrane lining the internal auditory canal.

Course and Relations.—Beyond the jugular ganglion, the trunk of the pneumogastric remains intimately allied with the spinal accessory for about 8-10ths of an inch; at this point we have been unable to find the gangliform plexus described in Man, though, according to M. Bernard, it exists in the Rabbit. The two nerves then separate to allow the great hypoglossal nerve to pass between them: after which the pneumogastric nerve descends alone behind the guttural pouch, in proximity to the superior cervical ganglion.

Near the origin of the occipital artery it crosses to the inner side of that vessel, and beyond this is joined in the most intimate manner to the cervical portion of the sympathetic chain; the single cord resulting from this fusion follows the common carotid artery, above which it is situated, to near the entrance of the thorax. The two nerves then resume their reciprocal independence, the pneumogastric penetrating the thorax a little

Fig. 338.

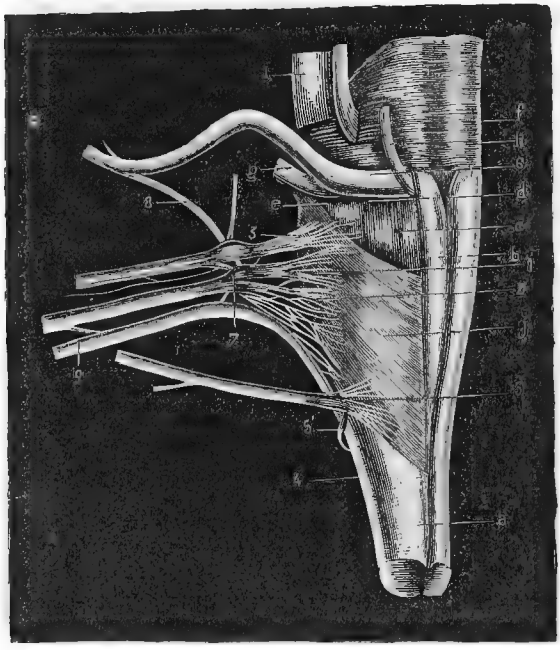

ORIGIN OF THE NERVES SPRINGING FROM THE MEDULLA OBLONGATA, AND PARTICULARLY THAT OF THE PNEUMOGASTRIC, SPINAL, HYPOGLOSSAL, AND GLOSSO-PHARYNGEAL.

a, Medulla oblongata; *b*, Pyramids; *c*, Enlargement simulating the olivary body; *d*, Lateral posterior fissure; *e*, Fissure limiting superiorly the respiratory tract of Ch. Bell; *f*, Corpus restiforme; *g*, Auditory nerve; *h*, External oculo-motor; *i*, Trigeminus; *j*, Arciform fibres of the medulla oblongata.—1, Pneumogastric; 2, Spinal, inner root; 3, Glosso-pharyngeal; 4, Spinal, medullary column; 5, Inferior, or anterior, root of the great hypoglossal; 5′, Its ganglionic root; 6, Facial; 7, Jugular ganglion; 8, Anastomosis of the pneumogastric with the facial; 9, Ramuscule from the external branch of the spinal passing to the pneumogastric.—From Toussaint's Thesis on the 'Anatomie Comparée du Nerf Pneumogastrique.' Lyons, 1869.

below the sympathetic, in passing among the lymphatic glands existing between the two first ribs.

In this course, the two pneumogastrics affect nearly the same relations; though there is something special connected with the left, which corresponds with the œsophagus towards the lower part of the neck.

Within the chest, however, these two nerves comport themselves a

Fig. 339.

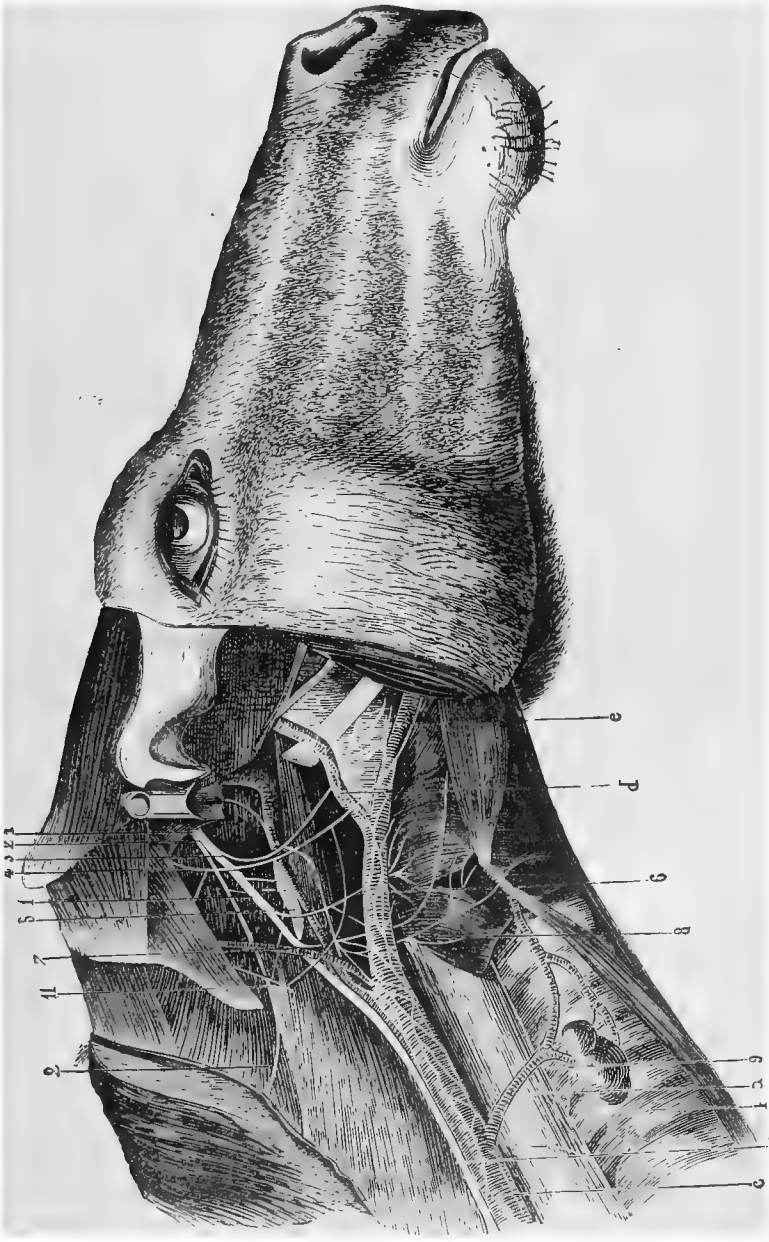

PNEUMOGASTRIC NERVE, WITH ITS BRANCHES IN THE UPPER PART OF THE NECK. *a*, Œsophagus; *b*, Trachea; *c*, Common carotid; *d*, Internal maxillary artery; *e*, Glosso-facial artery; 1, 1, Pneumogastric nerve; 2, Spinal accessory; 3, Glosso-

Fig. 340.

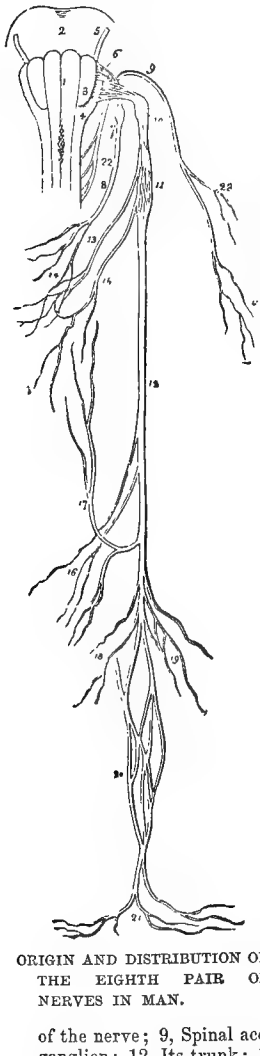

little differently. The right passes round the axillary artery very obliquely, upwards, outwards, and backwards beneath the mediastinal pleura, to follow the external face of the trachea to above the origin of the bronchi, where this nerve terminates. The left also passes below the brachial trunk; but instead of turning round the trachea, it merely lies beside that tube, and reaches the root of the lung, after crossing, outwardly, the origin of the two aortæ.

When these nerves arrive above the bifurcation of the trachea, they terminate by forming the *bronchial plexus and œsophageal nerves*—the latter being prolonged to the stomach and the solar plexus.

Beneath the jugular ganglion, but in the upper part of the neck, the pneumogastric receives filaments from the spinal accessory, ganglion of Andersch, sympathetic, hypoglossal, and the two first cervical. These different nerves cross each other in a very complex manner on the surface of the guttural pouch, the pharynx, and divisions of the carotids, and form the guttural, pharyngeal, and carotid plexuses.

Distribution.—The branches furnished by the pneumogastric on its course are:

1. *Communicating filaments with the superior cervical ganglion.*
2. *Pharyngeal branch.*
3. *Superior laryngeal nerve.*
4. *Communicating filaments with the inferior cervical ganglion.*
5. *Inferior laryngeal nerve.*

We will pass in review these collateral divisions before studying the terminal branches, which are:

1. Those forming the *bronchial plexus.*
2. Those constituting the *œsophageal nerves.*

ORIGIN AND DISTRIBUTION OF THE EIGHTH PAIR OF NERVES IN MAN.

1, 3, 4, Medulla oblongata; 1, Corpus pyramidale of one side; 2, Pons Varolii; 3, Corpus olivare; 4, Corpus restiforme; 5, Facial nerve; 6, Origin of glosso-pharyngeal nerve; 7, Ganglion of Andersch; 8, Trunk of the nerve; 9, Spinal accessory; 10, Ganglion of pneumogastric; 11, Its plexiform ganglion; 12, Its trunk; 13, Its pharyngeal branch, forming the pharyngeal plexus, 14, assisted by a branch from the glosso-pharyngeal, 8, and one from the superior laryngeal, 15; 16, Cardiac branches; 17, Recurrent laryngeal branch; 18, Anterior pulmonary branches; 19, Posterior pulmonary branches; 20, Œsophageal plexus; 21, Gastric branches; 22, Origin of the spinal accessory nerve; 23, Its branches distributed to the sterno-maxillaris and mastoido-humeralis; 24, Its branches to the trapezius muscle.

---

pharyngeal nerve; 4, Great hypoglossal nerve; 5, Superior cervical ganglion of the sympathetic; 6, Pharyngeal nerve; 7, Superior laryngeal; 8, External laryngeal; 9, Inferior laryngeal; 10, Cord of the pneumogastric and sympathetic; 11, First cervical nerve, with the loop it sends to the hypoglossus.—From Toussaint's work.

COLLATERAL BRANCHES OF THE PNEUMOGASTRIC NERVE.—1. FILAMENTS OF THE INFERIOR CERVICAL GANGLION.—Always very slender, these sometimes come from the pharyngeal ramuscule.

2. PHARYNGEAL NERVE (Figs. 339, 6; 342, 15).—Originating from the pneumogastric nerve at the middle part of the superior cervical ganglion, the pharyngeal passes forwards and downwards on the side of the guttural pouch, and gains the upper face of the pharynx, where it terminates in forming a plexus with the pharyngeal branch of the ninth pair. This is a sensory-motor branch. It gives off a large division that passes backwards to the surface of the middle and posterior constrictor muscles, to which it gives branches, and, throwing off a filament to the external laryngeal nerve, reaches the commencement of the œsophagus; it descends on the outside of that canal by becoming distributed in its muscular tunic. This division, which we have named the *œsophageal branch of the pharyngeal nerve*, may be traced on the œsophagus to the lower part of the neck, and in some subjects even into the thoracic cavity.

3. SUPERIOR LARYNGEAL NERVE (Fig. 339, 7).—More voluminous than the preceding, and arising a little lower, this nerve follows an analogous course to reach the side of the larynx, where it enters the aperture below the appendix of the superior border of the thyroid cartilage, to be almost entirely expended in the laryngeal mucous membrane, to which it communicates a very exquisite degree of sensibility.

At the inner face of the thyroid cartilage, it presents several branches that are directed forward, upward, and backward. The first pass to the mucous membrane at the base of the tongue and the two faces of the epiglottis. The second are distributed in the lateral walls of the pharynx. Of the third, some are destined to the mucous membrane of the arytenoid cartilages and that of the œsophagus; while others descend on the thyro-arytenoid and lateral crico-arytenoid muscles, to unite with the branches coming from the recurrent, and form an anastomosis analogous to the *anastomosis of Galien* (Fig. 341, 5).

Before penetrating the larynx, and even very near its commencement, it furnishes a motor filament to the crico-pharyngeal and crico-thyroid muscles; this filament either arises directly from the pneumogastric nerve, or, as is most frequently the case, from the pharyngeal ramuscule; this is the *external laryngeal* nerve of anthropotomists (Fig. 339, 8). It receives accessory branches from the superior cervical ganglion, the œsophageal branch, and the pharyngeal nerve, and is then distributed to the muscular tunic of the œsophagus. It is to the union of this branch with the œsophageal branch of the pharyngeal nerve, that we have given the name of *superior œsophageal nerves.*[1]

4. COMMUNICATING FILAMENTS WITH THE INFERIOR CERVICAL GANGLION.—These do not always directly enter this ganglion, for when the middle cervical ganglion exists they pass to it. They are not similarly disposed on both sides. The filaments of the right pneumogastric, two or three in number, are extremely short, though voluminous. The left pneumogastric usually only furnishes a single, long, thin ramuscule, which is detached in the region of the neck near the point where the pneumogastric commences to separate from the cervical branch of the sympathetic, and reaches the inferior cervical ganglion by remaining alongside the principal nerve.

[1] Toussaint has seen this branch leave the œsophagus to lie beside the recurrent; but its filaments always return to that canal as ascending twigs.

5. Inferior Laryngeal Nerve (Fig. 362, 27, 28).—Also named the *recurrent*, or *tracheal recurrent*, because of its disposition. It begins in the thoracic cavity and ascends along the trachea to the larynx, all of whose intrinsic muscles it animates, with the exception of the crico-thyroid.

Fig. 341.

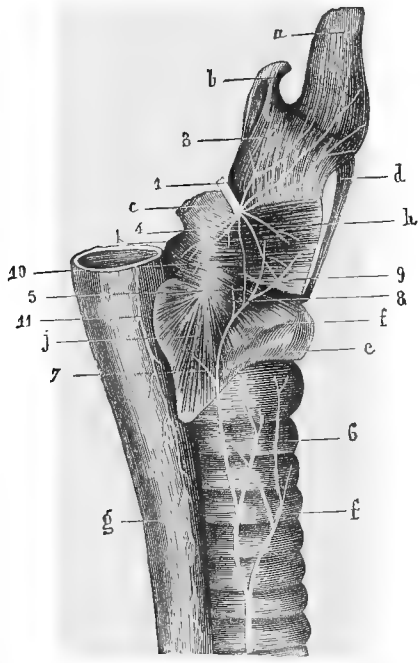

DISTRIBUTION OF THE NERVES IN THE LARYNX OF THE HORSE.

a, Base of the tongue; *b*, Epiglottis; *c*, Arytenoid muscles; *d*, Section of the thyroid cartilage to show the parts it covers; *e*, Cricoid cartilage; *f*, Trachea; *g*, Œsophagus; *h*, Thyro-arytenoid muscle; *i*, Lateral crico-arytenoid muscle; *j*, Posterior crico-arytenoid muscle; *k*, Arytenoid muscle.—1, Superior laryngeal nerve; 2, Inferior laryngeal; 3, Branches of the superior laryngeal passing to the epiglottis and tongue; 4, Branches of the superior laryngeal passing to the œsophagus; 5, Very fine multiple anastomoses between the two laryngeals; 6, Tracheal branches; 7, Branch to the posterior crico-arytenoid muscle; a portion is distributed, through the muscles, to the subjacent mucous membrane; 10, Branch passing to the arytenoid muscle; 11, Œsophageal branch of the pharyngeal nerve; it sometimes comes from the external laryngeal.—From Toussaint's work.

The two recurrent nerves are not quite symmetrical at their origin. That of the right side is detached from the pneumogastric below the axillary artery, nearly at the dorso-cervical arterial trunk. It is immediately reflected forward in embracing the origin of that trunk, which it crosses inwards to be placed against the trachea, in the middle of the principal cardiac nerves, with some of which it contracts intimate adherences.

On the left side, it is only when the pneumogastric nerve arrives near the root of the lung that it gives off its recurrent. To be reflected forward, the latter turns from left to right behind the arch of the aorta, and arrives beneath the inferior face of the trachea, among the cardiac nerves, with which it communicates like the right.

The inferior laryngeal nerves are in this way mixed, at a greater or less distance from their commencement, with those sympathetic nervous branches which collectively constitute the tracheal plexus. They are soon disengaged, however, and leave the chest, but always in proceeding along the inferior face of the trachea, then ascending on its sides, below the carotid arteries, which they gradually approach, and finally attain the larynx in penetrating beneath the crico-pharyngeal muscle.

According to Goubaux, the left recurrent must be situated more super-

ficially than the right in the lower part of the neck, and for this reason should be more exposed to compression. He thus explains why, in chronic "roaring" the alterations observed are nearly always in the left muscles of the larynx.

The terminal divisions of the recurrents are distributed to the posterior and lateral crico-arytenoid, and the arytenoid and thyro-arytenoid muscles, as well as to the subglottic mucous membrane.

In their long course, they emit collateral ramuscules that also ascend, and are distributed to the mucous membrane and muscular layer of the trachea, as well as to that of the œsophagus.

The *recurrent œsophageal ramuscules* are all sensitive, and form five groups: the first and second arise, on the left side, close to the arch of the aorta, ascend on the sides of the trachea, and pass to the portion of the œsophagus lying between that canal and the thoracic section of the longus colli muscle. The third, more considerable, springs from a branch that is given off at the brachial trunks; it is markedly recurrent, and forms on the side of the trachea, with the second, a small plexus, and then lies closely alongside the œsophagus, which it accompanies for a distance of eight inches from the first rib. The branch constituting the fourth group is the longest of all; it is detached about two or two and a-half inches in front of the first rib, and after emitting several long tracheal filaments, it ascends on the side of the trachea close to the border of the œsophagus, where it generally disappears at about six or eight inches from the pharynx. The fifth group is composed of a branch detached from the recurrent, about the point where the preceding terminates; it goes entirely to the origin of the canal.

TERMINAL BRANCHES OF THE PNEUMOGASTRIC NERVES.

1. Bronchial Plexus (Fig. 362, 29).—The bronchial plexus is formed by several branches from the pneumogastric, on the arrival of that nerve above the roots of the lungs, and which interlace in a network and ramify around the bronchial divisions following these into the texture of the pulmonary organ. It is these branches which give to the mucous membrane its great sensibility, and which provoke those evident contractions of which it is the seat.

2. Œsophageal Branches (Fig. 362, 30, 31).—After emitting the ramuscules of the bronchial plexus, each pneumogastric is continued along the œsophagus by two branches—a superior and inferior—making four branches for the two nerves. The two superior lie together, and are confounded in a single cord, either immediately, or after a certain course; the two inferior comport themselves in the same manner with one another; making a double anastomosis, from which arise the two nerves we are about to describe, and which are designated the *œsophageal nerves*, because of their situation. The right nerve forms a large portion of the superior cord; the left, especially, gives ramuscules to the inferior.

Placed between the layers of the posterior mediastinum, these two nerves follow the œsophagus for a certain distance, one above, the other below, giving off some ramuscules to that muscular canal, detaching one or two communicating branches, and traversing the opening in the right pillar of the diaphragm to penetrate the abdominal cavity.

The *inferior* terminates in the parietes of the stomach, by forming on the small curvature, to the right of the cardia, a very rich plexus

which throws the majority of its ramuscules into the right sac of that viscus.

The *superior* passes to the left of the œsophageal insertion, along with the gastro-pulmonary artery, and is lost in the solar plexus, after giving off numerous divisions on the left sac of the stomach, mixing with the sympathetic ramuscules that encircle the gastric artery, and anastomosing around the cardia with those of the inferior cord. It is very difficult to follow the filaments of this cord from the pneumogastrics after their arrival at the solar plexus; we nevertheless observe some of them passing to the liver, others accompanying the sympathetic branches that come from the solar to the posterior mesenteric plexus in following the small mesaraïc vein; no doubt the others find their way among the filaments of the trisplanchnic nerve, which proceed with the anterior mesenteric artery.

Functions of the Pneumogastric.—Formed by the two orders of fibres, the pneumogastric is a sensory-motor nerve, and the seat of reflux currents which make it play a very important part in several acts of vegetative life, and bring it into relationship with the great sympathetic nerve, with which we have seen that the tenth pair maintains anastomotic connexions in several points of its course.

It is the pneumogastric nerve that gives to the mucous membrane of the larynx the exquisite sensibility it enjoys.

It stimulates the motor muscles of that organ into movement.

To it is also due the sensibility of the broncho-pulmonary mucous membrane.

It excites the contractions of the muscular fibres in the broncho-tracheal passages—contractions which are involuntary, and under the influence of the reflex power.

It also provokes the movements of the œsophagus and stomach, which are also involuntary and due to reflex currents.

Perhaps it acts in an analogous manner—by reflex action—in the secretion of the gastric fluid and the functions of the liver; but these are points which science has not yet decided upon.

It appears proved that it does not exercise any direct influence on the essential phenomena of respiration.

It also appears proved that it acts on the heart in a very energetic manner, though this has been imperfectly determined. We only know that after its section in the region of the neck, the movements of the heart become very precipitate, and that we may diminish the force of these movements, or even completely arrest them, by galvanising the peripheral end of the nerve.

11. *Eleventh Pair, Spinal Nerves, or Accessory Nerves of the Pneumogastrics.* (Fig. 338, 2, 4.)

The spinal accessory is an exclusively motor nerve, which, at its exit from the cranium, is so intimately connected with the pneumogastric, that we might perhaps follow the example of Müller, and describe the two as forming one and the same pair.

Origin.—This nerve exhibits a singular disposition, in that it arises from the whole extent of the cervical spinal cord, and ascends in the spinal canal to near the pneumogastric, with which it leaves the cranium by the posterior foramen lacerum. It is also described as an encephalic nerve, in consequence of the latter peculiarity; but from its origin it is rather a

spinal nerve, a fact which is sufficiently indicated by the name generally given to it.

In the interior of the spinal canal, it is a long cord measuring from 27 to 31 inches in middle-sized animals. It commences, by a very fine point, at the cervical or brachio-rachidian bulb of the spinal cord, follows that organ in an ascending course, lying close to its lateral column, and passing between the roots of the two orders of cervical nerves until it arrives at the medulla oblongata, where it is inflected outwards at the foramen lacerum posterius, into which it passes to leave the cranium.

In this ascending track, it gradually increases in volume, as it at intervals receives additional filaments from the lateral column of the spinal cord, like the radicular extremity of the nerve itself. Before making its escape from the cranium, it receives, besides, some of the posterior or motor roots of the pneumogastric nerve. In the foramen lacerum, it becomes applied against the ganglion (jugular) of that nerve, in the manner of motor fibres of mixed nerves, and gives it some of its proper filaments.

The long cord here described as the root of the spinal accessory, is considered by some authorities as only a portion of this nerve, to which they give the name of *external* or *medullary root of the spinal accessory.* They designate as the *internal* or *bulbous root* of that nerve, the anastomosing filaments already described as the motor roots of the pneumogastric. According to them, this internal root only lies beside the pneumogastric for a very short distance, ultimately leaving it and forming the superior laryngeal and pharyngeal nerves, which seem to arise from the vagus rather than the accessory of Willis.

Distribution.—Beyond the ganglion of the pneumogastric, the spinal accessory remains beside the trunk of the pneumogastric for scarcely an inch; it then separates from it at an acute angle whose sinus is occupied by the great hypoglossal nerve, is directed backwards, passing beneath the superior extremity of the maxillary gland and levator humeri, gains the supero-posterior border of that muscle, and follows it to the front of the shoulder. Here it slightly ascends, crosses that region below the inner face of the cervical trapezius, and is distributed to the dorsal trapezius.

On its passage it emits: 1. One or two thick filaments to the superior cervical ganglion, proceeding from the spinal by a small plexiform network where the nerve separates from the pneumogastric; 2, Near the maxillary gland, a thick branch to the sterno-maxillaris muscle; 3, Slightly beyond this, another branch destined to the anterior portion of the levator humeri; 4, A series of ramuscules to the cervical trapezius.

In its course, the spinal accessory traverses the anterior part of the superficial cervical plexus, and receives additional ramuscules from the first, second, third, fourth, fifth, and sometimes even from the sixth cervical nerves.

Reduced to its medullary root, as has been described, the spinal accessory animates the muscles to which it is distributed, and through them has a share in expiration. By the contraction of these muscles, the ribs may be maintained raised for a certain period, and cause the air to be slowly expelled; also allowing the sounds or voice produced by its passage through the larynx to be modulated. Crowing is no longer possible in birds when the medullary root of the spinal accessory has been divided, as has been demonstrated by Bernard.

12. *Twelfth Pair, or Great Hypoglossal Nerves.* (Figs. 111, 22; 338, 5; 342.)

The *great*, or simply the *hypoglossal* nerve, is exclusively motor, and animates the muscles of the tongue.

Fig. 342.



DEEP NERVES OF THE HEAD.

1, Superior maxillary nerve at its exit from the foramen lacerum; 2, Trunk of the masseteric; 3, Trunk of the subzygomatic; 4, Buccal; 5, Lingual or gustatory; 6, Chorda tympani; 7, Inferior maxillary, cut near where it enters the maxillo-dental canal; 8, Trunk of the mylo-hyoideus; 9, Pterygoid; 10, Glosso-pharyngeal; 11, Its pharyngeal branch; 12, Its lingual branch; 13, Pneumogastric; 14, Superior laryngeal branch of that nerve; 15, Its pharyngeal branch; 16, Spinal accessory of Willis; 17, Great hypoglossal; 18, Origin of the cervical cord of the great sympathetic; 19, The same after its union with the pneumogastric.—*A*, Common carotid artery; *B*, Accessory thyroid artery; *C*, Thyro-laryngeal artery; *D*, Origin of the internal carotid artery—the vessel is concealed by the guttural pouch; *E*, Occipital artery; *F*, External carotid artery; *G*, Internal maxillary artery; *H*, Pharyngeal artery (drawn too large); *I*, External maxillary artery; *J*, Lingual artery; *K*, Origin of the maxillo-muscular artery; *L*, Posterior auricular artery; *M*, Trunk or origin of the superficial temporal artery; *O*, Inferior dental artery; *P*, Posterior deep temporal artery; *Q*, Anterior deep temporal artery; *R*, Maxillary gland; *S*, Wharton's duct; *T*, Sublingual gland. The letter *N* placed at the upper end of the large cornu of the hyoid bone has no signification.

Origin.—It originates at the lower face of the medulla oblongata, from

the prolongation of the line of insertion of the inferior spinal roots, by a dozen converging filaments. These traverse the dura mater in two or three bundles, which enter the condyloid foramen of the occipital bone, where they unite to form a single cord. The hypoglossal has also a ganglionic root which Toussaint constantly found in the Ass, Mule, Ox, and Dog, and which had been previously seen by Meyer and Vulpian. The ganglion of the hypoglossal in the Horse is fusiform, and the size of a small lentil (Fig. 338, 5′). It is sometimes absent.

Distribution.—The hypoglossal nerve thus constituted, immediately after its departure from the condyloid foramen, communicates with the first cervical pair by means of a transverse ramuscule; it then passes between the spinal accessory and pneumogastric nerves, descends on the external face of the guttural pouch, where it is connected with the superior cervical ganglion of the sympathetic by numerous filaments, which in great part form the plexiform network called the "guttural plexus." The nerve afterwards crosses to the outside of the external carotid artery, in proceeding forward and downward on the side of the pharynx and larynx, receiving at that point a slender ramuscule from the first cervical; it then passes within the inferior extremity of the stylo-hyoid muscle and the glosso-facial artery, which it crosses very obliquely, is prolonged between the mylo-hyoid and hyo-glossus brevis muscles, sends numerous small filaments to the latter and a ramuscule to the genio-hyoideus, and finally terminates in a series of branches analogous to those of the gustatory nerve, and which mix with them.

These branches are therefore reflected upwards, bending round the posterior border of the hyo-glossus brevis, and pass into the interstice between that muscle and the genio-glossus. They are distributed to all the muscles of the tongue.

The hypoglossals, being motor nerves, cause the contraction of the muscles of the tongue during the movements proper to mastication and the production of the voice. Though they most frequently act together, yet they may do so separately, as in the unilateral movements of the tongue.

DIFFERENTIAL CHARACTERS IN THE CRANIAL NERVES OF OTHER THAN SOLIPED ANIMALS.

In the domesticated mammals, the cranial nerves offer the greatest analogies; their origin is the same in all, and it is only in their distribution that we find some variety, due to the difference in the form of the head. Consequently, in this comparative analysis we shall not discover any fundamental differential characters.

RUMINANTS.—There is no difference to note in the *four first pairs.*

Trigeminal nerve.—Divided into three branches as in Solipeds. It has been stated that in Ruminants the ophthalmic branches are distributed to the majority of the muscles of the eye; in the *Sheep* we have only seen the *palpebro-nasal* nerve offering this relationship to the motor organs of that part. The anterior palatine nerve is relatively voluminous.

Facial nerve.—Towards the middle of its subparotideal course, this gives off a large *anterior auricular nerve:* when it arrives at the middle of the posterior border of the masseter muscle, it divides into two branches. The *inferior branch* passes obliquely downwards and forwards, towards the mental foramen, where it terminates as in the Horse; it furnishes an anastomotic branch to the *superior.* The latter crosses the middle portion of the masseter, and becomes mixed with the suborbital ramuscules of the fifth pair; about the middle of its course it receives a filament from the superficial temporal nerve. We need not allude to the *auditory* and *glosso-pharyngeal nerves,* except to say that the latter communicates with the pneumogastric soon after its exit from the foramen lacerum.

Pneumogastric nerve.—This offers numerous differences in its roots and distribution.

In the *Ox* and *Sheep,* the *sensitive roots* arise from an irregularly elliptical surface comprising the whole of the respiratory tract. They are from fifteen to twenty in

Fig. 343

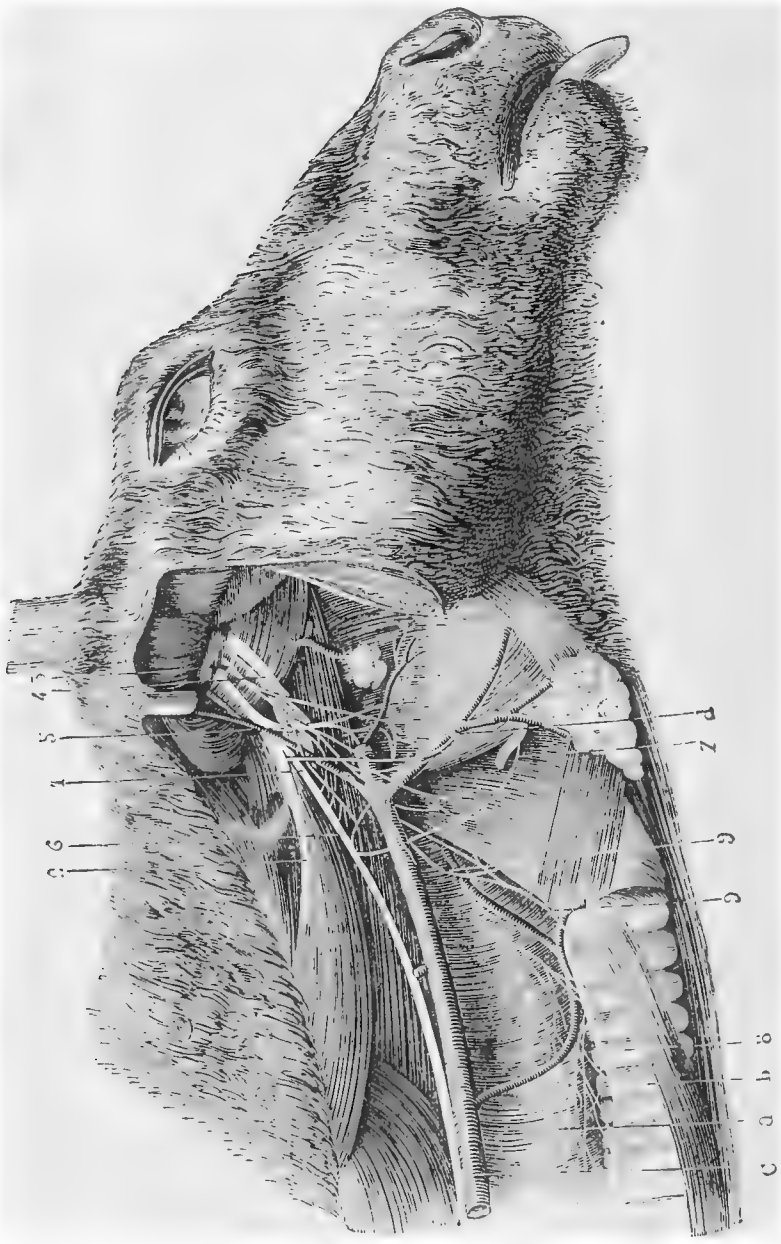

NERVES OF THE GUTTURAL REGION IN THE OX.

a, Œsophagus; *b*, Trachea; *c*, Common carotid artery; *d*, Glosso-facial artery; 1, Pneumogastric nerve; 2, Spinal accessory; 3, Glosso-pharyngeal; 4, Great sym-

number, and often join each other; they may divided into three principal fasciculi rising at slight distances.

The *motor roots* are a little larger than in the Horse; before joining the sensitive roots they are confounded in a small ganglion that pertains to them.

The *jugular ganglion* is voluminous, but apart from this it presents the same features as in the Horse, receiving all the proper roots of the pneumogastric and internal root of the spinal accessory, and even those which are united in their own ganglion. The portion of the ganglion that is more especially formed by the roots of the spinal accessory is rather an intrication of nerve-fibres than a real ganglion; it is impossible by the most minute dissection to separate it from the rest of the ganglion.

The jugular ganglion also receives a division of the glosso-pharyngeal, and it gives one to this nerve and the external branch of the spinal accessory.

The pneumogastric nerve, in the *guttural portion*, is much larger than in the Horse. This peculiarity is noticeable throughout its whole extent, and is indicated at its roots.

The ganglionic plexus is absent in the *Ox*. The course and relations of the nerve in this portion are analogous to those observed in Solipeds.

The *pharyngeal* nerve is voluminous, and the branch it sends to the œsophagus is the largest of its divisions: this branch passes backwards to the surface of the constrictors of the pharynx, joins the external laryngeal, gives a large branch to the thyro-pharyngeus, and is insinuated on the sides of the œsophagus, between it and the thyroid gland; there it divides into two portions, one of which descends on the sides of the œsophagus where it forms a very rich plexus with the branches from the inferior laryngeal, while the other is lost immediately in the recurrent nerve at the thyroid gland.

The *external laryngeal* arises at a short distance above the superior laryngeal, where it receives a large branch from the glosso-pharyngeal and another from the sympathetic, and immediately passes alongside the œsophageal branch of the pharyngeal nerve. With a little attention, we may dissect a fasciculus coming from the external laryngeal and passing to the crico-thyroid muscle, and the thyroid gland and its vessels, after receiving a branch from the superior laryngeal. In the *Sheep*, the external laryngeal sometimes gives a branch to the œsophagus, and which anastomoses with the inferior laryngeal, or descends on the side of the tube, conjointly with the œsophageal branch of the pharyngeal.

The *superior laryngeal* rises below the preceding; it is very voluminous, and communicates with the sympathetic, either directly or through the medium of the guttural plexus, and with the pharyngeal nerves and external laryngeal. Beneath the thyroid cartilage, a large division anastomoses with the inferior laryngeal, and is finally lost in that nerve below the larynx. It is easily seen that this branch gives, in the cervical region, a great number of filaments to the œsophagus and trachea.

With the exception of some insignificant peculiarities, the pneumogastric comports itself in the *cervical and thoracic regions* as in the Horse.

The *recurrents* arise as in Solipeds, but their relations are somewhat different in the cervical region. They are placed in the channel formed by the trachea and œsophagus, and are separated from the carotid artery and the cord common to the sympathetic and pneumogastric by the very great width of the œsophagus. Their distribution to the muscles of the larynx takes place as in the Horse; the only noteworthy feature is the anastomosis of the nerve, end to end, with the superior laryngeal. In the whole of its cervical portion, the branches to the œsophagus are more numerous and voluminous than in Solipeds, although they all have the same physiological office, except those that are derived from the branch of the superior laryngeal, which are motor.

The differences remarked in the nerve in the *abdominal cavity*, are in relation to the volume and form of the stomach and its compartments.

The following is what we have observed in the *Sheep*:

After receiving a large filament from the superior cord, the *inferior œsophageal nerve* divides into three principal branches: one passes to the left, furnishing nerves to the anterior face and greater curvature of the reticulum and the upper border of the rumen; a median, which is distributed to the anterior face of the psalterium, reaches the substance of the mesentery, follows the abomasum, to which it sends some filaments, and finally anastomoses with the retrograde nerves coming from a rich plexus that exists on the posterior face of the liver and gall-bladder; it forms, conjointly with the divisions of the

---

pathetic and cervical ganglion; 5, Pharyngeal nerve; 6, External laryngeal; 7, Superior laryngeal; 8, Inferior laryngeal; 9, 9, Œsophageal branches of the pharyngeal and external laryngeal.

solar plexus and superior œsophageal nerve, a rich plexus, from which arise branches to the liver, abomasum, and duodenum.

The *superior œsophageal nerve* is chiefly distributed to the rumen. Before reaching the stomach, it gives several divisions to the plexus already mentioned—and which might be named the "hepatic plexus," receives a large branch from the solar plexus, and sends to it a smaller one. It afterwards divides into two principal branches, the largest of which passes along the superior fissure of the rumen, along with the vessels of that organ. According to Lavocat, this branch forms a large plexus there, which has in its centre a ganglionic enlargement, whence emanate the ramuscules that go to the whole of the upper face, sides, and lower surface of the rumen. In the Sheep we have not found a ganglion, but this does not prevent this branch from being distributed to all the parts indicated by Lavocat.

The other branch is very large, and situated in the omentum until it arrives at its convex border, when it leaves it to be distributed to the left side of the abomasum; while the analogous nerve from the inferior œsophageal passes more especially to the right face.

Spinal accessory.—The origin of this nerve offers slight differences, which we have indicated in speaking of the motor roots of the pneumogastric. With regard to its distribution in the *Ox*, it offers the following features: At the inferior extremity of the transverse process of the atlas it divides into two branches, a superior and inferior. The first is a little larger than the spinal accessory of the Horse, and comports itself as in that animal. The inferior branch is directed downward and backward, traverses the muscle we have named the sterno-suboccipital, beneath a tendon that runs across the muscular fibres, and arrives between that muscle and the sterno-maxillaris. At this point it separates into a certain number of ramuscules, the first three or four of which are slightly recurrent, and enter the upper part of the sterno-maxillaris; the others are large and directed towards the sternum, to be distributed to the latter muscle, or to it and the sterno-suboccipitalis.

These branches of the spinal accessory represent the branch which, in the Horse, passes exclusively to the sterno-maxillaris. In reflecting on the distribution they offer in the *Ox*, we are brought to the conclusion that the sternal band, which has been described as belonging to the first, forms, with the sterno-suboccipitalis, one and the same muscle—the analogue of the sterno-maxillaris or sterno-mastoideus of Solipeds. These two muscular fasciculi are, otherwise, closely attached to each other, if not confounded near their origin at the anterior prolongation of the sternum.

Lastly, the *great hypoglossal nerve*, before crossing the pneumogastric, communicates with the first cervical by a considerable branch; lower, it gives off a long ramuscule that descends on the carotid artery.

Pig.—We need not refer to the *olfactory*, *optic*, or *motor nerve of the eye*, neither to the *glosso-pharyngeal*, as what has been said about them in Solipeds holds good in this animal.

Trigeminal nerve.—This also divides into three principal branches. The palpebro-nasal ramuscule of the *ophthalmic branch* anastomoses with a motor nerve of the eye on the deep face of the external rectus muscle. The *superior maxillary nerve* leaves the cranium by the great sphenoidal slit, and immediately enters the superior dental foramen; its orbital course is therefore very short.

Its *spheno-palatine branch* passes at once below the alveolar tuberosity, where it divides into several ramuscules: one, entering the palatine fissure, forms the *posterior palatine nerve;* the others pass into the palatine arch at various distances, to constitute the *middle palatine nerves;* some of them even enter the palatine canal with the *anterior palatine* or *palato-labial nerve.*

Facial.—Beneath the parotid gland, this divides into several branches, of which there are three principal. One is directed upwards, and passes in front of the ear; this is the smallest. The second proceeds forward, crosses the masseter near the zygomatic process, unites with the inferior branch, and is expended among the suborbital ramuscules of the superior maxillary. The third passes downward and forward, under the parotid gland, arrives in the intermaxillary space, is inflected in front of the masseter to become superficial, and terminates with the middle branch. Towards the maxillo-labialis muscle, this inferior branch gives off a ramuscule to the lower lip.

Pneumogastric.—This joins the great sympathetic near the upper third of the neck, and at its point of union offers a greyish enlargement resembling the gangliform plexus of Man. Until the origin of the œsophageal nerves, the pneumogastric of the Pig resembles that of the Horse. The latter is voluminous, and does not divide into two branches immediately beyond the bronchial plexus, but at some distance from it. Numerous anastomoses exist between the two œsophageal nerves—superior and inferior.

At their termination they differ much from each other in volume; the inferior is very small, and terminates on the anterior face of the stomach; the superior, much larger, partly remains at the stomach, and partly crosses the small curvature of that viscus to enter the solar plexus.

Spinal accessory.—This nerve commences and terminates as in Solipeds. After being inflected backward on the anterior border of the mastoido-humeralis, it divides into two ramuscules—a deep and superficial. The first is confounded with a cervical nerve, near the intervertebral foramen through which the latter passes; the second goes to the trapezius muscle, in which it is expended.

Near the base of the tongue, the *hypoglossal* gives off a filament that passes to the genio-hyoideus muscle.

CARNIVORA.—In these animals, the majority of the cranial nerves do not offer any important differences. We will, therefore, say nothing concerning the first two pairs, the motores oculorum, spinal accessory, and glosso-pharyngeal, except that the motor nerves of the eye are mixed with the filament of the ophthalmic branch among the muscles of the orbit.

Trigeminal nerve.—When the branch constituting the *superficial temporal nerve* reaches the posterior border of the maxilla, it divides into several ramuscules; one portion lies beside the middle branch of the facial, the other accompanies the anterior auricular nerve by becoming intimately united to it. We have also found, in the *Dog*, a branch that is detached from the inferior maxillary, almost immediately after its exit from the cranium; it descends into the intermaxillary space, in company with the facial artery; at the posterior border of the mylo-hyoideus muscle it separates into two ramuscules: one is applied to that muscle, and follows it to near the symphysis of the jaw; the other is inflected outwards and upwards, in front of the masseter muscle, and joins the inferior branch of the facial. Owing to this arrangement, each of the branches of the facial is provided with a sensitive ramuscule from the fifth pair.

Facial.—At its exit from the external auditory hiatus, it divides into four branches, three of which appear to form its termination. The first, the smallest, is directed downwards across the parotid gland, and constitutes the cervical ramuscule. The other three are distinguished as superior, middle, and inferior.

The *superior branch*, the largest, ascends towards the forehead, and describes a curve whose convexity is upwards, turns round the orbit, and terminates near its nasal angle. In its course it furnishes: 1, An anterior auricular ramuscule; 2, Above the insertion of the masseter, several muscular filaments; 3, It is crossed, above the eye, by the superciliary filaments of the ophthalmic nerve. The *middle branch* accompanies Stenon's duct to the surface of the cheek; reaching the anterior border of the masseter, it anastomoses in a very flexuous manner with the ramuscule of the inferior branch, and terminates in the upper lip and the end of the nose. The *inferior branch* passes towards the maxillary fissure; there it receives the sensitive ramuscule sent to it by the fifth pair, gives off filaments to the middle branch, and is then continued into the lower lip.

Pneumogastric.—The *sensitive roots* closely resemble, in their disposition, those in the Ox. The *motor roots* are separated into two series of filaments; the anterior unite in a small ganglion, then pass into the jugular ganglion; the posterior lie beside the medullary root of the spinal accessory, but leave it to become united with the jugular ganglion.

Below the foramen lacerum, the pneumogastric nerve gives off the pharyngeal nerve before forming the analogue of the plexiform ganglion of Man. This plexus is better defined than in him, and is a real fusiform elongated *ganglion*, at the grey basis of which some white filaments are seen. It is situated a little farther from the cranium than the superior cervical ganglion. The ganglion itself furnishes the superior laryngeal nerve, which gives off, as in Man, the *external laryngeal* nerve.

There is nothing to indicate in the pharyngeal nerve, its disposition being absolutely the same as in the Ox.

In the *Dog* the *superior laryngeal* has a curious disposition, which has not yet, to our knowledge, been described. Reaching the inner face of the thyroid cartilage, it gives off, as in the other animals, filaments to the glottis, epiglottis, base of the tongue, and œsophagus; but the ramuscule of Galien, which nearly equals the superior laryngeal in volume, does not anastomose with the inferior laryngeal; it gives a large branch to the crico-arytenoid muscle in passing to its surface, and then leaves the larynx to the inside of the recurrent, descending on the trachea as far as the entrance to the chest. In that cavity, the descending branch of the superior laryngeal forms two divisions that communicate with the ramuscules of various other nerves passing into this region. On the right side, the largest division receives a voluminous branch from the inferior cervical ganglion; then the two divisions unite, and join the pneumogastric after it has turned round the brachial trunk, a little behind the point of emergence of the inferior laryngeal

On the left side the same arrangement is found; the anastomoses are larger and more numerous than on the right side; the branch follows, in an inverse direction, the course pursued by the recurrent nerve, to join the pneumogastric at the part where the recurrent originates from the latter.

In this course, the branch gives large ramuscules to the œsophagus and trachea; those distributed to the former either pass along the muscular tunic and return again to the nerve, or continue along the surface of that tube. In all cases, there is found on the sides of the œsophagus a rich plexus formed by these filaments, as well as by those coming from the pharyngeal nerve.

This branch also offers other peculiarities. Thus, it is very often found alongside the laryngeal nerve for some distance, and sometimes at several points. When this happens in the upper part, at the larynx, as occurs in many cases, it appears to have an anastomosis as in the Ox; but it is always easy to separate the two nerves, even in fresh specimens, and this separation is greatly facilitated if the piece has been steeped in water acidulated by nitric acid.

In the *cervical portion*, the pneumogastric nerve is closely united to the sympathetic, the separation of the nerves being no longer possible as in the Horse and Ox.

We have already described a portion of the *inferior laryngeal* nerve, in speaking of the *tracheo-œsophageal* branch of the superior laryngeal. Comparison with other animals requires that we should transfer the latter to the recurrent. In the *Dog*, the inferior laryngeal rises by two distinct branches, a short distance from each other, on the right and left sides; these may, or may not, lie together for some distance, but they never become fused. The external part of the nerve receives at intervals filaments proceeding from the superior laryngeal branch, and it rarely gives very fine twigs to the trachea and œsophagus. The communications with the cardiac and tracheal nerves are also chiefly made by the tracheo-œsophageal branch.

The *bronchial nerves* are large and numerous.

The œsophageal plexus, which is furnished by the nerves of the same name, is larger and finer than in the Horse.

There is nothing to note particularly in the termination of the nerves in the stomach.

The *hypoglossal* gives a long branch that passes to the sides of the larynx, and enters the muscles on the anterior face of the trachea.

COMPARISON OF THE CRANIAL NERVES OF MAN WITH THOSE OF ANIMALS.

The few modifications offered by the cranial nerves of *Man*, when compared with those of animals, are dictated by the disposition of the parts and organs to which they are distributed.

We have spoken of the *olfactory lobes* when studying the brain, so that we need not again refer to them. The three succeeding nerves offer nothing worthy of mention.

Trigeminal nerve.—This has the same origin and divisions as in animals.

The *frontal nerve* of the ophthalmic portion divides into two branches; these are inflected upwards on the margin of the orbit, and distributed to the skin of the forehead. These two branches, well developed in the Dog, are distinguished as internal and external. The latter anastomoses with a branch of the facial. The *nasal nerve*, after spreading over the surface of the turbinated bones and the meatus, gives off a ramuscule that becomes subcutaneous in passing between the inferior border of the nasal bone and cartilage of the nostril; this is the *naso-lobular* nerve.

The *superior maxillary nerve* leaves the cranium by the foramen rotundum, reaches the suborbital furrow, and spreads over the face by suborbital branches. Like that of animals, it gives rise to an *orbital ramuscule*, and posterior and anterior dental branches. Differences appear in the other branches which are furnished, in animals, by the superior maxillary nerve: in Man these branches leave Meckel's ganglion. The filaments leaving this ganglion are: 1, The *pharyngeal nerve of Bock* which is distributed in the upper portion of the mucous membrane of the pharynx, in that of the Eustachian tube and the posterior orifice of the nasal cavities; 2, The *palatine nerves—great* or *anterior*—sent to the mucous membrane of the anterior portion of the palate; *middle palatine*, distributed to that of the soft palate, and *posterior palatine*, that goes to the two faces of the soft palate and its muscles; 3, The *nasal* or *spheno-palatine nerve*.

The *inferior maxillary nerve* closely resembles that of animals, the only differences consisting in: 1, The deep middle temporal nerve rising direct from the maxillary; 2, The lingual nerve is detached near the base of the cranium; 3, The superficial temporal nerve furnishes, independently of the filaments uniting it to the facial, an

auriculo-temporal branch that ascends in front of the ear, and terminates in the skin of the temporal region.

In Man, there is annexed to the fifth pair the *submaxillary ganglion*, which receives a sensitive branch from the lingual, a motor filament from the chorda tympani, and sympathetic filaments; it gives off several emergent filaments, nearly all of which pass into the maxillary gland. There is nothing to say of the *internal motores oculorum.*

Facial.—In its collateral branches, the facial nerve of Man is absolutely the same as in animals. It has, however, a branch not described in them—the *ramuscule of*

Fig. 344.

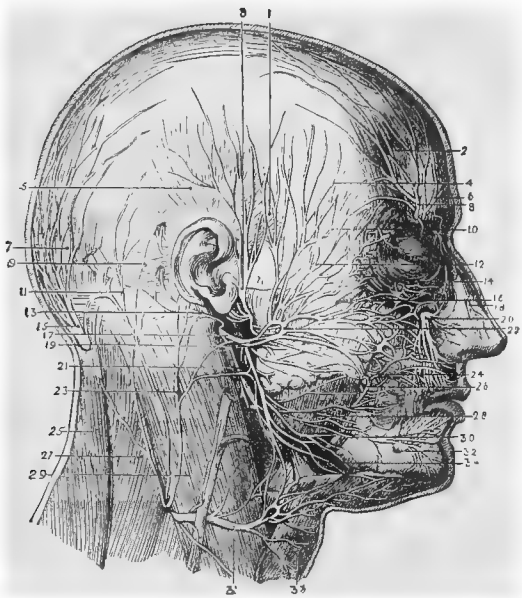

NERVES OF THE FACE AND SCALP.

1, Attrahens aurem muscle; 2, Anterior belly of occipito-frontalis; 3, Auriculo-temporal nerve; 4, Temporal branches of facial; 5, Attolens aurem muscle; 6, Supra-trochlear (5th); 7, Posterior belly of occipito-frontalis; 8, Supra-orbital; 9, Retrahens aurem muscle; 10, Temporal branch of temporo-orbital; 11, Small occipital; 12, Malar branches of facial; 13, Posterior auricular (7th); 14, Malar branch of temporo-malar (5); 15, Great occipital; 16, Infra-orbital branches of facial; 17, Facial; 18, Nasal; 19, Cervico-facial division of 7th; 20, Infra-orbital; 21, Branches of digastric and stylo-hyoid; 22, Temporo-facial division of 7th; 23, Great auricular; 24, Buccal branches of facial; 25, Trapezius muscle; 26, Buccinator (5th); 27, Splenius capitis; 28, Masseter; 29, Sterno-mastoideus; 30, Supermaxillary branches of facial nerve; 31, Superficial cervical; 32, Mental; 33, Platysma muscle; 34, Submaxillary branches of facial nerve.

Hirschfeld, which reaches the base of the tongue, where it is distributed by mixing with the glosso-pharyngeal. The termination much resembles that of the Dog. Two principal branches have been named the *temporo-facial* and the *cervico-facial.* The first receives the superficial temporal nerve, and describes an arch from which are detached the temporal, frontal, palpebral, suborbital, and buccal ramuscules, which form the subparotideal plexus. The second, lodged in the parotid, passes towards the angle of the jaw, where it anastomoses with the cervical plexus; it furnishes the inferior buccal, mental, and cervical branches.

Glosso-pharyngeal.—This nerve commences and terminates as in Solipeds, and has the same relations. It furnishes the *branches of the digastric* and *stylo-hyoid muscles*, the

Fig. 345.

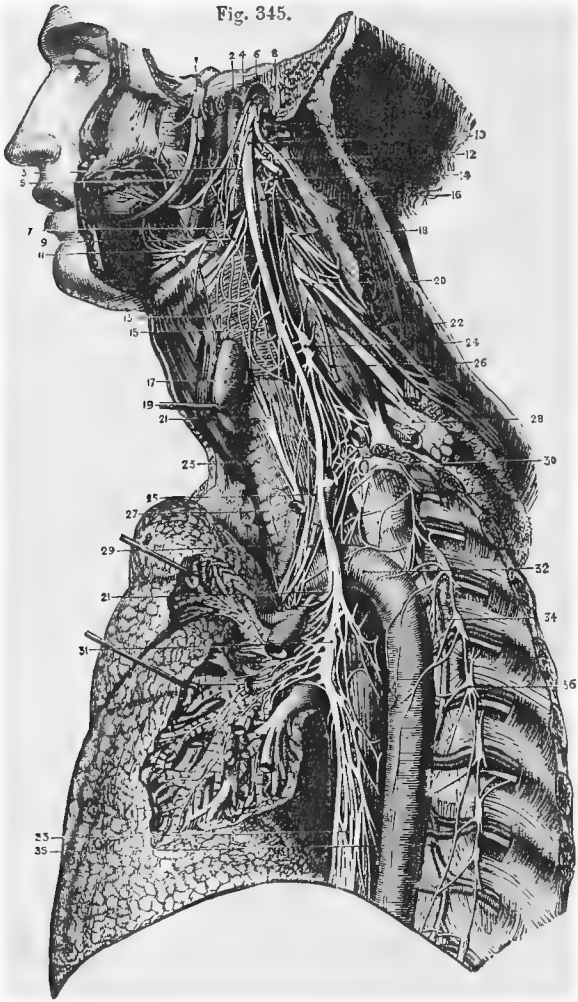

DISTRIBUTION OF THE EIGHTH PAIR OF NERVES ON LEFT SIDE.

1, Gasserian ganglion of 5th nerve; 2, Internal carotid artery; 3, Pharyngeal branch of pneumogastric; 4, Glosso-pharyngeal nerve; 5, Lingual nerve; 6, Spinal accessory; 7, Middle constrictor of pharynx; 8, Jugular (internal) vein, cut; 9, Superior laryngeal nerve; 10, Ganglion of trunk of pneumogastric; 11, Hypoglossal nerve on hyoglossus; 12, Ditto communicating with 8th and 1st cervical nerve; 13, External laryngeal nerve; 14, Second cervical looping with the first, 15, Pharyngeal plexus or inferior constrictor; 16, Superior cervical ganglion of sympathetic; 17, Superior cardiac nerve of pneumogastric; 18, Third cervical nerve; 19, Thyroid body; 20, Fourth cervical nerve; 21, 21, Left recurrent laryngeal nerve; 22, Spinal accessory communicating with cervical nerves; 23, Trachea; 24, Middle cervical ganglion of sympathetic; 25, Middle cardiac nerve of pneumogastric; 26, Phrenic nerve (cut); 27, Left carotid artery; 28, Brachial plexus; 29, Phrenic nerve (cut); 30, Inferior cervical ganglion of sympathetic; 31, Pulmonary plexus of pneumogastric; 32, Thoracic aorta 33, Œsophageal plexus; 34, Vena azygos superior; 35, Vena azygos minor, 36, Gangliated cord of sympathetic.

filament of the *stylo-glossus muscle*, and, finally, the tonsilitic ramuscules that form, around the amygdala, the *tonsilar plexus*.

Pneumogastric.—Formed by the union of the sensitive roots, the pneumogastric leaves the cranial cavity by the posterior foramen lacerum; in the interior of that foramen it shows the jugular ganglion; a little lower, it has a second fusiform enlargement, the *gangliform plexus*, which is found in the Dog. Here it receives the internal branch of the spinal accessory, or otherwise its motor roots. Beyond this gangliform enlargement, the pneumogastric is placed a little within the sympathetic, descends along the neck, enters the chest, and terminates on the stomach and in the solar plexus. The relations of the two pneumogastrics in the thoracic cavity are the same as in animals. In terminating in the semilunar ganglion, the two pneumogastrics unite and form an arch named the *memorable loop of Wrisberg*

The various anastomoses of the pneumogastric in Man offer nothing particular.

The *pharyngeal branches* leave the gangliform plexus, and are constituted by the filaments carried to the pneumogastric by the internal root of the spinal accessory. They are two, three, or four in number, and form the pharyngeal plexus.

The *superior laryngeal nerve* also arises from the gangliform plexus, and offers, as in Ruminants, a Galien branch that anastomoses, end to end, with a branch of the inferior laryngeal. The *external laryngeal* is furnished by this nerve; it is distributed to the inferior constrictor muscle of the pharynx, the crico-thyroid muscle, and the mucous membrane of the subglottic portion of the larynx and the ventricle of the glottis.

The *recurrent nerves* affect a distribution analogous to that already made known.

The pneumogastric also gives *cardiac*, *pulmonary*, and *œsophageal branches*. The cardiac lie beside those coming from the sympathetic and recurrents, and enter the ganglion of Wrisberg, situated at the base of the heart. The œsophageal branches are remarkable for their number and complexity, and form a veritable œsophageal plexus. The gastric branches are also very numerous.

Spinal accessory.—It presents bulbous roots which are well known, and medullary roots which usually extend to the fifth cervical, and sometimes to the first dorsal. After its exit from the posterior foramen lacerum, it divides into two branches—an internal and external. The internal branch, formed by the bulbous roots, enters the gangliform plexus of the pneumogastric. The external branch comports itself as in animals.

The *hypoglossal* resembles that of Carnivora, and, like it, possesses a branch for the hyo-thyroideus and genio-hyoideus.

CHAPTER II.

SPINAL NERVES.

We designate as *spinal*, *vertebral*, or *rachidian nerves*, those which emanate from the spinal cord, and leave the vertebral canal by the intervertebral foramina to proceed to the various organs.

They are estimated at 42 or 43 pairs, and are apportioned as follows in the five regions of the spine: *cervical*, 8 pairs; *dorsal*, 17 pairs; *lumbar*, 6 pairs; *sacral*, 5 pairs; and *coccygeal*, 6 to 7 pairs.

They differ from the encephalic nerves in closely resembling each other in the fundamental points of their constitution. All proceed from the lateral aspects of the spinal cord by two orders of roots: one motor, the other sensitive (Fig. 317). In all, these two roots unite in a very short trunk in passing through the intervertebral foramen; and this trunk divides almost immediately into two terminal branches: a superior, destined to the spinal muscles and the integuments covering them; the other, inferior, passes to the lateral and lower parts of the trunk or to the members. All send, from their inferior branch, one or more ramuscules to form the great sympathetic.

The roots of the spinal nerves offer everywhere the same disposition; each nerve is formed by two fasciculi of converging filaments, superior and inferior, which are naturally more numerous and large when they belong to

voluminous trunks, as may be remarked in those proceeding from the two enlargements (or bulbs) of the spinal cord. The common axis of these two fasciculi affects a transverse direction in nearly all the spinal pairs; but that of the posterior nerves inclines more backwards as they reach the terminal extremity of the cord.

The filaments of the superior fasciculi, or *sensitive roots*, are larger than the others, and emerge from the collateral sulcus of the spinal cord. They may be followed to the cells of the superior grey cornua.

The filaments of the inferior fasciculi, or *motor roots*, arise opposite to the preceding, on the lower face of the cord, at a short distance from the middle line, and on the limits of the inferior and lateral columns. They may also be traced to the interior of the cord, as far as the inferior grey cornua.

These filaments do not unite to form their common trunk until after they have passed through the dura mater; this is an extremely short trunk that occupies the corresponding intervertebral foramen, and presents on its upper face a ganglionic enlargement, which is exclusively placed on the course of its sensitive fibres; the motor filaments being simply laid beside them, and do not mix with them until beyond the ganglion. Immediately after this union, a small filament is given off that enters the spinal canal to be distributed to the sinuses and the vertebræ.

Fig. 346.

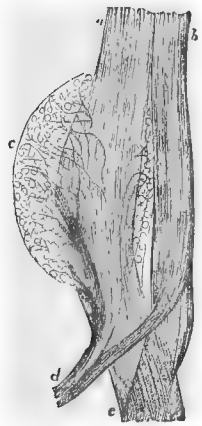

GANGLION OF A SPINAL NERVE FROM THE LUMBAR REGION OF A PUPPY.

a, Superior root; *b*, Inferior root; *c*, Ganglion on the superior root; *d*, *e*, Junction of the fibres from the inferior and superior roots with those coming from the ganglion. *d*, Superior trunk of spinal nerve; *e*, Its inferior trunk.

After leaving the meningeal sheath, the radicular fasciculi of the nerves furnished by the terminal extremity of the spinal cord, run a somewhat long course in the sacral canal, before finally uniting and passing into the tissues; the common fasciculus they collectively form at the posterior extremity of the spinal canal is named the *cauda equina*.

The distributive branches of the spinal nerves cannot be considered in a general manner, because of their diversity. We will study them successively in each region of the spine.

Article I.—Cervical Nerves (8 Pairs).

Superior Branches.—The *first* passes through the superior foramen of the atlas, in company with the cerebro-spinal artery. It arrives in the interstice between the small oblique muscle of the head and the posterior straight muscles, and divides immediately into several divergent branches which are distributed to the three above-named muscles, the anterior extremity of the great complexus, and the cervico- and temporo-auricular muscles. The ramuscule sent to the latter ascends within the concha, and breaks up into several filaments that supply the skin of the external ear.

The *second* immediately furnishes some ramuscules to the great oblique muscle, beneath which it is placed, as well as to the small oblique. It is afterwards directed backwards, comporting itself like the succeeding ones.

These diminish in volume from the third to the eighth. All pass through the intertransversales-colli muscles, and divide into several

branches, which are distributed to the muscles and integuments of the superior cervical region. Among these, the superficial, which are almost rudimentary in the two last pairs, reach the inner face of the splenius. The others, deep and more voluminous, cross the semispinalis colli, and, dividing, ascend between the great complexus and cervical ligament, to near the superior border of that large elastic lamina. They generally intercommunicate by several filaments, and in this way form a network on the inner face of the great complexus, which Girard named the *deep cervical plexus.*

Inferior Branches.—These branches augment in size from the first to the last, and separate into two perfectly distinct groups. The divisions of the first six cover the lateral and anterior parts of the neck, as well as the muscles of the breast. Usually anastomosing with each other by long communicating branches, they in this way form a vast nervous network traversed by two important nerves—the spinal accessory and cervical filament of the facial ; this is the *superficial cervical plexus.* The other two are united with the preceding by a filament passing between the sixth and seventh, soon becoming confounded with each other, as well as with the two first branches of the dorsal region ; they constitute, in common with the latter, the *brachial plexus.*

Without saying any more as to the disposition of this double plexus, we will pass to the particular description of each cervical pair of nerves.

First.—Deeply situated beneath the transverse process of the atlas, this nerve leaves the anterior foramen of that vertebra, and accompanies the occipital artery and vein to place itself immediately between the anterior small rectus capitis and rectus lateralis muscles. It then crosses the anterior great rectus capitis and the spinal accessory nerve, which it separates ; and arrives, after describing a slight curve forward, near the thyroid gland, finally entering the subscapulo-hyoideus by several terminal divisions.

Near its origin, this inferior branch of the first cervical nerve furnishes collateral ramuscules to the three recti muscles. Lower, it is in communication with the superior cervical ganglion and the spinal accessory nerve by several filaments. At the carotid artery, it sends forwards, to the side of the larynx, a very fine branch that quickly divides into two ramuscules, one of which joins the great hypoglossal nerve, and the other goes to the thyrohyoid muscle. It then throws off, from its convex side, several small descending nerves, all of which are destined to the subscapulo-hyoid, sterno-hyoid, and thyroid muscles.

One of these filaments, joined by a ramuscule from the second pair, is distinguished for its great length ; it may be followed to near the sternum, where it is expended in the fleshy mass common to the four muscles that extend from that bone to the larynx and os hyoides. Its constant disposition should obtain for it the name of *precervical nerve.*

Second.—This descends beneath the great oblique muscle (obliquus posticus), crossing the direction of the rectus anticus major, and ramifying therein by numerous branches. We specially indicate : 1, Those furnished to the latter muscle, and which are the shortest and deepest ; 2, The *atloid loop,* a long, thick superficial branch, which enters the anterior portion of the levator humeri, and is directed forward and upward on the parotid gland, bending round the transverse process of the atlas : this ramuscule gives off filaments to the parotido-auricularis, as well as to the subcutaneous muscle of the face, and terminates in two branches of unequal volume, the largest of which ascends on the outer side of the concha, and the other, situated behind, reaches the cervico-auricular muscles ; 3, Another superficial

branch, which passes over the jugular, near the junction of the glosso-facial, and divides into two ramuscules; these proceed forward with the glosso-facial vein to the intermaxillary space, where they are distributed to the skin and subcutaneous muscle; 4, Anastomosing filaments, which unite it to the two branches of the spinal nerve; 5, Accessory ramuscules to the cervical filament of the facial nerve; 6, Two communicating branches which pass beneath the rectus anticus major: one going to the first, the other to the third pair of nerves; 7, A deep branch going to join the precervical filament of the first pair, and directly throwing off some fine divisions to the subscapulo-hyoid muscle; 8, A last branch that arises at the intervertebral foramen, and passes at first, with the vertebral artery, into the trachelian (posterior) foramen of the second vertebra, and afterwards those of the succeeding vertebræ, to enter the inferior cervical ganglion of the great sympathetic nerve, receiving on its course filaments from the 3rd, 4th, 5th, 6th, and 7th pairs.

Third, fourth, fifth, and sixth.—Each of these crosses the intertransversales colli by a different interstice to that through which the corresponding superior branch passes. They gain the inner face of the levator humeri, where they divide into deep and superficial ramifications.

The first are distributed to the deep muscles of the sides and anterior part of the neck and shoulders. Among them ought to be distinguished those which form a communication between the four pairs, and the third with the second. Very long and thin, these filaments lie on the side of the large muscular column formed in front of the cervical stalk by the rectus anticus, longus colli, and scalenus muscles, where they form sometimes arches, and at other times anastomoses by convergence. Those of the fifth and sixth pairs, uniting at the anterior border of the scalenus with a branch of the brachial plexus, constitute the *diaphragmatic nerve*, which will be noticed hereafter.

The superficial ramuscules gain the external surface of the levator humeri by traversing its substance, or passing between its two portions. Much more numerous and larger than the preceding, they are distributed, in front, to the subcutaneous muscle of the neck, behind, to the trapezius, or below, to the levator humeri and superficial pectoral. Those passing to the last two muscles are very long and voluminous; they represent the *acromial* and *clavicular* branches of the *cervical plexus* of Man. It may be remarked that the posterior filaments generally communicate with the spinal accessory, while the anterior ones, in meeting the cervical branch of the facial nerve on the jugular, often give it some anastomosing fibres.

Seventh.—An enormous branch comes from the interstice between the two portions of the scalenus, to pass entirely into the brachial plexus. It usually receives an anastomosing twig from the diaphragmatic filament furnished by the sixth pair.

Eighth.—This is thicker than the preceding, and comports itself like it. It directly furnishes its anastomotic branch to the inferior cervical ganglion.

Article II.—Dorsal Nerves (17 Pairs).

These nerves, numbering seventeen pairs, comport themselves in an extremely simple and almost identical manner; so that their description is not nearly so complicated as that of the nerves of the cervical region.

Superior Branches.—They present two principal ramuscules destined to the spinal muscles, and to the skin of the dorso-lumbar region. One

ascends towards the summit of the spinous processes of the dorsal vertebræ, by passing between the semispinalis and longissimus dorsi; the other is directed outwards, in traversing the substance of the latter muscle.

Inferior Branches.—These are more considerable in size than the preceding, and descend into the intercostal spaces, between the pleura and the internal intercostal muscles, or even in the texture of these. With the exception of the first, whose arrangement is different, they all pass at first over the head of the posterior rib to reach the convex border of the anterior one, and follow it to the extremity of the intercostal space.

There they terminate in the following manner: those of the sternal ribs traverse the pectoral muscles, giving filaments to these, and are expended in the skin of the subthoracic region. Those of the asternal ribs enter the abdominal muscles, passing between the transversalis and rectus abdominis; they also give cutaneous filaments to the skin of the belly.

Near their origin, the inferior branches communicate with the great sympathetic, for the most part, by several filaments.

In their course they furnish numerous fine ramuscules to the intercostal muscles, and, in addition, give off, about the middle of their length, a very thick division—the *perforating intercostal branch*, which traverses the costal muscles and descends beneath the panniculus carnosus, ramifying partly in that muscle and partly in the skin. The most anterior perforating branches generally anastomose with the subcutaneous thoracic branch of the brachial plexus.

With regard to the first dorsal pair, its inferior branch enters the latter plexus; but it nevertheless furnishes an intercostal branch, always extremely slender, which passes over the external intercostal muscle to be expended in its substance before arriving at the sternum. The second pair also concurs in the formation of the brachial plexus, though only by a small branch.

Article III.—Lumbar Nerves (6 Pairs).

Superior Branches.—Destined to the spinal muscles and the integuments of the loins and croup, these are larger than the corresponding branches of the dorsal region, and present an analogous disposition; they give superior ramuscules to the muscles of the spine, and very long external divisions which pass through these muscles to be distributed to the skin of the croup.

Inferior Branches.—The *first*, comprised in the interval separating the last rib from the first lumbar transverse process, between the quadratus lumborum and the psoas magnus, passes downwards and backwards until it gets between the transverse and internal oblique muscles of the abdomen, to which it gives filaments, and is finally distributed in the great rectus muscle.

Above the superior border of the internal oblique muscle, it furnishes a perforating branch to the skin of the flank and the posterior part of the panniculus carnosus.

The *second*, disposed in the same manner as the preceding, follows an analogous course, and breaks up into several divisions which are lost in the small oblique muscle. From one of these sometimes emanates a slender filament, which joins one of the inguinal nerves of the third pair. We must not overlook, in the enumeration of the branches emitted by this second pair of lumbar nerves, the two perforating branches which descend in front, and on the inside, of the thigh, to be distributed to the skin of the flank and the internal crural region.

The *third*,[1] also passes outwards, above the psoas muscles, which receive from it several divisions, and ramifies in the muscles of the flank. It has also perforating nerves, destined to the inguinal region, and these comport themselves in a sufficiently interesting manner to merit particular mention. They are usually three in number: an *internal* and two *external inguinal nerves*. The three pass at first beneath the peritoneum, and are directed backwards, downwards, and outwards, towards the inguinal canal, which they enter, one to the inside, the other to the outside of the spermatic cord. They give off some filaments to the cremaster and abdominal muscles, and at last ramify in the envelopes of the testicle, the sheath, and the skin of the inguinal region. The two external nerves are often confounded in a single trunk on their arrival at the cremaster muscle. The disposition they affect at their origin is extremely variable; sometimes they have each a distinct commencement, and separately traverse either the small or large psoas muscle, or the space between these; and, at other times, the internal and one of the external inguinal nerves proceed from a common trunk at the intervertebral foramen, the second external nerve then arising alone towards the external border of the great psoas muscle. Most frequently, the internal nerve receives a branch from the fourth pair, and it is even sometimes entirely formed by that branch. This variation in arrangement is not, however, the exclusive appanage of the inguinal nerves; we have seen the third pair only supply these three nerves and the filaments of the psoas muscles, without being prolonged into the muscles of the flank.

The *fourth*[2] pierces the small psoas muscle, and enters the space separating it from its congener—the great psoas. After passing between the peritoneum and the lumbo-iliac aponeurosis, it arrives below the angle of the haunch, and makes its exit from the abdomen; it then descends within, and in front of, the fascia lata muscle, and accompanying the divisions of the circumflex iliac artery, it is prolonged to the stifle, where it is expended in the skin. At its origin, it abandons: 1, A thick, short branch to the great psoas muscle; 2, A large anastomosing branch which concurs in the formation of the lumbo-sacral plexus; 3, A filament that joins the internal inguinal nerve furnished by the third pair. We have already mentioned that this nerve sometimes emanates entirely from the fourth pair.

The *fifth* and *sixth*, much more voluminous than the preceding, unite, and, with the three first sacral pairs, form the nervous plexus of the abdominal limb.

All the inferior lumbar branches communicate with the great sympathetic by several filaments, which pass across the fasciculi of the small psoas muscle; and all communicate with each other: the two last by fusion of their fibres, and the first five by means of more or less voluminous anastomotic branches which are far from being constant.

Article IV.—Sacral Nerves (5 Pairs).

We describe, as *sacral nerves*, not only the four double cords which escape by the lateral foramina of the os sacrum, but also the nerve that passes through the intervertebral foramen between that bone and the last lumbar vertebra.

Superior Branches.—These are small ramuscules that pass through the

[1] Representing the *abdomino-genital* and *femoro-genital* branches of Man.
[2] The *femoro-cutaneous branch of the lumbar plexus* of Man.

supersacral foramen, reach the muscles lodged on the sides of the sacral spine, and terminate in the skin of the croup.

Inferior Branches.—Thick nervous trunks, which diminish in volume from the first to the fifth, and leave the sacral canal to pass downwards and backwards on the sides of the pelvic cavity.

The *first*, *second*, and *third* are directed towards the great ischiatic opening, and are united into a wide nervous band that constitutes the pelvic portion of the lumbo-sacral plexus, to be described at another time.

The *fourth* and *fifth* course along the side of the pelvic cavity, in the texture of the sacro-sciatic ligament, or even within it; united at their base by an anastomosing filament, they do not usually communicate in a direct manner with the fasciculus formed by the three first pairs.

The *fourth* constitutes the *internal pudic* nerve, which passes between the two roots of the corpora cavernosa in bending round the ischial arch, where it lies nearly alongside its fellow of the opposite side. This nerve afterwards descends on the dorsal border of the penis in the midst of the magnificent venous plexus of that organ, describing flexuosities which allow it to adapt itself to the elongation of the penis. Arriving at the extremity of the organ, it terminates in numerous divisions in the proper erectile tissue of this part, or in the mucous membrane covering it. On its course it emits very long flexuous branches, whose ultimate ramifications enter the corpora cavernosa, or go to the urethral canal; before leaving the pelvis, it gives off, behind, two thin ramuscules destined to the muscles and skin of the perineo-anal region. These ramuscules, like the principal trunk, receive anastomotic filaments from one of the ischio-muscular branches of the lumbo-sacral plexus.

The *fifth* is the *anal* or *hæmorrhoidal* nerve. It passes backward, above the preceding, and is distributed to the sphincter muscle and the surrounding integuments. Before quitting the pelvis, it gives a ramuscule to the levator ani.

The five inferior sacral branches emit, near their origin, a more or less slender filament that proceeds to the pelvic or hypogastric plexus. The anastomotic divisions, through which they communicate with the sympathetic chain, are generally thick, short, and multiple.

Article V.—Coccygeal Nerves (6 to 7 Pairs).

In the coccygeal region are found two pairs of nerves, one placed beneath the depressor muscle of the tail, the other below the lateral sacro-coccygeal muscle. These two nerves extend to the extremity of the tail, throwing off on their track some muscular and cutaneous filaments. They are formed by the superior and inferior branches of the coccygeal nerves, which gradually amalgamate to form the two trunks.

These coccygeal branches are six or seven in number, and very distinct; they diminish in volume from the first to the last. The first only gives a slender filament for the formation of each coccygeal trunk; it is chiefly expended in the integuments and muscles at the base of the tail.

Article VI.—Composite Nerves formed by the Inferior Branches of the Spinal Nerves.

We already know that these nerves represent three groups: 1, The *diaphragmatic nerve*; 2, The *brachial plexus*; 3, The *lumbo-sacral plexus*. They will be studied in this order.

DIAPHRAGMATIC (OR PHRENIC) NERVE.

The *diaphragmatic nerve* (the *internal respiratory nerve* of Bell) is formed by two principal branches, and a small accessory ramuscule whose presence is not constant. The latter comes from the fifth cervical pair; the two others proceed, one from the next pair, the other from the brachial plexus. The branch from the sixth pair pierces the inferior scalenus muscle from within to without, gives off a filament to the brachial plexus, and descends obliquely backwards to the surface of the muscle it passes through, to unite, at the entrance to the chest, with the branch of that plexus. This latter branch, generally shorter and thicker, comes exclusively from the seventh cervical pair.

The trunk of the diaphragmatic nerve, formed in this manner, after receiving the branch of the fifth pair—when it exists, passes within the axillary artery, along with the pneumogastric nerve, and often at this point, though not always, obtains a filament from the great sympathetic. It then gains the side of the base of the heart, passing beneath the pleura, and finally attains the phrenic centre, after a course of at least eight inches between the two laminæ of the posterior mediastinum—the left nerve being in the proper mediastinum, while that of the right side lies in the serous septum intended for the posterior vena cava.

Even before its arrival at the aponeurotic centre, this nerve divides into several branches, whose ramifications pass to the sides of the pillars of the muscle.

BRACHIAL PLEXUS.

This plexus comprises an enormous fasciculus of nerves, situated between the thoracic parietes and the inner face of the anterior member, formed by the inferior branches of the sixth, seventh and eighth cervical, and the two first dorsal pairs, and principally destined to the muscles and integuments of that limb.

Mode of constitution.—The sixth cervical pair only assists in the formation of this plexus by the slender filament from its diaphragmatic branch; but the next two are entirely devoted to it, as well as the first dorsal, with the exception of a very thin ramuscule, which constitutes the first intercostal nerve. The root furnished by the second dorsal pair only represents a very small part of its inferior branch, the other portion forming a somewhat voluminous intercostal nerve.

The various branches converge towards each other, and gain the interstice between the two portions of the scalenus muscle (if we consider it as one), where they unite, and become confounded into a single fasciculus by sending filaments and ramuscules to each other, this fasciculus soon separates into a certain number of divisions, whose disposition will be referred to presently. It will be remarked that the intercrossing of the branches composing the brachial plexus does not occur in a confused and irregular fashion, and if the reticulation of the ramuscules passing from one to another does not take place in a constant manner, it is, at any rate, far from being inextricable. It is easy to follow the filaments from any pair of nerves for a certain distance in the divisions given off by the brachial plexus, especially after maceration in dilute nitric acid. This originating fasciculus of the brachial plexus is very wide and short. It is at first comprised between the superior portion of the scalenus (or superior scalenus) and the longus colli. In passing between the two portions of that muscle, it bends round the first rib

by its posterior border, and corresponds inwardly to the vertebral artery and vein, as well as to the nervous vertebral filament proceeding to the sympathetic, and accompanying these vessels.

Mode of distribution.—Immediately after leaving the interspace in the scalenus, the brachial plexus arrives beneath the shoulder, near the scapulo-humeral angle. There it divides into a certain number of branches, amongst which it is impossible to distinguish the terminal divisions and collateral ramuscules. Without noticing this distinction, however, we will describe them in succession, commencing with those that pass to the trunk, and afterwards those which are destined for the limb. The latter will be examined in the following order: first, the shortest, or those which proceed to the upper parts of the member, and next, the longest branches, or those passing to the foot.

All these divisions are named and classified in the following enumeration:

1. *Diaphragmatic branches.*
2. *Angularis and rhomboideal branch.*
3. *Serratus magnus or superior thoracic branch.*
4. *Pectoral or inferior thoracic branches.*
5. *Subcutaneous thoracic branch.*
6. *Latissimus dorsi or great dorsal branch.*
7. *Axillary nerve.*
8. *Adductor brachii or teres major branches.*
9. *Subscapular branches.*
10. *Superscapular nerve.*
11. *Anterior brachial or musculo-cutaneous nerve.*
12. *Radial nerve.*
13. *Ulnar or cubito-cutaneous nerve.*
14. *Median or cubito-plantar nerve.*

PREPARATION OF THE BRACHIAL PLEXUS.—The animal is placed in the first position, and slightly inclined to one side by allowing one of the anterior limbs to hang unrestrained. The pectoral muscles are then excised close to their insertion in the unfixed limb, and turned upwards, maintaining them in this position by the chain tentacula which are detached superiorly to a band that unites the extremities of the two suspensory diagonal bars. Care should be taken to separate the pectoralis magnus from the panniculis, in allowing the latter to fall on the table along with the limb. By tearing through the considerable mass of cellular tissue surrounding the nerves of the brachial plexus, these soon appear, and may be isolated with the greatest facility. It is advisable in this dissection to preserve the arteries; and it is also of importance to leave the perforating intercostal branches intact, in order to observe the anastomoses of these with the subcutaneous thoracic division.

In this operation, the anterior limb is very much separated from the trunk, and the relations of the nerves are necessarily more or less changed; but it exhibits the whole of the plexus in the most perfect manner.

To trace the divisions of the principal nerves from this plexus, a limb entirely removed from the body is made use of, and, if possible, with the arteries injected. The nerves are then found in their natural relations, and can be more readily dissected. Figures 347, 348 will guide the student in looking for these nervous divisions.

1. *Diaphragmatic Branches.*

See the description of the diaphragmatic nerve above.

2. *The Angularis and Rhomboideal Branch.* (Fig. 347, 7.)

Entirely furnished by the sixth cervical pair, this branch is directed upwards to the surface of the angularis (anterior portion of the serratus

magnus). It soon divides into several filaments, which are wholly expended in the substance of that muscle, the serratus magnus, and the rhomboïdeus. The filament supplying the latter is slender and very long, and, to reach its destination, passes through the angularis.

3. *Serratus Magnus, or Superior Thoracic Branch.* (Fig. 347, 8.)

This very remarkable branch proceeds by two principal portions from the fasciculus common to all the divisions of the brachial plexus: one emanating from the sixth cervical pair; the other from the seventh, and always traversing the last fasciculus of the scalenus before joining the first. The single branch resulting from the union of these two roots is thin and very wide. It passes back to the surface of the serratus magnus, crossing the direction of its fibres, and is expended in its substance, sending regularly-arranged ramifications upwards and downwards.

This is the respiratory nerve of Bell.

4. *Pectoral or Inferior Thoracic Branches.*

Five principal are distinguished:

1. One emanating from the sixth and seventh cervical pairs, particularly the former, and passing to the internal face of the sterno-prescapularis (or pectoralis), to ramify exclusively among its fibres, after dividing into two branches: an anterior, short and thick, and a posterior, long and slender (Fig. 347, 10).

2. A second branch, arising from the anterior brachial and cubito-plantar, or median nerves, by two roots, which join in forming an arch beneath the maxillary artery.

It passes between the two portions of the deep pectoral muscle, and terminates in the superficial one, after furnishing some ramuscules to the pectoralis magnus by means of a long thin filament which is carried back to the external surface of that muscle (Fig. 347, 11).

3. The other three, destined to the pectoralis magnus, generally come from the trunk that constitutes the subcutaneous thoracic branch. Comprised between the serratus magnus, and pectoralis magnus, they are directed downward and backward, and enter the latter muscle. One of them, longer and thicker than the other, follows the course of the spur vein.

5 *Subcutaneous Thoracic Branch.* (Fig. 347, 9.)

This is a very remarkable nerve, arising from the brachial plexus by a trunk common to it and the ulnar nerve. Placed at first to the inside of that nerve, it soon leaves it to pass backward to the internal face of the caput magnum and the panniculus carnosus. In its long course, it acts as a satellite to the spur vein, above which it is situated. It may be followed to the flank, where its terminal divisions are lost in the substance of the subcutaneous muscle. Those it gives off are also destined to that muscle; they anastomose with the majority of the perforating intercostal nerves, forming an elaborate network on the inner face of the panniculus.

One of its branches, along with a voluminous perforating nerve, bends round the inferior border of the latissimus dorsi, and passes forward to enter the scapulo-humeral portion of the subcutaneous muscle.

Fig. 347.

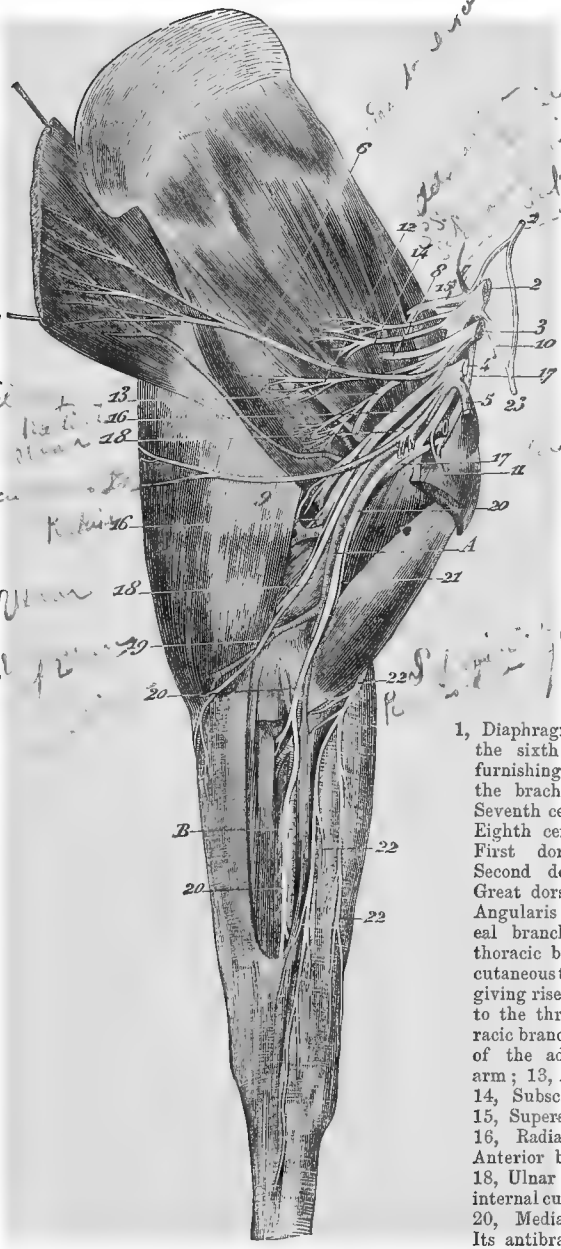

NERVES OF THE BRACHIAL PLEXUS.

1, Diaphragmatic branch of the sixth cervical pair, furnishing a branch to the brachial plexus; 2, Seventh cervical pair; 3, Eighth cervical pair; 4, First dorsal pair; 5, Second dorsal pair; 6, Great dorsal branch; 7, Angularis and rhomboideal branch; 8, Superior thoracic branch; 9, Subcutaneous thoracic branch, giving rise, near its origin, to the three inferior thoracic branches; 12, Nerve of the adductor of the arm; 13, Axillary nerve; 14, Subscapular nerves; 15, Superscapular nerve; 16, Radial nerve; 17, Anterior brachial nerve; 18, Ulnar nerve; 19, Its internal cutaneous branch; 20, Median nerve; 21, Its antibrachial musculocutaneous branch; 22, 22, 22, Superficial ramuscules of that branch.—A, Humeral artery; B, Posterior radial artery.

6. *Great Dorsal Branch.* (Fig. 347, 6.)

Formed of fibres, the larger portion of which come from the eighth cervical pair, this branch proceeds backwards and upwards to the internal face of the latissimus dorsi, and is soon expended in that muscle. It is long and thick.

7. *Axillary or Circumflex Nerve.* (Fig. 347, 13.)

Somewhat considerable in volume, this nerve is furnished directly by the eighth cervical pair. It passes backward and downward on the internal face of the subscapularis muscle, to the interstice between it and the adductor of the arm, where it crosses the subscapular artery. It proceeds behind the scapulo-humeral articulation, along with the circumflex artery, enters between the short abductor of the arm and the caput magnum and medium, and arriving beneath the abductor brachii, it divides into several diverging branches, destined to the two abductors, the levator humeri, and even to the integuments covering the anterior region of the arm.

Before entering the space that lodges the subscapular artery, it sends filaments to the teres internus.

8. *Nerve of the Adductor of the Arm or Teres Major.* (Fig. 347, 12.)

This arises from the eighth cervical pair, like the preceding, by the same trunk, and passes backward, at first on the subscapularis muscle, then the adductor, in the substance of which it disappears by numerous filaments.

9. *Subscapular Branches.* (Fig. 347, 14.)

These branches are two in number, and are generally derived from the trunk of the seventh pair. After a short course backwards, they divide into several ramuscules which pass among the fibres of the subscapularis muscle.

10. *Superscapular Nerve.* (Fig. 347, 15).

Very short and thick, this nerve is formed by the sixth and seventh cervical pairs. After a brief course backwards, between the angularis on the one side, and the pectoralis prescapularis and superspinatus on the other, it gains the space between the latter muscle and the subscapularis, and enters it a little above the super- or prescapular artery. It is then carried to the external face of the scapula, after bending round the anterior border of that bone, passes across the acromion spine, and ascends to the subspinous fossa, to expend itself in the muscle occupying this space. On its passage beneath the superspinatus, it gives off several ramuscules to that muscle.

11. *Anterior Brachial or Musculo-cutaneous Nerve.* (Fig. 347, 17.)

This nerve proceeds from the seventh and eighth cervical pairs, descends to the internal face of the scapulo-humeral articulation, and meets the axillary artery, which it crosses outwardly, at an acute angle. It then joins the median nerve by a large short branch, that passes beneath the artery and forms a loop around it; descending in front of the median nerve, to the bifurcation of the coraco-humeralis, it insinuates itself between the two branches of that muscle, and breaking up into several ascending

and descending ramuscules, enters the substance of the coraco-radialis. It also furnishes filaments to the coraco-humeralis, before its passage between the two branches of that muscle. Besides this, it concurs, by a small branch, in the formation of one of the anterior thoracic nerves.

12. *Radial Nerve.* (Figs. 347, 16; 348, 3.)

This is certainly the largest nerve furnished by the brachial plexus. It arises chiefly from the first dorsal pair, and is directed backwards and downwards, on the inner face of the subscapularis and adductor muscle of the arm, whose direction it crosses. In this portion of its course, it proceeds parallel to the humeral artery, from which it is separated by the ulnar nerve. Arriving at the deep humeral artery, which it leaves on the outside, it passes behind the humerus with the divisions of that artery, and enters between the large extensor and short flexor of the fore-arm. After creeping along the posterior border of the latter muscle, it gains the anterior face of the ulnar and radial articulations, where it is covered by the two principal extensors of the metacarpus and the phalanges, and meeting the radial artery, accompanies it on to the oblique extensor of the metacarpus. There it terminates by two branches which enter the texture of that muscle.

Fig. 348.

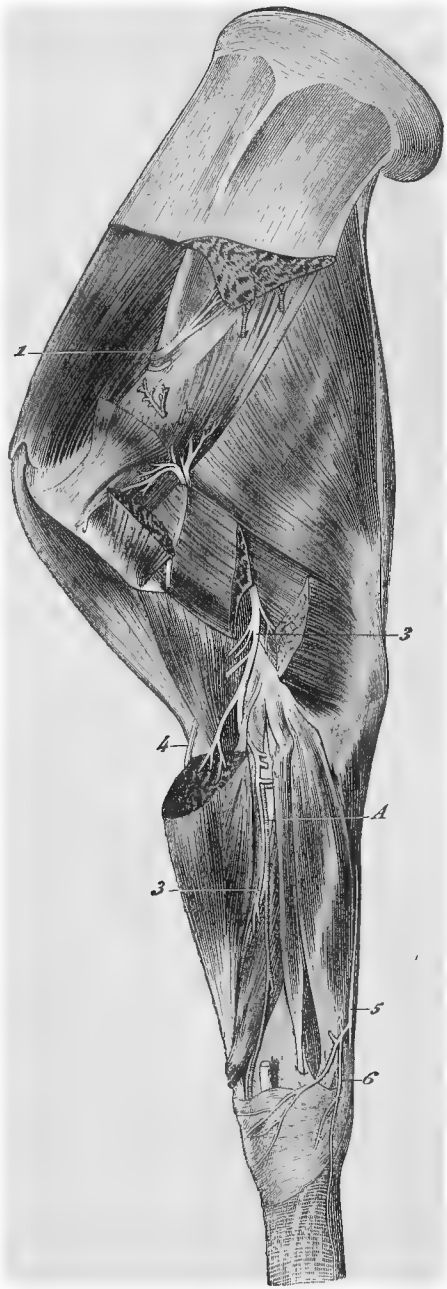

EXTERNAL NERVES OF THE ANTERIOR LIMB.

1, Subscapular nerve; 2, Axillary nerve; 3, Radial nerve; 4, Superficial ramuscule of the musculo-cutaneous nerve; 5, Ulnar nerve; 6, Its terminal cutaneous branch.—A, Anterior radial artery.

In its course, it successively gives off:

1. Before leaving the internal face of the limb, to pass beneath the mass of extensor muscles of the fore-arm, a very thick fasciculus, composed of several branches—descending and ascending. The latter bend round the terminal tendon common to the latissimus dorsi and teres internus, to become lost in the body of the great extensor; the others reach either the long and middle extensors, or the inferior portion of the principal muscle—the large extensor.

2. Behind the arm, filaments to the short and small extensors of the fore-arm, and several cutaneous ramuscules, disengaged from beneath the short extensor, that descend beneath the skin on the anterior face of that part.

3. In the antibrachial region, branches to the anterior extensor and external flexor of the metacarpus, and the two extensors of the digit.

In brief, we see that the radial nerve animates the whole mass of the extensor muscles of the fore-arm and foot, besides a flexor of the latter, and that it endows the integument of the anterior antibrachial region with sensibility.

13. *Ulnar, or Cubito-cutaneous Nerve.* (Figs. 347, 18; 348, 5.)

Chiefly formed by fibres from the dorsal pairs, this nerve, less considerable in volume than the preceding, proceeds backward and downward, and places itself behind the humeral artery, which it accompanies to below the origin of the deep humeral. After crossing the latter vessel, it passes between the long and middle extensors of the fore-arm, and gains the inner side of the elbow, running over the epicondyle, below the ulnar band of the oblique flexor of the metacarpus. It follows the posterior border of that muscle to near the supercarpal or pisiform bone, where it terminates by two branches. In the latter part of its course, it lies beneath the antibrachial aponeurosis, accompanied by a division of the epicondyloid artery.

One of the two branches, the *cutaneous* (Fig. 348, 6), crosses the space between the terminal tendons of the external and oblique flexor muscles of the metacarpus, as well as the antibrachial aponeurosis, to spread itself in several ascending horizontal and descending filaments, beneath the skin of the fore-arm, the anterior face of the knee, and the external side of the cannon. The other branch, with a ramuscule from the median nerve, constitutes the *external plantar nerve.*

In its course, the ulnar nerve gives off two fasciculi of collateral branches. The first (Fig. 347, 19) is detached from the principal trunk a little above the epicondyloid artery, and passes backward and downward between the long extensor of the fore-arm and the pectoralis transversus, supplying some filaments to the latter, and traverses it to become subcutaneous, and to be distributed to the skin of the fore-arm, beneath the elbow. The second arises at the epicondyle, and is destined to all the muscles of the posterior antibrachial region, except the external and internal flexors of the metacarpus.

14. *Median, or Cubito-plantar Nerve.* (Fig. 347, 20.)

This nerve is composed of fibres coming from the dorsal and eighth cervical pairs. It is detached from the posterior part of the trunk of the plexus to proceed to the axillary artery, where it forms an anastomosis with

the anterior brachial nerve, through the loop already noticed when describing that nerve as being formed by filaments passing from one cord to the other.

Leaving this point, it is placed in front of the humeral artery, and accompanies it to its terminal bifurcation; then it continues to descend on the inner face of the limb, along with the principal branch of that artery—the posterior radial—until it reaches the ulnar articulation, where it responds to the internal ligament of that joint, and where it crosses, at a very acute angle, the direction of its satellite vessel to become posterior. This position it inverts below the articulation, when it assumes, and preserves for the greatest part of its extent, its antibrachial course, remaining always a little more superficial than the artery. Above the lower third of the fore-arm, it bifurcates to form the *plantar nerves.*

In its course, this nerve successively furnishes:

1. Before its arrival on the axillary artery, one of the originating branches of the thoracic nerve destined to the superficial pectoral muscle.

2. At the middle of the humerus, a long branch, represented in Man by that portion of the *musculo-cutaneous nerve* which proceeds to the anterior brachial muscle and the skin of the fore-arm. This branch enters beneath the coraco-radialis or biceps, and forms two divisions; one of which is expended in the short flexor of the fore-arm; while the other passes between that muscle and its congener, the long flexor, to become superficial and gain the internal aspect of the limb, when it breaks up into two principal filaments, which pass to the external face of the antibrachial aponeurosis, and accompany with their divisions the two subcutaneous veins of the fore-arm to below the carpal region (Fig. 347, 21, 22).

3. In the antibrachial region, and at various elevations, but particularly below the ulnar articulation, ramifications to the internal flexor of the metacarpus and the two flexors of the phalanges.

Plantar Nerves.—These nerves, two in number, are distinguished as *internal* and *external.*

The *internal plantar nerve*, one of the terminal branches of the median nerve, lies beside the collateral artery of the cannon, and follows that vessel along the perforans tendon to near the fetlock, where it ends in several digital branches. In its track it furnishes a number of cutaneous metacarpal ramuscules, and an anastomosing branch, which, after being detached from the principal trunk, about the middle of the cannon, bends obliquely behind the flexor tendons to join the *external plantar nerve.* This is formed by the union of two branches: one coming from the ulnar nerve, the other from the median, and joining the first at the upper border of the pisiform bone, after passing beneath the inferior extremity of the oblique flexor of the metacarpus. This nerve, which accompanies the external collateral vein of the cannon for its entire length, descends with it, and with an arteriole that concurs in forming the subcarpal arch, outside the flexor tendons, in a special fibrous channel of the carpal sheath. Near the superior extremity of the cannon, within the head of the external metacarpal bone, it sends on the posterior face of the suspensory ligament of the fetlock a *deep plantar* branch, chiefly destined to the fleshy portion of the interosseous muscles. It is the analogue of the *deep palmar branch* of the ulnar nerve in Man. Continuing its descending course along the perforans tendon, it throws off some superficial metacarpal ramuscules, receives the accessory branch supplied by the internal nerve, and terminates, like the latter, in a number of digital branches on arriving at the fetlock; these it now remains for us to examine.

The *digital* branches, or *collaterals of the digit*, and the terminal branches of the plantar nerves, are three in number on each side, and accompany the digital artery and vein, which, at some points, they cover with their divisions.

Fig. 349.

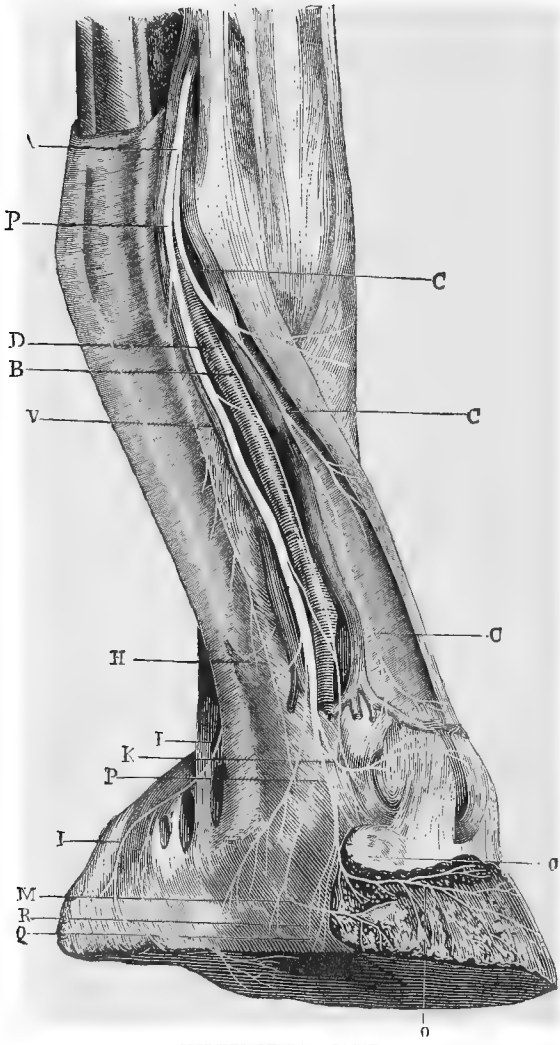

NERVES OF THE DIGIT.

P, Plantar nerve; B, Median branch; C, Anterior branch; D, Digital artery; H, Inconstant division given off to the cartilaginous bulbs; I, I, Branch to the plantar cushion; K, Transverse coronary branch; M, Podophyllous branch; O, Preplantar branch; Q, Descending ramuscule to the fissure of the patilobes; R, Ramuscules accompanying the digital artery in the plantar fissure; V, Vein whose presence is not constant, and which sometimes accompanies the plantar nerve throughout its phalangeal course.

They separate from one another nearly at the insertion of the suspensory ligament into the sesamoid bones. One of them descends in front of the vein; another passes between the two vessels; while the third follows the artery behind. They may, therefore, be distinguished, according to their position, into *anterior*, *middle*, and *posterior* (Fig. 349, M, O, R).

The *anterior branch* distributes its collateral divisions to the skin on the anterior face of the digit, and its terminal ramuscules in the coronary cushion.

The *middle branch* frequently anastomoses with the other two, particularly with the anterior, and to such a degree as to be scarcely distinguished from it; it enters the coronary cushion and the podophyllous tissue.

The *posterior branch*, much more considerable than the preceding, and a veritable continuation of the plantar nerve, is at first superposed on the digital artery, then it is placed immediately behind that vessel. It descends with it to near the basilar process of the third phalanx, follows the preplantar ungueal artery into the lateral fissure of that phalanx, and, like that vessel, expends itself in the midst of the podophyllous tissue, as well as in the osseous structure. This branch gives off numerous ramuscules on its course. Of these there may be more particularly noticed: 1, Some posterior divisions, distributed behind the flexor tendons, especially at the fetlock; 2, A satellite branch to the artery of the plantar cushion; 3, A filament arising below the lateral cartilage, passing forward, in proximity to the anterior branch of the arterial coronary circle, and becoming lost in the meshes of the deep venous network of the cartilage; 4, A small podophyllous division, whose point of origin is placed at the same height as the preceding filament, but opposite it, and which descends on the retrossal process, where it traverses the cartilaginous tissue to pass to the podophyllous reticulation, after distributing posterior ramuscules to the plantar cushion; 5, Several extremely fine filaments enlaced around the plantar ungueal artery, and with it penetrating to the interior of the os pedis; some of these filaments ascend to the nerve of the opposite side.[1]

DIFFERENTIAL CHARACTERS IN THE BRACHIAL PLEXUS OF OTHER THAN SOLIPED ANIMALS.

In the domesticated mammals, the nerves of the brachial plexus do not offer any very important differences in the upper part of the limb; these only become apparent in its last section.

RUMINANTS.—The branches of the plexus, the same in number as in the Horse, are relatively more voluminous than in that animal. In the *Ox* they are often flexuous in their upper part. In the *Sheep*, we have found that the *diaphragmatic nerve* is formed by a single filament, detached from the branch the sixth cervical nerve gives to the brachial plexus. There are no differences to signalise in the *branch of the angularis and rhomboideus*, in the *branches of the pectoral muscles*, the *subcutaneous thoracic branch*, or the *anterior brachial* or *musculo-cutaneous nerve*.

---

[1] It is because we conform to established usages, and are unwilling to force analogies, that we preserve the designations of "plantar nerves," and "digital branches," as well as the above manner of describing them. Comparative anatomy desires other names and a different description; for it demonstrates that the external plantar nerve corresponds to the interosseous of the first space in pentadactylous animals; the internal plantar to the interosseous of the third space, and the branch extending from the internal to the external plantar, to the interosseous of the second space, and which only virtually exists in the Horse, in consequence of the fusion of the second and third metacarpal bone, and which is prolonged to the phalanges. It also shows that the digital branches are the exact representatives of the collaterals of the digits which result, in the pentadactylous species, from a bifurcation of each interosseous nerve.

The *nerve of the serratus magnus* does not show the branch which, in the Horse, arises from the sixth nerve and passes through the scalenus; but on the surface of the serratus magnus it receives a filament from the branch of the angularis. The latter is detached from the sixth.

The branch of the *great dorsal muscle* and the *axillary nerve* are confounded at their origin, and also adhere to one of the two branches of the *subscapularis nerve.* The

Fig. 350.

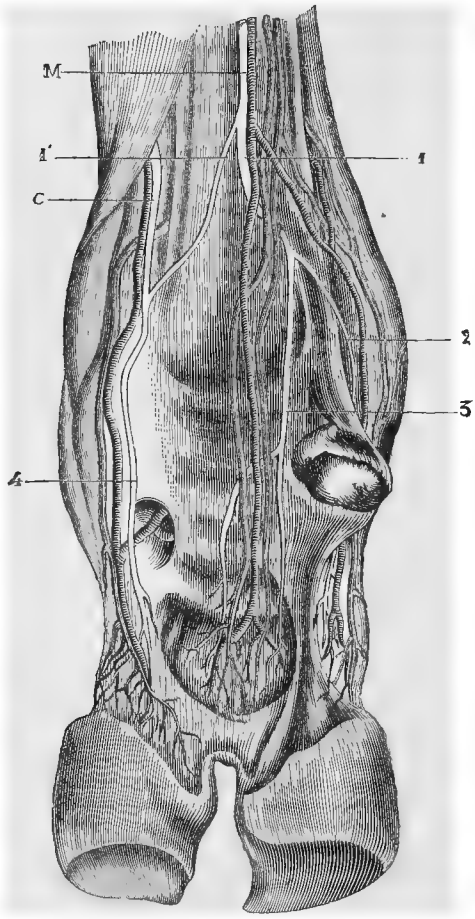

NERVES OF THE DIGITAL REGION OF RUMINANTS; POSTERIOR FACE.

M, Internal plantar nerve, a continuation of the median; C, Internal plantar nerve, a continuation of the ulnar; 1, Branch of the plantar, furnishing, 2, the internal collateral nerve of the internal digit; 3, Branch giving off the internal collaterals of the digits; 1', Branch of the internal plantar that joins the external plantar; 4, External collateral of the external digit.

second branch of the latter is free throughout, and distributed in the muscle of the same name, along with some filaments furnished by the *superscapularis.*

The *radial nerve*, when it reaches the teres major, divides into three branches: one is

buried in the long extensor of the fore-arm; the other traverses the middle extensor; and the third is inflected on the tendon of the great dorsal muscle, and passes between the middle and large extensor of the fore-arm. When the radial nerve turns outwards around the arm, and is placed between the anterior brachial and the mass of the olecranian muscles, it furnishes: 1, Muscular branches that pass immediately beneath the extensors of the metacarpus and phalanges; 2, A sensitive branch that leaves this muscular interstice to become subcutaneous. This cutaneous branch of the radial gains the inner face of the fore-arm, and divides in two branches that descend parallel to the median subcutaneous vein. One of these is lost around the carpus; the other is placed a little in front of the metacarpus, and reaches the metacarpo-phalangeal articulation, where it terminates by two principal filaments that constitute the *dorsal collaterals of the digits;* there is a third which crosses the interdigital to anastomose with the palmar collaterals.

The *ulnar* and *median nerve* of Ruminants lie beside each other, as far as the middle of the arm. This double cord is situated at the surface of the humeral artery; at the carpus the two nerves offer the same distribution as in the Horse, but beyond this there are some differences.

The *ulnar* does not receive a branch from the median at the carpus, and it forms the *external plantar nerve* or interosseous palmar of the first space, placed at the external border of the flexor tendons. This nerve is reinforced by a filament detached from the external plantar, that joins it a little above the fetlock-joint; it gives ramuscules to the ergot, and is then continued by the external collateral nerve of the outer digit, into the horny claw.

The *median* is continued by the *internal plantar*, or interosseous palmar of the third space. Towards the inferior third of the metacarpus, it divides into three branches: the third passes to the external plantar; the second proceeds to the interdigital space, where it bifurcates to form the *internal collateral palmar nerves of the external digit*, and *external collateral of the internal digit;* the third gives some filaments to the ergot, and passes along the digital region, where it constitutes the *internal collateral of the internal digit.*

Pig.—Three fasciculi are detached from the brachial plexus; the posterior is the most voluminous, and furnishes the radial, median, and cubital.

The branches of the plexus that pass to the trunk and the first rays of the anterior limb much resemble those of Ruminants; the *branch of the serratus magnus* is remarkable for its length and size.

The *median nerve* is disposed like that of Solipeds and Ruminants. as far as the carpus; from this point it passes beneath the flexor tendons of the phalanges, gives filaments to the interosseous palmar muscles, and at the two rudimentary digits divides into four branches: the two upper are the smallest, and form the collaterals of the rudimentary digits; the inferior two are the longest, and reach the principal interdigital space, forming the collaterals of the two great digits.

The *ulnar* gives off, towards the middle of the arm, a branch that passes to the ulna; at the ulna it furnishes several muscular branches. The nerve then bends round to the outside of the fore-arm, and on arriving above the pisiform bone, bifurcates: one branch goes along the outer border of the flexor tendons, and is continued by the collateral of the external digit; the other is placed on the anterior face of the metacarpus, and also bifurcates to give the external digits their dorsal collateral nerves.

Carnivora.—The four last cervical and first dorsal compose the brachial plexus in the Carnivora; the fifth cervical gives an insignificant filament. When the plexus is unravelled, its principal branches are observed to send fibres to each other.

The number of the distributive branches is the same as in Solipeds, and the disposition of the superior branches is so analogous as to call for no remark; so we will only describe the anterior brachial, radial, median and cubital nerve.

The *anterior brachial*, or *musculo-cutaneous*, is constituted by a filament from the sixth cervical and the more voluminous branches coming from the seventh. Placed in front of the axillary artery, this cord arrives at the scapulo-humeral articulation, where it bifurcates: one of the branches passes forward to the biceps: the other remains alongside the anterior border of the humeral artery, and terminates by a slightly recurrent branch that is buried in the anterior brachial muscle, and by a very fine filament that becomes subcutaneous at the elbow, and descends on the inner border of the fore-arm to be lost in the vicinity of the carpus. The anterior brachial is, therefore, in these animals, a musculo-cutaneous nerve. The branch uniting it to the median nerve is situated a little below the middle of the humerus, instead of being beneath the axillary artery, as in Solipeds.

The *radial nerve*, in the *Dog*, is exclusively formed by the eighth cervical; it receives filaments from the median, ulnar, and axillary nerve, and gives branches to these three.

When it reaches the interstice of the triceps and anterior brachial, it crosses the limb above the outer face of the elbow, and divides into two series of terminal branches.

Fig. 351.

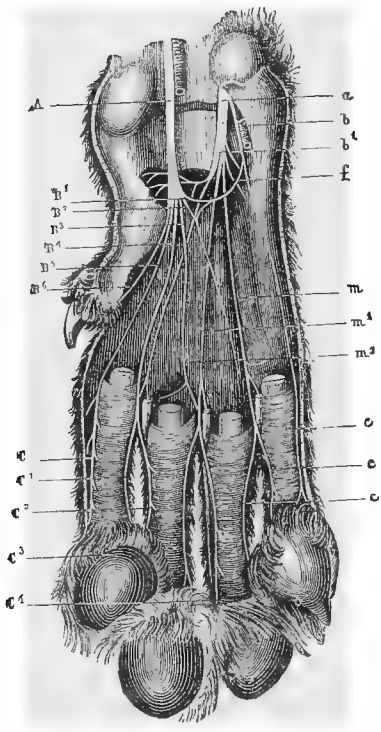

NERVES OF THE PALMAR FACE; DOG.

A, Trunk of the median dividing into six branches; B1, Branch of the superficial nervous arch; B2, Branch disappearing on a vessel; B3, B4, Branches uniting with the corresponding ramuscules of the ulnar; B5, Branch forming the internal collateral of the index; B6, Rudimentary branch passing to the thumb; C, Collateral given off by the median; C1, C2, C3, C4, Collaterals furnished by the median and ulnar. —*a*, Palmar branch of the ulnar; *b*, Superficial branch giving off a filament to the hypothenar, and a second that forms the superficial nervous arch; *b*1, Deep branch passing to the muscles of the skin; *m*, Not anastomosing with the median; *m*1, *m*2, Anastomosing with the corresponding branch of the median; the innermost passes to the muscles of the thumb; *c*, *c*, *c*, Collaterals furnished by the ulnar

The muscular branch enters beneath the muscles on the anterior face of the fore-arm. The cutaneous bifurcates immediately: the smallest branch, passing inwards, extends beyond the bend of the elbow, lies at the inner border of the median subcutaneous vein, and is distributed to the lower moiety of the fore-arm, the thumb, and internal border of the index digit. The largest lies at the outer side of the median subcutaneous vein; it sends a recurrent ramuscule to the bend of the elbow, and, at the elbow, detaches three filaments to the first, second, and third dorsal intermetacarpal spaces; these filaments bifurcate at the dorsum of the digits to constitute the *collateral dorsal nerves*. The first metacarpal nerve anastomoses, by a fine transverse branch, with the ulnar ramuscule that constitutes the external dorsal collateral of the small digit.

To resume: the radial of the Dog gives branches to the dorsal face of all the digits, except the external border of the first digit, or auricularis.

In the *Cat*, there are some differences. The internal branch of the *radial* sometimes lies with the external branch; it is placed at the inner border of the metacarpus, gives off a filament to the dorsal face of the thumb, and afterwards forms the internal dorsal collateral nerve of the index. The external branch leaves the anterior face of the carpus, and is situated at the origin of the third interosseous space, where it divides into three metacarpal branches; the external of these is very fine, and directed obliquely outwards, anastomosing with the dorsal branch of the ulnar, between the first and second digits.

The *median* of the *Dog* is united to the ulnar as far as the lower fourth of the arm; it is situated behind the humeral artery, and the filament it receives from the musculo-cutaneous joins it at a short distance from the elbow-joint. Placed beside the radial artery, the median is, towards the lower third of the fore-arm, immediately below the posterior border of the great palmar tendon; it afterwards passes through the carpal sheath, giving a branch that constitutes the *internal palmar collaterals of the thumb*, and *external of the index;* it finally forms three branches, the first of which anastomoses with the ulnar, at the surface of the palmar arch, and is lost on an artery; the other two, receiving a filament from the ulnar at the origin of the digits, bifurcate to form the *internal palmar collateral of the annularis*, and *collaterals of the medius and index*. The second gives, in addition, a slender branch, that is lost in the internal and middle lobe of the large cushion of the paw. In fine, the median of

the Dog furnishes branches to all the digits, except the auricularis and external border of the annularis.

In the *Cat*, the median traverses the bony canal at the lower extremity of the humerus, and separates below the carpal arch into three branches. The internal branch is destined to the rudimentary thumb, and the internal palmar border of the index. The middle branch descends in the third interosseous space, furnishes a filament to the large cushion of the paw, and divides to form the external palmar collaterals of the index and internal of the medius. Finally, the external branch is placed in the second intermetacarpal space, and gives the following *palmar collaterals:* the *external of the medius* and *internal of the annularis.*

Fig. 352.

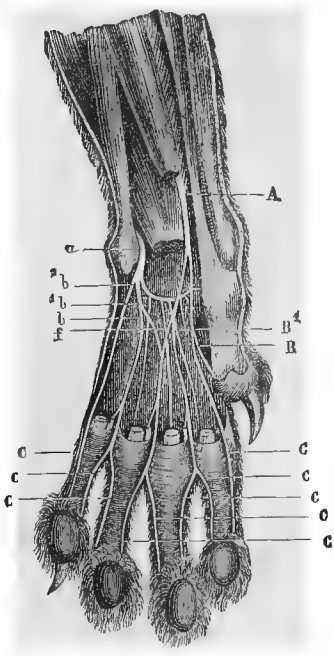

NERVES OF THE PALMAR FACE; CAT.

A, Trunk of the median dividing into two branches; B, Internal branch, giving a rudimentary filament to the thumb; B1, External branch, receiving a filament, *f*, from the ulnar; c, c, c, c, Collaterals furnished by the median.—*a*, Palmar branch of the ulnar dividing into three branches; *b*, Internal branch, detaching the filament, *f*, to the median; *b*1, External branch; *b*2, Deep branch; *c*, *c*, *c*, Collaterals furnished by the ulnar.

The *ulnar nerve* of the *Dog*, below the elbow, lies beside the ulnar artery to the lower third of that vessel; there it forms two branches—a dorsal and palmar. The *dorsal branch* becomes subcutaneous, passes along the external border of the fore-arm, metacarpus, and small digit, and constitutes the external dorsal collateral nerve of the latter.

The *palmar branch* leaves the carpal sheath, gives off, at the trapezoides, a ramuscule that passes to the surface of the palmar muscles to form the external collateral palmar of the auricularis, and then, at the surface of the deep palmar arch, divides into eight terminal ramuscules. The smallest of these is expended in the rudimentary muscles of the thumb, the small digit, and interosseous muscles; the largest, three in number, lie on the interosseous arteries, and bifurcate at the digits to form the palmar collaterals; the two internal ramuscules are previously confounded with the corresponding branches of the median. From this arrangement, it results that the ulnar nerve supplies the palmar surface of all the digits, except the internal border of the index.

The *ulnar* of the *Cat* also divides into a dorsal and a palmar branch, but the distribution of these is not the same as in the Dog.

The *dorsal branch* bifurcates at the carpus: one of the filaments forms the external dorsal collateral of the small digit; the other reaches the first interosseous space, receives a branch from the radial, and afterwards gives off the internal dorsal collateral of the small digit, and external of the auricularis.

The *palmar branch* does not extend to all the digits as in the Dog. Passing within the pisiform bone, it divides into several filaments: some of these are distributed to the muscles of the small digit and thumb; another follows the external border of the small digit, and constitutes its external palmar collateral; one of the longest is lodged in the first intermetacarpal space, giving a filament to the large cushion of the paw, and the internal palmar collaterals of the small digit and external of the annularis.

COMPARISON OF THE BRACHIAL PLEXUS OF MAN WITH THAT OF ANIMALS.

The brachial plexus of *Man*, like that of the Dog, is constituted by the anterior branches of the four last cervical, and the last dorsal nerves. The few variations observed

are very slight, and are to be ascribed to the difference in form of the regions to which the nerves are distributed.

The shoulder of Man being short, and the other rays of the limb long and well detached, the branches of the brachial plexus can be divided into collateral and terminal.

The *collateral* branches are: 1, The *subclavian branch*, which is not found in our animals, they having no subclavian muscle; 2, The nerve of the *angularis;* 3, Nerve of the *rhomboideus;* 4, *Superscapular nerve;* 5, The *serratus magnus* (*posterior thoracic*) nerve; 6, *Subscapular*, which is divided at its origin into two branches as in the Sheep and Carnivora; 7, The nerves of the *great and small pectorals* (*anterior thoracic*); 8, The

Fig. 353.

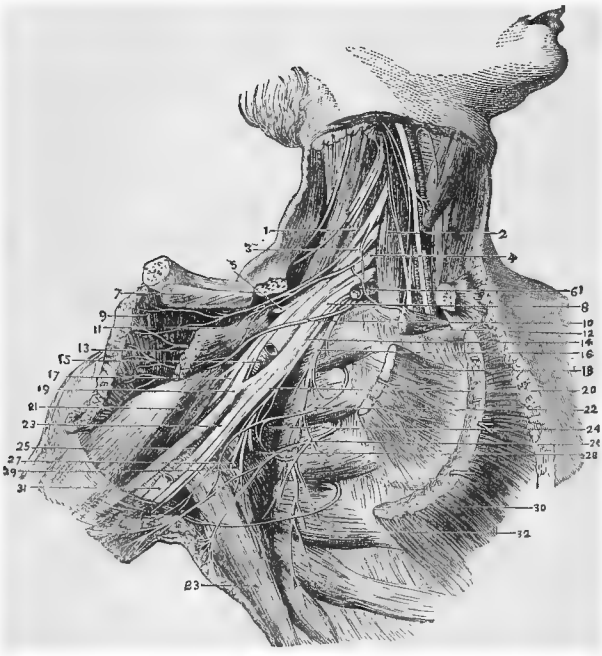

THE NERVES OF THE AXILLA OF MAN.

1, Scalenus medius; 2, Scalenus anticus; 3, Cord formed by 5th and 6th cervical nerves; 4, Seventh cervical nerve; 5, Superscapular nerve; 6, Subclavian artery, cut; 7, Insertion of subclavius; 8, Cord formed by 8th cervical and 1st dorsal nerves; 9, Pectoralis major, reflected; 10, Internal anterior thoracic nerve; 12, Origin of subclavius; 13, Pectoralis minor, reflected; 14, Internal cutaneous nerve; 15, Axillary artery, cut; 16, Posterior thoracic nerve, 17, Musculo-cutaneous nerve; 18, Origin of pectoralis minor; 19, Median nerve; 20, Nerve of Wrisberg; 21, Coraco-brachialis; 22, Intercosto-humeral nerve; 23, Ulnar nerve; 24, Subscapularis; 25, Brachial artery; 26, Lateral cutaneous branch of 3rd intercostal nerve; 27, Middle subscapular nerve; 28, Short subscapular nerve; 29, Pectoralis major, cut; 31, Basilic vein; 32, Serratus magnus; 33, Latissimus dorsi.

accessory nerve of the internal cutaneous, represented in quadrupeds by the subcutaneous thoracic; 9, The nerve of the *great dorsal;* 10, The *nerve of the teres major.*

The *terminal branches* go to the arm, fore-arm, and hand. They are:

1. The *internal cutaneous*, which in the Horse is furnished by the ulnar nerve. It becomes subcutaneous at the upper third of the arm, and a little above the elbow bifurcates; the anterior is spread on the front face of the arm to the wrist; the posterior

passes backwards, and is expended in the skin of the back, and inner part of the fore-arm.

2. The *musculo-cutaneous* or *perforans casserii*, whose disposition is analogous to that of Carnivora.

3. The *axillary nerve*, regarding which there is nothing to say.

4. The *radial nerve* (*musculo-spiral*) passes as in animals, lies in the twisted furrow of the humerus, gives off an internal and external cutaneous branch, and reaches the antero-external part of the arm, in the space between the anterior brachial and long supinator, where it terminates by two branches. The *anterior* of these reaches the back of the hand, and gives off three ramuscules there, which are distributed as follows: the first forms the external dorsal collateral of the thumb; the second bifurcates, and constitutes the internal dorsal collateral of the thumb and external collateral of the index; lastly, the third supplies the internal collateral of the index and external of the medius. This branch always anastomoses with the dorsal branch of the ulnar. The *posterior branch*, motor, is expended in the muscles on the posterior and external aspect of the fore-arm.

5. The *median nerve* commences by two branches: one arises in common with the musculo-cutaneous or anterior brachial, and corresponds to the anastomosis found around the axillary artery of the Horse; the other is detached from the trunk common to the ulnar and internal cutaneous. The median runs along the biceps, passes in front of the elbow, and lies beneath the annular ligament of the carpus, where it terminates in furnishing: 1, A filament to the short abductor of the thumb; 2, Palmar ramuscules to the thumb, index, and medius, and external border of the annularis. This disposition of the medius, therefore, much resembles that of the Cat.

6. The *ulnar nerve* passes along the inner border of the arm and fore-arm, and divides, a little above the inferior extremity of the olecranon, into two terminal branches—a *dorsal* and *palmar*. The first is directed on the back of the hand, and separates into three metacarpal branches, which, in their course, furnish the dorsal collaterals of the auricularis and annularis, and internal collateral of the medius; the other parts of the hand are supplied by the radial. The second, or palmar branch, is superficial, and detaches the palmar collaterals of the little finger and internal collateral of the annularis, as well as a deep ramuscule that lies across the interosseous muscles, and is a motor nerve. To resume, we see that this distribution of the terminal branches of the brachial plexus of Man much resembles that described in Carnivora, and especially in the Cat.

Fig. 354.

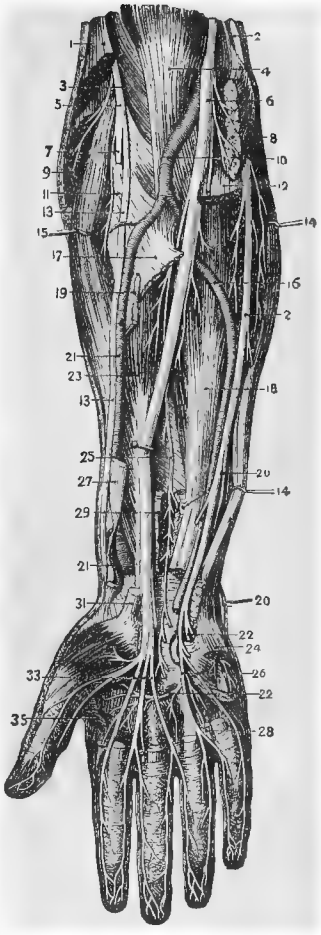

NERVES OF THE FRONT OF FORE-ARM AND HAND OF MAN.

1, Supinator longus, cut; 2, Ulnar nerve; 3, Brachialis anticus; 4, Biceps; 5, Musculo-spiral nerve, 6, Median nerve; 7, Posterior interosseous nerve, 8, Pronator teres and flexor carpi radialis, cut; 9, Extensor carpi radialis longior, cut; 10, Brachial artery; 11, Supinator brevis; 12, Flexor sublimis digitorum, cut; 13, 13, Radial nerve; 14, 14, Flexor carpi ulnaris; 15, Extensor carpi radialis brevior, 16, Ulnar artery; 17, Radial origin of flexor sublimis digitorum, cut; 18, Flexor profundus digitorum; 19, Tendon of pronator teres; 20, 20, Dorsal branch of ulnar nerve; 21, 21, Radial artery; 22, 22, Deep branch of ulnar nerve; 23, Flexor longus pollicis; 24, Abductor minimi digiti; 25, Anterior interosseous nerve; 26, Digital branches of ulnar nerve; 27, Tendon of supinator longus; 28, One of the lumbricales muscles; 29, Pronator quadratus; 31, Tendon of flexor carpi radialis; 33, Digital branches of median nerve; 35, Adductor pollicis.

LUMBO-SACRAL PLEXUS.

The last two lumbar pairs, and the three first sacral, in becoming fused together, form the *lumbo-sacral plexus*, which corresponds in every respect, by its constitution, as well as by its mode of distribution, to the plexus of the thoracic limb.

It is usual, in human anatomy, to describe a *lumbar* and a *sacral plexus*, each formed by the inferior branches of all the spinal pairs, whose names they bear. In our opinion, this proceeding has two inconveniences: at first, it separates into two fasciculi the nerves of the abdominal member, and, besides, in including in the description of these nerves the first lumbar pair and the last sacral, elements are introduced in this description which are altogether foreign to it. It may be remarked, that the four first lumbar pairs, when they anastomose with each other, only do so by very slender filaments; that they only send some subcutaneous filaments to the posterior limb; that the two last sacral branches, principally destined to the genito-urinary organs and the posterior extremity of the digestive tube, are ordinarily without any direct communication with the others; that the two last lumbar pairs and the three first sacral *are alone fused in the same manner as the brachial plexus, and comport themselves like that plexus in the distribution of their branches.*

It is with some reason, then, that we have described, in a special manner, the inferior branches of the four lumbar pairs and the two last sacral, reserving the fasciculus formed by the five intermediate pairs for a special description, under the name of the *lumbo-sacral plexus.*

Mode of constitution.—In glancing at this plexus, we may perceive that it is divided into two portions—an anterior and posterior, each having a thick trunk in the centre.

The first of these trunks is formed by the two above-named lumbar pairs, which join each other after a short course, and after receiving an accessory branch from the fourth pair. The second, wider and thinner than the preceding, comprises the fibres of the three sacral pairs which escape from beneath the subsacral vessels, and unite in a single fasciculus. These two trunks are connected with each other by one or two branches proceeding from the first sacral pair to the obturator nerve—one of the distributive branches of the first.

Relations.—The *anterior portion* of the lumbo-sacral plexus is concealed beneath the small psoas muscle, and separated by the internal iliac artery from the *posterior portion.* The latter, placed above and on the side of the pelvis, at the great sciatic opening, corresponds, inwardly, to the subsacral vessels; outwardly, and in front, to the gluteal vessels.

Mode of distribution.—The anterior portion of the plexus at first gives off several small branches to the psoas muscle, and particularly to the iliacus: these branches were designated by Girard the *iliaco-muscular nerves;* it then terminates in two large branches—the *crural* and *obturator nerves.* The *posterior portion* is continued by two important trunks, the *great* and *small femoro-popliteal nerves.* At the base of the latter, it emits the *anterior* and *posterior gluteal nerves.* These branches and their ramifications will be successively studied.

Preparation of the lumbo-sacral plexus.—After removing the skin and abdominal viscera, the hind quarters are isolated by sawing through the vertebral column behind the last rib; then, by means of a section almost in the middle of the pelvis, one of the limbs is cut off, and the pieces, disposed as in figure 355, should be maintained in the

Fig. 355.

LUMBO-SACRAL PLEXUS AND INTERNAL NERVES OF THE POSTERIOR LIMB.

1, 1, Lumbo-sacral plexus; 2, Anterior femoral nerve; 3, Internal saphena nerve; 4, Obturator nerve; 5, Originating fasciculus of the great and small femoro-popliteal nerves; 6, Superficial ramuscules of the posterior gluteal nerves; 7, Great femoro-popliteal nerve; 8, Internal pudic nerve; 9, Hæmorrhoidal, or anal nerve; 10, Internal plantar nerve; 11, 12, Its digital ramifications.

NOTE.—In the above figure is seen the posterior part of the plexus formed by the nervous branches which pass through the three first subsacral foramina. That which escapes from the foramen between the sacrum and last lumbar vertebra, only gives a fine branch to this part of the plexus, and sends the greater portion of its fibres, in two cords, to the anterior part. This arrangement is not rare, and is generally seen, we believe, when there are only five lumbar vertebræ: as is remarked in the Ass and Mule, and sometimes in the Horse. It will, therefore, be understood that the nerve described by us as the first sacral becomes the last lumbar.

first position: that is, with the croup resting on the dissecting table near one of the bars, and the limb suspended vertically, the foot upwards, by a cord attached to the ring of the bar.

Afterwards, the preparation is executed in two stages. In the first, after the excision of the pelvic organs and the small psoas muscle, the whole of the plexus and its formative branches are dissected, taking figure 355 as a guide. In the second, the posterior part of the plexus, with the nerves it gives off, are exposed on the external side, by excising the greater portion of the principal gluteal muscle and the anterior portion of the long vastus (abductor magnus, or triceps abductor femoris), as in figure 356.

To follow the various divisions of the nerves emanating from the plexus, to their terminations, it is well to use the other limb, which, not being fixed, can be laid on a table, and in this way is more convenient than the first for this part of the operation.

1. *Iliaco-muscular Nerves.*

These nerves are of little importance. The principal one accompanies the iliaco-muscular artery across the substance of the iliacus muscle.

2. *Crural or Anterior Femoral Nerve.* (Fig. 355, 2.)

This is the largest of the branches arising from the anterior portion of the plexus. It descends between the psoas magnus and parvus, to the common conical extremity of the latter muscle and the iliacus, where it is covered by the long adductor of the leg; there it terminates in a wide tuft of branches, destined to the mass of the triceps extensor cruris.

Below the adductor, it successively emits two long branches, which deserve a particular description.

The first represents the nervous fasciculus which, in Man, comprises the crural *musculo-cutaneous branches.* We have named it the *accessory branch of the internal saphena.* It reaches the interstice between the two adductors, in crossing the crural vessels very obliquely forward. Leaving this space, it becomes subcutaneous in forming numerous divisions which surround the saphena artery and vein.

The second, or *internal saphena nerve*, passes at first between the long adductor of the leg and the vastus internus, and parallel to the first, which is situated more inwardly and posteriorly. Near the inferior extremity of the interstice separating the two adductors of the leg, it escapes and becomes subcutaneous, dividing into a number of filaments which meet those of the accessory nerve.

These two branches communicate by deep or superficial anastomosing loops. Before leaving the space between the adductors, they give some slender filaments to these two muscles, particularly to the anterior. Near their origin, they even distribute some to the iliacus. Becoming subcutaneous, their ramuscles cover the inner face of the thigh and leg; the longest of these accompany the saphena vein to the anterior aspect of the hock.

It sometimes, indeed most frequently, happens that the internal saphena nerve and its accessory form only a single branch, whose muscular or cutaneous divisions otherwise comport themselves exactly like the above. This is exemplified in the dissection represented in figure 355.

3. *Obturator Nerve.* (Fig. 355, 4.)

Situated underneath the peritoneum, to the inner side of the iliac vessels which it accompanies to the origin of the obturator artery, this nerve follows the latter to the upper face of the pubis, and passes with it beneath the internal obturator muscle, to traverse the foramen ovale. In this way it

arrives outside the pelvis, where it nevertheless remains deeply concealed by the muscular masses on the internal aspect of the thigh. Its terminal ramifications are expended in the obturator externus, the adductors of the thigh, the pectineus, and the short adductor of the leg. The branch destined to the latter muscle is the longest; it leaves the space between the pectineus and the small adductor of the thigh, and descends backwards on the internal face of the muscle to which it is distributed.

4. *Small Sciatic or Anterior and Posterior Gluteal Nerves.*

The small sciatic of the Horse is composed of several cords that issue from the pelvis by the upper part of the great ischiatic notch, and which have

Fig. 356.

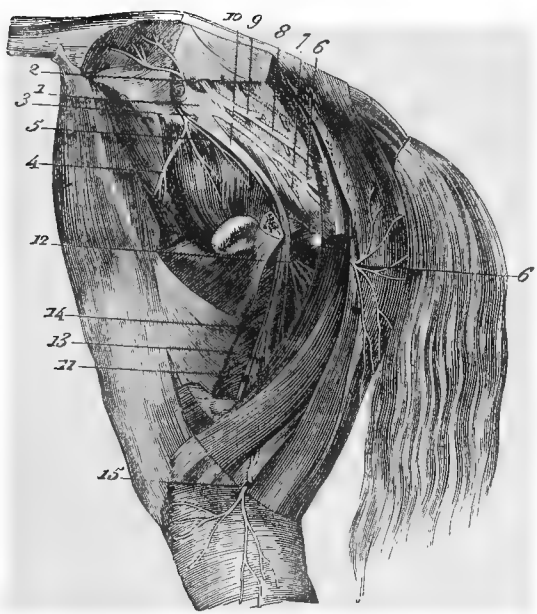

POSTERIOR PORTION OF THE LUMBO-SACRAL PLEXUS.

1, Conjoining fasciculi of the three first sacral nerves; 2, 3, 4, 5, Anterior gluteal nerves; 6, 6′, 8, Posterior gluteal nerves; 7, 9, Branches which traverse the great sciatic ligament, and communicate between the posterior gluteal branches and the divisions of the internal pudic nerve; 10, 11, 12, 13, Great sciatic nerve and its crural branches; 14, Small femoro-popliteal nerve; 15 Its cutaneous or peroneal-cutaneous branch.

been for a long time described as the anterior and posterior gluteal nerves.

The *anterior gluteal* or *ilio-muscular nerves* (Fig. 356, 2, 3, 4, 5) are four or five in number, and arise either separately or in groups from the posterior portion of the lumbo-sacral plexus. They appear to be more particularly furnished by the two first sacral branches. All leave the pelvic cavity by the great sciatic opening, along with the anterior gluteal vessels. The

principal branches are lost in the middle gluteal muscle. One of them (Fig. 356, 4,) crosses the neck of the ilium above the small (or internal) gluteal muscle, and passes outwards to be distributed to the muscle of the fascia lata (tensor vaginæ femoris). The last, which is the most slender, descends to the external surface of the gluteus internus, and is distributed in its substance (Fig. 356, 5).

The *posterior gluteal*, or *ischio-muscular nerves* (Fig. 356, 6, 6′, 8), are usually two in number—a superior and inferior.

The first escapes through the great sacro-ischiatic notch, along with the femoro-popliteal nerves, and is situated on the external surface of the ischiatic ligament. It passes backward, between this ligament and the gluteus medius, to beneath the anterior or croupal portion of the triceps extensor cruris, in which it is distributed by several filaments. Besides these, it gives: 1, In passing beneath the gluteus medius, a slender, but constant filament to the posterior portion of that muscle; 2, Another, and more considerable branch, which bends round the posterior border of that muscle, to be directed forward and outward to the gluteus externus.

The second nerve, situated beneath the preceding, appears to be detached from the posterior border of the great sciatic. It is placed at the external surface of the sciatic ligament, is directed backwards in passing below the croupal portion of the triceps cruris, traverses that muscle above the ischial tuberosity, descending underneath the sacral portion of the semitendinosus, soon to leave its deep track and become superficial. It escapes from between the latter muscle and the triceps cruris, and is lost beneath the skin covering the posterior part of the thigh. Its deep portion gives off collateral branches which reinforce the divisions of the internal pudic nerve, as well as filaments to the long branch of the semitendinosus muscle.

5. *Great Sciatic or Great Femoro-popliteal Nerve.* (Figs. 135, 13; 357, 1, 2.)

This enormous nervous trunk issues by the great sciatic opening in the form of a wide band, which is applied to the external face of the ischiatic ligament. Comprised at first between that ligament and the gluteus medius, it is directed backwards in passing over the fixed insertion of the gluteus internus, and arrives behind the gemini and quadratus femoris muscles. On leaving this point, it is inflected to descend behind the thigh, where it is lodged in the muscular sheath formed for it by the triceps cruris, the semitendinosus and membranosus, and the great adductor of the thigh. Arriving towards the superior extremity of the leg, it enters between the two bellies of the gastrocnemii muscles, passes along the posterior aspect of the perforatus muscle, and descends in the channel of the hock, beneath the tibial aponeurosis, following the internal border of the fibrous band that reinforces the tendon of the hock. It finally terminates at the calcis by two branches; the *external* and *internal plantar nerves.*

From the point at which the great sciatic enters between the bellies of the gastrocnemii muscles, and as far as the furrow of the calcis, this nerve corresponds to the branch named in Man the internal popliteal—a branch that is continued by the posterior tibial, which terminates in the plantar filaments.

In its long course, this nerve successively emits: 1, The external popliteal nerve; 2, A branch to the muscles of the deep pelvi-crural region; 3, Another to the posterior crural muscles; 4, The external saphenous nerve; 5, A voluminous fasciculus to the muscles of the posterior tibial

region. All these branches will be studied, more especially the external popliteal; which is so disposed in Solipeds, that Veterinary authorities have described it as a special trunk, by the name of the small femoro-popliteal, and even as the small sciatic nerve. We will afterwards pass to the terminal branches.

COLLATERAL BRANCHES.

1. External Sciatic-popliteal, or Small Femoro-popliteal Nerve.—This nerve separates from the great sciatic at the gemini muscles of the pelvis. It is then directed forward and downward, proceeds between the triceps cruris and the gastrocnemius muscles, and arrives outside the superior extremity of the leg, behind the lateral ligament of the femoro-tibial articulation, where it terminates by two branches: the *musculo-cutaneous*, and the *anterior tibial nerve.*

In the long course it follows from its origin to its bifurcation, the external sciatic popliteal nerve only furnishes a single collateral branch: this is the cutaneous nerve which is detached from the parent trunk above the gastrocnemius, and which traverses the inferior extremity of the triceps cruris, to terminate by divergent ramuscles destined to the skin of the leg. It might be named the *peroneal-cutaneous branch.* Before becoming superficial, this cutaneous nerve gives off a small descending filament which goes to reinforce the external saphenous nerve, after creeping over the aponeurotic layer of the external gastrocnemius. This branch, which might be designated the *accessory of the external saphenous*, sometimes proceeds directly from the popliteal, as may be remarked in Fig. 357.

Terminal Branches.—These two branches influence the contractility of the muscles belonging to the anterior tibial region, and endow the skin on the anterior face of the foot with sensation.

The *musculo-cutaneous nerve* is situated beneath the tibial aponeurosis; it first sends a bundle of ramuscules to the lateral extensor of the phalanges, and continues to descend between that muscle and its congener, the anterior extensor, to the middle of the tibia. It then traverses the fibrous envelope of the tibial muscle, becomes subcutaneous, and gains the anterior face of the metatarsus, where it is lost in the skin. Some of its terminal filaments may be followed to the fetlock, and even beyond it (Fig. 357, 6).

The *anterior tibial nerve* passes in front of the preceding, to one side of the superior extremity of the leg, and then plunges beneath the anterior extensor of the phalanges, giving to that muscle and the flexor of the metatarsus short, but thick, ramuscules. It descends to the front of the tarsus, always covered by the anterior extensor of the phalanges, and placed at the external side of the anterior tibial vessels. When it arrives below the tibia, it lies immediately alongside the pedal artery, and follows it, in its metatarsal portion, to near the fetlock. It then separates from its satellite vessel, and passes on the side of the digit, where it ends by the emission of cutaneous filaments (Fig. 357, 5).

Among the ramuscules this nerve abandons in its course, are cited those which carry nervous influence to the pedal muscle.

2. Branches to the Muscles of the Deep Pelvi-crural Region.—It is known that this region comprises the obturator internus, gemini, and quadratus femoris muscles. The nervous branch sent to them is long and attenuated; it is detached from the sciatic trunk at the middle of the supercotyloid ridge, and descends with that trunk behind the coxo-femoral articulation, to distribute its terminal divisions to the above-named muscles.

The longest and thickest of these goes to the quadratus femoris. That passing to the obturator internus re-enters the pelvic-cavity by the small ischiatic notch, and ascends to the vicinity of the ilio-sacral articulation.

Fig. 357.

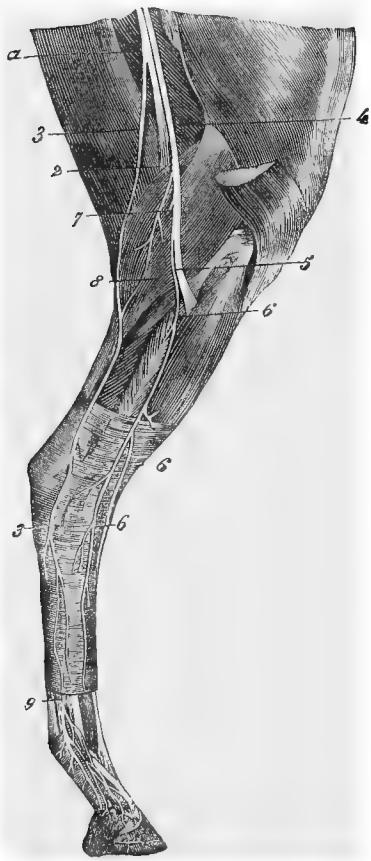

EXTERNAL NERVES OF THE POSTERIOR LIMB.

1, 2, Great sciatic nerve; 3, External saphena nerve; 4, External popliteal nerve; 5, Anterior tibial nerve; 6, Musculo-cutaneous nerve; 7, Origin of the peroneal-cutaneous branch; 8, Accessory branch of the external saphenous nerve; 9, External plantar nerve with its divisions, which cover the digital artery and vein.

3. Branch to the Ischio-tibial or Posterior Crural Muscles.—This branch is thick and short; it arises from the bend formed by the great femoro-popliteal nerve at the gemini muscles, and soon divides into several ramifications which are distributed to the short portion of the triceps cruris, the middle and inferior parts of the semitendinosus, and into the semimembranosus. Some of the filaments destined to the latter muscle pass between it and the great adductor of the thigh, in which they partly terminate (Fig. 356, 12).

4. External Saphenous Nerve.—This branch commences at from 2 to 6 inches from the point where the great sciatic nerve dips between the gastrocnemii muscles. It is placed on the external gastrocnemius, and descends underneath the special aponeurotic layer covering that muscle, to the origin of the tendon of the hock. It then receives its *accessory nerve*—the reinforcing filament which comes from the cutaneous branch of the small femoro-popliteal nerve, and is prolonged beneath the tibial aponeurosis into the channel of the hock, accompanying the external saphenous vein, and following the external border of the fibrous band that goes to strengthen the tendo-Achillis. In this way, it occupies the same situation outside the hock that the great sciatic does on the inner side. It afterwards passes over the tarsal region, and is expended on the outside of the metatarsus in several filaments, some of which descend to the outer aspect of the digit (Figs. 356, 13; 357, 3).

5. Fasciculi to the Posterior Tibial Muscles.—This fasciculus is composed of numerous branches, which are detached together from the sciatic nerve on its passage between the gastrocnemii muscles, in the form of a thick short trunk. The muscles of the superficial layer—the gastrocnemii, perforatus. and the thin fleshy band, improperly designated the small plantaris by Veterinarians—receive ramuscules which are remarkable for their

large number and their shortness. Those of the deep layer are supplied by filaments from a single long and thick branch, which descends between the perforatus and the internal gastrocnemius. It may be remarked, that the filament going to the so-called small plantar muscle, passes underneath the external gastrocnemius, outside the perforatus, and that, by its position, it exactly represents the soleus ramuscule of Man. We are, therefore, with Vicq-d'Azyr, Cuvier, and others, justified in naming this little muscle the solearis (soleus), instead of continuing to designate it the small plantaris, which appellation is given to another muscular element.

6. In its course along the tendo-Achillis, the sciatic nerve emits some slender cutaneous filaments, which we do not consider worthy of further notice.

TERMINAL BRANCHES.

Plantar Nerves (Fig. 355, 10, 12).—These two nerves enter the tarsal sheath, behind the perforans tendon, along with the plantar arteries. Towards the superior extremity of the cannon, they definitively separate from each other; the external is carried outwards between the precited tendon and the rudimentary metatarsal bone; the internal is placed with that tendon, and follows the posterior border of the inner metatarsal bone. Both afterwards descend on the fetlock, where they comport themselves like the analogous nerves of the anterior limb.

DIFFERENTIAL CHARACTERS IN THE LUMBO-SACRAL PLEXUS OF OTHER THAN SOLIPED ANIMALS.

As was the case with the brachial plexus, so with this; the differences observed being trifling in the upper part of the limb, but more numerous and important in the region of the foot, the complexity of arrangement varying with the species.

Ruminants.—The lumbo-sacral plexus of these animals is constituted by two lumbar and three sacral nerves, as in Solipeds; but the third sacral only gives a very fine filament, which reaches the second in passing downward and forward.

At the femoro-tibial articulation, the branches of the plexus are similar to those in the Horse. Below that articulation, the following disposition has been observed in the *Sheep*.

The *musculo-cutaneous branch* of the popliteal is long and thick. It descends on the anterior face of the metatarsus, and at the metatarso-phalangeal articulation bifurcates, the branches forming the dorsal collaterals of the digits. The *anterior tibial nerve* presents two branches parallel to the tibial vessels; one passes along the metatarsal region, and when it arrives at the bottom of the groove between the condyles of the metatarsus, it divides into two branches that constitute the deep collaterals of the digits; these collaterals furnish filaments to the posterior face of the digital region.

The *great sciatic* resembles that of Solipeds. Its terminal branches, or *plantar nerves*, differ from those of the Horse in the absence of the transverse anastomosis that unites the two cords in the region of the tendons.

Pig.—The lumbo-sacral plexus of this animal is composed of two lumbar and three sacral nerves reckoning, of course, as a sacral nerve, the trunk that escapes from between the last lumbar vertebra and the sacrum. The plexus may be divided into two portions, the first furnishing a femoral and an obturator nerve. The *internal saphenous branch of the femoral nerve* is long and voluminous; at its origin it is as large as the branch passing to the anterior muscles of the thigh, and it descends on the inner face of the metatarsus, forming the dorsal collateral of the internal digit.

The *great sciatic* is voluminous and round. The branches it gives to the muscles of the pelvis and femur are disposed nearly as in Solipeds and Ruminants; but differences are observed in the *external popliteal* and the terminal branches.

The *musculo cutaneous nerve* reaches the metatarsal region, where it separates into three branches, which form the dorsal collaterals of the digits.

The *anterior tibial nerve* descends between the two principal metatarsals, and at the root of the middle digits divides to anastomose with the plantar nerves. Of these the external is small, and gives collaterals to the two external digits; the internal, the

largest, descends between the two principal digits, where it bifurcates; above, it gives a branch to the internal digit.

CARNIVORA.—In these animals, the lumbo-sacral plexus is formed by the last four lumbar and the first two sacral.

The *crural* and *obturator nerves*, which arise from the fourth, fifth, and sixth lumbar nerves, offer nothing particular in their disposition.

The *internal saphenous* branch is as long as in the Pig; it passes to the internal face of the tarsus, lies alongside the fourth metatarsal bone, and forms the internal dorsal collateral of the fourth toe.

The *great sciatic* may be described as having, as in Man, two terminal branches which separate a little above the posterior face of the femoro-tibial articulation. The *external popliteal nerve* passes to the surface of the external gastrocnemius, enters between the common long flexor of the toes and the long lateral peroneal muscle, where it bifurcates. The *musculo-cutaneous* branch descends beneath the latter muscle to the lower third of the leg, when it becomes superficial, and, accompanied by a vein, is lodged in the interspace between that muscle and the anterior tibial; it passes in front of the tarsus, and reaches the upper part of the metatarsus, where it divides into three divisions. It must be mentioned that at the tibio-tarsal articulation is thrown off a very fine cord, which is directed outwards, and forms the external dorsal collateral of the first toe. Each of its three terminal branches courses along an intermetatarsal space, and at the metatarso-phalangeal articulations separates into two filaments, whence results the following distribution: the external branch forms the internal dorsal collaterals of the first toe and external of the second; the middle constitutes the internal dorsal collaterals of the second toe and external of the third; lastly, the internal furnishes the internal dorsal collaterals of the third toe and external of the fourth. The *anterior tibial nerve* accompanies the artery of that name, descends along the external face of the tibia, and terminates in two branches at the tarsus. Of these, one is distributed to the tarsal articulations and the pedal muscle; the other, internal, enters the intermetatarsal space, and at the corresponding metatarso-phalangeal joints anastomoses with the internal branch of the musculo-cutaneous nerve, and is lost in the same parts. The *internal popliteus* forms the second terminal branch of the great sciatic nerve, and in the *Dog* and *Cat* represents that portion of the latter which, in the Horse, is situated behind the femoro-tibial articulation. It is continued by the *posterior tibial nerve*, which terminates by the two plantar nerves. During its course, the external popliteal furnishes articular and muscular filaments, as well as cutaneous twigs subsequently; among the latter may be mentioned the *external saphenous*, which arises by two branches, and is expended behind the malleolus, at the outer side of the tarsus. The *plantar nerves* are external and internal; the latter lies at the inner border of the tendon of the superficial flexor muscles of the phalanges, and when it joins the middle of the metatarsus, it detaches a fine filament that forms the internal plantar collateral of the fourth toe; it then passes obliquely towards the first toe, at the deep face of the above-named tendon, and successively gives off three filaments—one for each intermetatarsal space. These filaments anastomose with the terminal branches of the external plantar, at the metatarso-phalangeal articulations; the first two filaments supply the large cushion of the paw.

The *external plantar nerve* passes between the two flexor tendons of the toes, where it gives a filament that constitutes the external plantar collateral of the first toe. It is afterwards placed outside the deep flexor, then enters beneath the short flexor and divides into several branches, muscular and digital. Each of the latter, three in number, passes into a corresponding interosseous space and bifurcates at the metatarso-phalangeal articulations, receiving filaments from the internal plantar, and forming the following plantar collaterals: the internal of the first toe, internal and external of the second, internal and external of the third, and external of the fourth digit.

COMPARISON OF THE LUMBO-SACRAL PLEXUS OF MAN WITH THAT OF ANIMALS.

It is usual, in human anatomy, to describe a lumbar and a sacral plexus.

The *lumbar plexus* is constituted by the anastomoses of the anterior branches of the five lumbar nerves;[1] these are united by fine filaments, which are not intricately associated. The divisions of this plexus are distinguished as *collateral* and *terminal branches*. The first, destined to the upper part of the limb and the skin covering the

---

([1] Wilson says the four upper lumbar nerves and the last dorsal; Heath gives the same constitution.)

external genital organs, are represented in Solipeds by the ramifications of the lumbar nerves, which have been separately described. The terminal branches are the *obturator crural*, and *anterior femoral* (or *anterior crural*). There is nothing to be said respecting the obturator nerve; it leaves the pelvis by the obturator foramen, as in all the animals mentioned. The crural has been described as having four terminal branches: the *internal* and *external musculo-cutaneous*, the *nerve of the triceps crureus* (*muscular branch*), and the *internal saphenous*. The two *musculo-cutaneous branches* have their analogue in the Horse, in the filament we have named the accessory branch of the internal saphenous. The nerve of the triceps is expended in the anterior rectus, and the vastus internus and externus. The saphenous descends between the muscles of the inner aspect of the thigh, beneath the aponeurosis, and becomes superficial at a short distance from the condyle of the femur, giving a patellar branch that divides in the skin of the knee, and a tibial branch that is expended on the inner face of the tarsal articulations and the foot.

Fig. 358.

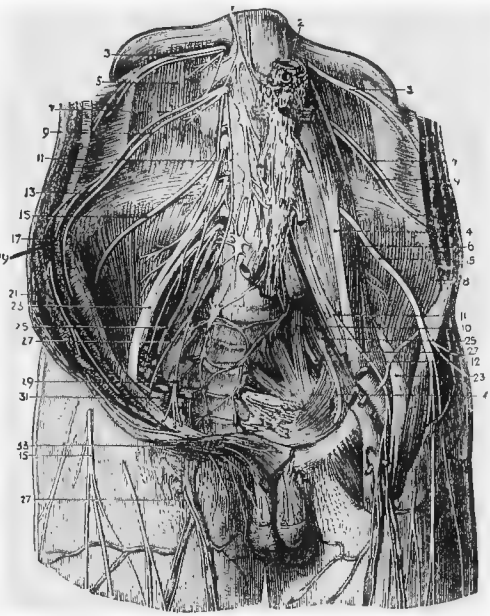

LUMBAR PLEXUS OF MAN.

1, Right gangliated cord of sympathetic; 2, Abdominal aorta; 3, 3, Last dorsal nerves; 4, Psoas parvus; 5, Quadratus lumborum; 6, Psoas magnus; 7, 7, Ilio-hypogastric nerves; 8, Iliacus internus; 9, 9, Ilio-inguinal nerve; 10, Lumbo-sacral nerve; 11, Genito-crural nerve; 12, Gluteal nerve; 13, Iliac branch of ilio-hypogastric nerve; 14, Sacral plexus; 15, 15, 15, External cutaneous nerves; 17, Transversalis abdominis; 19, Obliquus internus; 21, Obliquus externus; 23, 23, Anterior crural nerves; 25, 25, Obturator nerves; 27, 27, Crural branch of genito-crural nerve; 29, Genital branch of genito-crural nerve; 31, External iliac artery; 33, External abdominal ring.

The *sacral plexus* comprises the first three sacral nerves, to which is added a lumbo-sacral branch furnished by the lumbar nerves, and a fine filament that ascends from the fourth sacral.

Ten collaterals and a terminal branch arise from this plexus.

The *collateral branches* are divided into intrapelvic and extrapelvic: they are five in each group. The first are destined to the muscles of the inner aspect of the pelvis, and to those of the perineum and the skin of this region. The second are distributed to the muscles on the outer aspect of the pelvis, and the skin on the posterior face of the thigh. They are:

1. *Visceral branches* that descend on the sides of the rectum and are lost in the hypogastric plexus; 2, *Nerve of the elevator of the anus*; 3, *Hæmorrhoidal* or *anal nerve*; 4, *Nerve of the internal obturator* that appears to arise, in the Horse, from the sciatic trunk; 5, *Internal pudic*, which has been described with the sacral nerves. In Man this nerve leaves the pelvis by the great sciatic notch (or foramen), and returns to it by the lesser; within the ischiatic tuberosity it divides into two branches: an inferior or *perineal*, and a superior or *dorsalis penis nerve*. The latter is placed on the dorsum of the penis, and reaches the mucous membrane of the glans and prepuce; the former does not go beyond the muscles and integuments of the perineum. 6, The *superior gluteal nerve*; 7, *Nerve of the pyramidalis*, 8, *Nerve of the superior gemellus*; 9, *Nerve of the inferior gemellus and quadratus cruralis*, 10, The *small sciatic*, or *inferior gluteal nerve*, the inferior or femoral branch of which is very long, descending, as it does, to the middle of the posterior face of the thigh, beneath the crural aponeurosis, to the popliteal space, where it becomes superficial, and terminates in the skin of the upper portion of the leg.

Fig. 359.

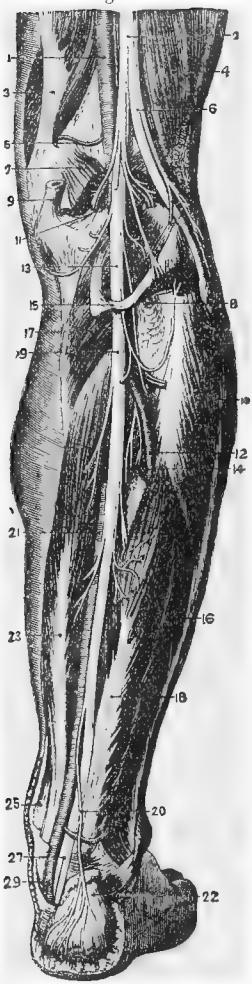

NERVES AT THE POSTERIOR ASPECT OF HUMAN LEG.

1, Popliteal artery; 2, Great sciatic nerve; 3, Adductor magnus; 4, Biceps; 5, Superior internal articular artery; 6, External popliteal nerve; 7, Gastrocnemius, cut; 8, Anterior tibial artery; 9, Tendon of semimembranosus; 10, Peroneus longus; 11, Sural arteries and nerves; 12, Peroneal artery; 13, Internal popliteal nerve; 14, Tibialis posticus; 15, Portion of soleus; 16, Peroneus brevis; 17, Popliteus; 18, Flexor longus pollicis; 19, Posterior tibial nerve; 20, Calcanean branch of posterior tibial nerve; 21, Posterior tibial artery; 22, Tendo-Achillis; 23, Flexor longus digitorum; 25, Tendon of tibialis posticus; 27, Plantar nerves; 29, Plantar arteries.

Fig. 360.

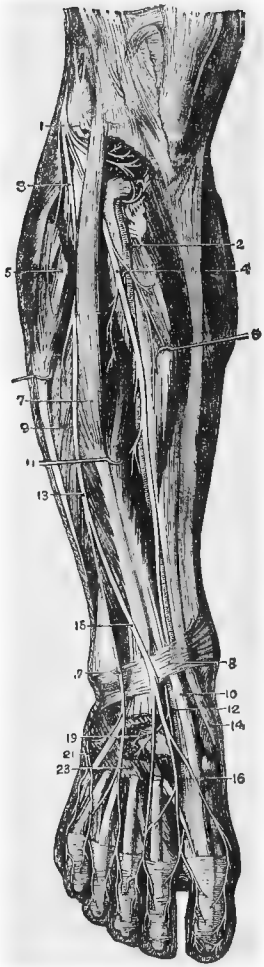

NERVES AT THE FRONT ASPECT OF HUMAN LEG.

1, External popliteal nerve; 2, Anterior tibial artery; 3, Musculo-cutaneous nerve; 4, Anterior tibial nerve; 5, Peroneus longus; 6, Tibialis anticus; 7, Extensor longus digitorum; 8, Anterior annular ligament; 9, Peroneus brevis; 10, Tendon of extensor proprius pollicis; 11, Extensor proprius pollicis; 12, Dorsal artery of foot; 13, Point at which the musculo-cutaneous nerve pierces the fascia and bifurcates; 14, Tendon of tibialis anticus; 15, Internal branch of musculo-cutaneous nerve; 16, Cutaneous branch of anterior tibial nerve; 17, External branch of musculo-cutaneous nerve; 19, Deep branch of anterior tibial nerve; 21, External saphenous nerve; 23, Extensor brevis digitorum.

The *terminal branch* of the sacral plexus forms the *great sciatic nerve*, whose distribution is the same as that of Carnivora. The collateral ramuscules of the great sciatic are the branch of the long portion of the biceps; the semitendinosus and semimembranosus branch; the branch to the great adductor; and, lastly, that to the short portion of the biceps. It terminates by the external and internal popliteal.

The *musculo-cutaneous* and *anterior tibial*, continuations of the external popliteus, comport themselves almost the same as in the Dog. They form dorsal collaterals to the third, fourth, and fifth toes, as well as to the second.

The *internal popliteal* presents an external saphenous nerve that passes along the external border of the foot, and has, in addition, a branch that ascends on the dorsum of that organ. The external saphenous furnishes the dorsal collaterals to the first toe, and the external collateral to the second. The *posterior tibial nerve* continues the internal sciatic in the leg; it terminates in the *plantar nerves*. The internal plantar furnishes the collateral nerves to the fifth, fourth, and third toes, and the internal collateral of the second toe. The external divides into three branches: the two superficial branches form the collaterals of the first toe, and the external collateral of the second; the deep branch passes inwards, behind the interosseous muscles, and is expended in those of the fourth space, after giving filaments to the oblique abductor of the large toe, transverse abductor, last two lumbricales, to the interosseous, and very fine filaments to the articulations of the tarsus with the metatarsus.

It will therefore be seen that, in Man, the branches of the deep trunk of the external plantar join those of the internal plantar, to form the collateral nerves.

CHAPTER III.

THE GREAT SYMPATHETIC NERVOUS SYSTEM.

PREPARATION OF THE GREAT SYMPATHETIC.—*The same subject ought to suffice for the preparation of this, as well as the pneumogastric and spinal nerves.* After placing the animal in the first position, the intestines are removed, one of the posterior limbs cut off, and the greater portion of the os innominatum cleared away by sawing through the symphysis pubis and the neck of the ilium; the dissection of all the abdomino-pelvic portion of the system, and that of the terminal branches of the pneumogastric nerve, is then proceeded with. The anterior limb of the same side should be afterwards detached, the scapula having been previously sawn across its middle part, and the thorax thrown open by the ablation of the entire costal wall, in sawing through the sternal cartilages below, and the ribs above, at their superior extremity All the thoracic portion of the ganglionic nervous apparatus, and the pneumogastric nerves may then be prepared. Nothing more remains to be accomplished except the dissection of the sympathetic and the vagus nerve in the cervico-cephalic region, with that of the spinal nerve; this operation is not attended with any difficulty, and should be preceded by the extirpation of a branch of the inferior maxilla. It is useful to inject the arteries previously; as then the filaments of the sympathetic that lie alongside the vessels of the different organs in the abdominal cavity can be more easily followed.

The *great sympathetic*, also named the *trisplanchnic system* (σπλανχνον —an intestine or viscus), because of its position and destination, is the nervous apparatus of the organs of vegetative life.

As has been already shown in the general consideration of the nerves and the whole nervous system, this apparatus has for its base two long cords extending from the head to the tail, underneath the vertebral column, and to the right and left of the median line. Towards the last sacral vertebra, a portion of these two cords converge towards each other, and lie beside the median coccygeal artery. Some anatomists think that the great sympathetic does not stop at this point, but is prolonged beneath the coccygeal vertebræ, where it enters a ganglion that has been described of late years as the "coccygeal gland," and whose nature has been very much contested.

Each cord presents on its course numerous ganglia, to whose presence it

owes its chain-like aspect; they are usually elliptical in shape, though they may also be round or semilunar; in all cases they are studded with prolongations at their borders. Beneath each of the regions of the spine they are equal in number to the vertebræ, with the exception of the cervical region, in which are only two—one at the top, the other at the bottom, of the neck.

To this chain arrive *afferent branches*, by the union of which it is constituted; these branches are furnished by the nerves of the medulla oblongata and the inferior spinal branches, except those of the coccygeal region. The afferent branches join the sympathetic at each ganglion; but as there are only two ganglia in the region of the neck, the afferent filaments of the cervical nerves are grouped in such a manner as to reach the superior and inferior ganglion.

Those nerves which are given off from the ganglia to be distributed to the viscera, are named the *efferent* or *emergent branches*. They are interlaced around the arteries to reach their destination, forming *plexuses* on the surface of these vessels.

This general idea of the disposition of the great sympathetic is sufficient to show that its double ganglionic chain does not represent two particular nerves arising at one determinate point, and ending at another. Properly speaking, they have neither origin nor termination: they are always giving off branches which are as frequently replaced by others: in this way they might be compared, in this respect, to the median spinal artery, which offers somewhat the same mode of constitution—with its *afferents* supplied by the spinal branches from the intervertebral foramina, and its *efferents* destined to the substance of the spinal medulla.

Fig. 361.

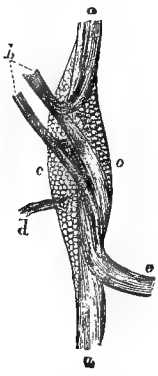

SYMPATHETIC GANGLION FROM A PUPPY.

a, *a*, Trunk of the sympathetic nerve; *b*, Communicating branches from a spinal nerve; these divide into two fasciculi which pass upwards and downwards in the trunk; *c*, *c*, The ganglion composed of ganglion cells; *d*, Small branch, probably destined to accompany an artery; *e*, Visceral branch.

Structure.—The ganglia of the great sympathetic differ but little in their structure from the spinal ganglia, whose constitution has been already made known. They have an envelope of connective tissue, which sends very fine septa into their interior. In the spaces are cells a little smaller and paler than those of the spinal ganglia; they are round, or furnished with poles that bring them into communication with the afferent and efferent nerve-tubes; there are also, in the ganglia, tubes which only pass through it, and merely lie beside the cells.

The *afferent branches of the ganglia* have the white tint of the cerebro-spinal nerves, and are named the *grey nerves*. They owe their colour to the *fibres of Remak*, which they contain in large quantity. With these nucleated fibres are associated fine nerve-fibres, and double-contoured fibres which proceed from the *communicating rami*, or afferent filaments supplied by the spinal nerves; these fibres often leave the ganglia to pass directly to organs.

In describing the sympathetic chain, it is divided into five sections: a *cephalic*, *cervical*, *dorsal*, *lumbar*, and *sacral*.

1. *Cephalic Portion of the Sympathetic.*

This is composed of the *spheno-palatine*, *ophthalmic*, and *otic ganglia*, all of which communicate with the superior cervical

ganglion. Their description has been given with that of the fifth encephalic pair of nerves.

2. *Cervical Portion of the Sympathetic.*

The cervical section of the ganglionic chain is formed by two large ganglia placed one at the top, the other at the bottom, of the neck, and united to each other by an intermediate cord.

A. Superior Cervical or Guttural Ganglion (Fig. 362, 1).—This ganglion is a very elongated fusiform body, lying beside the internal carotid artery, comprised with it in a particular fold of the membrane forming the guttural pouch, and therefore situated in front of the transverse process of the atlas, in proximity to the glosso-pharyngeal, pneumogastric, spinal, and hypoglossal nerves, as well as the inferior branch of the first cervical pair. All these nerves communicate with the ganglion by slender filaments, and in this way form around it a veritable plexus, which has been designated the *guttural plexus* by Veterinary Anatomists.

Afferent Branches.—These are communicating filaments belonging to the nerves already enumerated. They do not possess sufficient importance to merit particular mention. We may notice the existence of the filaments supplied by the inferior branches of the first four cervical nerves.

Emergent Branches.—These are: 1, Branches accompanying the internal carotid artery into the cranium; 2, A thick fasciculus which reaches the origin of the three terminal divisions of the common carotid; 3, Small filaments to the membrane of the guttural pouch and the wall of the pharynx.

The following are the principal anatomical characters of these three orders of branches:

a. The *satellite branches of the internal carotid artery* arise at the superior extremity of the ganglion. They may vary in number. We have generally found two of unequal volume—a *posterior*, and an *anterior*, which is the smallest. They interlace around the internal carotid in anastomosing with each other, and with that vessel enter the cavernous sinus, where they form, by their divisions, a little plexiform apparatus named the *cavernous plexus*, the diverse branches of which connect it with several of the encephalic nerves. Among these branches are remarked: 1, Some filaments joined to analogous filaments from the opposite side, on the transverse anastomosis which unites the two internal carotids in the cavernous sinus; 2, A branch lying beside the great petrosal nerve, and concurring in the formation of the Vidian nerve, which enters the spheno-palatine ganglion; 3, A ramuscule going to the ophthalmic ganglion, in company with fibres from the ophthalmic branch of the fifth pair; 4, Several filaments passing to the Gasserian ganglion; 5, Branches which mix with the fibres of the three motor nerves of the eye.

b. The *inferior carotid fasciculus*, destined to the terminal extremity of the common carotid, escapes from the inferior part of the guttural ganglion. Frequently at its origin it is only a thick cord, but ordinarily it is composed, from its commencement, of several branches bound to one another by communicating filaments. Reaching their destination, these branches meet ramuscules emanating from the glosso-pharyngeal and pneumogastric nerves, and anastomose with them to form, around the origin of the three terminal branches of the common carotid, the so-called *carotid plexus*, whose ramifications almost exclusively follow the external carotid, and the greater part of which are distributed to the glands and the salivary lobules. In Man, the

Fig. 362.

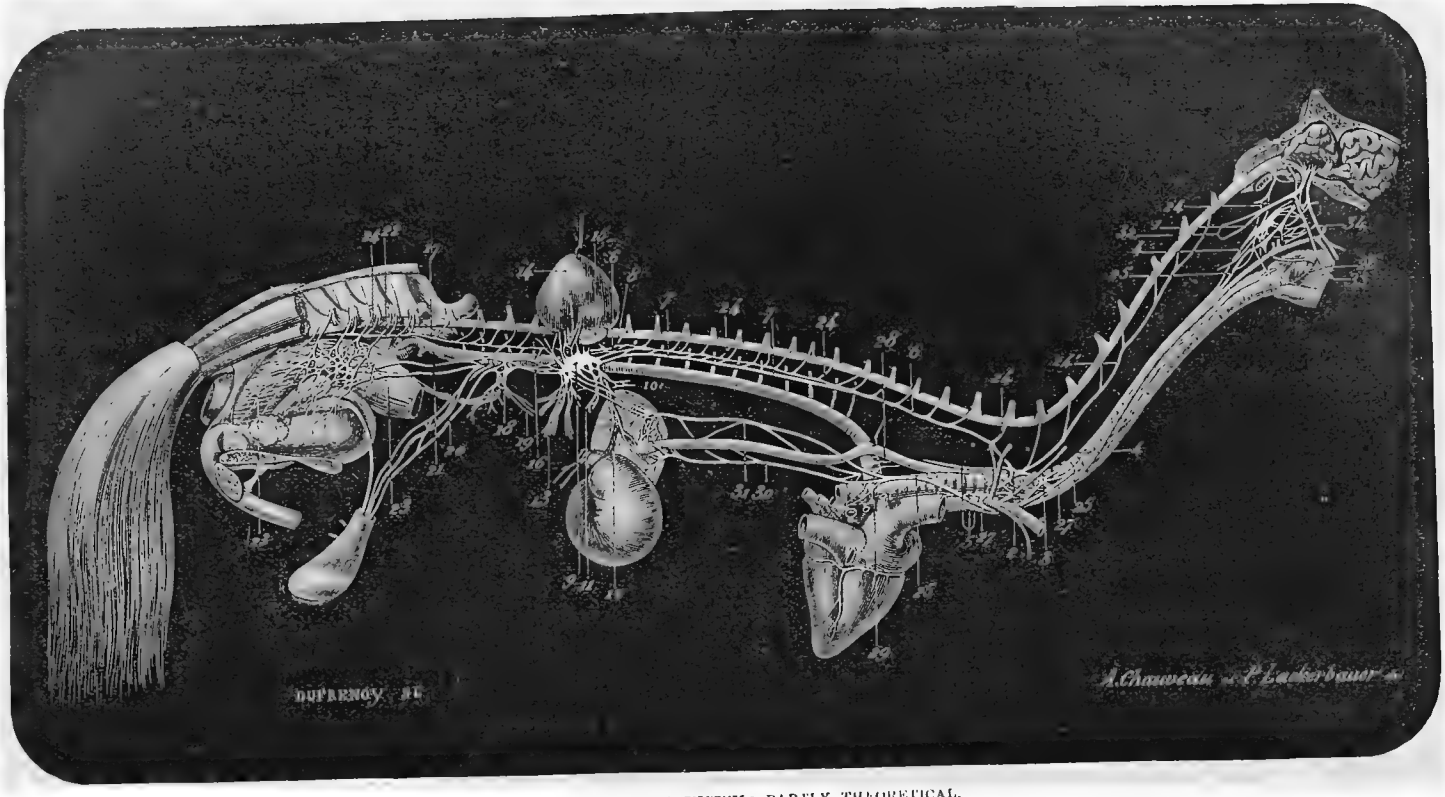

THE SYMPATHETIC SYSTEM; PARTLY THEORETICAL.

The spinal cord has been deprived of its bony case throughout the whole extent of its cervical, dorsal, and lumbar portions.

[*For Description see p.* 785.

division which follows the spheno-spinal artery passes to the otic ganglion; the same takes place, no doubt, in animals.

c. The *guttural* or *pharyngeal filaments*, arising from the anterior border of the ganglion and the inferior carotidean fasciculus, are generally very delicate. Those which reach the superior wall of the pharynx concur, with the glosso-pharyngeal and the pneumogastric, to form the *pharyngeal plexus.*

B. Intermediate Cord of the Two Cervical Ganglia.—This cord leaves the inferior extremity of the superior cervical ganglion, lies close beside the pneumogastric nerve, which always surpasses it in volume, and descends to the entrance of the thorax, where it separates from the vagus nerve, and joins the inferior cervical ganglion. It neither receives or gives off any branch in its course.

C. Inferior Cervical Ganglion (Fig. 362, 2).—Generally thicker than the superior, this ganglion is placed within the costal insertion of the inferior scalenus. The right, always a little more anterior than the other, is applied immediately against the side of the trachea. That of the left side is separated from it by the œsophagus. Both are related, externally to the vertebral artery.

The inferior cervical ganglion is very liable to vary, and, become irregular in form. It is sometimes lenticular, at others more or less elongated, always stellate, and not unfrequently double. In the latter case, which is perhaps more frequent in the left than the right, its two portions are distinguished into anterior and posterior: the last forms the *inferior cervical ganglion*, properly called (Fig. 362, 2): the former is much smaller, and is bound to the other by a wide and short greyish band, constituting what has been designated in Man the *middle cervical ganglion* (Fig. 362, 3).

In front, the ganglion which we are describing receives the cord intermediate to the two ganglionic enlargements in the region of the neck, either directly, or through the medium of the middle cervical ganglion, when that is present. It is continued backwards with the dorsal portion of the sympathetic chain.

Afferent Branches.—These are two, proceeding from the cervical pairs.

One is a thick nerve, satellite to the cervical vertebral artery, and lodged with it in the foramina of the cervical vertebræ; it is formed by filaments emanating from the second, third, fourth, fifth, sixth, and seventh pairs of

---

1 to 2, *Cervical portion of the sympathetic chain;* 1, Superior cervical ganglion, in the middle of the guttural plexus; 2, Inferior cervical ganglion; 3, Middle cervical ganglion; 4, Intermediate cervical cord, intimately united at its middle portion with the pneumogastric nerve; 5, Cardiac nerves; 6, *Dorsal portion of the sympathetic chain;* 7, Great splanchnic nerve; 8, Lesser splanchnic nerve; 9, Semilunar ganglion, centre of the solar plexus; 10, Portion of the hepatic artery encircled by its plexus; 11, The splenic artery, ditto; 12, The gastric artery, ditto; 13, The anterior mesenteric artery, ditto; 14, Kidney, elevated, receiving the renal plexus; 15, The suprarenal capsule with its plexus; 16, Lumbo-aortic plexus; 17, *Lumbar portion of the sympathetic chain;* 18, Posterior mesenteric plexus; 19, Branches from it passing to the anterior mesenteric plexus; 20, Spermatic plexus; 21, Branches going to the pelvic plexus; 22, *Sacral portion of the sympathetic chain;* 23, Pelvic plexus; 24, Afferent branches furnished to the sympathetic by the spinal pairs; 24′, The cord which receives six of the cervical ramuscules; 25, *Pneumogastric nerve;* 26, Superior laryngeal; the pharyngeal branch is seen to be detached from the pneumogastric a little below; 27, Inferior laryngeal nerve of the right side; 28, That of the left side at the point where it bends round the arch of the aorta; 29, Nerves of the bronchial plexus; 30, Superior œsophageal branch; 31, Inferior ditto; 32, *Spinal nerve;* 33, Hypoglossal nerve; 34, Glosso-pharyngeal nerve, represented too thick.

cervical nerves, and thus carries in a mass, to the great sympathetic, the contingent of afferent nerve-fibres of the majority of these nerves (Fig. 362, 24′).

The other branch is an isolated one, proceeding from the eighth cervical pair.

Besides these afferents, there ought to be noticed the filaments sent by the pneumogastric nerve, and which join the middle cervical ganglion, when it is present. *See the description of the pneumogastric nerve.*

Emergent Branches. — These are detached from the posterior and inferior part of the ganglion, and for the most part proceed to the heart. Some extremely fine filaments go to the anterior mediastinum, or pass on to the collateral arteries of the brachial trunk.

The *cardiac nerves* (Fig. 362, 5) cross the base of the pericardium, alongside the common aorta, and are then distributed to the tissue of the auricles and ventricles. Some follow the divisions of the pulmonary artery. and concur in the formation of the bronchial plexus.

To arrive at the heart, these nerves accompany the axillary arteries and the trachea, giving rise, on the inferior face of the latter, to a very large fasciculus, named, in Veterinary anatomy, the *tracheal plexus;* this is single, and is traversed from behind to before by the two recurrent nerves, which give or receive from it numerous filaments.

The *cardiac nerves* in the Horse are five in number; two proceed from the *left*, and three from the *right cervical ganglion.* Of the first two, one is formed by easily-separated filaments, and is applied to the left brachial trunk of the anterior aorta, which it follows to its commencement. There it divides into several ramuscules; some of these pass into the furrow between the right auricle and the origin of the pulmonary artery; the others pass between the latter and the common carotid, to reach the root of the lung. This nerve furnishes very fine filaments to the anterior border of the heart. The second left cardiac nerve commences by two branches that leave the middle and inferior cervical ganglia; from their union results a long cord that is directed downward, backward, and to the right, crossing the lower face of the trachea; arrived at the right side of the posterior aorta, beneath the recurrent nerve, it is distributed to the heart and lungs.

The cardiac nerves arising on the right side are thus disposed. The largest emerges from the middle cervical ganglion, and lies alongside the pneumogastric, bending with it beneath the axillary artery, and becoming detached a little beyond that vessel; here it receives ramuscules from the left recurrent and enters the base of the heart, after giving off some filaments that pass to the bronchial plexus. The second, much smaller, is also detached from the middle ganglion, receives some branches from the right recurrent, and is applied to the surface of the anterior aorta as far as the upper face of the auricles. Lastly, the third, as large as the preceding, proceeds from the right recurrent, the inferior cervical ganglion, and the pneumogastric; it is imbedded in the heart, to the right of the aorta.

3. *Dorsal Portion of the Sympathetic Chain.*

The cord represented by this portion of the sympathetic chain leaves the inferior cervical ganglion, and extends from before to behind, towards the diaphragm, passing beneath the superior extremities of the ribs—or rather, below the vertebro-costal articulations, against which it is maintained by the pleura—and crossing the intercostal arteries. It is continued in the abdominal

cavity by the lumbar portion, after passing through the arch of the superior border of the diaphragm, along with the psoas parvus.

Along its course, this cord exhibits, at each intercostal space, a small fusiform ganglionic enlargement—seventeen in all. The two or three first are most frequently absent; but then the anterior extremity of the nerve has for some extent the appearance of a ribbon-shaped ganglion, which seems to be due to the elongation, posteriorly, of the inferior grey mass of the cervical portion.

Afferent Branches.—Furnished by the inferior branches of the dorsal nerves, these ramuscules number from one to three for each ganglion. To proceed from the intervertebral foramina to the sympathetic, they traverse the superior extremity of the intercostal space, passing sometimes behind, sometimes before, the arteries of that name.

Emergent Branches.—A very few delicate branches pass to the pleuræ; those which demand notice are the *great* and *lesser splanchnic nerves.*

a. Great splanchnic nerves (Fig. 362, 7).—This commences to be detached from the dorsal chain towards the sixth or seventh ganglion, is directed backwards by the external side of that chain, receives an accessory branch from each of the enlargements it passes by, except the last two or three, and enters the abdominal cavity through the arch of the psoas parvus, where it usually looks like a small ganglionic mass; after which, it is inflected inwards, and terminates on the side of the aorta, between the cœliac and mesenteric trunks, by a second and enormously developed mass—the *solar ganglion.* The two *solar*, or *semilunar ganglia*, as they have also been designated, and which are the largest in the body, are elongated from before to behind, and flattened from above to below. They communicate with one another by means of a wide and thick greyish cord, which encircles, posteriorly, the trunk of the great mesenteric artery, and by a multitude of filaments which pass from the left to the right, in front of that vessel. From this arrangement results a single plexus situated at the inferior face of the aorta, between the origin of the two precited arterial trunks.

This plexus, named the *solar*, receives some branches from the superior œsophageal cord of the pneumogastric nerve. It subdivides on its periphery into several secondary plexuses, which leave, as from a centre, the principal network, and whose ramifications, very large and numerous, proceed to the neighbouring organs in accompanying the arterial divisions, around which we see them interlacing and anastomosing in a very complicated manner. It is for this reason that there have been described separately: 1, *A gastric plexus*, going to the stomach, on whose parietes its branches anastomose with those of the pneumogastrics; 2, *A hepatic plexus*, destined to the liver, duodenum, pylorus, and pancreas; 3, *A splenic plexus*, one part of which passes to the spleen, the other to the stomach; 4, *An anterior mesenteric plexus*, the most considerable of all, is distributed to the same organs as the artery of that name; 5, *A renal* and a *suprarenal plexus:* the latter two doubled, and scarcely distinct from each other, their terminal divisions arriving at the kidneys and suprarenal capsules. The termination of the filaments of these plexuses has been already described in the Splanchnology.

It is necessary to add to this rich nervous apparatus, the *lumbo-aortic plexus*, formed by the large and numerous branches which spring from the solar plexus behind the great mesenteric artery, creep along the sides and the inferior face of the aorta, frequently anastomose with each other, and reunite at the posterior mesenteric plexus.

b. Lesser splanchnic nerve (Fig. 362, 8).—This branch is composed of two or three filaments that emanate from the last subdorsal ganglia, and which, instead of joining the great splanchnic nerve like the others, with which they communicate by one or two fine divisions, collect in a short thin cord, whose ramifications pass directly into the solar plexus, or are confounded with the nerves of the kidney and the suprarenal capsule.

4. *Lumbar Portion of the Sympathetic.*

This is a cord similar to that of the dorsal portion, and provided with fusiform ganglionic enlargements equal in number to the pairs of lumbar nerves. This cord is applied against the psoas parvus, near the common inferior vertebral ligament, and is covered on the left by the aorta, on the right by the posterior vena cava. It is directly continued by the sacral portion of the sympathetic chain at the lumbo-sacral articulation.

Afferent Branches.—Furnished by the inferior branches of the lumbar nerves, these ramuscules comport themselves exactly like those of the dorsal region.

Emergent Branches.—These are short filaments, analogous to those which, by their union, constitute the splanchnic nerves. Their number is not constant, and is generally less than that of the ganglia. Two or three join the lumbo-aortic plexus; the others gain the origin of the small mesenteric artery, anastomose around it with the posterior extremities of the branches of that plexus, and thus form another single nervous network designated the *posterior mesenteric plexus* (Fig. 362, 18).

This plexus, in whose centre is a more or less voluminous ganglion, sends to the various branches of the small mesenteric artery ramifications destined for the walls of the small colon and the rectum.

It supplies besides: 1. Two or three large branches which follow the posterior mesenteric vein, and join the anterior mesenteric plexus, after giving off some divisions to the tissue of the colic mesentery (Fig. 362, 19).

2. Satellite branches to the two spermatic arteries, constituting the plexus of that name (Fig. 362, 20).

3. Two or three long divisions (Fig. 362, 21) which enter on each side of the pelvis by passing beneath the external face of the peritoneum, and reach the lateral plane of the rectum, where they meet the filaments emanating directly from the inferior sacral nerves. From the anastomoses of these divisions results a rich nervous network, called in Man the *hypogastric plexus*, and which we have designated the *pelvic plexus;* this network is destined to all the organs contained in the pelvic cavity (Fig. 362, 23).

5. *Sacral Portion of the Sympathetic.*

A continuation of the lumbar cord, this portion of the sympathetic chain is situated beneath the sacrum, to the inner side of the inferior sacral nerves. It offers four very elongated ganglia, which communicate with these nerves by one or more filaments, and which give rise to several very fine ramuscules that are lost in the cellular tissue on the inferior face of the sacrum.

Its posterior extremity, which terminates behind the great sympathetic, does not always comport itself in the same manner. We sometimes see it become attenuated to a very delicate ramuscule, which passes on to the median coccygeal artery, and anastomoses with that of the opposite side.

But sometimes, also, this ramuscule cannot be distinguished, and the sub-sacral cord seems to be abruptly terminated by the filament of communication from the last sacral pair.

FUNCTIONS.—The functions of the sympathetic are yet but little known, notwithstanding the labours of many physiologists, at whose head must be placed Claude Bernard. In a physiological condition, this nerve possesses an extremely obscure sensibility, but which may become very acute in pathological cases. It conveys to organs the unconscious motor excitations originating in the spinal cord; and through the filaments it furnishes to the vessels—the vaso-motor nerves—it holds under its control the circulatory phenomena, especially in the capillary plexuses, causing these canals to dilate or contract, and thus diminish or accelerate the flow of blood in them. By this action on the blood-vessels, it may have a secondary influence on the nutrition of the organs to which these vessels are distributed.

DIFFERENTIAL CHARACTERS IN THE GREAT SYMPATHETIC OF OTHER THAN SOLIPED ANIMALS.

In all the domesticated mammals, the general disposition of the great sympathetic is very similar; so that there are but few and slight differences to note.

In the *Ox*, the cervical filament does not arise from the lower extremity of the superior ganglion, but from its middle portion; it is divisible into two or three filaments for a certain distance, after which it lies beside the pneumogastric. The ramuscule that leaves the lower end of the cervical ganglion is very large, and reaches the division of the common carotid, that which accompanies the internal carotid artery is also of a considerable size. (Ruminants have 13 thoracic and 6 lumbar ganglia.)

In the *Dog*, the cervical sympathetic cord is closely united with the pneumogastric, and it is not possible to separate them from each other, as can be done in Solipeds and Ruminants. (In the Carnivora there are 13 thoracic and 7 lumbar ganglia.)

The *Pig* has a superior cervical ganglion, which is fusiform and very long; at its lower extremity it gives off several filaments, one of which lies beside the pneumogastric in the cervical region, but separates from it to join the middle cervical ganglion, the others pass to the tenth nerve, and are confounded with it at the ganglionic enlargement it shows behind the pharynx. At the entrance to the chest, a branch separates from the pneumogastric, passes along with the axillary arteries, and finally enters the heart. This branch is perhaps formed by the filaments of the sympathetic that joined the pneumogastric at the upper part of the neck. (The inferior cervical ganglion, according to Leyh, is completely isolated from the thoracic ganglion. The Pig has 14 thoracic and 7 lumbar ganglia.

COMPARISON OF THE GREAT SYMPATHETIC OF MAN WITH THAT OF ANIMALS.

It is divided and disposed as in animals. The *cervical portion* is composed of a superior fusiform ganglion, from which emerge many branches which have been studied with the greatest care. There are described: 1, Superior or intercranial branches; 2, External or anastomosing branches with the first four spinal nerves; 3, Internal or visceral branches, which mix with the pharyngeal and laryngeal filaments of the pneumogastric; 4, Anterior or external carotideal branches, which pass to the common carotid and the middle of a small ganglion, the intercarotid; 5, Posterior, muscular, or osseous branches. All these are present in the Horse. A cervical filament and two inferior ganglia—middle and inferior—complete this region, of which there is nothing more to be said.

The *thoracic portion* is absolutely identical in its disposition with that of animals; it gives rise to a great splanchnic nerve, and terminates in the semilunar ganglia.

There are no differences to note in the *lumbar* and *sacral portions*, which we have described as the pelvic.

CHAPTER IV.

THE NERVOUS SYSTEM IN BIRDS.

Protective Parts of the Cerebro-spinal Axis.—The protective parts of the nervous centres are the same in all vertebrate animals; consequently, there is nothing to remark regarding those of Birds. The *envelopes* or *meninges* are three in number, and disposed as in mammals.

"The *falx cerebri* is found in birds; in the *Turkey* it has the form of the segment of a circle, and extends from the middle of the interval of the openings for the olfactory nerves to the tentorium cerebelli. The *falx cerebelli* is absent; the *tentorium* is small and sustained by a bony plate, and there are, in addition, two particular folds, one on each side, that separate the hemispheres from the tubercula quadrigemina."—*Cuvier.* Owing to the absence of the falx cerebelli, the meninges of birds are closer together than those of Solipeds or Man. According to Leydig, the falx cerebri is partially ossified in birds.

Spinal Cord.—In Birds, the spinal cord is perforated by a central canal, and also offers, as in mammals, two enlargements—a cervico-dorsal and lumbar. It is prolonged into the coccygeal vertebræ, and thus furnishes another proof against the assertion of certain naturalists, who desire to establish a relation between the length of the spinal cord posteriorly, and the development of the coccygeal region. The two fasciculi of the medullary axis are separated from one another at the lumbar enlargement, and afterwards join in the sacral region. Between them is an elliptical space, the *rhomboidal sinus*, which is filled by transparent gelatinous connective substance—a kind of efflorescence of the ependymis of the central canal.

Encephalon.—In a medium-sized *Fowl*, the encephalon weighs about 2½ drams, and comprises the three portions present in the mammalia.

The *medulla oblongata* is not divided into two sections by the pons Varolii, which is absent in birds; the crura cerebelli are immediately connected with the corpora restiformia. The lower face of the isthmus is very convex posteriorly, in front, the tubercula bigemina are united to each other by a comparatively large transverse cord, formed by the optic nerves intercrossing in the median line. The superior face is depressed above the cerebellum, so as to constitute a fourth ventricle, also shaped like the point of a pen: in front of this ventricle are the tubercula bigemina. These are two voluminous tubercules separated from each other above, where they embrace the cerebellum, and salient on the sides of the lower face. They are hollow internally, and communicate with the aqueduct of Sylvius, the thalami optici are little developed.

The *cerebellum* is almost reduced to the median lobe, the lateral lobes, situated behind and below it, being very small and conical. By its anterior extremity, this cerebral ganglion passes between the corpora bigemini, and touches the cerebral hemispheres. The cerebellum is annulated transversely to its surface, and between the principal furrows are secondary ones, as in mammals. The white substance forms, in its interior, an arborisation in relation, by the number of its branches, with the simplicity observed on the surface of the organ. In the centre of the cerebellum of birds is a small cavity communicating with the fourth ventricles.

The *cerebrum*, divided into two hemispheres by a shallow sulcus, has the shape of the heart on a playing card, more particularly when viewed on its lower face. The convolutions are absent on the upper and lateral faces of the organ, and on the inferior is a vestige of the fissure of Sylvius, which is directed obliquely forward and outward. The olfactory lobes are little developed, and are placed together in the median line.

The two ventricles are confounded, there being no corpus callosum nor septum lucidum. There is no reflected portion in the ventricle; consequently the hippocampi and mastoid lobules are absent; the corpora striata are, on the contrary, large and occupy nearly the whole floor of the ventricles.

Cranial Nerves.—These are twelve pairs, as in mammals; and their origin is analogous, if not identical; the only trifling differences pertaining to the pons Varolii and the convexity of the lower face of the isthmus.

Olfactory nerve.—We have mentioned above how this is formed at the anterior portion of the cerebral hemispheres.

Optic nerve.—It appears to be detached from the tubercula bigemini, and, after a very short course, to intercross with that of the opposite side. In certain birds, especially in the diurnal rapacious kinds, the optic nerves are constituted by fasciculi of undulating nerve-tubes.

Common motores oculorum.—Pathetici.—External motores oculorum.—There is nothing particular to be cited respecting these.

Trigeminal nerve.—This nerve divides into three principal branches, as in the domesticated animals. The *ophthalmic branch* has a nasal ramuscule that becomes superficial, and extends to the extremity of the beak; as well as a third filament that is lost around the inferior orifice of the nasal cavities

The *superior maxillary* issues from the cranium by the opening through which the lower maxillary nerve passes, creeps below the orbit, traverses the maxillary bone, and terminates on the sides of the beak by filaments that resemble the infra-orbital ramuscules of the Horse.

The *inferior maxillary* furnishes two branches: one passes through the dental canal and arrives at the extremity of the lower mandible; the other is spread in the subcorneus integuments of the same.

Facial nerve.—This is small in birds. "It is distributed to the muscles of the jaws and the small muscles which erect the feathers of the crest."—*Cuvier.*

Glosso-pharyngeal nerve.—This calls for no remark.

Pneumogastric nerve.—There are few differences observed in this; it is as extensive as in mammals, and its anastomoses and relations are nearly the same. It is not entirely formed at its exit from the cranium, and always offers two or three constituent filaments that join it, and are confounded at some distance from the point of emergence. The recurrents furnish ramuscules to the crop.

Spinal accessory nerve.—This likewise has a medullary root that appears at the third cervical vertebra; it runs along with the vagus nerve to become superficial.

Hypoglossal nerve.—The same origin as in quadrupeds. Where it crosses the pneumogastric, it detaches a long filament that passes along with the jugular vein towards the chest. On the sides of the larynx it bifurcates; one branch proceeds forward beneath the tongue, the other follows in the same direction, but on the upper surface of that organ.

Spinal Nerves.—We need only notice the nerves of the wing and pelvic limb, the others being disposed in a similar manner to those above described.

Brachial plexus.—Three principal branches—the last cervical and first two dorsal—form this plexus in *Palmipeds;* in the *Gallinaceæ* there are four — the last three cervical and first dorsal. These branches anastomose beneath the deep face of the scapulo-humeral articulation. When fully constituted, the plexus gives off some collateral ramuscules, and terminates by two fasciculi of branches. The first collateral goes to the deep pectoral muscle; another is distributed to the muscles surrounding the head of the humerus, as well as to the articular capsule. The fasciculi of terminal branches may be distinguished, after their situation, as anterior and posterior. The latter represents the internal cutaneous and radial nerve; it gives off muscular and cutaneous ramuscules that extend to the digits at the extremity of the wing. The anterior fasciculus is larger, and is also extended to the whole of the limb, being expended in motor and sensitive filaments; near its origin it furnishes ramuscules to the superficial pectoral muscle. This fasciculus represents the *median, ulnar,* and *anterior brachial,* or musculo-cutaneous of mammals.

Lumbo-sacral plexus.—Two lumbar and four sacral nerves constitute this plexus. In the *Fowl* it is distinctly divisible into two portions, an anterior and posterior, considerably wide apart.

The *anterior portion* is composed of the lumbar branches and a portion of the first sacral; their fusion takes place on the salient bony ridge that separates the lumbar from the sacral regions. It gives origin to four or five branches, among which are clearly discernible: 1, A *filament to the fascia lata muscle;* 2, A *crural* or *femoral nerve;* 3, An *internal saphenous nerve* that descends to the leg; 4, An *obturator nerve.* The latter is very slender, and directed downwards and backwards, passing into the muscle that closes the obturator foramen.

The *posterior portion* comprises a portion of the first sacral, and the whole of the three succeeding nerves. These are directed outwards, towards the sciatic notch, where they unite; during their course in the interior of the pelvis, they are surrounded by the tissue of the kidney. The distribution of this portion of the plexus resembles that of the Horse. Thus, in leaving the sciatic notch, it gives off the *anterior* and *posterior gluteal nerves,* then two long branches that lie together as far as the gemelli; these branches are: 1, The *great sciatic,* with a ramuscule for the gemelli and the posterior tibial muscles; 2, The *external popliteal,* which, outside the superior extremity of the leg, divides into the *musculo-cutaneous* and *anterior tibial nevre*

BOOK VII.

Apparatus of Sense.

Among the nerves described in the preceding book, those which have been designated *sensory nerves* have for their principal, or even exclusive function, the carrying to the brain the excitations derived from the surrounding physical world. These nerves are, therefore, the essential instruments of sensation, and the organs to which they are distributed constitute the apparatus of the senses. These are admirably disposed for the reception of the cerebral excitations, and are five in number: the *apparatus of touch, taste, smell, vision*, and *hearing*. The principal charateristics of these will be briefly enumerated

---

CHAPTER I.

APPARATUS OF TOUCH.

The sense of touch is destined for the appreciation of tactile sensations, and, incidentally, those resulting from variations of temperature. The apparatus composing it is formed by the peripheric radicles of the nerves of general sensibility distributed in the skin: the resisting membrane closely investing the whole of the body, and continuous, at the margin of the natural openings, with the mucous or internal membrane.

The entire skin, therefore, represents the organ of touch; but, as in Man, this membrane has certain privileged regions which are more active than others in the exercise of this faculty: these are the four extremities and the lips.

The structure of the skin, though pertaining to general anatomy, shall be studied here somewhat in detail, and then the arrangement of its appendages —the hair and horny productions—will be examined.

Article I.—The Skin Proper.

The skin, properly speaking, is composed of two layers: the *derma* and *epidermis*.

The Derma.—The *derma* or *chorion* (*corium cutis*), forms nearly the entire thickness of the membrane. Its inner face adheres more or less closely to the subjacent parts, through the medium of a cellulo-adipose expansion. Its external face, covered by the epidermis, which it secretes (or forms), is perforated by openings through which the hairs pass, or through which the secretion of the sudoriparous and sebaceous glands is thrown out upon the surface of the skin; this external face also shows a multitude of little elevations termed *papillæ*, in which the majority of the nerves terminate

The derma is not of the same thickness everywhere, being much thinner where it is protected from external injury, as on the under-surface of the belly, the inner side of the legs, thighs, etc.; it is also thin around the margin of the natural openings, to permit the transition between the two membranes, and endow these apertures with their necessary dilatability.

Fig. 363.

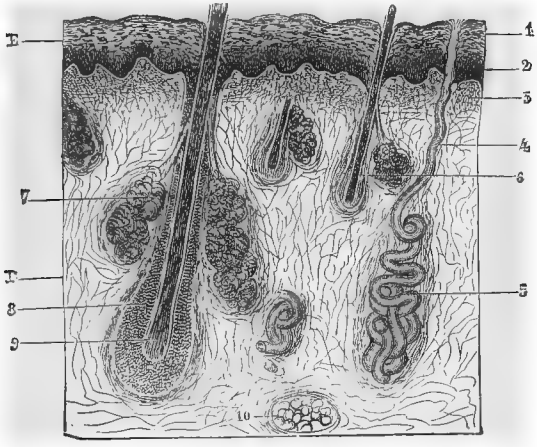

SECTION OF HORSE'S SKIN; FROM WING OF THE NOSTRIL.

E, Epidermis; D, Derma; 1, Horny layer of the epidermis; 2, Rete mucosum; 3, Papillary layer of the derma; 4, Excretory duct of a sudoriparous gland; 5, Glomerule of a sudoriparous gland; 6, Hair follicle; 7, Sebaceous gland; 8, Internal sheath of the hair follicle 9, Bulb of the hair: 10, Mass of adipose tissue.

STRUCTURE.—The derma is composed of fasciculi of conjunctival tissue interwoven and matted in a solid manner, and in the meshes of which are some smooth muscular fibres, which, by their contraction, produce the condition of the skin known as the *cutis anserina* (*goose-skin*). Somewhat loosely woven in its deepest part to form the *reticular layer* (or *corium*), the derma contains the roots of the pilous follicles, the sudoriparous (or *sweat*) glands, and small masses of adipose tissue; superficially, its structure is very condensed, to constitute the *papillary layer*, whose uppermost limit forms an amorphous border.

Fig. 364.



CAPILLARY LOOPS IN THE CUTANEOUS PAPILLÆ OF THE LIPS.

The *papillæ* are of two kinds—vascular and nervous, and are regularly arranged in parallel series: they are most numerous in those parts of the skin specially destined for the exercise of touch, as at the lips, in the keratogenous membrane (of the foot), and other parts where sensibility is very acute—such as the scrotum, sheath, and integuments of the penis. The papillary prolongations of the derma are conical or fungiform, and pediculated; their dimensions are very variable; measuring from $\frac{1}{118}$th to $\frac{1}{276}$th of an inch in length, and from $\frac{1}{18}$th to

$\frac{1}{384}$th of an inch in width at their base. The nervous papillæ are the organs of touch, and contain either the *corpuscula tactûs* (or *axile bodies*) of Meissner or of Kraüse.

Fig. 365.

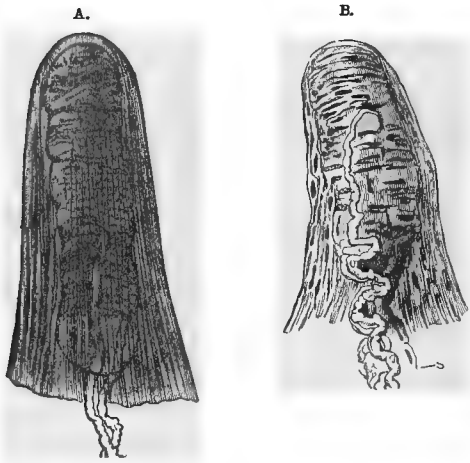

TACTILE PAPILLÆ FROM THE SKIN, SHOWING THE *tactile corpuscles*, OR "AXILE BODIES."
A, In the natural state; B, Treated with acetic acid.

The SEBACEOUS GLANDS lie beside the hair follicles, each hair being flanked by two glands. These small organs are composed of a very granular epithelium, and are usually oval in shape. (They are imbedded in the substance of the derma, and present every degree of complexity, from the simplest follicle to the compound lobulated gland. In some situations, their excretory ducts open independently on the surface of the epidermis. Those associated with the hairs are raceiform and lobulated, consisting of glandular vesicles, which open by short pedunculated tubuli into a common excretory duct, and the latter, after a short course, into the hair follicle. In some parts the ducts are short and straight; in others, where the skin is thick, they are spiral. They are lined by an inversion of the epidermis, which forms a thick and funnel-shaped cone at its commencement, but soon becomes soft and uniform. Sebaceous glands are met with in all parts of the body, but are most abundant in those parts which are naturally exposed to the influence of friction, or require to be supple. Müller found in the Pig a special cutaneous gland, somewhat resembling the sebaceous glands. It is situated on the inner and posterior aspect of the knee, and is from $\frac{3}{4}$ths to 2 inches in length, and from $\frac{1}{4}$ to $\frac{1}{2}$ inch in width. In the Sheep, there is found in the skin between the claws, a particular inversion of the integument that forms a small elongated pouch, curving upwards and terminating in a *cul-de-sac*. This is the *interungulate gland*, *sinus*, or *biflex canal* (*sinus cutaneus ungularum*); it secretes a viscid matter from glands which, according to Ercolani, are analogous to the sebaceous glands. The pouch is lined with very fine hairs.)

Fig. 366.

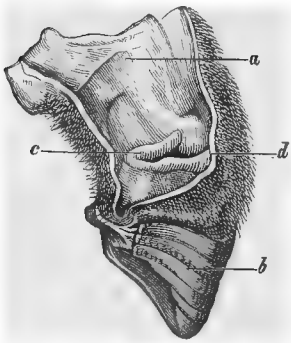

INTERUNGULATE GLAND OF SHEEP.
a, Inner aspect of first phalanx; *b*, Hoof, or claw; *c*, Interungulate gland; *d*, Orifice of its duct.

The SUDORIPAROUS GLANDS are deeper situated than the last (passing even into the subcutaneous areolar tissue, where they are surrounded by adipose cells). They consist of a convoluted tube (or several tubuli produced by dichotomous subdivision) imbedded in the reticular layer of the

derma (or corium), and forming an elliptical glomerule, generally lying obliquely to the surface of the skin in the Horse. The excretory canal is detached from this glomerule, and passes through the derma and epidermis in a spiral manner.

The *blood-vessels* form a very rich network in the papillary layer of the derma, and also surround the sebaceous and sudoriparous glands. The *lymphatics* are disposed like the capillaries.

The *nerves* are arranged in two layers: one loosely distributed in the corium; the other is very close, and is lodged in the papillary layer of the derma, which is traversed by recurrent fibres giving off tubes that pass into the nervous corpuscles of the papillæ.

Fig. 367.

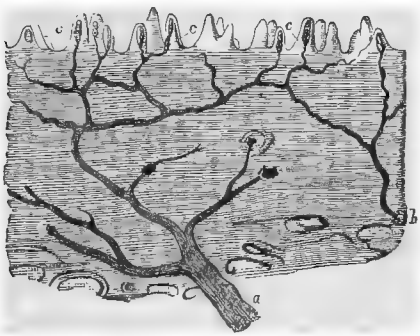

VERTICAL SECTION OF THE SKIN TREATED WITH A SOLUTION OF CAUSTIC SODA, showing the branches of cutaneous nerves, *a*, *b*, inosculating to form a terminal plexus, of which the ultimate ramifications pass into the papillæ, *c*, *c*, *c*.

Fig. 368.



SUDORIPAROUS GLAND, MAGNIFIED 40 DIAMETERS.

a, *a*, Contorted tubes composing the gland, and uniting in two excretory ducts, *b*, *b*, which join into one spiral canal that perforates the epidermis at *c*, and opens on its surface at *d*; the gland is imbedded in fat vesicles. *e*, *e*.

EPIDERMIS.—The *epidermis* is a thin pellicle, covering the superficial face of the derma; it is destitute of nerves and blood-vessels, and is formed of cells which are being continually deposited on the corium; these cells become flattened in layers as they are pushed up from the latter, and are destroyed by friction on the surface of the skin. The deep face of the epidermis is moulded on the upper surface of the derma; consequently, it lodges the papillæ, and dips into the follicles and excretory ducts of the glands of the skin; its external face is not a very exact repetition of the surface of the derma, and is covered with hair. The epidermis tends to equalise, and to fill up, the depressions existing between the papillæ.

STRUCTURE.—The epidermis comprises two layers, which are not very distinct from each other in the Horse. The *deep layer*, or *rete mucosum*, is composed of soft, nucleated, pigmentary cells, which are round on the surface of the derma, and polyhedric elsewhere. The *superficial*, or *horny layer*, is constituted by hard, horny, flattened cells, which still contain some pigment-granules, and are insensibly confounded with those of the rete mucosum.

(The theory of growth of the epidermis is believed to be as follows:—a layer of plastic lymph is thrown out on the surface of the derma, and is converted into granules, which are termed *cell-germs*, or *cytoblasts*. These imbibe serum from the lymph and adjacent tissues, so that the outermost covering of the cytoblast is gradually distended; the latter becomes a cell, and its solid portion, which always remains adherent to some point of the inner surface of the cell membrane, forms the nucleus of the cell. Within this nucleus one or more nuclei are developed; these are named *nucleoli*. The process of imbibition continuing, the cell becomes more or less spherical; so that, after a certain time, the papillary layer of the derma is covered by a thin stratum of spherical cells pressed closely together, and corresponding with every irregularity of the papillæ. New cells being continually produced before the formation of the others has been quite completed, these are removed in layers further and further from the surface of the derma, and becoming subjected to the influence of physical laws, their fluid contents evaporate: they collapse, flatten, and gradually assume an elliptical shape; then they are a mass of completely flat cells, with an included nucleolated nucleus, and finally become a thin membranous scale, in which the nucleus is scarcely apparent).

Fig. 369.

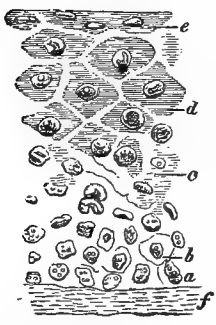

OBLIQUE SECTION OF EPIDERMIS, SHOWING THE PROGRESSIVE DEVELOPMENT OF ITS COMPONENT CELLS.

a, Nuclei resting upon the surface of the derma, *f*; these nuclei are gradually developed into cells at *b*, *c*, and *d*, and the cells are flattened into lamellæ, forming the outer surface of the epidermis, *e*.

In Solipeds and other animals, the epidermis is generally dark-coloured, from the presence of pigment corpuscles, the number of which increases with their depth in the membrane. This coloration is intended to prevent the rubefacient effects of the heat of the sun's rays, by augmenting the absorbing and dispersing power of the cutaneous surface. In the majority of cases, this coloration is absent in the Sheep, whose skin is protected by a thick fleece; and also in the Pig, whose habits in the wild, as in a domesticated condition, keep it out of the direct action of the sun.

(In some regions of the body of all animals, the skin forms folds, as at the junction of the fore-limb with the body, the flank, and between the thighs. In the Cow, it forms the large pendulous layer at the throat and breast, known as the "dewlap;" and in the Goat and Pig, it not unfrequently constitutes teat-like prolongations depending from the throat, which nearly always contain a small cartilaginous nucleus and some muscular fasciculi. The thickness of the epidermis is sometimes greatly increased by wear and friction, as we frequently see in the skin covering the knees of Sheep, etc.)

(The functions of the skin are, as we have seen, tactile and secretory; in addition, it is eminently protective. Its secretory action is always more or less active, but the production of perspiration is greatest when the body is

at a high temperature, as during active exertion; at other times the perspiration is *insensible*. In this respect, the skin has intimate sympathetic relations with other organs which have somewhat analogous functions, such as the lungs, kidneys, intestines, etc., and when its function is disordered or checked, it induces alterations in the secretions of one or all of these organs. The skin is also the seat of a constant and important respiratory action, as it absorbs oxygen and throws off carbonic acid, and any interruption to this process is injurious.)

Article II.—Appendages of the Skin.

The appendages of the skin are *hairs* and *horny productions*, dependents of the epidermic layer.

HAIRS.

The *hairs* are the filaments which, collectively, form the external covering of the skins of animals.

In the Horse, the bristly appendages known as *horse-hair* should be distinguished from the *hair proper;* the latter are fine and short, particularly in the regions where the skin is thin, imbricated on each other, and spread over the entire surface of the body in a continuous layer which is designated the *coat;* the former are long and flowing, occupy the summit of the head, where they constitute the *forelock*, the upper border of the neck, where they form the *mane*, and cover the caudal appendage with a splendid tuft, the *tail.* Some of these also form special organs on the free margin of the eyelids, and are termed *eyelashes;* while others inserted about the lips and below the eyes, are named *tentacula.* (The eyelashes are chiefly implanted in the upper lid. The hairs of the tail are the longest and strongest in the body. These particular hairs also grow on the posterior aspect of the limbs, generally from about the knees and hocks to the hoofs; at the sesamoid bones they constitute a long tuft, the *fetlock*, which surrounds the horny growth named the "ergot." These "foot-locks" are peculiar to the Horse, and vary in length and coarseness with the breed of the animal.)

When the hair is fine, long, and wavy, it forms *wool;* and when straight and rigid, as in the Pig, it is known as *bristles.*

In the *Ass* and *Mule*, the forelock and mane are rudimentary or absent, and the hair of the tail is limited to a small tuft at the extremity of the organ in the former animal, while in the latter it is much less abundant than in the Horse.

In the *Ox*, these hairs are not present, except at the extremity of the tail, as with the Ass.

There are scarcely any other animals which have other hairs than those composing the coat.

(The ordinary hair of the coat is soft and elastic, inclined in particular directions, and varies in length not only according to the regions of the body on which it grows, but also according to the season or climate. In the Horse, the direction of the hair of the coat gives rise to curiously-formed waves, lines, and circles, the most constant of which is on the forehead.

In the *Cow*, the hair is frizzly on the forehead; on the posterior part of the thighs it has a particular direction, while on the outer side it passes downwards, and from the posterior part of the mammæ it ascends as high as the vulva; this characteristic disposition forms what the French have termed *écussons*, by which some have pretended to recognise the lactiferous qualities of the animal.

In the *Sheep*, real hair, not wool, is found on the lower part of the face, and the extremities of the limbs.

In the *Goat*, the hairs of the beard are very long, and compose a distinctive tuft; this animal has also a fine crisp *duvet* or *down* beneath the ordinary hair.

In the *Pig*, the bristles are very strong in the region of the back: in old animals they are usually bi- or trifurcated at their free extremity; there also exists a fine soft hair on this animal. It has no tentacular hairs.

In the *Dog*, the length, fineness, and consistency of the hair depends on the breed.

In the *Cat*, the hair, in some breeds, as in the Angora, is remarkable for its length and softness. This creature has the tentacula enormously developed as a moustache.

In none of these animals is there a "foot-lock.")

Structure.—The hairs are implanted in the texture of the derma, and sometimes even in the subjacent tissues, their base being enclosed in a follicle, at the bottom of which their elements are developed. It is therefore necessary to study: 1, The structure of the hair; 2, That of the hair-follicle.

1. The *hair* presents a free portion, the *shaft*, and another concealed in the follicle, the *root;* the latter widens at its base—the *bulb* of the hair—to embrace the *papilla* or *hair-germ.*

Three superposed layers compose a hair. The *epidermis* is a thin lamella of horny flattened cells, imbricated like tiles on a roof. Its elements are marked on the surface of the hair by shaded lines anastomosing to form a network; they enlarge, and become more apparent under the influence of an alkali. The epidermis belongs to the shaft and a portion of the root; near the bulb it is replaced by soft nucleated cells, which are implanted vertically.

The *cortical substance* forms the largest part of the thickness of the hair. It is striped longitudinally, and provided with pigment granules, whose number varies with the colour of the coat. In white hairs these granulations are absent, but there are found in them, as well as in coloured hairs, small spaces containing air, and which exhibit a dark colour under the microscope. Treated by potass or sulphuric acid, the cortical substance is reduced to elongated spindles, which again may be decomposed into epithelial lamellæ—narrow, and with nuclei. On arriving at the root, the cells change their character, becoming polyhedric, filled with fluid, and exhibiting a perfectly distinct nucleus and more or less pigment. The *medullary substance* occupies a narrow irregular cavity in the centre of the hair, extending from the bulb or termination of the root, to the point. It has for its base rectangular, rarely circular, cells, which, according to Kölliker, contain fat granulations and air globules.

2. The *hair-follicle* is a narrow cavity, slightly contracted at its orifice and dilated at the bottom, where the hair papilla is placed. It is a simple involution of the skin, as its structure demonstrates. It presents, externally, a loose conjunctival layer, analogous to the reticular layer of the derma; next, an internal dermic layer, dense and close like the papillary layer of the skin; an amorphous limiting membrane; an epidermic zone, the *external sheath of the hair*, formed by cells, similar to those of the rete mucosum; and a second epidermic zone, the *internal sheath of the hair*, which repeats the horny layer of the epidermis, and is confounded with the termination of the epidermis of the hair towards the lower third of the follicle.

The *papilla* or *hair-germ*, is a small, conical, vascular, and nervous

prolongation rising up into the hair-bulb. It furnishes the hair with nutrition and the elements of growth. The walls of the follicles of the large hairs, or *tentacula*, which garnish the lips of the Horse, or bristle from those of the Cat, are provided with nervous ramifications which endow these appendages with a high degree of sensibility, and enable them to play an important part in the exercise of touch.

Two *sebaceous glands*, and a *smooth muscular fasciculus*, are annexed to the pilous follicle. The sebaceous glands, which have been already described, open into the sheath of the hair by a small excretory canal, which traverses the fibrillous walls of the follicle. The muscular fasciculus is situated on the side to which the hair and its follicle are inclined; it arises from the superficial face of the derma, and terminates at the bottom of the follicle, which it erects by contracting. When the fasciculi contract over a wide surface, the extent of the skin is diminished, and the hairs are erected and partially ejected from their follicles (producing the *cutis anserina*).

(The formation of a hair is identical with the formation of the epidermis by the papillary layer of the derma. The capillary plexus of the follicle throws out plastic lymph which is converted into granules, then into cells which become elongated into fibres. The cells that are to form the surface of the hair, are converted into flat scales that inclose the fibrous structure of the interior. As these are successively produced, they overlap those previously formed, and give rise to the waving lines seen on the circumference of the hair; this overlapping also causes the roughness experienced in drawing a hair between the fingers from its point to the bulb. The latter is the newly-formed part of the hair, its expanded form being due to the greater bulk of the fresh-cells.

The colour of the hair is very varied in animals, ranging from black to white, red and brown, with all the intervening shades. The tint also changes at different periods of life, being sometimes altogether altered between the juvenile and adult periods; dark-coloured Horses becoming light-coloured as age advances. Besides, it is never uniform in the same animal; black Horses not unfrequently having white patches and diverse tints, with other dissimilarities. The disease termed "melanosis" is very common in old white Horses which were previously grey, and is supposed to be due to the localization of the black pigment at certain limited points. The hair grows according to the climate, seasons, food, etc., and varies with the species and breed. The *coat* in every animal is shed at certain times, and is replaced by new hairs.

The hair preserves the skin from unhealthy external influences—wet and cold for example. It is a bad conductor of heat, and therefore keeps the body warm. The tentacula are very useful as tactile organs: while the mane, forelock, and tail keep away insects, and the long hairs of the fetlock and pastern protect these parts from the injurious effects of cold and wet, and the action of foreign bodies.)

HORNY PRODUCTIONS.

(*Preparation.*—The hoof and its contents may be examined by sections made in different directions. The hoof can be removed by prolonged maceration, or by roasting on a fire, when it may be cut and torn off by means of the farrier's knife and pincers.)

The horny tissues form several groups the first comprises the *horns* of Ruminants; the second, the so-called *chesnuts* of Solipeds; the third, the protective layer enveloping the digital extremities, and constituting the *claws* of Carnivora, the Pig, Ox, Sheep, and Goat, and the *hoofs* of the Horse, Ass,

and Mule. These latter productions, ranking as they do among the most important organs of the locomotory apparatus of Solipeds, will first receive notice.

1. *The Hoof of Solipeds.*

The *hoof* of Solipeds is an extremely important study, because of the numerous diseases which affect this region. Consequently, it has been the subject of several voluminous works, to which the student must be referred for a more complete description of its organisation;[1] as we cannot do more here than give some essentially descriptive details, necessary to fill up the outline that we have traced out.

We will at first glance at the parts contained in the hoof, returning afterwards to a description of the horny case itself.

Fig. 370.

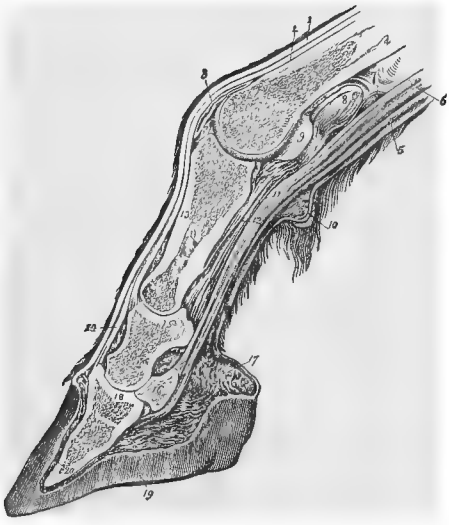

LONGITUDINAL MEDIAN SECTION OF THE FOOT.

1, Anterior extensor of the phalanges, or extensor pedis; 2, Lateral extensor, or extensor suffraginis; 3, Capsule of metacarpo-phalangeal articulation; 4, Large metacarpal bone; 5, Superficial flexor of the phalanges, or perforatus; 6, Deep flexor, or perforans; 7, Sheath; 8, Bursa; 9, Sesamoid bone; 10, Ergot and fatty cushion of fetlock; 11, Crucial ligament; 12, Short sesamoid ligament; 13, First phalanx; 14, Bursa; 15, Second phalanx; 16, Navicular bone; 17, Plantar cushion; 18, Third phalanx; 19, Plantar surface of hoof; 20, Sensitive or keratogenous membrane of third phalanx.

a. The Parts Contained in the Hoof.

Proceeding from within to without, we find, in the interior of the horny box: 1, The third phalanx, navicular bone, and lower part of the second phalanx, forming the articulation of the foot; 2, The four ligaments that bind this articulation; 3, The tendon of the common extensor of the phalanges which covers the articulation in front, and that of the perforans which supports it behind, in becoming inserted into the pedal bone, after gliding over the posterior surface of the navicular bone; 4, The complementary apparatus of the third phalanx; 5, The matrix of the hoof, or keratogenous membrane—a continuation of the derma covering the digital region. To these parts must be added the vessels and nerves.

The description of the bones has been given at pages 84, 85, 86;

Of the articulation and its ligaments, at pages 157, 158;

Of the tendon of the anterior extensor of the phalanges, at page 263;

Of the perforans tendon, at page 286;

Of the arteries, at pages 553, 554, 555;

[1] See particularly, among the most recent and complete French works, the 'Traité de l'Organisation du Pied du Cheval,' by M. H. Bouley. (See also the still more recent work by Leisering, 'Der Futz des Pferdes,' Dresden, 1870. Also a long series of papers by me on this subject in the 'Veterinarian' for 1871–2.)

Of the veins, at pages 612 to 616;

Of the nerves, at pages 762, 763.

It remains to notice the *complementary apparatus of the third phalanx*, and the *keratogenous membrane.*

A. Complementary Apparatus of the Pedal Bone.—In the indication we gave of this apparatus at page 85, we said that it was composed of two lateral pieces—the *fibro-cartilages*, united behind and below by the *plantar cushion:* a fibrous, elastic mass, on which the navicular bone rests, through the medium of the perforans tendon. We will take this distinction as the basis of our study.

1. Fibro-cartilages of the Pedal Bone.—Each of these pieces represents a plate flattened on both sides, having the form of an oblique-angled parallelogram, and prolonged behind the third phalanx. The *external face* is convex, and pierced with openings for the passage of veins; it slightly overhangs that of the pedal bone. The *internal face* is concave, channeled by vascular furrows, and covers, in front, the pedal articulation, and the synovial *cul-de-sac* which projects between the two lateral ligaments of that joint; below and behind, it is united to the plantar cushion, either through continuity of tissue, as at the inferior border, or by fibrous bands passing from one to the other. The *upper border*, sometimes convex, sometimes rectilinear, is thin and bevelled like a shell; it is separated from the posterior margin by an obtuse angle, in front of which this border is often broken by a deep notch that gives passage to the vessels and nerves of the digital portion. The *inferior border* is attached, in front, to the basilar and retrossal processes behind the latter, it is reflected inwards to become continuous with the tissue on the lower face of the plantar cushion. The *posterior border* is oblique from before to behind, and above to below, and joins the preceding two. The *anterior border* is oblique in the same direction, and is united so intimately with the anterior lateral ligament of the pedal articulation, that it cannot be separated from it except by an artifice of dissection. It sends to this ligament, and to the tendon of the anterior extensor of the phalanges, a fibrous expansion that becomes fused with that of the opposite side.

Fig. 371.

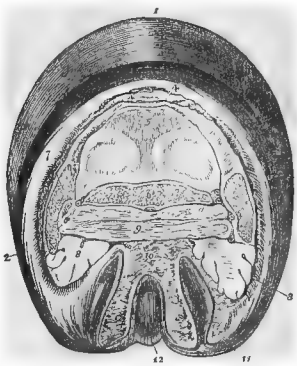

HORIZONTAL SECTION OF THE HORSE'S FOOT.

1, Front, or toe of the hoof; 2, Thickness of the wall; 3, Laminæ; 4, Insertion of the extensor pedis; 5, Os pedis; 6, Navicular bone; 7, Wings of the os pedis; 8, Lateral cartilage; 9, Flexor pedis tendon; 10, Plantar cushion; 11, Inflexion of the wall, or "bar;" 12, Horny frog.

The fibro-cartilages comprise in their structure a mixture of fibrous and cartilaginous tissue, though the mixture of these is far from being perfectly homogeneous, or everywhere in the same proportions.

The cartilages of the fore-feet are thicker and more extensive than those of the hind ones.

(The lateral fibro-cartilages are peculiar to Solipeds.)

2. Plantar Cushion.—The plantar cushion is a kind of wedge, situated in the space between the two cartilaginous plates of the third phalanx, and between the perforans tendon and the lower part of the horny box. Its shape

allows it to be considered as having an *antero-superior* and an *infero-posterior face*, a *base*, *summit*, and two *lateral borders*.

The *antero-superior face* is moulded on the aponeurotic expansion of the perforans tendon, and is "covered by a cellulo-fibrous membrane, the *proper tunic of the plantar cushion*, which is continuous, on its inner face, with the fibrous septa by which this organ is traversed, and adheres by its external or anterior face to the reinforcing sheath interposed between it and the perforans tendon."—*Bouley*. This expansion is prolonged, above, to the fetlock, where it is confounded with the superficial fascia of the metacarpal region; it is margined, laterally, by two small, very strong ligamentous bands which, at their middle portion, cross, in a very oblique manner, the fasciculus formed by the vessels and nerves of the digit. Each of these bands is fixed, superiorly, to the base of the rudimentary digit known as the *ergot*, and to the knob of the lateral metacarpal bone; their inferior extremity is attached within the retrossal process.

Fig. 372.

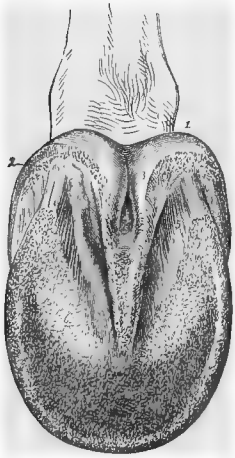

LOWER FACE OF THE HORSE'S FOOT, THE HOOF BEING REMOVED.

1, Heel; 2, Coronary cushion; 3, Branch of the plantar cushion; 4, Median lacuna; 5, Laminæ of the bars; 6 Velvety tissue of the sole.

The *infero-posterior face* of the cushion is covered by the keratogenous membrane, and presents at its middle the *pyramidal body*, a prominence exactly like that of the frog, to which it corresponds. It shows, then, in front, a single conical prolongation, and behind, two divergent prominences separated by a median excavation.

The *base* of the apparatus lies behind, and is inclined upwards; it is divided by a depression into two lateral masses—the *bulbs of the plantar cushion*—on the inside of which the posterior prominences of the pyramidal body reach, and which become confounded, outwardly, with the posterior and inferior angle of the cartilaginous plates. This portion of the cushion is, like the anterior face, covered by a cellulo-fibrous expansion, which separates it from the skin of the pastern; this expansion is attached, by its lateral margins, to the posterior border of the cartilages, and continued, superiorly, on the surface of the anterior expansion, with which it soon unites.

The *summit* (*point* or *apex*) forms a sharp border, more or less regularly convex; it is fixed into the plantar face of the pedal bone, in front of the semilunar ridge and the insertion of the perforans tendon, with which the plantar cushion mixes its fibres at this part.

The *lateral borders* are wider behind than before, in consequence of the wedge-like shape of the whole organ; they are continuous with the inner face of the lateral cartilages, as already indicated in describing the latter.

The *organisation* of the plantar cushion differs much from that of the cartilages. It has for its base a fibrous structure, continuous with that which constitutes the fundamental framework of these; this structure is very close towards the infero-posterior part of the organ, and becomes gradually looser as it leaves this region; the meshes it contains are filled with a yellow pulp composed of fine, elastic, and connective fibres, in the midst of which some adipose cells are found. (I have attentively examined this yellow pulp, and

can perceive that it is essentially constituted by adipose tissue.) Numerous blood-vessels and nerves complete this structure.

B. The Keratogenous Membrane, or Subcorneus Integument.—The keratogenous membrane envelops the extremity of the digit, by spreading over the terminal expansion of the tendon of the extensor pedis, through the medium of a fibrous fascia—a dependency of the lateral cartilages; and also over the inferior moiety of the external face of these cartilages, the bulbs of the plantar cushion, pyramidal body, anterior part of the plantar face of the third phalanx, and over the anterior surface of the same bone. It covers all these parts like a sock, and the hoof incloses it, as a shoe does the human foot.

This membrane becomes continuous with the skin of the digital region at a circular line that intersects the middle portion of the second phalanx, and inclines obliquely downward from behind to before. Below this line, in front and laterally, the subungular tissues form a semicylindrical protuberance, covered with villi, and designated the "bourrelet." (This elastic prominence has received several most inappropriate names from English farriers and hippotomists, such as "coronary ligament," "coronary substance," "cutiduris," etc. From its function, structure, situation, and its analogy to the plantar cushion, I have designated it the "coronary cushion.")

On the plantar cushion and the lower face of the pedal bone, this membrane is also a villous tunic—the *velvety tissue*, which is continuous, towards the bulbs, with the extremities of the coronary cushion.

The portion spread over the anterior face of the third phalanx constitutes the laminal or "leafy tissue," so called because of the laminæ or parallel leaves seen on its surface.

Fig. 373.

LATERAL VIEW OF THE HORSE'S FOOT, AFTER REMOVAL OF THE HOOF.

1, Perioplic ring, divided by a narrow groove from the coronary cushion, 2, which is continuous with the plantar cushion, 4, and joins the vascular laminæ, 3, through the medium of the white zone.

The three regions of the keratogenous apparatus will be successively studied.

1. Coronary Cushion.—This part is the matrix of the wall of the hoof, and is lodged in a cavity excavated at the upper border of this part of the horny case. It forms, according to the expression employed by M. Bouley, a rounded prominence, which projects like a cornice above the podophyllous tissue.

Its *inferior border* is separated by a white zone from the upper extremity of the laminæ, which constitute this boundary.

The *superior border* is limited by a slightly projecting margin named the *perioplic ring*, because it originates the horn of the periople. Between this margin and the cushion is a sharply defined groove.

The *extremities*, narrower than the middle portion, on arriving at the bulbs of the plantar cushion, bend downwards into the lateral lacunæ of the pyramidal body, where they become confounded with the velvety tissue.

The *surface* of the organ shows filiform prolongations, a little constricted at their base, and named *papillæ, villo-papillæ, villi*, and *villous loops*, whose

size is greatest towards the lower part of the cushion; those of the perioplic ring are smallest. Contained within the minute apertures at the upper part of the wall, these papillæ, considered as a whole, and when the hoof has been removed by maceration, form a tufty surface most perfectly seen when the foot is immersed in water.

The structure of the coronary cushion resembles that of the derma, of which it is in reality only a continuation. It comprises a fibrous framework, remarkable for its thickness and its condensation, with a considerable number of vessels and nerves, whose ramifications may be followed to the extremity of the villi. It owes to its great vascularity the bright red colour it shows on its surface; this colour is sometimes masked by the black pigment belonging to the mucous portion of the hoof.

(I have found a notable quantity of adipose tissue in the cushion.)

2. Velvety Tissue.—Much thinner than the plantar cushion, the *velvety tissue*, the formative organ of the sole and frog, extends over the whole of the plantar region of the third phalanx, as well as the plantar cushion, whose bulbs and pyramidal prominence it covers by adapting itself exactly to the irregularities of this elastic mass.

Its *surface*, which altogether resembles the general configuration of the plantar surface of the hoof, is divisible into two regions: a central, corresponding to the pyramidal body and the frog, and continuous on the bulbs of the cushion with the extremities of the coronary cushion and the perioplic ring, but chiefly with the latter; the other, peripheral, is covered by the horny sole, separated from the podophyllous tissue by the plantar border of the foot, somewhat encroached upon posteriorly by the laminæ corresponding to the bars, and is continuous, above these laminæ, with the plantar cushion.

The surface of the velvety tissue is studded with villi similar to those of the coronary cushion, and about the same in size. The longest are towards the circumference of this surface, and the shortest in the median lacuna of the pyramidal body; all are lodged in the porosities on the inner surface of the horny sole and frog.

This tissue shows the same organisation as the coronary cushion. The vascular corium, forming its base, is thickened at its peripheral portion by a fibrous network named the *plantar reticulum*, in the meshes of which are sustained the veins of the inferior face of the foot.

3. Laminal Tissue.—This part of the keratogenous membrane is also very frequently designated the *podophyllous tissue* (and still more frequently, in this country, as merely the *laminæ*). It is spread over the anterior face of the third phalanx, occupying the interval between the plantar border of that bone and the lower margin of the coronary cushion; its width is, therefore, greater at the anterior part of the phalanx than on its sides, where the extremities of the membrane are reflected below the bulbs of the plantar cushion on to the velvety tissue.

This membrane owes its name to the leaves it exhibits on its superficies; these are from five to six hundred in number, run parallel to each other, and are separated by deep channels, into which are dovetailed analogous leaves on the inner side of the wall of the hoof; they extend from the white zone that limits the inferior border of the coronary cushion—where they are not so salient—to the plantar border of the foot, where they each terminate in five or six very large villous prolongations, which are lodged in the horny tubes at the circumference of the sole.

The *leaves* (*laminæ*) of the podophyllous tissue increase in width from above to below; their free margin is finely denticulated, and, under the

influence of any inflammatory cause (laminitis, ablation of the wall), these denticulæ become largely developed, and transformed into veritable papillæ. Their sides are traversed by folds, about sixty in number, which pass uninteruptedly from top to bottom. These secondary leaves, or lamellæ, are fixed obliquely on the sides of the laminæ, as the barbules of a feather are attached to the barbs.

The podophyllous tissue is not in immediate contact with that of the keraphyllous tissue, or horny laminæ; between the two there is a mass of soft, elliptical cells, always destitute of pigment, easily stained with carmine, and appearing to stud the ramifications of the vascular laminæ. A transverse section of the union of the hoof with these laminæ, when treated with carmine, presents a very fine aspect, appearing as so many fern or acacia-of-Judea leaves placed between the keraphyllous laminæ: the principal nerve, and the secondary nervules of the leaves, being represented by the lamina and its lateral ridges, the limb of the leaves by the young cells spread around the latter.

The structure of the podophyllous membrane resembles that of the other parts of the keratogenous apparatus. Its corium is, like that of the peripheral portion of the velvety tissue, separated from the os pedis by a fibrous *reticulum*, which supports the veins, and forms, to some extent, the periosteum of the third phalanx.

The leaves of the podophyllous membrane are immense lamellar papillæ, which should be included among the principal instruments concerned in the tactile sensibility of the Horse's foot, and which play a really mechanical part, in concurring, by their dovetailing with the keraphyllous (or horny) laminæ, to assure the solidity of the union of the hoof with the living parts. The cells which multiply on their surface have usually but little share in the formation of the horn. This will, however, be alluded to hereafter.

b. Description of the Hoof.

The hoof of the Horse, considered as a whole, represents a kind of box that envelops the inferior extremity of the digit, by fitting closely on the keratogenous membrane, to which it is united in the most intimate manner by a reciprocal penetration of the prolongations into the cavities that exist on the surfaces in contact.

Its general shape is, as was demonstrated by Bracy Clark, that of the moiety of a cylinder cut obliquely across its middle, and resting on the surface of this section. In nearly all feet, however, it is slightly conical.

Prolonged maceration separates it into three portions: the *wall*, *sole*, and *frog*.

Wall.—The *wall*, also named the *crust*, is that part of the hoof which is apparent when the foot rests on the ground. This thick plate of horn covers the anterior face of the foot, and, gradually narrowing in width and diminishing in thickness, passes round each side until it reaches the bulbs of the plantar cushion, when its extremities are sharply inflected inwards, between the frog and internal border of the sole, becoming confounded with the latter about its middle or anterior third, after being greatly reduced in breadth and substance.

The middle, or anterior part, of this horny envelope is popularly known as the *toe*, the two sides of which are designated as *outside* and *inside toe;* the lateral regions constitute the *quarters;* the *heels* are formed by the angles

of inflexion of its extremities; while these extremities themselves, passing along the inner border of the sole, are termed the *bars*.

Fig. 374.

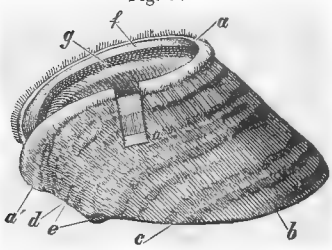

HOOF JUST REMOVED FROM THE FOOT; SIDE VIEW.

a, Inner surface of periople, or coronary frog-band, with some hairs passing through; *a'*, Outer surface of same at posterior part of foot; *a''*, A section through the wall to show its thickness; *b* to *c*, Quarter of the hoof, from *b* to the front is the outside (or inside) toe; from *c* to *d* the outside (or inside heel); *e*, Frog; *f*, Bevel on upper margin of wall for reception of coronary cushion; *g*, Keraphylla, or horny laminæ.

Examined with regard to the direction that it affects in its relations with the ground, this envelope is seen to be much inclined in its middle region or toe, and this obliquity gradually diminishes until the posterior part of the quarters is reached; at this point the wall is nearly perpendicular.

The following are the characters it offers in the conformation of its faces, borders, and extremities:

The *external face*, convex from side to side, and perfectly straight from the upper to the lower border, is smooth, polished, and shining: an appearance it owes to a thin horny layer, independent of the wall proper, designated the *periople*.

This *periople* forms, on the upper part of the wall, a kind of ring, continuous with the bulbs of the plantar cushion, and with the frog, of which it is only a dependency; responding, by its upper margin, to the perioplic ring, which secretes it; towards the lower part of the wall it is gradually lost, friction incessantly thinning and destroying it.

Fig. 375.

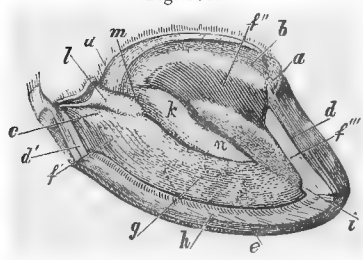

HOOF, WITH OUTER PORTION OF THE WALL REMOVED TO SHOW ITS INTERIOR.

a, *a*, Periople, or coronary frog-band; *b*, Cavity in upper part of wall for coronary cushion; *c*, Upper, or inner, surface of "bar;" *d*, Vertical section of wall; *d'*, The same at the heel; *e*, Horizontal section of ditto; *f'*, Horny laminæ of bar; *f''*, Ditto of wall; *f'''*, Lateral aspect of a lamina; *g*, Upper, or inner surface of the horny sole; *h*, Junction of the horny laminæ with the sole (the "white line"); *i*, Toe-stay at the middle of the toe; *k*, Upper, or inner surface of the horny frog; *l*, Frog-stay; *m*, Cavity corresponding to a branch of the frog; *n*, Ditto corresponding to the body of the frog.

The *inner face* presents, over its entire extent, the white parallel leaves which dovetail with the laminæ of the podophyllous tissue. Collectively, these are named the *keraphyllous tissue*.

The *superior border* is bevelled-off, on its inner aspect, into a circular concavity, into which the plantar cushion is received. This excavation is named the *cutigeral cavity*, because of its relations; it offers on its surface a multitude of minute openings—the commencement of the horny canaliculi which receive the villosities of the cutiduris.

The *inferior border*, in contact with the ground, and subjected to wear in unshod animals, is united inwardly, and in the most intimate manner, with the circumference of the sole.

The *extremities*, constituted by the reflected and re-entering prolongations known as the *bars*, form, outwardly, the external side of the lateral lacunæ of the frog: they are provided, inwardly, with laminæ like the rest of the wall. The upper margin of these prolonga-

tions is confounded with the frog and sole; the lower appears between these two parts, and is effaced at a certain distance from the point of the frog.

Sole.—The sole is a thick horny plate comprised between the inner border of the wall and its reflected prolongations; thus occupying the inferior face of the hoof. It offers two faces and two borders or circumferences.

The *inferior*, or *external face*, forms a more or less concave surface, according to circumstances. The *superior*, or *internal face*, corresponds to the peripheral portion of the velvety tissue; it shows a multitude of little apertures analogous to those of the cutigeral cavity, into which are inserted the papillæ of the keratogenous membrane.

The *external border*, or *large circumference*, is united, throughout its extent, to the inner contour of the lower border of the wall, by means of its denticulæ, which are reciprocally dovetailed into those on the inner face of the wall near its inferior border. The *internal border*, or *small circumference*, is a deep, V-shaped notch, widest behind, which corresponds to the bars, and at the bottom of which the point of the frog is fixed.

Fig. 376.

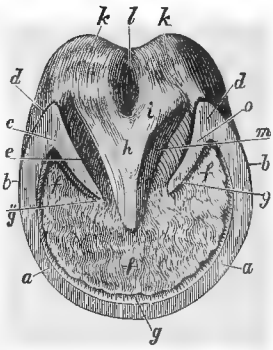

PLANTAR OR GROUND SURFACE OF A HOOF; RIGHT FOOT.

The interval from *a* to *a* represents the toe; From *a* to *b*, *b*, outside and inside quarters; *c*, *o*, Commencement of bars; *d*, *d*, Inflexions of wall at the heels, or "buttresses;" *e*, Lateral lacuna; *f*, *f*, *f*, Sole; *g*, White line; *g'*, *g'*, Ditto between the sole and bar; *h*, Body of frog; *i*, Branch of frog; *k*, *k*, Glomes, or heels of frog; *l*, Median lacuna.

Frog.—This is a mass of horn, pyramidal in shape, and lodged between the two re-entering portions of the wall. It offers four *planes* (or *sides*), a *base*, and a *summit* (or *point*).

The *inferior* and the *two lateral planes* constitute the *external surface* of the organ. The first is hollowed by a longitudinal excavation, which is shallow in well-formed hoofs, and is named the *median lacuna* of the frog, separating the two salient portions, or branches, which diverge posteriorly and join the heels. The other two planes are directed obliquely downwards and inwards; they adhere closely, at their upper third, to the external side of the bars, and anteriorly to the inner border of the sole. "This union is so close that no line of demarcation is apparent between these parts, and their separation can only be obtained by prolonged maceration. The non-adherent, or free portion, forms the inner side of the angular cavities known as the *lateral lacunæ*, or *commissures of the frog*, whose external side is constituted by the inferior face of the bars."—*Bouley.*

The *superior plane*, forming the internal face of the frog, is cribbled with holes like that of the sole, and is exactly moulded on the pyramidal body of the plantar cushion. It also offers a triangular excavation, divided posteriorly into two latter channels by a prominence directed from before backwards, to which Bracy Clark gave the name of *frog-stay*, but which M. Bouley prefers to designate the *spine or ridge* (*arête*) *of the frog.*

The *base* or *posterior extremity* of the frog, constituted by the extremities of its branches, forms two rounded, flexible, and elastic eminences separated from each other by the median lacuna; they cover the angles of inflexion of the wall, and are continuous at this point with the perioplic band. Bracy Clark named them the *glomes* of the frog.

With regard to the *summit*, or anterior extremity of the organ, it is a

point wedged in the re-entering angle comprised between the two portions of the inner border of the sole.

In the *Ass* and *Mule*, the hoof is always narrower, laterally, than that of the horse; the wall is always higher and thicker, the sole more concave, the frog smaller and deeper seated at the bottom of the excavation formed by the sole, and the horn is much more hard and resisting.

(The angle of the wall of the hoof in front varies from 50° to 56°, though usually erroneously stated to be 45°. The inner face of the wall, at the middle of the toe, and in a line with the frog-stay, frequently shows a more or less salient and conical prominence—base towards the lower margin of the wall—which corresponds to a vertical depression in the os pedis. Vallada imagined that this projection served to unite the wall and sole more closely, but it is far more probable that its function is the same as that of the frog-stay—to maintain the position of the os pedis, and prevent its rotation within the hoof. I have, therefore, named it the "toe-stay.")

Structure of the Hoof-horn.—The structure of the horn has been the object of a great number of researches; Gurlt, Delafond, Bouley, Gourdon, and Ercolani[1] have given descriptions of it, and we have also some details to add to the labours of these authorities.

The *horny substance* constituting the hoof of Solipeds, has a fibrous appearance; this is most conspicuous in the wall, less apparent in the frog and deeper portions of the sole, but impossible to distinguish in the superficial layer of the latter, where the disintegration continually taking place separates the horn in scaly fragments of varying thickness and extent. The consistence of the horn is always less in the frog than in the sole and wall. Its tint is in some hoofs black, in others white, and in others again a mixture of these two. The inner face of the wall, however, is never black; and when the lower part of the limb is partially or wholly white, we may be sure that all the thickness of the wall will either be white at corresponding points in the former, or entirely so in the latter.

Except in the keraphyllous tissue, the minute structure of the hoof-horn always exhibits the same characters; everywhere it is perforated by cylindrical canals whose upper end is funnel-shaped, and these contain the papillæ of the matrix, whether they belong to the coronary cushion or velvety tissue; while the lower end reaches the inferior border of the wall, or lower face of the sole and frog, according to their situation. It is rare to find them in the horny laminæ. All are rectilinear, with the exception of those of the frog, which are somewhat flexuous; and all have the same oblique direction downward and forward, following the inclination of the anterior portion of the wall. They are, therefore, almost exactly parallel to each other, not only in the same, but in the two different regions. Their diameter varies considerably, though the smallest are always those of the periople; in the wall, they are smaller as they approach the outer surface.

These tubes are not mere canals hollowed out of the horny substance; on the contrary, they have very thick walls which are formed of numerous concentric layers, one within the other, and the horny tissue connecting them has not the same apparent stratiform disposition. Filled by the papillæ of the keratogenous membrane at their superior extremity, these

[1] (The researches of Professor Rawitsch must not be omitted. They will be found in Volume xxviii. of the 'Magazin für Thierheilkunde,' and also in a little *brochure* entitled '*Ueber den feineren Bau und das Wachsthum des Hufhorns.*' Berlin, 1863. Leisering must likewise be referred to. My own researches are published in the '*Veterinarian*' for 1871.)

canals are not empty for the remainder of their extent; but contain a particular white substance, which is so opaque that it appears of a fine black hue when examined as a transparency in the microscope. This matter is not deposited in a uniform manner in the canals, but irregularly-looking, like a knotted cord or a necklet of beads; and, where it does exist, it does not always exactly fill the calibre of the tube, an interval being observed between the inner face of the latter and the intratubular deposit. Sometimes it is seen without the canals, among their concentric lamellæ, and even in the horny intertubular substance.

If we are desirous of completing our knowledge of the minute organisation of the hoof-horn by studying the anatomical elements constituting it, we will find that it is formed of epithelial cells belonging to the kind most wide-spread in the economy—pavement epithelium. These horn *epithelial cells* are very thin, pale, polygonal, and generally oblong, have sharply defined borders and finely granular faces, sometimes showing a nucleus containing a single or multiple nucleolus. The nuclei sometimes occupy the centre, at other times another part of the cells—even their margins; and they also contain pigment granules more or less coloured and numerous. Acetic acid acts very slowly on them, and is limited to making them more transparent. Potass and soda at first softens, then distends them, causing their granulated aspect to disappear, and rounding their contours; afterwards, they become quite diaphanous, and finish by being completely dissolved.

Fig. 377.

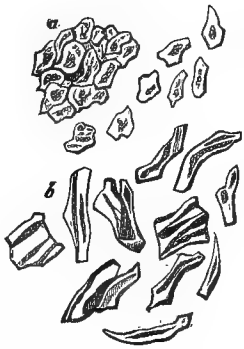

HORN-CELLS FROM THE SOLE OF THE HOOF.

a, Young cells from the upper surface of the sole; *b*, Cells from the lower surface, or dead horn of the sole.

Examined in their reciprocal relations, these epithelial cells are not seen to be agglomerated confusedly together, but are, on the contrary, disposed in a regular manner, forming a real framework that wonderfully concurs in assuring solidity and flexibility. In the walls of the tubes we see them arranged horizontally around the canal, and stratified from within to without, so as to form successive concentric layers. In the intertubular horn they are disposed differently, their stratification being no longer parallel to the direction of the tubes, but perpendicular to it, and piled upon each other in the intervals separating the latter. This change of direction does not occur suddenly; at the limits of the tubes epithelial cells are seen lying obliquely.

In a transverse section of the wall, there are observed around the tubes, in the intertubular substance, as well as in the horny laminæ, small irregularly elliptical spaces containing a solid denticulated mass of a brownish tint, which is easily stained with carmine. These bodies are more elongated in the intertubular substance than in the walls of the tubes, and have a certain resemblance to the cartilaginous capsules, but especially to the bone cavities filled by their contents.

Independently of the hard, dry, and flattened cells, there is found an opaque substance that partly fills the tubes, and which is also sometimes met with in their walls. This material does not differ from the last in its nature; it is also formed, as has been asserted by Gourdon and Ercolani, of irregular granular cells which are stained by the carminate of ammonia.

Pigmentary-corpuscles exist in the substance of the coloured horn, and are disposed singly, or in small masses, in the epithelial cells of the intertubular substance. The presence of these corpuscles has been denied, and the coloration has been attributed to a greater condensation, at certain points, of the epithelial elements. Fine pigment-granules are disseminated in the cells, but it is evident that beyond these there are at different points pigment-corpuscles; for, after treating a section of coloured horn with soda, the epithelial elements are distended, become pale, and disappear, leaving, however, here and there, masses of black granulations. These pigmentary-corpuscles are absent in white horn.

Fig. 378.

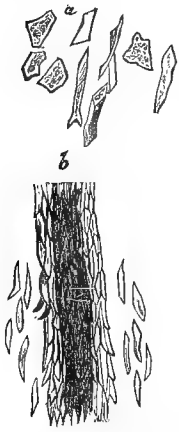

CONSTITUENT ELEMENTS OF THE WALL.

a, Horn-cells; *b*, Horn-fibre from the hoof of a new-born foal, showing the vertical disposition of the cells.

Development of the Hoof.—The hoof being a dependency of the epidermis, is developed like it: that is, by the incessant formation of cells in the layer that corresponds to the rete mucosum, at the expense of the plasma thrown out by the numerous vessels in the keratogenous membrane. The velvety tissue forms the sole and frog; the perioplic ring the periople, and the coronary cushion the wall. In these different parts, the epithelial cells multiply, and become flattened in layers parallel to the surface that secretes them, and in proportion as they recede from that surface; so that the wall grows from its superior to its inferior border, and the other two parts of the hoof from their internal to their external face.

The villosities of the coronary cushion and the velvety tissue are the organs around which the epithelial lamellæ are grouped, and their presence determines the tubular structure of the horn; their function is completed by the exhalation of a particular fluid that maintains the flexibility of the hoof, and, probably, by the development on their surface of the irregular cells which cluster in the interior of the tubes.

The leafy tissue, in a normal condition, does not concur to any extent in the development of the wall. The cells covering it are multiplied in describing a downward and forward movement; and though they are certainly applied to the inner face of the wall, yet they do not constitute the horny laminæ. The latter are formed on the coronary cushion, at the commencement of the vascular laminæ, and they descend with the wall in gliding along the surface of the layer of cells separating them from the latter; this downward movement is facilitated by the multiplication, in the same sense, of these cells. This opinion as to the function of the vascular laminæ is based on comparative anatomy, on the presence of some longitudinal tubes in the horny laminæ, and on pathological observations.

When the podophyllous tissue is inflamed, whether or not it is exposed, its latent activity is quickly manifested, and it rapidly throws out a large quantity of hard consistent horn, traversed by tubes which, according to M. Gourdon, are directed obliquely backwards. These tubes are more irregular than those of the normal wall, are disposed in parallel series, and are formed around the villo-papillæ developed on the free border of the laminæ. In this horn, produced by the vascular laminæ only, there are never observed between these latter the horny plates of cells—sharp and

distinct in the midst of the other cells, as in those of the wall formed by the coronary cushion.

The horn thrown out on the surface of the podophyllæ, immediately after the removal of a fragment of the wall, is not a definitive horn, but must be replaced by that from the coronet. This substitution is complete; as a microscopal examination proves that the wall which descends from the

Fig. 379.



HORIZONTAL SECTION OF THE JUNCTION OF THE WALL WITH THE SOLE OF THE HOOF.

a, Wall, with its horn-tubes; *b*, *b*, Horny laminæ projecting from the wall; *c*, *c*, Horn-tubes formed by the terminal villi of the vascular laminæ, the horn surrounding them and occupying the spaces between the horny laminæ, constituting the "white line;" *d*, Horny sole, with its tubes.

cushion, and is furnished with horny laminæ, passes beneath the provisional wall, and glides downward—by the combined action already mentioned—over the surface of the soft cells of the vascular laminæ. As soon as the latter are covered by the proper wall, their marginal papillæ become atrophied, and they again assume the limited function pertaining to their physiological condition.

Fig. 380.

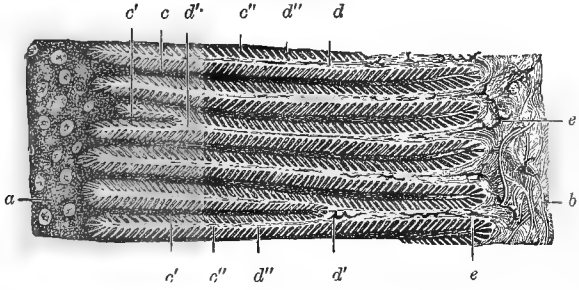

HORIZONTAL SECTION OF THE WALL, AND HORNY, AND VASCULAR LAMINÆ, TO SHOW THE JUNCTION OF THE LATTER AND THE LAMINELLÆ.

a, Inner portion of the wall with the laminæ arising from it; *b*, Vascular laminæ; *c*, Horny lamina of average length; *c′*, *c′*, Unusually short laminæ; *c″*, *c″*, Laminellæ on the sides of the horny laminæ; *d*, Vascular lamina passing between two horny ditto; *d′*, Vascular lamina passing between three horny laminæ; *d″*, Lateral laminellæ; *e*, *e*, Arteries of vascular laminæ which have been injected.

(The description of the disposition of the epithelial cells given by Chauveau does not coincide with my own observations. As he correctly

states, these cells are formed in planes parallel with the surface that secretes them; consequently, around the papillæ they are more or less vertical, while between them they are horizontal. The walls of the tubes, or fibres, are therefore composed of cells disposed in a vertical manner; while in the interfibrous horny matter they are arranged in the opposite direction. The loose nodulated contents of the tubes is composed of cells thrown off from the termination of the papilla, and corresponds to the pith of feathers. The soft cells interposed between the vascular and horny laminæ are carried down to the lower margin of the wall, where, with the elastic horn secreted by the papillæ which terminate the former, they constitute the peculiar light-coloured band, or "white line," which marks the junction of the sole with the wall (Fig. 379). This intermediate band of soft flexible horn at this point obviates tearing of the sole from the wall, and fracture of the former. The cells of the horny laminæ are more or less fusiform.

M. Chauveau has also evidently overlooked the presence of beautiful lateral leaflets on the sides of the horny laminæ, corresponding to those on the vascular leaves. These were observed by me in 1858; in 1862 they were described by Rawitsch and Ercolani, and, at a later period, by Colin of Alfort and Leisering of Dresden. They are very conspicuous in a well-prepared section (Fig. 380, *d''*).

It should be observed that the growth of the wall of the hoof is indefinite, but that the sole and frog, after attaining a certain thickness, exfoliate. For complete details as to the physiology of the Horse's foot, the student is referred to the 'Veterinarian' for 1871.)

2. *The Claws of Ruminants and Pachyderms.*

In the *Ox*, *Sheep*, and *Pig*, the plantar cushion covers the bulb of the heel of each digit, where it forms a convex mass: it extends to the insertion of the deep flexor tendons of the phalanges, in becoming triangular in shape, and thinner. The horny envelope covering the extremity of the digits of these animals is a kind of cupola, having almost the form of the third phalanx; it is usually named the *claw*.

The *claw* of the *Ox* has an outer face resembling the wall of the Horse's hoof, and an inner face which is slightly concave, and marked by undulating grooves; owing to this concavity, the two claws of each foot only touch at the extremities of their adjacent faces. The plantar region of the claw is slightly depressed, and but little developed; it is chiefly made up of the plantar cushion, which is covered by a thin layer of supple tubular horn. On the interior of the claw is seen a wide shallow cutigeral cavity, perforated by very fine openings, and laminæ thinner and more numerous than in the Horse's hoof. The tubes of the claw-horn are very small, being surpassed in diameter by those of the periople and sole.

Above and behind each claw are two little rudimentary horny capsules, which are named *ergots*. (Each contains a small bone, which is not attached to the skeleton in Ruminants. In the *Pig*, these rudimentary claws are larger, and are connected with the bones of the leg. In this animal the horn of the claws is altogether thinner, softer, and less resisting than in Solipeds. The ergot is the representative of those digits which are apparently absent in the solid and cloven foot.)

3. *The Claws of Carnivora.*

In these animals, the third phalanx of the digits is enveloped in a conical horny sheath that curves downwards like the bone itself. This covering is designated the *claw* or *nail*, and offers somewhat the same organisation as the horns of Ruminants; it is developed, and grows in the same manner, as the hoof of Solipeds, its matrix being a prolongation of the corium which extends over the third phalanx, after dipping into the circular furrow at the base of that bone.

Placed at the extremity of the digital region, the claw in these animals is not utilised in locomotion, as the foot does not rest on the ground by the extremities of the

digits, but by the whole plantar surface. Therefore it is, that we find on this face a kind of epidermic pad covering five fibro-adipose tubercles: four small ones placed along the four principal digits—the fifth or thumb not being sufficiently developed to reach the ground—and a large central one, circumscribed in front by the others. This arrangement is destined to diffuse the pressure caused by the weight of the body (and, doubtless, to ameliorate the concussion arising from the exertions these animals make, as well as to insure their footsteps being noiseless in approaching their prey). In the *Dog*, the claws may be used for burrowing in the ground.

In the *Cat*, the claws are very sharp and retractile; being capable of erection and depression in the interdigital spaces, by means of a small yellow elastic ligament passing from the second to the third phalanx. This animal's claws constitute its most powerful weapon of attack and defence.

4. *The Frontal Horns.*

These are conical horny sheaths, more or less large, crooked, and annulated transversely, formed by concentric layers of epithelial cells and some pigment corpuscles. The horns grow like the epidermis and the hair, their elements being secreted by that portion of the corium spread over the osseous cores of the frontal bones, and which completely envelope these; this portion of the skin is remarkable for its great vascularity.

(The length, direction, and general form of the horns varies in Ruminants, not only with regard to species, age, and race, but also the sex. The *Bull*, in the Bovine species, generally has short, thick, powerful horns; the *Cow* long and slender ones; and the *Ox* large, long, and strong ones. Some breeds have no horns at all; the same with the *Goat* species, though generally the horns in these are long, flattened, and curved backwards and downwards. With the *Ram*, the horns are sometimes immense and very powerful, being of a spiral form. They are usually less, or altogether deficient, in the *Ewe*. In the Bovine species, the transverse rings on the horns serve to indicate the age, the first appearing after two years.)

5. *The Chesnuts.*

This name is given to a little horny (oval or round) plate found, in the Horse, on the inner face of the fore-arm—in the lower third of the region, and at the upper extremity of the inner face of the metatarsal bone. It is composed of a mass of epithelial cells, arranged in tubes like the horn of the hoof. In Solipeds, the chesnut is the representative of the thumb. That on the posterior limbs is absent in the *Ass;* in the *Mule* it is very small.

(In fine-bred Horses, this horny production is much less developed than in the coarser breeds. It is always smaller in the hind limbs.

In the hind and fore-legs, we also find a similar, but smaller corneous mass, growing from the skin of the fetlock, and named the *ergot*. Like the chesnut, it bears the same relative development in fine and coarse-bred horses.)

CHAPTER II.

APPARATUS OF TASTE.

THE sense of taste permits the appreciation of savours, or the sapid properties of bodies.

Two nerves—the chorda tympani and the lingual branch of the ninth pair—appear at present to be the only sensory filaments endowed with the exercise of this function. They ramify in the lingual mucous membrane, which is thus made the organ of taste.

The tongue and its investing membrane having been described at page 335, their anatomy need not again be referred to; but we must glance at the organisation of the latter in considering it as the special apparatus of gustation. This will necessitate a few words on the *free surface of the membrane* which comes into contact with the sapid bodies, and some considerations on the *terminations of the nerves* which transmit the impressions produced by these bodies to the brain.

Free Surface of the Lingual Mucous Membrane.—This surface is studded by a multitude of papillary prolongations, which are nearly all limited to the upper surface of the tongue, to which they give a tufty appearance. Their form and volume, as mentioned at page 336, are very variable, according to their situation: some are microscopic, while others form voluminous caruncles; others, again, are long, conical, and filiform; another variety is round or depressed, representing a hemispherical tubercle scarcely projected beyond the general surface, or placed at the bottom of an excavation in the mucous membrane. The latter constitute the *calyciform papillæ* (*p. circumvallatæ*, *p. lenticulares*), and are considered the true organs of gustation; the others are the *fungiform* (*p. capitatæ*) and *filiform papillæ*, which play a mechanical part on the surface of the tongue.

The *calyciform papillæ* in the Horse are two in number, and situated near the base of the tongue; their diameter is so considerable that they have been named the blind or cæcal openings (*trous borgnes*). They are the principal, but not the only organs of taste. Their surface is mammillated, each prominence corresponding to a single papilla, and being placed below the level of the raised border encircling them. A deep fossa surrounds them, and limits at their base a pedicle, which unites them to the other portions of the mucous membrane.

The calyciform papillæ show, around their peduncle, a band of adenoid tissue; and in their substance conglomerate glands, as in other parts of the mucous membrane. They are covered by an epithelium containing some scattered pigment granules, the thickness of which is much diminished at the bottom of the fossa circumscribing them.

Termination of the Gustatory Nerves.—The hypoglossal is the motor nerve of the tongue, the lingual the nerve of general sensibility, and the chorda tympani and glosso-pharyngeal the filaments of special sensibility: this appears to be clearly ascertained from the recent experiments and observations of Lussana. The lingual branch of the glosso-pharyngeal nerve gives gustatory sensibility to the posterior third of the tongue; the chorda tympani to the anterior two-thirds.

The gustatory nerves present, as do all those of the organs of sense, a particular mode of termination. First indicated by Axel Key, their special manner of terminating has been carefully studied by Lowen and Schwalbe. According to these anatomists, the terminal nerve-tubes lose their medullary envelope and, reduced to their axis-cylinder, are thrown out in small oval masses which might be termed *gustative bulbs*. These bulbs are more particularly placed around the pedicles of the calyciform papillæ, in the substance of the epithelium. They are fusiform, their inner extremity rests on the mucous derma, where they receive the terminal nerve-tubes; and their external extremity reaches the epithelial layer, where they are seen either between two cells, or in an orifice pierced in a single pavement cell. Each bulb is composed of a small cluster of cells, which are distinguished from each other by their character and position; those occupying the axis of the organule are the *gustative cells;* they are in communication with the

nerve-tubes on one side, and on the other are furnished, for the most part, with rods which attain the free surface of the tongue. The superficial, or *protective cells*, completely envelop the preceding; they are a kind of epithelial-cells imbricated like the skins of an onion.

These sensitive organs are very numerous in the walls of the calyciform papillæ. Schwalbe reckoned their number at 35,000 in the papillæ of the Ox. They are not met with in these papillæ only; Lowen has found them in a large quantity of fungiform papillæ, if not in all. There is nothing extraordinary in this, as the whole surface of the tongue may, in various degrees, appreciate savours. (Szabadföldy has described small oval or pyriform bodies, lying with their long diameter parallel to the surface. The axis-cylinders of the gustatory nerves enter these, and terminate at their lower part in a slight swelling; so that they resemble small Paccinian bodies).

DIFFERENTIAL CHARACTERS IN THE APPARATUS OF TASTE IN OTHER THAN SOLIPED ANIMALS.

In the domestic mammifers, the differences in this apparatus are found in the number and variety of forms of the papillæ of the tongue.

In *Ruminants*, the calyciform papillæ are disposed in two rows at the base of the tongue; they are smaller than in the Horse, but more numerous—about a dozen being counted in each row. In the *Ox*. the filiform papillæ are covered by a horny sheath, which renders them hard to the touch.

The *Pig*, like Solipeds, has only two calyciform papillæ.

In the *Dog* and *Cat*, there are two principal papillæ, and in their vicinity some smaller calyces. The filiform papillæ are composite, and covered by a thick horny layer. Between them, regularly placed, are seen the fungiform papillæ, which have a brilliant aspect when looked at obliquely to the surface of the tongue.

COMPARISON OF THE APPARATUS OF TASTE IN MAN WITH THAT OF ANIMALS.

This has been already alluded to at page 364.

CHAPTER III.

APPARATUS OF SMELL.

THE sense of smell gives the appreciation of odorous emanations to animals. The active instruments of this sense are the filaments of the first pair of encephalic nerves, which ramify in the upper part of the pituitary membrane; this becomes, with the cavities it lines, the *olfactory apparatus*. These parts have been already referred to at page 444.

(The olfactory filaments, passing down from the olfactory ganglion, form a plexus upon the surface of the pituitary membrane. These filaments, as already noted, differ widely from those of the ordinary cephalic nerves, in containing no white substance of Schwann, but are nucleated and finely-granular in structure, and resemble greatly the gelatinous form of nerve-fibres. Their distribution is limited to the membrane at the upper third of the nasal septum, the upper part of the turbinated bones, and the wall of the nasal cavities adjoining the cribriform plate of the ethmoid bone: all this surface being covered with an epithelium of a rich sepia-brown hue. As has also been mentioned, Schultze divides these cells into two sets:

one (Fig. 382, *a*) being described as terminating externally by truncated flat surfaces, which cannot be observed to be covered by any membrane separate from the contents of the cell. These contents appear to consist of protoplasma with a yellow granular aspect externally, while at the lower part an oval nucleus imbedded in transparent protoplasm can be easily seen. At their attached end, these cells become attenuated, and may be traced inwards for a considerable distance until they expand into a broad flat sheet or plate, which is never coloured, though it frequently presents a granular appearance. The processes passing off from this appear to be continuous with the fibres of the submucous connective tissue. Towards the margin of the true olfactory region, cells perfectly analogous to these are met with, the only difference being that they present a well-defined band or seam at their free extremity, which is surrounded by a circle of cilia (Fig. 382, *c*). The cells of the second set (Fig. 382, *b*) are continuations of the nerves, and have been named *olfactory cells*. They are thin, fibrous, or rod-like bodies, terminating at the same level as the proper epithelial cells, and presenting, when traced inwards, a series of varicose swellings directly continuous with the prolongations of deeper-seated nerve-cells. Clarke states that the nerve-fibres, on reaching the base of the epithelial layer, divide into finer and finer branches, to form a network with numerous interspersed nuclei, through which they are probably connected with the olfactory cells (Fig. 382, *f*). The proper epithelial cylinders (*d*, *e*) are connected at their bases with the septa formed of the connective tissue belonging to the subepithelial glandular layer.)

Fig. 381.

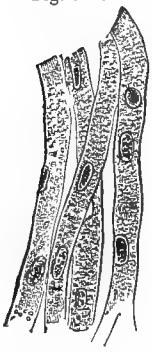

FIBRES OF ULTIMATE RAMIFICATIONS OF OLFACTORY NERVES OF DOG.

Fig. 382.

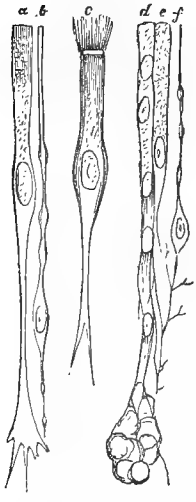

CELLS OF THE OLFACTORY MUCOUS MEMBRANE.
a, *b*, *c*, After Schultze; *d*, *e*, *f*, After Lockhart Clarke.

CHAPTER IV.

APPARATUS OF VISION.

Designed for the perception of external images rendered visible by the luminous rays, the sense of sight depends upon the excitability of the optic nerve, the terminal extremity of which is expanded as a thin membrane at the back of each *eye*. The latter is a globular organ lodged in the orbital cavity, attached to muscles which can move it in various directions, and protected by membranous and movable screens known as the *eyelids*, whose play over the surface of the eye is facilitated by the lachrymal fluid, which keeps their inner surface constantly moist.

The *essential organ of vision*, or *globe of the eye*, will be first described; then, under the designation of the *accessory portions of the visual apparatus*, we will notice the receptacle

of this globe, or *orbital cavity*, the *muscles* that move it, the protective membranes or *eyelids*, the *membrana nictitans* or *accessory eyelid*, and, lastly, the *lachrymal apparatus*, which concurs in the protection of the ocular globe by the fluid it incessantly throws out upon its surface.

Article I.—The Essential Organ of Vision, or Ocular Globe. (Fig. 383.)

(*Preparation.*—The eye should be as fresh as possible. All the fat and muscles should be carefully removed with scissors, the optic nerve being allowed to remain.)

The *globe*, or *ball of the eye*, is a spherical shell, whose interior is filled with fluid or semifluid parts, named the *humours* or *media of the eye*. The wall of this shell is formed by a continuous, very resisting, colourless envelope, limpid and translucid in its anterior portion, which constitutes the *transparent cornea*, and white and opaque for the remainder of its extent, known as the *sclerotica*.

On the inner face of the sclerotica is a second tunic—the *choroid*: a black membrane that lines the posterior face of the *retina*, and which, near where the two constituent portions of the external envelope unite, projects into the interior of the eye an elliptical diaphragm with a large opening in its centre —the *iris*. Immediately behind this disc is suspended or set, like a rose-brilliant, in the centre of a circular zone depending from the choroid, a biconvex body—the *crystalline lens*, one of the media of the eye, and which divides the interior of its cavity into two compartments: a posterior, very large, occupied by the *vitreous humour*; and an anterior, itself divided by the iris into two chambers of unequal dimensions, which contains the aqueous *humour*.

Viewed externally, and as a whole, the organ resulting from the union of all these parts represents a globular body, the anterior region of which corresponds to the cornea, and is more convex than the other points: a circumstance that tends to increase the antero-posterior diameter of the eye. But as this ocular sphere, to which is added, in front, this segment of a smaller sphere, is sensibly depressed from before to behind, it results that the other two principal diameters — the vertical and transversal — offer about the same dimensions as the first; Girard has even stated that the latter is the least. With an eye hardened by chromic acid, we have found that the transverse diameter measured $0^m,036$, and the vertical $0^m,040$ ($1 \cdot 417 \times 1 \cdot 575$ inches).

Two paragraphs will be devoted to the description of the constituent parts of the globe: one for the *membranes*, the other for the *media*.

THE MEMBRANES OF THE EYE.

1. *The Sclerotic.* (Fig. 383, *b*.)

The *sclerotic* is a white, very solid membrane, forming in itself about four-fifths of the external shell of the eye.

Its *external face*, in relation with the recti muscles and adipose tissue, receives posteriorly, though lower than the middle, the insertion of the optic nerve, which passes through it and the choroid to form the retina. Its internal face is loosely united to the choroid by vessels, nerves, and cellular tissue.

In front, the sclerotic shows an *elliptical opening* whose greatest diameter

is transversal, and whose border, bevelled on the inner side, is closely united to the circumference of the cornea. The substance of this membrane is traversed by numerous vessels and nerves, and is not of the same thickness throughout; at the back, around the entrance of the optic nerve, it is thickest; it then diminishes gradually towards the larger axis of the organ, and afterwards increases until it meets the cornea.

Fig. 383.

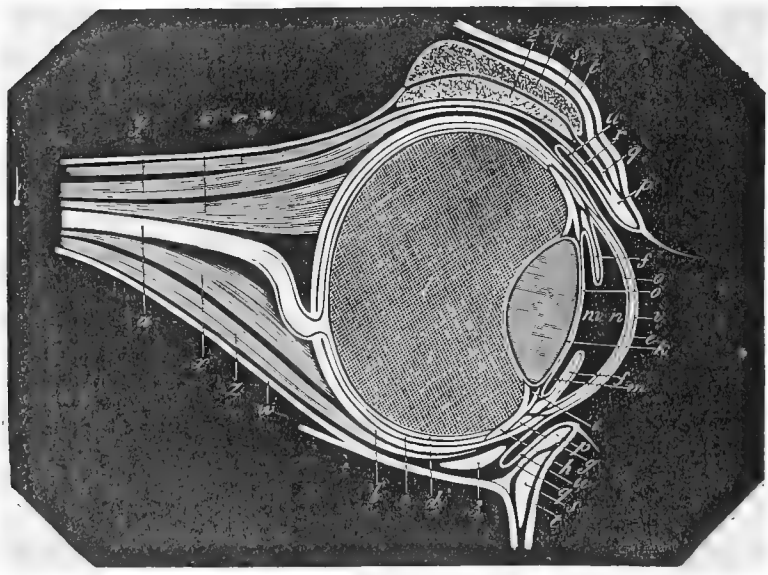

THEORETICAL SECTION OF THE HORSE'S EYE.

a, Optic nerve; *b*, Sclerotic, *c*, Choroid; *d*, Retina; *e*, Cornea; *f*, Iris; *g*, *h*, Ciliary circle (or ligament) and processes given off by the choroid, though represented as isolated from it, in order to indicate their limits more clearly; *i*, Insertion of the ciliary processes on the crystalline lens, *j*, Crystalline lens; *k*, Crystalline capsule; *l*, Vitreous body; *m*, *n*, Anterior and posterior chambers; *o*, Theoretical indication of the membrane of the aqueous humour; *p*, *p*, Tarsi; *q*, *q*, Fibrous membrane of the eyelids; *r*, Elevator muscle of the upper eyelid; *s*, *s*, Orbicularis muscle of the eyelids; *t*, *t*, Skin of the eyelids; *u*, Conjunctiva; *v*, Epidermic layer of this membrane covering the cornea; *x*, Posterior rectus muscle; *y*, Superior rectus muscle, *z*, Inferior rectus muscle; *w*, Fibrous sheath of the orbit (or orbital membrane).

Structure.—The sclerotic is wholly composed of fasciculi of fibro-cellular tissue interwoven in a very close manner, with some elastic fibres and little masses of pigment, especially at its back part. Among these fasciculi a large number pass from before to behind, and these are intersected by others which are placed in a circular manner around the globe. The superficial fibres are continuous with the neurilemma of the optic nerve. (The optic nerve, at its entrance into the sclerotic, is very much constricted, and passes through a funnel-shaped, porous mesh of fibrous tissue named the *lamina cribrosa*, in the centre of which is a larger opening than the others, for the passage of the arteria centralis retinæ—the *porus opticus*. The inner

surface of the sclerotic is coated by a thin layer of areolar tissue stained with black pigment—the *lamina fusca.*)

The *arteries* of the sclerotic are derived from the anterior and posterior ciliary arteries; the *veins* pass into trunks lying parallel to the ciliary arteries. *Nerves* have been found in the sclerotic of the Rabbit, but in none other of the domesticated animals. "It is frequently found that in the Ass, particularly when it is old, the back part of the sclerotic is encrusted with an unmistakable layer of bony matter. This fact was unknown to Carus, who states that in none of the mammalia does this membrane become ossified."—*Lecoq.* (In Birds, bony plates are found in this region, and some reptiles also have them.)

2. *The Cornea.* (Fig. 383, *e.*)

(*Preparation.*—The cornea should be removed with the sclerotic coat, by immersing the eye under water, and making a circular incision with scissors about a quarter of an inch from the margin of the membrane).

The *cornea* is a transparent membrane forming the anterior part of the eye, to whose interior it allows the light to pass. It closes up the anterior opening of the sclerotic, and thus completes the external envelope or shell of the globe, of which it forms about a fifth part.

Elliptical, like the opening it closes, the cornea presents: 1, Two *faces*, perfectly smooth—one *external*, convex, the other *internal*, concave—form the external wall of the anterior chamber; 2, A *circumference*, bevelled on its outer edge, and received into the similar bevel around the sclerotic opening, like the glass of a watch into its case.

Structure.—Three layers enter into the composition of the cornea: an *external*, *internal*, and *middle.*

Middle layer.—This, the *proper cornea*, is remarkable for its thickness. When pressed between the fingers, its two faces can be easily made to glide over each other, a proof that its tissue is disposed in superposed and parallel planes; it is indeed possible to decompose the cornea into several laminæ and lamellæ, but as their number varies with the amount of skill employed in their separation, they should be considered as an artificial production of dissection. Microscopically examined, it is found to be formed by bundles of excessively fine conjuntival fibrillæ, slightly undulating, and arranged parallel to the surface of the cornea. These wavy fasciculi, when placed alongside each other, leave numerous spaces which are oval in a transverse section; these communicate by means of fine canaliculi, and contain round cellular elements which may move from one space to another.

Between the fasciculi of the cornea is found a fluid amorphous substance, "a kind of transparent serosity like the cornea itself, which maintains its flexibility, and which, like it, also loses its transparency under the influence of different causes. It is only necessary, in a fresh eye, to squeeze the globe in order to produce a degree of opacity in the cornea which will be more or less great in proportion to the amount of pressure exercised. Is a similar effect produced by the swelling of the eye when the cornea becomes opaque in ophthalmia?"—*Lecoq.*

The *external layer* is only the conjunctival epithelium spread over the anterior face of the cornea. This epithelium is stratified, flattened on its surface, but cylindrical below, where it rests on the middle layer, and from which it is not separated, as in many species of animals, by a proper limitary membrane.

The *inner layer* is a portion of the membrane of the aqueous humour.

It is composed of a membrane that becomes slightly fibrous at the periphery of the cornea, where it forms, in passing on to the iris, the *pectinated ligament*. It has also a covering of polygonal epithelial cells, which are provided with a large nucleus.

(Some authorities give five layers to the cornea, the first being the conjunctival. The second consists of a very elastic tissue, perfectly structureless, and possessing a remarkable tendency to curl up; while boiling, or the action of acids, does not render it opaque as with the other layers; very fine fibres pass obliquely between it and the next layer—the cornea proper—consisting of a large number of strata with branched fusiform cells. The fourth layer is also elastic and like the second, though thinner. The fifth layer consists of the epithelial cells already mentioned. Wilson says that the opacity of the cornea produced by pressure on the globe, results from the infiltration of fluid into the areolar tissue connecting its layers, and that this appearance cannot be produced in a sound living eye, although a small quantity of serous fluid (*liquor corneæ*) is said to occupy the spaces in that tissue.)

Vessels.—The cornea has but little vascularity. The vessels form loops around its borders, and in the Sheep they advance to near the middle of its surface.

Nerves.—These were discovered by Schlemm. They penetrate by the periphery of the cornea, and form a network on its surface. According to Kühne, Hoyer, and Conheim, the ultimate nervous ramifications pass into the epithelium of the anterior face, and arrive between the most superficial cells.

3. *The Choroid Coat.* (Fig. 383 *c.*)

(*Preparation.*—If the cornea has not yet been removed, it and the sclerotic may now be dissected away from the choroid or second tunic. The connections between them are closest at the circumference of the iris, and at the entrance of the optic and ciliary nerves and arteries. Fine blunt-pointed scissors are necessary. A small portion of the sclerotic, near its anterior circumference, is pinched up and clipped off, the edge of the incision is raised, the circumference of the sclerotic divided, and that tunic removed piecemeal; a gentle pressure with the edge of the knife will remove it from its attachments around the circumference of the iris. This dissection is best conducted under water. The ciliary nerves and long ciliary arteries will be seen passing forward, between the sclerotic and choroid, to the iris.)

The *choroid* is a thin, dark-coloured membrane spread over the inner face of the sclerotic, whose general conformation it repeats. It is divided into two zones by the *ora serrata*—a denticulated line which corresponds to the point where the retina changes its characters.

Posterior or choroid zone.—Throughout the extent of this zone the choroid is uniformly thin, and corresponds, by its *external face*, to the sclerotic; by its *internal face*, it is in contact with the retina, but does not adhere to it. Posteriorly, it shows an opening through which the optic nerve passes. In front, at the anterior opening of the sclerotic, it is continuous with the anterior zone.

The inner face of the choroid is not uniform in colour, being perfectly black in the lower part of the eye; this is abruptly terminated at a horizontal line that passes about the 8th or 9th part of an inch above the optic papilla. From this line, on the segment of a circle from $\frac{4}{10}$ to $\frac{6}{10}$ of an inch in height, it shows most brilliant colours: at first blue, then an azure-blue, afterwards a brownish-blue, and after this the remainder of the eye is occupied by an intense black. The bright portion is the *tapetum.*

Anterior or ciliary zone.—This includes two parts: the "ciliary circle

(or ligament)" and the "ciliary body." The *ciliary circle, ligament,* or *muscle* (*annulus albidus*) varies in width from one to two millimètres; its external face adheres closely to the sclerotic, and its internal is confounded with the ciliary body; the posterior border is continuous with the choroid zone, near the *canal of Fontana* (*ciliary canal*). The anterior border gives attachment to the greater circumference of the iris. Its structure and uses will be referred to hereafter.

The *ciliary body* (*corpus ciliare*) forms a kind of zone or ring, wider than the ciliary ligament, and consequently overlaps the latter before and behind. It extends, on one side, on the inner face of the choroid, and on the other, on the posterior face of the iris. When the cornea and sclerotic are removed so as to expose the ciliary ligament, this zone is not seen; and to discover it, it is necessary to excise all the posterior part of the shell of the eye by a circular incision, and evacuate the vitreous humour. We then observe, around the crystalline lens, a wide, black circle, forming very regular radiating folds (*ciliary processes*) projecting inwards by their inner extremities, and appearing in the posterior chamber of the eye, after cutting away the iris; all abut by these extremities on the circumference of the lens, which they do not quite reach, although the latter is sustained by, and "set" in, the middle of the ligament.

These radiating folds (Fig. 384, 4) are from 110 to 120 in number in the Horse, and are constituted by little parallel leaves, wider at their inner than their outer extremity; the furrows that separate them posteriorly are partly concealed by the prolongation of the retina that constitutes the zonula of Zinn. The coronet formed by the ciliary processes is usually asymmetrical.

(Between the sclerotic, the cornea, and the ciliary ligament, exists a minute circular canal—the *ciliary canal, canal of Schlemm, sinus circularis iridis, circulus venosus orbiculi ciliaris,* or *canal of Fontana,* from its discoverer. It is surmised to be a venous sinus, as it can always be injected from the arteries.)

Fig. 384.



ANTERIOR SEGMENT OF A TRANSVERSE SECTION OF THE GLOBE OF THE EYE (HUMAN), SEEN FROM WITHIN.

1, Divided edge of the three tunics, sclerotic, choroid (the dark layer), and retina; 2, Pupil; 3, Iris, the uvea; 4, Ciliary processes; 5, Denticulated anterior border of the retina.

STRUCTURE.—The *choroid zone* is composed of four superposed layers: 1, The *external* is formed by a network of connective elastic fibres, among which are disseminated a great number of pigment cells; 2, The *second layer* is constituted by a network of large arteries and veins—the posterior ciliary—and a plexus of nerves (ciliary) accompanied by ganglia and some (stellate) pigment cells. (The veins are arranged with great regularity in drooping branches, to form the *vasa vorticosa* (Fig. 386, 2, 4); these are chiefly on the outer surface of the layer, the arteries ramifying on the inner surface.) 3, The *third layer,* or *tunica Ruyschiana,* has for its basis an amorphous substance containing a network of exceedingly fine capillaries (extending to the ciliary processes); 4, The *internal layer* is composed of hexagonal cells, regularly placed one upon the

other on the surface of a structureless laminæ; the cells are provided with a nucleus, and contain pigment-granules which exclusively occupy their anterior moiety. (On the choroid this cell formation is single, but on the iris and ciliary processes there are several layers. A very delicate membrane—*membrane of Bruch*—has been described as lining the inner surface of the choroid, and retaining the pigment in its place; this membrane may be seen on the posterior surface of the iris, and it probably prevents the pigment being removed by the aqueous humour.) The use of the choroid membrane is to convert the ocular globe into a veritable darkened chamber. (The pigment absorbs the rays of light which pass through the retina, and thus prevents their becoming reflected and confusing the vision. The brilliant metallic-coloured layer named the *tapetum* is more particularly observed in nocturnal animals, and especially in the Carnivora; it is due to the presence of a thick layer of wavy fibrous tissue outside the choroidal epithelium. By reflecting the rays of light a second time through the retina, it probably enables the animal to see better at night. It is the cause of the glare perceived in the eyes of Cats and other creatures in the dark.)

Fig. 385.

CELLS FROM PIGMENTUM NIGRUM.

a, Pigmentary granules concealing the nucleus; *b*, The nucleus distinct.

The *ciliary ligament* is a contractile body, being composed of unstriped muscular fibres which are arranged in orbicular fasciculi, or extend backwards (and are lost in the choroid, behind the ciliary processes). These fibres are intermixed in the plexus of ciliary nerves, on whose track small ganglia are formed. By its contractions, the ciliary muscle (or ligament) plays an important part in accommodating the eye to the perception of objects at different distances. (In Birds, the muscular fibres are striped.)

The *ciliary body* or *processes* are formed by intercrossed fasciculi of connective tissue, vessels, and some unstriped fibres; their inner surface is covered by pigment, like that of the choroid zone.

4. *The Iris.* (Figs. 383 *f*; 386, 6.)

The *iris* forms in the interior of the eye, at the anterior opening of the sclerotic, and in front of the crystalline lens, a veritable diaphragm pierced with a central opening—the *pupil*—which contracts or dilates according to the intensity of the light and the distance of the objects to which the vision is directed. This diaphragm divides the space between the cornea and the anterior face of the lens and internal extremities of the ciliary processes, into two compartments or chambers of unequal size: the anterior being the largest, and the posterior having only a virtual existence, the iris being close to the crystalline lens.

In shape, the iris is elliptical, like the cornea and the sclerotic aperture. Its *anterior face* is flat or very slightly convex, and has very marked circular furrows and radiating striæ, noticeable only at the outer circumference of the membrane. It is diversely coloured, not only according to species, but also in individuals. In Solipeds, it has nearly always a brownish-yellow hue; though sometimes it is nearly white or bright grey, when the animal is said to be "wall-eyed."

The *posterior face*, in relation with the lens and ciliary processes, is

covered by a very thick layer of pigment named the *uvea:* portions of which, supported by a small pedicle, frequently pass through the pupillary aperture and appear in the anterior chamber of the eye, where

Fig. 386.

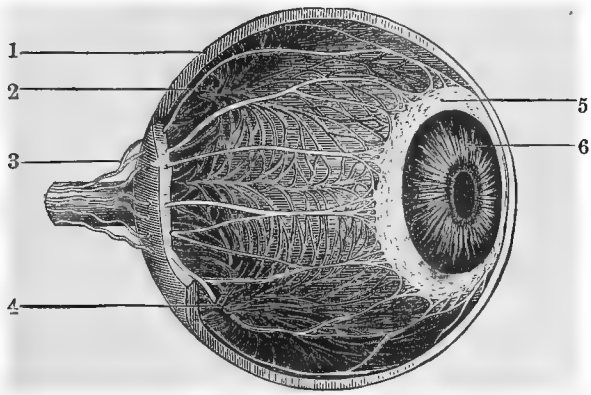

THE EYE (HUMAN) WITH THE SCLEROTIC COAT REMOVED.

1, Sclerotic coat; 2, Veins of the choroid; 3, Ciliary nerves; 4, Veins of the choroid; 5, Ciliary ligament; 6, Iris.

they are known as "soot-balls" or *corpora nigra.* (There are frequently several of these black spongy masses, which are generally attached to the upper border of the pupil; on the lower margin, when present, they are much smaller. Their colour is a brownish-black. They are sometimes so large as to give rise to apprehensions of injury to the vision.)

The *larger circumference* of the iris is attached to the ciliary ligament, which unites it to the choroid; it is also related to the margin of the cornea, as well as to that of the sclerotic opening.

The *lesser*, or *internal circumference*, is elliptical, and circumscribes the pupillary aperture.

Fig. 387.

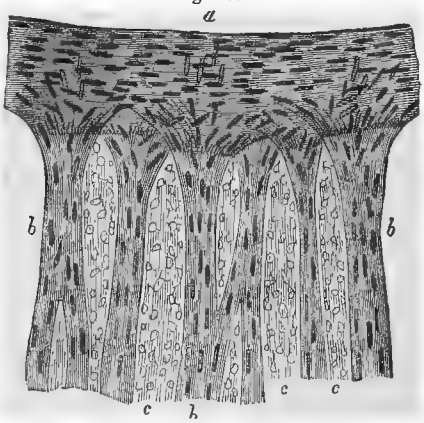

MUSCULAR STRUCTURE OF THE IRIS OF A WHITE RABBIT.

a, Sphincter of the pupil; *b*, *b*, Radiating fasciculi of dilator muscle; *c*, *c*, Connective tissue with its corpuscles.

STRUCTURE.—The organisation of the iris has been much discussed; but at present it is admitted that its principal element is unstriped muscular fibre. A proper membrane and two epithelial layers enter into its formation. The *proper membrane* has, for its framework, circular or radiating fasciculi of wavy connective tissue, with pigment cells. Between the fasciculi are placed the unstriped fibres; these are disposed in a circular manner around the pupil to constitute the *pupillary sphincter*, and others radiate from the lesser

circumference towards the ciliary ligament to form the *dilator of the pupil.* The very fine radiating vessels are disseminated among these fibres, and pass to the anterior ciliary trunks. The nerves supplied to the iris are from the ciliary plexus.

The *anterior epithelial layer* is composed of the polygonal cells of the aqueous-humour membrane, already described as existing on the posterior surface of the cornea.

The *posterior epithelial layer*, or *uvea*, is constituted by pigment cells analogous to those of the choroid, but less regular in shape.

In the fœtus, the pupil is closed by a very thin transparent membrane—the *membrana pupillaris.* (It is identical with the anterior layer of the capsule of the crystalline lens.)

5. *The Retina.* (Fig. 383, *d.*)

(*Preparation.*—The choroid must be removed under water by means of forceps and scissors, after the lens and vitreous humour have been evacuated. A good view of the retina is to be had by looking through the vitreous humour, after the lens and iris have been excised from an eye.)

The *retina*, the essential portion of the eye, considered as the terminal expansion of the optic nerve, extends over the internal face of the choroid, from which it is easily separated, and lies between that membrane and the vitreous humour. On arriving at the ciliary body, it is exactly moulded on the radiating folds of its posterior face, and with them is prolonged to the circumference of the crystalline lens, on the capsule of which it appears to become lost, after being closely united to it. It also adheres so firmly to the ciliary processes that, in the fresh eye, it is impossible to detach it. When the eye has been kept some time, however, the two are easily separated; the cornea is removed with a portion of the sclerotic; then dividing the iris into several pieces by diverging incisions, each is turned outwards by a slight traction that ruptures the ciliary zone and the choroid; the retina being thus divested of the parts which cover it anteriorly, is seen to form around the lens a kind of Elizabethan ruff, dovetailing with the ciliary processes. This plaited collar has been named the *zonula of Zinn* (*zonula ciliaris*, and *ora serrata*). The majority of anatomists, through having neglected to study this part in fresh eyes, have wrongly considered it as distinct from the retina.

At the point where the optic nerve enters the eye, there is found on the retina a small oval elevation, whose larger axis is about $\frac{1}{5}$ inch; this little prominence is the *optic papilla* or *punctum cæcum* (*papilla conica*). From its centre emerge the vessels of the retina.

Structure.—The retina is the most important of the three tunics of the eye, and it is also the thinnest and most delicate. It forms a soft, pulpy, transparent expansion when quite fresh, but is white and opalescent soon after death. It is composed of connective tissue and nerve elements, which are arranged to form nine or ten superposed layers

Connective Tissue.—This is very delicate and nucleated, and forms two thin laminæ named the *external* and *internal limitary membranes;* these are connected by radiating fibres which pass through the nerve elements, and anastomose very closely in the molecular layer.

Nerve Elements.—These are distributed in seven layers, which present the following characters:

1. *Layer of rods and cones.* (Fig. 388, 1.)—This is also termed the *mem-*

brana Jacobi (*bacillary* or *columnar layer*). It is situated between the inner face of the choroid and the external limitary membrane.

Rods and *cones*, regularly mixed, make up its structure. Each of these comprises two portions or segments (separated by a bright transverse line). The *outer segment* (or *shaft*) is brilliant and refractive, and consists of a small stalk terminating in a point for the cones; with a shorter stalk than the *inner segment* for the latter, and equal in length to this segment for the rods. The *inner segment* is a small granular shaft for the rods, and an enlargement whose base is towards the centre of the eye for the cones. The elements of this layer quickly alter after death.

Fig. 388.

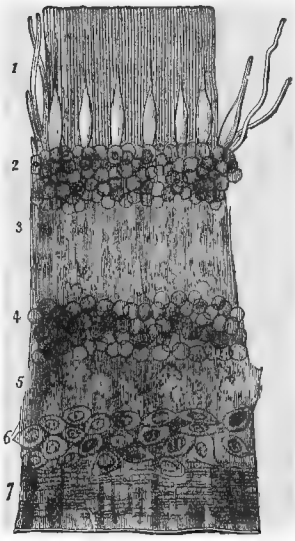

VERTICAL SECTION OF RETINA.

1, Bacillar layer; 2, Outer granular layer; 3, Intermediate fibrous layer; 4, Inner granular layer; 5, Finely-granular grey layer; 6, Layer of nerve-cells; 7, Layer of fibres of optic nerve; 8, Limitary membrane.

2. *External granular layer* (2).—This is comprised between the external limitary and the intermediate membrane. It is formed by the *granulations of the cones* and those of the *rods:* small oval nucleated cells, furnished with an external prolongation that joins them to the base of the cones and rods, and an external varicose prolongation which often enlarges on arriving at the intermediate layer.

3. *Intermediate layer* (3).—This is very thin, and composed of flexuous fibrillæ, which are connected with the adjoining elements.

4. *Inner granular layer* (4).—In this we find cells whose membrane is in contact with the nucleus; these cells have minute prolongments analogous to those of the external granular layer, and which connects them with the surrounding layers.

5. *Molecular layer* (5).—One of the thickest, this layer (the grey vesicular) presents a granulous aspect; in its mass, the connective tissue forms a close mesh, in the midst of which are seen fine fibrillæ passing in every direction.

6. *Ganglionic layer* (6).—This is composed of a single stratum of ramified nerve-cells, whose prolongations pass into the molecular layer, where they join the filaments of the next layer.

7. *Layer of optic-nerve fibres* (7).—The fibres (ultimate fibrils) of the optic nerve, in passing through the sclerotic and choroid, anastomose with each other, and arrange themselves in a cone shape, whose apex corresponds to the papilla conica; at this point they suddenly spread out in every direction, between the ganglionic layer and the limitary membrane.

To sum up, the retina comprises the following layers, reckoning from before to behind: 1, Internal limitary membrane; 2, Layer of optic-nerve fibres; 3, Layer of nerve-cells; 4, Molecular layer; 5, Inner granular layer; 6, Intermediate granule layer; 7, Outer granular layer; 8, Outer limitary membrane; 9, Columnar layer; 10, Pigmentary layer of the choroid, if this be attached to the retina, as Schultze proposes.

It is to be remarked, that at the ora serrata all the nerve elements of the retina disappear, and the membrane, reduced to its connective tissue, is

continuous with the posterior face of the ciliary processes, where it afterwards forms the zonula of Zinn.

Fig. 389.

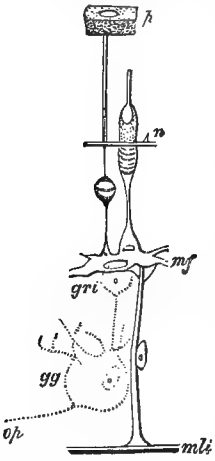

DIAGRAM OF THE STRUCTURE OF THE RETINA.

p, Pigment cell of the retina connected with a rod; *n*, Cone seated on the membrana limitans externa, the inner segment containing a cone ellipsoid, and a needle; *m*, *f*, Proper fibre connecting rod and cone with one of the cells of the membrana fenestra, whose cells are in communication with the membrana limitans interna, *m*, *l*, *i*, by means of a thick radial fibre with an oval nucleus attached; *g*, *g*, Multipolar ganglion of nerve elements; *o*, *p*, Optic fibrilla; *g*, *r*, *i*, Supposed connection of the nucleus with prolongation of a ganglion cell.

(At the papilla conica, all the other elements than the nerve-fibres are entirely absent; hence this is presumed to be a "blind spot.")

Blood-vessels.—The retina possesses a particular vascular distribution. The *arteria centralis retinæ*, with its *vein*, enters the optic nerve at a short distance from the globe, and with it passes into the eye; they traverse the papilla, and immediately divide into two branches, one of which is directed upwards, the other downwards. Close and fine anastomoses unite the vessels of the retina with the ciliary vessels at the back of the sclerotic.

Fig. 390.

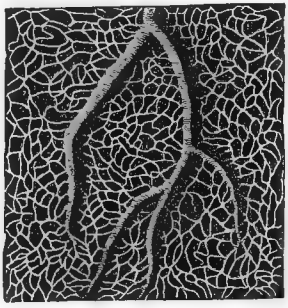

CAPILLARIES IN THE VASCULAR LAYER OF THE RETINA.

THE MEDIA OF THE EYE.

The Crystalline Lens. (Fig. 383, *j*.)

The *lens*, as its name implies, is a (solid) transparent body, sustained at the smaller circumference of the zone formed by the ciliary processes (behind the pupil, and partially imbedded in the vitreous humour). It is biconvex in shape, and flatter on its anterior than its posterior surface. We have measured the lens of the Horse's eye, and find the following dimensions: vertical diameter $\frac{6}{10}$ths, and transverse diameter $\frac{5}{10}$ths of an inch. The posterior face is evidently more convex than the anterior, for we found the transverse diameter of the last to be $\frac{4}{10}$ths, and that of the first $\frac{3}{10}$ths of an inch.

Structure.—The lens is enveloped in a transparent membrane, the *capsule*, which contracts no adhesions with it. Its thickness is uniform in the Horse, and its tissue is slightly striated transversely; its internal face is lined by a layer of pavement epithelium.

The *proper tissue* of the lens is disposed in concentric layers, which the microscope proves to be composed of fibres; the outer layers are almost fluid (gelatinous), but their consistence gradually increases towards the centre. Between the proper tissue and the epithelium of the capsule are two or three layers of round cells, whose dissolution some time after death forms the *liquor Morgagni*—which is consequently nothing more than the result of a cadaveric phenomenon.

(The *capsule* of the lens is composed of tissue exactly similar to the

elastic layer of the cornea. To examine the structure of the lens, it is best to boil it, or to immerse it in alcohol or nitric acid, which renders it hard and opaque. It is then found to be divided into three equal parts by three lines, which radiate from the centre to within one-third of the circumference; so that each of these portions is composed of hundreds of concentric layers, arranged within one another, like the coats of an onion. According to Kölliker, these fibres are tubular, and contain an albuminous fluid. If any single layer is examined with the microscope, it is found to be made up of these parallel fibres, which measure about $\frac{1}{5000}$th of an inch in thickness, and are united with each other by finely serrated or scalloped borders that dovetail in the most beautiful manner.

The lens is nourished by means of the extremely delicate layer of nucleated cells on its surface, which absorb nutriment from the capsule.)

The lens receives neither vessels nor nerves. In the fœtus, the arteria centralis gives off a branch which passes forward through the vitreous humour, and enters the posterior face of the lens; but this vessel disappears long before birth.

(The use of the lens is to bring the rays of light to a focus upon the retina, they being greatly refracted in passing through it.)

2. *The Vitreous Humour.* (Fig. 383, *l.*)

The *vitreous body*, or *humour*, occupies all the cavity of the eye behind the lens (about two-thirds of the interior of the eye).

It is a kind of colourless, transparent jelly, much more fluid than the lens, and entirely amorphous, according to Ch. Robin; though the majority of anatomists add some embryonic cells. At the surface of the vitreous mass is a very thin structure, the *hyaloid membrane*, which is in contact, externally, with the retina and the posterior face of the lens.

(This hyaloid membrane forms cells, in which the watery fluid constituting the humour is contained; the cells communicate freely, and are rendered apparent by freezing the eye or steeping it in chromic acid, when it is found that the humour is intersected by a large number of delicate partitions, with a cylindrical space in the axis for the passage of the central artery in the fœtus. The membrane is firmer on the surface than elsewhere, so that it serves as a capsule for the humour, and suffices to keep it in shape after the outer envelopes of the eye are removed. As mentioned, the lens is maintained in *situ* by the zone of Zinn.)

There has been described around the lens, between the hyaloid membrane and the zone of Zinn a circular passage named the *canal godronne* (*canal of Petit*), because of its form. I look upon this canal as an artificial production, and due to the means employed to demonstrate it in mankind and animals.

(This humour concurs in refracting the rays of light.)

3. *The Aqueous Humour.*

This is a liquid that owes its name to its great fluidity; it is contained in the anterior and posterior chambers of the eye, in front of the lens. It is secreted by a particular membrane, the *membrane of the aqueous humour*, or *membrane of Descemet* or *Demours;* this is an extremely thin serous layer, easily distinguished on the posterior face of the cornea, and admitted to exist on the two faces of the iris, the ciliary processes, and anterior face of the capsule of the lens, where it is reduced to epithelium only.

(The chief function of this humour appears to be to maintain the convexity of the cornea, and to facilitate the movements of the iris and lens; as well as to assist, to some extent, in refracting the light that passes through it to the lens and retina. The rapidity with which this fluid can be regenerated is very striking; absorption also takes place very rapidly in the anterior chamber of the eye. The frequency of adhesions between the iris and lens, after attacks of ophthalmia, is accounted for by the small quantity of this fluid that exists between them, as owing to the smallness of the posterior chamber this is reduced to a mere film.)

Article II.—Accessory Organs of the Visual Apparatus.

ORBITAL CAVITY.

Situated at the side of the head, at the point corresponding to the union of the cranium and face, the *orbital cavity* is circumscribed by a bony margin, in the formation of which the orbital process, frontal, lachrymal, malar, and a small portion of the zygomatic process of the temporal bone, concur. Posteriorly, however, there are no bony walls, and the cavity, in the skeleton, is confounded with the temporal fossa. A fibrous membrane completes this cavity in the domesticated animals, and keeps it distinct from the fossa.

Designated the *ocular sheath* (*ocular membrane* or *periorbita*), this fibrous structure is attached, posteriorly, to the border of the orbital hiatus, and anteriorly to the inner face of the orbit; being prolonged beyond the external lip of this osseous rim to form the fibrous membrane of the eyelids. Strong externally, the ocular sheath is thin within the cavity. It is traversed by vessels and nerves, and is composed of a mixture of elastic and inelastic fibres. (Unstriped muscular fibres have also been described as existing in this orbital periosteum.)

Thus completed, the orbital cavity has the form of a regular hollow cone, open at its base, and closed at the apex, which corresponds to the orbital hiatus.

In the ordinary position of the head, the opening of this cone is directed forwards, downwards, and outwards.

Independently of the globe of the eye, this cavity lodges the muscles that move it, the membrana nictitans, and the lachrymal gland.

MUSCLES OF THE EYE. (Fig. 391.)

These are seven in number: five termed *recti muscles*, and distinguished as *posterior*, *superior*, *inferior*, *external*, and *internal*; two named *oblique*—a *large* and *small*.

(*Preparation.*—Detach the eyelids from the margin of the orbit, cutting away the lower, but leaving the upper. Saw through the zygomatic process of the temporal bone, in front of the temporo-maxillary articulation, also through the temporal process of the zygomaticus, and the base of the orbital process of the frontal bone; remove the excised piece of bone, and the temporal fossa and ocular sheath are exposed. Cutting through the latter, the muscles of the eye are seen disposed in a conical manner around the globe; dissect away the fat lodged among them, in order to isolate them.)

1. Posterior Rectus Muscle (or *retractor oculi*).—This muscle completely envelops the extra-cranial portion of the optic nerve, being a muscular sheath resembling in shape the fibrous lining of the orbit. Its fibres are disposed longitudinally, arise around the optic foramen, and are

inserted into the posterior part of the external face of the sclerotic. It is always more or less fasciculated, and is most frequently separated into four portions—superior, inferior, external, and internal.

In contracting, it retracts the globe towards the back of the orbit. The physiological finality of this movement will be noticed hereafter.

2. Superior, Inferior, External, and Internal Recti Muscles.—These four muscles are placed longitudinally on the preceding, and repeat, on a large scale, the disposition of its four bundles. As their borders are in contact, they constitute a fleshy sheath around it, analogous to that which it forms around the optic nerve. Exactly resembling each other, these four muscles compose so natural a group, that they may be described together. Each is a flat band, formed of parallel fibres, firmly attached by its posterior extremity to the back of the sheath, and to the interior of the subsphenoidal canal; anteriorly, it is inserted by a thin aponeurosis into the sclerotic, at the margin of the cornea. Isolated from one another, and from the retractor, by the mass of fat belonging to the membrana nictitans, these small muscles are related, externally, to the ocular sheath.

Fig. 391.

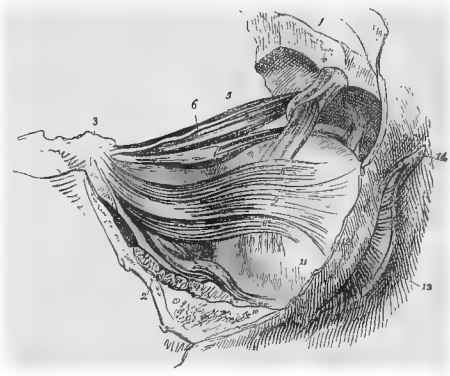

MUSCLES OF THE EYEBALL, VIEWED FROM ABOVE.

1, Section of orbital process of frontal bone to which the fibro-cartilaginous pulley, 4, of the superior oblique muscle, 5, is attached; 2, Zygomatic process of the temporal bone; 3, Portion of sphenoid bone into which the recti and superior oblique muscles are implanted; 6, Pathetici nerve; 7, Internal rectus; 8, Superior rectus; 9, Levator palpebræ muscle; 10, External rectus; 11, Eyeball; 12, Upper eyelid; 13, Lower eyelid; 14, Inner canthus of eye.

There is nothing particular to be noted regarding them, their position being sufficiently indicated by their names. Their function is to bring the pupillary opening into contact with the rays of light, by inclining the cornea towards them, either upwards, downwards, inwards, or outwards; or into intermediate positions, which happens when two adjacent muscles—the inferior and external rectus, for instance—combine their action at the same moment.

3. Great Oblique Muscle (*trochlearis*, or *obliquus superior oculi*).—Lying to the side of the internal and superior rectus, and formed, like them, of a fleshy band terminated by a thin aponeurosis, this muscle differs from the preceding in its interrupted course. Arising from the back of the orbit, and passing forward against the inner wall of that cavity, it reaches a strong fibro-cartilaginous, pulley-like, process—a dependency of the aponeurosis of the orbit—attached by its extremities to the frontal bone, at the base of the orbital process; it passes through this loop, and then bends outwards, to insinuate itself below the terminal extremity of the superior rectus, and become inserted into the sclerotic, between the latter muscle and the external rectus.

This muscle pivots the eye inwards and upwards in the orbit, carrying the outer aspect of the globe upwards, and its lower part outwards; this

faculty it owes to its reflexion in the cartilaginous loop, as it acts as if its insertion was at the angle it forms there.

4. Small Oblique Muscle (*obliquus inferior oculi*).—Much thicker, though very much shorter than the preceding, and almost entirely fleshy, this muscle is placed in a transverse direction on the globe of the eye, being nearly parallel to the reflected portion of the great oblique. It arises in the lachrymal fossa, passes outwards, and terminates in the sclerotic, between the external and inferior recti muscles.

It is an antagonist of the great oblique, pivoting the eye in a contrary direction.

It is to be noted that the double rotatory movement executed by the oblique muscles is altogether involuntary, and that it is constantly produced when the animal inclines its head to one side: doubtless to maintain the visual axis always in the identical relations with the same point of the retina. This movement is well seen in Man when the head is brought round to either shoulder: the eye then pivots in the orbit in an inverse direction to that to which the head inclines, so that a mark placed at the upper part of the iris when the head is straight would occupy the same position after the lateral movement. Simultaneous in both eyes, this pivoting is executed by certain muscles in each; the great oblique for one, the small oblique for the other, according to the direction in which the head is turned.

(A third, or *middle oblique* muscle, has been mentioned by the late Professor Strangeways, of the Edinburgh Veterinary School, as sometimes, if not always, found between the superior and inferior oblique muscles. It has been described as arising by a fine tendon from a small depression in the upper part of the orbital process of the frontal bone, between the origin of the inferior oblique and the pulley of the superior oblique muscle. This tendon is succeeded by a fusiform fleshy mass, about three lines in diameter and an inch long, imbedded in adipose tissue; it passes obliquely upwards and outwards on the external face of the rectus muscle, and terminates in a thin flat tendon which accompanies the upper belly of the superior oblique for a short distance, and becomes confounded with the tendon of that muscle as it runs beneath the superior rectus. It is supposed to be an accessory of the superior oblique, and to regulate and facilitate the gliding of that muscle through the acute angle formed by its pulley.)

PROTECTIVE ORGANS OF THE EYE.

1. *The Eyelids.* (Figs. 383, 391.)

The surface of the eye is covered and protected in front, by two movable membranous curtains—the *eyelids* (*palpebræ*): one *superior*, the other *inferior*.

Attached to the circumference of the orbit by their external border, the eyelids have a convex *external* face formed by the skin, and a concave *internal* face, moulded on the anterior surface of the eye, and lined by the conjunctiva which is reflected above and below on the eyeball: the duplicatures constituting the *superior* and the *inferior conjunctival* (or *palpebral*) *sinuses*.

Each lid has also a *free border* opposed to that of its fellow, with which it unites at an angle by its extremities, so as to form two *commissures* (or *canthi*). This border is slightly bevelled on the inner side, and shows a series of small openings—the excretory orifices of the *Meibomian glands*; as

well as a row of erect hairs, the eyelashes: these will be described presently.

When the two lids are closed by the approximation of their free borders, they completely cover the eye, and form a narrow fissure comparable to a closed button-hole. When they are separated, they circumscribe an oval space (*fissura palpebrarum*), whose greater axis is directed obliquely downwards, forwards, and inwards. The upper lip or contour of this space, formed by the free margin of the superior eyelid, is always more curved than the lower. The superior commissure (or canthus) has also been named the *temporal angle of the eye.* The *nasal angle*, constituted by the inferior commissure, is always rounder than the other; it lodges the lachrymal caruncle (in the *lachus lachrymalis*).

Structure of the Eyelids.—A fibrous plate, terminated, towards the free border of the lid, by a small tendinous arch named the *tarsus;* a sphincter muscle, the *orbicularis palpebræ*, in contact with the fibrous membrane; the *levator palpebræ*, a muscle partly lodged in the ocular sheath, and terminated anteriorly by a very thin and wide expansion placed beneath the superior fibrous plate; a cutaneous envelope in two parts, containing the above: an *external*, the skin; and an *internal* of mucous membrane, the conjunctiva, joining at the free border of the lid;—these are the elements which enter into the composition of the protective coverings of the eye.

1. Fibrous Membrane.—Usually thicker in the lower than the upper lid, this membrane is attached, by its adherent border, to the rim of the orbit, where it is continuous with the periosteum and the fibrous wall of the ocular sheath. Its free border is margined by the tarsus.

2. Tarsus.—This is a fibrous lamella that forms a solid frame for the free border of the lid: it is elongated, narrow at its extremities, thin at its fixed border, where it is confounded with the fibrous membrane, and channeled on its inner face by several transverse parallel grooves which lodge the *Meibomian glands.* This small fibrous arc regulates the contraction of the orbicularis muscle, and prevents the lid being drawn into wrinkles; by the rigidity it bestows on the eyelids, it allows these to meet, border to border, without puckering, when that muscle is in action.

3. Orbicular Muscle of the Eyelids (*musculus ciliaris*).—This is a wide thin sphincter common to the two lids, applied to the fibrous membrane and the bone forming the rim of the orbit. Its external face is covered by the skin, to which it closely adheres. A small tendon that passes to the lachrymal tubercle of the nasal angle of the eye, is generally considered as the origin of the fibres of this muscle, the majority of which, directed upwards, are disposed in a circular manner in the substance of the upper lid; while the others go to the lower lid, both joining at the temporal angle of the eye.

The contraction of this muscle causes the occlusion of the palpebral opening. (It is a prominent agent in defending the eye from external injury.) We may regard as an appendage of the orbicularis, a little short, flat fasciculus, usually designated the *fronto-superciliary muscle* from its attachments (or *corrugator supercilii*, from its function). It arises from the outer face of the frontal bone, passes downwards and outwards, and mixes its fibres with those of the latter muscle at the superorbital foramen, which it covers, and in the skin of the eyebrow. It has been erroneously considered an elevator of the upper lid, for when it contracts, it only corrugates the skin of the eyebrow by slightly drawing the nasal angle of the eye outwards; this it does as well when the lids are closed as when they are open.

4. Elevator Muscle of the Upper Eyelid, or Orbito-palpebralis (*Levator palpebræ*).—When the ocular sphincter ceases to contract, the lower eyelid droops from its own weight; the upper lid, however, requires some special muscular agency to raise it, and this it finds in the levator. This is a very thin, narrow, fleshy-band, lodged in the ocular sheath with the other muscles of the eyeball, and is related to the superior rectus, whose course it follows. On reaching the lachrymal gland, it expands into a wide aponeurotic membrane that passes between the conjunctiva and the fibrous plate of the eyelid, and terminates on the tarsus.

It will be seen that this muscle is inflected on the eyeball in a pulley-like manner, and it is owing to this disposition that it has the power of raising the lid. If the eyeball were not present, the muscle would draw the free margin of the lid towards the back of the orbit, instead of elevating it.

5. Integuments of the Eyelids.—The different layers enumerated are comprised between two tegumentary folds, the *skin* and *conjunctiva*, which are continuous at the border of the eyelids. We will examine these, with their appendages—the *eyelashes* and *Meibomian glands*.

a. Skin.—Intimately adhering, by its inner face, to the orbicularis muscle, this membrane is thin (smooth), and covered with numerous fine short hairs. In the fœtus, it shows at the orbital arch, when the skin everywhere else is nude, a well-marked semicircle of hairs—the eyebrow. Fat is never found beneath it.

b. Conjunctiva.—The conjunctiva, as its name indicates, joins the eyelids to the eyeball. Very fine and highly vascular, this mucous membrane is a continuation of the skin at the border of the lids, lines the inner face of each of them, envelops the anterior portion of the membrana nictitans in a particular fold, covers the caruncula lachrymalis, and enters the puncta; it is then reflected, at the adherent border of the eyelids, on to the eyeball, extending over the sclerotic and terminal aponeurotic expansion of the recti muscles. On arriving at the margin of the cornea, it is impossible to trace it further; though it is represented by the thin layer of pavement epithelium already described. At the surface of the lachrymal caruncle, it shows some very fine hair bulbs. It possesses some papillæ (on the palpebral portion only, the ocular reflection being thinner, and having none of these nervous processes), and tubular and aggregate glands, as well as closed follicles. We have found large numbers of the latter, whose volume was considerable; they form a corona around the cornea.

The nerves of the conjunctiva terminate by small oval enlargements, the *corpuscles of Krause*.

(The ocular portion has generally very few blood-vessels visible in health; when inflamed it becomes intensely red and vascular.)

c. Eyelashes.—These are two rows of hairs (*cilia*) implanted in the free border of the lids, and destined to prevent the entrance of dust and small particles of foreign matter into the eye. They are much longer, and more abundant and stronger, in the upper than the lower lid, their presence there being more necessary, as extraneous particles are most likely to enter the eye when falling. But if the eyelashes of the lower lid are few and rudimentary, this is compensated for by the presence on its surface of some long bristly hairs, scattered here and there, and exactly like the tentacula of the lips.

Like all hairs, without exception, the eyelashes are flanked at their base by two or three small sebaceous glands, whose duct opens into their follicle.

d. Meibomian glands.—These are little masses, analogous to sebaceous

glands, which open alternately into a common, very long excretory canal. They are lodged in the transverse grooves observed on the inner face of the tarsal ligaments. The unctuous matter they secrete is thrown out on the free border of the lids, and enables these to retain the tears more easily within the ocular cavity. In sick animals, this secretion accumulates at the canthi and base of the lids. (Each gland consists of a central tube, with a number of openings round its sides leading to short cæcal dilatations. The secretion also facilitates the movements of the lids.)

6. Vessels and Nerves of the Eyelids.—These membranous curtains receive their blood, for the most part, by the supra-orbital and lachrymal arteries, and the orbital branch of the superior dental artery. The terminal extremities of the three sensitive nerves of the eye, formed by the ophthalmic branch of the fifth pair and the orbital filaments of the superior maxillary branch, ramify in them. The anterior auricular nerve endows the orbicularis muscle with contractility. The motor filaments of the levator palpebræ are derived from the third pair.

2. *Membrana Nictitans.*

"This organ, which is also named the *third eyelid, winking eyelid*, etc., is placed at the great (inner) angle of the eye, whence it extends over the eyeball to relieve it from foreign bodies which may fall upon it. It has for its framework a fibro-cartilage—elastic—irregular in shape, thick and nearly prismatic at its base, and thin anteriorly where it is covered by the conjunctiva; it is continued, behind, by a strong adipose cushion, which is insinuated between all the muscles of the eye, and to which it is loosely attached. No muscle directly concurs in the movements of this body: they are entirely mechanical. When the eye is in its usual position, there is only perceived the fold of conjunctiva that terminates it in front; the remainder is concealed in the fibrous case of the eye. When, however, the latter is withdrawn into the orbit by the contraction of its recti muscles, the globe compresses the fatty cushion belonging to the cartilage; this cushion, pressing outwards, pushes the membrana before it, and the latter then entirely conceals the whole front of the globe. This movement is instantaneous, but it may be momentarily fixed by pressing gently on the eye when the animal retracts it within the orbital cavity.

"The use of the membrana is, as will be seen from the above, to maintain the healthy condition of the eye, by removing any matters that have escaped the eyelids; and what clearly demonstrates this function, is the inverse relation that always exists between the development of this body, and the facility with which animals can rub their eyes with their anterior limbs. So it is that, with the Horse and Ox, whose thoracic member cannot be applied to this purpose, the membrana is very developed; and in the Dog, which may use its paw to some extent when it requires to brush its eye, it is smaller; in the Cat it is still less; while in the Monkey and in Mankind, whose hands are perfect, it is rudimentary. In tetanus, the membrana nictitans often remains permanently over the eye, in consequence of the continued contraction of the recti muscles."—*F. Lecoq.*

(Towards the middle of the outer face of the membrana is a small yellowish-red gland, the *gland of Harder*, covered by a strong fibrous membrane, and surrounded by adipose tissue; it secretes a thick unctuous matter, which escapes by two or three small apertures on the inner face of the membrana.)

LACHRYMAL APPARATUS.

"This apparatus comprises: 1, A gland which secretes the tears; 2, A series of canals that carry the superfluous fluid to the external orifice of the nasal cavities.

"*Lachrymal gland.*—This gland, situated between the orbital process and the upper part of the eyeball, from which it is separated by the superior rectus and levator palpebræ muscles, is convex on its upper face, and concave inferiorly, in accordance with the parts it adjoins. But little developed, it is formed of very small granulations, united by fine connective tissue; from these arise minute radicles, whose junction forms a certain number of very narrow ducts which open on the inner face of the temporal (outer) angle of the eyelids. These are the *hygrophthalmic canals.*

"The lachrymal gland secretes the tears destined to lubrify the anterior surface of the eye. This fluid escapes upon the organ at the temporal angle of the lids, and is carried between them and the eyeball towards the nasal angle. Its secretion is incessant, but it is increased by anything that irritates the conjunctiva, and its character may even change under the same influences.

"The lachrymal gland belongs to the category of conglomerate glands; consequently, it is analogous to the salivary glands. (The gland is maintained *in situ* by a capsule formed by the fascia of the orbit.)

"The hygrophthalmic canals have a thin fibrous membrane for their walls; this is covered by cylindrical epithelium.

"*Caruncula lachrymalis.*—This name is given to a small round (or fusiform) body, frequently entirely, or partially black (or brown), slightly uneven, and situated in the nasal angle of the eye; it is nothing more than a small fold of conjunctiva covering some agglomerated follicles, and the bulbs of several fine hairs, which are readily seen on its surface. It may be regarded as designed to direct the tears towards the puncta, or to separate the extraneous particles that this fluid may carry towards it.

"It has for its base a small mass of connective tissue, in the midst of which are some hair-roots, and some rather large glandules, lined by an epithelium charged with fat granules. Nerve-tubes ramify around the hair bulbs.

"*Puncta lachrymalia.*—These are two little openings, situated one in each eyelid, a short distance from the nasal commissure, by which the tears pass from the oculo-palpebral surface into the lachrymal ducts.

"*Lachrymal ducts.*—These are continuations of the last, and, like them, are very narrow; they carry the tears into the lachrymal sac. The superior is longer than the inferior duct, and arrives at the sac behind it. The mucous membrane lining these ducts is thin, and covered by a stratified pavement epithelium, similar to that of the conjunctiva.

"*Lachrymal sac.*—This little reservoir, lodged in the infundibulum that precedes the lachrymal foramen in the bone of that name, receives the tears from the two ducts, and passes them into the lachrymal canal. Its mucous membrane only differs from that of the ducts in being covered with ciliated epithelium.

"*Lachrymal canal* (*nasal duct*).—The tears accumulated in the sac flow into this long duct, which extends to the lower aperture of the nostril. About one half of its course is in the osseous canal of the lachrymal bone which protects it, and which terminates between the two turbinated bones. The remainder of the canal is beneath the nasal mucous membrane, whence

it passes to the inner surface of the outer wing of the nostril; there it terminates by an orifice, sometimes two, that looks as if punched out of the membrane, towards the lower commissure, near the point where there is a line of demarcation between the dark colour of the skin, and the rosy tint of the mucous lining.

"This aperture constitutes the 'nasal outlet' (*égout nasal*).

"The epithelium of the membrane lining the canal is ciliated in its bony, stratified in its nasal, portion. On the surface of the membrane are to be seen the openings of the secretory ducts of some conglomerate glands, which are lodged in the walls of the canal. Throughout its extent, the canal is lined by a continuation of the mucous membrane of the lachrymal sac. In Solipeds, this canal opens on the cutaneous surface at the entrance of the nostrils; and it therefore happens that in these animals the conjunctiva, with its dependencies, forms a particular mucous membrane, really apart from the great gastro-pulmonary membrane.

"In the Ass and Mule, the orifice of the lachrymal canal is situated at the inner face of the outer wing of the nostril, and not near the inferior commissure, as in the Horse."—*F. Lecoq: 'Extérieur du Cheval,' etc.*

(Sometimes this outlet is double. The lachrymal secretion is not only useful in facilitating the movements of the eyelids over the eyeball, but it washes away dust and hurtful matter from off the surface of the cornea, keeping the latter clean, moist, and healthy.)

DIFFERENTIAL CHARACTERS IN THE VISUAL APPARATUS IN OTHER THAN SOLIPED ANIMALS.

Essential Organ of Vision.—In the *Ox*, the eyeball resembles in shape that of the Horse; but in small animals, particularly the *Dog*, it is much more spherical. In *Birds*, it is very convex in front; its largest diameter is the antero-posterior.

Sclerotic.—This is the same in all the domesticated quadrupeds. In *Birds*, however, it has some curious features. Posteriorly, it has for base a cartilaginous layer, covered on both sides by fibrous tissue; this layer frequently ossifies around the optic nerve, where it forms the posterior sclerotic ring. Around the cornea, there is the anterior sclerotic ring, composed of small bony imbricated scales, capable of moving on each other, and modifying the shape of the globe of the eye.

Cornea.—In the *Dog* and *Cat*, the structure of the cornea is similar to that of the Horse. (Kölliker states that he observed lymphatics in the cornea of a young Cat.) In the *Ox*, *Sheep*, and *Pig*, there are two limitary membranes; one beneath the epithelium of the anterior face. In *Birds*, this limitary membrane is thickest in front.

Choroid.—In mammifers, there are some slight differences in the coloration of the tapetum. Thus, in the *Ox*, it is golden green, which becomes blue at the circumference; in the *Sheep*, it is a pale golden green; a golden yellow in the *Cat*; and white, bordered with blue, in the *Dog*. (It is absent in the *Pig*.) In *Birds*, it is uniformly black; this membrane has also a network of non-striped muscular fibres, and, in addition, "*Crampton's muscle*, which arises from the inner face of the osseous ring, and is inserted into the cornea."—*Leydig*. (According to Hassenstein, in rapacious animals there is, behind the tapetum, a layer of corpuscles composed of lime salts; to this is owing the brilliancy of their eyes in the dark.)

Iris.—In all animals the iris is muscular. In mammifers, the contractile fibres are non-striped; in *Birds*, they are striped. (In the *Ox*, its anterior face has a brighter colour than in the Horse. In the *Sheep* it is a brownish-yellow; in the *Goat* blue.) In the Dog its colour is a more or less bright golden-yellow; in the adult *Cat* green; and in young animals a bright blue. The pupil is elliptical in the *Ox*, as in Solipeds (in the *Sheep* and *Goat* it is more elongated); in the *Dog* it is circular, and, when very much dilated, it is the same in the *Cat*; but, when contracted, it becomes elliptical vertically, and may be so narrow as to represent nothing more than a thin perpendicular slit. (In the *Pig* it is round.)

There are no differences worthy of note in the other parts of the eye.

Accessory Organs of the Visual Apparatus.—The motor organs are nearly the same in all the other animals.

(The posterior rectus, or retractor muscle, is most developed in Ruminants, which, during their whole time of feeding, have the head in a dependent position. In most of the Carnivora, instead of this muscle forming a complete hollow cone, as in Ruminants, there are four distinct strips, almost resembling a second set of recti muscles, but deep-seated, and inserted into the posterior, instead of the anterior, portion of the globe.)

Muscles.—*Birds* have only six muscles: four recti, and two oblique. The latter arise from the anterior wall of the orbit; consequently, the great oblique does not pass through a pulley.

Eyelids.—The disposition of these is the same in all mammifers. In *Birds*, the lower lid is the largest, and is furnished with a particular depressor muscle; there are no Meibomian glands. There is a third eyelid, corresponding to the membrana nictitans of quadrupeds; it is sufficiently extensive to cover the entire front of the eye.

Glands.—In *Ruminants*, the *Pig*, and in *Birds*, there is found, annexed to the membrana nictitans, *Harder's gland*—a conglomerate gland, with adipose epithelium in mammifers, and cylindrical and granular in Birds. It secretes a thick white matter, which is thrown out on the membrana by one or two orifices. Its use is, doubtless, to favour the movements of that organ over the surface of the eye, as well as those of the eyelids. (In the *Ox*, this gland and its ducts are large. The lachrymal gland is also voluminous and its nasal opening is situated higher in the nostril than with the Horse. In the *Sheep*, there are found, near the lachrymal fossa, several adipose follicles which do not properly belong to this apparatus, and which secrete a consistent, unctuous, yellow matter. In the *Pig*, the lachrymal ducts are separated, by a bony partition, into two sets, as far as the lachrymal sac.)

(*Orbital cavity.*—In *Ruminants*, the frontal and superior extremity of the maxillary bones contribute largely to the formation of this cavity. In the *Pig*, the upper part of the orbit is not completed by the orbital process of the frontal bone, which is short; it is continued by a ligament. In the *Dog*, the superior portion of the cavity is entirely formed by a ligament, which replaces the orbital arch; in the *Cat*, this ligament is smaller, and the orbital process of the zygomatic concurs with that of the frontal bone to form the upper wall.)

COMPARISON OF THE VISUAL APPARATUS OF MAN WITH THAT OF ANIMALS.

Essential Organ of Vision.—The *eyeball* of Man is almost spherical, as in the Carnivora. The *sclerotic* does not differ much. The *cornea* has two limitary membranes, and is much less elliptical than in Solipeds. The choroid has the same zones as in animals; it is uniformly brown. The ciliary processes, seventy to eighty in number, are a little longer than in the Horse, and do not exceed, in front, the ciliary ligament, to the inner face of which they adhere throughout their external border. The pupillary opening of the iris is always round. The *retina* is the same in structure as already described. A little above the optic papilla, there is a circular or oval patch, about $\frac{1}{24}$ of an inch in diameter, in the centre of which is a transparent spot; this is the *yellow spot* (*macula lutea*), with the *fossa centralis of the retina* (*fovea centralis, foramen of Soemmering*).

At this patch, the tissue of the retina is slightly modified, especially at the fossa; there are only cones in the columnar layer, and all the other layers appear to be confounded into one granular mass. (This spot only exists in animals which have the axes of the eyeballs parallel with each other, as in Man, the Quadrumana, and some saurian reptiles.)

There is nothing particular in the aqueous humour, lens, or vitreous humour.

Accessory Organs of the Visual Apparatus.—The *orbital cavity* of Man is entirely inclosed by bony walls, and there is no fibrous sheath. (A fold of the orbital fascia has been described as separating the eye from its surrounding adipose tissue, and which, like a "tunica vaginalis," enables the globe to roll with rapidity and precision.) The muscles are six in number—four recti, and two oblique; the great oblique is the same as in animals. Only the rudiment of a *caruncula lachrymalis* is present. The *nasal duct* opens at some distance up on the surface of the inferior meatus.

CHAPTER V.

AUDITORY APPARATUS.

THE sense of hearing, destined for the perception of sounds produced by the vibration of bodies, has for essential agents the auditory or eighth pair of encephalic nerves, whose terminal fibrillæ ramify in the membranous walls of a system of cavities forming the *internal ear;* these cavities are excavated in the substance of the petrous bone, and communicate, externally, by means of two other systems of diverticuli, which constitute the *middle* and *external ear.*

ARTICLE I.—INTERNAL EAR, OR LABYRINTH.

(*Preparation.*—The dissection of this part, from its minuteness and complexity, as well as the density of the bone surrounding it, cannot be made with advantage by the student. He is, therefore, recommended to study it in special preparations, and in the following description.)

The cavities which, together, compose this part of the auditory apparatus, being entirely channeled within the petrous portion of the temporal bone, have their walls, forming the *osseous labyrinth,* constituted by that bone. They contain the soft parts, named the *membranous labyrinth,* and fluids (*endolymph*).

THE OSSEOUS LABYRINTH.

This is composed of three portions: the *vestibule, semicircular canals,* and

1. *The Vestibule.*

This is a small, somewhat oval cavity, in the centre of the bone, and outside the perforated bony plate that forms the bottom of the internal auditory hiatus. It is a real vestibule, with regard to the other parts of the labyrinth, which all open into it.

On its *external wall* is the *fenestra ovalis* (*fenestra vestibuli*), an opening closed by the stapes. The *inner* shows the foramina through which the filaments of the vestibular branch of the acoustic nerve pass. *Below,* and *in front,* is a large orifice, the commencement of the scala cochleæ; *above,* are five little apertures, the openings of the semicircular canals.

2. *The Semicircular Canals.*

Three in number, and very narrow, these canals owe their name to their form. They are placed above the vestibule, like three semicircular arches united in a triangular manner at their base, and are distinguished as *superior* or *anterior, posterior,* and *external.* The first two open together, by their adjacent extremities, into the vestibule; consequently, there are only five orifices of the semicircular canals in this cavity; in addition, the adjoining openings of the posterior and external canals are so close to each other, that they appear to be sometimes united at the bottom of a short common canal.

3. *The Cochlea.*

Situated external to, and below the vestibule, at the inner wall of the cavity of the tympanum, the *snail-shell* or *cochlea* is well named, as it presents exactly the form of certain molluscs' shells. It is a spiral conical canal,

twisting downwards, forwards, and upwards, around a central conical axis (the *modiolus*); so that its centre nearly corresponds to the inner wall of the tympanum. A partition—the *lamina spiralis*, spiral like the cavity—divides it into two distinct sections or *scalæ*: a *superior* and *inferior*; this lamina is attached by its inner border to the central axis of the cochlea, but is free at its external margin, which does not quite reach the periphery of the cavity. The two scalæ, therefore, communicate, in the skeleton, by means of an opening (the *helico-trema*) that follows the free border of the lamina spiralis throughout its extent.

Fig. 392.

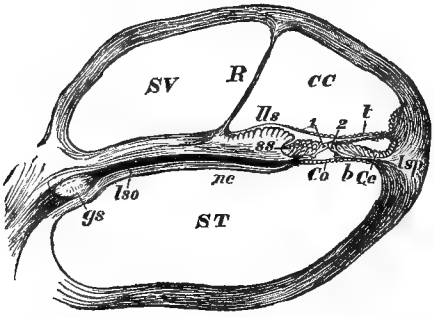

SECTION THROUGH ONE OF THE COILS OF THE COCHLEA.

ST, Scala tympani; SV, Scala vestibuli; CC, Canalis cochleæ; membrana of Reissner.—*lls* to *lsp*, Lamina spiralis membranacea; *lls*, Limbus laminæ spiralis; *ss*, Sulcus spiralis; *gs*, Ganglion spirale situated on *nc*, the nervous cochlearis indicated by the black line; *lso*, Lamina spiralis ossea; *l*, Membrana tectoria; *b*, Membrana basilaris; *co*, Organ of Corti; *lsp*, Ligamentum spirale; *cc*, Cells of Claudius.—1, Rod of Corti of the first order; 2, Rod of Corti of the second order.

The *inferior scale* (or *scala vestibuli*) enters the vestibule; the commencement of the *superior scale*, or *scala tympani*, is formed by the fenestra rotunda (*fenestra cochleæ*), which brings it into communication with the middle ear, without the presence of a membrane exactly closing that aperture.

THE MEMBRANOUS LABYRINTH.

The membranous labyrinth comprises three parts, corresponding to the three cavities of the osseous labyrinth: 1, The *vestibule*; 2, The *semicircular canals*; 3, The *cochlea*.

1. *The Membranous Vestibule.*

This is composed of two sacs with thin, soft walls, lodged in the osseous labyrinth; the *superior* is the largest, is oval-shaped,

Fig. 393.

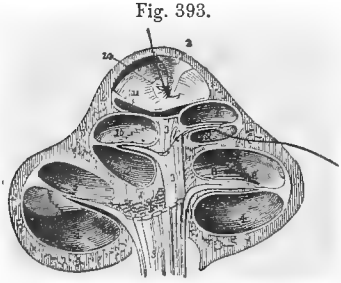

SECTION OF THE COCHLEA PARALLEL TO ITS AXIS, THROUGH THE CENTRE OF THE MODIOLUS.

1, Modiolus; 2, Infundibulum in which the modiolus terminates; 3, 3, Cochlear nerve, sending its filaments through the centre of the modiolus; 4, 4, Scala tympani of the first turn of the cochlea; 5, 5, Scala vestibuli of the first turn; the septum between 4 and 5 is the lamina spiralis; a filament of the cochlear nerve is seen passing between the layers of the lamina to be distributed in the membrane investing the lamina; 8, Loops formed by the filaments of the cochlear nerve on the lamina spiralis; 9, 9, Scala tympani of the second turn of the cochlea; 10, 10, Scala vestibuli of the second turn; the septum is the lamina spiralis; 11, The remaining half turn of the scala vestibuli; the dome above is the cupola, the line passing through it leads to the remaining half turn of the scala tympani. The osseous lamina forming the floor of the scala vestibuli curves spirally round to constitute the infundibulum (2); 14, The helicotrema through which a bristle is passed; its lower extremity issues from the scala tympani of the middle turn of the cochlea.

and is named the *utriculus;* it communicates with the semicircular canals, of which it is a confluent. The *inferior* is smaller, spherical in shape, and forms the *sacculus;* it appears to be perfectly closed, though in contact with the utriculus.

The membranous vestibule is composed of two distinct layers: an external, *cellular*, and an internal, *epithelial*, resting on an amorphous membrane. At the expansion of the nervous filaments, the latter is absent, and is replaced by a white calcareous substance (minute crystalline particles of carbonate and phosphate of lime) which, in the domesticated animals, appears as a powder, and is named the *calcareous powder of the vestibule, ear dust*, or *otoconites* (*otoliths*).

(Some authorities give four layers: an external or *serous*, derived from the lining membrane of the labyrinth; a *vascular*, with multitudes of vessels; a *nervous*, formed by the expansion of the filaments of the vestibular nerve; and an internal *serous* membrane, which secretes the limpid fluid contained in its interior. Spots of pigment are constantly found in the tissue of the membranous labyrinth.)

2. *The Membranous Semicircular Canals.*

These are three thin tubes, which correspond exactly with, though they are of smaller diameter than, the osseous semicircular canals; they open into the utriculus in the same manner as the latter do into the bony vestibule. Each has one of its two extremities dilated into a sac or ampulla (*sinus-ampullaceus*); for the two superior and external canals it is the anterior extremity, and for the posterior canal the outer extremity.

In structure they resemble the vestibular sacs.

3. *The Membranous Cochlea.*

The membranous cochlea is represented by two membranes, which complete the lamina spiralis; they continue the osseous laminæ of the latter, and are inserted into the external wall of the cochlea.

They give rise to three cavities, or scales, in the interior of this portion of the ear: an inferior, or *tympanic scala;* a superior, or *vestibular scala;* and a middle or *auditive scala*, in which the *organ of Corti* is lodged. The vestibular scale is itself divided by the *membrane of Reissner* into two canals —the *proper vestibular scala*, and *Lowenberg's*, or the *collateral scala;* so that, in reality, there are four cochlean scales.

We do not, therefore, find in the cochlea, as in the other regions of the labyrinth, a system of membranous cavities included in osseous cavities.

The structure of the membranes that limit the auditive scala is not perfectly known, and is still disputed by anatomists; but connective, epithelial, and nervous elements appear to form their base.

With regard to the *organ of Corti*, it is a very curious and interesting portion of the auditory scala, being formed by a series of solid and elastic arches resting by their extremities on the membrane—*the basilar*—that separates the auditory from the tympanic scala, their convexity being towards the superior, or *membrane of Corti*. These arches number about three thousand in Man, and are composed of two portions or articles: an external and an internal, united by a thickening in the vicinity of the membrane of Corti. To these elastic arches are added conical or fusiform cells, whose nature is not yet determined.

FLUIDS OF THE LABYRINTH.

These liquids are of two kinds: one is contained in the membranous labyrinth, the other in the osseous labyrinth.

The *fluid of the membranous labyrinth*, or *endo-lymph* of Breschet, is contained in the sacs and tubes constituting the membranous vestibule and semicircular canals. It is limpid and fluid like water. The *fluid of the osseous labyrinth*, or *peri-lymph* of Breschet, fills the two scalæ of the cochlea, and bathes the external surface of the vestibule and membranous semicircular canals, which it separates from the corresponding walls of the osseous labyrinth.

DISTRIBUTION AND TERMINATION OF THE AUDITORY NERVE IN THE MEMBRANOUS LABYRINTH.

This nerve (the portio mollis of the seventh pair) divides, as we have said, into two branches: a *cochlear* and a *vestibular*.

The cochlear branch, the largest, reaches the base of the cochlea, where it breaks up into a large number of fasciculi, one portion of which expands over the first turn of the lamina spiralis, the other on the second, and a third on the third; the latter ramifications penetrate to the *auditory scala*, and terminate above or below on the organ of Corti.

The vestibular branch divides into three portions, whose terminal filaments ramify in the wall of the sacculus, utriculus, and the ampullæ at the extremities of the three semicircular canals.

The precise manner in which these filaments of the auditory nerve terminate is doubtful. (Breschet says they communicate and form a series of minute arches. Some of the filaments of the other nerves pass into the sac, and come into contact with the otoconies or ear-dust in its interior.)

(The membrane of the labyrinth is supplied with blood-vessels by a branch of the basilar artery, which passes with the auditory nerve to the bottom of the meatus, and divides into twigs corresponding with the nerve divisions; its ultimate ramifications terminating, in the form of a fine network, on the membranous labyrinth and the spiral lamina of the cochlea. The blood is returned by the auditory vein, which enters the superior petrosal sinus.)

ARTICLE II.—MIDDLE EAR OR TYMPANUM.

Excavated in the substance of the tuberous portion of the temporal bone, on the limit of the petrous and mastoid sections, but chiefly in the latter, the middle ear constitutes an irregular cavity, which we may consider as composed of two *walls* and a *circumference*.

The *external wall* is principally constituted by the *membrane of the tympanum*. The *internal wall*, formed by the petrous bone, offers two openings—the *fenestra ovalis* and *fenestra rotunda*, the one situated behind the other, and separated by a small eminence named the *promontory*. The *circumference* is occupied for nearly the whole of its extent by the *mastoid cells*, large open cavities in the tympanum.

Internally, the tympanum contains a *chain of small bones* named the *malleus, incus, os orbiculare*, and *stapes;* these bones form the medium of communication between the tympanum and the fenestra ovalis—from one wall to the other of the cavity of the tympanum.

This cavity is lined by a fine *mucous membrane*, which is continuous with

that lining the pharynx by means of a cartilaginous canal—the *Eustachian tube*, which conveys the external air to the middle ear.

We will glance briefly at the anatomical characters of the parts enumerated, and which enter into the formation of the middle ear.

1. *Membrana Tympani.*

Situated on the external wall of the middle ear, which it separates from the bottom of the auditory canal, this membrane is oval in shape. It is thin, dry, and capable of vibrating. Its *inner face*, inclining inwards and slightly convex, is adherent to the handle of the malleus. Its *external face* is slightly concave (towards the meatus). The circumference is fixed in a bony frame named the *tympanal circle*, which is sharply defined, but

Fig. 394.

RIGHT TYMPANIC CAVITY OF THE HORSE'S EAR; ANTERIOR PLANE, VERTICAL AND TRANSVERSE SECTION.

A, Auditory canal; B, Membrana tympani; C, Malleus; D, Incus; E, Os orbiculare; F, Stapes; G, Mastoid cells; H, Fenestra ovalis; I, Vestibule; J, K, L, Outline of the semicircular canals; M, Cochlea; N, Commencement of the tympanic scala.

incomplete at its upper part, and enveloped by the mastoid cells, whose cavities radiate around this circle.

Although very thin, this membrane is composed of three layers: a

middle, of a fibrous (and muscular) character (fibres radiating towards the centre, and also circular); an external, epidermic; and an internal, the mucous membrane of the middle ear. It has vessels and nerves in the external and internal layers. (This membrane receives those vibrations of the air which set in movement the chain of bones in the ear, and thus propagates them to the fenestra ovalis and labyrinth.)

2. *The Promontory, Fenestra Ovalis, and Fenestra Rotunda.*

Placed in the upper part of the tympanic wall, the *promontory* is only a very small eminence separating the fenestra rotunda from the fenestra ovalis. (It is marked by grooves in which lie the branches of the tympanic nerves.)

The *fenestra ovalis (fenestra vestibuli)*, situated in front of the promontory, is an opening whose form is sufficiently indicated by its name. It is the opening of communication between the tympanum and osseous vestibule, and is closed by the base of the stapes and the lining membrane of both cavities.

The *fenestra rotunda (fenestra cochleæ)* is separated from the preceding by the promontory, and, placed behind this small projection, it is closed in the fresh state by a thin membrane (*m. tympani secundaria*), that forms a kind of diaphragm between the middle ear and the tympanic scala of the cochlea. (The *aqueduct of Fallopius* is a canal commencing at the internal ear, passing above the fenestræa and promontory, and terminating at the mastoid foramen. It contains the facial nerve, which passes through the tympanic cavity.)

3. *The Mastoid Cells.*

These cells occupy all the circumference of the tympanic cavity, except above. They are small, more or less irregular, and deep spaces, separated by thin partitions radiating around the tympanic circle, and whose free margin is turned towards the centre of the cavity.

In several animals, and particularly the Carnivora, the mastoid cells form a special compartment in the tympanic case, communicating with the latter by a single opening. (In the *Sheep* and *Goat*, the mastoid cells and their bony septa are entirely absent.)

4. *The Bones of the Middle Ear.* (Fig. 395.)

Four articulating bones (*ossicula auditûs*) named the *malleus*, *incus*, *os orbiculare*, and *stapes*, compose the bony chain of the middle ear; this chain extends in a broken course from the external to the internal wall of the tympanum. The pieces are movable on each other, and are united by *ligaments* and moved by *muscles*.

1. Malleus (*hammer*).—This is the longest of the bones, and offers a *handle* and a *head*. The *handle* (*manubrium*) is placed almost vertical, and firmly fixed to the inner face of the membrana tympani. The *head*, directed upwards, has a diarthrodial facet for articulation with the incus. The *neck*, or upper part of the handle, shows two small processes for insertion (*processes gracilis* and *brevis*), the innermost of which is very developed.

2. Incus (*anvil*).—This bone presents a *body* or middle portion, and two *branches*. The *body* is channeled externally by a diarthrodial facet corresponding to that on the malleus. Of the two *branches*, the *superior* terminates in a blunt point; while the other, *inferior*, is united at its extremity to the os orbiculare.

3. Os Orbiculare.—This is a little, circular, discoid bone, included between the inferior branch of the incus and stapes.

4. Stapes (*stirrup*).—Remarkable for its shape, which is exactly that of a stirrup, this bone is placed almost horizontally. Its *summit* (or *head*) articulates with the os orbiculare; its *middle part* is divided into two *branches*, having between them an aperture that is closed by the tympanic mucous membrane. Its base is received into the fenestra ovalis, and resembles that cavity in shape; it is maintained in its position by the mucous

Fig. 395.

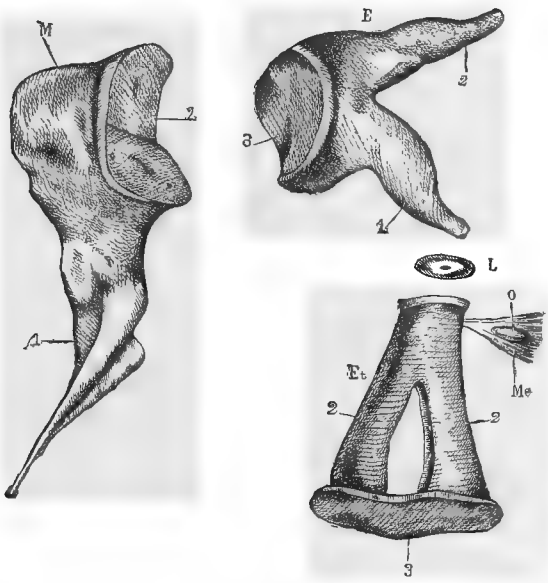

Bones of the middle ear of the horse.—*From an unpublished Drawing by Lavocat.*
M, Malleus; 1, Handle; 2, Head.—E, Incus; 1, Inferior branch; 2, Superior branch; 3, Body.—L, Os orbiculare; Et, Stapes; 1, Summit; 2, 2, Branches; 3, Base.—Me, Muscle of the stapes; O, Bony nucleus in the terminal tendon.

lining of the tympanum, which passes over the stapes, after being reflected around the margin of the fenestra ovalis.

(These bones transmit the vibrations of the membrana tympani to the fluid in the labyrinth.)

5. Ligaments of the Auditory Bones.—We need only mention the existence of these here, as they are too small and unimportant to merit a particular description.

6. Muscles of the Auditory Bones.—Four muscles have been described: three destined to move the malleus, and one for the stapes. But two of these being extremely small, and their muscular character doubtful to many anatomists, we will only notice the *internal muscle of the malleus* and that of the *stapes*.

a. The internal muscle of the malleus (*tensor tympani, musculus internus mallei*).—This is a little elongated fasciculus, lodged in a particular groove in the mastoid portion of the temporal bone, and arises near the superior

extremity of the Eustachian tube; it passes downwards and backwards, and terminates by a tendon which is reflected outwards, in front of the fenestra ovalis, to be inserted into the neck of the malleus.

b. Muscle of the stapes (stapedius).—Lodged in an excavation in the inner wall of the tympanum, near the fenestra vestibuli, on the course of the aquæductus Fallopii, this muscle is remarkable for its brevity, its relatively considerable thickness, and its conical shape. It terminates by a small tendon in front of the head of the stapes. In the Horse, Ox, and Sheep, a small bony nucleus is found in the tendon (Fig. 395, o).

(The tensor tympani retracts the bones of the ear inwards. In contracting it draws the handle of the malleus towards the cavity of the tympanum, and this brings the membrane with it; consequently, the convexity of the latter is increased and its tension is augmented. In addition, while the handle of the malleus is carried inwards, its head is turned outwards by a pivoting motion, and this pulls the body of the incus also, the long process of which is raised and inclined inwards, pushing the os orbiculare and stapes towards the fenestra ovalis. The base of the latter bone being in contact with the fluid in the vestibule, this is stirred; so that this muscle likewise acts indirectly in producing the undulations in this fluid. The muscles of the tympanum are classed as *tensors* and *laxators*. It is well to know that *all* are tensors and none of them act as relaxors; relaxation of the membrane occurring when the muscles are not in action.)

5. *The Mucous Membrane of the Tympanum.*

Very fine and vascular, this membrane covers all the angularities of the middle ear, is reflected on the chain of bones, and continued into the mastoid cells. It is continuous with that lining the Eustachian tube, and thenceforward should be considered as a prolongation of the tegumentary membrane spread over the walls of the pharyngeal vestibule. It is covered by a simple pavement epithelium.

6. *Eustachian Tube.*

The *Eustachian tube* is a fibro-cartilaginous canal that communicates between the cavity of the middle ear and the pharynx.

Extending in a straight line beneath the base of the cranium, from the tympanic case to the upper and lateral part of the pharyngeal cavity, this canal is also named the *guttural duct* of the tympanum; it is nearly four inches long in Solipeds, "is flattened on both sides, and bordered by the stylo-pharyngeus muscle. Its *upper* or *tympanic orifice* is narrow; the *inferior, guttural,* or *pharyngeal orifice*, situated near and behind the guttural openings of the nasal cavities, is wide, and represents a great slit extending obliquely downwards and outwards; the contiguous borders of this aperture are sustained by a cartilaginous plate—a kind of pavilion formed by the expansion of the tissue constituting the base of the tube.

"In its length, the guttural duct is cleft inferiorly, and by this long aperture the mucous membrane escapes and descends to form the large sac peculiar to monodactyles, known as the *guttural pouch.*

7. *Guttural Pouches.*

"The mucous membrane lining the Eustachian tube is continuous, forward, with that of the pharynx; above and behind, it is prolonged into the tympanic cavity, which it lines. Below, it is dilated and forms the *guttural pouch.*

"Two in number, one being on each side, the guttural pouches lie against each other in the median plane, and descend to the larynx, where they terminate in a *cul-de-sac* constituting their *fundus*. Before and behind, they extend from the anterior part of the pharynx to the inferior face of the atlas. The capacity of each is about $\frac{3}{4}$ths of a pint; but in consequence of the extensibility of the mucous membrane, the extent and capacity of the guttural pouches are particularly variable.

"Irregular in shape, like the space which it occupies, the guttural pouch corresponds, behind and above, to the base of the occipital and sphenoid bones. When this reservoir is distended, its lower part, or *fundus*, descends on the lateral portions of the pharynx and larynx, to the lower extremity of the parotid gland, in the loose cellular tissue of that region.

"Externally, the guttural pouch contracts numerous different relations in the *intermaxillary* and *parotideal regions*, and in its *posterior* portion.

"*a.* In the *intermaxillary* region, it is in relation with the tensor palati, pterygoideus and hyo-pharyngeus muscles, as well as with the internal maxillary artery and lingual nerve; it envelops the large branch of the hyoid bone, and covers the inner face of the internal pterygoideus muscle.

"*b.* In the *parotideal region*, the guttural pouch responds, above, to the inner face of the parotid gland, from which it is separated by the auricular vessels and nerves; a little lower, at the posterior angle of the hyoid bone, to the stylo-hyoideus muscle and the styloid process of the occipital bone; here the auricular artery passes obliquely upwards and backwards, and the membrane of the pouch is more closely united to the parts covering it.

"Below this, the guttural pouch is in relation with the stylo-maxillaris muscle, external carotid, and the nerves forming the guttural plexus, such as the ninth and twelfth pairs, the great sympathetic, etc. Lower, it is related to the parotid gland, to the inferior extremity of which it may be prolonged.

"*c. Posteriorly.*—The guttural pouch is in relation with the atlas, flexor muscles of the head, occipital artery, etc.; it forms a fold that envelops principally the pneumogastric and sympathetic nerves, and, anteriorly, another fold that incloses the internal carotid.

"The *mucous membrane* of the guttural pouches is thicker and stronger than that lining the Eustachian tube and the cavity of the tympanum. Only slightly adherent to the adjacent parts, except at the branch of the hyoid, the inner face of the stylo-hyoideus, etc., it is smooth internally, and lubrified by the mucus it secretes. It may become the seat of purulent collections, which compress the larynx and obstruct the respiration, and it is in such cases that the pouch is punctured. This membrane receives numerous fine *vascular* and *nervous* ramifications from the neighbouring branches.

"The guttural pouches communicate with the pharynx and cavity of the tympanum, and usually contain air; the quantity of this may vary in health, according to the degree of dilatation of these membranous sacs. Their dilatation is chiefly produced by the palato-pharyngeus muscle, several fibres from which extend to their mucous membrane; and, besides, when the ear is erected this membrane is thrown into a state of tension, through the adhesion of the lower prolongation of the concha to its surface.

"The functions of the guttural pouches are far from being known. It cannot be affirmed that they increase phonation; indeed, their use appears to be rather related to audition, if it be considered that these annexes of the guttural duct of the tympanum coincide, in Solipeds, with a less development of the mastoid cells than in the other animals.

"With regard to the Eustachian tube, it serves to renew the air in the tympanic cavity, this renewal being indispensable to the perfect accomplishment of hearing."—*Lavocat.*

(It is essential that the equilibrium between the external air and that in the cavity of the tympanum should be maintained, in order to avert irregular tension, and even rupture of the membrana tympani. Perosino states that the guttural pouches are filled with warm air during expiration, and that this is partly changed for cold air in inspiration.)

Article III.—The External Ear.

The external ear comprises the *external auditory canal*, and a widened appendage opening outwardly, designated the *concha* or *pavilion.*

THE EXTERNAL AUDITORY CANAL.

This canal (*meatus auditorius externus*), described in the osteology (as situated in the petrous bone), has at the bottom the membrana tympani, which separates it from the middle ear. Its entrance, the *external auditory hiatus*, gives attachment to the infundibulum of the conchal apparatus. It is lined by a thin integumentary membrane intermediate in character between the skin and mucous membrane, and has in its substance a large number of glands and convoluted tubes, analogous to the sudoriparous glands, but here named *ceruminous glands*, as they secrete an unctuous matter, the *cerumen.*

THE CONCHA OR PAVILION.

The external trumpet-shaped appendage named the concha (*concha auris*) varies much in shape in the different animals, though in all it offers the same details in organisation: a *cartilaginous framework* composed of three pieces, *muscles* to move these, an *adipose cushion* to insure liberty of movement, and *integuments* covering the whole.

1. *Cartilages of the Concha.*

The three pieces composing the concha are: 1, The *conchal cartilage;* 2, *Annular cartilage;* 3, *Scutiform cartilage.*

1. Conchal Cartilage.—The principal portion of the pavilion, this cartilage determines its general configuration. In shape, it resembles a trumpet with a wide opening on one side. Its entrance is elliptical, and elongated vertically, being circumscribed by two thin borders which unite above at a point that constitutes the summit (apex) of the organ. Its *base*, bulging in a *cul-de-sac*, terminates in front by a constricted infundibulum; it is attached to the margin of the auditory hiatus by means of the annular cartilage, and to the surface of the guttural pouch by a pointed prolongation that descends outside this annular cartilage, beneath the parotid gland, and terminates by several fibrous filaments. This portion of the framework of the concha is a cartilaginous plate, rolled on itself in such a manner as to circumscribe, between its borders, the entrance to the ear, and to form, inferiorly, the complete infundibuliform canal just mentioned. In Solipeds, this plate is rigid and erect, and much more developed in the Ass and Mule than in the Horse. (Externally, the integument of the ear is covered by ordinary hair, but internally there are long fine hairs, especially near the entrance; these prevent the intrusion of foreign substances.)

2. Annular Cartilage.—By this name is known a little ring-shaped

plate, placed at the lower part of the conchal plate, intermediate between it and the auditory canal. The internal integumentary membrane, with some yellow elastic fasciculi, unite this cartilage to the other two portions between which it is situated. Its relations with these are such, that it receives within its lower border the bony circular prominence forming the margin of the auditory hiatus, while it may itself be received into the infundibuliform canal of the conchal cartilage—an arrangement resembling the tubes of a telescope.

3. Scutiform Cartilage.—This is a small cartilaginous plate, situated in front of the base of the concha, at the surface of the temporal muscle; it is irregularly triangular, is attached to the conchal cartilage by some muscular fasciculi, and transmits to that cartilage the action of some other muscles which are fixed on the cranial bones.

(The arteries of the concha proceed from branches of the external carotid, and the veins pass to a trunk of the same name; the nerves are divisions of the facial and the first cervical pair.)

2. *Muscles of the External Ear.*

There are found, on the surface of the concha, within and without, some fleshy fibres, which are veritable *intrinsic muscles.* But the slight importance of these induces us to pass them over, in order to study exclusively the *extrinsic muscles*, which move the conchal apparatus. These are ten in number: in the first layer are the *zygomatico-auricularis, temporo-auricularis externus, scuto-auricularis externus*, three *cervico-auriculares*, and the *parotido-auricularis;* in the second layer, the *temporo-auricularis internus, scuto-auricularis internus*, and the *mastoido-auricularis.*

1. Zygomatico-auricularis (*attolens anterior — Percivall; temporo-auricularis—Leyh.* Figs. 110, 5; 396).—This muscle is generally composed of two fleshy bands joined by cellular tissue, and rising from the zygomatic process of the temporal bone by means of an aponeurosis common to it and the orbicularis palpebræ. The inferior of these two bands is inserted to the outside of the base of the concha, its fibres mixing with those of the parotido-auricularis; the superior band terminates on the outer border of the scutiform cartilage.

Placed immediately beneath the skin, this muscle partly covers the superior extremity of the parotid gland, and the zygomatic process.

It draws the ear forward.

2. Temporo-auricularis Externus (*attolens maximus—Percivall.* Figs. 110, 1; 396).—A very thin, wide muscle, covered by the skin, lying on the temporal muscle, united posteriorly to the superior cervico-auricularis, in front and outwardly to the zygomatico-auricularis. It arises from the whole of the parietal crest or ridge,[1] mixing in its upper half or third with the muscle of the opposite side; it terminates, by one portion, on the inner margin of the scutiform cartilage, and by another, on the inner side of the conchal cartilage, by means of a thin fascia that covers part of the former cartilage and the external scuto-auricularis.

It acts as an adductor of the concha, drawing it inwards; it also carries it forwards, and concurs in making it pivot on itself, so as to bring the opening of the ear forward. (In the *Ox*, the common muscles of the ear do

[1] Owing to this crest bordering the temporal fossa, Girard has thought proper to give to the two muscles of the ear attached thereto, the name of temporo-auriculares; but it would be more appropriate to designate them the *parieto-auriculares.*

not join on the median line, but are placed at the sides of the head, below the horns.).

3. Scuto-auricularis Externus (*anterior conchæ—Percivall.* Fig. 396). —This muscle may be said to be a dependency of the preceding, whose action it transmits to the conchal cartilage, and renders it more complete.

Extending from the external face of the scutiform cartilage to the inner side of the concha, and generally composed of two fasciculi, it is covered by the skin and the conchal band of the external temporo-auricularis, while it covers part of the internal scuto-auricular muscle.

Fig. 396.

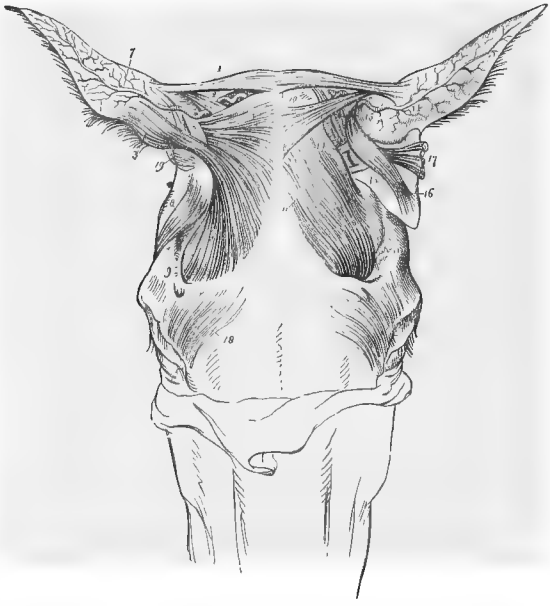

MUSCLES OF THE EAR.

1, Cervico-auricularis superficialis; 2, Temporo-auricularis internus; 3, 4, Temporo-auricularis externus; 5, Scutiform cartilage; 6, Scuto-auricularis externus; 7, Posterior auricular artery; 8, Portion of the zygomatico-auricularis; 9, Orbital process; 10, Temporo-auricularis internus; 11, Temporal muscle; 12, Scutiform cartilage; 13, Ditto; 14, Concha of the ear; 15, Scuto-auricularis externus; 16, Internal scuto-auricularis; 17, Parotido-auricularis; 18, Corrugator supercilii; 19, Zygomatico-auricularis.

When this muscle contracts, it principally participates in producing the rotatory movement that carries the opening of the concha outwards.

4. Cervico-auriculares.—(Percivall apparently makes one muscle of these three—the *retrahentes aurem;* Leyh designates them as the *cervico-auriculares externus, medius,* and *internus.* (Fig. 396). Three in number, and situated behind the ear, these muscles are broad, thin bands, extending from the cervical ligament to the conchal cartilage. With regard to their superposition at their origin, they may be distinguished as *superficial, middle,*

and *deep;* the situation of their point of insertion in the concha also permits their being classed as *superior*, *middle*, and *inferior*.

The *superior*, or *superficial cervico-auricularis*, closely united to the external temporo-auricularis, and covered by the skin, covers the middle cervico-auricular, and internal temporo-auricular muscles. Attached by its terminal extremity to the middle of the posterior face of the concha, it draws that cartilage backwards and downwards.

The *middle cervico-auricularis*, comprised at its origin between the other two, and intimately attached to them, especially the deep one, is in relation with the skin for the greater part of its superficies. Its terminal extremity is very wide and thin, and passes over the upper end of the parotid gland, to be inserted outwardly into the base of the concha, after being slightly insinuated beneath the parotido-auricular muscle. This is a rotator muscle, turning the opening of the ear outwards and backwards.

The *inferior*, or *deep cervico-auricularis*, concealed beneath the upper extremity of the parotid, to which it adheres closely, is inserted at the base of the concha. Its action is similar to that of the middle muscle.

5. Parotido-auricularis (*abducens*, or *deprimens aurem — Percivall.* Fig. 110, 7).—Lying on the external face of the parotid gland, this is a long, thin, ribbon-like band, narrower and thicker at its upper than its under extremity. It arises on the tissue of the gland, and terminates outside the base of the concha, below the inferior commissure formed by the two borders of that cartilage.

Covered externally by a very thin portion of the cervico-facial cutaneous muscle, the parotido-auricularis is an abductor of the ear, inclining it outwards.

6. Temporo-auricularis Internus (*attolens posterior—Percivall.* Fig. 110, 3).—Situated beneath the superficial muscle of this name, and partly covered by the superior cervico-auricularis, this muscle is long and triangular in shape, bright-red in colour, and extending transversely on the surface of the temporalis; it is attached, inwardly, to the sagittal or spur-like ridge of the parietal bones, and outwardly, by means of a small tendon, to the inner side of the concha, within the terminal insertion of the superficial cervico-auricularis. It is an adductor of the ear.

(In the *Ox*, this muscle is not covered by the external temporo-auricularis. In the *Sheep* and *Goat*, it is placed between the parietal bone and that muscle, and, to reach the concha, it passes beneath the scutiform cartilage.)

7. Scuto-auricularis Internus. (*Posterior conchæ—Percivall.* Leyh makes two muscles of it—small and great.)—This is a muscle composed of two short, pale fasciculi, which cross each other very obliquely, are concealed beneath the scutiform cartilage and the scuto-auricularis externus, and lie directly on the adipose cushion of the ear. They arise from the inner face of the scutiform plate, pass backwards, and terminate at the base of the concha, behind the infundibuliform cavity which that cartilage forms at its root. This muscle is antagonistic to the superficial muscle of that name, as it turns the opening of the ear outwards, and even backwards.

8. Mastoido-auricularis.—This name is given to a very thin fasciculus lying vertically on the inner side of the cartilage, at the entrance to the ear. Arising from the margin of the auditory external hiatus, and attached to the base of the concha, this little muscle, in contracting, constricts the cartilaginous tube with which it is in contact.

3. *Adipose Cushion of the External Ear.*

This cushion, which is never absent, even in the most emaciated animals, envelops the base of the concha in front, inwardly, and posteriorly. It facilitates the movements of that organ.

4. *Integuments of the External Ear.*

The skin covering the concha is covered with fine close hairs. That lining its interior is very thin and vascular, adheres closely to the cartilage, and is furnished with long silky hairs, to prevent the entrance of dust into the ear.

DIFFERENTIAL CHARACTERS IN THE AUDITORY APPARATUS OF OTHER THAN SOLIPED ANIMALS.

There are no notable differences in the *internal ear.*

In the *middle ear*, there are some modifications, either in the bones or accessory parts. In *Ruminants*, the auditory bones are like those of the Horse, except that the handle of the *malleus* is more curved, and the body of the *incus* is longer. In the *Dog*, the handle of the *malleus* is covered with small, pointed processes, and the *branches of the stapes* are long and thick. In the *Pig*, the branches of the latter are slight and inflected, and the base is wide and thin: in a word, the stapes of this animal bears no resemblance to a stirrup; the *malleus* is very much inflected forwards. In the last two animals, no osseous nucleus is found in the tendon of the stapedian muscle.

It is needless to say that the fenestra ovalis varies with the base of the stapes. (The absence of the mastoid cells in the *Sheep* and *Goat* has been already noted.)

The *Eustachian tube* exists in all the animals, but the guttural pouches are only found in Solipeds.

In the *external ear*, the *conchal cartilage* varies much in shape. It is thin, inclined outwards, and widely opened in *Ruminants*. In the *Pig*, it differs a little, according to breed, though it is always much developed, sometimes erect, but most frequently drooping. It is always short, pointed, erect, and open in front, in the *Cat*. (In this animal a small duplicature of the external margin of the concha is often seen.) In *Birds*, the external ear is limited to the auditory canal.

(The differences in the muscular arrangement have been noted elsewhere.)

COMPARISON BETWEEN THE AUDITORY APPARATUS IN MAN AND THAT OF ANIMALS.

There is nothing to be said regarding the *internal ear*. The middle ear comprises the same parts as that of mammifers other than Solipeds. The handle of the *malleus* is straighter, the *incus* more voluminous, and the *stapes* thinner, proportionately, than in animals. There is no bony nucleus in the *stapedian muscle*. The *muscle of the malleus* is lodged in a distinct canal belonging to the Eustachian tube.

The *external ear* is composed of only two cartilages: one, forming the base of the concha, represents that cartilage in animals; the other, belonging to the auditory canal, resembles the annular cartilage in the Horse. The *concha* is very irregular in shape, and stands at an angle of from 15° to 45° from the temporal bone; it is convex superiorly, and terminates inferiorly by a small *lobe*. On its anterior face it presents prominences and depressions; the former are four in number: the *helix*, a fold encircling the ear behind and above; the *antihelix*, a concentric prominence, almost parallel with the preceding; the *tragus*, a triangular, pointed process, covered with hair, situated in front of the auditory canal (*meatus*); the *antitragus*, opposite the tragus, behind the canal, and above the lobule. The depressions are: the *concha*, a wide cavity, limited by the antihelix; the *scaphoid fossa* (*fossa innominata*) situated above the latter; and the *fossa triangularis* comprised between the helix and antihelix.

The pavilion of the ear is traversed by several muscular fasciculi, which can have no influence on its movements. The concha has also extrinsic muscles—the *anterior auricularis* (*attrahens aurem*), *auricularis superioris* (*attolens aurem*), and the *auricularis posteriores* (*retrahens aurem*). The action of these on the concha is very slight.

BOOK VIII.

Generative Apparatus.

Individuals in the organic kingdom possess the faculty of reproduction, and thus perpetuate the species to which they belong: a grand and beautiful law of the vital force, which holds under its care the preservation of the organised world. In mammifers, the *generation* of a new being demands the concurrence of two individuals—a *male* and *female*—who have intercourse under certain determinate circumstances. The female furnishes a germ—the *ovum*, and the male a fertilizing fluid—the *semen*, which vivifies the ovum, and renders it capable of development.

We have, therefore, to study separately the *generative*, or *genital organs of the male*, and those of the *female*.

CHAPTER I.

GENITAL ORGANS OF THE MALE.

The semen is elaborated in the structure of the two *testicles:* lobular glands, each of which is provided with an excretory duct, doubled a great number of times on itself at its commencement, to form the *epididymis*, and destitute of sinuosities for the remainder of its extent, which is named the *deferent canal (vas deferens)*. This canal carries the fecundating fluid into the *vesiculæ seminales*, reservoirs with contractile walls, where it accumulates, and whence it is expelled during copulation by passing through the *ejaculatory canals* (or *ducts*), and the *urethral canal*. The latter is a single canal common to the two apparatus of generation and urinary depuration; it is provided in its course with three accessory glands – the *prostate*, and *Cowper's glands*, and is supported by an erectile stalk, the *corpus cavernosum*, with which it forms an elongated organ, the *penis*, which, in the act of copulation, is introduced into the vagina, to the bottom of which it carries the spermatic fluid.

We will successively consider the *secretory organs* or *testicles*, and the *excretory apparatus*, comprising all the other organs.

THE TESTICLES, OR SECRETORY ORGANS OF THE SEMEN.

The *testicles* (*testes*) are two glands suspended on each side of the pines, between the thighs, where each occupies a particular serous pouch, the *vaginal sheath* (*tunica vaginalis*). We will commence by describing this cavity, and afterwards the organ it contains.

1. *Tunica Vaginalis.*

The *tunica vaginalis*, in the domesticated animals, is only a diverticulum of the abdominal cavity, the serous membrane of which—the peritoneum—becomes a hernia in the inguinal canal, passing through the upper (internal) inguinal ring, and prolonged below the inferior (external) ring, so as to form a serous sac, which is enveloped by membranous walls.

We have to study, in the vaginal sheath: 1, Its *interior;* 2, The *enveloping membranes* which form the external walls, and to which we give the common name of *scrotum.*

Interior.—The serous sac constituting the tunica vaginalis, is vertically elongated, and slightly inclined downwards, inwards, and backwards. Its *inferior extremity*, forming the bottom, or *cul-de-sac*, is pear-shaped, and lodges the testicle and its epididymis. Its *middle portion*, contracted into a narrow canal, contains the spermatic cord. The *superior extremity*, or *entrance*, is open, to maintain communication with the abdominal cavity; through it pass the spermatic vessels and vas deferens.

As has been said, the peritoneum forms the vaginal sac. As in the abdomen, it is divisible into two layers—*parietal* and *visceral.* The latter (*tunica vaginalis propria*) covers the testicle and the cord; while the former (*tunica vaginalis communis*, or *reflexa*) lines the innermost of the membranous coverings which serve as a wall to the tunica vaginalis. These two layers are made continuous by a serous frænum, analogous to the mesentery which sustains the floating colon; like it, it is formed by the junction of the two layers. Flat, elongated from above to below, and extending vertically from one end of the sheath to the other, this frænum is attached, by its upper border, behind the spermatic cord; its lower extremity passes over the epididymis, and from it on to the testicle; above, it is continued into the abdominal cavity, in accompanying the different canals composing the cord.

(A small quantity of serous fluid is usually present in the tunica vaginalis. When in excess it gives rise to hydrocele.)

Enveloping Membranes.—The stratified layers that form the external walls of the vaginal sheath, and which are generally described in anatomical treatises, with the two serous layers, as the *envelopes of the testicle,* are four in number. Reckoning them from within to without, they are the *fibrous tunic*, *cremaster muscle*, *dartos*, and *scrotum.*

Fibrous Tunic (*infundibuliform fascia*).—This forms the most complete covering to the tunica vaginalis, extending, as it does, over the whole surface of the parietal serous layer, to which it is closely adherent. Very thin, especially at the points corresponding to the cremaster, this membrane is continuous, around the upper inguinal ring, with the transversalis fascia, of which it is only a dependency; its external face is in relation with the cremaster and dartos.

Cremaster.—This muscle is usually described as an envelope of the testicle, by the name of *tunica erythroïdes.* In the domesticated animals, it is a bright-red band, attached, above, to the inner or peritoneal surface of the ilio-lumbar aponeurosis; it descends into the inguinal canal, envelops outwardly only the middle portion of the sheath of the testicle, and expands below on the *cul-de-sac*, where its fibres terminate by small tendons, which are inserted into the external surface of the fibrous tunic. Therefore it is that the envelope the cremaster forms is very incomplete, the greater portion of the testicle, and the inner side of the cord, being left unprotected by this muscular tunic. It is in relation, inwardly, with the fibrous membrane, to

which it is united by a plentiful cellular tissue; externally, it responds to the posterior wall of the inguinal canal and the dartos.

It is the contraction of the cremaster that causes the sudden ascent of the testicle.

Dartos.—The tissue composing this tunic is contractile; it is constituted by a mixture of elastic and unstriped muscular fibres. The dartoïc tunic does not reach the inguinal canal; consequently, it does not cover that part of the tunica vaginalis. It forms a pouch below the inguinal ring, and is spread from around the margin of this on to the neighouring parts, to which it adheres somewhat closely; it is prolonged, gradually thinning, into the sheath of, and even on to the penis itself, and to the tunica abdominalis, as well as between the thighs. The two pouches it forms are quite independent of each other, never becoming confounded, though placed in contact on the mesial line to form a double partition (*septum scroti*), whose leaves are separated above for the passage of the penis. The dartos is in relation, inwardly, with the fibrous and erythroid tunics, from which it is isolated by an abundance of lamellar cellular tissue, which is very condensed towards the globus major epididymis, and forms at this point a kind of cord that passes from the fibrous tunic to the dartos, adhering strongly to each. Externally, the dartos is covered by the scrotum.

This tunic determines the vermicular movements of which the scrotum is the seat.

Scrotum.—The different membranes enumerated above are double, one being for each tunica vaginalis; but the scrotum constitutes a single pouch, enveloping the two testicles at the same time. It is merely the portion of skin covering this region, and is thin, and so closely adherent to the dartos, that it can only with difficulty be separated from it. It is covered by very short fine hair, and the extremely numerous sebaceous follicles in its texture secrete an unctuous matter that renders its surface soft to the touch.

(There are also numerous sudoriparous glands, and these, with the sebaceous glands, keep the skin soft and pliable, and modify the effects of friction during progression. On its surface it shows a *raphé* or seam in the middle, which is a trace of its primary division, and corresponds to the median septum separating the testicles.)

2. *The Testicles.* (Figs. 397, 398, 401.)

External Conformation.—Each testicle is oval in shape, flattened on both sides, lodged in the *cul-de-sac* of the tunica vaginalis,[1] and suspended at the extremity of the spermatic cord. The description of this organ is extremely simple; it offers for study *two faces*, *two borders*, and *two extremities*.

The *faces*, *external* and *internal* are smooth and round. The *inferior border* is convex and free, like the faces; the *superior*, almost straight, is related to the epididymis, which adheres to it by its head and tail.

Means of Attachment.—The testicle is freely pendent in the lower part of the tunica vaginalis, where it cannot readily be displaced, because of the narrowness of the space containing it. It is suspended, by its upper

[1] One or both testicles may be retained in the constricted portion of the tunica vaginalis, or remain in the abdomen; animals in which this occurs are named *monorchids* or *cryptorchids*. The absence of one or two testicles (*anorchidism*) is extremely rare. *Ectopiæ of the testicles* is the designation applied to these organs when they are found elsewhere than in their ordinary situation.

border, to the *testicular* or *spermatic cord*:[1] a thick funiculus contained in the middle portion of the vaginal sheath, and formed by the aggregation of the spermatic vessels with the vas deferens.

This cord is itself sustained in the sheath by the frænum that unites the two serous tunics of that cavity.

STRUCTURE.—Independently of the serous tunic that covers the exterior of the testicle, there enter into its structure a *fibrous membrane*, *tissue proper*, and *vessels* and *nerves*. The excretory duct will be studied separately.

Fibrous Membrane.—This membrane, designated the *tunica albuginea*, forms a strong resisting shell around the testicle, and its texture is channeled by sinuous spaces which lodge the large spermatic vessels. It is covered by the visceral layer of the tunica vaginalis, to which it closely adheres; its inner face sends thin septa into the proper substance of the gland, which divide the latter into the spermatic lobules. Towards the upper border of the testicle, and in front, the tunica albuginea is slightly thickened; this part is named the *corpus Higmori* (or *mediastinum testis*), and at this point the seminal ducts pass through it to reach the epididymis.

(This membrane is dense and inelastic, being composed of white fibrous tissue interlacing in every direction.)

Tissue proper.—The proper substance of the testicle resembles a greyish-yellow pulp, contained in the tunic albuginea; it is divided by the prolongations which that tunic sends into its interior into small distinct lobules (*lobuli testis*), independent of each other. These lobules vary in number, from two to three hundred, and all have the same organisation, each being constituted by two or three extremely convoluted filiform tubuli, about from one to two yards in length. These tubes, the *tubuli seminiferi*, anastomose frequently with each other near their extremities, twine together, and can be unwound like a ball of thread. One of their extremities terminates in a *cul-de-sac*, the other being detached from the lobule, and enters a central system of excretory ducts which will be referred to immediately.

Fig. 397.

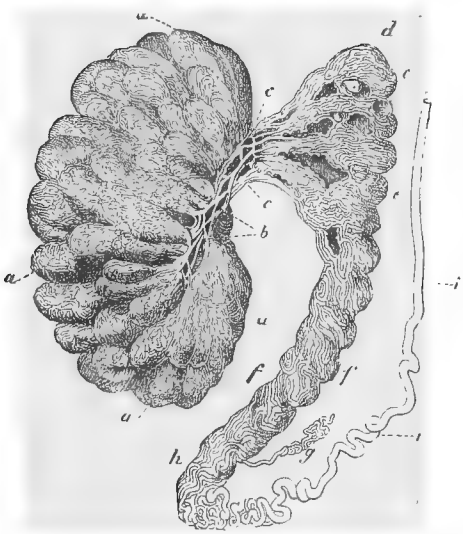

A TESTICLE (HUMAN) INJECTED WITH MERCURY.

a, *a*, Lobules formed of seminiferous tubes; *b*, Rete testis; *c*, Vasa efferentia; *d*, Flexures of the efferent vessels passing into the head, *e*, *e*, of the epididymis; *f*, Body of the epididymis; *g*, Appendix; *h*, Cauda; *i*, Vas deferens

When we cut through a testicle vertically and lengthways, so as to divide the *corpus Highmori* into two lateral portions, there is seen in its substance a whitish

[1] In surgical anatomy, there is sometimes included in the spermatic cord the middle portion of the tunica vaginalis and all its envelopes—the serous, fibrous, and erythroid tunics.

framework, sometimes not very apparent, which, curving upwards at both extremities, extends from that body to the posterior end of the testicle, where it disappears; from this are given off a large number of fibrillæ (*trabeculæ testis*), which diverge in all directions. A mercurial injection by the vas deferens, shows that this part of the testicle is chiefly formed by a ramifying system of rectilinear canals with very thin walls, which open into each other, and unite, on reaching the corpus Highmori, into about twenty principal trunks. These are named the *straight canaliculi* (*vasa recta*), to distinguish them from the convoluted tubuli; they receive the latter at their exit from the lobules, and are surrounded by numerous blood-vessels and sustained by the fibrous septa of the tunica albuginea, which appear to converge towards the point they occupy. At the corpus Highmori, the vasa recta pass through that body, forming in its texture an anastomosing network, the *rete testis*, and are continued into the epididymis as the *efferent canals* (*vasa efferentia*).

The *seminiferous tubes* in the lobules are from $\frac{1}{195}$ to the $\frac{1}{170}$ of an inch in diameter. They are composed of a very thin fibrous membrane (firmer than that in the walls of similar gland canals elsewhere); slightly elastic, and made up of connective tissue with longitudinal nuclei, this membrane is lined internally by a proper amorphous membrane (*basement*) and epithelium. The latter almost completely fills the tubuli; near the wall of the canal it is composed of polygonal cells, but towards the centre these increase in volume, become circular and transparent, and show several nuclei in various stages of transformation; finally, in the axes of the tubuli can be perceived spermatozoa and the detritus of the spermatic cells.

Fig. 398.

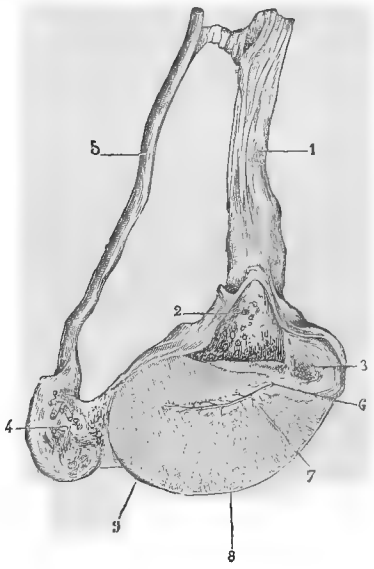

VERTICAL SECTION OF THE TESTICLE (HORSE'S), PASSING THROUGH THE CORPUS HIGHMORI.

1, Spermatic cord, with its serous covering; 2, Sections of the flexuous vessels of the cord; 3, Head of the epididymis, or globus major; 4, Tail of the epididymis, or globus minor; 5, Vas deferens; 6, Corpus Highmori; 7, Rete testis; 8, Tunica albuginea sending prolongations from its inner face, and which divide the testicle into lobules; 9, Surface of the tunica albuginea.

Vessels and nerves.—The blood is carried to the testicle by the spermatic artery, which is almost exclusively appropriated to it; this vessel, after describing a great number of very remarkable flexions, enters the upper border of the gland, a little behind the epididymis. It does not immediately plunge into its substance, however, but passes within the texture of the tunica albuginea, along the borders of the testicle, and forms a complete circle around it. From this circle it sends off divisions, which spread over the sides of the organ, detaching fine arterial ramifications that penetrate its proper tissue in accompanying the interlobular septa. (There is generally described a *tunica vasculosa* that forms one of the coverings of the testicle.

This, in reality, is not a distinct coat, but merely the fine ramifications of the spermatic artery spreading beneath the tunica albuginea, and held together by delicate cellular tissue.)

The veins are very voluminous and frequently varicose, and comport themselves like the arteries; they unite in a single trunk that enters the posterior vena cava, near the renal veins. (On the cord, in addition to their sometimes varicose condition, the spermatic veins have been observed to form a network, named the *pampiniform plexus.*)

The *lymphatics* are most numerous beneath the serous layer and the tunica albuginea. They commence in the lacunæ between the seminal tubes and vessels, and terminate in the sublumbar glands.

The *nerves* of the testicle are derived from the sympathetic (and pass from the abdomen with the blood-vessels); they form a small particular plexus around the artery. (The nerves pierce the membrana propria of the tubuli seminiferi, and end in a more or less pyramidal mass of protoplasm, in which lie clear elliptical nuclei. The ends of the fibres, therefore, lie in close proximity to the outer layer of secreting cells.)

Development.—In the fœtus, at an early age, the testicle floats in the abdominal cavity, being suspended from the sublumbar region, near the flank, by a wide peritoneal fold, at the anterior border of which are the spermatic vessels (Fig. 399, *e.*); the tunica vaginalis is not yet present. The mechanism of the formation of this is very simple, and easy to understand. The visceral layer of the tunica vaginalis, which envelops the testicle and the cord, being already formed, as well as the serous frænum that establishes continuity between this and the parietal layer in the adult animal, it only remains to explain how nature proceeds to construct the vaginal sac in which the gland is afterwards contained.

We have remarked, that to the posterior extremity of the testicle is attached a thick round funicle, the other end of which passes into the upper inguinal ring, being enveloped by the peritoneum, and fixed to the posterior border of the serous layer that suspends the testicle. This funicle is the *gubernaculum testis,* and is continuous, by its inguinal extremity, with the dartos, whose structure it apparently shares, and which alone acts as the scrotal sac to it. The serous layer covering it has on its outer adherent face the cremaster muscle, which is attached to the ilio-lumbar aponeurosis in the vicinity of the inguinal ring, enters the serous tube formed by the peritoneal envelope of the gubernaculum, and advances by its terminal extremity to near the testicle. To this organ is due the principal share in the formation of the vaginal pouch.

When the progress of development in the fœtus pushes the testicle towards the inguinal region, the gubernaculum acts as a guide, as its picturesque name sufficiently indicates. It is the first to descend into the inguinal opening, drawing the testicle after it. But in performing this movement it also carries along its peritoneal covering, which gradually leaves it to become related, by its adherent face, to the walls of the inguinal canal; and thus this membrane becomes reflected, just as would a sock everted or turned down from the leg to the foot, the latter being supposed to represent the testicle.

The parietal layer of the vaginal sac is, then, nothing more than the serous tube that, in the fœtus, enveloped the gubernaculum testis while in the abdomen, and which is reversed on the testicle and cord after their descent into the scrotum, the cremaster muscle on its adherent face having become external.

In all species, the descent of the testicle commences before birth: in the Bovidæ it is even achieved in the early months of intra-uterine existence. In Solipeds, however, the testicle most frequently remains in the inguinal canal until the animal is from six to ten months old.

Fig. 399.

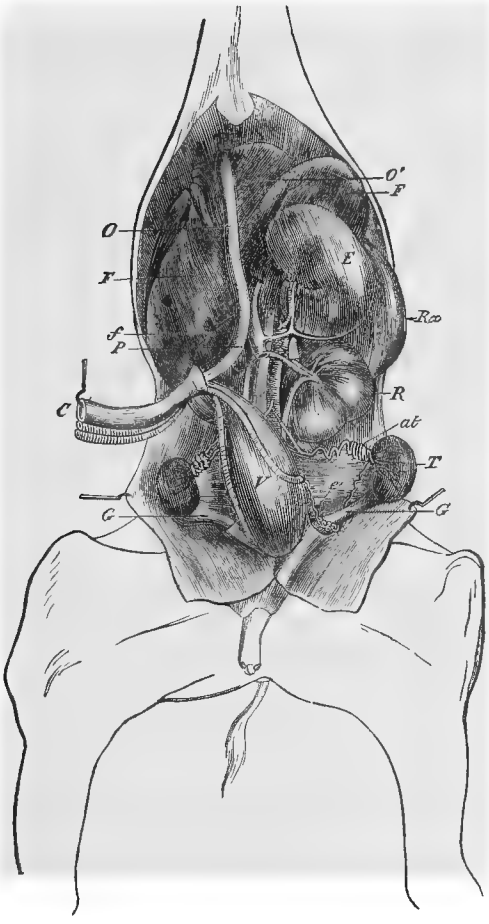

THE INTERNAL GENITO-URINARY ORGANS, WITH THE STOMACH, LIVER, AND SPLEEN, IN THE FŒTUS OF A MARE.

R, Left kidney; V, Bladder; T, Testicle; *at*, Spermatic artery; G, Gubernaculum testis; *e*, Epididymus—the letter is placed in the centre of the serous layer which suspends the testicle and spermatic vessels from the sublumbar region, and after the descent of the gland, forms the frænum between the two layers in the vaginal sheath; E, Stomach; F, Liver; *f*, Lobus Spigelii; P, Vena portæ; *c*, Umbilical cord; O, Umbilical vein; O', Intrahepatic course of that vein, indicated by a double dotted line.

FUNCTION.—The testicles secrete the spermatic (or seminal) fluid. *Pure semen*, such as is derived from these glands, is a white, viscid, odorless,

and slightly alkaline fluid. It contains a small quantity of liquid matter (*liquor seminis*), in which is an innumerable mass of *spermatozoa*. After the semen has passed through the genital canals, it is made much more aqueous by the addition of the fluids secreted by the walls of these excretory ducts, or by the glands annexed to them.

The *spermatozoa*, *zoösperma*, *spermatozoïdes*, or *spermatic filaments*, are little elongated bodies from $\frac{1}{600}$ to $\frac{1}{800}$ of a line in length. They have a pyriform, flattened, or lancet-shaped *head*, and a filiform *tail* terminating in a point; this tail is often furnished at its origin with an enlargement, or unilateral or bilateral alæ. Their form is slightly modified during their course through the excretory ducts. (In the different species, though possessing certain fixed characters, the spermatozoa yet offer some curious diversities. Some of these are well exhibited in the annexed representations of these particles, found in the semen of very dissimilar animals.)

Fig. 400.

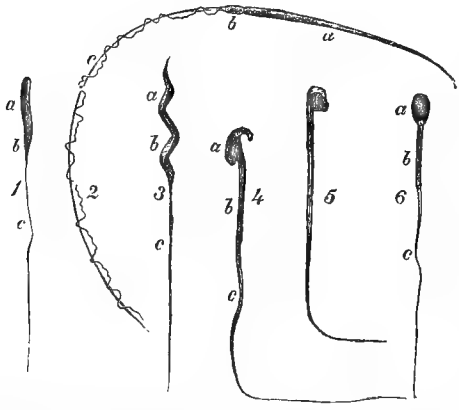

1, Spermatozoon of the frog; 2, Of the triton; 3, Of the finch; 4, Of the field-mouse; 5, Of the hedge-hog; 6, Sheep; *a*, Head with nucleus; *b*, Body; *c*, Tail.

The spermatozoa move by undulations of the tail (Grohe attributes the motion to the contractile protoplasm contained in the head). Their movements persist for several days in the genital organs of the female; they are suddenly arrested by water, acids, and the electric spark; on the contrary, they are animated by alkaline fluids. (The movements cease when the spermatozoa are exposed to a temperature of 120° Fahrenheit.) These bodies are developed in the cells of the tubuli seminiferi by a modification of their contents. The cells (vesicles of evolution) become round in the centre of these canals, and have from one to ten nuclei; the latter are elongated, and throw out a prolongation that gradually extends and forms the tail of the spermatozoon. When all the nuclei are thus transformed, the cell-wall ruptures and liberates the spermatozoa, which swim about in the minute quantity of fluid resulting from the destruction of the cells.

EXCRETORY APPARATUS OF THE SEMEN.

1. *The Epididymis and Deferent Canal.* (Figs. 397, 398, 399, 401, 402.)

Epididymis.—The organ thus named commences the excretory canal of the testicle. It is a body elongated from before to behind, placed against the upper border, and a little to the outside, of the spermatic gland. It has a *middle portion* and *two extremities*.

The *middle* is contracted, flat on both sides, and free outwardly; it is related, inwardly, to the spermatic vessels and the testicle, to which it is attached by a very short serous layer. The *extremities* are expanded, and adhere intimately to the testicle. The *anterior*, the largest, is named the

head of the epididymis or *globus major*. The *posterior*, the *tail of the epididymis*, or *globus minor*, is more detached from the testicle, and is curved upwards to be continued by the deferent canal (*vas deferens*).

STRUCTURE.—The epididymis is constituted by a long duct doubled a great number of times on itself, and whose convolutions, after injection with mercury, can be very readily seen through the serous membrane. This duct results from the union of from twelve to twenty small tubes, the *efferent ducts*, which, arising from the rete testis, open together, at a variable distance, into the globus major. Towards the globus minor there is only one duct, which is more voluminous and less flexuous, and finishes by becoming detached from the posterior lobe of the epididymis to constitute the vas deferens.

The organisation of the walls of these ducts is not the same throughout. Thus, in the *efferent ducts*, it comprises a simple ciliated epithelium, resting on a proper amorphous membrane, which again is placed on unstriped circular fibres attached to a thin fibrous tunic; while beyond, there is observed a stratified ciliated epithelium, a proper membrane, two layers of unstriped fibres—circular and longitudinal—and also a fibrous tunic. The thickness of the muscular layers increases from before to behind.

The epididymis receives its arteries and nerves from the same sources as the testicle.

DEFERENT CANAL (*vas deferens*).—This duct is about the thickness of a goose-quill, and is at first flexuous, then straight. It lies parallel with, but behind and to the inner side of, the spermatic vessels, as far as the opening of the tunica vaginalis; passing through this opening, it enters the pelvic cavity, and crosses obliquely the ureter and obliterated cord of the umbilical artery. It is then inflected backwards, placed above the bladder, suddenly dilates, and is prolonged as far as the neck of that reservoir, where it terminates; after having penetrated beneath the prostate gland by a sudden contraction, at the origin of which, and outwardly, the vesicula seminalis opens, and is continued by the ejaculatory ducts.

Fig. 401.

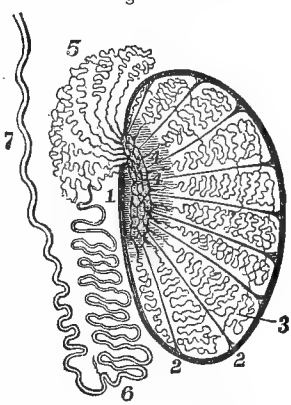

DIAGRAM OF THE TESTICLE (HUMAN).

1, Mediastinum testis, containing the rete testis; 2, 2, Trabeculi; 3, One of the lobules; 4, 4, Vas recta; 5, Globus major; 6, Globus minor; 7, Vas deferens.

The vas deferens is sustained in the tunica vaginalis by a very short serous fold, a dependency of the frænum, whose two layers envelope the spermatic vessels, within and behind which this duct is situated. In the abdominal cavity, it is fixed by the prolongation of this serous duplicature. Its dilated or pelvic portion is in contact, superiorly, with the vesiculæ seminales, and is finally united to its dilated homologue of the opposite side, which it has been gradually approaching, by means of a triangular peritoneal fold, that comprises between its two layers a small club-shaped cavity which will be alluded to again.

The calibre of the vas deferens is very small in its vaginal and abdominal portions, but is greater towards the pelvic dilatation, where the walls of the duct offer a well-marked areolated disposition.

STRUCTURE.—The vas deferens is formed, internally, by a very fine mucous membrane covered with cylindrical epithelium, and to this is added, externally, a *contractile* and a *fibrous tunic*. The contractile layer is formed of three planes of unstriped fibres: the deep and superficial planes have longitudinal, and the middle circular fibres. It is, proportionately, very thick at the dilated portion of the duct, and it is to its great density that the vas deferens owes its consistence as a hard, rigid cord. The mucous membrane of the pelvic dilatation has tubular and acinous glands.

2. *The Vesiculæ Seminales and Ejaculatory Ducts.* (Fig. 326.)

The *vesiculæ seminales* are two oval pouches whose volume varies with their contents, and which are placed in the pelvic cavity, above the bladder and the vas deferens. Each vesicula has a *middle portion* and *two extremities*. The *middle portion* is enveloped by a loose abundant cellular tissue, and is in relation with the rectum above, and below with the bladder and vas deferens.

Fig. 402.

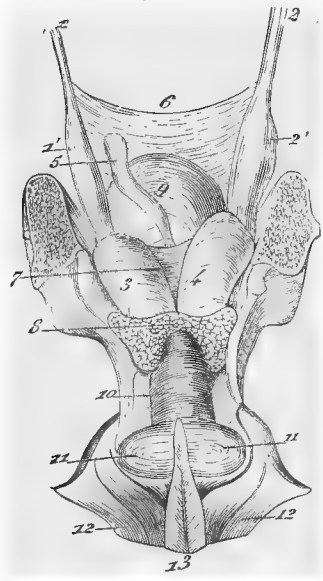

SUPERIOR VIEW OF THE PELVIC PORTION OF THE VASA DEFERENTIA, VESICULÆ SEMINALES, PROSTATE GLAND, COWPER'S GLANDS, AND THE INTRAPELVIC PORTION OF THE URETHRA.

1, Left vas deferens; 1', Its pelvic dilatation; 2, 2, The same on the right side; 3, 4, Vesiculæ seminales; 5, The third vesicula; 6, Serous layer uniting the vasa deferentia; 7, That comprised between the two vesiculæ; 8, Prostate gland; 9, Bladder seen through the serous fold of the vasa deferentia; 10, Membranous or intrapelvic portion of the urethral canal, covered by Wilson's muscle; 11, 11, Cowper's glands enveloped by that muscle; 12, 12, Ischio-cavernosus muscle; 13, Accelerator urinæ muscle.

The *anterior extremity* is the largest, and forms a rounded *cul-de-sac*, covered in almost the same manner as the bladder by the peritoneum, which at this point furnishes a very small triangular frænum (the *recto-vesical fold*) that unites the two vesiculæ. The *posterior extremity* tapers to a narrow neck, which passes beneath the prostate gland, and joins at a very acute angle the terminal extremity of the vas deferens, to constitute the ejaculatory duct.

The walls of this pouch are composed of three membranes: an internal *mucous*, a middle *muscular*, and an external *fibrous*. The *mucous* layer is continuous with that of the ejaculatory ducts, and is very thin, delicate, and follicular. It shows numerous folds, which disappear with distention of the duct. The *middle layer* evidently belongs to the class of muscular membranes; its identity with that of the bladder is complete. At the bottom of the *cul-de-sac* it gives off several fasciculi, which radiate on the external surface of the peritoneum. (In addition to these, the vesiculæ and vasa deferentia have a muscular covering whose fibres are arranged in a longitudinal and transverse direction, the latter being the most superficial. This muscular layer being continuous over the vesiculæ seminales and vas deferens, when it contracts, will compress and shorten these; consequently, it has been named the *compressor vesiculæ et ductus*

seminalis. The fibrous coat of the vesiculæ is merely condensed cellular tissue.) The mucous and muscular coats are supplied with blood by the vesico-prostatic artery (*inferior vesical*); their nerves are derived from the pelvic plexus.

The richness in glands of the mucous membrane of the vesiculæ seminales, has led several anatomists to consider them as organs of secretion, and not as reservoirs for the semen. But the large cavity that each forms, appears to demonstrate that they serve as reservoirs and secretory organs at the same time. Their fluid production is added to the semen, as is the secretion of the prostate and Cowper's glands.

The *ejaculatory duct* is very short, and succeeds the narrow canal of the vesicula after the latter opens into the vas deferens. The two ducts pass between the prostate gland and urethra, and, after a brief course, terminate in the latter, on the side of the *veru montanum*—a tubercle which will be noticed presently.

Near to, and in front of this tubercle, is a third very small orifice—the opening of the third pouch included between the serous duplicatures joining the vasa deferentia. (This is the *sinus pocularis*, or *utriculus prostatia*, *vesicula seminalis tertia* or *media* of Gurlt.) Improperly designated the *third vesicula*, or *masculine uterus* (Weber), this pouch (sometimes double) secretes a fluid which is thrown into the urethra. (This third vesicula is present in all the domesticated animals.)

The ejaculatory ducts may become obliterated; then the secretion of the vesiculæ seminales accumulates in their interior, and gradually distends them until they attain enormous dimensions. We found, in a Gelding, a vesicula which was nearly as large as the bladder; it contained a brownish, sticky fluid, holding in suspension epithelial cells, free nuclei, and mucus corpuscles.

(The vesiculæ seminales, in addition to their own secretion, receive the semen conveyed by the spermatic ducts, and keep it in reserve until copulation; when the contraction of its muscular apparatus expels it into the ejaculatory ducts, and from these into the urethral canal.)

3. *The Urethra.*

The *urethra* is a canal with membranous and erectile walls, commencing at the neck of the bladder, and terminating at the free extremity of the penis.

Course.—When followed from its origin to its termination, it is seen to proceed at first horizontally backwards, then bend downwards at the ischial arch to leave the cavity of the pelvis, placing itself between the two roots of the corpus cavernosum, and passing forward in the channel formed at the lower border of these, until it arrives at the head (*glans*) of the penis, where it terminates by forming a small (cylindrical) prolongation, named the *urethral tube.* In its track, the urethra is divided into two very distinct portions: the *intrapelvic*, the shortest, and the *extrapelvic*, the most extensive, and supported by the corpora cavernosa. The latter division being alone enveloped by the erectile tissue that enters into the formation of the urethral walls, has been also named the *spongy portion*, the first being designated the *membranous portion.*

Interior.—Internally, this canal has not the same width throughout. Very constricted at its origin, towards the neck of the bladder, it expands somewhat suddenly at the prostate gland; its dilatation, improperly named in Man the *cul-de-sac of the bulb* (*bulbous portion*), or, better, the *ventriculus*,

extends to its curve over the ischial arch, where it gradually contracts. After this it preserves the same reduced dimensions throughout its course, though these dimensions may be increased during the passage of the urine or semen. There is, however, behind the urethral tube a small oval dilatation, named the *fossa navicularis* (Fig. 403). Even throughout its extrapelvic portion, the inner surface of the urethra offers, near the neck of the bladder, and on its upper wall, the excretory orifices of the prostate gland, and which form two lateral lines of minute perforated tubercles. Between these two lines is found the *urethral ridge* or *veru montanum* (*caput gallinaginus*), a little eminence elongated from before to behind, on the sides of which the ejaculatory ducts open. Behind this are the excretory orifices of Cowper's glands.

Relations.—The intrapelvic portion of the urethra is in relation, above, with the prostate, which adheres closely to it, and with the rectum, to which it is united by the abundant loose connective tissue in this part of the pelvis; below, it lies on the internal obturator muscle; laterally, it is related to the muscles and ligamentous or aponeurotic expansions that close in the sides of the pelvis. Without the pelvic cavity, the urethra is united in the most intimate manner to the corpora cavernosa, which embrace its anterior border. By its posterior border, it is related to the suspensory ligament of the penis.

Structure.—The urethra is composed of: 1, *Mucous membrane;* 2, *An erectile envelope;* 3, *Muscles;* 4, *Vessels and nerves;* and, 5, we will add some remarks concerning the *perineal aponeuroses*, which are in immediate relations with this canal.

1. Mucous Membrane.—This is rather delicate, and forms the lining of the canal; it is continuous, posteriorly, with that of the bladder, and in front with the integument enveloping the head (*glans*) of the penis; it is also prolonged into the excretory ducts of the glands annexed to the urethra and the ejaculatory ducts. It has longitudinal folds, and is always in contact with itself, except during the passage of urine or semen; it has scarcely any papillæ, only a few being found near the anterior extremity of the canal.

The epithelium of this membrane is stratified and cylindrical, but at the portion furnished with papillæ it becomes pavemental.

2. Erectile Envelope.—This envelope, lying outside the mucous membrane, does not cover the intrapelvic portion of the canal. It commences a little above the ischial contour, behind Cowper's glands, by a very thick bulging portion, named the *bulb of the urethra.* In front, it terminates by another bulbous enlargement, into which the anterior extremities of the corpora cavernosa enter, named the *head of the penis* (*glans penis*).

The tissue composing this envelope has the same organisation as other erectile apparatus, being a network of communicating cavities separated by elastic septa, the latter showing in their structure some contractile elements.

3. Muscles.—Behind the prostate gland, the mucous membrane of the urethra is covered by a fleshy layer of circular fibres, forming *Wilson's muscle.* Another muscular envelope, constituting the *bulbo-cavernous* or *accelerator*, also covers the erectile tissue of the urethra, accompanying it to near the glans, where it gradually disappears. To these two principal muscles of the urethra are added two pairs of secondary fasciculi—the *ischio-urethral* and *transversus perinei.* This is the description of the muscular apparatus:

a. Wilson's muscle.—This may be described as a single muscle composed of two portions, an inferior and superior. Both are formed by

transverse fibres thrown over the membranous portion of the urethra, and united at their extremities, which are attached by means of aponeurotic fasciculi, to the lateral walls of the pelvis. Behind, the superior fibres cover Cowper's glands, and, like the inferior, are mixed with the accelerator urinæ.

b. Accelerator Urinæ.—Composed of transverse fibres encircling the urethra from the ischial arch to the free extremity of the penis, this will also be studied as a single organ, separated into two lateral portions by a median raphé passing along the whole posterior face of the urethra. The fibres pass from this raphé to the right and left, enter the furrow of the corpora cavernosa, and reach the upper surface of the urethra, where they advance towards each other; they do not join; so that the circle formed by this muscle is necessarily incomplete.

c. Ischio-urethral muscle (*compressor urethræ*).—This is a thin fleshy band, pair, situated below and at the side of the membranous portion of the urethra. Attached by some aponeurotic fibres to the ischial arch, this muscle passes forward on Cowper's gland, whose lower face it covers. At the periphery of that organ, it is confounded with the portion of Wilson's muscle that envelops its upper surface.

d. Transversus perinei.—This is a very thin ribbon-like fasciculus, often scarcely distinguishable from the ischio-anal muscle (*levator ani*). It extends transversely from the ischial tuberosity—to which it is attached through the medium of the sacro-sciatic ligament, to the mesial line of the perineum, where its fibres, confounded with those of its homologue on the opposite side, appear to be inserted in the accelerator urinæ at its origin.

e. Action of the urethral muscles.—1. *Wilson's muscle*, when it contracts, compresses between its two layers the membranous portion of the urethra. It is a veritable sphincter, and opposes the escape of the urine; when the semen is thrown from the vesiculæ seminales into the urethra, it also prevents that fluid entering the bladder, by permitting the accelerator to empty, from before to behind, the initial dilatation of that canal. 2. The *accelerator* is correctly named from the part it plays in ejecting the semen from the urethra, it being the chief agent in this act. 3. The *ischio-urethral* muscle pulls back the membranous portion of the urethra, with Cowper's glands, and, like Wilson's muscle, acts as a compressor to these. 4. The *transversus perinei* dilates the bulbous portion of the urethra, by drawing it out laterally.

4. Vessels and Nerves.—The urethra is supplied with blood by the bulbo-urethral arteries and the two pairs of arteries—the *dorsal of the penis.* Voluminous *veins*, frequently varicose, and satellites of the arteries, carry it away. The *lymphatics* form a very rich plexus beneath the mucous membrane; their trunks pass to the inguinal, and some to the sublumbar glands. The *nervous* filaments are from the internal pudic and great sympathetic.

5. Aponeuroses of the Perineum.—In the perineal region, the urethra is covered by two superposed fibrous layers. The *superficial aponeurosis* is fibro-elastic, and appears to arise from the inner surface of the thighs, where it is mixed with the dartos; it covers the perineum, and its fibres, becoming disassociated, disappear on the sides of the sphincter ani. This membrane is in relation, externally, with the skin, and, internally, with the deep aponeurosis. On the middle of its external face, it receives the insertion of a muscular fasciculus, which is detached from the sphincter.

The *deep aponeurosis*, formed of white inelastic fibrous tissue, adheres to

the latter by its outer face, and to the accelerator and ischio-cavernous muscles by its inner face. Above, it is lost around the termination of the rectum; below, it expands between the thighs; it is seen insinuating itself, to the right and left, between the ischio-cavernous and semimembranosus muscles, to be attached to the ischiatic tuberosity.

4. *The Glands annexed to the Urethra.*

A. Prostate (Fig. 402, 8)—This single and symmetrical gland is situated at the commencement of the urethra, and lies across the neck of the bladder. A constriction in the middle divides it into two voluminous lateral lobes inclining slightly forward. Its upper face corresponds to the rectum, through the medium of the cellular tissue at the bottom of the pelvic cavity. Its inferior face, moulded on the neck of the bladder, embraces it above and laterally, and is closely attached to it; it covers the terminal extremity of the deferent and ejaculatory ducts, and the neck of the vesiculæ seminales.

Structure.—The tissue composing this gland forms a number of communicating cells, which are larger in the Ass than the Horse; in these is collected a quantity of viscid fluid (*succus prostaticus*) secreted by their walls, and which is ejected into the urethra by the two rows of orifices arranged on the sides of the veru montanum. These communicating cells are nothing more than conglomerate glands, which are distributed in a stroma of connective tissue and unstriped muscular fibres.

B. Cowper's Glands.—In Veterinary anatomy, these are frequently named the *small prostates.* They are two globular bodies, denser in texture than the prostate gland, but otherwise the same in organisation, and are situated on each side of the urethra, in the perineal region, above the ischial arch; they are completely enveloped by a somewhat thick fleshy covering, formed by the fibres of Wilson's and the ischio-urethral muscles (Fig. 402, 11).

The fluid they secrete is thrown into the urethral canal by numerous orifices disposed in several rows. It has the same physical properties as that of the prostate, and both are poured into the urethra in abundance immediately before ejaculation; the expulsion of the semen is by this means facilitated.

5. *The Corpus Cavernosum.*

The *corpus cavernosum* is an erectile stalk, which forms the base of the penis and supports the urethra; it is situated between the thighs, prolonged beneath the abdomen, attached behind to the ischial arch, and terminates in front by a free extremity, which is received into the erectile enlargement named the glans penis.

External conformation.—Flattened on both sides, this body offers for study two *lateral faces*, two *borders*, and two *extremities.* The *faces* are plane, and present no interesting features. The *superior*, or *dorsal border*, is the thickest, and is rounded. The *inferior* is channeled throughout its extent by a deep furrow which lodges the urethra. The *posterior extremity* is bifurcated, the two branches constituting the *roots* (*corpora* or *crura*) *of the penis;* they are fixed to the ischial arch, one to the right, the other to the left, and are covered by the two *ischio-cavernosus* (*erector penis*) *muscles:* short, thick, and strong masses intersected by numerous tendinous fibres, and partly concealed by the semimembranosus muscles. These erector penis muscles

arise from the ischial crest, and terminate on the membrane enveloping the crura of the penis, which they cover posteriorly and externally.

The *anterior extremity* of the corpus cavernosum forms a blunt point, and is surrounded by the spongy tissue of the glans.

Mode of attachment of the corpus cavernosum.—The chief attachment is constituted by the insertion of the two crura into the ischial arch. There is also a double *suspensory ligament* proceeding from the ischio-pubic symphysis, where it is confounded with the superior attachments of the short adductor of the thigh, and passes to the dorsal border of the corpus cavernosum, a little in front of the point of union of its crura.

Structure.—This erectile organ is composed, externally, of a white, elastic, fibrous envelope, remarkable for its thickness, especially on the dorsum; it gives off, from its inner face, a certain number of lamellar trabeculæ which partition the interior of the cavity it forms. One of these septa (*septum pectiniform*) is directed vertically from the upper to the lower border, and divides the corpus cavernosum into two lateral portions (*corpora cavernosa*), which would indicate that the crura are not one mass at their point of union, but merely joined to each other. In the Horse, this septum is generally very incomplete, and rarely extends the whole length of the organ.

The lamellar prolongations sustain other elastic and contractile bands, which circumscribe the cavities in which is lodged the essential portion of the erectile tissue. According to Legros, the latter is composed of a network of capillaries interposed between the arterial and venous twigs, and which shows abrupt or regular dilatations of variable diameter. These successively dilated capillaries have very thin walls, which are adherent to the contractile prolongations of the envelope, and are lined by a very delicate pavement epithelium. In the areolæ of the cavernous tissue, particularly towards the base of the organ, the arteries offer a special disposition; their walls are very thick, and they soon divide into a bouquet of branches which enter the areolæ, where they terminate either by a *cul-de-sac*, or, which is most frequent, give off small free branches convoluted in a spiral manner. These are the *arteriæ helicinæ* described by Müller and Rouget. (The walls of the cells are composed of white and yellow fibrous tissue, and unstriped muscular fibres. The cells themselves are in reality venous sinuses. Kölliker found a minute artery to proceed from each of the cæcal terminations of the helicine arteries, and terminate, like the other capillaries, in the veins. The dilated vessels have been regarded by some anatomists as only vascular loops. The cells, during the erection of the penis, are distended with blood.)

The *arteries* of the corpus cavernosum and dorsales penis pass into the erectile structure, and supply this organ with blood. The collateral *veins* of these arteries arise near the surface. The *nerves* come from the internal pudic and great sympathetic.

6. *The Penis.*

The *penis* is the male organ of copulation, and results from the union of the corpus cavernosum and the spongy portion of the urethra. These parts have already been described; it now remains to consider the organ in its entirety.

The penis commences at the ischial arch, passes between the thighs and the two dartoid sacs containing the testicles, and is prolonged beneath the belly, where it terminates in a free extremity.

All the portion comprised between the ischial arch and the scrotum, is maintained and deeply covered by the surrounding textures, and is named the *fixed portion* of the penis. The remainder of the organ—its anterior moiety—is, on the contrary, its *free portion*, as it forms a detached appendage sustained by a cutaneous fold, the *sheath* (or *prepuce*).

The Fixed Portion occupies the perineal region and that between the thighs, where it is enveloped by the arteries, veins, and nerves already known, as well as by a large quantity of connective tissue (and the skin).

The Free Portion is lodged in the sheath during the inactive condition of the organ, but protrudes from it when in a state of erection. It is then seen to be covered by a smooth, unctuous tegumentary membrane with numerous papillæ, and of variable colour, though most frequently it is black or variegated. Its *base* presents a slight circular enlargement, due to the accumulation, beneath the mucous membrane, of a small annular mass of elastic and contractile tissue. Its *extremity* or *glans* is also a circular enlargement limited behind by a salient collar—the *corona glandis*—which is notched inferiorly, and at the moment of ejaculation assumes a considerable development, its shape being then not unlike the rose of a watering-can. This enlargement has for its basis the terminal expansion of the urethral erectile tissue, and presents on its anterior face: 1, In the centre, a rounded prominence due to the point of the corpus cavernosum; 2, Beneath this, the *urethral tube* encircled by a fossa; 3, At the bottom of the fossa, and below the urethra, the orifice of a bilocular cavity—the *urethral sinus*, which widens at the bottom, and in which accumulates sebaceous matter that sometimes becomes so hard as to prevent the flow of the urine by compressing the tube; 4, Inferiorly, the *suburethral notch.*

Fig. 403.

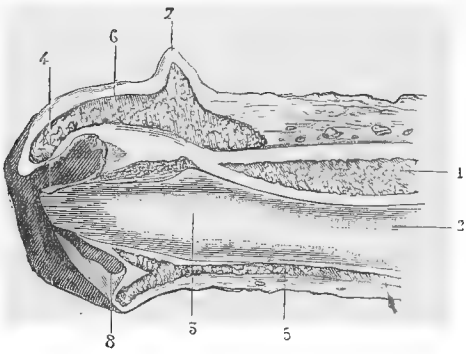

LONGITUDINAL SECTION OF THE FREE EXTREMITY OF THE HORSE'S PENIS IN A RELAXED STATE.

1, Erectile tissue of the corpus cavernosum; 2, Urethra; 3, Fossa navicularis; 4, Urethral tube; 5, Erectile tissue of the urethra; 6, *Ditto* of the glans; 7, Corona glandis; 8, Urethral sinus.

The skin covering the extremity of the penis is rich in nerves which, according to Kraüse, have round dilatations which he designates as "terminal genital corpuscles."

To complete the description of the penis, there only remain to be described: 1, Two suspensory and retractile cords which concur, with the natural elasticity of the fibrous envelope of the corpus cavernosum, to return the organ to its ordinary position when the phenomenon of erection has ceased; 2, The tegumentary fold, or sheath, which envelops the free portion of the penis when in its ordinary state of repose.

A. Suspensory and Retractile Cords of the Penis.—Two in number, these cords arise from the lower face of the sacrum, descend as flat bands in front of the sphincter ani, between the retractor muscle of the anus and the rectum, to which they give numerous short fasciculi from their posterior

border; they then unite at the mesial line, below the anal opening, thus forming around the terminal extremity of the rectum a real suspensory ring. Lying together, and intimately united, they are continued on the accelerator, which they follow at the raphé, and are eventually lost in its texture near the free extremity of the penis.

These cords are composed of unstriped muscular fibres.

B. Sheath (*prepuce*).—The sheath is a cavity formed by a fold of the abdominal integument, and lodges the free portion of the penis; it is entirely effaced at the moment of erection, when the copulatory organ is lengthened and enlarged. The skin at the opening of the sheath enters its cavity, and, on arriving at the free portion of the penis, forms a circular *cul-de-sac* in becoming reflected over the organ, which it envelops.

This lining integument of the sheath is fine, and very irregularly plicated; it is destitute of hair, and holds a middle place, with regard to organisation, between the skin and mucous membranes. It contains in, or beneath, its substance a considerable number of sebaceous or *præputial* glands that secrete an unctuous fatty matter (exhaling a pecular odour, and dark-grey in colour, the *smegma præputii*), which is spread over the surface of the membrane.

Above, the inner integument of the sheath is applied to the fibrous tunic of the abdomen. Below, and on each side, the cutaneous fold constituting this cavity contains between its layers an expansion of yellow elastic fibrous-tissue, the lateral portions of which, attached to the abdominal tunic, are named the *suspensory ligaments of the sheath.*

In the *Ass*, there exists, near the entrance to the sheath, and on each side, a small tubercle which may be looked upon as a rudimentary teat of the female.

(The prepuce protects the penis, and sustains it when in a flaccid state. In certain Horses, a gurgling sound is produced in trotting, from the air entering and leaving the sheath suddenly.)

DIFFERENTIAL CHARACTERS IN THE MALE GENITAL ORGANS OF OTHER THAN SOLIPED ANIMALS.

Ruminants.—*Testicles.*—In these animals, the testicles are very voluminous, oval, and vertically elongated. They, with their envelopes, form a pendant mass that occupies the inguinal region. The scrotum is always of a pale colour. In the interior of the testicle, the corpus Highmorianum and the rete testis are very marked. (The proper tissue is yellow, and the septa formed by the prolongations of the tunica albuginea are not very distinctly seen.)

Epididymis.—Vas deferens.—The head of the epididymis is wide and flat, and partly covers the anterior border of the testicle. The middle portion, smaller than in Solipeds, represents a narrow cord lying outside the posterior border of the seminal gland. The tail is a little free appendage, inflected inwards and upwards to become continuous with the vas deferens. The latter is dilated, as in the Horse, when it arrives above the bladder, and lies beside the duct of the opposite side. The two, thus joined, increase from before to behind, leave the neck of the bladder in passing above the vesiculæ seminales, then go beneath the prostate, and terminate in the urethra, on the summit of a ridge, by two elliptical orifices.

Vesiculæ seminales.—In the *Bull*, the vesiculæ seminales have not the same appearance as in the Horse, and they have not so large a cavity in their interior. They are two elongated masses, lobulated on their surface, yellow in colour, and possessing quite a glandular aspect. They have sometimes been designated the lateral prostates. They are composed of aciniform glands, inclosed in a mass of connective tissue and unstriped fibres; they open into a common central canal which terminates in the vas deferens.

Urethra.—This canal is inflected like the letter S. Its diameter regularly diminishes from its commencement to its termination, which is not provided with a urethral tube, as in Solipeds. Internally it presents: 1, Immediately beyond the neck of the bladder

a short, but very salient *veru montanum*, which divides into two mucous columns, that gradually subside posteriorly; 2, Towards the ischial arch, a valve whose free border, directed downwards, covers a *cul-de-sac* about 3-4ths to 1 inch deep.

The structure of the urethra is also different. The walls of the *membranous portion* are thicker than in the Horse; they have a layer of erectile tissue, and a Wilson's muscle, very thick below and laterally, and whose fibres are inserted in the middle of the upper surface, into an aponeurotic raphé.

At the ischial arch, when the canal bends downwards, the spongy tissue becomes more abundant to form the *bulb of the urethra;* but the prominence at this point is chiefly due to the accelerator urinæ, as is shown in figure 404, c, 4. This muscle is extremely powerful, but it soon ceases beneath the ischial arch. The *transversus perinei* is as strong as in Solipeds.

Fig. 404.

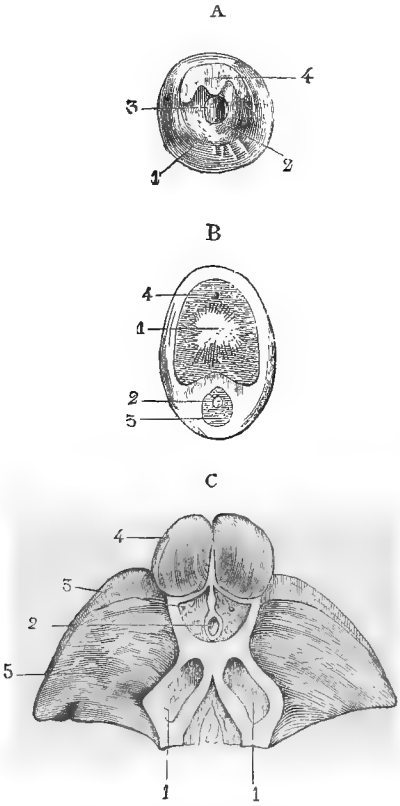

SECTIONS OF THE URETHRA OF THE OX AT DIFFERENT POINTS.

A, *Intrapelvic portion;* 1, Wilson's muscle; 2, Erectile tissue; 3, Urethral canal; 4, Prostate gland.—B, *The middle of the penis;* 1, Fibrous cord of the corpus cavernosum; 2, Urethral canal; 3, Its erectile tissue; 4, Envelope of the corpus cavernosum.—C, *At the crura of the penis;* 1, 1, Crura of the corpus cavernosum; 2, Urethral canal; 3, Its erectile tissue; 4, Accelerator urinæ; 5, Ischio-cavernosus muscle.

Glands annexed to the urethra.—*Cowper's glands* are absent. The prostate gland is not voluminous, and forms, at the commencement of the urethra, a little transverse yellow mass, beneath which pass the vasa deferentia; it also lies beneath Wilson's muscle, and is prolonged for some distance on the membranous portion of the urethra.

Penis.—In the *Bull*, the penis is long and thin, and carried well forward beneath the belly. It is inclosed at the perineum in an aponeurotic sheath, which is covered by the ischio-tibial muscles. This sheath is double, its superficial layer being continuous with the dartos, and has the same physical characters; the deep layer is thin, white, and inelastic.

In front of the pubis, the penis describes two successive curves—the *S of the penis*—the first with its convexity forwards, the second backwards. It is at the second curve that the *suspensory ligaments* join the penis, and continue along its sides to its extremity.

The free portion of the organ, very tapering, is covered by a fine, papillated, very sensitive, rose-coloured mucous membrane.

It is lodged in a narrow sheath that advances much more forward beneath the abdomen than in Solipeds, and has at its opening a bunch of long stiff hairs. This cutaneous sheath is moved by four subcutaneous muscles: two posterior or *retractors* (Fig. 405, 2) which draw the sheath backwards, and concur in exposing the penis at the moments of its erection; and two anterior or *protractor* muscles (Fig. 405, 1) which carry the sheath forward to its former position. The latter are found in the *Cow*, and do not appear to be of any use.

The two constituent portions of the copulatory organ are not joined in the same manner as in Solipeds, the channel for the lodgment of the urethra being transformed into a complete canal by a narrow layer of the fibrous envelope of the corpus

cavernosum. The latter is little developed, and presents, internally, a longitudinal fibrous cord; it is not much dilated during erection. In this act, the penis is elongated by the straightening out of its curvatures, rather than by any real lengthening; when erection ceases, the organ is retracted into the preputial cavity by the contraction of the suspensory cords, which reform its double inflection behind the scrotum.

In the *Ram* and *He-goat*, the disposition of these parts is somewhat similar. (In the former, the extremity of the urethra has the form of a narrow cylinder curved backwards, its opening being a longitudinal slit. In Ruminants, towards the extremity of the sheath are small teats; these, in the *He-goat*, are sometimes glandular, and secrete a fluid analogous to milk.)

Fig. 405.

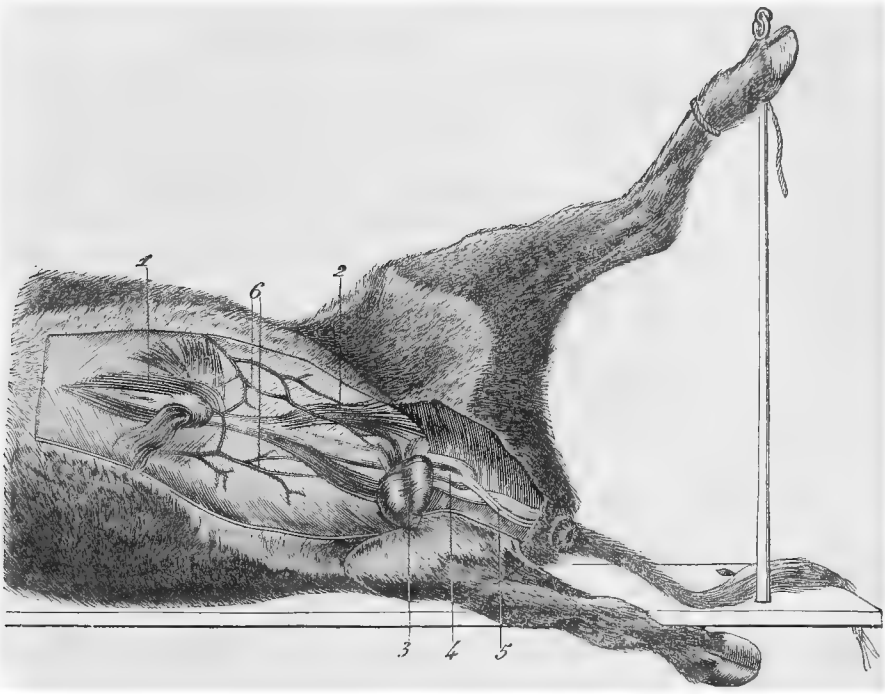

PENIS AND MUSCLES OF THE SHEATH OF THE BULL.

1, Protractor muscle of the sheath; 2, Retractor of ditto; 3, Testicles in the scrotum; 4, The *S* of the penis; 5, Suspensory cords of the penis attached to the second curve: 6, Subcutaneous abdominal vein.

Pig.—The *testicles* of this animal are round, and placed in the perineal region. The scrotum is narrow, and but little detached: the pouches of which it is composed appearing simply as two hemispherical prominences on the surface of the perineum. There is nothing particular to be remarked in the *epididymis* and *vas deferens;* (the *tail* of the first is very voluminous; the latter has no pelvic dilatation.)

The *vesiculæ seminales*, with regard to disposition, are intermediate between those of the Horse and Ox Their walls are thick and very glandular, and their interior is diverticulated. (They are, proportionately, very large, and, in structure, closely resemble those of Ruminants; indeed, in these animals they rather appear to be organs for the secretion of a milky liquid that is mixed with the semen, than reservoirs for the fecundating matter, as that fluid never contains any spermatozoa.) There are two *prostates:* one disposed as in the Ox; the other placed across the neck of the bladder, as in Solipeds. The *penis* resembles that of Ruminants, except in the absence of the muscles of the sheath; it has also a particular preputial sheath, which has been studied

by Lacauchie. (When flaccid, the penis of the *Pig* is twisted in a spiral manner at the extremity. The sheath is narrow, and longer than in Ruminants. At the upper part of its opening is the special pouch mentioned by Chauveau, and which is formed by a fold of the skin It opens into the sheath, and secretes, in the *Boar*, an unctuous fluid, possessing a particularly disagreeable smell, and which is mixed with the urine. The odour of the secretion even taints the flesh of this creature.)

CARNIVORA.—The testicles of the *Cat* are formed like, and placed in the same situation as, those of the Pig; those of the *Dog* are more oval, and are pendent.

The Carnivora have no *vesiculæ seminales*. The *prostate gland* surrounds the neck of the bladder; it is of a yellow colour, concave on its upper surface, and divided into two lateral lobes on its lower face. *Cowper's glands* are absent in the *Dog;* they exist in the *Cat* (in which they are very small, and excrete their secretion by separate efferent canals). The *urethra* (in its pelvic portion) is very long; towards the ischial arch it shows an enlargement or *bulb*, though this is less, proportionately, than in the Ox; the accelerator muscle is continued for a longer distance around it. (The spongy portion is thinner in the *Cat* than the *Dog*.)

"In the *Dog*, the *penis* is long and pointed. The posterior half is constituted by the corpus cavernosum, which is little developed, and has not a complete middle septum. The anterior moiety has for its base a bone, found in several other mammifers, which is intended to favour the introduction of the penis into the genital organs of the female.

"The *penien*, or *penial*, bone is elongated, conical, and incurvated, so as to constitute a furrow inferiorly, in which is lodged the urethra when it leaves the fibrous channel of the corpus cavernosum; its apex, anteriorly, partly forms the point of the penis; its base is intimately united to the anterior portion of the corpus cavernosum: the median septum, which is very dense, is fixed in this bone, as is the fibrous envelope which mixes with its periosteum.

"The penial bone almost entirely constitutes the base of all that portion of the penis included within the sheath; in addition, this part possesses two distinct *erectile enlargements*—an *anterior* and *posterior*. The first is analogous to that of the glans penis of the Horse, and is formed by an expansion of the erectile tissue of the urethra; club-shaped at its anterior base, it has there a point suddenly bent downwards, beneath which is pierced the urethral orifice; posteriorly it is thin, and partially covers the other erectile mass. The latter is supplementary; it begins at the base of the free portion of the penis, where the integument of the sheath is folded in a circular manner around it. From 1 to $1\frac{1}{2}$ inches long, it embraces the upper border and sides of the bone; pyramidal in shape, its base, which is posterior, is $\frac{3}{4}$ to $1\frac{1}{4}$ inches thick; in front, it thins away beneath the erectile tissue of the head.

"Such are the two erectile masses, whose summits overlap, so that the free portion of the penis, bulging in front, and still more so behind, is narrowest in the middle. Although contiguous, these two vascular dilatations are independent of each other; the posterior has, likewise, no communication with the corpus cavernosum, and possesses two particular veins which pass backward in a lateral groove. Each is erected separately during copulation, when they assume a large size; the great volume of the posterior enlargement prolongs the duration of this act, until flaccidity ensues. This peculiarity is a consequence of the absence of the seminal reservoirs (the vesiculæ seminales).

"In the *Dog*, two small *muscles* are found which appear to be destined to elevate the penis and direct it during its introduction into the sexual parts of the female, as its erection is always feeble. These are two fasciculi which proceed from the crura of the penis, and pass forward to unite in a common tendon implanted on the dorsal border of the organ; they thus resemble the chord of an arc.

"The subpenial muscular cords exist as in the other animals. The *sheath* is narrow and long, and, as in the didactyles, has *protractor* muscles; the integument is thin and rose-coloured, like that covering the free portion of the penis.

"In the *Cat*, the penis is short, and directed backwards; but in a state of erection it is inclined forwards for copulation. Its free portion presents some peculiarities. It is conical, and its summit, near which is pierced the urethral opening, has for its basis a small incomplete penial bone, that encloses a layer of erectile tissue—an expansion of that of the urethra. This free portion is covered by an integument studded with somewhat rigid papillæ directed backwards, and capable of being made erect during copulation. These points, which are met with in nearly all the *Cat* kind, are analogous to the hairs, scales, strong spines, and even the cartilaginous saws, of certain other animals, and which appear to be related to the degree of sensitiveness of the female sexual organs."—*A. Lavocat.*

COMPARISON OF THE GENITAL ORGANS OF MAN WITH THOSE OF ANIMALS.

Coverings of the testicles.—The *scrotum*, *dartos*, *tunica erythryoidea*, and *tunica vaginalis* have the same organisation as in Solipeds. The scrotum is rich in sebaceous glands, and the tunica vaginalis is separated by a serous layer from the peritoneal cavity.

Testicles.—These are ovoid, and situated in an oblique direction downwards and inwards; their largest curvature is forwards.

The *epididymis* offers the same arrangement as already noticed, except that the vas deferens, in being detached from the globus minor, is bent somewhat suddenly to reach the abdominal cavity. There are several diverticuli annexed to the epididymis, named the *pediculated hydatid of Morgagni*, *non-pediculated hydatid aberrant vessels*, and *corpus innominatum* of Giraldès.

Fig. 406.

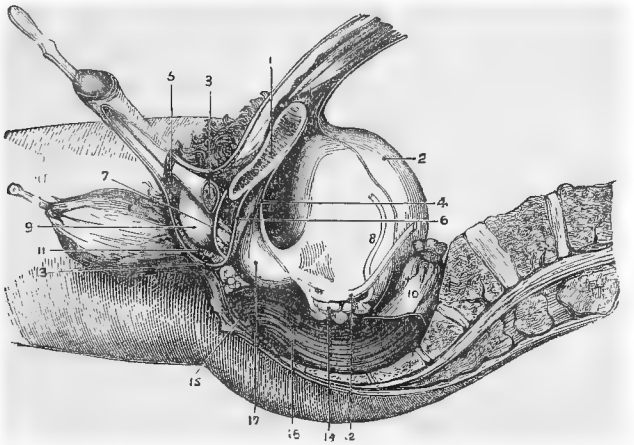

SECTION OF PELVIS TO THE LEFT OF THE MEDIAN LINE AT THE PUBES, AND THROUGH THE MIDDLE OF THE SACRUM.

1, Section of left pubic bone; 2, Peritoneum on bladder; 3, Left crus penis; 4, Pelvic fascia forming anterior ligaments of bladder; 5, Part of accelerator urinæ; 6, Posterior layer of triangular ligament forming the capsule of the prostate; 7, Anterior layer of triangular ligament; Between 6 and 7 are seen the membranous urethra, deep muscles of urethra (insertion), and Cowper's gland of the left side; 8, Vas deferens; 9, Bulb of urethra; 10, Rectum; 11, Cut edges of accelerator urinæ and transversus perinæi; 12, Left ureter; 13, Reflection of deep layer of superficial fascia round transversus perinæi; 14, Left vesicula seminalis; 15, Cut edge of levator ani; 16, Rectum; 17, Prostate gland.

The *hydatid of Morgagni* is a little projection at the head of the epididymis, filled with a serous fluid which is never mixed with the semen. The *non-pediculated hydatid* is a small white mass which rises from the testicle at some distance from the globus major; it has a cavity that communicates with the duct of the epididymis. The *aberrant vessels* are fine flexuous ducts given off from the globus minor, and soon terminate in a *cul-de-sac*. The *corpus innominatum* of Giraldès is a small mass of ramifying tubes included in the connective tissue uniting the globus major to the testicle. All these appendages of the testicle or epididymis, are the remains of the Wolffian body.

Vas deferens.—This is not united to its fellow by a peritoneal fold; it is slightly dilated on arriving at the neck of the bladder, as in the Horse. The vesiculæ seminales are elongated, and lobulated on their surface, as in Ruminants.

Urethra.—This canal has a fixed and a free portion: the first is slightly inclined downwards and forwards; the second is suddenly inflected, and, with the preceding, forms the prepubic angle, which disappears with erection. Its diameter increases a little at the *bulb*, and again at the meatus, to form the *fossa navicularis*. Its erectile envelope forms a considerable enlargement at its commencement—the *bulb*, and this is covered, as in the Ox, by the accelerator urinæ; it also composes another, the *glans*, that

constitutes the head of the penis. On its inner surface are some valvular folds, some depressions, the *lacunæ of Morgagni*, the *veru montanum*, and towards the summit of this a small pouch—the *male uterus* (*sinus pocularis*), which, on a very reduced scale, represents the third vesicula of Solipeds. The muscles of the urethra are the *ischio-cavernosum*, *accelerator urinæ*, *Wilson's muscle*, and the *transversus perinæi—superficial* and *deep*. On emerging from the pelvic cavity, the urethra traverses an aponeurotic membrane named the ligament of Carcassonne.

Corpus cavernosum.—This offers nothing particular in its disposition.

Penis.—This organ is free, and is suspended in front of the pubis. It is enveloped by a fibrous covering—the *superficial fascia*, and a cutaneous cylinder—the *sheath*. It is attached by two supensory ligaments: the superficial is elastic, and arises from the linea alba; the deep is inelastic, and is detached from the symphysis pubis and the anterior pillar of the inguinal ring. (It is usual to describe only one ligament—the *ligamentum suspensorium penis*, separating to form two layers which give passage to the dorsal vessels, and nerves of the penis.) The *glans* is separated from the rest of the organ by a constriction designated the *cervix*, and around this the skin forms a (circular) fold—the *prepuce*, which covers the glans more or less completely. It is attached to the middle of its lower face by a thin fold—the *frænum præputii*. The inner surface of the prepuce has a large number of sebaceous glands.

CHAPTER II.

GENITAL ORGANS OF THE FEMALE.

THESE organs resemble those of the male in their general disposition. Thus we find in the female: 1, Two secretory organs, the *ovaries*, analogous to the testicles, and charged with the elaboration of the germ; 2, The *uterine* (*Fallopian*) *tube*, disposed, like the epididymis and vas deferens, as a flexuous canal, through which the ovum passes on leaving the ovary; 3, The *uterus*, a single reservoir formed of two lateral moieties which may be compared to the vesiculæ seminales, as it is there that the germ remains until it is fully developed; 4, The *vagina*, a membranous canal analogous to the urethra, and giving passage to the fœtus after it has been formed in the uterus: this canal, which receives the penis during copulation, also shows, at its exterior opening, the *vulva*, an erectile apparatus, and the *clitoris*, which is nothing more than a rudimentary corpus cavernosum of the male. The female has also certain glands, which, in many species, exist in a rudimentary form in the male: for instance, the mammæ, organs for the secretion of milk, the first nourishment of the young animal.

(The glands of Duverney, in the female vagina, seem to be analogous to Cowper's glands in the male, as they are present in the females of all animals where the latter exist in the male, and their secretion appears to be of the same character.)

It may be remarked, after this enunciation, that the male and female genital apparatus are constructed on the same type: a circumstance which is most clearly demonstrated at an early period of intra-uterine life, when it is impossible to distinguish the sexes.

1. *The Ovaries.* (Fig. 411, 1.)

Situation—Form—Relations.—The *ovaries* (*testes muliebres*), the essential organs of generation in the female, are two ovoid bodies, smaller than the testicles, though of the same shape, situated in the abdominal cavity,[1] and

[1] The ovaries sometimes leave this situation. Thus M. Dupont, of Plazac, has observed them, in four swine, occupying little cavities, analogous to those of the male scrotum, in the perineal region.—'Journal des Vétérinaires du Midi,' December, 1869.

suspended from the sublumbar region, where they correspond with the intestinal convolutions, a little behind the kidneys. Smooth on the surface, these organs present, in the middle of their upper face, a deep, and more or less oblique fissure, resembling the *hilus* of the kidney; this gives attachment to the pavilion of the tube.

Means of attachment.—The ovary floats at the anterior border of the broad ligament; it is also sustained by the vessels which enter it, and by a small cord of unstriped muscular fibres, the *ligament of the ovary*, which attaches it to the uterus.

STRUCTURE.—The organisation of the ovaries comprises a *serous membrane*, a *tunica albuginea*, *proper tissue*, and the *Graafian vesicles* imbedded therein.

Serous membrane.—This is a continuation of the broad ligaments; it covers the whole organ (except at the hilus), adhering closely to the tunica albuginea.

Tunica albuginea.—This is similar to that enveloping the testicle, being a very resisting fibrous case which sends prolongations into the substance of the ovary.

Proper tissue.—The proper tissue, or stroma, of the ovary is more consistent than that of the testicle; it is hard, grates on being cut into, and is greyish-red in colour. It is divisible into two layers, distinguishable by their aspect and structure.

1. The *medullary layer*, that nearest the hilus, is slightly red and spongy; it is formed by an interlacing of the connective fibres, unstriped muscular fibres, and a large number of vessels that radiate from the centre towards the periphery.

2. The *cortical layer* has the elements of connective tissue for its base; it is but little vascular, and contains in its substance the *Graafian vesicles* or *follicles* (*ovisacs*), and is consequently often named the *ovigenous layer*. These ovisacs are in various stages of development; the smallest are situated beneath the tunica albuginea, and gradually increase as they lie deeper. When fully developed, they are filled with a transparent, citron-coloured fluid; the ovigenous layer can then no longer contain them, and they protrude more or less from the surface of the ovary.

A *Graafian vesicle*, in its perfect state, is composed of an envelope and its contents. The envelope comprises: a *fibrous membrane* (*tunica fibrosa*), which is confounded with the stroma of the ovary, and in it we may recognise two layers, the internal of which is rich in vessels; and an *epithelium*, or *membrana granulosa*, consisting of round or polygonal granular cells. At the bottom of the ovisac, this epithelium forms a small mass—the *cumulus proligerus* (or *germinal eminence*), in the centre of which is the *ovulum* or egg of the mammal. The *contents* (*liquor folliculi*) are a clear yellow fluid, which becomes red on admixture with blood when the vesicle ruptures.

The *ovulum* or *ovum* is a cell about 1-100th of an inch in diameter, inclosed in the *discus proligerus* or *cumulus proligerus*. The ovulum is invested by an amorphous, thick cell-membrane—the *zona pellucida* (*membrana vitellina*); its granular contents are named the *vitellus* or *yelk*; and its (vesicular nucleated) nucleus, designated the *germinal vesicle*, and lying at a certain point on the zona pellucida, has in its centre a white patch—the *germinal spot*.

Vessels and nerves.—The thick, flexuous, arterial divisions are given off by the *utero-ovarian artery*; they ramify in the spaces formed by the tunica albuginea, before reaching the proper tissue by entering the hilus. The

veins are of large calibre, and form a very rich network around the gland —the *bulb of the ovary;* they terminate in the vena cava, near the renal veins. The *lymphatics* pass to the sublumbar glands. The nerves emanate from the small mesenteric plexus.

Development.—The ovary of Solipeds is of great size in the fœtus, being often nearly as large as in the adult animal. It becomes wasted in aged animals.

Functions.—The productive organs of the germ or ovum, the ovaries are the *testicles* of the female. They form the ovulum, and then at a certain period set it at liberty. As the ovulæ are contained in the ovisacs, it is necessary to study: 1, The development of these ovisacs; 2, Their rupture or dehisence; 3, The phenomena occuring in them after this rupture.

Development of the Ovisacs.—The ovisacs already exist in the ovary of the fœtus and the young animal, but only assume their greatest activity at the age of puberty. They are not all formed at birth, but are incessantly re-developed, this development taking place beneath the tunica albuginea. (At puberty, the stroma of the ovary is crowded with ovisacs so minute, that in the Cow it has been computed that a cubic inch would contain two hundred millions of them.)

Fig. 407.

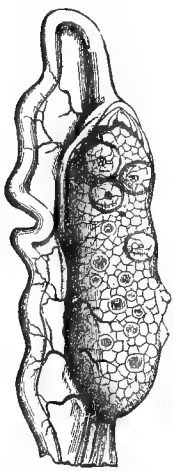

OVARIUM OF THE RABBIT AT THE PERIOD OF ŒSTRUM, SHOWING VARIOUS STAGES OF THE EXTRUSION OF OVA.

At first the ovisac consists of a small cell, which presents all the constituent parts of the ovulum. As it becomes developed it sinks into the cortical layer, being pushed deeper into it by the cells that grow outside it; and it is also surrounded by a granular membrane, formed at the expense of the nuclear elements of the adjacent connective tissue. This membrane soon separates at a given point into two layers, to form a cavity that gradually extends and becomes filled with fluid: this is the cavity of the ovulum. As the separation is not complete, the ovulum, enveloped by the internal granular membrane, remains beside the external granular membrane, and while the cavity is increasing, the tissue of the ovary, pressed around it, is condensed, constituting the fibrous wall of the ovisac, which afterwards receives a network of vessels.

Rupture of the Ovisacs.—Until puberty, the ovisacs do not exhibit any very marked phenomena; at this period, however, the ovary becomes vascularised, and a certain number of Graafian vesicles increase in volume. At the period of œstrum, one or more of these, according to the species, participate in the change in the ovary, become vascular and distended, and finish by rupturing and evacuating the discus proligerus and ovulum. The latter is received into the Fallopian tube and conveyed towards the uterus.

Corpus Luteum.—After the rupture of a Graafian vesicle, its cavity is filled by a clot of blood which gradually contracts and loses its colour; at the same time the fibrous membrane becomes hypertrophied, and the granular layer is wrinkled and transformed into cylindrical epithelium. To this period of progression succeeds one of regression, during which the cylindrical cells become infiltrated with fat and are gradually absorbed.

The term *corpus luteum* is given to the cicatrix resulting from the rupture of the ovisac.

The progress of the phenomena of hypertrophy and regression is much slower when the escape of the ovulum has been followed by impregnation;

Fig. 408.

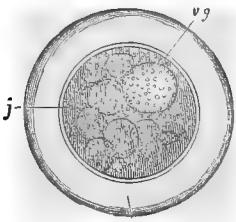

Fig. 409.

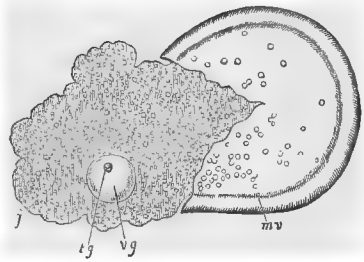

CONSTITUENT PARTS OF MAMMALIAN OVUM.

Fig. 408, Entire ovum; Fig. 409, Ovum ruptured, with the contents escaping; *mv*, Vitelline membrane; *j*, Yolk; *vg*, Germinal vesicle; *tg*, Germinal spot.

so that we have *false corpora lutea* (those which are independent of pregnancy), and *true corpora lutea*, those of gestation, and which do not disappear until several weeks after parturition. (The true corpora lutea are recognisable, after parturition, as small white or dark-coloured masses, the *corpora albicans vel nigrum.* The yellow colour to which they owe their name is due to the infiltration of the cylindrical cells with fat.)

Fig. 410.

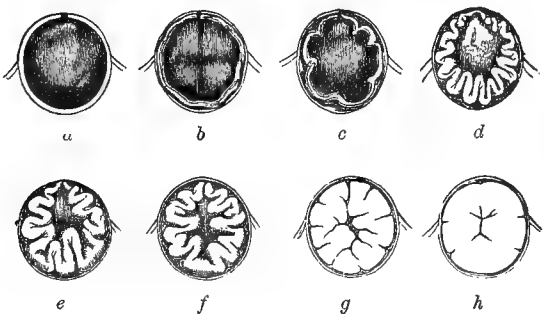

SUCCESSIVE STAGES IN THE FORMATION OF THE CORPUS LUTEUM IN THE GRAAFIAN FOLLICLE OF A SOW; VERTICAL SECTION.

a, The follicle immediately after the expulsion of the ovum, its cavity being filled with blood, and no ostensible increase of its epithelial lining having yet taken place; at *b*, a thickening of this lining has become apparent; at *c*, it begins to present folds which are deepened at *d*, and the clot of blood is being absorbed and decolorized; a continuance of the same process, as shown at *e*, *f*, *g*, *h*, forms the corpus luteum, with its stellate cicatrix.

Such are, very briefly, the functions of the ovary.

(Beneath the hilus of the ovary, and between the layers of the broad ligament and the round ligament, is found a small body, usually described as the *parovarium*, consisting of a number of fine tubes with blind extremities. It is considered as the remains of the Wolffian body: a fœtal structure that forms the epididymis in the male, and has been named the *organ of Rosenmuller* in the female. Chauveau does not mention its existence in the domesticated animals, though Leyh does.)

2. *The Oviducts, or Fallopian or Uterine Tubes.* (Fig. 411, 2.)

The *uterine tube* is a little flexuous canal, lodged in the broad ligament, near its anterior border. It commences at the ovary by a free, expanding extremity—the *pavilion of the tube* (or *ostium abdominale*), and terminates in the *cul-de-sac* of the uterine horn by opening into it (the *ostium uterinum*). Its canal at the middle is so narrow as scarcely to admit more than a very thin straw, and its calibre is still less towards the uterine extremity; near the ovary, however, it is wide enough for the passage of a thick goose-quill.

The orifice of the *uterine extremity* opens in a small and very hard tubercle. The *ovarian extremity*, in all mammalia, offers a very remarkable arrangement. It opens into the peritoneal cavity, near the fissure of the ovary, and in the centre of the expansion named the *pavilion of the tube*, which is also designated the *fimbriated extremity* (or *morsus diaboli*). This pavilion is attached to the external side of the ovary, and has a very irregular outline: notched as it is into several lancet-shaped, unequal prolongations (*fimbriæ*), which float freely in the abdomen. Here are, then, two important anatomical facts: the discontinuity between a gland and its excretory canal, and the communication of a serous cavity with the exterior.

Structure.—The oviduct is formed of a serous, a contractile, and a mucous tunic. The *serous* (*external*) is furnished by the broad ligament, and is derived from the peritoneum. The *contractile* (*middle*) is constituted by unstriped muscular fibres, which extend into the pavilion. (They are arranged as *circular*—internal, and *longitudinal*—external fibres, and are continuous with those of the uterus; they are mixed with immature nucleated areolar tissue.) The *mucous membrane* is in longitudinal folds in the tube, but in the pavilion these folds are radiating; it is covered by a ciliated cylindrical epithelium (the vibrations of the cilia being towards the uterus.) (It has very few glands and no villi.) At the margin, or fimbriæ, of the pavilion it suddenly ceases, and is continued by the peritoneum (a serous cyst is frequently found in this situation; at the other extremity the mucous membrane is continuous with that of the uterus).

Functions.—The excretory duct of the ovary, the uterine tube, seizes the ovulum expelled from the ovisac, and carries it to the uterus. It is therefore necessary that, at the moment of rupture of the ovisac, the fimbriæ should be applied to the ovary, in order to receive the germ and bring it to the abdominal orifice of the tube. The application of the pavilion to the ovary is brought about either by the contraction of the muscular fibres it contains, or through the distention of the bulb of the ovary. Sometimes this mechanism is insufficient, and the ovulum falls into the abdominal cavity, becomes fixed there, and is developed if it has been previously fecundated; this occurrence constitutes the most remarkable variety of extra-uterine gestation.

The oviduct also conveys the seminal fluid of the male to the ovulum.

3. *The Uterus.* (Figs. 411, 412.)

The *uterus* is a membranous sac to which the ovulum is carried, and in which it is developed.

Situation.—It is situated in the abdominal cavity, in the sublumbar region, at the entrance to the pelvic cavity, where its posterior extremity is placed.

Form and relations.—In its posterior moiety, the uterus is a single cylindrical reservoir, slightly depressed above and below; this is the *body* of the uterus. Its anterior moiety is bifid, and gives rise to *two cornua*, which curve upwards.

The *body* is related, by its upper face, to the rectum, which lies on it after passing between the two cornua; it receives, on the sides of this face, the attachment of the broad ligaments; its lateral and anterior faces are related to the intestinal convolutions. (*Inferiorly*, it is in relation with the bladder.) Its *anterior extremity* (or *fundus*) is continuous, without interruption, with each of the cornua; the *posterior* is separated from the vagina by a constriction of the *neck* (*cervix*) *of the uterus.*

The *cornua*, mingled with the different portions of intestine which occupy the same region, offer: a free and convex *inferior curvature;* a *superior curvature*, to which the suspensory ligaments are attached; a *posterior extremity*, or *base*, fixed to the body of the organ; and an *anterior extremity* or *summit*—a rounded blind pouch looking downwards, and showing the entrance of the oviduct.

Means of attachment.—Floating in the abdominal cavity, like the intestines, the uterus is also, like them, attached by lamellar bands which suspend it to the sublumbar region, and which for this reason have been named the *suspensory* or *broad ligaments of the uterus.*

These bands are two in number, are irregularly triangular in shape, and are more developed before than behind. Close to each other posteriorly, and separating in front like the branches of the letter V, they leave the sublumbar surface and descend towards the uterus, to be attached by their inferior border to the sides of the upper face of the body and the small curvature of the cornua. Their anterior body is free; they sustain the oviducts and ovaries, the former being placed between the two serous layers of the ligament, and the latter, placed within this ligament, receives a band detached from the principal layer, forming with it, beneath the ovary, a kind of small cupola.

There is also another little narrow long band outside the broad ligament, and which can be traced as far as the upper inguinal ring. Anteriorly, it has a small enlarged appendix; between the two layers forming this fold is found a thin muscle, altogether like the male cremaster before the descent of the testicle into the scrotum. This may be looked upon as the analogue of the *round ligament* of Woman.

The uterus is also fixed in its situation by its continuity with the vagina.

Interior.—The inner surface of this organ offers mucous folds, which exist even in the fœtus; they are arranged in a longitudinal series, and are not effacable by distension; though they disappear during gestation, consequent on the enlargement that takes place in the uterine cavity.

This cavity has three compartments: the *cavity of the body*, and those of the *cornua.* The latter are pierced, at their extremity, by the uterine orifice of the Fallopian tube; while the former communicates with the

Fig. 411.

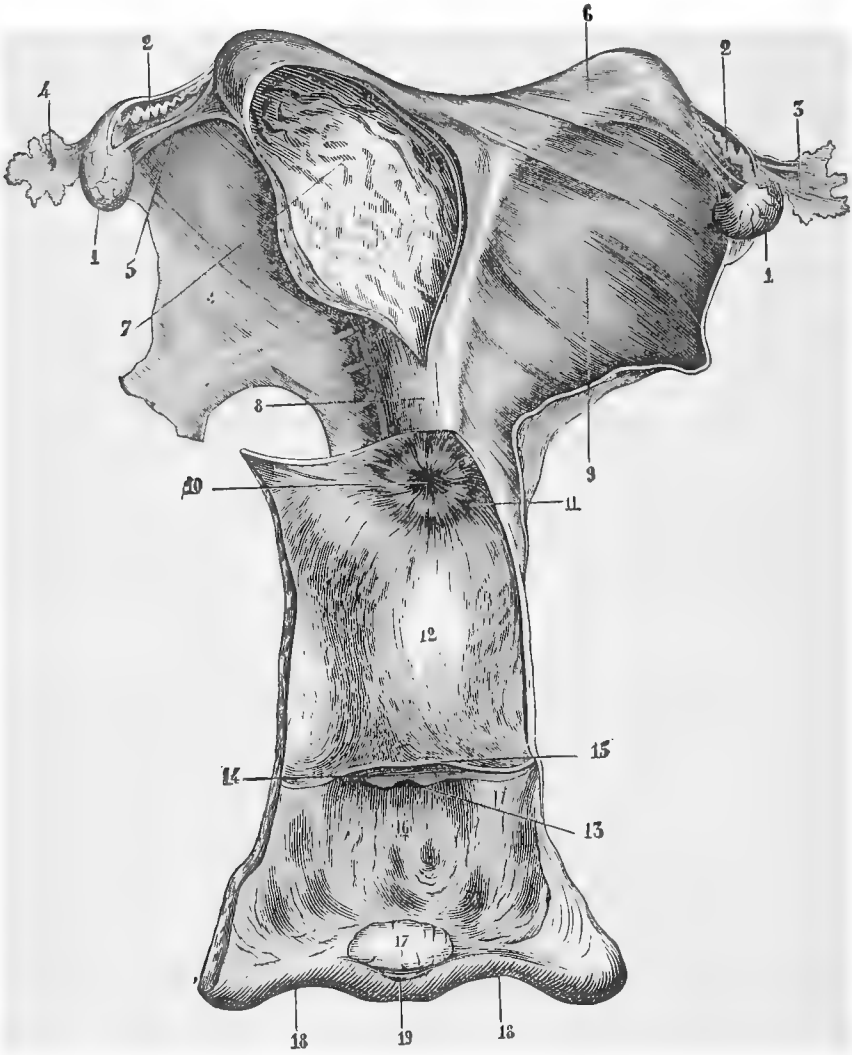

GENERATIVE ORGANS OF THE MARE, ISOLATED AND PARTLY OPENED.

1, 1, Ovaries; 2, 2, Fallopian tubes; 3, Pavilion of the tube, external face; 4, Ibid., inner face, showing the opening in the middle; 5, Ligament of the ovary; 6, Intact horn of the uterus; 7, A horn thrown open; 8, Body of the uterus, upper face; 9, Broad ligament; 10, Cervix, with its mucous folds; 11, *Cul-de-sac* of the vagina; 12, Interior of the vagina, with its folds of mucous membrane; 13, Urinary meatus, and its valve, 14; 15, Mucous fold, a vestige of the hymen; 16, Interior of the vulva; 17, Clitoris; 18, 18, Labia of the vulva; 19, Inferior commissure of the vulva.

vagina by a narrow canal that passes through the posterior constriction of the uterus (cervix), and which is, in Human anatomy, named *the cavity (or canal) of the cervix* (*os uteri, os externum, os tricæ*). In all the domesticated animals, except the Rabbit, the uterine canal is prolonged to the bottom of the vagina, in something the same fashion as a tap is into the interior of a barrel; and in this way it always forms a very marked projection in the vaginal cavity. Around this projection, the utero-vaginal mucous membrane is raised in transverse folds disposed in a circular manner, which give it the appearance of a radiated flower; in Veterinary anatomy, this projection of the cervix is consequently named the "expanded flower"—*fleur épanouie*; it is the *tench's nose* of the Human being.

STRUCTURE.—The walls of the uterus are composed of three membranes: an external, *serous;* a middle, *muscular;* and an internal, *mucous;* with vessels and nerves.

The *serous tunic* envelops all the organ; it is an expansion of the broad ligaments, which are prolonged backwards on the posterior extremity of the vagina, and are afterwards doubled in a circular fashion around that canal, to pass over either the rectum, the bladder, or the lateral walls of the pelvis. Between the two cornua this membrane forms a particular frænum, which is but slightly developed in Solipeds.

The *muscular layer* comprises longitudinal (superficial), and circular (deep) fibres, analogous to those of the small intestine. Near the insertion of the broad ligaments, they give off a series of fasciculi which are prolonged between the two layers of these ligaments. These are not the only muscular fibres met with in the ligaments, however; for Rouget has found others throughout their whole extent, but particularly in the vicinity of the ovaries.[1] (Around the cervix uteri, the circular fibres are most dense and numerous.)

In the pregnant animal, the number of fibres composing this layer is much more considerable than in ordinary circumstances; and this increase has for its object to permit the dilatation of the uterus, without allowing its parietes to become too attenuated; they do become more or less thin, notwithstanding, according to the species. It has also been remarked that, during pregnancy, the muscular fibres present a manifest striation. (The elements of these fibres are short fusiform cells with long oval nuclei, mixed with a large quantity of immature nucleated areolar tissue.)

The *mucous membrane* is thin, delicate, and raised into folds. It is covered by ciliated epithelium, which becomes cylindrical in the canal of the cervix, and pavemental around the os uteri. (The cilia vibrate towards the fundus of the organ. The membrane is closely connected with the muscular tunic, and is composed of immature nucleated areolar tissue without elastic fibres.) The uterine mucous membrane is destitute of papillæ (except at the cervix, where, according to Leyh, there are many highly vascular papillæ); but it lodges numerous simple or ramified glands, which are straight or slightly flexuous at their extremities. At the cervix, these glands enlarge at the bottom, and assume something of the appearance of acinous glands.

(These mucous glands are designated *simple* and *cylindrical.* The first are most numerous towards the cervix; some, here and there, with their orifices closed, are enlarged, and form small vesicular tumours, the *ovula Nabothi;* they secrete the peculiar transparent mucus found here. The

[1] Unstriped contractile fibres are also found, in the male, along the spermatic cord, beneath the visceral layer of the tunica vaginalis.

cylindrical, *uterine*, or *utricular* glands are closely clustered together, sometimes bifurcated, often twisted in a spiral fashion, and terminating in a *cul-de-sac* in the substance of the membrane. In structure they resemble other mucous glands, consisting of a membrana propria, an epithelium of spheroidal cells at the bottom of the tube, and of columnar cells in its duct. During gestation they are much enlarged, and receive the cotyledonal processes of the placenta. At the period of œstrum, the glandular secretion of the uterus is more active than at other times.)

Vessels—Nerves.—The blood brought to the uterus by the *uterine* and *utero-ovarian arteries*, is conveyed from it by veins corresponding to the latter. In animals which have been pregnant several times, the vessels are remarkable for their enormous volume and their tortuousness. (The arteries freely anastomose; they ramify through the muscular and mucous tunics, constituting coarse and fine networks which ultimately end in the veins. These are very large and have no valves; the plexuses they form are considerable.)

The *lymphatics* that pass from the uterus are as remarkable for their number as their dimensions; they reach the sublumbar region.

The *nerves* supplying the organ come from the small mesenteric and pelvic plexuses. (In the uterus there are several important nervous ganglia; and during gestation it has been ascertained that the nerves, like the vessels, enlarge, and after parturition return to their former size.)

Development.—Narrow in the fœtus, and in the adult which has not been impregnated, the uterus increases in size in animals which have had young several times.

Functions.—The uterus is the sac in which the embryo is developed. The ovulum grafts itself upon the mucous membrane of the organ by its placental apparatus, in order to draw indirectly, from the maternal blood, the materials for its development. This function of the uterus gives rise to most interesting anatomical and physiological considerations, which will be referred to when giving the history of the ovum.

4. *The Vagina.* (Figs. 411, 412.)

The *vagina* is a membranous canal with thin walls; it succeeds the uterus, and terminates posteriorly by an external opening—the *vulva.*

Situation and Relations.—Situated in the pelvic cavity, which it passes horizontally across, the vagina is in relation with the rectum above, below with the bladder, and laterally with the sides of the pelvis and ureters. Loose connective and adipose tissue surround it posteriorly.

Internal conformation.—The inner surface of the vagina is always lubricated by an abundance of mucus, and is ridged by longitudinal folds (*columnæ rugosæ*). In front, at the bottom of the canal, is observed the projection formed by the cervix uteri; posteriorly, this surface is continuous with that of the vulva.

Structure.—The vagina is formed of two tunics; an inner, *mucous*, and an external, *muscular*. The *mucous membrane* (pale-red in colour) is continuous with that lining the vulva and the uterus (and bladder); it is provided with papillæ, and is lined by stratified pavement (squamous) epithelium. (It consists of connective and elastic tissue, to which its extensibility and firmness are due.)

The *muscular coat* is rose-coloured, and traversed by a large number of vessels; it is surrounded, for the greater part of its extent, by an abundance

of connective tissue which joins it to the organs contained in the pelvic cavity; in front, however, it is enveloped by the peritoneum which surrounds the vagina before passing to the uterus. (This connective tissue is

Fig. 412.

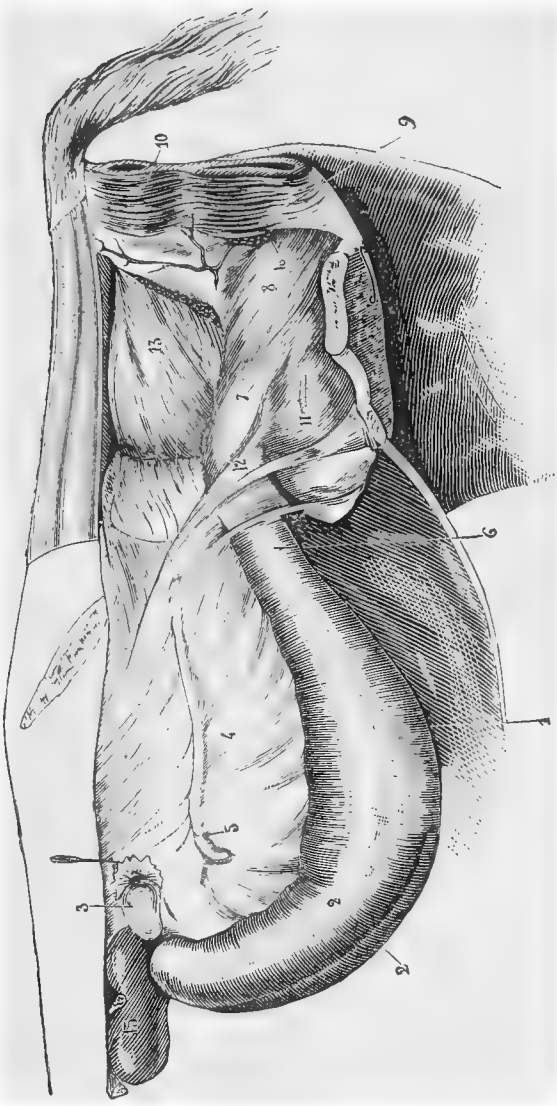

GENERATIVE ORGANS OF THE MARE *in situ*.

1, Body of the uterus; 2, 2, Cornua; 3, Ovary, with the pavilion of the tube hooked back; 4, Broad ligament; 5, Rudimentary round ligament; 6, Cervix uteri; 7, Vagina; 8, Anterior constrictor of the vulva; 9, Posterior ditto; 10, Sphincter of the anus; 11, Bladder; 12, Ureter; 13, Rectum; 14, Circular fold of peritoneum surrounding the Rectum; 15, Kidney; 16, Bulb of the vagina.

sometimes designated the *third* or *fibrous* tunic of the vagina. The muscular fibres are unstriped, and arranged in circular and longitudinal series; towards the posterior portion of the canal they are redder than in front.)

Vessels and nerves.—The vagina is supplied with blood by the *internal*

pudic artery; this fluid is carried from it by numerous veins, which are disposed in a plexus around the canal, and enter the satellite of the artery. The *nerves* come from the pelvic plexus. (The *lymphatics* accompany the veins, and pass to the pelvic glands.)

Function.—The vagina receives the male organ during copulation, and through it the fœtus passes during parturition.

5. *The Vulva.* (Fig. 411.)

The external orifice of the vagina, the *vulva* is situated in the perineal region, immediately below the anus. We will consider in succession its *external opening*, its *cavity*, and its *structure*.

External Opening.—This is a vertical elongated slit, presenting *two lips* and *two commissures*. The *lips* (*labia vulvæ*) are covered externally by a fine smooth, unctuous, and (almost) hairless skin, rich in colouring pigment, and lined internally by mucous membrane; on their free margin, the limits of these two membranes are well marked. The *superior commissure* is very acute, and almost meets the anus, from which it is nevertheless separated by a narrow space—the *perineum*. The *inferior commissure* is obtuse and rounded; it lodges the clitoris.

Cavity of the Vulva.—By all Veterinary authorities, this cavity is described as belonging to the vagina, to which it forms the entrance; but considering the analogies that exist between the genital parts of Woman and those of animals, this cavity must be distinguished from that of the vagina. It offers for study the *hymen*, which separates the two cavities, the *meatus urinarius* and its *valve*, and the *clitoris*.

The Clitoris.—Exactly similar to the corpus cavernosum of the male, which it represents in miniature, and 2 to 3 inches in length, the clitoris commences by two crura fixed to the ischial arch, and covered by a rudimentary ischio-cavernosum muscle. After being attached to the symphysis by means of a suspensory ligament analogous to that of the male, it passes backwards and protrudes into the vulvular cavity, towards the inferior commissure. Its free extremity, lodged in that cavity, is enveloped by a mucous cap—the *prepuce of the clitoris* (*præputium clitoridis*), which is folded in various directions, and excavated about the centre of the tubercle by a small *follicular cavity* that represents the extremity of the male penis. The organisation of the clitoris resembles in every particular that of the corpus cavernosum of the penis: a fibrous framework, erectile tissue, and cavernous vessels. It is the contact of the penis with this organ during copulation that chiefly occasions the venereal excitation.

The Meatus Urinarius and its Valve.—The urethral canal in the female is very short. It passes immediately beneath the anterior sphincter muscle of the vulva, and after a brief course in the texture of the floor of the vagina, it opens into the vulvular cavity by an orifice covered by a large mucous valve: this is the *meatus urinarius* and its *valve*. The *urinary opening*, placed at the bottom of the cavity, at from 3½ to 5 inches from the external opening, is wider than the male urethra, and will admit sounds of somewhat large calibre, for the catheterism of the bladder. The *valve* has its free border inclining backwards, to direct the flow of urine towards the exterior, and prevent its reflux into the vagina.

(The female urethra is composed of two tunics: a *mucous*, continuous with that of the bladder and vagina; and a *muscular* coat, also a continuation of that belonging to these organs, and chiefly made up of circular

fibres; some flat fasciculi attach it to the periosteum of the ischia. The urethra is not surrounded by a spongy body as in the male.)

THE HYMEN.—This membrane, when it exists, distinctly separates the vulvular from the vaginal cavity. It is rarely present, however; though we have observed it several times in the adult Mare. It forms a circular partition, fixed by its margin to the vulvo-vaginal walls, as well as to the valve of the meatus urinarius, and is perforated by one or more openings which establish a communication between the vulva and vagina. On many occasions we have found, in old brood-mares, pediculated appendages, the remains of this septum.

STRUCTURE OF THE VULVA.—The vulva offers for study in its structure: 1, The *mucous membrane* lining its interior; 2, An erectile body lying on that membrane, and named the *vaginal bulb;* 3, *Two constrictor muscles—anterior* and *posterior;* 4, *Two muscular ligaments;* 5. The *external skin.*

1. *Mucous membrane.*—Continuous with that of the vagina and bladder, this membrane has a rosy colour, which may become a bright-red at the period of heat. It often shows, near the free border of the labia, black pigment patches, which give it a speckled appearance. It has in its substance a greater quantity of mucous follicles and sebaceous glands. The latter exist near the free border, particularly about the clitoris, and especially in the space between that erectile body and the inferior commissure of the vulva, where they meet in several small sinuses. (These glands secrete an unctuous matter possessing a special odour; they are most active during œstrum.)

2. *Vaginal bulb.*—This is an organ entirely formed of erectile tissue with wide areolæ; it is divided into two branches (*bulbi vestibuli*), which arise from the vicinity of the crura of the clitoris and pass on the sides of the vulva, where they terminate in a round lobe. Covered by the posterior constrictor of the vulva, the vaginal bulb communicates, inferiorly, with the veins of the corpus cavernosum. The influx of blood into the cells of its tissue contracts the vulvular cavity, and concurs to render the coaptation of the copulatory organs more perfect during coition.

3. *Muscles of the vulva.*—Imperfectly described and determined in books on Veterinary Anatomy, these belong to the category of voluntary muscles. We recognise two, which will be described as the *posterior* and *anterior constrictors.*

POSTERIOR CONSTRICTOR OF THE VULVA.—Analogous to the *constrictor vaginæ* of Woman, this muscle, included in the labia of the vulva, forms a veritable sphincter. Above, its fibres are mixed with those of the sphincter ani, and are attached to the sacrum through the medium of the suspensory ligaments. Inferiorly, the most anterior are fixed to the base of the clitoris; the middle are prolonged to between the thighs, and are inserted into the inner surface of the skin.

Inwardly, it is in relation with the vaginal bulb and the mucous membrane of the vulva. Its external face is separated from the skin of the labia by a very vascular cellulo-fibrous tissue capable of contraction, and in the midst of which are always found isolated red fasciculi—dependencies of the principal muscle.

This muscle, in contracting during copulation, constricts the aperture of the vagina and compresses the penis; and as, in consequence of its attachment to the clitoris, it cannot act without raising that erectile body, it applies this to the male organ and causes a greater degree of excitement. With animals in heat, the movements of the clitoris are frequently observed

to propel that organ outwards, especially after micturation; in this case, the fibres of the constrictor attached to the clitoris erect it by its base, while those which are fixed into the skin between the thighs depress the inferior commissure of the vulva. This double action necessarily exposes the erectile tubercle lodged in that commissure.

Anterior Constrictor of the Vulva.—Analogous to Wilson's muscle in the male, this constrictor is formed of arciform fibres which envelop, below and laterally, the vaginal walls at the entrance of the canal; its extremities are continued, by means of aponeurotic fascia, to the sides of the rectum, where they are lost. By its posterior border, this muscle is mixed with the preceding.

4. *Muscular ligaments of the vulva.*—Traces of the suspensory cords of the male penis, these ligaments are disposed in the same manner at their origin. After becoming united beneath the rectum, they descend in several fasciculi into the labia of the vulva, and disappear among the fibres of the posterior constrictor.

5. *External skin.*—This is fine and black (or light-coloured), destitute of hair, smooth and unctuous, and adheres closely to the subjacent tissues.

6. *The Mammæ.*

The *mammæ* are glandular organs, which secrete the fluid that should nourish the young animal during the early months of its life. They are rudimentary in youth, and become developed with the advent of puberty, assuming their greatest development towards the end of gestation; they are most active after parturition, and cease their function, as well as diminish in volume, when the period of lactation has terminated.

Situation.—These glands are two in number, placed beside each other in the inguinal region, where they occupy the situation of the scrotum in the male.

Form.—They are two hemispherical masses, separated from each other by a shallow furrow, and showing in their centre a prolongation called the *teat, nipple* (*dug*), or *mammilla*, which is pierced at its free extremity by several orifices for the escape of the milk; it is by this prolongation that the young animal effects suction.

The two glands are fixed in their position by the skin which covers them, and which is thin, black, covered with a fine down, and altogether destitute of hair in the vicinity of, or on, the teat, where the cutaneous surface is smooth, greasy, and supple. They are also attached to the tunica abdominalis by several wide, but short, elastic bands, which resemble the ligaments of the sheath in the male.

Structure.—Structurally, the mammary glands offer for study: 1, A *yellow* (elastic) *fibrous envelope;* 2, *Glandular tissue;* 3, The *galactoferous reservoirs* or *sinuses;* 4, The *excretory canals* or *mammary ducts.*

The *elastic envelope*, placed in the middle, beside its fellow of the opposite side, is mixed with the suspensory bands that descend from the abdominal tunic, and sends into the substance of the gland a number of septa, which are interposed between the principal lobules.

The *glandular tissue* is a compound of *gland vesicles* or *acini*, clustered in groups around the lactiferous ducts. (The gland vesicles are made up of an amorphous membrane, *membrana propria*, lined with spheroidal nucleated cells. They are about 1–200th of an inch in diameter.) The lactiferous ducts commence by blind extremities, and run into each other to constitute

a certain number of principal canals: these open into the galactoferous sinuses (each a *sacculus vel sinus lactiferus*). The glandular *culs-de-sac* are lined with a polyhedral epithelium, which becomes spherical and infiltrated with fat during lactation.

Fig. 413.

GLAND-VESICLES, WITH THEIR EXCRETORY DUCTS TERMINATING IN A DUCTUS LACTIFEROUS: FROM A MERCURIAL INJECTION; MAGNIFIED FOUR TIMES.

Fig. 414.

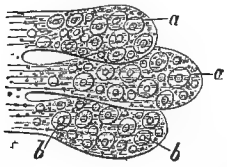

ULTIMATE FOLLICLES, OR GLAND VESICLES, WITH THEIR EPITHELIUM OR SECRETING CELLS, *a*, *a*, AND NUCLEI, *b*, *b*.

Placed at the base of the teat, the *galactoferous sinuses* or *reservoirs* are generally two in number, but sometimes there are three, and even four; they nearly always communicate with each other, and are continued into the mammilla by an equal number of independent excretory canals—the *definitive ducts*, whose orifices are very small, and are seen beside each other at the free extremity of the teat. A fine mucous membrane lines the inner face of this excretory apparatus; it is doubled in the teat by a thick layer of tissue, which again is covered by the skin that adheres closely to it. (Between the external and internal tunic of the teats, are found numerous fasciculi of unstriped muscular fibres, arranged in a circular and longitudinal manner around these ducts.)

Connective tissue, *vessels* and *nerves*, complete this organisation. (The *arteries* are from the external pudic trunk; the *veins* are very numerous, and pass to the trunk of the same name; the *nerves* are derived from the first lumbar pair.)

Fig. 415.



MICROSCOPIC APPEARANCE OF MILK, WITH AN INTERMIXTURE OF COLOSTRIC CORPUSCLES AT *a*, *a*, AND ELSEWHERE.

FUNCTIONS.—The mammæ secrete the milk; they undergo remarkable modifications at puberty and at the end of each gestation—modifications which are related not only to their volume and secretion, but also to their minute structure. After gestation, the gland-vesicles shrink: become, as it were, atrophied, and have only a polygonal epithelium. At the termination of gestation, they are enlarged, new vesicles are developed, and the epithelium changes its character: filling the gland cavities, assuming a spherical shape, and becoming charged with fat granulations. The period of lactation being completed, the mammæ take on their former character. (In Mares which have not been bred from, the mammæ are hard and small, the teats but slightly prominent, and the glandular tissue scanty. In old brood-mares,

on the contrary, they are flaccid and pendant, and the teats somewhat lengthened. The milk secreted by the mammary glands is a white fluid, possessing a sweet taste, and composed of an albuminous water containing caseine in solution, milk sugar, salts, and fatty matter in globules—the *butter*. Usually a small quantity is secreted some days before parturition; that which is yielded for a short time after that period is named *colostrum;* it is rich in white corpuscles and has purgative properties. The colostrum is of a rich yellow colour, less fluid than the milk of a later period, of a higher specific gravity, slightly acid, and containing large oil-globules, a few irregular flakes, probably epithelium scales, a little granular curd-like matter, and a small number of granular corpuscles.)

DIFFERENTIAL CHARACTERS IN THE FEMALE GENITAL ORGANS OF OTHER THAN SOLIPED ANIMALS.

Certain organs offer some differences worthy of notice, while others are formed as in Solipeds.

RUMINANTS.—*Ovaries.*—In the *Cow*, the ovaries are relatively much smaller than in the Mare, but their form and structure are identical. (The Graafian vesicles are visible through the tunica albuginea.)

Uterus.—The uterus of the *Cow*, compared with that of the Mare, offers but few differences with regard to its general disposition in the pelvic and abdominal cavities, except that it is not so advanced in the latter. Supposing the uterus to be perfectly horizontal, a transverse line drawn through the plane of the abdomen, before the external angle of the ilium, is exceeded by the extremity of the cornua about 1½ to 2 inches; so that if the animal were on its back, the uterus would be only prolonged to the fourth or fifth lumbar vertebra.

With regard to form, the uterus of the Cow presents a very remarkable disposition, which it is necessary to note: the concave curvature of the cornua looks downwards, while in the Mare it looks upwards; though in both the sublumbar ligaments are attached to this concavity. Therefore it is that in the Cow, if we consider the uterus as freely suspended in the abdomen, the extremity of the cornua is twisted outwards and upwards, while the base, although drawn in the same direction by these ligaments, maintains its direction, because it is in a manner fixed by the body of the uterus. The latter receives, like the cornua, the insertion of the broad ligaments on its lower plane, so that it overlaps them, while the uterus of the Mare projects below them. Otherwise, these ligaments are very ample, especially at their anterior border; they are wide apart in front, towards their lumbar attachment, which is prolonged even on the parietes of the flank. The ligaments may be altogether compared to a triangular cravat, one angle of which is attached to the bottom of the pelvic cavity, and the other two to the tuberosities of the ilium. On this cravat lies the body and part of the cornua of the uterus.

The uterine cornua are thin and tapering at their anterior extremity. The body is short and narrow.

The interior of the uterus of the *Cow* is less ample than that of the Mare. Its surface is studded with rounded tubercles, known as *cotyledons*, which will be studied hereafter. It is only necessary to say here that they are numerous in the cornua, but small and few in the body of the organ.

The cervix uteri, about from 2¾ to 3¼ inches long, is narrow and irregular. The "expanded flower," more finely plicated than in the Mare, is almost cartilaginous. Three other plicated rings, each smaller than the other, are échelonned in the cavity of the cervix, from the external orifice to the body (corresponding to the *plicæ palmatæ* or *arbor vitæ uterina* of Woman).

In structure, the muscular layer is generally thicker than in Solipeds.

In the *Sheep* and *Goat*, the arrangement is the same as in the Cow, except that the cotyledons are hollowed like a cup in their centre, and deserve their name. (The cornua are longer and more pendent than in the Cow.)

Vagina.—In the *Cow*, the sides of the vagina are traversed, for a certain distance, by a mucous canal that opens into the vulvular cavity, beside the meatus urinarius. These ducts, the use of which is unknown, are designated the *canals of Gærtner*. They are not present in the *Sheep* or *Goat*. (In Ruminants, the vagina is longer and its external tunic thicker than in the Mare. Leyh describes the canals of Gærtner as present in the Mare, though rarely.)

Vulva.—This has thick lips in the *Cow*. The inferior commissure is acute, and

furnished with a tuft of hair. (The corpus cavernosum of the clitoris is longer, thinner, and more flexuous, and the gland much smaller than in the Mare.) The meatus urinarius is disposed as in the mare; but there exists, on the floor of the urethra, a valve whose free border is directed backwards. This valve surmounts a small *cul-de-sac* which it is necessary to avoid in catheterism of the bladder. At about an inch from the entrance to the vulva, there are found in the texture of the labia the *vulvo-vaginal glands* (*glands of Bartholine*). Discovered by Duverney, described by Bartholine, and recently by Colin,[1] these glands (two in number) are about the size of a large almond; their wide extremity is directed upwards, and the narrow end, situated in the vicinity of the *ischio-clitoridis* muscle, gives origin to the excretory canaliculi. They are racemose, and their ducts unite to form a kind of sinus, which at length opens in the vaginal cavity, about 4 inches from the labia of the vulva. (These *glandulæ vaginæ* are supposed to be analogous to the prostate glands, and are covered by muscular fasciculi. They are composed of pyriform glandular vesicles, lined by squamous epithelium, and surrounded by a dense nucleated connective tissue; the excretory ducts are invested by columnar epithelium, and surrounded by a thin layer of smooth muscle-cells, disposed longitudinally. Their secretion is a clear, yellowish, viscid mucus.)

(In the *Sheep* and *Goat*, the labia of the vulva have several folds externally, and the inferior commissure terminates in a point.)

Mammæ.—In the *Cow*, each lateral mammary mass, although enclosed in a single fibrous capsule, is composed of two distinct glands, each having its *teat;* so that this animal really has *four mammæ* and *four teats.* There are also frequently found behind these, two rudimentary imperforate (sometimes, though very rarely, perforate) teats.

In the centre of each gland, at the base of the teat, is a single *galactoferous sinus*, the general confluent of all the *lactiferous ducts*—a wide cavity opening at the extremity of the teat by a definitive excretory canal. (The mammæ of the *Cow* occupy the same region as those of the Mare, and the teats are longer and thicker.)

In the *Sheep* and *Goat*, there are only two mammæ, as in the Mare and Ass, though they are formed as in the Cow. The Goat has frequently two posterior rudimentary mammæ.

Pig.—The ovary of the *Sow* has a lobulated aspect, like the ovary of birds This appearance is due to the ovisacs which, when they are well developed, project beyond the surface of the ovarium, instead of remaining encysted in its stroma. The oviduct is less flexuous, but its length is proportionately greater than in the other species. The body of the *uterus* is short, but the cornua are very long and folded, and float amongst the intestinal convolutions. (Its cervix does not project into the vagina, and the two cavities, vagina and uterus, are continued into each other without any marked limit between them. The mucous membrane is very loose, soft, and fine to the touch, and its surface is gathered up into numerous folds of various forms. The broad ligaments resemble the mesentery, and the cornua join the Fallopian tubes without any very perceptible limit.)

The vagina shows Gærtner's canals, as in the Cow. (Its mucous membrane has numerou. longitudinal folds anteriorly; and in front a multitude of fine points, which are the excretory ducts of small glands analogous to the prostates. On the sides of the *meatus urinarius* are two small fossettes surrounded by a ring. There is no *vaginal valve.*) The inferior commissure of the *vulva* is more acute than in Ruminants. The mammæ are ten in number, disposed in two rows, extending from the inguinal region to below the chest. They have no galactoferous reservoirs, as in the larger Ruminants: the lactiferous ducts uniting directly into a variable number of definitive canals that pass through the teat, to pierce its extremity by from five to ten orifices. (There are, of course, five or six glands in each row, each with its teat.)

Carnivora.—In the *Dog* and *Cat*, the *ovaries* and *uterus* are disposed as in the Pig; the ovaries (are situated behind the kidneys, and) are lodged in a particular fold of the broad ligaments, which forms a kind of cup. There are no Gærtner's canals in the *vagina.* The *vulva* of the *Dog* is triangular, and acute at its inferior commissure. The *Cat* has a small bone in the clitoris. The *mammæ* are ten in number in the *Dog*, and eight in the *Cat;* they are distinguished, as in the Pig, into *inguinal*, *abdominal*, and *pectoral.* (Each teat has from eight to ten orifices. The *vagina* is long, and wider at the vulva than towards the uterus. Beside the smooth muscular fibres of its external coat, it has white fibres which give it greater thickness and resistance. The mucous membrane forms longitudinal, intersected by transverse, folds; the valve of the meatus urinarius scarcely exists. The cervix of the uterus projects into the vagina, and is even more voluminous than the body, which is short; it is hard to the touch.)

---

[1] 'Traité de Physiologie Comparée des Animaux Domestiques.' Paris, 1871.

COMPARISON OF THE GENERATIVE ORGANS OF WOMAN WITH THOSE OF ANIMALS.

Ovaries.—These organs are oval, about 1½ inches long and 8-10ths of an inch broad, and are lodged in the posterior layer of the broad ligaments. They are attached to the uterus by the ligament of the ovary, and united to the Fallopian tubes by the Fallopio-ovarian ligament. Their structure is the same as in animals. A Graafian vesicle usually ripens every month; its rupture corresponds with the menstrual period. Annexed to the human ovary is found the *organ of Rosenmüller*, composed of from fifteen to twenty tortuous tubes opening into a transverse branch; these tubes are lined by ciliated epithelium, and filled with a yellow fluid; they form a closed system included in the broad ligament, between the ovary and oviduct.

Oviduct.—Placed at the upper border of the broad ligament, it is nearly straight, and terminates by a pavilion notched into about fifteen unequal fringes.

Uterus.—The human uterus is situated between the bladder and rectum, being inclined

Fig. 416.

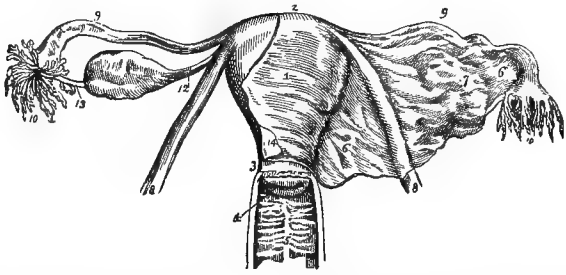

UTERUS WITH ITS APPENDAGES, VIEWED FROM THE FRONT.

1, Body of the uterus; 2, Fundus; 3, Cervix; 4, Os uteri; 5, Vagina, with its columna and transverse rugæ; 6, 6, Broad ligament of the uterus; 7, Convexity of the broad ligament formed by the ovary; 8, 8, Round ligaments of the uterus; 9, 9, Fallopian tubes; 10, 10, Their fimbriated extremities; 11, Ovary; 12, Utero-ovarian ligament; 13, Fallopio-ovarian ligament; 14, Peritoneum of anterior surface of uterus; it is removed at the left side, but on the right is continuous with the anterior layer of the broad ligament.

slightly downwards, from before to behind. Its form is very different from the uterus of the animals we have described, being that of a flattened gourd; its volume varies with age and the number of gestations; it weighs about two ounces. It is described as having a body and cervix. The *body* is triangular, and at the extremities of its upper border the oviducts open into it. The *cervix* is fusiform; the projection it makes at the bottom of the vagina is the *tench's nose*—a transversal slit bordered by two unequal lips. The inner face of the cervix shows the *plicæ palmatæ*, arborisations formed by the mucous membrane.

There is nothing special to be noticed in its structure.

The *broad* ligaments comprise a quantity of muscular fibres between their layers, and which accumulate at certain points to form accessory folds; among these the most important are the *round ligaments*. These leave the anterior face of the uterus, pass forward and outward, enter the inguinal canal, and terminate in the connective tissue of the mons Veneris.

Vagina.—This canal is about 2¾ inches wide; it is in contact with the rectum, and responds in front, by connective tissue, to the bladder and urethra. Its internal face has longitudinal folds, the *columnæ of the vagina*, which are intersected by transverse folds. Below the orifice of the urethra is the *entrance to the vagina*, a circular opening partially closed by the *hymen* in virgins. Rarely complete, this membrane may affect different shapes, and consequently receive various names, as *horse-shoe*, *bilabial*, *semilunar*, *annular*, and *fringed hymen*. When ruptured, it retracts very much, but there always remain some vestiges of it, and which are designated *carunculæ myrtiformes*.

Vulva.—This presents a cavity and an orifice, as in the domesticated animals; but the cavity is not so deep, and is named the *vestibule;* it extends to the hymen or its *débris*. The *entrance to the vulva* occurs in the middle of a cuneiform prominence which is confounded, above, with a kind of eminence, the *mons Veneris*, which appears to protect the pubic symphysis. It is margined by two folds: one cutaneous, the *labia*

majora; the other mucous, the *labia minora* (or *nymphæ*). The *labia majora* are convex externally, continuous above with the mons Veneris, and unite below to form an acute angle, named the *fourchette*; they are covered externally with hair. The *labia minora*, more or less developed, leave the fourchette, and extend around the entrance to the vagina, uniting above the clitoris, and forming the prepuce of that organ.

The *clitoris* is lodged in the superior commissure of the vulva; its point is directed downwards, especially during erection; its base is attached, on each side, to the two erectile lobes which constitute the *bulb of the vagina* (*bulbi vestibuli*).

Two racemose glands, the *vulvo-vaginal* or *glands of Bartholine*, pour their secretion over the walls of the vestibule.

Mammæ.—These are pectoral, and two in number. In their centre, they present an enormous papilla—the *nipple*—into which the excretory canals open; it is surrounded by a brown circle, the *areola of the nipple*.

CHAPTER III.

GENERATIVE APPARATUS OF BIRDS.

1. *Male Generative Organs.*

THE generative organs of the male are the testicles, and an excretory apparatus much simpler than that of mammals.

Testicles.—These organs are placed in the sublumbar region of the abdominal cavity, behind the lungs, and below the anterior extremity of the kidneys. Their form is usually oval, and their volume varies with the different species, as well as at different seasons; at the breeding season they are greatly developed.

Excretory Apparatus.—In birds there is not, properly speaking, any epididymis. The vas deferens passes from within the posterior extremity of the testicle, is directed in a flexuous manner backwards, draws near to the ureter on its own side, going along the kidney with it, and arriving at the cloaca, where it terminates by an orifice to be alluded to hereafter. In the Duck, it has near its termination a small oval vesicle, always filled with spermatic fluid.

Organ of Copulation.—This varies with the species. In the *Gallinaceæ*, it is only a small papilla placed below, near the margin of the cloacal opening, and between the two orifices of the deferent canals. This papilla is traversed by a furrow through which the semen flows. In the *Palmipedes*, this organ is much more developed, and is peculiar. Contained within a tubular cavity in the cloaca, it is protruded externally at the moment of copulation by the eversion of this cavity, like a finger out of a glove; it then appears as a long pendant appendage, twisted like a cork-screw.

2. *Generative Organs of the Female.*

The development of the young animal taking place external to the female, the generative organs are limited to that producing the ovum, and the duct through which it passes on leaving the ovary.

Ovary.—In birds there is only one ovary, which is situated on the left side, the right one becoming atrophied very early in nearly all species. This ovary is situated, like the testicles, in the sublumbar region of the abdominal cavity, and constitutes a more or less voluminous body, composed of a variable number of ovules in process of development: some very young, little, and white; others more advanced in age, being larger and yellow in colour. The ova are enveloped in a very vascular cellular membrane, which, when they are ripe, splits in a circular manner, following an equatorial line, and permits the escape of the essential part of the egg—the *yellow* (*yelk*), or *vitellus*.

Oviduct.—This duct is long, very wide and dilatable, and very flexuous. It begins, near the ovary, by an unfringed pavilion, and terminates in the cloaca by a somewhat narrow orifice, which is considerably widened when the egg passes through it. The egg, composed, on entering the oviduct, of the fundamental part named the yelk, or *vitellus*, is enveloped in an albuminous sphere during its progress towards the cloaca, and afterwards with a protecting shell. The oviduct of birds is, therefore, something more than an excretory canal, as it participates in the formation of the ovum. It is composed of three membranes: an *external*, serous, maintains the tortuous tube; a *middle*, muscular; and an *internal*, mucous.

BOOK IX.

EMBRYOLOGY.

EMBRYOLOGY has for its study the modifications to which the ovulum is submitted, from the moment when it is fecundated until it is transformed into a new being capable of living in the external world.

The points of this subject belonging to the domain of anatomy, will be divided into three chapters. In the first, the transformations of the ovulum which produce the ovum and embryo will be examined. In the second, the various portions of the ovum—the annexes of the fœtus—will be studied; and the third will be occupied with the development of the fœtus.

CHAPTER I.

THE OVULUM AND ITS MODIFICATIONS AFTER FECUNDATION.

ARTICLE I.—THE OVULUM.

THE ovulum of the domestic mammifers is a vesicle about $\frac{1}{1800}$ of an inch in diameter (the germinal spot being from $\frac{1}{3600}$ to $\frac{1}{2400}$ of an inch), contained in the ovisac, in the midst of the cumulus proligera. It possesses all the elements of a complete cell, comprising: 1, An amorphous, transparent enveloping membrane, named the *vitelline membrane*, or *zona pellucida;* 2, A hazy viscous fluid, holding in suspension a large number of dark granulations and fat globules: this is the *vitellus* or *yelk;* 3, The *germinative vesicle*, a spherical, transparent nucleus lying to one side of the vesicle, and readily altered; 4, The *germinal spot*, a kind of very brilliant nucleolus seen in the centre of the nucleus. According to Balbiani, there also exists in the ovulum of all animals, from insects up to mammals, beside the germinative vesicle, a second nucleus—named *Balbiani's* or the *embryogenous vesicle*—which plays a very important part in the nutrition of the ovulum and the phenomena succeeding fecundation.

ARTICLE II.—MODIFICATIONS IN THE OVULUM UNTIL THE APPEARANCE OF THE EMBRYO.

These include the *segmentation of the vitellus*, the *formation of the blastoderm*, and the *appearance of the embryo.*

1. SEGMENTATION OF THE VITELLUS.—Several times spermatozoa have been seen in the vitelline zone of the fecundated ovulum. This fact is merely alluded to, as we have to speak of the consequences of fecundation, and not

of fecundation itself. After it has taken place, the germinal vesicle is not perceived; has it disappeared, or changed its character if it does yet exist? This question cannot be answered; all that is known is that it has ceased to be visible. Then the contraction of the vitellus begins; it leaves its enveloping membrane, becomes depressed in a circular manner, and ends by forming two independent masses, each provided with a nucleus. These two *globes of segmentation* (or *cleavage masses*)—for such is the name given to

Fig. 417.

A. B. C.



PROGRESSIVE STAGES IN THE SEGMENTATION OF THE YOLK OF THE MAMMALIAN OVUM.
A, Its first division into halves, with the spermatozoa around its circumference; B, Subdivision of each half into two; C, Further subdivision producing numerous segments.

them—are, in their turn, divided into other two globes, the number now being four. These four are once more divided, and these again subdivided, until the whole mass of the vitellus is completely transformed into *globules* (or *embryo-cells*), composed of a nucleus covered by a thin membrane.

Fig. 418.

A. B.



LATER STAGE IN THE SEGMENTATION PROCESS.
A, Mulberry mass formed by the minute subdivision of the vitelline spheres; B, A further increase has brought its surface into contact with the vitelline membrane, against which the spherules are flattened.

This is the segmentation of the ovulum: an operation that is always preceded by the retraction of the vitellus, and the appearance of one or two small globules about the point where it commences to be depressed; these Robin has designated *polar globules*.

2. Formation of the Blastoderm.—Soon a fluid is formed at the centre of the ovulum, in the midst of the mass of vitelline globules, or rather the mass of young cells that take the place of the vitellus. This fluid presses the globules outwards against the inner face of the vitelline membrane, and the pressure increasing as it augments, these become flattened like the elements of pavement epithelium, until, finally, they constitute a membrane lining the zona pellucida. This is the *blastoderm.*

The blastodermic vesicle (as it has been termed) does not remain simple, but soon divides into two layers: an *external* and *internal blastodermic layer*, which are readily recognisable, as the elements of the first are pale or slightly granular, while the cells of the second are filled with fat granules, and consequently are less distinct and darker coloured.

3. Appearance of the Embryo.—While the blastoderm is dividing into layers, there is observed another modification taking place in the ovulum, from which results the first lineaments of the embryo. As soon as the blastodermic vesicle is formed, a small round thickening takes place at a point of its surface, due to a multiplication of cells. This mass destroys the transparency of the blastoderm, and is designated the *embryonic spot* or *area germinativa.*

The area germinativa is the centre where commences the separation of the blastoderm into external or internal layers. The middle layer, which is to form the fœtal organs, does not extend beyond this area.

By a proliferation of the elements of the external and middle layers, the area germinativa increases in surface and thickness; it becomes dark, prominent, and buckler-shaped, and is named the *opaque area;* this is soon transparent in its centre—the *area pellucida.* The area pellucida becomes elongated and constricted in its middle to form the *embryonic area;* in the middle of this appears a dark line, the *primitive trace* or *furrow*, and below is perceived a round cord—the *chorda dorsalis*—which develops the spinal axis.

The inner layer, in its turn, becomes two layers at the point corresponding to the embryo, and this gives rise to the *middle layer.*

In fine, towards the twelfth day after fecundation, the ovum, having arrived in the uterus, measures from $\frac{1}{276}$th to $\frac{1}{364}$th of an inch in diameter, and is composed of four shells contained one within the other, three of which are complete, viz: 1, The zona pellucida; 2, The external layer of the blastoderm; 3, The middle layer; 4, The internal layer. At this time the first membrane, destined to become the chorion, is already studded with fine villosities.

Article III.—Development of the Blastodermic Layers.

By ulterior metamorphoses, the layers of the blastoderm give rise to the annexes of the fœtus and its various organs. Therefore it is that these layers receive other names than those which designate their situation. Thus the external, or serous, is named the *sensitive layer*, because it forms the skin and organs of sense; the middle is the *vascular* or *germinative*, as it contains the principal vessels of the embryo, and in its substance are developed the organs of locomotion; lastly, the internal layer is termed the *mucous* or *intestino-glandular*, in consequence of its constituting the mucous membranes, and its chief portion forming the intestines and their glands.

Each blastodermic layer, then, in becoming developed, furnishes the intrafœtal and extrafœtal parts. We will study this development, having

the extrafœtal parts particularly in view, and reserving the others until we come to examine the development of the fœtus.

EXTERNAL LAYER.

a. Intrafœtal parts.—The external or sensitive layer (*serous stratum-epiblast*) forms several parts belonging to the fœtus; these are: 1, The epidermis and its dependencies, such as the hair, hoofs, horns, glands of the skin; 2, The central nervous system: the organs of the senses, such as the retina and the labyrinth.

b. Extrafœtal parts.—So long as the fœtus is represented by a kind of shield at a given point of the blastodermic layers, the external layer is everywhere continuous, and extends to the inner face of the chorion and the surface of the embryo without any line of demarcation. But the embryo soon becomes inflected at its two extremities; the external layer of the blastoderm is depressed so as to give rise to two layers: the *cephalic hood*, which covers the cephalic extremity, and the *caudal hood*, which envelops the other extremity of the embryo.

The lateral parts of the fœtus also become inflected towards one another, as may be proved by a transverse section; thus closing-in, laterally, the thoraco-abdominal cavity of the young creature which, during this movement, is more deeply placed in the serous layer. The latter soon comes into contact with itself, above the back of the embryo.

A short pedicle, the *superior umbilicus*, unites the two portions of the blastodermic layer. This pedicle is not long before it becomes obliterated, then breaks, when the fœtus is found to be inclosed in an independent sac, which is nothing more than the amnion.

Fig. 419.

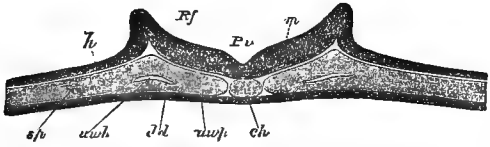

TRANSVERSE SECTION THROUGH THE EMBRYO OF THE CHICK AT THE CLOSE OF THE FIRST DAY OF INCUBATION; MAGNIFIED ABOUT 100 DIAMETERS.

ch, Chorda dorsalis; *h*, External serous, or corneal layer; *m*, Medullary position of serous layer; Pv, Primitive groove between the dorsal laminæ, Rf and *m*; *dd*, Intestinal epithelial, or glandular layer (mucous layer); *wwp*, Prevertebral mass, in which the primary, or protovertebræ, are formed, and which is continuous with the middle lamina, *sp*; *wwh*, Fissure in the middle lamina, presenting the first indication of the pleuro-peritoneal (thoraco-abdominal) cavity, and of the subsequent division of the middle lamina into two layers.

The sensitive layer is therefore resolved into two sections: an internal, the *amnion*; and an external, the *serous vesicle* (*false amnion* of Pander, the *serous covering* of Von Baer), which is applied to the inner face of the zona pellucida, and concurs in forming the chorion.

MIDDLE LAYER.

All the parts to which the middle layer gives rise, belong to the organs of the fœtus; the development of this layer will be more appropriately studied in the chapter devoted to the fœtus.

INTERNAL LAYER.

a. Intrafœtal parts.—The mucous layer of the blastoderm forms the epithelium of the intestines, the glands annexed to them, the respiratory apparatus, the kidneys, and the bladder. These organs are developed at the same time as the extra fœtal portions, and will be referred to presently.

b. Extrafœtal parts.—In incurving on itself, the embryo incloses in its cavity a portion of the internal blastodermic layer. The union between the free and the imprisoned portions is extensive; but before long it is only represented by a narrow canal that occupies the *inferior umbilical ring.* The mucous layer is then divided into two distinct portions: the *intestinal groove*, or intrafœtal portion; and the *umbilical vesicle* (*vesicula alba*), or extrafœtal portion; they communicate by the *omphalo-mesenteric* or *vitelline duct.*

Fig. 420.

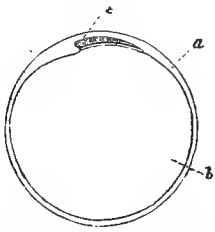

PLAN OF EARLY UTERINE OVUM.

Within the external ring, or zona pellucida, are: the serous lamina, *a*; the yolk, *b*; and the incipient embryo, *c*.

Fig. 421.

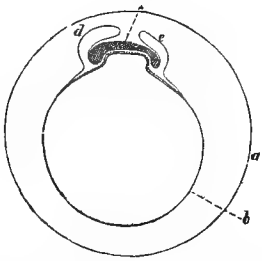

DIAGRAM OF OVUM AT THE FORMATION OF THE AMNION.

a, Chorion; *b*, Yolk-sac; *c*, Embryo; *d* and *e*, Folds of the serous layer rising up to form the amnion.

The umbilical vesicle is filled with a granular fluid, which is conveyed, for the nutrition of the fœtus, by the omphalo-mesenteric vessels. When this alimentary reserve is nearly expended, the allantois appears.

The *allantois* commences by a small enlargement, which is thrown out by the intestinal furrow on the inferior abdominal wall. This bud becomes elongated, and gradually enlarges by drawing the umbilical vessels to its border: appearing as a small vesicle that at length extends through the umbilicus, and spreads itself over the inner face of the chorion, between it and the amnion.

This new organ is divided into two *sacs* by a neck—the *urachus*—at the umbilical ring; the internal is the smallest and forms the *bladder*, and the external, the most voluminous, constitutes the *allantois proper.*

CHAPTER II.

THE FŒTAL ENVELOPES OF SOLIPEDS.

We have seen, in the preceding chapter, that the vitelline membrane lined by the serous vesicle forms a complete shell around the developing ovum; and we have also noted that the layers of the blastoderm, in becoming metamorphosed, constitute three membranous sacs, which contain the fœtus. These various membranes are described as the *envelopes* or *annexes* of the fœtus. There are also added to these the cord of vessels and the capillary ramifications which establish the relations that exist between the mother and the young creature.

The *annexes of the fœtus* comprise: 1, A membranous envelope exactly moulded on the uterus, and known as the *chorion;* 2, A second ovoid sac included in the first, and directly containing the fœtus: this is the *amnion;* 3, The *allantois*, a membrane formed of two layers spread over the inner surface of the chorion and the external face of the amnion, as well as covering the parts between these two envelopes; 4, A small pyriform bladder constituting the *umbilical vesicle;* 5, The *placenta*, a collection of vascular tufts which graft the young creature to the mother; 6, The *umbilical cord*, composed of vessels that attach the fœtus to the envelopes surrounding it, and which ramify in the placental tufts.

1. *The Chorion.* (Fig. 422.)

The outermost envelope of the ovum, the *chorion* is a vast membranous and perfectly-closed sac, whose shape exactly corresponds to that of the uterus.

Fig. 422.

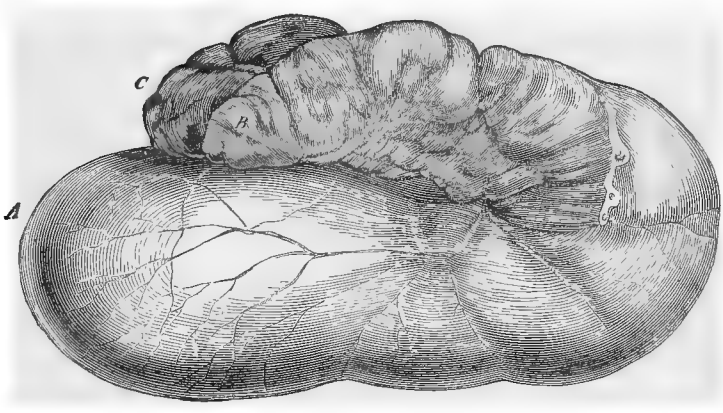

EXTERIOR OF THE CHORIAL SAC; MARE.
A, Body; B, C, Cornua.

It has a *body* and two *cornua*. The latter, when inflated, are plicated and bosselated like the cæcum, and are always unequal in volume: that in which the fœtus is developed having by far the largest dimensions.

The *external face* is studded with small red tubercles, formed by the

placental tufts. It adheres to the internal surface of the uterus. Between the two membranes there is found a small quantity of sanguinolent fluid.

The *internal face*, lined by the external layer of the allantois, is united in the closest manner to that membrane, except at the umbilical cord, where there exists a kind of conical infundibulum occupied by the umbilical vesicle.

Structure.—The chorion is a delicate fibrous membrane, traversed by the vascular ramifications of the placenta. It is formed by the vitelline membrane, to the inner face of which the serous vesicle is applied. It is stated that the zona pellucida, or *primitive chorion*, as it is called, disappears when the serous vesicle, the *definitive chorion*, becomes independent of the amnion.

Fig. 423.

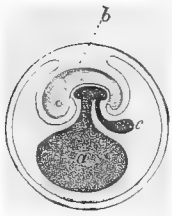

FECUNDATED EGG, SHOWING FORMATION OF AMNION AND ALLANTOIS.
a, Umbilical vesicle; *b*, Amniotic cavity; *c*, Allantois.

The chorion is destitute of vessels until the allantois is developed.

2. *The Amnion.* (Figs. 423, 424.)

The second sac enveloping the fœtus, the *amnion* floats freely in the interior of the chorion, to which it is only united at one point through the medium of the umbilical cord. It contains the young creature, which is also attached to its inner face by the vessels of the cord. It is oval in shape, and has thin transparent walls.

Its *external face* is covered by the inner layer of the allantois, to which it adheres slightly. The *internal face* is perfectly smooth, and is applied more or less directly to the skin of the fœtus. It exhales a fluid in which the latter floats—the *liquor amnii.*

Fig. 424.

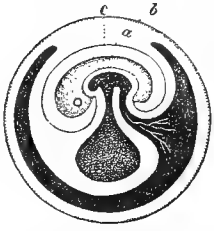

FECUNDATED EGG OF FOWL WITH ALLANTOIS NEARLY COMPLETED.
a, Inner lamina of amniotic fold; *b*, Outer lamina of the same; *c*, Point where the amniotic folds come in contact with each other; the allantois is seen penetrating between the inner and outer laminæ of the amniotic fold.

Liquor amnii.—Inclosed with the fœtus in the cavity of the amnion, this fluid is more or less abundant, according to the period of gestation; its relative quantity being always less as the fœtus is advanced in development. At an early period it is somewhat milky in appearance, but later it assumes a citrine or slightly reddish tint. It has a salt taste, and contains 99 per cent of water, with albumen and salts, the principal of which are chloride of sodium and the sulphate and phosphate of lime.

3. *The Allantois.* (Fig. 423.)

The *allantois* is a membrane that covers the inner face of the chorion, and is folded around the insertion of the umbilical cord, to spread itself over the whole external surface of the amnion. It thus transforms the chorial sac into a kind of serous cavity, in which the amnios is inclosed as a viscus.

The *inner*, or *amniotic lamina*, is attached to the amnios "so slightly that dissection, and especially insufflation, easily destroys its adhesion. When the second of these measures is resorted to, in order to separate the two membranes, the allantoid surface assumes a bosselated

or blistered appearance, due to the numerous cellular bands that attach it to the amnion. These bands rupture when the inflation is forced, and a noise is heard analogous to that produced by the rumpling of parchment. With a little care, the whole of this portion of the allantois, whose extent equals that of the amnion, may be entirely detached.

"The degree of adhesion of the *chorial allantois* is more marked. Ordinary dissection, which is easy along the first divisions of the cord, is much more difficult towards the chorion, and soon becomes, if not impossible, at least very arduous, if we desire to separate it. But here, again, inflation demonstrates the existence of the membrane, and its continuity with the portion so easily dissected from the amnion. If, after opening the allantoid sac by cutting through the chorion and the lamina lining it, a tube is introduced between the two membranes—which is readily done near a large vessel, by a slight inflation the air enters between the allantois and chorion, though it only follows the track of vessels of a certain size, to the sides of which there is but little adherence. If the inflation is pushed, the air, following the smallest vascular ramifications, renders the membrane more apparent, though without detaching it from the points where the vessels have almost become capillaries.

"If, instead of injecting the air towards the ramifications, it is directed in the opposite direction, it will soon be perceived to extend towards the allantoid portion of the umbilical cord, and insinuate itself between the amnion and the allantois covering it: an evident proof of the continuity of the two layers which have been separated for the purpose of studying them, but which are, in reality, only two portions of the same membrane that forms a complete sac." [1]

The cavity of this sac communicates with the bladder by means of the *urachus*, a narrow canal contained in the amniotic portion of the umbilical cord, and expanding towards the origin of the allantoid part (at D, Fig. 425), where its walls are continuous, one part with the amniotic layer of the membrane, the other with the chorial layer, after being prolonged as a sheath around the cord (B). This arrangement shows the true character of the allantoid cavity, which is evidently a kind of urinary reservoir, a dependency of the bladder, whose fundus is prolonged to the umbilicus to constitute the urachus. The latter follows the umbilical vessels in the amniotic portion of the cord, and soon expands in forming the allantoid cavity.

Structure.—The allantois arises from the intestinal furrow, or otherwise the included portion of the internal blastodermic lamina. It comprises a slightly fibrous framework, and an epithelial layer. It carries the umbilical vessels to its surface, from the umbilicus to the chorion.

Allantoid Fluid.—This cavity contains a fluid analogous to the liquor amnii, and which has almost the same physical qualities. Analysis demonstrates that, during the early months of fœtal life, this fluid contains a somewhat large proportion of sugar; this gradually diminishes, and at last disappears altogether. The fluid has been considered, towards the termination of gestation, as the urine of the fœtus.

Hippomanes.—This name is given to small brown masses, more or less numerous—though often there is only one—which float in the allantoid fluid. "These bodies, of the consistency of gluten, and elastic like it, are flattened, thinner at the borders than towards the centre, oval or irregularly circular, and about the diameter of a five-franc piece. It is difficult to explain the

[1] *F. Lecoq.* 'Des Annexes du Fœtus.'

presence of the hippomanes in the allantoid sac. Nothing in its appearance indicates that it may be formed at the expense of the liquid contained in this membrane. Sometimes pediculated hippomanes are found, and these may assist in explaining the formation of the free hippomanes. Bourgelat speaks in his 'Anatomie' of pediculated hippomanes, and I have been able to make the following observations, through having met with a large number on a fœtus:

Fig. 425.

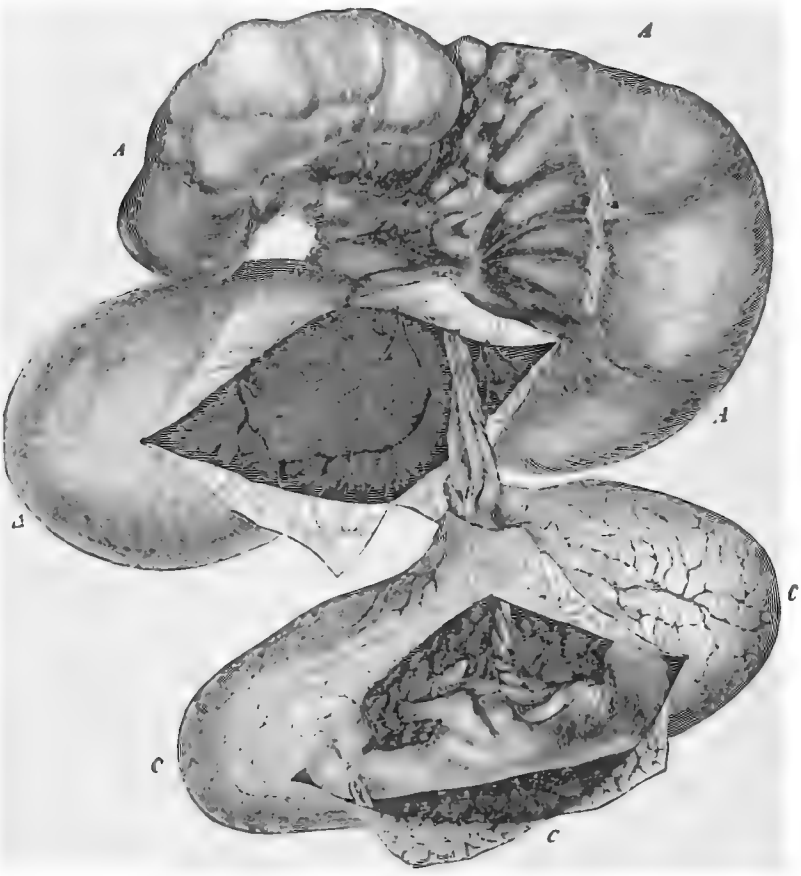

FŒTUS OF THE MARE WITH ITS ENVELOPES.

A, Chorion; C, Amnion removed from the allantoid cavity, and opened to expose the fœtus; D, Infundibulum of the urachus; B, Allantoid portion of the umbilical cord.—*b*, Point of the external surface of the chorion, destitute of placental villi, and corresponding to the part where the three pediculated hippomanes are attached.

"Besides the free hippomanes found floating in the allantoid fluid, there were remarked, on the outer wall of the sac, a great number of small tear-shaped bodies of variable size, adhering by a pedicle which was more or less narrow as the mass was more developed. Their colour was the same as

that of the principal hippomanes, and if pressed between the fingers, the brown matter contained in a thin-walled sac escaped by the pedicle, and spread itself over the external surface of the chorion. There the villosities of the placenta were absent at the margin of the opening, which was surrounded by a whitish areola (Fig. 425, *b*).

"Might it not be admitted, from this disposition, that the hippomanes is developed between the placenta and the uterus, and is carried inward, by pushing before it the chorion and layer of the allantois covering it, until, on reaching the allantoid cavity, it becomes detached, like certain fibrous or cartilaginous bodies in the synovial or serous cavities?"—*F. Lecoq.*

4. *The Umbilical Vesicle.*

The *umbilical vesicle* is a small fusiform or pyriform pouch, lodged in the infundibulum at the extremity of the umbilical cord. Its fundus adheres to the chorion; the opposite extremity is prolonged to a variable depth in the substance of the cord, and is even continued, in the very young fœtus, to the abdominal cavity, by a narrow canal that communicates with the terminal portion of the small intestine.

This pouch has a red colour, from its great vascularity; its walls receiving a special artery derived from the anterior mesenteric, the corresponding vein passing to the portal vein. These are the two *omphalo-mesenteric vessels.*

In the last months of fœtal life, the umbilical vesicle is always more or less atrophied; its cavity has disappeared, and it is no more than a thin reddish-brown cord. Its vessels also become atrophied in the same manner, and nearly always nothing is found but the artery reduced to the dimensions of a thread.

5. *The Placenta.*

In Solipeds, the *placenta* is composed of a multitude of small tubercles, spread uniformly over the external surface of the chorion, which they almost completely cover. These small tubercles are formed by an aggregation of extremely vascular villi, which implant themselves in the follicles of the uterine mucous membrane. The terminal ramifications of the vessels of the cord constitute the vascular apparatus of these villi (Fig. 426).

Fig. 426.

PORTION OF THE ULTIMATE RAMIFICATIONS OF THE UMBILICAL VESSELS, FORMING THE FŒTAL VILLI OF THE PLACENTA.

Structure.—The villosities of the placenta are composed of a small quantity of delicate nucleated connective tissue (and a basement membrane), covered by simple epithelium; at their centre, they present the capillary ramifications of the vessels of the cord, which generally form loops that return towards the base of the papilla (Fig. 427).

The villous tufts penetrate the maternal uterine mucous membrane, in such a manner that the two capillary systems of mother and fœtus are only separated by the very thin walls of the vessels and the epithelium of the

villi. The fusion of these two systems has never been observed, and all the interchanges between the female and its young take place through the capillaries by osmotic force only.

6. *The Umbilical Cord.*

The *cord* is formed by the vessels which, in the fœtus, carry the blood to the envelopes, and chiefly to the placenta. It is divided into two portions: an *amniotic*, the longest, which is always twisted on itself like a cord, and covered externally by the amnion that is prolonged on its surface, to be continued with the skin around the umbilicus; the other, the *allantoid* portion (Fig. 425, B), much shorter and less twisted, is enveloped by the sheath that continues the two laminæ of the allantois, and is inserted into the superior wall of the chorion, between the two cornua.

Fig. 427.

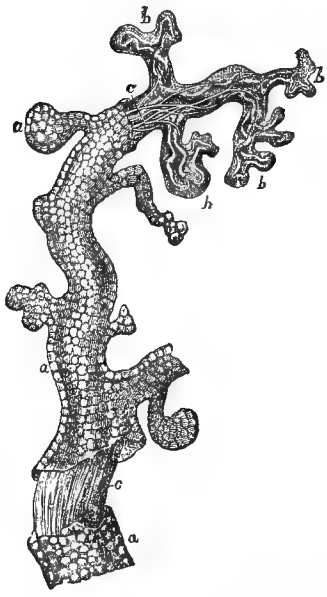

PORTION OF ONE OF THE FŒTAL VILLI, ABOUT TO FORM PART OF THE PLACENTA, HIGHLY MAGNIFIED.

a, a, Its cellular covering; *b, b, b,* Its looped vessels; *c, c,* Its basis of connective tissue.

Three vessels compose the cord: two *arteries* and a *vein;* these are covered by a layer of embryonic tissue, the *gelatine of Wharton,* which makes them appear much larger than they really are.

The Umbilical Arteries arise from the internal iliac, and pass along the sides of the bladder; escaping by the umbilicus, they arrive at the terminal extremity of the amniotic portion of the cord, and giving off some branches to the amnion, they are continued to the extremity of the allantoid portion, where they end in an expansion of placental ramifications. The *amniotic divisions* of these arteries are few, and extremely flexuous; they are included between the allantoid layer and the amniotic membrane, within which they may be seen. The *placental* or *chorial divisions,* infinitely larger and more numerous, leave the end of the cord, and pass in every direction between the chorion and external lamina of the allantois, beneath which they project. By their anastomoses they form a very rich network, from which proceed the capillary twigs that enter the villosities of the placenta. Observation demonstrates that these twigs do not communicate with the maternal vessels, and that they are continued by venous radicles, the origin of the following vessel.

The Umbilical Vein commences by these capillary radicles of the placental villosities, which unite between the chorion and amnion to form a network of more voluminous divisions and complexity than that of the arteries. Two principal branches are, finally, the result of the coalescing; and these soon unite into a single trunk, which accompanies the two arteries in the cord. On reaching the umbilicus, this, the *umbilical vein,* bends forward on the inner face of the abdominal parietes, where it is

covered by the peritoneum, and arrives at the liver, into which it enters and opens directly into the vena portæ; the junction of the two vessels giving rise to a single canal from which proceed the hepatic veins. In other animals than Solipeds, this vessel gives off a particular trunk of somewhat

Fig. 428.

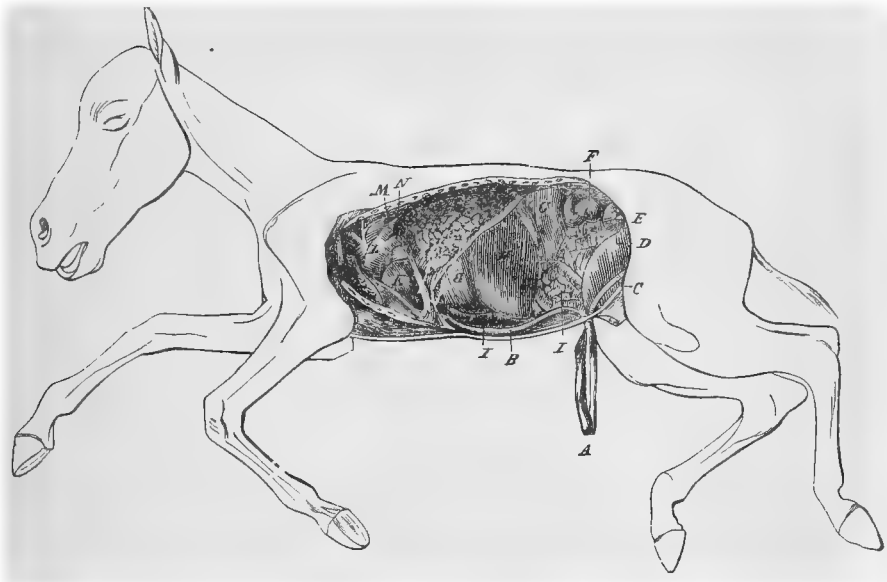

A FŒTUS OPENED ON THE LEFT SIDE TO SHOW THE COURSE OF THE UMBILICAL VESSELS IN THE BODY.

A, Umbilical cord; B, Umbilical vein; C, Umbilical artery; D, Bladder; E, Testicle; F, Kidney; G, Spleen; H, Liver; I, Intestine, J, Lung; K, Heart; L, Pulmonary artery; M, Ductus arteriosus; N, Thymus gland.

considerable volume, which passes directly to the posterior vena cava, forming what is named the *ductus venosus* (Figs. 429, 430).

Such are the umbilical vessels, and it will be seen that they form a part of the circulatory system of the young creature which will be more completely studied hereafter.

DIFFERENTIAL CHARACTERS IN THE ANNEXES OF THE FŒTUS OF OTHER THAN SOLIPED ANIMALS.

1. Ruminants.—*Placenta.*—The placental apparatus of the *Cow* is not uniformly spread over the outer surface of the chorion, but is constituted by a variable number of vascular bodies, about sixty on an average, disseminated here and there, and dovetailed by reciprocal penetration of prominences and cavities, into analogous bodies on the inner surface of the uterus, designated *cotyledons.* These are only thickened points of the mucous membrane, the follicles of which are enormously enlarged. They exist, we have seen, before gestation; but observation demonstrates that they may be afterwards formed or entirely renewed, especially in those cases in which accidental circumstances have rendered those present insufficient for their office. The largest are found in the body of the uterus; in the cornua they are smaller as they are nearer the extremity. Their form is generally elliptical, and they are attached to the uterine surface by a wide mucous

Fig. 429.

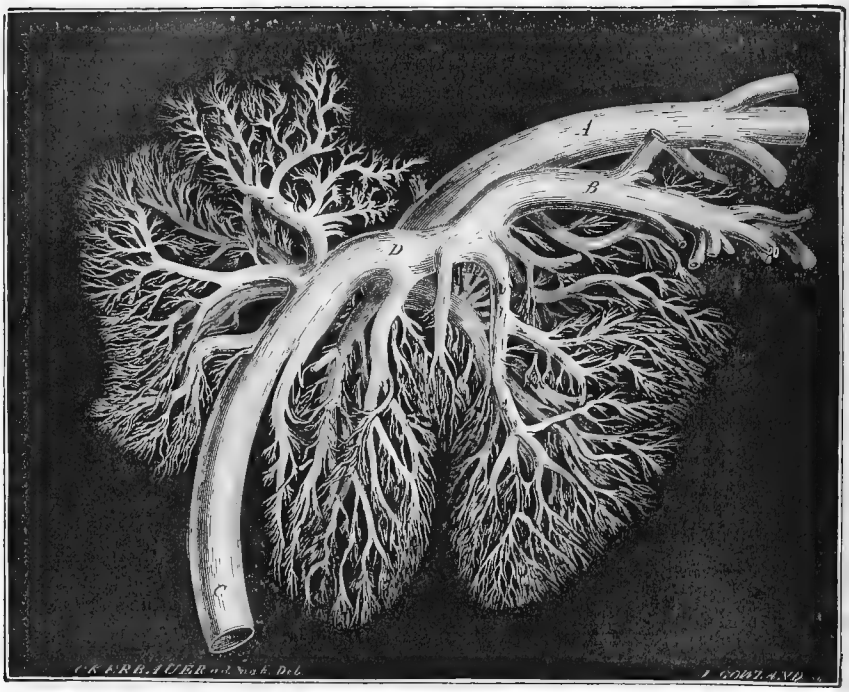

BLOOD-VESSELS IN THE LIVER OF AN EQUINE FŒTUS AT MID-TERM.
A, Umbilical vein; B, Its anastomoses with the portal vein, C; D, Ductus venosus; E, Posterior vena cava.

Fig. 430.

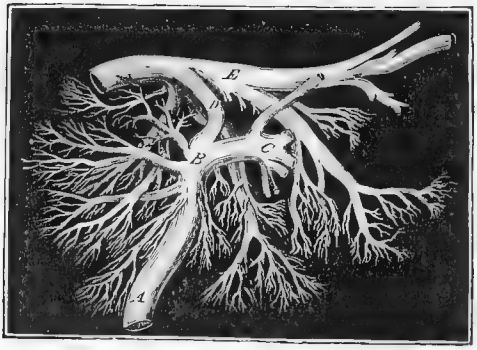

LIVER OF A LAMB AT BIRTH.
A, Posterior vena cava; B, Vena portæ; C, Umbilical vein; D, Anastomosis of the umbilical vein with the vena portæ.

pedicle; their surface is convex, and perforated by numerous openings, into which the placental tufts pass. They have always a yellowish colour which, added to their external characteristics, gives them the appearance of a moril mushroom.

With regard to the *placentæ*, they repeat, on the surface of the chorion, the disposition of the cotyledons on the uterus. They are vascular, concave patches, closely embracing the cotyledons, and showing on their surface a multitude of long ramifying papillæ, which bury themselves in the cotyledonal cavities. They are attached to the chorion by a very thick, short, vascular pedicle.

In the *Sheep* and *Goat* the arrangement is the same, except that the cotyledons are hollowed out in their centre, like a cup, and into this cavity the placenta is inserted.

Chorion.—This membrane corresponds to the inner face of the uterus, in the interplacental points; its internal surface is united by lamellar connective tissue to the amnion and allantois. Its general form is a repetition of that of the uterine cavity.

Allantois.—Very different from that of the Mare, and otherwise much less complicated, the allantois of Ruminants is a very elongated cavity, whose middle portion receives the insertion of the urachus, and whose extremities are prolonged into the two cornua of the chorion. This sac, which is an expansion of the urachus, is always reversed on one of the sides of the amnion. At times the hippomanes is found floating in the liquid it contains.

Amnion.—Altogether like that of Solipeds, this membrane is readily resolved into two lamina, and presents on its inner surface a great number of little, yellowish-white, epidermic patches, more especially visible on the amniotic covering of the cord.

Umbilical cord.—This comprises two arteries and two veins; the latter forming one trunk on their entering the abdomen. To reach the chorion, these vessels only traverse the amniotic cavity. They are accompanied by the urachus, which at their extremity presents the dilatation that results in the allantoid sac.

Umbilical vesicle.—This pouch disappears at an early period, and not a vestige of it is to be found after the formation of the abdominal parietes.

2. Pig.—The *placenta* is formed by an expansion of the villous tubercles, as in Solipeds.

The *chorion* has not a body and two cornua, but is merely an elongated sac, whose two extremities are in relation with the adjacent fœtuses. The inner face corresponds, as in Ruminants, with the amnion and allantois. The latter is the same as in the Cow, though it is very much shorter.

The *umbilical vesicle*, *amnion*, and *cord* are also the same as in Ruminants.

3. Carnivora.—The *placenta* is a thick cincture, surrounding the middle portion of the chorion. The latter resembles that of the Pig.

The *allantois* is disposed, in principle, as in Solipeds.

The *umbilical vesicle*, which remains very developed at all periods of fœtal life, resembles in shape the allantois of the Pig: being a transversely elongated sac included between the amnion and the inner allantoid lamina, and provided at its middle portion with a narrow pedicle, which is prolonged into the umbilical cord; its walls are extremely vascular.

The *amnion* is lined, internally, by the inner lamina of the allantois.

The *umbilical cord* has, as in Solipeds, an allantoid portion; but it is extremely short, and enveloped in a wide fold of the allantois.

Results.—The comparative examination of the disposition of the placenta may furnish valuable indications as to the procedure to be adopted in practising artificial delivery; as the surgical manœuvres should necessarily vary with the extent and disposition of the points of union existing between the uterus and the fœtal envelopes.

With this practical object in view, we believe that it is useful to divide the domesticated animals into two groups: those which have a *simple*, and those which have a *multiple placenta*. The first group may be subdivided, according as the simple placenta is *general* or *local*.

This division is summed up in the following table:

Animals	Simple Placenta	General	Mare. Sow.
		Local and Circular .	Bitch. Cat.
	Multiple Placenta	. . . . .	Cow. Sheep. Goat.

COMPARISON OF THE ANNEXES OF THE HUMAN FŒTUS WITH THOSE OF ANIMALS.

The human fœtus, like that of the domesticated mammals, is enveloped by an *amnion* and *chorion*, which are generally identical in disposition with those already described. The *umbilical vesicle* submits to the same change as in the Mare, becoming so quickly atrophied that scarcely any traces of it can be found at birth. It is impossible to isolate the amnion from the inner face of the chorion; so that some anatomists only admit its presence by analogy with what is observed in animals.

Fig. 431.

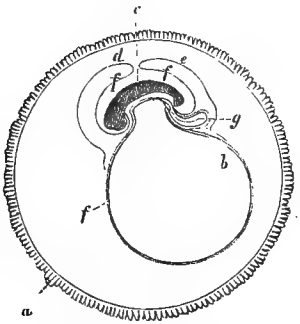

DIAGRAM OF AN EARLY HUMAN OVUM, SHOWING THE AMNION IN PROCESS OF FORMATION, AND THE ALLANTOIS BEGINNING TO APPEAR.

a, Chorion; *b*, Vitelline mass, surrounded by the blastodermic vesicle; *c*, Embryo; *d*, *e*, *f*, External and internal folds of the serous layer, forming the amnion; *g*, Incipient allantois.

Fig. 432.

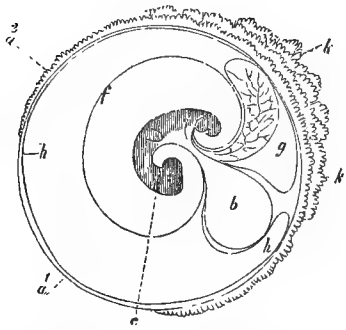

DIAGRAM OF A HUMAN OVUM IN SECOND MONTH, SHOWING THE COMPLETION OF THE SAC OF THE AMNION, AND A FURTHER DEVELOPMENT OF THE ALLANTOIS.

*a*1, Smooth portion of the chorion; *a*2, Its villous portion; *k*, *k*, Elongated villi collecting into placenta; *b*, Vitelline, or umbilical vesicle; *c*, Embryo; *f*, Amnion, inner layer; *h*, Its outer layer coalescing with the chorion.

The *umbilical cord* offers nothing particular. The *placenta* is circular; its diameter at the termination of pregnancy being from 6 to 8 inches, and its thickness from 1 to 1½ inches. There is distinguished the *fœtal placenta*, in the midst of which the umbilical cord arrives; and the *maternal placenta*, whose villosities dovetail with those of the former.

The insertion of the placenta takes place towards the fundus of the uterus, near one of the Fallopian tubes. When there are more than one fœtus, there are a corresponding number of placentæ.

Independently of those annexes, which are the same in all, there is described for the human fœtus a special envelope, external to the chorion; this is the *membrana decidua*. This is formed by the hypertrophied mucous membrane, which is doubled around the ovum, when the latter is lodged in the uterine cavity. Consequently, there results the division of the decidua into two parts: the *true decidua* (*decidua vera*) which covers the uterus, and the *reflected decidua* (*decidua reflexa*) which envelops the chorion. These present the characters of the hypertrophied uterine mucous membrane.

CHAPTER III.

DEVELOPMENT OF THE FŒTUS.

In the two preceding chapters, we have seen how the fecundated ovulum is modified to furnish the earliest lineaments of the fœtus and the organs annexed to it; this chapter will be devoted to an examination of the manner in which the fœtus is developed.

The young creature is designated an *embryo* during the early period of gestation, before it has assumed any definite shape; but as soon as it exhibits the form of the species to which it belongs, it is named a *fœtus*. The transition between these two states, though they have different names, is altogether inappreciable; so that we content ourselves with studying the first phases of development under the heading of the formation of the embryo, and the last under that of the development of the organs.

Article I.—Formation of the Embryo.

When the embryo has assumed the form of an elongated streak, and shows in its middle the primitive groove, there appear in the middle lamina of the blastoderm the *chorda dorsalis*, the *vertebral laminæ*, and the *lateral laminæ*.

DEVELOPMENT OF THE CHORDA DORSALIS AND VERTEBRAL LAMINÆ.

The *chorda dorsalis* is a cylindrical cord, slightly attenuated at both extremities, which is developed beneath the primitive groove. On its sides is a series of small opaque quadrangular masses—the *vertebral laminæ*—which are nothing more than the *protovertebræ*, or first traces of the fœtal vertebræ. Each of these little masses is soon perforated by an opening, and is then divisible into three portions: the *protovertebral cavity*, the *muscular lamina*, situated above the cavity, and the *protovertebræ*, placed below it.

The *muscular laminæ*, in augmenting in volume, are inflected upwards, and unite in the middle line of the back. They form, in great part, the muscles of the vertebral furrows; they also give off, below, prolongations which concur in the development of the intercostal and abdominal muscles, as well as those of the extremities.

The *protovertebræ* curve upwards and downwards in such a fashion as to surround the protovertebral cavity or medullary canal, and the dorsal cord. The superior ring is the rudiment of the annular portion of the vertebræ, and the inferior ring and dorsal cord constitute the vertebral bodies and the discs uniting them.

DEVELOPMENT OF THE LATERAL AND CEPHALIC LAMINÆ.

The *lateral laminæ* is the name given to that part of the middle lamina of the blastoderm which is placed to the right and left of the vertebral laminæ. In the region of the trunk, these laminæ are separated for a certain period

from the vertebral laminæ; in the cephalic region they always remain adherent to them, and at this point they are named the *cephalic laminæ*.

1. The *proper lateral laminæ* are divided into two layers: an external and an internal, united by the *middle lamina*, and including between them a cavity which becomes that of the pleura and peritoneum—the *pleuro-peritoneal* cavity. It is after these primary modifications that the lateral laminæ are fused to the vertebral laminæ.

The internal lamina, also named the *fibro-intestinal lamina*, envelops the deep portion of the blastodermic layer or intestinal furrow, the umbilical vesicle, and the allantois. It constitutes the fibrous and vascular part of these membranes, and carries the vessels to the inner face of the chorion.

The *external* or *cutaneous lamina* is developed in two directions. Above, it passes between the muscular laminæ and the fœtal portion of the external layer of the blastoderm, to form the skin of the back. Below, it separates into two other laminæ, which receive between them the prolongations of the muscular laminæ, destined to the formation of the intercostal and abdominal muscles and the ribs. Of these two secondary laminæ, the external forms the skin of the trunk, and the internal the parietal layer of the peritoneum.

The cutaneous laminæ also have an extra-fœtal prolongation—the fibrous layer of the amnion.

Fig. 433.

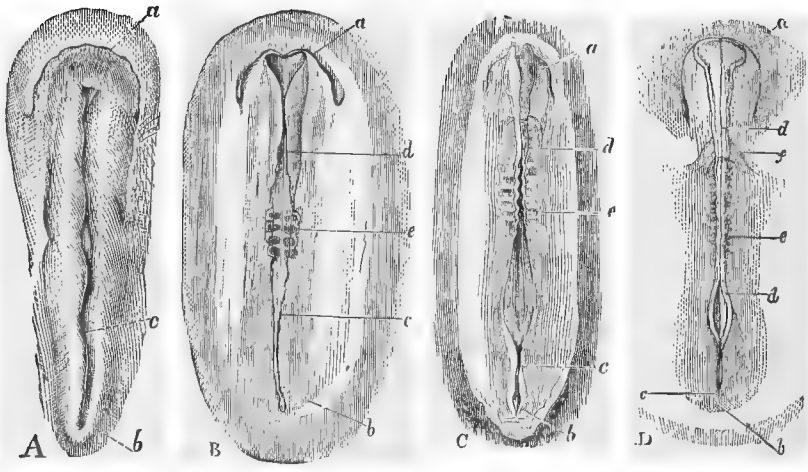

THE EARLY STAGES OF THE DEVELOPMENT OF THE BODY OF A FOWL.

A, The first rudiment of the embryo; *a*, Its cephalic, and *b*, its caudal end; *c*, The primitive groove.—B, The embryo further advanced; *a*, *b*, *c*, As before; *d*, The dorsal laminæ as yet developed only in the cephalic region, and not quite united in the middle line; *e*, The protovertebræ.—C, The letters as before. The dorsal laminæ have united throughout the greater part of the cephalic region, and are beginning to unite in the anterior spinal region.—D, Embryo further advanced, the dorsal laminæ having united throughout nearly their whole length; the protovertebræ have increased in number, and the omphalo-mesenteric veins, *f*, are visible.

With regard to the *middle* or *mesenteric laminæ*, they are confounded in the mesial line, and in their texture are developed the Wolffian bodies and the principal vessels of the trunk.

2. The *cephalic laminæ* always remain adherent to the vertebral laminæ, and are inflected inwards with them to form the anterior portion of the cephalo-intestinal cavity. The latter is divided into two parts: the *pharyngeal* and the *œsophageal* cavities.

The pharyngeal cavity opens externally by the mouth; it is partially closed, laterally, by the pharyngeal arches. The œsophageal cavity soon offers a diverticulum, which shortly after communicates with the pleuro-peritoneal cavity; this diverticulum lodges the heart, and is named the *cardiac cavity*.

The cephalic laminæ also form the derm of the cranium, and the fibrous layer in which some of the cranial bones are developed.

Article II.—Development of the various Organs of the Animal Economy.

DEVELOPMENT OF THE NERVOUS SYSTEM.

We will at first glance at the development of the nervous centres—the *brain* and *spinal cord*; then their peripheral parts, the *nerves*.

1. Development of the Brain.—We have seen in the preceding article how the primitive groove appears, and afterwards the medullary cavity. The latter, the first trace of the nervous centres, offers an enlargement at each of its extremities; the posterior, or *rhomboidal sinus*, gives off the nerves of the sacro-lumbar plexus; the anterior gives rise to the brain.

The latter enlargement is resolved into three successive dilatations—the *cells* or *cerebral vesicles*—distinguished as anterior, middle, and posterior. They are filled with fluid, and the middle slightly surmounts the other two, which gives the three together a triangular shape.

The vesicles increase irregularly in volume; their walls are gradually developed, and form the nervous tissue; while their cavity persists, and becomes the ventricles of each portion of the encephalon. Thus, the *anterior vesicle* represents the cerebral hemispheres, the thalami optici, and the lateral ventricles. The *middle vesicle* forms the cerebral crura, the corpora quadrigemina, and the aqueduct of Sylvius or middle ventricle. The posterior vesicle gives rise to the medulla oblongata, pons Varolii, and the fourth ventricle.

The middle vesicle is that which, at first, increases most rapidly in volume; it soon, however, ceases, to allow the anterior cell to become developed, when the encephalon assumes its ovoid form, with a predominance of the anterior part.

Towards the end of the first third of intra-uterine life, nearly all the parts of the brain are distinct: the two hemispheres have become isolable by the development of the septum lucidum; the convolutions appear on their surface; the corpora quadrigemina and cerebral crura are distinctly defined. It is not until a little later that the cerebellum is distinguishable, as well as the pons Varolii, medulla oblongata, corpora restiformia, and corpora pyramidalia.

2. Development of the Spinal Cord.—The medullary (spinal) canal is the first trace of the spinal cord; it occupies the whole length of the vertebral column, and its cavity communicates, in front, with the fourth ventricle. When the spine is developed, the marrow does not increase proportionately in quantity, and appears to ascend in the vertebral canal;

it stops about the middle of the sacrum in the equine fœtus, but ascends higher in the other species. During this apparently ascensional movement is developed the *filum terminale*, and the nerves of the cauda equina.

The walls of the medullary canal, at first very thin, increase in thickness by the appearance of the nervous matter of the cord. Soon they divide into two layers: an internal, the *epithelium* of the central canal; the other external, the *grey substance* of the cord. Gradually the canal contracts, and the marrow is seen, with its longitudinal furrows.

At the end of the first month, the inferior roots are in existence, as well as the spinal ganglia; the latter are developed at the expense of the protovertebræ, as will be shown presently. The superior roots are formed some time afterwards.

The *envelopes* of the cerebro-spinal centres are furnished by the protovertebral laminæ; they are developed after the sixth week, progressing with the growth of the parts they are destined to cover.

Fig. 434.

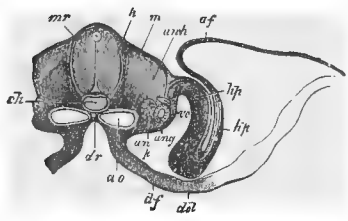

TRANSVERSE SECTION OF THE EMBRYO OF A FOWL AT THE BEGINNING OF THE THIRD DAY OF INCUBATION × 90–100.

ch, Chorda dorsalis; *wwh*, Position of a thinning, or cavity in the protovertebral mass, dividing it into an anterior and posterior portion; *hp*, Parietal lamina; *df*, Intestinal fibrous lamina, *dd*, Intestinal glandular lamina; *dr*, Primitive intestinal groove; *h*, Corneal lamina; *mr*, Medullary tube—spinal cord; *m*, Muscular lamina; *p*, Pleuro-peritoneal cavity; *af*, Fold of the amnion; *ao*, Primitive aorta; *vc*, Vena cardinalis; *un*, Wolffian body; *ung*, Duct of the Wolffian body.

3. Development of the Nerves.—The development of the nerves is somewhat obscure. The motor roots seem to arise from the cord; but the spinal ganglia are formed separately in the protovertebræ, and perhaps originate the sensitive roots. The nervous ramifications begin by elongated ramifying cells, which become fused to each other by their extremities; the nuclei of the cells lying at the periphery becoming the nuclei of the white substance of Schwann, the proper nervous tissue being afterwards gradually deposited between the axis-cylinder and the envelope.

The great sympathetic is early seen as a nodulated cord. It is probably developed in the same manner as the other nerves.

DEVELOPMENT OF THE ORGANS OF SENSE.

The principal portion of the organs of sense belong to the dependencies of the nervous system, and are developed with it; the other parts belong to the external epithelial lamina, the skin, and the germinative lamina.

1. Visual Apparatus.—From the anterior cerebral vesicle are given off two tubular prolongations, which are directed forward, and terminate by the *primitive eye-vesicles*, traces of the ocular globes. The hollow protrusions form the optic nerves; the vesicles furnish the retina and choroid. The crystalline lens, vitreous humour, cornea, and sclerotica arise from the external blastodermic layer. These modifications take place in the following manner:

The external integument of the fœtus passes over the front of the primitive eye-vesicles. Here it shows a slight depression on its outer surface, and on its inner face a cellular protrusion (Fig. 435, 1, *o*), which, becoming developed, surrounds the external depression, completely closes it,

and constitutes the commencement of the *crystalline lens* (Fig. 435, 2, *l*). The latter, thus formed, presses on the primitive eye-vesicle, pushes it backwards (2), and gives rise to a *secondary eye-vesicle*, whose anterior wall becomes the retina, and the posterior wall the choroid. The lens is, therefore, a dependency of the epithelial lamina; the cells composing it become elongated into fibres in the centre, and are disposed at its circumference as a primary amorphous envelope—the *crystalline capsule*—and afterwards as a secondary envelope rich in vessels.

Fig. 435.

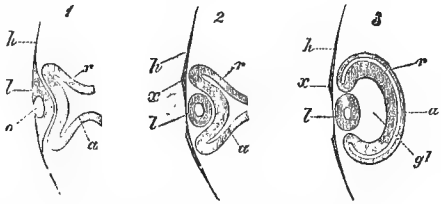

LONGITUDINAL SECTION OF THE EYE OF EMBRYO FOWL.

1, From an embryo at about the 65th hour of incubation; 2, From an embryo a few hours older; 3, From an embryo at the 4th day of incubation. —*h*, Corneal lamina; *l*, Lens in Fig. 1, still connected with the corneal lamina, and possessing a small cavity, *o*, in its interior (in Figs. 2 and 3 it is seen detached, but still hollow); *r*, Introverted portion of the primitive optic vesicle, subsequently becoming the retina; *a*, Posterior part of the optic vesicle, which, according to Remak, probably becomes the choroid coat, ciliary processes, and iris, and in Figs. 1 and 2 is still connected with the brain by the hollow optic nerve; *x*, Thickening of the corneal lamina around the spot from which the lens has detached itself; *gl*, Vitreous body, or humour.

The portion of the integument which is not doubled to form the lens envelops the globe, and gives rise to the *sclerotica* and *cornea;* the epidermis furnishes the epithelium of the latter, which becomes distinct from the sclerotica in the course of the fourth month.

An aperture—the *sclerotic cleft*—is made at the lower part of the fibrous envelope of the eye; this is connected with the development of the *vitreous body:* a prolongation of the derm—a kind of conjunctival bud passing through this opening, and placing itself between the crystalline lens and the anterior wall of the secondary eye-vesicle (3, *gl*), where it is developed and transformed into the vitreous body. At first it is encircled by vessels like the lens, but these disappear before the termination of gestation.

The *optic nerve* is developed in the pedicle uniting the eye-vesicle to the anterior cerebral vesicle. The *retina* is formed by the inner lamina of the secondary eye-vesicle; it extends to the lens in changing its character anteriorly. According to Remak, the *choroid* is constituted by the posterior lamina of the eye-vesicle; it advances at first to the lens, and then becomes inflected in front to form the *iris*. The borders of the pupil are attached to the vascular envelope of the lens, and this gives rise to the *pupillary diaphragm*, which disappears before birth.

The motor and protective organs of the eye are gradually developed around the globe. The *eyelids* are small cutaneous folds that appear towards the first third of uterine life; they increase, and unite at their margin until immediately before, or soon after birth, when they separate.

The *lachrymal gland* is a dependency of the epithelial lamina which is pushed in above the globe. At first solid, it gradually becomes channeled out by cavities, from which arise the excretory ducts.

2. Auditory Apparatus.—The internal ear, auditory nerve, and middle ear, are developed separately. The *labyrinth* appears in the shape of a vesicle, which is not in direct relation with the posterior cerebral cell; it is constituted by a depression of the epidermic lamina, the *auditory fossa*, which

is gradually developed, and at last become a closed cavity. At this time, the wall of the labyrinth is only a simple epithelial membrane; this is soon covered, outwardly, by a vascular connective membrane that separates into three layers: an internal, joined to the epithelium to form the membranous labyrinth; an external, that lines the cartilaginous labyrinth; and a middle, whose soft, embryonic, connective tissue disappears, and is replaced by the *perilymph*. At the same time that these changes of structure are occurring, the vesicular form of the labyrinth is modified, and shows the *cochlea*, *semicircular canals*, *utriculus*, and *sacculus*.

The *middle* and *external ear* arise from the first pharyngeal (branchial) cleft, which is never completely closed, while the others disappear. At first, then, we find a cavity communicating externally with the pharynx; this cavity contracts, and is separated into two portions by a partition that spreads across its middle, and which becomes the *membrana tympani*; the internal portion is the *middle ear* and *Eustachian tube*; the external portion is the *external auditory canal*.

Fig. 436.

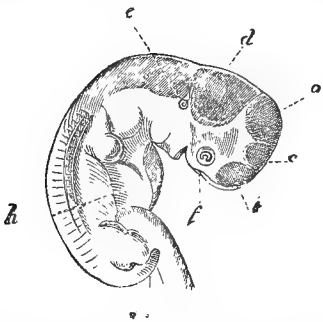

AN EMBRYO (HUMAN) OF FOUR WEEKS, ENLARGED ABOUT THREE TIMES.

a, Vesicle of corpora quadrigemina; *b*, Vesicle of cerebral hemispheres; *c*, Vesicle of third ventricle; *d*, Vesicle for cerebellum and medulla oblongata; *e*, Auditory vesicle; *f*, Olfactory fossa; *h*, Liver; * *, Caudal extremity.

The *ossicula auditûs* appear in a cartilaginous state towards the third month; they gradually ossify, and have scarcely acquired their definitive volume at birth. The external ear (*concha*) is developed above the integument after the second month.

3. Olfactory Apparatus.—This commences by two depressions of the epidermic lamina, analogous to the auditory fossa and that of the lens. These two olfactory fossæ appear below the ocular vesicles, and become more and more distinct, being margined by small projections which increase their depth. Behind, they communicate with the pharynx. The appearance of the palate separates them in front from the buccal cavity, and from this period the nasal fossæ are constituted. They are completed by the development of the bones of the face.

The *olfactory bulbs* and *nerves* are primarily hollow, and joined to the anterior cerebral cell. The nostrils are formed, in the young fœtus, by a mass of mucus and epithelium; towards the middle of gestation they are open.

4. Gustatory Apparatus.—*See*, subsequently, the *development of the tongue* in *digestive apparatus*.

5. Tactile Apparatus.—*The skin and its dependencies.*—The skin is developed at the expense of the epidermic lamina of the middle layer of the blastoderm. The cutaneous laminæ, by the modification of their elements, form the *derma*, in which the blood-vessels are very apparent at the third month. In the *epidermis*, the mucous and the horny layers are soon distinguished; in the first, the pigment is visible at the commencement of the fifth month in the larger quadrupeds. When the fœtus increases in volume, the epidermis exfoliates and its *débris* floats in the liquor amnii.

In the third month, the *hairs* are seen in the fœtus of the Mare and Cow; they appear at first on the eyebrows, lips, and the joints of the limbs; at

the sixth or seventh month they cover the body. They may be shed and renewed before birth. They are developed in a prolongation of the epidermic lamina, which is imbedded in the substance of the derm; it is shaped like a little bottle, and is composed of a mass of cells; in its centre, these cells are modified and collected together to form a small cone, whose base covers the growing papilla. This cone becomes elongated, touches the surface of the epidermis, doubles under the effort to push through it, and finally makes its exit, after which it can grow freely.

The *sebaceous* and *sudoriparous* glands are developed in the same manner, towards the middle period of uterine existence.

"The horny productions—the *claws*, *hoofs*, *ergots*, *chesnuts*—begin to show themselves early. Towards the end of the second month, in the fœtus of the Cow, there is perceived, at the extremity of each limb, a small, pale, translucid, conical tubercle, which is the rudiment of the hoof. At the commencement of the fourth month, or thereabouts, the hoof, better defined, has become firm and opaque, and has assumed a fine yellow tint. At mid-term, brown or black patches are manifest if the coronet is provided with pigment; it is only about the end of gestation that the hoof towards the coronet begins to have the greenish hue peculiar to horn destitute of pigment, but the remainder of this production, especially at the inferior part, preserves its yellow colour until birth. In Solipeds, the "chesnuts" are shown at mid-term in the shape of thin brown plates, which are soon darker-coloured."[1]

The horn of the hoof is not at first tubular; after birth it is shed and is succeeded by a more consistent tubular horn, which had been forming beneath it.

DEVELOPMENT OF THE LOCOMOTORY APPARATUS.

1. THE SKELETON.—We have seen at page 16 how the development and growth of the bones takes place; it is therefore needless to recur to this subject here; so we will limit ourselves to an examination of the mode of development of the principal sections of the skeleton.

A. DEVELOPMENT OF THE VERTEBRAL COLUMN.—The vertebral column is the first portion of the skeleton manifested in the embryo; it is represented by the chorda dorsalis, a stalk constituted by a mass of cells situated in the interior of a transparent sheath. The *protovertebræ* appear on each side of the chorda dorsalis; in becoming developed, these parts encircle the latter and the medullary canal; from this results the *external theca of the cord*, and the *superior uniting membrane*. From this time the vertebral column exists in the shape of a membranous axis.

Soon this membranous spine is segmented to give rise to the vertebræ, and its various portions gradually become cartilaginous. Each persistent vertebra does not exactly correspond to a protovertebra; in reality, the latter takes a share in the formation of two vertebræ, and divides into two portions: an inferior, which constitutes the posterior moiety of a permanent vertebra; and a superior, which forms the anterior moiety of the persistent vertebra immediately behind the preceding and the intervertebral disc.

The bodies of the vertebræ are developed more rapidly than their spinal portion: thus, towards the end of the second month, all the vertebral bodies are already cartilaginous, while the vertebral laminæ are yet membranous.

[1] Colin. 'Traité de Physiologie Comparée des Animaux.' 2nd Edition, Paris, 1873.

It is only in the third month that ossification begins in the vertebral column. The number of osseous nuclei, primary and complementary, is not the same in all species; they have been enumerated at page 20. In a large number, the spinous process is regarded as the result of the joining together of the two moieties of the vertebral arch; in the Sheep, on the contrary, the spinous process forms a nucleus altogether independent of the vertebral arches. Thomas has noted this disposition, and he considers it

Fig. 437.

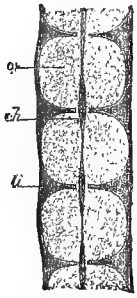

DIAGRAM SHOWING THE ATTENUATION OF THE CHORDA DORSALIS IN THE MIDDLE OF THE BODIES OF THE VERTEBRA, WHILST PRESERVING ITS ORIGINAL DIAMETER IN THE INTERVERTEBRAL SPACES.

ch, Chorda dorsalis; *v*, Body of vertebra; *li*, Intervertebral spaces.

Fig. 438.

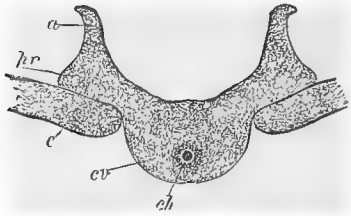

DIAGRAM SHOWING THE POSITION OF THE CHORDA DORSALIS IN THE BODY OF THE VERTEBRA, AND THE FORMATION OF THE NEURAL ARCHES.

ch, Chorda dorsalis; *cv*, Body of the vertebra; *a*, Neural arch, or neurapophysis; *c*, Rib; *pr*, Transverse process.

as peculiar to animals whose anterior dorsal vertebræ are furnished with a long spinous process.

During ossification, the chorda dorsalis disappears, except between the vertebræ, where it is developed to form the intervertebral substance or discs.

B. Development of the Cranium and Face.—The encephalon is enveloped by a membrane formed at the expense of the protovertebral laminæ. This *cranial membrane* becomes partly cartilaginous, partly fibrous; the cartilage exists at the base of the cranium, and seems to prolong the bodies of the vertebræ into this region; indeed it is known that the skull may be resolved into four portions, each corresponding to a vertebra. The cartilage is insensibly transformed into bone; while the fibrous part, composing the roof of the skull and its lateral walls, passes directly into an osseous state.

The bones of the face are developed at the expense of the *pharyngeal arches*. This designation is given to four laminæ (or *lamellæ*) which spring from the anterior extremity of the chorda dorsalis, and double downward and inward to join those of the opposite side. They are also named the *branchial* and *visceral arches*, and the spaces between them are called the *pharyngeal clefts*. The upper jaw, mouth, nasal cavities: *i.e.* the nasal, maxillary, and palate bones, are furnished by the first arch. Meckel's cartilage, which arises from the handle of the malleus to pass towards the inferior maxilla, is also a dependency of this branchial arch; it disappears towards the sixth or seventh month. It is to be remarked that, at the commencement, the mouth communicates with the nasal cavities; the palate is developed in two moieties

which advance towards each other, though they remain a long time apart; so that at this time the young animal really has a hare-lip. The second pharyngeal arch forms the stapes, the pyramidal process of the temporal bone, styloid arch, and branch of the hyoid. The third develops the hyoid with its cornua; while the fourth arch only constitutes the soft parts of the neck.

Fig. 439.

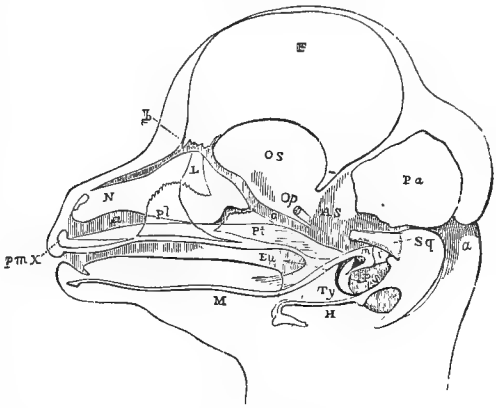

THE HEAD OF A FŒTAL LAMB DISSECTED TO SHOW MECKEL'S CARTILAGE.

M*m*, The malleus; *i*, Incus; Z*y*, The tympanic; H, The hyoid; S*q*, The squamosal; P*t*, Pterygoid; *pl*, Palatine; L, Lachrymal; *pmx*, Premaxilla; N, Nasal sac; E*u*, Eustachian tube.

C. Development of the Thorax.—The ribs are dependencies of the protovertebral laminæ, which curve towards the lower face of the vertebral column. The true ribs are most rapidly developed, and before attaining the middle line are united by their internal extremity, and form a moiety of the sternum. A fissure separates the costal arches of the right side from those of the left: this gradually contracts, and finally disappears, and the sternum is then formed. The ribs are, after the petrous bone, the parts of the skeleton which are most promptly ossified, ossification commencing in the middle ribs.

The costal arches do not belong exclusively to the dorsal vertebræ, but have a tendency to form along the whole length of the spine; and it is not rare to see, attached to the lumbar vertebræ, a small cartilaginous nucleus which is soon lost in the texture of the abdominal walls. This nucleus assumes large dimensions on the last cervical vertebræ of birds.

The form of the thorax varies with the species; in some it is circular, in others it is flattened laterally; and in all cases it is less developed in the fœtus and young animal than in the adult. It is in the latter that the thoracic cavity presents, proportionately, its greatest dimensions.

D. Development of the Limbs.—The limbs do not show themselves until after the formation of the spinal column, the pharyngeal arches, and the thoracic parietes. They appear as four little prolongations from the thorax and pelvis, and are slightly enlarged at their origin and constricted in the middle. Their free extremity is flattened, and either divides or remains single, as the animal has one or more apparent digits. It is in these prolongations that the cartilaginous rays are developed, which, at a later period, become the bones of the limbs. For the manner in which ossification is carried on in each bone, reference must be made to Articles IV. and V., pages 71 and 91.

2. Muscles.—The muscles are developed around the bones when these have become perfectly distinct. They may be divided into four groups: the *vertebral muscles*, which come from the muscular laminæ of the protovertebræ; the *visceral muscles*—thoracic and abdominal cavities, neck and jaw—having

the same origin; the *cutaneous muscles*, which are developed at the expense of the cutaneous laminæ of the middle layer of the blastoderm; and the *muscles* of the limbs, whose development is not yet perfectly known.

It was at one time believed that the muscular fibres were formed by the junction, end to end, of several elongated cells; but it is now known that they are constituted by a single cell which lengthens, and whose nuclei multiply and lie at the surface, while its contents are transformed into a substance which offers the characteristics of contractile tissue. The sarcolemma is formed after the fibre, by a modification of the connective tissue surrounding it.

Fig. 440.

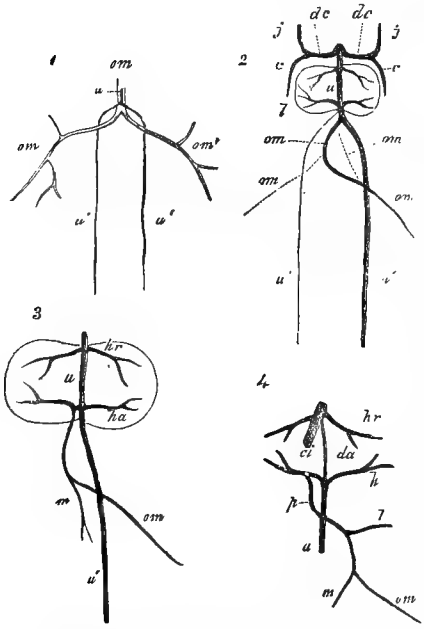

DIAGRAM OF THE FORMATION OF THE VENÆ OMPHALO-MESENTERICÆ AND UMBILICALES.

1, At the time of the first appearance of the umbilicales, and the commencement of the omphalo-mesentericæ; 2, At the time of the first appearance of the branches to and from the liver, and the diminution of the omphalo-mesenteric vessels; 3, 4, At the period of complete fœtal circulation in 1, Omphalo-mesenteric trunk; in 2, 3, Remains of it; in 4, Vein of the yolk sac alone; *om'*, Right, and *om''*, Left vena omphalo-mesentericæ; *u*, Trunk of the umbilical vein; *u'*, Right, and *u''*, Left vena umbilicalis; *dc*, Ductus Cuvieri; *j*, Jugularis; *c*, Cardinalis; *l*, Liver; *ha*, hepatica advehentes; *hr*, Hepaticæ revehentes; *m*, Mesentericæ; *da*, Ductus venosus Arantii; *ci*, Cava inferior; *p*, Vena portæ; *l*, Lienalis; *m*, Mesenterica superior.

DEVELOPMENT OF THE CIRCULATORY APPARATUS.

During the first days which follow the appearance of the embryo in the substance of the blastodermic layer, there is no trace of vessels in the area germinativa. It is not long, however, before the heart and some blood-vessels are seen in the middle layer, the vessels extending to the surface of the umbilical vesicle, which gradually shows itself. While the contents of the vitelline vesicle are being absorbed by the embryo, the heart is being completed, the vessels are developing, the allantois is formed, and the placental circulation, which continues until birth, is established. From this time the circulatory apparatus has acquired its definitive disposition.

1. Appearance of the Heart.—Circulation in the Umbilical Vesicle.—The pleuro-peritoneal cavity of the embryo presents, anteriorly, a diverticulum, the *cardiac cavity*, in the interior of which the heart is developed. This organ appears at first as a small mass of cells, the innermost of which become separated from each other to create a cavity and constitute the blood-globules. As soon as it shows itself, the heart contracts and dilates alternately, the movements being very slow, though they gradually become quicker. Towards the twelfth day, the central organ of the circulation has the form of a contractile cylindrical tube.

From its anterior part spring two branches, the *aortic arches* (*arcus aortæ*), which are directed towards the head of the embryo, and are afterwards inflected downwards and backwards. They join together to constitute the *single aorta*, which, in its turn, divides into two trunks, the *arteriæ vertebralis* or *primitive aortæ*. These vessels pass along the lower surface of the embryo, parallel to each other, and furnish during their course four or five divisions, the *omphalo-mesenteric arteries*, which ramify in the area germinativa, and open into a limitary vein named the *sinus* (or *vena*) *terminalis*. From the network of the area and the sinus arise two vessels, the *venæ omphalo-mesentericæ*, which enter the posterior extremity of the heart.

The circulation in the umbilical vesicle is somewhat ephemeral in several species, and it has been already stated that the vesicle is atrophied at an early period of fœtal life. In birds it is most extensive; and its presence may be noted in the Carnivora during the whole term of uterine existence.

2. Development of the Heart and Vessels.—Placental Circulation.—The heart which, until now, was a cylindrical tube, is considerably modified before it attains its complete development. In its different phases, it successively offers all the forms known to exist in vertebrate animals. The first change consists in an inflexion; the tube curves in an S manner, so

Fig. 441.

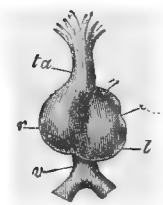

HEART OF THE EMBRYO OF RABBIT, SEEN FROM BEFORE.

ta, Truncus arteriosus; *l*, Left ventricle; *r*, Right ventricle; *a*, Auricle; *v*, Venous sinus.

Fig. 442.

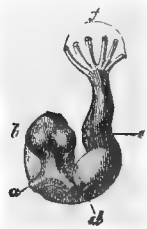

THE SAME, SEEN FROM BEHIND.

a, Venæ omphalo-mesentericæ; *d*, Right auricle; *e*, Bulbus aortæ; *f*, The six aortic arches; *c*, Atrium; *b*, Auriculæ

that its inferior part becomes superior; it then dilates at three points: the anterior and superior dilatation situated at the origin of the aorta is named the *aortic bulb* (*bulbus aortæ*); the middle dilatation, the *ventricular cavity*; and the posterior dilatation, the *auricular cavity*. *Haller's passage* is the name given to the constriction between the auricle and ventricle, which at this time are single. They do not remain long so, however. The ventricular cavity is the first to be divided into two compartments, and the division is marked externally by a groove which appears on the surface of the heart of the Ovine embryo towards the nineteenth day, and on the twenty-fifth in the Equine fœtus. This groove corresponds to an interventricular septum which insensibly rises from the bottom of the ventricles; when it reaches the auricles it concurs in forming the auriculo-ventricular openings. The margins of these openings are provided with a small slightly salient lip, which afterwards, in developing, originates the mitral and tricuspid valves. The heart has now three cavities: two ventricles and an auricle; but in a brief period the latter is doubled, and the compartments are then four in number. Externally, there is observed a depression which shows the division

in the auricles; at a point corresponding to it, a septum is developed in their interior which remains incomplete during the whole of fœtal life, being perforated by the *foramen of Botal.* With regard to the aortic bulb, it contracts and divides into two vessels, the aorta and pulmonary artery.

Fig. 443.

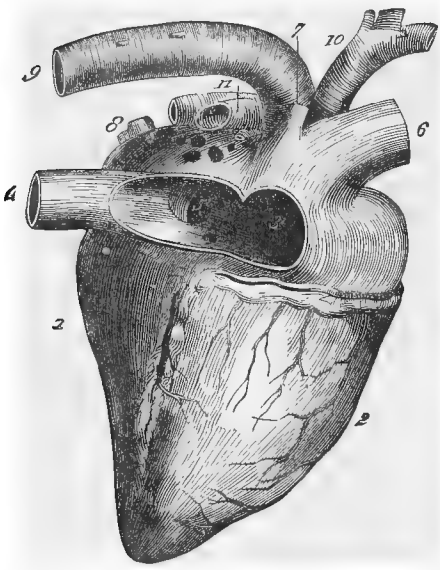

HEART OF AN EQUINE FŒTUS. THE RIGHT AURICLE AND POSTERIOR VENA CAVA HAVE BEEN OPENED TO SHOW THE FORAMEN OF BOTAL.

1, Left ventricle; 2, Right ventricle; 3, Interior of the right auricle; 4, Posterior vena cava; 5, Foramen of Botal.

The *arteries* are developed partly at the expense of the vessels of the primary circulation, and partly in the vascular lamina of the embryo. The heart, when it was only a simple cylindrical tube, presented at its anterior extremity two aortic arches, which curved backwards and united to form the single aorta, then the vertebral or common aortæ. The aortic arches are situated at the inner face of the two first pharyngeal arches; afterwards more are developed, which are placed within the other pairs of arches, until the number is increased to five, though they never all exist at the same time. Some atrophy, while others are being developed: the two first entirely disappear; the third form the carotids: the fourth the axillary arteries and the arch of the aorta; the fifth atrophies on the right, and on the left originates the pulmonary artery, the ductus arteriosus, and the aorta. The latter is continued along the spine by the fusion of the two primitive aortæ; they present, at their posterior extremity, the pelvic vessels, which are very small, and the umbilical arteries, which are, on the contrary, remarkable for their volume.

The peripheral arteries arise, independently of the central vessels, on the interior of the vascular lamina. They appear in the form of solid cellular branches, which are hollowed in the centre by a cavity in which the cells become free. In proportion as these new vessels are developed, the omphalo-mesenteric vessels disappear, until at last there only remain one or two ducts that pass to the umbilical vesicle.

The *umbilical veins* are developed immediately after the formation of the omphalo-mesenteric veins; they enter the common trunk of the latter, and when its ramifications diminish in volume, the umbilical veins increase rapidly; when the liver is formed around them, they throw into it branches, which are the rudiments of the hepatic network. Between the hepatic and subhepatic veins, the umbilical vein communicates with the vena cava by the *ductus venosus of Aranzi*, which, according to M. Colin, does not exist in the fœtus of Solipeds in the last moiety of uterine life.

The veins of the embryo form four principal trunks at first: two anterior,

the *anterior cardinal veins;* and two posterior, the *posterior cardinal veins.* The veins of the same side unite in twos, from which result the *Cuvierian ducts;* these open transversely into the omphalo-mesenteric trunk close to the auricular cavity.

The anterior cardinal veins issue from the cranium; they form the jugular veins, and communicate by an anastomosis that extends transversely

Fig. 444.

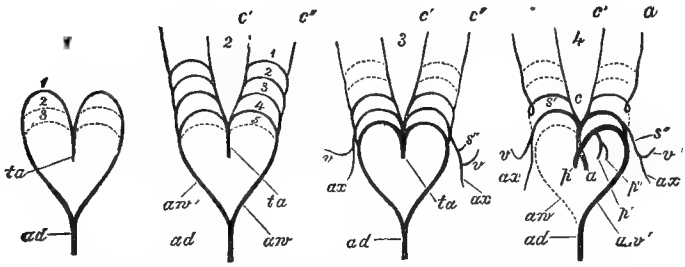

PLAN OF THE AORTA AND ITS ARCHES AT AN EARLY PERIOD.

1, Truncus arteriosus, with one pair of aortic arches, and dotted lines indicating the position of the second and third pairs. 2, The same, with four pairs of aortic arches, and indications of the fifth. 3, The same, with the three posterior pairs of aortic arches, from which the permanent vessels of the embryo are developed, with dotted outlines showing the position of the two (now) obliterated anterior arches. 4, Permanent arterial trunks in their primitive form, the obliterated portions still shown in dotted outline, 1–5, Primitive aortic arches.—*a*, Aorta; *p*, Pulmonary artery; *p'*, *p''*, Branches to the lungs; *aw'*, Root of thoracic aorta (*ad*) on left side; *aw*, Obliterated root springing from right side; *s''*, *s'*, Subclavian artery; *v*, Vertebral; *ax*, Axillary; *c*, Common carotid; *c'*, External carotid; *c''*, Internal carotid.

from left to right. Below this anastomosis, the left vein gradually atrophies, as does the Cuvierian duct of the same side; but the canal on the right side increases, and becomes the anterior vena cava.

The *posterior vena cava* appears behind the liver towards the fifth month; it receives the veins of the kidneys and Wolffian bodies, and, behind, it anastomoses with the cardinal veins. The latter disappear in their middle portion, and are replaced by the *vertebral veins*, the right of which forms the vena azygos. There only remain the two extremities of the cardinal veins; the anterior enters the Cuvierian duct, and the posterior constitutes the hypogastric and crural veins. From this disposition, it will be seen that at first the venous system of the fœtus is perfectly symmetrical, but that in the adult animal it becomes asymmetrical.

In consequence of these successive developments, the placental circulation is instituted, and continues the same until the termination of intra-uterine life. The heart is always the organ that propels the blood, and this passes into the arteries, reaches the umbilical arteries, and is carried to the placenta. There it is renewed, becomes *arterial* through contact with the maternal blood, and is returned by the umbilical veins. In the substance of the liver it is mixed with the venous blood of the intestines and posterior extremities, through the medium of the ductus venosus, and at last arrives at the right auricle, then the right ventricle, from which it is propelled by a contraction. Instead of going to the lungs, which do not act as respiratory organs, the blood, being pressed by the contraction of the right ventricle, passes into the aorta

Fig. 445.

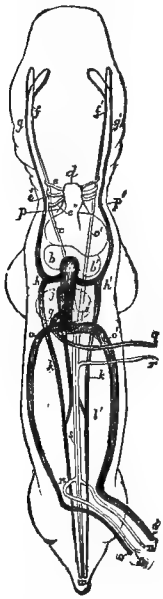

DIAGRAM OF THE CIRCULATION AT THE COMMENCEMENT OF THE FORMATION OF THE PLACENTA: SEEN FROM THE FRONT.

a, Venous sinus receiving all the systemic veins; *b*, Right auricle; *b'*, Left auricle; *c*, Right ventricle; *c'*, Left ventricle; *d*, Bulbus aorticus, subdividing into, *e*, *e'*, *e''*, Branchial branches; *f*, *f'*, Arterial trunks formed by their confluence; *g*, *g'*, Vena azygos superior; *h*, *h'*, Confluence of the superior and inferior azygos; *j*, Vena cava inferior; *k*, *k'*, Vena azygos inferior; *m*, Descending aorta; *n*, *n*, Umbilical arteries proceeding from it; *o*, *o'*, Umbilical veins; *q*, Omphalo-mesenteric vein; *r*, Omphalo-mesenteric artery distributed on the walls of the vitelline vesicle, *t*; *v*, Ductus venosus; *y*, Vitelline duct; *z*, Chorion.

by the ductus arteriosus. To sum up, the fœtus never receives pure arterial blood into its organs, this being always mingled with venous blood, the mixture taking place at several points: 1, By the foramen of Botal; 2, In the aorta by the ductus arteriosus; 3, In the liver by the ductus venosus. The head and neck are the parts which receive the purest arterial blood, a fact which explains the predominance of the anterior over the posterior portion of the body of the fœtus.

At birth, the conditions of existence being suddenly changed, marked modifications take place in the circulatory apparatus. The lungs become the organs of respiration, and rapidly increase in capacity; the pulmonary artery dilates to give passage to the blood that flows to them; while the ductus arteriosus is obliterated, in order to isolate the arterial from the venous blood. This separation of the two fluids also takes place in the liver by the atrophy of the ductus venosus, and in the heart by the occlusion of the foramen of Botal; though, according to M. Goubaux, that orifice frequently remains open in young animals. Its persistence has also been noted in the human adult. Notwithstanding the presence of this foramen, the circulation cannot be much disturbed; as when the heart contracts, the auricles become isolated by the constricting of the orifice and the raising of a valve.

DEVELOPMENT OF THE RESPIRATORY APPARATUS.

Observers are not unanimous as to the development of the *lungs*. According to Reichert and Bischoff, they arise from two small solid cellular masses lying on the surface of the anterior portion of the intestinal canal. These become channeled out into numerous ramifying cavities (by the deliquescence or fusion of the internal cells), which communicate with the trachea. Costa states that they commence by a median, bud-like, hollow process that opens into the œsophagus. The walls of the communicating aperture elongate considerably, and at a later period form the trachea and larynx; while the hollow bud divides into two pyriform sacs, each of which becomes broken up into a multitude of subdivisions to constitute the pulmonary lobes, with their vesicles and infundibula.

The *trachea* is completed by the development of the cartilaginous rings in the tube that binds the lungs to the œsophagus. They appear at the commencement of the third month.

The *larynx* is developed in the same manner at the pharyngeal opening; it is always somewhat undefined

during youth, and its definitive volume is not acquired until the period of puberty.

The *thymus gland* appears as a process of the respiratory mucous membrane; it seems to be formed at the larynx, and gradually descends along the trachea to the entrance of the thorax.

Fig. 446.

FIRST APPEARANCE OF THE LUNGS; *a*, In a Fowl at four days; *b*, At six days; *c*, Termination of bronchus in a very young Pig.

DEVELOPMENT OF THE DIGESTIVE APPARATUS.

In this paragraph, the development of the alimentary canal will be first studied, then that of the organs annexed to it.

A. ALIMENTARY CANAL.—We have seen how the embryo, in becoming incurvated, divides the blastodermic vesicle into two parts which communicate by a large pedicle. The external portion is the umbilical vesicle; the pedicle is the omphalo-mesenteric duct, and the inner part the intestinal cavity.

The latter may be decomposed into three portions: the *anterior intestine*,

Fig. 447.

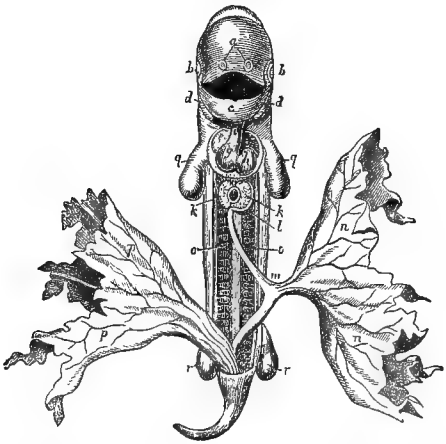

EMBRYO OF DOG, TWENTY-FIVE DAYS AFTER LAST COPULATION.

a, *a*, Nostrils; *b*, *b*, Eyes; *c*, *c*, First visceral arches, forming the lower jaw; *d*, *d*, Second visceral arches; *e*, Right auricle; *f*, Left auricle; *g*, Right ventricle; *h*, Left ventricle; *i*, Aortic bulb; *k*, *k*, Liver, between the two lobes of which is seen the divided orifice of the omphalo-mesenteric vein; *l*, Stomach; *m*, Intestine, communicating with the umbilical vesicle, *n*, *n*; *o*, *o*, Corpora Wolffiana; *p*, Allantois; *q*, *q*, Anterior extremities; *r*, *r*, Posterior extremities.

which forms the pharynx and œsophagus; the *posterior intestine*, that gives rise to the rectum; and the *middle* intestine, which becomes the stomach and intestines.

The middle intestine appears at first as a uniform cylindrical tube, whose diameter is afterwards modified to constitute the organs comprised between the œsophagus and rectum.

1. *Mouth.*—It begins by a depression limited by the maxillary buds; this blind pouch gradually enlarges inwardly, and proceeds to meet the pharynx, from which it is only separated, at a certain period, by a thin membrane; this is at last absorbed, and the two cavities then communicate. Until the third month, the mouth is confounded with the nasal cavities; at this time the palate appears, and eventually isolates them.

2. *Tongue.*—Appearing at first as a small prominence from the maxillary buds, the tongue is completed by the addition to it of a bud from the second branchial arch. Its epithelium and glands come from the external blastodermic lamina; they are developed in the third and fourth months.

3. *Pharynx and Œsophagus.*—These two organs become enlarged and elongated as the fœtus grows. The œsophagus communicates at first with the trachea; but it slowly closes, and finally separates completely from that canal.

4. *Stomach.*—This is formed by the dilatation of the anterior part of the middle intestine; this dilatation is fusiform, and its largest axis longitudinal; it soon incurvates, and its longest axis is then transversal. In Ruminants, the stomach is at its first appearance simple; but before long it shows grooves on its surface, and in its interior septa, as in the normal state. During fœtal life this organ is small; but after birth, when solid food begins to be taken, it augments rapidly in volume. During lactation in Ruminants, there is remarked a predominance of the fourth over the other gastric compartments; but immediately the young animal commences to consume fibrous aliment, the rumen quickly increases in size, and it is not long before it becomes the most considerable division.

5. *Intestines.*—The intestinal tube is primarily of a uniform calibre, though in a short time there can be distinguished the various regions of which it is composed. According to A. Baer, the cæcum is early seen in hoofed animals, and is situated in the vicinity of the omphalo-mesenteric duct. This duct detaches itself from the extremity of an intestinal loop, which is drawn towards the umbilical ring; when the latter is becoming atrophied and progressing towards complete obliteration, this loop re-ascends into the abdominal cavity.

The intestines are smooth on their inner face during the first two months; but during the third they show their villosities and the glands of Lieberkühn. The Brunnerian and solitary glands are a little later in showing themselves.

6. *Rectum.*—This is derived from the posterior intestine, and is developed like the other portions.

7. *Anus.*—Towards the caudal extremity of the fœtus is observed a depression analogous to the buccal *cul-de-sac.* This gradually deepens, and is joined to the rectum and genito-urinary organs. Later, it is separated from the latter, and then belongs exclusively to the alimentary canal.

B. Annexes of the Alimentary Canal.—These are the salivary glands, teeth, liver, pancreas, and spleen.

1. *Salivary glands.*—These are developed in a solid cellular bud, which is related to the epithelium at the commencement of the digestive apparatus. This bud increases, and at the same time is hollowed into glandular pouches. The submaxillary gland is the first to appear; according to Bischoff, it is entirely formed in the fœtus of a Cow only an inch in length. The parotid gland is the last to be formed.

2. *Teeth.*—These organs are developed in the interior of a cavity, named the *dental follicle* or *sac*, by means of the elements of three germs: one belonging to the ivory, another to the enamel, and a third to the cementum.

Follicle.—The *dental follicle* is an oval cavity with walls composed of two layers: the external is fibrous and complete; the internal, soft or gelatinous, is allied at the bottom to the *ivory germ.* The latter is a prominence which is detached from the bottom of the follicle, and has the exact shape of the tooth. Its structure comprises, in the centre, delicate connective tissue provided with vessels and nerves, and on the surface a layer of elongated cells. At the summit of the follicle, facing the ivory germ, is the *enamel germ;* it is exactly applied to the dental pulp which it invests like a cap, and is composed of a small mass of mucous connective tissue covered by a layer of cylindrical cells, joined to the buccal epithelium by the *gubernaculum dentis.* The *cementum organ* manifestly exists in the Foal, according to M. Magitot. The base of the ivory germ has been found, but it disappears rapidly after having performed its function.

How are the different parts of the dental follicle developed? On the free borders of the maxillæ the epithelium of the buccal mucous membrane forms an elongated eminence—the *dental ridge.* Below this ridge, the epithelium constitutes a bud which develops in size, and is sunk in the mucous membrane: this is the enamel germ; it has a layer of cylindrical cells on its deep surface, and in its centre are round cells. After a certain time, it is only joined to the epithelium by a very thin line of cells—the *gubernaculum dentis.* While this enamel germ grows downwards, it covers, by its base, a connective bud which rises from the mucous derma. The two buds are reciprocally adapted to each other, and around them the connective tissue condenses, and gives rise to the walls of the follicle. It will therefore be seen, that the enamel organ is a dependency of the epithelium, and the ivory organ a production of the mucous derma.

Formation of the ivory, enamel, and cementum.—The ivory and enamel are developed by the modification of the elements situated at the surface of their germ.

It has been shown that the germ of the ivory, or dental pulp, had exactly the form of the future tooth; consequently the ivory which arises from its periphery offers the shape of this tooth. The *ivory* (*dentine*) is constituted by the cells of the germ, which elongate, send out prolongations —the *dental fibres*—that ramify and anastomose, and by an intercellular substance which is impregnated with calcareous matter, is moulded around these fibres, and forms the dental canaliculi.

The *enamel* is derived from the deep cells of its germ, which are elongated and prism-shaped, and are calcified in becoming applied to the surface of the ivory.

The *cementum* is developed at the expense of the walls of the follicle, according to the mode of ossification of the connective tissue.

Eruption.—As the ivory is formed, the tooth increases in length and presses the enamel germ upwards; the latter, constantly compressed, becomes atrophied, and finally disappears when the tooth has reached the summit of the follicle. In the same way the young organ pierces the dental follicle and gum, and makes its eruption externally.

Such is the mode of development of the caducous teeth, and the permanent ones are formed in the same manner. There is seen, during the development of the enamel germ of the temporary tooth, a bud detaching

itself from this germ, and passing backward to serve, at a later period, in forming the persistent tooth.

3. *The liver.*—This gland commences to be developed very early in all the species. It appears on the surface of the duodenum in the form of two or more buds, according to the number of lobules in the adult liver. To these external buds are corresponding internal ones, arising from the intestinal epithelium. The first enlarge and envelope the omphalo-mesenteric vein; the second ramify in their interior, and form the system of biliary canals.

Fig. 448.

ORIGIN OF THE LIVER FROM THE INTESTINAL WALL IN THE EMBRYO OF THE FOWL, ON THE FOURTH DAY OF INCUBATION.

a, Heart; *b*, Intestine; *c*, Everted portion, giving origin to liver; *d*, Liver; *e*, Portion of vitelline vesicle.

The liver grows rapidly, and, towards the third month, almost entirely fills the abdominal cavity; at a later period its growth is less marked, although at birth it is yet proportionally larger than in adult life.

4. *Pancreas.*—The pancreas first appear, like the salivary glands, in the form of a solid cellular bud, which afterwards is channeled into ramescent cavities.

5. *Spleen.*—According to Bischoff, this body is developed, during the second month, on the large curvature of the stomach. Arnold states that it is formed at the same time as the liver, in a strip extending from the stomach to the duodenum. It subsequently separates from the pancreas and becomes fixed to the stomach, where its elements assume the character of spleen tissue.

Fig. 449.

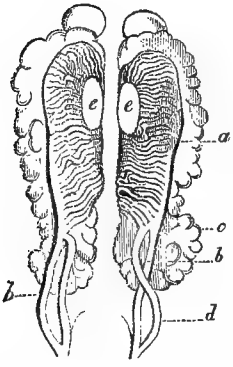

STATE OF THE GENITO-URINARY APPARATUS IN THE EARLY EMBRYO OF THE BIRD.

a, Corpora Wolffiana; *b*, *b*, Their excretory ducts; *c*, Kidneys; *d*, Ureter; *e*, *e*, Testes.

DEVELOPMENT OF THE GENITO-URINARY APPARATUS.

The development of the genital is related to that of the urinary organs, as the apparatus they form have some parts in common.

Immediately after the formation of the intestines, the genito-urinary organs are supplied by the Wolffian bodies. These, also named the *primordial kidneys* and *bodies of Oken*, are glandular in structure, and extend in front of the vertebral column from the heart to the pelvis. They are composed of small transverse canals, filled with a whitish fluid, which enter a common excretory duct that lies parallel to the spine, and opens inferiorly into that portion of the allantois that becomes the bladder. The Wolffian bodies are placed behind the peritoneum, and are attached by two serous folds: an anterior, the *diaphragmatic ligament*, and a posterior, the *lumbar ligament of the corpora Wolffiana*. The organs furnish a liquid analogous to the urine; though it is not long before their secretion undergoes great modifications; indeed, these bodies soon atrophy, and disappear more or less rapidly, according to species. One portion serves for

the development of the genital organs; the other gives rise to organs whose signification is unknown—such as the organ of Rosenmüller, which is very developed in the Mare, and the canals of Gaertner, visible in the Cow (Mare, and Pig).

A. Urinary Organs.—We have seen above how the allantois is derived from the terminal portion of the intestine; it has now to be stated that the *bladder* is derived from the allantois. This reservoir is the result of the dilatation of the abdominal portion of the allantois. During fœtal life, the bladder is extended by the *urachus* to the umbilical ring; but after birth the urachus is obliterated, and the bladder is withdrawn into the pelvic cavity. Hereafter we shall study the urethra.

The *kidneys* appear a long time after the Wolffian bodies, in the shape of two blind pouches constituted by a pushing back of the upper wall of the small vesicle of the allantois. These little *culs-de-sac* ramify, and are afterwards replaced by solid buds, in whose interior are developed the uriniferous canals and Malpighian bodies. According to certain observers, the kidneys subsequently communicate with the ureters, which are developed separately in the middle layer of the blastoderm.

(In the female, the Wolffian bodies do not entirely disappear; the canals of Gaertner and the bodies of Rosenmüller, situated in the broad ligaments, between the ovaries and Fallopian tubes, are their remains in adult life; traces of them are also found in the male, near the head of the epididymis, where they constitute the *vas aberrans* of the testicles. The *suprarenal capsules* are very large in the Equine fœtus, being nearly one half the size of the kidneys.)

B. Genital Organs.—The genital apparatus of the male and female are at first very much alike; indeed, during a certain period it is impossible to distinguish the sexes; so that some authorities have proposed to term this period the "indifferent state of the genital organs." Later, the sexes are defined; and this period of development may be studied in the internal and external organs.

1. *Indifferent state of the internal genital organs.*—Towards the sixth week, there is observed on the lower face, and near the inner border of the Wolffian bodies, a little white cord, which increases in volume and maintains almost the same position. This is the *genital gland*, which is attached to the Wolffian body by serous folds, and is formed by a mass of young cells sustained by an enveloping membrane.

The development of this gland is accompanied by the formation of the *genital* or *Müller's duct*, which is seen to the inside, and in front of, the Wolffian duct. Müller's duct is at first a solid cellular column, which afterwards becomes a canal; it terminates above in a blind pouch, and opens, below, into the bladder, near the Wolffian duct.

Development of the internal genital organs of the male.—These result from modifications of the genital gland and Müller's duct. The testicle arises from the gland, which shortens and widens a little, while its tissue is transformed into seminiferous canaliculi. The *head* (*globus major*) *of the epididymis* is formed by the middle portion of the Wolffian body; the *tail* (or *globus minor*), *vas deferens*, and *ejaculatory duct*, are derived from the Wolffian duct. Lastly, the *vesiculæ seminales* and the *origin of the urethra* are formed by the posterior extremity of Müller's ducts, which join and open into the *uro-genital sinus*, as the very short canal is named which communicates between the bladder and cloaca. The developed testicle remains in the abdominal cavity, or descends through the inguinal canal

into the scrotum. The mechanism of this descent has been already explained.

(It may be only necessary here to state, that in the Equine species the testicles do not usually descend into the scrotum until some time after birth—about six months; while in other animals they reach that sac during fœtal life. In the Bovine species, the testes are in the scrotum about the twentieth week of gestation, and in the Sheep and Goat about the fifteenth week; indeed, it has been observed that in all Ruminants their descent is effected before the skin is covered with hair. In the Carnivora, they are usually in the scrotum a few days before birth.)

Development of the internal genital organs of the female.—The *ovary* is derived from the genital gland, whose anatomical elements are so disposed as to form the stroma, Graafian follicles, and ovules. The *Fallopian tube* and its pavilion are formed by the anterior part of Müller's duct, whose extremity shows a small linear orifice. The *uterus* and *vagina* arise from the posterior part of Müller's ducts. These lie beside each other, and end by joining behind to constitute a single canal; this fusion giving origin to the body of the uterus and the vagina.

The two diverging portions of the ducts comprised between the point of junction and the Fallopian tubes, compose the cornua of the uterus.

The uterus and vagina are at first placed end to end, without any apparent separation; but towards the sixth month the neck of the uterus commences to be defined.

2. *Indifferent state of the external genital organs.*—The intestine is terminated by the *cloaca*, a cavity into which the digestive canal and bladder open by the uro-genital sinus. This confusion quickly ceases by the development of a transverse septum that divides the cloaca into two compartments: the *anal opening*, and the *uro-genital canal*. At the inferior end of the latter appears the *genital tubercle*, a rudiment of the penis or clitoris, and which is surrounded by cutaneous folds—the *genital folds*. This tubercle increases in volume, and has a furrow passing from behind to before. Up to this moment it is impossible to distinguish the sexes.

Development of the external genital organs of the male.—The male sex is marked by the rapid development of the genital tubercle, which becomes the penis, the extremity of which enlarges to constitute the glans. The genital furrow closes posteriorly, and forms the urethra. The folds draw round to each other below the penis, unite in the middle line, and thus produce the scrotum. Owing to these modifications, the digestive apparatus is completely separated from the genito-urinary organs, and the urethral canal is connected with the bladder and the excretory ducts of the testicle.

Development of the external genital organs of the female.—The indifferent state of the genital organs is readily succeeded by the feminine type. The uro-genital sinus forms the vulvular cavity or vestibulum of the vagina, which is so marked in the lower animals. The genital tubercle becomes the clitoris; the genital furrow closes at a certain part to constitute the perineum; while the genital folds form the labia of the vulva. The mammæ, dependencies of the generative organs, appear after the first month of uterine life.

CHAPTER IV.

THE OVA OF BIRDS.

It has been stated, with regard to the ovaries of birds, that the ovules compose nearly the whole mass of these organs. When it leaves the ovary, the ovum presents the same parts as that of mammals, only differing in volume, which is enormous in birds. It is in passing through the oviduct that it is covered with a thick layer of albumen and enveloped in a white membrane, and then a shell, to compose what is usually known as an *egg*. It is therefore composed of the *ovulum* and *accessory parts* (Fig. 450).

Ovulum.—There is found in the ovulum: 1, A *vitelline membrane* (2), thinner, proportionately, than that of mammals; it is fibrous, and shows on a certain point of its surface: 2, The *cicatricula* (8), a yellowish-white disc, in the centre of which exists, 3, *Purkinje's vesicle*, or the *germinal vesicle;* the *yolk* or *vitellus* (1), which fills the enveloping membrane. In the mass of the vitellus is seen what appears to be a bottle-shaped cavity, the long neck of which is applied to the cicatricula.

The vitellus of the egg of birds differs from that of mammals in its anatomical composition, being entirely composed of what are designated *vitelline globules.* These globules are white in the centre of the egg, and have only a few nuclei; in the remainder of the mass they are much more voluminous, and contain a large number of granulations which give them their yellow colour. It is the presence of the clear vitelline nucleated globules in the centre of the egg, which has given rise to the surmise that the bottle-shaped figure, named the *latebra* (9) by Purkinje, is a cavity.

Fig. 450.

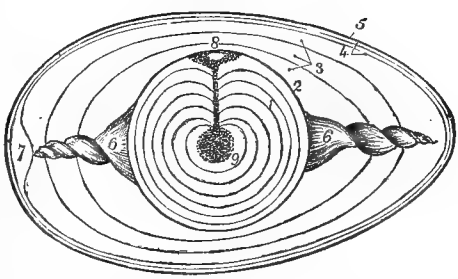

SECTIONAL VIEW OF FOWL'S EGG.

1, Yellow yolk composed of successive layers; 2, Vitelline membrane; 3, Layers of albumen; 4, Two principal layers of the lining membrane of the shell; 5, Calcareous shell; 6, Chalazæ; 7, Air-space between the two layers of the shell; 8, Cicatricula, with its nucleus, beneath which is seen the canal leading down to the white yolk cavity, or latebra, 9.

Accessory Parts.—These comprise: 1, the *white* or *albumen* (3), disposed in three layers of different densities, and which are deposited around the yolk at three different periods during its course along the oviduct; 2, The *chalazæ* (6), species of albuminous ligaments twisted in a spiral manner, and attaching the yolk to the testaceous membrane; 3, The *testaceous* or *shell-membrane* (4), which offers towards the obtuse pole a doubling into two layers, between which are found: 4, The *air-chamber* (7), so named from the air it contains; 5, The *shell* (5), decomposable into several layers.

The *testaceous* or *shell membrane* is composed of a closely woven fibroid tissue; it owes its opacity to the air it contains in its meshes.

The shell is very solid, and impregnated with calcareous salts; it is perforated by a multitude of cavities opening on its surface. When closely examined, it is found to have a more or less shining aspect, and in its mass fine sand-like particles.

Landois, who has completed the researches of Wittich on the ovum of birds, distinguishes several layers in the shell; otherwise their number varies with the species. The shell, acting merely as a protecting covering, is all the more solid and complicated as the eggs are more exposed to the inclemency of the weather.

Independently of the testaceous membrane which Landois attaches to the shell as a fibrous layer, this authority also recognises the *uterine gland layer* and the *spongy layer*. The former is much impregnated with calcareous salts, and deeply studded with little round bodies which are the remains of the uterine glands, and give to the shell its sandy appearance. The spongy layer is structureless, and analogous to solidified mucus.

This description demonstrates that the ovum of birds is distinguished by the considerable volume of its vitellus, and the addition to it of those accessory parts which give the egg its large dimensions and solidity. These differences will readily be understood, when it is remembered that the embryo must find in it all the materials necessary for its development, which takes place external to the parent. It is from the vitellus and the albumen that the young creature derives the elements which the mammal finds in the uterine mucous membrane to which it is fixed.

INDEX.

PAGE

ABDOMEN 380
Abdominal aorta 524
—— cavity 380
—— —— comparison of 385
—— —— differential characters in . 384
—— —— divisions of 381
—— —— —— of inferior . . . 238
—— —— lining membrane of . . 381
—— —— regions of . . . . . ib.
—— —— reservoirs 481
—— —— rings of 241
—— —— viscera in 385
Abdominal salivary gland . . . 427
Abomasum 399
—— structure of . . . . . ib.
Absorbent vessels 627
Accessory portion of visual apparatus, 816, 817
Acervulus 681
Adipose cushion of ear 850
Adrenals 494
Affluents of thoracic duct . . . 637
Aggregate follicles 404
Air-cells of lungs 468
Air-chamber of egg 925
Alimentary canal 385, 400
Allantoid fluid 897
Allantois. 894, 895, 896
—— chorial 897
—— structure of . . . . . ib.
Alveoli of glands 390
—— lymphatic 632
Alveolo-dental periosteum 347
Amnii, liquor 896
Amnion 893, 896
—— false 893
Amniotic lamina 896
Amphiarthroses 129
—— classification of . . . . . ib.
Ampulla of Vater 425, 428
Amygdalæ 335
Amygdaloid cavity . . . . . ib.
Anastomoses 517
—— by arches . . . . . ib.
—— inosculation . . . . . ib.
—— composite . . . . . ib.
—— convergent . . . . . ib.
—— mixed . . . . . ib.
—— transverse communicating . . ib.
—— of nerves 701

PAGE

Anatomical elements 3
Anatomy 1
—— comparative . . . . . ib.
—— definition of . . . . . ib.
—— descriptive . . . . . ib.
—— general . . . . . ib.
—— philosophical . . . . . ib.
—— physiological . . . . . ib.
—— regional . . . . . ib.
—— special . . . . . ib.
—— surgical . . . . . ib.
—— topographical . . . . . ib.
—— transcendental . . . . . ib.
—— veterinary . . . . . ib.
Ancyroid cavity 691
Andersch's ganglion 727
Aneurism 529
Angiology 326, 499
Animal amidon 423
Annular cartilage 846
—— protuberance 675
Annulus albidus 821
—— ovalis 506
Anomalies in arteries 520
Anorchidism 853
Ansiform tube of Henle 488
Anterior antibrachial region . . . 262
—— aorta 559
—— brachial region 255
—— cerebellar peduncle 678
—— crural region 283
—— mediastinum 464
—— peduncles of conarium . . . 680
—— tibial region 298
—— white commissure of brain . . 682
Anus 413, 414
—— development of 920
Aorta 522
—— anterior 559
—— common 522
—— comparison of 538
—— —— of anterior 559
—— differential characters in . . . 535
—— —— —— carnivora 537
—— —— —— pig . . . . . ib.
—— —— —— ruminants . . . 535
—— parietal branches of 525
—— posterior 523
—— preparation of 524

PAGE
Aorta, visceral branches of . . . 526
Aortæ, primitive 915
Aortic heart 506
Aponeurosis 179
—— antibrachial 261
—— contentive 183
—— crural 241
—— —— internal . . . . . ib.
—— fascia lata 284
—— gluteal 280
—— perineal 863
—— —— deep . . . . . ib.
—— —— superficial . . . . . ib.
—— plantar 268, 308
—— tibial 297
Apparatus 5
—— circulatory, in mammalia . . 498
—— —— in birds 647
—— digestive, in mammalia . . . 325
—— —— in birds 435
—— generative 851
—— innervation, of 650
—— olfactory 815
—— respiratory, in mammalia . . 439
—— —— in birds 475
—— sense, of . . . 792, 815,
—— smell, of 815
—— taste, of 813
—— touch, of 792
—— urinary 484
—— vision, of 816
Appendix auricularis 503
Aqueduct of Fallopius 842
—— of Sylvius 682, 683
Aqueous humour 827
—— —— membrane of . . . . ib.
Arachnoid membrane 663
—— —— cranial 664
—— —— spinal 663
—— —— structure . . . . ib.
—— —— ventricular . . . 694
Arantius, nodule of 505
Aranzi, duct of 901, 916
Arbor vitæ cerebelli 688
Arciform fibres of bulb 685
Arch of aorta 523
—— hæmal 119
—— ischial 96
—— ischiatic . . . . . ib.
—— neural 119
—— pharyngeal 912
Arcus aortæ 915
Area germinativa 892
—— pellucida . . . . . ib.
Arm, bones of 73
Arms of pelvis of kidney 486
Arnold's ganglion 720
Arterial zones of heart 508
Arteriæ helicinæ 865
—— vertebralis 915
Arteries 515
—— anastomoses of 517
—— anomalies 520
—— course 516

PAGE
Arteries, direction 516
—— dissection 521
—— form 515
—— general considerations . . ib.
—— —— form . . . . . ib.
—— injection 520
—— mode of distribution . . . 517
—— —— of origin 515
—— preparation 520
—— relations 516
—— structure 518
—— termination 518
—— vessels and nerves 520
—— abdominal, anterior 563
—— —— posterior 547
—— —— subcutaneous 548
—— accessory thyroid 576
—— anterior dorsal of penis . . . 548
—— —— tibial 551
—— asternal 563
—— atloido-muscular 577
—— auricular, anterior 586
—— —— posterior 585
—— axillary 559
—— —— collaterals 560
—— —— comparison of 574
—— —— differential characters in . 570
—— basilar 578
—— brachial 559
—— bronchial 526
—— broncho-œsophageal . . . . ib.
—— buccal 589
—— bulb 540
—— cæcal 531
—— cardiac 523
—— —— left . . . . . ib.
—— —— right . . . . . ib.
—— carotid, common 575
—— —— collateral branches . . 576
—— —— comparison of 579
—— —— differential characters in . 590
—— —— external 581
—— —— internal 579
—— —— primitive 915
—— centralis retinæ 588, 826
—— cerebellar, anterior 578
—— —— posterior . . . . . ib.
—— cerebral, anterior 581
—— —— middle . . . . . ib.
—— —— posterior 579
—— cerebro-spinal 578
—— cervical, deep 561
—— —— inferior 564
—— —— superior 561
—— cervico-muscular . . . . ib.
—— —— transverse 560
—— ciliary 588
—— circumflex, of coronary cushion . 554
—— —— anterior, of shoulder . 565
—— —— posterior, of shoulder . . 564
—— —— inferior, of foot 554
—— circumflex iliac 545
—— coccygeal, lateral 541
—— —— middle . . . . . ib.

PAGE
Arteries cœliac 527
—— colic, direct or right 531
—— —— left or retrograde . . . ib.
—— collateral of the cannon . . 551, 569
—— —— branches 569
—— —— of the digit 552
—— colon, first of small colon . . 532
—— coraco-radial 566
—— coronary 584
—— coronary circle 554
—— corpus cavernosum 543
—— cremasteric 535
—— crural 545
—— dental, inferior 587
—— —— superior 589
—— diaphragmatic 526
—— digital 552
—— dorsal 560
—— —— anterior of penis ib.
—— —— posterior of penis . . 543
—— duodenal 528
—— elbow, external collateral . . 565
—— —— internal collateral . . 566
—— emulgent 534
—— epicondyloid . . . 566
—— epigastric . . . 547
—— external pudic . . ib.
—— facial 581
—— femoral 547
—— femoro-popliteal . 549
—— gastric 528
—— gastro-epiploica dextra . . ib.
—— —— —— sinistra . . . ib.
—— glosso-facial 581
—— gluteal 542
—— great posterior of thigh . . 548
—— —— testicular 534
—— gutturo-maxillary 586
—— helicine 865
—— hepatic 528
—— humeral 565
—— —— collateral branches . ib.
—— —— deep . . . . . ib.
—— iliac, external 545
—— —— —— comparison of . . 557
—— —— —— differential characters in, 555
—— —— internal 538
—— —— —— comparison of . . 546
—— —— —— differential characters in, 543
—— iliaco-cæcal 531
—— ——femoral 543
—— ilio-lumbar 541
—— ——-muscular . . . . . ib.
—— inferior circumflex of foot . 555
—— —— communicating „ . ib.
—— —— vesical 861
—— innominata 559
—— innominate branches of great mesenteric 532
—— intercostal 525
—— internal pudic 540
—— —— —— of female . . . ib.
—— —— —— of male . . ib.
—— interosseous, of fore-arm . . . 567

PAGE
Arteries, interosseous anterior . . . 569
—— —— metacarpal 568
—— —— posterior . . . . . ib.
—— intestinal, small 529
—— ischiatic 541
—— labial, inferior 584
—— —— superior 584
—— lachrymal 588
—— laminal, anterior 555
—— lateral sacral 540
—— —— —— collateral branches . 541
—— —— middle 526
—— —— —— terminal branches . 541
—— lingual 582
—— lumbar 526
—— mammary 548
—— —— external 563
—— —— internal 563
—— masseteric 586
—— mastoid 577
—— maxillary, external . . 581
—— —— internal 586
—— maxillo-muscular 585
—— median-spinal 579
—— meningeal, great 587
—— mesenteric, great 529
—— —— —— anastomoses . . 532
—— —— anterior 531
—— —— —— of left fasciculus . . 529
—— —— —— of right fasciculus . 531
—— —— —— innominate branches . 532
—— —— small . . . . . ib.
—— metatarso-pedal 551
—— muscular, deep 548
—— —— great anterior . . . . ib.
—— —— small 549
—— —— superficial 548
—— nasal 589
—— obturator 542
—— occipital 577
—— —— collateral branches . . . ib.
—— occipito-muscular 578
—— œsophageal 526
—— omental 528
—— omphalo-mesenteric . . . 915
—— ophthalmic 588
—— palatine 589
—— palato-labial . . . . . ib.
—— pancreatic 528
—— pedal 551
—— perforating . . . . . ib.
—— perpendicular 553
—— pharyngeal 582
—— phrenic 526
—— plantar 550
—— —— cushion 553
—— —— interosseous 550
—— —— ungual 555
—— popliteal 549
—— posterior auricular 585
—— —— communicating . . . 581
—— —— dorsal of penis . . . 543
—— —— tibial 550
—— —— —— collateral branches . ib.

PAGE
Arteries, posterior tibial terminal branches ib.
—— prehumeral 565
—— preplantar ungueal 554
—— prepubic 547
—— prevertebral 577
—— profunda femoris 548
—— pterygoid 587
—— pulmonary 521
—— —— preparation of . . . . ib.
—— pyloric 528
—— radial, anterior 566
—— —— posterior 567
—— renal 534
—— retrograde 577
—— sacral, lateral 540
—— sacra media 526
—— saphena 549
—— scapulo-humeral 564
—— small testicular 535
—— spermatic 534
—— spheno-palatine 589
—— —— spinous 587
—— staphylin 589
—— subcostal 561
—— sublingual 584
—— subsacral 540
—— subscapular 564
—— subzygomatic 586
—— superficial temporal 585
—— superscapular 564
—— supra-orbital 588
—— temporal 585
—— —— deep anterior 588
—— —— —— posterior 587
—— terminalis 915
—— testicular, great 534
—— —— small 535
—— thoracic, anterior 563
—— —— external . . . . . ib.
—— —— inferior . . . . . ib.
—— —— internal . . . . . ib.
—— —— —— terminal branches . ib.
—— thyro-laryngeal 576
—— trachelo-muscular 564
—— transverse-cervical 560
—— tranverse of face 586
—— tympanic 587
—— ulnar 566
—— umbilical 538
—— uterine 535
—— utero-ovarian . . . . . ib.
—— vasa brevia 528
—— —— intestini tenuis 529
—— vertebral 561
—— vertebralis 915
—— vesico-prostatic 540, 861
Arthrodia 128
Arthrology 123
Articular cartilages . . . . . ib.
—— surfaces 121
Articulations . . . . . ib.
—— in general . . . . . ib.
—— in particular 129
—— nomenclature 128

PAGE
Articulations, anterior limbs, of . . . 143
—— atlo-axoid 135
—— calcaneo-astragaloid 170
—— carpal 148
—— carpo-metacarpal 150
—— chondro-costal 142
—— chondro-sternal 141
—— —— transverse . . . . . ib.
—— —— vertebral 143
—— coxæ 160
—— coxo-femoral 161
—— elbow 144
—— femoro-tibial 163
—— head 135
—— humero-radial 144
—— hyoideal 139
—— interchrondral 142
—— interhyoideal 139
—— intermetacarpal 152
—— interphalangeal 156
—— —— first . . . . . ib.
—— —— second . . . . . ib.
—— —— third 157
—— intertarsal 171
—— intervertebral 130
—— ischio-pubic 160
—— laryngeal cartilages, of . . . 451
—— metacarpo-phalangeal 153
—— occipito-atloid 137
—— pedal 157
—— pelvic 159
—— posterior limbs . . . . . ib.
—— radio-carpal 149
—— —— ulnar 147
—— sacro-iliac 159
—— scapulo-humeral 143
—— tarsal 168
—— tarso-metatarsal 172
—— temporo-maxillary 138
—— —— hyoideal 139
—— thoracic 140, 142
—— tibio-fibular 167
—— —— tarsal 168
Arytenoid cartilages 451
Auditive scala 839
Auditory apparatus 837
Auricles 505, 507
Auricular facet 92
—— mass 500
Auriculo-ventricular opening . . . 504
—— —— zones 508
Axile bodies 794
Axillary region 231
Axis, cœliac 527
—— cylinder 652
—— —— of arteries 515

Baccated fibres of tooth 346
Bacillary layer of retina 825
Balbiani's vesicle 890
Band of Reil 678
Barbs 334, 369
Bars of hoof 806
Bartholine, glands of 887

PAGE
Basement membranes 5, 327
Basilar membranes 839
—— process of os pedis 85
Bauhini, valvula 402
Bellini's tubes 487
Bicipital tuberosity 256
Bicuspid valve 507
Biflex canal 794
Biliary ducts 423
Bipolar nerve-cells 653
Bladder 491
—— attachments . . . . . ib.
—— development 493, 923
—— form 491
—— functions 493
—— interior . . . . . ib.
—— position 491
—— relations . . . . . ib.
—— structure 493
—— weight 491
Blastema 327
Blastoderm, formation of 892
—— development . . . . . ib.
Blind spot 826
Blood 498
Bones, in general 6
—— absolute form 11
—— blood-vessels 15
—— cavities 12
—— cells of 18
—— configuration 11
—— conformation, internal . . . 13
—— development 16, 17
—— direction 11
—— eminences . . . . . ib.
—— external peculiarities . . . ib.
—— general principles 10
—— imprints 11
—— internal conformation . . . 13
—— lymphatics 15
—— medulla . . . . . ib.
—— names 10
—— nerves 15
—— number 9
—— nutrition 17
—— periosteum 14
—— regions 12
—— relative form 11
—— situation 10
—— structure 13
—— in birds 112
—— anterior maxillary 45
—— astragalus 102
—— atlas 21
—— axis . . . . . ib.
—— calcaneus 103
—— calcis . . . . . ib.
—— capitatum 80
—— carpus 78
—— cervical vertebræ 21
—— coccygeal vertebræ 27
—— coccyx 27
—— costæ 67
—— coxæ 91

PAGE
Bones cuboid 103
—— cuneiform 79
—— dentata 21
—— dorsal vertebra 24
—— ethmoid 37
—— falciform 36
—— femur 98
—— fibula 101
—— first metacarpal 81
—— frontal 36
—— great cuneiform 104
—— hamatum 80
—— heart, of 513
—— humerus 73
—— hyoid 53
—— ilium 91
—— incisive 45
—— incus 841
—— inferior maxillary 51
—— intermaxillary 45
—— interparietal 36
—— ischium 94
—— lachrymal 48
—— large cuneiform 104
—— lumbar vertebræ 25
—— lunare 79
—— magnum 80
—— malar 48
—— malleus 841
—— maxillary, inferior 51
—— —— superior 44
—— metacarpals 81
—— metacarpus . . . . . ib.
—— metatarsus 105
—— middle cuneiform 104
—— nasal 48
—— navicular 86
—— occipital 33
—— os coronæ 84
—— — innominatum 91
—— — orbiculare 842
—— — pedis 84
—— — penis 870
—— palate 46
—— parietal 35
—— patella 102
—— pedal 84
—— pelvis 91
—— penial 870
—— peroneus 101
—— pisiform 79
—— premaxilla 45
—— prominens 23
—— pterygoid 47
—— pubis 93
—— pyramidal 79
—— radius 75
—— ribs 67
—— sacrum 26
—— scaphoid of carpus 80
—— —— of tarsus 104
—— second phalanx 84
—— semilunar 79
—— sesamoids 84

PAGE
Bones, small cuneiform . . 104
—— small sesamoid 86
—— sphenoid 39
—— stapes 842
—— sternum 66
—— styloid 54
—— supercarpal 79
—— superior maxillary . . 44
—— supermaxilla . . . . . *ib.*
—— tarsus 102
—— temporal 41
—— third phalanx 84
—— tibia 100
—— trapezium 79
—— trapezoides 81
—— tricuspid 23
—— turbinated 49, 442
—— ulnar 76
—— unciform 80
—— vertebra dentata 21
—— —— prominens 23
—— —— tricuspid . . . *ib.*
—— vertebræ 20
—— —— cervical 21
—— —— coccygeal . . . 27
—— —— dorsal . . . 24
—— —— lumbar . . . 25
—— vomer 51
—— zygomatic 47
Botal, foramen of . . . 503, 916
Bourrelet 803
Brachial bulb 668
Brachio-rachidian bulb . . . *ib.*
Brain 672
Bristles 797
Bronchi 460
—— cartilages 461
—— disposition 460
—— form 461
—— glands 642
—— relations 461
—— structure . . . . *ib.*
—— volume . . . . . *ib.*
Bronchial cartilages . . . . *ib.*
—— glands 642
—— tubes 461
Bruch, membrane of . . . 822
Brunner's glands 403
Buccal mucous membrane . . 332
Bulbi fornicis 678
—— vestibuli 883
Bulb of ovary 874
—— of plantar cushion . . 802
—— of urethra 862
Bulbus aortæ 915
—— olfactorius 692
—— rachidicus 675
Bursæ, serous 183

Caducous teeth 348
Cæcum 407
—— of mastoid lobule 692, 696
—— of Morgagni 335
—— pharyngeal 373

PAGE
Calamus scriptorius 677
Calcareous powder of vestibule . . . 839
Calices 497
Calyciform papillæ 336, 814
Canal, biflex 794
—— Fontana 821
—— Gærtner 886
—— godronne 827
—— Haversian 13
—— hygrophthalmic 834
—— inguinal 242
—— Jacobson 443
—— perivascular 665
—— Petit 827
—— Schlemm 821
—— spinal 659
—— Sylvius 682, 683
Canine teeth 344, 352
Canthi of eyelids 831
Capillaries 519
Capillary system 518
Capsular ligaments 125
Capsule of Glisson 422
—— of lens 826
Capsules, suprarenal 494
Caput gallinaginus 862
Cardiac cavity 907, 914
—— ligament 389
—— orifice 388
—— septum 503
Carpal sheath 267
Carpus 78
—— articulations 148
—— bones 78
—— movements 152
Cartilage 16, 124
—— of the tongue 336
Cartilages, complementary fibro- . . 124
—— incrustation 123
—— interarticular 124
—— interosseous . . . . . *ib.*
—— stratiform 125
—— cariniform 66
—— costal 69
—— ensiform 67
—— interarticular of jaw 138
—— semilunar 163
—— Wrisberg, of 451
—— xiphoid 67
Cartilaginification 16
Caruncula lachrymalis 834
—— sublingualis 372
Cauda equina 748
Cava, vena 600
Cavernous sinus 606
Cavities 12
Cell-germs 796
Cells 3
—— multiplication of . . . *ib.*
—— bone 14
—— calcigerous 16
—— connective 4
—— hepatic 422
—— medullary 4

PAGE
Pes hippocampi 679
Petit, canal of 827
Petrosal sinuses 606
Peyer's glands 404
Phalanges 82, 105
Pharyngeal arches 912
—— cæcum 373
—— clefts 912
Pharynx 372
—— development of 920
—— disposition 372
—— form . . . . . ib.
—— functions 376
—— muscles 374
—— relations 373
—— structure 374
Phillips's muscle 264
Phrenic centre 246
Pia mater 665
—— —— cranial . . . . . ib.
—— —— spinal . . . . . ib.
Pigment cells 821
Pigmentary corpuscles of horn . . . 810
—— granules 822
Pigmentum nigrum 822
Pillars of diaphragm 247
—— of fornix, anterior 695
—— —— posterior 694
—— of heart 503
—— of inguinal canal 242
—— of rumen 395
—— of soft palate 341
—— —— —— anterior . . . . . ib.
—— —— —— posterior . . . . . ib.
—— of tongue, anterior 335
—— —— posterior . . . . . ib.
Pineal gland 680
Pisiform tubercle 678
Pituitary fold of dura mater 662, 663
—— gland 681
—— membrane 444
—— —— glands of 445
—— —— nerves of . . . . . ib.
—— stalk 681
Placenta 895, 899
—— structure of 899
—— multiple 903
—— simple . . . . . ib.
Plantar arcade or arch 555
—— cushion 801
—— —— bulbs of 802
—— —— structure of . . . . . ib.
—— —— tunic, of . . . . . ib.
—— nerves 761
—— reticulum 612, 804
Pleuræ 464
—— structure 465
Pleuritis, effusion of 466
Pleuro-peritoneal cavity 906
Plexus, general anatomy 701
—— anterior auricular 726
—— —— mesenteric 787
—— brachial 749, 754
—— bronchial 732, 735

PAG
Plexus, carotid 78
—— capillary, of lungs 46
—— cavernous 78
—— cervical, deep 74
—— —— superficial 74
—— choroides 68
—— —— cerebellar 68
—— coronary (venous) 612, 61
—— gastric 78
—— guttural 78
—— hypogastric 78
—— lumbo-aortic 78
—— —— sacral 77
—— lymphatic 62
—— mesenteric, anterior 78
—— —— posterior 78
—— myenteric 40
—— pampiniform 85
—— pelvic 78
—— pharyngeal 728, 78
—— podophyllous, venous 612, 61
—— renal 78
—— solar, venous 61
—— splenic 78
—— subzygomatic 722, 72
—— superficial cervical 74
—— suprarenal 78
—— sympathetic 78
—— tracheal 78
—— vaginal 42
—— venous 59
Plicæ palmatæ 88
Pneumogastric lobule 68
Podophyllous tissue 80
Pons Valorii 675, 67
Popliteal glands 64
Portio dura 72
—— mollis 72
Porus opticus 81
Pouches, guttural 84
Poupart's ligament 24
Præputial glands 86
Præputium clitoridis 88
Precervical nerve 79
Precrural glands 64
PREPARATION:—arteries 52
—— —— dissection 52
—— —— injection 52
—— arteries, anterior tibial 55
—— —— aorta, posterior 52
—— —— axillary 56
—— —— femoral 54
—— —— head, of 57
—— —— iliac, internal 53
—— —— internal iliac . . . . . ib
—— —— popliteal 54
—— —— posterior tibial 55
—— —— pulmonary 52
—— —— tibial, anterior 55
—— —— —— posterior 55
—— articulations 13
—— —— atlo-axoid 13
—— —— carpal 148, 14
—— —— chondro-sternal 14

PAGE
Omentum, gastro-colic 382, 389
—— gastro-splenic 383, 429
—— great 382, 389
Omphalo-mesenteric duct 894
—— —— vessels 899, 915
Opaque area 892
Ophthalmic nerve 711
Optic chiasma 707
—— commissure . . . . . *ib.*
—— layers 675
—— nerves 706
—— papilla 824
—— thalami 675
Ora serrata 820, 824
Orbiculare, os 843
Orbital cavity 817, 828
Organ of Corti 839
—— of Jacobson 443
—— of Rosenmüller 876, 923
Organic life, nerves of 652, 653
Organs 5
—— hollow 326
—— —— structure of . . . . . *ib.*
—— solid 328
—— —— structure of 328, 329
Os orbiculare 843
—— externum 879
—— tricæ . . . . . *ib.*
—— uteri . . . . . *ib.*
Osseous labyrinth 837
Ossicula auditus 842
Ossification, centres of 16
Osteo-dentine 347
—— desm 118
Osteogeny 16
Osteology 6
Ostium abdominalis 876
—— uterinum . . . . . *ib.*
Otoconites 839
Otoliths . . . . . *ib.*
Ova of Birds 925
Ovaries 872
—— development 874, 924
—— functions 874
—— situation 872
—— structure 873
Oviducts 876
Ovisacs 873
—— development 874
—— rupture . . . . . *ib.*
—— structure 873
Ovula Nabothi 879
Ovulum 873, 890
—— modifications in 890
Ovum 873

Pacchionian glands 663
Pacinian corpuscles 703
Palate 332, 356, 359
—— hard 333, 356, 359, 360
—— —— functions of 334
—— —— structure 333
—— soft 340, 357, 359, 360
—— —— functions of 343

PAGE
Palate, soft, muscles 342
—— —— structure 342
Palatine glands 370
Palatum molle 340
Palmar arch 575
Palpebræ 830
Palpebral sinuses . . . . . *ib.*
Pampiniform plexus 856
Pancreas 427
—— development 922
—— excretory apparatus 428
—— form 427
—— functions 428
—— relations 427
—— situation . . . . . *ib.*
—— structure 428
Pancreatic ring 427
Papilla cornica 824
Papillæ 327
—— of foot 803
—— of skin 792, 793
—— of tongue 336
—— calyciformes 336, 814
—— capitatæ . . . . . *ib.*
—— circumvallatæ . . . . *ib.*
—— filiformes . . . . . *ib.*
—— fossulate 336
—— fungiformes 336, 814
—— lenticulares . . . . . *ib.*
Parieto-temporal confluents 608
Parotid duct 367
—— gland 365, 370, 371
Parovarium 867
Pathetici nerves 709
Pavilion of Fallopian tube 876
Pecklin's glands 404
Pecquet, cistern of 634
Pectoral cavity 462
Pedunculi cerebelli 675
—— cerebri 675, 677
Pelvis 91
—— difference in sexes 97
—— in general 95
Penis 865
Peptic glands 391
Perforans tendon, sheath of 269
Pericardium 512
—— muscle of . . . . . *ib.*
Perilymph 840
Perimysium 179
Perineum 882
—— aponeuroses of 863
Perineurium 653
Periople 806
Perioplic ring 803
Periorbita 828
Periosteum 14
Peritoneum 381
—— structure of 384
Perivascular canals 665
Perspiration 797
Perspiratory ducts 794
—— glands . . . . . *ib.*
Pes anserinus 712

PAGE
Nerves, maxillary, superior 712
—— median 759
—— mental 717
—— musculo-cutaneous . . . 774, 757
—— —— spiral 768
—— mylo-hyoid 717
—— nasal 713
—— obturator 771
—— occipito-styloid 725
—— oculo-motor, common . . 708
—— —— —— external . . . 721
—— —— —— internal 709
—— œsophageal 732, 735
—— —— recurrent 735
—— —— superior 733
—— olfactory 705
—— ophthalmic of Willis . . . 711
—— optic 706
—— orbital 712
—— palatine, anterior . . . . . ib.
—— —— posterior 713
—— palmar 766
—— palpebro-nasal 712
—— pathetici 709
—— pectoral 755
—— perforating intercostal . . . 750
—— peroneal cutaneous 774
—— petrous, great deep 728
—— —— —— superficial 722
—— —— small deep 728
—— —— —— superficial 724
—— pharyngeal 733
—— phrenic 753
—— plantar 760, 766
—— —— external 760
—— —— deep . . . . . ib.
—— —— internal . . . . . ib.
—— pneumogastric 728
—— popliteal, external 774
—— portio-dura 721
—— —— intermedia 722
—— —— mollis 727
—— pterygoid, internal 716
—— pudic, internal 752
—— radial 758
—— recurrent 734
—— —— œsophageal 735
—— respiratory 755
—— —— internal 753
—— rhomboideal 754
—— sacral 751
—— saphena, external 775
—— —— internal 771
—— —— —— accessory 771
—— sciatic, great 773
—— —— small 772
—— spheno palatine 713
—— spinal 746, 752
—— —— accessory 736
—— splanchnic, great 786
—— —— lesser 787
—— staphylin 713
—— stylo-hyoid 725
—— subclavian 767

PAGE
Nerves, sublingual 717
—— subzygomatic 716
—— superscapular 757
—— temporal, anterior deep . . . 716
—— —— middle deep 715
—— —— posterior deep . . . . ib.
—— —— superficial 716
—— thoracic, inferior 755
—— —— subcutaneous . . . . . ib.
—— —— superior . . . . . ib.
—— tibial, anterior 774
—— —— posterior 775
—— tracheal, recurrent 734
—— trifacial 710
—— trigeminus . . . . . ib.
—— trochlearis 709
—— tympanic 724
—— tympano-lingual 717, 724
—— ulnar 759
—— vestibular 727, 840
—— Vidian 719
—— Wrisberg, of 723
Nerve-tubes of spinal cord . . . 671
Nervous colline 180
—— glands 495
—— medulla 652
—— sheath . . . . . ib.
—— system 650
—— —— general comformation . . 651
—— —— of Birds 790
—— tissue 5
Neural arch 119
Neurilemma 653, 700
Neurility 655
Neuroglia 670, 671
Nodule of Arantius 505
Nodus encephali 675
Nomenclature 326
Non-medullated fibres 652
Nostrils 439, 440
—— framework 440
—— functions 441
Nucleated nerve-fibres 652
Nuclei of corpus striatum 696
—— of nerves 671, 705

Obturator foramen 93
Occipito-atloid sinus 606
Ocular membrane 822
—— sheath 828
Œsophageal groove 397
Œsophagus 377
—— course . . . . . ib.
—— form . . . . . ib.
—— functions 380
—— relations 377
—— structure 379
Oken's bodies 922
Olfactory apparatus 815
—— cells 445, 816
—— lobules 691, 692
—— nerves 705
Omasum 397
—— structure 399

PAGE
Muscles, temporo-auricularis internus . 849
—— tensor palati 343
—— —— tympani 843
—— —— vaginæ 880
—— teres major 249, 253
—— —— minor 250
—— thyro-arytenoideus 454
—— —— pharyngeus 374
—— tracheal 459
—— transversalis abdominis 244
—— —— costarum 208
—— —— hyoidei 228
—— —— nasi 221
—— transverse of abdomen 244
—— —— of ribs 236
—— —— spinous of back and loins . 209
—— transversus perinei 863
—— trachelo-mastoideus 191
—— trapezius 203
—— triangularis of sternum 237
—— triceps extensor brachii 258
—— trochlearis 829
—— ureters, of 490
—— urethra, of 862
—— uterus, of 879
—— vagina, of 880
—— Wilson's muscle 493, 862
—— zygomatico-auricularis 847
—— zygomatico-labialis 219
—— zygomaticus . . . . . *ib.*
Muscular cell-fibres 429
—— fibre 4, 178
—— insertions, table of 315
—— lamina 905
—— tissue 5
—— —— non-striped . . . . . *ib.*
—— —— striped . . . . . *ib.*
—— —— of heart 508
Musculi papillares 503
—— pectinati 506
Myeloplaxes 4, 15
Myolemma 178

Nasal cavities 439, 440
—— duct 834
—— fossæ 441
—— meatuses 442
Navicular sheath 269
Navicularthritis 158
Nerve-cells 4, 652
—— corpuscles 652
—— fibres 4
—— tubes 652
NERVES:—cerebro-spinal 700
—— cranial 703
—— distribution 701
—— division 700
—— ganglionic 652, 701
—— mixed 700
—— organic life, of 652
—— origin 701
—— structure 700
—— termination 702
—— vegetative life, of 652

PAGE
Nerves, in Birds 789
—— abducentes 721
—— accesory of external saphena . 774
—— —— of internal saphena . . . 771
—— acromial 749
—— anal 752
—— angularis 754
—— anterior brachial 759
—— —— femoral 771
—— —— gluteal 772
—— —— tibial 774
—— auditory 727
—— auricular, anterior 725
—— —— middle . . . . . *ib.*
—— —— posterior . . . . . *ib.*
—— axillary 757
—— brachial, anterior . . . . . *ib.*
—— buccal 715
—— cardiac 785
—— chorda-tympani 717, 724
—— ciliary 718
—— circumflex 757
—— clavicular 749
—— coccygeal 752
—— cochlear 727
—— collateral-dorsal 765
—— crural 771
—— cubito-cutaneous 759
—— —— plantar . . . . . *ib.*
—— dental 713, 717
—— —— anterior 713
—— —— middle . . . . . *ib.*
—— —— posterior . . . . . *ib.*
—— diaphragmatic 749, 753
—— digastric 725
—— dorsal, collateral 765
—— —— great 757
—— facial 721
—— femoral, anterior 771
—— femoro-popliteal, great 773
—— —— —— small 774
—— frontal 711
—— glosso-pharyngeal 727
—— gluteal, anterior 772
—— —— posterior 773
—— gustatory 716
—— hæmorrhoidal 752
—— hypoglossal 737
—— —— great . . . . . *ib.*
—— —— small 716
—— iliaco-muscular 771, 772
—— inguinal, external 751
—— —— internal . . . . . *ib.*
—— infra-orbital 713
—— infratrochlear 712
—— ischio-muscular 773
—— Jacobson's 728
—— lachrymal 711
—— laryngeal, external 733
—— —— inferior 734
—— —— superior 733
—— lingual 716
—— masseteric 715
—— maxillary, inferior 714

PAGE
Muscles, obliquus oculi superior . . 822
—— obturator externus 292
—— —— internus . . . . . ib.
—— occipito-styloideus 227
—— œsophageal 379
—— omo-brachialis 254
—— —— hyoideus 198
—— orbicularis oculis 832
—— —— oris 217
—— —— palpebræ 831
—— orbito-palpebral 832
—— panniculus carnosus 186
—— palato-glossus 339
—— —— pharyngeus 342, 374
—— —— staphyleus 342
—— palmaris magnus 266
—— pectineus 289
—— pectoralis magnus. 233
—— —— parvus 234
—— —— transversus 231
—— pedal 311
—— perforans 268, 302, 568
—— perforatus 267, 304
—— pericardium 512
—— peristaphyleus externus . . . 343
—— —— internus . . . . . ib.
—— peroneus 298
—— pharyngo-glossus 339
—— —— staphyleus 342, 374
—— plantaris 304
—— popliteus . . . . . ib.
—— postea spinatus 251
—— posterior constrictor of vulva . 883
—— —— great rectus of head . . 195
—— —— medius 222
—— —— ulnaris 265
—— protractor of sheath 868
—— psoas magnus 212
—— —— parvus 214
—— pterygoideus internus 224
—— pterygo-pharyngeus 374
—— quadratus cruralis 292
—— —— lumborum 214
—— retractor ani 414
—— —— oculi 827
—— —— of sheath 868
—— rectus 284
—— —— abdominis 243
—— —— capitis anticus major . . 199
—— —— —— —— minor . . . . ib.
—— —— —— posticus major . . 195
—— —— —— —— minor . . . . ib.
—— —— oculi externus 829
—— —— —— inferior . . . . . ib.
—— —— —— internus . . . . . ib.
—— —— —— posterior 828
—— —— —— superior 829
—— retractor oculi 828
—— rhomboideus 188
—— sacro-coccygeal 215
—— —— coccygeus inferior . . . 216
—— —— —— lateral . . . . . ib.
—— —— —— superior . . . . . ib.
—— —— lumbalis 214

PAGE
Muscles, sartorius 288
—— scalenus 200
—— scuto-auricularis externus . . 848
—— —— internus 849
—— semimembranosus 288
—— semispinalis dorsi 209
—— semitendinosus 287
—— serratus magnus 236
—— short abductor of arm 250
—— —— adductor of leg 289
—— —— extensor of fore-arm . . . 259
—— —— flexor of fore-arm 256
—— small adductor of thigh 291
—— —— anterior rectus of head . . 199
—— —— anterior serrated 205
—— —— complexus 191
—— —— extensor of fore-arm . . . 269
—— —— hyoglossus 330
—— —— lateral rectus 199
—— —— oblique of abdomen . . . 242
—— —— —— of head 194
—— —— posterior rectus 195
—— —— —— serrated 205
—— —— psoas 214
—— —— scapulo-humeralis 254
—— —— supermaxillo-nasalis . . . 221
—— solearis 304
—— soleus . . . . . ib.
—— sphincter ani 414
—— —— vaginæ 880
—— spinalis colli 193
—— —— dorsi 209
—— splenius 189
—— square crural 292
—— —— of loins 214
—— stapedius 843
—— sterno-aponeuroticus 232
—— —— costales 237
—— —— humeralis 232
—— —— hyoideus 198
—— —— maxillaris . . . . . ib.
—— —— prescapularis 234
—— —— thyro-hyoideus 198
—— —— thyroideus . . . . . ib.
—— —— trochlearis 233
—— stylo-glossus 337
—— —— hyoideus 227
—— —— maxillaris 225
—— —— pharyngeus 343, 375
—— subcutaneous of neck 196
—— sublimis of phalanges 267
—— subscapularis 252
—— subscapulo-hyoideus 198
—— subspinatus 251
—— supercostals 237
—— superficialis costarum. 205
—— superficial gluteus 280
—— —— flexor of phalanges . . 267, 304
—— —— pectoral 231
—— superior constrictor of pharynx . 374
—— supermaxillo-labialis 220
—— superspinatus 251
—— temporal 223
—— temporo-auricularis externus . 847

PAGE
Muscles, depressor labii superioris . 222
—— diaphragm 245
—— digastricus 225
—— dilatator naris anterior . . . 221
—— —— —— lateralis . . . . *ib.*
—— erector clitoridis 882
—— —— coccygeus 216
—— —— penis 864
—— extensor metacarpi magnus . . 262
—— —— —— obliquus 263
—— —— pedis 263, 298
—— —— suffraginis 264
—— external flexor of metacarpus . 265
—— —— intercostals 237
—— —— oblique of abdomen . . 240
—— —— obturator 292
—— —— pterygoid 224
—— —— vastus 285
—— extrinsic of tongue 337
—— fascia lata 284
—— fleshy panniculus 186
—— flexor brachii 255
—— —— metacarpi externus . . . 265
—— —— —— internus 266
—— —— —— medius . . . . *ib.*
—— —— metatarsi 300
—— —— —— parvus 311
—— —— pedis 305
—— —— —— accessorius . . . 306
—— —— —— perforans 268
—— —— —— perforatus 267
—— fronto-superciliary 431
—— gastric 389
—— gastrocnemii 302
—— gastrocnemius externus . . . *ib.*
—— —— internus 304
—— gemelli of pelvis 293
—— —— of tibia 302
—— gemini 293
—— genio-glossus 338
—— —— hyo-glossus . . . . . *ib.*
—— —— hyoideus 226
—— gluteus externus 280
—— —— internus 282
—— —— maximus 281
—— —— medius . . . . . *ib.*
—— gracilis 289
—— great adductor of thigh 291
—— —— anterior straight of head . 199
—— —— complexus 191
—— —— dorsal 203
—— —— hyo-glossus 337
—— —— oblique, of abdomen . 248
—— —— —— of head 193
—— —— psoas 212
—— —— rectus, of abdomen . . . 243
—— —— serratus 236
—— —— supermaxillo-nasalis . . 221
—— heart, of 509
—— humeralis externus 256
—— hyo-epiglottideus 453
—— —— glossus brevis 337
—— —— —— longus . . . . . *ib.*
—— —— pharyngeus 374

PAGE
Muscles, hyo-thyroideus 453
—— hyoideus magnus 227
—— —— parvus . . . . . *ib.*
—— iliac psoas 212
—— iliacus . . . . . *ib.*
—— ilio-spinal 206
—— internal flexor of metacarpus . 266
—— —— intercostals 237
—— —— oblique of abdomen . . 242
—— —— obturator 292
—— —— pterygoid 224
—— —— vastus 285
—— interossei 278
—— intertransversales lumborum . 215
—— intertransverse of loins . . *ib.*
—— —— of neck 193
—— intestinal 402, 212, 414
—— intrinsic of tongue 337
—— ischio-cavernosus 864
—— —— coccygeus 217
—— —— urethral 863
—— kerato-glossus 337
—— kerato-hyoideus 227
—— labialis 217
—— lachrymal 320
—— lachrymo-labialis 220
—— large extensor of fore-arm . . 258
—— lateral extensor of phalanges 264, 298
—— lateralis sterni 236
—— latissimus dorsi 203
—— levator ani 863
—— —— humeri 197
—— —— labii superioris 220
—— —— menti 222
—— —— palpebræ 832
—— levatores costarum 237
—— lingualis 339
—— —— superficialis 337
—— long abductor of arm 249
—— —— adductor of leg 288
—— —— extensor of fore-arm . . 258
—— —— flexor of fore-arm . . . 255
—— —— of neck 200
—— longissimus dorsi 206
—— longus colli 200
—— lumbrici 278
—— masseter 223
—— mastoido-auricularis 849
—— —— humeralis 196
—— maxillo-labialis 222
—— mento-labialis . . . . . *ib.*
—— middle extensor of fore-arm . 259
—— mylo-hyoideus 225
—— nasalis brevis 221
—— —— longus 220
—— oblique extensor of metacarpus . 263
—— —— flexor of metacarpus . 266
—— —— —— of phalanges . . . 306
—— obliquus capitis anticus . . . 199
—— —— —— inferior 123
—— —— —— superior 194
—— —— externus abdominis . . . 240
—— —— internus abdominis . . . 242
—— —— oculi inferior 830

PAGE
Molar teeth 352, 359, 361
Monorchids 853
Monro, foramen of . . . 682, 693, 694
Mons veneris 888
Morgagni, cæcum of 335
—— hydatid of 871
—— liquor of 826
Morsus diaboli 876
Motores oculorum 708
Mouth 330
—— development of 920
—— in general 355
Mucous derm 327
—— corium . . . . . *ib.*
—— membrane 326
—— —— of bladder 493
—— —— of bronchi 461
—— —— of cheeks 331
—— —— of Fallopian tubes . . 876
—— —— of guttural pouches . . 845
—— —— of internal ear 840
—— —— of intestines, large . . . 410
—— —— —— small 402
—— —— of larynx 455
—— —— of lips 331
—— —— lymphatics in 629
—— —— of mouth 355
—— —— of œsophagus 379
—— —— olfactory 444
—— —— of pharynx 374
—— —— of sinuses of head . . . 447
—— —— of soft palate 343
—— —— of stomach 390
—— —— of tongue 335
—— —— of trachea 459
—— —— of tympanum 844
—— —— of ureters 490
—— —— of uterus 879
—— —— of vagina 880
—— —— of vulva 883
Müller's duct 923
Multipolar nerve-cells 653
Muscle-plasma 181
MUSCLES:—striped in general . . . 174
—— action 182
—— attachments 175
—— appendages 183
—— classification . . . . . *ib.*
—— contractility 181
—— development 181, 913
—— direction 175
—— form 174
—— general table of 315
—— in Birds 313
—— insertions 175
—— lymphatics 180
—— manner of studying 183
—— nomenclature 176
—— physico-chemical properties . 180
—— physiological properties . . *ib.*
—— preparation of 184
—— preservation of 185
—— relations 176
—— situation 174

PAGE
Muscles, structure 178
—— tissue . . . . . *ib.*
—— uses 182
—— vessels and nerves 180
—— volume 174
—— unstriped 174, 328
—— accelerator urinæ 862, 863
—— adductor of arm 253
—— adductor femoris 291
—— —— longus . . . . . *ib.*
—— —— tibialis 287
—— alveolo-labialis 218
—— anconeus 260
—— angularis scapulæ 189
—— antea-spinatus 251
—— anterior constrictor of vulva . 884
—— —— extensor of metacarpus . 262
—— —— —— of phalanges . . 263, 298
—— —— medius 222
—— —— straight of thigh 284
—— —— ulnaris 266
—— arytenoideus 455
—— aryteno-pharyngeus 375
—— basio-glossus 337
—— biceps abductor femoris . . . 286
—— brachial biceps 255
—— bronchial 461
—— buccinator 218
—— bulbo-cavernous 862
—— caput magnum 258
—— —— medium 259
—— —— parvum . . . . . *ib.*
—— ciliaris 821
—— circumflexus palati 342
—— common intercostals 208
—— complexus major 191
—— —— minor 195
—— compressor coccygis 217
—— —— urethræ 863
—— —— vesiculæ 860
—— constrictor of pharynx, first middle 374
—— —— —— inferior . . . . . *ib.*
—— —— —— second middle . *ib.*
—— —— —— superior . . *ib.*
—— —— vaginæ 883
—— —— vulvæ, anterior 884
—— —— —— posterior 883
—— coraco-brachialis 254
—— —— humeralis . . . . . *ib.*
—— corrugator supercilii 831
—— cremaster 852
—— crico-arytenoideus lateralis . . 454
—— —— —— posticus . . . . . *ib.*
—— —— pharyngeus 374
—— —— thyroideus 453
—— crotaphitic 223
—— crural triceps 284
—— curvator coccygis 216
—— dartos 853
—— deep flexor of phalanges . . 268, 305
—— —— gluteal 282
—— —— pectoral 233
—— depressor coccygeus 216
—— —— labii inferioris 222

PAGE
Lymphatics, muscle, in 180, 630
—— nervous tissue, in 630
—— nostrils, in 441
—— ovary, in 874
—— penis, in 863
—— peritoneum, in 384
—— pharyngeal 643
—— pia mater, in 665
—— pituitary 446, 447
—— popliteal 640
—— precrural . . . . . *ib.*
—— prepectoral 643
—— prescapular 644
—— rectum, in 640
—— serous membranes, in 630
—— skin, in 629, 795
—— small intestines, in 406
—— spleen, in 431, 642
—— stomach, in 392, 641
—— subglossal 644
—— sublumbar 638
—— submaxillary 644
—— suprarenal capsules, in 494
—— testicle, in 856
—— thorax, in 642
—— thymus gland, in 473
—— thyroid gland, in 472
—— urethra, in 863
—— uterus, in 880
—— vagina, in 882
—— vessels, in 630
Lymphatic sheaths 520, 630
—— sinuses 632

Macula lutea 836
Malleus 842
Malpighian corpuscles 430, 487
—— glomerules 489
Mammæ 884
—— form . . . . . *ib.*
—— functions 885
—— situation 884
—— structure . . . . . *ib.*
Mammary ducts . . . . . *ib.*
—— glands . . . . . *ib.*
Mammilla . . . . . *ib.*
Mammillary tubercle 687
Manubrium 842
Manyplies 397
Masculine uterus 861
Mastoid cells of ear 840, 842
—— lobule of brain 691, 692
Matrix of hoof 800
Maxillary gland 367
Meatus auditorius externus 846
—— nasal 442
—— urinarius, female 882
—— —— valve of . . . . . *ib.*
Meckel's cartilage 912
—— ganglion 719
Meconium 427
Median lacuna of frog 807
—— sinus 606
Mediastinal pleura 464

PAGE
Mediastinum, anterior 464
—— posterior . . . . . *ib.*
—— testis 854
Medulla of bones 15
Medulla oblongata 675, 676
Medullary cells 4, 15
—— layer of kidney 487
Medullated nerve-fibres. 652
Medullo-cells 4, 15
Meibomian glands 830, 831, 832
Meissner, corpuscula tactus of . . . 794
Membrana dentata 666
—— granulosa 873
—— Jacobi 825
—— nictitans 833
—— pupillaris 824, 909
—— tympani 841
—— —— secundaria 842
—— vitellina 873
Membrane of aqueous humour . . . 827
—— basilar 839
—— Bruch, of 822
—— choroid 820
—— conjunctival 832
—— Corti, of 839
—— Demours, of 827
—— dentated 662
—— Descemet, of 827
—— eye, of 817
—— fenestrated 519
—— hyaloid 827
—— keratogenous 803
—— mucous 326
—— Reissner, of 839
—— serous 328
Membranous cochlea 839
—— semicircular canals . . . . . *ib.*
—— urethra 861
—— vestibule 838
Meningeal granulations 663
Meninges of cerebro-spinal axis . . 660
Meniscii, interarticular 163
Mesenteric glands 641
Mesenteric lamina 906
Mesentery 383, 401
—— colic 383, 384, 413
—— proper 383
Meso-cæcum 383, 407
Mesocephalon 675, 677
Meso-colon 383
Meso-rectum 413
Metacarpo-phalangeal sheath . . . 267
Metacarpus 81
Metatarsus 105
Middle cerebellar peduncle 678
—— ear 840
—— septum of nose 444
—— ventricle of brain 682
Milk 885
Milk-fountains 625
Mitral valves 507
Mixed nerves 700
Modiolus 838
Molar glands 369

PAGE
Ligaments, odontoid 136
—— ovarian 384, 873
—— patellar 164
—— pectinated 819
—— peripheral, inferior 140
—— Poupart's 241
—— pubio-femoral 162
—— radio-carpal 149
—— radio-ulnar, interosseous . . . 147
—— —— —— peripheral . . . . *ib.*
—— —— —— external transverse . *ib.*
—— round, of uterus 384, 877
—— sacro-iliac 159
—— —— ischiatic 160
—— —— sciatic . . . . . *ib.*
—— scaphoido-cunean 171
—— sesamoid 153
—— —— inferior . . . . . *ib.*
—— —— lateral 154
—— spleen, of 429
—— stellate 140, 141
—— —— inferior 142
—— subflava 133
—— superdorso-lumbar 132
—— superspinous cervical . . . . *ib.*
—— suspensory of fetlock 154
—— —— of penis . . . 865, 866, 872
—— —— of sheath 867
—— —— of uterus 877
—— tarsal 168
—— tarso-metatarsal, posterior . . 172
—— teres 162
—— tibio-fibular 167
—— tracheal 459
—— transverse 136
—— umbilical 491
—— uterine, broad 384, 877
—— —— round . . . . . *ib.*
—— —— suspensory 877
—— vulvular 884
—— Wolffiani, of corpora 922
Limbs in general 109
—— their parallelism 110
Limitary membranes 5, 327
Linea alba 239, 240
Lineæ transversæ 693
Lingual canal 334
—— glands 370
—— glandulæ 335
—— lacunæ 335
—— mucous membrane 814
Linguetta laminosa 679
Lips 330, 356, 359
—— functions of 332
—— structure of 331
Liquor amnii 896
—— corneæ 820
—— folliculi 873
—— labyrinthi 840
—— Morgagni 826
—— seminis 858
Liver 419
—— attachments 420
—— development 427, 922

PAGE
Liver, direction 419
—— form . . . . . *ib.*
—— functions 426
—— proper tissue 422
—— relations 420
—— situation 419
—— structure 422
—— weight 419
Lobes of liver 420
Lobular bronchial tube 468
Lobulated glands 329
Lobule, anterior of lung 467
Lobuli testis 854
Lobulus pneumogastricus 467
Lobus Spigelii 420
Locomotory apparatus 6
Longitudinal fissure of brain 690
Lowenberg's scala 839
Lumbar nerves 751
—— vertebræ 25
Lumbo-rachidian bulb 668
Lumbo-sacral plexus 770
Lungs 466
—— development 470, 918
—— form 466
—— functions 470
—— fundamental tissue 467
—— general disposition 466
—— relations . . . . . *ib.*
—— serous envelope 467
—— situation 466
—— structure 467
Lymph 498
Lymphatic glands and vessels 628
—— —— —— course 631
—— —— —— form 628
—— —— —— number . . . . *ib.*
—— —— —— origin . . . . *ib.*
—— —— —— plexuses . . . 629, 631
—— —— —— preparation of . 663
—— —— —— rete mirabile . . 631
—— —— —— structure . . 628, 633
—— —— —— termination . . 631
Lymphatics, Birds, in 649
—— bladder, in 493
—— bone, in 15, 630
—— brachial 644
—— bronchial 642, 461
—— cæcum, in 641
—— colon, large, in . . . . . *ib.*
—— —— small, in 640
—— guttural 643
—— heart, in 511
—— hepatic lobules, in 424
—— iliac 640
—— inguinal, deep 638
—— —— superficial . . . . . *ib.*
—— intestines, in 641, 406, 410
—— kidneys, in 489
—— laryngeal 455
—— lips, in 331
—— liver, in 425
—— lungs, in 470
—— mucous membranes, in 629

PAGE
Lachrymal ducts 834
—— gland . . . . . ib.
—— nerve 711
—— sac 834
Lachus lachrymalis 831
Lacteal vessels 402
Lactiferous ducts 884
Lamellæ of foot 850
Lamina cinerea 683
—— cribrosa 708, 818
—— fusca 819
—— spiralis 838
Laminæ of foot 804
Laminal tissue . . . . . ib.
Lancisii, chordæ longitudinalis of . . 693
Large intestine 407
Larynx 449
—— articulations 451
—— development 918
—— entrance 456
—— external surface . . . . . ib.
—— form 449
—— functions 456
—— internal surface . . . . . ib.
—— muscles 453
—— nerves 455, 734
—— situation 449
—— structure 450
—— ventricles 456
—— vessels 455
Latebra 925
Lateral columns of spinal cord . 669
—— fibro-cartilages 801
—— lacunæ of frog 807
—— laminæ of embryo 905
—— triangular fasciculus of isthmus . 678
—— ventricles 692, 693
Left auricle of heart 507
—— ventricle of heart 506
Leg, bones of 100
—— muscles of 288
Lens, crystalline 826
—— —— capsule of 826
—— —— structure of. . . . . ib.
Lenticular ganglion 718
—— glands 404
—— papillæ 336, 814
Leucocytes 4
Lieberkühn's follicles 403
—— glands . . . . . ib.
LIGAMENTS 125
—— capsular . . . . . ib.
—— funicular. . . . . ib.
—— general considerations . . ib.
—— interosseous 126
—— membraniform 125
—— peripheral . . . . . ib.
—— white. . . . . ib.
—— yellow 126
—— anterior of carpus . . . 148, 149
—— arteriosum 522
—— astragalo-metatarsal 171
—— atlo-axoid, inferior 136
—— —— superior . . . . . ib.

PAGE
Ligaments, auditory 842, 843
—— bladder, of. 491
—— broad 384, 877
—— calcaneo-astragaloid 170
—— calcaneo-metatarsal 171
—— capsular of atlo-axoid articulation 136
—— —— of carpal ,, 151
—— —— of costo-sternal ,, 141
—— —— of coxo-femoral ,, 162
—— —— of femoro-patellar ,, 165
—— —— of humero-radial ,, 146
—— —— of hyoideal ,, 139
—— —— of metacarpo-phalangeal ,, 154
—— —— of occipito-atloid ,, 137
—— —— of scapulo-humeral ,, 143
—— —— of temporo-maxillary ,, 138
—— —— of vertebral ,, 134
—— cardiac 382
—— carpo-metacarpal 150
—— carpal, anterior 148, 149
—— cervical 132
—— chondro-xiphoid 142
—— ciliary 822
—— common carpal 151
—— —— inferior vertebral . . . 131
—— —— superior cervical . . ib.
—— —— superspinous 132
—— costo-sternal, inferior . . . 142
—— —— —— superior 141
—— costo-transverse, anterior . ib.
—— —— —— posterior . . . ib.
—— cotyloid 162
—— coxo-femoral . . . . . ib.
—— crico-trachealis 453
—— cruciform 137
—— cuboido-cunean 171
—— cuboido-scaphoid . . . . . ib.
—— denticulated 665
—— diaphragmatic. . . . 922
—— Fallopii 241
—— femoro-patellar 165
—— glosso-epiglottic 335
—— hepatic 420
—— hepatico-renal 383
—— humero-radial, external lateral 145
—— —— —— internal lateral . . ib.
—— ilio-sacral, inferior 159
—— —— —— superior . . . . ib.
—— interannular 133
—— interarticular costo-vertebral . 140
—— intercarpal 150
—— interlamellar 133
—— interosseous of carpus . . 148, 149
—— —— radio-ulnar 147
—— interphalangeal, first 157
—— —— second . . . . . ib.
—— intersesamoid 153
—— interspinous 133
—— intervertebral 131
—— latum pulmonis 467
—— nuchæ 133
—— lobus Spigelii, of 383
—— lumbar of corpora Wolffiani . . 922
—— metacarpo-phalangeal 154

PAGE
Hilum pulmonis 466
Hippocampus 693, 695
Hippomanes 897
Hollow organs 326
—— —— structure of . . . . . ib.
Honeycomb glands 404
Hoof 800
—— contents of 800
—— description of 805
—— development of 810
—— structure of 808
—— wall of. 805
Hoof-horn 808
—— structure of . . . . . ib.
Horn cells 809
Horns, frontal 813
Horny production 799
Horse-hair 797
Humours of eye 817, 827
Hyaloid membrane 827
Hydatid of Morgagni 871
Hygrophthalmic canals 834
Hymen 883
Hyoideal region 225
Hypochondriac region 381
Hypogastric region . . . . . ib.
Hypophysis cerebri 681

Ileo-cæcal valve 402, 408
Ileum 401
Imprint 11
Incisor teeth . 344, 349, 357, 359, 361
Incus 842
Inferior umbilical ring 894
Infundibuli of lungs 468
Infundibuliform fascia 852
Infundibulum 681
Inguinal canal 242
—— hernia 547
—— ring 242
Injection of arteries 520
—— of veins 599
Inosculation 517
Insulæ 635
Integuments of external ear . . . 850
Interarticular meniscii 163
Interauricular partition 503
Intercarotid ganglion 789
Interglobular spaces of Czermak . . 345
Interlobular fissure 690
—— veins 423
Internal crural region 288
—— ear 837
—— —— nerves of 840
Interosseous cartilages 124
Interpeduncular fissure 678
Interstitial substance 178
Interungulate gland 794
Interventricular septum 503
Intervertebral fibro-cartilages . . . 130
—— foramen 24
Intestinal groove 894
Intestines 400
—— development 920

PAGE
—— large 407
Intestines, large, attachment . . . 407
—— —— capacity . . . . . ib.
—— —— dimensions . . . . . ib.
—— —— direction . . . . . ib.
—— —— functions 410
—— —— interior 408
—— —— relations 407
—— —— situation . . . . . ib.
—— —— structure 410
—— small 400
—— —— attachment 401
—— —— course . . . . . ib.
—— —— development 406
—— —— form 400
—— —— functions 406
—— —— interior 401
—— —— relations . . . . . ib.
—— —— structure 402
Intralobular veins 424
Iris 822
—— structure of 823
Ischiatic spine 93
Isthmus of encephalon . . 673, 675, 676
—— —— external conformation of . 675
—— —— internal conformation of 682
—— —— structure of 683
—— of fauces 373
Iter ad infundibulum 682
—— —— quartum ventriculum . . ib.
Ivory 345, 921

Jacob's membrane 825
Jacobson, nerve of 728
—— organ of 443
Jejunum 401
Jugular channel 601
—— vein . . . . . ib.

Keraphyllous tissue 806
Keratogenous membrane 803
Kidneys 484
—— conformation, external . . . ib.
—— —— internal 486
—— development 489, 923
—— functions 490
—— primordial. 922
—— proper tissue 487
—— relations 486
—— situation 484
—— structure 486
—— tunic 487
—— weight 486
Krause, corpuscles of 703, 832
—— —— terminal genital . . . 866

Labia vulvæ 882
Labial glands 331, 370
Labyrinth 837
—— osseous. . . . . ib.
—— membranous 837, 838
Lachrymal apparatus 834
—— canal . . . . . ib.

PAGE
Glands, laryngeal 455
—— lenticular 404
—— Lieberkühn's 403, 410
—— lingual 335, 370
—— liver 419, 642
—— lobulated 329
—— lymphatic 632
—— mammary 884
—— maxillary 367, 371
—— Meibomian 832
—— molar 369, 371
—— mucous of stomach 391
—— Nuhn's 372
—— odoriferous 445
—— Pacchionian 663
—— palate, soft 343, 370
—— pancreas 427
—— parotid 365, 370, 371
—— Pecklin, of 404
—— peptic 391
—— perspiratory 794
—— Peyer's 404
—— pharyngeal 643
—— pineal 680
—— pituitary 445, 681
—— popliteal 640
—— præputial 867
—— precrural 640
—— prepectoral 643
—— prescapular 644
—— prostate 864
—— racemose 329, 339
—— rectum, of 640
—— salivary 364
—— simple 329
—— socia parotidis 372
—— solitary 404, 410
—— spleen, of 642
—— staphyline 370
—— stomach, of 641
—— subglossal 644
—— sublingual 369, 371
—— sublumbar 638
—— submaxillary 367, 371, 644
—— sudoriparous 794
—— thoracic 642
—— thymus 473
—— thyroid 472
—— tracheal 459
—— tubular 329
—— uterine 879
—— utricular 880
—— vulvo-vaginal 887
Glandular *culs-de-sac* 365
—— tissue 4
Glans clitoridis 882
—— penis 862
Glenoid cavity 73
Glisson, capsule of 422
Globes of segmentation 891
Globus major epididymis 859
—— minor . . . . . *ib.*
Glomes of frog 807
Glomeruli of kidney 488

PAGE
Glottis 456
Gluteal aponeurosis 280
—— region . . . . . *ib.*
Goose-skin 793
Graafian vesicles 873
Granules, fat 3
—— pigmentary . . . . . *ib.*
—— proteic . . . . . *ib.*
Great lymphatic vein 644
—— sympathetic system 781
—— —— —— structure 782
—— transverse cerebral fissure . . . 691
Grey nerve-fibres 652
—— root of optic nerves 683
—— substance of isthmus 685
Gubernaculum dentis 347, 921
—— testis 856
Gum 347
Gustative bulbs 814
—— cells 815
Guttural pouches 845
Gyrus fornicatus 695

Habenæ 681
Hæmal arch 119
Hæmaties 4
Hairs 797
—— follicles 798
—— formation of 799
—— functions . . . . . *ib.*
—— germ of 798
—— horse, of 797
—— sheath of 798
Haller's passage 915
Hand 89
Harder, glands of 833, 836
Harmonia suture 129
Haversian canals 13
Head, bones of 33
—— in general 54
Heart 499
—— action 513
—— capacity 500
—— direction . . . . . *ib.*
—— external conformation . . . . *ib.*
—— form . . . . . *ib.*
—— general sketch 499
—— interior 503
—— nerves and vessels of 510
—— serous membrane 511
—— situation 500
—— structure 507
—— volume 500
—— weight . . . . . *ib.*
Helicine arteries 865
Helico-trema 838
Hemispheres, cerebral 673
Hepatic cells 422
—— ducts 423
—— lobules 422
Hernia, inguinal 547
Herophilus, wine-press of 606
Highmorianum, corpus 854
Hilum of kidney 486

PAGE
Foramen obturator 93
—— occipital 34
—— ovale 40, 503
—— rotundum 40
—— Soemmering, of 836
—— spinal 19
—— spinosum 40
—— stylo-mastoid 43
—— subpubic 93
—— subsphenoidal 40
—— superciliary 36
—— supersacral 27
—— supra-orbital 36
—— trachelian 34
—— vertebral . . . . . *ib.*
—— Vidian 39
—— Winslow 383
Forceps major 699
Fore-arm, bones of 75
Fore-foot, bones of 77
Fore-lock 797
Formation of embryo 905
Fornix 679, 692, 694
Fossa centralis retinæ 836
—— ovalis 506
—— navicularis 862
Fossulate papillæ 336
Fourchette 889
Fourth ventricle of brain 679
Fovea centralis 836
Frænum linguæ 335
—— præputii 872
Frog of hoof 807
Frog-stay 807
Frontal horns 813
—— sinus 446
Functional vessels of lungs 470
Fundus of bladder 491
Fungiform papillæ 336, 874
Funicular ligaments 125, 126
Furrow, primitive 892

Galactoferous ducts 884, 885
—— sinuses . . . . . *ib.*
Galeati's glands 403
Ganglia 780
—— structure . . . . . *ib.*
—— Andersch's 727
—— Arnold's 720
—— cervical, inferior 784
—— —— middle . . . . . *ib.*
—— —— superior 782
—— ciliary 718
—— Cloquet's . . . . . *ib.*
—— Ehrenritter's 729
—— Gasserian 710, 711
—— geniculare 722
—— guttural 782
—— hypoglossal 739
—— inferior cervical 784
—— intumescentia 722
—— jugular 728, 729
—— lenticular 718
—— Meckel's 719

PAGE
Ganglia, middle cervical 784
—— naso-palatine 718
—— ophthalmic 786
—— otic 720
—— petrosum 727
—— semilunar 711, 786
—— solar 786
—— spheno-palatine 719
—— submaxillary 718
—— superior cervical 782
Ganglion cells 653
Ganglion, intercarotid 789
Ganglionic nerves 652, 701
Gasserian ganglion 710, 711
Gastro-colic omentum 382, 389
Gastro-hepatic omentum 389
Gastro-splenic omentum 383
Gelatine of Wharton 900
Gelatinous substance of Rolando . . 670
Gemmation 3
Generative apparatus 851
—— —— of Birds 889
Genital duct 923
—— gland . . . . . *ib.*
—— organs of female 872
—— —— of male 851
—— tubercle 924
Genu of corpus callosum 693
Germ of hair 798
Germinal eminence 873
—— spot . . . . . *ib.*
—— vesicle 873, 925
Ginglymus 128
Glandulæ agminatæ 404
—— solitariæ 404
Glands 329
—— agminated 404
—— Bartholine, of 887
—— brachial 644
—— Brunner, of 403
—— cæcal 641
—— ceruminous 846
—— cheeks, of 332
—— coccygeal 781
—— colon, of 641
—— conglomerate 329
—— Cowper's 864
—— cutaneous, of Pig 794
—— duodenal 403
—— Duverney, of 872
—— follicular 339
—— Galeati's 403
—— gastric 391
—— genital 923
—— guttural 643
—— Harder's 833, 836
—— honeycomb 404
—— iliac 640
—— inguinal, deep 638
—— —— superficial . . . . . *ib.*
—— intestinal 641
—— interungulate of Sheep 794
—— labial 331, 339, 370
—— lachrymal 834

PAGE
Embryonic area 892
Emergent veins of spinal sinuses . . 609
Eminences 11
Enamel 345, 346, 921
Enamel organ 347, 921
Enarthrosis 127
Encephalic arachnoid 664
—— dura mater 662
—— pia mater 666
Encephalon 672
—— as a whole . . . . . *ib.*
—— constitution . . . . . *ib.*
—— general form . . . . . *ib.*
—— isthmus 673
—— volume . . . . . *ib.*
—— weight . . . . . *ib.*
Endocardium 511
Endolymph 837, 840
Ensiform cartilage 67
Envelopes of cerebro-spinal axis . . 660
Ependymis of spinal cord . . . 668, 683
Epidermis 795
—— growth of 796
—— structure . . . . . *ib.*
Epididymis 858
—— structure 859
Epiglottis 451
Epithelial cells 4
—— tissue 4
Epithelium 327
—— ciliated . . . . . *ib.*
—— columnar . . . . . *ib.*
—— cylindrical . . . . . *ib.*
—— pavement . . . . . *ib.*
—— simple . . . . . *ib.*
—— spherical . . . . . *ib.*
—— squamous . . . . . *ib.*
—— stratified . . . . . *ib.*
Erectile tissues 578
Ergot 797, 802, 812
Ergot of Morand 699
Essential organ of vision 816
Ethmoidal lobule 691, 692
—— sinus 447
Eustachian tube 841, 844
—— valve 506, 514
External auditory hiatus 846
Eye 817
Eyelashes 832
Eyelids 816, 830
—— commissures 830
—— integuments 832
—— structure 831
Eye-vesicles, primitive 908

Falciform ligament 382
Fallopian tubes 876
—— —— functions . . . . . *ib.*
—— —— structure . . . . . *ib.*
False glands 633
—— nostril 440
Falx cerebelli 666
—— cerebri 662
Fang of tooth 345, 350

PAGE
Fascia infundibuliform 852
—— lata 284
—— transversalis 242, 245
Fasciculus, primitive 178
Fatty nucleus of Baur 337
Fauces 373
—— isthmus of . . . . . *ib.*
Femoral region 283
Fenestra cochlea 838
—— ovalis 837, 840, 842
—— rotunda 838, 840, 842
—— vestibuli 837, 842
Fenestrated membrane 519
Fetlocks 797
Fibres 4
—— of Remak 652, 782
Fibro-cartilages, complementary . . 124
—— —— intervertebral 130
—— —— pedal bone 801
Fibro-intestinal lamina 906
Fibrous tissue 4
Fibrous zones of heart 508
Filiform papillæ 336, 814
Filum terminale 665, 908
Fimbriæ of Fallopian tube 876
Fimbriated extremity of oviduct . . *ib.*
Fissure of Bichât 691
—— interlobular 690
—— interpeduncular 678
—— plantar 85
—— of Sylvius 691, 692
Fissura glaseri 587
—— longitudinalis, inferior . . . 668
—— —— superior . . . . . *ib.*
—— palpebrarum 831
Flocculus 689
Fluid of labyrinth 840
Fœtus, development of 905
—— circulation in 915
Follicles, aggregated 405
—— closed 340
—— hair 798
—— Lieberkühn 403
—— mucous 327, 391
—— simple 403
—— solitary 329, 404
—— structure of 329, 402
—— ultimate 365
Follicular glands 339
—— cavity of clitoris 882
Fontana, canal of 821
Foramen of Botal 503, 916
—— cœcum of Morgagni 335
—— —— of Vicq-d'Azyr 658
—— commune anterius 680, 682
—— —— posterius 682
—— condyloid 34
—— infra-orbital 44
—— intervertebral 24
—— lacera basis cranii 40
—— lacerum, anterior 34
—— —— posterior . . . . . *ib.*
—— Monro, of 682, 693, 694
—— nutrient 15

PAGE
Differential characters, scapulo-humeral 144
—— —— —— sternal 142
—— —— —— tarsal 172
—— —— —— temporo-maxillary . 139
—— —— —— tibio-fibular . . . 168
—— —— auditory apparatus . . . 850
—— —— axillary arteries . . . 570
—— —— brachial plexus 763
—— —— carotid arteries 590
—— —— cerebellum 689
—— —— cerebrum 698
—— —— cranial nerves 739
—— —— envelopes of cerebro-spinal axis 666
—— —— external iliac arteries . . 555
—— —— genital organs of female . 886
—— —— —— —— of male . . . 867
—— —— great sympathetic system . 789
—— —— head 55
—— —— heart 513
—— —— intestines 414
—— —— internal iliac arteries . . 543
—— —— isthmus of brain . . . 685
—— —— liver 432
—— —— lumbo-sacral plexus . . 777
—— —— lungs 470
—— —— lymphatic system . . . 645
—— —— mouth 356
—— —— muscles . . . . . .
—— —— —— abdominal region . 245
—— —— —— anterior foot . . . 279
—— —— —— arm 260
—— —— —— axillary region . . 235
—— —— —— cervical region . . 201
—— —— —— —— inferior . . . *ib.*
—— —— —— —— superior . . *ib.*
—— —— —— costal region . . . 238
—— —— —— diaphragm . . . 248
—— —— —— facial region . . . 228
—— —— —— fore-arm 270
—— —— —— gluteal region . . 283
—— —— —— head 228
—— —— —— hyoid region . . . 230
—— —— —— leg 306
—— —— —— masseteric region . 229
—— —— —— panniculus carnosus . 187
—— —— —— shoulder 254
—— —— —— spinal region . . . 209
—— —— —— sublumbar region . 215
—— —— —— thigh 294
—— —— —— tunica abdominalis . 240
—— —— nasal cavities 448
—— —— œsophagus 380
—— —— pancreas 434
—— —— pharynx 376
—— —— posterior aorta 535
—— —— —— limb 105
—— —— salivary glands 370
—— —— spinal cord 672
—— —— spine 135
—— —— spleen 434
—— —— stomach 393
—— —— thorax 70, 466
—— —— thymus gland 475

PAGE
Differential characters, thyroid gland . 744
—— —— urinary apparatus . . . 495
—— —— venous system 625
—— —— vertebral column . . . 29
—— —— visual apparatus . . 835, 836
Digestive apparatus 325, 330
—— —— of Birds 435
Dilator of the pupil. 824
Dissection of arteries 873
Discus proligerus 521
Dorsal nerves 750
—— nucleus of Stilling 671
—— vertebræ 24
Double-contoured nerve-fibres . . . 652
Double semicircular centre of Vieussens 698
Duct of Stenon 367
—— of Stenson 443
—— of Wharton 369
—— of Wirsung 428
Ducts, accessory pancreatic . . . *ib.*
—— biliary 423
—— Cuvierian 917
—— genital 923
—— guttural 844
—— mammary 884
—— Müller's 923
—— omphalo-mesenteric 894
—— parotid 367
—— perspiratory 794
—— salivary 367, 369
—— thymic 474
Ductus ad nasum 834
—— arteriosus 470, 916
—— choledochus 424
—— —— course 424
—— —— structure 425
—— cysticus 432
—— ejaculatorius 860, 861
—— galactoferus 884
—— hepaticus 423
—— lactiferus 884
—— lymphaticus dexter 614
—— pancreaticus minor 428
—— prostaticus 864
—— Riviniani 369
—— thoracicus 634
—— venosus of Aranzi. . . . 901, 916
Duodenal glands 403
Duodenum 401
Dura mater 660, 661
—— —— structure 661
Duverney, glands of 872

Ear, external 846
—— internal nerves of . . . 837, 840
—— middle 840
Ear-dust 839
Ectopiæ of testicles 853
Effluent canals of dura mater sinuses . 608
Ejaculatory ducts 860, 861
Elastic fibres 4
Embryo-cells 891
Embryogenous vesicle 890
Embryology . . . . . *ib.*

PAGE
Corpus rhomboideum 688
—— striatum 693, 695
Corpuscula tactus 794
Corpuscles of Krause 703, 832
—— of Meissner 703, 794
—— Pacinian 703
—— terminal genital 866
Cortical layer of kidney 487
Corti, membrane of 839
—— organ of . . . . . *ib.*
Costæ 67
Costal cartilages. 69
—— pleura 464
—— region 235
Cotyledons 886
Cotyloid cavity 91
Cowper's glands 864
Cranial arachnoid 664
—— cavity 660
—— dura mater 662
—— membrane 912
—— nerves 703
—— —— origin of 704
—— pia mater 666
Cranium, bones of 33
Cremaster 852
Cricoid cartilage 450
Crico-thyroid membrane 452
—— trachealis ligament 453
Crown of tooth 345
Crura cerebelli 678
—— cerebri 675, 677
—— of fornix 694, 695
—— of penis 864
Crural aponeurosis 241
—— arch . . . . . *ib.*
—— bulb 668
—— internal region 288
—— ring 241
Crus ad medullam oblongatum . . 678
—— cerebelli ad pontem 678
Crusta petrosa 346
Cryptæ mucosæ 403
Cryptorchids 853
Crystalline lens 817, 826
—— —— capsule of 826, 909
—— —— structure of 818, 826
Cumulus proligerus 873
Cuneiform cartilages 451
Cutaneous gland of Pig 794
—— lamina 906
Cuticle 792
Cutiduris 803
Cutigeral cavity. 806
Cutis anserina 793, 799
Cuvierian ducts 917
Cysterna chyli 634
Cytoblasts 796
Czermak, interglobular spaces of . . 345

Dartos 853
Deciduous teeth 348, 358
Deferent canal 858, 859
—— —— structure of. 860

PAGE
Deglutition 376
Demours, membrane of 827
Dental follicle 347, 921
—— germ 348, 921
—— pulp 345, 347
—— tubuli 345
Dentated membrane 662
Dentine 345
Derma 792
—— structure of 793
Descemet, membrane of 827
Development of annexes of alimentary canal 920
—— of auditory apparatus 909
—— of brain 907
—— of cephalic laminæ 905
—— of chorda dorsalis . . . . . *ib.*
—— of circulatory apparatus . . . 914
—— of cranium and face 912
—— of digestive apparatus 919
—— of fœtus 905
—— of genital organs 923
—— of genito-urinary apparatus . . 922
—— of gustatory apparatus 910
—— of heart and vessels 915
—— of lateral laminæ 905
—— of limbs 913
—— of locomotory apparatus . . . 911
—— of lungs 918
—— of muscles 913
—— of nerves 908
—— of nervous system 907
—— of olfactory apparatus 910
—— of respiratory apparatus . . . 918
—— of skeleton 911
—— of spinal cord 907
—— of tactile apparatus 910
—— of thorax 913
—— of urinary organs 923
—— of vertebral column 911
—— —— lamina 905
—— of visual apparatus 908
Dewlap 796
Diaphragmatic pleura 464
—— region 245
Diarthroses 123
Diastole of heart 573
Differential characters in abdominal cavity 384
—— —— air-tube 461
—— —— annexes of fœtus 901
—— —— anterior limbs 86
—— —— apparatus of taste 815
—— —— articulations.
—— —— —— atlo-axoid 135
—— —— —— carpal 155
—— —— —— chondro-costal . . . 142
—— —— —— coxo-femoral . . . 162
—— —— —— femoro-tibial . . . 167
—— —— —— humero-radial . . . 146
—— —— —— interphalangeal, first 157
—— —— —— —— second . . . 158
—— —— —— occipito-atloid . . . 137
—— —— —— radio-ulnar 147

PAGE
Commisures of vulva 882
Common aorta 522
Comparison of abdominal cavity . . 385
—— of abdominal limb 187
—— of annexes of fœtus 904
—— of aorta 538
—— of apparatus of taste 814
—— articulations, carpal 156
—— —— coxo-femoral 163
—— —— humero-radial 147
—— —— interphalangeal 159
—— —— radio-ulnar 148
—— —— scapulo-humeral 144
—— —— tibia-fibular 168
—— auditory apparatus 850
—— axillary arteries 574
—— bronchi 472
—— carotid arteries 595
—— cerebellum 689
—— cerebro-spinal axis 666
—— cerebrum 698
—— external iliac arteries . . . 557
—— genital organs, female . . . 888
—— —— —— male 871
—— head 63
—— heart 514
—— internal iliac arteries 545
—— intestines 417
—— isthmus of brain 685
—— larynx 471
—— liver 434
—— lungs 472
—— mouth 362
—— muscles of abdominal region . . 245
—— —— arm 260
—— —— back 209
—— —— costal region 238
—— —— diaphragm 248
—— —— fore-arm 274
—— —— gluteal region 283
—— —— hand 279
—— —— head 230
—— —— leg 310
—— —— shoulder 255
—— —— sublumbar region . . . 215
—— —— thigh 295
—— nasal cavities 449
—— nerves, brachial plexus . . . 767
—— —— cranial 740
—— —— great sympathetic . . . 789
—— —— lumbo-sacral plexus . . 778
—— œsophagus 380
—— pancreas 434
—— pharynx 377
—— salivary glands 372
—— spleen 435
—— spinal cord 672
—— stomach 400
—— thoracic limb 89
—— thorax 71
—— thymus gland 475
—— thyroid gland . . . . . ib.
—— trachea 472
—— urinary apparatus 496

PAGE
Comparison, venous system 626
—— vertebral column 32
—— visual apparatus 836
Complementary apparatus of pedal bone 801
Composite nerves 753
Compressor vesiculæ 860
Conarium 680
Concha auris. 846
—— —— cartilages . . . . . ib.
—— —— muscles . . . . . ib.
Conchal cartilage . . . . . ib.
Confluent of jugulars 601
Confluents of subarachnoid fluid . . 664
Congestion of liver 427
Conglomerate glands 329
Conjunctivæ 832
Conjunctival tissue 4
Connective cells . . . . . ib.
—— fibres . . . . . ib.
—— tissue . . . . . ib.
Consistence 329
Contractile cells 4
—— fibrillæ 178
Convoluted tube of kidney . . . 488
Coracoid process 73
Corium cutis 792, 793
Cornea 819
—— structure of . . . . . ib.
Cornu Ammonis 679, 695
Cornua of spinal cord 669
—— of uterus 877
—— of ventricles 695
Corona glandis 866
Coronæ tubulorum 404
Coronaria ventriculi 527
Coronary cushion 803
—— ligament . . . . . ib.
—— substance . . . . . ib.
—— —— structure 804
Corpora albicans vel nigrum . . . 875
—— cavernosa 865
—— fimbriata of fornix 694
—— geniculata 680
—— Malpighiana 488
—— nigra 823
—— pyramidalia 676, 684
—— quadrigemina 675, 679
—— restiformia 677, 684
Corpus albicans 678, 695
—— Arantius 505
—— callosum 692, 693
—— cavernosum 864, 865
—— —— external conformation . . 864
—— —— structure 865
—— ciliare 821
—— dentatum 688
—— fimbriatum 695
—— geniculatum, externum . . . 680
—— —— internum 679, 680
—— Highmorianum 854
—— luteum 874
—— —— false 875
—— —— true . . . . . ib.
—— olivare 677

PAGE
Cells, nerve 4, 652
—— olfactory 445
Cellular tissue 4
Cementum 345, 346, 921
Central canal of spinal cord 668
Central suprahepatic veins 424
Centres of ossification 16
Centrifugal conductibility 656
—— nerves . . . . . *ib.*
Centripetal conductibility . . . . . *ib.*
—— nerves . . . . . *ib.*
Centrum 118
—— ovale of Vieussens 697
Cephalic hood 893
—— laminæ 907
Cerebellar crura 678
—— peduncles 675
—— ventricle 679, 683, 688
Cerebellum 672, 686
—— external conformation 686
—— internal conformation 688
Cerebral hemispheres 673
—— peduncles 675, 677
—— trigonal 679
—— ventricles 692
—— vesicles 907
Cerebro-spinal axis 651
—— —— nerves 700
Cerebrum 689
—— convolutions 689, 691
—— external conformation 690
—— hemispheres 689, 691
—— structure 697
Cerumen 846
Ceruminous glands . . . . . *ib.*
Cervical ganglia 782
—— nerves 784
—— vertebræ 21
Cervix of bladder 491
—— of uterus 877
Chalazæ 925
Chambers of the eye 817
Cheeks 332, 356, 359, 360
—— functions 332
—— structure . . . . . *ib.*
Chesnuts 799, 812
Chiasma of optic nerves 678
Chorda dorsalis 892, 905
Chordæ longitudinales 693
—— tendinæ 504
—— vocales 452
—— Willisii 606
Chorion of skin 792
—— of fœtus 895
—— definitive 896
—— primitive . . . . . *ib.*
Choroid membrane or coat 820
—— —— —— anterior . . . . *ib.*
—— —— —— posterior . . . . *ib.*
—— —— —— structure 821
—— plexus, cerebral 693, 696
—— zone 820
Chyle 498
Cicatricula 925

PAGE
Cilia 832
Ciliary body 821, 822
—— canal 821
—— circle 820
—— ligament 821, 822
—— processes 821, 822
—— zone 820
Ciliated epithelium 327
Circulation, adult 498
—— fœtus 914
Circulatory apparatus 498
—— —— in birds 647
Circulus venosus orbiculi ciliaris . . 821
Circumvallate papillæ 336, 814
Cistern of Pecquet 634
Clark, vesicular column of 671
Claws 812
Cleavage masses 891
Clefts, pharyngeal 912
Clitoris 882
—— præputium of . . . . . *ib.*
Closed follicles 340
Coat 797
Coccygeal gland 781
—— muscles 215
—— nerves 753
—— vertebræ 27
Cochlea 837
—— membranous 839
Cœliac axis 527
Cohesion 329
Colic mesentery 383, 413
Collateral scala 839
—— vessels 517
Colon 410
—— double . . . . . *ib.*
—— —— attachments 411
—— —— capacity 410
—— —— course 411
—— —— form . . . . . *ib.*
—— —— functions 413
—— —— length 410
—— —— relations 411
—— —— structure 412
—— small . . . . . *ib.*
—— —— attachment 413
—— —— course 412
—— —— form . . . . . *ib.*
—— —— interior 413
—— —— length 412
—— —— relations . . . . . *ib.*
—— —— structure 413
Colostrum 886
Columnæ carnæ 503
—— papillares . . . . . *ib.*
—— rugosæ 880
Columnar epithelium 327
Columns of spinal cord 669, 671
Commissures of frog 807
—— of inguinal canal 242
—— of lips 331
—— of nostril 440
—— of optic nerves 707
—— of spinal cord 669

PAGE
Preparation, articulations, costo-sternal 141
—— —— coxo-femoral . . . 161
—— —— femoro-tibial 163
—— —— first interphalangeal . . 156
—— —— humero-radial 144
—— —— hyoideal 139
—— —— interphalangeal, first . . 156
—— —— —— second 157
—— —— metacarpo-phalangeal . . 153
—— —— occipito atloid . . . 137
—— —— pelvis 159
—— —— scapulo-humeral . . 143
—— —— spine, of 130
—— —— tarsus 168
—— —— temporo-maxillary . . 138
—— auditory apparatus 837
—— brachial plexus 755
—— bronchi 460
—— choroid coat 820
—— cornea 819
—— cranial nerves 705
—— ear, internal 877
—— encephalon 674
—— eye 817
—— great sympathetic nervous system 781
—— heart 503
—— —— structure of 507
—— hoof 799
—— internal ear 877
—— intestines 400
—— larynx 449
—— liver 419
—— lumbo-sacral plexus . . 770
—— lungs 466
—— lymphatics 633
—— maxillary gland 367
—— mouth 330
—— muscles 184
—— —— abdominal region, inferior 239
—— —— alveolo-labialis . . . 218
—— —— anterior brachial region 255
—— —— —— crural region . . . 283
—— —— —— medius 231
—— —— axillary region . . . . *ib.*
—— —— brachial region, anterior . 255
—— —— —— —— posterior . . 258
—— —— cervical region, inferior . 196
—— —— —— —— superior . . 187
—— —— costal region 235
—— —— crural region 283
—— —— —— —— anterior . . . *ib.*
—— —— —— —— internal . . . 288
—— —— —— —— posterior . . 286
—— —— diaphragmatic region . . 245
—— —— external scapular region . 249
—— —— eye 828
—— —— femoral region 283
—— —— flexor, short, of fore-arm 256
—— —— fore-arm, of 261
—— —— gluteal region 280
—— —— hyoideal region 225
—— —— inferior abdominal region . 239
—— —— —— cervical 196
—— —— —— lumbar region . . 211

PAGE
Preparation, muscles, internal scapular region 252
—— —— labialis 217
—— —— leg 297
—— —— lumbar region, inferior . . 211
—— —— masseteric region . . . 223
—— —— mastoido-humeralis . . . 196
—— —— medius, anterior . . 222, 223
—— —— panniculus 186
—— —— scapular region, external . 249
—— —— —— —— internal . . . 252
—— —— spinal region of back and loins 203
—— —— sublumbar region . 211
—— —— superior cervical . . . 187
—— —— temporo-maxillary region . 223
—— nasal cavities 440
—— œsophagus 377
—— palate 332
—— pancreas 419
—— parotid gland 365
—— pericardium 512
—— pharynx 372
—— retina 824
—— soft palate 340
—— spinal cord 666
—— spleen 419
—— stomach 385
—— submaxillary gland . . . 367
—— sympathetic nervous system . . 781
—— thoracic duct 643
—— tongue 334
—— trachea 457
—— urinary apparatus 484
—— veins 599
Prepuce 867
—— of clitoris 882
Preservation of muscles . . . 185
Primitive aortæ 915
—— band of Remak 652
—— chorion 896
—— eye-vesicles 908
—— fasciculus 178
—— furrow 892
—— trace . . . . . *ib.*
Primordial kidneys 922
Processes e cerebello ad testes . . 678
Promontory of ear 840, 842
Properties of nervous system . . . 655
Prostate gland 864
—— —— structure . . . . . *ib.*
Protoplasm 3
Protuberantia annularis 675
Protovertebræ 905, 911
Protovertebral cavity 905
Pulmonary artery 521
—— heart 503
—— lobes 466
—— lobules 468
—— opening of heart 505
—— pleura 464
—— tissue 467
—— vesicles 468
Puncta lachrymalia 834

PAGE
Punctum cæcum 824
Pupil 822
Pupillary membrane . . . 824
—— sphincter 823
Purkinje's vesicle 925
Pylorus 388
Pyramidal eminence of os pedis . . 85
Pyramids of the bulb 676

Racemose glands 329, 339
Rachidian bulb 675
Raphé of scrotum 853
Receptaculum chyli 634
Recto-vesicle fold 860
Rectum 413
—— attachment 413
—— development 920
—— relations 413
—— structure 414
Recurrent sensibility 650
Reflex power 657
Reil, band of 678
Reissner, membrane of 839
Remak, primitive band of 652
Renal glomerules 488
—— pelvis 486
Reseau admirable 590, 591, 593
Reservoir of thymus gland 473
Respiratory apparatus 439
—— —— of Birds 475
—— —— of Mammifers 439
—— —— nerves 704
Rete mirabile 593, 594, 631
—— mucosum 796
—— ophthalmicum 595
—— testis 855
Reticular layer of the derma . . . 793
Reticulum 397
—— structure . . . . . *ib.*
—— processigerum 613
Retina 824
Retrossal process of os pelis . . . 85
Rhomboidal sinus 907
Ribs 67
Right auricle of heart 505
—— ventricle „ 503
Rima glottis 456
Ring, inguinal 242
—— pancreatic 427
—— umbilical, inferior 894
—— Vieussens, of 506
Rings of trachea 468
Rivinian ducts 369
Rolando, gelatinous substance of . . 670
Root of lungs 461, 466
Rosenmüller, organ of 866, 923
Rudimentary sinuses 606
Rumen 394
—— structure of 396

Sacculus of ear 839
Sacral nerves 752
Sacrum 26
Salivary glands 364

PAGE
Salivary glands, development of . . 920
—— —— ducts 357, 369
—— lobules 364
Saphena veins 624
Sarcolemma 178
Sarcous elements . . . . . *ib.*
Scala, auditive 839
—— collateral . . . . . *ib.*
—— Lowenberg's . . . . . *ib.*
—— tympani 838, 839
—— vestibuli . . . . . *ib.*
—— —— proper 839
Schindylesis 129
Schneiderian membrane 444
—— —— structure of 445
Schwann, white substance of . . . 652
Sclerotica 817
Sclerotic cleft 909
Scrotum 853
Scutiform cartilage 846
Sebaceous glands 794
Secondary dentine 347
Segmentation of vitellus 890
Semen 857
Semicircular anastomoses 555
—— band 680
—— canals 837
—— ganglia 711
—— valves 505
Semilunar crest of pedal bone . . . 84
—— fibro-cartilages 163
Seminiferous tubes 855
Sensitivo-motor centre 657
Sensorial functions 658
Septum auricularum 503
—— lucidum 692, 694
—— pectiniforme 865
—— scroti 853
—— ventricularum 503
Serous bursæ 183
—— membrane 328
—— stratum of epiblast 893
—— vesicle . . . . . *ib.*
Sesamoid bones 84
Sheaths, arteries of 516
—— hair of 798
—— lymphatic 630
—— metacarpo-phalangeal 267
—— navicular 269
—— ocular 54, 828
—— penis, of 837, 868
—— perforans tendon, of 269
—— Schwann, of 652
—— tarsal 305
Shell, egg of 925
—— membrane . . . . . *ib.*
Shoulder, bones of 72
Sigmoid valves 505, 507
Simple follicles 404
—— glands 329
—— placenta 903
Sinus ampullaceous 839
—— aortici 522
—— circularis iridis 821

PAGE
Sinus cutaneous ungularum . . . 724
—— lactiferus 884, 885
—— pocularis 861
—— renalis 486
—— rhomboidalis 683, 907
—— terminalis 915
—— Valsalvæ 522
Sinuses, structure of 597
—— aortic 522
—— dura mater, of 605
—— —— —— in general . . . 606
—— —— —— in particular . . . *ib.*
—— cavernous . . . . . *ib.*
—— falx cerebri, of . . . . . *ib.*
—— median . . . . . *ib.*
—— occipito-atloid . . . . . *ib.*
—— petrosal . . . . . *ib.*
—— rudimentary . . . . . *ib.*
—— sphenoidal 447
—— spinal in particular 608
—— transverse 606
—— galactoferous 884, 885
—— head, of 446
—— —— development of . . . 447
—— —— functions of 448
—— —— ethmoidal 447
—— —— frontal 446
—— —— maxillary, inferior . . . 447
—— —— —— superior . . . . . *ib.*
—— —— sphenoidal . . . . . *ib.*
—— lymphatic 532
—— palpebral 830
—— renal 486
—— rhomboidal 683, 907
—— subarytenoid 456
—— subepiglottic . . . . . *ib.*
—— terminalis 915
—— Valsalva, of 522
Skeleton 7
Skin 792
—— appendages of 797
—— derma 792
—— epidermis 795
—— functions 796
—— structure 792, 796
Small intestines 400
Smegma præputii 867
Smell, apparatus of 815
Socia parotidis 372
Soemmering, foramen of 836
Soft palate 340, 357, 359, 360
Sole of hoof 807
Solid organs 328
—— —— structure of 328, 329
Solitary glands 404, 410
Speculum Helmontii 246
Spermatic cord 856
Sphincter ani 414
—— pupillaris 823
—— vaginæ 880, 883
Spinal arachnoid 663
—— canal 659
—— cord 666
—— —— external surface of . . . 668

PAGE
Spinal cord, figure . . . . . *ib.*
—— —— general view of 666
—— —— internal conformation . . 668
—— —— structure 668, 669
—— —— volume 668
—— —— weight . . . . . *ib.*
—— dura mater 661
—— marrow 651
—— nerves 747
—— —— constitution 748
—— —— nerve-tubes of 671
—— pia-mater 665
Spine, the, in general 28
Splanchnology 326
Spleen 428
—— attachment 429
—— development 922
—— direction 428
—— form . . . . . *ib.*
—— functions 431
—— relations 428
—— situation . . . . . *ib.*
—— structure 429
—— weight . . . . . *ib.*
Splenic corpuscles 430
—— pulp 429
Spongy portion of urethra 862
Spontaneous voluntary movements . 657
Stapes 843
Staphyline glands 370, 371
Stars of Verheyen 489
Stenon's duct 367
Stenson's duct 443
Stilling, dorsal nucleus of 671
Stomach in Solipeds 385
—— —— development 920
—— —— dimensions 386
—— —— form . . . . . *ib.*
—— —— functions 393
—— —— interior 388
—— —— ligaments 389
—— —— muscular membrane . . . *ib.*
—— —— orifices 388
—— —— situation 386
—— —— structure 389
—— Carnivora 393
—— Pig . . . . . *ib.*
—— Ruminants . . . . . *ib.*
—— —— functions 399
Subarachnoid fluid 663, 664
Subarytenoid sinus 456
Subcorneous integument 803
Subcutaneous region 106
Subepiglottic sinus 456
Subhepatic veins 423
Sublingual crest 334
—— gland 369, 371
Sublobular veins 424, 425
Sublumbar reservoir 634
Submaxillary gland 367, 371
Subpodophyllous reticulum 613
Subsphenoidal confluents 608
Substantia gelatinosa 670
—— ostoidea 346

PAGE
Substantia perforata 692
Suburethral notch 866
Succus prostaticus 864
Sudoriparous glands 794
Sulci horizontalis 686
Superior umbilicus 893
Suprarenal capsules 494
—— —— development 495
—— —— form 494
—— —— functions 495
—— —— relations 494
—— —— situation . . . . . ib.
—— —— structure . . . . . ib.
Suprasphenoidal appendage 681
Suspensory ligament of fetlock . . . 154
—— —— penis . 865, 866, 872
—— —— sheath 867
—— —— uterus 877
Sylvius, fissure of 691, 692
Sympathetic nervous system 781
—— —— —— functions 789
—— —— —— structure . . . . . ib.
Symphyses 129
Synarthroses 128
—— classification of 129
Synovia 127
Synovial capsules 126
—— fossæ 123
—— fringes 127
Syntonine 181
Systole of heart 513

Tactile corpuscles 703
Tænia hippocampi 695
—— semicircularis 680, 695
Tail 797
Tapetum 820, 822
Tarin, valves of 687, 689
Tarsal sheath 305
Tarsi 831
Tarsus 102
Taste, apparatus of 813
Teats 884
Teeth 344
—— characters of . . . . . ib.
—— development of 347, 921
—— disposition of 344
—— eruption of 921
—— external conformation . . . 344
—— structure 345
—— of Carnivora 261
—— Pig 359
—— Ruminants 357
—— Solipeds 349
Tegumentary membranes 5
Temporal fossa 55
Tela choroidea 696
Tendinous sheaths 183
—— synovial membranes . . . . . ib.
Tendo-Achilles 302
Tendons 179
—— anterior extensor of metacarpus 262
—— common, of abdominal muscles . 240
—— deep flexor 268

PAGE
Tendons, extensor pedis 263
—— external flexor of metacarpus . 266
—— flexor, of metatarsus 300
—— —— hock 302
—— gastrocnemii . . . . . ib.
—— great dorsal 294
—— large extensor of fore-arm . . 258
—— lateral extensor of phalanges . 264
—— middle „ 259
—— oblique flexor 266
—— perforatus 267, 304
—— perforans 267, 268, 305
—— prepubic 240
Tentorium cerebelli 662, 663
Tentacula 797, 798
Terminal genital corpuscles 866
—— motor plate 180, 702
—— vessels 517
Testaceous membrane 925
Testes cerebelli 678
—— muliebres 872
—— tubercula 679
Testicles 851, 853
—— attachment of 853
—— descent of 942
—— development of 856, 923
—— ectopiæ of 853
—— envelopes of 852
—— external conformation . . . 853
—— function of 857
—— structure of 854
Testicular cord . . . . . ib.
Thalami optici 675, 679
Thebesius, valve of 506
Theca vertebralis 661
Thiernesse's muscle 264
Third ventricle of brain 682
Thoracic aorta 524
—— cavity 462
—— duct 634
—— —— affluents of 637
—— —— course of 634
—— —— extent . . . . . ib.
—— —— origin . . . . . ib.
—— —— termination 635
—— —— varieties in . . . . . ib.
Thorax 66, 462
—— functions of 466
—— in general 70
—— internal conformation . . . 462
—— situation . . . . . ib.
Thymic ducts 474
Thymus gland 473
—— —— development 919
—— —— functions 473
—— —— structure . . . . . ib.
Thyroid cartilage 450
Thyro-hyoid membrane 452
Thyroid gland 472
—— —— functions 473
—— —— structure 472
Tibial aponeurosis 297
Tissues 4
Toe-stay 808

PAGE
Tongue 334, 357, 359, 360
—— conformation of 334
—— development of 920
—— functions of 340
—— muscles of 336
—— pillars of 335
—— situation of 334
—— structure of 335
Tonsils 335
—— of cerebellum 689
Torcular Herophili 606
Trabeculæ of spleen 429
—— testis 855
Trachea 457
—— course . . . . . *ib.*
—— development . . . 918
—— form 457
—— relations . . . . *ib.*
—— structure 458
Trace, primitive 892
Tracheal glands 459
Tractus longitudinalis . . . 693
—— opticus 707
—— respiratorius 704
Transverse sinuses 606
Tricuspid valves 504
Trifacial nerve 710
Trigeminii . . . . . *ib.*
Trigonum vesicæ 493
Trisplanchnic system 781
Trochlea 128
Trochlearis nerve 709
Tuber annulare 677
—— cinerium 681
Tubercula nates 679
—— quadrigemina . . . . . *ib.*
—— testes . . . . . *ib.*
Tuberculum Loweri 506
Tubular glands 322
Tubuli seminiferi 854
—— uriniferi 487
Tuft of chin 331
Tunic of plantar cushion 802
Tunica abdominalis 239
—— albuginea of ovary 873
—— —— of testicle 854
—— erythroides 852
—— Ruyschiana 821
—— vaginalis 852
—— —— communis . . . . . *ib.*
—— —— propria . . . . . *ib.*
—— —— reflexa . . . . . *ib.*
—— vasculosa testis 855
Tympanal circle 841
Tympanic scala 839
Tympanum 840
Ultimate follicles 365

Umbilical cord 895, 900
—— arteries 900
—— region 381
—— veins 900
—— vesicle 894, 895, 899
Umbilicus, superior 893

PAGE
Unipolar nerve-cells 653
Uniting tube of kidney 488
Unstriped muscular fibres . . . 327, 328
Urachus 894, 897
Ureters 490
—— direction . . . . . *ib.*
—— form . . . . . *ib.*
—— origin . . . . . *ib.*
—— structure . . . . . *ib.*
—— termination . . . . . *ib.*
Urethra 493
—— male, of 861
—— —— course . . . . . *ib.*
—— —— interior . . . . . *ib.*
—— —— relations 862
—— —— structure . . . . . *ib.*
—— female, of 882
Urethral ridge 862
—— sinus 866
Urinary apparatus 484
Uro-genital sinus 923
Uterine glands 879
—— tubes 876
—— —— functions of . . . . . *ib.*
—— —— structure . . . . . *ib.*
Uterus 877
—— attachment . . . . . *ib.*
—— development 880
—— form 877
—— functions 880
—— interior 877
—— masculine 861
—— situation 877
—— structure 878
Utricular glands 880
Utriculus of ear 839
—— prostatic 861
Uvula of cerebellum 689

Vagina 880
—— functions 882
—— internal conformation . . . 880
—— situation . . . . . *ib.*
—— structure . . . . . *ib.*
Vaginal bulb 883
—— sheath 852
—— synovial membrane 183
Valsalva, sinus of 552
Valves, Bauhin, of 402
—— bicuspid 507
—— Eustachian 506, 514
—— ilio-cæcal 402, 408
—— Kerking, of 402
—— lymphatic 627
—— meatus urinarius 882
—— mitral 507
—— Renault, of 683, 686
—— semicircular 505
—— sigmoid 505, 507
—— Tarin, of 687, 689
—— Thebesius, of 506
—— tricuspid 504
—— veins, of 597
—— Vieussens, of 675, 679

PAGE
Valves, vulvo-vaginal 887
Valvulæ conniventes 402
Varolii, pons 675, 677
Vasa afferentia 632
—— efferentia 632, 855
—— inferentia 632
—— recta 855
—— vasorum 520
—— —— of veins 598
—— vorticosa 821
Vascular blood glands 330
Vas deferens 859
—— —— structure of . . . 860
Vegetative life, nerves of . . . 652
VEINS:—definition 596
—— external conformation . . *ib.*
—— general considerations . . *ib.*
—— injection of 599
—— internal conformation . . 597
—— structure 599
—— abdominal, subcutaneous . . . 625
—— alveolar 602
—— angular of eye . . . . . *ib.*
—— auricular, anterior 604
—— —— posterior 602
—— axillary 609
—— basilic 611
—— basium vertebrarium . . . 131
—— buccal 603, 605
—— cæcal 620
—— cardiac 599
—— cardinal, anterior 917
—— —— posterior . . . . . *ib.*
—— cephalic 603, 611
—— central of foot 613
—— —— of retina 825
—— cervical, superior 600
—— circumflex of foot 613
—— collateral of cannon, external . 611
—— —— —— internal . . . . . *ib.*
—— coronary, great 599
—— —— small . . . . . *ib.*
—— —— of foot 614
—— dental, inferior 605
—— —— superior 603
—— diaphragmatic. 617
—— digital 612, 625
—— dorsal 600
—— femoral 623
—— Galeni 608
—— gastric, anterior 621
—— gastro-epiploic, left 621
—— —— —— right . . . . . *ib.*
—— glosso-facial 602
—— hæmorrhoidal 621
—— humeral 610
—— iliac, common 622
—— —— external 623
—— —— internal 622
—— ilio-cæcal 620
—— innominate 603
—— interlobular of liver 423
—— interosseous 612
—— intralobular of liver 424

PAGE
Veins, intra-osseous of foot. 616
—— jugular 601
—— labial 603
—— lingual 605
—— mammary, internal 600
—— maxillary, external 602
—— —— internal 601, 605
—— maxillo-muscular 601
—— median spinal 608
—— —— subcutaneous 611
—— mesenteric, great 620
—— —— small 621
—— meseraic, anterior. 620
—— —— posterior 621
—— metacarpal 611
—— metatarsal 624
—— —— deep . . . . . *ib.*
—— —— external . . . . . *ib.*
—— —— internal . . . . . *ib.*
—— nasal 603
—— occipital 602
—— omphalo-mesenteric 915
—— pelvi-crural 622
—— plat 603
—— podophyllous 613
—— popliteal 623
—— portal 617
—— posterior communicating, of foot 615
—— pterygoid 605
—— pulmonary. 599
—— radial, anterior 610, 611
—— —— subcutaneous 611
—— renal 621
—— saphena, external 624
—— —— internal . . . . . *ib.*
—— solar 612
—— spermatic 621
—— splenic . . . . . *ib.*
—— spur 610
—— subcutaneous, abdominal . . . 625
—— —— internal 611
—— —— thoracic 610
—— subhepatic 619
—— sublingual 603
—— subscapular 610
—— subzygomatic 605
—— superficial temporal 601, 603
—— suprahepatic 619
—— temporal, deep 605
—— —— superficial 601, 603
—— testicular 622
—— Thebesii 599
—— thoracic, internal 600
—— thyroid 603
—— tibial, anterior 623
—— —— posterior 624
—— ulnar 610
—— umbilical 916
—— ungual 612
—— utero-ovarian 622
—— vertebral 600, 917
—— cava, anterior . . . . . *ib.*
—— —— posterior . . . . . *ib.*
Velum interpositum 691, 696

PAGE
Velum pendulum palati 340
—— vasculosum 696
Velvety tissue of foot . . . 803, 804
Vena azygos, great 600
—— —— small . . . . . ib.
—— cava, anterior 600
—— —— posterior 617
—— Galeni 691, 696
—— portæ 617
Venæ comites 598
—— vorticosa 821
Ventricles of brain . . 682, 683, 692, 693
—— —— cerebellar 688
—— —— cerebral 693
—— —— lateral 692, 693
—— —— middle 682
—— —— posterior 683
—— —— third 682
—— —— thalami optici of . . . 628
—— of heart 500
—— of larynx 456
Ventricular arachnoid 694
—— mass of heart 500
Vermiform appendix 418
—— processes of cerebellum . . . 686
—— —— —— anterior . . . . ib.
—— —— —— posterior . . . . ib.
Vermis of cerebellum 687
Vertebræ 18
—— characters common to . . . 19
—— —— proper to 21
—— development 20, 911
—— structure 20
Vertebral column 18
—— —— development of 911
—— constitution of skeleton . . . 118
—— laminæ 905
Vertebro-costal channels 462
Veru montanum 861
Vesicle, serous 893
—— umbilical 899
Vesicles, Graafian 873
—— pulmonary 468
Vesicula alba 894
—— seminalis tertia 861
Vesiculæ seminales 860
Vestibular scala 839
Vestibule of ear 837
Vibratile cilia 327
Vibrissæ 449
Vicq-d'Azyr, cæcum of 658

PAGE
Vidian canal 724
—— fissure . . . . . ib.
—— nerve 719
Vieussens, centrum ovale of . . 697
Villi, intestinal 402
Villosities 327
Villo-papillæ of foot 803
Villous loops of foot . . . . . ib.
Vitellus 873, 890
Vitreous body 827
—— humour . . . . . ib.
Viscera 326
Visceral pleura 464
Vision, apparatus of 816
Vitelline duct 894
—— globules 925
Vocal cords 452
—— —— superior 453
Voluntary movements 658
Vulva 882
—— cavity of . . . . . ib.
—— external opening of . . . . ib.
—— structure 883
Vulva of brain 699
Vulvæ, labia 882

Wall of hoof 805
—— —— angle of 808
—— —— structure of . . . . . ib.
Wharton's duct 368
—— gelatine of 900
White line of hoof 812
—— substance of Schwann . . . 652
—— —— spinal cord 671
—— longitudinal fibres of brain 685
—— transverse " " . . . ib.
Wilson's muscle 862, 863
Winepress of Herophilus 606
Winslow, foramen of 383
Wirsung, duct of 428
Wolffian bodies 922, 923
Wrisberg, nerve of 723

Xiphoid appendage of sternum . 67

Yelk 873, 890
Yolk of egg 925

Zona pellucida 873, 890
Zonula ciliaris 821, 824
—— of Zinn . . . . . ib.
Zoösperma 858