

ANIMAL CASTRATION

SF
889
W 58
1913

CORNELL UNIVERSITY

THE

Flower Veterinary Library

FOUNDED BY

ROSWELL P. FLOWER

for the use of the

N. Y. STATE VETERINARY COLLEGE
1897

This Volume is the Gift of

Alice L. Dustan

from the library of

Dr. Henry W. Dunstan '98


Cornell University Library
SF 889.W58 1914

Animal castration,a book for the use of



3 1924 021 949 601

VET



Cornell University Library

The original of this book is in
the Cornell University Library.

There are no known copyright restrictions in
the United States on the use of the text.

<http://www.archive.org/details/cu31924021949601>

ANIMAL CASTRATION

A Book for the Use of
STUDENTS AND PRACTITIONERS

240 Pages

with over 200 Halftone Illustrations from Original Photographs

BY

GEORGE R. WHITE, M.D., D.V.S.

Graduate Columbian University (Veterinary Department), and
University of Nashville (Medical Department)

MEMBER

American Veterinary Medical Association

Tennessee Veterinary Medical Association

American Medical Association

Tennessee Medical Association

Nashville Academy of Medicine, and

Davidson County Medical Society

Tennessee Academy of Science,

United States Live Stock Sanitary Association, etc.

Professor Veterinary Medicine—Knapp School of Country Life

TEACHER SURGICAL RESTRAINT AND CASTRATION AND SPAYING

Chicago Veterinary College

Terre Haute Veterinary College

Indiana Veterinary College, and

Alabama Polytechnic Institute (Veterinary Department)

Author "Restraint of Domestic Animals," etc.



PUBLISHED BY THE AUTHOR

NASHVILLE, TENN.

1914

Copyrighted 1914
by
GEORGE R. WHITE

1914
FOSTER & PARKES COMPANY,
Nashville, Tenn.

DEDICATION

TO

PROFESSOR CHARLES ALLEN CARY, B.S., D.V.M.,

As a slight token of personal friendship and esteem, as well as for his successful efforts in undertaking the apparently insurmountable task of establishing and successfully conducting the first accredited Veterinary College in the South

THE AUTHOR

PREFACE

To those entrusted with the onerous task of castrating and spaying domestic animals the scantness of modern literature—especially that printed in English and by American authors—dealing with the subject must have always proved a matter of considerable embarrassment.

This universally recognized lack of a well illustrated book on the important subject of unsexing animals has induced the author to write and publish this volume.

It is offered with the desire and hope that it will—in a measure at least—close this wide gap in our English speaking literature.

Twenty-one years' actual and active experience in city and rural practice as well as several years as a teacher of this particular subject leads me to believe that a text-book well illustrated, written by an American, based on American methods, will be acceptable to the student and practitioner who really has a desire to become proficient in performing the operations of castration and spaying. The illustrations and text are for the most part original. The methods described are those employed in actual every-day practice by the author.

In presenting this volume to the indulgence of veterinarians the author's only regret is that during its preparation he was State Veterinarian of Tennessee, and did not have the time at his disposal to insure the best authorship results. Hence he is constrained to appeal for lenient judgment and criticism on the book prepared under no common stress of duties—administrative, professional, social and political.

GEORGE R. WHITE.

FOREWORD

INSTRUMENTS

The first essential to the proper performance of the operations of castration and spaying is instruments of modern and approved design made from material of unquestioned quality.

Instruments of the same external appearance—which usually means nothing more nor less than finish, and finish in turn merely means polish and plate—may vary greatly in quality of material and workmanship.

Never purchase cheap instruments at any price, as they are not satisfactory or dependable. The best are none too good, as oftentimes an instrument will make or unmake a man's reputation as an operator.

If these operations—castration and spaying—are to be done neatly and with dexterity, antiquated instruments have no place in the operative technique. Nothing conduces quite so much to awkwardness in operating and an all around "bunglesome job" as do instruments of improper construction.

There are numerous castrating and spaying instruments offered to the public by many commercial firms that are bad and others worse than worthless for the purpose for which they are intended. The one admonition the author would offer above all others is to exercise extreme care and good judgment in selecting castrating and spaying instruments.

Most manufacturers of surgical instruments and their shop mechanics have little or no conception or practical knowledge of the actual requirements of the instruments which they make and sell.

Unless the purchaser knows what he wants he is at the mercy of the ignorant manufacturer and is liable to make mistakes in purchasing which will cause embarrassment later when actually engaged in operating.

Remember that there are several grades and many designs of

castrating and spaying instruments. Always call for "A grade," and see to it that you get exactly what you call for and select the design best suited for your requirements.

It will be observed that numerous instruments are illustrated and described in the following pages. Where only one pattern of an instrument is shown this means that in the author's opinion this particular instrument has advantages over all others and is the proper one to purchase. Where two or more instruments of the same character are shown it means that the author has no preference and that both instruments are equally satisfactory, and either may be purchased without making a mistake.

Each and every instrument illustrated in this volume possesses merit, and no mistake will be made in selecting them or either of them. Our only object in thus illustrating and describing the instruments is that in so doing the amateur may have the advantage of the author's twenty-one years' experience in selecting and using this class of surgical instruments, and with the hope that the information herein contained may in a measure at least protect the inexperienced prospective castrator from waking up later to the fact that he is in possession of a lot of "useless junk" which has been sold to him for castrating and spaying instruments.

METHODS

It will be further observed that only one method of operating is illustrated and described, which is quite a revolution in this class of literature. All antiquated methods and operative technique have been purposely eliminated in order to avoid confusion and embarrassment. The methods mentioned are those which most appeal to the author's fancy, and while he considers them the best, safest, and most satisfactory, still he lays no claim to their being the only good methods, and he is perfectly willing to be charitable to the extent of granting to others the privilege of operating differently if they so desire.

RESTRAINT

Restraint of domestic animals, in the broadest acceptation of the term, means much to the average busy and active practitioner of veterinary surgery.

Each species of our domestic animals is endowed with one or more means of defense. These are oftentimes—in individuals of certain temperament—converted into weapons of offense. The horse will strike, kick and bite; the ox will gore and kick; the dog and hog will bite. It is with these weapons of offense that we are called upon to contend and overcome by restraint. These animals must be rendered harmless by the means of restraint which we have at hand. Of course the particular method employed depends largely upon the animal and the degree of restraint necessary.

While we constantly find it necessary to employ methods of restraint in order to confine the animal, we should always do so in as humane a manner as possible. Humanitarian treatment applies here as well as elsewhere in the practice of veterinary science. We should never take advantage of an animal when confined in order to cause torture or to inflict unnecessary pain of any kind.

The surgeon is confronted with problems pertaining to restraint or some method of subjection almost every hour of each day of his professional career.

Not only does the restraint problem confront and concern the surgeon alone, but his client and patient are also directly interested to a well marked degree. The surgeon owes it to his client, his patient and himself to become proficient in properly and securely restraining animals for examination and operation. Without efficient means of restraint the surgeon is in constant danger of great bodily harm; the animal in danger of self-inflicted injuries as a result of its own efforts at resistance, thereby causing the owner financial loss, which could and should have been avoided by proper methods of procedure.

In order to cast and secure an animal properly and successfully the operator should possess a level head associated with plenty of courage and confidence. He should retain his equilibrium in spite of any untoward accident or emergency which may chance to take place. Self-confidence and good judgment are both valuable assets in performing work of the character which this book undertakes to illustrate and describe. The surgeon should get control and remain in control from the time the twitch

is placed on the animal preparatory to applying the hobbles or casting harness until the animal is again on its feet. Experience and dexterity are not to be underrated in the operator who is to undertake the task of securing and properly confining the larger of our domestic animals. Do not allow yourself to become excited or unduly alarmed or aggravated should everything not transpire as smoothly as you expect or desire, for in so doing the surgeon is not in possession of his mental faculties sufficiently to do justice either to himself, his patient or his client.

Perfect, or even good, surgery is impossible without perfect restraint. The surgeon is no better than the restraint method which he uses. It is rare to see a surgeon handle a knife any more skillfully than he handles his restraint technique. Imperfect restraint means an imperfect operation.

The particular methods of restraint necessary for each operation and the details pertaining to same will be specifically described under the proper headings.

G. R. W.

TABLE OF CONTENTS.

PART I.

Castration.

- Chapter I. Castration of the Stallion.
Chapter II. Castration of the Colt.
Chapter III. Castration of the Mule.
Chapter IV. Complications Encountered in Castrating—viz.:
Inguinal Hernia, Scrotal Hernia, Cryptorchid,
Monorchid, Orchitis, and Hermaphrodite.
Chapter V. Sequelae of Castration—viz.: Septic Infection,
Tetanus, Prolapse of the Omentum, Injuries
from Casting, Peritonitis, Colic, Prolapse of
the Intestine, Azoturia, Hemorrhage, Oedema
of Sheath, Schirrous Cord, Exuberant Gran-
ulations, and Hydrocele.
Chapter VI. Castration of the Bull.
Chapter VII. Castration of the Boar.
Chapter VIII. Castration of the Ram.
Chapter IX. Castration of the Dog.
Chapter X. Castration of the Cat.
Chapter XI. Caponizing.
-

PART II.

Spaying.

- Chapter I. Mare Spaying.
Chapter II. Cow, Heifer and Calf Spaying.
Chapter III. Sow Spaying.
Chapter IV. Sheep Spaying.
Chapter V. Bitch Spaying.
Chapter VI. Cat Spaying.
Chapter VII. Poulardizing.
Chapter VIII. Deodorizing the Skunk.

PART I.

CASTRATION.

Definition—Orchectomy; excision of one or more testicles. The term castration is also applied to removal of ovaries from the female. However, when the word castration appears in this volume—with exception of title—it has reference to unsexing the male animal.

History—Castration is one of the most ancient of surgical operations upon animals. It was advocated and practiced as early as seven centuries before the Christian era. Time and tradition have not lessened its application or usefulness. In fact, during recent years the popularity of the operation has rapidly increased until now it is considered one of the most useful and valuable in animal surgery.

It is practiced without hesitancy upon all domestic and wild animals, and its economic value cannot be overestimated.

The earlier modes of operating were as follows: Martelage, Tearing, Scraping, Torsion, Firing, Bistournage, Ligature and Clamps. These ancient methods were extremely painful, and by some considered cruel and inhumane. They have all been superseded by less painful and more modern ones, the most recent of which are Emasculator, Vasectomy, Bisection, Vaso-Ligation and lastly Vas-occlusion recently advocated by Dr. Napoleon Berdozzi, of Italy. While the above have been mentioned simply from an historic viewpoint, one of them, viz., Emasculator, stands out prominently as the best, most widely practiced and satisfactory method of operating, and on this account the “Emasculator method” will be adhered to in all instances where it is applicable in this volume.

CHAPTER I.

CASTRATION OF THE STALLION.

Objects and Indications—While the operation is most often practiced as an economic procedure in order to increase the animal's monetary value and usefulness to mankind, it is nevertheless valuable as a corrector of many acquired vices, such as masturbation, viciousness, etc. It is also indicated in impotency, some diseases of penis, scrotum, spermatic cord, and testicle. Its effect is both mental and physical.

The operation has a decided tendency to render the animal quiet and docile and to alter the conformation in some material respects such as lessening development of the shoulders, chest, neck and withers. While on the other hand the development of the hind quarters is stimulated.

Castrated stallions are known as geldings.

Age—Stallions may be safely castrated at any age provided they are in good physical condition.

Season—Spring and early fall.

Preparation—The intestinal tract should be practically empty at time of castration. This is attained by withholding food for 24 to 30 hours before operating. By heeding the above admonition the danger of rupturing internal viscera during the operation and colic afterwards will be obviated.

CASTRATING IN THE RECUMBENT POSTURE.

Restraint—When it has been decided to cast the animal, we should, first of all, carefully survey the surroundings and select the most satisfactory location. Of course circumstances and existing conditions play an important role in making our selection. When the weather will permit the operation being performed out of doors, there is no place better adapted than an open field or lawn. It is here that we have ample room to manipulate our restraint technique without interruption. When we have selected

the location, the next problem which confronts us is the "casting bed." The ideal operating mat or mattress is a plot of green grass grown upon smooth ground. Always avoid the manure heap or the "rotten straw pile" whenever possible. They are both hotbeds of all forms of bacterial growth and are directly responsible for many cases of fatal septic infections. If we are forced to cast an animal inside of doors, then we must make the best of our misfortune and get busy in devising means and methods to best overcome that handicap. Select the place—be it hallway, stall



Fig. 1—Stallion Cast on Left Side With Conkey Self-Lock Buckle Hobbles.
Leg P Drawn from Over Field of Operation by Rope R. S.

or operating room—where the most room is available. Then a proper bed must be prepared. This may be done by the use of tanbark, soft wood shavings, straw, hay, excelsior, sawdust, etc., or a specially constructed mattress or pad may be used.

Lead animal to proper position, put on twitch, apply the Conkey self-lock buckle hobbles and cast him on the left side. (See Fig. 1.)

When cast, the off hind leg should be released from hobble

strap and with a 15-foot rope looped above ankle (P) and passed over withers (Q) and under neck then back above hock (R) the leg is drawn from over field of operation. In this position the largest stallion can be castrated without difficulty.

INSTRUMENTS.

1. *Knife*—Of course a properly constructed knife is the first essential instrument required in performing this operation. The Williams all-metal stiff-handle aseptic castrating knife (Fig. 2) is entirely satisfactory for castrating stallions in the recumbent posture.



Fig. 2—Williams' All-Metal Stiff Handle Aseptic Castrating Knife.

2. *Emasculator*—The only other instrument necessary is an emasculator for the purpose of crushing the spermatic cord in such manner as to assist nature in controlling hemorrhage.

There are many designs of emasculators on the American market; however, many of them are inferior and unsatisfactory both in design and workmanship. In order for an emasculator to perform the task for which it is intended it must first of all be constructed with straight cutting and crimping edges. (See D, C,




Fig. 3—A Perfectly Made and Well Designed Emasculator.

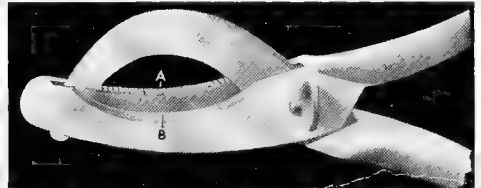


Fig. 4—An Imperfectly Made and Badly Designed Emasculator.

Fig. 3.) This simply means that the lower or female jaw must be on a straight line. When thus constructed the cord is grasped and crushed before it is severed. Any emasculator made with curved cutting and crimping edges (see A, B, Fig. 4), which

means that the lower or female jaw is on a curved line, is not dependable in controlling hemorrhage, hence is unsafe and unsatisfactory. Fig. 5 illustrates an emasculator of proper design and good construction.



Fig. 5—A Safe and Satisfactory "Single Crimp Emasculator."

The "triple crimp emasculators" (Figs. 6, 7 and 8) are somewhat safer in controlling hemorrhage than the "single crimp" instrument, as it crushes the cord in three directions. The author has used a "triple crimp" instrument for several years with good results. Many of the "triple crimp emasculators" now on the market are imperfectly constructed and unsatisfactory in that not enough space has been left between the male (upper) crushing plate and the female (lower) plate—when the instrument is closed—to receive the cord of a large stallion. Figs. 6, 7 and 8 illustrate two "triple crimp" emasculators both of which are satisfactory. Fig. 8 is equipped with a self-adjusting auxiliary attachment. The block attached to the male blade and longitudinally serrated, is self-adjusting, by which means the compressing surfaces maintain a parallel position when operated, thereby preventing the cord and arteries from being mashed, cut or torn at point nearest the hinge of the instrument.

The spring device operating the auxiliary attachment permits

automatic expansion, thereby making the instrument adjustable to large cords, which in many cases cannot be cut by other forms of "triple crimp" emasculators in which the crushing block is not expansible.

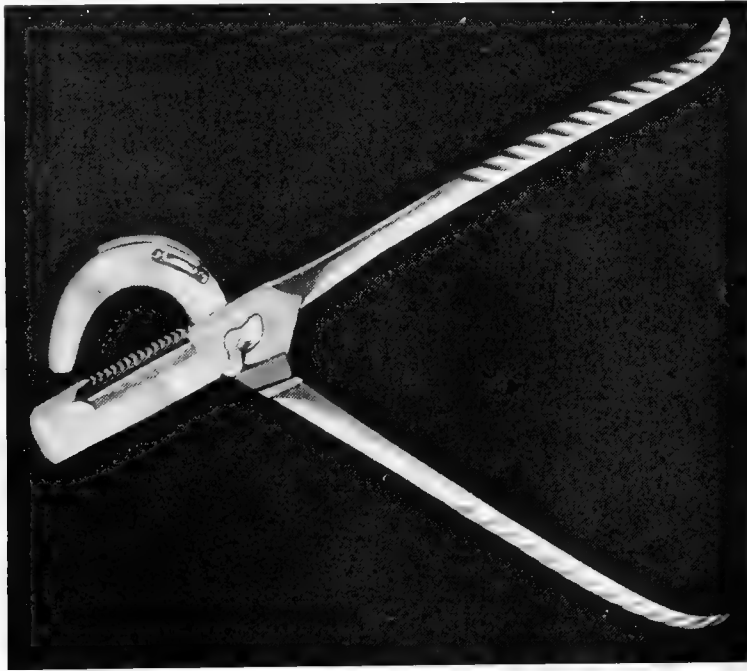


Fig. 6—"Triple Crimp Emasculator." (Front View.)



Fig. 7—"Triple Crimp Emasculator." (Back View.)

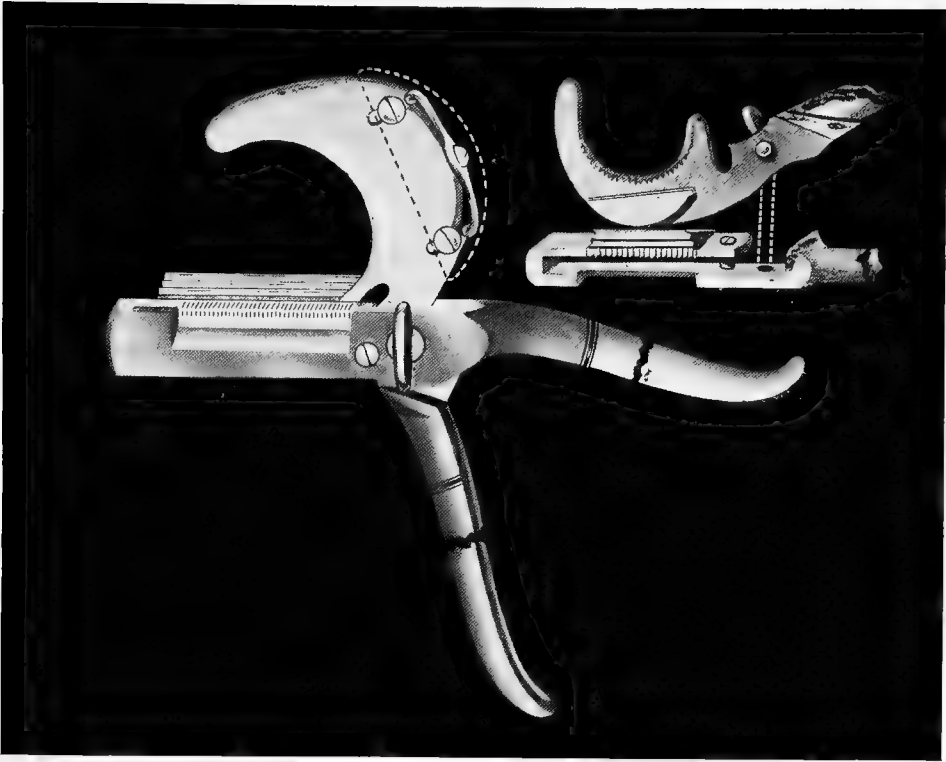


Fig. 8—Anseptic Triple Crimp Emasculator With Self-Adjusting Auxiliary Attachment.

Anatomy—A comprehensive knowledge of the anatomy of the inguinal and scrotal regions is imperative if a man is ever to be anything like a thrilling success in performing the various necessary operations that are to be described later. However, on account of the limited space at my disposal it will be impossible to go into minute details here. For complete and detailed anatomical description the reader is respectfully referred to Sisson, Chauveau and Strangeway's text-books on Veterinary Anatomy.

Scrotum—Is a sac or bag made up externally by a layer of skin which has been continued from the sheath, abdomen and flanks. This skin is smooth, soft and hairless compared with the other integument on the body. The scrotum consists of two cavities divided by a longitudinal raphe ("median line"). Below the skin

is the *dortos* which forms the scrotal tunic proper and consists of thin elastic tissue and muscle. The *dortos* is a continuation of the abdominal fascia. Under the *dortos* is the spermatic fascia which is a continuation of the external oblique muscle. This muscle is attached to the external abdominal ring. Inside is the cremasteric fascia, an expansion of the cremaster muscle which passes through the inguinal canal over the cord and surrounds

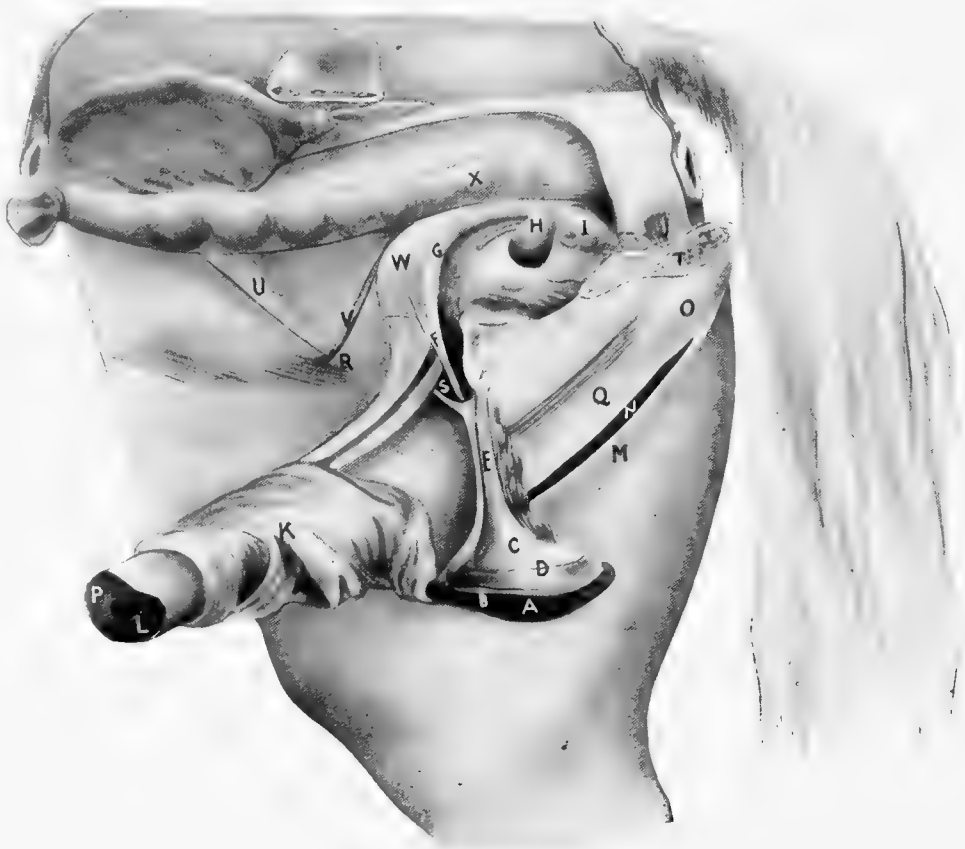


Fig. 9—Internal and External Generative Organs of the Stallion: A, Scrotum; B, Skin; C, Tunica Vaginalis; D, Dortos; E, Cremaster Muscle; F, Left Vas Deferens; G, Bulbos Portion of Vas Deferens; H, Vesicula Seminalis; I, Postate Gland; J, Cowpers Gland; K, Sheath; L, Meatus Urinarius; M, Retractor Muscle of Penis; N, Accelerator Muscle Surrounding Urethra; O, Erector Penis Muscle; P, Glans Penis; Q, Corpus Cavernosum; R, Right Internal Abdominal Ring; S, Left Internal Abdominal Ring; T, Symphysis Pubis; U, Peritoneal Fold Through Which the Spermatic Blood Vessels and Nerves Pass; V, Right Vas Deferens; W, Bladder; X, Rectum.

the testicle. Deeper we have the funnel-shaped infundibuliform fascia which originates at the internal abdominal ring. This fascia is simply a sheath over the testicle, the cord and their tunics.

Inguinal Canal—This canal is situated obliquely between the crural arch and the internal oblique muscle. The arch forms its posterior and the muscle its anterior wall. It is compressed laterally and through it pass the spermatic cord and the pudic artery. Its external orifice is termed the external abdominal ring. This ring is oval in shape and its direction is backwards and upwards. The internal abdominal ring is a small aperture in the abdominal wall and is situated at the uppermost part of the inguinal canal, which is about 8 to 10 inches above the external abdominal ring. The contents of the inguinal canal pass through the internal abdominal ring in making their exit from the abdominal cavity.

Sheath—The sheath is a loose conglomeration of skin extending from the scrotum forward, and contains the free portion of the penis. The anterior loose double fold of sheath is known as the prepuce or foreskin, which is corrugated to accommodate the penis during erection and protrusion. Opening into the sheath are ducts from the glandulae odoriferae which secrete an odorous matter peculiar to the sheath. The sheath is suspended from the abdominal walls by suspensory ligaments.

Spermatic Cord—The testicle is suspended in the scrotum by the spermatic cord which migrates through the inguinal canal from the abdominal cavity to the scrotum. The following structures enter into its formation: Spermatic vein, spermatic artery, nerves, vas deferens, lymphatics, cremaster muscle and tunica vaginalis. The vas deferens is situated in the posterior part of the cord and is enclosed in a special fold detached from the inner surface of the tunica vaginalis.

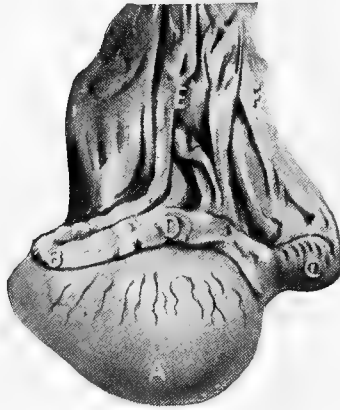

Fig. 10—External View of Left Testicle and Spermatic Cord: A, Testes; B, Globus Major; C, Globus Minor; D, Body of Epididymus; E F, Spermatic Cord.

Testicle—The testicle is a compound tubular gland, ovoid in form, suspended by the spermatic cord and occupying space in the scrotum, inguinal canal or abdominal cavity. When in the scrotum it is contained in a sac known as the tunica vaginalis.

They vary much in size in different subjects and are often of unequal size in the same individual. The epididymus (D, Fig. 10) is an elongated body extending along upper border of the testes (A). It consists of a body (D), a head or globus major (B), and a tail or globus minor (C).

Vas Deferens—The vas deferens is a firm hard tube which, after leaving the globus minor, ascends the back of the spermatic cord through the external abdominal ring, inguinal canal, and internal abdominal ring to the abdominal cavity, where it enters the pelvis, passing to the antero-lateral aspect of the bladder, where it is joined by the duct of the vesicula seminales. This union of ducts takes place in the vicinity of the postate gland.

NATURE'S METHODS OF CONTROLLING HEMORRHAGE.

It is well to always bear in mind the fact that nature is a great factor in controlling arterial hemorrhage. To understand exactly what nature causes to take place when an artery is severed is knowledge which is never harmful to the surgeon, to say the least of it. The following happens as soon as an artery is severed:

(1) Contraction of the mouth of the vessel (see B, Fig. 11); (2) retraction of the vessel into its sheath (see C, Fig. 11); (3) clot formation (see D, Fig. 11); (4) syncope.



Fig. 11—Diagrammatic Illustration Showing Three of Nature's Methods of Controlling Arterial Hemorrhage; A, Severed Artery; B, Contraction; C, Retraction; D, Clot Formation.

The function of the emasculator is to assist nature in preventing primary and secondary hemorrhage. This is done by crushing the cord which crimps or closes the spermatic artery to the extent of making the field more favorable for clot formation. Never place an emasculator on a cord in any position except at right angle to the cord. (See Fig. 12.) If the cord is severed at any other angle (see Fig. 13) fatal hemorrhage is liable to occur.

Warning—Before beginning to operate always carefully examine the animal for inguinal and scrotal hernia (“rupture”), abnormalities in development and diseases of the scrotum testicle and cord. It is also well to look out for constitutional diseases which would have a tendency to endanger the life of the animal or interfere with convalescence. Never castrate if the animal is




Fig. 12—Correct Position of Emasculator on the Spermatic Cord.




Fig. 13—Incorrect Position of Emasculator on the Spermatic Cord.

affected with strangles, influenza, pleurisy, pneumonia, bronchitis, catarrhal fever, or purpura haemorrhagica. Be careful in casting and tying, and above all satisfy yourself that the testicles are actually in the scrotum.

Sterilization of Instruments and Cleansing Operator's Hands
 —If good results are to be expected all instruments should be sterilized by boiling for 15 to 20 minutes; after boiling immerse them in a porcelain bowl or granite pan into which has been put one tablespoonful of either Lysol or Cresol Compound U. S. P. to each quart of water. In the absence of the above, carbolic acid in 2 per cent solution is permissible. ¶ Where there are several animals to be operated upon it is not practicable nor is it necessary or desirable to boil the instruments between each operation. However, they should be washed and placed back in the antiseptic solution. ¶ The operator's hands should be thoroughly washed with soap and warm water—using a scrub or nail brush—before beginning a job of castrating and he should wash them in

an antiseptic solution between operations. The cleaner you are with your work the fewer cases of sepsis you will have to follow.

Operative Technique—After the animal is cast and tied and the instruments and hands of the operator prepared, the field of operation and the surrounding parts should be thoroughly washed with Lysol or Cresol Compound U. S. P. in the strength of one tablespoonful to each quart of water. I will here take advantage of this opportunity to condemn in the strongest and most emphatic terms possible “sheath washing” at time of castrating. What is here meant by “sheath washing” is washing or undertaking in any manner to cleanse the interior of the sheath. Washing the sheath at or immediately before castration will not only contaminate the field of operation and thereby increase the danger of sepsis, but it invariably encourages the early development of aggravated cases of oedema and oftentimes paraphimosis. The sheath should be washed several days before operating or it should be let alone until after the animal has completely recovered. With the animal,

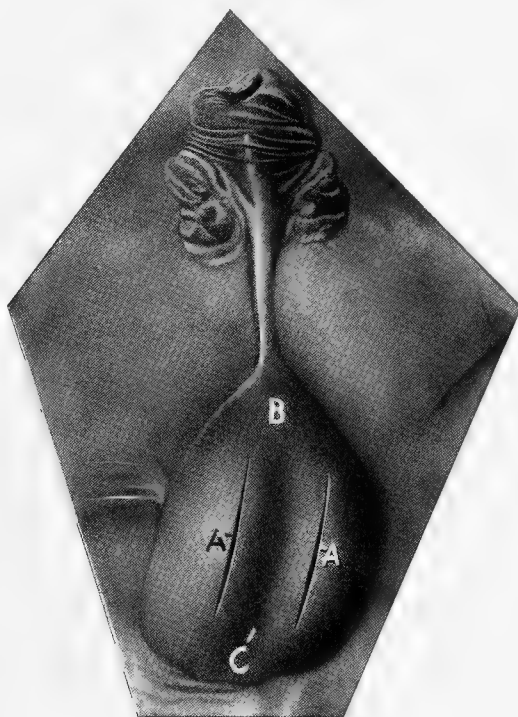


Fig. 14—General External View of Scrotum and Sheath. AA, Incisions $\frac{3}{4}$ -inch on each side of Median Line, 4 inches long and parallel to the line.

instruments and operator's hands prepared, the scrotal incision is made by grasping both testicles in the left hand and with two bold strokes of the knife cut through skin of scrotum and testicular coverings without hesitation. Expose both testicles to view. The larger the incision the better the results. They should not be less than $3\frac{1}{2}$ to 4 inches long and about $\frac{3}{4}$ to 1 inch on each side of the raphe ("median line") and parallel to it (see Fig. 14).

The testicles are now exposed. Grasp one of them with the left hand, being careful not to touch the cord above where it is to be severed. Place the emasculator on the cord, being careful to see that the crimping side is next to the scrotum. Now lift the testicle upwards at direct right angles to the animal by making from two to three pounds—depending upon size of horse—tension on the cord, at the same time pushing the emasculator well down against the scrotum and at right angles to the cord, after which close the instrument quickly and firmly until the cord and all its coverings are severed as close to the scrotum as possible. (See Fig. 15.)



Fig. 15—Severing Spermatic Cord with the Emasculator. A, Left Testicle; B, Right Testicle; C, Emasculator Applied to Spermatic Cord.

As soon as the cord is severed quickly release it and hasten to remove the opposite testicle. It is a useless waste of time and energy to allow the cord to remain in the instrument for several minutes as some operators advocate. The quicker the cord is released the less the pain and the quicker the blood will clot about mouth of artery. By the time the jaws of the emasculator have come together the instrument has done all for the cord that it can possibly do. Why procrastinate in removing it?

By reference to Fig. 16 you will observe the correct position of the emasculator on cord; also exactly what structures are severed.

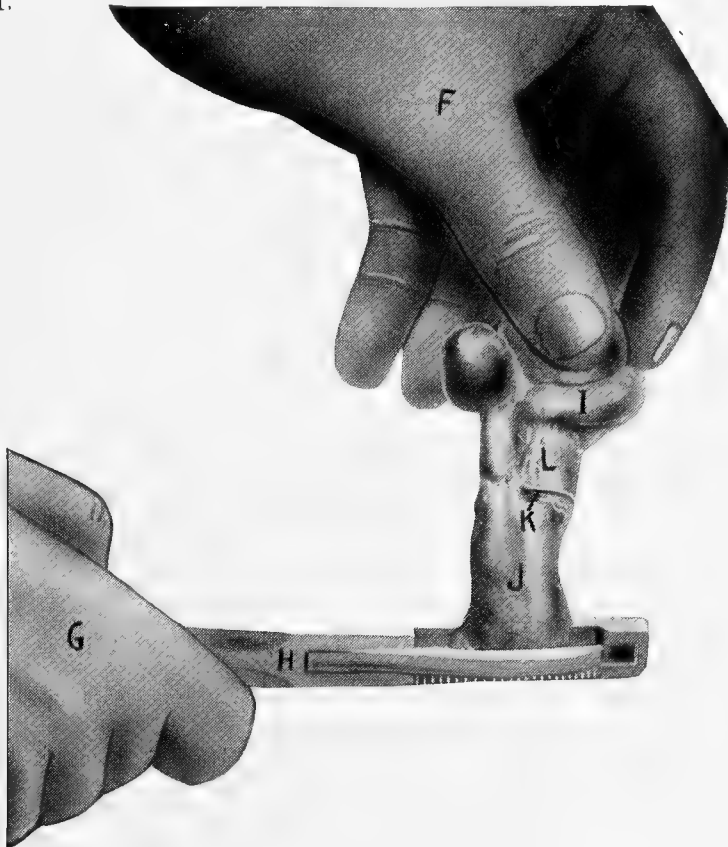

Fig. 16—Spermatic Cord and its Coverings Severed with the Emasculator.
 F, Left Hand of Operator; G, Right Hand of Operator; H, Emasculator;
 I, Body of Epididymus; J, Tunica Vaginalis; K, Incised Portion
 of Tunica Vaginalis Retracted on Cord; L, Spermatic Cord.

The all too common practice of “cord dissection” is also an unnecessary and uncalled for waste of the operator’s time and

energy to say nothing of the additional pain inflicted upon the patient as a result of prolonged surgical interference.

After Care and Treatment.—A small per cent of stallions after castration will become unusually and uncomfortably restless and suffer what appears to be excruciating pain. Sometimes this pain is inter-abdominal and sometimes not. In such cases Fluid Extract Cannabis Indica should be administered in ounce doses at two-hour intervals. The animal should be frequently observed for appearance of secondary hemorrhage and other sequelae which may arise. The diet should be limited, and plenty of exercise allowed. Best to run at pasture during recovery and convalescence. Endeavor to keep them away from stable and barnyard manure. If the lips of the incisions should adhere together to the extent of stopping free drainage from the scrotum, the parts should be thoroughly washed and reopened by forcing one or more clean fingers through the scrotal incisions. In some instances it becomes necessary to “open up” every two days for six or seven days. However, so long as the wounds are draining “opening up” is unnecessary.

After castration it is not necessary to protect stallions, colts and mules from flies, as this class of animals prevent “fly contamination” of the scrotal wounds by the free and well-directed use of their tails. Even in the midst of “fly time” we never have maggots develop in their scrotums.

Contrary to the teachings of some, the author’s experience would indicate that warm showers and even rains on animals after castration are not harmful and are to be greatly preferred over allowing the animals to remain in the barn and barnyard in constant danger of wound contamination from manure, dirt, etc.

Treatment of the various sequelae of castration will be taken up in subsequent pages.

Prognosis—Under parallel conditions and surroundings there appears to be very little or no more danger in castrating aged stallions than colts. However, on the other hand, when we face the fact that a large per cent of stallions are affected with cord, scrotal, testicular and other diseases which must be taken into consideration in comparing the danger of castrating stallions with that of colts we are constrained to state the danger to old stallions far exceeds that of younger animals.

CASTRATION OF THE STALLION IN STANDING POSTURE.

Objects and Indications—See page 14.

Age—Any time after testicle has descended into the scrotum, preferably in aged stallions.

Season—See page 14.

Restraint—A well-made and properly applied twitch in the hands of a fearless and physically strong assistant.

Instruments—1. Emasculator. (See Figs. 3, 4, 5, 6, 7 and 8.)
2. Knife. It is necessary to have a knife with a sharp point and devoid of “belly” in order that it may be easily thrust into the testicle. Robinson’s Castrating Knife (Fig. 17) and Williams’ Castrating Knife (modified) (Fig. 18) are probably the most satisfactory ones for performing this operation.




Fig. 17—Robinson’s Knife.



Fig. 18—Williams’ Castrating Knife (Modified).

The extremely sharp point, short cutting surface and roughened handles of the Robinson knife are its meritorious features. The author’s modification of the Williams castrating knife makes it a desirable instrument for castrating in the standing posture. It will be observed by comparing this knife with the original Williams’ (Fig. 2) that the “belly” has been ground out and the point sharpened in order to facilitate thrusting it into the testicle.

Anatomy—See pages 19-21.

Warning—Before undertaking to operate take the time and precaution to satisfy yourself on the following points:

1. That the animal is not of a disposition or temperament which would make operating in the standing posture counter-indicated.

2. That the testicle is actually in the scrotum.

3. That no hernia is present.

4. That the animal is not affected with those local diseases of the scrotum, testicle or cord which would counter-indicate the operation.

5. That he is not suffering from any specific constitutional disease which would cause the operation of castration by any method to hazard his life.

6. That you have a dependable—preferably an experienced—assistant in charge of the twitch and be sure the twitch is a good one.

Sterilization of Instruments and Cleansing Operator's Hands—See page 24.

Preparation of Patient—At first thought it would be considered proper to disinfect the field of operation by some form of washing with one of the many excellent antiseptic preparations. However, experience and close observation lead me to state that the advisability and practicability of undertaking the disinfection of the field of operation at this particular juncture—after the twitch is applied—is, to say the most of it, a debatable question. Aseptic or even antiseptic surgery would suggest it, but the author is willing to chance running the gauntlet of criticism by here going on record as opposing disinfection of the operative field. His only reason for so doing is simply on account of the fact that if a man is to do a satisfactory and successful operation with the animal in the standing posture it is imperative that the operation begin as soon as the twitch is applied and end at the earliest possible moment, otherwise the twitch as an implement of subjection is not a success and, of course, the violent struggles and efforts to escape on part of the animal would make the operation a failure. I realize that in making the above statement I “run counter” to some eminent authority, but since I have never yet seen a single successful operator on stallions in the standing pos-

ture who procrastinated to the extent of disinfecting the field of operation immediately prior to operating I am ready and willing to suffer the consequences. Such procedure is not practicable, neither is it necessary or even desirable. If the operator's hands are clean and his instruments sterile, there is not near the danger of septic infection from the unwashed scrotum as there is from a bunglesome and imperfect operation on account of struggles on the part of the animal occasioned by delay in beginning and finishing the operation.

Operative Technique—With the twitch applied and the animal forced into the corner of a box stall or fence the operator approaches from the left side—if he be right-handed—at the same time instructs the assistant, who is holding the twitch, to at all hazards keep the animal forced well back into the corner. The operator stands slightly out of the range of a kick with his head and shoulders firmly pressed into the left flank of the animal. (See Fig. 19.)



Fig. 19—Side View Showing Position of Patient and Operator Castrating in the Standing Posture.



Fig. 20—Posterior View of Stallion While Undergoing Castration in Standing Posture. A, Scrotum; B, Knife; C, Left Hand; D, Right Hand.

With the left hand firmly grasp the scrotum above both testicles, at the same time do not underestimate the strength of the cremaster muscles.

Expect to hold on to your scrotal grasp regardless of the maneuvers or antics of the animal. Since you have already agreed with your assistant to hold the scrotum as long as he holds the twitch you are honor bound to do so, and by so doing you will come out victorious in nineteen out of twenty attempts. With

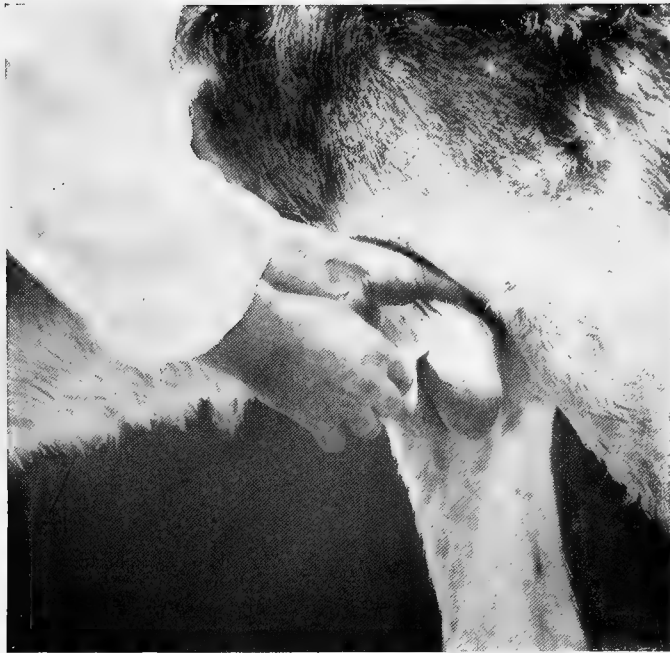

Fig. 21—Side View with Animal in Standing Posture Showing Positions of Right Hand, Knife, Left Hand and Scrotum Prior to Making Incisions. Observe that the knife is thrust into the testicle well forward on the scrotum. The incision is made by a single sweep of the knife backwards.

knife in right hand begin well forward on scrotum and with two quick bold sweeps of the knife make backward slashes which will expose, or a better term would be “drop,” both testicles from the scrotum before you turn loose. These slashes should be parallel to the raphe or median line. Now with the emasculator which is handed you by a second assistant, or better still carried in a specially constructed pocket in your overalls, sever the spermatic cords as high up in the flank as possible, after which release the animal. If you have been dexterous and have not “loafed on your job” you have consumed the whole of six to ten seconds’ time. However, if you have been engaged as long as fifteen or twenty seconds you need have no remorse of conscience, as oftentimes it takes—what otherwise would be considered a fairly good veterinary surgeon—as long as twenty minutes to finally succeed, after much effort and a great fight, in removing as many as two testicles from the scrotum of a stallion in the standing posture, and some of them even after graduation and many years’ ex-

perience in practice cannot do it at all. Console yourself with the thought that there are *others*.

Care and Treatment—See page 28.

Prognosis—See page 28.

Sequelae—See under proper heading in subsequent pages.

Advantages of Operating in Standing Posture—(1) Conservation of time and energy on the part of the operator, as it is possible for an experienced and dexterous operator to castrate a stallion in the standing position in six to fifteen seconds' time, provided the animal behaves well. Whereas in the recumbent posture it requires from six to fifteen minutes to cast, tie and castrate. It is much easier on the operator to castrate in the standing posture as less work and exertion are required. (2) Safety and comfort to the patient, since the danger of casting and tying is obviated and the animal is not exerted or "heated up" near to the extent which he would be were he cast, tied and castrated in the recumbent posture. (3) By castrating in the standing posture—provided same is done with dexterity—the surgeon makes a favorable and lasting impression upon his client, an impression which will "not wear off." (4) Since the operator is not called upon to handle dirty ropes, etc immediately before operating and the operative field itself is not on or in close proximity to the manure and dirt—as is the case in recumbent position—there is no doubt but what less wound contamination takes place in standing method.

Disadvantages—(1) Danger to the operator has been heralded to the four winds of this country as argument against castrating stallions in the standing posture. The author's twenty years or more experience with operating in both the standing and recumbent postures leads him to believe, in fact know, that the danger to the operator has been highly colored and over-exaggerated with reference to castrating in the standing posture unless the operating surgeon was an amateur or an extremely awkward and careless person. Of course it could not reasonably be expected that everyone could, even by time and practice, become an adept at such an undertaking. In order to be a success it is necessary for the operator to possess a level head, a steady nerve, plenty of self-confidence, and more than average courage, together with a re-

serve of physical strength and activity. He should retain his equilibrium in spite of any untoward accident or emergency which may chance to take place. Good judgment is never amiss at any stage of the operation. The author has never been kicked or injured in any way while castrating stallions in the standing posture. He cannot say as much in relating his experience operating in the recumbent posture, for many is the time when he has received the kick while applying the hobble straps and a few while releasing the animal. (2) Difficulty of securing the testicles has been urged against the standing operation. Such embarrassment is never encountered if the testicle has descended into the scrotum and the mere fact of the testicle not being in the scrotum is a counter-indication to operating in the standing posture. By all means and at all hazards cast this class of animals and castrate them in the recumbent posture. (3) Prolapse of bowel or mesentery from the scrotal incision on account of previously existing scrotal or inguinal hernia. A careful manual examination of the scrotal region prior to operating would obviate such embarrassment to the operator and danger to the patient. If you decide to operate in the standing posture make it routine practice to examine the scrotum prior to operation. (4) Impossibility of operating upon many wild and vicious animals. We must admit that every animal cannot be castrated in the standing posture, and foolish indeed would the surgeon be who would undertake such a hazardous and impossible task. If you encounter such an animal, have no hesitancy in casting and operating in the recumbent posture. Do not attempt the dangerous, the impracticable or the impossible. Exercise a little good judgment here as well as elsewhere in the daily affairs of life.

CHAPTER II.

CASTRATION OF THE COLT.

Definition—What is here meant by castration of colts is unsexing male animals of the equine species less than twenty months of age.

Objects and Indications—Same as stallion. (See page 14.)

Age—The testicle does not usually descend into the scrotum to a noticeable degree until the colt is at least eight or ten months old. From the standpoint of danger the earlier the operation the safer. From the viewpoint of development and symmetry it is not well to operate too early. Viewing the problem from every angle, the preferable age at which to castrate a colt is ten to twelve months. However, it may be done earlier or even later.

Season—Spring and early fall.

Preparation—Same as stallion. (See page 14.)

Restraint—Since colts should usually be castrated in the recumbent posture—primarily on account of the uncertainty of descent of testicle into scrotum—it becomes necessary to cast and tie them. Of all the casting harness and hobbles used for this class of operation there is no doubt but what the “Miles’ Colt Hobbles” possess many advantages over all others. Hence the Miles method of casting colts is recommended and will be described.

“*Farmer*” *Miles’ Method of Casting a Colt*—Fig. 22 represents the Miles’ colt hobbles applied (first position). The hobbles of Miles’ consist of four loop hobbles and a main rope. These are of the loop variety. The material used in making the loops may be either rawhide (plaited), leather, or rope. These hobbles are each from fifteen to eighteen inches long and are applied by looping. The main rope is three-fourths inch cotton, and eighteen feet long.




Fig. 22—Miles' Colt Hobbles Applied—First Position.

Upon one end is a two-inch metal "D." This main rope is also used as the master hobble. It will be observed that there is one hobble rope on each hind pastern and two hobble ropes on off fore leg—one around pastern and the other below the knee. The main rope is applied around pastern of near fore leg (F). It is now passed across through hobble ring on off fore pastern (K), then backward to off hind (L), thence across to near hind (M), and back to hobble ring (N) below off knee. The object of this arrangement of the ropes (two hobbles on off fore leg) is that when traction is made on free end of main rope (O) the off fore foot is raised or lifted off the ground. This in itself unbalances an animal and puts it to a decided disadvantage, besides by lifting the off fore foot the animal will go down on the shoulder of that side and will in all probability receive an easy fall. The animal is cast as illustrated in Fig. 23 (second position), and secured by taking two or more half hitches with the main rope around uppermost hind pastern. This is done by an assistant. The operator stands opposite the assistant and behind the animal



Fig. 23—Miles' Colt Hobbles—Second Position.



Fig. 24—Miles' Colt Hobbles—Third Position.

and is handed the main rope (W) by the assistant (after it is fixed about the upper hind pastern). The rope is carried over the loins and under the colt, thence to the lower hind pastern. Now by rolling colt on his back (Fig. 24, third position) and making downward pressure on the off hind foot with the left hand, at the same time drawing the rope tight by upward pull with the right hand, the hocks are flexed and all four feet brought down close to the abdomen.

The Miles' method affords us a light, portable, strong, convenient, safe, and in every respect an efficient and satisfactory means of casting and securing the colt. The colt is held balanced in the dorsal position by an assistant on each side, in which position the field of operation is accessible and extremely convenient, and so long as the colt is balanced on back he is absolutely helpless.

Instruments—(1) Emasculator: same as stallion (see Figs. 5, 6, 7, 8, 12 and 13). (2) Knife: The knife recommended for colt castration is "Farmer" Miles' hook knife (Fig. 25). Many hook




Fig. 25—"Farmer" Miles' All-Metal Stiff Handle Hook Castrating Knife.

knives of improper design and inferior construction are on the market; on this account it is well for the reader to know the exact essentials of a properly designed hook knife. The main essential is that the cutting surface of the blade be at an angle of 45 degrees to the handle and that the cutting surface be sharp up to the handle. It is necessary that the blade cut, not tear. With a blade thus constructed good work can be done. The blades with a decided hook are never satisfactory. Such knives drag or tear through the tissues instead of cut. Avoid them. To the beginner a hook knife is awkward to handle; however, after some practice he usually finds it to be an indispensable instrument.

Anatomy—Same as stallion. (See pages 19-21.)

Warning—Same as stallion. (See page 23.)

Sterilization of Instruments and Cleansing Operator's Hands—Same as stallion. (See page 24.)

Operative Technique—With the colt cast and tied and balanced on his back (Dorsal position) by one or more assistants (see Fig. 25), the scrotum, hands of the operator, etc., disinfected, the animal is now ready for operation.



Fig. 26—Castrating the Colt. 9, Left Hand; 10, Scrotum; 11, Beginning of Left Scrotal Incision; 12, End of Left Scrotal Incision; 13, Beginning of Right Scrotal Incision; 14, End of Right Scrotal Incision; 15, Knife; 16, Right Hand.

Proceed as follows: With left hand (9) grasp sheath (10) and with forward and upward traction stretch the scrotum to the extent of making it taut. With knife (15) in right hand (16) begin left incision (11-12) well forward on scrotum (10) and extending backward for $3\frac{1}{2}$ to 4 inches. The right incision (13-14)

is made likewise. These incisions should be parallel to each other, three-fourths inch on each side of the raphe or "median line" and parallel to it.

The object of drawing the scrotum upwards is to form a cavity between the skin and subcutaneous connective tissue of scrotum above and the scrotal plexus of veins below. This cavity or space protects the scrotal plexus of veins from being knicked by point of the knife while the incisions are being made. Release hold on sheath and grasp each testicle in turn and with a knick of the knife open the tunica vaginalis and allow the testicles to escape.

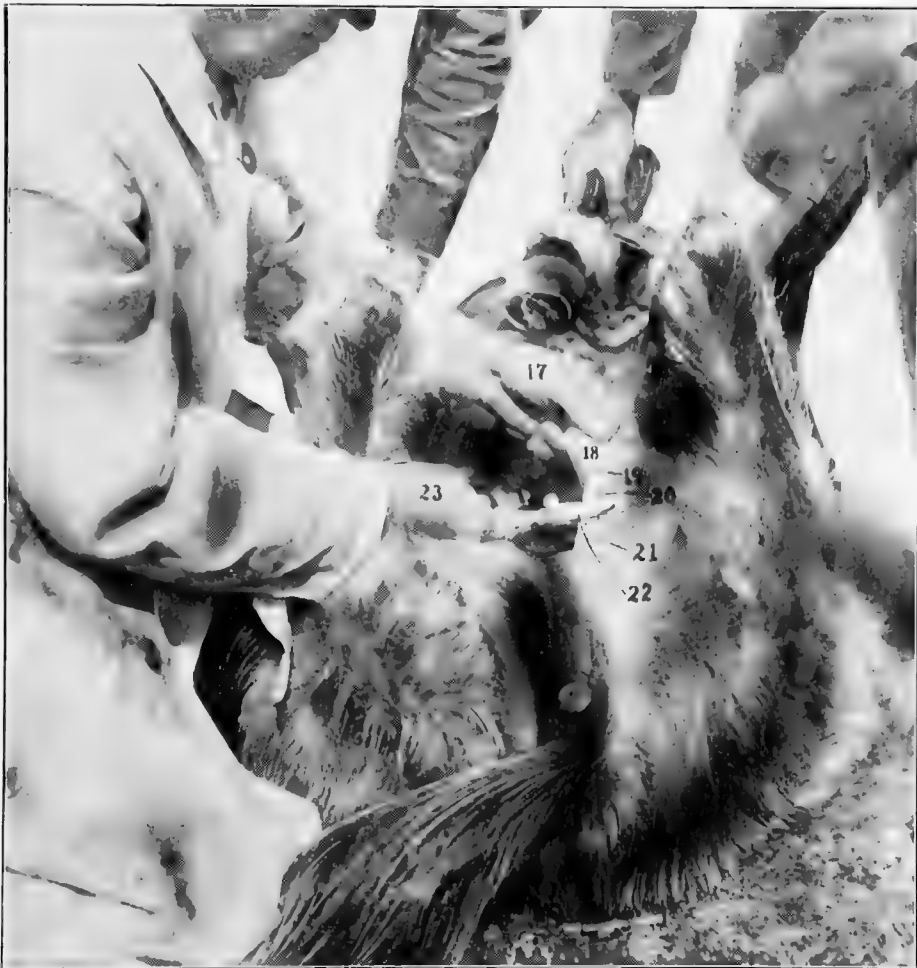

Fig. 27—Castrating the Colt. 17, Left Hand; 18, Testicle; 19, Spermatic Cord, 20, Tunica Vaginalis; 21, Scrotum; 22, Emasculator; 23, Right Hand.

The next step is to grasp the left testicle (18, Fig. 27) with the left hand (17) and draw testicle upwards—at direct right angles to the animal—at the same time producing from one to two pounds traction on the cord. With the right hand (23) apply the emasculator (22) to the cord (19) and force instrument well down against the scrotum (21) in such a manner as to sever the spermatic cord and all of its coverings as close to the skin incision as possible. The right testicle is removed in like manner and the animal released. By reference to Fig. 16, page 24, the reader may observe the exact position of the emasculator on the cord and what structures are severed in operating.

After Care and Treatment—Same as stallion. (See page 28.)

Prognosis—(See page 28.)

CHAPTER III.

CASTRATION OF THE MULE.

Objects and Indications—Since the mule is a hybrid and valueless for service as a breeding animal it falls to his lot to undergo castration without exception. Without castration—before the age of two years—the mule becomes exceedingly disagreeable and troublesome among other classes of live stock and oftentimes vicious and dangerous to the owner. Apparently the only object in castrating the mule is to cause his sexual desire to permanently subside to the extent of making him a useful farm animal.

Age—“Yearlings,” never later unless unavoidable.

Season—Preferably spring.

Preparation—Same as stallion. (See page 14.)

Restraint—Same as colt. (See pages 36-39.)

Instruments—Same as colt. (See page 39.)

Anatomy—Same as stallion. (See pages 19-21.)

Warning—Same as stallion. (See page 23.)

Sterilization of Instruments and Cleansing Operator's Hands—Same as stallion. (See page 24.)

Operative Technique—The operative technique in mule castration resembles in most material respects that of colt castration as outlined on pages 36-41. The only material difference being the manner in which the coverings of the spermatic cord are severed and the extent of them removed.

With the mule cast, tied and balanced on his back, Dorsal position (Fig. 27) he is ready for operation. The scrotal region and hands of operator are washed with Lysol or Cresol Compound U. S. P. in the strength of one tablespoonful to the quart of water. With left hand (M) grasp the sheath (N) and with forward and upward traction stretch the scrotum until it

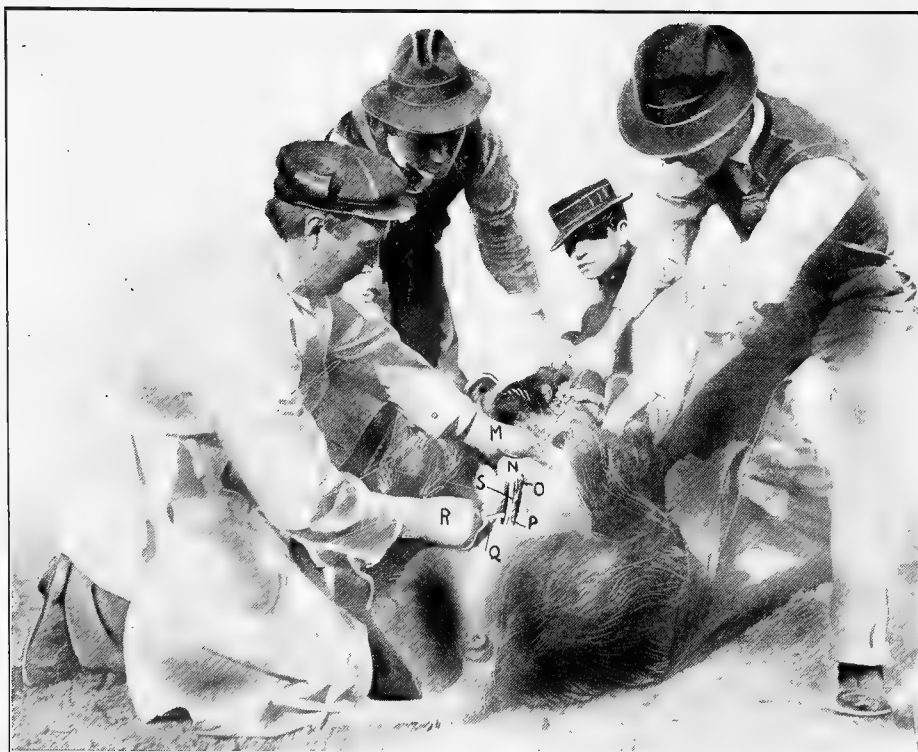

Fig. 28—Castrating the Mule. M, Left Hand; N, Scrotum; O P, Scrotal Incision; Q, Knife; R, Right Hand; S, Raphe or "Median Line."

is taut. With knife (Q) in right hand (R) make the two scrotal incisions (O, P) beginning well forward (O) and extending backward (P) from $3\frac{1}{4}$ to 4 inches. These incisions should be three-fourths inch from and parallel to the raphe or "median line" (S). Release hold on sheath and grasp each testicle in turn and with a nick of the knife open the tunica vaginalis and allow the testicles to escape.

After the testicles are released from the tunica vaginalis one of them is grasped with the left hand (T) (Fig. 29) and drawn upward at direct right angles to the body of the animal by making from one to two pounds traction on the cord. With the right hand (Y) apply emasculator (Z) to the cord and force instrument downward against the scrotum (X) in such manner as to sever the spermatic cord and all of its coverings as close to the skin incision as possible. See to it that you cut off not less than one inch of the tunica vaginalis in order to avoid that all too frequent sequelae



Fig. 29—Castrating the Mule. T, Left Hand; U, Testicle; V, Spermatic Cord; W, Tunica Vaginalis; X, Scrotum; Y, Right Hand; Z, Emasculator.



Fig. 30—Proper Position of the Emasculator and Relation of Testicle, Spermatic Cord, Tunica Vaginalis and Scrotum in Mule Castration.

of mule castration, viz.: hydrocele (“water bag”), a condition invariably produced by severing the cord below—with mule in standing posture—the tunica vaginalis. Of course the opposite testicle is removed in like manner and the animal released. Figs. 30 and 31 are worthy of careful study on the part of all who contemplate castrating mules. They graphically and plainly illustrate all the important essentials in handling the emasculator in such a manner as to avoid hydrocele (“water bag”).

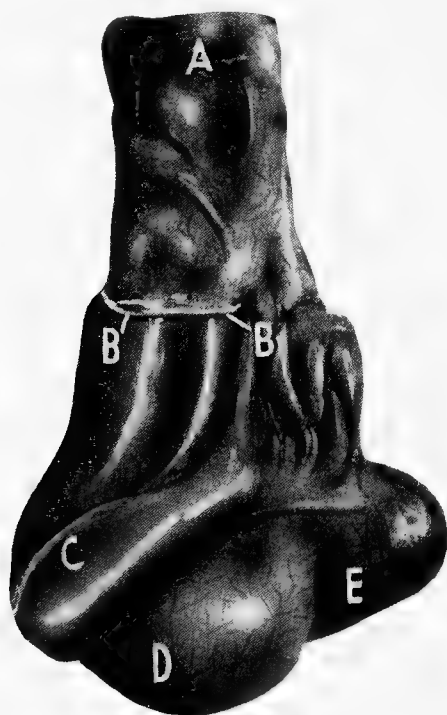

Fig. 31—Testicle of Mule After Removal. A, Tunica Vaginalis Covering Spermatic Cord; B B, Incised Portion of Tunica Vaginalis Deflected on Cord. It will be observed that at least one inch of this tunic has been removed. C, Epididymus; D, Testes.

After Care and Treatment—Same as stallion. (See page 28.)

Prognosis—Same as stallion and colts. (See page 28.)

CHAPTER IV.

COMPLICATIONS ENCOUNTERED IN CASTRATION.

Inguinal and Scrotal Hernia (Rupture).

Definition—Inguinal hernia is a condition where a loop of the intestine and sometimes mesentery migrates or protrudes through the internal abdominal ring into the inguinal canal. (See Fig. 32.)



Fig. 32—Inguinal Hernia (Rupture). A A, Internal Abdominal Wall; B, Internal Abdominal Ring; C, Spermatic Cord; D D, Intestine; E, Loop of Intestine in the Inguinal Canal; F, Spermatic Cord in the Canal; G, Scrotum.

Scrotal hernia is a condition where a loop of the intestine and sometimes mesentery migrates or protrudes through the internal

abdominal ring, inguinal canal and external abdominal ring into the scrotum. (See Fig. 33.)

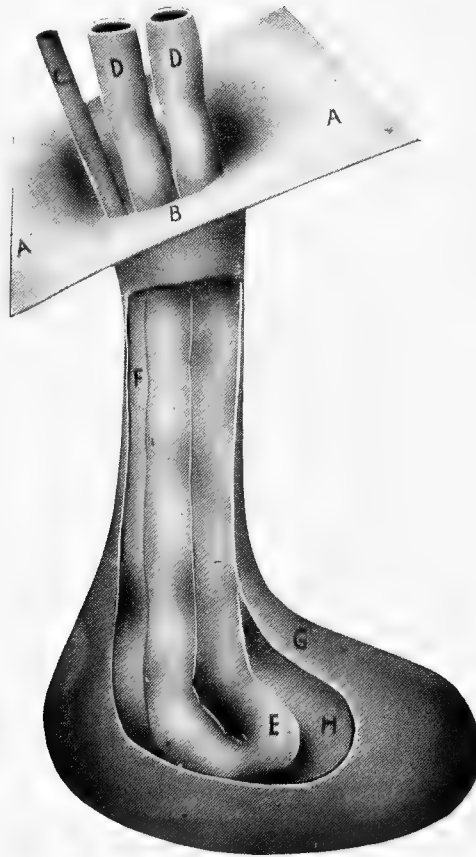


Fig. 33—Scrotal Hernia (Rupture). A A, Internal Abdominal Wall; B, Internal Abdominal Ring; C, Spermatic Cord; D D, Intestine; E, Loop of Intestine in the Scrotum; F, Spermatic Cord in Inguinal Canal; G, Scrotum; H, Testicle.

Most all scrotal hernias were originally inguinal hernias.

Diagnosis—The presence or absence of hernia is determined by carefully feeling the scrotum and close scrutiny of its size and shape. It is oftentimes—in fact most times—impossible to diagnose inguinal hernia except on post-mortem examination.

Indications for Operation—The mere fact that the presence of hernia has been determined is sufficient indication for operation unless there be a good reason for postponing surgical interference until a later date. In all instances the operation necessitates sacrifice of the testicle and of course since this be true the

ideal time to operate is at time of castration. If the surgeon is aware of the presence of hernia and is prepared for the operation, then the reduction of hernia by surgical interference is a comparatively easy task. However, if the reverse is true—no knowledge of its existence and non-preparedness—then he is up against what is referred to as “the real thing,” an attitude most of us have been caught in to our chagrin and sorrow. So long as hernia does not interfere with the health and usefulness of a stallion in service it may not be advisable to operate. The ideal age to operate is eight to twelve months. Oftentimes scrotal hernias in “sucklings” disappear spontaneously before they are a year old.

Restraint—The animal should be cast and tied, and placed in the dorsal position. For colts the ordinary “Farmer” Miles’ method of casting (Figs. 22, 23 and 24, pages 36-39) is ideal. For older animals more secure restraint is necessary, such as Knowles’ Casting Harness, described and illustrated on pages 55-57.

Instruments—(1) Emasculator, Figs. 5, 6, 7, and 8. (2) Miles’ hook knife, Fig. 25. (3) Curved probe point Bistoury. (4) Medium size curved needle. (5) Chromicized catgut (fourteen day) largest size. (6) Needle holder (Richter’s), Fig. 34. (7) Small trocar and canula. (8) Curved scissors (six-inch), Fig. 35. (9) Haemostatic forceps.

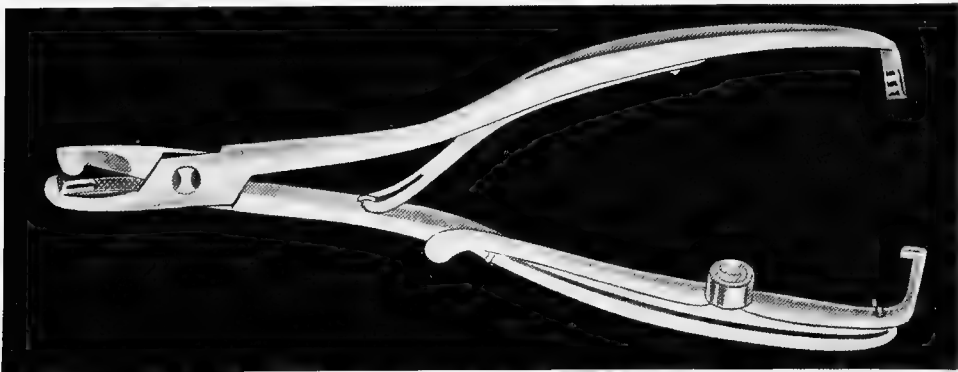


Fig. 34.—Richter's Needle Holder.




Fig. 35—Curved Scissors (6-inch).

Preparation—Empty the intestinal tract by withholding food for twenty-four to thirty hours. If constipated, oil in sufficient amount to purge several days before operating. ♀

Sterilization of Instruments and Cleansing Operator's Hands—See page 24.

Operative Technique—Cleanse and disinfect field of operation by washing with Lysol or Cresol Compound U. S. P. in the strength of one tablespoonful to each quart of water. With Miles' hook knife cautiously make incision into scrotum, being careful not to open the tunica vaginalis. The scrotal incision should begin well forward and extend backward for five to six inches parallel to the raphe or "median line" and one to one and a half inches from it.

The sac (tunica vaginalis) containing the testicle should now be isolated or detached by blunt dissection and tearing up the inguinal canal to within about two inches of the internal abdominal ring.

Before proceeding further all blood vessels of sufficient size should be ligated. The sac (tunica vaginalis) should now be opened and the testicle taken charge of and held with one hand while the loop of intestine (J) is gradually replaced through the internal inguinal ring (P) (See Fig. 36) into the abdominal cavity. The testicle itself is now removed with the emasculator in the usual way. The stump of spermatic cord (K) is now placed into the abdominal cavity and the tunica vaginalis (L) ligated with chromicized catgut (fourteen day) largest size (M) as close to the internal abdominal ring as possible. The loose portion of the tunica vaginalis is now removed by severing below the liga-

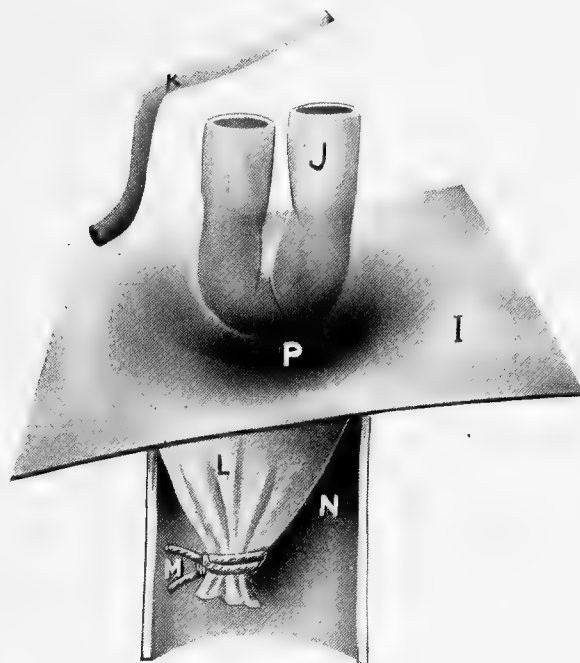


Fig. 36—Diagrammatic Sketch of Operation for Inguinal and Scrotal Hernia (Rupture). I, Internal Abdominal Wall; J, Loop of Intestine Replaced Into the Abdominal Cavity; K, Stump of Spermatic Cord from Which the Testicle Has Been Removed; L, Tunica Vaginalis in Close Proximity to the Internal Abdominal Ring; M, Ligature; N, Inguinal Canal; P, Internal Abdominal Ring.

ture. Sometimes it becomes necessary to enlarge the internal abdominal ring before the hernia can be reduced. This can be readily done with probe point bistoury passed up the inguinal canal. If loop of bowel happens to be distended by gas it should be punctured with a small trocar and canula.

The scrotum may be packed with sterile gauze if considered advisable. However, scrotum packing is not usually necessary.

After Care and Treatment—Same as castration. (See page 28.)

Castration of the Cryptorchid and Monorchid ("Ridgling").

Definition—A cryptorchid is an animal in which both testicles have failed to descend into the scrotum.

A monorchid is an animal in which only one testicle has failed to descend into the scrotum.

Classification—Since the degree of descent of the testicle varies in different animals it becomes necessary to classify "ridglings"

into at least three groups or classes. They were formerly classified by "Farmer" Miles as—

No. 1. Testicles not in scrotum but in inguinal canal. Such testicles can be felt on deep pressure. ("Low flanker.")

No. 2. Testicles high up in inguinal canal—too high to be felt even upon deep pressure. ("High flanker.")

No. 3. Testicles inside abdominal cavity.

No. 4. Testes inside abdominal cavity with part of the spermatic cord and sometimes epididymus protruded through internal abdominal ring into the inguinal canal.

No. 5. Pathological ("diseased") testicles.

While the above classification by Miles is not what may be termed anatomically and surgically scientific, it was nevertheless valuable in arriving at the exact status of a "Ridgling" case. While acknowledging the value of the work done by my first teacher—"Farmer" Miles—and the usefulness of his classification of ridgling horses into Nos. 1, 2, 3, 4 and 5, nevertheless such classification was crude and in this day of progress and development would not pass muster from a scientific viewpoint. The anatomical classification possesses many advantages and will be adhered to in handling this subject.

Miles' No. 1 cannot properly be classed as a cryptorchid ("Ridgling") in any respect.

(a) Supra scrotal is a condition where the testicle with spermatic cord is in the inguinal canal, however too high to be felt even on deep pressure. ("High flanker.") This is the class oftenest encountered in young animals and corresponds with Miles' No. 2. The testicle is usually firm and fairly well developed.

(b) Intra-abdominal is a condition where the testicles are located inside the abdominal cavity. This is a genuine cryptorchid ("Ridgling") in fact as well as in name. In such cases the testicles are usually soft and flabby and not of the characteristic shape met with in stallions. This variety corresponds to Miles' No. 3.

(c) Intra-inguinal is a condition in which the testes is inside abdominal cavity with a portion of the spermatic cord and sometimes epididymus high up in the inguinal canal. (See Fig. 50,

page 67.) This corresponds to Miles' No. 4. Such cases are usually very confusing to the operator; especially is this true if the operator belongs to the amateur fraternity.

(d) Anomalous cryptorchids is a condition wherein abnormally developed or "diseased" testicles are encountered, viz.: hypertrophy, cysts—including dermoid and dentigeous—solid tumors (sarcoceulous), atrophy and adhesions of testicle to the parietal peritoneum, etc. Some of the above enumerated anomalies and curiosities encountered in cyptorchid castration complicate the operative technique and have a tendency to cause the operator no little anxiety, annoyance and oftentimes embarrassment.

Objects and Indications—All "Ridgling" should be castrated for the principal reason that they are sterile as breeding animals and a public and private nuisance among other classes of live stock. Some of them even acquire viciousness, in which event they are dangerous both to the owner and other animals. The mere fact that the testicle is inside the abdominal cavity, small, undeveloped and sterile does not in any way reduce the sexual desire of its possessor. On the other hand it appears that sexual desire is abnormally stimulated. A horse with undescended testicle is as undesirable as a mare affected with nymphomania. They are useless as service or breeding animals. There is no argument why they should not be castrated and every reason why they should.

Diagnosis—By all means secure an accurate history of the subject if possible, as this is a necessary adjunct to operating satisfactorily and successfully. Ascertain the following:

1. If any previous unsuccessful attempt has been made to operate.
2. If either testicle has been successfully removed. If so, on which side was it located and how long since removal?

The information obtained is not always trustworthy, so as an additional precaution the operator is not justified in proceeding with the operation until he has personally carefully examined the animal.

1. Search scrotum carefully for cicatrix ("scar") of former operation. If the operation was performed by either the ecraseur

or emasculator—some time previously—there may be no distinct scar present.

2. Examine inguinal canal for stump of cord. If the previous operation was performed at an early age the stump of cord may be atrophied to such an extent that its presence in the canal cannot be determined.

If after questioning the owner or attendant and examining the patient you are still in doubt as to which testicle is undescended, the proper method of procedure would be to invade the left, as four-fifths of all monorehids are leftsided. If you should make a mistake and invade the wrong side, proceed at once to turn the patient over and go in on the other side. The diagnostic value of rectal exploration at any time is doubtful. But such rectal examination immediately before operating is bad practice and not justified.

Age—Ordinarily the question of age is not one left to the choice of the operator. He is forced to take them at any age he finds them. It is not well to operate upon a ridgling until he is at least two years old. The ideal age is three years, as at this time the animal is larger and better developed, which, of course, means that there is much more room in the inguinal canal and groin in which to work. Besides, at three years old the abdominal wall is thicker and stronger and there is less liability of rupturing the internal and external oblique abdominal muscles with the operating hand. Ridglings at any age above three years are acceptable for operation.

Season—Preferably spring and early fall.

Preparation—The main object to be attained in preparing the patient is to have an unirritated and empty alimentary (intestinal) tract at time of operation. This is usually accomplished by withholding food for thirty hours before castration. No physic should be allowed, as an empty bowel irritated by purgative medication is a predisposing cause of dangerous sequelae such as colic, peritonitis, volvulus, etc. An empty alimentary tract is desirable on account of affording greater intra-abdominal room and lessening the possibility of bowel protrusion through the inguinal canal.

Restraint—There are many kinds and styles of restraint har-

ness and ropes with which a ridgling horse may be cast and tied satisfactorily. The main object to be constantly borne in mind is the fact that first of all the restraint must be safe and secure. The animal must be tied in such a manner that the latitude for movement is minimized as much as possible. Position must also be considered. One of the simplest and most satisfactory casting harness for castration of "Ridglings" is that of Knowles'. The Knowles' harness have been used for several years by the author with satisfactory results.




Fig. 37—Knowles' Casting Harness Applied.

The casting and securing harness illustrated in Fig. 37 were designed by W. F. Knowles. These harness are made in large and small sizes. The large size fits horses weighing 900 pounds or more, and small size harness fits those of from 400 to 900 pounds.

This apparatus is light, compact, and convenient to carry. When properly used it affords ample restraint for all ordinary purposes. It consists of a flat webbing collar, two main ropes and two hobbles. The collar (B) is in two sections; each section is connected on each side of the horse by heavy double rings, one of which is of special design to afford easy passage of the two main ropes (D, G). The ropes (D, G) are each five-eighths inch in

diameter and thirty feet long. One end is securely fastened into the inner ring of the webbing breast collar. Around each pastern (E, H) is placed a webbing hobble. In each end of this webbing hobble is fixed a specially constructed metal, rounded "D" through which the ropes pass. To apply this harness the breast collar is placed over the head and adjusted to the shoulders. One section fits over the withers and the other section is dropped down below point of shoulders (K). The free end of the ropes (D, G) pass downward to and through each "D" of webbing hobble, then upward to and through "D" of breast collar. If desired to cast horse on off side, the off fore foot is to be raised and secured by some form of knee strap. The free end of main rope on near side should be carried backward over back and held by two assistants. The free end of main rope (I) on off side should be carried forward, well in front of the animal, and there held by two assistants. To cast the animal traction is made on each rope, and at the same time the animal is forced backward a step by assistant in charge of the head. The head is pulled to the right and the animal is cast on off side.



Fig. 38—Animal Cast and Secured with Knowles' Harness.

In order to securely tie the animal after he is cast (see Fig. 38) the main ropes (N, N) are fastened around pasterns by two half

hitches. They are then passed behind hocks (P, P) in figure 8 fashion a couple of times, after which fix them about pasterns (O, O) by half hitches. The opposite side is secured likewise after the animal is turned over. See to it that the hocks are completely flexed and that the feet are not extended too far forward. After the hind legs are secured apply knee strap (M) to off fore leg. The Miles' spreaders (Fig. 39) are now applied, after which the animal is secured for operation.

While I do not dispute the possibility of castrating a "Ridgling" horse on the operating table, nevertheless its practicability is seriously doubted.

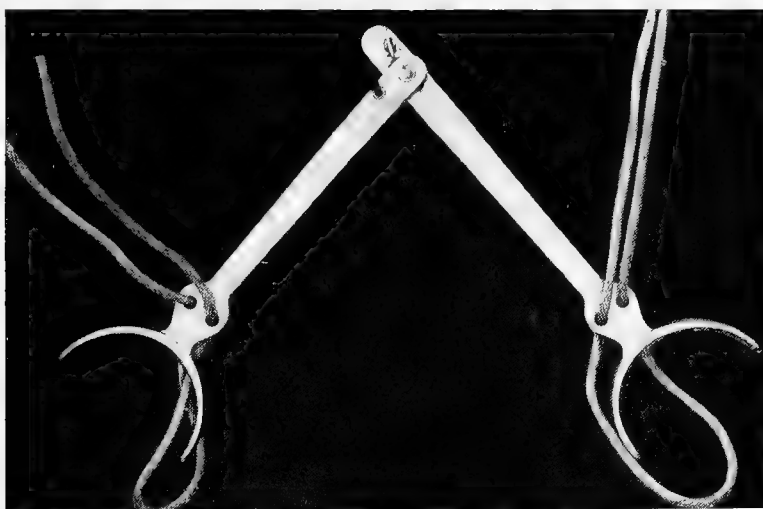


Fig. 39—Miles' Ridgling Spreaders.

Position—Lateral recumbent position with side of undescended testicle uppermost. Hocks completely flexed. Hind feet not too far forward and thigh complete abducted.

Instruments and Equipment—(1) Miles' all-metal hook castrating knife (see Fig. 25). (2) Peritoneum perforator (see Fig. 40).




Fig. 40—Peritoneum Perforator.

The peritoneum perforator referred to here is a piece of nickel-plated steel wire sixteen inches long with handle on one end and right angle hook on the other. This hook is one inch in length and its perforating surface is slightly dulled. The function of this instrument, as its name indicates, is to make the opening through the thin abdominal wall.

(3) Ecraseur. The most satisfactory ecraseur yet offered to the veterinary profession in this country is shown in Fig. 41. This instrument is strong, well constructed and its design ideal. The advantages of this instrument over others consists of an ar-

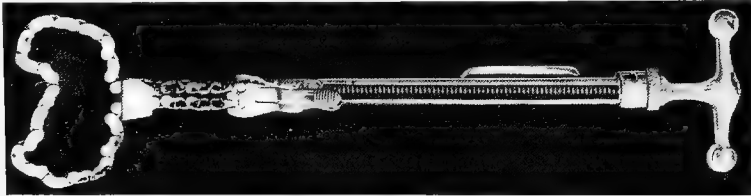


Fig. 41—Dunn's Ecraseur.

angement by which, with the thumb and finger of one hand (the other hand left free) the ecraseur can be held, and the slack of the chain taken up at once without drawing out the screw or lengthening the instrument.

The thumb-piece, on the end of which the female thread is cut, works automatically, engaging the screw at all times until released by the pressure of the thumb; this insures perfect safety, as the chain cannot slip from imperfect or careless adjustment, which often occurs in other ecraseurs. It is also thoroughly aseptic, as it can be taken apart without the aid of a screwdriver in a few seconds' time by a half turn of the collar near the handle. Made with or without the improved head. Get the one with improved head.

(4) Surgeon's needle threaded for purpose of suturing up scrotum after packing.

(5) Sterile gauze to use in packing scrotum.

(6) Carbolized olive oil for lubricating parts.

(7) Antiseptic solution in plentiful amount. As a precaution against some untoward accident or emergency it is well to fortify yourself by having in reserve the following: (1) Vulsellum for-

ceps (see Fig. 55); (2) haemostatic forceps; (3) extra ecraseur; (4) needles containing ligatures and sutures; (5) trocar and canula (ordinary horse size).

Anatomy—Same as for stallion castration. (See pages 19-21.)

Warning—Before beginning to operate, diagnose the case if possible. Examine inguinal and scrotal regions for hernia (rupture), abnormalities in development, diseases of the scrotum, etc. Look out for constitutional diseases which would have a tendency to endanger the life of animal or interfere with convalescence. These diseases are strangles, influenza, pneumonia, pleurisy, bronchitis, catarrhal fever, purpura hemorrhagica, etc.

Don't thrust your whole hand through the abdominal wall, because your index and second finger will do enough damage to the wall and besides they are ample inside the abdomen.

Don't explore the whole abdominal cavity in an effort to locate the testicle. You wouldn't recognize it if you found it. Better feel for the spermatic cord—something you can recognize if you feel it—which is within two inches of the abdominal incision, provided you puncture the abdominal wall at the right place. Let the testicle take care of itself until later.

Take your time and do the operation well at all hazards.

Be careful in casting and tying and above all else don't get excited. Remember that it is not you that is being operated upon. It is the horse, and he does not even belong to you. If you should happen to make a failure, remember that you are not the only one whom such a misfortune has befallen.

Sterilization of Instruments—Same as for castration of the stallion. (See page 24.)

Cleansing and Disinfecting the Field of Operation—Of all the operations in the domain of veterinary surgery where cleanliness stands out prominently as being pre-eminently important it is in "Ridgling" castration. With tincture of green soap, warm water and scrub brush thoroughly wash—by diligent scrubbing—the inguinal and scrotal regions, also inner aspect of the thighs. After washing, sponge parts with absolute alcohol. Then paint scrotum with tincture iodine and allow it time to dry before making incisions.

Operative Technique as Applied in Castrating the Intra-Abdominal "Ridgling" (Miles' No. 3).

(a) *Scrotal Incision*—With rubber glove on left hand (R) and Miles' hook castrating knife (T) in the right hand (S), the point of sheath (V) is grasped with the left (R) and traction made upward and forward. (See Fig. 42.) Beginning well forward on scrotum the knife is drawn backward, making incision (U) through skin, subcutaneous connective tissue and dartos only. This incision (U) should be five inches long, parallel to and one



Fig. 42—Making Scrotal Incision. R, Left Hand; S, Right Hand; T, Knife; U, Scrotal Incision; V, Point of Sheath.

inch to the side of raphe or "median line." (See Figs. 42 and 43.) When the incision or incisions are completed remove rubber glove from previously washed left hand and, if necessary, rewash both hands before proceeding further.

(b) *Opening and Entering the Inguinal Canal*—With the four fingers of each hand, placed back to back, separate, by tearing, the tissues down to the external abdominal ring, which is the entrance to inguinal canal. The next step is to lubricate the scrotal wound

and operating hand with carbolized olive oil. Then proceed, by fixing fingers in shape of cone (see Fig. 44) and using a limited

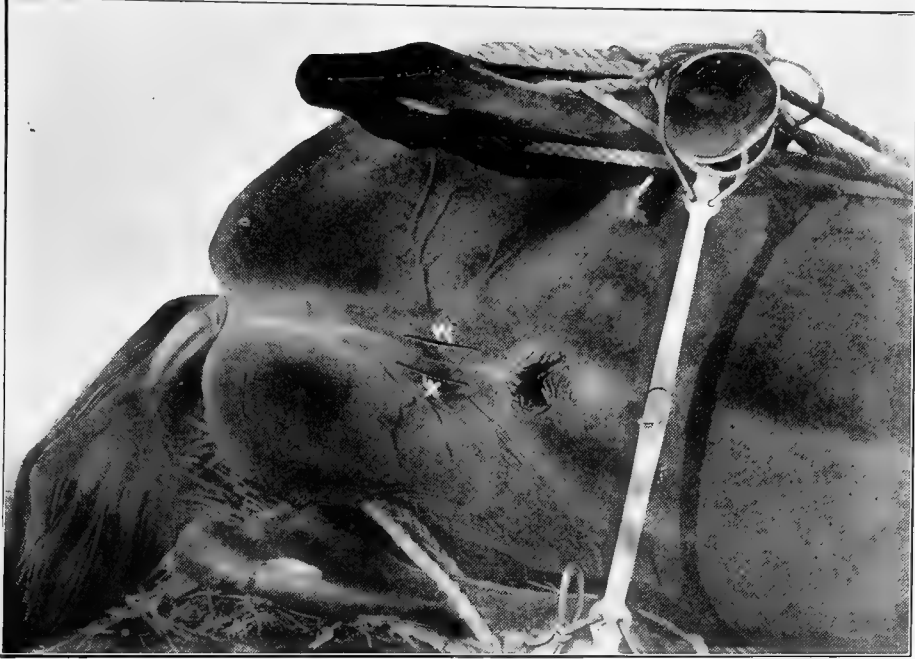

Fig. 43—Scrotal Incisions.

amount of force, to open and enter the inguinal canal until the internal abdominal ring is reached. Remember the direction of the canal is upwards and backwards. This ring is our landmark for site of entering the abdominal cavity. You may expect to find the ring at a distance of six to ten inches above the scrotal incision, depending, of course, on size of animal.



Fig. 44—Position of Fingers in Opening and Entering the Inguinal Canal.



Fig. 45—Entering the Abdominal Cavity by Perforating the Thin Abdominal Wall. A, Right Hand in the Inguinal Canal; B, Peritoneum Perforator in Action; C, Incision; D, Left Hand Manipulating Perforator.

(c) *Entering Abdominal Cavity from Inguinal Canal*—With the internal abdominal ring as one guide, we select a site one inch above and one inch in front of it, where we proceed with peritoneum perforator to rupture through the thin abdominal wall, which at this point consists of the transversalis fascia and peritoneum, as we are now above the upper border of the internal oblique muscle. This affords us access to the abdominal cavity. This perforation should not exceed one inch in length.

(d) *Locating the Spermatic Cord*—With the index and second finger enlarge, by stretching, the abdominal perforation sufficiently to admit both fingers (see Fig. 46). The cord (C) is almost invariably located within two inches of the abdominal perforation (F). To find the cord, pass the second finger downwards against

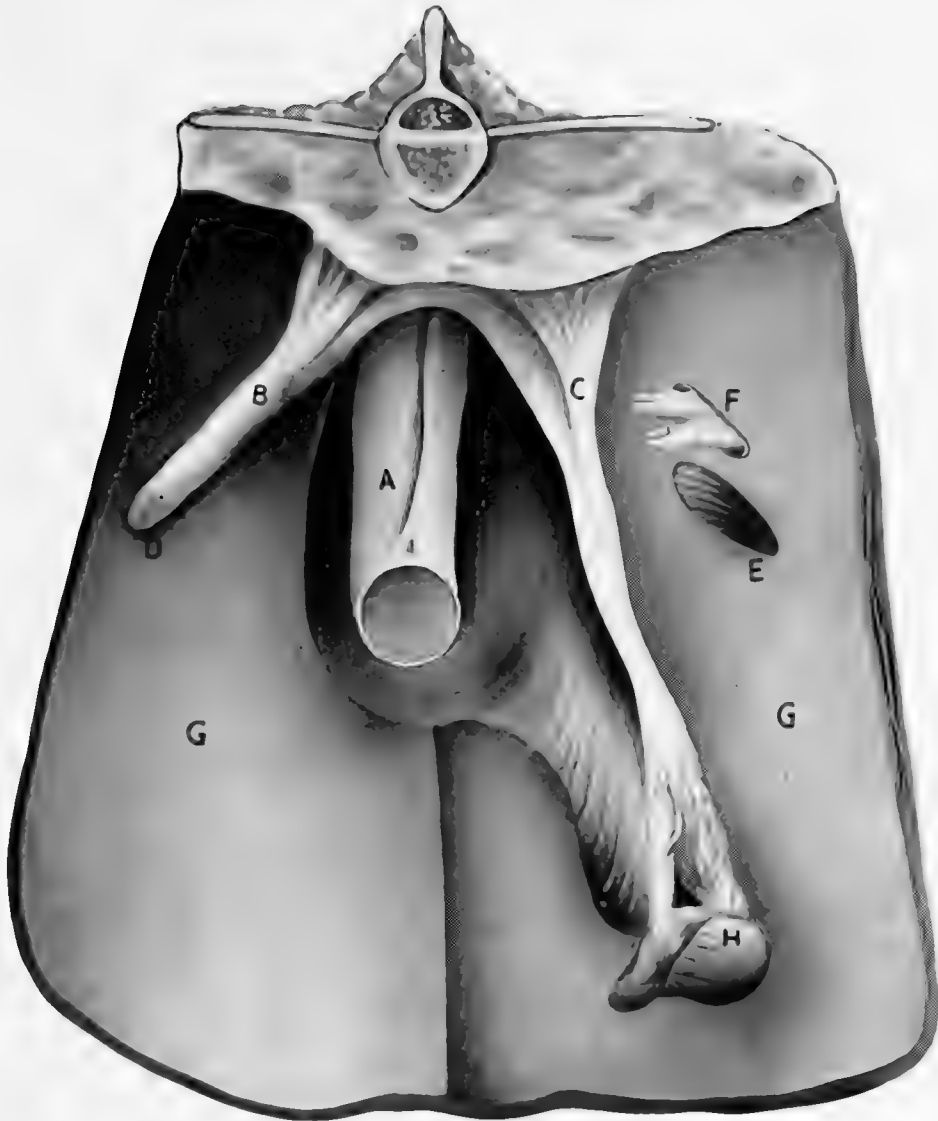


Fig. 46—A Diagrammatic Illustration Showing Important Facts Relative to "Ridgling" Castration. This and the next cut illustrate far better than words could describe some of the covered steps of the operation. A, Rectum; B, Cord of Right Descended Testicle; C, Cord of Left Undescended Testicle; D, Right Internal Abdominal Ring; E, Left Internal Abdominal Ring; F, Incision through the Abdominal Wall 1 inch above and 1 inch in front of the Internal Abdominal Ring. Observe index and second finger protruding through incision searching for Spermatic Cord. G G, Internal Abdominal Walls; H, Undescended Testicle floating loose in Abdominal Cavity attached to end of the Spermatic Cord.

internal abdominal wall (G) and the index finger directly forward, slightly upward toward center of abdominal cavity. By bringing these two fingers together (Fig. 47) the cord (C) is caught be-

tween them. In order to distinguish it (cord) from other abdominal viscera it is rubbed between the fingers and the vas deferens—a hard, wire-like cord—is plainly felt. Nothing else inside the abdominal cavity has this wire cord like feel, and when it is felt between the fingers the cord is positively identified.

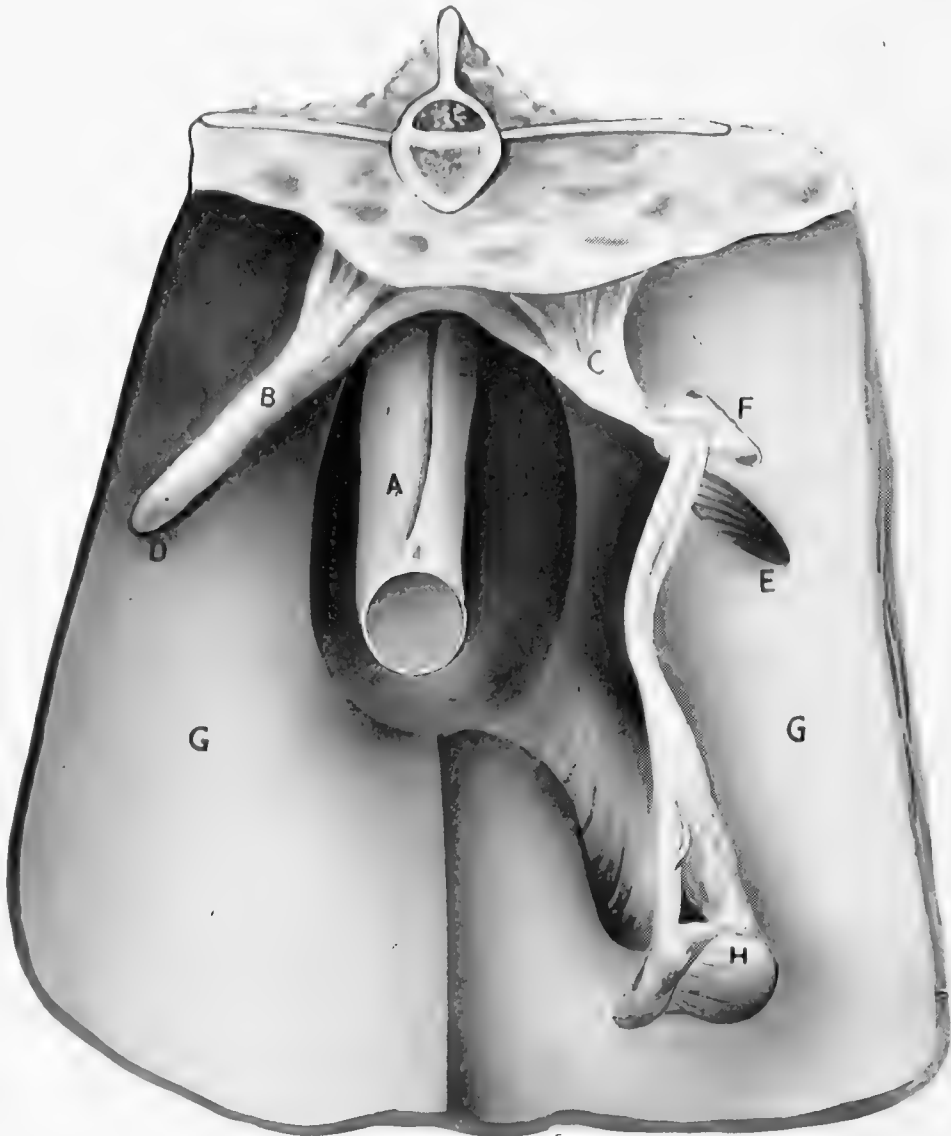


Fig. 47—A, Rectum; B, Cord of Right Descended Testicle; C, Cord of Left Undescended Testicle; D, Right Internal Abdominal Ring; E, Left Internal Abdominal Ring; F, Abdominal Perforation through which is protruded index and second finger of the operating hand grasping cord (C) of Undescended Testicle; G G, Internal Abdominal Walls; H, Undescended (Left) Testicle.

(e) *Removing Testicle From the Abdominal Cavity*—With the cord (C)—and identified as such—between the two fingers moderate traction is made and the unattached end of the cord containing the testicle will follow through the abdominal perforation (F) into the inguinal canal and out through scrotal incision.

Removing Testicle From Cord—Grasp testicle with left hand, with right hand apply chain or ecraseur to cord. With two pounds traction on cord force the ecraseur chain well up in scrotum—at right angles to the cord—take up slack of chain and proceed to sever cord.



Fig. 48—Removing the Testicle from Cord. E, Testicle; F, Ecraseur.

(f) *Final Step*—Wash scrotum and surrounding parts with antiseptic solution, being careful to remove all blood clots, etc., after which pack—scrotum only—using one yard sterile gauze,

and suture skin incision securely with uninterrupted suture. Packing the scrotum cannot do any harm and there is a possibility, in fact a probability, of this precaution saving the life of a patient. Especially is this true should colicky pains ensue within

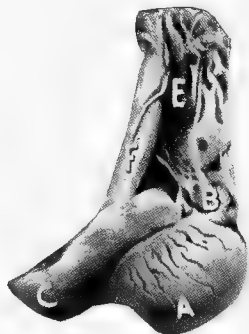

Fig. 49—Testicle of a "Ridgling" Horse.

twelve hours after operating, in which event the rolling and tumbling of the animal would have a tendency to cause bowel protrusion. As a precautionary measure I cannot too strongly recommend packing the scrotum before the animal is allowed to rise to his feet. If a monorchid, your job is completed; if a cryptorchid, turn the animal over and proceed to repeat the operation on the other side without delay. Never attempt to remove both testicles from the one abdominal opening, as in doing so it is necessary to enlarge the opening sufficiently to admit the whole hand; such a large abdominal wall perforation is dangerous and such procedure would be considered bad practice.

Intra-Inguinal "Ridgling."

This is the variety in which the testicle (testes) is inside the abdominal cavity while a portion of the spermatic cord and sometimes the epididymus is in upper part of the inguinal canal, of course surrounded by the tunica vaginalis. (See Fig. 50.) This corresponds to Miles' No. 4.

This is the class which is calculated to confuse the inexperienced operator.

Objects and indications, age, season, preparation, restraint, position, instruments, anatomy, washing, sterilization of instruments, cleansing operator's hands and disinfection of operative field are all the same as are employed in castrating the intra-abdominal ridgling.

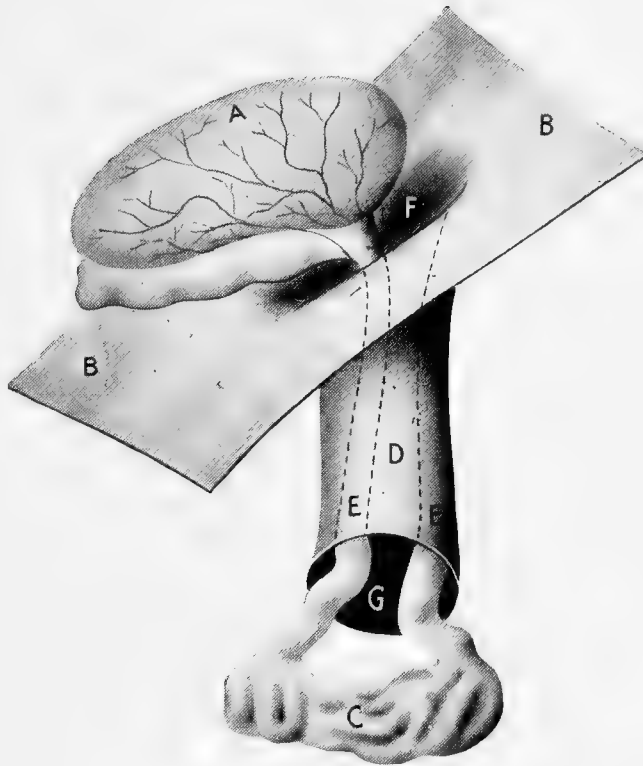


Fig. 50—Intra-Inguinal Cryptorchid (Bayer). A, Testes Inside Abdominal Cavity; B B, Internal Abdominal Wall; C, Spermatic Cord Inside Inguinal Canal; D, Tunica Vaginalis; E E, Dotted lines indicate outlines of Spermatic Cord; F, Internal Abdominal Ring; G, Inguinal Canal.

Operative Technique—The incisions are made and the scrotum and inguinal invaded in the same manner as that employed in the intra-abdominal variety.

Location of the Testicle—The testicle is located by proceeding carefully up the inguinal canal, at the same time making strict search for the tunica vaginalis containing the spermatic cord and sometimes the epididymus. As soon as tunic is encountered examine it carefully in order that no mistake in diagnosis be made. When satisfied that you are in possession of the tunica vaginalis, pass hook knife up the canal sufficiently high to nick the tunic and allow its contents—be they what they may—to escape into the inguinal canal. You are now in possession of the spermatic cord and are justified in applying a limited amount of traction in an effort to bring the testicle from the abdominal cavity through the internal abdominal ring into the inguinal canal. If successful,

then all that remains to be done is to sever the spermatic cord with the ecraseur and allow the animal to rise to his feet. Oftentimes the amount of traction which can safely be applied to the cord will not suffice to bring the testicle out of the abdominal cavity. The proper method of procedure in such a case is to perforate the abdominal wall with the peritoneum perforator (Fig. 40) one inch above and one inch forward of the internal abdominal ring. With the index and second finger in the abdominal cavity return the cord, and such other parts of it or the testicle as are in the inguinal canal, to the abdominal cavity, after which the cord can easily be brought through the abdominal perforation into the inguinal canal and there is no way for the testicle to fail to follow. In other words, we make an intra-abdominal "ridgling" out of the intra-inguinal "ridgling" and castrate him as described in detail on pages 51-62.

Supra Scrotal "Ridgling"—This is the variety where the testicle and spermatic cord are in the inguinal canal, however, too high up to be felt even on deep pressure ("High flanker"). This class is the usual one encountered in young animals, and corresponds to Miles' No. 2.

Not being in possession of knowledge which would indicate to us in advance that the testicle is not actually in the abdominal cavity we are forced to proceed accordingly and prepare patient, sterilize instruments, cast and tie, disinfect field of operation, make scrotal incisions, invade scrotum and inguinal canal, the same as we would for a "ridgling" of the intra-abdominal variety. However, encountering the tunica vaginalis containing the testicle high up in the inguinal canal—outside of abdominal cavity—we are spared the effort and the animal the danger of perforating the abdominal wall. All that is necessary to be done is to pass the hook knife up the canal, knick the tunica vaginalis, allow the testicle to escape, sever the cord with emasculator, and allow the animal to rise to his feet.

Secondary Operation—Oftentimes a previous attempt—by an incompetent operator—has been made to remove an undescended testicle. In such cases the scrotum and groin are filled with sear tissue to the extent of complicating the entrance to inguinal canal and abdominal cavity and otherwise making the operation difficult, unpleasant and unsatisfactory. In such cases the conva-

lescence is prolonged besides the mortality is greater than it would have been had this unsuccessful previous attempt not been made. In operating upon this class of cases the scrotum is entered in the usual way, after which cut through and break down scar tissue in the canal until the internal abdominal ring is reached. In doing this it often becomes necessary to control profuse hemorrhage by ligation. When the internal abdominal ring is reached we use it as a landmark and proceed to finish the operation in the usual manner. Such cases are referred to as "Repeats."

(d) *Anomalous "Ridgling"*—This is the variety in which pathological ("diseased") testicles are encountered, and corresponds to Miles' No. 5. The diseased conditions most often observed are as follows: Hypertrophy, Cysts—including dermoid, simple serous, and dentigeous varieties—Solid Tumors (Sarcocelous), etc. In operating upon "ridglings" belonging to this class the same general principles are employed as apply in castrating intra-abdominal "ridglings" with exception of size of the perforation through the abdominal wall and methods of removing the testicle therefrom. Instead of making a perforation only sufficiently large to admit two fingers, it is usually necessary to make one that will admit the whole hand. When cystic testicles are encountered it oftentimes becomes necessary to free them of their fluid contents by use of trocar and canula before they can be withdrawn through abdominal incision. In removing large, solid tumors which are too voluminous to be brought down the inguinal canal then the flank method of operating must be resorted to. The operative technique must be modified step by step as the circumstances and condition met justify. The operator must solve the problems as they arise. No fixed *modus operandi* applicable to such pathological conditions can be intelligently outlined. It is "up to the individual operator," and my best advice is for you to "go to it" and do your best.

After Care and Treatment—Place animal in a sanitary, well-bedded box stall immediately after operation is completed. Halter head up in such manner as to prevent him from lying down for 24 hours. If suffering severe pain (colicky) 1 ounce fluid extract Cannabis Indica may be given in capsule at 2-hour intervals. Allow plenty of water, but no feed during first 12 hours. At the ex-

piration of 24 hours remove packing, unhalter animal, and if possible turn him to pasture. Turning to pasture is advocated for two reasons, viz.: first, for exercise, which is a very essential part of the after treatment; second, to get the patient away from the dirt and manure around the barnyard and stable, thus avoiding the greatest danger of wound contamination.

Moderate daily exercise is essential even should it become necessary to force the patient to take it. Violent exercise is harmful, and is not called for at any stage of the game. Usually as soon as the swelling appears and the soreness develops—the very time they need exercise most—there is a tendency on part of the patient to stand still in one place for hours without moving. Should such happen, the animal must be led in a walk at end of halter rein about a mile morning and night until after the eighth or ninth day. If lips of skin wound adhere together in such manner as to interfere with free inguinal and scrotal drainage, then the parts and the operator's fingers should be thoroughly washed and the scrotum opened, after which irrigate the wound.

Keep bowels lax by bran mashes and green food.

Sequelae—Septic Infection (see page 74). Tetanus (see page 74). Abscess of Scrotum and Inguinal Canal (see page 74). Colic (see page 77). Prolapse of Intestine (see page 76). Injuries from Casting (see page 76). Peritonitis (see page 77). Primary and Secondary Hemorrhage (see page 79). Oedema of Sheath and Ventral Surface of Abdomen (see page 79). Paraphimosis (see page 81). Azoturia (see page 77). Schirrous Cord (see page 82.)

Remarks—If the foregoing illustrations and description of the “ridgling” operation are not plain and self-explanatory, then the author must confess that he is incapable of imparting knowledge or information of this character. An extra effort was purposely and honestly made to dispense with much superfluous “stuff” often termed “information” widely used by some in describing the modus operandi of “ridgling” castration. The reader is here assured that the author's only object was to level the technique down to a plain, solid, practical basis in order that this most necessary economic operation could be learned and more generally practiced for the benefit of mankind in general and the American horse raising industry in particular.

Orchitis—Both acute and chronic orchitis are not infrequently encountered in castration operation.

Definition—Inflammation of the testicle.

Symptoms—(a) *Ante Orchitis*—Swelling of testicle accompanied by heat, also pain on pressure. Arching the loins, stiffness and straddling gait are usually observed. (b) *Chronic Orchitis*—Enlargement and hardening of the testicle accompanied by adhesion of that organ to the tunica vaginalis.

Advisability of Castration—(a) *Acute Orchitis*—When an acute case of orchitis is encountered and its presence recognized before the scrotum is opened it is always advisable to postpone operation until a later date in order to give the inflammation time to subside.

(b) *Chronic Orchitis*—There is no special reason why an animal cannot be safely castrated while affected with chronic orchitis, even though the case be an aggravated one. In such event the testicle itself would be quite voluminous in size and completely surrounded by adhesions firmly connecting it to the tunica vaginalis. The method of procedure when such a complication as this is encountered is to proceed as you would in castrating a stallion in normal condition, with the exception that it will be found necessary to detach the testicle from the tunica vaginalis by tearing and blunt and sharp dissection of the adhesions. Sometimes the hemorrhage from blood vessels in the tunic is quite profuse and must be controlled by hemostatic forceps and ligatures.

Adhesions—See *Chronic Orchitis* above.

HERMAPHRODITE.

Definition—An animal affected with hermaphroditism, a condition in which both sexes are manifested.

Objects and Indications—In those cases of hermaphroditism in which the male genitals are most developed the animal will have the same habits and exhibit most of the objectionable qualities observed in the “ridgling.” In such cases it is oftentimes advisable to undertake the removal of the testicles. In fact, the veterinarian is called upon to perform this operation much oftener than is usually imagined.

Age—Same as castration of the stallion. (See page 14.)

Season—Spring and fall.

Preparation—Same as castration of the stallion. (See page 14.)

Restraint—Same as castration of the “ridgling.” (See page 54.)

Anatomy—The general anatomy of the parts is, of course, the same as that of the stallion. (See pages 19-21.) However, the testicles in this class of animals are indefinitely located. There is no hard and fast rule with reference to their location which would be a definite guide in finding them. They are usually outside the abdominal cavity. Most frequently in the inguinal canal, but in



Fig. 51—Hermaphrodite Horse.

some instances they are in posterior part of scrotum. Figure 51 illustrates one of the author's cases where one testicle was high up in the inguinal canal and the other in the scrotum.

Instruments—Same as castration of the “ridgling.” (See pages 57-59.)

Position—Dorsal.

Sterilization of Instruments and Cleansing Operator's Hands—Same as castration of the stallion. (See page 24.)

Operative Technique—With animal cast a careful search should be made in every conceivable direction and in every logical location for the testicles. If they can be felt then the operation is greatly simplified. If they are concealed then the proper course to pursue is to open the scrotum and proceed up the inguinal canal as you would in castrating a “ridgling.” When found the testicles should be brought out of scrotal incision provided the spermatic cords are not too short to permit it. If cords are short, then pass the ecraseur up the canals and sever them.

After Care and Treatment—Same as “ridgling.” (See page 69.)

CHAPTER VI.

SEQUELAE OF CASTRATION.

Septic Infection—Contamination of the wound either during operation or afterwards may result in Septicaemia, Pyaemia, Peritonitis, Tetanus, Abscess, etc.

Abscess of Scrotum and Inguinal Canal—This condition arises as a consequence of septic infection associated with the skin incisions adhering together too early after the operation.

Treatment—Evacuation by lancing in such site and manner as to afford free drainage. Followed by daily irrigation with any reliable antiseptic solution is the extent of treatment.

Tetanus (“Lock Jaw”) is the most frequent sequelae of castration in the Southern States, and from all information at hand I am inclined to believe that this sequelae is no less frequent in other sections of the United States.

Cause—We know that tetanus is caused by the Tetanus Bacillus gaining access to the wound. This may take place either at time of operation or later. Whenever a case of tetanus develops after castration the owner will invariably censure the operator. However, experience has led me to conclude that the operator should be held blameless in the great majority of instances. At least ninety per cent of animals which develop tetanus after castration contract the infection from lying down in manure and dirt, thus contaminating the wound, after the actual operation has been performed. In every castration operation there is a possibility of post-operative infection.

Period of Incubation—The period of incubation varies from 8 to 30 days.

Symptoms—Stiffness and contraction of all the voluntary muscles, more especially those of the tail and jaws. As a result of this muscular stiffness the tail and head are protruded, the jaws stiff—partial or complete—straddling and awkward gait. When the head is raised the nictitating membrane (“haw”) protrudes over the eyeball. (See Fig. 52.)




Fig. 52—A Colt with Tetanus 18 Days After Castration.

Treatment—Is both prophylactic and curative. Prophylactic treatment consists in the administration of 1,500 units of tetanus antitoxin immediately after each castration operation.

Curative treatment consists of casting the animal, opening up the scrotal wound and swabbing it out thoroughly with tincture of iodine, after which place him in a quiet box stall away from other live stock and noise and administer 30 grains powdered extract *Cannabis Indica* three times a day. The diet should consist of sloppy foods.

Mortality—The mortality will vary from 30 to 75 per cent.

Prolapse of the Omentum—While prolapse of the omentum is a rare sequelae of castration, nevertheless, it does sometimes occur, and when it does take place prompt and heroic measures in the way of treatment are imperative if the life of the animal is to be saved. Usually when the omentum protrudes from the scrotal incision it is simply a forerunner of what is to happen later, viz.: protrusion of the intestine and death of the animal unless intelligently directed relief measures are promptly instituted.

Operative Technique—Cast and secure patient in Dorsal position, after which cleanse parts and hands of the operator by carefully and thoroughly washing with antiseptic solution. Sever protruding portion of omentum with the emasculator, after which replace that portion which remains in the inguinal canal back through the internal abdominal ring into the abdominal cavity. If there is evidence of the internal abdominal ring being abnormally enlarged it is safest, in fact advisable, to gather up the tunica vaginalis and ligate it as near the internal abdominal ring as possible with chromicized catgut (14 day) large size. Proceed same as for inguinal and scrotal hernia, pages 47-51. If thought advisable there is no special objection to packing scrotum with sterile gauze and suturing up. Remove sutures and packing in 24 to 30 hours and irrigate the canal and scrotum once daily for 8 days with Lysol or Cresol Compound, U. S. P., in the strength of 1 tablespoonful to each quart of water. Daily exercise at pasture or to halter is advisable.

Prolapse of Intestine—This is another rare though dangerous and annoying sequelae of castration, one which is always fatal unless treated promptly and properly.

Operative Technique—Same as outlined above for treatment of prolapse of omentum with the exception that if the loop of intestine is distended by gas it should be allowed to escape by use of small trocar and canula. If internal abdominal ring is contracted or too small to permit return of intestinal loop then it becomes necessary to enlarge the ring (Kelotomy) by using probed point bistoury.

Injuries as Result of Casting—It is possible for the animal to receive halter burns, lacerations and abrasions of different kinds. Rupture of muscles and tendons sometimes occur. The vertebrae and other bones may become fractured. Some horses present radical paralysis as a sequelae of casting, while others become exhausted and never rise after being released. The correct treatment of the above will be left to the judgment of the operator. They are mentioned here more as a warning to him to exercise care, good judgment, and discretion in manipulating his restraint technique than for any other reason. "Safety first" should be the watchword.

Colic—Post-operative colic characterized by abdominal and scrotal pain, and not infrequently by more or less flatulence is a by no means rare occurrence, especially in old stallions and cryptorchids.

Treatment—Choral hydrate or fluid extract Cannabis Indica in 1 ounce doses at 2-hour intervals until pain subsides.

Peritonitis—Septic infection is the direct cause of peritonitis as a sequelae of castration. The infection can be introduced at time of operation by contaminated instruments or hands of the operator or it may be of post-operative origin as a result of wound infection from manure and dirt in barnyard or pasture.

Peritonitis develops most often as a sequelae of cryptorchid (“ridgling”) castration than otherwise. It is one of if not the most serious sequelae of castration.

Symptoms—Peritonitis as a result of sepsis usually ensues 2 to 5 days after operation. Its development is characterized by chilly sensations, indisposition to move about, and in the event of moving there is a well marked stiffness and soreness of gait. Restlessness, pawing with the fore feet, and striking at abdomen with hind ones. Abdomen and flanks tucked up and decidedly rigid. Constipation is usually evident, and colicky pains may be shown. Tenderness on pressure to the abdominal wall, particularly shown when this pressure is made in the flank region. Elevated temperature (102 to 105 degrees F.), quick breathing, hard and wiry pulse. If death does not ensue in a short time, there is usually an extensive effusion of fluid in the abdominal cavity.

Treatment—Purgatives should never be administered. If necessary to secure bowel movement better resort to and depend entirely upon enemas. To allay the pain there is nothing better than tincture opium 1 ounce given in capsules at intervals of 4 hours. A mustard plaster applied to abdominal wall is indicated in the majority of cases.

Prognosis—Unfavorable.

Azoturia—This is a disease caused by hyper-nutrition and lack of bodily exercise, the development of which—as a sequelae of castration—is extremely embarrassing to say the least of it. Azoturia never develops where daily exercise either at work or in pasture is allowed. However, with animals that have been well

fed and kept confined in stall it is a condition which we may encounter at any time when casting and confining such animal.

On account of the danger of azoturia it is well to know whether the animal has had sufficient exercise before you undertake to operate.

Symptoms—After the operation is completed and the restraint apparatus removed the animal may fail to rise to his feet altogether, or upon rising may be stiff in one or more legs—most frequently the hind legs—perspiring freely, evincing pain by pawing, and restlessness. If urine is voided we observe the characteristic “coffee color.” Swelling and rigidity of muscles of haunch (*Glutius Maximus*) knuckling in hind ankles, etc., are diagnostic symptoms of this affection.

Prevention—Daily exercise.

Treatment—Catheterization. Stimulating liniments rubbed on affected muscles. Internally, F. E. belladonna ½ ounce, sweet spirits nitra 1 ounce, in capsules, at 2-hour intervals. An aloes purge is sometimes beneficial. If the case is a mild one and the animal can stand upon its feet it is advisable to halter head up to prevent lying down.

POST-OPERATIVE HEMORRHAGE—PRIMARY AND SECONDARY.

(a) *Primary Hemorrhage*—May ensue immediately after the operation from failure of emasculator to close the spermatic artery or from the scrotal plexis of veins being severed with point of knife at time incision is made.

Treatment—It is only in extremely rare instances that it becomes necessary to artificially control hemorrhage of this source and character. Nature will, as a rule, relieve the surgeon of such responsibility, provided he will be patient for 20 to 30 minutes and allow her time to do it. It is more often necessary to treat the owner while his animal is bleeding than it is to treat the animal itself. During twenty-one years' experience, in which time more than 14,000 stallions, colts and mules were castrated, not a single animal died as a result of primary hemorrhage, and not a single cord was ligated nor a scrotum packed. If you procure a properly constructed emasculator the next thing is to impose the utmost confidence in it, in which event you will not

become unduly alarmed every time a stallion or colt bleeds freely for a few minutes after castration. Remember that it is impossible to do a bloodless operation with the emasculator. If you are expecting a bloodless job you will as a rule be disappointed except in extremely enemic colts. If you are afraid of hemorrhage, remember that the only method of operation in which you do not get more or less blood is the antiquated ligature. If a stallion bleeds freely after castration operation the best way to proceed is to place him in a box stall, shut the door and go with the owner to dinner. After dinner take a leisurely smoke with the owner—this usually consumes about an hour's time—after which examine the patient and you will find that nature has come to your rescue and hemorrhage has ceased.

(b) *Secondary Hemorrhage*—This form of hemorrhage invariably ensues from the spermatic artery and contrary to primary hemorrhage is dangerous, and may result in death of animal unless controlled. It usually occurs from one to six hours after castration; however, it sometimes occurs several days after operation. Hemorrhage of this character is usually caused by diseased conditions of the arteries (Haemophilia), increased heart action, sloughing of spermatic cord, etc. The blood comes in spurts directly from the artery in a good size stream.

Treatment—Nature cannot be depended upon to control this class of hemorrhage. Sometimes it is possible to apply haemostatic forceps to mouth of the bleeding vessel. When this cannot be done with the animal in standing posture then cast and secure the patient in dorsal position, thoroughly cleanse the parts with antiseptic solution and make an effort to ligate the artery. This should always be done with chromicized catgut (10 day). If silk or any other form of unabsorbable ligature material is used a scrotal fistula is liable to result. In the event it is found impossible to locate and ligate the artery, then you would be justified in packing the canal and scrotum with sterile gauze and suturing the skin incision. Remove the packing in 24 hours, after which irrigate parts once daily with antiseptic solution.

Oedema of Sheath and Ventral Surface of Abdomen—Oedema as a sequelae of castration (See Fig. 53) is a condition which we may reasonably expect in the great majority of instances, espe-

cially may we expect it in aged stallions and those which are kept stabled and not allowed the requisite amount of exercise. Unless the sheath and abdominal swelling is associated with a local or systemic septic infection or it becomes so voluminous as to cause interference with voiding the urine, it is harmless and requires no treatment aside from free scrotal drainage and exercise. The swelling begins to appear on the third day and gradually enlarges until the sixth day, after which it begins to recede rapidly until the eighth or ninth day, at which time complete recovery has usually taken place.

Treatment—When treatment is required the first thing to be done is to wash the scrotal and inguinal and sheath regions with Lysol or Cresol Compound, U. S. P., in the strength of one tablespoonful to each quart of water. Cleanse the hands in like



Fig. 53—Oedema of Sheath Fourth Day After Castration.

manner. With twitch applied and held by an assistant, two fingers are introduced into the scrotal wound by forcing the lips of the incision apart sufficiently to afford free scrotal and inguinal canal drainage, after which irrigate the parts with antiseptic solution. With a sharp-pointed bistoury the point of sheath (anterior portion) may be punctured at the several dependent sites in order to allow the accumulated fluid to escape by oozing out. In scarifying the sheath the blade of the knife should be guarded with the thumb in such a way as to prevent too deep puncturing.

Paraphimosis—Prolapse of the penis (See Fig. 54) may result from extensive inflammation and swelling of the spermatic



Fig. 54—Paraphimosis Eight Days After Castration.

cords (funiculitis) and extensive oedema of the sheath. Generally the penis protrusion is merely a temporary affair, and as soon as the swelling and inflammation of the spermatic cords,

sheath and scrotum subsides the penis assumes its normal position in the sheath.

Treatment—The first essential is to support the pendulent penis, as its great weight and position are unfavorable for absorption of the fluid and reduction of the swelling. Bathe the swollen parts with plenty of warm water to which has been added sugar of lead (plumbii acetate) in the strength of one ounce to each gallon of water. With a properly constructed suspensory a warm pack saturated with the above solution may be kept applied to the parts.

Schirrous Cord or Chronic Funiculitis (Champignon)—Is an enlarging and hardening of the stump of the spermatic cord. It sometimes reaches enormous proportions, sufficiently large in some instances to fill and distend the whole inguinal canal and groin. In long standing chronic cases the cord is surrounded by dense adhesions. A genuine schirrous cord never reduces in size spontaneously, but has a tendency to grow larger and become harder.

Cause—There are two principle reasons for this sequelae of castration:

1. Operator leaving stump of cord sufficiently long to be caught between lips of scrotal incisions during the healing process. This, of course, strangulates the cord and causes it to enlarge and harden.

2. Infection either actinomycotic, streptococcic, or botryomycotic. This accounts for the constant pus discharge and numerous abscesses which make their appearance from time to time. Either ignorance or carelessness on the part of operator is responsible for this unappreciated condition. By removing enough cord and practicing cleanliness at the outset schirrous cord would be to a large degree eliminated. The development of schirrous cords was largely reduced when the emasculator superceded the old-style clamp method of operating.

Treatment—In the acute stage of development—which means two to six weeks after castration—the scrotal region should be frequently cleansed by washing. The scrotal wound itself should be painted once every two days with tincture iodine. During this period it is well to give iodide potash in 4-drachm doses once a day.

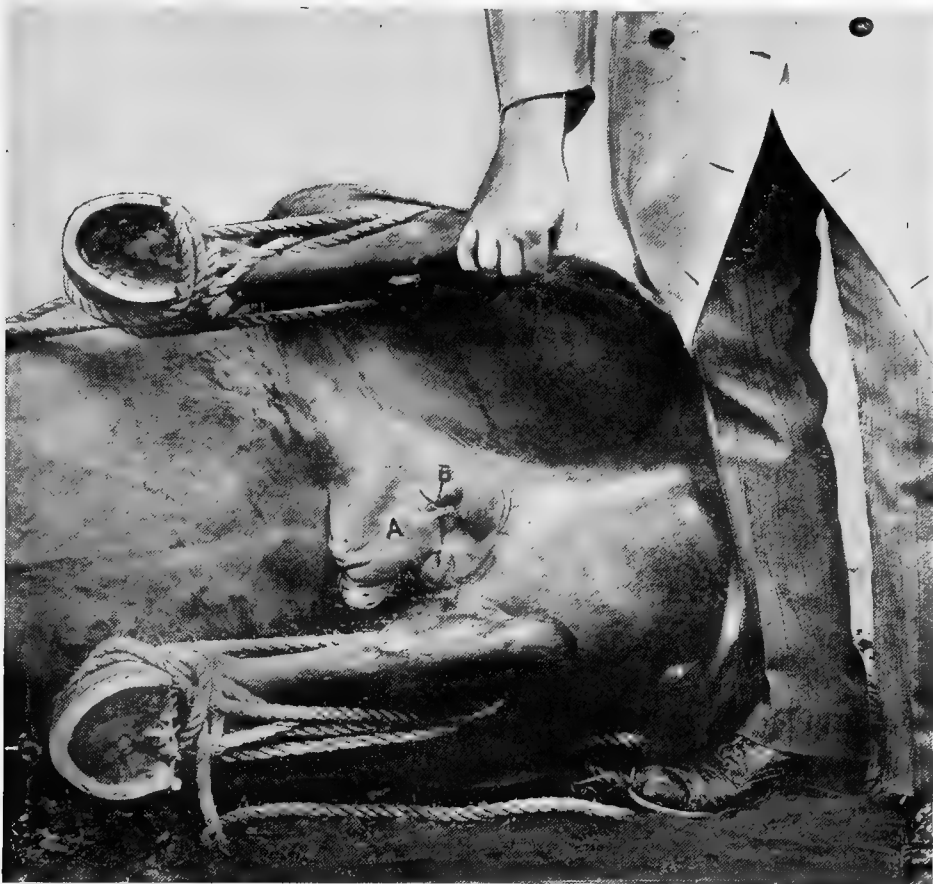

Fig. 55—A Well Developed Schirrous Cord.

If at the end of six weeks the tumefaction still persists, then the radical operation—which consists in total ablation—is justified and in fact indicated.

Restraint—Same as for ridgling castration, see page 54.

Position—Dorsal.

General Anaesthesia is always indicated when possible, as the operation is extremely painful and usually prolonged for a considerable length of time in order to control hemorrhage.

Instruments, etc.—

1. Ecraseur (Figs. 5, 6, 7, and 8).
2. Threaded needles for ligating blood vessels, suturing skin incision and ligating cord if for any reason the ecraseur fails to sever it.

3. Sterile gauze in liberal amount.
4. Haemostatic forceps (several pairs).
5. Sharp scalpel.
6. Vulsellum forceps (Fig. 56.)
7. Thumb tissue forceps.

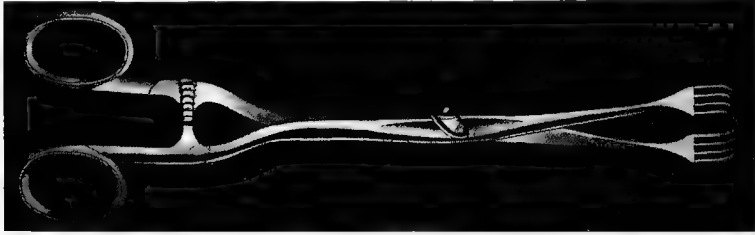


Fig. 56—Vulsellum Forceps (8-inch).

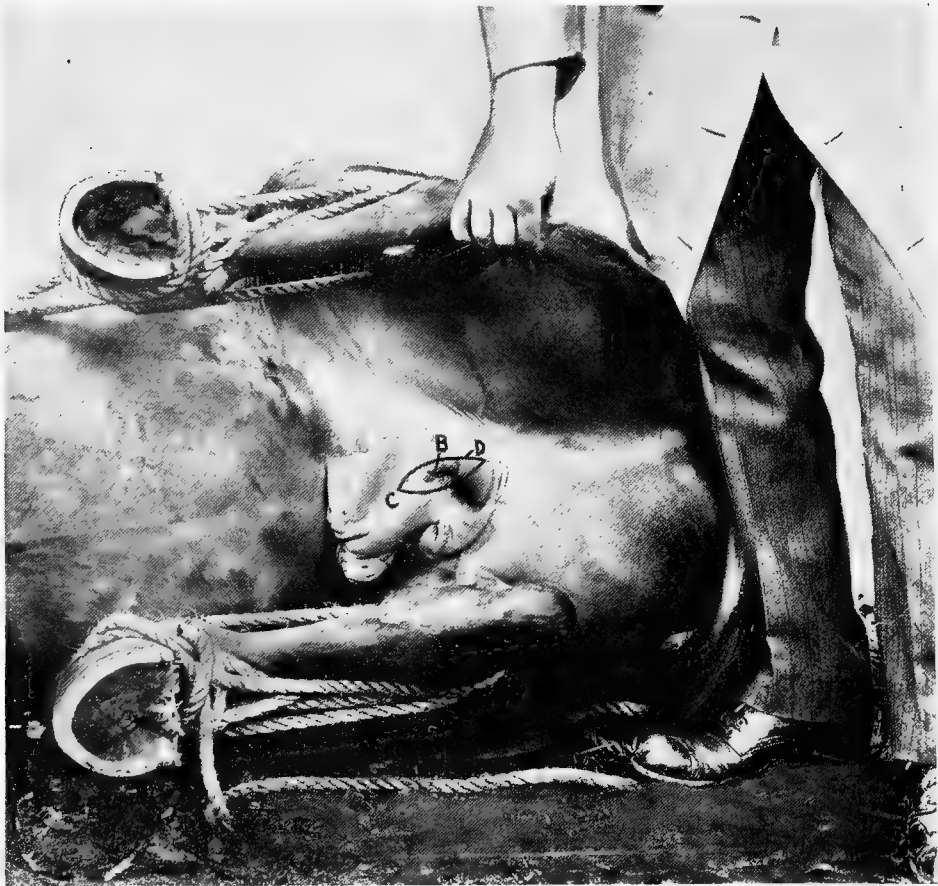

Fig. 57—Schirrous Cord, Showing Skin Incision. B, Old Cicatrix with Imprisoned End of Cord; C, Scrotum; D, Elliptical Skin Incisions for Ablating the Growth.

Sterilization of Instruments, Cleansing Operator's Hands and Field of Operation—Same as castration of the stallion. (See page 24.)

Operative Technique—With field of operation, operator's hands, and instruments sterile and animal in dorsal position, proceed to operate as follows: With scalpel in right hand make two curved elliptical incisions (D, Fig. 57) 5 inches long with the original cicatrix (scar) B as the center. These incisions should penetrate skin and subcutaneous connective tissue only. By careful dissection (both sharp and blunt) the cord is gradually loosened and isolated by breaking down the numerous dense adhesions surrounding it. The elliptical section of skin which is removed on end of cord should be sufficiently large to include all external




Fig. 58—Removing Schirrous Cord with Ecraseur. E, Schirrous Cord with Ecraseur Chain Around It; F, Vulsellum Forceps; G, Ecraseur; H, Right Hand of Operator.

diseased tissue, such as scars, granulations, etc. The tumor is now grasped with the vulsellum forceps (Fig. 58.) These are held by an assistant in such manner as to afford considerable direct upward traction. With the cord tense from traction the careful dissection is continued up the inguinal canal until a point is reached well above the diseased or indurated portion of the cord. If the entire cord is diseased, then we should proceed up the canal to a point in close proximity to the internal abdominal ring. Usually after the cord is released from its scrotal adhesions the remainder of the dissection process can be completed by tearing with the fingers. All freely bleeding blood vessels—except those in cord itself—should be ligated as you proceed. When the growth is freed from all surrounding attachments the ecraseur chain should be placed around it as high up as necessary and with continued traction from vulsellum forceps the cord is quickly severed.

If cord is too large to be severed by the ecraseur, then the ligature must be resorted to. In such event the cord should be transfixed and ligated in several sections. The scrotal wound should now be irrigated thoroughly with bichloride mercury solution in the strength of 1-1000, after which pack tightly with formalized gauze and suture up securely.

After Treatment—If upon completion of the operation decided shock is imminent the animal should have strychnine $\frac{1}{2}$ grain, nitro-glycerine $\frac{1}{4}$ grain, hypodermically. If a large amount of blood has been lost normal saline solution injected intravenously is indicated. Remove packing in 36 hours and irrigate the wound daily with Lysol or Cresol Compound, U. S. P., in the strength of a tablespoonful to each quart of water.

Exuberant Granulations—On account of some mishap in operative technique or some character of infection, exuberant granulations sometimes appear as a sequelae of castration. They are, of course, first acute and in most instances disappear without treatment. However, if a cure is not effected in the acute stage, then they assume a chronic form and may reach enormous proportions in size. (See Fig. 59.) They are usually extra-scrotal.

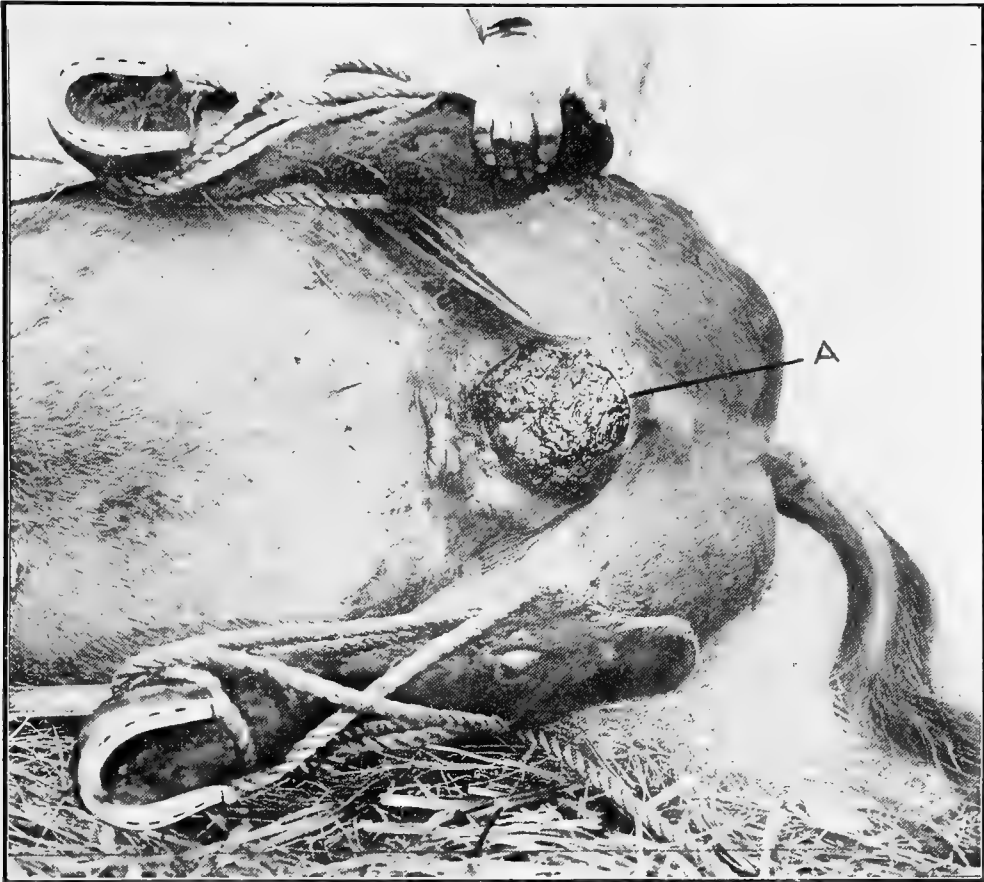


Fig. 59—Exuberant Granulations Which Have Assumed the Chronic Form and Reached Enormous Size.

If not attached to cord their removal and after treatment is a simple matter, consisting in removing the skin by dissection well around their base, controlling cutaneous hemorrhage and daily washing the wound with antiseptic solution.

Hydrocele (“*Water Bag*”)—Is simply an accumulation of serous fluid in the testicular sac (tunica vaginalis), from which the testicle itself has been removed.

Cause—There is only one cause for this condition. It may be directly attributed to either the operator’s carelessness or ignorance. The only reason for the development of hydrocele as a sequelae of castration is leaving too much of the tunica vaginalis

in the scrotum at time of severing the spermatic cord. If at least one inch of the tunica be removed then there is no occasion, in fact, no possibility of a hydrocele developing.

Frequency—It is rare to see hydrocele in the stallion and colt, however, the reverse is true as regards the mule. Hydrocele is decidedly the most frequent sequelae of mule castration, and nothing reflects quite so much—in mule raising centers—upon a man's ability and qualification as having numerous mules which he cas-

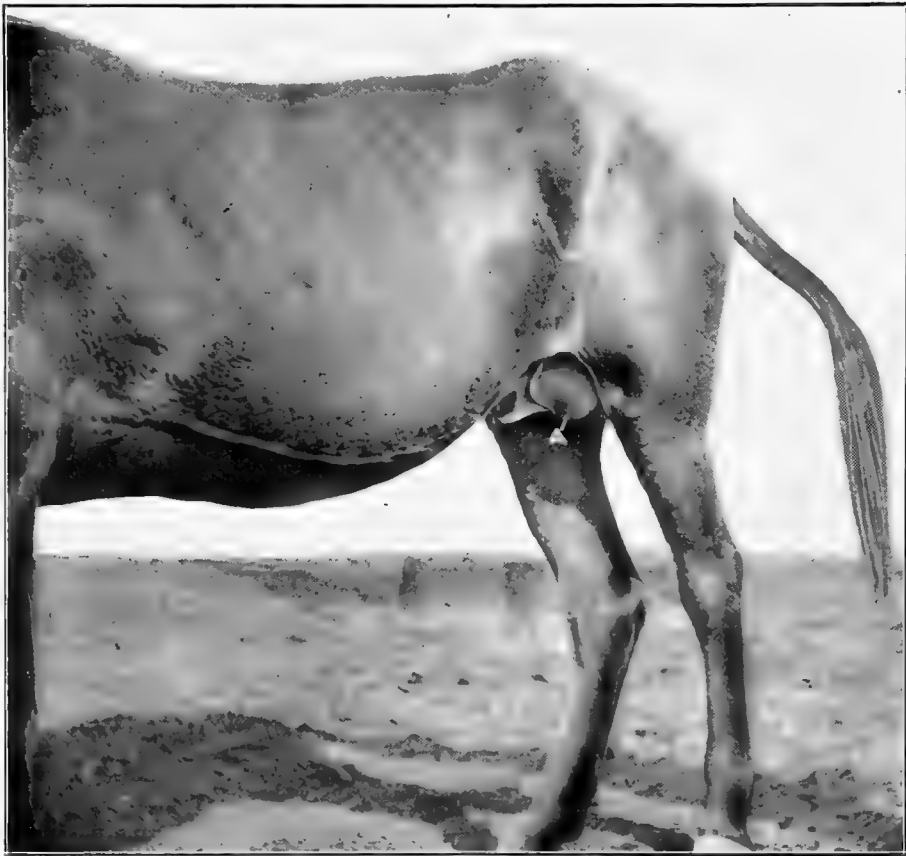

Fig. 60—Well Developed Hydrocele ("Water Bag") in a Three-Year-Old Mule.
A, Hydrocele.

trates turn up later with "water bags." While they do not interfere in the least with the general health and usefulness of the animal they are nevertheless great "eye sores," and depreciate the animal's marketable value, hence should in every instance be

removed by surgical interference. They may be unilateral or bilateral.

Preparation—Same as for castration of the stallion. (See page 14.)

Sterilization of Instruments and Operator's Hands—Same as for castrating the stallion. (See page 24.)

Restraint—For small mules, same as for castration of the colt. (See page 36.) For large mules, same as for castration of the "ridgling." (See pages 54-56.)

Position—Dorsal.

Instruments—

1. Miles' hook castrating knife. (See Fig. 25.)
2. Vulsellum forceps. (See Fig. 56.)
3. Ecraseur. (See Fig. 41.)
4. Haemostatic forceps.

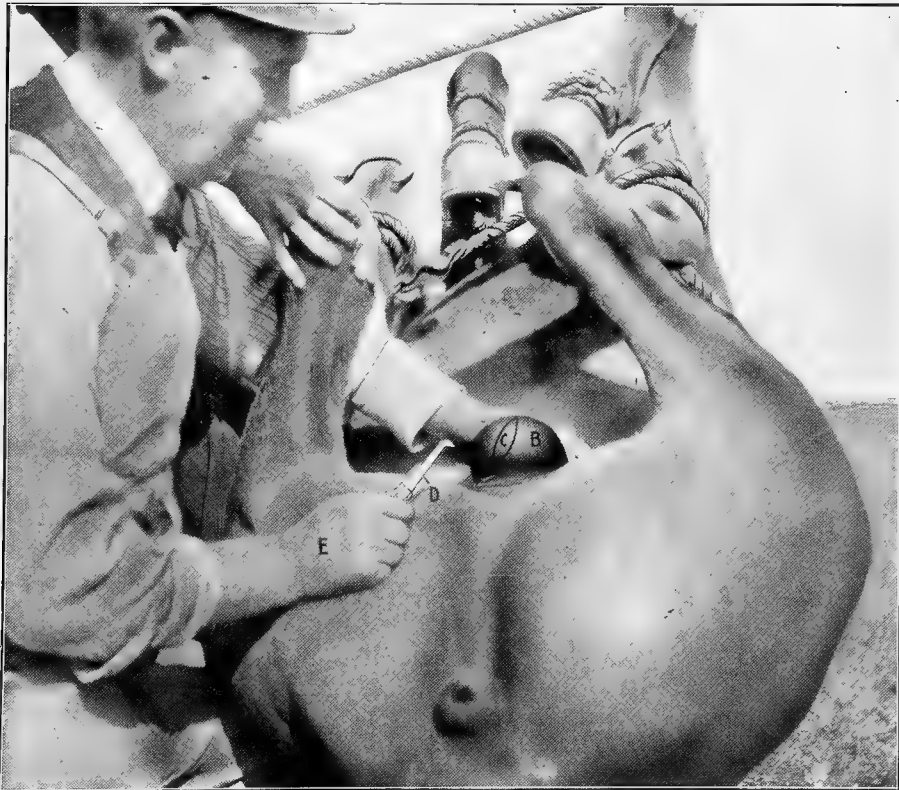


Fig. 61—Hydrocele Showing Skin Incisions. B, Hydrocele; C, Incisions; D, Knife; E, Right Hand of Operator.

Sterilization of Field of Operation—Same as castration of the stallion. (See page 24.)

Technique of Operation—With Miles' hook castrating knife in right hand (E) two curved or elliptical incisions are made (C, Fig. 61) to the right and left of the most prominent part of the hydrocele (B). This means that the old cicatrix (scar) is in center of section of skin removed. These incisions should be made from 4 to 5 inches long—depending upon size of the hydrocele. They should extend through skin and subcutaneous connective tissue only. With the vulsellum forceps grasp elliptical section of



Fig. 62—Hydrocele Showing Method of Removal by the Ecraseur. F, Left Hand of Operator; G, Vulsellum Forceps; H, Hydrocele; I, Ecraseur; J, Right Hand of Operator.

skin which is to be removed with the hydrocele. Have assistant make upward traction while the superficial subcutaneous adhesions are being carefully broken down by sharp dissection. These adhesions never extend deep and are readily broken down. If necessary ligate spurting blood vessels as you proceed. As soon as the scrotal adhesions are removed from around tunica vaginalis the

operator takes charge of the vulsellum forceps with his left hand and with fingers of the right tears the tunica vaginalis loose from its delicate fascia attachments until a point is reached on the spermatic cord well above where it was formerly severed. The chain of the ecraseur is now applied to tunica ("sac") and the same, including the stump of spermatic cord, is severed. It is rarely ever necessary to pack the scrotum in order to control hemorrhage.



Fig. 63—Hydrocele After Removal.

After Care and Treatment—About all this is necessary is daily observation in order to see that everything proceeds well. If sequelae arise they must be treated as outlined under their respective headings.

CHAPTER VII.

CASTRATION OF THE BULL.

Objects and Indications—The operation is usually performed for purely economic purposes. However, in some instances, on account of diseased conditions of the scrotum, testicle and spermatic cord, it becomes necessary to castrate. On the other hand some bulls become vicious to the extent of being a source of danger and annoyance to their owners and attendants, in which event castration must be resorted to. As an economic operation—especially in young animals—its value is beyond estimate. Castration increases physical development and hastens early growth as well as improving the texture, odor, wholesomeness and nutritive properties of the beef. Bulls are also castrated for the purpose of making work oxen.

Castrated bulls are known as “steers.”

Age—From several days to several years. The younger the better. Most calves are submitted to the operation at about two to three months old.

Season—Early spring, late fall and winter. The bull or calf should never be submitted to castration operation during “fly time.” Bovine animals do not possess the same instinct in protecting themselves from flies—by warding them off with tail—as does the equine species. On this account late spring, early fall and summer are unfavorable seasons for castrating this class of animals. Bulls are castrated in both the standing and recumbent posture.

Preparation—No special preparation is necessary unless the animal is to be cast and tied, in which event have the alimentary tract empty by withholding feed for 24 hours before operating.

CASTRATION OF THE BULL IN THE RECUMBENT POSTURE.

Restraint—When it becomes necessary to cast and tie the animal for this operation an excellent method of doing so is with the Conkey self-lock buckle hobbles. (Fig. 64.)

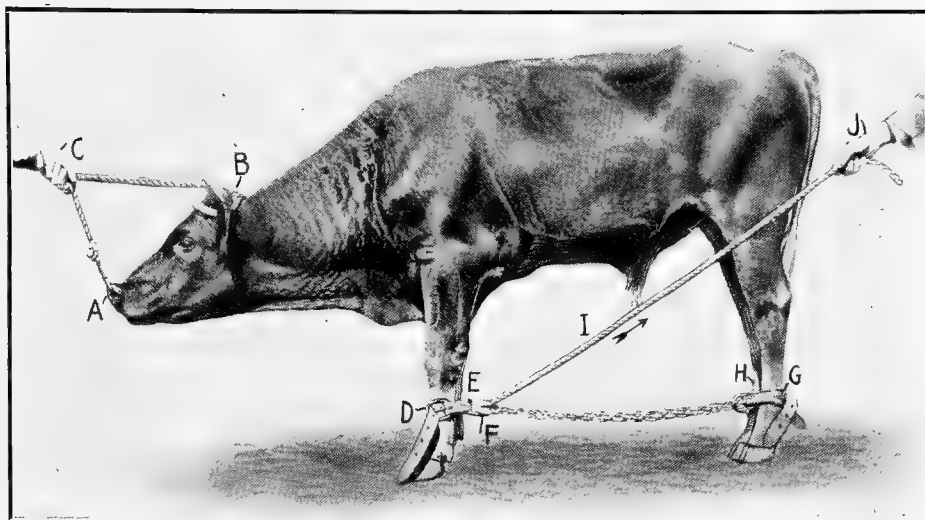


Fig. 64—Conkey's Self Lock Buckle Hobbles Applied.

These hobbles have the advantage of being strong, safe, quick to apply and easy to remove. The degree of restraint afforded by them is ample, especially when used in conjunction with a 15-foot rope. In applying hobble straps to cattle always buckle or loop them above the ankles, otherwise there is a tendency for them to slip over the foot and off. The hobbles are applied as follows (Fig. 64): With an assistant (C) at the head, a "holder" in the nose (A) and rope around horns (B) buckle a hobble strap above ankles of both hind (G, H) and the right fore (E). Buckle master hobble strap above left fore ankle (D). Pass the end of rope through hobble strap (G) then through (H), then through (E), and lastly across through self-lock buckle (F). By making tension on rope (I) from (J)—at direct right angles to the animal—he is cast on the right side. After the animal is cast (See Fig. 65) the uppermost hind ankle (N) is released from its hobble strap and the end of a 15-foot rope looped on instead of the hobble strap. This rope (P) is passed over withers (O) under neck (Q) and above hock (R) in such manner as to draw the foot against the abdomen and flex the hock to a certain degree. In this position of the animal the operation can be proceeded with without danger to either the operator or patient. Calves may be held without tying by one or more assistants.

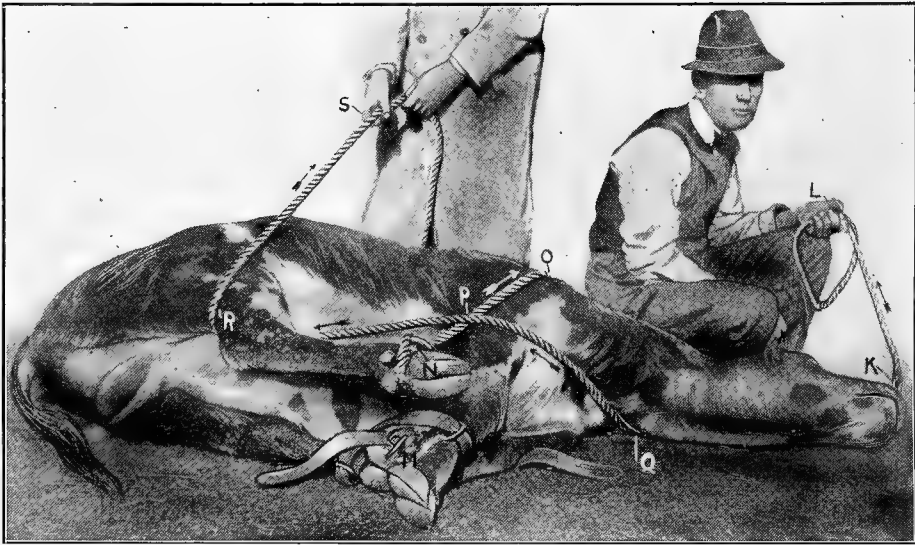

Fig. 65—Bull Cast and Tied for Castration Operation.

Instruments—The emasculator (Figs. 5, 6, 7, and 8) and castrating knife are the only instruments needed. The Miles hook castrating knife (Fig. 25) and the Williams castrating knife (Fig. 2) are equally satisfactory for this operation.

ANATOMY.

In order to operate intelligently some knowledge of the anatomy of the scrotum, testicle and inguinal canal is necessary. However, lack of space prevents going into details here. By reference to Fig. 66 a general idea of the relation and position of the generative or reproductive organs of the bull may be had.

Testicle—The testicle is a compound tubular gland ovoid in shape and well developed with its long axis vertical. On the epididymus is a well developed globus major.

Penis—The penis is round in shape and long in length. It projects far under the abdomen and possesses the well recognized S-shape curve. Its gland is small and pointed.

Prepuce—The prepuce is located well under the abdomen. It is simply an elastic sheath, surrounded at its external opening by long stiff hairs. Its cavity is from 10 to 15 inches long.

Scrotum—The scrotum is long and pendulous, and has a well marked neck. It is suspended between the thighs somewhat further forward than in the stallion.

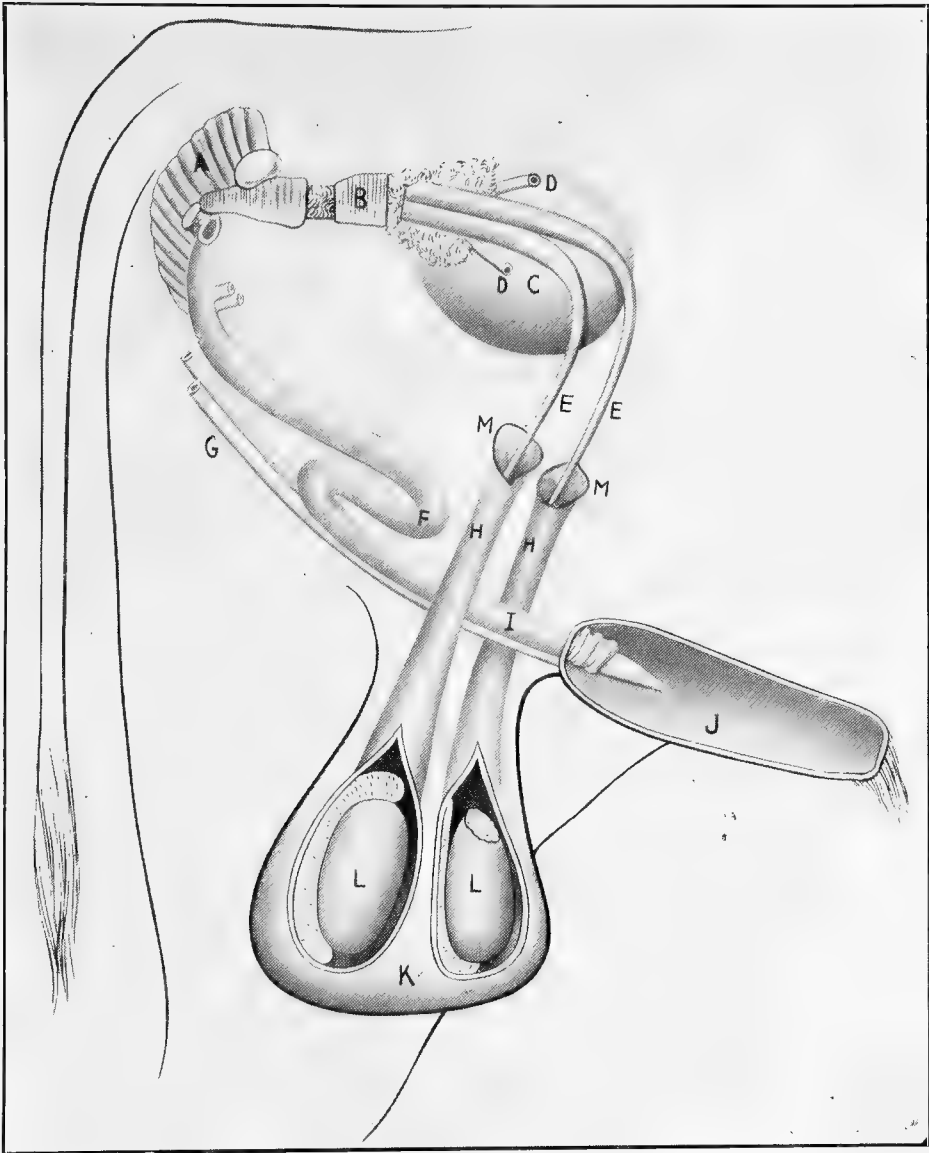


Fig. 66—Generative or Reproductive Organs of the Bull. A, Ejaculator Seminis; D, Intrapelvic Portion of Urethra; C, Urinary Bladder; D, D, Ureters; E, E, Intra-Abdominal Portion of Spermatic Cords; F, S-Shape Curve in Penis; G, Retractor Muscles of Sheath; H, H, Tunica Vaginalis; I, Penis; J, Prepuce; K, Scrotum; L, L, Testicles; M, M, Internal Abdominal Rings.

Spermatic Cord—The spermatic cord and its covering—tunica vaginalis—is much longer than in the stallion.

Inguinal Canal—This canal is long and narrow, and directed almost perpendicular to the scrotum.




Fig. 67—Testicle of Bull. A, Spermatic Cord; B, Testes; C, Globus Major of Epididymus; D, Epididymus.

Sterilization of Instruments and Cleansing Operator's Hands—Same as castration of the stallion. (See page 24.)

Disinfection of the Operative Field—While this step in the operative procedure is usually ignored entirely or if done at all it is usually done in a perfunctory manner, nevertheless such neglect is inexcusable. On account of the danger of sepsis and other sequelae known to follow bull castration, the operator should take the time and precaution necessary to disinfect the field of operation. This may be quickly done as follows:—

(a) Scrub scrotum and inside of thighs with soap and warm water until all visible dirt is removed.

(b) Wash parts with Lysol or Cresol Compound, U. S. P., in the strength of one tablespoonful to each quart of water.

Operative Technique—There are two methods of making the

scrotal incision, (a) lateral or side incisions (see Fig. 68); (b) end incision (see Fig. 69).

Lateral or Side Incision—This method is the most popular one, as after recovery there is less mutilation of the scrotum.

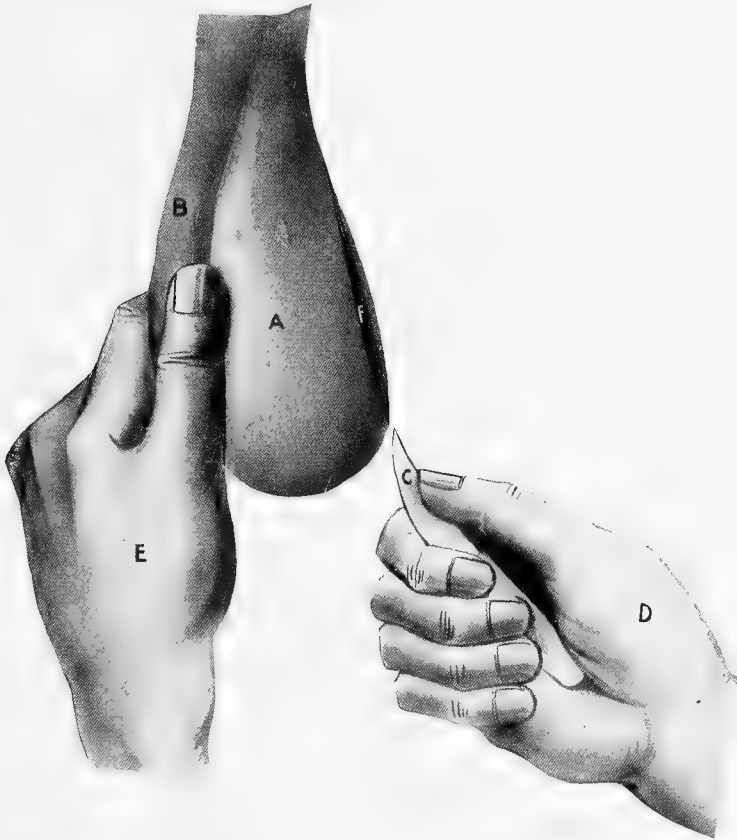


Fig. 68—Method of Making Lateral or Side Scrotal Incisions. A, Right Testicle in Scrotum; B, Scrotum; C, Knife; D, Right Hand; E, Left Hand; F, Incision.

Grasp left side of scrotum in left hand and by compressing it force right testicle to the right until the skin of scrotum is stretched tight. With sterilized knife in right hand begin incision 4 inches above apex of scrotum and bring it down to near the apex. The incision should be made through the skin, subcutaneous connective tissue dartos and tunica vaginalis. This exposes the testicle. Grasp the testicle with the right hand and with the left strip the attached scrotal tissue from the cord until the cord itself is isolated well up to summit (top) of scrotum. The final

step of the operation consists in grasping testicle with left hand and making two pounds tension on its cord. With right hand apply emasculator to the spermatic cord and force it (emasculator) well to the summit (top) of scrotum. By bringing handles together the cord and its coverings are severed. The opposite testicle is likewise removed.

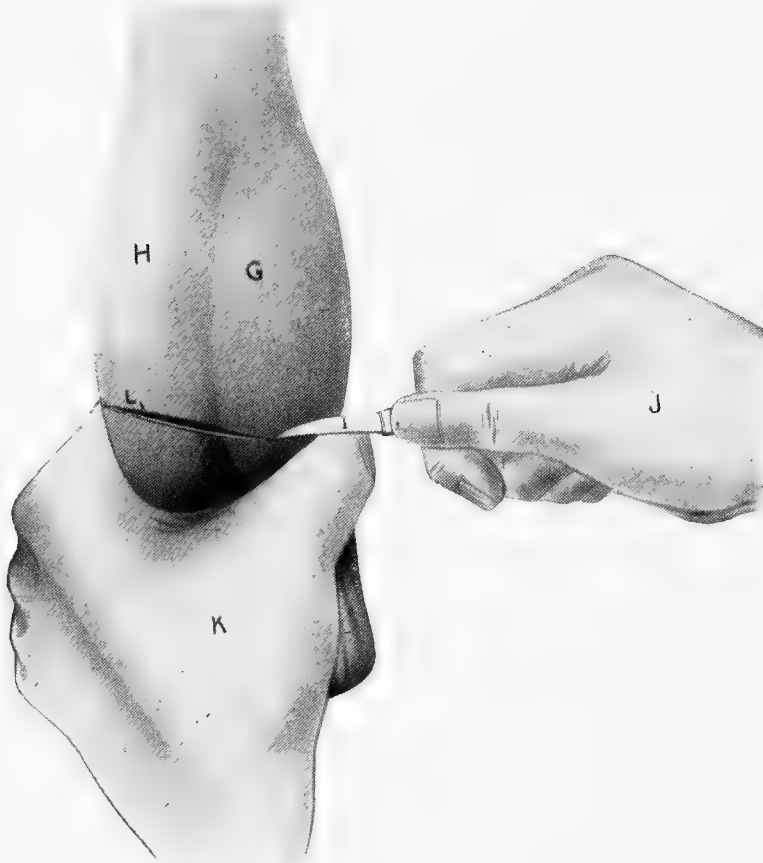


Fig. 69—Method of Operating in Which Apex (Bottom) of Scrotum Is Removed. G, H, Testicles in Scrotum; I, Knife; J, Right Hand; K, Left Hand; L, Incision.

(b) The other method of scrotal incisions (Fig. 69) consists in grasping apex (bottom) of scrotum with left hand and by compressing it force the testicles upward until the lower one-third of the scrotum may be severed without injuring them. With knife in right hand it is an easy affair to remove the lower one-third of the scrotal sac.

The tunica vaginalis containing the testicles drops outside the

remaining portion of scrotum. By nicking the tunic the testicles themselves are exposed. With right hand grasp one of them and make two pounds traction on the cord, with left hand strip the scrotal tissue from the cord until it is isolated well up to summit (top) of scrotum. Next grasp testicle with left hand and make two pounds traction on cord. With right hand apply the emasculator and force it upward to summit (top) of scrotum in order that a sufficient amount of spermatic cord will be removed. By bringing handles of emasculator together the cord and all its coverings are severed. This method has the advantage of affording ideal scrotal drainage.

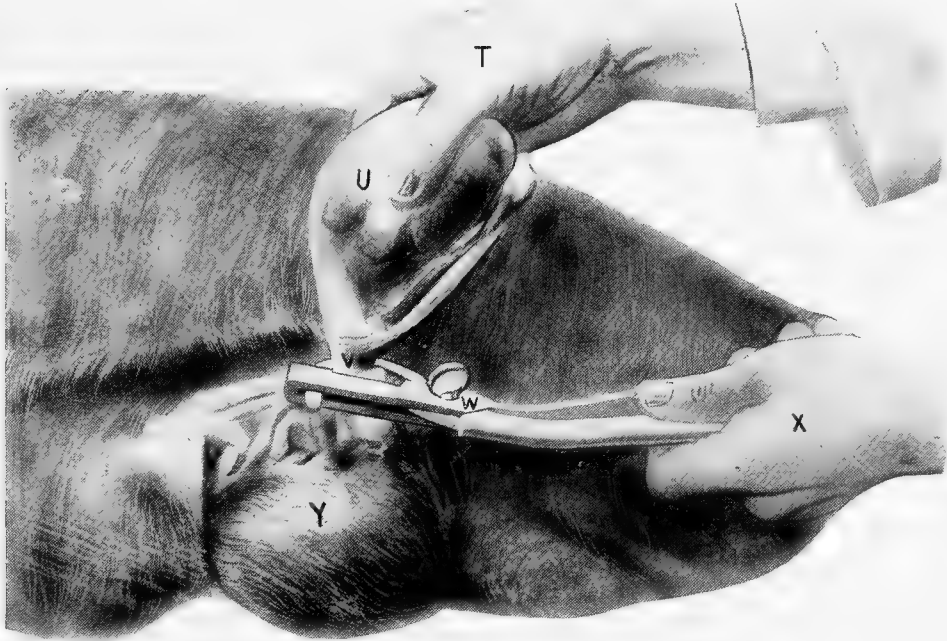


Fig. 70—Severing Spermatic Cord with Emasculator (Recumbent Posture). T, Right Hand; U, Testicle; V, Spermatic Cord and Its Coverings; W, Emasculator X, Left Hand; Y, Opposite Testicle.

After Care and Treatment—Turn to pasture and make daily observation to see that all is going well. If the scrotal wound closes in such manner as to interfere with drainage and cause extensive swelling, then it should be opened and the scrotum irrigated with antiseptic solution.

CASTRATION OF THE BULL IN STANDING POSTURE.

Restraint—If the animal possesses horns a strong rope may be looped around them and his head drawn close up to a post. In most instances this is all the restraint employed. Contrary to the prevalent popular opinion the bull can actually kick backwards about as hard as he can sidewise. In castrating most bulls in the standing posture the operator must either stand out of range of the hind feet, confine them by means of ropes, or take his chances on the kicking proposition. In castrating young bulls (3 to 6




Fig. 71—Castration of the Bull in Standing Posture. E, Post; F, Rope; G, Left Hand; H, Scrotum; I, Incision; J, Right Hand; K, Knife.

months of age) the standing posture is ideal and injury to the operator by kicks is extremely rare.

The same instruments, preparation, disinfection of site of operation, sterilization of instruments, scrotal incisions, etc., are employed here as castrating bulls in the recumbent posture. The operator should—while making scrotal incision—have his knife under thorough control as at this time there is almost invariably an abrupt movement on part of the animal which might result in the knife coming in contact with the tendo-achillis (“hamstring”) and doing irreparable damage. Calves are castrated in the same manner as bulls.

CASTRATION OF THE CRYPTORCHID AND MONORCHID
 (“RIDGLING”) BULL.

Compared with the horse and hog, cryptorchidism in cattle is extremely rare. However, such a complication does actually exist, and it behooves those who are expected to perform such classes of operations to qualify themselves for this one.

Objects and Indications—Same as castration of the bull. See page 92.

Age—Six to twelve months.

Preparation—Withhold all food for twenty-four hours previous to operating.

Position—Standing.

Restraint—A simple, quick and efficient method of handling a bull for this operation is illustrated in Fig. 72. With a rope around horns (B), if “polled” use halter, and holder in nose (A), the head is made fast to gate post (C). While assistant continues to hold rope attached to nose the second assistant grasps tail (D) and draws it between slats of gate or fence (E). With animal in this position and thus secured he can be castrated with little annoyance in so far as body movement is concerned. If stocks are available of course they should be used in preference to this method.

Instruments—

1. Miles' hook castrating knife. (Fig. 25.)
2. Emasculator. (Figs. 5, 6, 7 and 8.)
3. Hair clippers. (Fig. 145.)
4. Spraying needle. (Fig. 152.)
5. Strong flax or braided silk for flank sutures.




Fig. 72—Ridgling Bull Confined for Castration.

Sterilization of Instruments and Cleansing Hands of Operator—The instruments should be boiled for 15 to 20 minutes. Operator's hands should be thoroughly washed with soap and warm water, using scrub brush, after which wash in Lysol or Cresol Compound, U. S. P., in the strength of one tablespoonful to each quart of water.

Preparation of Operative Field—With clippers the hair in flank region should be removed, after which thoroughly wash parts with soap and warm water, using scrub brush, then with Lysol or Cresol Compound, U. S. P., in the strength of one tablespoonful to each quart of water. As a further precaution against septic infection the skin should be painted with tincture iodine.

Operative Technique—The most popular and satisfactory method of operating is flank laparotomy, which is as follows: With Miles' hook castrating knife make flank incision in the same manner and the same size as for heifer spaying. All the details of this incision are well illustrated and described under head of heifer spaying, and the reader is strongly advised to refer to this reference before reading further in regard to the technique of the operation.



Fig. 73—Removing Testicle of “Ridgling” Bull with Emasculator. G, Flank Incision; H, Emasculator; I, Testicle; J, Hand.

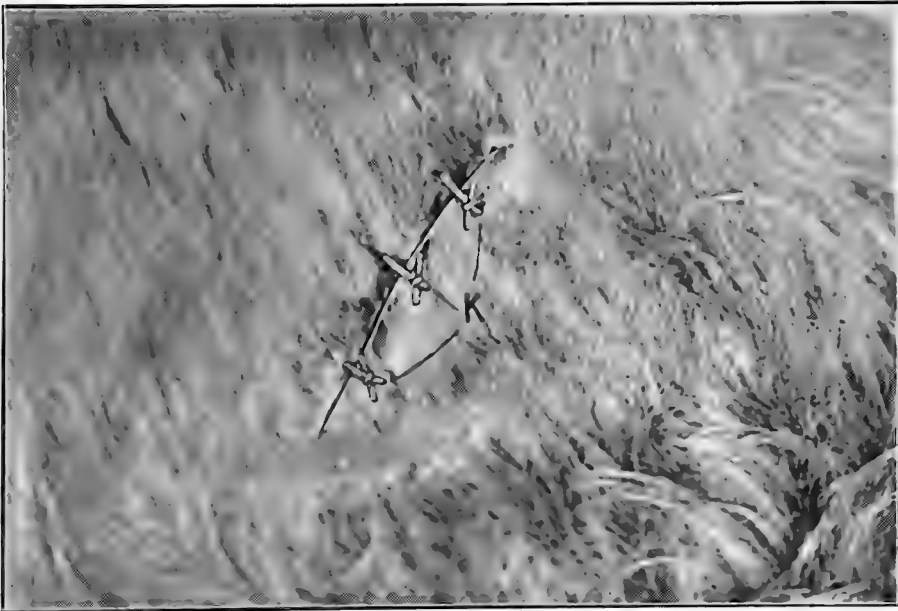


Fig. 74—Flank Incision Closed by Three Interrupted Sutures. K, Sutures.

The flank incision itself is by far the most important step of the operation, and remember that there is only one proper way to make it. Learn how it should be made and make it that way.

If we are invading the left flank the operator's left hand should be forced through the abdominal incision and a careful search made—toward the pelvic region—for either the testicle or spermatic cord. One or both of them will soon be encountered. Bring the testicle outside the abdominal cavity if the cord is sufficiently long to permit it. Then sever cord with emasculator and drop stump of cord back into the abdominal cavity. If the cord is not long enough to permit testicle being brought out of abdomen, then the emasculator or ecraseur may be passed through the incision and cord severed inside.

The wound is now sponged off with antiseptic solution and closed by three interrupted sutures.

After Care and Treatment—Limited diet for five days. Removal of sutures at expiration of eight days. If stitch abscess forms the suture may be removed at an earlier date.

CHAPTER VIII.

CASTRATION OF THE BOAR.

Objects and Indications—Pigs are castrated in order to facilitate their growth and fattening. Aside from the above the operation has a tendency to improve their behavior when associated with other hogs, especially sows. Older hogs (boars) are often castrated when having reached the limit of usefulness as breeding animals, it is decided to prepare them for market. Even when castrated, boars never make choice meat. However, they take on flesh (fatten) very readily and their characteristic odor disappears to a decided degree. Castrated boars are known as “stags.” Castrated pigs are referred to as “barrows” and it is a well-recognized fact that “barrows” command a higher market price than do boars.

Castration is an operation which is universally practiced wherever swine are raised.

Age—Pigs are best castrated either two weeks before or two weeks after weaning. If the operation is performed at or near weaning time it has a tendency to retard their growth and development. If allowed to run too long they become “boarish” besides the operation is more painful than it would have been if they had been operated on younger.

Season—Hogs should not be castrated during the summer months while flies are prevalent. Best to operate during late fall, winter and early spring.

Preparation—No special preparation is necessary unless it be to have the animals empty, which would lessen the danger of injury from handling.

Restraint—In castrating large boars it is necessary to take advantage of the animal to a very decided degree. This is essential, first, on account of the great strength of the animal compared to its size, and, second, on account of there being no favorable part or appendage of the hog by which a firm hand hold can be taken. Satisfactory restraint may be had by several different

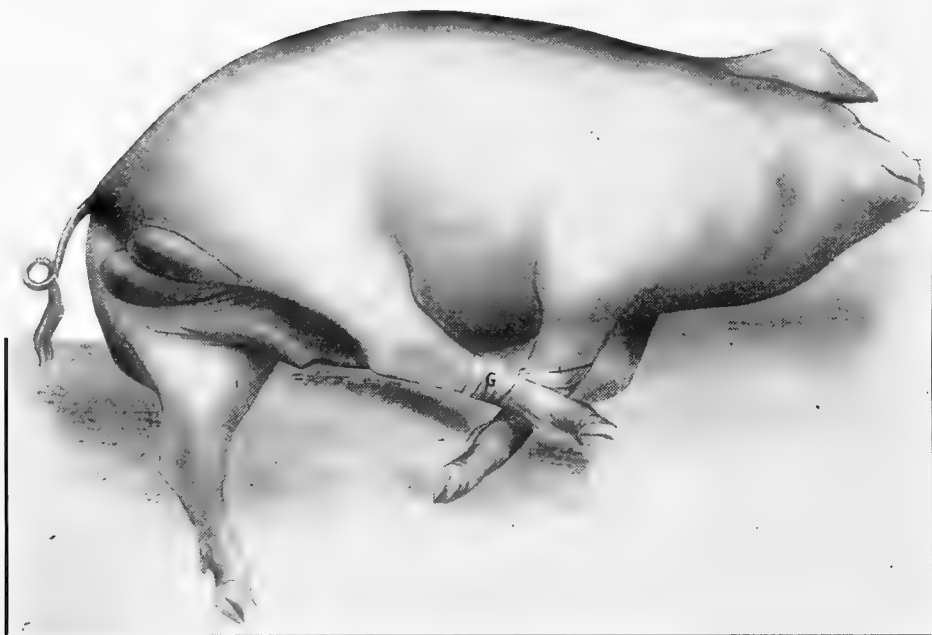

Fig. 75—Restraint for Castration.



Fig. 76—Restraint of Large Boar for Castration.

methods. Fig. 75 illustrates casting and tying the animal by bringing three feet together.

To thus secure a large hog requires considerable time and much effort besides the services of several assistants. A favorite method of the author for handling large boars for this operation is graphically illustrated in Fig. 76.

It consists in placing the loop of a half or three-quarter inch rope over the neck and behind one shoulder, after which throw the rope over beam above and allow the assistant to draw the forefeet of the hog off the floor by tension on the rope. This renders the animal absolutely helpless. By such a method the operator with one assistant can handle the largest size hog.

Another quick method of restraint for operation of this character is illustrated in Fig. 77.




Fig. 77—Restraint for Castration.

This consists in placing a rail or bar over the neck of the hog where it is held by weight of an assistant.

Figs. 78 and 79 illustrate two methods of holding pigs and small shoats for operation.

Instruments—

1. Williams' castrating knife. (Fig. 2.)
2. Emasculator. (Fig. 80.) This is an instrument specially



Fig. 78—Holding Pig for Castration.

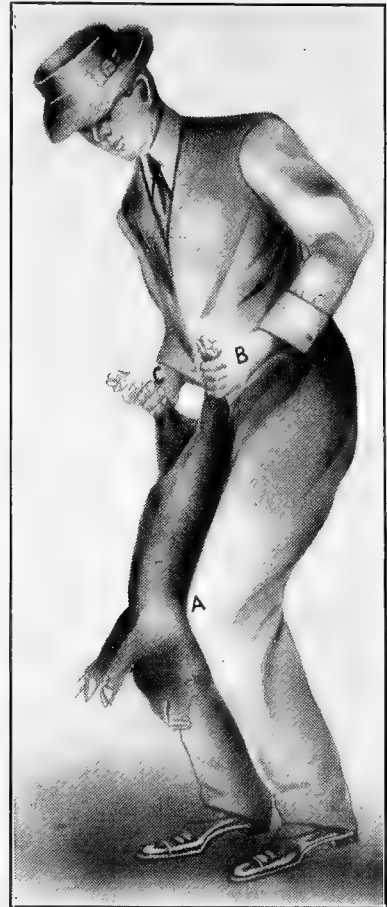


Fig. 79—Holding Pig for Castration.

constructed for castrating swine and sheep, and is about one-half the size of the one used in castrating stallions and colts and about twice the size of the canine and feline instrument.

Anatomy—The scrotum consists of two pouches formed by skin subcutaneous connective tissue, etc. These pouches are divided by a raphe or “median line” and fit up close to the perineal region. These pouches each contain a testicle (Fig. 81) which is decidedly shorter and more rounded than the testicle of many of the other domestic animals. Their long axis is vertical.

Disinfection of Operative Field—Same as for castration of the bull. (See page 96.)

Operative Technique—With sterile instruments, clean hands,

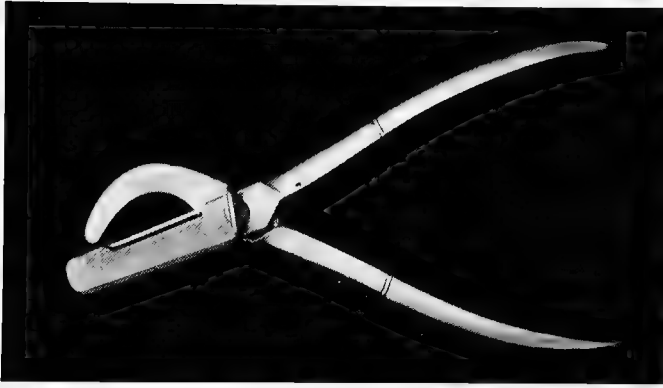


Fig. 80—Swine and Sheep Emasculator.

and the animal properly secured this operation is simple and an extremely easy one to perform. The scrotum is firmly grasped with the left hand and two bold incisions made. (H, I, Fig. 82.)

Sterilization of Instruments and Cleansing Hands of Operator—Same as for castration of the bull. (See page 96.)

These incisions should begin well forward on the scrotum and extend sufficiently far backward to allow the testicle to be removed from the scrotum without effort. The larger the incision the better. These incisions should be parallel to each other and to the “median line.” They should be from one-half to one

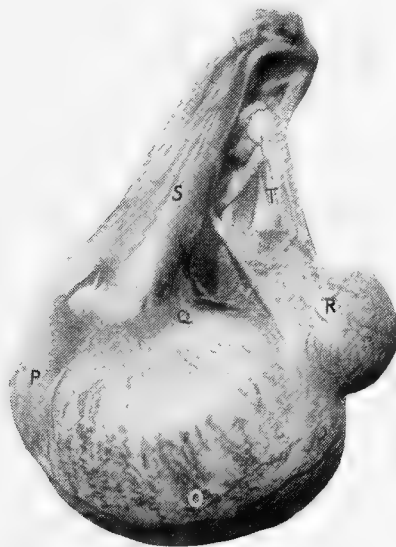

Fig. 81—Testicle of Boar. O, Testes; P, R, Epididymus; S, T, Spermatic Cord.




Fig. 82—J, Hand; H, I, Incisions in Scrotum.

inch, depending on the size of the hog, to each side of the “median line.” If for any reason the first incision was not sufficiently deep to penetrate the tunica vaginalis (sac covering testicle) and completely releasing the testicle from scrotum, then with another stroke of the knife this tunic is incised, which allows the testicle to escape from the scrotum. The testicle is now grasped with the left hand, by which it is advisable to apply about one to two pounds traction on the cord, after which apply the emasculator (M) to cord and its coverings (L) as close to the skin or scrotal incision as possible, being careful that the instrument is at direct right angles to the cord, after which the cord is severed by bringing the handles of the instrument together. (See Fig. 83.) The opposite testicle is now removed in like manner.

After Care and Treatment—Immediately after castration it is well to turn animals to pasture—preferably where there is running water. In any event get them away from the barn and barnyard and do not allow them access to stagnant and filthy “wallow holes.” Recovery is usually prompt and the mortality is small.

Sequelae—Septicaemia (blood poison), peritonitis, schirrous cord, tetanus (lock jaw), hemorrhage.

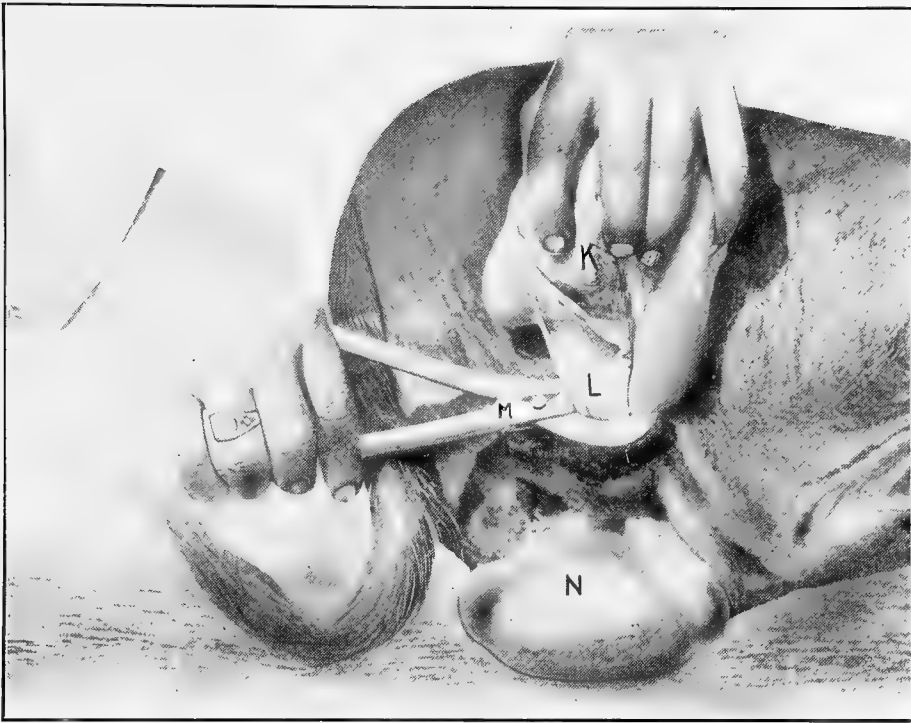


Fig. 83—Severing Spermatic Cord and Its Covering with Emasculator. K, Testicle; L, Spermatic Cord and Its Covering; M, Emasculator; N, Opposite Testicle.

CASTRATION OF THE CRYPTORCHID AND MONORCHID ("RIDGLING") BOAR.

Objects and Indications—All "ridgling" boars and pigs should be castrated. The principal reasons for so doing are outlined under proper heading in describing castration of the boar. (Page 105.) Furthermore, operation is strongly advised since the modus operandi itself is easy and comparatively simple and attended with so little danger if proper procedure is adhered to.

Age—At about 25 to 35 pounds weight.

Preparation—The pig must be empty. This is done by withholding all food for twenty-four hours previous to operating. A plentiful amount of water may be allowed.

Warning—The pig should be free from constitutional diseases and in good physical condition. Before operating, see that the testicle is not located in the inguinal canal. This precaution is

essential on account of the fact that if the testicle is in the canal it cannot be withdrawn through the abdominal incision.

Restraint—Since the operation consists in median line laparotomy the animal should be suspended from the ground to a post or beam above until the site of incision is about opposite the operator's breast.

Instruments—

1. Miles' hook castrating knife. (Fig. 25.)
2. Emasculator. (Fig. 80.)
3. Hagerdorn needle (Fig. 84) carrying 20 inches of braided silk No. 12 for abdominal sutures.
4. Richter's needle holder (Fig. 34).
5. Curved scissors (6-inch) (Fig. 35.)



Fig. 84—Hagerdorn's Needle No. 3. (Actual Size.)

Position—Hanging.

Sterilization of Instruments and Cleansing Hands of Operator—Satisfactory recoveries largely depend upon cleanliness and it behooves the operator to take extra precautions in this particular regard. Simply because the animal is a hog is no reason why it should be carelessly operated upon. Boil the instruments for 15 to 20 minutes, after which immerse them in clean pans con-

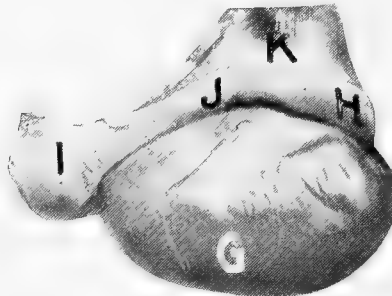


Fig. 85—Testicle of "Ridgling" Boar. G, Testes; H, Globus Major; I, Globus Minor; J, Body of Epididymus; K, Spermatic Cord.

taining Lysol or Cresol Compound, U. S. P., in the strength of one tablespoonful to each quart of water.

Disinfection of Operative Field—Clip hair from belly wall from umbilicus to brim of pubis. Wash parts with tincture green soap and warm water, using scrub brush, after which paint the skin with tincture iodine.

Operative Technique—With animal hanging, instruments sterilized, hands of operator and site of incision cleansed and disinfected, proceed as follows: Select a site either to the right or left of the median line of abdomen two inches below brim of pubis for the abdominal incision (A) (See Fig. 86.) Care must be exercised in order to avoid the urethra, etc., whose course is

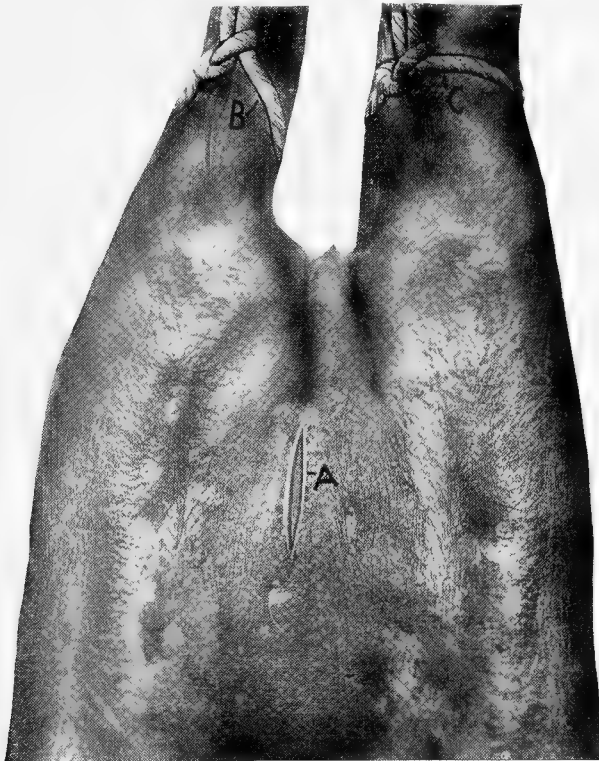

Fig. 86—Abdominal Incision.

in the median line. This incision should be three inches long and penetrate all the coats of abdominal wall. The index and second finger are now introduced into the abdominal cavity and a search



Fig. 87—Severing Spermatic Cord with Emasculator.

made for the testicle. This organ is usually short corded and hangs against posterior abdominal wall, directly in front of the abdominal incision. If the spermatic cord be long then the testicle itself may be quite a distance below the abdominal incision, in which event the cord is located and drawn through abdominal incision and the natural consequence is that the testicle will follow. The spermatic cord is now severed and its stump replaced in the abdominal cavity. If a cryptorchid (both testicles undescended) both testicles should be removed through the one abdominal incision. The abdominal wall should now be closed with three interrupted sutures. These sutures should be what is known as the "through and through" variety—all coats of the abdominal wall included in them.

After Care and Treatment—The animal should be confined for eight or nine days in a small, clean pen; during this period the

diet should be limited. Nature will ordinarily take care of removing the sutures.

CASTRATION OF THE "RUPTURED" BOAR.

Scrotal hernia ("rupture") in the boar occurs invariably and directly as a result of dilation or enlargement of the internal abdominal ring. The anatomical function of the internal abdom-

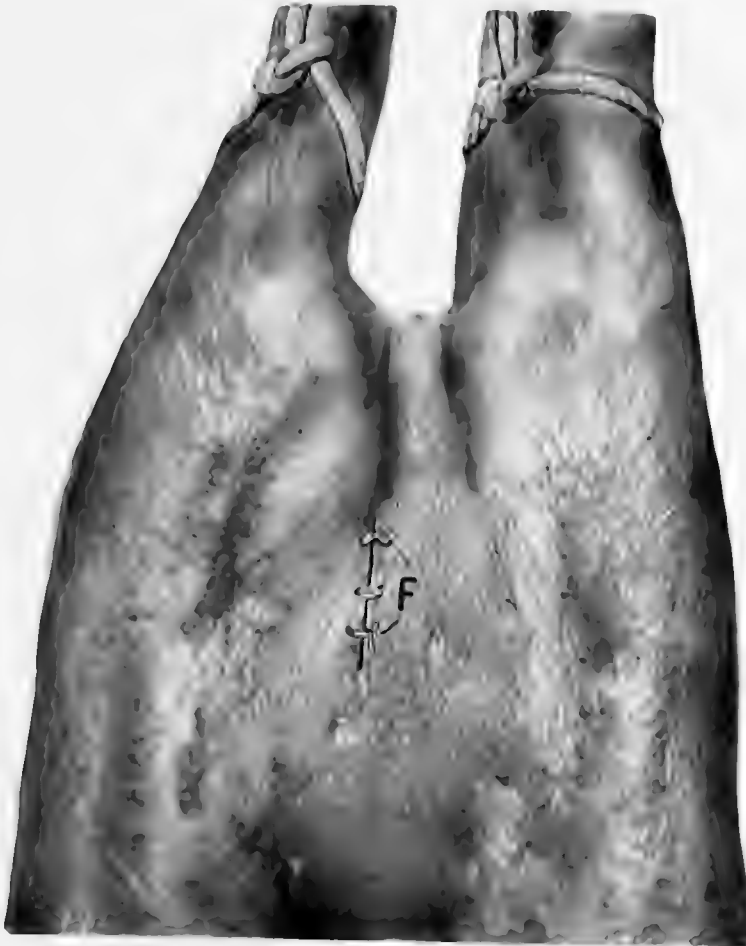

Fig. 88—Abdominal Wall Closed by Three Interrupted Sutures.

inal ring is to allow the spermatic cord to pass from the abdominal cavity into the inguinal canal and at the same time prohibit the passage of any portion of the intestines from the cavity into that canal.

Causes—The experience of others and my own observation lead me to believe that scrotal hernia of the boar is one condition which can be truthfully laid at the door of hereditary transmission in 95 per cent of cases. They are of congenital origin. The internal abdominal ring being open at time of birth and nature fails to close it afterwards. In my own practice I recall one sow in particular which presented her owner with a bunch of ruptured pigs twice each year. This sow gave birth to large litters and was kept as a brood sow on that account. These litters were usually about equally divided between boar and sow pigs. During the three years that this sow was under my observation each and every boar pig to which she gave birth was “ruptured.” Twice each year her owner would come—five miles distance—with the pigs in a market wagon for operation, and strange indeed to say he never lost a pig as a result therefrom.




Fig. 89—“Ruptured” Boar.

Objects and Indications—All “ruptured” boars should be castrated for at least three reasons: (a) Stop their breed in order to lessen the birth of congenitally “ruptured” pigs. (b) For

the same reason that boars are usually castrated, viz.: in order to increase their usefulness and value for food purposes. (c) In order that they may peacefully commingle with other hogs without exhibiting the natural and acquired sexual habits of the boar.

Most that has been written and published in regard to methods of procedure is vague and some of it misleading. If the operator follows the directions given by some so-called and so considered authorities—namely, operation via scrotal incision—he will make a haphazard job and be a monumental failure so far as his permanent results are concerned. Since the direct cause for the bowel protruding into the inguinal canal and scrotum is on account of open condition of the internal abdominal ring, then how can a scrotal operation correct the trouble? Especially is this true when we recognize the fact that by no known means can the internal abdominal ring be reached by a scrotal incision unless it be by a probe and a very long and small size probe at that. Since the internal abdominal ring must be closed in order to correct the condition and since this ring cannot be reached via a scrotal incision, it becomes necessary if we expect success to operate by an incision immediately over and in close proximity to the ring. This operation is the one which we will now illustrate and describe.

Age—At 25 to 35 pounds weight.

Season—Early spring, late fall and winter.

Preparation—Withhold food for twenty-four hours in order to have alimentary tract empty.

Restraint—Suspended by means of a rope looped above hocks and attached to a beam above.

Position—Hanging just high enough so that the operative field will be opposite the operator's breast.

Instruments—

1. Miles' hook castrating knife. (Fig. 25.)
2. Emasculator. (Fig. 80.)
3. Hagerdorn No. 3 needle (Fig. 84) carrying 20 inches braided silk No. 12 for suturing skin incision.
4. Surgeon's full curved needle No. 5 (Fig. 180 *b*) carrying a sufficient amount of chromicized catgut (ten-day) to close the internal abdominal ring.
5. Richter's needle holder. (Fig. 34.)

Sterilization of Instruments, Cleansing Operator's Hands and Operative Field—Same as for castration of the "ridgling" boar. (See page 109.)

Operative Technique—With the pig in position, the instruments sterilized, hands of operator and operative field cleansed and disinfected, we proceed as follows: Locate the internal abdominal ring. This can usually be done by pressure applied externally in the inguinal region. With location of the ring as

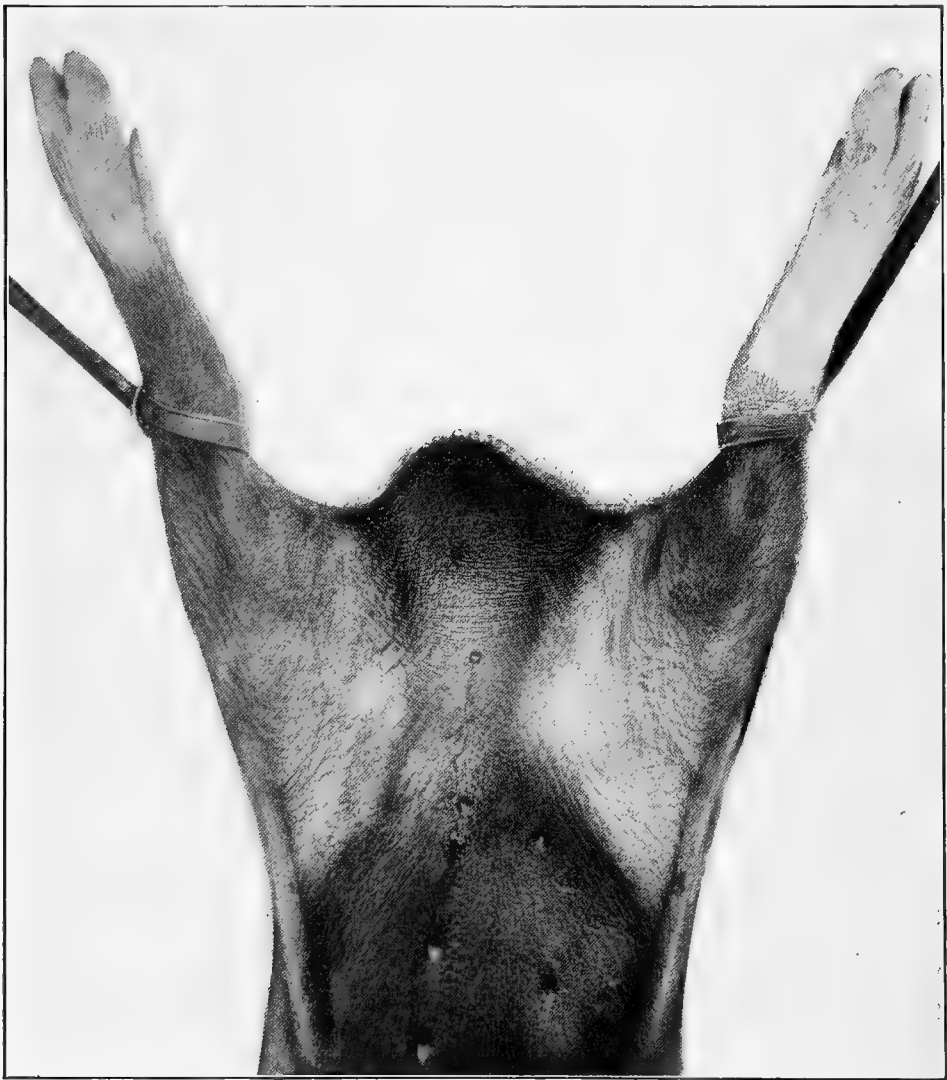

Fig. 90—View of the Scrotum After Animal Is Hung Up for Operation.

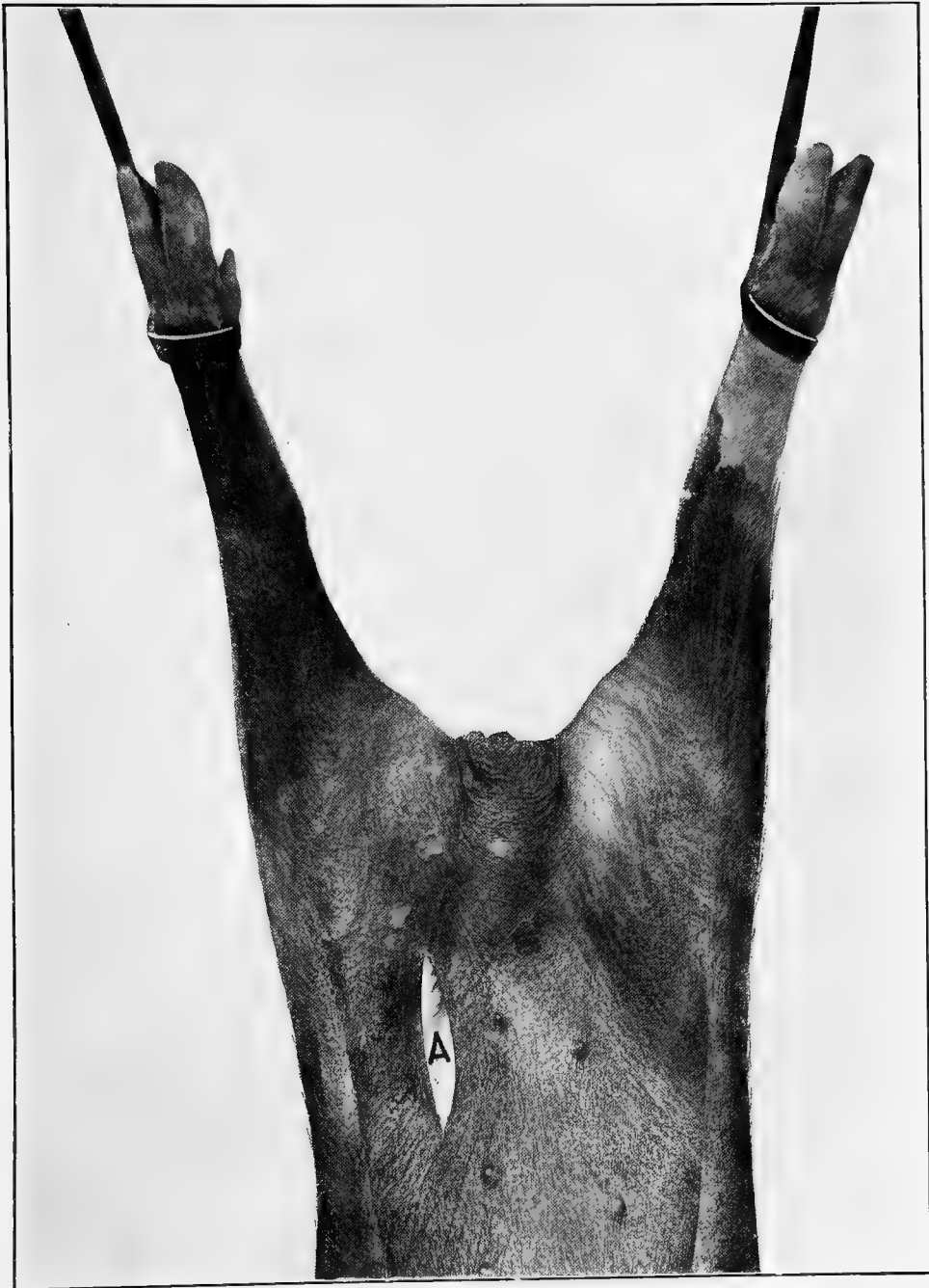

Fig. 91—Incision in Groin Immediately Over the Internal Abdominal Ring.

a land mark, make the incision through the skin and subcutaneous connective tissue down to the muscular coat of the abdominal wall. This incision should be made about three to four inches long and its center should be directly over center of the internal abdominal ring.



Fig. 92—View of Testicle, Spermatic Cord and Internal Abdominal Ring. B, Internal Abdominal Ring; C, Spermatic Cord; D, Testicle.

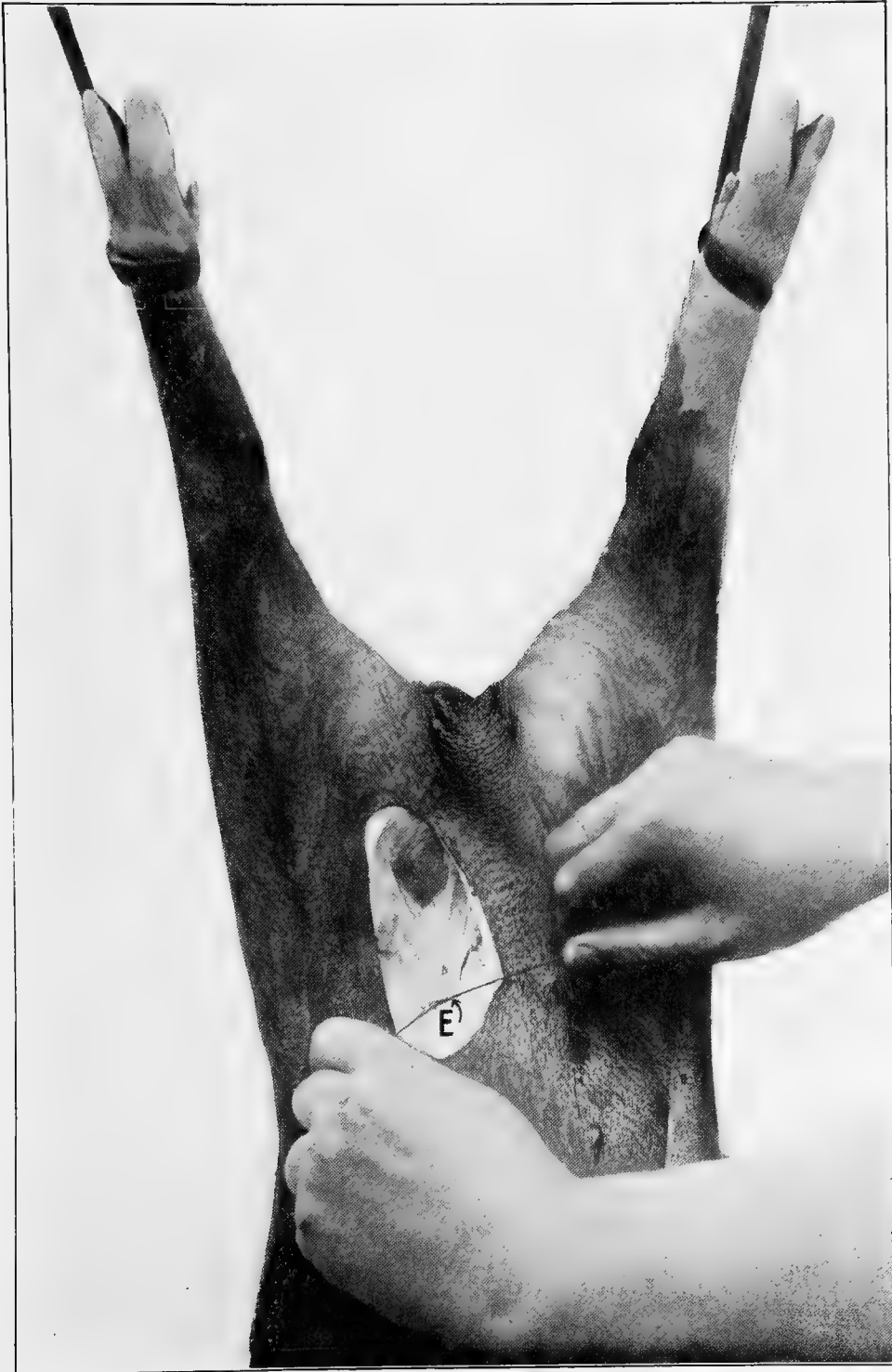

Fig. 93—Closing Internal Abdominal Ring with a Purse String Suture.

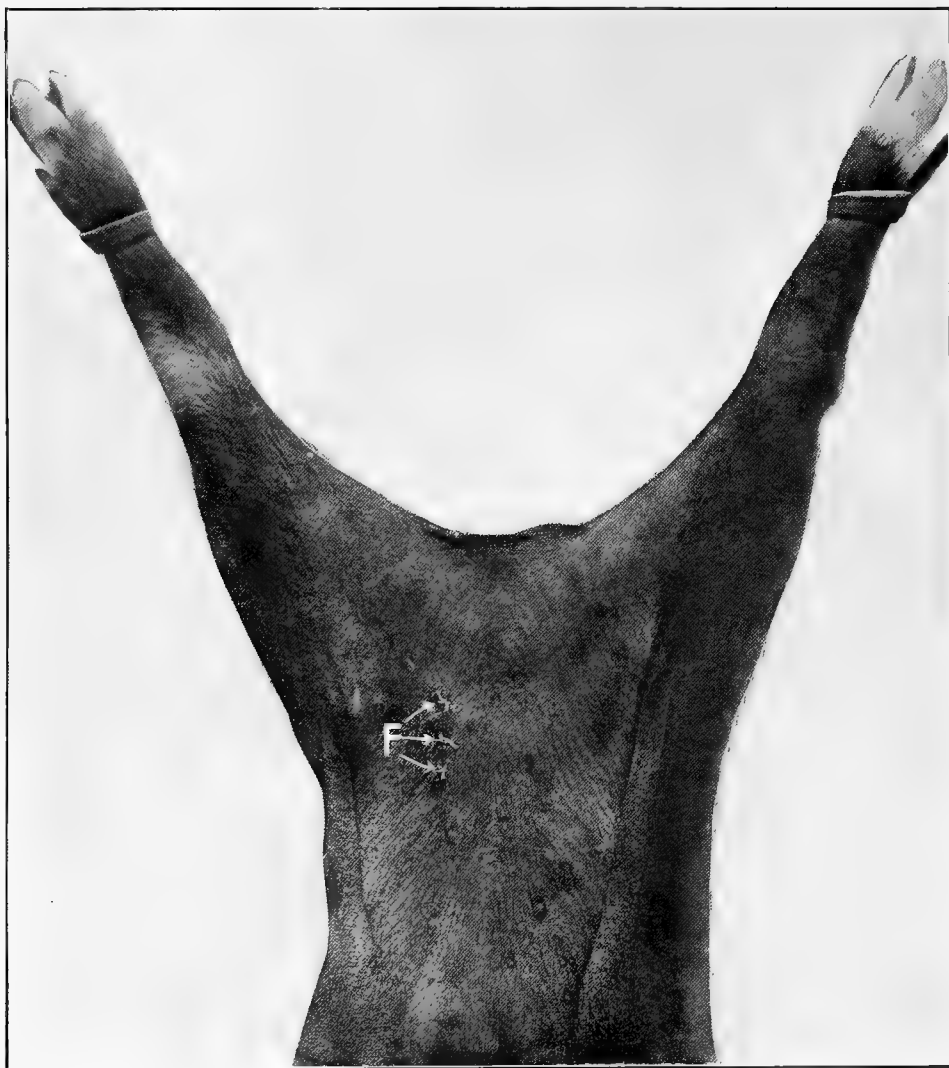

Fig. 94—Operation Completed by Three Interrupted Sutures.

Usually by this time the intestines have already—by gravity—returned to the abdominal cavity. The next step is to incise the tunica vaginalis near the ring, which exposes the cord. By traction on the cord the testicle can usually be withdrawn from the scrotum, through the inguinal canal and out of the incision. The testicle is now removed by severing its spermatic cord with emasculator, after which drop stump of severed cord back into the

abdominal cavity. Figs. 91 and 92 afford a comprehensive idea of how the operation has been proceeded with up to this point. Now by reference to Figs. 93 and 94 you will observe how it is completed. Next we close the inguinal ring by means of a "purse-string" suture applied in such a manner as to bring the serous surfaces of the peritoneum in close apposition. It is important that the suture be of absorbable material, otherwise it might do damage in the wound.

The only thing now remaining to be done is to close the skin incision which is easily and quickly done by three interrupted sutures. (See F, Fig. 94.)

Sometimes on account of small size of the external abdominal ring it is impossible to withdraw testicle from the scrotum by tension on cord. In such cases a scrotal incision is made for purpose of removing the testicle only. After which proceed to drop cord into the abdominal cavity and close ring and skin incision in the usual way.

After Care and Treatment—Confine the animal in clean pen of small size for ten days; during this period limit the feed. Nature will take care of removing the sutures.

CHAPTER IX.

CASTRATION OF THE RAM.

Objects and Indications—The operation is rarely ever performed upon aged rams. Its greatest application is to lambs. Castration hastens growth and development and improves the character of the mutton and fleece. Castrated rams and lambs are known as “weathers” and “weathers” command a much higher market price than rams. If male sheep are to be raised to full maturity for mutton purposes they should always be castrated as lambs.

Age—From a week to 10 days old is a popular and safe age at which to castrate. However, some prefer operating later. There is no doubt but what the mortality rate following castration rapidly increases with age. For that reason if for no other the early operation is most advantageous.

Season—Winter and early spring. Weather conditions play an important part in the success of the operation. Cold rains and sudden drops in temperature should be avoided as much as possible. Make an extra effort to select seasonable weather.

Preparation—Limited diet for 24 hours before operating.

Restraint and Position—A favorite method—both as regards restraint and position—is for the assistant to grasp the legs and place the animal on its rump as shown in Figure 95.

Figure 96 illustrates a satisfactory method of confining large and heavy rams for castration. Both fore and the right hind legs are fixed together by means of a cord (E). The assistant grasps left hind leg (F) and flexes it against the body. With right hand (G) he controls the head. With a ram in this position the scrotum is readily accessible.

- Instruments*—1. Williams' castrating knife. (Fig. 2.)
2. Swine and sheep emasculator. (Fig. 80.)



Fig. 95—Restraint and Position for Castration. X, Y, Right and Left Hand of Assistant; Z, Scrotum.

Anatomy—The scrotum is decidedly pouch shaped and possesses a distinct constricted neck at its summit. The skin of scrotum is covered by short, dense wool. The testicles are similar in shape to those of the bull and their long axis is almost vertical. In comparison to size of animal the testicles of the ram are unusually large. The testicle of a 60 pound lamb will weigh as much as the testicle of a 1400 pound horse.

Sterilization of Instruments and Cleansing Hands of the Operator—Boil instruments for 15 to 20 minutes after which immerse



Fig. 96—Restraint and Position for Castration of Large Rams. E, Three Feet Fixed Together; F, Assistant's Left Hand; G, Assistant's Right Hand; H, Scrotum.



Fig. 97—Testicle of Ram. L, Globus Major of Epididymus; M, Testes; N, Spermatic Cord.

them in clean vessel containing Lysol or Cresol compound U. S. P. in the strength of one tablespoonful to each quart of water.

Disinfection of Operative Field—The scrotum should be soaked by means of pledget of cotton saturated with antiseptic solution. Cleanliness here goes far in obtaining successful results. If time is not too limited it is best to remove wool from scrotum by clipping.

Operative Technique—There are two methods of making the scrotal incisions.

- (a) Lateral, Figure 98.
- (b) End, Figure 99.

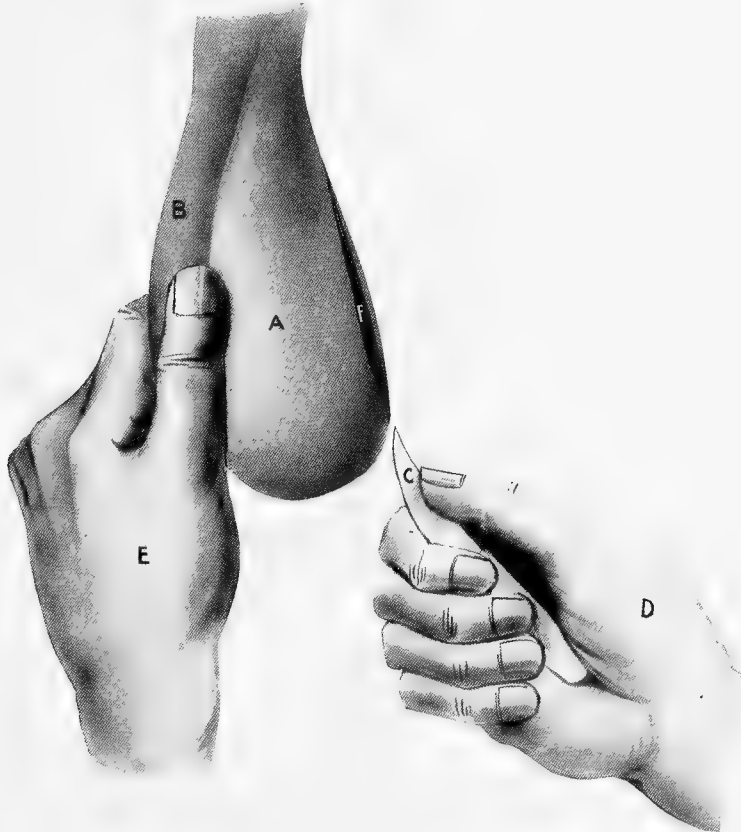


Fig. 98—Lateral Incision. A, Right Testicle in Scrotum; B, Scrotum; C, Knife; D, Right Hand; E, Left Hand; F, Incision.

In making the lateral or side incision (Figure 98) the left side of scrotum is grasped by left hand of operator and sufficient ten-

sion made—by squeezing—to render skin of right side tense. With knife in right hand the incision is made by one sweep of the knife through all coats of the scrotum and the testicle itself exposed. This incision should be about 3 1-2 inches long and extend well down to the apex. The opposite scrotal incision is made in like manner. With the right hand grasp the testicles and with the left hand strip the spermatic cords of their coverings until they are

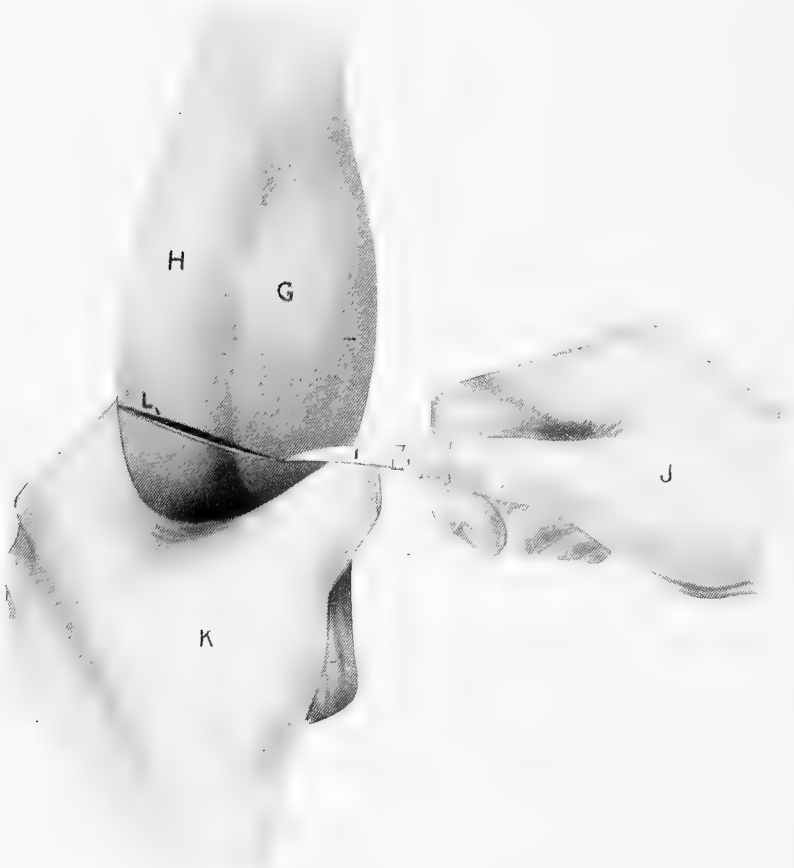


Fig. 99—End Incision. H, Left Testicle in Scrotum; G, Right Testicle in Scrotum; I, Knife; J, Right Hand; K, Left Hand; L, Incision.

well isolated as high as the summit of the scrotum. With left hand grasp testicle and make two pounds traction on the cord—outwards—at the same time apply emasculator to cord and force it well up near summit of scrotum. Then by bringing the handles of the instrument together the cord and its coverings are severed.

The end incision method (Figure 99), has many advantages

over the one already described and is to be preferred. Grasp apex of scrotum in left hand and remove one third of it—from the apex—by one sweep of the knife. The testicles surrounded by their tunica vaginalis will now drop down below the incision. By a knick of the knife incise the tunics and expose the testicles, after which grasp them (of course separately) with the right hand and make outward traction, at the same time isolate the cords by stripping them of their coverings to a point near summit of scrotum. Next with left hand grasp the testicle, at the same time producing two pounds outward traction on the spermatic cord. With right hand apply emasculator to cord and by forcing it well up to summit of scrotum sever the cord and its coverings by bringing handles of instrument together. Figure 100 illustrates manner in which cords are severed with the emasculator.

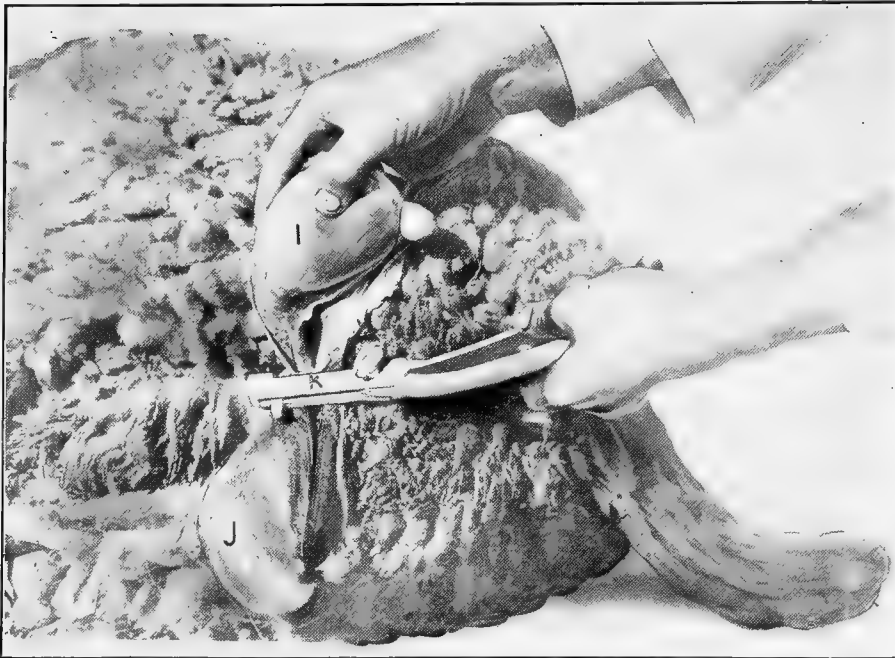

Fig. 100—Severing Spermatic Cords and Their Coverings with Emasculator.

After Care and Treatment—The most essential precaution to be taken after rams and lambs are castrated is to place them in sanitary surroundings, away from danger of wound contamination by barn and barnyard manure and dirt. In favorable weather pas-

ture is the ideal place. In bad weather a previously cleaned hallway or shed well bedded with fresh straw is to be desired. Sheep are quite prone to septic infection, hence to attain successful results infection must be strictly guarded against for several days after castration. Never operate during "fly time."

CHAPTER X.

CASTRATION OF THE DOG.

Objects and Indications—The principal object to be attained in castrating the dog is to deprive him of his nightly habit of “visiting the society female members of the canine species in his neighborhood and oftentimes in some other male dog’s neighborhood.” Castration has the direct and immediate effect of inducing a male dog to be contented with his home surroundings. The only other reason for castration would be for the relief of certain pathological conditions of the scrotum, testicle, inguinal canal and penis.

Age—Dogs can be safely castrated at almost any age. However, the younger the better. Puppies may be easily castrated at 4 weeks old.

Season—The selection of season does not play any important part in castration of the dog. The operation may be done at any season.

Preparation—None.

Restraint—Always apply a tape muzzle to begin with. Small dogs can be easily and safely held by an assistant as shown in Figure 101. The fore and hind legs are crossed over one another and held tightly. The index finger of each hand is crossed under the throat and the thumbs are passed back behind the head. In this position and held in this manner the scrotum is available and the operation may be safely proceeded with.

Large dogs may be held by two or more assistants or they may be secured by tying the legs together as illustrated in Figure 105. The operator should stand out of range of the strong stream of urine which is sure to come as soon as the knife strikes the testicle.

- Instruments*—1. Williams’ castrating knife. (Figure 2.)
2. Canine and feline emasculator (Figures 102 and 103.)

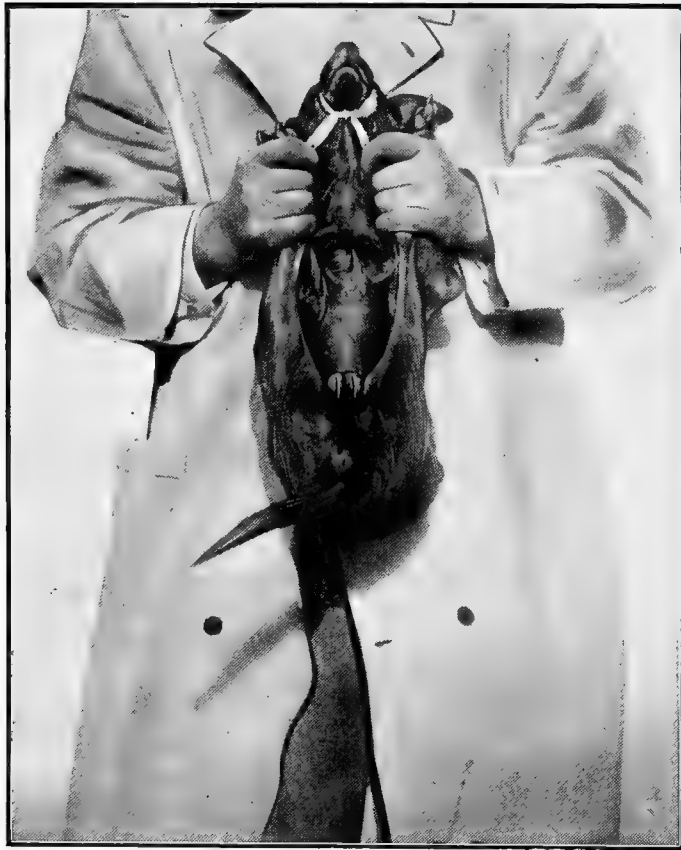

Fig. 101—Restraint of Dog for Castration.




Fig. 102—McKillip's Canine and Feline Emasculator.




Fig. 103—Canine and Feline Emasculator.

Anatomy—The scrotum is suspended below the anus. The raphe or “median line” is not well marked. The skin covering the scrotum is soft and thin and covered sparsely with short stiff hairs.

Spermatic Cord—The spermatic cord and its covering—tunica vaginalis—are slender in size and long.

Testicle—The testicle is oval in shape and comparatively small. Its long axis is oblique.

Sterilization of Instruments and Cleansing Operator’s Hands—Boil instruments for 15 to 20 minutes, after which immerse them in Lysol or Cresol Compound U. S. P., in the strength of one tablespoonful to each quart of warm water. The operator’s hands should be thoroughly washed with tincture green soap and warm water—using scrub brush—after which wash them in above mentioned antiseptic solution.

Preparation of Operative Field—If much hair is present on the scrotum it should be clipped off, after which wash scrotum with antiseptic solution and paint it with tincture iodine.

Operative Technique—The modus operandi is very simple and only requires a few seconds time in its performance. With left thumb and index finger grasp scrotum above testicles and make its skin tense by squeezing. With knife in right hand—by two sweeps

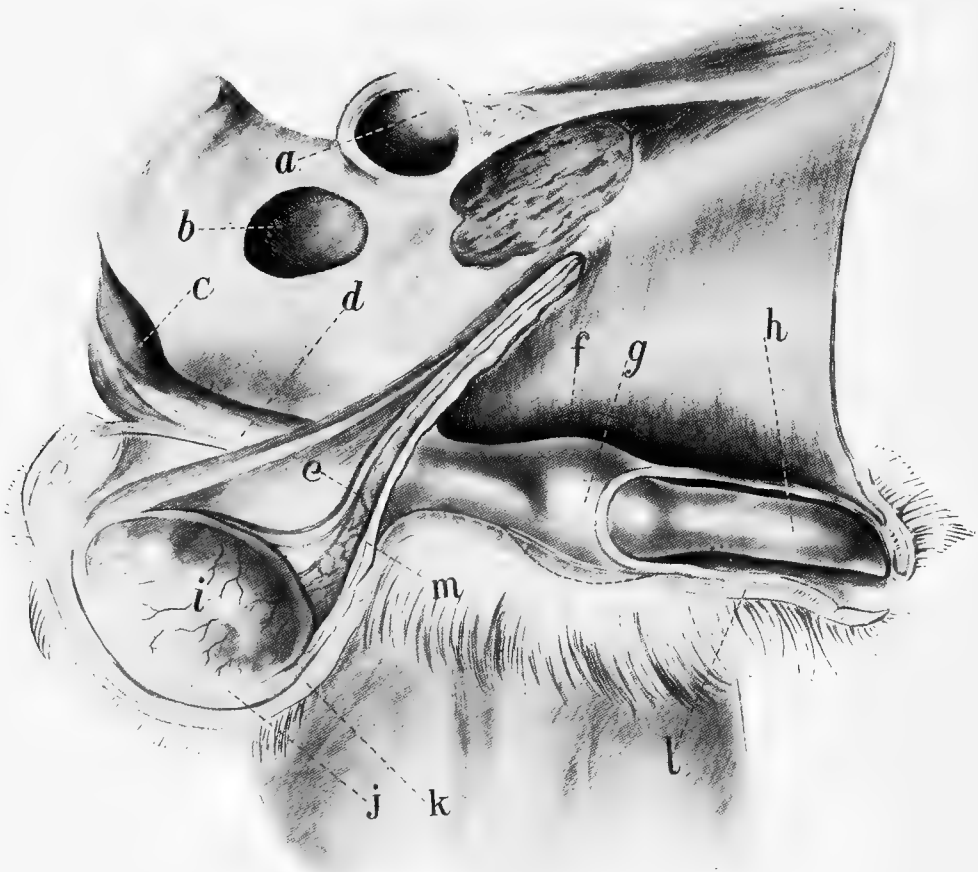


Fig. 104—Genitals of the Dog. (Ellenberger-Leisering Atlas.) a, Acetabulum; b, Obturator Foramen; c, Ischio—Cavernosum Porton; e, Vas Deferens; f, Bulbus Glandis; i, Testicle; j, Tunica Vaginalis; k, Scrotum; l, Prepuce; m, Spermatic Cord.

—the two scrotal incisions are made exposing both testicles. These incisions should be amply large and extend well down to lower portion of scrotum in order to afford free drainage.

The concluding step is to grasp testicle with left hand at the same time making slight traction on the cord. With right hand the emasculator is placed on the cord and forced down close to the scrotal incisions. The cord is now severed by bringing handles of instrument together.

After Care and Treatment—About all that is necessary is exer-

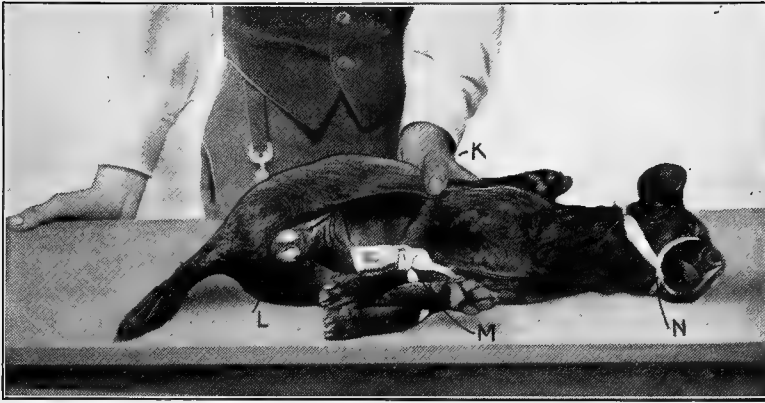


Fig. 105—Scrotal Incisions. K, Left Hand of Assistant; L, Scrotal Incisions; M, Legs Fixed Together with Cord; N, Muzzle.

cise and sanitary surroundings with daily observation for purpose of detecting the appearance of the several sequelae of castration.

CASTRATION OF THE CRYPTORCHID AND MONORCHID DOG.

(“RIDGLING.”)

Objects and Indications—On account of the universally recognized fact that cryptorchidism in animals is transmitted by heredity, it is very important that such a dog should not be used for stud purposes. This applies more particularly to the monorchid than it does to the cryptorchid. On account of the former—

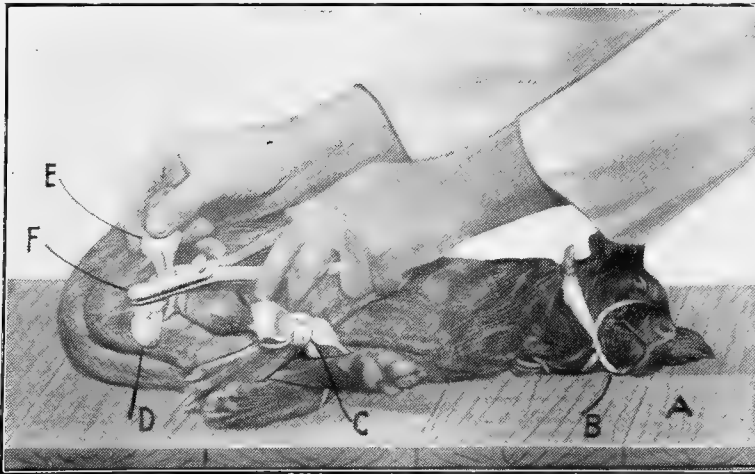


Fig. 106—Severing Spermatic Cord with Emasculator. A, Table; B, Muzzle; C, Legs Fixed Together with Cord; D, Left Testicle; E, Right Testicle; F, Emasculator.

with one testicle descended—being able to propagate his species while the latter—both testicles inside the abdominal cavity—is incapable of reproduction. In order to cause the breed of such animals to cease castration should be resorted to. Aside from the above reason for castration the operation is valuable in causing a dog to remain contented at home.

Age—All ages, preferably young dogs.

Season—All seasons.

Preparation—It is essential to have the alimentary tract empty. This is accomplished by withholding food for 24 hours previous to operating.

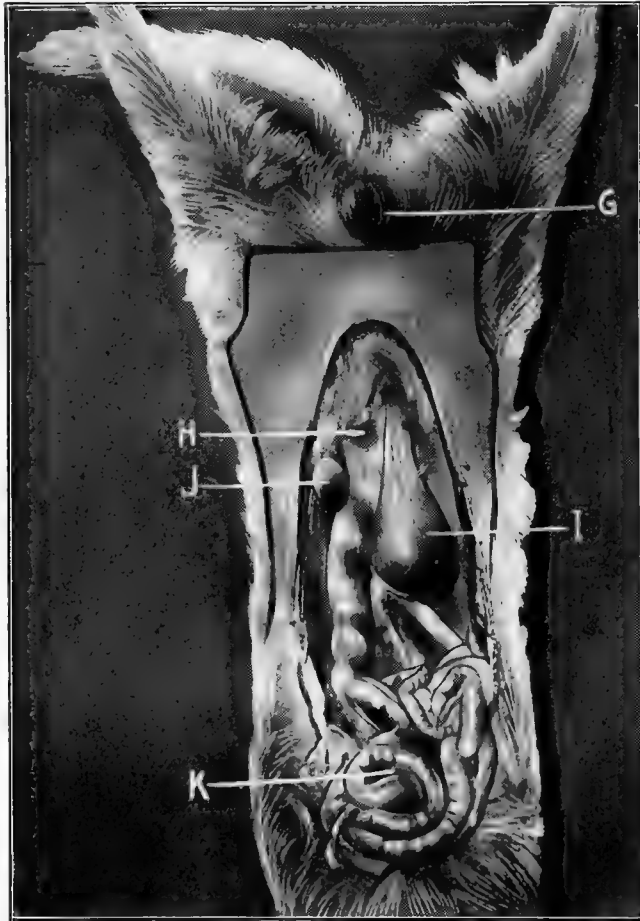


Fig. 107—View of Internal Abdominal Organs. G, Descended Testicle; H, Rectum; I, Urinary Bladder; J, Undescended Testicle Located in the Sub-Lumbar Region; K, Intestines.

Restraint—Preferably on operating table elevated to perpendicular position or in the absence of a table the animal may be hung up to a wall or post. In either event the tape muzzle is applied as a protection against bites.

- Instruments*—1. Miles' hook castrating knife. (Figure 25.)
2. Emasculator. (Figures 102 and 103.)
3. Richter's needle holder. (Figure 34.)
4. Surgeon's needle (full curved) carrying 20 inches of No. 12 braided silk for sutures.

Anatomy—A comprehensive idea of the location and relation of

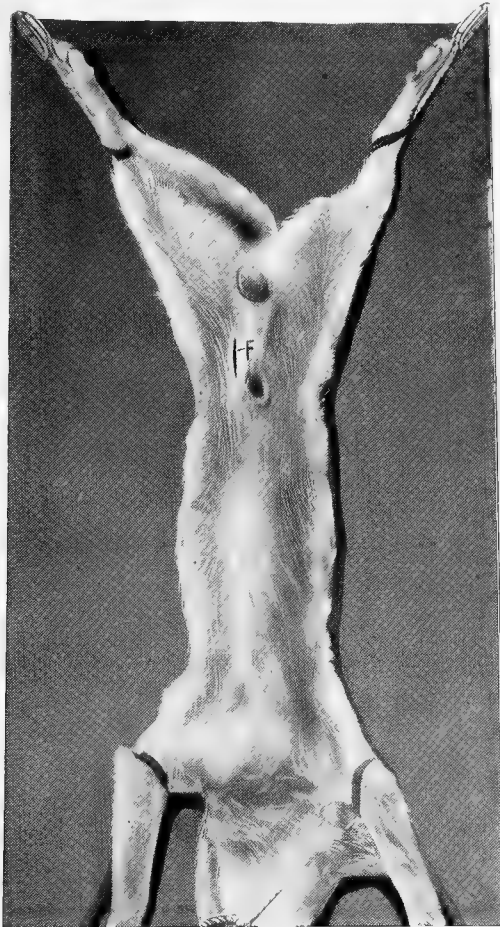


Fig. 108—Abdominal Incision.

the parts concerned in this operation can be had by reference to Figure 107.

Sterilization of Instruments and Cleansing Operator's Hands—Boil instruments for 15 to 20 minutes, after which immerse them in Lysol or Cresol Compound U. S. P., in the strength of one tablespoonful to one quart of warm water. Wash hands thoroughly with soap and warm water, using scrub brush.

Disinfection of Operative Field—Clip or shave hair from field of operation after which wash with soap and warm water until parts are visibly clean. Sponge off with antiseptic solution and paint with tincture iodine.

Operative Technique—If left testicle is the one undescended a

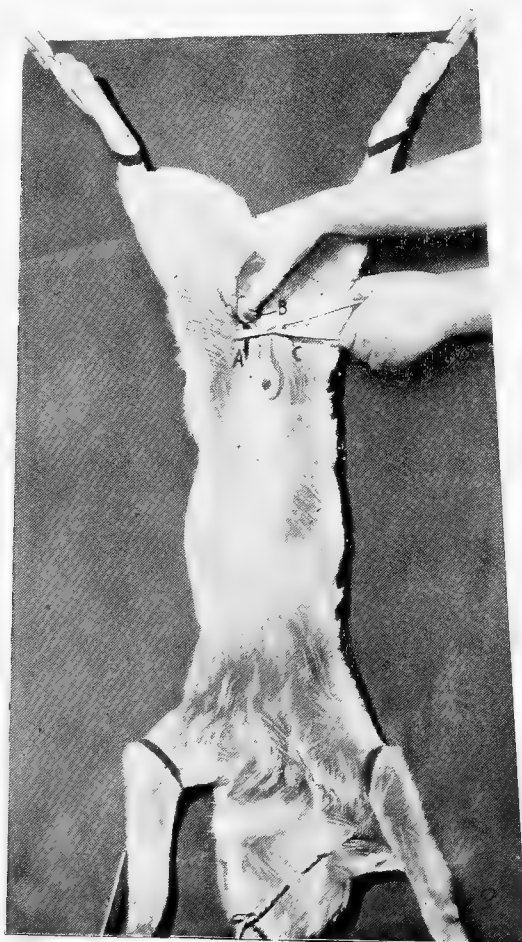


Fig. 109—Severing Spermatic Cord with the Emasculator. A, Incision; B, Testicle; C, Emasculator.

point is selected to the left of the median line of the abdomen and about midway between brim of pelvis and prepuce (See Figure 108).

The incision is made 2 1-2 inches long—through all coats of the abdominal wall. Through this incision the index finger of right hand is passed and a search made in the sub-lumbar region for the spermatic cord. This cord is usually easy to locate. Withdraw cord through abdominal incision and the testicle follows naturally. Sever cord with the emasculator (Figure 109) and replace its stump in abdominal cavity. All that remains to be done is to suture up abdominal incision. This is done by two “through and through” interrupted sutures. See Figure 110.

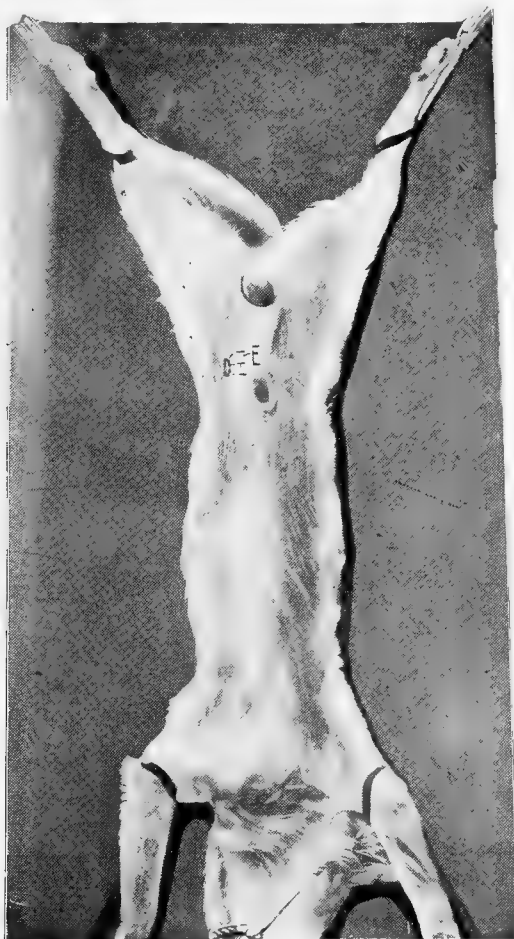


Fig. 110—Incision Closed with 3 Interrupted Sutures. D, Sutures; E, Incision.

After Care and Treatment—The dog should be placed in sanitary close quarters for 6 or 7 days; during this period no exercise must be allowed and the diet should be of a light, easily digestible character, and limited. The two end sutures may be removed on the third day and the middle one on the fifth day.

CHAPTER XI.

CASTRATION OF THE CAT.

Objects and Indications—In order that they will remain contented at home.

Age—The operation can be done safely at any age.

Season—All seasons.

Preparation—Same as for castration of the dog.

Restraint—Remember that a cat will scratch as well as bite and we must take the necessary precautions to protect ourselves from both. Two favorite methods of restraint—either of which are satisfactory—are as follows:

(a) With all four feet tucked up against the abdomen, wrap the animal in a towel, leaving its posterior portion exposed. See Figure 111.

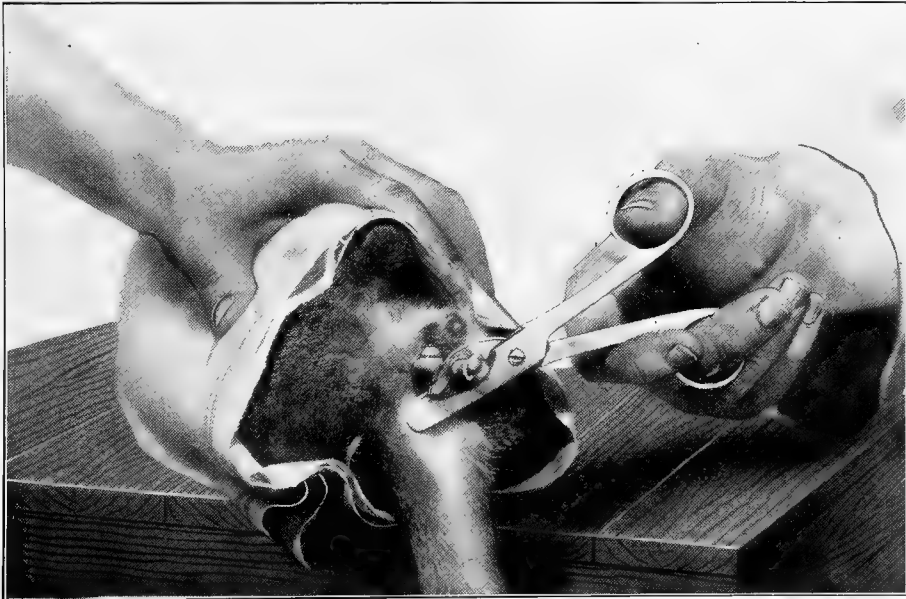


Fig. 111—Castration with Cat Wrapped in Towel.

(b) Place animal in an ordinary rubber boot with hind legs thrust through the finger straps. See Figure 112.

Position—Dorsal.

Instruments—Same as for castration of the dog. See page 131.

Anatomy—Similar to that of the dog except on a smaller scale.

Sterilization of Instruments and Cleansing Operator's Hands—Same as for castration of the dog. See page 133.

Preparation of Operative Field—Same as that for castration of the dog, with the exception that special pains must be taken to see that the hair from scrotum is removed. See page 133.

Operative Technique—Same as for castration of the dog. See pages 133-134.

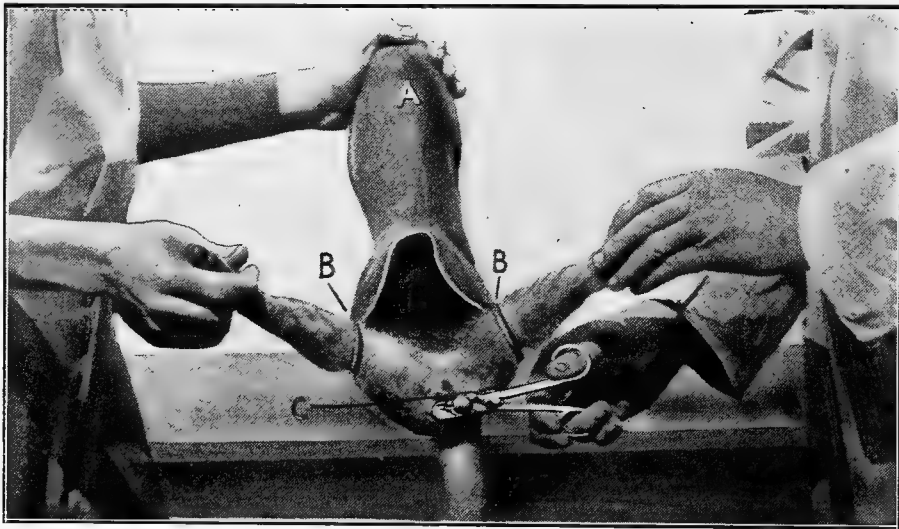


Fig. 112—Castration with Cat in a Rubber Boot. A, Boot; B, B, Finger Straps; C, Severing Spermatic Cord with the Emasculator.

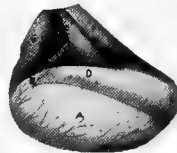

Fig. 113—Testicle After Removal.

After Care and Treatment—Daily observation for the appearance of sequelae of castration.

CHAPTER XII.

CAPONIZING.

Definition—Caponizing is a term applied to castrating fowls. In this country the operation is practiced almost exclusively on male chickens (“roosters”), and sometimes turkeys. Such fowls when castrated are known as capons. The capon bears the same relation to the “rooster” as the “steer” does to the bull, the “barrow” to the boar, etc.

History—It is impossible to say just how long the operation of caponizing has been performed. It seems quite certain, however, that the practice was familiar to the Chinese more than two thousand years ago. Later it was practiced by the Greeks and Romans and through medieval times, by the people of middle and southern Europe, until in recent years it has been introduced into America. At present capons are most universally known and appreciated in France, although within the last few years the business of producing them has advanced rapidly in this country. Much of the larger part of the industry is confined to that portion of the United States east of Philadelphia, though increasing numbers of capons are being raised in the North Central States. During the winter months “capon” is regularly quoted in the markets of the larger eastern cities. Massachusetts and New Jersey are the great centers for the growing of capons, while Boston, New York and Philadelphia are the great markets.

Objects and Indications—Caponizing changes a male chicken’s disposition to the extent that he no longer shows an inclination to fight, becomes sluggish and quiet and more docile than formerly. The true capon never crows. The comb and wattles cease growing. His society is not sought by other chickens—either roosters or hens—he becomes an outcast and on this account oftentimes takes up with baby chicks even to the extent of becoming a mother to them; scratch and work for them by day and hover them by night. On account of the more peaceful disposition of the capon his body develops rapidly and he grows larger and takes on fat more readily

than the ordinary male bird. At same time the body is developing the texture of the flesh is improving, and it is now a well recognized fact that the flavor and texture of the flesh of a capon is as much improvement over that of a rooster as the meat of a steer is over that of a bull. Hence capons are entitled to and do command a higher market price than either roosters or hens. Capons are less trouble to care for and to keep within prescribed bounds than other chickens. The economic value of caponizing justifies its more general practice.

Selection of Breeds—Always select from the large breeds, viz: Light Brahmas, Cochins, Plymouth Rocks, Langshans, Wyandotts, Orpingtons, etc.

Age—Two or three months is the best age at which to operate. The chicken should weigh from 1 1-2 to 2 pounds. Never operate after five months old. The mortality is low in young fowls and increases with age.

Season—Summer—June, July and August.




Fig. 114—Restraint of the Fowl for Caponizing. A, A, Weight at Ends of Cords; B, Cords Looped Around Legs; C, Cord Looped Around Wings.

Restraint—The most economical and at the same time most satisfactory method of restraint is illustrated in Figure 114. With a barrel or box used as an improvised operating table one cord is looped around the wings and another around the legs. The length of these cords will depend upon the size of box or barrel being used. To the free end of each cord a weight—one half brick—is attached. The fowl is now laid on table and the weights will produce sufficient traction on cords to hold it in proper position.

Another method of restraint favored and used by some is a specially constructed board. See Figure 115. It will be observed that a self-locking staple is used to confine the wings, while the legs are confined by a loop strap with a weight suspended at its end. The holes through board makes it adjustable to all size fowls.

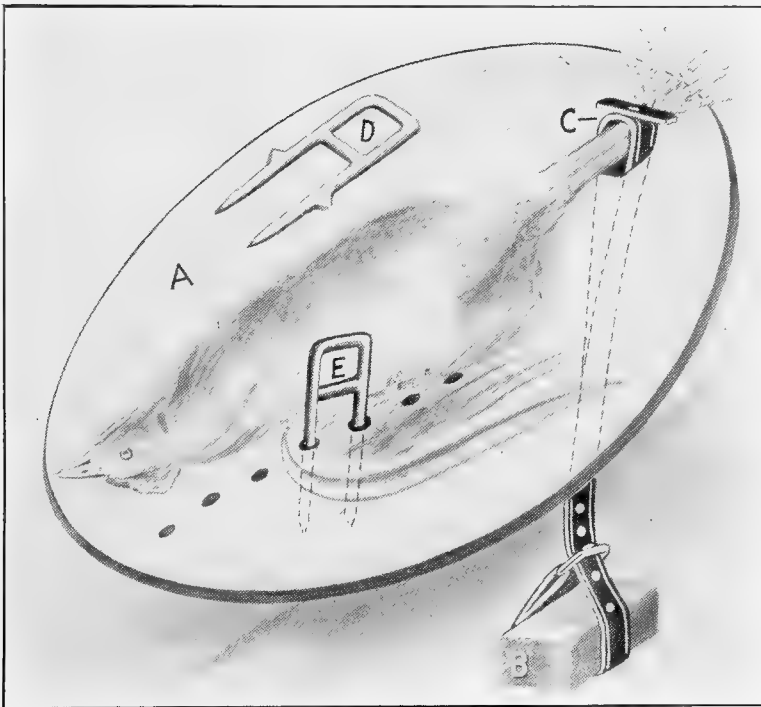


Fig. 115—Caponizing Board. A, Board; C, Feet Imprisoned in Strap Loop; B, Weight on End of Strap; E, Wings Imprisoned in Staple.

Instruments—several different styles and kinds of instruments for performing the caponizing operation are on the American

market. Most of them are satisfactory after the operator becomes accustomed to handling them. They consist of:

1. Knife for making abdominal incision.
2. Spreaders or retractors for separating the ribs.
3. Appliances for removing the testicle.

Some of the best of each of these are illustrated below. The operator should make his own selection. The author's preference is the "Farmer" Miles set.




Fig. 116—Miles' Caponizing Knife.




Fig. 117—Miles' Spreaders.




Fig. 118—Spring Spreader




Fig. 119—Wire Spring Spreader.

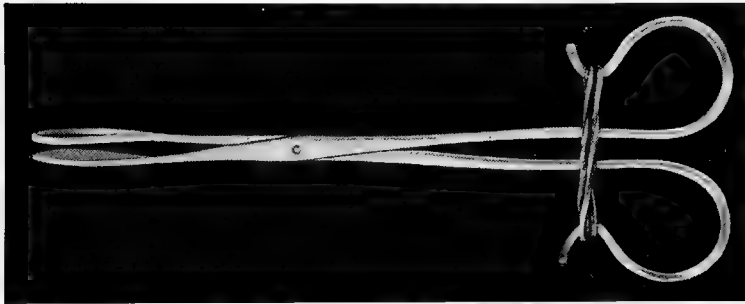


Fig. 120—Miles' Forceps.



Fig. 121—Scoop and Hook.



Fig. 122—Clipping Knife, Scoop and Hook.

Anatomy—The testicles are situated in the abdominal cavity. They are small, bean-shaped, soft, very friable and light colored. Their location is on each side of the vertebral column, immediately behind the lungs and in front of the kidneys. See Figure 123. They are opposite the last intercostal space. Above them is the aorta and vena cava.

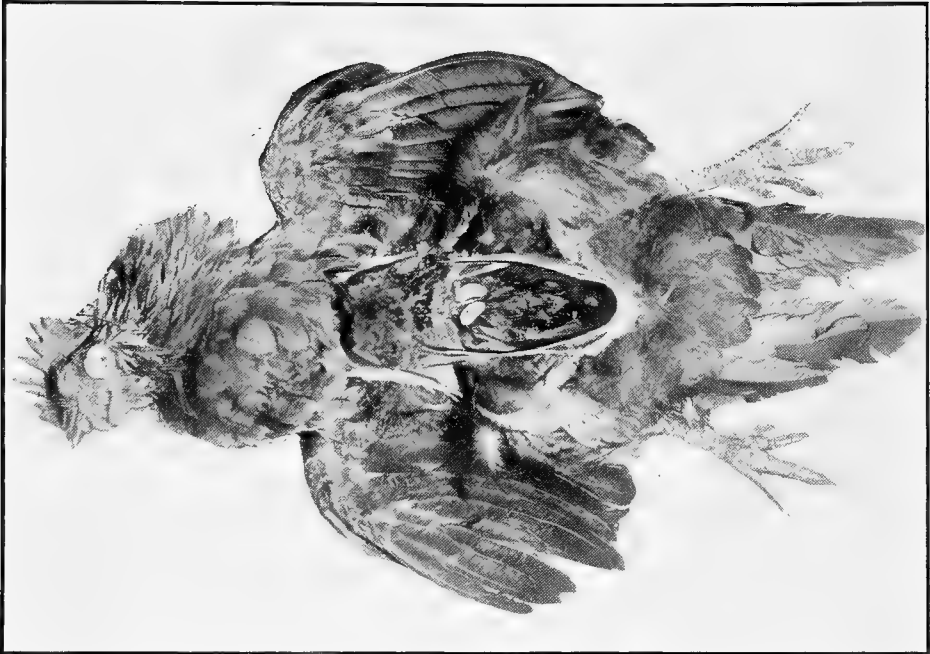

Fig. 123—View of Testicles.

Preparation—The most essential step connected with caponizing is to have the fowls entirely empty at time of operating. This is accomplished by withholding food and water for 30 hours. Never attempt to operate upon a “full” chicken unless you are looking for trouble.

Operative Technique—Unless a satisfactory artificial light is available the proper time of day at which to operate is between the hours of 10 a. m. and 2 p. m., as at this time the sun is high and in proper position to reflect its bright light into the abdominal cavity. Good light is one of the essentials. Never attempt to operate without it. With fowl properly confined and in such position as will enable the sunlight to illuminate the abdominal cavity—operate out of doors—instruments and hands of operator clean, proceed as follows:

1. Pluck feathers from field of operation.
2. Chill parts by glass full of ice water being slowly poured over skin. This chilling process has a good influence in preventing cutaneous hemorrhage.

3. With knife in right hand make abdominal incision by incising the muscles in last intercostal space (between last two ribs). Since the intercostal artery passes along the posterior (back) border of the ribs, this incision should closely follow the anterior (front) border of the last rib. The first incision includes all layers of the abdominal wall with exception of the peritoneum.

4. Insert spreaders and spread the ribs apart sufficiently to admit scoop or forceps.

5. Knick peritoneum. This will open the abdominal cavity.

6. The testicles are now located and if both are to be removed from one abdominal incision the lowermost one should be removed first, otherwise the hemorrhage incident to removing the upper one would interfere with removal of the lower. There is not serious objection to operating from both sides, in which event the uppermost testicle is removed first.




Fig. 124—Diagrammatic Illustration Showing Position of Testicles and the Method of Their Removal. A, Right Testicle; B, Left Testicle; C, Scoop Applied to Spermatic Cord; D, Vertebral Column; E, Incision in Last Intercostal Space; F, Spreader.

With scoop or forceps applied to the spermatic cord—care being taken not to include the aorta or vena cava—the testicle is removed by twisting the cord with several turns of the instrument. Be sure and remove the entire testicle as if any portion of it is left, the fowl will crow, and be what is known as a “slip.” “Slips” are not capons and are undesirable.

7. Remove the spreaders. This allows the ribs to come together and close the abdominal wound. If a mistake has been made by severing either the aorta or vena cava the fowl will die in a very few minutes from internal hemorrhage. Should death occur from such source the fowl can be used for food.

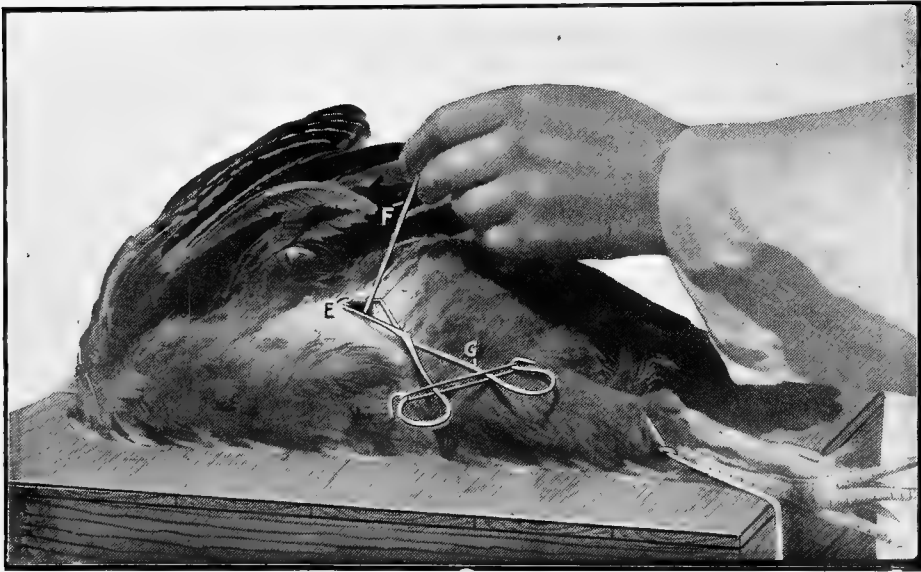

Fig. 125—Removing Testicle with Scoop. E, Abdominal Incision in Last Intercostal Space; F, Scoop Applied; G, Spreaders Applied.

On account of the almost complete immunity of the chicken from septic infection, healing of wound usually takes place by first intrusion and the fowl makes a quick and satisfactory recovery.

After Care and Treatment—Upon being released from the operating table the capons are usually put in a closed yard where they can find shelter, food and water and can be kept quiet. No roosts are provided, as the less flying and jumping they do the sooner will the wound heal. The capons seem to be very little



Fig. 126—Removing Testicle with Miles' Forceps. J, Spreaders Applied; K, Forceps Applied; L, Abdominal Incision.

inconvenienced by the operation, and water and soft feed mixed with sweet skim milk can be given immediately. Some feeders give this in unlimited quantity, while others feed more sparingly for a time.

For a week or ten days the newly made capons should be carefully observed to see whether they become "wind puffed." This is a condition caused by air gathering under and puffing out the skin near the wound. When observed it can be readily relieved by pricking the skin with a needle or knife and pressing out the air.

Mortality—About 1 to 2 per cent.

PART II.**SPAYING.**

Synonyms—Ovariectomy, Oophorectomy, Ovariotomy.

Definition—Spaying is a term applied to the operation of unsexing the female.

CHAPTER I.

MARE SPAYING.

Objects and Indications—The principle indication for removing the ovaries from mare is to correct the disagreeable and dangerous vice known as nymphomania, the symptoms of which are as follows: Usually when such animals are touched, especially while applying harness and saddles, they squat, switch their tails, kick, bite, urinate, etc., while at the same time the clitoris moves actively. This behavior of the clitoris is similar to its action during oestrus (heat). Some nymphomaniac mares are affected with such behavior continuously, while in others it is periodical. The intensity of the vice also varies in degree in different individuals. Some are affected to the extent of actual viciousness. Such animals are a public and private nuisance, undesirable to own and dangerous to the attendant. Usually removal of the ovaries from this class of mares will correct the trouble. The results of the operation are not immediate. In fact, even apparent improvement may not be had until several weeks—possibly several months—have elapsed. The improvement is gradual and oftentimes slow, even after it actually begins. Spaying is always justified in mares of this class.

Age—Spay regardless of age when operation is indicated.

Season—Spring, winter and fall.

Preparation—It is necessary for the intestinal tract—rectum in particular—to be empty. This is usually accomplished by withholding feed for 30 hours previous to operating. To make sure that the rectum is empty it is well to administer an enema immediately previous to operating. Douche out the vagina and wash anis, vulva, tail and surrounding parts with Lysol or Cresol compound U. S. P., in the strength of one tablespoonful to each quart of water. Bandage upper one-third of tail. Chloral or cannabis Indica administered 30 or 40 minutes before operating is helpful in most instances.

Position—Standing.

Restraint—If a suitable operating stock is available it should be used. In lieu of the stocks a narrow box stall and slings are the next best method of restraint for spaying operation. When narrow stall and sling are used it becomes necessary to confine the hind feet in such a way that the operator is not subjected to the danger of kicks. The simplest method which will answer the purpose is illustrated in Figure 127. It consists of the nose twitch applied and held by an assistant; also an 18-foot $\frac{3}{4}$ -inch cotton rope and one hobble strap. Loop end of rope around off hind pastern, then pass it through D of near hind, then upwards and forwards between fore legs, over withers and under main rope behind elbow. Another method is the Hippo Lasso. (See Figs. 135 and 136.)




Fig. 127—Restraint for Spaying in Standing Posture.

While the last two methods described are simple and will answer the purpose, there is at least one quite serious objection to them, viz: The animal may in her struggles cast herself, or she may voluntarily lie down, which greatly interferes with the progress

of the operation. Whenever possible it is always advisable to fortify yourself against the animal lying down.

Instruments—1. Colin's Scalpel (Fig. 128) is decidedly the most satisfactory knife for vaginal spaying. This knife possesses a heavy blade with wide belly guarded by an easily manipulated sliding shield. A knife thus constructed can be safely handled inside the vaginal canal.




Fig. 128—Colin's Scalpel.

2. Williams' Ratchet Spaying Ecraseur (Fig. 129). This instrument is so constructed that it takes up very little space in the vaginal canal, and is sufficiently long to reach the ovaries of the



Fig. 129—Williams' Ratchet Spaying Ecraseur.

largest mare or cow. The ratchet handle enables operator to manipulate the instrument with one hand while the other hand remains in the cavity. If an extra assistant is available for the purpose of handling the instrument on the outside, then Dunn's spaying ecraseur (Fig. 130) is an excellent instrument.



Fig. 130—Dunn's Spaying Ecraseur.

3. Vaginal spaying speculum. There are two satisfactory spaying speculums now on the market. A, Williams' Speculum (Fig. 133); B, Paseley's Speculum (Fig. 134).

Anatomy—In order to spay mares satisfactorily it is essential that a general idea of the anatomy of vulva, vagina, uterus and ovaries be possessed. Lack of space here forbids going into minute detail. However, the more important points will have attention.

Vulva—The vulva is the external opening of the genital and urinary tracts. It is an ovoid slit situated in the perineal region

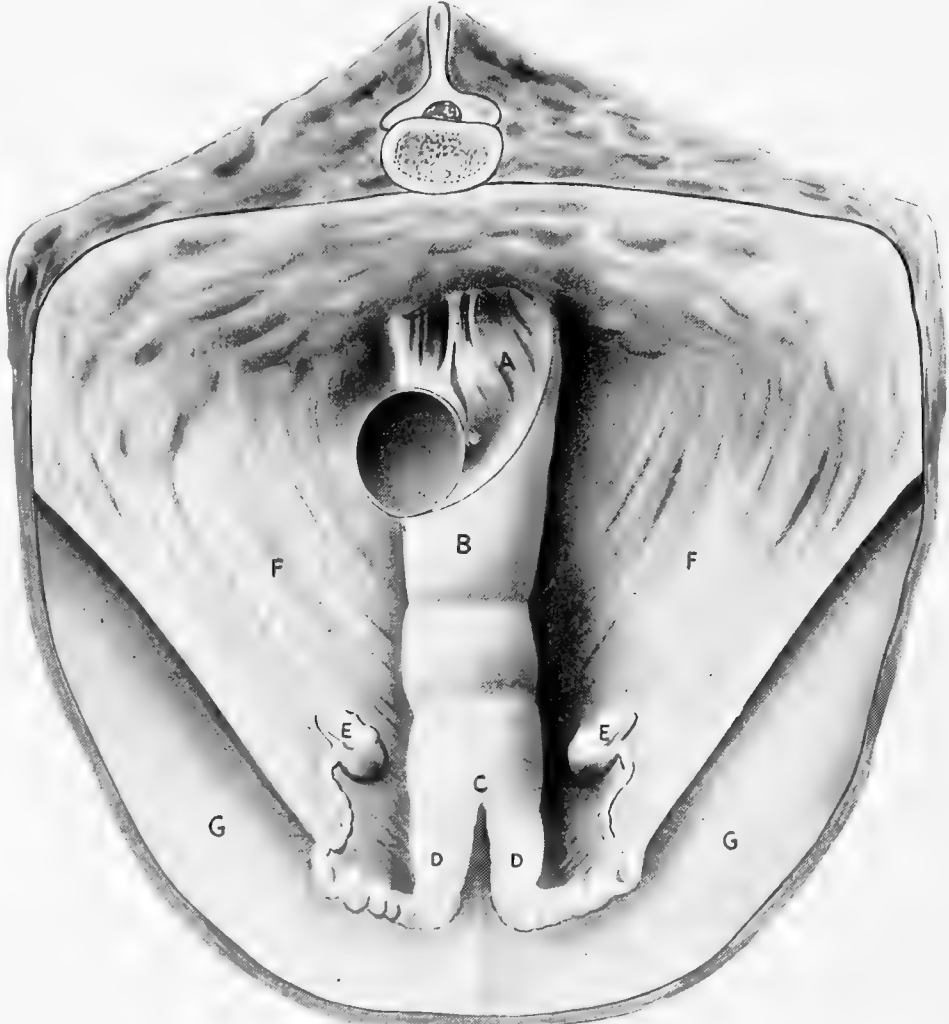


Fig. 131—View of Internal Genitals. A, Rectum; B, Vagina; C, Uterus; D, D, Cornua; E, E, Ovaries; F, F, Broad Ligaments; G, G, Abdominal Walls.

below the anus, and consists of two lips and two commissures. The space between the vulva below and the anus above is the perineum. In a depression on its floor (Fossa Navicularis) lies the clitoris.

In virgin mares the hymen separates the vulva from the vagina. Inside, on the floor of the vulva, opens the meatus urinarius, which is the outlet from the bladder. The mucous membrane lining inside of vulva is rose colored, and the skin covering it externally is soft, thin and devoid of hair.

Vagina—The vagina is situated between the rectum and bladder, and is tubular in shape. It extends horizontally through the pelvic cavity from the cervix to the vulva. Its walls are capable of great distension. The vagina varies in length in different individuals. It is usually from 8 to 10 inches long. Superiorly it is related to the rectum, inferiorly to the bladder, laterally to the pelvic wall.

Uterus—The uterus (womb) is a musculo-membranous sac situated partly in the pelvic region. It consists of a body and two



Fig. 132—External and Internal Genital Organs of Mare. A, Vulva; B, Vagina; C, Cervix (neck of womb); D, D, Horns and Fallopian Tubes; E, E, Ovaries; F, Fundus.

cornua. Superiorly it is related with the rectum, which passes between its horns while it is suspended laterally by the broad ligaments. Inferiorly it is related with the bladder and convolutions of the intestines. Its anterior extremity is known as the fundus, and is continuous with the cornua. Its posterior extremity is continuous with the vagina, constituting the cervix or neck of

the womb. This cervix is round, hard and thick. In its center is a tube like opening (Fissure). The cornua spring laterally from the anterior extremity of the uterus and pass upwards and forwards, and to these the suspensory ligaments are attached. At their summit the fallopian tubes enter. The uterus has three openings, viz: Ostium Internum leading through the cervix, and the Ostium Uterinum at the end of each horn.

Fallopian Tubes—These are prolongations of the uterus and are for the purpose of conveying the ovum from the ovaries to the uterus. They are 10 to 12 inches long and extend from the ovaries above to the cornua below. At the upper outlet of the fallopian tubes is the fimbriated extremity, which is funnel-shaped and receives the ovum direct from the ovary.

Ovaries—The ovaries are bean-shaped and weigh from 1 to 3 ounces. They are situated in the sublumbar region of the abdominal cavity about 4 to 5 inches behind each kidney. They hang about 2 to 3 inches to each side of center of vertebral column. They are attached above in the sublumbar region by the anterior part of the broad ligament. In old animals the ovaries are usually hard and fibrous. However, cysts are by no means uncommon. The ovarian artery supplies nutrition to the ovary.

Warning—The rectum must be empty, otherwise it is liable to injury from point of knife when thrust through vaginal roof. In making incision be sure and press the cervix downwards and forwards with spaying speculum. This is done in order to get site of incision away from rectal wall.

Sterilization of Instruments and Cleansing Operator's Hands—The instruments should be boiled for 15 to 20 minutes, after which place them in Lysol or Cresol Compound U. S. P., in the strength of one tablespoonful to each quart of water. The operator's hands should be thoroughly washed with tincture green soap, using scrub brush, after which wash them in above mentioned antiseptic solution.

Operative Technique—1. With right hand lubricated with carbolyzed olive oil, carry the spaying speculum (Figs. 133 and 134) into the vagina, and insert its tip into the cervix (neck of womb).

2. Withdraw the hand, and with Colin's scalpel reenter the vagina.



Fig. 133—Williams' Spaying Speculum, Showing Hand and Knife in Position for Making the Vaginal Incision.

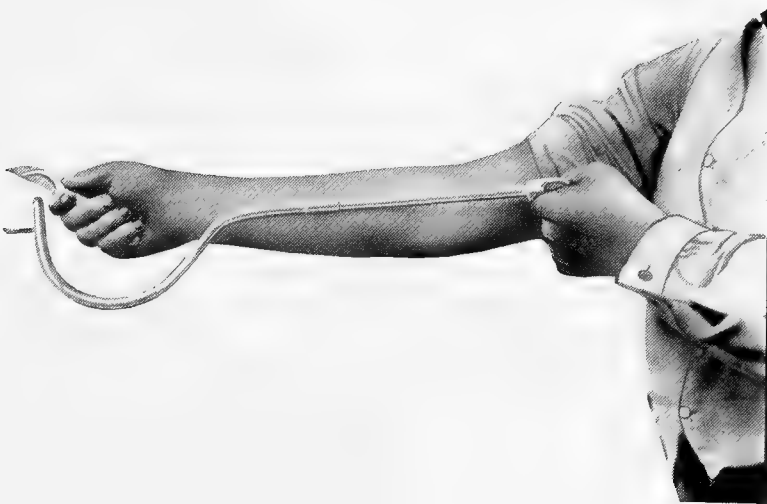

Fig. 134—Paseley's Spaying Speculum, Showing Position of Hand and Knife for Making the Vaginal Incision.

3. With left hand elevate handle of speculum and make sufficient pressure downwards and forwards to stretch the roof of the vagina.

4. With blade guarded it is pressed against the roof of the vagina directly over the cervix.



Fig. 135—Mare Confined by Hippo Lasso. A, Right Hand Carrying Colin's Scalpel; B, Left Hand Manipulating Spaying Speculum.

5. Unguard and thrust the blade through the roof of the vagina.

6. Reguard the blade and withdraw the knife, at the same time spaying speculum should also be withdrawn.

7. With left hand enter the vagina and enlarge the opening




Fig. 136—Removing Ovaries. D, Right Arm; E, Spaying Ecraseur; F, Left Arm.

by stretching with fingers until the whole hand will enter the abdominal cavity.

8. Introduce ecraseur and locate and sever the ovaries from their attachment. These are severed by placing loop of chain above ovary, and with the operating hand the ratchet handle is

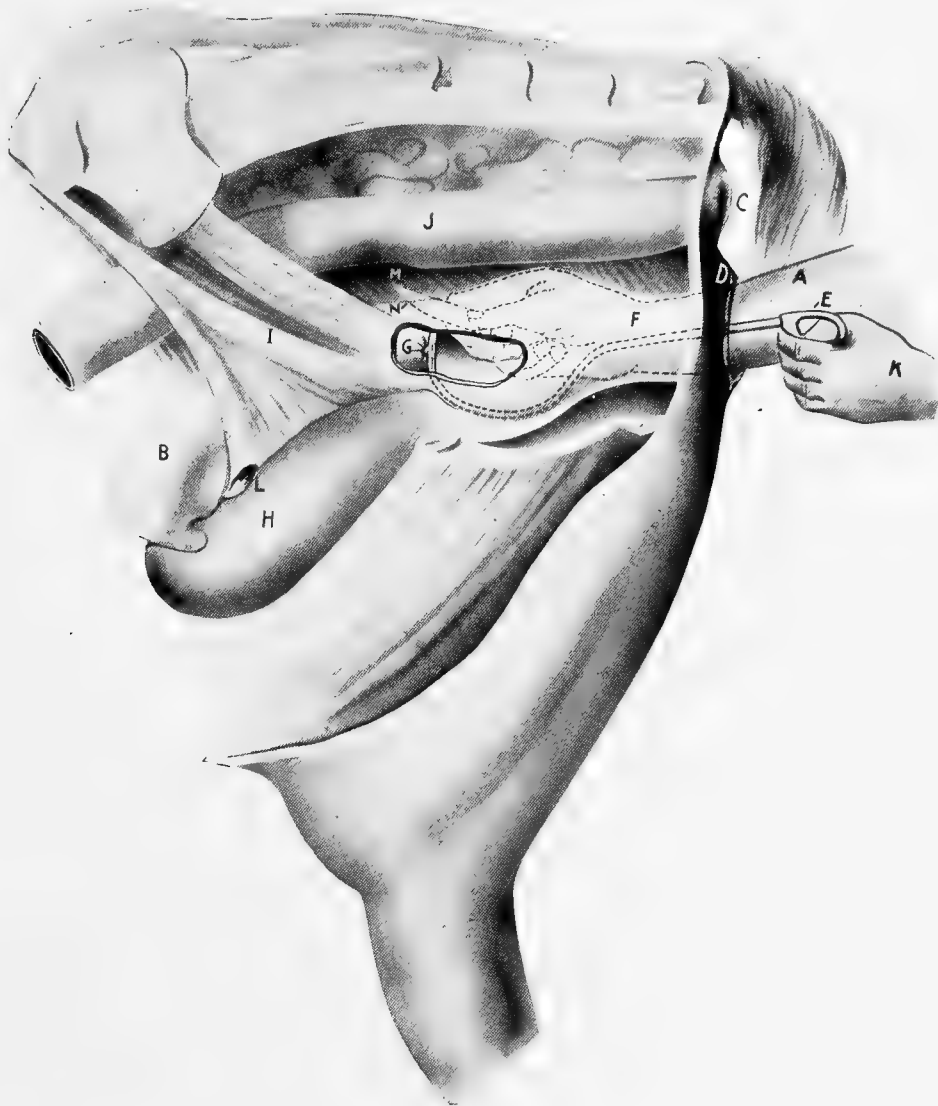

Fig. 137—Making Vaginal Incision. A, Right Arm; B, Uterus; C, Anis; D, Vulva; E, Spaying Speculum; F, Vagina; G, Cervix; H, Urinary Bladder; I, Broad Ligament; J, Rectum; K, Left Hand; L, Left Ovary; M, Point of Knife Thrust Through Roof of Vagina; N, Vaginal Incision.

manipulated back and forth until the ovary is severed. Withdraw severed ovary from abdominal cavity and drop it in the vagina. The opposite ovary is then severed in like manner, after which withdraw both ovaries and the ecraseur. The operation is now completed. By reference to Figures 137 and 138 a compre-

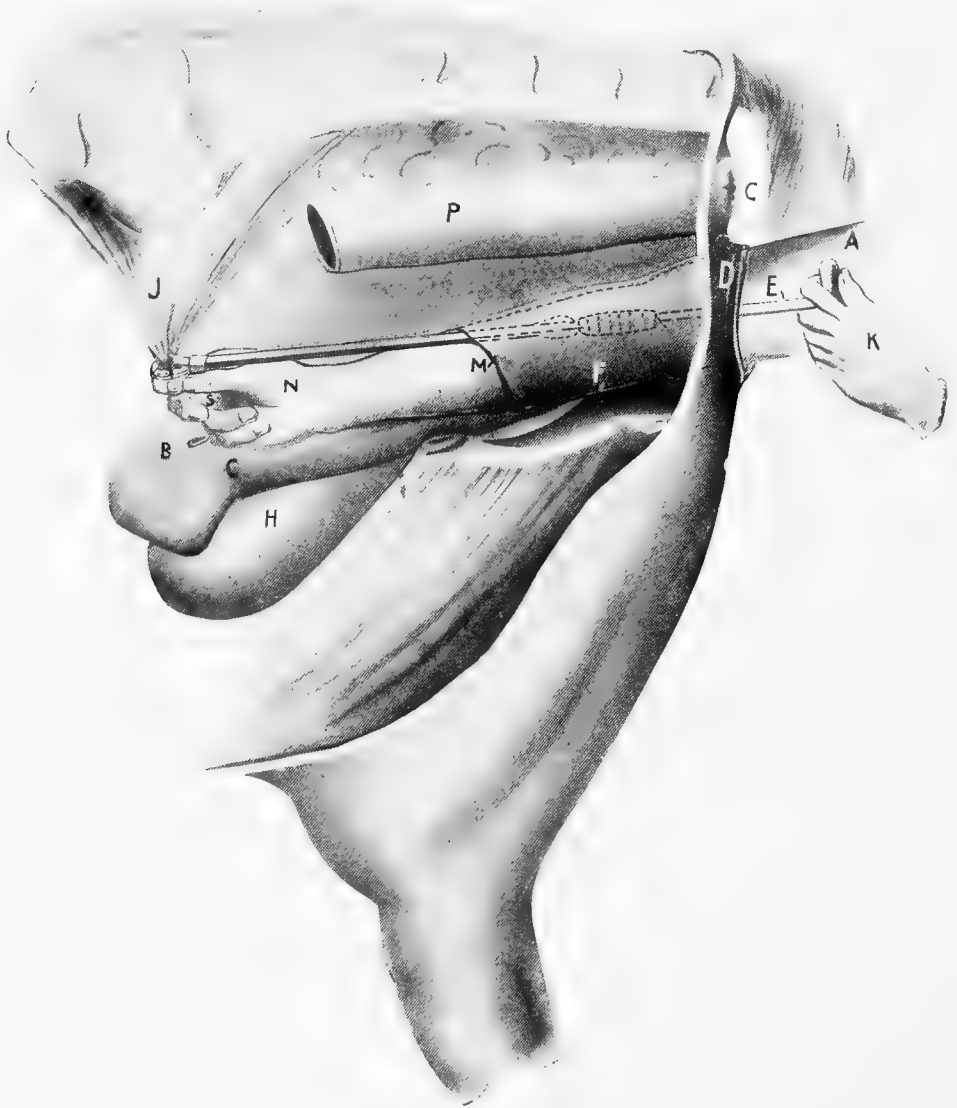

Fig. 138—Removing the Ovary with Ecraseur. A, Right Arm; B, Uterus; C, Anis; D, Vulva; E, Ecraseur; F, Vagina; H, Urinary Bladder; J, Broad Ligament; M, Vaginal Incision; N, Right Hand; P, Rectum; S, Ovary.

hensive idea in regard to the covered steps of the operation may be obtained.

After Care and Treatment—Keep head haltered up for 24 hours to prevent lying down. The vaginal wound requires no treatment. The mare is simply placed in a sanitary box stall, where she is allowed to remain for 10 to 12 days, after which she should be put back to hard, steady work until the habit is forgotten.

Sequelae—Colic and Peritonitis.

CHAPTER II.

COW, HEIFER AND CALF SPAYING.

COW SPAYING.

Objects and Indications—Cows are spayed for two principal reasons: 1st, to correct that disagreeable condition known as nymphomania; 2d, to increase duration of lactation period. Spaying is the only rational treatment for nymphomania, and cows thus affected should always be submitted to the operation or else sent to the butcher. While the operation has not been generally and extensively practiced as a means of controlling lactation, nevertheless it is a well recognized fact that spaying a milch cow during the height of lactation will not only cause her lactation period to last for from 2 to 3 years—uninterrupted by oestrus and pregnancy—but the quantity and quality of the milk is increased and improved. Milk from spayed cows contains an increased amount of cream, casein and sugar. It is more palatable and more wholesome than milk from unspayed cows. When lactation finally ceases a spayed cow readily takes on fat and is easily put in shape for the butcher. The results attained wherever the operation has been practiced justifies its more general adoption.

Age—For treatment of nymphomania they are spayed regardless of age. For increasing duration of lactation period it is best to operate after the udder has attained its full development and while at height of lactation. This would mean when the second or third calf is about 3 to 4 weeks old. Some cows are in their prime with second calf, while others are not until the third calf. The udder never develops and the milk flow never increases after spaying, hence it behooves the operator not to make a mistake in selecting the proper time to operate. Never operate during the period of "heat."

Season—Since the vaginal operation is the method recommended the season does not play an important part. They may be spayed with safety at any season.

Preparation—The alimentary tract, especially rectum, should




Fig. 139—Spaying Chute and Stocks.

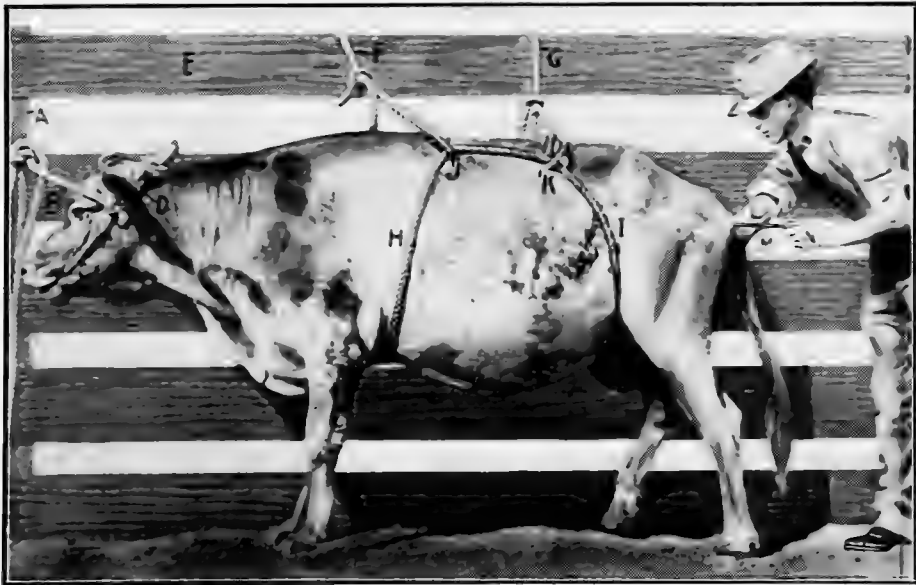


Fig. 140—Cow Fixed to Fence by Means of Ropes for Spaying Operation.

be empty. Hence it becomes necessary to withhold feed for 30 hours previous to operating. Immediately before operating the rectum should be emptied of its contents either by "back raking" or a copious enema.

Restraint—The operation should always be performed with animal in the standing posture. Stocks (Fig. 139) are preferable when they are available. However, when stocks are not at hand the animal may be quickly fixed to wall or fence with ropes (Fig. 140). The head is first fastened to post, after which a 30-foot rope is looped around body and fastened to fence or wall as shown. In this position the animal can be readily spayed without lying down, etc.

Position—Standing.

Instruments—1. Colin's Scalpel. (Fig. 128.)

2. Williams' Ratchet Spaying Ecraseur (Fig. 129), or Dunn's Spaying Ecraseur (Fig. 130).

3. Williams' Spaying Speculum (Fig. 133), or Palsey's Spaying Speculum (Fig. 134).

4. Injection pump.

Anatomy—The anatomy of internal and external generative organs of cow simulate those of mare to some extent. However, in order that the comparative may be studied, we will take up briefly each organ separately.

Vulva—The vulva possesses two thickened labia and two sharp commissures, the lower of which is pointed and contains a number of long, stiff hairs.

The clitoris is small and located in lower commissure of the vulva.



Fig. 141—Internal and External Genitals of the Cow. A, Vulva; B, Vagina; C, Uterus; D, D, Horns; E, E, Ovaries.

Vagina—The vagina is larger and longer than that of the mare, varying in length from 8 to 14 inches. Its wall is thick. The meatus urinarius opens into its floor about 5 inches from vulva.

Uterus—The uterus is short and lies almost entirely in the abdominal cavity. Its cornua are very long and gradually taper toward the fallopian tubes. The cervix is $4\frac{1}{2}$ to $5\frac{1}{2}$ inches long and possesses a thick, tough wall. Its lumen (cervical canal) is spiral shaped and small. The internal wall of uterus and horns are studded with cotyledons. These are oval in shape and about 80 to 90 in number.

Fallopian Tubes—The tubes are longer than in mare. Their junction with cornua are not so abrupt as in mare.

Ovaries—The ovaries are very small when compared to size of animal. They are oval in shape and situated usually a little above the middle of the lateral margin of the pelvic inlet. However, it is by no means uncommon to find them several inches from this location.

Warning—Unless the rectum is empty and the cervix forced downward and forward with spaying speculum, the rectal wall is liable to be punctured with point of knife.

Sterilization of Instruments and Cleansing Operator's Hands—Every instrument used in connection with this operation should be sterilized by boiling 15 to 20 minutes, after which place them in Lysol or Cresol Compound, U. S. P., in the strength of 1 tablespoonful to each quart of water. The operator's hands should be thoroughly washed with tincture green soap, using scrub brush, after which wash them in above specified antiseptic solution. The operator should not be required to assist in handling the animal. Better leave this to assistants.

Operative Technique—1. Douche out vagina thoroughly with antiseptic solution, using injection pump.

2. Wash upper one-third of tail, rectum and vulva with antiseptic solution, using cotton sponges.

3. Lubricate right hand and arm with carbolized olive oil.

4. With handle of spaying speculum in left hand the right is passed into vagina and the tip of speculum is placed in cervix.

5. Withdraw right hand, and with Colin's scalpel reenter the

vagina and place knife—with bladed guarded—against roof of vagina immediately over the cervix. (See Fig. 142.)

6. With left hand raise handle of spaying speculum and make downward and forward pressure sufficient to stretch walls of vagina taut.

7. Unguard blade of knife and thrust it through the vaginal

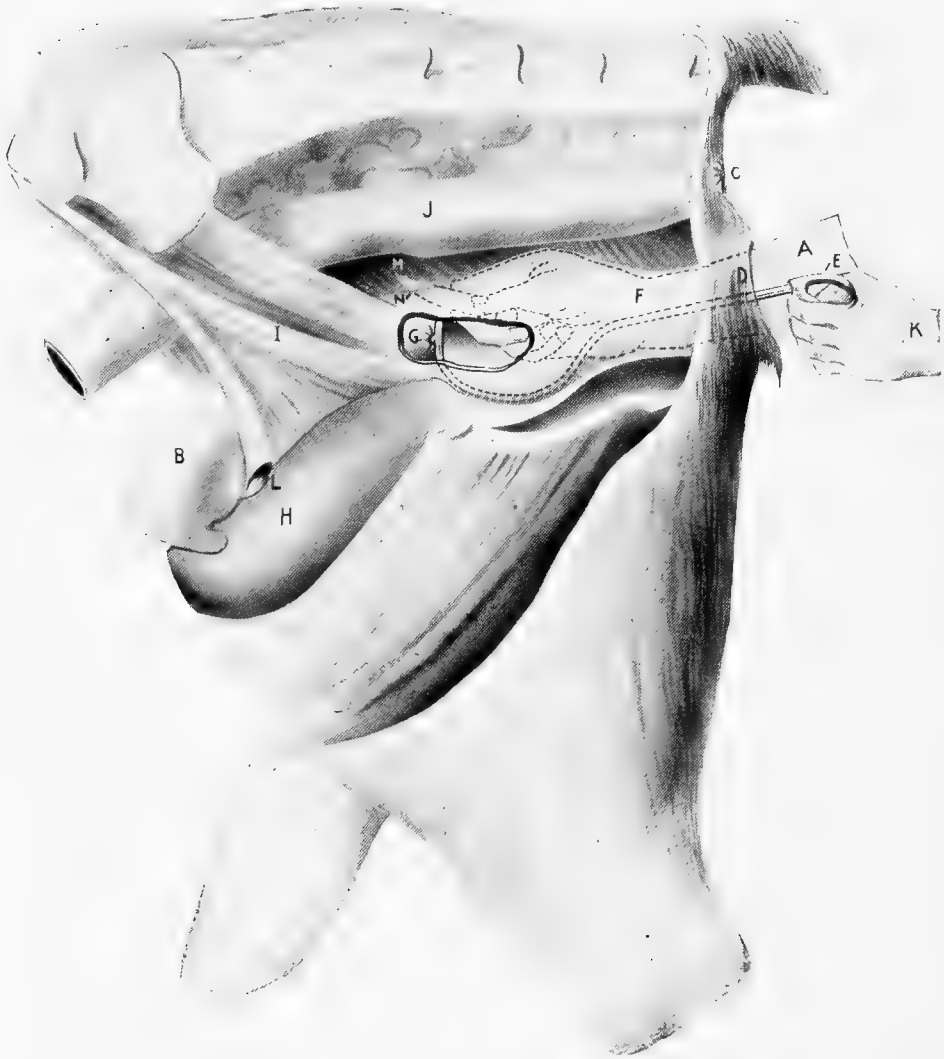

Fig. 142—Making Incision Through Vaginal Roof. A, Right Arm; B, Uterus; C, Rectum; D, Vulva; E, Spaying Speculum; F, Vagina; G, Cervix; H, Urinary Bladder; I, Broad Ligament; J, Rectum; K, Left Hand; L, Ovary; M, Point of Knife; N, Perforation in Roof of Vagina.

roof, including peritoneum, after which re-guard blade and drop knife on floor of vagina.

8. With index and second finger enlarge the perforation by stretching and tearing until the whole hand can be thrust into the abdominal cavity. (See Fig. 143.)

9. With left hand pass ecraseur into vagina, where its chain is grasped with right hand and carried into abdominal cavity. One

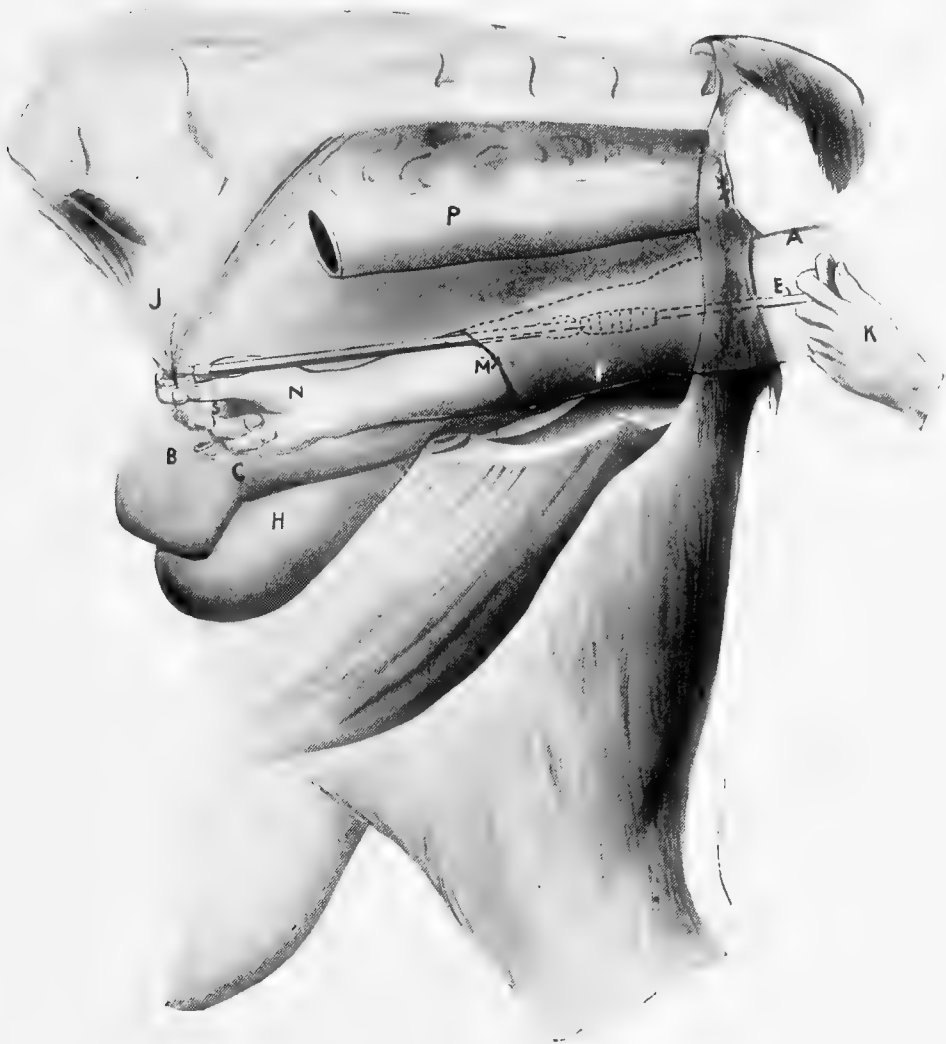

Fig. 143—Severing Ovary with Ecraseur. A, Right Arm; B, Uterus; E, Ecraseur; F, Vagina; H, Urinary Bladder; J, Broad Ligament; K, Left Hand; M, Vaginal Perforation; N, Right Hand; P, Rectum; S, Ovary.

of the ovaries is now located, the chain loop placed above it, and by ratchet movement of handle the chain loop is closed and the ovaries' attachment severed. The opposite one is removed in like manner, and both are brought out when hand and ecraseur are withdrawn.

After Care and Treatment—Sanitary quarters and limited diet for several days constitute the necessary after care and treatment.

HEIFER SPAYING.

Objects and Indications—Heifers are spayed for the sole purpose of growing them for desirable beef animals. Spaying appears to modify or alter the whole organism, especially as regards external symmetry and muscular development. There is a decided tendency to quicker growth, and spayed heifers are prone to take on fat rapidly at most any age. Such animals can be grown to maturity without the inconveniences of "heat" and pregnancy, and command the same price on the market as steers. They may be allowed to comingle with other animals in the herd—including bulls—with the assurance that pregnancy will not occur. The operation has been practiced extensively for years on the Western ranches with gratifying results. It should be encouraged and more widely practiced everywhere beef cattle are grown. As an economic operation its value is hard to overestimate. It is indeed a simple and easy operation to perform, and is accompanied by a low mortality rate. Where once introduced its many merits will usually commend its more general practice.

Age—The most preferable age is 8 to 12 months, care being taken to spay before the heifer becomes pregnant.

Season—Spring and fall. Spaying should be done in the spring before flies appear, and in the fall after they disappear. Not advisable to operate during fly time.

Preparation—Withhold feed for 24 hours previous to operating in order to have alimentary tract comparatively empty. Water in limited amount may be allowed.

Position—*Standing.*

Restraint—Spaying stocks (Fig. 139) are ideal means of restraint. When stocks are not available the quickest and at the

same time one of the best methods of restraint is to tie head to gate post and have an assistant draw tail between slats of gate above the animal. (See Fig. 144). The object in using crack above the animal is to prevent lying down. A good strong assistant by traction on tail can hold animal against gate in such manner as to limit movement from side to side and up and down. In this position the flank region is readily available for operation.




Fig. 144—Restraint of Heifer for Flank Operation.

Instruments—1. Hair clippers. (Fig. 145.)

2. Curved head spaying emasculator. (Fig. 146.) This is by far the most satisfactory instrument yet devised for flank spaying. It is easy to handle, takes up very little space in the incision and abdominal cavity, besides controls hemorrhage perfectly. Two other spaying emasculators (Figs. 147 and 148) are fairly satisfactory. Especially is Figure 147 a good one.

3. “Farmer” Miles’ hook castrating knife (Fig. 25), or Jamison’s spaying knife (Fig. 149). The author prefers the Miles’ knife.

4. Suturing fork. (Fig. 150.) The object of this fork is to hold edges of skin wound while the needle is being thrust through.

It is also provided with a knife for purpose of cutting suture material.

5. Suturing needle. There are two needles suitable for purpose of closing the wound: (a) Miles' palm needle (Fig. 151), and Mooy's ring handle needle (Fig. 152). The author prefers the Miles' needle. However, in the West many spayers use the other style needle.

6. Curved scissors. (Fig. 35.)

7. Suture material. This may be either linen or silk. The author prefers No. 15 braided silk.

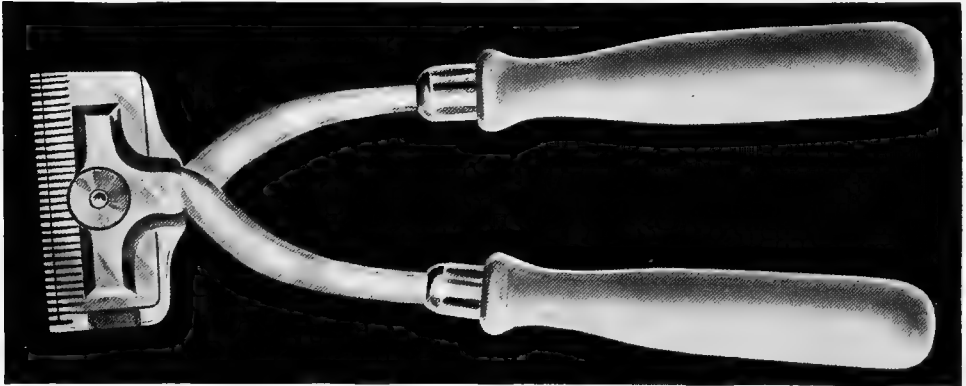


Fig. 145—Hair Clipper.

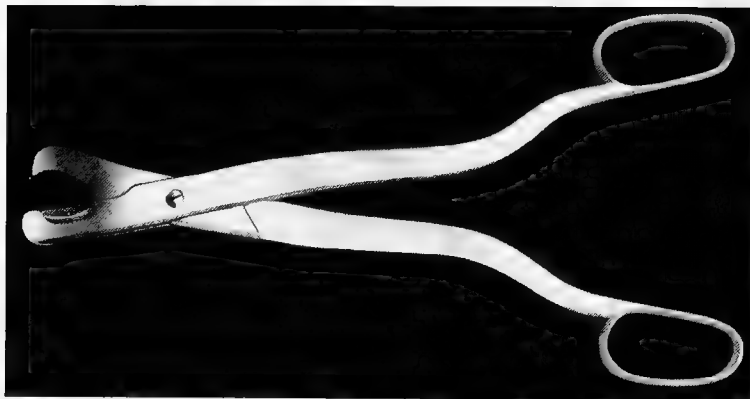


Fig. 146—Curved Head Spaying Emasculator.




Fig. 147—Spaying Emasculator.




Fig. 148—Spaying Emasculator.




Fig. 149—Jamison's Spaying Knife.




Fig. 150—Suturing Fork.



Fig. 151—Miles' Palm Needle.



Fig. 152—Mooy's Needle.

Anatomy—The anatomy of internal and external genital organs are same as cow. (See page 166.) The flank region possesses a well defined triangle, through the center of which the abdominal incision is made. The tissues penetrated by this incision are as follows: Skin, subcutaneous connective tissue, fascia, external and internal oblique abdominal muscles and peritoneum.

Sterilization of Instruments and Cleansing Hands of Operator—Same as for cow spaying. (See page 167.) If the operator is right-handed, it is best to invade the left flank. If left-handed, the right flank should be invaded.

Operative Technique—1. Clip hair from site of operation.

2. Wash parts with soap and warm water, using scrub brush. Special care should be taken to remove all loose hair from the field, and sponge off with antiseptic solution. As a further precaution against septic infection it is well to paint skin with tincture iodine. Iodine.

3. With knife in right hand, beginning 2 inches below transverse process of lumbar vertebrae, a slightly diagonal incision $3\frac{1}{2}$ inches long should be made through the skin *only*. The exact site of this incision is through middle of triangle between the external angle of the ilium and posterior border of the last rib. (See L, Figs. 153 and F, 154.)

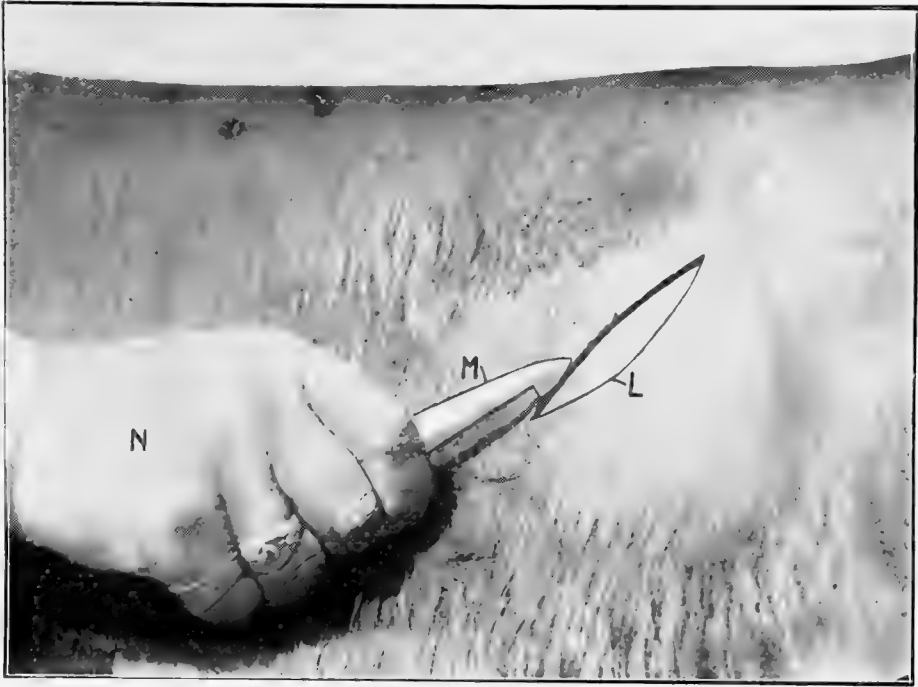


Fig. 153—Making Skin Incision. L, Incision; M, Knife; N, Right Hand.



Fig. 154—Skin Incision. F, External Oblique Abdominal Muscle.

4. In the center of this skin incision the knife point should be thrust through the abdominal wall, making a perforation large enough to admit one finger only. The knife is now put aside, as you have no further use for it.

5. One finger of the operating hand is thrust through the abdominal wall perforation, and by stretching the wound two fingers are admitted—index fingers of each hand. With these two fingers tear the muscular fibers apart sufficiently to admit the whole hand.

6. With left hand inside the abdominal cavity the body of the uterus is located, after which follow its right cornua upwards and backwards until right ovary is encountered.

7. With right hand the emasculator is now passed along the

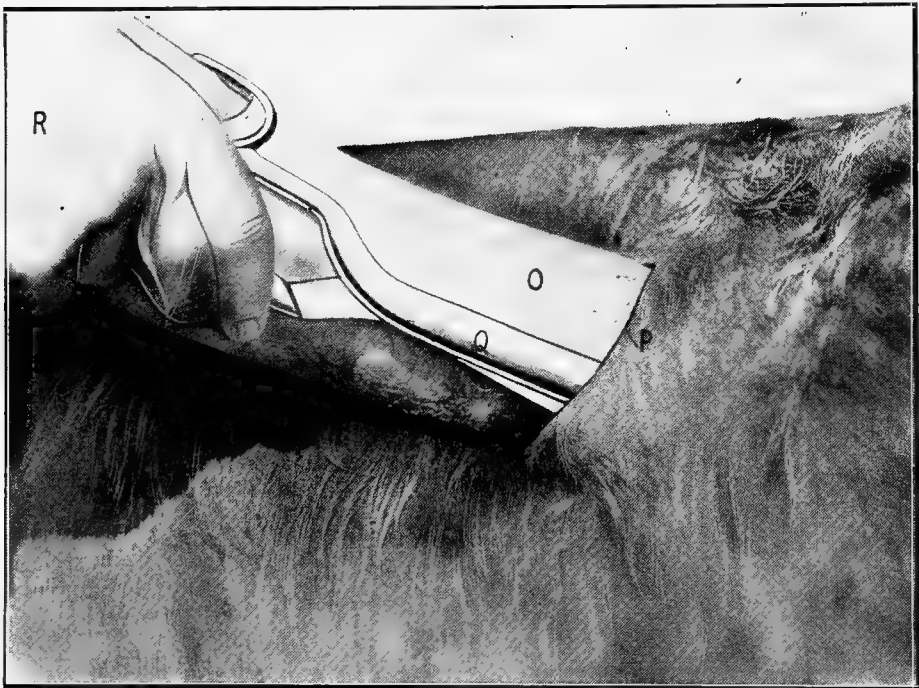


Fig. 155—Severing the Ovaries. O, Left Arm; P, Incision; Q, Emasculator; R, Right Hand.

left arm through the incision, and its head placed above the ovary, and by bringing the handles together the ovary is severed from its attachment. (See Fig. 155.)

8. The left ovary is now located by following the right cornua

back to the body of uterus where the left cornua is encountered. By following it upwards and backwards the left ovary is encountered and severed in like manner.

9. Withdraw the hand—containing both ovaries—with instrument. When this is done the fibers of the internal and external oblique abdominal muscles come together and anatomically close the wound with the exception of the skin incision.

10. With 3 interrupted sutures the skin incision is closed and the operation is completed. (See Fig. 156.)

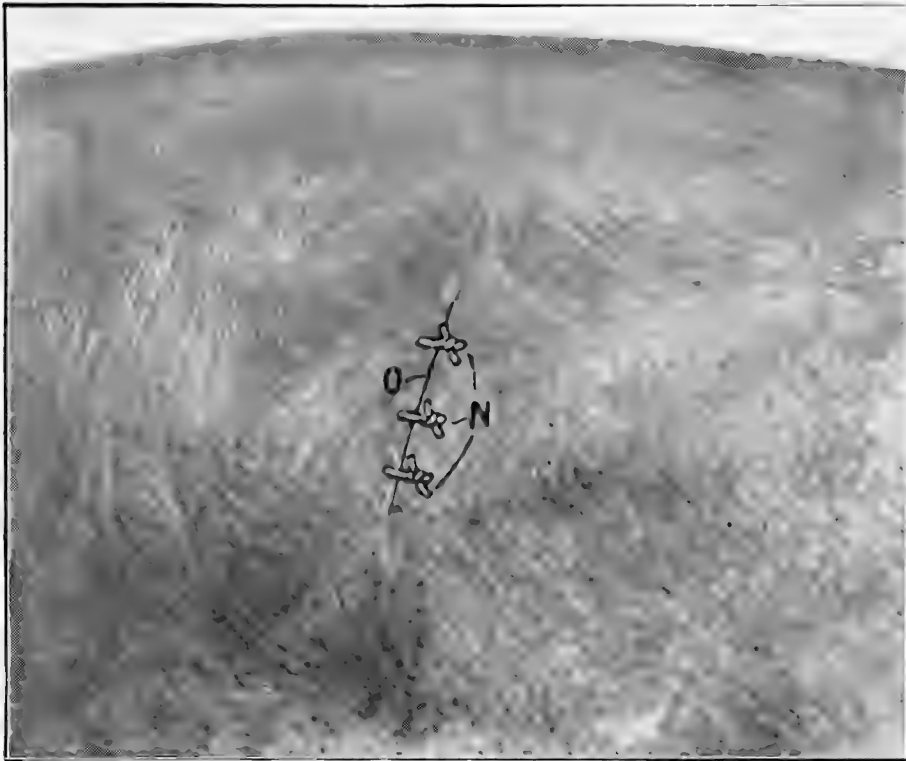


Fig. 156—The Skin Incision Closed by Three Interrupted Sutures. N, Sutures; O, Incision,

Incision Illustrated and Explained—The exact method of invading the abdominal cavity through the flank incision is of special importance if successful spaying is to be done. Undoubtedly the incision is the most important step of the whole operation. It is made and closed as follows: (See Figs. 157, 158 and 159. Study these illustrations carefully.) With knife in right hand the skin incision G G, (Fig. 157) is made. Thrust point of knife through

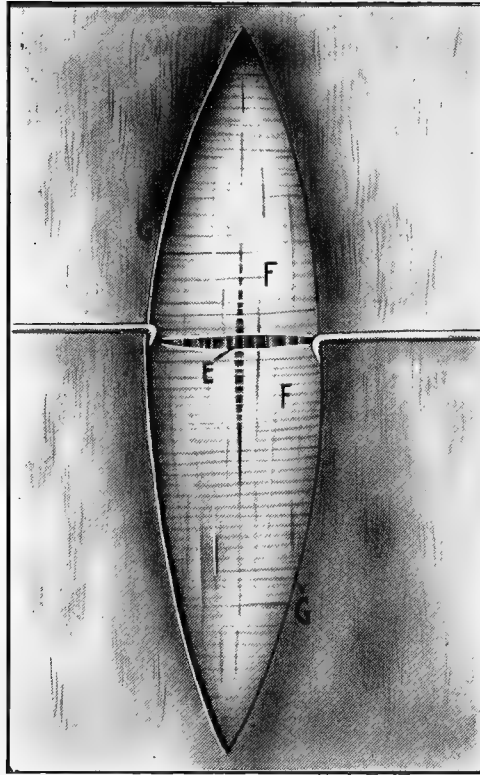


Fig. 157—E, Muscular Fibers of Internal Oblique and External Oblique Slightly Divided; F, F, External Oblique Abdominal Muscle; G, G, Lips of Skin Incision.

remaining portion of the abdominal wall (external oblique and internal oblique abdominal muscles and peritoneum). With fingers this perforation (A, Fig. 158) is enlarged by tearing the fibers of the external oblique apart B, B, and at the same time those of the internal oblique C, C are separated in the opposite direction until the whole hand is admitted. When the hand is withdrawn the muscular fibers anatomically come together (see Fig. 157) and practically close the wound with exception of the skin incision. With three interrupted sutures the skin incision is closed and the operation completed (see Fig. 159).

This method of making flank incision far excels in every respect the one which requires cutting through the abdominal muscles. When these muscle fibers are cut you have a large gaping wound which requires weeks and oftentimes months for healing.

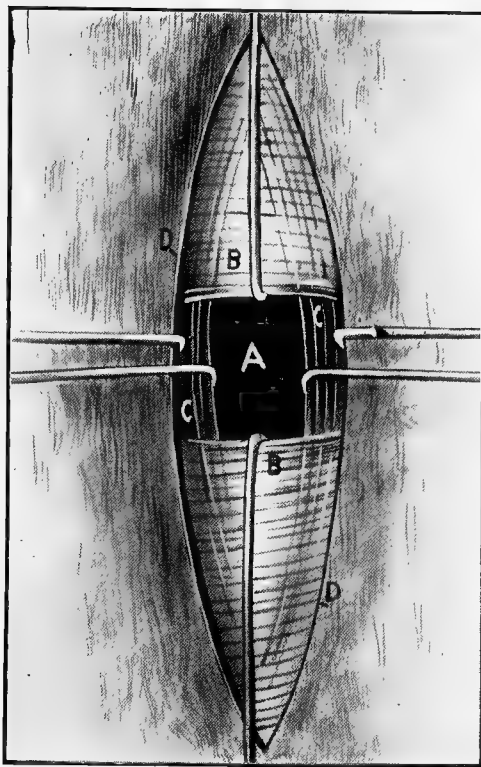


Fig. 158.

With fibers divided by tearing, the skin alone is sutured and the whole wound heals rapidly.

After Care and Treatment—Place animals on pasture or in sanitary quarters. The wounds should be observed from day to day for stitch abscesses, etc. Should abscesses develop the suture should be removed and the pus allowed to escape. The sutures should be removed, when possible, about the eighth day. Oftentimes the sutures are not removed, in which event they finally slough out.

CALF SPAYING.

Objects and Indications—Calves are spayed for the same purposes that heifers are spayed, viz.: the operation hastens their growth and development, besides improves the texture and nutritive properties of the meat. Spayed calves may be raised to full maturity without the bother of either “heat” or pregnancy. An-

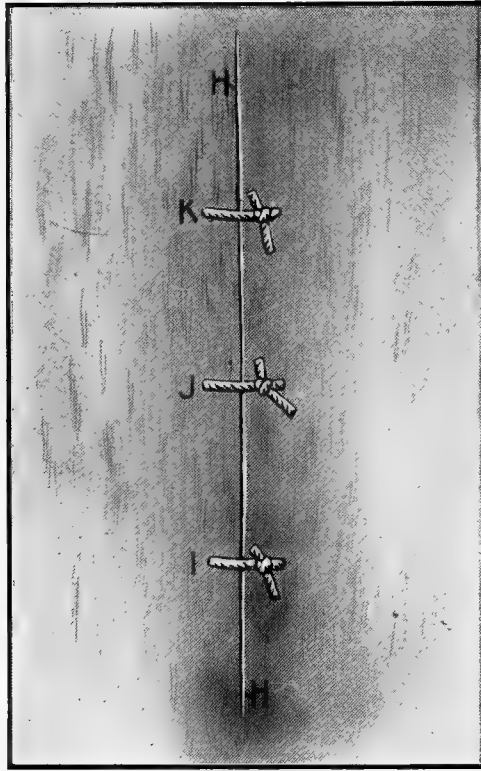


Fig. 159—Skin Incision Closed by Three Interrupted Sutures. H, H, Lips of Skin Incisions; I, J, K, Sutures.

other reason for calf spaying is that the mortality rate is less in young than in older animals. There are two approved methods of spaying calves, viz.: belly method and flank method.

Age—The favorite age for calf spaying is two to four months old.

Season—Spring and fall.

Preparation—Same as heifer spaying.

Position—Lateral, recumbent or hanging, depending upon whether the belly or flank is to be invaded.

Restraint—For flank operation the calf is simply stretched full length on the ground by rope looped above hind and fore ankles. (See Fig. 160.) For belly operation the animal is suspended by cord or small size rope looped over both hocks and

attached to a beam or hook above. The site of incision should be about opposite breast of the operator.

Instruments—Same as heifer spaying. (See pages 171-173.)

Sterilization of Instruments and Cleansing Operator's Hands—Same as for heifer spaying. (See page 174.)




Fig. 160—Calf Cast and Tied for Spaying Operation. (Flank Method.)

Operative Technique—(Flank Method.) The hair is clipped from over site of incision. Parts washed with soap and warm

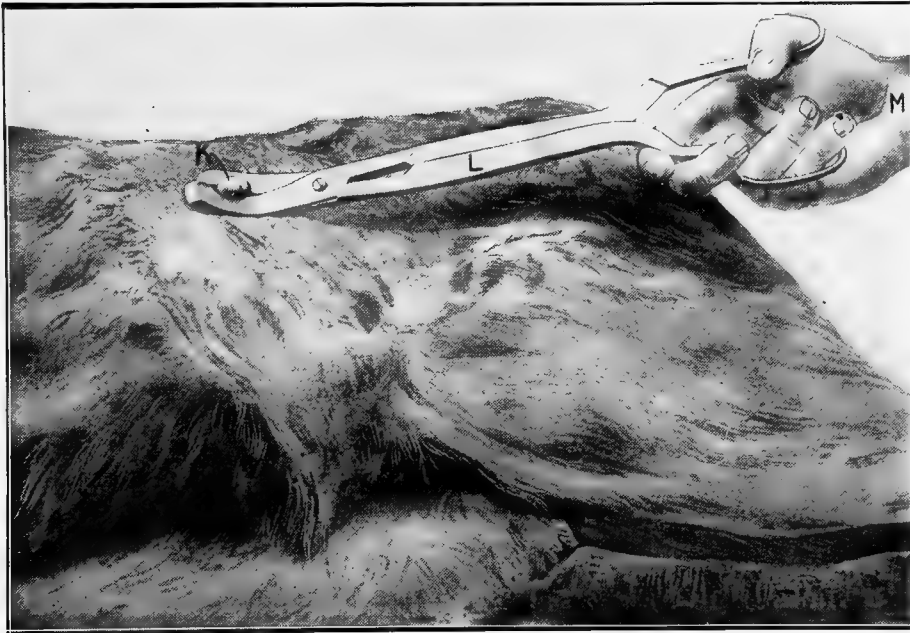


Fig. 161—Removing Ovary from Calf (flank method). K, Ovary; L, Emasculator; M, Hand.

water, after which sponge off with antiseptic solution. As a further precaution against septic infection it is well to paint the skin with tincture iodine. The incision is made similar to that employed in heifer spaying (pages 177-179) with the exception that in the calf a much smaller one is used since only the index and second finger are introduced into the abdominal cavity, whereas in heifer spaying the whole hand is inserted. With the two fingers inside the abdominal cavity a search is made for the uppermost




Fig. 162—Incision (Belly Method).

fallopian tube or ovary. One or the other of these is usually found with little difficulty by wiping downwards and backwards towards pubic brim. When located the ovary is brought up into the incision and its attachments severed with the emasculator.

The opposite ovary is located and removed in like manner. (See Fig. 161.) The skin incision is closed by two interrupted sutures.

Operative Technique (Belly Method)—With calf suspended in hanging position the hair is clipped from site of incision and the parts thoroughly washed and disinfected the same as for spaying by the flank method. With knife in right hand begin the incision two inches below the brim of the pubis in the median line and extend it downwards for three inches, penetrating all the coats of the abdominal wall. (See Fig. 162.) With index and second finger inside the abdomen the ovaries are readily located and brought into the incision and their attachments severed with the emasculator. (See Fig. 163.) The incision is now closed by three or four “through and through” sutures. (See Fig. 164.)

After Care and Treatment—Same as heifers. (See page 179.)



Fig. 163—Removing Ovary (Belly Method). C, Incision; D, Ovary; E, Emasculator.

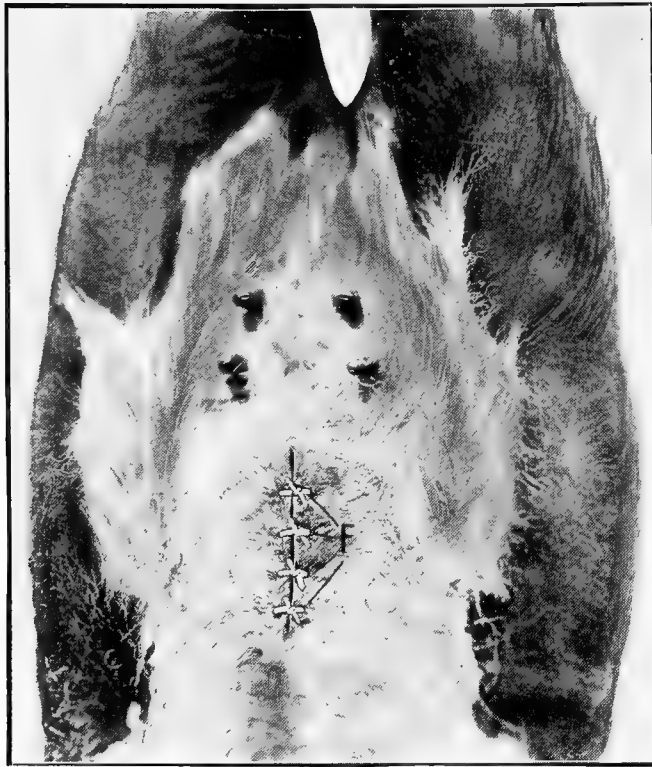


Fig. 164—Incision Closed by Interrupted Sutures.

Sequelae of Cattle Spaying—Hemorrhage, septic peritonitis, abscess, general sepsis, hernia and bloating are the most usual sequelae.

CHAPTER III.

SPAYING SOWS.

Objects and Indications—The one and only beneficial result of this operation is to facilitate growth, fattening, marketing and slaughter without the handicap of early pregnancy. The economic importance of sow spaying is well recognized by many swine owners. Formerly the operation was more generally practiced than it is at the present day. This may be accounted for by the fact that what would have formerly been termed revolutionary methods are now in vogue in the great swine-raising sections of the Middle West and Central States in raising and marketing hogs. This practice enables swine owners to grow, fatten and market hogs as early as six to ten months of age, and is becoming more universal each and every year. Of course under such circumstances spaying would not be an essential operation. However, in the South and Southwest the older methods of swine-raising still prevail to a limited degree, hence it is in this section that the operation of spaying is still practiced to a limited extent.

Age—The operation is best performed at four months. However, it is permissible to operate any time from sixty days to maturity, or even old age.

Season—Sows should not be spayed during “fly time” or in extremely cold weather. Best to operate in the fall, early winter and spring.

Preparation—One of the most important essentials to success in spaying sows is to have the alimentary tract absolutely empty before undertaking to operate. This can best be done by withholding the feed for from twenty-four to thirty hours previously. During this time there is no special objection to allowing the animal free access to water. The danger of septic infection can be greatly minimized by providing clean quarters before and after operation. Another essential is to not allow the boar access to the sows previous to spaying. It is not best to operate during the

period of "heat." Pregnancy is a counter-indication to successful spaying.

Restraint—Proper restraint technique is as much an essential in spaying operation of sows as it is in most any operation in animal surgery. This operation calls for the simple and easily applied rather than the complicated and intrinsic methods oftentimes employed in other operations. The method of restraint used must of course depend upon whether the flank or the belly opera-

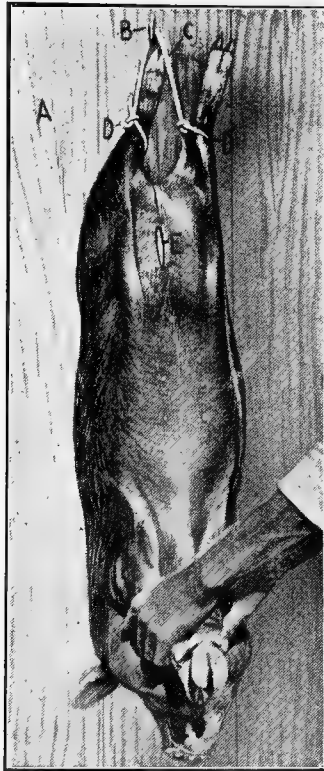


Fig. 165—Restraint for Spaying (Belly Method.)

tion is to be performed. If the abdominal cavity is to be invaded from below (belly) the most simple and satisfactory method of restraint would consist in looping a strong cord (window sash cord) or small size rope above the hocks, by which the animal can be readily suspended to a post or wall in the hanging posture (Fig. 165.)

If the flank incision is to be resorted to then it is necessary

for the animal to be confined in the recumbent posture at an angle of about thirty degrees on either right or left side, depending upon which flank is to be invaded. One of the best and most satisfactory methods the author has ever employed is as follows: Procure a piece of three-eighths inch soft rope about six feet long. Tie the free ends together, forming a loop as shown in Fig. 166.

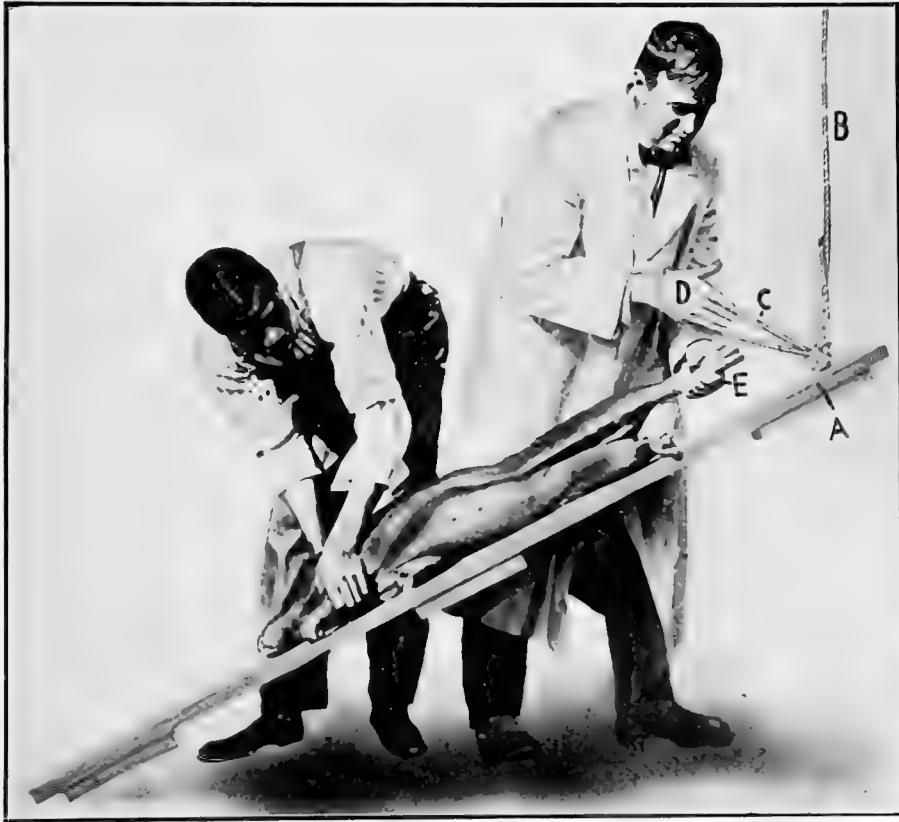

Fig. 166—Restraint for Spaying (Flank Method.) First Step. A, Board with End Elevated; B, Rope Suspending the Board; C, Rope Loop; D, Right Hand; E, Left Hand.

Next secure a 2 x 14 inch plank about 12 feet long; place one end on the floor or ground as the case may be, either spike the other end fast to the wall or suspend it by means of a rope from above. Now make your rope loop fast to the upper end of the plank with a screw eye or a spike (A), or it may be fastened by boring a hole through the plank large enough to allow the rope to be drawn up through and held secure by a large knot in its ends. This should

be so arranged that when the hog is fastened to the plank it is to be about waist high to the operator as shown in the following illustrations. The plank should assume a position of about thirty degrees. The operator standing facing the plank with his right hand towards the lower end passes right hand (D) through the loop (C) and instructs assistant to grasp right legs of the hog and bring the hog to him placing it on the board. As the assistant approaches with the hog pass your left hand under the right hand and rope, grasping left hind leg (E), while your right hand grasps the right hind leg (Fig. 167). Now guide the left leg to your right hand, which grasps it. The left hand now contains both hind feet, while the right hand grasps the loop from over left wrist and carries it back, dropping it above ankles. As you drop the rope back of the ankle you are to say "pull," meaning that your assistant is to pull the hog downward on the plank, making

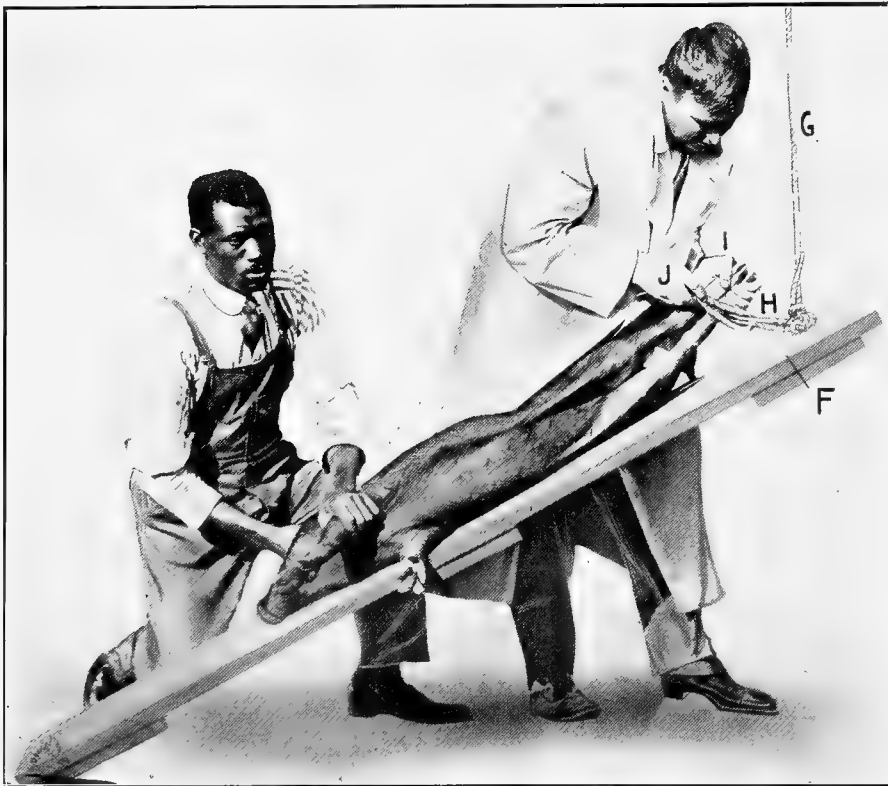


Fig. 167—Restraint for Spaying Operation (Flank Method.) Second Step. F, Board; G, Rope; H, Rope Loop; I, Left Hand; J, Right Hand.




Fig. 168—Restraint for Spaying Operation (Flank Method.) Third Step. K, Board; L, Rope; M, Rope Loop; N, Hind Legs Fixed; O, Flank Incision.

the rope taut as shown in Fig. 168. With a little practice a sow can be secured by this method in less than five seconds.

Instruments—1. Curved scissors (Fig. 35) for clipping hair from site of incision.

2. Miles' hook knife (Fig. 25).
3. Swine and sheep emasculator (Fig. 80).
4. Hagedorn's needle (half circle) No. 3 (Fig. 84).
5. Richter's needle holder (Fig. 34).
6. Braided silk No. 12 or linen for sutures.

Anatomy—It is well to remember that the fallopian tubes and horns of uterus in sows are extremely long in comparison to size of animal and that their course is decidedly tortuous in the pelvis and abdominal cavities. The importance of the above can be more thoroughly comprehended and appreciated if you will carefully observe these parts and their relation, which is plainly




Fig. 169—Internal Genital Organs of Sow. A, Rectum; B, Vagina; C, Bladder; D, Uterus; E, Left Fallopian Tube or "Horn"; F, Right Fallopian Tube or "Horn"; G, Ovary; H, Intestines; I, Kidney.

illustrated, in a diagrammatic way, in Fig. 169. The body of the uterus is unusually short when the length of its tubes are taken into consideration. The cervix (neck of womb) does not project into the vagina in such manner as is observed in most other domestic and wild animals. On the other hand, the vagina and uterus of the sow are continued into each other without any circumscribed limit intervening between them. The "horns" float loosely in the abdominal cavity and are found closely associated with the convolutions of the intestines. The broad ligaments are mesenteric in conformation and character and are extremely thin and lax.

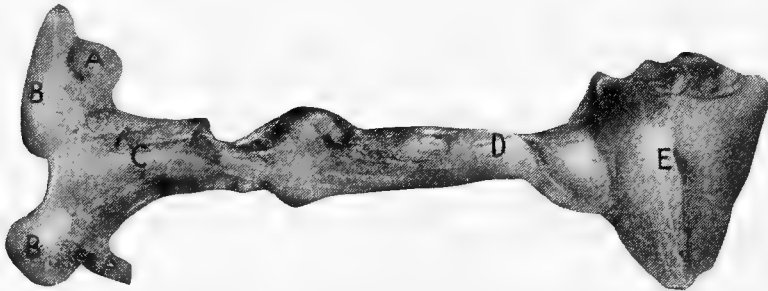


Fig. 170—External and Internal Generative Organs of the Sow. A, Ovaries; B, Fallopian Tubes; C, Uterus; D, Vagina; E, Vulva.

The ovaries are decidedly lobulated and closely resemble grape cluster, being suspended to the right and left of the vertebral column near the median line of the body. Fig. 170 illustrates the external as well as internal generative organs of the sow.

The abdominal wall in the flank region is quite thick and contains much fat. This fat is encountered between the skin and the external oblique abdominal muscle. More fat is encountered in mature sows than in younger hogs. The skin is dense and tough in consistency, while the external and internal oblique muscles and peritoneum are comparatively thin and delicate in conformation. The above description applies equally as well to the belly wall at site of spaying operation except that the wall in the latter region is somewhat thinner.

Methods of Operating—There are two standard methods, viz.: flank, and median line or “belly.” Each have their advantages and disadvantages; however, taking everything into consideration the author greatly prefers the flank method.

Operative Technique (Flank Method)—The animal should be properly secured as illustrated in Figs. 166, 167 and 168, and placed on the right side. Remove hair from flank by clipping with scissors. Wash hands of operator and left flank of animal with Lysol or Cresol Compound U. S. P. in the strength of one tablespoonful to each quart of water. With hook knife make oblique incision one inch to an inch and a half long, beginning high in flank, one to two inches posterior (behind) the last rib. This incision should run downward and backward at an angle of 45 degrees (see O, Fig. 168). The incision should penetrate skin, subcutaneous connective tissue, fat and external and internal oblique abdominal muscles. By this we mean all tissues down to the peritoneum (lining of the abdominal cavity). The peritoneum is now carefully punctured with the point of knife, after which stretch or enlarge the incision sufficiently to admit index finger of the left hand. With this finger inside of abdomen the left (upper) ovary is located by passing the finger backward near fungus of bladder and upward toward vertebral column (backbone). The ovary can be readily distinguished from the other inter-abdominal viscera by its peculiar feel, as it consists of hard lobules arranged in cluster form simulating small grapes. The left ovary and its

accompanying fallopian tubes are drawn through the incision. In young sows the left tube is now withdrawn from abdominal cavity and followed back to the bifurcation where the right tube is encountered. The right tube is withdrawn from abdominal cavity and followed until right ovary is located, after which draw the ovary out of abdomen through incision and place both ovaries (P) in emasculator and sever their attachments by closing handles of instrument. The tubes (Q) are now washed and replaced in the abdominal cavity (see Fig. 171), after which the incision is closed by two interrupted sutures. These sutures should be made with a No. 3 half circle Hagedorn needle and No. 12 braided silk. They should extend through all layers of the abdominal wall, including skin and peritoneum, or in other words, should be what is known as the "through and through" sutures. (See Fig. 172.) Sponge off wound with antiseptic solution and release the animal.

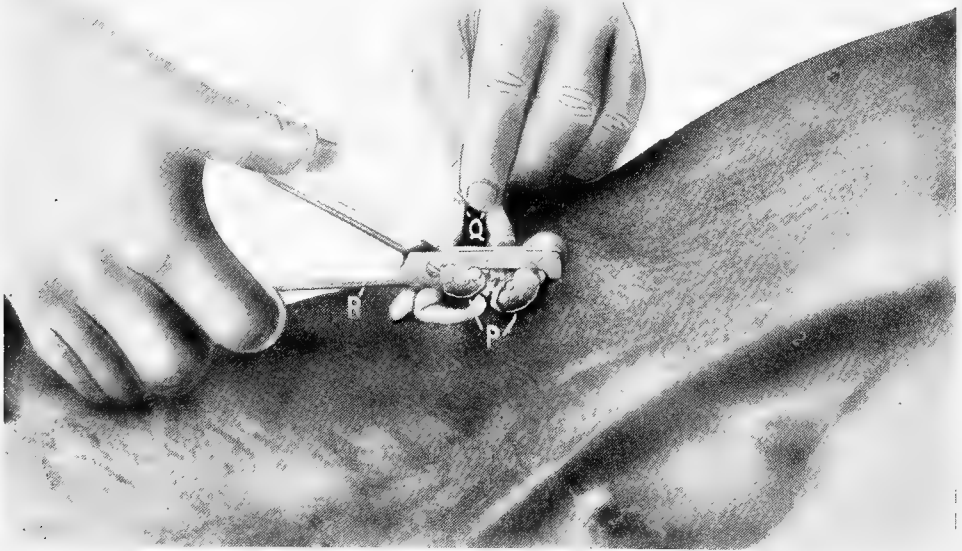

Fig. 171—P, Ovaries; Q, Fallopian Tubes (Horns); R, Emasculator.

In sows which have given birth to one or more litters of pigs the fallopian tubes are oftentimes so large that the left one must be replaced in the abdomen before the right one can be withdrawn. In such vent, of course, only one ovary can be removed at a time. However, both ovaries can always be removed through the same flank incision.

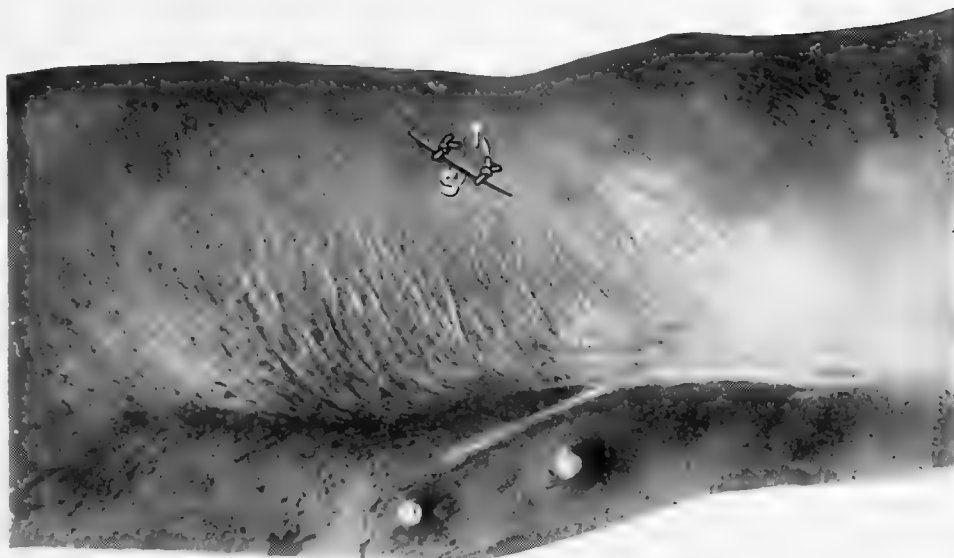


Fig. 172—Abdominal Incision, Closed with Two Interrupted Sutures. S, T, Sutures.

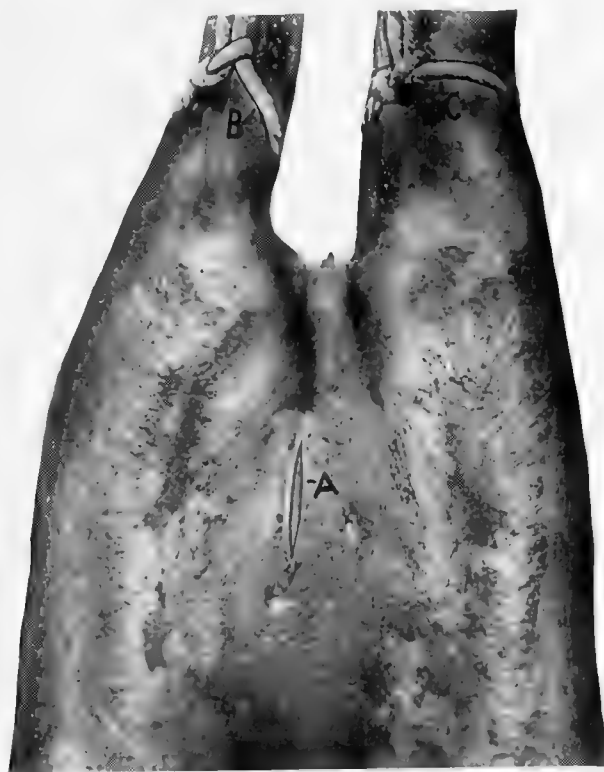

Fig. 173—Belly Incision.

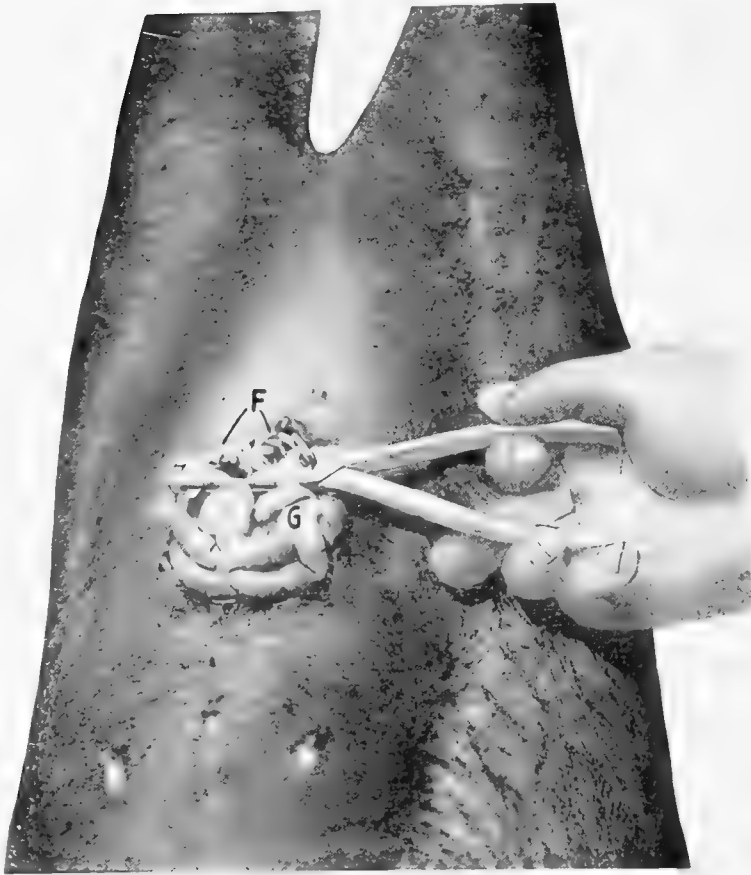

Fig. 174—F, Ovaries; G, Fallopian Tubes or "Horns"; H, Emasculator.

Operative Technique (Median Line or "Belly" Method)—Sterilize instruments and wash hands same as for flank operation. With the animal properly secured in the hanging posture (Fig. 173) the hair is removed from site of incision and parts cleansed same as for flank method. With hook knife begin incision two to three inches below brim of pubis and one-half inch to either right or left of the median line. This incision should be extended downwards about one and one-half to two inches, and should include all layers of the abdominal wall, down to the peritoneum.

The peritoneum is now punctured with the point of the hook knife, after which enlarge incision to admit index finger of left

hand. With this finger the ovaries and tubes are readily located near the median line of the body. They are drawn through the incision (see Fig. 174) and removed with emasculator same as by flank method.

The tubes are now sponged off with antiseptic solution, after which they are replaced in the abdominal cavity and the wound closed by two or three interrupted "through and through" sutures (see J, Fig. 175), using the same needle and the same size silk as flank method. The animal is now released.

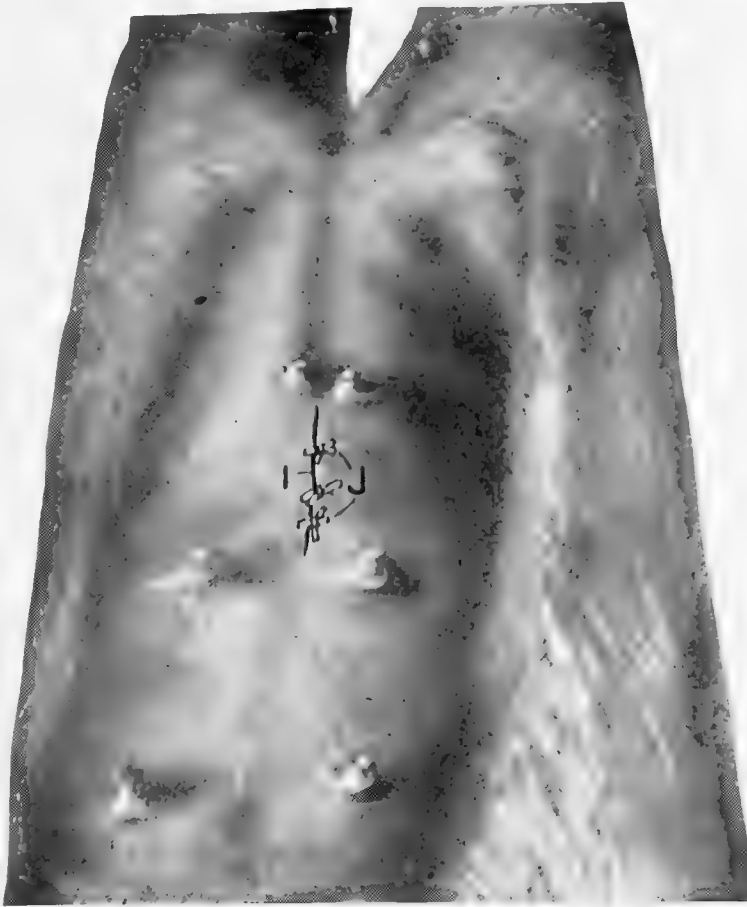


Fig. 175—Wound Closed (Belly Method).

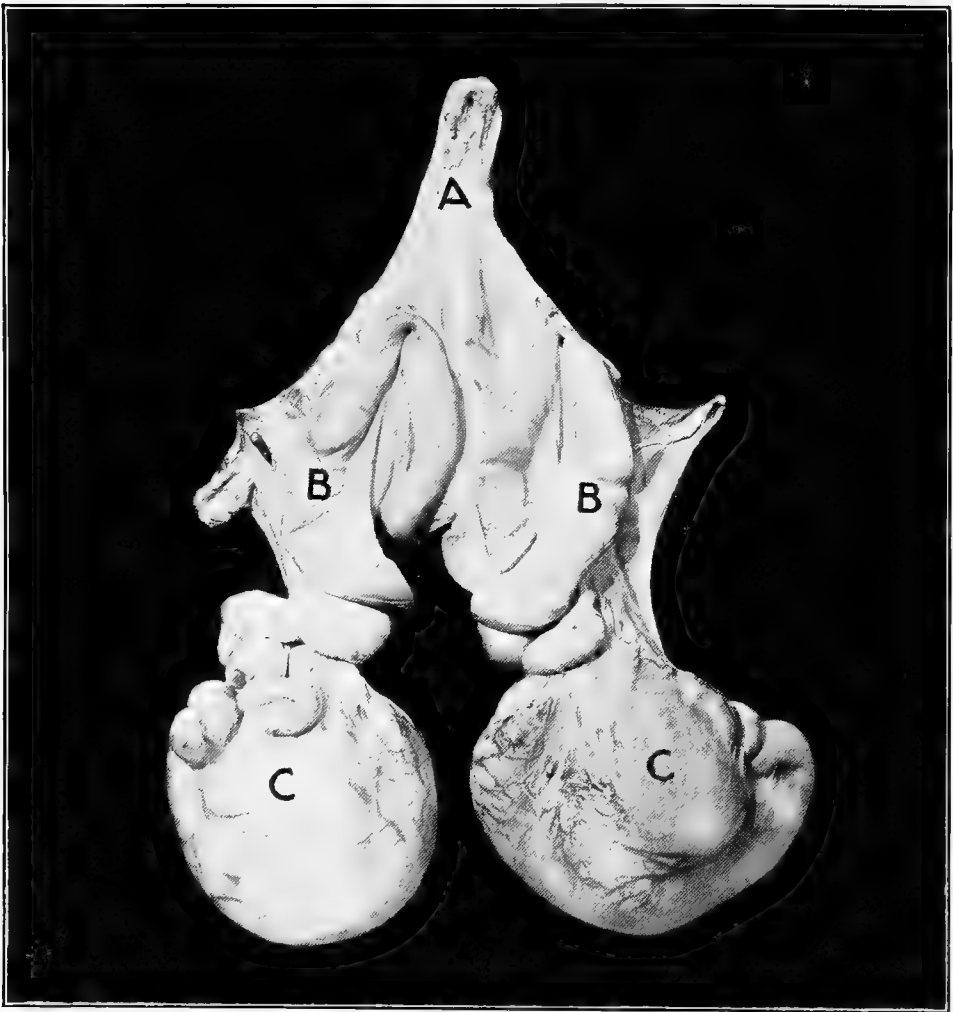


Fig. 176—Cystic Ovaries Weighing 4 Pounds Removed from a Sow of 170 Pounds Weight. A, Uterus; B-B, Horns; C-C, Ovaries.

CHAPTER IV.

EWE SPAYING.

Objects and Indications—Sheep spaying is rarely ever practiced in this country on account of the ewe being more valuable as a breeding animal than she is for mutton purposes. Spayed ewes will mature earlier, grow larger and take on fat faster and more of it than will entire ewes. On this account they are sometimes spayed for fat stock show and exhibition purposes.

Age—2½ to 3 months is the desirable age.

Season—Late winter and early spring.

Preparation—Empty alimentary tract by withholding feed for 24 to 30 hours previous to operating.

Position—Hanging.

Restraint—The ewe is exceedingly docile and submits kindly to operation. With a small rope or large cord looped above each hock the animal is suspended from a hook or beam above. The field of operation should be on a level with breast of operator.

Instruments—1. Curved scissors (Fig. 35) for clipping wool from site of incision. 2. Miles' hook knife (Fig. 25). 3. Swine and sheep emasculator (Fig. 80). 4. Hagedorn's needle ½ circle, No. 3 (Fig. 84). 5. Richter's needle holder (Fig. 34). 6. Braided silk No. 12 for suturing.



Fig. 177—External and Internal Genital Organs of the Ewe. G, Vulva; H, Vagina; I, Uterus; J-J, Horns; K-K, Ovaries; L-L, Broad Ligament.

Anatomy—The conformation and anatomical relation of the internal generative organs of the ewe are almost a facsimile duplicate of those of the cow except on a much smaller scale. The abdominal wall at site of incision is very thin and exceedingly delicate.

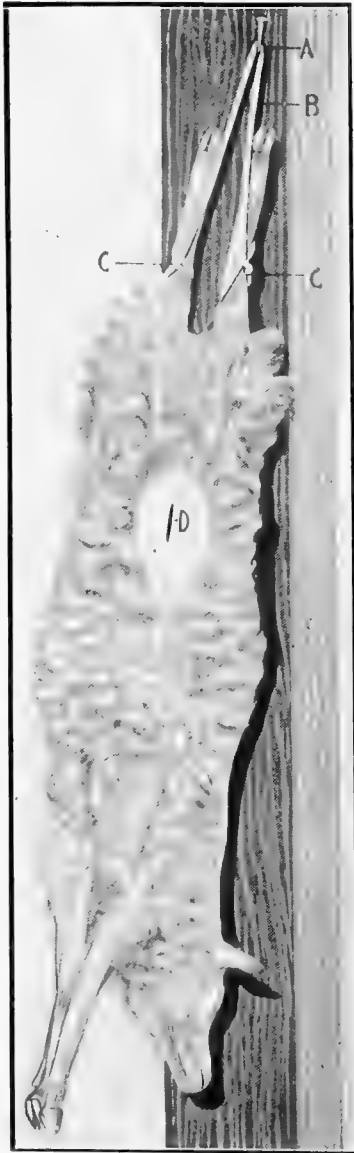


Fig. 178—Abdominal Incision.

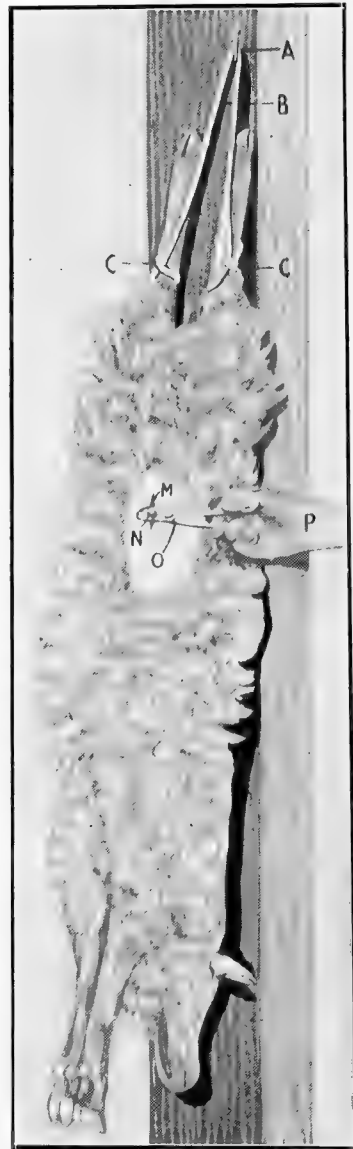


Fig. 179—Removing Ovary.
M, Incision; N, Ovary; O, Emasculator.

Warning—On account of the thin and delicate structure of the abdominal wall exceeding care must be exercised in suturing the incision.

Sterilization of Instruments and Cleansing Hands of Operator
—Same as for calf spaying.

Operative Technique—With ewe in the hanging posture the

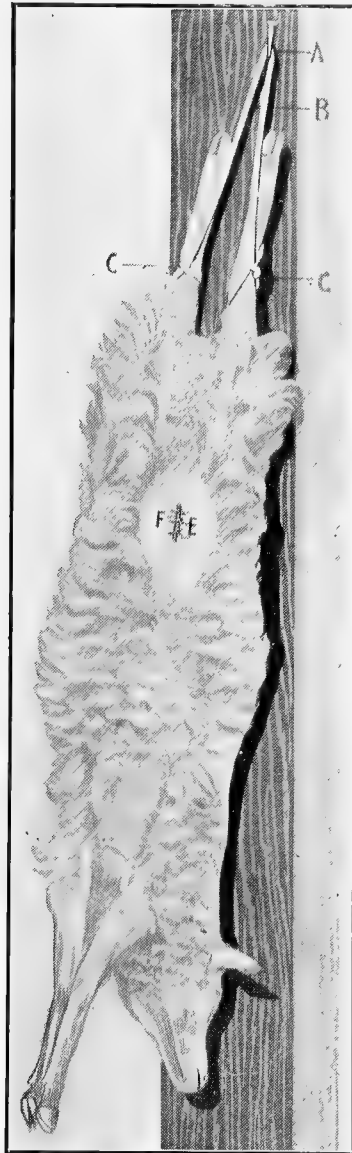


Fig. 180—Wound Sutured. E, Wound; F, Sutures.

wool is clipped from field of operation, after which it is cleansed by washing with soap and water and disinfected by painting with tincture iodine. 1. With knife in right hand begin the incision in the median line 3 inches below the brim of pubis, and extend it downwards for a distance of $2\frac{1}{2}$ or 3 inches. (See Fig. 178.) This incision should penetrate all layers of the abdominal wall. 2. With index and second finger inside the abdomen the horns and ovaries are readily located, after which withdraw each ovary in turn and sever them from their attachments. (See Fig. 179.) 3. The abdominal incision is now closed by three interrupted "through and through" sutures, care being taken to see that each coat of the abdominal wall is in direct apposition.

After Care and Treatment—The spayed animals should be turned to pasture if weather conditions are favorable, otherwise sanitary well bedded quarters are to be provided. If sutures do not slough out they should be removed about the eighth day.

CHAPTER V.

BITCH SPAYING.

Objects and Indications—Bitches are submitted to spaying operation for the purpose of preventing "heat" and pregnancy, both of which are necessarily preceded by obscene and vulgar behavior which is particularly objectionable to home folks as well as neighbors. A bitch in "heat" is an ideal illustration of a private as well as public nuisance. She is undesirable at home and unwelcome abroad. To obviate this, spaying is the only recourse. The spayed bitch is a more desirable animal in many respects than the unspayed one. She remains contented at home. She is always present and ready when called for. She is more kind, docile and reliable than the entire bitch.

Age—In order to secure the best results it is advisable to spay the bitch puppy before she comes in heat the first time. The preferable age is 3 to 6 months. Aged bitches which have given birth to several litters of pups previous to spaying sometimes "come in heat" after they are spayed. Whether or not such phenomenon is an acquired habit the author is unable to say.

Season—Winter, spring and fall.

Preparation—An empty alimentary tract is one of the most important adjuncts to spaying. Food should be withheld for 36 hours previous to time of operating, and if there is the slightest evidence of constipation a dose of castor oil should be administered 12 hours before spaying.

Methods of Operating—There are two well defined methods of operating, viz.: Flank method and belly method. They both have their ardent advocates. Some good surgeons prefer and advocate the belly method while some better surgeons strongly indorse the flank method. The author greatly prefers the belly method.

Anaesthesia—With qualified and trained assistants and hospital facilities at hand the operation should be performed under

general anaesthesia. However, when these safeguards and conveniences are not available it is permissible to operate without anaesthesia.

Instruments—1. Miles' hook knife (Fig. 25). 2. Canine and feline emasculator (Figs. 102 and 103). 3. Wound retractor (Fig. 180 a). While the wound retractor is not absolutely essential, nevertheless its application greatly facilitates locating the uterus and fallopian tubes by enabling the operator to view them inside the




Fig. 180 a—Wound Retractor. (Actual Size.)




Fig. 180 b—Surgeon's Full Curved Needle No. 5. (Actual Size.)

abdomen. If these parts are seen they can be readily grasped with haemostatic forceps and withdrawn, without introducing the finger (Fig. 180 b), carrying 20 inches No. 10 braided silk for sutures. 5. Uterine sound (Fig. 180 c). 6. Haemostatic forceps. 7. Richter's needle holder (Fig. 34).



Fig. 180 c—Uterine Sound.



Fig. 181—External and Internal Genital Organs of Bitch. A, Vulva; B, Vagina; C, Uterus; D-D, Horns; E-E, Ovaries.

Anatomy—There is little or no doubt—on account of anatomical conformation—that the bitch is the most tedious and difficult of all domestic animals to spay unless it be one exception—the cat. In order to make satisfactory progress to any degree whatsoever in bitch spaying the operator must possess some familiarity with the anatomy of the organs and parts involved.

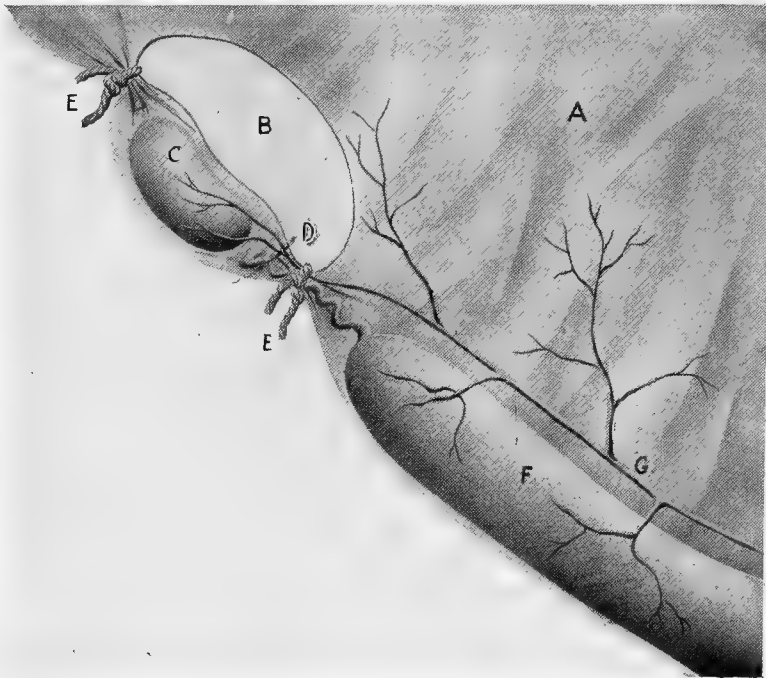


Fig. 182—A, Broad Ligament; B, Rent in Ligament; C, Ovary; D, Fallopian Tubes; E-E, Ligatures; F, Horn; G, Artery.

Vulva—The vulva has thick labia which form a pointed inferior commissure.

Vagina—The vagina is tubular in form and relatively long. Its walls are thick, consisting principally of circular muscular fibers. It is closely related with the rectum above and the bladder below.

Uterus—The body of the uterus is exceedingly short, rarely exceeding one inch in length. Its two cornua (horns) are long, and their diameter small. They vary in length in different size sluts from 4 to 8 inches. They lie loosely inside abdominal cavity closely associated with the intestinal convolutions. Their bifurca-

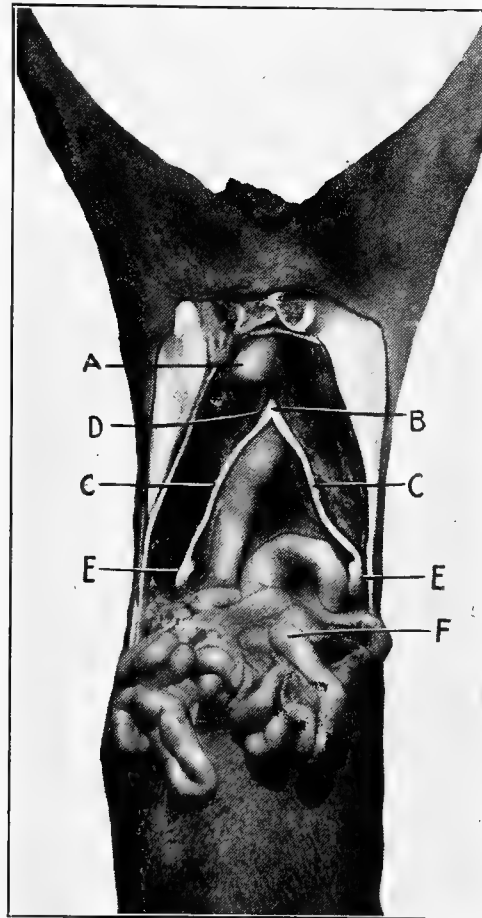


Fig. 183—View of Interior of Abdominal Cavity, Showing Internal Genital Organs and Their Relations. A, Urinary Bladder; B, Uterus; C-C, Horns; D, Bifurcations of Horns; E-E, Ovaries; F, Intestines.

tion is V shaped, and takes place immediately under fundus of bladder. The broad ligaments are long, especially in their middle. (See Fig. 182.) The fallopian tubes are small in diameter and 1 to 2½ inches long.

Ovaries—The ovaries are bean shaped and small in size. Their surface is smooth. They are enclosed in a peritoneal pouch (sac) and are attached immediately posterior to the kidneys. (Fig. 183).

Sterilization of Instruments and Cleansing Hands of Operator—All instruments, sutures, ligatures, etc., used in connection with the operation should be sterilized by boiling for 15 or 20 minutes, after which immerse them in Lysol or Cresol Compound, U. S. P., in the strength of one tablespoonful to each quart of water. The hands should be thoroughly cleansed with tincture green soap and




Fig. 184—Bitch on Table. A-B, Hind Hobbles; C-D, Front Hobbles; E, Incision; F, Tape Muzzle.

warm water, using scrub brush, after which rinse them in the above prescribed antiseptic solution.

Preparation of Operative Field—Clip or shave hair from site of incision. Wash with tincture green soap and warm water, using scrub brush. Rinse with antiseptic solution, after which paint with tincture iodine.

Restraint and Position (Belly Method)—Always apply the muzzle to begin with. If suitable operating table is available it should be utilized. What we mean by suitable table is one in which top will elevate to the perpendicular or almost perpendicular position. Tables made with stationary tops have no place in this operation. If a table is not used then an inexpensive as well as a safe and satisfactory method is that designed, taught and practiced by “Farmer” Miles (see Fig. 185), as follows: A tape muzzle (F) is applied. With a strong cord looped above hocks (B-B) and thrown over spike or hook (A) in post or wall (C) the animal



Fig. 185—"Farmer" Miles Method of Restraint for Spaying Operation.

is suspended sufficiently high for the site of operation to be on a level with operator's breast. With another strong cord (D) looped above elbows (E-E), the operator's leg (G) is placed through its loop for the purpose of making sufficient downward traction to limit movement of animal. In this position the intestines gravitate downward against diaphragm, which greatly assists in locating and removing the ovaries.

Operative Technique—A site is selected slightly to right or left of the median line about 2 to 3 inches below the pubic brim for the




Fig. 186—Abdominal Incision.



Fig. 187—Removing Ovaries with Emasculator. I, Bifurcation; J-J, Horns; K, Ovaries; L, Emasculator.



Fig. 188—Incision Closed with 3 Interrupted Sutures.

beginning of abdominal incision. This incision should extend downwards for $1\frac{1}{2}$ to 2 inches, and penetrate all coats of the abdominal wall, care being taken not to injure bladder with point of knife. (See Fig. 186.) If preferred there is no objection to

introducing the wound retractors, in which event if your bitch is empty and the light bright—either the body of the uterus or its horns can plainly be seen. With either tissue or haemostatic forceps the horn is picked up and drawn out abdominal incision where it is grasped between the index and second finger of the left hand. With index finger of right, follow the horn and tube downward to its attachment, and with a limited amount of traction on horn the ovary is torn loose with the finger nail and brought to the outside. With free end of tube and ovary in one hand the horn is followed up to its bifurcation. When bifurcation is reached the opposite horn is grasped and opposite ovary located and removed from abdomen in like manner. Both ovaries are now removed from their fallopian tubes with emasculator. The stump of tubes and horns are replaced in abdominal cavity. Recleanse the wound by sponging with antiseptic solution, after which close with two or three interrupted “through and through” sutures. The animal is now ready to release. If inexperienced it is well for the operator to insert uterine sound or probe into the vagina, as by this means the finding of uterus and horns is oftentimes greatly facilitated. With the experienced operator the sound is superfluous.

Restraint (Flank Method)—The usual means of restraint when spaying by this method is the application of a tape muzzle and fixing the right hind and both fore feet together with a strong

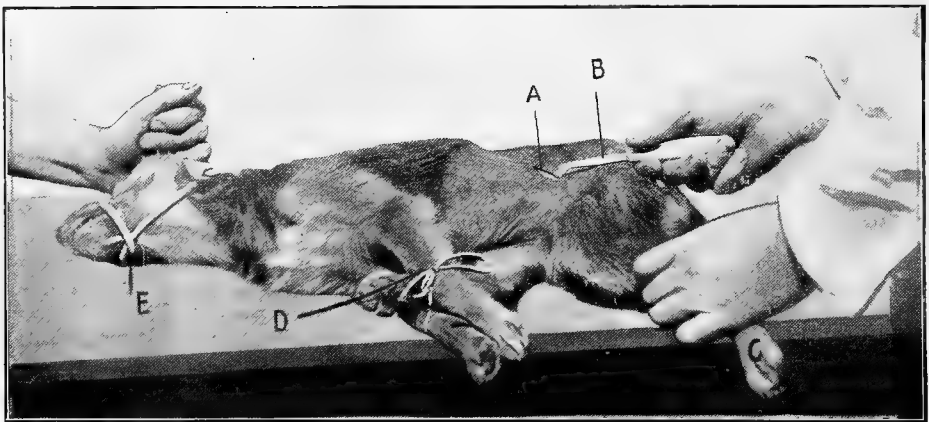


Fig. 189—Bitch Spaying (Flank Method.) A, Abdominal Incision; B, Knife; C, Left Leg; D, Three Legs Fixed Together; E, Muzzle.

cord. With one assistant at the head and another with left hind leg, the animal is sufficiently secure for the operation.

Operative Technique—The site of incision is in triangle of flank. This triangle is bound superiorly by transverse processes of lumbar vertebrae. Anteriorly by posterior border of last rib and posteriorly by external angle of illium. The direction of incision should be slightly diagonal, extending downward and backward. About $1\frac{1}{2}$ inches is the usual length. (See Fig. 189.) This incision should penetrate all coats of the abdominal wall (skin, subcutaneous connective tissue, fascia, external and internal oblique abdominal muscles and peritoneum). With the index finger introduced into the abdominal cavity the uppermost horn is located and drawn out through incision. This horn and tube are followed up—with one finger—until its ovary is located. The ovary is torn loose from its attachment and brought outside the abdominal cavity. (See Fig. 190.) By making limited traction on this horn with one hand, and following it to the bifurcation with index finger on other hand, the opposite horn is located and drawn

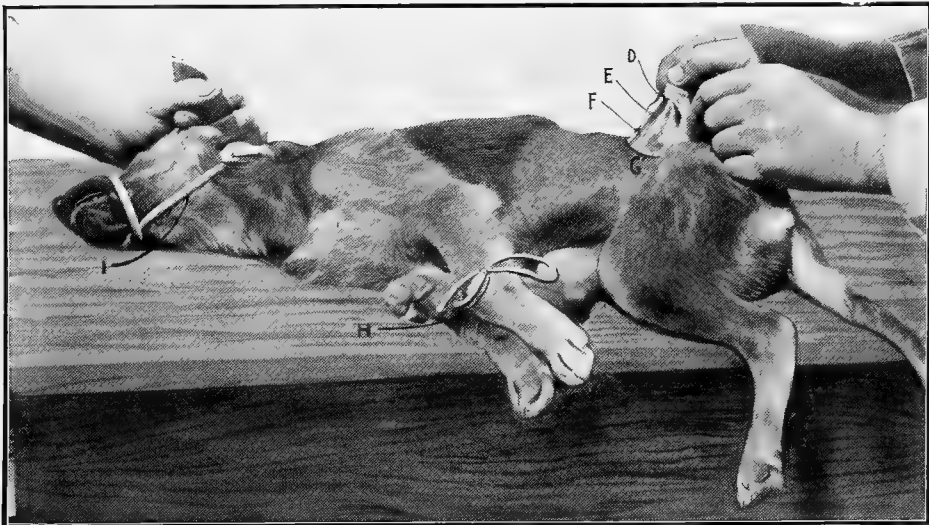


Fig. 190—Bitch Spaying (Flank Method.)

outside the cavity. With finger inside the cavity the ovary is torn from its attachment and brought outside. The tubes may now be severed with emasculator or they may be ligated with chromacized catgut (10-day). Thoroughly cleanse by sponging with antiseptic



Fig. 191—Wound Closed by Interrupted Sutures. (P) Bitches after spaying should have the wounds protected as a safeguard against infection as well as tearing out sutures with the teeth. Two methods of wound protection are illustrated in Figs. 192 and 193.




Fig. 192—Protection of Wound After Spaying.

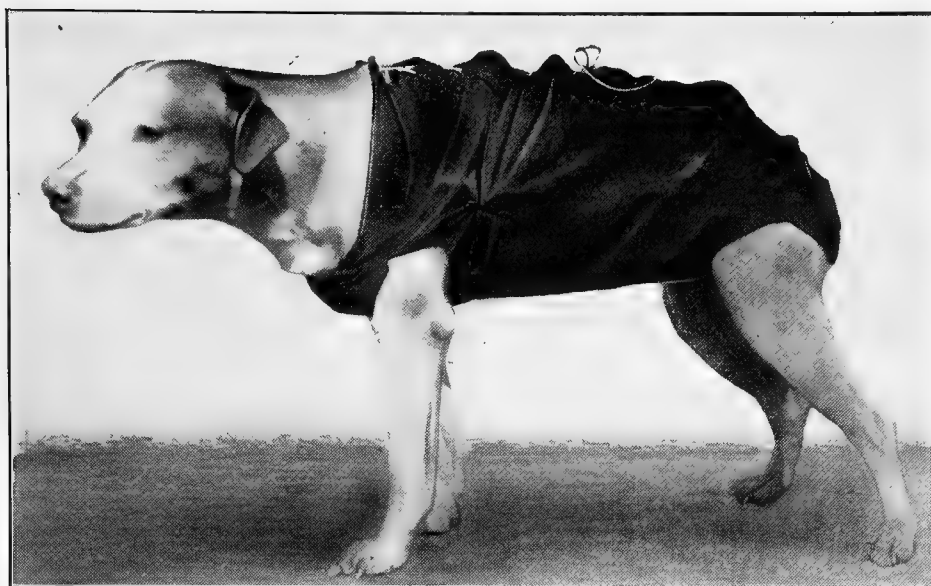


Fig. 193—Protection of Wound After Spaying.

solution everything that is outside the abdominal cavity, after which replace the stumps of tubes and suture up with two or three “through and through” sutures. (See Fig. 191.) Special care should be exercised to see that the peritoneum is included in sutures. Bitches after spaying should have the wounds protected as a safeguard against infection as well as tearing out sutures with the teeth. Two methods of wound protection are illustrated in Figs. 192 and 193.

After Care and Treatment—The bitch should be confined in small sanitary quarters for 6 or 7 days. Exercise during this period is harmful and oftentimes dangerous. Remove sutures in from 3 to 5 days, depending upon condition of wound.

Sequelae—The chief sequelae to be faced are septic peritonitis, shock, internal hemorrhage, hernia and anorexia.

1. *Septic Peritonitis.* The cause of septic peritonitis may be attributed to uncleanliness on part of surgeon while operating, unclean hands, contaminated instruments, failure to properly cleanse and disinfect site of operation, etc. While the bitch possesses considerable more immunity to septic infection than some other animals, nevertheless it behoves the operator to be on the constant

lookout for sepsis, and to take all reasonable precautions to prevent it.

2. *Shock.* When the operation is unnecessarily prolonged and considerable blood lost, shock is by no means an unusual sequelae. Shock is not so liable to occur when general anaesthesia is employed. If shock is of such a desperate character as to require treatment proceed as follows: Protect the body from cold by placing patient in a warm room and blanketing. Strychnine and nitro-glycerine, or adrenalin chloride, may be administered hypodermically. Alcohol and ammonia internally. If reaction does not begin quite promptly resort should be had to normal saline solution subcutaneously or intra-veinously.

3. *Internal Hemorrhage.* If for any reason the emasculator fails to properly crush the artery internal hemorrhage to a lesser or greater degree may be reasonably expected. If at the time of spaying the bitch is in "heat," or in event of pregnancy, the horns and tubes are greatly congested and enlarged. In such cases the emasculator should not be depended upon to control the hemorrhage. The ligature should be resorted to. Nature will do much to prevent internal hemorrhage. However, death from such a cause sometimes occurs. Unless the hemorrhage is very profuse reopening the abdomen for purpose of controlling it is of doubtful value. Ordinarily, the best plan is to administer stimulants, consisting of strychnine, nitro-glycerine, adrenalin, chloride and saline solution, and leave the abdominal cavity alone.

4. *Hernia.* Careless or improper suturing and septic infection are the causes of hernia following spaying operation. By exercising extreme care in suturing the wound and fortifying against sepsis by taking the necessary aseptie and antiseptic precautions the occurrence of hernia will be extremely rare.

5. *Anorexia.* In a few instances it is extremely difficult—even in the absence of any perceptible grave systemic disturbance—to induce the recently spayed bitch to eat and drink. They sometimes actually die from starvation. Forced feeding with malted milk or coco-emulsion cod liver oil is indicated. Drugs are of little avail.

CHAPTER VI.

CAT SPAYING.

Objects and Indications—Cats are submitted to spaying operation for the purpose of preventing “heat” and pregnancy, principally the latter. After spaying they remain at home better and are more desirable pets than before.

Age—The best results are attained if the cat is spayed before she “comes in heat” the first time (prior to puberty). On account of small size of cat—especially if an attempt is made at an early age—the operation is extremely tedious. Best to operate at 6 to 8 months old.

Season—Winter, spring and fall.

Preparation—Withhold food for 24 to 30 hours previous to operating in order that the alimentary tract may be empty.

Methods—Flank method and belly method. The author prefers the belly method.

Anaesthesia—On account of a natural as well as an acquired tendency to bite and scratch ferociously whenever submitted to operation of almost any character, general anaesthesia should be employed whenever possible.

Instruments—1. Miles’ hook knife (Fig. 25). 2. Canine and feline emasculator (Figs. 102, 103). 3. Wound retractor (Fig. 180 *a*). 4. Surgeon’s full curved needle No. 5 (Fig. 180 *b*), carrying 18 inches sterilized braided silk No. 10. 5. Long, slender probe. 6. Haemostatic forceps.

Anatomy—The cat is the most difficult and tedious of all domestic animals to spay. The anatomical conformation and small size of the parts and organs concerned in the operation largely account for its extreme tediousness. As for the author’s part he would greatly prefer spaying ten heifers to one cat. In fact, he would prefer spaying twice ten heifers to spaying one kitten. As a general proposition the internal generative organs of the cat

are similar in all material respects to those of the bitch except, of course, those of cat are on a much smaller scale. Their conforma-



Fig. 194—External and Internal Genitals of Cat.

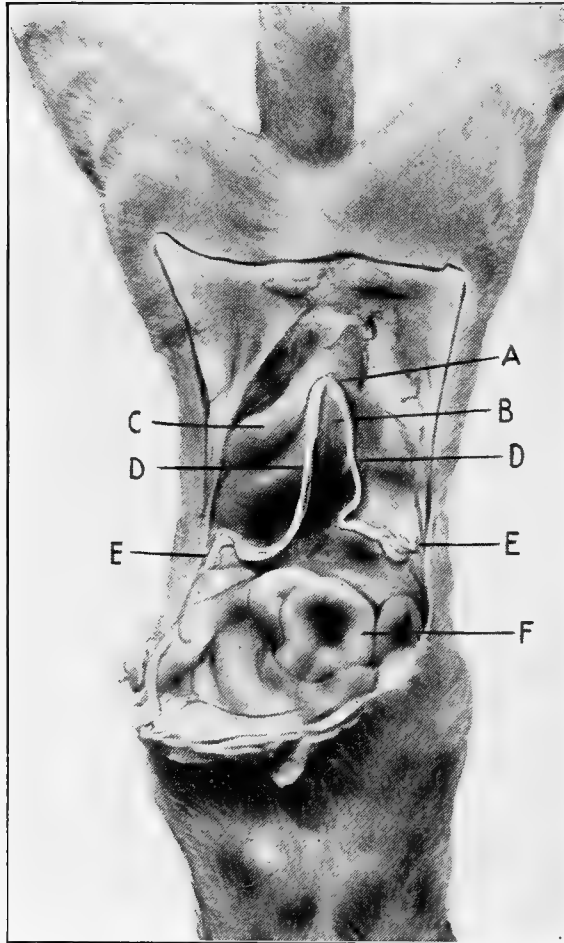


Fig. 195—View of Interior of Abdominal Cavity. A, Bifurcation; B, Rectum; C, Bladder; D-D, Horns; E-E, Ovaries; F, Intestines.

tion and anatomical relation are the same in both animals. (See Figs. 194 and 195.)

Sterilization of Instruments and Cleansing Hands of Operator—Same as for bitch spaying. See page 205.

Preparation of Operative Field—Same as for bitch spaying. See page 206.

Restraint (Belly Method)—It is desirable to fix the cat securely to operating table (Figs. 196 and 197). In event table is not available a wide board may be used.

Operative Technique—Same as for bitch spaying.

Restraint (Flank Method)—Right hind and both fore legs are fixed together with strong cord. Left hind leg and head are held by assistant. (See Fig. 198).

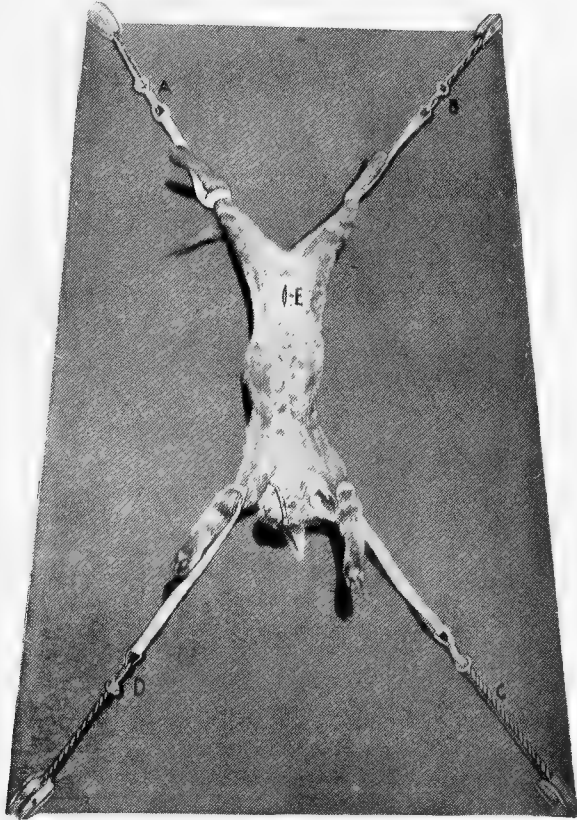


Fig. 196—Cat Fixed to Table for Spaying Operation. E, Abdominal Incision.




Fig. 197—Incision Closed with Two Interrupted Sutures.

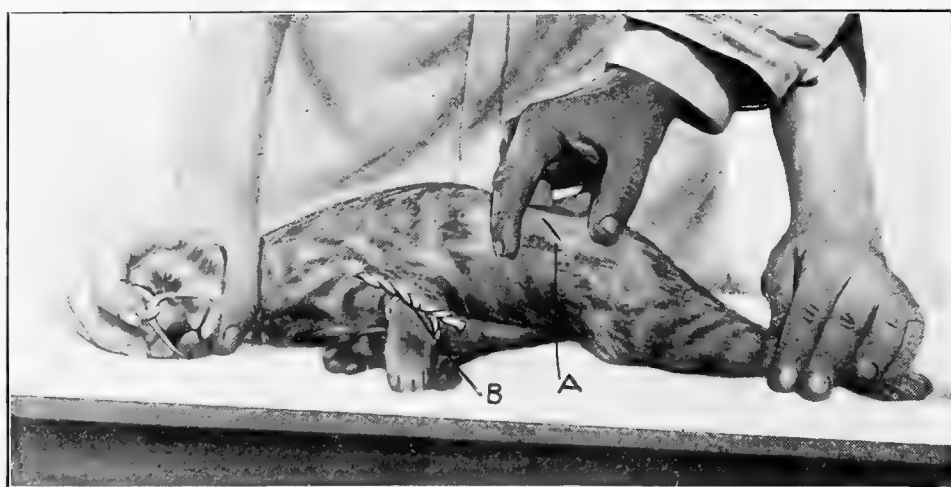

Fig. 198—Cat Tied and in Proper Position for Flank Spaying. A, Incision; B, Legs Fixed Together.

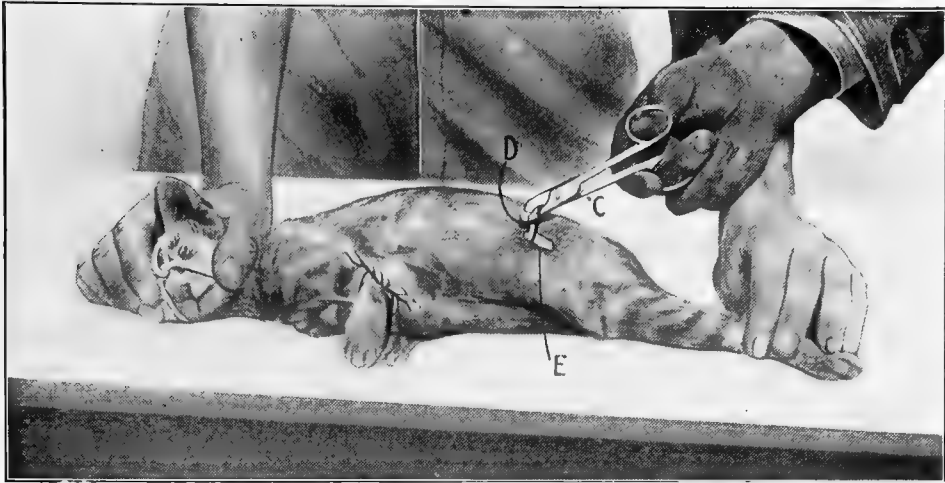


Fig. 199—Cat Spaying (Flank Method). E, Emasculator; D, Ovary; F, Abdominal Incision.

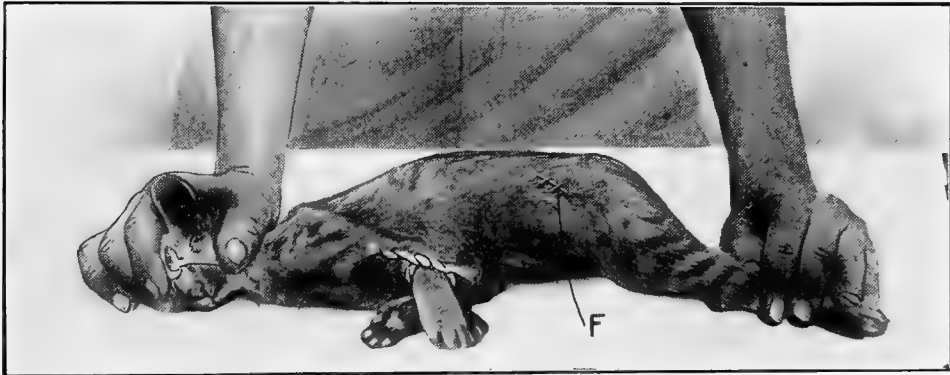


Fig. 200—Wound Closed with Two Interrupted Sutures. F, Sutures.

Operative Technique—Same as for bitch spaying. (See pages 207-209.)

After Care and Treatment—Same as for bitch spaying. See page 211.

Sequelae—Same as for bitch spaying. (See page 211.)

CHAPTER VII.

POULARDIZING.

The operation of poulardizing simply means unsexing the female chicken. In other words, spaying the pullet.

Objects and Indications—The primary object in making poulardes of pullets is for the purpose of growing them to quick maturity without the handicap of egg production. It is a positively known fact that poulardes mature and develop more rapidly than the entire pullet or hen. The texture, flavor and nutritive properties of their meat is greatly improved. Poulardes meat bears the same relation to that of the hen as the meat of a spayed heifer bears to that of the old cow. The operation has been practiced on a large scale for many years in France and Germany, and to a limited extent in America. The results would justify its more universal adoption. The poularde never cackles, and like the capon becomes an outcast.

Age—Two to three months.

Season—Late spring, summer and early fall.

Preparation—Withhold all food for at least 30 hours before operating. It is impossible to do a satisfactory operation on a pullet with full alimentary tract. To begin with a full abdominal cavity prevents locating and examining the egg cluster, to say nothing of its interference with the operation itself.

Restraint—On a box or barrel acting as an operating table the pullet is confined for operation same as for that of caponizing. Two pieces of strong cord are procured, upon each end a loop is made. To one end a weight is attached (see A-A, Fig. 201), after which the free end of one cord is looped above feet and the other cord is looped around wings. The pullet is now stretched full length—left side uppermost—on table. This is a quick and inexpensive method of restraint and at the same time a satisfactory one for the operation.

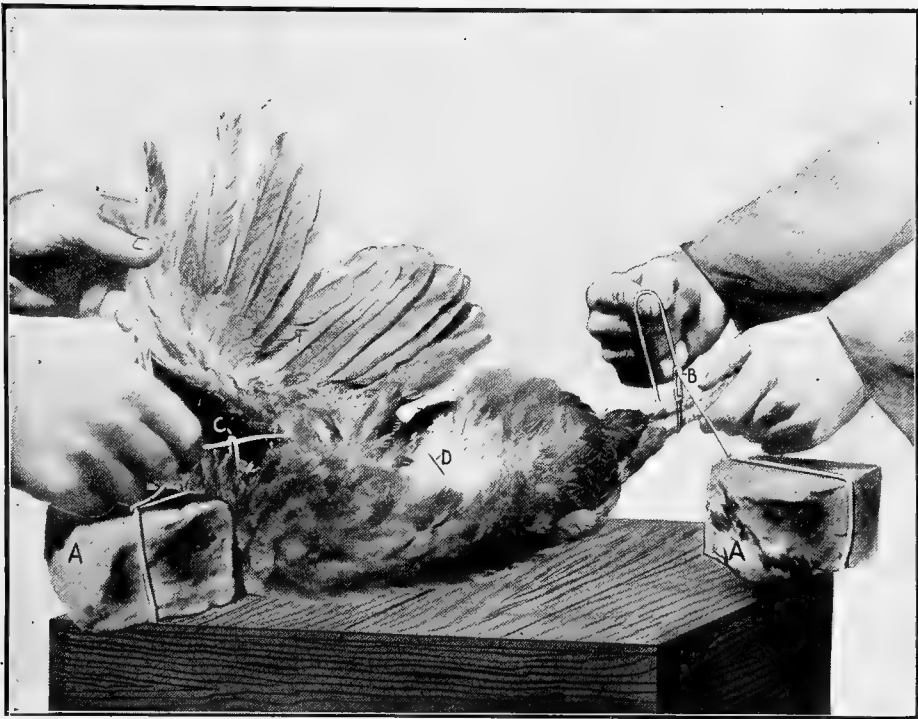


Fig. 201—Restraint for Poulardeing. A-A, Weights at End of Cords; B, Leg of Fowl in Loop; C, Wings in Loop; D, Incision.

Instruments—1. Caponizing knife (Fig. 116). 2. Spreaders (Figs. 117, 118, 119). 3. Haemostatic or tissue forceps (small size). 4. Curved scissors (Fig. 35).

Breeds—It is not profitable to attempt to make poulardes from the small breeds of chickens. Better select those of the larger breeds, viz.: Indian Games, Brahmas, Cochins, Langshans, Plymouth Rocks, Orpingtons, Wyandottes, etc. All make good poulardes.

Anatomy—Some idea of the anatomy of the parts involved and their relation is necessary before progress can be made with this operation. Fig. 202 shows the egg cluster (E) which corresponds to the ovary in animals, and egg passage (F) which corresponds to the uterus in animals. This illustration was purposely made from a grown hen. One object in doing so was to enable the amateur operator to know the comparative between the internal genitals of a hen and those of a pullet of proper age and size for oper-

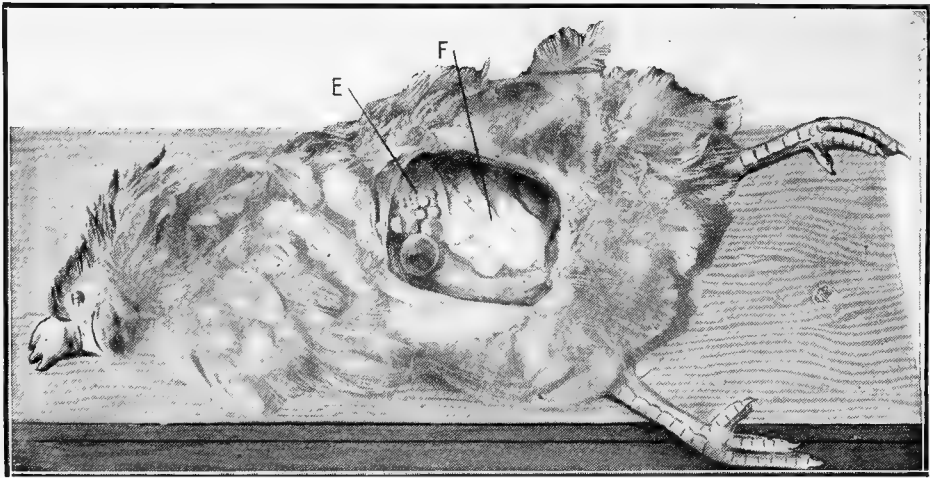


Fig. 202—Internal Genital Organs of Hen. E, Egg Cluster; F, Egg Passage.




Fig. 203—Internal Genitals of Hen. A, Egg Cluster; B-B, Egg Passage; C, Cloaca; D, Frimbriated Extremity of Fallopian Tube.

ation. Fig. 203 shows the organs removed from the abdominal cavity of hen. They consist of (A) egg cluster, (B-B) egg passage, (C) cloaca, (D) frimbriated extremity of fallopian tubes. The egg cluster lies in close proximity to the vertebral column, slightly posterior to the lungs. From it the fallopian tubes and egg passage proceed backward—in close relation to the vertebral column, aorta and vena cava—to its outlet—cloaca. In the pullet the egg cluster and egg passage are small. (See Fig. 204.)

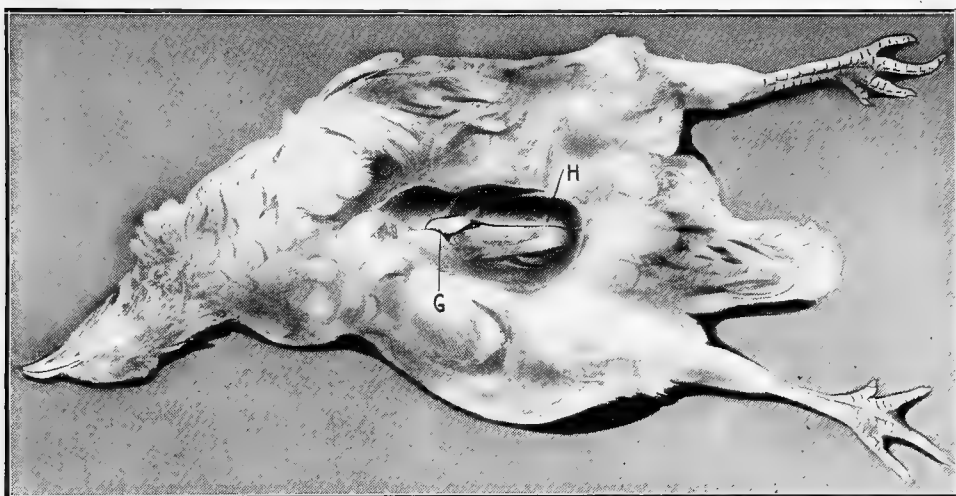

Fig. 204—Intestines Removed in Order to Show Position of Egg Cluster and Egg Passage. G, Egg Cluster; H, Egg Passage.

In a pullet of proper age for operation the egg passage is no larger than an average size broom straw. The egg cluster in such a pullet is small and flat, and shows no evidence of egg formation. Beginners are urgently advised to kill and carefully examine these parts in a full grown hen, also a three-months-old pullet before operating.

Warning—In removing section from egg passage caution should be exercised not to sever either the aorta or vena cava. Both are large and important blood vessels, and should either of them be severed death from internal hemorrhage is almost instantaneous. It is important to have extra good light in order that the abdominal cavity be illuminated sufficiently to locate the parts. Bright sunshine is the ideal light for this operation. Out-of-doors is the place, and from 10 a. m. to 2 p. m. is the time.

Operative Technique—With left side uppermost the feathers are plucked from site of incision—last intercostal space. The skin is chilled by allowing a glass of cold water to slowly trickle over it. This chilling process has a tendency to reduce capillary hemorrhage from the skin. With knife begin high between the last two ribs and make an incision 1 to 1½ inches long, severing through skin and both layers of intercostal muscle down to the transparent peritoneum. Since the intercostal artery follows closely the posterior (back) border of the rib this incision should be made as close to the anterior border (front) of the last rib as possible. The spreaders are now inserted. This opens the wound,

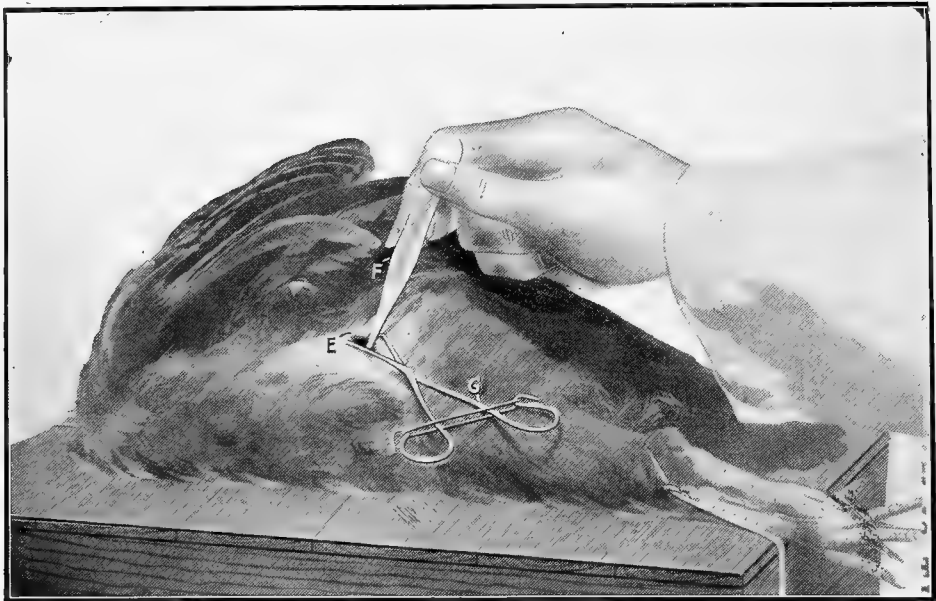


Fig. 205—Making a Poularde. E, Abdominal Incision; G, Spreaders; F, Thumb Forceps.

and through the transparent membrane (peritoneum) covering the intestines the egg cluster is examined. If there is evidence of advanced egg formation it is not profitable to make a poularde. More profitable to release her for egg production, in which event the abdominal cavity is not opened. The spreaders are simply removed and the fowl released. On the other hand, if, upon examination of the egg cluster—through the transparent peritoneum—there is no evidence of egg formation the peritoneum is knicked sufficient to open the abdominal cavity. Beginning close to the

egg cluster a one-inch section of the egg passage is removed with forceps and scissors. This stops egg formation. By reference to Fig. 206 an idea may be had of the exact location of the egg passage and the part of it to be removed in operating. The spreader is now removed. This allows the ribs to come together, which automatically closes the incision.

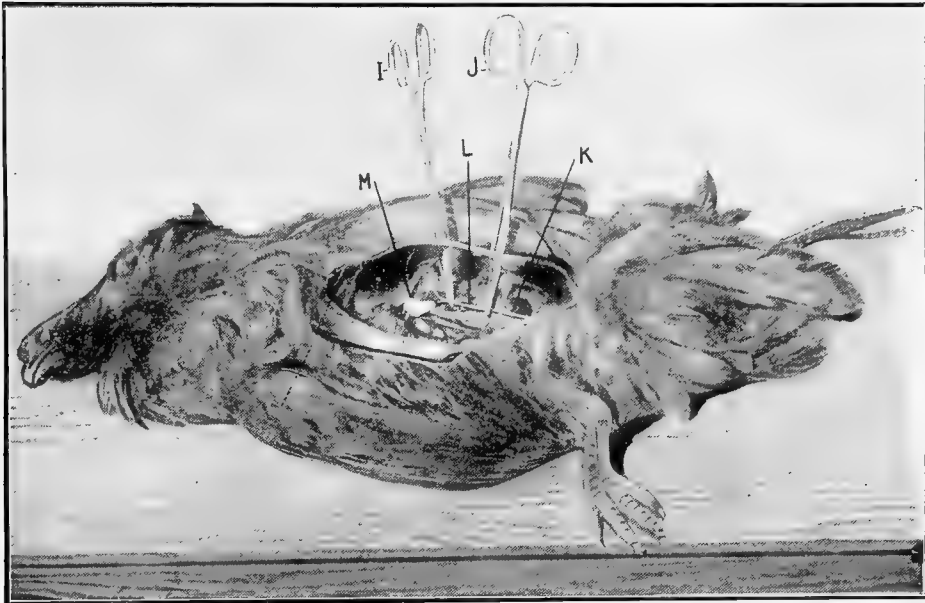


Fig. 206—Removing Section from Egg Passage. I-J, Forceps; K, Egg Passage; L, The Section of Egg Passage Between Forceps is to be Removed; M, Egg Cluster.

After Care and Treatment—Upon being released from the operating table poulardes are usually put in a closed yard where they can find shelter, food and water, and can be kept quiet. No roosts are provided, as the less flying and jumping they do the sooner will the wound heal. The poulardes seem to be very little inconvenienced by the operation, and water and soft feed mixed with sweet skim milk can be given immediately. Some feeders give this in unlimited quantity, while others feed more sparingly for a time.

For a week or ten days the newly made poulardes should be carefully observed to see whether they become “wind-puffed.” This is a condition caused by air gathering under and puffing out the skin near the wound. When observed it can be readily relieved by pricking the skin with a needle or knife and pressing out the air.

CHAPTER VIII.

DEODORIZING THE SKUNK.

While removing the scent from a skunk has not the remotest relation—either directly or indirectly—with animal castration, nevertheless, on account of its novelty and the dearth of reliable literature with reference to the subject the author considers it of sufficient interest and importance for brief mention in the concluding pages of this volume.

Objects and Indications—It should be remembered that the skunk has no effective means of protection or defense aside from the scent fluid which it possesses and uses without stint when it becomes necessary. Ordinarily, the fluid discharged by the skunk is amply sufficient to ward off most any character of attack and protect the animal from danger. The scent fluid is only discharged when the animal is alarmed or frightened, and contrary to the prevailing popular opinion, is not urine, and has no connection with the urinary apparatus. Skunks are deodorized for the purpose of converting them into desirable household pets. Such animals never scratch and rarely ever bite. They are absolutely harmless.

Age—They should be operated upon at an early age (15 to 30 days old), as the mortality rate following operation in the mature skunk is very high.

Season—Whenever you can succeed in catching them. This is one animal at least you must catch before you can operate.

Preparation—If possible the young animals (kittens) should be kept and fondled for several days before they are submitted to operation. They should become accustomed to being handled. By thus preparing them they may be handled through the preparatory stages of the operation without voiding the scent fluid.

Restraint—The operation must be done under a glass in order to protect operator and assistants. A large pane of window glass

should be supported at each end and raised about 10 inches from the floor. Two assistants are necessary. Rubber gloves should be worn by the operator and both assistants. The animal is carefully placed under the glass, after which one assistant should grasp the head and fore feet and the other assistant grasp hind feet, and hold the posterior parts in such position as to cause the discharged scent fluid to be deposited against under side of glass. Most of the fluid will at this time be discharged quite promptly. Very little will be kept in reserve. In fact, the operation could be proceeded with to completion without the glass.

Instruments—1. Scalpel. 2. “Rat tooth” haemostatic forceps. 3. Curved scissors (Fig. 35).

Anatomy—The anis is a large irregular elliptical depression surrounded by loose flabby skin which bulges over site of anal (scent) glands. These glands are two in number located on each side (laterally) of the anis. There is about one-half inch space between the anis and center of the anal glands.

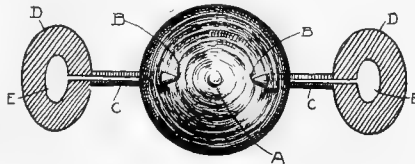


Fig. 207—Diagrammatic Illustration Showing Scent Secreting and Expelling Apparatus. A, Anis; B-B, Jet or Nipple-like Openings of Anal Ducts; C-C, Ducts; D-D, Anal Glands; E-E, Sacs or Reservoirs.

The scent secreting apparatus is large, and consists of numerous small glands—closely associated—surrounding a sac or reservoir for storing up the fluid. They are covered by skin, subcutaneous connective tissue, and two thin layers of muscular fiber, viz.: Ischio cavernous and bulbo-cavernous muscles. The glandular organ is surrounded by a well defined envelope. Each gland is supplied with an excretory duct. These ducts project through the lateral walls of rectum immediately anterior to anis. Their openings are nipple or jet-like for the purpose of governing direction of the stream. Whenever the skunk considers itself in danger its behavior is as follows: 1. Turns posterior parts toward the object of attack. 2. Elevates tail. 3. Inverts rectum which exposes

nipple-like openings of the ducts. 4. By voluntary muscular contraction the sac or scent reservoir is compressed and the scent fluid expelled. This fluid may be thrown for a distance of 12 to 15 feet, and the direction of the stream is under thorough control of the skunk. Of course, the amount of fluid is quite limited, but it is usually sufficient to suffice. The character of the fluid is dirty brown and fetid, and is slightly phosphorescent at night.

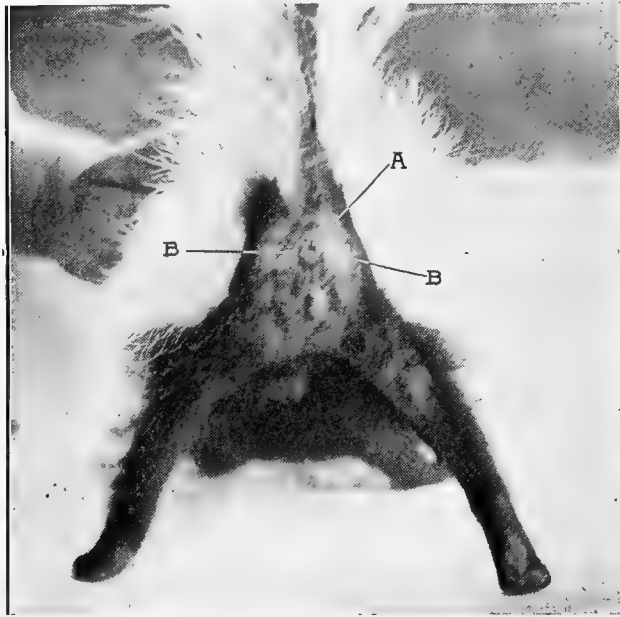


Fig. 208—View of Posterior Aspect of Skunk. A, Anis; B-B, Anal Glands.

Sterilization of Instruments and Cleansing Operator's Hands—The instruments should be sterilized by boiling 15 to 20 minutes, after which immerse them in Lysol or Cresol Compound, U. S. P., in the strength of one tablespoonful to each quart of water. Wash hands with tincture green soap, using scrub brush, after which rinse them with the above mentioned antiseptic solution.

Preparation of Operative Field—Don't forget that the skunk is now supposed to be under the glass. Clip hair from around the rectum for a distance—in each direction—of at least one inch. Wash parts with antiseptic solution and paint skin over site of incisions with tincture iodine.

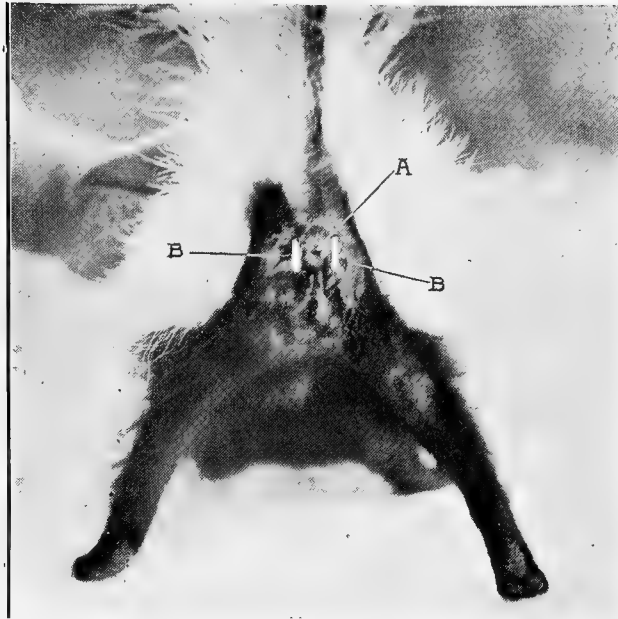


Fig. 209—View Showing Incisions Over Site of Anal Glands. A, Rectum; B-B, Incision.

Warning—In making incisions and dissecting out anal glands exercise extreme care in order to avoid injury to either rectal or anal walls, or to the genito-urinary passages.

Operative Technique—Locate the glands—on each side of rectum—by palpitation. A perpendicular incision one inch long is made directly over center of most prominent part of each gland, about one-half inch from rectum (see Fig. 209). These incisions should penetrate skin and subcutaneous connective tissue only. With rat tooth haemostatic forceps or small size vulsellum forceps the glandular organ is grasped, and with limited traction applied by forceps the parts are isolated by careful dissection, after which sever the duct close to rectal wall and the operation is completed. The incision should be left open to heal by granulation.

After Care and Treatment—About all that is necessary is to place the animal in warm sanitary quarters. The wounds will heal and complete recovery take place by the tenth day.

INDEX.

INDEX

	<i>Page</i>
ABSCESS	74
AZOTURIA	77-78
BITCH SPAYING	201-212
Objects and Indications	201
Age	201
Season	201
Preparation	201
Methods of Operating	201
Anaesthesia	201-202
Instruments	202
Anatomy	203-205
Restraint (Belly Method)	206-207
Operative Technique (Belly Method) ..	207-208
Restraint (Flank Method)	208-209
Operative Technique (Flank Method) ..	209-211
After Care and Treatment	211
Sequelae	211-212
BOAR—CASTRATION OF THE	105-110
Objects and Indications	105
Age	105
Season	105
Preparation	105
Restraint	105-107
Instruments	107-108
Operative Technique	108-110
After Care and Treatment	110
Sequelae	110
BOAR—CASTRATION OF THE MONORCHID AND CRYPT- ORCHID	111-115
Objects and Indications	111
Age	111
Preparation	111
Warning	111-112
Restraint	112
Instruments	112
Operative Technique	113-114
After Care and Treatment	114-115

INDEX—Continued.

	<i>Page</i>
BOAR—CASTRATION OF THE RUPTURED	115-123
Objects and Indications	116-117
Age	117
Season	117
Preparation	117
Restraint	117
Instruments	117
Operative Technique	118-123
After Care and Treatment	123
BULL CASTRATION	92-101
Objects and Indications	92
Age	92
Season	92
Preparation	92
Anatomy	94-95
After Care and Treatment	99
BULL—CASTRATION IN RECUMBENT POSTURE	92-99
Restraint for	92-94
Operative Technique	96-99
BULL—CASTRATION IN THE STANDING POSTURE ..	100-101
CAPONIZING	143-151
Definition	143
History	143
Objects and Indications	143-144
Selection of Breeds	144
Age	144
Season	144
Restraint	145
Instruments	145-147
Anatomy	147
Preparation	148
Operative Technique	148-150
After Care and Treatment	150-151
Mortality	151
CALF SPAYING	179-184
Objects and Indications	179-180
Age	180
Season	180
Preparation	170
Restraint	180-181
Instruments	181
Operative Technique (Flank Method) ..	181-183
Operative Technique (Belly Method) ..	183
Sequelae	184

INDEX—Continued.

	<i>Page</i>
CASTING—INJURIES FROM	76
CASTRATION—DEFINITION OF	13
History of	13
Ancient Methods of	13
Modern Methods of	13
CASTRATION OF THE BOAR	105-110
Objects and Indications	105
Age	105
Season	105
Preparation	105
Restraint	105-107
Instruments	107-108
Operative Technique	108-110
After Care and Treatment	110
Sequelae	110
CASTRATION OF THE CRYPTORCHID AND MONORCHID	
BOAR	111-115
Objects and Indications	111
Age	111
Preparation	111
Warning	111-112
Restraint	112
Instruments	112
Operative Technique	113-114
After Care and Treatment	114-115
CASTRATION OF THE RUPTURED BOAR	115-123
Objects and Indications	116-117
Age	117
Season	117
Preparation	117
Restraint	117
Instruments	117
Operative Technique	118-123
After Care and Treatment	123
CASTRATION OF THE BULL	92-101
Objects and Indications	92
Age	92
Season	92
Preparation	92
Anatomy	94-95
After Care and Treatment	99
CASTRATION OF THE BULL IN RECUMBENT POSTURE	92-99
Restraint for	92-94
Operative Technique	96-99

INDEX—Continued.

	<i>Page</i>
CASTRATION OF THE BULL IN STANDING POSTURE . . .	100-101
CASTRATION OF THE CRYPTORCHID AND MONORCHID	
BULL	101-104
Objects and Indications	92
Age	101
Preparation	101
Restraint	101
Instruments	101
Operative Technique	102-104
After Care and Treatment	104
CASTRATION OF THE CAT	141-142
Objects and Indications	141
Age	141
Season	141
Preparation	141
Restraint	141-142
Instruments	131
Anatomy	142
Operative Technique	133-134
After Care and Treatment	142
CASTRATION OF THE COLT	36-42
Objects and Indications	14
Age.	36
Season	36
Preparation	14
Anatomy	19-22
Complications in	47-73
Restraint for	36-39
Instruments for	39
Warning	23-24
Operative Technique	40-42
After Care and Treatment	28
Sequelae	74-91
Prognosis	28
CASTRATION OF THE DOG	131-135
Objects and Indications	131
Age	131
Season	131
Preparation	131
Restraint	131
Instruments	131
Anatomy	133
Operative Technique	33-134
After Care and Treatment	134-135

INDEX—Continued.

	<i>Page</i>
CASTRATION OF THE CRYPTORCHID AND MONORCHID	
Dog	135-140
Objects and Indications	135-136
Age	136
Season	136
Preparation	136
Restraint	137
Instruments	137
Anatomy	137-138
Operative Technique	138-139
After Care and Treatment	140
CASTRATION OF THE HERMAPHRODITE	71-73
Definition	71
Objects and Indications	71
Age	14
Season	72
Preparation	14
Restraint	54-57
Anatomy	72
Instruments	57-59
Operative Technique	73
After Care and Treatment	69-70
CASTRATION OF THE MULE	43-46
Objects and Indications	43
Age	43
Season	43
Preparation	14
Restraint for	36-39
Instruments for	39
Warning	23-24
Operative Technique	43-46
After Care and Treatment	28
Sequelae	74-91
CASTRATION OF THE RAM	124-130
Objects and Indications	124
Age	124
Season	124
Preparation	124
Restraint	124
Instruments	124
Anatomy	125
Operative Technique	127-129
After Care and Treatment	129

INDEX—Continued.

	<i>Page</i>
CASTRATION OF THE STALLION	14-35
Objects and Indications	14
Age	14
Season	14
Preparation	14
Anatomy	19-22
Complications in	47-73
After Care and Treatment	28
Sequelae	74-91
Prognosis	28
CASTRATION OF STALLION IN RECUMBENT POSTURE	14-28
Restraint for	14-16
Instruments for	16-19
Warning	23-24
Operative Technique	25-27
CASTRATION OF STALLION IN STANDING POSTURE..	29-35
Restraint for	29
Instruments for	29
Warning	30
Operative Technique	31-34
Advantages	34
Disadvantages	34
CASTRATION OF THE CRYPTORCHID AND MONORCHID	
STALLION	51-70
Definition	51
Classification	51-53
Objects and Indications	53
Diagnosis	53
Age	54
Season	54
Preparation	54
Restraint	54-57
Instruments	57-59
Anatomy	19-22
Warning	59
Cleansing and Disinfecting Field of Op- eration	59
Operative Technique	60-66
After Care and Treatment	69-70
Sequelae	70
CAT—CASTRATION OF THE	141-142
Objects and Indications	141
Age	141

INDEX—Continued.

	<i>Page</i>
Season	141
Preparation	141
Restraint	141-142
Instruments	131
Anatomy	142
Operative Technique	133-134
After Care and Treatment	142
CAT SPAYING	213-217
Objects and Indications	213
Age	213
Season	213
Preparation	213
Methods	213
Anaesthesia	213
Instruments	213
Anatomy	213-215
Restraint (Belly Method)	215
Operative Technique (Belly Method) ..	207-209
Restraint (Flank Method)	215-217
Operative Technique (Flank Method) ..	209-211
Sequelae	211-212
COLT—CASTRATION OF THE	36-42
Objects and Indications	14
Age	36
Season	36
Preparation	14
Anatomy	19-22
Complications in	47-73
Restraint for	36-39
Instruments for	39
Warning	23-24
Operative Technique	40-42
After Care and Treatment	28
Sequelae	74-91
Prognosis	28
COLIC	77
CORD—SCHIRROUS	82-86
COW SPAYING	164-170
Objects and Indications	164
Age	164
Season	164
Preparation	164-166
Restraint	166
Instruments	166

INDEX—Continued.

	<i>Page</i>
Anatomy	166-167
Warning	167
Operative Technique	167-170
After Care and Treatment	170
DEODORIZING THE SKUNK	224-227
Objects and Indications	224
Age	224
Season	224
Preparation	224
Restraint	224-225
Instruments	225
Anatomy	225-226
Warning	227
Operative Technique	227
After Care and Treatment	227
DOG—CASTRATION OF THE	131-135
Objects and Indications	131
Age	131
Season	131
Preparation	131
Restraint	131
Instruments	131
Anatomy	133
Operative Technique	133-134
After Care and Treatment	134-135
DOG—CRYPTORCHID AND MONORCHID, CASTRATION OF	135-140
Objects and Indications	135-136
Age	136
Season	136
Preparation	136
Restraint	137
Instruments	137
Anatomy	137-138
Operative Technique	138-139
After Care and Treatment	140
EWE SPAYING	197-200
Objects and Indications	197
Age	197
Season	197
Preparation	197
Restraint	197
Instruments	197
Anatomy	198

INDEX—Continued.

	<i>Page</i>
Warning	199
Operative Technique	199-200
After Care and Treatment	200
EXUBERANT GRANULATIONS	86-87
GRANULATIONS—EXUBERANT	86-87
HEIFER SPAYING	170-179
Objects and Indications	170
Age	170
Season	170
Preparation	170
Restraint	170-171
Instruments	171-173
Operative Technique	174-179
HEMORRHAGE—NATURE'S METHODS OF CONTROLL- ING	22-23
Primary	78-79
Secondary	79
HERNIA—INGUINAL	47-51
Scrotal	47-51
HYDROCELE	87-91
HERMAPHRODITE—CASTRATION OF THE	71-73
Definition	71
Objects and Indications	71
Age	14
Season	72
Preparation	14
Restraint	54-57
Anatomy	72
Instruments	57-59
Operative Technique	73
After Care and Treatment	69-70
INFECTION—SEPTIC	74
INGUINAL HERNIA	47-51
INJURIES FROM CASTING	76
INTESTINE—PROLAPSE OF THE	76
MARE SPAYING	153-163
Objects and Indications	153
Age	153
Season	153
Preparation	153
Restraint	154-155
Instruments	155
Anatomy	156-158
Warning	158

INDEX—Continued.

	<i>Page</i>
Operative Technique	158-163
After Care and Treatment	163
Sequelae	163
MULE—CASTRATION OF THE	43-46
Objects and Indications	43
Age	43
Season	43
Preparation	14
Restraint for	36-39
Instruments for	39
Warning	23-24
Operative Technique	43-46
After Care and Treatment	29
Sequelae	74-91
NATURE'S METHODS OF CONTROLLING HEMORRHAGE	22-23
OEDEMA OF SHEATH AND VENTRAL SURFACE OF ABDOMEN	79-81
OMENTUM—PROLAPSE OF THE	75-76
ORCHITIS	71
PARAPHIMOSIS	81-82
PERITONITIS	77
POULARDIZING	218-223
Objects and Indications	218
Age	218
Season	218
Preparation	218
Restraint	218-219
Instruments	219
Breeds	219
Anatomy	219-221
Warning	221
Operative Technique	222-223
After Care and Treatment	223
PRIMARY HEMORRHAGE	78-79
PROLAPSE OF INTESTINE	76
PROLAPSE OF OMENTUM	75-76

INDEX—Continued.

	<i>Page</i>
RAM—CASTRATION OF THE	124-130
Objects and Indications	124
Age	124
Season	124
Preparation	124
Restraint	124
Instruments	124
Anatomy	125
Operative Technique	127-129
After Care and Treatment	129
RUPTURED BOAR—CASTRATION OF	115-123
SCHIRROUS CORD	82-86
SCROTAL HERNIA (BOAR)	115-123
(STALLION)	47-51
SECONDARY HEMORRHAGE	79
SEPTIC INFECTION	74
SEQUELAE OF CASTRATION	74-91
SHEATH—OEDEMA OF THE	79-81
SKUNK—DEODORIZING THE	224-227
Objects and Indications	224
Age	224
Season	224
Preparation	224
Restraint	224-225
Instruments	225
Anatomy	225-226
Warning	227
Operative Technique	227
After Care and Treatment	227
SPAYING THE BITCH	201-212
Objects and Indications	201
Age	201
Season	201
Preparation	201
Methods of Operating	201
Anaesthesia	201-202
Instruments	202
Anatomy	203-205
Restraint (Belly Method)	206-207
Operative Technique (Belly Method) ..	207-208
Restraint (Flank Method)	208-209
Operative Technique (Flank Method) ..	209-211
After Care and Treatment	211
Sequelae	211-212

INDEX – Continued.

	<i>Page</i>
SPAYING THE CALF	179-180
Objects and Indications	179-180
Age	180
Season	180
Preparation	170
Restraint	180-181
Instruments	181
Operative Technique (Flank Method) ..	181-183
Operative Technique (Belly Method) ..	183
Sequelae	184
SPAYING THE CAT	213-217
Objects and Indications	213
Age	213
Season	213
Preparation	213
Methods	213
Anaesthesia	213
Instruments	213
Anatomy	213-215
Restraint (Belly Method)	215
Operative Technique (Belly Method) ..	207-208
Restraint (Flank Method)	215-217
Operative Technique (Flank Method) ..	209-211
Sequelae	211-212
SPAYING THE COW	164-170
Objects and Indications	164
Age	164
Season	164
Preparation	164-166
Restraint	166
Instruments	166
Anatomy	166-167
Warning	167
Operative Technique	167-170
After Care and Treatment	170
SPAYING THE EWE	197-200
Objects and Indications	197
Age	197
Season	197
Preparation	197
Restraint	197
Instruments	197

INDEX—Continued.

	<i>Page</i>
Anatomy	198
Warning	199
Operative Technique	199-200
After Care and Treatment	200
SPAYING THE HEIFER	170-179
Objects and Indications	170
Age	170
Season	170
Preparation	170
Restraint	170-171
Instruments	171-173
Operative Technique	174-179
SPAYING THE MARE	153-163
Objects and Indications	153
Age	153
Season	153
Preparation	153
Restraint	154-155
Instruments	155
Anatomy	156-158
Warning	158
Operative Technique	158-163
After Care and Treatment	163
Sequelae	163
SPAYING SOWS	185-195
Objects and Indications	185
Age	185
Season	185
Preparation	185
Restraint	186-189
Instruments	189
Anatomy	189-191
Operative Technique (Flank Method) ..	191-193
Operative Technique (Belly Method) ..	194-195
STALLION—CASTRATION OF THE	14-35
Objects and Indications	14
Age	14
Season	14
Preparation	14
Anatomy	19-22
Complications in	47-73
After Care and Treatment	28

INDEX—Continued

	<i>Page</i>
Sequelae	74-91
Prognosis	28
STALLION—CASTRATION OF IN RECUMBENT POSTURE	14-28
Restraint for	14-16
Instruments for	16-19
Warning	23-24
Operative Technique	25-27
STALLION—CASTRATION OF IN STANDING POSTURE.	29-35
Restraint for	29
Instruments for	29
Warning	30
Operative Technique	31-34
Advantages	34
Disadvantages	34
TETANUS	74-75
“WATER BAG”—See Hydrocele.	

Restraint of Domestic Animals

(2nd Edition)

A BOOK FOR STUDENTS AND PRACTITIONERS

With 312 illustrations from drawings by one of the best pen artists in the United States, and 26 halftones from original photographs

— BY —

GEORGE R. WHITE, M.D., D.V.S.

NASHVILLE, TENNESSEE

This book contains over 300 pages and illustrates and fully describes every known means of Restraint of the Horse, Ox, Dog and Hog. It is by far the best illustrated book ever written in America on any branch of Veterinary Science.

“Restraint of Domestic Animals” has already been adopted as a **Text Book** in **18** of the **21** Veterinary Colleges of America.

Its sale has been phenomenal.

Every practitioner should secure one for study and reference.

Published and for sale by the author; also sold by all veterinary booksellers.

 **PRICE, \$3.75 POSTPAID, TO ANY ADDRESS** 

A FEW EXPRESSIONS FROM THE PROFESSION

DR. JOHN G. RUTHERFORD, President American Veterinary Medical Association.

“Your handsome and comprehensive book on ‘Restraint of Domestic Animals’ received, and I am convinced that it is a most valuable book. The illustrations are exceedingly well done and the letterpress is very clear and fully explains the methods of using the various appliances. You are to be congratulated upon striking an entirely new line in veterinary authorship.”

PROF. J. MACQUEEN, Royal Veterinary College, London, England.

“I have looked through the book on ‘Restraint.’ It seems to be a very useful work. In this country there is a growing tendency to operate under general anaesthesia. To those who experience difficulty in casting and fixing their patients for operation your book should be very welcome.”

PROF. W. L. WILLIAMS, Professor Surgery, New York State Veterinary College, Cornell University.

“I have heartily recommended your excellent book to our students.”

PROF. LOUIS A. MERILLAT, Professor Surgery, Chicago Veterinary College.

"I have looked over the book carefully and beg to express my appreciation of your successful effort. The book is needed by the teacher, by the student, and by the practitioner, and it will undoubtedly tend to standardize methods of restraint—a reformation that is very desirable in veterinary surgery. I have already adopted it as a text-book and predict that it will be as favorably received wherever the importance of good surgical restraint is comprehended."

PROF. HARRY D. GILL, Professor Surgery New York American Veterinary College.

"I desire to compliment you on its comprehensiveness, and to assure you that it fills the widest gap in veterinary literature existing today. It is an indispensable reference not only for teachers, but practitioners and students as well.

"To thoroughly appreciate your work the reader should have witnessed your demonstrations along this line as I have, and I cannot understand why you have not long since been employed by the various colleges to teach this most important subject."

PROF. D. E. SALMON, University of Montevideo, Uruguay.

"I desire to congratulate you upon the completion of a book which has certainly required much time and labor in its preparation. It will be a useful handbook for both the student and practitioner of veterinary surgery."

WILFRED S. PLASKETT, D.V.S., Clinton, Mass.

"It is a capital book, and will be appreciated alike by the student and practitioner. The text is graphic and the illustrations are the 'best ever.' One can see the modus operandi from a glance at the cuts. I trust the book will be received by the profession and that the second edition will be shortly forthcoming. The book is neatly gotten out and is a credit to the publishing house and the printer.

"You have filled a long felt want. I think I was one of the first to suggest that you undertake the work, consequently will watch its merited reception by the profession with a selfish interest."

PROF. E. A. A. GRANGE, V.S., M.S., Principal Ontario Veterinary College.

"I think you have approached a subject which has hitherto been almost neglected, and you have done it in a manner that is both terse and comprehensive, and nicely illustrated.

"I think your volume will be a boon to young men who are just entering the practice of the veterinary profession, and no doubt to many who have been in practice for a long time.

"I have added it to our list of text-books."

PROF. SESCO STEWART, M.D., D.V.M., Dean Kansas City Veterinary College.

"We have adopted 'Restraint of Domestic Animals' as a text-book, feeling that it affords students very valuable instruction and guidance not readily obtainable elsewhere. I feel that the profession is greatly indebted to you for placing this matter in their hands in such an excellent form."

PROF. DAVID S. WHITE, Dean Veterinary Department Ohio State University.

"This is to inform you that we recommend the book to our students and they are supplying themselves with them. Let me congratulate you upon adding so valuable a work to our literature and at the same time in a very practical way offering a kind of information to veterinary students much neglected at most veterinary colleges."

PROF. LOUIS P. COOK, D.V.S., Dean Cincinnati Veterinary College.

"The work has been adopted as a text-book at this college, and we regret that it was not issued earlier. It fills a long felt need. Had it been issued before our session of 1908-09 was so nearly over we would have required senior and junior students to obtain copies. I regard the work as one of merit and value to students and practitioners, and I trust you will be repaid for the trouble you have evidently gone to to get the work together. Congratulating you on your success as an author and with best wishes."

PROF. GEORGE H. GLOVER, Veterinary Department Colorado State College of Agriculture.

"We are now using your text-book, 'Restraint of Domestic Animals,' and find it satisfactory in every respect. It fills a long felt want and does you great credit."

PROF. CHARLES KEANE, D.V.S., President San Francisco Veterinary College.

"We consider this work a much needed book and will adopt same as text-book at this institution."

PROF. C. A. CARY, B.S., D.V.M., Veterinary Department Alabama Polytechnic Institute.

"It impresses me very favorably. Indeed, I think it supplies a vacant place in our literature. It will be used as a text-book in this school."

PROF. W. J. R. FOWLER, V.S., Professor Surgery Ontario Veterinary College.

"I find it to be a book which has long been needed. It is a complete work and will give a student or practitioner a thorough idea of the subject of restraint."

PROF. C. E. STEEL, D.V.S., Dean St. Joseph Veterinary College.

"Your book, entitled 'Restraint of Domestic Animals,' has my hearty endorsement. I think it supplies a long felt want in veterinary literature."

PROF. D. E. BUCKINGHAM, Dean Department of Veterinary Medicine, George Washington University.

"I am constrained to say that a master of the art has described all the methods of restraint, and the book is a masterpiece. I have adopted it as a text-book in this school."

PROF. F. S. SCHOENLEBER, D.V.S., Veterinary Department Kansas Agricultural College.

"I can see that it fills a gap in our work and will prove a very valuable acquisition to the college course of study. I wish you the full measure of success that the book deserves."

PROF. GEO. B. MCKILLIP, M.D.V., Secretary and Treasurer McKillip Veterinary College.

"I am pleased to inform you that your book on 'Restraint of Domestic Animals' has already been adopted as a text-book in the McKillip Veterinary College."

PROF. JOHN R. SCULLY, Secretary Terre Haute Veterinary College.

"This book is most complete and concise. For a text-book I am positive that it cannot but be well liked by both the practitioner and student."

PROF. H. L. SCHUH, Professor Surgery Grand Rapids Veterinary College.

"Your book on 'Restraint of Domestic Animals' received and we think it a very useful work. This book will be placed upon the list of recommended books for the student to buy, and we will do all in our power to assist you in getting 'Restraint of Domestic Animals' in the hands of students and practitioners."

PROF. H. E. BEMIS, D.V.M., Assistant Professor Surgery, Division Veterinary Medicine, Iowa State College.

"I consider the volume full of most practical and therefore useful information upon the subject of animal restraint. I gladly recommend it to our students, and they, too, seem much interested."

PROF. R. C. MOORE, D.V.S., President Kansas City Veterinary College.

"I think the work is most excellent and one that certainly is of very great value to every practitioner."

PROF. FREDERICK R. WHIPPLE, M.D.V., Instructor in Veterinary Science, West Virginia University.

"You have covered the subject of 'Restraint of Domestic Animals' well, and I shall recommend the book to every student in our school. Proper restraint means better surgery. All good surgeons are cranks in securing their patients, indifferent surgeons should study this book and become cranks on the subject of restraint."

RICHARD P. LYMAN, B.S., M.D.V., Secretary American Veterinary Medical Association.

"I am led to believe that it is going to fill a valuable place in the library of the veterinarian as well as being a great aid to the student and instructor. This latter appeals to me especially because I am so intimately associated with the demonstration of animal restraint which is included in the course I am giving in surgical exercises at the Kansas City Veterinary College."

PROF. J. H. SKINNER, Dean School of Agriculture and Professor of Animal Husbandry, Purdue University.

"The book is certainly complete and one which offers many valuable suggestions to farmers and others interested in the restraint of animals. The illustrations are splendid and description all that is necessary."

PROF. L. M. HURT, D.V.M., Professor Veterinary Science, Michigan Agricultural College.

"I feel that its general nature is such that it supplies a long felt want. I can and will recommend it to our students."

PROF. F. B. HADLEY, D.V.M., Professor Surgery, Veterinary Department Washington State College.

"The copy of 'Restraint of Domestic Animals' at hand, and after a careful review of its contents can say that I consider it of great value and have recommended that each of my students purchase a volume. It seems of particular worth to such men as intend to practice and have not the funds to install an operating table at once, as its many extremely practical methods of restraint are well illustrated so that the application of each is very simple."

DRS. JACOB & SHAW, Knoxville, Tenn.

"It will undoubtedly prove a valuable addition to American veterinary literature."

DR. WILLIAM P. HILL, Veterinarian Twelfth Cavalry, U. S. Army.

"The volume on 'Restraint of Domestic Animals' is quite complete. I consider it an excellent book."

PROF. GEO. C. HUMPHREY, Professor Animal Husbandry, University of Wisconsin.

"I feel that it will be of special interest to our agricultural students in pursuing their courses in veterinary science and animal husbandry."

DR. A. M. FARRINGTON, Assistant Chief Bureau Animal Industry, U. S. Department of Agriculture.

"I congratulate you on the production and believe it is the most complete work on the subject which has ever been printed."

G. B. GILTNER, V.S., Murfreesboro, Tenn.

"I find it very interesting as well as instructive, and desire to congratulate you in your successful effort in placing so valuable a work in the hands of the veterinary profession."

PROF. FREDERICK W. WILSON, Animal Husbandman, Agricultural Experiment Station, Phoenix, Arizona.

"I think without doubt that this is one of the books that should be found in each practitioner's library. It is also an invaluable book for the farmer as well."

J. M. PHILLIPS, D.V.S., St. Louis, Mo.

"The illustrations are clear and the descriptions easily understood. It is surely a volume deserving a place in the library of every veterinarian."

