


UC-NRLF



B 4 096 732

ANTHONY B. DIEPENBROCK M.D.

UNIVERSITY OF CALIFORNIA  
MEDICAL CENTER LIBRARY  
SAN FRANCISCO



Gift of  
A.P. Diepenbrock, M.D.





Digitized by the Internet Archive  
in 2007 with funding from  
Microsoft Corporation





MANUAL OF ANATOMY

PUBLISHED BY THE JOINT COMMITTEE OF HENRY FROWDE AND HODDER & STOUGHTON  
AT THE OXFORD PRESS WAREHOUSE, 17 WARWICK SQUARE, LONDON, E.C.4



CUNNINGHAM'S MANUAL  
OF  
PRACTICAL ANATOMY

REVISED AND EDITED BY

ARTHUR ROBINSON

PROFESSOR OF ANATOMY IN THE UNIVERSITY OF EDINBURGH

SEVENTH EDITION

*VOLUME FIRST*

SUPERIOR EXTREMITY; INFERIOR EXTREMITY

*WITH 203 ILLUSTRATIONS, MANY OF WHICH ARE COLOURED*

NEW YORK,  
WILLIAM WOOD AND COMPANY  
EDINBURGH, GLASGOW, AND LONDON  
HENRY FROWDE AND HODDER & STOUGHTON

1921

*Printed in Great Britain by R. & R. CLARK, LIMITED, Edinburgh.*

*1st Edition, 1896.*

*2nd Edition, 1903.*

*3rd Edition, 1906.*

*4th Edition, 1907.*

*5th Edition, 1912.*

*6th Edition, 1914.*

*6th Edition, 2nd Impression, 1917.*

*6th Edition, 3rd Impression, 1918.*

*7th Edition, 1920.*

*7th Edition, 2nd Impression, 1921*

*All rights reserved.*

QM 34  
Q97  
v. 1  
1920

PREFACE TO  
THE SEVENTH EDITION



IN this edition the general text has been revised, many new figures, representing dissections, sections and radiographs, have been introduced. The instructions for dissection have been printed in a distinctive indented type; in many cases they have been rewritten and in some cases amplified.

The latter changes, together with the additional figures, have caused so much increase of size that it has been deemed advisable to publish the book in three volumes. Vol. I.: Superior Extremity and Inferior Extremity; Vol. II.: Thorax and Abdomen; Vol. III.: Head and Neck.

As was the case in previous editions, I am indebted to Dr. E. B. Jamieson for many suggestions, for his invaluable help in the revision of the text and for the preparation of the Index.

My thanks are due to Dr. Robert Knox, to Major A. W. Pirie and to Major T. Rankin for the use of radiographs, which they very kindly prepared for me, and to Mr. J. T. Murray for the new drawings of sections and dissections.

ARTHUR ROBINSON.

Oct. 11, 1919.

92793

GIFT OF A. F. DICTERSON



# CONTENTS

## THE SUPERIOR EXTREMITY.

	PAGE
AXILLA, . . . . .	I
DISSECTION OF THE BACK, . . . . .	47
SHOULDER—SCAPULAR REGION, . . . . .	75
THE FRONT OF THE ARM, . . . . .	93
DORSUM OF THE ARM, . . . . .	112
SHOULDER-JOINT, . . . . .	119
FOREARM AND HAND, . . . . .	127
VOLAR SURFACE AND MEDIAL BORDER OF THE FOREARM, . . . . .	129
WRIST AND PALM, . . . . .	148
DORSUM AND LATERAL BORDER OF THE FOREARM, . . . . .	172
DORSAL ASPECT OF THE WRIST AND HAND, . . . . .	189
ARTICULATIONS, . . . . .	195

## THE INFERIOR EXTREMITY.

INTRODUCTION, . . . . .	213
THE THIGH, . . . . .	218
THE ANTERIOR FEMORAL AND MEDIAL FEMORAL REGIONS AND THE ANTERIOR REGION OF THE KNEE, . . . . .	221
DEEP DISSECTION OF THE ANTERIOR AND MEDIAL PARTS OF THE THIGH, . . . . .	236
MEDIAL SIDE OF THE THIGH, . . . . .	266
GLUTEAL REGION, . . . . .	279
POPLITEAL SPACE, . . . . .	304
BACK OF THE THIGH, . . . . .	318

	PAGE
THE LEG, . . . . .	332
ANTERIOR CRURAL REGION AND DORSUM OF FOOT, . . .	334
LATERAL CRURAL OR PERONEAL REGION, . . . . .	354
MEDIAL CRURAL REGION, . . . . .	357
POSTERIOR CRURAL REGION, . . . . .	357
SOLE OF THE FOOT, . . . . .	381
ARTICULATIONS, . . . . .	401
INDEX, . . . . .	441

# A GLOSSARY

## OF THE

### INTERNATIONAL (B.N.A.)

### ANATOMICAL TERMINOLOGY

#### GENERAL TERMS.

##### TERMS INDICATING SITUATION AND DIRECTION.

Longitudinalis	Longitudinal	} Referring to the long axis of the body.
Verticalis	Vertical	
Anterior	Anterior	} Referring to the position of the long axis of the body in the erect posture.
Posterior	Posterior	
Ventral	Ventral	} Referring to the front and back of the body or of the limbs.
Dorsal	Dorsal	} Referring to the anterior and posterior aspects, respectively, of the body, and to the flexor and extensor aspects of the limbs, respectively.
Cranial	Cranial	
		} Referring to position nearer the head or the tail end of the long axis.
Caudal	Caudal	
Superior	Superior	} Used only in reference to parts of the head, neck, or trunk.
Inferior	Inferior	
Proximalis	Proximal	} Used in reference to the head, neck, and trunk. Equivalent to cranial and caudal respectively.
Distalis	Distal	} Used only in reference to the limbs. Proximal nearer the attached end. Distal nearer the free end.
Sagittalis	Sagittal	} Used in reference to planes parallel with the sagittal suture of the skull, <i>i.e.</i> vertical antero-posterior planes.
Frontalis	Frontal	} Used in reference to planes parallel with the coronal suture of the skull, <i>i.e.</i> transverse vertical planes.

Horizontalis	Horizontal	{	Used in reference to planes at right angles to vertical planes.
Medianus	Median		
Medialis	Medial	}	{ Referring to the median vertical antero-posterior plane of the body.
Lateralis	Lateral		
Intermedius	Intermediate	}	{ Referring to structures relatively nearer to or further away from the median plane.
Superficialis	Superficial		
Profundus	Deep	}	{ Referring to structures situated between more medial and more lateral structures.
Externus	External		
Internus	Internal	}	{ Referring to structures nearer to and further away from the surface.
Ulnaris	Ulnar		
Radialis	Radial	}	{ Referring, with few exceptions, to the walls of cavities and hollow organs. <i>Not</i> to be used as synonymous with medial and lateral.
Tibial	Tibial		
Fibular	Fibular	}	{ Used in reference to the medial and lateral borders of the forearm, respectively.
		}	{ Used in reference to the medial and lateral borders of the leg, respectively.

## THE BONES.

## B.N.A. TERMINOLOGY.

**Vertebræ**  
 Fovea costalis superior  
 Fovea costalis inferior  
 Fovea costalis transversalis  
 Radix arcus vertebræ

**Atlas**  
 Fovea dentis

**Epistropheus**  
 Dens

**Sternum**  
 Corpus sterni  
 Processus xiphoideus  
 Incisura jugularis  
 Planum sternale

**Ossa Cranii.**

**Os frontale**  
 Spina frontalis  
 Processus zygomaticus  
 Facies cerebralis  
 Facies frontalis  
 Pars orbitalis

## OLD TERMINOLOGY.

**Vertebræ**  
 Incomplete facet for head of rib, upper  
 Incomplete facet for head of rib, lower  
 Facet for tubercle of the rib  
 Pedicle

**Atlas**  
 Facet for odontoid process

**Axis**  
 Odontoid process

**Sternum**  
 Gladiolus  
 Ensiform process  
 Supra-sternal notch  
 Anterior surface

**Bones of Skull.**

**Frontal**  
 Nasal spine  
 External angular process  
 Internal surface  
 Frontal surface  
 Orbital plate



## B. N. A. TERMINOLOGY.

**Os parietale**

Lineæ temporales  
Sulcus transversus  
Sulcus sagittalis

**Os occipitale**

Canalis hypoglossi  
Foramen occipitale magnum  
Canalis condyloideus  
Sulcus transversus  
Sulcus sagittalis  
Clivus

Linea nuchæ suprema  
Linea nuchæ superior  
Linea nuchæ inferior

**Os sphenoidale**

Crista infratemporalis  
Sulcus chiasmatis  
Crista sphenoidalis  
Spina angularis  
Lamina medialis processus pterygoidei  
Lamina lateralis processus pterygoidei  
Canalis pterygoideus [Vidii]  
Fossa hypophyseos  
Sulcus caroticus  
Conchæ sphenoidales  
Hamulus pterygoideus  
Canalis pharyngeus  
Tuberculum sellæ  
Fissura orbitalis superior

**Os temporale**

Canalis facialis [Fallopil]  
Hiatus canalis facialis  
Vagina processus styloidei  
Incisura mastoidea  
Impressio trigemini  
Eminentia arcuata

Sulcus sigmoideus  
Fissura petrotympanica  
Fossa mandibularis  
Semicanalis tubæ auditivæ

**Os ethmoidale**

Labyrinthus ethmoidalis  
Lamina papyracea  
Processus uncinatus

## OLD TERMINOLOGY.

**Parietal**

Temporal ridges  
Groove for lateral sinus  
Groove for sup. long. sinus

**Occipital**

Anterior condyloid foramen  
Foramen magnum  
Posterior condyloid foramen  
Groove for lateral sinus  
Groove for sup. long. sinus  
Median part of upper surface of basi-occipital  
Highest curved line  
Superior curved line  
Inferior curved line

**Sphenoid**

Pterygoid ridge  
Optic groove  
Ethmoidal crest  
Spinous process  
Internal pterygoid plate  
External pterygoid plate  
Vidian canal  
Pituitary fossa  
Cavernous groove  
Sphenoidal turbinal bones  
Hamular process  
Pterygo-palatine canal  
Olivary eminence  
Sphenoidal fissure

**Temporal Bone**

Aqueduct of Fallopius  
Hiatus Fallopii  
Vaginal process of tympanic bone  
Digastric fossa  
Impression for Gasserian ganglion  
Eminence for sup. semicircular canal  
Fossa sigmoidea  
Glaserian fissure  
Glenoid cavity  
Eustachian tube

**Ethmoid**

Lateral mass  
Os planum  
Unciform process

## B. N. A. TERMINOLOGY.

**Os lacrimale**

- Hamulus lacrimalis
- Crista lacrimalis posterior

**Os nasale**

- Sulcus ethmoidalis

**Maxilla**

- Facies anterior
- Facies infra-temporalis
- Sinus maxillaris
- Processus frontalis
- Processus zygomaticus
- Canales alveolares
- Canalis naso-lacrimalis
- Os incisivum
- Foramen incisivum

**Os palatinum**

- Pars perpendicularis
- Crista conchalis
- Crista ethmoidalis
- Pars horizontalis

**Os zygomaticum**

- Processus temporalis
- Processus fronto-sphenoidalis
- Foramen zygomatico-orbitale
- Foramen zygomatico-faciale

**Mandibula**

- Spina mentalis
- Linea obliqua
- Linea mylohyoidea
- Incisura mandibulæ
- Foramen mandibulare
- Canalis mandibulæ
- Protuberantia mentalis

## OLD TERMINOLOGY.

**Lachrymal Bone**

- Hamular process
- Lachrymal crest

**Nasal Bone**

- Groove for nasal nerve

**Superior Maxillary Bone**

- Facial or external surface
- Zygomatic surface
- Antrum of Highmore
- Nasal process
- Malar process
- Posterior dental canals
- Lacrimal groove
- Premaxilla
- Anterior palatine foramen

**Palate Bone**

- Vertical plate
- Inferior turbinate crest
- Superior turbinate crest
- Horizontal plate

**Malar Bone**

- Zygomatic process
- Frontal process
- Tempora-malar canal
- Malar foramen

**Inferior Maxillary Bone**

- Genial tubercle or spine
- External oblique line
- Internal oblique line
- Sigmoid notch
- Inferior dental foramen
- Inferior dental canal
- Mental process

**The Skull as a Whole.**

- Ossa suturarum
- Foveolæ granulares (Pacchioni)
- Fossa pterygo-palatina
- Canalis pterygo-palatinus
- Foramen lacerum
- Choanæ
- Fissura orbitalis superior
- Fissura orbitalis inferior

- Wormian bones
- Pacchionian depressions
- Spheno-maxillary fossa
- Posterior palatine canal
- Foramen lacerum medium
- Posterior nares
- Sphenoidal fissure
- Spheno-maxillary fissure

## Upper Extremity.

## B. N. A. TERMINOLOGY.

## OLD TERMINOLOGY.

**Clavicula**

- Tuberositas coracoidea
- Tuberositas costalis

**Scapula**

- Incisura scapularis
- Angulus lateralis
- Angulus medialis

**Humerus**

- Sulcus intertubercularis
- Crista tuberculi majoris
- Crista tuberculi minoris
- Facies anterior medialis
- Facies anterior lateralis
- Margo medialis
- Margo lateralis
- Sulcus nervi radialis
- Capitulum
- Epicondylus medialis
- Epicondylus lateralis

**Ulna**

- Incisura semilunaris
- Incisura radialis
- Crista interossea
- Facies dorsalis
- Facies volaris
- Facies medialis
- Margo dorsalis
- Margo volaris

**Radius**

- Tuberositas radii
- Incisura ulnaris
- Crista interossea
- Facies dorsalis
- Facies volaris
- Facies lateralis
- Margo dorsalis
- Margo volaris

**Carpus**

- Os naviculare
- Os lunatum
- Os triquetrum
- Os multangulum majus
- Os multangulum minus
- Os capitatum
- Os hamatum

**Clavicle**

- Impression for conoid ligament
- Impression for rhomboid ligament

**Scapula**

- Supra-scapular notch
- Anterior or lateral angle
- Superior angle

**Humerus**

- Bicipital groove
- External lip
- Internal lip
- Internal surface
- External surface
- Internal border
- External border
- Musculo-spiral groove
- Capitellum
- Internal condyle
- External condyle

**Ulna**

- Greater sigmoid cavity
- Lesser sigmoid cavity
- External or interosseous border
- Posterior surface
- Anterior surface
- Internal surface
- Posterior border
- Anterior border

**Radius**

- Bicipital tuberosity
- Sigmoid cavity
- Internal or interosseous border
- Posterior surface
- Anterior surface
- External surface
- Posterior border
- Anterior border

**Carpus**

- Scaphoid
- Semilunar
- Cuneiform
- Trapezium
- Trapezoid
- Os magnum
- Unciform

## Lower Extremity.

## B.N.A. TERMINOLOGY.

**Os coxæ**

Linea glutæa anterior  
 Linea glutæa posterior  
 Linea terminalis  
 Spina ischiadica  
 Incisura ischiadica major  
 Incisura ischiadica minor  
 Tuberculum pubicum  
 Ramus inferior oss. pubis  
 Ramus superior oss. pubis  
 Ramus superior ossis ischii  
 Ramus inferior oss. ischii  
 Pecten ossis pubis  
 Facies symphyseos

**Pelvis**

Pelvis major  
 Pelvis minor  
 Apertura pelvis minoris superior  
 Apertura pelvis minoris inferior  
 Linea terminalis

**Femur**

Fossa trochanterica  
 Linea intertrochanterica  
 Crista intertrochanterica  
 Condylus medialis  
 Condylus lateralis  
 Epicondylus medialis  
 Epicondylus lateralis

**Tibia**

Condylus medialis  
 Condylus lateralis  
 Eminentia intercondyloidea  
 Tuberositas tibie  
 Malleolus medialis

**Fibula**

Malleolus lateralis  
 Apex capituli fibule

## OLD TERMINOLOGY.

**Innominate Bone**

Middle curved line  
 Superior curved line  
 Margin of inlet of true pelvis  
 Spine of the ischium  
 Great sacro-sciatic notch  
 Lesser sacro-sciatic notch  
 Spine of pubis  
 Descending ramus of pubis  
 Ascending ramus of pubis  
 Body of ischium  
 Ramus of ischium  
 Pubic part of ilio-pectineal line  
 Symphysis pubis

**Pelvis**

False pelvis  
 True pelvis  
 Pelvic inlet  
 Pelvic outlet  
 Margin of inlet of true pelvis

**Femur**

Digital fossa  
 Spiral line  
 Post. intertrochanteric line  
 Inner condyle  
 Outer condyle  
 Inner tuberosity  
 Outer tuberosity

**Tibia**

Internal tuberosity  
 External tuberosity  
 Spine  
 Tubercle  
 Internal malleolus

**Fibula**

External malleolus  
 Styloid process

## Bones of the Foot.

**Talus****Calcaneus**

Tuber calcanei  
 Processus medialis tuberis calcanei  
 Processus lateralis tuberis calcanei

**Os cuneiforme primum****Os cuneiforme secundum****Os cuneiforme tertium****Astragalus****Os calcis**

Tuberosity of  
 Inner  
 Outer

**Inner cuneiform****Middle cuneiform****Outer cuneiform**

## THE LIGAMENTS.

## Ligaments of the Spine.

## B. N. A. TERMINOLOGY.

Lig. longitudinale anterius  
 Lig. longitudinale posterius  
 Lig. flava  
 Membrana tectoria  
 Articulatio atlanto-epistrophica  
 Lig. alaria  
 Lig. apicis dentis

## OLD TERMINOLOGY.

Anterior common ligament  
 Posterior common ligament  
 Ligamenta subflava  
 Posterior occipito-axial ligament  
 Joint between the atlas and the axis  
 Odontoid or check ligaments  
 Suspensory ligament

## The Ribs.

Lig. capituli costæ radiatum	Anterior costo-vertebral or stellate ligament
Lig. sterno-costale interarticulare	Interarticular chondro-sternal ligament
Lig. sterno-costalia radiata	Anterior and posterior chondro-sternal ligament
Lig. costoxiphoidea	Chondro-xiphoid ligaments

## The Jaw.

Lig. temporo-mandibulare	External lateral ligament of the jaw
Lig. spheno-mandibulare	Internal lateral ligament of the jaw
Lig. stylo-mandibulare	Stylo-maxillary ligament

## Upper Extremity.

Lig. costo-claviculare	Rhomboid ligament
Labrum glenoidale	Glenoid ligament
Articulatio radio-ulnaris proximalis	Superior radio-ulnar joint
Lig. collaterale ulnare	Internal lateral ligament of elbow joint
Lig. collaterale radiale	External lateral ligament
Lig. annulare radii	Orbicular ligament
Chorda obliqua	Oblique ligament of ulna
Articulatio radio-ulnaris distalis	Inferior radio-ulnar joint
Discus articularis	Triangular fibro-cartilage
Recessus sacciformis	Membrana sacciformis
Lig. radio-carpeum volare	Anterior ligament of the radio-carpal joint
Lig. radio-carpeum dorsale	Posterior ligament of the radio-carpal joint
Lig. collaterale carpi ulnare	Internal lateral ligament of the wrist joint

## B.N.A. TERMINOLOGY.

Lig. collaterale carpi radiale  
 Articulationes intercarpæ  
 Lig. accessoria volaria  
 Lig. capitulorum (oss. metacar-  
 palium) transversa  
 Lig. collateralia

## OLD TERMINOLOGY.

External lateral ligament of the  
 wrist joint  
 Carpal joints  
 Palmar ligaments of the metacarpo-  
 phalangeal joints  
 Transverse metacarpal ligament  
 Lateral phalangeal ligaments

**The Lower Extremity.**

Lig. arcuatum  
 Lig. sacro-tuberosum  
 Processus falciformis  
 Lig. sacro-spinosum  
 Labrum glenoidale  
 Zona orbicularis  
 Ligamentum iliofemorale  
 Lig. ischio-capsulare  
 Lig. pubo-capsulare  
 Lig. popliteum obliquum  
 Lig. collaterale fibulare  
 Lig. collaterale tibiale  
 Lig. popliteum arcuatum  
 Meniscus lateralis  
 Meniscus medialis  
 Plica synovialis patellaris  
 Plicæ alares  
 Articulatio tibio-fibularis  
 Lig. capituli fibulæ  
 Syndesmosis tibio-fibularis  
 Lig. deltoideum  
 Lig. talo-fibulare anterius  
 Lig. talo-fibulare posterius  
 Lig. calcaneo-fibulare  
 Lig. talo-calcaneum laterale  
 Lig. talo-calcaneum mediale  
 Lig. calcaneo-naviculare plantare  
 Lig. talo-naviculare  
 Pars calcaneo-navicularis } lig.  
 Pars calcaneo-cuboidea } bifur-  
 catum

Subpubic ligament  
 Great sacro-sciatic ligament  
 Falciform process  
 Small sacro-sciatic ligament  
 Cotyloid ligament  
 Zonular band  
 Y-shaped ligament  
 Ischio-capsular band  
 Pubo-femoral ligament  
 Ligament of Winslow  
 Long external lateral ligament  
 Internal lateral ligament  
 Arcuate popliteal ligament  
 External semilunar cartilage  
 Internal semilunar cartilage  
 Lig. mucosum  
 Ligamenta alaria  
 Superior tibio-fibular articulation  
 Anterior and posterior superior  
 tibio-fibular ligaments  
 Inferior tibio-fibular articulation  
 Internal lateral ligament of ankle  
 Anterior fasciculus of external  
 lateral ligament  
 Posterior fasciculus of external  
 lateral ligament  
 Middle fasciculus of external lateral  
 ligament  
 External calcaneo-astragaloid liga-  
 ment  
 Internal calcaneo-astragaloid liga-  
 ment  
 Inferior calcaneo-navicular ligament  
 Astragalo-scaphoid ligament  
 Superior calcaneo-scaphoid liga-  
 ment  
 Internal calcaneo-cuboid ligament

## THE MUSCLES.

## Muscles of the Back.

## Superficial.

## B. N. A. TERMINOLOGY.

Levator scapulæ

## OLD TERMINOLOGY.

Levator anguli scapulæ

## Muscles of the Chest.

Serratus anterior

Serratus magnus

## Muscles of Upper Extremity.

Biceps brachii

Lacertus fibrosus

Brachialis

Triceps brachii

Caput mediale

Caput laterale

Pronator teres

Caput ulnare

Brachio-radialis

Supinator

Extensor carpi radialis longus

Extensor carpi radialis brevis

Extensor indicis proprius

Extensor digiti quinti proprius

Abductor pollicis longus

Abductor pollicis brevis

Extensor pollicis brevis

Extensor pollicis longus

Lig. carpi transversum

Lig. carpi dorsale

Biceps

Bicipital fascia

Brachialis anticus

Triceps

Inner head

Outer head

Pronator radii teres

Coronoid head

Supinator longus

Supinator brevis

Extensor carpi radialis longior

Extensor carpi radialis brevior

Extensor indicis

Extensor minimi digiti

Extensor ossis metacarpi pollicis

Abductor pollicis

Extensor primi internodii pollicis

Extensor secundi internodii pollicis

Anterior annular ligament

Posterior annular ligament

## Muscles of Lower Extremity.

Tensor fasciæ latæ

Canalis adductorius (Hunteri)

Trigonum femorale (fossa Scarpæ  
major)

Canalis femoralis

Annulus femoralis

M. quadriceps femoris—

Rectus femoris

Vastus lateralis

Vastus intermedius

Vastus medialis

M. articularis genu

Tibialis anterior

Tensor fasciæ femoris

Hunter's canal

Scarpa's triangle

Crural canal

Crural ring

Quadriceps—

Rectus femoris

Vastus externus

Crureus

Vastus internus

Subcrureus

Tibialis anticus

## B. N. A. TERMINOLOGY.

Tendo calcaneus  
 Tibialis posterior  
 Quadratus plantæ  
 Lig. transversum cruris  
 Lig. cruciatum cruris  
 Lig. laciniatum  
 Retinaculum musculorum peroneorum superiorum }  
 Retinaculum musculorum peroneorum inferiorum }

## OLD TERMINOLOGY.

Tendo Achillis  
 Tibialis posticus  
 Accessorius  
 Upper anterior annular ligament  
 Lower anterior annular ligament  
 Internal annular ligament  
 External annular ligament

**Axial Muscles.****Muscles of the Back.**

Serratus posterior superior	Serratus posticus superior
Serratus posterior inferior	Serratus posticus inferior
Splenius cervicis	Splenius colli
Sacro-spinalis	Erector spinæ
<b>Ilio-costalis—</b>	<b>Ilio-costalis—</b>
Lumborum	Sacro-lumbalis
Dorsi	Accessorius
Cervicis	Cervicalis ascendens
<b>Longissimus—</b>	<b>Longissimus—</b>
Dorsi	Dorsi
Cervicis	Transversalis cervicis
Capitis	Trachelo-mastoid
<b>Spinalis—</b>	<b>Spinalis—</b>
Dorsi	Dorsi
Cervicis	Colli
Capitis	Capitis
<b>Semispinalis—</b>	<b>Semispinalis—</b>
Dorsi	Dorsi
Cervicis	Colli
Capitis	Complexus
Multifidus	Multifidus spinæ

**Muscles of Head and Neck.**

Epicranius	Occipito-frontalis
Galea aponeurotica	Epicranial aponeurosis
Procerus	Pyramidalis nasi
Pars transversa (nasalis)	Compressor naris
Pars alaris (nasalis)	Dilatatoris naris
Auricularis anterior	Attrahens aurem
Auricularis posterior	Retrahens aurem
Auricularis superior	Attollens aurem
Orbicularis oculi	Orbicularis palpebrarum
Pars lacrimalis	Tensor tarsi



## B. N. A. TERMINOLOGY.

Triangularis  
 Quadratus labii superioris—  
   Caput zygomaticum  
   Caput infraorbitale  
   Caput angulare  
 Zygomaticus  
 Caninus  
 Quadratus labii inferioris  
 Mentalis  
 Platysma  
 Sterno-thyreoid  
 Thyreo-hyoid

## OLD TERMINOLOGY.

Depressor anguli oris  
 Zygomaticus minor  
 Levator labii superioris  
 Levator labii superioris alæque nasi  
 Zygomaticus major  
 Levator anguli oris  
 Depressor labii inferioris  
 Levator menti  
 Platysma myoides  
 Sterno-thyroid  
 Thyro-hyoid

**Muscles and Fascia of the Orbit.**

Fascia bulbi	Capsule of Tenon
Septum orbitale	Palpebral ligaments
Rectus lateralis	Rectus externus
Rectus medialis	Rectus internus

**Muscles of the Tongue.**

Genio-glossus	Genio-hyo-glossus
Longitudinalis superior	Superior lingualis
Longitudinalis inferior	Inferior lingualis
Transversus linguæ	Transverse fibres
Verticalis linguæ	Vertical fibres

**Muscles of the Pharynx.**

Pharyngo-palatinus	Palato-pharyngeus
M. uvulæ	Azygos uvulæ
Levator veli palatini	Levator palati
Tensor veli palatini	Tensor palati
Glosso-palatinus	Palato-glossus

**Deep Lateral Muscles of Neck.**

Scalenus anterior	Scalenus anticus
Scalenus posterior	Scalenus posticus
Longus capitis	Rectus capitis anticus major
Rectus capitis anterior	Rectus capitis anticus minor

**Muscles of Thorax.**

Transversus thoracis	Triangularis sterni
Diaphragma	Diaphragm
Crus mediale	Crura and origins from arcuate ligaments
Crus intermedium	
Crus laterale	
Arcus lumbo - costalis medialis (Halleri)	Ligamentum arcuatum internum
Arcus lumbo - costalis lateralis (Halleri)	Ligamentum arcuatum externum

**Muscles of the Abdomen.**

## B. N. A. TERMINOLOGY.

Ligamentum inguinale (Pouparti)  
 Ligamentum lacunare (Gimbernati)  
 Fibræ intercrurales  
 Ligamentum inguinale reflexum  
 (Collesi)  
 Annulus inguinalis subcutaneus  
   Crus superius  
   Crus inferius  
 Falx aponeurotica inguinalis  
 M. transversus abdominis  
 Linea semicircularis (Douglasi)  
 Annulus inguinalis abdominalis

## OLD TERMINOLOGY.

Poupart's ligament  
 Gimbernati's ligament  
 Intercolumnar fibres  
 Triangular fascia  
 External abdominal ring  
   Internal pillar  
   External pillar  
 Conjoined tendon  
 Transversalis muscle  
 Fold of Douglas  
 Internal abdominal ring

**Perineum and Pelvis.**

Transversus perinei superficialis  
 M. sphincter urethræ membranaceæ  
 Diaphragma urogenitale

Fascia diaphragmatis urogenitalis  
 superior  
 Fascia diaphragmatis urogenitalis  
 inferior  
 Arcus tendineus fasciæ pelvis  
 Ligamenta puboprostatica

Fascia diaphragmatis pelvis superior  
 Fascia diaphragmatis pelvis inferior

Transversus perinei  
 Compressor urethræ  
 Deep transverse muscle and sphinc-  
 ter urethræ  
 Deep layer of triangular ligament  
 Superficial layer of the triangular  
 ligament  
 White line of pelvis  
 Anterior and lateral true ligaments  
 of bladder  
 Visceral layer of pelvic fascia  
 Anal fascia

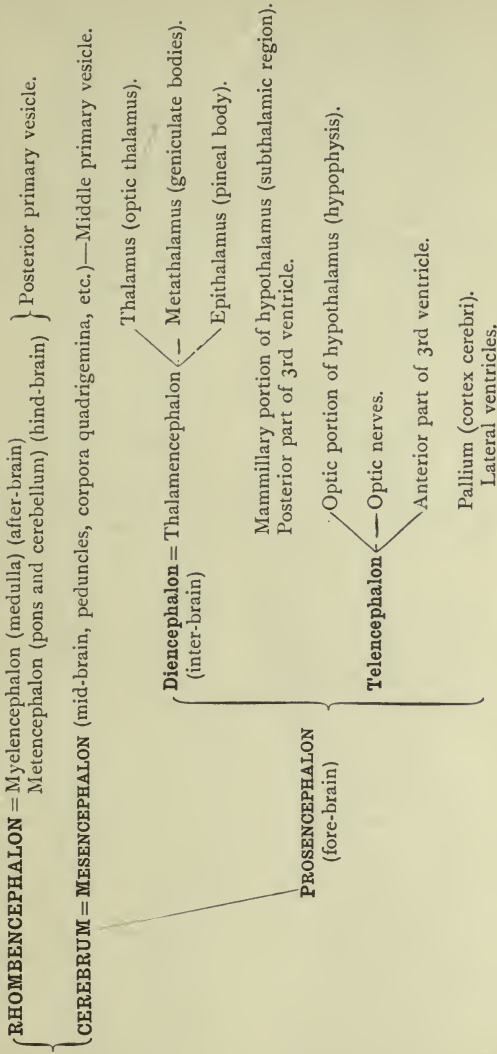
**THE NERVOUS SYSTEM.****Medulla Spinalis.**

Fasciculus anterior proprius (Flech-  
 sig)  
 Fasciculus lateralis proprius  
 Nucleus dorsalis  
 Pars thoracalis  
 Sulcus intermedius posterior  
 Columnæ anteriores, etc.  
 Fasciculus cerebro-spinalis anterior  
 Fasciculus cerebro-spinalis lateralis  
 (pyramidalis)  
 Fasciculus cerebello-spinalis  
 Fasciculus antero-lateralis super-  
 ficialis

**Spinal Cord.**

Anterior ground or basis bundle  
 Lateral ground bundle  
 Clarke's column  
 Dorsal part of spinal cord  
 Paramedian furrow  
 Anterior grey column  
 Direct pyramidal tract  
 Crossed pyramidal tract  
 Direct cerebellar tract  
 Gowers' tract

The Brain or **Encephalon** is divided into parts as follows :—



## Brain.

## B.N.A. TERMINOLOGY.

**Rhombencephalon**

Eminentia medialis  
 Ala cinerea  
 Ala acustica  
 Nucleus nervi abducentis  
 Nuclei n. acustici  
 Fasciculus longitudinalis medialis  
 Corpus trapezoideum  
 Incisura cerebelli anterior  
 Incisura cerebelli posterior  
 Sulcus horizontalis cerebelli  
 Lobulus centralis  
 Folium vermis  
 Tuber vermis  
 Lobulus quadrangularis  
 Brachium conjunctivum cerebelli  
 Lobulus semilunaris superior  
 Lobulus semilunaris inferior

**Cerebrum**

Pedunculus cerebri  
 Colliculus superior  
 Colliculus inferior  
 Aqueductus cerebri  
  
 Foramen interventriculare  
 Hypothalamus  
 Sulcus hypothalamicus  
 Massa intermedia  
 Fasciculus thalamo-mammillaris  
 Pars opercularis  
 Thalamus  
 Pallium  
 Gyri transitivi  
 Fissura cerebri lateralis  
 Gyrus temporalis superior  
 Gyrus temporalis medius  
 Gyrus temporalis inferior  
 Sulcus centralis (Rolandi)  
 Sulcus temporalis superior  
 Sulcus temporalis medius  
 Sulcus circularis  
 Sulcus temporalis inferior  
 Gyrus fusiformis  
 Sulcus interparietalis  
 Sulcus corporis callosi  
 Sulcus cinguli  
 Fissura hippocampi  
 Gyrus cinguli

## OLD TERMINOLOGY.

Eminentia teres  
 Trigonum vagi  
 Trigonum acusticum  
 Nucleus of 6th nerve  
 Auditory nucleus  
 Posterior longitudinal bundle  
 Corpus trapezoides  
 Semilunar notch (of cerebellum)  
 Marsupial notch  
 Great horizontal fissure  
 Lobus centralis  
 Folium cacuminis  
 Tuber valvulæ  
 Quadrangle lobule  
 Superior cerebellar peduncle  
 Postero-superior lobule  
 Postero-inferior lobule  
  
 Crus cerebri  
 Anterior corpus quadrigeminum  
 Posterior corpus quadrigeminum  
 Iter e tertio ad quartum ventriculum, or aqued. of Sylvius  
 Foramen of Monro  
 Subthalamic region  
 Sulcus of Monro  
 Middle commissure  
 Bundle of Vicq d'Azyr  
 Pars basilaris  
 Optic thalamus  
 Cortex cerebri  
 Annectant gyri  
 Fissure of Sylvius  
 First temporal gyrus  
 Second temporal gyrus  
 Third temporal gyrus  
 Fissure of Rolando  
 Parallel sulcus  
 Second temporal sulcus  
 Limiting sulcus of Reil  
 Occipito-temporal sulcus  
 Occipito-temporal convolution  
 Intraparietal sulcus  
 Callosal sulcus  
 Calloso-marginal fissure  
 Dentate fissure  
 Callosal convolution

## B. N. A. TERMINOLOGY.

Stria terminalis  
 Trigonum collaterale  
 Hippocampus  
 Digitationes hippocampi  
 Fascia dentata hippocampi  
 Columna fornicis  
 Septum pellucidum  
 Inferior cornu  
 Commissura hippocampi  
 Nucleus lentiformis  
 Pars frontalis capsulæ internæ  
 Pars occipitalis capsulæ internæ  
 Radiatio occipito-thalamica  
 Radiatio corporis callosi  
   Pars frontalis  
   Pars occipitalis

## OLD TERMINOLOGY.

Tænia semicircularis  
 Trigonum ventriculi  
 Hippocampus major  
 Pes hippocampi  
 Gyrus dentatus  
 Anterior pillar of fornix  
 Septum lucidum  
 Descending horn of lateral ventricle  
 Lyra  
 Lenticular nucleus  
 Anterior limb (of internal capsule)  
 Posterior limb (of internal capsule)  
 Optic radiation  
 Radiation of corpus callosum  
   Forceps minor  
   Forceps major

**Membranes of Brain.**

Cisterna cerebello-medullaris  
 Cisterna interpeduncularis  
 Granulationes arachnoideales  
 Tela chorioidea ventriculi tertii  
 Tela chorioidea ventriculi quarti

Cisterna magna  
 Cisterna basalis  
 Pacchionian bodies  
 Velum interpositum  
 Tela chorioidea inferior

**Cerebral Nerves.**

N. oculomotorius  
 N. trochlearis  
 N. trigeminus  
   Ganglion semilunare (Gasseri)  
   N. naso-ciliaris  
   N. maxillaris  
   N. meningeus (medius)  
   N. zygomaticus  
   Rami alveolares superiores posteriores  
   Rami alveolares superiores medii  
   Rami alveolares superiores anteriores  
   Ganglion speno-palatinum  
   N. palatinus medius  
   N. mandibularis  
   Nervus spinosus  
   N. alveolaris inferior  
 N. abducens  
 N. facialis  
 N. intermedius  
 N. acusticus

Third nerve  
 Fourth nerve  
 Fifth nerve  
   Gasserian ganglion  
   Nasal nerve  
   Superior maxillary nerve  
   Recurrent meningeal nerve  
   Temporo-malar nerve  
   Posterior superior dental  
  
   Middle superior dental  
   Anterior superior dental  
  
   Meckel's ganglion  
   External palatine nerve  
   Inferior maxillary nerve  
   Recurrent nerve  
   Inferior dental  
 Sixth nerve  
 Seventh nerve  
   Pars intermedia of Wrisberg  
 Eighth or auditory nerve

## B. N. A. TERMINOLOGY.

Ganglion superius  
 N. recurrens  
 Ganglion jugulare  
 Ganglion nodosum  
 Plexus œsophageus anterior }  
 Plexus œsophageus posterior }  
 Nervus accessorius  
     Ramus internus  
  
 Ramus externus

## OLD TERMINOLOGY.

Jugular ganglion of 9th nerve  
 Recurrent laryngeal nerve  
 Ganglion of root } of vagus  
 Ganglion of trunk }  
 Plexus gulæ  
 Spinal accessory  
     Accessory portion of spinal  
     accessory nerve  
 Spinal portion

## Spinal Nerves.

Rami posteriores	Posterior primary divisions
Rami anteriores	Anterior primary divisions
N. cutaneus colli	Superficial cervical nerve
Nn. supraclaviculares anteriores	Suprasternal nerves
Nn. supraclaviculares medii	Supraclavicular nerves
Nn. supraclaviculares posteriores	Supra-acromial nerves
N. dorsalis scapulæ	Nerve to the rhomboids
Nn. intercosto-brachiales	Intercosto-humeral nerve
N. thoracalis longus	Nerve of Bell
N. thoraco-dorsalis	Long subscapular nerve
N. cutaneus brachii medialis	Lesser internal cutaneous nerve
N. cutaneus brachii lateralis	Cutaneous branch of circumflex nerve
Fasciculus lateralis	Outer cord (of plexus)
Fasciculus medialis	Inner cord
N. cutaneus antibrachii lateralis	Cutaneous branch of musculo-cutaneous nerve
N. cutaneus antibrachii medialis	Internal cutaneous nerve
Ramus volaris	Anterior branch
Ramus ulnaris	Posterior branch
N. cutaneus antibrachii dorsalis	External cutaneous branch of musculo-spiral
N. axillaris	Circumflex nerve
N. interosseus volaris	Anterior interosseous
Ramus palmaris N. mediani	Palmar cutaneous branch of the median nerve
Nn. digitales volares proprii	Collateral palmar digital branches of median nerve
Ramus dorsalis manus	Dorsal cutaneous branch of ulnar nerve
Ramus cutaneus palmaris	Palmar cutaneous branch of ulnar nerve
N. radialis	Musculo-spiral nerve
N. cutaneus brachii posterior	Internal cutaneous branch of musculo-spiral nerve
N. cutaneus antibrachii dorsalis	External cutaneous branches of musculo-spiral nerve

## B.N.A. TERMINOLOGY.

- N. radialis (*contd.*)—  
 Ramus superficialis  
 N. interosseus dorsalis  
 Nn. digitales dorsales  
 N. ilio-hypogastricus  
 Ramus cutaneus lateralis  
  
 Ramus cutaneus anterior  
  
 N. genito-femoralis  
 N. lumbo-inguinalis  
  
 N. spermaticus externus  
  
 N. cutaneus femoris lateralis  
 N. femoralis  
 N. saphenus  
 Ramus infrapatellaris  
  
 N. ischiadicus  
 N. peronæus communis  
 Ramus anastomoticus peronæus  
 N. peronæus superficialis  
 N. peronæus profundus  
 N. tibialis  
 N. cutaneus suræ medialis  
 N. suralis  
 N. plantaris medialis  
 N. plantaris lateralis  
 N. pudendus

## OLD TERMINOLOGY.

- Musculo-spiral nerve (*contd.*)—  
 Radial nerve  
 Posterior interosseous nerve  
 Dorsal digital nerves  
 Ilio-hypogastric nerve  
 Iliac branch of ilio-hypogastric nerve  
 Hypogastric branch of ilio-hypogastric nerve  
 Genito-crural nerve  
 Crural branch of genito-crural nerve  
 Genital branch of genito-crural nerve  
 External cutaneous nerve  
 Anterior crural nerve  
 Long saphenous nerve  
 Patellar branch of long saphenous nerve  
 Great sciatic nerve  
 External popliteal nerve  
 Nervus communicans fibularis  
  
 Musculo-cutaneous nerve  
 Anterior tibial nerve  
 Internal popliteal nerve  
 Nervus communicans tibialis  
 Short saphenous nerve  
 Internal plantar  
 External plantar  
 Pudic nerve

## THE HEART AND BLOOD VESSELS.

## Heart.

- |                                |                                  |
|--------------------------------|----------------------------------|
| Atrium                         | Auricle                          |
| Auricula cordis                | Auricular appendix               |
| Incisura cordis                | Notch at apex of heart           |
| Trabeculæ carneæ               | Columnæ carneæ                   |
| Tuberculum intervenosum        | Intervenous tubercle of Lower    |
| Sulcus longitudinalis anterior | Anterior interventricular groove |
| Sulcus coronarius              | Auriculo-ventricular groove      |
| Limbus fossæ ovalis            | Annulus ovalis                   |
| Valvula venæ cavæ              | Eustachian valve                 |
| Valvula sinus coronarii        | Valve of Thebesius               |

## Arteries.

## B. N. A. TERMINOLOGY.

Sinus aortæ  
 A. profunda linguæ  
 A. maxillaris externa  
 A. alveolaris inferior  
 Ramus meningeus accessorius  
 A. buccinatoria  
 A. alveolaris superior posterior  
 Aa. alveolares superiores anteriores  
 Ramus carotico-tympanicus  
 A. chorioidea  
 A. auditiva interna  
 Rami ad pontem  
  
 A. pericardiaco-phrenica  
 Rami intercostales (A. mammaria interna)  
 Truncus thyreo-cervicalis  
 A. transversa scapulæ  
 A. intercostalis suprema  
 A. transversa colli  
 A. thoracalis suprema  
 A. thoraco-acromialis  
 A. thoracalis lateralis  
 A. circumflexa scapulæ  
 A. profunda brachii  
 A. collateralis radialis  
 A. collateralis ulnaris superior  
 A. collateralis ulnaris inferior  
 Ramus carpeus volaris  
 Ramus carpeus dorsalis  
 Aa. metacarpeæ dorsales  
 A. volaris indicis radialis  
 Arcus volaris superficialis  
 Arcus volaris profundus  
 A. interossea dorsalis  
 A. interossea recurrens  
  
 A. interossea volaris  
 Ramus carpeus dorsalis  
 Ramus carpeus volaris  
 Aa. digitales volares communes  
 Aa. digitales volares propriae  
 Arteriæ intestinales  
  
 A. suprarenalis media  
 A. hypogastrica  
 A. umbilicalis  
 A. pudenda interna  
 A. epigastrica inferior

## OLD TERMINOLOGY.

Sinuses of Valsalva  
 Ranine artery  
 Facial artery  
 Inferior dental artery  
 Small meningeal artery  
 Buccal artery  
 Posterior dental artery  
 Anterior superior dental arteries  
 Tympanic branch of int. carotid  
 Anterior choroidal artery  
 Auditory artery  
 Transverse arteries (branches of Basilar artery)  
 Arteria comes nervi phrenici  
 Anterior intercostal arteries  
  
 Thyroid axis  
 Suprascapular artery  
 Superior intercostal  
 Transversalis colli  
 Superior thoracic artery  
 Acromio-thoracic artery  
 Long thoracic artery  
 Dorsalis scapulæ  
 Superior profunda  
 Anterior branch of superior profunda  
 Inferior profunda  
 Anastomotica magna  
 Anterior radial carpal  
 Posterior radial carpal  
 Dorsal interosseous arteries  
 Radialis indicis  
 Superficial palmar arch  
 Deep palmar arch  
 Posterior interosseous artery  
 Posterior interosseous recurrent artery  
 Anterior interosseous artery  
 Posterior ulnar carpal  
 Anterior ulnar carpal  
 Palmar digital arteries  
 Collateral digital arteries  
 Intestinal branches of sup. mesenteric  
 Middle capsular artery  
 Internal iliac artery  
 Obliterated hypogastric  
 Internal pudic artery  
 Deep epigastric artery



## B.N.A. TERMINOLOGY.

A.\* spermatica externa  
 Aa. pudendæ externæ  
 A. circumflexa femoris medialis  
 A. circumflexa femoris lateralis  
 A. genu suprema  
 A. genu superior lateralis  
 A. genu superior medialis  
 A. genu media  
 A. genu inferior lateralis  
 A. genu inferior medialis  
 A. malleolaris anterior lateralis  
 A. malleolaris anterior medialis  
 A. peronæa  
     Ramus perforans  
     A. malleolaris posterior lateralis  
 A. malleolaris posterior medialis  
 Rami calcanei laterales  
 Rami calcanei mediales  
 A. plantaris medialis  
 A. plantaris lateralis  
 Aa. metatarsæ plantares  
 Aa. digitales plantares

## OLD TERMINOLOGY.

Cremasteric artery  
 Superficial and deep external pudic arteries  
 Internal circumflex artery  
 External circumflex artery  
 Anastomotica magna  
 Superior external articular artery  
 Superior internal articular artery  
 Azygos articular artery  
 Inferior external articular artery  
 Inferior internal articular artery  
 External malleolar artery  
 Internal malleolar artery  
 Peroneal artery  
     Anterior peroneal artery  
     Posterior peroneal artery  
 Internal malleolar artery  
 External calcanean artery  
 Internal calcanean artery  
 Internal plantar artery  
 External plantar artery  
 Digital branches  
 Collateral digital branches

## Veins.

V. cordis magna  
 V. obliqua atrii sinistri  
 Lig. venæ cavæ sinistræ  
 Vv. cordis minimæ  
 Sinus transversus  
 Confluens sinuum  
 Plexus basilaris  
 Sinus sagittalis superior  
 Sinus sagittalis inferior  
 Spheno-parietal sinus  
 V. cerebri internæ  
 V. cerebri magna  
 V. terminalis  
 V. basalis  
 V. transversa scapulæ  
 V. thoraco-acromialis  
 Vv. transversæ colli  
 V. thoracalis lateralis  
 V. azygos  
 V. hemiazygos  
 V. hemiazygos accessoria  
 V. hypogastrica  
 V. epigastrica inferior  
 V. saphena magna  
 V. saphena parva

Great cardiac vein  
 Oblique vein of Marshall  
 Vestigial fold of Marshall  
 Veins of Thebesius  
 Lateral sinus  
 Torcular Herophili  
 Basilar sinus  
 Superior longitudinal sinus  
 Inferior longitudinal sinus  
 Sinus alæ parvæ  
 Veins of Galen  
 Vena magna Galeni  
 Vein of the corpus striatum  
 Basilar vein  
 Suprascapular vein  
 Acromio-thoracic vein  
 Transversalis colli veins  
 Long thoracic vein  
 Vena azygos major  
 Vena azygos minor inferior  
 Vena azygos minor superior  
 Internal iliac vein  
 Deep epigastric vein  
 Internal saphenous vein  
 External saphenous vein

**Lymphatics.**

B. N. A. TERMINOLOGY.

OLD TERMINOLOGY.

Cisterna chyli

Receptaculum chyli

## THE VISCERA.

**Digestive Apparatus.**

Arcus glosso-palatinus	Anterior pillar of fauces
Arcus pharyngo-palatinus	Posterior pillar of fauces
Gl. lingualis anterior	Gland of Nuhn
Ductus submaxillaris	Wharton's duct
Gl. parotis accessoria	Socia parotidis
Ductus parotideus (Stenonis)	Stenson's duct
Dentes præmolares	Bicuspid teeth
Dens serotinus	Wisdom tooth
Papillæ vallatæ	Circumvallate papillæ
Recessus pharyngeus	Lateral recess of pharynx
Tela submucosa	Pharyngeal aponeurosis
Plicæ circulares	Valvulæ conniventes
Gl. intestinales	Crypts of Lieberkuhn
Valvula coli	Ileo-cæcal valve
Columnæ rectales	Columns of Morgagni
Plicæ transversales recti	Valves of Houston
Valvula spiralis	Valves of Heister
Noduli lymphatici aggregati (Peyeri)	Peyer's patches
Intestinum jejunum	Jejunum
Intestinum ileum	Ileum
Noduli lymphatici lienales (Malpighii)	Malpighian corpuscles

**Respiratory Apparatus.****Larynx**

Prominentia laryngea	Adam's apple
Incisura thyreoidea superior	Superior thyroid notch
M. ary-epiglotticus	Aryteno-epiglottidean muscle
M. vocalis	Internal thyro-arytenoid muscle
M. thyreo-epiglotticus	Thyro-epiglottidean muscle
Appendix ventriculi laryngis	Laryngeal sac
Plica vocalis	True vocal cord
Plica ventricularis	False vocal cord
Ligamentum ventriculare	Superior thyro-arytenoid ligament
Ligamentum vocale	Inferior thyro-arytenoid ligament
Glottis	Glottis vera
Rima vestibuli	Glottis spuria
Cartilago thyreoidea	Thyroid cartilage

## B.N.A. TERMINOLOGY.

Membrana hyo-thyreoidea  
 Cartilago corniculata (Santorini)  
 Tuberculum epiglotticum  
 Pars intermembranacea (rimæ  
 glottidis)  
 Pars intercartilaginea (rimæ  
 glottidis)  
 Conus elasticus (membranæ  
 elasticæ larynges)  
 Glandula thyreoidea  
 Glomus caroticum

## Nose

Concha nasalis suprema (Santorini)  
 Concha nasalis superior  
 Concha nasalis media  
 Concha nasalis inferior

## OLD TERMINOLOGY.

Thyro-hyoid membrane  
 Cartilage of Santorini  
 Cushion of epiglottis  
 Glottis vocalis  
 Glottis respiratoria  
 Crico-thyroid membrane  
 Thyroid gland  
 Intercarotid gland or body

Highest turbinate bone  
 Superior turbinate bone  
 Middle turbinate bone  
 Inferior turbinate bone

## Urogenital Apparatus.

Corpuscula renis  
 Paradidymis  
 Appendix testis  
 Ductus deferens  
 Gl. urethrales  
 Glandula bulbo-urethralis (Cowperi)  
 Folliculi oophori vesiculosi  
 Cumulus oophorus  
 Tuba uterina  
 Epoophoron  
 Appendices vesiculosi  
 Ductus epoophori longitudinalis  
 Orificium internum uteri  
 Orificium externum  
 Processus vaginalis  
 Glandula magna vestibuli

Malpighian corpuscles  
 Organ of Giraldés  
 Hydatid of Morgagni (male)  
 Vas deferens  
 Glands of Littré  
 Cowper's gland  
 Graafian follicles  
 Discus proligerus  
 Fallopian tube  
 Parovarium  
 Hydatids of Morgagni (female)  
 Gärtner's duct  
 Internal os (of uterus)  
 External os  
 Canal of Nuck  
 Bartholin's gland

## Peritoneum.

Bursa omentalis  
 Foramen epiploicum  
 Lig. phrenico-colicum  
 Excavatio recto-uterina (cavum  
 Douglasi)  
 Lig. gastro-lienale

Lesser peritoneal sac  
 Foramen of Winslow  
 Costo-colic ligament  
 Pouch of Douglas  
 Gastro-splenic omentum

## SENSE ORGANS.

## The Eye.

Sclera  
 Lamina elastica anterior (Bowmani)

Sclerotic coat  
 Bowman's membrane

B.N.A. TERMINOLOGY.	OLD TERMINOLOGY.
Lamina elastica posterior (Descemeti)	Descemet's membrane
Spatia anguli iridis	Spaces of Fontana
Angulus iridis	Irido-corneal junction
Zonula ciliaris	Zonule of Zinn
Septum orbitale	Palpebral ligament
Fascia bulbi	Capsule of Tenon
Commissura palpebrarum lateralis	External canthus
Commissura palpebrarum medialis	Internal canthus
Tarsus superior	Superior tarsal plate
Tarsus inferior	Inferior tarsal plate
Lig. palpebrale mediale	Internal tarsal ligament
Raphe palpebralis lateralis	External tarsal ligament
Tarsal glands	Meibomian glands

### The Ear.

Canalis semicircularis lateralis	External semicircular canal
Ductus reuniens	Canalis reuniens
Ductus cochlearis	Membranous cochlea
Recessus sphericus	Fovea hemispherica
Recessus ellipticus	Fovea hemi-elliptica
Paries jugularis	Floor of tympanum
Paries labyrinthica	Inner wall
Fenestra vestibuli	Fenestra ovalis
Fenestra cochleæ	Fenestra rotunda
Paries mastoidea	Posterior wall
Antrum tympanicum	Mastoid antrum
Paries carotica	Anterior wall
Processus lateralis	Processus brevis (of malleus)
Processus anterior	Processus gracilis

# MANUAL

OF

## PRACTICAL ANATOMY.



### THE SUPERIOR EXTREMITY.

**Introduction.**—The superior extremity consists of the *brachium* or arm, which extends from the shoulder to the elbow; the *antibrachium* or forearm, which lies between the elbow and the wrist; the *wrist*, which connects the forearm with the hand; and the *manus* or hand. Belonging to it also are the bones of the shoulder girdle, the clavicle and scapula, by means of which it is articulated with the skeleton of the trunk; it is also attached to the trunk by means of a number of muscles. The angle which lies between the arm and the upper part of the trunk is the axilla or armpit.

**Surface Anatomy.**—Before commencing the actual dissection of any region of the body the student should be quite familiar with the bones of the region, for they are the landmarks by means of which the positions of the soft parts which lie beneath the skin can be defined, both in the dead and in the living body. The outlines of many of the bones and the projecting parts of others can be seen, for they cause prominences on the surface. Many portions of bone which cannot be seen can be felt quite easily when the finger is passed lightly over the places where they lie; slight pressure must be used in other places where the bones lie more deeply. Some parts of the skeleton, however, can be neither seen nor felt until the soft parts have been removed.

It is essential, therefore, that the student should train his eyes to see all that can be seen, and his fingers to feel all that can be felt, and he must remember that anything which he can see or feel in the case of the body of another person he can almost equally well see and feel in the case of his own body.

The bones of the superior extremity are the *clavicle* (collar bone) and the *scapula* (shoulder blade), the *humerus*, the *radius* and the *ulna*, *eight carpal bones*, *five metacarpal bones*, and *fourteen phalanges* (Figs. 1, 2, 3).

The scapula and clavicle, together, form the shoulder girdle, by means of which the arm is articulated with the skeleton of the trunk.

The clavicle can be seen and felt at the lower part of the front of the neck. It extends from the shoulder to the upper end of the sternum (breast bone), which lies in the middle part of the front of the chest. Below the junction of its intermediate and lateral thirds is a depression of the surface, the *delto-pectoral triangle*. The soft prominence to the medial side of the delto-pectoral triangle is caused by the portion of the pectoralis major muscle which is attached to the front of the medial half of the clavicle, and the prominence on the lateral side of the triangle is due to the anterior part of the deltoid muscle which springs from the front of the lateral third of the clavicle. If the finger is pressed upwards and backwards at the upper part of the lateral margin of the delto-pectoral triangle, a prominence of bone called the *coracoid process* of the scapula will be felt. It lies under cover of the medial edge of the deltoid muscle, and is an important landmark (Figs. 1, 2, 55, 56, 57).

Beyond and behind the lateral end of the clavicle a more or less quadrangular plate of bone can be felt. It is the *acromion* of the scapula. Its medial margin articulates with the lateral end of the clavicle, at the *acromio-clavicular joint*. Its lateral margin lies at the *tip of the shoulder*, and it is the upper point from which the length of the superior extremity is measured.

On the posterior aspect of the body running, medially, backwards and slightly downwards, from the acromion is a prominent and easily felt ridge of bone. It is the posterior border or *crest of the spine of the scapula*.

In the arm there is one bone, the *humerus*. It extends

PLATE I

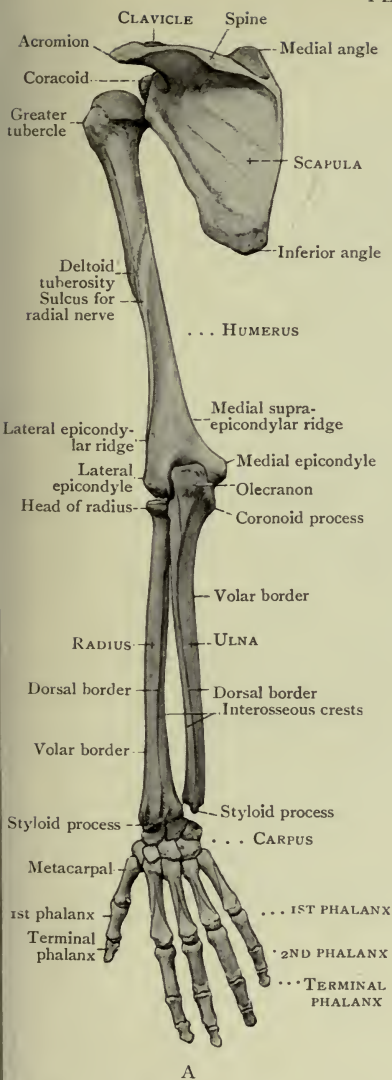


FIG. 1.—Bones of Upper Limb.  
 Posterior view.

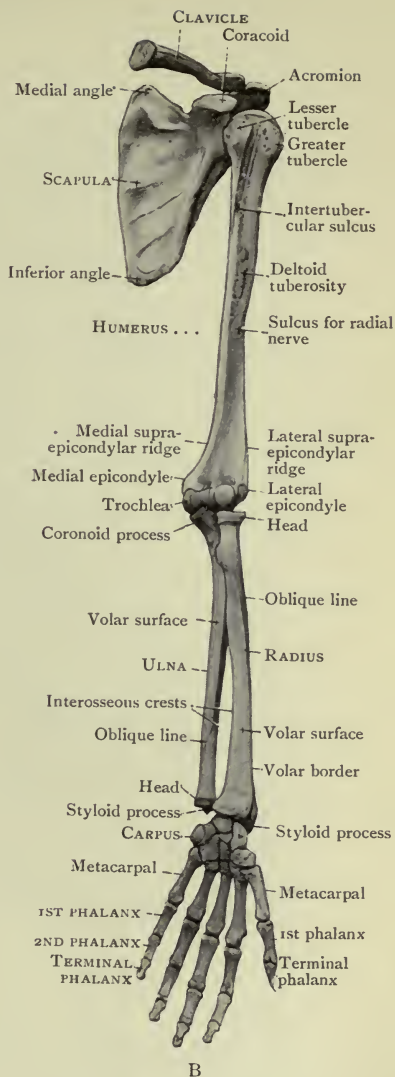


FIG. 2.—Bones of Upper Limb.  
 Anterior view.

PLATE II

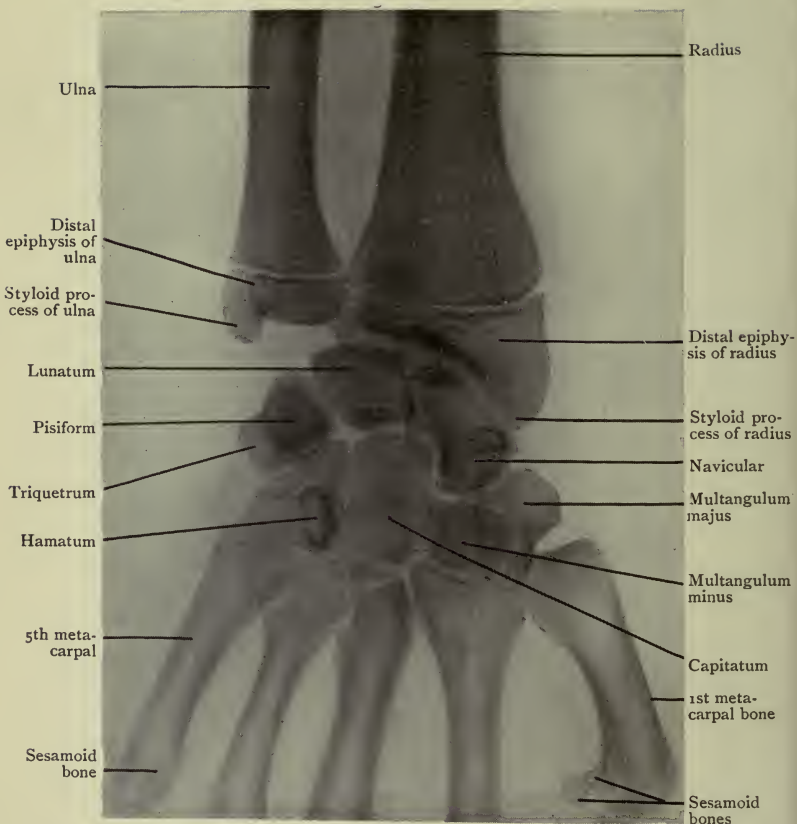


FIG. 3.—Antero-posterior Radiograph of the Wrist of a person of 19 years.

- Note (1) The epiphyseal lines of the radius and ulna.  
 (2) The difference in level of the styloid process of the ulna as contrasted with the styloid process of the radius.  
 (3) The overlap of the shadows of adjacent bones.



from the shoulder, where it articulates with the scapula, to the elbow, where it articulates with the bones of the forearm; they are the *radius* on the thumb or lateral side, and the *ulna* on the medial or little finger side.

When the fingers are placed on the lateral side of the arm immediately below the acromion and the arm is moved in any direction, the proximal end of the humerus can be felt moving under cover of the deltoid muscle; the part of the humerus which is felt is mainly *the greater tubercle* (Figs. 1, 2, 55, 56).

The angular interval between the proximal part of the arm and the chest wall is the *axilla*. It contains important blood-vessels, nerves, and lymph glands. If the fingers are pushed well up into the axilla and the arm is moved, the lower part of the rounded head of the humerus, which articulates with the scapula, can be felt. In front of the fingers will be the anterior wall of the axilla, formed almost entirely by muscle; behind them will be the posterior wall, formed by muscles and by the axillary border of the scapula, which can be felt. To the medial side are the upper ribs of the chest wall, covered by a muscle called the *serratus anterior*; and laterally is the humerus.

The student should follow the body or shaft of the humerus from its proximal to its distal end, squeezing the soft parts between his thumb and fingers; as the region of the elbow is approached he will find that the humerus expands greatly from side to side and that its medial and lateral margins terminate in projections, which are called the *epicondyles of the humerus* (Figs. 1, 2, 85).

Both are landmarks. Behind the *medial epicondyle* lies the ulnar nerve; it can be felt quite easily in the living body if a finger is pressed against the back of the epicondyle and is moved from side to side. If the pressure is sufficiently strong it gives rise to a tingling sensation along the medial part of the hand.

Anterior to the *lateral epicondyle* and somewhat to its medial side another large nerve, the *radial*, breaks up into its terminal branches; it cannot, however, be felt.

The *posterior border of the ulna* is subcutaneous in the whole of its length. It extends from the *olecranon*, which is the prominence at the back of the elbow, to a small pointed process called the *styloid process of the ulna* which lies at the medial side of the back of the wrist (Figs. 1, 2, 3, 97, 98, 99).

Just lateral to the styloid process and slightly proximal to it there is a rounded piece of bone called the *head of the ulna*. It is best seen and felt when the palm of the hand is turned downwards.

The radius is more deeply buried than the ulna, but there is no difficulty in locating its proximal and distal ends. The proximal end, called the *head of the radius*, lies a short distance distal to the lateral epicondyle of the humerus. Its position is marked on the back of the forearm by a dimple of the skin. If a finger is placed in the dimple the head of the radius can be felt rotating when the palm of the hand is turned alternately upwards and downwards.

The distal end of the radius is the quadrangular mass of bone which can be felt at the lateral side and the back of the wrist. It lies lateral to the head of the ulna and it terminates on the lateral side in a pointed process, the *styloid process of the radius*.

The *eight carpal bones* of the wrist lie in the interval between the styloid processes of the radius and ulna, beyond which they extend distally for a short distance (Figs. 3, 67, 77).

The *five metacarpal bones of the hand*, one for each digit, extend from the carpus to the phalanges.

They are numbered one to five from the thumb to the little finger side, and all are easily felt at the back of the hand, where the heads or distal ends form the prominences known as the "knuckles."

The *fourteen phalanges* are in the free parts of the digits: two in the thumb, *first* or proximal and *second* or distal; three in each finger, proximal or *first*, middle or *second*, and distal or *third*. The second phalanx of the thumb and the third phalanges of the fingers are frequently called terminal phalanges.

The structures connected and associated with all the bones mentioned have to be examined by the dissector of the superior extremity, and whilst waiting to commence the dissection the dissector should verify all the points above mentioned upon his own body with the aid of his fingers and a looking-glass.

Since many students commence dissecting before they have attended either lectures or demonstrations on Anatomy, they are unacquainted with terms which must be used in the instructions given regarding the dissections which are to be

made. Fortunately most of the terms used, like those already mentioned, refer to things which can be seen and felt; they, therefore, are easily understood. There are, however, certain terms, used when branches of spinal nerves are under consideration, which are not self-explanatory, and it is necessary, therefore, that the student should possess a knowledge of the terms used in connection with spinal nerves and their branches before the actual work of dissection is commenced. The following points should be noted: (1) Every spinal nerve is attached to the spinal medulla (spinal cord) by two roots, an *anterior root* and a *posterior root*. The anterior root is *non-ganglionated* and the posterior root is *ganglionated*. (2) As the roots are leaving the vertebral canal, through an intervertebral foramen, they unite to form a *trunk*. (3) Immediately after its exit from the intervertebral foramen the trunk divides into a *posterior ramus* and an *anterior ramus* of which the anterior ramus is, with few exceptions, much the larger. (4) Each posterior ramus divides into a *medial branch* and a *lateral branch*. (5) Each anterior ramus divides into a *lateral branch* and an *anterior branch* (Fig. 4).<sup>1</sup>

Every anterior root consists of nerve fibres which spring from nerve cells in the spinal medulla and pass to the muscle fibres of various muscles. They carry motor impulses to the muscles. Each posterior root consists of nerve fibres passing to and from the nerve cells of the ganglion of the posterior root. The posterior root fibres carry sensory impulses, such as cold, heat, pain, etc. The sensory impulses pass through the cells of the ganglion of the posterior root and then onwards to the spinal medulla.

The trunk of every spinal nerve, therefore, contains both *motor* or *efferent* and *sensory* or *afferent nerve fibres*, and the posterior and anterior rami into which it divides also contain both sets of fibres. The branches of the rami may contain either both sets of fibres or only one or the other set. Eventually, however, the peripheral parts of the fibres conveying impulses from and those conveying impulses to the spinal medulla separate from one another. The fibres which convey impulses from the spinal medulla become the motor nerves which end in the muscle fibres, whilst the fibres which

<sup>1</sup> This division is not always obvious, and in certain situations the lateral and anterior branches are called, respectively, posterior and anterior branches.

convey sensory impulses only are the sensory nerve fibres. The sensory nerve fibres which convey sensory impulses from the skin are termed *cutaneous nerves*.

The dissector of the upper extremity must begin work on

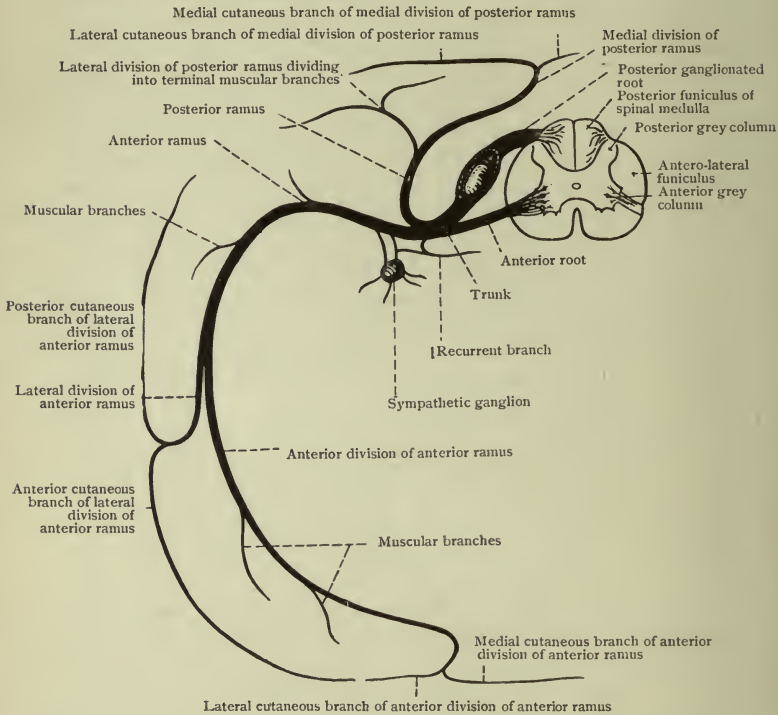


FIG. 4.—Diagram of a Spinal Nerve. Note that the medial divisions of the posterior ramus is represented as distributed to skin, whilst the lateral division terminates at a deeper level in muscle. In some situations the reverse condition occurs, and the medial and lateral divisions of all posterior rami supply muscles.

the fourth day after the subject has been placed in the dissecting-room. He will find the body lying upon its back. The thorax will be raised to a convenient height by means of blocks, and a long board will be placed under the shoulders for the purpose of supporting the arms when they are abducted from the sides.

Until the dissection of the axilla is completed the dissectors of the arm and of the head and neck will find it advantageous to arrange to work at different hours. The dissector of the head and neck, at this stage, is engaged on the posterior triangle of the neck, and the dissection of the triangle cannot be well done unless the arm is placed close to the side and the shoulder depressed. For the dissection of the axilla the arm should be stretched out at right angles to the thorax. A compromise between these two positions always results in discomfort to both dissectors.

Five days are allowed for the examination of the axilla and the muscles which pass to the upper extremity from the anterior portion of the thoracic region of the body. The following table will be found useful in regulating the amount of work which should be carried out on each day:—

**First Day.**—(a) Surface anatomy; (b) reflection of the skin; (c) cutaneous vessels and nerves of the anterior and lateral aspects of the thorax; (d) examination of the fascia of the pectoralis major and the axillary fascia; (e) the cleaning of the pectoralis major; (f) the reflection of the pectoralis major.

**Second Day.**—(a) The examination of the costo-coracoid membrane and the structures piercing it; (b) the removal of the costo-coracoid membrane and the examination of the structures posterior to it.

**Third Day.**—(a) The cleaning of the pectoralis minor; (b) the cleaning of the contents of the axilla below the pectoralis minor.

**Fourth Day.**—(a) The reflection of the pectoralis minor; (b) the completion of the cleaning of the contents of the axilla; (c) the cleaning of the serratus anterior; (d) the cleaning of the posterior wall of the axilla; (e) the reflection of the subclavius; (f) the examination of the sternoclavicular articulation and the disarticulation of the clavicle at the sternoclavicular joint.

**Fifth Day.**—(a) The brachial plexus and a general review of the axilla and its contents.

Before commencing the dissection of the axillary region draw your finger along the clavicle from its sternal to its acromial end. Note that in the medial two-thirds of its length the bone curves forwards to give room for the passage of vessels and nerves from the neck to the axilla. The lateral third is curved backwards. Place your finger in the deltopectoral triangle below the junction of the intermediate and lateral thirds of the clavicle, and note that the great pectoral muscle lies to its medial side and the deltoid muscle to its lateral side; both muscles spring from the anterior aspect of the clavicle (see Fig. 10). Push your finger upwards and backwards in the triangle under the medial border of the deltoid until the coracoid process is distinctly felt. Next examine the articulations of the clavicle. Little or no prominence is formed by the lateral extremity of the bone—its superior surface lies in the same plane as the superior

surface of the acromion of the scapula. When the upper limb is moved, however, the joint can easily be detected. In strong contrast to the inconspicuous acromio-clavicular joint is the sterno-clavicular joint, where the medial end of the clavicle can be felt as a marked projection, although it is masked, to the eye, by the sternal part of the sterno-cleido-mastoid muscle which causes the ridge-like prominence at the side of the neck as it extends from the sternum and clavicle to the skull behind the ear. Place the index finger in the *jugular notch* on the upper border of the manubrium sterni, between the clavicles, and carry it downwards, along the middle of the sternum, in the interval between the attachments of the great pectoral muscles. The portion of the sternum uncovered by the two greater pectoral muscles is narrow above, but it widens out below, and as the finger passes along it a prominent ridge will be felt. The ridge marks the junction of the manubrium sterni with the body of the sternum, and also the level at which the costal cartilages of the second ribs join the sternum. It is easily felt and can often be seen. It is, therefore, an excellent landmark, indicating the positions of the second pair of ribs, from which the counting of the other ribs should always commence. At the lower end of the body of the sternum, the finger, as it is carried downwards, will sink suddenly into a depression, between the cartilages of the seventh pair of ribs, and rest against the xiphoid process of the sternum. The depression is termed the *infrasternal fossa*, or pit of the stomach. The costal arches, below the first, are easily recognised, but the first rib lies deeply under the clavicle, and can be felt only in front, at its junction with the manubrium sterni. The arm should now be abducted (*i.e.* carried laterally from the trunk), when the hollow of the axilla and the two rounded folds, which bound it in front and behind, will be brought into view. The anterior fold of the axilla is formed by the lower border of the pectoralis major, and to a small extent also by the lower border of the pectoralis minor. The posterior fold, which is formed by the latissimus dorsi as it winds round the teres major muscle, is carried downwards to a lower level than the anterior fold. This, as will be seen later, is an important point in connection with the anatomy of the axilla. If the finger is pushed upwards into the axilla the globular head of the humerus will be felt, when the arm is rotated. One other

point demands the attention of the student before the dissection is commenced, and that is the position of the nipple. As a rule it lies superficial to the interspace between the fourth and fifth ribs, and it is situated rather more than four inches from the median line.

The student should examine these various landmarks, not only upon the dead body but also upon himself and his friends, until he is perfectly familiar with them, both by touch and sight, and can at once put his finger on any given point, whatever the position of the limb may be.

**Dissection.**—Reflection of the Skin.—Incisions:—(1) Along the middle line of the body from the upper margin of the manubrium sterni to the tip of the xiphoid process. (2) Upwards and laterally from the tip of the xiphoid process to the nipple. At the nipple the incision must bifurcate, to encircle the dark patch of skin around the nipple which is called the areola, then it must be continued along the anterior fold of the axilla to the arm. As soon as it reaches the arm it must be carried downwards for about 63 mm. (two inches and a half), and then transversely to the lateral border of the arm. (3) From the tip of the xiphoid process transversely across the front and side of the chest to the plane of the posterior fold of the axilla (Fig. 5).

To make a clean incision in the skin place the point of the scalpel on one end of the line of incision, and, holding the scalpel at right angles to the surface to be incised, force the point through the skin till it enters the soft superficial fascia which lies beneath. Then incline the blade to an angle of  $45^{\circ}$  to the surface of the skin, and, pressing firmly on the back of the blade with the forefinger, carry it steadily to the opposite end of the line of incision, but as the end of the line is approached bring the blade again to a right angle with the surface, and so withdraw it from the incision.

To reflect the skin take hold of one of the angles of the flap marked out by the incisions with the forceps; in the case of the upper flap (1, Fig. 5), which should be dealt with first, the superior medial angle on the right side and the inferior medial angle on the left side, and with the edge of the scalpel detach it from the soft fat beneath.

As soon as the angle selected is sufficiently detached discard the forceps, and, holding the detached angle of skin between the thumb and forefinger of the left hand, keep it tense and draw the edge of the scalpel across the skin at its junction with the fat from one edge of the flap to the other, always keeping the edge of the knife against the skin. Be careful not to take any fat away with the skin. Continue the reflection until the lateral border of the shoulder region is reached. Leave the flap hanging along that border and turn to flap 2, Fig. 5. Commence at the medial angle, proceed as with flap 1, and continue the reflection until the posterior fold of the axilla is reached.

As the skin flaps are reflected towards the arm and the side of the chest the small patch around the nipple must be left untouched.

## THE SUPERIOR EXTREMITY

As that reflection proceeds note that the connection between the superficial fascia and the skin is stronger in some places than in others. In the female definite fibrous strands will be

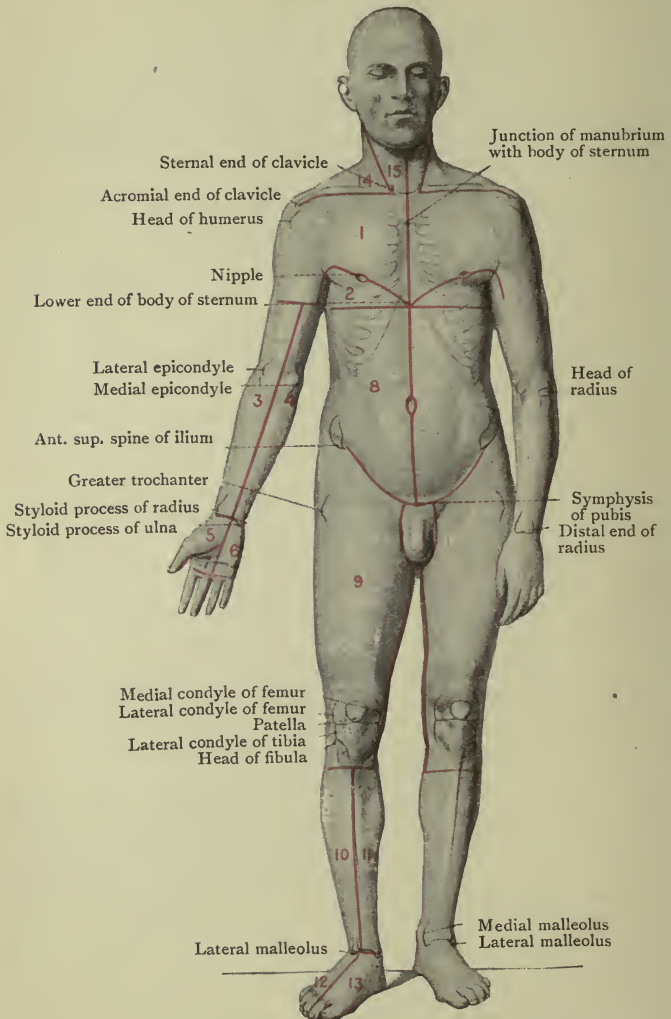


FIG. 5.—Surface view showing Incisions and Bony Points.



found passing from the substance of the mammary gland to the skin; they are called the *ligaments of Cooper*.

When the reflection of the flaps is completed the superficial fascia is exposed.

**Superficial Fascia (Panniculus Adiposus).**—The superficial fascia is found not only in the region now under consideration but over the whole of the body. Its structure is slightly different in different areas. In all parts, with the exception of the region of the scrotum, it contains yellowish fat, the amount of fat varying with the regions and with the obesity of the subject. In some regions muscle fibres of reddish tint are found in the deeper part of the superficial fascia; in the anterior part of the neck and the adjacent portion of the upper part of the chest they form, on each side, a definite sheet of muscle called the *platysma*; and in the region of the scrotum they entirely replace the fat.

In the superficial fascia lie the cutaneous vessels and nerves, and the deeper portions of the hairs and the sweat glands. In some regions the deeper parts of the sebaceous glands of the skin penetrate into it, and in the thoracic region, the *mammary glands*, which are modified subcutaneous glands, are developed in its substance. It contains also the superficial lymph glands.

Under cover of the superficial fascia and intervening between it and the muscles there is a more membranous layer of fibrous tissue called *deep fascia*.

The superficial fascia, therefore, intervenes between the skin and the deep fascia, and it is attached to both by fibrous strands which pass through the fat. As it lies between the skin and the deep fascia it forms a soft elastic cushion upon which the skin rests, and which, by its elasticity, allows the skin to be moved over the deeper parts. It rounds off the angularities of the body and it forms the bed in which the cutaneous vessels and nerves ramify before they enter the skin.

In the region at present exposed, the fat is not usually very plentiful except in female bodies, where it is abundant in the region of the mamma. In the neighbourhood of the clavicle a reddish striation due to the lower part of the *platysma* is usually visible, and if it is not seen the fibres of the muscle can be exposed quite easily by the removal of the thin layer of fat which lies superficial to them.

After the general characters of the superficial fascia have

been noted the nerves and vessels which pass through it to the skin must be sought for. They are:—

*Nervi Cutanei.*

Supraclavicular, from the cervical plexus.

Anterior cutaneous } from the anterior (intercostal) rami of the thoracic  
Lateral cutaneous } nerves.

*Arteriæ Cutaneæ.*

Cutaneous twigs from the branches of the thoraco-acromial artery:—

From the clavicular branch.

From the acromial branch.

From the deltoid branch.

Perforating branches of the internal mammary artery.

Branches form the lateral thoracic artery.

Branches form the transverse scapular artery.

**Dissection.**—Cut through the superficial fascia to the deep fascia along the lateral margin of the sternum. The level of the deep fascia will be recognised by the increased resistance offered to the knife, and by its bluish-white colour when it is exposed. As regards the difference of resistance the dissector must educate his fingers to recognise the different “feel” of the various structures. As the edge of the knife touches them, superficial fascia, deep fascia, nerves, vessels, muscles, they all cause a different sensation, recognisable by the educated touch, which can only be acquired by attention and practice.

As soon as the level of the deep fascia is reached raise the cut margin of the superficial fascia with the forceps or fingers and, with the edge of the scalpel, sever the strands which attach the deep surface of the superficial fascia to the deep fascia, cutting against the deep fascia and removing the whole of the superficial fascia. As the separation proceeds pull the detached superficial fascia away from the sternum, and as soon as the anterior ends of the intercostal spaces are reached look for the *anterior cutaneous nerves* and the *perforating branches of the internal mammary artery*, which pierce the deep fascia near the margin of the sternum. If the arteries are well injected one should be found in each of the upper six intercostal spaces. It is not probable that a nerve will be found in the first space, but one should be found in each of the other five spaces. The arteries will be recognised by the red injection which they contain; each is accompanied by a small vein. The nerves are whitish threads, not unlike thin white thread. They are much firmer to the touch, and much stronger than the blood-vessels.

Trace both the vessels and nerves as far laterally as possible. When the anterior cutaneous nerves and the accompanying vessels have been secured look for the *supraclavicular nerves*; to find them cut through the fibres of the platysma along the upper border of the clavicle from the sternum to the shoulder, and turn the lower part of the severed muscle and fascia downwards, detaching it from the fascia beneath with the edge of the scalpel. As this is done look for the nerves which appear as whitish strands running downwards across the clavicle and passing from the deeper into the more superficial layer. Two or three should be found about the middle of the clavicle, one

near its sternal end, and one near its acromial end descending in the fascia over the anterior part of the deltoid muscle. Follow the nerves downwards through the superficial fascia as far as possible; they descend to the level of the second or third rib, and are sometimes accompanied by small *branches of the transverse scapular artery* which pierce the deep fascia above the clavicle. Near the sternal end of the clavicle small twigs of the *clavicular branch of the thoraco-acromial artery* may be seen. Near the acromion twigs of the *acromial branch of the same artery* may be found; and in the delto-pectoral triangle twigs of the *deltoid branch* are occasionally visible.

After the supraclavicular nerves have been found and followed to their terminations cut through the superficial fascia along the line of the anterior fold of the axilla and the lower margin of the pectoralis major. As soon as the level of the deep fascia is reached turn the anterior part of the superficial fascia towards the median plane, and look for the *anterior branches of the lateral cutaneous nerves*, as they turn round the border of the pectoralis major, pierce the deep fascia, and run medially in the superficial fascia.

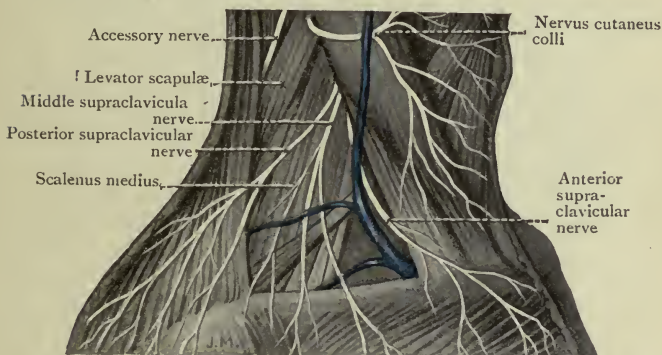


FIG. 6.—The Supraclavicular Branches of the Cervical Plexus.

**Nervi supraclaviculares.**—The *supraclavicular nerves* arise in the neck, from the third and fourth cervical nerves. They spread out as they descend, pierce the deep fascia of the neck, and they cross the clavicle under cover of the platysma. They are classified, according to their positions, into the anterior, the middle, and the posterior branches (Fig. 6). The *anterior* are the smallest of the series; they cross the medial part of the clavicle to end in the skin immediately below. The *middle branches* pass over the middle of the clavicle and extend downwards, in the superficial fascia over the pectoralis major, as far as the third rib. The *posterior* cross the lateral

third of the clavicle, and will be afterwards followed to the skin of the shoulder. They are frequently accompanied by cutaneous branches of the transverse scapular artery.

**Nervi Cutanei Anteriores.**—The *anterior cutaneous nerves* are the minute terminal twigs of the anterior rami of the thoracic nerves. They become superficial by piercing the pectoralis major muscle and the deep fascia, close to the margin of the sternum. One will be found in each intercostal interval except the first; and they are accompanied by the *cutaneous perforating branches* of the internal mammary artery, which serve as the best guides to the nerves. The nerves and the arteries give slender twigs to the skin over the sternum, and larger branches which run laterally and may be traced as far as the anterior fold of the axilla. The cutaneous perforating artery which appears through the third intercostal space is usually the largest of the series, especially in the female.

**Nervi Cutanei Laterales.**—The *lateral cutaneous nerves*, much larger than the anterior, arise from the anterior rami of the thoracic nerves, and appear, on the side of the thorax, along a line situated a little behind the anterior fold of the axilla. They pierce the wall of the thorax in the interspaces between the ribs, and divide into anterior and posterior branches under cover of the serratus anterior muscle. At a later stage the branches will be found appearing between the digitations of the serratus anterior. The *anterior branches* appear, as a rule, about an inch in front of the corresponding posterior branches, and then pass forwards over the lower border of the pectoralis major muscle. From the lower members of this series some minute twigs are given off, which enter the superficial surfaces of the digitations of the external oblique muscle of the abdomen which will be exposed by the dissection of the abdomen. The *posterior branches* run backwards, to the dorsal aspect of the trunk, over the anterior border of the latissimus dorsi muscle (Fig. 16).

It is not advisable to attempt to secure the posterior branches of the lateral cutaneous nerves in the meantime. They are best dissected along with the other contents of the axilla.

**The Mamma (Mammary Gland or Breast).**—In the female the mamma forms a rounded prominence on the front and also, to some extent, on the lateral aspect, of the thorax. It

lies *in* the superficial fascia, and its smooth contour is largely due to the invasion of its substance by the fatty tissue of that fascia.

A little below its mid-point, and at a level which usually corresponds to the fourth intercostal space, the mamma is surmounted by a conical elevation termed the *papilla mammæ* or nipple. The nipple stands in the middle of a circular patch of coloured skin which is called the *areola mammæ*.

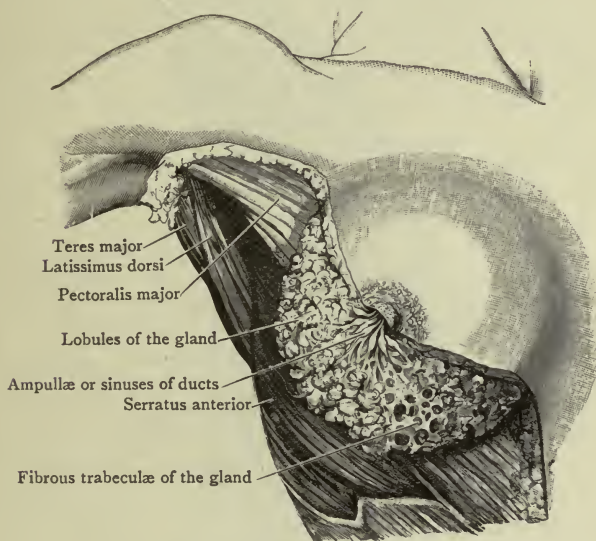


FIG. 7.—Dissection of the Mamma.

Within the nipple, and also subjacent to the areola, there is no fat. A curious change of colour occurs in this region in the female during the second month of pregnancy. At that time the delicate pink colour of the skin of the nipple and areola which was present in the virgin becomes converted to brown, by the deposition of pigment, and it never again resumes its original appearance.

The mamma extends, in a horizontal direction, from the side of the sternum almost to the mid-axillary line on the side of the thorax, and, in a vertical direction, from the second costal arch above to the sixth costal cartilage

below. About two-thirds of the gland are placed upon the pectoralis major muscle, whilst the remaining part, which corresponds to its inferior and lateral third, extends beyond the anterior fold of the axilla, and lies upon the serratus anterior muscle. From the part which lies in relation to the lower border of the pectoralis major a prolongation extends upwards into the axilla, and reaches as high as the third rib.

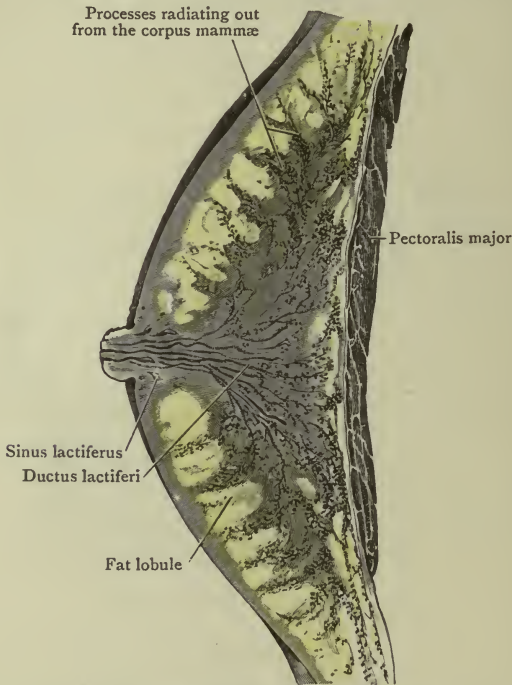


FIG. 8.—Section through a Mammary Gland prepared by the method recommended by Sir Harold Stiles.

The mamma is not enclosed in a capsule, and in that respect it differs from many other glands. Its lobules and lobes are embedded between strands of fibrous tissue which pass through the superficial fascia from the skin to the deep fascia. The strands form the stroma or framework of the gland. They support and bind together the various parts of

the true glandular tissue, which consists of cell-lined tubes, and they attach the gland both to the skin and to the deep fascia. The strands which pass to the skin have been called the *ligaments of Cooper*.

The stroma and the gland tissue together form a conical mass called the *corpus mammae*. From the surfaces and borders of the general mass of the corpus mammae many processes of stroma and gland substance project, and in the hollows between the projections is deposited the fat upon which the smooth and rounded contour of the organ depends.

The portions of the tubes of the gland which form the secretion called milk are grouped together in smaller and larger masses, called lobules and lobes, in the interstices of the fibrous stroma of the gland. The portions of the tubes which carry the secretion towards the nipple are called ducts. The smaller ducts fuse with others to form larger ducts until finally some fifteen or more terminal ducts, called *lactiferous ducts*, converge towards the base of the nipple. Subjacent to the areola each duct expands into a fusiform dilatation called a *lactiferous sinus*, then it contracts, traverses the substance of the nipple, and opens on its apex (Figs. 7 and 8).

In a well-injected subject twigs from the *intercostal arteries*, and also from the *perforating branches* of the *internal mammary artery*, may be traced into the mamma; and other vessels, called the *external mammary branches* of the *lateral thoracic artery*, may be seen winding round the edge of the pectoralis major, or piercing its lower fibres, to reach the gland.

By means of lymph vessels which issue from it in the neighbourhood of the areola, and from its borders and its deep surface, the mammae is connected with the axillary, the sternal and the infraclavicular lymph glands, and with the lymph vessels of the abdomen (Figs. 9, 14). The lymph vessels are not, as a rule, visible in an ordinary dissecting-room subject, for special methods of preparation are necessary for their proper display, but they must be remembered, because they are of the greatest importance in connection with the spread of any malignant disease which has commenced in the mamma.

In the male the mamma (*mamma virilis*) is quite rudimentary. The nipple is small and pointed, and the areola is surrounded by sparse hairs, which are never present in the female.

**Dissection.**—If the subject is a female the dissector should endeavour to make out some of the details described above. The strands called the ligaments of Cooper were noted, as the skin was removed from the surface of the gland (p. 17). Now the skin of the areola must be detached from the surface of the gland, and reflected towards the nipple. As that is done try to make out the lactiferous sinuses (Fig. 7) and the terminal ducts. If possible pass a bristle into one or other of the ducts at the apex of the nipple and trace the duct to a lactiferous sinus, and from the sinus trace the deeper part of the duct into the substance of the gland. Next, with the aid of the scalpel, gradually detach the gland from the deep fascia. Begin at the upper border, and, as the gland is displaced, note the strands of the stroma which connect its deep surface with the deep fascia. It is along those strands that blood-vessels and lymph vessels, which pierce the substance of the pectoralis major, enter and leave the gland. Trace a process of the lateral margin of the gland into the axilla behind the anterior axillary fold. Finally, remove the gland by cutting the mammary branches of the lateral thoracic artery at the lateral margin, and the mammary branches of the anterior perforating arteries at the medial margin, then examine the deep fascia of the pectoral and axillary regions.

**Deep Fascia.**—The deep fascia of the pectoral region is a thin membrane which closely invests the pectoralis major. It is attached above to the clavicle, and medially to the front of the sternum. Below, it is continuous with the deep fascia covering the abdominal muscles, and, at the lower border of the pectoralis major muscle, it is continuous with the axillary fascia. At the delto-pectoral triangle a process from its deep surface dips in, between the deltoid and pectoralis major muscles, to join the costo-coracoid membrane, whilst, further laterally, it becomes continuous with the fascia covering the deltoid muscle. The costo-coracoid membrane will be described later (p. 24).

**Fascia Axillaris.**—The axillary fascia is a dense felted membrane which extends across the base of the axilla. It is continuous anteriorly with the deep fascia over the pectoralis major, posteriorly with the fascial sheaths of the latissimus dorsi and the teres major muscles, medially with the deep fascia on the surface of the serratus anterior, whilst laterally it is continuous with the deep fascia on the medial surface of the proximal part of the arm. It is drawn up towards the hollow of the axilla, and the elevation is due chiefly to the connection of its deep surface with the fascial sheath of the pectoralis minor, and partly to its attachment to the areolar tissue which fills the axillary



space. In a well-injected subject a small artery, from the distal part of the axillary trunk, may be seen ramifying on the surface of the fascia.

**Dissection.**—Cut through the deep fascia along the sulcus between the pectoralis major and the deltoid, and display the *cephalic vein* (Figs. 31, 33) and the *deltoid branch of the thoraco-acromial artery* which accompanies it. “Clean” them by removing the loose fascia in which they are embedded. Follow both vessels upwards to the delto-pectoral triangle where they disappear under cover of the upper border of the pectoralis major.

In the delto-pectoral triangle look for the *delto-pectoral lymph glands* which are sometimes present. Lymph glands are rounded or ovoid masses of fairly dense tissue, which vary in colour; they may be yellowish-pink, rose-pink, reddish-brown, purple-brown, or in some regions quite black. Their surfaces are usually glistening, and attached to the borders and surfaces are many fine white vessels, the lymph vessels, which convey a fluid called lymph to and from the glands. Lymph glands vary very much in size, and the delto-pectoral glands may be as small as a pin-head or as large as a good-sized pea. After the contents of the delto-pectoral triangle have been studied, clean the anterior part of the deltoid and the whole of the pectoralis major muscle, and note the natural separation of the latter muscle into sternal and clavicular parts.

The “cleaning” of a muscle means the removal of the whole of the deep fascia from its surface. To do this successfully the dissector must follow three rules. (1) He must cut boldly down through the deep fascia till he exposes the red fibres of the muscle. (2) As he removes the fascia he must keep the knife edge playing against the fibres of the muscle. (3) As he makes his cuts he must carry the knife blade in the direction of the fibres of the muscle. If he follows rules 1 and 2 he will not leave a thin film of fascia on the muscle, and as he follows rule 3 he will find that the direction of his incisions changes as the course of the fibres of the muscle changes. If the work is well done the deep fascia should be removed from the muscle as a continuous unperforated layer of fibrous tissue, and the surface of the muscle will be clean.

To clean the anterior part of the deltoid, cut through the deep fascia along the anterior border of the muscle, and reflect the fascia until the base of the skin flap is reached. As the fascia is reflected some cutaneous twigs of the axillary nerve may be noted piercing the surface of the muscle, and filaments of the lateral cutaneous nerve of the arm will also be found (see Figs. 31, 32, 33).

To clean the pectoralis major commence at the upper border of the muscle on the right side, and at the lower border on the left side, reflecting the fascia in the first case downwards, and in the second upwards. Before the removal of the fascia is begun make the muscle tense by abducting the arm.

The delto-pectoral glands, sometimes represented by a single gland, receive lymph from the lateral side of the arm

and from the shoulder by lymph vessels which accompany the cephalic vein, and they transmit it to lymph vessels which connect the delto-pectoral glands with the infraclavicular glands (see Figs. 9, 30).

**M. Pectoralis Major.**—The powerful pectoralis major muscle extends from the anterior aspect of the thorax to the humerus. It is divided by a deep fissure into a clavicular and

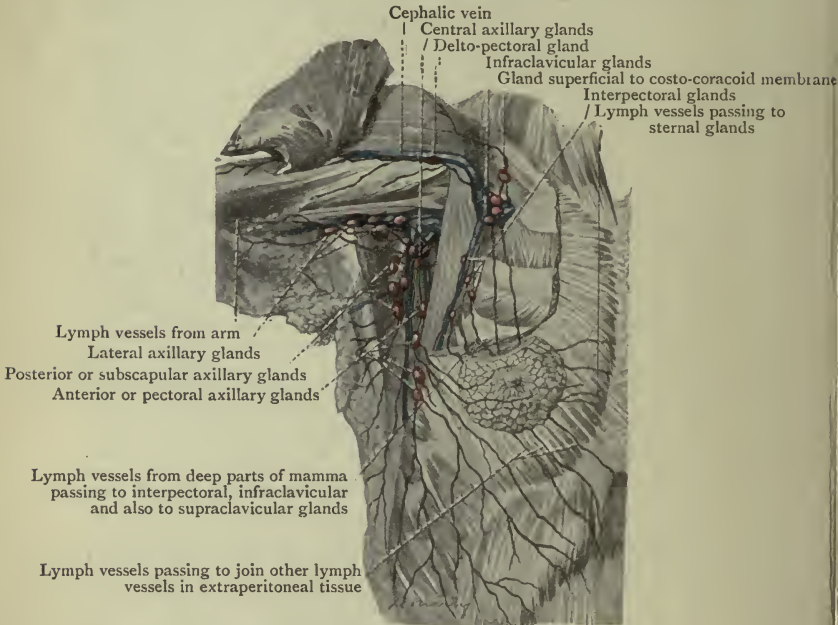


FIG. 9.—The Lymph Glands and Vessels of the Axilla and Mamma.

a sternocostal portion. The fissure penetrates through the entire thickness of the muscle, the clavicular and sternocostal portions being distinct, except close to their insertions. The *clavicular portion* arises by short tendinous and muscular fibres from an impression on the medial half of the anterior surface of the clavicle. The superficial part of the *sternocostal portion* takes origin, by fleshy fibres, (1) from the anterior surface of the sternum, (2) from the aponeurosis of the external oblique muscle, and (3) occasionally from the sixth rib near its

cartilage. The deeper part arises by a variable number of muscular slips from the cartilages of the upper six ribs.

The muscle is inserted, by a flattened bilaminar tendon, into the lateral lip of the intertubercular sulcus of the humerus, and the fibres of the muscle undergo a rearrangement as they converge upon the tendon. The greater part of the clavicular portion joins the anterior lamina of the common tendon; some of the most medial clavicular fibres, however, are inserted directly into the humerus, whilst a few gain attachment to the deep fascia of the arm, and others become adherent to the adjacent part of the deltoid.

The fibres of the sternocostal portion of the muscle do not all pass in the same direction but they all join the laminae

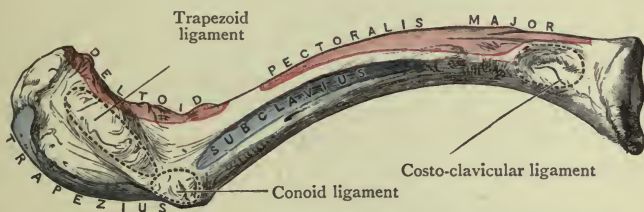


FIG. 10.—Inferior Surface of the Clavicle with the Attachments of the Muscles mapped out.

of the tendon of insertion. The superior fibres descend slightly, the intermediate fibres pass horizontally, whilst the inferior fibres ascend, and, at the same time, gain the deep surface of the rest of the muscle. A smooth, full, and rounded lower border of the muscle is thus formed; it constitutes the anterior fold of the axilla. The attachments of the muscle to the humerus will be studied in detail at a later stage of the dissection (p. 87).

The pectoralis major is supplied by the *medial* and *lateral anterior thoracic nerves*. It is an adductor of the superior extremity and a medial rotator of the humerus.

**Axilla.**—The axilla is the hollow or recess between the upper part of the side of the thorax and the proximal part of the arm. When the arm is abducted from the trunk, and the areolo-fatty tissue which occupies the axilla is removed, the space disclosed has the form of a four-sided pyramid. The apex, or narrow part of the space, lies

immediately to the medial side of the coracoid process, and is directed upwards towards the root of the neck, whilst the wider part or base of the space looks downwards. The medial wall, formed by the thorax, is of greater extent than the lateral wall which is formed by the arm. It follows, therefore, that the anterior and posterior walls converge as they proceed laterally, and, because the posterior wall is longer, from above downwards, than the anterior, the posterior border of the base is lower than the anterior.

Before beginning the dissection of the space, the dissector should have a general knowledge of its boundaries and of the manner in which the contents are disposed in relation to the boundaries.

**Boundaries of the Axilla.**—The four walls of the axilla are (1) anterior, (2) posterior, (3) medial, and (4) lateral. The *anterior wall* is formed by the two pectoral muscles, the subclavius and the fascia which surrounds the pectoralis minor and attaches its upper border to the clavicle and its lower border to the floor of the axilla, and to the deep fascia on the medial side of the arm. The pectoralis major forms the superficial stratum, and is spread out over the entire extent of the anterior wall. The pectoralis minor lies posterior to the pectoralis major, and takes part in the formation of the middle third of the anterior boundary. The fascia which fills the gap between the pectoralis minor and the clavicle is called the costo-coracoid membrane; it splits above to enclose the subclavius muscle, and along the lower border of that muscle it is stronger than elsewhere. The lower border of the anterior wall is the *anterior fold* of the axilla. It is formed by the lower border of the pectoralis major, strengthened, medially, by the lower border of the pectoralis minor, which projects beyond the major near the side of the thorax.

The *posterior wall* of the axilla is formed by the lateral part of the subscapularis muscle, by a portion of the latissimus dorsi and its tendon, and by the teres major muscle. The subscapularis covers the costal surface of the scapula. The latissimus dorsi winds from the back, round the medial part of the lower border of the teres major to gain its anterior surface; thus the lower border of the posterior wall, which constitutes the *posterior fold* of the axilla, is formed in its medial part by the latissimus dorsi, and laterally by the inferior margin of the teres major.

In the *medial wall* are parts of the upper five ribs with the intervening intercostal muscles; they are covered by the corresponding digitations of the serratus anterior muscle.

The *lateral wall* is formed by the humerus and the conjoined proximal parts of the coraco-brachialis and the short head of the biceps brachii muscles.

At the *apex* of the space is the narrow triangular interval through which the axilla communicates with the neck; it is frequently called the *cervico-axillary canal*. It is bounded anteriorly by the clavicle, medially by the outer border of the first rib, and posteriorly by the superior margin of the scapula; through it pass the axillary vessels and the big nerve cords of the brachial plexus on their way from the

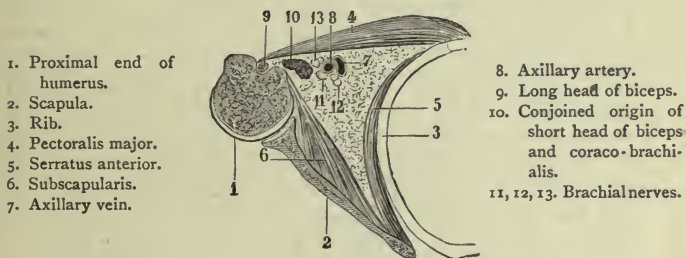


FIG. 11.—Diagram of section through the Axilla of the Left Side.

neck to the arm. The wide *base* or floor of the space is closed by the vaulted axillary fascia.

**Contents of the Axilla.**—The axillary artery and vein, with the large brachial nerves, which supply the superior extremity, and the axillary lymph vessels and lymph glands, are the most important contents of the axilla. They are all embedded in the soft axillary fat. Except at the apex of the space, the great vessels and nerves lie close to the lateral wall, and follow it in all the movements of the arm.

**Dissection.**—Cut through the clavicular fibres of the pectoralis major, immediately below their attachment to the clavicle, and turn them towards their insertion. At the same time, secure the branches of the lateral anterior thoracic nerve which pass into the deep surface of the muscle. Follow the cephalic vein and the deltoid branch of the thoraco-acromial artery medially, under cover of the clavicular part of the pectoralis major, and secure the acromial and pectoral branches of the latter artery. Clean those vessels and, directly below the clavicle, display the *costo-coracoid membrane*, and, more inferiorly and laterally, the fascia

on the lateral part of the pectoralis minor. Cut through the sternocostal part of the pectoralis major about two inches from the lateral border of the sternum. Turn the medial part towards the median plane; verify its attachment to the costal cartilages and to the sternum and to the aponeurosis of the external oblique muscle of the abdomen. Turn the lateral part of the muscle towards the arm; whilst doing that, secure the medial anterior thoracic nerve, which perforates the pectoralis minor and ends in the pectoralis major. Examine the insertion of the pectoralis major. Note that the tendon of insertion consists of two laminæ which are united together below; in other words, the tendon is folded on itself; and between the two laminæ a *mucous bursa* is frequently interposed. The clavicular fibres and the upper sternocostal fibres are attached to the anterior lamina, the lower sternocostal fibres to the posterior lamina. Both laminæ are attached to the lateral lip of the intertubercular sulcus of the humerus, but the deep lamina ascends to a more proximal level, and becomes continuous with a layer of fascia which is attached to the lesser tubercle of the humerus. The inferior border of the tendon of insertion is continuous with the deep fascia of the arm.

When the pectoralis major is completely reflected a continuous sheet of fascia is exposed, which extends from the clavicle superiorly to the axillary fascia inferiorly, and from the wall of the thorax medially to the arm laterally; the sheet of fascia is the so-called *clavipectoral fascia* or *suspensory ligament of the axilla*. It is because of the attachment of that fascial sheet to the clavicle superiorly and to the axillary fascia inferiorly that the floor of the axilla is raised as the arm is abducted from the side and the clavicle is elevated. The pectoralis minor muscle, passing obliquely from its origin on the thoracic wall to its insertion into the coracoid process of the scapula, runs through the substance of the clavipectoral fascia and divides it into three parts: (1) the part above the muscle, (2) the part which encloses the muscle, and (3) the part below the muscle. The uppermost part is the costo-coracoid membrane, the intermediate part is the sheath of the pectoralis minor. No special term is applied to the lowest part, but it should be noted that it lies posterior to the lower part of the pectoralis major, and that it covers the distal portions of the axillary vessels and nerves.

**Membrana Costocoracoidea.**—The costo-coracoid membrane occupies the gap between the clavicle and the pectoralis minor. It extends from the first rib medially to the coracoid process laterally, and from the clavicle above to the pectoralis minor below. Its upper part is split into two layers, an anterior and a posterior, which are attached to the corresponding borders of the clavicle. Enclosed between them is the subclavius muscle. The strongest part of the membrane is that which extends along the lower border of the subclavius, from the first rib to the coracoid process; that portion is frequently called the *costo-coracoid ligament*. The membrane is continuous below with the fascial sheath of the pectoralis

minor and posteriorly with the fascial sheath of the axillary vessels (Fig. 12). It is perforated, above the upper border of the pectoralis minor, by the cephalic vein, the thoraco-acromial vessels, and the lateral anterior thoracic nerve. Note (1) that the fibres of the membrane run medio-laterally, (2) that they are put on the stretch when the arm is abducted, and (3) that they are relaxed when the arm is by the side. The surgeon takes advantage of these facts when he is ligaturing the first part of the axillary artery.

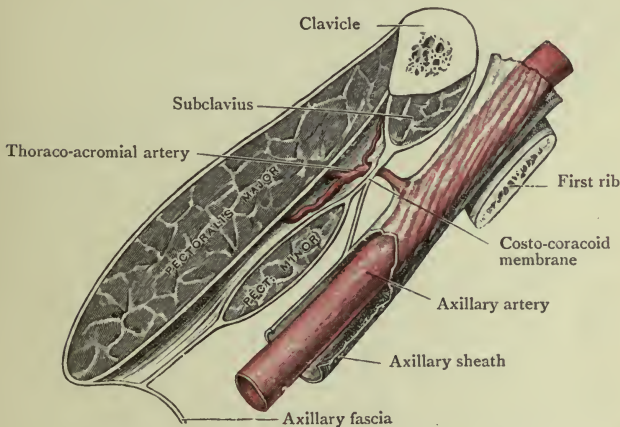


FIG. 12.—Diagram of the Costo-coracoid Membrane.

**Dissection.**—Cut through the anterior layer of the upper part of the costo-coracoid membrane and expose the subclavius muscle. Pass the handle of a knife below the lower border of the subclavius and upwards behind the muscle and demonstrate the posterior layer of the upper part of the membrane. Clear away the remains of the membrane and follow the cephalic vein to its junction with the axillary vein, the thoraco-acromial artery to the axillary trunk, and the lateral anterior thoracic nerve to the lateral cord of the brachial plexus. Clean the proximal parts of the axillary artery and vein and the lateral cord of the brachial plexus. Note that the axillary vein lies to the medial side of the artery, on a somewhat anterior plane, and that as the arm is abducted from the side the vein passes more and more in front of the artery. The lateral cord of the plexus lies to the lateral side of the artery and on a posterior plane. Behind the upper border of the pectoralis minor find the medial anterior thoracic nerve, and note that a communication is formed between the medial and lateral anterior thoracic nerves, across the front of the axillary artery and behind the costo-coracoid membrane.

Clean the pectoralis minor muscle without injuring the medial anterior thoracic nerve, which pierces it.

**M. Pectoralis Minor.**—The pectoralis minor muscle is triangular in outline. It arises (1) from the anterior ends of the third, fourth, and fifth ribs, close to their junctions with their cartilages, and (2) from the fascia covering the intercostal muscles in the intervening spaces. Its fibres pass upwards and laterally, and its tendon of insertion is attached to the upper surface and the antero-medial border of the horizontal part of the coracoid process, near its lateral extremity. When the muscle is in action it draws the scapula downwards and forwards, and depresses the shoulder. It is supplied by the *medial anterior thoracic nerve*. The greater portion of the pectoralis minor is concealed by the pectoralis major, but the lower and medial part of its inferior border appears on the lateral wall of the thorax below the pectoralis major; its insertion is concealed by the anterior fibres of the deltoid.

**Dissection.**—Clear away the clavipectoral fascia below the level of the pectoralis minor and open up the lower part of the axilla; remove also the deep fascia of the arm in the region of the lateral boundary of the axilla.

Commence at the lateral part of the area below the pectoralis minor and clean the coraco-brachialis and the short head of the biceps, as they descend into the arm from the tip of the coracoid process. Find the distal part of the axillary artery at the medial border of the coraco-brachialis. The trunk of the median nerve lies between the artery and the muscle, and at the lower border of the pectoralis minor the medial head of the nerve crosses the front of the artery. Pull the coraco-brachialis laterally and find the musculo-cutaneous nerve entering its deep surface, just below the pectoralis minor. Above and to the lateral side of the trunk of the musculo-cutaneous nerve find the branch from it which supplies the coraco-brachialis. The axillary vein lies along the medial side of the artery, and in the interval between the artery and vein, anteriorly, is the medial cutaneous nerve of the forearm (O.T. internal cutaneous). Running along the medial side of the vein is the medial cutaneous nerve of the arm (O.T. lesser internal cutaneous nerve); secure it and follow it upwards to the communication which it receives from the intercosto-brachial nerve (Fig. 13). At the same time identify and preserve the lateral group of axillary lymph glands, which lie along the medial side of the axillary vein. Secure the intercosto-brachial nerve and follow it medially, to the point where it emerges from the second intercostal space, and laterally to the medial and posterior aspect of the arm, where it is distributed.

In order to display the distribution of the intercosto-brachial nerve, and to give better access to the medial and posterior walls of the axilla, the axillary fascia must be separated from the fascia



of the arm. When that has been done the dissector should turn to the medial wall of the axilla and find the anterior and posterior divisions of the lateral branches of the intercostal nerves, as they

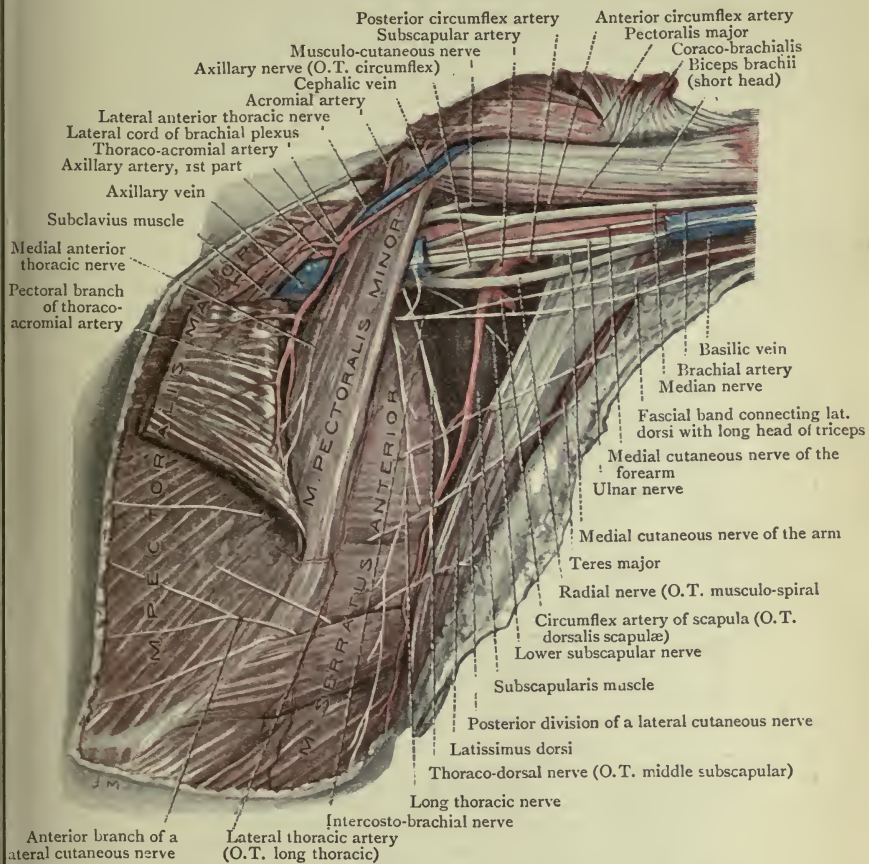


FIG. 13.—The contents of the Axillary Space exposed by the reflection of the Pectoralis Major and the subjacent fascia, and the removal of the fat and glands.

emerge between the digitations of the serratus anterior, behind the inferior border of the pectoralis minor. He must trace them forwards and backwards respectively, and he may expect to find communications between the posterior division of the third lateral branch and the intercosto-brachial nerve. At the junction of the anterior and medial walls of the axilla and at the lower border

of the pectoralis minor, find the lateral thoracic artery ; clean the artery and the medial group of axillary lymph glands, which lie along its course.

At the junction of the posterior third and anterior two-thirds of the medial wall of the axilla find the long thoracic nerve, which supplies the serratus anterior and descends along its lateral surface, from the apex to the base of the axilla. After the nerve has been secured the serratus anterior must be cleaned. When that has been done the dissector should clean the distal parts of the large vessels and nerves and their branches and tributaries.

With chain and hooks pull the axillary artery and the medial cutaneous nerve of the forearm towards the arm and displace the axillary vein in the opposite direction ; then find the ulnar nerve which lies in the posterior part of the interval between the artery and vein ; pull the ulnar nerve laterally, and behind the artery find the large radial nerve (O.T. musculo-spiral). Pull it medially and follow its lateral border upwards. At the lower border of the subscapularis muscle on the lateral side of the radial nerve secure the axillary nerve as it turns backwards into the posterior wall of the axilla. Near the axillary nerve is the large subscapular branch of the axillary artery accompanied by the corresponding vein. The subscapular artery springs from the medial side of the axillary artery. A short distance below its origin it divides into two branches, the circumflex scapular and the thoraco-dorsal. The circumflex scapular passes backwards into the posterior wall of the axilla. The thoraco-dorsal artery descends along the lower border of the subscapularis muscle to the angle where the posterior wall joins the medial wall of the axilla. Follow the artery downwards, taking care not to injure the intercosto-brachial nerve and the posterior branches of the lateral rami of the 3rd, 4th, and 5th intercostal nerves which cross in front of it. Note the posterior group of axillary lymph glands which lie along its course, and near its lower end secure the thoraco-dorsal nerve, which crosses in front of the artery, on its way to the latissimus dorsi, which it supplies. Return to the division of the subscapular artery. Dissect in the angle between its circumflex scapular and its thoraco-dorsal branches and secure the second subscapular nerve, which supplies the teres major muscle ; follow it to the muscle.

Return to the radial nerve and find springing from its medial border near the lower margin of the subscapularis the posterior brachial cutaneous nerve, and branches to the long and medial heads of the triceps muscle. Not uncommonly all those branches are conjoined at their origin, and separate as they pass to their destinations. The posterior brachial cutaneous nerve, on its way to the middle of the posterior aspect of the arm, passes behind the intercosto-brachial nerve. The nerve to the long head of the triceps enters the proximal part of that muscle. There are usually two branches to the medial head of the triceps ; one enters the proximal part of the muscle, and the other, known as the *ulnar collateral*, because it runs by the side of the ulnar nerve, passes to the distal part. It will be traced to its termination at a later period.

The anterior and posterior humeral circumflex branches of the axillary artery will be found springing from the artery a short distance distal to the subscapular branch, the former

arising from the anterior, and the latter from the posterior aspect of the axillary trunk.

After the lower part of the axilla has been thoroughly cleaned, the pectoralis minor must be divided, about midway between its origin and insertion, and the two parts must be turned aside. When that has been done the upper subscapular nerve must be found as it enters the upper part of the subscapularis, and then the remaining areolar tissue must be removed from the axillary space, the trunks and branches of the axillary vessels and nerves must be thoroughly cleaned, and the contents of the space must be studied in detail.

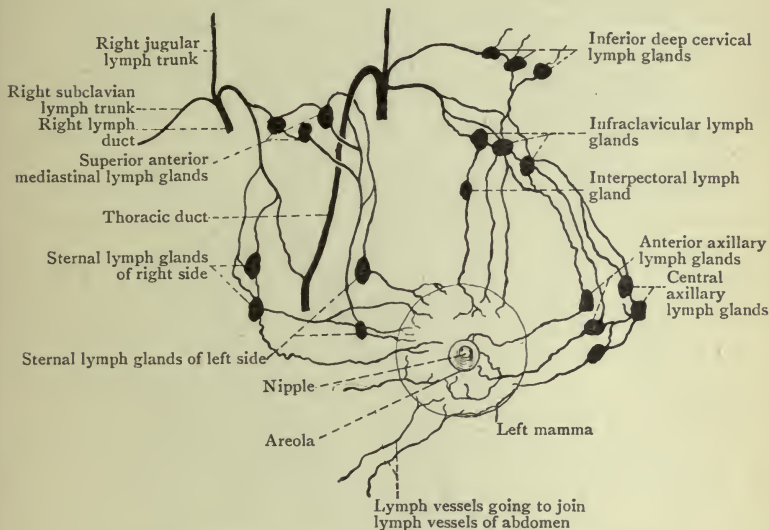


FIG. 14.—Diagram of the Connections of the Lymph Vessels of the Mamma.

**Lymphoglandulæ Axillares (Axillary Lymph Glands).—**

The lymph glands in the axillary region are spoken of, collectively, as the axillary glands, but for convenience of description, and to facilitate a more precise knowledge of their connections and associations, they are subdivided into several subordinate groups. Some of the glands have been removed as the dissection proceeded, and others are so small that they may have escaped the attention of the dissector; but if he has followed the directions given above he will have noted at least four groups of glands. (1) A lateral or brachial group consisting of six or more glands, which lie

along the axillary vessels. They receive the lymph vessels from the greater part of the upper extremity, and those at the upper part of the chain also receive lymph from the deep part of the mamma. (2) A pectoral group, or anterior group, which lies in the angle between the anterior and medial walls of the axilla. This is subdivisible into two parts: (a) an upper group of two or three small glands which lie behind the pectoralis major in the region of the second and third intercostal spaces—these receive lymph from the anterior wall of the thorax and from the lateral two-thirds of the mamma; (b) an inferior group which lies along the posterior border of the lateral thoracic artery, and receives lymph from the lateral wall of the thorax. (3) A posterior or subscapular group, which lies along the subscapular artery on the posterior wall of the axilla, and receives lymph vessels from the back. (4) The delto-pectoral glands, a group of two or three small glands which lie in the delto-pectoral triangle and receive lymph from the proximal and lateral parts of the arm.

In addition to the lymph glands which are usually seen in an ordinary dissection, there are three other groups of glands. (a) *Inter-pectoral glands*, from one to three or four, which lie on the anterior surface of the pectoralis minor; they receive lymph from the deep part of the mamma by lymph vessels which pierce the pectoralis major. (b) The *central glands*, which are very variable; they lie either on the surface of the axillary fascia, in a pocket of its substance, or deep to it in the fat of the middle part of the axilla; they have no afferents from any definite region, but are connected with the other groups. (c) The *infraclavicular glands*, which lie in the apex of the axilla behind the costo-coracoid membrane. They receive efferents from all the lower groups, and their efferents unite to form a subclavian lymph trunk which terminates on the left side in the *thoracic duct*, and on the right side in the right *lymph duct* (Fig. 14).

**Rami Laterales (O.T. Lateral Cutaneous Branches) of the Anterior Branches of the Second and Third Thoracic Nerves.**—As a rule, the first thoracic nerve does not give off a lateral branch. That which springs from the second thoracic nerve is the largest of the series, and differs from the others in not dividing into an anterior and a posterior branch. It is termed the *intercosto-brachial nerve*, on account of its being distributed to the skin on the medial and dorsal aspects of the proximal

part of the arm. To reach this destination it crosses the axilla and pierces the deep fascia. But before piercing the fascia it establishes communications and forms a plexiform arrangement in the axilla with the medial cutaneous nerve of the arm, and the lateral branch of the third thoracic nerve. The plexus so formed may be joined by another twig which

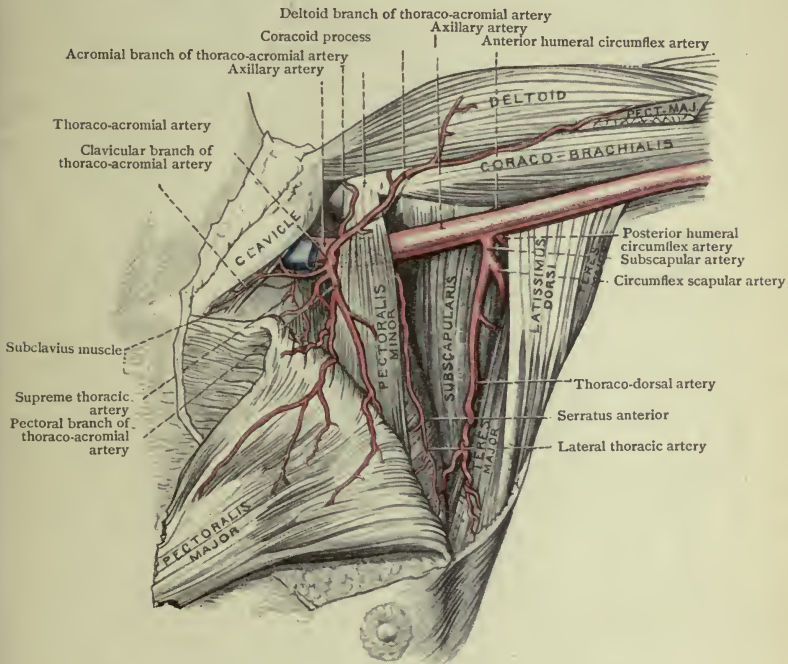


FIG. 15.—Dissection of the Axillary Artery and its Branches.

is occasionally present, viz., the minute lateral cutaneous branch of the first thoracic nerve.

The *lateral branch* of the third thoracic nerve divides into an anterior and posterior part, which are distributed in the ordinary way. From the posterior branch twigs are given to the skin of the axilla, and the terminal twigs are distributed to the integument on the proximal part of the medial aspect of the arm.

**Arteria Axillaris.**—The axillary artery is the chief artery

of the upper limb. It enters the axilla at its apex, at the outer border of the first rib, commencing as the continuation of the subclavian artery. It lies, for a short distance,

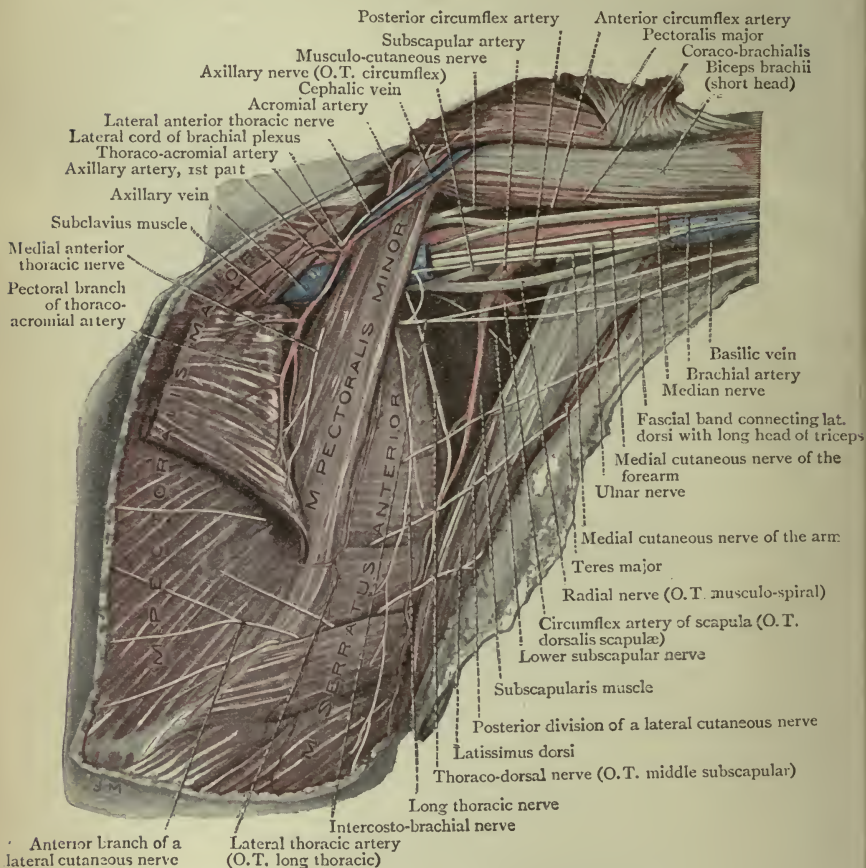


FIG. 16.—The contents of the Axillary Space exposed by the reflection of the Pectoralis Major and the subjacent fascia, and the removal of the fat and the lymph glands. Part of the axillary vein has been removed to expose the medial cutaneous nerve of the forearm and the ulnar nerve.

on the medial wall of the axilla, crosses the fat in the angle between the medial and posterior walls, and then runs along the lateral wall to the lower border of the teres major; there it

leaves the axilla and passes into the arm, where it becomes the brachial artery. For convenience of description it is usually divided into three parts—the part above, the part behind, and the part below the pectoralis minor, which are known respectively as the first, second, and third parts. The direction which the artery takes varies with the position of the limb. When the arm is at a right angle with the body, the direction is that of a straight line from the centre of the clavicle to the middle of the bend of the elbow. When the arm is by the side, the artery describes a curve with the convexity directed laterally; and if the arm is raised above the head the curve formed by the artery is convex in the reverse direction.

The *first part* of the axillary artery lies very deeply. It is covered, anteriorly, by the skin, superficial fascia, deep fascia, the clavicular part of the pectoralis major, the costo-coracoid membrane, and the vessels and nerves superficial to it. Even when those are removed the vessel is not completely exposed, because it is enveloped, along with the axillary vein and great nerves, by a funnel-shaped sheath, which is prolonged upon them from the deep cervical fascia (Fig. 12), and it is crossed by the loop of communication between the two anterior thoracic nerves which lies in front of the sheath. *Behind* this part of the vessel are the first intercostal space and the first digitation of the serratus anterior muscle; the long thoracic nerve and the medial cord of the brachial plexus also cross behind it. To its *medial side*, and somewhat overlapping it, is the axillary vein, whilst *above* and to its *lateral side* are the lateral and posterior cords of the brachial plexus.

The *second part* of the axillary artery is placed behind the two pectoral muscles, and has the three cords of the brachial plexus disposed around it. The medial cord lies upon its medial side, the lateral cord upon its lateral side, and the posterior cord behind it. The axillary vein is still upon its medial side, but is separated from the artery by the medial nerve-cord. Strictly speaking, it is not in apposition with any muscle posteriorly, being separated from the subscapularis muscle by areolo-fatty tissue.

The *third and longest part* of the axillary artery is superficial in its distal half, because the anterior wall of the axilla does not extend so far down as the posterior wall. Therefore,

whilst the third part of the axillary artery is covered, in its proximal half, by the pectoralis major, its distal half is covered only by the skin and fasciæ. Behind it, proximo-distally, are the subscapularis, the tendon of the latissimus dorsi, and the teres major; but it is separated from the subscapularis muscle by the axillary (O.T. circumflex) and radial (O.T. musculospiral) nerves, and from the latissimus dorsi and the teres major by the radial nerve. To its lateral side is the

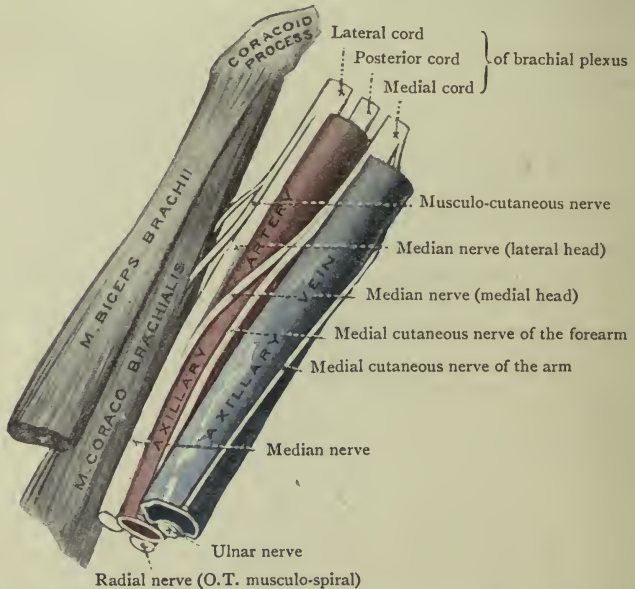


FIG. 17.—Diagram to show relations of Axillary Vessels and Nerves.

coraco-brachialis muscle, but between the muscle and the artery are the musculo-cutaneous and the median nerves. To the medial side of the artery is the vein, with the medial cutaneous nerve of the forearm in the anterior angle between the artery and vein, and the ulnar nerve in the posterior angle between the artery and vein. The medial cutaneous nerve of the arm lies along the medial side of the vein (Fig. 17).

The **branches of the axillary artery** have been seen at different stages of the dissection. They should now be examined more fully (Fig. 15). They are:—



A. thoracalis suprema	} from the first part.	A. subscapularis .	} from the third part.
A. thoraco-acromialis		A. circumflexa humeri anterior	
A. thoracalis lateralis	} from the second part.	A. circumflexa humeri posterior	

**Arteria Thoracalis Suprema (O.T. Superior Thoracic).—**

The supreme thoracic artery is a small branch which springs from the axillary at the lower border of the subclavius. It ramifies upon the upper part of the medial wall of the axilla and supplies twigs to adjacent structures (Fig. 15).

**Art. Thoraco-acromialis (O.T. Acromio-thoracic or Thoracic Axis).—**The thoraco-acromial artery is a short, wide trunk, which takes origin under cover of the pectoralis minor. It winds round the upper border of that muscle, pierces the costo-coracoid membrane, and immediately divides into branches; the branches receive different names, and are arranged as follows:—(a) The *clavicular branch*, a small twig, which runs upwards to the clavicle and then turns medially along that bone, between the clavicular part of the pectoralis major and the costo-coracoid membrane. (b) The *pectoral branches*, of larger size, run downwards between the two pectoral muscles; they give branches to both muscles, and they anastomose with the lateral thoracic and the lateral branches of the intercostal arteries. (c) The *acromial branch* runs laterally, upon the tendon of the pectoralis minor and the coracoid process. Some of its twigs supply the deltoid, whilst others pierce it to reach the superior surface of the acromion. It anastomoses with the transverse scapular (O.T. suprascapular) and posterior humeral circumflex arteries. (d) The *deltoid branch*, as a rule, takes origin from a trunk common to it and the preceding artery. It runs distally in the intermuscular interval between the pectoralis major and the deltoid, and supplies both muscles.

**Arteria Thoracalis Lateralis.**—The lateral thoracic artery takes the lower border of the pectoralis minor as its guide, and proceeds downwards and medially to the side of the thorax. It gives branches to the neighbouring muscles. It anastomoses with twigs from the intercostal arteries, and it also supplies the mamma, giving off, as a rule, an *external mammary branch*, which winds round or pierces the lower border of the pectoralis major on its way to the gland.

**Alar Thoracic.**—This small artery supplies the fat and lymph glands in the axilla, but it is rarely present as a separate branch, and its place is usually taken by twigs from the subscapular and lateral thoracic arteries.

**Arteria Subscapularis.**—The subscapular branch of the axillary is a relatively large and comparatively short branch which springs from the parent trunk at the lower border of the subscapularis muscle. It descends, for about one inch, along the lower border of the subscapularis, and then divides into two terminal branches, the a. circumflexa scapulæ, and the a. thoraco-dorsalis. The *circumflex scapular branch* turns round the axillary border of the scapula on its way to the infraspinous fossa of that bone, where it anastomoses with branches of the transverse cervical and transverse scapular arteries. It gives numerous branches to the adjacent muscles. The *thoraco-dorsal branch* descends along the lower border of the subscapularis to the inferior angle of the scapula. It gives branches to the adjacent muscles and anastomoses with the lateral thoracic artery and with branches from the intercostal arteries. It sends branches also into the subscapular fossa which anastomose with twigs of the transverse and circumflex scapular arteries, and with branches of the descending branch of the transverse cervical artery.

**Aa. Circumflexæ Humeri, Anterior et Posterior (O.T. Anterior and Posterior Circumflex Arteries).**—The anterior and the posterior humeral circumflex arteries both arise from the axillary at the same level, a short distance distal to the origin of the subscapular artery. The *posterior humeral circumflex artery* is much the larger of the two. Only a small portion of it can be seen at the present stage. It springs from the posterior aspect of the axillary artery, and at once passes backwards, with the axillary nerve, in the interval between the subscapularis and teres major muscles on the medial side of the surgical neck of the humerus. The smaller *anterior humeral circumflex artery* takes origin from the lateral aspect of the axillary artery, and runs laterally, in front of the surgical neck of the humerus, under cover of the coraco-brachialis and short head of the biceps brachii. Reaching the intertubercular sulcus, it divides into two branches. One of the two is directed proximally, along the long head of the biceps brachii, to the shoulder-joint; the other passes laterally, to the deep surface of the deltoid, and

finally anastomoses with some of the terminal twigs of the posterior circumflex artery of the humerus.

**Vena Axillaris.**—The axillary vein has the same extent as the artery. It begins at the lower border of the teres major, as the proximal continuation of the basilic vein of the arm, and it becomes the subclavian vein at the outer margin of the first rib. At the lower margin of the subscapularis it receives the two *venæ comites* of the brachial artery, and above the level of the pectoralis minor it is joined by the cephalic vein. Its other tributaries correspond, more or less closely, to the branches of the axillary artery.

**M. Subclavius.**—The subclavius is a small muscle which lies immediately below the clavicle, enclosed between the two layers of the costo-coracoid membrane. It takes origin, by a short rounded tendon, from the superior surface of the first costal arch, at the junction of the bone with the cartilage, and the fleshy belly is inserted into the shallow groove on the inferior surface of the clavicle. The nerve of supply is derived from the fifth and sixth cervical nerves and enters the posterior surface of the muscle. When the muscle contracts it depresses the clavicle and draws it slightly forwards.

**Dissection.**—When the subclavius has been examined it must be divided horizontally, and when that has been done the costo-clavicular ligament will be found behind the medial end of the muscle.

At this stage, with the assistance of the dissector of the head and neck, the clavicular part of the sterno-cleido-mastoid muscle must be detached from the superior border of the clavicle and the sternal part of the muscle must be pulled towards the median plane.

**Articulatio Sternoclavicularis.**—The sterno-clavicular joint is a diarthrodial joint, formed by the sternal end of the clavicle, the lateral part of the superior border of the manubrium sterni, and the superior surface of the sternal end of the cartilage of the first rib. It helps to increase the range of the forward, backward, and upward movements of the arm. The clavicle is attached to the sternum and the first rib by a strong fibrous capsule. Within the capsule is an articular disc which separates the joint cavity into two parts. It is attached to the superior border of the sternal end of the clavicle, to the superior surface of the first costal cartilage, and to the anterior and posterior parts of the capsule. On the

lateral aspect of the capsule there is a strong accessory ligament, the *costo-clavicular ligament*, which lies behind the origin of the subclavius muscle and passes upwards, backwards, and laterally from the first rib to the costal tubercle on the lower surface of the clavicle. In the capsule itself there are three thickened bands, an anterior, a posterior, and a superior, and as some of the fibres of the latter pass from one clavicle to the other, it is called the *interclavicular ligament*.

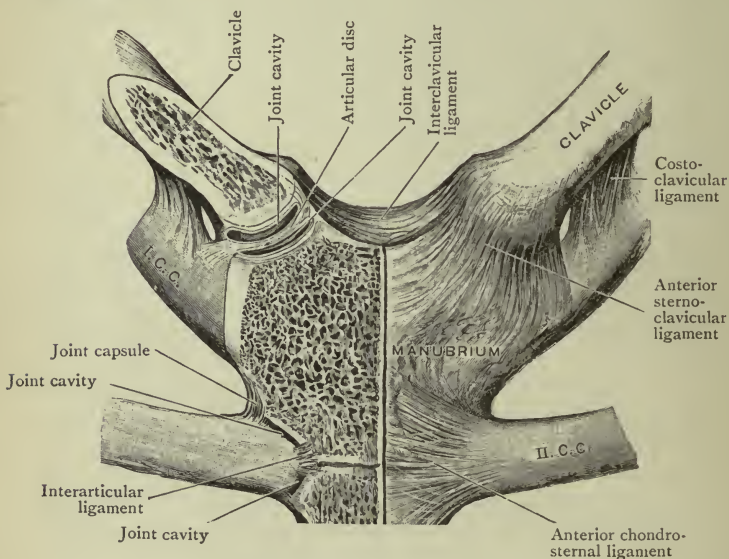


FIG. 18.—Sterno-clavicular and Costo-sternal Joints.

**Dissection.**—Pull the sternal head of the sterno-cleido-mastoid muscle towards the median plane. Cut through the anterior part of the capsule of the joint close to the sternum. Pass the knife behind the capsule, avoiding the anterior jugular vein, which runs laterally behind the upper border of the joint, and detach the fibres of origin of the sterno-hyoid muscle which spring from the back of the capsule. Cut through the posterior ligament and pull the clavicle laterally. The articular disc is now exposed. Detach it from the first rib; then carry the knife laterally below the clavicle and cut through the lower part of the capsule and the costo-clavicular ligament. The clavicle can now be displaced sufficiently upwards and laterally to bring the whole of the brachial plexus into view. Before studying the plexus, the dissector should note that behind the sterno-

clavicular joint there are the lower fibres of the sterno-hyoid and sterno-thyreoid muscles which intervene, on the right side, between the capsule of the joint and the bifurcation of the innominate artery into its right common carotid and subclavian branches, and, on the left side, between the joint and the left common carotid artery.

**Plexus Brachialis (Brachial Plexus).**—This important

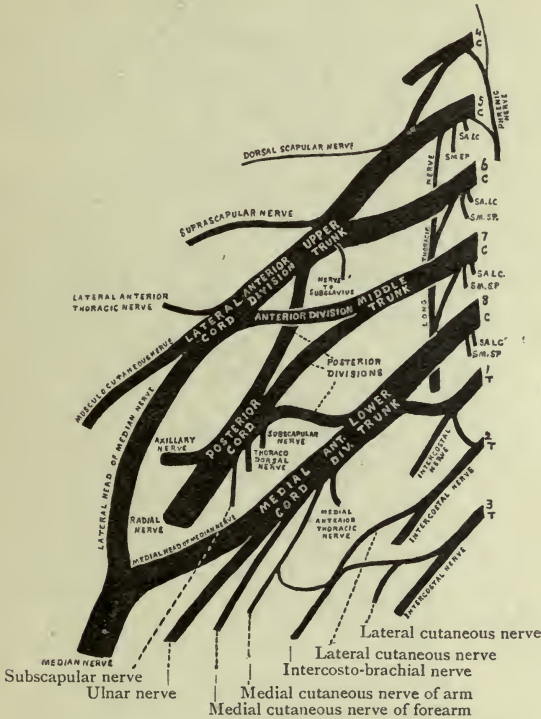


FIG. 19.—Diagram of Brachial Plexus and its Branches.

plexus is formed by the anterior rami of the lower four cervical nerves and the greater part of the anterior ramus of the first thoracic nerve. The plexus is further reinforced, above, by a small twig of communication which passes from the fourth to the fifth cervical nerve, whilst, below, a similar connecting twig not infrequently passes upwards, in front of the neck of the second rib, from the second to

the first thoracic nerve. The manner in which the nerves join to form the plexus is very constant. The *fifth* and *sixth cervical* nerves unite to form an *upper trunk*; the *seventh* remains single and proceeds distally as a *middle trunk*; whilst the

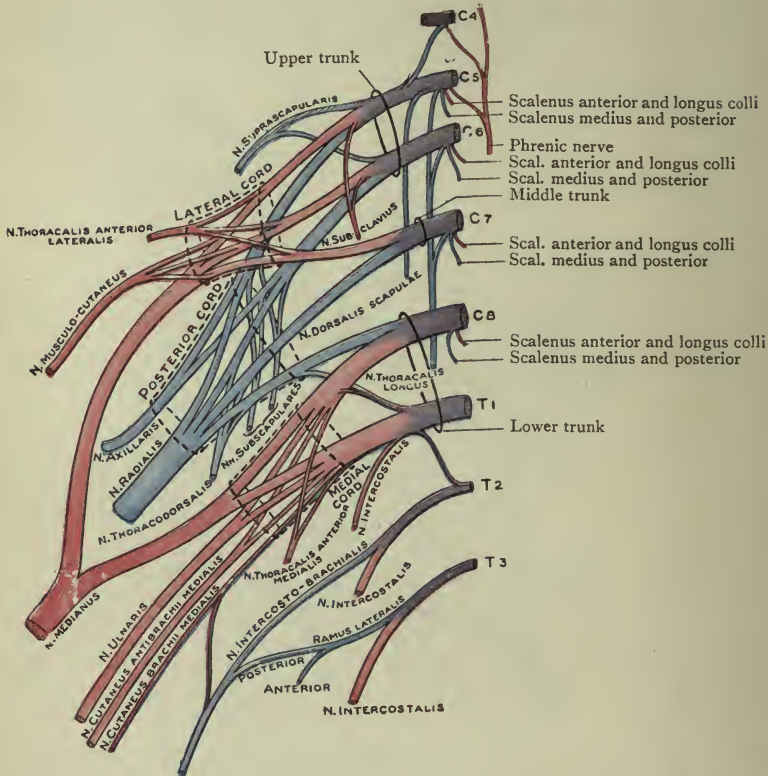


FIG. 20.—Diagram of the Brachial Plexus. (After Paterson.)

*eighth* and *first thoracic* nerves join, to constitute a *third* or *lower trunk*. A short distance above the clavicle each of the three trunks splits into an *anterior* and a *posterior division*. When the three anterior divisions are raised on the handle of a knife, the three posterior divisions will be seen uniting to form the *posterior cord* of the plexus. It should be noted that the lowest or most medial of the posterior divisions is much

smaller than the other two. Of the three anterior divisions the *two upper* join to constitute the *lateral cord*, whilst the *lower* passes distally by itself, as the *medial cord* of the plexus. From the three cords of the plexus the branches are given off which supply the superior extremity (Figs. 19, 20, 22).

From the above description it will be seen that the plexus may be divided into four stages:—

- |                     |     |  |
|---------------------|-----|--|
| <i>First Stage</i>  | . . | Five separate nerves (viz., lower four cervical and first thoracic). |
| <i>Second Stage</i> | . . | Three nerve-trunks (viz., an upper, middle, and lower).              |
| <i>Third Stage</i>  | . . | Three anterior divisions and three posterior divisions.              |
| <i>Fourth Stage</i> | . . | Three nerve-cords (viz., a lateral, a medial, and a posterior).      |

The plexus extends from the lateral border of the scalenus anterior to the lower border of the pectoralis minor, and it lies in the lower and medial part of the posterior triangle of the neck, behind the middle third of the clavicle, and in the axilla. As a rule, the first two stages are in the neck, the third stage is behind the clavicle, and the last stage is in the axilla (Figs. 21, 22).

It has been customary to divide the branches of the plexus into supraclavicular and infraclavicular groups, but such a division is neither scientifically accurate nor of practical importance. The branches of the plexus spring either from its roots, or its trunks, or its cords.

The parts of the plexus above the clavicle, and the branches given off in the supraclavicular region, must be found and cleaned by the dissector of the head and neck; the remaining parts of the plexus and its branches should be displayed by the dissector of the upper extremity, but the two dissectors must combine to examine thoroughly the general relations and the branches of the plexus.

**The Relations of the Plexus.**—*Superficial* to the cervical part of the plexus lie the skin, the superficial fascia, the platysma, the deep fascia, the external jugular vein, the transverse cervical and transverse scapular veins, the posterior belly of the omo-hyoid muscle, and the transverse cervical artery. *Behind it* is the scalenus medius muscle (Fig. 21).

In the interval between the neck and the axilla, the clavicle and the transverse scapular artery and vein are in front of it; and the third part of the subclavian artery is anterior to its lowest trunk. The scalenus medius is still behind it.

In the axilla it has *in front of it* the integument, the fasciæ,

the platysma, the pectoralis major, the pectoralis minor, the costo-coracoid membrane, the cephalic vein, and the axillary artery; *behind it* lie the upper serration of the serratus anterior, the fascia-filled interval between the medial and posterior walls of the axilla, and the subscapularis muscle (Fig. 22).

**The Branches of the Plexus.**—The branches from the roots of the plexus are: (1) Branches to the scalenus anterior, the longus colli, the scalenus medius, and the scalenus posterior (from C. v., vi., vii., viii.). (2) A communication to the phrenic nerve (from C. v., or v. and vi.).

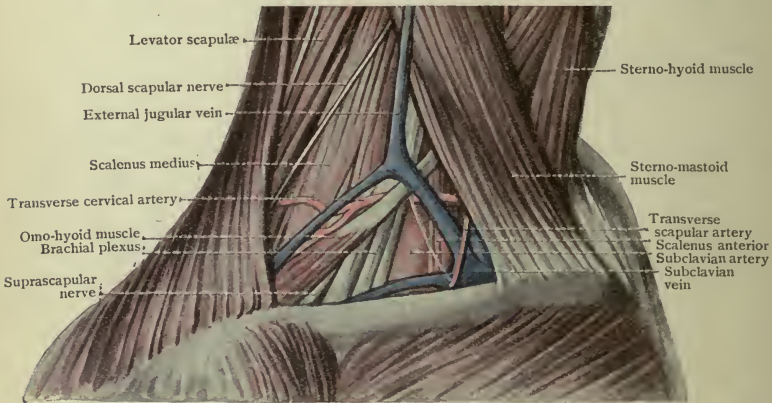


FIG. 21.—Dissection of the lower part of the Posterior Triangle of the Neck, showing the Supraclavicular Part of the Brachial Plexus.

(3) The dorsalis scapulæ nerve, which supplies the rhomboid muscles (from C. v.). (4) The long thoracic nerve, which supplies the serratus anterior (from C. v., vi., vii.).

The branches from the trunks of the plexus are: (1) The nerve to the subclavius, from the upper trunk (from C. v., vi.). It has already been seen piercing the posterior surface of the costo-coracoid membrane and entering the posterior aspect of the subclavius (p. 37). (2) The suprascapular nerve, from the upper trunk (from C. v., vi.). It will be found crossing the lower part of the posterior triangle, deep to the posterior belly of the omo-hyoid muscle, and disappearing through the scapular notch on its way to the dorsum scapulæ (Fig. 22).



The branches from the cords are—

From the lateral cord :

**Nervus thoracalis anterior lateralis** (O.T. External Anterior Thoracic) (from C. v., VI., VII.).

**N. musculocutaneus** (from C. v., VI., VII.).

**N. medianus, caput lateralis** (O.T. Outer Head of Median) (from C. v., VI., VII.).

From the medial cord :

**N. thoracalis anterior medialis** (O.T. Internal Anterior Thoracic) (from C. VIII., T. I.).

**N. cutaneus antibrachii medialis** (O.T. Internal Cutaneous) (from C. VIII., T. I.).

**N. cutaneus brachii medialis** (O.T. Lesser Internal Cutaneous) (from T. I.).

**N. medianus, caput medialis** (O.T. Inner Head of Median) (from C. VIII., T. I.).

**N. ulnaris** (from C. VIII., T. I.).

From the posterior cord :

**Nn. subscapulares** (O.T. Upper and Lower) (from C. v., VI.).

**N. thoracodorsalis** (O.T. Long Subscapular) (from C. VI., VII., VIII.).

**N. axillaris** (O.T. Circumflex) (from C. v., VI.).

**N. radialis** (O.T. Musculospiral) (from C. v., VI., VII., VIII., T. I.).

In the above table the different spinal nerves from which the fibres of the several branches are derived are indicated.

**Nn. Thoracales Anteriores.**—The anterior thoracic nerves supply the pectoral muscles. They are two in number, the lateral and the medial. The *lateral anterior thoracic nerve* springs from the lateral cord of the plexus, passes forwards across the lateral side of the first part of the axillary artery, communicates, in front of the artery, with the medial nerve, pierces the costo-coracoid membrane, and breaks up into branches which end in the pectoralis major. The *medial anterior thoracic nerve* is smaller than the lateral. It springs from the medial cord of the plexus, passes forwards between the axillary artery and vein, communicates, in front of the artery, with the lateral nerve, gives twigs of supply to the pectoralis minor, then pierces that muscle and ends in the pectoralis major, which it supplies. The pectoralis major is, therefore, supplied by both anterior thoracic nerves, the pectoralis minor by the medial nerve alone.

**Nn. Subscapulares.**—The subscapular nerves are two in number—the *upper* and the *lower*. They spring from the posterior cord of the plexus. After a very short course the upper nerve sinks into and supplies the upper and posterior part of the subscapularis. The lower subscapular nerve

passes downwards and laterally, gives branches to the lower part of the subscapularis, then passes through the angle

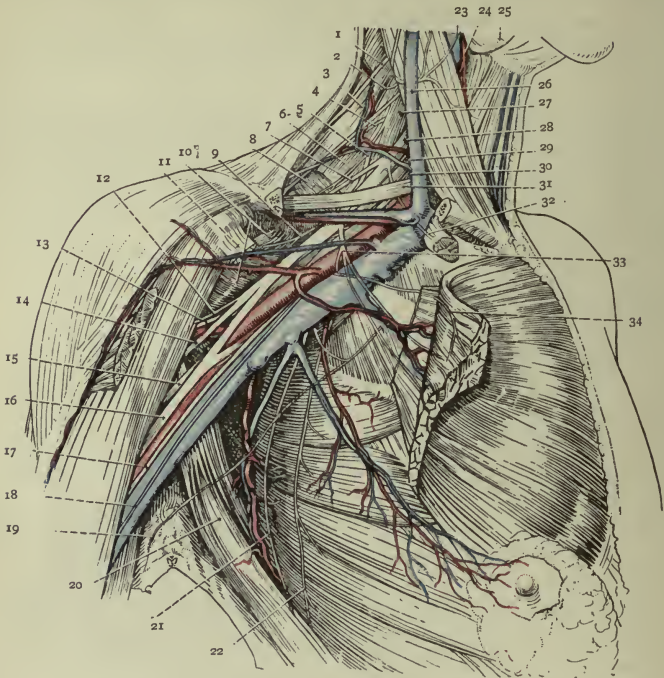


FIG. 16.—Dissection to show the General Relations of the Brachial Plexus.

- |  |                                      |
|--|--------------------------------------|
| 1. Accessory nerve.                    | 18. Medial cutaneous nerve of arm.   |
| 2. Nerve to levator scapulae.          | 19. Intercosto-brachial nerve.       |
| 3. Levator scapulae.                   | 20. Latissimus dorsi.                |
| 4. Dorsal scapular nerve.              | 21. Thoraco-dorsal nerve.            |
| 5. Long thoracic nerve.                | 22. Long thoracic nerve.             |
| 6. Scalenus medius.                    | 23. Internal jugular vein.           |
| 7. Suprascapular nerve.                | 24. Superior thyreoid artery.        |
| 8. Serratus anterior.                  | 25. Submaxillary gland.              |
| 9. Upper subscapular nerve.            | 26. External jugular vein.           |
| 10. Subscapularis.                     | 27. Scalenus medius.                 |
| 11. Pectoralis minor.                  | 28. Upper trunk of brachial plexus.  |
| 12. Nerve to coraco-brachialis.        | 29. Middle trunk of brachial plexus. |
| 13. Axillary nerve.                    | 30. Eighth cervical nerve.           |
| 14. Musculo-cutaneous nerve.           | 31. Omo-hyoid.                       |
| 15. Radial nerve.                      | 32. Nerve to subclavius.             |
| 16. Median nerve.                      | 33. Lateral anterior thoracic nerve. |
| 17. Medial cutaneous nerve of forearm. | 34. Medial anterior thoracic nerve.  |

between the thoraco-dorsal and circumflex scapulae arteries and ends in the teres major, which it supplies.

**N. Thoracodorsalis (O.T. Long Subscapular Nerve).**—The thoraco-dorsal nerve springs from the posterior cord of the plexus, passes obliquely downwards and laterally, through the axilla, and joins the thoraco-dorsal artery near the lower part of the lateral border of the subscapularis muscle. After cross-

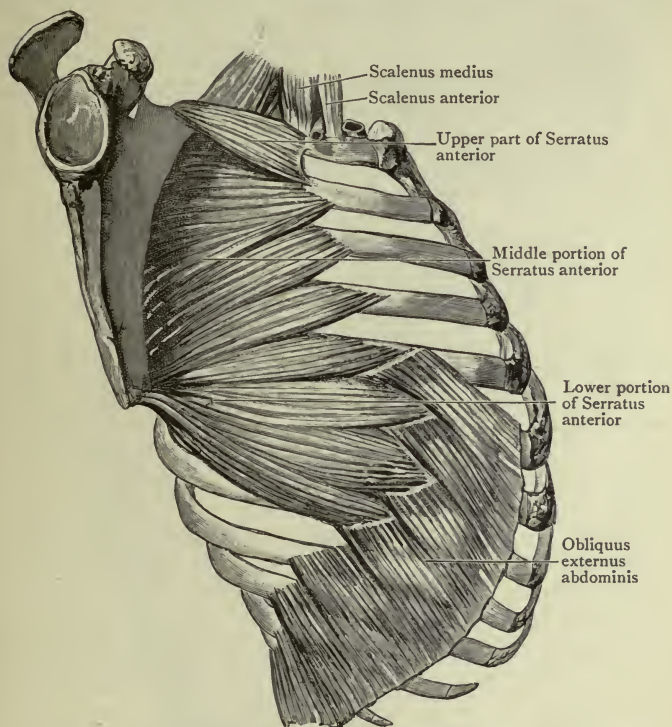


FIG. 23.—Serratus Anterior muscle and origin of the External Oblique muscle ; the scapula is drawn away from the side of the chest.

ing in front of the artery it terminates in the latissimus dorsi, which it supplies.

**N. Thoracalis Longus (O.T. Posterior Thoracic or External Respiratory Nerve of Bell).**—The long thoracic nerve may now be studied in its whole length. It passes downwards on the lateral surface of the serratus anterior, and is the nerve of supply to that muscle. It arises, in the root of

the neck, from the brachial plexus, by three roots. The upper two roots (one from the fifth cervical and the other from the sixth cervical nerve) pierce the scalenus medius, and, uniting

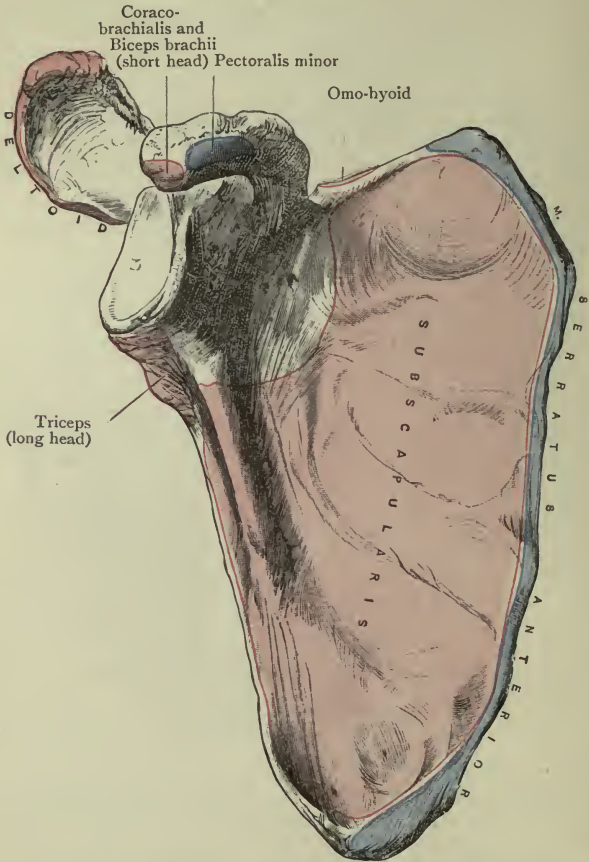


FIG. 24.—Costal aspect of the Scapula with the Attachments of Muscles mapped out.

into one stem, give off branches to the upper part of the serratus anterior. The third root takes origin from the seventh cervical nerve, passes in front of the scalenus medius, and runs downwards for a considerable distance on the surface of

the serratus anterior, before it unites with the other part of the nerve. The entire nerve can be followed to the lower part of the serratus anterior, giving twigs to each of its digitations.

**M. Serratus Anterior (O.T. Serratus Magnus).**—The serratus anterior arises by fleshy digitations from the upper eight ribs, about midway between their angles and cartilages. The slips are arranged on the chest wall so as to present a gentle curve convex forwards. The lower three interdigitate with the external oblique muscle of the abdomen. The serratus anterior is inserted into the entire length of the anterior lip of the vertebral margin of the scapula, and it falls naturally into three parts. (a) The *upper part*, composed of the large first digitation alone, arises from the first and second ribs, and from a tendinous arch between them. The fibres converge, to be inserted into a somewhat triangular surface on the costal aspect of the medial angle of the scapula. (b) The *middle part* consists of two digitations which take origin from the second and third ribs. The upper slip is very broad, and springs from the lower border of the second rib. The fibres of the middle part diverge to form a thin muscular sheet, which is inserted into the anterior lip of the vertebral margin of the scapula, between the insertions of the upper and lower portions. (c) The *lower part* is formed by the remaining digitations of the muscle. They converge to form a thick mass, which is inserted into a rough surface upon the costal aspect of the inferior angle of the scapula. The deep surface of the serratus anterior is in contact with the chest wall. It is the most powerful protractor of the whole upper extremity.

## DISSECTION OF THE BACK.

**Dissection.**—At the end of the fifth day, after the dissector has examined the serratus anterior and carefully revised the contents of the axilla, he must replace the clavicle, pack the axilla with tow or rags steeped with preservative solution and fix the skin flaps to the wall of the thorax with a few stitches. When he returns on the sixth day he will find that the body has been placed upon its face, with blocks supporting the chest and the pelvis. It will remain in that position for five days, and during the first two of those the dissector of the upper extremity must examine the structures which connect the limb with the posterior aspect of the trunk.

**Surface Anatomy.**—In the median line of the back there

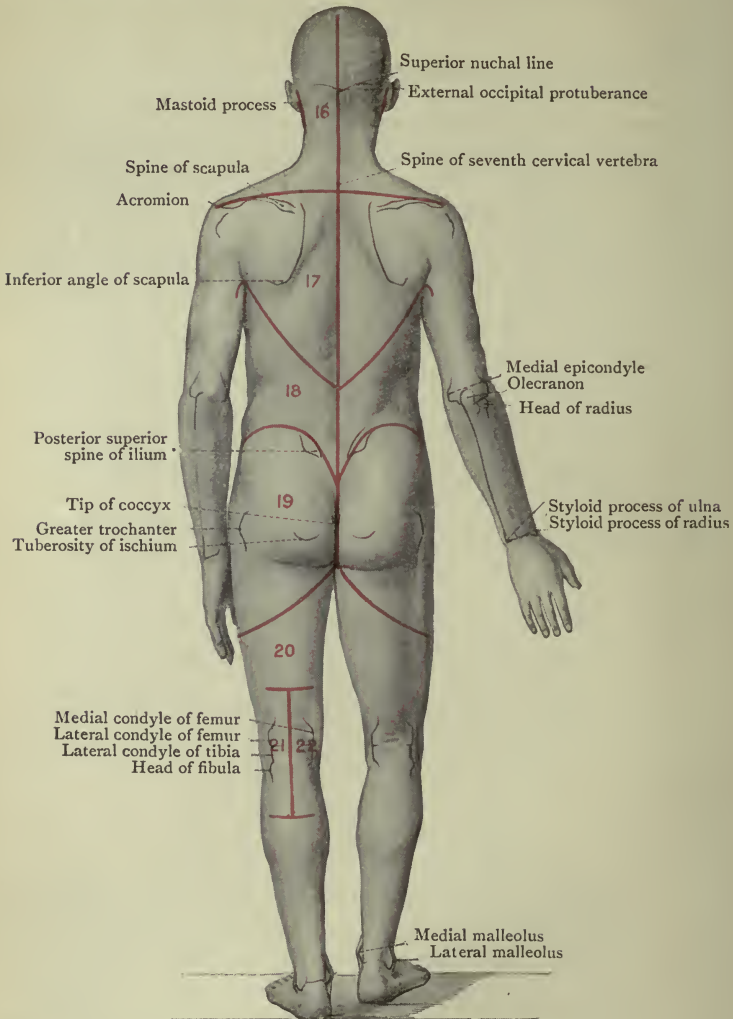


FIG. 25.—Surface View showing Incisions and Bony Points.

is little difficulty in recognising the tips of the spinous processes

of the vertebræ (Fig. 25). They follow each other in consecutive order, and it may be noted, when the finger is passed over them, that all of them do not lie in the median plane; some may be deflected, in a slight degree, to one side or the other. The spines of the vertebræ are the only parts of the spinal column which come to the surface; they alone yield direct information, by touch, to the surgeon as to the condition of the spine. At the lower end of the neck, the spine of the seventh cervical vertebra (*vertebra prominens*) makes a visible projection; and the spines of the first two thoracic vertebræ likewise are very prominent. As a rule, the most evident of the three is that of the first thoracic vertebra. At a lower level, in subjects of good muscular development, a median furrow is produced by the prominence of the sacrospinalis muscle on each side, and the spines of the vertebræ may be felt at the bottom of the groove. The furrow attains its greatest depth in the upper part of the lumbar region, and it fades away, below, at the level of the spine of the third sacral vertebra. The finger should next be passed downwards from the third sacral spine, between the buttocks, along the lower part of the tuberculated posterior surface of the sacrum, and along the posterior surface of the coccyx to the tip of the coccyx, which is the inferior extremity of the vertebral column. Afterwards the finger should be carried along the crest of the ilium. It commences at the posterior superior spine of the ilium which can easily be detected because its position is indicated by a small but distinct dimple which lies at the level of the second sacral spine. From the posterior superior spine the crest of the ilium pursues a sigmoid course, laterally and forwards. The highest point it reaches is on a level with the spine of the fourth lumbar vertebra, and it terminates in front in a prominence called the anterior superior spine.

The scapula, or shoulder blade, is, for the most part, thickly covered by muscles; but, in spite of that, its general outline can be made out (Fig. 25). It covers a considerable area of the upper portion of the posterior aspect of the thorax. With the hand by the side its medial angle lies over the second rib, the root of its spine is placed opposite the spine of the third thoracic vertebra, whilst its inferior angle reaches down as far as the seventh, or even the eighth, rib. The

scapula is very mobile, and moves to a greater or less degree with every movement of the limb. The spine and acromion of the scapula are subcutaneous throughout. Below the scapula the lower five ribs can be distinguished, and the tip of the last rib can be felt at a point about two inches or less above the iliac crest.

As the back is dissected the following are the parts which must be examined:—

- |  |            |
|--|------------|
| 1. The cutaneous vessels and nerves of the back.   | } 1st day. |
| 2. The trapezius muscle.   |            |
| 3. The latissimus dorsi muscle.  |            |
| 4. The rhomboid muscles and their nerve.   |            |
| 5. The levator scapulæ muscle.   | } 2nd day. |
| 6. The accessory nerve and the nerves from the cervical plexus which supply the trapezius. |            |
| 7. The transverse cervical artery and its two terminal branches.                           |            |
| 8. The posterior belly of the omo-hyoid muscle.  |            |
| 9. The transverse scapular artery and the suprascapular nerve.                             |            |

This dissection must be completed *in two days*, in order that the dissector of the head and neck may be enabled to continue the deeper dissection of the back. The *first day's work* should comprise—(1) the reflection of the skin; (2) the dissection of the cutaneous nerves and vessels; and (3) the cleaning of the latissimus dorsi and trapezius muscles. The remainder of the dissection can be undertaken on *the second day*.

**Dissection.**—Reflection of the Skin.—The following incisions are necessary:—1. From the tip of the coccyx, at the lower end of the vertebral column, upwards, along the median line of the body, to the spine of the seventh cervical vertebra. 2. From the upper end of 1 transversely, to the tip of the acromion of the scapula. 3. From the lower extremity of the median incision in a curved direction laterally and forwards, along the crest of the ilium, to within two inches of the anterior superior iliac spine. 4. An oblique incision from the spine of the first lumbar vertebra, upwards and laterally, to the posterior fold of the axilla, and along the latter to the arm. The two large flaps (17 and 18, Fig. 25) which are now mapped out upon the back must be carefully raised from the subjacent fatty tissue. Reflect the upper triangular flap first, and then the lower flap.

**Panniculus Adiposus (Superficial Fascia).**—In subjects which have been allowed to lie for some time on the back the superficial fascia is usually more or less infiltrated with fluid which has gravitated into its meshes; otherwise it has the ordinary characters of superficial fascia (p. 11).



**Dissection.**—When searching for the cutaneous nerves cut boldly down through the superficial fascia, in the direction in which the nerves run (Fig. 26), until the plane is reached at which the superficial and deep fascia blend. It is there that the main trunks are to be found, and in a well-injected subject the cutaneous arteries will serve as guides. A more rapid way of finding the cutaneous nerves in this region is to reflect the superficial and deep fascia laterally, from the vertebral spines, in one layer; the nerves are then found as they issue from the muscles. This plan, however, should be adopted only by the senior student.

**Nervi Cutanei et Vasa Cutanea (Cutaneous Nerves and Vessels).**—The *cutaneous nerves* of the back are derived from the posterior rami of the spinal nerves. As the posterior rami pass backwards, they subdivide into medial and lateral divisions. Both divisions supply twigs to the muscles amongst which they lie; but one or the other also contains some sensory fibres which come to the surface, in the shape of a cutaneous nerve, to supply the skin.

In the *thoracic region* the *upper six* or *seven* cutaneous nerves are the terminations of the medial divisions of the posterior rami of the thoracic nerves. They become superficial close to the vertebral spines, and are to be sought for near the median plane. It is not uncommon to find one or more of them piercing the trapezius, one or two inches lateral to the line of emergence of the others. The branch which comes from the second thoracic nerve is the largest of the series; and it may be traced laterally, across the spine of the scapula, towards the shoulder. The *lower five* or *six* cutaneous nerves in the *thoracic region* are the terminal twigs of the lateral divisions of the posterior rami of the thoracic nerves; and, consequently, they must be looked for at a short distance from the middle line of the back. The upper nerves of this group reach the surface after piercing the latissimus dorsi muscle on the line of the angles of the ribs. The lower nerves of the group pierce the lumbo-dorsal fascia at the lateral margin of the sacrospinalis muscle. In every case the cutaneous branches derived from the thoracic nerves turn laterally, in the superficial fascia, and may be traced for a varying distance in that direction.

It is important to note that the area of skin supplied by each of these cutaneous nerves is placed at a lower level than the origin of the posterior ramus from which it arises.

In the *lumbar region* three cutaneous nerves reach the surface after piercing the lumbo-dorsal fascia at the lateral

margin of the sacrospinalis muscle, a short distance above the ilium. They are the terminal twigs of the lateral divisions of the posterior rami of the upper three lumbar spinal nerves ;

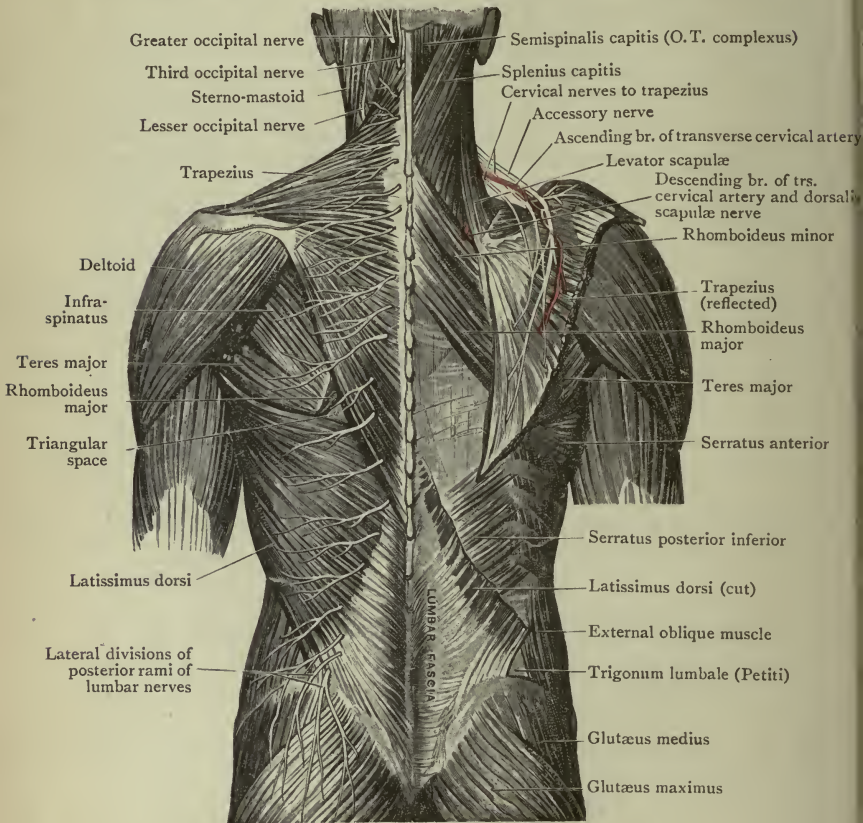


FIG. 26.—Dissection of the Superficial Muscles and Nerves of the Back.

and they differ from the nerves above, inasmuch as they turn downwards over the crest of the ilium to supply the skin of the gluteal region (Fig. 26).

The *cutaneous arteries* which accompany the cutaneous nerves of the back are derived from the posterior branches of the intercostal and lumbar arteries.

**Muscles connecting the Limb to the Dorsal Aspect of the Trunk.**—This group consists of five muscles, and they are arranged in two strata. Two form the *superficial stratum*, viz., the trapezius and the latissimus dorsi. Both are broad, flat muscles which cover the greater part of the dorsal aspect of the trunk, from the occiput above to the ilium below. The trapezius lies over the back of the neck and the thorax. The latissimus dorsi is placed lower down. The *deeper stratum* of muscles, composed of the levator scapulæ and the two rhomboid muscles, is under cover of the trapezius.

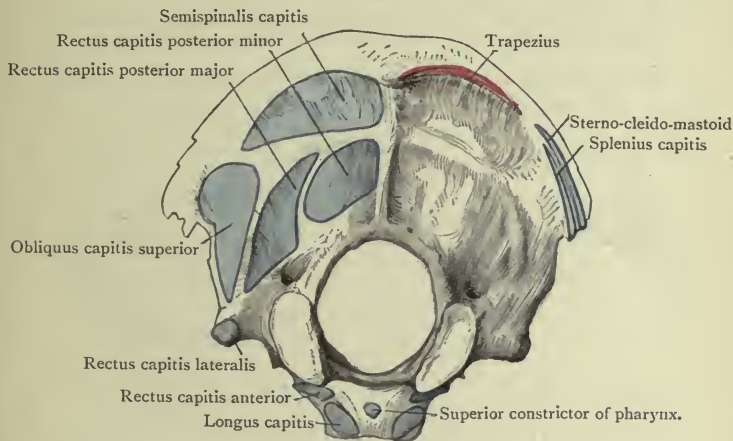


FIG. 27.—Muscle-Attachments to the Occipital Bone.

**Dissection.**—After the cutaneous nerves and vessels have been displayed and followed to their terminations, clean away the remains of the fatty superficial fascia in the area of the trapezius, but do not injure the deep fascia or the cutaneous nerves; then proceed to clean the trapezius, which is the most superficial muscle of the back. The trapezius belongs only in part to the dissector of the upper extremity. The portion of it which lies above the prominent spine of the seventh cervical vertebra is the property of the dissector of the head and neck, and must be dissected by him. The two dissectors should work in conjunction with each other; and when the entire muscle is exposed, each should give the other an opportunity of studying it in its entirety.

If the dissection is being made on the right side, place the arm close to the trunk and drag the scapula forwards over the end of the block which supports the thorax. Cut through the deep

fascia from the seventh cervical spine to the acromion; the incision will correspond with the direction of the fibres of the muscle at the level selected. Work gradually downwards, raising the fascia in a continuous layer from the surface of the muscle. Always carry the scalpel in the direction of the muscle fibres, and take care to leave none of the fascia on the surface of the muscle. As the direction of the muscle fibres changes, alter the position of the arm to keep the fibres which are being cleaned on the stretch. In the case of the *left trapezius*, the preliminary incision through the fascia must be made along the lower margin of the muscle, and the surface of the muscle must be cleaned, from below upwards, to the level of the seventh cervical vertebra. As the deep fascia is removed from the trapezius, and indeed throughout the whole dissection of the back, the cutaneous nerves must be carefully preserved, in order that the dissector of the head and neck may have an opportunity of establishing their continuity with the trunks from which they arise.

**M. Trapezius.**—The trapezius is a flat, triangular muscle, which lies, in its entire extent, immediately subjacent to the

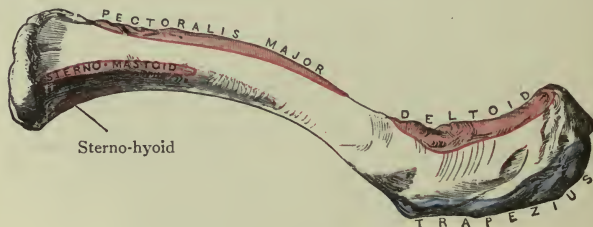

FIG. 28.—Upper Surface of the Right Clavicle.

deep fascia. It has a very long origin, which extends along the median plane, from the occiput above to the level of the last thoracic vertebra below. It arises from—(1) the medial third or less of the superior nuchal line of the occipital bone and the external occipital protuberance; (2) the ligamentum nuchæ and the spine of the seventh cervical vertebra; (3) the tips of the spines of all the thoracic vertebræ, as well as the supraspinous ligaments which bridge across the intervals between them (Figs. 26, 27).

In the lower cervical and upper thoracic regions the tendinous fibres by which the muscle arises lengthen out so as to form a flat tendon, which, taken in conjunction with the corresponding aponeurosis of the opposite side, exhibits an oval outline.

As the fibres of the trapezius pass laterally they converge to their insertions into the two bones of the shoulder-girdle. The *occipital* and *upper cervical fibres* incline downwards, and,

turning forwards over the shoulder, are inserted into the posterior border of the lateral third of the clavicle (Fig. 28); the *lower cervical* and *upper thoracic fibres* pass more or less transversely to gain an insertion into the medial border of the acromion and the upper margin of the posterior border of the spine of the scapula; while the *lower thoracic fibres* are directed upwards and, at the vertebral border of the scapula, end in a flat, triangular tendon, which plays over the smooth surface at the apex of the scapular spine, and is inserted into a rough tubercle on the spine immediately beyond that surface (Fig. 38, p. 83). To facilitate the movement of the tendon upon the bone a small bursa mucosa is interposed between them.

The trapezius is supplied by the *accessory nerve* and by twigs from the *third* and *fourth cervical nerves*. It is an elevator and depressor of the shoulder; and a rotator and adductor of the scapula.

**Dissection.**—The latissimus dorsi is now to be dissected. It is a difficult muscle to clean, not only on account of the varying direction of its fibres, but also because its upper part is generally very thin, and its upper border ill-defined. Near the spines of the vertebræ its upper portion is overlapped by the trapezius, but in its greater part the muscle is subcutaneous. Both the superficial and the deep fascia should be raised at the same time from its surface, and its fibres may be stretched by raising the arm and folding it under the neck.

On the *right side* cut through the fascia along the upper border of the muscle from the point where that margin disappears under the trapezius to the posterior fold of the axilla, and work downwards. Define carefully the attachment to the superficial layer of the lumbo-dorsal fascia. Clean that fascia, but do not injure it; it is the property of the dissector of the head and neck. Next define the attachment of the lower end of the muscle to the crest of the ilium; and when the lower part of the lateral border of the muscle is reached, clean the slips of the latissimus which are attached to the lowest three or four ribs, and clean also the slips of the external oblique muscle of the abdomen which interdigitate with the costal slips of the latissimus dorsi.

On the *left side* cut through the fascia from the crest of the ilium to the posterior fold of the axilla, and work medially and upwards; and when the main part of the muscle has been cleaned, return to the lower part of the lateral border and display the costal attachments of the muscle and the interdigitations of the external oblique.

After the costal slips of the muscle have been defined, evert the upper margin of the muscle, as it crosses the inferior angle of the scapula, to display the slip of fibres which springs from that angle and joins the deep aspect of the upper border of the muscle; it is apt to be mistaken for a piece of the teres major upon which it lies.

**M. Latissimus Dorsi.**—The latissimus dorsi is a wide, flat muscle, which covers the back from the level of the sixth thoracic vertebra down to the crest of the ilium (Fig. 26, p. 52). It arises—(1) from the tips of the spinous processes of the lower six thoracic vertebræ and the supraspinous ligaments in connection with them; (2) from the superficial lamella of the lumbo-dorsal fascia (Fig. 26); (3) by a thin tendinous origin from a small extent of the outer lip of the crest of the ilium, in

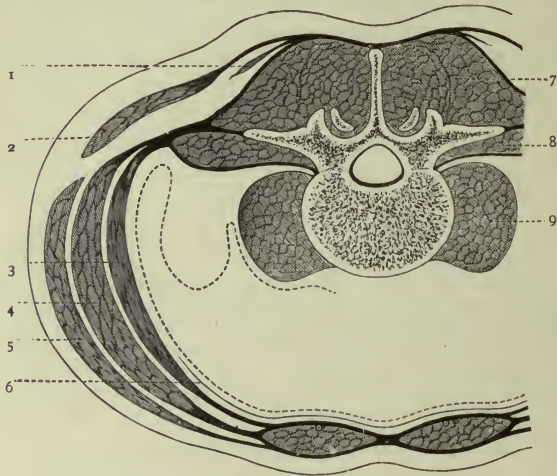


FIG. 29.—Diagram of the Lumbo-dorsal Fascia.

- |                                 |                          |
|---------------------------------|--------------------------|
| 1. Serratus posterior inferior. | 6. Fascia transversalis. |
| 2. Latissimus dorsi.            | 7. Sacrospinalis.        |
| 3. Transversus abdominis.       | 8. Quadratus lumborum.   |
| 4. Obliquus internus.           | 9. Psoas major.          |
| 5. Obliquus externus.           |                          |

front of the lumbo-dorsal fascia (Fig. 26, p. 52); (4) by three or four digitations from the lower three or four ribs; and (5) by a fleshy slip from the dorsal aspect of the inferior angle of the scapula (Fig. 38, p. 83). By means of its origin from the posterior lamella of lumbo-dorsal fascia, it attains an indirect attachment to the spines of the lumbar and upper sacral vertebræ, and also to the posterior part of the crest of the ilium. The costal slips of origin interdigitate with the lower digitations of the external oblique muscle of the abdominal wall.

The fibres of the latissimus dorsi converge rapidly as

they approach the lower part of the scapula. The highest fibres pass almost horizontally towards that point; the lowest fibres ascend almost vertically; whilst the intermediate fibres show varying degrees of obliquity. As a result of the convergence of fibres, the muscle is greatly reduced in width; and it sweeps over the inferior angle of the scapula in the form of a thick, fleshy band, which winds round the lower margin of the *teres major* muscle and terminates in a narrow, flat tendon, which is inserted into the floor of the intertubercular sulcus of the humerus (Fig. 45, p. 107). The insertion cannot be studied at present, but will be seen later. With the *teres major* muscle, the *latissimus dorsi* forms the posterior fold of the axilla. At first it is placed on the dorsal aspect of the *teres major*, then it is folded round its lower border, and finally it is inserted in front of it. To the peculiar relationship of the two muscles is due the full, rounded appearance of the posterior axillary fold.

The *latissimus dorsi* is supplied by the *thoraco-dorsal nerve*. It is an adductor, retractor, and medial rotator of the upper extremity.

**Two Intermuscular Spaces.**—(1) A triangular space mapped out by the inferior border of the trapezius, the superior border of the *latissimus dorsi*, and the base of the scapula, should now be noticed (Fig. 26, p. 52). Within the limits of that triangle a small portion of the *rhomboideus major* can be seen, and also a varying amount of the wall of the thorax—a part of the sixth intercostal space and the borders of the ribs which bound it above and below. It is well to note that this is the only part of the thoracic wall on the posterior aspect of the trunk which is not covered by muscles. (2) Between the last rib and the crest of the ilium the anterior border of the *latissimus dorsi* generally overlaps the posterior border of the external oblique muscle of the abdominal wall. Sometimes, however, a narrow triangular interval exists between the two muscles, in which is seen a small part of the internal oblique muscle. That space is termed the *trigonum lumbale (Petiti)* (Fig. 26, p. 52). It is a weak part of the wall of the abdomen, and occasionally some of the contents of the abdomen are protruded through it, forming a *lumbar hernia*.

**Dissection.**—Reflection of the Trapezius.—On the *second day* the dissector must begin by reflecting the trapezius, working, it

possible, in conjunction with the dissector of the head and neck. Divide the muscle about two inches from the spines of the vertebræ, and throw it laterally, towards its insertion. The trapezius is very thin at its origin, and the greatest care must therefore be taken not to injure the subjacent rhomboid muscles. The small bursa between the tendon of insertion of the lower part of the trapezius and the flattened apex of the spine of the scapula must not be overlooked, and the nerves and vessels on the deep surface of the muscle must be cleaned and preserved. They are the accessory nerve and branches of the third and fourth cervical nerves, the ascending branch of the transverse cervical artery, and branches of the descending branch of the transverse cervical artery: The latter pass into the trapezius from between the muscles of the second layer.

**Nerves and Vessels of Supply to the Trapezius.**—A dissection of the deep surface of the reflected muscle will reveal the following structures:—

- a. The accessory nerve.
- b. Two or three nerves from the cervical plexus.
- c. The ascending branch of the transverse cervical artery.
- d. Twigs of the descending branch of the transverse cervical artery.

These constitute the nervous and vascular supply of the trapezius.

The nerves have already been displayed by the dissector of the head and neck, as they cross the posterior triangle of the neck. The branches from the cervical plexus come from the *third and fourth cervical nerves*. On the deep surface of the trapezius they join with branches of the accessory nerve to form the *subtrapezial plexus*, from which twigs proceed into the substance of the muscle. The terminal twig of the *accessory nerve* can be traced nearly to the lower margin of the trapezius.

The *ascending branch of the transverse cervical artery*, which accompanies the accessory nerve, must be followed to the anterior border of the trapezius, where it will be seen to spring from the trunk of the artery at the point where it divides into its ascending and descending branches.

The *twigs from the descending branch of the transverse cervical artery* pierce the muscles of the second layer or pass between them, close to the vertebral border of the scapula.

**Dissection.**—The posterior belly of the omo-hyoid, the transverse scapular artery, and suprascapular nerve must now be displayed, and the clavicular and scapular insertions of the trapezius must be examined. Divide the trapezius into an upper



and a lower part by a transverse cut at the level of the angle between the clavicle and the spine of the scapula, and verify the attachment of the upper part to the posterior border of the lateral third of the clavicle and the attachment of the lower part to the medial border of the acromion and the upper margin of the posterior border of the spine of the scapula. Next clean away the fat in the area exposed and display the posterior belly of the omo-hyoid muscle, the transverse scapular artery, the suprascapular nerve and the fascia over the supraspinatus. The supraspinatus covers the scapula between the spine and the upper border of the bone. The posterior belly of the omo-hyoid is attached to the lateral part of the upper border. The transverse scapular artery crosses the upper border immediately lateral to the omo-hyoid, resting on the superior transverse ligament, which passes from the upper border to the coracoid process, and separates the transverse scapular artery from the suprascapular nerve.

When the structures mentioned have been defined, draw the scapula well over the edge of the block which supports the thorax, and examine the muscles which attach the vertebral border of the scapula to the vertebral column; they are (1) the *levator scapulæ*, (2) the *rhomboideus minor*, (3) the *rhomboideus major*. The levator scapulæ is attached to the scapula from the medial angle of the scapula to the flattened apex of the spine of the scapula, the rhomboideus minor opposite the flattened apex and the rhomboideus major from the flattened apex to the inferior angle.

Cut through the fascia between the levator scapulæ and the rhomboideus minor about one inch medial to the scapula, and find the *dorsalis scapulæ nerve* which supplies the rhomboid muscles and the descending branch of the transverse cervical artery which accompanies it. (Fig. 26, p. 52.) These structures will be traced to their terminations when the levator scapulæ and the rhomboids are reflected.

**M. Omo-hyoides, Arteria Transversa Scapulæ (O.T. Suprascapular Artery) et N. Suprascapularis.**—The slender *posterior belly of the omo-hyoid muscle* will be seen to arise from the upper margin of the scapula, immediately medial to the scapular notch. It derives fibres also from the ligament which bridges across this notch. It is supplied by a twig from a nerve loop in the neck called the *ansa hypoglossi*. The *transverse scapular artery* will be noticed to enter the supraspinous fossa of the scapula by passing over the superior transverse scapular ligament, whilst the *suprascapular nerve* proceeds into the fossa under cover of that ligament (Fig. 38).

**Mm. Rhomboidei.**—The two rhomboid muscles constitute a thin quadrangular sheet of muscular fibres, which extends from the spinous processes of the vertebræ to the vertebral margin of the scapula.

The *rhomboideus minor* is a narrow, ribbon-like fleshy

band which runs parallel to the upper border of the major rhomboid. It springs from the lower part of the ligamentum nuchæ, the spine of the seventh cervical vertebra, and frequently also from the spine of the first thoracic vertebræ. It is inserted into the vertebral margin of the scapula opposite the triangular surface at the flattened apex of its spine (Fig. 38, p. 83). It is entirely covered by the trapezius.

The *rhomboideus major* arises from the upper four or five thoracic spines, and the corresponding parts of the supraspinous ligaments. Its fibres run obliquely downwards and laterally, and end in a tendinous arch, which is attached to the vertebral margin of the scapula, from the inferior angle to the apex of the spine. The main attachment of the fibrous arch is to the inferior angle, but it is bound to the vertebral border from that point to the spine by fairly firm areolar tissue (Fig. 38, p. 83). The greater part of the rhomboideus major is covered by the trapezius; only a small portion near the inferior angle of the scapula lies immediately subjacent to the deep fascia.

**M. Levator Scapulæ.**—The levator scapulæ is an elongated muscle which arises by four, more or less tendinous, slips from the posterior tubercles of the transverse processes of the upper four cervical vertebræ. It passes downwards and backwards to be inserted into the vertebral margin of the scapula, from the medial angle to the spine. It is supplied by branches from the *third* and *fourth cervical nerves*.

**Dissection.**—Clean the levator scapulæ, taking care not to injure the nerves which supply it. The muscle belongs partly to the dissector of the head and neck and partly to the dissector of the superior extremity. When both of them have studied its attachment and nerve-supply, the muscle must be divided at the middle of its length. The lower half is then to be turned downwards and laterally to its insertion, and the dorsalis scapulæ nerve and the descending branch of the transverse cervical artery, which lie deep to the muscle, are to be preserved and followed to the upper margin of the rhomboideus minor.

Next cut through the rhomboids, from above downwards, midway between the scapula and the spines of the vertebræ; remember that they are very thin, and take care not to injure the serratus posterior superior, which is immediately subjacent to them. Turn the medial part of each muscle towards the vertebral spine and verify its attachment. Turn the lateral parts towards the scapula and follow the dorsalis scapulæ nerve and the descending branch of the transverse cervical artery to their terminations. The nerve gives branches to the levator scapulæ and to both the rhomboid muscles, and the artery not only supplies the rhomboids but also the adjacent muscles on the scapula.

**Nervus Dorsalis Scapulæ (O.T. Nerve to the Rhomboids).**—This long slender nerve arises, in the neck, from the fifth cervical nerve, usually in common with the upper root of the long thoracic nerve. It pierces the scalenus medius, and passes downwards, under cover of the levator scapulæ, to the deep surface of the rhomboidei muscles. It ends in those muscles, but it supplies, also, one or two twigs to the levator scapulæ.

The root twigs of origin of the dorsalis scapulæ nerve sometimes pierce the levator scapulæ separately, and then unite in a plexiform manner.

**Ramus Descendens of the Art. Transversa Colli (O.T. Posterior Scapular Artery).**—The descending branch of the transverse cervical artery takes origin in the lower part of the neck close to the lateral margin of the levator scapulæ. At first it runs medially under cover of the levator scapulæ, but it soon changes its direction and then runs downwards along the vertebral border of the scapula, under cover of the rhomboid muscles (Fig. 26, p. 52). It gives numerous branches to both the costal and dorsal aspects of the scapula, and its terminal twigs may enter the latissimus dorsi. One large branch usually passes backwards, in the interval between the rhomboid muscles or through the greater rhomboid, to reach the trapezius muscle; and another branch, the *supraspinal*, is given to the supraspinatus muscle and the structures superficial to it.

**Dissection.**—Reflection of the Latissimus Dorsi and the removal of the Superior Extremity.—Divide the latissimus dorsi. Commence the division at the upper border three inches from the vertebral spine, and carry the knife obliquely downwards and laterally to a point just below where the last digitation of the muscle springs from the last rib. Remember that the muscle is thin, and do not injure the parts subjacent to it. Turn the medial portion towards the vertebral spines, taking care not to injure the serratus posterior inferior in the region of the lower four ribs, and verify the origin of the muscle from the spines and supraspinous ligaments, lumbar fascia and iliac crest. Throw the lateral part of the muscle laterally and forwards, clean the deep surfaces of the slips attached to the lower three or four ribs, and note that they interdigitate with the external oblique muscle of the abdomen. At the inferior angle of the scapula find the thoraco-dorsal nerve and the thoraco-dorsal artery. They supply the muscle and enter its deep surface.

**The Removal of the Superior Extremity.**—(1) Divide the transverse scapular artery and the suprascapular nerve and the

posterior belly of the omo-hyoid at the upper border of the scapula.

(2) Divide the dorsal scapular nerve and the descending branch of the transverse cervical artery near the medial angle of the scapula.

(3) Pull the vertebral border of the scapula away from the ribs to expose the posterior part of the serratus anterior on the costal surface of the scapula.

(4) Cut through the posterior part of the serratus anterior from its upper to its lower border about one inch from the vertebral margin of the scapula.

(5) Pull the scapula still further away from the thorax and divide the axillary vessels and nerves at the outer border of the first rib.

(6) Detach the anterior skin flap previously stitched to the anterior wall of the thorax, and take the limb to the table provided, where the further dissection is to be completed.

Tie the divided axillary vessels and nerves to a piece of wood, about 37.5 mm. ( $1\frac{1}{2}$  inches) long, in their proper order (a piece of a broken penholder will serve the purpose), and then by means of a loop fix the wood to the coracoid process; by that means the vessels and nerves will be retained in their proper relationships during the further stages of dissection, and they can be released from the coracoid process when it is necessary to examine anything which lies behind them.

After the superior extremity has been separated proceed to remove the whole of the skin which covers it whilst the subcutaneous tissues are still in good condition, and in order that a general view of the cutaneous veins and nerves may be obtained. The main cutaneous veins carry blood to the axillary vein, and the cutaneous nerves are either direct branches of the brachial plexus or they spring from the main terminal branches of the plexus. The following steps must be taken: (1) place the limb on its posterior aspect; (2) make an incision along the anterior aspect from the region already denuded to the tip of the middle finger (Fig. 5); (3) make a transverse incision at the wrist; (4) a transverse incision at the proximal ends of the fingers; (5) an oblique incision from the middle of wrist to the tip of the thumb; (6) incisions along the middle of the index, the ring, and the little finger. Turn the lateral flaps 3 and 5 (Fig. 5) laterally, the medial flaps 4 and 6 medially round the respective margins of the limb, and then dissect them from the dorsal aspect. Treat the flaps 5 and 7 and those of the fingers in the same way, and dissect flap 6 distally to the angle between the thumb and the index finger.

Take great care whilst removing the flaps not to injure the cutaneous vessels and nerves which lie in the superficial fascia immediately subjacent to the skin.

Note that the skin is readily separated from the superficial fascia in the arm and forearm and on the dorsal aspect of the hand. It is slightly more adherent over the epicondyles of the humerus and the olecranon. In the regions of the palm and the volar aspects of the digits, the skin and superficial fascia are closely adherent, for there the skin is bound to the deep fascia by fibrous strands which pass through the superficial fascia. In the ulnar part of the palm, about 25 mm. distal to the wrist,

some muscle fibres will be brought into view ; they connect the skin on the ulnar margin of the palm with the deep fascia, and constitute the *palmaris brevis muscle*.

When the skin is completely removed it must not be thrown away but must be kept to be wrapped round the part where the dissection is not proceeding.

**Cutaneous Veins of the Superior Extremity.**—After the skin has been removed proceed to display the cutaneous veins, because they are, except here and there, the most superficial structures, but be careful to preserve any nerves met with as the veins are being cleaned (Figs. 31, 32).

Commence at the interval between the pectoralis major and the deltoid and follow the cephalic vein distally, being careful to preserve the tributaries which join it. At the bend of the elbow secure a large communicating branch called the *median cubital vein* ; it runs obliquely, proximally, and medially, and joins the *basilic vein*, about 30 mm. proximal to the level of the medial epicondyle. The median cubital vein is joined at its distal border by a vein which pierces the deep fascia and connects the median cubital vein with the deep veins of the forearm. After the median cubital vein and its connections have been displayed, follow the cephalic vein distally, along the forearm and round its radial margin, to the dorsum of the hand where it commences, dorsal to the first metacarpal bone, in the radial extremity of the *dorsal venous arch*. The dorsal venous arch crosses the dorsum of the hand, from the radial to the ulnar side, and at its ulnar end, which lies opposite the interspace between the fourth and fifth metacarpal bones, the *basilic vein* commences. Follow the basilic vein proximally. It passes at first along the dorsal aspect of the ulnar border of the forearm, then turns round the ulnar border to the front, and ascends to the arm, where it is joined by the median cubital vein already dissected. Follow the basilic vein proximally beyond its junction with the median cubital vein to the middle of the arm where it pierces the deep fascia, at the level of the insertion of the coraco-brachialis muscle. As you clean it, in the lower part of the arm, look for some superficial cubital lymph glands which lie in the superficial fascia ; a little proximal to the elbow they receive lymph from the fingers, palm, and the anterior aspect of the forearm, and are apt to become inflamed and painful when wounds of those parts become septic. The cephalic and the basilic veins receive tributaries, which vary in number and size, both from the dorsal and the volar surfaces of the forearm and hand.

When the cephalic and basilic veins and their main tributaries have been cleaned, return to the dorsum of the hand, clean the dorsal venous arch and the tributaries which pass to it from the digits ; they are (1) *three dorsal metacarpal veins*, one opposite each of the three medial interdigital clefts ; (2) the *radial dorsal digital vein* from the index finger. On the dorsum of each digit look for two *dorsal digital veins*, one along the radial and one along the ulnar border. The dorsal digital veins of the thumb join the cephalic vein ; the ulnar dorsal digital vein of the little finger usually joins the basilic vein ; the other dorsal digital veins terminate in the dorsal metacarpal veins. The two dorsal digital veins on each finger are united by many channels which form a series of arcades, the *dorsal digital venous arches*. The

superficial veins on the dorsum of the hand communicate through the interdigital clefts with the deep and superficial veins of the palm.

The superficial veins on the volar aspects of the fingers and in the palm are small, and cannot as a rule be displayed in an ordinary dissection, but, springing from a network in the superficial fascia of the palm, or appearing in the superficial fascia of the volar aspect of the wrist, there is occasionally a *median antebrachial vein* which passes proximally, along the middle of the volar aspect of the forearm, towards the elbow. A short distance distal to the elbow it either joins the median cubital vein or it divides into two branches, the median basilic and the median cephalic, which terminate respectively in the basilic and cephalic veins.

Accompanying the various superficial veins of the superior extremity there are numerous lymph vessels which collect lymph from the regions drained by the veins. Those which accompany the proximal part of the cephalic vein, and which are derived partly from the dorsum of the forearm and partly from the dorsum of the arm and the lateral part of the shoulder, pass to the delto-pectoral and infraclavicular lymph glands; some of the lymph vessels which accompany the basilic vein end in the superficial cubital glands, above the medial epicondyle; the remainder, and the efferents of the superficial cubital glands, accompany the proximal part of the basilic vein, and, after piercing the deep fascia, they terminate either in the brachial glands or the lateral group of axillary glands (Fig. 9).

The superficial lymph glands can often be found by a careful dissector, but the superficial lymph vessels are difficult to demonstrate in an ordinary dissecting-room "part." They appear as fine white strands, and are most easily distinguished as they enter or leave the glands.

**Vena Cephalica.**—The cephalic vein commences at the radial end of the venous arch on the dorsum of the hand. It receives the two dorsal digital veins from the thumb, and then turns round the radial border of the distal part of the forearm and ascends to the region of the elbow; there the greater part of the blood which it carries is transmitted to the basilic vein by the large median cubital vein. Proximal to the level of the median cubital vein, the cephalic vein ascends either along the lateral part of the biceps, or in the groove at the lateral border of the biceps, to the lower border of the pectoralis major; there it pierces the deep fascia (Fig. 31), and then continues proximally in the groove between the pectoralis major and the deltoid to the delto-pectoral triangle. In the delto-pectoral triangle it crosses the lateral part of the pectoralis minor, and turns medially between the clavicular part of the pectoralis major and the costo-coracoid membrane. In this terminal part of its course it lies anterior to the axillary artery, but is separated from the artery by the costo-coracoid membrane. Finally it pierces the costo-coracoid membrane and joins the axillary vein. It receives (1) the dorsal digital veins

of the thumb, (2) tributaries from the volar and dorsal aspects of the forearm, (3) tributaries from the lateral and dorsal aspects of the arm, (4) a tributary from the side of the shoulder, and (5), immediately before it pierces the costo-coracoid membrane, it is joined by the venæ comites of the deltoid and acromial branches of the thoraco-acromial artery. It is accompanied by lymph vessels from the dorsum of the hand, and the lateral and dorsal sides of the forearm and arm; those vessels terminate in the delto-pectoral lymph glands.

**Vena Basilica.**—The basilic vein commences at the ulnar end of the dorsal venous arch of the hand. It receives the dorsal digital vein from the ulnar side of the little finger and then ascends on the ulnar part of the dorsal surface of the forearm. Below the elbow it turns round the ulnar border of the forearm and ascends to the groove along the medial border of the biceps brachii. About 30 mm. above the medial epicondyle it is joined by the median cubital vein, then it continues proximally to the level of the middle of the arm, where it pierces the deep fascia. After it has pierced the deep fascia, it runs along the medial side of the brachial artery to the lower border of the teres major, where it becomes the axillary vein; only the termination of this part of the vein can be seen at present, the remainder will be displayed in a later dissection. The tributaries of the basilic vein are (1) the ulnar dorsal digital vein of the little finger, (2) tributaries from the volar and dorsal aspects of the forearm, (3) the median cubital vein, (4) tributaries from the medial and posterior parts of the arm. It is accompanied by lymph vessels from the dorsum and palm of the hand and the volar and dorsal aspects of the forearm. Some of the accompanying lymph vessels end in the superficial cubital glands, which lie proximal to the medial epicondyle. Others pass directly to the brachial and the lateral axillary glands.

**Vena Mediana Cubiti.**—The median cubital vein is a large communicating vein which springs from the cephalic vein about 25 mm. below the bend of the elbow, and terminates in the basilic vein 30 mm. above the medial epicondyle. As it crosses from the cephalic to the basilic vein it receives tributaries from the volar aspect of the forearm, it is separated from the distal part of the brachial artery by a thickened portion of deep fascia called the

*lacertus fibrosus*,<sup>1</sup> and it is crossed either deeply or superficially by the volar branch of the medial cutaneous nerve of the forearm (Fig. 31).

**The Lymph Vessels and Lymph Glands of the Superior Extremity.**—With the exception of a few lymph vessels which the dissector may have

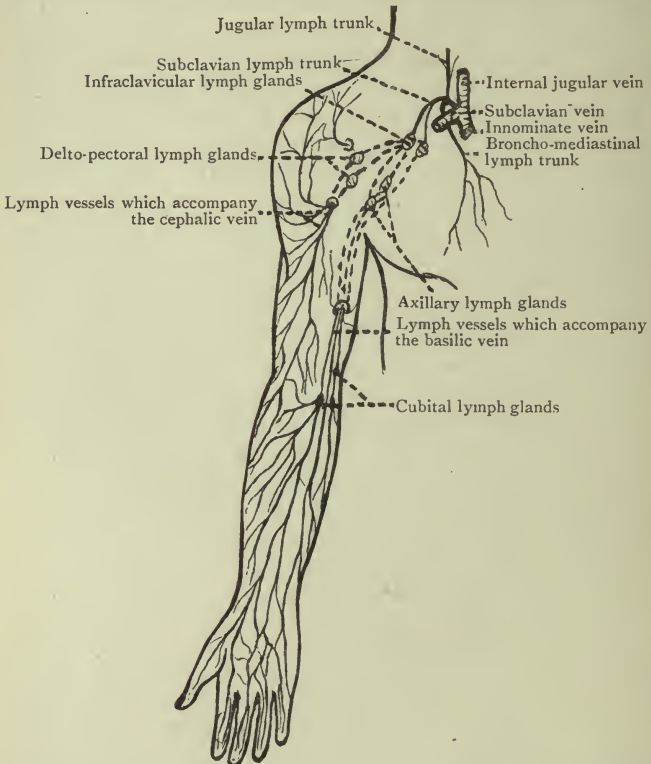


FIG. 30.—Diagram of the Superficial Lymph Vessels and Lymph Glands of the Right Superior Extremity.

found passing to and from the axillary lymph glands (p. 29), the lymph vessels of the superior extremity cannot be displayed in an ordinary dissecting-room "part," and it is only occasionally in the hospital, the post-mortem room, and in specially prepared subjects that an opportunity for seeing the lymph vessels will occur. It is unfortunate that this should

<sup>1</sup> The strengthening fibres of the *lacertus fibrosus* are derived from the tendon of insertion of the *biceps brachii*.



be the case, because the lymph vessels and lymph glands are of great clinical importance, and their positions and connections must always be kept in mind when infection by micro-organisms and the spread of malignant growths is under consideration (Fig. 30).

For the main part the lymph vessels accompany the blood-vessels, but they are much more numerous than the latter; they are present in all tissues, except cartilage; and they contain a colourless fluid called *lymph*, which drains into the smaller lymph vessels from the tissues amidst which they lie. The lymph vessels unite together, like the veins, to form gradually larger and larger vessels, which are however always relatively small as contrasted with blood-vessels, and the lymph they carry finally enters two terminal lymph vessels, the *right lymph duct* and the *thoracic duct*. Both the terminal lymph vessels join big veins at the root of the neck behind the sternal part of the clavicle, the right lymph duct ending in the right innominate vein and the thoracic duct in the left innominate vein. Therefore, eventually, all the lymph gathered from the tissues is poured into the blood. In ordinary circumstances the lymph carries materials which are distributed by the blood throughout the body, to the organs which must utilise them or excrete them in order that the bodily health may be maintained, but if micro-organisms have invaded the tissues or malignant tumours have formed amidst them, the micro-organisms or the poisons they form and cells of the malignant tumours may enter the lymph vessels, and when that occurs it necessarily follows that they may be distributed by the blood to all parts of the body. That naturally occurs rapidly in the cases of any dissolved poisons, but the process may be delayed in the cases of micro-organisms and the cells of malignant tumours, for the lymph glands are interposed, like small filters, in the courses of the lymph vessels, and micro-organisms and malignant cells are frequently caught in them. The micro-organisms so caught may cause inflammation of the glands and the malignant cells develop into new malignant tumour formations. It is important therefore, in the consideration of all cases of micro-organic infection and malignant tumour growth, that the doctor should have a very clear idea of the possible lymph pathways by which the infection or the tumour may spread, and the positions of the lymph glands which may, for a time, retard disaster and give him the opportunity to deal successfully with the conditions which are threatening.

It is probable that all lymph passes through at least one lymph gland before it enters the terminal lymph vessels, and most lymph passes through many glands. The lymph vessels which convey lymph to lymph glands are called *afferent* lymph vessels, and those which convey it from glands are *efferent* lymph vessels. Both the lymph vessels and the lymph glands in the superior extremity, as in other parts of the body, form two main groups, *deep* and *superficial*.

The *deep glands* are: (1) the deep cubital glands; (2) the brachial glands; (3) the axillary glands: (*a*) lateral, (*b*) anterior, and (*c*) posterior (see p. 29); (4) the delto-pectoral glands; (5) in some cases there are a few scattered lymph glands associated with the deep arteries of the front of the forearm.

The lymph from all the structures deep to the deep fascia is carried by lymph vessels which accompany the blood-vessels to the nearest available lymph glands. The deep cubital glands receive the lymph from the deep parts of the hand and forearm, and part of the lymph from the elbow, and pass it on to the brachial glands, which also receive lymph from the elbow and the deep parts of the arm. From the brachial glands the lymph passes to the lateral group of axillary glands.

The *superficial lymph glands* are the superficial cubital glands which lie in the fat of the front of the medial side of the arm immediately proximal to the medial epicondyle (see p. 63).

The lymph from the skin and subcutaneous tissues of the superior extremity forms two main streams. (1) From the palm, the ulnar border and the ulnar part of the dorsal surface of the hand, the greater part of the front, the ulnar border, and the ulnar part of the dorsal surface of the forearm, it flows through a series of superficial lymph vessels which accompany the tributaries and the distal part of the trunk of the basilic vein to the superficial cubital glands. The efferent vessels from the superficial cubital glands, reinforced by lymph vessels from the medial part of the arm, accompany the proximal part of the basilic vein through the deep fascia; some of them end in the brachial glands, but the majority pass to the lateral axillary glands. (2) The second stream flows from the radial part of the dorsal aspect of the hand, the radial border, and the radial part of the posterior surface of the forearm and the lateral part of the arm, through a series of lymph vessels which accompany the cephalic vein. They end in the delto-pectoral glands, which receive lymph also from the region of the shoulder. The lymph from the lateral axillary glands and the delto-pectoral glands passes to the infraclavicular glands, and thence on the right side to the right lymph duct, and on the left side to the thoracic duct.

The lymph from the deep and superficial parts of the scapular region flows mainly to the posterior axillary glands, and through them to the infraclavicular glands. The superficial and deep lymph vessels of the anterior axillary region have already been traced. They carry lymph partly to the anterior axillary and interpectoral glands, whence it passes to the infraclavicular glands, and partly directly to the infraclavicular glands, but they also convey it to the sternal lymph glands, and they communicate with the lymph vessels of the upper and anterior part of the abdomen (see p. 17 and Fig. 14).

When the superficial veins and their connections have been cleaned and studied, the cutaneous nerves of the superior extremity must be found and cleaned; they are:

- |   |   |   |
|---|---|---|
| 1. The posterior supraclavicular nerves.  | } | To the skin of the arm.                 |
| 2. The intercosto-brachial nerve.   |   |   |
| 3. The medial cutaneous nerve of the arm.                                       |   |   |
| 4. The lateral brachial cutaneous nerve.  |   |   |
| 5. The posterior cutaneous nerve of the arm.                                    |   |   |
| 6. The medial cutaneous nerve of the forearm.                                   | } | To the skin of the arm and the forearm. |
| 7. The dorsal cutaneous nerve of the forearm.                                   |   |   |
| 8. The lateral cutaneous nerve of the forearm.                                  |   |   |
| 9. The palmar cutaneous branch of the median nerve.                             | } | To the forearm and ball of the thumb.   |
| 10. The palmar cutaneous branch of the ulnar nerve.                             |   |   |
| 11. The digital branches of the median nerve.                                   | } | To the skin of the palm.                |
| 12. The digital branches of the ulnar nerve.                                    |   |   |
| 13. The superficial branch of the radial nerve and its dorsal digital branches. |   |   |
| 14. The dorsal branch of the ulnar nerve and its dorsal digital branches.       |   |   |

**Dissection.**—Turn to the proximal end of the limb and commence with the *intercosto-brachial nerve*, which was severed when the superior extremity was removed from the trunk. It lies in the posterior part of the medial side of the arm, and is at first deep to the deep fascia. Note the point at which it pierces the deep fascia (Figs. 31, 32) and trace it to its termination near the elbow. By means of its various branches it supplies the skin on the medial side of the posterior part of the arm (Figs. 31, 32).

Find, next, the *medial cutaneous nerve of the arm*. It pierces the deep of the fascia proximal third of the arm on the medial side, and its branches supply the skin as far as the elbow in an area anterior to that supplied by the intercosto-brachial nerve.

After the medial cutaneous nerve of the arm has been cleaned, look for the branches of the *medial cutaneous nerve of the forearm*, which supply the medial part of the skin of the arm. They vary in number and size, but they usually pierce the deep fascia along the line of the medial border of the biceps brachii and they communicate with one another (Fig. 31).

The trunk of the medial cutaneous nerve of the forearm either pierces the deep fascia close to the basilic vein, or it passes through the same opening as the vein, and divides into its *volar* and *ulnar terminal branches*. The volar branch passes either deep or superficial to the median cubital vein and then descends to the wrist. It supplies the skin of the ulnar half of the volar aspect of the forearm. The ulnar branch passes either anterior or posterior to the medial epicondyle and then along the ulnar margin of the forearm. It supplies the skin of the ulnar margin and of the ulnar part of the dorsum of the forearm as far as the wrist.

After the medial cutaneous nerve of the forearm has been dissected, trace the remains of the posterior supraclavicular nerves through the fat over the proximal part of the deltoid; they supply the skin over the proximal half of the deltoid muscle. When they have been traced to their terminations make an incision through the fat along the distal half of the posterior border of the deltoid and secure the *lateral cutaneous nerve of the arm*. It is a branch of the axillary nerve and will be found turning round the posterior border of the deltoid at the junction of the proximal two-thirds with the distal-third of the muscle (Figs. 31, 32, 33). It runs forwards across the muscle and supplies the skin over its distal half.

To find the *proximal* and *distal branches* of the *dorsal cutaneous nerve of the forearm* dissect in the fat between the lateral epicondyle of the humerus and the insertion of the deltoid. They are branches of the radial nerve and both are occasionally difficult to find. The proximal branch usually pierces the deep fascia a little distal to the insertion of the deltoid (Figs. 31, 32). It supplies the skin of the lateral part of the anterior aspect of the arm as far as the elbow. The distal branch will be found about one inch nearer the lateral epicondyle. It passes behind the lateral epicondyle and then descends along the dorsal aspect of the forearm to the wrist.

After the distal branch of the dorsal cutaneous nerve of the forearm has been traced to its termination, find the *lateral cutaneous nerve of the forearm*. It is the continuation of the musculocutaneous nerve. It appears at the lateral border of

the biceps under cover of the cephalic vein, about 25 mm. above the point where the medial cubital vein leaves the cephalic vein. Soon after it enters the superficial fascia it divides into a volar and a dorsal branch. The volar branch descends along the radial part of the volar aspect of the forearm to the ball of the thumb, and the dorsal branch may be traced distally on the dorsal aspect of the radial side of the forearm as far as the wrist.

The *posterior cutaneous nerve of the arm* was found during the dissection of the axilla springing from the proximal part of the radial nerve. Now it must be traced along the dorsal aspect of the arm to the elbow. It supplies the skin of the dorsum of the arm from the axilla to the elbow (Fig. 32).

After the posterior cutaneous nerve of the arm has been cleaned, place the limb on its dorsal surface and look for the palmar cutaneous branches of the median and ulnar nerves.

They both pierce the deep fascia of the forearm about 30 mm. proximal to the wrist. The *palmar cutaneous branch of the median nerve* lies in the line of the medial border of the proximal end of the ball of the thumb (thenar eminence) and it extends to the middle of the palm. The *palmar cutaneous branch of the ulnar nerve* lies in the line of the middle of the ball of the little finger (hypothelar eminence); it also extends to the level of the middle of the palm (Fig. 31).

After the distribution of the palmar cutaneous nerves has been seen clear away the superficial fascia of the palm from the interval between the thenar and hypothelar eminences to the bases of the digits to expose the intermediate part of the *palmar aponeurosis*, that is, the deep fascia of the palm. Note that the superficial fascia in the area under consideration is dense. It is divided into small lobules by fibrous septa which pass from the skin to the palmar aponeurosis. When the intermediate part of the palmar aponeurosis is exposed it will be found to be triangular in outline. The apex lies at the wrist where it is continuous with the deep fascia of the forearm. The base is at the level of the distal ends of the metacarpal bones, and it divides into five pieces, one for each finger and a less definite slip for the thumb. A bundle of transverse fibres will be met with in the fold of skin which crosses the proximal ends of the interdigital clefts. It is the *superficial transverse ligament* of the hand, and it must be divided opposite the clefts in order that the volar digital nerves which supply the adjacent sides of the clefts may be followed.

The volar digital nerves are seven in number. The first and second pass to the thumb, one to its radial and one to its ulnar side. They are accompanied by branches of the *princeps pollicis* artery. They will be found at the medial margin of the thenar eminence and must be traced to the end of the thumb. The third appears at the lateral margin of the slip of the palmar aponeurosis to the index-finger. It runs along the radial side of the finger accompanied by the volar *radialis indicis* artery. The fourth, fifth, and sixth will be found between the slips of the intermediate part of the palmar aponeurosis in line with the first, second, and third interdigital clefts respectively. Each is accompanied by a volar digital artery, and like the artery it divides to supply the adjacent sides of the fingers which bound the cleft opposite which it lies. The seventh supplies the ulnar side of the little finger. It appears at the distal border of the palmaris

PLATE III

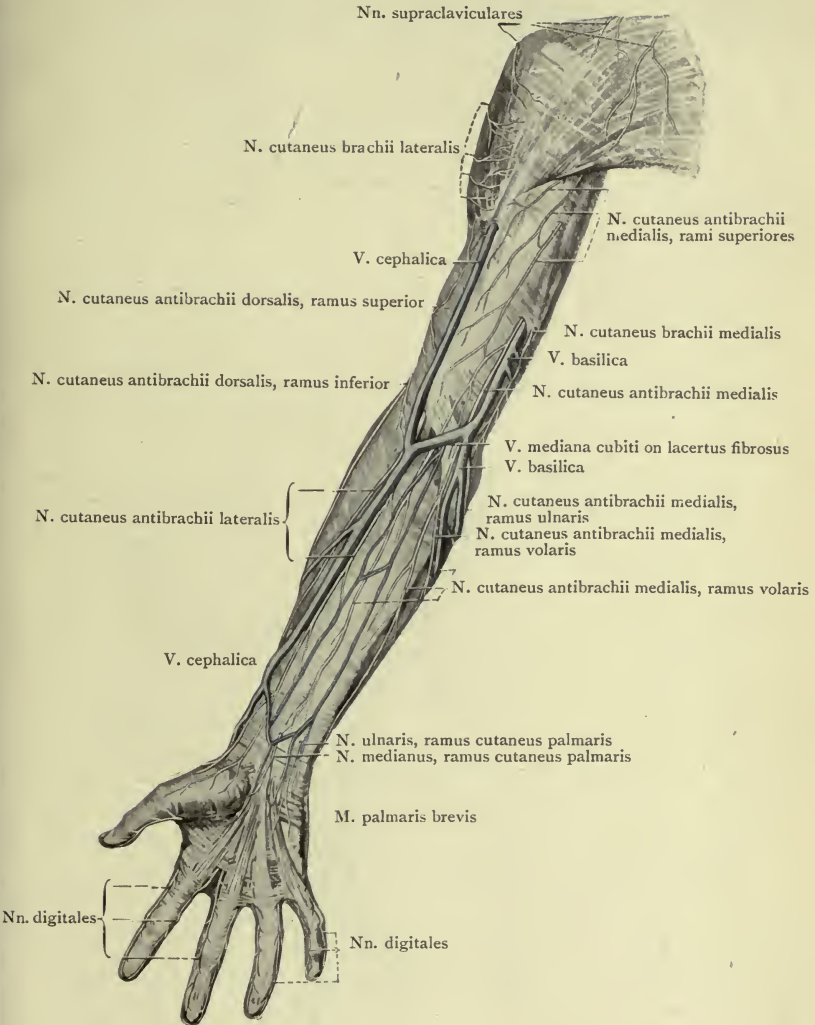


FIG. 31.—Superficial Nerves and Veins of the Anterior Aspect of the Superior Extremity.

PLATE IV

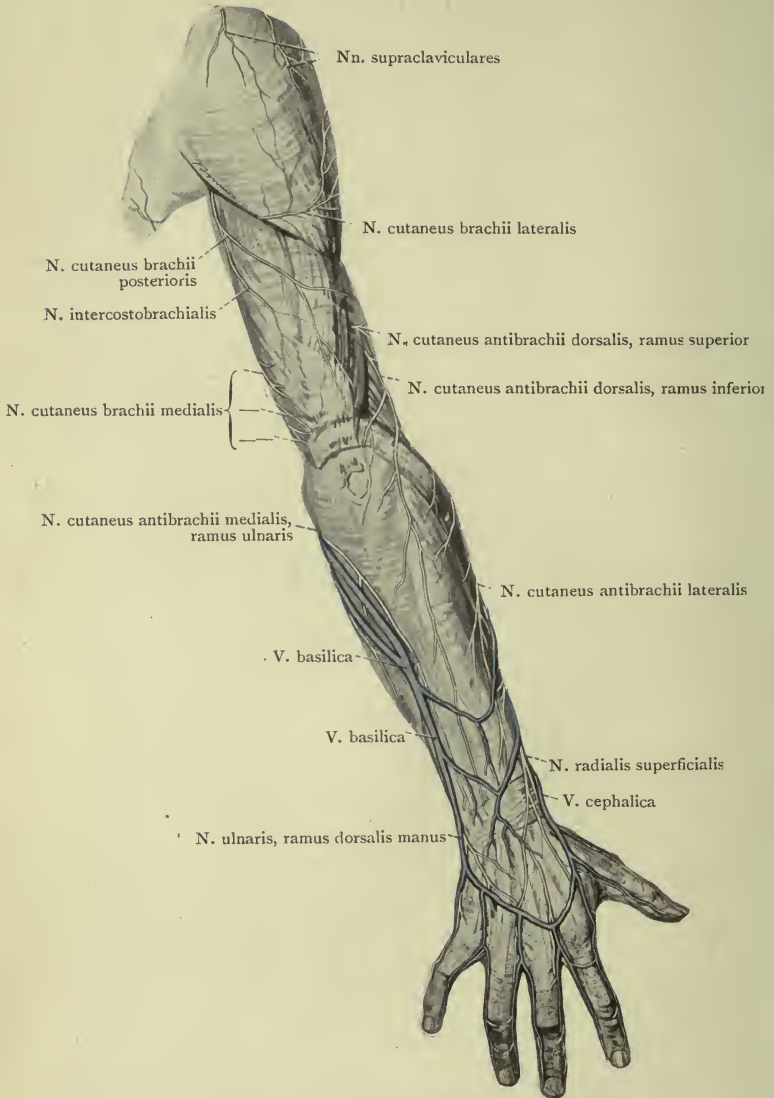


FIG. 32.—Superficial Veins and Nerves of the Posterior Aspect of the Superior Extremity.

brevis muscle and is accompanied by a digital artery. The five most lateral digital nerves are branches of the median nerve, the two most medial are branches of the ulnar nerve, therefore the median nerve supplies three and a half digits, the thumb, the index, the middle and half the ring digit, and the ulnar supplies the remaining one and a half, viz., the little finger and half the ring finger.

As the branches of the median nerve to the fingers are followed along the fingers they will be found to send branches not only to the volar surfaces but also to the dorsal surfaces in the regions of the second and terminal phalanges.

The careful dissector will note that some of the finer branches of the digital nerves terminate in minute ovoid bodies embedded in the fat. They are the Pacinian touch corpuscles and are associated with the sense of touch.

Two other cutaneous nerves have still to be dissected; they are the dorsal branch of the ulnar nerve and the superficial division of the radial nerve. Both are distributed to the dorsum of the hand and to the dorsal aspects of the digits.

The *dorsal branch of the ulnar nerve* must be sought for as it turns round the ulnar border of the wrist immediately distal to the styloid process of the ulna. It gives a branch to the ulnar side of the little finger and a branch to supply the adjacent sides of the ring and little fingers; the latter communicates with the most medial branch of the superficial division of the radial nerve.

The *superficial branch of the radial nerve* will be found at the radial border of the forearm. It appears from under cover of the tendon of the brachio-radialis about 8 cm. ( $3\frac{1}{4}$  inches) above the wrist, and, as it descends to the hand, it breaks up into five branches;—one to each side of the thumb, one to the radial side of the index-finger, one to the adjacent sides of the index and middle fingers, and one to the adjacent sides of the middle and ring fingers. The last branch is connected with the adjacent ramus of the dorsal branch of the ulnar nerve by a communicating twig. A palmar cutaneous branch is distributed to the ball of the thumb either from the trunk of the superficial part of the radial nerve or from the branch to the radial side of the thumb. The dorsal digital nerves of the thumb can be traced to the end of the thumb, those of the index digit to the proximal end of the second phalanx, those of the middle finger to the middle of the second phalanx and those of the ring and little fingers to the proximal end of the terminal phalanx. The remaining parts of the dorsal aspects of the fingers are supplied by the volar digital nerves. The important practical point is that parts of the dorsal surface of the index, middle, and ring digits are supplied not by the radial but by the median nerve.

The arrangement of the nerves on the dorsum of the hand is very variable. That described above is usually met with, but not uncommonly the ulnar nerve supplies a larger and the radial nerve a smaller area. The reverse arrangement is also found.

When the dissection of the cutaneous nerves of the superior extremity is completed remove the remains of the fatty superficial fascia and proceed to the study of the deep fascia.

**Deep Fascia.**—The deep fascia of the superior extremity consists chiefly of transverse fibres, which are bound together by oblique and longitudinal fibres. The oblique and longitudinal fibres become specially developed in certain situations which will be noted later. The deep fascia is fairly strong in the region of the shoulder over the deltoid muscle. Over the posterior part of the deltoid and the adjoining part of the infraspinatus, which covers the lower part of the back of the scapula, it becomes dense, and it is closely attached by deep processes to the axillary border of the scapula. Over the front of the arm, where it covers the biceps muscle, it is thin, but it is much stronger at the back of the arm, over the triceps. On each side, extending proximally from the lateral and the medial epicondyles deep expansions bind it to the lateral and medial supra-epicondylar ridges of the humerus. The expansions are known as the *lateral* and *medial intermuscular septa*, because they separate the muscles on the front from those at the back of the arm. At the elbow it is thickened and strengthened by tendinous fibres, which pass to it from the biceps and triceps muscles, and it is closely attached to the lateral and medial epicondyles of the humerus and to the olecranon of the ulna. A special thickening called the *lacertus fibrosus* (Fig. 31) is found at the front of the elbow. It extends from the medial border of the proximal part of the biceps tendon and the adjacent part of the muscle to the medial side of the proximal part of the forearm. It separates the median cubital vein, which lies superficial to it, from the brachial artery, which is deep to it. The volar branch of the medial cutaneous nerve of the forearm usually passes between the lacertus fibrosus and the median cubital vein.

In the forearm the deep fascia is strong over the proximal parts of the muscles which spring from the medial and the lateral epicondyle. Then it becomes thin, especially on the volar aspect. On the dorsal aspect it is bound to the whole length of the posterior border of the ulna by a deep extension which intervenes between the muscles on the dorsal and volar parts of the medial side of the forearm.

At the wrist the transverse fibres of the deep fascia become very obvious, and they form two marked transverse bands; one on the volar aspect called the *transverse carpal ligament* and one on the dorsal aspect called the *dorsal carpal ligament*.



Both the bands are bound to the adjacent bones and they act as straps which bind down the tendons, which pass deep to them, and prevent them from springing away from the bones when the hand is bent volarwards or dorsally.

The transverse carpal ligament is attached on the ulnar side to the pisiform bone and the hook of the hamatum, and on the radial side to the tubercle of the navicular bone and the ridges on the volar surface of the multangulum majus.

Five structures cross the superficial aspect of the transverse carpal ligament: (1) the ulnar artery; (2) the ulnar nerve; (3) the palmar cutaneous branch of the ulnar nerve; (4) the palmar cutaneous branch of the median nerve; (5) the tendon of the palmaris longus. The palmar cutaneous branches of the median and ulnar nerves have already been seen. The ulnar artery and nerve pierce the deep fascia proximal to the transverse carpal ligament, pass across its superficial surface close to the lateral side of the pisiform bone and disappear deep to the palmaris brevis. As they cross the ligament they are bound down to it by a slip of fascia, called the *volar carpal ligament*, which passes from the pisiform bone to the superficial surface of the transverse carpal ligament. The tendon of the palmaris longus pierces the deep fascia proximal to the transverse carpal ligament, crosses it and blends with the apex of the intermediate part of the palmar aponeurosis which is attached to the distal border of the ligament.

Distal to the transverse carpal ligament the deep fascia is called the *palmar aponeurosis*, of which there are three parts. (1) A relatively thin lateral part which covers the muscles of the thenar eminence; (2) a relatively thin medial part over the muscles of the hypothenar eminence; and (3) a strong intermediate part which conceals and protects the main vessels, nerves, and the tendons passing to the fingers. The lateral and medial parts consist mainly of transverse fibres; the intermediate part on the other hand is formed principally by strong longitudinal fibres bound together by transverse fibres.

The *intermediate part of the palmar aponeurosis* is triangular in outline. Its apex blends with the tendon of the palmaris longus and the transverse carpal ligament. Its borders blend with the thinner lateral and medial parts, and from them septa, which will be dissected later, pass into the depths

of the palm. The distal margin or base lies at the level of the heads of the metacarpal bones, and it divides into five processes, one for each finger and a more slender process for the thumb. Each process passes to the corresponding digit where it blends with the volar surface of the sheath of the flexor tendons, and it sends a process on each side of the digit which join the deep fascia on the dorsal surface.

The *dorsal carpal ligament* is attached on the radial side to the volar margin of the styloid process of the radius and on the ulnar side to the fascia on the medial side of the wrist. The space between it and the distal ends of the radius and ulna is divided into six compartments by septa, which pass from its deep surface to the ridges on the radius and to the head and styloid process of the ulna. The compartments transmit the tendons which pass from the dorsum of the forearm to the dorsum of the hand and to the dorsal aspects of the fingers. Its superficial surface is crossed by the terminal branches of the superficial division of the radial nerve and by the cephalic and basilic veins. The distal border of the dorsal carpal ligament is continuous with the thin deep fascia of the hand, which is prolonged into the dorsal aspects of the digits.

When the study of the deep fascia of the superior extremity has been completed return to the shoulder region; verify again the attachments of the muscles which connected the scapula and the clavicle with the trunk; afterwards cut away the superfluous parts of the muscles, leaving about one inch of each for revision. Then proceed to the general study of the shoulder region.

**Muscles inserted into the Clavicle and Scapula.**—The insertions of the muscles which have already been divided must first engage the attention of the student. They should be carefully defined and the precise extent of each studied. Begin with the *omo-hyoid*, which springs from the superior border of the scapula; then deal in the same way with the *levator scapulae*, *rhomboideus minor* and *major*, which are attached to the vertebral border of the bone, and the *serratus anterior*, which is inserted into the costal aspect of the medial and inferior angles, and the intervening portion of the vertebral border of the scapula. The insertion of the *pectoralis minor* into the coracoid process, and of the *trapezius* into both clavicle and scapula, should also be thoroughly examined.

## SHOULDER—SCAPULAR REGION.

In the dissection of this region the following parts must be studied:—

1. Cutaneous nerves of the shoulder.
2. Deep fascia.
3. Deltoid muscle.
4. Sub-acromial bursa.
5. Anterior and posterior circumflex vessels of the humerus.
6. Axillary (circumflex) nerve.
7. Circumflex scapular artery.
8. Subscapularis muscle.
9. Supraspinatus, infraspinatus, teres minor, and teres major muscles.
10. Bursæ in connection with the shoulder-joint.
11. Suprascapular nerve and transverse scapular artery.
12. Acromio-clavicular joint, and the coraco-acromial arch.

**Nervi Cutanei (Cutaneous Nerves).**—The nerves which lie in the superficial fascia of the shoulder region are derived from two different sources. They are:—

1. Posterior supraclavicular nerves from the third and fourth cervical nerves.
2. Cutaneous branches from the axillary nerve (circumflex).

They have already been secured and cleaned.

The *posterior supraclavicular nerves* cross the lateral third of the clavicle and the insertion of the trapezius, under cover of the platysma. They were divided when the limb was removed, and the distal ends have been followed over the proximal half of the deltoid.

The *cutaneous branches* of the *axillary nerve* consist—  
(a) of a large branch, the *lateral cutaneous nerve of the arm*, which turns round the posterior border of the deltoid muscle, and (b) of several fine filaments which pierce the substance of the deltoid muscle, and appear at irregular intervals on its surface (Fig. 33). The latter are difficult to secure, but the lateral brachial cutaneous nerve has already been found and cleaned (see p. 69). It turns round the posterior border, and is distributed over the distal part of the deltoid region.

**Deep Fascia.**—It has already been noted that the deep fascia over the deltoid is fairly strong, and that as it passes from the deltoid to the muscles which spring from the lower part of the posterior aspect of the scapula, it becomes strong and dense over the infraspinatus, the teres minor and the teres major. In the lower scapular region it is firmly attached to the limits of the infraspinous fossa in which the infra-

spinatus takes origin, and it presents other very apparent connections. Thus, a strong septum, proceeding from its

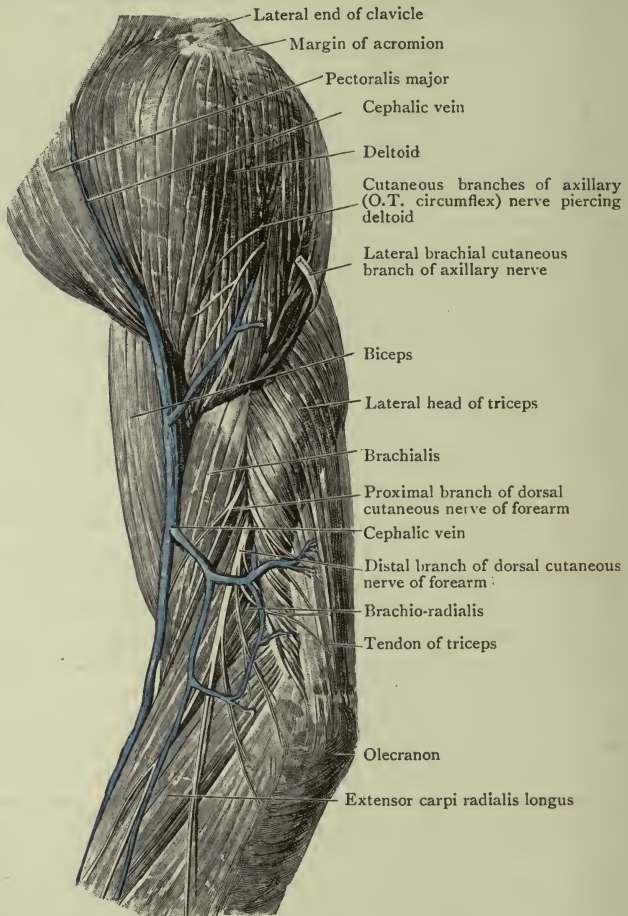


FIG. 33.—The Deltoid Muscle and the lateral aspect of the Arm.

deep surface, will be noticed to dip in between the infra-spinatus and teres minor muscles, and then, as it proceeds forwards, it gives a thin covering to the teres minor, teres major, and the deltoid. Indeed, it may be said to split into

two lamellæ—a superficial and a deep,—which, as they pass forwards, enclose between them the deltoid muscle.

**Dissection.**—Place a small block in the axilla, fix the scapula to it with hooks and bend the arm over the block to make the fibres of the deltoid tense. Detach the lateral brachial cutaneous branch of the axillary nerve from the deep fascia, and turn it backwards to the point where it curves round the posterior border of the deltoid; then clean the deltoid. On the left side commence at its posterior border, make an incision through the deep fascia along the whole length of that border and reflect the deep fascia forwards. On the right side commence in front, where the fascia has already been partly reflected during the dissection of the axillary region, and reflect the fascia backwards.

**M. Deltoideus.**—The deltoid muscle is composed of short, coarse fasciculi, and as its name implies it is of triangular form. Its proximal end or base arises: (1) from the anterior border and the adjacent part of the upper surface of the lateral third of the clavicle; (2) from the lateral border of the acromion; and (3) from the inferior lip of the posterior border of the spine of the scapula. Its origin corresponds closely with the insertion of the trapezius. Its fasciculi converge rapidly as they pass distally to the pointed tendinous insertion on the rough *deltoid tubercle* situated in the middle of the antero-lateral surface of the body of the humerus (Fig. 45). The muscle is an abductor, and a medial and lateral rotator of the humerus, and it is supplied by branches of the anterior division of the axillary nerve which enter its deep surface.

**Dissection.**—Place the limb on its posterior aspect. Release the axillary vessels, and the nerves, from the coracoid process and clean the angle between the humerus and the scapula. Follow the axillary nerve and the posterior circumflex humeral artery backwards. They will be found to enter a cleft between the subscapularis above and the teres major below. Separate those muscles and a triangular interval will be displayed. It is bounded laterally by the surgical neck of the humerus. Crossing the space from above downwards, behind the subscapularis and the teres major is the long head of the triceps. It divides the triangular interval into a lateral part called the *quadrangular space* and a medial part called the *triangular space*. The axillary nerve and the posterior humeral circumflex artery pass through the quadrangular space. Now reverse the limb, push the posterior border of the deltoid forwards and find the axillary nerve and the posterior humeral circumflex artery. They emerge from the quadrangular space and pass forwards round the lateral surface of the surgical neck of the humerus.

At this stage of the dissection the deltoid muscle must be reflected. Cut it away from its origin from the clavicle, acromion,

and spine of the scapula, and turn it towards its insertion into the humerus, taking care not to injure the circumflex humeral arteries and the axillary nerve. Note the tendinous intersections which run through the substance of the muscle, then clean the vessels and nerves which are exposed. The axillary nerve enters the back part of the shoulder region through the posterior part of the quadrangular space, accompanied by the posterior humeral circumflex vessels, and at once divides into an anterior and a posterior division. Before it divides, whilst it is in the quadrangular space, immediately below the shoulder-joint, it gives off an articular twig to the joint, which should be secured. The anterior division accompanies the posterior humeral circumflex artery round the surgical neck of the humerus. It supplies the deltoid and sends branches through it to the skin on its superficial surface. Clean both the nerve and the vessel; then turn to the posterior branch and secure the twig to the teres minor muscle, upon which there is a gangliform enlargement. The posterior branch terminates as the lateral cutaneous nerve of the arm, which turns round the posterior border of the deltoid to gain its superficial surface. It has already been dissected (see p. 69). Clean the teres major and minor muscles which spring from the posterior surface of the axillary border of the scapula, and pass to the humerus, and note the strong septum of deep fascia which separates them. Clean the long head of the triceps which arises from the upper part of the axillary border of the scapula. Then examine the subacromial bursa, which lies directly below the acromion, on the insertion of the supraspinatus. If the wall of the bursa is quite entire a blow-pipe may be thrust into it. It can then be distended, and if unilocular it may be inflated to about the average size of a hen's egg. It varies much in size, however, in different subjects. Open the bursa and examine its extent with the finger or a blunt probe. Its interior is sometimes divided by fibrous partitions into two or more loculi. Now turn the limb on to its posterior aspect and clean the proximal parts of the coracobrachialis and the short head of the biceps brachii which spring, by a common tendon, from the tip of the coracoid process of the scapula. Pull the short head of the biceps and the coracobrachialis medially and expose the tendon of the long head of the biceps lying in the intertubercular sulcus of the humerus, but do not displace it at present. Now pull the short head of the biceps and the coraco-brachialis laterally and clean the insertion of the subscapularis—it is inserted into the lesser tubercle of the humerus on the medial side of the intertubercular sulcus. Clean also the anterior humeral circumflex artery, trace it to its division into an ascending branch, which runs to the shoulder-joint along the intertubercular sulcus, and a transverse branch, which anastomoses with the posterior humeral circumflex artery, and then re-examine the structures which lie directly under cover of the deltoid and note their relative positions.

**PARTS UNDER COVER OF THE DELTOID.**—The deltoid covers the proximal part of the humerus, and envelops the region of the shoulder-joint behind, laterally, and in front. It also covers the coracoid process of the scapula. It is

separated from the shoulder-joint by the muscles which are attached to the proximal end of the humerus and by the subacromial bursa. The full, rounded appearance of the shoulder is due to the deltoid passing over the proximal end of the humerus and the muscles attached to it. When the head of the humerus is dislocated the muscle passes vertically

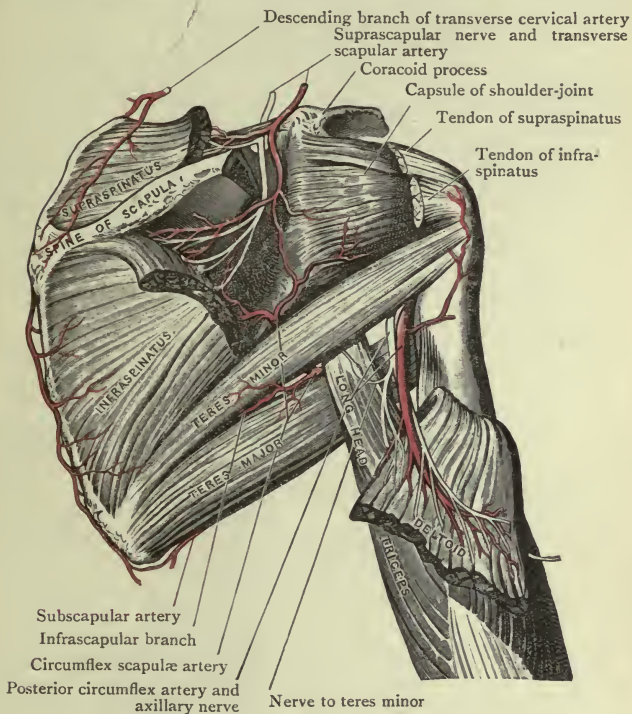


FIG. 34.—Dissection of the Posterior Scapular Region.

from its origin to its insertion, and the dislocation is recognised by the squareness or flatness of the shoulder. Under cover of the posterior part of the deltoid are portions of the muscles which spring from the posterior surface of the scapula, viz., the infraspinatus, teres major, and teres minor, and the proximal part of the long head of the triceps, which arises from the upper part of the axillary border of the scapula. Under its middle part lie the insertion of the

supraspinatus, covered by the subacromial bursa, and the upper portion of the lateral aspect of the body of the humerus. Its anterior part covers the coracoid process and

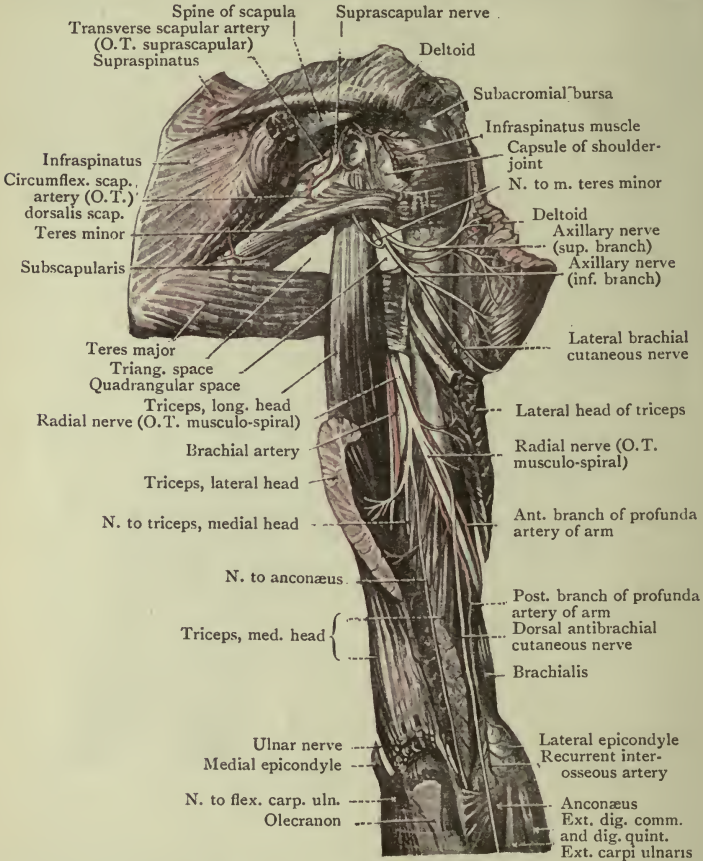


FIG. 35.—Dissection of the dorsal aspect of the Arm. The lateral head of the Triceps has been divided and turned aside to expose the sulcus on the Humerus for the radial nerve.

the muscles and ligaments which are attached to it, the long head of the biceps muscle descending in the intertubercular sulcus, and the insertion of the subscapularis into the lesser tubercle of the humerus. The muscle also covers the greater



part of the axillary nerve and the anterior and posterior humeral circumflex vessels.

**Bursa Subacromialis.**—The subacromial bursa is a large bursal sac which intervenes between the acromion and deltoid above, and the muscles which immediately cover the upper aspect of the capsule of the shoulder-joint below. It facilitates the play of the proximal end of the humerus and the

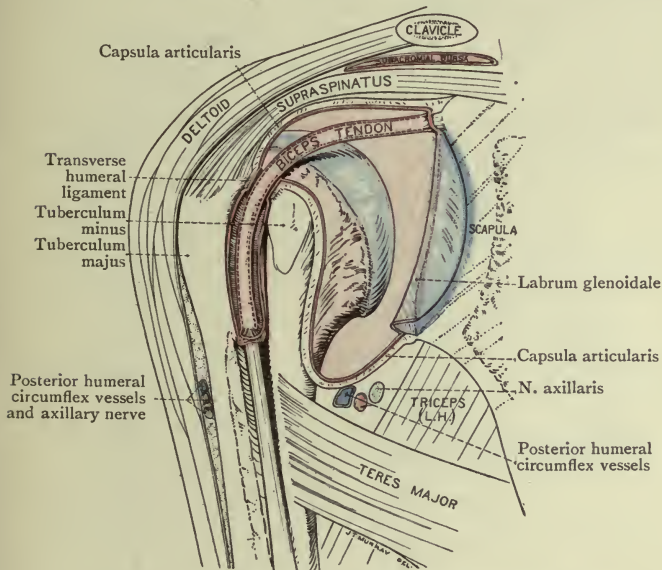


FIG. 36.—Diagram of a Frontal Section of the Right Shoulder.

attached muscles on the under aspect of the acromion and deltoid.

**The Quadrangular and Triangular Spaces.**—Neither of these so-called spaces has any real existence until the boundaries are artificially separated from one another. When viewed from the front the triangular space is bounded above by the subscapularis, below by the teres major, and laterally by the long head of the triceps, but at the back the teres minor replaces the subscapularis as the upper boundary. The circumflex scapular branch of the subscapular artery enters the space from the front, turns round the axillary

border of the scapula, anterior to the teres minor, and enters the infraspinous fossa.

The boundaries of the quadrangular space, as seen from the front, are the subscapularis above, the teres major below, the long head of the triceps medially, and the surgical neck of the humerus laterally. At the back the teres minor replaces the subscapularis as the upper boundary. Between the subscapularis anteriorly, and the teres minor posteriorly, the inferior surface of the capsule of the shoulder-joint forms the upper boundary of the space, and through the space, directly below the capsule, pass the axillary nerve and the posterior humeral circumflex vessels.

**Arteriæ Circumflexæ Humeri (O.T. Circumflex Arteries).—**

The *posterior humeral circumflex artery* has been already

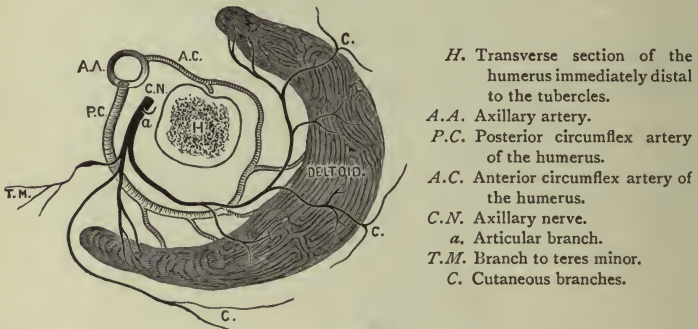


FIG. 37.—Diagram of the Circumflex Vessels and the Axillary Nerve.

observed to arise, within the axilla, from the posterior aspect of the axillary artery, a short distance distal to the subscapular branch. It at once passes backwards, through the quadrilateral space, and, winding round the surgical neck of the humerus, it is distributed in numerous branches to the deep surface of the deltoid muscle. Several twigs are given also to the shoulder-joint and the integument. It anastomoses with the acromial branch of the thoraco-acromial artery and with the anterior humeral circumflex artery, and also, by one or more twigs, which it sends distally to the long head of the triceps, with the profunda branch of the brachial artery.

The termination of the *anterior humeral circumflex artery* can now be more satisfactorily studied, and its anastomosis

with the posterior humeral circumflex artery established, if the injection has flowed well. By the anastomosis the arterial ring which encircles the proximal part of the humerus is completed.

**Nervus Axillaris (O.T. Circumflex Nerve).**—The axillary

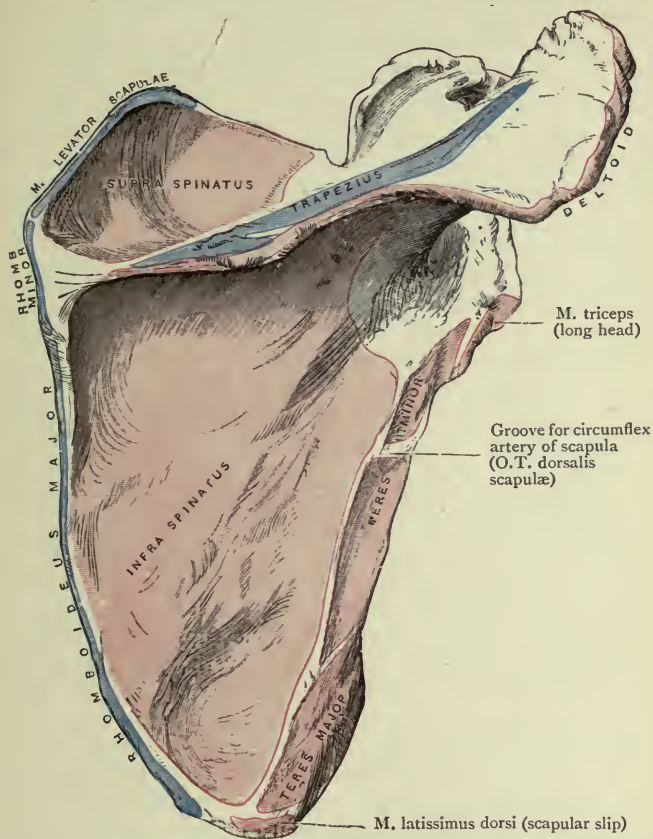


FIG. 38.—Dorsum of Scapula with the Attachments of the Muscles mapped out.

nerve accompanies the posterior humeral circumflex artery. It supplies: (1) an *articular twig* to the shoulder-joint; (2) *muscular branches* to the deltoid and teres minor; and (3) *cutaneous branches* to the skin over the distal part of the

deltoid. It springs from the posterior cord of the brachial plexus, turns round the lower border of the subscapularis, and passes backwards, with the posterior humeral circumflex artery, through the quadrilateral space to the back of the limb. There it divides into an anterior and a posterior division. The *articular branch* takes origin from the trunk of the nerve in the quadrilateral space, and enters the joint from below. The *posterior division* gives off the branch to the teres minor, and, after furnishing a few twigs to the posterior part of the deltoid, is continued onwards, as the *lateral cutaneous nerve of the arm*, which has already been dissected in the superficial fascia over the distal part of the deltoid (Figs. 31, 32, 35). The nerve to the teres minor is distinguished by the presence of an oval, gangliform swelling upon it.

The *anterior division* proceeds round the humerus with the posterior circumflex artery of the humerus, and ends near the anterior border of the deltoid. It is distributed, by many branches, to the deep surface of the muscle, whilst a few fine filaments pierce the deltoid and reach the skin.

**Dissection.**—Clean the coraco-acromial ligament, which extends from the coracoid process to the acromion. Note that the coracoid process, the coraco-acromial ligament, and the acromion form an arch—the *coraco-acromial arch*. The arch lies above the shoulder-joint, but is separated from it by the subacromial bursa, and the humeral ends of the supraspinatus, the infraspinatus, and the subscapularis.

**Arcus Coracoacromialis.**—The coraco-acromial arch should be examined at the present stage, in order that its relationship to the subacromial bursa and the supraspinatus may be appreciated. It is the arch which overhangs the shoulder-joint and protects it from above. It is formed by the coracoid process, the acromion, and a ligament—the coraco-acromial—which stretches between them.

The *coraco-acromial ligament* is a strong band of a somewhat triangular shape. By its base it is attached to the lateral border of the coracoid process, whilst by its apex it is attached to the extremity of the acromion (Figs. 51, 52, 54).

The coraco-acromial arch plays a very important part in the mechanism of the shoulder; it might almost be said to form a secondary socket for the humerus. The large subacromial bursa, which intervenes between the acromion and the muscles immediately covering the capsule of the shoulder-

joint, facilitates the movements of the proximal end of the humerus on the inferior surface of the arch; it has already been noted (p. 78).

**Dissection.**—Clear away the subacromial bursa and clean the supraspinatus, following it below the coraco-acromial arch to its insertion into the greater tubercle of the humerus. Then clean the fascia from the surface of the subscapularis; it is a fairly strong fascia and, near the vertebral border of the scapula, some of the fibres of the serratus anterior are usually inserted into it. Now turn the limb on its anterior aspect and remove the strong fascia which covers the posterior surfaces of the infraspinatus, the teres minor and the teres major. Divide first the fascia over the infraspinatus. Incise it from the vertebral border of the scapula to the greater tubercle of the humerus. Reflect the upper part to its attachment to the spine of the scapula and the lower part to the septum which separates the infraspinatus from the teres minor and major muscles. Then clear the fascia from the teres minor and major muscles. As the septum between the teres minor and the infraspinatus is being investigated be careful to avoid injury to the circumflex scapular artery. The scapular muscles may now be examined.

**M. Supraspinatus.**—The supraspinatus muscle arises from the medial two-thirds of the supraspinous fossa, and also, to a slight degree, from the supraspinous fascia, which covers it. From this origin the fibres converge, as they pass laterally, and, proceeding under the acromion, they end in a short, stout tendon, which is inserted into the uppermost of the three impressions on the greater tubercle of the humerus (Fig. 45, p. 107). The tendon is closely adherent to the capsule of the shoulder-joint. A portion of the supraspinatus is covered by the trapezius, and in the loose fat which intervenes between that muscle and the supraspinous fascia some twigs of the ascending branch of the transverse cervical artery ramify. The supraspinatus is supplied by the *suprascapular nerve*; and it is an abductor of the arm.

**M. Infraspinatus.**—The infraspinatus muscle arises from the whole of the infraspinous fossa, with the exception of a small part of it near the neck of the scapula. It derives fibres also from the fascia which covers it. Its tendon of insertion is closely adherent to the capsule of the shoulder-joint, and is attached to the middle impression on the greater tubercle of the humerus (Fig. 48, p. 113). It is supplied by the *suprascapular nerve*; and it is an adductor and lateral rotator of the arm.

**M. Teres Minor.**—The teres minor is the small muscle

which lies along the lower border of the infraspinatus. It arises from an elongated flat impression on the dorsal aspect of the axillary border of the scapula, and from the fascial septa which intervene between it and the two muscles between which it lies, viz. the infraspinatus and teres major. It is inserted into the lowest of the three impressions on the greater tubercle of the humerus, and also, by fleshy fibres, into the body of the bone for about 12.5 mm. (half an inch) distal to the tubercle (Fig. 48, p. 113). As it approaches its insertion it is separated from the teres major by the long head of the triceps brachii. The teres minor is supplied by a branch from the *axillary nerve*. It is an adductor and lateral rotator of the arm.

**M. Teres Major.**—The part which the teres major plays in the formation of the quadrilateral and triangular spaces has already been seen. It arises from the oval surface on the dorsum of the scapula close to the inferior angle of the bone (Fig. 38, p. 83), and also from the septum which the infraspinous fascia sends in to separate it from the infraspinatus and teres minor muscles. It is inserted into the medial lip of the intertubercular sulcus on the proximal part of the humerus (Fig. 45, p. 107). It is supplied by the lower subscapular nerve, and it is an adductor, a medial rotator and an extensor of the arm.

**M. Subscapularis.**—The subscapularis muscle arises from the whole of the subscapular fossa, with the exception of a small portion near the neck of the scapula; it takes origin also from the groove which is present on the costal aspect of the axillary border of the bone (Fig. 24, p. 46). Its origin is strengthened by tendinous intersections, which are attached to the ridges on the costal surface of the scapula. The fleshy fibres thus derived converge upon a stout tendon, which is inserted into the lesser tubercle of the humerus; a few of the lower fibres, however, gain independent insertion into the body of the humerus distal to the tubercle (Fig. 45).

As the muscle proceeds laterally to its insertion, it passes under an arch formed by the coracoid process and the conjoined origin of the short head of the biceps brachii and the coraco-brachialis. The subscapularis is supplied by the *upper* and *lower subscapular nerves*. It is an adductor and medial rotator of the arm.

**Dissection.**—Pull the long head of the biceps out of the intertubercular sulcus. Separate the tendon of insertion of the latissimus dorsi from the anterior surface of the teres major, noting the small fibrous slip which passes from its inferior margin to the fascia on the long head of the triceps muscle (Fig. 16); then follow the tendon of the latissimus to its insertion into the floor of the intertubercular sulcus. The tendon of the latissimus is more or less adherent to the teres major, but near the humerus a small bursa frequently intervenes between the two tendons. Now examine carefully the insertions of the pectoralis major, the latissimus dorsi and the teres major.

**Insertions of the Pectoralis Major and Latissimus Dorsi.**—

As the pectoralis major passes to its insertion into the lateral lip of the intertubercular sulcus it lies anterior to the great vessels and nerves of the axilla, to the two heads of the biceps humeri, and to the coraco-brachialis, whilst the latissimus dorsi lies behind those structures. The teres major accompanies the latissimus dorsi as far as the medial lip of the intertubercular sulcus. It therefore does not pass behind the long head of the biceps humeri.

The tendon of the *pectoralis major* consists of two laminæ. A separation of the clavicular and sternal portions of the muscle will bring both laminæ into view, and the following points should be noted in connection with them: (*a*) that they are continuous with each other below, or, in other words, that the tendon is simply folded upon itself; (*b*) that the posterior lamina extends to a more proximal level on the humerus than the anterior, and that a fibrous expansion proceeds proximally from its superior border, to seek attachment to the capsule of the shoulder-joint and the lesser tubercle of the humerus; (*c*) that the lower border is connected with the fascia of the arm.

The narrow, thin, flat, band-like tendon of the *latissimus dorsi* lies in front of the insertion of the teres major, but does not extend so far downwards. Therefore the teres major is the lowest muscle in the lateral part of the posterior wall of the axilla, and consequently the last muscle of the posterior axillary wall upon which the axillary artery rests. The slip of fascia which passes from the lower margin of the tendon of the latissimus to the fascia on the long head of the triceps is of interest inasmuch as it represents the dorsi-epitrochlearis muscle of other animals.

**Dissection.**—Depress the upper border of the subscapularis as it passes below the coracoid process, and expose the subscapular

bursa. Inflate the bursa with a blowpipe, and notice that, as air is blown in, the capsule of the shoulder-joint is distended. If the wall of the bursa has been injured in the course of previous dissections, open it with the scalpel and examine the interior with a blunt probe. Note its extent and its continuity with the interior of the shoulder-joint through a large aperture in the anterior part of the articular capsule.

**Bursa Subscapularis.**—The subscapular bursa is formed by the prolongation of the synovial stratum of the capsule of the shoulder-joint through an aperture in the upper and anterior part of the fibrous stratum. It extends laterally between the subscapularis and the medial part of the articular capsule, medially between the subscapularis and the anterior surface of the neck of the scapula and the root of the coracoid process, and it facilitates the movement of the subscapularis on the front of the head and neck of the scapula.

**Dissection.**—Cut through the subscapularis vertically below the coracoid process, and detach from its deep surface the bursa, which lies between it and the scapula and the capsule of the shoulder. Turn the medial part of the muscle towards the vertebral border of the scapula, and as you detach it from the bone note the tendinous intersections by which it is connected with the ridges on the costal surface of the scapula. Note also the anastomosis between branches of the subscapular and transverse scapular arteries which ramify on its deep surface. Turn the lateral portion towards the humerus, detaching it from the lateral part of the front of the capsule of the shoulder to which it is adherent, and verify its attachment to the lesser tubercle of the humerus and to the bone immediately distal to the tubercle. Do not fail to notice that, as it crosses the shoulder-joint to its insertion, it lies behind the coraco-brachialis and the short head of the biceps.

Divide the supraspinatus medial to the coracoid process. Turn the medial part towards the vertebral border of the scapula and verify its attachment to the spine and to the dorsal surface of the scapula, and dissect out the branches of the transverse scapular artery and the suprascapular nerve which pass to its deep surface. Turn the lateral part towards the humerus, forcing it beneath the coraco-acromial arch, and as you do that avoid injury to the transverse scapular vessels and the suprascapular nerve which lie beneath it. Note that as the tendon of the muscle crosses the top of the shoulder-joint it is firmly attached to the capsule before it reaches its insertion into the superior facet on the greater tubercle of the humerus. Divide the infrapinatus medial to the lateral border of the spine of the scapula. Verify the attachment of the medial part to the inferior surface of the spine and the dorsal surface of the body of the scapula, dissecting out the vessels and nerves from its deep surface. Follow the lateral part to its insertion into the middle facet on the greater tubercle of the humerus, and, as the muscle is displaced, take care not to injure the transverse scapular



vessels, the suprascapular nerve, and the circumflex scapular vessels which lie between it and the bone. Occasionally there is a small bursa between it and the posterior surface of the capsule of the shoulder-joint which communicates with the cavity of the joint.

Divide the *teres minor* where the circumflex scapular artery passes between it and the posterior surface of the axillary border of the scapula, and verify its origin from the scapula and its insertion into the inferior facet on the greater tubercle of the humerus, and to the ridge which descends from the tubercle.

When the *infraspinatus* and *teres minor* have been reflected, look for the *inferior transverse ligament of the scapula*. It is a band of fascia which passes from the lateral border of the spine of the scapula to the posterior border of the glenoid fossa, arching across the great scapular notch. It protects the *infraspinous* branch of the transverse scapular artery and the suprascapular nerve as they pass behind the neck of the scapula from the supra- to the *infraspinous fossa*.

Now clean the transverse scapular vessels, and the suprascapular nerve and the circumflex scapulæ branch of the subscapular artery. Commence with the transverse scapular artery as it lies medial to the coracoid process, and the suprascapular nerve which accompanies it. The artery lies on the *superior transverse ligament of the scapula*, immediately medial to the coracoid process. The nerve passes through the notch on the superior border of the scapula beneath the ligament. Follow the artery and nerve behind the neck of the scapula into the *infraspinous fossa*, and note that both pass between the neck of the scapula and the inferior transverse ligament. Then clean the circumflex scapular artery, and study the transverse ligaments of the scapula and the arterial anastomosis round the scapula.

**Ligamenta Transversa Scapulæ.**—There are two transverse scapular ligaments—(1) a superior, *ligamentum transversum scapulæ superius*; (2) an inferior, *ligamentum transversum scapulæ inferius* (O.T. *spino-glenoid*). Both the transverse ligaments are associated with the transverse scapular vessels and the suprascapular nerve. The superior transverse ligament bridges across the notch in the superior border of the scapula and converts it into a foramen. It lies between the transverse scapular artery, which passes above it, and the suprascapular nerve, which lies in the notch below it. In not a few cases it is ossified. The inferior transverse ligament is a weaker band which bridges across the great scapular notch at the back of the neck of the scapula, passing from the lateral border of the spine of the scapula to the posterior margin of the glenoid cavity. The *infraspinous* branch of the transverse scapular artery and the suprascapular nerve lie in the notch, deep to the ligament.

**Dissection.**—Revise the arteries which lie in relation with the borders and surfaces of the scapula, and dissect out the anastomosis between their branches. Descending along the vertebral border is the descending branch of the transverse cervical artery. Crossing the superior border is the supra-scapular artery. The subscapular artery was seen during the dissection of the axilla; it springs from the third part of the axillary, descends for about 25-30 mm. along the inferior border of the subscapularis, and then divides into circumflex scapular and thoraco-dorsal branches. The circumflex scapular at once turns round the axillary border of the scapula and passes, deep to the teres minor, to the infraspinous fossa. Follow the ramifications of both branches to their anastomoses with the adjacent arteries.

**The Anastomosis around the Scapula.**—An important and free anastomosis takes place between the branches of three arteries which lie in close relation with the scapula, viz.: (1) the descending branch of the transverse cervical artery; (2) the transverse scapular artery; (3) the circumflex scapulæ and thoraco-dorsal branches of the subscapular artery.

**The Descending Branch of the Transverse Cervical Artery** was seen when the levator scapulæ and the rhomboids were reflected. It runs downwards along the vertebral border of the scapula in the angle between the levator scapulæ and the rhomboids, which are behind it, and the insertion of the serratus anterior, which is in front of it. It sends branches into the subscapular fossa and into the supra- and infraspinous fossæ, which anastomose in all three regions with branches of the transverse scapular and subscapular arteries, and at the inferior angle of the scapula it anastomoses with the terminal branches of the thoraco-dorsal branch of the subscapular artery.

**Arteria Transversa Scapulæ (O.T. Suprascapular Artery).**—The transverse scapular artery enters the suprascapular fossa by passing over the ligament which bridges across the scapular notch. It divides, under cover of the suprascapular muscle, into a *suprascapular* and an *infraspinous branch*. The former supplies the suprascapular muscle, and gives off the chief nutrient artery to the scapula; the latter proceeds downwards through the great scapular notch, under cover of the inferior transverse scapular ligament, to reach the deep surface of the infraspinatus muscle, to which it is distributed.

At the superior border of the scapula the transverse artery of the scapula gives off a *subscapular branch*, which enters the subscapular fossa, under cover of the subscapularis muscle.

**Arteria Circumflexa Scapulæ (O.T. Dorsalis Scapulæ Artery).**—The circumflex scapular artery, as already noted, arises from the subscapular branch of the axillary and enters the triangular space. While there it supplies one or two *ventral branches*, which pass, under cover of the subscapular muscle, to the subscapular fossa, and a larger *infrascapular branch*, which runs downwards, in the interval between the teres major and teres minor, to the inferior angle of the scapula (Figs. 34, 35, pp. 79, 80). After those branches are given off, the circumflex scapular artery leaves the triangular space by turning round the axillary border of the scapula, under cover of the teres minor. It now enters the infraspinous fossa, where it ramifies, and supplies branches to the infraspinatus muscle.

**Arteria Thoracodorsalis.**—The thoraco-dorsal branch of the subscapular artery runs along the axillary border of the scapula on the lower margin of the subscapularis. It sends branches into the subscapular fossa which supply the subscapularis and anastomose with branches of the descending branch of the transverse cervical artery, and the transverse scapular and circumflex scapulæ arteries.

When the dissector has followed the branches of the four arteries just considered, he will realise that the arterial anastomosis around the scapula is very complete. In the supraspinous fossa branches of the descending branch of the transverse cervical artery and the transverse scapular artery anastomose. In the infraspinous fossa branches of the descending branch of the transverse cervical, the transverse scapular, and the subscapular artery anastomose, and branches of the same three arteries anastomose in the subscapular fossa. The importance of these free communications is manifest when it is remembered that two of the main arteries, viz., the descending branch of the transverse cervical artery and the transverse artery of the scapula, spring indirectly from the first part of the subclavian; whilst the third, viz., the subscapular, arises from the third part of the axillary. When, therefore, a ligature is applied to any part of the great arterial trunk of the upper limb, between the first stage of the subclavian and the third part of the axillary, the anastomosis round the scapula affords ample means of re-establishing the circulation.

**Nervus Suprascapularis.** — The suprascapular nerve

accompanies the transverse artery of the scapula, but it enters the supraspinous fossa by passing through the scapular notch, under cover of the upper transverse ligament of the scapula. It supplies the supraspinatus, and ends in the infraspinatus muscle. It usually sends *two articular twigs* to the posterior aspect of the shoulder-joint, viz., one while in the supraspinous fossa and the second as it lies in the infraspinous fossa.

The ligaments which connect the clavicle with the scapula should now be examined; they are (1) the coraco-clavicular ligament, which is found between the clavicle and the coracoid process of the scapula and the capsule of the acromio-clavicular joint.

**Dissection.**—Clean the surfaces and borders of the coraco-clavicular ligament, and note that it consists of two segments—a medial segment called the *conoid ligament* and a lateral segment called the *trapezoid ligament*. The two segments meet at an angle which is open in front, and in the angle a small bursa is sometimes found. After the coraco-clavicular ligament has been fully defined, remove the remains of the deltoid and trapezius muscles from the capsule of the acromio-clavicular joint and clean the external surface of the capsule.

**Lig. Coracoclaviculare.**—The coraco-clavicular ligament is a powerful ligament which binds the inferior surface of the clavicle to the coracoid process. It consists of two parts, which are termed the conoid and the trapezoid ligaments.

The *ligamentum conoideum* lies posterior and medial to the lig. trapezoideum. It is broad above, where it is attached to the coracoid tubercle of the clavicle (Fig. 10, p. 21), and somewhat narrower below, at its attachment to the bend of the coracoid process. The *ligamentum trapezoideum* is a flatter band. Above, it is attached along the trapezoid line of the clavicle (Fig. 10, p. 21), whilst below it is fixed to the upper aspect of the coracoid process.

The coraco-clavicular ligament helps to prevent dislocation of the acromial end of the clavicle, and, to a certain extent, it limits the movements of the acromio-clavicular joint. It is therefore an accessory ligament of that joint. It is the main medium by which the scapula, and, indirectly, the other parts of the superior extremity, are suspended from the clavicle. If it is cut when the body is erect, the superior extremity as a whole at once falls, and the same thing occurs

if the clavicle is broken medial to the attachment of the ligament.

**Articulatio Acromio-Clavicularis.**—The acromio-clavicular joint is a diarthrodial joint; and the ligaments which bind the bones together at the joint are :

Articular Capsule :

Superior acromio-clavicular ligament.

Inferior acromio-clavicular ligament.

Accessory Ligament, not connected with the capsule :

Coraco-clavicular.

The superior and inferior acromio-clavicular ligaments are simply thickened parts of the fibrous stratum of the articular capsule.

The *superior acromio-clavicular ligament* is a broad band, composed of stout fibres, which is placed on the upper aspect of the joint. The *inferior acromio-clavicular ligament*, which closes the joint below, is not so strongly developed. In front and behind, the two ligaments are connected with each other so as to constitute a capsule. The joint should now be opened to display the synovial stratum of the capsule and an imperfect articular disc which is usually present. The disc is wedge-shaped, and connected by its base to the superior ligament, whilst its free margin is directed downwards between the bones.

The two surfaces of the joint are flat and are ovoid in outline, and each slopes obliquely downwards and medially. There is therefore a tendency for the clavicle to glide, upwards and laterally, on to the upper surface of the acromion. The tendency is counteracted by the strength of the superior acromio-clavicular ligament.

## THE FRONT OF THE ARM.

In the anterior region of the arm the following structures have to be studied :—

Cutaneous veins.

Cutaneous nerves of the arm.

Parts of the cutaneous nerves of the forearm.

The brachial fascia.

The brachial artery and its branches.

The median, ulnar, radial and musculo-cutaneous nerves.

The biceps, coraco-brachialis and brachialis muscles.

It is convenient to study at the same time the cubital fossa in front of the elbow.

The skin has already been removed, and the cutaneous veins and nerves have been seen (see pp. 62, 63). Now they must be re-studied, and the main points of the surface anatomy of the region must be revised.

**Surface Anatomy.**—In a muscular limb the prominence formed by the biceps muscle along the front of the arm is very apparent. Every one is familiar with the rounded swelling which the muscle produces when powerfully contracted in the living subject. On each side of the biceps there is a feebly marked furrow, and ascending in each of these there is a large superficial vein. In the lateral sulcus is the cephalic vein; in the distal part of the medial sulcus is the basilic vein. In the proximal part of the medial bicipital sulcus is an elongated bulging produced by the subjacent coraco-brachialis muscle; it is useful as a guide to the distal part of the axillary and the proximal part of the brachial arteries, which lie immediately behind and to the medial side of it. The humerus is thickly clothed by muscles; but towards its distal part the two epicondylar ridges, leading to the epicondylar eminences, may be felt. The lateral ridge is the more salient of the two, and therefore the more evident to touch.

The bony points around the elbow must be studied with especial care. It is by a proper knowledge of the normal relative positions of them that the surgeon is able to distinguish between the different forms of fracture and dislocation which so frequently occur in the elbow region. First note the medial epicondyle of the humerus. It constitutes a prominence appreciable to the eye; grasp it between the finger and thumb, and note that it inclines posteriorly as well as medially. In a well-developed, fully extended arm, the lateral epicondyle does not form a projection on the surface, but can be felt at the bottom of a slight depression on the dorsal aspect of the limb. It becomes apparent to the eye as a prominence when the elbow is semi-flexed. The olecranon produces a marked projection on the dorsum of the elbow between the two epicondyles. It is placed slightly

nearer to the medial than to the lateral epicondyle. The loose skin which covers the olecranon moves freely over its subcutaneous surface, owing to the interposition of a bursa. The different positions which are assumed by the olecranon, in relation to the epicondyles of the humerus in the movements of the forearm at the elbow-joint, must be carefully examined. That can be done best by placing the thumb on one epicondyle, the middle finger on the other, and the fore-

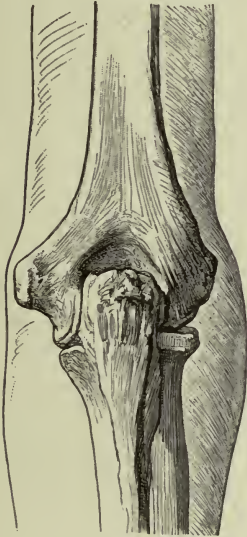


FIG. 39.—Relation of Bones of Elbow to the surface. Dorsal view; elbow fully extended.

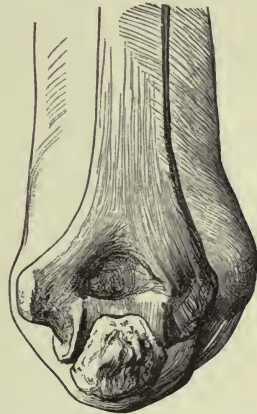

FIG. 40.—Relation of the Bones of the Elbow to the surface. Dorsal view; elbow bent.

finger on the olecranon. The limb should then be alternately flexed and extended, so as to make clear the extent of the excursion performed by the olecranon. In full extension at the elbow-joint the three prominences lie in the same horizontal plane; when the forearm is bent at a right angle the three bony points are placed at the angles of an equilateral triangle, of which one angle points distally.

When the forearm is extended a marked depression on the dorsal aspect of the elbow indicates the position of the articula-

tion between the radius and the humerus. Immediately distal to it the head of the radius lies near to the surface, and can readily be felt, especially when it is made to roll under the finger by inducing alternately the movements of pronation and supination. The head of the radius is placed about 25 mm. (one inch) distal to the lateral epicondyle.

**Venæ Superficiales.**—Portions of two large cutaneous veins are met with in the arm, the cephalic vein and the basilic vein. They were dissected and studied when the cutaneous nerves of the superior extremity were examined (see p. 63). Their positions in the arm should now be revised. Both ascend from the back of the hand, and they communicate with one another across the fascial roof of the cubital fossa at the front of the elbow, by means of the median cubital vein.

In the arm the *cephalic vein* ascends along the groove at the lateral border of the biceps or along the lateral part of the eminence caused by the biceps muscle, to the delto-pectoral sulcus. There it pierces the deep fascia, and it continues upwards to the delto-pectoral triangle where it turns medially, crosses superficial to the pectoralis minor, pierces the costo-coracoid membrane, under cover of the pectoralis major, and terminates in the axillary vein.

The portion of the *basilic vein* which lies in the arm ascends in the groove along the medial border of the biceps muscle. At the middle of the arm it pierces the deep fascia, and runs along the medial side of the brachial artery to the axilla, where it becomes the axillary vein.

**Nervi Cutanei.**—The cutaneous nerves found in the region of the arm at a previous stage of the dissection were:—

- Nn. supraclaviculares (the posterior group) from the cervical plexus.
- N. cutaneus brachii lateralis from the axillary nerve.
- N. intercosto-brachialis from the second intercostal nerve.
- N. cutaneus brachii medialis from the brachial plexus.
- N. cutaneus antibrachii medialis from the brachial plexus.
- N. cutaneus brachii posterior from the radial nerve.
- N. cutaneus antibrachii dorsalis from the radial nerve.
- N. cutaneus antibrachii lateralis from the musculo-cutaneous nerve.



All these nerves have already been studied (p. 69); the supraclavicular nerves were removed, and the lateral brachial cutaneous nerve was displaced when the shoulder region was examined. Their general positions and distribution of the remaining nerves should now be revised.

The *intercosto-brachial nerve* supplies the skin of the posterior part of the medial aspect of the arm and the adjacent part of the back of the arm from the axilla to the elbow (Figs. 31, 32).

The *medial cutaneous nerve of the arm* pierces the deep fascia at the middle of the arm, on the medial side, and supplies the skin of the distal half of the medial aspect of the arm. Before it pierces the fascia it gives off no branches of distribution, but it may communicate with the intercosto-brachial nerve (Figs. 31, 16).

The *medial cutaneous nerve of the forearm* pierces the deep fascia at the middle of the arm, on the medial side, sometimes passing through the opening which admits the basilic vein. Before it becomes superficial it gives off several branches which pierce the deep fascia at varying points from the axilla to the middle of the arm; those branches, together with others given off after the nerve pierces the deep fascia, supply the skin on the medial part of the anterior aspect and the anterior part of the medial aspect of the arm, from the axilla to the elbow. The two terminal branches of the nerve, *volar and ulnar*, supply the skin of the medial part of the volar aspect, and the ulnar border of the forearm as far as the wrist. As the volar branch leaves the arm it usually passes between the median cubital vein and the lacertus fibrosus. The ulnar branch descends either in front of or behind the medial epicondyle (Figs. 31, 32).

The *posterior brachial cutaneous nerve* supplies the skin of the middle of the back of the arm from the axilla to the elbow.

The *dorsal cutaneous nerve of the forearm* usually pierces the deep fascia in two parts, a short distance distal to the insertion of the deltoid. The proximal branch supplies some twigs to the lateral part of the back of the arm, and then turns forwards to supply the skin of the lateral part of the front of the arm, from the level of the insertion of the deltoid to the elbow. The distal branch supplies twigs

to the distal part of the arm, both on the anterior and posterior aspects, and then descends to supply the skin of the middle of the back of the forearm as far as the wrist (Figs. 31, 32).

The *lateral cutaneous nerve of the forearm* pierces the deep fascia proximal to the elbow, passes deep to the cephalic vein, and supplies the skin on the lateral parts of the volar and dorsal aspects of the forearm as far as the wrist. It also supplies the skin of the proximal part of the thenar eminence (Figs. 31, 32).

**Fascia Brachii.**—After the cutaneous nerves have been revised re-examine the deep fascia of the arm. Note—(1) that it consists largely of transverse fibres; (2) its close attachment to the bony prominences at the elbow and to the distal parts of the medial and lateral borders of the humerus; (3) its connection with the muscles which spring from the medial and lateral epicondyles of the humerus; (4) the thickened band of fibres called the *lacertus fibrosus* which passes from the distal part of the medial border of the biceps to the medial side of the proximal part of the forearm (Figs. 31, 61). It is also connected with the tendons of insertion of the deltoid, the pectoralis major and the latissimus dorsi, but those connections were severed when the muscles were cleaned.

**Dissection.**—(1) Cut through the deep fascia along the proximal and distal borders of the lacertus fibrosus, from the medial margin of the biceps to the medial margin of the forearm, and leave the lacertus fibrosus in position when the remainder of the deep fascia is reflected. (2) Make a longitudinal incision through the deep fascia along the middle line of the biceps. (3) At the level of the epicondyles make a transverse incision through each of the flaps marked out by the longitudinal incision, and (4) reflect each of the two flaps to its own side. As the reflection proceeds it will become evident that septa pass from the deep surface of the deep fascia between the various muscles. Thus a septum passes transversely from side to side between the biceps and brachialis muscles (Figs. 42, 43). In it is embedded the musculo-cutaneous nerve. A septum dips backwards between the brachialis and the muscles which spring from the anterior lip of the distal half of the lateral border of the humerus. The radial nerve and anterior branch of the profunda artery are embedded in it (Fig. 42), but the strongest and most important septa are the lateral and medial intermuscular septa which separate the structures at the back of the arm from those at the front. Each is attached to the whole length of the corresponding border of the body of the humerus, but the distal halves are the strongest parts. The medial inter-

muscular septum is stronger than the lateral. It is easily traced from the medial epicondyle to the insertion of the coracobrachialis muscle. The distal half of the lateral intermuscular septum is quite definite from the lateral epicondyle to the insertion of the deltoid muscle. The two septa, together with the humerus, divide the arm into an anterior and a posterior osteo-fascial compartment.

**Structures in the Anterior Compartment.**—The anterior osteo-fascial compartment has been opened by the reflection of the anterior part of the deep fascia; the relative positions of its contents must now be examined. The contents are: Three muscles which belong mainly to the arm, the biceps,

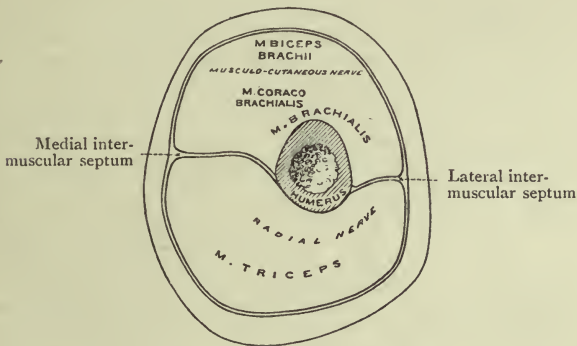


FIG. 41.—Diagram (after Turner) to show how the Arm is divided by the intermuscular septa and the bone into an anterior and a posterior compartment. These compartments are represented in transverse section.

the coraco-brachialis, and the brachialis; parts of two muscles which belong chiefly to the forearm—the brachioradialis and the extensor carpi radialis longus; parts of the terminal branches of all the cords of the brachial plexus except the axillary nerve; the brachial artery, its venae comites, part of the basilic vein, with accompanying lymph vessels and a few small brachial lymph glands which lie along the course of the brachial artery.

The biceps brachii is the most anterior muscle; under cover of its distal half and closely applied to the anterior aspect of the humerus is the brachialis, whilst the slender coraco-brachialis lies along the medial side of the proximal half of the biceps. The brachioradialis and the extensor

carpi radialis longus lie in the distal part of the compartment along the lateral side of the brachialis, to which they are closely applied. The brachial artery and its venæ comites traverse the whole length of the compartment in relation with the medial border of the biceps. The median nerve also runs through the whole length of the compartment lying, in the proximal half, lateral to the brachial artery, and in the distal half, medial to it. The basilic vein enters the compartment at the middle of the arm, where it pierces the deep fascia, and then ascends along the medial side of the brachial artery.

**Dissection.**—If the piece of wood, to which the axillary artery and the nerves were previously fixed, has been detached from the coracoid process, retie it to that process and proceed to clean the brachial artery and its branches, its venæ comites, the deep proximal part of the basilic vein, and the accompanying nerves. It is important that the artery should be disturbed as little as possible before its relations are studied. Therefore commence the dissection by cleaning the nerves and the veins, and take care not to injure the branches of the artery. Begin with the medial cutaneous nerve of the arm, trace it along the medial side of the basilic vein and through the opening in the deep fascia to its termination. As a rule it gives off no branches of distribution before it pierces the deep fascia, but it communicates with the intercosto-brachial nerve (Fig. 16). Next follow the median cutaneous nerve of the forearm along the groove between the anterior border of the basilic vein and the brachial artery, and through the opening in the deep fascia to the bend of the elbow. It gives off several branches before it pierces the deep fascia (p. 69). Now clean the basilic vein, displace it forwards and follow the ulnar nerve, which descends, along the posterior angle between the brachial artery and the basilic vein, to the middle of the arm. Then, at the level of the insertion of the coraco-brachialis, it passes backwards, accompanied by the superior ulnar collateral branch of the brachial artery, pierces the medial intermuscular septum, and enters the posterior compartment of the arm, where it will be dissected at a later period. The median nerve should next be cleaned. Follow it along the lateral margin of the proximal part of the brachial artery to the middle of the arm, there it crosses anterior to the artery and then descends, on its medial side, to the cubital fossa; note that the nerve gives off no branches till the cubital fossa is reached. After the median nerve has been cleaned, clean the venæ comites of the artery. Note that they anastomose across the artery frequently, and that at the lower border of the subscapularis they end in the axillary vein. Now displace the proximal part of the brachial artery forwards and follow the radial (*musculo-spiral*) nerve behind it, to the proximal end of the sulcus for the radial nerve at the back of the humerus. The radial nerve is accompanied by the profunda branch of the brachial artery. Clean the branches which pass from the lateral side of the artery to the biceps,

coraco-brachialis, and brachialis. A little distal to the middle of the arm, on the medial side of the artery, seek for its nutrient branch to the humerus. Clean the superior profunda branch, which accompanies the radial nerve, and the superior ulnar collateral branch which accompanies the ulnar nerve. About two inches proximal to the elbow, find the inferior ulnar collateral branch, follow it towards the medial intermuscular septum, and note its division into two branches, an anterior which descends in the front of the medial epicondyle to anastomose with the volar ulnar recurrent, and a posterior which pierces the medial intermuscular septum. Lastly, clean the brachial artery itself.

**Nervus Medianus.**—The median nerve arises in the axilla by two heads, one from the medial and one from the lateral cord of the brachial plexus. The medial head crosses the front of the axillary artery to unite with the lateral head. The nerve thus formed descends, along the lateral side of the distal part of the axillary artery and the proximal half of the brachial artery, to the level of the insertion of the coraco-brachialis; there it crosses in front of the brachial artery (sometimes behind) and descends along its medial side to the bend of the elbow. It gives off no branches either in the axilla or in the arm.

**Nervus Ulnaris.**—The ulnar nerve is the largest branch of the medial cord of the brachial plexus. It descends, along the medial sides of the third part of the axillary artery and of the proximal half of the brachial artery, to the insertion of the coraco-brachialis; then it leaves the brachial artery and, accompanied by the superior ulnar collateral artery, passes distally and backwards through the medial intermuscular septum, into the posterior compartment. In the posterior compartment it descends, along the medial head of the triceps, to the back of the medial epicondyle. Do not follow it into the posterior compartment at present; it will be dissected there at a later period. Like the median nerve it gives off no branches whilst it is in the axilla and the arm. Accompanying the ulnar nerve will be found the ulnar collateral branch of the radial nerve which descends to the distal part of the medial head of the triceps.

**Arteria Brachialis.**—The brachial artery is the direct continuation of the axillary artery; it begins, therefore, at the lower border of the teres major, and it passes, distally and slightly laterally, to the cubital fossa, where, at the level of the neck of the radius, it divides into its two terminal branches—the radial

and the ulnar arteries. In the proximal part of the arm it lies to the medial side of the humerus, but as it approaches the elbow it passes to the front of the humerus.

This change of position must be borne in mind when pressure is applied to the vessel with the view of controlling the flow of blood through it. In the proximal part of the arm the pressure must be directed laterally and backwards, and in the distal part directly backwards.

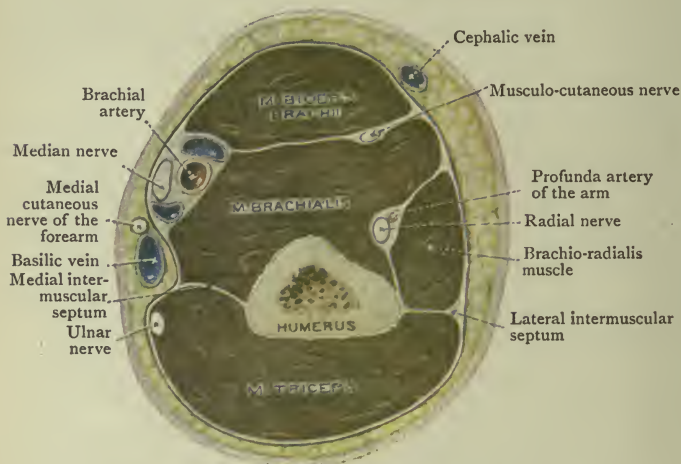


FIG. 42.—Transverse section through the Distal Third of the Right Arm.

**Relations.**—The brachial artery is superficial in the whole of its length. To expose it, therefore, it is necessary to reflect only the skin and the fascia; but it is overlapped, from the lateral side, by the medial margins of the coracobrachialis and biceps brachii (see Figs. 10, 41). At the bend of the elbow it is crossed superficially by the lacertus fibrosus, which intervenes between it and the median cubital vein.

The basilic vein lies to the medial side of the artery and on a somewhat posterior plane. In the distal part of the arm it is separated from the artery by the deep fascia; but in the proximal part, after the vein has pierced the fascia, it comes into closer relationship with the artery. The two venæ comites are closely applied to the sides of the artery,

and the numerous connecting branches which pass between them, both in front of and behind the artery, make the relationship still more intimate.

Behind the brachial artery there are four muscles. Proximo-distally, they are—(1) the long head of the triceps, which is separated from the artery by the radial nerve and the profunda vessels; (2) the medial head of the triceps; (3) the insertion of the coraco-brachialis; (4) in the remainder of its course the brachialis forms the posterior relation.

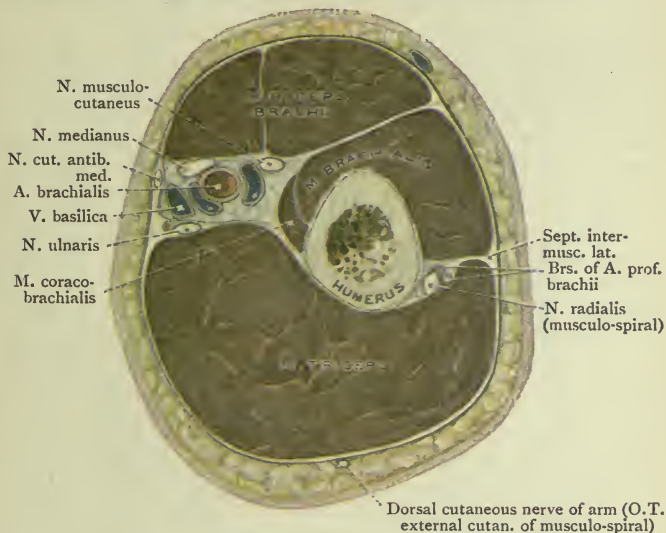


FIG. 43.—Transverse section through Middle of the Arm.

With the exception of the musculo-cutaneous nerve, all the terminal branches of the brachial plexus lie in relation to the brachial artery. The median nerve lies on the lateral side and somewhat anteriorly in the proximal half of the arm; it crosses anterior to the artery at the level of the insertion of the coraco-brachialis, and in the distal half of the arm and in the cubital fossa it is to the medial side of the artery. The ulnar nerve and the medial cutaneous nerve of the forearm lie close to the medial side of the artery as far as the insertion of the coraco-brachialis; then they leave it. The ulnar nerve inclines backwards, pierces the medial inter-

muscular septum, and, passing behind the medial epicondyle, enters the forearm. The medial cutaneous nerve of the forearm inclines forwards and medially, pierces the fascia brachii and becomes superficial. The radial nerve is behind the proximal part of the artery, but it soon leaves it by passing distally and laterally into the sulcus for the radial nerve, between the medial and the lateral heads of the triceps.

**Branches of the Brachial Artery.**—Several branches arise from the brachial artery. Those which arise from its lateral aspect are irregular in number, origin, and size. They are termed the *lateral branches*, and are distributed to the muscles and integument on the front of the arm. The series of *medial branches* which proceed from the medial and posterior aspect of the parent trunk are named as follows as they arise proximo-distally:—

- |                                      |  |                                      |
|--------------------------------------|--|--------------------------------------|
| 1. A. profunda brachii.              |  | 3. A. nutricia humeri.               |
| 2. A. collateralis ulnaris superior. |  | 4. A. collateralis ulnaris inferior. |

The *profunda artery* (O.T. superior profunda) is the largest of the branches which spring from the brachial trunk. It takes origin about 25 mm. (one inch) or so distal to the lower margin of the teres major, and associates itself with the radial (musculo-spiral) nerve, which it accompanies to the back of the arm. Consequently, only a short part of the vessel is seen in the present dissection. It soon disappears from view between the long and medial heads of the triceps.

The *superior ulnar collateral artery* (O.T. inferior profunda) is a long slender artery, which can be recognised from the fact that it follows closely the course pursued by the ulnar nerve. Its origin is somewhat variable. As a general rule, it issues from the brachial artery opposite the insertion of the coraco-brachialis, but very frequently it arises in common with the profunda brachii. It pierces the medial intermuscular septum, with the ulnar nerve, and descends behind that fascial partition to the interval between the olecranon and the medial epicondyle of the humerus.

The *nutrient artery* may arise directly from the brachial trunk, or take origin from the superior ulnar collateral artery. It should be sought for at the distal border of the insertion of the coraco-brachialis, and the dissector should not be satisfied until he has traced it into the



nutrient foramen of the bone. When the nutrient artery is not seen in its usual position it will probably be found in the dissection of the back of the arm, taking origin from the profunda artery.

The *inferior ulnar collateral artery* (O.T. anastomotica)

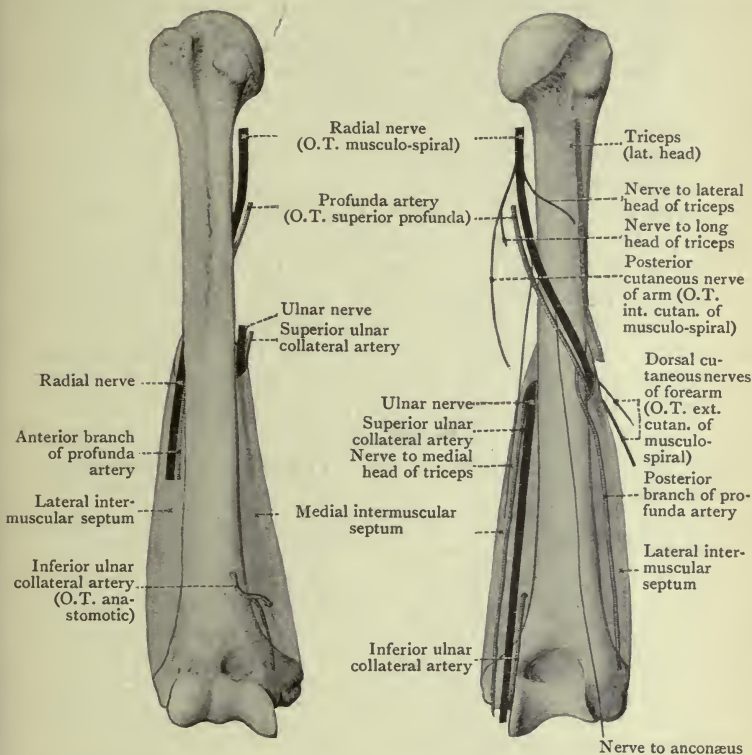


FIG. 44.—Diagram to show relation of Radial Nerve (O.T. Musculo-spiral) to the Humerus, and of Vessels and Nerves to the Intermuscular Septa.

arises about 50 mm. (two inches) proximal to the bend of the elbow, and runs medially upon the brachialis. It soon divides into a small anterior and a larger posterior branch. The *anterior branch* is carried distally in front of the medial epicondyle of the humerus, in the interval between the brachialis and the pronator teres. It anastomoses with the

volar ulnar recurrent artery. The *posterior branch* pierces the medial intermuscular septum, and will be seen, at a later stage, in the posterior compartment of the arm.

**Dissection.**—Clean the biceps brachii. Clean the coracobrachialis; separate it carefully from the short head of the biceps, and find the musculo-cutaneous nerve as it leaves the lateral surface of the coraco-brachialis. Follow the musculo-cutaneous nerve, between the biceps and the brachialis, to the point where it emerges at the lateral border of the tendon of the biceps and becomes the lateral cutaneous nerve of the forearm. Clean the brachialis as far as the bend of the elbow, but do not injure the lacertus fibrosus.

**Nervus Musculocutaneus.**—The musculo-cutaneous nerve arises from the lateral cord of the brachial plexus, at the lower border of the pectoralis minor. Inclining laterally, it perforates the coraco-brachialis, and passes between the biceps brachii and the brachialis. It proceeds obliquely distally, between those muscles, until it reaches the bend of the elbow, where it comes to the surface at the lateral border of the tendon of the biceps brachii. From that point onwards it has already been traced as the lateral cutaneous nerve of the forearm (p. 69).

In the arm the musculo-cutaneous nerve supplies branches to three muscles of the region. The branch to the coracobrachialis is given off before the parent trunk enters the substance of the muscle; the branches to the biceps brachii and brachialis issue from it as it lies between them.

**M. Coracobrachialis.**—The coraco-brachialis is an elongated muscle, which takes origin from the tip of the coracoid process, in conjunction with the short head of the biceps brachii. It proceeds distally, along the medial margin of the biceps brachii, and obtains insertion into a linear ridge situated upon the medial aspect of the body of the humerus, about its middle.

**M. Biceps Brachii.**—The biceps brachii muscle arises from the scapula by two distinct heads of origin. The *short or medial head* springs from the tip of the coracoid process in conjunction with the coraco-brachialis (Fig. 24, p. 46). The *long or lateral head* is a rounded tendon, which occupies the intertubercular sulcus of the humerus. Its origin cannot be studied at this stage of the dissection, because it is placed within the capsule of the shoulder-joint, where it arises from an impression on the scapula immediately above the glenoid cavity.

Both heads swell out into elongated fleshy bellies, which, at first, are merely closely applied to each other, but afterwards are united in the distal third of the arm. Towards the bend of the elbow the fleshy fibres converge upon a stout, short tendon, which is inserted into the dorsal part of the tuberosity of the radius. The insertion will be more fully examined at a later period, but it may be noticed, in the meantime, that the tendon is twisted so as to present its margins to the front and dorsal aspect of the limb, and, further, that a bursa mucosa is interposed between it and the smooth, volar part of the radial tuberosity.

The dissector has already taken notice of the *lacertus fibrosus*, and has separated it, artificially, from the deep fascia of the arm, and of the forearm. Observe now that it springs from the anterior margin of the tendon of the biceps brachii, and also from the short head of the muscle. It is supplied by the musculo-cutaneous nerve and is a supinator of the forearm and a flexor of the elbow-joint.

**M. Brachialis (O.T.)**

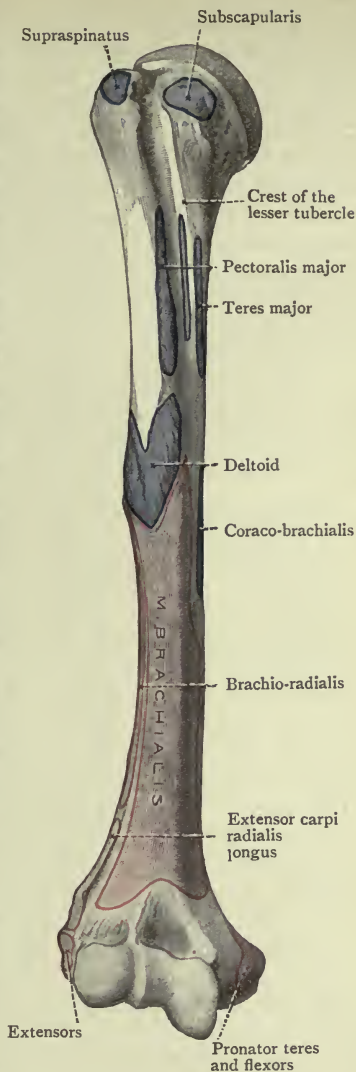


FIG. 45.—Anterior aspect of Humerus with Muscular Attachments mapped out.

**Brachialis Anticus**).—The brachialis arises from the entire width of the anterior aspect of the distal half of the body of the humerus, from the medial intermuscular septum, and from a small part of the lateral intermuscular septum proximal to the brachio-radialis. The origin from the bone is prolonged proximally in two slips which partially embrace the insertion of the deltoid. The fibres converge to be inserted into the base of the coronoid process of the ulna by a short, thick tendon. The muscle lies partly under cover of the biceps brachii, but projects beyond it on each side. It is overlapped on its medial side by the pronator teres, and on the lateral side by the brachio-radialis and extensor carpi radialis longus. Its deep surface is closely connected to the anterior part of the capsule of the elbow-joint. Its chief nerve of supply, from the *musculo-cutaneous*, has already been secured, but it receives also one or two small twigs from the radial (*musculo-spiral*) nerve which are given off under cover of the brachio-radialis. It is a flexor of the elbow-joint.

**Dissection**.—Separate the brachio-radialis from the brachialis muscle, and dissect out the radial nerve, with the anterior terminal branch of the profunda brachii artery, which lie deeply in the interval between the muscles. There also, in a well-injected subject, the anastomosis between the profunda brachii artery and the radial recurrent artery may be made out; and the twigs which are given by the radial nerve to the brachialis, the brachio-radialis, and the extensor carpi radialis longus, should be looked for.

**Fossa Cubitalis**.—The cubital fossa is the hollow in front of the elbow. It is triangular in outline and it corresponds generally with the popliteal fossa at the back of the knee.

It possesses a roof or superficial boundary; a floor or deep boundary; medial and lateral boundaries; a base and an apex.

The roof is formed by the deep fascia in which lies the thickened band called the lacertus fibrosus. It is pierced by a communication from the deep veins of the forearm to the median cubital vein. It is covered by the skin and superficial fascia, and upon it, in the superficial fascia, lie a portion of the cephalic vein, a portion of the basilic vein, the median cubital vein, the volar branch of the medial cutaneous nerve of the forearm, and the lateral cutaneous nerve of the forearm.

The "base" is an imaginary line drawn between the two epicondyles of the humerus. The medial border, formed by the lateral margin of the pronator teres muscle

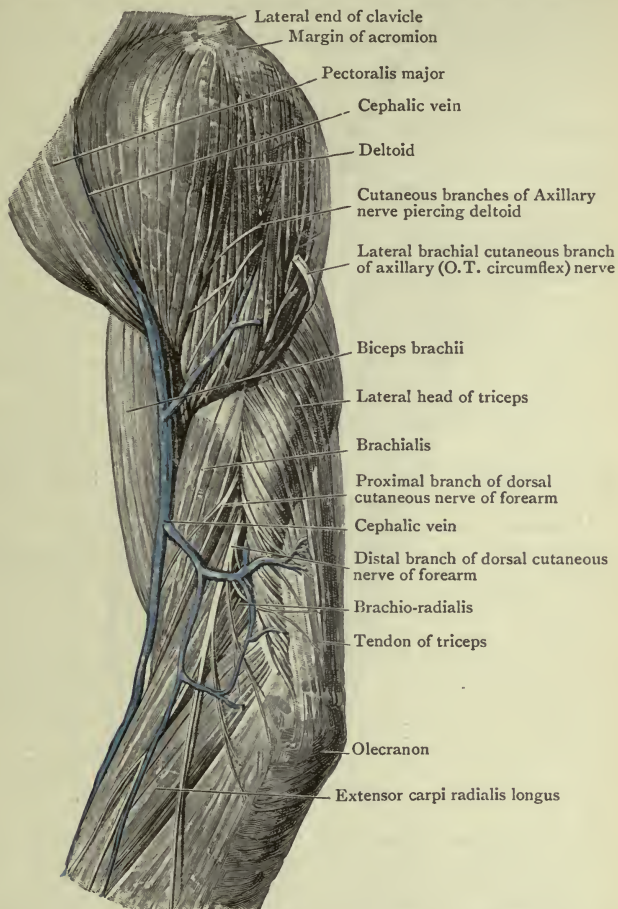


FIG. 46.—The Deltoid Muscle and the lateral aspect of the Arm.

descending from the medial epicondyle, and the lateral border, formed by the medial margin of the brachio-radialis, as it descends from the lateral supra-epicondylar ridge, meet distally at the apex where the brachio-radialis overlaps

the pronator teres. The floor is formed by the distal part of the brachialis muscle and the anterior part of the supinator.

Within the fossa are the termination of the brachial artery, and the proximal parts of the radial and ulnar arteries, into which it divides. To the lateral side of the main vessel

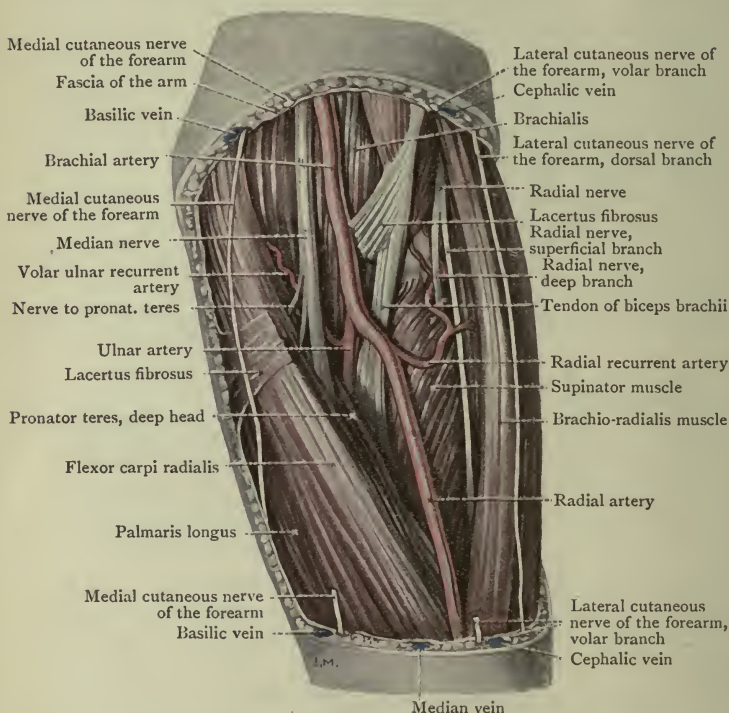


FIG. 47.—Dissection of the Left Cubital Fossa.

is placed the tendon of the biceps brachii, and to its medial side, the median nerve. A quantity of loose fat also is present. The ulnar artery leaves the space by passing under cover of the pronator teres; the radial artery is continued distally beyond the apex of the fossa, overlapped by the brachio-radialis. The median nerve disappears between the two heads of the pronator teres, and the tendon of the biceps brachii inclines posteriorly, between the two bones of the forearm, to reach its insertion into the radial tuberosity.

Other structures which are under cover of the boundaries but are not strictly within the fossa are:—the termination of the radial nerve and parts of its deep and superficial divisions; the anterior terminal branch of the profunda artery; the radial recurrent artery; the volar and dorsal ulnar recurrent arteries and twigs of the superior and inferior ulnar collateral arteries.

*Dissection.*—The fascial roof of the cubital fossa was partially destroyed when the deep fascia of the front of the arm was reflected, but the lacertus fibrosus is still in position. Now cut across the lacertus near the biceps (Fig. 47), and reflect it towards the medial border of the forearm, then proceed to clean the contents of the fossa. Pull aside the medial and lateral boundaries with hooks and then commence with the median nerve. Follow it from above downwards to the point where it disappears between the two heads of the pronator teres, and secure the branches which spring from its medial side and pass to the muscles which arise from the medial epicondyle of the humerus.

Next clean the brachial artery, also from above downwards. If its venæ comites are in the way remove them. Follow the artery to its division into its radial and ulnar branches, then follow the radial artery to the apex of the fossa, and the ulnar artery to the point where it disappears behind the deep head of the pronator teres. Do not injure the radial recurrent branch which springs from the lateral side of the radial artery, or the volar and dorsal ulnar recurrent branches which arise from the medial side of the ulnar artery. Now clean the tendon of the biceps brachii and follow it to its insertion into the posterior part of the tuberosity of the radius, and note that, as it passes to its insertion, it twists so that its anterior surface becomes lateral, and its posterior surface becomes medial. The tendon is separated from the anterior part of the tuberosity by a small bursa which may be opened with the point of the scalpel.

To facilitate the cleaning of the floor and to expose structures which are not strictly contents of the fossa, but which lie close to it, under cover of its medial and lateral boundaries, flex the elbow slightly, and pull the medial and lateral boundaries of the fossa still wider apart. Find the termination of the radial nerve, and the anterior terminal branch of the profunda artery at the level of the lateral epicondyle between the brachio-radialis and the brachialis. Follow the deep and superficial terminal branches of the nerve, downwards in front of the lateral part of the capsule of the elbow-joint. The deep branch disappears into the substance of the supinator. The superficial division descends between the brachio-radialis and the supinator, either superficial or deep to the branches of the radial recurrent artery. The termination of the superficial division has already been dissected on the dorsum of the hand where it supplies the lateral three-and-a-half digits (see p. 71). Next follow the radial recurrent artery to the lateral epicondyle, where it anastomoses with the anterior terminal branch of the profunda artery. Then trace the volar and dorsal recurrent branches of the ulnar artery to

the medial epicondyle where they anastomose with the superior and inferior ulnar collateral branches of the brachial artery.

After the relative positions of the contents of the cubital fossa have been studied turn to the dissection of the back of the arm.

### DORSUM OF THE ARM.

In this region in addition to the cutaneous nerves the following are the structures which must be studied:—

1. The triceps muscle.
2. The profunda brachii artery, and the radial nerve.
3. The superior ulnar collateral artery, and the ulnar nerve.
4. The posterior branch of the inferior ulnar collateral artery.
5. The subanconæus muscle.

The skin and the superficial fascia have already been removed but the cutaneous nerves are still present, and the dissector should revise them before proceeding with the dissection.

On the medial side are branches of the intercosto-brachial nerve; lateral to them lies the posterior brachial cutaneous branch of the radial nerve, and, along the lateral margin of the arm, is the dorsal cutaneous nerve of the forearm, also a branch of the radial nerve.

**Dissection.**—Make a vertical incision through the deep fascia as far as the olecranon of the ulna, and a transverse incision across the olecranon from one epicondyle to the other, taking care not to injure the dorsal cutaneous nerve of the forearm. Reflect the flaps of deep fascia to their respective sides until their continuity with the medial and lateral intermuscular septa respectively is demonstrated. As the medial flap is reflected, avoid injury to the ulnar nerve which descends towards the medial epicondyle on the medial head of the triceps. It is accompanied by the superior ulnar collateral artery. When the reflection of the flaps is completed clean the triceps muscle and define carefully its attachments to the scapula, to the humerus, and to the ulna.

**M. Triceps Brachii.**—The triceps muscle occupies the entire posterior osteo-fascial compartment of the arm. It arises by a *long head* from the scapula, and by two shorter heads, *lateral* and *medial*, from the humerus. The fleshy fibres of the three heads join a common tendon, which is inserted into the proximal surface of the olecranon of the



ulna. The superficial part of the muscle is, for the most part, formed by the long head and the lateral head of the muscle. The medial head is deeply placed; only a very small portion of it appears superficially, in the distal part of the arm, on each side of the common tendon of insertion.

The *long head* of the triceps arises, by a flattened tendon, from the rough triangular impression on the upper part of the axillary border and the lower aspect of the neck of the scapula in the interval between the teres minor and subscapularis muscles (Fig. 24, p. 46).

The *two humeral heads* take origin from the posterior aspect of the humerus; and if it is borne in mind that no fibres arise from the sulcus for the radial nerve and that the groove intervenes between the origins of the two heads, their relations will be easily understood. The dissector should provide himself with a humerus, and, having first identified the sulcus for the radial nerve, proceed to map out the areas of attachment of the humeral heads of the triceps as they are exhibited in the dissected part.

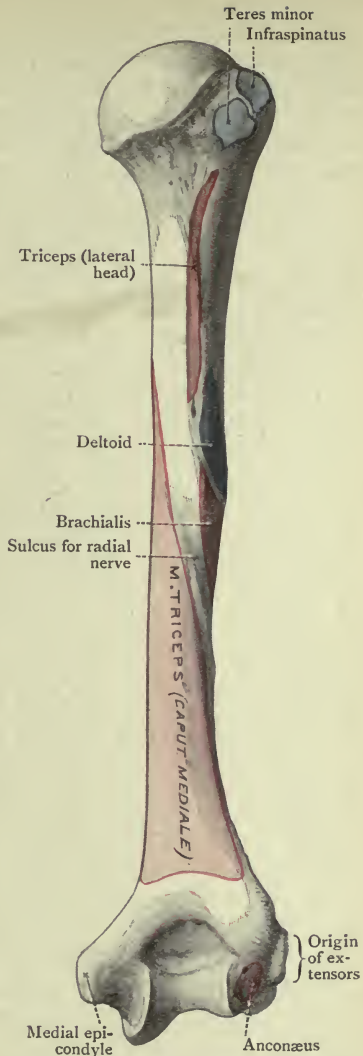


FIG. 48.—Dorsal aspect of the Humerus with Attachments of Muscles mapped out.

The *lateral head* of the triceps arises from the lateral and posterior aspect of the body of the humerus, proximal to the sulcus for the radial nerve. It takes origin, by short tendinous fibres, along a line which passes distally from the insertion of the teres minor to the proximal border of the sulcus for the radial nerve. But it derives fibres also from a strong fascial bridge or arch which is thrown over the groove so as to give protection to the profunda brachii artery and the radial nerve. The strength and position of this arch can be estimated by thrusting the handle of the knife distally and laterally in the sulcus for the radial nerve, and along the course of the nerve and artery, under the lateral head of the triceps. By its distal end the arch is connected with the lateral intermuscular septum.

The *medial head* of the triceps is placed distal to the sulcus for the radial nerve. Its proximal end, which is narrow and pointed, lies close to the distal end of the insertion of the teres major. The origin gradually widens as the sulcus for the radial nerve passes towards the lateral border of the humerus, and in the distal third of the arm it covers the posterior surface of the humerus from the lateral to the medial border (Fig. 48). It springs also from the posterior surface of the medial intermuscular septum, and from the distal part of the corresponding surface of the lateral intermuscular septum. The medial head of the triceps, therefore, has very much the same origin from the posterior surface of the bone that the brachialis has from the anterior aspect.

The dissector should now study the *common tendon of insertion* of the triceps. The long and the lateral heads end in a broad, flat tendon, which is inserted into the back part of the proximal surface of the olecranon, and at the same time gives off, on the lateral side, a strong expansion to the fascia of the forearm as it covers the anconæus muscle. The short fleshy fibres of the medial head are, for the most part, inserted into the deep surface of the common tendon, but a considerable number find direct attachment to the olecranon, whilst a few of the deepest fibres are inserted into the loose posterior part of the capsule of the elbow-joint. The latter fibres have been described as a separate muscle under the name of *subanconæus*. The triceps is supplied by branches from the *radial nerve*. It is an extensor of the elbow-joint and an adductor of the arm.

*Dissection.*—In order that the radial nerve and the profunda brachii artery may be fully exposed, the lateral head of the triceps must be divided. Thrust the handle of a knife along the sulcus for the radial nerve, and under the muscle. The handle will then give the direction in which the lateral head of the triceps should be severed. Beyond cleaning the nerve and its branches, and the profunda brachii artery, as they lie in the groove, no further dissection is necessary.

**Nervus Radialis (O.T. Musculo-Spiral Nerve).**—The radial nerve is the direct continuation of the posterior cord of the brachial plexus after it has furnished, in the axilla, the two subscapular nerves, the thoraco-dorsal nerve, and the axillary nerve. In the first instance, the radial nerve proceeds distally, behind the distal part of the axillary artery and the proximal part of the brachial artery. It soon leaves the anterior aspect of the arm, however, and, inclining backwards, with the *profunda brachii artery*, enters the interval between the long and the medial heads of the triceps, and reaches the sulcus for the radial nerve. In that it passes round the back of the body of the humerus, under cover of the lateral head of the triceps, and on the lateral side of the limb it pierces the lateral intermuscular septum and passes into the anterior compartment of the arm, where it has already been dissected. There it lies deeply, in the interval between the brachialis on the medial side and the brachio-radialis and extensor carpi radialis longus on the lateral side, and it ends at the level of the lateral epicondyle of the humerus by dividing into two terminal branches, viz., the ramus superficialis (O.T. radial) and the ramus profundus (O.T. posterior interosseous). The radial nerve presents, therefore, very different relations as it is traced from its origin to its termination: (1) between the subscapularis, latissimus dorsi, teres major, and long head of the triceps, which support it behind, and the axillary and brachial arteries which are placed in front of it; (2) between the long and the medial heads of the triceps; (3) in the sulcus for the radial nerve, between the bone and the lateral head of the triceps; (4) in the interval between the brachialis on the medial side, and the brachio-radialis and extensor carpi radialis longus on the lateral side.

The branches which proceed from the radial nerve are *muscular, cutaneous, articular* and *terminal*.

The *cutaneous branches* are two in number, and have already been traced. They are—(1) the posterior cutaneous nerve of

the arm, and (2) and (3) the dorsal cutaneous nerves of the forearm.

The *muscular branches* are distributed to the three heads

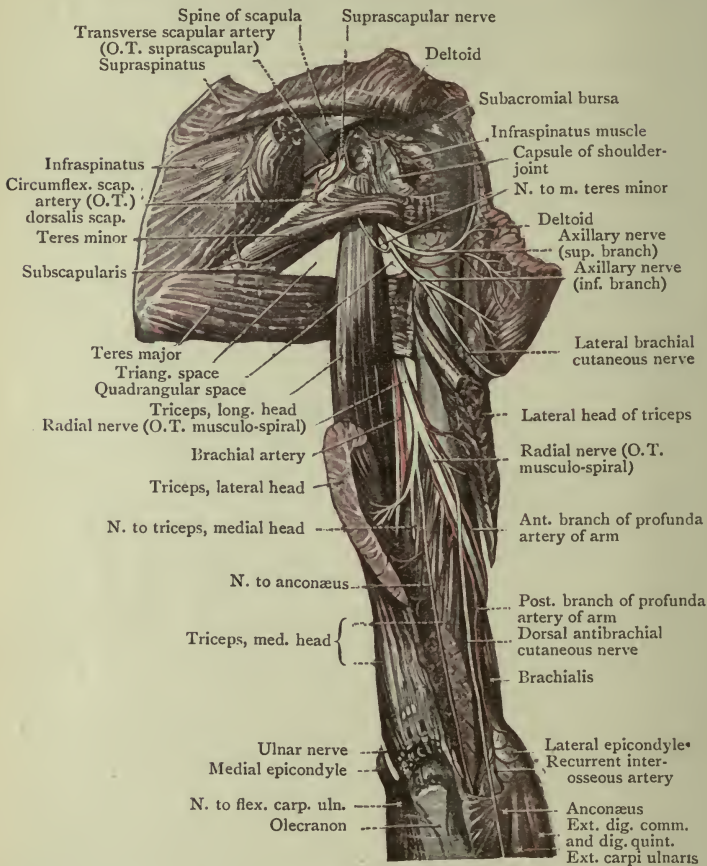


FIG. 49.—Dissection of the dorsal aspect of the Arm. The lateral head of the Triceps has been divided and turned aside to expose the sulcus on the Humerus for the radial nerve.

of the triceps, to the anconæus, to the lateral fibres of the brachialis, to the brachio-radialis, and to the extensor carpi radialis longus. The branches to the three last-named muscles spring from the trunk of the nerve after it has

pierced the lateral intermuscular septum. One of the branches to the medial head of the triceps is a long slender nerve, termed the *ulnar collateral nerve*, on account of its association with the ulnar nerve in the arm. The branch to the anconæus is a long slender twig which passes through the substance of the medial head of the triceps on its way to the anconæus (Fig. 49).

The *terminal branches* are the *superficial ramus*, which is a purely cutaneous nerve, and the *deep ramus*, which is continued into the dorsal part of the forearm as the dorsal interosseous nerve, and is distributed to the muscles on the dorsal aspect of the forearm, and to the radio-carpal joint. These nerves will be followed later.

**Arteria Profunda Brachii.**—The profunda brachii artery has been already seen taking origin from the brachial trunk, about 25 mm. distal to the lower margin of the teres major muscle. It accompanies the radial nerve, and its relations to the three heads of the triceps and the sulcus for the radial nerve are exactly the same as those of the nerve. Before it reaches the lateral intermuscular septum, it ends by dividing into two terminal branches—an anterior and a posterior. The *anterior* and *smaller branch* accompanies the radial nerve through the septum, and follows it distally to the anterior aspect of the lateral epicondyle of the humerus, where it anastomoses with the radial recurrent artery. The *posterior, larger branch* descends on the posterior surface of the lateral intermuscular septum, and anastomoses on the back of the lateral epicondyle of the humerus with the interosseous recurrent artery.

The branches which proceed from the *profunda brachii artery* are distributed chiefly to the three heads of the triceps muscle. One twig runs proximally between the long and lateral heads of the muscle, and anastomoses with the *posterior circumflex artery of the humerus*. In that way a link is established between the axillary and brachial systems of branches.

**Dissection.**—The ulnar nerve, with the superior ulnar collateral artery, and the slender ulnar collateral nerve, can now be satisfactorily followed, as they proceed distally upon the posterior aspect of the medial intermuscular septum. They are covered by a thin layer of fleshy fibres belonging to the medial head of the triceps. The posterior branch of the inferior ulnar collateral artery, after it has pierced the medial septum, should

also be dissected out. As a rule, a transverse anastomosing twig passes between that vessel and the posterior terminal part of the profunda brachii artery. It lies upon the posterior aspect of the humerus, immediately proximal to the elbow-joint, and can be exposed by dividing the triceps muscle a short distance proximal to the olecranon. At the same time the fleshy fibres of the medial head of the triceps, which are inserted into the posterior part of the capsule of the elbow-joint, and constitute the *subanconæus muscle*, should be examined. Lastly, raise the distal piece of the triceps from the elbow-joint, and look for a small bursa mucosa between the deep surface of the triceps tendon and the anterior part of the proximal aspect of the olecranon. Then revise the medial and lateral intermuscular septa which are now fully exposed.

**The Medial and Lateral Intermuscular Septa.**—The medial intermuscular septum is the stronger; it separates the medial part of the medial head of the triceps from the brachialis, gives attachment to both the muscles, and extends, as a strong membrane, from the medial epicondyle to the insertion of the coraco-brachialis. Then it becomes less distinct, but it can be traced proximally to the lower part of the medial lip of the intertubercular sulcus. At the level of the insertion of the coraco-brachialis it is pierced by the ulnar nerve and the superior ulnar collateral artery, which descend posterior to it to the medial epicondyle. A short distance above the medial epicondyle it is pierced by the posterior branch of the inferior ulnar collateral artery.

The lateral intermuscular septum is weaker than the medial. It extends from the lateral epicondyle to the insertion of the deltoid muscle, with which it blends, and it separates the lateral part of the medial head of the triceps, which is attached to its posterior surface, from the upper lateral part of the brachialis, the brachio-radialis and the extensor carpi radialis longus which spring from its anterior surface. At the junction of the middle and distal thirds of the arm it is pierced by the radial nerve and the anterior branch of the profunda artery, which afterwards descend along its anterior aspect, between the brachialis medially and the brachio-radialis and the extensor carpi radialis longus laterally.

## ARTICULATIO HUMERI (SHOULDER-JOINT).

After the structures situated in the arm have been examined the dissection of the shoulder-joint should be commenced, in order that the ligaments may be examined before they have become too dry.

The shoulder-joint belongs to the enarthrodial or ball and

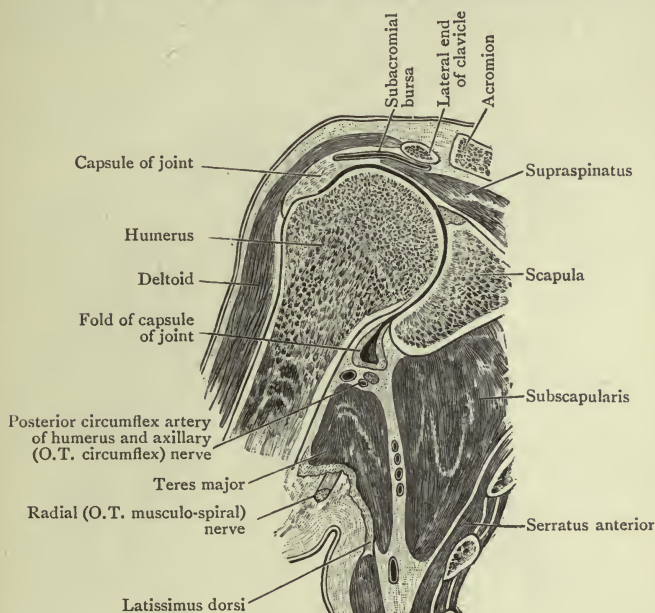


FIG. 50.—Frontal or vertical transverse section through the Left Shoulder-joint. (Viewed from behind.)

socket sub-group of the diarthrodial or completely movable joints. The socket is formed by the glenoid cavity of the scapula and the ball is the spheroidal head of the humerus.

In no joint in the body are the movements so free and so varied in their character as in the shoulder-joint. This is rendered necessary by the many functions which are performed by the upper limb. Freedom of movement is provided for in two ways—(1) by the large size of the head of the humerus, in comparison with the small dimensions and shallow character

of the glenoid cavity ; (2) by the great laxity of the ligamentous structures which connect the humerus with the scapula. These provisions for allowing an extensive range of movement at this articulation might, at first sight, lead one to doubt the security of the joint. Its strength certainly does not lie in the adaptation of the bony surfaces to one another, nor in the strength of its ligaments. It lies—(1) in the powerful muscles by which it is closely surrounded ; (2) in the overhanging coraco-acromial arch, which forms, as it were, a

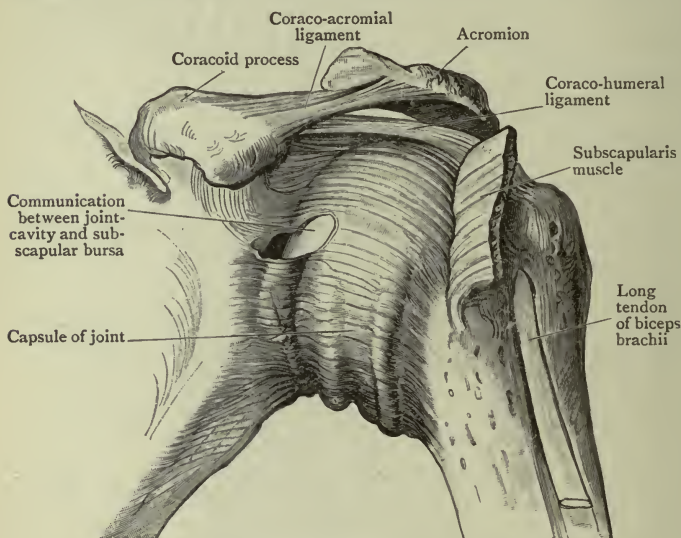


FIG. 51.—Shoulder-joint as seen from the front.

secondary socket for the head of the humerus, and effectually prevents any displacement in an upward direction ; and (3) in atmospheric pressure, which exercises a powerful influence in keeping the opposed surfaces in contact with each other.

On all aspects, except over a small area below, the loose, ligamentous capsule which envelops the shoulder-joint is supported by muscles, the tendons of which are more or less intimately connected with it. *Above*, it is covered by the supraspinatus ; *behind*, the infraspinatus and teres minor are applied to it ; *in front* is the subscapularis. *Below*, the capsule is to a certain extent unsupported by muscles, and



there it is prolonged downwards, in the form of a fold, in the ordinary dependent position of the limb (Figs. 50, 53). When, however, the arm is abducted, the fold is obliterated, and the head of the bone rests upon the inferior part of the capsule, which now receives partial support from two muscles which are stretched under it, viz. the long head of the triceps and the teres major. Still, this must be regarded as the weakest part of the joint, and consequently dislocation of the head of the humerus downwards into the axilla, through the inferior part of the capsule, is an occurrence of considerable frequency. When the dislocation occurs, the axillary vessels and nerve which lie close to the capsule may be injured.

*Dissection.*—The capsule of the shoulder-joint has already been exposed by the reflection of the muscles immediately adjacent to its anterior, superior, and posterior aspects, and the bursa between its anterior surface and the subscapularis has been examined. To expose the capsule more fully, untie the axillary vessels and nerves from the coracoid process; cut through the tendon of origin of the coraco-brachialis and the short head of the biceps brachii and displace the muscles downwards. Cut through the teres major about its middle and the long head of the triceps about 25 mm. (one inch) distal to its origin and turn both muscles aside. Turn aside the divided subscapularis, supraspinatus, infraspinatus and teres minor muscles. Note that whilst the supraspinatus, infraspinatus and teres minor completely cover the upper and posterior part of the capsule, a small interval exists between the anterior border of the supraspinatus and the upper border of the subscapularis. In that interval the subacromial bursa is in relation with the capsule, and occasionally, but very rarely, a communication exists between the cavity of the bursa and the cavity of the joint. Re-examine the bursa which lies between the subscapularis and the front of the capsule, and note that its aperture of communication with the joint is situated near the root of the coracoid process. Thoroughly clean the outer surface of the capsule. Note the laxity of the capsule, and define its attachments to the margin of the glenoid cavity and to the lateral border of the root of the coracoid process.

The ligaments of the shoulder-joint are:—

Capsula articularis—

Lig. coracohumerale.

Lig. glenohumerale superius.

” ” ” medium.

” ” ” inferius.

Labrum glenoidale.

*Capsula Articularis.*—The *fibrous stratum* of the articular capsule is a fairly dense and strong membrane which envelops

the articulation on all sides. It is attached to the scapula around the margin of the glenoid cavity, but is attached directly to the bone only at the upper part; elsewhere it blends with the outer surface of the labrum glenoidale, which is attached to the margin of the cavity for the purpose of increasing its depth. Laterally the capsule is attached to

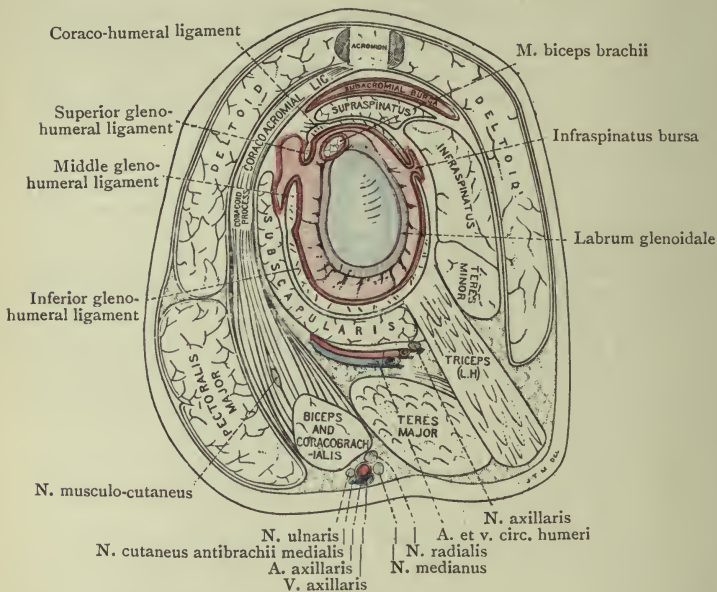


FIG. 52.—Semi-diagrammatic representation of a dissection of a Sagittal section through the Right Shoulder. The subscapular bursa is shown connected with the cavity of the joint between the superior and middle gleno-humeral bands of the articular capsule.

the anatomical neck of the humerus and to the transverse ligament of the humerus, which bridges across the top of the intertubercular sulcus from the greater to the lesser tubercle. The attachment of the upper part of the fibrous stratum to the humerus is quite close to the articular surface of the head, but the attachment of the lower part is some distance (12-16 mm.) from the articular surface; consequently a considerable part of the lower portion of the anatomical neck is inside the fibrous stratum of the capsule and is covered by

the synovial stratum (Fig. 53). This cannot be seen until the capsule has been opened.

The fibrous stratum of the capsule is not complete at all points. Its continuity is always broken by two and sometimes by three or four apertures, and where the lateral margin of the fibrous stratum is attached to the transverse ligament of the humerus there is an aperture below the margin. Prolongations of the synovial stratum are protruded through

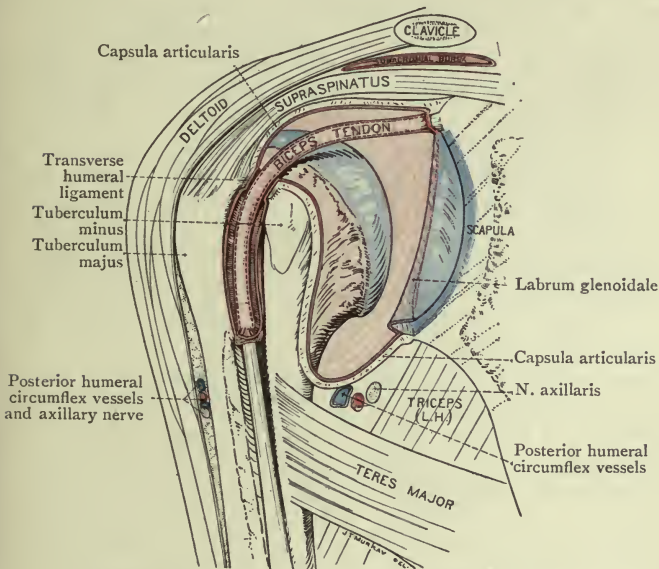


FIG. 53.—Diagram of a Frontal Section of the Right Shoulder

all the apertures which are present. The largest opening is in the antero-medial part near the root of the coracoid process, and the prolongation of the synovial stratum which passes through it forms the subscapular bursa, which separates the subscapularis from the front of the capsule and from the front of the neck of the scapula. The dissector should note carefully the size and the position of this opening because the head of the humerus is occasionally driven through it, instead of through the lower part of the capsule, when the joint is dislocated.

The second constant aperture is that below the transverse ligament of the humerus at the top of the intertubercular sulcus. It is much smaller than the aperture in front, and through it the tendon of the long head of the biceps, which springs from the apex of the glenoid cavity, emerges from the joint. The tendon is enclosed in a tubular prolongation of the synovial stratum which surrounds it and lines the intertubercular sulcus (Fig. 53). It is not often that a third opening is found in the fibrous stratum. It is situated, when present, in the postero-lateral part of the capsule and permits the protrusion of the synovial stratum to form a bursa under cover of the infraspinatus muscle (Fig. 52). Still more rarely the subacromial bursa communicates with the cavity of the joint through an opening which is situated between the supraspinatus and subscapularis muscles.

In four situations the fibrous stratum of the capsule is thickened by longitudinal bands of fibres which pass from the scapula to the humerus. One of the thickenings, the *coraco-humeral ligament*, can be seen from the exterior; the other three, the *gleno-humeral ligaments*, are thickenings of the inner surface of the fibrous stratum of the capsule and can be seen only from the interior of the joint.

**Ligamentum Coracohumerale.**—The coraco-humeral ligament is placed upon the superior aspect of the joint. It is a broad band of great strength, which is more or less completely incorporated with the capsule. Proximally, it is fixed to the root and lateral border of the coracoid process of the scapula, and it passes thence, obliquely distally and laterally, to gain attachment to the two tubercles of the humerus, and to the transverse humeral ligament, which forms a strong arch over the upper part of the intertubercular sulcus.

**Ligamenta Glenohumeralia.**—There are three gleno-humeral ligaments. To see them the posterior part of the capsule must be divided by a vertical incision and the head of the humerus must be turned aside or removed. The *superior gleno-humeral ligament* springs from the margin of the glenoid cavity immediately anterior to the tendon of the long head of the biceps brachii, and it passes to a small pit situated on the proximal extremity of the humerus close to the top of the intertubercular sulcus. The *middle gleno-humeral ligament* is attached to the scapula immediately above the notch on the anterior margin of the glenoid cavity,

and to the humerus in the region of the small tubercle. Between it and the superior gleno-humeral ligament is the opening from the joint into the subscapular bursa. The *inferior gleno-humeral ligament* is a fan-shaped thickening. It is attached by its smaller extremity to the scapula below the notch in the anterior margin of the glenoid cavity, and, by its broader end, to the neck of the humerus along a line

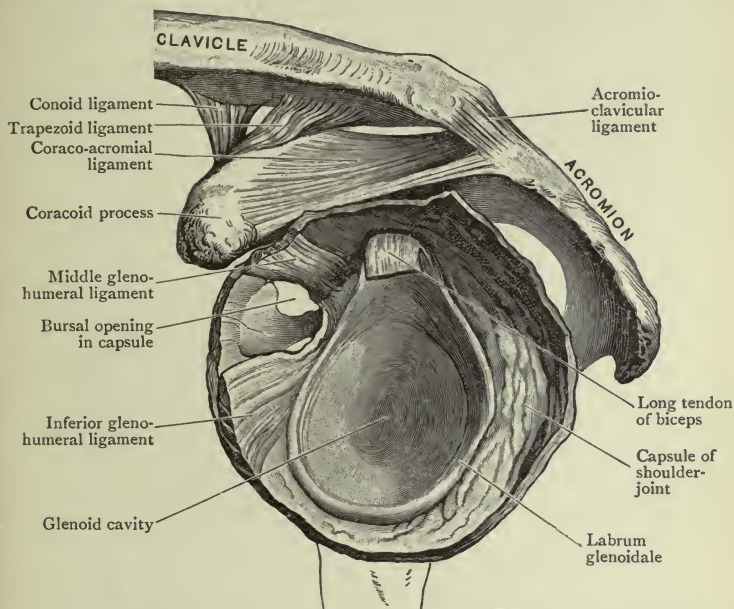


FIG. 54.—Shoulder-joint. The Articular Capsule has been cut across and the Humerus removed.

passing from a lower part of the lesser to the greater tubercle. It strengthens the lower and anterior part of the capsule which is situated above the quadrilateral space.

**Dissection.**—Complete the division of the capsular ligament, divide the tendon of the biceps brachii and draw it through the intertubercular aperture in the capsule, then separate the two bones from one another.

**Labrum Glenoidale (O.T. Glenoid Ligament).**—The labrum glenoidale is the dense fibro-cartilaginous band which surrounds the margin of the glenoid cavity of the scapula,

and is attached to its rim. It deepens, and at the same time serves to extend, the articular socket of the scapula. The intimate connection which it presents with the capsule of the joint can now be studied. Two tendons are also closely associated with it, viz. the long head of the triceps brachii below, and the long head of the biceps brachii above.

**Long Head of the Biceps.**—The tendon of the long head of the biceps is an important factor in the mechanism of the shoulder-joint. It enters the capsule through the opening between the two tubercles of the humerus, and is prolonged over the head of the bone to the apex of the glenoid cavity. Its attachment to the scapula should now be examined. The tendon divides into three portions, viz. a large intermediate part, which obtains direct attachment to the scapula, and two smaller collateral parts, which diverge from each other and blend with the labrum glenoidale. The long head of the biceps brachii, by its position within the capsule and in the deep sulcus between the tubercles of the humerus, serves to keep the head of the bone in place, and to steady it in the various movements at the shoulder-joint.

The *synovial stratum* lines the fibrous stratum of the capsule of the joint, and is reflected from it upon the anatomical neck of the humerus as far as the articular margin of the head of the bone. The bursal protrusion of the *bursa subscapularis*, under the tendon of the subscapularis muscle, has already been noticed. The tendon of the biceps, as it traverses the joint, is enveloped in a tubular sheath of the membrane; this sheath bulges out through the opening of the capsule in the form of a bursa which lines the intertubercular sulcus (Fig. 53).

**Articular Surfaces.**—The smooth, glistening articular cartilage which coats the head of the humerus is thickest in the centre, and thins as it passes towards the edges. In the case of the glenoid cavity the reverse of this will be noticed.

**Movements at the Shoulder-joint.**—The shoulder is a ball-and-socket joint (enarthrosis), and consequently movement in every direction is permitted, viz.—(1) *flexion*, or forward movement; (2) *extension*, or backward movement (checked in its extent by the coraco-humeral ligament); (3) *abduction*, or lateral movement (checked by the coraco-acromial arch); (4) *adduction*, or medial movement (limited

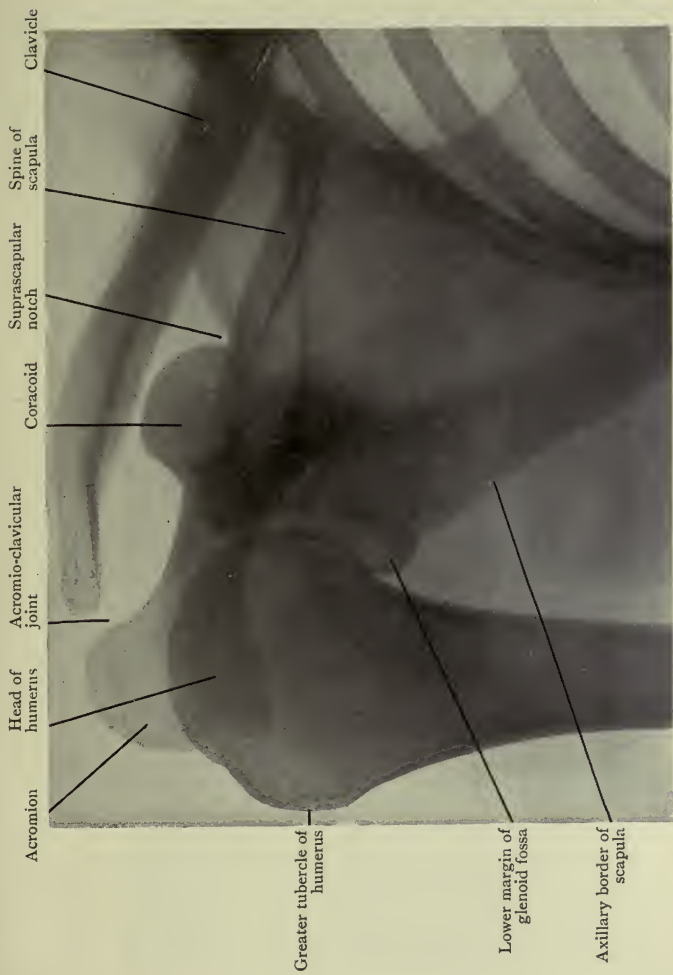


FIG. 55.—Radiograph of Shoulder Region with Arm by Side.

Note the relation of the acromion to the head and the greater tubercle of the humerus and compare with Figs. 56*a*, 56*b*.

PLATE VI

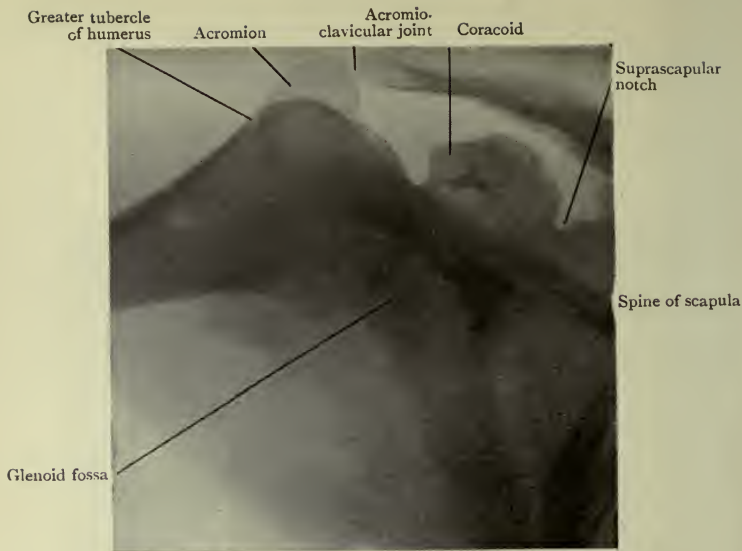


FIG. 56a.—Radiograph of Shoulder Region with Arm fully abducted.

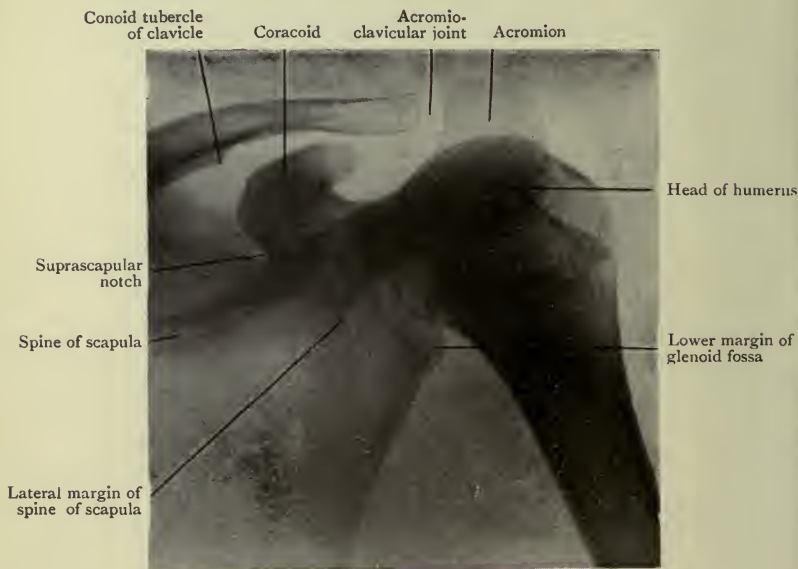


FIG. 56b.—Radiograph of Shoulder Region with Arm partly abducted.

Note (1) That the glenoid fossa is always directed slightly upwards.

(2) The relative positions of the head of the humerus and the greater tubercle to the acromion. Compare with Fig. 55.



by the coraco-humeral ligament). By combination of the angular movements, in regular sequence, *circumduction* is produced; and *rotation* of the humerus, to the extent of quarter of a circle, occurs also.

The muscles chiefly concerned in producing these movements are:—*flexion*—the pectoralis major and the anterior part of the deltoid; *extension*—latissimus dorsi, posterior part of the deltoid, and the teres major; *abduction*—the deltoid and supraspinatus; *adduction*—pectoralis major, coracobrachialis, teres major, and latissimus dorsi; *rotation medially*—subscapularis, pectoralis major, latissimus dorsi, teres major; *rotation laterally*—infraspinatus, and teres minor; *circumduction* is produced by the action of different combinations of these muscles.

The relations of the capsule are shown in Figs. 52, 53.

## FOREARM AND HAND.

The skin has already been removed from the forearm and hand, and the cutaneous veins and nerves have been exposed and studied, but before proceeding with the deeper dissection the dissector should re-examine the cutaneous veins and nerves.

**Venæ Superficiales.**—The two large superficial veins, the basilic and the cephalic, both spring from the venous arch on the dorsum of the hand in which the superficial veins from the fingers terminate (p. 63), and they are reinforced by numerous tributaries from the dorsal and volar surfaces of the limb. The basilic vein curves round the proximal part of the ulnar border of the forearm on its way towards the arm, whilst the cephalic vein turns round the distal part of the radial border (Figs. 31, 32).

**Nervi Cutanei.**—*Two nerves* supply the skin of the volar aspect of the forearm: *the volar branch of the medial cutaneous nerve of the forearm* on the medial side, and *the lateral cutaneous continuation of the musculo-cutaneous nerve* on the lateral side.

*Three nerves* supply the skin on the dorsal aspect of the forearm: *the dorsal branch of the medial cutaneous nerve of the forearm* on the medial side, branches of *the lateral cutaneous nerve* on the lateral side, whilst the intermediate area is

supplied by *the distal branch of the dorsal cutaneous nerve of the forearm*, which is a branch of the radial nerve.

*Four nerves* supply the skin of the palm of the hand: in the region of the hypothenar eminence *the palmar cutaneous branch of the ulnar nerve*, in the region of the thenar eminence *the lateral cutaneous nerve of the forearm*, and a twig from the *superficial division of the radial nerve*, whilst the intermediate part is supplied by *the palmar cutaneous branch of the median nerve*.

*Two nerves* supply branches to the skin of the dorsum of the hand: on the lateral part *the superficial branch of the radial nerve*, and on the medial part *the dorsal branch of the ulnar nerve*.

*Two nerves* supply the skin of the volar aspects of the digits: *the median* and *the ulnar*. Three and a half digits fall to the digital branches of the median nerve: the thumb, the index, the middle, and the lateral half of the ring finger; and one and a half to the digital branches of the ulnar nerve, the little finger and the medial half of the ring finger.

*Three nerves* supply the skin of the dorsal aspects of the digits. Speaking generally, the proximal halves of the thumb, the index, middle, and half the ring finger are supplied by branches of *the superficial division of the radial nerve*. The distal halves of the index, middle, and half the ring finger are supplied by twigs of *the digital branches of the median nerve*, and the remaining half of the ring finger and the little finger receive twigs from *the ulnar nerve*.

After the cutaneous veins and nerves have been re-examined the deep fascia of the forearm should be thoroughly cleaned, if that has not already been done, and its special points should be re-studied.

**Fascia Antibrachii (Fascia of the Forearm).**—The deep fascia which envelops the forearm is of considerable strength and density. More particularly is that the case on the dorsal aspect of the limb. In its proximal part it receives an accession of fibres from the tendon of the biceps brachii, in the form of the lacertus fibrosus. Some fibres are given to it by the tendon of the triceps also. Near the elbow it serves as a surface of origin for the numerous muscles which spring from the epicondyles of the humerus, and from its deep aspect dense septa pass between the fleshy bellies. The septal partitions are indicated on the surface by a series of

white lines. At the wrist it becomes continuous, anteriorly, with the *volar carpal ligament* and the *transverse carpal ligament* (O.T. *ant. annular lig.*), whilst posteriorly it forms an obliquely placed, thickened band, the *dorsal carpal ligament* (post. annular lig.).

#### VOLAR SURFACE AND MEDIAL BORDER OF THE FOREARM.

In this dissection the following structures will be displayed:—

1. The radial and ulnar arteries and their branches.
2. The median and ulnar nerves and their branches.
3. The deep branch and the superficial branch of the radial nerve.
4. The group of pronator and flexor muscles.

**Dissection.**—The deep fascia must now be removed from the forearm. Make two incisions through it, (1) a transverse incision at the proximal border of the transverse carpal ligament; (2) a longitudinal incision from the apex of the cubital fossa to the transverse incision. As the transverse incision is made be careful not to injure the palmar cutaneous branches of the median and ulnar nerves, the tendon of the palmaris longus, the ulnar nerve and artery, and the mucous sheaths of the flexors. The two palmar cutaneous nerves and the tendon of the palmaris longus and the ulnar nerve and artery pierce the deep fascia proximal to the transverse ligament and pass across its superficial surface, but the ulnar nerve and artery are bound down to the ligament by a more superficial band called the *volar carpal ligament*, which passes from the pisiform bone to the front of the transverse carpal ligament. The volar carpal ligament is apt to be mistaken for the transverse ligament, but the mistake should not be made, because the volar carpal ligament lies superficial to the ulnar artery and nerve, whilst the transverse ligament is deep to those structures. Retain the volar carpal ligament in the meantime. The mucous sheaths of the tendons lie immediately subjacent to the deep fascia. Turn the two flaps marked out by the incisions to their respective sides, dividing the septa which pass from their deep surfaces between the adjacent muscles. Both flaps can be followed to the dorsal border of the ulna, to the whole length of which the deep fascia is attached, but for the present do not reflect the lateral flap beyond the radial border of the forearm. Near the elbow the muscles which spring from the medial and lateral epicondyles gain additional origin from the deep surface of the fascia. Where that is the case the fascia must be left *in situ*, for attempts to remove it will only result in laceration of the muscles.

**Muscles of the Volar Aspect of the Forearm.**—The muscles of the volar aspect of the forearm are arranged in a superficial and a deep group. They comprise the flexors of the wrist and digits, and also the pronators of the forearm.

In the *superficial group* are the brachio-radialis, pronator teres, the flexor carpi radialis, the palmaris longus, and the flexor carpi ulnaris, in that order from the lateral to the medial side. On a deeper plane lies the fleshy belly of the flexor digitorum sublimis which only partially comes to the surface. The *deep group* is composed of three muscles, placed in contact with the bones and interosseous membrane of the forearm, viz., the flexor digitorum profundus, in relation to the ulna, the flexor pollicis longus, in relation to the radius, and the pronator quadratus, closely applied to the distal ends of both bones. The brachio-radialis lies along the lateral border of the volar aspect.

The brachio-radialis extends from the lateral supra-condylar ridge of the humerus to the distal end of the radius. The pronator teres ends at the middle of the radius. The flexor carpi radialis passes to the ball of the thumb, where its tendon disappears into a cleft in the lateral border of the transverse carpal ligament. The tendon of the palmaris longus lies medial to the tendon of the flexor carpi radialis; it passes anterior to the transverse carpal ligament to join the intermediate part of the palmar aponeurosis. Still more medial, descending to the pisiform bone, is the tendon of the flexor carpi ulnaris. The tendons of the flexor digitorum sublimis, enclosed in their mucous sheath, lie deep to the palmaris longus between the flexor carpi radialis and the flexor carpi ulnaris.

**Dissection.**—Clean the brachio-radialis, from its origin from the humerus to its insertion into the base of the styloid process of the radius. To expose the insertion it will be necessary to push backwards the tendons of the abductor pollicis longus and the extensor pollicis brevis which overlap it posteriorly. Pull the brachio-radialis aside and clean the radial artery and its branches and the superficial branch of the radial nerve.

**Arteria Radialis.**—The radial artery is the smaller of the two terminal branches of the brachial artery, but its direction gives it the appearance of being the continuation of the parent trunk in the forearm. It takes origin in the cubital fossa, opposite the neck of the radius, and it proceeds distally, in the lateral part of the front of the limb, until it reaches the distal end of the radius. There it turns round the lateral border of the wrist and leaves the present dissection. At first it lies between the pronator teres and the brachio-radialis, and is overlapped to some extent on the lateral side

by the fleshy belly of the latter muscle (Fig. 61). At a more distal level it is placed between the brachio-radialis, on the lateral side, and the flexor carpi radialis, upon the medial side; and that position it maintains as far as the wrist. Where the muscles mentioned are fleshy the artery lies at some depth from the surface; but when their tendons appear it assumes a superficial position, and is covered merely by the integument and fasciæ. Throughout its whole length it is closely accompanied by the *venæ comites*, and the superficial division of the radial nerve lies along its lateral side in the middle third of the forearm. More proximally, the nerve is separated from the vessel by a slight interval; whilst distally, the nerve leaves the artery and turns round the lateral margin of the forearm, under cover of the tendon of the brachio-radialis.

*Posteriorly*, the radial artery is supported by the muscles which clothe and find attachment to the front of the radius. At its origin it rests upon the tendon of the biceps brachii; next it lies in front of the supinator, with some adipose tissue intervening; thence distally it is in contact with the pronator teres, the thin radial head of the flexor digitorum sublimis, the flexor pollicis longus, the pronator quadratus, and, lastly, the distal end of the radius.

The radial artery is usually selected for the determination of the *pulse*. When the tips of the fingers are placed upon the distal part of the forearm, in the interval between the tendons of the brachio-radialis and flexor carpi radialis, the pulsations of the vessel, in the living person, can readily be felt.

**Branches of the Radial Artery.**—In the forearm the radial artery gives off the following branches, viz. :—

1. The a. recurrens radialis.
2. The a. volaris superficialis.
3. The a. carpea volaris radialis.
4. Rami musculares.

The *muscular branches* are very numerous, and proceed from the radial artery, at irregular points, throughout its whole course in the forearm (Fig. 62).

The *radial recurrent artery* is a branch of some size. It takes origin close to the commencement of the radial artery, and, in the first instance, runs laterally between the brachio-radialis and the supinator. There it comes into relation with

branches of the radial nerve, and gives off several twigs for the supply of the muscles arising from the lateral epicondyle of the humerus. Somewhat reduced in size, it now turns proximally, in the interval between the brachio-radialis and brachialis, and ends, in front of the lateral epicondyle of the humerus, by anastomosing with the anterior terminal branch of the profunda brachii artery. It may be represented by two or more vessels.

The *superficial volar artery* is a small, variable branch, which arises a short distance proximal to the wrist, and runs distally to end in the muscles of the ball of the thumb. Sometimes, however, it attains a larger size and a special importance, because it is continued into the palm to complete the superficial volar arch, on the lateral side.

The *volar radial carpal artery* is a minute twig which springs from the radial at the distal border of the pronator quadratus muscle. It runs medially, under cover of the flexor tendons, and joins with the corresponding branch of the ulnar artery to form the *volar carpal arch*.

**The Ramus Superficialis and the Ramus Profundus of the Nervus Radialis (O.T. Radial and Posterior Interosseous Nerves).**—It has already been noted that the radial nerve ends proximal to the elbow, under cover of the brachio-radialis muscle, by dividing into two terminal branches, the superficial branch and the deep branch. Both branches may now be studied in so far as they lie in the volar part of the forearm. The *ramus profundus* soon disappears from view by passing backwards, on the lateral side of the radius, through the fibres of the supinator muscle.

The *superficial branch* proceeds distally, under cover of the fleshy belly of the brachio-radialis. In the middle third of the forearm it lies along the lateral side of the radial artery; then it leaves the artery and winds round the lateral margin of the limb, under cover of the tendon of the brachio-radialis. It has been traced in the rest of its course (p. 71). The superficial branch is a purely cutaneous nerve; and it gives off no branches until it gains the dorsal aspect of the distal part of the forearm.

**Dissection.**—Before the cleaning of the superficial flexor muscles is commenced an attempt should be made to demonstrate the mucous sheaths of the flexor tendons. They are the common

sheath of the flexor digitorum sublimis and the flexor digitorum profundus, the sheath of the flexor pollicis longus and the sheath of the flexor carpi radialis.

If the sheaths are uninjured they can be distended with air by means of a blowpipe, or by fluid forced in through a syringe. If they have been injured they can still be explored with a blunt probe.

Examine, first, the common sheath of the flexor tendons of the fingers. Pick up a fold of the medial part of its anterior wall within the forceps, and introduce the blowpipe or the needle of the syringe into the base of the fold. Notice that as

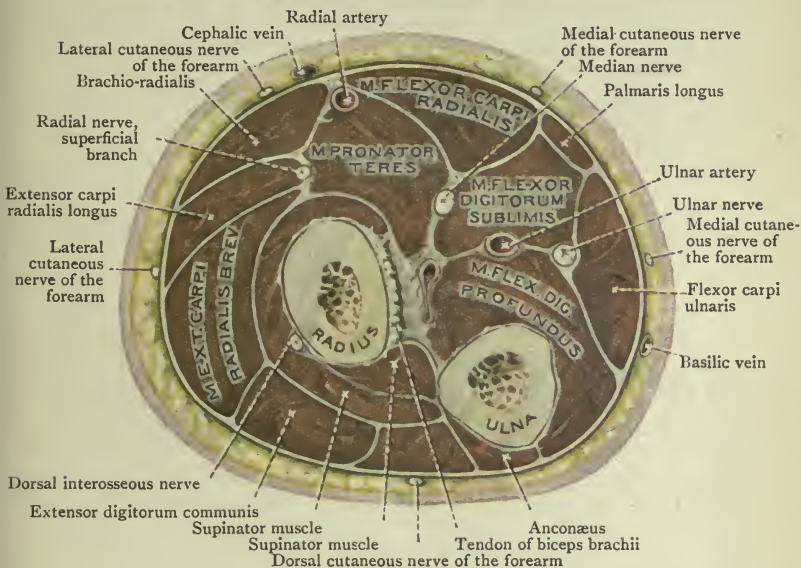


FIG. 57.—Transverse section through the Proximal Third of the left Forearm.

the air or fluid enters it the sheath is distended, at first proximally, to about 25 mm. above the transverse carpal ligament, then the distension passes distally, behind the transverse carpal ligament, to the middle of the palm and along the little finger, as far as the terminal phalanx, showing that the common flexor sheath is continuous with the flexor sheath of the little finger. It may also extend along the thumb, for, in a certain number of cases, the sheath of the flexor pollicis longus communicates with the common flexor sheath.

The sheath of the flexor carpi radialis is not easily distended because it is enclosed for the greater part of its extent in an osteo-fibrous canal. It extends from a short distance proximal to the transverse carpal ligament to the base of the metacarpal bone of the index finger. Open it at the proximal border of the

ligament and investigate its course and direction with the aid of a blunt probe.

If the sheath of the flexor pollicis longus has not already been distended by the air or fluid thrown into the common flexor sheath, pull the tendon of the flexor carpi radialis medially, find the tendon of the flexor pollicis longus which lies behind it, and either distend its sheath in the manner indicated or examine it with a probe. It extends from one inch above the transverse carpal ligament to the base of the terminal phalanx of the thumb.

Now turn to the middle finger and make a small longitudinal incision through the flexor sheath opposite the middle of the second phalanx. A blunt probe introduced through the incision can be passed distally to the base of the terminal phalanx and proximally to the level of the head of the metacarpal bone. The conditions are the same in the cases of the index and ring fingers, therefore the digital sheaths of the index, middle, and ring fingers do not communicate with the common flexor sheath. If the digital sheath of the little finger is opened in a similar manner no difficulty will be experienced in passing a probe along it into the common flexor sheath, and if the digital sheath of the thumb is opened and a little care exercised a probe can be passed along it, and behind the transverse carpal ligament, to the proximal limit of the mucous sheath of the flexor pollicis longus tendon.

**Mucous Sheaths of the Flexor Tendons.**—As the tendons of the flexor digitorum sublimis, the flexor digitorum profundus, and the flexor pollicis longus pass behind the transverse carpal ligament they are accompanied by the median nerve and they are enveloped in two mucous sheaths (Fig. 58). One sheath surrounds the flexor pollicis longus, the other surrounds the tendons of both the flexor sublimis and the flexor profundus, and it may enclose also the median nerve. The sheaths, therefore, line a "carpal tunnel" which is bounded superficially by the transverse carpal ligament and dorsally by the carpal bones, and they greatly facilitate the free play of the tendons between the transverse carpal ligament and the carpus. As already stated, the sheaths are two in number. Both sheaths are prolonged proximally, into the forearm, for 25 mm. (one inch) or more, and both are carried distally into the palm in the form of diverticula upon the diverging tendons. The diverticula in relation to the tendons which go to the index, middle, and ring fingers end near the middle of the palm. Those upon the tendons of the thumb and little finger, however, are prolonged distally into the digits, and line the fibrous sheaths which confine the tendons upon the volar aspects of the phalanges (Fig. 57).



The mucous sheath which invests the tendons of the flexor

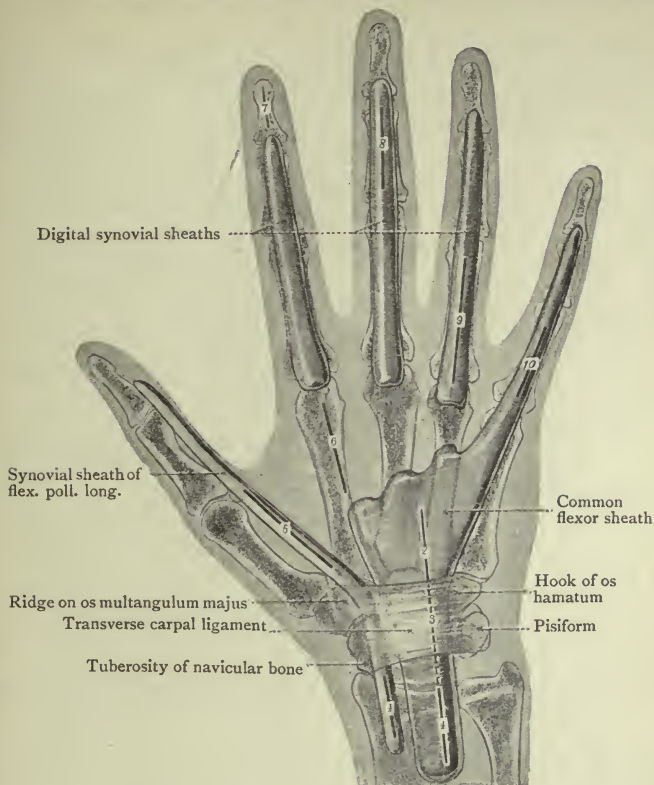


FIG. 58.—The Synovial Sheaths of the Wrist and Hand. The positions of various incisions for the evacuation of pus are also shown.

1 and 2. Incisions into the common palmar sheath, placed between the median and ulnar nerves.

3. Incision uniting 1 and 2.

4. Incision into the proximal part of the sheath of flexor pollicis longus. It is placed between the radial artery and the median nerve.

5. Incision into the distal part of the sheath of flexor pollicis longus.

6. Incision into the thenar space.

7. Incision over terminal phalanx.

8, 9 and 10. Incisions into the digital sheaths. They lie opposite the shafts of the phalanges.

digitorum sublimis and flexor digitorum profundus is sometimes divided by a vertical partition into two compartments, and the lateral of them communicates, by means of a small

aperture near the proximal border of the transverse carpal ligament, with the mucous sheath of the tendon of the flexor pollicis longus.

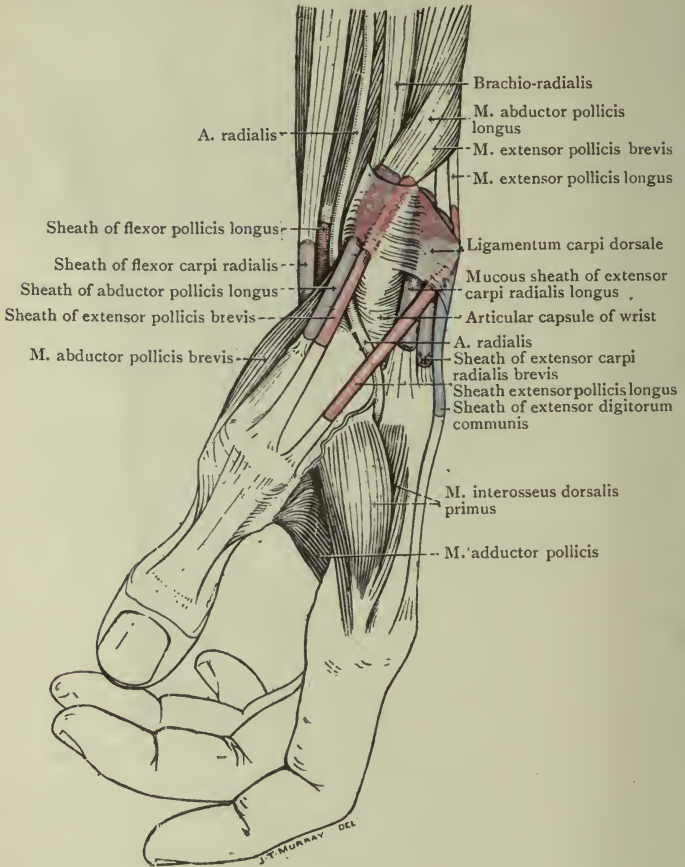


FIG. 59.—Dissection of the Lateral Side of the Left Wrist and Hand showing Mucous Sheaths of Tendons.

**The Constitution of Mucous Sheaths of Tendons.**—The student should understand the nature of mucous sheaths which surround tendons, where they pass through fascial or osteo-fascial canals. The majority of the mucous sheaths

are double-walled tubes. At their extremities the outer and inner walls are bound together, and the space between the two walls, the so-called cavity of the sheath, is thus closed. The cavity of the sheath is a potential cavity only, and it contains merely sufficient mucous fluid to lubricate the adjacent surfaces, and facilitate their free play over one another.

The inner wall of the tube surrounds the tendon and adheres to its surface. The outer wall lines the canal through which the tendon passes and adheres to it. But the ends of the sheaths project beyond the limits of the canals which they line; therefore, as the tendons move

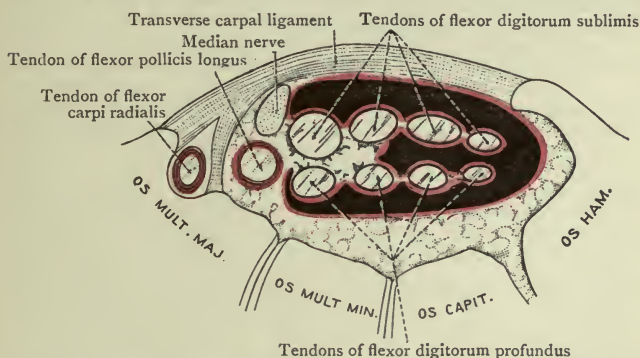


FIG. 60.—Diagram illustrating the relation of the Synovial Sheaths to the Flexor Tendons at the level of the transverse carpal ligament.

proximally and distally, the opposite ends of the sheaths can be invaginated and evaginated, thus allowing for the free play of the tendons.

When a sheath becomes inflamed the adjacent surfaces of its two walls are at first roughened, and when the tendon moves, friction, which can be heard and felt, occurs and pain is caused. Then the fluid between the two walls increases in amount, the sheath becomes distended as if it had been injected, and its position becomes apparent. At the same time the friction ceases, but the distension of the walls stretches the nerves, and pain is still felt.

Some mucous sheaths, for example the mucous sheath of the flexors of the fingers, are not complete tubes, but merely invaginated sacs (Fig. 60).

*Dissection.*—The superficial muscles which arise from the medial epicondyle of the humerus must now be cleaned. Commence with the most lateral of the group, the pronator teres, and follow it from its origin to its insertion into the middle of the lateral surface of the radius. To expose the insertion the brachio-radialis and the long and short radial extensors of the carpus which cover it must be pulled aside. As the distal part of the pronator teres is being cleaned be careful not to injure the thin radial origin of the flexor digitorum sublimis which lies behind it. Separate the proximal part of the pronator teres from the flexor carpi radialis by dividing the intermuscular septum between them. Divide the superficial head of the pronator teres, turn the proximal part towards the medial epicondyle and the distal part towards the radius and follow the deep head between the median nerve and the ulnar artery to its origin from the coronoid process of the ulna. After the pronator teres has been examined clean the flexor carpi radialis, but do not follow its tendon of insertion beyond the proximal edge of the transverse carpal ligament, where it enters a special osteo-fibrous canal through which it will be traced in a later dissection. Now clean the palmaris longus; trace its tendon to the intermediate part of the palmar aponeurosis, and note that as it crosses the transverse carpal ligament its deep surface is attached to the ligament.<sup>1</sup>

The most medial muscle of the group, the flexor carpi ulnaris, must now be cleaned. Note that its tendon of insertion lies along the volar border of the distal part of the muscle. This is a point of practical importance, for the tendon is used as a guide during operations upon the ulnar nerve and artery in the distal part of the forearm. Clean both heads of origin of the flexor carpi ulnaris, one from the medial epicondyle and one from the medial border of the olecranon of the ulna, and note that the ulnar nerve, accompanied by the superior ulnar collateral artery, disappears between them. Separate the proximal part of the flexor carpi ulnaris from the adjacent parts of the palmaris longus and the flexor digitorum sublimis by splitting the septa between them; secure the ulnar nerve and its branches to the flexor carpi ulnaris and the flexor digitorum profundus on the deep surface of the flexor carpi ulnaris. Follow the ulnar nerve distally. At the junction of the proximal and middle thirds of the forearm it is joined by the ulnar artery, which appears from under cover of the medial border of the flexor digitorum sublimis. Clean the artery and nerve, as far as the lateral side of the pisiform bone, and find the origins of the dorsal and palmar branches of the nerve, which were seen when the superficial structures of the palm and on the dorsum of the hand were dissected (p. 70). Secure also the volar carpal branch of the artery which arises near the proximal border of the transverse carpal ligament.

To get a good view of the flexor digitorum sublimis divide the palmaris longus and the flexor carpi radialis at the middle of the forearm. Turn the proximal parts of both the muscles upwards and separate them from the pronator teres and the flexor sublimis by splitting the intervening intermuscular septa.

<sup>1</sup> The palmaris longus is not uncommonly absent.

Pull the pronator teres laterally and secure the median nerve as it emerges between the superficial and deep heads of the muscle and before it disappears between the radial and humeral parts of the flexor digitorum sublimis. Then clean the flexor sublimis, being careful not to injure the thin sheet of fibres by which it takes origin from the volar border of the radius. Clean the four tendons in which the flexor sublimis terminates. They are arranged in pairs, two anterior which pass to the middle and ring fingers, and two posterior for the index and little fingers. Pull upon the tendons and note the results. Note also that the median nerve, after it emerges from between the two heads of the pronator teres, disappears again between the humeral and radial origins of the flexor sublimis to reappear at the lateral border of the muscle a short distance proximal to the wrist, where it lies under cover of the radial border of the tendon of the palmaris longus. The tendons of the flexor digitorum sublimis must not be followed further than the transverse carpal ligament at present. The terminal parts will be displayed in a later dissection.

**Common Origin of the Superficial Muscles.**—The five muscles which constitute the superficial group are very closely associated with each other at the elbow—indeed, they may be said to arise by a common origin from the front of the medial epicondyle of the humerus. In addition they all derive fibres from the investing deep fascia of the limb, near the elbow, and from the strong fibrous septa which pass between the muscles from the deep surface of investing fascia. The pronator teres, the flexor sublimis, and the flexor carpi ulnaris, have additional heads of origin (Figs. 61, 62).

**M. Pronator Teres.**—The pronator teres muscle crosses the proximal half of the front of the forearm obliquely. It arises by two heads, viz., a humeral and an ulnar. The *humeral head* constitutes the chief bulk of the muscle. It springs from the proximal part of the medial epicondyle of the humerus, and also slightly, by fleshy fibres, from the distal part of the medial epicondylar ridge. The fascia covering it and the fibrous septum on its medial side also contribute fibres. The *ulnar head* is placed deeply, and it may be recognised from the fact that it intervenes between the median nerve and the ulnar artery. The ulnar head is very variable in size. As a rule, it is a small fleshy slip, but sometimes it is chiefly fibrous. It arises from the medial border of the coronoid process of the ulna (Fig. 64, p. 147), and soon joins the deep surface of the humeral head. The muscle, thus formed, passes obliquely distally and laterally, and ends in a tendon which gains insertion into a rough impression upon the middle of the lateral surface of the radius (Fig. 64,

p. 147). This attachment is placed on the summit of the chief curve of the radius, an arrangement which enables the muscle to exercise its pronating action at a great advantage. Close to its insertion the pronator teres is crossed by the radial artery and it is covered by the brachio-radialis muscle. It is supplied by the *median nerve*. It is a pronator of the forearm and hand and a flexor of the elbow.

**M. Flexor Carpi Radialis.**—The flexor carpi radialis arises from the common tendon, from the fascia of the forearm and the fibrous septa which intervene between it and the adjacent muscles. Its fleshy belly gives place, a short distance distal to the middle of the forearm, to a long flattened tendon, which, at the wrist, traverses the groove on the front of the os multangulum majus, in a special compartment of the transverse carpal ligament (Fig. 60, p. 137). It is inserted into the volar aspect of the base of the metacarpal bone of the index, and slightly also into the base of the metacarpal bone of the middle finger. Its relations to the transverse carpal ligament, and also its attachment to the metacarpus, will be exposed and studied at a later stage of the dissection. It is a flexor of the wrist and elbow joints and assists in producing abduction of the hand. It is supplied by the *median nerve*.

**M. Palmaris Longus.**—The palmaris longus is a long slender muscle, which is not always present. It springs from the common origin, the fascial investment of the forearm and the fibrous septum on each side of it. Its tendon pierces the deep fascia immediately proximal to the wrist, and then passes distally, superficial to the transverse carpal ligament, to join the strong intermediate portion of the palmar aponeurosis. Very frequently it gives a slip to the abductor pollicis brevis. It is supplied by the *median nerve*, and is a flexor of the radio-carpal and elbow joints.

**M. Flexor Carpi Ulnaris.**—The ulnar flexor of the carpus muscle arises by two heads. One of them is incorporated with the common origin from the medial epicondyle; the other springs from the medial border of the olecranon of the ulna, and also by an aponeurotic attachment from the dorsal border of the same bone in its proximal two-thirds. Fibres are derived also from the investing fascia and the inter-muscular septum on its lateral side. The two heads of origin of the flexor carpi ulnaris bridge across the interval between

PLATE VII

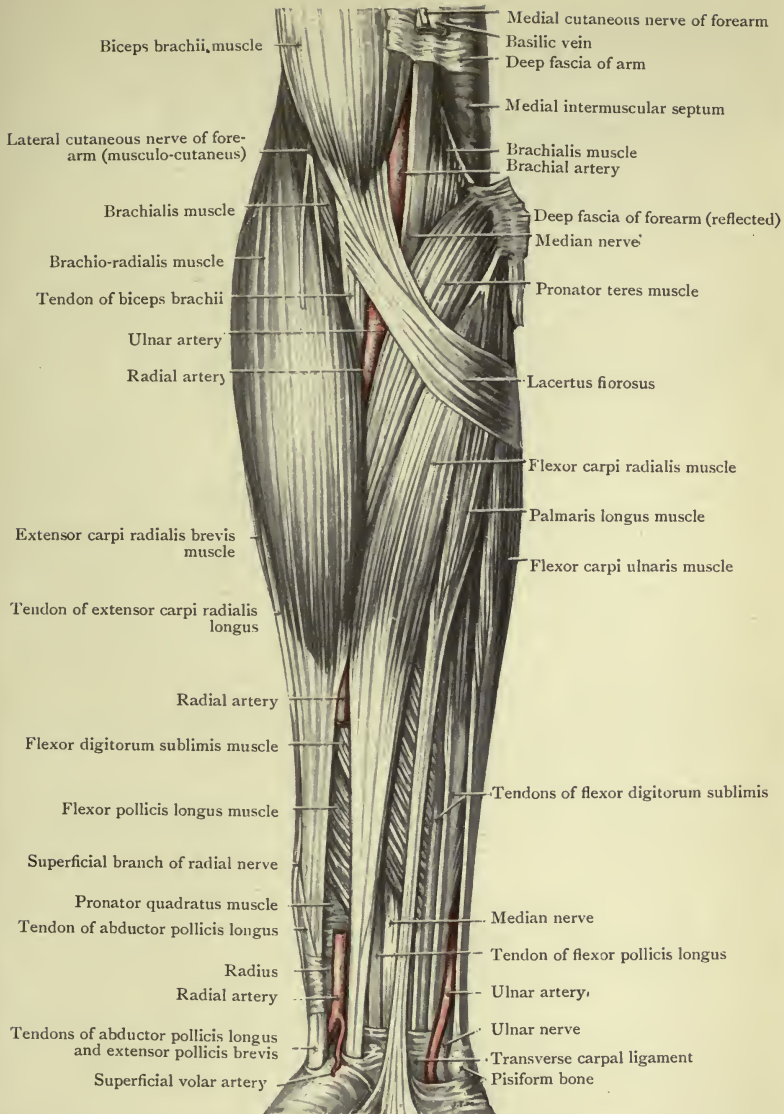


FIG. 61.—Superficial Dissection of the Muscles, Arteries, and Nerves of the Anterior Aspect of the Forearm.

Part of the radial artery was removed to show some of its deep relations.

PLATE VIII

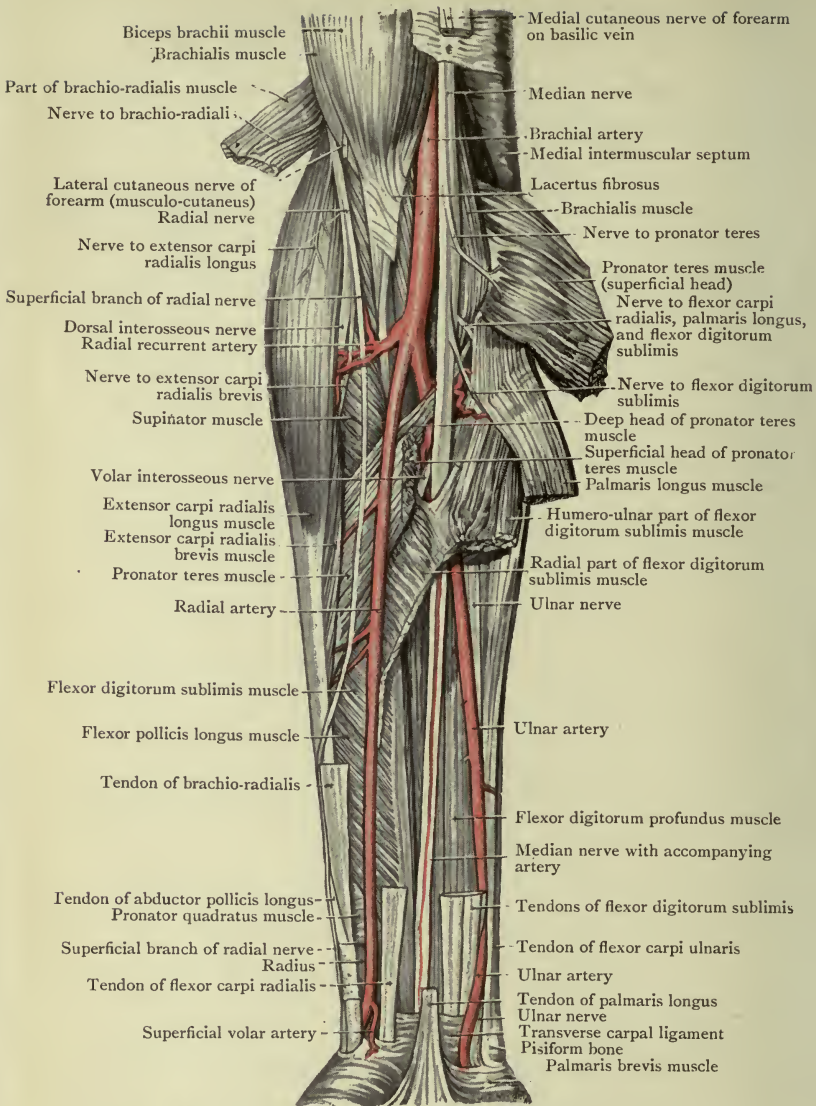


FIG. 62.—Deep Dissection of the Muscles, Vessels, and Nerves of the front of the Forearm.



the medial epicondyle of the humerus and the olecranon, and between them the ulnar nerve is prolonged distally into the forearm. The tendon appears upon the volar border of the muscle, and is inserted into the pisiform bone. The flexor carpi ulnaris is supplied by the *ulnar nerve*. It is a flexor and adductor of the hand and a flexor of the elbow.

**M. Flexor Digitorum Sublimis.**—The flexor sublimis receives this name because it is placed upon the superficial aspect of the flexor profundus. For the most part it lies deeper than the other superficial muscles (Fig. 61). It is a powerful muscle which arises from the medial epicondyle of the humerus by the common tendon; it takes origin also from the ulnar collateral ligament of the elbow-joint, from the medial margin of the coronoid process of the ulna, the volar surface of the radius (Figs. 45, 64), and the fascial intermuscular septa in relation to it. The radial head of origin is a thin fleshy stratum which is attached to the volar border of the radius, from its proximal end to a variable distance beyond the insertion of the pronator teres muscle. Four tendons issue from the fleshy mass; they enter the palm by passing under cover of the transverse carpal ligament, and go to the medial four digits. Their insertions will be seen later, but, in the meantime, note that at the wrist, and for a short distance proximal to it, they are enveloped by the mucous sheath previously mentioned, and also that, as they pass behind the transverse carpal ligament, they lie in pairs—the tendons to the ring and middle fingers being placed on the volar aspect of those for the index and little fingers. The flexor digitorum sublimis is supplied by the *median nerve*. It is a flexor of the first interphalangeal joints of the fingers, the metacarpo-phalangeal joints, the wrist joint, and the elbow joint.

The dissector who examines the flexor digitorum sublimis in detail will find that the part which arises from the humerus divides into a superficial and a deep portion, and that each portion subdivides in two parts, a lateral and a medial. The lateral part of the superficial portion unites with fibres which spring from the radius; then the combined fibres pass to the tendon for the middle finger. The medial part of the superficial portion receives additional fibres from the deeper portion, and ends in the tendon for the ring finger. The lateral part of the deeper portion is a digastric muscle; it ends in the tendon for the index finger. The medial part of the deeper portion ends in the tendon for the little finger; it is a small muscular belly which frequently receives fibres from the intermediate tendon of the lateral part of the deeper portion of the muscle.

**Dissection.**—Cut through the radial part of the flexor digitorum sublimis at its union with the humeral portion. Pull the main mass of the muscle towards the medial side of the forearm, and turn the radial portion towards its origin. Then clean the median nerve, the branch of the anterior interosseous artery which accompanies the nerve, and the anterior surface of the flexor pollicis longus which springs from the volar surface of the radius; and the flexor digitorum profundus, which arises from the volar and medial surfaces of the ulna. Then secure the volar interosseous branch of the median nerve. It springs from the median nerve as the latter emerges from between the two heads of the pronator teres. Find also the common interosseous branch of the ulnar artery. It arises in, or immediately distal to, the cubital fossa, and must be looked for behind the deep head of the pronator teres. Almost at once it divides into volar and dorsal interosseous branches. The dorsal branch passes backwards above the interosseous membrane to the dorsal part of the forearm, where it will be dissected later. Now separate the adjacent borders of the flexor pollicis longus and the flexor digitorum profundus and follow the volar interosseous artery and nerve to the point where they disappear behind the pronator quadratus in the distal third of the forearm. Clean the pronator quadratus, then proceed to study the structures exposed.

**Arteria Ulnaris.**—The ulnar artery is the larger of the two terminal branches of the brachial trunk. It takes origin, in the cubital fossa, at the level of the neck of the radius. In the proximal third of the forearm it inclines obliquely distally and medially, and then it proceeds straight down to the wrist. It enters the palm by passing anterior to the transverse carpal ligament. In the proximal oblique portion of its course the vessel is deeply placed, and is crossed by both heads of the pronator teres, the flexor carpi radialis, the palmaris longus, the flexor digitorum sublimis and the median nerve. Its distal, vertical part is overlapped on the medial side by the flexor carpi ulnaris, but a short distance proximal to the wrist it becomes superficial, and lies in the interval between the tendon of the flexor carpi ulnaris on the medial side and the tendons of the flexor sublimis on the lateral side. As it lies on the transverse carpal ligament it is separated from the lateral side of the pisiform bone by the ulnar nerve, and is covered by a strong band of fascia, the volar carpal ligament (pp. 129, 162), which lies superficial to the transverse ligament. Throughout its entire course it is accompanied by two *venæ comites*. It has important relationships with the median and ulnar nerves. The *median nerve*, which lies upon its medial side at its origin, soon crosses it, but at the point of crossing the nerve is separated from the artery

by the deep head of the pronator teres. The *ulnar nerve* in the proximal third of the forearm is separated from the vessel by a wide interval, but in the distal two-thirds of the forearm it closely accompanies the artery, and lies on its medial side.

In the cubital fossa the ulnar artery rests upon the brachialis; more distally it is in contact posteriorly with the flexor digitorum profundus; whilst at the wrist the artery lies upon the superficial surface of the *transverse carpal ligament*.

**Branches of the Ulnar Artery.**—In the forearm the ulnar artery gives off the following branches:—

- |                                   |  |                        |
|-----------------------------------|--|------------------------|
| 1. A. recurrens ulnaris volaris.  |  | 4. A. carpea volaris.  |
| 2. A. recurrens ulnaris dorsalis. |  | 5. A. carpea dorsalis. |
| 3. A. interossea communis.        |  | 6. Rami musculares.    |

The *muscular branches* are of small size, and come off at variable points for the supply of the neighbouring muscles.

The *volar ulnar recurrent artery* (O.T. *anterior ulnar recurrent*) is the smaller of the two recurrent branches. It runs proximally, anterior to the medial epicondyle of the humerus, in the interval between the pronator teres and the brachialis muscles, and it anastomoses with the anterior terminal branch of the inferior ulnar collateral artery.

The *dorsal ulnar recurrent artery* (O.T. *posterior ulnar recurrent*) passes medially, under cover of the flexor digitorum sublimis, and then turns proximally, between the two heads of origin of the flexor carpi ulnaris, to gain the interval between the medial epicondyle of the humerus and the olecranon, on the dorsal aspect of the limb. There it becomes associated with the ulnar nerve, and anastomoses with the posterior terminal branch of the inferior ulnar collateral artery and with the superior ulnar collateral artery.

It is not uncommon to find the two recurrent arteries arising from the ulnar trunk by a short common stem.

The *common interosseous artery* is a short, wide trunk, which takes origin immediately distal to the recurrent branches, about 25 mm. (one inch) from the commencement of the ulnar artery. It passes dorsally to the proximal margin of the interosseous membrane, where it divides into two terminal branches, viz., the *volar* (O.T. *anterior*) and the *dorsal* (O.T. *posterior*) *interosseous arteries*.

The *arteria interossea dorsalis* passes backwards above

the proximal border of the interosseous membrane to the dorsal part of the forearm, where it will be dissected at a later period.

The *arteria interossea volaris* descends on the anterior surface of the interosseous membrane, between the adjacent margins of the flexor pollicis longus and the flexor digitorum profundus, which must be separated as the artery is followed. At the proximal border of the pronator quadratus it pierces the interosseous membrane and passes to the dorsal part of the forearm, where its terminal part will be seen at a later period. As it descends on the volar surface of the interosseous membrane it gives twigs to the adjacent muscles, and the following named branches:—

1. Arteria mediana.
- 2 and 3. Nutrient to radius and ulna.
4. Volar communicating.

The *arteria mediana* is a long slender vessel which accompanies the median nerve to the palm of the hand, where it sometimes terminates in the superficial volar arch. The *nutrient arteries* enter the nutrient foramina of the radius and ulna. The *volar communicating artery* descends on the volar surface of the interosseous membrane, deep to the pronator quadratus, to the carpus, where it terminates in the volar carpal arch.

The *ulnar carpal arteries* are two small arteries, which partially encircle the wrist. The *volar ulnar carpal artery* runs laterally, under cover of the tendons of the flexor digitorum profundus, and anastomoses with the volar carpal branch of the radial artery. From the arch, thus formed, small twigs are given to the volar aspect of the carpal bones and joints. The *dorsal ulnar carpal artery* gains the dorsal aspect of the carpus by winding round the medial margin of the limb immediately proximal to the pisiform bone, and under cover of the tendon of the flexor carpi ulnaris.

**Nervus Ulnaris.**—The ulnar nerve, which was traced in the dissection of the arm as far as the interval between the olecranon and medial epicondyle of the humerus, enters the forearm between the two heads of the flexor carpi ulnaris. It proceeds distally, on the volar surface of the flexor digitorum profundus and under cover of the flexor carpi ulnaris, in the volar part of the medial side of the forearm. Close to

the wrist it becomes superficial, upon the lateral side of the

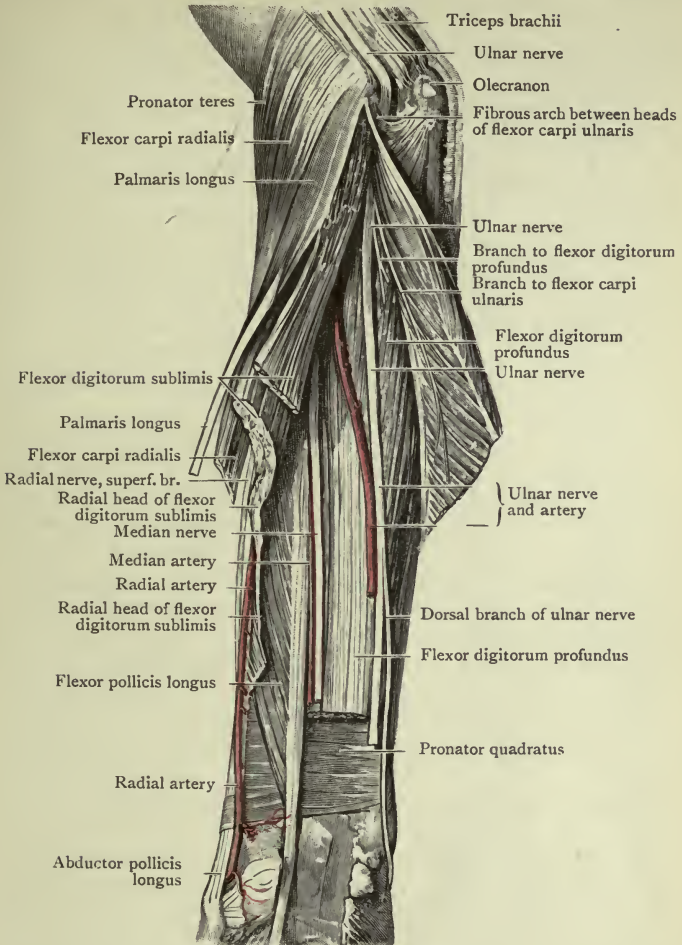


FIG. 63.—Dissection of the volar aspect of the Forearm; the superficial muscles are cut short and turned aside, and the deeper parts are still further displayed by the separation of the flexor digitorum sublimis from the flexor carpi ulnaris along the line of the intermuscular septum which intervenes between them.

tendon of the flexor carpi ulnaris, and it reaches the palm by

passing superficial to the transverse carpal ligament. In the proximal third of the forearm the ulnar nerve is separated from the ulnar artery by a considerable interval, but in the distal two-thirds it is closely applied to the medial side of the vessel.

In the forearm the ulnar nerve gives off:—

1. Rami articulares.
2. Rami Musculares,  $\left\{ \begin{array}{l} \text{to the flexor carpi ulnaris and the medial part} \\ \text{of the flexor digitorum profundus.} \end{array} \right.$
3. Rami cutanei,  $\left\{ \begin{array}{l} \text{ramus cutaneus palmaris.} \\ \text{ramus dorsalis manus.} \end{array} \right.$

The *articular branches* spring from the ulnar nerve as it lies in the interval between the olecranon and the medial epicondyle of the humerus, and pass to the elbow-joint.

The *muscular branches* are given off immediately distal to the articular branches. They supply the flexor carpi ulnaris and the medial part of the flexor digitorum profundus.

The *palmar cutaneous branch* is a minute twig which has already been seen piercing the fascia of the forearm, immediately proximal to the transverse carpal ligament. It arises about the middle of the forearm and proceeds distally upon the ulnar artery, to be distributed in the palm of the hand.

The *dorsal branch* is a nerve of some size which springs from the ulnar trunk about 6–7.5 cm. (two and a half or three inches) proximal to the wrist. It winds round the medial margin of the forearm, under cover of the flexor carpi ulnaris, and reaches the dorsum of the hand immediately distal to the prominence formed by the distal end of the ulna. From that point onwards it has been traced in the superficial dissection (p. 71).

**Nervus Medianus.**—As its name implies, the median nerve passes down the middle of the forearm.

In the proximal part of the forearm the median nerve lies in the cubital fossa upon the medial side of the ulnar artery. It leaves the fossa by passing between the two heads of the pronator teres, and as it does so it crosses the ulnar artery, but is separated from it by the ulnar head of the muscle. From that point the median nerve runs distally between the flexor digitorum sublimis superficially and the flexor digitorum profundus deeply. Near the wrist it becomes superficial, and lies in the interval between the tendons of the palmaris longus, on the medial side, and the flexor carpi radialis, on the lateral

side. Finally it leaves the forearm by passing deep to the transverse carpal ligament. A small artery, the *a. mediana*, a branch of the volar interosseous artery, accompanies the median nerve. Sometimes this vessel attains a considerable size.

As the median nerve enters the forearm it gives off numerous branches for the supply of muscles, and near the wrist it supplies a *palmar branch*, which has already been dissected (p. 70).

The *muscular branches* supply all the muscles which spring from the medial epicondyle of the humerus, with the single exception of the flexor carpi ulnaris; viz., the pronator teres, the flexor carpi radialis, the palmaris longus, and the flexor digitorum sublimis.

It supplies also a long slender twig—*volar interosseous nerve*—which goes to the deep muscles on the volar aspect of the forearm.

**Deep Structures on the front of the Forearm.**—The connections of the deep muscles must now be studied.

The flexor digitorum profundus is the large muscle which clothes the volar and medial surfaces of the ulna; the flexor pollicis longus is placed

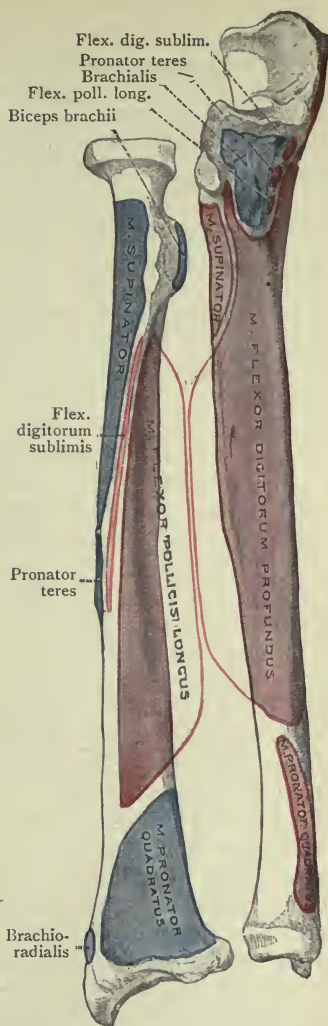


FIG. 64. — Volar aspect of Bones of Forearm with Muscular Attachments mapped out.

upon the volar surface of the radius; while the pronator quadratus is a quadrate fleshy layer closely applied to both bones immediately proximal to the wrist. The volar interosseous artery and nerve proceed distally in the interval between the flexor profundus and flexor pollicis longus.

**M. Flexor Digitorum Profundus.**—The deep flexor of the fingers springs from the volar and medial surfaces of the ulna in its proximal three-fourths. It derives fibres also from the volar surface of the interosseous membrane and the aponeurosis by which the flexor carpi ulnaris takes origin from the dorsal border of the ulna. The fleshy mass gives place to four tendons for the medial four digits, but only one of them—that for the index finger—becomes separate and distinct in the forearm. The tendons proceed distally, *deep to* the transverse carpal ligament, into the palm. The flexor digitorum profundus is supplied by the *volar interosseous branch of the median* and by the *ulnar nerve*. It is a flexor of all the joints of the fingers, and of the wrist.

**M. Flexor Pollicis Longus.**—The flexor pollicis longus arises from the proximal two-thirds of the volar surface of the radius. It takes origin also from the adjacent part of the volar surface of the interosseous membrane. A rounded tendon issues from the fleshy belly, and proceeds into the palm, deep to the transverse carpal ligament.

In many cases the flexor pollicis longus has an additional slender head of origin, which springs from the medial border of the coronoid process of the ulna, or the medial epicondyle of the humerus. The flexor pollicis longus is supplied by the *volar interosseous nerve*. It is a flexor of all the joints of the thumb and of the wrist.

**M. Pronator Quadratus.**—The quadrate pronator muscle takes origin from the distal fourth of the volar surface of the ulna, and is inserted into the distal third of the volar surface of the radius. It is supplied by the *volar interosseous nerve*. It is pronator of the forearm and hand.

**Dissection.**—Divide the pronator quadratus vertically and clean the part of the volar interosseous artery which lies behind it.

#### WRIST AND PALM.

In this dissection the following structures will be found:—



1. Palmaris brevis muscle and the palmar cutaneous nerves.
2. Palmar aponeurosis.
3. Superficial volar arch and its branches.
4. Median and ulnar nerves and their branches.
5. Volar carpal ligament, transverse carpal ligament, the flexor tendons, and their mucous sheaths.
6. The lumbrical muscles.
7. Short muscles of the thumb and little finger.
8. Deep volar arch and its branches.
9. Princeps pollicis artery and radial volar artery of the index finger.

Before proceeding with the dissection of the palm the student should revise the surface anatomy of the region, making use of his own hands as well as of his "part" for the purpose; and he should re-study the superficial vessels and nerves, and the deep fascia which have already been displayed (p. 73). After the revision is completed, the attachments and relations of the palmaris brevis muscle must be noted.

**Surface Anatomy.**—In the centre of the palm the depression, known as the "hollow of the hand," may be noted. Along the medial border of the palm the hollow is bounded by a rounded elevation, called the *hypothenar* eminence, which is produced by the subjacent short, intrinsic, muscles of the little finger. The *thenar* eminence, or ball of the thumb, formed by the short muscles of that digit, is the marked prominence which limits the palmar hollow proximally and on the lateral side; whilst the transverse elevation at the roots of the fingers, which corresponds to the metacarpo-phalangeal articulations, constitutes the distal boundary of the central palmar depression. Two pronounced bony projections on the anterior aspect of the wrist cannot fail to attract attention when the hand is bent dorsally. The more prominent of the two is situated at the proximal extremity of the thenar eminence, and is formed by the tubercle of the navicular bone and the vertical ridge on the volar surface of the os multangulum majus; the other is placed at the proximal end of the hypothenar eminence, and is somewhat obscured by the soft parts attached to it. It is caused by the pisiform bone, and when taken firmly between the finger and thumb a slight degree of gliding movement can be communicated to it. Traversing the thick integument of the palm, three strongly marked furrows are apparent. One begins at the elevation formed by the navicular and os multangulum majus and curves distally and laterally, round the base of the thenar eminence, to the lateral margin of the

hand. A second crosses the palm transversely. Commencing at the middle of the lateral border of the hand, where the first furrow ends, it runs medially, but, as a general rule,

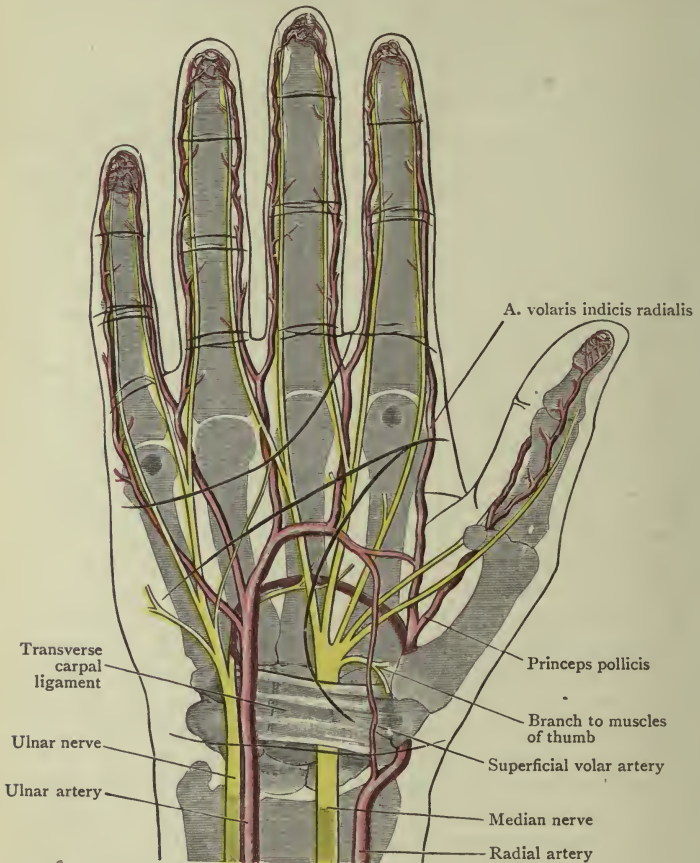


FIG. 65.—Diagram of Nerves and Vessels of Hand in relation to Bones and Skin Markings.

it fades away upon the hypothenar eminence. The third furrow begins near the cleft between the index and middle fingers, and proceeds medially, with a gentle curve across the hypothenar eminence, to the medial margin of the hand. The transverse cutaneous furrows at the roots of the fingers,

and on the palmar aspects of the interphalangeal joints, should also be noticed. The furrows at the roots of the fingers are

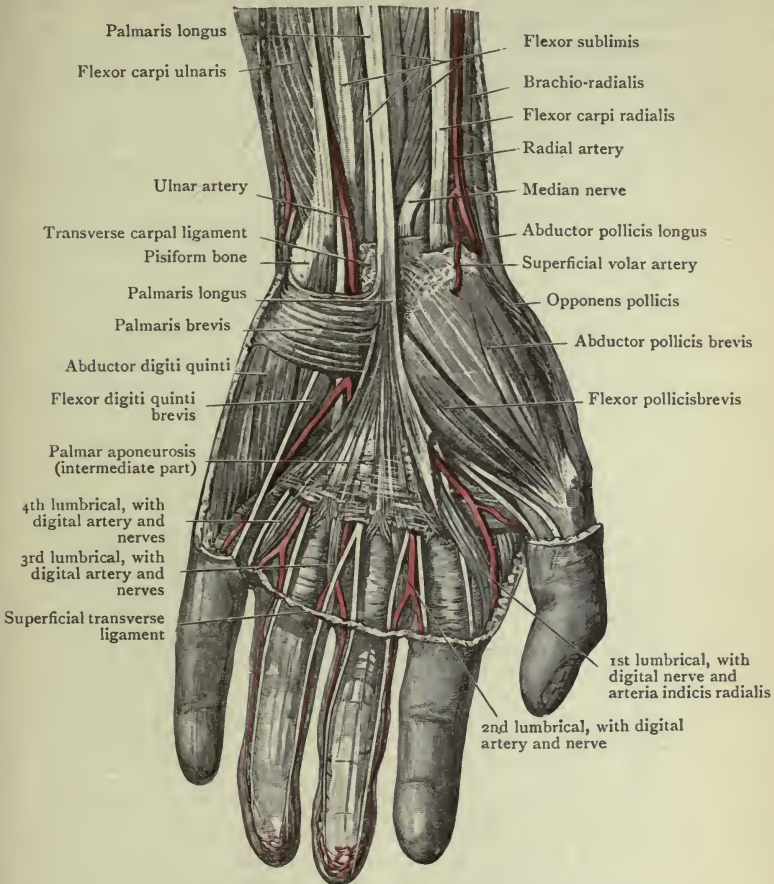

FIG. 66.—Superficial Dissection of the Palm. The intermediate part of the palmar aponeurosis has been left in position, whilst the lateral and medial portions have been removed to display the short muscles of the thumb and little finger.

placed over the palmar aspects of the proximal phalanges, about 25 mm. (one inch) distal to the metacarpo-phalangeal joints. The proximal of the two furrows on the front of a

proximal interphalangeal joint is placed immediately over the articulation, whilst in the case of the distal interphalangeal joints the single crease which is usually present is situated immediately proximal to the articulation. On the back of the hand the metacarpal bones can be readily felt, whilst their distal extremities, or heads, form the prominences known as the "knuckles."

**M. Palmaris Brevis.**—This small cutaneous muscle consists of a series of fasciculi which are frequently separated from one another by distinct intervals. As a whole it forms a thin fleshy layer which covers the deep fascia on the proximal one and a half inches of the hypothenar eminence. It springs from the distal margin of the transverse carpal ligament and the medial border of the strong intermediate part of the palmar aponeurosis, and it is inserted into the skin of the medial border of the hand. It lies superficial to the ulnar artery, the superficial part of the ulnar nerve, and to the deep fascia covering the muscles of the hypothenar eminence. It is supplied by the superficial division of the ulnar nerve.

**Dissection.**—Reflect the palmaris brevis to its origin from the intermediate part of the palmar aponeurosis, and secure the branch from the superficial division of the ulnar nerve which supplies it. Remove the medial part of the palmar aponeurosis from the muscles of the hypothenar eminence. Clean the ulnar artery to the point where it disappears under cover of the intermediate part of the palmar aponeurosis. Note that, as it passes by the *medial side* of the hook of the os hamatum, it sends a deep branch into the substance of the palm. Clean the ulnar nerve as it lies on the medial side of the hook of the hamatum and secure its two terminal branches: (1) A superficial branch, which divides into the digital branch for the medial side of the little finger, and a branch which divides to supply the adjacent sides of the little and ring fingers; and (2) a deep branch which accompanies the deep branch of the ulnar artery into the depths of the palm. Find the branches which the deep division of the ulnar nerve gives to the short muscles of the little finger; then insert the handle of the scalpel into the cleft into which the deep divisions of the artery and nerve pass, and carry it distally to separate the abductor digiti quinti muscle, on the medial side, from the flexor digiti quinti brevis and the opponens digiti quinti on the lateral side. The opponens lies on a deeper plane than the short flexor.

**Short Muscles of the Little Finger.**—There are three short muscles of the little finger: the abductor, the short flexor, and the opponens. They are all supplied by the deep branch of the *ulnar nerve*.

**M. Abductor Digiti Quinti.**—The abductor is the largest of the three short muscles of the little finger. It arises from the pisiform bone, and is inserted into the medial side of the base of the first phalanx of the little finger.

**M. Flexor Digiti Quinti Brevis.**—The short flexor of the little finger is a muscle of very variable size. It springs from the hook of the os hamatum and the adjacent part of the distal border of the transverse carpal ligament, and is inserted, with the abductor digiti quinti, into the medial side

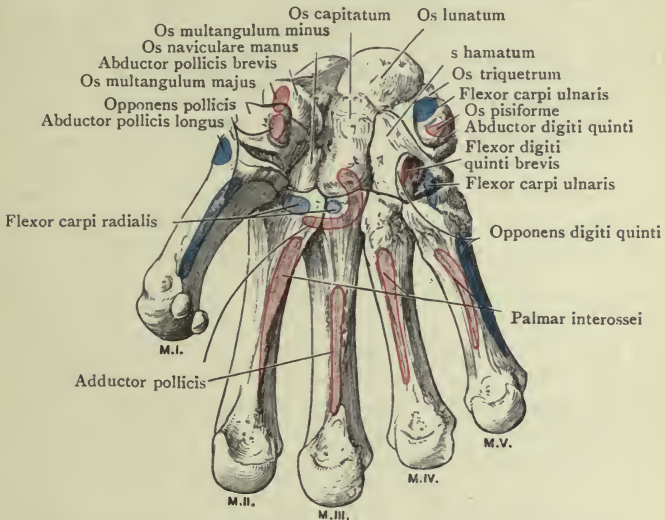


FIG. 67.—Volar aspect of the Bones of the Carpus and Metacarpus with Muscular Attachments mapped out.

of the base of the first phalanx of the little finger. It is not uncommonly incorporated, to a greater or less extent, with the opponens digiti quinti.

**M. Opponens Digiti Quinti.**—The opponens of the little finger lies on a deeper plane than the short flexor. It arises from the hook of the os hamatum and the distal border of the transverse carpal ligament, and is inserted into the whole length of the medial part of the volar aspect of the metacarpal bone of the little finger.

**Dissection.**—After the short muscles of the little finger have been studied, clean away the slip of the palmar aponeurosis

which goes to the thumb, taking care to avoid injury to the digital nerves of the thumb. Next separate the apex of the intermediate part of the palmar aponeurosis from the tendon of the palmaris longus and from the transverse carpal ligament, and reflect the intermediate part of the aponeurosis distally to the roots of the fingers. Do not fail to note that, from its medial and lateral margins, septa pass dorsally into the palm separating the muscles of the thenar and hypothenar eminences from the tendons of the long flexors of the fingers. The septa must be divided as the aponeurosis is reflected. Continue the reflection until the deep surfaces of the processes which pass to the fingers are fully exposed. Note that, at the roots of the fingers, each process divides into two slips. As the two slips pass dorsally they form an arch over the two flexor tendons which pass into the tendon sheath of the finger, and they become attached to the sheath of the tendons, to the transverse ligament which binds the heads of the metacarpal bones together, and to the deep fascia of the dorsum of the finger. Define the distal border of the transverse carpal ligament, but leave in position the part of the volar carpal ligament which binds the ulnar artery and nerve to the volar aspect of the transverse carpal ligament.

The structures exposed by the reflection of the intermediate part of the palmar aponeurosis are the contents of the intermediate compartment of the palm. They are:

1. The continuation of the ulnar artery as the superficial volar arch.
2. The digital branches from the arch to the clefts between the fingers and to the medial side of the little finger.
3. The terminal branches of the median nerve.
4. The branch of the superficial division of the ulnar nerve to the adjacent sides of the ring and little fingers.
5. The flexor tendons, surrounded by their mucous sheath.
6. The proximal parts of the mucous sheaths of the index, middle, and ring fingers.
7. The four lumbrical muscles.

**Fascial Compartments of the Palm.**—The two septa which pass from the margins of the intermediate part of the palmar aponeurosis into the depths of the palm have been noted as they were divided. They join a layer of fascia which lies on the volar surfaces of the interosseous muscles and the adductor of the thumb and the deep volar arterial arch. There are, therefore, in the palm, three fascial compartments, which lie deep to the palmar aponeurosis. (1) An intermediate compartment which contains the flexor tendons, the lumbrical muscles, the superficial volar arch and its branches, and the terminal branches of the median



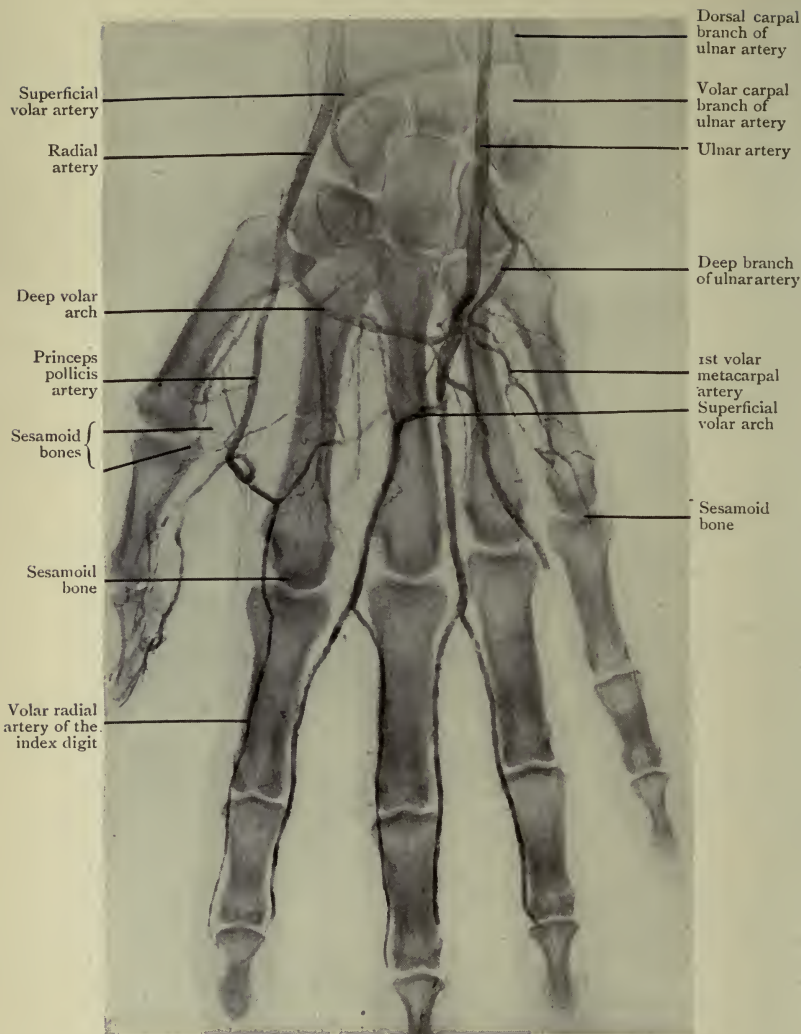


FIG. 68.—Radiograph of a Hand in which the Arteries were injected.

- Note (1) That the injection is incomplete.  
 (2) That the superficial volar arch is formed by the anastomosis of the superficial branch of the ulnar artery with the princeps pollicis artery.  
 (3) That the volar radial artery of the index finger is a branch of the superficial volar arch.  
 (4) The relation of the deep volar arch to the metacarpal bones.



nerve; (2) a medial compartment enclosing the short muscles of the little finger, and the superficial division of the ulnar nerve; (3) a lateral compartment enclosing the muscles of the thumb. Fluid or pus which collects in the intermediate compartment can spread into the forearm behind the transverse carpal ligament, and distally to the clefts between the fingers, but it is excluded from the lateral and medial compartments by the septa which pass into the palm from the margins of the intermediate part of the palmar aponeurosis.

**Dissection.**—Clean the superficial volar arch from the ulnar to the radial side, where it is completed by the anastomosis of the ulnar artery either with the superficial volar branch of the radial artery, with the *radialis indicis*, or with a branch of the *princeps pollicis* artery. Clean also the four digital branches which the arch gives to the fingers. Then clean the palmar part of the median nerve and its branches. The median nerve enters the palm at the distal border of the transverse carpal ligament. There it is flattened from before backwards and expanded from side to side. It divides, almost immediately, into two branches, a smaller lateral and a larger medial. Follow the lateral branch first. Soon after its origin it gives off, from its lateral side, a stout branch to supply the short muscles of the thumb. Secure that branch at once, and follow it across the superficial surface of the *flexor pollicis brevis* to the point where it disappears under cover of the *abductor pollicis brevis*. More distally the lateral branch of the median nerve divides into three digital branches, two for the thumb and one for the radial side of the index finger. No especial care is needed as the branches to the thumb are cleaned, but the branch to the index finger gives a fine twig to the first lumbrical which will be destroyed unless care is exercised. The larger medial division of the median nerve divides into two branches, one for the adjacent sides of the index and middle fingers, and one for the adjacent sides of the middle and ring fingers. Care must be exercised as each is cleaned, for the first gives a fine twig to the second lumbrical muscle which should not be missed, and the second is connected with the lateral branch of the superficial division of the ulnar nerve by a communicating twig which should be secured now if it was not found when the ulnar nerve was cleaned.

**Arcus Volaris Superficialis (O.T. Superficial Palmar Arch).**—The term superficial volar arch is applied to an arterial arcade which lies immediately subjacent to the intermediate part of the palmar aponeurosis, its most distal point being situated at the level of the distal border of the fully abducted thumb. It is formed by the ulnar artery. That artery crosses the volar surface of the transverse carpal ligament, immediately lateral to the pisiform bone, then it passes across

the medial side of the apex of the hook of the os hamatum. A short distance distal to the hook of the os hamatum it turns laterally, pierces the septum which separates the medial from the intermediate fascial compartment of the palm, and crosses the intermediate compartment, lying between the intermediate part of the palmar aponeurosis, which is superficial to it, and the terminal branches of the median nerve and the flexor tendons, which are deep to it. At the lateral border of the intermediate fascial compartment it unites with a branch of the radial artery, either the superficial volar, or the radialis indicis, or the princeps pollicis. The arch lies, therefore, in the medial and intermediate fascial compartments of the palm. In the medial compartment it lies upon the flexor brevis and opponens digiti quinti muscles and is covered by the palmaris brevis. In the intermediate compartment it lies upon the flexor tendons and the digital branches of the median nerve, and it is covered by the intermediate part of the palmar aponeurosis.

As the ulnar artery lies on the transverse carpal ligament, before it becomes the superficial volar arch, it gives off a *profunda branch* which passes deeply into the palm, with the deep division of the ulnar nerve, between the abductor digiti quinti muscle medially and the flexor digiti quinti brevis laterally. That branch will be traced in the deep dissection of the palm. From the superficial arch itself small twigs are given off to the adjacent tendons and fascia, but the chief branches are the *four digital arteries* which spring from the convexity of the arch. The first of the four remains undivided. It runs to the medial border of the little finger, along which it passes to the terminal phalanx. The other three branches, 2nd, 3rd, 4th, pass towards the interdigital clefts, where each divides, at the level of the bases of the first phalanges, into two branches, which supply the sides of the adjacent fingers, the second supplying the little and ring fingers, the third the ring and middle, and the fourth the middle and index fingers (Figs. 68, 69).

There are certain practical points to be noted in association with the digital arteries. The first crosses the lateral branch of the superficial division of the ulnar nerve and the short muscles of the little finger. The undivided parts of the second, third, and fourth lie in line with the interdigital clefts between the fingers; each is situated between

a pair of flexor tendons and is superficial to a digital nerve and a lumbrical muscle. As the branches run along the sides of the fingers their relationship to the nerves is

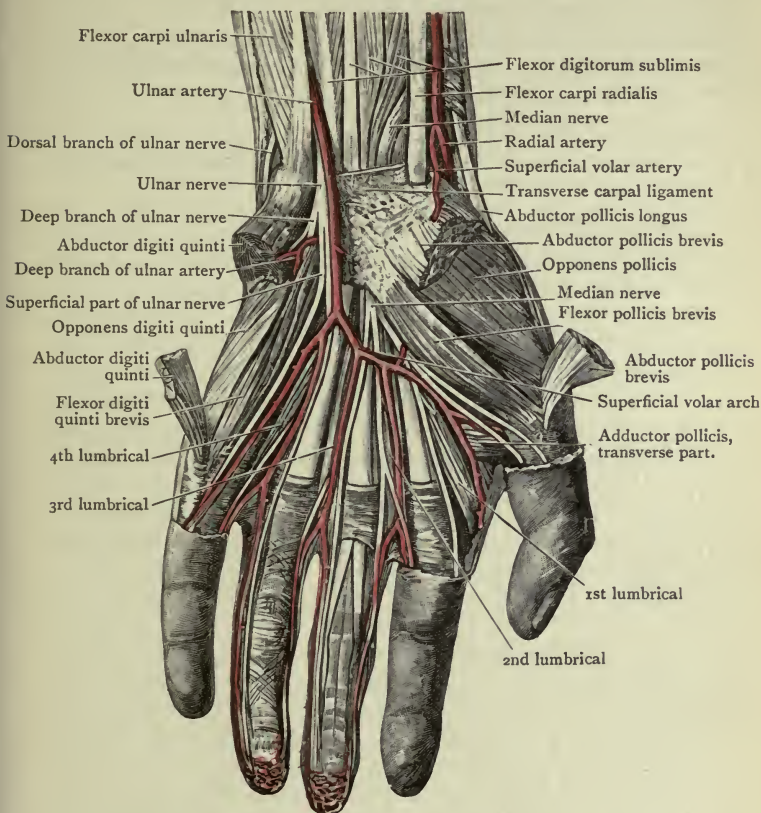


FIG. 69.—The parts in the Palm which are displayed by the removal of the Palmar Aponeurosis. In the specimen from which the drawing was taken the arteria volaris indicis radialis and the arteria princeps pollicis took origin from the superficial volar arch.

changed; the nerves become superficial or volar and the arteries lie behind the nerves. Opposite the terminal phalanx the two arteries of each finger join to form an arch from which a great number of fine branches are distributed

to the pulp of the finger and to the bed upon which the nail rests.

At the cleft of the finger immediately before it divides, each digital artery is joined by the corresponding volar metacarpal artery from the deep volar arch; and, as the branches run along the sides of the fingers, they give off numerous twigs to supply the skin, the flexor tendons and the joints of the fingers.

The superficial volar arch is not uncommonly absent in whole or in part. In such cases the digital arteries are replaced by the volar metacarpal branches of the deep volar arch.

**Nervus Medianus.**—The median nerve was traced to the proximal border of the transverse carpal ligament when the front of the forearm was dissected. As it passes from the forearm to the palm of the hand it lies behind the transverse carpal ligament at the lateral margin of the tendons of the flexor digitorum sublimis (Fig. 60) and in close relation with the mucous sheath which surrounds those tendons. Near the distal border of the transverse carpal ligament it is first flattened antero-posteriorly and then it divides into a smaller lateral, and a larger medial division. The *lateral division* gives off a branch which supplies the short abductor, the opponens and the short flexor of the thumb; then it divides into three digital branches, of which two go to the sides of the thumb and the third to the radial side of the index finger. The digital branches supply the skin, tendons, ligaments and joints of the regions to which they are distributed. In addition the branches to the medial side of the thumb and the radial side of the index digit give branches to the fold of integument which stretches between the roots of those digits, and the nerve to the index finger also gives a branch to the first lumbrical muscle.

The larger medial division divides into two branches. One runs towards the cleft between the index and middle fingers and divides to supply the adjacent sides of those fingers; before it divides it gives a muscular branch to the second lumbrical muscle. The second branch of the medial division divides, in a similar manner, to supply the adjacent sides of the middle and ring digits, but before it divides it gives a communicating twig to the lateral branch of the superficial division of the ulnar nerve. It sometimes gives a muscular

branch to the third lumbrical muscle. In the palm the digital branches of the median nerve pass distally deep to the superficial volar arch and its digital branches, but as they approach the fingers they become superficial to the digital arteries. Further, it should be noted that those branches of the median nerve which supply the adjacent sides of fingers divide at a more proximal level than that at which the digital arteries divide.

As they run along the sides of the fingers the digital nerves send branches to the skin of the whole of the volar aspect, and to the skin of the dorsal aspects of the second and third phalanges. At the extremity of the finger each nerve of supply divides into two branches. One of the two ramifies in the pulp of the finger and the other passes dorsally to the bed of the nail.

If the dissector exercises sufficient care in the dissection of the branches of the digital nerves he will find minute oval, seed-like bodies attached to the smaller twigs. They are special sensory end organs called *Pacinian Bodies*.

It follows, from what has already been pointed out, that, in the region of the hand, the median nerve supplies five muscles and the skin of three and a half digits. The muscles are the abductor pollicis brevis, the opponens pollicis, the superficial head of the flexor pollicis brevis and the two most lateral lumbrical muscles; the digits are the pollex, the index, the medius and the radial half of the annularis.

**Nervus Ulnaris.**—The palmar continuation of the ulnar nerve enters the palm by passing *superficial* to the transverse carpal ligament. As it lies secure from the effects of pressure, under the shelter of the pisiform bone and upon the medial side of the ulnar artery, it divides into two terminal branches—a superficial and a deep.

The *deep branch* passes to the medial side of the hook of the os hamatum and then dips, deeply, into the palm, with the deep branch of the ulnar artery, through the cleft between the abductor digiti quinti and the flexor digiti quinti brevis. It supplies the short muscles of the little finger as it passes between them, and afterwards gives branches to numerous other muscles. Its further course and distribution will be seen when the deep part of the palm is dissected (p. 170).

The *superficial branch* passes distally, under cover of the palmaris brevis, to which it gives a twig of supply. Whilst under cover of the palmaris brevis it divides into two digital branches. The medial of the two branches passes to the medial side of the little finger. The lateral branch pierces the septum which passes dorsally from the medial border of the intermediate part of the palmar aponeurosis, and enters the intermediate compartment of the palm. There it is joined by a communicating branch from the first medial digital branch of the median nerve, and then it divides into two branches which supply the adjacent sides of the ring and little fingers.

**Dissection.**—After the branches of the median and ulnar nerves have been examined, remove the lateral part of the palmar aponeurosis from the muscles of the thenar eminence, but preserve their nerve of supply, which has already been found. As soon as the aponeurosis is removed two muscles are exposed; they are the abductor pollicis brevis and the superficial head of the flexor pollicis brevis. The abductor is the lateral muscle; pass the handle of the scapel behind its lateral border and lift the muscle from the subjacent opponens pollicis, then divide the abductor about the middle of its length; turn the proximal part towards its origin, and the distal part towards its insertion. When that has been done the opponens will be exposed, and must be cleaned. Next divide the short flexor at its middle and reflect it towards its extremities. The reflection of the short flexor will bring into view parts of the adductor of the thumb, emerging from behind the flexor tendons of the fingers, and along the medial border of the opponens pollicis the tendon of the flexor pollicis longus will be seen; it is enclosed in its mucous sheath, which should not be injured.

At this stage the mucous sheaths of the flexor tendons may be re-examined (see p. 134) by inflation or with the aid of a blunt probe.

Note that the common sheath which envelops the tendons of the flexor digitorum sublimis and the flexor digitorum profundus extends, from the distal part of the forearm, behind the transverse carpal ligament, to the middle of the palm. Its proximal limit is about 25 mm. above the transverse ligament. At its distal limit, which is at the middle of the palm, practically at the same level as the most distal part of the superficial volar arch, it terminates, opposite the index, middle and ring fingers, in blunt protusions on the tendons of the corresponding fingers, but on its ulnar side it is prolonged into and is continuous with the flexor digital sheath of the little finger, which is prolonged to the base of the terminal phalanx of the little finger (Fig. 58). The continuity is easily demonstrated, if inflation fails, by making a small incision into the flexor sheath of the little finger and passing a probe through the incision and along the sheath.

The synovial sheath of the flexor pollicis longus reaches the same proximal level as the common flexor sheath, and it is pro-

longed, distally, to the base of the terminal phalanx of the thumb. The extent of this sheath can be investigated by a blunt probe introduced through a small opening made opposite the first phalanx of the thumb.

In some cases the mucous sheath which ensheaths the flexor tendons of the fingers is divided into a medial and a lateral compartment by a fibrous septum, and the lateral compartment may communicate with the sheath of the flexor pollicis longus by means of a small aperture situated at the proximal margin of the transverse carpal ligament.

**Ligamentum Carpi Transversum (O.T. Anterior Annular Ligament).**—The transverse carpal ligament should now be

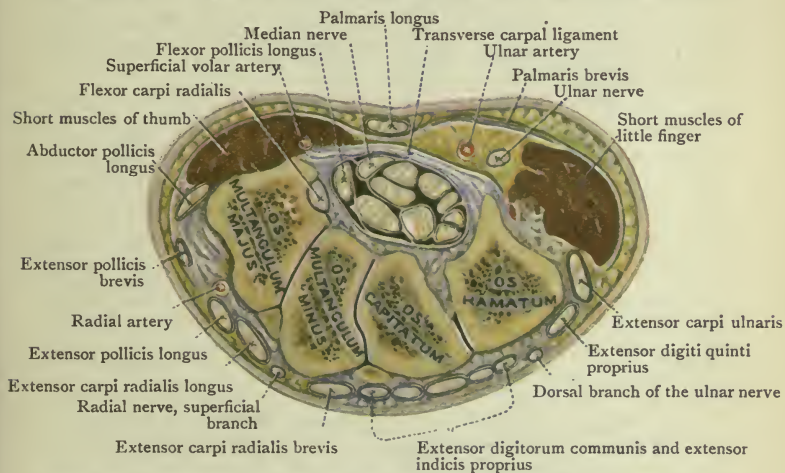


FIG. 70.—Transverse section through the Wrist at the level of the Distal Row of Carpal Bones to show the Carpal Tunnel. The Tendons of the Flexor Digitorum Sublimis, Flexor Digitorum Profundus, and Flexor Pollicis Longus are seen within the Tunnel.

thoroughly examined before it is divided to expose the portions of the flexor tendons, which lie behind it. It is a thick, dense, fibrous band, which stretches across the volar aspect of the concavity of the carpus, and converts it into an osteo-fibrous tunnel for the passage of the flexor tendons into the palm. On each side it is attached to the piers of the carpal arch, viz., on the *lateral side* to the tubercle of the navicular bone and the ridge of the greater multangular bone, and on the *medial side* to the pisiform bone and the hook of the os hamatum. Its proximal margin is continuous with the deep fascia of the forearm, of which it may be

considered to be a thickened part; whilst distally it is connected with the palmar aponeurosis.

Upon the volar surface of the transverse carpal ligament the expanded tendon of the palmaris longus is prolonged distally to the intermediate part of the palmar aponeurosis, whilst from its sides some of the short muscles of the thumb and little finger take origin. Close to its medial attachment the ulnar artery and nerve find their way into the palm by passing superficial to it and deep to a more superficial fascial band, the *volar carpal ligament*, which is attached on the medial side to the pisiform and the hook of the os hamatum, and on the lateral side to the volar surface of the transverse carpal ligament.

The tunnel which the transverse carpal ligament forms with the volar concavity of the carpus is transversely oval in shape, and it opens distally into the intermediate compartment of the palm. Through it pass the tendons of the flexor digitorum sublimis, the flexor digitorum profundus, the tendon of the flexor pollicis longus and the median nerve. The relation of the tendon of the flexor carpi radialis to the transverse carpal ligament is peculiar. It pierces the lateral attachment of the ligament, and proceeds distally, in the groove of the os multangulum majus, in a special compartment provided with a special mucous sheath.

**Dissection.**—Clean the fibrous sheaths of the flexor tendons of the fingers and the thumb. They lie immediately subjacent to the superficial fascia and the digital vessels and nerves, and they bind the tendons to the volar aspects of the phalanges and the interphalangeal joints.

**Flexor Sheaths.**—Immediately subjacent to the skin, the superficial fascia and the volar digital arteries and nerves, lie the fibrous sheaths which bind the flexor tendons to the volar surfaces of the phalanges, and to the volar accessory ligaments of the metacarpo-phalangeal and interphalangeal joints. Each fibrous sheath consists of a number of parts of which the two strongest, the *digital vaginal ligaments*, lie opposite the bodies of, and are attached to the margins of, the first and second phalanges. Such strong bands placed opposite the metacarpo-phalangeal and interphalangeal joints would seriously interfere with their movements; therefore, in those regions, weaker transverse bands, the *annular ligaments*, are formed. In addition, cruciate bands—the *cruciate*



*ligaments*—are often found intervening between the annular ligaments and the stronger portions of the sheaths. The

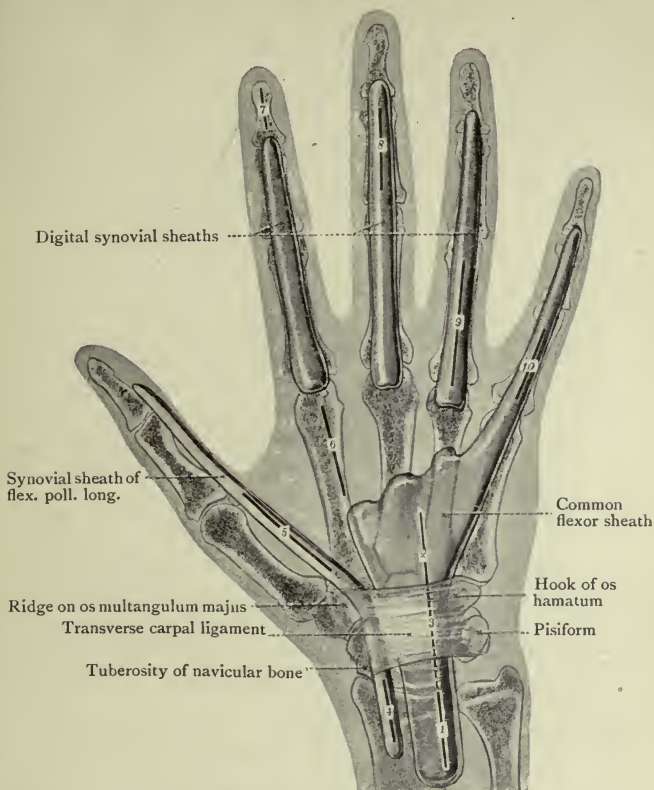


FIG. 71.—The Synovial Sheaths of the Wrist and Hand. The positions of various incisions for the evacuation of pus are also shown.

1 and 2. Incisions into the common palmar sheath, placed between the median and ulnar nerves.

3. Incision uniting 1 and 2.

4. Incision into the proximal part of the sheath of flexor pollicis longus. It is placed between the radial artery and the median nerve.

5. Incision into the distal part of the sheath of flexor pollicis longus.

6. Incision into the thenar space.

7. Incision over terminal phalanx.

8, 9 and 10. Incisions into the digital sheaths. They lie opposite the shafts of the phalanges.

fibrous sheath, together with the phalanges and the volar accessory ligaments of the metacarpo-phalangeal and inter-

phalangeal joints, forms, in each finger, an osteo-fibrous canal, in which are enclosed the tendons of the flexor digitorum sublimis and the flexor digitorum profundus together with their surrounding mucous sheath.

Leave the fibrous sheath of the middle finger intact for revision, but open the other fibrous sheaths by longitudinal incisions. They will be seen to be lined with a mucous sheath which is reflected over the enclosed tendons so as to give each a separate investment. Examine the extent of each mucous sheath with the aid of a blunt probe. The mucous sheath of the little finger has been seen to be a direct prolongation from the common mucous sheath of the flexor tendons; the other three are distinct from that, but they are carried proximally into the palm. They envelop the tendons of the ring, index and middle fingers, as far as a line drawn across the palm immediately proximal to the heads of the metacarpal bones.

If the flexor tendons are raised from the phalanges, certain mucous folds will be noticed connecting them to the bones. These are termed the *vincula tendinum*. Two kinds of them are distinguished, viz., *vincula brevia* and *longa*. In the accompanying illustration (Fig. 72) the connections of these may be seen. The *vincula brevia* are triangular folds which connect the tendons, near their insertions, to the volar aspect of the more proximal phalanx. The *vincula longa* are not invariably present. They are placed more proximally, and are narrow, weak strands which pass between the tendons and the bones.

**Insertions of the Flexor Tendons.**—The insertions of the two flexor tendons can now be studied. On the volar side of the first phalanx the tendon of the flexor sublimis becomes flattened and folded round the subjacent cylindrical tendon of the flexor profundus. It then splits into two parts, which pass dorsal to the tendon of the flexor profundus, and allow the latter to proceed onwards between them. Dorsal to the deep tendon the two portions of the tendon of the flexor sublimis fuse together, and then, again, they diverge, to be inserted into the borders of the body of the second phalanx. By this arrangement the flattened tendon of the flexor sublimis forms a ring, or short tubular passage, through which the tendon of the flexor profundus proceeds onwards to the base of the unguis phalanx, into which it is

inserted. In each of the four fingers the same arrangement is found; the tendon of the flexor sublimis is inserted by two slips into the margins of the volar surface of the second phalanx, whilst the tendon of the flexor profundus is inserted into the volar aspect of the base of the terminal phalanx.

**Dissection.**—Open the carpal tunnel by making a vertical incision through the middle of the transverse carpal ligament. Clean the mucous sheaths from the flexor tendons, and separate the tendons from one another, but be careful not to injure the lumbrical muscles which spring from the tendons of the flexor digitorum profundus. Be careful also not to injure the nerves

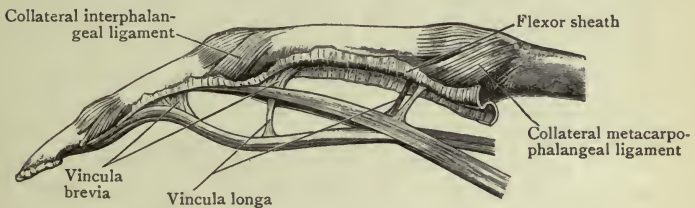


FIG. 72.—Flexor Tendons of the Finger with Vincula tendinum.

of supply from the lateral two lumbricals. They are twigs from the digital branches of the median nerve, and have already been found. The nerves to the medial two lumbricals are from the deep division of the ulnar nerve. They will be found at a later stage of the dissection. Clean the lumbrical muscles and then examine the arrangement of the flexor tendons and the origins and insertions of the lumbrical muscles.

**Flexor Tendons.**—The four tendons of the *flexor sublimis* are arranged in pairs deep to the transverse carpal ligament; those for the little and the index fingers lie dorsal to those for the ring and middle fingers. Of the tendons of the *flexor profundus*, only that for the index finger is distinct and separate; the other three, as a rule, remain united until they emerge from under cover of the distal border of the transverse carpal ligament.

In the intermediate compartment of the palm the flexor tendons diverge from each other, and two, viz., one from the flexor sublimis, and one from the flexor profundus, go to each of the four fingers. From the tendons of the flexor profundus the lumbrical muscles take origin, and those muscles, and the volar digital nerves and arteries, will be seen occupying the

intervals between the tendons as they approach the roots of the fingers.

In the *fingers* the two flexor tendons run distally, upon the volar aspects of the phalanges, and are held in position by the flexor sheaths, which have already been studied.

The tendon of the *flexor pollicis longus* occupies the lateral part of the tunnel, and, gaining the palm, turns laterally to reach the terminal phalanx of the thumb.

**Tendon of the Flexor Pollicis Longus.**—The tendon of the long flexor of the thumb proceeds distally, in the interval between two of the short muscles of the thumb (*viz.*, the superficial head of the flexor pollicis brevis and the oblique part of the adductor pollicis), and also in the interval between the two sesamoid bones which play upon the head of the metacarpal bone. At the base of the proximal phalanx it enters a fibrous flexor sheath constructed upon a similar plan to those of the fingers, and passes along it to the base of the terminal phalanx, into which it is inserted. The mucous sheath which surrounds the tendon during its passage through the carpal tunnel is continuous with the sheath which invests the tendon in front of the phalanges.

**Mm. Lumbricales.**—The lumbrical muscles are four slender fleshy bellies which arise from the tendons of the flexor digitorum profundus as they traverse the palm. The *first lumbrical* arises from the lateral side of the tendon for the index finger; the *second lumbrical* springs from the lateral border of the tendon for the middle finger; whilst the *third* and *fourth lumbricales* take origin from the adjacent sides of the tendons between which they lie (*viz.*, the tendons for the middle, ring, and little fingers). The little muscles pass distally, and end in delicate tendons on the lateral sides of the fingers. Each tendon is inserted into the lateral margin of the expansion of the extensor tendon, which lies upon the dorsal aspect of the proximal phalanx.

**Dissection.**—Divide the flexor digitorum profundus in the forearm, and turn the distal part towards the fingers. As the tendons and the lumbrical muscles which are attached to them are raised, secure the fine twigs of supply which pass to the medial two lumbricales from the deep division of the ulnar nerve. They are easily found if ordinary caution is observed. The deep volar arch and the deep division of the ulnar nerve are now exposed. Clean both the arch and the nerve, and trace the branches of the nerve to the interossei muscles and to the adductor pollicis and the deep head of the flexor pollicis brevis. Then

examine the relations of the deep volar arch, and the deep division of the ulnar nerve.

**Arcus Volaris Profundus (O.T. Deep Palmar Arch).—**

Two arteries take part in the formation of the deep volar arch, the radial and the profunda branch of the ulnar. The radial, which plays the chief part, enters the palm through the proximal end of the first interosseous space, between the two heads of the first dorsal interosseous muscle, and in the present stage of dissection it is seen appearing through the cleft between the oblique and transverse parts of the adductor pollicis. The arterial arcade formed by its union with the profunda branch of the ulnar artery lies across the metacarpal bones, immediately distal to their bases, and across the interosseous muscles in the intervening interosseous spaces. The deep arch is, therefore, about a finger's breadth proximal to the superficial volar arch, but it is in a much deeper plane, for it is separated from the superficial volar arch by the flexor tendons of the fingers and their mucous sheath, the lumbrical muscles, branches of the median nerve and the flexor digiti quinti brevis. The convexity of the deep arch, which is less marked than that of the superficial arch, is directed towards the fingers, and in its concavity lies the deep branch of the ulnar nerve.

The *branches* which spring from the deep volar arch are: (1) the *recurrent*—a few small twigs which run proximally, in front of the carpus, to anastomose with branches of the volar carpal arch; (2) *perforating branches*, which pass dorsally in the proximal parts of the interosseous spaces to anastomose with the dorsal metacarpal arteries; and (3) the *volar metacarpal branches*—three in number—which pass distally, volar to the interosseous spaces, and unite, near the roots of the fingers, with the corresponding volar digital arteries from the superficial volar arch. Sometimes the volar metacarpal branches are large and take the place of the corresponding volar digital arteries.

**Ramus Profundus Nervi Ulnaris.**—The deep branch of the ulnar nerve springs from the parent trunk on the volar aspect of the transverse carpal ligament, and gives off a branch which supplies the three short muscles of the little finger. Accompanied by the deep branch of the ulnar artery, it sinks into the interval between the abductor and flexor digiti quinti brevis, and turns laterally across the palm,

deep to the flexor tendons. Near the lateral border of the palm the deep branch of the ulnar nerve breaks up into terminal twigs which supply the adductor pollicis and the first dorsal interosseous muscle. In its course across the palm it lies along the concavity or proximal border of the deep volar arch, and sends three fine branches distally in front of the three interosseous spaces. They supply the interosseous muscles in the spaces, while the medial two give branches

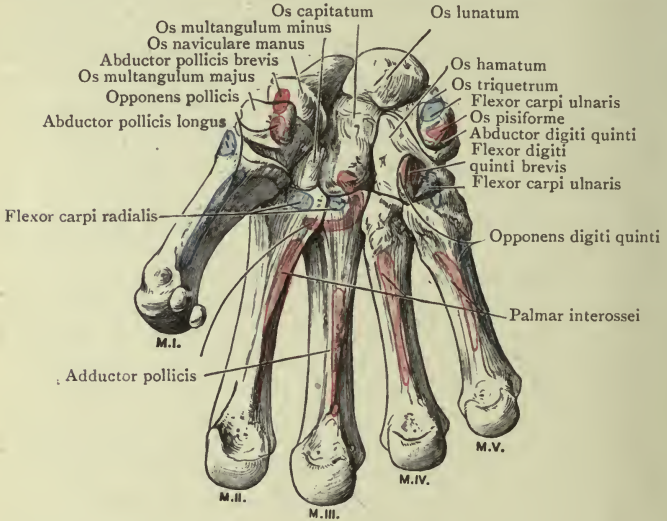


FIG. 73.—Volar aspect of the Bones of the Carpus and Metacarpus with Muscular Attachments mapped out.

also to the medial two lumbrical muscles. The third lumbrical has frequently a double nerve supply; it receives a branch from the deep part of the ulnar nerve, and, not uncommonly, a second twig from the median nerve enters its volar aspect.

The deep branch of the ulnar nerve may, therefore, be said to supply all the muscles of the palm which lie to the medial side of the tendon of the flexor pollicis longus, whilst the median nerve supplies the three muscles which lie to the lateral side of that tendon. There are two exceptions to this generalisation, viz., the lateral two lumbrical muscles, which lie

upon the medial side of the tendon, and are yet supplied by the median nerve.

**Dissection.**—Clean the adductor of the thumb and then examine the short muscles of the thumb and revise the short muscles of the little finger.

**The Short Muscles of the Thumb.**—Three of the short muscles of the thumb have already been dissected. All four are now displayed, with the exception of the deep head of the short flexor, which cannot be seen until the adductor has been reflected. Their relations and attachments should now be studied. Three of the four, the abductor pollicis brevis, the superficial head of the flexor pollicis brevis and the opponens pollicis lie on the lateral side of the tendon of the flexor pollicis longus; the fourth muscle, the adductor pollicis, is on the medial side of that tendon.

The *abductor pollicis brevis* forms the most prominent and lateral part of the ball of the thumb. The *superficial head of the flexor pollicis brevis* is immediately medial to the abductor; the *opponens* is deep to both of them and is exposed when they are pulled apart, or when they are reflected. The fan-shaped *adductor pollicis* lies deeply in the palm. It is imperfectly separated into a proximal or oblique portion and a distal or transverse portion. The separation is produced by the radial artery as it enters the palm through the first interosseous space. The deep head of the flexor pollicis brevis is concealed by the adductor, and cannot be seen at this stage of the dissection.

The branch of the median nerve which supplies the three muscles which lie lateral to the tendon of the flexor pollicis longus has already been found (p. 155), and the twigs to the adductor which are derived from the deep branch of the ulnar nerve have also been traced (p. 166).

**M. Abductor Pollicis Brevis.**—The short abductor of the thumb arises from the volar aspect of the transverse carpal ligament and from the ridge on the os multangulum majus. It is inserted into the lateral sesamoid bone of the thumb, into the lateral side of the base of the first phalanx, and to a slight extent into the extensor tendon on the dorsum of the first phalanx. It is supplied by the *median nerve*.

**M. Flexor Pollicis Brevis (Caput Superficialis).**—The

superficial head of the short flexor of the thumb takes origin from the transverse carpal ligament. It is inserted into the lateral sesamoid bone of the thumb, and into the lateral side of the proximal phalanx, and it is supplied by the *median nerve*. (For the deep head see below.)

**M. Opponens Pollicis.**—The opponens muscle of the thumb springs from the transverse carpal ligament and the ridge on the volar surface of the os multangulum majus. Its fibres spread out as they approach their insertion into the whole length of the radial border and the adjacent part of the volar surface of the metacarpal bone of the thumb. It is supplied by the *median nerve*.

**M. Adductor Pollicis.**—The adductor of the thumb consists of an oblique and a transverse part. The oblique part arises from the os capitatum, and the bases of the second and third metacarpal bones (Fig. 73). In some cases it has a slip of origin from the os multangulum minus. The transverse part springs from the distal two-thirds of the volar border of the third metacarpal bone. The two parts converge as they pass to their insertion into the medial sesamoid bone of the thumb and the medial side of its proximal phalanx. In many cases a slip of muscle fibres leaves the lateral side of the oblique part of the adductor, passes dorsal to the tendon of the flexor pollicis longus, and fuses with the superficial head of the flexor pollicis brevis. Both parts of the muscle are supplied by twigs from the deep division of the *ulnar nerve*.

At this stage of the dissection the short muscles of the little finger, the abductor, the short flexor and the opponens, should be revised (see p. 152).

**Dissection.**—To display the branches of the palmar parts of the radial artery and the deep head of the flexor pollicis brevis, cut through the two parts of the adductor pollicis midway between their origins and insertions, and turn the separated portions aside. The deep head of the flexor pollicis brevis lies along the ulnar border of the metacarpal bone of the thumb, and the radial artery will be found entering the palm between the two heads of the first dorsal interosseous muscle at the proximal end of the first interosseous space. Its last two branches, the princeps pollicis and the volar radial artery of the index finger, spring from it as soon as it enters the palm, and whilst it still lies behind the oblique part of the adductor pollicis.

**The Deep Head of the Flexor Pollicis Brevis.**—This weak slip of muscle lies along the medial side of the metacarpal bone of the thumb



between the radial head of the first dorsal interosseous muscle and the adductor pollicis. It arises from the ulnar side of the base of the first metacarpal bone and is inserted into the ulnar side of the base of the first phalanx of the thumb. It is supplied by a twig from the deep division of the ulnar nerve.

**Arteria Volaris Indicis Radialis, et Arteria Princeps Pollicis (O.T. Radialis Indicis and Princeps Pollicis Arteries).**—These arteries spring from the radial, as it enters the palm, between the first and second metacarpal bones.

The *volar radial artery of the index digit* runs distally between the transverse part of the adductor pollicis and the first dorsal interosseous muscle to the lateral border of the index, along which it proceeds as its lateral volar digital artery.

The *princeps pollicis artery* takes a course distally and laterally, under cover of the oblique part of the adductor pollicis, and gains the volar aspect of the metacarpal bone of the thumb. There it lies dorsal to the tendon of the flexor pollicis longus, and divides into two terminal branches, one for each side of the free part of the thumb. The branches make their appearance in the interval between the adductor and the superficial head of the flexor pollicis brevis, and run distally, one on each side of the tendon of the long flexor.

**Surgical Anatomy of the Palm and Fingers.**—When an abscess forms in the intermediate compartment of the palm early surgical interference is urgently called for. The dense palmar aponeurosis effectually prevents the passage of the pus to the surface of the palm, whilst an easy route proximally, into the forearm, is offered to it by the open carpal tunnel, through which the flexor tendons enter the palm. It is necessary, therefore, that before this can occur the surgeon should make an opening in the palm by means of which the pus can escape.

In making such an incision it is important to bear in mind the position of the various vessels which occupy the intermediate compartment of the palm. As previously stated, the level of the superficial volar arch can be indicated by drawing a line transversely across the palm from the distal margin of the outstretched thumb. The deep volar arch lies half an inch more proximally. The volar digital arteries, which spring from the convexity of the superficial volar arch, run in line with the clefts between the fingers. An incision, therefore, which is made distal to the superficial volar arch and in a direction corresponding to the central line of one of the fingers, may be considered free from danger in so far as the vessels are concerned.

The loose mucous sheath which envelops the flexor tendons as they pass deep to the transverse carpal ligament has been seen to extend proximally into the distal part of the forearm, and distally into the palm. When the sheath is attacked by inflammatory action it is apt to become distended with fluid (thecal ganglion), and the anatomical arrangement of the parts at once offers an explanation of the appearance which is presented. There is a bulging in the palm, and a bulging in the distal part of the forearm, but no swelling at all at the wrist. There the dense transverse carpal ligament resists the expansion of the mucous sheath, and an hour-glass constriction

is evident at that level. The lines along which incisions should be made into the volar compartments of the palm and the mucous sheaths of the flexor tendon are shown in Fig. 71.

The fingers are subject to an inflammatory process, termed *whitlow*, and, in connection with this, it is essential to remember that the flexor fibrous sheath ends on the base of the distal phalanx in each digit. When the whitlow occurs more distally, in the pulp of the finger, the vitality of the distal part of the ungual phalanx is endangered, but the flexor tendons may be regarded as being tolerably safe. When the inflammation occurs more proximally, and involves the flexor sheath, as it generally does, sloughing of the tendons is to be apprehended, unless an immediate opening is made. No slight superficial incision will suffice. The knife must be carried deep into the centre of the finger, so as to freely lay open the sheath containing the tendons. Early interference in cases of whitlow of the thumb and little finger is even more urgently required than in the case of the other three digits, because the digital mucous sheaths of the former are, as a rule, connected with the great common mucous sheath of the flexor tendons, and so offer a ready means for the proximal extension of the inflammatory action.

Every amputation of the fingers proximal to the insertion of the tendons of the flexor profundus involves the opening of the flexor sheaths, and no doubt explains the occasional occurrence of palmar trouble after operations of that kind. The open tubes offer a ready passage by means of which septic material may travel proximally into the palm, and, in the case of the thumb and little finger, into the carpal tunnel and distal part of the forearm.

#### DORSUM AND LATERAL BORDER OF THE FOREARM.

The structures which still remain to be dissected in this region are:—

1. The supinator and extensor muscles.
2. The dorsal interosseous artery.
3. The perforating or terminal branch of the volar interosseous artery.
4. The dorsal interosseous nerve.

Before the dissection is proceeded with, the cutaneous veins and nerves and the deep fascia, previously displayed, should be re-examined. The two main cutaneous veins are seen. Both ascend from the venous plexus on the dorsum of the hand, and both turn round a border of the forearm to gain its volar surface, but whilst the cephalic vein turns round the distal third of the radial border, the basilic ascends to a much more proximal level before it turns round the ulnar border.

The cutaneous nerves are four in number:—(1) The dorsal branch of the lateral cutaneous nerve of the forearm, on the lateral side; (2) the dorsal branch of the medial cutaneous nerve of the forearm on the medial side; (3) in the

intermediate area the distal branch of the dorsal cutaneous nerve of the forearm; (4) the superficial division of the radial nerve appearing from under cover of the brachio-radialis about 8 cm. ( $3\frac{1}{4}$  inches) proximal to the wrist. Thus three of the terminal branches of the brachial plexus are represented on the dorsum of the forearm—the musculo-cutaneous nerve by the lateral cutaneous nerve of the forearm; the medial cutaneous nerve of the forearm; and the radial nerve by its superficial division, and by the dorsal cutaneous nerve of the forearm.

In the dorsum of the hand the distribution of the superficial branch of the radial nerve and the dorsal branch of the ulnar nerve have already been examined (pp. 71, 72); the radial nerve supplies the greater part of the skin of the dorsum of the hand and three and a half digits—the thumb, and the proximal parts of the index, the middle, and half the ring fingers—whilst the dorsal branch of the ulnar nerve supplies the remaining half of the ring finger and the little finger. The skin of the distal parts of the index, the middle, and half the ring fingers is supplied, as already noted (p. 159), by twigs of the digital branches of the median nerve.

**Dissection.**—Remove the cutaneous vessels and nerves from the dorsum of the forearm and hand, then revise the deep fascia.

**The Deep Fascia.**—The deep fascia of the dorsum of the forearm is stronger than the deep fascia of the volar aspect. Its proximal part is strengthened by expansion from the triceps, and near the elbow it is intimately connected with the muscles of the back of the forearm which take part of their origin from its deep surface. It is closely attached to the whole length of the dorsal border of the ulna, and in the regions of the distal ends of the radius and ulna and the back of the carpus it is thickened by numerous transverse fibres which constitute the ligamentum carpi dorsale.

**Dissection.**—The dorsal carpal ligament must be left *in situ* until the dissection of the dorsal parts of the forearm and hand is completed. To secure its retention in an uninjured condition, isolate it by cutting carefully through the deep fascia parallel with its proximal border. Whilst making the incision, care must be taken to avoid injury to the mucous sheaths of the extensor tendons which lie immediately subjacent to the deep fascia. When the front of the forearm was dissected, the radial flap of deep fascia was reflected only as far as the radial border of the

forearm. Now continue the reflection until the attachment of the flap to the posterior border of the ulna is reached. As the reflection proceeds, the intermuscular septa which pass from the deep surface of the deep fascia between the muscles of the dorsum of the forearm must be divided.

**Superficial Muscles.**—The muscles in this region consist of a superficial and a deep group. The *superficial muscles*, named from the lateral to the medial border of the forearm, are:—(1) the brachio-radialis; (2) the extensor carpi radialis longus; (3) the extensor carpi radialis brevis; (4) the extensor digitorum communis; (5) the extensor digiti quinti proprius; (6) the extensor carpi ulnaris; and (7) the anconæus. This group therefore comprises one flexor of the elbow, three extensors of the wrist, two extensors of the fingers, and a feeble extensor of the forearm at the elbow joint, viz., the anconæus. In the distal part of the forearm the extensor digitorum communis is separated from the extensor carpi radialis brevis by a narrow interval, in which appear two muscles belonging to the deep group. The two muscles in question turn round the lateral margin of the forearm, superficial to the radial extensors of the wrist, and end in tendons which go to the thumb. The proximal of the two muscles is the abductor pollicis longus, the distal is the extensor pollicis brevis, but they lie in such close contact, and so intimately are their tendons connected, that in many cases they appear, at first sight, to be blended together by their margins. After they have become superficial, the abductor pollicis longus and the extensor pollicis brevis turn round the radial border of the forearm superficial to the radial extensors of the wrist, and as they descend to the thumb they lie in the groove on the lateral surface of the styloid process of the radius in which they are retained by the most lateral part of the dorsal carpal ligament (Fig. 74).

A short distance proximal to the dorsal carpal ligament on the radial side of the tendons of the extensor digitorum a third muscle of the deep group also comes into view; it is the extensor pollicis longus. Its tendon crosses the radial extensors of the wrist at the distal border of the dorsal carpal ligament.

**Dissection.**—The skin of the dorsum of the hand has already been removed, and the cutaneous nerves and veins have been displayed. The thin deep fascia is still in position, but it will not prevent a successful demonstration of the mucous sheaths

PLATE X

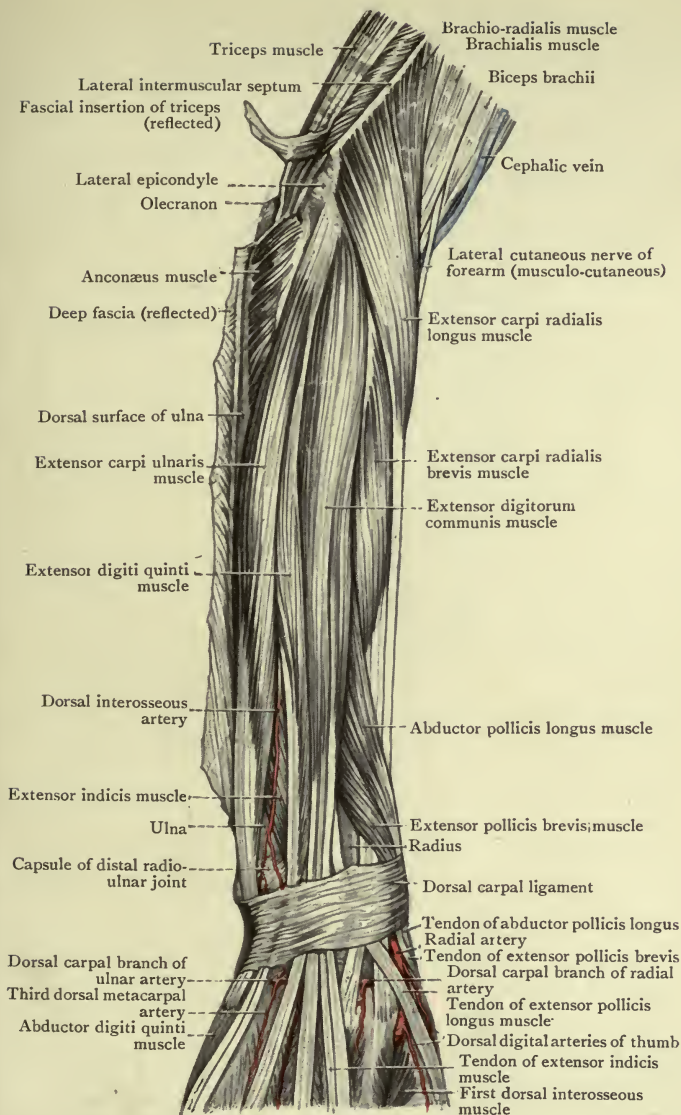


FIG. 74.—Dissection of the Dorsal Aspect of the Forearm.



of the extensor tendons, which should be attempted before the superficial extensor muscles are cleaned. Introduce a blow-pipe into each mucous sheath immediately proximal to the

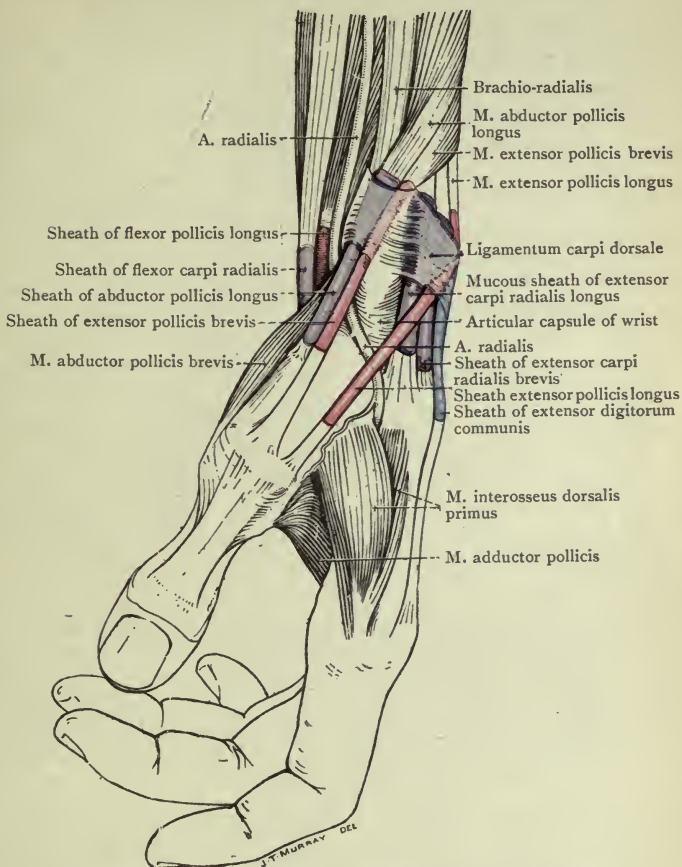


FIG. 75.—Dissection of the Lateral Side of the Left Wrist and Hand showing Mucous Sheaths of Tendons.

dorsal carpal ligament and then inflate the sheath. Commence with the sheath of the abductor pollicis longus and the extensor pollicis brevis; then inflate in succession the sheaths of the radial extensors of the wrist, the common extensor of the fingers, the extensor digiti quinti, and the extensor carpi ulnaris. A better demonstration of the mucous sheaths may be made by

injecting them, by means of a large hypodermic syringe, with a thin solution of coloured starch. If the sheaths have been injured, and it is not possible to distend them, then open each and examine its extent with the aid of a blunt probe.

**The Mucous Sheaths of the Extensor Tendons.**—Seven mucous sheaths surround the tendons which pass under cover of the dorsal carpal ligament. Two lie along the distal part of the radial border of the forearm; they are the sheaths of the abductor pollicis longus and the extensor pollicis brevis. They may communicate with one another. From the radial to the ulnar border the remaining five sheaths are arranged in the following order: the sheath of the extensor carpi radialis longus, the sheath of the extensor carpi radialis brevis, a sheath common to the extensor digitorum communis and the extensor indicis, the sheath of the extensor digiti quinti, and the sheath of the extensor carpi ulnaris.

The proximal limit of the sheaths lies at, or slightly proximal to, the dorsal carpal ligament. The sheaths of the abductor pollicis longus and the radial and ulnar extensors of the carpus are prolonged distally to the insertions of the tendons of these muscles. As regards the sheaths of the extensors of the fingers and thumb, it may be said, speaking generally, that they terminate distally about the level of the mid-length of the hand (Figs. 75, 76).

**Dissection.**—The brachio-radialis has already been dissected; the other superficial muscles must now be cleaned and, as far as possible, isolated from one another. The isolation of the distal parts is not difficult, but the proximal parts spring not only from the humerus and the superjacent deep fascia, but also from strong intermuscular septa which intervene between adjacent muscles. To isolate the proximal parts of the muscles, therefore, the dissector must split the intermuscular septa with the scalpel and so isolate each muscle as far as its bony origin.

**M. Brachio-radialis (O.T. Supinator Longus).**—The brachio-radialis muscle lies more on the volar than on the dorsal surface of the forearm. It takes origin, in the arm, from the proximal two-thirds of the lateral epicondylar ridge of the humerus and from the lateral intermuscular septum. Near the middle of the forearm a flat tendon emerges from its fleshy belly, and proceeds distally to gain insertion into the lateral aspect of the expanded distal extremity of the radius, at the base of the styloid process. The nerve of supply is a branch of the *radial nerve* (O.T. *musculo-spiral*), which



enters the muscle proximal to the elbow. The main action of the muscle is flexion of the elbow, but it can help to initiate supination of the prone forearm and pronation of the supine forearm.

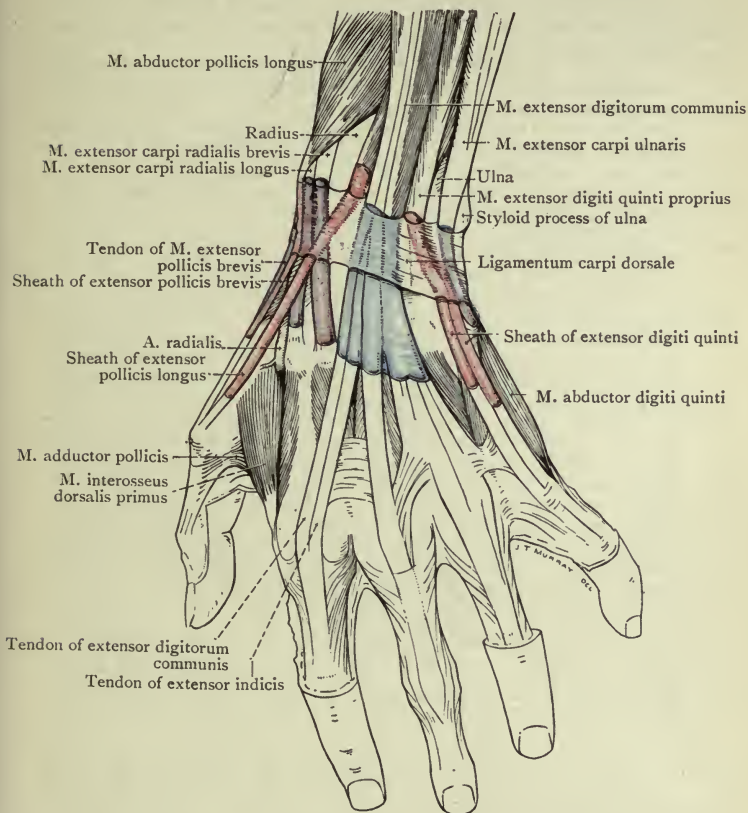


FIG. 76.—Dissection of the Back of the Forearm, Wrist, and Hand, showing Mucous Sheaths of Tendons.

**Dissection.**—Remove the thin deep fascia of the dorsum of the hand, clear away the mucous sheaths of the tendons and clean the tendons, but do not injure (1) the dorsal carpal ligament, (2) the blood-vessels which lie deep to and in the intervals between the tendons, (3) the slips which connect the tendon to the ring finger with that on each side of it. Three tendons must

be followed to the thumb, that of the abductor pollicis longus to the base of the metacarpal bone, that of the extensor pollicis brevis to the base of the first phalanx, and the tendon of the extensor pollicis longus to the base of the terminal phalanx.

There are four tendons of the extensor digitorum communis, one for each finger. Each of the four expands, on the dorsum of the first phalanx of the finger to which it belongs, into an *extensor expansion* which covers the whole of the dorsum of the phalanx.

Near the distal extremity of the first phalanx the extensor expansion divides into three pieces, an intermediate piece and two collateral pieces. The weaker intermediate piece is inserted into the base of the second phalanx. The lateral pieces unite with one another on the dorsum of the second phalanx before they are inserted into the base of the terminal phalanx. Carefully define this arrangement on at least one finger. The tendon of the extensor indicis passes along the ulnar side of the tendon of the extensor digitorum communis to join the extensor expansion of the index finger, and the two tendons of the extensor digiti quinti join the extensor expansion of the little finger.

Clean the margins of the extensor expansion of one or more fingers, and pass the handle of a scalpel between the expansion and the middle of the first phalanx, then note, as the expansion is put on the stretch, that, just beyond the metacarpo-phalangeal joint, the expansion is joined, on each side, by structures which pass to it through the interosseous spaces. On the radial side it is joined by the tendon of a lumbrical muscle and by a slip from the tendon of an interosseous muscle, and, on the ulnar sides, by a slip from a tendon of an interosseous muscle, except in the case of the little finger where there is, of course, no interosseous muscle on the ulnar side. The dissector will have no difficulty in displaying the association of the lumbrical muscles with the extensor expansions at the present stage of the dissection. The connections of the interossei cannot be properly demonstrated until a later stage.

**The Extensor Expansions on the Fingers.**—The dissector who has carefully followed the above instructions will have recognised that by means of the extensor expansions a common extensor tendon, a lumbrical, and one or more interossei gain insertion into the dorsal aspects of the bases of the second and terminal phalanges of each finger, and through the same medium the second and terminal phalanges of the index and little fingers are attached to the special extensors of those digits. The dissector should now note the movements he can make with his own fingers: (1) by use of the flexor muscles alone he can flex all three joints of the fingers, the metacarpo-phalangeal, and the proximal and distal interphalangeal joints; (2) by use of the extensor muscles alone he can extend all three joints; (3) by use of the flexors and extensors simultaneously he can flex the interphalangeal and

extend the metacarpo-phalangeal joints ; (4) he can also flex the metacarpo-phalangeal joints and extend the interphalangeal joints. The last combination of movements is called "putting the fingers in the writing position." It is due mainly to the actions of the lumbricals and interossei, which pass from the volar to the dorsal aspect across the metacarpo-phalangeal joints, and so are enabled to flex those joints, whilst by virtue of their attachments to the extensor expansions they can extend the interphalangeal joints.

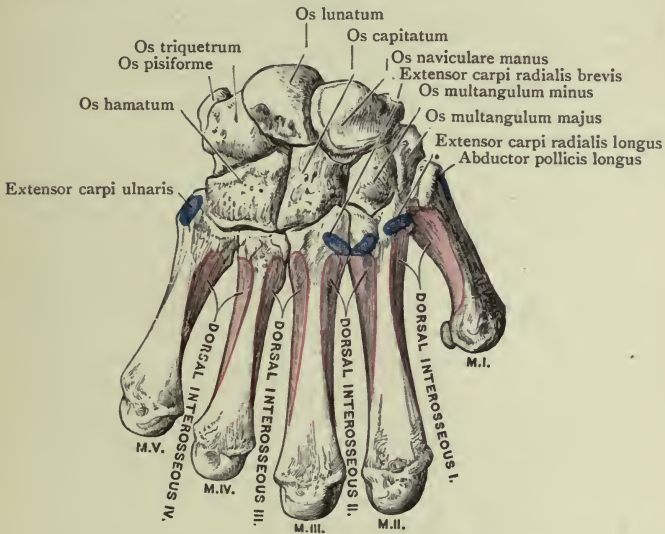


FIG. 77.—Dorsal aspect of the Bones of the Carpus and Metacarpus, with Muscular Attachments mapped out.

**M. Extensor Carpi Radialis Longus.**—The long radial extensor of the carpus is placed dorsal to the brachio-radialis. It arises from the distal third of the lateral epicondylar ridge of the humerus, and from the lateral intermuscular septum. From the fleshy portion of the muscle a long tendon proceeds, which passes under cover of the dorsal carpal ligament, and is inserted into the dorsal aspect of the base of the metacarpal bone of the index finger. The muscle is supplied by a branch of the trunk of the *radial nerve* (*O.T. musculospiral*) which enters it proximal to the elbow. The long

radial extensor of the wrist helps to extend and abduct the hand at the wrist-joint, and it assists in flexion of the elbow (Figs. 74, 75, 76).

**M. Extensor Carpi Radialis Brevis.**—The extensor carpi radialis brevis is closely associated with the preceding muscle. It arises, by the common extensor tendon, from the lateral epicondyle of the humerus; it derives fibres also from the radial collateral ligament of the elbow-joint, from the investing deep fascia, and the fibrous septa in connection with it. The tendon of the muscle accompanies that of the long radial extensor under cover of the dorsal carpal ligament, and is inserted into the dorsal aspect of the base of the third metacarpal bone, immediately beyond the root of its styloid process. This muscle is supplied by the *deep branch of the radial nerve* by a twig given off before the nerve pierces the supinator muscle. It is an extensor of the wrist and the elbow, and an abductor of the hand at the wrist-joint.

**M. Extensor Digitorum Communis.**—The extensor digitorum communis takes origin, by the common tendon, from the lateral epicondyle of the humerus. The deep fascia and the intermuscular septa in relation to it also contribute fibres. Its fleshy belly, in the distal part of the forearm, ends in four tendons, which pass under cover of the dorsal carpal ligament. On the dorsum of the hand they diverge and proceed onwards to the four fingers. Their arrangement and attachments on the dorsum of the hand and fingers have already been considered (p. 177). The muscle is supplied by the *dorsal interosseous nerve*. It is an extensor of all the joints of the fingers, of the wrist, and of the elbow.

**M. Extensor Digiti Quinti Proprius (O.T. Extensor Minimi Digiti).**—The extensor digiti quinti proprius is a slender fleshy belly which at first sight appears to be a part of the preceding muscle, but its tendon passes through a special compartment in the dorsal carpal ligament. It arises in common with the extensor digitorum communis. Its tendon of insertion splits into two parts. The lateral of the two joins the tendon of the extensor digitorum communis, which passes to the little finger, and the medial part ends in the extensor expansion on the dorsum of the first phalanx of the little finger. The muscle is supplied by the *dorsal interosseous nerve*. It is an extensor of all the joints of the little finger, and it aids in extension of the wrist and elbow.

**M. Extensor Carpi Ulnaris.**—The extensor carpi ulnaris arises, by means of the common extensor tendon, from the lateral epicondyle of the humerus; from the fascia of the forearm, and from the intermuscular septum between it and the extensor digiti quinti proprius. In the middle third of the forearm it receives some fibres from the strong fascial layer which binds it to the dorsal border of the ulna. The tendon does not become free from the fleshy fibres until it approaches close to the wrist. It occupies the groove on the dorsal aspect of the distal end of the ulna, between the head and styloid process, and, passing under cover of the dorsal carpal ligament, is inserted into the tubercle on the base of the metacarpal bone of the little finger. The muscle is supplied by the *dorsal interosseous nerve*. It is an extensor of the wrist and elbow, and it takes part in the movement of adduction at the wrist, when it acts simultaneously with the flexor carpi ulnaris.

**M. Anconæus.**—The anconæus lies at the lateral part of the dorsal aspect of the elbow joint. It is a small, short muscle, of triangular outline, which arises, by a relatively small origin, from the back of the lateral epicondyle of the humerus. The insertion is into the lateral border of the olecranon of the ulna and the proximal third of the dorsal surface of the body of the ulna. The nerve of supply has already been dissected. It is a long slender branch which is given off from the trunk of the radial nerve, behind the middle third of the humerus, and it descends through the substance of the medial head of the triceps before it reaches the anconæus. In addition, the distal part of the muscle sometimes receives a branch from the dorsal interosseous nerve. It is an extensor of the elbow joint.

**Dissection.**—To expose the deep muscles of the back of the forearm and the dorsal interosseous vessels and nerve the extensor digitorum communis and the extensor digiti quinti must be reflected. Divide the fleshy portion of each, about the middle of its length, and turn the proximal parts of the divided muscles towards their origins and the distal parts towards the insertions. As the muscles are reflected care must be taken to secure and preserve the twigs from the dorsal interosseous nerve which enter their deep surfaces. When the reflection is completed pull aside the extensor carpi ulnaris; then the greater parts of the dorsal interosseous vessels and nerve and the deep muscles of the forearm will be exposed. The muscles which are exposed are, from above downwards, the supinator, the abductor pollicis longus, the extensor pollicis brevis, and the

extensor indicis. The dorsal interosseous nerve appears through the substance of the supinator, crosses the surface of the abductor pollicis longus, and dips deep to the extensor pollicis longus. The dorsal interosseous artery appears between the adjacent borders of the supinator and the abductor pollicis longus and descends along the radial border of the extensor carpi ulnaris superficial to the extensor pollicis longus and the extensor indicis. First clean the dorsal interosseous nerve and secure its branches. After it pierces the supinator it gives branches of supply to all the deep muscles except the supinator, and to three of the superficial muscles, viz., the extensor digitorum communis, the extensor digiti quinti, and the extensor carpi ulnaris. The branches to the superficial muscles were found as the extensor digitorum communis and the extensor digiti quinti were reflected. The branch to the extensor indicis is given off before the nerve dips deep to the extensor pollicis longus, and it crosses the superficial surface of the long extensor of the thumb. When it has been found pull the extensor pollicis longus and the extensor indicis towards the medial side, and follow the dorsal interosseous nerve, which passes deep to both of them, to the back of the radius where it enters the osteo-fascial compartment through which the extensor digitorum communis and the extensor indicis pass to the dorsum of the hand. Where it lies under cover of the extensor pollicis longus it is joined by the perforating branch of the volar interosseous artery, which pierces the interosseous membrane about 50 mm. above the wrist, and then accompanies the dorsal interosseous nerve. Pull aside the tendons of the extensor communis and the extensor indicis beyond the dorsal carpal ligament and find the terminal part of the nerve and the continuation of the artery, deep to the tendons on the back of the wrist joint. The nerve ends in a gangliform enlargement from which twigs are distributed to the ligaments of the wrist joint, and the volar interosseous artery terminates by joining the dorsal carpal arterial arch.

Now clean the deep muscles, note the osteo-fascial compartments on the back of the radius through which they pass to the hand, and trace their tendons to their insertions.

**Deep Muscles.**—These are—(1) the supinator; (2) the abductor pollicis longus; (3) the extensor pollicis brevis; (4) the extensor pollicis longus; and (5) the extensor indicis proprius (Fig. 79).

The supinator will be recognised from the close manner in which it is applied to the proximal part of the body of the radius. The other muscles take origin proximo-distally in the order in which they have been named. The attachments of the supinator cannot be satisfactorily studied at present. They will be described at a later stage of the dissection.

**M. Abductor Pollicis Longus (O.T. Extensor Ossis Metacarpi Pollicis).**—The long abductor of the thumb arises

from both bones of the forearm, and from the interosseous membrane, which stretches between them. Its *origin from the radius* corresponds to the middle third of the dorsal surface of that bone; its *origin from the ulna* is more proximal, from the lateral part of the dorsal surface of the body, immediately distal to the oblique line which marks the distal limit of the insertion of the anconæus. The muscle proceeds distally and laterally, and comes to the surface in the interval between the extensor digitorum communis and the extensor carpi radialis brevis. Then it crosses the two radial extensors, closely accompanied by the extensor pollicis brevis. The tendon which issues from it, as it becomes superficial, is continued distally, over the lateral side of the expanded distal end of the radius, and under cover of the dorsal carpal ligament, and is inserted into the lateral side of the base of the metacarpal bone of the thumb. The muscle is supplied by the *dorsal interosseous nerve*. In addition to being an abductor of the thumb it assists in producing supination and abduction of the hand (Figs. 74, 75, 76, 79).

**M. Extensor Pollicis Brevis (O.T. Extensor Primi Internodii Pollicis).**—The short extensor of the thumb is placed along the distal border of the preceding muscle. It arises from a small portion of the dorsal surface of the radius, and also from the interosseous membrane. Its tendon is closely applied to that of the abductor pollicis longus, and accompanies it deep to the dorsal carpal ligament. It must be traced, on the dorsal aspect of the metacarpal bone of the thumb, to the base of the proximal phalanx, into which it is inserted. The muscle is supplied by the *dorsal interosseous nerve*. It is an extensor of the first interphalangeal joint and of the metacarpo-phalangeal joint of the thumb, and it takes a subsidiary part in the production of abduction of the hand.

**M. Extensor Pollicis Longus (O.T. Extensor Secundi Internodii Pollicis).**—The long extensor of the thumb takes origin from the lateral part of the dorsal surface of the body of the ulna, in its middle third, and also from the interosseous membrane. It overlaps, to some extent, the preceding muscle, and it ends in a tendon which passes under cover of the dorsal carpal ligament, where it occupies a deep narrow groove on the dorsum of the distal end of the radius. On the carpus it takes an oblique course, and, after crossing

the tendons of the two radial extensors and the radial artery, it reaches the thumb. It is inserted into the base of the distal phalanx of the thumb and is supplied by a branch of the *dorsal interosseous nerve*.

It is an extensor of all the joints of the thumb, and it takes part in the initiation of supination of the forearm (Figs. 78, 74, 75, 76, 79).

When the thumb is powerfully extended, in the living person, the tendons of its three last-mentioned muscles become prominent on the lateral aspect of the wrist. The oblique course of the tendon of the extensor pollicis longus is rendered evident, and a distinct depression between it and the other two tendons is seen.

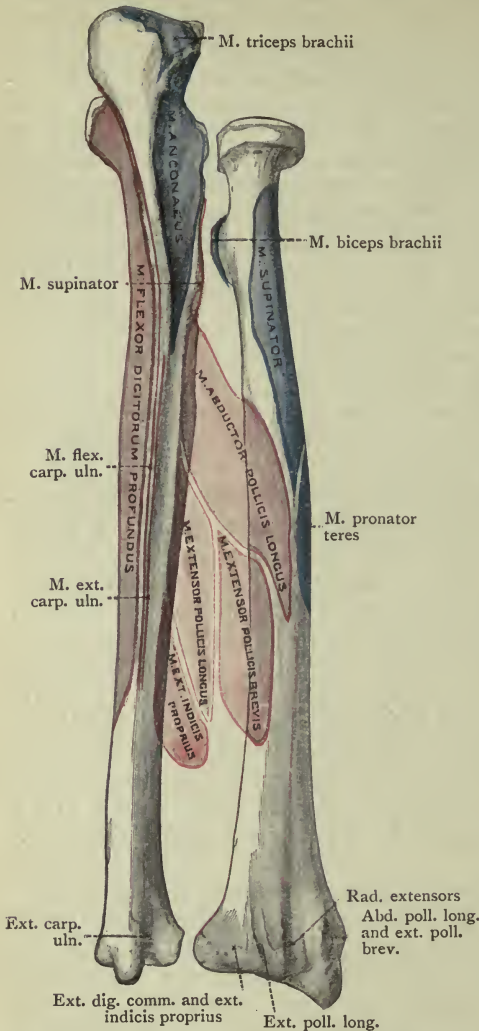


FIG. 78.—Dorsal aspect of the Bones of the Forearm, with Attachments of Muscles mapped out.

**M. Extensor Indicis Proprius.**—The

special extensor of the index finger arises, distal to the pre-



ceding muscle, from a limited area on the dorsal surface of the ulna and from the adjacent part of the interosseous membrane. Its tendon accompanies the tendons of the extensor digitorum communis through the most medial groove on the back of the radius, under cover of the dorsal carpal ligament, and is enclosed in the same mucous sheath. On the dorsum of the hand it lies along the medial side of the most lateral tendon of the common extensor, and it terminates in the expansion of that tendon on the dorsum of the first phalanx of the index finger. It is supplied by a branch of the *dorsal interosseous nerve*. It is an extensor of all the joints of the index finger, and it takes part in the production of extension of the wrist joint.

**Arteria Interossea Dorsalis.** — The dorsal interosseous artery arises, in the front part of the forearm, from the common interosseous branch of the ulnar artery. It at once proceeds dorsally, between the two bones of the forearm, in the interval between the oblique cord and the proximal border of the interosseous membrane. It appears in the back of the forearm between the contiguous borders of the supinator and the abductor pollicis longus, and then it extends distally between the superficial and deep muscles on the dorsum of the forearm. It gives branches to the adjacent muscles, and before it reaches the distal end of the forearm it is greatly reduced in size. In a well-injected limb it will be seen to end on the dorsum of the carpus by anastomosing with the volar interosseous artery and the dorsal carpal arteries. In addition to the branches which it supplies to the muscles, it gives off one large branch called the *interosseous recurrent artery* (Fig. 79).

The *arteria interossea recurrens* takes origin from the parent trunk as it appears between the supinator and the abductor pollicis longus, and turns proximally, under cover of the anconæus muscle, to reach the dorsal aspect of the lateral epicondyle of the humerus.

**Nervus Interosseus Dorsalis.**—The dorsal interosseous nerve is the continuation of the deep terminal branch of the radial (musculo-spiral) nerve. It reaches the dorsum of the forearm by traversing the substance of the supinator, and at the same time winding round the lateral aspect of the body of the radius. It emerges from the supinator a short distance proximal to the distal border of the muscle, and passes

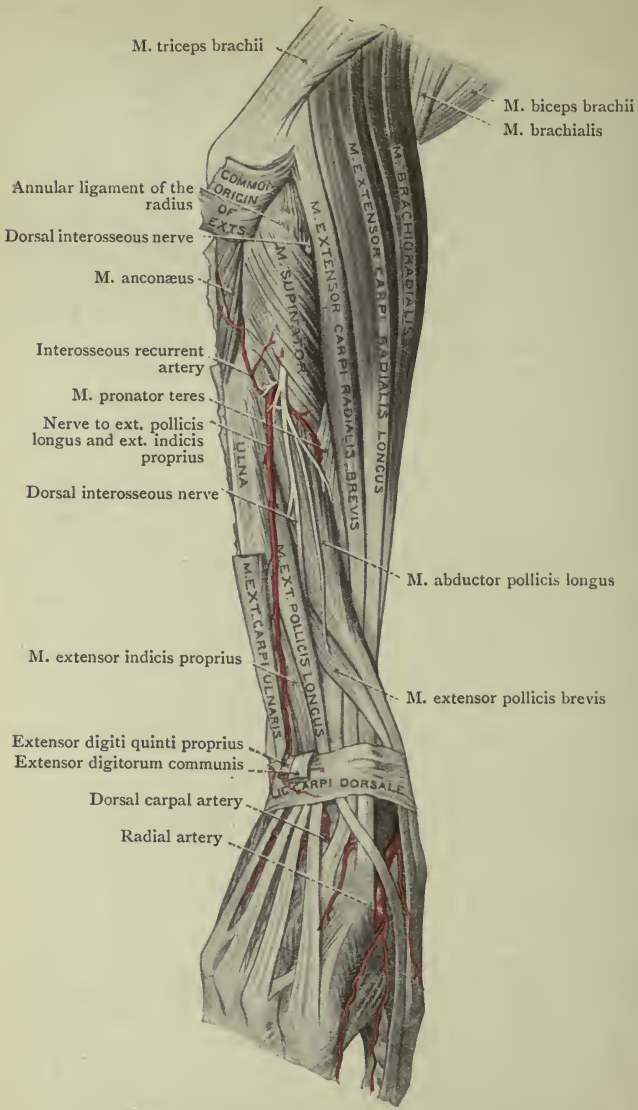


FIG. 79.—Dissection of the Dorsum of the Forearm and Hand.

distally between the superficial and deep muscles on the back of the forearm. At the proximal border of the extensor pollicis longus, it leaves the dorsal interosseous artery, dips anterior to the extensor pollicis longus, and joins the perforating branch of the volar interosseous artery on the dorsal aspect of the interosseous membrane. Accompanied by that artery it descends, through the most medial groove on the back of the radius with the tendons of the extensor digitorum communis and the extensor indicis proprius, to the back of the wrist where it ends in a gangliform enlargement which lies between the extensor tendons and the posterior ligament of the wrist.

The *branches* which spring from the dorsal interosseous nerve in the forearm are given entirely to muscles. Before the deep branch of the radial nerve pierces the supinator and becomes the dorsal interosseous nerve, it gives branches both to the supinator and to the extensor carpi radialis brevis. After it appears on the dorsum of the forearm, as the dorsal interosseous nerve, it supplies the extensor digitorum communis, the extensor digiti quinti proprius, the extensor carpi ulnaris, the abductor pollicis longus, two extensors of the thumb, and the extensor indicis proprius.

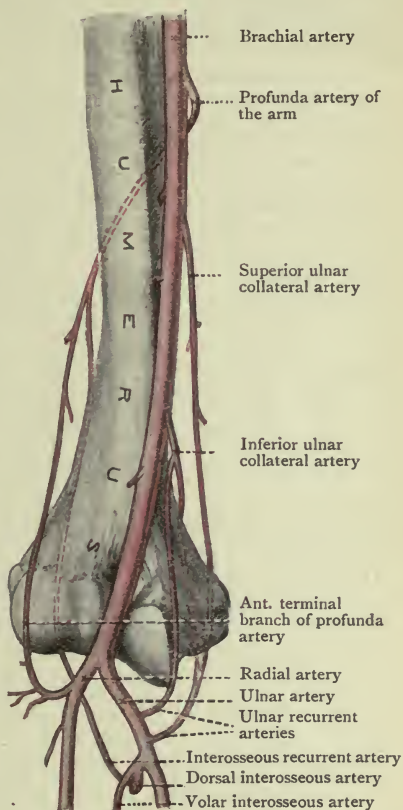


FIG. 80.—Diagram of Anastomosis around the Elbow Joint.

It supplies, therefore, all the muscles on the lateral and dorsal aspects of the forearm, with the exception of the brachio-radialis and the extensor carpi radialis longus, which derive their nerve-supply directly from the *radial nerve* (O.T. *musculo-spiral*). The anconæus derives its main nerve of supply from the radial nerve, but not infrequently it also obtains a second twig from the dorsal interosseous nerve.

**Dissection.**—Detach the anconæus from its origin and throw it towards its insertion in order to display the course of the dorsal interosseous recurrent artery. Trace that artery to the back of the lateral epicondyle, and then examine the arterial anastomosis around the elbow-joint.

**Anastomosis around the Elbow Joint.**—The series of inosculation around the elbow should now be reviewed as a whole. A distinct inosculation will be found to take place upon both the anterior and posterior aspect of each epicondyle of the humerus. Behind the lateral epicondyle the *interosseous recurrent artery* joins the *posterior branch* of the *profunda brachii artery*: anterior to the same epicondyle the *anterior branch* of the *profunda brachii artery* communicates with the *radial recurrent*. On the medial side of the joint the *anterior* and *posterior ulnar recurrent arteries* ascend respectively in front of and behind the medial epicondyle; the former anastomoses with the *anterior branch* of the *inferior ulnar collateral artery*, and the latter with the *posterior branch* of the same artery and with the *superior ulnar collateral artery*.

In this account of the anastomosis around the elbow joint only the leading inosculation are mentioned. Rich networks of fine vessels are formed over the olecranon and the two epicondyles of the humerus. One very distinct and fairly constant arch requires special mention. It is formed by a branch which crosses the posterior aspect of the humerus, immediately proximal to the olecranon fossa, and connects the posterior branch of the profunda brachii artery with the posterior branch of the inferior ulnar collateral artery.

**Terminal Branch of the Arteria Interossea Volaris.**—The so-called perforating branch of the volar interosseous artery is a vessel of some size, and is, really, the main continuation of the artery. It perforates the interosseous membrane about 50 mm. proximal to the distal end of the radius, and is at once joined by the dorsal interosseous nerve. It descends, with the nerve, in the most medial groove on the

dorsum of the distal end of the radius, to the dorsum of the carpus, where it anastomoses with the end of the dorsal interosseous artery and terminates in the dorsal carpal arterial arch. As it crosses the back of the distal end of the radius it lies between the bone and the mucous sheath, which encloses the tendons of the extensor digitorum communis and the extensor indicis.

#### DORSAL ASPECT OF THE WRIST AND HAND.

Upon the dorsal aspect of the wrist and hand the following structures have still to be examined:—

1. The dorsal carpal ligament.
2. The radial artery and its branches.
3. The extensor tendons of the fingers.

**Ligamentum Carpi Dorsale.**—The dorsal carpal ligament is a fascial band which stretches obliquely across the wrist. It is merely a thickened portion of the deep fascia, and its attachments are so arranged that it does not interfere with the free movement of the radius and hand during pronation and supination. On the lateral side it is fixed to the lateral margin of the distal end of the radius, whilst on the medial side it is attached to the os triquetrum and os pisiforme, and also to the palmar aponeurosis. In the case of the transverse carpal ligament one large compartment, or tunnel, is formed for the flexor tendons; not so in the case of the dorsal carpal ligament. Partitions or processes proceed from its deep surface, and are attached to the ridges on the dorsal aspect of the distal end of the radius, so as to form a series of six bridges or compartments for the tendons. Each compartment is lined by a mucous sheath which envelops the tendon or tendons which pass through it, and facilitates their play between the ligament and the bone. The different compartments should now be successively opened up so that the arrangement of the tendons with reference to the dorsal carpal ligament may be studied.

The *first compartment* is placed on the lateral side of the base of the styloid process of the radius, and corresponds with the broad oblique groove which is present in that part of the bone. It contains two tendons, viz., the tendons of the abductor pollicis longus and the extensor pollicis brevis, with their mucous sheaths. The *second compartment* corresponds with the most lateral groove on the dorsal aspect of the radius.

It is broad and shallow, and it holds the tendons of the extensor carpi radialis longus and extensor carpi radialis brevis

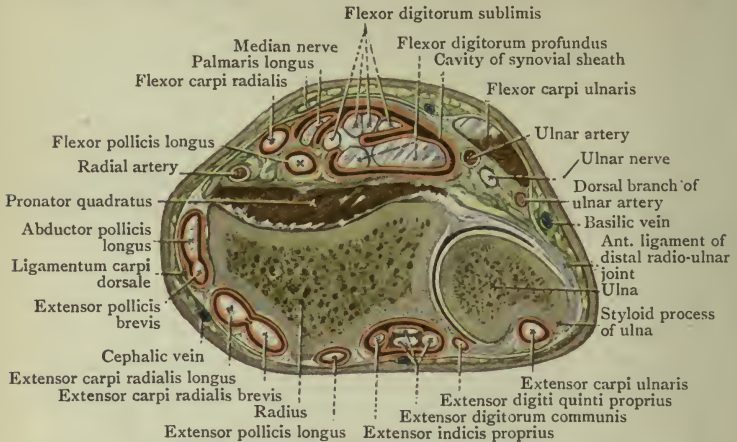


FIG. 81.—Transverse section through Forearm proximal to the Ligamentum Carpi Transversum. Showing the relation of the mucous sheaths to the tendons.

and their mucous sheaths. The *third compartment* is formed over the narrow, deep, oblique intermediate groove on the dorsum of the distal end of the radius. It contains the tendon

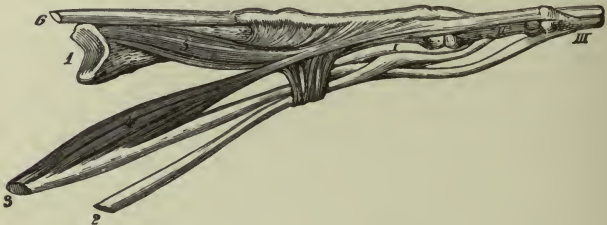


FIG. 82.—(From Luschka.)

- |  |                                       |
|--|---------------------------------------|
| 1. Middle metacarpal bone.               | 4. Second lumbrical muscle.           |
| 2. Tendon of flexor digitorum sublimis.  | 5. Second dorsal interosseous muscle. |
| 3. Tendon of flexor digitorum profundus. | 6. Common extensor tendon.            |
- I., II., and III. The three phalanges.

of the extensor pollicis longus and its mucous sheath. The *fourth compartment* is placed over the wide shallow groove which marks the medial part of the dorsal aspect of the distal

end of the radius. It is traversed by tendons of the extensor digitorum communis and the tendon of the extensor indicis proprius and their mucous sheath, and by the terminal parts of the dorsal interosseous nerve and the perforating branch of the volar interosseous artery. The *fifth compartment* is situated over the interval between the distal ends of the radius and ulna. It contains the slender tendon of the extensor digiti quinti proprius and its mucous sheath. The *sixth and most medial compartment*, which corresponds with the groove on the dorsum of the distal end of the ulna, encloses the tendon of the extensor carpi ulnaris and its mucous sheath (see Fig. 76).

**Dissection.** — After the compartments of the dorsal carpal ligament and their contents have been examined displace the various tendons as far as may be necessary, and clean the dorsal part of the radial artery and its branches. The artery enters the dorsal part of the wrist region by curling round the lateral border of the wrist deep to the tendons of the abductor pollicis longus and the short and long extensors of the thumb, and it disappears into the palm, at the proximal end of the first interosseous space, between the two heads of the first dorsal interosseous muscle. As it lies at the side of the wrist two dorsal arteries of the thumb and the dorsal radial carpal branch spring from it, and just before it disappears it gives off the dorsal artery to the index finger, and the first dorsal metacarpal artery, unless that branch rises in common with the dorsal radial carpal artery.

**Radial Artery.** — Only a small portion of the radial artery is seen in this dissection. At the distal end of the radius the vessel turns dorsally, distal to the styloid process and upon the radial collateral ligament of the radio-carpal joint. Having gained the dorsal aspect of the carpus, it runs distally upon the navicular and os multangulum majus, and finally disappears from view by turning volarwards, through the proximal part of the first interosseous space and between the heads of origin of the first dorsal interosseous muscle (Figs. 75, 76). In the palm it takes the chief share in the formation of the deep volar arch.

While the radial artery rests on the radial collateral carpal ligament, it is deeply placed, and is crossed by the tendons of the abductor pollicis longus and the extensor pollicis brevis. On the carpus it lies nearer the surface, and is crossed obliquely by the extensor pollicis longus. It is accompanied by two *venæ comites* and some fine filaments from the lateral cutaneous nerve of the forearm which twine around it.

The *branches* which spring from the radial artery in this part of its course are of small size. They are :—

1. Ramus carpeus dorsalis.
2. Aa. metacarpeæ dorsales.
3. Aa. digitales { Two dorsal arteries of the thumb.  
dorsales. { One dorsal artery of the index digit.

The *dorsal radial carpal artery* takes origin on the lateral aspect of the wrist, and runs medially, upon the carpus, to join the corresponding carpal branch of the ulnar artery. The arch thus formed is placed under cover of the extensor tendons, and gives off two branches which run distally in the third and fourth inter-metacarpal intervals. They are termed the *second* and *third dorsal metacarpal arteries*.

The *first dorsal metacarpal artery* arises, as a rule, from the radial trunk, although not infrequently it may be seen to spring from the dorsal carpal arch. It extends distally in the second interosseous space.

The three dorsal metacarpal arteries are brought into connection with the arteries in the palm by communicating branches. They are joined by the three perforating twigs of the deep volar arch, which make their appearance on the dorsum of the hand between the heads of the medial three dorsal interosseous muscles. Further, at the distal ends of the interosseous spaces the dorsal metacarpal arteries usually send *distal perforating branches* to join the corresponding common volar digital arteries in the palm.

The *two dorsal arteries of the thumb* run distally one upon each side of that digit.

The *dorsal artery of the index* is distributed on the lateral side of the index finger.

**Dissection.**—The limb should now be turned round, so that the transverse metacarpal ligament which stretches across the volar aspects of the heads of the metacarpal bones may be examined previous to the dissection of the interosseous muscles.

**Ligamentum Capitulorum Transversum.**—The transverse ligament of the heads of the metacarpal bones is a strong band, composed of transverse fibres, which crosses the volar aspects of the heads of the four metacarpal bones of the fingers. Commencing on the lateral side, upon the distal extremity of the index metacarpal, it ends at the medial margin of the hand, upon the head of the metacarpal bone of the little finger.



It is not directly attached to the bones, but is fixed to the powerful volar accessory ligaments of the medial four metacarpophalangeal joints, and it effectually prevents excessive separation of the metacarpal bones from each other.

**Dissection.**—To obtain a satisfactory view of the interosseous muscles, the transverse part of the adductor pollicis, if not previously reflected, should be detached from its origin, and thrown laterally towards its insertion into the thumb. The transverse metacarpal ligament also must be divided in the intervals between the fingers. Then the palmar and dorsal interossei must be cleaned and their limits must be defined. As the fascia is cleaned from their surfaces the margins of the muscles become evident. There is one dorsal interosseous muscle in each intermetacarpal space, and in the medial three spaces there is also a volar interosseous muscle.

**Mm. Interossei.**—The interosseous muscles occupy the intervals between the metacarpal bones. They are seven in number, and are arranged in two groups, viz. a dorsal and a volar.

The three *volar interossei* can be seen only on the palmar aspect of the hand. They act as adductors of the index, ring, and little fingers towards the middle digit, and each muscle is placed upon the metacarpal bone of the finger upon which it acts. The *first volar interosseous muscle* therefore arises from the metacarpal bone of the index finger, and its delicate tendon is inserted upon the medial side of that digit, partly into the base of the first phalanx, and partly into the extensor expansion. The *second volar interosseous muscle* springs from the metacarpal bone of the ring finger, and has a similar insertion into the lateral side of that digit. The *third volar interosseous muscle* takes origin from the metacarpal bone of the little finger, and is inserted into the lateral side of the first phalanx and the extensor expansion of that finger.

The *dorsal interossei* are four in number, and are larger than the volar muscles. They are seen best on the dorsal aspect of the hand, but they are visible in the palm also. They act as abductors of the fingers from the central line of the middle digit, and their insertions are arranged in accordance with that action. Each muscle arises by two heads from the contiguous surfaces of the two metacarpal bones between which it lies, and the fibres converge in a pennate manner upon a delicate tendon. In the case of the

*first* or *most lateral dorsal interosseous muscle*, the tendon is inserted into the lateral side of the base of the first phalanx, and also into the lateral margin of the dorsal expansion of the extensor tendon of the index. The *second* and *third dorsal interosseous muscles* are inserted in a similar manner, one on each side of the base of the first phalanx of the middle finger; whilst the *fourth* has a corresponding insertion upon the medial aspect of the base of the first phalanx of the ring finger.

The first dorsal interosseous muscle is frequently termed the *abductor indicis*; and between its two heads of origin the radial artery enters the palm. Between the heads of the other three muscles the small perforating arteries pass.

In addition to acting as adductors or abductors of the fingers the interossei flex the metacarpo-phalangeal joints and help to extend the interphalangeal joints (see p. 178). The interosseous muscles are supplied by the *deep branch* of the *ulnar nerve*.

**Tendon of the Flexor Carpi Radialis.**—The tendon of the radial flexor of the carpus should now be traced through the groove on the volar aspect of the os multangulum majus to its insertion into the base of the metacarpal bone of the index finger. It presents also a minor attachment to the base of the middle metacarpal bone. On its way to its insertion it passes behind the tendon of the flexor pollicis longus.

**Dissection.**—All the muscles around the elbow joint should be removed. As the brachialis and the triceps are raised from the anterior and posterior aspects of the articulation, some care is required to avoid injury to the anterior and posterior parts of the capsule. It is advisable to remove the supinator last, because it is only when that muscle is completely isolated that a proper idea of its attachments and mode of action can be obtained. Before it is removed its attachments and actions must be studied.

**M. Supinator (O.T. Supinator Brevis).**—The supinator muscle envelops the proximal part of the body and the neck of the radius, covering it completely, except on its medial side (Figs. 64, 78). It arises from the deep depression distal to the radial notch of the ulna, and also from the radial collateral ligament of the elbow and the annular ligament of the radius. From their origin the fibres sweep round the dorsal, lateral, and volar surfaces of the radius, and clothe its body as far distally as the insertion of the pronator teres. The dorsal interosseous nerve supplies the muscle, traverses its substance, and separates it into two layers.

## ARTICULATIONS.

## ARTICULATIO CUBITI (ELBOW JOINT).

This joint includes (1) the articulatio humero-ulnaris, (2) the articulatio humero-radialis, and (3) the articulatio radio-ulnaris proximalis. In the humero-ulnar articulation the trochlea of the humerus is grasped by the *semilunar notch* of the ulna. In the radio-humeral articulation the *capitulum of the humerus* rests in the shallow *fovea capituli* of the radius, and in the proximal radio-ulnar articulation the *articular circumference* of the head of the radius is held in apposition with the *radial notch* of the ulna by the *annular ligament* (Figs. 85, 96).

The joint is surrounded by a capsule which is reinforced at the sides by collateral ligaments; in addition, the interosseous membrane, which passes between the interosseous crests of the radius and ulna, and the oblique cord, which connects the tuberosity of the ulna with the proximal part of the interosseous crest of the radius, help to keep the radius and ulna in apposition, and are therefore included in the ligaments of the elbow joint. The ligaments of the elbow joint are therefore—

- |                              |                                     |
|------------------------------|-------------------------------------|
| 1. Capsula articularis.      | 4. Lig. annulare radii.             |
| 2. Lig. collaterale ulnare.  | 5. Membrana interossea antibrachii. |
| 3. Lig. collaterale radiale. | 6. Chorda obliqua.                  |

The *articular capsule* is attached proximally to the antero-medial and antero-lateral surfaces of the humerus, proximal to the coronoid and radial fossæ, respectively. At the sides, it is attached to the epicondyles; and, posteriorly, to the posterior surface, on which the line of attachment passes through the proximal part of the olecranon fossa. Distally, the capsule is attached to the anterior margin of the proximal, medial, and lateral surfaces of the olecranon; to the medial and volar margins of the coronoid process of the ulna, and to the annular ligament of the radius. The anterior part of the capsule consists of fibres which take an irregular course over the anterior aspect of the joint. The posterior part of the capsule is weaker than the anterior and its attachment to the posterior surface of the humerus is comparatively loose.

The cavity of the joint is closed distally on the radial side by lax fibres which pass from the distal border of the annular ligament to the neck of the radius, and by a thin sheet of fibres, called the *ligamentum quadratum*, which extends

from the medial side of the neck of the radius to the distal border of the radial notch of the ulna.

**Ligamentum Collaterale Radiale (O.T. External Lateral Ligament).**—The radial collateral ligament is a strong but short band which is attached proximally to the distal aspect of the lateral epicondyle of the humerus. Distally, it is fixed to the annular ligament of the radius, and also, more posteriorly, to the lateral side of the olecranon of the ulna. The annular ligament is a strong ligamentous collar which surrounds the head of the radius, and retains it in the radial notch of the ulna.

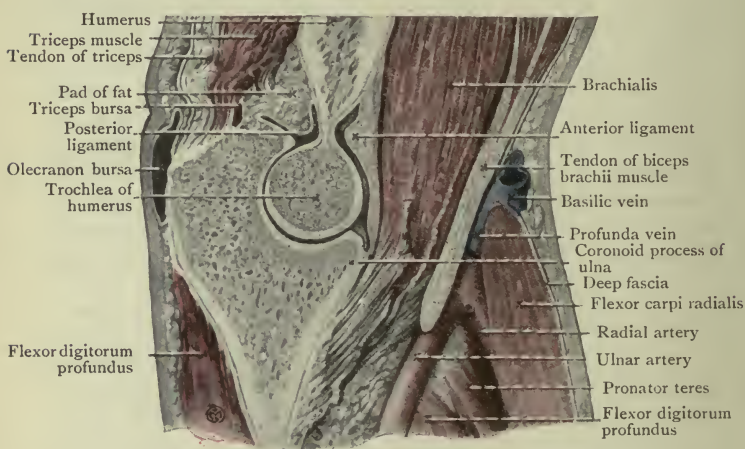


FIG. 83.—Sagittal section of the Right Elbow Region.

**Ligamentum Collaterale Ulnare (O.T. Internal Lateral Ligament).**—The ulnar collateral ligament, taken as a whole, is fan-shaped. By its proximal pointed part it is attached to the medial epicondyle of the humerus. Distally it spreads out and is inserted into the coronoid process and the olecranon. It consists of three very distinct portions, viz., an anterior, a posterior, and a transverse (Fig. 84).

The *anterior part* springs from the distal and anterior part of the medial epicondyle, and is attached to the medial margin of the coronoid process of the ulna. The *posterior part* is attached, proximally, to the distal and dorsal part of the medial epicondyle, whilst distally, it is fixed to the medial border of

the olecranon. The *transverse part* consists of a band of fibres which bridges across the notch between the olecranon and the coronoid process, to both of which it is attached.

The annular ligament and the oblique cord will be described later (see pp. 202-204).

**Stratum Synoviale (Synovial Membrane).**—The joint should be opened by making a transverse incision through the anterior part of the capsule. The synovial stratum will be seen lining the deep surface of the capsule, from which it is

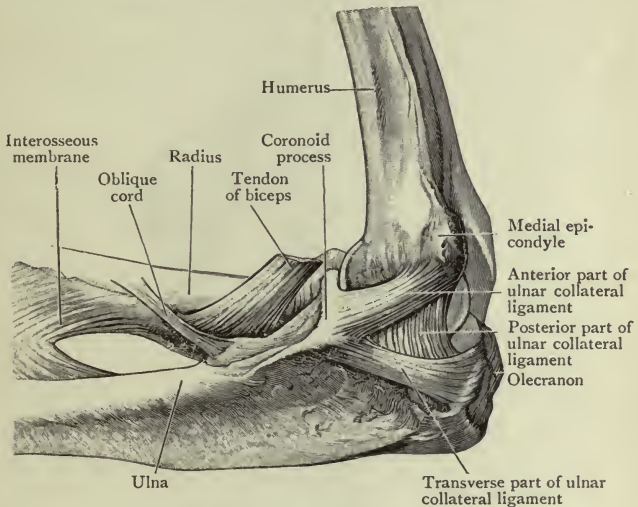


FIG. 84.—Medial aspect of Elbow Joint.

reflected upon the non-articular parts of the bones which are enclosed within the capsule. Anterior to the humerus it lines the radial and coronoid fossæ, and posteriorly it is prolonged proximally, in the form of a loose diverticulum, into the olecranon fossa. In the fossæ a quantity of soft oily fat is developed between the bone and the synovial stratum. In that way pliable pads are formed which occupy the recesses when the bony processes are withdrawn from them.

Distally, the synovial stratum of the elbow joint is prolonged into the proximal radio-ulnar joint, so that both articulations possess a single, continuous synovial cavity.

The nerve supply of the joint is derived from the median, ulnar, and radial nerves.

**Movements at the Elbow Joint.**—The movements at the elbow joint must not be confounded with those that take place at the proximal radio-ulnar joint. At the elbow joint two movements, viz., *flexion*, or forward movement of the forearm, and *extension*, or backward movement of the forearm, are permitted.

The *muscles* which are chiefly concerned in flexing the forearm upon the

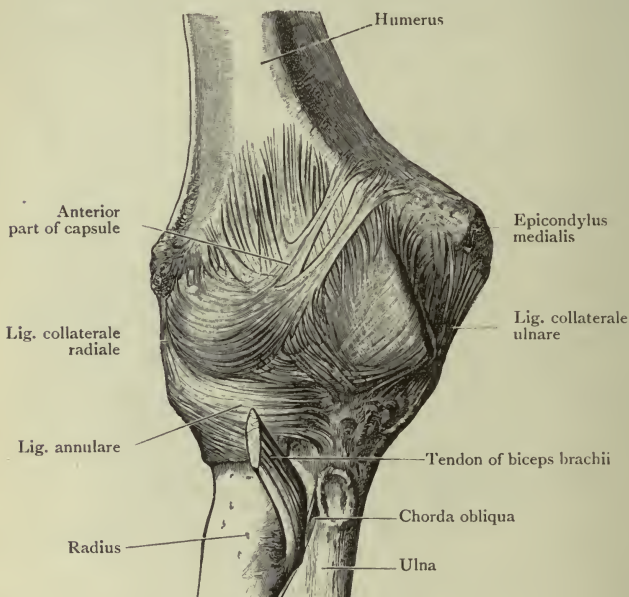


FIG. 85.—Anterior aspect of the Elbow Joint.

arm at the elbow joint are the biceps, the brachialis, the muscles attached to the medial epicondyle, and the brachio-radialis. The muscles which extend the forearm are the triceps and anconæus and the muscles which spring from the lateral epicondyle.

**Dissection.**—It is advisable to study the radio-carpal or wrist joint, before the articulations between the two bones of the forearm are examined. The transverse, volar, and dorsal carpal ligaments, together with the extensor and flexor tendons, should be completely removed from the wrist. No attempt, however, should be made to detach the extensor tendons from the dorsal aspects of the fingers and thumb. The short muscles of the thenar and hypothenar eminences must also be taken away.

PLATE XI

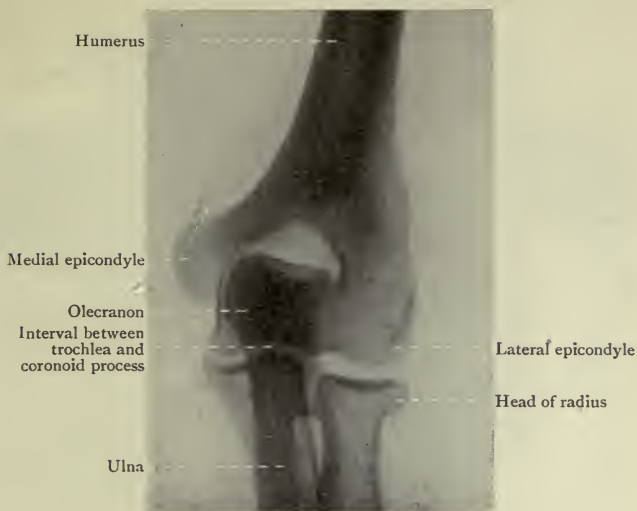

FIG. 86.—Antero-posterior Radiograph of extended Elbow Joint.  
(Mr. A. D. Reid.)

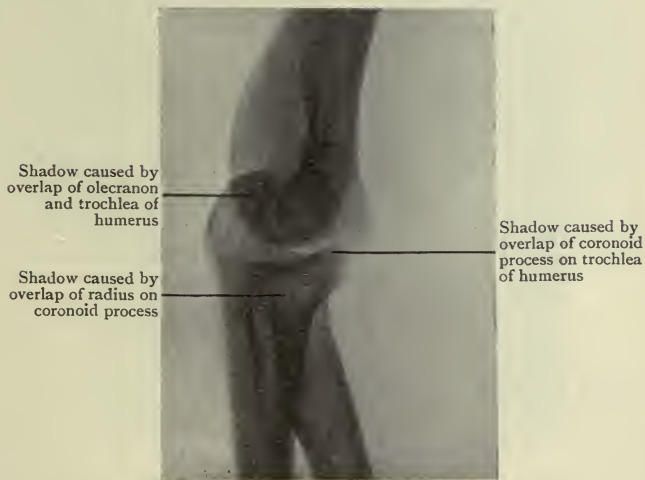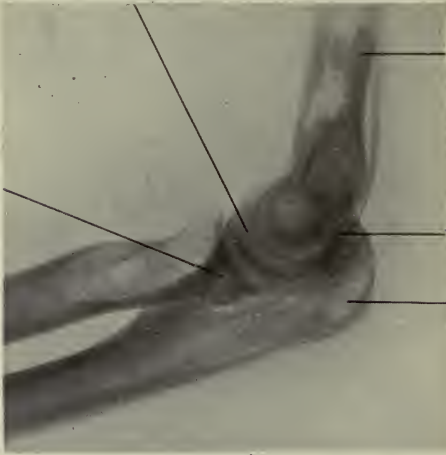


FIG. 87.—Lateral Radiograph of extended Elbow Joint.  
(Dr. R. Knox.)

PLATE XII

Overlap of coronoid process  
on trochlea of humerus

Overlap of head of  
radius on coronoid  
process of ulna



Humerus

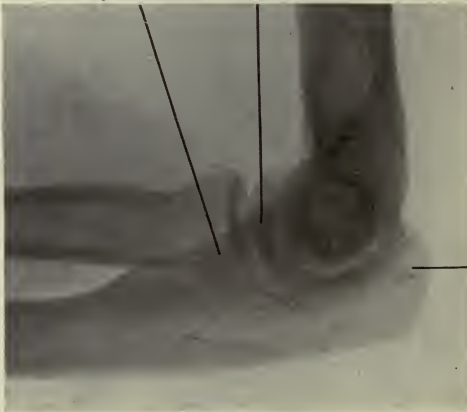
Overlap of ole-  
cranon on trochlea  
of humerus

Olecranon

FIG. 88.—Lateral Radiograph of partly bent Elbow.

Overlap of head of radius  
on coronoid process

Overlap of coronoid process  
on trochlea



Olecranon

FIG. 89.—Lateral Radiograph of half-bent Elbow.  
(Mr. Martin.)



PLATE XIII

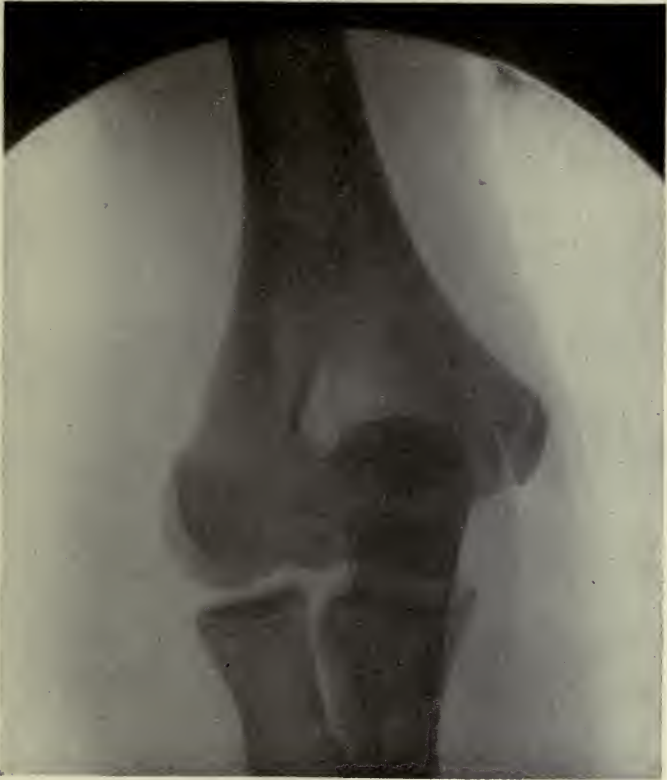

FIG. 90.—Radiograph of the Elbow Joint.

- Note (1) The medial epicondyle has not yet united with the shaft.  
(2) The proximal epiphysis of the radius.  
(3) That the nodular epiphysis of the olecranon is not distinctly visible.  
(4) That all the distal epiphyses of the humerus have fused with the shaft except the epiphysis of the medial epicondyle.

(Mr. A. D. Reid.)

PLATE XIV

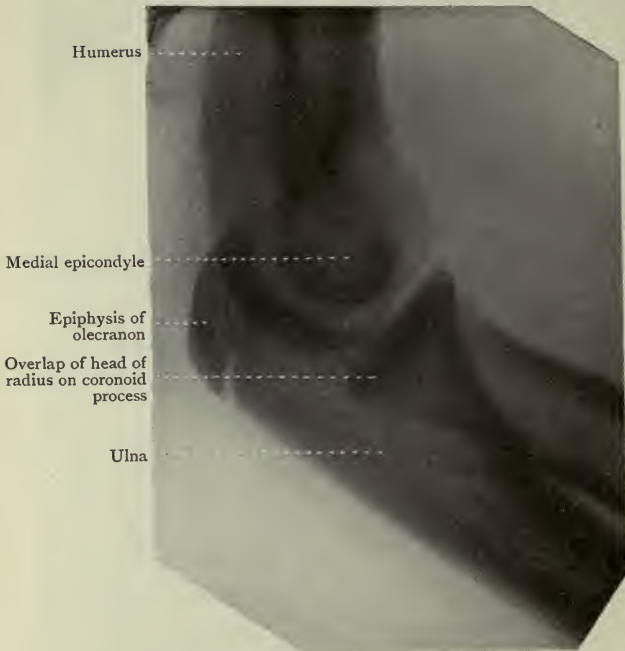


FIG. 91.—Lateral Radiograph of a partly bent Elbow Joint, showing Epiphysis of Olecranon.

(Mr. A. D. Reid.)

PLATE XV

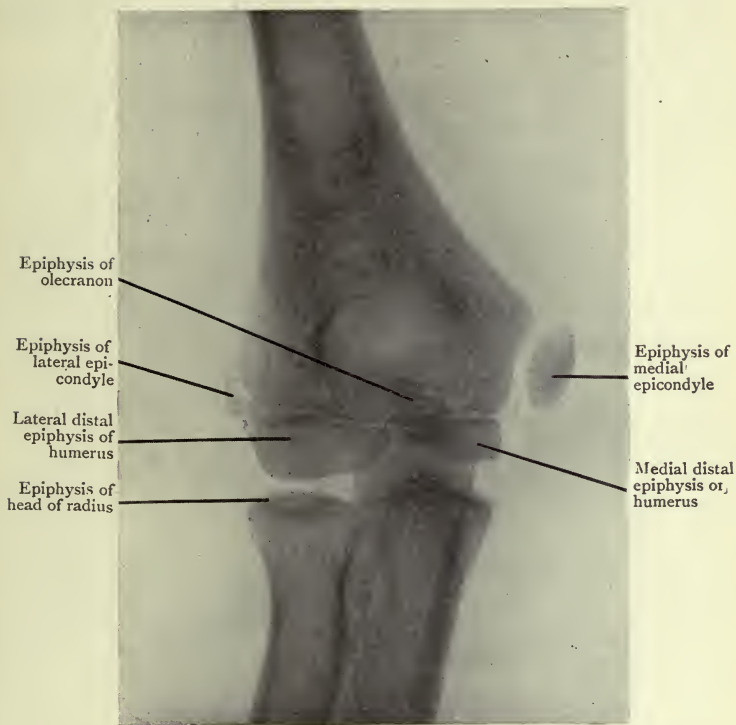


FIG. 92.—Antero-posterior Radiograph of young Elbow Joint, showing all Epiphyses.

PLATE XVI

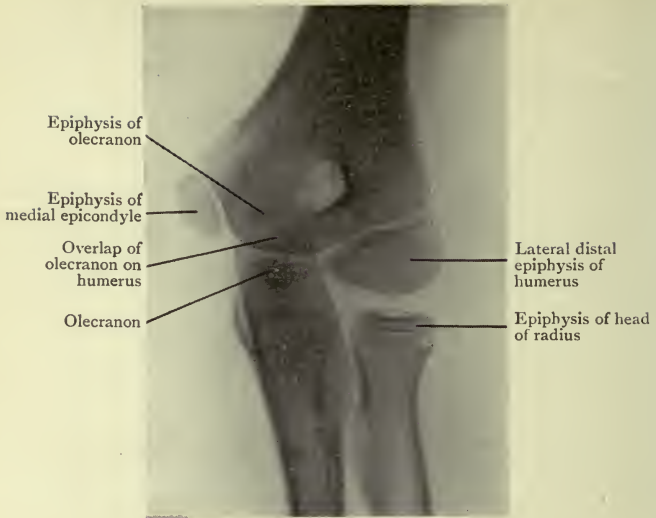


FIG. 93.—Antero-posterior Radiograph of young Elbow Joint. The epiphysis of the lateral epicondyle of the humerus has not yet appeared.

Note that the lateral distal epiphysis forms not only the capitulum of the humerus but also a part of the trochlea.

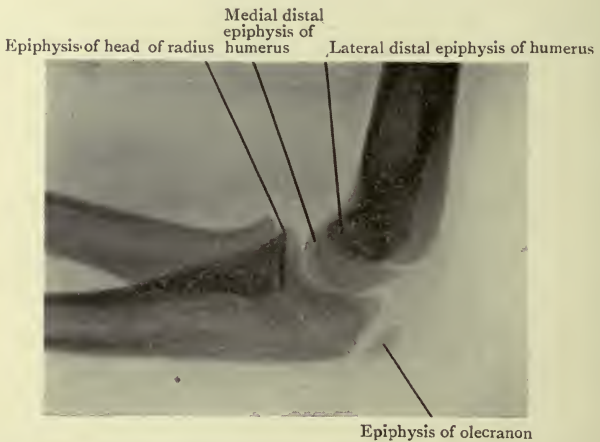


FIG. 94.—Lateral Radiograph of a half-bent young Elbow Joint.

## ARTICULATIO RADIO-CARPEA (WRIST JOINT).

The radio-carpal or wrist joint is the joint between the forearm and the hand. The proximal face of the joint is formed by the distal articular surface of the radius and the *discus articularis*; and the distal surface consists of the navicular, lunate, and triquetral bones, and the two interosseous ligaments which connect them together. The opposed surfaces are retained in apposition by an *articular capsule* in which at least four thickened bands can be recognised, they are:—

- |                               |  |                              |
|-------------------------------|--|------------------------------|
| 1. Lig. radiocarpeum volare.  |  | 3. Lig. collaterale radiale. |
| 2. Lig. radiocarpeum dorsale. |  | 4. Lig. collaterale ulnare.  |

The *capsule* is attached proximally to the borders of the distal ends of the radius and the ulna, and to the borders of the articular disc. Distally it is connected with the bones of the proximal row of the carpus, with the exception of the pisiform, and some of its fibres can be traced to the capitate bone.

The *volar radio-carpal ligament* springs from the anterior border of the styloid process of the radius and the adjacent part of the anterior border of the distal end of the radius. Distally it breaks up into flat bands which are attached to the navicular, lunate, and capitate bones. In many cases a *volar ulnar-carpal ligament* also is found. When present, it extends from the anterior aspect of the base of the styloid process and the adjacent anterior part of the head of the ulna to the triquetral, pisiform, and capitate bones.

The *dorsal radio-carpal band* springs from the posterior border of the distal end of the radius, and is attached distally to all the bones of the proximal row of the carpus, except the pisiform. Its fibres are often separable into a number of distinct bands.

The *radial collateral carpal ligament* passes from the tip of the styloid process of the radius to the lateral part of the navicular; and the *ulnar collateral carpal ligament* connects the styloid process of the ulna with the triquetral bone.

**Articular Surfaces.**—Divide the anterior and collateral parts of the capsule by a transverse incision carried across the front of the articulation. The hand can now be bent backwards, so as to expose fully the articular surfaces opposed to each other in this joint.

The *carpal surface* is composed of the proximal articular facets of the navicular and lunate bones, and a very small

articular facet on the extreme lateral part of the proximal surface of the triquetral bone. Two interosseous ligaments stretch across the narrow intervals between the three bones—one on each side of the lunate bone—and complete the carpal surface. The carpal surface thus formed is convex in all directions. Further, it should be observed that the articular surface extends distally to a greater extent on the dorsal than on the volar aspect.

The *proximal surface or socket* (Fig. 97) is elongated from side to side, and concave in all directions. The greater part of it is formed by the distal end of the radius, but, on the medial side, the articular disc of the distal radio-

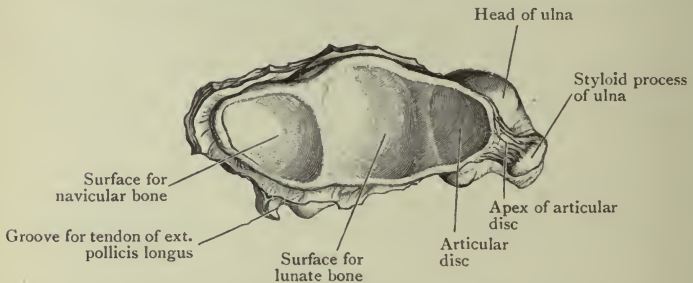


FIG. 95.—Carpal Articular Surfaces of the Radius and of the Articular Disc of the Wrist.

ular joint also enters into its construction. The distal articular surface of the radius extends further distally on its dorsal and lateral sides than on its volar and medial sides, and it is divided by a low ridge into a lateral triangular and a medial quadrilateral facet. The lateral facet, in the ordinary position of the hand, is in contact with the greater extent of the proximal articular surface of the navicular bone. The medial facet of the radius, together with the articular disc, forms a much larger surface, triangular in outline, which is opposed to the proximal articular surface of the lunate bone. When the hand is placed in line with the forearm no part of the proximal articular surface is allotted to the triquetral bone: its small articular facet rests against the medial part of the capsule of the joint. When the hand is moved medially (*i.e.* adducted), however, the triquetral bone travels laterally, and its articular surface comes into

contact with the distal surface of the articular disc. The lunate bone at the same time crosses the bounding ridge on the distal surface of the radius, and encroaches on the territory of the navicular bone, whilst a considerable part of the surface of the navicular bone leaves the radius and comes into contact with the lateral part of the capsule.

**Stratum Synoviale.**—The synovial stratum of the radio-carpal joint lines the fibrous capsule and it covers the proximal surfaces of the two interosseous ligaments which complete the carpal surface. Sometimes the articular disc is imperfect, and in those cases the synovial stratum of the radio-carpal joint becomes continuous with the synovial stratum of the distal radio-ulnar joint.

The nerve supply is derived from the volar and dorsal interosseous nerves.

**Movements at the Radio-carpal Joint.**—The hand can be moved in four directions at the radio-carpal joint. Thus we have—(a) volar movement, or *flexion*; (b) dorsal movement, or *extension*; (c) ulnar movement, or *adduction*; (d) radial movement, or *abduction*. In estimating the extent of these movements in the living person the student is apt to be misled by the increase of range which is contributed by the carpal joints. Thus, flexion is in reality more limited than extension, although by the combined action of both carpal and radio-carpal joints the hand can be carried much more freely volarwards than dorsalwards. Adduction, or ulnar flexion, can be produced to a greater extent than abduction, or radial flexion. In both cases the extent of movement at the radio-carpal joint proper is very slight, but the range is extended by movements of the carpal bones. The styloid process of the radius interferes with abduction.

The *muscles* which are chiefly concerned in producing the different movements of the hand at this joint are the following:—(a) *flexors*—the flexor carpi radialis, the palmaris longus, and the flexor carpi ulnaris; (b) *extensors*—extensor carpi radialis longus, the extensor carpi radialis brevis, and the extensor carpi ulnaris; (c) *abductors*, or *radial flexors*—flexor carpi radialis, extensor carpi radialis longus, abductor pollicis longus, and the extensor pollicis brevis; (d) *adductors*, or *ulnar flexors*—extensor carpi ulnaris and flexor carpi ulnaris.

In addition, all the muscles whose tendons cross the volar aspect of the joint can, under certain conditions, assist in the production of flexion, and the muscles whose tendons cross the dorsal surface can assist in the production of extension.

#### ARTICULATIONES RADIO-ULNARES (RADIO-ULNAR JOINTS).

At the two radio-ulnar joints, proximal and distal, the movements of pronation and supination take place. At the *proximal joint* the medial part of the head of the radius fits into the radial notch of the ulna; at the *distal joint* the

small capitulum of the ulna is received into the ulnar notch on the medial side of the distal end of the radius. In connection with these joints there are special ligaments which retain the bones in apposition. They are—(1) for the proximal radio-ulnar joint, *the annular ligament*; and (2) for the distal radio-ulnar joint, (a) a *capsule*, and (b) the *discus articularis*.

In addition there are other ligaments which pass between the bodies of the two bones of the forearm, and are, therefore, common to the two articulations, viz., the *oblique cord* and the *interosseous membrane*.

**Dissection.**—To expose the oblique cord and the interosseous membrane, remove, completely, the volar and dorsal muscles of the forearm.

**Ligamentum Annulare Radii (O.T. Orbicular Ligament).**

—The annular ligament is a strong fibrous collar which

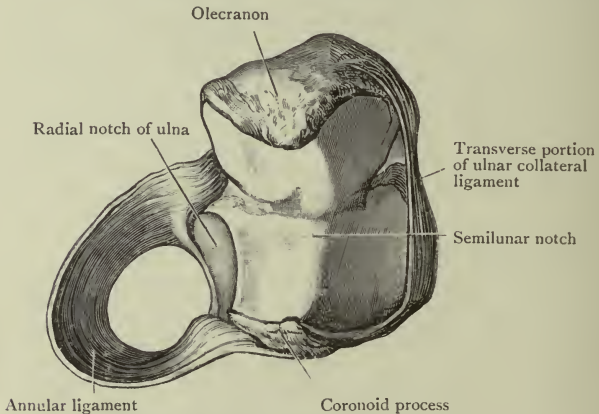


FIG. 96.—Annular Ligament of the Radius.

encircles the head of the radius and retains it in the radial notch of the ulna. It forms four-fifths of a circle, and is attached by its extremities to the volar and dorsal margins of the radial notch of the ulna. It is somewhat narrower distally than proximally, so that, under ordinary circumstances, the head of the radius cannot be withdrawn from it in a distal direction, and it is braced tightly towards the elbow, and greatly strengthened by the anterior and posterior portions



of the capsule of the elbow joint and by the radial collateral ligament, which are attached to its proximal border. Its distal border is attached, loosely, to the neck of the radius by a prolongation of the synovial stratum, which is covered externally by a thin layer of fibrous tissue.

**The Capsule of the Distal Radio-ulnar Joint.**—This capsule consists of lax fibres which can have little influence in retaining the distal extremities of the bones in apposition. It is attached to the volar and dorsal surfaces of both bones of the forearm, to the most distal parts of the interosseous crests and to the volar and dorsal borders of the articular disc. A diverticulum of the capsule, which is prolonged from the joint area for some distance proximally, between the bones of the forearm, is called the *recessus sacciformis*.

**Discus Articularis (O.T. Triangular Fibro-Cartilage).**—The articular disc is the true bond of union at the distal radio-ulnar joint. It has already been noticed in connection with the radio-carpal joint, where it extends the radial articular surface in a medial direction, and is interposed between the distal end of the ulna and the lunate and triquetral bones. It is a thick, firm plate, attached by its base to the distal margin of the ulnar notch of the radius. The apex of the disc is placed medially, and is fixed to the depression on the distal end of the ulna at the root of the styloid process. It intervenes between the distal radio-ulnar joint and the radio-carpal joint (Fig. 97).

**Stratum Synoviale (Synovial Membrane).**—The synovial stratum of the proximal radio-ulnar joint is continuous with that of the elbow joint. It is prolonged distally to line the annular ligament, and it protrudes beyond that ligament for a short distance upon the neck of the radius.

The cavity of the distal radio-ulnar joint and the synovial stratum are prolonged between the head of the ulna and the articular disc.

Sometimes the articular disc is perforated; when that is the case, the distal radio-ulnar joint-cavity communicates with the cavity of the radio-carpal joint.

**Membrana Interossea Antibrachii.**—The interosseous membrane is a fibrous membrane which stretches across the interval between the two bones of the forearm, and is attached to the crista interossea of each. Its proximal border

is situated about 25 mm. (one inch) distal to the tuberosity of the radius. Distally, it blends with the capsule of the distal radio-ulnar joint. The fibres which compose it run for the most part obliquely distally and medially from the radius to the ulna, although several strands may be noticed taking an opposite direction. The dorsal interosseous vessels pass backwards, above its proximal margin, between the two bones of the forearm; whilst the terminal branch of the volar interosseous artery pierces it about two inches from its distal end. The membrane braces the two bones together in such a manner that forces, passing proximally through the radius, are transmitted from the radius to the ulna; and it extends the surface of origin for the muscles of the forearm. By its volar surface it gives origin to the flexor digitorum profundus and the flexor pollicis longus muscles, whilst from its dorsal surface spring fibres of the two extensor muscles of the thumb, the abductor pollicis longus, and the extensor indicis proprius.

**Chorda Obliqua (O.T. Oblique Ligament).**—The oblique cord is a weak band of fibres which springs from the tuberosity of the ulna. It extends obliquely, distally and laterally, to find its attachment to the radius, immediately distal to the tuberosity of that bone. It crosses the open space between the bones of the forearm proximal to the proximal border of the interosseous membrane. The oblique cord is often absent; and unless the utmost care is taken in removing the adjacent muscles it is apt to be injured.

**Movements at the Radio-ulnar Joints.**—The movements of pronation and supination take place at the radio-ulnar joints. When the limb is in a condition of complete supination the thumb is directed laterally, the two bones of the forearm are parallel, the radius lying along the lateral side of the ulna. In the movement of pronation the radius is thrown across the ulna, so that its distal end comes to lie across the volar surface and on the medial side of the ulna. Further, the hand moves with the radius, and when the movement is completed the dorsal aspects of the hand and the forearm are directed forwards, and the thumb is turned medially.

The dissector should analyse, as far as possible in the part upon which he is engaged, the movements at the two radio-ulnar joints which produce these effects. At the same time it is to be remembered that results obtained from a limb in which the dissection has proceeded so far are apt to be deceptive. Therefore the dissector should use himself and his friends as subjects on which to study the movements.

In the case of the *proximal radio-ulnar joint* the movement is simple enough. The head of the radius merely rotates within the annular ligament, and accuracy of motion is obtained by the fovea capituli radii resting and moving upon the distal end of the humerus. It should

be noticed that the head of the radius does not fit accurately upon the capitulum in all positions of the elbow joint. In extreme extension and extreme flexion of the elbow it is only partially in contact with it. Therefore the semi-flexed condition of the elbow joint places the radius in the most favourable position for free and precise movement at the proximal radio-ulnar joint (Figs. 86, 87, 88, 91, 92, 93).

At the *distal radio-ulnar joint* the distal end of the radius revolves around the distal end of the ulna. It carries the hand with it, and describes the arc of a circle, the centre of which corresponds to the attachment of the articular disc to the distal end of the ulna. As the movement occurs the articular disc moves with the radius, and travels dorsally on the distal end of the ulna in supination, and towards the volar surface in pronation.

But the question may be asked, Does the ulna move during pronation and supination? When the elbow joint is extended to its fullest extent the ulna remains almost immovable. When, however, pronation and supination are conducted in the semi-flexed limb, the ulna does move. A small degree of lateral movement at the elbow joint is allowed, and the distal end of the ulna during pronation is carried slightly dorsally and laterally, and in the reverse direction during supination.

The *muscles* which are chiefly concerned in producing *supination* of the forearm are—the biceps brachii, the brachio-radialis and the supinator. They are aided by the long abductor and the long extensor of the thumb. The biceps brachii, from its insertion into the dorsal part of the tuberosity of the radius, is placed in a very favourable position, in so far as its supinating action is concerned. The muscles which act as *pronators* of the limb are—the pronator teres, the pronator quadratus, and, to a certain extent, the flexor carpi radialis. The pronator teres, from its insertion into the point of maximum lateral curvature of radius, can exercise its pronating action to great advantage. The balance of power is in favour of the supinators, on account of the preponderating influence of the biceps.

**Dissection.**—The annular ligament should be cut through, and the oblique cord and the interosseous membrane should be divided proximo-distally. By drawing the radius laterally and opening the capsule of the distal radio-ulnar joint, the proximal surface of the discus articularis of the wrist will be displayed and its attachments more fully appreciated.

#### ARTICULATIONES CARPEÆ (CARPAL JOINTS).

In the carpus two joints are recognised—

1. Articulatio ossis pisiformis.
2. Articulatio intercarpea.

**Pisiform Joint.**—The pisiform bone articulates with the volar surface of the triquetral bone, to which it is attached by an articular capsule. The cavity of the pisiform joint is quite distinct from those of the adjacent joints.

The dissector has previously noted that the tendon of the flexor carpi ulnaris is inserted into the pisiform bone, and as the capsule would be quite incapable by itself of with-

standing the strain to which this muscle subjects the articulation, certain accessory bands are provided which anchor the pisiform firmly in place—they are the piso-hamate and the piso-metacarpal bands. The former passes from the distal end of the pisiform to the hook of the hamate bone; and the latter attaches the pisiform to the proximal ends of the fourth and fifth metacarpal bones.

#### ARTICULATIO INTERCARPEA (INTERCARPAL JOINT).

The intercarpal joint has one joint cavity, but it includes not only the articulations between the proximal and distal

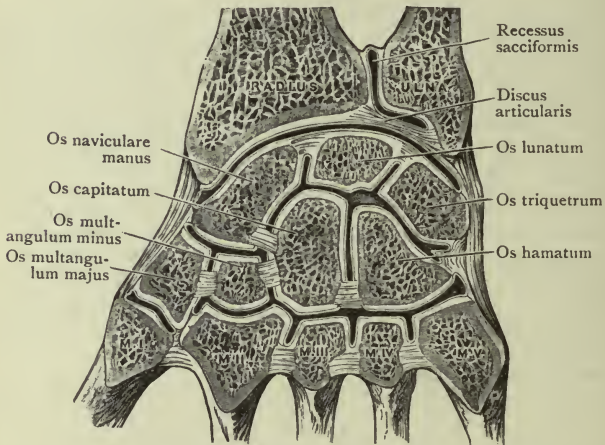


FIG. 97. — Frontal section through Radio-carpal, Carpal, and Carpo-metacarpal and Inter-metacarpal Joints to show Joint Cavities and Interosseous Ligaments (diagrammatic).

rows of carpal bones, which form the *transverse part* of the joint, but also the articulations between the bones of the proximal row and those between the bones of the distal row. The main part of the cavity of the joint lies between the proximal and distal rows; but two prolongations pass proximally, one between the lunate and navicular bones, and the other between the lunate and triquetral bones, and three diverticula are prolonged between the bones of the

distal row, beyond which they become continuous with the cavity of the carpo-metacarpal joint (Fig. 97).

The bones of the proximal row are connected together by two dorsal, two volar, and two interosseous ligaments, which pass from the lunate bone to the navicular and triquetral bones, which lie to either side of it. The two interosseous ligaments are composed of short, stout fibres which pass between the non-articular portions of the opposed surfaces of the bones. They are readily seen from the proximal aspect, where they complete the distal surface of the radio-carpal joint.

The members of the distal row of carpal bones are bound together by three dorsal, three volar, and three interosseous ligaments which pass transversely between the adjacent bones. The interosseous ligament between the capitate and the hamate bones is very strong; that between the capitate bone and the lesser multangular bone is weak and not uncommonly absent.

At present the interosseous ligaments between the bones of the distal row are hidden from view, but they can be studied when the transverse part of the intercarpal joint is opened.

The transverse part of the intercarpal joint lies between the proximal and distal rows of carpal bones. The two rows of bones are bound together by an articular capsule which is attached to the volar and dorsal surfaces and the medial and lateral borders of each row. The lateral and medial parts of the capsule are sometimes spoken of as the radial and ulnar ligaments of the transverse carpal joint. The volar and dorsal parts of the capsule are strengthened by numerous bands of fibres. The bands on the dorsal surface are irregular in number and strength, but those on the volar surface are better marked and, for the most part, they radiate from the capitate to the surrounding bones, forming the *ligamentum carpi radiatum*. One of the bands of this ligament passes from the capitate bone to the styloid process of the radius and blends with the radial collateral ligament of the radio-carpal joint.

**Articular Surfaces.**—The individual bones of the proximal row and the individual bones of the distal row articulate with one another by flat surfaces. In the transverse part of the intercarpal articulation the proximal parts of the capitate bone and the hamate bone form a high convexity which fits into a

concavity formed by the distal surfaces of the triquetral and lunate bones and the distal part of the medial surface of the navicular bone; and the convex distal surface of the navicular bone is received into a concavity formed by the proximal surfaces of the greater and lesser multangular bones. The two opposed surfaces of the transverse part of the joint are, therefore, concavo-convex from side to side, and adapted one to the other (Figs. 97, 98).

**Movements at the Carpal Joints.**—The movements at the carpal joints supplement those at the radio-carpal joint, and tend greatly to increase the range of movement at the wrist. Between the individual bones of each row the movement is of a gliding character, and very limited. At the transverse intercarpal joint volar and dorsal movements (flexion and extension) alone are allowed.

By the multiplicity of joints in this part of the limb, strength and elasticity are contributed to the wrist.

The nerve supply of the radio-carpal and intercarpal joints is derived from the median, ulnar, radial and musculo-cutaneous nerves.

**Dissection.**—The interosseous muscles should now be removed from the metacarpal bones. At the same time the flexor tendons and lumbrical muscles may be detached from the fingers. The extensor tendons, however, should be left in position on the dorsal surfaces of the metacarpo-phalangeal and interphalangeal joints. The ligaments which connect the carpus and metacarpus, and those which pass between the bases of the medial four metacarpal bones, should be cleaned and defined.

#### ARTICULATIONES INTERMETACARPEÆ (INTERMETACARPAL JOINTS).

The four metacarpal bones of the fingers articulate with one another by their basal or proximal extremities, and are united together by strong ligaments. The metacarpal bone of the thumb stands aloof from its neighbours, and enjoys a much greater freedom of movement.

The ligaments which bind the medial four metacarpal bones to each other are—

1. A series of *volar* and *dorsal* bands, which pass transversely and connect their basal extremities.

2. *Three stout interosseous ligaments*, which occupy the intervals between the basal ends of the bones.

3. The *transverse ligaments of the heads*, which connect the heads or distal extremities of the bones (p. 192). This ligament has been removed in the dissection of the interosseous muscles.

PLATE XVII

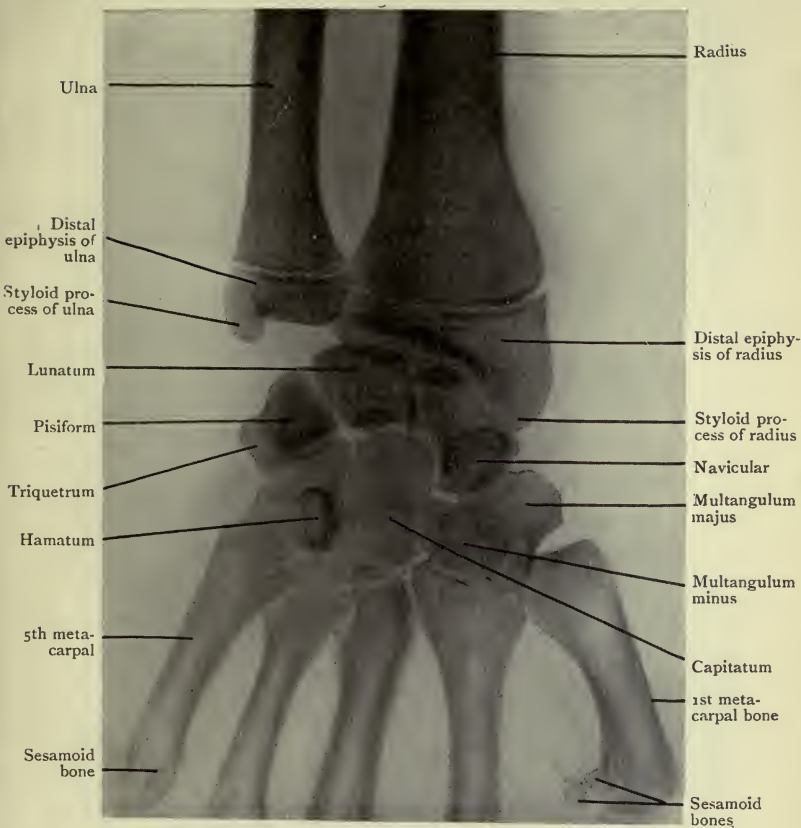
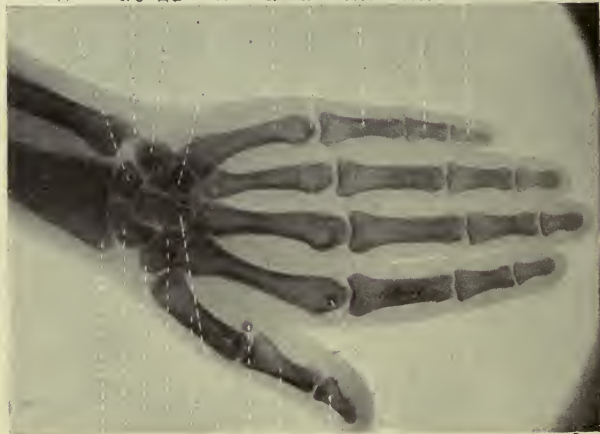

FIG. 98.—Antero-posterior Radiograph of the Wrist of a Person of 19 years.

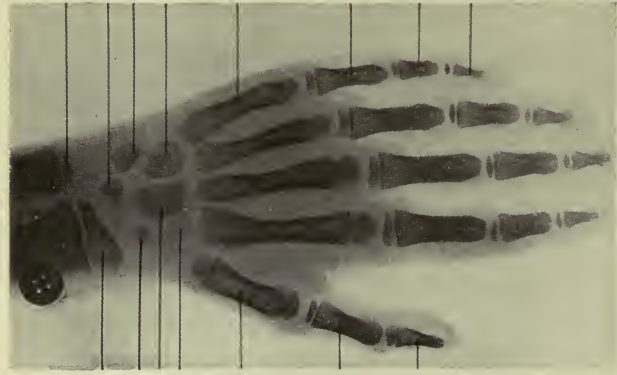- Note (1) The epiphyseal lines of the radius and ulna.  
 (2) The difference in level of the styloid process of the ulna as contrasted with the styloid process of the radius.  
 (3) The overlap of the shadows of adjacent bones.

PLATE XVIII



Styloid process of radius  
 Navicular  
 Multangulum majus minus  
 1st metacarpal  
 Capitulum  
 Sesamoid bone  
 Proximal phalanx  
 Distal phalanx  
 Sesamoid bone

FIG. 99. — Radiograph of the Bones of the Adult Wrist and Hand. (Dr. C. Goulesbrough),<sup>1</sup>



Lunatum  
 Styloid process of ulna  
 Pisiform and triquetrum  
 Hamatum  
 5th metacarpal  
 Sesamoid bone  
 Proximal phalanx  
 Middle phalanx  
 Distal phalanx

Distal epiphysis of radius  
 Navicular  
 Capitulum  
 Multangulum minus  
 1st metacarpal with proximal epiphysis  
 Proximal phalanx with proximal epiphysis  
 Distal phalanx with proximal epiphysis

Distal epiphysis of ulna  
 Lunatum  
 Triquetrum  
 Hamatum  
 5th metacarpal with distal epiphysis  
 Proximal phalanx with proximal epiphysis  
 Middle phalanx with proximal epiphysis  
 Distal phalanx with proximal epiphysis

FIG. 100. — Radiograph of the Wrist and Hand of a Child 5 years old. Note the epiphyses of the various bones and the absence of any trace of the multangulum majus.



The *interosseous ligaments* cannot be seen at present, but can be studied later when the bases of the metacarpal bones are separated from each other.

#### ARTICULATIONES CARPOMETACARPEÆ (CARPO-METACARPAL JOINTS).

The *metacarpal bone* of the *thumb* articulates with the greater multangular bone by a joint which is quite distinct from the other carpo-metacarpal articulations. An articular capsule surrounds the joint, and is sufficiently lax to allow a very considerable range of movement. On the dorsal and lateral aspects of the articulation it is specially thickened. Its cavity is distinct from that of the adjacent articulations.

The *medial four metacarpal bones* are connected to the carpus by *volar* and *dorsal ligaments*, and by *one interosseous ligament*.

Each of these metacarpal bones, with the exception of the fifth, possesses, as a rule, two dorsal ligaments and one volar ligament. The articulation of the fifth metacarpal bone is also closed on the medial side by ligamentous fibres.

The *interosseous ligament* springs from the contiguous distal margins of the capitate and hamate bones, and passes to the medial side of the base of the third metacarpal bone.

**Dissection.**—To display the interosseous ligament, divide the bands which connect the bases of the third and fourth metacarpal bones, and sever the dorsal ligaments which bind the medial two metacarpal bones to the carpus. The metacarpal bones thus set free can then be forcibly bent volarwards, when the ligament in question will come into view.

**Synovial Membranes of the Carpal, Carpo-metacarpal, and Intermetacarpal Joints.**—The articulation between the pisiform and the triquetral bones and the carpo-metacarpal joint of the thumb both possess separate capsules; but the various ligaments of the intercarpal, carpo-metacarpal, and proximal intermetacarpal joints, though they are spoken of individually as separate ligaments, constitute collectively a single capsule, which surrounds a continuous joint cavity. The synovial stratum of the capsule is prolonged over all parts of the bones, enclosed within the capsule, which are not covered by articular cartilage, and it is continued proximally between the three bones of the proximal row of the carpus as far as the interosseous ligaments which connect the bones together. It covers the distal surfaces of those ligaments and is

excluded by them from the radio-carpal joint. It passes also between the four bones of the distal row of the carpus and covers the inner surfaces of the ligaments of the carpo-metacarpal joints and the ligaments of the medial four intermetacarpal articulations.

In some cases the interosseous ligament which connects the base of the third metacarpal to the capitate and hamate bones shuts off the articulation of the hamate bone with the medial two metacarpal bones, and converts the articulation of the hamate bone with the medial two metacarpal bones into a separate segment of the carpo-metacarpal joint.

**Dissection.**—To display the articular surfaces of the carpo-metacarpal articulations, the metacarpus should be detached from the carpus. The interosseous ligaments between the carpal bones of the second row, and also between the bases of the medial four metacarpal bones, can likewise be demonstrated by carrying the knife between the bones, and dividing the ligaments.

**Articular Surfaces.**—The base of the metacarpal bone of the index will be seen to be hollowed out for the reception of the lesser multangular bone. On the lateral side it also articulates with the greater multangular bone, and on the medial side with the capitate bone. The base of the third metacarpal rests against the capitate bone alone. The base of the metacarpal bone of the ring finger rests upon the hamate bone, but articulates slightly with the capitate bone also. The fifth metacarpal bone articulates with the hamate bone (Figs. 73, 77, 98, 99, 100).

**Movements of the Metacarpal Bones.**—The opposed saddle-shaped surfaces of the greater multangular bone and the metacarpal bone of the thumb allow free movement at that joint. Thus the metacarpal bone of the thumb can be moved—(1) dorso-laterally (extension); (2) volarwards and medially (flexion); (3) medially towards the index (adduction); (4) laterally (abduction); (5) medially across the palm towards the little finger (opposition); (6) a combination of the above-mentioned movements, occurring one after the other, constitutes circumduction. The muscles which operate on the thumb are—(1) the two special extensors, brevis and longus, and the abductor pollicis longus, producing extension; (2) the flexor pollicis brevis, the opponens pollicis, and the adductor pollicis, producing flexion and opposition, two movements which are similar in character; (3) the abductor pollicis longus and the abductor pollicis brevis, producing abduction; (4) the adductor pollicis and the first dorsal interosseous muscle, which give rise to adduction.

The metacarpal bones of the index and middle fingers possess very little power of independent movement. The metacarpal bone of the ring finger, and more especially the metacarpal bone of the little finger, are not so tightly bound to the carpus. When the hand is clenched they both

move volarwards. The metacarpal bone of the little finger is provided with an opponens muscle, and has a feeble power of moving volarwards and laterally towards the thumb.

The carpo-metacarpal and intermetacarpal joints are supplied by the radial, ulnar and median nerves.

ARTICULATIONES METACARPOPHALANGÆ ET DIGITORUM  
(METACARPO-PHALANGEAL AND INTERPHALANGEAL JOINTS).

The ligaments which connect the metacarpal bones with the phalanges and those which connect together the phalanges of adjacent rows are practically similar in character although the joints belong to different groups. The ligaments of each joint are:—

1. Capsula articularis.
2. Lig. accessorium volare.
3. Ligg. collateralia.

**Capsula Articularis.**—The fibrous stratum of the articular capsule is blended, on the volar aspect, with the accessory volar ligament and at the sides with the collateral ligaments. Dorsally it is absent, and there the synovial stratum of the capsule lies in direct relation with the extensor tendon or tendons which cross the joint.

**Ligamentum Accessorium Volare.**—The volar accessory ligament is a strong fibrous plate which is firmly attached to the volar aspect of the base of the distal bone of the joint. It extends proximally over the volar aspect of the head of the proximal bone of the joint and is loosely attached to its neck. Its margins are connected with the collateral ligaments and with the fibrous flexor sheath of the finger. The volar surfaces of the volar accessory ligaments of the metacarpophalangeal joints are grooved by the flexor tendons and they are connected with one another by the transverse ligament of the heads of the metacarpal bones. Two sesamoid bones are usually developed in the volar accessory ligaments of the metacarpophalangeal joint of the thumb and not uncommonly sesamoid bones are found in the corresponding ligaments of other metacarpophalangeal joints (Figs. 98, 99).

**Dissection.**—The extensor tendons should now be raised from the dorsal surfaces of the metacarpophalangeal joints. If this is done carefully the dorsal part of the capsule of each joint will be left intact. It is very thin, and consists, practically,

of the synovial stratum only, the protection afforded by the extensor tendon rendering the presence of the fibrous stratum unnecessary.

**Movements of the Metacarpo-phalangeal Joints.**—In each metacarpo-phalangeal joint the single concavity at the proximal end of the first phalanx articulates with the rounded distal extremity or head of the metacarpal bone. The joints are condyloid joints, therefore the movements which occur at them are: (1) flexion, (2) extension, (3) abduction, (4) adduction, (5) circumduction.

During flexion of the fingers the first phalanx travels volarwards with the thick accessory volar ligament upon the head of the metacarpal bone. The *interosseous* and *lumbrical* muscles are chiefly instrumental in producing this movement, but they are aided by the long and short flexors of the digits.

The first phalanges of the fingers, in the movement of extension, can be carried dorsally only to a very slight degree beyond the line of the metacarpal bones. The *extensor communis* and the *special extensors* of the *index* and *little finger* are the muscles which operate in this case.

Abduction and adduction are movements of the first phalanx away from and towards a line prolonged distally through the middle finger, and are seen when the fingers are spread out and again drawn together. The *abductor digiti quinti* and the *dorsal interosseous muscles* act as abductors of the fingers, whilst the *volar interosseous muscles* operate as adductors of the little, ring, and index fingers. In the case of the middle digit, the *second* and *third dorsal interosseous muscles* act alternately as abductors and as adductors. In connection with the movements of abduction and adduction, it should be noticed that in the extended position of the fingers they are very free; but if flexion is induced, the power of separating the fingers becomes more and more restricted, until it becomes lost when the hand is closed. An examination of the collateral ligaments will afford the explanation of this fact. They "are attached so far dorsally on the metacarpal bones, as to be much nearer to their distal ends than to their volar aspects" (Cleland). Consequently, while they are comparatively lax in the extended position of the fingers, the further flexion advances the tighter they become, and in this way they interfere with the lateral movements of the first phalanges.

The first phalanx of the thumb has only a limited range of movement at the metacarpo-phalangeal joint.

**Movements of the Interphalangeal Joints.**—The interphalangeal joints are hinge joints, therefore the only movements possible are flexion and extension. Flexion of the second phalanges of the fingers is brought about by the flexor sublimis, and of the ungual phalanges by the flexor profundus. Extension of the phalanges at the interphalangeal joints is produced not only by the extensors of the digits but also by the interosseous and lumbrical muscles acting through the extensor expansions, into which they are inserted. The interossei and lumbricals, therefore, flex the first phalanges at the metacarpo-phalangeal joints and extend the second and ungual phalanges at the interphalangeal joints.

In the case of the thumb, the flexor pollicis longus and the extensor pollicis longus operate at the interphalangeal joint.

Some of the metacarpo-phalangeal joints and interphalangeal joints are supplied by the median and some by the ulnar nerve.

PLATE XIX

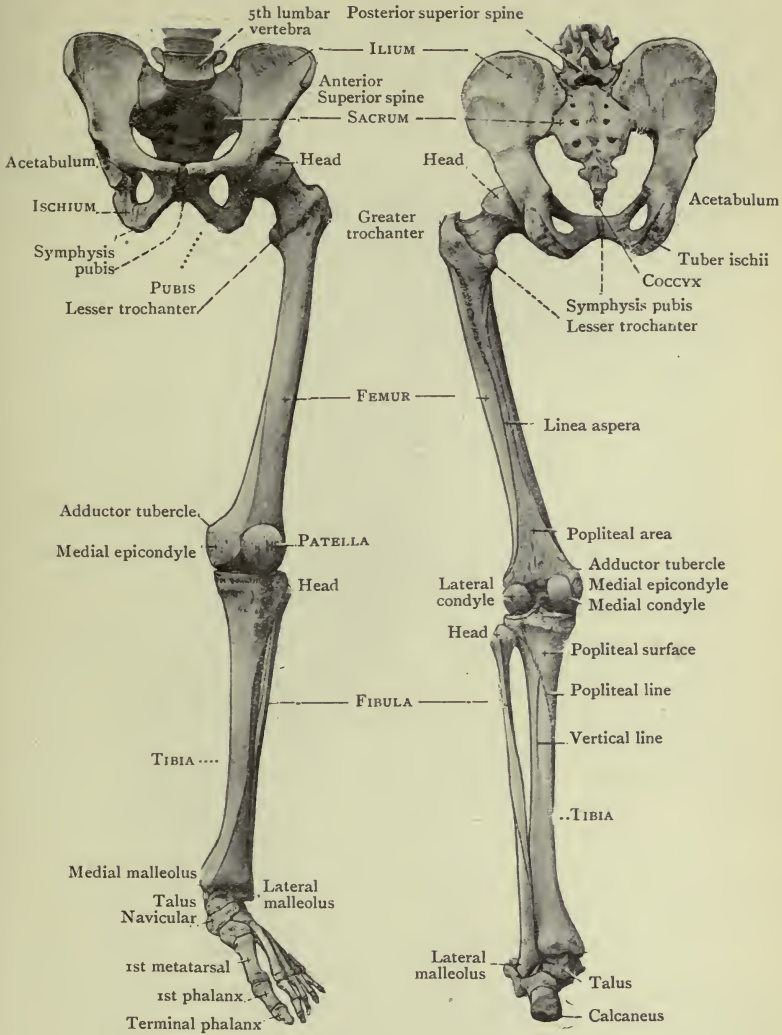


FIG. 101.—Bones of Inferior Extremity.

A. Anterior view.

FIG. 102.—Bones of Inferior Extremity.

B. Posterior view.

PLATE XX

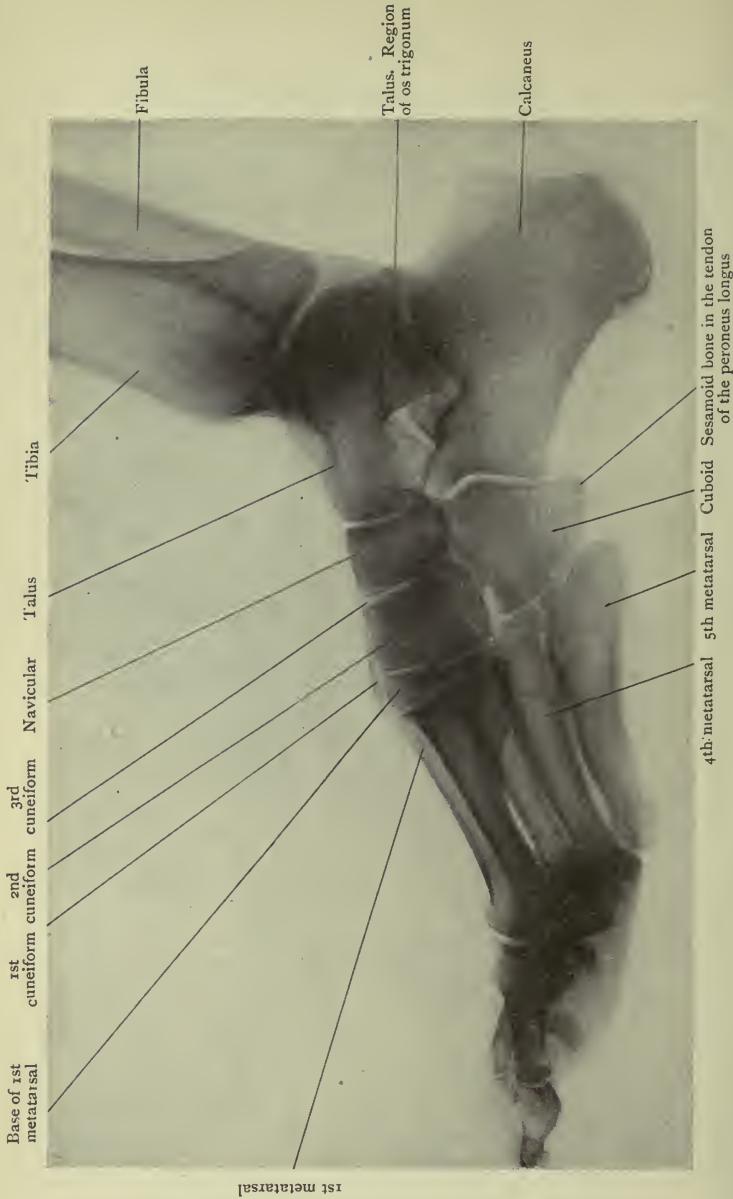

FIG. 103.—Radiograph of the Foot of an adult.  
(Major T. Rankine.)

## INFERIOR EXTREMITY.

**Introduction.**—Before commencing the dissection the student should be familiar with the bones of the region to be dissected and with the surface markings which indicate the positions of the structures which are to be displayed. He should also possess a general knowledge of the constitution and distribution of a spinal nerve.

The bones of the inferior extremity are : The *os coxæ* or hip bone ; the *femur* or thigh bone ; the *patella* or knee-cap ; the *tibia* and *fibula*, which are the bones of the leg ; seven *tarsal* and five *metatarsal bones*, which are the bones of the foot ; and fourteen *phalanges*, which are the bones of the toes, three for each except the great toe, which has only two phalanges (Figs. 101, 102, 103).

The *os coxæ* or hip bone lies in the lower part of the trunk. It is jointed posteriorly to the vertebral column, whilst in front it meets its fellow of the opposite side in the median plane, at the *symphysis pubis*. The upper part of the *os coxæ* is called the ilium. Its highest part forms a curved ridge, the *crest of the ilium*, which is easily felt at the side of the body and is a little below the level of the elbow when the arm hangs by the side. The posterior end of the crest of the ilium is the *posterior superior spine of the ilium*. The anterior end of the crest is the *anterior superior spine of the ilium*.

The lower and posterior part of the *os coxæ*, upon which the body rests in the sitting posture, is the *ischium* ; it is a landmark of importance when the posterior part of the inferior extremity is being dissected.

The lower and front part of the *os coxæ* is the *pubis*. It meets its fellow of the opposite side, in the median plane, at the symphysis pubis, where it is easily felt. From the upper end of the symphysis pubis a ridge, called the *crest of the pubis*, runs laterally and terminates in a projection termed the *pubic tubercle*.

A faint groove, called the *inguinal sulcus*, extends from the pubic tubercle to the anterior superior spine of the ilium. It indicates the separation between the lower or inguinal region of the trunk and the upper or subinguinal region of the front of the thigh. If pressure is made along the line of the inguinal sulcus, elastic resistance will be felt ; it is due to

a fibrous band called the *ligamentum inguinale* (Poupartii), which is attached medially to the pubic tubercle and laterally to the anterior superior spine of the ilium.

The finger should now be carried, downwards, along the symphysis pubis to its lower margin, which is at the apex of the *pubic arch*. From its apex the pubic arch must be traced laterally and backwards. It is formed by the rami of the pubis and ischium, and it terminates posteriorly at the *tuber ischiadicum*, which is the protuberant inferior end of the ischial part of the os coxæ. The pubic arch marks the superior boundary of the medial side of the thigh, which is called the *medial femoral region*.

Between the region of the hip and the knee lies the region of the *thigh*, which is the proximal segment of the free part of the inferior extremity. The bone of the thigh is the *femur*. It articulates proximally with the lateral aspect of the os coxæ at the junction of the three segments of that bone, and distally it articulates with the *tibia*, which is one of the bones of the leg, and with the *patella* or knee-cap (Fig. 101).

In the greater part of its extent the femur is deeply embedded amidst the muscles of the hip and thigh and cannot easily be felt, but two parts of its proximal end can be distinguished, viz., the head of the femur and the greater trochanter. If pressure is made below the middle of the inguinal sulcus whilst the thigh is rotated, the rounded *head of the femur* can be distinguished as it moves in the cavity of the hip joint. A more readily felt portion of the proximal end of the femur is the prominent projection called the *greater trochanter*. It lies about ten centimetres (4 inches) below the iliac crest, on a level with the pubic crest, and its highest point is crossed by a line drawn from the anterior superior spine of the ilium to the inferior end of the tuberosity of the ischium. The position of the greater trochanter is indicated, on the surface, by a prominence due to the projection of the bone, and the region of the prominence is the *trochanteric region*. The area between the trochanteric region and the crest of the ilium is the *region of the hip*. The lateral part of the thigh, distal to the trochanteric region, is the *lateral femoral region*.

At the distal end of the anterior part of the thigh is the *regio genu anterior*. In the middle of the region lies the patella. The outline of the patella can be seen as well as



felt. When the knee is straight (extended) the extensor muscles of the anterior part of the thigh are relaxed and the patella is freely movable; it lies on the front of the distal end of the femur. As the knee is bent the patella moves off the front of the femur and passes into contact with its distal surface; then the patellar surface on the front of the distal end of the femur can be felt beneath the skin (Figs. 183, 184, 185). The patellar surface is formed by the fused anterior parts of the two condyles which constitute the expanded distal extremity of the femur. The *lateral condyle* lies at the distal end of the lateral femoral area. It is easily palpated, and upon its lateral surface, nearer the posterior than the anterior end, a small rounded eminence can be distinguished; it is the *lateral epicondyle*. The *medial condyle*, which lies at the distal end of the medial femoral region, is more prominent than the lateral condyle. Near its posterior end the large rounded *medial epicondyle* is very obvious to the touch. Above the medial epicondyle, on the upper border of the condyle, is a much smaller and less easily felt prominence, the *adductor tubercle*, so called because the tendon of a muscle called the adductor magnus is attached to it (Figs. 101, 102).

Immediately distal to the condyles of the femur are the *condyles of the tibia*, and below them, in front, is the *tuberosity of the tibia*. Extending from the patella to the tuberosity of the tibia is a thick, broad band called the *ligamentum patellæ*, which is most easily felt when the knee joint is half bent. Immediately distal to the posterior part of the lateral condyle of the femur, on the same horizontal plane as the tuberosity of the tibia, lies the *head of the fibula*. The rounded tendon descending to it, from the thigh, is the tendon of the *biceps femoris*.

Between the knee and the ankle lies the *region of the leg*. In it there are two bones, the *tibia* and the *fibula*. The tibia is the more medial, the more anterior, and much the stronger and more massive of the two bones. It lies immediately beneath the skin and extends the whole way from the knee to the ankle, where it terminates, on the medial side of the ankle, in a visible projection, called the *medial malleolus*. Its anterior border is *the shin*; it is easily traced from the tuberosity of the tibia to the anterior border of the medial malleolus. The proximal end of the tibia articulates by its condyles with the condyles of the femur at the knee joint. Its distal end

articulates at the ankle with a bone of the foot called the *talus*. Unlike the tibia, the fibula is deeply situated in the greater part of its length, but its proximal end, the *head* of the fibula, is easily felt immediately below the posterior part of the lateral condyle of the tibia; its distal end, which is called the *lateral malleolus*, is also superficial, and forms a prominent visible projection on the lateral side of the ankle. The fibula takes no part in the formation of the knee joint, for its proximal end reaches only to the lateral condyle of the tibia with which it articulates. Its distal end articulates with the lateral surface of the distal end of the tibia and with the lateral surface of the talus; it enters therefore into the formation of the ankle joint (Figs. 101, 102, 103).

The region below the ankle joint is the foot. In it are seven *tarsal bones*, five *metatarsal bones*, and fourteen *phalanges*. The tarsal bones form the skeleton of the posterior half of the foot; the metatarsal bones are situated in the anterior half of the foot; they are numbered one to five from the medial to the lateral side. The phalanges are in the toes; two in the great toe, and three in each of the other toes.

Each of the tarsal bones is named. The highest of the group, the *talus*, takes part in the formation of the ankle joint, where it lies directly below the tibia, wedged between the malleoli of the tibia and the fibula. It articulates therefore with both the bones of the leg. Its anterior part, the *head*, can be felt below the tibia and in front of the lateral malleolus. The inferior surface of the talus rests upon the *calcaneus*, which projects backwards, behind the malleoli, to form the prominence of the heel. The strong tendon which descends in the back of the leg to the prominence of the heel is the *tendo calcaneus*. In front of the talus, in the medial part of the foot, is the *os naviculare*. Its tuberosity, which is an important landmark, can be felt about 25 mm. (*one inch*) in front of the tip of the medial malleolus (Fig. 103).

In front of the navicular lie the three *cuneiform* bones, first, second, and third from the medial to the lateral side. The first can be felt in front of the tuberosity of the navicular. The other two can be recognised by pressure applied in the dorsum of the foot, but they are not easily distinguished in the undissected foot. In the lateral border of the foot, in front of the calcaneus, is the last of the seven tarsal bones, the *cuboid*. It is difficult to palpate, but immediately in front

of it, about seven and a half centimetres anterior to the lateral malleolus, is the prominent posterior end of the fifth metatarsal bone, and the joint between the posterior surface of the cuboid and the anterior end of the calcaneus is about midway between the lateral malleolus and the posterior end of the fifth metatarsal (Fig. 103).

All the metatarsal bones can be felt from the dorsum of the foot, but the large first and the fifth are the most easily distinguishable. The first lies in the medial border of the foot between the first cuneiform and the first phalanx of the great toe. The second and third lie respectively between the second and third cuneiform and the first phalanges of the second and third toes. The fourth and fifth extend from the cuboid behind to the first phalanges of the fourth and fifth toes respectively.

All the above-mentioned points can be verified by the dissector upon his own person whilst he is waiting to commence the dissection of his "part."

Since many students commence dissecting before they have attended lectures or demonstrations on anatomy, they are unacquainted with terms which must be used in the instructions given regarding the dissections which are to be made. Fortunately most of the terms used refer to things which can be seen and felt. They, therefore, are easily understood. There are, however, certain terms used when branches of spinal nerves are under consideration which are not self-explanatory, and it is necessary, therefore, that the student should possess a knowledge of the terms used in connection with spinal nerves before the actual work of dissection is commenced. The following points should be noted: (1) Every spinal nerve is attached to the spinal medulla (spinal cord) by two roots, an *anterior* and a *posterior*; (2) as they are leaving the vertebral canal through an intervertebral foramen the two roots unite to form a *nerve trunk*; (3) immediately after its exit from the intervertebral foramen the trunk breaks up into a *posterior ramus* and an *anterior ramus*, of which except in a few cases the posterior is the smaller; (4) each posterior ramus divides into a *medial branch* and a *lateral branch*; (5) each anterior ramus divides into a *lateral branch* and an *anterior branch* (Fig. 4, p. 6).

Every anterior root consists of nerve fibres passing from

nerve cells in the spinal medulla to the fibres of the muscles; they carry motor impulses to the muscles. Each posterior root consists of nerve fibres passing to and from the nerve cells in the ganglion of the root. The fibres of the posterior root convey sensory impulses—pain, heat, cold, etc. The sensory impulses pass through the nerve cells of the ganglion and then onwards to the spinal medulla. The trunk of every spinal nerve, therefore, contains both motor and sensory nerve fibres, and the posterior and anterior rami into which it divides also contain both motor and sensory fibres. The branches of the rami may contain both motor and sensory rami or one or the other only; eventually, however, the peripheral parts of the fibres conveying impulses from the spinal medulla and those conveying impulses to the spinal medulla separate from one another. Every nerve consists of one or more fibres. The fibres which convey impulses from the spinal medulla become the motor nerves which end in muscle fibres, whilst the fibres which convey impulses to the spinal medulla are the sensory nerves, and those sensory nerves which carry impulses from the skin are called cutaneous nerves.

### THE THIGH.

On the morning of the fourth day after the subject has been brought into the dissecting room, it is placed upon the table lying upon its back; the pelvis is supported by two blocks, and the inferior extremities are stretched out at full length. In this position it is allowed to remain for five days, and during that period the dissector of the inferior extremity has a very extensive dissection to perform. He has to dissect (1) the anterior region of the thigh, including the *trigonum femorale* and its contents, (2) the medial region of the thigh, including the adductor canal and its contents. With so much work to be completed, within a limited time, he must apportion the five days to the best advantage. During the first day he should dissect the superficial structures of the whole of the anterior and medial aspects of the thigh. During the second and third days he should complete the dissection of the *femoral triangle* and the anterior region of the thigh, and the remainder of the period should be devoted to the dissection of the medial region.

**Surface Anatomy.**—Before making the preliminary incisions

in the skin the dissector must verify the positions of the most

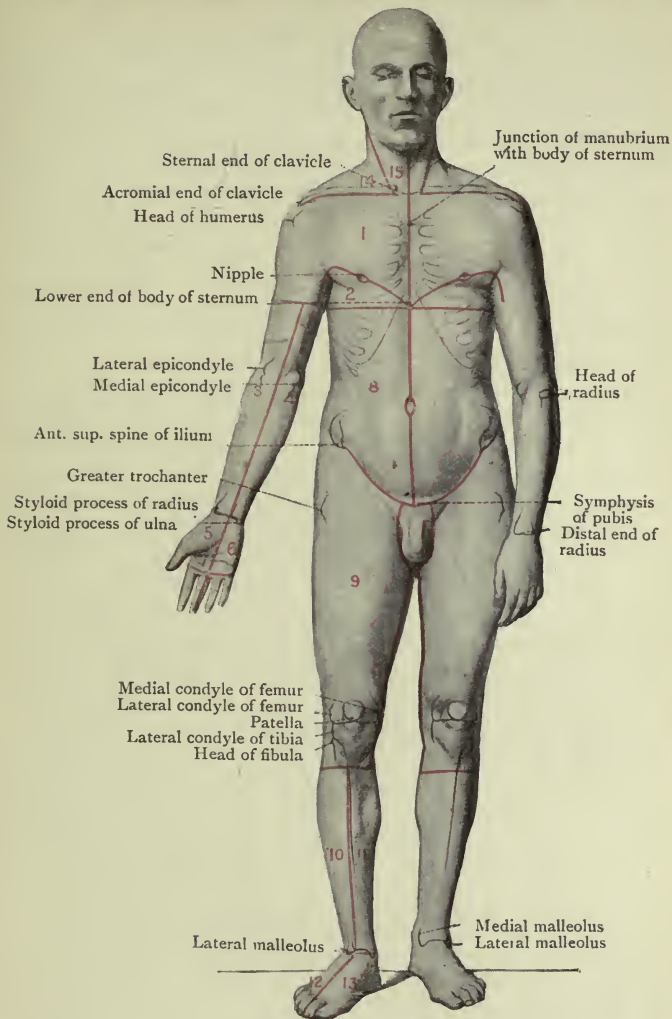


FIG. 104.—Anterior Surface of Body.

prominent landmarks of the anterior, medial, and lateral femoral regions and of the anterior region of the knee.

A faint sulcus at the proximal extremity of the *anterior region* is the boundary line between the *inguinal region* of the abdomen and the *subinguinal region* of the thigh. The resistance felt deep to the sulcus is due to the *ligamentum inguinale*, which is attached, at the lateral and superior end of the sulcus, to the *anterior superior iliac spine*, and, at its inferior and medial end, to the *pubic tubercle*. From the anterior superior iliac spine the *iliac crest* can be traced backwards to the posterior superior spine; from the pubic tubercle the finger should be carried medially, along the *pubic crest*, to the upper end of the *symphysis pubis*. Next, the finger should be passed downwards, along the front of the *symphysis pubis*, to the apex of the *pubic arch* and thence downwards and backwards along the *rami* of the *pubis* and *ischium*, which mark the superior boundary of the *medial femoral region*, to the *tuber ischiadicum*. About ten centimetres below the highest part of the iliac crest, and on the plane of the pubic crest, is the *trochanteric region*, indicated by an eminence due to the prominence of the trochanter major of the femur. Above the trochanteric region, and between it and the iliac crest is the *region of the hip* (*regio coxæ*), and below the trochanteric region is the *lateral femoral region*. At the distal end of the anterior part of the thigh is the *regio genu anterior*. In the centre of the anterior part of the knee lies the *patella* or knee-cap, the outline of which can be seen as well as felt. From the distal end of the patella the *ligamentum patellæ* should be followed to the tuberosity of the tibia.

At the distal end of the lateral region of the thigh the outline of the *lateral condyle* of the *femur* is easily recognised. Directly distal to it is the *lateral condyle* of the *tibia*, and at the distal and posterior part of the latter is the head of the fibula. The tendon which can be traced proximally from the head of the *fibula*, on the border line between the lateral and posterior femoral regions, is the tendon of the *biceps femoris*; and the dense, longitudinal band of fascia immediately anterior to the tendon of the biceps is the *ilio-tibial tract* of the fascia lata—a fascial band which is more easily distinguishable in the living than in the dead body.

At the distal end of the medial part of the thigh is the outline of the *medial condyle* of the *femur*, which should be palpated; and immediately distal to it the *medial condyle* of the *tibia* is easily recognised beneath the integument.

The tendons behind the medial condyle of the femur are more easily felt in the living than the dead body; they are the tendons of the *semitendinosus* and *semimembranosus* muscles. The less easily palpated tendon of the *adductor magnus* should be distinguished as it descends to the proximal border of the medial femoral condyle.

The dissector should verify all these points of surface anatomy not only on the dead body but also on the bodies of himself and his friends, and he should examine them repeatedly until he is quite familiar with them both by sight and by touch.

#### THE ANTERIOR FEMORAL AND MEDIAL FEMORAL REGIONS AND THE ANTERIOR REGION OF THE KNEE.

**Superficial Dissection.**—This dissection comprises the examination of the following parts:—

1. Superficial fascia.
2. The great saphenous vein and its tributaries.
3. The superficial external pudendal artery.
4. The superficial epigastric artery.
5. The superficial circumflex iliac artery.
6. Lymph glands and vessels.
7. The fossa ovalis.
8. Cutaneous nerves.
9. The fascia femoris (deep fascia of the thigh).
10. The bursæ patellæ.

**Dissection.**—Reflection of the Skin.—*Incisions.*—(1) From the anterior superior iliac spine along the line of the inguinal ligament to the symphysis pubis; (2) from the medial extremity of the first incision downwards along the margin of the scrotum, then along the junction of the medial with the posterior aspect of the thigh and across the medial aspect of the knee to the level of the tuberosity of the tibia; (3) from the distal end of the vertical incision transversely across the anterior surface of the leg to its lateral border. The quadrilateral flap of integument, thus mapped out (9, Fig. 104), must be raised carefully from the subjacent superficial fascia and turned laterally, particular care being taken in the region of the knee to avoid injury to the patellar plexus of cutaneous nerves.

To make a *clean incision* through the skin hold the scalpel at right angles to the surface and force the point through the skin into the subjacent soft superficial fascia at the point of commencement of the incision, then incline the blade to an angle of forty-five degrees and, pressing firmly on the back of the blade with the forefinger, draw it along the line of incision. When the opposite end of the incision is reached bring the scalpel to a right angle with the surface again and withdraw it.

To *reflect the skin* take hold of the most convenient angle of the flap—the upper or the lower medial angle in the present dissection—with the forceps, and with the edge of the scalpel detach it from the soft fat beneath.

As soon as the angle selected is sufficiently detached discard the forceps, seize the detached angle between the thumb and forefinger of the left hand, and pull it away from the fat, keeping it stretched and tense; then draw the edge of the scalpel across the skin, at its junction with the fat, from one edge of the flap to the other, always keeping the edge of the knife against the skin. If the work is done properly the leathery-looking deep surface of the skin will be entirely freed from fat, as the flap is reflected, and the superficial nerves and vessels which lie in the fat will not be injured. When the skin is reflected the superficial fascia is exposed.

**Superficial Fascia (Panniculus Adiposus).**—The superficial fascia is found over the whole surface of the body. It varies in structure in different parts, but in all parts, with the exception of the region of the scrotum, it contains a greater or a smaller amount of yellowish fat, the amount varying not only with the part under consideration but also with the general obesity or thinness of the subject. In some regions, such as the anterior part of the neck and the adjacent part of the chest, reddish muscle fibres are present in the deeper part of the fat; in the scrotum the muscle fibres entirely replace the fat. The fat is interspersed and divided into lobules by lamellæ of denser tissue called *fibrous tissue*, and in the deeper part of the superficial fascia the fibrous tissue becomes more predominant, forming a membrane which is the deeper or membranous layer of the superficial fascia. In the superficial fascia lie the cutaneous vessels and nerves and the deeper parts of the hair follicles and skin glands and the superficial lymph glands. Under the superficial fascia is a more firm membranous layer, the *deep fascia*, surrounding the muscles and deeper parts.

The superficial fascia intervenes therefore between the skin and the deep fascia, and it is attached to both by fibrous strands which pass through the fat. As it lies between the skin and the deep fascia it provides a soft elastic cushion upon which the skin rests, and which, by its elasticity, allows the skin to be moved over the deeper parts. It rounds off the angularities of the deeper parts and forms a bed in which the cutaneous vessels and nerves ramify before they enter the skin.

In most parts of the body the laxity of the superficial



fascia allows the skin to be moved freely over the subjacent deep fascia, but in other situations, such as the palms of the hands and the soles of the feet, movement of the skin is limited because the fibrous septa which pass from the skin to the deep fascia are numerous and strong.

In the region now exposed the fat of the superficial fascia is usually abundant. And the membranous deeper layer is well

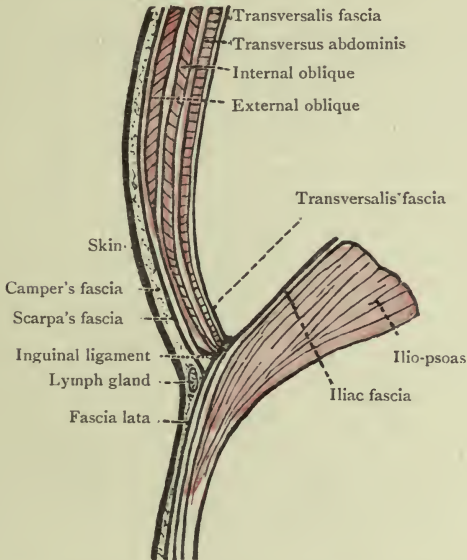


FIG. 105.—Diagram of the Fasciæ and Muscles of the Inguinal and Subinguinal Regions lateral to the Fossa Ovalis.

marked, especially in the proximal part of the region where the lymph glands and the superficial vessels lie between the two layers. Moreover, in the uppermost part of the region the deep membranous layer of the superficial fascia is closely attached to the deep fascia immediately distal to the line of the inguinal ligament, where it is continuous with the corresponding layer of the superficial fascia of the abdominal wall. This is a point of some practical importance, and to demonstrate it the dissectors of the inferior extremity and the abdomen must work in conjunction with each other. A

transverse incision must be made through the entire thickness of the superficial fascia on the front of the abdomen from the anterior superior spine of the ilium to the middle line of the body. When the lower edge of the divided fascia is raised its two layers are easily distinguished. The deeper membranous stratum is known as Scarpa's fascia (Fig. 105). Insinuate the fingers behind Scarpa's fascia between it and the pearly-looking tendon of the external oblique muscle. Little resistance will be encountered, for the fascia and the tendon are only connected by some fragile areolar tissue, and the fingers can be passed downwards as far as the inguinal ligament. At or immediately beyond the inguinal ligament the passage of the hand into the thigh is barred by the union of Scarpa's fascia with the deep fascia of the thigh, which is called the *fascia lata*. If the fingers are carried medially along the line of union of the two fasciæ, it will be found that the line of attachment descends across the front of the pubis to the rami of the pubis and ischium, that is, into the *region of the perineum*, which is the interval between the thighs. In the perineum the deep layer of the superficial fascia is no longer called Scarpa's fascia; it becomes Colles' fascia, and has definite connections, which will be studied by the dissector of the abdomen.

If urine or other fluid is effused into the anterior part of the perineum, it cannot get into the medial femoral region because of the attachment of the deep layer of superficial fascia to the rami of the pubis and ischium and to the front of the pubis, but it can ascend, in the areolar tissue between the deep layer of superficial fascia and the deep fascia, to the wall of the abdomen. Having reached the wall of the abdomen it cannot descend into the anterior femoral region because of the connection between the deep layer of the superficial fascia and the fascia lata at or a short distance distal to the inguinal ligament.

**Dissection.**—The dissection of the contents of the superficial fascia of the subinguinal and anterior femoral regions is one of the most difficult dissections which fall to the lot of the dissector of the inferior extremity. The structures to be displayed are. (1) Four veins—the great saphenous, the superficial external pudendal, the superficial epigastric, and the superficial circumflex iliac. (2) Three arteries—the superficial external pudendal, the superficial epigastric, and the superficial circumflex iliac. (3) The proximal and distal groups of subinguinal lymph glands and the lymph vessels which enter

and leave them. The proximal group lies parallel with the inguinal ligament, the distal group lies along the sides of the proximal part of the great saphenous vein. (4) Six nerves—the ilio-inguinal, the lumbo-inguinal, the lateral cutaneous nerve of the thigh, the intermediate cutaneous nerve of the thigh, the medial cutaneous nerve of the thigh, the saphenous nerve. The first three nerves mentioned are derived directly from a plexus of nerves inside the abdomen called the lumbar plexus and the last three are branches of the femoral nerve, which is itself a branch of the lumbar plexus. (5) The fossa ovalis. (6) The patellar bursa, and (7) the deep fascia of the thigh.

Commence by cleaning the great saphenous vein. It is easily found about the mid-length of the thigh, near the medial border. Cut down upon it there and then, with the point and handle of the scalpel, clean away the fascia from its walls, but do not injure its tributaries. Follow the vein, distally, to the posterior border of the medial side of the knee and, proximally, towards a point situated about 4 cm. below and lateral to the pubic tubercle.

As the proximal end of the vein is approached lift it from the bed of superficial fascia in which it lies; insert the handle of the scalpel behind the vein and push it upwards, until it slips through an opening in the fascia lata through which the vein passes on its way to join to the femoral vein. The opening in the fascia lata is the *fossa ovalis*. The layer of the deep fascia which covers the fossa ovalis is called the *cribriform fascia*. The centre of the opening is situated about 35-40 mm. distal and lateral to the pubic tubercle, and its distal margin is always easily demonstrated in the way already indicated. Do not attempt at present to display its other boundaries; they will be dissected later. When the proximal part of the vein is being cleaned a number of the more distal subinguinal lymph glands will be seen, some lying lateral and some medial to the vein. They are rounded or ovoid bodies of greyish or yellowish-pink colour, and they vary greatly in size, some being as small as a pin-head, others as large as a large bean. Connected with them the dissector will find a large number of fine white strands which are the lymph vessels passing to and from the glands. Clean the glands and some of the lymph vessels, but do not disturb them from their positions at present. Then proceed to clean the other superficial blood-vessels. They are the superficial external pudendal, the superficial epigastric, and the superficial circumflex iliac veins and arteries. Begin with the veins which terminate in the great saphenous vein before it passes through the fossa ovalis. Follow them from their terminations towards their commencements, and at the same time clean the accompanying arteries, which are branches of the femoral artery, but avoid injury to the superficial lymph glands which will be met with as the dissection proceeds. Two of the arteries, the superficial external pudendal and the superficial epigastric, emerge through the fossa ovalis: the superficial circumflex iliac artery will be found, as a rule, piercing the deep fascia lateral to the fossa. The lymph glands will be recognised by their firm consistence and their greyish or yellowish-pink colour.

If the subject is a male the dissector will have noted that as the superficial external pudendal vessels pass towards the symphysis pubis they cross superficial to a thick cord, the *funiculus spermaticus*, which emerges from the abdominal wall above the pubic tubercle, and descends across the upper and medial angle of the front of the thigh into the scrotum. In the female the round ligament of the uterus, which is less prominent and less easy to define, lies in the position occupied by the spermatic cord in the male. At the upper part of the lateral margin of the spermatic cord look for the ilio-inguinal nerve which leaves the abdomen with the spermatic cord and sends branches to the upper and medial part of the thigh (Fig. 107).

When the ilio-inguinal nerve has been secured clean the subinguinal lymph glands which lie along the line of the inguinal ligament, and trace some of the fine white lymph vessels which enter and leave them. The subinguinal lymph glands form two groups: a proximal group which lies parallel with the inguinal ligament and a distal group, already displayed, at the sides of the proximal part of the great saphenous vein. Many of them are usually of fairly large size; indeed they are so large that, as a rule, they can be felt easily through the skin in the living subject. They are recognised in the dissection, as already stated, by their firm consistence and their yellowish-pink colour (Figs. 105, 106).

After the lymph glands have been located and cleaned proceed to define the lateral and superior borders of the fossa ovalis (Fig. 106). Commence at its inferior border, which has already been displayed. Note that as the inferior border, which is called the *inferior cornu*, passes medially it blends with the upper part of the fascia lata which covers the muscles of the medial part of the front of the thigh; that part of the fascia is known as the pectineal part of the fascia lata to distinguish it from that part of the deep fascia which lies lateral to the fossa ovalis and is called the iliac part of the fascia lata.

The lateral end of the inferior cornu is continuous with the *falciform margin* of the fossa ovalis which curves upwards and medially to terminate in the *superior cornu*. The superior cornu bends medially as the superior margin of the fossa and is attached to the tubercle of the pubis and to the *ligamentum lacunare*, which is an expansion of the medial end of the inguinal ligament. The edge of the scalpel is needed to define the falciform margin and the superior cornu, for both are closely blended with the *cribriform fascia* which extends across the fossa from the falciform margin and superior cornu to the pectineal part of the fascia lata.

Clear away the cribriform fascia, dissecting out the arteries and lymph vessels which pierce it, and display behind it the anterior wall of the *femoral sheath*, a layer of fascia, which surrounds the femoral vessels. Insinuate the handle of the scalpel between the falciform margin and the femoral sheath to demonstrate their independence, then pass the handle of the scalpel behind the medial border of the femoral sheath to demonstrate the fact that the pectineal part of the fascia lata passes behind the femoral sheath.

After the relations of the margins of the fossa ovalis have been defined seek the remaining superficial nerves. Close to

the falciform margin of the fossa ovalis find the lumbo-inguinal nerve which pierces the fascia lata a short distance distal to the inguinal ligament. About 50 mm. (two inches) distal to the anterior superior spine of the ilium find the posterior branch of the *lateral cutaneous nerve of the thigh* as it pierces the fascia lata and 50 mm. more distally the anterior branch of the same nerve. About midway between the lateral cutaneous nerve and the great saphenous vein seek for the intermediate cutaneous nerve of the thigh, and along the anterior margin of the great saphenous vein, in the distal third of the thigh, look for the anterior branch of the medial cutaneous nerve of the thigh. Follow the lateral, the intermediate, and the medial cutaneous nerves towards the patella, where they join the *patellar plexus* (Fig. 107). Behind the great saphenous vein, near the knee, look for the posterior branch of the medial cutaneous nerve. Near the distal end of the medial femoral region in front of the great saphenous vein, find the infra-patellar branch of the saphenous nerve and trace it to the patellar plexus, then, at the posterior border of the medial side of the knee, behind the great saphenous vein, find the saphenous nerve itself as it pierces the deep fascia (Fig. 163).

**Superficial Inguinal Vessels.**—Three small arteries, termed the superficial epigastric, the superficial external pudendal and the superficial circumflex iliac, pierce the deep fascia of the thigh below the inguinal ligament, and radiate from each other for the supply of the lymph glands and integument of the subinguinal and inguinal regions. They all spring from the femoral artery immediately after it enters the thigh.

*Art. Pudenda externa superficialis.*—The *superficial external pudendal artery* passes forwards, through the fascia cribrosa, which is spread over the fossa ovalis, and runs medially and upwards across the spermatic cord. It supplies the skin of the scrotum and penis or labium majus (Fig. 106).

*Art. Epigastrica superficialis.*—The *superficial epigastric artery* also pierces the cribriform fascia, turns upwards and leaves the thigh by crossing the inguinal ligament about its middle. It is distributed chiefly to the skin on the front of the abdomen.

*Art. Circumflexa ilium superficialis.*—The *superficial circumflex iliac artery* pierces the fascia lata lateral to the falciform margin of the fossa ovalis. It is very small, and courses proximally and laterally, along the inguinal ligament, towards the anterior superior spine of the ilium (Fig. 106).

The *veins* which accompany these arteries converge towards the *fossa ovalis* and join the *great saphenous vein* before it pierces the fascia cribrosa.

**Lymph Glands and Vessels.**—The disposition of the superficial *subinguinal lymph glands* into two groups will now be evident—a proximal *subinguinal group* along the line of the inguinal ligament, immediately distal to the attachment of

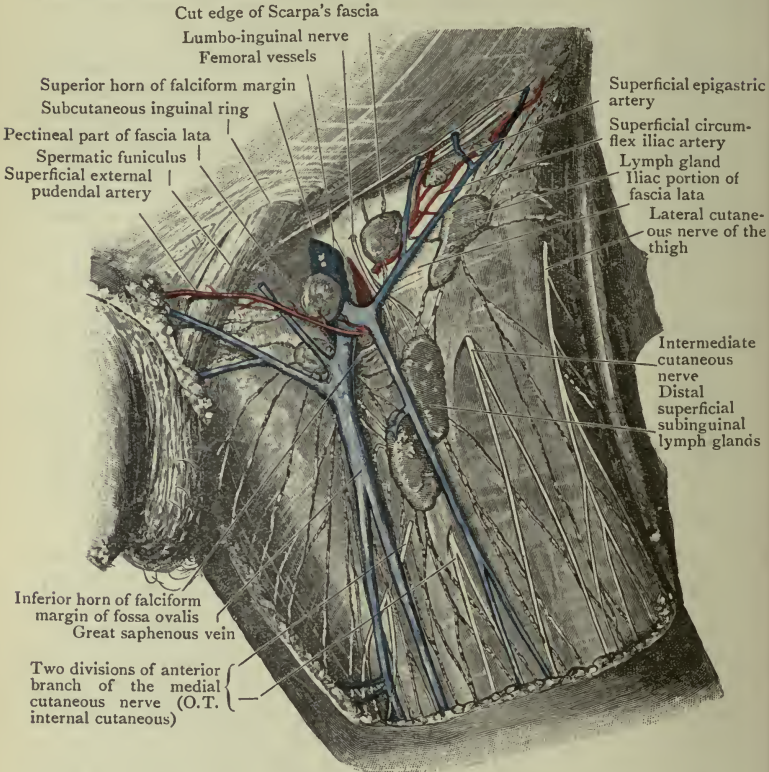


FIG. 106.—Superficial Dissection of the Proximal Part of the Front of the Thigh. The fossa ovalis (O.T. saphenous opening), the superficial lymph glands and vessels of the groin are displayed. The lymph vessels may be recognised by their beaded appearance.

Scarpa's fascia to the fascia lata, and a distal group, which extends for a short distance distally along the line of the great saphenous vein. Both groups are separable into medial and lateral parts.

In a spare subject, or, better still, in a dropsical subject, the

general arrangement of the lymph vessels may also be made out. To the subinguinal group of glands proceed the superficial lymph vessels of the lower extremity, and lymph vessels from the external genitals, the perineum, and the lower part of the abdominal wall. These are termed the *afferent vessels*. In addition to them, numerous other vessels connect the glands with one another. The lymph vessels which lead the lymph away from the glands are called the *efferent vessels*. A large number of them pass through the fossa ovalis, others pierce the fascia lata. They join the *deep subinguinal glands* and the external iliac glands, which lie in relation to the femoral and external iliac arteries (Figs. 159, 160).

**Fossa Ovalis.**—The fossa ovalis is an aperture in the deep fascia of the thigh, through which the great saphenous vein passes before it pierces the femoral sheath and joins the femoral vein. The fossa lies in the upper and medial angle of the front of the thigh, its centre being situated about 37 mm. lateral and distal to the pubic tubercle (Fig. 106). It is bounded, laterally, by a thin curved margin, the *margo falciformis*. The margo falciformis is the medial margin of the more lateral portion of the fascia lata, which, because it is attached to the inguinal ligament superficial to the iliacus muscle, and the anterior part of the iliac crest, is called the *iliac part of the fascia lata*. The proximal end of the margo falciformis is the *superior cornu* (Fig. 106). It turns medially to gain attachment to the pubic tubercle and to the ligamentum lacunare, and so forms the proximal boundary of the fossa. The distal end of the margo falciformis also turns medially, forming the *inferior cornu*, which lies posterior to the upper end of the great saphenous vein, on the medial side of which it terminates by blending with the *pectineal part of the fascia lata*, so called because it ascends superficial to the pectineus muscle to the pectineal line of the pubis (Figs. 106, 113). The manner in which the fascia lata surrounds the muscles of the proximal part of the inferior extremity, so that the iliac portion lies anterior to the femoral sheath and the pectineal portion passes posterior to the sheath, is shown in the section represented in Fig. 113.

The fossa ovalis is closed by the cribriform fascia, a thin stratum of the fascia lata which passes from the falciform margin and the cornua to the pectineal fascia. The cribriform fascia is pierced by the great saphenous vein, the

superficial external pudendal and superficial epigastric arteries, and by the efferent lymph vessels from the subinguinal glands on their way to join the deeper subinguinal glands, which lie in the femoral sheath.

**Vena Saphena Magna (O.T. Internal Saphenous Vein).—**

The great saphenous vein is the largest superficial vein of the inferior extremity. It commences on the dorsum of the foot, passes anterior to the medial malleolus and ascends through the leg across the medial surface of the distal third of the tibia, and then along the medial margin of the tibia. It enters the area of dissection at present under consideration at the level of the tuberosity of the tibia, ascends in the posterior part of the medial genicular region, then, inclining forwards and laterally, it passes upwards to the fossa ovalis, where it pierces the fascia cribrosa and the femoral sheath, and terminates in the femoral vein. In its course through the thigh it communicates through the deep fascia with the deep veins, and it receives the following tributaries: (1) The *lateral femoral circumflex vein*, from the anterior and lateral parts of the thigh. (2) The *medial femoral circumflex vein*, which commences at the back of the knee where it frequently communicates with the small saphenous vein. The medial femoral circumflex vein runs upwards, curves round the medial side of the thigh and joins the great saphenous vein mid-way between the hip and the knee. (3) The external superficial pudendal vein. (4) The superficial epigastric vein; and (5) the superficial circumflex vein. The last three tributaries join the great saphenous vein immediately before it passes through the fossa ovalis. There are several valves in the interior of the great saphenous vein which help to divide the column of blood into sections, and so reduce the pressure on the walls of the distal part of the vein.

**Nervi Cutanei.**—The cutaneous nerves met with in the area of the present dissection are:—

From the lumbar plexus,	$\left\{ \begin{array}{l} \text{Ilio-inguinal nerve.} \\ \text{Lumbo-inguinal nerve.} \\ \text{Lateral cutaneous nerve of the thigh.} \end{array} \right.$	
From the femoral nerve,		$\left\{ \begin{array}{l} \text{Intermediate cutaneous nerve of the thigh.} \\ \text{Medial cutaneous nerve of the thigh.} \\ \text{Saphenous nerve.} \end{array} \right.$

They have already been found and cleaned. Now their positions and distributions should be more fully studied.



**N. Ilio-inguinalis.**—The ilio-inguinal nerve escapes from the subcutaneous inguinal ring (O.T. ext. abdominal) in company with the spermatic funiculus. Most of its branches go either to the scrotum or to the labium majus, but some are distributed to the skin of the adjacent part of the thigh.

**N. Lumboinguinalis** (O.T. **Crural branch of Genito-crural**).—The lumbo-inguinal nerve pierces the fascia lata a little way distal to the inguinal ligament, and to the lateral side of the falciform margin of the fossa ovalis. It supplies a limited area of skin on the proximal part of the anterior aspect of the thigh. With a little care a communication between this nerve and the intermediate cutaneous nerve of the thigh may be made out (Fig. 106).

**N. Femoris Lateralis** (O.T. **External Cutaneous**).—The lateral cutaneous nerve of the thigh is distributed on the lateral area of the thigh. It pierces the fascia lata in two parts. Of these, one—the *posterior division*—appears about two inches distal to the anterior superior spine of the ilium, and proceeds posteriorly and distally; some twigs of it may be followed to the lower part of the gluteal region. The *anterior division* comes to the surface about two inches more distally. It is the larger of the two, and has a wide area of distribution. It may extend to the knee. Previous to its division the lateral cutaneous nerve of the thigh lies in a prominent ridge of the fascia lata which descends vertically from the anterior superior spine of the ilium. This must be slit up to expose the nerve.

The intermediate and medial cutaneous nerves belong to the “anterior cutaneous branches of the femoral nerve,” but for convenience and for the purposes of more precise description, they are defined by special names.

The **intermediate cutaneous nerve of the thigh** (O.T. *middle cutaneous nerve*), a branch of the femoral nerve, pierces the fascia lata in the middle line of the thigh about three or four inches distal to the inguinal ligament. It appears usually as two branches which perforate the fascia at two points a short distance from each other. Both branches extend distally to the knee, which they reach on its medial aspect.

The **medial cutaneous nerve of the thigh** (O.T. *internal cutaneous nerve*), a branch of the femoral nerve, like the lateral cutaneous nerve of the thigh and the intermediate cutaneous nerve, divides into two portions—an anterior and a posterior—which perforate the deep fascia on the medial aspect of the thigh, and at some distance

from each other. The *anterior division* makes its appearance through the fascia lata in the distal third of the thigh, anterior to the great saphenous vein. It descends towards the knee, and its terminal branches turn forwards and laterally to the anterior aspect of the patella. The *posterior division* reaches the surface on the medial side of the knee, behind the great saphenous vein, and proceeds distally to supply the integument on the medial side of the proximal part of the leg. But the main stem of the medial cutaneous nerve, before it divides, also sends a few twigs through the fascia lata to reach the skin on the proximal part of the medial aspect of the thigh. These make their appearance along the line of the great saphenous vein.

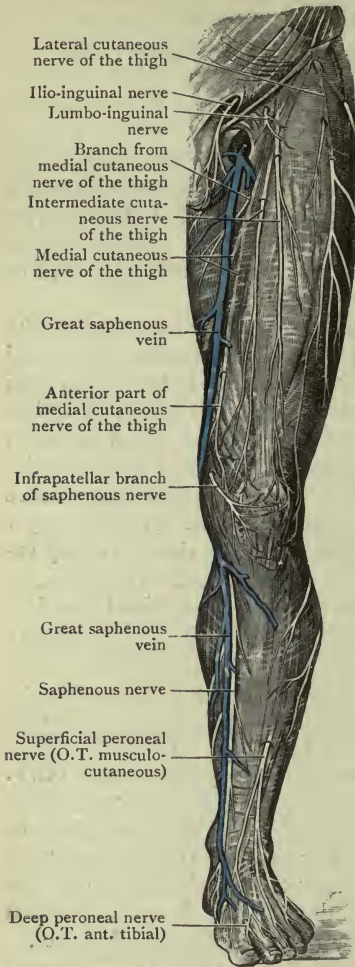


FIG. 107.—Cutaneous Nerves on the Front of the Inferior Extremity.

**N. Saphenus (O.T. Long Saphenous).**—The saphenous nerve becomes cutaneous on the medial side of the knee by perforating the fascia between the tendons of the sartorius and gracilis muscles. The guide to it is the saphenous branch of the *arteria genu suprema*, which descends alongside

of it. It follows the course of the great saphenous vein into the leg. Before it pierces the fascia it gives off an infrapatellar branch.

The *infrapatellar branch* pierces the sartorius muscle and the fascia lata on the medial side of the knee, and turns laterally towards the anterior aspect of the joint, distal to the level of the patella (Fig. 107).

**Patellar Plexus.**—Twigs of four of the cutaneous nerves of the thigh have been traced to the skin of the knee, viz., the anterior division of the lateral cutaneous nerve of the thigh, the intermediate cutaneous, the anterior division of the medial cutaneous, and the saphenous nerve. These nerves communicate with each other and form an interlacement which is situated over the patella, the ligamentum patellæ, and proximal part of the tibia. The interlacement is termed the *patellar plexus*.

On the medial side of the thigh two minute cutaneous nerve twigs sometimes make their appearance which do not belong to any of the above main cutaneous trunks. One appears distal to the ilio-inguinal nerve, and is a twig from the perineal branch of the posterior cutaneous nerve of the thigh; the other pierces the deep fascia at the middle of the medial area of the thigh, and comes from the obturator nerve.

**Dissection.**—After the cutaneous nerves have been cleaned the remains of the superficial fascia must be removed in order that the fascia lata may be studied.

**Fascia Lata.**—This is the name which is given to that portion of the general fascial investment of the inferior extremity which clothes the thigh and preserves its figure. Only a portion of it is displayed at present, but the dissector should obtain a general idea of its attachments and parts before proceeding further with the dissection of the anterior femoral region. One of its striking features is the marked difference in strength which it shows in the lateral and medial aspects of the thigh. In the lateral side of the limb it is generally so dense and strong that it appears to be more aponeurotic than fascial in its character, whilst, in addition, a special band called the *tractus ilio-tibialis* is formed in it. The *tractus ilio-tibialis* extends from the crest of the ilium to the lateral condyle of the tibia and the head of the fibula, and into it are inserted the tensor fasciæ latæ and the greater part of the glutæus maximus muscle; its distal part, therefore, serves as an aponeurotic tendon by means of which the two muscles gain insertion into the lateral condyle of the tibia and the head of the fibula. The ilio-tibial tract serves as a powerful brace, on the lateral aspect of the limb, which, in the erect posture, helps to steady the pelvis and at the same time keep the knee joint firmly extended. On the medial

side of the thigh the fascia lata is so exceedingly delicate and thin that the subjacent muscular fibres shine through it, and it is very apt to be removed with the superficial fascia unless care is exercised in the dissection.

Proximally, around the root of the limb, the fascia lata is attached to the inguinal ligament and the bones of the pelvis. Thus, *posteriorly*, it is continuous with the fascia of the buttock, and through that it is fixed to the coccyx, sacrum, and crest of the ilium. On the *lateral side* it is attached to the crest of the ilium; and on the *medial side*, to the body of the pubis, the margin of the pubic arch, and to the tuberosity of the ischium.

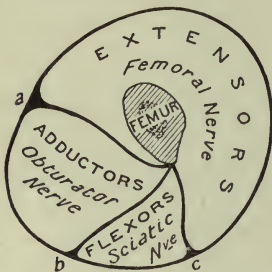


FIG. 108.—Diagram to show the arrangement of the three intermuscular septa and the three osteo-fascial compartments of the thigh. (After Turner.)

- a. Medial intermuscular septum.
- b. Posterior intermuscular septum.
- c. Lateral intermuscular septum.

*Anteriorly*, its proximal attachment is complicated by the presence of the fossa ovalis. That aperture separates the fascia lata into a lateral or iliac portion and a medial or pectineal portion, now known as the *fascia pectinea*. The subdivision extends distally only to the distal border of the fossa ovalis. The *iliac portion* is attached along the whole length of the inguinal ligament. Its medial crescentic margin bounds the fossa ovalis laterally and forms its falciform edge. The cornu superius of that edge blends with the lig. lacunare (O.T. Gimbernat's liga-

ment) an expansion of the medial end of the inguinal ligament. Its inferior cornu joins the pectineal portion of the fascia lata. The *fascia pectinea* clothes the proximal portions of the adductor longus and pectineus muscles. It recedes from the surface as it is traced laterally, passes posterior to the sheath of the femoral vessels, and blends with the capsule of the hip joint, with the deep intermuscular septa, and with the fascia iliaca, which covers the ilio-psoas muscle (Fig. 113). To the medial side of the femoral vessels the fascia pectinea is attached proximally to the pectineal line of the pubic bone. The *fascia cribrosa*, as previously stated, is to be regarded as a thin piece of the fascia lata, stretched across the fossa ovalis. Laterally, it is continuous

with the falciform edge of the iliac portion of the fascia; medially, it blends with the front of the fascia pectinea.

In the neighbourhood of the knee the fascia lata is continuous posteriorly with the popliteal fascia, whilst on the sides and front of the joint it is attached to the various bony prominences and to the different tendons in those localities, and it helps to strengthen and support the capsule of the knee joint.

**Septa Intermuscularia (Intermuscular Septa).**—The fascia lata has other offices to perform besides that of forming a continuous investment for the thigh. From its deep surface processes pass off which penetrate the limb and constitute sheaths for the muscles and other structures. Three of the processes, which are especially strong, form distinct septa or partitions which reach the femur and are attached to the *linea aspera* on its posterior aspect. These partitions are termed the intermuscular septa, and are so disposed that they intervene between the three great groups of muscles in the thigh. The *lateral intermuscular septum* is placed between the extensor muscles in the anterior area of the thigh and the hamstring muscles in the posterior region; the *medial intermuscular septum* intervenes between the extensor muscles and the adductor muscles in the medial region; whilst the *posterior intermuscular septum*, weak and inconspicuous in comparison with the other two, is interposed between the adductor and the hamstring muscles. The three septal partitions will be disclosed in the subsequent dissection. In the meantime, merely note that the medial and the lateral septa show on the surface of the fascia, in the distal part of the thigh, as white lines. By means of the three septa the thigh is divided into three osteo-fascial compartments, viz., an *anterior*, containing the extensor muscles and the femoral nerve; a *posterior*, holding the hamstrings and the sciatic nerve; and a *medial*, for the adductors with the obturator nerve (Fig. 108).

**Bursæ Patellares (Patellar Bursæ).**—Several mucous bursæ are situated in the patellar region. Those which lie superficially may be investigated now, and the more deeply placed bursæ should be examined at later stages of the dissection, as opportunity occurs.

The bursæ are—(1) The *subcutaneous prepatellar bursa*, which lies immediately beneath the skin opposite the distal part

of the patella. (2) The *subfascial prepatellar bursa*, situated between the fascia lata superficially and the proximal part of the patella and the adjacent part of the tendon of the quadriceps deeply; this bursa may be displayed by an incision made through the fascia lata in the area indicated. (3) The *subtendinous prepatellar bursa*, lying between the superficial fibres of the tendon of the quadriceps and the periosteum of the anterior surface of the patella. (4) The *suprapatellar bursa*. This lies proximal to the patella, behind the tendon of the quadriceps and in front of the distal part of the anterior surface of the femur it usually communicates with the cavity of the knee joint. (5) The *subcutaneous infrapatellar bursa*, placed directly beneath the skin, anterior to the proximal part of the ligamentum patellæ. (6) The *deep infrapatellar bursa*, which is placed between the ligamentum patellæ and the anterior surface of the proximal part of the tibia. The suprapatellar bursa and the deep infrapatellar bursæ are practically always present, but one or more of the subcutaneous and subfascial bursæ may be absent. Not uncommonly a subfascial and an adjacent subcutaneous bursa may communicate through an aperture in the deep fascia. The subcutaneous bursæ are often destroyed during the reflection of the skin, but the deeper bursæ can usually be found, if looked for carefully, in the situations mentioned above.

#### DEEP DISSECTION OF THE ANTERIOR AND MEDIAL PARTS OF THE THIGH.

In the course of the deep dissection of the anterior and medial femoral regions the following structures will be met with and must be examined:—

1. The femoral sheath.
2. Nervus lumboinguinalis.
3. Nervus cutaneus femoris lateralis.
4. M. sartorius.
5. Nervus femoralis and its rami.
6. Arteria femoralis and its rami.
7. Vena femoralis.
8. M. ilio-psoas.
9. M. quadriceps femoris
 

}	M. rectus femoris.
	M. vastus lateralis.
	M. vastus intermedius.
	M. vastus medialis.

10. *M. articularis genu.*
11. *M. tensor fasciæ latæ.*
12. Deep part of the *tractus ilio-tibialis fasciæ latæ.*
13. The intermuscular septa, lateral and medial.

**Ligament Inguinale (O.T. Poupart's Ligament) and Ligamentum Lacunare (O.T. Gimbernat's Ligament).**—Although both of these ligaments belong more to the abdominal wall

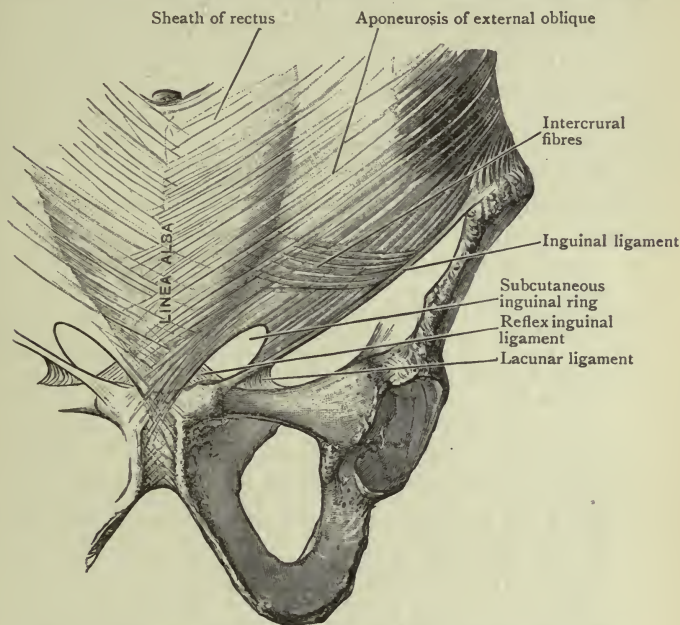


FIG. 109.—Dissection to show the connections of the Inguinal Ligament.

than to the thigh, it is essential that the dissector of the inferior extremity should obtain some knowledge of their connections before he proceeds further with his dissection. The *inguinal ligament* is merely the thickened lower border of the aponeurosis of the external oblique muscle of the abdominal wall folded backwards upon itself. Therefore it presents a rounded surface towards the thigh, and a grooved surface towards the cavity of the abdomen. Its lateral extremity is fixed to the anterior superior spine of the ilium. Medially, it has a double attachment, viz.—(1) to the

pubic tubercle, (2) through the medium of the lacunar ligament to the medial part of the pectineal line. The inguinal ligament pursues an oblique course between its iliac and pubic attachments, and at the same time describes a gentle curve, the convexity of which is turned distally. By its distal border it affords attachment to the iliac part of the fascia lata, and when that is divided it loses its curvature.

The *ligamentum lacunare* (O.T. *Gimbernal's ligament*) is a small triangular piece of aponeurosis which occupies the interval between the medial part of the inguinal ligament and the medial inch of the pectineal line—being attached by its margins to both. Its base, which looks laterally, is sharp, crescentic, and free, and abuts against the femoral sheath. The lacunar ligament occupies a very oblique plane; its femoral surface looks distally and laterally, whilst its abdominal surface is directed upwards and medially (Fig. 109).

**Dissection.**—The exposure of the femoral sheath is the next step in the dissection of the thigh. To display it the *iliac portion* of the fascia lata must be partially reflected. Divide the superior horn of the lateral crescentic margin of the fossa ovalis, and then carry the knife laterally along the lower border of the inguinal ligament, so as to sever the attachment of the fascia lata to that thickened band. The incision should extend to within an inch of the anterior superior spine of the ilium. The piece of fascia marked out by the incision above, and by the lateral free margin of the fossa ovalis medially, must be carefully raised from the subjacent femoral sheath and thrown distally and laterally. On the removal of a little loose fat, the *femoral sheath* will be brought into view as it enters the thigh under the inguinal ligament. Isolate it carefully from adjacent and surrounding parts, by carrying the handle of the knife gently round it as far as possible. Insinuate the handle of the knife, first between the sheath and the *inguinal ligament*, next between the sheath and the *lacunar ligament*, which lies medial to it, and finally behind the sheath along the front of the pectineal fascia. Laterally and posteriorly the sheath is fused with the iliac fascia<sup>1</sup> on the psoas muscle, and in that situation it will be necessary to use the edge of the knife before the sheath can be isolated (Fig. 111).

**Femoral Sheath.**—The funnel-shaped appearance of the femoral sheath will now be apparent—the wide mouth of the membranous tube is directed upwards towards the abdomen, whilst the narrow distal part gradually closes

<sup>1</sup> Do not confuse the *iliac fascia* with the *iliac part of the fascia lata*. The iliac fascia is a fascia which descends from the abdomen on the anterior surfaces of the psoas and iliacus muscles. The iliac part of the fascia lata is part of the deep fascia of the thigh (see p. 229).



upon the vessels, and fuses with their coats about the level of the distal limit of the fossa ovalis. It should be noticed that the sides of the funnel-shaped sheath do not slope equally towards one another. The lateral border of the sheath is nearly vertical in its direction, whilst the medial wall proceeds very obliquely distally and laterally. If the dissection has been successfully performed, the *lumbo-inguinal nerve* should be seen piercing the lateral wall of the sheath, whilst the great saphenous vein and some lymph vessels perforate its anterior wall. Further, if the subject is spare and the fasciæ well marked, the dissector will in all probability notice that the anterior wall of the sheath, in its proximal part, is strengthened by some transverse fibres which pursue an arched course across it. To those fibres the name of *deep femoral arch* is given, in contradistinction to the term *superficial femoral arch*, which is sometimes applied to the inguinal ligament. The deep femoral arch springs from the deep surface of the inguinal ligament about its middle, then traverses the front of the sheath, and expanding somewhat, is attached by its medial extremity to the pectineal line of the pubic bone behind the lacunar ligament.

**Constitution of the Femoral Sheath.**—The sources from which the femoral sheath is derived, and the manner in which it is formed, must next be considered. The consideration entails the study of some of the structures concerned in the construction of the abdominal wall, and it is possible that the dissection of the abdomen will not be in a sufficiently advanced state for their examination.

A small portion of the medial part of the interval between the inguinal ligament and the hip bone is filled up by the lacunar ligament. Immediately to the lateral side of the lacunar ligament the femoral vessels, enclosed within the femoral sheath, enter the thigh from the abdominal cavity, whilst still more laterally the interval is occupied by the ilio-psoas muscle. Three nerves also find their way into the thigh through the interval, viz., the lumbo-inguinal nerve, which passes distally in the femoral sheath; the femoral (O.T. anterior crural) nerve, which occupies the interval between the psoas and iliacus muscles; and the lateral cutaneous nerve of the thigh, which runs behind the inguinal ligament, close to its iliac attachment (Fig. 111).

The arrangement of the fascial lining of the abdominal cavity, with reference to this interval of communication between abdomen and thigh, also requires attention. The lower part of the posterior wall of the abdomen, immediately above the thigh, is formed by the iliacus and psoas muscles. These are covered by that part of the fascial lining of the abdomen which receives the name of the *fascia*

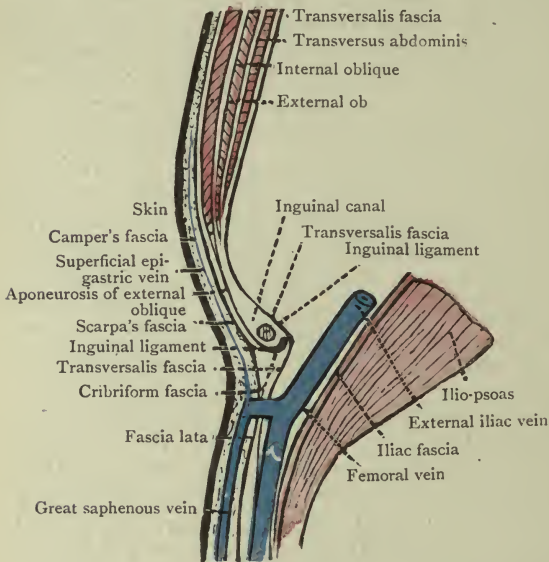


FIG. 110.—Diagram of the Fasciæ and Muscles of the Inguinal and Subinguinal Regions in the line of the Fossa Ovalis.

*iliaca*.<sup>1</sup> The anterior wall of the abdomen is lined, in like manner, by a portion of the general lining, termed the *fascia transversalis*. To the lateral side of the femoral vessels these two fascial layers become continuous with each other, and at the same time are attached to the back of the inguinal ligament (Fig. 105). It is behind this union that the ilio-psoas, the femoral nerve, and the lateral cutaneous nerve of the thigh are carried distally into the thigh. But the external

<sup>1</sup> The dissector must bear in mind the distinction between the *fascia iliaca* and the *iliac portion* of the *fascia lata*. The former is a part of the general fascial lining of the abdomen, and the latter is a part of the deep fascia of the thigh.

iliac vessels (which become the femoral vessels in the thigh), with the lumbo-inguinal nerve, lie anterior to the fascia iliaca, or, in other words, within the fascial lining of the abdomen, and, as they proceed distally behind the inguinal ligament, they carry with them a funnel-shaped prolongation of the lining, which is the femoral sheath.

The dissector will now readily understand that the *anterior wall* of the sheath is formed of *fascia transversalis* from

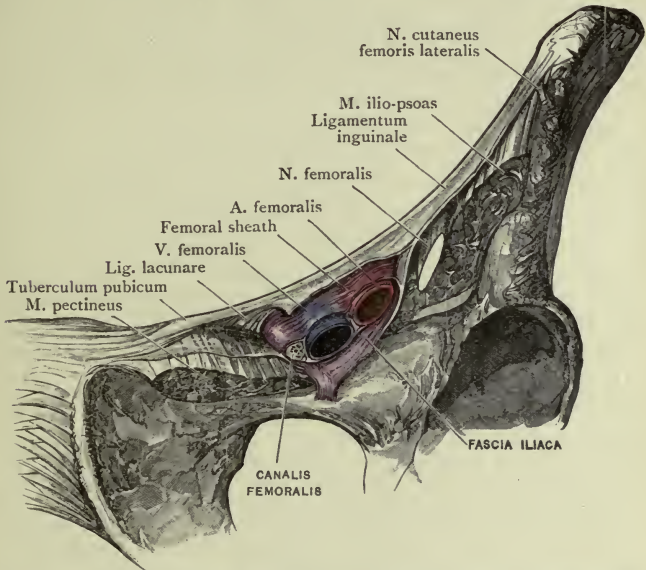


FIG. 111.—Dissection to show the Femoral Sheath and the other Structures which pass between the Inguinal Ligament and the Hip Bone.

the anterior wall of the abdomen, while the *posterior wall* is formed of *fascia iliaca*, prolonged distally, from the posterior abdominal wall (Fig. 110).

**Posterior Wall of the Femoral Sheath.**—There are still some additional facts relating to the posterior wall of the femoral sheath which require to be mentioned. It is formed, as stated above, by the fascia iliaca; but as that enters the thigh it blends with the lateral part of the (Fig. 113) fascia pectinea, and further, it is firmly fixed in position by certain connections which it establishes in the thigh. Thus,

lateral to the femoral sheath, it is prolonged over the ilio-psoas muscle; whilst from its posterior aspect a lamina is given off which passes posterior to that muscle and joins the capsule of the hip joint (Fig. 113).

**Dissection.**—The femoral sheath must be opened, in order that the arrangement of parts inside may be displayed. Make three vertical and parallel incisions through the anterior wall—one over the femoral artery, which occupies the lateral part of the sheath, another over the femoral vein in the line of the great saphenous vein, and the third about half an inch medial to the second. The first two should begin at the level of the inguinal ligament, and should extend distally for an inch and a half. The most medial of the three incisions should commence at the same level, but should be carried distally only for half an inch or less.

**Interior of the Femoral Sheath.**—A little dissection will show that the sheath is subdivided, by two antero-posterior partitions, into three compartments. The femoral artery and lumbo-inguinal nerve occupy the *most lateral compartment*; the femoral vein fills up the *intermediate compartment*; whilst in the *most medial compartment* are lodged a little loose areolar tissue, a small lymph gland, and some lymph vessels. This last compartment, from its relation to femoral hernia, has the special name of *femoral canal* applied to it.

**Canalis Femoralis.**—The boundaries and extent of the femoral canal must be very thoroughly studied. The best way to commence the study is to introduce the little finger into the canal and push it gently upwards. The length of the canal is not nearly so great as that of the other two compartments. Indeed, it is not more than half an inch long. Distally it is closed, and it rapidly diminishes in width proximo-distally. Its proximal aperture lies on the lateral side of the base of the lacunar ligament, and is called the *femoral ring*. It is closed by the closely applied extra-peritoneal fatty tissue of the abdominal wall. The parts which immediately surround the opening can be readily detected with the finger: laterally the *femoral vein*, medially the sharp crescentic base of the *lacunar ligament*, anteriorly the *inguinal ligament*, and posteriorly the *pubic bone* covered by the *pectineus muscle*. The portion of the extra-peritoneal fatty tissue which closes the ring is called the *septum femorale*. On the abdominal surface of the septum femorale is the peritoneal lining of the abdominal cavity, and when examined from above both are seen to be slightly depressed

into the opening so as to produce the appearance of a dimple.

**Femoral Hernia.**—Femoral hernia is the name applied to a pathological condition which consists of the protrusion of some of the contents of the abdominal cavity into the thigh. As they descend they pass behind the inguinal ligament into the *femoral canal* or *most medial compartment* of the femoral sheath. The arrangement of the parts which occupy the interval between the hip bone and the inguinal ligament has been carefully considered, and the dissector should therefore be in a position to understand how the occurrence of such a protrusion is possible. To the medial side of the femoral sheath the interval is closed by the lacunar ligament, which, by its strength and firm connections, constitutes an impassable barrier in that locality. To the lateral side of the femoral sheath a hernial protrusion is equally impossible. There the fascia transversalis on the anterior wall of the abdomen becomes continuous with the fascia iliaca on the posterior wall of the abdomen, and along the line of union both are firmly attached to the inguinal ligament (Fig. 105).

It is in the region of the femoral sheath, then, that femoral hernia takes place. The three compartments of the sheath open above into the abdominal cavity, but there is an essential difference between the three openings. The lateral two, which hold the artery and the vein, are completely filled up by their contents. The femoral canal, or most medial compartment, is not completely filled, for it is wider than is necessary for the passage of the fine lymph vessels which traverse it. Further, its widest part is the upper opening or *femoral ring*. It has been noted that that is wide enough to admit the point of the little finger, and it forms a weak point in the parietes of the abdomen; a source of weakness which is greater in the female than in the male, seeing that in the former the distance between the iliac spine and the pubic tubercle is proportionally greater, and that, in consequence, the femoral ring is wider. Femoral hernia, therefore, is more common in the female (Fig. 105).

When attempts are made to reduce a femoral hernia, it is necessary that the course which the protrusion has taken should be kept constantly before the mind of the operator. In the first instance it passes distally for a short distance in a perpendicular direction. It then turns forwards and bulges through the fossa ovalis. Should it still continue to enlarge, it bends upwards over the inguinal ligament, and pushes its way laterally towards the anterior superior spine of the ilium. The protrusion is thus bent upon itself, and if it is to be reduced successfully it must be made to retrace its steps. In other words, it must be drawn down, and then pushed gently backwards and upwards. The position of the limb during this procedure must be attended to. When the thigh is fully extended and rotated laterally all the fascial structures in the neighbourhood of the femoral canal are rendered tense. When, on the other hand, the limb is flexed at the hip-joint and rotated medially, the upper horn of the margin of the fossa ovalis, and even the lacunar ligament, are relaxed. That, then, is the position in which the limb should be placed during the reduction of the hernia.

As the hernia descends it carries before it, in the form of coverings, the various layers which it meets. First it pushes before it the peritoneum, and that forms the *hernial sac*. The other coverings from within outwards are—(1) the septum femorale; (2) the wall of the femoral sheath; (3) the fascia cribrosa; and lastly, (4) the superficial fascia and skin.

The femoral canal, as already noted, is surrounded by very unyielding structures. Strangulation due to pressure is, therefore, of very common

occurrence in cases of femoral hernia. The sharp tense base of the lacunar ligament and the superior cornu of the margin of the fossa ovalis are especially apt to bring about that condition.

**Abnormal Obturator Artery.**—The account of the surgical anatomy of femoral hernia cannot be complete without mention of the relation which the obturator artery frequently bears to the femoral ring. In two out of every five subjects the obturator artery, on one or on both sides, takes origin from the inferior epigastric artery. In those cases it passes posterior to the pubic bone to gain the obturator sulcus in the upper part

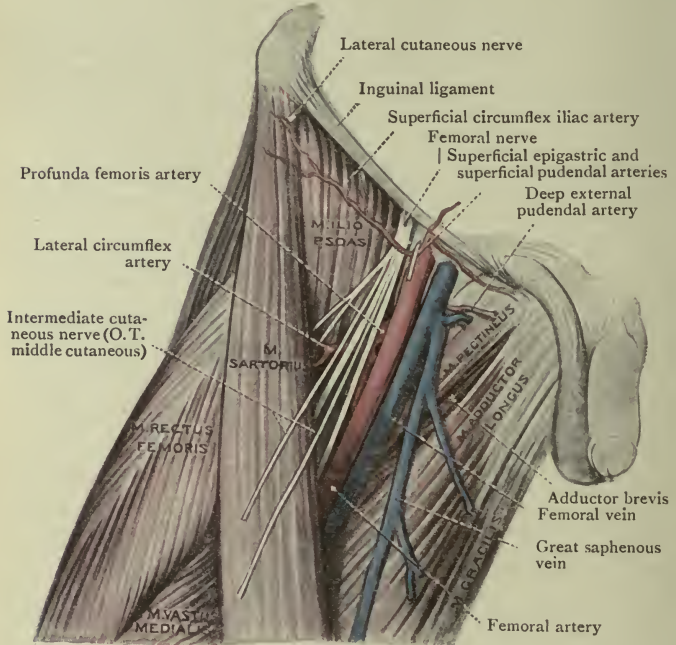


FIG. 112 —Dissection of the Femoral Triangle of the right side

of the obturator foramen, and according to the point at which it arises from the epigastric trunk, it presents different relations to the femoral ring. In the majority of cases it lies in close contact with the external iliac vein and on the lateral side of the femoral ring. In that position it is in no danger of being wounded in operations undertaken for the relief of a strictured femoral hernia. In about thirty-seven per cent., however, of the cases in which it exists, the artery is placed less favourably. In those it either passes medially, across the septum femorale which closes the opening into the femoral canal, or it arches over it and turns posteriorly, on the medial side of the ring, upon the deep aspect of the base of the lacunar ligament. In the latter situation it is in a position of great danger,

seeing that it is the base of the lacunar ligament against which the surgeon's knife is generally directed for the relief of strictured femoral hernia.

**Dissection.**—The boundaries and contents of the femoral triangle, which occupies the proximal third of the anterior part of the thigh, must now be dissected. Commence by cleaning the medial and lateral boundaries. The lateral boundary is formed by the proximal third of the sartorius muscle, and the medial boundary by the medial border of the adductor longus muscle. To clean a muscle properly the following rules must be observed: (1) Keep the muscle tense by bending or straightening the limb or by rotating it. (2) Make all cuts with the scalpel parallel with muscle fibres. (3) Remove the fascia in one continuous layer from one border of the muscle to another. (4) Define very carefully the borders of the muscle.

As the deep fascia is removed the scalpel must cut not only parallel with the muscle fibres but also against them, in order that none of the deep fascia may be left on the muscle.

Clean the sartorius first from its origin on the anterior border of the ilium, below the anterior superior spine, to the point where it crosses the adductor longus at the junction of the proximal and middle thirds of the thigh. Begin at its medial or its lateral border, whichever is more convenient, and take care not to injure the lateral cutaneous nerve of the thigh, which crosses superficial to the muscle near its origin, and the intermediate cutaneous nerve, which either pierces or crosses the muscle near the middle line of the thigh.

Next clean the pectineal fascia from the anterior surface of the adductor longus from the point where the muscle arises from the front of the pubis to the point where it disappears behind the sartorius at the apex of the femoral trigone.

When the medial and lateral boundaries of the trigone have been displayed proceed to the dissection of the femoral nerve and its branches. Place a block under the knee in order to flex the hip-joint and relax the boundaries and contents of the triangle, then follow the intermediate cutaneous nerve upwards to the point where it springs from the front of the trunk of the femoral nerve, next clean the lateral border of the trunk, and inserting the handle of a spare scalpel behind the nerve raise it from the groove between the iliacus and psoas in which it lies. Leave the spare scalpel behind the nerve trunk and clean its various branches so far as they lie in the femoral trigone. Medial to the intermediate cutaneous nerve lies the medial cutaneous nerve of the thigh. It springs from the front of the trunk of the femoral nerve, runs along the lateral border of the femoral sheath and crosses the front of the femoral artery at the apex of the trigone. On a plane posterior to the intermediate and medial cutaneous nerves lie the deeper branches of the femoral nerve. They radiate from the extremity of the trunk of the nerve and are arranged in the following order from above and laterally downwards and medially: the nerve to the rectus femoris, the nerve to the vastus lateralis, the nerve to the vastus intermedius, the nerve to the vastus medialis, and the saphenous nerve. The nerve to the sartorius is usually a branch of the intermediate cutaneous nerve. As the muscular branches are being cleaned take care to avoid injury to the

lateral femoral circumflex artery, which passes laterally either behind or between the nerves. After the nerves mentioned have been cleaned pull the trunk of the femoral nerve laterally and secure the nerve to the pectineus, which springs from the medial border of the femoral nerve and passes medially behind the femoral sheath. Follow it as far as possible behind the sheath and keep it in mind during the next stage of the dissection, which includes the removal of the femoral sheath and the cleaning of the femoral artery and its branches and the femoral vein and its tributaries. As many of the branches of the artery as possible should be retained, but small branches to the muscles may be removed if they obstruct the cleaning of the larger vessels. The main trunks of the veins must also be kept and cleaned, but the *venæ comites* of the smaller arteries should be removed.

Commence with the femoral artery. Trace the superficial branches already displayed back to their origin from the trunk as it lies in the femoral sheath, then raise the trunk of the artery from the sheath, and completely remove that portion of the sheath which surrounded the artery, but do not forget the nerve to the pectineus which lies immediately behind the sheath. As the arterial part of the femoral sheath is removed, find the deep external pudendal artery, which springs from the proximal part of the trunk; then clean the distal part of the femoral artery as far as the apex of the trigone. First clean the medial side, from which no important branches arise. Then clean along the lateral side, from above downwards, and about 50 mm. distal to the inguinal ligament find the large *profunda femoris* branch, which springs from the postero-lateral aspect of the parent trunk. Follow the profunda artery distally and medially behind the femoral and profunda veins and secure its first two branches, the *medial* and the *lateral femoral circumflex arteries*. The medial femoral circumflex artery passes backwards into the deep part of the trigone; the lateral femoral circumflex artery runs laterally, behind or between the muscular branches of the femoral nerve, to the lateral border of the femoral trigone, where it breaks up into ascending, transverse and descending branches. Not uncommonly one or both the femoral circumflex arteries spring from the trunk of the femoral artery, and the dissector must be prepared to meet with such variations.

After the arteries are displayed, clean the femoral and profunda veins, both of which lie posterior to the femoral artery in the distal part of the trigone. As the posterior aspect of the proximal part of the femoral vein is cleaned the nerve to the pectineus must be followed to its termination in the pectineus muscle; then the remaining parts of the pectineal fascia must be removed from the pectineus and adductor longus. As that is done, an interval will come into view between the lower border of the pectineus and the upper border of the adductor longus, in which the superficial division of the obturator nerve should be found. Lastly, the iliac fascia must be cleaned from the surfaces of the iliacus and psoas, and the fat in the angle between the psoas and pectineus must be removed.

**Trigonum Femorale.**—The femoral triangle is the name given to the triangular hollow which lies in the proximal



third of the thigh distal to the inguinal ligament. It possesses a roof or anterior boundary; a floor or posterior boundary; a medial boundary; and a lateral boundary; a base, which is situated proximally at the junction of the thigh with the abdomen; and an apex, which lies distally at the junction of the proximal and middle thirds of the thigh (Fig. 112).

The *lateral boundary* is formed by the medial border of the sartorius muscle as it runs distally and medially across the thigh from the anterior superior spine of the ilium, and, more deeply in the distal part of the triangle, by the medial border of the rectus femoris. The *medial boundary* is constituted by the prominent medial border of the adductor longus, and the two muscles meet below at the front of the apex of the triangle. The *anterior boundary*, or roof, is formed by the iliac part of the fascia lata and the cribriform fascia. It is perforated by the structures which pass through the fascia cribrosa (see p. 229), by the lumbo-inguinal nerve, and the intermediate cutaneous nerve of the thigh, and it is covered by the superficial fascia and skin. The *posterior boundary*, or floor, slopes backwards from the medial and lateral boundaries; the triangle is, therefore, triangular in section as well as in superficial outline. The medial part of the floor is constituted mainly by the anterior surfaces of the adductor longus and the pectineus, but, if an interval exists between the adjacent borders of those two muscles, a part of the anterior surface of the adductor brevis also appears in the medial part of the floor. The lateral part of the floor is formed by the anterior surfaces of the iliacus and the psoas major. The medial femoral circumflex artery passes through the floor, between the adjacent borders of the psoas and the pectineus, and the profunda artery leaves the triangle by passing behind the upper margin of the adductor longus, close to the femur; it is accompanied by the profunda vein. The *apex* is bounded medially by the adductor longus, laterally by the vastus medialis, and anteriorly by the sartorius; through it the femoral vessels, accompanied by the saphenous nerve, pass from the femoral triangle into the adductor canal. The *base* is situated at the junction of the thigh with the abdomen; it is bounded, superficially, by the inguinal ligament; medially, by the lacunar ligament; laterally, by the anterior border of the ilium; and posteriorly, by the pectineus,

the psoas major and the iliacus. Through it pass the femoral artery and vein, the deep femoral lymph vessels, the femoral and lumbo-inguinal nerves, and the lateral cutaneous nerve of the thigh.

**Arteria Pudenda Externa Profunda.**—The deep external pudental artery is a small twig which arises from the medial side of the femoral artery, distal to the inguinal ligament. It runs medially, upon the pectineus and adductor longus muscles, and, after piercing the fascia lata, ends, according to the sex, in the integument of the scrotum or of the labium majus pudendi.

**Dissection.**—Before the other contents of the femoral triangle are studied, complete the dissection of the remains of the anterior and medial regions of the thigh and knee.

First clean the remainder of the sartorius as far as its insertion into the tibia, but avoid injury to the nerves which lie in relation with it. The lateral cutaneous nerve of the thigh, which crosses anterior to the muscle near the anterior superior spine of the ilium, and the intermediate cutaneous nerve, which either crosses or pierces it, have already been secured. Below the apex of the femoral triangle the anterior branch of the medial cutaneous nerve crosses superficial to the sartorius, and the posterior branch of the same nerve runs along its posterior border. A short distance proximal to the knee the infrapatellar branch of the saphenous nerve pierces it, and the trunk of the saphenous nerve emerges between its posterior border and the tendon of the gracilis at the medial side of the knee accompanied by the saphenous branch of the arteria genu suprema, which serves as a guide to its position. After the sartorius is displayed, turn to the tensor fasciæ latae, which lies immediately lateral to the proximal part of the sartorius. At the lateral border of the proximal part of the sartorius the iliac part of the fascia lata splits into two layers. One layer passes superficial to the sartorius, and has been removed to expose the muscle; the other passes deep to the tensor fasciæ to blend with the tendon of the rectus femoris. Trace the tensor fasciæ to its attachment to the ilio-tibial tract of the fascia lata, into which it is inserted; then cut through the fascia lata vertically, along the anterior border of the ilio-tibial tract down to the lateral condyle of the tibia. Pull the distal part of the ilio-tibial tract laterally, and demonstrate the lateral intermuscular septum which passes from its deep surface to the lateral supracondylar ridge of the femur. Now clean away the whole of the fascia lata between the tensor fasciæ latae and the ilio-tibial tract on the lateral side, and the sartorius on the medial side. The muscles which will then be brought into view are the rectus femoris along the middle of the front of the thigh. It will be recognised by the bipennate arrangement of its fibres. Between it and the ilio-tibial tract are parts of the vastus lateralis and vastus intermedius, the latter below the former; and between it and the sartorius in the distal third of the thigh the distal part of the vastus medialis will be seen.

A short distance proximal to the knee the rectus femoris ends in a tendon which is inserted into the proximal border of the patella, and the vasti end in aponeurotic expansions which are attached to the borders of the patella.

Push the proximal part of the sartorius medially, pull the tensor fasciæ laterally, and find its nerve of supply from the

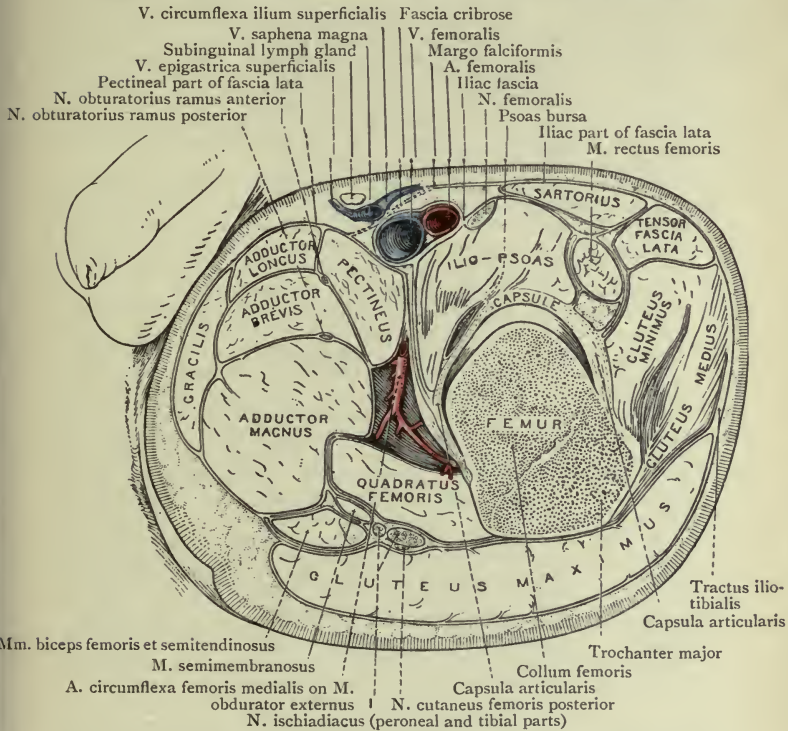


FIG. 113.—Dissection of an oblique transverse Section through upper part of Thigh showing the relation of the Fascia to the Muscles.

superior gluteal nerve. It enters the deep surface of the muscle a little above the middle of its length. When the nerve is secured, follow it backwards till it disappears between the adjacent anterior borders of the glutæus medius and minimus at the anterior margin of the greater trochanter; then clear away the septum of deep fascia which passes deep to the tensor fasciæ to blend medially with the tendon of the rectus femoris and laterally with the front of the capsule of the hip joint. As the deep part of the septum is removed, find and clean the ascending branch of the lateral femoral circumflex artery, and look for

the twig which springs from it and pierces the fibrous capsule of the joint; then clean the straight head of the rectus femoris to its origin from the anterior inferior spine of the ilium, and follow the reflected tendon backwards to the upper border of the acetabulum where it is embedded in the fibrous stratum of the capsule of the hip joint. Note that the interval between the tensor fasciæ and the sartorius is a path by which the surgeon gets easy access to the front of the hip joint without endangering any structures of importance. Clean and define the anterior borders of the glutæus medius and minimus. The nerve to the tensor fasciæ emerges between the closely apposed borders of the two muscles and indicates the line of separation. Not uncommonly the anterior border of the medius is blended with the deep surface of the tensor fasciæ; if that is the case, separate the two muscles with the scalpel.

Turn now to the medial side of the middle third of the thigh, and pull the sartorius laterally. Posterior to it there is an angular interval bounded laterally by the vastus medialis and medially by the adductor longus above and the adductor magnus below. The interval is crossed by a strong layer of fascia which forms the roof of the *adductor canal* (Hunter's) (Figs. 114, 115). On the fascia lies some loose areolar issue in which is embedded the subsartorial plexus of nerves. The plexus is not always easily demonstrable, but if the dissector is successful he will find that it is formed by interlacing twigs from the medial cutaneous, the saphenous, and the obturator nerves. Clean the plexus and areolar tissue away and clean the fascial roof of the canal. It is attached laterally to the vastus medialis, and medially to the adductors magnus and longus. Its proximal extremity fades away indefinitely at the apex of the femoral triangle, but at its distal end it terminates in a sharp crescentic border which extends from the vastus medialis to the adductor magnus, at the junction of the middle and distal thirds of the thigh. The saphenous nerve accompanied by the saphenous branch of the arteria genu suprema will be seen emerging from the canal behind the distal crescentic border of the fascial roof. To display the contents of the canal, divide the fascial roof by a vertical incision extending from its proximal to its distal end, and then clean the contents, which are the femoral artery, the femoral vein, the saphenous nerve, and the nerve to the vastus medialis.

**M. Sartorius.** — The sartorius is a long slender muscle, which arises from the anterior superior spine of the ilium and the upper part of the notch on the anterior border of the bone immediately below the spine. It crosses the front of the proximal third of the thigh obliquely, and, gaining the medial side of the limb, it takes a nearly straight course distally to a point beyond the medial prominence of the knee. There it turns forwards, and ends in a thin, expanded aponeurotic tendon, which is inserted into the medial surface of the body of the tibia, posterior to the tuberosity (Fig. 139, p. 322). By its distal border the tendon is connected with the fascia

of the leg, whilst by its proximal border it is joined to the capsule of the knee joint.

In its proximal, oblique part, the sartorius muscle forms the lateral boundary of the femoral triangle, and lies anterior to

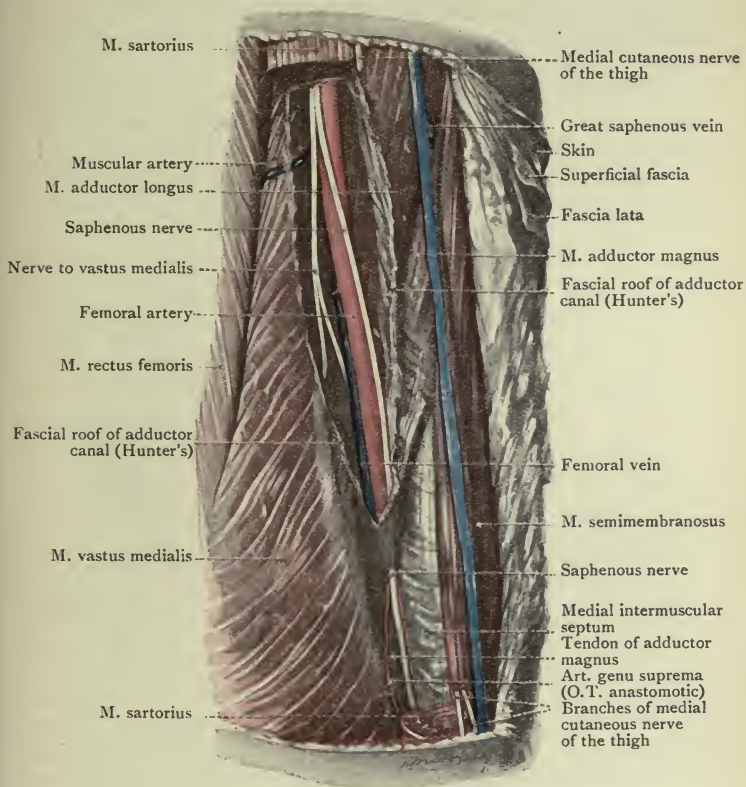


FIG. 114.—Dissection of the Adductor Canal (Hunter's) in the right lower limb. A portion of the Sartorius has been removed.

the iliacus, the rectus femoris, and the adductor longus muscles. More distally, it is placed anterior to the femoral vessels as far as an opening in the adductor magnus through which they pass into the popliteal fossa. At its insertion its expanded tendon lies anterior and superficial to the tendons of

insertion of the gracilis and semitendinosus, but is separated from them by a bursa. The sartorius is supplied by the *femoral nerve*. It is a flexor of the knee and a medial rotator of the leg, a flexor of the hip joint and a lateral rotator of the thigh.

**Canalis Adductorius Hunteri (O.T. Hunter's Canal).**—When the femoral artery leaves the femoral triangle it is continued distally, in the medial region of the thigh, in a deep furrow, which is bounded anteriorly by the vastus medialis muscle, and posteriorly by the fascia on the anterior surfaces of the adductor longus and magnus muscles, which is the medial intermuscular septum of the thigh. At its proximal end this furrow is continuous with the deeper, wider, and more apparent

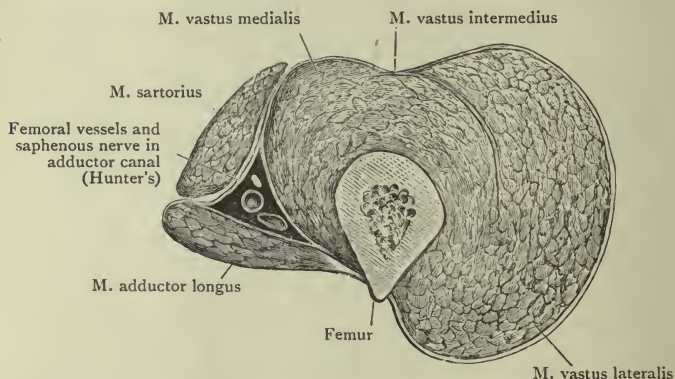


FIG. 115.—Transverse Section through the Adductor Canal.

hollow, which has been described as the femoral triangle. Further, the furrow is converted into a canal, triangular on transverse section, by a strong fibrous membrane which stretches across it, and upon the surface of which the sartorius muscle is placed (Fig. 115). The tunnel thus formed is called the *adductor canal* (Hunter's). The fibrous expansion which roofs in the canal stretches from the adductor longus and the adductor magnus posteriorly to the vastus medialis anteriorly. When it is traced proximally, it is seen to become thin and ill-defined as it approaches the femoral triangle; when traced in the opposite direction, however, it becomes dense and strong, and below the opening in the adductor magnus,

at the distal end of the canal, it presents a thick, sharply defined margin. In its distal part the posterior wall of the canal, where it is formed by the adductor magnus, presents a deficiency or aperture which leads backwards into the popliteal fossa. The appearance and construction of this aperture will be studied at a later stage. It is called *the hiatus tendineus* or *opening in the adductor magnus*.

The femoral vessels and the saphenous nerve traverse the adductor canal. Whilst the femoral artery is in the canal it gives off some muscular twigs and the *arteria genu suprema*. The femoral vessels leave the canal at its distal end by inclining posteriorly through the opening in the adductor magnus and entering the popliteal fossa. The saphenous nerve, accompanied by the saphenous branch of the *arteria genu suprema*, escape from the canal by passing under cover of the distal thickened margin of the fibrous expansion which forms the roof. They can be seen in the present stage of the dissection in that situation.

**Arteria Femoralis (O.T. Femoral Artery, Common and Superficial).**—By the dissections which have been made the whole of the femoral artery has been exposed, and its course and relations may now be studied. It is the direct continuation of the external iliac artery and is the great arterial trunk of the inferior extremity. It begins at the inguinal ligament, behind which it enters the thigh, and it extends, distally, through the proximal two-thirds of the thigh to the opening in the adductor magnus, through which it passes into the popliteal fossa and becomes the popliteal artery. The course of the femoral artery may be marked on the surface, when the thigh is slightly flexed, abducted and rotated laterally, by a line drawn from a point situated midway between the anterior superior spine of the ilium and the symphysis pubis to the adductor tubercle on the medial condyle of the femur.

The relations which the artery bears to the femur are important. As it enters the femoral triangle it leaves the brim of the pelvis and lies in front of the medial part of the head of the femur, from which it is separated by the *psaos major* muscle. Although its relation to the head of the femur is fairly intimate, that situation should not be chosen for applying compression, for, on account of the mobility of the head of the

bone, the vessel is apt to slip from under the fingers. It is much safer to compress it against the hip bone. Distal to the head of the femur, during the remainder of its course through the femoral triangle, the artery is not in direct relation to the bone. It crosses anterior to the angular interval between the neck and body of the femur. Towards the apex of the triangle, however, it comes into relation with the medial side of the body of the femur, and that position it holds to its termination.

In the triangle the proximal part of the femoral artery is enveloped by the femoral sheath, and is separated from the surface by the skin, superficial fascia, and deep fascia; whilst more distally it is crossed by the medial cutaneous branch (O.T. internal cutaneous) of the femoral nerve, which runs along the medial border of the sartorius muscle. The extent of the artery which lies in the femoral triangle varies with the development of the sartorius muscle, but as a rule it measures from 7.5 to 10 cm. At the apex of the triangle the artery enters the adductor canal.

In the adductor canal the artery lies more deeply, and is separated from the surface not only by the skin, superficial fascia and deep fascia, but also by the sartorius muscle, the sub-sartorial plexus of nerves, and the fascial roof of the canal, and, at the mid-length of the canal, the saphenous nerve crosses the front of the artery from the lateral to the medial side.

Lateral to the artery, in the proximal part of the femoral trigone, is the femoral nerve. The two are not, however, in close contact, for the lateral part of the femoral sheath and the projecting lateral border of the psoas major muscle intervene between them. In the distal part of the triangle the medial cutaneous nerve lies lateral to the artery, but it is replaced, in the proximal half of the adductor canal, by the saphenous nerve, and beyond the middle of the adductor canal, where the saphenous nerve passes to the front of the artery, the artery itself is in relation, on its lateral side, with the vastus medialis muscle.

In the proximal part of the femoral triangle the femoral vein lies medial to the artery, separated from it by the lateral septum of the femoral sheath. Beyond the femoral sheath the vein passes behind the artery and no other structure forms a direct medial relation till the distal part of the



adductor canal is reached, where the saphenous nerve lies along the medial face of the distal part of the artery.

Posterior to the artery are the psoas, the pectineus, the adductor longus and the adductor magnus muscles, but the artery is separated from the psoas by the posterior part of the femoral sheath and the nerve to the pectineus, and from the pectineus by fatty areolar tissue in which lie the femoral vein, which has passed from the medial to the posterior aspect of the artery, the profunda vein and the profunda artery, in that order from before backwards. It is separated from the adductors longus and magnus by the femoral vein alone, because the profunda vein and artery dip backwards between the pectineus and the adductor longus and descend behind the latter muscle.

The branches which the artery gives off in the femoral triangle have already been enumerated, and some of them have been followed to their terminations, whilst others will be traced in later dissections. The branches which arise in the adductor canal are muscular twigs which supply adjacent muscles and the *arteria genu suprema*.

**Arteria Genu Suprema (O.T. Anastomotic).**—The *arteria genu suprema* springs from the femoral trunk, a short distance proximal to the point where the latter enters the popliteal fossa by passing through the opening in the adductor magnus. Almost immediately after its origin it divides into a saphenous and a musculo-articular branch: frequently, the two branches have separate origins from the femoral artery.

The *saphenous branch* accompanies the saphenous nerve; it leaves the adductor canal by passing under cover of the distal border of the fibrous expansion which is stretched over the canal. On the medial side of the knee it appears between the gracilis and sartorius, and it ends in branches to the integument on the medial aspect of the proximal part of the leg.

The *musculo-articular branch* enters the substance of the vastus medialis and proceeds distally, anterior to the tendon of the adductor magnus. It gives some twigs to the vastus medialis and others which spread out over the proximal and medial aspects of the knee joint, and it anastomoses with branches of the medial genicular arteries. One well-marked branch runs laterally, proximal to the patella, to anastomose with the lateral superior genicular artery.

**Vena Femoralis.**—The femoral vein is the direct proximal continuation of the popliteal vein. It begins at the opening in the adductor magnus, through which it enters the adductor canal; its proximal end passes behind the inguinal ligament and becomes continuous with the external iliac vein. It accompanies the femoral artery, but the relations of the two vessels to each other differ at different stages of their course. In the distal part of the adductor canal the vein lies posterior to the artery and on its lateral side, but it inclines medially as it ascends, and in the proximal part of the thigh it lies on the medial side of the artery and on the same plane. The crossing from one side to the other takes place posterior to the artery and is very gradual, so that for a considerable distance the femoral vein lies directly posterior to the femoral artery. For a distance of two inches distal to the inguinal ligament it is enclosed within the femoral sheath, of which it occupies the intermediate compartment.

As it ascends in the thigh the femoral vein receives tributaries which, for the most part, correspond with the branches of the femoral artery. At the fossa ovalis it is joined by the great saphenous vein. The dissector should slit the femoral vein open with the scissors. Several valves will then be seen. One is almost invariably found immediately proximal to the entrance of the vein which corresponds to the profunda artery.

**Nervus Femoralis (O.T. Anterior Crural).**—The femoral nerve is a large nerve which arises, within the abdomen, from the lumbar plexus. It enters the thigh by passing distally in the interval between the psoas and iliacus muscles, posterior to the inguinal ligament and the fascia iliaca. In the proximal part of the thigh it lies to the lateral side of the femoral artery, and is separated from it by a small portion of the psoas major muscle and the femoral sheath (Fig. 111). A short distance below the inguinal ligament it divides into an anterior and a posterior portion; they at once resolve themselves into a large number of cutaneous and muscular branches which are named in the following list:—

Anterior division,	$\left\{ \begin{array}{l} \text{Rami musculares,} \\ \\ \text{Rami cutanei anteriores,} \end{array} \right.$	$\left\{ \begin{array}{l} \text{To the pectineus.} \\ \text{,, sartorius.} \\ \text{Intermediate cutaneous} \\ \text{nerve of the thigh.} \\ \text{Medial cutaneous nerve} \\ \text{of the thigh.} \end{array} \right.$

Posterior division,	{ Rami musculares,  Ramus cutaneus, Rami articulares.	{ To the rectus femoris. ,, vastus medialis. ,, vastus lateralis. ,, vastus inter- medius. ,, m. articularis genu. Saphenous nerve.

With the exception of the saphenous nerve, which is distributed upon the medial side of the leg and foot, the distribution of the cutaneous branches of the femoral nerve has been already examined (p. 230).

The *nerve to the pectineus* arises a short distance distal to the inguinal ligament and turns medially, posterior to the femoral vessels, to reach its destination. The *branches to the sartorius* are two or three in number. As a rule, they take origin in common with the intermediate cutaneous nerve.

The *intermediate cutaneous nerve* (O.T. *middle cutaneous*) sometimes pierces the proximal border of the sartorius. It divides into two branches which perforate the fascia lata about three or four inches distal to the inguinal ligament.

The *medial cutaneous nerve* (O.T. *internal cutaneous*) inclines distally and medially, crosses anterior to the femoral artery at the apex of the femoral triangle, and divides into an anterior and a posterior portion, which become superficial, at different levels, on the medial side of the limb. From the trunk of the nerve a few cutaneous twigs are given to the skin over the proximal and medial parts of the thigh. The *anterior branch* crosses the sartorius muscle and makes its appearance through the fascia lata in the distal part of the thigh, a short distance anterior to the great saphenous vein. The *posterior branch* runs distally, along the posterior border of the sartorius, and pierces the deep fascia on the medial side of the knee, behind the sartorius and the saphenous nerve.

A short distance distal to the middle of the thigh the posterior branch of the medial cutaneous nerve forms, with filaments from the obturator nerve and the saphenous nerve, a plexiform interlacement, the *sub-sartorial plexus*, which is placed deep to the sartorius muscle as it lies over the adductor canal (Hunter's). The twig from the obturator nerve appears at the medial border of the adductor longus.

The *saphenous nerve* (O.T. *internal saphenous nerve*) is the longest branch of the femoral nerve. It springs from the

posterior division of that nerve and runs distally at first on the lateral side of the femoral artery. In the adductor canal it crosses in front of the femoral artery. It emerges from the distal end of the canal by passing under cover of the thickened border of the fibrous expansion which stretches between the vastus medialis and the adductor muscles, and, accompanied by the saphenous branch of the arteria genu suprema, it escapes from under cover of the sartorius, passing between it and the tendon of the gracilis. Then it pierces the deep fascia at the medial side of the knee. After it quits the adductor canal it gives off the *infrapatellar branch*, which pierces the sartorius and appears on the surface of the fascia lata on the medial side of the knee (Fig. 107).

Several large branches of the posterior part of the femoral nerve enter the four segments which compose the great quadriceps extensor muscle of the thigh. From some of the branches, articular filaments are given either to the hip or to the knee joint.

The *branch to the rectus femoris* sinks into the deep surface of that muscle. It supplies an articular twig to the hip joint. The large *branch to the vastus medialis* accompanies the saphenous nerve and enters the proximal part of the adductor canal. It can readily be distinguished, because it sinks into the medial aspect of the vastus medialis, about the middle of the thigh. In the substance of the muscle it extends distally, and near the knee joins the articular branch of the arteria genu suprema. It gives an articular nerve to the synovial layer of the knee joint. The *nerve to the vastus lateralis* is associated with the descending branch of the lateral circumflex artery. Very frequently it gives an articular twig to the knee joint. The *nerves to the vastus intermedius* are two or three in number, and they sink into its anterior surface. The most medial of them is a long slender nerve, which can be traced distally, under the anterior border of the vastus medialis, to the articular muscle of the knee. Its terminal twigs are given to the synovial stratum of the knee joint.

Thus, one filament from the femoral nerve goes to the hip joint; two, and frequently three, filaments go to the knee joint.

**Tractus Ilio-tibialis of the Fascia Lata (O.T. Ilio-tibial Band).**—The thick band of fascia lata on the lateral aspect

of the thigh which receives this name should now be examined, and its connections ascertained. It is attached superiorly to the tubercle on the outer lip of the crest of the ilium, behind the tensor fasciæ latæ, and, inferiorly, to the lateral condyle of the tibia and the head of the fibula. On the lateral condyle of the tibia it is attached to a prominent ridge which extends from the fibular facet forwards and downwards to the tuberosity. It is covered by skin and superficial fascia, and from above downwards it lies superficial to part of the glutæus medius, the greater trochanter, the vastus lateralis, the lower lateral part of the vastus intermedius, the lateral condyle of the femur, and the lateral border of the knee joint. Two muscles are inserted into it: the glutæus maximus posteriorly at the level of the greater trochanter, and the tensor fasciæ anteriorly in the proximal third of the thigh. Above the insertion of the glutæus maximus its posterior border is continuous with the thick fascia on the superficial surface of the glutæus medius, and its anterior border splits into a superficial and a deep lamella, both of which have already been cleared away; for the superficial lamella covered the superficial surface of the tensor fasciæ, and the deep lamella is the layer on the deep surface of the tensor fasciæ which extends medially to become continuous with the tendon of the rectus femoris and the front of the capsule of the hip joint (see p. 248). In the distal half of the thigh its deep surface is attached to the lateral supracondylar ridge of the femur and to the lower part of the linea aspera by the lateral intermuscular septum.

**M. Tensor Fasciæ Latæ (O.T. Tensor Fasciæ Femoris).—**

The tensor of the fascia lata is a small muscle which is placed on the lateral and anterior aspect of the proximal third of the thigh. It lies between the two lamellæ of the proximal part of the ilio-tibial tract, in the interval between the sartorius muscle anteriorly and the glutæus medius muscle posteriorly. Its nerve of supply, a branch of the superior gluteal nerve which enters the deep surface of the muscle a little above the middle of its length, has already been exposed (p. 249).

The *tensor fasciæ latæ* arises from a small portion of the anterior part of the outer lip of the crest of the ilium; from the upper part of the margin of the notch below the anterior superior spine of the ilium; and by some fibres from the fascia

covering the glutæus medius. It extends distally, with a slight inclination posteriorly, and is inserted into the *ilio-tibial tract of the fascia lata*.

**Arteria Circumflexa Femoris Lateralis** (O.T. **External Circumflex Artery**).—The lateral femoral circumflex artery is the largest branch which springs from the profunda femoris artery. It arises near the origin of the latter, and runs laterally, between the divisions of the femoral nerve and then

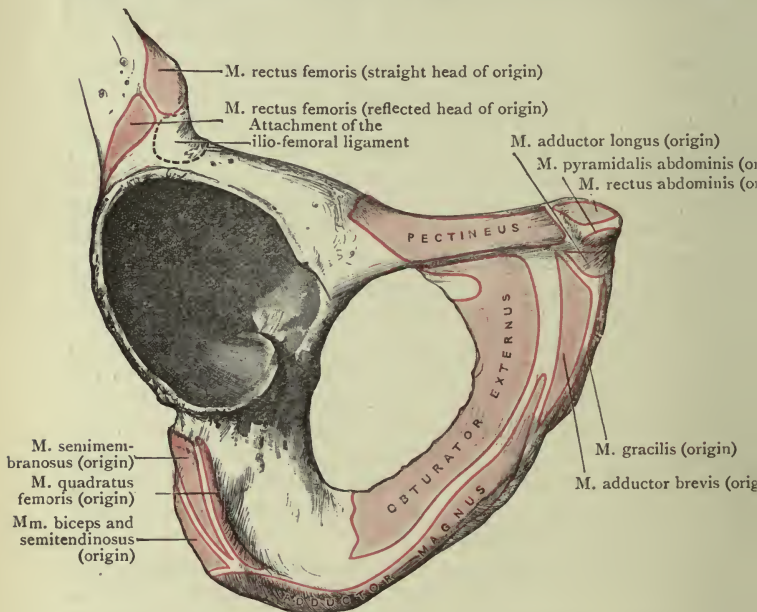


FIG. 116.—External Surface of the Pubis and Ischium, with the Attachments of Muscles mapped out.

under cover of the sartorius, to the deep surface of the rectus femoris muscle, where it ends by dividing into ascending, transverse, and descending branches.

The *ascending branch* reaches the external surface of the upper part of the ilium by ascending along the intertrochanteric line of the femur under cover of the deep surface of the tensor fasciæ latæ. As it ascends it gives a branch to the hip joint, twigs to the adjacent muscles, and its terminal twigs anastomose with branches of the superior gluteal artery.

The *transverse branch* is of small size. It passes to the deep surface of the vastus lateralis, reaches the posterior part of the thigh, and inosculates with the medial femoral circumflex artery and the first perforating artery. The *descending branch* gives twigs to the vastus intermedius and rectus femoris, and one long branch, which may be traced distally, amid the fibres of the vastus lateralis, to the knee, where it anastomoses with the lateral superior genicular artery.

**Dissection.**—Divide the ilio-tibial tract of the fascia lata, distal to the tensor fasciæ latæ, in order to obtain a better demonstration of the limits of the lateral intermuscular septum and a better view of the vastus lateralis muscle. Take hold of the distal part of the ilio-tibial tract and pull it laterally, at the same time push the vastus lateralis medially, then the strong fibrous lateral intermuscular septum will be seen passing towards the linea aspera on the back of the femur.

**Intermuscular Septa.**—There are three intermuscular septa of the thigh: lateral, medial, and posterior (p. 235). The lateral is strong, the other two are both weak. Only the lateral and medial are to be examined at present.

The *lateral intermuscular septum* is a fibrous partition interposed between the vastus lateralis and intermedius anteriorly, and the popliteal fossa and the short head of the biceps femoris posteriorly. It springs from the deep surface of the ilio-tibial tract, and its deep border is attached to the lateral supracondylar ridge and to the lateral lip of the linea aspera of the femur. Parts of the vastus intermedius and vastus lateralis arise from its anterior surface, and some of the fibres of the short head of the biceps femoris spring from its posterior surface. Immediately proximal to the lateral condyle of the femur it is pierced by the *lateral superior genicular artery and nerve*. The *medial intermuscular septum*, which is thin in comparison with the lateral septum, should now be examined. It is interposed between the adductors and the vastus medialis. Its distal part, which is most distinct, passes laterally, from the fascia lata on the medial side of the thigh, behind the posterior border of the sartorius and behind the saphenous nerve, to the medial supracondylar ridge, and it lies in front of the distal part of the adductor magnus. Its proximal part is the thin layer of fascia on the anterior surfaces of the adductors magnus and longus, which is continuous above with the pectineal fascia.

**M. Quadriceps Femoris.**—The quadriceps femoris muscle

is composed of four portions: the rectus femoris, which is placed in the anterior part of the thigh, and is quite distinct from the others, except at its insertion; the vastus lateralis, the vastus intermedius, and the vastus medialis, which clothe the body of the femur on its lateral, anterior, and medial aspects, and are more or less blended with each other.

**M. Rectus Femoris.**—The rectus femoris muscle arises by two tendinous heads of origin, which were exposed when the dissection was carried deeply in the interval between the iliacus and tensor of the fascia lata (p. 250). The *anterior* or *straight head* springs from the anterior inferior spine of the ilium (Fig. 116); the *posterior* or *reflected head* arises, under cover of the

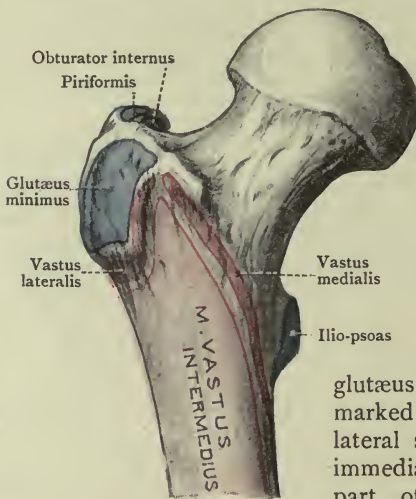


FIG. 117.—Anterior Aspect of Proximal Portion of Femur with Attachments of Muscles mapped out.

glutæus minimus, from a marked impression on the lateral surface of the ilium, immediately above the upper part of the rim of the acetabulum (Fig. 116). It is connected both with the capsule of the hip joint and

the deep lamina of the ilio-tibial tract of the fascia lata.

At the present stage of dissection only the anterior part of the reflected head is visible; the posterior part will be seen when the gluteal region is dissected.

The two heads of origin of the rectus femoris join at a right angle, immediately beyond the margin of the acetabulum, and form a strong, flattened tendon, which gives place to a fusiform, fleshy belly. The tendon of origin spreads out on the anterior surface of the proximal part of the muscle in the form of an aponeurosis. About three inches proximal to the knee joint the rectus femoris ends in a strong tendon of



insertion, which is prolonged for some distance proximally, on its deep surface, in the form of an aponeurosis. As it nears the knee the tendon of the rectus femoris joins the other tendons of the quadriceps, and forms with them a common tendon which is inserted into the proximal border of the patella. The rectus femoris is supplied by the *femoral nerve*.

**M. Vastus Lateralis.**—The lateral vastus muscle forms the greater part of the prominent mass on the lateral side of the thigh. Its surface is covered by a glistening aponeurosis. The descending branch of the lateral circumflex artery constitutes the best guide to its anterior border, and when that margin is raised it will be seen that the muscle lies upon, and is partially blended with, the vastus intermedius.

The vastus lateralis arises—(1) from the upper part of the intertrochanteric line; (2) from the front of the trochanter major, distal to the insertion of the glutæus minimus; (3) from the inferior part of the trochanter major distal to the insertion of the glutæus medius; (4) from the lateral part of the gluteal tuberosity, anterior to the insertion of the glutæus maximus; (5) from the proximal part of the linea aspera; and (6) from the lateral intermuscular septum (Figs. 117, 118, 121). The fleshy fibres are for the most part directed distally and forwards. By means of the common tendon of insertion the muscle gains attachment to the patella and, at the same time, gives an expansion to the capsule of the knee joint. It is supplied by the *femoral nerve*.

**Dissection.**—Divide the rectus femoris about its middle, and pull the distal part forcibly towards the foot. The narrow interval between the tendons of the vastus intermedius and vastus medialis will then become apparent, and will serve as a guide to the line along which the muscles must be separated. Another guide to the line of separation is the long, slender nerve of supply to the articular muscle of the knee; it runs along the medial edge of the vastus intermedius. When the anterior border of the vastus medialis is raised from the vastus intermedius the medial surface of the body of the femur will be seen to be almost bare. Few muscular fibres arise from that bony surface. The fleshy mass of the vastus medialis may now, with advantage, be divided transversely about two inches proximal to the patella. The muscle can then be thrown medially, and its origin studied.

**M. Vastus Medialis.**—The vastus medialis is intimately connected with the vastus intermedius, but not to such an extent as might be inferred from a superficial inspection. In

its proximal part the anterior border, which is fleshy, is either contiguous to or blended with the intermedius; distally, the

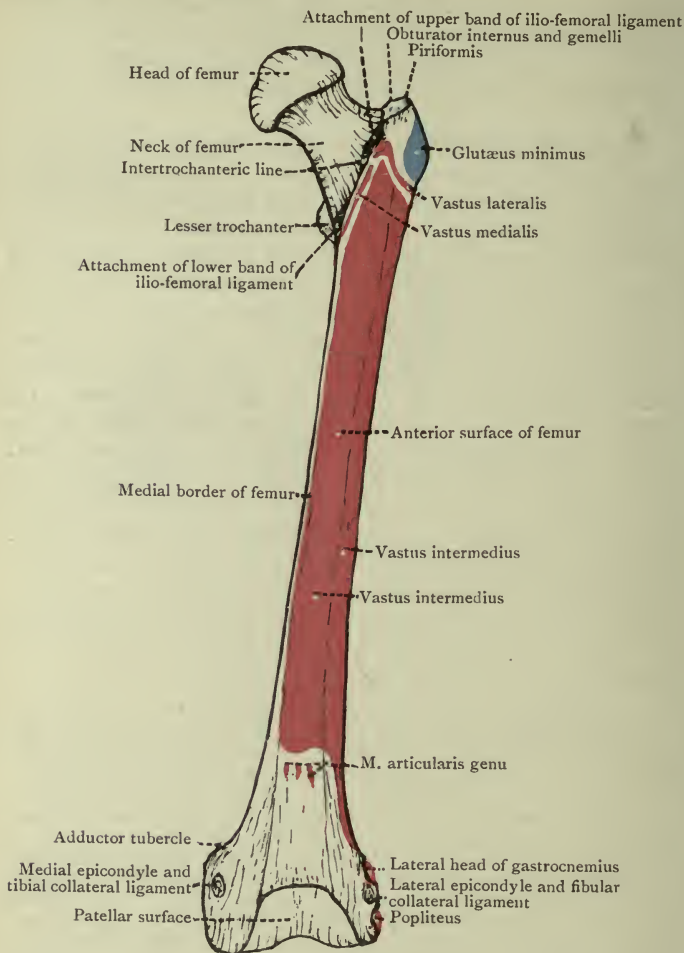


FIG. 118.—Diagram of the Femur seen from in front.

anterior border is tendinous and overlaps the intermedius, but it is not, as a rule, fused with it.

The vastus medialis arises—(1) from the lower part of the

intertrochanteric line; (2) from the line extending from the intertrochanteric line to the linea aspera; (3) from the medial lip of the linea aspera; (4) from the proximal part of the medial supracondylar line as far distally as the opening in the adductor magnus (Figs. 118, 121); (5) from the rounded tendon of the adductor magnus. The fleshy fibres are directed distally and anteriorly, and end in the common tendon of the quadriceps muscle, which is inserted into the patella and becomes connected with the capsule of the knee joint. The muscle is supplied by the *femoral nerve*.

**M. Vastus Intermedius (O.T. Crureus).**—The vastus intermedius covers the anterior and lateral aspects of the body of the femur, from both of which, as well as from the distal part of the lateral intermuscular septum, it takes origin. It is inserted into the patella through the medium of the common tendon. It is supplied by the *femoral nerve*.

**Common Tendon of the Quadriceps.**—It should now be noticed that the common tendon of the quadriceps muscle closes the knee joint proximal to the patella. It is inserted into the proximal border of that bone, and is intimately connected with the capsule of the knee joint. Some fibres are carried distally, across the surface of the patella, into the ligamentum patellæ. A pouch of the synovial stratum is prolonged proximally beyond the level of the patella, between the quadriceps and the bone. Into the wall of that pouch the articular muscle of the knee is inserted.

**Dissection.**—The vastus intermedius should be divided in a vertical direction, so as to bring the little articular muscle into view, and at the same time the long, slender nerve-filament which runs along the medial border of the vastus intermedius may be traced to the muscle and the synovial stratum of the knee joint. The articular muscle consists of a few slips of muscle fibres which spring from the lower part of the front of the femur. They are inserted into the upper part of the synovial stratum of the capsule of the knee joint.

The *ligamentum patellæ*, which connects the patella with the tuberosity of the tibia, and through which the quadriceps is attached to that bone, will be studied in connection with the knee joint. It may be noted now that it is a broad, thick tendon, which extends from the patella to the tuberosity of the tibia.

The quadriceps femoris, acting as a whole, is an extensor of the knee, but the rectus femoris can also flex the hip joint.

The articularis genu merely lifts the upper part of the synovial stratum of the capsule of the knee to prevent its being caught between the bones as the knee joint is extended.

### MEDIAL SIDE OF THE THIGH.

The group of adductor muscles on the medial aspect of the thigh, together with the blood-vessels and nerves associated with them, must next be dissected. As the dissection proceeds the following structures will be displayed:—

Muscles,	{	Pectineus.
		Adductor longus.
		Adductor brevis.
		Adductor magnus.
		Gracilis.
		Obturator externus.
Arteries,	{	Profunda femoris (and its branches).
		Obturator.
Nerves,	{	The two divisions of the obturator nerve.
		The accessory obturator nerve, when present.

The adductor muscles are disposed in three strata. The *anterior stratum* is formed by the pectineus and the adductor longus, which lie in the same plane. Their adjacent borders touch one another proximally, but distally they are separated by a small interval. The *second stratum* is formed by the adductor brevis; and the *third*, or *posterior layer*, by the adductor magnus. The gracilis muscle, also an adductor, extends along the medial aspect of the thigh. It is a long, strap-like muscle, applied against the adductor brevis and adductor magnus. Interposed between the three muscular layers are the two divisions of the *obturator nerve*. The *anterior division* is placed between the anterior and middle layers; the *posterior division* lies between the middle and posterior layers. In other words, the adductor brevis intervenes between them. At the distal border of the adductor longus, a fine branch from the anterior division of the nerve makes its appearance; it takes part in the formation of the sub-sartorial nerve plexus already dissected. The profunda artery and its branches also are to be followed. For a part of its course this vessel is placed between the anterior and middle muscular strata.

**M. Adductor Longus.**—The adductor longus muscle is

placed on the medial side of the pectineus. It is somewhat triangular in shape, being narrow at its origin and expanded at its insertion. It arises by a short, but strong, tendon from the anterior surface of the body of the pubis, immediately below the pubic crest (Fig. 116), and it is inserted into the medial lip of the linea aspera of the femur by a thin, tendinous expansion. It is supplied by the *anterior division* of the *obturator nerve*. It acts like the adductor brevis (p. 272).

**Dissection.**—Divide the adductor longus 25 mm. below its origin. Turn the proximal part upwards and notice how the flat tendon is so curved upon itself that it simulates the appearance of a round tendon. Turn the distal portion towards the femur, and secure its nerve of supply from the anterior division of the obturator nerve, which lies posterior to the muscle. As the femur is approached the muscle fibres will be found to terminate in a thin aponeurosis, by which the muscle is attached to the linea aspera. This aponeurosis of insertion is intimately connected anteriorly with the vastus medialis and posteriorly with the adductor magnus. Separate it from both as far as possible; especially from the adductor magnus, in order to display the profunda vessels, which lie, in part of their course, between the adductors longus and magnus.

**Art. Profunda Femoris.**—This large vessel is the chief artery of supply to the muscles of the thigh. It arises, in the femoral triangle, from the lateral and posterior aspect of the femoral artery, about an inch and a half distal to the inguinal ligament. At first it is placed on the iliacus, but, as it proceeds distally, it inclines medially, and thus it crosses posterior to the femoral artery, and comes to lie on the pectineus. Reaching the upper border of the adductor longus, it passes posterior to that muscle, and is continued distally, close to the body of the femur, in front of the adductor brevis and adductor magnus. Numerous large branches spring from the profunda femoris, so that it rapidly diminishes in size. Ultimately it is reduced to a fine terminal twig, which turns backwards through the adductor magnus, and receives the name of the *fourth perforating artery*. The following are the relations of the profunda femoris:—(1) It lies anterior to the iliacus, on the lateral side of the femoral artery. (2) It is anterior to the pectineus and posterior to the femoral artery, but separated from it by the femoral vein and the profunda femoris vein. (3) It is anterior to the adductor brevis, and, more distally, to the adductor magnus, and it is posterior to the adductor longus, which separates it from the femoral vessels.

(4) The terminal twig, called the fourth perforating artery, pierces the adductor magnus in the middle third of the thigh.

The *branches* which spring from the profunda femoris are:—the two femoral circumflex arteries, the four perforating arteries, and some muscular branches.

The *lateral femoral circumflex artery* arises from the lateral aspect of the profunda, close to its origin. It has already been followed to its distribution (p. 260). The *medial*

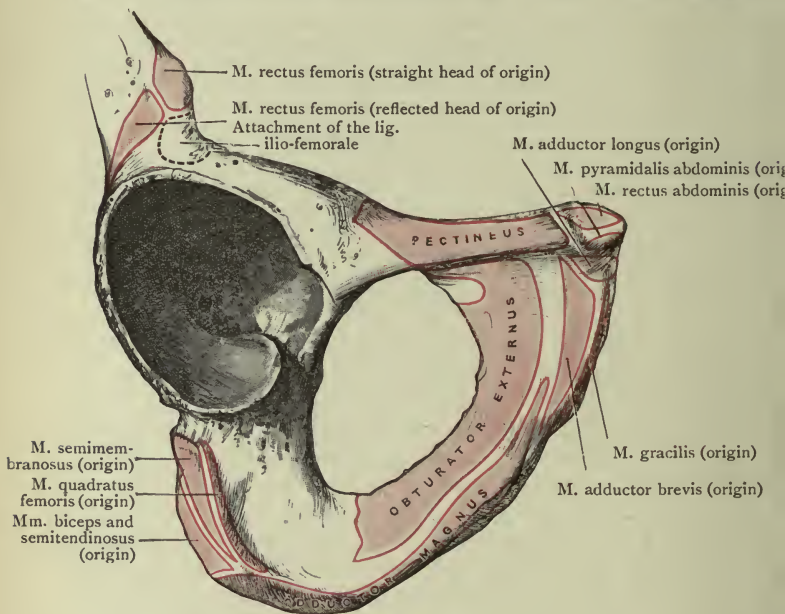


FIG. 119.—External Surface of the Os Pubis and Ischium, with Attachments of Muscles mapped out.

*femoral circumflex artery* which takes origin at the same level, but from the medial and posterior aspect of the profunda, will be studied when the pectineus muscle is reflected. The medial femoral circumflex artery frequently arises from the femoral trunk. The *muscular branches* are irregular both in origin and size. They supply the adductor muscles, and give twigs which pierce the adductor magnus to reach the hamstring muscles.

**Arteriæ Perforantes.**—The perforating arteries arise in

series from the profunda femoris, and pass backwards through the adductor muscles to the posterior region of the thigh. They may be recognised from the close relation which they bear to the linea aspera of the femur. The *first perforating artery* comes off at the level of the distal or medial border of the pectineus. It proceeds backwards through the adductor brevis and adductor magnus. The *second perforating artery* takes origin a short distance distal to the first perforating, or perhaps by a common trunk with it. It pierces the same muscles, viz., the adductor brevis and adductor magnus. The *third perforating artery* springs from the profunda, distal to the adductor brevis, and passes backwards through the adductor magnus. The *fourth perforating artery*, as before noted, is the terminal branch of the profunda femoris; it pierces the adductor magnus alone.

The *superior nutrient artery* of the femur may spring from either the second or the third perforating branch. An *inferior nutrient artery* is frequently present; it is often derived from the fourth perforating artery.

When the adductor magnus is more fully exposed it will be seen that the perforating arteries, as they pierce its tendon, are protected by a series of fibrous arches. The

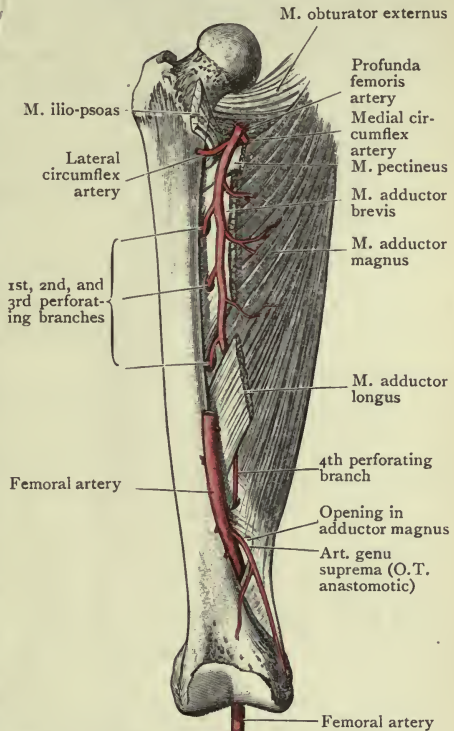


FIG. 120.—The Profunda Femoris Artery and its Branches.

further course of the perforating arteries is dealt with on p. 323.

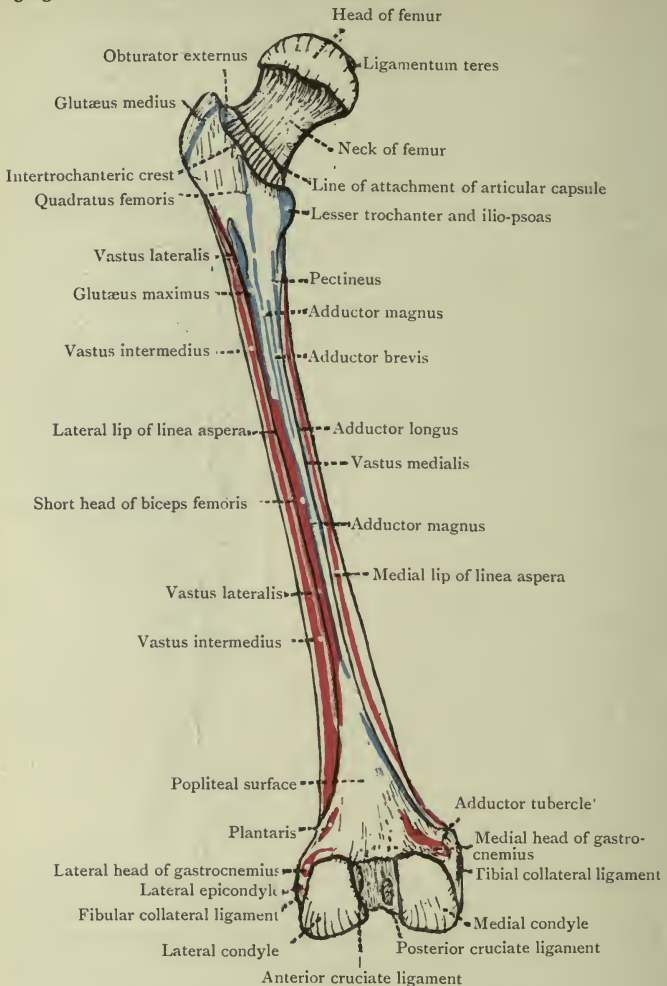


FIG. 121.—Diagram of the Femur seen from behind.

**M. Pectineus.**—The pectineus muscle is placed between the adductor longus and the ilio-psoas. It is flat and somewhat broader at its origin from the brim of the pelvis than



at its insertion into the femur. It has a fleshy origin, from the pectineal line of the pubis, and from the surface of the hip bone anterior to it (Fig. 116). Some fibres are derived also from the lacunar ligament. It descends obliquely, laterally and backwards, and gains insertion into the back of the femur, lateral to the lesser trochanter, and to a certain extent also into the line which leads from that prominence towards the linea aspera (Figs. 121, 122). It is supplied by the *femoral nerve*. The pectineus adducts the femur and rotates the thigh laterally. It also assists in flexion of the hip joint.

**Dissection.** — Detach the pectineus from its origin, and throw it towards its insertion. Whilst separating the muscle from the pubis the dissector must bear in mind that in some cases an *accessory obturator nerve* descends into the thigh, under cover of its lateral margin, and over the pubis. Care must also be taken not to injure (1) the anterior division of the obturator nerve which lies posterior to the muscle, or (2) the medial femoral circumflex artery which passes posteriorly in contact with the lateral border of the muscle (Fig. 113).

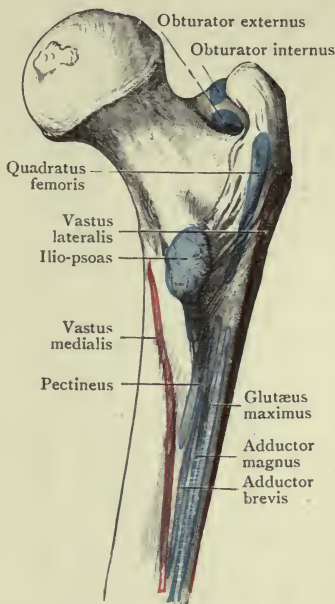


FIG. 122.—Posterior Aspect of Proximal Portion of Femur, with the Attachments of Muscles mapped out.

**Nervus Obturatorius Accessorius.**—The accessory obturator nerve, when present, arises within the abdomen either from the lumbar plexus or from the obturator trunk near its origin (Fig. 124). In the thigh it gives a branch to the hip joint and joins the anterior division of the obturator nerve. It is very rare to find a twig given to the pectineus either by it or by the trunk of the obturator nerve itself.

**Art. Circumflexa Femoris Medialis.**—The medial femoral circumflex artery springs from the medial and posterior aspect

of the profunda femoris artery, at the same level as the lateral femoral circumflex branch. It passes posteriorly between the adjacent margins of the psoas and the pectineus, and then between the adductor brevis and the obturator externus, to the posterior region of the thigh, where, close to the lesser trochanter, it divides into an ascending and a transverse terminal branch. Before the main trunk divides it gives off (1) a superficial branch which passes, medially, across the front of the pectineus and then between the adductors longus and brevis, and (2) an articular branch which enters the hip joint through the acetabular notch. The terminal branches will be examined in the dissection of the gluteal region.

**Branches of the Femoral Artery.**—In every region of the thigh the dissector has met with branches of the femoral artery. It is well now that he should revert to this vessel and study its branches in the order in which they arise. The following Table may aid him in doing this:—

A. femoralis.	{	Aa. pudendæ externæ.	}	Superficial inguinal.
		A. epigastrica superficialis.		
A. circumflexa ilium superficialis.				
A. profunda.	{	A. circumflexa femoris lateralis.	}	Aa. Nutritiæ.
		A. circumflexa femoris medialis.		
		A. perforans prima.		
		A. perforans secunda.		
		A. perforans tertia.		
		A. perforans quarta (terminal).		
Rami Musculares.				
A. genu suprema.				

**M. Adductor Brevis.**—The short adductor muscle lies posterior to the adductor longus and the pectineus. It arises, below the origin of the adductor longus, from the anterior aspect of the body and the inferior ramus of the os pubis (Fig. 116). As it descends it inclines posteriorly and laterally; and it is inserted, posterior to the pectineus, into the greater part of the line which extends from the lesser trochanter to the linea aspera (Fig. 121), and into the proximal part of the linea aspera, lateral to the adductor longus. It is supplied by the *obturator nerve*. It is an adductor and a lateral rotator of the thigh and a flexor of the hip joint.

**Dissection.**—Divide the adductor brevis, parallel with and close to its origin, and turn it towards its insertion, but do not injure the anterior division of the obturator nerve which lies in front of it. When the muscle is reflected the posterior division of the obturator nerve will be exposed. Trace the nerve, proximally, to the point where it pierces the obturator

externus at the obturator foramen, and, distally, to its disappearance in the adductor magnus.

**Nervus Obturatorius.**—The obturator nerve is a branch of the lumbar plexus. It escapes from the pelvis by passing,

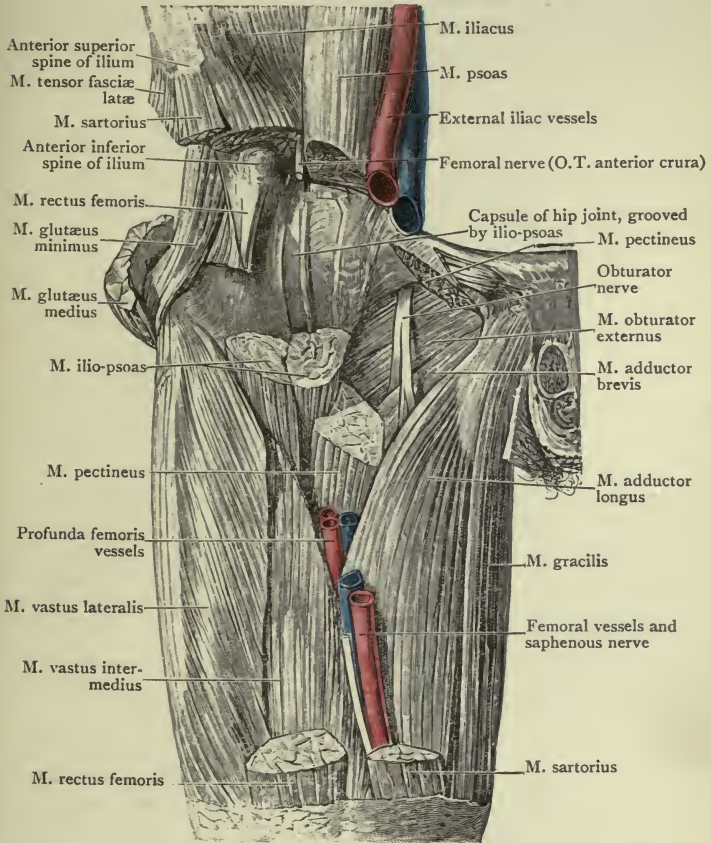


FIG. 123.—Dissection of the Front of the Thigh. The hip joint has been exposed by removing portions of the muscles which lie anterior to it.

with its companion vessels, through the upper part of the obturator foramen of the hip bone (Fig. 125). While still within the foramen it divides into an anterior and a posterior division.

The *anterior division* of the obturator nerve enters the thigh over the upper border of the obturator externus muscle, and proceeds, distally, upon the anterior surface of the adductor brevis. Anterior to it are the pectineus and adductor longus muscles. It gives branches to three muscles, viz., the adductor longus, the adductor brevis, and the gracilis. Very rarely

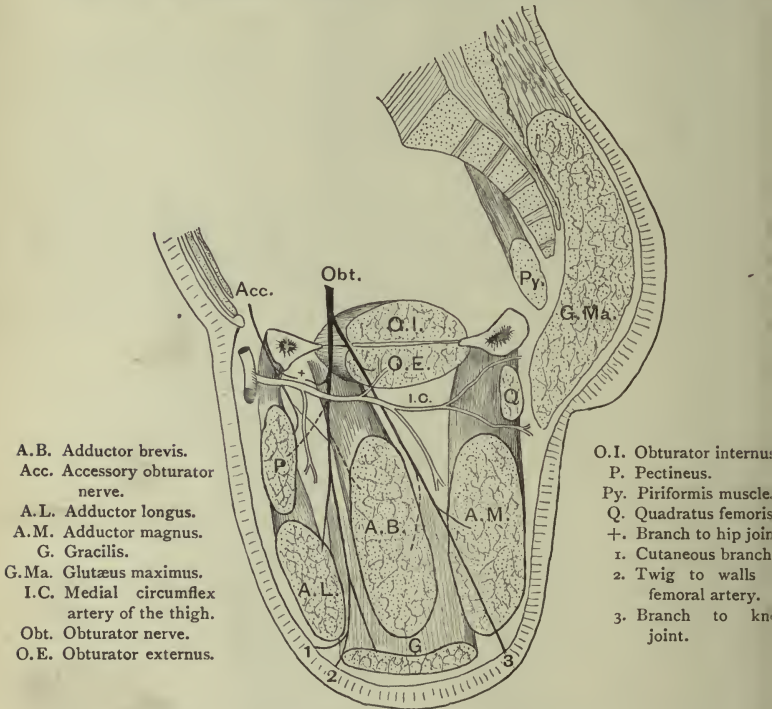


FIG. 124.—Diagram to illustrate the distribution of the Obturator Nerve and the general disposition of the Adductor Muscles of the Thigh (Paterson).

it supplies a twig to the pectineus. In addition to these branches it also supplies—(1) an *articular branch* to the hip joint (Fig. 124. +); (2) a fine twig, which appears at the distal border of the adductor longus, to join the sub-sartorial plexus; and (3) a *terminal twig*, which goes to the femoral artery—(Fig. 124)—and breaks up into fine filaments upon its walls.

The *posterior branch* of the obturator nerve, as it enters the thigh, pierces the upper border of the obturator externus. It extends distally, between the adductor brevis and the adductor magnus, and is expended chiefly in the supply of the latter muscle. It gives also, however, a branch to the obturator externus and an *articular branch* to the knee joint. The latter branch pierces the distal part of the

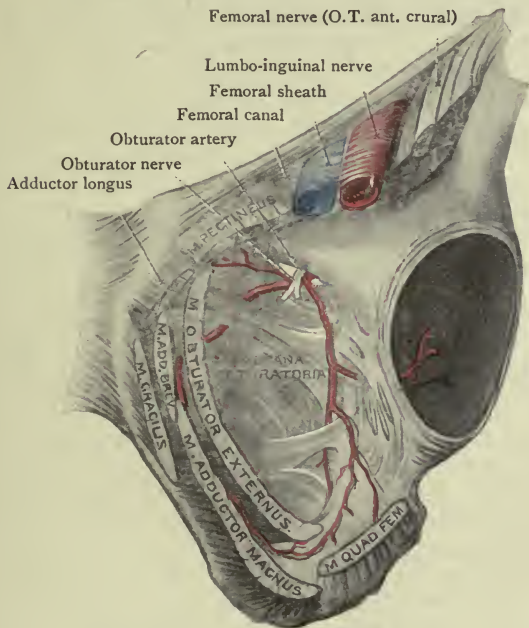


FIG. 125.—Dissection to show the Structures surrounding the Obturator Foramen of the Hip Bone.

adductor magnus, close to the linea aspera, and may be seen in the popliteal fossa, lying posterior to the popliteal artery.

**M. Gracilis.**—The gracilis is a long, strap-like muscle, which lies along the medial aspect of the thigh and knee. It springs, by a thin tendon, from the lower half of the body of the pubis, close to the symphysis, and also from the upper half of the pubic arch (Fig. 119). It ends in a slender, rounded

tendon which inclines forwards, distal to the knee, and then expands and is inserted into the proximal part of the medial surface of the tibia, under cover of the tendon of the sartorius, and at a higher level than the insertion of the semitendinosus (Fig. 139, p. 322). A mucous bursa separates the expanded tendon of the gracilis from the tibial collateral ligament of the knee joint, and is prolonged proximally, so as to intervene between it and the tendon of the sartorius. The gracilis is supplied by the *anterior division* of the *obturator nerve*. It adducts the thigh, flexes the knee joint and rotates the leg medially.

**M. Adductor Magnus.**—The adductor magnus is one of the most powerful muscles of the thigh. It forms a flat, fleshy mass, which springs from the anterior surface of the entire length of the pubic arch of the corresponding side, and from the lower part of the ischial tuberosity (Figs. 128, 129). The fibres which arise from the pubic arch spread out as they approach the posterior aspect of the femur; the more medial in origin are the more horizontal in direction; the more lateral in origin are the more oblique in direction. They are inserted into the posterior part of the femur, just medial to the gluteal tuberosity, into the *linea aspera*, and into a small portion of the proximal part of the medial supracondylar ridge (Figs. 121, 122). The fibres which take origin from the ischial tuberosity descend almost vertically and form the thick medial border of the muscle. In the distal third of the thigh they end in a strong, rounded tendon, which is inserted into the adductor tubercle on the medial condyle of the femur (Figs. 120, 121). This tendon is further attached to the femur by the medial intermuscular septum which stretches between it and the medial supracondylar line. Close to the *linea aspera* are the fibrous arches, formed in connection with the insertion of the adductor magnus, for the passage of the perforating arteries, and in series with them is the opening through which the femoral artery enters the popliteal fossa. The opening is a gap between two portions of the muscle, and is situated at the junction of the proximal two-thirds with the distal third of the thigh (Fig. 120).

The adductor magnus has a double nerve supply. The fibres which spring from the pubic arch are supplied by the posterior branch of the *obturator nerve*. Those which arise from the ischial tuberosity are supplied by the *sciatic nerve*.

The fibres which spring from the rami of the pubis and ischium act like the fibres of the other adductor muscles, that is, they adduct the thigh, rotate it laterally, and help to flex the hip joint, but the fibres which arise from the tuberosity of the ischium and are inserted, by tendon, into the adductor tubercle of the femur extend the hip joint.

**Dissection.**—Detach the adductor magnus from its origin from the pubic and ischial rami, in order that the obturator externus muscle and the obturator artery may be more fully examined.

**M. Obturator Externus.**—The obturator externus is a flat, fan-shaped muscle, which is placed over the anterior aspect of the obturator foramen of the hip bone. It springs from the medial half of the membrane which closes the foramen, and also from the medial and lower part of its bony margin (Figs. 119, 128). It passes backwards and laterally, below and behind the neck of the femur and the capsule of the hip joint, and ends in a stout tendon which obtains insertion into the trochanteric fossa (Figs. 121, 122). This tendon will be examined in the dissection of the gluteal region. The obturator externus is supplied by the *posterior division* of the *obturator nerve*. It is a flexor of the hip joint and an adductor and lateral rotator of the thigh.

**Art. Obturatoria.**—The obturator artery appears in the thigh through the upper part of the obturator foramen of the hip bone. It at once divides into two terminal branches, which diverge from each other and form an arterial circle upon the obturator membrane, under cover of the obturator externus. The muscle must therefore be detached in order that the vessels may be followed. Both branches give twigs to the neighbouring muscles, whilst the *posterior branch* sends an *articular twig* through the acetabular notch into the hip joint. When the joint is opened this twig may be followed, in a well-injected subject, along the ligamentum teres into the head of the femur.

**Mm. Psoas Major and Iliacus.**—Both the psoas major and the iliacus muscles arise within the abdomen, and they enter the thigh posterior to the inguinal ligament. A tendon appears on the lateral side of the psoas major, and into this the fibres of the iliacus are for the most part inserted. The conjoined tendon of the ilio-psoas is implanted into the lesser trochanter of the femur, but a certain proportion of the fleshy

fibres of the iliacus obtain direct insertion into the body of the femur, distal to that prominence (Figs. 121, 122).

The action of the psoas major and the iliacus depend upon the position of the hip joint when the muscles are in action. If the hip joint is extended they flex it, and rotate it medially until it is flexed; then they rotate it laterally.

**Dissection.**—Divide the femoral vessels and the femoral nerve, about an inch distal to the inguinal ligament, and having tied them together with twine throw them distally. Now cut through the sartorius and the rectus femoris, about two inches from their origins, and turn them aside. The tendon of the ilio-psoas must next be detached from its insertion and, with the muscle, turned upwards. This will expose the anterior surface of the capsule of the hip joint. An intervening mucous bursa also will be displayed. Open this and ascertain its extent by introducing the finger. It facilitates the play of the ilio-psoas upon the front of the hip joint, and in some cases its cavity will be found to be directly continuous with the cavity of the joint, through an aperture in the capsule. The intimate connection which exists between the capsule of the hip joint and the tendon of the glutæus minimus, the reflected head of the rectus femoris, and the deep layer of the ilio-tibial tract, should be noticed. Lastly, turn aside the tensor fasciæ latae, and carefully clean the anterior aspect of the capsule of the hip joint.

At the end of the fifth day the dissector must paint the various parts of the anterior and medial regions of the thigh with preservative solution, replace them in position and fix the skin flaps over them with a few points of suture.

On the morning of the sixth day, after the dissection of the lower limb has been begun, the subject is placed upon the table with its face downwards and its thorax and pelvis supported by blocks. In that position it is allowed to remain for *five* days, and during that time the dissector of the lower extremity has a very extensive dissection to perform. He has to dissect—(1) the gluteal region; (2) the popliteal fossa; and (3) the posterior region of the thigh. With so much work before him, and being limited as to the time in which it must be done, it is necessary that he should apportion the five days at his disposal so as to complete the dissection before the body is turned again. The *first two* → *days* he should devote to the study of the gluteal region; the *third* and *fourth days* may be given to the popliteal fossa; and on the *fifth day* he should undertake the dissection of the back of the thigh, and revise the work of the preceding four days.



## GLUTEAL REGION.

In the gluteal region the following parts will be displayed in the course of the dissection :—

1. Superficial fascia.
2. Cutaneous nerves and blood-vessels.
3. Deep fascia.
4. { Glutæus maximus (and after this has been reflected),  
Three mucous bursæ.  
The glutæus medius and minimus.  
The two gemelli muscles and the tendon of the obturator internus.  
Tendon of the obturator externus.  
Proximal border of the adductor magnus.  
The origin of the hamstrings from the ischial tuberosity.  
The proximal part of the vastus lateralis.
5. The sacro-tuberous ligament. (O.T. great sciatic lig.)
6. Arteries. { Superior gluteal.  
Inferior gluteal (O.T. sciatic).  
Internal pudendal.  
Medial femoral circumflex.
7. Nerves . . . { Superior gluteal.  
Sciatic.  
Posterior cutaneous of the thigh.  
Pudendal.  
Nerve to obturator internus.  
Nerve to quadratus femoris.  
Inferior gluteal.

Supposing that *two days* are allowed for the above dissection, the **first day's work** should consist of—(1) the dissection of the parts superficial to the glutæus maximus ; (2) the cleaning and reflecting of that muscle ; (3) the tracing and defining of the various nerves and blood-vessels which enter its deep surface. **On the second day** the parts which are exposed by the reflection of the glutæus maximus should be dissected.

**Surface Anatomy.**—Before the skin is reflected the surface markings of the gluteal region must be examined. On each side the prominence of the nates forms a round, smooth elevation. Inferiorly the nates are separated, in the middle line, by a deep fissure—the *natal cleft*. The cleft can be traced upwards over the coccyx to the level of the lower part of the sacrum where it disappears. The crest of the ilium can be felt along its whole length, and in the well-formed male its position is indicated by a groove—the *iliac furrow*. The anterior end of the crest terminates in the anterior superior spine of the ilium ; the posterior end is the posterior superior spine of the ilium. The position of the latter is indicated by a faint depression or dimple which lies on a level with the second spine of the

sacrum, and it corresponds with the middle of the sacro-iliac articulation. The prominence of the nates is formed chiefly by the glutæus maximus muscle, covered by a thick layer of fat. A deep transverse groove, produced by a fold of skin and fascia, limits the gluteal elevation below. The groove is called the *gluteal sulcus*, and is sometimes said to correspond with the distal border of the glutæus maximus muscle. It can easily be shown that this is not the case. Its medial end lies distal to the inferior margin of the muscle, but as the sulcus proceeds transversely it crosses the border of the muscle, and finally comes to lie on the surface of the muscle. In disease of the hip joint, the buttock loses its prominence, whilst the gluteal sulcus becomes faint. The tuberosity of the ischium may be felt, deep to the lower border of the glutæus maximus, if the fingers are placed in the medial part of the gluteal sulcus and pressed upwards. A line drawn from the most prominent part of this tuberosity to the anterior superior spine of the ilium is called *Nelaton's line*; it passes over the top of the greater trochanter and crosses the centre of the acetabulum; and it is used by the surgeon in the diagnosis of dislocations and other injuries of the hip joint. The greater trochanter of the femur may be felt at a point about six inches below the highest part of the crest of the ilium. It can be seen in thin subjects, but it does not form so projecting a feature of this region as might be expected from an inspection of the skeleton, because the thick tendon of the glutæus medius is inserted into its lateral surface, and it is covered also by the aponeurotic insertion of the glutæus maximus.

**Dissection.**—**Reflection of Skin.**—**Incisions.**—(1) From the posterior superior spine of the ilium in a curved direction along the crest of the ilium, as far forwards as the position of the body will permit; (2) from the posterior extremity of this curved incision obliquely downwards and medially to the middle line of the sacral region, and then perpendicularly to the tip of the coccyx; (3) from the tip of the coccyx obliquely distally and laterally over the back of the thigh, to the junction of the proximal and distal halves of the posterior border of the lateral area of the thigh.

A large flap of skin is thus marked out, and this must be raised from the subjacent superficial fascia and thrown laterally. On the right side of the body the dissector begins at the crest of the ilium and works downwards and forwards; whilst on the left side he commences over the coccyx and works upwards and forwards.

Superficial Fascia (Panniculus Adiposus).—After the skin

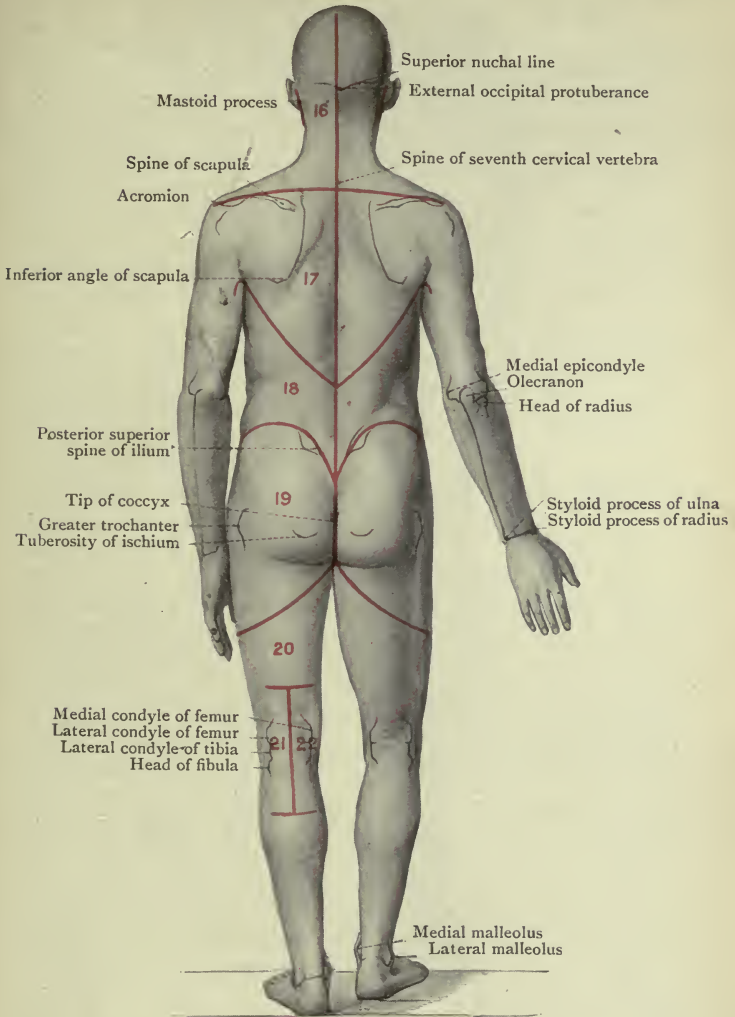


FIG. 126.—Surface view, showing incisions and bony points.

is reflected the superficial fascia which is exposed, is seen to

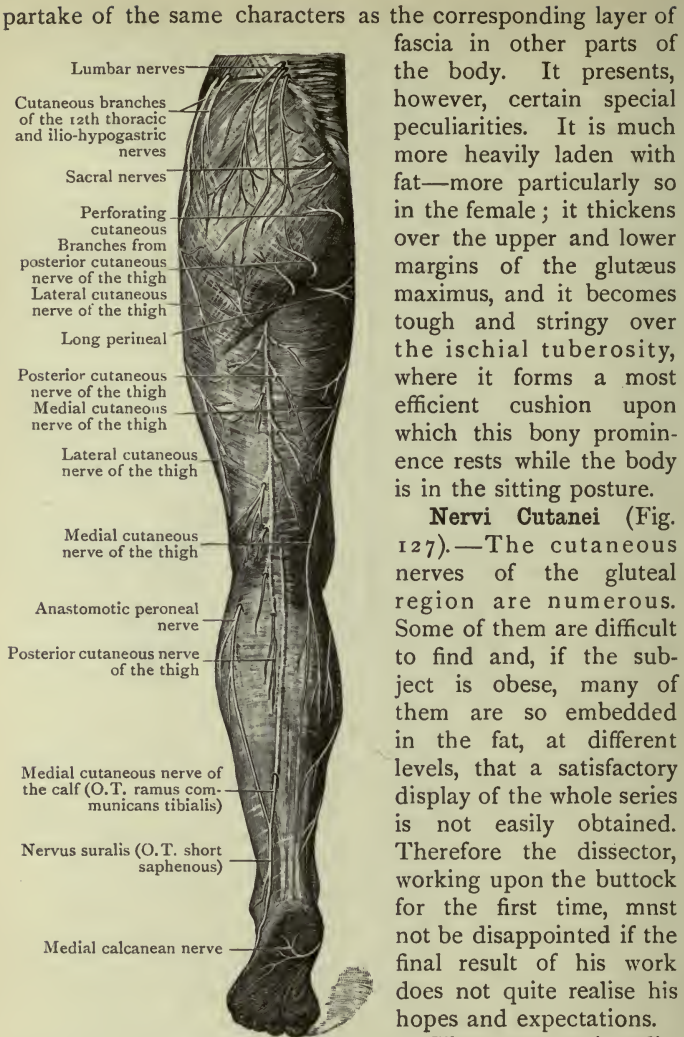


FIG. 127.—Cutaneous Nerves on the posterior aspect of the Inferior Extremity.

derived from the anterior ramus of the last thoracic and from the anterior and posterior rami of the lumbar and

**Nervi Cutanei** (Fig. 127).—The cutaneous nerves of the gluteal region are numerous. Some of them are difficult to find and, if the subject is obese, many of them are so embedded in the fat, at different levels, that a satisfactory display of the whole series is not easily obtained. Therefore the dissector, working upon the buttock for the first time, must not be disappointed if the final result of his work does not quite realise his hopes and expectations.

The nerve twigs distributed to the skin of the gluteal region are

sacral nerves, and they ramify, as in other regions, in the superficial fascia on their way towards their terminations.

The nerves which must be sought for are—

Branches of anterior rami of spinal nerves.	{ Lateral branch of last thoracic. Lateral branch of the ilio-hypogastric. Twigs from the posterior branch of the lateral cutaneous nerve of the thigh. Twigs from the posterior cutaneous nerve of the thigh. The perforating cutaneous nerve.	
Branches of posterior rami of spinal nerves.		
		{ Branches from the three upper lumbar nerves. Three branches from the sacral nerves.

The branches of the sacral nerves supply the skin of the lower and medial area of the buttock. The lumbar nerves are distributed to the upper part of the medial area and to the upper two-thirds of the intermediate area. The lateral branches of the ilio-hypogastric, the last thoracic nerve, and the lateral cutaneous nerve of the thigh supply the lateral area, and the lower area along the fold of the buttock receives the perforating cutaneous nerve and twigs from the posterior cutaneous nerve of the thigh (Fig. 127).

**Dissection.**—Seek first for the branches of the posterior rami of the sacral nerves. Make an incision through the superficial fascia along a line, commencing 2 cm. medial to the posterior superior spine of the ilium and terminating at the tip of the coccyx. Then reflect the lateral part of the superficial fascia away from the median plane and secure the nerves as they pierce the deep fascia superficial to the sacral and coccygeal origins of the glutæus maximus muscle. They are usually three in number; all are small, but the middle of the three is usually the largest of the series, and as a rule they are situated about 25 mm. from one another.

The branches of the posterior rami of the lumbar nerves should next be sought. Make an incision *into* but *not through* the superficial fascia along the line of the crest of the ilium. The object of the incision is to enable the dissector to raise a superficial layer of the superficial fascia, and its depth must vary with the obesity of the subject. In a very fat subject it may be 3 or 4 mm. deep, but in a thin subject it must not be more than 2 mm. deep. After the incision is made, raise a superficial layer of the lower part of the superficial fascia, throw it towards the trochanter major, and secure twigs of the lumbar nerves as they pass from the deeper to the more superficial layers of the fascia. As soon as a twig is found, follow it towards the iliac crest; it will lead to the trunk from which the twig issues. As soon as the trunk is secured, trace it and its branches towards their terminations. As the branches are being cleaned twigs from the adjacent lumbar nerves are certain to be exposed, for

the twigs from adjacent nerves cross one another and sometimes unite with one another. Trace such twigs to their sources of origin; when the trunk from which they arise is found, follow it and its branches to their peripheral distribution. If the plan outlined is followed the dissector will demonstrate the branches of the lumbar nerves without any great difficulty. He should then attempt to find the lateral branches of the ilio-hypogastric and last thoracic nerves, following the same plan of search. The trunks of the two branches cross the iliac crest anterior to the lumbar nerves, the lateral branch of the last thoracic about 5 cm. posterior to the anterior superior spine of the ilium and the lateral branch of the ilio-hypogastric a centimetre or more further back. If the branches of the posterior division of the lateral cutaneous nerve of the thigh were found and left in position when the anterior part of the thigh was dissected, they may be revised now, otherwise the dissector need waste no time in looking for them, for they will have been already removed. No time need be lost in looking for the perforating cutaneous nerve. It pierces the deep fascia and enters the superficial fascia near the medial part of the lower border of the glutæus maximus about 2 or 3 cm. from the tip of the coccyx and medial to the ischial tuberosity, and it has either been displayed and left *in situ* by the dissector of the perineum, or it has been removed. To display the gluteal branches of the posterior cutaneous nerve of the thigh, cut through the superficial fascia along the lower border of the glutæus maximus till the deep fascia is exposed, then reflect the superficial fascia upwards and secure the branches sought for as they pierce the deep fascia about midway between the trochanter major and the tuber ischii.

In well-injected subjects many of the nerves mentioned are accompanied by small injected arteries which serve as guides to the nerves, but such arteries cannot be depended upon, and the dissector should rely upon his senses of sight and touch to enable him to distinguish the firmer nerve fibres from the strands of connective tissue which permeate the fat.

After the cutaneous nerves have been demonstrated the remains of the superficial must be removed both from the region of the glutæus maximus and the region anterior to it in order that the deep fascia may be examined.

**Deep Fascia.**—The deep fascia now exposed differs in character in the anterior and posterior parts of its extent. In front of the glutæus maximus, where the fascia lies over the anterior part of the glutæus medius, it is dense in texture and opaque and pearly white in colour. That part stands in marked contrast with the deep fascia over the glutæus maximus itself, which is thin and transparent. Subsequent dissection will show that the dense fascia over the anterior part of the glutæus medius, when it reaches the anterior border of the glutæus maximus, splits into two lamellæ which enclose the glutæus maximus between them.

**Dissection.**—Follow the branches of the posterior cutaneous

nerve of the thigh to the trunk of that nerve at the lower border of the glutæus maximus, and after the trunk of the nerve is secured, proceed to clean the glutæus maximus. The dissector of the right inferior extremity should begin at the upper border of the muscle and work downwards, the dissector of the left limb should work upwards from the inferior border. On the right side the dissector should cut through the deep fascia a little below the upper border of the muscle, then he should raise the upper portion of the divided fascia until the upper border of the muscle is exposed, and the fascia superficial to it is found to blend with the strong fascia covering the glutæus medius. The upper border of the muscle should now be raised and drawn downwards to display the layer of deep fascia subjacent to it. When this has been done the dissector will readily realise that the strong fascia on the more anterior part of the glutæus medius splits at the upper border of the maximus into a superficial layer which covers the maximus and a deep layer which passes downwards over the lower part of the glutæus medius and the muscles which lie more distally at the back of the hip joint. The dissector on the left side will demonstrate the same facts when he reaches the upper border of the muscle, for he will find the deep fascia which he has raised from the surface of the glutæus maximus blends with the strong fascia on the glutæus medius, and by lifting the upper border of the maximus he will display the deeper layer of fascia.

The glutæus maximus is a difficult muscle to clean, as the fasciculi are exceedingly coarse. It is necessary therefore not only to remove the fascia which covers the muscle, but at the same time to follow, for a short distance, the septa which penetrate between the fasciculi and to remove them also. Do not remove the thick opaque fascia which covers the insertion of the muscle.

If the work is to be done well the dissector must keep clearly before him the rules which have already been laid down regarding the cleaning of a muscle: (1) Render the fibres as tense as possible by rotating the limb medially; (2) remove the fascia in one continuous layer; (3) always cut in the direction of the muscular fibres; (4) define very carefully the borders of the muscle.

**M. Glutæus Maximus.**—The glutæus maximus is a powerful muscle which arises—(1) from a narrow, rough area on the dorsum ilii, which is included between the posterior curved line and the outer lip of the crest; (2) from the sides of the lower two pieces of the sacrum and the upper three pieces of the coccyx; (3) from the entire posterior surface of the sacro-tuberous ligament (O.T. great sciatic); and (4), slightly, from the posterior layer of the lumbo-dorsal fascia, at the attachment of that fascia to the crest of the ilium.

From this extensive origin the coarse fasciculi of the muscle proceed obliquely downwards and forwards towards the proximal portion of the femur; but only a comparatively

small proportion of them receive direct insertion into that bone. The greater part of the muscle is inserted into the fascia lata. To be more precise, it may be said that the deeper fibres of the lower half of the muscle are directly attached

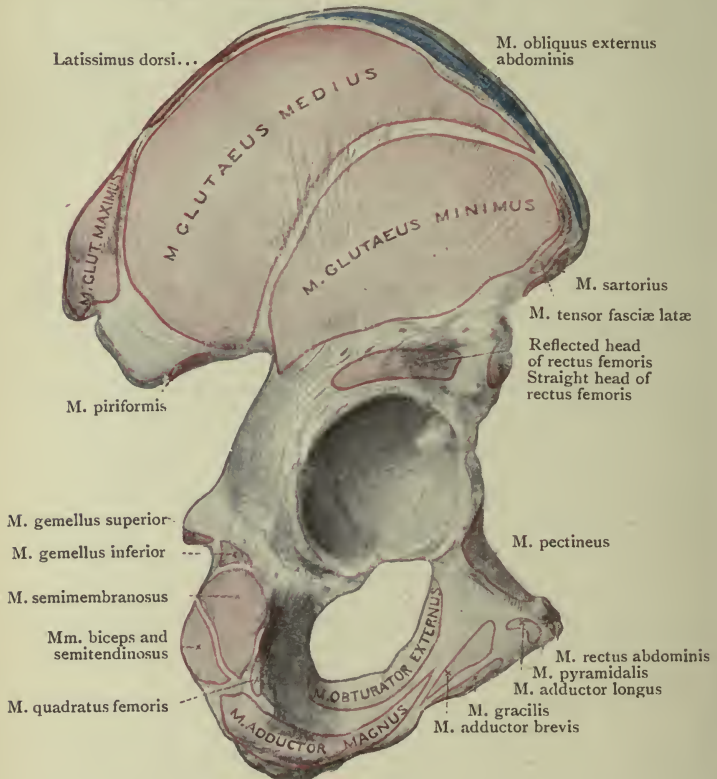


FIG. 128.—External aspect of the Hip Bone, with the Attachments of the Muscles mapped out.

to the gluteal tuberosity on the back of the femur (*i.e.* the ridge which extends from the greater trochanter to the linea aspera). (Fig. 122, p. 271.) All the remaining fibres of the muscle are inserted into the fascia lata along the posterior border of the proximal part of the ilio-tibial tract. The



glutæus maximus is supplied by the *inferior gluteal nerve*. The glutæus maximus is an extensor of the hip joint and a lateral rotator of the thigh. Its upper fibres can abduct the thigh, acting with the tensor fasciæ, and the lower fibres assist in producing adduction.

**Dissection.**—Reflection of the Glutæus Maximus.—As the glutæus maximus is reflected the dissector must be careful not to injure the vessels and nerves which lie closely subjacent to it. The nerves most liable to injury are the posterior cutaneous nerve of the thigh, which has already been identified and secured if previous instructions have been followed (see p. 284), and the perforating cutaneous nerve, which is very liable to injury when the fibres of the glutæus maximus are being raised from the sacro-tuberous ligament.

The incision through the muscle should extend from a point on its superior border 3 cm. above the trochanter major to a point on the inferior border 2.5 cm. medial to the insertion of the muscle into the femur. The procedure differs on the two sides. On the right side the dissector should detach the superior border of the muscle from the fascia on the glutæus medius at the point selected, and then pass one or two fingers downwards, on the deep surface of the muscle, along the line of incision. The part of the muscle thus freed from the deeper structures must then be divided with the scalpel, and the process must be repeated until the lower border of the muscle is reached. On the left side the dissector must commence at the inferior border, and, adopting the method above described, divide the muscle from below upwards. When the muscle is divided, reflect the lateral part to its insertion, the inferior fibres to their attachment to the gluteal tuberosity, the upper fibres to their attachment into the ilio-tibial tract. As the upper fibres of the muscle are followed to the aponeurotic insertion two bursæ will come into view, one between the aponeurotic insertion of the muscle and the lateral surface of the trochanter major, and a second, more distally placed, between the aponeurotic insertion and the lateral surface of the tendon of origin of the vastus medialis. Open both bursæ and examine their extents with the tip of the index finger. Then turn to the medial part of the muscle and reflect it towards its origin. As the reflection proceeds keep the edge of the scalpel close to the deep surface of the muscle to avoid injuring the posterior cutaneous nerve of the thigh, and as soon as the vessels and nerves which enter the deep surface of the muscle appear clean them and turn them medially with the muscle. As the upper part of the muscle is followed towards the ilium, branches of the superficial division of the superior gluteal artery will be met with, accompanied by their voluminous venæ comites. Clear the veins away, but keep the arteries. As the lower fibres are turned towards the tuberosity of the ischium branches of the inferior gluteal vessels and nerve will be found entering the deep surface of the muscle. Clear away the veins, but clean and keep the arteries and nerves. Between the muscle and the tuber ischii lies a mucous bursa. If it has not already been removed by the dissector of the perineum, open it. It is frequently multilocular, and its walls are closely

attached by fibre strands to the glutæus maximus and to the tuberosity. Immediately medial and superior to the ischial tuberosity the deep fibres of the muscle spring from the superficial surface of the sacro-tuberous ligament; detach them carefully from the ligament and secure the perforating cutaneous nerve and the coccygeal branches of the inferior gluteal artery which pierce the ligament. The arteries must be divided in order that the reflection of the muscle can be continued, but the nerve should if possible be preserved. Continue the detachment of the muscle from the sacro-tuberous ligament until the margins of the sacrum and coccyx are reached, and as they are approached look for the posterior branches of the sacral nerves which form a plexus on the superficial surface of the ligament deep to the muscle.

The method of dissection suggested above is one best adapted to avoid injury to the branches of the inferior gluteal nerve which supplies the muscle; and it gives a view of the structures subjacent to the muscle similar to that obtained by the surgeon operating on the proximal part of the sciatic nerve.

The method of dissection previously adopted in this Manual was to detach the muscle from its origin from the ilium, the sacrum, the coccyx, and the sacro-tuberous ligament, and to throw it towards its insertion. That method also gives an excellent display of the subjacent structures, from a purely anatomical point of view, and the student who is dissecting the buttock for the second time might employ it with advantage, but it is not a plan which could be adopted by the surgeon. The dissector who employs that method must commence by clearing the upper and lower borders of the muscle. When that has been done the left hand must be insinuated between the muscle and the deeper structures, on the medial side of the greater trochanter, either from above or from below according to the side on which the limb is being dissected. Then, when the muscle has been gently raised from the deeper structures the reflection should be commenced, but the plan to be adopted is different on the two sides. On the left side the muscle must be detached from its origins from above downwards, commencing at the posterior part of the ilium. When the surface of the dorsum ilii from which it springs is cleared the upper margin of the greater sciatic notch is reached. There the dissector must proceed with caution, because through the notch pass the gluteal vessels, and their branches enter the deep surface of the glutæus maximus muscle. When these are secured the muscle must be detached from the side of the sacrum; then the piriformis muscle, emerging from under cover of the sacrum, comes into sight. The muscular fibres may now be raised from the surface of the sacro-tuberous ligament and separated from the side of the coccyx. As this is being done, care should be taken to preserve the three sacral cutaneous nerves intact, in order that they may be subsequently traced to their origins. As the surface of the sacro-tuberous ligament is gradually laid bare, a number of small arteries (the coccygeal branches of the inferior gluteal artery) will be seen piercing it and immediately sinking into the substance of the glutæus maximus. These cannot be retained. It is necessary to sever them in order that the muscle may be freed. The perforating cutaneous nerve, which winds

round the lower border of the glutæus maximus near the coccyx, must also be remembered and traced to the sacro-tuberous ligament, which it will be seen to pierce.

On the right side commence the reflection in the reverse manner. Raise the muscle from the ischial tuberosity and

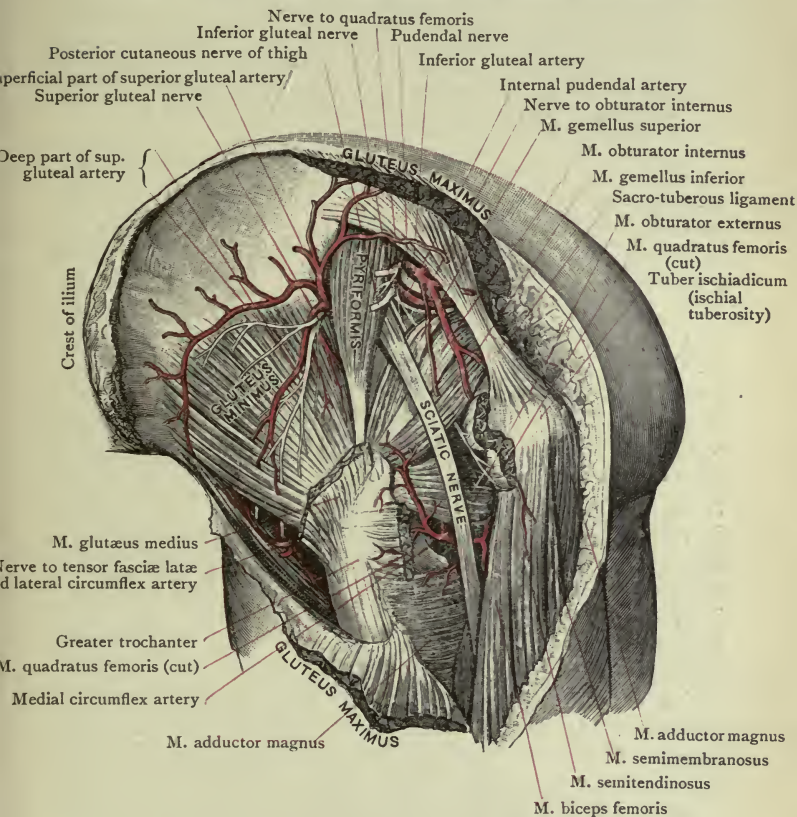


FIG. 129.—Dissection of the Gluteal Region. The Glutæus Maximus and the Glutæus Medius have been removed, and the Quadratus Femoris has been reflected.

separate it first from the coccyx, then from the sacro-tuberous ligament and the side of the sacrum, and finally from the ilium. Even when the muscle is completely separated from the parts from which it arises it still cannot be thrown towards its insertion, for it is tied to its place by blood-vessels and nerves which enter its deep surface. These are (1) the branches of the *superficial division* of the *superior gluteal artery*, which appear at the upper

border of the piriformis ; (2) branches of the *inferior gluteal artery* and the *inferior gluteal nerve* below the level of the piriformis. The venæ comites of the arteries may at once be removed, but the arteries and nerves must be cleaned as they come into view and followed into the substance of the *glutæus maximus*. Finally, in order to allow the complete reflection of the muscle, the arteries and nerves must be cut, but a small portion of the muscle should be left in connection with their cut ends so that they may be readily recognisable during the further stages of the dissection. The whole muscle can now be thrown distally and laterally, and, after a little dissection, an excellent view of its insertion can be obtained.

When the reflection of the muscle is completed note carefully the positions of the following parts: (1) the posterior border of the trochanter major; (2) the gluteal tuberosity which lies immediately distal to (1); (3) the tuberosity of the ischium; (4) the sacro-tuberous ligament.

The trochanter major is situated in the lower and lateral part of the area exposed by the reflection of the *glutæus maximus*. Immediately distal to it is the gluteal tuberosity into which the lower deep fibres of the *glutæus maximus* are inserted. The ischial tuberosity lies about 7 or 8 cm. medial to the distal part of the trochanter major. If the thigh is rotated laterally the trochanter is approximated to the tuberosity, and it recedes from the tuberosity when the thigh is rotated medially.<sup>1</sup> The sacro-tuberous ligament extends upwards and medially, from the tuberosity of the ischium to the margins of the sacrum and coccyx, and to the posterior inferior and superior spines of the ilium. The inferior border of the ligament is relatively straight. It forms the posterior boundary of the ischio-rectal fossa of the perineum, which has already been explored by the dissector of the abdomen. Its upper margin is curved, with the concavity directed forwards and upwards, and immediately in front of it are the greater and lesser sciatic foramina, which are separated from one another by the sacro-spinous ligament. The sacro-spinous ligament can be felt where it is attached to the spine of the ischium, 2.5 cm. above the upper border of the tuberosity of the ischium. Note also a group of muscles which are attached to the tuberosity and descend from it into the posterior region of the thigh. They are the hamstring muscles; do not clean them at present.

<sup>1</sup> The thigh is said to be rotated medially when its anterior surface is turned towards the median plane, and laterally when the anterior surface is turned away from the median plane.

**Bursæ Mucosæ under cover of the Glutæus Maximus.—**

Three bursæ lie under cover of the glutæus maximus: one between its inferior margin and the ischial tuberosity, and two under cover of the aponeurotic part of its insertion, one between the aponeurosis and the trochanter major, and the other between the aponeurosis and the proximal part of the vastus lateralis.

The bursa between the ischial tuberosity and the glutæus maximus is frequently multilocular, being divided into several compartments by fibrous septa which pass from the bone to the deep surface of the muscle. The other two bursæ are unilocular, and not infrequently they communicate with one another.

On the second day after the body is turned on its face the dissector must examine the muscles, vessels, and nerves which lie directly subjacent to the glutæus maximus, as well as other structures situated in a deeper plane.

Before the work is commenced a pelvis with the ligaments *in situ* should be obtained and the skeletal peculiarities of the region should be studied. The interval between the posterior part of the hip bone and the margins of the sacrum and coccyx is divided into two foramina, the greater and lesser sciatic foramina, by two ligaments, the sacro-tuberous and the sacro-spinous. The sacro-tuberous ligament is the more superficial. It extends from the posterior part of the ilium and the margins of the lower part of the sacrum and the coccyx to the tuberosity of the ischium. The sacro-spinous ligament is partly covered by the sacro-tuberous ligament. It passes from the margin of the lower part of the sacrum and the margin of the coccyx to the spine of the ischium. The large foramen above the sacro-spinous ligament is the greater sciatic foramen. It lies below and behind the lower part of the ilium, and behind the upper part of the ischium. The foramen bounded above by the sacro-spinous and below by the sacro-tuberous ligament is the small sciatic foramen. It lies behind the lower part of the ischium. Through both foramina important structures pass to or from the gluteal region.

Emerging through the greater sciatic foramen are the piriformis muscle, the superior gluteal vessels and nerves, the inferior gluteal vessels and nerve, the posterior cutaneous nerve of the thigh, the sciatic nerve, the internal pudendal

vessels, the pudendal nerve, the nerve to the obturator internus and superior gemellus, and the nerve to the quadratus femoris and inferior gemellus. Through the lesser sciatic foramen pass the obturator internus muscle, the pudendal nerve, the nerve to the obturator internus and the internal pudendal vessels (Fig. 129). All the structures mentioned, as well as other muscles, vessels, and nerves, have to be cleaned and examined. Therefore the second day's dissection is extensive and complicated, and unless it is proceeded with in a regular and definite manner it will not be successfully completed.

**Dissection.**—Commence with the superficial branches of the superior gluteal artery, which enter the upper part of the deep surface of the glutæus maximus, and follow them to the point where they emerge through the cleft between the border of the glutæus medius and the upper border of the adjacent piriformis muscle. Then clean the piriformis, from the great sciatic foramen, through which it emerges, to the greater trochanter, where its tendon disappears under cover of the glutæus medius. After the piriformis is defined, clean the posterior cutaneous nerve of the thigh, following it upward to its exit from the greater sciatic foramen at the lower border of the piriformis. Secure its perineal branch, which springs from its medial border and passes forwards and medially towards the perineum, anterior to the tuber ischii, and note the cutaneous branches which were seen on the lower part of the glutæus maximus. The posterior cutaneous nerve is sometimes accompanied by a branch of the inferior gluteal artery. If the inferior gluteal vessels and nerve, which lie medial to the posterior cutaneous nerve, were not displayed as the glutæus maximus was reflected, clean them now, and follow them to the lower border of the piriformis. When the inferior gluteal artery and its branches have been cleaned, place the leg on a large block to flex the knee, so that the structures in the buttock and the back of the thigh may be relaxed, then proceed to secure and clean the sciatic nerve. It is the large white firm cord which lies immediately deep to the posterior cutaneous nerve. Therefore pull the latter nerve medially with hooks, then at the level of the top of the trochanter major cut longitudinally through the fascia on the sciatic nerve till the nerve is exposed. Insert the handle of the scalpel into the incision in the fascia and run it upwards, along the *lateral border* of the nerve, to the greater sciatic foramen and downwards to the point where the nerve passes anterior to the biceps femoris and leaves the area of the present dissection. Clean the fascia from the back of the nerve from the lateral to the medial border, and secure the branches to the hamstring muscles, which spring from the medial border, at or a little distal to the level of the tuber ischii. Follow the branches to the muscles and preserve the branches of the medial femoral circumflex artery which join the nerves as they approach their terminations.

After the branches of the sciatic nerve to the hamstrings have been cleaned, pull the proximal part of the sciatic nerve laterally, to expose the nerve to the quadratus femoris, which lies between the sciatic nerve and the posterior surface of the ischium. The nerve to the quadratus femoris is frequently accompanied by a small branch of the inferior gluteal artery. On the medial side of the nerve to the quadratus femoris, lying on the spine of the ischium, find the nerve to the obturator internus, the internal pudendal vessels, and the pudendal nerve in that order from the lateral to the medial side. Clean away the venæ comites of the artery, but carefully preserve the artery itself and the nerves.

After the nerves and vessels mentioned have been identified and cleaned, proceed to the examination of the muscles which lie deep (anterior) to the sciatic nerve. They are, from above downwards, the superior gemellus, the obturator internus, the inferior gemellus, the quadratus femoris, and the proximal part of the adductor magnus. Emerging between the adjacent borders of the quadratus femoris and the adductor magnus the transverse terminal branch of the medial femoral circumflex artery will be found, and, piercing the adductor magnus at the medial border of the gluteal tuberosity of the femur, in a well-injected subject, the first perforating branch of the profunda artery may be seen. Clean the arteries, and then clean the muscles from above downwards. Note that the obturator internus emerges from the small sciatic foramen and that as it emerges it overlaps both the gemelli, whilst near the trochanter major, toward which all three muscles converge, the gemelli overlap the tendon of the obturator internus.

After the muscles are cleaned, divide the tendon of the obturator internus about 15 mm. from the lesser sciatic foramen. When the medial part of the tendon is raised and turned backwards the dissector will note that its deep surface is cleft into four or five strands, and that the margin of the lesser sciatic foramen, on which the tendon glides, is covered with smooth cartilage which is raised into ridges corresponding with the grooves on the deep surface of the tendon. A large bursa intervenes between the tendon and the bone.

Turn next to the hamstring muscles, which spring from the tuberosity of the ischium, and separate the common tendon of the biceps femoris and the semitendinosus from the flattened tendon of the semimembranosus, which lies immediately subjacent. Then pull the hamstrings laterally and display the origin of the adductor magnus from the inferior part of the tuber ischii.

**Parts under Cover of the Glutæus Maximus.**—Four groups of structures lie under cover of the glutæus maximus, viz., bursæ, muscles, vessels and nerves.

The bursæ, which have already been examined (see p. 291), are three in number; (1) a bursa between the middle of the inferior border of the glutæus maximus and the tuber ischii, (2) the bursa between the tendinous insertion of the glutæus maximus and the trochanter major, and (3), immediately

distal to the last, the bursa between the tendinous insertion of the glutæus maximus and the vastus lateralis.

The muscles met with between the dorsum ilii above and the tuber ischii and the posterior area of the thigh

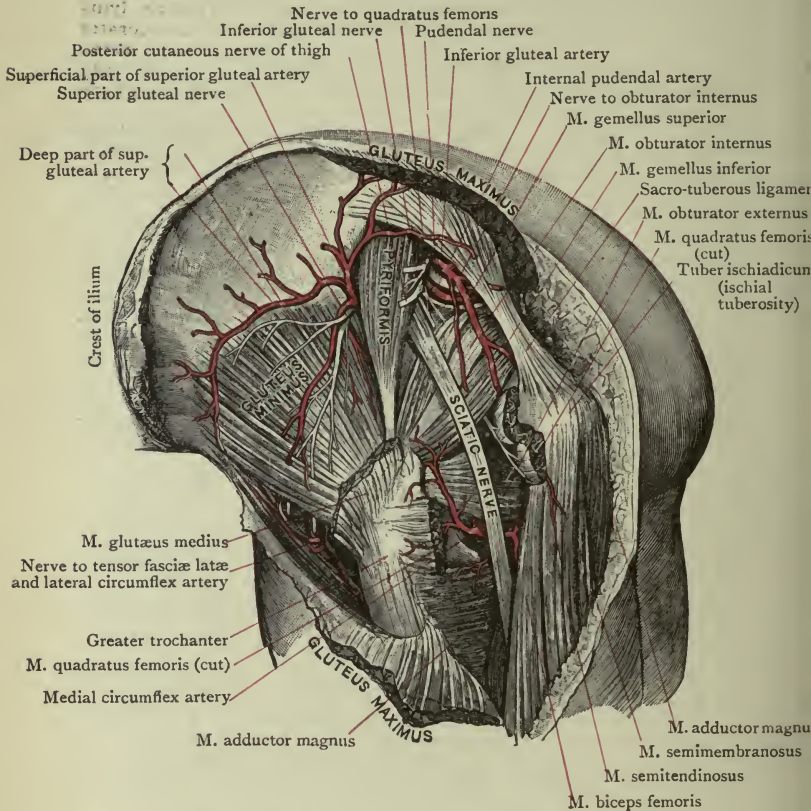


FIG. 130.—Dissection of the Gluteal Region. The Glutæus Maximus and the Glutæus Medius have been removed, and the Quadratus Femoris has been reflected.

below are :—(1) The posterior part of the glutæus medius ; (2) the piriformis, issuing from the pelvis through the greater sciatic foramen ; (3) the tendon of the obturator internus, passing through the lesser sciatic foramen ; (4) the gemellus superior, attached to the upper border of the obturator



internus; (5) the gemellus inferior, attached to the inferior border of the obturator internus; (6) the quadratus femoris, attached medially to the ischial tuberosity and laterally to the distal part of the trochanter major, and to the proximal part of the body of the femur; (7) the proximal part of the adductor magnus, immediately distal to the quadratus femoris; (8, 9, and 10) the biceps femoris, the semitendinosus and the semimembranosus (hamstrings), springing from the tuberosity of the ischium. In addition to the above-mentioned muscles the dissector should note (11) that the proximal part of the vastus lateralis is under cover of the tendinous insertion of the glutæus maximus, distal to the lateral part of the trochanter major, and (12 and 13) that the lower and medial part of the glutæus maximus, which forms the posterior boundary of the ischio-rectal fossa, is separated by a pad of fat from the levator ani and the coccygeus muscles, which form the medial wall of the fossa.

The vessels and nerves under cover of the glutæus maximus are also numerous; they are:—

(1) Issuing between the adjacent borders of the glutæus medius and piriformis and passing into the deep surface of the glutæus maximus, *superficial branches of the superior gluteal artery*. The trunk from which the branches spring, and the superior gluteal nerve, which accompanies it, can be seen if the borders of the muscles are separated.

(2) In the interval between the lower border of the piriformis and the upper border of the superior gemellus two arteries and six nerves emerge through the greater sciatic foramen into the buttock, viz.:—

Arteries,	{	1. Arteria glutæa inferior.
	{	2. Arteria pudenda interna.
Nerves,	{	1. Nervus glutæus inferior.
	{	2. Nervus cutaneus femoris posterior.
	{	3. Nervus ischiadicus.
	{	4. Nervus pudendus.
	{	5. Nerve to the obturator internus.
	{	6. Nerve to the quadratus femoris.

(3) In the interval between the gemellus inferior and the quadratus femoris, the *ascending terminal branch of the medial femoral circumflex artery* will be seen.

(4) At the distal border of the quadratus femoris the *transverse terminal branch of the medial femoral circumflex artery* passes backwards to the hamstring muscles; and the first perforating

branch of the profunda artery pierces the adductor magnus close to the distal part of the gluteal tuberosity of the femur.

**Nervus Glutæus Inferior.**—The inferior gluteal nerve is the nerve of supply to the glutæus maximus. It springs from the sacral plexus, and enters the gluteal region through the lower part of the great sciatic foramen. When the glutæus maximus was reflected the nerve was seen breaking up into numerous twigs which entered the deep surface of the muscle.

**Arteria Glutæa Inferior (O.T. Sciatic).**—The inferior gluteal artery, a branch of the hypogastric artery (O.T. internal iliac), issues from the pelvis, through the great sciatic foramen, below the piriformis muscle, and proceeds distally, with the sciatic nerve, under cover of the glutæus maximus, in the hollow between the greater trochanter and the ischial tuberosity. At the lower border of the glutæus maximus it is continued, as a fine cutaneous twig, to the posterior aspect of the thigh, in company with the posterior cutaneous nerve. It gives off numerous branches in the gluteal region. Of these the large muscular offsets to the glutæus maximus, and the cutaneous twigs that accompany the branches of the posterior cutaneous nerve of the thigh which turn round the distal border of that muscle, have been already studied. The following three branches remain to be examined:—(1) the *coccygeal branch*, which passes medially between the sacro-tuberous and sacro-spinous ligaments to reach the integument and fascia in the region of the coccyx; a number of twigs derived from this branch have been previously noticed piercing the sacro-tuberous ligament and ending in the glutæus maximus; (2) *arteria comitans nervi ischiadici*, a minute artery, which runs distally on the sciatic nerve and finally penetrates into its substance; (3) the *artery to the quadratus femoris*, which accompanies the nerve to that muscle; it will be found lying on the hip bone under cover of the sciatic nerve.

In a well-injected body the anastomosis between the inferior gluteal artery, the two terminal branches of the medial circumflex artery, and the first perforating artery may be made out.

**Nervus Cutaneus Femoris Posterior (O.T. Small Sciatic Nerve).**—The posterior cutaneous nerve of the thigh arises, within the pelvis, from the sacral plexus. After escaping through the greater sciatic foramen it extends distally, with the

inferior gluteal artery, under cover of the glutæus maximus. From the inferior border of the glutæus maximus it proceeds distally, on the back of the thigh, immediately subjacent to the deep fascia. It will afterwards be traced to the posterior aspect of the calf of the leg.

In the gluteal region it gives off several cutaneous branches,

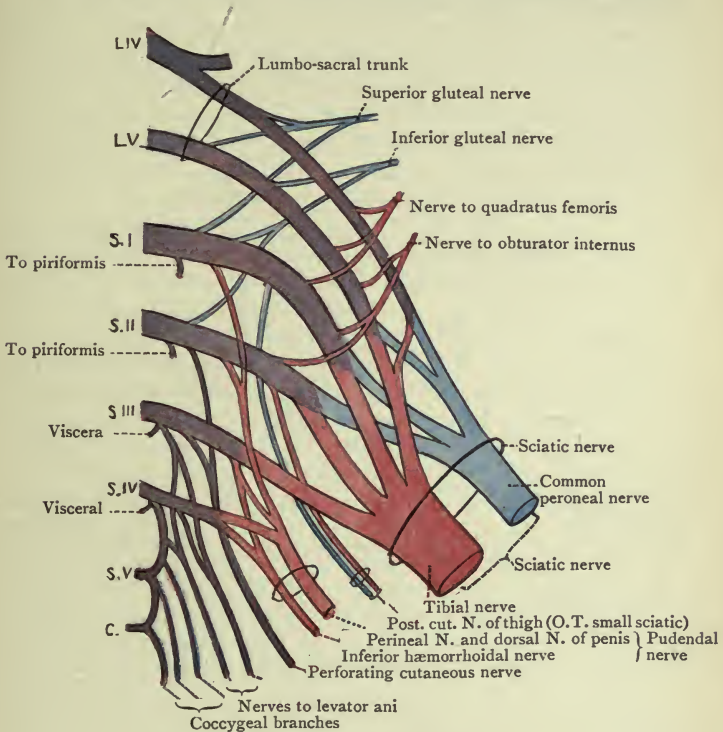


FIG. 131.—Diagram of Sacral Plexus.

viz.—(1) inferior nerves of the buttock, which wind round the inferior border of the glutæus maximus to supply a limited area of the skin of the buttock; (2) a few twigs to the skin to the medial region of the thigh; and (3) the perineal branches, of which one is known as the *long perineal nerve* (O.T. *long pudendal*). This branch turns medially, round the origin of the hamstring muscles, to reach the perineum.

**Nervus Ischiadicus (O.T. Great Sciatic Nerve).**—The sciatic nerve, the largest nerve in the body, comes from the sacral plexus, and enters the gluteal region through the lower part of the great sciatic foramen. At first it has the form of a flattened band, but soon it becomes oval or round, as seen in section. Covered by the glutæus maximus, the sciatic nerve traverses the gluteal region in the interval between the greater trochanter of the femur and the tuberosity of the ischium. From above downwards it lies on the body of the ischium and the nerve to the quadratus femoris, the tendon of the obturator internus with the two gemelli muscles, the quadratus femoris, and the adductor magnus. The nerves to one or more of the hamstring muscles issue from the main trunk near the lower border of the glutæus maximus.

The sciatic nerve frequently escapes from the pelvis in the form of two trunks (the two divisions into which it normally divides in the thigh, viz., the tibial and the common peroneal) which enclose between them a portion of the piriformis muscle.

**Arteria Pudenda Interna, Nervus Pudendus (O.T. Internal Pudic), and the Nerve to the Obturator Internus.**—The internal pudendal artery, the pudendal nerve and the nerve to the obturator internus muscle are exposed, in the present dissection, only in a very short part of their extent. They all emerge from the greater sciatic foramen and cross the spine of the ischium or the adjacent part of the sacro-spinous ligament; then they enter the lesser sciatic foramen and pass out of view. The *nerve to the obturator internus* is placed most laterally. It lies on the base of the ischial spine, and furnishes a twig to the gemellus superior. The *internal pudendal artery*, with a companion vein on each side, crosses the tip of the spine. The *pudendal nerve* is placed most medially, and lies on the sacro-spinous ligament, close to its attachment to the spine. In some cases, however, the pudendal nerve unites in a plexiform manner with the nerve to the obturator internus, so that the whole, or a part, of it may lie lateral to the pudendal vessels.

**Small Lateral Rotator Muscles of the Thigh.**—Under this heading are included the piriformis, the obturator internus, and the two gemelli, the quadratus femoris, and the obturator externus. They all lie directly under cover of the glutæus maximus in the greater part of their extent, except the obturator externus which lies deep (anterior) to the quadratus

femoris, and cannot be properly seen from behind until that muscle has been reflected; they are all inserted into, or in the neighbourhood of, the greater trochanter of the femur, and they are applied to the posterior surface of the capsule of the hip joint. The first five are lateral rotators of the thigh, when the hip joint is extended, but they become abductors when the joint is flexed. The obturator externus is a lateral rotator in both positions.

**M. Piriformis.**—The piriformis arises within the pelvis from the three middle pieces of the sacrum, and slightly from the upper margin of the great sciatic notch of the hip bone. The sacral origin cannot be seen at present, but the iliac origin should be made out. After it has passed through the great sciatic foramen, the muscle is directed downwards, laterally, and forwards. Its fleshy belly rapidly tapers and it ends in a rounded tendon, which crosses superficial to the common tendon of the obturator internus and gemelli, and is inserted into a small impression on the highest part of the greater trochanter of the femur (Fig. 117, p. 262). It is closely adherent to the subjacent obturator tendon for some distance. The piriformis is supplied by branches from the *first* and *second sacral nerves*.

**Mm. Obturator Internus et Gemelli.**—These muscles, together, constitute a tricipital muscle with one large intra-pelvic belly (obturator internus), and two small extra-pelvic bellies (gemellus superior and inferior). The common tendon is inserted into an impression on the upper part of the greater trochanter of the femur, immediately posterior to and below the insertion of the piriformis (Fig. 117, p. 262).

The *gemellus superior* arises from the spine of the ischium, at the upper margin of the small sciatic notch. Its fibres pass laterally, along the superior border of the tendon of the obturator internus, and are inserted obliquely into that tendon.

The *gemellus inferior* arises from the tuberosity of the ischium, at the lower margin of the lesser sciatic notch, and is inserted into the lower border of the obturator tendon, in a similar manner to the gemellus superior. Close to their origins the gemelli meet under cover of the obturator tendon, and form a fleshy bed on which the tendon lies; near the trochanter the fibres of the gemelli overlap the obturator tendon, and tend to cover its superficial surface.

The *tendon of the obturator internus* has already been

divided and the peculiarities of its deep surface have been examined (see p. 293).

**M. Quadratus Femoris.**—The quadratus femoris lies between the gemellus inferior and the adductor magnus. It arises from the lateral border of the ischial tuberosity, and proceeds horizontally to gain insertion into the quadrate tubercle, and into a line which extends distally from it, on the back of the femur, for about two inches (Figs. 121, 122).

**Dissection.**—The nerve to the quadratus femoris should now be traced to its termination. It lies deep to the two gemelli, the obturator internus, and the quadratus femoris. The obturator internus has already been divided. Now divide the two gemelli muscles, lateral to the nerve. Raise the medial parts and follow the nerve behind them. As the inferior gemellus is approached secure the twig which the nerve supplies to it. Lastly, divide the flat quadratus femoris, midway between the tuberosity of the ischium and the femur and throw the two parts aside. When the dissection is completed not only is the whole length of the nerve to the quadratus femoris exposed, but also a considerable portion of the posterior aspect of the capsule of the hip joint is laid bare; further, part of the obturator externus muscle, the termination of the medial circumflex artery, and the insertion of the ilio-psoas are brought into view. The exposed posterior part of the capsule of the hip joint consists largely of circularly arranged fibres.

**Nerve to the Quadratus Femoris.**—The small nerve to the quadratus femoris runs distally on the hip bone and passes successively anterior to the following structures: the sciatic nerve, the gemellus superior, the tendon of the obturator internus, the gemellus inferior. It gives the nerve of supply to the gemellus inferior and a twig to the hip joint, and ends by sinking into the deep surface of the quadratus femoris.

**M. Obturator Externus.**—The terminal part of the obturator externus muscle can now be seen winding round the neck of the femur. It ends in a rounded tendon which is implanted into the fossa trochanterica of the femur (Fig. 122, p. 271). Its origin has already been examined (p. 277).

**Arteria Circumflexa Femoris Medialis.**—The medial circumflex artery comes to an end at the proximal border of the adductor magnus by dividing into its ascending and transverse terminal branches. The *ascending branch* runs obliquely upwards and laterally, anterior to the quadratus femoris and upon the posterior surface of the obturator externus. Its terminal twigs ramify in the neighbourhood of the trochanteric fossa, where they anastomose with twigs from

the inferior and superior gluteal arteries. The *transverse branch* passes posteriorly, between the quadratus femoris and the adductor magnus, and enters the hamstring muscles. It anastomoses with the terminal twig of the middle division of the lateral circumflex artery, which, in a well-injected subject, will be noticed appearing from amidst the fibres of the proximal part of the vastus lateralis. An arterial circle is thus completed, around the proximal part of the femur; it communicates proximally with the inferior gluteal artery and distally with the first perforating artery. This series of inosculation is sometimes spoken of as the *crucial anastomosis* of the thigh.

The dissector has now examined all the structures in the gluteal region which lie below the level of the piriformis. He should, in the next place, turn his attention to that portion of the dissection which lies above the level of that muscle. There he will find several structures which lie in close relation to the dorsum ilii. These are the glutæus medius, the glutæus minimus, and the tensor fasciæ latæ, together with the blood-vessels and nerve which supply them, viz., the superior gluteal artery and vein, and the superior gluteal nerve.

The posterior part of the glutæus medius muscle was covered by the glutæus maximus. Its anterior border is overlapped by the tensor fasciæ latæ, and the intermediate area is invested by the dense fascial layer already referred to.

**Dissection.**—Remove the fascia from the superficial surface of the glutæus medius and pull the tensor fasciæ latæ forward.

**M. Glutæus Medius.**—The glutæus medius arises from that part of the dorsum ilii which is bounded above by the posterior curved line and the anterior four-fifths of the crest of the ilium, and below by the anterior gluteal line (Fig. 128, p. 286); it derives fibres also from the strong fascia which covers it. The fibres converge to form a flattened band, partly fleshy and partly tendinous, which is inserted into an oblique line on the lateral aspect of the greater trochanter of the femur, and into the surface immediately above it. The glutæus medius muscle is supplied by the *superior gluteal nerve*. As a whole the muscle is an abductor of the thigh, but its anterior fibres can rotate the thigh medially, and the posterior fibres can rotate it laterally.

**Dissection.**—The glutæus medius must now be reflected. Keep the tensor fasciæ pulled well forward. Insert the fingers between the posterior borders of the glutæus medius and minimus, and separate the muscles, from behind forwards, to their anterior margins, which were exposed and defined in the dissection of the anterior part of the thigh (see p. 249). Then divide the medius two inches above the trochanter major. Turn the lower part towards the trochanter, into which it is inserted, and the upper part towards its origin from the ilium. As the lower part of the muscle is reflected to its insertion into the oblique line on the lateral surface of the trochanter major, a small bursa will be displayed between the muscle and the upper and anterior part of the lateral surface of the trochanter. When the upper part of the muscle is raised, towards its origin, the branches of the superior gluteal vessels and the superior gluteal nerve, which lie between the glutæus medius and minimus, will be exposed; they must be carefully cleaned and preserved, except the smaller twigs which enter the deep surface of the glutæus medius which may be cut if they interfere with the reflection of the muscle. As the branches of the artery and nerve are followed the superficial surface of the glutæus minimus must be cleaned.

**Nervus Glutæus Superior.**—After emerging from the pelvis, through the greater sciatic foramen, the superior gluteal nerve turns forward, between the glutæus medius and minimus, and immediately divides into an upper and a lower branch. The upper branch follows the upper border of the glutæus minimus and it gives branches to the glutæus medius. The lower branch of the nerve crosses the middle of the glutæus minimus with the lower branch of the superior gluteal artery. It supplies branches to both the glutæus medius and minimus, then passes between the anterior borders of those two muscles and ends in the tensor fasciæ latae.

**Arteria Glutæa Superior.**—The superior gluteal artery is a large vessel which springs from the hypogastric artery and escapes from the pelvis, through the upper part of the great sciatic foramen, above the level of the piriformis.

Immediately after its exit, it divides into a superficial and a deep division. The *superficial division* has been already seen during the reflection of the glutæus maximus. Its branches are distributed to the deep surface of that muscle.

The *deep division* bifurcates, close to its origin, into a superior and an inferior branch, which run forwards between the glutæus medius and minimus. The *superior branch* follows accurately the anterior gluteal line on the dorsum ilii, and, at the anterior superior spine, terminates by anastomosing with the superficial and deep circumflex iliac arteries,



and with the ascending branch of the lateral femoral circumflex artery. The latter has already been noticed passing proximally under cover of the tensor fasciæ latae. The *inferior branch* runs forwards across the middle of the glutæus minimus, with the inferior branch of the superior gluteal nerve. It supplies the two gluteal muscles between which it lies and the tensor fasciæ latae. It gives twigs to the hip joint, and others of its branches anastomose with twigs of the ascending branch of the lateral femoral circumflex artery.

**M. Glutæus Minimus.**—The glutæus minimus muscle arises from the broad area on the dorsum ilii, which is included between the anterior and inferior curved lines (Fig. 128, p. 286). The muscular fibres pass gradually into an aponeurotic tendon, which covers the superficial surface of the distal part of the muscle. The tendon, as it passes distally, narrows into a flattened band, which is inserted into a special impression on the lower and lateral part of the anterior aspect of the greater trochanter of the femur (Figs. 117, 118, p. 262). It is intimately connected, near its insertion, with the capsule of the hip joint, and it is separated from the upper and anterior part of the trochanter major by a small bursa. The glutæus minimus is supplied by the *superior gluteal nerve*. Its actions are the same as those of the glutæus medius (see p. 301).

**Dissection.**—After the superior gluteal vessels and nerve have been studied the glutæus minimus must be reflected. Detach it from its origin and turn it downwards.

**Parts under Cover of the Glutæus Minimus.**—As the glutæus minimus is reflected three structures are displayed:—(1) part of the capsule of the hip joint; (2) the reflected tendon of the rectus femoris; and (3) the bursa between the tendon of the glutæus minimus and the upper part of the anterior aspect of the greater trochanter. The bursa should be opened in order that its extent may be examined.

At this stage the dissector should examine not only the part of the capsule of the hip joint exposed by the reflection of the glutæus minimus, but also the parts exposed by the reflection of the quadratus femoris (see p. 300), and the obturator internus (see p. 293); collectively they are the upper and posterior portions. They are all loosely attached to the back and upper part of the neck of the femur, about a finger's breadth medial to the trochanter, but they are firmly

attached to the acetabular rim. Many of the fibres of the posterior part of the capsule run circularly round the neck of the femur. Others run parallel with the neck, at right angles to the circular fibres, and in the lower part of the capsule, which is covered by the obturator externus, is a band of fibres, the *ischio-capsular band*, which runs upwards and laterally parallel with the course of the obturator externus.

The reflected tendon of the rectus femoris is attached to the floor of a groove situated immediately above the upper part of the margin of the acetabulum, and is there embedded in the superficial fibres of the capsule which must be removed, to expose it, by cutting through them parallel with the direction of the tendon.

### FOSSA POPLITEA (POPLITEAL SPACE).

The popliteal fossa should be dissected, if possible, before the posterior region of the thigh is disturbed, in order that its contents may be examined before the medial and lateral boundaries of its proximal portion are displaced from their positions. During the dissection the following structures will be met with :—

1. Superficial fascia.
2. The small saphenous vein.
3. The posterior cutaneous nerve of the thigh.
4. Popliteal fascia.
5. Muscles which bound the fossa.
 

{	Biceps femoris.
	Semitendinosus.
	Semimembranosus.
	Gastrocnemius.
	Plantaris.
6. The tibial and common peroneal nerves and their branches.
7. The popliteal artery and vein and their branches and tributaries.
8. A few lymph glands.
9. A slender branch from the obturator nerve.
10. The popliteus muscle.

**Surface Anatomy.**—The area of the popliteal fossa is popularly called *the ham*. It is situated in the posterior region of the knee, and it lies behind the distal third of the femur, the knee joint, and the proximal fifth of the tibia. It appears as a hollow when the knee joint is flexed, but forms a slight prominence when the joint is fully extended.

In the sides of the area, about the middle of its length, the condyles of the femur are easily distinguished; distal to them lie the condyles of the tibia. The head of the fibula is posterior and a little distal to the most projecting part of the lateral condyle of the tibia.

The tendons which form the medial and lateral boundaries of the proximal part of the popliteal fossa are the tendons of the hamstring muscles; the biceps femoris on the lateral side and the semitendinosus and semimembranosus on the medial side. They can be seen in both the extended and flexed positions of the knee, but they are most obvious when the knee is flexed. When the knee is flexed and deep pressure is made in the middle of the hollow between the hamstring tendons, the (injected) popliteal artery can be distinguished, and in the living subject the pulsations of the artery can be felt. The biceps tendon should be followed to its insertion into the head of the fibula whilst the knee is flexed, then the knee should be extended. When that has been done and pressure is made immediately above the head of the fibula, at the anterior border of the biceps tendon, the proximal part of the cord-like fibular collateral ligament of the knee joint may be distinguished, whilst, on the medial side of the posterior border of the biceps tendon, the common peroneal nerve can be felt. When a little care is exercised the nerve can be rotated against the posterior part of the lateral condyle of the femur, but palpation of the nerve is more easily done in the living than the dead body. The nerve should be followed to the back of the head of the fibula where it can be pressed against the proximal part of the soleus muscle. When the knee joint is extended the rounded tendon of the adductor magnus can be felt, as it passes to its insertion into the adductor tubercle, which lies on the upper border of the medial condyle at the distal end of the medial supracondylar ridge. The adductor tubercle is an important practical landmark, for it indicates the plane of junction of the body of the femur with the distal epiphysis.

In muscular subjects the two heads of the gastrocnemius muscle form prominent rounded cushions which extend from the distal part of the popliteal area into the proximal part of the posterior region of the leg.

Proximal to the popliteal region the posterior region of the thigh presents a smooth rounded surface, on which, in thin

subjects, indications of the outlines of the bellies of the hamstring muscles may be seen.

**Dissection.**—Reflection of the Skin.—Place a block under the knee to support the limb and to render tense the muscles which form the boundaries of the popliteal fossa. **Incisions**—(1) A vertical incision along the median line of the limb from the junction of the middle and distal thirds of the thigh to the junction of the proximal fourth with the distal three-fourths of the leg. (2) A transverse incision at the proximal end of the vertical incision. (3) A transverse incision at the distal end of the vertical incision. Each of the two transverse incisions should extend halfway round the limb.

The two flaps of skin defined by the incisions (21 and 22, Fig. 126) must be separated from the superficial fascia and turned to their respective sides.

**Superficial Fascia—Vena Saphena Parva (O.T. External Saphenous Vein)—Branches of the Posterior Cutaneous Nerve of the Thigh (O.T. Small Sciatic).**—When the skin is reflected the fatty layer of the superficial fascia of the popliteal region is brought into view. It presents no peculiar features, and, as a rule, it contains only a moderate amount of fat, amidst which the following structures must be sought: (1) The proximal part of the *small saphenous vein*; (2) the terminal part of the posterior cutaneous nerve of the thigh; (3) branches of the posterior cutaneous nerve of the thigh; (4) the posterior branch of the medial cutaneous nerve of the thigh; (5) the anastomotic peroneal nerve.

**Dissection.**—Look first for the small saphenous vein. It ascends along the middle line of the back of the calf and pierces the deep fascia over the distal part of the popliteal fossa. As the proximal part of the vein is being cleaned secure the terminal part of the posterior cutaneous nerve of the thigh which runs alongside of the vein. At a higher level, in the fat in the middle line of the proximal part of the popliteal area one or more twigs from the posterior cutaneous nerve of the thigh may be found, piercing the deep fascia on their way to the skin.

When the medial side of the thigh was dissected the posterior branch of the medial cutaneous nerve of the thigh was found descending along the posterior border of the sartorius muscle (Fig. 127). It should be followed now as it descends behind the medial boundary of the popliteal fossa to the back of the calf. The peroneal anastomotic nerve may be found at the lower and lateral part of the popliteal area as it pierces the deep fascia covering the lateral head of the gastrocnemius muscle (Fig. 127). In some cases, however, the nerve pierces the deep fascia at a much more distal level. In such cases it will not be found until the back of the leg is dissected. After the small saphenous vein and the nerves mentioned have been secured and cleaned, remove the remains of the superficial fascia, but be careful to avoid injury to the deep fascia which is somewhat thin.

**Fascia Poplitea (Popliteal Fascia).**—Although it is thin, the deep fascia of the popliteal region possesses considerable strength owing to the transverse fibres which are interwoven amidst its longitudinal fibres. As the dissector removes the fascia he will notice that it is firmly attached on each side to the tendons of the muscles which bound the fossa poplitea. Proximally, it is continuous with the fascia lata of the thigh.

Before the popliteal fascia is interfered with the dissector is recommended to read the following two paragraphs, which deal in a general way with the boundaries and contents of the popliteal fossa.

**Boundaries.**—The popliteal fossa is diamond-shaped. Proximally and laterally it is bounded by the *biceps femoris muscle*; whilst proximally and medially are the *semitendinosus* and the *semimembranosus muscles*, the former lying upon the posterior surface of the latter. On the medial side of the knee, anterior to the semimembranosus, lie the *gracilis*, the *sartorius*, and the tendon of the *adductor magnus*. The fossa is bounded, distally, by the converging heads of the *gastrocnemius*. In the formation of the distal and lateral boundary the lateral head of the gastrocnemius is assisted by the small *plantaris muscle*.

**Contents of the Fossa.**—The principal objects within the popliteal fossa are the *tibial* and *common peroneal nerves* and the *popliteal artery* and *vein*, with their branches and tributaries, but the most superficial structure, in the proximal part of the space, is the *posterior cutaneous nerve of the thigh*, which runs along the middle line, immediately subjacent to the popliteal fascia, until it pierces that fascia in the distal part of the space. Separated from the posterior cutaneous nerve of the thigh by a thin layer of fat is the large tibial nerve. It lies superficial to the popliteal vein and artery which are situated in a much deeper plane in close contact with one another. The common peroneal nerve lies along the upper lateral boundary of the fossa, under cover of the posterior margin of the biceps femoris. Both the tibial and the common peroneal nerves give off branches of which the majority are easily found, but their articular twigs are delicate and are easily destroyed by the dissector who does not exercise sufficient care. One of the articular nerves, however, is derived neither from the tibial nor the common peroneal nerve, but from the deep division of the obturator

nerve previously dissected (p. 273). It descends in close apposition to the popliteal artery. Other important contents of the fossa are lymph-glands, some of which lie relatively superficial, near the point where the small saphenous vein

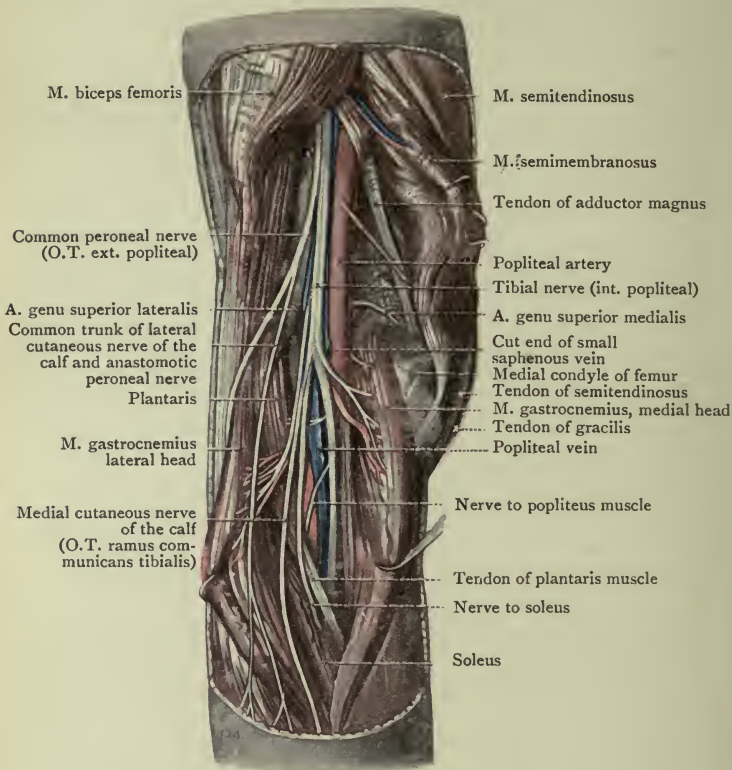


FIG. 132.—Dissection of the Left Popliteal Fossa. The proximal boundaries have been pulled apart and the aponeurosis into which the two heads of the gastrocnemius is attached has been split and the heads have been displaced to their respective sides.

pierces the popliteal fascia, but the majority are deeply placed adjacent to the popliteal vein and artery.

**Dissection.**—Do not attempt to open up the popliteal fossa and display its contents until its proximal boundaries have been cleaned and their relationships to the fossa have been defined.

The distal boundaries will be cleaned and displayed as some of the contents of the fossa are secured and followed towards their terminations.

Clean first the proximal lateral boundary. Make an incision through the deep fascia along its medial margin, turn the fascia laterally and expose the biceps femoris. Clean the muscle and its tendon, follow the tendon to its insertion into the head of the fibula, and note that at the level of the knee the biceps femoris crosses the lateral head of the gastrocnemius. After the distal part of the biceps femoris has been cleaned, turn to the proximal medial border of the space; make an incision through the deep fascia along its lateral margin, and reflect the fascia covering it towards the medial side to expose the semitendinosus and semimembranosus muscle; follow the tendon of the more superficial semitendinosus muscle to the level of the medial condyle of the tibia. Then pull the semitendinosus aside and clean the distal part of the semimembranosus, and follow its tendon to its insertion into the medial condyle of the tibia. Preserve if possible the muscular branches of the popliteal artery which enter the lateral part of the muscle, and note that the tendon of insertion springs mainly from the lateral border and anterior (deep) surface of the muscle. Pull the part of the muscle which lies at the level of the medial condyle of the femur towards the medial side of the knee and display the semimembranosus bursa, which lies between the semimembranosus and the medial head of the gastrocnemius as they cross one another. The semimembranosus bursa often communicates, round the medial border of the gastrocnemius, with a bursa which lies between the medial head of the gastrocnemius and the back of the knee joint, and that, in turn, communicates with the cavity of the knee joint. Open the bursa and, if possible, display the communications which have been mentioned with the aid of a probe. Now pull the semitendinosus and semimembranosus laterally and clean the gracilis, which lies medial and anterior to them. At the anterior border of the gracilis the saphenous nerve emerges between the gracilis and the posterior border of the sartorius accompanied by the saphenous branch of the arteria genu suprema; secure the artery and nerve and follow them downwards to the medial border of the tibia and note that they accompany the *great* saphenous vein, which was exposed when the medial side of the thigh was dissected. Then pull the gracilis medially and clean the distal part of the adductor magnus which lies lateral to it.

When the proximal boundaries of the fossa have been cleaned and examined, seize the posterior cutaneous nerve of the thigh at the point where it pierces the popliteal fascia (see p. 306), and follow it to the proximal angle of the fossa, dividing the popliteal fascia which lies superficial to it; then remove the remains of the popliteal fascia from the proximal part of the popliteal area. Now pull the posterior cutaneous nerve aside, with a hook, and cut through the fat in the proximal apex of the fossa till the large tibial nerve is exposed. Follow the tibial nerve distally, cleaning it, partly with the aid of the handle of the scalpel and partly by occasional touches with the point of the scalpel, and secure its cutaneous, muscular, and articular branches. Its cutaneous branch, *the medial cutaneous nerve of the calf*, arises

from its posterior aspect and descends between the two heads of the gastrocnemius. Follow that branch to the distal angle of the fossa, dividing the popliteal fascia superficial to it. The articular branches are three in number, *superior medial genicular*, *inferior medial genicular*, and *middle genicular*. All three branches spring from the medial side of the tibial nerve, the superior branch at or above the proximal angle of the fossa, and the other two at more distal levels. Each joins a corresponding branch of the popliteal artery, and is distributed with it. The superior branch leaves the fossa above the medial condyle of the femur, the inferior branch turns medially below the medial condyle of the tibia, and the middle branch pierces the posterior ligament of the knee joint. The *muscular branches* arise about the middle of the fossa and pass to the two heads of the gastrocnemius, the plantaris, the soleus, and the popliteus; the heads of the gastrocnemius must be separated to obtain a proper view of these branches. The branch to the soleus will be recognised because it passes between the plantaris and the lateral head of the gastrocnemius. The nerve to the popliteus lies deeply in the angle between the heads of the gastrocnemius superficial to the popliteal artery. It will be followed to its termination in a subsequent dissection (see p. 403).

When the tibial nerve and its branches have been cleaned return to the proximal angle of the fossa, dissect in the fat lateral to the tibial nerve at the medial border of the biceps, and secure the common peroneal nerve. It descends along the medial border of the biceps, and leaves the fossa at the lateral angle, crossing superficial to the plantaris and the lateral head of the gastrocnemius (Fig. 132). Follow the nerve carefully from above downwards. Whilst it is in the fossa it gives off two articular branches, *superior lateral genicular*, and *inferior lateral genicular*, and a cutaneous branch, the *anastomotic peroneal nerve*, which crosses the lateral head of the gastrocnemius. As the common peroneal nerve lies superficial to the lateral head of the gastrocnemius it gives off the *lateral cutaneous nerve of the calf*; then it passes posterior to the head of the fibula, from which it is separated by the highest fibres of the soleus, and disappears between the peroneus longus and the neck of the fibula. The superior lateral articular branch leaves the fossa proximal to the lateral condyle of the femur with the corresponding branch of the popliteal artery. The inferior lateral articular branch joins the inferior lateral genicular branch of the popliteal artery at the lateral side of the knee between the head of the fibula and the lateral condyle of the femur. The lateral cutaneous nerve of the calf and the anastomotic peroneal cutaneous branch sometimes arise from the common peroneal nerve by a common stem (see Fig. 132). When the nerves mentioned have been found and cleaned, clean the two heads of the gastrocnemius and separate the plantaris from the medial border of the lateral head, taking care not to injure the nerve to the soleus which passes between the plantaris and the lateral head of the gastrocnemius. As the muscles are cleaned, note the branches of the popliteal artery which pass to them, but divide those branches if they interfere with the separation of the muscles.

The popliteal vein and its tributaries and the popliteal artery



and its branches must now be cleaned. Pull the tibial nerve laterally and clear away the fat on the lateral side of the semi-membranosus at the proximal part of the fossa. The artery enters the fossa a little distal to the proximal angle, on the medial side, where it lies close to the *floor* or anterior boundary of the fossa. It leaves the fossa at the distal angle at the distal border of the popliteus muscle. In the proximal part of the fossa the vein is lateral to the artery. In the middle part of the fossa it is posterior to the artery, and in the distal part it is medial to the artery, always intervening between the artery and the tibial nerve. In the angle between the artery and the vein, in the proximal part of the fossa, look for the slender genicular branch of the obturator nerve, and, having secured it, follow it to the point where it pierces the posterior ligament of the knee joint with the middle genicular artery. Then proceed to clean the popliteal artery and its branches and the popliteal vein. Not uncommonly in addition to the main vein, whose position has been described, there are two or more accessory venous channels which communicate with the main vein and anastomose with one another round the artery; if they are present clear them away, but take care, whilst doing so, not to injure the branches of the artery. The branches of the artery to the hamstring muscles and the muscles of the calf are numerous, and, if they interfere with the cleaning of the main structures, they must be divided, but the articular branches must be carefully preserved; they are five in number, the superior and inferior medial genicular arteries, the superior and inferior lateral genicular arteries, and the middle genicular artery. They all lie close to the floor of the space and are liable to be injured as the soft fat around the popliteal artery is cleared away. The superior genicular branches lie at the level of the proximal borders of the condyles of the femur. They run transversely and they leave the space, the medial by piercing the posterior intermuscular septum of the thigh, and the lateral by piercing the lateral intermuscular septum. The inferior lateral genicular artery also runs transversely, at the level of the interval between the lateral condyle of the femur and the head of the fibula, but the inferior medial genicular branch descends obliquely, deep to the medial head of the gastrocnemius, and then turns forwards, distal to the medial condyle of the tibia. The middle genicular artery accompanies the genicular branch of the obturator nerve through the middle part of the posterior ligament of the knee joint. The final step of the dissection is the cleaning of the fat from the floor of the fossa. With the handle of the scalpel scrape the fat away from the posterior surface of the femur, the posterior ligament of the knee joint, and the posterior surface of the fascia covering the popliteus, taking care not to injure the genicular arteries.

**Floor of the Fossa.**—The floor is formed proximo-distally by—(1) the popliteal surface of the femur; (2) the oblique popliteal ligament of the knee joint; and (3) by the strong fascia which covers the popliteus muscle.

**The Fossa Poplitea as seen in a Section through the Frozen Knee.**—The diamond-shaped space on the back of the knee joint which is brought

into view by dissection differs widely from the condition which is observed when transverse sections are made through this part of the frozen limb (Fig. 133). Before the integuments and fasciæ are removed all the parts are tightly braced together, and the fossa poplitea is represented merely by a small intermuscular interval between the distal parts of the hamstring muscles. The fossa in this condition is rather under an inch wide at its broadest part. The popliteal artery, therefore, as it traverses the space, is covered by muscles throughout its whole course, with the exception of a very small part immediately proximal to the knee joint.

**Nervus Cutaneus Femoris Posterior (O.T. Small Sciatic).—**

The posterior cutaneous nerve of the thigh enters the popliteal fossa at its proximal angle, and passes distally, immediately subjacent to the deep fascia. It gives one or two twigs through the fascia to the skin, and finally pierces the fascia in the distal part of the fossa. Its terminal twigs are distributed to the skin over the proximal part of the calf of the leg.

**Nervus Tibialis (O.T. Internal Popliteal Nerve).—**The tibial nerve enters the fossa at its proximal angle, emerging from under cover of the biceps femoris. It runs vertically downwards to the distal angle and thus bisects the fossa longitudinally. It commences about the middle of the thigh as the larger of the two terminal branches of the sciatic nerve, and it leaves the fossa at the lower border of the popliteus muscle, and enters the posterior region of the leg. Its superficial position in the fossa has already been referred to. When it enters the fossa it lies on the lateral side of the popliteal vessels, at the mid-length of the space it crosses superficial to them, and in the distal part of the space it is medial to them; consequently the muscular branches given off, in the lower part of the fossa, to the lateral head of the gastrocnemius, the plantaris, the soleus, and the popliteus pass posterior to the vessels on their way to the muscles they supply.

The branches of the nerve in the popliteal fossa are classified as cutaneous, muscular, and articular.

The *medial cutaneous nerve of the calf* is the cutaneous branch. It arises about the middle of the fossa, and proceeds distally in the furrow between the two heads of the gastrocnemius. It will afterwards be seen to unite with the peroneal anastomotic nerve, a little distal to the middle of the calf of the leg, to form the *nervus suralis* (Fig. 127).

The *muscular branches* supply both heads of the gastrocnemius, the plantaris, the soleus, and the popliteus: they come off in the distal part of the fossa. The branch to the

popliteus requires special notice. It arises more distally than the others, and crosses the superficial surface of the popliteal artery to reach the lateral side of that vessel. It then runs distally on the posterior surface of the popliteus muscle, and gains the anterior surface by winding round the distal border. This will be better seen when the popliteus muscle is dissected.

The *articular branches* are three in number. They are given off by the tibial nerve in the proximal part of the fossa, sometimes even proximal to the fossa, and they accompany the middle genicular artery and the two medial genicular

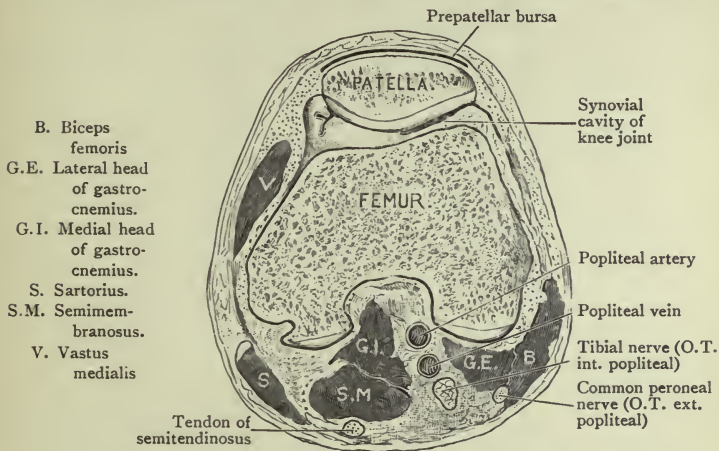


FIG. 133.—Transverse section through the Popliteal Fossa of the Right Inferior Extremity.

arteries. That which accompanies the inferior medial artery is larger than the other two, and can, as a rule, be easily discovered as it runs along the proximal border of the popliteus muscle.

**Nervus Peronæus Communis (O.T. External Popliteal).—**The common peroneal nerve is the smaller of the two terminal branches of the sciatic nerve. It arises, from the sciatic nerve, about the middle of the length of the thigh, and it terminates at the lateral side of the neck of the fibula, under cover of the peroneus longus, by dividing into a superficial and a deep peroneal terminal branch. It does not traverse the entire length of the popliteal fossa, for, as it runs distally

and laterally along the medial border of the biceps femoris, it leaves the fossa at its lateral angle, where it crosses the plantaris and the lateral head of the gastrocnemius; then it passes behind the head of the fibula, from which it is

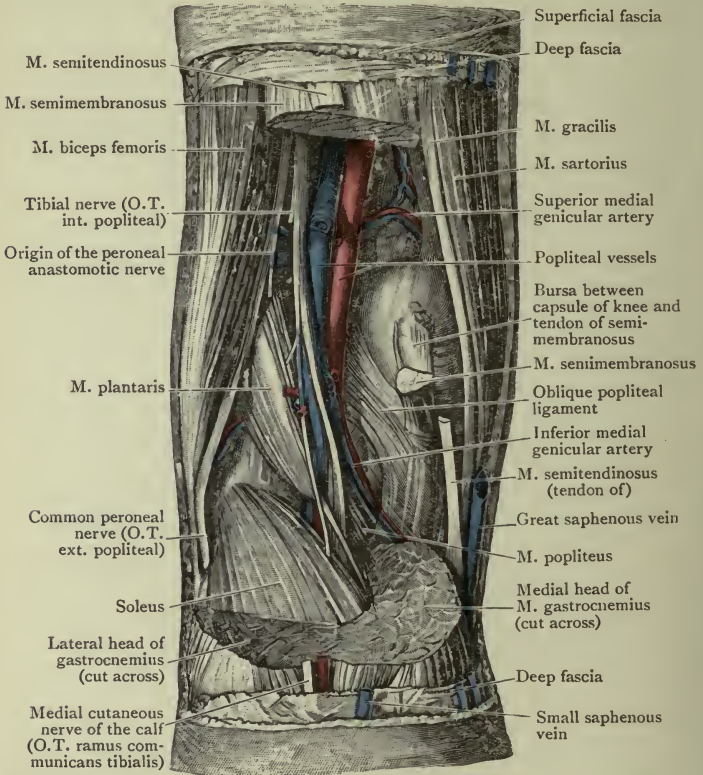


FIG. 134.—Popliteal Fossa. The two heads of the gastrocnemius and portions of the semimembranosus and semitendinosus have been removed so as to display more fully the contents of the fossa.

separated by the upper part of the soleus; finally it turns forwards, to its termination, between the lateral side of the neck of the fibula and the proximal part of the origin of the peroneus longus. It gives off two cutaneous and three articular branches.

The *cutaneous branches* are two in number, viz., the anasto-

PLATE XXI

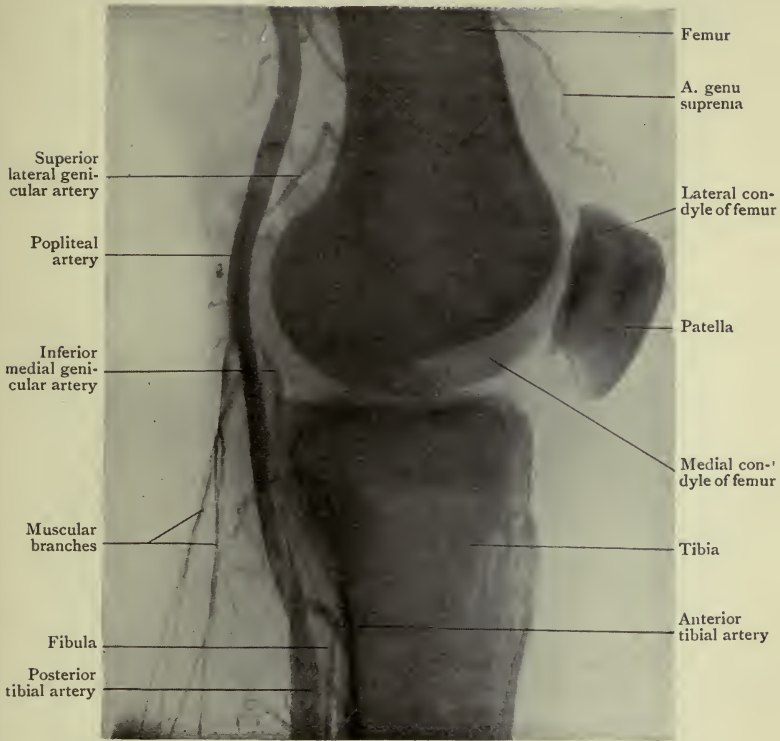


FIG. 135.—Radiograph of the Knee Region of an injected inferior extremity.  
(Major T. Rankine.)

PLATE XXII

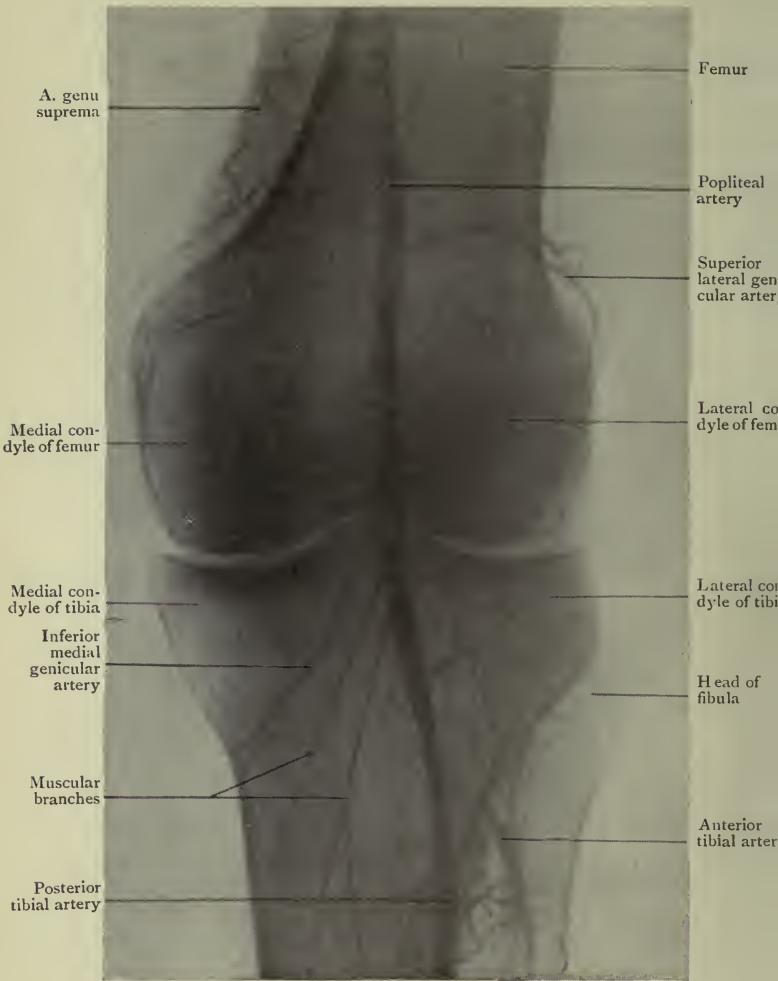

FIG. 136.—Radiograph of the Knee Region of an injected inferior extremity.  
(Major T. Rankine.)

otic peroneal nerve, and the lateral cutaneous nerve of the calf, which supplies the skin on the anterior and lateral aspect of the proximal part of the leg. They frequently take origin by a common stem. The *anastomotic peroneal nerve* arises from the common peroneal trunk in the popliteal fossa, and is continued distally over the lateral head of the gastrocnemius. It ultimately unites with the medial cutaneous nerve of the calf to form the *nervus suralis*.

The *articular branches* are three in number. They are the superior and inferior lateral articular branches and the recurrent articular nerve. The first two accompany the superior and inferior lateral genicular branches of the popliteal artery respectively. They are of small size and are difficult to find. The *recurrent articular nerve* which springs from the termination of the common peroneal nerve will be dissected at a later stage (p. 356).

**Arteria Poplitea.**—The popliteal artery is the continuation of the femoral artery, and is therefore part of the great arterial trunk of the lower limb. It begins at the opening in the adductor magnus, where the femoral artery ends; and it terminates at the distal border of the popliteus muscle by dividing into the anterior and posterior tibial arteries. The division is hidden from view, at the present stage of the dissection, by the proximal border of the soleus muscle, but it will be exposed when the leg is dissected.

The course which the popliteal artery takes through the popliteal fossa is not straight. At first it descends vertically and so reaches the middle of the fossa between the condyles of the femur. From that point to its termination it inclines obliquely, distally and laterally. Throughout the greater part of its length it is placed deeply. In the proximal part of the fossa it is covered by the semimembranosus, but where it lies in the interval between the two condyles, although it is placed deeply in the fat of the fossa, it is covered merely by the integuments and fasciæ of the tibial nerve, and the popliteal vein. That part of the vessel is very short, however,—not more than about 25 mm.; then it passes between and anterior to the two heads of the gastrocnemius, is crossed by the plantaris, and finally, at its termination, it sinks under cover of the proximal border of the soleus. Throughout its whole course the popliteal artery rests against the floor of the popliteal

fossa. In its proximal part it is separated from the femur by some fatty tissue; at the level of the interval between the condyles of the femur it crosses the oblique ligament of the knee joint; and, in the distal part of the fossa, it is in contact with the fascia covering the popliteus muscle.

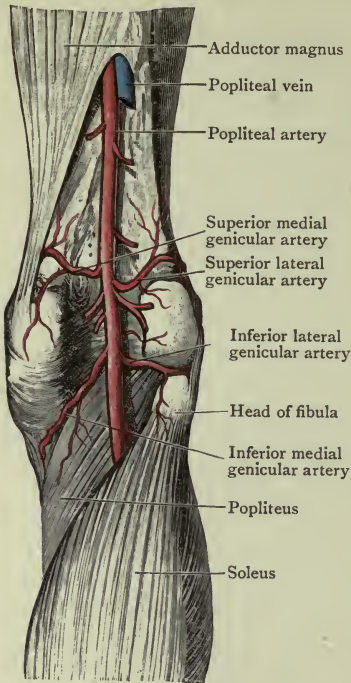


FIG. 137.—Right Popliteal Artery and its Branches.

in the proximal part of the fossa it lies lateral to the vein, but in the distal part it lies on the medial side. Figs. 132, 133, 134.

The *branches of the popliteal artery* are:—

1. Muscular.
2. Cutaneous.
3. Genicular.

The *muscular branches* consist of a proximal and a distal set. The *proximal branches* are distributed to the hamstring muscles near their insertions. The *distal branches*, termed the *sural arteries*, end chiefly in the two heads of the gastrocnemius; but twigs go also to the soleus and plantaris.

The *cutaneous branch*, called the *superficial sural*, frequently

The *popliteal vein* lies in a more superficial plane, and crosses the artery. In the proximal part of the fossa it is placed upon the lateral side of the artery, whilst in the distal part it is situated upon its medial side. The two vessels, however, are in close association throughout, and are bound together by a dense fibrous sheath.

The *tibial nerve* is superficial to both vessels, and crosses both from the lateral to the medial side; in the proximal part of the



arises from one of the sural muscular branches, and supplies the integument over the proximal part of the calf of the leg. It lies in the groove between the two heads of the gastrocnemius, with the medial cutaneous nerve of the calf.

The *genicular arteries* are five in number, viz., two superior, two inferior, and one middle or azygos.

**Arteriæ Genu Superiores (Superior Articular Arteries).—**

The two superior genicular arteries spring from the main trunk in the interval between the condyles of the femur. One proceeds from each side of the popliteal artery, and they are called *medial* and *lateral*, according to the direction which they take. They were found resting directly upon the popliteal surface of the femur, and will be observed to incline slightly upwards, and then to wind round the bone immediately proximal to the condyles. The lateral artery is the larger of the two. The student is apt to mistake a muscular branch for one or other of these vessels; but their close apposition to the femur should in all cases be sufficient to distinguish them.

The *superior lateral genicular artery* runs laterally under cover of the biceps femoris, and disappears from the popliteal fossa by piercing the lateral intermuscular septum and entering the substance of the vastus intermedius. The *superior medial genicular artery* proceeds medially under cover of the semimembranosus, and leaves the popliteal fossa by piercing the posterior intermuscular septum; then it passes forwards, under cover of the tendon of the adductor magnus, to reach the deep surface of the vastus medialis.

**Arteriæ Genu Inferiores (Inferior Articular Arteries).**

—The two inferior genicular arteries arise from the popliteal as it lies against the distal part of the oblique popliteal ligament. The *lateral inferior genicular artery* takes a transverse course laterally, under cover of the plantaris and lateral head of the gastrocnemius, to gain a point on the lateral side of the knee, immediately proximal to the head of the fibula. It proceeds onwards under cover of the fibular collateral ligament of the knee joint. The *medial inferior genicular artery* takes an oblique course, distally and medially, under cover of the medial head of the gastrocnemius, and along the proximal border of the popliteus muscle, to gain the medial side of the tibia distal to the medial condyle. There it turns forwards under cover of the tibial collateral ligament of the knee.

**Arteria Genu Media (O.T. Azygos Articular Artery).—**The

middle genicular artery springs from the popliteal as it lies upon the oblique popliteal ligament of the knee joint. It pierces that ligament to reach the cruciate ligaments and the synovial layer.

**Vena Poplitea.**—The popliteal vein is formed, near the distal border of the popliteus muscle, by the union of the venæ comites of the anterior and posterior tibial arteries. It runs proximally through the popliteal fossa, and, entering the adductor canal, through the opening in the adductor magnus, it becomes the femoral vein. The relations which it presents to the popliteal artery have already been detailed. In addition to tributaries corresponding to branches of the artery, it receives the small saphenous vein, which has been seen piercing the popliteal fascia to join it. By slitting it open with the scissors the dissector will see that it possesses three (sometimes four) valves in its interior.

The *Genicular Branch of the Obturator Nerve*.—This slender continuation of the posterior division of the obturator nerve usually lies upon the posterior aspect of the popliteal artery. It enters the popliteal fossa by piercing the distal fibres of the adductor magnus; and it enters the knee joint after passing through the oblique popliteal ligament.

### BACK OF THE THIGH.

The dissection of the back of the thigh must be completed on the fifth day. The following are the structures which are to be displayed:—

1. Superficial fascia.
2. Cutaneous nerves.
3. Deep fascia.
4. Muscles, {
  - Biceps femoris.
  - Semitendinosus.
  - Semimembranosus.
  - Adductor magnus.
5. Nerves, {
  - Posterior cutaneous of thigh.
  - Sciatic.
6. Arteries, Four perforating.

**Dissection.**—*Reflection of Skin.*—A vertical incision must be made, in the median line of the thigh, through the belt of skin which still encircles the limb posteriorly. The two flaps can then be reflected, the one laterally, and the other medially.

**Superficial Fascia—Cutaneous Nerves.**—The superficial

fascia of the back of the thigh presents no features of special interest, but in it there ramify cutaneous nerves derived from four sources, (1) from the *posterior cutaneous nerve of the thigh*, (2) from the *lateral cutaneous nerve of the thigh*, (3) from the *posterior branch of the medial cutaneous nerve*, and (4) from the *obturator nerve*.

**Dissection.**—The branches of the posterior cutaneous nerve of the thigh must be sought in the superficial fascia along the middle of the back of thigh; they vary in number, and they pierce the deep fascia at varying levels (Fig. 127). The search for them will be facilitated if the dissector pulls gently on the trunk of the nerve where it is already exposed in the lower part of the gluteal region. The branches of the lateral and medial cutaneous nerves should be followed from the portions of those nerves which were displayed when the front and medial sides of the thigh were dissected (pp. 227, 248). No time need be lost in seeking for the cutaneous branch of the obturator nerve, for it is not only very variable in size and position, but also it is not uncommonly absent. When present it lies usually in the distal and medial part of the posterior area of the thigh.

When the cutaneous nerves of the back of the thigh have been studied the remains of the superficial fascia must be removed to display the deep fascia.

**Deep Fascia.**—The deep fascia of the back of the thigh is thin but fairly strong. It consists of longitudinal fibres blended with transverse fibres which serve to bind the hamstring muscles together.

**Dissection.**—Divide the deep fascia by a longitudinal incision running along the middle of the back of the thigh, and be careful not to injure the posterior cutaneous nerve of the thigh, which lies immediately under cover of the fascia. Turn the two flaps of deep fascia aside, and then follow and clean the posterior cutaneous nerve which is now exposed in the whole of its length.

After the trunk of the posterior cutaneous nerve of the thigh has been secured clean the posterior surfaces of the hamstring muscles. They are three in number, the biceps femoris, the semitendinosus, and the semimembranosus. The long head of the biceps springs from the posterior part of the tuberosity of the ischium, by means of a tendon common to it and the semitendinosus. It is recognised by the fact that it runs distally and laterally, whilst the semitendinosus and semimembranosus run distally and medially. The short head arises from the body of the femur. Pull the long head of the biceps medially to expose the sciatic nerve, which lies deep (anterior) to it; then follow the lateral border of the sciatic nerve to secure the branch which goes from it to the short head of the biceps. Next pull the sciatic nerve laterally and clean the branches which pass from it to the long head of the biceps, the semitendinosus, the semimembranosus, and the adductor magnus. As a rule there is one branch to the long head of the biceps, a branch which

divides to supply the semimembranosus and the adductor magnus,

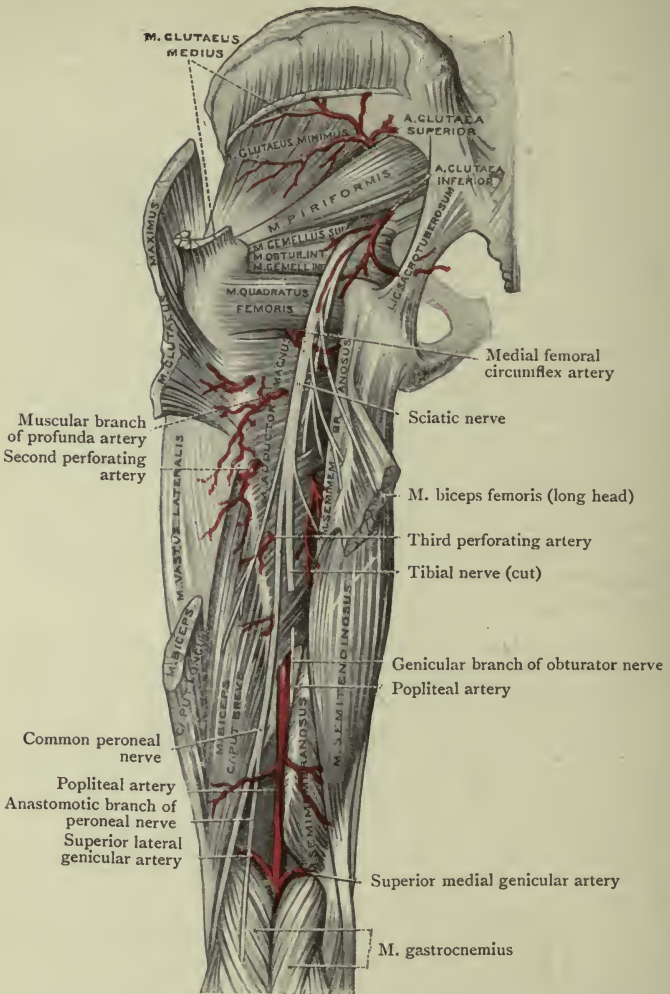


FIG. 138.—Dissection of the Posterior Region of the Thigh.

and there are two branches to the semitendinosus, an upper and a lower. The lower branch to the semitendinosus will be found

about the middle of the thigh; the other branches arise about the level of the ischial tuberosity.

As the nerves to the muscles are being followed; arteries will be found piercing the adductor magnus and passing into the hamstring muscles; they are branches of the profunda artery. As many of them as possible should be preserved and cleaned. After the nerves and arteries have been secured, pull the long head of the biceps and the semitendinosus laterally, and clean the semimembranosus, which lies on a deeper plane.

**M. Biceps Femoris.**—The biceps femoris arises by two heads—a *long* or *ischial*, and a *short* or *femoral*,—and is inserted, chiefly, into the head of the fibula. The *long head* arises from the ischium by a tendon, common to it and the semitendinosus (Fig. 128, p. 286), which is implanted into the medial of the two impressions on the upper part of the ischial tuberosity. Some fibres from the sacro-tuberous ligament are continued into it. The *short head* arises from the back of the femur, distal to the insertion of the glutæus maximus, viz., from the lateral lip of the linea aspera, from the proximal half of the lateral supracondylar ridge, and from the lateral intermuscular septum. Its parallel fibres run obliquely distally and laterally, and join the anterior and medial surface of the tendon of insertion. This tendon, on the lateral aspect of the knee joint, is split into an anterior and a posterior part by the fibular collateral ligament. Both parts are inserted into the upper aspect of the head of the fibula anterior to the apex capituli, but, in addition, the posterior part sends an aponeurotic expansion to the deep fascia of the leg, and by means of a similar expansion the anterior part gains attachment to the lateral condyle of the tibia. Each head of the biceps femoris receives its nerve supply from the sciatic nerve. The twigs to the long head are derived from the tibial part of the sciatic nerve, and that to the short head from the common peroneal part. Both heads flex the knee joint and rotate the leg laterally. The long head is also an extensor of the hip joint.

**M. Semitendinosus.**—The semitendinosus muscle arises from the medial impression on the superior part of the tuberosity of the ischium by a tendon common to it and the long head of the biceps femoris (Fig. 128, p. 286). The muscular belly ends, in the distal third of the thigh, in a long cylindrical tendon which passes downwards on the semimembranosus muscle. At the medial side of the knee the tendon bends forwards,

crosses the tibial collateral ligament of the knee joint, and, becoming flattened, is inserted into the proximal part of the medial surface of the body of the tibia, near the anterior crest of that bone, and immediately distal to the tendon of the gracilis. From its distal border aponeurotic fibres pass into the deep fascia of the leg; its proximal border is adherent to the gracilis for about half an inch from its insertion, and both tendons are concealed by the expanded insertion of the sartorius. A mucous bursa lies between the three tendons and the tibial collateral ligament of the knee joint.

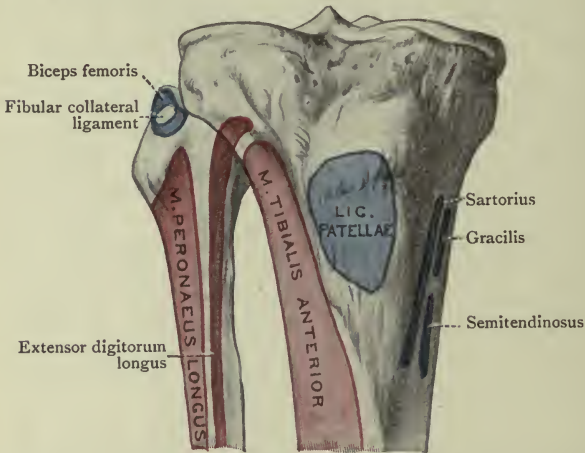


FIG. 139.—Anterior aspect of Proximal Portions of Bones of Leg with Attachments of Muscles mapped out.

The muscular belly of the semitendinosus is divided into proximal and distal parts by a very oblique tendinous intersection, and each part receives a branch from the sciatic nerve. The muscle is a flexor of the knee, a medial rotator of the leg, and an extensor of the hip joint.

**M. Semimembranosus.**—The semimembranosus muscle arises from the lateral impression on the upper part of the tuberosity of the ischium (Fig. 128, p. 286). The tendon of origin is broad at its attachment to the bone, and narrows as it passes medially anterior to the origin of the biceps femoris; it then expands again, and, passing distally and medially, anterior to the semitendinosus, is folded in such a manner

as to form a groove, in which the semitendinosus lies. The tendon of insertion is attached chiefly to the floor of the groove on the back of the medial condyle of the tibia, under cover of the tibial collateral ligament of the knee joint. Three additional attachments, however, must be noted. These are effected by aponeurotic extensions from the tendon of insertion—(1) to the back of the capsule of the knee joint, forming a considerable part of the oblique popliteal ligament; (2) to the surface of the popliteus muscle, which is covered by the expansion; and (3) to the tibial collateral ligament of the knee joint. The semimembranosus is supplied by the sciatic nerve. Its actions are the same as those of the semitendinosus (see p. 322).

**Nervus Ischiadicus (O.T. Great Sciatic Nerve).**—The sciatic nerve commences at the lower border of the greater sciatic foramen, and usually terminates about the middle of the thigh, but occasionally at a higher level, by dividing into the tibial nerve and common peroneal nerve. Its relations in the gluteal region have already been studied. In the thigh it lies on the posterior surface of the adductor magnus muscle, and is covered by the long head of the biceps femoris. It gives branches to both heads of the biceps, to the semitendinosus, to the semimembranosus, and to the adductor magnus; the branches to the two last-named muscles arise by a common trunk. In a few cases it gives off a long articular twig, which enters the popliteal fossa and takes the place of the lateral superior articular nerve, which, as a rule, is a branch of the common peroneal nerve.

**Dissection.**—To bring the adductor magnus more fully into view, and to facilitate the cleaning of its posterior surface, and at the same time to follow the terminal parts of the perforating arteries, the hamstring muscles should be detached from their origins and thrown distally. First detach the common tendon of the biceps femoris and semitendinosus from the ischial tuberosity. When that has been done the exact attachment of the semimembranosus is displayed, and after that muscle has been again examined, under the present more advantageous circumstances, it also must be detached from its origin and turned distally. The posterior surface of the adductor magnus will then be fully exposed, and its attachment to the femur and its relations to the perforating arteries can be studied.

**Arteriæ Perforantes.**—Four perforating arteries will be found in the posterior part of the thigh between the adductor magnus muscle and the femur, close to the linea aspera.

They are branches of the profunda femoris and are called *first*, *second*, *third*, and *fourth*, according to the level at which they appear, proximo-distally. The *fourth* is the terminal branch of the profunda, it makes its appearance about 25 mm. (one inch) proximal to the opening in the adductor magnus muscle through which the popliteal artery enters the popliteal fossa. The perforating arteries and their branches must be thoroughly cleaned, together with the apertures in the adductor magnus through which they pass. It will then be seen that they do not pierce the fleshy substance of the muscle, for behind each is a tendinous arch, and the arteries reach the posterior region of the thigh by passing between the arches and the linea aspera, to which the piers of the arches are attached.

The openings are in the same line with and are in all respects analogous to the large opening in the adductor magnus muscle for the popliteal artery. The result obtained is the same in each case; when the muscle contracts, the vessels are protected from pressure.

After passing the tendinous arches the perforating arteries wind round the posterior border of the femur on their way to the vastus lateralis muscle, in which they end, and in which they anastomose with branches of the lateral femoral circumflex artery. The highest perforating artery pierces the insertion of the glutæus maximus before it reaches the vastus lateralis, and the lower three pierce the femoral head of the biceps femoris and the lateral intermuscular septum.

**Anastomoses on the Posterior Aspect of the Thigh.**—In a well-injected subject a chain of arterial anastomoses can be traced from the gluteal region to the popliteal fossa, and the present is the best time to examine it. Commencing proximally, in the gluteal region, the superior gluteal artery is found anastomosing with the inferior gluteal, and the inferior gluteal with the terminal branches of the medial femoral circumflex artery. In the posterior part of the thigh the chain of anastomoses is carried distally by the medial and lateral femoral circumflex arteries anastomosing with the first perforating artery, and by anastomoses between the perforating arteries. The chain is completed distally by anastomoses between the most distal perforating arteries and the muscular branches given from the popliteal artery to the hamstring muscles.



**Dissection.**—At the end of the fifth day after the subject has been placed upon its face, the dissector must paint the various parts in the gluteal and thigh regions with the preservative solution, replace them in position, and fix the skin flaps over them with a few points of suture. On the morning of the following day he will find the body replaced upon its back, with the pelvis and thorax supported by blocks, and he must at once proceed to study any part of the medial region of the thigh previously left undissected, and to examine the hip joint.

**Articulatio Coxæ (Hip Joint).**—The hip joint is the most perfect example of an enarthrosis or ball-and-socket joint in the body. It does not allow so free a range of movement as that which takes place at the shoulder joint, but what it loses in this respect it gains in strength and stability. Its great strength and security depend—(1) upon the depth of the acetabulum and the thorough manner in which the head of the femur is received into it; (2) upon the tension and power of the ligaments; (3) upon the length and oblique direction of the neck of the femur; (4) upon atmospheric pressure and upon the strength of the surrounding muscles.

The *ligaments* in connection with the hip joint are:—

- |  |                                |
|--|--------------------------------|
| 1. Capsula articularis.<br>Lig. ilio-femorale.<br>Lig. ischio-capsulare.<br>Lig. pubo-capsulare. | 3. Labrum glenoidale.          |
| 2. Ligamentum teres.   | 4. Lig. transversum acetabuli. |

The capsule and the ligamentum teres are attached to both bones entering into the construction of the joint. The transverse ligament and the labrum glenoidale are connected with the hip bone only; the former partially fills the acetabular notch, whilst the latter surrounds the circumference of the acetabulum in a ring-like fashion, and serves to deepen it still further.

**Capsula Articularis.**—The fibrous stratum of the articular capsule is exceedingly strong, and surrounds the joint on all sides. *Proximally*, it is attached around the acetabulum; above and posteriorly, directly to the hip bone, just beyond the rim of the cavity; anteriorly, to the superficial aspect of the labrum glenoidale; and below, to the transverse ligament. *Distally*, it clasps the neck of the femur; anteriorly, it is attached to the whole length of the intertrochanteric line, and to the root of the greater trochanter; this attachment is very firm and strong; posteriorly, it falls short of the intertrochanteric

crest by about half an inch, and its attachment to the distal part of the posterior surface of the neck of the femur is weak.

When the capsule of the hip joint has been carefully cleaned it will be seen that the fibres which compose it run in two different directions. The majority pass longitudinally from the hip bone to the femur. There are, however, other fibres which lie more or less at right angles to the longitudinal fibres. They constitute the *zona orbicularis* and are seen to

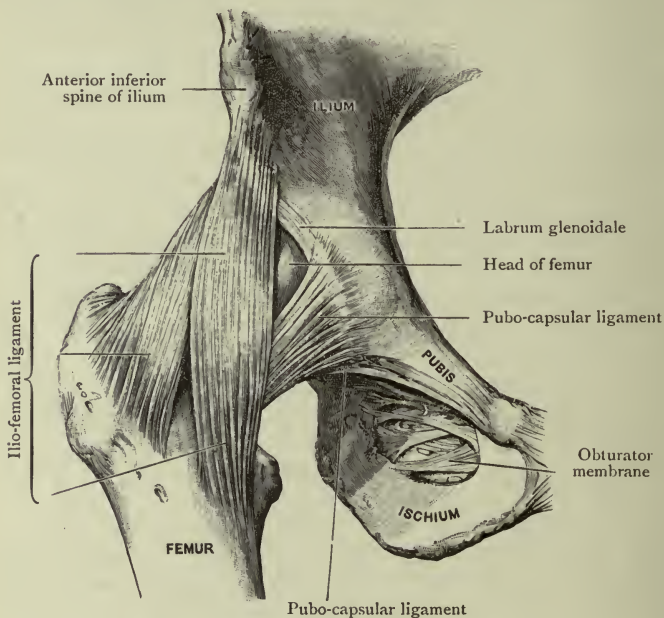


FIG. 140.—Dissection of Hip Joint from the front.

advantage only on the posterior aspect of the capsule, where they were noted during the dissection of the gluteal region (p. 304). The longitudinal fibres are most massed on the front of the joint.

Certain thickened portions of the capsule, with more or less distinct attachments, are described under special names. They are:—

- |                            |  |                                  |
|----------------------------|--|----------------------------------|
| 1. Ilio-femoral ligament.  |  | 3. Ischio-capsular ligament.     |
| 2. Pubo-capsular ligament. |  | 4. The <i>zona orbicularis</i> . |

*Ligamentum Ilio-femorale*.—The ilio-femoral ligament is placed over the front of the articulation, and constitutes the thickest and most powerful part of the capsule. Proximally it is attached to the anterior inferior spine of the ilium and to the depressed surface immediately lateral to that spine.

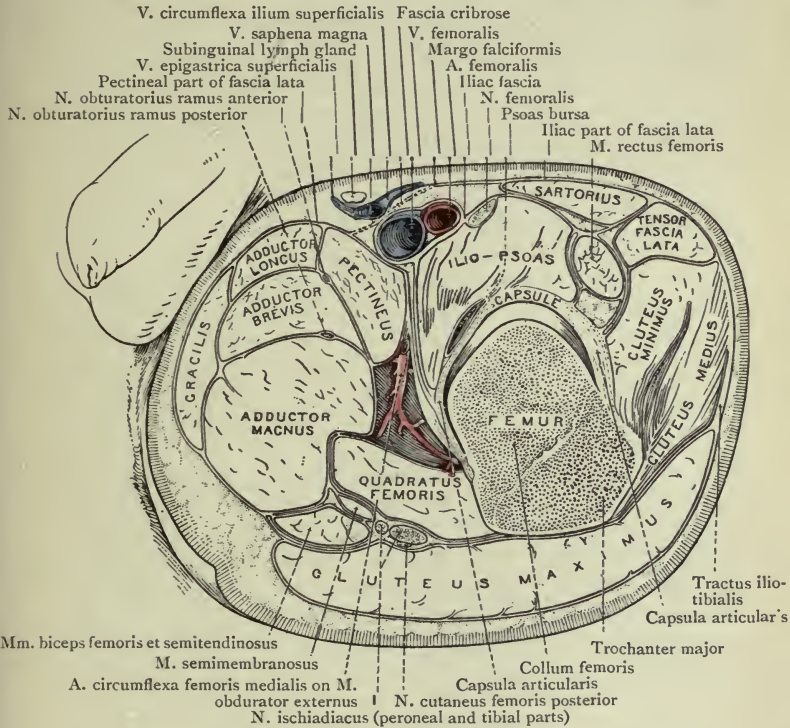


FIG. 141.—Dissection of an oblique transverse Section through upper part of Thigh showing the relation of the Fascia to the Muscles.

Distally it is attached to the intertrochanteric line of the femur. At its upper or iliac end it is a single mass of fibres, but as it passes distally, it divides into a *lateral* and a *medial* band (Fig. 140).

The lateral and shorter band is implanted into the upper part of the intertrochanteric line and to the adjacent part of the greater trochanter. It is sometimes called the *ilio-*

*trochanteric band.* The more medial and longer band is almost vertical, and its distal end is attached to the lower part of the intertrochanteric line. The interval between the two diverging bands is occupied by a thinner portion of the capsule which is perforated by an articular twig from the ascending branch of the lateral femoral circumflex artery. The ilio-femoral ligament is sometimes called the *Y-shaped ligament*, but, in making use of this term, remember that the shape it presents is that of an inverted Y.

*Ligamentum Pubocapsulare* (O.T. *Pubo-femoral Ligament*).—The pubo-capsular ligament is the name applied to fasciculi which spring from the pubic bone and the obturator membrane, and join the lower and anterior aspect of the capsule. In cases where the bursa under the ilio-psoas is continuous with the cavity of the joint, the aperture of communication is placed between this band and the ilio-femoral ligament.

*Ligamentum Ischiocapsulare* (O.T. *Ischio-femoral Ligament*).—The ischio-capsular ligament is a comparatively weak band which springs from the ischium, below the acetabulum, and passes upwards and laterally, anterior to the tendon of the obturator externus. It terminates in the capsule.

*Zona Orbicularis* (O.T. *Orbicular Ligament*).—The zona orbicularis is composed of circular fibres, which are most distinct on the posterior aspect of the capsule. It encircles the neck of the femur posteriorly and below, but is lost as it is traced anteriorly towards the upper and anterior parts of the capsule.

The dissector has already noted the close connection which is exhibited between the capsule of the hip joint and the tendons of the glutæus minimus, and the reflected head of the rectus femoris. Reinforcing fibres are contributed to the capsule by both of those tendons.

**Movements permitted at the Hip Joint.**—Before the capsule of the joint is opened the range of movement which is permitted at the hip joint should be tested. *Flexion*, or forward movement, is very free, and is checked by the anterior surface of the thigh coming into contact with the abdominal wall. *Extension*, or backward movement, is limited by the ilio-femoral ligament. That powerful ligament has a most important part to play in preserving the upright attitude with the least possible expenditure of muscular exertion. In the erect posture the line of gravity falls slightly behind the line joining the central points of the two hip joints. In the upright attitude the ilio-femoral ligaments are tense, and prevent the pelvis from rolling backwards on the heads of the femora. *Abduction*, or lateral movement of the limb, is checked by the pubo-capsular ligament. *Adduction*, or medial movement (*e.g.* as in crossing one thigh over the other), is limited

by the proximal portion of the ilio-femoral ligament and the upper part of the capsule. *Rotation medially* tightens the ischio-capsular ligament, and is therefore, in a measure, restrained by it. *Rotation laterally* is limited by the lateral portion of the ilio-femoral ligament. In *circumduction*, which is produced by combination of the movements of flexion, abduction, extension, and adduction, different parts of the capsular ligament are tightened at different stages of the movement.

The *flexor muscles* of the hip joint are chiefly—(1) the ilio-psoas, (2) the rectus femoris, (3) the pectineus, (4) the adductors longus and brevis and the pubic fibres of the adductor magnus; the *extensors* are—(1) the glutæus maximus, (2) the hamstrings, (3) the ischial fibres of the adductor magnus, (4) the posterior fibres of the glutæus medius, (5) the posterior fibres of the glutæus minimus; the *adductor muscles* are—(1) the three adductors, (2) the gracilis, (3) the pectineus, (4) the obturator externus, (5) the lowest fibres of the glutæus maximus, (6) the quadratus femoris; the *abductors* are—(1) the upper part of the glutæus maximus, (2) the tensor fasciæ latæ, (3) the glutæus medius, (4) the glutæus minimus.

The *medial rotators* are—(1) the ilio-psoas, (2) the anterior part of the glutæus medius, (3) the anterior part of the glutæus minimus, (4) the tensor fasciæ latæ; the *lateral rotators* are—(1) the two obturator muscles, (2) the gemelli, (3) the piriformis, (4) the quadratus femoris, (5) the three adductors, (6) the pectineus, (7) the inferior fibres of the glutæus maximus, (8) the ilio-psoas.

It must be noted that the obturator muscles, the piriformis, and the gemelli, which act as lateral rotators when the body is erect, become abductors when the joint is flexed, and that the ilio-psoas is a flexor of the hip joint and a medial rotator of the thigh until flexion is almost complete, then it becomes a lateral rotator.

**Dissection.**—The hip joint should now be opened. Make one incision along the upper border and another along the medial border of the ilio-femoral ligament in order to isolate that band from the rest of the capsule, then remove all other parts of the capsule. The object of this dissection is to enable the dissector to appreciate the great strength of the ilio-femoral ligament. It is fully a quarter of an inch thick, and a strain varying from 250 lbs. to 750 lbs. is required for its rupture (Bigelow). It is very rarely torn asunder in dislocations, and consequently the surgeon is enabled in most cases to reduce the displacement by manipulation. The ilio-femoral ligament may now be removed.

**Labrum Glenoidale (O. T. Cotyloid Ligament).**—The labrum glenoidale is a firm fibro-cartilaginous ring, which is fixed to the brim or margin of the acetabulum; it bridges across the notch, in the lower margin of the acetabulum, and thus completes the circumference of the cavity, deepens it, and at the same time narrows its mouth to a slight extent. The labrum glenoidale fits closely upon the head of the femur, and, acting like a sucker, exercises an important influence in retaining it in place. Both surfaces of the labrum are covered with synovial membrane; its free margin is thin, but it is much thicker at its attachment to the acetabular brim.

**Ligamentum Transversum Acetabuli.**—The transverse ligament consists of transverse fibres which bridge across the acetabular notch, and are attached to its margins. It lies between the labrum glenoidale laterally and the bottom of the notch medially, but a space is left between the medial

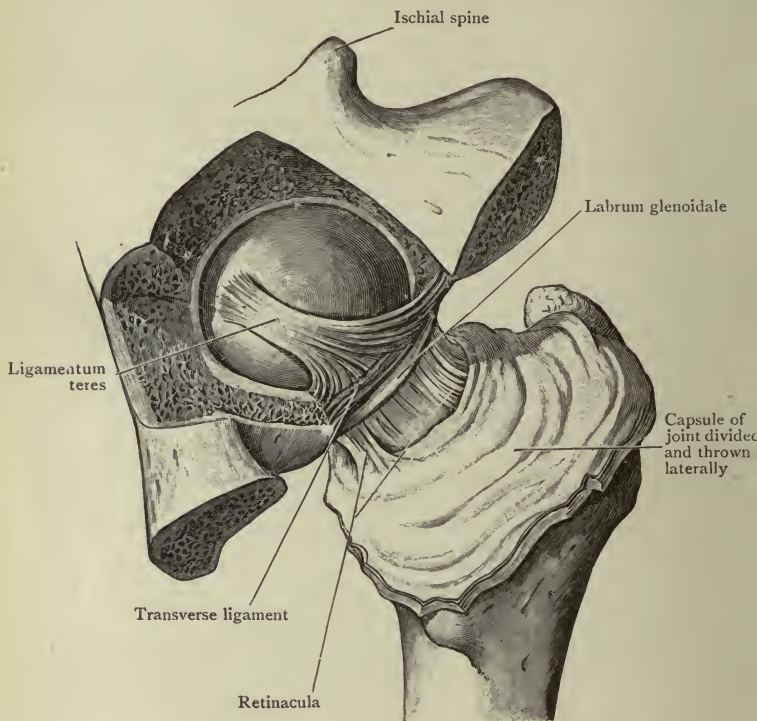


FIG. 142.—Dissection of Hip Joint from behind. The bottom of the acetabulum has been removed to show the ligamentum teres.

margin of the ligament and the bottom of the incisura through which vessels and nerves enter the joint. The lateral margin of the ligament is attached to the labrum glenoidale.

**Ligamentum Teres Femoris.**—The ligamentum teres is not round, as its name might lead one to expect, but is somewhat flattened and fan-like in shape. Its narrow

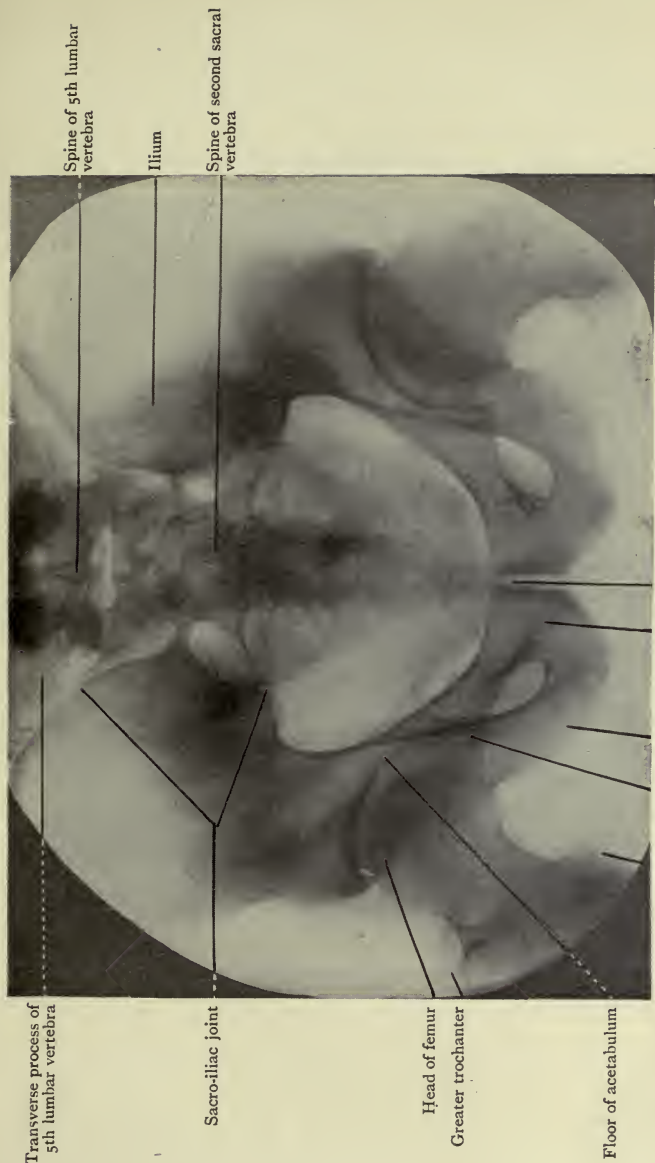


FIG. 143.—Radiograph of the Pelvis of an adult.

(Dr. D. Knorr)

PLATE XXIV

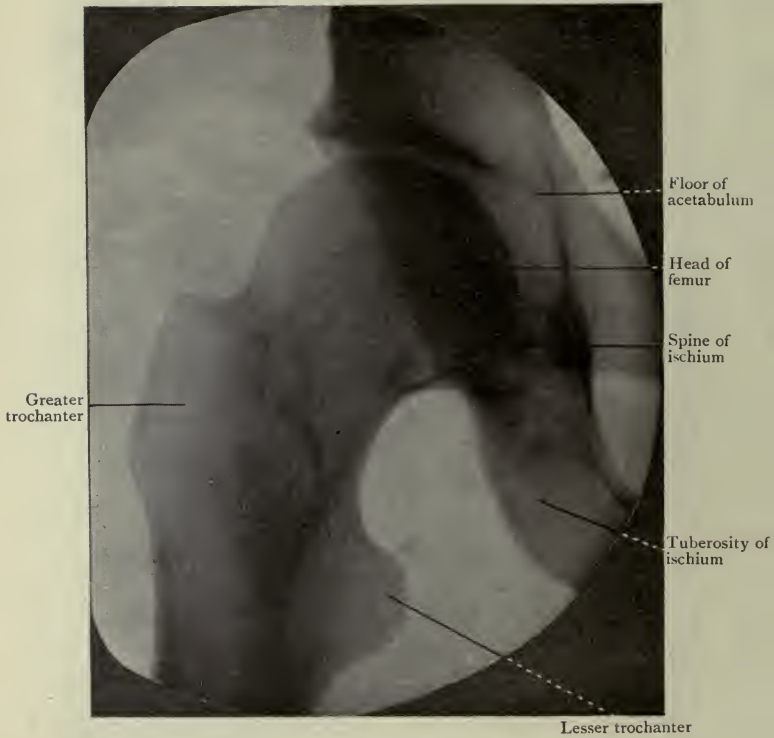


FIG. 144.—Radiograph of the Hip Joint of an adult.  
(Dr. R. Knox.)



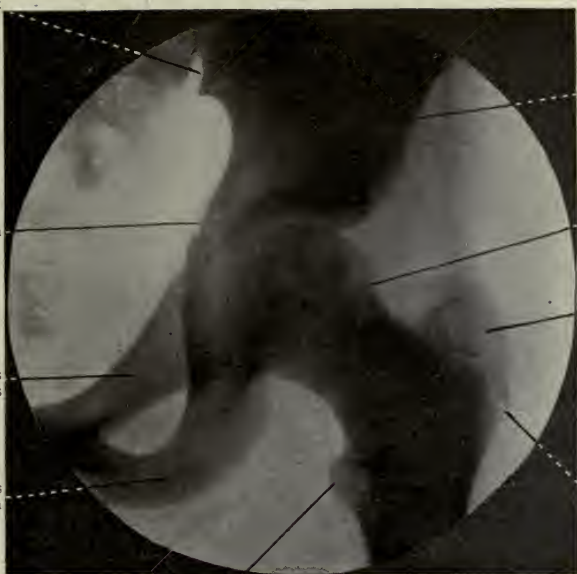
PLATE XXV

Sacro-iliac joint

Spine of ischium

Superior ramus  
of pubis

Inferior ramus  
of ischium



Ilium

Unossified  
cartilage  
between the  
head and the  
neck of the  
femur

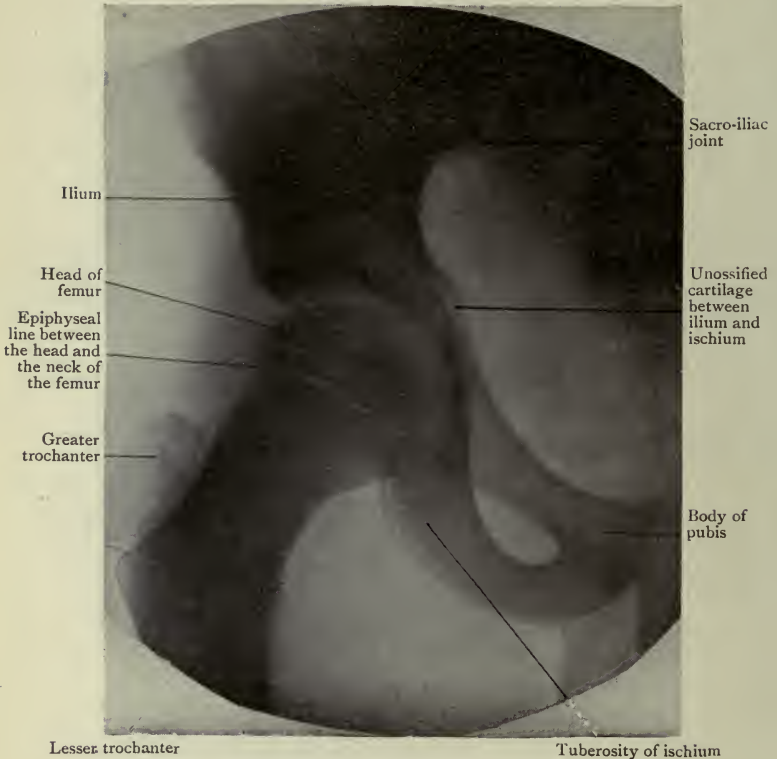
Greater  
trochanter

Unossified  
cartilage  
between  
greater  
trochanter

Lesser trochanter

FIG. 145.—Radiograph of the Hip Region of a child.  
The rami of the pubis and ischium have fused. The epiphyseal line  
of the lesser trochanter is visible.

PLATE XXVI



Lesser trochanter Tuberosity of ischium

FIG. 146.—Radiograph of the Hip Region of a child 11 years old.

The epiphysis of the lesser trochanter has not yet appeared. The inferior rami of the pubis and ischium have fused.

PLATE XXVII

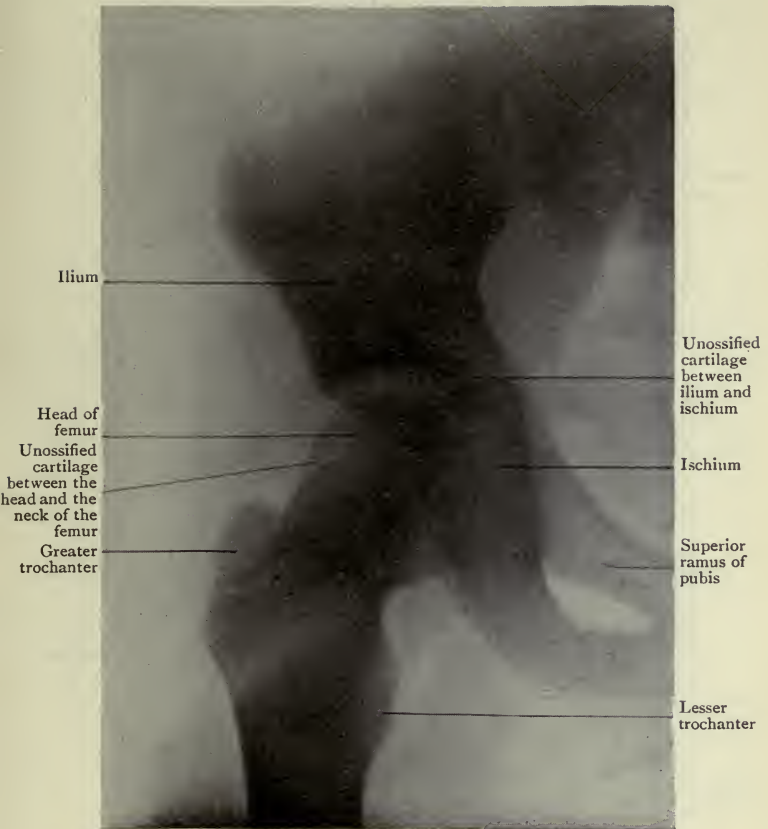


FIG. 147.—Radiograph of the Hip Region of a child.  
The epiphysis of the lesser trochanter has not yet appeared, but the inferior rami of the pubis and ischium have fused.

PLATE XXVIII

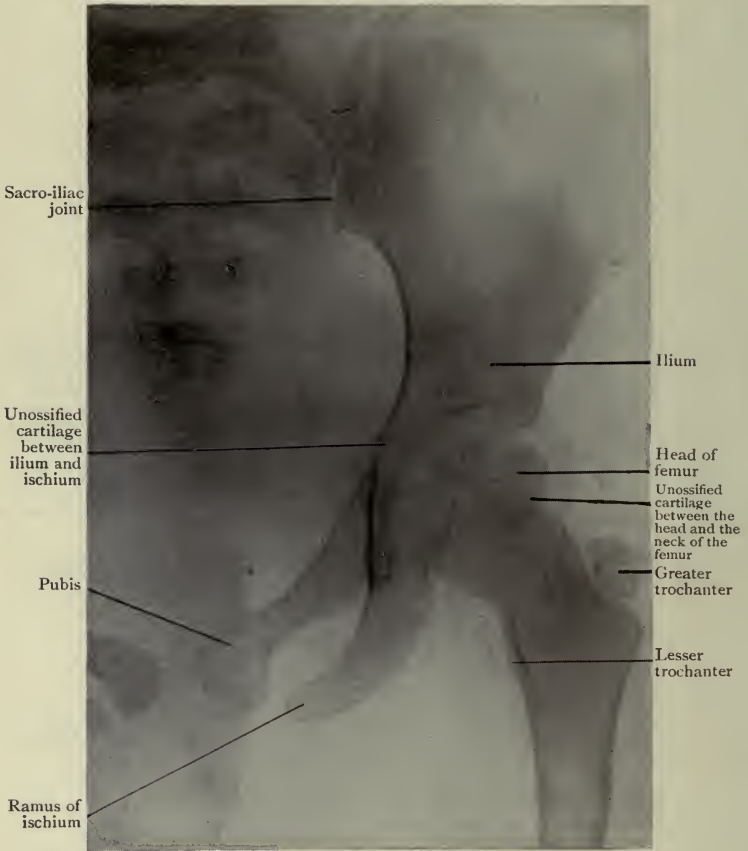


FIG. 148.—Radiograph of the Hip Region of a child.

The epiphysis of the lesser trochanter has not yet appeared, and the inferior rami of the pubis and ischium have not yet united.

PLATE XXIX

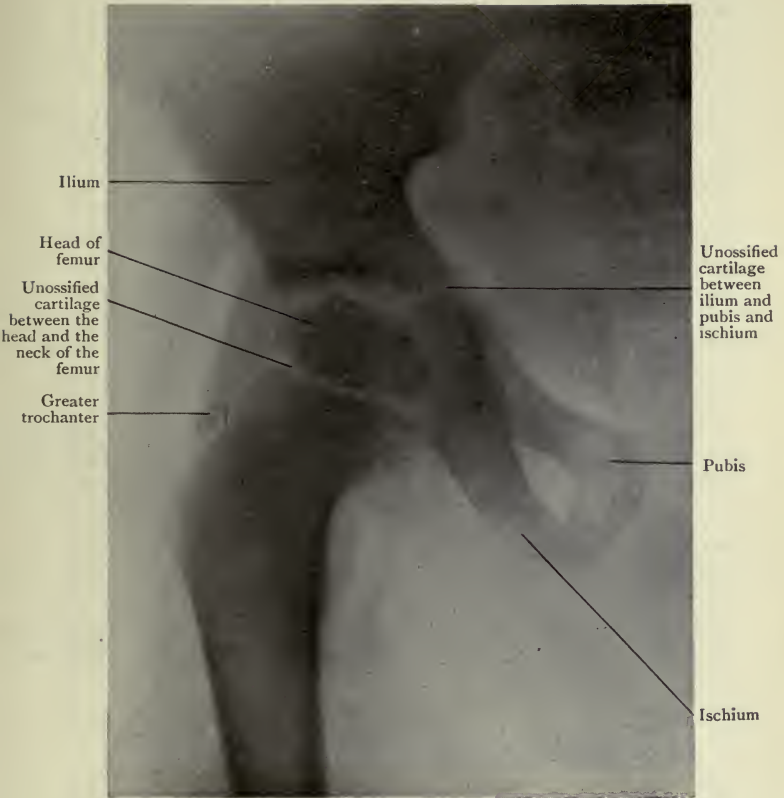


FIG. 149.—Radiograph of the Hip Region of a child.  
The epiphysis of the greater trochanter has just appeared. The inferior rami of the pubis and ischium have not yet united.

PLATE XXX

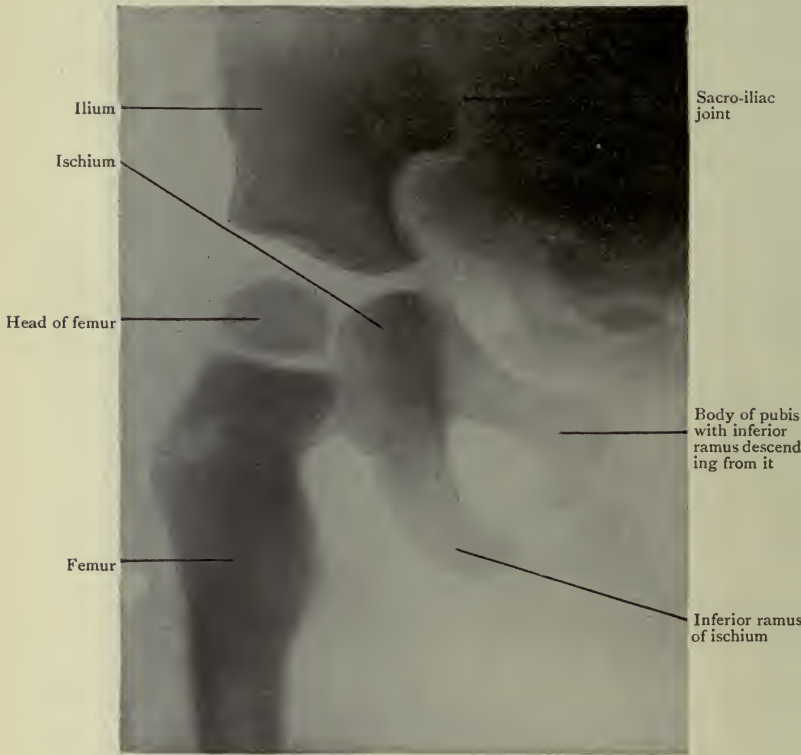


FIG. 150.—Radiograph of the Hip Region of a child.  
The gaps between the various segments of the bones indicate the sizes of the intervening cartilage segments.

femoral extremity is implanted into the fovea capitis femoris, whilst its flattened acetabular end is bifid, and is fixed to the margins of the acetabular notch, and also to the transverse ligament. This attachment can be defined by the removal of the synovial layer and some areolar tissue. The ligamentum teres is surrounded by a prolongation of the synovial layer, and a small artery runs along it to the head of the femur.

It is difficult to understand the part which the ligamentum teres plays in the mechanism of the hip joint. It presents very different degrees of strength in different subjects. It becomes very tense when the thigh is slightly flexed and then adducted.

**The Interior of the Joint and the Synovial Stratum.**—A mass of soft fat occupies the non-articular bottom of the acetabulum. Upon this the ligamentum teres is placed, and blood-vessels and nerves enter it by passing through the notch under cover of the transverse ligament. The vessels are derived from the medial femoral circumflex and the obturator arteries, and the nerves are twigs from the anterior branch of the obturator nerve, from the accessory obturator, when it is present, and from the nerve to the rectus femoris muscle. A nerve-twig is also supplied to the posterior part of the joint by the nerve to the quadratus femoris.

The *synovial stratum* lines the inner surface of the fibrous stratum of the capsule. From the fibrous stratum it is reflected on to the neck of the femur, and it clothes the bone as far as the margin of the articular cartilage which covers the head. Along the line of reflection some fibres of the fibrous stratum proceed proximally on the neck of the femur and raise the synovial layer in the form of ridges. These fibres are termed the *retinacula* or *cervical ligaments*.

The *retinacula* are of some surgical importance. In intracapsular fracture of the neck of the femur they may escape rupture, and they may then, to some extent, help to retain the fragments in apposition. Hence examinations of this class of fracture must be conducted gently, lest by rupturing this ligamentous connection the fragments be permanently displaced.

At the acetabular attachment of the capsule the synovial membrane is reflected on to the labrum glenoidale and invests both its surfaces. It also covers the articular surface of the transverse ligament and the cushion of fat which

occupies the bottom of the cavity. Lastly, it gives a tubular investment to the ligamentum teres.

**Removal of the Limb.**—The limb must now be removed from the trunk by dividing the ligamentum teres. It should then be taken to one of the tables set aside for the dissection of separate parts. Before proceeding to the dissection of the leg the attachments of the various muscles to the femur should be revised. The bulk of the muscles may be removed, but a small portion of each should be left, so that the attachments may again be revised, should it be found necessary to do so, at a later period.

## THE LEG.

**Surface Anatomy.**—Before the dissection of the leg is commenced, the relations of the tibia and fibula to the surface should be carefully investigated. The sharp *anterior crest* or *shin* of the tibia does not form a projection visible to the naked eye, but, nevertheless, it is subcutaneous and can be felt very distinctly when the finger is passed along it. It extends from the tuberosity of the tibia to the anterior border of the medial malleolus, pursuing a slightly sinuous course, and in its distal part it is rounded off and indistinct.

The broad flat medial surface of the body of the tibia is also subcutaneous, distal to the level of the insertion of the sartorius, and the medial border of the bone which forms its posterior boundary can be followed by the finger throughout its entire length from the medial condyle, to the posterior border of the medial malleolus. It indicates the position of the great saphenous vein and the saphenous nerve.

The fibula, on the whole, is more deeply placed. The head is easily distinguished below and posterior to the lateral condyle of the tibia; the trunk of the peroneal nerve lies behind it. The proximal half of the body of the bone is concealed by the surrounding muscles and cannot be palpated satisfactorily. The distal end of the bone, which forms the lateral malleolus, and the distal part of the body, proximal to the malleolus, are subcutaneous in a triangular area which will be found to be bounded anteriorly by the peronæus tertius, and by the peronæus longus and brevis muscles posteriorly.

The two malleoli form marked projections in the region of the ankle. The medial malleolus is the broader and more





PLATE XXXI

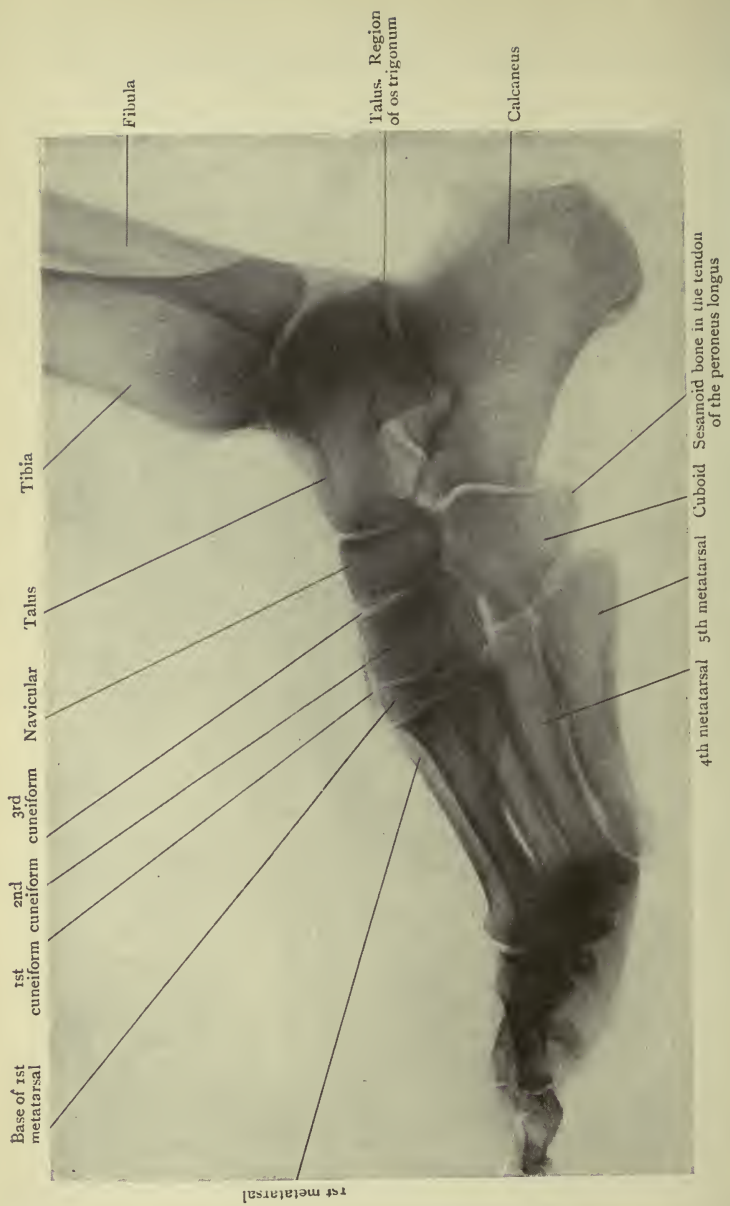

FIG. 151.—Radiograph of the Foot of an Adult.  
(Major T. Rankine.)

prominent of the two; it does not pass so far distally, but its anterior border is situated more anteriorly than the lateral malleolus. This is due to its greater breadth; because, when examined from behind, the posterior borders of the two projections are seen to occupy very nearly the same transverse plane.

On the posterior aspect of the leg the prominence known as the "calf of the leg" is visible. This is largely due to the fleshy bellies of the gastrocnemius muscle. Distal to the calf, and immediately proximal to the heel, the powerful tendo calcaneus can be felt. Anterior to that tendon a slight hollow is apparent on each side of the limb.

The skin will be reflected from the dorsum of the foot during the dissection of the leg; therefore the present opportunity should be seized for studying the surface anatomy of the foot. The individual tarsal bones cannot be recognised through the integument which covers the dorsum of the foot; but if the foot is powerfully extended, the head of the talus will be brought into view, in the shape of a slight prominence, which lies below and anterior to the ankle joint. The margins of the foot require careful study, because it is by the recognition of certain bony projections in them that the surgeon is enabled to determine the point at which to enter the knife when he is called upon to perform partial amputation of the foot. Examine the *medial margin* first. Begin posteriorly, at the projection formed by the medial process of the calcaneus, and proceed forwards. About one inch below the medial malleolus the medial edge of the sustentaculum tali may be recognised, and about one inch, or a little more, anterior to that, is the tubercle of the navicular. Then comes the first cuneiform bone, which is succeeded by the first metatarsal bone. None of these bony points can be said to form visible prominences on the surface. In order to distinguish them the medial margin of the foot must be carefully palpated. On the *lateral margin* of the foot the tuberosity on the base of the fifth metatarsal bone stands out as a distinct landmark. Posterior to it is the cuboid, and still more posterior the lateral surface of the calcaneus, which is almost completely subcutaneous. When present in a well-developed form, the trochlear process (O.T. peroneal tubercle) on this surface may be distinguished, about one inch distal and a little anterior to the lateral malleolus. If the foot is

strongly inverted the anterior end of the calcaneus will be seen to project on the surface.

**Subdivision of the Leg into Regions.**—In the dissection of the leg four distinct regions may be recognised, viz. :—

1. An *anterior crural region*, in which are placed those structures which lie anterior to the interosseous membrane, and between the two bones of the leg.
2. A *medial crural region*, corresponding to the subcutaneous or medial surface of the body of the tibia.
3. A *lateral crural region*, which includes the parts in relation to the lateral surface of the fibula.
4. A *posterior crural region*, in which are placed the parts, on the back of the leg, which lie posterior to the interosseous membrane and the two bones of the leg.

#### ANTERIOR CRURAL REGION AND DORSUM OF FOOT.

The anterior crural region should be dissected first, and it is usual to conjoin with this the dissection of the dorsum of the foot. The following parts are exposed :—

- |  |   |
|--|---|
| <ol style="list-style-type: none"> <li>1. Superficial veins.</li> <li>2. Cutaneous nerves.</li> <li>3. Deep fascia, with its inter-muscular septa, the transverse ligament of the leg, the lig. laciniatum, and the cruciate ligament of the leg.</li> <li>4. Tibialis anterior.</li> <li>5. Extensor digitorum longus.</li> <li>6. Peronæus tertius.</li> </ol> | <ol style="list-style-type: none"> <li>7. Extensor hallucis longus.</li> <li>8. Anterior tibial vessels.</li> <li>9. Perforating branch of the peroneal artery.</li> <li>10. Deep peroneal nerve.</li> <li>11. Recurrent articular branch from the common peroneal nerve.</li> <li>12. Extensor digitorum brevis.</li> <li>13. Dorsalis pedis vessels.</li> </ol> |
|--|---|

**Dissection.**—**Reflection of Skin.**—To place the limb in a convenient position for the dissection of this region, a block should be introduced beneath the knee, and the foot should be extended and fastened firmly to the table by means of hooks. The skin should be reflected from the *tibial* and *peroneal* (*medial* and *lateral*) *crural* regions at the same time. **Incisions** :—(1) a vertical cut along the median line of the leg and dorsum of the foot to the base of the middle toe ; (2) a transverse incision across the ankle joint ; (3) a transverse incision across the dorsum of the foot at the roots of the toes.

The four flaps of skin, thus mapped out (10, 11, 12, 13, Fig. 104), must now be raised from the subjacent fatty tissue, and the superficial veins and nerves dissected out.

**Superficial Fascia.**—The superficial fascia of the front and the medial and lateral sides of the leg and the dorsum of the foot presents no peculiar features ; and it contains as a rule only a moderate amount of fat, in which lie the cutaneous veins and nerves.

The veins which will be met with in it during the dissection are :—

- |  |   |
|--|---|
| 1. The dorsal digital veins of the toes. | 3. The distal part of the great saphenous vein. |
| 2. The dorsal venous arch.               | 4. The distal part of the small saphenous vein. |

The cutaneous nerves or their branches which should be secured as they pass through the superficial fascia are :—

- |                                |                               |
|--------------------------------|-------------------------------|
| 1. N. cutaneus suræ lateralis. | 4. N. peronæus superficialis. |
| 2. N. suralis.                 | 5. N. peronæus profundus.     |
| 3. N. saphenus.                |                               |

**Dissection.**—The lateral cutaneous nerve of the calf was displayed in the dissection of the popliteal space, arising from the common peroneal nerve or in common with the peroneal anastomotic branch. Trace it now to its termination on the antero-lateral aspect of the leg.

After the lateral cutaneous nerve of the calf has been traced to its termination, the cutaneous veins should be dissected, for, on the dorsum of the foot, they lie more superficially than the nerves, and in other situations they serve as guides to the positions of some of the nerves. Commence with the dorsal venous arch of the foot. It lies opposite the anterior parts of the bodies of the metatarsal bones and is usually visible, after the skin has been reflected, in at least part of its extent. Follow it medially to the medial border of the foot, where it joins with the medial dorsal digital vein of the great toe to form the commencement of the great saphenous vein. Next follow the great saphenous vein upwards, in front of the medial malleolus and obliquely across the medial surface of the distal third of the tibia to the medial border of the tibia. The remainder of the great saphenous vein will be displayed when the medial sural region is dissected, therefore do not follow it further at present, but secure the distal part of the saphenous nerve, which lies close to it, and follow the nerve to the middle of the medial border of the foot, where it ends. When the dissection of the saphenous nerve is completed follow the dorsal venous arch laterally to the lateral margin of the foot, where it unites with the lateral dorsal digital vein of the little toe to form the small saphenous vein. Follow the small saphenous vein backwards below the lateral malleolus and there secure the sural nerve, which lies adjacent to the vein. Follow the sural nerve forwards. About the middle of the lateral border of the foot it gives a twig of communication, to a branch of the lateral division of the superficial peroneal nerve, and then continues onwards to the lateral part of the dorsal aspect of the little toe. Follow it to its termination. Now clean the dorsal digital veins which join the convex anterior border of the dorsal venous arch. They are four in number, one opposite each interdigital cleft. Follow them to the clefts, and trace their tributaries into the toes. The terminal part of the superficial peroneal nerve must now be secured. If either the communicating twig from the saphenous nerve to the most

medial terminal branch of the superficial peroneal nerve was found, or the communicating branch from the sural nerve to the lateral terminal branch of the superficial peroneal nerve was found, follow one or the other of those branches upwards to the trunk. Otherwise cut down through the fat, at the junction of the middle and distal thirds of the leg, about 25 mm. to the medial side of the fibula, and secure the trunk of the superficial peroneal nerve as it pierces the deep fascia. Follow it distally to its division into medial and lateral branches, and then trace each of the branches and their subdivisions to their terminations on the toes. One of the subdivisions passes to the medial side of the great toe. A second passes to the cleft between the first and second toe; follow it with care, and find, springing from its medial side, a twig of communication to the medial division of the deep peroneal nerve. Follow the twig of communication, secure the medial division of the deep peroneal nerve, and follow its two terminal branches to the adjacent sides of the first and second toes.

**Venæ Superficiales (the Cutaneous Veins of the Dorsum of the Foot and the Front of the Leg).**—The cutaneous veins of the dorsum of the foot and the anterior region of the leg are the digital veins, the dorsal venous arch, and the parts of the great and small saphenous veins.

There are two *dorsal digital veins* in each toe, one on each side of the dorsum of the toe. The medial dorsal digital vein of the great toe joins with the medial end of the dorsal venous arch to form the commencement of the great saphenous vein, and the lateral dorsal digital vein of the little toe unites with the lateral end of the dorsal venous arch to form the small saphenous vein. The two dorsal digital veins which run along the adjacent sides of each of the four interdigital clefts unite at the apices of the clefts to form a common stem, and the four stems thus formed, which are sometimes called the common digital veins, end in the dorsal venous arch.

The *dorsal venous arch* lies in the superficial fascia on the anterior parts of the bodies of the metatarsal bones, superficial to the terminal branches of the superficial peroneal nerve. Its medial end, joining with the medial dorsal digital vein of the great toe, forms the commencement of the great saphenous vein, and its lateral end unites with the lateral dorsal digital vein of the little toe in the formation of the small saphenous vein.

The majority of the superficial veins of the front of the leg pass medially and upwards, and they terminate in the great saphenous vein, and as the great saphenous vein lies

in front of the medial malleolus it receives tributaries from the medial side of the foot.

**The Superficial Lymph Vessels of the Dorsum of the Foot and the Front of the Leg.**—The main superficial lymph vessels accompany the veins. The greater part of the lymph from the dorsum of the foot passes along vessels which accompany the great saphenous vein to the distal set of superficial subinguinal lymph glands (p. 228), but some of the lymph vessels from the lateral border of the foot, and the lateral part of the dorsum, accompany the small saphenous vein and terminate in the lymph glands in the popliteal fossa. The lymph vessels from the front of the leg pass to the larger lymph vessels which accompany the great saphenous vein (Fig. 159).

**Nervi Cutanei (the cutaneous nerves of the dorsum of the foot and the front of the leg).**—The dissector should note that branches of three nerves supply the skin of the front of the leg, branches of three nerves supply the dorsum of the foot, and that the dorsal aspects of the toes are, for the main part, supplied by branches of three nerves, but that only one nerve, the superficial peroneal, is common to all three regions.

The proximal part of the front of the leg, below the patella, is supplied by the *infrapatellar branch of the saphenous nerve* (Figs. 107, 163).

The *lateral cutaneous nerve of the leg*, a branch of the *common peroneal nerve*, is distributed to the skin of the anterior surface from the infrapatellar region to the junction of the middle and distal thirds of the leg, and the remainder of the front of the leg is supplied by the *superficial peroneal nerve*.

The medial side of the dorsum of the foot is supplied by the *saphenous nerve*, the lateral side by the *sural nerve*, and the intermediate area by the superficial peroneal nerve.

The adjacent sides of the first and second toes are supplied by the *medial division of the deep peroneal nerve*, the lateral sides of the little toe by the *sural nerve*, and all the remaining parts by branches of the *superficial peroneal nerve*.

The skin over the terminal phalanges of the first, second, third and the medial part of the fourth toes is supplied by branches of the *medial plantar nerve*.

**Nervus Peronæus Superficialis.**—The superficial peroneal

nerve pierces the deep fascia at the junction of the middle and distal thirds of the leg, and either at once or shortly afterwards it divides into a medial and a lateral division, which are quite unnecessarily called the medial and intermediate dorsal cutaneous nerves of the foot, the sural nerve, when it reaches the dorsum of the foot, being called the lateral dorsal cutaneous nerve of the foot to make the series complete. The medial division supplies the medial part of the dorsum of the foot and divides into two branches, one of which is distributed to the medial side of the great toe, and the other to the adjacent sides of the second and third toes; it also gives a communicating twig to the deep peroneal nerve (Fig. 107). The lateral division supplies the intermediate part of the dorsum of the foot, and also divides into two branches, one of which supplies the adjacent sides of the third and fourth toes, and the other, after receiving a twig from the sural nerve, supplies the adjacent sides of the fourth and fifth toes (Fig. 107). The branches of both divisions lie deep to the dorsal venous arch.

**Nervus Suralis.**—The sural nerve is formed at the back of the leg by the union of the anastomotic branch of the common peroneal nerve with the medial cutaneous nerve of the calf from the tibial nerve (Fig. 163). It accompanies the small saphenous vein, passes behind and below the lateral malleolus, and then runs along the lateral border of the foot, where it gives off a twig to the most lateral branch of the superficial peroneal nerve (Fig. 164), and then runs on to supply the lateral part of the dorsum of the little toe.

The account given above of the cutaneous nerves of the dorsum of the foot and toes indicates the general arrangement frequently met with, but the dissector must be prepared to meet with many variations, especially on the lateral side, where the sural nerve and the lateral division of the superficial peroneal nerve not uncommonly replace one another to a greater or a less extent.

**Dissection.**—After the cutaneous veins and nerves of the dorsum of the foot and the front of the leg have been examined, the remains of the fatty superficial fascia must be removed to display the deep fascia.

**Deep Fascia.**—The deep fascia does not form a complete investment for the leg. It is absent over the medial area of the tibia, and is attached to the anterior and medial borders of that bone. It is also absent over the triangular subcutaneous surface on the distal part of the fibula, being attached to the



ridges which limit that area anteriorly and posteriorly. It is not equally dense throughout, but becomes thinner towards the distal part of the leg until the region of the ankle is reached, where thickened bands are formed in it; beyond the ankle in the region of the dorsum of the foot it becomes exceedingly thin and fine. Its great strength in the proximal part of the anterior crural region is due to the fact that there it gives origin to fibres of the subjacent muscles. The bands in the region of the ankle are formed to retain the tendons in position when the muscles which move the joint are in action. Four of the bands must be examined at this stage of the dissection, viz., the *ligamentum transversum cruris*, the *ligamentum cruciatum cruris*, and the superior and inferior retinacula of the peroneal muscles.<sup>1</sup>

The *ligamentum transversum cruris* (O.T. *upper part of anterior annular ligament*) is a strong, broad band which stretches across the front of the leg, immediately proximal to the ankle joint. By one extremity it is attached to the fibula, and by the other to the tibia. The *lig. cruciatum cruris* (O.T. *lower part of anterior annular ligament*) is placed over the ankle joint. Laterally it presents the appearance of a narrow, well-defined band, which is fixed firmly to the anterior part of the calcaneus. As it passes medially it divides into two diverging limbs. Of these the proximal is attached to the medial malleolus, whilst the distal passes to the medial margin of the foot, and becomes connected with the plantar aponeurosis. The transverse and the cruciate ligaments of the leg are merely portions of the deep fascia which are distinguishable on account of their thickness (Figs. 153, 154).

The *superior peroneal retinaculum* is a thickened portion of the deep fascia which passes from the posterior and distal part of the lateral malleolus to the upper and posterior part of the lateral surface of the calcaneus (Fig. 158).

The *inferior peroneal retinaculum* springs from the anterior part of the upper surface of the calcaneus, where it is continuous with the lateral extremity of the cruciate ligament; its opposite extremity is attached, on the lateral border of the foot, to the trochlear process of the calcaneus and to the lateral surface of the calcaneus below that process. The

<sup>1</sup> In the old terminology the first two bands were respectively the upper and lower parts of the anterior annular ligament of the ankle, and the last two were included under the term external annular ligament.

peroneal retinacula bind the tendons of the peronæus longus and brevis to the lateral surface of the calcaneus (Fig. 158).

**Intermuscular Septa.**—As the deep fascia of the leg passes backwards over the fibular region, two strong intermuscular septa are given off from its deep surface. These are distinguished as the anterior and posterior fibular septa. The *anterior fibular septum* intervenes between the peroneal muscles and the extensor muscles of the toes, and is attached to the anterior crest of the fibula. The *posterior fibular septum* is interposed between the peroneal muscles and the muscles on the back of the leg, and is attached to the lateral crest of the fibula.

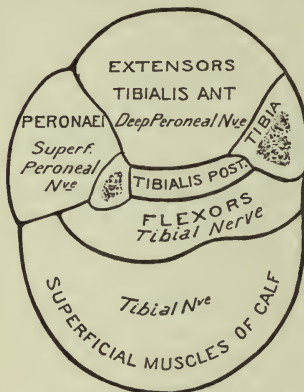


FIG. 152.—Diagrammatic representation of the Fascia of the Leg. The fascia of the tibialis posterior is more a muscular aponeurosis than a true fascial septum; but it is convenient for descriptive purposes to regard it as one of the partitions.

The leg is thus subdivided into three osteofascial compartments, corresponding to the anterior, lateral, and posterior crural regions. The *anterior compartment* is bounded by the investing deep fascia, the anterior fibular septum, the anterior part of the medial surface of the fibula (that part which lies anterior to the interosseous crest), the interosseous membrane,

and the lateral surface of the tibia. The *lateral compartment* is bounded by the lateral surface of the fibula, the investing fascia, and the two fibular septa. The *posterior compartment*, which will be studied later, is much the largest; its walls are formed by the posterior surface of the tibia, the posterior part of the medial surface and the whole of the posterior surface of the fibula, the interosseous membrane, the posterior fibular septum, and the investing deep fascia.

**Dissection.**—The anterior compartment of the leg should now be opened by the removal of the deep fascia. The transverse and cruciate ligaments, however, must be retained, and their borders should be separated artificially, by the knife, from the

deep fascia with which they are continuous. Great care must be taken not to injure the mucous sheaths of the tibialis anterior and the extensor tendons of the toes, when the margins of the transverse and cruciate ligaments are being defined, and whilst the deep fascia is being reflected. They lie close to the deep surface of the deep fascia. In the proximal part of the leg it will be found impossible to raise the deep fascia from the subjacent muscles without lacerating their surfaces. It should, therefore, be left in position. At a more distal level it can readily be separated. Divide it in a longitudinal direction midway between the tibia and fibula. Turn the medial piece to the medial side, until its attachment to the anterior border of the tibia is demonstrated; then turn the lateral piece to the lateral side, until its continuity with the anterior fibular septum is displayed.

After the medial and lateral attachments of the deep fascia have been studied attempt to distend the synovial sheaths of the tendons, either by inflation with a blow-pipe, or by the injection of some fluid by means of a small syringe. Three sheaths are to be examined; from the medial to the lateral side they are, the sheath of the tibialis anterior, the sheath of the extensor hallucis longus, and the sheath common to the extensor digitorum longus and the peronæus tertius (see Fig. 153, p. 342). If the blow-pipe is used make a small incision through the deep fascia of the foot into each sheath in turn, either between the two bands of the cruciate ligament or beyond the lower border of the cruciate ligament, and if a syringe is used insert the needle into the sheaths in the same regions. If inflation or injection fails, the positions and extents of the sheaths can be fairly satisfactorily demonstrated by the use of a blunt probe, introduced into the cavities of the sheaths through the openings made through their boundaries.

**The Mucous Sheaths on the Dorsum of the Foot.**—Three mucous sheaths are found in the region of the front of the ankle and on the dorsum of the foot—one round the tendon of the tibialis anterior, the second round the tendon of the extensor hallucis longus, and the third encloses the tendons of the extensor digitorum longus and the peronæus tertius. The first extends from the proximal border of the transverse ligament to within a short distance of the insertion of the tibialis anterior into the medial side of the first cuneiform bone. The second extends from behind the lower part of the transverse ligament to the first phalanx of the great toe; and the limits of the third are the lower border of the transverse ligament, proximally, and the middle of the dorsum of the foot distally. The sheaths facilitate the movements of the tendons behind the ligaments when the muscles are in action, and they are of surgical importance because they are liable to become inflamed.

After the mucous sheaths have been examined, the contents of the anterior crural compartment may be investigated.

**Contents of the Anterior Crural Compartment.**—Four muscles are brought into view when the deep fascia of the

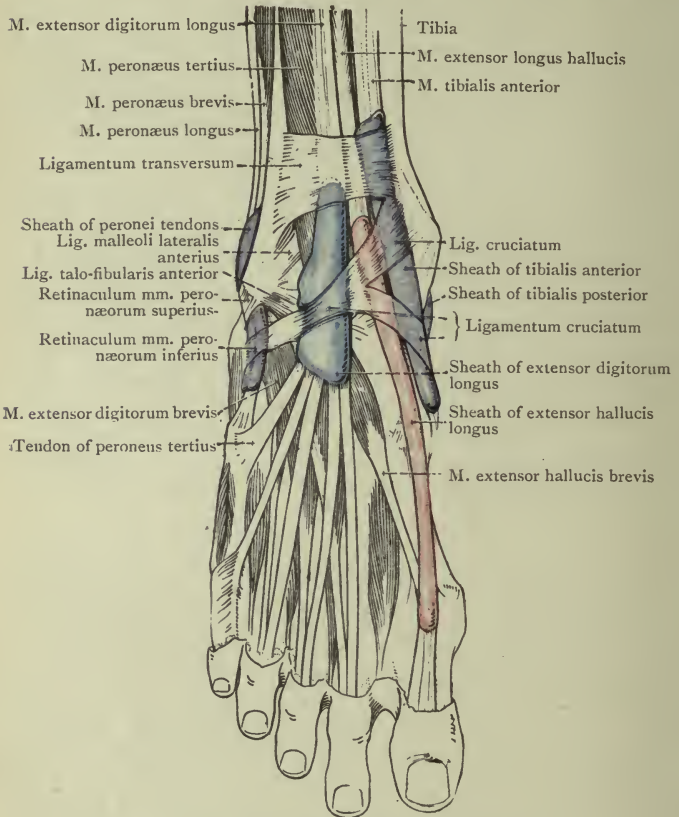


FIG. 153.—Mucous sheath of the Dorsum of the Foot.

front of the leg has been removed, viz., the tibialis anterior, the extensor digitorum longus, the extensor hallucis longus, and the peronæus tertius. The *tibialis anterior* lies in relation to the tibia; the *extensor digitorum longus* is placed along the fibula; and when those muscles are separated from one another the *extensor hallucis longus* will be seen in the interval between

them. The *peronæus tertius* lies upon the distal portion of

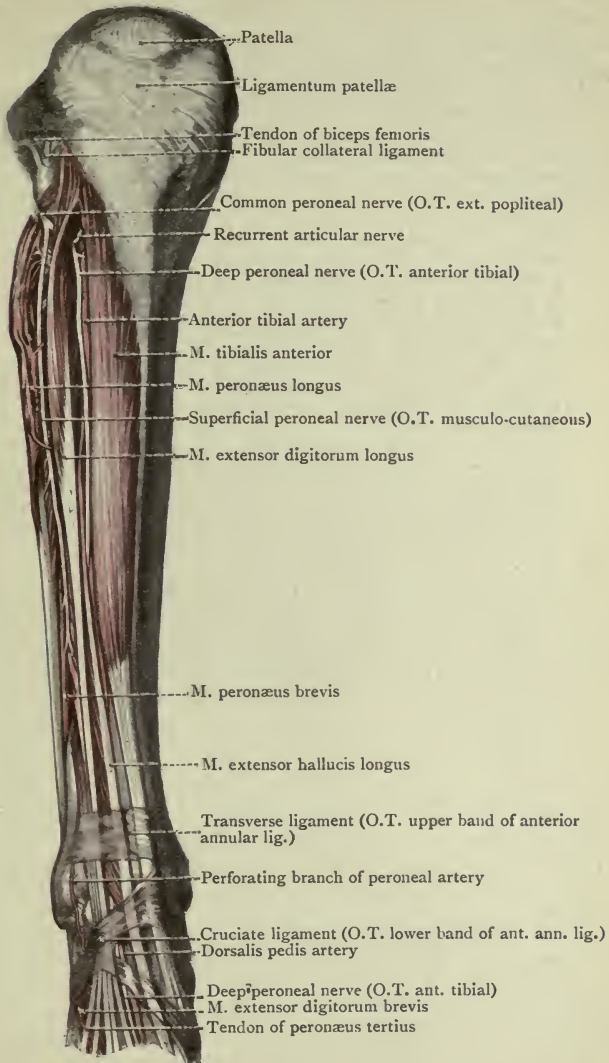


FIG. 154.—Dissection of the Anterior and Lateral Crural Regions, I—22 c

the fibula, and in most cases is continuous with the extensor digitorum longus. The *anterior tibial vessels* and the *deep peroneal nerve* (O.T. *anterior tibial*) proceed distally in this compartment. At first they are deeply placed, but as they approach the ankle they come nearer to the surface.

**Dissection.**—To expose the anterior tibial vessels and the deep peroneal nerve in their entire course on the front of the leg, the tibialis anterior and the extensor digitorum longus must be separated from each other, along the line of a strong intermuscular septum which dips backwards between them, and affords a surface of origin to each. The knife should be carried proximally along the plane of this septum. If the peronæus tertius muscle is drawn aside, the *perforating branch of the peroneal artery* will be seen piercing the interosseous membrane. It is a small artery which descends upon the distal end of the fibula. As the structures in the anterior crural compartment are being exposed and cleaned, the dissector should, at the same time, carry on the dissection of the dorsum of the foot. There the tendons of the muscles on the front of the leg must be followed to their insertions, then the tendons of the extensor digitorum longus must be pulled aside in order that the extensor hallucis brevis and the extensor digitorum brevis, which lie deep to the tendons of the long extensor of the toes, may be cleaned and their tendons followed to their terminations. The dorsalis pedis artery, which is the continuation of the anterior tibial artery, and the deep peroneal nerve, and their branches, must also be cleaned and followed to their terminations.

**M. Tibialis Anterior** (O.T. *Tibialis Anticus*).—The tibialis anterior is a powerful muscle, which takes origin from the distal part of the lateral condyle of the tibia, and from the proximal half of the lateral surface of its body (Fig. 154, p. 343). It derives many fibres also from the deep fascia which covers it, from the fascial septum between it and the extensor digitorum longus, and from the portion of the interosseous membrane on which it rests. In other words, it springs from the structures which form the walls of the medial portion of the osteo-fascial compartment in which it lies.<sup>1</sup> A strong tendon issues from its fleshy belly in the distal third of the leg, and this reaches the dorsum of the foot by passing

<sup>1</sup> To understand the attachments of the muscles of the leg, it is necessary to bear in mind that the interosseous membrane, which stretches across the interval between the two bones of the leg, and thus extends the surface of origin for these muscles, is attached to the *interosseous crest* of the tibia (*i.e.* between its lateral and posterior surfaces) and to the interosseous crest of the fibula. The interosseous crest of the fibula traverses the medial surface of that bone, and divides it into an anterior and a posterior part. The anterior part gives origin to the extensor muscles and the posterior part to the tibialis posterior.

through both the transverse and cruciate ligaments. On the foot it inclines medially, and, turning round the medial margin, gains insertion, by two slips, into the medial and distal part of the first cuneiform bone, and into the adjoining part of the base of the first metatarsal bone. The tibialis anterior is supplied by the *deep peroneal nerve*. It is a dorsiflexor and an inverter of the foot.

**M. Extensor Digitorum Longus.**—The extensor longus digitorum muscle arises, for the most part, from the structures which form the lateral portion of the wall of the

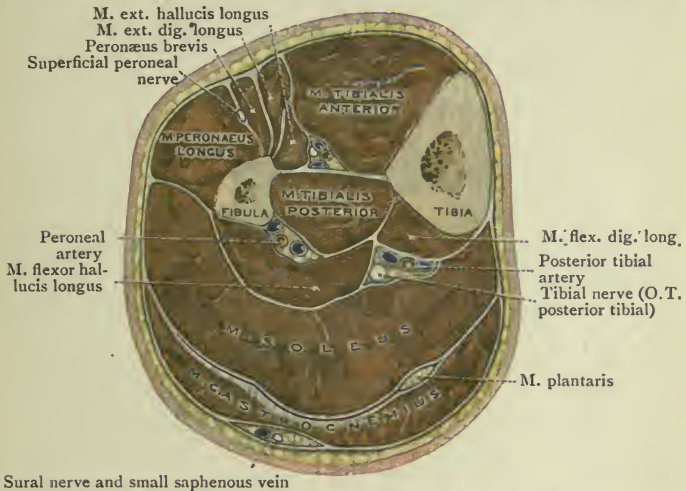


FIG. 155.—Transverse section through the Middle of the Leg.

anterior crural region. Thus, it springs from the distal part of the lateral condyle of the tibia, from the head of the fibula, and from the proximal three-fourths of the anterior part of the medial surface of the body of the fibula (Fig. 154, p. 343). It takes origin also from a small portion of the proximal part of the interosseous membrane, the deep investing fascia of the leg, the anterior fibular septum, and the inter-muscular septum which lies between it and the tibialis anterior. The tendon of the extensor digitorum longus descends anterior to the ankle joint, and, passing through the transverse and cruciate ligaments (p. 339), divides into four slips, which diverge from each other on

the dorsum of the foot to reach the lateral four toes. On the dorsum of the first phalanx of each of the medial three of the lateral four toes each slip is joined, on its lateral side, by a tendon from the extensor digitorum brevis.

The manner in which the four tendons of the long extensor are inserted is similar, in all essential respects, to that in which the corresponding tendons of the fingers are attached, but there are slight differences, and as the dissector of the foot may not have dissected the hand a description of the conditions met with is necessary. The tendons of the extensor digitorum longus go to the second, third, fourth, and fifth toes, and those of the extensor digitorum brevis to the first, second, third, and fourth toes. In the cases of the second, third, and fourth toes the tendons of the long and short extensors unite, and the conjoined tendons form an expansion on the dorsal aspect of the first phalanx. The expansion is joined by the slender tendons of one lumbrical and two interossei, and then it divides into a central and two collateral parts. The slender central part is inserted into the base of the second phalanx; the stronger collateral parts are prolonged forwards, and, after they have united together, they are inserted into the base of the terminal phalanx; thus five tendons gain insertion into the dorsal aspects of the bases of each of the second and terminal phalanges of the second, third, and fourth toes, and movements become possible which could not be readily obtained in any other way, for whilst the flexor tendons flex the metacarpo-phalangeal joints the lumbricals and interossei can extend the interphalangeal joints by virtue of their connection with the extensor expansion. In the case of the foot this is not a very important matter, but in the case of the hand it is of extreme importance, for it is only by the means indicated that it is possible to place the fingers in the "writing position," and use them in the usual manner adopted for writing (see p. 178). The extensor digitorum longus is supplied by the *deep peroneal nerve*. It is an extensor of the interphalangeal and metatarso-phalangeal joints of the lateral four toes and it dorsi-flexes the foot.

**M. Extensor Hallucis Longus.**—The long extensor of the great toe is placed in the interval between the tibialis anterior and the extensor digitorum longus. In its proximal part it is hidden from view by those muscles, but near the ankle it



comes to the surface. It takes origin posterior to the extensor digitorum longus, from an extremely narrow strip of the anterior part of the medial surface of the body of the fibula, in its middle two-fourths, and also from the adjoining part of the interosseous membrane. Its tendon passes deep to the transverse ligament, crosses in front of the distal part of the anterior tibial artery, and passing distally in front of the ankle joint reaches the dorsum of the foot deep to the cruciate ligament (Fig. 342). It is inserted into the dorsal aspect of the base of the unguis phalanx of the great toe.<sup>1</sup> It is *not joined* by the most medial tendon of the extensor digitorum brevis. The extensor hallucis longus is supplied by the *deep peroneal nerve*. It is an extensor of all the joints of the great toe and a dorsi-flexor of the foot.

**M. Peronæus Tertius.**—The peronæus tertius is a small muscle which is continuous at its origin with the extensor digitorum longus. It arises from the distal fourth of the anterior part of the medial surface of the fibula, and from a corresponding extent of the interosseous membrane. It receives fibres also from the distal part of the anterior fibular septum, which intervenes between it and the peronæus brevis. Its slender tendon is inserted into the dorsal surface of the expanded base of the fifth metatarsal bone. It is supplied by the *deep peroneal nerve*. It is a dorsi-flexor of the ankle joint and an evertor of the foot.

**Arteria Tibialis Anterior.**—The anterior tibial artery is the smaller of the two terminal branches of the popliteal. It takes origin in the posterior region of the leg, at the distal border of the popliteus muscle, and at the level of the tuberosity of the tibia (see Fig. 135). It enters the anterior crural region by passing forwards through the opening in the proximal part of the interosseous membrane. As it passes forwards it lies close to the medial side of the neck of the fibula, where it appears in the present dissection. In the anterior part of the leg it takes a straight course distally to the ankle joint. Then it reaches the dorsum of the foot, and receives the name of *dorsalis pedis*.

In the proximal two-thirds of the leg the anterior tibial artery is very deeply placed. It lies upon the interosseous membrane, in the interval between the tibialis anterior on the medial side, and the extensor digitorum longus and the

<sup>1</sup> In most cases it gives a slip to the base of the proximal phalanx also.

extensor hallucis longus on the lateral side. In the distal third of the leg, where the muscles give place to their tendons, the artery comes nearer to the surface. In that part of its course it rests upon the tibia and is overlapped on the lateral side by the extensor hallucis longus. Immediately proximal to the ankle joint the tendon of the extensor hallucis longus crosses superficial to the artery and so comes to lie on its medial side.

Two *venæ comites* closely accompany the anterior tibial artery, and send short communicating branches both anterior and posterior to it. The *deep peroneal nerve* is also intimately related to it. It joins the artery a short distance distal to the knee, and soon takes up a position anterior to the vessel. Near the ankle joint the nerve, as a rule, again lies on the lateral side of the artery. Whilst the artery is still in the back part of the leg it gives off a fibular and a posterior tibial recurrent branch which will be seen in a subsequent dissection (see p. 403).

On the front of the leg the anterior tibial artery gives off the following *branches* :—

- |                                    |  |                                       |
|------------------------------------|--|---------------------------------------|
| 1. Muscular.                       |  | 3. A. malleolaris anterior medialis.  |
| 2. A. recurrens tibialis anterior. |  | 4. A. malleolaris anterior lateralis. |

The *muscular branches* are numerous, and come off at irregular points along the whole length of the artery. They supply the muscles of the *anterior crural region*.

The **anterior tibial recurrent artery** is a small vessel which springs from the anterior tibial immediately after it reaches the front of the leg. It turns proximally, on the lateral condyle of the tibia, in the fibres of the tibialis anterior muscle. Its terminal twigs reach the front of the knee joint, and anastomose with the inferior genicular branches of the popliteal artery.

**Malleolar Arteries.**—These arteries take origin immediately proximal to the ankle joint. The *lateral anterior malleolar artery* is the larger of the two. It passes laterally under cover of the tendons of the extensor digitorum longus and peronæus tertius, to reach the lateral surface of the lateral malleolus, and it anastomoses with the perforating branch of the peroneal artery and with the lateral tarsal artery. The *medial anterior malleolar artery* runs medially, under cover of the

tendons of the extensor hallucis longus and tibialis anterior. It inosculates with branches from the posterior tibial artery.

**Arteria Dorsalis Pedis.**—The dorsal artery of the foot is the continuation of the anterior tibial. It begins, anterior to the ankle joint, at a point midway between the two malleoli, and it extends forwards, upon the dorsal part of the talus, and across the navicular, and the second cuneiform bone, to the posterior part of the first interosseous space. There it leaves the dorsum of the foot,

by dipping plantarwards between the two heads of the first dorsal interosseous muscle, to reach the plantar region, where it unites with the lateral plantar artery in the formation of the plantar arch. Its relations on the dorsum of the foot are very simple.

(1) It lies in the interval between the tendon of the extensor hallucis longus on the medial side and the most medial tendon of the extensor digitorum longus on the lateral side.

(2) It is crossed first by the proximal band of the cruciate ligament, then by the distal band, and near its termination it is crossed by the tendon of the extensor hallucis brevis; with those exceptions the vessel is covered merely by the integu-

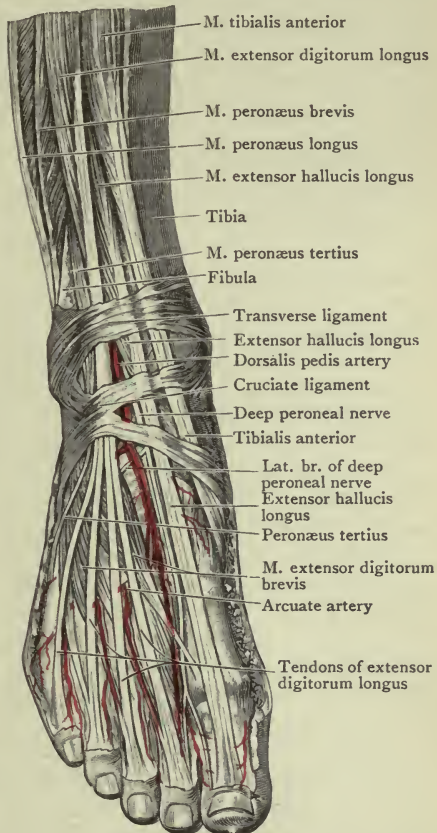


FIG. 156.—Dissection of the Dorsum of the Foot.

ment and fasciæ. (3) The medial terminal branch of the deep peroneal nerve lies along its lateral side,<sup>1</sup> and two *venæ comites* accompany it.

As the dorsalis pedis artery traverses the dorsum of the foot it gives off several twigs to the medial margin of the foot, and three named branches which pass laterally:—

1. Aa. tarseæ mediales.
2. A. tarsea lateralis.
3. A. arcuata.
4. A. metatarsea dorsalis prima.

**Arteriæ Tarseæ Mediales.**—The medial tarsal branches two or more in number, spring from the medial side of the dorsalis pedis and descend across the medial border of the foot to anastomose with branches of the medial plantar artery.

**A. Tarsea Lateralis et A. Arcuata (O.T. Tarsal and Metatarsal).**—The *lateral tarsal artery* arises opposite the navicular bone, and the *arcuate artery* arises near the bases of the metatarsal bones. They both run laterally, under cover of the extensor hallucis brevis and the extensor digitorum brevis, to reach the lateral margin of the foot. There they anastomose with branches of the lateral plantar artery. The lateral tarsal artery anastomoses also with the lateral malleolar and peroneal arteries.

From the arch which is formed by the arcuate artery *three dorsal metatarsal arteries* proceed, one to each of the lateral three interosseous spaces, and at the clefts between the toes they divide and supply *dorsal digital twigs* to the adjacent sides of the second, third, fourth, and fifth toes. From the most lateral dorsal metatarsal artery a twig is given to the lateral side of the little toe.

**A. Metatarsea Dorsalis Prima (O.T. First Dorsal Interosseous).**—The first dorsal metatarsal artery is a small vessel which takes origin from the dorsalis pedis, at the point where that vessel turns plantarwards to reach the plantar region of the foot. From its origin it continues forwards, upon the first dorsal interosseous muscle, and divides into *dorsal digital branches* for the medial side of the great toe and the adjacent sides of the great toe and second toe.<sup>2</sup>

**Perforating Branch of Peroneal Artery (O.T. Anterior**

<sup>1</sup> The nerve sometimes descends along its medial side.

<sup>2</sup> For the branches from the dorsalis pedis in the plantar region see p. 398.

**Peroneal Artery).**—This branch of the peroneal artery arises in the posterior region of the leg. It pierces the interosseous membrane from 35 to 50 mm. above the lateral malleolus, and so enters the anterior region. There it descends upon the distal part of the fibula, under cover of the peronæus tertius, and its terminal branches anastomose with the lateral malleolar and lateral tarsal arteries.

**Mm. Extensor Hallucis Brevis et Extensor Digitorum Brevis.**—The short extensor of the great toe and the short extensor of the toes may now be examined. They are the muscles which form the fleshy cushion on the dorsum of the foot. They arise together from the anterior part of the dorsal surface of the calcaneus, immediately posterior to the cuboid bone, and also from the stem of the cruciate ligament. The common muscular mass breaks up into four segments. The most medial of the four is called the *short extensor of the great toe*. It ends in a tendon which is inserted into the base of the first phalanx of the great toe. On its way from its origin to its insertion it crosses the superficial surface of the distal part of the dorsalis pedis artery. It is supplied by the lateral branch of the deep peroneal nerve and it is an extensor of the metatarso-phalangeal joint of the great toe.

The remaining three segments of the muscular mass are described collectively as the *short extensor of the toes*. They end in tendons which join the long extensor tendons going to the second, third, and fourth toes, and, by means of the extensor expansion (see p. 346), they gain insertion into the second and terminal phalanges of those toes. The short extensor of the toes like the extensor hallucis brevis is supplied by the lateral branch of the deep peroneal nerve, and it acts as an extensor of the interphalangeal and metatarso-phalangeal joints of the toes to which it is distributed.

**Nervus Peronæus Profundus (O.T. Anterior Tibial).**—The deep peroneal nerve is one of the terminal branches of the common peroneal nerve. It arises between the proximal part of the peronæus longus and the neck of the fibula, then it pierces the anterior fibular septum and the extensor digitorum longus, and so enters the anterior compartment of the leg. In that compartment it descends obliquely until it joins the anterior tibial vessels, a short distance distal to the lateral condyle of the tibia. In the remainder of its course it accompanies the anterior tibial vessels, in the first

instance lying lateral to them, then anterior; but near the ankle joint it again, as a rule, lies on their lateral side. It passes posterior to the transverse and cruciate ligaments, and ends by dividing into a medial and a lateral branch.

In its course through the leg the deep peroneal nerve gives *muscular branches* to the extensor digitorum longus, the tibialis anterior, the extensor hallucis longus, and the peronæus tertius; and a fine *articular twig* to the ankle joint.

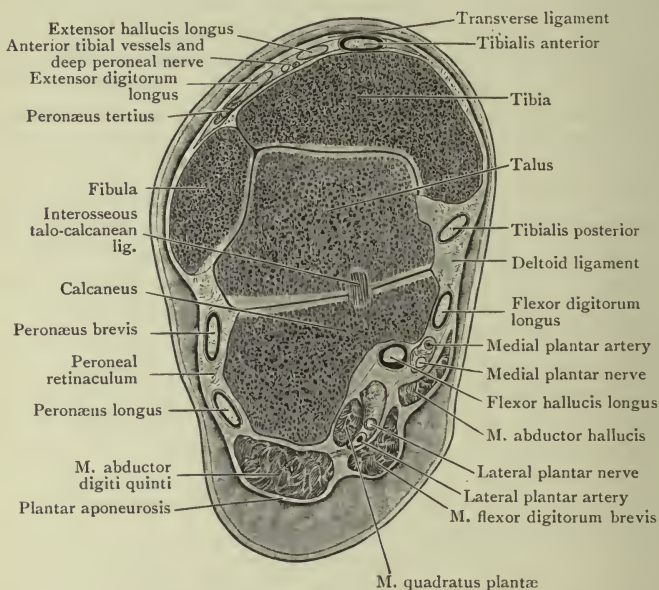


FIG. 157.—Frontal section through the Left Ankle Joint, Talus, and Calcaneus (Paterson).

The *medial terminal branch* of the deep peroneal nerve is continued forwards upon the dorsum of the foot along the lateral side of the dorsalis pedis artery.<sup>1</sup> At the posterior end of the first interosseous space, it pierces the deep fascia, and divides to supply the contiguous margins of the great toe and the second toe (p. 337). Before it reaches the surface, it furnishes *articular twigs* to the tarso-metatarsal and metatarso-

<sup>1</sup> Not uncommonly it crosses superficial to the artery and descends along its medial side.

phalangeal joints of the great toe, and frequently, also, a fine *muscular twig* to the dorsal surface of the first dorsal interosseous muscle.

The *lateral terminal branch* of the deep peroneal nerve turns abruptly laterally, under cover of the extensor digitorum brevis, and ends on the dorsum of the tarsus in a gangliform enlargement. Branches proceed from the enlargement to supply the extensor digitorum brevis and the numerous articulations in the neighbourhood. One fine filament can, in some cases, be traced to the second dorsal interosseous muscle. The terminal swelling resembles closely the corresponding enlargement in which the dorsal interosseous nerve of the superior extremity ends (see p. 185).

**Ligamentum Transversum Cruris et Ligamentum Cruciatum** (O.T. **Anterior Annular Ligament**).—The dissector should now re-examine the transverse and cruciate ligaments, and the arrangement of the structures which pass deep to them. The *transverse ligament* is attached to the fibula by its lateral end, and to the tibia by its medial extremity. If the fibular attachment is divided, and the ligament is thrown medially, it will be seen to contain a distinct compartment for the tibialis anterior and its mucous sheath.

The *cruciate ligament* is the more important of the two. Its attachments have already been noted (p. 339). Examine the manner in which it holds the tendons in position. It consists of two layers, and these, by separating at certain points and becoming reunited at others, form three distinct compartments. The tendon of the tibialis anterior passes through the *medial* compartment, the tendon of the extensor hallucis longus traverses the *intermediate* one, and the tendons of the extensor digitorum longus and peronæus tertius are transmitted through the *lateral* compartment. As the tendons pass through the compartments of the ligaments, and for some distance proximal to the transverse ligament and distal to the cruciate ligament, they are surrounded by mucous sheaths (see p. 341). Lastly, note the position of the anterior tibial vessels and the deep peroneal nerve as they pass under cover of the ligaments. They lie between the extensor hallucis longus and the extensor digitorum longus (Fig. 156, p. 349).

## PERONEAL OR LATERAL CRURAL REGION.

Before the peroneal region is opened up, the dissector should examine the mucous sheaths of the tendons of the peronæus longus and brevis. Behind and below the lateral malleolus the two tendons are enclosed in a common sheath, but immediately posterior to the trochlear process of the calcaneus the common sheath is separated into two portions,

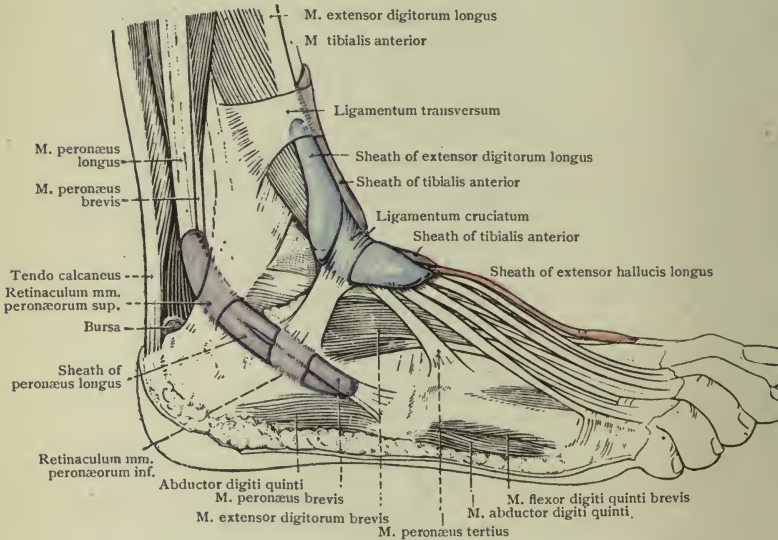


FIG. 158.—Dissection of Leg and Foot showing Mucous Sheath of Tendons.

one for each tendon (Fig. 158). The upper portion, which surrounds the continuation of the peronæus brevis tendon, extends forwards almost to the insertion of the tendon into the base of the fifth metatarsal bone. The lower portion, which surrounds the continuation of the peronæus longus tendon, may accompany that tendon to its insertion into the lateral side of the base of the first metatarsal bone, or it may end, at the lateral border of the cuboid bone, as the tendon turns medially into the sole of the foot. In the latter case the part of the tendon which lies in the sole has a separate mucous sheath. The sheaths should either be inflated, or



injected, or examined with a probe in the manner indicated when the sheaths of the extensors were described (see p. 341).

**Dissection.**—After the mucous sheaths of the peronæi tendons have been examined, the lateral compartment of the leg must be opened up to display its contents. Divide the deep fascia over the peronæi muscles by a longitudinal incision, and turn the flaps aside until their continuity with the anterior and posterior fibular septa is demonstrated, but do not injure the peroneal retinacula.

Enclosed within the lateral compartment of the leg are the following structures:—

1. The peronæus longus.
2. The peronæus brevis.
3. The termination of the common peroneal nerve.
4. The superficial peroneal nerve.

**M. Peronæus Longus.**—The peronæus longus muscle arises from the head and from the lateral surface of the shaft of the fibula in its proximal two-thirds. Surfaces of origin are also afforded to it by the fascia which covers it, and by the two fibular intermuscular septa. It ends, a short distance proximal to the ankle, in a long tendon, which is continued distally posterior to the lateral malleolus. Gaining the lateral border of the foot, it proceeds forwards, on the lateral surface of the calcaneus, to the groove on the plantar surface of the cuboid, which conducts it obliquely into the sole. Its insertion will be examined at a later period (see p. 400). It is supplied by the *superficial peroneal nerve* (O.T. *musculo-cutaneous*) and is a plantar flexor and evertor of the foot.

**M. Peronæus Brevis.**—The peronæus brevis muscle arises from the distal two-thirds of the lateral surface of the body of the fibula, anterior and distal to the peronæus longus, and from the fibular intermuscular septum on each side of it. Its tendon descends, posterior to the lateral malleolus, and then turns forwards, on the lateral surface of the calcaneus, to gain an insertion into the projecting base of the metatarsal bone of the little toe.<sup>1</sup>

As the tendons of the two peronæi muscles proceed distally, in the hollow between the lateral malleolus and the posterior prominence of the calcaneus, they are held in place by the *superior peroneal retinaculum*, and their movements are

<sup>1</sup> A small tendinous slip will, sometimes, be observed to proceed forwards from the tendon of the peronæus brevis to join the tendon of the long extensor on the dorsum of the little toe. This is the *peronæus digiti quinti*.

facilitated by the presence of a common mucous sheath. On the lateral surface of the calcaneus the tendons are retained in position by the *inferior peroneal retinaculum*, but each tendon lies in a separate compartment surrounded by its own special prolongation of the mucous sheath. At the back of the lateral malleolus, the tendon of the peronæus brevis is anterior to the tendon of the peronæus longus and therefore between it and the fibula, consequently as the two tendons turn forwards along the lateral side of the calcaneus the tendon of the peronæus brevis occupies a higher position than the tendon of the peronæus longus and passes above the trochlear process of the calcaneus, which intervenes between the mucous sheaths of the two tendons. The peronæus brevis is supplied by the *superficial peroneal nerve*. It is a plantar flexor and an evertor of the foot.

**N. Peronæus Communis (O.T. External Popliteal Nerve).**—The common peroneal nerve has previously been traced as far as the neck of the fibula. At that point it disappears from view by passing forwards between the peronæus longus muscle and the bone. The muscle must therefore be carefully turned aside from its origin in order that the nerve may be followed to its termination. As it lies between the peronæus longus and the neck of the fibula it gives off a small *recurrent articular branch* to the knee joint, and then divides into the *deep* and *superficial peroneal nerves*.

The *recurrent branch* pierces the extensor digitorum longus, and then accompanies the anterior tibial recurrent artery through the upper fibres of the tibialis anterior. It gives twigs to the tibialis anterior, but its terminal filaments are distributed to the synovial stratum of the capsule of the knee joint.

The *deep peroneal nerve* pierces the proximal part of the extensor digitorum longus to reach the anterior region of the leg, where it has already been dissected.

**N. Peronæus Superficialis (O.T. Musculo-Cutaneous Nerve).**—The superficial peroneal nerve passes distally in the substance of the peronæus longus; reaches the interval between the two peronæi muscles; gives branches to both; and then lies between the peronæus brevis and the extensor digitorum longus. In the distal third of the leg it pierces the deep fascia, becomes cutaneous, and divides into a medial and a lateral branch, which have been called the medial and intermediate dorsal cutaneous nerves of the foot (p. 338).

## MEDIAL CRURAL REGION.

This region corresponds to the subcutaneous or medial surface of the tibia. The deep fascia blends with the periosteum of the bone, and the structures which have to be examined are:—

1. The great saphenous vein.
2. The saphenous nerve.
3. The expanded tendons of insertion of the sartorius, semitendinosus, and gracilis.
4. The tibial collateral ligament of the knee joint.
5. The inferior medial genicular artery.
6. The inferior medial articular nerve.

**Dissection.**—The great saphenous vein and the saphenous nerve have already been cleaned where they lie upon the distal third of the medial surface of the tibia. Now remove the remains of the superficial fascia from the region of the medial surface of the tibia, then again examine the insertions of the sartorius, gracilis, and semitendinosus.

The expanded terminal parts of the tendons of the sartorius, gracilis, and semitendinosus are all inserted into the proximal third of the medial surface of the tibia. Note how the sartorius overlaps the tendons of the other two, and how the tendon of the gracilis overlaps the proximal part of the tendon of the semitendinosus. Mucous bursæ separate the tendons from each other.

Under cover of the sartorius, gracilis, and semitendinosus, and separated from them by a bursa, the *tibial collateral ligament* of the knee joint extends distally, for a short distance, upon the medial aspect of the body of the tibia. Passing forwards under cover of the ligament, so as to gain the anterior aspect of the knee, are the *inferior medial genicular vessels* and the *inferior medial articular nerve*.

As the great saphenous vein and the saphenous nerve cross the distal third of the medial surface of the tibia, they are very liable to injury because they lie quite superficially between the skin and the bone.

## POSTERIOR CRURAL REGION.

The following is a list of the structures which are met with in this dissection:—

1. Superficial veins, { Great saphenous vein.  
Small saphenous vein.
2. Cutaneous nerves.
3. Deep fascia.
4. Superficial muscles of the calf, { Gastrocnemius.  
Plantaris.  
Soleus.
5. Tendo calcaneus (Achillis) and its bursa.
6. Posterior tibial vessels.
7. Tibial nerve.
8. Deep muscles, { Popliteus.  
Flexor hallucis longus.  
Tibialis posterior.  
Flexor digitorum longus.
9. Ligamentum laciniatum.

**Dissection.**—**Reflection of Skin.**—The limb must now be placed on its anterior aspect, and the muscles of the calf rendered tense by dorsi-flexing the foot at the ankle joint. That position should be maintained by the aid of hooks, fastened to the toes and to the under surface of the table. The skin has already been reflected to the medial and lateral borders of the leg and foot. Now make a transverse incision across the distal part of the heel and carry the extremities of the incision forwards, along the medial and lateral borders of the foot respectively, then remove the skin from the whole of the back of the leg, commencing the reflection either from the medial or lateral border as may be most convenient. As the reflection proceeds keep the edge of the knife always against the skin to avoid injury to the superficial veins and nerves.

**Superficial Fascia.**—The superficial fascia of the posterior crural region presents no special or peculiar features, but it contains the following structures which must be displayed by the dissector:—

Superficial veins, { Part of the great saphenous vein.  
Part of the small saphenous vein.

Superficial lymph vessels.

Cutaneous nerves, { Part of the saphenous nerve.  
The terminal part of the posterior branch of the medial cutaneous nerve of the thigh.  
The terminal part of the posterior cutaneous nerve of the thigh.  
The medial cutaneous nerve of the calf.  
The anastomotic peroneal nerve.  
The sural nerve.  
The medial calcanean nerves.

**Dissection.**—The superficial veins and the cutaneous nerves must now be followed and cleaned. The lymph vessels cannot be demonstrated in an ordinary dissection; the majority of them accompany the veins and their tributaries. The great saphenous vein and the saphenous nerve have already been traced across the distal third of the medial surface of the tibia

(p. 336). Now follow them proximally along the posterior margin of the medial surface of the tibia to the medial side of the knee, where they were displayed when the superficial part of the medial region of the thigh was dissected (p. 227). The vein and nerve lie close together.

The posterior branch of the medial cutaneous nerve of the thigh was also found when the medial side of the thigh was dissected. In the calf it lies lateral and posterior to the saphenous nerve, and should now be traced to its termination in the area of the medial head of the gastrocnemius (Fig. 161).

The terminal part of the posterior cutaneous nerve of the thigh was found when the popliteal area was being dissected (p. 306). It pierces the popliteal part of the deep fascia a little below the middle of its length, and should now be traced as it descends through the superficial fascia to the middle of the calf (Fig. 161). Deep to the terminal part of the posterior cutaneous nerve of the thigh, in the groove between the two heads of the gastrocnemius, lie the upper part of the small saphenous vein and the medial cutaneous nerve of the calf. Both structures have been already partially investigated. When the popliteal fossa (p. 309) was dissected the vein was found piercing the popliteal fascia and ending in the popliteal vein, whilst the nerve was found arising from the tibial nerve; and, in the dissection of the dorsum of the foot (p. 336), the vein was seen commencing from the lateral end of the dorsal venous arch, whence it passed backwards below, and upwards behind the lateral malleolus. The remaining part of the vein must now be cleaned. It ascends along the lateral border of the tendo calcaneus, accompanied by the sural nerve, and then in the groove between the two heads of the gastrocnemius, accompanied by the medial cutaneous nerve of the calf. The sural nerve was found, in a previous dissection (p. 338), lying in close association with the small saphenous vein behind the lateral malleolus. Trace it upwards to the point where it is formed by the union of the medial cutaneous nerve of the calf and the anastomotic peroneal nerve; the union usually takes place at the lateral border of the proximal part of the tendo calcaneus. From the commencement of the sural nerve follow the medial cutaneous nerve of the calf upwards to the point where it pierces the deep fascia, about midway between the knee and the ankle, then follow the peroneal anastomotic nerve to the point where it pierces the deep fascia in the proximal part of the calf, superficial to the lateral head of the gastrocnemius (Fig. 161). The medial calcanean nerves will be found piercing the thickened portion of deep fascia called the ligamentum laciniatum which crosses the interval between the medial malleolus and the calcaneus. They are accompanied by small branches of the posterior tibial artery.

At this stage the dissector should revise the saphenous veins and the cutaneous nerves which have been seen in previous dissections, but which are now, for the first time, displayed from beginning to end (Figs. 163, 164, 107).

**Vena Saphena Magna.**—The great saphenous vein com-

mences at the medial border of the foot, where it is formed by the union of the medial end of the dorsal venous arch of the foot with the medial digital vein of the great toe. It ascends anterior to the medial malleolus, passes obliquely upwards and backwards across the medial surface of the distal third of the tibia, and then vertically upwards, along the medial border of the tibia, to the posterior part of the medial side of the knee. Thence it passes obliquely upwards, forwards, and laterally, through the superficial fascia of the medial and anterior areas of the thigh, to the fossa ovalis, where it pierces the cribriform fascia and the femoral sheath and terminates in the femoral vein (Figs. 163, 107, 106).

Its named tributaries are the dorsal venous arch, the medial digital vein of the great toe, the lateral and medial femoral circumflex veins (p. 230), the superficial pudendal, epigastric, and circumflex iliac veins (p. 230), but it receives in addition numerous other tributaries from the dorsum of the foot, and from the front, medial side, and back of the leg. Further, it forms numerous communications with the deep veins of the limb by anastomosing channels which pierce the deep fascia. A fairly large communicating vein pierces the ligamentum laciniatum and curves below the medial malleolus to join the great saphenous vein at the anterior border of that process; others pierce the deep fascia along the medial borders of the tibia and in the distal third of the thigh.

The great saphenous vein is accompanied by numerous superficial lymph vessels. They drain the regions from which the tributaries of the vein issue, and they terminate in the medial and lateral groups of subinguinal lymph glands, which lie at the sides of the proximal part of the vein in the region of the femoral triangle. It is also accompanied by several cutaneous nerves—from the fossa ovalis to the middle of the thigh by branches of the medial cutaneous nerve of the thigh, from the middle of the thigh to the knee by the anterior terminal branch of the medial cutaneous nerve of the thigh, and from the knee to the medial border of the foot by the saphenous nerve.

It contains a number of valves which help to divide the long column of blood into a series of segments, and so diminish the pressure on the walls of the more distal parts of the vein.

**Vena Saphena Parva.**—The small saphenous vein is formed, in the lateral border of the foot, by the union of the lateral digital vein of the little toe with the lateral end of the dorsal venous arch of the foot. From its point of commencement it runs backwards below the lateral malleolus, and then upwards behind the lateral malleolus, in company with the sural nerve, and superficial to the peroneal retinacula. Afterwards it ascends, parallel with the lateral border of the tendo calcaneus, where it is still associated with the sural nerve. Above the level of the tendo calcaneus it ascends along the median line of the calf to the lower part of the popliteal region, where it pierces the popliteal fascia and terminates in the popliteal vein. In the lower part of its ascent along the median line of the calf it is associated with the medial cutaneous nerve of the calf, and in the upper part by the distal portion of the posterior cutaneous nerve of the thigh. The small saphenous vein receives tributaries from the lateral border of the foot, the heel, and the back of the calf. It is accompanied by superficial lymph vessels which commence in the areas in which the tributaries of the vein arise, and which terminate in the popliteal lymph glands (Figs. 163, 164).

The two saphenous veins are connected together by the medial femoral circumflex vein, which commences from the small saphenous vein, immediately before it pierces the deep fascia, and terminates in the great saphenous vein above the middle of the thigh. In some cases the medial femoral circumflex vein forms the direct continuation of the small saphenous vein, and in those cases the small saphenous vein has either only a very small connection, or no connection at all, with the popliteal vein.

**The Lymph Vessels and Lymph Glands of the Inferior Extremity.**—The lymph vessels of the inferior extremity cannot be displayed in an ordinary "part," but some at least of the lymph glands are always found, and as both lymph vessels and lymph glands are of great practical importance, it is essential that the dissector should have a general knowledge of their positions and functions. The lymph vessels contain a colourless fluid called *lymph*, which drains into their finer tributaries from the surrounding tissues. Micro-organisms which have gained access to the tissues, and the cells of malignant tumours growing in the tissues, may enter the lymph vessels and so be carried onwards in the lymph stream. The lymph carried by the lymph vessels eventually passes into two terminal trunks, the *thoracic duct* and the right lymph duct, each of which terminates in a large vein; therefore the lymph, and micro-organisms or poisons formed by micro-organisms which have entered the lymph, are

eventually poured into the blood, and by it are dispersed to all parts of the body. Both terminal lymph vessels end at the root of the neck behind the sternal end of the clavicle, the thoracic duct in the left innominate vein and the right lymph duct in the right innominate vein (Fig. 14).

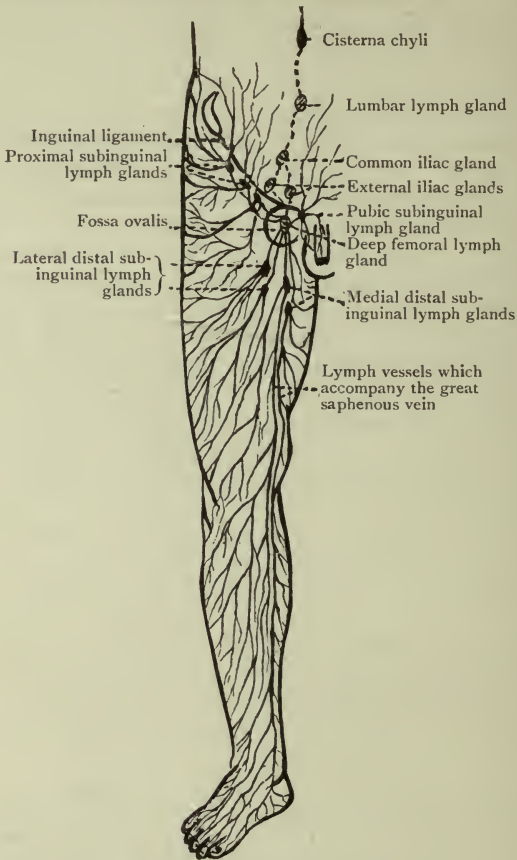


FIG. 159.—Diagram of the Lymph Vessels of the front of the Inferior Extremity.

All the lymph, however, before it reaches the terminal lymph vessels, passes through one or several lymph glands, usually several, for the glands are interposed, like small filtering sponges, in the courses of the lymph vessels; therefore the lymph collected from the tissues is carried in the first instance to a lymph gland, and then, as a rule, it passes through several other glands before it reaches terminal lymph vessels. The lymph vessels



which carry lymph to a gland are called *afferent lymph vessels*, and those which carry it away are *efferent lymph vessels*. All the lymph from both inferior extremities flows to the commencement of the thoracic duct which lies in the abdominal region in front of the second lumbar vertebra, where it frequently possesses a dilated extremity called the *cisterna chyli*. On its way it passes through a series of glands, and as noxious materials which have entered the lymph vessels may be caught in the glands and there set up inflammation or produce new malignant growths, it is important to bear in mind constantly the general positions of the glands and the areas from which they receive lymph.

There are two sets of lymph vessels and lymph glands in the inferior extremity, the deep and the superficial.

The deep lymph glands are, (1) the anterior tibial, (2) the popliteal, (3) the deep subinguinal. The anterior tibial gland lies close to the proximal end of the anterior tibial artery in the anterior compartment of the leg. The popliteal glands lie in the popliteal fossa around the popliteal vessels. The deep subinguinal glands are situated in the femoral triangle, in the femoral canal of the femoral sheath. The deep lymph vessels which pass to the deep glands run along the main blood-vessels, and they carry lymph drained from all the deeper structures of the limb, the muscles, ligaments, bones, and joints. The lymph from the deep parts of the leg, foot, and knee passes through the popliteal glands to the deep subinguinal glands; that from the medial, anterior, and lateral parts of the thigh is carried to the deep subinguinal glands; but the lymph from the deep parts of the back of the thigh and the buttock, flowing through lymph vessels which accompany the inferior and superior gluteal vessels, passes into the pelvis to the hypogastric glands, and through them to the common iliac and lumbar glands on its way to the thoracic duct.

The superficial lymph glands of the inferior extremity are the subinguinal lymph glands to which attention was directed in association with the

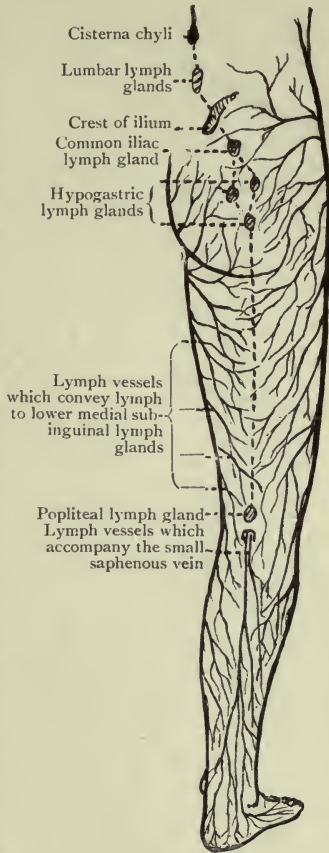


FIG. 160.—Diagram of the Lymph Vessels of the back of the Inferior Extremity.

superficial dissection of the anterior part of the thigh (see p. 228). They form two groups, a proximal and a distal. The proximal group was found lying parallel with and close to the inguinal ligament, and the distal group at the sides of the proximal part of the great saphenous vein (Figs. 106, 159).

All the lymph from the skin and the subcutaneous structures of the inferior extremity, except that derived from the lateral side of the foot, the back of the heel, and the back of the leg, passes through one or other of the two groups of superficial subinguinal glands, and from them it is carried to the deep subinguinal glands by efferent vessels which pierce the cribriform fascia and the anterior wall of the femoral sheath. The lymph from the dorsum and medial side of the foot, the front and medial side of the leg, the medial side and the greater part of the front of the thigh, is conveyed to larger lymph vessels which accompany the great saphenous vein and end in the distal subinguinal glands. The lymph from the buttock and back of the thigh flows to the proximal subinguinal glands. The lymph from the lateral side of the foot, the back of the heel and the leg, passes into lymph vessels which accompany the small saphenous vein and terminate in the popliteal lymph glands.

It follows, from what has already been stated, that all the lymph of the inferior extremity, except that from the deep parts of the buttock and back of the thigh, passes through the deep subinguinal glands. From the deep subinguinal glands the lymph passes into the external iliac glands, which lie in the lower and anterior part of the abdomen close to the inferior end of the external iliac artery and immediately above the inguinal ligament, and from them it is conveyed through the common iliac glands, which lie at a higher level, to the lumbar glands. The lumbar glands are situated still higher in the abdomen opposite the lumbar vertebræ at the sides of the aorta, and they are the last glands through which the lymph of the inferior extremities passes before it enters the thoracic duct (Figs. 159, 160).

**Nervi Cutanei.**—Before proceeding to display the deep fascia of the back of the leg the dissector should revise the numerous cutaneous nerves.

**N. Saphenus.**—The saphenous nerve is the most medial of the deeper group of branches of the femoral nerve. It commences therefore in the femoral triangle, where it descends along the lateral border of the femoral artery; it accompanies the artery through the adductor canal, lying first on its lateral side, then in front of it, and finally in the distal part of the canal on its medial side. It does not accompany the artery through the opening in the adductor magnus, but, at the distal end of the adductor canal it passes between the sartorius and gracilis muscles accompanied by the saphenous branch of the arteria genu suprema. At the medial side of the knee it pierces the deep fascia, enters the superficial fascia, and then it accompanies the great saphenous vein to the medial border of the foot. In the adductor canal it gives twigs to the subsartorial plexus. After it leaves the canal, and before it emerges between the

sartorius and gracilis, it gives off an infrapatellar branch, which pierces the sartorius on its way to the patellar plexus. Beyond the knee its branches are distributed to the skin of the medial side of the leg, including the medial crural region, the medial part of the posterior crural region, and the medial part of the dorsum of the foot.

**N. Cutaneus Suræ Medialis.**—The medial cutaneous nerve of the calf springs from the tibial nerve in the popliteal fossa, descends between the two heads of the gastrocnemius, pierces the deep fascia of the leg, about midway between the knee and the ankle, and unites with the anastomotic branch of the peroneal nerve to form the sural nerve at the lateral border of the proximal part of the tendo calcaneus. It supplies the skin of the middle part of the calf of the leg.

**N. Anastomoticus Peronæus.**—The anastomotic branch of the common peroneal nerve springs from the common peroneal nerve in the popliteal fossa, crosses superficial to the lateral head of the gastrocnemius, where, as a rule, it pierces the deep fascia; then it passes downwards and medially to the proximal end of the lateral border of the

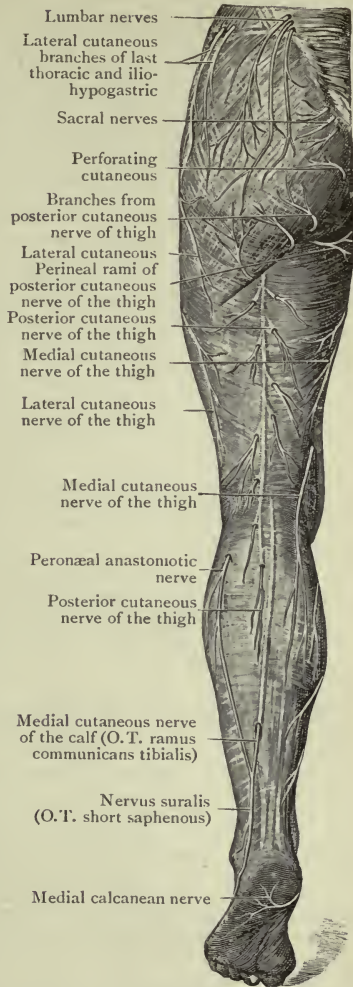


FIG. 161.—Cutaneous Nerves on the posterior aspect of the Inferior Extremity.

tendo calcaneus, where it joins with the medial cutaneous nerve of the calf in the formation of the sural nerve. It supplies the skin of the proximal two-thirds of the posterior surface of the calf.

**N. Suralis.**—The sural nerve is formed, by the union of the anastomotic branch of the peroneal nerve and the medial cutaneous nerve of the calf, in the superficial fascia at the level of the proximal end of the lateral border of the tendo calcaneus. It descends, alongside of the small saphenous vein, behind the lateral malleolus; then it turns forwards, below the lateral malleolus, to the lateral border of the dorsum of the foot; there it gives a communicating twig to the branch of the superficial peroneal nerve which is distributed in the adjacent sides of the fourth and fifth toes, and then continues forwards to the lateral part of the dorsum of the little toe. In the region of the dorsum of the foot it is known as the lateral dorsal cutaneous nerve of the foot, a superfluous and unnecessary term.

The medial cutaneous nerve of the thigh, the posterior cutaneous nerve of the thigh, and the lateral cutaneous nerve of the leg have already been sufficiently described (see pp. 257, 306, 315).

**Dissection.**—After the cutaneous veins and nerves of the posterior region of the leg have been studied, remove the remains of the fatty superficial fascia, and clean the deep fascia which lies subjacent to it.

**Deep Fascia.**—In the proximal part of the calf the deep fascia is thin and transparent; it thickens considerably as the region of the heel is approached. In no part of its extent is it very dense, but as it passes from the back of the leg to the medial side of the ankle, and covers the interval between the medial malleolus and the calcaneus, it is greatly strengthened to form the ligamentum laciniatum (O.T. internal annular ligament), whilst at the lateral side of the ankle it is also thickened to form the peroneal retinacula (p. 339).

It is continuous proximally with the popliteal fascia, and, a short distance distal to the knee on the medial side, it receives reinforcements of fibres from the tendons of the sartorius, gracilis, and semitendinosus. Distally, on the medial side, it is continuous with the ligamentum laciniatum (O.T. internal

annular ligament), which crosses the interval between the medial malleolus and the calcaneus, and, on the lateral side, with the superior peroneal retinaculum which extends from the lateral malleolus to the calcaneus. On the medial side the deep fascia is attached to the medial border of the tibia, where it blends with the periosteum on the medial surface of that bone, and on the lateral side it joins the posterior fibular intermuscular septum, by which it is attached to the lateral crest of the fibula (Figs. 152, 155), thus it forms the posterior boundary of the great posterior osteo-fascial compartment of the leg.

**Posterior Osteo-fascial Compartment of the Leg.**—The posterior osteo-fascial compartment of the leg is bounded, posteriorly, by the deep fascia and, anteriorly, by the tibia, the interosseous membrane, and the fibula. It contains the muscles, vessels, and nerves of the back of the leg, and is divided into three portions by two fascial partitions which stretch across it. The first partition is attached, medially, to the popliteal line of the tibia (Fig. 152), and to the distal two-thirds of the medial border of the tibia, and, laterally, to the posterior surface of the fibula, below the attachment of the soleus, and to the lateral crest of the fibula (Fig. 152). Its upper portion forms a fibrous arch which covers the terminal part of the popliteal artery, and, in the distal part of the leg, it blends with and plays a very important part in the formation of the lacinate ligament. It separates the gastrocnemius, soleus, and plantaris, which lie in the posterior portion of the osteo-fascial compartment, from the flexor digitorum longus, the flexor hallucis longus, the tibial nerve and the posterior tibial artery and its branches which lie in the middle area.

The second septum, known as the fascia covering the tibialis posterior, is attached, medially, to the proximal part of the popliteal line of the tibia and to the vertical ridge on the posterior surface of the tibia and, laterally, to the medial crest of the fibula. Above, it blends with the interosseous membrane, and below it fuses with the deep surface of the first septum in the distal part of the leg. It separates the structures in the middle part of the osteo-fascial compartment from the tibialis posterior which occupies the anterior section of the compartment. Parts of the flexor hallucis longus and the flexor digitorum longus arise from its posterior surface, and fibres of the tibialis posterior spring from its anterior surface.

It follows, from what has been stated, that the great posterior osteo-fascial compartment of the leg is divided into three sections—posterior, middle, and anterior. The posterior section is bounded behind by the deep fascia of the leg and in front by the first septum. It contains the gastrocnemius, the soleus, the plantaris, which are called the superficial muscles of the calf, and the tendo calcaneus, which is the common tendon of insertion of the gastrocnemius and the soleus.

The middle section is bounded posteriorly by the first septum and anteriorly by the medial part of the tibia, the second septum, and the posterior surface of the fibula. It contains the long flexor of the toes, the long flexor of the great toe, the tibial nerve and its branches, and the posterior tibial vessels and their branches and tributaries.

The anterior section of the compartment is bounded posteriorly by the second fascial septum, and anteriorly by the tibia and the interosseous membrane. It contains the tibialis posterior muscle (Fig. 142).

**Dissection.**—The dissector must now proceed to the dissection of the contents of the three sections of the posterior osteo-fascial compartment, commencing with the superficial section.

First clean carefully the lacinate ligament, and secure the medial calcanean branches of the posterior tibial artery and of the tibial nerve which pierce it. Note that it is continuous proximally with the deep fascia of the posterior part of the leg, and that distally it gives attachment to the abductor hallucis; then make a longitudinal incision through the deep fascia, down the middle of the back of the leg, from the popliteal region proximally to the calcaneus distally. Turn the two flaps so defined to the medial and lateral sides respectively. Detach the distal end of the medial flap from the ligamentum laciniatum, but do not injure that ligament, and detach the distal end of the lateral flap from the superior peroneal retinaculum, but, if possible, avoid injury to the retinaculum. Note the attachment of the medial flap to the medial border of the tibia, and the connection of the lateral flap with the posterior fibular septum, by means of which attachment to the lateral crest of the fibula is attained (Figs. 152, 155).

When the connections of the deep fascia have been displayed, make an opening into the mucous sheath of the tendo calcaneus, at one or other border of the tendon, and, by inflation, injection or exploration with a blunt probe, attempt to demonstrate the extent of the sheath, which is somewhat variable. Next clean the gastrocnemius and the tendo calcaneus, and remove the thick pad of fat which lies in front of the tendo calcaneus, and separates it from the first fascial septum of the posterior compartment. Now examine the distal portion of the first fascial septum and note the important part it plays in binding down the muscles of the middle section of the compartment, and in the formation of the ligamentum laciniatum.

If the medial head of the gastrocnemius was not divided when the popliteal fossa was dissected, divide it now, at the level of the knee joint, and turn it laterally; then clean the sural arteries from the popliteal trunk, and the branches of the tibial nerve which supply the gastrocnemius. Raise the proximal part of the divided muscle, and note the bursa which intervenes between it and the semimembranosus. The bursa usually communicates with a bursa under cover of the semimembranosus which, in its turn, communicates with the cavity of the knee joint. Open the bursa and explore its extent with a blunt probe, if that has not already been done (see p. 309). Next follow the nerve to the soleus, which was found when the popliteal fossa was dissected (see p. 310). It springs from the tibial nerve in the popliteal fossa, on the medial side of the popliteal artery, crosses the posterior surface of the distal part of the artery, passes between the plantaris and the lateral head of the gastrocnemius, and enters the posterior surface of the soleus. When the nerve to the soleus has been cleaned and followed to its termination, clean the plantaris, and follow its slender tendon to its insertion into the posterior surface of the calcaneus on the medial side of the tendo calcaneus.

**Superficial Muscles.**—The superficial muscles of the calf of the leg are three in number, viz., the gastrocnemius, the

plantaris, and the soleus. The gastrocnemius is the most superficial; the soleus is placed under cover of the gastrocnemius; whilst the slender plantaris extends distally and medially between them. The tendons of insertion of the gastrocnemius and soleus unite to form the tendo calcaneus (tendo Achillis).

**M. Gastrocnemius.**—The gastrocnemius is a strong muscle. It arises, by two heads, from the posterior part of the distal end of the femur. Both heads have been already studied in connection with the popliteal fossa, which they bound in its distal part. The *lateral head* springs from an impression on the lateral surface of the lateral condyle of the femur, and also from a small portion of the popliteal area of the bone, immediately proximal to the lateral condyle. The *medial head* takes origin from the proximal part of the medial condyle, and also from a rough ridge on the adjacent part of the popliteal surface of the femur. The two fleshy bellies swell out as they pass distally, and end, near the middle of the leg, in a thin aponeurotic tendon. They do not blend with each other, and are usually separated by a furrow, at the bottom of which the flattened tendon, to which the fasciculi of both heads are attached, may be seen. The medial head is the more bulky of the two, and it extends further distally than the lateral head. The flattened tendon in which they terminate narrows slightly as it descends, and, a short distance distal to the middle of the leg, it blends with the stouter tendon of the soleus to form the tendo calcaneus (tendo Achillis).

The gastrocnemius is supplied by the *tibial nerve*. It is a plantar flexor of the foot and a flexor of the knee, but it cannot act efficiently both on the knee and the ankle joint at the same time. Therefore, if the foot is in the position of

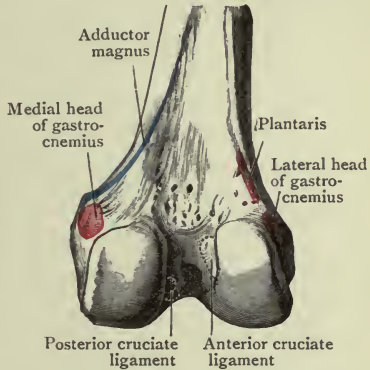


FIG. 162.—Posterior aspect of distal portion of Femur, with Attachments of Muscles mapped out.

plantar flexion it cannot flex the knee, and if the knee is flexed it cannot act upon the ankle. It is important to remember these facts in association with fractures of the distal part of the femur.

**M. Plantaris.**—The small fleshy belly of the plantaris is not more than three or four inches long. It lies along the medial side, and partly under cover, of the lateral head of the gastrocnemius. It arises from the popliteal surface of the femur, immediately proximal to the lateral condyle. It ends in a slender tendon, which is remarkable for its great length. The tendon proceeds distally and medially, between the gastrocnemius and soleus, and then runs along the medial side of the tendo calcaneus (Achillis) to gain insertion into the posterior aspect of the calcaneus. It is frequently closely connected with the tendo calcaneus, and sometimes becomes blended with it, or with the fascia of the leg above the level of calcaneus.

The plantaris is supplied by a branch from the *tibial nerve*. Its actions are similar to those of the gastrocnemius.

**Dissection.**—Divide the lateral head of the gastrocnemius, at the level of the knee joint. Turn the proximal part upwards, and examine it to see if it contains a sesamoid bone which is sometimes present (Fig. 185); then look for a bursa which is occasionally present between it and the posterior part of the capsule of the knee joint. Turn the distal part downwards and note the manner in which the two heads join their thin aponeurotic tendon, and the union of the tendon with the tendon of the soleus to form the tendo calcaneus. Now clean the posterior surface of the soleus, note its origin from (1) the back of the head, and the proximal part of the posterior surface of the body of the fibula, (2) the fibrous arch over the distal end of the popliteal artery, (3) the oblique line of the tibia, and (4) the middle third of the medial border of the tibia. Note also the manner in which the majority of its fibres end in the strong tendon which blends with the tendon of the gastrocnemius to form the tendo calcaneus, whilst some of them pass directly to the deep surface of the tendo calcaneus.

**M. Soleus.**—The soleus is a flat, thick, and powerful muscle which arises from both bones of the leg, as well as from a strong fibrous arch which is thrown across the popliteal vessels. Its *fibular origin* is from the posterior surface of the head and the proximal third of the posterior surface of the body of the bone; by its *tibial origin* it is attached to the linea poplitea of the tibia, distal to the popliteal surface, and, more distally, to the medial border of the bone as far as the middle of the leg (Fig. 166, p. 376). The soleus ends



in a strong, stout tendon which joins with the tendon of the gastrocnemius to form the tendo calcaneus (Achillis). Branches from the *tibial nerve* supply the soleus. It is a plantar flexor of the foot.

**Tendo Calcaneus (Achillis).**—This is the most powerful tendon in the body. It narrows as it descends, but near the heel it again expands slightly. It is inserted into the middle portion of the posterior surface of the calcaneus. The fleshy fibres of the soleus are continued distally on its deep surface to within a short distance of the heel. A mucous bursa intervenes between the tendo calcaneus and the proximal part of the posterior surface of the calcaneus.

**Dissection.**—Divide the soleus muscle along its line of origin from the tibia and separate it from the fibrous arch over the vessels and the tibial nerve; then turn it to the lateral side and secure the branches which the muscle receives from the peroneal and posterior tibial arteries.

The first fascial septum which stretches across the posterior osteo-fascial compartment is now fully exposed. Note its attachments to the tibia and fibula (see p. 367), and its continuity, distally, with the laciniated ligament. Separate it carefully from the laciniated ligament, but do not injure the ligament; then divide it longitudinally along the middle line of the leg and turn the two pieces, one medially and the other laterally. The middle section of the posterior osteo-fascial compartment is now opened up and two muscles, the tibial nerve, the termination of the popliteal artery, the commencements of the anterior and posterior tibial arteries are exposed, the vessels and the nerve being embedded in some loose areolar tissue. The muscle on the medial side is the long flexor of the toes, the muscle on the lateral side is the long flexor of the great toe. In the distal part of the leg, emerging from under cover of the medial border of the tendon of the long flexor of the toes, the tendon of the tibialis posterior will be seen. Clean first the tibial nerve and secure the branches which it gives to the flexor digitorum longus, the flexor hallucis longus, and the tibialis posterior; they arise as a rule in the upper part of the leg. Next clean the termination of the popliteal artery, the first part of the anterior tibial artery and its fibular and posterior tibial recurrent branches, then the posterior tibial vessels and their branches and tributaries. The peroneal branch of the posterior tibial artery arises about 25 mm. distal to the commencement of the parent trunk, and immediately proximal to the point where the tibial nerve crosses posterior to the posterior tibial artery. It soon disappears under cover of the flexor hallucis longus; do not trace it at present beyond the point of disappearance. After the nerve and vessels are displayed clean first the flexor digitorum longus and then the flexor hallucis longus. When that has been done separate the two muscles and push the flexor hallucis longus laterally, separating its deep surface from the posterior surface of the second fascial septum of the

posterior osteo-fascial compartment, and from the distal part of the interosseous membrane, to both of which it is attached. As the fibula is approached the peroneal branch of the posterior tibial artery will be found descending between the flexor hallucis longus and the posterior surface of the second fascial septum, which separates it from the tibialis posterior. Trace the artery distally. Below the level of the origin of the tibialis posterior it lies on the posterior surface of the interosseous membrane, and immediately above the distal tibio-fibular joint it gives off the perforating branch, which was seen in the dissection of the dorsum of the foot (p. 350). Now pull the distal part of the flexor hallucis longus medially and follow the distal part of the peroneal artery behind the ankle joint and along the medial side of the peronæi tendons to the lateral side of the calcaneus. In order to expose its terminal branches the peroneal retinacula must be divided, and it may be necessary to displace the peroneal tendons.

**Termination of the Popliteal Artery.**—The termination of the popliteal artery, which was concealed by the proximal border of the soleus, is now fully exposed. It ends at the distal border of the popliteus, where it divides into its two terminal branches, the anterior and posterior tibial arteries. At the same point the venæ comites of the anterior and posterior tibial arteries join to form the commencement of the popliteal vein.

**Arteria Tibialis Anterior.**—The anterior tibial artery passes forwards, between the two heads of the tibialis posterior muscle, to the anterior region of the leg, where it has already been dissected. Whilst still in the back of the leg the anterior tibial artery gives off a posterior recurrent tibial and a fibular branch. The *posterior tibial recurrent* is a small twig which is not always present. It runs proximally, under cover of the popliteus muscle, to the back of the knee joint. The *fibular branch* runs laterally, on the neck of the fibula, and is distributed to the muscles and integument in that neighbourhood.

**Arteria Tibialis Posterior.**—The posterior tibial artery is the larger of the two terminal branches of the popliteal trunk. It takes origin at the distal border of the popliteus muscle and ends, by dividing into the lateral and medial plantar arteries in the hollow on the medial side of the calcaneus, under cover of the ligamentum laciniatum. In the first instance the artery is placed, between the two bones of the leg, upon the fascia covering the posterior surface of the tibialis posterior muscle; but, as it passes distally it inclines gradually medially,

PLATE XXXII

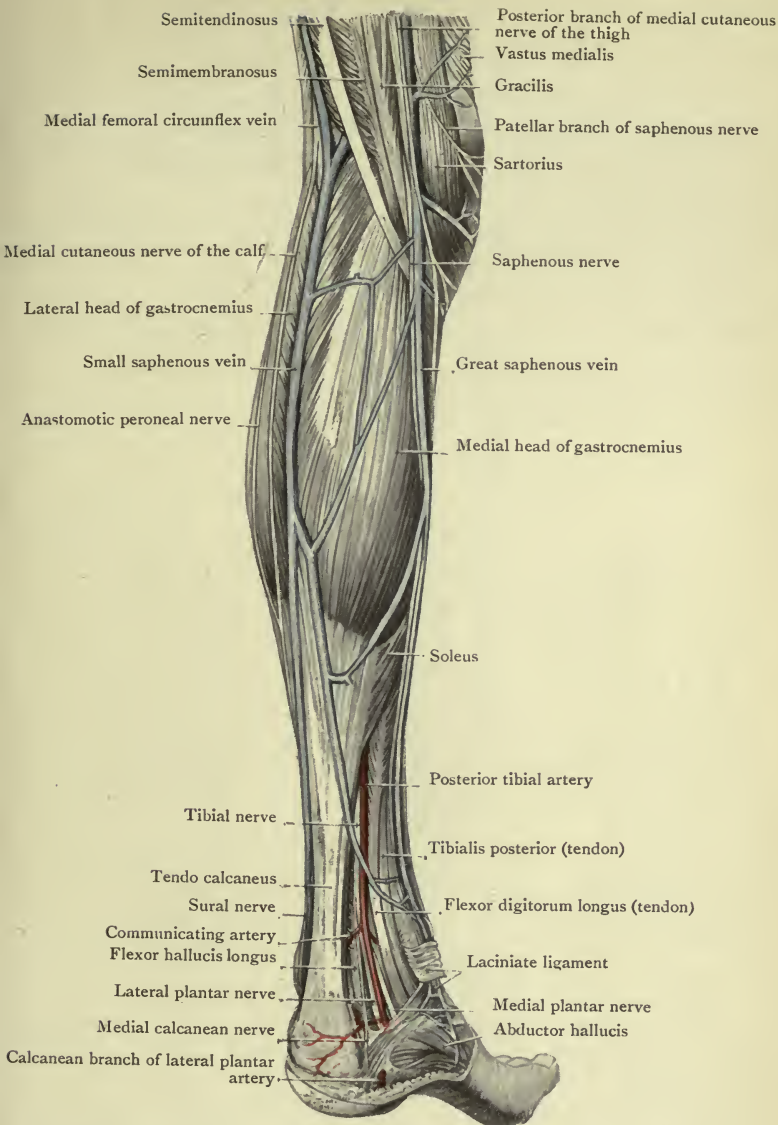


FIG. 163.—Dissection of the Posterior Aspect of the Leg viewed from behind and medially.

Note the numerous anastomoses between the great and the small saphenous veins.

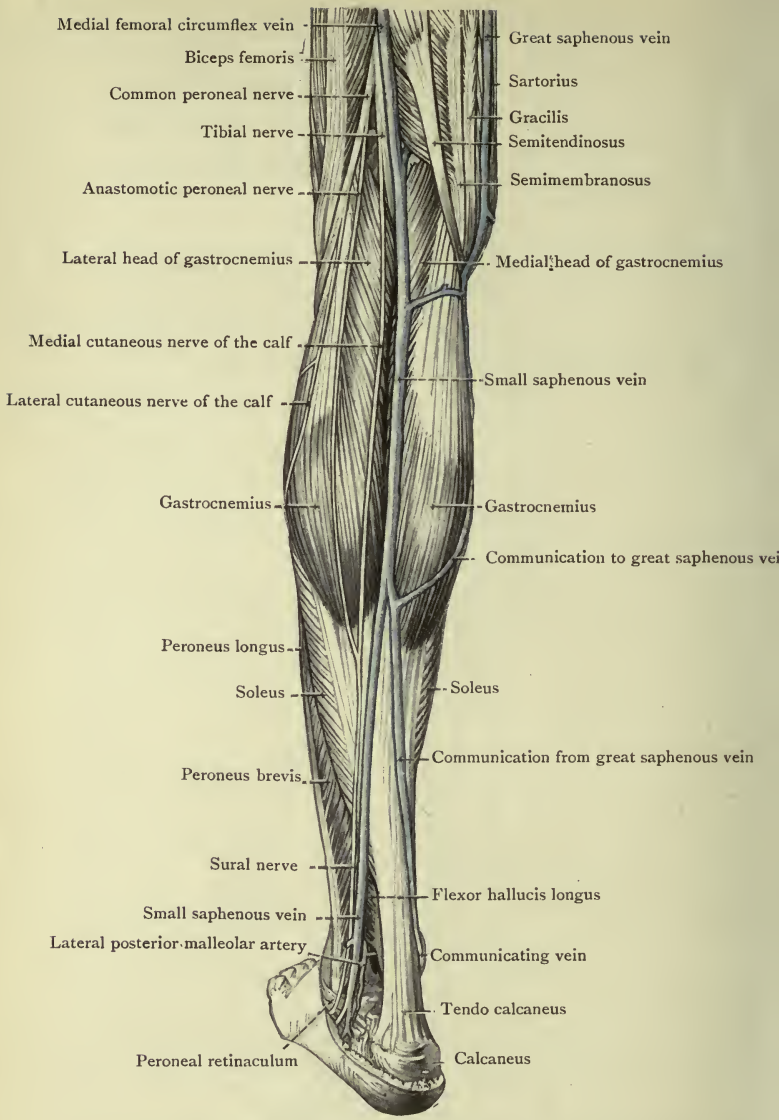


FIG. 164.—Dissection of the Posterior Aspect of the Leg viewed from behind and laterally.

In the specimen there were numerous large anastomosing channels between the small and the great saphenous vein.

and at its termination it lies midway between the prominence of the calcaneus and the medial malleolus.

In its proximal two-thirds the posterior tibial artery is situated deeply, being covered by the superficial muscles of the calf. In the distal third of the leg, where it lies between the tendo calcaneus and the medial border of the tibia, it is relatively superficial and is covered merely by the integument and two layers of fascia. More distally it is covered by the ligamentum laciniatum. Proximo-distally it rests against the fascia on the tibialis posterior, the flexor digitorum longus, the tibia, and the posterior aspect of the ankle joint (Fig. 163).

Throughout its entire course the posterior tibial artery is closely accompanied by two *venæ comites*. The *tibial nerve* is at first on its medial side, but it soon crosses behind the vessel, and then proceeds distally on its lateral side.

The following are the branches which issue from the posterior tibial artery:—

- |                       |  |                            |
|-----------------------|--|----------------------------|
| 1. Rami musculares.   |  | 5. Rami calcanei mediales. |
| 2. Rami cutanei.      |  | 6. Ramus communicans.      |
| 3. A. nutricia tibiæ. |  | 7. A. plantaris medialis.  |
| 4. A. peronæa.        |  | 8. A. plantaris lateralis. |

**Arteria Peronæa.**—Although the *peroneal artery* is not the first it is, as a rule, the largest branch of the posterior tibial. It arises about 25 mm. or so distal to the commencement of the parent trunk, and at first runs, obliquely distally, and laterally, to the fibula. In this first part of its course it rests against the fascia covering the tibialis posterior and it is covered by the soleus; then it descends along the medial crest of the fibula, covered by the flexor hallucis longus and lying first, against the fascia covering the tibialis posterior, and next, against the interosseous membrane. Immediately above the ankle joint it emerges from under cover of the flexor hallucis longus, passes behind the distal tibio-fibular joint and the ankle joint, medial to the peronæi tendons, and it breaks up on the lateral aspect of the calcaneus into a number of lateral calcanean branches.

The branches of the peroneal artery are: (1) muscular branches to the adjacent muscles; (2) a nutrient branch to the fibula; (3) the perforating branch which pierces the interosseous membrane near the distal tibio-fibular joint, and has already been dissected on the dorsum of the foot (see

p. 305); (4) a communicating branch, which springs from the

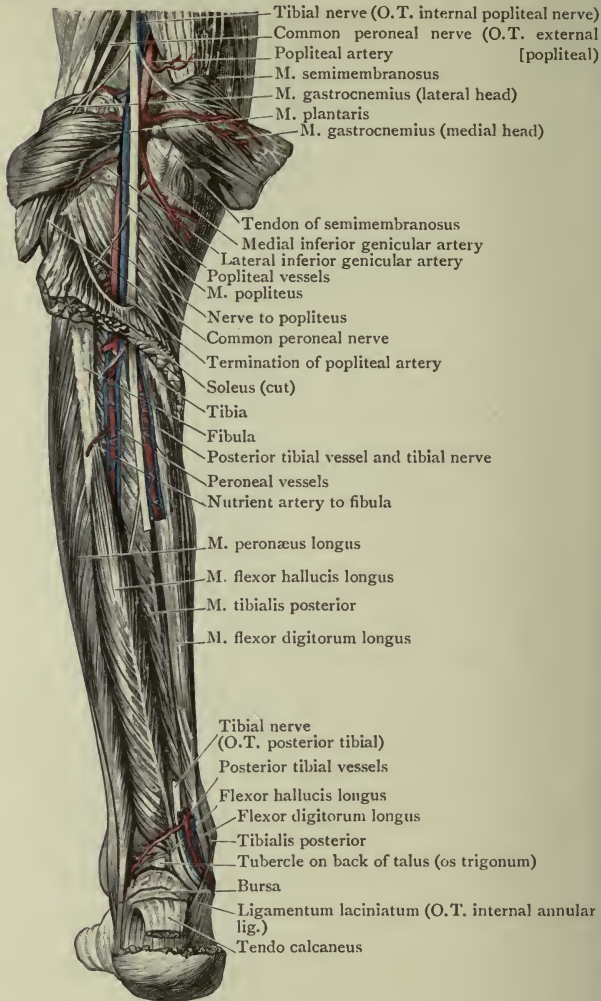


FIG. 165.—Deep Dissection of the Back of the Leg.

medial side of the peroneal artery about one inch proximal to the distal end of the tibia, and passes medially, anterior

or posterior to flexor hallucis longus, to join the posterior tibial artery; (5) the terminal lateral calcanean branches.

The peroneal artery is sometimes as large as the continuation of the posterior tibial artery beyond the point of origin of the peroneal. In such cases the perforating branch may be large, and may partially or entirely replace the dorsalis pedis artery, or the communicating branch to the posterior tibial artery may be large.

The peroneal artery is accompanied by venæ comites, and, in the proximal part of its extent, it is also accompanied by the nerve to the flexor hallucis longus.

The *nutrient artery* springs from the posterior tibial close to its origin, and, after giving some twigs to muscles, enters the nutrient foramen of the tibia. It is remarkable on account of its large size.

The *muscular branches* supply the deep muscles on the back of the leg, and one or two of large size enter the soleus.

The *cutaneous branches* are given to the skin on the medial aspect of the leg.


The *communicating branch* is given off about an inch proximal to the distal end of the tibia. It passes transversely laterally, under cover of the flexor hallucis longus or superficial to it, and joins the peroneal artery (Figs. 163, 164, 165).

The *medial calcanean branches* pierce the ligamentum laciniatum, and accompany the nerves of the same name to the skin of the heel and the sole.

**Crural Part of Nervus Tibialis (O.T. Posterior Tibial Nerve).**—The tibial nerve is continued from the popliteal fossa through the posterior region of the leg to the hollow between the heel and the medial malleolus, where it divides into the lateral and medial plantar nerves. The division takes place proximal to the division of the posterior tibial artery. The nerve accompanies the posterior tibial vessels, and presents the same relations. For a short distance, in the proximal part of the leg, it lies on the medial side of the posterior tibial artery, but it soon crosses superficial to the artery, and is then continued distally, and, for the remainder of its course, lies on the lateral side of the vessel.

It supplies—(a) *muscular branches* to the tibialis posterior, flexor hallucis longus, flexor digitorum longus, and soleus; (b) *cutaneous twigs*—the *medial calcanean branches*—which spring from it close to its termination, and pierce the ligamentum

M. semimembranosus



Groove for tibialis posterior  
Groove for flexor hallucis longus

FIG. 166. — Posterior aspect of Bones of Leg with Attachments of Muscles mapped out.

laciniatum to reach the integument of the heel and sole of the foot; and (c) *articular filaments* to the ankle joint.

**Deep Muscles.**—The *popliteus muscle* will be seen lying upon the posterior aspect of the knee joint and upon the posterior surface of the tibia proximal to the linea poplitea. Its tendon of origin lies within the capsule of the knee joint, and cannot be properly studied until that articulation is dissected.

Note the strong fascia which covers the posterior surface of the popliteus, and trace it proximally and medially to the medial side of the knee. There it becomes continuous with the tendon of the semimembranosus, and through it, therefore, the semimembranosus may be regarded as having an insertion into the linea poplitea of the tibia.

The *flexor hallucis longus* is placed upon the posterior aspect of the fibula, and its tendon will be noticed grooving the posterior border of the talus as it passes distally and forwards to gain the sole of the foot. The *flexor digitorum longus* lies upon the tibia. The *tibialis posterior* rests upon the interosseous membrane and between the fleshy bellies of the two flexors but upon a deeper plane.

**M. Popliteus.**—The popliteus muscle arises by a stout narrow tendon, within the capsule of the knee joint, from the



anterior part of the popliteal groove on the lateral surface of the lateral condyle of the femur. The tendon pierces the posterior part of the capsule of the knee joint, and the fleshy fibres which arise from it are directed medially and distally, and spread out to obtain insertion into the posterior surface of the tibia proximal to the linea poplitea, and also into the fascia which covers the muscle.

The nerve to the popliteus has already been seen to arise from the *tibial nerve*. It can now be seen hooking round the distal margin of the muscle to reach its anterior surface. The popliteus is a flexor of the knee and a medial rotator of the leg.

**M. Flexor Hallucis Longus.**—The long flexor of the great toe is a powerful muscle which arises from the posterior surface of the fibula, distal to the origin of the soleus, from the posterior fibular septum, and from the surface of the fascia covering the tibialis posterior. After passing behind the ankle joint its tendon occupies a deep groove on the posterior border of the talus, then it turns forwards under cover of the ligamentum laciniatum to gain the sole of the foot. The flexor hallucis longus is supplied by the *tibial nerve*. It is a flexor of the interphalangeal and metatarso-phalangeal joints of the great toe, a plantar flexor of the foot, and it assists in producing inversion of the foot.

**M. Flexor Digitorum Longus.**—The flexor digitorum longus arises from the posterior surface of the body of the tibia, distal to the popliteus, and medial to the vertical ridge which descends from the linea poplitea. It also derives fibres from the surface of the fascia which covers the tibialis posterior. After crossing superficial to the distal part of the tibialis posterior, its tendon grooves the back of the medial malleolus on the lateral side of the tendon of the tibialis posterior. It is continued under cover of the ligament laciniatum into the sole of the foot. The flexor digitorum longus is supplied by the *tibial nerve*. It is a flexor of the interphalangeal and metatarso-phalangeal joints of the lateral four toes, and it assists in producing plantar flexion and inversion of the foot.

**M. Tibialis Posterior (O.T. Tibialis Posticus).**—The tibialis posterior takes origin from the posterior surface of the interosseous membrane, from the posterior part of the medial surface of the body of the fibula, from the posterior surface of the body of the tibia, on the lateral side of the

flexor digitorum longus, and from the fascia which covers it. In Fig. 152, p. 340, the compartment which it occupies is shown in a diagrammatic manner, and the surfaces from which it takes origin are indicated. Towards the distal part of the leg the tibialis posterior inclines medially, under cover of the flexor digitorum longus, and its strong flattened tendon grooves the back of the medial malleolus to the medial side of the tendon of that muscle. Proceeding under cover of the ligamentum laciniatum, its tendon is

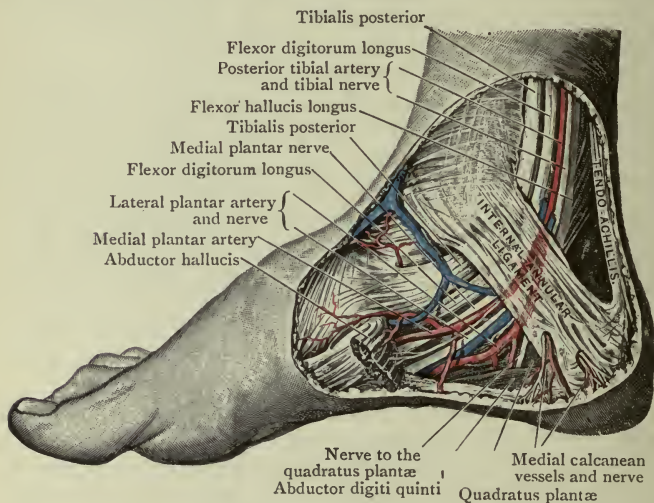


FIG. 167.—Dissection of the medial side of the Ankle, showing the relations of the lig. laciniatum (O.T. internal annular lig.).

inserted into the tubercle of the navicular bone, and also, by a number of slips, into certain of the tarsal and metatarsal bones. Those slips will be dissected later. The tibialis posterior is supplied by the *tibial nerve*. It is a plantar flexor and an inverter of the foot.

**Ligamentum Laciniatum.**—The connections of this thickened band of the deep fascia should now be carefully re-examined. It bridges across the hollow between the medial malleolus and the medial prominence of the calcaneus, and is attached to both. It has already been shown that its proximal border is continuous not only with the deep fascia

covering the superficial muscles of the calf but also with the septum which separates those muscles from the deeper muscles of the leg (see p. 367), and it has been pointed out that the septum takes a more important part in the formation of the ligament than the more superficial layer of deep fascia. Its distal or anterior margin is continuous with the medial part of the plantar aponeurosis, and it gives attachment to the abductor hallucis muscle which is subjacent to that aponeurosis. It is pierced by the medial calcanean branches of the posterior tibial artery and the tibial nerve, and by a communicating vein which connects the great saphenous vein with the venæ comites of the posterior tibial artery.

The dissector should note that under cover of the ligament lie (1) the termination of the posterior tibial artery and the commencement of its two terminal branches, the medial and lateral plantar arteries, with their accompanying veins; (2) the distal part of the posterior tibial nerve and its medial and lateral plantar terminal branches; (3) the tendon of the tibialis posterior; (4) the tendon of the flexor digitorum longus; (5) the tendon of the flexor hallucis longus. From the medial to the lateral side the structures lie in the following order:—

1. Tendon of tibialis posterior.
2. Tendon of flexor digitorum longus.
3. Posterior tibial vessels.
4. Tibial nerve.
5. Tendon of flexor hallucis longus.

The tendons are isolated from one another, and from the vessels and nerve, by septa which pass from the deep surface of the ligament to ridges on the adjacent bones. The septa can be demonstrated by slitting open the ligament for a short distance along the line of each tendon. Each of the three compartments will then be seen to be lined with a glistening mucous sheath, and the dissector should investigate the extent of each sheath as far as possible, with the aid of a blunt probe, for as the sheaths have been freely opened it will not be possible to inflate or inject them. The sheaths end proximally about 25 mm. above the medial malleolus. Distally the sheath of the tibialis posterior reaches to the insertion of the tendon into the tubercle of the navicular bone. The sheath of the flexor digitorum longus extends to about the middle of the length of the foot, and that of the flexor hallucis longus can be traced, under favourable circum-

stances as far as the middle of the metatarsal bone of the great toe (Fig. 168).

**Anastomosis around the Ankle Joint.**—The dissector should next satisfy himself with regard to the anastomosis of arteries which takes place around the ankle joint. On the *lateral aspect* of the joint he will observe inosculations taking

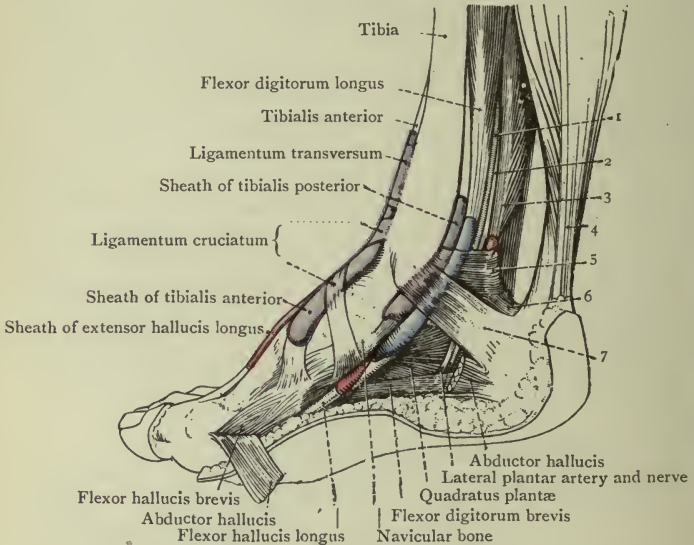


FIG. 168.—Dissection of Leg and Foot showing Mucous Sheaths of Tendons.

1. Arteria tibialis posterior.
3. Flexor hallucis longus.
5. First intermuscular septum of posterior crural region taking part in the formation of the ligamentum laciniatum.

2. Nervus tibialis.
4. Tendo calcaneus
6. Calcaneus.
7. Ligamentum laciniatum.

place between branches of the following arteries:—(a) lateral malleolar; (b) perforating branch of peroneal; (c) terminal part of peroneal; and (d) lateral tarsal.

On the *medial aspect* of the joint the medial malleolar branch of the anterior tibial anastomoses with small twigs from the medial calcanean branches of the posterior tibial.

## SOLE OF THE FOOT.

In this dissection the dissector will meet with the following structures:—

1. Superficial fascia and cutaneous vessels and nerves.
2. Plantar aponeurosis.
3. Superficial muscles,  $\left\{ \begin{array}{l} \text{Abductor hallucis.} \\ \text{Flexor digitorum brevis.} \\ \text{Abductor digiti quinti.} \end{array} \right.$
4. Lateral and medial plantar vessels.
5. Lateral and medial plantar nerves.
6. Tendons of flexor hallucis longus and flexor digitorum longus.
7. Quadratus plantæ and lumbrical muscles.
8. Flexor hallucis brevis. Adductor hallucis, transverse and oblique heads.
9. Flexor brevis digiti quinti.
10. Plantar arterial arch.
11. Plantar metatarsal arteries.
12. Plantar digital arteries.
13. Tendons of peronæus longus and tibialis posterior.
14. Interosseous muscles.

Before commencing the dissection of the sole of the foot the dissector should note the thickness of the skin over the heel, on the balls of the toes, which correspond with the heads of the metatarsal bones, and, to a less extent, along the lateral border of the foot, on all of which parts the weight of the body presses in the erect posture. Other noticeable features are the relative shortness of the toes as contrasted with the length of the fingers, and the fact that the longest digit of the foot is either the second or the first, and not, as in the case of the hand, the middle digit.

**Dissection.**—**Reflection of Skin.**—The limb should be placed upon the table, with the sole of the foot facing the dissector, and the ankle supported by a good-sized block. Two incisions are required—(1) a longitudinal incision along the middle line of the sole, from the heel to the root of the middle toe; (2) a transverse cut, at the digital extremity of the median incision, across the sole at the roots of the toes. The skin should also be reflected from the plantar surface of each of the toes. This can be done after a longitudinal incision has been made along its middle line.

**Superficial Fascia.**—When the flaps of skin mapped out are reflected, the peculiar character of superficial fascia becomes apparent. Along the lateral border of the foot, over the heads of the metatarsal bones, and in the region of the heel, it is thick. It is tough and granular, and in

some respects resembles the superficial fascia which covers the ischial tuberosity. Traversing it are tough fibrous

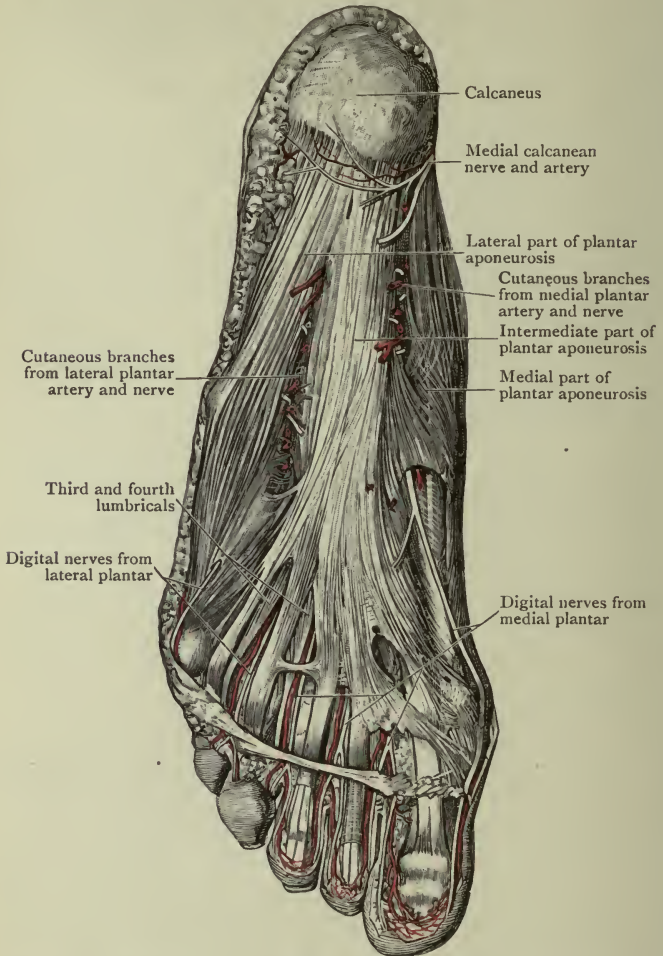


FIG. 169.—Superficial Dissection of the Sole of the Foot ; the Skin and Superficial Fascia alone removed.

bands, which subdivide the fatty tissue into small lobules, and connect the thick skin of the sole with the plantar aponeurosis.

**Dissection.**—The *medial calcanean nerves*, which have already been found piercing the ligamentum laciniatum, should be traced to their distribution. They supply the skin of the sole in the neighbourhood of the heel, and are accompanied by ramifications of the medial calcanean branches of the posterior tibial and lateral plantar arteries.

The superficial fascia may now be removed. Divide it along the middle line of the sole, and turn it laterally and medially, cleaning at the same time the plantar aponeurosis. As the dissector approaches the lateral and medial margins of the foot respectively, he will note, on each side, a furrow; the furrows extend forwards at the sides of the intermediate part of the plantar aponeurosis. Along the furrows a number of blood-vessels and some nerves will be seen piercing the deep fascia in order to reach the skin. Towards the intervals between the heads of the metatarsal bones the metatarsal arteries and the plantar digital nerves are unprotected by the aponeurosis, and the dissector must proceed cautiously. The nerves and vessels which go to the medial side of the great toe and to the fibular side of the little toe are especially liable to injury, as they perforate the aponeurosis farther back than the others. A band of transverse fibres, which crosses the roots of the toes and lies over the digital vessels and nerves, should be noticed. It is the *superficial transverse ligament* of the toes, and is closely connected with the skin where that forms the cutaneous webs between the toes. By forcibly separating the toes its connections will become evident. When the relations of the ligament have been studied it may be removed.

**Aponeurosis Plantaris (O.T. Plantar Fascia).**—The plantar aponeurosis, which is now brought into view, consists of three portions—(a) a medial, (b) an intermediate, and (c) a lateral part. The subdivision is indicated by a difference in the density of the three parts and by two shallow furrows which traverse the foot in a longitudinal direction, one upon each side of the strong intermediate portion of the aponeurosis. Each of the three portions is in relation to a subjacent muscle. The *intermediate portion* covers the flexor digitorum brevis; the *lateral part* clothes the abductor digiti quinti; and the *medial part* covers the abductor hallucis.

The *intermediate portion* of the plantar aponeurosis stands out in marked contrast to the lateral and medial portions in point of strength and density. Posteriorly, where it is attached to the medial process of the calcaneus, it is narrow, but it expands as it passes forwards, and, near the heads of the metatarsal bones, splits into five processes, which are bound together by transverse fibres. In the intervals between the digital slips the metatarsal vessels, the digital nerves, and the lumbrical muscles appear. Trace the processes forwards. One goes to the root of each toe;

there it divides into two slips. The two slips embrace the flexor tendons of the toe, and become fixed to the flexor sheaths, and to the transverse ligament of the heads of the metatarsal bones. The general characters, therefore, of the intermediate part of the plantar aponeurosis closely resemble those of the intermediate part of the palmar aponeurosis.

The *lateral and medial parts* of the plantar aponeurosis are weak, in comparison with the intermediate portion. They merely constitute fascial coverings for the muscles which lie subjacent. A strong band is to be noted in connection with the *lateral part*. It stretches between the prominence formed by the base of the fifth metatarsal bone and the lateral process of the tubercle of the calcaneus.

In connection with the plantar aponeurosis two *intermuscular septa* also have to be studied. These pass dorsally into the sole, along the lines of the longitudinal furrows which mark off the intermediate from the medial and lateral parts of the aponeurosis. They consequently lie one upon each side of the flexor digitorum brevis, and form partitions which separate it from the abductor hallucis on the one side, and the abductor digiti quinti on the other.

**Dissection.**—To demonstrate the above-mentioned septa, make a transverse incision through the intermediate portion of the plantar aponeurosis, about an inch in front of the medial process of the tubercle of the calcaneus, and also a longitudinal cut through the same piece of aponeurosis, extending from the first incision along the middle line of the foot. Now raise the divided aponeurosis and throw it laterally and medially. Some difficulty will be experienced owing to the deep surface of the aponeurosis affording origin, in its posterior part, to the subjacent flexor digitorum brevis. As the margins of this muscle are approached the septa are brought into view. As the anterior part of the divided aponeurosis is reflected, care must be taken to avoid injury to the plantar digital arteries and nerves which lie close to the deep surface of the aponeurosis.

**Muscles and Tendons of the Sole.**—It is customary to look upon the muscles and tendons found in the dissection of the sole as being disposed in four strata, in or between which lie the plantar vessels and nerves and their branches, whilst the layers themselves are separated from one another by fibrous partitions, viz. :—

First layer.	{	Abductor hallucis.
		Flexor digitorum brevis.
		Abductor digiti quinti.



Second layer.	{	Tendon of flexor digitorum longus. Quadratus plantæ. Lumbrical muscles. Tendon of flexor hallucis longus.
Third layer.	{	Flexor hallucis brevis. Adductor hallucis, oblique and transverse heads. Flexor digiti quinti brevis.
Fourth layer.	{	Interosseous muscles. Tendon of peronæus longus. Tendon of tibialis posterior.

**Dissection.**—Separate the lateral and medial portions of the plantar aponeurosis from the subjacent muscles. Whilst that is being done great care must be taken to avoid injury to the digital branch from the lateral plantar nerve to the lateral side of the little toe, and the digital branch of the medial plantar nerve and the digital artery to the medial side of the great toe. To avoid injuring those structures seize a reflected portion of the intermediate part of the plantar aponeurosis and cut, horizontally through the septum which dips deeply from it at the side of the flexor digitorum brevis, lateral or medial side as the case may be, then keep the edge of the scalpel playing closely against the deep part of the aponeurosis from which the septum springs. Difficulty will be experienced in the posterior part of the foot, where the deep surface of each piece of the aponeurosis gives origin to fibres of the subjacent muscle. The muscular fibres must be detached and the posterior ends of the two pieces of aponeurosis must be separated from the calcaneus.

When the reflection of the medial and lateral parts of the aponeurosis is completed the following structures are exposed. Medially, the abductor hallucis and the digital artery and nerve to the medial side of the great toe. Laterally, the abductor digiti quinti and the digital artery and nerve to the lateral side of the little toe. In the intermediate area, the flexor digitorum brevis and its four terminal tendons, and the tendon of the flexor hallucis longus will be found, with the digital vessels and nerves and the lumbrical muscles in the intervals between the flexor tendons; whilst deep to the tendon of the flexor hallucis longus, part of the flexor hallucis brevis is visible, and between the abductor digiti quinti and the flexor digitorum brevis the flexor digiti quinti brevis and the interossei in the fourth space can be seen.

When the structures mentioned have been identified cut down into the posterior part of the interval between the abductor hallucis and the flexor digitorum brevis, immediately in front of the medial process of the calcaneus, and secure the posterior parts of the medial and lateral plantar nerves and arteries; then follow the medial plantar nerve forwards and secure first the branches which it gives to the abductor hallucis and the flexor digitorum brevis, and then its four terminal digital branches. As the first digital branch, that to the medial side of the great toe, is followed it will be found to give a twig to the flexor hallucis brevis, whilst the second digital branch, which supplies the adjacent sides of the first and second toes, gives a twig to the first lumbrical muscle, and the fourth digital branch is connected by a communicating strand with the medial digital branch of the lateral plantar nerve.

The trunk and branches of the relatively small medial plantar artery accompany the trunk and branches of the medial plantar nerve, and must be cleaned as the nerve and its branches are dissected out of the surrounding fascia.

When the medial plantar vessels and nerves have been displayed, cut down into the interval between the flexor digitorum brevis and the abductor digiti quinti, behind the projecting base of the metatarsal bone of the fifth toe, and secure the trunk of the lateral plantar nerve, before it divides into its superficial and deep divisions, and the accompanying lateral plantar artery which lies lateral to the nerve. As the nerve passes forwards it divides into a superficial and a deep branch, at the level of the base of the fifth metatarsal bone and, at the same level, the lateral plantar artery, accompanied by the deep branch of the nerve, turns medially and deeply to become the *plantar arterial arch*. Follow the superficial division of the nerve forwards, and secure (1) the muscular branches which it gives to the flexor digiti quinti brevis, and the interossei of the fourth interosseous space; (2) its two digital branches, one to the lateral side of the little toe, and one which divides to supply the adjacent sides of the fourth and fifth toes; the latter is connected, by a communicating twig, with the fourth digital branch of the medial plantar nerve. Clean also the arteries which accompany the nerves. Now divide the muscular belly of the flexor digitorum brevis, transversely, at the middle of its length; turn the posterior part backwards, and define its attachments to the medial and lateral processes of the calcaneus; throw the anterior part forwards towards the toes where its tendons enter the flexor sheaths, which will be examined later. Next detach the abductor hallucis from the medial process of the calcaneus, but not from the lacinate ligament, and turn it medially. The structures now exposed are—(1) the first parts of the lateral plantar vessels and nerve, and their branches; (2) deep to the vessels and nerve, the quadratus plantæ; (3) posteriorly, between the two heads of the quadratus plantæ, the posterior part of the long plantar ligament; (4) medial to the quadratus plantæ the tendon of the flexor digitorum longus dividing, anteriorly, into four slips from which the lumbrical muscles arise; (5) medial to the flexor longus digitorum a further portion of the tendon of the flexor hallucis longus lying between the two heads of the flexor hallucis brevis (Figs. 170, 171).

Clean, first, the lateral plantar nerve and its muscular branches. The first branch is the branch to the abductor digiti quinti. It lies far back, close to the processes of the calcaneus. The branch to the quadratus plantæ is a little further forward. In addition there are a number of cutaneous branches which become superficial along the interval between the abductor digiti quinti and the flexor digitorum brevis. Next clean the lateral plantar artery and follow its medial calcanean branch to the posterior part of the interval between the flexor digitorum brevis and the abductor hallucis where it becomes superficial. It is distributed to the fat and skin of the heel. After the vessels and nerves are cleaned clean the muscles and tendons.

**M. Flexor Digitorum Brevis.**—The short flexor of the toes arises from the medial process of the calcaneus, from

PLATE XXXIV

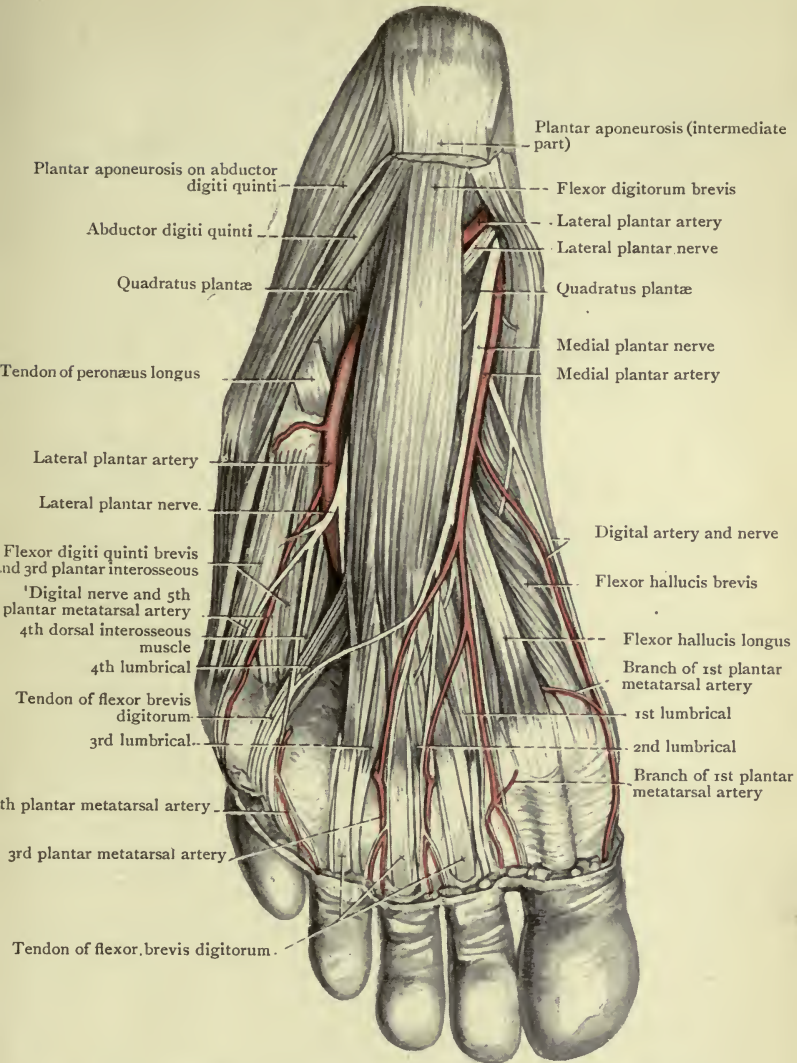


FIG. 170.—Superficial dissection of the Sole of the Foot. The plantar aponeurosis has been removed. The abductor digiti quinti and the abductor hallucis have been pulled aside.



the deep surface of the intermediate part of the plantar aponeurosis, and from the intermuscular septum on each side of it. About the middle of the sole the fleshy belly divides into four slips, which end in slender tendons for the lateral four toes. The tendons enter the fibrous flexor sheaths of the toes, and will be afterwards studied. The flexor digitorum brevis is supplied by the *medial plantar nerve*. It is a flexor of the first interphalangeal joints and the metatarso-phalangeal joints of the lateral four toes.

**M. Abductor Hallucis.**—The abductor of the great toe takes origin from the medial aspect of the medial process of the tubercle of the calcaneus, from the medial intermuscular septum, from the distal border of the ligamentum laciniatum, and from the medial part of the plantar aponeurosis, which covers it. A strong tendon issues from the fleshy belly. This is joined, on its lateral and deep surface, by fibres of the medial head of the flexor hallucis brevis, and it is inserted into the medial aspect of the base of the proximal phalanx of the great toe. The abductor hallucis is supplied by the *medial plantar nerve*. It abducts the great toe from the middle line of the second toe.

**M. Abductor Digiti Quinti (O.T. Abductor Minimi Digiti).**—The origin of the abductor of the little toe extends medially under cover of the flexor digitorum brevis. The posterior part of the latter muscle which has already been divided must, therefore, be turned well backwards to expose the medial part of the origin of the abductor of the little toe. The abductor digiti quinti is then seen to have a broad origin from both the medial and lateral processes of the calcaneus. It also arises from the lateral intermuscular septum, and the lateral part of the plantar aponeurosis, which covers it. Its tendon is inserted into the lateral aspect of the base of the first phalanx of the little toe. The abductor digiti quinti is supplied by the *lateral plantar nerve*. It abducts the little toe from the middle line of the second toe.

**Dissection.**—The abductor hallucis has already been separated from the medial side of the medial process of the calcaneus. Separate it now from the distal border of the lacinate ligament, and turn it medially; then divide the lacinate ligament until the origins of the plantar arteries and nerves are exposed. They are the terminal branches of the posterior tibial artery and the tibial nerve, and they arise from the distal part of the leg under cover of the proximal part of the lacinate ligament.

**Art. Plantaris Medialis (O.T. Internal Plantar Artery).**—The medial plantar artery is the smaller of the two terminal branches of the posterior tibial artery. It arises in the hollow between the medial malleolus and the prominence of the calcaneus, under cover of the ligamentum laciniatum. At the distal border of the ligamentum laciniatum it passes under cover of the abductor hallucis; but, as it proceeds forwards, it appears in the interval between that muscle and the flexor digitorum brevis. Finally, at the root of the great toe, it ends by joining the plantar metatarsal artery to the medial side of the hallux.

The *branches* which proceed from the medial plantar artery are small but very numerous. They are—(1) three twigs which accompany the digital branches of the medial plantar nerve to the clefts between the medial four toes—they end by joining the metatarsal branches of the plantar arch; (2) a series of cutaneous branches to the skin of the sole, which pierce the aponeurosis in the furrow between its medial and intermediate parts; (3) a number of branches to the muscles in the vicinity; (4) some offsets which pass medially under cover of the abductor hallucis to reach the medial border of the foot.

**Art. Plantaris Lateralis (O.T. External Plantar Artery).**—The lateral plantar artery is much larger than the medial plantar. It is accompanied by the lateral plantar nerve and two *venæ comites*. From its origin in the hollow of the calcaneus, under cover of the lacinate ligament, it passes laterally, across the sole, to reach the interval between the flexor digitorum brevis and the abductor digiti quinti. In that interval it is continued forwards for a short distance, and then, at the level of the base of the fifth metatarsal bone, it turns suddenly to the medial side, and crosses the sole a second time, under cover of the flexor tendons and the adductor hallucis, forming the plantar arch. In the present stage of the dissection it is displayed only as far as the base of the fifth metatarsal bone. Between its origin and that point its relations are as follows:—(1) it is under cover of the lacinate ligament; (2) it is placed between the abductor hallucis and the hollow of the calcaneus; (3) it lies between the flexor digitorum brevis and the quadratus plantæ; (4) it occupies the interval between the flexor digitorum brevis and the abductor digiti quinti. In the latter situation it is near

the surface, and is covered merely by the integument and fasciæ.

The *branches* which proceed from this part of the vessel are—(1) twigs to the neighbouring muscles; (2) *medial calcanean branches*, which arise near its origin, and gain the heel by passing through the cleft between the flexor digitorum brevis and the abductor hallucis or by piercing the origin of the abductor hallucis; (3) cutaneous branches, which appear through the plantar aponeurosis along the line of the lateral intermuscular septum; (4) twigs to the lateral margin of the foot, which anastomose with the lateral tarsal and arcuate branches of the dorsalis pedis.

**Nervus Plantaris Medialis (O.T. Internal Plantar Nerve).**

—The medial plantar nerve arises as the larger of the two terminal branches of the tibial nerve in the hollow of the calcaneus, under cover of the ligamentum laciniatum. It accompanies the medial plantar artery, and has similar relations. After it emerges from under cover of the abductor hallucis it gives off a digital branch to the medial side of the hallux, and then ends, in the interval between the abductor hallucis and the flexor digitorum brevis, by dividing into three terminal digital branches.

The *branches* of the medial plantar nerve are:—

1. Cutaneous twigs to the skin of the sole.
2. Muscular branches.
3. Four digital branches.

The *cutaneous twigs* to the integument of the sole spring from the trunk of the nerve, and pierce the aponeurosis in the line of the medial intermuscular septum.

The digital branches of the medial plantar nerve supply the skin of the plantar surfaces of three and a half toes, the first, second, third, and half the fourth. They also supply the skin over the dorsal aspects of the terminal phalanges of those toes and the joints and ligaments of the toes to which they are distributed.

The *digital nerve to the great toe* supplies the medial side of that toe.

The *three terminal digital branches* pass to the proximal ends of the medial three interdigital clefts, where each divides to supply the adjacent sides of the toes which bound the clefts. From the third terminal digital branch of the

medial plantar nerve a communication is given to the superficial part of the lateral plantar nerve. The digital distribution

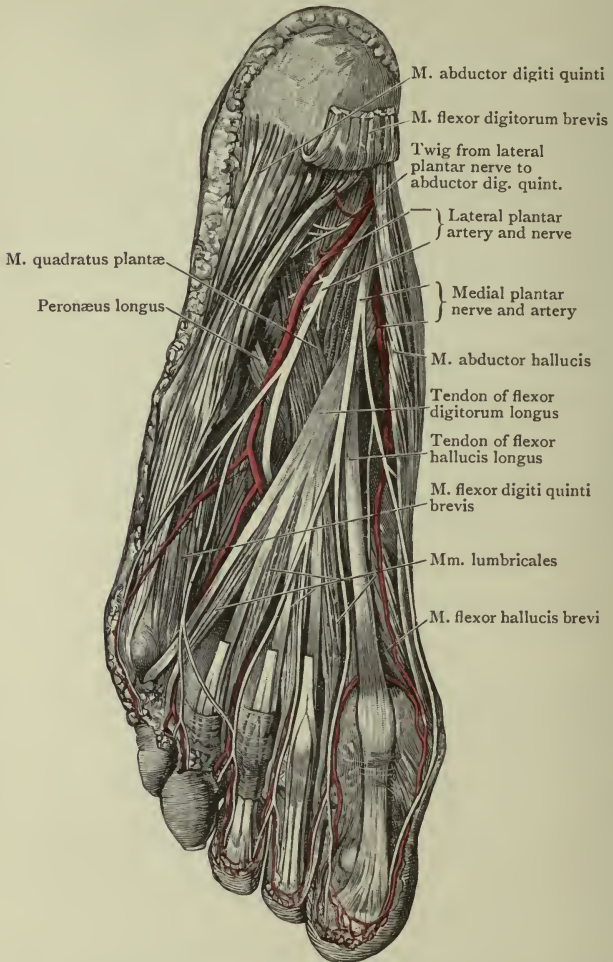


FIG. 171.—Dissection of the Sole of the Foot; the Flexor Digitorum Brevis has been reflected.

of the medial plantar nerve in the foot closely resembles that of the median nerve in the hand.



The *muscular branches* go to four muscles of the sole, viz., the abductor hallucis, the flexor digitorum brevis, the flexor hallucis brevis, and the most medial or first lumbrical muscle. The branches which supply the abductor hallucis and the flexor digitorum brevis arise from the trunk of the medial plantar nerve a short distance from its origin. The nerve to the flexor hallucis brevis arises from the digital nerve to the medial side of the great toe, and the nerve to the first lumbrical muscle springs from the digital nerve which supplies the adjacent sides of the first and second toes.

**Nervus Plantaris Lateralis (O.T. External Plantar Nerve).**

—The lateral plantar nerve corresponds to the ulnar nerve in the palm of the hand. It accompanies the lateral plantar artery and possesses the same relations. In the interval between the abductor digiti quinti and the flexor digitorum brevis, opposite the base of the fifth metatarsal bone, it divides into a deep and a superficial part. The *deep division* follows the plantar arch, under cover of the flexor tendons. The *superficial division* divides into two digital branches.

From the trunk of the lateral plantar nerve proceed *two muscular branches*, viz., to the abductor digiti quinti and to the quadratus plantæ.

The *first or lateral digital branch* of the superficial part of the lateral plantar nerve goes to the lateral side of the little toe. It also gives muscular twigs to the flexor brevis digiti quinti and the interosseous muscles in the fourth intermetatarsal space.

The *second digital branch* divides to supply the adjacent sides of the fourth toe and little toe. It sends also a twig of communication to the third terminal digital branch of the medial plantar nerve.

**Dissection.**—Detach the abductor digiti quinti from its origin, and turn it forwards, in order that a good display may be obtained of the structures composing the second stratum of the sole.

**Second Layer of Muscles and Tendons.**—As the tendon of the *flexor hallucis longus* enters the sole it grooves the plantar surface of the sustentaculum tali and inclines medially, deep to the tendon of the flexor digitorum longus, towards the great toe. The tendon of the *flexor digitorum longus*, on the other hand, inclines laterally superficial to the tendon of the flexor hallucis longus to reach the middle of the foot,

where it divides into four tendons for the lateral four toes. Where the tendons cross, the tendon of the flexor hallucis longus gives a slip to the deep surface of the tendon of the flexor digitorum longus.

Sir William Turner called attention to the fact that the slip, which passes from the tendon of the flexor hallucis longus to the tendon of the flexor longus digitorum, varies greatly in magnitude and in the manner in which it is connected with the flexor tendons of the toes. In the majority of cases it goes to the tendons of the second and third toes or to the tendons of the second, third, and fourth toes; in some cases, however, only to the tendon of the second toe. Very rarely does it divide so as to bring all the tendons of the flexor digitorum longus into connection with the tendon of the flexor hallucis longus.

The *musculus quadratus plantæ*, which is inserted into the tendon of the long flexor of the toes, and also the four *lumbrical muscles*, which arise from the flexor tendons, can now be distinguished. Note the position of the long plantar ligament between the two heads of origin of the quadratus plantæ.

**Dissection.**—Before the flexor tendons are traced forwards to the toes, the fibrous flexor sheaths of the toes must be displayed and examined. The skin on the plantar aspects of the toes has already been reflected and the digital vessels and nerves have been cleaned. Now remove the remains of the superficial fascia and expose the flexor sheaths.

Each sheath consists of two strong portions, called the digital vaginal ligaments, which lie opposite the bodies of the first and second phalanges and are attached to their margins, and weaker portions, opposite the interphalangeal joints, which are attached to the ends of the adjacent phalanges and the margins of the plantar accessory ligaments of the joints. The stronger parts are to prevent the tendons springing away from the bones when the joints are flexed, whilst the weaker parts allow the movements of the joints to take place.

Clean the surfaces of at least two sheaths, then open one of them by a longitudinal incision, to display the mucous lining and the two tendons which are enclosed by the sheath.

**The Flexor Sheaths of the Digits and the Insertions of the Flexor Tendons.**—In each digit an osteo-fibrous canal is formed. It is bounded, dorsally, by the plantar surfaces of the phalanges and the plantar ligaments of the interphalangeal joints, and, plantarwards and at the sides, by the fibrous flexor sheaths. Two tendons enter each canal—a tendon of the short flexor of the toe and a tendon of the long flexor. Opposite the posterior part of the first phalanx the short flexor is superficial and the tendon of the long flexor lies

between it and the bone, but at the middle of the phalanx the tendon of the short flexor is perforated by the tendon of the long flexor, which passes forwards to be inserted into the base of the terminal phalanx, whilst the tendon of the short flexor, beyond the perforation, splits into two parts which are attached to the margins of the second phalanx.

The osteo-fibrous canal is lined with a mucous sheath, which not only facilitates the play of the tendons, when the muscles are in action, but also forms folds called *vincula* which aid in attaching the tendons to the bones.

There are two sets of vincula, short and long. Two short vincula are present in each sheath. They are short triangular folds containing some yellow elastic tissue. One of them connects the tendon of the long flexor to the plantar ligament of the terminal interphalangeal joint and the adjacent part of the second phalanx, and the other connects the tendon of the short flexor in a similar manner to the plantar ligament of the first interphalangeal joint and to the adjacent part of the first phalanx.

The condition is exactly similar to that found in the fingers (Fig. 72). The vincula longa are more slender, they are irregular in number and position.

**Tendon of the Flexor Hallucis Longus.**—After giving its slip to the tendon of the flexor digitorum longus, the tendon of the flexor hallucis longus is prolonged forwards to the great toe. On the plantar aspect of the hallux it is retained in place by a fibrous flexor sheath, and, finally, it is inserted into the base of the terminal phalanx.

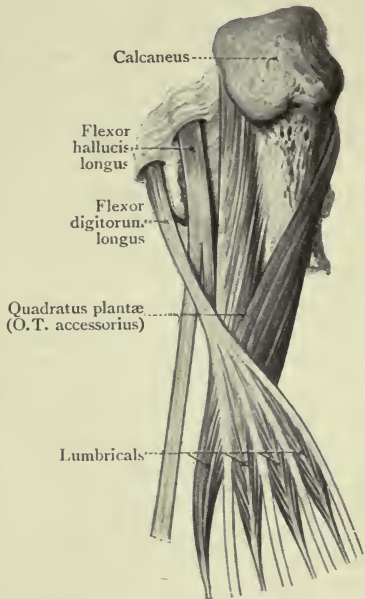


FIG. 172.—Second layer of Muscles and Tendons in the Sole of the Foot.

**M. Quadratus Plantæ (O.T. Flexor Accessorius).**—This muscle takes a course straight forwards from the heel, and acts as a direct flexor of the toes. It also tends to bring the tendons of the long flexor muscle into a line with the toes upon which they operate. It arises by two heads which embrace the calcaneus and the long plantar ligament. The *medial head*, wide and fleshy, springs from the medial concave surface of the calcaneus; the *lateral head*, narrow, pointed, and tendinous, takes origin from the lateral surface of the calcaneus, and also from the long plantar ligament. The quadratus plantæ is inserted into the tendon of the flexor digitorum longus in the middle of the sole. It is supplied by a branch from the *lateral plantar nerve*.

**Mm. Lumbricales.**—The lumbrical muscles of the foot are not so strong as the corresponding muscles in the palm of the hand. They are four in number, and arise from the tendons of the flexor digitorum longus. The lateral three lumbricales spring from the adjacent sides of the tendons between which they lie; the first or most medial muscle takes origin from the medial side of the tendon of the long flexor which goes to the second toe. The slender tendons of the lumbrical muscles proceed to the medial sides of the lateral four toes, and are inserted into the expansions of the extensor tendons on the dorsal aspects of the proximal phalanges (see p. 346). The *first or most medial lumbrical* is supplied by the *medial plantar nerve*: the *others* are supplied by the *lateral plantar nerve*.

**Dissection.**—To bring the third layer of muscles into view the following dissection must be made:—Divide the two heads of the quadratus plantæ and draw the muscle forwards from under the lateral plantar vessels and nerve. Sever also the tendons of the flexor digitorum longus and the flexor hallucis longus at the point where they emerge from under cover of the ligamentum laciniatum, and turn them towards the toes, after cutting the branch from the lateral plantar nerve to the quadratus plantæ. As the tendons of the long flexor of the toes are turned forwards the lumbrical muscles will be raised, and the twigs which are furnished to the *second, third, and fourth* by the deep division of the lateral plantar nerve must be looked for. That for the second lumbrical muscle will be seen to take a recurrent course round the transverse head of the adductor hallucis muscle. Lastly, cut the medial plantar nerve close to its origin and turn it aside.

**Third Layer of Muscles.**—The *flexor hallucis brevis* lies along the lateral side of the abductor hallucis.

The *oblique head of the adductor hallucis* has a very oblique

position in the sole, and hides the interosseous muscles to a great extent. It lies to the lateral side of the flexor hallucis brevis.

The *transverse head of the adductor hallucis* is placed transversely across the heads of the metatarsal bones and the plantar ligaments of the metatarso-phalangeal joints.

The *flexor digiti quinti brevis* (O.T. *minimi digiti*) lies upon the fifth metatarsal bone.

The deep division of the lateral plantar nerve and the plantar arterial arch are partially exposed, but they will be more fully displayed at a later stage.

**Dissection.**—Clean all the above-named muscles from their origins to their insertions. Clean also the exposed part of the plantar arch.

**M. Flexor Hallucis Brevis.**—The short flexor of the great toe arises from the slip from the tendon of the tibialis posterior muscle which goes to the second and third cuneiform bones and from the adjoining part of the *cuboid bone*. It is narrow and tendinous at its origin, but it soon divides into two separate fleshy bellies, which are ultimately inserted one upon each side of the base of the proximal phalanx of the great toe. In the tendons of insertion two large sesamoid bones are developed (Fig. 174). The medial head of the flexor hallucis brevis is closely connected with the tendon of the abductor hallucis, and is inserted in common with it. The flexor hallucis brevis is supplied by the *medial plantar nerve*. It is a flexor of the metatarso-phalangeal joint of the great toe.

**M. Adductor Hallucis** (O.T. **Adductor Obliquus Hallucis and Adductor Transversus Hallucis**).—The adductor hallucis consists of two separate portions called the oblique and the transverse heads of the muscle. The **oblique head** arises from the sheath of the peronæus longus tendon and from the bases of the second, third, and fourth metatarsal bones. It tapers as it approaches the root of the hallux, and is inserted, with the lateral head of the flexor hallucis brevis, into the lateral aspect of the base of the proximal phalanx of the great toe. It is supplied by the *deep division* of the *lateral plantar nerve*. The **transverse head** springs by a series of slips from the plantar metatarso-phalangeal ligaments of the third, fourth, and fifth toes, and proceeds transversely medially, under cover of the flexor tendons, to find insertion into the lateral side of the base of the

proximal phalanx of the great toe, in common with the oblique head. Its nerve of supply comes from the *deep*

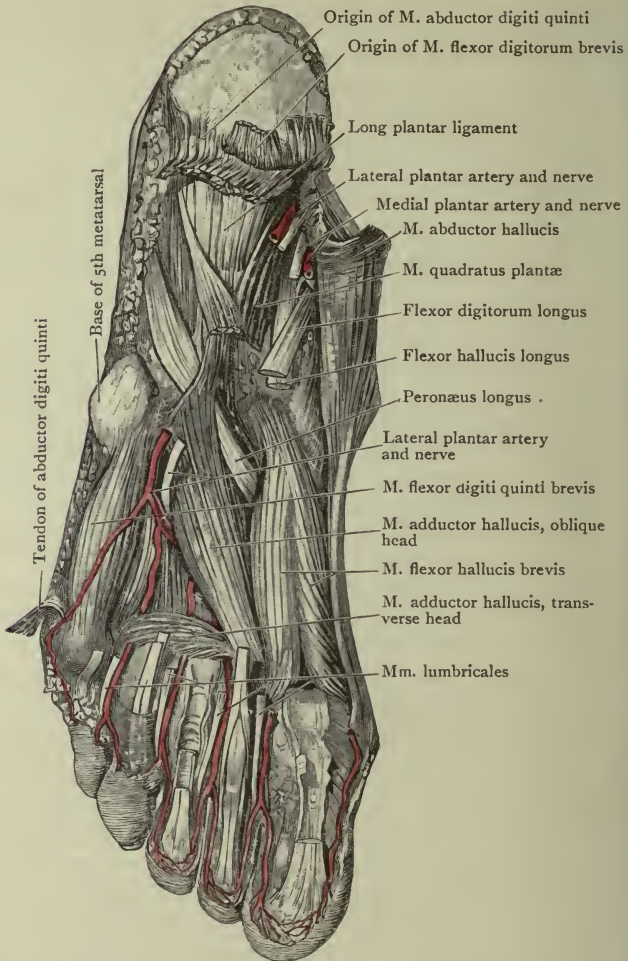


FIG. 173.—Deep Dissection of the Foot ; the Superficial Muscles and also the Flexor Tendons, etc., have been removed.

*division of the lateral plantar nerve.* It is an adductor of the great toe.

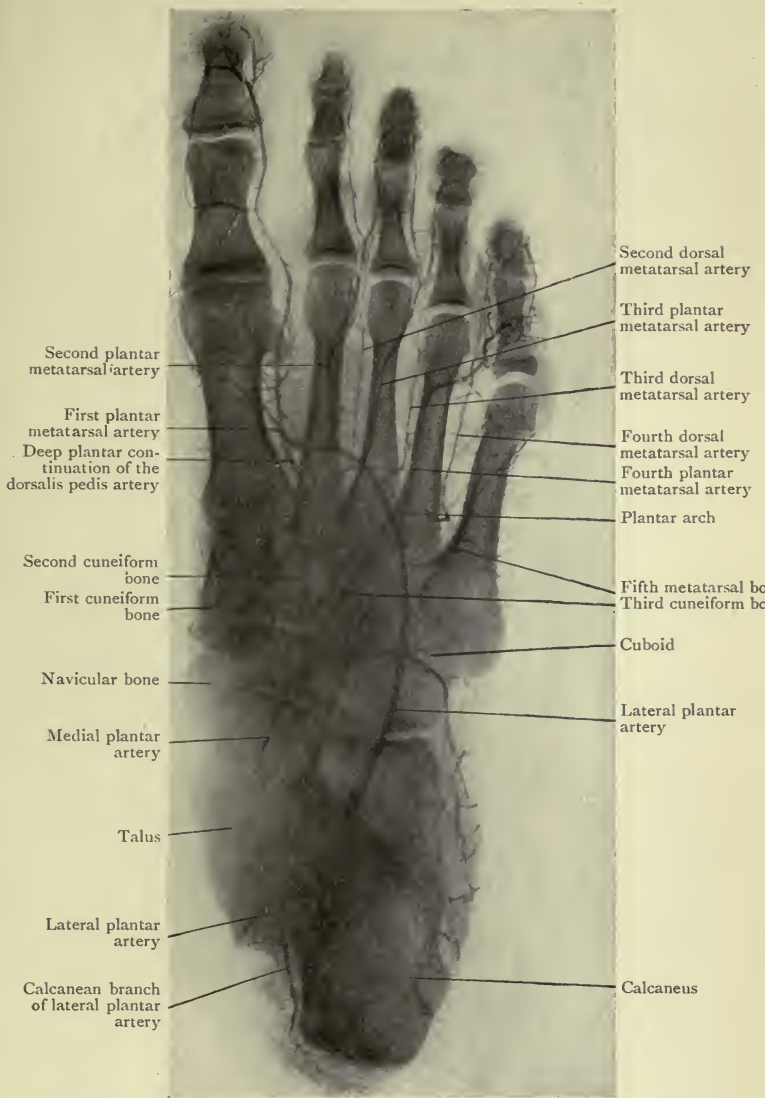


FIG. 174.—Radiograph of an Injected Foot showing the relations of some of the arteries to the bones.





**Flexor Digiti Quinti Brevis (O.T. Flexor Brevis Minimi Digiti).**—The short flexor of the little toe is a single fleshy slip, which springs from the base of the fifth metatarsal bone and the sheath of the peronæus longus tendon. It is inserted into the lateral side of the base of the proximal phalanx of the little toe. Its nerve of supply arises from the *superficial division* of the *lateral plantar nerve*. It is a flexor of the metatarso-phalangeal joint of the little toe.

**Dissection.**—The oblique head of the adductor hallucis, and the flexor hallucis brevis, must now be detached from their origins and thrown towards their insertions, in order that the entire length of the plantar arterial arch, the deep division of the lateral plantar nerve, and the termination of the dorsalis pedis artery may be displayed. As the oblique head of the adductor hallucis is raised the branch which is given to it by the deep division of the lateral plantar nerve must be secured and retained.

**Arcus Plantaris.**—The plantar arterial arch is the continuation of the lateral plantar artery across the sole of the foot. It runs from the level of the base of the fifth metatarsal bone to the base of the first interosseous space, where it is joined by the terminal plantar portion of the dorsalis pedis artery. The arch is deeply placed; it rests against the interosseous muscles, close to the proximal ends of the metatarsal bones (Figs. 174, 175), and it is concealed by the flexor tendons, the lumbrical muscles, and the oblique head of the adductor hallucis. It is accompanied by the deep division of the lateral plantar nerve and by two venæ comites.

The branches which proceed from the arch are:—

1. Articular.
2. Posterior perforating.
3. Second, third, and fourth plantar metatarsal arteries.
4. Plantar digital artery to the lateral side of the little toe.

The *articular branches* arise from the concavity of the arch, and run posteriorly to supply the tarsal joints.

The *posterior perforating branches* are three in number. They pass dorsally through the posterior ends of the lateral three intermetatarsal spaces and between the heads of the corresponding dorsal interosseous muscles. Each ends, on the dorsum of the foot, by joining the corresponding dorsal metatarsal artery.

The *second, third, and fourth plantar metatarsal branches*

run forwards opposite the second, third, and fourth intermetatarsal spaces, pass dorsal to the transverse head of the adductor hallucis, and, at the proximal end of the corresponding interdigital cleft, each plantar metatarsal artery ends by dividing into two branches which supply the adjacent sides of the digits bounding the cleft. The branches of the second plantar metatarsal artery supply the adjacent sides of the second and third toes; those of the third supply the adjacent sides of the third and fourth toes; and those of the fourth the adjacent sides of the fourth and fifth toes.

Immediately before it divides, each plantar metatarsal artery sends dorsally an anterior perforating artery which joins the corresponding dorsal metatarsal artery.

Upon the sides of the toes the plantar digital branches of the metatarsal arteries are distributed in exactly the same manner as the digital arteries of the fingers (see p. 155).

The plantar metatarsal branch to the lateral border of the little toe springs from the lateral extremity of the plantar arch, crosses the plantar surface of the flexor digiti quinti brevis, and runs forwards to the distal end of the toe.

The **First Plantar Metatarsal Artery** (O.T. *Arteria Magna Hallucis*) corresponds with the *arteria volaris indicis radialis* and the *arteria princeps pollicis* of the hand. It arises from the plantar extremity of the *dorsalis pedis*, at the point where the latter joins the plantar arch, and runs forwards to the cleft between the great toe and the second toe, where it divides into two branches for the supply of the adjacent sides of the first and second toes. Before it divides, it gives off a branch to the medial side of the great toe which is joined by the terminal part of the medial plantar artery.

**Deep Division of the Lateral Plantar Nerve.**—The deep division of the lateral plantar nerve accompanies the plantar arch in its course medialwards across the sole. It lies posterior to the arch, and ends in the deep surface of the oblique head of the adductor hallucis. In addition to that muscle it supplies all the interosseous muscles (with the exception of those in the fourth space), the transverse head of the adductor hallucis, and the lateral *three* lumbrical muscles. The twig to the second lumbrical takes a recurrent course round the anterior border of the transverse head of the adductor hallucis.

**Dissection.**—Detach the transverse head of the adductor hallucis from its origin and throw it medially, towards the hallux, to display the transverse ligament of the heads of the metatarsal bones.

**Transverse Ligament of the Heads of the Metatarsal Bones.**—The transverse ligament of the heads of the meta-

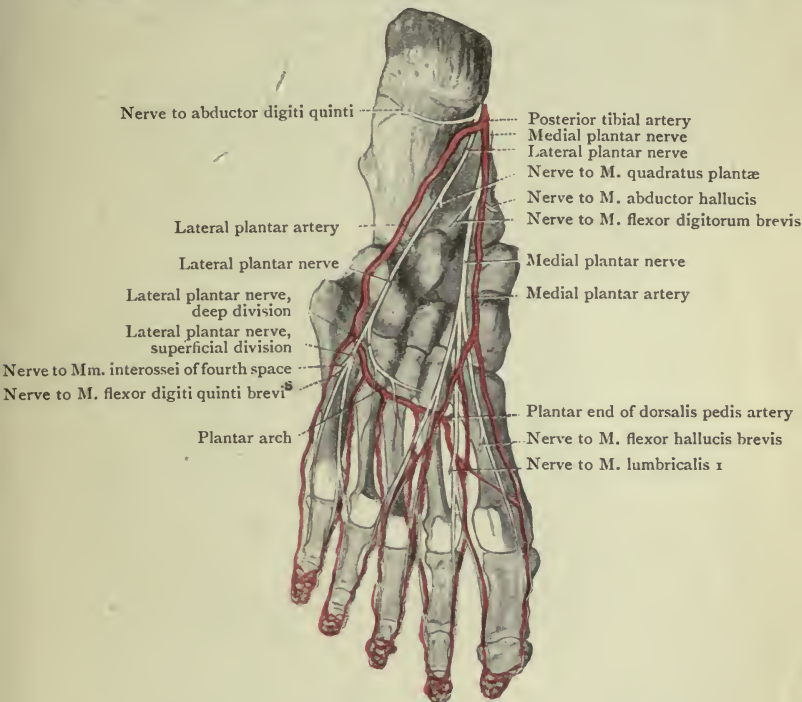


FIG. 175.—Arteries and Nerves of the Sole of the Foot. (Diagram.)

The plantar nerves and their branches are uncoloured.

tarsal bones is a strong fibrous band which stretches across and is attached to the plantar accessory ligaments of the five metatarso-phalangeal joints. It differs from the corresponding ligament of the hand, inasmuch as it includes within its grasp the plantar accessory ligament of the metatarso-phalangeal joint of the first digit.

**Dissection.**—A satisfactory display of the *interosseous muscles* cannot be obtained unless the transverse ligament is divided

between the heads of the various metatarsal bones. The toes can then be separated more freely from each other, and the interosseous muscles traced to their insertions. It is well, at this stage, to reflect the flexor digiti quinti brevis also.

**Interosseous Muscles.**—There are seven interosseous muscles, three plantar and four dorsal. The *plantar interosseous muscles* are so placed that they adduct the lateral three toes towards the middle line of the second toe. They arise from the plantar aspects and parts of the medial surfaces of the lateral three metatarsal bones, and each is inserted upon the medial side of the first phalanx of the corresponding toe. The *dorsal interosseous muscles* occupy the four intermetatarsal spaces, and consequently they must be dissected upon both plantar and dorsal aspects of the foot. They are arranged so as to abduct the second, third, and fourth toes from the middle line of the second toe. Each arises by two heads from the dorsal parts of the adjacent sides of the metatarsal bones which bound the cleft in which it lies. They are inserted as follows: the *first*, upon the medial side of the first phalanx of the second toe; the *second*, upon the lateral side of the same phalanx; the *third*, upon the lateral side of the first phalanx of the third toe; and the *fourth*, upon the lateral side of the first phalanx of the fourth toe. The slender tendons of the interosseous muscles are only very slightly attached to the bases of the proximal phalanges. They are inserted for the most part into the expansions of the extensor tendons on the dorsal aspect of the toes (p. 346).

**Tendons of the Tibialis Posterior and Peronæus Longus.**—Before leaving the sole of the foot the dissector must determine the precise insertions of the tendons of the tibialis posterior and of the peronæus longus. The tendon of the *tibialis posterior* is inserted not merely into the tuberosity of the navicular bone. Fibrous slips are seen to spread out from it, and these may be traced to every bone of the tarsus, with the exception of the talus, and also to the bases of the second, third, and fourth metatarsal bones. As it lies under and gives support to the head of the talus, the tendon of the tibialis posterior has developed within it a sesamoid nodule of fibro-cartilage, and in some cases a sesamoid bone (Fig. 103).

The tendon of the *peronæus longus* turns round the lateral margin of the foot, and runs medially, across the

sole, in the groove on the plantar surface of the cuboid bone, to reach the base of the first metatarsal bone. As it traverses the sole it is enclosed in a fibrous sheath. The sheath is formed mainly by fibres derived from the long plantar ligament. Open the sheath, and its smooth, glistening internal surface will be displayed. The glistening appearance is due to the mucous layer which lines it (see p. 354). The tendon is inserted into the plantar part of the base of the first metatarsal bone, and also to a slight degree into the adjacent part of the first cuneiform bone. In some cases it sends a slip to the base of the second metatarsal bone also. As the tendon winds round the cuboid bone it is thickened, and contains a nodule of fibro-cartilage, or a sesamoid bone.

**Dissection.** — The dissection of the sole of the foot is brought to an end by disarticulating the proximal end of the first metatarsal bone. A good view is thus obtained of the continuity between the dorsalis pedis artery and the plantar arch.

M. adductor hallucis (oblique head)

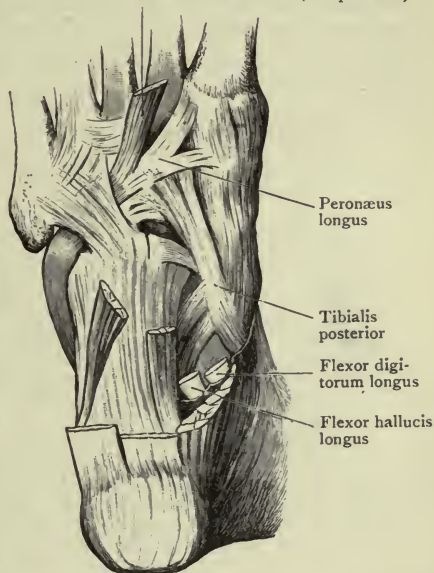


FIG. 176. — The insertions of the Tibialis Posterior and Peronæus Longus Muscles in the Right Foot. (Paterson.)

## ARTICULATIONS.

The dissection of the knee joint, the ankle joint, the tibio-fibular joints, and the various articulations of the foot, may now be proceeded with. It is possible that the ligaments may have become hard and dry. If that is the case, soak the joints in water for an hour or two.

## ARTICULATIO GENU (KNEE JOINT).

In the knee-joint three bones are in apposition, viz., the distal end of the femur, the proximal end of the tibia, and the patella. It is the largest and most complicated articulation in the body; and, when the bones are examined in the dried skeleton, the joint presents an apparent insecurity, because the bony surfaces show little adaptation the one to the other. In reality, however, the knee joint is very strong, and, on account of the strength of the ligaments which retain the bones in place, it very rarely suffers dislocation. The ligaments on the exterior of the joint are:—

1. The capsular ligament.
2. Two collateral ligaments—fibular and tibial.
3. The ligamentum patellæ (or anterior ligament).
4. The oblique popliteal ligament.

*Dissection.*—Before the dissection of the knee joint itself is commenced, the nerves which supply it, and the arteries which anastomose around it and provide its blood supply should be displayed and studied. To a certain extent they can be dissected simultaneously. The superior, inferior, and middle articular branches of the tibial nerve, the superior and inferior articular branches of the common peroneal nerve, and the articular branch of the obturator nerve were found during the dissection of the popliteal fossa, each being accompanied by a genicular branch of the popliteal artery.

Note that the middle genicular branch of the tibial nerve, the accompanying artery, and the articular branch of the obturator nerve pierce the posterior ligament of the knee joint. They supply structures inside the capsule, but the demonstration of their distribution is very difficult, and no attempt must be made to follow them further at present.

The branches of the femoral nerve to the vastus medialis, the vastus intermedius, and the vastus lateralis send twigs to the knee, and twigs of the descending branch of the lateral femoral circumflex artery descend with the nerve to vastus lateralis to take part in the anastomosis round the joint. The nerves and the artery mentioned were found during the dissection of the thigh. Attempt to trace them now to the knee, and demonstrate, if possible, the anastomosis of the descending branch of the lateral femoral circumflex artery with the superior lateral genicular branch of the popliteal artery, and with the muscular branches of the arteria genu suprema. Next trace the superior genicular branches of the popliteal artery and the accompanying nerves. The medial superior genicular artery, as it leaves the popliteal fossa, pierces the posterior intermuscular septum of the thigh, and then passes between the tendon of the adductor magnus and the femur before it enters the vastus medialis, where it anastomoses with the adjacent arteries. The lateral superior genicular artery, and the accompanying nerve, must be followed

through the lateral intermuscular septum, and between the biceps femoris and the bone, into the substance of the vastus intermedius.

As the inferior genicular vessels and nerves are followed care must be taken to avoid injury to the collateral ligaments of the knee joint. Cut through the biceps femoris at the level of the proximal part of the lateral condyle of the femur, pull the distal part downwards, and clean the fibular collateral ligament, which descends from the lateral epicondyle of the femur through the tendon of the biceps to the head of the fibula (Fig. 178). Then follow the inferior lateral genicular artery and nerve forward, between the fibular collateral ligament and the fibrous capsule to the front of the knee. Next throw the tendons of the sartorius, gracilis, and semitendinosus forwards; clean the broad tibial collateral ligament, which descends from the medial epicondyle of the femur to the medial condyle and the medial surface of the tibia; then follow the inferior genicular artery and the accompanying nerve along the proximal border of the popliteus to the point where they disappear under cover of the tibial collateral ligament below the medial condyle of the tibia. Turn now to the anterior border of the tibial collateral ligament, and secure the inferior medial genicular artery as it issues from under cover of the tibial collateral ligament, and, if possible, display its anastomoses with the adjacent arteries.

Now turn to the recurrent branches of the anterior tibial artery. The posterior tibial recurrent artery springs from the anterior tibial artery at the back of the leg and ascends to the knee anterior to the popliteus; therefore that muscle must be reflected. Cut through the narrow part of the muscle, immediately medial to the proximal tibio-fibular joint, and turn the medial part to the medial side; then follow the artery to its termination and at the same time note the termination of the nerve to the popliteus; it enters the anterior surface of the muscle.

The anterior tibial recurrent artery and the accompanying branch of the common peroneal nerve were displayed during the dissection of the anterior and lateral regions of the leg. Follow them now through the proximal part of the origin of the tibialis anterior to their terminations.

**Anastomosis around the Knee Joint.**—The most important of the anastomoses around the knee joint are placed on the anterior aspect of the articulation, and take the form of three transverse arches. The *most proximal* of these *arterial arcades* passes through the superficial fibres of the quadriceps extensor, close to the proximal border of the patella, and is formed by the union of a branch from the superior lateral genicular artery with a twig from the articular branch of the *arteria genu suprema*. The middle and the distal transverse arches are both placed under cover of the *ligamentum patellæ*. The *middle arch* runs across in the fatty tissue close to the distal end of the patella. It is formed by the inferior lateral

genicular artery, and a branch which results from the union of a twig from the arteria genu suprema, and another from the superior medial genicular artery. The *most distal arch* lies on the tibia, immediately above its tuberosity, and results from the anastomosis of the anterior recurrent tibial and inferior medial genicular arteries. The proximal and middle of these transverse arches are connected, on each side of the patella, by ascending and descending branches, which anastomose with one another, and thus enclose the patella in an irregularly quadrilateral arterial framework. From all sides of this arterial enclosure, twigs are given off which enter small

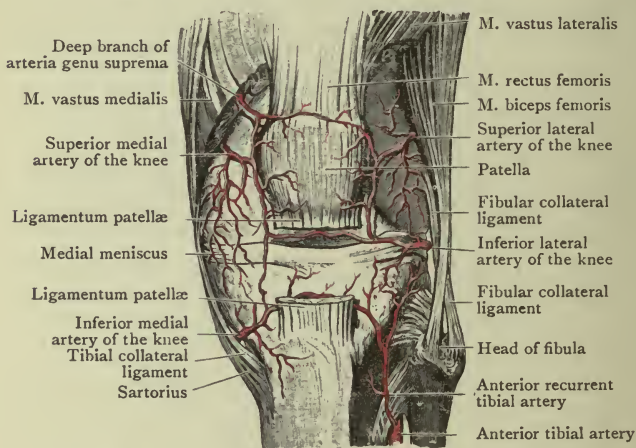


FIG. 177.—Anastomosis on the front of the Left Knee Joint.

foramina on the anterior surface of the patella to supply the osseous substance. Six arteries, therefore, take part in the formation of this system of anastomoses on the front and lateral aspects of the joint, viz., the musculo-articular branch of the arteria genu suprema, the two superior and the two inferior genicular branches of the popliteal, and the anterior recurrent branch of the anterior tibial. In addition to the twigs which proceed from these to form the arterial arches, numerous branches are given which spread over the bones in the form of a close meshwork. During the dissection of the articulation these vessels will become apparent.



The knee joint is supplied on its posterior aspect by twigs derived from all the genicular branches of the popliteal. These twigs are variable in their origin; and the anastomoses which are formed between them are unimportant and inconstant. They are supplemented by another artery, the *posterior recurrent tibial*. This small vessel ramifies over the distal part of the oblique popliteal ligament, and inosculates with the two inferior genicular branches of the popliteal.

The *middle genicular artery* is destined chiefly for the supply of the interior of the joint. It pierces the oblique popliteal ligament, passes forwards between the cruciate ligaments, and ramifies in the fatty tissue in that situation. Its terminal twigs usually anastomose with the middle arch in front of the knee joint. It will be dissected, at a later stage, in the interior of the joint.

**Articular Nerves of the Knee Joint.**—The knee joint is richly supplied with nerves. No less than ten distinct branches may be traced to it. The femoral nerve, the common peroneal, and the tibial nerve trunks contribute three twigs apiece to this articulation, and the obturator nerve furnishes a filament to its posterior aspect. The *femoral nerve* supplies the joint through branches which proceed from the nerves to the vastus lateralis, vastus medialis, and to the musculus articularis genu portion of the vastus intermedius. These nerves pierce the fibres of the quadriceps muscle, and are distributed to the proximal and anterior part of the articulation. The articular branch from the nerve to the vastus medialis is of larger size than the other two, and it accompanies an articular branch of the arteria genu suprema. The *common peroneal nerve* gives off—(1) the superior and inferior lateral articular nerves, which accompany the corresponding genicular arteries, and end in fine filaments which pierce the capsule of the joint; and (2) the recurrent articular nerve, which accompanies the anterior recurrent tibial artery. This nerve ends chiefly in the tibialis anterior muscle; but a fine twig may reach the distal part of the anterior aspect of the knee joint. The *tibial nerve* furnishes the knee joint with superior and inferior medial articular branches and a middle articular nerve, which accompany the corresponding genicular arteries. The branch from the *obturator nerve* descends on the postero-medial aspect of the popliteal artery as far as the back of the knee joint. At that point it leaves the artery and, inclining forwards, breaks up into several filaments which pierce the oblique popliteal ligament separately.

**Dissection.**—Remove the popliteal vessels, tibial and common peroneal nerves, and the muscles surrounding the knee joint.

Portions of the tendons of the biceps femoris, semimembranosus, sartorius, semitendinosus, gracilis, and popliteus, together with small pieces of the heads of the gastrocnemius, should be left in place in order that their connections with the ligaments of the joint may be studied. The quadriceps extensor may be divided about three inches proximal to the patella, and the distal part allowed to remain in position.

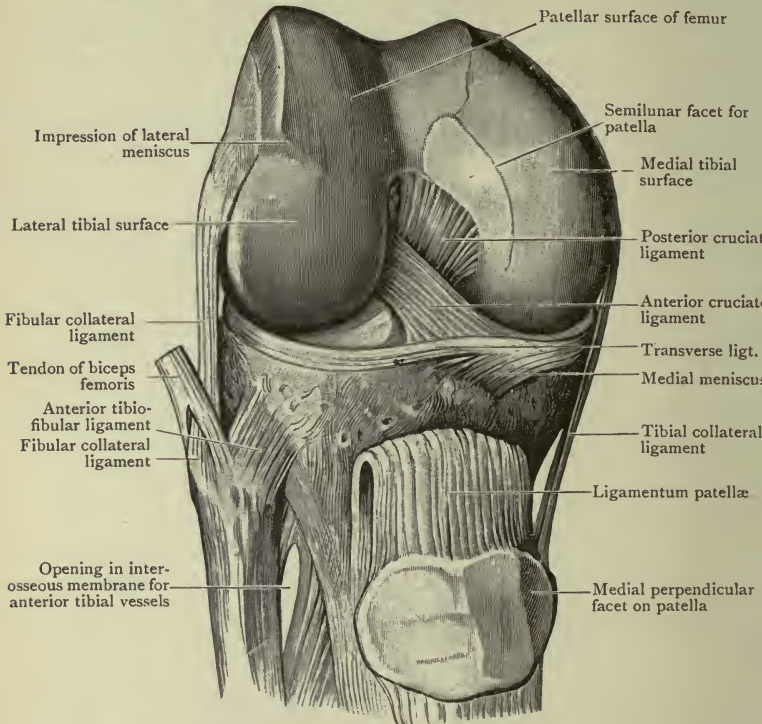


FIG. 178.—Dissection of the interior of the Knee Joint from the front.

**Capsula Articularis.**—The capsule of the knee joint, together with the tibial collateral ligament and the oblique popliteal ligament, form a complete investment for the joint. In some places the fibrous or peripheral part of the capsule has disappeared and has been replaced either by bone and cartilage or by tendon, and in other places it has been strengthened and extended by the incorporation of adjacent portions of fascia and tendons; thus, anteriorly, the patella

entirely replaces a portion of the capsule. Proximal to the patella the capsule is represented merely by the synovial stratum covering the posterior surface of the tendon of the quadriceps muscle; on the other hand the antero-medial and the antero-lateral parts of the capsule have been strengthened by fusion with expansions from the vasti portions of the quadriceps and with the superjacent parts of the fascia lata. The position and attachments of the original capsule are still indicated, in the adult, by the synovial layer which forms a continuous enclosing membrane except in the region of the patella.

**Ligamentum Patellæ.**—The patellar ligament is situated in relation to the distal part of the front of the capsule. It constitutes, at the same time, the tendon of insertion of the quadriceps extensor muscle and a ligament connecting the patella with the tuberosity of the tibia. Its anterior surface and margins should be carefully defined.

The ligament is a strong band, about two inches long, which is attached proximally to the apex of the patella, and distally to the smooth proximal part of the tuberosity of the tibia. Its superficial fibres are directly continuous, over the surface of the patella, with the central part of the common tendon of the quadriceps extensor. Its deep surface is separated proximally from the synovial layer by the infrapatellar pad of fat, and distally it is separated from the anterior surface of the proximal end of the tibia by the deep infrapatellar bursa (Fig. 181).

**Ligamentum Collaterale Fibulare (O.T. External Lateral Ligament).**—The fibular collateral ligament is rounded and cord-like. It stands well away from the joint cavity, and takes no part in the formation of the articular capsule. It is attached proximally to a tubercle on the lateral condyle of the femur; distally, it is fixed to the head of the fibula, anterior to the apex. It is closely associated with the tendon of the biceps femoris and the tendon of the popliteus. It splits the tendon of the biceps into two pieces, and extends between them to its fibular attachment. The tendon of the popliteus takes origin from the lateral condyle of the femur distal to and anterior to the femoral attachment of the fibular collateral ligament. As the tendon runs backwards it lies under cover of the fibular collateral ligament, but is separated from it by the articular capsule.

An additional slip is sometimes described as the *posterior part* of the fibular collateral ligament. When present it ends above in the capsule, under cover of the lateral head of the gastrocnemius. Below, it is implanted into the apex of the head of the fibula.

**Ligamentum Collaterale Tibiale (O. T. Internal Lateral Ligament).**—The tibial collateral ligament is a long, flat band, broader in the middle than at either extremity. It springs from the medial epicondyle of the femur, distal to the adductor tubercle. As it descends it inclines slightly forwards, and,

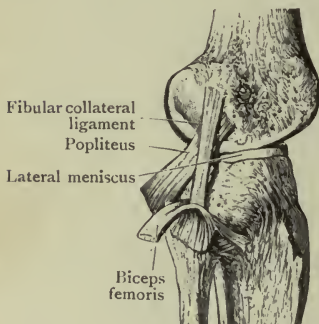


FIG. 179.—The Fibular Collateral Ligament of the Knee Joint.

finally, it gains attachment to the margin of the medial condyle and to the proximal fourth of the body of the tibia below the medial condyle. At the level of the interval between the femur and the tibia its deep surface is fused with and takes part in the formation of the fibrous stratum of the articular capsule. The main part of the tendon of the semimembranosus extends forwards, under cover of its posterior border, to gain an insertion into the medial condyle of the tibia, whilst, more distally, the inferior medial genicular vessels are carried forwards between it and the tibia. The tendons of the sartorius, gracilis, and semitendinosus lie upon the lower part of its superficial surface, but are separated from it by an intervening bursa.

**The Posterior Part of the Capsule and the Ligamentum Popliteum Obliquum (O. T. Posterior Ligament).**—The posterior part of the capsule extends as a continuous sheet across the posterior aspect of the joint; laterally it is continuous with the lateral part of the capsule, which lies medial to the fibular collateral ligament, and medially it fuses with the deep surface of the tibial collateral ligament as the latter crosses the line of the joint. The lateral head of the gastrocnemius fuses with the proximal part of its lateral portion, and the tendon of the popliteus passes through the distal part of the same portion. The medial part of the posterior portion of the capsule is separated from the medial head of the gastrocnemius

by a bursa which communicates round the medial border of the gastrocnemius with the bursa between the medial head of the gastrocnemius and the semimembranosus, and it may communicate with the cavity of the joint, through an aperture in the capsule. The medial and lateral parts of the posterior portion of the capsule, which are covered by

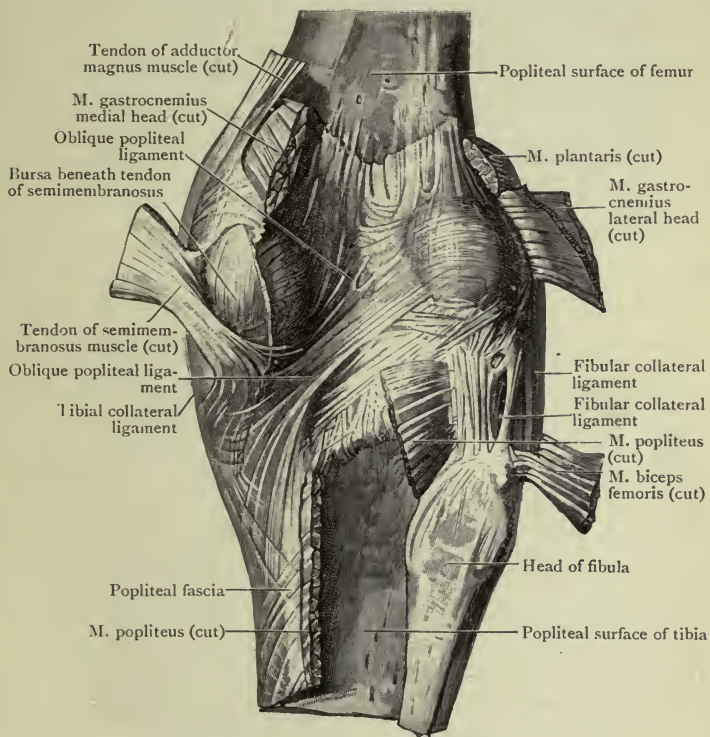


FIG. 180.—The Knee Joint. Posterior view.

the heads of the gastrocnemius, are thin, but the intermediate portion, which forms part of the anterior boundary of the popliteal fossa, is strengthened by a strong oblique band, the *oblique popliteal ligament*, which passes upwards and laterally, from the distal part of the tendon of the semimembranosus to the medial border of the lateral condyle of the femur.

In addition to the apertures through which the bursa

under cover of the medial head of the gastrocnemius communicates with the cavity of the joint, and that through which the tendon of the popliteus emerges, there are several small apertures in the posterior part of the capsule for the transmission of vessels and nerves into the interior of the joint.

**Dissection.**—Make a transverse incision through the quadriceps extensor, immediately proximal to the patella, and prolong each end of the incision downwards, about 37 mm. posterior to the patella, to the condyles of the tibia, then turn the patella downwards. The joint is now opened from the front and the following structures can be seen and examined, viz., the synovial lining, the cruciate ligaments, which connect the femur with the tibia, and the menisci, which lie upon and are attached to the tibia. Immediately above the joint, between the distal part of the quadriceps extensor and the front of the femur there is a large *suprapatellar bursa* which is frequently continuous with the joint cavity. To display the extent of that bursa, split the lower part of the quadriceps by a vertical incision in the middle line of the thigh and turn the two parts aside.

**Interior of the Joint.**—First note the great pad of soft fat which is placed on the deep surface of the ligamentum patellæ. In vertical section the fatty mass is triangular in form (Fig. 181). It is termed the *infra-patellar pad*, and it fills up the interval between the patella, femur, and tibia, and adapts itself to the varied forms which that recess assumes in the different movements of the joint. It is separated from the interior of the joint by a covering of the synovial layer, and from its surface a fold of that layer extends backwards and upwards to the anterior margin of the intercondylar fossa of the femur, where it is attached. That band is termed the *patellar synovial fold* (O.T. *ligamentum mucosum*). As it approaches the femur it becomes narrow and slender; but where it covers the surface of the infra-patellar pad it is broad and triangular, and presents two free margins which extend along the borders of the distal part of the patella, and receive the name of *plicæ alares* (O.T. *ligamenta alaria*). It must be clearly understood that these are not ligaments in the ordinary sense of the word, but merely folds of the synovial layer.

**Stratum Synoviale** (O.T. **Synovial Membrane**).—As the knee joint is the largest joint in the body its synovial stratum is more extensive than that of any other joint. It lines the deep surfaces of the ligamentous structures of the lateral, medial and anterior parts of the joint. It lines the deep surfaces

of the medial and lateral portions of the posterior part of the capsule also, and from them it is prolonged anteriorly, along the sides and round the front of the cruciate ligaments. In the anterior part of the joint it is prolonged upwards, beyond the articular surface of the distal end of the femur, in the form of a great *cul-de-sac*, under cover of the tendon of the quadriceps (Fig. 181). The proximal extremity of this *cul-de-sac* usually communicates by an orifice of greater or less width with the suprapatellar bursa. The synovial layer also invests the menisci, and a pouch-like diverticulum is prolonged posteriorly and distally, along the tendon of the popliteus, which it partially ensheaths, across the posterior part of the external border of the lateral meniscus to the posterior aspect of the proximal end of the tibia. That prolongation lies in close relation with the capsule of the tibio-fibular joint, and in some cases a communication is established between the cavity of the diverticulum and the cavity of the tibio-fibular joint.

**Dissection.**—Divide the patellar synovial fold and remove the infrapatellar pad of fat. Then open and examine the bursa between the ligamentum patellæ and the proximal part of the tibia. Next dissect away the intermediate part of the posterior portion of the capsule (oblique popliteal ligament) and trace the middle genicular artery, which pierces it, forwards to the cruciate ligaments. It will now be seen that the posterior surface of the posterior cruciate ligament is not covered by the synovial layer, and that it is connected by areolar tissue to the deep surface of the posterior part of the fibrous stratum of the capsule. Define the attachments of the cruciate ligaments by removing the synovial layer which covers them at the sides and in front, and the areolar tissue in connection with them. The menisci also should receive the attention of the dissector, and the manner in which their fibrous, pointed extremities are fixed to the tibia must be studied. At this stage the changes produced in the degree of tension of the cruciate ligaments, and the change in the position of the menisci brought about by movements of the joint, should be examined.

**Movements at the Knee Joint.**—The movements of the knee joint are those of flexion and extension. The leg can be bent posteriorly until the prominence of the calf comes into contact with the posterior aspect of the thigh; but in extension the movement is brought to a close when the leg comes into a line with the thigh. In that position the joint is firmly locked, and the anterior cruciate, the tibial and the fibular collateral ligaments, and the posterior part of the capsule with the oblique popliteal ligament being fully stretched, the leg and thigh are converted into a rigid column of support. In flexion, however, the ligaments mentioned are relaxed, and a certain amount of rotation of the tibia upon the femur is allowed.

Flex the joint acutely, and examine the cartilage-covered surface of the distal end of the femur. It consists of an anterior trochlear portion

for the patella, and two condylar surfaces which move on the menisci and tibia. The trochlea is separated from the surface of the lateral condyle by a faintly marked groove, which takes a slightly curved course, from the lateral border of the distal end of the femur, medially and posteriorly to the fore part of the intercondylar fossa. At each extremity this groove widens out into a distinct depression. In full extension the lateral depression rests upon the anterior part of the lateral meniscus, whilst the medial depression rests against the anterior border of the lateral tubercle of the intercondyloid eminence of the tibia (Bruce Young). The line of demarcation between the trochlea and the distal surface of the medial condyle of the femur is not so distinct. Close to the medial margin of the bone there is a

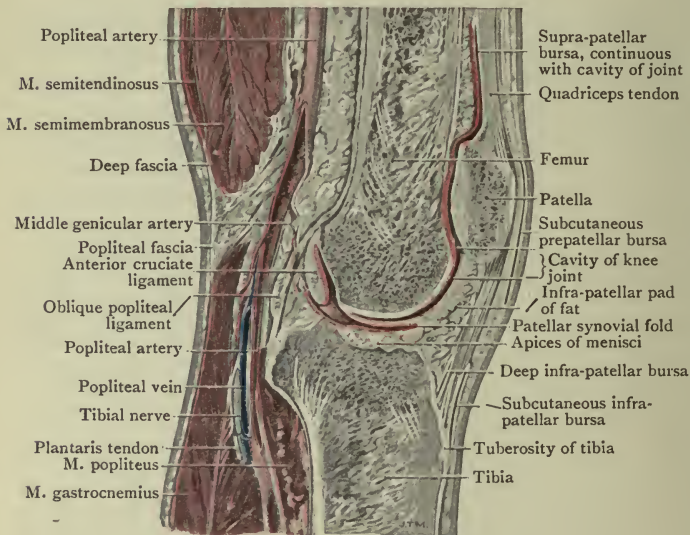


FIG. 181.—Sagittal Section of the Knee Joint.

depression which, in full extension, rests upon part of the anterior horn of the medial meniscus (Bruce Young): but lateral to this the trochlear surface is prolonged posteriorly for a certain distance along the anterior and medial margin of the intercondylar fossa. A portion of the medial condyle is thus included in the trochlear surface, viz., the portion skirting the medial border of the anterior part of the intercondylar fossa, and this is termed the "crescentic facet" of the medial condyle.

The posterior surface of the patella may next be examined (Fig. 178), and its movements in connection with flexion and extension of the knee joint studied. A high vertical ridge divides the posterior surface into a large lateral and a smaller medial area. Each of these is still further subdivided by faint ridges on the cartilage which coats the surface. A faint line upon the medial area of the patella descends in a vertical direction so as to mark off a narrow strip close to the medial border of the bone. This strip is



called the *medial perpendicular facet*. Two horizontal lines extend laterally from the lateral border of the medial perpendicular facet to the lateral border of the bone, and subdivide the remainder of the medial area and the whole of the lateral area into three facets each. In a well-marked patella, therefore, the posterior cartilage-covered surface shows seven facets, viz., a proximal pair, a middle pair, a distal pair, and a medial perpendicular facet (Goodsir).

The faceted appearance of the posterior surface of the patella indicates that, in the movements of that bone upon the trochlear surface of the femur, the entire articular surface is never in contact with the femur at the same time. In flexion and extension of the knee, the patella moves distally and proximally in a curved path, the concavity of which looks upwards, backwards, and laterally. The different facets come into contact and break contact with the femur in regular succession. Let us suppose the knee joint to be acutely flexed: in that condition of the limb the medial perpendicular facet of the patella rests upon the crescentic facet of the medial condyle of the femur, while the lateral of the two proximal patellar facets is in contact with the lateral lip of the trochlear surface of the femur. No part of the patella touches the medial lip of the trochlear surface. As the leg is moved from the fully flexed to the fully extended position, the two proximal facets, then the two middle facets, and, lastly, the two distal facets, come successively into contact with the trochlear surface of the femur (Goodsir). In Fig. 182, 183, 187 the position of the patella in the fully extended knee is exhibited.

Now examine the condylar surfaces of the femur (Fig. 178). The posterior two-thirds of the medial condyle will be seen to be of equal extent with, and parallel to, the lateral condyle. The anterior third of the medial condyle, however, turns obliquely laterally to join the trochlear surface. The lateral condylar surface has no corresponding part. The obliquely directed part of the medial condyle gives rise to the "screw-home" movement, which is so characteristic of the knee joint when fully extended. At the commencement of flexion and at the completion of extension there is a screw movement, or a movement of rotation of the tibia and femur on each other. As the leg is moved forwards from the condition of acute flexion, the condyles of the femur roll and glide over the surfaces of the menisci and the proximal end of the tibia until the surface of the lateral condyle, and the corresponding part of the medial condyle, are exhausted. This movement of the femoral condyles has been compared to that of "a wheel partially restrained by a drag" (Goodsir). Any additional movement must necessarily take place in connection with the anterior oblique third of the medial condyle, and the result is a rotation or screw-like motion of the femur medially. The medial condyle travels backwards round the intercondyloid eminence of the tibia, and the anterior part of the intercondylar fossa comes into contact with the anterior cruciate ligament and the medial tubercle of the intercondyloid eminence (Bruce Young). The joint is now "screwed home" or locked. In the initial stage of flexion the reverse movement must be accomplished. The unlocking of the joint can be brought about only by a rotation medially of the tibia, or a rotation laterally of the femur.

When fully extended, the joint is locked, and the posterior part of the capsule, the collateral ligaments, and the anterior cruciate ligaments are tense. The limb is converted into a rigid column, and the upright posture is thereby maintained with the smallest possible degree of muscular exertion.

The *muscles* which operate upon the bones of the leg so as to produce flexion and extension of the limb at the knee joint are:—(1) *extensors*, the four parts of the quadriceps extensor; (2) *flexors*, the biceps femoris,

popliteus, sartorius, gracilis, semitendinosus, and semimembranosus. Of these, only one is inserted on the lateral side of the limb, viz., the biceps. The other five are inserted into the tibia on the medial side of the leg.

Medial rotation is produced by the popliteus, gracilis, sartorius, semitendinosus, and semimembranosus. Lateral rotation by the biceps femoris.

**Dissection.**—In order to obtain a proper view of the attachments of the cruciate ligaments the following dissection must be made:—The femur must be sawn across about two inches proximal to its distal articular surface. When that has been done divide the distal part of the bone by a vertical, antero-posterior saw-cut, which should end distally in the intercondylar fossa between the condyles and between the proximal attachments of the two cruciate ligaments. After this procedure the cruciate ligaments can be studied singly, or together, and their relation to the collateral ligaments of the joint can be examined. It will be seen that the fibular collateral ligament and the anterior cruciate ligament constitute a pair of ligaments which are fixed to opposite sides of the lateral condyle. The tibial collateral and the posterior cruciate ligaments belong to the medial condyle of the femur, and are attached to its medial and lateral surfaces, respectively. When that relationship has been noted, the tibial collateral ligament may be divided to free the medial condyle, and give greater space for the study of the cruciate ligaments.

**Ligamenta Cruciate Genu (O.T. Crucial Ligaments).**—The cruciate ligaments are well named, because they cross each other, like the limbs of the letter X, in the interval between the two condyles of the femur. This cruciate arrangement is seen whether they are viewed from the side, by the removal of the distal part of one condyle, or from the front or the back of the joint. The anterior cruciate ligament is attached to the tibia in front of the intercondylar eminence and to the medial surface of the lateral condyle of the femur, whilst the posterior is fixed to the tibia behind the intercondylar eminence and to the lateral surface of the medial condyle of the femur.

The *anterior cruciate ligament* springs from the intermediate rough area on the proximal surface of the tibia, in the anterior intercondylar fossa of the tibia, immediately anterior to the medial tubercle which surmounts the intercondylar eminence. Thence it proceeds upwards, backwards, and laterally, to gain attachment to the posterior part of the medial surface of the lateral condyle of the femur (Fig. 186).

The *posterior cruciate ligament* springs from the posterior intercondylar fossa of the tibia posterior to the intercondyloid eminence, and posterior also to the attachments of the posterior horns of both menisci. It passes upwards,

PLATE XXXVI

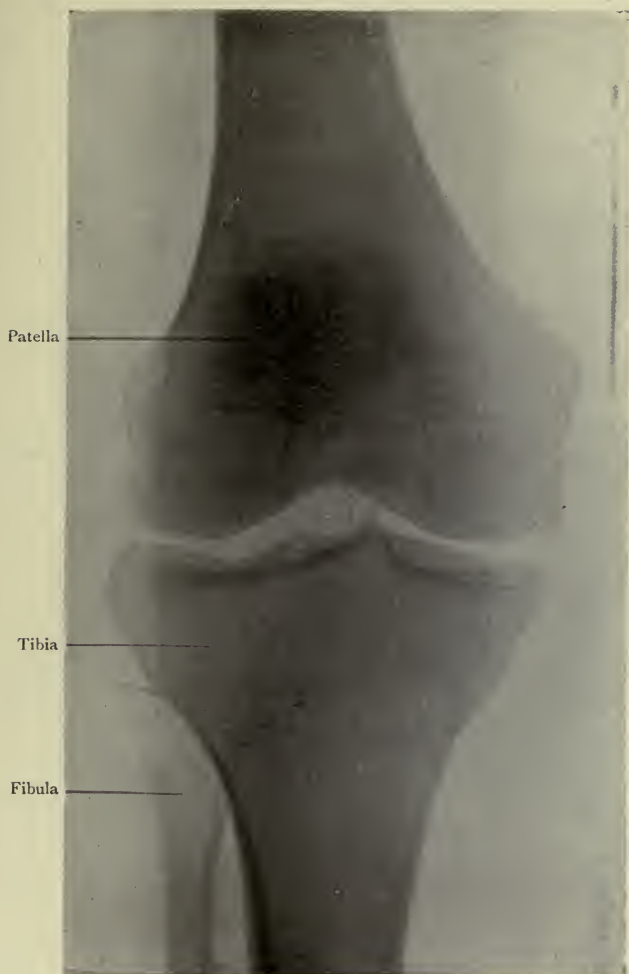

FIG. 182.—Radiograph of the Knee of an adult.  
(Major T. Rankine.)

PLATE XXXVII

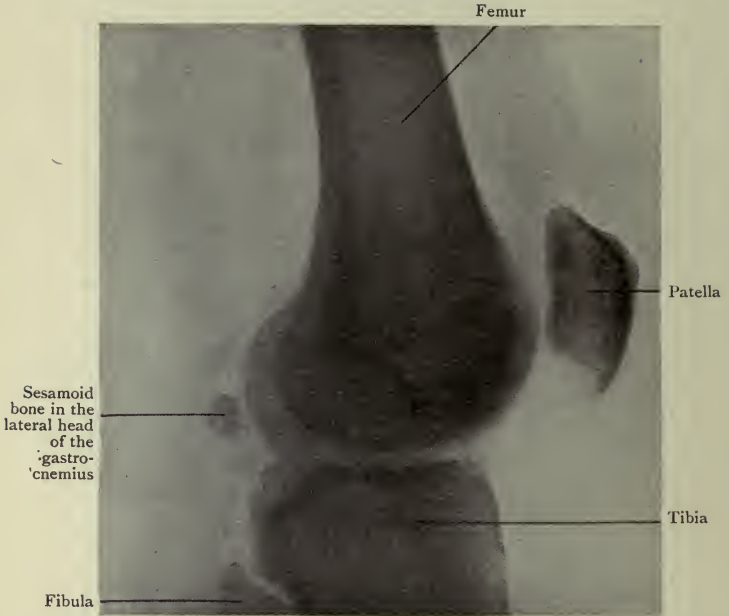

FIG. 183.—Radiograph of the Knee of an adult in extension.

(Prof. Alexis Thomson.)

Note the relations of the femur to the patella and to the tibia,

PLATE XXXVIII

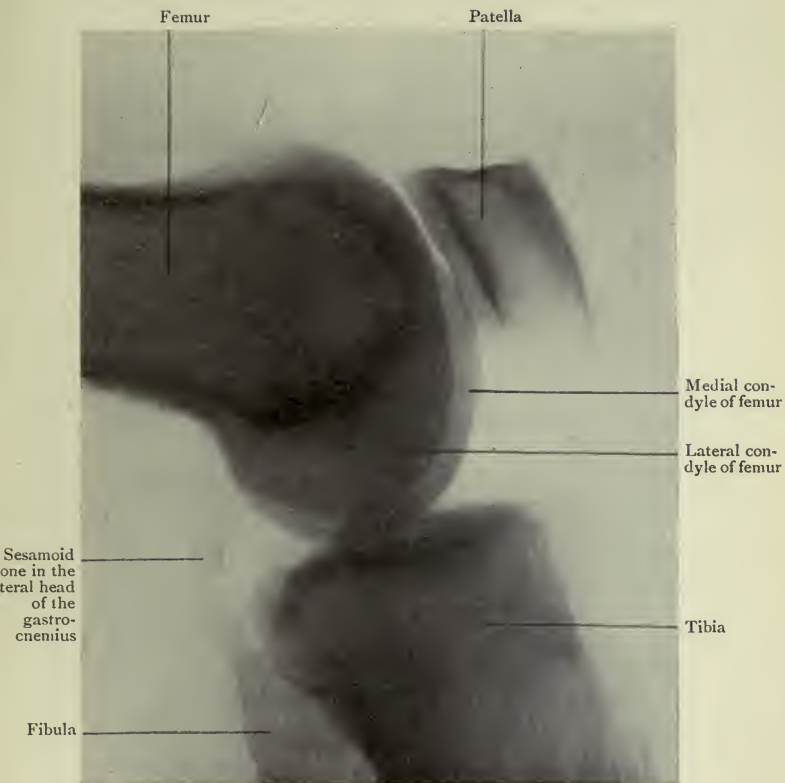

FIG. 184.—Radiograph of a Semiflexed Knee.

(Mr. Hugh M. Martin.)

Note the relations of the femur to the patella and the tibia.

PLATE XXXIX

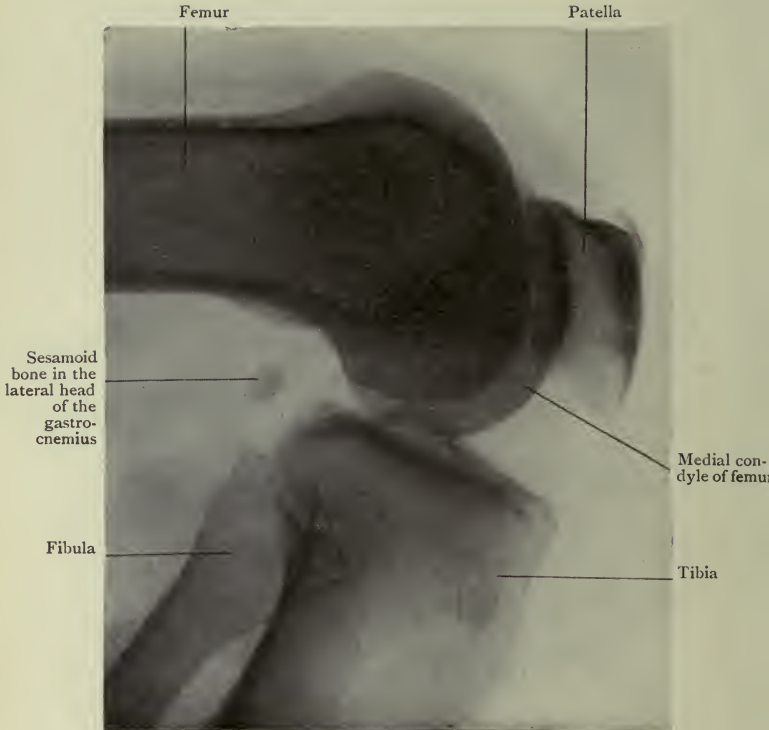


FIG. 185.—Radiograph of a fully flexed Knee.

(Mr. Hugh M. Martin.)

Note the relations of the femur to the patella and the tibia.

forwards, and somewhat medially, and, crossing the anterior cruciate ligament obliquely, is attached to the anterior portion of the lateral surface of the medial condyle. It receives one, or sometimes two, strong slips from the posterior horn of the lateral meniscus (Fig. 186).

The anterior cruciate ligament is tight *in extension*, and

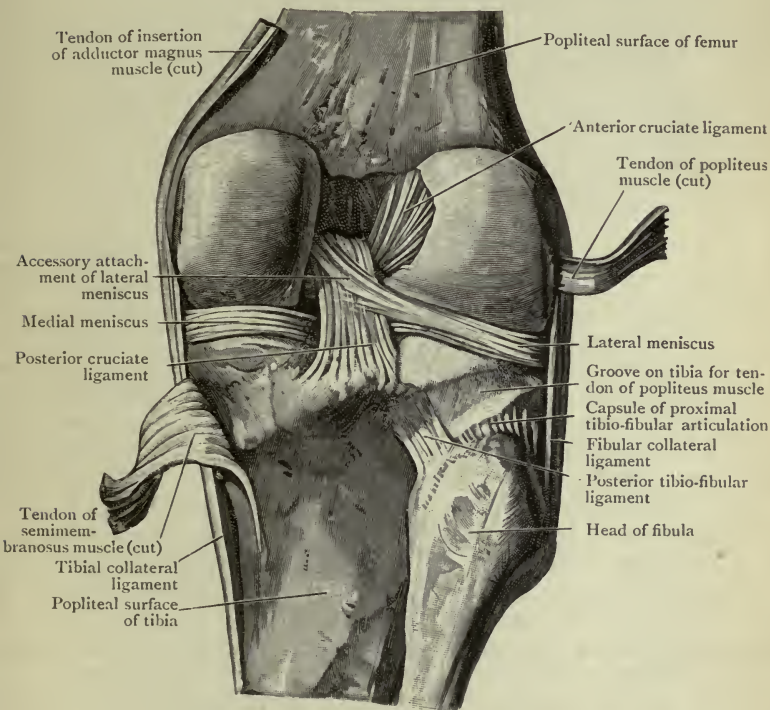


FIG. 186.—The Knee Joint opened from behind by the removal of the Posterior part of the Capsule.

the posterior cruciate ligament is tight *in flexion* of the knee joint.

**Menisci (O. T. Semilunar Cartilages).**—The menisci are two crescentic plates of fibro-cartilage which are placed on the condylar surfaces of the tibia. They deepen the surfaces upon which the condyles of the femur roll, and, being movable, they fill up the gaps which would otherwise arise during the move-

ments of the joint. Each meniscus presents two fibrous extremities, or horns, which are attached to the rough intermediate surface on the proximal end of the tibia. They are thick towards the circumference of the joint, but thin away to a fine free concave edge in the opposite direction. Both surfaces are smooth and covered with the synovial layer. They do not cover the entire extent of the condylar surfaces of the tibia. The central parts of the latter, as well as the sloping surfaces of the tubercles of the intercondyloid eminence, are free. When the cartilages are raised from the surface upon which they rest, distinct impressions, similar in shape and extent, are seen on the subjacent encrusting cartilage of the tibia.

**Dissection.**—Carefully define the attachments of the fibrous horns of the menisci.

The lateral meniscus is usually somewhat thicker around its circumference than the medial meniscus. It forms the segment of a smaller circle, and its horns being fixed to the tibia close together, a very nearly complete circle is formed. The anterior fibrous horn is attached, immediately in front of the intercondylar eminence, to the lateral side of and partly under cover of the attachment of the anterior cruciate ligament. The posterior horn is fixed to the summit of the intercondylar eminence in the interval between the two tubercles. It gives a strong slip also to the posterior cruciate ligament. The fibular collateral ligament is separated from the lateral meniscus by the lateral part of the articular capsule and also by the tendon of the popliteus which lies inside the fibrous stratum of the lateral part of the capsule. The tendon of the popliteus grooves the posterior part of the lateral border of the lateral meniscus, but behind and in front of the groove the peripheral margin of the lateral meniscus is blended with the internal surface of the fibrous stratum of the articular capsule.

The medial meniscus is semicircular in outline, and forms the segment of a much larger circle than the lateral meniscus. Its anterior fibrous horn is fixed to the anterior part of the anterior intercondylar fossa of the tibia, in front of the attachment of the anterior cruciate ligament; its posterior horn is attached in the posterior intercondylar fossa of the tibia, behind the intercondylar eminence and in front of the attachment of the posterior cruciate ligament. The greater



PLATE XL

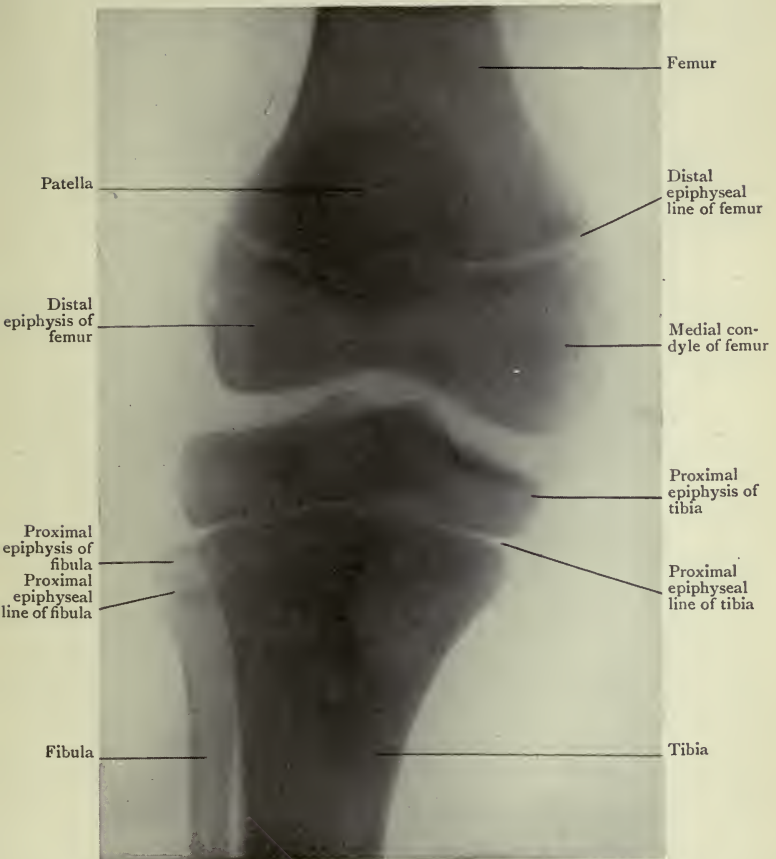


FIG. 187.—Radiograph of the Knee of a child.

PLATE XLI

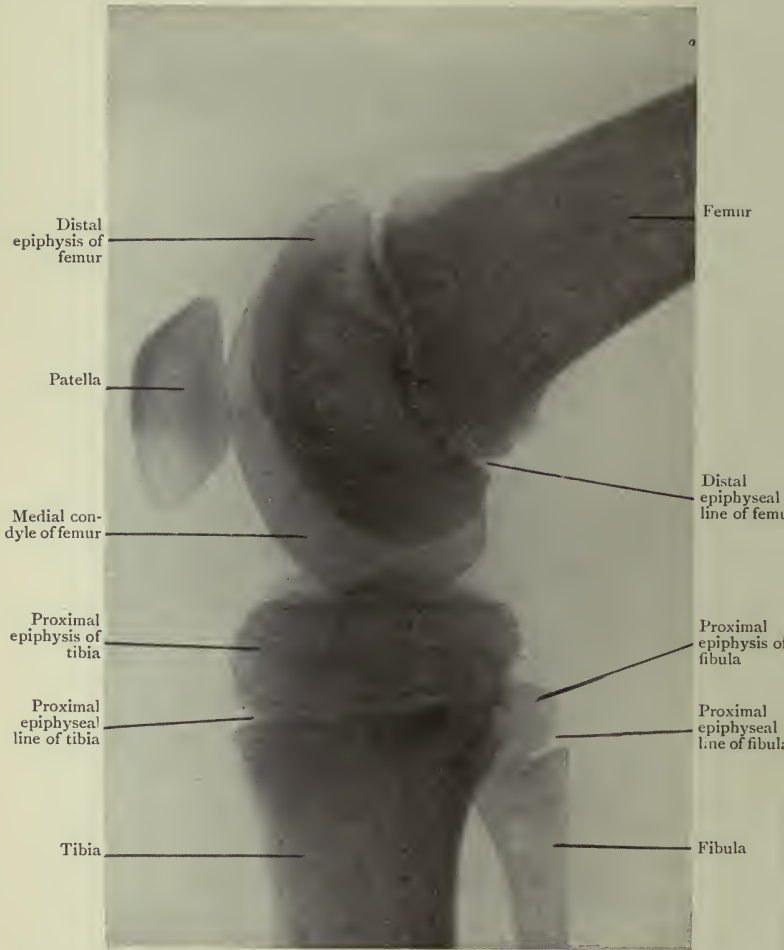


FIG. 188.—Radiograph of the partly flexed Knee of a child.  
Note the relations of the femur to the patella and the tibia.

PLATE XLII

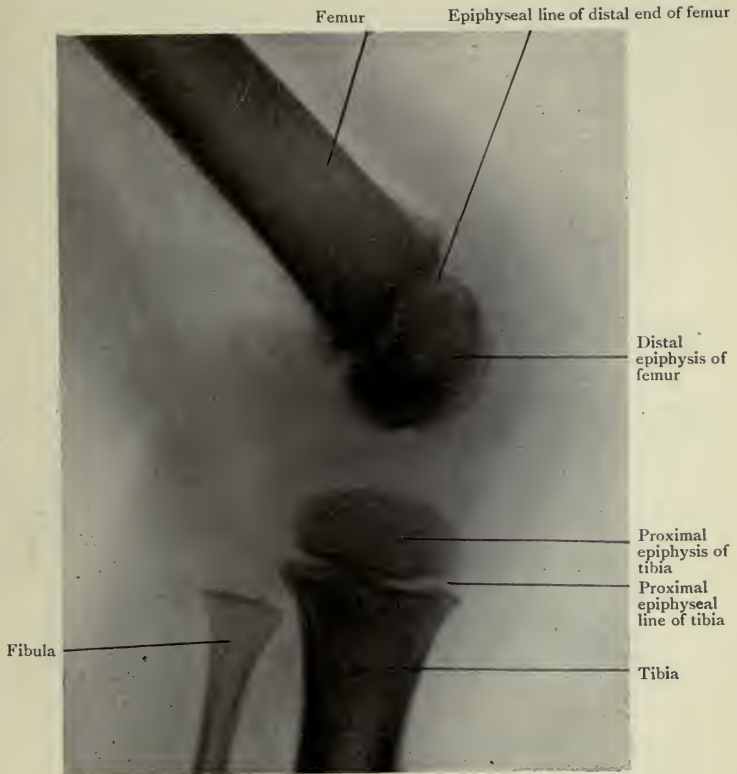


FIG. 189.—Radiograph of the Knee of a child.

Ossification of the patella and the proximal end of the fibula has not yet commenced.

PLATE XLIII

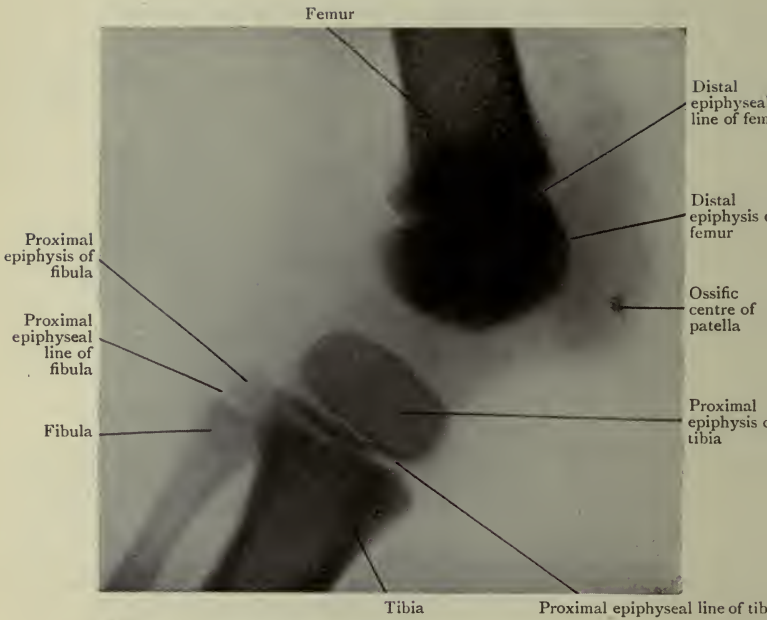


FIG. 190.—Radiograph of the Knee of a child.

Ossification of the patella has commenced.

part of the peripheral border of the medial meniscus is closely connected with the deep surface of the fibrous stratum of the articular capsule. Through their connections with the fibrous stratum of the articular capsule both menisci gain attachment to the distal end of the femur and the proximal end of the tibia.

**Ligamentum Transversum Genu.**—The transverse ligament is a fibrous band which stretches across from the anterior part

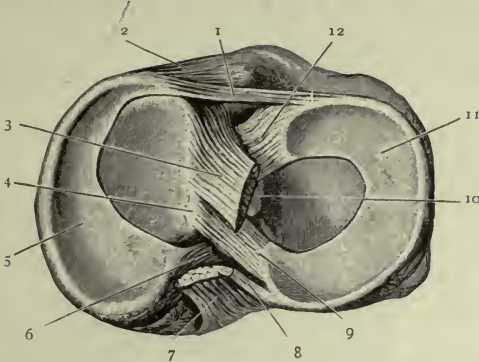


FIG. 191.—Parts attached to the proximal end of the Right Tibia.

- |   |   |
|---|---|
| 1. Transverse ligament.                                 | 8. Fasciculus from lateral meniscus to posterior cruciate ligament. |
| 2. Anterior cornu of medial meniscus.                   | 9. Posterior cornu of lateral meniscus.                             |
| 3. Anterior cruciate ligament.                          | 10. Lateral tubercle of intercondyloid eminence of tibia.           |
| 4. Medial tubercle of intercondyloid eminence of tibia. | 11. Lateral meniscus.   |
| 5. Medial meniscus.                                     | 12. Anterior cornu of lateral meniscus.                             |
| 6. Posterior cornu of medial meniscus.                  |   |
| 7. Posterior cruciate ligament.                         |   |

of one meniscus to the corresponding part of the other, constituting a bond of union between them.

**Dissection.**—The condyles of the femur should now be detached by dividing the fibular collateral ligament, the cruciate ligaments, and the remains of the articular capsule close to their femoral attachments.

#### Attachment of Parts to the Proximal Surface of the Tibia.

—The ligamentous structures and the menisci are attached to the intermediate area on the proximal surface of the tibia in the following order from before backwards:—(1) The anterior horn of the medial meniscus, on the medial side of the extreme anterior part of the area. (2) and (3) The anterior cruciate ligament and the anterior horn of the lateral

meniscus: these are placed side by side, but the attachment of the ligament, which lies to the medial side, overlaps that of the lateral meniscus. (4) The posterior horn of the lateral meniscus, on the summit of the intercondylar eminence between its two tubercles. (5) The posterior horn of the medial meniscus, immediately behind the intercondylar eminence. (6) The posterior cruciate ligament, at the posterior part of the area.

### ARTICULATIO TALOCRURALIS (ANKLE JOINT).

The ankle joint is a diarthrodial articulation of the ginglymus or hinge variety. The articulation takes place

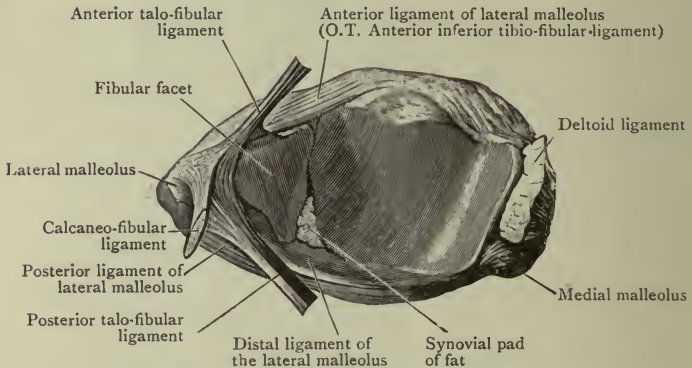


FIG. 192.—Articular Surfaces of Tibia and Fibula which articulate with the Talus.

between the bones of the leg and the talus, and the weight of the body is transferred through it to the foot. It is a joint of great strength; its stability being ensured not only by the powerful ligaments which surround it, but also by the close interlocking of the articulating surfaces.

The bones which enter into the formation of the ankle joint are the distal ends of the tibia and fibula and the proximal, medial, and lateral surfaces of the talus. The distal ends of the leg bones are very firmly united together by interosseous and other ligaments which give the joint a certain amount of elasticity or spring. They form a deep hollow

resembling a mortice and the upper part of the talus is received into the cavity.

**Dissection.**—Remove the remains of the laciniate and transverse ligaments and cut through and displace the tendons which are in relation with the joint, but do not remove them. Then

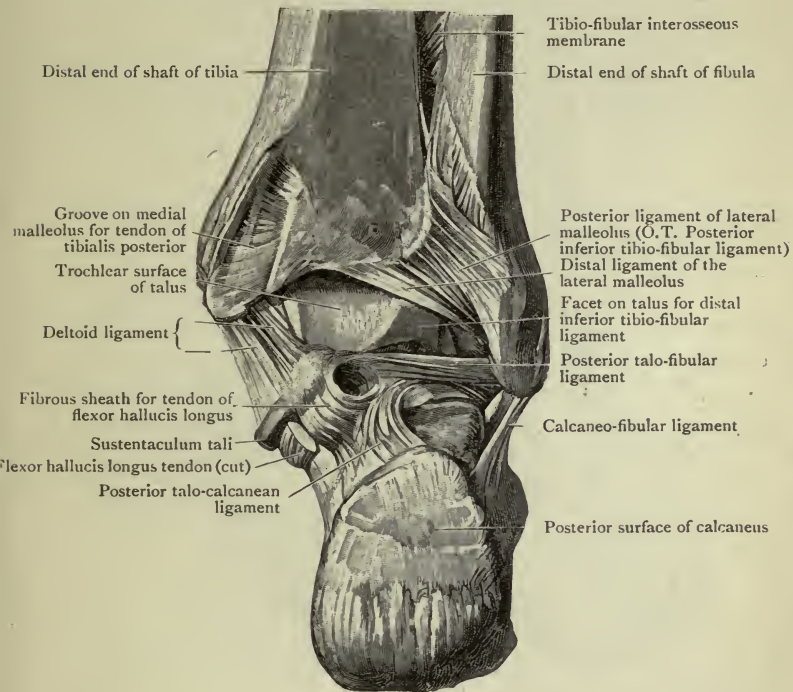


FIG. 193.—Ankle Joint dissected from behind, with part of the Articular Capsule removed.

endeavour to trace out the anastomoses between the arteries in the neighbourhood of the joint, and if possible secure the twigs from the tibial and deep peroneal nerves which supply the joint.

**The Arterial Anastomosis around the Ankle Joint.**—The arteries which anastomose around the ankle joint are: (1) the malleolar branches of the anterior tibial artery, (2) the perforating branch of the peroneal artery, (3) the terminal part of the peroneal artery. All the vessels are very variable

in size, and the malleolar branches of the anterior tibial artery are frequently not injected in ordinary subjects.

**The Ligaments of the Ankle Joint are :—**

1. Capsula articularis.
2. Ligamentum deltoideum.
3. Ligamentum talofibulare anterius.
4. Ligamentum talofibulare posterius.
5. Ligamentum calcaneo-fibulare.

**Dissection.**—After the arterial anastomoses around the ankle joint have been studied pull aside the remains of the arteries and

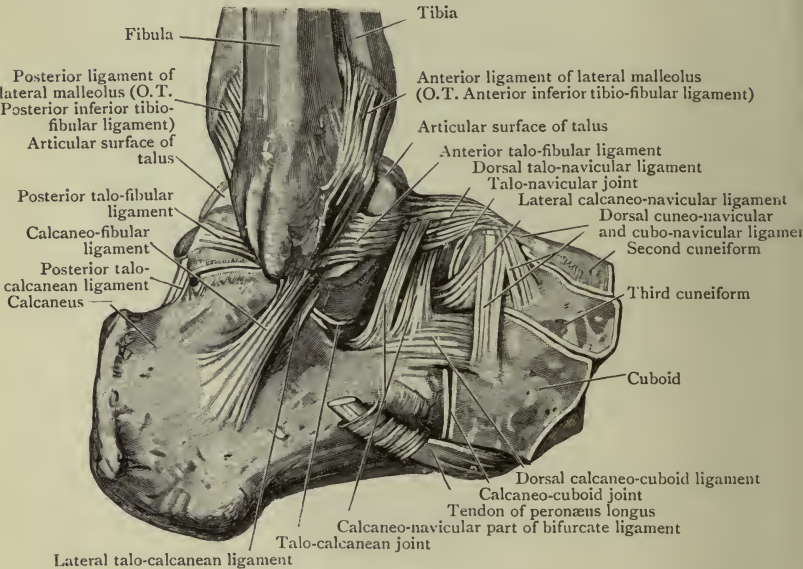


FIG. 194.—Ligaments on the Lateral Aspect of the Ankle Joint and on the Dorsum of the Tarsus.

nerves, and clean carefully the anterior and posterior parts of the capsule, both of which are extremely thin and easily injured. When the attachments and relations of the anterior and posterior parts of the capsule have been demonstrated remove both parts in order to bring the medial and lateral accessory ligaments more fully into relief.

**Capsula Articularis.**—The anterior and posterior parts of the fibrous stratum of the articular capsule are very thin. Medially the fibrous stratum blends with the deep surface of



the deltoid accessory ligament, and laterally it is fused with the deep surfaces of the anterior and posterior talo-fibular ligaments, but it has little or no connection with the calcaneo-fibular ligament. The anterior part of the capsule (O.T. anterior ligament) extends from the anterior margin of the distal articular surface of the tibia to the anterior part of the

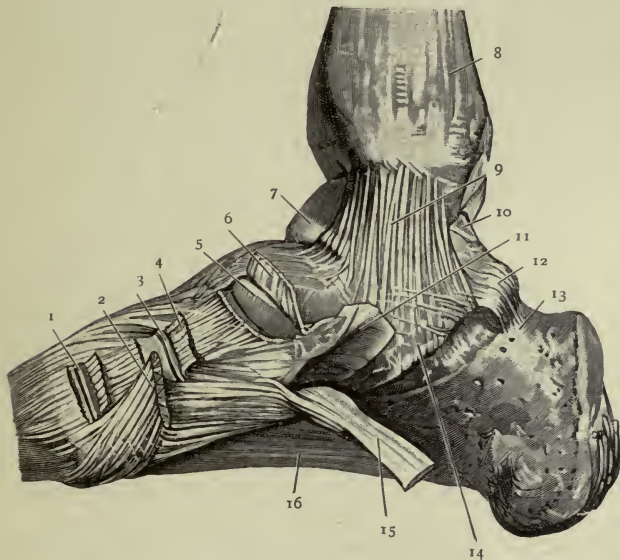


FIG. 195.—Ankle and Tarsal Joints from the Medial Aspect.

- |  |  |
|--|--|
| 1. First tarso-metatarsal joint (opened).    | 10. Trochlear surface of talus.  |
| 2. Tendon of tibialis anterior muscle (cut). | 11. Groove for tendon of tibialis posterior muscle on plantar calcaneo-navicular ligament. |
| 3. Medial cuneo-navicular joint (opened).    | 12. Groove and tunnel for the tendon of flexor hallucis longus muscle.                     |
| 4. Dorsal cuneo-navicular ligament.          | 13. Calcaneus.   |
| 5. Head of talus.                            | 14. Sustentaculum tali.  |
| 6. Dorsal talo-navicular ligament.           | 15. Tendon of tibialis posterior muscle (cut).   |
| 7. Trochlear surface of talus.               | 16. Long plantar ligament.   |
| 8. Medial malleolus.                         |  |
| 9. Deltoid ligament of the ankle.            |  |

dorsal surface of the neck of the talus. Therefore a transverse vertical cut through the dorsum of the foot, immediately in front of the tibia, will open the ankle joint (see Fig. 197). The very short posterior part of the capsule (O.T. posterior ligament) is attached to the margins of the articular surfaces.

The majority of the fibres of both the anterior and posterior parts of the fibrous stratum of the capsule run transversely.

**The Lateral Accessory Bands (O.T. External Lateral Ligament).**—The lateral accessory bands of the capsule of the ankle joint are three in number. (1) The **anterior talo-fibular ligament**; (2) the **posterior talo-fibular ligament**; (3) the **calcaneo-fibular ligament**.

The *anterior talo-fibular ligament* is the most anterior of the three. It is a flattened band which passes forwards from the anterior border of the lateral malleolus to the body of the talus immediately adjacent to the fibular facet.

The *posterior talo-fibular ligament* is the strongest and the most posterior of the three bands. It runs almost horizontally, from the deep pit posterior to the distal articular surface of the fibula to a prominent tubercle on the posterior surface of the talus.

This tubercle is termed the posterior process of the talus. Generally in the child, and sometimes in the adult, it is a separate piece of bone, attached to the talus by a layer of cartilage and the surrounding periosteum. In such cases it forms a supernumerary tarsal bone which represents the *os trigonum* found in some mammals. If this fact is not kept in mind a fracture of the talus may be diagnosed when the separate bone is seen in a radiograph of an injured ankle (Figs. 200, 201).

The *calcaneo-fibular ligament* is a round, cord-like band which passes from the distal end of the lateral malleolus to the lateral surface of the calcaneus.

**Ligamentum Deltoideum (O.T. Internal Lateral Lig.)**.—The deltoid ligament is an accessory band on the medial side of the joint. It is strong and of triangular form. Its apex is attached to a shallow pit on the distal end of the medial malleolus. Its fibres diverge from the apex, and are attached in a continuous line, from before backwards, to the navicular bone, the talus, sustentaculum tali of the calcaneus, and posterior to that to the talus again.

**Stratum Synoviale.**—The synovial layer lines the internal surface of the fibrous stratum of the capsule described above, and in some cases it sends a small process proximally between the tibia and fibula. It is thrown into a transverse fold anteriorly when the joint is flexed, and into a similar fold posteriorly when the joint is extended.

**Relations.**—Before the further examination of the joint is proceeded with, replace the tendons, vessels, and nerves

and note their relations to the anterior and posterior parts of the articular capsule. Anteriorly, from the medial to the lateral side lie the tibialis anterior, the flexor hallucis longus, the anterior tibial artery, the deep peroneal nerve, and the extensor digitorum longus with the peronæus tertius. The

anastomotic branch of the peroneal artery descends across the anterior talo-fibular ligament lateral to the peronæus tertius (Fig. 154). Behind the joint, from the medial to the lateral side, the structures in close relation with the capsule are, the tibialis posterior, the flexor digitorum longus, the posterior tibial artery, the tibial nerve, the flexor hallucis longus, and the terminal part of the peroneal artery. More posteriorly, separated from the flexor hallucis longus by a large pad of fat, is the tendo calcaneus with the tendon of the plantaris on its medial side. The tendons of the tibialis posterior and the flexor digi-

torum longus lie against the superficial surface of the deltoid ligament, and the tendons of the peronæus longus and brevis cross the lateral surface of the calcaneo-fibular ligament.

**Dissection.**—Cut through the anterior talo-fibular ligament, the calcaneo-fibular ligament, and the greater part of the deltoid

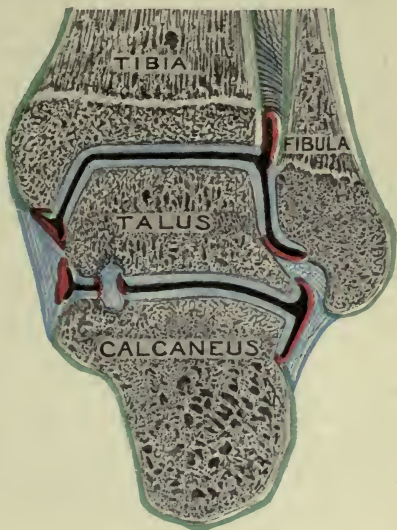


FIG. 196.—Frontal Section through the Ankle Joint, the Tibio-Fibular Syndesmosis, and the Talo-Calcaneal Joints. The deltoid ligament, on the medial side, and the posterior talo-fibular and the calcaneo-fibular ligaments, on the lateral side, are shown in the section. The strong interosseous talo-calcanean ligament is seen forming the lateral boundary of the joint between the head of the talus and the sustentaculum tali. The positions of the distal epiphyseal lines of the tibia and fibula should be observed.

Light blue = articular cartilage.

Striped blue = ligaments.

Green = periosteum.

Red = synovial membrane.

ligament, so that the articular surfaces can be separated and examined.

**The Articular Surfaces of the Ankle Joint.**—The proximal articular area is formed by the distal surface of the tibia, the lateral surface of the medial malleolus, and the medial surface of the lateral malleolus. The three surfaces together form the boundaries of a socket. It is important to note that the socket is wider in front than it is behind, and that it is concave both from side to side and from before backwards. The distal articular area is formed by the dorsal surface of the body of the talus and by parts of its medial and lateral surfaces. It also is broader in front than behind. It is generally convex both from before backwards and from side to side, and it fits into the socket formed by the bones of the leg. When the joint is dorsi-flexed, that is, when the toes are turned upwards, the broad part of the distal articular area rotates backwards into the narrow part of the proximal articular area and the joint becomes locked. When the joint is plantar-flexed, that is, when the toes are turned downwards, the narrow part of the distal articular area moves forwards into the wide part of the proximal articular area and a small amount of side to side movement becomes possible.

**Movements.**—The movements which take place at the ankle joint are—(1) dorsal-flexion (sometimes called flexion); (2) plantar-flexion (sometimes called extension); and (3) a very limited degree of lateral movement when plantar-flexion is complete. The two principal movements (dorsi-flexion and plantar-flexion) take place around a horizontal axis, which is not transverse, but which is directed laterally and posteriorly, so that it is inclined to the median plane of the body at an angle of about 60° (Krause). This horizontal axis passes through or near the interosseous canal between the calcaneus and talus (Henle). As the articular cavity formed by the tibia and fibula, and also the part of the talus which plays in it, are broader in front than behind, it follows that the more completely the ankle joint is dorsi-flexed, the more tightly will the talus be grasped between the two malleoli. In the erect position the talus is held firmly in the bony socket, and portions of its articular surface project both in front of and behind the tibia. The line of the centre of gravity falls anterior to the ankle joint, and as a result the bones are kept firmly locked. When, on the other hand, the ankle joint is fully plantar-flexed (as when we rise on tip-toe) the narrower posterior part of the talus is brought into the socket, and thus a limited amount of lateral movement is allowed. In *dorsi-flexion* the calcaneo-fibular and posterior talo-fibular bands, the greater part of the deltoid ligament, and the posterior part of the capsule are put on the stretch. In *plantar-flexion* the anterior talo-fibular ligament, the anterior fibres of the deltoid ligament, and the anterior part of the capsule are rendered tense.

The **Muscles** principally concerned in producing dorsi-flexion of the

foot at the ankle joint are the tibialis anterior, the extensor digitorum longus, the extensor hallucis longus and the peronæus tertius; those which operate as plantar-flexors are the superficial muscles of the calf, the tibialis posterior, the long flexors of the toes, and the peronæus longus and brevis.

### TIBIO-FIBULAR JOINTS.

The fibula articulates with the tibia by both its proximal and its distal extremity. The proximal of the two joints, the *articulatio tibiofibularis*, is a diarthrodial joint, possessing a cavity and a capsule with accessory thickenings. The distal joint is a syndesmosis, the *syndesmosis tibiofibularis*, but in some cases a prolongation of the cavity of the ankle joint projects between the distal ends of the tibia and fibula (Fig. 196). The interosseous membrane which occupies the interval between the bodies of the bones may be regarded as a ligament common to both joints.

**Dissection.**—Preparatory to the examination of the tibio-fibular joints the foot must be removed by dividing the remains of the ligaments on the medial and lateral aspects of the ankle joint. The muscles also must be detached from both aspects of the interosseous membrane and from the bones of the leg. The ligaments may now be defined.

**Membrana Interossea Cruris.**—The interosseous membrane is a strong membrane which stretches across the interval between the two bones of the leg, and greatly extends the surface for the origin of muscles. It is attached on the one hand to the interosseous border of the tibia, and on the other to the interosseous border of the fibula. It is composed of strong oblique fibres, which take a direction distally and laterally from the tibia to the fibula. In the proximal part of the membrane, immediately distal to the lateral condyle of the tibia, there is an oval opening for the passage of the anterior tibial vessels, whilst a small aperture, a short distance proximal to the ankle joint, marks the point where the membrane is pierced by the perforating branch of the peroneal artery.

**Articulatio Tibiofibularis (O.T. Superior Tibio-fibular Joint).**—At the tibio-fibular joint the bones are held in apposition by a capsule which is strengthened anteriorly and posteriorly. The fibres of the strengthening bands pass, distally and laterally, from the lateral condyle of the tibia to the head

of the fibula. The posterior band is the weaker of the two, and the tendon of the popliteus with its synovial investment rests upon its proximal part. The investment is a prolongation from the synovial layer of the knee joint, and in some cases it will be found to be directly continuous with the synovial layer of the capsule of the tibio-fibular joint.

The fibular collateral ligament of the knee joint and the tendon of the biceps femoris muscle have important relations

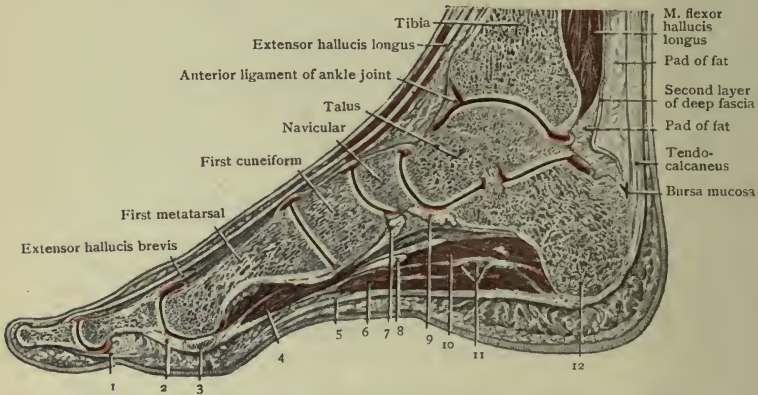


FIG. 197.—Oblique sagittal section through the Foot, along a plane extending from the centre of the heel behind to the centre of the great toe in front.

- |   |   |
|---|---|
| 1. Flexor hallucis longus.                          | 7. Tibialis posterior tendon.           |
| 2. Plantar accessory metatarso-phalangeal ligament. | 8. Flexor digitorum longus tendon.      |
| 3. Sesamoid bone.                                   | 9. Plantar calcaneo-navicular ligament. |
| 4. Flexor hallucis brevis.                          | 10. M. quadratus plantæ.                |
| 5. Plantar aponeurosis.                             | 11. Lateral plantar vessels and nerve.  |
| 6. M. flexor digitorum brevis.                      | 12. Calcaneus.                          |

to the joint. Both are attached to the head of the fibula, lateral to the joint, and some of the tendinous fibres of the biceps extend forwards to the lateral condyle of the tibia. Additional support is thus afforded to the proximal tibio-fibular joint.

**Syndesmosis Tibiofibularis (O.T. Inferior Tibio-fibular Joint)** (Figs. 193 and 196).—The distal tibio-fibular articulation is constructed upon a stronger plan than the proximal, because the strength of the ankle joint very largely depends upon its security. *In some cases* a very narrow strip of the

distal part of each of the opposing surfaces of the bones is articular and coated with cartilage continuous with the cartilage on the distal ends of the tibia and fibula where they take part in the formation of the ankle joint; *in other cases articular cartilage is entirely absent.* The surfaces of the proximal part of the syndesmosis are always rough, and are held together by an exceedingly strong *interosseous ligament.*

In addition to the important interosseous ligament three other ligaments are present:—

1. Lig. malleoli lateralis anterior (O.T. Ant. inf. tibio-fibular ligament).
2. Lig. malleoli lateralis posterior (O.T. Post. inf. tibio-fibular ligament).
3. Distal ligament of the lateral malleolus.

The *anterior* and *posterior ligaments* are flat strong bands which pass from the tibia to the fibula, in an oblique direction, laterally and distally.

The distal part of the posterior ligament forms a strong narrow band of yellowish fibres, which takes a transverse course on the back of the joint and is firmly attached to both tibia and fibula, filling up the interval between them. It constitutes a part of the tibio-fibular socket for the talus at the ankle joint (Figs. 192 and 193); and on the proximal aspect of the articular surface of the talus, the area over which it plays is usually easily distinguished. This portion of the posterior ligament is called the *distal ligament* of the lateral malleolus.

**Dissection.**—To see the interosseous ligament of the tibio-fibular syndesmosis the bones of the leg may be sawn through about two inches from the distal end of the tibia, and then divided with the saw proximo-distally in a vertical-transverse, or frontal direction. This cut should be planned so as to pass through the tibio-fibular syndesmosis. The short strong fibres of the interosseous ligament will then be seen, and also the short narrow articular interval between the distal portions of the opposing surfaces of the bones when that interval is present. If a cavity is present in the distal part of the joint the synovial layer of the capsule of the ankle joint is prolonged proximally over the inner surface of those parts of the ligaments of the tibio-fibular syndesmosis which help to form the boundaries of the cavity.

#### ARTICULATIONS OF THE FOOT.

The articulations of the foot are very numerous. They consist of:—

1. Articulationes intertarsæ, tarsometatarsæ, and intermetatarsæ.
2. Articulationes metatarso-phalangeæ.
3. Articulationes digitorum pedis.

The bones which enter into these articulations are the seven tarsal bones, the metatarsal bones, and the phalanges. The tarsal and metatarsal bones are bound together by interosseous, plantar, and dorsal ligaments, and are disposed in the form of two arches, viz., a longitudinal and a transverse. The integrity of these arches is maintained: (1) partly by the forms of the bones; (2) partly by the tension of the ligaments; (3) partly by supporting tendons; and (4) partly by the tension of the plantar aponeurosis.

The longitudinal arch presents a greater height and a wider span along the medial than along the lateral side of the foot. The talus lies at the summit of this arch and forms its keystone. The posterior pillar of the longitudinal plantar arch is short and solid, being formed by the calcaneus alone; the anterior pillar, much longer, is composed of several bones, viz., the navicular, the cuboid, the three cuneiforms, and the metatarsus. Further, the anterior pillar may be considered as being formed of a medial column composed of the navicular, the three cuneiform, and the medial three metatarsal bones, and a lateral column composed of the cuboid and the lateral two metatarsal bones. The weight of the body is transmitted to the summit of the arch through the talus, and the most important ligaments concerned in the prevention of excessive flattening of the arch lie in the plantar concavity; they are the *plantar calcaneo-navicular*, the *long plantar ligament*, the *plantar calcaneo-cuboid ligament*. The various slips of the *tendon of the tibialis posterior*, as they pass to find attachment to the different tarsal and metatarsal bones, give additional support. The *plantar aponeurosis* is also an important factor, for, as it extends between the two pillars and is attached to both, it operates, as the late Sir George Humphry once pointed out, in the same manner as the "tie-beam" of a roof. The transverse arch of the foot is seen to best advantage across the line of the tarso-metatarsal articulations.

**Dissection.**—The muscles and tendons which have hitherto been only partially detached from the bones of the foot should now be completely removed and the ligaments defined.

• **Taloid Articulations.**—The talus articulates by means of the large posterior facet on the plantar surface of its body



with the corresponding posterior facet on the dorsal surface of the calcaneus. Its head, on the other hand, is received into a large socket, which is formed for it by the sustentaculum tali of the calcaneus, the navicular, and two ligaments which pass between the calcaneus and the navicular—viz., one below, the plantar calcaneo-navicular, and another on the lateral side, the calcaneo-navicular part of the bifurcate ligament. The two taloid articulations are quite distinct.

The ligaments which hold the talus in its place are five in number. Four are attached to the calcaneus and one to the navicular bone. They are :—

1. Lig. talo-calcaneum interosseum.
2. Lig. talo-calcaneum laterale.
3. Lig. talo-calcaneum mediale.
4. Lig. talo-calcaneum posterius.
5. Lig. talo-naviculare [dorsale].

The *interosseous talo-calcanean ligament* is by far the most powerful. It occupies the tarsal canal, and consists of strong fibres attached distally to the groove between the articular facets on the dorsal surface of the calcaneus, and proximally to the corresponding groove on the plantar surface of the talus.

The *lateral ligament* is a short band of fibres which proceeds from the lateral surface of the talus to the lateral surface of the calcaneus. It is parallel with the calcaneo-fibular ligament of the ankle joint, but it is placed on a deeper plane, and lies somewhat more anteriorly.

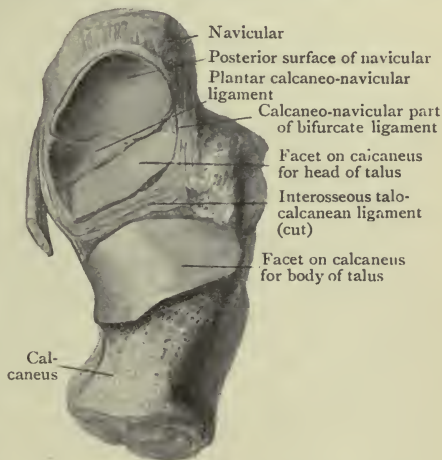


FIG. 198.—Talus removed so as to show the socket for its head.

The *medial talo-calcanean ligament* passes distally and

forwards, from the medial border of the groove on the talus for the flexor hallucis longus to the sustentaculum tali.

The *posterior talo-calcanean ligament* passes from the posterior border of the talus to the calcaneus. It closes the posterior talo-calcanean articulation behind.

The *dorsal talo-navicular ligament* extends, on the dorsum of the foot, from the head of the talus to the navicular bone. It is thin and membranous.

The medial and lateral parts of the capsule of the ankle joint also help to keep the talus in its place.

**Dissection.**—Divide the various ligaments which hold the talus in place, and remove the bone. When that has been done the different parts which form the socket for the head of the talus can be examined, and it will be obvious that the posterior talo-calcanean articulation is completely cut off from the anterior by the strong interosseous talo-calcanean ligament. The great strength of that ligament can now be appreciated, and the three facets on the head of the talus studied:—(1) a convex surface which looks forwards and articulates with the navicular; (2) an elongated facet on its plantar aspect (sometimes divided into two), which rests upon the sustentaculum tali; and (3) between 1 and 2, a triangular facet which corresponds with the dorsal surface of the plantar calcaneo-navicular ligament. In the recent state (and indeed usually also in the macerated condition of the bone) these three facets are very distinctly mapped off from each other by intervening ridges.

**Calcaneo-navicular Ligaments.**—Although the calcaneus does not directly articulate with the navicular bone, it is connected with it by two powerful ligaments, viz., a plantar calcaneo-navicular ligament and the calcaneo-navicular part of the bifurcate ligament.

The upper surface of the *plantar calcaneo-navicular ligament* (O.T. *inferior calcaneo-scaploid ligament*) is brought into view by the removal of the talus. It fills up the angular gap between the sustentaculum tali and the navicular bone, and enters into the formation of the socket for the head of the talus (Fig. 198). Its upper surface is smooth and covered with a synovial layer; its plantar surface is supported by the tendon of the tibialis posterior. This ligament has an important part to play in maintaining the integrity of the longitudinal arch of the foot. Posteriorly it is attached to the anterior border of the sustentaculum tali, whilst anteriorly it is fixed to the plantar surface of the navicular bone.

The *calcaneo-navicular part of the bifurcate ligament* (O.T.

*external calcaneo-scaphoid ligament*) also forms a part of the socket for the head of the talus. It is placed deeply in the anterior part of the depression between the calcaneus and the head of the talus, and is the medial part of the V-shaped *ligamentum bifurcatum*, which springs from the

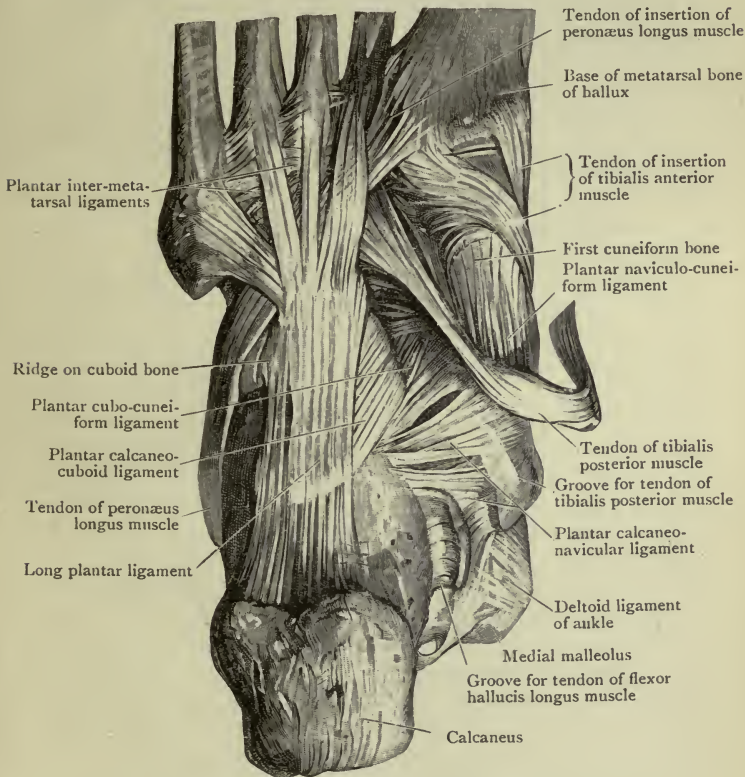


FIG. 199.—Plantar Aspect of Tarsal and Tarso-metatarsal Joints.

anterior part of the upper surface of the calcaneus and immediately divides into a medial or navicular part and a lateral or cuboid portion. The calcaneo-navicular part is continuous below and medially with the plantar calcaneo-navicular ligament, and dorsally with the talo-navicular ligament.

**Calcaneo-cuboid Articulation.**—In the calcaneo-cuboid joint the concavo-convex surface on the anterior aspect of the calcaneus articulates with the corresponding surface on the posterior aspect of the os cuboideum. It is a distinct joint, that is, its cavity does not communicate with the cavities of neighbouring joints. The *ligaments* which bind the two bones together are :—

1. Capsula articularis.
2. Ligamentum calcaneo-cuboideum plantare.
3. Ligamentum plantare longum.

The *capsule* completely surrounds the joint and its dorsal and medial parts, which are somewhat thickened, are sometimes called the dorsal and medial ligaments of the joint. The medial ligament is the calcaneo-cuboid part of the lig. bifurcatum mentioned above.

The *long plantar ligament* springs from the plantar surface of the calcaneus, immediately anterior to the tuber calcanei. It extends forwards to the plantar surface of the cuboid bone where it broadens out and is, for the most part, attached to the tuberosity of that bone. Numerous strong fibres, however, are prolonged forwards, across the tendon of the peronæus longus, to gain attachment to the bases of the second, third, and fourth metatarsal bones. The long plantar ligament, therefore, extends over the greater part of the plantar aspect of the lateral portion of the tarsus, and is the longest of the tarsal ligaments. Further, it forms the greater part of the sheath of the tendon of the peronæus longus.

The *plantar calcaneo-cuboid ligament* (O.T. *short plantar ligament*) is placed under cover of the long plantar ligament. Slip the knife between them and carry the cutting edge backwards so as to detach the long plantar ligament from the plantar surface of the calcaneus. When the detached band is thrown forwards the plantar calcaneo-cuboid ligament comes into view, and little dissection is required to make its connections apparent. It is composed of short, strong fibres, not more than an inch in length. They spring from the small tubercle on the anterior part of the plantar surface of the calcaneus, and are attached, anteriorly, to the plantar surface of the cuboid, posterior to its tuberosity. The ligament is broader than the long plantar ligament and could be seen at the medial border of the latter before it was reflected.

In the maintenance of the longitudinal arch of the foot,

the long plantar ligament and the plantar calcaneo-cuboid ligament have an importance which is surpassed only by that of the plantar calcaneo-navicular ligament.

The joint between the talus and the navicular and that between the calcaneus and the cuboid are frequently referred to together as the *transverse tarsal joint*. It is there that some parts of the movements of eversion and inversion of the foot take place. It should be noted that all the ligaments which connect together the anterior and the posterior segments of the tarsus at this joint, except one, are attached posteriorly to the calcaneus. They are :—

Plantar calcaneo-navicular,	}	Attached to the calcaneus.
Bifurcate,		
Long plantar,		
Plantar calcaneo-cuboid,		
Calcaneo-cuboid capsule,		
Dorsal talo-navicular,	}	Attached to the talus.

**Inter-cuneiform Articulations.**—The three cuneiform bones are held together so firmly that very little individual movement is permitted. The chief uniting structures are *two* strong *interosseous ligaments* which pass between the non-articular portions of their opposed surfaces. These can be seen only when the bones are separated from each other. *Dorsal inter-cuneiform ligaments* also are present. These are short, flat, transversely-placed bands.

**Cuneo-navicular Articulation.**—The three cuneiform bones articulate with the anterior surface of the navicular. They are held in position by *dorsal ligaments*, which pass from the dorsal surface of the navicular to the dorsal surface of each of the cuneiform bones, and by *plantar ligaments*, which are similarly disposed. The strength of the plantar ligaments is greater than that of the dorsal ligaments, and they are reinforced very largely by slips from the tendon of the tibialis posterior.

**Dissection.**—The dissector may now divide freely all the dorsal and the most medial of the plantar cuneo-navicular ligaments. The navicular bone can then be drawn backwards so as to expose the interior of the joint. The knife may also be carried round the lateral side of the lateral calcaneo-navicular ligament. A much better view of this ligament is thus obtained, although this dissection entails the division of the dorsal cubo-navicular ligament.

The convex anterior articular surface of the navicular fits into a transversely concave socket, which is formed for it by the posterior surfaces of the three cuneiform bones, and, often,

by a small facet on the medial surface of the cuboid as well. The articular surface of the navicular is divided by prominent ridges into areas or facets corresponding with the different parts of the socket in which it lies. The *synovial stratum*, which lines this joint, is prolonged forwards into the intercuneiform joints.

**Cubo-navicular and Cubo-cuneiform Articulations.**—It has been noted that the anterior pillar of the longitudinal arch of the foot consists of a lateral and a medial column. The tarsal portions of these are connected together by the cubo-navicular and the cubo-cuneiform articulations.

It is only occasionally that the navicular touches and articulates directly with the medial surface of the cuboid. When it does so, the facet on the cuboid lies in series with the articular surfaces on the posterior ends of the cuneiform bones, and forms with them the socket for the anterior surface of the navicular. The *ligaments* which bind the navicular to the cuboid are disposed transversely, and consist of—(1) a series of short strong *interosseous* fibres which bind the opposed surfaces together; (2) a dorsal band; and (3) a plantar band.

The dorsal band has previously been divided in exposing the interior of the cuneo-navicular joint and in defining the lateral calcaneo-navicular ligament, but the interosseous and plantar ligaments may be readily displayed.

The cuboid, by an oval facet on its medial surface, articulates with the third cuneiform bone, forming thereby the *cubo-cuneiform joint*. The two bones are bound together by *interosseous*, *dorsal*, and *plantar ligaments*. By dividing the dorsal ligament and insinuating the knife between the two bones the interosseous ligament may be detected. It is the strongest of the three ligaments.

The *synovial layer* which lines the cuneo-navicular articulation is prolonged into the cubo-cuneiform joint and also into the naviculo-cuboid joint, when that exists.

**Tarso-metatarsal Articulations.**—The bases of the five metatarsal bones articulate with the three cuneiform bones and the cuboid bone, and are very firmly attached to them by dorsal, plantar, and interosseous ligaments. It is particularly important to note that the line of articulation is irregular, and that the base of the second metatarsal bone is wedged between the first and third cuneiform bones.

The *dorsal ligaments* are flat, distinct bands which can readily be defined by the careful dissector. *One* such ligament passes to the base of the first metatarsal from the first cuneiform; *three*, one from each of the cuneiform bones, proceed to the base of the second metatarsal; *one* extends from the third cuneiform to the base of the third metatarsal; *two*, of which one proceeds from the third cuneiform and the other from the cuboid, go to the base of the fourth metatarsal; and *one* passes from the cuboid to the base of the fifth metatarsal.

The *plantar ligaments* are not so regularly disposed. Those in connection with the first and second metatarsal bones are very strong. Some of the bands have an oblique direction, and those which go to the bases of the second, third, and fourth metatarsal bones are more or less connected with the sheath of the tendon of the peronæus longus, and therefore with the long plantar ligament.

To bring the *interosseous ligaments* into view, divide freely the dorsal ligaments, and then forcibly bend the metatarsus plantarwards upon the tarsus. The interosseous ligaments will resist this proceeding, and on looking into the joints the dissector will see them stretched and tense. If the force is continued they will rupture. The interosseous ligaments are three in number, viz., a medial, an intermediate, and a lateral.

The *medial interosseous ligament* is an exceedingly strong band, which passes laterally from the anterior part of the lateral surface of the first cuneiform bone to the adjacent surface of the base of the second metatarsal bone. The *intermediate interosseous ligament* is small. It passes between the anterior part of the medial surface of the third cuneiform and the adjacent surface of the base of the second metatarsal. The *lateral interosseous ligament* passes from the lateral surface of the third cuneiform bone to the medial side of the base of the fourth metatarsal. One interosseous ligament, therefore, passes from the first cuneiform bone and two from the third cuneiform; and of these, two are attached to the base of the second, and the third to the base of the fourth metatarsal bone.

**Tarso-metatarsal Articular Surfaces.**—The manner in which the metatarsus is implanted upon the tarsus should now be examined. The *first metatarsal* rests against the first cuneiform, and this joint possesses a separate synovial

cavity. The *second metatarsal* rests against the second cuneiform, but its base is grasped by the projecting anterior ends of the first and third cuneiform bones, with both of which it articulates, and with both of which it is connected by interosseous ligaments. It is not surprising, therefore, that this metatarsal should possess so little power of independent movement, and present a difficulty to the surgeon when he is called upon to amputate the anterior part of the foot through the tarso-metatarsal articulation. The *third metatarsal* rests against the third cuneiform. The *synovial layer* which lines the joints between the tarsus and the second and third metatarsal bones is continuous with that which is present between the first and second cuneiform bones, and through that with the synovial layer of the cuneo-navicular articulation. The bases of the *fourth* and *fifth metatarsal bones* are supported by the cuboid, but that of the fourth, by its medial margin, articulates also with the third cuneiform. The joint formed between the lateral two metatarsal bones and the tarsus has a capsule and a cavity separate from that of the adjacent joints.

**Intermetatarsal Joints.**—The bases of adjacent metatarsal bones, with the exception of the first, articulate with each other, and are very firmly bound together.

The ligaments which connect the bases of the four lateral metatarsal bones are *dorsal*, *plantar*, and *interosseous*. They are strong bands which pass between the non-articular portions of the basal parts of the bones, and they constitute the chief bonds of union.

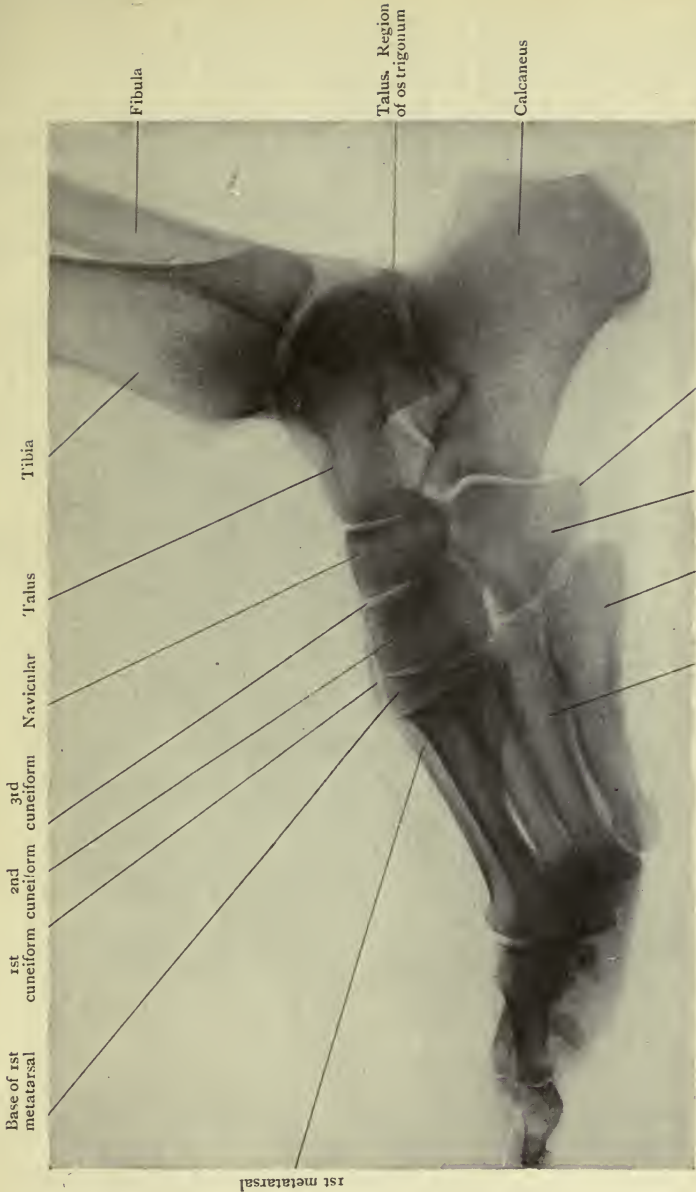
**Dissection.**—To bring the interosseous ligaments into view divide the dorsal ligaments and then forcibly separate the bases of the bones from one another.

In addition to the ligaments which connect the basal ends of the metatarsal bones, the strong *transverse metatarsal ligament* of the heads of the metatarsal bones unites the distal extremities of the bones together. That ligament has been previously described (p. 399).

**Joint Cavities of the Foot.**—There are six separate joint cavities in connection with the tarsal, tarso-metatarsal, and intermetatarsal articulations, viz.—(1) The cavity between the posterior facets of the talus and calcaneus. (2) The calcaneo-cuboid joint cavity. (3) The cavity of the



PLATE XLIV



4th metatarsal 5th metatarsal Cuboid Sesamoid bone in the tendon of the peroneus longus

FIG. 200. — Radiograph of the Foot of an adult.

PLATE XLV



Fourth metatarsal    Fifth metatarsal    Cuboid  
 Fig. 201.—Radiograph of the Foot of a Child 11 years old.

PLATE XLVI

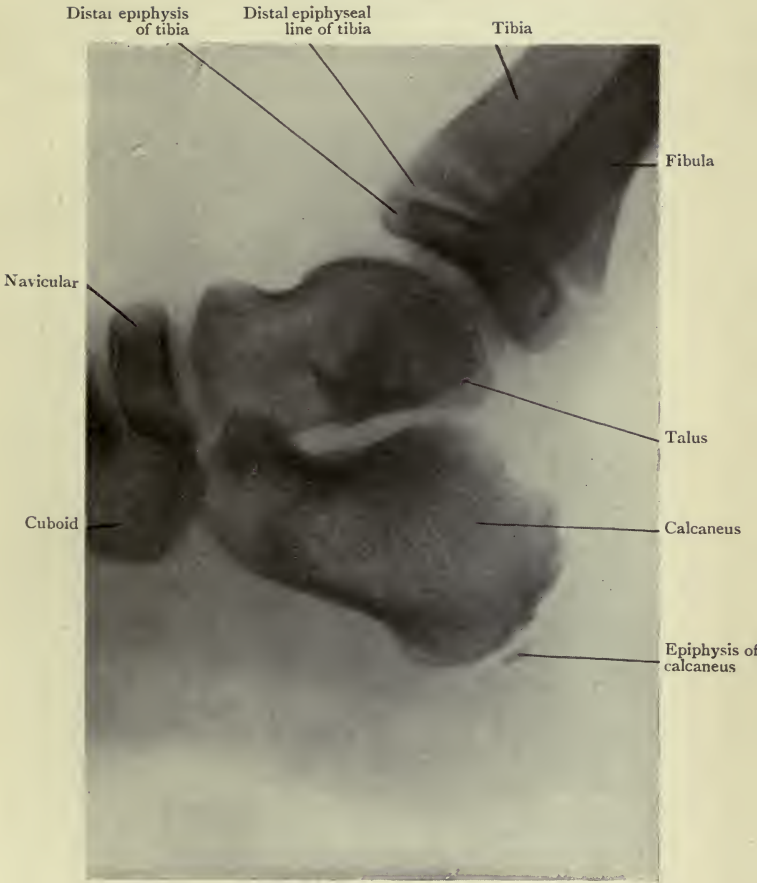

FIG. 202.—Radiograph of the Foot of a Child 6 years old.

Note (1). That the ossification of the epiphysis of the calcaneus has just commenced and that there is no indication of the os trigonum (see Fig. 201).

(2) That the distal epiphyseal line of the fibula runs parallel with the upper border of the talus.

PLATE XLVII

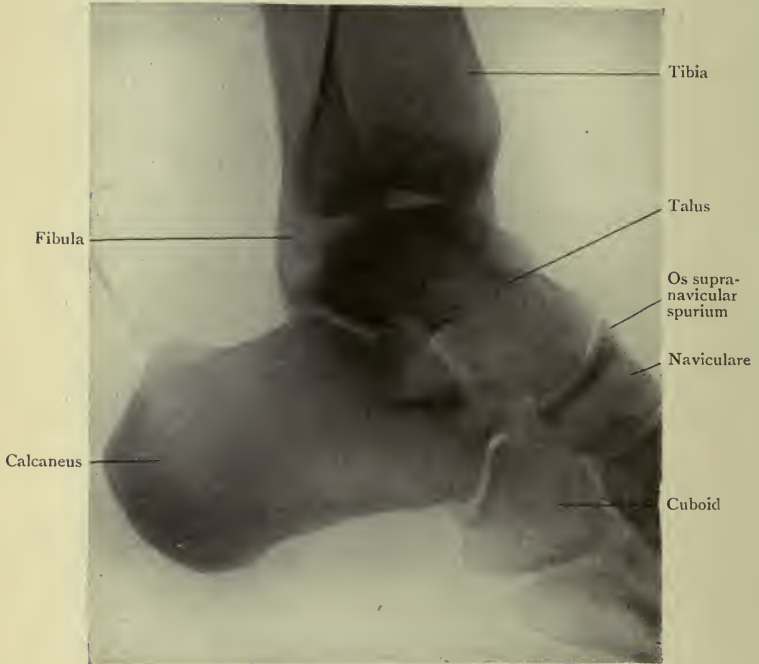


FIG. 203.—Radiograph of the Foot of an Adult showing an occasional variation.

(Major A. W. Pirie.)

joint formed by the head of the talus, the navicular, the sustentaculum tali, the plantar calcaneo-navicular ligament, the navicular part of the bifurcate ligament and talo-navicular ligament. (4) The cavity of the naviculo-cuneiform articulation, which is prolonged forwards between the cuneiforms, and also between the cuboid and third cuneiform bones; that cavity extends beyond the tarsus, and is continuous with the cavity between the second and third metatarsal bones and the tarsus, as well as with the cavities of the joints between the bases of the second, third, and fourth metatarsal bones.<sup>1</sup> (5) A separate cavity lies between the first metatarsal and the first cuneiform. (6) A distinct cavity for the articulations between the cuboid and the lateral two metatarsal bones; this is prolonged distally into the joint between the bases of these two metatarsals.

**Metatarso-phalangeal and Interphalangeal Joints.**—The metatarso-phalangeal and interphalangeal joints of the foot are constructed on a plan which is practically identical with that met with in the cases of the corresponding joints of the hand. In the cases of the metatarso-phalangeal joints the slightly cupped bases of the first phalanges articulate with the rounded heads of the metatarsal bones. The joints so formed are of the condyloid variety and allow flexion, extension, abduction, adduction, and circumduction. The interphalangeal joints, on the other hand, are hinge joints, which permit only flexion and extension. In them there are two cup-shaped depressions at the proximal end of the distal bone, which fit against the condyles of the trochlear surface of the distal end of the proximal bone. In both the metatarso-phalangeal joints and the interphalangeal joints the articular surfaces on the distal bones of the joints are limited, strictly, to the proximal ends of the bones, but the articular surfaces on the distal ends of the proximal bones are more extensive and are prolonged for a considerable distance on the plantar surface of the distal end of each bone. The result of this arrangement is that when the joints are extended a considerable part of the convex articular surface of the proximal bone rests upon the plantar accessory ligament of the joint capsule,

<sup>1</sup> The lateral interosseous tarso-metatarsal ligament, which passes from the third cuneiform bone (frequently from the cuboid bone) to the base of the fourth metatarsal bone, separates the cavity between the fourth and fifth metatarsal bones and the cuboid from the general tarsal articular cavity.

or, in the cases of the metatarso-phalangeal joint of the great toe, and occasionally of some of the other toes also, upon the sesamoid bones developed in the plantar accessory ligament (Fig. 197). When the joints are flexed the proximal end of the distal bone moves to the plantar aspect of the distal end of the proximal bone, and the extremities of the distal bones are then covered only by the extensor tendons and the skin. When the joints are flexed, therefore, they are easily opened from the dorsal aspects by cutting transversely directly against the heads of the proximal bones. The dissector should open one or more joints in that manner.

Each joint possesses the following ligaments :

Capsula articularis,  
Ligamenta collateralia,  
Ligamentum accessorium plantare.

**Capsula Articularis.**—The fibrous stratum of the articular capsule is deficient dorsally, and there the extensor tendons lie in direct relation with the synovial stratum which lines the interior of the fibrous stratum. At the sides the fibrous stratum is blended with the collateral ligaments, and on the plantar aspect with the plantar accessory ligament.

**Ligamenta Accessoria Plantaria.**—Each plantar accessory ligament is a dense fibrous plate which is firmly attached to the plantar aspect of the base of the distal bone of the joint, whilst it is loosely attached to the plantar aspect of the neck of the proximal bone of the joint. The collateral ligaments and the flexor sheath are fixed to its margins, and the transverse ligament of the heads of the metatarsal bones is attached to the plantar accessory ligaments of the metacarpo-phalangeal joints. The plantar accessory ligaments always move with the distal bones.

**Ligamenta Collateralia.**—The collateral ligaments are strong, thick triangular bands placed one on each side of each joint. The apex of the band is attached to the tubercle and the depression on the corresponding side of the head of the proximal bone of the joint, and the expanded base is attached to the side of the base of the distal bone and to the corresponding margin of the plantar accessory ligament.

**Movements.**—It has already been pointed out that at the *interphalangeal joints*, which are *hinge joints*, only the movements of flexion and extension are permitted, whilst the

*metatarso-phalangeal joints*, which are *condyloid joints*, permit also abduction, adduction, and circumduction. At all the joints the movements of extension are produced by the extensors of the toes, but extension of the interphalangeal joints of the lateral four toes is produced also by the action of the lumbrical and interossei muscles, which act by means of their attachments to the extensor expansions. Flexion of the terminal interphalangeal joints of the lateral four is produced by the flexor digitorum longus; flexion of the first interphalangeal joint by the short flexor of the toes, aided by the long flexor of the toes. In flexion of the metatarso-phalangeal joints the long and short flexors play a part, but they are aided by the lumbrical and interossei muscles, and in the case of the little toe by the flexor digiti quinti brevis.

Flexion and extension of the interphalangeal joint of the great toe are produced by the long flexor and extensor respectively, and flexion and extension of the metatarso-phalangeal joint by the short flexor and extensor, aided by the long flexor and extensor. The dissector should remember that the lumbrical and interossei are flexors of the metatarso-phalangeal joints and extensors of the interphalangeal joints.

Abduction and adduction of the toes at the metatarso-phalangeal joints are produced by the interossei and the special abductors and adductors. The movements take place from and towards a line drawn longitudinally along the middle of the second toe. The lateral three toes are adducted by the plantar interossei, the great toe by the oblique and transverse adductors. The great toe and the little have each a special abductor muscle. The second toe is alternately abducted and adducted away from or towards its own middle line by the first and second dorsal interosseous muscles. The third toe is abducted by the third, and the fourth toe by the fourth dorsal interosseous muscle.





## INDEX.

---

Acromion, 2, 8, 49  
**Anastomosis** around ankle, 380,  
 419  
   of back of thigh, 324  
   crucial, 296, 301  
   around elbow, 188  
   around knee, 403  
   around scapula, 90  
**Antibrachium**, 1  
**Aponeurosis**, palmar, 70, 73, 152,  
 154  
   plantar, 383, 428  
**Arch**, carpal, dorsal, 192  
   volar, 132  
   coraco-acromial, 84  
   femoral, deep, 239  
   superficial, 239  
   of foot, 428, 432, 434  
   plantar arterial, 386, 397  
   pubic, 214  
   *venous*, dorsal digital, 63  
     dorsal, of foot, 335, 336  
     of hand, 63  
   volar, deep, 167, 171  
     superficial, 155, 171  
**Areola mammæ**, 15  
   in male, 17  
**Armpit**, 1, 3, 7, 8, 16, 21  
**Arteries**—  
   arcuate, 350  
   axillary, 25, 26, 31, 65, 94  
   brachial, 94, 100, 101, 110  
   calcanean, lateral, 373  
     medial, 375, 383, 389  
   carotid, common, 39  
   *carpal*, radial, dorsal, 192  
     volar, 132  
   ulnar, dorsal, 144  
     volar, 144  
   cervical, transverse, 41, 58

### **Arteries** (*contd.*)—

  cervical, transverse, ascending  
     branch of, 58, 85  
     descending branch of, 58, 60,  
     61, 90  
   *circumflex*, femoral, lateral, 246,  
     260, 268, 402  
     medial, 246, 247, 268, 271,  
     293, 295, 300  
   humeral, anterior, 28, 36, 78,  
     82  
     posterior, 28, 36, 77, 82  
   iliac, superficial, 225, 227  
   scapular, 28, 36, 91  
   coccygeal, 288, 296  
   collateral, ulnar, inferior, 101,  
     105, 188  
     superior, 101, 104, 188  
   comitans nervi ischiadici, 296  
   communicating, volar, 144  
   digital, of foot, 350, 388, 398  
     of hand, 70, 156  
   dorsalis indicis, 192  
     pedis, 344, 349, 397  
     pollicis, 192  
   epigastric, superficial, 225, 227  
   femoral, 246, 247, 253, 272  
     branches of, 272  
   genicular, 311, 317, 357, 402  
   genu suprema, 250, 251, 255, 402  
   gluteal, inferior, 287, 292, 295,  
     296  
     superior, 287, 292, 295, 302  
   of hip-joint, 250, 260, 272, 277,  
     303, 328, 331  
   iliac, circumflex, superficial, 225,  
     227  
   infrascapular, 91  
   inguinal, superficial, 227  
   innominate, 39

**Arteries (contd.)—**

- intercostal, 17
- interosseous*, common, 142, 143
  - dorsal, 143, 185
  - recurrent, 185, 188
  - volar, 144, 148, 182, 188, 191
- malleolar, 348, 419
- mammary, external, 17, 35
  - internal, 12, 14, 17
- median, 144, 147
- metacarpal, dorsal, 192
  - volar, 67
- metatarsal, dorsal, 350
  - plantar, 397, 398
- musculo-articular, 255
- nutrient*, of femur, 269
  - of fibula, 373
  - of humerus, 101, 104
  - of radius, 144
  - of scapula, 90
  - of tibia, 375
  - of ulna, 144
- obturator, 277
  - abnormal, 244
- perforating*, of foot, 397, 398
  - of hand, 167, 192
  - of internal mammary, 13, 14, 17
  - of peroneal, 344, 350, 373, 419
  - of profunda femoris, 267, 268, 293, 295, 323
- peroneal, 371, 373, 419
- plantar, lateral, 385, 388
  - medial, 385, 388
- popliteal, 305, 307, 311, 315, 371, 372
- princeps pollicis, 70, 170, 171
- profunda brachii, 98, 101, 104, 111, 117, 188
  - femoris, 246, 247, 267
- pubdental, external, deep, 246, 248
  - superficial, 225, 227
  - internal, 293, 295, 298
- to quadratus femoris, 296
- radial, 110, 130, 170, 191
  - recurrent, 131, 188
- radialis indicis volaris, 70, 170, 171
- recurrent*, of elbow, 111
  - interosseous, 185, 188
  - radial, 131, 188
  - tibial, anterior, 348, 403
    - posterior, 372, 403
  - ulnar, dorsal, 143, 188
  - volar, 143, 188

**Arteries, recurrent (contd.)—**

- of volar arch, 167
- saphenous, 250, 251, 255, 309
- scapular, circumflex, 28, 36, 91
  - transverse, 13, 41, 59, 90
- subclavian, 39
- subscapular, 28, 36
  - of transverse scapular, 90
- sural, 316
- tarsal, lateral, 350
  - medial, 350
- thoracalis suprema, 35
- thoracic, alar, 36
  - lateral, 17, 28, 35, 36
- thoraco-acromial, 13, 19, 23, 25, 35
- thoraco-dorsal, 28, 36, 61, 91
- tibial, anterior, 344, 347, 371, 372
  - posterior, 371, 372
- transverse cervical, 41, 58
  - ascending branch of, 58, 85
  - descending branch of, 58, 60, 61, 90
- scapular, 13, 41, 59, 90
- ulnar, 73, 110, 129, 142, 152
  - deep branch of, 156
- ulnar collateral, inferior, 101, 105, 188
  - superior, 101, 104, 188
- volar, superficial, 132
- volaris indicis radialis, 70, 170, 171

**Articulations. See Joints**

Axilla, 1, 3, 7, 8, 16, 21

Bodies, Pacinian, 71, 159

Brachium, 1

Breast, 14

Breast-bone, 2, 8

**Bursæ—**

- biceps brachii, 107
- coraco-clavicular, 92
- gastrocnemius, 309, 368, 370, 409
- gluteus maximus, 287, 291, 293
  - medius, 302
  - minimus, 303
- gracilis, 276, 322, 357, 408
- ilio-psoas, 278, 328
- infra-patellar, 236, 411
- infraspinatus, 89
- latissimus dorsi, 87
- obturator internus, 293
- olecranon, 95
- patellar, 235

**Bursæ (contd.)—**

- pectoralis major, 24
- pre-patellar, 235, 236
- sartorius, 252, 322, 357, 408
- semimembranosus, 309, 368, 409
- semitendinosus, 322, 357, 408
- subacromial, 78, 81, 84
- subscapular, 88, 123
- supra-patellar, 236, 410
- tendo calcaneus, 371
- trapezius, 55, 58
- triceps brachii, 118

Calcaneus, 216, 333, 334

**Canal**, adductor, 247, 250, 252

cervico-axillary, 23

femoral, 242

Carpal bones, 2, 4

Cartilage, costal, second, 8  
seventh, 8

Chorda obliqua, 204

Cisterna chyli, 363

Clavicle, 1, 2, 7, 8

Cleft, natal, 279

Coccyx, 49

Condyles of femur, 215, 305

of tibia, 215, 305

Cord, spermatic, 226

spinal, 5, 217

Corpuscles, Pacinian, 71, 159

**Crest** of ilium, 49, 213, 279

of pubis, 213

of scapula, 2

Cuboid bone, 216, 333

Cuneiform bones, 216, 333

Disc, articular, of wrist, 203

**Dissections of upper limb—**

arm, front, 98, 100, 106, 108, 111

back, 112, 115, 117

articular disc of wrist, 205

axilla, 23, 25, 26, 47

back of trunk, 50, 51, 53, 55, 57,  
58, 60, 61

brachial plexus, 38

carpo-metacarpal joints, 208, 209,  
210

coraco-acromial arch, 84

coraco-clavicular ligament, 92

costo-coracoid membrane, 25

cubital fossa, 111

delto-pectoral triangle, 19

dorsal carpal ligament, 173

elbow joint, 194

extensor sheaths, 174

fingers, 162

**Dissections of upper limb (contd.)—**

flexor sheaths, 132, 160, 162

forearm, back, 173, 174, 176,  
181, 188, 191

front, 129, 130, 138, 142, 148

hand, back, 177

hypothernar eminence, 152

interosseous membrane, 202

muscles, 193

mammary gland, 18

metacarpo-phalangeal joints, 211

palm, 152, 153, 155, 160, 165,  
166, 169, 170, 193

palmar aponeurosis, 153

pectoral region, 9, 12, 19

removal of limb, 61

scapular anastomosis, 90

region, 77, 84, 85, 87, 88, 90,  
92

shoulder joint, 121, 125

sterno-clavicular joint, 37, 38

subscapular bursa, 87

superficial structures, 62, 69

thenar eminence, 160

wrist joint, 198, 199

**Dissections of lower limb—**

ankle joint, 419, 420, 423

arteries around knee, 402

articularis genu, 265

extensor sheaths, 340

fascia lata, 233

femoral sheath, 238, 242

triangle, 245

flexor sheaths, 379

foot, dorsum, 334, 335, 338, 344

sole, 381, 384, 385, 387, 391,

392, 394, 395, 397, 399, 401

gluteal region, 280, 283, 284,

287, 292, 300, 301, 302, 303,

325

hip joint, 329

ilio-psoas bursa, 278

joints of foot, 428, 430, 433, 436

knee joint, 402, 405, 410, 411,

414, 416, 417

lateral intermuscular septum, 261

leg, back, 358, 366, 367, 370, 371

front, 334, 335, 338, 340, 344

obturator artery, 277

nerve, 272

peroneal region, 354

popliteal fossa, 306, 308

profunda femoris artery, 267

quadratus femoris, 300

removal of limb, 332

thigh, back, 318, 319, 323, 325

- Dissections of lower limb** (*contd.*)—  
 thigh, front, 221, 224, 233, 238,  
 242, 245, 248, 261, 278  
 medial side, 267, 271, 272, 277  
 superficial structures, 221, 224  
 tibial region, 357  
 tibio-fibular joints, 425, 427
- Duct**, lactiferous, 17, 18  
 lymphatic, right, 67, 68, 361  
 thoracic, 67, 68, 361, 363
- Eminence**, hypothenar, 149  
 thenar, 149
- Epicondyles of femur**, 215  
 of humerus, 3, 94
- Extensor expansion of fingers**, 178  
 of toes, 346
- Fascia**, *deep*, 11, 222  
 of arm, 98  
 axillary, 18  
 of buttock, 284  
 of calf, 366  
 clavi-pectoral, 24  
 cribriform, 225, 226, 229,  
 234, 243  
 of foot, dorsum, 339  
 sole, 383  
 of forearm, 128, 173  
 of hand, dorsum, 174, 177  
 palm, 154  
 iliaca, 238, 240, 241, 243  
 infraspinatus, 75  
 lata, 233, 319  
 iliac part of, 229, 234, 238,  
 248  
 pectineal part of, 229, 234  
 of leg, 338, 366  
 lumbo-dorsal, 51, 55  
 pectinea, 229, 234  
 of pectoral region, 18  
 popliteal, 307  
 of shoulder, 75  
 subscapular, 85  
 of thigh, 233, 319  
 transversalis, 240, 241, 243  
 of upper limb, 72  
*superficial*, 11, 222  
 of arm, 62  
 of back, 50  
 of buttock, 281  
 of foot, dorsum, 334  
 sole, 223, 381  
 of forearm, 62  
 of hand, dorsum, 62  
 palm, 62, 70, 223
- Fascia**, *superficial* (*contd.*)—  
 of leg, back, 358  
 front, 334  
 of lower limb, 222  
 of pectoral region, 11  
 of thigh, 223, 318  
 of Colles, 224  
 of Scarpa, 224
- Femur**, 214
- Fibula**, 215, 216, 305, 332
- Flexor sheaths of fingers**, 133, 134,  
 160, 162  
 of toes, 379, 392
- Fold**, alar, 410  
 of axilla, 8, 21, 22, 57  
 gluteal. *See* **Sulcus**  
 synovial, patellar, 410
- Follicles**, hair, 11, 222
- Foramen**, sciatic, greater, 290, 291  
 lesser, 290, 291, 292
- Fossa**, cubital, 108  
 infrasternal, 8  
 ischio-rectal, 290  
 ovalis of thigh, 225, 226, 229,  
 243  
 popliteal, 304
- Funiculus spermaticus**, 226
- Furrow**, iliac, 279
- Ganglia**, spinal, 5, 218
- Girdle**, shoulder, 1
- Glands**, **lymph**, 11  
 axillary, 26, 28, 29, 67  
 brachial, 67  
 cubital, 63, 67, 68  
 delto-pectoral, 19, 67  
 hypogastric, 363  
 iliac, common, 363  
 infraclavicular, 68  
 of lower limb, 361  
 lumbar, 363  
 popliteal, 308, 363  
 subinguinal, 225, 226, 228,  
 360, 363  
 tibial, anterior, 363  
 of upper limb, 66
- Glands**, **mammary**, 11, 14  
 sebaceous, 11, 222  
 sweat, 11, 222
- Groove**, inguinal, 213
- Hair follicles**, 11, 222
- Ham**, 304
- Hamate bone**, 152
- Hernia**, femoral, 243

Hernia, lumbar, 57  
 Hiatus tendineus, 253  
 Hip, 213  
 Humerus, 2, 3, 8, 23  
 Hypothenar, 149  
 Ilium, 49, 213, 279  
 Ischium, 213  
**Joints—**  
 acromio-clavicular, 2, 8, 93  
 ankle, 418  
   arteries of, 380, 419  
   nerves of, 352, 376  
 carpal, 205  
   cavities in, 206, 209  
 carpo-metacarpal, 209  
 cubo-cuneiform, 434  
 cubo-navicular, 434  
 cuneo-navicular, 433  
 elbow, 195  
   arteries of, 188  
   nerves of, 115, 146, 198  
 of foot, 427  
   cavities in, 436  
 of hand, 205  
   cavities in, 206, 209  
 hip, 250, 259, 273, 299, 300, 303,  
   325  
   arteries of, 250, 260, 272, 277,  
   303, 328, 331  
   nerves of, 256, 258, 274, 300,  
   331  
 intercarpal, 206  
 intercuneiform, 433  
 intermetacarpal, 208  
 intermetatarsal, 436  
 interphalangeal, of foot, 437  
   of hand, 152, 211  
 intertarsal, 428  
 knee, 402  
   arteries of, 403  
   movements, 412  
   nerves of, 258, 275, 310, 313,  
   315, 318, 357, 402, 405  
   synovial membrane, 410  
 metacarpo-phalangeal, 151, 211  
 metatarso-phalangeal, 437  
 phalangeal, of foot, 437  
   of hand, 152, 211  
 pisiform, 205  
 radio-carpal, 199  
 radio-ulnar, 201  
 shoulder, 119  
   arteries of, 36, 82  
   nerves of, 78, 84, 92

**Joints (contd.)—**  
 sterno-clavicular, 8, 37  
 of talus, 428  
 tarsal, 428  
   cavities in, 436  
   transverse, 433  
 tarso-metatarsal, 434  
 tibio-fibular, 425  
 wrist, 199  
   nerves of, 182, 201, 208

Knuckles, 4, 152

Labrum glenoidale of hip joint, 329  
 of shoulder joint, 125

Lacertus fibrosus, 66, 72, 98, 107,  
 128

**Ligaments—**

accessory, plantar, 438  
   volar, 211  
 acromio-clavicular, 93  
 of ankle, 420  
 annular, of fingers, 162  
   of radius, 196, 202  
 bifurcatum, 430  
 calcaneo-cuboid, 428, 431, 432  
 calcaneo-fibular, 422  
 calcaneo-navicular, 428, 430  
 capitulum transversum of meta-  
   carpals, 192  
   of metatarsals, 399  
*carpal*, dorsal, 72, 74, 129, 173,  
   189  
   transverse, 72, 73, 129, 161  
   volar, 73, 129, 162  
 carpi radiatum, 207  
 of carpus, 205  
 cervical, of hip joint, 331  
*collateral*, of elbow, 196  
   of fingers, 211  
   of knee, fibular, 305, 403, 407,  
   426  
   tibial, 403, 408  
   of toes, 438  
   of wrist, 199  
 conoid, 92  
 of Cooper, 11, 17  
 coraco-acromial, 84  
 coraco-clavicular, 92  
 coraco-humeral, 124  
 costo-clavicular, 37, 38  
 costo-coracoid, 24  
 cruciatum cruris, 339, 349, 353  
   of fingers, 162  
   genu, 411, 414, 417  
 cubo-cuneiform, 434

**Ligaments (contd.)—**

- cubo-navicular, 434
- cuneo-navicular, 433
- deltoid, 422
- of elbow, 195
- gleno-humeral, 124
- of hip, 325
- ilio-femoral, 327
- inguinal, 214, 220, 237, 247
- intercarpal, 205
- interclavicular, 38
- intercuneiform, 433
- intermetacarpal, 208
- intermetatarsal, 436
- interosseous, tibio-fibular, 427
- interphalangeal, of foot, 438
  - of hand, 211
- intertarsal, 429
- ischio-capsular, 328
- of knee, 407, 414
- laciniatum, 366, 368, 378, 387
- lacunar, 238, 243, 247
- of lateral malleolus, 427
- metacarpal, transverse, 192
- metacarpo-phalangeal, 211
- metatarsal, transverse, 399
- metatarso-phalangeal, 438
- patellæ, 215, 265, 407
- piso-hamate, 206
- piso-metacarpal, 206
- plantar accessory, 438
- plantar, long, 386, 392, 428, 432
- popliteal, oblique, 408, 409
- pubo-capsular, 328
- quadratum, 195
- radio-carpal, 199
- round, of femur, 330
  - of uterus, 226
- sacro-spinous, 290, 291
- sacro-tuberosus, 288, 290, 291
- of scapula, transverse, inferior, 89
  - superior, 59, 89
- of shoulder, 119
- suspensory, of axilla, 24
- talo-calcanean, 429, 430
- talo-fibular, anterior, 422
  - posterior, 422
- talo-navicular, 430
- tarso-metatarsal, 435
- of tarsus, 429
- teres femoris, 330
  - uteri, 226
- transverse*, of acetabulum, 330
  - cruris, 339, 353
  - of humerus, 122

**Ligaments, transverse (contd.)—**

- of knee, 417
- of metacarpals, 192
- of metatarsals, 399
- of scapula, inferior, 89
  - superior, 59, 89
- superficial, of foot, 383
  - of hand, 70
- trapezoid, 92
- ulnar-carpal, 199
- vaginal, of fingers, 162
  - of toes, 392
- volar accessory, 211
- Y-shaped, 327
- Line, Nélaton's, 280
- Lymph-glands**, axillary, 26, 28, 29, 67
  - brachial, 67
  - cubital, 63, 67, 68
  - decto-pectoral, 19, 67
  - hypogastric, 363
  - iliac, common, 363
  - infraclavicular, 68
  - of lower limb, 361
  - lumbar, 363
  - popliteal, 308, 363
  - subinguinal, 225, 226, 228, 360, 363
  - tibial, anterior, 363
  - of upper limb, 66
- Lymph-vessels**, afferent, 229, 363
  - efferent, 229, 363
  - of leg, 337
  - of mammary gland, 17
  - of lower limb, 361
  - of upper limb, 66
- Malleoli, 215, 216, 332, 333
- Mamma, 11, 14
  - lymph vessels of, 17
  - in male, 17
- Manubrium, 8
- Manus, 1
- Margo falciformis, 229
- Medulla spinalis, 5
- Membrane**, costo-coracoid, 18, 22, 23, 24
  - interosseous, of forearm, 203
  - of leg, 425
- Menisci of knee, 415
- Metacarpal bones, 2, 4
- Metatarsal bones, 216, 333
- Multangulum majus, 149
- Muscles**—
  - abductor* digiti quinti, of foot, 385, 387

**Muscles (contd.)—**

- abductor* digiti quinti, of hand,  
153  
hallucis, 385, 387  
indicis, 194  
pollicis brevis, 160, 169  
longus, 174, 182, 189  
*adductor* brevis, 266, 272  
hallucis, 395  
longus, 245, 266  
magnus, 266, 276, 293, 295,  
305, 307  
opening in, 253  
pollicis, 160, 170  
anconæus, 174, 181  
articularis genu, 265, 266  
biceps brachii, 23, 26, 94, 99,  
106  
long head, 126  
femoris, 215, 307, 319, 321,  
426  
brachialis, 99, 108  
brachio-radialis, 99, 130, 174, 176  
coccygeus, 295  
coraco-brachialis, 23, 26, 94, 99,  
106  
deltoid, 2, 7, 18, 77  
relations of, 78  
dorso-epitrochlearis, 87  
*extensor* carpi radialis brevis,  
174, 180, 190  
longus, 100, 174, 179, 190  
ulnaris, 174, 181, 191  
common origin, 180, 181  
digiti quinti proprius, 174, 180,  
191  
digitorum brevis, 351  
communis, 174, 178, 180, 191  
longus, 342, 345  
expansion of fingers, 178  
of toes, 346  
hallucis brevis, 351  
longus, 342, 346  
indicis proprius, 184, 191  
pollicis brevis, 174, 183, 189  
longus, 174, 183, 190  
external oblique, of abdomen, 14,  
47, 55  
*flexor* carpi radialis, 130, 140,  
162, 194  
ulnaris, 130, 138, 140, 206  
common origin, 139  
digiti quinti brevis of foot, 385,  
395, 397  
of hand, 153  
digitorum brevis, 385, 386

**Muscles (contd.)—**

- flexor* digitorum longus, 371, 376,  
377, 386, 391  
profundus, 147, 148, 164  
sublimis, 130, 139, 141, 164  
hallucis brevis, 385, 394, 395  
longus, 371, 376, 377, 385,  
391, 393  
pollicis brevis, 160, 169  
deep head, 170  
longus, 147, 148, 160, 166  
gastrocnemius, 305, 307, 369  
gemellus inferior, 293, 295, 299  
superior, 293, 294, 299  
glutæus maximus, 233, 285, 295  
medius, 249, 250, 301  
minimus, 249, 250, 303  
gracilis, 266, 275, 307, 357  
hamstring, 290, 293, 295, 305,  
319, 321  
iliacus, 277  
infraspinatus, 85, 88  
intercostal, 23  
interossei of foot, 385, 400  
of hand, 178, 193  
latissimus dorsi, 8, 14, 18, 22,  
53, 55, 56  
insertion, 87  
levator ani, 295  
scapulæ, 53, 59, 60  
lumbricales of foot, 385, 392, 394  
of hand, 166, 178  
oblique, external, of abdomen, 14,  
47, 55  
obturator externus, 277, 300  
internus, 293, 294, 299  
omohyoid, 41, 59  
opponens digiti quinti, 153  
pollicis, 160, 169, 170  
palmaris brevis, 63, 152  
longus, 73, 129, 130, 138, 140  
pectineus, 266, 270  
pectoralis major, 2, 7, 8, 14, 16,  
18, 20, 22, 24  
insertion, 87  
minor, 8, 22, 24, 26, 27  
peronæus brevis, 355  
digiti quinti, 355  
longus, 355  
insertion, 400  
tertius, 343, 347  
piriformis, 292, 294, 299  
plantaris, 307, 370  
platysma, 11, 41  
popliteus, 376, 407, 408, 411  
pronator quadratus, 148

**Muscles** (*contd.*)—

- pronator teres, 130, 139  
 psoas major, 277  
 quadratus femoris, 293, 295, 300  
   plantæ, 386, 392, 394  
 quadriceps femoris, 261  
   insertion, 265  
 rectus femoris, 248, 262  
   reflected head, 250, 304  
 rhomboideus major, 53, 59, 60  
   minor, 53, 59  
 sacro-spinalis, 49  
 sartorius, 245, 248, 250, 307, 357  
 scalenus anterior, 41  
   medius, 41, 46  
 semimembranosus, 221, 307, 319,  
   322, 376  
 semitendinosus, 221, 307, 319,  
   321, 357  
 serratus anterior, 3, 14, 16, 18,  
   23, 27, 47  
   posterior inferior, 61  
   superior, 60  
 soleus, 370  
 sterno-hyoid, 39  
 sterno-mastoid, 8  
 sterno-thyreoid, 39  
 sub-anconæus, 114, 118  
 subclavius, 24, 25, 37  
 subscapularis, 22, 78, 86, 88  
 supinator, 110, 194  
 supraspinatus, 59, 85, 88  
 tensor fasciæ latæ, 233, 248, 259  
 teres major, 8, 18, 22, 32, 86  
   minor, 85, 89  
 tibialis anterior, 342, 344  
   posterior, 371, 376, 377, 428  
   insertion, 400  
 trapezius, 51, 53, 54  
   nerves of, 55, 58  
 triceps brachii, 112  
 vastus intermedius, 248, 265  
   lateralis, 248, 263, 295  
   medialis, 248, 263

Navicular bone of foot, 216  
 of hand, 149

**Nerves**—

- accessory, 55, 58  
 afferent, 5, 218  
 of ankle joint, 352, 376  
*articular*, to ankle, 352, 376  
   to carpal joints, 208  
   to carpo-metacarpal joints, 211  
   to elbow, 115, 146, 198  
   to hip, 256, 258, 274, 300, 331

**Nerves, articular** (*contd.*)—

- to intermetacarpal joints, 211  
 to interphalangeal joints of  
   hand, 212  
 to knee, 258, 275, 310, 313,  
   315, 318, 357, 402, 405  
 to metacarpo-phalangeal joints,  
   212  
 to metatarso-phalangeal joints,  
   352  
 to shoulder, 78, 84, 92  
 to tarsal joints, 353  
 to tarso-metatarsal joints, 352  
 to wrist, 182, 201, 208  
 axillary, 28, 43, 77, 83  
 calcanean, medial, 359, 375, 383  
 of carpal joints, 208  
 of carpo-metacarpal joints, 211  
 collateral, ulnar, 28, 117  
*cutaneous*, 6, 11, 218  
   of arm, lateral, 68, 69, 75, 84  
   medial, 26, 43, 68, 69, 97,  
   100  
   posterior, 28, 70, 97  
 of back, 51  
 of buttock, 282  
 of calf, lateral, 310, 315, 335,  
   337  
   medial, 309, 312, 359, 365  
 of chest, anterior, 12, 14  
   lateral, 13, 14, 27, 30  
 dorsal, of ulnar, 68, 71, 128,  
   146  
 of foot, intermediate, 338  
   lateral, 338, 366  
   medial, 338  
 of forearm, dorsal, 68, 69, 97,  
   128, 173  
   lateral, 68, 69, 98, 127, 128,  
   172  
   medial, 26, 43, 66, 68, 69,  
   97, 100, 127, 172  
 of iliohypogastric, lateral, 283  
 of intercostals, anterior, 12, 14  
   lateral, 13, 14, 27, 30  
 of leg. *See* of calf  
 of lumbar posterior rami, 51,  
   283  
 palmar, of median, 68, 70, 73,  
   128, 129, 147  
   of radial, 71, 128  
   of ulnar, 68, 70, 73, 128,  
   129, 146  
 perforating, 283, 284, 287, 288  
 of sacral posterior rami, 283,  
   288



**Nerves, cutaneous (contd.)—**  
 of thigh, intermediate, 227, 231, 245, 247, 248, 257  
 lateral, 227, 231, 239, 245, 248, 283, 319  
 medial, 227, 231, 245, 248, 257, 306, 319, 359  
 posterior, 283, 284, 292, 295, 296, 306, 307, 312, 319, 359  
 of thoracic nerves, anterior, 12, 14  
 lateral, 13, 14, 27, 30  
 of thoracic posterior rami, 51  
 of twelfth thoracic, lateral, 283  
 of upper limb, 68  
*digital*, of foot, 335, 336, 337, 338, 352, 385, 386, 389, 391  
 of hand, 68, 70, 71, 128, 158, 160, 173  
 of median, 68, 70, 128, 158  
 of peroneal, 336, 337, 338, 352  
 of plantar, 385, 386, 389, 391  
 of radial, 68, 71, 128, 173  
 of ulnar, 68, 70, 71, 128, 160, 173  
*dorsalis manus*, 146, 173  
 scapulæ, 42, 60, 61  
 efferent, 5, 218  
 of elbow joint, 115, 146, 198  
 femoral, 239, 245, 256  
 to femoral artery, 274  
 genicular, 310, 313, 315, 357, 402, 405  
 of obturator, 318  
 gluteal, inferior, 292, 295, 296  
 superior, 249, 295, 302  
 of hip joint, 256, 258, 274, 300, 331  
 ilio-inguinal, 226, 231  
 infra-patellar, 337  
 intercosto-brachial, 26, 30, 68, 69, 97  
 of intermetacarpal joints, 211  
 interosseous, dorsal, 182, 185, 191  
 volar, 147, 148  
 of interphalangeal joints, 212  
 of knee joint, 258, 275, 310, 313, 315, 318, 357, 402, 405  
 to longus colli, 42  
 lumbo-inguinal, 227, 231, 239, 247  
 to lumbrical, second, of foot, 394, 398

**Nerves (contd.)—**  
 median, 26, 43, 100, 101, 110, 139, 142, 146, 155, 158  
 of metacarpo-phalangeal joints, 212  
 of metatarso-phalangeal joints, 352  
 musculo-cutaneous, 26, 43, 98, 106, 173  
 obturator, 246, 266, 272, 273, 318  
 accessory, 271  
 to obturator internus, 293, 295, 298  
 perineal, long, 233, 292, 297  
 peroneal anastomotic, 306, 310, 315, 359, 365  
 common, 305, 307, 313, 356  
 deep, 337, 344, 348, 351, 356  
 superficial, 335, 337, 356  
 plantar, lateral, 385, 391, 397, 398  
 medial, 337, 385, 389  
 pudendal, 293, 295, 298  
 to quadratus femoris, 293, 295, 300  
 radial, 3, 28, 43, 98, 100, 111, 115  
 deep branch of, 117, 132  
 superficial branch of, 68, 71, 117, 128, 132, 173  
 saphenous, 227, 232, 245, 247, 248, 257, 309, 335, 337, 357, 359, 364  
 to scalene muscles, 42  
 sciatic, 292, 295, 298, 319, 323  
 of shoulder joint, 78, 84, 92  
 spinal, 5, 217  
 to subclavius, 42  
 subscapular, 28, 29, 43  
 supraclavicular, 12, 13, 68, 69, 75  
 suprascapular, 42, 59, 91  
 suralis, 335, 337, 338, 359, 366  
 of tarsal joints, 353  
 of tarso-metatarsal joints, 352  
 thoracic, anterior, lateral, 25, 43  
 medial, 24, 25, 43  
 long, 28, 42, 45  
 thoraco-dorsal, 43, 45, 61  
 tibial, 307, 312, 316, 371, 373, 375  
 to trapezius, 58  
 ulnar, 3, 28, 43, 73, 100, 101, 112, 129, 143, 144, 152, 159, 167

- Nerves** (*contd.*)—  
 ulnar, deep branch, 167  
     dorsal branch, 146, 173  
 ulnar collateral, 28, 117  
 of wrist joint, 182, 201, 208
- Nipple**, 9, 15  
 in male, 17
- Notch**, jugular, 8
- Olecranon**, 3, 94
- Opening** in adductor magnus, 253, 276
- Os coxæ**, 213
- Os hamatum**, 152
- Os multangulum majus**, 149
- Os trigonum**, 422
- Pacinian corpuscles**, 71, 159
- Pad**, infrapatellar, 410
- Panniculus adiposus**, 11, 222. *See also Fascia, superficial*
- Papilla mammæ**, 15, 17
- Patella**, 214
- Phalanges of fingers**, 2, 4
- Pisiform bone**, 149
- Pit of stomach**, 8
- Plexus**, brachial, 25, 33, 39  
     obturator, 250, 257  
     patellar, 227, 233  
     subsartorial, 250, 257  
     subtrapezial, 58
- Plicæ**. *See also Fold*  
 alares, 410
- Process**, coracoid, 2, 7  
     styloid, of radius, 4  
     of ulna, 3  
     of talus, posterior, 422  
     trochlear, 333  
     xiphoid, 8
- Pubis**, 213
- Radius**, 2, 3, 4, 96
- Retinacula of hip joint**, 331  
     peroneal, 339, 355, 367
- Rib**, first, 8  
     second, 8  
     seventh, 8  
     twelfth, 50
- Ring**, femoral, 242
- Scapula**, 1, 2, 3, 49
- Scrotum**, 11, 222
- Septa, intermuscular**, 72  
     of arm, 98, 118  
     of forearm, 128, 138
- Septa, intermuscular** (*contd.*)—  
     of leg, of calf, 367, 371  
     fibular, 340  
     of front, 344  
     of palm of hand, 154  
     of scapular region, 76, 78  
     of sole of foot, 384  
     of thigh, 235, 261
- Septum, femoral**, 242
- Sesamoid bones** in—  
     adductor pollicis, 170, 211  
     flexor hallucis brevis, 395, 438  
     flexor pollicis brevis, 170, 211  
     gastrocnemius, 370  
     metacarpo-phalangeal joints, 170, 211  
     metatarso-phalangeal joints, 395, 438  
     peroneus longus, 401  
     tibialis posterior, 400
- Sheaths, fascial or fibrous**—  
     axillary, 33  
     femoral, 226, 238  
     flexor, of fingers, 162  
     of toes, 392  
     *mucous or synovial*  
     of biceps brachii, long head, 124, 126  
     of extensors in lower limb, 341, 353  
     in upper limb, 175, 176  
     of flexors in lower limb, 379, 393  
     in upper limb, 133, 134, 160, 164  
     of peronæi, 354, 401  
     of popliteus, 411  
     of tendo calcaneus, 368  
     of tibialis anterior, 341, 353  
     of tibialis posterior, 379
- Shin**, 215, 332
- Shoulder girdle**, 1
- Sinus**, lactiferous, 17, 18
- Space**, quadrilateral, 77, 82  
     triangular, 77, 81
- Spinal cord or medulla**, 5, 217
- Spines of ilium**, superior, 49, 213, 279  
     of scapula, 2, 49  
     of vertebræ, 48
- Sternum**, 2, 8
- Stomach**, pit of, 8
- Sulcus, gluteal**, 280  
     iliac, 279  
     inguinal, 213
- Surface anatomy**—  
     arm, 94

**Surface anatomy** (*contd.*)—

- axilla, 8
- back, 48
- elbow, 94
- foot, 333
- gluteal region, 279
- hand, 149, 171
- leg, 332
- lower limb, 213
- pectoral region, 7
- popliteal region, 304
- thigh, 218
- upper limb, 1
- Surgical anatomy of palm and fingers, 171
- Sustentaculum tali, 333
- Symphysis pubis, 213
- Syndesmosis tibio-fibularis, 425, 426

Talus, 216, 333

Tarsus, 216

Tendo calcaneus, 216, 333, 371

Thenar, 149

Tibia, 215, 332

Tract, ilio-tibial, 233, 248, 258

**Triangle** of auscultation, 57

delto-pectoral, 2, 7, 18

lumbar (Petit), 57

Trigone, femoral, 246

Trochanter major, 214, 280, 290

Tuber ischiadicum, 214, 280, 290

**Tubercle**, adductor, 215, 305

of humerus, greater, 3

pubic, 213

Tuberosity of femur, gluteal, 290

of tibia, 215

Ulna, 2, 3, 4

**Veins**—

antibrachial, median, 64

axillary, 25, 26, 37, 65, 66

basilic, 63, 65, 94, 96, 100, 127, 172

**Veins** (*contd.*)—

basilic, median, 64

brachial, 37

cephalic, 19, 23, 25, 63, 65, 94, 96, 127, 172

median, 64

cervical, transverse, 41

circumflex, femoral, lateral, 230  
medial, 230, 361

cubital, median, 63, 65, 66, 69

digital, dorsal, of foot, 335, 336  
of hand, 63

epigastric, superficial, 227, 230

femoral, 246, 247, 256

iliac, circumflex, superficial, 227, 230

inguinal, superficial, 227

innominate, 67, 362

jugular, anterior, 38

external, 41

metacarpal, dorsal, 63

popliteal, 307, 311, 318, 372

profunda femoris, 246, 247

pubental, external, superficial, 227, 230

saphenous, great, 225, 227, 229, 230, 239, 335, 357, 359

small, 306, 335, 359, 361

scapular, transverse, 41

Vertebra prominens, 49

**Vessels**, cutaneous, 11

lymph, afferent, 363

efferent, 363

of leg, 337

of lower limb, 361

of mamma, 17, 18

of upper limb, 66

Vincula tendinum, 164, 393

Whitlow, 172

Wrist and palm, 148

Zona orbicularis of hip-joint, 326, 328

END OF VOL. I







h 1863  
400

92793

