3 1761 06706719 9

Digitized by the Internet Archive
in 2007 with funding from
Microsoft Corporation

http://www.archive.org/details/descriptiveillu02royauoft

PRESENTED BY THE COUNCIL OF
THE ROYAL COLLEGE OF SURGEONS OF ENG

Zool
Morph
R

Royal College of Surgeons of England. Museum

DESCRIPTIVE AND ILLUSTRATED CATALOGUE

OF

THE PHYSIOLOGICAL SERIES

OF

COMPARATIVE ANATOMY

CONTAINED IN

THE MUSEUM

OF

THE ROYAL COLLEGE OF SURGEONS OF ENGLAND.

VOL. II.

SECOND EDITION.

59777
24/6/03

LONDON:
PRINTED FOR THE COLLEGE;
AND SOLD BY
TAYLOR AND FRANCIS, RED LION COURT, FLEET STREET.
MDCCCCII.

PRINTED BY TAYLOR AND FRANCIS,
RED LION COURT, FLEET STREET.

PREFACE

TO THE

SECOND VOLUME.

THE second volume of the Physiological Catalogue comprises descriptions of the Nervous System of the Invertebrata (exclusive of sense-organs), and of the Brain and Spinal Cord, with their membranes and blood-vessels, of the Vertebrata. The descriptions of the Invertebrata have been intrusted to Mr. R. H. Burne, B.A. Oxon., Assistant in the Museum, who has so largely enriched this department of the Collection ; he has also described the Brain and Spinal Cord of Fishes, Amphibia, and Birds, also Spinal Cords and Membranes.

Prof. G. Elliot Smith, M.D., Fellow of St. John's College, Cambridge, who has contributed so much to our knowledge of the Brains of Mammals, has described those of Reptiles and the Mammalia, his work forming by far the largest and most important part of this volume ; he was assisted in the Primates by Mr. W. L. H. Duckworth, M.A. Cantab.

The specimens of Mammalian Brains have all been remounted on the improved plan devised by Mr. William Pearson, our Prosector, that enables all the convolutions to be seen.

The generic and specific names used are those most recently adopted in the British Museum.

The value of the work has been greatly enhanced by the admirable drawings made by Mr. J. Green with his accustomed skill.

C. STEWART,
Conservator.

28 July, 1902.

CONTENTS.

VOL. II.

D.

NERVOUS SYSTEM.

INVERTEBRATA.

PROTOCHORDATA.

VERTEBRATA.

BRAIN.

PISCES.

CARNIVORA.

ÆLUROIDEA.

Nos.

CYNOIDEA.

ARCTOIDEA.

PINNIPEDIA.

UNGULATA.

PERISSODACTYLA.

ARTIODACTYLA.

CETACEA.

ODONTOCETI.

SPINAL CORD.

DESCRIPTIVE CATALOGUE

OF THE

PHYSIOLOGICAL SERIES.

D.

NERVOUS SYSTEM *.

At

INVERTEBRATA.

Loeb, Comparative Physiology of the Brain, 1901.

ECHINODERMATA.

Cuénot, Arch. de Biol., t. xi. 1891, p. 445 (*Anat.*).
Romanes & Ewart, Phil. Trans., vol. clxxii. 1881, p. 836 (*Physiol.*).

In the Echinodermata there are three distinct systems of central nervous organs—superficial oral, deep oral, and apical—that occur, either in the form of a circumaxial ring (apical system of Echinids and Ophiurids), radial cords (apical system of Asterids and deep oral system of Holothurians), or more usually as a combination of the two (superficial oral system). All three are not invariably present, and there is also variation in their respective importance. The superficial oral system occurs in all and usually predominates over the others, but in Crinoids it is relatively weak and the chief place is taken by the enormously developed apical system. The apical and deep oral systems are

---

* In this volume are included descriptions of the nervous system of Invertebrata and Protochordata and of the brain and spinal cord, with their membranes and blood-vessels, of Vertebrata.

sometimes absent. The whole central system, whether it is continuous with the general body-epithelium (Asteroidea) or is comparatively deep-seated, always retains strong indications of its epithelial origin. Two kinds of nuclei lie in the superficial parts of the nerve-cords—some large and with distinct nucleoli, belonging apparently to ganglion-cells, others small and deeply staining. The latter belong to attenuated supporting epithelial cells that traverse the cord at right angles to its surface. The spaces between them are filled by nerve-fibrillæ.

Fig. 1.

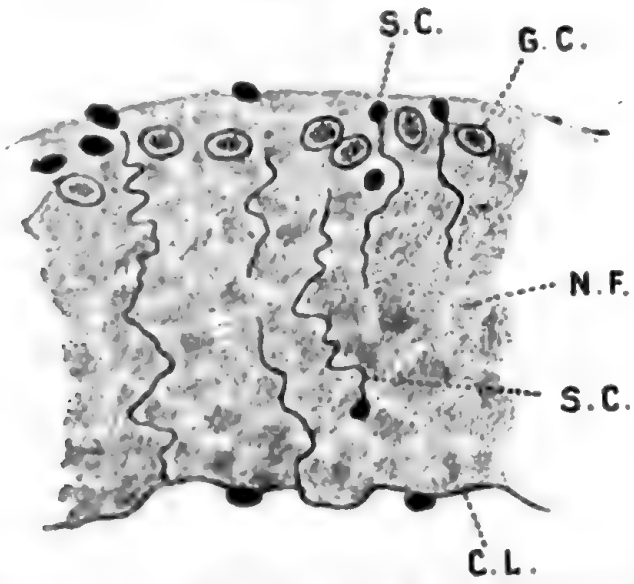

Transverse section through the Radial Cord of *Echinus esculentus*. × 700.

C.L. Connective-tissue lamina. G.C. Nuclei of ganglion (?) cells. S.C. Supporting cells. N.F. Nerve-fibrils.

Isolation of the several radial cords of the oral system from the circumoral ring destroys all power of co-ordinated action between the different arms or segments, although the movements of the individual parts of each are still in perfect harmony amongst themselves. From this fact the circumoral ring might be thought to be a co-ordinating centre for the general body movements, and thus of somewhat higher functional value than the radial cords, but it is probably nearer the truth to consider all parts of the system of equal value and the circumoral ring simply as the path along which stimuli may pass from one segment to another.

OPHIUROIDEA.

D. 1. Two specimens of the oral central nervous system of a Snake-armed Starfish (*Ophiocoma echinata*).

The superficial oral system consists of a pentagonal ring that surrounds the mouth near its passage into the œsophagus, and of five radial cords. Each cord arises from the ring at a point opposite one of the radii and passes down the arm between the vertebral ossicles and the ventral plates (fig. 2). A cavity (epineural canal) lies between the body-wall and the superficial surface of the oral ring and radial cords; it is usually single, but in *Ophiocoma* a partition of connective tissue divides it longitudinally into two separate channels.

Fig. 2.

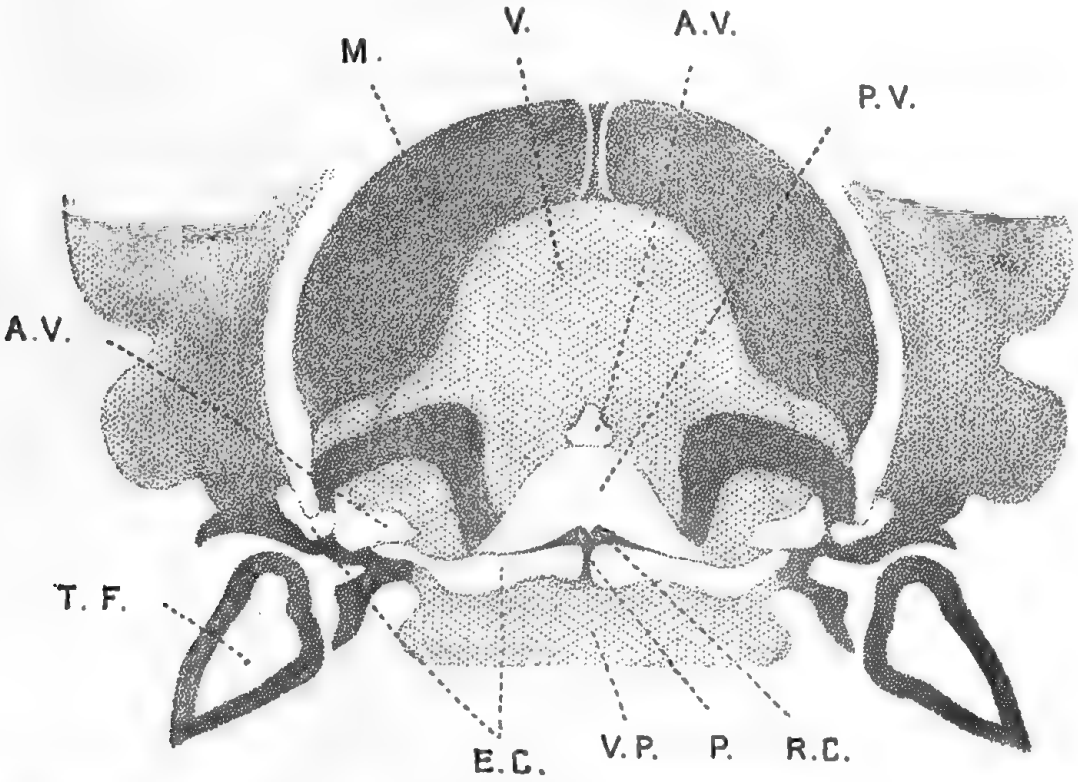

Diagrammatic transverse section of the Arm of *Ophiocoma echinata*. ×40.

A.V. Ambulacral vessel. E.C. Epineural canal. M. Intervertebral muscle. P. Median partition of epineural canal. P.V. Pseudhæmal vessel. R.C. Radial cord. T.F. Tube-foot. V. Vertebral ossicle. V.P. Ventral plate.

The superficial oral system is to a large extent sensory in function; it innervates the entire body surface, the ambulacra, the mouth, and alimentary canal. The deep oral system (not distinguishable in the specimen) forms a thin layer of nervous tissue upon the deep surface of the superficial system, separated from it by a delicate layer of connective tissue. Upon its deep surface lie the pseudhæmal and ambulacral vessels. The deep oral system is the motor centre for the intervertebral muscles of the arms, and probably also gives off fibres that accompany the peripheral and ambulacral nerves of the superficial system.

The oral ring and proximal parts of the radial cords are shown in an isolated state in the upper specimen, and in their relations to the disc in the lower; in both cases only the most general features can be seen. The apical system has been removed with the genital ring sinus in which it lies. O. C. A 1292 C. *Brit. Mus.*

Hamann, Jena. Zeitschr., Bd. xxiii. 1889, p. 235.

ECHINOIDEA.

D. 2. Part of the body-walls of a Sea-urchin (*Echinus esculentus*) showing the oral nervous system.

The superficial system corresponds in its main features to that of Ophiurids. The oral ring (indicated by black paper) lies around the mouth-opening between the teeth and the pharyngeal wall, separated from the latter by an epineural canal. Opposite each of the five radii it gives off a cord that leaves the lantern of Aristotle between the pyramids, passes under the arch of the auricula, and runs along the mid-line of the radius, separated from the inner surface of the ambulacral plates by an "epineural canal," and from the general body-cavity by the radial canals of the pseudhæmal, blood-vascular, and ambulacral systems. Near the apical pole the cords pass through the test and become lost in the general surface epithelium. From the oral ring a few fine nerves are given off to the alimentary canal, and from the radial cords arise a series of ambulacral and peripheral nerves. The latter perforate the test and form upon its outer surface an intricate plexus, by which the movements of the spines and pedicellariæ are controlled. The deep oral system (not visible in the specimen) is in a reduced condition, and is only present upon the inner surface of the oral ring at the point of origin of the radial cords; it innervates the masticatory apparatus, and is entirely wanting in agnathous forms.

In this specimen parts of the oral systems have been exposed, showing the circum-oral position of the nerve-ring and its relation to the radial cords. One of the latter with its ambulacral nerves has been isolated by the removal of the ambulacral plates of one radius. The apical system has been removed with the genital-ring sinus.

Hamann, Jena. Zeitschr. Bd. xxi. 1887, p. 119.

HOLOTHUROIDEA.

D. 3. A Sea-cucumber (*Holothuria nigra*) with the nervous system shown by the removal of the bivial body-walls.

The oral ring of the superficial system surrounds the mouth under cover of the calcareous ring and in close contact with the oral integument. The five radial cords given off from it pass beneath the radial pieces of the calcareous ring and along the radii; they are separated from the deep surface of the integument by an epineural canal.

The deep oral system (not visible in the specimen) is confined to the inner surface of the radial cords, and is separated from the muscles of the body-wall by the pseudhæmal, blood-vascular, and ambulacral vessels. The respective share taken by the two systems in the innervation of the body has not been satisfactorily determined. There is no apical system. Black paper has been inserted beneath the oral ring at the points of origin of the radial cords and in various places beneath the cords. The calcareous ring has been removed. O. C. A 1292 *b*.

Ludwig, Bronn's Thier-reich, Bd. ii. Abth. 3, 1889–1892, p. 64.

ANNELIDA.

Retzius, Biol. Untersuch., N.F. Bd. ii. p. 1, iii. p. 1, iv. p. 1, vii. p. 6, ix. p. 83, 1891–1900.

The central nervous system is bilaterally symmetrical; it consists typically of a pair of præoral (cerebral) ganglia situated in the prostomium, and of a series of post-oral ganglia, arranged segmentally in pairs along the ventral mid-line of the body and united together by transverse commissures and longitudinal connectives. This ventral chain of ganglia shows great diversity in the degree of concentration of its parts in a transverse direction. Longitudinal concentration is rare and never extreme. Frequently the segmental ganglionation is absent, and the chain is then represented by a fibrous cord with a continuous layer of ganglion-cells on its ventral surface. The size and complexity of structure of the cerebral ganglia depend entirely upon the degree of development of the cephalic sense-organs. Apart from particular functions due to their connection with these organs, they do not seem to differ in kind from the post-oral ganglia, and, except for a certain inhibitory power, cannot be regarded in any special way as controlling or co-ordinating centres for the rest of the nervous system. Each pair of ventral chain ganglia constitutes a reflex centre for its innervation area. In the ventral chain of many Annelids there are a limited number (usually three) of medullated giant nerve-tubes; in many instances connections have been seen between them and giant or medium-sized cells upon the ventral surface of the ganglia. Their function is still doubtful, but they are probably nerve-elements and not simply supporting structures. A definite visceral system is present connected with the cerebral or subœsophageal ganglia. In certain forms the central nervous system is still closely united to the epidermis (subcuticula), and in these cases the fibres of its supporting tissues can be traced directly to the elongated bases of the epidermal cells.

CHÆTOPODA.

Racovitza, Arch. Zool. Exp., sér. 3, t. iv. 1896, p. 133 (*Brain*).

D. 4. The anterior part of the body-walls of a Lug-worm (*Arenicola marina*) opened from the dorsal aspect.

The nervous system, as might be expected from the sluggish habits of the worm, is poorly developed. The cerebral ganglion is a small lobulated body situated, as in other Polychætes, in the prostomium (in the specimen the anterior part of the body-wall is turned inside out, so that the cerebral ganglion and inverted prostomium form a small excrescence above the cut edge of the pharynx). There are three distinct paired centres in the ganglion, constituting a fore-, mid-, and hind-brain; each is situated beneath and in close contact with a particular sensory area of the prostomial epithelium, upon which labial palps, tentacles and eyes, and a nuchal organ may respectively be developed in higher Polychætes. The cerebral ganglion is connected by a pair of long connectives (from which the nerves to the otocysts arise) to a ventral cord, that lies within the body-cavity internal to the circular muscles;

it shows no sign of metameric ganglionation, but on a level with each annular furrow gives off a delicate pair of nerves.

Neuropile* appears to be mainly confined to the cerebral ganglion. The medulla of the cord consists of a dorsal strand of nerve-fibres, covered on its ventral surface by a continuous layer of unipolar ganglion-cells, mostly of small size (fig. 3). At the point of union of the cord with the œsophageal connectives and on a level with the anterior end of each setigerous segment, are a pair of giant ganglion-cells. In several instances a direct connection has been traced between these cells and three giant fibres that lie along the dorsal aspect of the cord. The distribution of the giant fibres is still doubtful. The cord is surrounded by a neurilemma, and is permeated by a considerable quantity of neuroglia fibres. These are specially concentrated in the sagittal plane, and form a partial septum between the two halves of the cord. In the specimen the general form and position of the cerebral ganglion, circum-œsophageal connectives, and ventral chain can be seen, but

Fig. 3.

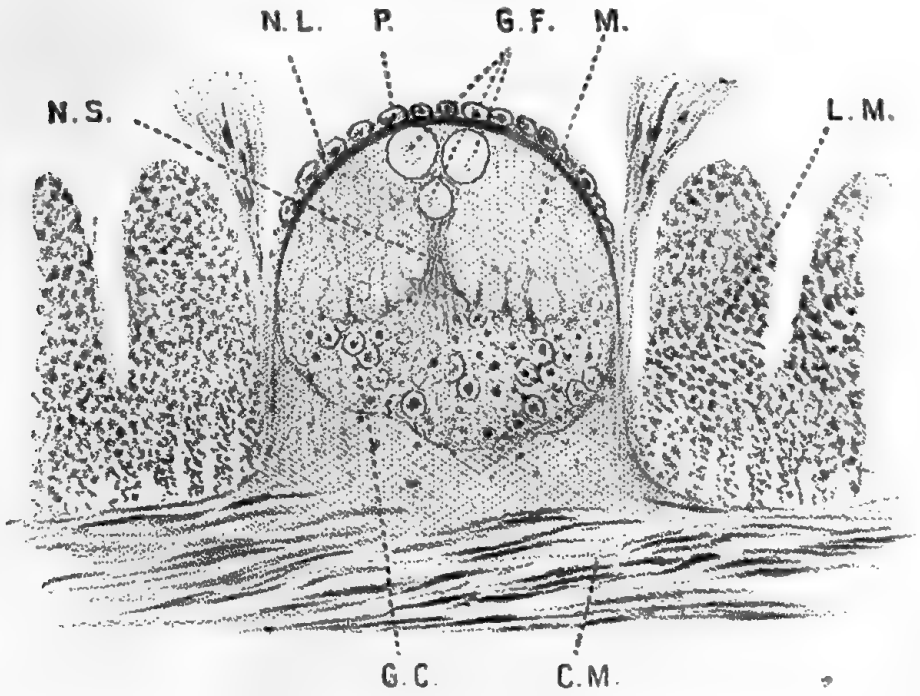

Transverse section through the Ventral Cord of *Arenicola marina*. × 50.

C.M. Circular muscles. G.C. Ganglion-cells. G.F. Giant fibres. L.M. Longitudinal muscles. M. Medulla. N.L. Neurilemma. N.S. Neuroglia septum. P. Peritoneum.

---

* The felt-work formed by the ultimate ramifications of ganglion-cell processes.

it is not possible to distinguish the nerves arising from them.

Gamble & Ashworth, Quart. Journ. Micro. Sci., vol. xliii. 1900, p. 468.

D. 5. Two specimens of the anterior part of the nervous system of a Polychæte (*Marphysa sanguinea*), shown respectively in an isolated state and from the left side within the body. In this active worm, with definite cephalic sense-organs, the cerebral ganglia are well developed (fig. 4). They lie in the prostomium at the base of the swollen palps, and are clearly separable into two main regions—fore- and mid-brain—each of which consists of a pair of neuropile masses united by a transverse commissure, and coated with small unipolar ganglion-cells. The fore-brain lies in front of and below the mid-brain, and is mainly concerned with the innervation of the palps, into which the anterior part of each of its lobes is prolonged as a bundle of arborescent ganglionic processes. Each lobe also sends a root from its ventral surface to the visceral nerve, and another from its lateral parts to the circumœsophageal connective.

Fig. 4.

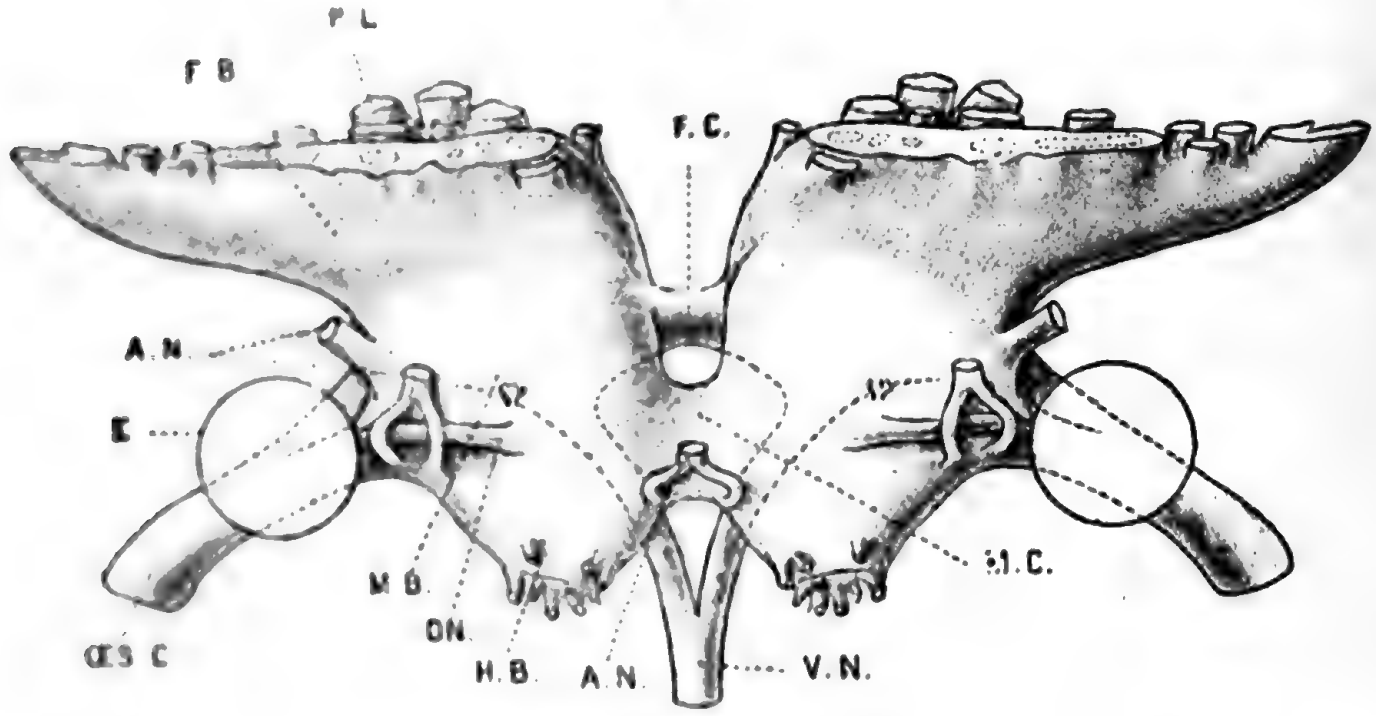

Brain of *Marphysa sanguinea*. × 25.

A.N. Antennary nerves. E. Eye. F.B. Fore-brain. F.C. Its commissure. H.B. Hind-brain. L.M. Longitudinal muscles M.B. Mid-brain. M.C. Its commissure. O.N. Optic nerve Œs.C. Œsophageal connective. P.L. Palp-lobules. V.N. Visceral nerve.

The mid-brain is the centre of origin for the nerves to the eyes and tentacles. Its postero-lateral parts are prolonged backwards to form a pair of indistinct lobes, from which fibres extend to the nuchal region—they apparently represent the third area of the Polychæte brain (hind-brain). From each side of the mid-brain a second root is given off to the circumœsophageal connective; it unites with the first (derived from the fore-brain) immediately outside the ganglion. The ganglia of the ventral chain lie close together, one in each segment, and are united by definite though short fibrous connectives. A pair of parapodial nerves rises from each ganglion. Upon the ventral surface of the cord runs a single large "giant fibre."

Fig. 5.

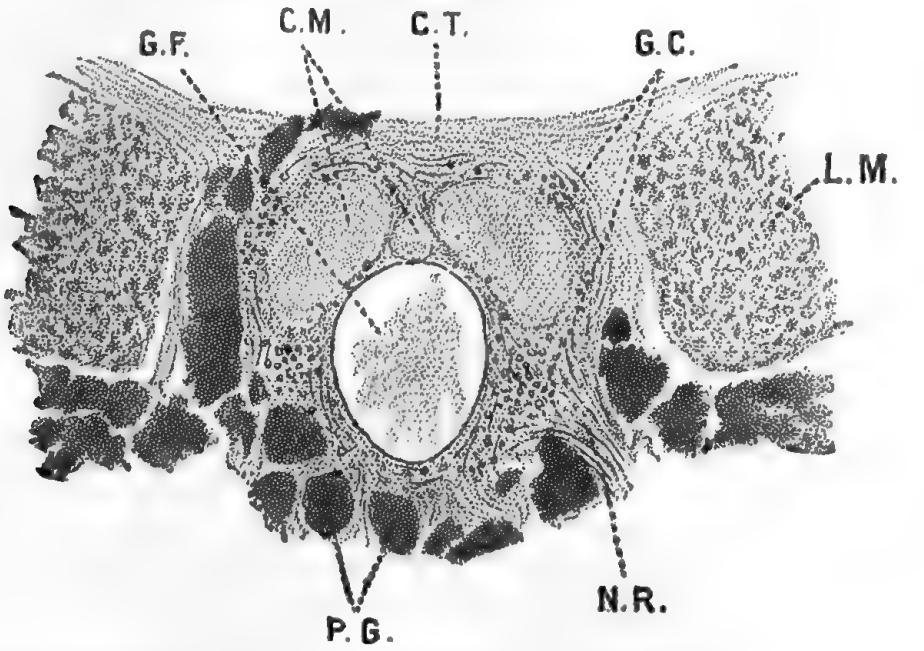

Transverse section through a Ventral-chain Ganglion of *Marphysa sanguinea.* × 75.

C.M. Central medulla. C.T. Connective tissue. G.C. Ganglion-cells. G.F. Giant fibre. L.M. Longitudinal muscles. N.R. Nerve-root. P.G. Pigment masses.

Jourdan, Ann. Sci. Nat., sér. 7, t. ii. 1887, p. 250.

D. 6. Two specimens of the nervous system of a Sea Mouse (*Aphrodite aculeata*). The cerebral ganglion is of large size and complicated structure; it lies in the prostomium and consists of a central mass of neuropile, separable into two main centres—the fore- and mid- brain. Between the two, on their posterior surface, lies a third, very definite mass of neuropile, from which a pair of stalk-like processes project upwards towards the dorsal integument. Each stalk expands somewhat at its distal end and is capped by a number of closely packed nuclei, surrounded by a limited amount of protoplasm. Small ganglion-cells of a similar nature (ganglionic nuclei) are found in connection with the sensory centres in many Invertebrates, and in this instance they complete the striking resemblance that these stalked structures bear to the fungiform bodies of Insects.

It is to be noticed that the neuropile at the base of the stalks is condensed here and there to form glomeruli similar to those found in the olfactory centres of Arthropods and Vertebrates. The relations of the "fungiform bodies" to the cephalic sense-organs is doubtful. The cerebral ganglion is enclosed in a thick capsule composed of large granular stellate cells lodged within a loose vacuolated connective tissue; a protecting and supporting layer of somewhat similar structure is present around the cerebral ganglion and ventral cord of Gephyrea. In the meshes of this tissue lie a number of moderate-sized ganglion-cells, forming a sparse layer around the brain. A pair of long slender connectives pass on either side of the pharynx to the anterior ganglion of the ventral chain. Each arises by two roots derived respectively from the fore- and mid-

Fig. 6.

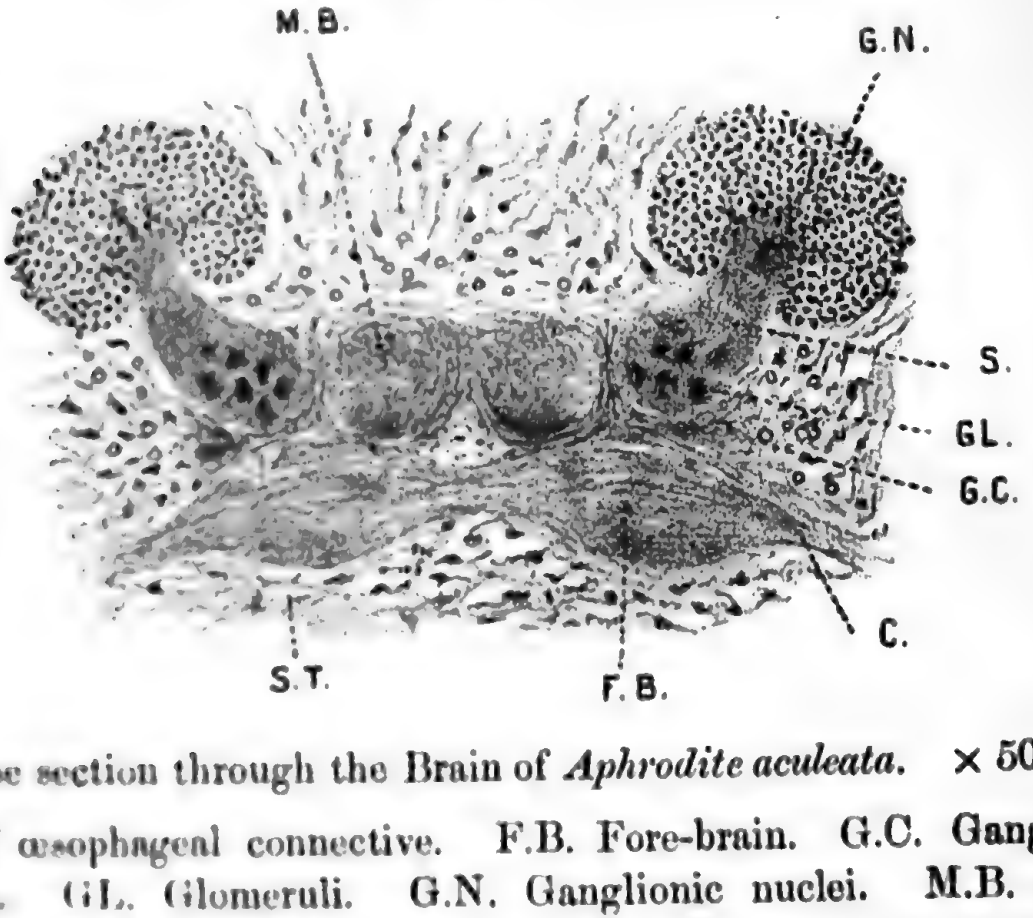

Transverse section through the Brain of *Aphrodite aculeata*. × 50.

C. Root of œsophageal connective. F.B. Fore-brain. G.C. Ganglion-cells. GL. Glomeruli. G.N. Ganglionic nuclei. M.B. Mid-brain. S. Stalk of "fungiform body." S.T. Supporting tissue.

brain. The ganglia of the ventral chain are transversely concentrated and show no external sign of their paired nature ; they are metamerically disposed and united to one another by a pair of closely approximated connectives. Each ganglion gives off three pairs of nerves, the largest of which arises furthest back and innervates the parapodia, while the two anterior pairs supply the trunk muscles and skin of the segment in which the ganglion lies. All parts of the ventral chain are enclosed in a thick fibrous neurilemma (subcuticular fibrous tissue), on the outer surface of which there is a delicate homogeneous membrane (fig. 7).

Fig. 7.

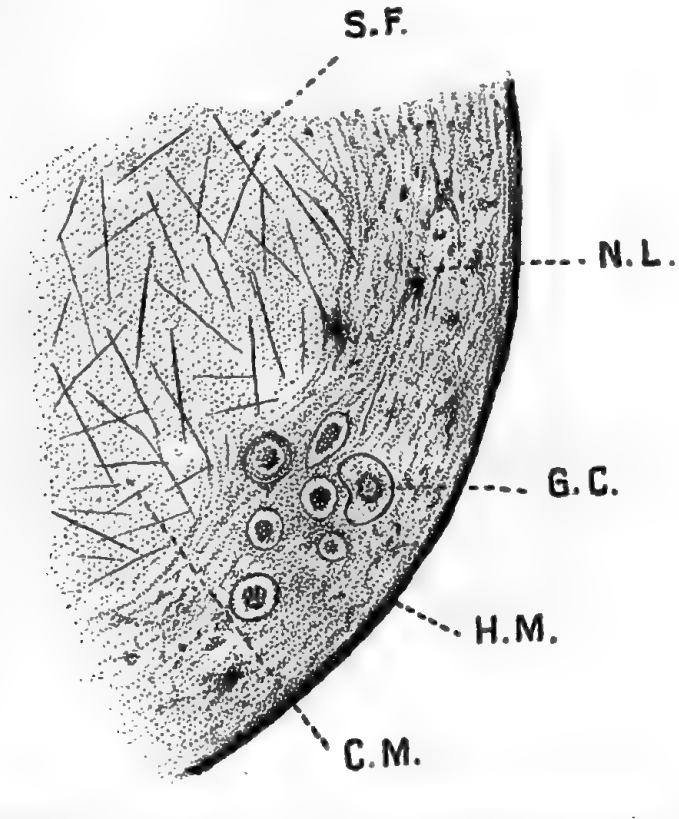

Part of a Ventral-chain Ganglion of *Aphrodite aculeata* in transverse section. × 150.

C.M. Central medulla. G.C. Ganglion-cells. H.M. Homogeneous membrane. N.L. Neurilemma. S.F. Supporting fibres.

Many delicate fibres derived from the neurilemma traverse the substance of the connectives and ganglia. Ganglion-cells are confined to the ventral surface of the ganglia; they are lodged in the meshes of the neurilemma.

In the upper specimen the anterior portion of the nervous system including the brain and 7 ventral chain ganglia is shown in an isolated condition. Below is an entire animal in which the nervous system is displayed *in situ* by the removal of the ventral body-walls from the mid-line.

Rohde, Zool. Beitr., Bd. ii. 1890, p. 1.

D. 7. Two specimens of the nervous system of an Earthworm (*Lumbricus terrestris*) showing the anterior part isolated and the whole system *in situ*.

The cerebral ganglion is small and bilobed. It is situated above the posterior part of the buccal cavity in the third body-segment, and is united by a pair of fibrous connectives to the ventral cord.

The latter lies free in the body-cavity, and swells slightly within each segment to form a ganglion, from which three pairs of nerves are given off to the body-walls. Between the ganglia, the cord is almost, though not quite, free from ganglion-cells. The central nervous system is surrounded by a neurilemma, in which two layers are distinguishable : (i.) an outer layer largely composed of longitudinal muscle-fibres, (ii.) an inner cuticular layer. Within the cuticle lie the connectives and ganglia embedded in a supporting fibrous tissue (? neuroglia) (fig. 8). Three medullated giant fibres run along the dorsal surface of the cord; their relations to the rest of the system are still obscure, but it is certain that at the hinder end of the cord the two lateral

Fig. 8.

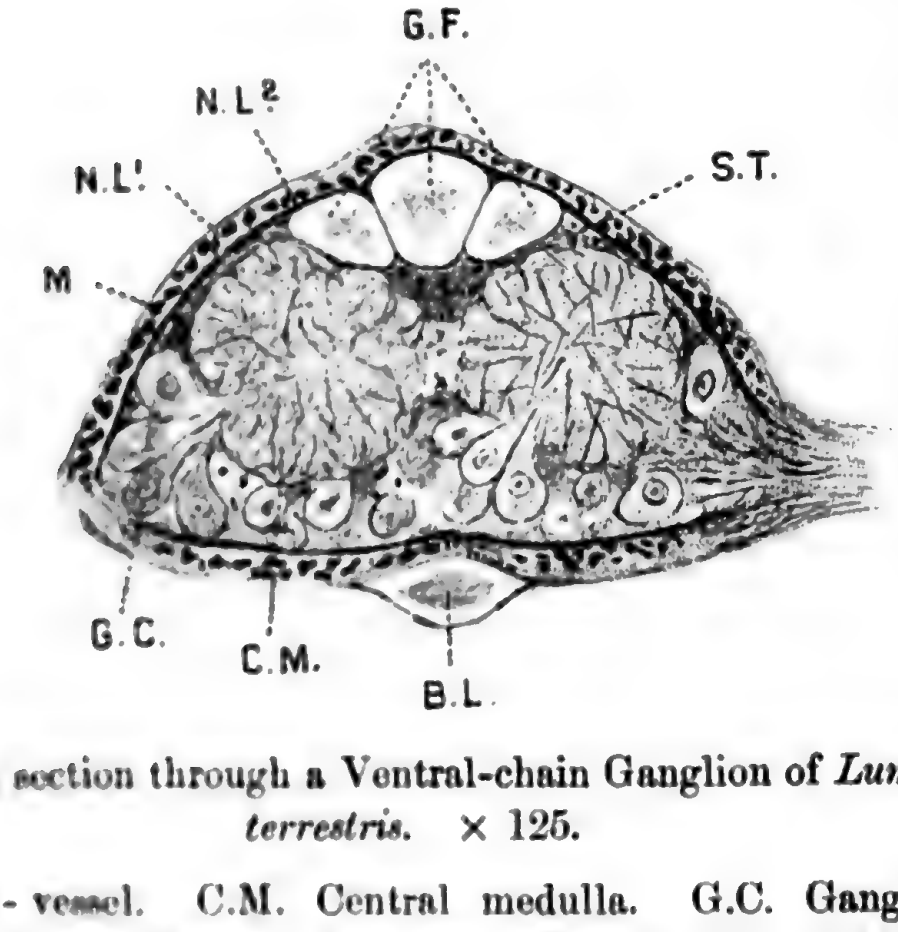

Transverse section through a Ventral-chain Ganglion of *Lumbricus terrestris*. × 125.

B.L. Blood-vessel. C.M. Central medulla. G.C. Ganglion-cells. G.F. Giant fibres. M. Muscle-fibres. NL^1, NL^2. The two layers of neurilemma. S.T. Supporting tissue.

fibres are in connection with ganglion-cells that lie in pairs on the ventral surface of a certain number of the posterior ganglia of the chain. Anteriorly the lateral fibres are said to break up in the subœsophageal ganglion. The median fibre apparently arises from cells in the same ganglion. Branches from all three fibres have been seen to enter the lateral nerves. It is probable that the giant fibres act as a direct path of communication between all regions of the nervous system, and are particularly concerned in bringing about the simultaneous contraction of the whole body-wall, such as takes place when the worm shoots back into its burrow. In creeping, contraction occurs slowly segment by segment. The co-ordination of this segmental contraction is apparently due, not so much to connections within the central nervous system as to an orderly sequence of independent stimuli, each of which is caused by the stretching of the integument of any one segment by the contraction of the longitudinal muscles of the segment in front.

Friedländer, Zeits. wiss. Zool., Bd. xlvii. 1888, p. 47, & Bd. lviii. 1894, p. 661 (*Anat.*).

Friedländer, Arch. ges. Physiol., Bd. lviii. 1894, p. 168 (*Physiol.*).

D. 8. An Earthworm (*Lumbricus terrestris*) with the ventral body-walls removed to show the nervous cords, their ganglia and lateral branches. O. C. 1296. *Hunterian.*

HIRUDINEA.

D. 9. The ventral body-walls of a Leech (*Hirudo medicinalis*) with the nervous system exposed from the dorsal aspect. The central system lies amongst the parenchyma internal to the body-walls. The cerebral ganglion is a small bilobed body situated close behind the jaws on the upper surface of the pharynx; it is of very simple construction and probably, as its removal causes no appreciable difference in the actions of the animal, differs little if at all in function from the ganglia of the ventral chain. It innervates the cephalic sense-organs, and jaws. A pair of extremely short connectives unite the cerebral ganglion around the anterior part of the pharynx to a series of (apparently) 23 transversely concentrated ventral-chain ganglia. The first of these (subœsophageal ganglion) is of some size and represents the four anterior ganglia of the chain ; the following 21 are simple rounded masses, situated segmentally, and each giving off two pairs of nerves to the body-walls of its segment. The terminal ganglion is a compound structure like the first, and represents a longitudinal concentration of at least 7 pairs of ganglia ; it supplies the anal sucker. The successive post-oral ganglia are united to one another by three connectives—a lateral pair similar to those of other worms and a delicate median ventral cord (nerve of Faivre) that originates in the subœsophageal ganglion and extends throughout the length of the chain ; it is lost in the dorsal parts of each ganglion (figs. 9 and 10).

Fig. 9.

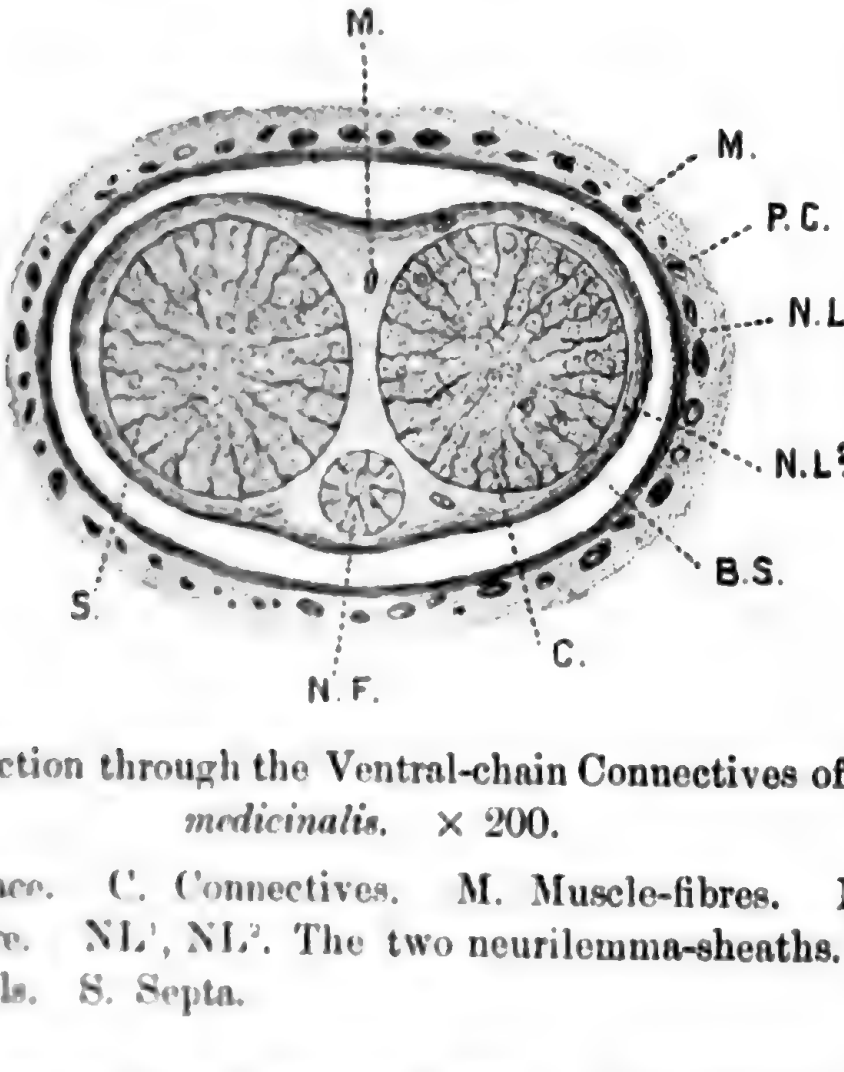

Transverse section through the Ventral-chain Connectives of *Hirudo medicinalis*. × 200.

B.S. Blood-space. C. Connectives. M. Muscle-fibres. N.F. Nerve of Faivre. NL^1, NL^2. The two neurilemma-sheaths. P.C. Pigment-cells. S. Septa.

Each simple post-oral ganglion consists of a laterally paired mass of neuropile, invested on its lateral and ventral surfaces by unipolar ganglion-cells of different sizes. Two of these at the anterior end of the ventral surface of each ganglion are of colossal proportions (·1 mm. diam.), and contribute fibres to the lateral nerves of the same side.

There are no giant fibres in the connectives. The ventral cord is surrounded by a double neurilemma-sheath—(i.) an outer sheath that loosely envelopes the cord and extends for some distance along the lateral nerves: it forms the outer wall of the perineural blood-vessel; (ii.) an inner sheath, that closely invests the cord and binds the three connectives into a single strand. Offshoots from this inner sheath penetrate amongst the fibres of the connectives and dip into the substance of the ganglia, where they separate the ganglion-cells into three definite groups and form an investment to the central medulla.

Fig. 10.

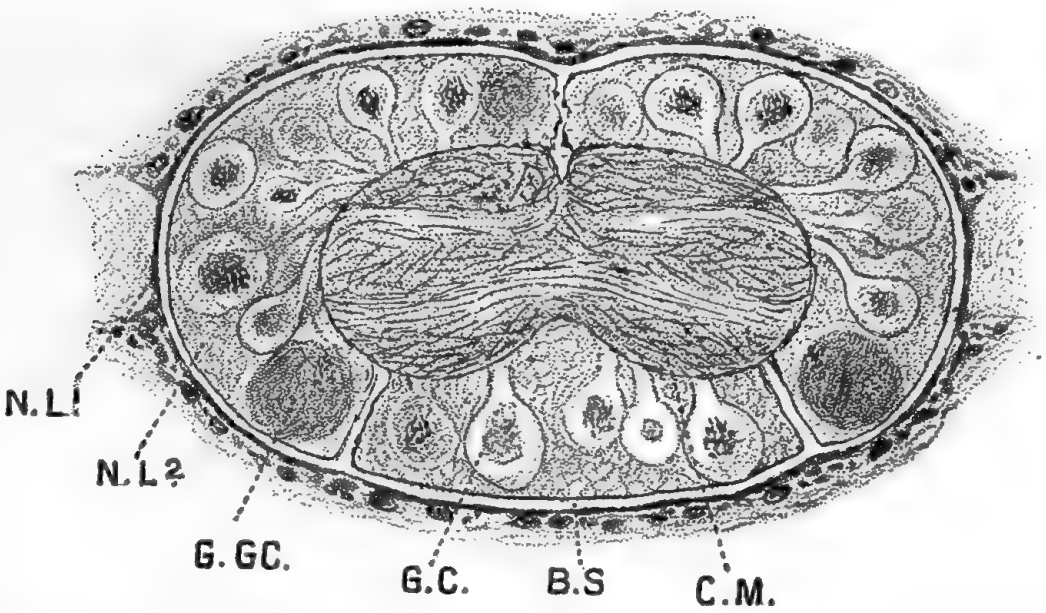

Transverse section through a Ventral-chain Ganglion of *Hirudo medicinalis*. × 125.

C.M. Central medulla. G.C. Ganglion-cells. G.GC. Giant ganglion-cells.

Both sheaths contain many muscle-fibres.

The outer neurilemma-sheath has been removed and black paper placed beneath the nerve-cord. O. C. 1295 B.

Leuckart, Die Parasiten des Menschen, Bd. i. 1894, p. 579.

GEPHYREA.

D. 10. The anterior and posterior parts of the body-walls of a Gephyrean (*Sipunculus nudus*) showing the nervous system. The cerebral ganglion is a rounded mass with slight lateral swellings, situated upon the dorsal surface of the œsophagus at the base of the tentacles. Nerves for the tentacles arise from its postero-lateral surface, and upon its anterior face are a number of finger-like processes of doubtful function (possibly sensory). It has been shown that a special reflex connection exists between the cerebral ganglion (a purely sensory centre?) and the motor centre that controls the retractors of the introvert. Two long (11 mm.) circum-œsophageal connectives (from which the nerves for the retractors of the introvert are given off) unite the cerebral ganglion to the ventral cord. The latter for the first part of its course lies loose in the body-cavity accompanied by a strand of muscle (mostly removed in the specimen); about 10 mm. in front of the nephridia it becomes closely applied to the body-wall, and runs in this position between two bundles of the longitudinal muscle-layer to the posterior extremity of the body, where it terminates in a spindle-shaped enlargement.

So long as the ventral cord lies close to the body-wall it gives off, about the middle of each circular muscle-band, a pair of lateral nerves, that run between the circular and diagonal muscle-layers towards the dorsal mid-line, but do not meet to form a complete ring round the body. In front of the nephridia the nerves come off more irregularly and are enveloped in strands of muscle; they supply the anterior end of the trunk and the introvert. No nerves arise from the cord within the introvert. The cord is a mixed motor and sensory centre in which impulses are slowly propagated (100–200 mm. per second) in either direction. The cerebral ganglion consists of a central mass of neuropile surrounded by unipolar ganglion-cells varying in size from 4-55 μ, and arranged in fairly definite groups; a few bipolar cells occur in the neighbourhood of the digitiform processes. The substance of the ganglion is permeated by a network of neuroglia fibres, and it is enclosed in a protective layer of large stellate cells (neuroglia cells?). The cord is composed of a fibrous core covered on its ventral surface by ganglion-cells; it shows no sign of ganglionation or lateral duplicity. It is surrounded by a double sheath of neurilemma, the space between the two being filled with stellate cells similar to those around the cerebral ganglion. The posterior enlargement does not differ in structure from the rest of the cord; its size is mainly due to an increase of the stellate cells between the neurilemma-sheaths.

In the specimen the introvert is retracted. A red rod has been placed in the mouth and black paper beneath the different parts of the nervous system.

Metalnikoff, Zeits. wiss. Zool., Bd. lxviii. 1900, p. 293 (*Anat.*).

Uexkull, Zeits. Biol., N.F. Bd. xv. 1896, p. 1 (*Physiol.*).

ARTHROPODA.

Bethe, Arch. f. ges. Physiol., Bd. lxviii. 1897, p. 449 (*Physiol.*).

The central nervous system agrees with that of Worms in its bilateral symmetry and general plan of construction, but is always entirely free from the integument. The cerebral ganglion is comparatively simple in many cases, but shows a gradual increase in size and complexity of structure as the cephalic sense organs become more perfect and the intelligence more pronounced. This brain development is noticeable in the increasing complication of the optic ganglia and in the development of glomerular condensations in the neuropile of the antennary lobes very similar to those in the olfactory lobes of Vertebrates, but is particularly marked by the appearance, among the higher orders, of peculiar cerebral organs (fungiform bodies) whose development seems to be linked in some obscure way with the growth of the intelligence. The visceral system is always clearly defined. Its centres of origin (œsophageal ganglia) show a gradual migration from their original post-oral position towards the cerebral ganglion, and finally fuse with it, although always united by a post-oral commissure. The ventral chain in all except the lowest groups shows a considerable degree of concentration laterally, but varies in longitudinal concentration within the widest limits—from the Phyllopods with a pair of ganglia to every pair of appendages, to the Brachyura, some Arachnids and Insects, in which it is represented by a single post-oral ganglionic mass.

The segmental character of the nervous system is functional as well as structural, for each ganglion forms an independent reflex centre for the activities of its innervation area. Coordination is mainly due to transmission of stimuli from ganglion to ganglion, but also, at least as concerns locomotive movements, to the influence of a definite centre of co-ordination—the subœsophageal ganglion. The cerebral ganglion exerts a higher controlling influence over the rest of the system than in Worms, owing to its increased inhibitory power and to the production of the general muscle tonus (state of constant partial contraction). It is hard to say whether any power of initiation should be assigned to the cerebral ganglion—its removal generally results in the cessation of spontaneous locomotion, but this may be due to decrease in muscle-power following upon loss of tonus.

CRUSTACEA.

D. 11. The isolated nervous system of a Phyllopod (*Apus productus*). The central system is in an essentially primitive

Fig. 11.

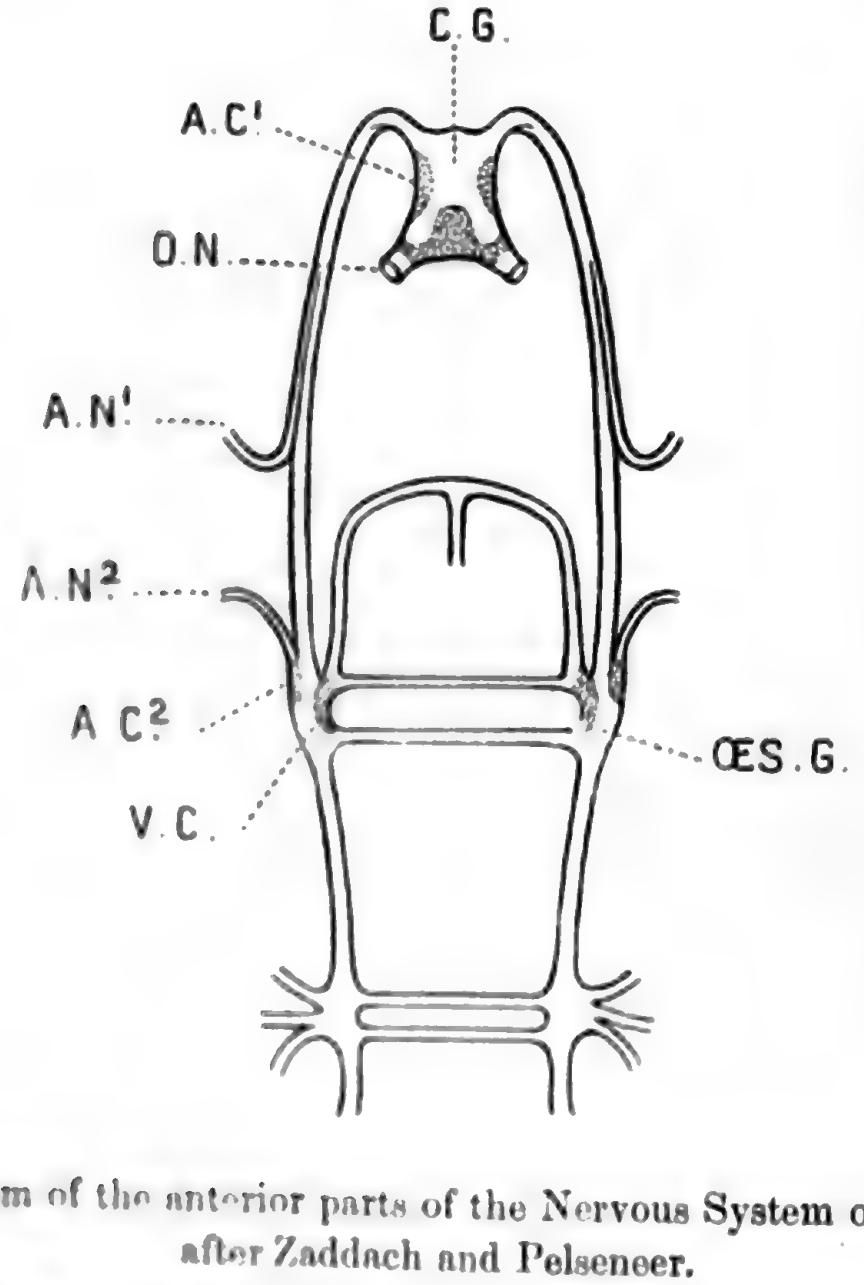

Diagram of the anterior parts of the Nervous System of *Apus*, after Zaddach and Pelseneer.

A.C¹, A.C². Centres for antennary nerves I. and II. A.N¹, A.N². Antennary nerves. ŒS.G. Œsophageal ganglion. C.G. Cerebral ganglion. O.N. Optic nerve. V.C. Visceral centre.

condition, and reminds one, in the ladder-like construction of its ventral chain, of that of certain Tube-worms (*e. g.* Serpula). The cerebral ganglion is a small quadrilateral body, situated in front of the œsophagus close beneath the eyes, and so placed that its proper ventral surface faces upwards and its anterior border backwards. It gives off a pair of nerves from the outer angles of its true anterior end to the eyes. The first pair of antennæ are supplied by a pair of small nerves that seem to rise from the circumœsophageal connectives; their true centres of origin are, however, situated in the lateral parts of the cerebral ganglion. On a level with the posterior margin of the mouth, each circumœsophageal connective enlarges to form an œsophageal ganglion, which gives off two nerves —a small one from its outer aspect to the second antenna, and a visceral nerve from its inner surface ; the two ganglia are united by a double commissure. The condition of the antennary nerves in *Apus* suggests that the direct origin of these nerves in the higher Crustacea from the cerebral ganglion is the result of an anterior concentration of centres originally separate and post-oral in position. The ganglia of the ventral chain are paired and, in the anterior region of the body, widely separate. They are united to one another transversely by a double commissure and longitudinally by a pair of connectives. In the posterior part of the body the ladder-like appearance of the chain is lost owing to the shortening of the commissures and connectives, although the individuality of the ganglia is maintained. The ganglia correspond in number and position to the appendages, and are thus more numerous than the body segments. The second pair of maxillæ alone seem to have no corresponding ganglia; their nerves arise from the connectives. The specimen is so small that only the most important of the above-mentioned characters are visible, such as the wide lateral separation of the ventral-chain ganglia and their gradual approximation to one another posteriorly. O. C. 1302 L.

Pelseneer, Quart. Journ. Micro. Sci., vol. xxv. 1885, p. 433.

D. 12. Two specimens of the nervous system of a Barnacle (*Lepas anatifera*). The small bilobed cerebral ganglion lies on the anterior wall of the œsophagus at its entry into the stomach; it gives off a large nerve on either side to the peduncle, and an extremely fine pair (not visible in the specimens) from its anterior surface to the vestigeal eye. The visceral nerves arise from the circumœsophageal connectives close behind the cerebral ganglion. The sub-œsophageal ganglion is the largest and most important nerve-centre in the body; it sends a large pair of nerves from its dorsal surface to the adductor scutarum muscle, and also supplies the mouth-parts and first pair of cirri. It is followed by a chain of four segmentally placed ganglia, each of which gives off a pair of nerves to the cirri of its segment; the terminal ganglion is slightly larger than the others, and represents a fusion of two, it innervates the last two pairs of cirri and the penis. The ganglia are moderately concentrated in a transverse direction, but the connectives—particularly at the anterior end of the chain—are distinctly separate. Between them runs a small median nerve (not visible in the specimens), that arises in the sub-œsophageal ganglion and is ultimately distributed to the rectum. In the upper specimen the nervous system is shown in an isolated state, and in the lower from the right side within the body. O. C. 1302 K.

Gruvel, Arch. Zool. Exp., sér. 3, t. i. 1893, p. 489.

D. 13 A Stomatopod (*Lysiosquilla*, sp.) with the nervous system displayed from above. The small quadrilateral cerebral ganglion lies in the second cephalic segment; it gives off three large pairs of nerves respectively to the eyes and to the two pairs of antennæ, as well as a few delicate branches (not shown in the specimen) to the neighbouring muscles and integument. The circumœsophageal connectives, owing to the extended character of the head-region, are remarkably long in front of the mouth; on either side of the œsophagus they swell slightly to form a pair of small œsophageal ganglia, that give off the visceral nerves and are united together behind the œsophagus by a single commissure. A short distance behind the œsophagus the connectives join the subœsophageal ganglion—an elongated mass formed by the longitudinal concentration and fusion of eight pairs of ganglia; it innervates the mandibles, maxillæ, and five anterior pairs of thoracic appendages. The last three thoracic and the six abdominal ganglia are segmental in position; each gives off three pairs of nerves, distributed respectively to the appendages and lateral muscles of the same segment and to the flexor muscles of the one behind. The terminal ganglion supplies the sixth abdominal segment and the telson. All the ventral-chain ganglia show a high degree of transverse concentration, combined (except in the case of the subœsophageal ganglion) with well-marked longitudinal separation. The connectives are bound up in a common neurilemma-sheath.

Bellonci, Ann. Mus. Civ. Stor. Nat. Genova, vol. xii. 1878, p. 518.

D. 14. Two specimens of the nervous system of a Lobster (*Homarus vulgaris*). The cerebral ganglion is lodged immediately below the bases of the eye-stalks; it is roughly quadrilateral in shape, with a pair of conspicuous rounded eminences (globuli) upon its lateral margins. Each of its upper angles is connected by a nervous tract to a rod-shaped optic ganglion that lies within the eye-stalk; from its lower angles arise the antennary and integumentary nerves; the circumœsophageal connectives are given off from the middle of the ventral border. The cerebral ganglion, as in other Decapods, has considerable structural complexity (fig. 12). Three regions can be traced in it, of which the anterior two correspond probably to the proto- and deuto-cerebrum of the Insect brain, while the third is a part of the tritocerebrum peculiar to Crustacea. The protocerebrum is the optic centre; it consists of the optic ganglia, and of a quadrilateral mass (protocerebral lobes) that forms the upper part of the cerebral ganglion. The protocerebral lobes are separated by a slight median furrow; they are traversed by numerous commissural fibres, and have in the middle of their substance a transverse bar of dense neuropile that probably represents the corpus centrale of the Insect.

Each optic ganglion contains four neuropile masses placed at intervals between the retina and the optic tract and united together by decussating fibres; upon the dorsal surface of the centre nearest the tract is a small excrescence that may possibly represent the fungiform body of the Insect brain in a very rudimentary state.

There are two pairs of centres in the deutocerebrum—the lateral lobes (globuli) united by a stout commissure, and, internal to them, two smaller neuropile masses contiguous in the mid-line: each pair gives rise on either side to a root of the first antennary nerve. The nature of the globuli is obscure; some compare them with the fungiform bodies, others with the antennary lobes of Insects. In support

Fig. 12.

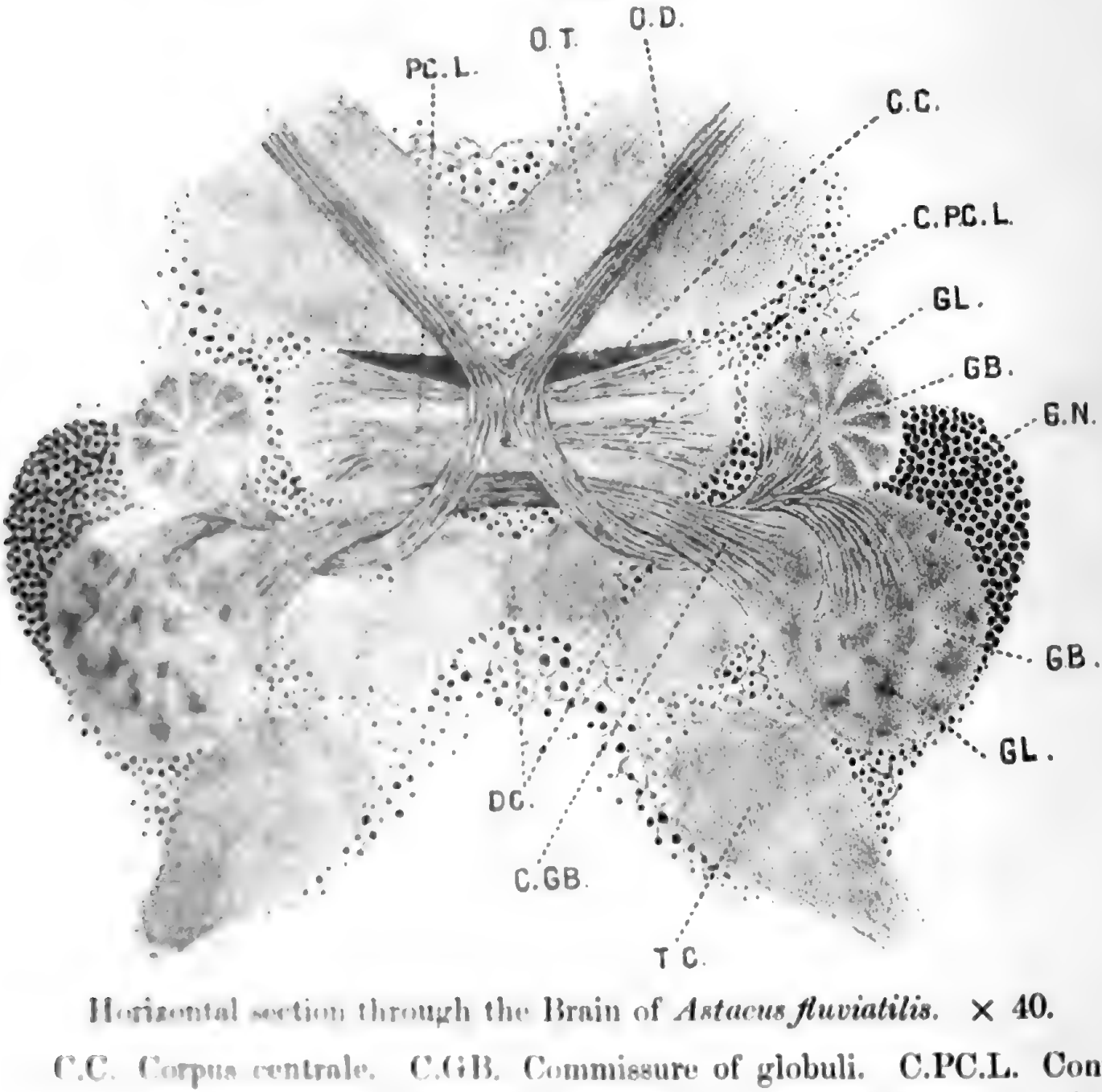

Horizontal section through the Brain of *Astacus fluviatilis*. × 40.

C.C. Corpus centrale. C.GB. Commissure of globuli. C.PC.L. Commissures of protocerebral lobes. D.C. Deutocerebrum. GB. Globulus. GL. Glomeruli. G.N. Ganglionic nuclei. O.D. Decussating bundle of optic tract. O.T. Optic tract. PC.L. Protocerebral lobe. T.C. Tritocerebrum.

of the latter view, it may be said that the globuli of Crustaceans agree with the antennary lobes of Insects in having glomerular condensations of their neuropile, in giving off a root to the antennary nerve, and in receiving a large decussating tract from the fungiform body of the opposite side, assuming such to be the nature of the protuberance on the optic ganglion of the Lobster.

The tritocerebrum constitutes the centre for the second antennary and the tegumentary nerves.

The complicated structure of the cerebral ganglion is apparently mainly due to its connection with highly developed sense-organs, yet the fact that its removal causes more disturbance to the normal activities of the creature than in Worms—particularly by destroying the capability of spontaneous locomotion—suggests that it possesses to some degree, at any rate, the power of controlling, or perhaps even of initiating, activities in the rest of the nervous system.

A pair of small œsophageal ganglia are situated upon the circumœsophageal connectives on a level with the œsophagus, but some distance in front of the post-œsophageal commissure by which they are united.

Each of them gives off, besides a few delicate filaments to the œsophagus, two stout nerves. One of these runs forward, parallel to the œsophageal connectives, half-way to the cerebral ganglion, and at this point unites with its fellow of the opposite side and with a median nerve derived from the cerebral ganglion, to form the gastric nerve—a trunk that runs in the median plane along the anterior and dorsal surfaces of the stomach to the pylorus, at which point it forms a small ganglion and divides into two lateral branches which are distributed to the intestine. The second of the two nerves supplies the upper lip and is connected by a branch to the components of the gastric nerve where they unite to form the median trunk. The subœsophageal ganglion innervates the mouth appendages and gives off from its dorsal surface a few nerves to the body-muscles; it is composed of six pairs of ganglia fused together. The removal of this ganglion occasions [in the Crayfish (*Astacus fluviatilis*)] the loss of all power of co-ordinated locomotion, although other co-ordinated movements of the limbs can still take place. The rest of the ventral-chain ganglia (five thoracic and six abdominal) are transversely concentrated but longitudinally widely separated. They are situated segmentally, and each gives off a pair of nerves to the appendages of its segment and a second pair to the neighbouring trunk-muscles. In the abdominal region, a third pair of purely motor nerves arise from the connectives behind each ganglion and are distributed to the great abdominal flexor. The terminal ganglion innervates the 6th abdominal segment and the telson; it also gives off a small rectal nerve, probably comparable to the median nerve in the ventral cord of *Lepas*.

The connectives of the ventral chain share in the lateral concentration seen in the ganglia; in the thorax they lie side by side and (except between the third and fourth ganglia where the sternal artery passes between them) are bound up in a common neurilemma-sheath. In the abdomen they are closely contiguous. The ganglion-cells of the central system are mostly unipolar, and vary much in size, from large pear-shaped cells ·2 mm. in diameter to ganglionic nuclei, in which the nucleus is surrounded by a mere film of protoplasm. The latter occur always in masses in connection with certain definite parts of the central system—*e. g.*, the globuli and a restricted area of the subœsophageal ganglion. The nerve-fibres derived from ganglion-cells that lie within the central system are tubular, with a thick neuroglia-sheath (in which myelin may occur) containing a semifluid substance. After leaving the ganglion-cell they give off a few lateral twigs, that break up in the neuropile and provide a means of communication between the different nerve-elements. The main fibre then passes either directly into one of the peripheral nerves and is distributed to the muscles, or runs within one of the connectives to a neighbouring or distant ganglion and there breaks up in the neuropile. The sensory fibres are very delicate; they arise, as in Worms, from cells in or close beneath the skin, and enter the ganglia as part of a peripheral nerve. Within the ganglion they divide into anterior and posterior branches, that run in the connectives to neighbouring or distant ganglia.

The ganglion-cells cover the lateral and ventral surfaces of the neuropile masses of the ventral-chain ganglia; the connectives occupy the dorsal surface. In each connective there is a giant nerve-tube; it originates in a large cell on the ventral surface of the cerebral ganglion and runs the whole length of the chain without apparently giving off lateral branches; it finally divides and passes into the nerves of the tail-fin (uropodites). The giant fibres in their origin and distribution present a striking parallel to Mauthner's fibres in the spinal cord of Fishes, and it has been suggested in both cases that possibly they put the steering and balancing apparatus under the direct control of the brain.

In the upper specimen the origin and course of the visceral nerves are seen from the left side, indicated by black paper; in the lower the nervous system is shown, as a whole, in its natural position from above. The left eye has been removed to expose the antennary nerves.

O. C. 1302 I.

Krieger, Zeits. wiss. Zool., Bd. xxxiii. p. 527 (*Anat.*).
Allen, Quart. Journ. Micr. Sci., vol. xxxvi. 1894, p. 483, & vol. xxxix. 1896, p. 33 (*Histol.*).
Bethe, Arch. f. Phys., Bd. lxviii. 1897, p. 449 (*Physiol.*).

D. 15. A Lobster (*Homarus vulgaris*), dissected to show from the ventral aspect the cerebral ganglion and ventral chain. The origins of the optic and antennary nerves are shown, also the divergence of the connectives for the passage of the œsophagus.

The degree of transverse approximation of the connectives in the region of the thorax has been made apparent by the removal of the common neurilemma-sheath, by which they are naturally bound together. O. C. 1301.
Hunterian.

D. 16. The cerebral ganglion with the eyes and the principal nerves given off from the ganglion, displayed *in situ*, from a Lobster (*Homarus vulgaris*). O. C. 1303. *Hunterian.*

D. 17. ***Scyllarus arctus,*** with the nervous system exposed. The cerebral ganglion is remarkable for its relatively large size; it gives off the usual nerves to the cephalic sense-organs, but the optic tracts and ganglia, owing to the great breadth of the head, are peculiarly long and slender. The subœsophageal and thoracic ganglia are longitudinally approximated, but (with the exception of the components of the subœsophageal ganglion) are not fused together. Between the 2nd and 3rd and 3rd and 4th thoracic ganglia the connectives are quite separate, leaving in the latter position a large opening between them for the passage of the sternal artery; elsewhere they are bound together by a common neurilemma-sheath. The last thoracic ganglion is connected with a chain of six segmentally placed abdominal ganglia. They are transversely concentrated, and are connected together by an apparently single cord, the result of the transverse concentration of the paired connectives.

Bouvier, Ann. Sci. Nat., sér. 7, t. vii. 1889, p. 73.

D. 18. The isolated nervous system of a Hermit Crab (*Eupagurus bernhardus*). The transverse and longitudinal concentration of the components of the subœsophageal-thoracic mass is greater than in *Scyllarus,* but posterior to the subœsophageal centre the outlines of four ganglia can be traced upon the ventral surface of the mass. Three of these are situated in front of the perforation for the sternal artery, and respectively innervate the three anterior pairs of thoracic appendages. The fourth centre is formed by the fusion of the last two thoracic ganglia with the first abdominal, it innervates the two posterior pairs of thoracic limbs and the anterior part of the abdomen. The mass is perforated between the 3rd and 4th thoracic ganglia by the sternal artery, and has also two minute openings between the 2nd and 3rd and 1st and 2nd; beyond the indication afforded by these apertures, all external traces of connectives are lost. The abdominal chain consists of five pairs of transversely concentrated ganglia united by separate connectives.

D. 19. A Spider-Crab (*Maia squinado*) dissected from above. The cerebral and œsophageal ganglia, with the nerves that arise from them, are essentially similar to those of the Lobster, except for the great development of the integumentary nerves given off from the posterior corners of the cerebral ganglion. The circumœsophageal connectives are remarkably long, owing to the position of the ganglia of the ventral chain. The latter are concentrated to the maximum degree in the longitudinal direction, and are fused together to form an oval mass in the middle of the cephalothorax, from which nerves radiate to the appendages and body. The large appendicular nerves are composed of bundles of small fibres without a common investment. From the dorsal surface of the central mass, at its anterior end, a pair of small nerves are given off to be distributed to the roof of the gill-chamber, and from the posterior end of the mass a bundle of nerves pass into the abdomen.

O. C. 1303 A *b*.

Audouin & Milne-Edwards, Ann. Sci. Nat., t. xiv. 1828, p. 92.

D. 20. A King-Crab (*Limulus polyphemus*) dissected from the dorsal aspect. The entire cephalothoracic part of the central nervous system is concentrated around the oral end of the œsophagus in the form of an oval ring. The præoral part of the ring represents the cerebral ganglion; it projects anteriorly as a subconical, feebly bilobed mass (protocerebrum) from whose anterior end nerves are given off to the lateral and median eyes, and to a ventral integumentary pit of unknown function situated in front of the mouth. From its dorsal surface, near its union with the lateral parts of the ring, arise a pair of delicate integumentary nerves that innervate the ventral skin of the cephalothorax external to the limbs. Between the protocerebrum and the lateral parts of the ring are a pair of centres (indistinguishable superficially) united by a small præ-oral commissure; they form part of the cerebral ganglion and give off nerves to the chelicerae and viscera. The protocerebrum is remarkable for an excessive development of a pair of outgrowths similar in many respects to the fungiform bodies of the Insect-brain (fig. 13). Each of them consists of an arborescent mass of peculiarly dense neuropile coated by a thick layer of ganglionic nuclei; they cover the whole surface of the protocerebral lobes with the exception of a small area on the dorsal surface. Their function is entirely unknown.

Fig. 13.

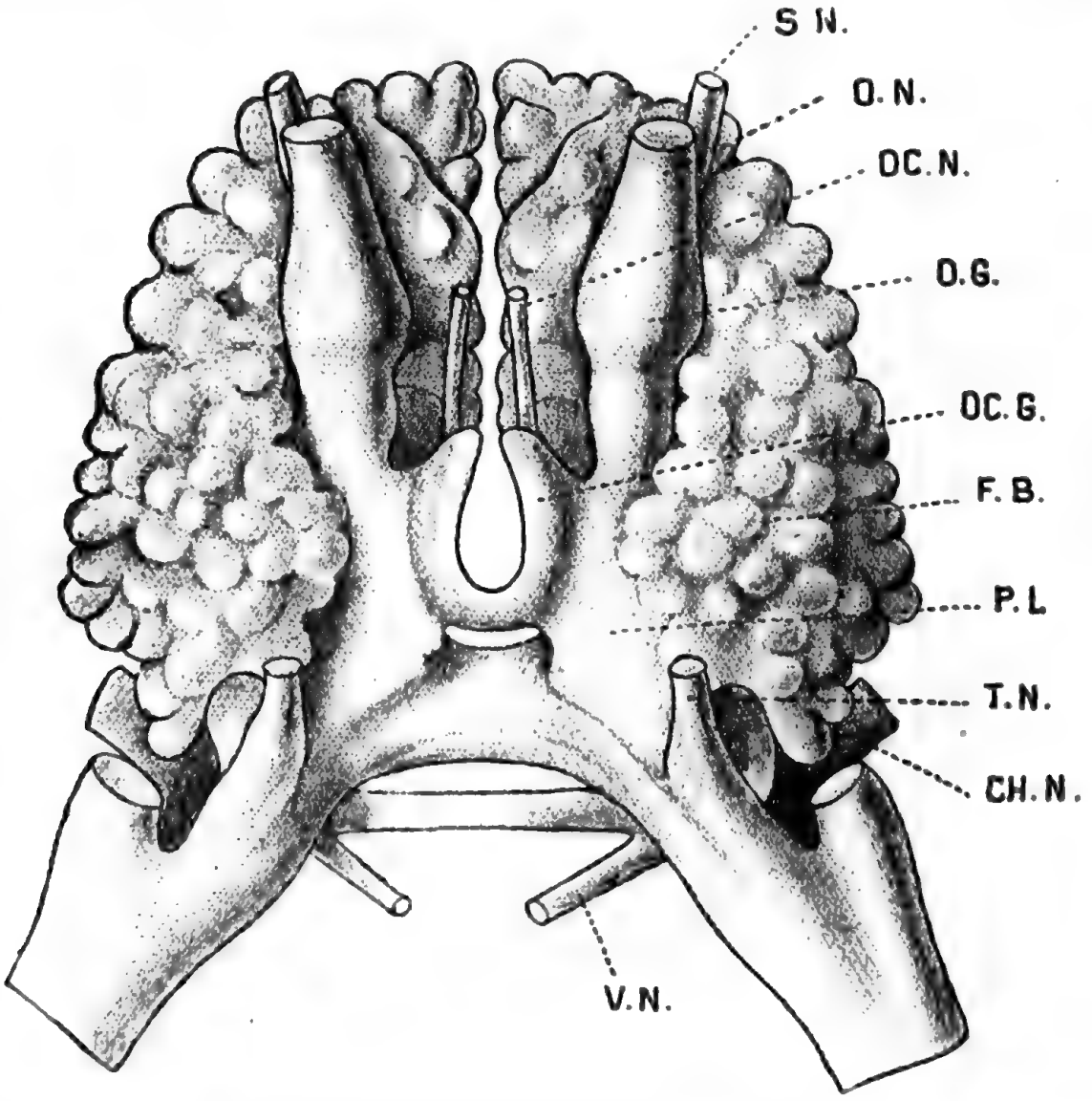

From an enlarged model of the Brain of *Limulus*, after Viallanes.

CH.N. Nerve to chelicerae. F.B. Fungiform body. O.G. Optic ganglion. O.N. Optic nerve. OC.G. Ocellary ganglion. OC.N. Ocellary nerve. P.L. Protocerebral lobe. SN. Nerve to sensory pit. V.N. Visceral nerve.

The lateral and posterior parts of the ring are composed of six pairs of ganglionic masses intimately fused together longitudinally and united transversely by a series of commissures; the posterior pair are fused in the mid-line to form a single "post-oral" ganglion.

Seven pairs of integumentary nerves are given off from the dorso-lateral margins of the ring, and from its ventro-lateral border six pairs of pedal nerves, distributed respectively to the five pairs of walking appendages and to the operculum. A pair of fine nerves for the chilaria arise from the ventral surface of the "post-oral" ganglion. The ring is united posteriorly by connectives to a chain of six pairs of transversely concentrated ganglia, situated in the abdomen. From each of these, except the last, two pairs of nerves are given off—one to the appendages (gills) of the segment proper to the ganglion, the other to the integument. The latter are united on either side external to the bases of the limbs by a longitudinal connecting cord, parts of which only are to be seen in the specimen. The three posterior ganglia are fused together to form a single mass, which sends nerves to the last two pairs of gills, the hinder extremity of the abdomen, and the post-anal spine.

The central nervous system, together with the motor and some few sensory nerves, is enveloped by a large arterial blood-space; a pair of arteries—branches of the anterior aorta—open into the space on either side above the anterior part of the nerve-ring. Experiments upon this nervous system show that, although parts of it are much concentrated, each segmental centre is entirely independent in its actions, the regulation and orderly sequence of the movements of different segments being due to the transmission of stimuli from centre to centre, and not to the influence of any one specialized centre of co-ordination.

Viallanes, Ann. Sci. Nat., sér. 7, t. xiv. p. 405 (*Anat.*).
Hyde, Journ. Morph., vol. ix. 1894, p. 431 (*Physiol.*).

ARACHNIDA.

St. Remy, Arch. Zool. Exp., t. v *bis*, 1887, p. 1.

D. 21. The nervous system of a Scorpion (*Pandinus imperator*), exposed from the dorsal aspect. The main part of the central system lies in the cephalothorax and is concentrated around the œsophagus in a compact mass that represents the cerebral and first nine ventral-chain ganglia. The cerebral part of the mass is bilobed ; it innervates the median and lateral eyes and the cheliceræ. On either side of the œsophagus it is continuous with the anterior region of the large oval subœsophageal ganglion—a composite mass from which nerves are given off to the mouth, the pedipalpi, the four pairs of walking-legs, and the first four segments of the abdomen. The cephalothoracic mass is united by a pair of delicate connectives to a chain of three abdominal and four post-abdominal ganglia, all of which are transversely concentrated but are united by separate connectives. The last abdominal and the first three post-abdominal ganglia lie severally in the segments that they innervate, but the first two free abdominal ganglia are approximated to the cephalothoracic mass, being respectively two segments and one segment in advance of their nerve distribution. The terminal ganglion of the chain lies in the 4th post-abdominal segment; it supplies the 4th and 5th segments of the post-abdomen and the post-anal spine. The three posterior ganglia and their connectives show a marked increase in size compared with those in front of them, correlated no doubt with the great activity of the post-abdomen. O. C. 1297 B.

Blanchard, L'organisation du Règne Animal (Arachnides), 1852, p. 39.

D. 22. A Spider (***Avicularia avicularia***) dissected from the dorsal aspect. The central nervous system is extremely concentrated; it lies in the middle of the cephalothorax behind the mouth, encircling the horizontal part of the œsophagus and extending backwards beneath the stomach. The supraœsophageal part of the system is small and feebly bilobed; it innervates the eyes and rostrum. On either side of the œsophagus it is connected to the subœsophageal mass by a pair of ganglionic centres that give off nerves to the cheliceræ and viscera. The third and largest part of the central system lies beneath the œsophagus and stomach, separated from them by the entosternite; it has an oval form and is composed of six pairs of fused ganglionic centres that represent the ganglia of the ventral chain. From this mass nerves are given off to the pedipalpi, to the four pairs of walking-legs, and to the abdomen. Fibrous partitions, derived from the neurilemma, penetrate to a certain extent between the several centres of the subœsophageal mass. O. C. 1300 A.

Schimkewitsch, Ann. Sci. Nat., sér. 6, t. xvii. 1884, p. 15.

D. 23. A *Pentastomum tænioides*, in which parts of the nervous system are shown from above (fig. 14). The central system is in a degenerate condition; it consists of a bilobed ganglionic mass, situated behind the œsophagus. Its lateral parts are united in front of the œsophagus by a delicate commissure, in which there is no sign of a præ-oral ganglion. The ganglionic mass gives rise from its posterior surface to a pair of longitudinal nerves of some size that extend to the hinder part of the body; it also gives off from its anterior and lateral regions several small nerves to the alimentary canal, body-muscles, and cephalic hooks and papillæ. The specimen shows little beyond the main ganglionic mass. O. C. 1294 c.

Spencer, Quart. Journ. Micr. Sci., vol. xxxiv. 1893, p. 33.

Fig. 14.

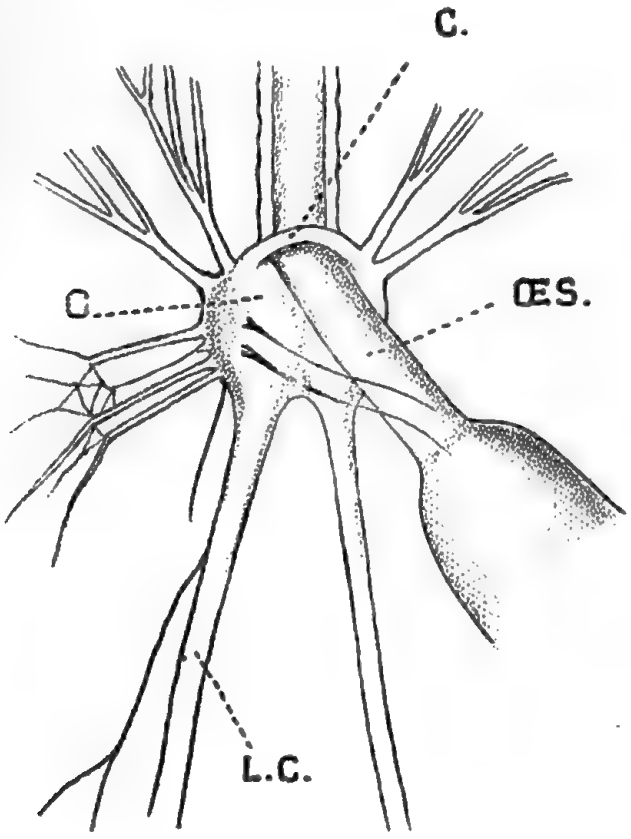

The Nervous System of *Pentastomum tænioides,* after Leuckart.

C. Præ-oral commissure. G. Ganglion. L.C. Longitudinal cords. ŒS. Œsophagus.

MYRIAPODA.

D. 24. Two specimens of the nervous system of a Centipede (*Ethmostigmus rubripes*). The central system shows the Arthropod type in a very simple condition; it consists of a bilobed cerebral ganglion of relatively uncomplicated structure, and of a chain of 22 transversely concentrated post-oral ganglia, united to one another by transversely separate connectives. The cerebral ganglion (fig. 15) is composed of two pyriform lobes on either side, situated one above the other with their long axes at right angles. The dorsal pair are set transversely to the axis of the body, and give off from their pointed outer ends a bundle of optic nerves. The ventral pair innervate the antennæ; they lie slightly in advance of the dorsal lobes with their axes longitudinal. In front they are continued into the antennary nerves, and behind into the circumœsophageal connectives. Glomerulated condensations occur in their neuropile similar to those found in the antennary lobes of other Arthropods, and from their posterior parts nerves are given off to the viscera. The subœsophageal ganglion is larger than the rest of those in the ventral chain; it innervates the jaws and other mouth appendages. The succeeding 21 ganglia are similar to one another. They are arranged segmentally, and each gives off four pairs of nerves—one to the limbs and the rest to the body-wall and tracheæ of the same segment.

Fig. 15.

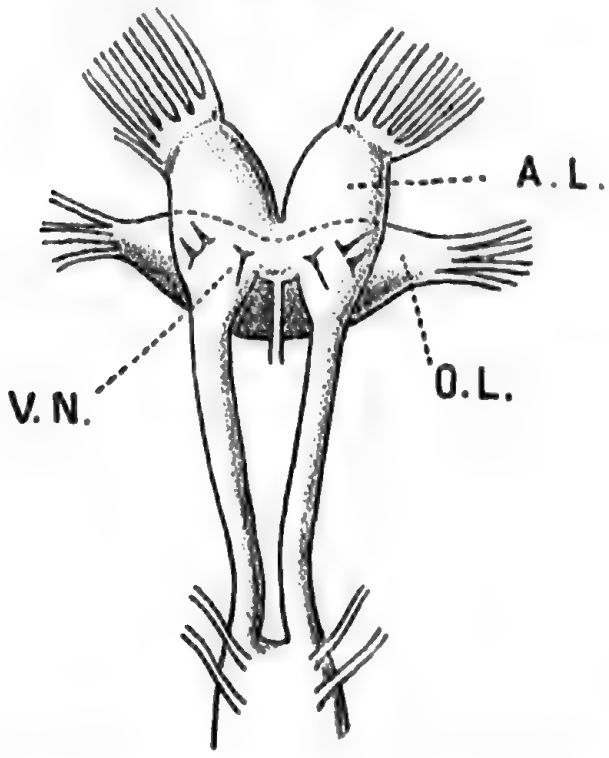

The Brain of *Scolopendra morsitans*, after St. Remy (Ventral aspect).

A.L. Antennary lobes. O.L. Optic lobes. V.N. Visceral nerves.

In the lower specimen the nervous system has been exposed from the dorsal aspect, the isolated anterior part of another being mounted above.

D. 25. A Centipede (*Scolopendra morsitans*) with the integument and muscles removed from the right side so as to give a lateral view of the nervous system. The Hunterian description of this specimen is as follows :—" Centipede—the brain a small roundish body laid bare : the two great nerves going to the tail with ganglions at the places where they give off nerves, as in the Lobster." The part above alluded to as the brain is the large subœsophageal ganglion; the union of the connectives above the œsophagus is not shown. The ventral position of the ganglia and the nerves given off from them are well displayed in this preparation.
O. C. 1298. *Hunterian.*

D. 26. The isolated nervous system of a Centipede (*Scolopendra* sp.). Preserved in Goadby solution.

INSECTA.

Viallanes, Ann. des Sci. Nat., sér. 7, t. xiv. p. 429.
Binet, Jour. de l'Anat., t. xxx. 1894, p. 449.
Brandt, Horæ Soc. Entom. Ross., t. xv. 1879, p. 2.

In the Insecta, apart from the complexity of the cerebral ganglion, one of the most noteworthy features is the variable degree of longitudinal concentration of the ganglia of the ventral chain, either when comparison is made between adults of different species or between the larva and imago of the same species. As a rule the nervous system of the adult is more concentrated than that of the larva. Concentration usually appears first amongst the abdominal ganglia, resulting in the fusion of some at the posterior end of the chain and the inclusion of some in front in the metathoracic ganglion. The thoracic ganglia also fuse in various ways, though less frequently. The pro- and mesothoracic, meso- and metathoracic, or all three, may thus unite.

Although in some Orders (*e. g.* Lepidoptera) a certain definite arrangement of the ganglia is fairly constant, in most it is not so, and a variety of stages of concentration occur within the Order. In the embryo the nervous system is usually entirely unconcentrated, and the adult condition is attained by the successive fusion of ganglia in the embryonic and pupal stages. Some embryos, however, have a single unsegmented post-oral mass, from which the ganglia of the adult are produced by subsequent segmentation.

D. 27. Models of the brain (cerebral ganglion) and right fungiform body of a Black-beetle (*Periplaneta orientalis*) × 60, with a drawing of a transverse section through the left half of the ganglion, the position of which is indicated by a black line on the model. The cerebral ganglion in Insects consists to a large extent of a pair of protocerebral lobes in connection with the optic ganglia; thus the size of the brain depends mainly upon the degree of development of the eyes, and need not necessarily afford an indication of the state of intelligence of the individual. The brain further comprises a second pair of centres (deutocerebrum), probably olfactory, in connection with the antennæ; and a third pair (tritocerebrum), situated in the roots of the circumœsophageal connectives, that innervates the labium and gives rise to the visceral system. It apparently corresponds to the œsophageal ganglia of Crustaceans.

The protocerebrum consists of the optic ganglia (not shown in the model) and of a pair of large protocerebral lobes, contiguous in the mid-line. The latter are united by commissures, and each contains several remarkable structures. The most striking of these are the fungiform bodies —organs that are possibly indicated in Crustacea, but reach their full and characteristic development in Insects. One is lodged in each protocerebral lobe; it consists of two masses of dense neuropile (calyces, F) deeply concave from side to side, and situated near the dorsal surface of the brain with their concavities facing upwards. (The calyces are exposed on the right side of the model.) Their neuropile derives its fibres from a cap of ganglionic nuclei (coloured yellow). Each calyx gives off from its lower (convex) surface a short pedicle, that unites with its fellow to form a common neuropile-stalk (peduncle, G). This stalk penetrates directly downwards through the substance of the protocerebral lobe till it reaches the mid-horizontal plane of the brain. Here it gives off two branches, one of which (cauliculus, H) curves forward and upward near the anterior surface of the brain to terminate in a rounded end close beneath the anterior lip of the outer calyx; the other (trabecula, I) runs diagonally downwards and inwards, till it meets its fellow, without fusion, in the mid-line. The fungiform bodies do not directly give rise to any nerves, but they enter into close relations with all parts of the brain by means of fibrous tracts, the most important of which pass to the optic ganglion of the same side, to the opposite fungiform body, to the corpus centrale, and to the antennary lobe of the opposite side. Fibres belonging to this latter tract continue directly past the fungiform body into the optic ganglion, and constitute an optico-olfactory chiasma similar to that seen in Decapod Crustacea.

In spite of the evident importance of these structures their function is still unknown, but it is noteworthy that within the same Order their size increases roughly in proportion to the intelligence of the Insect, and among social forms they may even vary in development between the persons of the society—being, for instance, proportionately larger in the Worker bee than in the Drone or Queen.

The protocerebral lobes are united across the mid-line by two bands of deeply staining neuropile. One of these (the pons) lies immediately below the dorsal point of union of the two halves of the brain; it is in the form of a forwardly directed horseshoe, and stands in close relation to the roots of the nerves to the white spots (vestigeal ocelli). A similar though backwardly directed horseshoe-shaped band gives origin to the ocellary nerves in *Limulus*, and there is a somewhat similar strand in the fore part of the brain in Decapod Crustacea.

The second commissural band (corpus centrale) is larger and of more complicated structure; it has the form of a crescentic plate hollowed below, and consists of two layers of neuropile. It lies approximately in the centre of the brain, and apparently forms a nucleus to which fibres from all parts converge. The most important tracts in connection with it are derived from the fungiform bodies and optic and antennary lobes ; beneath it lie a pair of small neuropile masses—the tubercles of the corpus centrale. (The corpus centrale and tubercles are shown in the drawing directly above the trabecula.) A similar though simpler median band lies between the protocerebral lobes in the Decapod Crustacea.

The antennary lobes (deutocerebrum) consist of two lobules on either side united by transverse commissures ; the ventral of the two gives off the larger part of the antennary nerve (probably olfactory) ; its neuropile is glomerulated. A second smaller root of the antennary nerve is derived from the dorsal lobule, it is chiefly motor in function. A small tegumentary nerve rises from the anterior face of the ventral lobule.

Each half of the tritocerebrum gives off a nerve from its anterior surface that meets its fellow in the mid-line to form a triangular ganglion (frontal ganglion, E) from which a median nerve runs back along the alimentary canal.

These models, which were cast from originals reconstructed from a series of transverse sections by Mr. E. T. Newton, have been diagrammatically painted and have certain parts and areas indicated by letters and numbers, the key to which is mounted below the models.

Newton, Quart. Journ. Micr. Sci., vol. xix. 1879, p. 340.

D. 28. Two specimens of a Cockroach (*Blatta americana*) dissected to show the nervous system from the dorsal and ventral aspects. The dorsal surface is shown in the left-hand specimen, the ventral in the right. The cerebral ganglion lies in the head, and is so placed that the optic lobes lie vertically above the antennary. The subœsophageal ganglion for the innervation of the mouth-parts is also situated in the head close below the cerebral; it is united by a pair of connectives to a ventral chain composed of 9 paired ganglia. The anterior three are larger than the rest, and lie one in each thoracic segment at equal distances apart. Each gives off nerves (seen best in the right-hand specimen) to the legs and body muscles, and (in the case of the posterior two) to the wings.

In the abdomen the ganglia of the chain are situated at irregular intervals—the first four fairly close together, the last three somewhat further apart. The terminal ganglion (6th) is larger than the rest and represents a fusion of the two posterior larval ganglia; it innervates the hinder end of the body, the rectum, the genital organs, and the cerci.

Each of the other abdominal ganglia gives off a single pair of nerves to the body-walls and tracheæ.

The ventral-chain ganglia are composed of definite dorsal and ventral masses of neuropile, from which the nerves arise by two or more independent roots, that apparently convey either motor or sensory impulses according as they spring from the dorsal or ventral mass. The probability of a localisation of motor and sensory functions in opposite regions of the cord of Arthropods has been discussed since the idea was brought forward by Newport. Later observations have tended to show that in the case of Crustacea such localisation does not occur, but that in Insects it most probably does. This latter conclusion rests not only upon physiological experiments, but is also based upon anatomical grounds—more particularly upon a comparison of the alar nerve-roots in flying beetles with those of beetles whose wing-cases are present but immoveable. In the former case each alar nerve rises by two main roots, one from the dorsal mass of neuropile, the other from the ventral. In the beetles with purely protective non-motile wing-cases (e. g. *Blaps mortisaga*) the dorsal root is entirely absent (Binet, *l. c.*).

Preserved in Goadby solution.

Miall & Denny, Life History and Structure of the Cockroach (*Periplaneta orientalis*), 1886, p. 86.

D. 29. A large female Orthopterous Insect (*Karabidion australe*) with the nervous system shown from the dorsal aspect. The thoracic ganglia are nearly equal in size, and lie, widely separated, in the three thoracic segments. There are six free abdominal ganglia, situated respectively in successive abdominal segments from the 2nd to the 7th. Each of the anterior five innervates the segment in which it lies; the 6th gives off nerves to the hinder end of the body. The 1st abdominal segment is supplied by the metathoracic ganglion. O. C. 1299 E.

D. 30. A Locust (*Tropidacris latreillei*) dissected from the dorsal aspect. The cerebral ganglion is small compared with the size of the head, and is united to the subœsophageal ganglion by relatively long connectives. The three thoracic ganglia are separate, although the meso- and metathoracic show a certain amount of approximation. The metathoracic ganglion is much larger than the other two; it sends a number of nerves to the anterior parts of the abdomen in addition to those to the metathorax, and probably represents a fusion of the true metathoracic ganglion with a certain number of abdominal ganglia. Within the abdomen there is a chain composed of five separate ganglia situated respectively in the 2nd, 4th, 6th, 7th, and 8th segments. The first of them innervates the fourth segment; the last is larger than the others and is no doubt a compound mass. O. C. 1299 C.

D. 31. A female Stick-insect (*Pseudobacteria ?*) showing the nervous system from the dorsal aspect. The entire system is of the most delicate nature and, in conformity with the general structure of the insect, is greatly extended longitudinally. The cerebral and subœsophageal ganglia are not visible. The three thoracic ganglia are separate; they are followed by a chain of five abdominal ganglia situated respectively in the 2nd to the 6th abdominal segments. The first of these free ganglia innervates the 2nd segment of the abdomen, so that presumably the first primitive abdominal ganglion is included in the metathoracic. The terminal ganglion innervates the posterior region of the body and the genitalia.

The genital organs are also shown in this specimen.

O. C. 1299 D.

Müller, Nov. Act. Nat. Curios., Bd. xii. 1825, p. 568.

D. 32. An immature Water-Scorpion (*Belostoma*) showing the nervous system. In all the Hemiptera the post-oral part of the central nervous system shows a high degree of longitudinal concentration, and in none perhaps more so than in the Water-Scorpions. In this example the subœsophageal ganglion lies close to the cerebral, in the prothorax; it is almost contiguous with the prothoracic ganglion, the approximation of the two being evidently due to the forward position of the 1st pair of legs. The meso- and metathoracic ganglia are fused with one another and with the abdominal chain to form a round central thoracic mass from which nerves are given off to the two posterior pair of thoracic limbs and to the abdomen. Owing to the half-macerated condition of the specimen, the component parts of the central thoracic mass are visible as three pairs of opaque centres representing respectively the meso- and metathoracic ganglia and the united ganglia of the abdominal chain. O. C. 1299 B.

D. 33. Two specimens of the nervous system of another species of Water-Scorpion (*Nepa cinerea*). In its main features this system corresponds with that shown in the last specimen, but the longitudinal concentration is even more marked. In this species the subœsophageal ganglion is completely fused with the prothoracic. In the upper specimen the nervous system is seen isolated; in the lower *in situ.* O. C. 1299 B *a*.

D. 34. The nervous system of a Lepidopterous larva exposed from the dorsal aspect. The cerebral ganglion consists of two small rounded lobes contiguous in the mid-line. It is united around the œsophagus by a pair of short connectives to a ventral chain, composed (as in the great majority of Lepidopterous larvæ) of 11 equal-sized ganglia—*i. e.*, 1 subœsophageal, 3 thoracic, and 7 abdominal. The subœsophageal and prothoracic ganglia are approximated to one another; but the remainder lie at about equal distances apart in successive segments of the body. The terminal ganglion is distinctly grooved transversely and represents a fusion of two embryonic ganglia. As in the adult, it innervates the reproductive organs in addition to the hinder region of the body-wall. The connectives of the ventral chain are very slender ; they lie close side by side, except between the three thoracic ganglia where they are transversely separated. O. C. 1299 G.

D. 35. The larva of a Moth (*Metura saundersii*) contained within its protective case and dissected from the ventral surface. The nervous system is of extreme delicacy. It does not differ in the number of its post-oral ganglia from that shown in the preceding specimen, but the altered positions of the ganglia relative to the body-segments and to one another suggest that those changes have begun, which finally, during the pupal stage, produce the longitudinal concentration of the nervous system found in the imago. The first abdominal ganglion is for example markedly approximated to the metathoracic, and lies with it in the metathoracic segment. O. C. 1299 F.

D. 36. Two specimens of the nervous system of the larva of a Goat Moth (*Cossus ligniperda*) : one *in situ* seen from above, the other isolated. The cerebral and subœsophageal ganglia are moderately separate, but the prothoracic is almost confluent with the subœsophageal. It is followed by a chain of 10 ganglia (2 thoracic and 8 abdominal). Between the thoracic ganglia the connectives diverge laterally, leaving an oval space. In the anterior of these spaces, in the left specimen, a small median nerve can be seen, which arises from the prothoracic ganglion and ends in two lateral branches close in front of the mesothoracic. It belongs to a series of median sympathetic nerves, found commonly among insects ; as a rule each rises from one of the two connectives close behind a ganglion, or from the ganglion itself, runs to the succeeding ganglion and there divides into two lateral branches, each of which joins one of the peripheral nerves and is distributed to the respiratory organs. The abdominal ganglia are situated at equal distances apart, with the exception of the first which is approximated to the metathoracic, and the last two which are almost contiguous.

Cattie, Zeits. wiss. Zool., Bd. xxxv. 1881, p. 304.

D. 37. A Lamellicorn Beetle (*Dynastes centaurus*) dissected from above to show the nervous system. The cerebral ganglion is comparatively small; it is united to the subœsophageal by connectives of moderate length. In the thorax there are three ganglionic masses, of which the anterior two are simple and respectively constitute the pro- and mesothoracic ganglia ; the posterior mass is elongated in shape, and consists of the true metathoracic ganglion fused with a short cylindrical appendage that represents a concentration of the abdominal chain ganglia, and innervates the abdomen. This arrangement of the ganglia is the one usually found among Lamellicorns.

D. 38. A male Longicorn Beetle (*Macrotoma*) showing the nervous system from above. The cerebral ganglion is small relative to the head, and is united to the subœsophageal ganglion by long connectives. The thoracic ganglia are separate, with approximation between the meso- and metathoracic. The latter innervates the anterior part of the abdomen, as well as the metathorax. There are four free abdominal ganglia, the first of which is situated on the boundary-line between the thorax and the abdomen. This number and arrangement of the ganglia is characteristic of this family of Beetles. O. C. 1299 A.

D. 39. The nervous system of a Hornet (*Vespa crabro*), isolated. The large size of the cerebral ganglion is due, partly to the bulk of the protocerebral lobes—the centres for the great compound eyes, and partly to the high degree of development of the fungiform bodies. The latter differ in many respects from those of the Black-beetle (D 27); their calyces are larger and arch to a considerable extent over the anterior and posterior surfaces of the protocerebral lobes; the peduncle and its two calycal branches are remarkably stout, but the cauliculus and trabecula are insignificant, and without definite outlines. The ocelli receive their nerves from three centres that lie directly beneath them. The cerebral ganglion is continuous around the œsophagus with the small subœsophageal ganglion. There are two ganglia in the thorax—the first is the prothoracic, the second a compound mass that represents a fusion of the meso- and metathoracic ganglia with the first two abdominal. In the abdomen there are five separate ganglia, the last of which is double and is formed by the fusion of two larval ganglia.

Viallanes, Ann. Sci. Nat., sér. 7, t. ii. 1887, p. 1 (*Brain*).

MOLLUSCA.

v. Ihering, Anat. des Nervensystemes . . . . der Mollusken, 1877.

Garstang, 'Science Progress,' vol. v. 1896, p. 38.

The central nervous system of the Mollusca may be compared with that of an Annelid or Arthropod in so far as it is essentially bilaterally symmetrical and consists of a paired præ-oral centre united around the œsophagus to a ventral system below the gut. But in Molluscs the ventral system, when longitudinally elongated, shows no true metameric segmentation, and thus differs fundamentally from the ventral chain system of Annelids and Arthropods, although it much resembles the ventral cords of a Turbellarian. In addition to the præ- and postoral centres common to most Invertebrates, there are present others peculiar to the Mollusca. The most important of these are certain pallio-visceral centres for the innervation of the mantle, gills, and parts of the viscera. They occur either as a simple ganglionic loop uniting the lateral parts of the circum-oral system, or as a number of isolated ganglia (pleural, branchial, abdominal) united together by a fibrous commissure and due apparently to the disintegration of some such generalised loop. Modification in the various groups of Molluscs tends either towards the concentration of all the centres towards the head (Gastropods, Cephalopods), or—in the Pelecypods—towards the diminution and suppression of the cerebral and pedal ganglia owing respectively to the absence of the head with its sense-organs and to the degeneration in many forms of the foot or byssal apparatus. Besides this reduction of the anterior ganglia, there is, in the Pelecypods, a backward migration of the pallio-branchial centres (visceral ganglia) and a progressive increase in their size, lateral concentration, and complexity of structure, depending upon the perfection of the mantle sense-organs or the formation of siphons.

PELECYPODA.

Rawitz, Jena. Zeits., Bd. xx. 1887, p. 384.

D. 40. A wax model of the nervous system of *Nucula nucleus*, × 25. The central system, as in other Pelecypods, consists of three pairs of ganglia united to one another by commissures and connectives. The cerebral ganglia lie in front of the mouth united by a short commissure ; each gives off three nerves that respectively innervate the anterior adductor, labial palps, and anterior part of the mantle. Posteriorly, the cerebral ganglia gradually diminish in thickness and pass insensibly into a pair of long cerebro-visceral connectives, by which they are united to the visceral ganglia. The latter are small and laterally separate ; they lie ventral to the gut at some little distance in front of the posterior adductor united by a definite commissure, and innervate the gills, posterior adductor, and posterior part of the mantle. The cerebro-pedal connectives arise from the inner ventral surface of each cerebral ganglion by two roots, that remain separate for a fourth of the distance to the pedal ganglion. The double origin of these connectives from each cerebral ganglion has been thought to indicate that the latter is a compound structure consisting of two ganglia comparable to the cerebral and pleural of the Gastropod. But it may be, that the posterior root of the cerebro-pedal connective is the proximal part of the otocystic nerve running free for the first part of its course and not completely united with the cerebro-pedal connective as in most other Pelecypods. It is suggestive in this connection that in *Solenomya* (another of the Protobranchia) the otocystic nerve is entirely free from cerebral ganglion to otocyst. The pedal ganglia lie in the substance of the foot closely united together by a double commissure; they innervate the pedal muscles. The nervous system shows its low organisation by the diffuse distribution of ganglion-cells upon its surface (indicated by yellow in the specimen). They not only form a layer of some thickness upon the three pairs of ganglia and the root of the branchial nerve as in other Pelecypods, but cover the outer and dorsal surfaces of the cerebro-visceral connectives and the cerebral and visceral commissures.

Pelseneer, Arch. de Biol., t. xi. 1891, p. 166.
Drew, Quart. Journ. Micro. Soc., vol. xliv. 1901, p. 373.

D. 41. The nervous system of an Edible Mussel (*Mytilus edulis*), isolated. The ganglia are small—the pedal and visceral of approximately equal size, the cerebral slightly smaller. The latter lie on either side of the mouth, united by a long præoral commissure. From the posterior extremity of each a single cord is given off, which shortly divides to form the cerebro-pedal and cerebro-visceral connectives. The pedal ganglia lie between the viscera and the foot; they are closely applied to one another, and each gives off two main nerves—a large one from its lateral border to the pedal muscles, and a smaller posterior one to the byssus gland. The visceral ganglia lie some distance apart upon the antero-ventral surface of the posterior adductor, united to one another by a slightly ganglionic commissure. Each ganglion gives off two principal nerves, an anterior ganglionic branchial nerve and a large posterior trunk that supplies the mantle and posterior adductor.

D. 42. Two specimens of the nervous system of a Scallop (*Pecten maximus*)—one isolated, the other shown within the body from the left side. The remarkable perfection of the sense-organs on the mantle-border of the Scallops, and the large size and energy of their adductor muscle, are accompanied by a corresponding development of the visceral ganglia, the centres from which these parts are mainly innervated. The ganglia are completely fused in the mid-line, and form a rectangular mass situated upon the ventral surface of the adductor, near the centre of the animal. Each anterior corner receives one of the cerebro-visceral connectives; external to these arise the branchial nerves, followed, along each lateral margin of the ganglion, by a series of lateral mantle-nerves, distributed to the middle region of the mantle-border. From each posterior corner arises another bundle of nerves (posterior pallial), which innervates the posterior adductor and the hinder sixth of the mantle-border. The branches of the pallial nerves just before their final distribution are united by a ganglionic cord (not shown in the specimen) that runs completely round the mantle parallel to its edge.

The cerebro-visceral connectives lie for their posterior third upon the surface of the adductor ; anterior to that point they traverse the superficial parts of the gonad to reach the small cerebral ganglia. The latter lie behind the mouth, united præorally by a very long and delicate commissure; they give off nerves to the anterior part of the mantle and labial palps. The pedal ganglia are small and contiguous in the mid-line ; they lie above the foot, between the cerebral ganglia. O. C. 1303 E *b*.

D. 43. Two specimens of the nervous system of a Pond-Mussel (*Anodonta cygnea*), shown respectively from the left side *in situ*, and isolated. The ganglia are more marked than in *Mytilus*, but show much the same relative proportions to one another. The cerebral lie at the postero-lateral margins of the mouth, and are united præorally by a long commissure ; each gives off the usual nerves to the mantle, palps, and anterior adductor. The pedal ganglia are closely applied to one another, and are situated in the upper part of the foot embedded in the viscera ; they give off numerous nerves to the pedal muscles and integument. The cerebro-visceral connectives run one on either side of the body on a level with the line of attachment of the gills; at their anterior end they lie far apart near the surface of the visceral mass, but towards the visceral ganglion run close together, between the organs of Bojanus. The visceral ganglia are larger than either cerebral or pedal ; they are fused together to form a bilobed mass situated on the ventral surface of the posterior adductor. They give off several small visceral filaments from their anterior surface, and two pairs of larger nerves from their lateral and posterior borders. The lateral pair supply the gills, and have at their origin a ganglionic area that underlies a special branchial sense-organ (osphradium). The posterior nerves are distributed to the mantle (particularly to the papillæ that surround the inhalent opening) and to the posterior adductor.

In the lower specimen black paper has been placed beneath the ganglia. O. C. 1303 E *a*.

AMPHINEURA.

Plate, Zool. Jahrb., Suppl.-Bd. iv. 1898, p. 151.

D. 44. The central nervous system of a Chiton (*Hanleya abyssorum*), showing some of its more important features. The nervous system in this and other Amphineura consists fundamentally of two pairs of longitudinal cords united anteriorly to a circumoral ring. An even layer of ganglion-cells covers all parts of the cords and ring, without local concentration to form special ganglia, except in the Aplacophora and one species of Chiton. The outermost pair of cords (lateral cords) lie in the body-walls above the branchial furrow, lodged between the main branchial vessels; they innervate the mantle with its sense-organs, and, from their slightly thickened posterior fourth, the gills and probably also the renal organs and heart. They are continuous with another above the rectum, and thus form an elongated loop, comparable, apart from its relation to the rectum, to the visceral loop of Gastropods and Pelecypods. The ventral or pedal cords extend throughout nearly the whole length of the foot, buried in its substance. They are united together by a large number of very delicate and somewhat irregularly disposed commissures, and give off from their outer and ventral surfaces numerous pedal nerves, that unite to form a rich plexus in the muscles of the foot. The first and last of the series of pedal commissures are far stouter than the rest, (in the specimen these two are perfect, the roots only of the other commissures and of the pedal nerves are shown). The pedal and lateral cords of the same side unite together in front to form the band-like anterior part of the circumoral ring. Behind the mouth the ring is completed by a slender strand, that terminates on either side in a swelling at the anterior end of the pedal cord. From these swellings, which much resemble the labial lobes of *Haliotis*, two pairs of connectives are given off—one to the ganglia of the subradular organ (imperfect in the specimen), the other to the buccal ganglia, which lie as usual upon the posterior surface of the buccal mass, between the œsophagus and radular sac. The buccal system in this and certain other species forms a second complete ring around the gut: the buccal ganglia being united by commissures both below the œsophagus and above the roof of the buccal mass. The buccal ganglia probably innervate the whole alimentary canal.

O. C. 1305 C.

Burne, Proc. Malac. Soc., vol. ii. 1896, p. 4.

D. 45. The anterior part of the nervous system of the same species of Chiton, isolated to show the two nervous rings (circumoral and buccal) that surround the alimentary canal. O. C. 1305 D.

GASTROPODA.

Bouvier, Ann. Sci. Nat., sér. 7, t. iii. 1887, p. 1.

D. 46. An isolated specimen of the nervous system of an Ormer (*Haliotis tuberculata*). The cerebral ganglia are small but fairly distinct, and are united in front of the mouth by a long ribbon-like commissure. From the lateral parts of each, two connectives pass beside the buccal mass to a compound pleuro-pedal ganglion beneath the gut. The greater part of this ganglion belongs to the pedal system, and extends backwards in the substance of the foot as a pair of flattened cords, fused to one another and to the pleural centres at their anterior end, and united at intervals by nine transverse commissures. Nerves are given off from this "ladder-like" pedal system to the foot and epipodium. The pleural ganglia form a pair of indefinite excrescences on the dorsal surface of the fused anterior ends of the pedal cords. They give off a pair of large mantle-nerves, and are united together, as in other Prosobranchs, by a commissural loop (visceral loop), that in its passage from ganglion to ganglion is twisted in the form of an 8. This twisted or streptoneurous loop is characteristic of the Prosobranchs, and always bears in its different parts a definite relation to the gut. The arm of the visceral loop that rises from the left pleural ganglion passes *beneath* the gut to the opposite side of the body ; here, at a point slightly posterior to the free tip of the gill, it forms a ganglion (subintestinal ganglion) from which the gill and olfactory organ (osphradium) are innervated. The loop continues its course round the margin of the mantle-cavity, and at its hindermost extremity forms another ganglion (abdominal ganglion), from which several nerves are given off to the viscera. On the left side of the mantle-cavity, opposite the subintestinal ganglion, a third ganglion (supraintestinal) is formed for the innervation of the left gill and osphradium. After leaving this ganglion the loop turns to the right over the *dorsal* surface of the intestine, and finally enters the right pleural ganglion.

Nerves are given off from the cerebral ganglia to the sense-organs and integument of the head ; those to the lips take their origin, in common with the buccal connectives, from a prominence on the antero-ventral surface of each ganglion (labial lobe). The buccal ganglia form a single horseshoe-shaped band, situated on the posterior wall of the buccal mass between the radular sac and œsophagus.

O. C. 1305 F.

Lacaze-Duthiers, Ann. Sci. Nat., sér. 4, t. xii. 1859, p. 247.

D. 47. The nervous system of a Limpet (*Patella vulgata*), isolated. This nervous system agrees in its general features with that of *Haliotis*, but differs from it in the following important particulars :—The ganglia are more pronounced and independent : this difference is particularly marked in the separation of the pleural and pedal ganglia. The pedal cords are not fused at their anterior end, but form a pair of ganglionic enlargements united by a stout commissure. Posteriorly they gradually become purely fibrous. The pedal cords are united by two commissures only. The labial lobes are detached from the cerebral ganglia. A nerve of some length is interposed between the sub- and supraintestinal ganglia and the visceral loop. O. C. 1305 E.

D. 48. The nervous system of an Apple-Snail (*Ampullaria urceus*), isolated excepting the pedal nerves of the right side. The nervous system of this Prosobranch affords a striking example of a condition of the visceral loop, known as zygoneury ; by this is meant the presence of certain connections between the sub- and supra-intestinal ganglia and the pleural ganglion of the same side, whereby a kind of false orthoneury arises that to a greater or less extent masks the original streptoneurous condition of the loop. These connections occur commonly among Prosobranchs, and can be present on one or both sides constituting right, left, or double zygoneury according as the nervous union takes place between the right pleural and subintestinal ganglia, the left pleural and supra-intestinal, or both. In this specimen double zygoneury is shown in an extreme form. The visceral loop passes from the left pleural ganglion beneath the intestine to a small subintestinal ganglion partially fused to the right pleural ganglion—this fusion constitutes the right zygoneurous connection. From the subintestinal ganglion the visceral loop runs round the margin of the mantle-cavity as usual, giving off a nerve to the mantle on the right side and several to the viscera from a bilobed abdominal ganglion situated at its posterior extremity. The left arm of the loop, after giving off a few small nerves, enters an elongated supra-intestinal ganglion, which gives origin to a stout nerve for the osphradium and several smaller branches that are said to pass across the roof of the mantle-cavity to the gill, which in this mollusc is displaced from the left to the right side by the development of the lung-sac. The supra-intestinal ganglion is connected by a large trunk to the left pleural ganglion (the left zygoneurous connection) and to the right pleural ganglion by a delicate filament that passes dorsal to the intestine and subintestinal ganglion, and represents the supra-intestinal arm of the streptoneurous loop in a very much reduced condition.

The pleural ganglia are fused to the pedal to form a pair of subœsophageal masses, in each of which the constituent parts are separated by a shallow depression. They are connected by three commissures—one between the pleural centres, the other two between the pedal. The nerves from the pleural ganglia innervate the mantle; one of those on the right side is of large size, and forms a considerable ganglion before breaking up to innervate the penis, rectum, and neighbouring parts. The pedal ganglia are continued backwards in the substance of the foot as a pair of longitudinal *fibrous* cords, connected together by 3 or 4 delicate commissures. From their outer sides a number of pedal nerves are given off, which towards the margin of the foot form a rich plexus with minute ganglia at the meeting-points of the nerve-filaments. The pedal system, except for the absence of ganglion-cells in the longitudinal cords, closely resembles the "ladder-like" system of *Vivipara* [*Paludina*]. The cerebral ganglia are united by a long ribbon-like commissure; they innervate the cephalic sense-organs, and are united by a pair of long connectives to two small buccal ganglia situated in the usual place on the posterior surface of the buccal mass and connected by a subœsophageal commissure. O. C. 1305 G.

Burne, Proc. Malac. Soc., vol. iii. 1899, p. 317.

D. 49. A Heteropod (*Carinaria mediterranea*) with the nervous system displayed from the left side. The system, which is very delicate compared with the size of the animal, bears many resemblances to that of a Prosobranch, particularly in the possession of a crossed (streptoneurous) visceral loop. The ganglia are considerably lobulated. There are two main pairs—(i.) the cerebral (fig. 16), from which nerves are given off to the large and highly-organised eyes, the otocyst, tentacles, and labial region of the integument; and (ii.) the pedal ganglia. The latter lie above the fin within the body; each is bilobed, with the two lobes one above and slightly in front of the other. The upper lobe receives a stout connective from the cerebral ganglion, and gives off from its hinder end a connective to the visceral ganglion of the same side, and from its upper surface 3 or 4 fine nerves that radiate to the body-wall. A large nerve for the penis rises from the upper lobe on the right side. The lower lobe sends nerves to the body-wall and to the various regions of the foot, that to the fin being particularly large. A pair of long slender connectives arise from a lobe (fig. 16, PL.L.) on the posterior surface of each cerebral ganglion and accompany the alimentary canal; near the visceral mass each crosses to the opposite side of the body—the left below the gut and the right above, and upon reaching the visceral mass is joined by the above-mentioned pedo-visceral connective, and swells to form a small visceral ganglion upon the surface of the gastric gland. These two visceral ganglia represent the supra- and subintestinal of a Prosobranch; each is united by a delicate filament to a large abdominal ganglion situated upon the gastric gland midway between the two. The gill is innervated from the supra-intestinal ganglion.

Fig. 16.

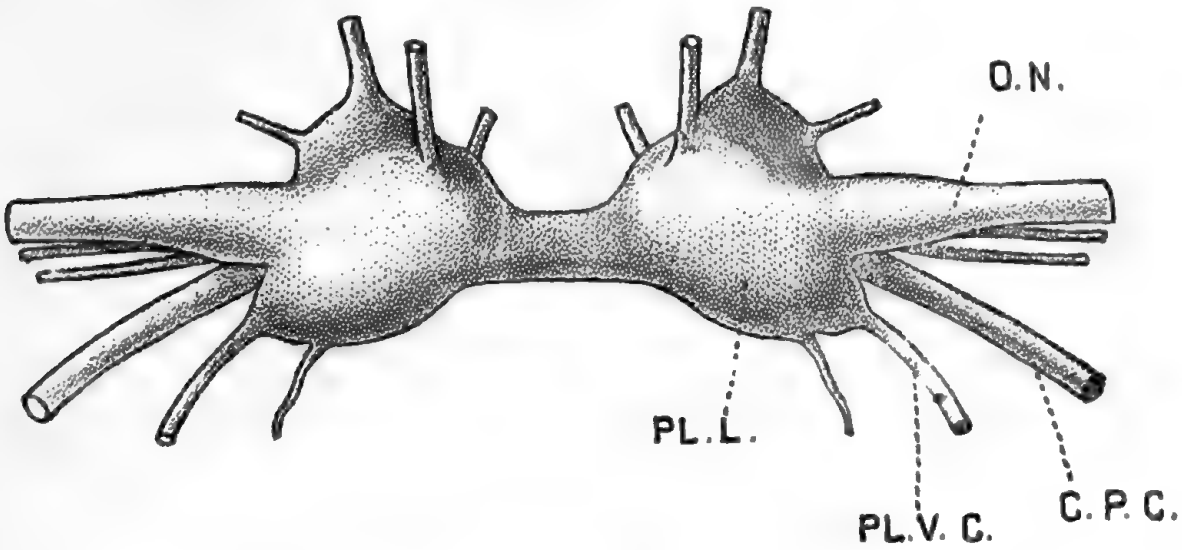

Cerebral Ganglia of *Carinaria mediterranea.*

C.P.C. Cerebro-pedal connective. O.N. Optic nerve. PL.L. Pleural lobe.
PL.V.C. Pleuro-visceral connective.

Ganglia comparable to the pleural of other Gasteropods are not present as independent centres; they are probably fused with the cerebral ganglia, forming the lobes from which the visceral loop arises.

Pelseneer, C. R. Acad. Sci., t. cxiv. 1892, p. 775.

D. 50. Two specimens of the nervous system of a Roman Snail (*Helix pomatia*), shown respectively *in situ* from the left side, and isolated.

The central system is much concentrated. It consists of two main ganglionic masses—(i.) a paired oblong cerebral ganglion, united by two connectives on either side of the œsophagus to (ii.) a large compound subœsophageal mass formed by the fusion of pedal and pleural ganglia with the four centres of the short untwisted (orthoneurous) visceral loop.

The two halves of the cerebral ganglion are united by a short commissure ; each is indistinctly lobulated, the most conspicuous lobe forming a conical projection (tentacular lobe) on its anterior surface, from which arises a large nerve for the optic tentacle and eye and a smaller one for the otocyst. From the antero-lateral margins of the ganglion, nerves are given off to the lips and anterior tentacles, and from its ventral surface a pair of delicate buccal connectives. The substance of the subœsophageal mass (fig. 17) is traversed between the pleuro-visceral and pedal centres by the anterior aorta. The pleural ganglia give off no nerves. Four large nerves rise from the ganglia of the visceral loop ; three of them innervate

Fig. 17.

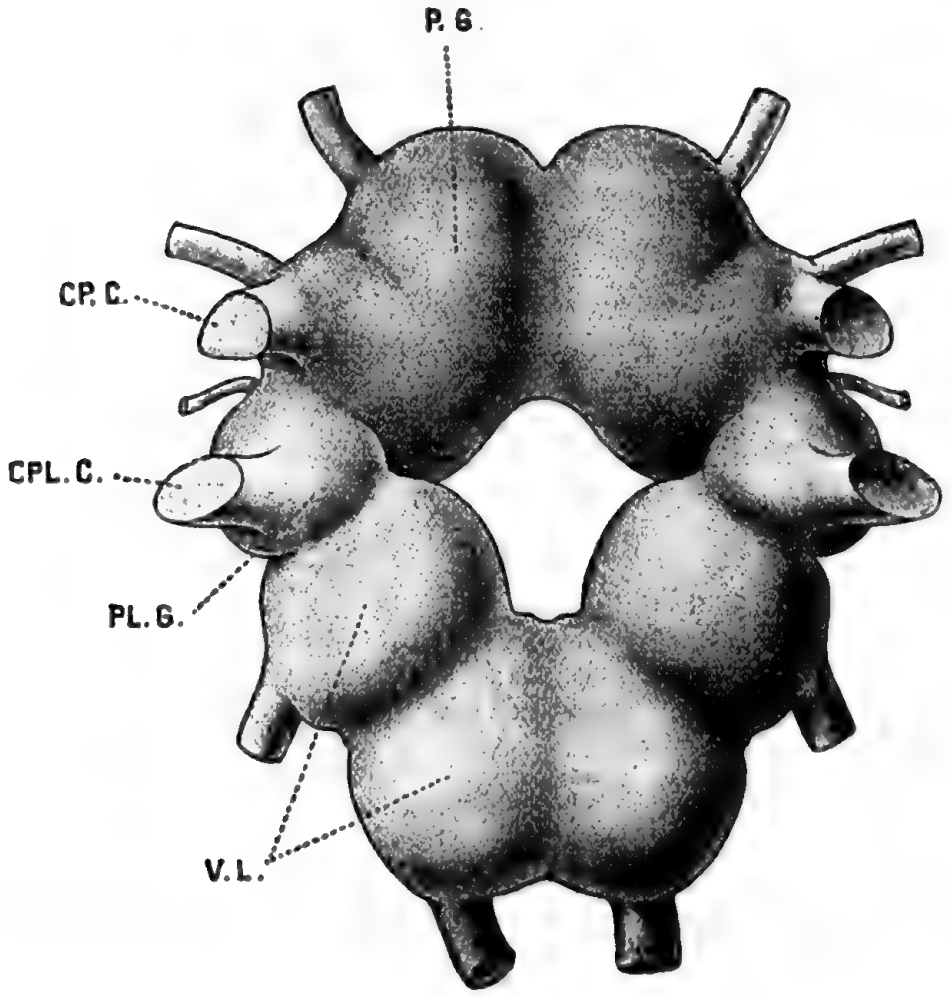

Diagrammatic reconstruction of the Pleuro-pedal mass of *Helix pomatia*. × 20.

C.P.C. Cerebro-pedal connective. C.PL.C. Cerebro-pleural connective. P.G. Pedal ganglion. PL.G. Pleural ganglion. V.L. Visceral loop.

the mantle and respiratory organs, the fourth enters the visceral mass and is distributed to the genital organs. The pedal ganglia are united by two distinct commissures; each gives off a large bundle of nerves to the foot.

The entire central system is enclosed in a thick sheath of connective tissue (fig. 18). There are two distinct kinds of ganglion-cells—large unipolar cells, some of immense size (·17 mm.) situated around the subœsophageal and buccal ganglia and on the posterior surface of the cerebral, and small cells with a minimum of protoplasm, very similar to the ganglionic nuclei of Arthropods, crowded together upon the lateral surface of the tentacular lobes of the cerebral ganglia. The neuropile of the tentacular lobes derived from these cells is peculiarly dense.

Fig. 18.

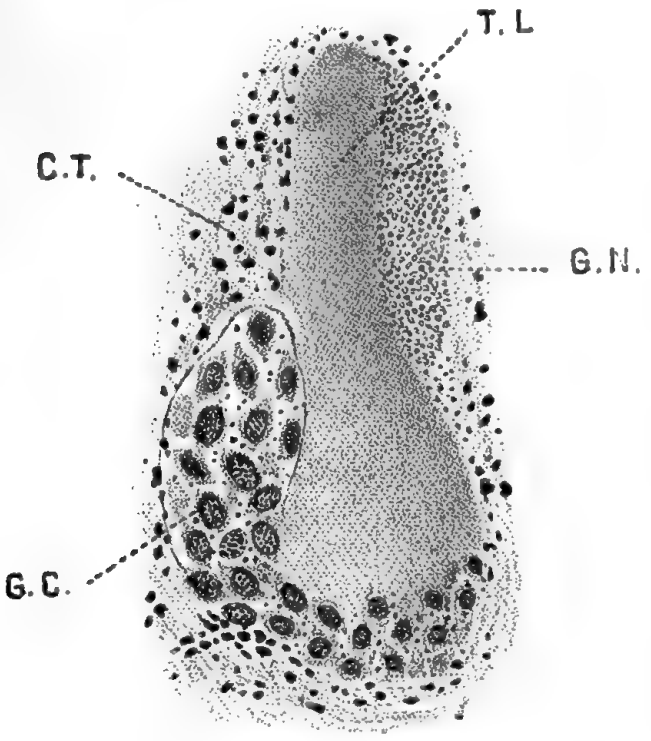

Horizontal section through the right Cerebral Ganglion of *Helix pomatia.* × 40.

C.T. Connective tissue. G.C. Large ganglion-cells. G.N. Ganglionic nuclei. T.L. Tentacular lobe.

In the upper (isolated) specimen blue paper has been placed beneath the four nerves that rise from the visceral loop, and in the lower specimen the main features of the nerve distribution have been indicated by black paper.

O. C. 1305 A *a.*

Nabias, Act. Soc. Linn. Bordeaux, sér. 5, t. vii. p. 10.

D. 51. A Slug (*Limax rufus*), laid open longitudinally along the back, and with the viscera removed, to show the nervous system. The cerebral ganglia are pear-shaped and situated at some distance apart united by a commissure. They innervate the same organs as in the Snail. The œsophageal nervous ring is completed below the gut by a larger ganglionic mass from which nerves radiate to supply the body. The principal nerves are the two inferior ones which extend on either side of the mid-line of the ventral surface straight to the hinder end of the body, giving off branches from their outer sides to the muscular foot. A small asymmetrical ganglion is formed on the nerve that supplies the heart and respiratory apparatus. The subœsophageal ganglion is a compound body, formed, as in the Snail, by the fusion of the pedal, pleural, and visceral ganglia.
O. C. 1304. *Hunterian.*

D. 52. The same species of Slug laid open along the ventral aspect, and with the viscera removed to show more especially the subœsophageal ganglion and its nerves. A bristle occupies the place of the œsophagus. O. C. 1305.
Hunterian.

D. 53. A Slug (*Limax* sp.) with the body-walls divided longitudinally along the ventral surface, and divaricated to show the nervous system in position. Preserved in Goadby solution.

D. 54. Two isolated specimens of the nervous system of a Pond-Snail (*Limnæa stagnalis*). The central nervous system although decidedly concentrated is much less so than in the Land-Snail. The three pairs of ganglia that form the circum-œsophageal ring (cerebral, pleural, and pedal) are independent and joined together by short commissures and connectives. The orthoneurous visceral loop is extremely short, yet its ganglia and the fibrous strands that unite them to one another and to the pleural ganglia can be clearly distinguished. The distribution of the nerves that arise from the various ganglia corresponds in the main with that seen in *Helix*, but it should be noticed that at the end of one of the terminal branches of the pallial nerve given off from the right visceral ganglion there is a small round ganglion; this underlies a sensory pit (probably olfactory) situated close to the respiratory orifice. The cerebral ganglia are considerably lobulated. Blue paper has been placed beneath the visceral loop in both specimens.

O. C. 1305 A *b*.

Lacaze-Duthiers, Arch. Zool. Exp., t. i. 1872, p. 437.

D. 55. Two specimens of the nervous system of a Sea-Hare (*Aplysia punctata*), seen from the dorsal aspect, isolated (upper specimen), and *in situ*. The several ganglia of the circum-œsophageal ring are separate, definite in outline, and of moderate size. The cerebral ganglia lie close together above the œsophagus, on either side of which they are united by a pair of short connectives to the pedal and pleural ganglia. Each pleural ganglion lies slightly behind and below the pedal ganglion of the same side, joined to it by a very short connective. The pedal ganglia are united by two commissures—one short and stout passing directly from ganglion to ganglion, the other longer and more delicate. The pleural ganglia give rise to a long untwisted (orthoneurous) visceral loop, that extends backwards through the cavity of the body to the pericardium. Here it is completed by a large bilobed ganglion, from which nerves are given off to the body-wall, generative organs, and gill. The branchial nerve arises from the upper of the two lobes, and at the base of the gill forms a small round ganglion that underlies a special sense-organ (osphradium). The chief nerve given off from the lower lobe supplies the genital organs. Although the visceral loop is essentially orthoneurous, it shows a variable but distinct tendency towards a streptoneurous twist. When seen from above its left arm appears in the posterior part of its course to lie directly beneath or even in some cases slightly to the right of the right arm. This partial streptoneury is interesting in view of the unmistakably twisted loop of another Opisthobranch (*Actæon*). The nerve distribution resembles that in other Gastropods; the sense-organs of the head and the integument around the mouth are supplied from the cerebral ganglia; the pleural nerves innervate the anterior parts of the lateral body-walls, while the ventral and posterior parts of the body receive nerves from the pedal ganglia. The buccal ganglia are contiguous in the mid-line; they lie on the posterior surface of the buccal mass between the œsophagus and radula-sac, and give off nerves as usual to the buccal mass and alimentary canal.

D. 56. A Sea-Hare (*Aplysia* sp.) opened longitudinally to the right of the dorsal mid-line, and with the body-walls spread to either side to show the nervous system *in situ.* The viscera have been removed with the exception of the buccal mass and part of the heart. The outlines of the ganglia are less distinct than in the previous specimen, as the connective-tissue sheath by which they are enveloped has not been removed. Preserved in Goadby solution.

D. 57. Two specimens of the nervous system of a Nudibranch (*Archidoris tuberculata*). The central system is extremely concentrated. It consists of a single supra-œsophageal lobulated mass, in which can be traced three pairs of centres that apparently represent cerebral, pleural, and pedal ganglia. The cerebral, which form the anterior part of the mass as seen in the lower specimen, give off, as usual, buccal connectives and nerves to the cephalic sense-organs. The pleural and pedal centres supply the body-wall and generative organs. The lateral parts of the compound ganglion are united below the œsophagus by a triple commissure; two of its constituents arise in the pedal ganglia and correspond to the two pedal commissures of Tectibranchs (e.g. *Aplysia*), the third (marked by black paper in the upper specimen) unites the pleural centres and may be regarded as an orthoneurous visceral loop. O. C. 1305 B *a.*

D. 58. A Nudibranch (*Tritonia hombergii*) with the nervous system exposed from above. The central system consists of four ganglionic masses concentrated in a transverse band above the anterior end of the œsophagus. The inner pair are contiguous with one another in the dorsal mid-line; each represents a fusion of a cerebral with a pleuro-visceral centre. From the anterior (cerebral) portion, nerves are given off to the integument and sense-organs of the head. The posterior (pleuro-visceral) part innervates the lateral and dorsal regions of the body-wall. The two outer centres represent the pedal ganglia; they are in contact with the lateral surfaces of the pleuro-visceral centres; each sends several large nerves to the foot. As in *Archidoris* the lateral parts of the supra-œsophageal mass are united below the gut by a triple commissure enclosed in a common neurilemma-sheath. Preserved in Goadby solution.

v. Ihering, Anat. des Nervensystemes . . . der Mollusken, 1877, p. 174.

CEPHALOPODA.

Note.—In describing the Cephalopod nervous system it has been assumed for convenience' sake that the funnel and mantle-cavity are situated on the ventral aspect of the animal, and the beak at the anterior end.

D. 59. The anterior parts of a male Pearly Nautilus (*Nautilus pompilius*) from which the viscera and left half of the body-walls and funnel have been removed to show the nervous system *in situ*. The central system shows no differentiation into separate ganglia, but is coated evenly in all parts by a continuous layer of ganglion-cells; it is situated entirely within the head region, supported by the upper part of the large cephalic cartilages. Above the œsophagus lies a transverse cylindrical bar of nervous tissue directly continuous at either end with an antero-posteriorly flattened optic ganglion. The extremities of the supra-œsophageal bar are connected below the œsophagus by two semicircular nervous bands that rise by a common origin from either end of the bar and slant respectively forwards and backwards towards the ventral surface of the œsophagus. The anterior semicircular band is thick at either end, but rapidly tapers towards its middle, until beneath the œsophagus it forms a narrow commissural strand. It gives off on either side from the lower end of its thickened region a stout nerve for the funnel, and from its anterior surface, between this point and its junction with the supra-œsophageal bar, a large number of nerves for the outer and lateral series of tentacles.

One of those on the left side is larger than the rest and innervates the spadix—an accessory sexual organ in the male formed by the modification of certain of the tentacles of the lateral series. The posterior semicircular band is of equal calibre throughout. From the hinder margin of its lateral parts a series of nerves are given off to the body-muscles, as well as a pair on either side to the posterior region of the funnel. From its postero-ventral border it gives rise to two large nerves that run backwards upon the ventral surface of the body to the neighbourhood of the gills; here each gives off two branchial branches and is said to then continue onwards to terminate among the viscera (this continuation is not shown). Nerves from the supra-œsophageal bar supply the olfactory tentacles and pit, the otocyst, and parts of the hood. This centre also gives origin near either end to two strong connectives, that after a sinuous course join a ganglion (pharyngeal ganglion) upon the lateral surface of the buccal mass. The pharyngeal ganglia of opposite sides are united beneath the gut by two commissures, one of which passes anteriorly along the inner border of the lower beak, giving off two large nerves to the tissues within it, while the other passes transversely between the œsophagus and radula-sac and has upon its course a pair of buccal ganglia from which nerves are distributed to the buccal mass and œsophagus.

Although the central nervous system shows a certain degree of specialisation in being concentrated in the head, it is on the whole in a very simple and primitive condition, and reminds one, especially in the band-like form of its several parts and the diffuse distribution of ganglion-cells upon its surface, of the condition observed in the Amphineura. The three nervous bands of which it is composed probably represent the typical centres of the Mollusca in a state of great simplification, namely:—cerebral (supra-œsophageal bar) for the innervation of the head region with its sense-organs, pedal (anterior semicircular band) innervating the tentacle complex and the funnel, and pleuro-visceral (posterior semicircular band) for the mantle, gills, and viscera. O. C. 1306 A *a*.

Graham Kerr, Proc. Zool. Soc. 1895, p. 673.

D. 60. The anterior or muscular part of the body of a female Pearly Nautilus (*Nautilus pompilius*) laid open longitudinally along the dorsal aspect, and with the sides divaricated to show the nervous system.

In the female the inner ring of tentacles consists not only of two lateral groups, as in the male, but also of a ventral series located in two lobes that lie one on either side of the ventral mid-line.

A pair of large nerves (the left one is indicated by black paper) for the innervation of these are given off from the anterior subœsophageal band on the outer side of the funnel-nerves. Each enlarges as it nears the tentacular lobe to form a triangular ganglion, from which branches radiate to the individual tentacles. O. C. 1306 A.

Owen, Memoir on the Pearly Nautilus (*Nautilus pompilius*), 1832, p. 36.

D. 61. The head of a Cuttle-fish (*Sepia officinalis*) dissected from the dorsal aspect to show the form and position of the central nervous system. It is extremely concentrated, and forms a compact ring around the fore part of the œsophagus protected externally by a cartilaginous capsule. The ring is divisible into a pyriform supra-œsophageal mass (cerebral ganglion) and a larger oblong subœsophageal ganglion, united together on either side of the œsophagus by stout connectives.

The cerebral ganglion is joined on either side by a short stalk to a large kidney-shaped optic ganglion, from whose distal margin a number of nerve-fibres arise and perforate the cartilaginous optic capsule to reach the retina. Upon the dorsal surface of each optic stalk there is a small rounded excrescence from which the olfactory nerve takes its origin (see Olfact. Organs, Section E). Upon the right side bristles have been placed beneath the superior ophthalmic nerve—a small nerve that rises from the hinder part of the subœsophageal mass close to the base of the circum-œsophageal connective, and innervates the globe of the eye and the integument on its dorsal surface. O. C. 1306 D.

D. 62. The central nervous system of a Cuttle-fish (*Sepia officinalis*), isolated to show the relations of its parts, the origin of the main nerves, and the anterior portion of the visceral system.

The pointed anterior extremity of the cerebral ganglion is joined by a pair of connectives to a small independent ganglion (supra-pharyngeal), which is probably a disconnected piece of the cerebral ganglion and not a part of the visceral system. This ganglion is situated on the dorsal surface of the œsophagus close behind the buccal mass, and innervates the peristomial membrane by a number of nerves that radiate from its anterior margin. It is united to the anterior part of the subœsophageal mass by a pair of connectives, that rise from its posterior surface, and by a second pair from its outer extremities to a buccal ganglion that lies below the œsophagus on the posterior wall of the buccal mass. Nerves from this latter centre supply the buccal mass, radula, and alimentary canal.

The cerebral ganglion is further united by connectives to the subœsophageal mass. There are two on either side—a small one that arises from its anterior extremity and joins the suprapharyngeo-subœsophageal connective close to the subœsophageal mass, and another, extremely short and stout, that forms the lateral part of the circum-œsophageal ring below the optic stalk. This last is superficially single, but internally two fibrous strands can be distinguished that pass respectively to the anterior and posterior parts of the subœsophageal mass, and represent cerebro-pedal and cerebro-pleural connectives. The subœsophageal mass may be divided into an anterior and a posterior region. The anterior innervates the arms and fore part of the funnel, and may be regarded as a pedal ganglion. The posterior region contains the pallial and visceral centres; it projects backwards beyond the cerebral ganglion and gives off three large pairs of nerves respectively to the mantle, to the posterior part of the funnel, and to the viscera and gills; two smaller pairs arise from its dorsal and ventral surfaces and innervate the superficial parts of the eyes.

O. C. 1306 F.

Pelseneer, Arch. Biol., t. viii. 1888, p. 723.

D. 63. The isolated nervous system of a Cuttle-fish (*Sepia officinalis*) showing the origin and course of the main nerves.

The innervation area of the cerebral ganglion includes the eyes (through the mediation of the optic ganglia), the olfactory pit, the otocyst (by nerves that perforate the subœsophageal mass), and, indirectly through the suprapharyngeal ganglion, the lips.

The anterior (pedal) region of the subœsophageal mass is composed of a brachial and an infundibular centre. The brachial nerves arise from the anterior margin of the former; they are 10 in number—8 for the non-retractile arms and 2 for the tentacles. Just before the separation of the 8 arms from their common muscular base, their nerves are united together by a circular commissure, the main part of which enters a small ganglionic enlargement upon each brachial nerve, while a smaller strand leaves the commissure on one side of the ganglion, passes across its inner surface, and joins the commissure again on the other side. In the free part of each arm the nerve is central in position and ganglionic. The nerves for the anterior part of the funnel arise from the ventral surface of the infundibular centre—their extremities can be seen in the specimen projecting beyond the optic ganglia.

A pair of large mantle-nerves are given off from the lateral posterior corners of the pleuro-visceral centre. Each of them runs diagonally backwards to the retractor capitis muscle; at this point it gives off a branch from its inner margin, and then passes through the substance of the muscle to the dorsal wall of the mantle-cavity. Here it divides into two branches, one of which shortly enters a large round ganglion (g. stellatum), from which nerves radiate to all parts of the mantle; the other passes along the median surface of the stellate ganglion and is distributed to the lateral-fin fold. The posterior infundibular nerves arise slightly in front of the pallial, from the ventral surface of the pleuro-visceral centre. The visceral nerves are given off close side by side from its posterior border. They run backwards to the ventral surface of the gastric gland, perforate the subhepatic cartilage and continue close beneath the skin, one on either side of the cephalic vein to the external renal openings. Just posterior to the subhepatic cartilage, each nerve gives off a branch from its lateral surface to the retractor infundibuli, and a little further back a second branch from its median side to the rectum and ink-sac.

Dorsal to the external renal openings the two main trunks are united by a plexiform commissure, and from this point continue along the antero-lateral margin of the kidneys till they reach the bases of the gills. Here each forms a ganglion and passes forwards along the gill to its anterior end. Numerous delicate fibres from the plexiform commissure ramify amongst the viscera and establish connections with a large splanchnic ganglion situated upon the stomach. The splanchnic ganglion is further connected to the buccal ganglia by an extremely fine pair of nerves that lie upon the walls of the œsophagus.

From the active predaceous habits of the Dibranch Cephalopods and the great concentration of their central nervous system, one may conclude that the latter is a highly-specialised and efficient organ, but as to its actual working little definite is known. It may be said, however, that :—The cerebral ganglion (in certain cases at any rate, though apparently not in all) exerts a general inhibitory influence over the rest of the system. In its anterior part is located a centre for the fixation of the arm-suckers, their relaxation depending on another centre in its posterior part. Each brachial nerve forms a reflex centre for the general movements of the arm in which it lies. The pleuro-visceral mass, and not as might be supposed the stellate ganglion, is the reflex centre for the respiratory movements of the mantle ; it is also the controlling centre for the chromatophores.

The action of the heart can take place independently of the cephalic central system, although its pulsations are regulated by the subœsophageal mass. O. C. 1306 E.

Chéron, Ann. Sci. Nat., sér. 5, t. v. 1866, p. 41.

D. 64. A section of the mantle of a large Cuttle-fish (*Sepia officinalis*) showing one of the pallial nerves with the ganglion stellatum. The branch of the pallial nerve that passes without being implicated in the ganglion, through the substance of the mantle to the muscle-fibres of the lateral fin, is indicated by a black bristle. O. C. 1307.

Hunterian.

PROTOCHORDATA.

TUNICATA.

D. 65. A Simple Ascidian (*Phallusia mammillata*) from which the dorsal parts of the test have been removed to show the nervous system. In the adult this is in a much reduced condition ; it is minute compared with the bulk of the animal, and consists of a rod-like ganglion that lies on the muscular body-wall upon the dorsal surface between the oral and atrial apertures, close in front of the latter. From either end it gives off a pair of nerves that respectively innervate the integument and muscles of the oral and atrial siphons. A few small nerves for the general body-wall arise from its lateral parts. The hinder end of the ganglion is prolonged backwards as a fine ganglionic cord, that runs along the dorsal edge of the branchial sac and terminates upon the liver. This cord (visceral cord) apparently innervates the anterior region of the alimentary canal ; it has been shown to be the degenerate remains of the portion of the larval dorsal cord that lies between the cerebral vesicle and the tail. O. C. 1307 A.

Presented by Prof. C. Stewart.

Van Beneden & Julin, Arch. de Biol., t. v. 1884, pp. 317 & 633.

CEPHALOCHORDA.

D. 66. The isolated central nervous system of a Lancelet (*Amphioxus lanceolatus*) showing its general form and some few of the spinal nerve roots. The central nervous system in *Amphioxus* consists of an unsegmented tubular cord of roughly triangular cross section. At either end it narrows to a point, but otherwise is of approximately similar calibre throughout. It lies upon the dorsal surface of the notochord, extending from its hinder extremity to a point some little distance behind its anterior end. The anterior pointed region terminates in a median eye-spot and gives off two pairs of purely sensory nerves to the snout. From the rest of the cord a series of mixed and motor nerves arise, that correspond in number and position to the septa between the myotomes and consequently alternate on either side. The central canal is lined by a supporting epithelium. This is surrounded, as in Vertebrates, by a layer of ganglion-cells, while the outer parts of the cord consist of non-medullated nerve-fibres of different sizes. Some of these, which arise from giant ganglion-cells that lie across the canal in the anterior and posterior thirds of the cord, are of remarkably large size and remind one of Müller's fibres in Cyclostomes or of the giant fibres in Invertebrates. In front the canal broadens out to form a cerebral vesicle, that probably corresponds with the three primary vesicles of the vertebrate brain. A small evagination of its dorso-anterior wall extends towards the olfactory pit and indicates the last closed connection of the central canal with the exterior (a similar excrescence occurs in the embryos of Vertebrates); while below, another median evagination apparently represents the infundibulum. As the walls of this "brain" region are thinner than in other parts of the cord, there is no external sign of a cerebral enlargement. O. C. A. 1347.

Willey, 'Amphioxus,' 1894, p. 82.

VERTEBRATA.

BRAIN.

Edinger, Anat. Central Nervous System, 5th ed. (Engl. trans.) 1899.

Edinger, Abhandl. Senckenberg. Gesell., Bd. xv. 1890 (*Cerebrum*).

Haller, Morph. Jahrb., Bd. xxvi. 1898, p. 632 (*Bibliog.*).

PISCES.

CYCLOSTOMI.

D. 67. The brain of a Sea Lamprey (*Petromyzon marinus*).

The Cyclostomes have an extremely simple brain, similar in many respects to that of a low Urodele or to the embryonic stages of higher Vertebrates. It consists of a slight enlargement of the anterior end of the cord accompanied by a corresponding increase in the size of the central canal and its partial transverse division into three ventricles. Upon this foundation certain excrescences have been developed in connection with the senses of sight and smell. The dorsal wall is to a very large extent purely epithelial, nervous matter being mainly confined to the floor and side walls. The primitive condition of the brain is also shown by the relatively large size of the ventricles, and by the absence of any special thickenings of their nervous walls.

Fig. 19.

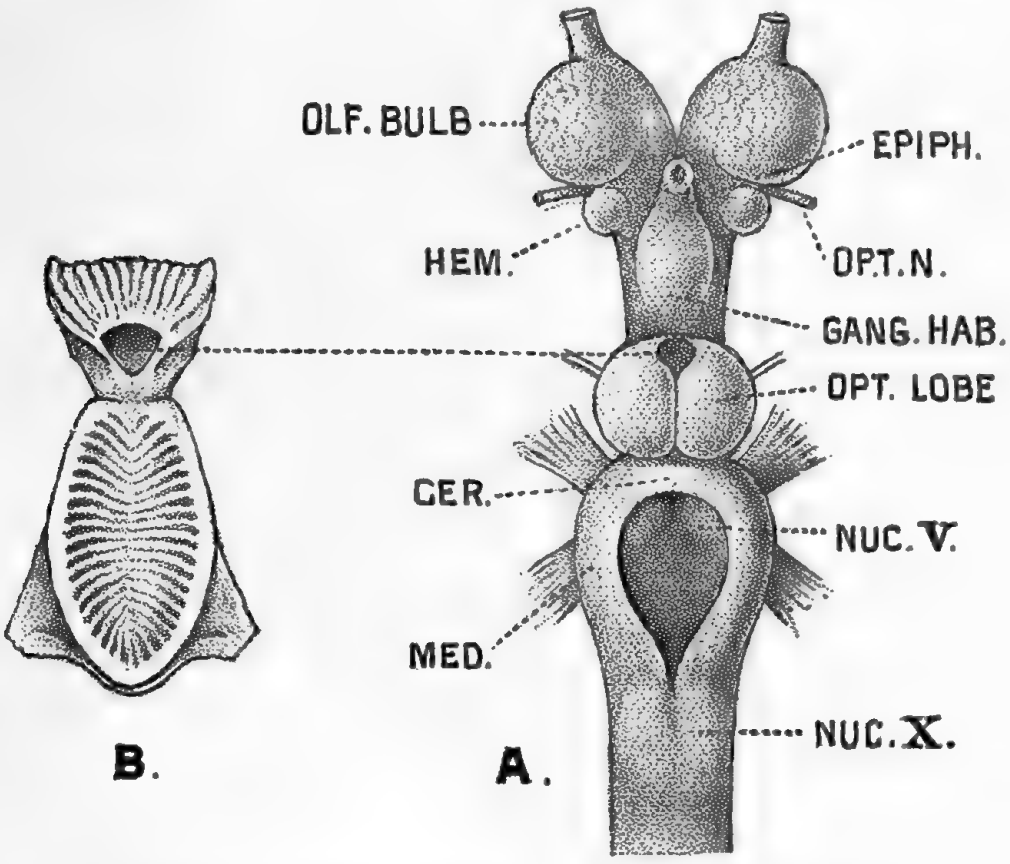

Brain of *Petromyzon marinus* (enlarged).
[For list of abbreviations, see page 508.]

The medulla forms nearly half the brain (fig. 19, A). It passes behind insensibly into the cord, and in front is laterally expanded with separation of its walls in the mid-dorsal line to enclose a large pyriform opening (fossa rhomboidalis) covered by a thin vascular membrane. This roof consists of an epithelium continuous with that lining the fourth ventricle, of pia mater and blood-vessels ; it is considerably larger than the fossa and in consequence projects in all directions into the cranial cavity, and in conjunction with the similar vascular roof of the optic lobes spreads out over a large part of the dorsal surface of the brain. These two choroid plexuses have been removed together and mounted at the side with their under surfaces exposed to show the complicated folding of their walls (fig. 19, B).

The roof of the medulla behind the open rhomboid fossa is slightly thickened on either side of the mid-line, and here gives origin to the hinder roots of the vagus (the roots are not shown in the specimen). Similar thickenings in the lateral walls of the fossa give origin to the 7th and 8th cranial nerves, and another pair of swellings in the floor of the fourth ventricle, seen through the open rhomboid fossa, are the motor nuclei of the 5th pair of nerves. The floor of the fourth ventricle is indented in the mid-line by a sharp furrow, on either side of which is a slight thickening due to a pair of tracts (fasciculi longitudinales posteriores) that connect the thalamencephalon with the cord and on their way form connections with the motor nuclei of the cranial nerves. They are particularly well marked in Fishes.

The rhomboid fossa is bounded in front by a narrow but slightly thickened lip—the cerebellum. The mid-brain consists above of a pair of very prominent rounded eminences —the optic lobes. They contain a common ventricle derived from the aqueduct of Sylvius and are superficially separated from one another in the dorsal mid-line by a groove. Their walls are composed for the most part of nervous tissue from the outer surface of which the optic nerves are given off, but this is replaced at the anterior end by an epithelial choroid plexus (the fore part of the specimen at the side) similar to that covering the rhomboid fossa. The removal of this plexus has exposed a minute opening situated at the anterior end of the optic lobes and bounded in front by a band of commissural fibres (posterior commissure)—not externally visible—that marks the boundary line between the mid-brain and thalamencephalon or primary fore-brain.

The thalamencephalon is remarkably deep from above downwards. Its roof is epithelial in its anterior part and projects beak-like above the cerebrum, but posteriorly it is nervous and swollen to form an asymmetrical pair of ganglia (ganglia habenulæ), the smaller (left) of which is in connection with the pineal body. In the specimen these ganglia can only be distinguished as a single median thickening in front of the optic lobes. The ganglia habenulæ are one of the most constant parts of the vertebrate brain. They are always present on either side close in front of the epiphysial evagination, are united by a commissure, and are always in connection by tracts with the olfactory area of the cerebrum and with the corpus interpedunculare. The latter can be seen in the specimen as a small median protuberance close behind the origin of the oculo-motor nerves. The floor of the thalamencephalon is expanded ventrally to form a capacious infundibulum. Lobi inferiores and saccus vasculosus are absent, but there is said to be a well marked saccus infundibuli in the posterior wall of the infundibulum. A similar structure occurs in Elasmobranchs and embryo Teleosts. The side walls consist mainly of tracts that connect the cerebrum with the more posterior regions of the brain. They are covered superficially by the optic tracts on their way downwards and forwards from the optic lobes to the chiasma in front of the infundibulum. The thalamencephalon is continuous at its anterior end, on either side of the mid-line, with a pair of hollow lobes—the secondary fore-brain—each consisting of two parts: a posterior lobe (the hemisphere), and a larger anterior lobe (the olfactory bulb) from which a nerve is given off to the nose. A slight lobulation observable upon the surface of the olfactory bulbs is due to a glomerular condensation of the neuropile close beneath the surface.

The hemispheres are mesially united by a commissure (anterior commissure) that lies in the dorsal parts of the anterior wall of the thalamencephalon (lamina terminalis). They have ganglion-cells scattered irregularly throughout their walls and show no signs of cortical structure.

Ahlborn, Zeits. wiss. Zool., Bd. xxxix. 1883, p. 191.

ELASMOBRANCHII.

Miklucho-Maclay, Beiträge z. vergl. Neurol. 1870.

Edinger, Arch. mikr. Anat., Bd. lviii. 1901, p. 661 (*Cerebellum*).

The brain of the Elasmobranchs only partially fills the cranial cavity. It has generally an elongated narrow form, with the several regions lineally arranged and, except in the case of the cerebellum, with but little overlapping of parts.

It is chiefly remarkable for the great development of the centres in connection with the sense of smell—olfactory bulbs and peduncles, and cerebrum. The lamina terminalis is more or less thickened—excessively so in Rays—and frequently is indented in the mid-line to form small lateral ventricles. The optic lobes are well marked, as are also the several parts of the hypothalamus (infundibulum, lobi inferiores, saccus vasculosus and saccus infundibuli). The cerebellum, as in Bony Fish and Birds, is strongly developed; it overlaps the optic lobes and medulla to varying degrees and frequently shows complex transverse folding. Posteriorly it is continued into the convoluted margins of the rhomboid fossa (medullary auricles). In Sharks the medulla is usually long and without definite separation from the cord, but is much shortened in Rays. It owes its large size mainly to the great development of the nuclei of the cranial nerves, especially those in connection with the respiratory nerves (x.) and the sensory nerves of the skin (v. and the lateral-line nerves). It also contains great longitudinal motor tracts (fasciculi longitudinales posteriores) in its floor, besides less developed tracts in connection with the optic lobes (fillet) and cerebellum. The walls of the brain are nervous except for the vascular epithelial roof of the rhomboid fossa and third ventricle. There is no sign of cortical formation in the cerebrum, but its walls consist of a relatively thin outer molecular stratum and a thick cellular layer surrounding the ventricles. In its base definite cell-masses give rise to the anterior commissure and to longitudinal tracts that pass to a large ganglion (nucleus rotundus) in the thalamus, which in turn gives off fibres to the hinder parts of the brain. A second pair of tracts pass from the cerebral roof (pallium) into the base of the thalamencephalon, and decussate behind the optic chiasma in close contiguity with tracts from the base of the mid-brain (decussatio post-optica). The thalamencephalon also contains in its dorsal parts a pair of ganglia habenulæ connected by tracts with the olfactory parts of the cerebrum, and with the tectum opticum, corpus interpedunculare (Meynert's bundle), and hypothalamus. In the lower parts of the thalamus lie another pair of ganglia (g. geniculata) situated under cover of the optic tracts. They are very constant throughout vertebrates and contribute fibres to the opticus. The hypothalamus, whose walls consist of a fibrous reticulum interspersed with numerous ganglion-cells, is the chief point of origin of the great fasciculi longitudinales posteriores; it is also connected with the cerebellum and tectum opticum.

In the roof of the mid-brain (tectum opticum) there are two chief layers—an outer layer consisting of the roots of the opticus and containing numerous ganglion-cells in its deeper parts; and a deep fibrous layer in which the fibres for the most part run transversely and constitute a tectal commissure, thickened in its anterior parts to form the posterior commissure. On either side the fibres pass backwards into the medulla (some crossing in the floor as the commissura ansulata), and constitute the anterior termination of a large sensory tract (fillet) that extends into the cord and is connected in the medulla with the sensory cranial-nerve nuclei. Part of this tract arises from a nucleus in the posterior part of the tectum—the homologue of the posterior corpora quadrigemina of Mammalia. A nucleus of large cells (roof nucleus) lies in the mid-line at the hinder extremity of the tectum beneath the transverse commissure; its meaning is doubtful, though probably it is a nucleus of the trigeminal nerve.

The cerebellum consists, as in all vertebrates, of four layers—molecular, intermediate (Purkinje's cells), fibrous, and nuclear; the fibrous being situated external to the nuclear, and not as in Teleosts, Birds, and Mammals, on its deep surface. The layers vary in thickness in different regions, the nuclear for instance being almost entirely concentrated in a pair of ridges, one on either side of the mid-line (longitudinal zones). Tracts connect the cerebellum with the thalamencephalon, mesencephalon, and spinal cord, but the greater part of the fibrous layer is in direct connection with the sensory cranial nerves.

SQUALIDA.

D. 68. The brain of *Notidanus griseus* exposed within the skull from the dorsal and ventral aspects.

The Elasmobranch brain is found in its simplest and most primitive condition in the Notidanidæ, and presents in them many features that in other members of the class are transient, occurring only during certain developmental stages. The following characters should be particularly noticed as indications of primitive construction:—The relatively great length and narrowness of the brain; the absence of any marked local thickening of its walls; their general thinness and the consequent spaciousness of the ventricles (for these and other internal features see Maclay, t. ii. fig. 12); the simple unconvoluted cerebellum; the great development of the medulla, its length, wide dorsal opening, and gradual passage into the cord.

The fore-brain (cerebrum) is deeply cleft anteriorly (more so than in any other Elasmobranch) by an infolding of the lamina terminalis; its cavity is thus separable into a posterior unpaired chamber—the fore part of the third ventricle—passing in front into a pair of anteriorly directed pockets, or lateral ventricles. The latter are continuous at their anterior end with the cavities of the long olfactory peduncles, by means of which the olfactory bulbs, which are situated directly beneath the olfactory organ, are connected to the rest of the brain. The olfactory bulb has always in Elasmobranchs (except it seems in *Echinorhinus*) this close relation to the olfactory organ, so that the length of the peduncle varies in different forms according to the position of the organ with regard to the brain. The peduncle is usually, as in this case, hollow, but sometimes when very long it is solid; it has the same structure as the olfactory bulb, and together with it is an outgrowth from the fore-brain.

The thalamencephalon is comparatively short and wide. The fore part of its roof is membranous and forms a conical sac-like protrusion (paraphysis) between the hemispheres. The hinder part is concealed by the optic lobes; it contains the ganglia habenulæ and gives origin to the thread-like epiphysis. The floor is evaginated in the mid-line to form the infundibulum. This is hidden in the specimen by the hypophysis — an ectodermic glandular structure closely attached to its ventral surface. The lateral parts of a large vascular dilatation of the posterior wall of the infundibulum (saccus vasculosus) can be seen protruding beyond the lateral parts of the hypophysis. On either side of the infundibulum, in front of the saccus vasculosus, are a pair of globular enlargements—the lobi inferiores. Each of them contains a cavity (not shown) in connection with that of the infundibulum.

The optic lobes are of considerable size, although neither here nor in any other member of the group do they reach the size and importance that they do in most Teleostean fishes. They are oval in form, separated dorsally by a superficial longitudinal groove, and contain a large common cavity. Their posterior part is covered by the anterior lobe of the cerebellum. No part of the Elasmobranch brain is subject to more variation than the cerebellum; in this species it occurs in its simplest form, although well developed when compared with that of certain other Vertebrate groups (e. g. Cyclostomes, Amphibia). It is superficially perfectly smooth except for a slight median longitudinal furrow, and when seen from above is diamond-shaped with pointed anterior and posterior lobes, within each of which extends a part of the common cavity. A single median opening leads from the latter into the fourth ventricle. On either side of the posterior cerebellar lobe lies a convoluted portion of the thickened margin of the rhomboid fossa; this ridge (medullary auricle) is clearly seen on the left side; it passes to the mid-line under cover of the posterior lobe of the cerebellum; here meets with its fellow of the opposite side, without fusion, and then, turning abruptly upwards into the cavity of the cerebellum, forms a projecting longitudinal ridge (dorsal longitudinal zone of Burckhardt) that runs close beside the mid-line to its anterior extremity. From their microscopic structure the medullary auricles should be included in the cerebellum. The course of this pair of zones is not visible in the specimen after they pass under cover of the cerebellum.

The medulla is large and remarkably long, with an extensive rhomboid fossa roofed over by a thin pleated vascular membrane (turned to one side in the specimen). Within the cavity certain ridges and swellings—due to tracts and nerve nuclei—show with great clearness. A particularly prominent pair on either side of the mid-ventral line are the fasciculi longitudinales posteriores. On the outer side of these lie a pair of lesser swellings—the motor nuclei of the vagus; and outside these again, on the lateral walls of the ventricle, another very pronounced pair, remarkable for their beaded appearance. They are the sensory nuclei of the vagus. In front they pass under cover of the auricles. In the swollen border of the rhomboid fossa, just before it bends to form the auricles, lie the nuclei of the acusticus and lateral line (tuberculum acusticum and lobus lineæ lateralis). O. C. 1311 B *d.*

Presented by Dr. Albert Günther.

D. 69. The brain of a Greenland Shark (*Læmargus borealis*). This brain differs little in its essential features from that of *Notidanus*. In detail the following differences are apparent:—The lamina terminalis is not so deeply indented, so that although the fore-brain is clearly separable into unpaired posterior and paired anterior regions, the latter are not so prominent. The optic lobes with their associated tracts and nerves are far less developed. The cerebellum is relatively larger and extends forward to the anterior border of the optic lobes. It shows upon its dorsal surface a shallow transverse indentation—the first indication of the transverse folding so strongly marked in some of the higher Elasmobranchs.

The dorsal walls of the cerebrum and thalamencephalon have been turned to one side, exposing the cavities of these parts and showing in the floor of the third ventricle a long slit leading into the infundibulum, saccus vasculosus, and lobi inferiores. The latter are prominent and about equal in size to the optic lobes. The thalamencephalon roof is epithelial and vascular; it is much convoluted on its inner surface, and forms a choroid plexus that hangs within the third ventricle and extends slightly into the lateral ventricles.

The cerebellum has been divided in the mid-line, and the two halves have been separated to show the large cerebellar cavity and the course of the longitudinal zones along the roof on either side of the mid-line. The latter are specially well seen coursing backwards upon the ventral wall of the anterior lobe.

The floor of the fourth ventricle has been exposed by turning the vascular roof to one side. Owing to the division of the cerebellum and to the somewhat unnatural separation of the side walls of the medulla, the fore parts of the fasciculi longitudinales and of the vagal lobes are brought into view. The fine transverse strands visible at intervals on either side of the fasciculi posteriores are tracts connecting them with the motor nuclei of the cranial nerves. The motor nucleus of the vagus and the relation of the root of the superficial ophthalmic lateral-line nerve to the lobus lineæ lateralis are particularly clear.

O. C. 1311 B *c*.
Presented by W. Cowan, Esq.

D. 70. Parts of the cranium of a Spinous Shark (*Echinorhinus spinosus*) with the brain shown from the dorsal aspect. This brain, like those of the two other representatives of the Spinacidæ (*Acanthias* and *Lœmargus*), is of an essentially simple type. This is particularly shown by the relatively large size of the medulla (it occupies about half the brain-length), its extensive rhomboid fossa and gradual passage into the cord. The cerebellum is rounded and, for that of an Elasmobranch, very poorly developed; it shows a feeble transverse groove. The parts of the brain in front of the cerebellum are somewhat indefinite in outline owing to imperfect preservation, but it can be seen that the optic lobes and nerves are small, the thalamencephalon fairly long, and the cerebrum of medium size, without median division and apparently with a considerable cavity.

From either side of the cerebrum is given off an immense solid olfactory nerve, without however any corresponding development either of the fore-brain or of an olfactory bulb; in fact it is stated that an olfactory bulb is absent. This marked disproportion in development between the olfactory nerves and the cerebrum, with the apparent absence of definite olfactory bulbs, suggests that the nerves, although evidently to a great extent fibrous, probably also have the nature of olfactory centres; it should be noticed in this connection that shortly before entering the cerebrum, each olfactory nerve undergoes a very perceptible enlargement. The poor development of the optic parts of the brain are probably to be accounted for by the deep habitat of this Shark. The brain occupies only a small part of the spacious cranial cavity.

This preparation is from a fish caught off the coast of Cornwall. O. C. 1311 B *a*.

Presented by F. Buckland, Esq.

Jackson & Clarke, Journ. Anat. & Physiol., vol. x. 1876, p. 76.

D. 71. Part of the skull of a Spiny Dog-fish (*Acanthias vulgaris*) with the brain exposed from the dorsal and ventral aspects. This is a simple brain like the preceding specimen, but shows certain differences that foreshadow more pronounced features in the relatively complex brains of higher Sharks; such are a pair of indistinct rounded eminences upon the dorsal surface of the fore-brain at its hinder end, and the deepening of the transverse cerebellar furrow. The median indentation of the fore part of the cerebrum is strongly marked and terminates on the dorsal surface in a rounded pit—a nutritive foramen of very constant occurrence among Elasmobranchs. The olfactory peduncles are slender and of moderate length with small olfactory bulbs; on the other hand, the visual organs and optic lobes are very strongly developed. The lobi inferiores are also well marked and oval in form. The medulla does not differ in any important way from that of previously described primitive forms. Its cavity is exposed on the right side.

D. 72. Part of the cranium of a Spotted Dog-fish (*Scyllium catulus*) with the brain *in situ*. This brain, in comparison with those previously described, shows a noticeable increase in the size of the parts in connection with the olfactory organs (olfactory bulbs, peduncles, and cerebrum). On the other hand, the optic region is weak. The olfactory bulbs are each partially divided into a right and left half by a shallow groove—an indication of incipient duplicity, of interest in view of the complete separation of the olfactory bulbs into two parts in *Carcharias.* They are united by short thick peduncles to the lateral parts of the cerebrum. The latter is strongly convex in front and shows but slight indications externally of separation into lateral lobes; its postero-dorsal parts are raised to form a pair of rounded eminences similar to those seen in *Acanthias.* The cerebrum is continuous behind with the remarkably long and narrow thalamencephalon. The tela choroidea forms a close-fitting membranous roof to this region, and shows very clearly between its posterior fourths an opaque band—the commissura habenulæ. The epiphysis, which rises close behind this commissure, is long and thread-like as in most Elasmobranchs; it extends forwards over the cerebrum and terminates on a level with the olfactory bulbs in a thickened end. In this and most other genera it is said to be solid except close to the brain, and to consist of cells embedded in a finely granular intercellular substance.

The cerebellum is quite simple, though of some size; it has a median longitudinal furrow and slight lateral indentations. (The asymmetry noticeable in this cerebellum is probably unnatural, due to distortion during hardening.) The medulla is of a higher type than in the previous specimens; it is shorter and broader and has a more definite limit towards the cord. The brain fills the greater part of the cranial cavity.

D. 73. The brain of a Spotted Dog-fish (*Scyllium catulus*) opened to show its internal structure (fig.20). The roof of the cerebrum has been removed to show the direct continuity of the unpaired part of the cerebral cavity with the third ventricle behind, and with the lateral ventricles in front. The latter are separated by a thick median septum, and are continued from their postero-lateral parts through the olfactory peduncles to the ventricles of the olfactory bulbs. The walls of the cerebrum are thick throughout, with no local swellings suggestive of corpora striata. On either side a choroid plexus projects downwards and forwards from the roof of the thalamencephalon into each lateral ventricle. Behind the cerebrum the brain has been longitudinally bisected and the two halves have been turned to either side. The saccus vasculosus has been opened from behind showing its cavity continuous with that of the infundibulum, as well as a pair of large oval apertures in the lateral walls of the infundibulum that communicate with the ventricles of the lobi inferiores.

Fig. 20.

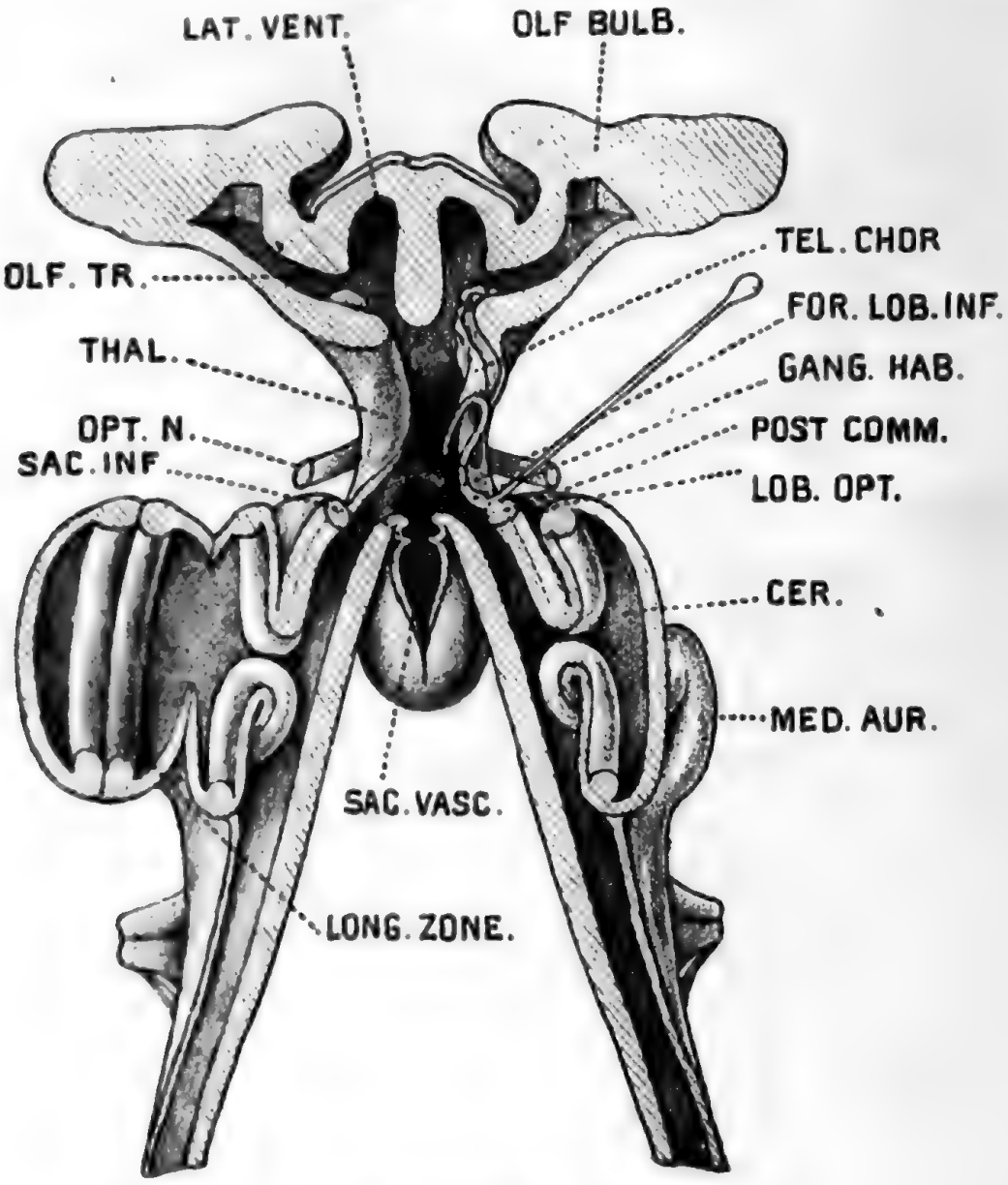

Brain of *Scyllium catulus* (dissected).

In the floor of the thalamencephalon in front of the chiasma there is a small median pit (recessus præopticus), and at the point of union between the wall of the saccus vasculosus and the floor of the mid-brain, another (saccus infundibuli) which is found also in Cyclostomes and embryo Teleosts.

Close behind the point of origin of the epiphysis, the cut edge of the roof of the brain is thickened by the presence of the posterior commissure. The mid-brain contains a considerable cavity (aqueduct of Sylvius) which sends lateral offshoots into the optic lobes. The roof (tectum opticum) of this region is moderately thick ; its division into outer and inner layers is very evident upon the section surface.

In dividing the cerebellum the roof has been cut along its right lateral margin and turned aside entire with the left half of the brain. The thin simple character of its walls, and the complete course of the longitudinal zones from the medullary auricles to the boundary line between the cerebellum and mesencephalon are shown.

D. 74. Part of the skull of a Basking Shark (*Selache maxima*) with the brain exposed from above. The brain is relatively small and somewhat shorter and broader than those previously described ; it occupies a small part only of the spacious cranial cavity. The cerebrum is globular with thickened (?) walls, and is superficially without signs of lateral division. The olfactory bulbs and peduncles have been destroyed, but the root of the (apparently solid) right peduncle can be seen rising from a slight eminence at the antero-lateral corner of the cerebrum. The thalamencephalon is very short, and is completely hidden in dorsal view between the cerebrum and optic lobes. The latter are of considerable size and are covered by the anterior lobe of the cerebellum. The cerebellum is large, with a series of twelve or so deep transverse fissures.

The fish from which this dissection was made was caught in the North Sea ; it measured 12 feet in length.

O. C. 1311 A *b*. *Presented by Dr. Albert Günther.*

D. 75. A similar dissection of the hinder part of the skull of a somewhat larger Basking Shark (*Selache maxima*). The parts of the brain anterior to the optic lobes are absent. In this specimen the large size and convoluted structure of the cerebellum are very clearly shown ; it should be noticed that the median transverse furrow is more pronounced than the rest; it is the representative of the single furrow in such forms as *Acanthias.* The medulla is a good example of the elongated open type; in it, the several prominences are very clear, more particularly the arrangement of the convoluted auricles and the lobus lineæ lateralis.

O. C. 1311 A. *Presented by Sir E. Home, Bart.*

D. 76. The brain of a Porbeagle (*Lamna cornubica*) divided in the median sagittal plane, and with the halves so mounted as to show the lateral and median surfaces.

This brain (fig. 21) reaches a comparatively high state of development; it is distinguished by its antero-posterior concentration, the large size of the fore-brain and optic lobes, and the excessive development and structural complication of the cerebellum. The fore-brain is globular and, owing to the immense thickening of the lamina terminalis, almost solid, its ventricle (best seen at the back of the left-hand specimen) being all but obliterated. The olfactory peduncles are narrow at their origin from the antero-lateral parts of the cerebrum and gradually become inflated as they approach the small olfactory bulbs. In this part their walls are extremely thin (see the cut edges of a square window in the figure). It seems likely that the small size of the olfactory bulbs is compensated by the great development of the cerebrum.

Fig. 21.

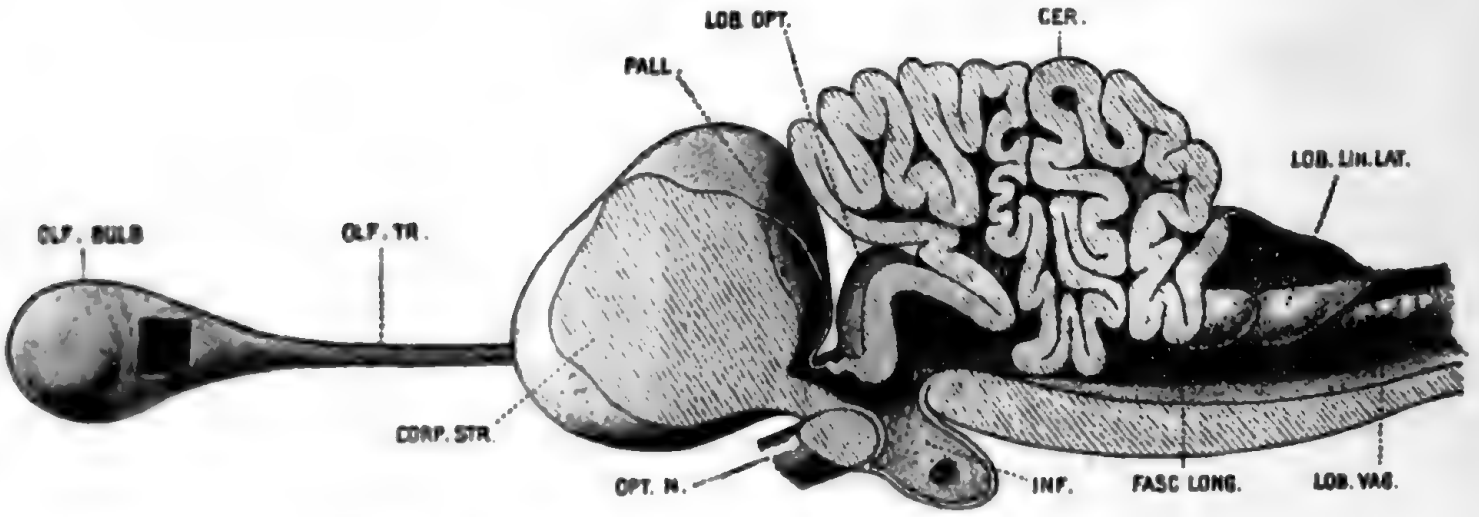

Brain of *Lamna cornubica*, in sagittal section.

The thalamencephalon is very short—compressed between the cerebrum and the large optic lobes. The latter are completely covered dorsally by the cerebellum. The structure of the cerebellum is well shown in the right-hand specimen:

although to all appearance nearly solid it will be seen to be formed of a single sheet of nervous tissue thrown into a complex series of transverse folds, between each of which penetrates a part of the general cavity of the organ. This complex folding is manifestly only a further extension of the simple transverse grooves seen in *Acanthias* or *Galeus*. The position of the original median transverse furrow is marked by the deepest and most complex fold.

The lobi inferiores are small and open widely into the infundibulum.

The medulla is considerably shortened antero-posteriorly.

O. C. 1311 B *b*.

D. 77. The cranium of a Tope (*Galeus communis*) showing the brain *in situ*. The brain affords in its general construction and proportions an excellent example of that of an Elasmobranch, in which all the typical features are strongly marked without any excessive specialisation of any one part. Thus it is long and narrow, though not so much so as in low types like *Notidanus*; the optic and more especially the olfactory centres are highly developed; the cerebellum is large and transversely furrowed, though not so complex as, for instance, in *Lamna*; the medulla is of some length, though far shorter than in primitive forms. Beyond these more general features, in which this brain occupies a central position among those of Elasmobranchs, it should be noticed that the olfactory bulbs, although not double as in *Carcharias*, are very distinctly bilobed. They are united to the cerebrum by short, thick, hollow peduncles.

The cerebrum is of the massive type with strongly thickened lamina terminalis, and has upon its dorsal surface two pairs of rounded eminences in place of the single pair noted in *Acanthias*; it shows no other external sign of lateral separation. The cerebellum has four main transverse fissures besides a few somewhat more partial and indistinct. The lobi inferiores, hypophysis, and saccus vasculosus are prominent, and very typical in form and arrangement.

D. 78. The brain of a Tope (*Galeus communis*) isolated. The vascular roof has been removed from the rhomboid fossa.

O. C. 1311. *Hunterian*.

D. 79. The brain of a Shark, probably a species of *Carcharias*.

The fore-part of this brain agrees in all important particulars with the published descriptions of that of the Blue Shark (*Carcharias glaucus*). The olfactory bulbs are completely double, each part being attached to the olfactory peduncle by a short separate stalk. The peduncles are long and apparently solid, and terminate on either side in an oval swelling upon the lateral parts of the cerebrum, far back towards the ventral surface. The large and massive cerebrum shows no external sign of division upon its dorsal aspect, but beneath there is a slight median furrow. Posteriorly it overhangs the thalamencephalon and meets the anterior surface of the optic lobes. In other respects this brain closely resembles that of *Galeus*. O. C. 1311 B.

D. 80. A specimen of the brain of a Shark, with the medulla removed. It is probable from the general form of the cerebrum, and more particularly from the characteristic method of origin of the olfactory peduncle (seen on the right), that this is the brain of a *Carcharias*. It is strongly bent artificially towards the ventral aspect, and a piece has been removed from the left side of the cerebrum by transverse and sagittal incisions, to show the immense thickness of the dorsal cerebral wall and the relatively small size of the ventricle. Upon the transverse sectional surface, a portion of the choroid plexus can be seen protruding from the ventricular cavity. The method of apposition of the medullary auricles in the mid-line can be clearly seen beneath the posterior lobe of the cerebellum. O. C. 1311 A *a*.

D. 81. The cranium of a Monk-fish (*Rhina squatina*), with the brain *in situ* exposed from the dorsal and ventral aspects. The brain in this fish is remarkable for the slight development of the olfactory centres, for not only are the bulbs and peduncles peculiarly small for an Elasmobranch, but the cerebrum is also feeble. The latter is thin-walled (so that its apparent size is deceptive), with a pair of rounded swellings on its dorsal aspect, and is deeply cleft anteriorly as in some of the lower Sharks. The low type of the brain is further shown by its long narrow form; and by the relatively great development of the medulla, its gradual passage into the cord, and widely open rhomboid fossa. In contrast to the large medulla, the cerebellum is small, its greater part consisting (as in the Rays) of the posterior lobe. Its sides are somewhat swollen to form a pair of lateral lobes (peduncles) close in front of the medullary auricles. The optic lobes are oval and of moderate size; the lobi inferiores scarcely distinguishable; the hypophysis small; and the saccus vasculosus and infundibulum very large. It should be particularly noticed that the brain combines features characteristic respectively of the Sharks and Rays—the cerebrum and medulla conforming to the former type, the cerebellum to the latter. The brain occupies only a small part of the spacious cranial cavity.

RAJIDA.

D. 82. The cranium of a Skate (*Raja batis*) with the brain exposed. The brain occupies only a small part of the cranial cavity, and is chiefly remarkable for the strong development of the olfactory centres and for the antero-posterior shortening of the medulla and the prominence of the auricles and lobi lineæ lateralis.

The olfactory bulbs are solid and differ considerably in shape from those of Sharks; each is laterally lengthened and bears a somewhat similar relation to its peduncle that the foot of a stocking does to the leg, the heel being represented by the swelling at the end of the peduncle, and the foot by the part of the bulb that extends outwards along the posterior surface of the olfactory capsule. The peduncles are solid and very long; each terminates in a strongly pronounced swelling on the lateral surface of the cerebrum. Owing to the presence of these the cerebrum is remarkably broad; it is convex anteriorly, but has no median groove; upon its dorsal surface are a pair of indistinct eminences. The thalamencephalon and mid-brain are well developed but in no way remarkable. The former is somewhat longer and narrower than in many Rays. The optic lobes, although dwarfed by the great size of the fore-brain, are in reality well-developed; the lobi inferiores, infundibulum, saccus vasculosus, and hypophysis are also strongly marked. The latter is connected (as in other Elasmobranchs) by a blood-vessel to a transverse bar of vascular connective tissue closely adherent to the perichondrium. The cerebellum differs from that of a Shark in the slight development of its anterior lobe. Its surface is smooth except for a single transverse furrow and slight lateral indentations. At the sides of the posterior lobe lie the strongly developed auricles and lobi lineæ lateralis; the latter apparently owe their size to the peculiarly large nerve-supply necessary for the lateral-line organs and ampullæ.

The medulla shows a very high degree of antero-posterior concentration, the rhomboid fossa extending only a short way beyond the cerebellum.

D. 83. The brain of a Skate (*Raja batis*) dissected to show its internal structure. The dorsal parts of the cerebrum have been removed to show the solidity of its walls and the extremely small size of the ventricle. The latter, although of some little extent in the horizontal plane, is reduced to a mere slit dorso-ventrally. Its outline can be traced with difficulty in the specimen; it is clearest towards the extremities of the lateral ventricles.

Fig. 22.

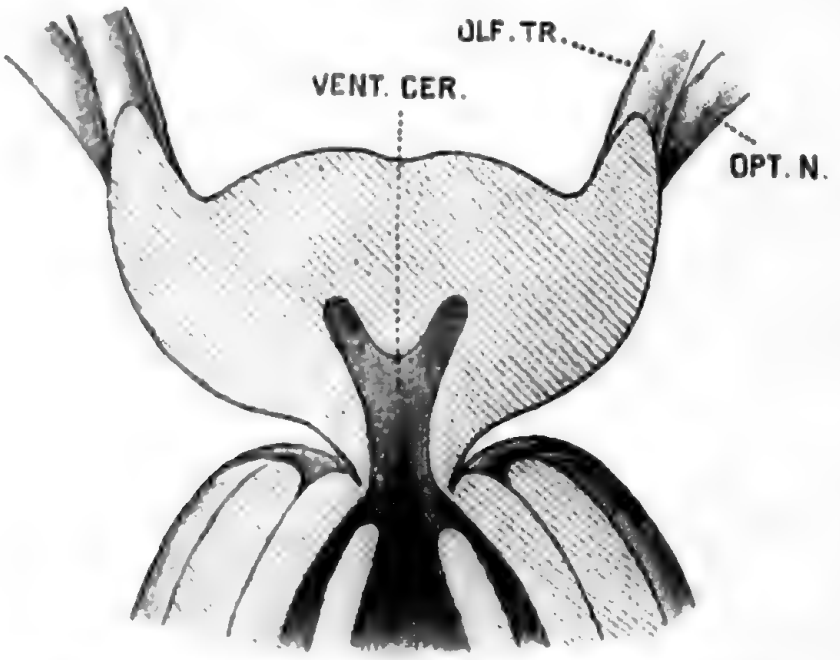

Cerebrum of *Raja batis* (horizontal section).

Behind the cerebrum, the brain has been divided by a mid-sagittal incision and its two halves have been separated. Its internal structure differs in several particulars from that of *Scyllium* (D. 73), the most noteworthy being the relatively small size of the cavities of the optic lobes, the more massive structure of the cerebellum, and the absence of a cavity in its anterior lobe.

Upon the right side, the posterior lobe of the cerebellum has been removed to show the complicated folding of the medullary auricle and its passage into the longitudinal zone of the cerebellum. The olfactory bulbs and the greater part of the peduncles have been removed. Transverse sections of them are mounted above to show that they do not contain a cavity.

D. 84. The cranium of a Torpedo (*Torpedo galvanii*) opened from above to expose the brain. A pair of immense electric lobes form the most striking and important feature of the brain; they are developed in the floor of the medulla, and apparently represent the motor vagal lobes of other Elasmobranchs in a state of excessive hypertrophy. Projecting upwards, they entirely fill and obliterate the rhomboid fossa and are bounded anteriorly by the auricles and cerebellum. Each gives rise to two large bundles of nerves for the electric organ. The electric lobes contain a number of gigantic ganglion-cells, the axis-cylinders of which pass directly into the electric nerves. The brain, with the exception of the electric lobes, is poorly developed. The cerebellum is very small, diamond-shaped, and, but for a cruciform furrow, smooth. The optic lobes are of moderate size, although the nerves are remarkably slender. The cerebrum is globular, with slight prominences on its dorsal surface ; it receives at its antero-lateral corners a pair of fine solid olfactory peduncles. O. C. 1310. *Hunterian.*

Rohon, Arb. Zool. Inst. Wien, t. i. 1878, p. 151.

HOLOCEPHALI.

D. 85. Two specimens of the brain of a Sea-Cat (*Chimæra monstrosa*). In the lower specimen the brain is seen *in situ* from above, the hypothalamus and neighbouring parts being also exposed through a window cut in the cranial floor. In the upper specimen the internal structure is shown by the removal of the roof of the thalamencephalon and the upper part of the left hemisphere, and by the sagittal division of the hinder parts of the brain and the turning to one side of the left half (fig. 23).

Fig. 23.

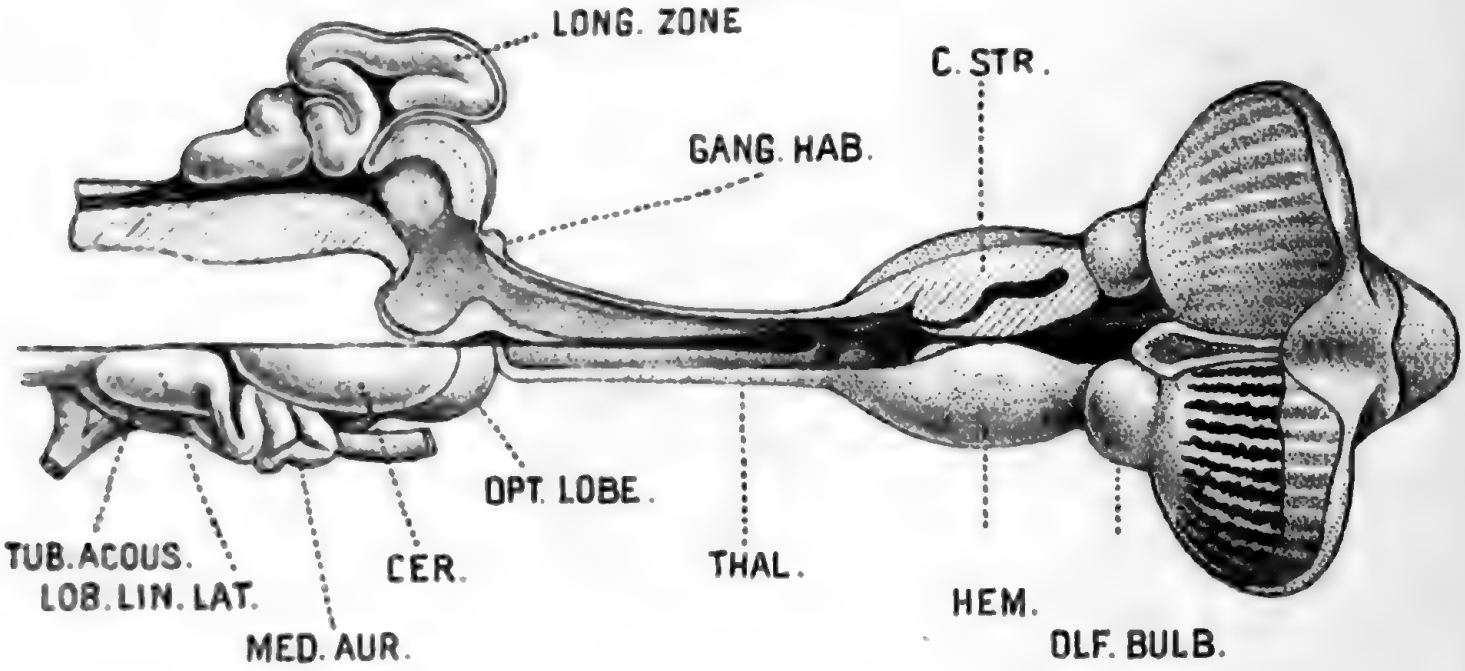

Brain of *Chimæra monstrosa* (dissected).

The brain is divisible into three well-defined regions :—(i.) A large anterior mass composed of two pairs of contiguous lobes, the anterior of which are small and in connection with the olfactory organs and the posterior united together in the mid-line; they are the olfactory bulbs and cerebral hemispheres. (ii.) A remarkably long and slender thalamencephalon. (iii.) The mid-brain, cerebellum, and medulla—a considerable mass, remarkable for its great dorso-ventral depth. This hinder part, owing to the resemblance that the sides of the thalamencephalon bear to olfactory peduncles, was formerly supposed to include the cerebrum. A more detailed examination will show that this brain, in spite of its obvious peculiarities, is, apart from the cerebrum, essentially that of an Elasmobranch. The olfactory bulbs are small and rounded in form; each is feebly bilobed. They are separated from the hemispheres by a furrow. Each hemisphere is fusiform, and is attached to its fellow near the middle of its median surface by a delicate lamina terminalis continuous above and below with the roof and the floor of the thalamencephalon. Slightly behind the lamina a large semicircular opening (foramen of Monro) leads on each side from the 3rd ventricle into a cavity that extends within the hemisphere to the olfactory bulb. The posterior part of this cavity is mainly occupied by a prominent swelling on the lateral wall of the hemisphere, that probably represents the corpus striatum.

The thalamencephalon forms a tube 25 mm. long ; its sides are ribbon-like and fairly thick, but the floor and roof are composed only of epithelium and pia mater. The roof is more extensive than the space between the lateral walls and thus bulges upwards, particularly in front, in a sac-like manner. It is infolded in the mid-line in its anterior two-thirds to form a choroid plexus, small processes of which project into the lateral ventricles. At its hinder end it forms a conical projection that accompanies the epiphysis. In front of the epiphysis the roof of the thalamencephalon is swollen to form a pair of prominent ganglia habenulæ which, as in the Amphibia, form a projecting lip when the tela choroidea is removed (upper specimen). Behind the epiphysis, the anterior border of the optic tectum is thickened to form the posterior commissure. The optic lobes are of considerable size, and contain a large ventricle, the lower half of which is partly filled by a swelling of the lateral walls. The cerebellum is simple, though well developed: it is diamond-shaped, with anterior and posterior lobes each containing an offshoot from the common ventricle; its surface is smooth with the exception of a longitudinal furrow and a feeble transverse indentation. The inner surface of the cerebellum is marked by a pair of prominent longitudinal ridges similar to those of Elasmobranchs, and, like them, continuous with the medullary auricles.

The medulla is strongly concentrated antero-posteriorly, and is remarkable for the great development of two pairs of lobes. One pair (lobus lineæ lateralis) is continuous with the auricles and gives origin on either side to the dorsal root of the ophthalmicus superficialis VII. The second pair (tuberculum acusticum) lie below them, and give rise to the lateralis and the lower roots of the lateral-line branches of the VII. nerve. The lobus vagi is nodulated as in Elasmobranchs. The lobi inferiores, though small, are remarkably prominent. The saccus vasculosus is well-developed.

From the above it will be seen that the hinder part of the brain is closely similar to that of an Elasmobranch, particularly in the conformation of the cerebellum and medulla. The optic lobes show a slight tendency towards the Teleostean type in having an enlargement on their lateral walls suggestive of the torus semicircularis, but the hypothalamus is essentially that of an Elasmobranch. The cerebrum in its relation to the olfactory bulbs, in the considerable separation of the hemispheres and the relative thickness of their dorsal and ventro-lateral walls, is closely similar to that of a Dipnoan or low Amphibian.

Wilder, Proc. Ac. Sci. Philad. 1877, p. 219.

GANOIDEI.

D. 86. Part of the skull of a Sturgeon (*Acipenser sturio*) with the brain exposed from the dorsal and ventral aspects. In comparison with the size of the fish (this individual weighed 154 lbs., and measured 6 ft. 4 in.) the central nervous system is peculiarly small. The brain occupies only a part of the spacious cranial cavity, and in its superficial features combines characters found in Elasmobranchs, Amphibia, and Teleostea: for example, the medulla resembles that of a low Shark or Amphibian, whereas the cerebellum is very similar to that of *Ceratodus* but is provided with a valvula as in Teleosts. Or, again, the mid-brain and thalamencephalon have a strong superficial likeness to those of *Ceratodus*, whereas the cerebrum resembles that of a Teleostean in having an epithelial pallium.

The medulla broadens gradually from the cord towards the cerebellum, and has a very widely-open rhomboid fossa covered by a strongly pleated vascular roof (removed and mounted on the left in the specimen). In its floor are a pair of well-marked fasciculi longitudinales, each of which sends a strong offshoot to the motor root of VII. In the hinder part of the rhomboid fossa on either side lie the sensory vagal lobes, nodulated as in Sharks. To the side and in front of the vagal lobes, the margin of the rhomboid fossa swells to form a conspicuous lobe on either side (lobus lineæ lateralis) that gives origin to certain nerves of the lateral line. In front of the lobus lineæ lateralis the margins of the rhomboid fossa bend upwards and slightly outwards to form the posterior crura of the cerebellum. The cerebellum forms an upstanding recurved anterior border to the rhomboid fossa. Its anterior parts (not shown in the specimen) project within the optic lobes, forming a valvula cerebelli as in Teleosts. Molecular, nuclear, and intermediate layers are present in the cerebellum, but, as in Elasmobranchs, the distribution of the nuclear layer is very partial, and Purkinje's cells are irregularly disposed. The optic lobes are very small and, as in Dipnoi and Urodeles, form a single globular enlargement without a distinct median furrow. They are said to contain small tori longitudinales and semicirculares similar to those of Teleosts.

The thalamencephalon is narrow and fairly long, with a well-developed hypothalamus. The sides of the infundibulum are swollen to form a pair of small lobi inferiores. The saccus vasculosus is well-developed. As in most Elasmobranchs and many Teleostea, the epiphysis is long and thread-like; towards its base it is in close contact with the roof of a large conical paraphysis. The cerebrum is of relatively small size, and consists of basal ganglia (striatum and epistriatum) covered by an epithelial roof, in which a few nerve-elements have been observed. The olfactory bulbs are sessile on the cerebrum; each contains a cavity in connection with the cerebral ventricle, and receives a large olfactory nerve indistinctly separable into two bundles.

Johnstone, Zool. Jahrb., Bd. xv. 1901, p. 59.

TELEOSTEA.

Rabl Ruckhard, Arch. Anat. u. Phys. 1898, p. 345 (*Pallium*).
Haller, Morph. Jahrb., Bd. xxvi. 1898, p. 632 (*Histol., Bibliogr.*).

The brain of Bony Fishes differs from that of Elasmobranchs in many important features. It is far more concentrated longitudinally, and is remarkable for the strong development of the optic lobes, which in some cases completely dominate the rest of the brain and render it nearly globular in form. On the other hand the olfactory region, whose great development forms one of the most striking features of the Elasmobranch brain, is peculiarly feeble in the Teleostea. The olfactory bulbs are small, either sessile upon the cerebrum or connected with it by long peduncles, and the cerebrum itself is represented by a pair of rounded basal ganglia roofed over by an epithelial non-nervous pallium (fig. 24).

The thalamencephalon shows essentially the same features in both groups, although much compressed antero-posteriorly in the Teleostea. The cerebellum is large, except in some sluggish bottom fish (e. g., *Lophius*, *Cyclopterus*), but is usually solid and not hollow as in the Elasmobranchs. Its anterior parts also are strongly developed, and protrude forward beneath the tectum opticum into the cavity of the optic lobes, forming the highly characteristic Teleostean valvula cerebelli. The medulla is in most cases much concentrated and often shows remarkably well-developed facial and vagal lobes. The basal ganglia of the cerebrum have much the same minute structure as in Elasmobranchs; they are united by commissural strands (c. interlobularis) that occupy a thickening of the floor of the common ventricle. These commissures are derived partly from the olfactory areas and partly from the striatum. Their relation to the anterior commissure of Mammals is doubtful.

Fig. 24.

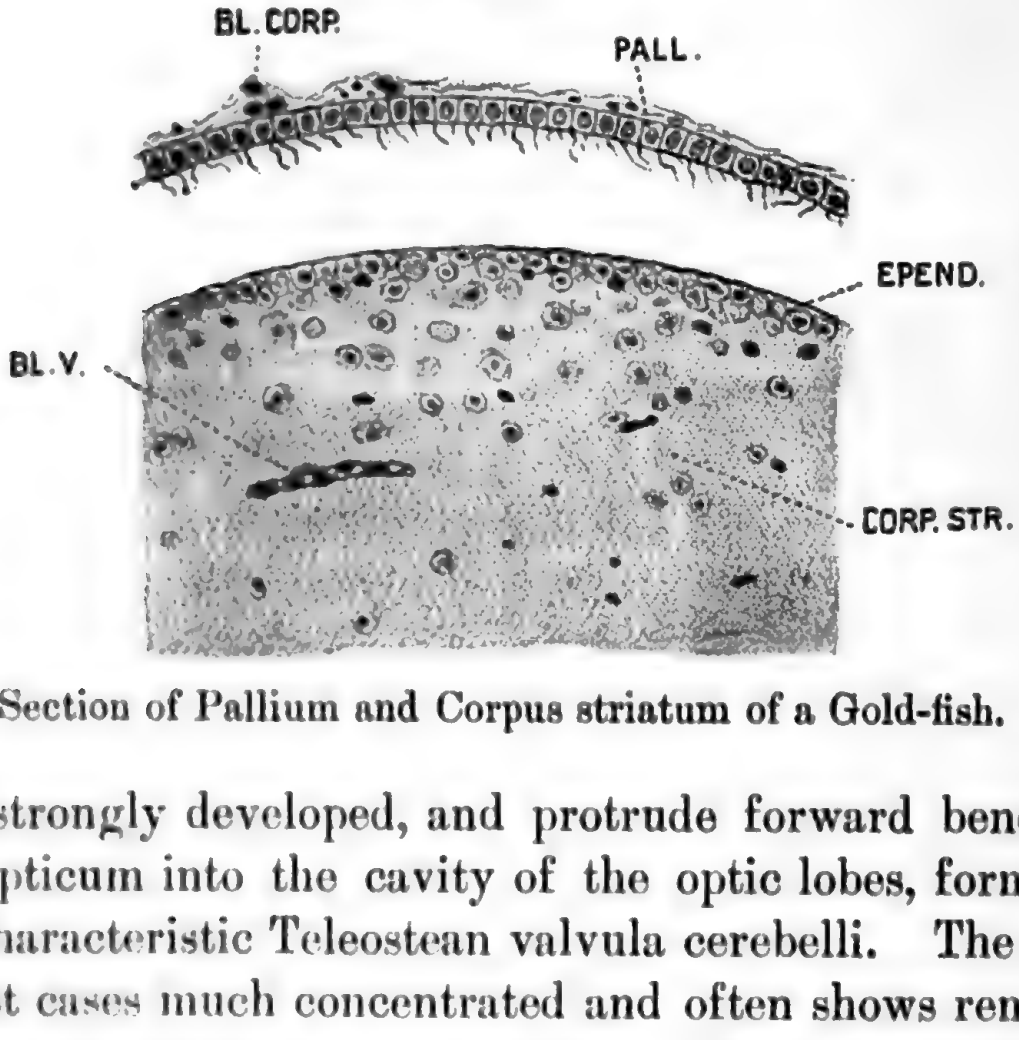

Section of Pallium and Corpus striatum of a Gold-fish.

The thalamencephalon, in minute structure and arrangement of tracts and nuclei, is approximately similar to that in Elasmobranchs, the cerebro-hypothalamic tracts being, however, specially strong. The tectum opticum has also essentially the same structure in both groups, although its elements are in Teleostea arranged somewhat more definitely in layers. The ependyma and nervous tissue also are greatly developed on either side of the mid-dorsal line of the tectum forming a pair of longitudinal ridges (tori longitudinales), traces of which are also found in Reptiles and Birds. The lateral parts of the optic lobes contain a pair of large nuclei (n. laterales), from which a considerable proportion of the fillet—a particularly well-developed tract in Teleosts—takes its origin. They are superficially visible as a pair of bulgings into the cavity of the optic lobes (tori semicirculares). The cerebellum and valvula show the structure common to the cerebellum of all Vertebrates; Purkinje's cells are, however, somewhat irregularly disposed. The valvula is connected by tracts to the lobi inferiores.

ANACANTHINI.

D. 87. The cranium of a Cod (*Gadus morrhua*) in sagittal section, showing the brain from the left side. The cranial cavity is very extensive, and is only partially occupied by the relatively small brain. The latter shows well the main Teleostean characters. The olfactory bulbs are small round bodies lying close beneath the olfactory capsules; they are connected by long delicate tubular peduncles (the ventral parts of which only are nervous) to the basal region of the cerebrum. The peduncles lie close side by side for the posterior two-thirds of their course; in front they diverge towards the olfactory capsules and gradually increase in calibre. The basal ganglia of the cerebrum form two pronounced swellings of the cerebral floor; they are separated from one another dorsally by a deep sagittal fissure and are ventrally united by a transverse commissure. Each is distinctly lobulated, the two main lobules (striatum and epistriatum) lying respectively antero-lateral and postero-mesial. The roof of the cerebrum (pallium) is entirely non-nervous and consists of a continuation of the ependyma that lines the brain-cavities, in conjunction with the pia mater. In front it is continuous with the epithelial roof of the olfactory tracts, and behind with that of the thalamencephalon. The dorsal and lateral parts of the thalamencephalon are much restricted, being buried to a considerable extent by the optic lobes ; but the hypothalamus is strongly developed, the lobi inferiores in particular being large and prominent: they lie almost directly below the optic lobes. The latter are of great size, of almost globular form, and are separated in the mid-line by a sharp furrow. The optic tracts arise mainly from their superficial parts, and pass forward on either side of the thalamus to the ventral surface of the cerebrum ; here they leave the brain and cross—the right below the left—to form the optic nerves. The cerebellum is tongue-shaped with its free end overhanging the rhomboid fossa. It is connected with the basal parts of the brain by a pair of prominent anterior crura that give passage to the cerebellar tracts and contain the nuclei of part of the trigemino-facial nerve complex. The medulla, in comparison with that of a Shark, is much concentrated. The rhomboid fossa is consequently small. Its borders show definite swellings, due to the posterior crura of the cerebellum and to the nuclei of the posterior cranial nerves.

D. 88. Parts of the head of a Cod (*Gadus morrhua*) with the brain exposed from the lower surface. The optic nerves, before entering the brain, cross one another, the left beneath the right. Behind this crossing lies the large spherical pituitary body attached to the antero-ventral surface of the infundibulum. It covers the anterior parts of the lobi inferiores. Behind it in the mid-line, separating the posterior parts of the lobi inferiores, is a small saccus vasculosus continuous with the distal end of the infundibulum.

In this specimen the distribution of the third pair of cranial nerves is shown. It sends branches to the inferior, superior, and internal recti and to the inferior oblique, as well as a ciliary branch to the eyeball. A bristle is placed beneath the branch to the inferior oblique.

O. C. 1380 A. 8.

D. 89. A sagittal section of the cranium and brain of a Cod (*Gadus morrhua*). Black paper, inserted behind the pallium, brings out clearly the relations of this membrane to the basal ganglia and olfactory tracts. At the root of the olfactory tract can be seen the cut edge of the commissura interlobularis (fig. 25, ANT. COMM.). The common cavity of the infundibulum and saccus vasculosus is clearly shown; in the side wall of the former is a minute opening that leads into the ventricle of the right lobus inferior.

At the anterior end of the tectum opticum lies the section surface of the small posterior commissure.

A narrow passage leads from the aqueduct of Sylvius into the cavity of the optic lobes *. In the section this cavity is largely obliterated by one of a pair of longitudinal ridges (tori longitudinales) that lie on either side of the mid-dorsal line of the tectum. The torus is thickest anteriorly where it abuts on the posterior commissure, and gradually fades away posteriorly.

Fig. 25.

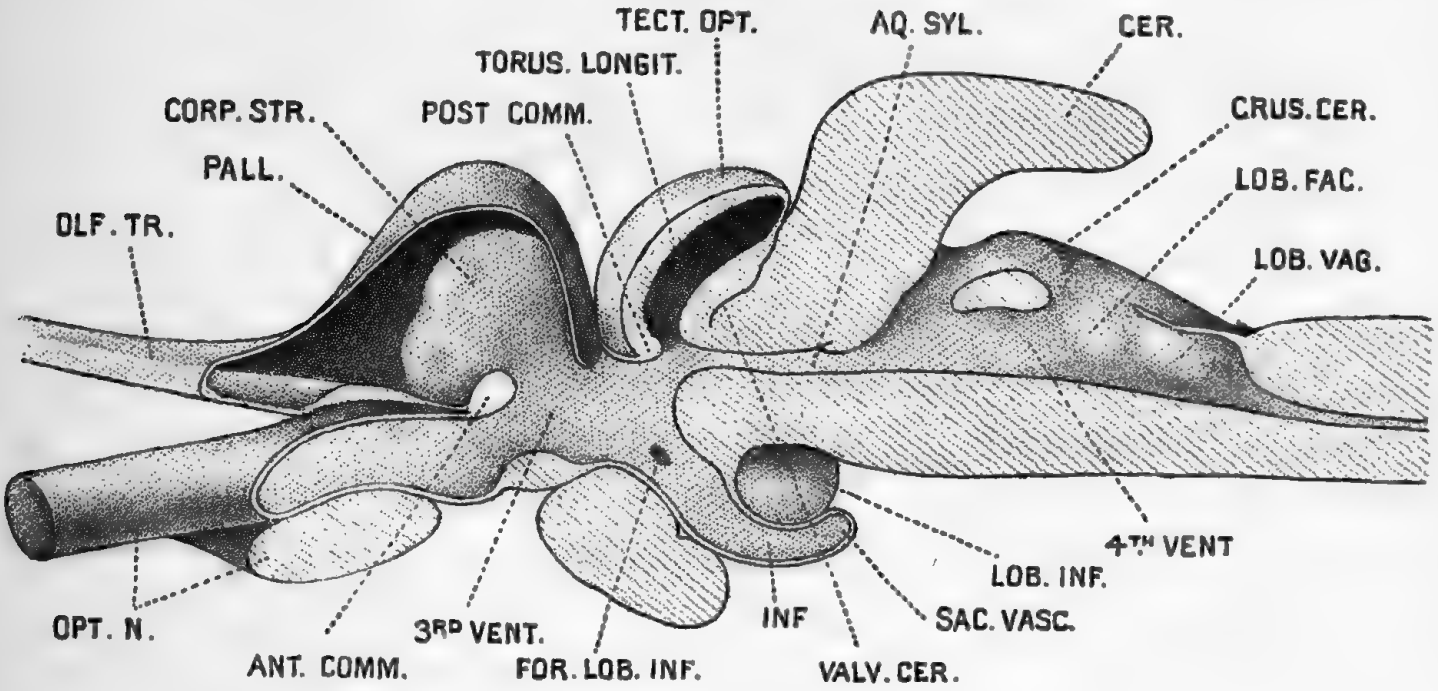

Brain of *Gadus morrhua* in sagittal section.

The hinder part of the optic ventricle is occupied by a forwardly projecting process of the cerebellum (valvula cerebelli). This structure is formed by the invagination of the anterior parts of the cerebellum into the cavity of the mid-brain, and thus in sagittal section shows two superposed layers—the lower one continuous behind with the cerebellum and passing in front by reduplication into the dorsal layer. The latter is closely applied to the first, and is continuous posteriorly with the hinder margin of the tectum opticum. Beneath the posterior lobe of the cerebellum can

---

* In fig. 25 the leading line from AQ.SYL. points somewhat too far back.

be seen the cut surface of the nervous bridge that unites the two posterior crura of the cerebellum, and behind this the lobus facialis and lobus vagi. O. C. 1308 o.

D. 90. A similar specimen in which the structure of the optic lobes and valvula cerebelli is more clearly visible.

In this specimen the left optic nerve crosses above the right.

D. 91. The brain of a Cod (*Gadus morrhua*) dissected from above.

The posterior lobe of the cerebellum and the tectum opticum with the exception of the torus longitudinalis have been removed, thus exposing the medulla and the cavity of the mid-brain. Within the optic ventricle are certain marked prominences: on either side a large semilunar excrescence (torus semicircularis) due to the presence at this spot within the latero-ventral walls of the mid-brain of a nucleus in connection with the fillet: in the central mid-line at the hinder end of the ventricle a subconical projection (valvula cerebelli), the structure and relations of which are shown in the previous specimens: and in the dorsal mid-line a pointed tongue-like process that extends from the posterior commissure to the hinder end of the tectum opticum. This structure, composed of the two tori longitudinales, consists of nerve elements and a local thickening of the ependyma that lines the brain-cavities. Beneath its broad anterior end lies the narrow opening by which the optic ventricle communicates with the aqueduct of Sylvius.

The dorsal surface of the medulla is occupied by a series of swellings that almost entirely close the rhomboid fossa, and are due mainly to the sensory nuclei of the cranial nerves (fig. 26). Judging by Goronowitsch's account of these structures in *Lota*, their relation to the several cranial nerves should be approximately as follows:—The prominent lateral crura of the cerebellum contain besides cerebellar tracts, a pair of large nuclei from which arise the acoustic and lateral-line nerves. These lobes apparently represent the tuberculum acusticum of Elasmobranchs (Johnstone, Zool. Jahrb. 1901, p. 159) or the Sturgeon shifted forward owing to the concentration of the medulla. Close behind the cerebellum and exposed by the removal of its free extremity, are a pair of prominent lobes (posterior crura of cerebellum); they are united above the fourth ventricle by a commissure, but otherwise are very similar in aspect to the lobi lineæ lateralis of Elasmobranchs. They must, however, be compared with the medullary auricles as they consist entirely of a backward prolongation of the cerebellum. Behind these, on a level with the exit of the vagus from the brain, are a pair of lobes almost contiguous in the mid-line and each indistinctly divided by a longitudinal furrow. They give origin to the sensory roots of the facial and glosso-pharyngeal and represent a dismembered portion of the lobus vagi of Elasmobranchs.

Fig. 26.

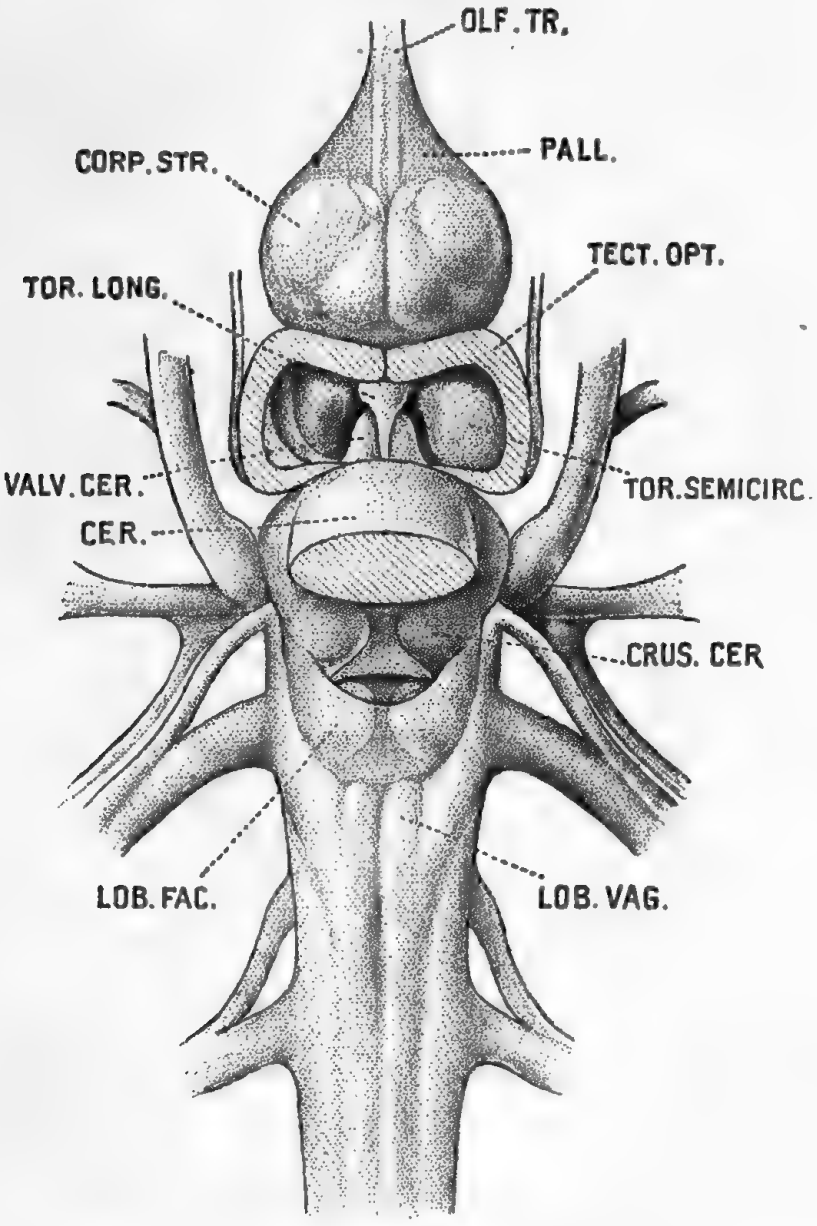

Brain of *Gadus morrhua* (dissected).

Behind and to the sides of these lobes are elongated and somewhat irregular excrescences from which arise the sensory roots of the vagus.

Goronowitsch, Festschr. für Gegenbaur, Bd. iii. 1897, p. 14 (*Lota*).

D. 92. The brain of a Bib (*Gadus luscus*) exposed from the left and ventral aspects.

In comparison with the brain of the Cod, there are noticeable differences in the relative proportions of the parts—the cerebral basal ganglia and optic lobes being much more nearly equal in size. This is due partly to an increase in the size of the basal ganglia, and partly to a decrease in the optic lobes relative to the brain as a whole. The right optic nerve crosses below the left. The saccus vasculosus is more prominent than in the Cod, and the pituitary body very much smaller. The lobi inferiores meet in the mid-line behind the saccus vasculosus.

O. C. 1380 A 5.

D. 93. The head of a Five-bearded Rockling (*Motella mustela*) with the ventral surface of the brain exposed. The optic nerves cross—the right below the left—at a considerable distance in front of the brain. In this specimen parts of the trigeminal nerve are also shown. O. C. 1380 A 7.

D. 94. The head of a Sole (*Solea vulgaris*) with the brain exposed. Owing to the torsion of the skull the fore part of the brain is rotated to the right, but the region behind the optic lobes is quite similar to that of other fishes except for a hardly perceptible tendency to bend towards the right. The medulla is fairly long, with a pair of very prominent lobes (facial ?) upon its dorsal surface. The cerebellum is small, nearly globular in shape, and projects slightly backwards over the rhomboid fossa. The optic lobes are also of moderate dimensions, and give off equal-sized optic nerves. The left nerve passes above the right and twists round above the sphenoid bone to reach the left eye which is displaced to the right side of the fish.

The thalamencephalon is remarkably elongated for a Teleostean, and forms a conspicuous neck between the optic lobes and corpora striata.

The olfactory bulbs are large and are separated from the basal ganglia by a considerable constriction. The parts of the fore-brain show a distinct tendency towards a linear arrangement, the olfactory bulb and corpus striatum of the left side being thrust to a marked degree behind the corresponding parts on the right.

The lobi inferiores are globular and prominent.

D. 95. The head of a Brill (*Rhombus lævis*) with the brain exposed from the right (blind) side. The brain is perfectly symmetrical. The optic lobes are relatively somewhat larger than in the Sole. The corpora striata are very small, with sessile olfactory bulbs at their anterior end. The left optic nerve passes below the right. O. C. 1380 A II.

D. 96. A similar specimen of the brain of a Hallibut (*Hippoglossus vulgaris*) exposed from the right (ocular) side. It closely resembles that of the Brill except for its larger size. The infundibulum and saccus vasculosus are very prominent. The right optic nerve is slightly smaller than the left, it crosses beneath it; both are of immense size.

ACANTHOPTERYGII.

D. 97. Part of the cranium of a Gilt-Head (*Chrysophrys aurata*) with the brain exposed from the right side. The small olfactory bulbs are sessile on the cerebrum; each gives rise to a stout olfactory nerve. The basal ganglia are immensely developed; each is a lobulated globular body slightly larger than one of the optic lobes. The latter are of moderate dimensions; the lobi inferiores are large and longitudinally elongated. The cerebellum is small, quadrilateral in outline, and of considerable dorso-ventral depth.

The right optic nerve crosses beneath the left; its distal part has been opened out to show its flat ribbon-like form and pleated folding. O. C. 1380 A 20.

D. 98. The brain of a Mackerel (*Scomber scombrus*) exposed from the right and dorsal aspects. The olfactory bulbs and corpora striata are small and closely contiguous, forming together a pyramidal anterior extremity to the brain. The lobi inferiores are small, but the optic lobes are of remarkable size, pressing in front against the corpora striata and overhung posteriorly by the cerebellum ; they are globular in shape, separated in the mid-dorsal line by a shallow groove. Upon the antero-lateral surface of each is an indentation from which emerges the main part of the optic tract. The lobule that lies postero-ventral to the indentation is due to an overlapping of the tectum opticum. The right optic nerve crosses below the left ; both are of great size, although the eyes in this fish are comparatively small. The cerebellum is of moderate size ; it is egg-shaped, with its narrow end projecting forwards over the hinder half of the optic lobes. The crura cerebelli are strongly pronounced. The medulla is much shortened antero-posteriorly. O. C. 1380 A 18.

D. 99. The cranium of a Mackerel (*Scomber scombrus*) with the brain exposed from above. The roof of the optic lobes and the anterior free end of the cerebellum have been removed to show the valvula cerebelli. This organ occupies the major part of the cavity of the optic lobes and is to a great extent responsible for their size. It consists of a central lobe directly continuous with the cerebellum, and of two lateral lobes or wings formed by the reduplication of the anterior ends of the central lobe.

Fig. 27.

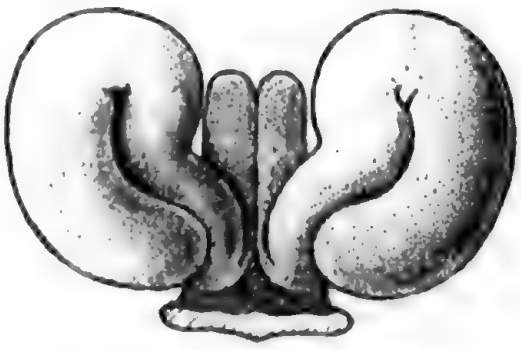

Valvula cerebelli of *Scomber scombrus.*

This relation of the lobes to each other is shown in the diagram (fig. 27).

D. 100. The skull of a Fishing-Frog (*Lophius piscatorius*) with the brain exposed from the dorsal and ventral aspects, and with the origins, and in some cases the peripheral parts, of the cranial nerves shown.

The brain is feebly developed and occupies only a small part of the spacious cranial cavity. The fore-brain is remarkably small; it forms a pyramidal eminence in front of the optic lobes. The bulbi olfactorii are sessile on the basal ganglia, but in this specimen are hardly to be distinguished. They give off delicate olfactory nerves. The optic lobes are large in comparison with the feeble development of the rest of the brain, but are not in reality particularly strong. They are separated in the mid-dorsal line by a shallow groove. The cerebellum is extremely small for a Teleostean, forming merely a little rounded excrescence between the hinder margins of the optic lobes. The medulla is followed by a swollen region of the cord with a single pair of eminences upon its dorsal surface. This enlargement is by some included in the medulla, and homologized with the vagal lobes, but from its microscopic character (Ussow, Arch. Biol. t. iii. p. 642) it seems that it more likely is a modified part of the cord, comparable to the metameric swellings found in this region in the Gurnard. It should be noticed that in both cases the anterior spinal nerves are strongly developed.

The pituitary body is a remarkable structure both for its enormous size and its position a centimetre or more in front of the brain. It is spherical and connected to the infundibulum by a long delicate pedicle. The pineal gland is situated in a similar way beneath the cranial roof far in front of its point of origin upon the roof of the thalamencephalon. The same forward shifting is noticeable to a less degree in the eyes, in the position of the optic chiasma, and in the point of exit from the brain of the trigeminal complex of nerves. Possibly in all cases it is due to the great development of the anterior face-region. The lobi inferiores are peculiarly small; they lie one on either side of a prominent saccus vasculosus.

In this specimen the spinal cord is also shown (for description see D. 754). O. C. 1308 N.

D. 101. The isolated brain of a Fishing-Frog (*Lophius piscatorius*). This specimen shows the features mentioned in the description of the previous specimen, but with greater clearness. The pedicle of the pituitary body is nearly 20 mm. long. O. C. 1308 M.

D. 102. The brain of a Gurnard (*Trigla hirundo*) exposed *in situ* from above. The olfactory bulbs are of some size; they are sessile on the cerebrum, and each gives origin to a stout olfactory nerve. The basal ganglia are globular, smooth, and very large; the optic lobes are also well developed and somewhat flattened antero-posteriorly. The small cerebellum projects slightly backwards; it has prominent crura. The medulla is short, with well marked vagal lobes on either side of the rhomboid fossa. The anterior part of the cord is much thickened, and shows upon its dorsal surface a series of 5 pairs of metameric enlargements, which are fully described in the section devoted to the spinal cord. O. C. 1308 H.

D. 103. A young Lump-Fish (*Cyclopterus lumpus*), 3·5 cm. long, with the brain and spinal cord exposed from above. The brain is similar in all essentials to that of the adult, but is shorter and broader in outline, larger relatively to the size of the body, and more nearly fills the cranial cavity. The latter feature is common to the young of many Teleosts.
O. C. 1308 L *a*.

D. 104. The head of a Lump-Fish (*Cyclopterus lumpus*) with the brain exposed from the dorsal and ventral aspects. The brain is poorly developed in every part. The minute olfactory bulbs are sessile upon the cerebrum. The optic lobes are oval in outline, and, although they form the largest region of the brain, are very small in comparison with those of most other Teleosteans. The cerebellum hangs backwards over the front part of the rhomboid fossa; it is oval, quite small, and without prominent crura. The medulla is remarkably long and narrow, and merges gradually into the cord much as in the lower Sharks. It shows no definite superficial eminences, and no doubt owes its simple unmodified character to the peculiarly feeble development of the cranial nerves.
Presented by W. B. Tegetmeier, Esq.

D. 105. A Dragonet (*Callionymus lyra*) with the brain and spinal cord exposed from above. The optic lobes are very strongly developed. The cerebellum very closely resembles that of *Lophius*; it is a small rounded eminence lodged between the hinder margins of the optic lobes, and protrudes slightly over the rhomboid fossa. The medulla is small and shows no clear separation from the cord. In this specimen the corpora striata have been removed. O. C. 1308 I.

PHARYNGOGNATHI.

D. 106. The head of a Wrasse (*Labrus* sp.) with the brain shown *in situ* from above. The brain occupies the greater part of the cranial cavity. It is remarkable for the great development of the basal ganglia, which equal, if they do not exceed, the optic lobes in size. Each is roughly triangular when seen from above, and is contiguous in the mid-line with its fellow by one of its sides. Their surface is distinctly lobulated. The cerebellum is tongue-shaped; its greater part hangs backwards over the rhomboid fossa but there is also a small anterior lobe. Its surface is crinkled, probably by shrinkage. The crura cerebelli are well-marked. O. C. 1308 G.

PHYSOSTOMI.

Mayser, Zeits. wiss. Zool. Bd. xxxvi. 1882, p. 259.

D. 107. The brain of a Carp (*Cyprinus carpio*) shown *in situ* from above (fig. 28). In the Carp family the brain is distinguished by the great development of the vagal and facial lobes. This development renders the medulla unusually broad and defines it abruptly from the cord. The vagal lobes form a pair of large wing-like swellings on either side of the rhomboid fossa, and embrace between their anterior ends the unpaired facial lobe—a rounded body situated in the dorsal mid-line behind the cerebellum. This "lobus impar" represents apparently a fusion of the two small facial lobes seen in the Cod (Goronowitch, *l. c.* p. 23). The cerebellum, though much elevated, is of moderate size; it hangs slightly backwards over the medulla. The optic lobes are superficially very large, but owe their size mainly to the great development of the valvula cerebelli. Their roof is composed as usual of two chief layers—an outer cellular and fibrous layer from which the optic tracts arise, and an inner commissural layer; but the outer layer is deficient over a large triangular area in the mid-dorsal parts, leaving a semitransparent membrane (the commissural layer) through which the wings of the valvula cerebelli can be seen (upon the right side black paper has been inserted beneath a part of this exposed commissural layer). The epiphysis is small and pear-shaped. The olfactory bulbs are situated close to the olfactory organs. The olfactory peduncles are somewhat widely separate, but are connected, as far as the bulbs, both dorsally and ventrally by a delicate membrane (black paper is inserted beneath its anterior end), the upper layer of which is a forward extension of the pallium.

Fig. 28.

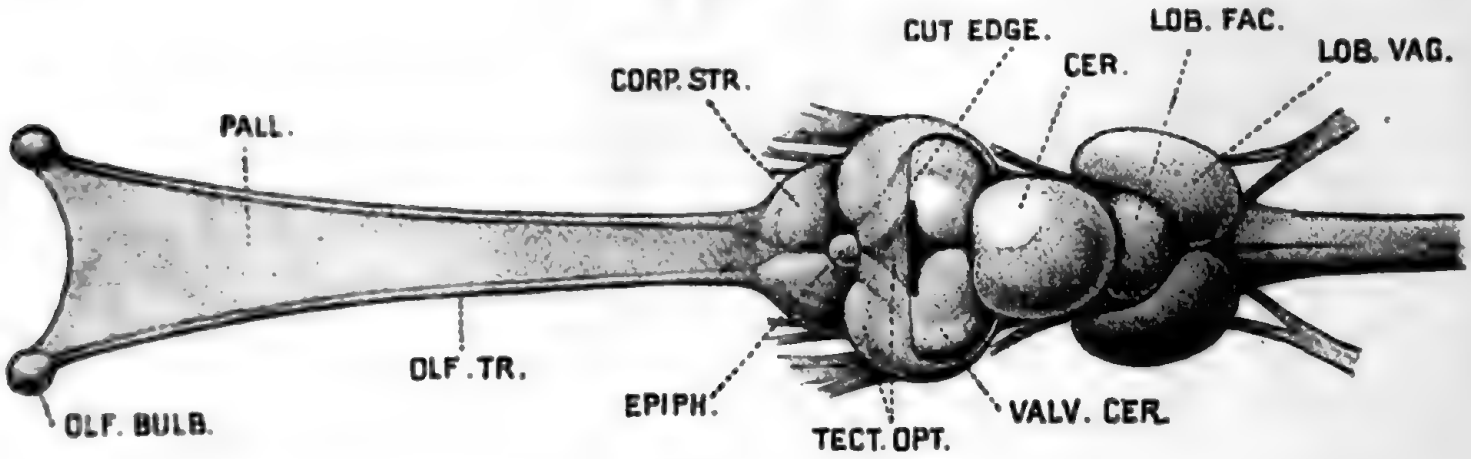

Brain of *Cyprinus carpio.*

D. 108. The head of a Tench (*Tinca vulgaris*) exposed from above. This brain has the same general characters as that of the Carp, but differs from it in the smaller size and more globular form of the cerebellum. The tectum opticum also has only a small median area deficient in the outer layer, from which—as this deficiency is apparently due to the thrusting aside of the lateral parts of the tectum by the contained valvula cerebelli—one may infer that the valvula is less developed.

Presented by T. W. H. Burne, Esq.

D. 109. The isolated brain of a smaller Tench (*Tinca vulgaris*). This specimen is similar to the last, but, in addition, shows the crossing of the optic nerves—the left below the right—as well as the union of the lobi inferiores in the mid-line behind the saccus vasculosus. The olfactory bulbs and peduncles have been removed. O. C. 1380 A 15.

D. 110. The head of a Barbel (*Barbus vulgaris*) with the brain exposed from above. The cerebellum is considerably larger than in the Tench; it is oblong and overhangs the anterior part of the medulla. The optic lobes are well-developed. In the mid-line the outer layers of the tectum are deficient, exposing a transparent commissural area of triangular outline through which the valvula cerebelli is indistinctly visible as in the Carp. The left basal ganglion has been removed, exposing the short thalamencephalon with the ganglia habenulæ—two small whitish excrescences on the dorsal margins of the thalamus. The crossing of the optic nerves—the left above the right—can also be seen. From the anterior end of the corpora striata delicate olfactory peduncles are given off. The olfactory bulbs in this and other Carps lie close to the olfactory capsules: they are not shown. O. C. 1308 E.

D. 111. Brain of a Bleak (*Alburnus alburnus*). It closely resembles that of the Tench (D. 108), except in the somewhat smaller relative size of the "lobus impar."

D. 112. The brain of a Roach (*Leuciscus rutilus*) exposed from above. The "lobus impar" and lobi vagi, though distinctly visible, are far less developed than in the other specimens of Cyprinoid brains.

Presented by Mr. S. Epprett.

D. 113. The head of a Pike (*Esox lucius*) with the brain exposed from above. For that of a Teleostean, the brain is long and narrow, with tapering medulla and open rhomboid fossa. The cerebellum and optic lobes are considerably developed, the latter having a long oval shape. The epiphysis is saccular and pear-shaped; it overhangs the small basal ganglia and extends forward to the anterior extremity of the olfactory bulbs, which are sessile on the cerebrum.

D. 114. The head of *Mormyrus jubelini* with the brain exposed from the left side. In the Mormyridæ the brain is remarkable for the immense development of the valvula cerebelli. This organ does not lie as in other Teleosts completely within the optic lobes, but projects through the tectum opticum, thrusting its lateral parts downwards to either side, and spreads out in three pairs of lobes or wings over the surface of the brain, completely concealing it from view when looked at from above, and extending so far down on either side as to leave exposed only the lower parts of the hemispheres and optic lobes. This unusual relation of the valvula cerebelli to the tectum opticum appears to be a further extension of some such process as that seen in the Carp (D. 107), in which the lateral parts of the tectum are divaricated and the central area much thinned out, but without extrusion of the valvula. The wings of the valvula are called from their position anterior, lateral or middle, and posterior. Their deep surface is occupied by a layer of small cells (nuclear layer) covered superficially by a number of parallel ridges each composed of molecular, nuclear, intermediate, and fibrous layers. In the specimen the exposed surface of the posterior wings has a finely corrugated appearance due to these ridges, but the anterior and lateral wings are smooth, because, by folding, the deep nuclear layer has become superficial in position.

The olfactory bulbs are small and are situated close to the olfactory organs. They are connected by delicate peduncles to the cerebrum. The left basal ganglion can be seen below the anterior wing of the valvula; it has a somewhat oblong shape. Close behind it, below the anterior part of the lateral wing of the valvula, lie two narrow masses of brain-substance. The anterior of the two is the laterally depressed left half of the tectum opticum; the other is part of the torus semicircularis.

Presented by J. S. Budgett, Esq.

D. 115. The brain of *Mormyrus kannume* exposed *in situ* from above. The wings of the valvula cerebelli have been removed from the left side to expose the underlying parts of the brain.

The basal ganglion is well developed and is clearly divided into two lobes, an outer and anterior, and a median and posterior—the striatum and epistriatum. The cavity of the optic lobe is bounded in front by the displaced tectum opticum and is occupied by the large torus semicircularis.

Fig. 29.

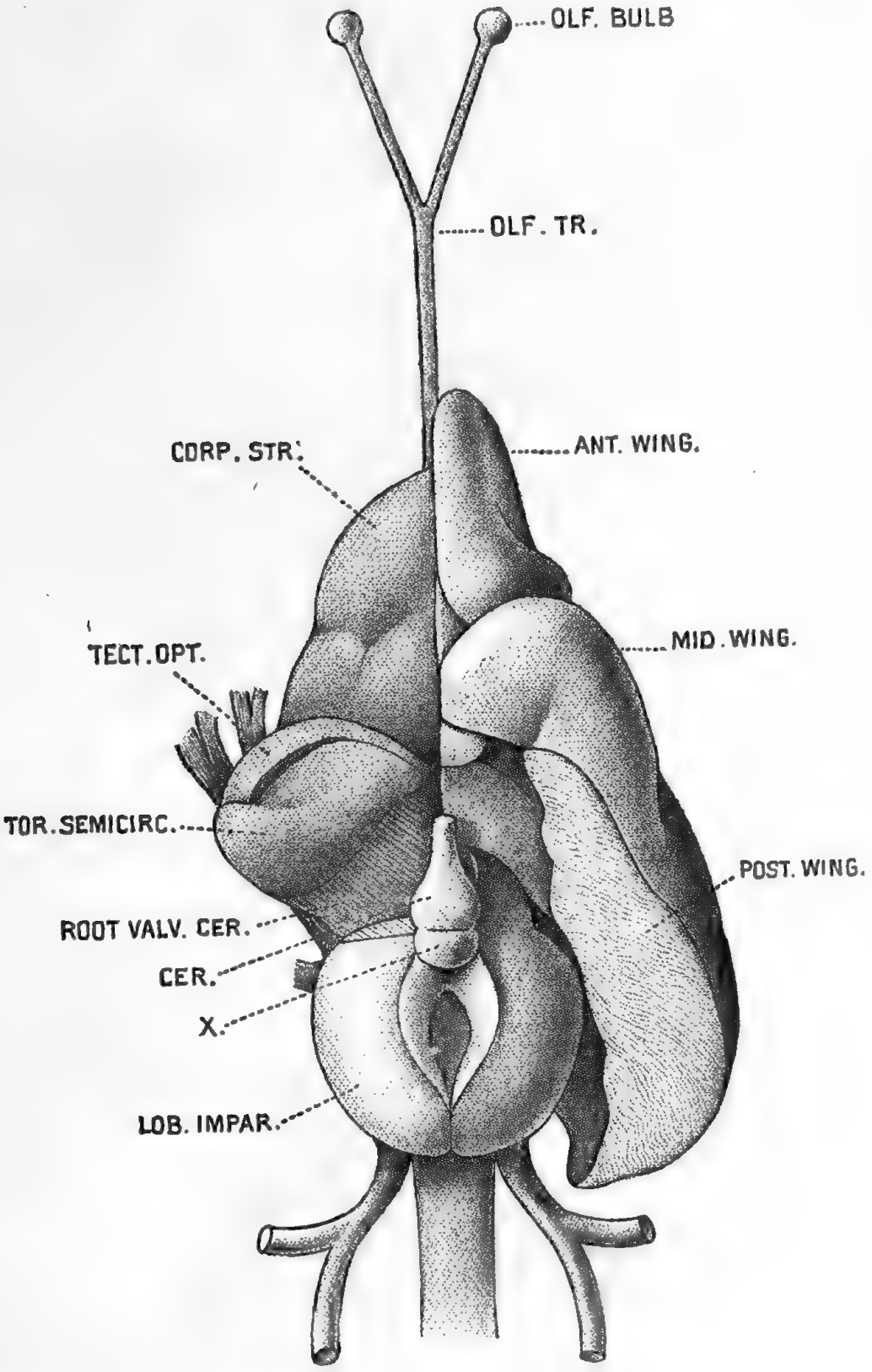

Brain of *Mormyrus kannume*.

The cerebellum is small and tongue-shaped, with its pointed apex directed forwards. Its base is separated in front by a transverse groove from a small rounded eminence—the posterior part of the root of the valvula. Behind, a similar but shallower groove divides it from a small lobe (fig. 29, x.) said to resemble in microscopical features the lobus impar of the medulla, although superficially it apparently forms part of the cerebellum. The medulla is remarkable for the immense development of a lobe upon its lateral and dorsal parts. This lobe (lobus impar) probably represents a fusion of a large median facial lobe, such as that seen in the Carps, with a pair of vagal lobes. The latter envelope the sides of the facial lobe and bound with their upper swollen borders a depressed central area—the median parts of the facial lobe.

Presented by G. A. Boulenger, Esq.

Saunders, Phil. Trans. vol. clxxiii. 1882, p. 927.

D. 116. The brain of a Herring (*Clupea harengus*) shown *in situ* from above. It is remarkable for the great size of the optic lobes and the shortness of the medulla. The optic lobes are oval with a slight lateral depression about the middle. The outer layers of the tectum are deficient in the mid-line at the posterior end, leaving a small triangular area of commissural fibres exposed.

The basal ganglia are very closely applied to one another in the mid-line, forming an apparently single globular mass ; they are continuous anteriorly with a pair of conical olfactory bulbs. The cerebellum is oblong and very deep from above downwards. The medulla is much concentrated, and has a well-marked facial lobe behind the cerebellum. O. C. 1308 c.

D. 117. The fore part of an Eel (*Anguilla vulgaris*) with the brain exposed from the dorsal aspect. In front of the medulla the several regions of the brain are of approximately equal size, and as each is more or less clearly bilobed, the brain appears to consist of four pairs of rounded equal-sized nodules situated one behind the other. The anterior pair (olfactory bulbs) are slightly pointed in front and give off two large olfactory nerves. The optic lobes and cerebellum are divided down the middle by a shallow groove. The cerebellum is considerably broader than long, with its anterior and posterior borders parallel. The medulla is small and much shortened.

D. 118. The head of a Conger Eel (*Conger vulgaris*) with the brain exposed from above. The brain is more elongated than in *Anguilla.* It is remarkable for the large size of its olfactory centres and the linear arrangement of its several parts. It also shows a very decided right-handed rotation of its anterior end.

The olfactory bulbs are of great size and are separated from the cerebrum by short peduncles. Each receives an immense nerve from the olfactory organ. The right bulb lies partly below the left, much as in the Sole. The basal ganglia of the cerebrum are considerably lobulated, and with the olfactory peduncles can be seen to be covered by a relatively close-fitting pallium. The thalamencephalon is remarkably long for a Teleostean, forming a narrow neck between the cerebrum and the moderately developed optic lobes. The cerebellum is quadrilateral with a marked longitudinal groove on either side. The medulla is small and much concentrated.

The fish from which this specimen was made measured 5 ft. 7 in. in length.

PLECTOGNATHI.

D. 119. A Globe Fish (*Diodon* sp.) opened along the dorsal surface to show the brain and spinal cord. The brain lies in a capacious cranial cavity, and in dorsal view has an outline very similar to the conventional club on a playing card; this is due mainly to the great development of the optic lobes. The basal ganglia are also large; each is distinctly divided by a furrow into a lateral and a median lobe. The olfactory bulbs are not shown. The cerebellum is oblong and overhangs the medulla and anterior part of the cord.

The spinal cord is remarkably short, ending in a fine filament less than 10 mm. behind the posterior border of the cerebellum. The remainder of the neural canal is occupied by a cauda equina, indicated on a level with the pectoral fins by black paper. O. C. 1308 K.

DIPNOI.

D. 120. Parts of the skull of *Ceratodus forsteri* with the brain exposed.

In most characters the brain is very primitive and closely resembles that of a Urodele Amphibian. It is, for instance, very long and narrow, with spacious ventricles enclosed by thin or, in parts, epithelial walls.

The medulla is very like that of a low Shark—long, and very broad in front with a widely open rhomboid fossa and well marked medullary auricles. It gradually merges into the cord behind. The highest development is shown by the cerebral hemispheres, which are large, like those of Amphibia, and greatly expanded in their ventral parts. They are separated from one another in the mid-line as far back as the anterior commissure. Their walls are thin and even purely epithelial in their dorso-median parts, where they are closely attached to a large glandular paraphysis that projects from the roof of the thalamencephalon wedge-like between them. In front, the lateral ventricles are continued by a narrow passage into the cavities of a pair of strong olfactory bulbs. In the possession of definite olfactory bulbs *Ceratodus* differs markedly from *Protopterus* or the Amphibia, and shows more resemblance to Elasmobranchs. A window has been cut in the left hemisphere and olfactory bulb to show the continuity of their cavities and the relation of the glandular paraphysis to the mesial wall of the hemisphere.

The thalamencephalon and mesencephalon, as in Urodeles, are very long and narrow. The former shows a pair of strongly marked ganglia habenulæ. The epiphysis, which is not shown in the specimen, is small. The optic lobes form a single prominence of small size between the thalamencephalon and the cerebellum. It is narrower in front than behind, and is divided mesially by a conspicuous but narrow dark band due to a local thinning of the roof. The cerebellum is slightly damaged ; it is more strongly developed than in Amphibia, though less so than in Fishes, and forms a broad transverse band behind the optic lobes, continuous laterally with the medullary auricles.

In the floor of the fourth ventricle lie a pair of small fasciculi longitudinales posteriores, and in the lateral walls, rather far back, a pair of longitudinal ridges—the vagal lobes, which in position resemble those of Sharks but are without their characteristic nodulation.

The epithelial roof of the rhomboid fossa is much pleated; it has been longitudinally bisected and turned to either side. Upon the lower surface of the brain, the great ventral expansion of the hemispheres and their clearly defined median separation can be seen. The hypophysis has been removed and mounted on the left, thus uncovering the large funnel-like infundibulum.

In this specimen the olfactory organs are also shown. On the left, the floor of the narial chamber has been removed to show the transversely pleated character of the roof. A red rod has been inserted into the anterior and posterior nares on the right. O. C. 1309 B.

Saunders, Ann. Mag. Nat. Hist. ser. 6, vol. iii. 1889, p. 157.

D. 121. The brain of a Mud-fish (*Protopterus annectens*). It chiefly differs from that of *Ceratodus* in being shorter and more compact, in the absence of separate olfactory bulbs, and in the feeble development of the cerebellum. In all these features it also more nearly resembles the brain of an Amphibian.

The cerebral hemispheres are remarkably deep dorso-ventrally, they are united at their posterior end by an anterior commissure situated in the lamina terminalis (this is not shown).

In front of the ganglia habenulæ the epithelial roof of the thalamencephalon is prolonged forwards as a conical paraphysis. The medulla is shorter than in *Ceratodus*, with the borders of the rhomboid fossa swollen and, half way between the calamus scriptorius and the cerebellum, curved inwards towards the mid-line. There are no definite lobi inferiores, but they are possibly represented by the slightly swollen lateral walls of the infundibulum.

Burckhardt, Centralnervensystem v. Protopterus, Berlin, 1892.

AMPHIBIA.

Osborn, Jour. Morph. vol. ii. 1889, p. 51.

In the Amphibia, and especially among the Urodeles, the brain is of a remarkably low type and closely resembles that of a Dipnoan.

With the exception of the medulla and cerebrum, all parts are very poorly developed. The medulla is similar in form to that of a low Shark, with wide open fossa rhomboidalis and no sharp boundary towards the cord. The hemispheres, including the olfactory bulbs which are at the best only slightly indicated, form the largest part of the brain, and show signs of incipient pseudo-occipital lobes. But their size is somewhat deceptive, as the walls are relatively thin throughout. They consist of an outer molecular and an inner cellular layer, and show no signs of cortical formation, unless possibly a small aggregation of cells in the outer layer of the median wall should be regarded as a rudimentary hippocampal cortex.

The hemispheres are united by an anterior commissure, in which two portions can be distinguished: one between the basal parts—the true anterior commissure; and the other connecting the olfactory regions of the pallium—a hippocampal commissure.

The hemispheres are connected to the thalamencephalon by a large basal tract on either side. The ganglia habenulæ are always well marked and externally visible, though not so strong as in the Cyclostomi and Dipnoi. The pineal gland is vestigeal. The optic lobes are only developed to any extent in the Anura, and in them have a many-layered tectum. The roof nucleus, in connection with the trigeminal nerve, is particularly strong in Urodeles. The cerebellum, although small, is composed of three layers—nuclear, intermediate and molecular, but an internal fibrous layer, owing to the small size of the cerebellar tracts, is not differentiated.

URODELA.

D. 122. A Menopoma (*Menopoma alleghaniensis*) with the brain and spinal cord exposed from above. This specimen, although somewhat damaged, shows clearly the chief superficial characters of the Urodele brain. The cerebral hemispheres are separate in the mid-line nearly to their posterior extremities. Each is large and oval in shape, and projects backwards to some exent over the lateral parts of the thalamencephalon, forming a rudimentary pseudo-occipital lobe. Independent olfactory bulbs are absent, but two strong double olfactory nerves arise from the antero-ventral parts of each hemisphere.

The thalamencephalon and mesencephalon differ little from one another in diameter, and form together a narrow cylindrical neck between the hemispheres and the broad anterior end of the medulla. A large hole between the hinder extremities of the hemispheres indicates the spot from which the conical vascular paraphysis has been removed; its posterior border is formed by two slight thickenings, the ganglia and commissura habenulæ. The optic lobes are very weak, and do not differ materially from those of *Protopterus*. The cerebellum is quite rudimentary—a mere narrow band of nervous tissue forming the anterior border of the rhomboid fossa. The medulla is flattened from above downwards. In front it is broad, but gradually narrows posteriorly, and merges imperceptibly into the cord. Its lateral walls diverge widely in front and bound an extensive rhomboid fossa. O. C. 1311 F.

D. 123. The head of a larval Axolotl (*Amblystoma tigrinum*) showing the brain. It differs little from that of *Menopoma* except for the stronger development of the optic lobes. In this specimen the paraphysis and ganglia habenulæ are very clear.

Stieda, Zeits. wiss. Zool., Bd. xxv. 1875, p. 285.

D. 124. A *Menobranchus lateralis* with the brain exposed from above. It agrees in all essentials with that of *Menopoma*. O. C. 1311 E.

D. 125. The head of a *Proteus anguinus* showing the brain. The olfactory bulbs are separated from the hemispheres by a slight constriction. The ganglia habenulæ are remarkably large; close behind them lies the minute epiphysis. The optic lobes, as might be expected in a blind creature, are scarcely differentiated.

ANURA.

D. 126. The head of a Bull Frog (*Rana catesbiana*) with the brain exposed from above.

This brain, though formed on a similar plan to that of a Urodele, differs from it in the relatively greater breadth of the thalamencephalon, in the larger size of the optic lobes, and in the stronger development of the cerebellum. The olfactory bulbs are separated from the hemispheres by a shallow constriction and are fused together in the mid-line. Behind this union the hemispheres are separate as far back as the anterior commissure. Between their posterior extremities there is, in the specimen, an oval aperture in the roof of the thalamencephalon caused by the removal of the paraphysis; its hinder margin is formed by the slightly protuberant ganglia habenulæ and their commissure.

The optic lobes form the broadest part of the brain. They are prominent oval bodies separated in the mid-line by a deep gutter. In front they diverge and expose a part of the tectal commissure. Between this and the thalamencephalon is a small crescentic pit at the base of which lies the posterior commissure. A deep furrow separates the optic lobes from the cerebellum.

The medulla is somewhat shorter than in the Urodeles. The epithelial and vascular roof of the rhomboid fossa has been removed and mounted at the side to show its pleated under surface.

Ecker, Anat. of the Frog (Engl. trans.), 1889, p. 141.

REPTILIA.

Edinger, Senckenberg. naturf. Gesell., Bd. xix. 1896 (*Cerebrum*) & Bd. xxii. 1899 (*Thalamencephalon*).

Haller, Morph. Jahrb., Bd. xxviii. 1900, p. 252.

The Reptilian brain is narrow and of considerable length, with moderately developed optic lobes and, except in swimming forms, with insignificant cerebellum. The medulla oblongata shows a strong longitudinal dorso-ventral curvature, convex below. In this class the brain differs most markedly from that of a lower Vertebrate in the great structural advance of the cerebrum, notably in the presence, for the first time in the Vertebrate series, of an undoubted cerebral cortex (fig. 30). The condition of the pallium is of special importance. It is not only much larger than that of an Amphibian, but is also much more highly differentiated. The mesial wall of the hemisphere is composed of a large dorsal area—the hippocampus, and a ventral spindle-shaped area—the tuberculum olfactorium (see fig. 31). A relatively narrow strip of thick ganglionic matter extending from the lamina terminalis behind to the olfactory peduncle in front separates these two areas; this body may be called paraterminal, because its most distinctive feature in the adult is that it lies alongside the lamina terminalis, and in the fœtal brain is developed from those parts of the walls of the neural tube which are placed alongside the end or terminal plate. Its surface forms the precommissural area, and in Mammals its upper part becomes stretched and otherwise modified to form the septum lucidum (*vide* Journ. of Anat. & Phys. vol. xxxii. p. 411).

Fig. 30.

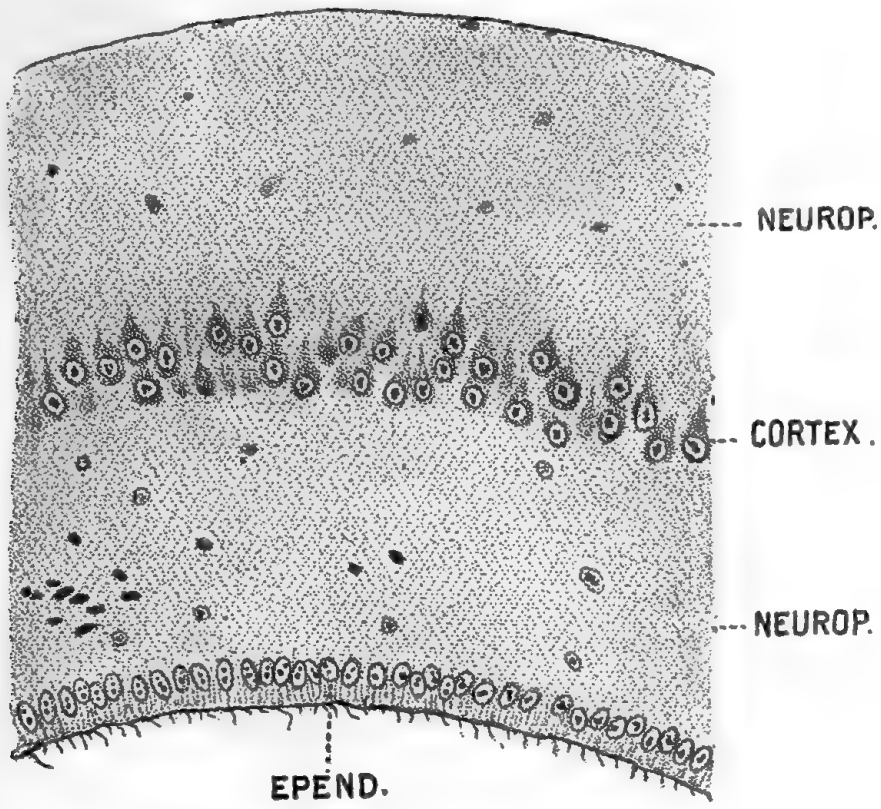

Section of pallium of *Tropidonotus natrix*, × 150.

In Reptiles and Monotremes the peculiar cortex, of which the tuberculum olfactorium is formed in Meta- and Eutherian mammals, although present, is ill-defined; so that the corpus striatum seems to extend to the surface of the ventral half of the brain.

A comparison with the condition found in the Monotremes (*vide infra*) and in the fœtal state of all mammals, clearly demonstrates that the whole of the mesial surface of the cerebral hemisphere of the reptilian brain, which is not precommissural area nor tuberculum olfactorium, represents and is homologous with the hippocampus of the mammalian brain (figs. 31, 32, & 33). This hippocampal formation also extends beyond the dorso-mesial edge of the hemisphere, and forms in different reptiles and birds a variable area of the dorsal surface (see "Further Observations on the Fornix," Journ. Anat. & Phys. vol. xxxii. p. 245).

The hippocampal formation presents a very different appearance to its mammalian homologue because that peculiar modification of the edge of the hippocampus which in Mammals produces the fascia dentata, has not yet occurred in the Sauropsida, although in many Sauria the first stage in the development of the fascia dentata, viz., a formation of numerous small cells at the ventral edge of the flat hippocampal plate, is distinctly recognizable.

Two simple rounded commissures are placed close together in the lamina terminalis. The dorsal of these represents the psalterium of Mammals, being derived from the hippocampus. In many Reptiles such as *Sphenodon* and the Lacertilia, the caudal half of this commissure is separated from the rest and crosses the middle line not in the lamina terminalis but in a fold of the roof between the paraphysis and dorsal sac. This "commissura aberrans hippocampi" (usually known by the misleading title "commissura pallii posterior") is probably a modified inheritance from the Amphibia, in which certain fibres from the caudal part of the cerebral hemisphere cross the mesial plane along with the fibres of the superior commissure (commissura habenulæ).

That part of the pallium which forms the bulk of the whole nervous system in Mammals is represented in Reptiles by a small insignificant area on the dorso-lateral aspect of the hemisphere, which is not sharply differentiated from the pyriform lobe below it. The neopallium (as I have called this part of the pallium [Journ. Anat. & Phys. vol. xxxv. 1901, p. 431]) is so poorly developed that the fibre-systems to which it gives rise—internal capsule, pes pedunculi, and pyramidal system, are absent in the reptilian brain. The chief cerebral tracts are in connection with the olfactory centres, and include some between the olfactory areas and the hippocampal cortex that are of special importance, as they are the first cortico-sensory connections to appear in the Vertebrate series.

In the thalamencephalon the tracts and nuclei are larger and more numerous than in lower forms, indicating a greater complexity of connection between the fore and hind parts of the brain, due mainly to the presence of cortical tracts. The nuclei rotundi, in which the main part of the strio-thalamic tracts terminate, are particularly large and form the greater part of the protuberant thalami. There are also two end nuclei of some of the optic fibres which are supposed to represent the lateral geniculate bodies. On the other hand, the connection between the hypothalamus and cerebellum is usually very weak. The fasciculus longitudinalis posterior rises partly from the hypothalamus, but mainly from a large-celled nucleus in the floor of the mid-brain.

The epiphysis is in most cases strongly developed, and in Lacertilia is in connection by its distal end with a median vestigial eye lodged in a foramen in the cranial roof.

The infundibulum shows scarcely any signs of a saccus vasculosus except in the swimming forms. The cerebellum, as in Amphibia, owing to the small size of the tracts that enter it, has no clearly defined inner fibrous layer. In the Reptiles there is an increase in the number of acoustic nuclei, corresponding to the development of a rudimentary cochlea (lagena).

LACERTILIA.

D. 127. The brain of a Monitor Lizard (*Varanus varius*).

In general form this is a typical example of the brain of a Reptile. The olfactory bulbs are long and narrow, and are united by short peduncles to the pear-shaped hemispheres. The hemispheres form the broadest part of the brain, and parts of them, representing the pyriform lobes, bulge downward behind the tuberculum olfactorium to form pseudo-temporal lobes. Posteriorly they are contiguous with the anterior face of the optic lobes and completely cover the thalamencephalon. In the dorsal mid-line, between the cerebrum and optic lobes lies the club-shaped epiphysis, with a small vestigial eye in connection with its distal end. The optic lobes are well developed, and form a pair of rounded eminences separated from one another in the mid-line by a deep furrow.

The cerebellum is of moderate dimensions and has the plate-like form usual among Reptiles. It is concave in front and arches forward slightly over the optic lobes. The medulla shows well the characteristic Reptilian flexure. Its fourth ventricle (rhomboid fossa) is considerably restricted.

OPHIDIA.

D. 128. A Ringed Snake (*Tropidonotus natrix*), shortly before hatching, with the brain exposed from above, showing in linear succession the olfactory bulbs, cerebral hemispheres, optic lobes, and medulla. The thalamencephalon and cerebellum are respectively covered by the caudal poles of the hemispheres and the hinder part of the optic lobes. The epiphysis forms a minute protuberance between the cerebrum and optic lobes.

Preserved in Goadby solution.

Rathke, Entwicklungsgesch. der Natter (*Coluber natrix*), 1839, pp. 36, 80, 130, 199.

D. 129. A similar specimen with the brain exposed from below.

Preserved in Goadby solution.

D. 130. A similar specimen with the left side of the brain laid bare. The flexure of the medulla oblongata is very marked. The relation between the form of the cerebral hemisphere and the developing globe of the eye is well shown.

Preserved in Goadby solution.

D. 131. The brain of a Python (*Python sebæ*). The brain is very long and narrow and peculiarly flat from above downwards. (In this specimen a certain amount of this flatness is due to artificial pressure during preservation.) The hemispheres are pear-shaped, moderately broad behind with well marked caudal (pseudo-occipital) and ventral (pseudo-temporal) lobes, and terminate in front in olfactory bulbs, each of which receives a stout bundle of nerves. Posteriorly they abut against the optic lobes. The cerebellum is poorly developed and forms a flat, almost horizontal, sheet of nervous tissue overlying the fore part of the fourth ventricle.

A small epiphysis lies between the hinder ends of the hemispheres. The infundibulum is prominent and gives attachment to a large spherical hypophysis. O. C. 1318 A.

D. 132. The brain of an Indian Python (*Python molurus*) in sagittal section seen from the left. The dorso-ventral flattening of the brain is well seen. The right olfactory bulb and peduncle and the cerebral hemisphere have been sagittally divided to show their cavities. That of the olfactory bulb is capacious and is connected with the lateral ventricle by an extremely delicate lumen in the ventral part of the peduncle. From the outer wall of the hemisphere a pair of lineally arranged eminences (corpus striatum) project into the ventricle. Beneath them can be seen the cut surface of the lower part of the striatum. The mesial wall of the hemisphere has been mounted on the right side to show the paraterminal body—a longitudinal ridge-like thickening of the wall that fits into a depression along the lower border of the striatum.

The flattened tectum opticum is separated into corpora quadrigemina by a longitudinal fissure (shown in the previous specimen) and by a shallower transverse groove, visible in this specimen as an indentation upon the cut edge between the posterior two thirds. The posterior eminences are formed by a pair of nuclei that contribute fibres to the fillet. In the Snakes the large trigeminal roof-nucleus situated along the mesial area of the tectum beneath the commissural layer is seen to advantage. The openings from the aqueduct of Sylvius into the lateral optic ventricles are small and situated far forward. The cerebellum, although small, is relatively thick. The rhomboid fossa is covered by a delicate membranous roof, the anterior part only of which, as in the Turtles, is pleated and vascular.

The hypophysis is mounted on the lèft, below the infundibulum; it shows well the two parts of which it is composed.

The Snake from which this specimen was obtained measured 15 feet in length.

Rabl-Ruckhard, Zeits. wiss. Zool., Bd. lviii. 1894, p. 694.

ORNITHOSAURIA.

D. 133. A cast of the cranium and parts of the cranial cavity of a Pterodactyl (*Scaphognathus purdoni*). The brain in this creature appears to have entirely filled the cranial cavity. It was of an essentially Avian type. The hemispheres were large and oval—longer and narrower than in most Birds, but rounder anteriorly than in recent Reptiles. They extended well back over the thalamencephalon and partially covered the optic lobes. The latter were enormously developed forming the broadest part of the brain, and occupied the usual Avian position upon the latero-ventral parts of the mesencephalon. In Birds this position is due to the thrusting aside of the optic lobes by the great forward development of the cerebellum. Thus it is legitimate to infer from the position of the optic lobes that in this creature the cerebellum was strongly developed, although it is not represented in this cast.

DINOSAURIA.

D. 134. The cast of the cranial cavity of a Dinosaur (*Iguanodon mantelli*). The description of the brain from such a cast as this must of necessity be to a large extent a matter of inference; for although the anterior and lateral parts of the cranial cavity seem to have approximately followed the contours ot the brain, such was evidently not the case in the mid-dorsal region.

The brain as a whole was long and narrow, with no very marked ventral flexure of the medulla. The hemispheres were peculiarly short and broad, and remind one more of those of a Bird than of a Reptile, being shorter and more abruptly tapering in front than even in the Crocodiles. They were strongly arched above, extremely prominent in their lateral parts, and flattish below. In the mid-line in front they were prolonged into either olfactory peduncles or bulbs, it is not apparent which.

The optic chiasma and infundibulum are strongly marked. The space between the dorsal parts of the cerebrum and the crest of the cerebellum shows no brain contours, as evidently here the brain did not reach the cranial roof.

The optic lobes, which apparently occupied this space (for no signs of them are visible in the Avian position upon the lateral or ventral surface) were probably of some size, to judge by the magnitude of the optic nerves. The cerebellum was of considerable extent in transverse and dorso-ventral directions, but whether it was also antero-posteriorly expanded as in Crocodiles, Chelonians, and Birds, or a mere transverse plate as in other Reptiles, it is difficult to say. The form of the projecting lateral parts favours the latter supposition.

Andrews, Ann. Mag. Nat. Hist. ser. 6, vol. xix. 1897, p. 585.

EMYDOSAURIA.

D. 135. The head of a young Sharp-nosed Crocodile (*Crocodilus americanus*) with the brain exposed from above. The hemispheres form by far the largest part of the brain. They are short and broad with a strongly arched dorsal surface, and in general features much resemble those of a Bird. Anteriorly they abruptly taper to form a pair of long olfactory peduncles, by which they are connected with two strong fusiform olfactory bulbs that lie side by side close behind the nasal chamber on a level with the anterior margin of the eyes. The optic lobes are moderately developed, and lie upon the dorsal surface of the brain between the hemispheres and the cerebellum. The cerebellum is very large for that of a Reptile and superficially bears some resemblance to that of a low Shark, being a smooth rounded protuberance above the anterior end of the fourth ventricle and showing upon its surface a feeble transverse furrow. O. C. 1317 A.

Rabl-Rückhard, Zeits. wiss. Zool., Bd. xxx. 1878, p. 336.

D. 136. "The brain of a Crocodile six feet long" *. This brain measures only 40 mm. in length, and does not equal 25 mm.

---

* This, in all probability, is the Crocodile alluded to in the following passage from a Hunterian MS. obtained from the executors of Sir Everard Home, and entitled 'Modern History of the Absorbing System':—

"In the beginning of the winter 1764–5 I got a Crocodile which had been in a show for several years in London before it died."

in breadth at the broadest part. The specimen is still largely covered by the dura and pia mater. The Bird-like form of the hemispheres is very striking. Upon the left side, part of the pallium has been removed to expose the lateral ventricle, which is reduced to a narrow slit by the great development of the corpus striatum. Openings have been also made through the walls of the left optic lobe and the cerebellum. The olfactory bulbs and tracts have been removed. O. C. 1318. *Hunterian.*

D.137. The brain of a young Crocodile divested of its membranes. The original description states that the brain is, "to appearance, made up of five parts; two, anterior, answering to the cerebrum; two behind these which answer to the 'nates and testes'; the posterior, the cerebellum." The transverse furrow upon the latter is very strongly marked. The left half of the medulla has been removed.
O. C. 1317. *Hunterian.*

D.138. A longitudinal section of the head of a young Crocodile, showing the brain in sagittal section from the left. The brain is too small to show the anterior and posterior commissures, but upon the inner wall of the thalamencephalon, towards the dorsal aspect, a roughened area is probably the cut surface of the median (soft) "commissure," which is found in certain Reptiles. The cavities of the right optic lobe and of the cerebellum and their connections with the aqueduct of Sylvius and the fourth ventricle are very clearly shown. A marked protuberance into the optic ventricle from the posterior wall of the lobe is due to the presence at this spot of a large lateral nucleus, similar to that found in Teleosts. The medullary flexure is strongly marked. O. C. 1315. *Hunterian.*

D. 139. The left half of the same head. The section in this case passes slightly to the left of the mid-line. By this means, although the olfactory peduncle is unavoidably removed, the ventricles of the hemisphere and olfactory bulb, and the relation of the latter to the nasal cavity are very clearly

shown. The pallium is quite thin and the lateral ventricle is to a great extent occupied by the corpus striatum, though apparently not so much so as in the adult. O. C. 1316.
Hunterian.

CHELONIA.

D. 140. The cranium of a Turtle (*Chelone mydas*) with the brain exposed from above. The Turtle's brain is very instructive, because it readily lends itself to comparison with the corresponding organ in the Amphibia and the lower Ichthyopsida on the one hand, and with that of the divergent Avian and Mammalian phyla on the other.

The brain does not fill the roomy cranial cavity, in which respect it resembles the condition found in Ichthyopsida and differs from birds, mammals, and many other reptiles. In this specimen, the olfactory nerves (*not* peduncles), the olfactory bulbs, the cerebral hemispheres, the mesencephalic roof, the cerebellum, and the medulla oblongata are visible in linear succession.

The true olfactory nerves (which are such short and insignificant filaments in most Vertebrates, and in man and all mammals have practically no intra-cranial course, because they enter the bulb as soon as they perforate the ethmoid bone) are collected into greatly elongated (40 mm.) rounded cords, that arise anteriorly from the mucous membrane of the nasal fossæ and end by being inserted into the olfactory bulbs. The fibres during their course are collected into three bundles—dorsal, ventral, and lateral—which end respectively in the dorsal, ventral, and lateral surfaces of the olfactory bulb. The latter is a hollow, laterally compressed vesicle, attached to the anterior extremity of the cerebral hemisphere by a cylindrical peduncle, which is so short that without close examination the bulb appears sessile.

The cerebral hemisphere is also a hollow, laterally compressed vesicle, more than thrice as long as, and proportionately deeper than, the olfactory bulb. It completely overlaps the thalamus, but does not cover the roof of the mesencephalon. The epiphysis, together with the dorsal sac and paraphysis, forms a large pyriform mass projecting upwards from between the hinder parts of the two hemispheres.

The optic lobes are rounded, of moderate size and sharply defined. They lie upon the dorsal surface of the brain in the depression between the cerebrum and cerebellum and are separated mesially by a sharp furrow. The cerebellum is a large hollow hemispherical protuberance hanging like a hood over the anterior end of the rhomboid fossa. Its walls are relatively thin. The fourth ventricle (rhomboid fossa) is spacious ; it is covered by a membranous roof, the lateral parts of which are extensively pleated and highly vascular (this vascular membrane has been removed and mounted on the left). In the floor of the fourth ventricle lie a pair of well marked fasciculi longitudinales.

Stieda, Zeits. wiss. Zool., Bd. xxv. 1875, p. 361.

D. 141. The brain of a Turtle (*Chelone mydas*) isolated and seen from the left side. The olfactory peduncle is continuous posteriorly upon the ventral surface with a rounded hemispherical boss, known as the tuberculum olfactorium, which extends backwards at the base of the brain almost to the optic chiasma, and includes also part of the lateral and mesial walls of the hemisphere. The hemisphere is relatively very deep dorso-ventrally, and is thus in striking contrast to that of *Testudo* or the Ophidia. The dorsal parts of the hemispheres extend back nearly to the optic lobes, but laterally leave a considerable area of the thalamencephalon, covered by the optic tracts, exposed. The infundibulum is very prominent. The ventral curvature of the medulla oblongata is well seen. O. C. 1312 D.

D. 142. The brain of a Turtle (*Chelone mydas*). The dura mater has been removed from the left side, and the vessels of the pia mater minutely injected. The partial removal of the dura shows how loosely it envelopes the brain and at the same time displays the form and disposition of the cerebral organs. A white bristle has been inserted into the infundibulum, and a black bristle into the ruptured distal extremity of the epiphysis. The sac-like membranous roof of the medulla is shown, with a bristle placed beneath its non-vascular median part. Black thread has been tied round the 6th, 9th, 10th, 11th, and 12th cranial nerves. The forward course of the accessorius roots to join the vagus are particularly clearly seen. O. C. 1312. *Hunterian.*

D. 143. The brain of a Turtle (*Chelone mydas*) in sagittal section seen from the left side. In this section the thin mesial wall of the right hemisphere has been exposed showing a tract of fibres radiating over the precommissural area. A similar though far more strongly marked tract (tr. hippocampo-mesencephalicus) is found in Birds; it forms a direct connection between the hippocampus and the tectum opticum. The anterior commissure and psalterium can be seen close together in front of and below the foramen of Monro. The optic thalamus is small; it is joined to its fellow across the cavity of the third ventricle, as in the Mammalia, by a large soft "commissure" in which is situated a central nucleus of considerable size. The roof of the third ventricle is evaginated to form a group of three successive elongated outgrowths, constituting together the club-shaped prominence seen in the previous specimen between the hinder parts of the hemispheres. The foremost outgrowth is the paraphysis, the intermediate and largest the dorsal sac, and the most caudal the epiphysis. The specimen also shows very clearly the large cavities of the optic lobes and

Fig. 31.

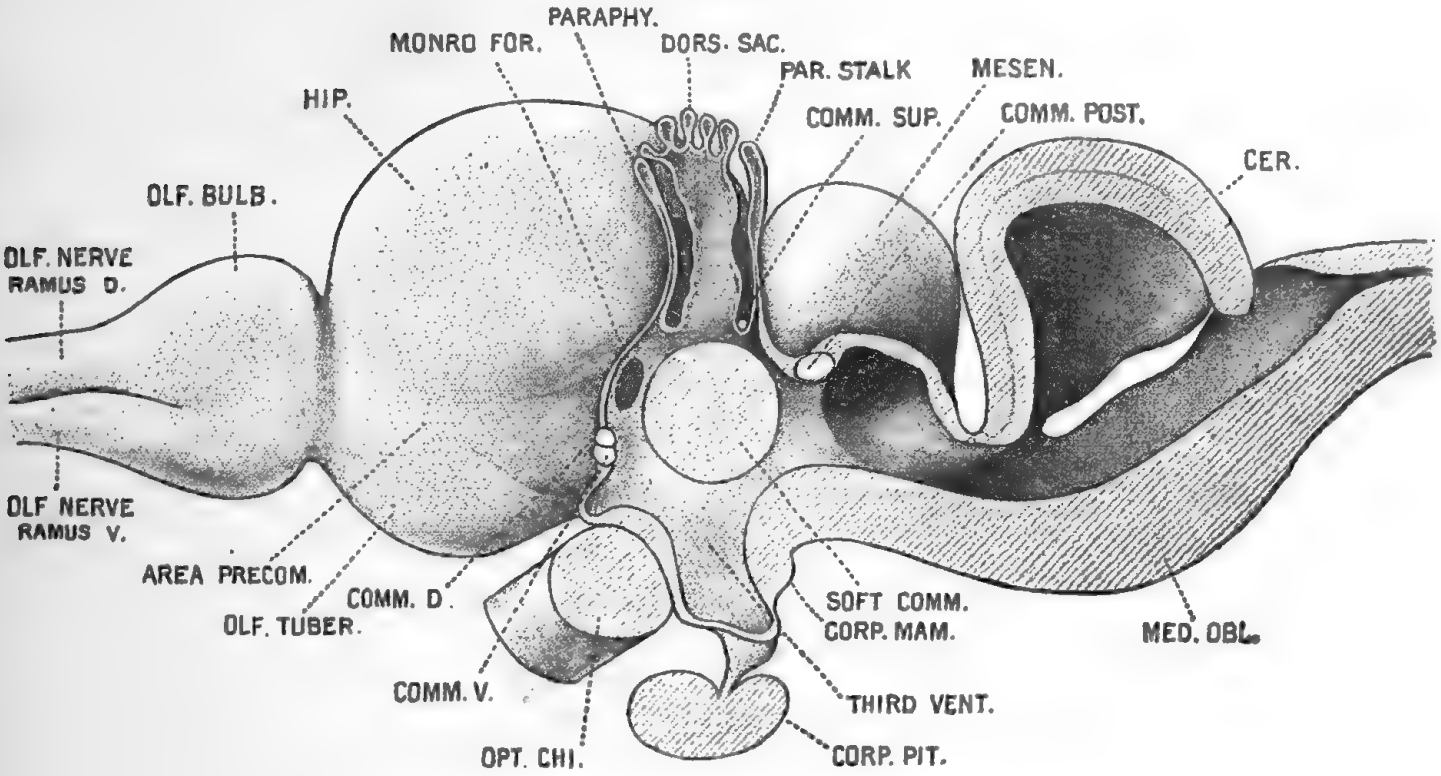

Brain of *Chelone mydas*, in sagittal section.

cerebellum, in open communication respectively with the aqueduct of Sylvius and the fourth ventricle. The limits of the vascular and non-vascular portions of the membranous roof of the fourth ventricle are also very clearly shown.

D 144. The left cerebral hemisphere of the previous specimen divided by a longitudinal vertical section and with the two halves mounted to show the internal surface.

Fig. 32.

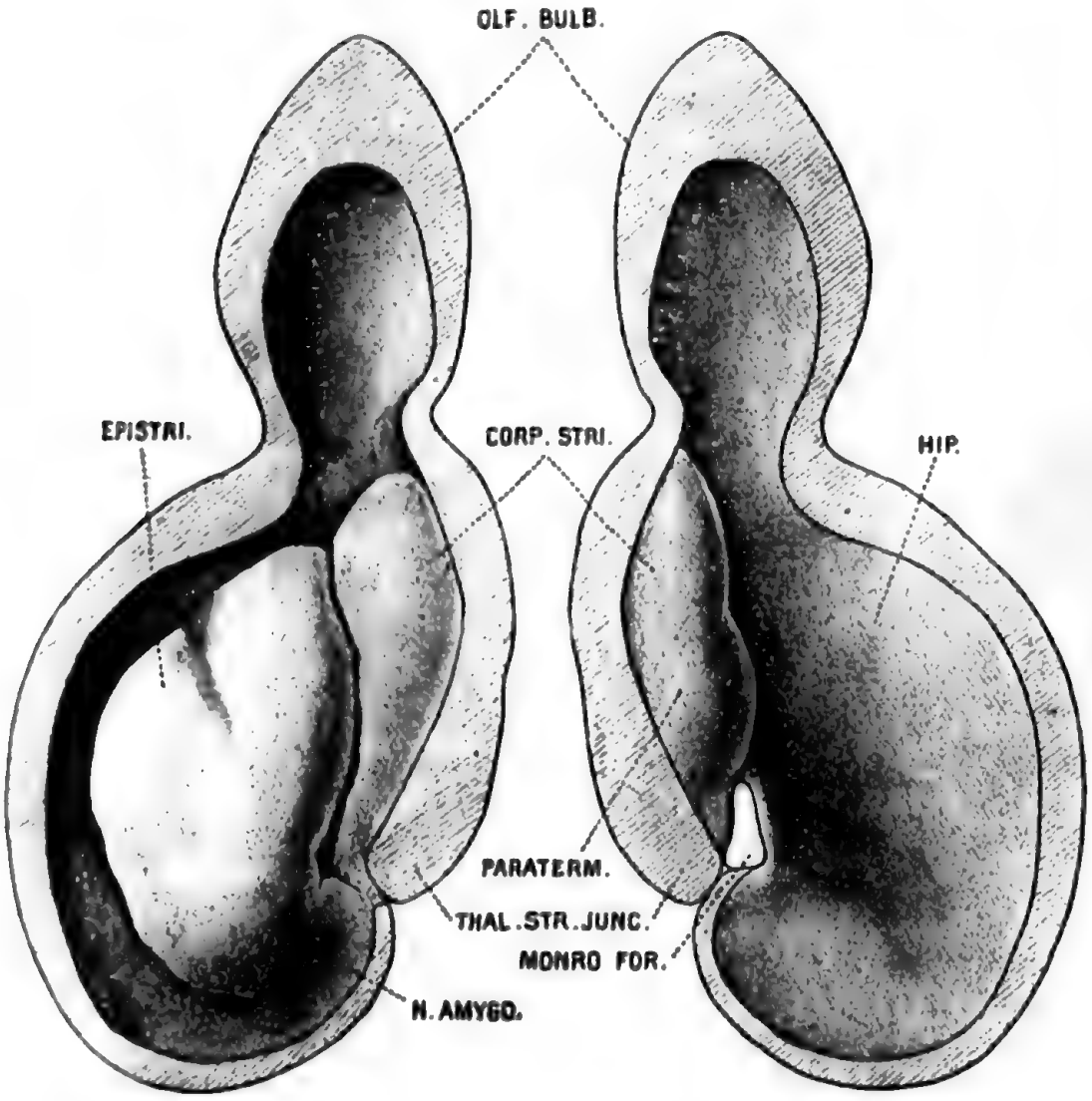

The lateral wall. The mesial wall.

Chelone mydas, left hemisphere.

The corpus striatum (which is seen in the lower part of the lateral and ventral walls of the ventricle) is relatively very small. It consists of a narrow and thin band of grey matter that extends, in the floor of the ventricle, from the olfactory peduncle in front to the anterior end of the optic thalamus behind, and fuses with the latter body beneath the foramen of Monro. In its slenderness and general relations it resembles the corpus striatum of Amphibia and *Sphenodon*, and differs in these respects markedly from that of Ophidia, Lacertilia, and Mammalia.

From the lateral wall of the hemisphere an enormous bulging extends into the ventricle and almost obliterates it. This has been called the epistriatum by Edinger ; its nature is best demonstrated in *Sphenodon* (fig. 33), in which it is clearly seen to be a large invaginate fold of the pallium (probably the homologue of the pyriform lobe of Mammals).

This eminence is prolonged further in the caudal direction than the corpus striatum and becomes continuous with a mass of grey matter, which represents the nucleus amygdalæ of Mammals. This nucleus consists of a thickening of the lateral wall of the small descending cornu of the lateral ventricle just behind the caudal extremity of the corpus striatum. On the lateral surface of the brain there is a triangular flattened area corresponding to this body, just as there is on the ventral surface in many mammals (e. g. *Erinaceus*, *Perameles*).

Fig. 33.

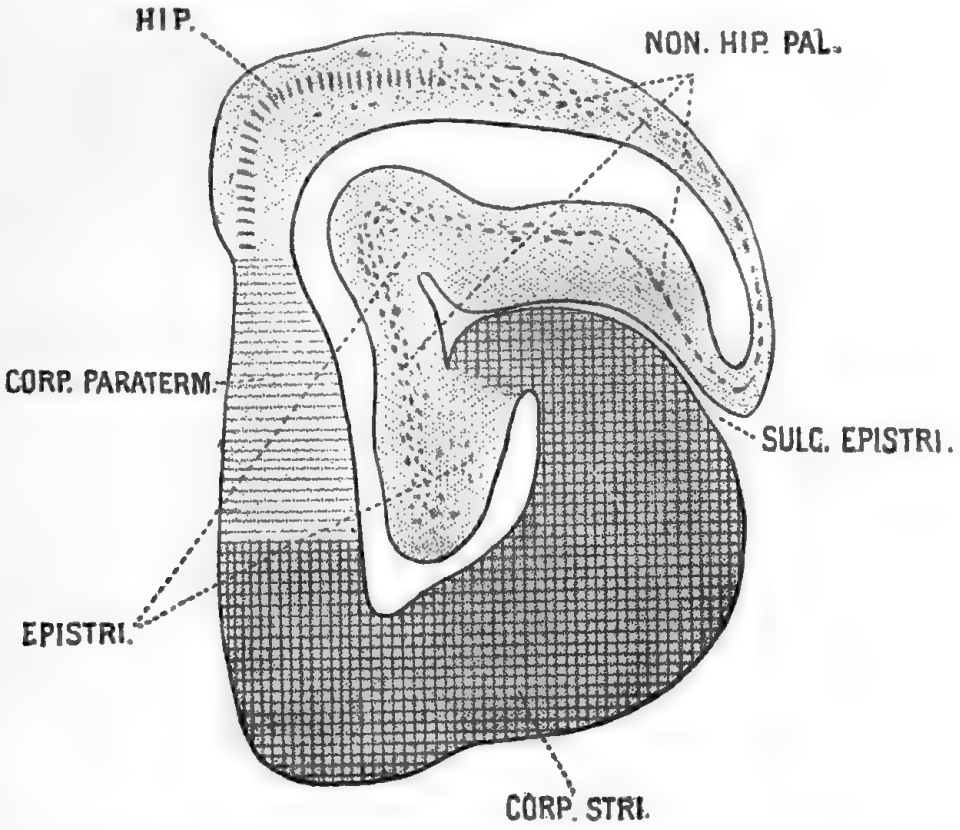

Diagrammatic transverse section through the hemisphere of *Sphenodon*.

D. 145. The brain of a large Turtle (*Chelone mydas*). The dura mater is reflected from the right side, showing its extensive development and the loose trabecular tissue by which the space between it and the pia mater is occupied. A particular development of this tissue consisting of parallel vertical strands occurs above the optic lobes; they give passage to numerous blood-vessels (not seen in the specimen). The ventricle of the right hemisphere has been opened showing the thinness of the pallium, the spaciousness of the cavity, and the prominence of the epistriatum. Part of the right side of the cerebellum has also been cut away to show its remarkably thin walls and large cavity continuous with the fourth ventricle. The epiphysis is well shown. The arteries in this specimen have been injected. O. C. 1313. *Hunterian.*

D. 146. The brain of a Turtle, with the ventricles of the cerebellum, optic lobes, and cerebral hemispheres laid open. The following is Mr. Hunter's description of this preparation:—"In the first or superior ventricle is an eminence which extends a little way into the olfactory nerve and runs through the whole length of the ventricle. The plexus choroideus is also seen in the ventricle. The ventricle of the nates is exposed, and a white bristle is placed in it, as is the ventricle of the cerebellum with a black bristle lying in it. At the lower part of the ventricle is a continuation of the tunica arachnoides, which shuts up or makes part of the ventricle. In the angle or quadrangle made by the cerebrum and nates, &c., is a duct or canal like the infundibulum leading from the upper part of the skull to the last ventricle."

In the above description the "first ventricle" is that of the right cerebral hemisphere with the epistriatum ("an eminence") exposed. The "nates" (optic lobes) include both nates and testes of Mammalia. The "continuation of the tunica arachnoides" is the non-vascular epithelial roof of the fourth ventricle; a small part of it can be seen at the hinder margin of the cerebellum on the right. The "canal" is the basal part of the epiphysis.

O. C. 1314. *Hunterian.*

D. 147. The brain of a Tortoise (*Testudo tabulata*). Relative to the size of the creature (the shell measured 280 mm. in length) the brain is extremely small. Its most highly developed parts are in connection with the olfactory organs; the olfactory bulbs in particular being very large—quite two thirds the size of the hemispheres. The main part of the hemispheres lies behind the foramen of Monro, forming extensive pseudo-occipital lobes that reach backwards on either side to the hinder margin of the mid-brain. The anterior parts of the hemispheres are very short. The epiphysis is remarkably well developed. The optic lobes and cerebellum do not essentially differ from those of the Turtle.

The roof has been removed from the left hemisphere and olfactory bulb showing the continuity of their ventricles, and in the case of the former the relatively slight prominence of the corpus striatum and the position of the choroid plexus. Upon the left side, the cavities of the optic lobe and cerebellum have been opened showing the thinness of their walls and the forward protrusion of the choroid plexus from the roof of the rhomboid fossa into the cavity of the cerebellum.

AVES.

Bumm, Zeits. wiss. Zool., Bd. xxxviii. 1883, p. 430 (*Cerebrum*).

Brandis, Arch. mikr. Anat., Bd. xli. 1893, p. 623; xliii. 1894, p. 96; xliv. 1895, p. 534.

Boyce & Warrington, Phil. Trans., vol cxci B. 1899, p. 293.

The brain is remarkably constant in form throughout the class of Birds, and may be readily distinguished by its form, and more particularly by the position of the optic lobes, from that of any other living vertebrate. It differs from the brain of lower forms mainly in its relatively greater breadth and in the shortening of its base. Its most characteristic features are the great development of the cerebrum, optic lobes, and cerebellum. The cerebrum is usually broader than long; its size is due almost entirely to the development of the corpora striata. The hemispheres cover the thalamus and frequently also the greater part of the optic lobes, and in addition to well-marked pseudo-occipital lobes usually have definite though rudimentary pseudo-temporal lobes. By the forward projection of the cerebellum, the optic lobes are always more or less depressed laterally towards the ventral surface. The olfactory bulbs and hypothalamus are weak; the medulla is flexed as in Reptiles though not so strongly.

The corpora striata are structurally separable into several areas, comparable apparently to the putamen, nucleus caudatus, and globus pallidus of Mammalia. They are connected with the nuclei of the thalamus by large and complex basal tracts. The pallium, except for an extension of its cortical area, is essentially the same as in Reptiles; it is in parts extremely thin. The cortico-thalamic tracts are, however, stronger and more numerous than in lower forms, and an important connection first appears in this group between the cortex of the pseudo-occipital lobe and the tectum opticum. Injury to this tract has been shown to interfere with the vision of the opposite eye. Another connection between the cerebrum and tectum opticum (traces of which occur in Reptiles) attains a strong development in Birds. This tract (tractus hippocampo-mesencephalicus) arises from the surface of the median wall of the hemisphere, coils round the cerebral peduncle and terminates in the tectum. Its function is not known.

The geniculate bodies are enormously developed. The tectum opticum is also highly differentiated, and shows many alternating layers of ganglion-cells and neuropile. The fillet is particularly large, and rises to a great extent as in Fish from a prominent lateral nucleus. The cerebellum is relatively greater than in any vertebrates other than Fish and Mammals. It corresponds, as in the lower groups, with the mammalian vermis. The tract of fibres connecting the cerebellum with the acoustic centre is particularly strong.

STRUTHIONIFORMES.

D. 148. The cast of the cranial cavity of a Moa (*Dinornis maximus*). This, which is probably a trustworthy representation of the brain, differs in several particulars from the brain of living Ratite Birds. It is as a whole somewhat more elongated, owing mainly to the greater length between the anterior extremities of the hemispheres and the optic chiasma. The hemispheres are less arched above, broader in front, and show more marked mesial eminences on either side of the dorsal mid-line. The olfactory bulbs are relatively large. The optic lobes and nerves are smaller actually than in the Ostrich. The cerebellum has the usual Avian form, but its apex seems to lie further forward than is usually the case. The medulla is only slightly flexed. The hypophysis is very large.

D. 149. The brain of an Ostrich (*Struthio camelus*). This specimen shows well the chief superficial characters of a Bird's brain : great longitudinal compression of the basal parts; minute olfactory bulbs sessile on the anterior extremities of the hemispheres; strong development of the cerebrum and optic lobes; depression of the latter towards the ventral surface, and great size of the cerebellum. These characters taken together at once distinguish this brain from that of any lower vertebrate, although the development of the optic lobes is equalled in many Teleosts and that of the cerebellum in the higher Sharks. Each cerebral hemisphere is short, and very broad behind, with an indentation on the base in the position of the mammalian Sylvian fissure, forming the anterior boundary of a small pseudo-temporal lobe, and with indications upon the dorsal surface of a longitudinal furrow that extends forwards to the base of the olfactory bulb and forms the lateral boundary of a mesial eminence.

The hemispheres are strongly arched above, contiguous in the mid-line, slightly concave below and bluntly pointed in front, with the points lying close side by side and terminating in a pair of small olfactory bulbs. The hemispheres extend backwards over the roof of the thalamencephalon and conceal the greater part of the optic lobes. The latter are a pair of oval prominences situated on the latero-ventral aspect of the mesencephalon with their long diameter directed downwards and forwards. At their anterior ends they pass directly into the optic tracts, which form a complete chiasma in front of the infundibulum. The chiasma has been partly dissected to show the crossing of the nerve-fibres. The cerebellum represents the Mammalian vermis; it is remarkably large, and forms an upstanding rounded or sub-conical eminence that projects forwards between the hemispheres above the roof of the mesencephalon, and backwards over the rhomboid fossa. It is slightly flattened from side to side and convex in front and behind, with a slight concavity in its anterior face where it abuts against the pseudo-occipital lobes of the cerebrum. It is deeply fissured transversely, as in higher Sharks and Mammals. The medulla is short and passes into the cord by a somewhat abrupt constriction. O. C. 1321 s.

D. 150. A similar specimen seen from the ventral surface. The optic lobes, tracts, and chiasma are well shown, as is also the sharp ventral flexure of the medulla. O. C. 1321 s *a*.

D. 151. The brain of an Ostrich (*Struthio camelus*) injected. The right lateral ventricle has been exposed by the removal of the lateral wall. It shows clearly the foramen of Monro, with a choroid plexus—an offshoot of the vascular epithelial roof of the thalamencephalon—projecting through it into the ventricle. On the left an opening has been made in the dorsal wall (pallium) of the hemisphere to show the natural position of the plexus. The outer wall of the right optic lobe has been removed by a tangential section to expose its cavity—a lateral diverticulum of the aqueduct of Sylvius. The thickness of its walls is somewhat exaggerated by the direction of the section. The dorsal parts of the cerebellum have also been cut away, showing the transverse folding of the organ, and laying bare the apex of the cerebellar ventricle—an offshoot of the fourth ventricle. A black bristle has been inserted into the ruptured end of the left olfactory bulb and others mark the positions of the chief cranial nerves. A brown bristle is placed in the cavity of the infundibulum. O. C. 1322. *Hunterian.*

D. 152. Part of the section of cerebellum removed from the preceding specimen. O. C. 1323. *Hunterian.*

D. 153. The brain of an Ostrich (*Struthio camelus*) with several of its cavities exposed from the right side. The corpus striatum has been entirely removed, showing the extent of the lateral ventricle in a sagittal plane, and the foramen of Monro (indicated by a blue rod). The right optic lobe has also been mostly cut away, to show the thickness of the midbrain floor and the relatively thin tectum—here upon the point of merging into the tectal commissure. The cerebellum is in sagittal section, showing its cavity and the depth of its transverse folding.

D. 154. Parts of the brain of an Ostrich (*Struthio camelus*). The anterior half of the cerebellum and the valve of Vieussens have been removed, exposing the anterior part of the fourth ventricle and the optic lobes. The latter are widely divaricated and are united by a broad commissural sheet (tectal commissure), which is slightly thickened on the boundary line between mid-brain and thalamencephalon to form the posterior commissure.

The dorsal parts of the thalamencephalon are also shown by the removal of the pseudo-occipital lobes of the hemispheres. The roof (tela choroidea) is epithelial and vascular; it is evaginated towards the anterior end to form the epiphysis (somewhat damaged), and in front sends a vascular offshoot into each of the lateral ventricles (on the right side the hemisphere has been cut through the middle of the foramen of Monro to show the continuity of this plexus with the tela choroidea). The side walls of the thalamencephalon are thick and appear, when seen from above, as two rounded eminences (optic thalami) covered laterally by the optic tracts. In the left hemisphere the relatively immense proportions of the corpora striata and the delicacy of the pallium are shown. O. C. 1321 S *c*.

D. 155. A cast of the cranial cavity of an Ostrich (*Struthio camelus*).

D. 156. Brain of a Rhea (*Rhea americana*). Upon the left side part of the pallium has been removed, exposing the corpus striatum. A small excrescence can be seen upon the right peduncle of the cerebellum, at the point towards which the ends of the transverse fissures converge. This prominence is not present in the specimens of *Struthio* (*cf.* especially D. 149), but is found in most other birds; it probably corresponds with the flocculus cerebelli of Mammals. O. C. 1321 R.

D. 157. Three transverse sections through the fore-brain of a Ki-wi (*Apteryx*) in front of the foramen of Monro. The uppermost section is taken close behind the olfactory bulbs; the middle one slightly in front of the lamina terminalis, and the lower through the anterior commissure. They show the relatively immense development of the corpora striata and the extreme thinness of the median walls of the hemispheres. The termination of the anterior commissure in the corpora striata and its relation to the anterior extremity of the third ventricle are also well displayed.

O. C. 1321 Q.

ANSERIFORMES.

D. 158. The head of a Wattled Brush-Turkey (*Catheturus lathami*) with the brain exposed from above. The cerebral hemispheres are slightly longer and more sharply pointed in front than in the preceding specimens. They show clearly the longitudinal dorsal furrows meeting in the mid-line close behind the olfactory bulbs. The small clavate epiphysis can be seen wedged in between the anterior end of the cerebellum and the cerebral hemispheres.

O. C. 1321 C.

D. 159. The brain of a Honduras Turkey (*Meleagris ocellata*) showing the small size and rounded form of the hemispheres. The longitudinal dorsal furrows are conspicuous at their anterior end. The cerebellum is well developed.

O. C. 1321 D.

D. 160. The brain of a Fowl (*Gallus ferrugineus* v. *domesticus*). The hemispheres have much the same proportions as in *Catheturus*, but do not extend so far back. The olfactory bulbs are clearly shown. The cerebellum has well marked flocculi. In this specimen also the strong ventral convexity of the medulla, characteristic of Birds and Reptiles, and the large size of the optic lobes, tracts and nerves are well marked. The hypophysis has been removed, exposing the open end of the infundibulum.

Presented by W. B. Tegetmeier, Esq.

D. 161. A sagittal section of the head and brain of a Polish Fowl (*Gallus ferrugineus* v. *domesticus*), showing the modified form of the brain correlated with the cranial protuberance characteristic of this breed. The entire brain is much lengthened. The cerebrum is pushed strongly forward and upward to occupy the cavity of the cranial protuberance, and is separated from the somewhat depressed cerebellum bya waist-like constricted region consisting of the thalamencephalon and mesencephalon. The distortion of the brain in this breed does not seem to entail any noticeable change in habits or intelligence.

This specimen also shows well the structure of the optic chiasma. Upon its section surface a number of stripes are visible, successively dark and light. This appearance is due to the cut edges of a series of band-like bundles of nerve-fibres derived alternately from either optic nerve.

O. C. 1321 E.

Presented by W. B. Tegetmeier, Esq.

Tegetmeier, Proc. Zool. Soc. 1856, p. 366.

D. 162. The brain of a Bustard (*Otis* sp.). The specimen, although in a bad state of preservation, shows the general form of the brain.

The cerebral hemispheres are remarkably short and broad and almost globular in contour. They leave most of the thalamencephalon exposed and cover no part of the optic lobes. (This may be due partly to artificial displacement.)

The tectal commissure is overhung posteriorly for about one-third of its extent by the anterior lobe of the cerebellum. In front it is separated by a transverse groove—the infolded posterior commissure—from the thalamencephalon. The roof of the third ventricle has been removed exposing its slit-like cavity bordered by the prominent optic thalami. Between the postero-median margins of the cerebral hemispheres lies the epiphysis. Its stalk originates from the thalamencephalon roof in front of the optic thalami. O. C. 1321 B.

D. 163. The brain of a Wattled Crane (*Grus carunculatus*). The cerebral hemispheres are strongly arched above, flat below, and from the dorsal aspect have an almost quadrangular outline. Their anterior ends are rounded and give attachment to the olfactory bulbs on their ventral surface. The dorsal furrows are well marked and bound a pair of strong median prominences. They meet in the mid-line behind the anterior border of the hemispheres. The hinder parts of the brain call for no remark. O. C. 1321 B *b*.

D. 164. Brain of a Stone-Curlew (*Œdicnemus bistriatus*). The bad condition of this specimen has apparently led to a certain amount of distortion (*e. g.* the large interval between the hemispheres and optic lobes is probably unnatural). The hemispheres are markedly globular with well-defined pseudo-temporal lobes. O. C. 1321 B *a*.

D. 165. The brain and spinal cord of a Goose (*Anser ferus*) at about the twelfth day of incubation. At this stage the brain shows much resemblance in its hinder parts to that of an adult Lizard, and in its hemispheres to that of an Amphibian or low Shark, e. g. *Notidanus*. The optic lobes are large, and occupy a dorsal position immediately in front of the cerebellum. The latter is as yet remarkably small, as in adult Amphibia or Reptilia. The medulla is strongly flexed, and the rhomboid fossa is lengthened and widely open in front, as in Urodeles. The thalamencephalon forms a distinct segment between the optic lobes and the elongated hemispheres. O. C. 1319. *Hunterian*.

D. 166. Median sagittal section of the brain of a Goose (*Anser ferus*). In this section the brain-cavities are shown. In front, the spacious third ventricle communicating by the foramen of Monro with the ventricle of the right hemisphere and prolonged ventrally behind the optic chiasma into the infundibulum. The anterior wall of this ventricle (lamina terminalis) gives passage to the double anterior commissure. Note the protuberant optic thalami in the upper part of the ventricle and the cut edge of the delicate tela choroidea.

Posteriorly the third ventricle is connected with the fourth by a narrow passage, the aqueduct of Sylvius, roofed over by the posterior and tectal commissures, and prolonged laterally to form the cavity of the optic lobes. In this specimen the large size of the cerebellum, its small cavity continuous with the fourth ventricle, and its composition of layers of white and grey matter are also clearly visible.

D. 167. The brain of a Goose (*Anser ferus*). The hemispheres have been pressed to either side to show the lamina terminalis and the anterior commissure. This method of treatment has also uncovered the dorsal surface of the thalamencephalon, the tectal commissure, and anterior lobe of the cerebellum. The origin of the tractus hippocampo-mesencephalicus can be clearly seen upon the surface of the median walls of the hemispheres. O. C. 1321 A.

D. 168. The brain of a Goose (*Anser ferus*) partially divided from above by a median sagittal incision and with the two halves turned aside to show the diverticulum of the fourth ventricle within the cerebellum and the arrangement of the layers of white and grey matter that form the arbor vitæ. The outer surface of the left optic lobe has been removed to expose its ventricle, and a bristle has been passed from it into the aqueduct of Sylvius to demonstrate the continuity of the two cavities. The right lateral ventricle has been opened by section of its thin mesial wall. Its extent and continuation into the olfactory bulb are thus shown, as well as the great disproportion in bulk between the corpus striatum and pallium. O. C. 1321. *Hunterian.*

D. 169. The brain of a Duck (*Anas boscas*) from which the greater part of the left side has been removed. The superficial appearance of the brain is very similar to that of the Goose. In taking away the left hemisphere the anterior commissure has been isolated and kept intact from its termination in the left corpus striatum to its entry into the right hemisphere. The optic tracts and chiasma have also been dissected, showing in the latter the interlacing of six large independent bundles of fibres (three belonging to each optic nerve) as they pass from one side to the other. All the fibres of the optic nerves cross to the opposite side of the brain in the chiasma. The course of the ascending root of the trigeminal nerve has also been dissected out, and a bristle is placed beneath the 4th nerve. The relation of the concave anterior surface of the cerebellum to the cerebrum is very clearly shown. The flocculus is strongly marked. O. C. 1380 15.

D. 170. The brain of a White Stork (*Ciconia alba*) from which the right hemisphere has been removed to show the optic tract upon that side. The optic lobes are peculiarly prominent. The emergence of the fourth pair of nerves from the valve of Vieussens is clearly shown. The great interval between the hemispheres and cerebellum is probably artificial. O. C. 1380 A 33.

D. 171. The brain of a Saddle-billed Stork (*Ephippiorhynchus senegalensis*). This specimen is badly preserved, but shows the rounded form of the hemispheres and their relations to the optic lobes and cerebellum. O. C. 1321 B *c*.

D. 172. The brain of a Brazilian Cormorant (*Phalacrocorax brasiliensis*) showing its elongated form and long oval hemispheres. O. C. 1321 A *a*.

D. 173. The brain of a Heron (*Ardea cinerea*).

FALCONIFORMES.

D. 174. The brain of a Sulphur-crested Cockatoo (*Cacatua sulphurea*). The hemispheres are remarkably large, extending back so as to completely cover the dorsal surface of the optic lobes. They are oval in shape, and have a strongly marked "Sylvian" fissure upon their ventral surface, behind which the hemisphere expands to form a very definite pseudo-temporal lobe. Dorsal longitudinal furrows are present, but in this specimen are indistinct. The Parrots are among the few Birds in which the cerebrum is longer than broad. The cerebellum and optic lobes are relatively rather small. O. C. 1321 H.

D. 175. The brain of a Cockatoo (*Cacatua triton*). This specimen shows similar features to the last, but owing to its better state of preservation the cerebral furrows are more pronounced. O. C. 1321 G *a*.

D. 176. The brain of a Great Horned Owl (*Bubo maximus*). This remarkable brain is distinguished by an immense lateral development of the hemispheres accompanied by a marked approximation of their anterior extremities to the optic chiasma. The enlargement chiefly affects the median part of each hemisphere between the dorsal longitudinal furrow and the mid-dorsal line. By the great development of this area the parts of the hemisphere external to, and including the anterior half of the dorsal longitudinal furrow have been thrust outwards and downwards, so that what under typical conditions would be the lateral parts of the hemisphere occupy a ventral position, and what in other birds would be its dorsal vault forms here its anterior and lateral border. This transformation of parts, accompanied by a marked shortening of the distance between the olfactory bulbs and the chiasma, gives to the long axis of the fore part of each hemisphere a nearly transverse direction. The ventral surface of this brain compares well with that of the Goose (D. 167), in which the dorsal parts of the hemispheres have been artificially thrust to either side. In other features, except for the strong development of the optic lobes, the brain is quite typical. O. C. 1321 K.

D. 177. A similar specimen, in which the upper part of the left hemisphere has been removed to show that the great lateral expansion of the cerebrum is due to an immense enlargement of the corpus striatum. O. C. 1321 K *a*.

D. 178. The hinder parts of the brain of an Owl (*Strix* sp.) showing the strong development of the optic lobes and thalami in this keen-sighted bird, and the relatively complex formation of the chiasma. In place of the half dozen large interlacing bundles seen in the chiasma of the Duck (D. 169), each optic nerve here splits into five delicate laminæ that interlace and alternate with one another as they pass through the chiasma to the optic tract of the opposite side. A certain number of fibres are said also to pass direct from each optic nerve to the tract of the same side—a condition apparently correlated with the frontal position of the eyes. O. C. 1380 16.

D. 179. The brain of a White-tailed Eagle (*Haliaëtus albicilla*). The hemispheres are very broad. The dorsal parts of the right one have been removed to show the ventricle, the large corpus striatum, and the narrow cut edge of the pallium. The lateral parts of the corpus striatum have been cut away on the left. The large optic lobes have been treated in a similar way on either side, showing in each the narrow slit-like ventricle and the thickness of the walls. The postero-ventral wall, owing to the presence of the large lateral nucleus, is peculiarly massive. The cerebellum is well developed; its right half has been removed. This specimen also shows very clearly the club-shaped epiphysis and the origin of its stalk from the roof of the thalamencephalon between the optic thalami.
O. C. 1321 L.

D. 180. The brain of a Sparrow Hawk (*Accipiter fringillarius*). The hemispheres are broad and somewhat globular in shape. They cover only the anterior parts of the optic lobes. The latter, as in all birds of prey, are very strongly developed.
O. C. 1321 M.

D. 181. The head of a Griffon Vulture (*Gyps* sp.), with the brain exposed from above. The hemispheres are strongly developed; they are remarkably broad in their posterior part, but much more pointed in front than in the previously described Falconiformes. O. C. 1321 O.

D. 182. Two parts of the brain of a Vulture (*Vultur*) in transverse section. The upper specimen is the anterior extremity of the cerebrum, seen from behind. In the lower specimen the section has also been made through the hemispheres, but somewhat further back, just in front of the optic chiasma, through the anterior commissure. The section surface faces to the front; it shows clearly the position and relations of the anterior commissure, as well as the lateral ventricles, corpora striata, and pallium.
O. C. 1321 P.

CORACIIFORMES

D. 183. The brain of a Condor (*Sarcorhamphus gryphus*). The hemispheres are much narrower and longer than in the Falconiformes. They extend backwards so as nearly to cover the optic lobes. The cerebellum and a great part of the left hemisphere have been removed exposing the left optic lobe and thalamus and the tectal commissure.
O. C. 1321 N.

PASSERIFORMES.

D. 184. The brain of a Touraco (*Turacus* sp.). This specimen is not well preserved, but shows that the hemispheres are globular and very moderate in size, extending back only over the anterior third of the optic lobes. The latter are somewhat exceptionally large. O. C. 1321 G.

D. 185. The brain of a Crowned Pigeon (*Goura coronata*). This specimen differs little from the last. The hemispheres are small and globular. They do not cover any part of the well-developed optic lobes. O. C. 1321 F.

D. 186. A cast of the cranial cavity of a Solitaire (*Pezophaps solitarius*), giving without doubt a trustworthy representation of the brain. The hemispheres are of moderate size with but slight indications of dorsal longitudinal furrows. They are widely separated mesially, especially in their posterior parts, and extend back over the anterior half of the optic lobes. The latter are well developed and strongly depressed towards the ventral surface. The cerebellum is of some size; its peduncles lie about midway between the anterior and posterior extremities. In front it extends between the hinder ends of the hemispheres. The hypophysis is small and narrow.

D. 187. The brain of a Lyre-bird (*Menura superba*). The hemispheres are of very large size. The area between each dorsal longitudinal fissure and the mid-line is strongly developed somewhat as in the Owl (D. 176). But instead of the hemispheres being short, as in that case, they are remarkably long—the distance between the olfactory bulbs and the chiasma being very considerable, and the hinder parts being prolonged backwards over the entire dorsal surface of the optic lobes. As these parts are also very deep dorso-ventrally the optic lobes are more depressed than usual, and lie entirely upon the ventral surface.

O. C. 1321 I.

D. 188. The brain of a Bower-bird (*Ptylonorhynchus violaceus*). The hemispheres are well developed, and completely cover the dorsal surface of the optic lobes. They are relatively broader and rounder than in the preceding specimen. No furrows are visible upon their surface. The cerebellum is comparatively small. O. C. 1321 I *a*.

MAMMALIA.

ORDER MONOTREMATA.

Family *ORNITHORHYNCHIDÆ*.

D. 189. The brain of a Duck-billed Platypus (*Ornithorhynchus anatinus*); also a right cerebral hemisphere, dissected to show the fascia dentata in the mesial wall.

This brain, in common with that of the Spiny Anteater, exhibits in the relative proportions of its various constituent parts and in their degree of histological differentiation unmistakeable evidence of its conformity to the mammalian type. But, on the other hand, the structural plan of several important regions of the brain (notably of the cerebral commissures and the neighbouring parts) differs in a very pronounced manner from that which obtains elsewhere among mammals (excluding the Marsupials in regard to certain of these features). It is significant that the general arrangement of the "commissural region," which is so peculiar in the Monotremes, essentially agrees with the structural plan which is common to most non-mammalian vertebrates.

Many of these peculiarities can be satisfactorily studied only by histological examination, and hence do not come within the scope of this account, but others may be appreciated by the naked eye even in specimens so imperfect as these.

The elliptical olfactory bulb (figs. 34, 35, 36, and 37) projects well beyond the anterior end of each cerebral hemisphere, and appears to have a pointed anterior pole. This is due to the fact that the true olfactory nerves are collected into a compact bundle (compare specimen 1380 I [O. C.]), which is inserted into the anterior pole of the olfactory bulb (fig. 35). Such an arrangement is commonly found among the Sauropsida and Ichthyopsida, and occurs nowhere else in the Mammalia, not even in the Spiny Anteater. The lateral wall of the olfactory bulb is peculiar in being deeply invaginated so as to practically obliterate the olfactory ventricle. On the left bulb, an oblique furrow indicates the situation of this invagination (fig. 34).

Fig. 34. (Nat. size.)

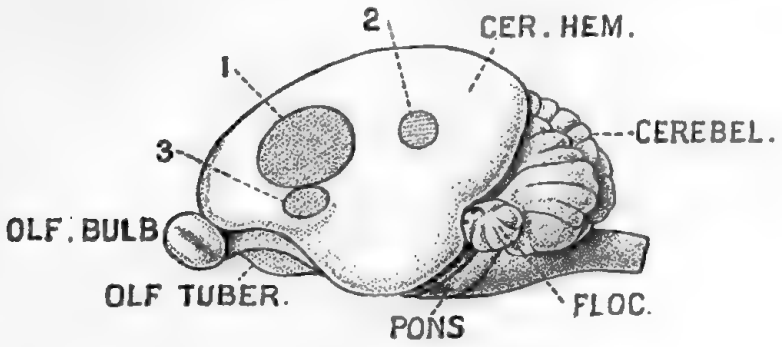

Fig. 35. (Nat. size.)

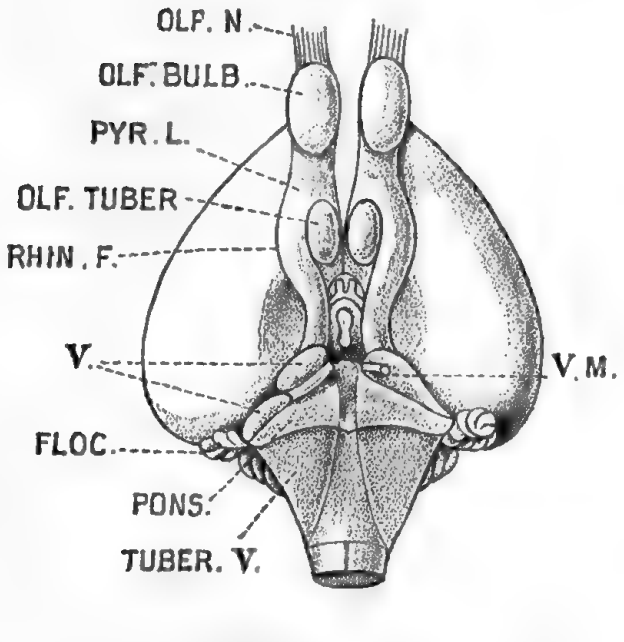

The pyriform lobe is seen upon the ventral surface of the hemisphere (fig. 35) as a very narrow, sinuous band prolonged backward from the peduncle of the olfactory bulb. In the separated hemisphere (fig. 36) its posterior extremity is seen to extend on to the mesial surface of the hemisphere, where it expands to form a pyriform tubercle, which is placed immediately below the "tail" of the hippocampus (fascia dentata). The pyriform lobe is separated from the rest of the "pallium" by an exceptionally deep rhinal fissure, which is seen in the specimen (fig. 35) as a mere line upon the ventral surface.

To the mesial side of the anterior half of the pyriform lobe there is a deep endorhinal fissure separating it from an elliptical projection of peculiar cortex, commonly known as the *tuberculum olfactorium*. The presence of a definite endorhinal fissure is peculiar to the Monotremes; in other mammals there is merely a shallow furrow in the corresponding situation lodging the compact (external) olfactory tract. In the Monotremes there is no such *compact* tract, because the fibres which proceed from the olfactory bulb to the pyriform lobe are scattered diffusely over the surface of the latter.

Fig. 36. (Nat. size.)

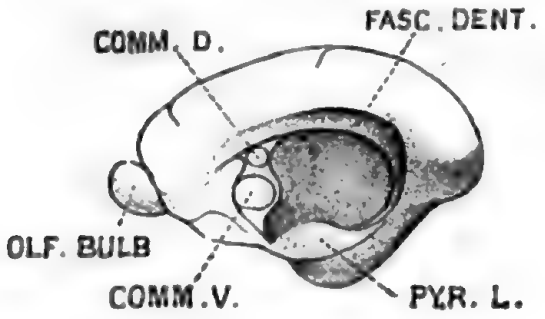

Fig. 37. (Nat. size.)

In comparison with the brains of most other mammals it will be found that these regions of the brain—olfactory bulb, olfactory tubercle, and pyriform lobe—are relatively small in the Platypus. This fact, which is especially noteworthy in a lowly-organised mammal, is readily explained by the lessened importance and value of the sense of smell to an animal whose active life is chiefly aquatic.

The optic and oculo-motor nerves and the associated parts of the brain are exceedingly small, because the sense of sight is of limited value to an animal which spends much of its time in dark burrows. Under such circumstances the sense of touch is a much more serviceable guide, and hence it is not surprising to find the organs of this sense highly developed. The chief tactile organ is the broadly expanded snout, covered with an extremely delicate soft skin. The latter is most richly supplied with numerous branches of the trigeminal nerve (see specimens 1380 H and 1380 I [O. C.]), which terminate in peculiarly modified end-organs (Wilson & Martin, Proc. Linn. Soc. N.S.W. 1895, p. 660).

The enormous development of the fifth nerves exercises a most marked influence upon the configuration of the region of the pons Varolii and medulla oblongata. The sensory nerves coming from the snout are inserted (wholly in front of the pons) as two large strands on each side—a mesial nerve coming from the maxillary region (representing the conjoint ophthalmic and superior maxillary divisions of Human Anatomy), and a lateral nerve from the mandibular region. At their insertion a huge mass of nerve-cells is developed as a receptive organ, so as to produce a great swelling, the *tuberculum quinti*, upon each side of the ventral surface of the hind-brain (fig. 35). The small narrow band of pontine fibres is stretched across this prominence at the situation of its greatest breadth. In the caudal direction, the tuberculum quinti tapers to a point upon the lateral aspect of the upper part of the spinal cord. The post-pontal part of the tuberculum quinti corresponds to the tubercle of Rolando in the brain of other mammals.

The motor root of the fifth nerve emerges on the deep aspect of the cephalic projection of the tuberculum quinti and, after extending around the mesial edge of the latter, extends transversely outward in front of the pons to join the mandibular root. Owen committed the peculiar error of mistaking it for the pons. On the left side of the specimen (fig. 35, V.M.) this motor root has been cut short.

The other cranial nerves conform to the usual mammalian plan, which is seen to better advantage in the brains of other animals (*vide infra*).

Perhaps the most inexplicable feature of the brain of the Platypus (as also of the Spiny Anteater) is the relatively large size of the so-called "pallium" of the cerebral hemisphere. The term "pallium" is at the present time used in a perplexing variety of ways by different writers, and all of these applications of the term are strangely at variance with that which Reichert intended to convey when he introduced the word "mantle" or "pallium." There are three distinct varieties of mantle in all mammalian hemispheres:—a basal pallium or pyriform lobe, a marginal pallium or hippocampus, and a more variable area intercalated between these two regions, which has hitherto received no exclusive title. To indicate this region I shall employ the distinctive, if hybrid, name "*neopallium*"*. Among lowly-organised mammals there is, according to Dubois, a more or less intimate relationship between the size of this cortical area and the extent of the various sensory surfaces of the body. In the case of the Platypus, in which the visual apparatus is very poorly represented and the auditory nerve is not remarkable for its large size, one naturally looks to the enormous trigeminal nerve for the explanation of the large neopallium. But that this cannot be regarded as the full explanation is shown by the still more obtrusive greatness of the neopallium in the Spiny Anteater, in which the trigeminal nerves are not extraordinarily large and none of the other cranial nerves attain to exceptionally great dimensions. As one is naturally loathe to explain this large neopallium as analogous to that of the Primates, in which the neopallium becomes enlarged and elaborated out of all proportion to the extent of the sensory areas in association with the development of the higher psychical faculties, a satisfactory

---

* Journ. Anat. & Phys. 1901, p. 431.

explanation of the large size of the neopallium in the Monotremes (and in *Tachyglossus* more especially) cannot be offered at present. Professor C. J. Martin has shown that stimulation of the cerebral cortex of Platypus in the situations shown in figures 34 and 37 gives rise to definite muscular actions: thus stimulation of the "arm-area" (1) produces a digging movement in the opposite fore-limb, of areas (2) and (3) produces movements of the eyelids, and of (4) retraction of the head (Journ. of Phys. vol. xxiii. 1898, p. 383). This shows that physiologically the cerebral cortex of Platypus reacts in a manner analogous to that of lowly placental mammals.

In striking contrast to the relatively large size of the cerebral cortex, is the smallness of the efferent tracts which pass from it to other regions of the central nervous system. The pes pedunculi and the pyramidal tract are so insignificant, that they give rise to no projection upon the surface of the brain. The pyramidal decussation is very diffuse.

With the exception of the hippocampal and rhinal fissures, which subdivide the pallium into its three fundamental constituent parts, the hemisphere of the Platypus is devoid of true fissures or sulci. The general smoothness of the neopallium is, however, disturbed by depressions for the bony capsules of the floccular lobes of the cerebellum (compare figs. 34 & 35) and by a series of vascular furrows. The most noteworthy of the latter consist of a series of large shallow channels produced by very large veins, which converge towards the apex of the hemisphere (fig. 37). The large size of these veins is due to the fact that the longitudinal venous sinus is practically, if not completely, obliterated (because the falx cerebri is bony), and the general cerebral veins enlarge to replace them. The spurious resemblance of the brain of Platypus to the avian type is thus considerably accentuated, because in many birds an analogous arrangement of the cerebral veins is found.

Several well-marked transverse furrows are produced by the branches of the middle and anterior cerebral arteries.

The cerebellum of *Ornithorhynchus* is a slightly simplified form of that of *Tachyglossus* (*vide infra*). The only marked difference, and that of no systematic significance, is the projection of the floccular lobes [which are lacking in this specimen]: in the Spiny Anteater's brain they are flattened and sessile.

In the separated cerebral hemisphere (fig. 36) part of the overhanging neopallium has been removed in order to expose the fascia dentata lying in the mesial wall of the hemisphere.

The peculiar position of this specialised fringe of the hippocampus and its relations to the commissures agree with the condition seen to much better advantage in the specimen of the Spiny Anteater's hemisphere (D. 191). In the Platypus, however, the caudo-ventral part of the hippocampal arc dwindles to much more insignificant proportions than is the case in *Tachyglossus*.

It thus happens that that (caudo-ventral) part of the arc, which alone persists in an undisturbed condition in the Eutherian brain, is here an exceedingly diminutive tail-like appendage of the chief mass of the hippocampus, which is placed further forward in the hemisphere on the dorsal aspect of the commissures. It is, moreover, a very significant fact that this, the most bulky part of the hippocampus in the Monotreme, occupies this cephalic (anterior) position in the mesial wall, which its representative in the Sauropsida and many Ichthyopsida occupies.

Presented by Prof. G. Elliot Smith.

Elliot Smith, Jour. Anat. & Phys., vol. xxxiii. 1899, p. 310.

D. 190. A cast of the cranial cavity of a Duck-billed Platypus (*Ornithorhynchus anatinus*).

This shows the actual size and shape (when viewed from the dorsal aspect) of the brain of Platypus. The configuration of the base of the brain cannot be accurately seen because the casts of the huge maxillary parts of the trigeminal nerve are superposed. The most prominent part of the mesial ridge between these nerves indicates the size and shape of the pituitary body.

Gervais, Nouv. Arch. Mus., t. v. 1869, p. 248.

Family *ECHIDNIDÆ.*

D. 191. The brain of a Spiny Anteater (*Tachyglossus* [*Echidna*] *aculeatus*), in which the greater part of the lateral and dorsal walls of the left cerebral hemisphere have been dissected away so as to expose the hippocampus in the lateral ventricle.

In spite of the marked contrast between the general appearance of this brain and that of the Platypus, there is the closest structural agreement in most of the essential features of the two.

The most obtrusive feature of this brain is the relatively enormous development of the cerebral hemispheres, which are much larger, both actually and relatively, than those of the Platypus. In addition the extent of the cortex is very considerably increased by numerous deep sulci. The meaning of this large neopallium is quite incomprehensible. The factors which the study of other mammalian brains has shown to be the determinants of the extent of the cortex, fail completely to explain how it is that a small animal of the lowliest status in the mammalian series comes to possess this large cortical apparatus. In other small, terrestrial, insect-eating mammals such as the Pangolins and the Anteaters, and in the fossorial Bandicoots, Hedgehogs, and Armadillos, we find highly macrosmatic brains with small neopallia: and yet in *Tachyglossus,* whose mode of life is not dissimilar to many of these mammals, we find alongside the large olfactory bulb and great pyriform lobe of the highly macrosmatic brain a huge complicated neopallium.

In the remarks concerning the brain of the Platypus (D. 189), it was tentatively suggested that the enormous development of the trigeminal nerves might explain to some extent the large size of the receptive organ and "storehouse," so to speak, for tactile impressions. But such a suggestion does not help us in the case of the Spiny Anteater, because the trigeminal nerves are much smaller than they are in the Platypus, and yet the neopallium is much larger. The eyes and optic tracts are still very small, as in the Platypus, so that another factor in determining a large pallial area is lacking.

The auditory nerves are indeed large, but the mesial geniculate body, which it is customary to regard as an integral part of the cortical acoustic path, cannot even be recognised as a projection behind the optic thalamus [see specimen D. 193]; so that it is unlikely that the cortical auditory tract is sufficiently largely developed to explain the large neopallium. Nor is the extent of the surface of the body, the tactile acuteness of which can hardly be heightened by its covering of spines, sufficient to explain a large tactile area in the cortex. Yet these are the factors which in lowly organised mammals are supposed to be the chief determinants of the extent of the neopallium.

Fig. 38. (Nat. size.)

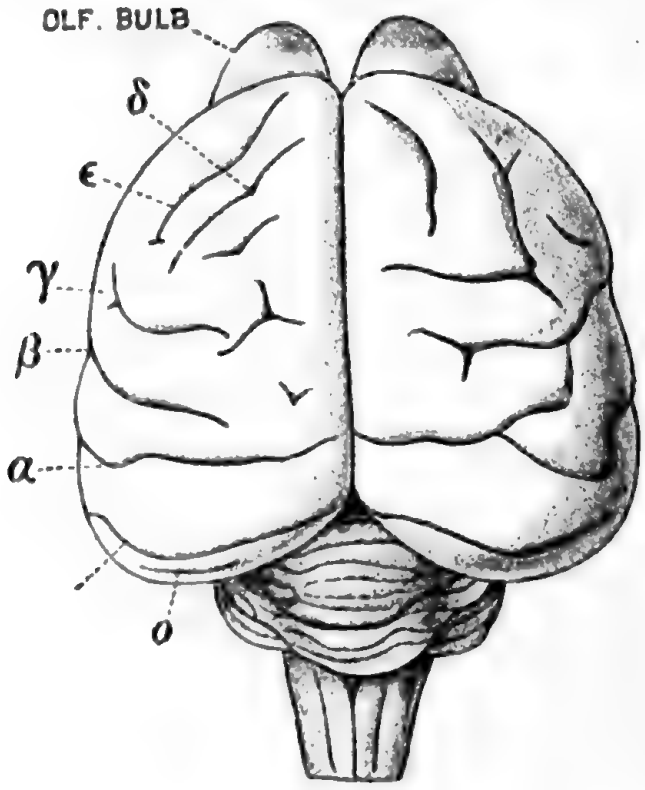

Dubois has clearly demonstrated that among the more lowly organised Mammalia the size of the cerebral cortex varies with the extent of the various sensory surfaces of the body, and that the lowlier the position of the creature in the Mammalian phylum the smaller this cortical representation becomes. But in the Spiny Anteater all these generalisations are upset: for this small animal, with no specially acute sense except that of smell—and a high degree of macrosmatism is usually associated with a small neopallium—occupies the lowliest status in the Mammalian hierarchy, and hence should have the feeblest cortical presentation for its sense-organs.

The cerebral hemispheres are short and broad (fig. 38). Their growth in the antero-posterior direction appears to have been restrained by the resistance of the cranium, and they have extended chiefly in the lateral direction. This lateral extension has been carried to an extreme degree in the postero-ventral region of the neopallium, which has grown downward and then mesially so as to produce a peculiar bending of the pyriform lobe (fig. 39).

Fig. 39. (Nat. size.)

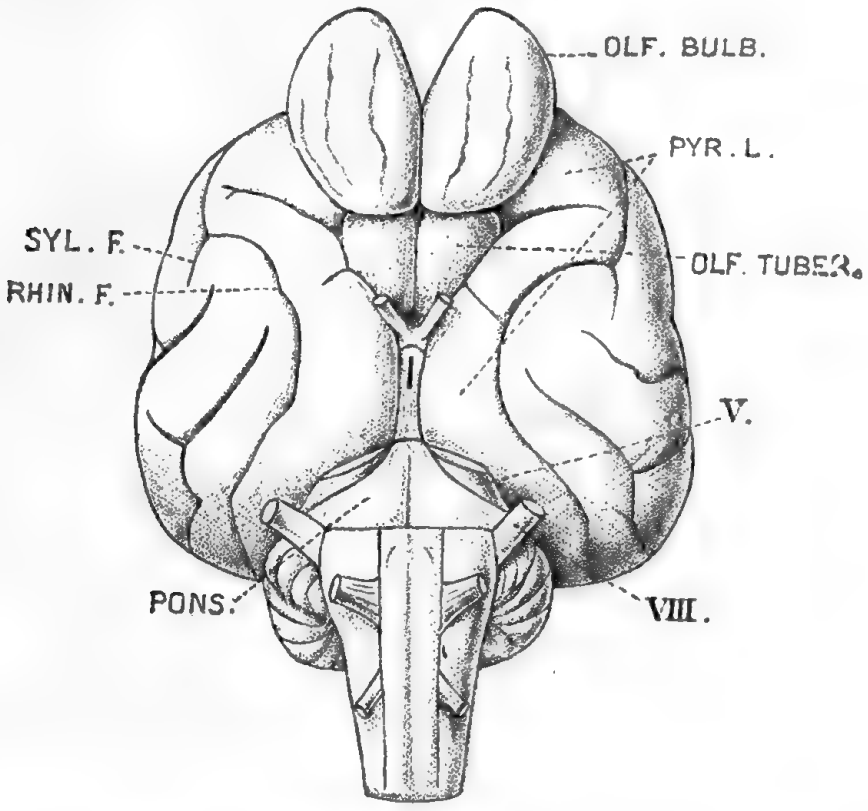

In all ant-eating mammals the snout is prolonged to form a long tubular structure which lodges the vermiform tongue. This elongation of the skull may involve the cranial cavity, and in that case the brain assumes an elongated form in adaptation to the shape of its bony case. The Great Anteater (*Myrmecophaga*, D. 282) and the Aardvark (*Orycteropus*, D. 288) afford instances of this. On the other hand, the elongation may be restricted to the beak, and the brain then becomes packed away, so to speak, in a short cranial cavity lying entirely behind the maxillary region. The brain of the Pangolin (*Manis*, D. 287) and that under consideration exemplify this type, in which the brain develops in a cavity which restricts its antero-posterior growth. The hemispheres thus expand chiefly in the lateral direction, and the restriction to elongation expresses itself in a series of transverse sulci, the disposition of which is re-described in the account of the next specimen.

The olfactory bulb is a large, flattened, foot-like mass partly overlapped by the anterior pole of the hemisphere.

It rests in the cranium upon a broad cribriform plate, through the numerous foramina of which small bundles of olfactory nerve-fibres proceed to the ventral surface of the olfactory bulb. A short peduncle connects the bulb to the cephalic extremity of the pyriform lobe. The latter is a peculiar, sinuously curved band of cortex, which extends along the whole length of the base of the hemispheres. The extraordinarily twisted form of the pyriform lobe is quite distinctive of this brain. This is seen to advantage on the left side, in which the neopallium has in great part been removed and the pyriform lobe left (fig. 40).

Fig. 40. (Nat. size.)

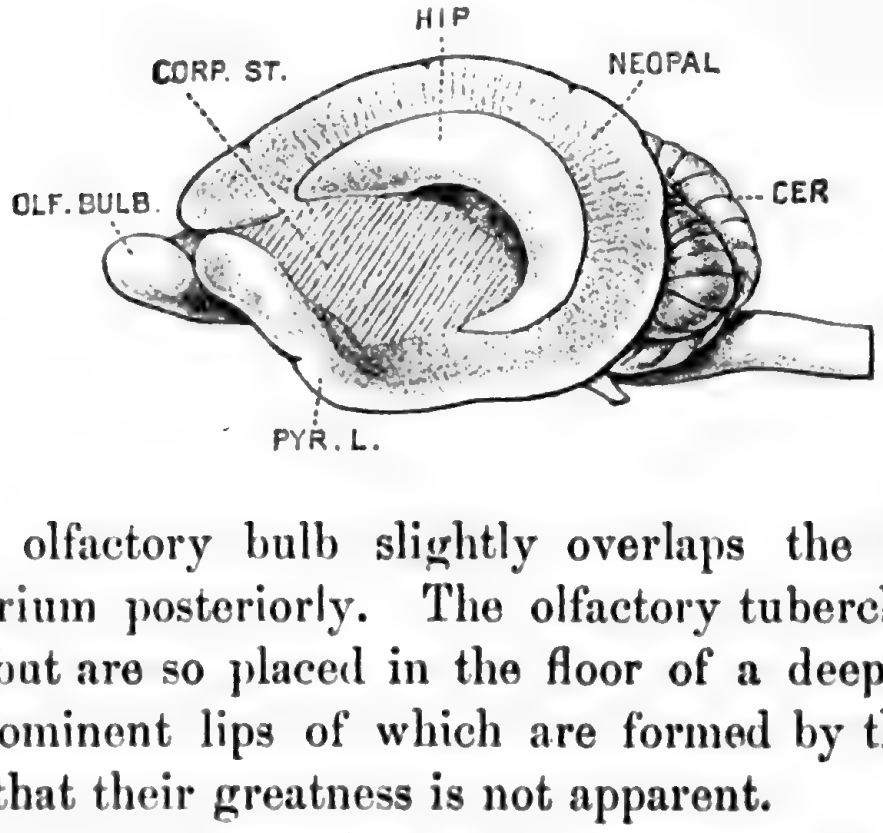

The olfactory bulb slightly overlaps the tuberculum olfactorium posteriorly. The olfactory tubercles are very large, but are so placed in the floor of a deep depression, the prominent lips of which are formed by the pyriform lobes, that their greatness is not apparent.

Behind this fossa the latter almost meet, so much are they bent towards the mesial plane (fig. 39). In the deep cleft between them the delicate optic nerves may be seen.

Emerging between the posterior part of the pyriform lobes and the pons Varolii are the ribbon-like trigeminal nerves. It is a peculiarity of the Monotremata that the trigeminal nerves are inserted into the brain-stem wholly in front of the pons.

Note the large size of the auditory nerve, which is placed immediately behind the point where the pontine fibres enter the cerebellum. The other cranial nerves call for no special comment.

In spite of the great size of the pallium, the pyramidal tracts are so insignificant that they form no prominence on the surface. The roots of the hypoglossal nerve, however, serve to indicate the lateral limit of each pyramid. There is a diffuse crossing of the fibres of the pyramids, instead of the compact decussations found in most mammals.

The trapezoid body, which is such an obtrusive feature of most mammalian brains, is not recognisable as such by the naked eye in the Monotremes.

The cerebellum is noteworthy for the small dimensions of its lateral parts, and from the fact that its structural plan cannot be certainly brought into harmony with that which is common to all the Meta- and Eutheria. It, however, closely agrees with that of the Platypus. But there is a large sessile floccular lobe, in marked contrast to the pedunculated, encapsuled flocculus of the Platypus.

In the left cerebral hemisphere the lateral ventricle has been opened so as to expose the hippocampus. The latter presents an appearance which is characteristic of the Monotremes. For, although the hippocampus also extends through the whole length of the lateral ventricle in the Marsupials, as it does here, it is only in the Monotremes that we find the largest and plumpest part of the hippocampal arc occupying the dorsal and cephalic position. The caudo-ventral part of the hippocampal arc rapidly tapers to a point in *Tachyglossus*, and even to a more marked degree in *Ornithorhynchus*. O. C. 1323*.

Ziehen, Semon's Forschungsreise, Jena. Denkschr. Bd. vi. 1897, p. 4.

D.192. The left cerebral hemisphere of a Spiny Anteater (*Tachyglossus* [*Echidna*] *aculeatus*): also a coronal section of another left hemisphere.

A rough area in the centre of the mesial surface of the hemisphere indicates the place from which the optic thalamus was detached (fig. 41). In front of this area the elliptical sections of two commissural bands are to be seen The lower or ventral commissure (COMM.V.) is much the larger of the two and contains nerve-fibres corresponding to the anterior commissure of other mammalian brains. But, as the coronal section (fig. 42) [which passes through the two commissures] clearly shows, the ventral commissure has a much wider distribution than the anterior commissure of most Eutheria, for it connects the whole of the two cerebral hemispheres, excepting the hippocampal formations only. Now in all Eutheria part of the neopallium is connected to the other hemisphere by means of the corpus callosum, so that the ventral commissure of the Spiny Anteater represents not only the anterior commissure, but also the corpus callosum of the Eutheria.

Fig. 41. (Nat. size.)

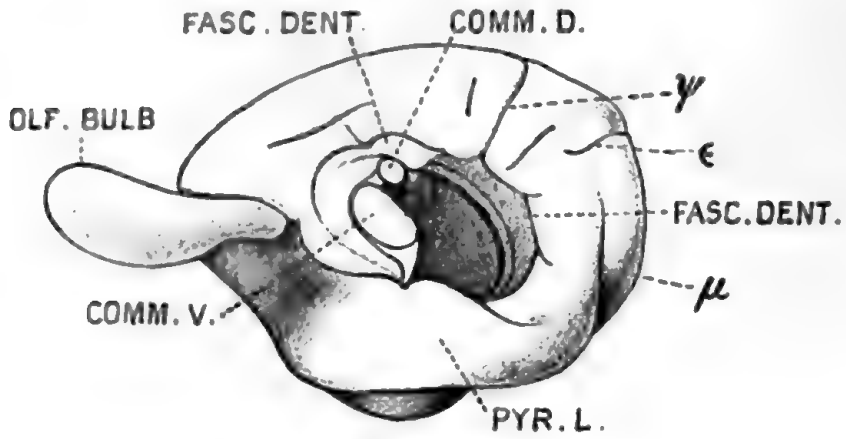

Fig. 42. (Nat. size.)

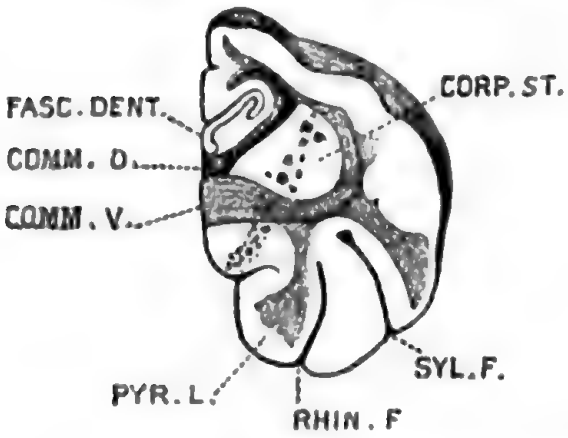

The dorsal or hippocampal commissure (COMM.D.) is much smaller. It was erroneously believed by Flower (Phil. Trans. 1865) to represent the corpus callosum ; but as it is wholly derived from the hippocampal formation by means of the fornix, it cannot be strictly regarded as the representative of a commissure (the corpus callosum) which is derived from cortical areas (neopallium) other than the hippocampus (Elliot Smith, Proc. Linn. Soc. N. S. W. vol. ix. 1895, p. 635) *.

---

* This view, which was originally stated by Owen in 1837, and conclusively demonstrated by modern methods by Symington (Journ. Anat. & Phys. 1892), has recently been called in question by several writers, without a tittle of evidence to justify their irrational refusal to recognise a fact which is unquestionable and so easily demonstrable.

Upon the upper surface of the dorsal commissure there is a narrow band of cortical substance, which is obviously the cephalic prolongation of the fascia dentata. A study of the mesial surface of the hemisphere shows this at a glance, and an examination of the coronal section confirms the opinion that the structure in question is really the fascia dentata.

The caudal portion of this structure may be seen (behind the rough area on the corpus striatum) occupying the position in which we are accustomed to look for it in the Eutherian brain. It appears to be depressed below the level of the rest of the surface, because the neopallium tends to bulge over the marginal hippocampal region. The clearly-defined hippocampal fissure separates the fascia dentata from the neopallium. But, unlike the arrangement found in the higher mammals, the fascia dentata (with the hippocampal fissure bounding it on its dorsal or peripheral side) extends far forward above the dorsal commissure. This explains the presence of the hippocampal formation in the peculiar position in which it is seen in the coronal section. There (fig. 42) we see the fibres of the small dorsal commissure spreading out to form the ventricular covering (or *alveus*) of the hippocampus, from which they are wholly derived. By means of this section, it is easy to correlate the appearance of the ventricular surface of the hippocampus (seen in the last specimen, fig. 40) with the mesial distribution of the fascia dentata (which is merely a specialised marginal fringe of the hippocampal formation) in the hemisphere of this specimen. It is now also possible to understand how it is that the dorsal commissure is derived from the hippocampus. (Elliot Smith, Journ. Anat. & Phys. vol. xxxii. 1897, p. 32.)

The hippocampal fissure extends only a short distance beyond (*i. e.* in front of) the dorsal commissure, so that the fascia dentata (of which it forms the dorsal boundary) appears [in a spirit-preserved specimen] to blend with the neopallium above it, and also with the precommissural area below it. In a fresh brain the fascia dentata may, however, be readily distinguished by its colour, and may be traced forward into close proximity to the olfactory peduncle.

[In this specimen the olfactory bulb has been removed, and the irregular cut surface of its peduncle can be seen upon the ventral surface of the anterior pole of the hemisphere.]

At the concave margin of the postcommissural part of the fascia dentata there is a strand of white fibres—the fimbria or fornix. This consists of a group of fibres collected from or going to the hippocampus. In all Marsupials and placental mammals the fimbria projects as a prominent crest; but in both Monotremes it consists merely of a slight thickening of the edge of the alveus, which does not project to form a ridge. Anteriorly its fibres appear in this specimen to pass bodily into the dorsal commissure, but many of them do not do so. A considerable proportion of the fibres of the fornix bend downward behind the ventral commissure as a compact bundle (the anterior pillar or column of the fornix), which enters the optic thalamus and proceeds toward the corpus mammillare: others again enter the precommissural area, and are known as the precommissural fibres (of Huxley). These fibres can be satisfactorily seen only in fresh specimens or in histological preparations (compare Journ. of Anat. & Phys. vol. xxxii. fig. 6, p. 36).

In this specimen the fissures and sulci may be studied with advantage.

The rhinal fissure is extraordinarily deep in the Monotremes, and especially in *Tachyglossus*, as the coronal section (fig. 42) shows. It pursues a very tortuous course on the lateral, ventral, and caudo-mesial surfaces of the hemisphere. Just before it leaves the lateral to reach the basal surface of the hemisphere, it gives off a short horizontal branch as deep as itself. This branch is probably produced by factors analogous to those which cause the so-called "Sylvian fissure" in other mammals; it is, in other words, a kink produced by the downward growth of the neopallium behind it, and, as such, has a claim to be called the "Sylvian fissure" equal to that of, say, the Cat's brain. At the same time there is no reason for regarding it as a strict homologue of the similarly-named fissure of other mammals. The same term is used simply as a matter of convenience in the same way that it is applied to the Edentate, Carnivore, Ungulate, and Primate brain respectively, in which no exact correspondence exists. We know from the distribution of the claustrum that the exact cortical areas from which the lips of the Sylvian fissure are formed in different higher Orders [or even Suborders and Families—compare the Cynoid, Arctoid, and Pinniped Carnivores and the progressive modifications in their various families] are not strictly homologous in different mammals ; so that if we use the term "Sylvian" for all these various types of fissure, we are also justified in using it for the fissure of the Spiny Anteater's brain, which is clearly caused by analogous factors of growth, without thereby implying any strict homology in the cortical areas which form its lips. It will avoid much confusion, however, if we call this sulcus (fig. 43, SYL.F.) "pseudosylvian."

Fig. 43. (Nat. size.)

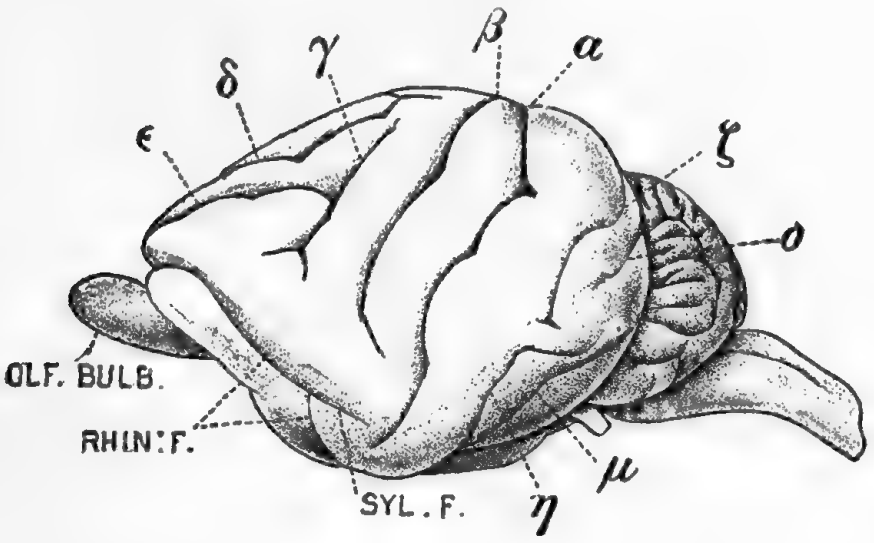

The sulci of the neopallium of the Spiny Anteater vary very considerably in different individuals, and there is no clue to indicate whether any of them should be regarded as the representative of a sulcus of other mammalian brains. On the other hand, the arrangement of the sulci suggests that they might be due to purely mechanical factors operating in an uniformly growing pallium, the longitudinal expansion of which is restricted.

The most constant of all the sulci are three distinguished as α, β, and ψ in the diagrams (figs. 38 and 43).

[The figures (38, 39, and 43) illustrating this account are drawn from the preceding specimen (D. 191) in order that both hemispheres might be represented. The description, however, applies more especially to this specimen (D. 192), in order that the arrangement of the sulci on the cranial surface may be compared with that of the mesial surface (fig. 41).]

The sulcus α begins immediately behind the pseudo-sylvian, and pursues a course upward, *i. e.* mesially, to terminate just in front of the caudo-mesial angle of the dorsal surface.

The sulcus ψ is the deepest and most constant of the radiating sulci on the mesial surface of the hemisphere. It appears to spring from the hippocampal fissure at a short distance behind the supracommissural exposed portion of the fascia dentata. In most brains it crosses the dorsal edge and joins the sulcus β on the dorsal surface. The latter pursues a course for a variable distance in front and parallel to the sulcus α. Its mode of termination is variable. In this specimen it bends forward opposite the mid-point of the sulcus α, and, after a short oblique course, ends in a bifid extremity. In the other specimen (D. 191) it behaves in a different manner (fig. 43, β). In specimen D. 192 there is a short sulcus below β, which may be regarded as a part of the same sulcus, as the two are commonly united as in specimen D. 191.

On the dorsal surface of the hemisphere there are commonly two oblique or sagittal sulci (fig. 38, δ and ϵ), and behind them a short sulcus γ, parallel to α and β. Behind β there are two sulci, ζ and η, and behind these again two others, o and μ.

The greater part of the hemisphere is thus divided into a series of slightly oblique transverse bands by the series of sulci, γ, β, α, $\zeta+\eta$, and $o+\mu$. The shallow sulcus π on the mesial surface (fig. 41) is placed above and parallel to the anterior part of the hippocampal fissure *.

It is very significant that the most constant and primitive sulci of the Meta- and Eutherian neopallium, such as the calcarine (splenial), orbital (presylvian), and suprasylvian sulci, are absent. This is one of the many manifestations of the great gap which separates the Monotremes from all other mammals. *Presented by Prof. G. Elliot Smith.*

Waldeyer (*Review only*), Merkel and Bonnet's Ergeb-

---

* The indicating letter π has been omitted in the figure.

nisse, Bd. viii. 1898, p. 372. (The more recent work by Bela Haller [Morph. Jahrb. 1900, p. 463] is quite misleading.)

D. 193. The left cerebral hemisphere of a Spiny Anteater (*Tachyglossus* [*Echidna*] *aculeatus*), dissected to show the hippocampus in the lateral ventricle.

In this specimen parts of the mesial wall have been torn asunder, and as a result the exact shape of the hippocampus can be seen to better advantage than in specimen D. 191. The latter specimen shows the same structures, however, *in situ.*

D. 194. A cast of the cranial cavity of a Spiny Anteater (*Tachyglossus aculeatus*).

Gervais, Nouv. Arch. d. Mus., t. v. 1870, p. 247.

D. 195. The optic thalami, mid-brain, cerebellum, and medulla oblongata of a Spiny Anteater (*Tachyglossus* [*Echidna*] *aculeatus*).

Fig. 44. (× 2.)

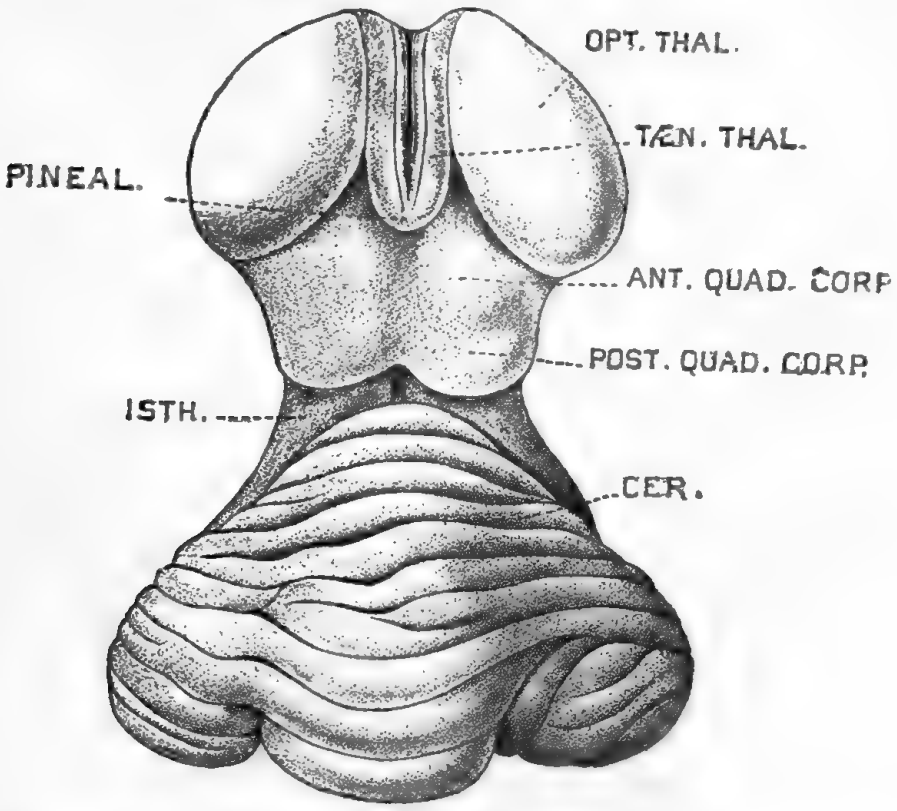

This specimen was prepared by the late Sir William (then Professor) Flower (see Proc. Zool. Soc. 1864, p. 18) to demonstrate the corpora quadrigemina, concerning the existence of the posterior pair of which some doubt had been raised by the writings of his predecessor, Sir Richard Owen.

On the dorsal aspect (fig. 44) the small oval masses of the optic thalami will be observed in front, separated by the narrow mesial slit-like third ventricle. At its caudal extremity a blunt rounded sac is found representing the pineal body, and in front of this the ganglion habenulæ and tænia thalami are found on each side of the ventricle, as in all other vertebrate brains. Perhaps the most significant feature of this specimen is the absence of any protuberance corresponding to the mesial geniculate body. In this respect the Monotreme brain differs most markedly from that of all other mammals. The absence of any markedly projecting lateral geniculate body is not so peculiar, not only because this body is not prominent among the lowlier mammals, but also because the visual apparatus, of which it forms an important part, is poorly developed in the Monotremes.

The quadrigeminal bodies are comparatively small and flat as comparedwith those of other mammals.

The pons Varolii is prolonged into a forwardly-projecting process or rostrum in the mesial plane, probably because the nuclei pontis are scattered throughout a much greater antero-posterior extent than the narrow lateral parts of the pons occupy. This peculiar rostrum is distinctive of the Monotremes, since it is also found in the Platypus. Immediately in front of the rostrum note the interpeduncular body, one of the oldest parts of the brain in the phylogenetic sense. The rounded knob formed by the corpora mammillaria, the oculo-motor nerves, and the delicate optic tracts conform to the usual mammalian type.

In comparison with the corresponding organ in other mammals, the cerebellum in the Monotremes presents features so peculiar that no exact comparisons with that of other mammals can be instituted with any degree of certainty. The fissura prima (præclivalis of Human Anatomy) is apparently placed very far back, so that the greater part of the cerebellum, including the whole of the anterior and the greater part of the dorsal surface, corresponds to the anterior lobe of other mammals (the combined lobus centralis and lobus culminis of Human Anatomy). Thus the whole of the postclival region, which in the higher mammals becomes so greatly expanded that it forms the bulk of the organ, becomes relegated to the caudo-ventral region of the cerebellum and is a narrow insignificant strip, which is expanded laterally only to a very slight degree. The region of the nodulus agrees with that of other mammals. The floccular lobe is sessile in *Tachyglossus,* but projects for a considerable distance in *Ornithorhynchus*. It is a simply foliated appendage, and is not divisible into flocculus and paraflocculus; nor can a ventral and dorsal segment be recognised as in other mammals, although the radiating feather-like arrangement of the folia in *Tachyglossus* is a simplified form of the two-layered type of paraflocculus.

The cerebellum differs in a most marked manner from that of other mammals, and seems to be a highly specialised modification of the primitive mammalian type. Its most significant feature is the relatively small size of its lateral parts. Seeing that most of its exposed part probably represents the anterior lobe of the mammalian cerebellum, in which there is no clear line of demarcation between vermis and lateral hemispheres, such distinctions are also lacking in the Monotreme. O. C. 1323**.

Ziehen, Semon's Forschungsreise, Jena. Denkschr. 1897, p. 23.

D. 196. The cranial cast of a so-called "Proechidna" (*Proechidna bruijni*).

The brain is distinctly larger than it is in *T. aculeatus*; the olfactory bulbs project much further beyond the hemispheres; the hemispheres are proportionately much longer than in the other species and are extremely large and richly convoluted for so lowly a mammal.

Gervais, Nouv. Arch. Mus., t. v. 1869, pl. xiv.

ORDER MARSUPIALIA.

Suborder POLYPROTODONTIA.

Family *DASYURIDÆ.*

D. 197. The brain of a Tasmanian Devil (*Sarcophilus* [*Dasyurus*] *ursinus*) (♀), in which the left cerebral hemisphere has been separated from the rest of the brain.

This is one of the simplest and most generalised types of the mammalian brain, and presents a marked contrast to the specialised Monotreme organ.

Its most obtrusive feature is the relatively enormous size of the olfactory bulbs, which are attached by short thick peduncles to the front of the cerebral hemispheres. In the great majority of mammals the olfactory apparatus is largely developed; and in the case of a terrestrial, offal-eating animal, like *Sarcophilus*, the importance of the sense of smell becomes enormously enhanced and it becomes the dominant sense. This finds expression (as in *Perameles*, *vide* fig. 52) in the huge development of the olfactory bulb, in the large elliptical olfactory tubercle on the base of the brain, in a pyriform lobe which forms a large part of the ventral surface and almost half of the lateral aspect of the hemisphere, and in a large hippocampal formation which forms a considerable part of the mesial wall.

Fig. 45. (Nat. size.)

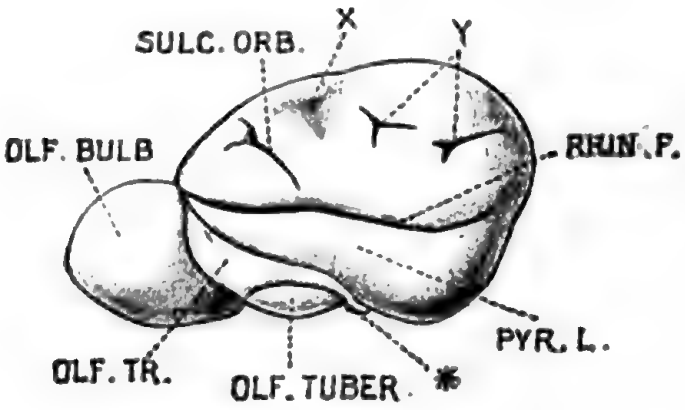

This brain shows very clearly the definite connections which the olfactory peduncle establishes with both the lateral and mesial walls of the cerebral hemisphere. Upon the lateral aspect (fig. 45) the peduncle is directly continued into the pyriform lobe, and a layer of medullary fibres upon the latter becomes collected into a definite bundle—the olfactory tract or so-called "external olfactory root"—which proceeds backwards in the shallow groove between the pyriform lobe and the olfactory tubercle, distributing fibres over the surfaces of both. The tract finally ends in a little nodule behind the olfactory tubercle (fig. 45, *), which may be called the tubercle of the olfactory tract [Retzius calls it the "gyrus intermedius"].

A well-defined rhinal fissure begins anteriorly in the cleft between the olfactory bulb and the apex of the hemisphere, and separates the pyriform lobe from the neopallium.

Upon the mesial surface (fig. 46) the olfactory bulb may be distinctly seen to be connected by a short cylindrical peduncle to the precommissural area of the mesial wall. The tuberculum olfactorium is seen immediately below the latter.

In the caudal region of the mesial wall the fascia dentata and fimbria are seen presenting features such as we find in most mammals. The prominent, broad fimbria at once distinguishes this hippocampal formation from that of the Monotremes.

Fig. 46. (Nat. size.)

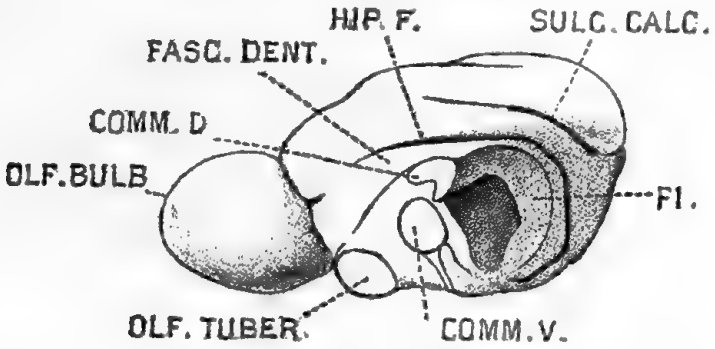

This fimbria is seen to pursue a regular arcuate course upward and forward to reach a point immediately above the large ventral (modified anterior) commissure; and many of its fibres then cross the middle line in close relation to the upper extremity of the lamina terminalis, so as to form a smaller dorsal commissure, which is thus derived by means of the fornix (fimbria) from the hippocampus. Histological examination shows that the fibres of this dorsal commissure are not grouped irregularly to form a round bundle, as in the Monotremes, but are compactly arranged in a crescentic form. In some Marsupials this dorsal commissure becomes more acutely bent so as to be distinctly bilaminar. Some of the fibres of the fimbria do not enter the dorsal commissure and are divided into two groups, a scattered anterior group of precommissural fibres and a posterior group—the so-called anterior pillar of the fornix—which proceeds behind the ventral commissure and passes through the optic thalamus toward the corpora mammillaria.

The fascia dentata (like the hippocampal fissure which marks its peripheral boundary) proceeds upward and forward alongside the fimbria as far as the dorsal commissure; and then it passes forward above the dorsal commissure and appears to lose itself in the precommissural area immediately above the attachment of the olfactory peduncle. In a fresh brain (or by means of histological examination) the fascia dentata may be traced forward practically into continuity with the olfactory peduncle (Trans. Linn. Soc., Zool. ser. 2, vol. vii. 1897, pl. 15. fig. 8). The hippocampal fissure accompanies the fascia dentata in the greater part of its course, but stops just as it approaches the neighbourhood of the olfactory peduncle. The mesial surface of the olfactory peduncle passes backward into direct continuity with the precommissural area, which is separated above by the fascia dentata from the neopallium. This precommissural area is continuous below with the tuberculum olfactorium, and is bounded posteriorly by the lamina terminalis containing the dorsal and ventral commissures.

The retention in an undisturbed state of the cephalic portions of this hippocampal formation is the most interesting feature in the brain of the Marsupial. In this it agrees with the Monotreme, but is the more instructive because the caudal parts of the hippocampus in the Marsupial have assumed the configuration which is met with in other mammals.

The cephalic parts of the hippocampal formation are retained in the Marsupial because the dorsal commissure is derived from the hippocampus, and the great non-hippocampal commissure (corpus callosum) has not yet made its appearance to disturb the integrity of the hippocampal arc.

It is the absence of the corpus callosum and the retention of the supracommissural and precommissural parts of the hippocampus undisturbed that renders the cerebral hemisphere in the Monotremata and Marsupialia so instructive to the student of the higher mammalian brains. For the corpus callosum consists of a series of fibres at first intermingled with those of the dorsal or hippocampal commissure, but distinguished from them by the fact that they come from a cortical area (the neopallium) other than the hippocampus and do not form part of the fornix. But as this series of neopallial fibres increases in number in the Eutherian brain, the corpus callosum rapidly extends and assumes the large dimensions which we usually associate with this body. As it does so it naturally stretches a portion of the great hippocampus (of which the fascia dentata forms the only part visible upon the surface), and the hippocampus atrophies in the region of stretching. Thus in all mammals possessing a corpus callosum, the hippocampus persists in an unchanged state only so far forward (or so far up) as the splenium of the corpus callosum, but its anterior part is represented by vestiges upon the upper surface of the corpus callosum and along a line joining the anterior extremity of the latter to the olfactory peduncle. In man these vestiges together with some longitudinal fibres in connection with them are generally known as the longitudinal striæ of Lancisius. (For a fuller elucidation of these peculiarities see Journ. Anat. & Phys. vol. xxxii. 1898, p. 30.)

The precommissural area is also of interest in the Marsupial, in view of the fact that in most other mammals the upper part of the corresponding region becomes stretched by the growing corpus callosum to form a folium of the septum lucidum in each hemisphere.

Upon the postero-superior region of the mesial wall of the hemisphere, there is a short arcuate sulcus running parallel to the hippocampal fissure. The corresponding sulcus in the Ungulata was named the "*fissura splenialis*" by Krueg, from its relationship to the splenium of the corpus callosum. There can be little doubt that this sulcus represents the anterior calcarine sulcus [*i. e.* the true calcarine fissure, the stem of the **Y**-shaped complex] in the human brain, and hence we may call it "calcarine" in *Sarcophilus* (Elliot Smith, Proc. Anat. Society, 1899) *.

---

* For the demonstration of this homology compare the conditions found in *Manis, Cholœpus, Daubentonia* and the other Primates.

The most diverse views are put forward by various writers as to the possibility of homologising the sulci of one brain with those of another. Some writers attempt to institute comparisons upon a purely topographical basis between the cerebral sulci of brains of even different Orders of

In the smaller *Dasyuridæ* this sulcus is not present.

The cranial surface of the hemisphere is not quite smooth. The rhinal fissure separates the pyriform lobe from the neopallium, and in addition the latter is also marked by several shallow furrows (figs. 45 and 47). Of these the

Fig. 47. (Nat. size.)

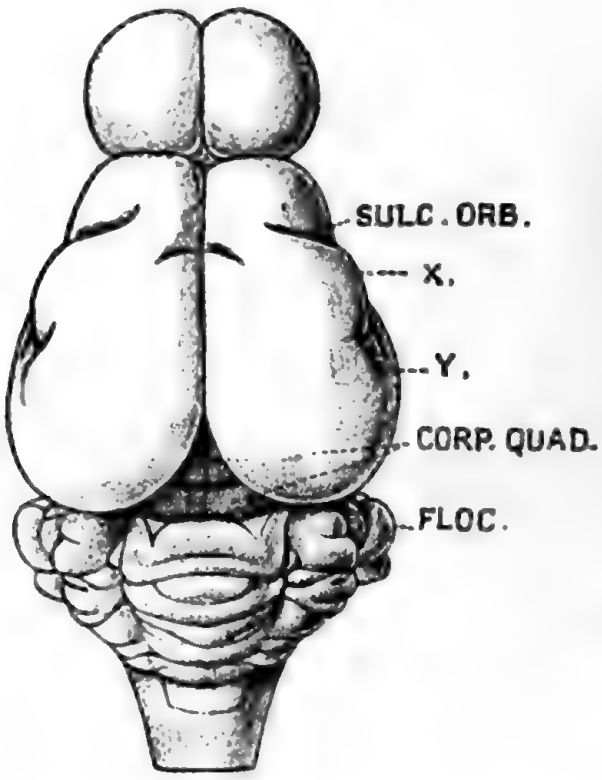

---

mammals; whereas others go to the opposite extreme and deny *in toto* the possibility of homologising the sulci found in one Order of mammals with those of another.

There can be little doubt that the fundamental constituents of many of the sulci found in the Metatheria and Eutheria are morphologically stable elements which can be certainly homologised in many different Orders.

The exact homology of the hippocampal and rhinal fissures in all mammals is beyond question, because the peculiar histological features of the lips of these fissures enable us to certainly identify them. The developmental history and the behaviour of the fundamental constituents of the calcarine sulcus of Primates and the upper part of the vertical ramus of the sulcus commonly called "splenial" in other mammals indicate their identity. In the same manner we can recognise the suprasylvian, lateral, coronal, and orbital (presylvian) sulci in the most diverse Orders of mammals. Most of these names were originally applied to the Carnivora (*vide infra*).

By "fundamental constituent" I mean the stable basis of a sulcus, which seems to be produced (even when the mechanical conditions must be vastly different) in various Orders of mammals in response to some factors other than the mere general expansion of the neopallium. The extending cortex may be accommodated in the neighbourhood of such a sulcus by the prolongation of the latter: or, again, the furrow in question may become confluent with various other sulci in different mammals. Thus the calcarine sulcus (*sensu stricto*, i. e. the short post-splenial furrow, which indents the wall of the deepest and most constant is a short oblique furrow situated just above the mid-point of the anterior rhinal sulcus (*i. e.*, the anterior horizontal part of the rhinal). It represents the presylvian sulcus, which is one of the most constant features of the mammalian neopallium. There are many reasons for regarding this presylvian sulcus as the earliest form of the sulcus known in Human Anatomy by the name "orbital." [Compare the account of the Prosimian brain.]

Behind the upper extremity of this sulcus there is a shallow transverse depression (figs. 45 & 47, X), which is of interest because the brain of *Thylacinus*, the large relative of *Sarcophilus*, exhibits a deep sulcus in the corresponding position.

Above and parallel to the posterior rhinal fissure there is a short horizontal sulcus, and in front of it a small triradiate sulcus (Y). These clearly represent the great sulcus, which I have distinguished as "horizontal" in the

---

ventricle and thus produces the calcar avis) is undoubtedly a definite morphological feature, which is the common property of the Meta- and Eutheria. Yet in the Carnivora, Ungulata, and many other mammals its ventral end may be prolonged almost or quite as far as the rhinal fissure, merely because the expanding cortex in this region is most readily accommodated by the extension of this already-existing sulcus. In the Carnivora and Ungulata the upper end of the calcarine sulcus becomes confluent with the intercalary sulcus, forming the so-called "splenial." In the Primates the lower end of the calcarine sulcus does not become prolonged and the upper (posterior) end joins, not the intercalary, but the postcalcarine sulcus. Now, in such a catalogue as this, it is quite impossible to explain on every occasion whether it is the "calcarine," or the "prolonged calcarine," or a "calcarine complex" to which we refer, without endless confusing periphrases, which would make the accounts hopelessly involved. The same kind of misunderstanding might arise also in the case of the suprasylvian, lateral, or orbital sulcus.

The reader must therefore bear in mind that the same names are employed in different Orders in order to indicateas concisely as possible where to look for the homologous sulci, rather than to suggest the identity of *the whole of any sulcus* called by any given name.

It is also impossible to discuss in a catalogue of limited dimensions all the reasons which have led to the adoption of the views set forth in the brief accounts of the various specimens.

The student who is not acquainted with the nomenclature used for the sulci is referred to the figures of the brain in the Carnivora (*infra*).

Thylacine (fig. 50). It is not possible to suggest any homology between this and a named sulcus of any other mammalian brain.

The neopallium in the Tasmanian Devil thus exhibits features of interest as a connecting link between the smooth hemispheres of the smaller Dasyurids and the deeply fissured hemispheres of the Thylacine, the sulcal pattern of which it so clearly foreshadows.

The base of the brain (compare with *Perameles*, fig. 52) presents features which differ in a very marked manner from those of the Monotreme brain, and closely agree with the characters of the vast majority of other mammals. Thus the pons presents the appearance of an almost uniform transverse band and lacks the peculiar rostrum of the Monotreme; moreover, the majority of its fibres pass in front of the trigeminal nerve; the pyramidal tracts appear as prominent bands which decussate in a more or less compact mass, and not as a diffuse crossing, as in the Monotremes: the trapezoid bodies, which are not recognisable as such to the naked eye in the Platypus and the Spiny Anteater, are now very prominent and well-defined features. Each half of the trapezoid body consists of a large strand of fibres which springs from the acoustic tubercle (where the nerve-fibres from the cochlea end), and, after pursuing a transverse course on the caudal side of the pons, dips into the medulla and passes chiefly into the lateral fillet of the opposite side. It constitutes the chief cerebral path for auditory impulses.

The pituitary body has been torn away with the infundibulum, so that the mesial slit-like third ventricle has been opened up between the large optic chiasma and the distinctly paired corpora mammillaria. In the depression behind the latter note the large interpeduncular body in contact with the pons.

The cerebellum conforms to a simple type such as we find in the Insectivora, Rodentia, Chiroptera, and Dasypodidæ (Edentata). Projecting upon each side there is a large irregular mass of folia resting upon the lateral aspect of the pons and medulla oblongata, and separated from the rest of the cerebellum by a deep fissure. This is the floccular lobe. In man the representative of this mass becomes reduced to very insignificant proportions and forms the flocculus. In this brain, however, the floccular lobe is almost, if not quite, equal in size to the whole of the rest of the so-called lateral lobe. Two shallow sagittal grooves separate the upper surface of the cerebellum into three projecting ridges, each of which is subdivided by a small series of transverse furrows. In each of these grooves a triangular area of medullary matter is exposed. The area seen in this specimen between the floccular lobes corresponds to that region of the human cerebellum which lies behind and below the preclival fissure and in front of the uvula. Part of the uvula in this specimen may be seen as a little tongue-like process extending backward and forming an operculum over the apex of the fourth ventricle. The most significant feature of this organ to the human anatomist is the extreme diminution of the lateral hemispheres; but when the intimate association existing between the cerebellar hemisphere and the opposite cerebral hemisphere is remembered, it is not surprising to find these parts of the cerebellum so poorly developed in a brain in which the pallium as a whole, and especially the neopallium, is so diminutive. The anterior lobe, which is relatively so large in the Monotremes, is completely hidden in this brain by an overhanging hood formed by the region lying behind the fissura prima (*vel* præclivalis). O. C. 1323 B *b*.

R. Owen, Todd's Cyclopædia, 1847, vol. iii. p. 291.

D. 198. The brain of a Tasmanian Devil (*Sarcophilus* [*Dasyurus*] *ursinus*).

This specimen shows the real proportions of the huge olfactory bulbs. The hemispheres have been drawn apart so that a much greater part of the corpora quadrigemina is exposed than when the parts are in their natural position. [Compare the casts D. 199 and fig. 47.]

This specimen is represented in Owen's 'Anatomy of Vertebrates,' vol. iii. p. 104. O. C. 1323 C *f*.

D. 199. Cast of the cranial cavity of a Tasmanian Devil (*Sarcophilus* [*Dasyurus*] *ursinus*). [In duplicate.]

This shows better than the actual specimen (which is liable to distortion) the large proportions of the olfactory bulbs and the relations of the cerebellum (the chief divisions of which are clearly seen) to the cerebral hemispheres.

Note the orbital sulcus on the hemisphere (fig. 45).

P. Gervais, Nouv. Archiv. Mus., t. v. 1869, Pl. xiv. fig. 8.

D. 200. A young Australian "Native Cat" (*Dasyurus viverrinus*), with the brain and spinal cord exposed *in situ*.

Parts of the hemispheres have been removed so as to expose the hippocampi from above. O. C. 1323 c *b*.

D. 201. The right half of the brain of an Australian "Native Cat" (*Dasyurus viverrinus*), separated by a mesial sagittal section.

Two white bristles have been inserted into the hippocampal fissure just above the prominent fascia dentata which rests upon the dorsal commissure. A black bristle has been inserted just below the ventral (anterior) commissure and another in the centre of the large "soft" or "middle commissure" (so-called). The cavity of the third ventricle in which the latter is placed may be clearly seen in this specimen. Its communication with the lateral ventricle, viz., the foramen of Monro, may be distinctly seen in the groove between the dorsal and soft commissures.

Note the large size of the aqueduct of Sylvius, which opens from the posterior extremity of the third ventricle into the mid-brain. The roominess of this canal is very suggestive when it is recalled that in most submammalian forms a ventricle exists in this situation and extends into the "optic lobes."

Note further the simplicity of the cerebellum. Its deepest fissure—the fissura prima—opens on the anterior surface near the apex of the organ: it is the homologue of the preclival fissure of Human Anatomy.

All of these features (excepting the arrangement of the hippocampus and the commissures) are common to other lowly mammalian brains, such as those of the Insectivora.

O. C. 1323 c.

D. 202. The right cerebral hemisphere, the caudal part of the left cerebral hemisphere, and the brain-stem and cerebellum of a Tasmanian "Wolf" (*Thylacinus cynocephalus*).

The mesial aspect of the hemisphere (fig. 48) presents the typical arrangement of the cerebral commissures and hippocampus; and, as such, this identical specimen was figured by the late Sir William Flower (Phil. Trans. 1865). He, however, erroneously regarded the dorsal commissure as a true corpus callosum. There is a well-developed calcarine sulcus beginning just above the caudal extremity of the rhinal fissure. It is prolonged upward and forward after the manner of the splenial complex in many orders. An oblique section has been made through the left hemisphere (fig. 49) (in the plane indicated in fig. 48) in the region of the deepest part of the calcarine sulcus. The latter is thus shown to be "complete" or "total"; in other words it gives rise to a bulging—the calcar avis or so-called hippocampus minor—in the ventricle immediately to the peripheral side of the true hippocampus.

Fig. 48. (×⅔.)

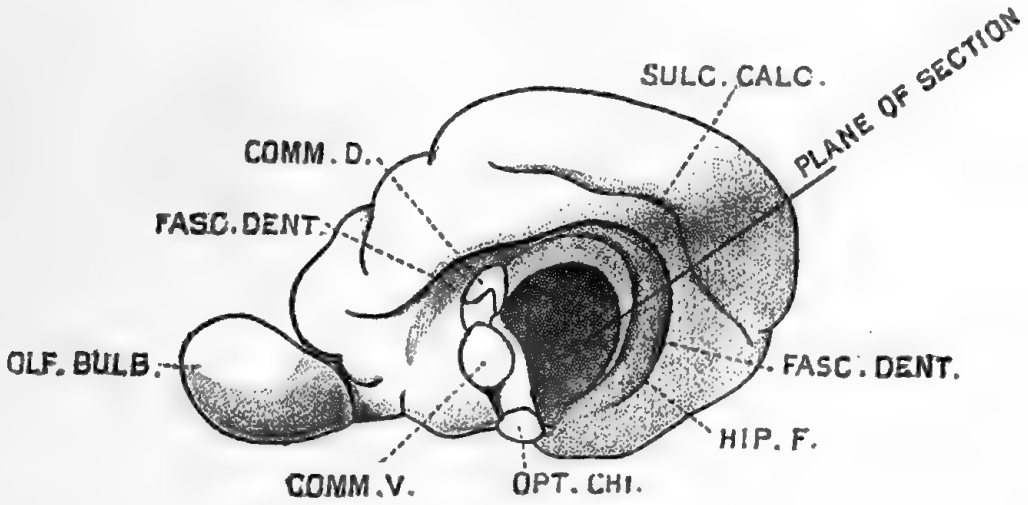

Fig. 49. (×⅔.)

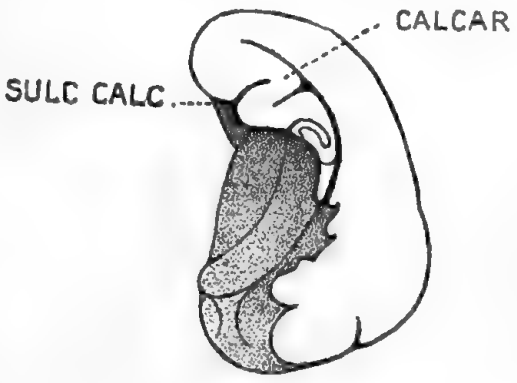

There is a deep and sharply-defined rhinal fissure, acutely bent at the junction of its anterior and posterior parts (fig. 50). A deep and extensive orbital (presylvian) sulcus springs from the rhinal a short distance in front of the angle and proceeds transversely across the hemisphere as two conjoined arcs. The upper arc, the convexity of which looks backward, was probably a distinct sulcus originally. Here it has fused with the orbital sulcus (figs. 50 and 51). It extends on to the mesial wall of the hemisphere (fig. 48), immediately behind a short upturned sulcus prolonged from the cephalic extremity of the hippocampal fissure.

Fig. 50. $(\times \frac{2}{3}.)$

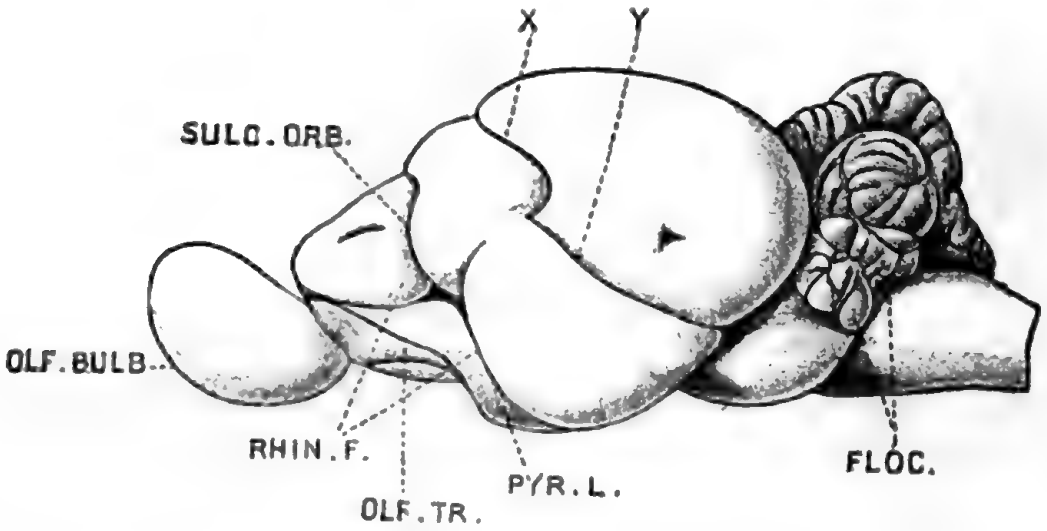

Fig. 51. $(\times \frac{2}{3}.)$

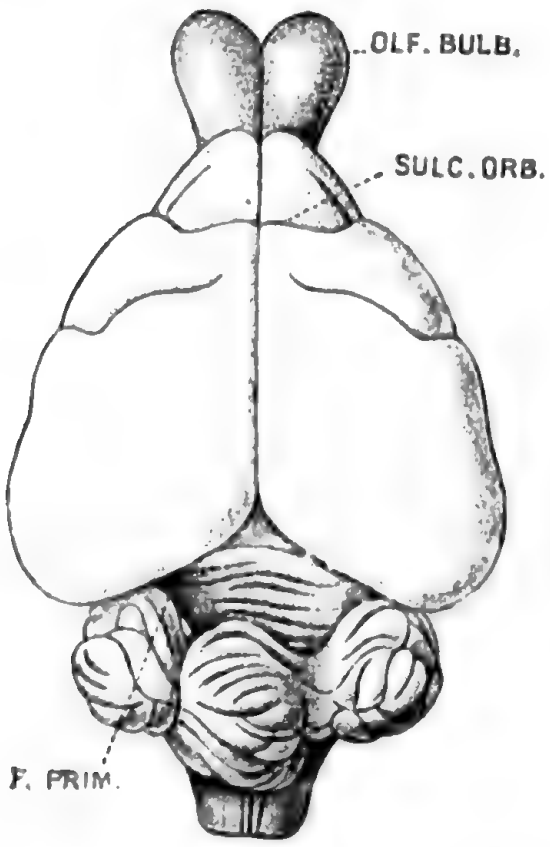

A short kink-like depression extends upward from the angle of the rhinal fissure for a short distance, and may be regarded as analogous to the "Sylvian fissure" of Carnivores *.

A deep sulcus (Y) begins near the posterior margin of the hemisphere and pursues a course parallel to the posterior rhinal almost as far forward as the "Sylvian fissure." Its anterior extremity is joined by a shallow oblique sulcus to a second deep furrow (X) which pursues the same direction as the posterior sulcus but on a slightly higher level. The whole complex forms a great sulcus crossing the hemisphere obliquely as far as the dorso-mesial edge, where it almost reaches the upper extremity of the prolongation of the calcarine sulcus (fig. 48). The determination of the homologies of these furrows is fraught with great difficulty; but it will be found, I believe, that the sulcus Y represents the suprasylvian and the furrow X the coronal sulci of other mammals. In the right hemisphere of a Thylacine described by Beddard the sulci X and Y overlap but do not join. In the left hemisphere of his specimen the condition described in this hemisphere is found.

In front of the presylvian there is a short separate horizontal sulcus analogous to that called "prorean" in the Carnivora. On the left hemisphere it joins the presylvian. There is a shallow olfactory sulcus (*i. e.* the depression in the neopallium which lodges the olfactory bulb and peduncle.)

There are also a few ill-defined punctate depressions below and above the X + Y complex sulcus.

The plan of the sulci is a more complete elaboration of that faintly foreshadowed in the Tasmanian Devil. It has undoubtedly considerably diverged from the plan found in most placental mammals, though not to such a marked extent as that of the Monotremes or even of the Diprotodont Marsupials.

The optic tract may be seen spreading out on the lateral tubercle of the optic thalamus. Behind the latter note the

---

* But this is a feature vastly different from the true Sylvian fissure of the Primates (*vide infra*). In the latter part of this work I have therefore discarded the erroneous name "Sylvian" and called it "pseudosylvian." The earlier part was already in print before I fully appreciated the utterly misleading effects of calling this furrow "Sylvian."

large mesial (posterior) geniculate body and the great corpora quadrigemina of which the anterior pair are especially prominent. The cerebellum conforms to the same plan as that of *Sarcophilus*. But the mesial and lateral parts of the region behind the primary fissure are unusually prominent. They are separated the one from the other by exceedingly deep broad furrows in which large medullary areas are exposed. The mesial "vermis" is twisted toward the right and the lateral areas are expanded in a feather-like pattern, such as is common in Carnivora, Edentata, and other Mammalian Orders.

F. E. Beddard, Proc. Zool. Soc. 1891, pp. 140–145.

D. 203. A cast of the cranial cavity of a Tasmanian Wolf (*Thylacinus cynocephalus*).

This shows that the olfactory bulbs are laterally compressed and of large size; they are borne on long peduncles so that they are placed almost wholly in front of the hemispheres.

The peculiar shape of the cerebral hemispheres is clearly demonstrated, and the relatively small size of the pointed apices which constitute the presylvian part of the hemispheres is shown. The positions of the sulci described in the actual brain are clearly indicated.

The peculiar configuration of the cerebellum is also shown in a very striking manner.

Gervais, Nouv. Arch. Mus., t. v. 1869, p. 229.

Family *PERAMELIDÆ*.

D. 204. The brain of a Rabbit-Bandicoot (*Thalacomys lagotis*).

[This specimen lacks the greater part of its olfactory bulbs and the projecting portions of the cerebellum.]

The general features of this brain are like those of the brain of *Dasyurus*, but the cerebral hemispheres are more distinctly conical. O. C. 1323 c *h*.

D. 205. The brain of a Bandicoot (probably *Perameles nasuta*).

This specimen was labelled "*Dasyurus*" in the old Catalogue; but the pointed cerebral hemispheres, the pronounced lateral "spreading" of the caudal parts of the pyriform lobes, the simplicity of the cerebellum, and its markedly-projecting, pedunculated floccular lobes clearly show that it is the brain of *Perameles*. In fact, it exhibits the characteristic features of the genus in a much more distinctive manner than the specimen (D. 206) labelled "*Perameles*." In both specimens the large olfactory bulbs are damaged so that their great size is not properly shown.

The brain of *Perameles* is even more generalised and simple than that of *Dasyurus*. It also closely resembles the brain of that most generalised of all Eutherian brains—the Hedgehog's—in all points except the arrangement of the commissures: for *Erinaceus*, like all Eutheria, possesses a true corpus callosum.

Fig. 52. (Nat. size.)

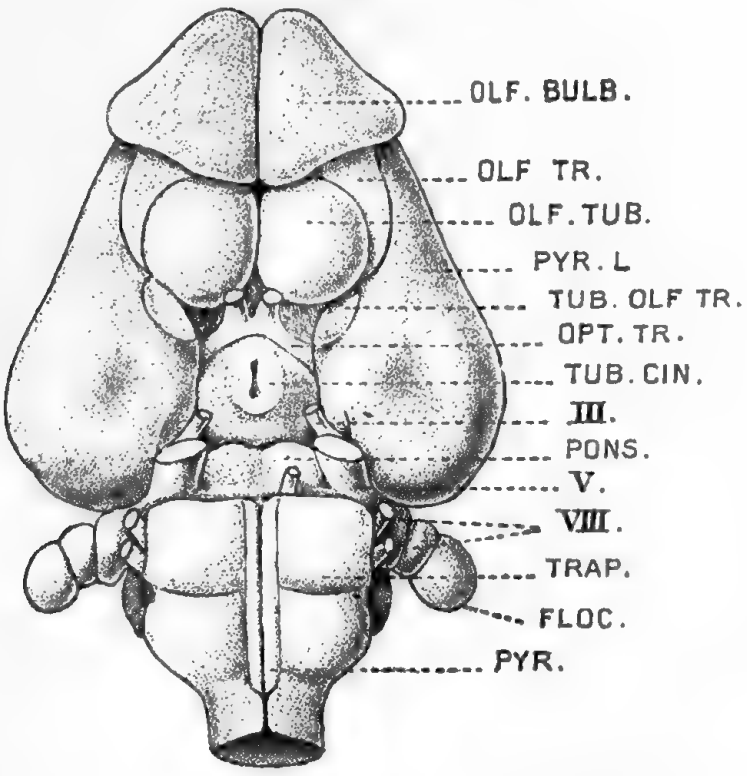

The rhinal fissure is shallower and shorter than it is in *Sarcophilus*: there is only a faint indication of the orbital (presylvian) sulcus, which closely resembles that of *Erinaceus*; the cerebellum is much simpler, and there are no exposed medullary areas between the mesial and lateral portions of the organ.

The accompanying drawing (fig. 52) represents the characteristic features of the base of the brain in a fresh specimen. O. C. 1323 c *d*.

Gervais, Nouv. Arch. Mus., t. v. 1869, p. 242.

[The reader is warned that Gervais' figure 12 on Plate xiii. obviously represents the brain of some small Macropod, and not a *Perameles* as it is labelled.]

D. 206. The brain of a Bandicoot (*Perameles* sp.).

The prominent floccular lobes (compare fig. 52) have been removed from this specimen. O. C. 1323 C *i*.

Family *DIDELPHYIDÆ*.

D. 207. The brain of a Virginian Opossum (*Didelphys marsupialis*).

This closely resembles the brain of *Perameles* and the *Dasyuridæ*. Note the well-defined rhinal fissure which does not extend the whole length of the hemisphere, so that posteriorly the pyriform lobe and the neopallium become freely continuous.

Note the shallow orbital (presylvian) sulcus, especially on the right hemisphere.

The hemispheres have been separated in order to expose the dorsal (hippocampal) commissure placed in front of the third ventricle.

The cerebellum is simple like that of *Perameles*.

O. C. 1323 B.

Herrick, Journ. Comp. Neurol. vol. ii. 1892, p. 1.

D. 208. The brain of an Opossum (*Didelphys*), with the arachnoid and pia mater *in situ*.

This shows the true proportions of the olfactory bulbs and also how much of the corpora quadrigemina is uncovered by the cerebellum and cerebral hemispheres.

O. C. 1323 B *a*.

Owen, Todd's Cyclopædia, 1847, vol. iii. p. 292.

Suborder DIPROTODONTIA.

Family *MACROPODIDÆ*.

D. 209. A series of five coronal sections of the cerebral hemispheres of a Bennett's Wallaby (*Macropus ruficollis*).

These specimens serve to demonstrate a peculiar bundle of fibres (seen in the second section), the presence of which is peculiarly distinctive of the Diprotodont Marsupials.

The uppermost section passes in front of the cerebral commissures and shows the relations of the precommissural part of the hippocampus to the neopallium above it and to the precommissural area below it. (These features are perhaps seen to better advantage on the back of the second slice.) (Fig. 53.)

Fig. 53. (×1½.)

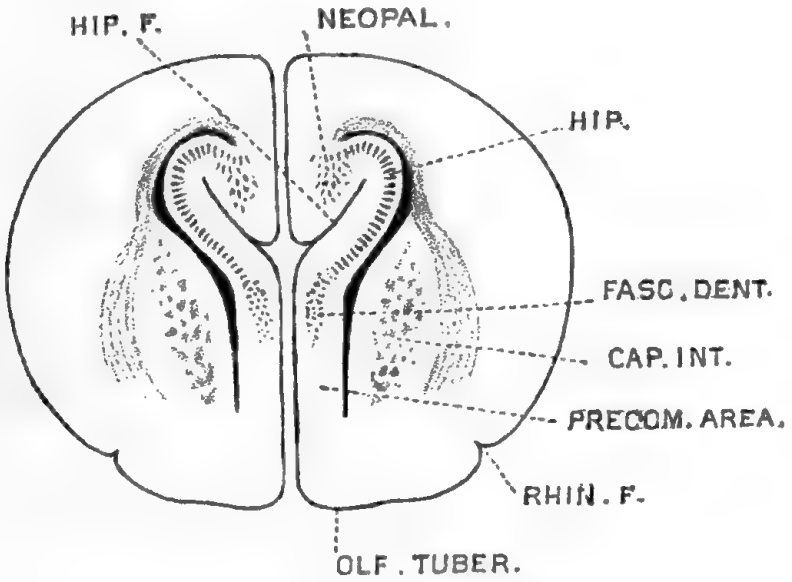

The second section (fig. 54) passes through the two cerebral commissures. The dorsal commissure is seen passing into the alveus of the hippocampus on each side. From this section it is possible to appreciate how the pallial operculum descends on the mesial side of the hippocampus toward the dorsal commissure, so as to shut out the fascia dentata in a view of the mesial wall (compare the specimens of the Black-faced Kangaroo).

Fig. 54. (×1½.)

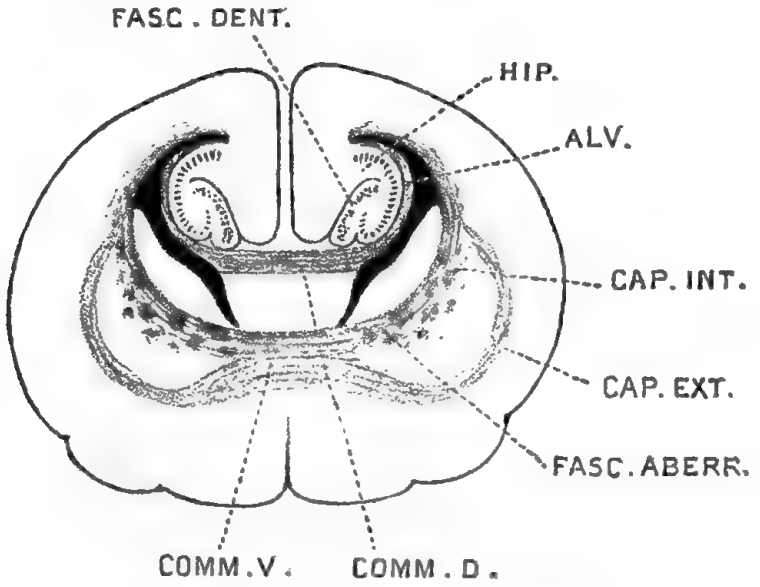

The ventral commissure is seen (in the second section) to split into two bundles in the corpus striatum. The ventral bundle, which includes about half the fibres of the commissure, passes transversely through the corpus striatum, and joins the external capsule. This is the manner in which the whole of the neopallial fibres of the ventral commissure behave in the Monotremata (fig. 42), the Polyprotodont Marsupialia, and the Eutheria. But in ALL the Diprotodont Marsupials the dorsal half of the ventral commissure bends upwards in the corpus striatum, as it does in this section, and ultimately reaches the neopallium by the same route as that pursued by the internal capsule. This dorsal bundle I have called the "*fasciculus aberrans.*" It was first represented in a figure by Flower (Phil. Trans. 1865), and first described by Symington (Journ. of Anat. & Phys. 1892) in *Macropus.* I have recently examined the brain in every genus of the Marsupialia (excepting *Caenolestes*), and found this "aberrant bundle" to be invariably present in the Diprotodontia, but never in the Polyprotodontia, nor in other mammals. [This fact is here recorded for the first time.]

The third section passes through the hemispheres a short distance behind the commissures, and the "splenium" of the hippocampal commissure is still seen in the depths of the slice above the slit-like third ventricle, which separates the optic thalami. This section passes through the optic chiasma.

The fourth section has been cut still further back. It exhibits the fimbria on the hippocampal formation, and it is easy to understand by comparison with the third section how the fibres of the fimbria reach the dorsal commissure.

O. C. 1323 A *l.*

Symington, Journ. of Anat. & Phys., vol. xxvii. 1892, p. 69.

D. 210. The left cerebral hemisphere of a Yellow-footed Rock-Wallaby (*Petrogale xanthopus*), from which the lateral wall of the ventricle has been removed in order to expose the hippocampus (fig. 55).

The disposition of the hippocampus is the most characteristic feature of the brain in Marsupials, in all of which, both Poly- and Diprotodont, it presents a constant arrangement such as this specimen exhibits. Instead of being restricted to the descending limb and posterior part of the body of the lateral ventricle, as is the case in most mammals, the hippocampus extends forward as a large arcuate bulging upon the mesial wall of the ventricle; this proceeds above the cerebral commissures, and reaches a point near the cephalic extremity of the hemisphere.

[Similar dissections have been made in brains of *Erinaceus* (*vide infrà*, D. 230) and *Lepus* (*vide infrà*, D. 264) in order to demonstrate the difference between the Meta- and Eutheria in regard to this feature.]

The anterior extremity of this great hippocampal arc is narrower than the more caudal part, and tapers to a rounded extremity. The inferior or caudal extremity is large and plump, and does not taper. In the Monotremes, which are the only other mammals possessing this hippocampal arc in its undisturbed simplicity, its caudal portion is relatively small, and tapers to a point. In regard to these features, the Marsupial approaches much more nearly to the Eutherian plan than does the Monotreme.

Fig. 55. (Nat. size.)

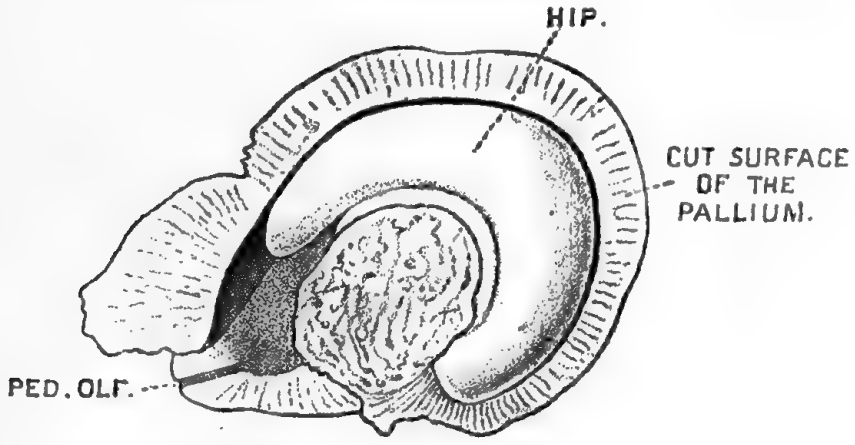

Upon close examination of the ventricular surface of the hippocampus a series of oblique fibres (*alveus*) may be seen proceeding from the hippocampus to form a fringe-like band at its concave margin. This is the *fimbria* or *fornix*, and is here seen in its most simple form.

Elliot Smith, Journal of Anat. & Phys., vol. xxxii. 1897, p. 30.

D. 211. The two cerebral hemispheres and the left half of the brain-stem and cerebellum of a Black-faced Kangaroo (*Macropus giganteus*, var. *melanops*).

Above the large elliptical ventral commissure, note the elongated, horizontally-placed, U-shaped dorsal (hippocampal) commissure, the shape of which is characteristic of the Macropodidæ. There is a typically complete hippocampal arc of the usual Marsupial type, but its dorsal part is hidden by a great pallial operculum which descends as far as the dorsal commissure, so as to produce a spurious resemblance to the Eutherian condition. Such a neopallial operculum is found in all large Marsupials, such, for instance, as the Thylacine. In the right hemisphere this pallial operculum has been removed by dissection (fig. 56), and the fascia dentata is thus seen to extend far forward above and beyond the dorsal commissure, just as it does in the Tasmanian Devil (D. 197) and in all Marsupials. The arrangement of the hippocampus in the ventricle may thus be correlated with the distribution of its specialised fringe (fascia dentata) in the mesial wall of the hemisphere.

Fig. 56. (Nat. size.)

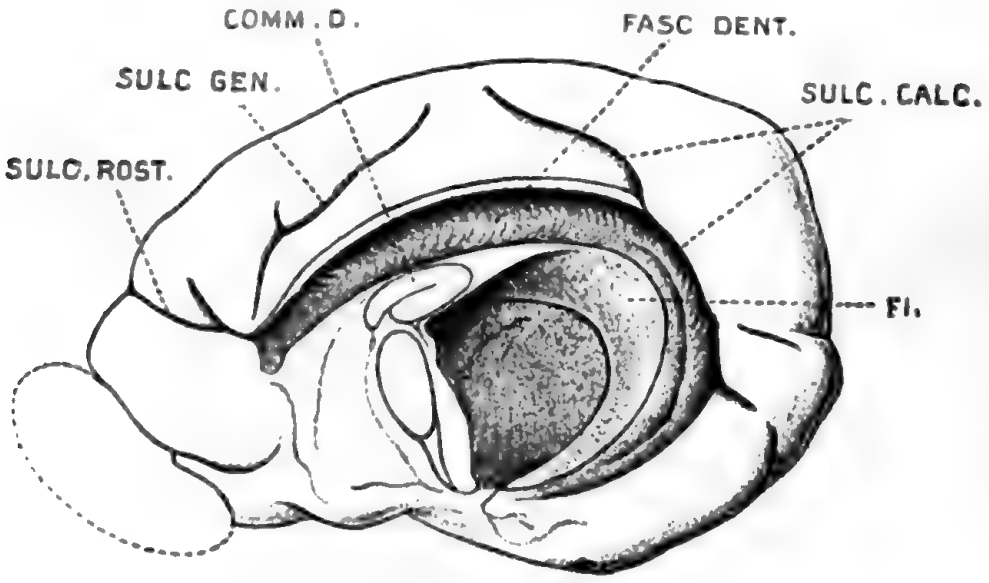

Above the upturned caudal extremity of the rhinal fissure a deep calcarine sulcus is found: it is prolonged obliquely upward and forward for a short distance so as to converge with an anterior oblique sulcus toward the dorsal edge of the hemisphere. This anterior oblique sulcus is apparently analogous to the genual sulcus of other mammalian orders. Immediately in front of the genual sulcus and the anterior extremity of the hippocampal fissure there is a short rostral sulcus extending obliquely upward and slightly forward. On the right side it bifurcates and becomes **Y**-shaped.

There is a deep and typically-bent rhinal fissure. From the neighbourhood of the angle of this fissure on the left hemisphere three sulci diverge widely in the neopallium.

The interpretation of these raises a question of great difficulty. There can be little doubt that the most anterior represents the orbital or presylvian sulcus of other mammals *. It does not actually open into the rhinal fissure, but begins near it, and proceeds obliquely upward and forward. In this course it is joined by the anterior extremity of a great inverted V-shaped sulcus, which may possibly represent the suprasylvian sulcus. But upon this question it is impossible to express a decided opinion at present †.

The other two sulci which diverge from the angle of the rhinal fissure are probably to be regarded as essentially "Sylvian" (in the sense in which this term is applied, say, in speaking of the Cat's brain). The more posterior, which we may distinguish as sulcus B, freely communicates with the rhinal fissure and with the sulcus tentatively called suprasylvian in such a manner that the presylvian and suprasylvian sulci, the sulcus B, and a short basal piece of rhinal fissure form a pentagonal pattern. The deep vertical sulcus which springs from the rhinal fissure between the lower ends of the presylvian sulcus and sulcus B may be distinguished as A. It ascends almost as far as the angle of the so-called "suprasylvian" sulcus.

The sulcus which it is customary to call "Sylvian fissure" in mammals other than the Primates is a feature of little morphological stability, and is to be regarded as essentially of the nature of a kink produced by the flexure of the hemisphere. Or perhaps it would be more accurate to speak of it as being developed in response to the stress produced in this region of the neopallium by the ventral extension of its ventro-caudal region. In the Kangaroo this stress seems to be relieved by the two sulci A and B

---

* Not the orbital pure and simple, but the orbital joined to a second more dorsal (mesial) sulcus, the direction and situation of which is probably determined by the bias given to the expanding cortex by the presence of the orbital sulcus. Compare the left hemisphere of specimen D. 216.

† Close examination shows that the anterior limb of the V—which is the smaller and more unstable element and may represent the coronal sulcus—is not joined to the caudal limb, which is the supposed homologue of the suprasylvian.

instead of the customary single sulcus, which is the so-called "Sylvian fissure." On the right hemisphere of this brain a third sulcus, which may be distinguished as C, shares the representation of the pseudosylvian furrow. The sulcus C is divided into two parts, but neither of these, nor the sulcus B joins the so-called suprasylvian. The latter is not joined to the orbital sulcus on the right side.

In each hemisphere there are two horizontal prorean sulci in front of the orbital sulcus. There is also an extensive vertical sulcus parallel to the sulcus B, near the posterior margin of the hemisphere.

(Ziehen describes a brain of *Macropus rufus*. Jena. Denkschr., Bd. vi. 1897, p. 54.)

D. 212. The brain and the upper portion of the spinal cord of a Giant Kangaroo (*Macropus giganteus*).

This is the largest brain found in any existing Marsupial, although the extinct forms *Thylacoleo* and *Diprotodon* possessed brains of much greater size.

In this specimen the large olfactory bulbs are missing, but the size and shape of these parts of the brain are well shown in the casts of the cranial cavity (D. 215).

The orbital (presylvian) sulcus and the sulci A and B all spring from the rhinal fissure. The sulcus B on the left side joins the suprasylvian sulcus, and the latter extends almost as far forward as the orbital (presylvian). A prorean sulcus is present. On the right side there is an additional sulcus between the sulci A and B, and the orbital sulcus is small.

It is a strange fact that the "paramedial" sulcus (compare fig. 58), which is such a characteristic feature of all other representatives of the Macropodidæ, is lacking in this, the largest member of the family.

Behind the sulcus B there are a number of small sulci, which on the whole assume a vertical (transverse) direction.

The characteristic features of the base of the mammalian brain are exceedingly clearly demonstrated in this specimen (fig. 57). Note especially the thin-walled pouch of the infundibulum, from which the pituitary body has been torn away.

The cerebellum conforms to the type presented by the smaller Marsupials, but the folia are much more numerous. In most other Orders of mammals we find in the larger members that the cerebellum becomes more compact, and the region behind the primary (preclival) fissure ceases to assume the hood-like form covering the anterior lobe. As a result of the slighter degree of expansion of this part of the cerebellum in such mammals, the exposed medullary area becomes greatly reduced, or even disappears. But in the Kangaroo this does not happen. The type of the smaller members of the Order with a hood-like covering for the anterior lobe and exposed medullary areas is retained, as it is in the Thylacine ; and the only difference consists in the larger size of the organ and a richer supply of fissures, and consequently more numerous folia.

Fig. 57. (× ¾.)

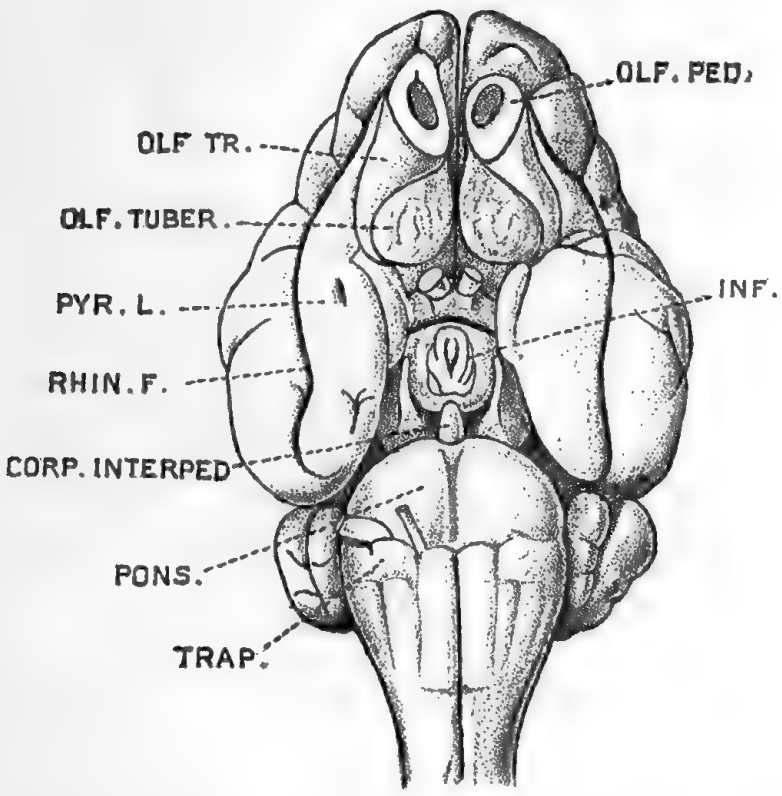

O. C. 1323 A *a*.

Ziehen, Jena. Denkschr., Bd. vi. 1897, p. 54.

D. 213. The left cerebral hemisphere, optic thalamus, and part of the mid-brain of a Giant Kangaroo (*Macropus giganteus*).

There is a typically prolonged calcarine sulcus, and the genual and rostral sulci are joined.

There is a well-developed sulcus A—the " Sylvian fissure" of most writers. The sulcus B, the " suprasylvian " sulcus, and the " coronal " sulcus are joined to form a large arc. There is a large presylvian sulcus.

The cephalic portion of the fascia dentata and the characteristically bilaminar dorsal commissure of the Macropodidæ are well demonstrated. O. C. 1323 A *i*.

D. 214. The right hemisphere of the same brain of the Giant Kangaroo (*Macropus giganteus*) as specimen D. 213, cut transversely through the two cerebral commissures.

Upon the mesial surface of the hinder [lower in bottle] fragment the arrangement of fascia dentata and fornix typical of the Marsupialia, and already described in the Black-faced Kangaroo, may be seen.

The features of a coronal section through the commissures are seen, perhaps, to better advantage than in specimen D. 209. O. C. 1323 A *k*.

D. 215. A cast of the cranial cavity of a Giant Kangaroo (*Macropus giganteus*). [In duplicate.]

This cast shows the true shape and proportions of the largest brain of an existing Marsupial, and permits us to compare the impression of the interior of the cranium with actual brains of the same species. We are thus able to appreciate to how great an extent we can rely upon casts of the cranial cavity in the interpretation of the features of the brain in such extinct forms as *Thylacoleo*.

The shape of the large projecting olfactory bulbs is shown more accurately than in the other specimens. This peculiar form of bulb occurs also in all the Lemuroidea and in many Ungulates. Note also the pronounced ventral extension of the postsylvian area of neopallium and the very marked tapering of the anterior poles of the hemispheres. The relation of the hemispheres to the cerebellum, olfactory bulbs, and the pituitary body is very strikingly demonstrated.

It will be seen that from such a cast as this it is possible to map out the pattern of the cerebral sulci with almost as much certainty as in the actual brain.

Thus we see the deep orbital and the shallower prorean sulci, just as clearly as in specimen D. 211. The two pseudosylvian sulci diverging from the angle of the rhinal are also clearly exposed. The great V-shaped sulcus which

I tentatively called "suprasylvian" is also seen to consist of two limbs. Of these the posterior (as a study of this series of Macropod brains shows) is much the more stable and represents in all, probably, the suprasylvian sulcus of other Orders, in spite of the fact that its topographical relations are so peculiar. The anterior limb of the V may represent the coronal sulcus of the Carnivora and Ungulata. We can also see a transverse sulcus extending inward from the angle of the V, just as we sometimes find in the actual brain (see D. 211). It is interesting to note that there is a large shallow depression in the place of the lateral ("paramedial") sulcus—a fact which is not demonstrable in the actual brains. This is of great interest when the peculiar absence of this sulcus in the larger, and not in the smaller, Macropods is recalled. There is a deep, long, postlateral sulcus.

D. 216. The brain of a Parry's Wallaby (*Macropus parryi*).

A short deep "Sylvian fissure"—sulcus A—extends almost vertically upward from the bend of the rhinal fissure (figs. 58 and 59).

Fig. 58. (Nat. size.)

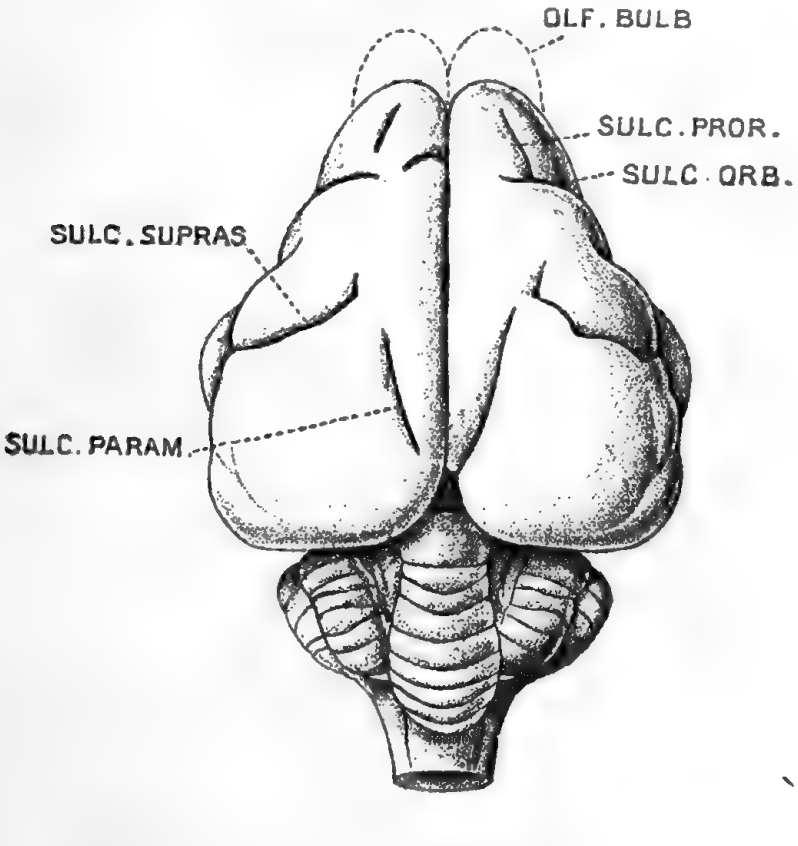

The orbital (presylvian) sulcus and the sulcus B both spring from the rhinal fissure, and diverge widely as they ascend. On the left hemisphere the short extent of the true orbital sulcus is seen, because it is not joined to the "false orbital." [This is *not* shown in fig. 59, which represents the condition found on the *right* hemisphere reversed.]

The suprasylvian sulcus is connected neither with the sulcus B nor with the orbital.

As in the Thylacine, the prorean sulcus joins the orbital on the right side only.

Fig. 59. (Nat. size.)

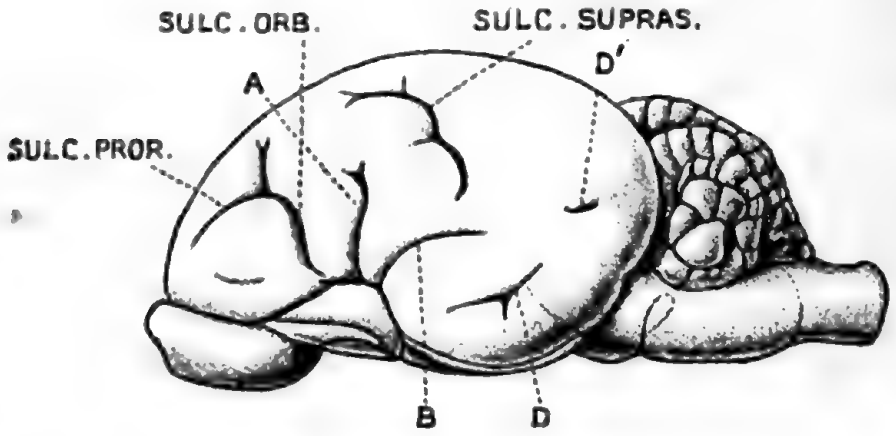

On the caudo-mesial angle of the dorsal surface the characteristically Macropod paramedial sulcus is found (fig. 58). It probably represents the earliest form of the sulcus called "lateral" in Carnivores and Ungulates and "intraparietal" in Primates.

There are two fragments (D and D′) of a vertical sulcus behind the sulcus B. O. C. 1323 A *c*.

D. 217. A rough dissection of the brain of a *Macropus*. On the right side almost the whole of the cerebral hemisphere has been removed. On the left side the roof of the hemisphere and the greater part of the hippocampus have been removed in order to expose the fornix (fimbria) proceeding obliquely across the optic thalamus to the dorsal commissure.

The nucleus caudatus is also exposed in the left hemisphere. This dissection was made by the late Sir Richard (then Professor) Owen for his memoir in the Phil. Trans. 1837. O. C. 1323 A *e*.

D. 218. The brain of a Bennett's Wallaby (*Macropus ruficollis*).

The general features of this brain resemble those of Parry's Wallaby (D. 216).

The arrangement of the sulci in this species is interesting because it is intermediate between that of the Kangaroo and the smaller Macropods. The arrangement of the three sulci which diverge from the region of the angle of the rhinal fissure is identical with that of the Giant Kangaroo. But there is a sulcus, the "paramedian," springing from the postero-superior part of the great arc formed by the suprasylvian and sulcus B, which is not represented in the Kangaroo's brain. It proceeds obliquely backward to the postero-mesial corner of the upper surface. This sulcus is seen in its typical form on the left hemisphere only: on the right side two small sulci take its place. The interest attaching to the paramedian sulcus is that it is a very characteristic feature of the smaller Macropodidæ. O. C. 1323 A *b*.

Ziehen, Jena. Denkschr., Bd. vi. 1897, p. 71.

[In Ziehen's specimen the sulcus A, his ψ, is much more imperfect than in this specimen.]

D. 219. The brain of a Derbian Wallaby (*Macropus derbianus*).

This is not unlike the brain of Bennett's Wallaby.

The cerebral hemispheres have been separated from above in order to expose the dorsal or hippocampal commissure, which may be seen as a narrow transverse band in front of the third ventricle. O. C. 1323 A *h*.

Ziehen, Jena. Denkschr., Bd. vi. 1897, p. 71.

D. 220. The brain of Rat-Kangaroo (*Bettongia gaimardi*) (♀).

The pallium is almost devoid of sulci, and in shape not unlike that of the Phalangers. There is, however, on the caudo-mesial angle of the dorsal surface the characteristic paramedian sulcus of the Macropodidæ. This sulcus probably represents the "lateral sulcus" of the Rodents, Ungulates, and Carnivores. O. C. 1323 A *q*.

Gervais, Nouv. Arch. Mus., t. v. 1869, p. 240.

D. 221. The brain of a Tree-Kangaroo (*Dendrolagus inustus*) (♀), in which the left hemisphere has been separated from the rest of the brain.

The olfactory bulbs have been removed. In shape the cerebral hemispheres and the cerebellum conform to the Macropod type. But the hemisphere is remarkable for the paucity of sulci. There is a short sulcus A ("Sylvian fissure") on the right side, but it is almost completely aborted on the left side. There is a short deep paramedian, the characteristic Macropod, sulcus; and also a small prorean sulcus. No other sulci are found on the cranial surface. But there are a number of shallow ill-defined depressions which conform to no known pattern.

On the mesial surface there is the characteristic, oblique, prolonged calcarine sulcus and a more characteristic intercalary sulcus than is usually found in Marsupials. The features of the cerebellum, and in fact of all parts of this brain, are demonstrated with exceptional clearness.

O. C. 1323 A *p*.

Beddard, Proc. Zool. Soc. 1895, p. 136.

Family *PHASCOLOMYIDÆ*.

D. 222. The brain of a Wombat (*Phascolomys ursinus*), in which the left hemisphere has been separated from the rest of the brain.

The short, broad, blunt anterior extremities of the hemispheres of this brain form a marked contrast to the pointed anterior poles of most other large Marsupials, such as the Kangaroos and especially the Thylacine.

The cerebral sulci are in many respects peculiar. Perhaps the most significant feature is the absence of a well-defined calcarine sulcus, which is such a constant feature in the Marsupialia, and also in the Eutheria with the exception of the peculiar Order of Rodents.

A typical orbital (presylvian) sulcus, such as we find in the Carnivora, appears to spring from the rhinal fissure far forward near the olfactory bulb. It is prolonged backward under a small operculum, which meets the lower (pyriform) lip of the rhinal fissure, and then appears to curve upward again in what may be called the Sylvian region (fig. 60, A). This apparent upturned caudal extremity of the orbital sulcus, which may be regarded as the representative of the sulcus A of the Kangaroos, presents a close resemblance to the arrangement found in many Viverridæ (*e. g.* the Civet, *vide infra*). [A comparison with the latter will indicate why the *two* sulci A and

B of the Kangaroo were spoken of (*supra*) as representing the so-called "Sylvian fissure" of the Carnivora.]

Behind the sulcus A there is a short deep sulcus B proceeding obliquely upward and backward from a triangular depression at the bend of the rhinal fissure.

Fig. 60. (Nat. size.)

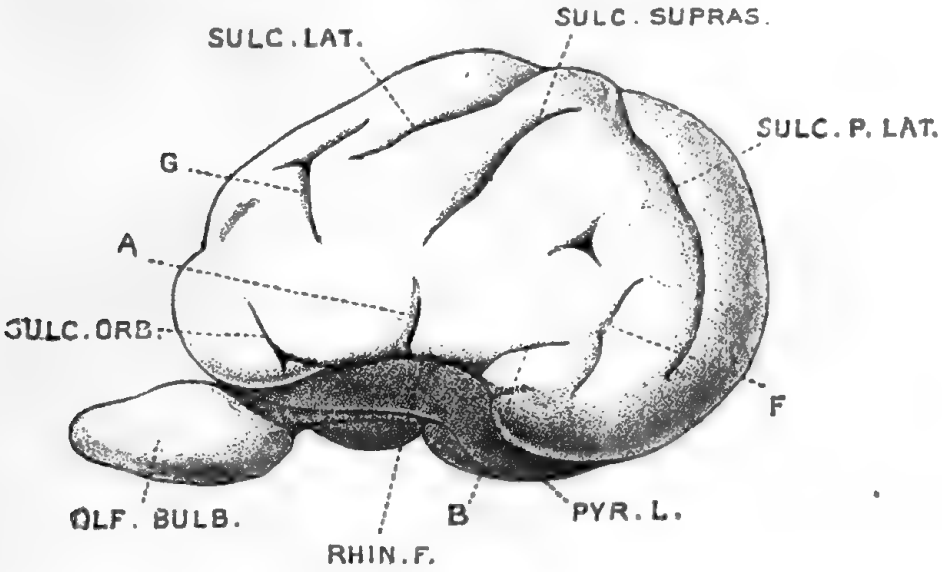

Above the sulcus A there is a long oblique suprasylvian sulcus (figs. 60 & 61). As this sulcus is directed upward and backward, it resembles the typical suprasylvian sulcus

Fig. 61. (Nat. size.)

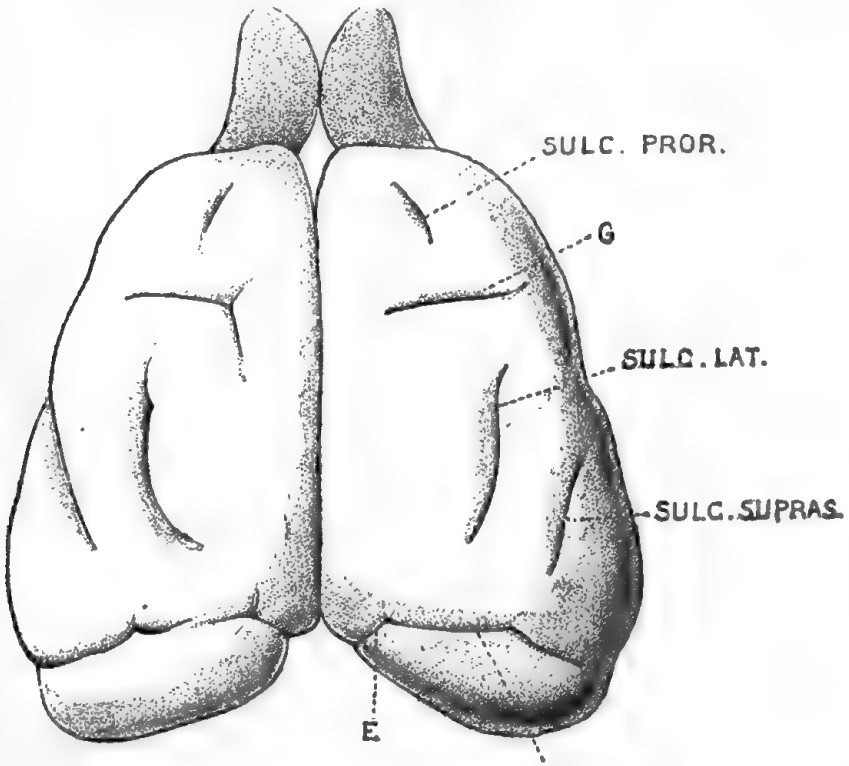

(*e.g.* in the Carnivora) much more closely than that of the smaller Macropods (*e.g.* Parry's Wallaby, fig. 59), the obliquity of which is upward and forward *.

---

* This difference may possibly be associated with the pronounced dwindling of the anterior regions of the hemisphere in the Macropodidæ.

To the mesial side of this suprasylvian sulcus there is a "lateral" sulcus placed midway between the anterior and posterior extremities of the hemisphere. It is widely separated from its morphological posterior extremity (fig. 61, E), which is a notch on the caudo-mesial angle. The latter may be regarded as the representative of the paramedian sulcus of the Kangaroos. On the right hemisphere it is joined to a long transverse "post-lateral" sulcus. The small sulcus F (fig. 60) may represent the postsylvian (posterior suprasylvian) sulcus of other Orders.

There is a small separate prorean sulcus (fig. 61), and behind it there is a short transverse sulcus G, which may represent the coronal sulcus of other Orders.

On the mesial surface (fig. 62) the typically Marsupial arrangement of commissures and hippocampal formation is seen. The dorsal commissure is not elongated to the same extent as in the Kangaroos, so that it more closely resembles that of the Polyprotodont Marsupials. The prolonged genual sulcus is like that of the Kangaroo, as is also the rostral sulcus. There is also the most extraordinary absence of the calcarine sulcus, in place of which there is merely a small irregular pit (H). Lower down we find a short horizontal sulcus above the rhinal fissure (fig. 62).

Fig. 62. (Nat. size.)

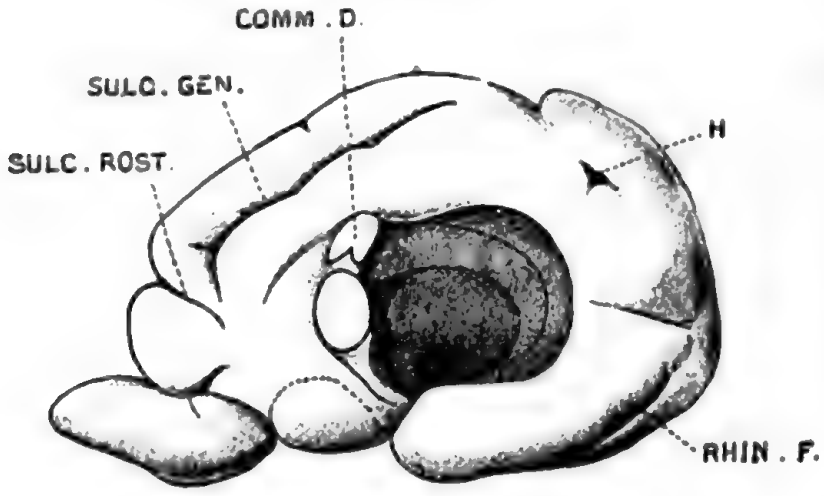

O. C. 1323 A *n.*

R. Owen, Todd's Cyclopædia, 1847, vol. iii. p. 293.
W. H. Flower, Phil. Trans. vol. clv. 1865, p. 646.

D. 223. Two casts of the cranial cavity of a Wombat (*Phascoomys ursinus*).

These casts admirably show the broad flattened cerebral hemispheres and the projecting olfactory bulbs, as in the Kangaroos. The cerebral sulci are very deep furrows, conforming to the same pattern as in the brain (D. 222).

Gervais, Nouv. Archiv. Mus., t. v. 1869, p. 235.

D. 224. The brain of a Wombat (*Phascolomys ursinus*), dissected to expose the dorsal or hippocampal commissure from above.

This dissection was made by the late Sir Richard (then Professor) Owen to demonstrate that the dorsal commissure of the Marsupial is derived from the fornix, *i. e.* that it is a hippocampal commissure or psalterium (Phil. Trans. 1837, p. 90; also Todd's Cyclopædia, vol. iii. p. 294, fig. 117; also 'Anatomy of Vertebrates,' vol. iii.).

The greater part of the cerebral hemispheres has been removed so as to expose the upper surface of the dorsal commissure, which may be seen passing into the fimbria upon each side.

On the right side the fascia dentata may be seen lying upon the fimbria and extending obliquely across the upper surface of the dorsal commissures so as to reach the mesial surface of the hemisphere in front of the commissure.

The corpora striata have been exposed in the lateral ventricles.

Part of the cerebellum has been removed so as to open up the fourth ventricle. O. C. 1323 A *o*.

Family *PHALANGERIDÆ.*

D. 225. The brain of a Brown Phalanger (*Trichosurus fuliginosus*).

In general appearance this brain is not unlike that of the Rat-Kangaroos. It exhibits a shallow depression in the situation where the characteristic paramedian sulcus occurs in the smaller Macropodidæ. Traces of a prorean sulcus and that called "suprasylvian" in the Kangaroo are present.

Although the neopallium is much larger than that of many of the smaller Polyprotodont Marsupials which possess a well-defined orbital sulcus, the latter feature is not clearly defined. O. C. 1323 A *m*.

Ziehen, Jena. Denkschr., Bd. vi. 1897, p. 84.

D. 226. The brain of a Flying Phalanger (*Petaurus breviceps*).

In all respects like a small specimen of *Trichosurus*. [The olfactory bulbs are lacking in this specimen.]

O. C. 1323 B *c*.

Gervais, Nouv. Arch. Mus., t. v. 1869, p. 243.

D. 227. The brain of a Koala or Australian "Native Bear" (*Phascolarctus cinereus*) (♂).

The most noteworthy feature of this brain, as in *Dendrolagus* (D. 221), is the paucity of sulci in such a relatively large neopallium.

The few sulci which are found are exceedingly variable, and it becomes very difficult to determine their homologies with any certainty.

The most pronounced sulcus (in this specimen) ascends from about the mid-point of the rhinal fissure, and may possibly represent the Carnivore pseudosylvian sulcus. In many cases, however, it is quite insignificant and does not join the rhinal fissure. In such cases there is often a much deeper sulcus behind it, which Ziehen calls "Sylvian."

In front of these pseudosylvian sulci there is a very faintly marked orbital (presylvian) sulcus.

In addition very shallow furrows traverse all parts of the neopallium.

The dorsal commissure is very small. The hippocampus presents the typical Marsupial arrangement.

There is a short calcarine (splenial) sulcus, which cannot be seen in this specimen. O. C. 1323 A *r*.

Ziehen, Jenaische Denkschr., Bd. vi. 1897, p. 98.

Elliot Smith, Journ. Anat. & Phys., vol. xxxiii. 1898, p. 30.

D. 228. The brain of a Koala (*Phascolarctus cinereus*), (♀).

The sulci are much more imperfectly developed in this specimen. There is a pseudosylvian sulcus on the left hemisphere only. O. C. 1323 A *s*.

D. 229. Casts of the cranial cavities of two skulls of the extinct *Thylacoleo carnifex*.

The same peculiar, broad, flattened shape which characterises the brain of *Phascolomys* is also presented by these two casts. The brain, however, was much larger than that of any living Marsupial, being about as large as that of a Pig, Hyæna, or Entellus Monkey.

It possessed very large olfactory bulbs lying almost wholly in front of the hemispheres.

There was a very deep vertical "orbital sulcus," resembling in position that of *Macropus* or *Phascolarctus* rather than that of *Phascolomys*. A very deep prorean sulcus; a deep (single), oblique, pseudosylvian sulcus (such as that labelled B in *Phascolomys*); suprasylvian and lateral sulci resembling those of *Phascolomys* rather than those of *Macropus*, and a postlateral sulcus are the most striking features of these hemispheres.

Gervais, Nouv. Arch. de Mus., t. v. 1869, p. 236.

ORDER INSECTIVORA.

Family *ERINACEIDÆ*.

D. 230. The left half of the brain of a Hedgehog (*Erinaceus europæus*), which had been divided by a mesial sagittal section (figs. 63, 64, & 65).

Also the left half of another Hedgehog's brain, dissected to show the hippocampus in the lateral ventricle.

Fig. 63. (×1½.)

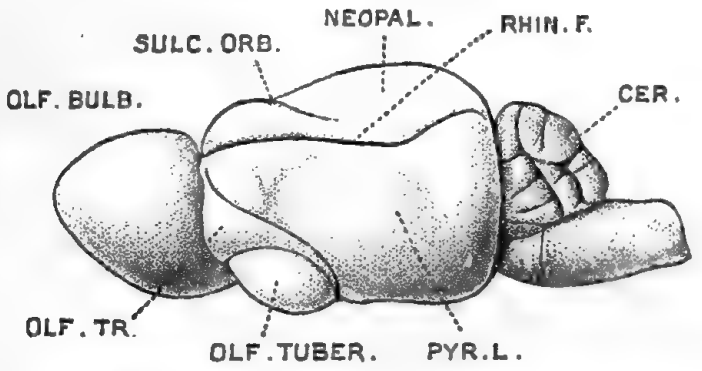

This is one of the simplest and most generalised of mammalian brains. It closely resembles the brain of the Polyprotodont Marsupials (and especially *Perameles*) in all points except the arrangement of the cerebral commissures and the hippocampus, because the Hedgehog possesses a small corpus callosum and the Marsupials have none in the true sense. The resemblance between the brains of the

Hedgehog and the Bandicoot is, however, very close, as a glance at figs. 52 and 65 so clearly demonstrates.

In the Hedgehog the olfactory apparatus is extraordinarily largely developed, as we might expect in such a lowly mammal of fossorial habits.

Fig. 64. (×1½.)

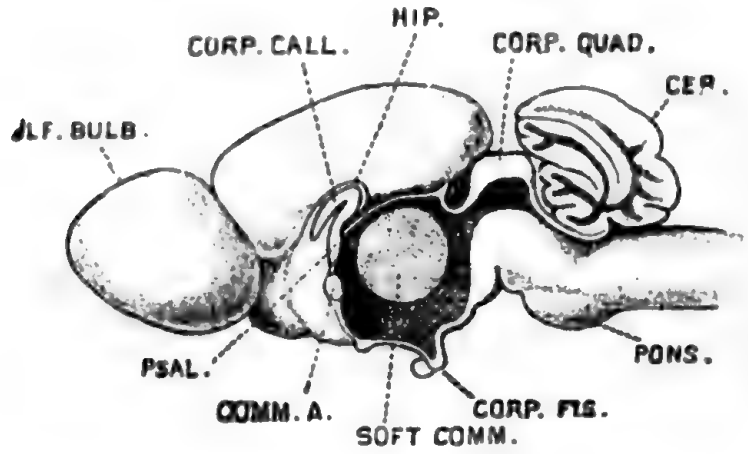

The neopallium is reduced to exceedingly diminutive proportions, so that the rhinal fissure (fig. 63) is placed very high up upon the lateral wall of the hemisphere. Thus the pyriform lobe forms the greater part of the lateral wall.

Fig. 65. (×1½.)

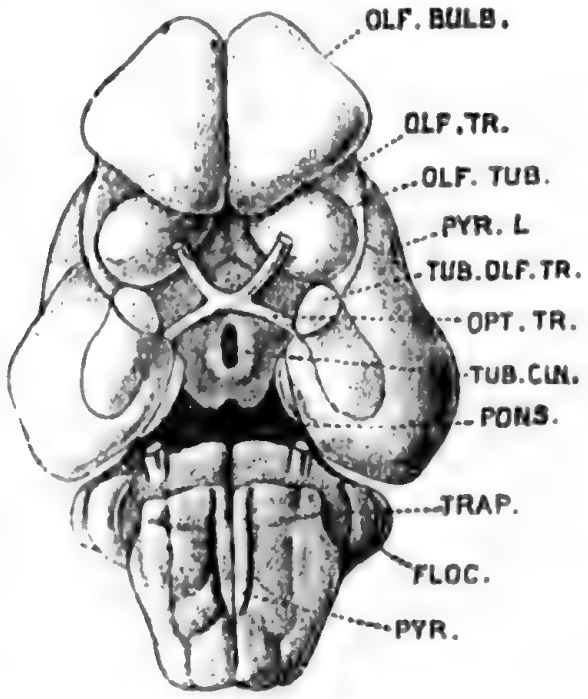

There is a short, very shallow, transverse orbital (presylvian) furrow on the dorsal surface, as in *Perameles* and *Sarcophilus*. In the nearly-related and larger *Gymnura* this shallow furrow becomes converted into a deep sulcus.

The fascia dentata makes its appearance upon the ventral surface of the hemisphere, on the mesial side of a depressed area corresponding to the nucleus amygdalæ.

The simple cerebellum is slightly more elaborated than that of *Perameles*, so that it comes to more closely resemble that of *Sarcophilus*. It has sessile flocculi (comp. figs. 65 and 52).

In the dissected specimen (fig. 66), the lateral ventricle is prolonged forward to communicate by a narrow channel with the large cavity in the olfactory bulb. The hippocampus is placed in the caudal part of the chief cavity, and does not extend so far forward as in the Marsupial (compare the Wallaby's brain, D. 210). The meaning of this is that when the corpus callosum makes its appearance (as it does for the first time in the Eutheria), the cephalic extremity of the hippocampus becomes reduced to a mere vestige lying partly upon the upper surface of the corpus callosum and partly in front of the latter body. The existence of a corpus callosum and the vestigial nature of the anterior part of the hippocampal arc are the great distinguishing features of the Eutherian brain, when compared with that of Marsupials and Monotremes.

Fig. 66. (×1½.)

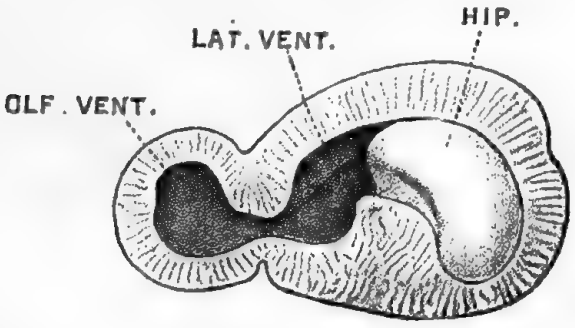

Flatau and Jacobsohn, Vergl. Anat. d. Centralnerv. 1900, p. 341).

Ganser, Morph. Jahrb., Bd. vii. 1882, p. 591.

Elliot Smith, Journ. Anat. & Phys., vol. xxxii. 1897, p. 44.

D. 231. A cast of the cranial cavity of a Hedgehog (*Erinaceus europæus*).

Shows the exact size and shape of the cerebral hemispheres and olfactory bulbs.

Family *TALPIDÆ.*

D. 232. The brain of a Mole (*Talpa europæa*) (♀), exposed *in situ.*

This simple, highly macrosmatic brain resembles that of the Hedgehog but shows signs of greater specialisation. It is, however, smaller, more flattened, and the optic parts of the brain are very poorly developed.

Ganser, Morph. Jahrb., Bd. vii. 1882, p. 591.

Family *TUPAIIDÆ.*

D. 233. A cast of the cranial cavity of a Tupaia (*Tupaia tana*).

Family *CENTETIDÆ.*

D. 234. The cast of the cranial cavity of a Tenrec (*Centetes ecaudatus*).

The olfactory bulbs are even larger in proportion to the size of the brain than they are in the Hedgehog.

Such brains as those of *Centetes* and *Erinaceus* enable us to appreciate the characters of the earliest Eutheria, and such forms as the Eocene Ungulate *Dinoceras.*

In the case of *Centetes,* however, the small size of the hemispheres is largely a secondary retrogressive change which occurs in the development of each individual (Forsyth Major).

Suborder DERMOPTERA.

Family *GALEOPITHECIDÆ.*

D. 235. The brain of a Colugo (*Galeopithecus volans*), which has been divided in the mesial sagittal plane; and the left cerebral hemisphere separated from the brain-stem (figs. 67, 68, 69, and 70).

This brain is of great interest because it presents a series of well-defined cerebral sulci, and at the same time exhibits features which justify the lowly status usually accorded to *Galeopithecus* in the mammalian series.

Thus the small size of the cerebral hemispheres which leave the greater part of the corpora quadrigemina exposed; the high degree of macrosmatism in an arboreal animal; the prominence of the hippocampus; the small dimensions of the corpus callosum; and the smallness and primitive simplicity of the cerebellum, all point to the lowly status of this peculiar mammal, not far removed from the Insectivora.

Fig. 67. (Nat. size.)

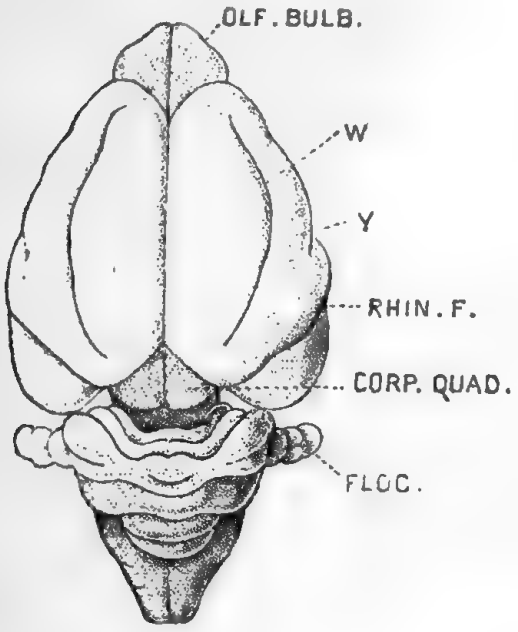

Fig. 68. (Nat. size.)

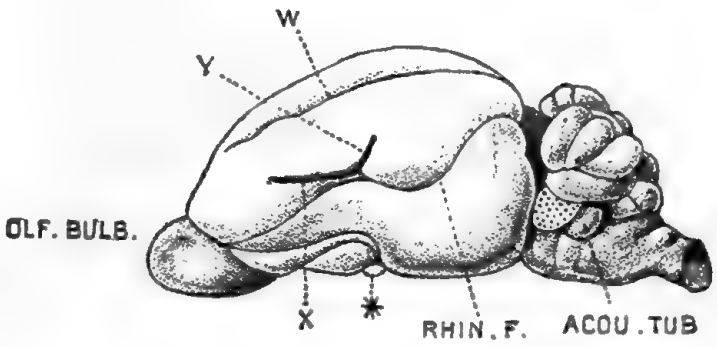

Fig. 69. (Nat. size.)

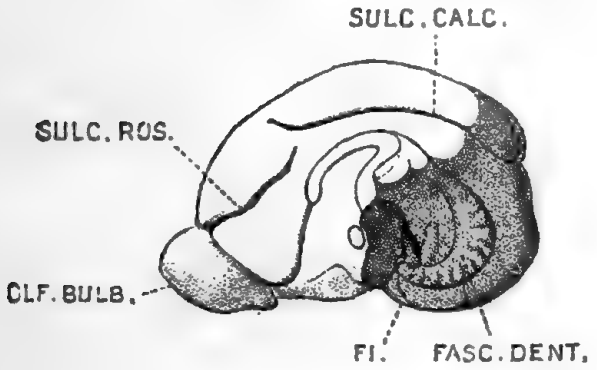

Fig. 70. (Nat. size.)

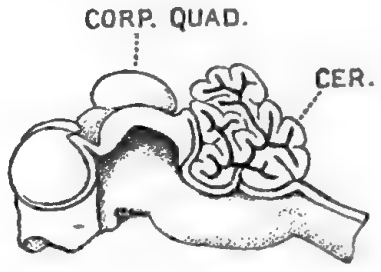

The very definite series of deep sulci on the cerebral hemisphere, however, at once separates *Galeopithecus* from the Insectivores proper.

On the mesial surface there is a relatively small and very obliquely-placed corpus callosum. The large fascia dentata is, to a great extent, exposed on the surface (fig. 69).

There is a deep calcarine (splenial) sulcus, beginning, as is usual, near the termination of the rhinal fissure and pursuing a course approximately horizontally forward. Its slightly upturned anterior extremity overlaps the posterior extremity of a sulcus curiously like the rostral sulcus of the Sloths (fig. 69).

The peculiarly-sinuous rhinal fissure is placed high up on the lateral wall of the hemisphere. Its posterior extremity rises to a much higher level than any other part of the fissure (fig. 68), as often happens also in the Eocene Mammalia.

In the small neopallium we find short sulci corresponding to the orbital (presylvian) sulcus (X), and the so-called "Sylvian fissure" (Y) of such mammals as the Three-toed Sloth and many Carnivores.

Midway between these sulci and the interhemispheral cleft there is a longitudinal sulcus almost as long as the hemisphere, presenting a slight concavity toward the mesial plane (fig. 67, W). There is nothing to help us to decide whether it represents either the suprasylvian or the lateral sulcus, unless it be the fact that the former is the more primitive and stable of the two sulci in mammals generally. But its resemblance to the conjoint suprasylvian and coronal sulci in such small Ungulates as *Dorcatherium* and *Tragulus* seems to be more than a fortuitous likeness.

The cerebellum is unusually small and presents all the primitive simplicity of the Insectivore organ. [The greatly-projecting floccular lobes have become knocked off in this specimen.]

The anterior quadrigeminal bodies are extremely large and bulge upward between the cerebellum and the cerebral hemispheres. The posterior quadrigeminal bodies and the mesial geniculate bodies are of moderate dimensions.

It is of interest to note that the tractus peduncularis transversus, which is feebly developed or perhaps absent in Marsupials and certain of the Insectivora and Edentata, is well-developed in *Galeopithecus*.

Presented by Prof. G. Elliot Smith *.

W. Leche, Kongl. Sv. Vet.-Akad. Handl., Bd. xxi. 1886, p. 48.

---

* This is one of several specimens which had been extracted and carefully preserved by Dr. Charles Hose, of Borneo, and generously given to the writer for examination.

D. 236. A cast of the cranial cavity of a Colugo (*Galeopithecus volans*). [In duplicate.]

This cast shows the true shape and proportions of the olfactory bulbs, cerebral hemispheres, and the main mass of the cerebellum. It gives some idea as to the exact area of the quadrigeminal bodies exposed.

The rhinal and "modified suprasylvian" furrows are well shown.

Gervais, Journn. de Zool., t. i. 1872, p. 445.

ORDER RODENTIA.

Section SCIUROMORPHA.

Family *CASTORIDÆ.*

D. 237. The brain of a European Beaver (*Castor fiber*).

Most parts of the brain of the Rodents present features such as are common to most of the Eutheria; but in respect to the arrangement of the sulci of the cerebral hemispheres, the Rodentia are the most aberrant group of the Eutheria (excepting perhaps the peculiarly-modified Sirenia).

The most noteworthy features in the brain of the Beaver are the obliteration of a great part of the rhinal fissure and the utter absence of sulci in the large pallium. The meaning of this is not altogether clear, but appearances suggest that the growth of the brain in a roomy cranial cavity which has exercised little restraint on the growing hemispheres may explain this absence of sulci and imperfection of the rhinal fissure. But even admitting this, the smoothness of such large hemispheres is a peculiar phenomenon, which is much rarer than is generally supposed. Thus even in the small *Erinaceus*, among the primitive Insectivores, there is a well-developed rhinal fissure and distinct traces of at least one neopallial sulcus; and in *Gymnura* and, especially, *Galeopithecus* there are deep sulci, in spite of the fact that these brains are much smaller than that of the Beaver and represent a more primitive type. Then, again, among the Hystricomorphine Rodents we find cerebral hemispheres of the same dimensions as, or even smaller than, the Sciuromorphine *Castor*, possessing numerous deep sulci.

This is one of the enigmas of cerebral morphology which we are utterly unable to satisfactorily explain at present. O. C. 1323 E.

Beddard, Proc. Zool. Soc. 1892, p. 597.

D. 238. The brain of a Beaver (*Castor fiber*), dissected to show the distribution of the fibres of the corpus callosum.

This dissection was made by Prof. Richard Owen for purposes of comparison with the brain of the Wombat (D. 224). Its object was to demonstrate by comparison the absence of the corpus callosum in the Marsupial.

R. Owen, Phil. Trans. 1837, p. 89. O. C. 1323 E *a*.

D. 239. The brain of a Beaver (*Castor fiber*), dissected to show the hippocampus and fornix.

This dissection was also made by the late Prof. Richard Owen. By comparison with D. 238, it will be seen that when the corpus callosum has been removed, as in this specimen, an arrangement of the fornix is exposed which is analogous to that which may be seen in the Marsupial (D. 224) without removing any such commissure. Hence, Owen argued, the corpus callosum is lacking in the Marsupial.

This rough dissection does not clearly demonstrate the further fact that in the Rodent the hippocampus does not extend forward so far as it does in the Marsupial.

O. C. 1323 E *b*.

D. 240. The brain of an American Beaver (*Castor canadensis*), (♂).

There is a shallow sagittal furrow on the dorsal surface of each hemisphere, which might represent either the corono-lateral or the suprasylvian sulcus. The latter is the more stable and precocious of the two sulci, and is rarely absent when the lateral sulcus exists. Yet we know for certain that this sometimes happens in the case of *Tamanduas* (Edentata).

From the position of the sulcus in this specimen and by comparison with the brains of *Dolichotis* and *Tamanduas*, it seems more likely to be a representative of the lateral (or combined lateral and coronary).

Note that the corpus callosum is rather short and plump, such as is found in the more primitive Insectivora.

O. C. 1323 E *l*.

D. 241. Two casts of the cranial cavity of an American Beaver (*Castor canadensis*).

Family *SCIURIDÆ*.

D. 242. The right half of the brain of a Squirrel (*Sciurus vulgaris*).

No sulci are present in the pallium.

The corpus callosum is long and narrow with a definite genual thickening.

The anterior quadrigeminal bodies are very large, probably because an active arboreal animal needs a well-developed visual apparatus. O. C. 1323 F.

D. 243. The brain of a Squirrel (*Sciurus capistratus*).

In spite of the large size of the anterior quadrigeminal bodies, they are completely hidden by the cerebral hemispheres. O. C. 1323 F *a*.

D. 244. The left half of the brain of a Squirrel (*Sciurus capistratus*).

Observe the large size of the optic nerve, with which the prominence of the anterior quadrigeminal bodies is associated. O. C. 1323 F *c*.

Section HYSTRICOMORPHA.

Family *OCTODONTIDÆ*.

D. 245. The brain of a Coypu (*Myocastor coypus*), (♀).

This brain resembles that of the Beaver but is much smaller. The rhinal fissure however is well developed.

The pallium is devoid of well-defined sulci, although there is a slight furrow on the caudal surface, possibly representing the calcarine (splenial) sulcus. It extends upward so as to slightly notch the dorso-caudal margin of the hemisphere.

The corpora quadrigemina are partially exposed.

According to Beddard other sulci may be present in the pallium. O. C. 1323 E *c*.

Gervais, Journn. de Zool., t. i. 1872, pl. xxiii. fig. 7. (In this memoir cranial casts of numerous Rodents are described.)

Family *Hystricidæ*.

D. 246. The brain of a Porcupine (*Hystrix* sp.).

The cerebral hemispheres are very broad. (Their posterior extremities do not diverge in the manner Beddard describes, and the corpora quadrigemina are quite hidden.)

The base of the brain resembles in shape that of the Beaver, but the rhinal fissures are deep and well-defined. There are two chief sulci and several pit-like depressions on the pallium.

A short shallow posterior furrow runs parallel to the interhemispheral cleft and resembles the paramedian sulcus of the Kangaroos.

There is a longer oblique sulcus further forward which cannot be strictly compared to any sulcus in other mammalian brains. It is impossible to say with any degree of certainty whether it represents the suprasylvian or a lateral element of such a form as the Capybara.

There is no Sylvian fissure, although Beddard describes such a fissure in his specimens. O. C. 1323 E *e*.

Beddard, Proc. Zool. Soc. 1892, p. 600.

D. 247. The brain of a Canadian Porcupine (*Erithizon dorsatum*).

This brain is much more like that of the Coypu than the Porcupine. Its pallium is quite devoid of sulci.

O. C. 1323 E *m*.

Presented by St. George Mivart, Esq.

D. 248. The brain of a Mexican Tree-Porcupine (*Cœnodon mexicanus*).

This brain resembles that of the Canadian Porcupine. Its pallium is entirely free from sulci, but is grooved in all directions by vascular furrows. O. C. 1323 E *k*.

Family *CHINCHILLIDÆ.*

D. 249. The brain of a Viscacha (*Viscaccia maxima*), in which the right cerebral hemisphere has been dissected to expose the hippocampus from above.

There is a vertically-placed, somewhat arched, deep sulcus above the mid-point of the rhinal fissure, but not communicating with it. It may be regarded as the representative of the sulcus in the brain of *Dolichotis* (figs. 74, 75, s), which has been called Sylvio-suprasylvian; in other words, it is the suprasylvian sulcus or the Prosimian Sylvian.

In front of this sulcus the hemisphere gradually tapers to a narrow anterior extremity, and behind the sulcus the hemisphere suddenly broadens.

There are two well-marked sagittal sulci representing the corono-lateral complex. According to Beddard other sulci may occur. O. C. 1323 E *f*.

Beddard, Proc. Zool. Soc. 1892, p. 599.

D. 250. The brain of a Viscacha (*Viscaccia maxima*).
O. C. 1323 G *g*.

D. 251. The brain of a Common Chinchilla (*Chinchilla lanigera*).

The pallium is apparently devoid of sulci. It is, however, hidden to some extent in this specimen by the membranes, in which the middle cerebral artery is very prominent. O. C. 1323 E *g*.

Family *DASYPROCTIDÆ.*

D. 252. The brain of an Agouti (*Dasyprocta aguti*).

In contradistinction to the flattening which characterizes the basal region of the hemispheres in many Rodents, the pyriform lobe and olfactory tubercle in this specimen present the plump, rounded features which distinguish these regions in macrosmatic brains of other Orders.

A deep and well-defined sulcus indents almost the whole length of the hemisphere parallel to and a short distance from the interhemispheral cleft. A comparison with the brains of *Orycteropus*, the Anteaters, and Carnivores would lead us to call this the lateral or the conjoint corono-lateral sulcus. Yet it is very unusual to find the lateral sulcus present, and the more precocious and fundamentally stable suprasylvian sulcus absent. If, for instance, we compare this brain with that of *Galeopithecus* and many of the smaller Ungulates, the possibility of it being the suprasylvian presents itself.

Taking all its features into consideration, one is inclined to regard it as the analogue of the lateral sulcus of such a form as *Tamanduas*. It is also clear that the anterior extremity of such a sulcus takes the place of the prorean sulcus found in the Marsupialia and Carnivora.

Two notch-like indentations in the upper lip of the rhinal fissure may represent the Carnivore pseudosylvian sulcus and the orbital sulcus.

Other sulci have been described in the Agouti ; in this specimen shallow depressions occupy the positions of all these sulci. O. C. 1323 G.

Beddard, Proc. Zool. Soc. 1892, p. 602.

D 253. The brain of the Paca (*Agouti paca*).

This brain agrees with that of the Agouti in presenting notch-like representatives of the orbital and pseudosylvian sulci in the upper lip of the rhinal fissure.

The longitudinal ("lateral") sulcus of the Agouti is here broken up into two fragments—anterior and posterior paramedian sulci respectively, and between them is a short oblique sulcus (which I shall call "ambiguus"), such as the Porcupine exhibits. O. C. 1323 G *b*.

Beddard, Proc. Zool. Soc. 1892, p. 604.

Family *CAVIIDÆ*.

D. 254. The brain of a Capybara (*Hydrochærus capybara*), in which the left cerebral hemisphere has been separated from the rest of the brain (figures 71, 72, and 73).

This brain is much the largest found in the Rodentia ;

and in virtue of the great extent of the mantle of the cerebral hemispheres there are numerous sulci. The aberrant character of the Rodent brain is therefore more strikingly exhibited than it is in the smaller and less-richly furrowed brains of the Order.

Fig. 71. (×⅔.)

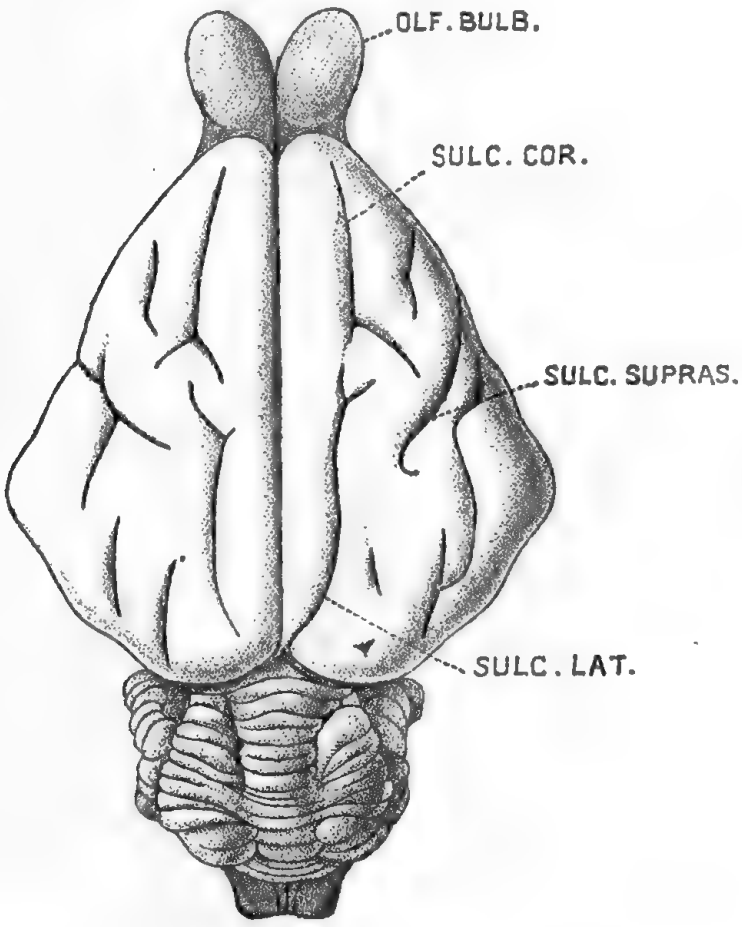

When viewed from above or below the cerebral hemispheres present a peculiar lozenge-shape, the lateral edge of each hemisphere being so shaped as to form a projecting angle slightly behind its mid-point. The large olfactory bulbs project freely in front of the hemispheres.

Fig. 72. (×⅔.)

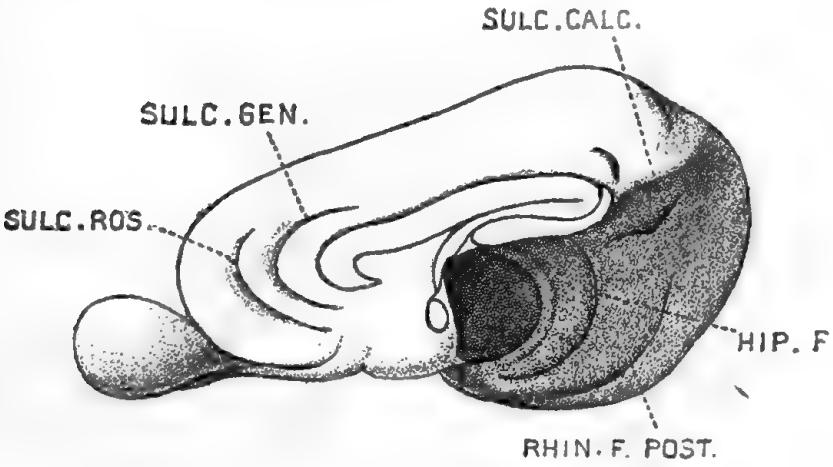

There is a well-formed corpus callosum with a particularly well-developed genu (fig. 72).

The hippocampal formation conforms to the usual Eutherian type.

The rhinal fissure however presents peculiar features. It consists of a deep, long horizontal anterior rhinal extending two-thirds of the length of the hemisphere and ending blindly in a triangular depression posteriorly. There is a shallow posterior rhinal fissure which is not joined to the anterior rhinal on the right hemisphere, and is connected to it only by a very shallow furrow on the left (fig. 73). In the region of approximation of these two fissures there is a deep triangular depression, in which the anterior rhinal fissure terminates. Holl has shown that this depression is formed by a sulcus which he calls the ectosylvian.

Fig. 73. (× $\frac{2}{3}$.)

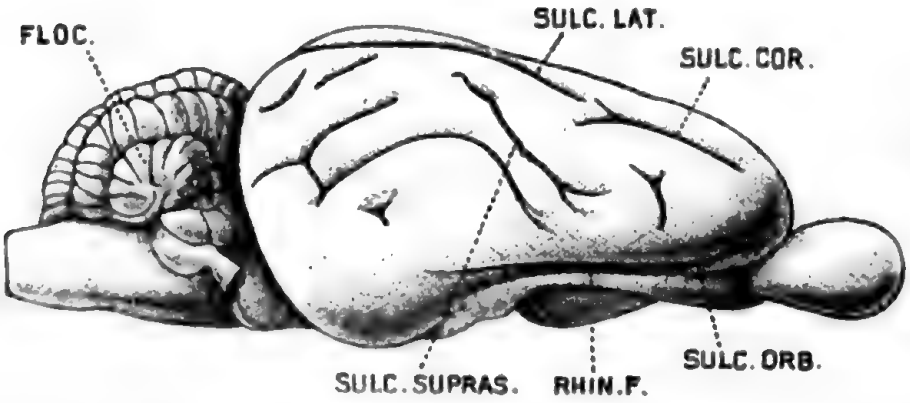

There is a typical presylvian (orbital) sulcus which is placed very far forward and pursues a very oblique, almost horizontal, course, to join Holl's ectosylvian sulcus. The upper lip of the latter sulcus is opercular and meets the lip of the rhinal fissure.

The suprasylvian sulcus is deep and oblique, and is often supplemented by a second arcuate element. This second element may be independent (see right hemisphere of this brain), or it may be fused to the true suprasylvian to form a triradiate sulcus (as in the *left* hemisphere of this and the right hemisphere of the next specimen).

Two sagittal sulci, the longer one placed behind the shorter, extend the whole length of the hemisphere parallel to the interhemispheral cleft. The anterior sulcus probably corresponds to the coronary, and the posterior to the lateral sulcus of other Orders. The adjacent ends of both sulci are bifid.

There are a number of other sulci on the cranial surface of the hemispheres, but they are so unstable that they differ considerably on the two hemispheres of the brain and to a much greater extent in different brains.

It is the sulci (or rather the absence of sulci) on the mesial surface of the Rodent's brain by which the aberrant character of this Order is indicated. The rhinal fissure extends high up on the mesial surface (of the Capybara's brain) parallel to the hippocampal fissure. The most striking fact, however, is the insignificant representative of the calcarine sulcus. There is only a small sulcus behind the splenium of the corpus callosum in the situation where we should expect the deep long calcarine sulcus. In most Rodents even this is missing, and in this brain the features of this small furrow are such as to render its homology somewhat questionable. But even granting that this sulcus in the Capybara is the true calcarine, its insignificance is very peculiar when we recall that in all other Eutherian Orders as well as in the Metatheria the deep, long calcarine sulcus is the most constant and best defined of all the sulci of the neopallium.

In the Capybara again, as in all Rodents, there is no intercalary sulcus, if we except the insignificant furrow near the upper surface of the splenium.

There is, however, a well-defined genual and also a large rostral sulcus.

The cerebellum is remarkable for its small size and compactness (fig. 71). Its folia are arranged in a simple transverse pattern, and as a result there is a close resemblance to the type prevalent in the Ungulata. There is a large floccular lobe. O. C. 1323 G *d*.

Beddard, Proc. Zool. Soc. 1899, p. 798.

Holl, Arch. f. Anat. und Phys. (Anat. Abth.) 1900, p. 295.

D. 255. The brain of a Capybara (*Hydrochœrus capybara*) (♂), in which the left hemisphere has been dissected to show the corpus callosum.

On the left hemisphere of this brain the peculiar characters of the rhinal fissure are very pronounced. The anterior part of the anterior rhinal fissure is so faintly marked, that the deep posterior part appears to be a backward extension of the orbital sulcus. It is separated by a wide interval from the posterior rhinal fissure.

Note the peculiar lozenge-shape of the brain. This is well shown in a figure of Retzius's (Biolog. Untersuch., Bd. viii. 1898, Taf. xii. fig. 1). O. C. 1323 G *a*.

D. 256. A cast of the cranial cavity of a Capybara (*Hydrochœrus capybara*). [In duplicate.]

This shows the true shape and proportions of the large projecting olfactory bulbs: and the peculiar lozenge-shape of the brain as a whole, each cerebral hemisphere having a most pronounced lateral angle slightly behind a point midway between the anterior and posterior poles.

Note also the exceedingly small relative size of the cerebellum.

Gervais, Journ. de Zool., t. i. 1872, p. 456.

D. 257. The brain of a Patagonian Cavy (*Dolichotis magellanica*) (♀), from which the left cerebral hemisphere has been separated (figs. 74 & 75).

This brain is not so strikingly aberrant as that of the Capybara. And yet the practical absence of well-defined sulci on the mesial surface shows that this peculiarity of the other Rodentia also occurs in this genus. There is however a faint trace of a genual sulcus and a shallow depression where one would expect to find the calcarine sulcus.

Unlike that of the Capybara, the brain of this Cavy presents a typical well-defined rhinal fissure, such as is seen elsewhere in the Rodentia, in the Rabbit for instance.

There is an extensive sagittal sulcus parallel to and coextensive with almost the whole length of the interhemispheral cleft. This corresponds to the corono-lateral sulcus of the Carnivora and Ungulata, and possibly also to the prorean sulcus fused to the coronary element.

A great vertical sulcus (s) pursues a slightly arched course upward from the junction of the anterior and posterior rhinal fissures. It probably represents a fusion of the so-called "Sylvian fissure" of most non-Primate orders and the suprasylvian sulcus. Such a fusion is found in the Great Anteater's brain (*vide infra*) and also, in all probability, in the Primates, in which the complex forms the true Sylvian fissure. In this brain, so as to avoid confusion, we may call it the "Sylvio-suprasylvian complex."

Fig. 74. (×$\frac{2}{3}$.)

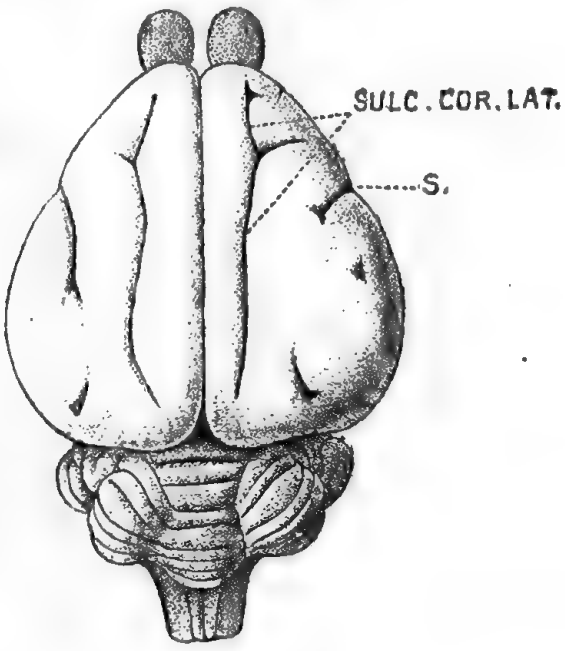

There is a small horizontal presylvian (or orbital) sulcus, which is not joined to the rhinal fissure.

There is also a short sulcus of doubtful significance on the external side of the caudal end of the lateral sulcus (figs. 74 & 75).

Fig. 75. (×$\frac{2}{3}$.)

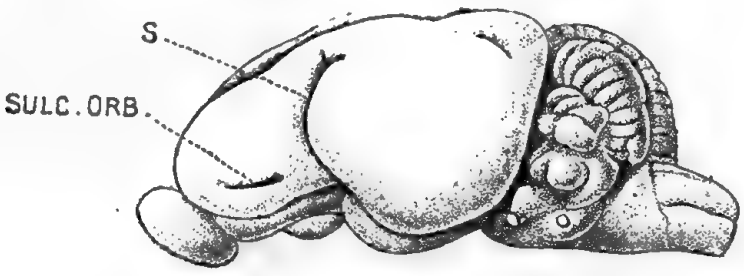

The resemblance between the cerebral sulci of this brain and those of the Lemurs is very instructive (*vide infra*).

There is a compact cerebellum, which is relatively larger and broader than that of the Capybara. It also conforms to a more generalized type found in many other Rodents, Edentates, Insectivores, and Marsupials.

The floccular lobes project like those of the Rabbit.

O. C. 1323 E *i*.

Beddard, Proc. Zool. Soc. 1892, p. 608.

Section MYOMORPHA.

Family *DIPODIDÆ.*

D. 258. The brain of a Jerboa (*Dipus sagitta*).

A simple smooth brain presenting no distinctive features. O. C. 1323 E *h.*

Family *MURIDÆ.*

D. 259. The brain of a Rat (*Mus rattus*), in which the left hemisphere has been in great part removed to show the mid-brain, and the right hemisphere has been dissected to show the hippocampus.

The typical arrangement of the lowly mammalian cerebellum is well shown. O. C. 1323 F *d.*

D. 260. The brain of a Rat (*Mus decumanus*).

Suborder DUPLICIDENTATA.

Family *LEPORIDÆ.*

D. 261. The head of a fœtal Hare (*Lepus europæus*) with the brain exposed *in situ.* O. C. 1323 G *c.*

D. 262. The brain of a Hare (*Lepus europæus*). O. C. 1323 G *f.*

D. 263. The brain of an English Wild Rabbit (*Lepus cuniculus*).

The only trace of sulci in the pallium is a shallow posterior paramedian (lateral) sulcus. O. C. 1323 G *e.*

Presented by H. Power, Esq.

Flatau and Jacobsohn, Vergl. Anat. d. Centralnerv. 1900, p. 351.

D. 264. The left cerebral hemisphere of a Rabbit (*Lepus cuniculus*), dissected to show the hippocampus (fig. 76).

Fig. 76. (Nat. size.)

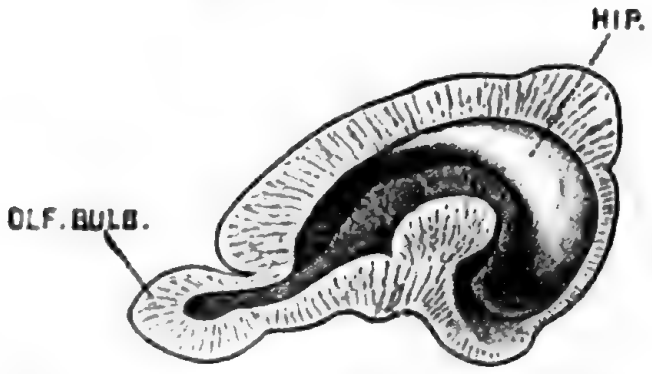

Being a larger brain, this shows more clearly than the Hedgehog's brain the difference between the Eutherian and

Metatherian hippocampus. The Rabbit's hippocampus is restricted to the caudal part of the ventricle and does not extend so far forward as that of the Wallaby (D. 210).

Note the continuity of the lateral ventricle with the cavity in the olfactory bulb.

D. 265. Two casts of the cranial cavity of a Rabbit (*Lepus cuniculus*).

ORDER CHIROPTERA.

D. 266. A cast of the cranial cavity of a Rousette Bat (*Pteropus vampyrus*).

The brain in the Chiroptera exhibits features which indicate its lowly status in the mammalian series. It does not show signs of any marked specialisation or divergence from the primitive type of the Insectivora.

The hemisphere is peculiar in that the rhinal fissure is almost completely deficient, although the well-developed pyriform lobe and neopallium present typical features. In the small bats the minute cerebral hemispheres are separated by a wide gap from the cerebellum so that almost the whole of the corpora quadrigemina is exposed. These hemispheres are, of course, quite smooth. In the larger forms, such as *Cynonycteris*, there is a well-developed splenial complex of calcarine and intercalary sulci of the typical form. In the largest representatives, such as *Pteropus*, this splenial arc becomes even more extensive.

On the cranial surface there is in *Cynonycteris* a very short, deep suprasylvian sulcus and a small shallow lateral sulcus. The latter may in some cases become deeper and more extensive. In this cranial cast of *Pteropus* there is a short, deep, suprasylvian and a short, shallow, lateral sulcus.

There is no orbital sulcus, nor is there any trace of a pseudosylvian sulcus.

In the larger Bats the cerebral commissures are well-developed and resemble those of *Galeopithecus*. But in many of the smallest Bats (e. g. *Nyctophilus* and *Vespertilio*) the corpus callosum becomes extremely reduced in size so that the commissures present a spurious resemblance to those of the Marsupialia (Trans. Linn. Soc. vol. vii. pt. 3, 1897, p. 47).

The cerebellum and the other parts of the brain closely resemble the corresponding organs in *Galeopithecus*.

In the small Bats the enormous development of the auditory tracts is specially noteworthy.

Flatau and Jacobsohn, Vergl. Anat. d. Centralnerv. 1900, p. 208.

Gervais, Journ. de Zool., t. i. 1872, p. 437. Also Retzius, Leche, Elliot Smith, and others.

ORDER EDENTATA.

Family *DASYPODIDÆ*.

D. 267. The brain of a Six-banded Armadillo (*Dasypus sexcinctus*).

This is a simple, highly macrosmatic brain resembling that of the generalised Insectivores in most of its features.

The rhinal fissure, however, consists of two fragments separated by a wide gap (fig. 77). The posterior of these (RHIN.F.POST.) is prolonged obliquely forward into continuity with a sulcus (β) of the neopallium, which probably corresponds to the orbital or presylvian sulcus of other mammalian brains. Above the posterior rhinal fissure there is a second oblique sulcus (δ) in the neopallium, which may be regarded as the representative of the suprasylvian sulcus of the Carnivora or of the Myrmecophagidæ.

Fig. 77. (Nat. size.)

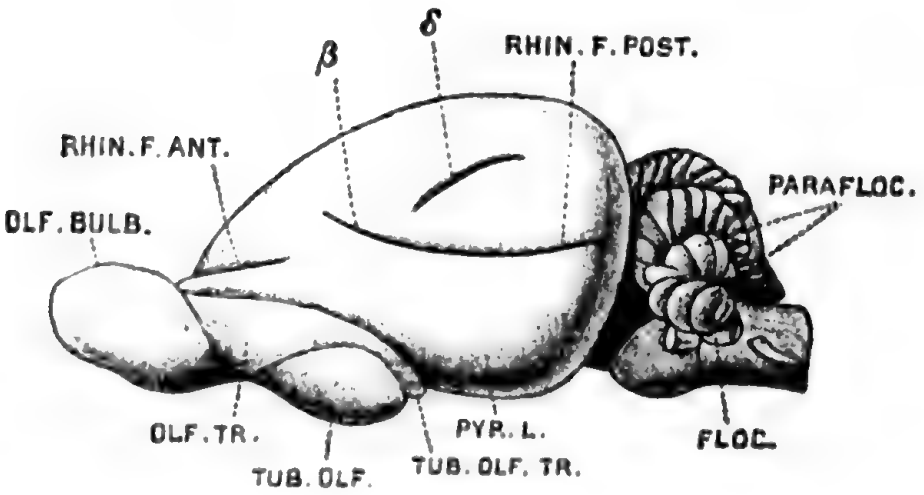

On the mesial surface of the hemisphere there is a sulcus which may possibly represent a highly placed calcarine, which has become prolonged forward after the manner of the so-called "splenial" sulcus of Krueg in most mammals.

The appearance of the diminutive corpus callosum (C.C.) and the large hippocampal commissure (PS.D., PS.V.) and anterior commissure (A.C.) are shown diagrammatically in the accompanying scheme (fig. 78), which also exhibits the relations of the fornix or fimbria (F), the fascia dentata (F.D.), *hippocampus nudus* (N.H.), and vestigial hippocampus (V.H.) to the commissures and precommissural area (P). O. C. 1323 I.

Fig. 78.

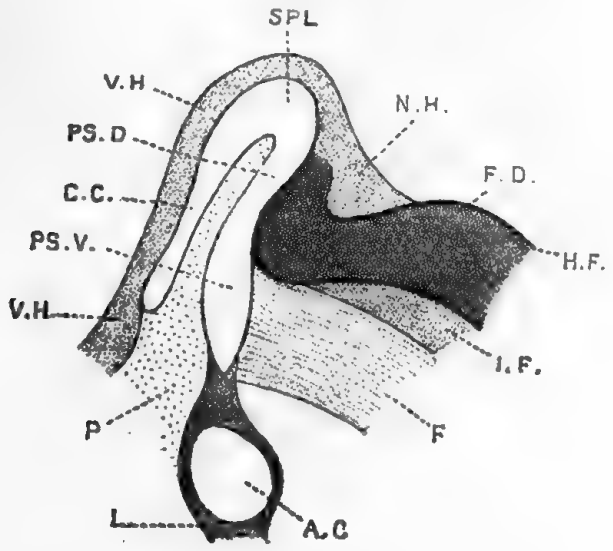

Elliot Smith, Trans. Linn. Soc. (2nd Series, Zool.) vol. vii. 1899, p. 297.

D. 268. The brain of a Cabassou (*Cabassous unicinctus*).

This is an excellent example of a simple, highly macrosmatic brain essentially similar to that of the Six-banded Armadillo, but relatively much shorter and broader than the latter.

The large olfactory bulbs are flattened against the anterior surface of the short cerebral hemispheres (figs. 79, 80, 81).

The posterior rhinal fissure is represented only by a very shallow depression (fig. 80), but the supposed representative of the orbital sulcus is exceedingly well developed (figs. 79 and 80).

The representative of the sulcus δ of *Dasypus* is much more insignificant in *Cabassous* (figs. 79 and 80) than it is in the former.

There is a small corpus callosum and large psalterium (fig. 81), as in *Dasypus* (compare fig. 78); and the vestiges of the supracallosal and precallosal parts of the hippocampal arc are exceptionally clearly demonstrated (fig. 81). The arrangement of these parts agrees with that shown diagrammatically for *Dasypus* in fig. 78.

Fig. 79.

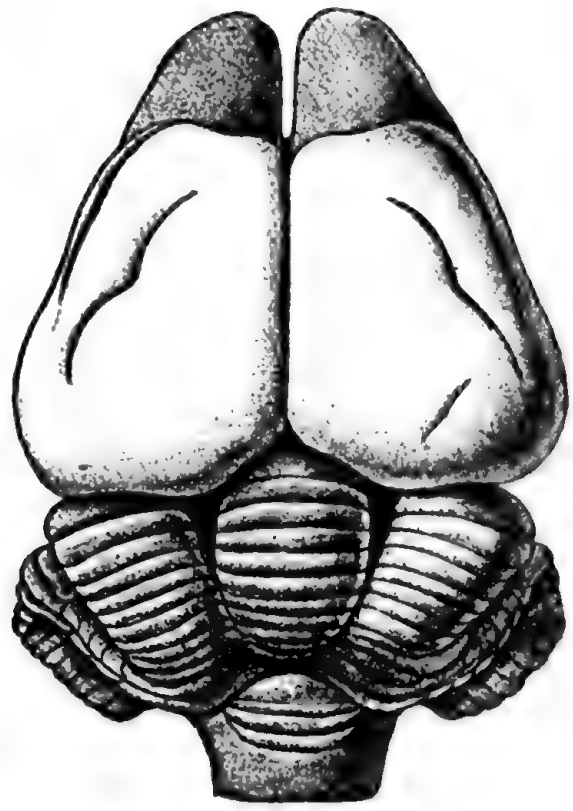

Fig. 80. (Nat. size.)

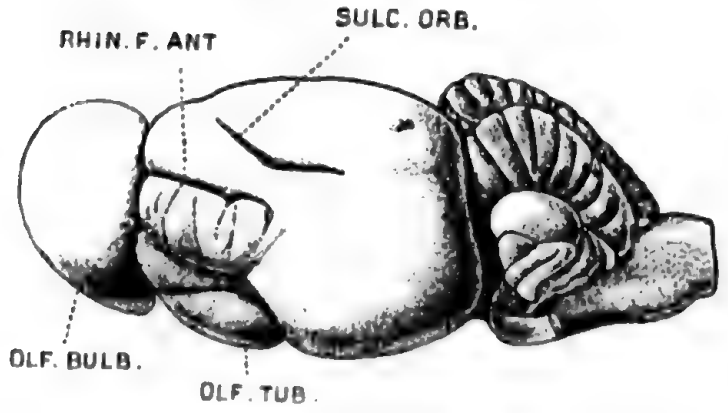

Fig. 81. (Nat. size.)

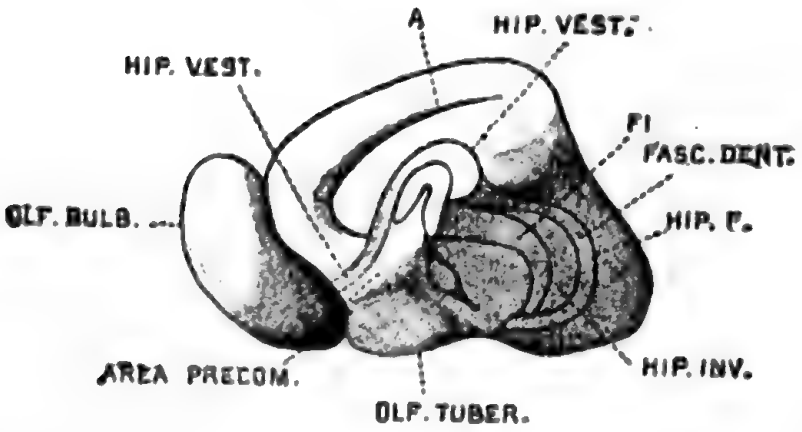

There is a very well-developed "splenial" sulcus, probably representing the conjoint calcarine, intercalary and genual sulci of other mammals. It extends much further forward than the analogous sulcus in other Armadillos.

The features of the typical, primitively simple mammalian cerebellum are unusually clearly shown in that of *Cabassous* (figs. 82, 83, 84, & 85). It closely resembles that of the Rabbit except that the large cake-like floccular lobe (composed of flocculus and paraflocculus) is here sessile and flattened against the rest of the cerebellum.

Fig. 82. (Nat. size.)

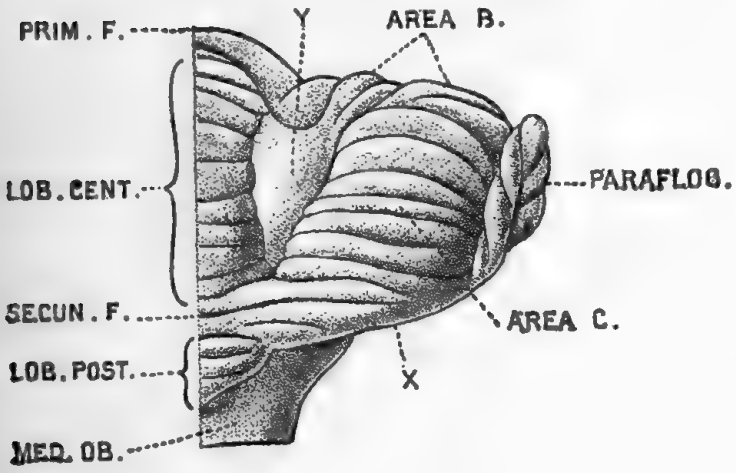

Fig. 83. (Nat. size.)

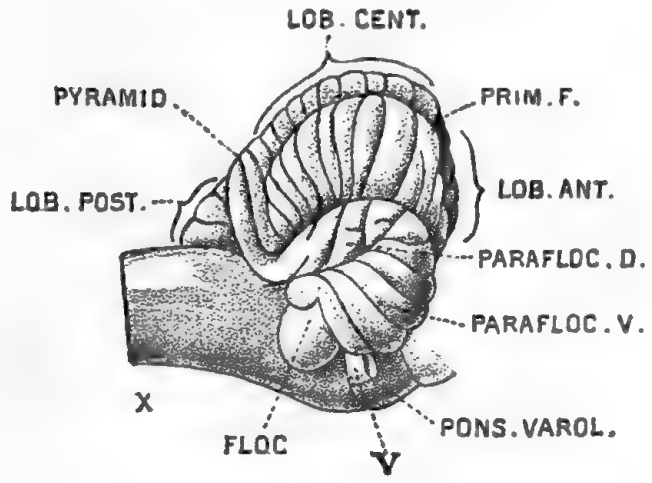

Fig. 84. (Nat. size.)

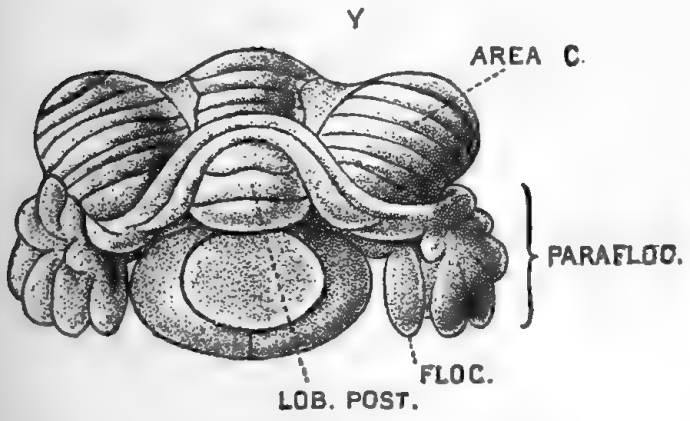

Fig. 85. (Nat. size.)

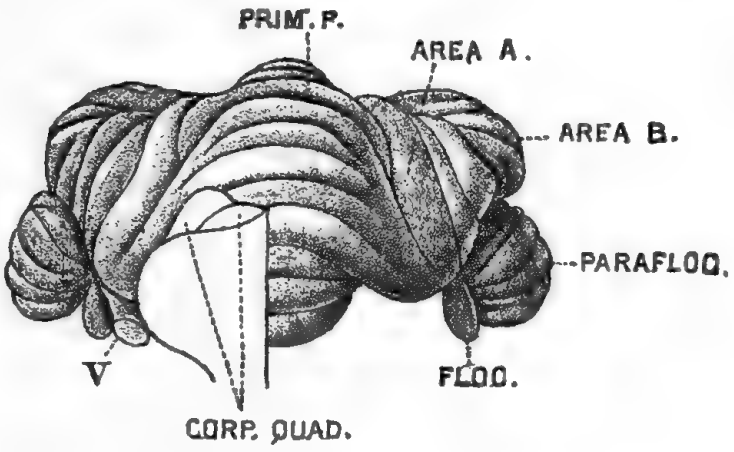

LOB. ANT. = Lobus centralis + Lobus culminis.
AREA A = Lobus clivi.
AREA B = Lobus cacuminis.
AREA C = Lobus tuberis.
X = Lobus biventralis + Amygdala.
LOB. POST. = Uvula + nodulus.

O. C. 1323 I *a*.

Elliot Smith, Trans. Linn. Soc., vol. vii. 1899, pp. 321 & 371.

D. 269. The brain of a Three-banded Armadillo (*Tolypeutes tricinctus*).

This brain is like that of *Cabassous*, but is smaller. The suprasylvian sulcus is absent, the orbital (presylvian) sulcus is shorter. There is no pallial sulcus on the mesial surface of the left hemisphere, but a faintly marked furrow is present above the corpus callosum in the right side. O. C. 1323 1 *b*.

Elliot Smith, Trans. Linn. Soc. *loc. cit.*

D. 270. The brains of two Pebas (*Tatu novemcincta*).

In most of their features these brains closely resemble that of *Cabassous*.

Fig. 86. (Nat. size.)

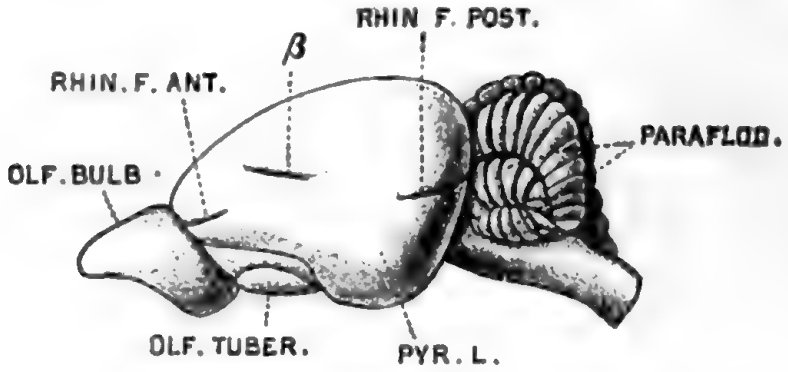

The posterior rhinal fissure is very small and the anterior rhinal is also very short. There is a well-defined presylvian (β) but no suprasylvian sulcus.

The most noteworthy feature is the large size of the corpus callosum in comparison with that of other Armadillos.

O. C. 1323 1 *c*.

Elliot Smith, Trans. Linn. Soc. *loc. cit.*

Family *GLYPTODONTIDÆ.*

D. 271. A cast of the cranial cavity of *Glyptodon claviceps*.

This is a replica of Gervais's model. It shows the extraordinarily small size of the brain in comparison with that of the body of the animal ; the enormous dimensions of the large, pedunculated and projecting olfactory bulbs ; the diminutive size of the cerebral hemispheres ; and the extraordinary greatness (especially in breadth) of the cerebellum.

The cerebral hemispheres are flattened, and the only trace of a sulcus is one in the " Sylvian region," which probably represents the so-called suprasylvian sulcus of the Armadillos, unless, after the analogy of *Galeopithecus* and many Eocene Mammals, it is a phenomenally high rhinal fissure.

Gervais, Nouv. Arch. Mus., t. v. 1869, p. 42.

D. 272. A cast of the cranial cavity of *Glyptodon claviceps* (two specimens).

This is a less perfect cast of a larger brain than D. 271.

Family *Bradypodidæ.*

D. 273. The brain of a Three-toed Sloth (*Bradypus tridactylus*).

[This specimen, having been preserved *in situ* in the cranium, exactly retains its normal shape, but is unfortunately too soft to permit the arachnoid and pia membranes to be removed. The latter, however, are sufficiently thin to permit the sulci to be distinctly seen.]

Fig. 87. (Nat. size.)

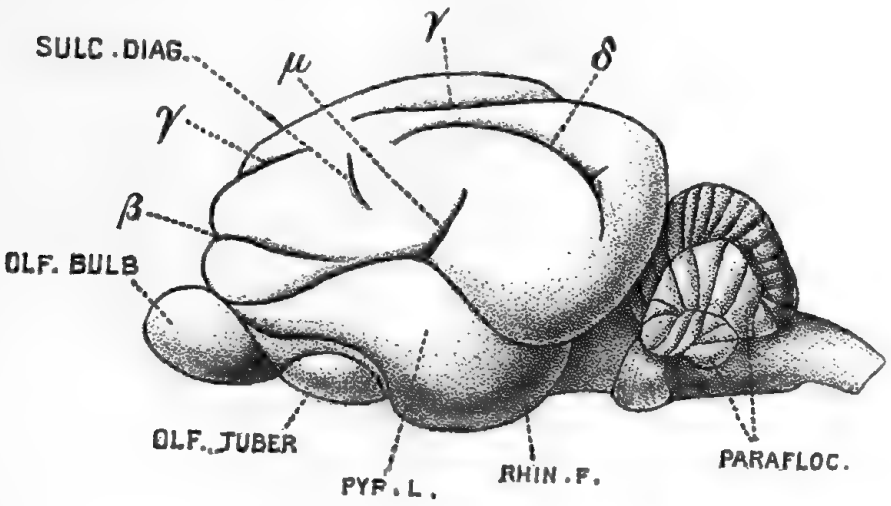

Fig. 88. (Nat. size.)

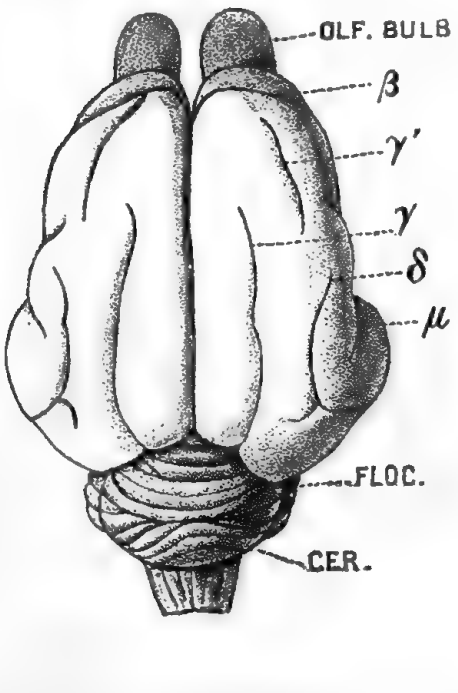

The contrast between this brain and that of an Armadillo is almost as pronounced as are the differences exhibited in a comparison of the brains of the Cat and the Hedgehog. The contrast between the habits of the fossorial, terrestrial

Armadillo and the arboreal herbivorous Sloth sufficiently explain the fact that the former is much more highly macrosmatic than the latter.

In the Sloth the neopallium is, in comparison with that of the Armadillo, very large, although it is considerably smaller than that of Carnivores of the same size. It is moreover richly supplied with deep sulci, which conform to a pattern curiously like that which prevails among the Carnivora.

Fig. 89. (× 2.)

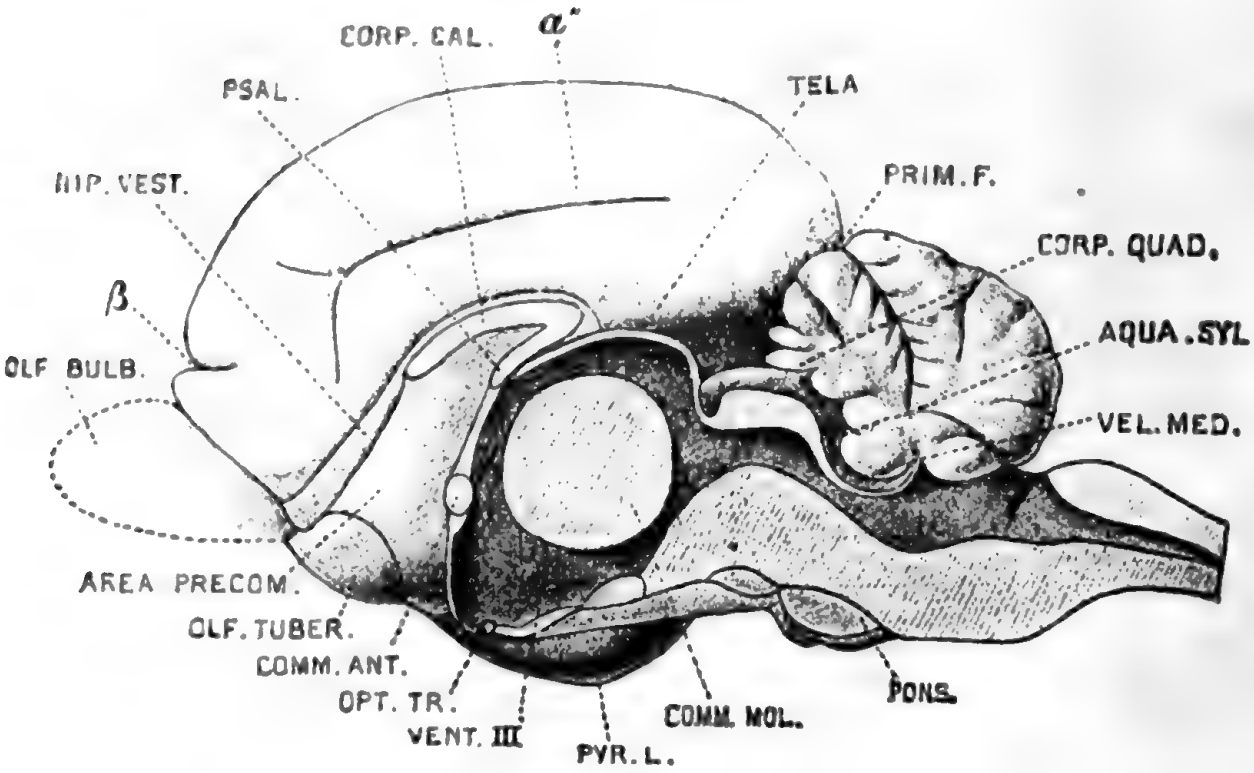

Fig. 90.

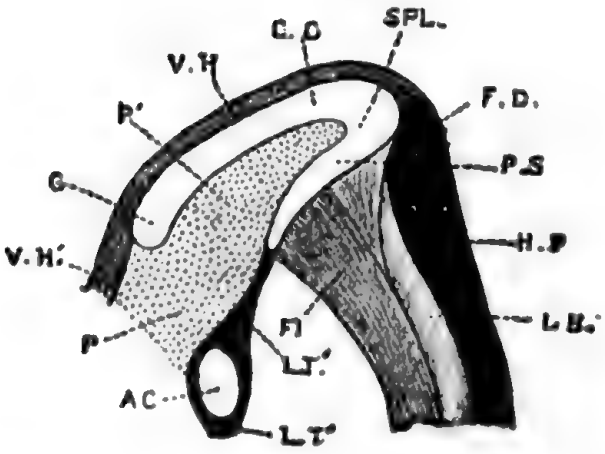

The cerebral hemispheres are sufficiently large to hide the corpora quadrigemina and to overlap the cerebellum to some slight extent ; it also partly overhangs the olfactory bulbs (fig. 87) but no olfactory sulcus is developed.

On the ventral surface the posterior part of the pyriform lobe forms a very pronounced protuberance, commonly known as the "natiform eminence," and as a result of this prominence there is a deep vallecula Sylvii separating the latter from the anterior part of the pyriform lobe and the olfactory tubercle.

In profile the brain presents a general resemblance to the Feline type, although there are many differences. The cerebral hemispheres of the Sloth are, in comparison with those of the Cat, much more highly macrosmatic ; or, to express the same fact more accurately, the neopallium is relatively smaller in the Sloth.

The anterior and posterior rhinal fissures meet in an upwardly-directed arc, and the resultant conjoint fissure is placed wholly upon the lateral aspect of the hemisphere and on a much higher plane than the corresponding fissure in the Cat's brain.

A distinctive "Sylvian fissure" of the Feline type springs from the apex of the rhinal arch and ascends with a slight backward inclination for a short distance (fig. 87, μ).

There is a deep sulcus (β) which clearly corresponds to the presylvian (or orbital) sulcus of the Carnivora. It pursues a horizontal course across the blunt cephalic pole of the hemisphere. Its mesial extremity (fig. 89, β) is prolonged on to the inner face ; this mesial prolongation may possibly represent a rostral sulcus. Its lateral extremity does not quite reach the rhinal fissure in this specimen (fig. 87, β), but in some cases it joins the rhinal fissure and presents relations to the latter and to the Sylvian fissure not unlike the arrangement found in the brain of *Galeopithecus*.

There can be little doubt as to the homology of the arcuate sulcus δ (figs. 87 & 88) with the combined suprasylvian and postsylvian sulci of the Carnivora. The anterior limb of this suprasylvian arc (so we may call it) is very short. There is a short horizontal branch from the posterior part of the arc such as is often found in an analogous situation in the Carnivore's brain.

There is a very small diagonal sulcus (compare the Cat's brain) in front of and slightly below the suprasylvian arc.

There is a sagittally-directed sulcus (γ) analogous to that called "lateral" in the Carnivora ; it pursues a course parallel to the posterior two-thirds of the interhemispheral cleft. It also crosses on to the caudal surface of the hemisphere and approaches, though it usually does not join, the upper extremity of the vertical calcarine This arrangement, which does not occur in the Carnivora, is of considerable interest in view of the relationship which exists between the calcarine and intraparietal (the probable representative of the lateral) sulcus and the newer intercalated parieto-occipital sulcus in certain of the Primates (*vide infra*).

The anterior extremity of the lateral sulcus (fig. 88, γ) is overlapped on its lateral aspect by a short sagittal sulcus (γ'), which may possibly represent the coronal sulcus of the Cat's brain (*vide infra*).

There is no crucial sulcus.

The mesial surface (compare figs. 89 and 90) [which is not exposed in this specimen] resembles that of the Two-toed Sloth in all its essential features (*vide* specimen D. 275).

The cerebellum appears to be relatively very small. The floccular lobes are large cake-like masses flattened against the lateral aspect of the organ. Each of these lobes is composed of the usual three parts, flocculus and dorsal and ventral paraflocculi. In marked contrast to the condition found in the Armadillos [*vide Cabassous*, fig. 83], the dorsal paraflocculus is much the largest part of the floccular lobe in the Sloth. The rest of the cerebellum is small, narrow and simple. Its lateral parts are not expanded to the same extent as the corresponding parts in the Carnivores, the Anteaters, or even the Armadillos. In this respect the cerebellum much more closely resembles that of such forms as *Dorcatherium* (Ungulata) and *Hydrochœrus* (Rodentia).

O. C. 1323 H *b*.

Elliot Smith, Trans. Linn. Soc. vol. vii. 1899, p. 296.

D. 274. The brain of a Three-toed Sloth (*Bradypus tridactylus*) (♂), enclosed in the vascular pia and arachnoid membranes.

In this specimen the independent intercalary sulcus can be seen on the mesial surface. The coronal and lateral sulci seem to be fused. O. C. 1323 H *a*.

D. 275. The brain of a Two-toed Sloth (*Cholœpus didactylus*).
(Figs. 92 and 93 are not drawn from this specimen.)

In most of its features this brain presents a most striking resemblance to that of the Three-toed Sloth. But this general similarity renders more remarkable the peculiar absence of the so-called "Sylvian fissure" in this larger of the two brains of the Family of Sloths.

Fig. 91. (Nat. size.)

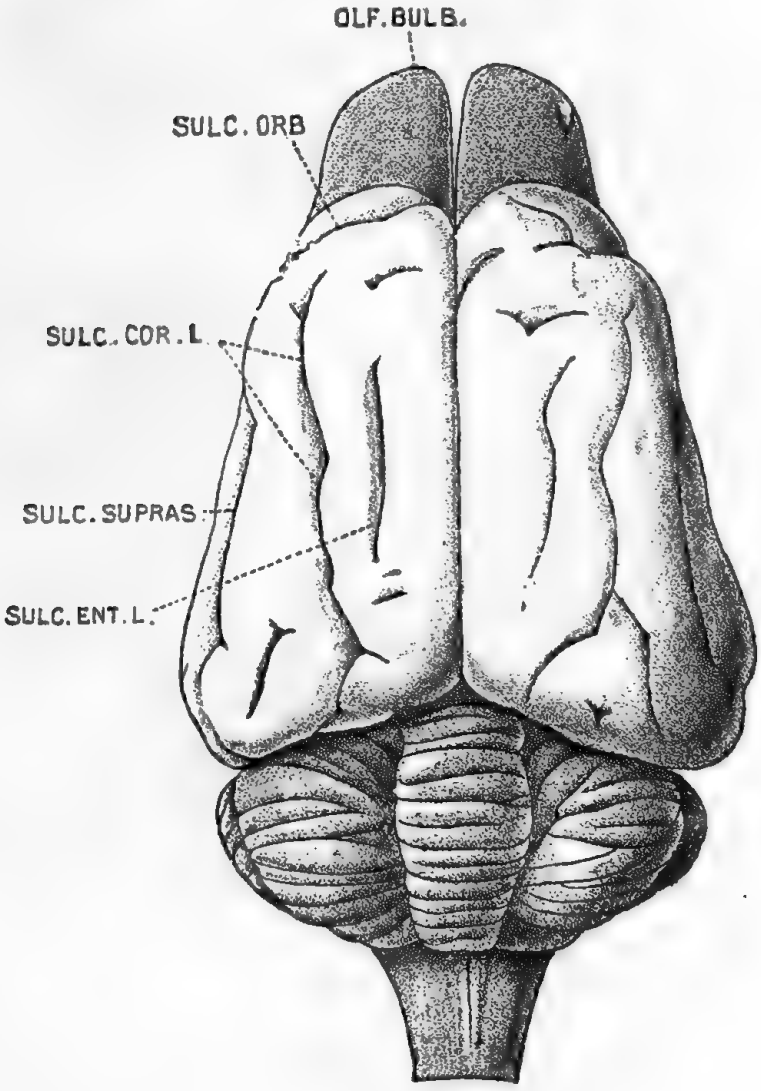

Fig. 92. (Nat. size.)

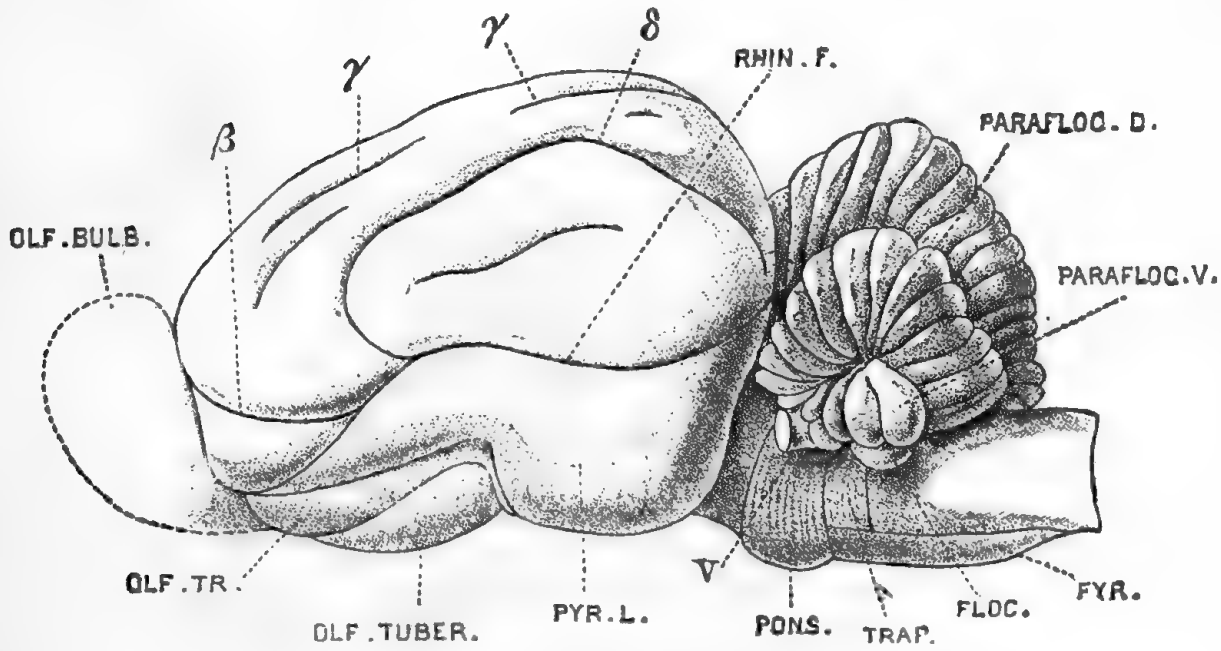

The natiform eminence is much less prominent than it is in the Three-toed Sloth; and the bending of the rhinal fissure is so slight that the whole fissure is approximately horizontal. These two facts are probably correlated with the peculiar absence of the so-called "Sylvian fissure" of the Three-toed Sloth. Whilst it is surprising to find this feature absent in the larger of the two brains, in which we should expect it to be better developed, it seems to emphasize the morphological instability of this so-called "Sylvian fissure," which a comprehensive survey of the Mammalia so clearly demonstrates. It also leads us to infer that what we may call the "feline type of Sylvian fissure" is a mere kink produced by mechanical factors, of which the most important is the downward extension of the caudo-ventral part of the neopallium. In *Bradypus* where such an extension has taken place (witness the ventral curve of the posterior rhinal fissure!), this so-called "Sylvian fissure"

Fig. 93. (Nat. size.)

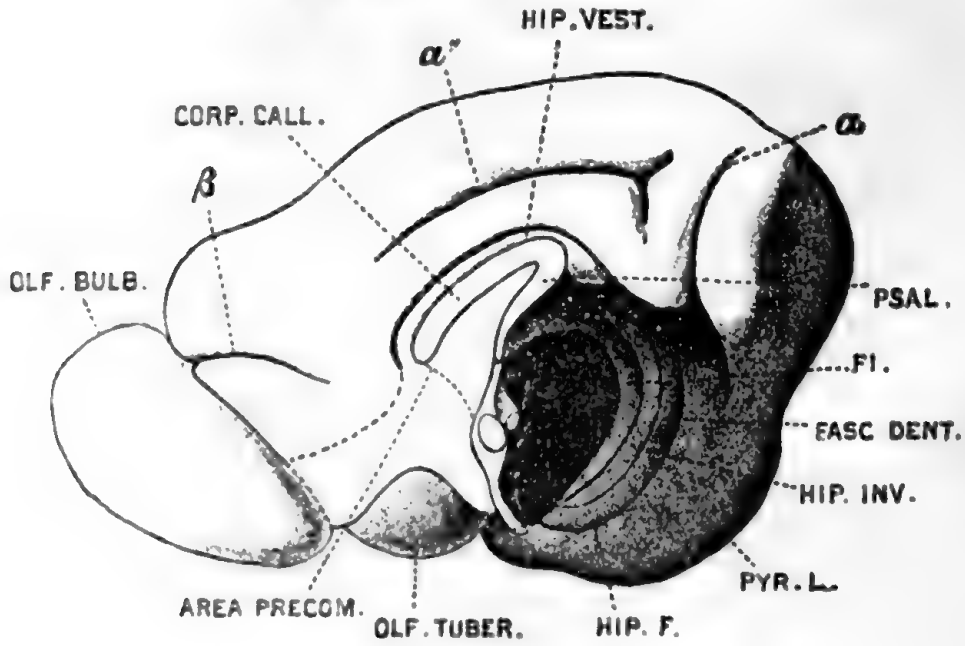

Fig. 94. (Nat. size.)

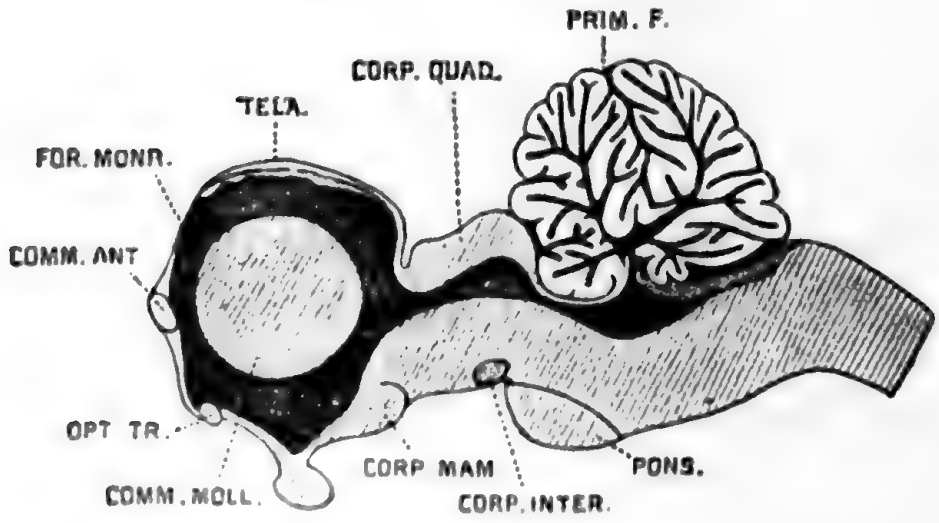

makes its appearance; whereas in *Cholœpus*, in which the neopallium has not extended downwards in its caudal region (witness the horizontal posterior rhinal fissure), there is no "Sylvian fissure" even though the cerebral hemisphere is larger and therefore the greater *à priori* reason for a Sylvian fissure.

The extensive and deep suprasylvian sulcus (fig. 92, δ) is also much less acutely flexed than is the corresponding feature in *Bradypus*. On its ventral side a short horizontal sulcus makes its appearance to compensate for the absence of the Sylvian element, thus affording further evidence of the mechanical mode of formation of the so-called "Sylvian fissure" of *Bradypus*.

The presylvian or orbital sulcus (β) joins the rhinal fissure in both hemispheres; otherwise it resembles that of *Bradypus*. On the left side it joins or becomes confluent with the rostral sulcus, but on the right side it terminates near the mesial edge just behind the upper extremity of the rostral, which is a small independent sulcus.

There is an extensive, sagittal, lateral sulcus, which bifurcates posteriorly. In this specimen (fig. 91) the lateral sulcus is fused with the coronal, but in that from which figure 92 was drawn these two elements were independent (γ and γ′). There is also a well-defined entolateral sulcus —*i. e.* a compensatory sulcus developed on the mesial side of the lateral.

The calcarine sulcus is peculiar in the Sloths in that it is independent of the intercalary sulcus (with which it is fused in most mammals to form the so-called "splenial" sulcus of Krueg). In this respect the Sloths agree with the true Anteaters, the Pangolins, and the Primates. This form of the calcarine sulcus is undoubtedly the primitive, ancestral type for all mammals.

The calcarine sulcus is vertical and terminates near the upper margin of the hemisphere (fig. 93, α).

The intercalary sulcus begins very far back between the splenium of the corpus callosum and the upper part of the calcarine sulcus. On the left side it extends horizontally forward almost as far as the rostral sulcus. On the right side its anterior extremity bends upward and notches the dorsal edge of the hemisphere in a manner curiously like the conjoint crucial and intercalary sulci of many Carnivores, such as the Civet. [Figure 93 does not represent this specimen.]

The corpus callosum (C.C.) and psalterium (P.S.) are relatively short and of a somewhat simple type (fig. 90), and the relations of the hippocampus to the commissures and to the supracallosal (V.H.) and precallosal (V.H.') vestiges of the hippocampal arc are clearly shown.

The posterior quadrigeminal bodies are more prominent than the anterior pair, and the mesial (posterior) geniculate body on each side is so large as to appear like a large caudal projection of the chief mass of the optic thalamus. It touches the cerebellum posteriorly. These features are some of the physical expressions of a highly acute sense of hearing.

The cerebellum resembles that of *Bradypus* but is considerably larger (figs. 92 and 94).

The large paraflocculus is seen to great advantage.

Elliot Smith, Trans. Linn. Soc. vol. vii. 1899, p. 309.

D. 276. The brain of a Two-toed Sloth (*Cholœpus didactylus*) (fig. 92).

In this brain the chief sulcus in the region where the "lateral" sulcus should be found obviously corresponds to that which in the last specimen was called "entolateral." There is, however, a coronal sulcus like that of *Bradypus* (D. 273), occupying the situation of the anterior part of the "lateral" sulcus of the last specimen; and also a short caudal sulcus on the lateral side of the "entolateral" which appears to join the calcarine.

This shows to how great an extent this group of sulci lacks morphological stability. They accommodate themselves to slight mechanical differences in the process of growth in such a way that no exact homology with apparently identical sulci in other groups can be said to exist.

O. C. 1323 H.

D. 277. A cast of the cranial cavity of a Two-toed Sloth (*Cholœpus didactylus*).

This shows the exact shape and size of the cerebellum, the cerebellar hemispheres, and especially of the olfactory bulbs.

Gervais, Nouv. Arch. Mus., t. v. 1869, p. 38.

D. 278. The brain of a Hoffmann's Sloth (*Cholœpus hoffmanni*).

This brain closely resembles that of the ordinary Two-toed Sloth.

In this specimen the anterior extremity of the suprasylvian sulcus opens into the rhinal fissure, and a curious triangular depression is found behind the junction. This is more pronounced on the right hemisphere and presents a curious resemblance to the fossa Sylvii. There is, however, no true Sylvian fissure, although on the left hemisphere the pit-like representatives of the compensatory suprasylvian sulci open into the rhinal fissure so as to produce a spurious resemblance to it.

It is instructive to note in this specimen how *in the pyriform lobe* the operation of factors such as produce the pseudosylvian sulcus in the neopallium of many mammals has converted the vallecula Sylvii into a sulcus like the neopallial pseudosylvian sulcus of other forms.

On the left hemisphere there are two coextensive sagittal sulci, the mesial of which may represent either the "lateral" or "entolateral" sulcus, and the external may be either the caudally prolonged "coronal" or the "lateral" (see account of specimen D. 276).

On the right hemisphere the condition resembles that of specimen D. 276. None of these cranial sulci join the calcarine.

There are well-developed post-lateral and paracalcarine sulci.

Turner, Journ. Anat. & Phys., vol. xxv. 1890, p. 122.

Family *MEGATHERIIDÆ*.

D. 279. A cast of the cranial cavity of a *Megatherium cuvieri*.

This presents an extraordinarily close resemblance to the Bear's brain, but is considerably larger.

There is a deep oblique depression in the "Sylvian region," and appearances suggest that there was a long oblique pseudosylvian sulcus, like that of the Bears, with an extensive suprasylvian arc presenting such an acute flexure as is seen only in the Arctoid Carnivores (of existing mammals). To complete the resemblance, the area between these two sulci is depressed, as it sometimes is in the Bears, and always in the Seals. There was an orbital sulcus and a lateral sulcus of the typical Carnivore pattern. In front of the latter there was a great transverse sulcus, like the crucial sulcus ; this may, however, be the coronal sulcus.

Gervais, Nouv. Arch. Mus., t. v. 1869, p. 39.

D. 280. A cast of the cranial cavity of a Pampean Ground-Sloth (*Grypotherium listai*).

"Compared with the brains of *Mylodon* and *Scelidotherium*, . . . that of *Grypotherium* is observed to be more elongated, with less divergent and prominent olfactory [bulbs], less constricted cerebral hemispheres, and a larger cerebellum. In the form and proportions of its cerebellum, it similarly differs from *Megatherium*. The cerebral hemispheres of the existing *Cholœpus didactylus* and *Bradypus tridactylus* are more tapering forward, and their cerebellum is relatively smaller than in *Grypotherium*." (Smith Woodward, Proc. Zool. Soc. 1900, p. 69.)

The cast shows only in a very vague manner the arrangement of pre- and suprasylvian sulci, resembling those of *Choloepus*. This specimen is, moreover, interesting as an illustration of the caution needed in drawing inferences from the general shape of a cranial cast ; for if the olfactory bulbs were broken, as so commonly happens, and the sulci a little more blurred, one might easily mistake this for the cast of some Dugong-like Sirenian.

Family *MYRMECOPHAGIDÆ.*

D. 281. The brain of a Great Anteater (*Myrmecophaga jubata*). The right cerebral hemisphere has been separated from the rest of the brain. [This drawing of the *right* hemisphere has been reversed.]

The elongated form of the cerebral hemispheres presents a marked contrast to that of the Sloths. The olfactory bulbs are very large.

The anterior rhinal fissure is horizontal and forms an angle of about 120° with the posterior rhinal, which crosses on to the ventral surface at a point midway between the vallecula Sylvii and the caudo-ventral angle of the hemisphere.

On the right hemisphere (fig. 95, *reversed*) there is a deep triangular depression communicating with the bend of the rhinal fissure. From the apex of this depression a very short sulcus (not more than 5 mm. long) extends upward and slightly backward; this undoubtedly corresponds to the so-called "Sylvian fissure" of *Bradypus* and *Felis*.

Fig. 95. (× $\frac{2}{3}$.)

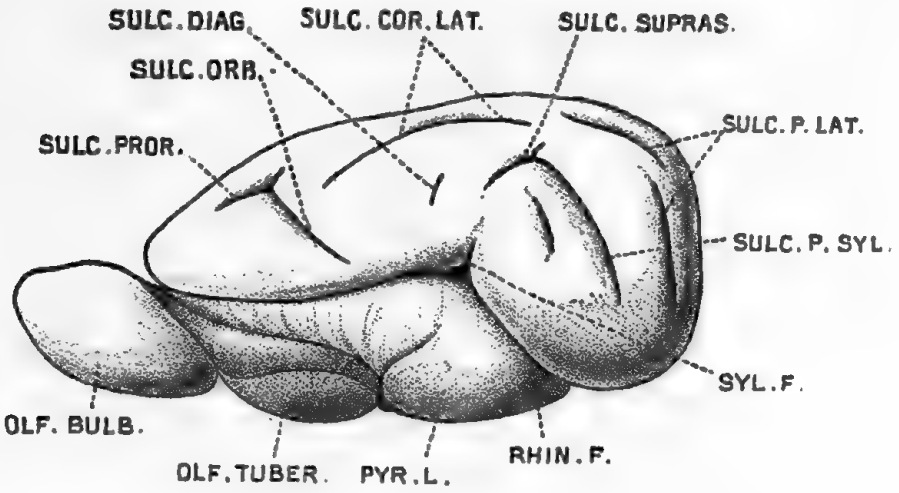

There is a short suprasylvian sulcus joined to a much longer postsylvian (or "posterior suprasylvian" as it is more generally called). In front of the suprasylvian sulcus there is a small deep sulcus analogous to the diagonal of *Bradypus* and the Carnivores.

There is a long, deep, presylvian or orbital sulcus; it is separated by a short interval from the anterior rhinal fissure and is joined to the prorean sulcus (*vide* the Carnivora), near the interhemispheral cleft.

There is a long, deep, lateral or conjoint corono-lateral sulcus in the posterior two-thirds of the hemisphere, and two short and relatively shallow post-lateral sulci behind it parallel to the postsylvian sulcus.

There is a deep, vertical calcarine sulcus on the medio-caudal aspect of the hemisphere. As in the Sloths it does not join the intercalary sulcus, which is represented in this hemisphere by two shallow sulci.

The chief interest of this brain is the wide separation of the so-called "Sylvian fissure" and the suprasylvian sulcus in the right hemisphere. The condition almost always found in *Myrmecophaga* is seen on the left hemisphere. There the so-called "Sylvian fissure" and the suprasylvian sulcus have become confluent so as to form a long, deep sulcus extending almost as far as the lateral sulcus. The postsylvian sulcus is not joined to the suprasylvian element.

This confluence of these two elements to form a Sylvio-suprasylvian complex is of great interest, because there are many reasons for believing that a similar fusion takes place in the Primates. If this be so, the "Sylvio-suprasylvian" complex of the Anteater is the nearest approach to the condition of the true Sylvian fissure of the Primates.

Now such a confluence of these two sulci may be regarded as the normal condition in the Great Anteater. The interest of this fact is enhanced when it is recalled that the calcarine sulcus is separated from the intercalary—another Primate feature. O. C. 1323 K.

Presented by the Zoological Society.

Elliot Smith, Trans. Linn. Soc. vol. vii. 1899, p. 293.

D. 282. The brain of a Great Anteater (*Myrmecophaga jubata*), in which the right hemisphere has been separated from the rest of the brain. (Figs. 96, 97, 98, 99.)

The sulci in this brain are exceedingly interesting when compared with those of the above specimen (D. 281).

The Sylvio-suprasylvian complex approaches so near to the upper extremity of the postsylvian, as to afford a striking resemblance to the suprasylvian arc on the right hemisphere of specimen D. 281; thus it further confirms the suprasylvian nature of the upper part of the "Sylvio-suprasylvian" sulcus.

There is no diagonal sulcus, such as is seen in the preceding specimen. There is a very short posterior ectosylvian sulcus on the right hemisphere and none on the left.

On the left hemisphere the orbital or presylvian sulcus opens into the anterior rhinal fissure. On the right hemisphere it does not do so; it is also quite independent of the small prorean sulcus on this side.

On the right hemisphere there is a typical corono-lateral sulcus; but on the left side the coronary sulcus is prolonged obliquely backward and mesially beyond the junction. The same phenomenon occurs on the left hemisphere of specimen D. 281.

Fig. 96. ($\times \frac{2}{3}$.)

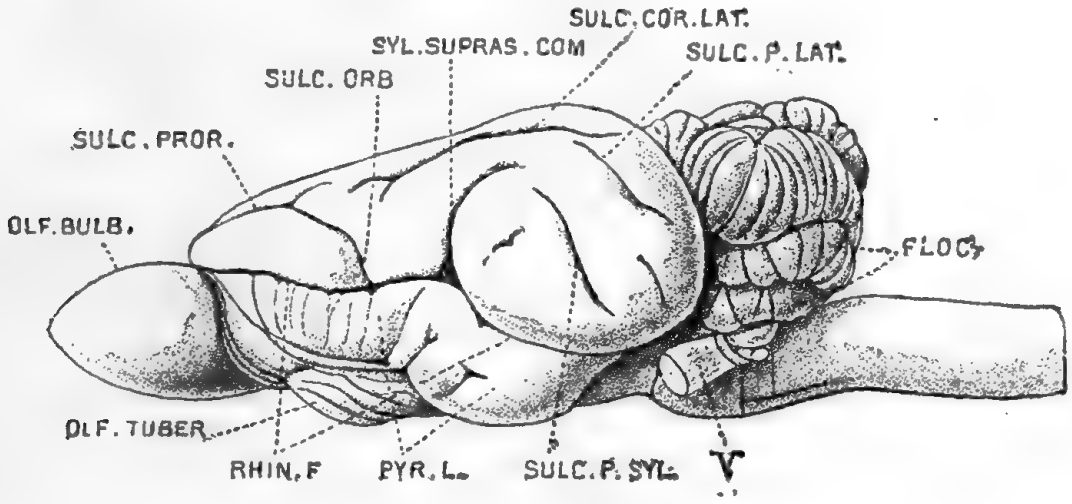

Fig. 97. ($\times \frac{2}{3}$.)

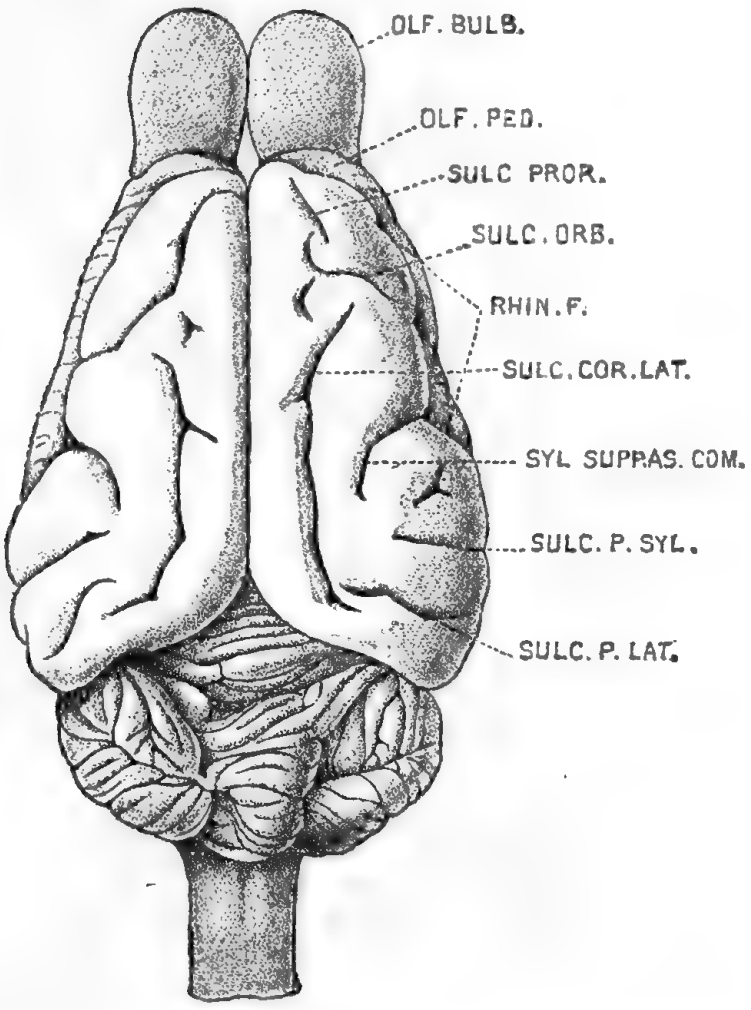

In the right hemisphere there is a single extensive intercalary sulcus, which is prolonged forward in a "genual manner" to join the rostral, which is very short On the left hemisphere we find the same condition as in specimen D. 281.

In this specimen the features of the typical hippocampus, pyriform lobe, olfactory tubercle, and the large tubercle of the olfactory tract are exceedingly well shown (fig. 99).

Note also the corpora quadrigemina and the large mesial geniculate body.

The features of the cerebellum, which resembles that of the Carnivores, are also very clearly shown. An exceptionally clear demonstration of the floccular lobe is afforded.

Fig. 98. (× $\frac{2}{3}$.)

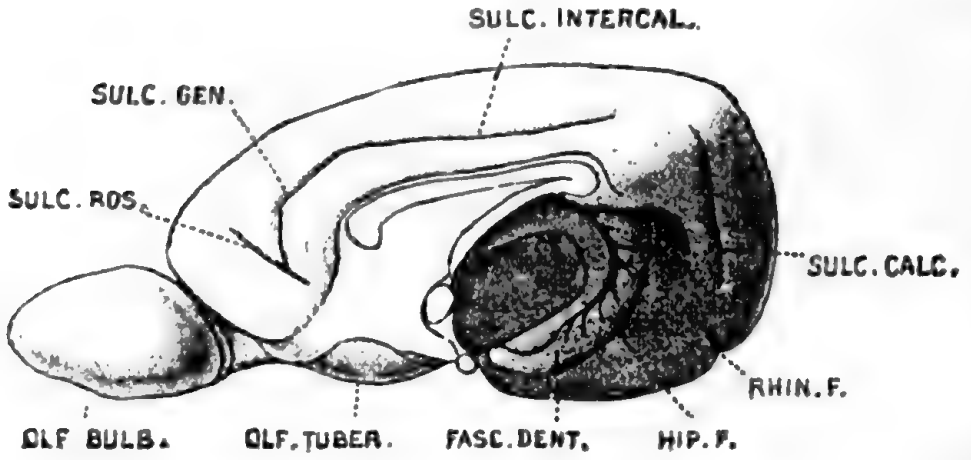

Fig. 99. (× $\frac{2}{3}$.)

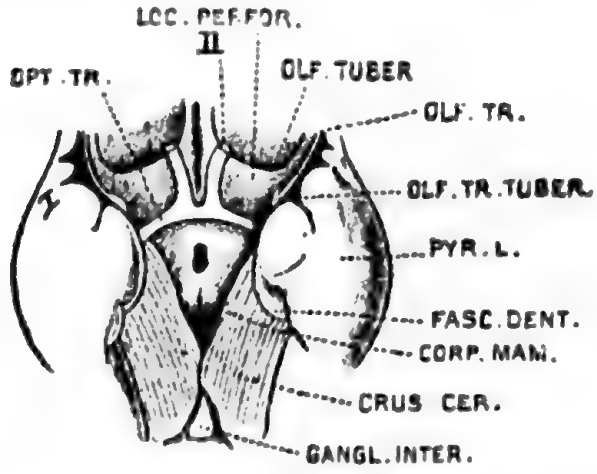

The paraflocculus consists of two plump, horizontal, vermiform bands, which become continuous in front but do not form any projecting petrosal lobule. The flocculus (*sensu stricto*) is a little mass wedged in between the ventral paraflocculus and the auditory nerve.

D. 283. The brain of a Great Anteater (*Myrmecophaga jubata*) (♀), in which the right hemisphere is separated (fig. 100).

This brain is of great interest because the lips (and especially the anterior) of the Sylvian trigone are so poorly developed that this depressed area is wholly exposed.

The suprasylvian element in the Sylvio-suprasylvian complex sulcus is very slightly developed on the left side, and there is a small diagonal sulcus (δ').

The Sylvian trigone shades away anteriorly on the right side, without any very definite terminal sulcus; but on the left side there is a faintly-marked oblique terminal sulcus, which reaches almost as far as the lower extremity of the presylvian sulcus (β).

Fig. 100. (× $\frac{2}{3}$.)

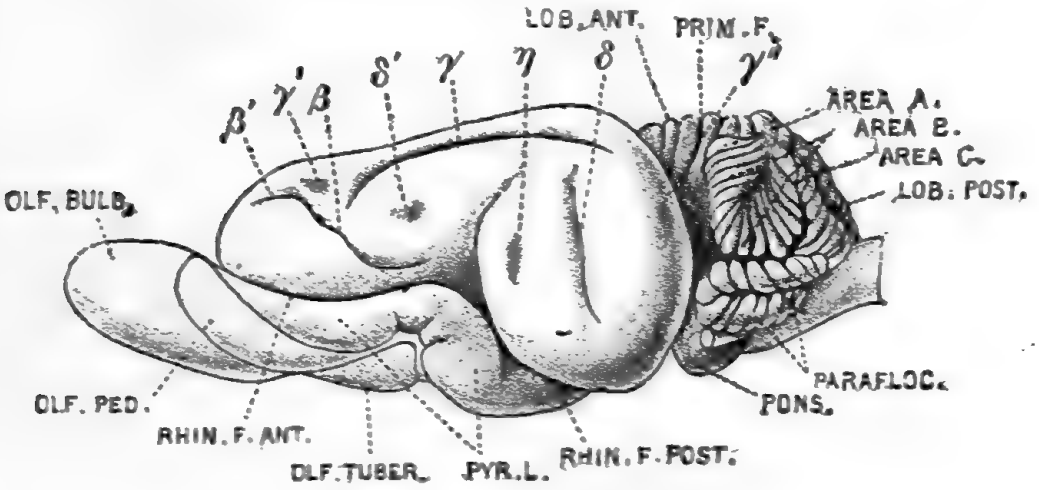

The prorean sulcus (β') is again separate only on the right side. O. C. 1323 K c.

Presented by the Zoological Society.

D. 284. The brain-stem, with part of the cerebral hemispheres, of a Great Anteater (*Myrmecophaga jubata*).

This specimen is intended to show the corpus striatum in the lateral ventricle; the communication of the latter with the olfactory ventricle; the optic tract spreading out on the optic thalami; the tænia thalami and mesial geniculate body; the corpora quadrigemina, of which the posterior pair are the more prominent; the insignificant tractus peduncularis transversus; and the broad pons overlapping to some extent the trapezoid bodies.

D. 285. The brain of a Tamandua (*Tamanduas tetradactyla*) (figs. 101, 102, 103, 104, 105 & 106).

This is a smaller and correspondingly simplified copy of the Great Anteater's brain. All traces of the "feline

Sylvian fissure" have vanished (fig. 102), but the more stable suprasylvian sulcus remains in this specimen (figs. 101 & 102) to add further confirmation to the interpretation of the Sylvian complex of *Myrmecophaga* (D. 281). [Sometimes, however, even the suprasylvian sulcus disappears in *Tamanduas* (fig. 103); this is especially helpful in interpreting the Rodent brain, for it shows that an undoubted lateral (or corono-lateral) sulcus may exist without the suprasylvian, which is usually the more precocious and stable feature.]

Fig. 101. (Nat. size.)

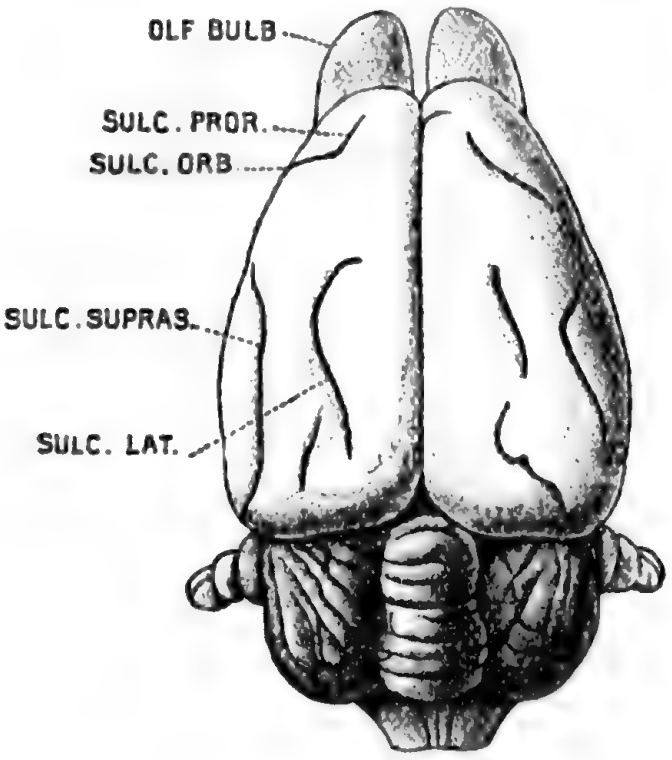

Fig. 102. (Nat. size.)

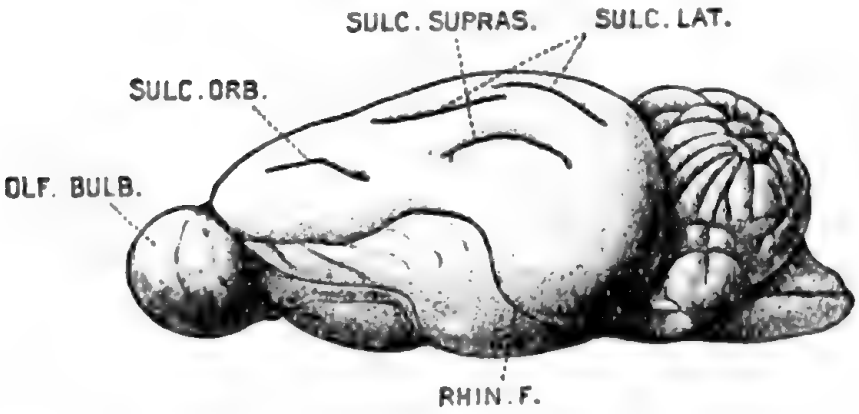

The lateral sulcus is very shallow. In this specimen it is unsymmetrical and consists of two irregular fragments on each side.

The cerebellum (compare fig. 103) is a simplified and smaller copy of that of the Great Anteater. The floccular lobes, however, project freely, whereas those of the Great Anteater are sessile.

The mesial surface of the cerebral hemisphere of *Tamanduas* (compare fig. 104) is instructive in showing the

Fig. 103. (Nat. size.)

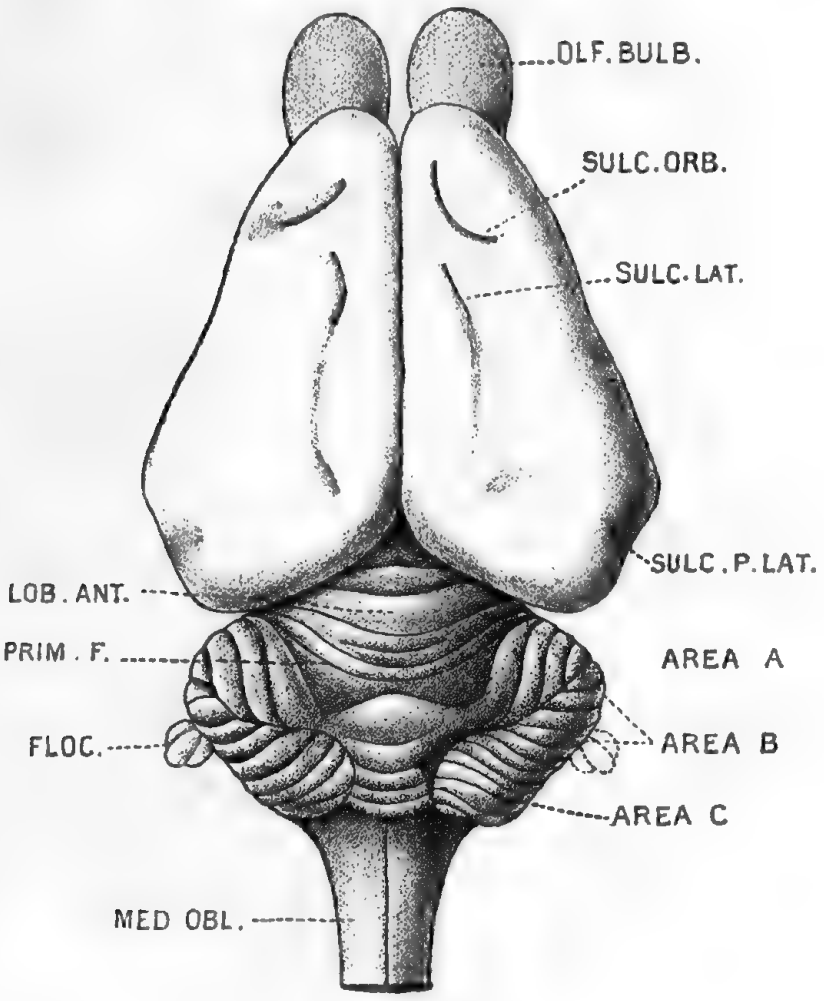

Fig. 104. (Nat. size.)

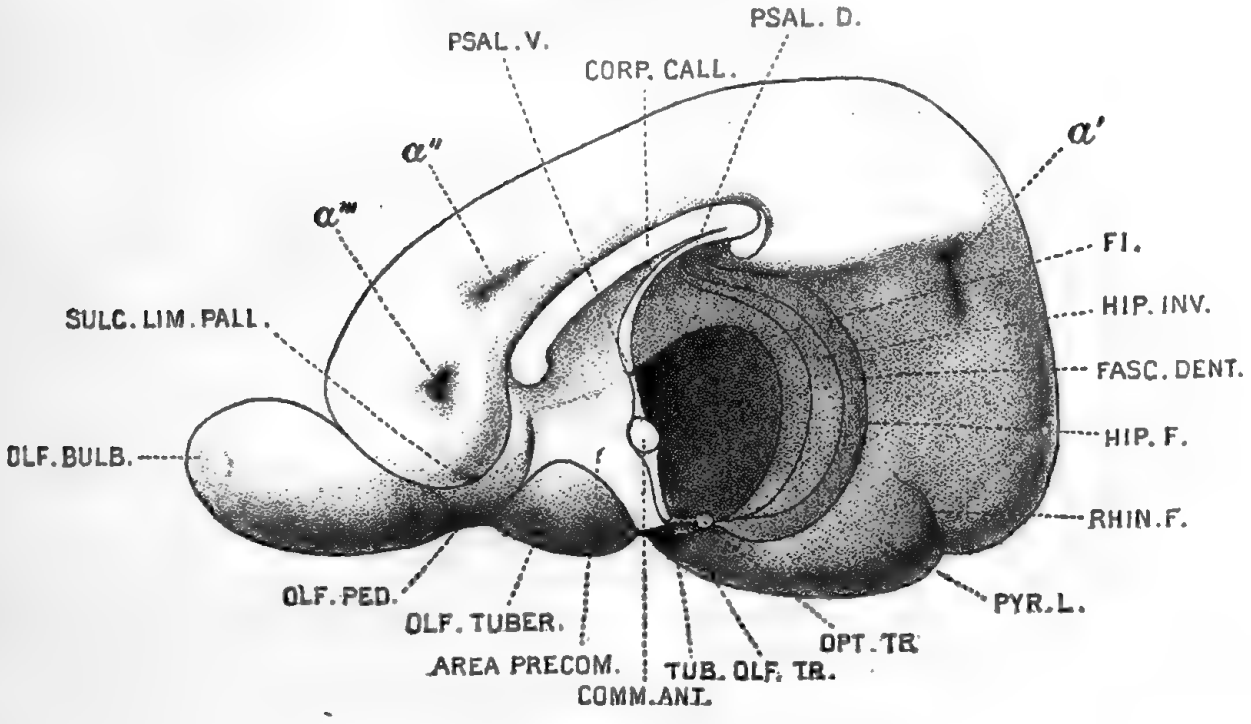

exceedingly rudimentary character of the sulci, in spite of the fact that this brain is much larger than that of the Sloths and Armadillos, which have well-defined mesial sulci. The cerebral commissures and hippocampus (figs. 104 & 105) have now assumed characters like those of the Carnivores and Ungulates.

Fig. 105. (Nat. size.)

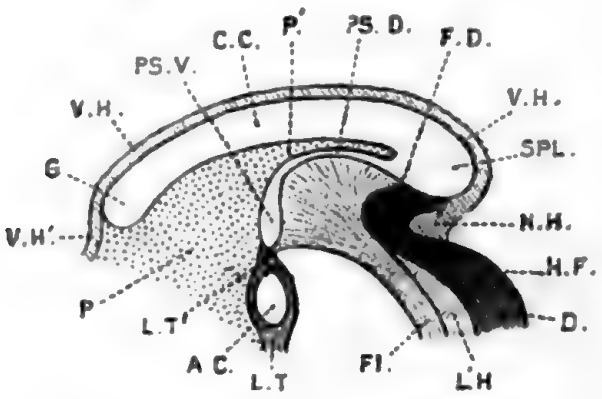

Fig. 106. (Nat. size.)

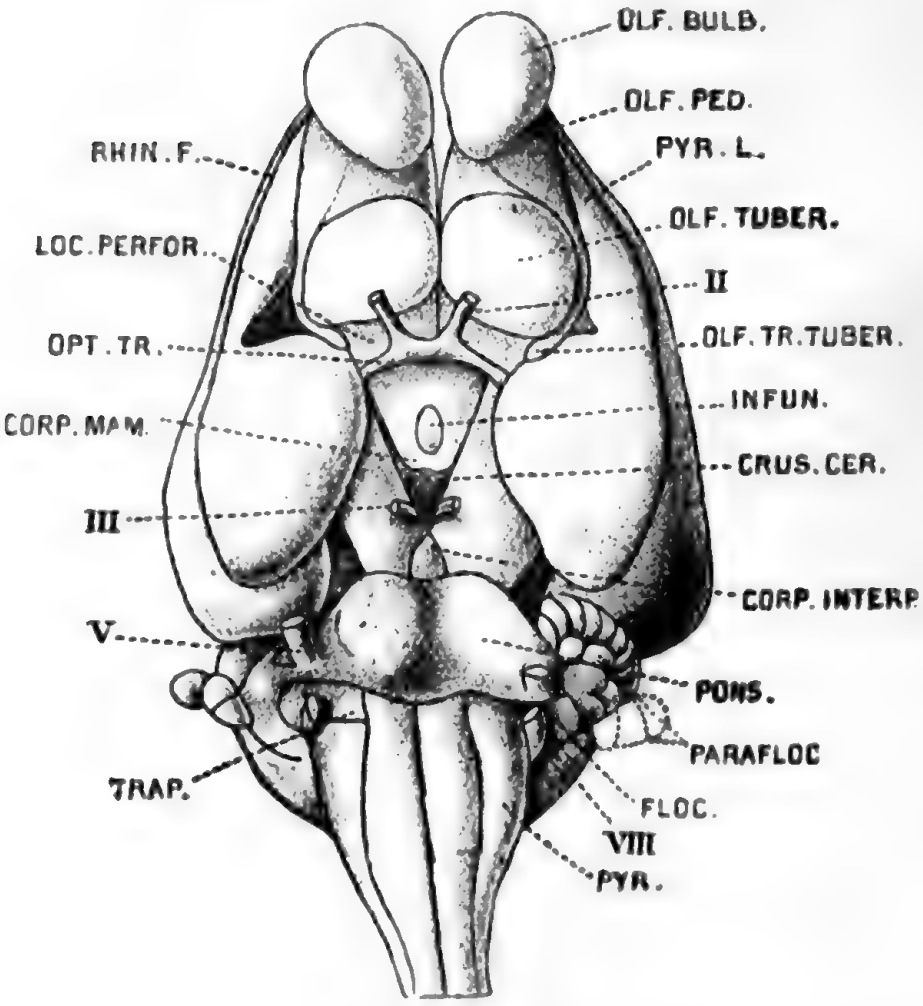

The typical features of the base of the brain are also well shown (fig. 106). O. C. 1323 K *b*.

Elliot Smith, Trans. Linn. Soc. vol. vii. 1899, p. 293.

D. 286. The brain of a Tamandua (*Tamanduas tetradactyla*), (♂).

There is no suprasylvian sulcus (compare fig. 103). The lateral sulcus is well marked and simple, as is also the presylvian or orbital. There is a small shallow postlateral sulcus. O. C. 1323 K *a*.

Family *Manidæ*.

D. 287. The brain of a Pangolin (*Manis tricuspis*), in which the two cerebral hemispheres have been separated from the brain-stem (figs. 107, 108, and 109).

Fig. 107. (Nat. size.)

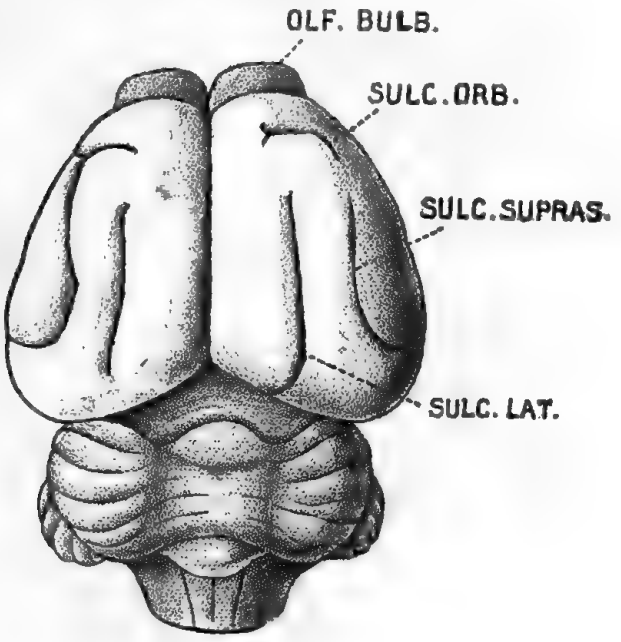

Fig. 108. (Nat. size.)

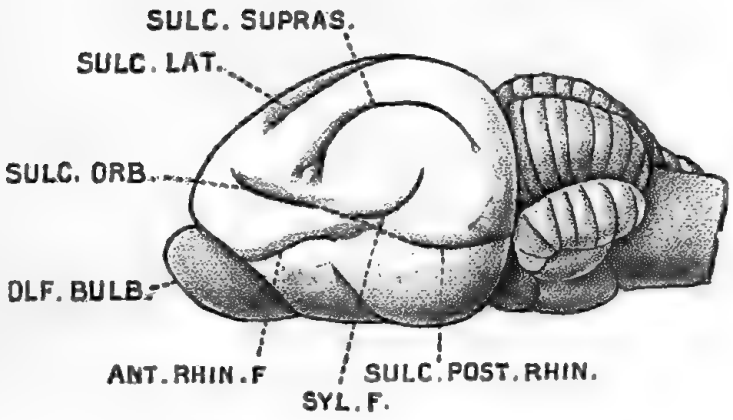

Fig. 109. (Nat. size.)

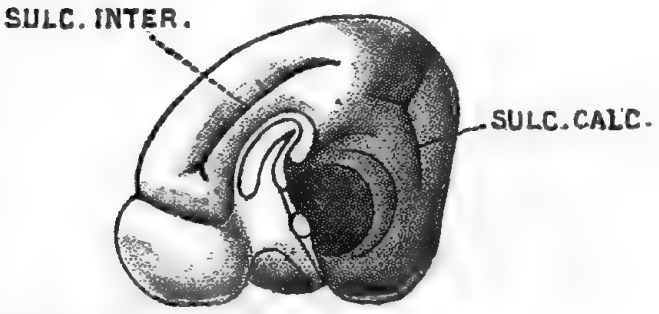

This brain is exceedingly small in proportion to the size of the animal, and yet its small, short cerebral hemispheres present a series of deep sulci, which conform to the most typical mammalian pattern. In many points of detail this pattern resembles that of the Three-toed Sloth, while in other respects it resembles that of the Armadillos.

There is a typical, short, vertical calcarine sulcus close behind the upper half of the hippocampal fissure. Like that of the Sloths, it does not join the intercalary sulcus. It, however, presents as an interesting peculiarity a short retro-calcarine branch, just as the homologous sulcus does in the Lemurs.

There is an elongated intercalary sulcus of about twice the length of the small corpus callosum. In front it joins a short, oblique, rostral sulcus.

It is a very suggestive fact that the intercalary sulcus, which is quite independent of the calcarine in the Anteaters and Sloths and in no other mammals except the Primates, should also be separated from the calcarine sulcus in the Pangolin.

The Sylvian region [which unfortunately is irretrievably damaged in this specimen] presents very interesting features. In another damaged specimen [in the Museum Store Room] the posterior rhinal fissure, which is placed high up on the lateral aspect, is prolonged forward into a very deep orbital (presylvian) sulcus. Gervais and Weber have recorded further instances of a similar condition in *Manis*. This complex of posterior rhinal fissure and orbital sulcus resembles the arrangement seen in the Armadillos and, more distantly, the condition found in *Orycteropus*, *Tapirus*, and *Moschus* (*vide infra*). In this particular specimen (D. 287), however, the left orbital sulcus is certainly not joined to the rhinal fissure.

The short anterior rhinal fissure does not reach so far back as the anterior extremity of the posterior rhinal. In this respect it resembles that of the Armadillos. A short, oblique "Sylvian fissure" springs from the posterior rhinal fissure, just where the latter joins, or appears to join, the orbital sulcus. The appearance of the "Sylvian" and orbital elements recalls that presented in *Galeopithecus*. There is a typical semicircular suprasylvian sulcus presenting an arcuate form. There is also a typical, sagittally-directed lateral sulcus.

The cerebellum and the other parts of the brain are not unlike those of the Sloths, or, rather, present features intermediate between those of the Armadillos and Sloths.

Considered as a whole, the brain of the Pangolin may be regarded as a smaller and correspondingly-simplified copy of that of the Three-toed Sloth. This fact, in view of the marked contrast in the modes of life of the two animals, must be allowed considerable systematic importance*.

O. C. 1323 M.

Presented by the Zoological Society.

Max Weber, Zool. Ergebnisse, Leyden, 1892, p. 87.

Family *ORYCTEROPODIDÆ.*

D. 288. The brain of an Aard-vark (*Orycteropus afer*), (♀) (figs. 110, 111, 112, 113, 114, & 115).

The brain is of approximately the same size and shape as that of the Great Anteater, but its features present a most striking contrast to it.

Fig. 110. (× ⅔.)

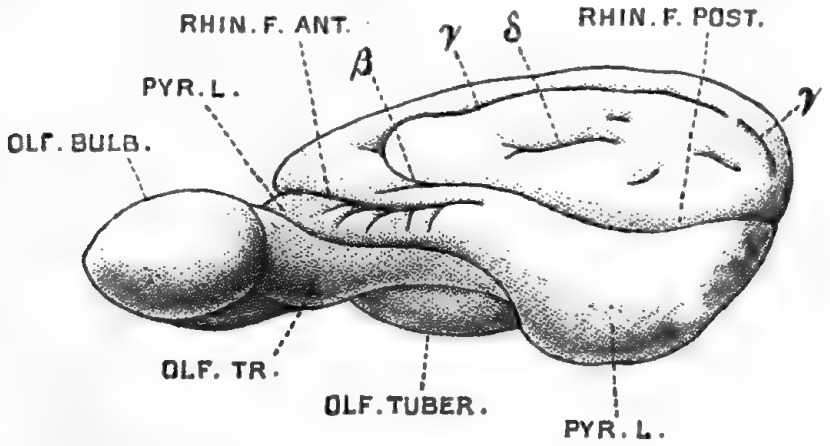

In neither of the specimens [in this collection] does the posterior rhinal fissure join the anterior rhinal, but the two fissures overlap (fig. 110) as they do in the Tapir (*vide infra*). Sometimes, however, the two fragments unite to form a

---

* When my memoir on the Edentate brain was written, I had not examined a good specimen of the brain of *Manis* and had to rely on Weber's account chiefly. I therefore saw no reason for associating *Manis* with the other Edentates, so far as the structure of its brain is concerned. Now that I know the brain itself, I quite agree with the conclusion drawn by Windle and Parsons from myological studies (P. Z. S. 1899), and believe that *Manis* shows undoubted affinities to all the other Edentates and especially to *Bradypus*.

great horizontal fissure (fig. 111), which divides the lateral wall into two approximately equal parts—an upper one of neopallium, and a lower composed of pyriform lobe, tuberculum olfactorium, and olfactory bulb.

There is no trace of a "Sylvian fissure." There is a typical orbital (presylvian) sulcus (β) which links the cephalic prolongation of the posterior rhinal fissure to the anterior extremity of the great sagittal lateral sulcus (figs. 110, 111, & 113, γ), and from the junction the prorean sulcus extends forwards.

Fig. 111. (× $\frac{2}{3}$.)

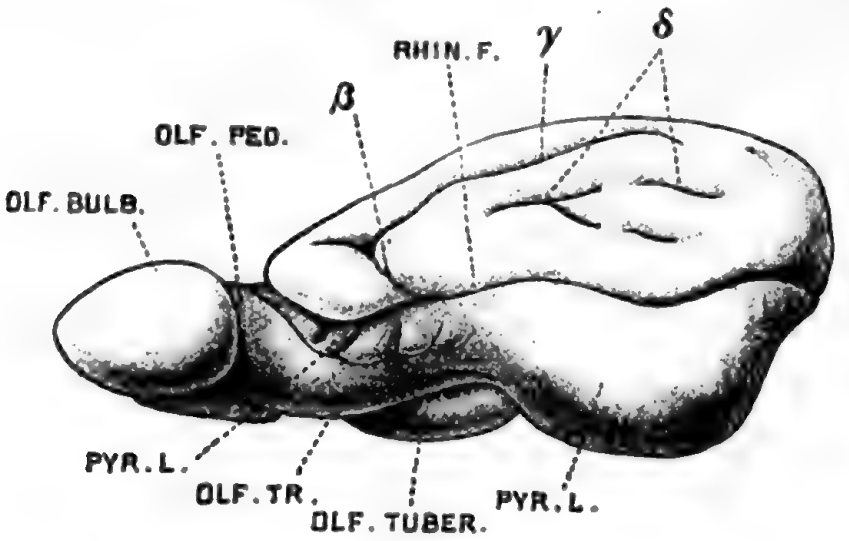

Fig. 112. (× $\frac{2}{3}$.)

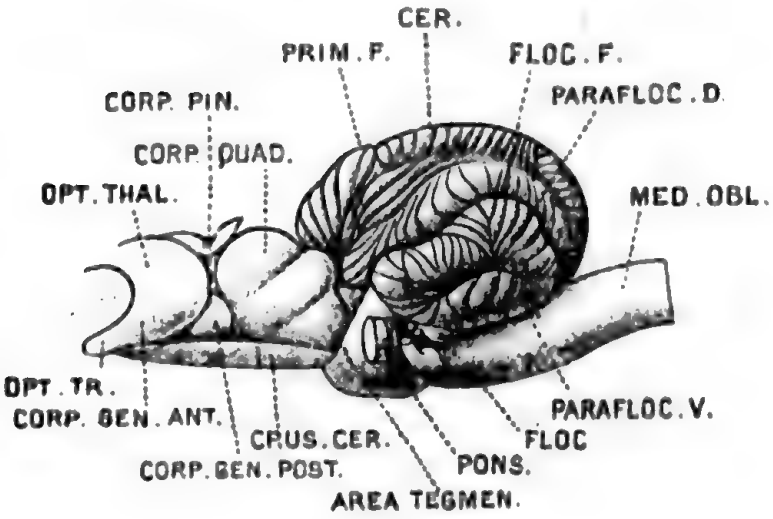

There is a short horizontal sulcus (δ) in the situation where we should look for the suprasylvian sulcus. This peculiar insignificance of the suprasylvian as compared with the lateral sulcus, which is also seen in *Tamanduas* and many Rodents, presents a marked contrast to the Ungulate condition, where just the opposite condition obtains.

On the mesial wall there is a large arcuate complex (fig. 114, α) of deep calcarine, intercalary, and genual sulci.

The latter joins the anterior extremity of the callosal sulcus.

The corpus callosum is short. There is a very large vestigial hippocampus on its upper surface.

Fig. 113. (× $\frac{2}{3}$.)

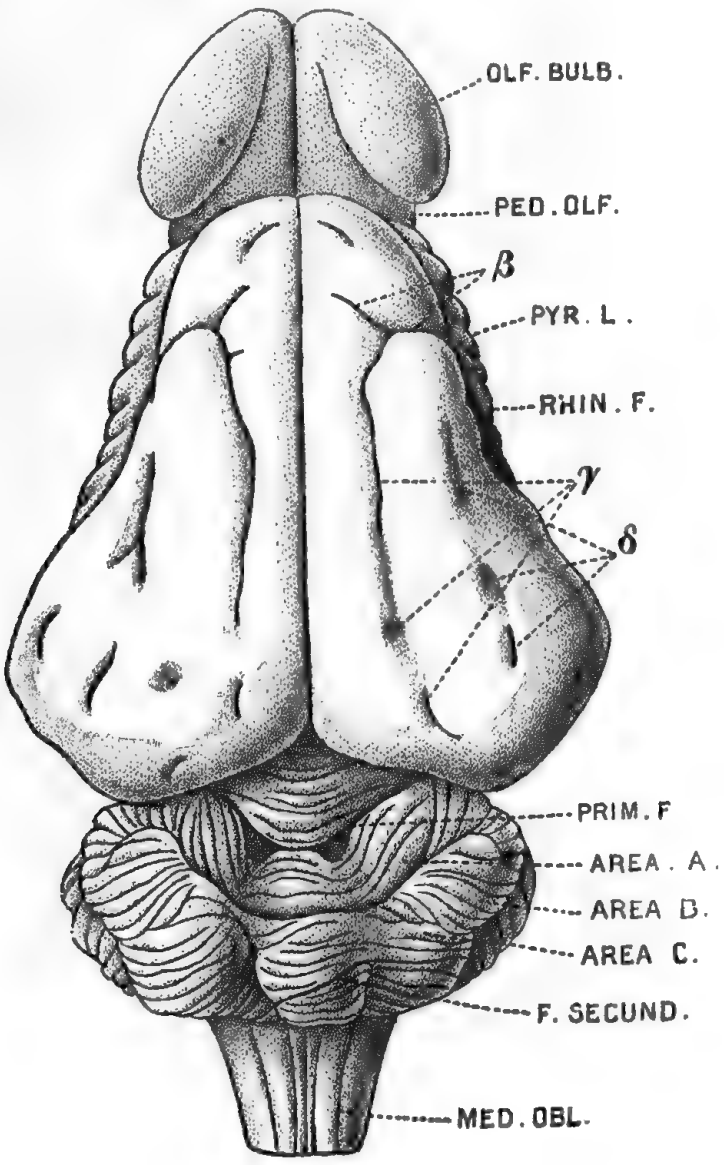

Fig. 114. (× $\frac{2}{3}$.)

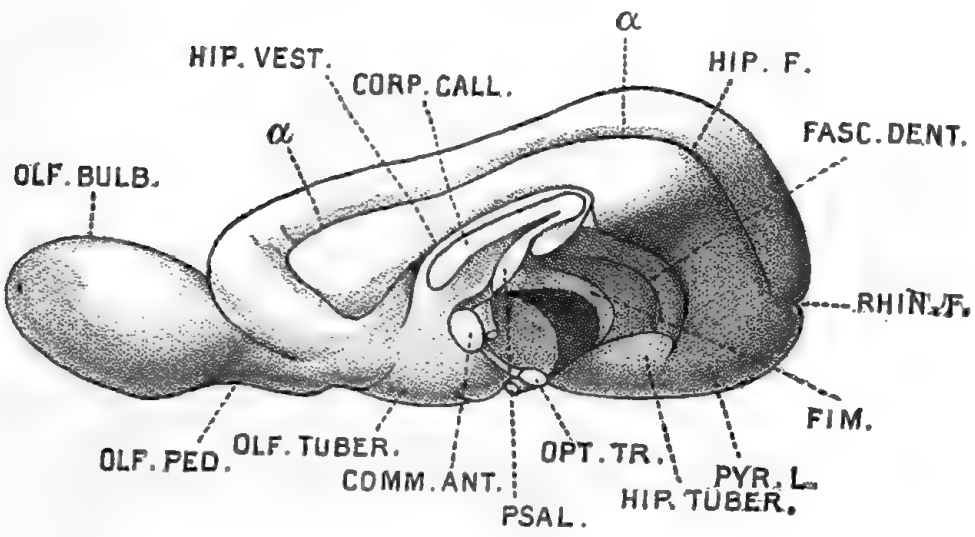

The other parts of the brain (*vide* fig. 112) are not unlike those of *Myrmecophaga*, although there is no evidence of any close affinity between the two forms.

In general appearance and in the arrangement of the horizontal rhinal fissure and its relation to the orbital sulcus, this brain presents some resemblance to that of an Ungulate. But the poor development of the suprasylvian sulcus is a point in which it differs markedly from the Ungulata. The cerebellum also differs most markedly from the simple, transversely-foliate, Ungulate type.

There is a peculiar feature in the lower extremity of the hippocampal formation—a hippocampal tubercle, which is not exposed in either of these specimens. Such a "hippocampal tubercle" of inverted hippocampus I have seen elsewhere only in one of three specimens of the Manatee and in the Primates.

Fig. 115. (× $\frac{2}{3}$.)

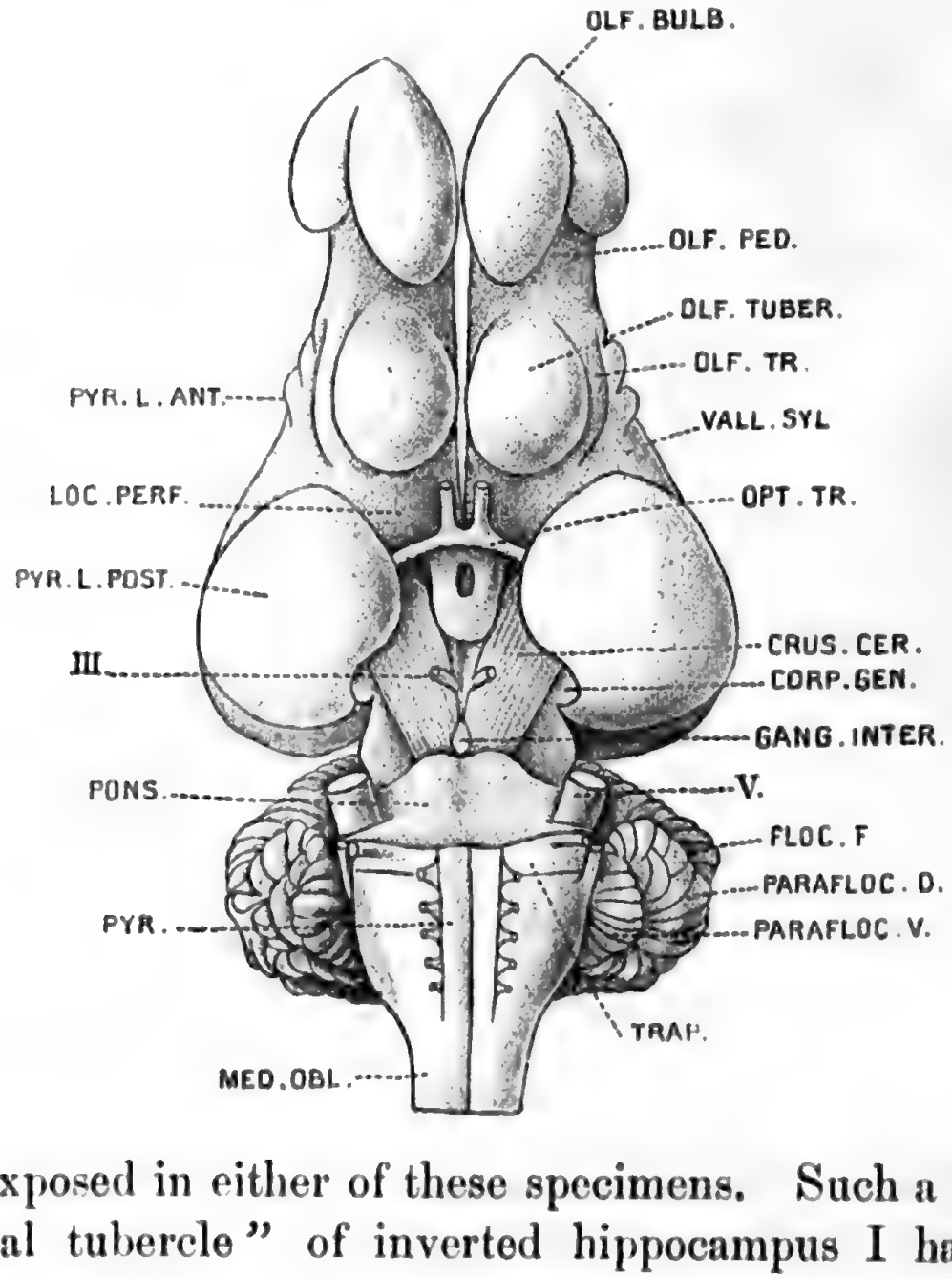

I also insert here a drawing (made from a better specimen) of the base of the brain, because it exhibits in such a striking manner the typical relations of the highly macrosmatic brain (fig. 115). O. C. 1323 L.

Presented by the Zoological Society.

Elliot Smith, Trans. Linn. Soc. vol. vii. 1899, p. 286.

D. 289. The brain of an Aard-Vark (*Orycteropus afer*), (♀).

This specimen resembles the preceding in most respects. The suprasylvian sulcus is very insignificant. The lateral sulcus is broken up into two fragments, the anterior (coronal?) of which does *not* join the orbital.

O. C. 1323 L*a*.

ORDER CARNIVORA.

Section ÆLUROIDEA.

Family *FELIDÆ.*

D. 290. The brain of a Domestic Cat (*Felis domestica*), divided by a mesial sagittal section and the right hemisphere separated from its half of the brain-stem.

The Cats exhibit in perhaps their most pronounced form the peculiarities distinctive of the true Carnivores, of which they form one of the most specialised types.

In the Carnivora the brain attains to much larger dimensions in proportion to the size of the animal than is the case in the Rodentia, Edentata, and Insectivora, and this increase in size is to be attributed almost entirely to the larger growth of the neopallium.

Among the secondary expressions of these larger dimensions of the neopallium the most noteworthy are:—A tendency of the dorso-caudal regions of the hemisphere to bulge over the cerebellum, so that the posterior margin of the hemisphere exhibits an increasing degree of obliquity: the hemisphere also grows forward so as to bulge over the olfactory bulb, and an olfactory sulcus developes on the ventral surface of this neopallium to lodge the bulb and its peduncle: and the arrangement of the sulci becomes more stable and, as it were, fixed. (Compare figs. 116–121, representing the Lion's brain.)

The brain is still macrosmatic; but the greater size of the neopallium renders the greatness of the parts of the brain chiefly concerned with olfactory functions less obtrusive than is the case in mammals with a smaller neopallium.

Hence we find in the case of the Cat's brain that the rhinal fissure (which is the line of demarcation upon the lateral aspect between the essentially olfactory pyriform lobe and the neopallium) is placed very low down on the lateral and partly on the basal surfaces of the hemisphere. [See the diagram of the Lion's brain, fig. 116.]

A short sulcus, generally known as the "Sylvian fissure," springs from the junction of the anterior and posterior rhinal fissures. This "fissure" does not correspond to that called "Sylvian" in the Bears, and it has moreover a significance very different to the Human Sylvian fissure.

Fig. 116. (× $\frac{2}{3}$.)

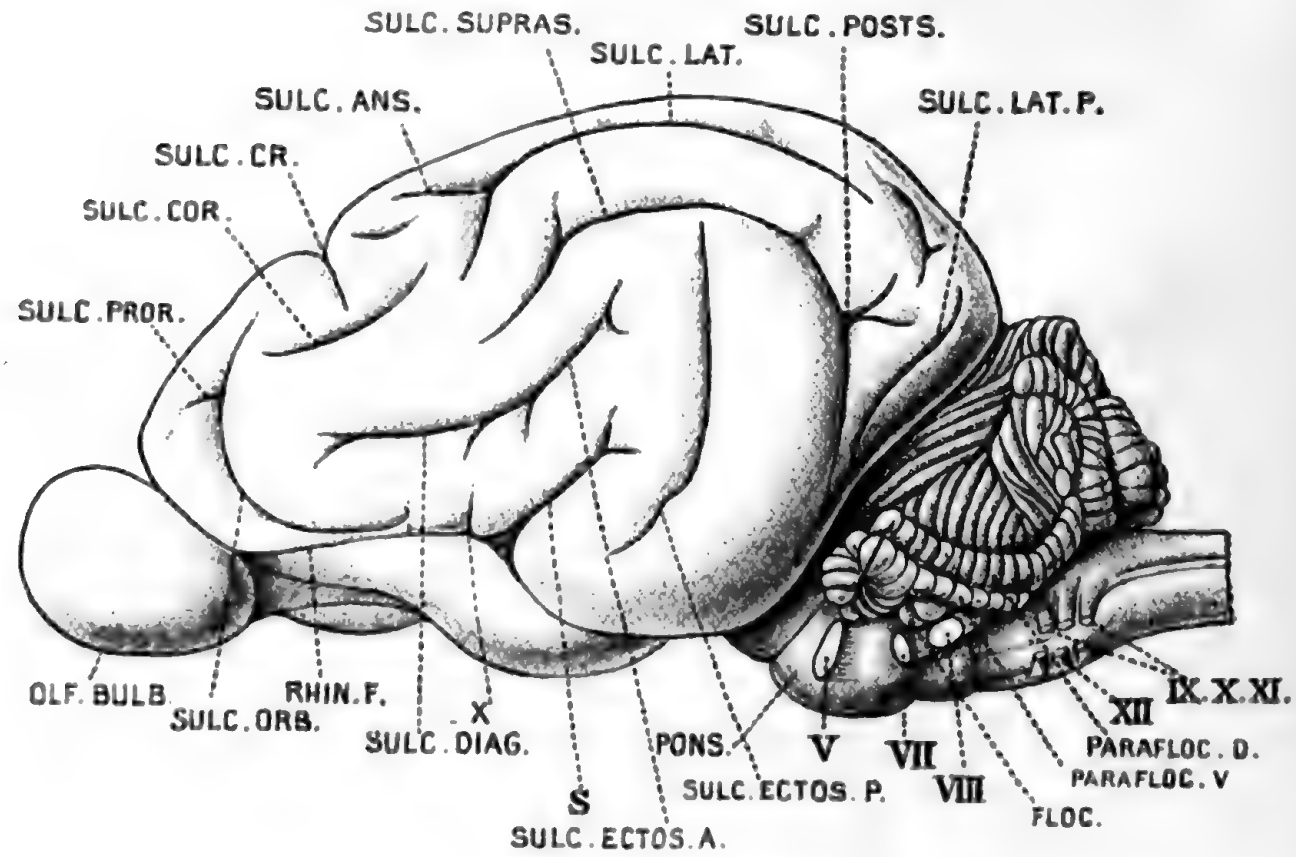

Hence it will conduce to accuracy and clearness if we call it the "Feline Sylvian fissure." It may be compared to that already noticed in the brain of the Three-toed Sloth.

In the left hemisphere the anterior lip of this fissure has been cut away, but there is no distinct area of cortex submerged in the fissure such as Holl describes (Arch. f. Anat. u. Entwick. 1899, p. 229). At the same time it will be noticed that the lower part of the fissure cuts into the hemisphere very obliquely, so that the anterior lip overlaps the posterior lip. In the larger Felidæ this becomes much more accentuated, so that a relatively large area of the posterior lip becomes overlapped by the anterior lip. In such forms, and sometimes also in the Cat, a short sulcus indents this submerged posterior lip and separates it from the general surface of the hemisphere, so that a much more definite submerged area is thus marked off.

The long, deep orbital (or presylvian) sulcus is placed far forward: it opens into the rhinal fissure, and it resembles that of the Sloths.

It is a characteristic of the Cats to have two vertical ectosylvian sulci—anterior and posterior—which do not unite above to form an arc as they do in the Dogs: thus a broad cortical bridge, which Meynert has called the "*gyrus felinus*," joins the first and second arcuate gyri of Leuret.

There is a deep suprasylvian sulcus which is almost horizontal; it becomes continuous with the vertical postsylvian (or posterior suprasylvian) sulcus of Owen.

The latter extends vertically downward to a point on the caudal margin of the hemisphere at the junction of its middle and lower thirds.

The "lateral" sulcus pursues a sagittal course midway between the suprasylvian sulcus and the mesial edge. In front it bends outward parallel to the suprasylvian and gives off an "ansate" branch.

The "post-lateral" sulcus begins anteriorly opposite the junction of the suprasylvian and postsylvian sulci, and pursues an arcuate course parallel to the medio-caudal "angle" of the hemisphere. On the right hemisphere it is joined to the lateral, but is separate on the left side. There is a large transverse crucial sulcus placed very far forward on the anterior pole of the hemisphere, immediately behind the mesial extremity of the orbital sulcus. It crosses the mesial edge and proceeds horizontally backward on the mesial surface for a short distance above the genu of the corpus callosum.

There is a short oblique coronal sulcus midway between the ends of the suprasylvian and crucial sulci. Its upper (posterior) end is opposite the angle between the lateral and ansate sulci, and its lower (anterior) end is close to the orbital. In front of the ventral extremity of the anterior ectosylvian sulcus there is a short oblique "diagonal sulcus." It is not uncommon to find the latter joined to the former sulcus. In other cases the diagonal sulcus may be absent.

On the mesial surface of the right hemisphere, note the olfactory peduncle passing into continuity with the precommissural area, the upper part of which fills up the gap between the corpus callosum and the psalterium, and is commonly known as a folium of the septum lucidum.

Underneath the splenium of the corpus callosum the subsplenial hippocampal flexure is visible, the pyriform upper part being formed by the fascia dentata rapidly dwindling away as it surrounds the splenium: below the tapering fascia dentata there is a little tubercle of exposed hippocampus — the *hippocampus nudus* (the so-called "Balkenwindung").

Behind the lower half of the typical hippocampal formation the caudal part of the rhinal fissure is seen. It ends in a bifid manner.

The calcarine sulcus begins above the latter, ascends vertically, and is then prolonged forward and with a slight obliquity upward, so as to overlap, without joining, the crucial sulcus: in other words, the calcarine is continuous with the intercalary sulcus. It is a feature of contrast between the Æluroidea and the Cynoidea that in the former the crucial sulcus and the intercalary (so-called "splenial") sulcus are usually separate, whereas they commonly join in the latter. There is a short marginal sulcus (Owen) above the intercalary in the region of the splenium.

On the mesial surface of the brain, note the cavity of the third ventricle bridged by the large "soft" or middle commissure: its anterior wall formed by the delicate lamina terminalis, which proceeds from the optic chiasma to the anterior commissure and then from the latter to the ventral extremity of the psalterium; behind the latter, the upper extremity of the lamina terminalis is seen as a little gelatinous-like nodule, the crista, to which the epithelial roof of the ventricle is attached. (The epithelial roof has been removed from the specimen.*)

---

* The general relations of all the structures enumerated in this and the following four paragraphs do not change to any great extent in the Eutheria. Hence the reader may consult a text-book of Human Anatomy for a fuller account of them.

Note the pear-shaped ganglion habenulæ and the tænia thalami; the habenular commissure, the pineal body, and the posterior commissure forming the upper lip of the opening of the aqueduct of Sylvius. The latter is a large canal, which expands posteriorly into a trumpet-shape.

The most noteworthy features upon the lateral aspect of the mid-brain are the huge size of the mesial (posterior) geniculate body and the prominence of the posterior quadrigeminal bodies. Both phenomena are probably related to the acuteness of hearing in Cats.

There is an extremely well-defined tractus peduncularis transversus.

The pons, anterior pyramids, and trapezoid bodies are exceedingly clearly defined, and a slight olivary eminence now makes its appearance at the lateral border of the pyramid. All the cranial nerves are well-developed and present the typical relations.

The cerebellum presents features closely resembling the corresponding organ in the larger Edentates and in some of the Rodents.

There is a large floccular lobe closely applied to the lateral aspect of the middle (or pontine) peduncle of the cerebellum and the tuberculum acusticum. The latter is easily recognised by the insertion of the auditory nerve. The floccular lobe consists of three parts, viz.:—A flattened body, the flocculus (*sensu stricto*), closely applied to the surface of the acoustic tubercle; a horizontal multifoliate band, the ventral paraflocculus, immediately external to this; and the dorsal paraflocculus, also a horizontal vermiform band continuous anteriorly with the ventral paraflocculus and posteriorly prolonged into continuity with the pyramid (a part of the general mass of the cerebellum).

The floccular lobes are separated from the general mass of the cerebellum by deep floccular fissures. [A similar floccular lobe may be seen to better advantage in *Myrmecophaga* (specimen D. 282): the fundamental plan is explained by a series of diagrams in the account of *Cabassous* (specimen D. 268).]

The interfloccular mass of the cerebellum may be subdivided for descriptive purposes into three main parts or azygos lobes.

The whole of the anterior surface of this mass is separated from the rest of the cerebellum by means of the deepest fissure which crosses the middle line. This we may distinguish as the anterior lobe, and its limiting fissure may be called "primary," as it is the first fissure to cross the middle line in the course of development. It corresponds to the preclival fissure of Human Anatomy. The anterior lobe represents the lobus centralis and lobus culminis of Human Anatomy. It is a large lozenge-shaped area, broad in the mesial plane and rapidly tapering towards the middle peduncle and the front of the paraflocculus on each side.

The most caudal or rather caudo-ventral part of the cerebellum consists of a small mesial mass, the grey matter of which is not continued laterally, as that of the rest of the mesial cerebellar areas is. This may be distinguished as the posterior lobe and its dorsal limiting fissure as "secondary." The lobe represents the nodulus and uvula of Human Anatomy. Laterally it appears to be prolonged into a narrow medullary band, which is closely connected with the posterior medullary velum and leads to the flocculus.

The great mass included between the primary and secondary fissures and limited laterally by the floccular fissures may be called the "central" or preferably (to avoid confusion with the "central lobe" of Human Anatomy) the "middle lobe."

The middle lobe is divisible into four parts, the behaviour of the lateral parts of each of which differs markedly from that of the others.

The anterior lobule consists of a narrow band, which becomes slightly constricted on each side of the middle line and then expands again to a slight extent to form a long tapering fissured band, which forms the posterior lip of the primary fissure. In Man this becomes greatly expanded to form the lobus clivi.

The second lobule is narrow in the mesial plane, but expands enormously to form the great suprafloccular (*i. e.* above the paraflocculus) mass, the folia of which are arranged in a feather-like pattern in all the Carnivora. It presents a similar arrangement in the Anteaters, the

Aard-vark, and many Rodents, but in many Ungulates and Rodents there is no such lateral expansion in a feather-like pattern, but a simple transverse arrangement of the folia.

In the Primates this region of the cerebellum becomes so enormously expanded that it forms the great mass of the organ.

The third lobule consists of an extremely narrow mesial bridge connecting two large vertical worm-like masses, which extend downward on the caudal surface and separate the posterior lobe from the paraflocculus.

The fourth lobule consists of the pyramid, which is laterally joined to the dorsal paraflocculus by a narrow band, which has become so compressed by the downward growth of the third lobule as to be recognised with difficulty in the Cat's brain. It is, however, clearly shown in such brains as that of *Lepus* and *Cabassous.*

Burt G. Wilder, Proc. Amer. Phil. Soc. 1881, p. 524.

D. 291. The brain of a Cat (*Felis domestica*), in which the corpus callosum has been cut through in a sagittal direction and the cerebral hemispheres widely divaricated.

The caudate nuclei lying in the lateral ventricles have been thus exposed. The optic thalami have been drawn asunder and the soft commissure partially torn through, so that the slit-like third ventricle has been converted into a widely open space the limits of which are indicated by the tæniæ thalami, which together form a semicircle. The corpora quadrigemina are exposed, and external to the anterior quadrigeminal body the large mesial geniculate body may be seen immediately behind the optic thalamus. This mesial geniculate body may also be well seen upon the left side of the base of the brain, the natiform portion of the pyriform lobe having been removed in order to expose it. O. C. 1325 D.

D. 292. The brain of a Cat (*Felis domestica*) presenting an anomalous arrangement of the cerebral sulci.

On the right hemisphere the pseudosylvian sulcus is very short, and on the left is reduced to a mere notch in the upper lip of the rhinal fissure. This arrangement is similar to that presented by the brain of *Herpestes*.

The ectosylvian sulci are very deep, as if to compensate for the diminutive size of the pseudosylvian. The anterior and posterior ectosylvian sulci *appear* to be joined into an arc on both sides as in Cynoidea; but they are in reality separated by a feline gyrus which is partly submerged. There are a series of fragmentary sulci between the posterior ectosylvian and the postsylvian. The postlateral is a short branch of the latter sulcus, and is quite independent of the lateral sulcus. The latter is continuous on the left side with a long and tortuous coronal sulcus. There are well-marked but shallow representatives of an entolateral sulcus on each hemisphere.

This specimen is of special interest as a further demonstration of the fact, which has already been noted in the Sloths and the lowlier Mammalian Orders generally, that the "Sylvian fissure" (so-called) is at first a very unstable feature and only becomes definitely "fixed" in the higher Mammalia. It further illustrates the reciprocally compensatory development of the pseudosylvian and the ectosylvian sulci, of which we meet many instances elsewhere*.

D. 293. The brain of a new born Lion (*Felis leo*).

The only noteworthy features in this specimen are a series of peculiar notchings in the upper lip of the rhinal fissure in front of the pseudosylvian sulcus, and the extreme irregularity of the latter and of the ectosylvian sulci.

O. C. 1325 A *a*.

D. 294. The brain of a Lioness (*Felis leo*), in which a dissection has been made to show the hippocampus in the left hemisphere.

The brain of the Lion when compared with that of the Cat affords an admirable demonstration of the influence of

---

* In the accentuation of the ecto- at the expense of the pseudosylvian sulcus this anomalous brain resembles the Ungulate type, the so-called "Sylvian fissure" of which is formed by the meeting of the lips of the two ectosylvian sulci. In this case also the feline pseudosylvian sulcus becomes greatly reduced or even disappears.

the size of the body upon the proportions and form of the brain. In animals of the same Order (and more especially of the same genus) the brain is much larger in the bigger species; but the increase in size is not proportionate to that of the bodily dimensions, the smaller animal having a brain relatively much larger than that of the bigger animal. This is due to the fact that in mammals of the same genus (*i. e.* in animals in which the other determining factors of the size of the brain may be neglected as being common to the two forms) the size of the pallium varies directly with that of the areas of the sensory surfaces, and these are relatively greater in a small than in a large animal. (See Dubois, Bull. d'Anthropol. de Paris, 1897, p. 337.)

As a result of the larger size of the neopallium, the sulci become deeper and longer and secondary sulci make their appearance.

Fig. 117.

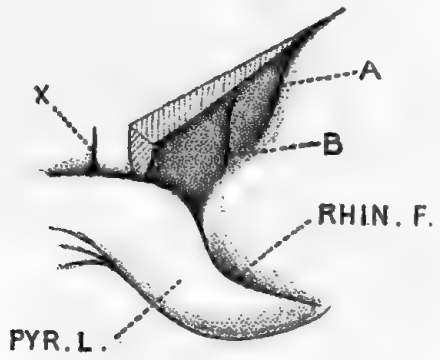

* The "Sylvian fissure" (so-called) is much deeper and cuts into the neopallium much more obliquely than is the case in the Cat's brain. Thus a large anterior lip is developed so as to overlap the depressed posterior lip, which is exposed by raising, or better by cutting away (fig. 117), the anterior lip. The submerged posterior lip is then seen to be indented by two sulci (fig. 117, A and B). In this specimen (D. 294) the condition thus described as typical of the Lion's brain does not obtain, and a condition essentially identical with that of the Jaguar's brain (***vide infra*** D. 297) is present.

---

* [The following remarks are based upon the careful examination of the brains of three Lions, which were removed from the skulls by the writer shortly after the death of the animals: thus a more accurate account is given than would be possible from the study of old Museum specimens.]

In front of the "Sylvian fissure" a short, deep, vertical sulcus extends upward from the rhinal fissure (figs. 116 & 117, x).

The anterior ectosylvian sulcus (fig. 116) is very deep, and its lips are puckered so as to produce short secondary sulci in some cases. In all of the eight hemispheres I have examined it is confluent with a very deep, long, horizontal "diagonal sulcus," which also in most cases gives off short secondary branches.

In some cases (fig. 118) the anterior limb of the first arcuate gyrus of Leuret becomes submerged in the "Sylvian fissure," so that the anterior ectosylvian sulcus becomes hidden in the latter and the diagonal sulcus appears (at a casual glance) to emerge from the Sylvian fissure itself.

Fig. 118. ($\times \frac{2}{3}$.)

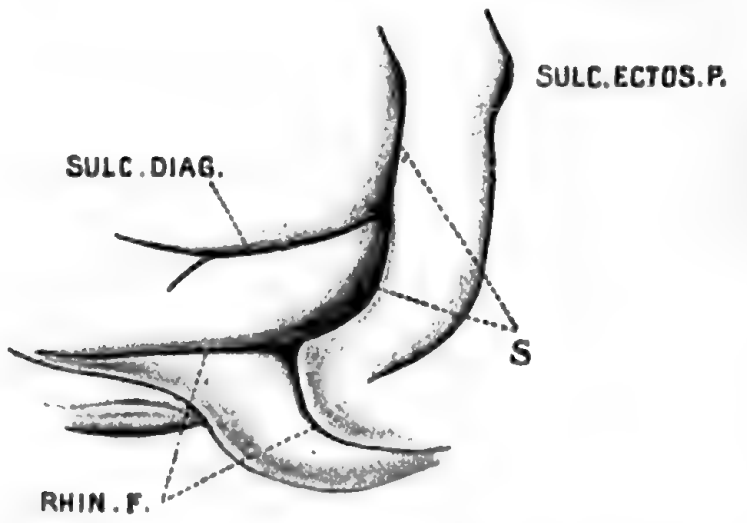

Such a phenomenon is of great interest as an indication of the very general tendency (among the Mammalia generally) for the cortical areas in front of the "feline Sylvian" fissure to become engulfed in it. In the Bears, not only the anterior limb but the whole of the first arcuate gyrus becomes swallowed up in the "Sylvian fissure."

It is unnecessary to describe in detail the effects of the deepening and development of secondary branches in the case of the posterior ectosylvian, suprasylvian, and coronolateral group of sulci. These are obvious at a glance (fig. 116).

It is of interest to note that the exceedingly deep orbital (presylvian) sulcus is independent of the rhinal fissure; a fact which is veiled in the Cat by the upper operculum of the sulcus meeting the pyriform lobe.

It is a very interesting fact that an undoubted precrucial sulcus is found in the deep crucial sulcus. Sometimes this sulcus is exposed (fig. 119); in other cases it is hidden by the opercular posterior lip of the crucial sulcus and is visible only after raising or removing this (fig. 120). So that in this Feline brain we find a very distinct "Ursine lozenge" of Mivart.

Fig. 119. (× $\frac{2}{3}$.)

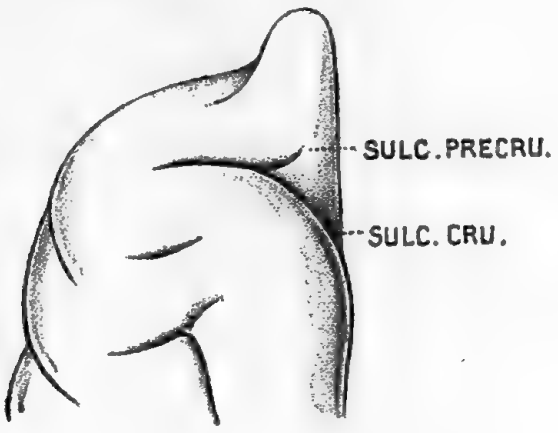

Fig. 120. (× $\frac{2}{3}$.)

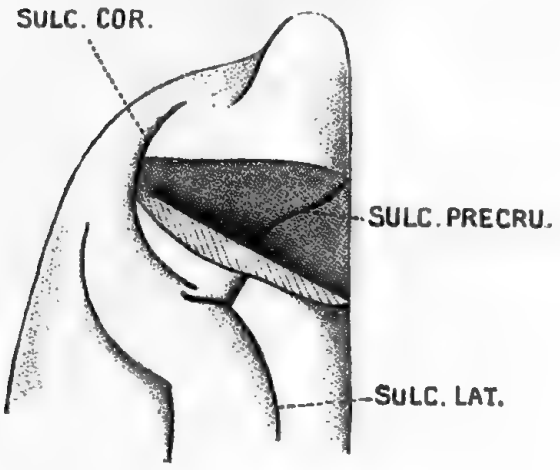

Fig. 121. (× $\frac{2}{3}$.)

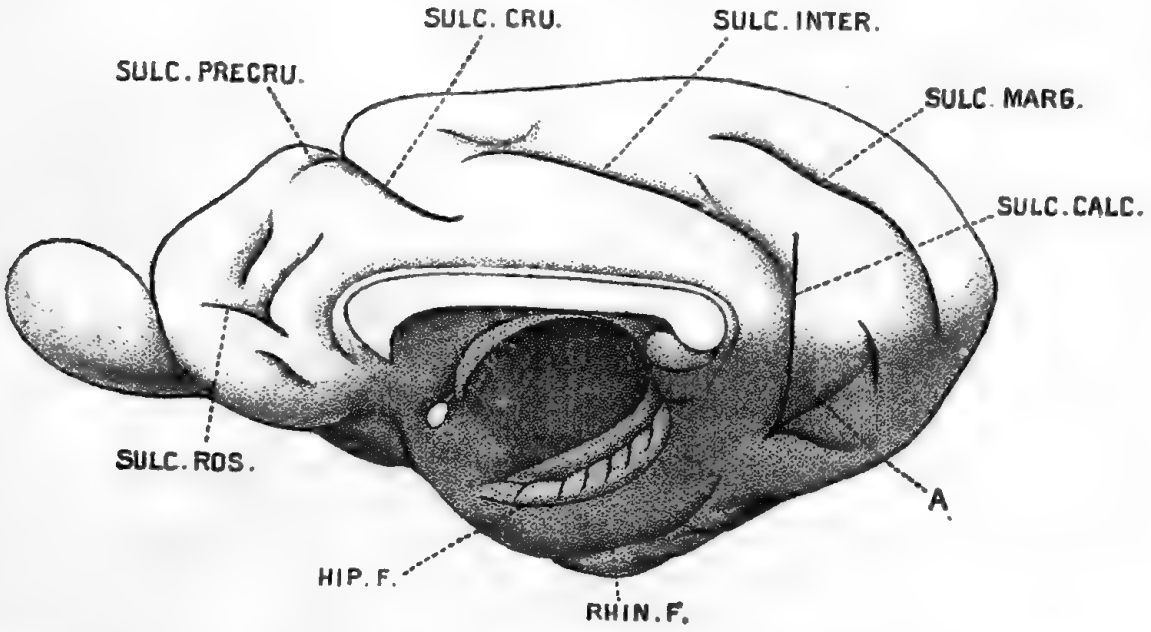

Another feature of great interest in the Lion's brain is exposed on separating the lips of the deep "splenial" complex, when it is seen that the calcarine sulcus is really distinct from the intercalary in this Carnivore, as it is in the Edentata and Primates (fig. 121). O. C. 1325 A.

Krueg, Zeitsch. f. wiss. Zool., Bd. xxxiii. 1880, p. 617.

D. 295. The brain of a Tiger (*Felis tigris*).

In a comparison of the brain of the Tiger with that of the Cat, we observe a series of changes analogous to those which are found in the Lion's brain when contrasted with the latter. The arrangement of the Sylvian region resembles that described as typical of the Lion (D. 292).

O. C. 1324. *Hunterian.*

D. 296. A cast of the cranial cavity of a Tiger (*Felis tigris*).

This shows the true proportions of the large flattened olfactory bulbs which are placed well in front of the hemispheres.

D. 297. The brain of a Jaguar (*Felis onca*).

Note the continuity of the anterior ectosylvian and the long diagonal sulcus ; also the apparent connection of the former with the upper part of the pseudosylvian sulcus, as in the Lion's brain (fig. 118): and the numerous secondary sulci springing from the convexity of the suprasylvian arc.

O. C. 1325 B.

D. 298. The brain of a Leopard (*Felis pardus*).

Note that the upturned cephalic extremity of the intercalary sulcus (the non-calcarine part of Krueg's splenial sulcus) crosses the dorso-mesial edge of the hemisphere so as to simulate the crucial sulcus. The true crucial sulcus is placed further forward and is completely separated from the intercalary sulcus, as is usual in the Felidæ.

Note the well-developed marginal sulcus of Owen (the conjoint supra- and post-splenial of many writers).

The anterior ectosylvian sulcus is continuous with the diagonal, and on the left hemisphere joins the posterior ectosylvian to form a complete ectosylvian arc as in the Cynoidea. O. C. 1325 B *a*.

Krueg, Zeitsch. f. wiss. Zool., Bd. xxxiii. 1880, p. 617.

D. 299. The brain of an Ocelot (*Felis pardalis*).
A typical simple Feline brain. O. C. 1325 B *b*.

D. 300. The brain of a Cheetah (*Cynœlurus jubatus*).

Note the exceptionally well-developed pseudo-crucial sulcus behind the ansate. It is merely the upturned anterior extremity of the intercalary sulcus. The right suprasylvian sulcus is not joined to the postsylvian.

As also in the Ocelot, the diagonal is an independent sulcus. O. C. 1325 C.

Holl, His's Archiv, 1899, p. 230.

Family *VIVERRIDÆ*.

D. 301. The brain of an African Civet (*Viverra civetta*), (♀), (figs. 122, 123, and 124).

Fig. 122. (Nat. size.)

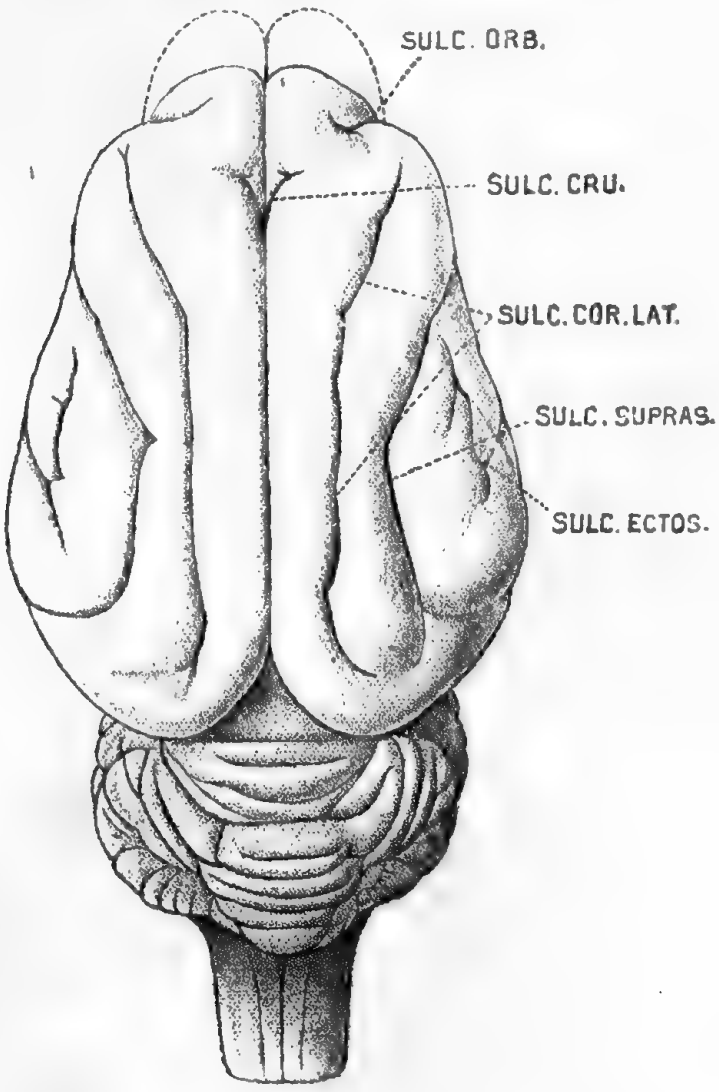

The features of the brain in this family are especially interesting because the instability of the "Sylvian fissure" (so-called) and the crucial sulcus are so strikingly demonstrated. In regard to these peculiarities, the brain of the

Civet and its near relations may be regarded as connecting links between the typical Carnivora and the lowlier mammalian orders in which the crucial sulcus is absent and the "Sylvian fissure" imperfect or wanting.

The orbital (presylvian), corono-lateral, and suprasylvian sulci are simple and quite typical (figs. 122 & 123). The suprasylvian sulcus is the deepest sulcus in the hemisphere.

Fig. 123. (Nat. size.)

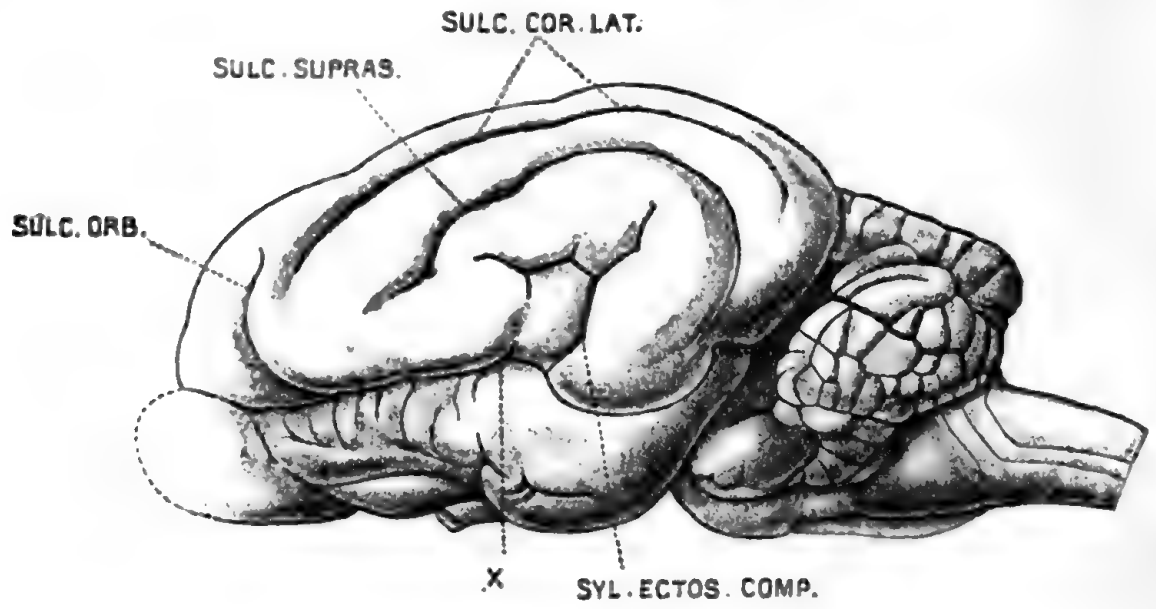

Fig. 124. (Nat. size.)

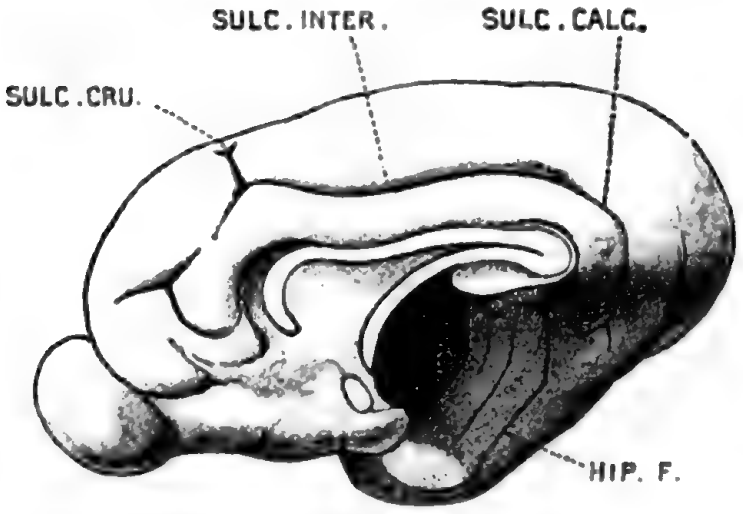

A very deep calcarine is prolonged forward into the intercalary sulcus which in turn joins the crucial sulcus (fig. 124). The latter is so small (fig. 122), that it barely reaches the dorsal surface.

The genual sulcus is joined to the crucial sulcus on the left hemisphere by a shallow furrow (fig. 124).

The "feline Sylvian fissure" is so ill-defined that there is a conflict of opinion as to which sulcus really represents it. This further exemplifies the morphological instability of this sulcus, which has already been noted in the Cats, Sloths, and other forms.

According to Holl the representative of the Sylvian fissure is found in a small notch above the bend in the rhinal fissure. But there can be little doubt that this really represents what Holl himself would call the "anterior terminal sulcus of the trigonum Sylvii." It is continuous, under the pallial operculum, with the orbital (presylvian) sulcus. On the right hemisphere this notch is so insignificant that it might easily pass unnoticed (fig. 123, x).

The sulcus which at a casual glance would be unquestionably called "Sylvian fissure" in this hemisphere is fairly deep and extensive, and opens freely into the rhinal fissure behind the before-mentioned notch or "Sylvian fissure" (according to Holl). Holl regards this sulcus as the posterior ectosylvian: and there can be no doubt that it does represent the posterior ectosylvian; but it is something more—a confluence of the latter and the sulcus which Holl calls "posterior terminal." In the case of an anomalous Cat's brain (*vide* specimen D. 292) it was seen that the ectosylvian sulcus and the "feline Sylvian fissure" might be compensatory factors in relieving the tension of pallial expansion in this region; we know also that it is not uncommon for the posterior ectosylvian sulcus to open into the Sylvian fissure or to join Holl's "posterior terminal sulcus"; it is also known to be unusual for the ectosylvian sulcus to join the rhinal fissure, whereas it is the usual arrangement of the Sylvian fissure: these facts and, finally, a comparison with other Viverridæ and with Carnivores of other families (see especially Holl's figures of the brain of a Cheetah [Taf. xi. fig. 2] and of a Fox's brain [Taf. xi. fig. 12]) show that this posterior sulcus (fig. 123) in the Civet ought to be regarded as the representative not only of the posterior ectosylvian sulcus, but also of the "feline Sylvian" fissure*.

---

* If we compare this brain with that of the Jaguar (D. 297), we can greatly simplify matters by calling the sulcus labelled "SYL. ECTOS. COMP." (fig. 123) simply "pseudosylvian," and the sulcus x the representative of that similarly labelled in figs. 116 and 117.

The object of this lengthy digression is not so much to interpret the individual condition here present—a question of small moment—but to emphasise the variability and morphological instability of the "feline Sylvian fissure" and its compensatory ectosylvian sulci. It is only when the "feline Sylvian" becomes blended with the stable suprasylvian sulcus, as in *Myrmecophaga* and the Primates, that the real "Sylvian fissure" can be said to exist in a really stable condition.

An irregular horizontal sulcus extends forward from the upper end of the ectosylvian in this specimen and, together with the several pit-like markings, represents the anterior ectosylvian sulcus. [Compare the condition in *Felis onca,* D. 297.]

Otherwise this specimen affords an admirable demonstration of the typical features of the Carnivore brain. Note the prominent tubercle of the olfactory tract in the vallecula Sylvii (the depression between the tuberculum olfactorium and the natiform, caudal part of the pyriform lobe) : the well-defined tractus peduncularis transversus of Gudden (Wilder's *cimbia*) on the lateral aspect of the crus cerebri: the large auditory nerve inserted into a very prominent and bulky acoustic tubercle, from which a large trapezium extends as far as the lateral edge of the exceptionally prominent pyramidal tract.

The features of the cerebellum, which is a simplified form of that of the Cat, are shown exceeding clearly.

O. C. 1325 I *a.*

Holl, Arch. f. Anat. u. Entwick. 1899, p. 243.

D. 302. The brain of an African Civet (*Viverra civetta*).

This specimen even more decisively than the last supports the contention that the larger, deeper and more posterior of the two sulci opening into the bend of the rhinal fissure represents not only the posterior ectosylvian sulcus but also the "feline Sylvian fissure." A comparison with the brain of the Mongoose (*vide infra*) shows this conclusively. It certainly cannot be regarded as the posterior ectosylvian only. The lower extremity of the latter can, in fact, be seen indenting the posterior lip of the sulcus at about its mid-point.

The posterior ectosylvian sulcus gives off no branches such as its representative in the other specimen exhibits.

The sulcus which Holl (*op. cit.*) would call the "anterior terminal" (*i. e.* the anterior limit of the area usually submerged in the "Sylvian fissure") is much longer in this specimen, especially on the right side. O. C. 1325 I.

D. 303. The brain of a Genet (*Genetta vulgaris*).

The brain of the Genet closely resembles that of the Civet as regards most of its features. There is no typical crucial sulcus. There is, however, a shallow depression on the dorsal surface, which is regarded by some writers as the representative of the crucial.

On the right side the intercalary sulcus extends obliquely forward and upward almost as far as the dorsal edge far forward in the hemisphere.

On the left side the true intercalary sulcus is quite distinct from an anterior sulcus which may possibly represent the crucial.

No ectosylvian sulcus can be recognised with any degree of certainty, but there is a pseudosylvian sulcus resembling that of the Cat. O. C. 1325 H *b*.

D. 304. The brain of a Genet (*Genetta vulgaris*). O. C. 1325 H.

D. 305. The brain of an African Genet (*Genetta tigrina*), (♀).

This resembles that of the Common Genet.

O. C. 1325 H *a*.

Presented by St. George Mivart, Esq.

D. 306. The brain of a Cape Mongoose (*Herpestes pulverulentus*), (♂).

This brain is peculiar in many respects.

There is a very extensive crucial sulcus placed far forward on the hemisphere and in free communication with the intercalary sulcus on the right side, but not on the left. This is all the more noteworthy when the slight development or absence of a crucial sulcus in other Viverridæ is recalled.

The orbital sulcus is very small, and placed so far forward on the apex of the hemisphere that it is hidden by the olfactory bulb, and is believed by many writers (*e. g.*, Ziehen, Arch. f. Psych. 1896) to be absent.

The deepest sulcus on the hemisphere is the suprasylvian which extends backward above, but without joining the vertical postsylvian (compare fig. 125).

Holl (*op. cit.* p. 238) considers that no Sylvian fissure is present, but we can have little hesitation in regarding the sulcus which springs from the junction of the deep anterior rhinal and the shallow post-rhinal fissures as the pseudo-sylvian sulcus. After a short oblique course upward and slightly backward, it joins the posterior ectosylvian which pursues a short course upward and forward and is then joined to the anterior ectosylvian sulcus (compare Holl's figure of *Herpestes ichneumon*).

Fig. 125. (Nat. size.)

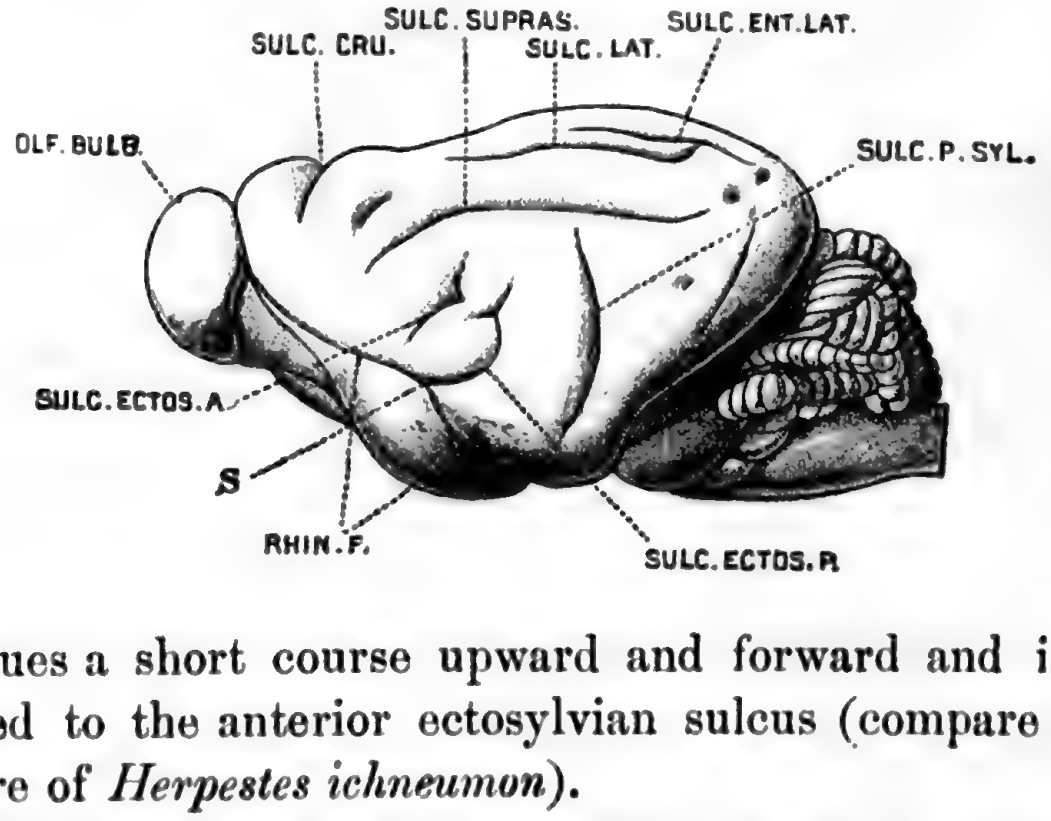

The lateral sulcus is apparently fused to an ansate element in front, but is not joined to the small oblique coronal sulcus.

The shallow postlateral is prolonged forward as a fragmentary entolateral sulcus. O. C. 1325 I *c*.

Holl, Arch. f. Anat. u. Entwick. 1899, p. 238.

Mivart, Journ. Linn. Soc., vol. xix. 1886, p. 7.

[Since this account was written I have examined the brains of two specimens of *Herpestes ichneumon*, and the interesting variations in these four hemispheres decisively show that the real nature of the sulci in question accords with the suggestions in the accounts already given.

On the left hemisphere of the first specimen (fig. 125), the "Sylvian fissure" is an extremely short notch in the upper lip of the rhinal fissure and the posterior ectosylvian sulcus (which is independent of the anterior ectosylvian) ends in very close proximity to this small pseudosylvian. On the right hemisphere the pseudosylvian is larger and surrounded by a distinct ectosylvian arc (fig. 126). In the left hemisphere of the second brain (fig. 127) there are two "Sylvian notches," of which the longer overlaps the posterior ectosylvian so that at a casual glance they might easily be mistaken for one fissure. On the right hemisphere (fig. 128) a similar arrangement of the only "Sylvian element" is found. Figure 129 represents yet another variety. These specimens clearly show the real nature of the pseudosylvian sulcus, or "Sylvian fissure" so-called, in the Viverridæ.]

Fig. 126.

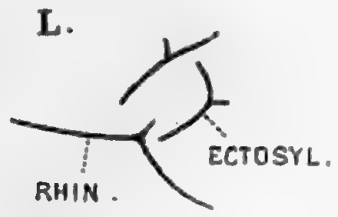

Fig 127.

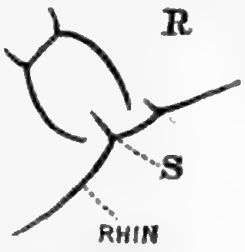

Fig. 128.

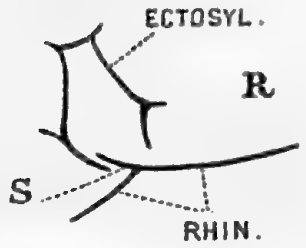

Fig. 129.



D. 307. The brain of an Ævisa (*Crossarchus obscurus*), (♀).

This may be regarded as a simplified Herpestine brain.

The "Sylvian fissure" seems to be absent in this specimen. O. C. 1325 I *b*.

D. 308. The brain of a Palm-Civet (*Paradoxurus typus*), (♀).

There is a typical "feline Sylvian fissure"; orbital and posterior ectosylvian sulci as in the Felidæ and Hyænidæ; a typical suprasylvian sulcus forming a regular arc with the postsylvian; conjoint coronal and lateral sulci without any ansate; and no true crucial sulcus. There are, however, some shallow pits, where the crucial sulcus occurs in other brains, and the coronal sulcus has an unusual inclination forward and inward. The intercalary sulcus (the cephalic extension of the calcarine—the "splenial" of Krueg) extends almost to the cephalic pole of the hemisphere. There is a short genual sulcus. O. C. 1325 G *c*.

Krueg, Zeitsch. f. wiss. Zool., Bd. xxxiii. 1880, p. 628.

D. 309. The brain of a Palm-Civet (*Paradoxurus typus*).

An ansate sulcus is present in this specimen, and in front of it there is a definite furrow which may represent the crucial sulcus. O. C. 1325 G *d*.

D. 310. The brain of *Hemigale hardwickii*.

This brain resembles that of *Paradoxurus*. Note, however, the upturning of the anterior end of the intercalary (or splenial) sulcus, which *may* represent the otherwise missing crucial sulcus. (This, however, hardly accords with the suggestion made concerning the representative of the crucial sulcus in *Paradoxurus*.) O. C. 1325 H *c*.

D. 311. The brain of a Binturong (*Arctictis binturong*).

In most respects this brain resembles those of *Paradoxurus* and *Hemigale*.

There appear, however, to be two "Sylvian-like" sulci opening into the angle of the rhinal fissure. They may be regarded as the two "terminal sulci" of Holl, the posterior of which is concurrent with the posterior ectosylvian sulcus. In many Carnivores there is a small submerged area in the Sylvian fissure called the "trigonum Sylvii" by Holl. The bounding fissures of this trigone he calls the terminal sulci: in this specimen they are exposed on the surface so that there is no true "feline Sylvian fissure."

On the right hemisphere there is a faintly-marked crucial sulcus quite independent of the forward prolongation of the so-called "splenial" sulcus. It is more indistinct on the left side. There is a broad gyrus between the corono-lateral sulcus and the mesial plane, indented by numerous short sulci on the right hemisphere and by pit-like short sulci on the left side. The ansate is represented by a peculiar arc-like sulcus quite independent of the lateral. O. C. 1325 F *a*.

Mivart, Journ. Linn. Soc., vol. xix. 1886, p. 7.

D. 312. The brain of the Suricate (*Suricata tetradactyla*), (♂).

In most respects this brain closely resembles that of *Herpestes.*

The "Sylvian fissure" is a mere notch in the upper lip of the rhinal fissure, surrounded by an arcuate ectosylvian sulcus: there is a large crucial sulcus and a small orbital (presylvian) sulcus, which, under normal conditions, would be completely hidden by the olfactory bulb. O. C. 1325 G.

Mivart, Journ. Linn. Soc., vol. xix. 1886, p. 8.

Presented by J. Lemage, Esq.

D. 313. The brain of *Nandinia binotata.*

This resembles the brain of the Genet in most of its features. The Sylvian region, however, resembles that of the Civet's brain, more especially as seen in specimen D. 302. O. C. 1325 G *a.*

Mivart, Journ. Linn. Soc., vol. xix. 1886, p. 6.

D. 314. The brain of *Nandinia binotata.*

Note the absence of the crucial sulcus and the insignificant proportions of the mere notch which represents the "Sylvian fissure." O. C. 1325 G *b.*

Family *HYÆNIDÆ.*

D. 315. The brain of a Hyæna (*Hyæna hyæna*), (♂).

The so-called "Sylvian fissure" (fig. 130) presents a marked contrast to the similarly-named feature of the Cat's brain; in the latter it is short and relatively shallow, whereas it is very long and deep in the Hyæna. At a

Fig. 130. (× ⅔.)

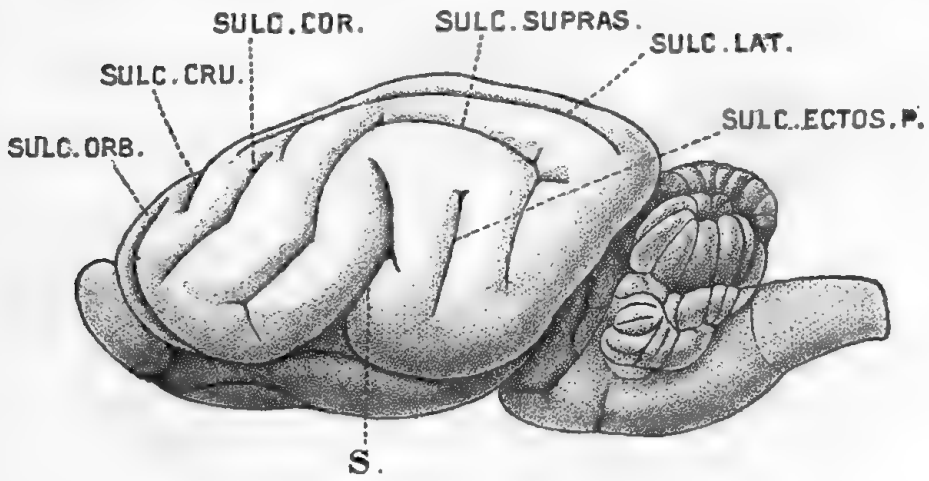

casual glance the anterior ectosylvian sulcus is absent, and this at once reminds us of the spurious or apparent lengthening of the "Sylvian fissure" in the Lion (*vide supra*), where the anterior ectosylvian sulcus becomes engulfed in the "Sylvian" (fig. 118). If the prominent opercula-like lips of the "Sylvian fissure" in the Hyæna be separated it will be found that the upper half of the "fissure" is really a submerged ectosylvian; in some cases (*vide* fig. 131), but not in this, the lower extremity of this ectosylvian element emerges from the "Sylvian" and deeply incises its anterior lip. But the condition in the Hyæna's brain is very different even from that of what we may call the anomalous Lion's brain (fig. 118). There is a very large triangular submerged area (which Holl would call "trigonum Sylvii") overlapped not only by a large anterior operculum but also by a still larger posterior operculum. This "trigone" is limited both in front and behind by well-defined limiting sulci. The inferior extremity of the posterior limiting sulcus may emerge from the "Sylvian" cleft a short distance above the rhinal fissure (fig. 131, C, also specimen D. 319). In the middle of the trigone there is a deep sulcus like the feline "Sylvian fissure" (fig. 132, A). But a careful study of the conditions existing here clearly shows that neither the superficial pattern formed by the meeting of the opercular lips nor this submerged sulcus can be regarded as strictly homologous to the "feline Sylvian fissure." The whole arrangement is a more or less direct mechanical adaptation of the growing cortex in this region of kinking, and varies in different families of the Carnivora

Fig. 131. (Nat. size.)

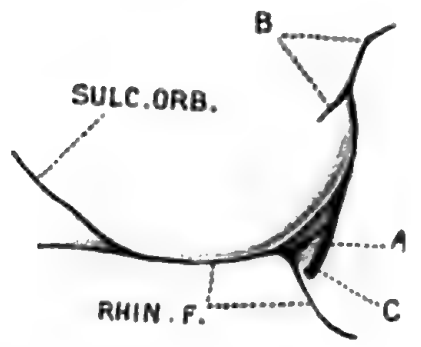

Fig. 132. (Nat. size.)

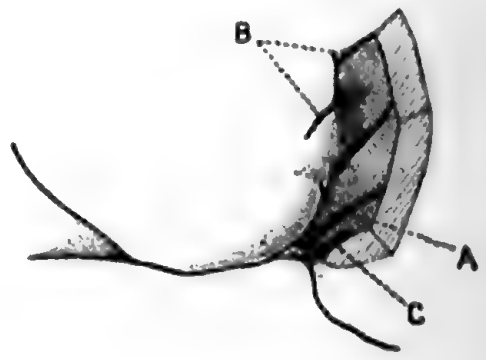

just as it frequently does even in members of the same genus and species.

There is a deep, simple, posterior ectosylvian sulcus, which is quite separate from the anterior sulcus, as in the Cats (fig. 130).

There is a great suprasylvian arc formed usually of conjoint diagonal, suprasylvian and postsylvian sulci, but sometimes the diagonal sulcus may be separate (figs. 130 & 133), as in the right side of specimen D. 317.

Fig. 133. ($\times\frac{2}{3}$.)

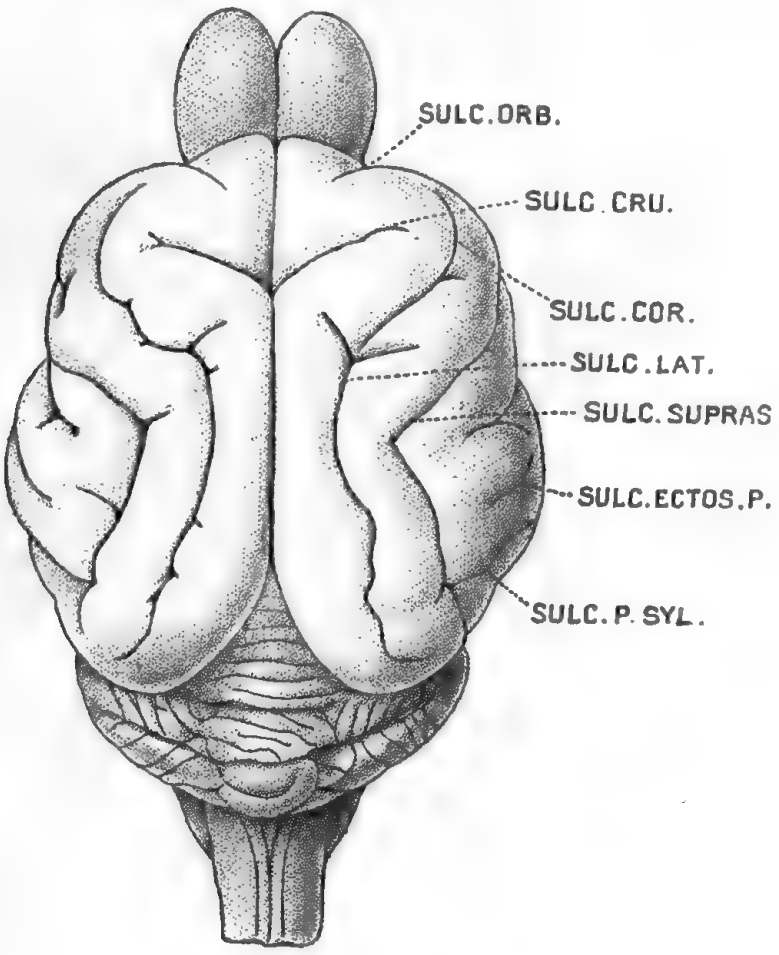

Fig. 134. ($\times\frac{2}{3}$.)

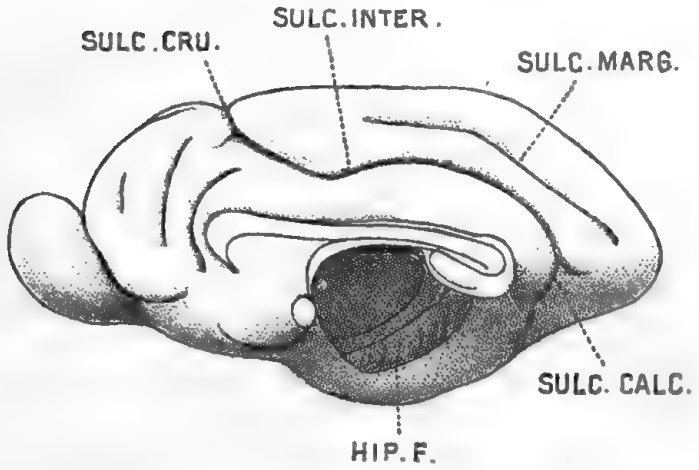

There are large typical coronal, lateral, and postlateral sulci and a very long deep orbital (presylvian) sulcus, with occasionally a small accessory orbital springing from the rhinal fissure still further forward.

There is a very deep, long, transverse, crucial sulcus (fig. 133); and in some cases, if it be opened up, a small indubitable precrucial sulcus is present. The crucial sulcus is joined by the intercalary to the deep calcarine sulcus, as is commonly the case in the Dogs (fig. 134). There are, in many Hyænas, numerous irregular accessory postcalcarine sulci—the irregular forerunners of the retrocalcarine and collateral sulci of the human brain. There is also a well-developed marginal ("suprasplenial") sulcus. The genual sulcus in some cases proceeds upward to join the precrucial. O. C. 1325 E *a.*

D. 316. The brain of a Hyæna (*Hyæna hyæna*). O. C. 1325 E *c.*

D. 317. The brain of a Hyæna (*Hyæna hyæna*), (♀). O. C. 1325 E *d.*

D. 318. The brain of a Hyæna (*Hyæna hyæna*), (♀). O. C. 1325 E *b.*

D. 319. A brain labelled "Hyæna." Although much larger than the other specimens of the Hyæna's brain, this specimen presents similar features.

The "Sylvian fissure," however, is more open and the sulcus which emerges and indents its posterior lip—perhaps the "posterior terminal sulcus" of Holl—is unusually well pronounced. O. C. 1325 E.

D. 320. A cast of the cranial cavity of a Spotted Hyæna (*Hyæna crocuta*).

This shows the size and shape of the olfactory bulbs, which are distorted in the specimens of the brains themselves. Note that the open condition of the pseudosylvian sulcus is natural, as it is seen in the cast.

Gervais, Nouv. Arch. d. Mus., t. vi. 1870, p. 125.

D. 321. The brain of a *Proteles cristatus*, (♂).

This closely resembles the brain of the Hyæna.

It is of interest to note a retrocalcarine sulcus extending backward and upward from the "splenial" complex of calcarine and intercalary sulci after the manner of the posterior calcarine sulcus in the Primates (figs. 135, 136, & 137). O. C. 1325 F.

Fig. 135. (×$\frac{2}{3}$.)

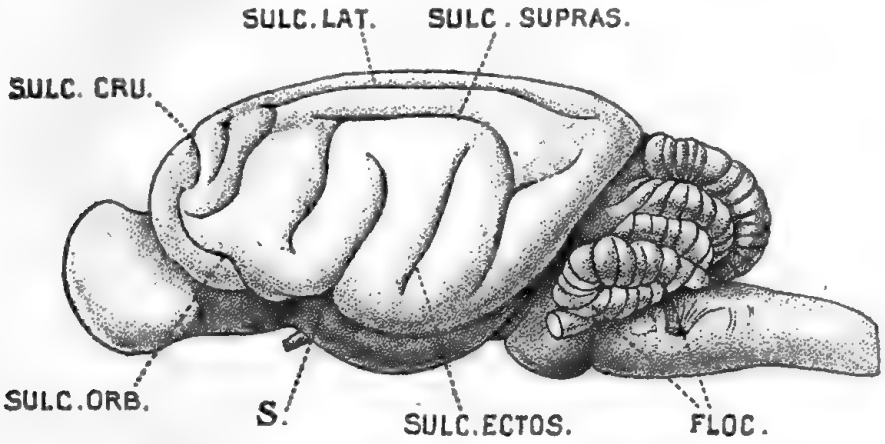

Fig. 136. (×$\frac{2}{3}$.)

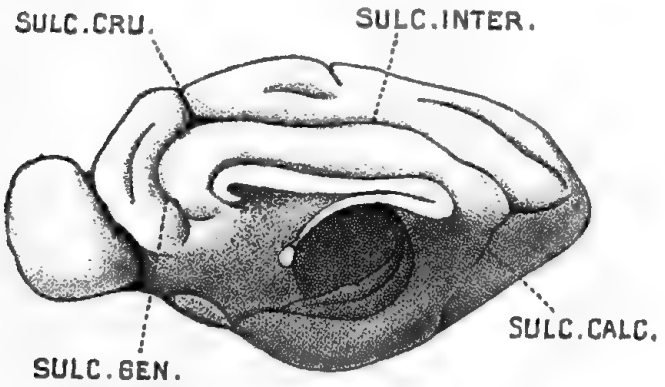

Fig. 137. (×$\frac{2}{3}$.)

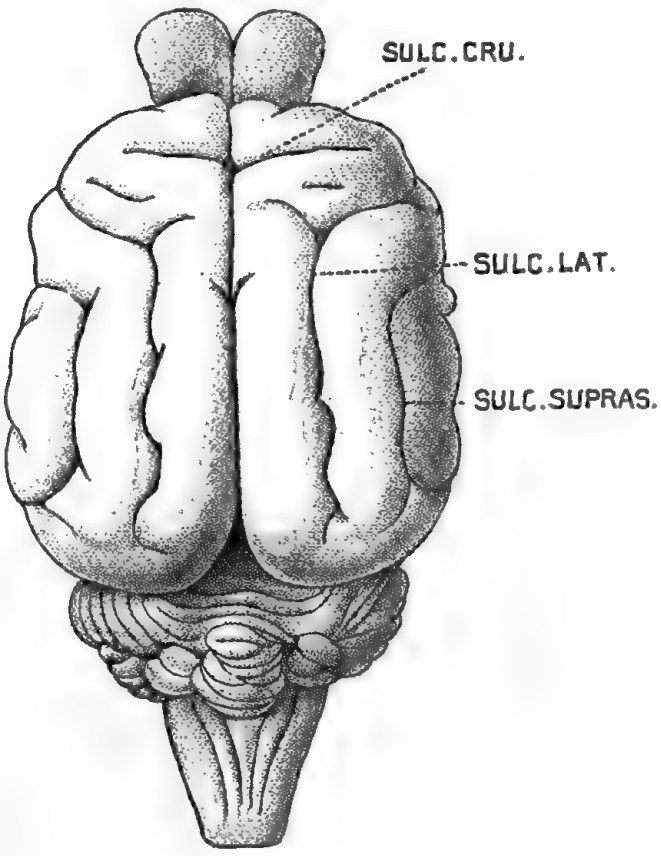

Flower, Proc. Zool. Soc. 1869, p. 478.

Section CYNOIDEA.

Family *CANIDÆ*.

D. 322. The brain of an Otocyon (*Otocyon megalotis*).

The anterior and posterior ectosylvian sulci meet and form a regular arc around the short Sylvian fissure. This is one distinctive feature of the Cynoidea in contrast to the Æluroidea. On the left hemisphere there is a short vertical offshoot from the ectosylvian arc.

The suprasylvian and postsylvian sulci are united into a regular arc and there is no separate diagonal sulcus.

The lateral and short postlateral sulci are joined on both sides, and on the left side the lateral joins the coronal.

There is a well-developed orbital (presylvian) and a short transverse crucial sulcus.

Midway between the postsylvian and postlateral sulci there is a short vertical "ectolateral" sulcus. This is a very characteristic feature of the Cynoid brain. O. C. 1325 M.

Gervais, Nouv. Arch. Mus., t. vi. 1870, p. 109.

D. 323. The brain and the upper part of the spinal cord of a Common Fox (*Vulpes vulpes*).

This specimen exhibits with diagrammatic clearness the typical Cynoid characters :—the three regular arcuate sulci (ectosylvian, suprasylvian, and corono-lateral respectively) surrounding the short oblique pseudosylvian. The characteristic ectolateral sulcus, the orbital and the deeply-incised oblique crucial sulci complete the picture. There is a small ansate sulcus joined to the coronal on the left side, and an altogether insignificant separate ansate on the right side.

It will be noted that such other parts of the brain as can be seen in this specimen resemble the corresponding parts in the Cat's brain. O. C. 1325 L.

Krueg, Zeitsch. f. wiss. Zool., Bd. xxxiii. 1880, p. 612.

D. 324. The brain of *Canis microtis*, in which the left cerebral hemisphere has been separated, (♂).

In this specimen we can see the continuity of the crucial and the intercalary (" splenial ") sulci (fig. 140)—another feature usually presented by the Dogs.

In addition it also exhibits (figs. 138 & 139) the other two Cynoid characters—the complete ectosylvian arc and the presence of the ectolateral sulcus—in a typical form. O. C. 1325 L*f.*

Fig. 138. $(\times\frac{2}{3}.)$

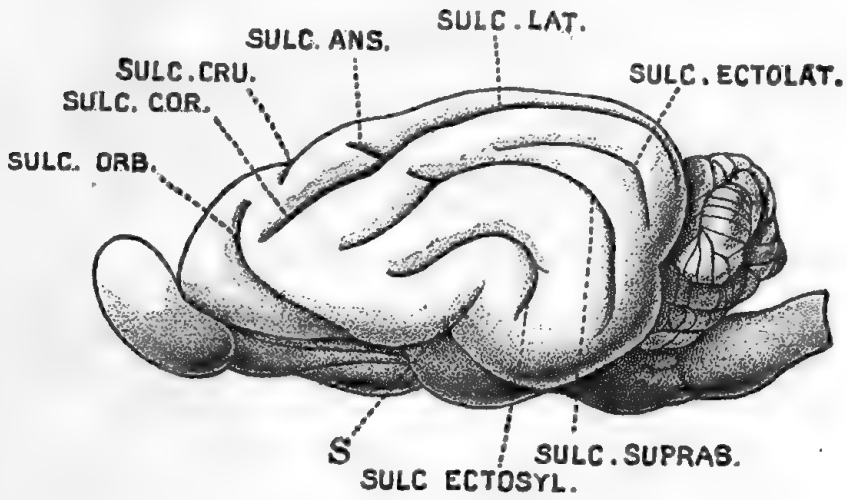

Fig. 139. $(\times\frac{2}{3}.)$

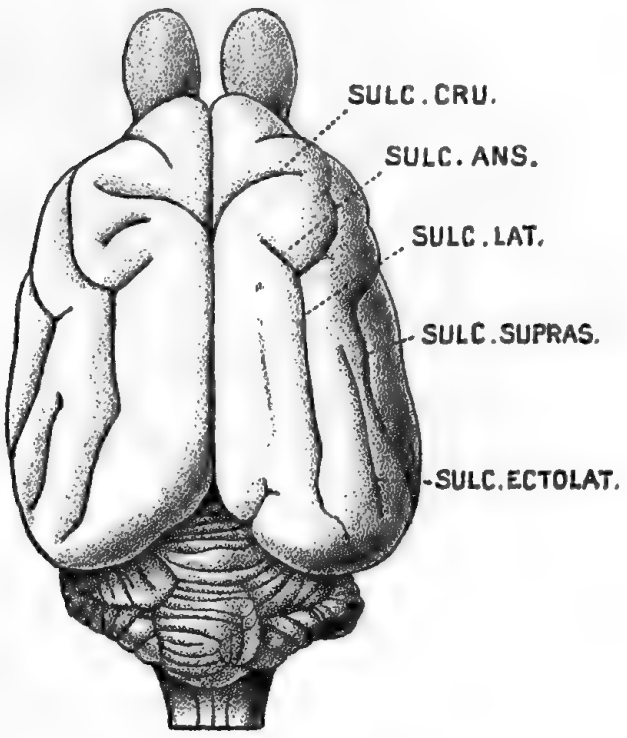

Fig. 140. $(\times\frac{2}{3}.)$

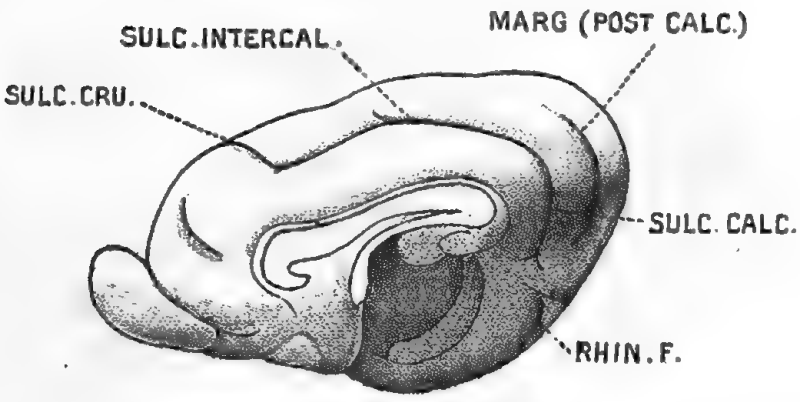

Mivart, Journ. Linn. Soc., vol. xix. 1886, p. 3.

D. 325. The brain of a Bush Dog (*Speothos venaticus*), (♀).

A complete ectosylvian arc is present only on the right side, and even there its anterior limb is short and appears to be joined to the "Sylvian fissure." On the left side the small posterior ectosylvian sulcus joins the pseudosylvian a short distance below the apex of the latter. A comparison of this condition with that of the Viverridæ is interesting.

Fig. 141. (×$\frac{2}{3}$.)

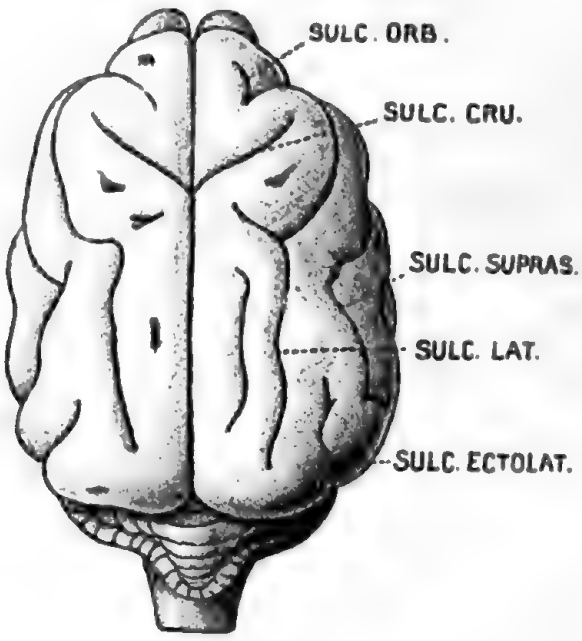

The postlateral sulcus is absent on the right side and represented merely by a shallow pit on the left side (fig. 141). O. C. 1325 L *d.*

Mivart, Journ. Linn. Soc., vol. xix. 1886, p. 4.

D. 326. The brain and upper part of the spinal cord of a Dog (*Canis familiaris*).

The cerebellum has been removed, the corpus callosum cut through, and the cerebral hemispheres widely divaricated. Upon the left side a portion of the pons Varolii has been cut away to demonstrate the continuity of the pyramidal tract with part of the crus cerebri.

The lateral ventricles have been opened so as to show the corpora striata, each of which is separated from the optic thalamus by a deep oblique furrow. On the right side the optic thalamus is to a great extent hidden by the upper extremity of the hippocampus and the fornix proceeding forward from it. On the left side the thalamus has been exposed by the removal of part of the fornix and hippocampus. The corpora quadrigemina are fully exposed, and the narrow, elongated, fourth ventricle opened up. Upon the dorsal aspect of the spinal cord note the exceedingly delicate columns of Goll alongside the mesial septum swelling out slightly at the calamus scriptorius to form the nuclei graciles. The columns of Burdach are much broader and swell out into the nuclei cuneati.

O. C. 1325 K *a*.

D. 327. The brain of a Dog (*Canis familiaris*).

In the left hemisphere the coronal is completely separate from the lateral sulcus. But the latter is connected with a deep and extensive ansate which passes into a minor ansate sulcus opening into the suprasylvian. The ectolateral sulcus also joins the minor ansate.

On the right side there is no communication of the minor ansate with either the lateral or ectolateral sulci.

The crucial sulcus presents the unusual phenomenon for a Cynoid of being bifid.

In this specimen all the cranial nerves except the trochlear (IV) are well shown in the usual positions.

O. C. 1325 K.

Langley, Journ. of Physiology, vol. iv. p. 248.

D. 328. The head of a Dog (*Canis familiaris*) cut in longitudinal section to show the relation of the brain to the skull.

Note especially the large olfactory bulb separated from the nasal fossa by the thin cribriform plate. O. C. 1325 K *b*.

D. 329. Two casts of the cranial cavity of a Dog (*Canis familiaris*). These casts show the true shape of the olfactory bulbs and their relations to the hemispheres.

D. 330. The brain of a South-American Fox-Wolf (*Canis azaræ*), (♀ juv.).

On the left hemisphere there appears to be a relatively extensive ectolateral sulcus, whereas on the right side this sulcus is seen to be very short, and the separate lower sulcus which represents the greater part of the apparent ectolateral of the other hemisphere is clearly the postlateral sulcus. O. C. 1325 L *e*.

D. 331. The brain of *Canis rudis.*

D. 332. The brain of a Japanese Raccoon-Dog (*Nyctereutes procyonoides*), (♀).

Note again how the ectolateral sulcus takes the place of the postlateral, which is absent. O. C. 1325 L *c.*

D. 333. The brain of a Japanese Raccoon-Dog (*Nyctereutes procyonoides*), (♂). O. C. 1325 L *b.*

D. 334. The brain of a Cape Hunting Dog (*Lycaon pictus*), (♂). O. C. 1325 L *a.*

Section ARCTOIDEA.

Family *PROCYONIDÆ.*

D. 335. The brain of a Raccoon (*Procyon lotor*). O. C. 1325 R *a**.
Presented by St. George Mivart, Esq.

D. 336. The brain of a Raccoon (*Procyon lotor*). O. C. 1325 R.

D. 337. The brain of a Raccoon (*Procyon lotor*).

It is distinctive of the Arctoid section of the Carnivora that the "Sylvian fissure" is very long and deep, and that the first arcuate gyrus has become wholly engulfed in this great cleft so that the lips of the "fissure" are formed by the second arcuate gyrus, and not by the first gyrus as in the Cynoid section; and a precrucial sulcus makes its appearance, even in many of the smallest members, so as to mark off the area which Mivart has called the "Ursine Lozenge." (Compare fig. 155.)

The crucial sulcus is long, very deep, and placed obliquely, and is usually quite independent of the intercalary (the cephalic part of the splenial) sulcus. There are no precrucial sulci in one (D. 335) of these specimens, in another (D. 336) they are faintly, whilst in the third they are well-developed.

A comparison of these three brains shows the great variations in the coronal, lateral, ansate, and postlateral sulci which may occur in one species. In one brain (D. 336) there is a definite postlateral sulcus and none in the other two. In one brain the coronal and ansate sulci are replaced by irregular triradiate and H-shaped sulci, whereas in the others we find the typical combination of ansate, coronal, and lateral sulci. O. C. 1325 R *a*.

Presented by St. George Mivart, Esq.

St. George Mivart, Journ. Linn. Soc., vol. xix. 1886, p. 10.

D. 338. The brain of a Crab-eating Raccoon (*Procyon cancrivorus*), (♂).

This closely resembles the Raccoon's brain.

On the right hemisphere there is a short postlateral sulcus, which extends forward between the lateral and the postsylvian sulci so as to simulate the ectolateral sulcus.

The latter, so characteristic of the Cynoidea, is absent in the Arctoidea, as it is also in the Æluroidea. O. C. 1325 R *b*.

Mivart, Journ. Linn. Soc., vol. xix. 1886, p. 11.

D. 339. The brain of a Coati (*Nasua nasua*).

This brain closely resembles that of the Raccoon.

There is no trace of the precrucial sulcus. The coronal and lateral sulci, and a moderately extensive postlateral sulcus are joined to form a great arc. The ansate is represented by several small postcrucial sulci.

There is a shallow entolateral sulcus, joined to the lateral in a different manner on the two hemispheres. O. C. 1325 Q *b*.

St. G. Mivart, Journ. Linn. Soc., vol. xix. 1886, p. 11.

D. 340. The brain of a Coati (*Nasua nasua*).

A small precrucial sulcus can be seen near the mesial edge.

The coronal, lateral, and postlateral sulci are each independent of the others on the left side, but on the right side the lateral and postlateral are joined. O. C. 1325 Q *c*.

Presented by St. George Mivart, Esq.

D. 341. The brain of a Mexican Coati (*Nasua narica*), (♂).

This brain resembles that of the common Coati. There is a very small "Ursine lozenge." O. C. 1325 Q *a*.

D. 342. The brain of a Mexican Coati (*Nasua narica*).

No precrucial sulci are present; the postlateral sulci are less well-developed. O. C. 1325 Q.

D. 343. The brain of a Raccoon Fox (*Bassariscus astutus*), in which the left hemisphere has been separated from the rest of the brain.

This is a smaller and correspondingly simplified copy of the brain of the Raccoon. The mesial prolongation of the crucial sulcus is overlapped but not joined by the cephalic prolongation of the calcarine. There are regular suprasylvian and corono-lateral arcs. There is a simple ansate and a triradiate compensatory ansate. There is a short vertical postlateral sulcus. In the left hemisphere the anterior lip of the pseudo-sylvian and the upper lip of the anterior rhinal fissures have been dissected away to show the submerged Sylvian trigone continued forward into the "orbital gyrus." There is no trace of an ectosylvian sulcus.

Beddard, Proc. Zool. Soc. 1898, p. 129.

D. 344. The brain of a *Bassaricyon alleni.*

This closely resembles the brain of *Bassariscus.* The crucial sulcus is, however, longer and placed slightly further back in the hemisphere; it also has a distinct notch-like precrucial sulcus, so that the "Ursine lozenge" can be distinctly recognised.

Beddard, Proc. Zool. Soc. 1900, p. 668, figs. 5 A & B.

D. 345. The brain of a Panda (*Ailurus fulgens*), (♂).

In most respects this brain (fig. 142) resembles those of *Procyon* and *Nasua.*

Fig. 142. ($\times \frac{2}{3}$.)

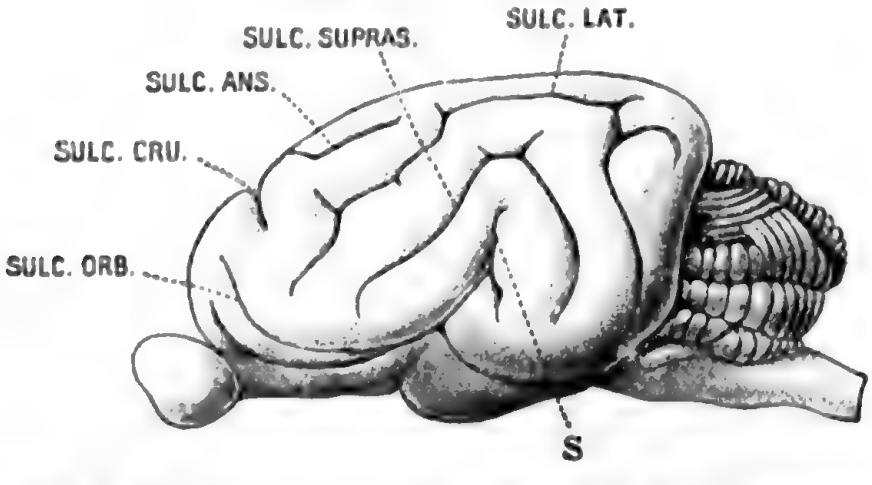

There is a very faint indication of the precrucial sulcus. A sulcus which probably represents the posterior ectosylvian emerges from the "Sylvian fissure" at about its mid-point. O. C. 1325 s.

Flower, Proc. Zool. Soc. 1870, p. 763.

D. 346. The brain of a Panda (*Ailurus fulgens*).

The small precrucial sulci (and consequently Mivart's "Ursine lozenge") are well marked in this specimen.

So much of the posterior ectosylvian sulcus is exposed that it appears to join the apex of the "Sylvian fissure." O. C. 1325 s *b*.

Mivart, Journ. Linn. Soc., vol. xix. 1886, p. 12.

D. 347. A cast of the cranial cavity of a Panda (*Ailurus fulgens*).

Note especially the deep broad depression corresponding to a part of the submerged first arcuate gyrus in the Sylvian region.

D. 348. The brain of a Kinkajou (*Potos caudivolvulus*), (♂).

The Sylvian region is very instructive in this brain. The "Sylvian trigone," or depressed area, can be partly seen, and behind it a large part of the posterior limb of the first arcuate gyrus makes its appearance. It is limited by the posterior ectosylvian sulcus, which appears to join the apex of the Sylvian fissure. The suprasylvian arc is complete, simple, and regular.

The conjoined postlateral and lateral sulci form a great arc which passes directly into the ansate in front. The large simple coronal sulcus is quite independent. There is a large very obliquely-placed crucial sulcus passing directly into the intercalary prolongation of the calcarine (splenial), as in the Cynoidea.

A faintly-marked notch in the anterior lip of the right crucial is the only indication of a precrucial sulcus. O. C. 1325 s *a*.

Mivart, Journ. Linn. Soc., vol. xix. 1886, p. 13.

Family *MUSTELIDÆ*.

D. 349. The brains of a Weasel (*Putorius vulgaris*) and of a Stoat or Ermine (*Putorius ermineus*).

It is very significant that in spite of the diminutive size of these brains—for they are much smaller than many smooth brains of the Rodent, Insectivore, and Marsupial Orders—they still present the typical Carnivore pattern of sulci. The pattern exhibited by these sulci essentially conforms to the Arctoid type.

The pseudosylvian sulcus corresponds to that of the Procyonidæ and not to that of the Dogs and Cats; the suprasylvian arc is acutely flexed; the lateral and coronal form one simple sulcus; there is neither an ansate nor a postlateral sulcus; there is a large transverse crucial sulcus but no definite precrucial. There is a large orbital sulcus. O. C. 1325 o.

Presented respectively by Dr. Rolleston and R. F. Tomes, Esq.

Mivart, Journ. Linn. Soc., vol. xix. 1886, p. 17.
Holl, Arch. f. Anat. u. Entwick. 1899, p. 239.

D. 350. The brain of a Glutton or Wolverine (*Gulo luscus*).

The typical Arctoid features are well shown in this specimen: the long "Sylvian fissure" encircled by the acutely flexed suprasylvian arc; the long crucial sulcus which does not join the cephalic prolongation of the calcarine (splenial) sulcus; and the large precrucial sulcus and consequently a well-defined Ursine lozenge.

The extensive postlateral joins the lateral sulcus and from the latter a large ansate extends forward. A large sulcus on the lateral side of the ansate is obviously a compensatory ansate sulcus; it opens into the great crucial sulcus. The coronal is not joined to the lateral.

On the left side the lips of the pseudosylvian sulcus have been removed to show the region of the "Sylvian trigone" and the first arcuate gyrus.

The cephalic prolongation of the calcarine is very short, as in the Bears and Seals. There is a short vertical genual sulcus. There is a long, deep, vertical postcalcarine.

In front of the crucial sulcus there is a sagittal prorean sulcus on the dorsal surface of the hemisphere.

Note the peculiar square shape of the posterior part of the hemisphere.

Beddard, Proc. Zool. Soc. 1895, p. 139.

D. 351. The brain of the Tayra (*Galera barbara*).

This brain resembles that of the Glutton.

It presents a similar crucial sulcus with a very long, transverse, dorsal extent and a very short mesial part (figs. 143 & 144). On the right side, however, it joins the intercalary prolongation of the calcarine, the true anterior extremity of which notches the dorsal edge behind the crucial.

Fig. 143. (Nat. size.)

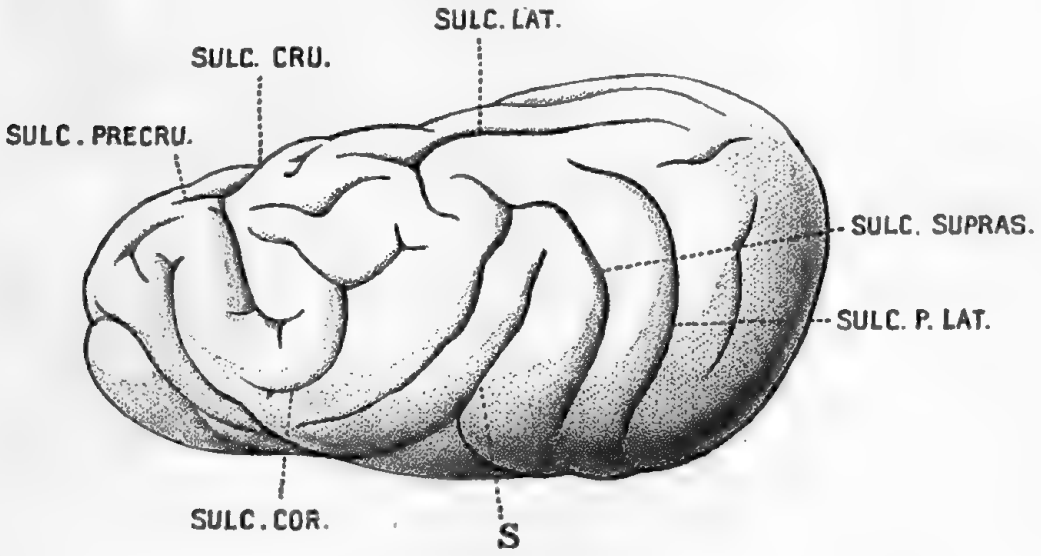

Fig. 144. (Nat. size.)

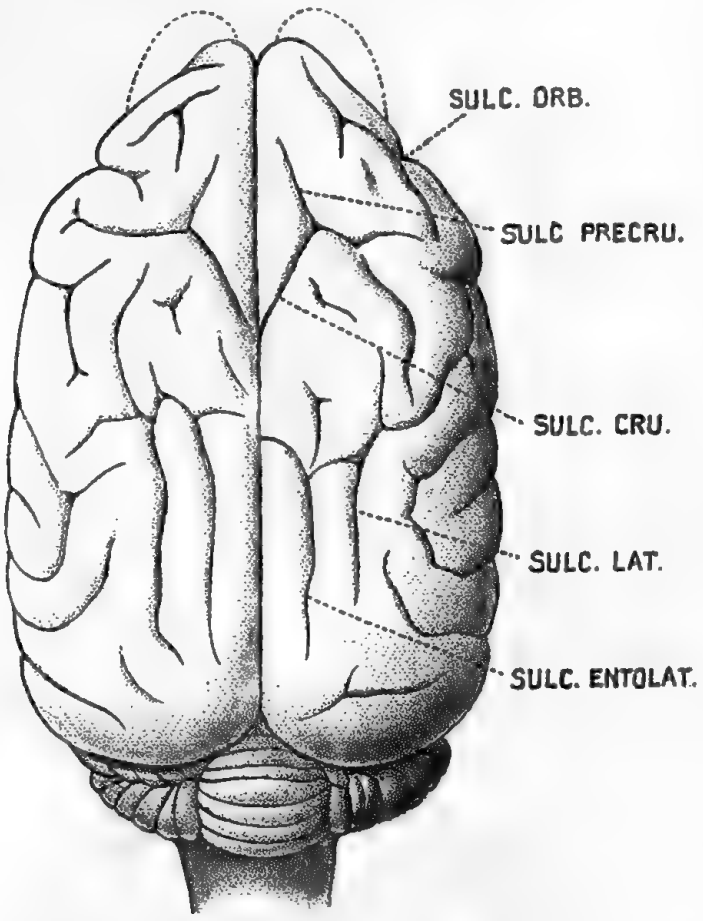

There is a well-developed precrucial sulcus. The postlateral is separated from the lateral. There is also an entolateral.

The compensatory ansate sulcus does not join the crucial sulcus. O. C. 1325 N *b*.

Mivart, Journ. Linn. Soc., vol. xix. 1886, p. 16, figs. 4 and 5.

D. 352. The brain of the Grison (*Galictis vittata*), (♂), (figs. 145 & 146).

Fig. 145. (Nat. size.)

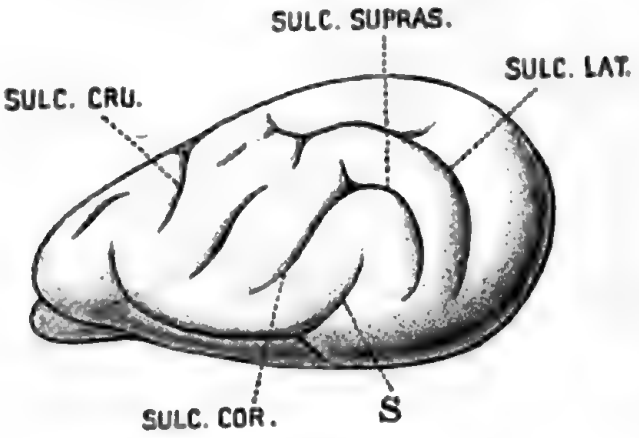

Fig. 146. (Nat. size.)

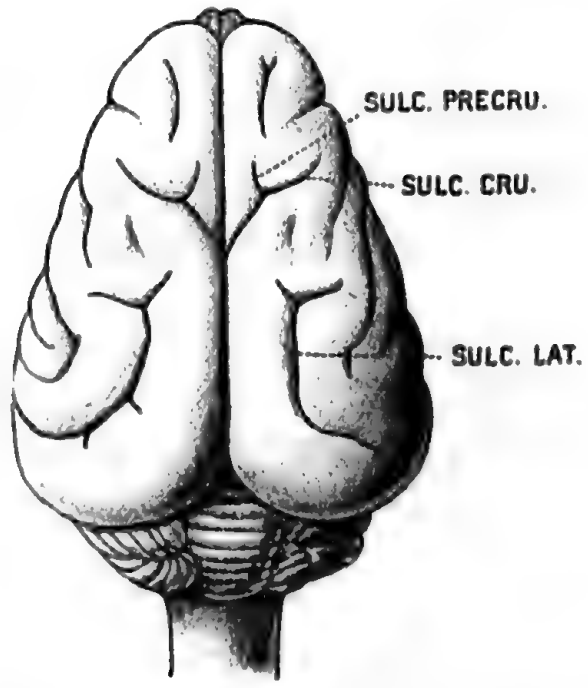

The crucial sulcus joins the prolongation of the calcarine; there is a very small precrucial sulcus near the mesial plane ; the prorean sulcus already noted in *Gulo* is present also in this, as it is in *Galera*. O. C. 1325 N *a*.

Mivart, Journ. Linn. Soc., vol. xix. 1886, p. 16.

D. 353. The brain of a Grison (*Galictis vittata*). O. C. 1325 N.

D. 354. The brain of a Zorilla (*Ictonyx zorilla*).

This brain resembles that of *Putorius* in almost all points. It, however, presents a small ansate sulcus, which is lacking in *Putorius*.

This brain incidentally illustrates various points in the arrangement of sulci. The greater stability of the postsylvian as compared with the postlateral is shown by the complete absence of the latter. The proximity of the suprasylvian to the "Sylvian" is suggestive of its absorption in the latter, as in the Seals and, in another sense, in the Primates. O. C. 1325 N c.

Mivart, Journ. Linn. Soc., vol. xix. 1886, p. 18.

D. 355. The brain of *Helictis subaurantiaca*, (♀).

Although this brain presents the common Arctoid characters, it conforms more especially to the Musteline type (fig. 147).

Fig. 147. (Nat. size.)

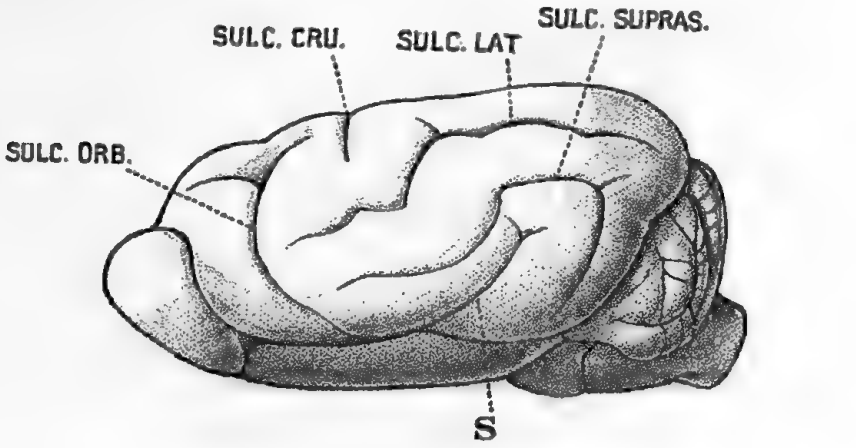

Fig. 148. (Nat. size.)

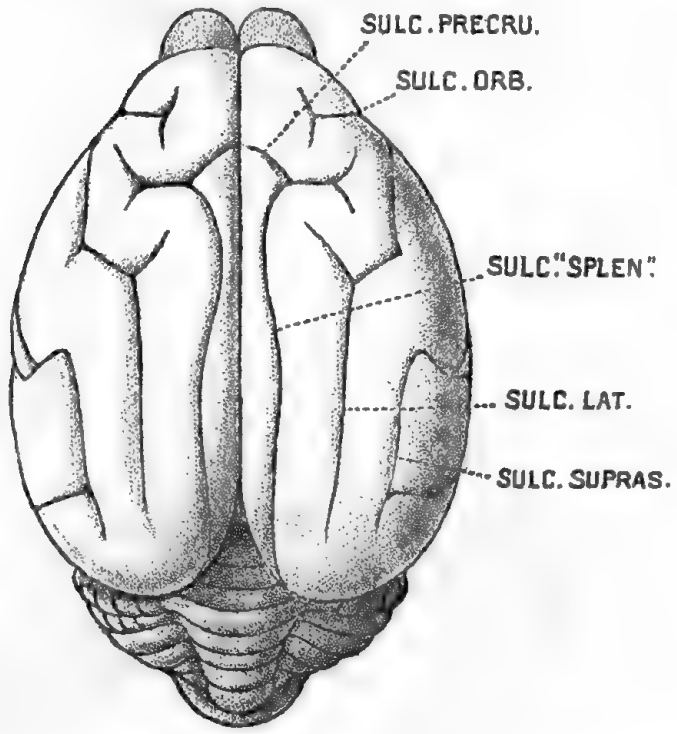

It presents a most extraordinary feature for a Carnivore in that the intercalary prolongation of the calcarine sulcus (the so-called "splenial") extends on to the dorsal surface and is prolonged forward parallel to the interhemispheral cleft and ultimately joins the transverse crucial (fig. 148).

Although this sulcus occupies a dorsal position in the Chevrotain, Musk-Deer, and others of the Ungulates, such behaviour is unknown elsewhere in the Carnivora.

The precrucial sulcus limiting the so-called "Ursine lozenge" is well developed (fig. 148).

As also in *Ictonyx*, the lateral sulcus does not extend far in the caudal direction. O. C. 1325 N *d*.

Garrod, Proc. Zool. Soc. 1879, p. 307.

D. 356. The brain of an Indian Ratel (*Mellivora indica*) (figs. 149 & 150).

Fig. 149. (Nat. size.)

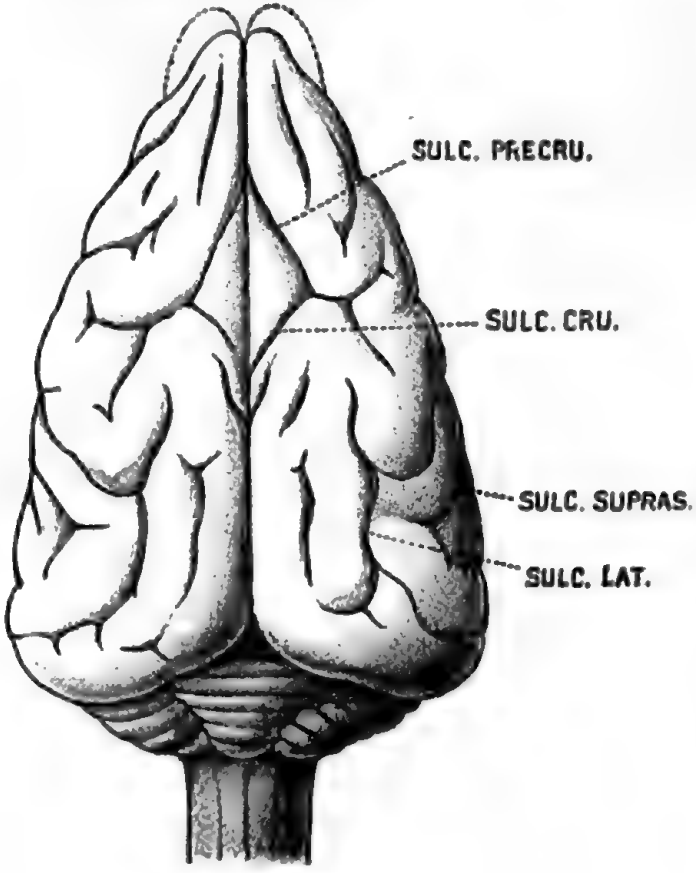

Fig. 150. (Nat. size.)

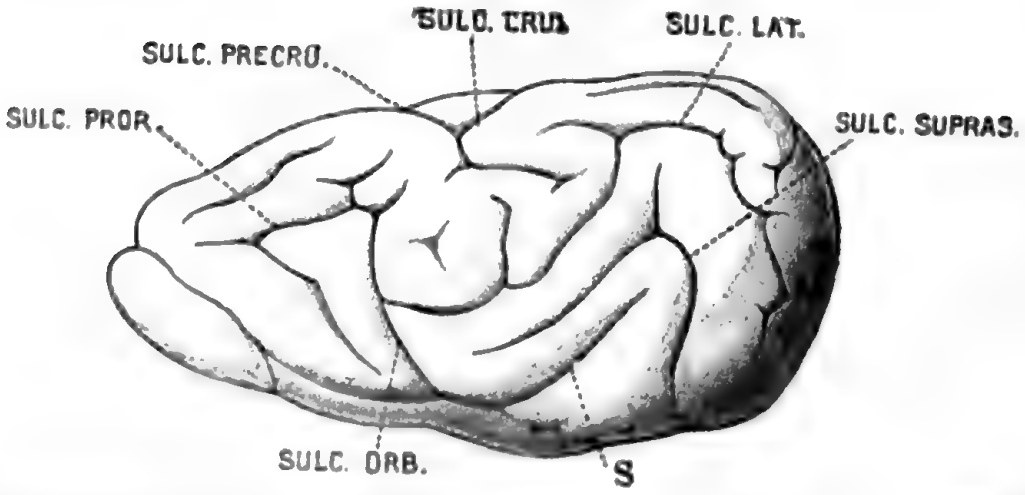

This brain resembles that of the Glutton. The crucial sulcus is practically confined to the dorsal surface of the brain; it has a large precrucial branch and also a compensatory ansate branch, as in *Gulo*. There is a shallow entolateral sulcus. O. C. 1325 N *e*.

Mivart, Journ. Linn. Soc., vol. xix. 1886, p. 14.

D 357. The brain of a Common Badger (*Meles meles*), in which the left hemisphere has been separated from the rest of the brain (figs. 151, 152, & 153).

Fig. 151. $(\times \frac{2}{3}.)$

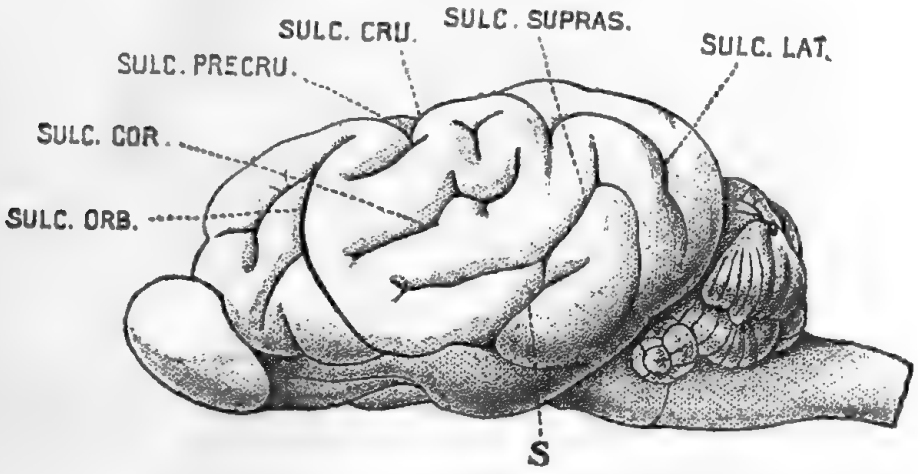

Fig. 152. $(\times \frac{2}{3}.)$

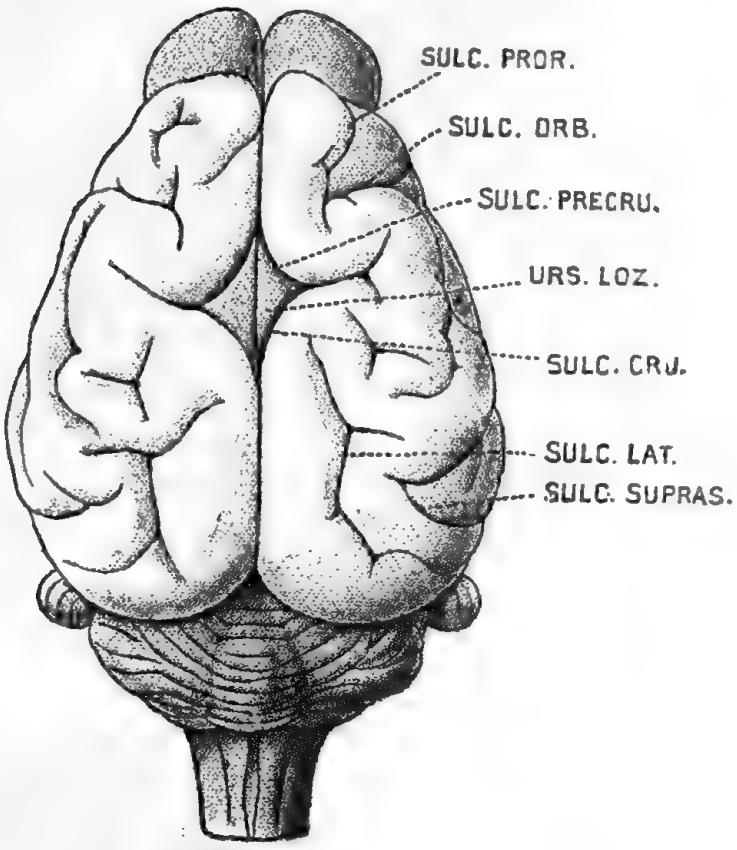

Fig. 153. $(\times \frac{2}{3}.)$

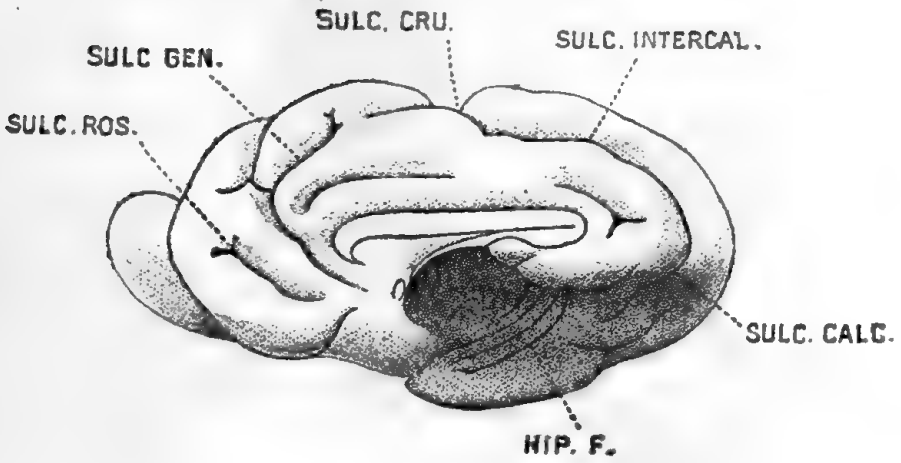

The exceedingly long transverse crucial sulcus is placed relatively far back in the hemisphere ; it appears to communicate freely with the intercalary prolongation of the calcarine (splenial) sulcus, but, in reality, the two sulci are often entirely separate. There is a deep precrucial sulcus, which extends on to the mesial wall in some cases, as it does here.

Just as in certain anomalous cases in the Felidæ and in all cases in the Hyænidæ, the anterior part of the first arcuate gyrus of Leuret becomes buried in the "Sylvian fissure," so in this brain the anterior of the *second* arcuate gyrus also tends to become buried in this great Sylvian cleft, which has already swallowed the whole of the first arcuate gyrus. Hence, in many cases, the upper part of the suprasylvian sulcus appears to join the "Sylvian fissure," while the postsylvian (posterior suprasylvian) remains exposed.

The great elongation of the "Sylvian fissure" in the Badger, as in the Arctoidea in general, is to be attributed to a factor such as that which elongates the corresponding fissure in the Hyæna and sometimes in the Lion. The first arcuate gyrus is buried in the "Sylvian" and the small "feline Sylvian" is found in the triangular submerged area.

The large orbital (presylvian) sulcus joins the prorean, and also frequently gives off a more lateral accessory prorean branch.

In this brain the gap between the coronal and lateral sulci is complicated by a triradiate compensatory ansate sulcus; but in other cases the conjoint corono-lateral gives off numerous short branches in this region.

Flatau and Jacobsohn, Vergl. Anat. d. Centraln. 1899.

D. 358. A cast of the cranial cavity of a Badger (*Meles meles*).

Besides showing the true shape and proportions of the cerebellum, olfactory bulbs, and cerebral hemisphere, this specimen clearly exhibits the arrangement of the chief sulci.

D. 359. A cast of the cranial cavity of the Common Otter (*Lutra lutra*).

The most noteworthy feature of this cast is the demonstration of the small size of the olfactory bulbs and the pyriform lobes—phenomena directly associated with the aquatic mode of life of the Otter.

The typical Arctoid plan of the sulci can be distinctly recognised. Note especially that the crucial sulci are placed very far forward and have well-marked precrucial branches.

Mivart, Journ. Linn. Soc., vol. xix. 1886, p. 20.

Family *Ursidæ*.

D. 360. The brain of a Polar Bear (*Ursus maritimus*), (♀), from which the left hemisphere has been separated.

The "Sylvian fissure" is distinguished by its great length and depth, and as a result the suprasylvian and corono-lateral arcs which are grouped around it become greatly elongated and acutely flexed.

Fig. 154. (Reversed, $\times \frac{2}{3}$.)

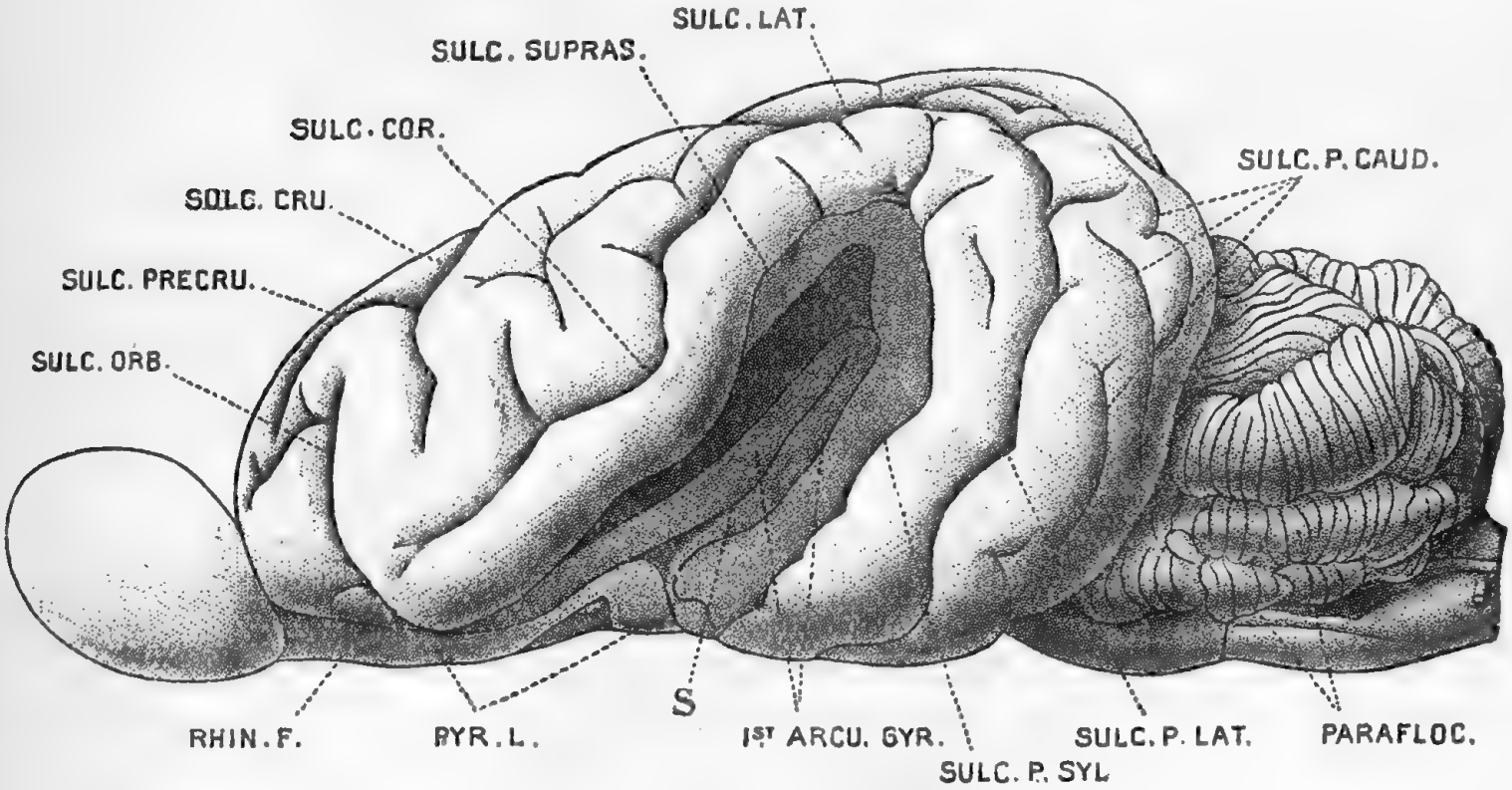

Sir William Turner long ago pointed out that the whole of the first arcuate gyrus of Leuret is hidden in the depths of this deep "Sylvian fissure." On the right hemisphere (fig. 154) a considerable portion of the second arcuate gyrus (from which the lips of the fissure are formed) has been cut away so as to expose this buried gyrus. It will be seen to be acutely flexed around a long sulcus, which clearly corresponds to the "feline Sylvian fissure." This arcuate gyrus is bounded by an extensive sulcus, which may be regarded as the ectosylvian.

The deep orbital sulcus presents the usual features and is joined to the prorean sulcus. The enormously elongated suprasylvian arc (conjoint suprasylvian and postsylvian sulci (is very deep and several deep kink-like radiating sulci proceed from its convexity.

Fig. 155. (×$\frac{2}{3}$.)

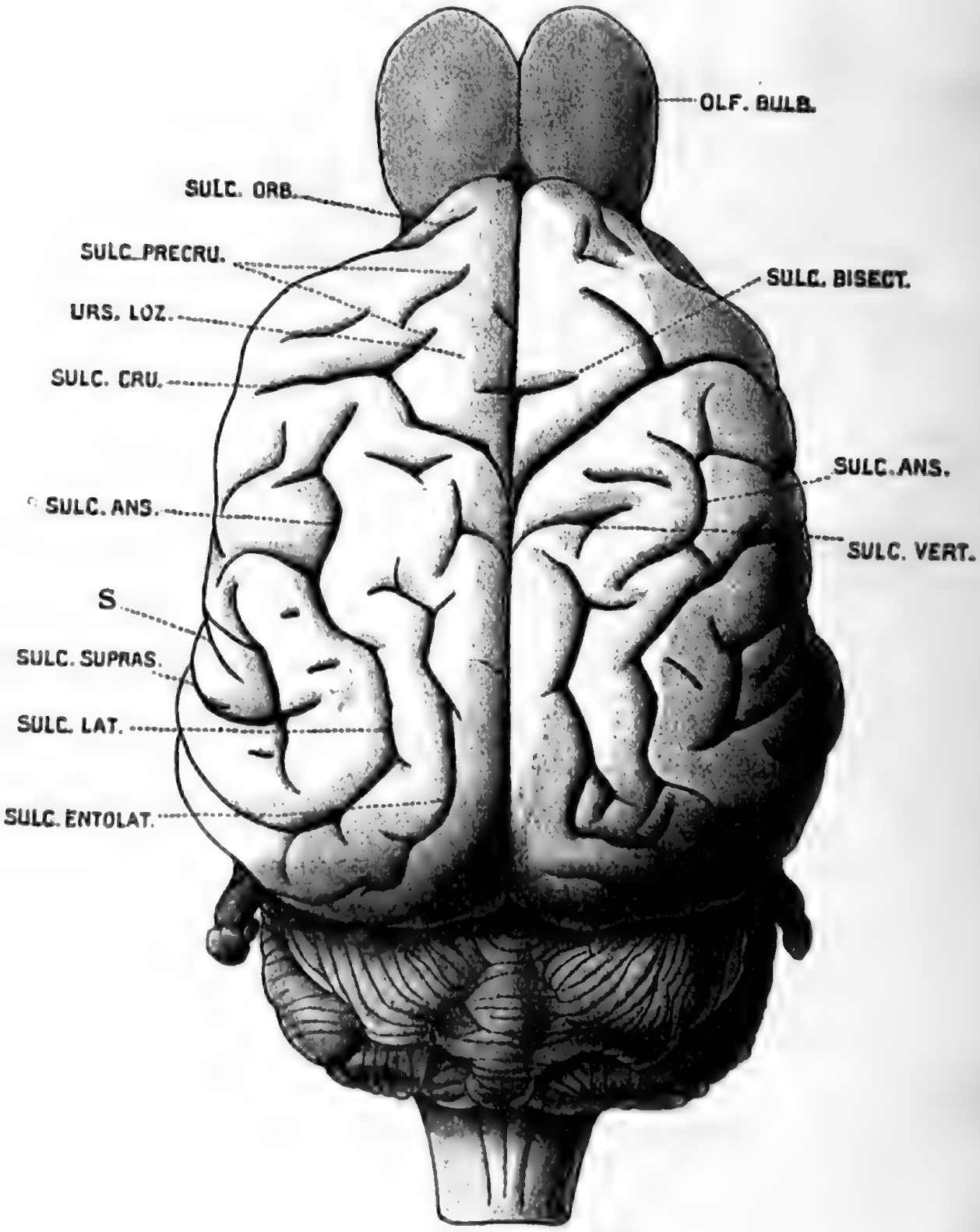

The combined coronal, lateral, and post-lateral sulci also form a great inverted-U-shaped arc, which is almost as acutely flexed as the suprasylvian (figs. 154 & 155).

One of the most distinctive features of the brain of the Bear is the nature of the crucial sulcus. This sulcus is of great length and depth and is almost wholly confined to the dorsal surface of the hemisphere (figs. 155 & 156), upon which it pursues an oblique course and is placed relatively far back on the hemisphere. After examining such a brain as this, we can readily appreciate the fact that this sulcus is the only one in the Carnivore which can, in any sense, be regarded as the representative of the sulcus of Rolando of the Primate brain. [Compare the crucial and precrucial sulci of a Bear (say D. 365) with the central and superior precentral sulci of a Gorilla (say D. 661).]

Fig. 156. (×$\frac{2}{3}$.)

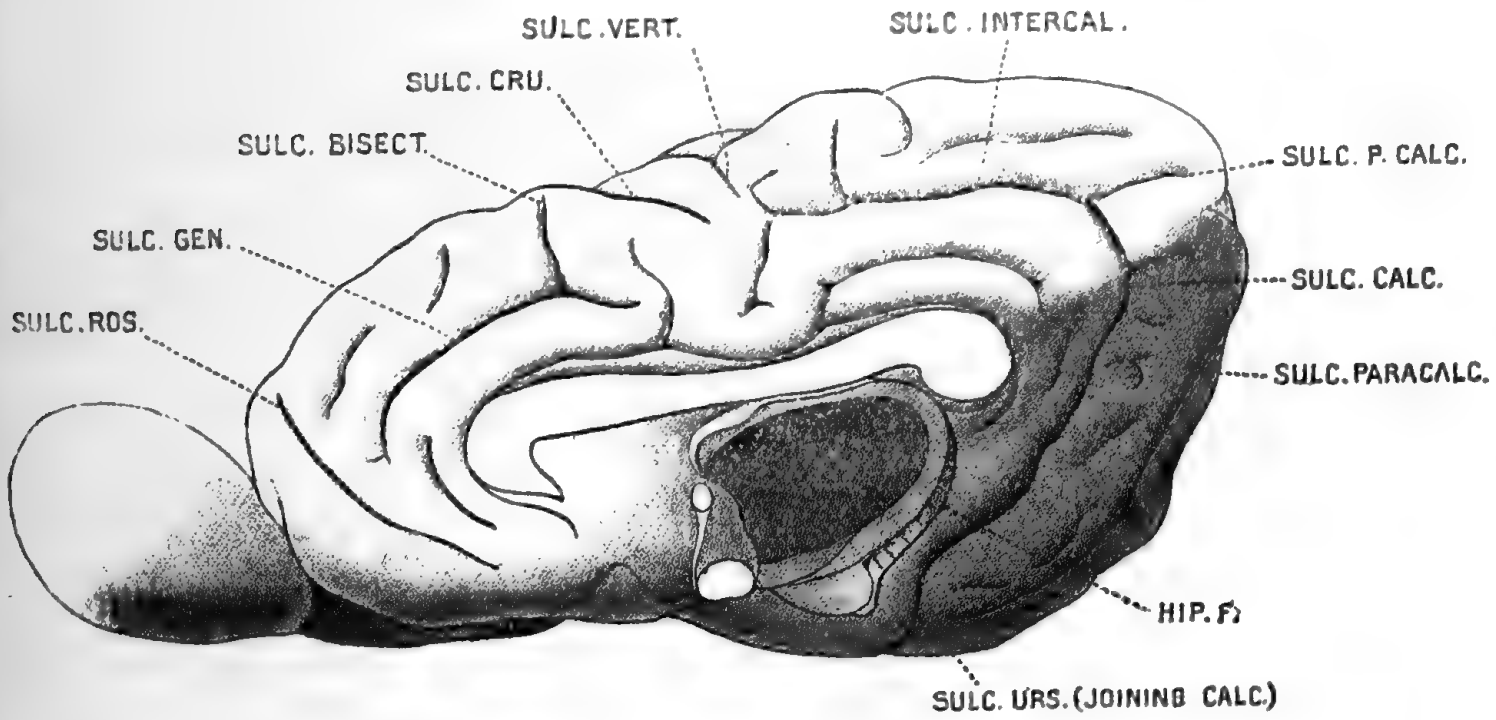

On the right hemisphere there is a deep, long, precrucial sulcus proceeding forward from the crucial, and distinctly mapping out the right lateral boundary of Mivart's "Ursine lozenge" (fig. 155); but on the left side the sulcus is much smaller and is supplemented by a larger "complementary precrucial," which is quite independent of the crucial sulcus.

Although precrucial sulci may make their appearance among the larger representatives of other families of the Carnivora, such, for instance, as the Lion and Hyæna, yet the presence of these sulci and the "Ursine lozenge," which they map out, is a valuable distinctive feature of the

Arctoid families, in which it attains its greatest development, and is found not only in the larger members but also in many brains of small animals (*vide supra*).

The great complications produced in the area behind the crucial sulcus by the development of "ansate" and "com pensatory ansate" sulci are shown in the drawings (figs. 154 & 155).

The broad gyrus which separates the lateral sulcus from the interhemispheral cleft is subdivided by a very deep entolateral sulcus, from which numerous offshoots are given off both on the mesial and lateral aspects (fig. 155).

The broad vertical gyrus between the postlateral sulcus and the caudal margin of the hemisphere is complicated by a series of three vertical sulci which are arranged in an imbricate manner. For convenience of reference I shall call them "paracaudal" (fig. 154).

The calcarine sulcus (fig. 156) is exceedingly deep. It joins the intercalary sulcus at an acute angle. The latter extends forward for a relatively short distance and ends in a shallow vertical sulcus behind the crucial. Between the intercalary and crucial sulci there is a small but deep sulcus, which for convenience of reference may be called "vertical." This crosses on to the dorsal surface and there bifurcates (figs. 155 & 156).

From the angle of junction of the calcarine and intercalary sulci two short, deep, posterior branches are given off (fig. 156).

On the extreme caudal edge of the mesial surface there is a deep sulcus parallel to and coextensive with the calcarine. It may be called the "paracalcarine" sulcus (fig. 156).

The lower extremity of the calcarine sulcus becomes freely continuous (in this individual specimen) with a sulcus which begins (fig. 156) opposite the lower extremity of the hippocampus, and proceeds as a deep cleft across the ventral surface of the hemisphere (fig. 157) just behind the natiform eminence of the pyriform lobe and the caudal extremity of the posterior rhinal fissure. Although small representatives of such a sulcus may occur among other Carnivores, this fully-developed form is so peculiar to the

Bears that I shall distinguish it as "ursine." In the brains of all other Bears that I have examined it is independent of the calcarine sulcus, but in some cases it joins the rhinal fissure.

There are typical genual and rostral sulci. The posterior extremity of the genual sulcus (in this specimen, fig. 156) is joined to a very constant vertical sulcus which bisects the "Ursine lozenge" (fig. 155). As reference will be made to this in speaking of the Seals, it may be distinguished as the "bisector sulcus."

Fig. 157. (×$\frac{2}{3}$.)

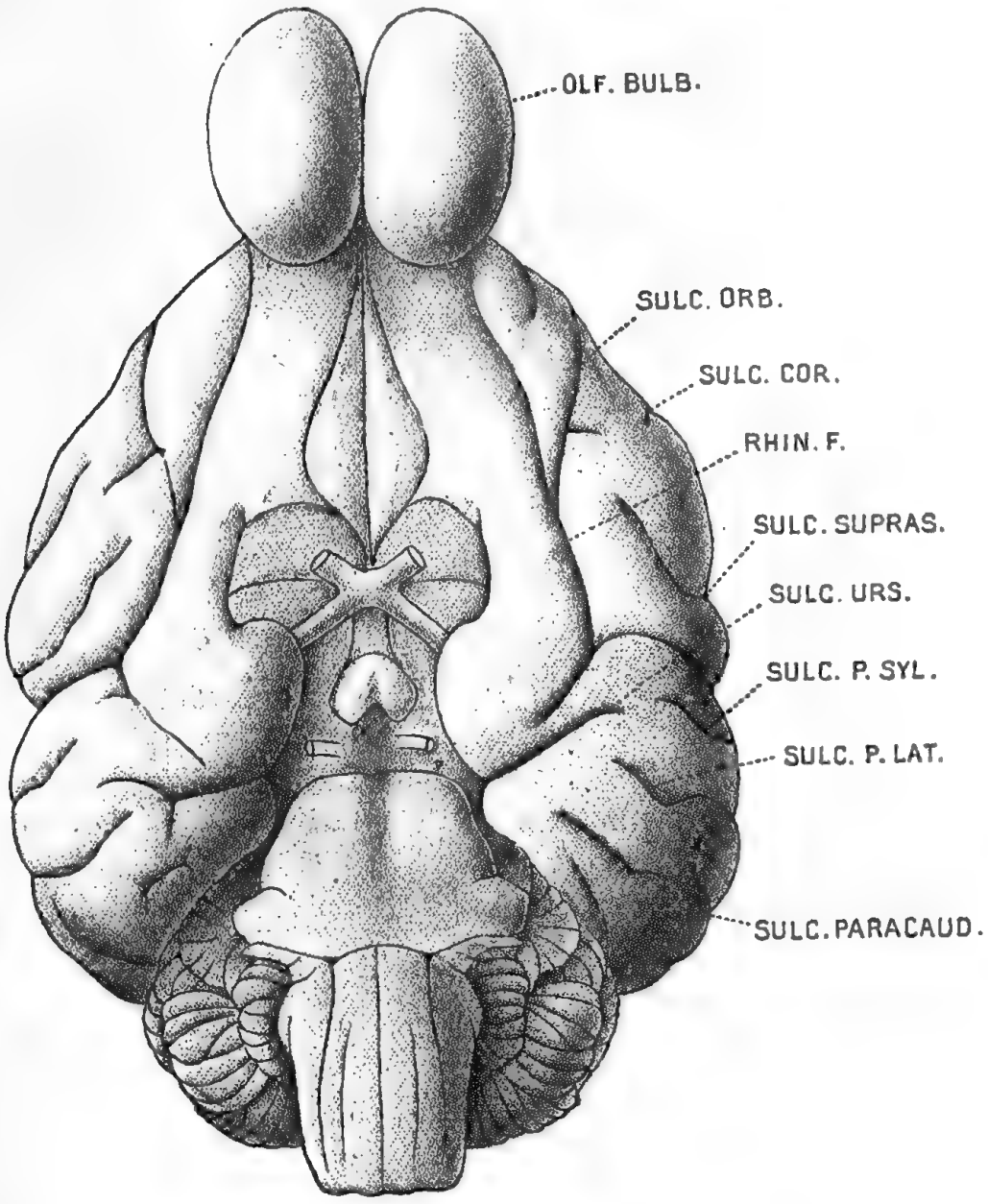

There is a shallow sulcus midway between the calcarine-intercalary complex (splenial). It is the "sublimbic" of Guldberg.

The typical characters of many other parts of the brain, such as the hippocampus, the cerebral commissures, the pyriform lobe, and especially the cerebellum, are exceedingly well-shown here. These features are remarkably constant throughout the Carnivora (*vide* account of Cat's brain). O. C. 1325 T *f*.

Mivart, Journ. Linn. Soc., vol. xix. 1886, p. 19.

D. 361. The brain of a Polar Bear (*Ursus maritimus*).

On each hemisphere there is an ansate sulcus joined to the corono-lateral sulcus, as well as complementary ansate sulci. There is a simple entolateral sulcus.

The posterior rhinal fissure appears to join the ursine sulcus in both hemispheres.

Note that the trapezoid bodies are partly overlapped by the pons. O. C. 1325 T *e*.

D. 362. A cast of the cranial cavity of a Polar Bear (*Ursus maritimus*).

The exact shape and size of the huge olfactory bulbs and pyriform lobes are clearly shown.

The great pseudosylvian cleft and all the sulci on the cranial aspect of the hemispheres are admirably demonstrated.

The examination of a cast such as this enables us to appreciate how closely the brain of the extinct *Megatherium* must have resembled that of *Ursus* not only in shape but also in the disposition of the pseudosylvian, suprasylvian, orbital, lateral and possibly even the crucial sulci.

D. 363. The brain of an American Black Bear (*Ursus americanus*).

In this specimen the precrucial sulci are independent of the crucial sulci, and the latter do not extend on to the mesial surface. Hence the boundaries of the "Ursine lozenge" are incomplete. This fact is of interest when it is recalled that certain writers (*vide* Soury) argue that the crucial sulcus of Carnivores cannot represent the sulcus of Rolando, because the former is "essentially a feature of the mesial surface."

The ursine sulcus is independent of both the calcarine sulcus and the rhinal fissure, and extends into the gap between these two furrows. O. C. 1325 T.

D. 364. The brain of an American Black Bear (*Ursus americanus*).

The region between the lateral sulcus and the interhemispheral cleft is broken up to an extraordinary degree by numerous irregular gyri. O. C. 1325 T *g*.

D. 365. A brain labelled Indian Bear—probably *Ursus labiatus.*

This is a small and comparatively simple Bear's brain; but it presents features of peculiar interest, which enable us to understand the arrangement of the sulci in the Seal's brain. The anterior limb of the third arcuate gyrus has grown backward in an operculum-like formation so as to overlap a considerable portion of the second arcuate gyrus, so that the "Sylvian fissure" and the suprasylvian sulcus (the anterior limb of the suprasylvian arc) appear to become confluent. The operculum of the third gyrus has been removed on the right hemisphere (fig. 158). Fig. 159 shows the appearance of the Sylvian region before the dissection was made.

Fig. 158. (×⅔.)

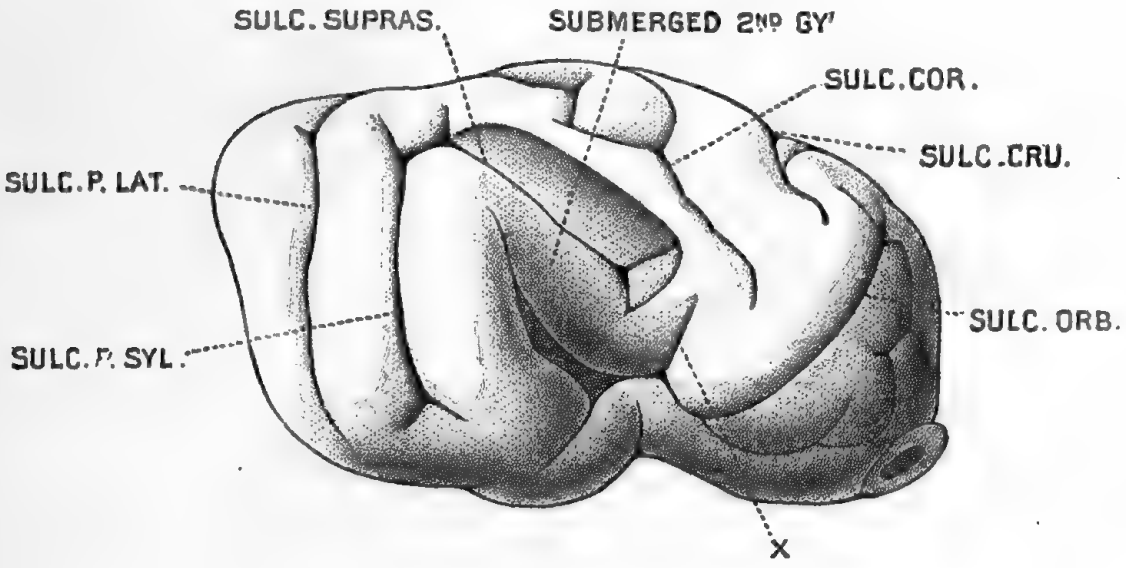

Fig. 159. (×⅔.)

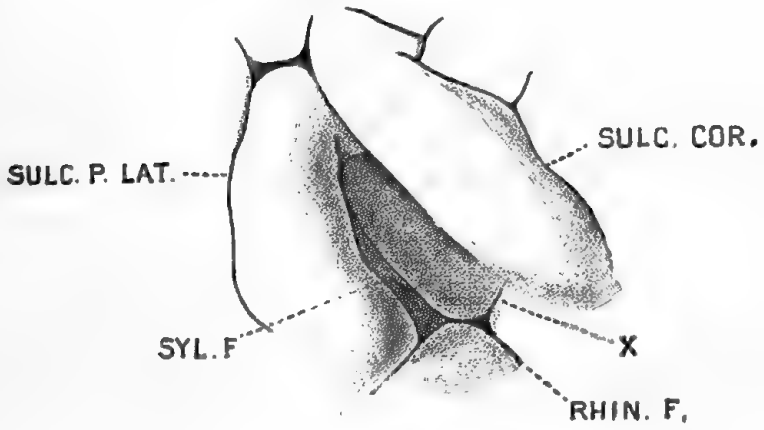

Similar phenomena occur in the Badger (*Meles, vide supra*) and in the Seals (*vide infra*).

There is a sulcus analogous to that distinguished by the letter x in the Lion's brain. O. C. 1325 T *c*.

D. 366. The brain of a "Bornean Sun-Bear" (*Ursus malayanus*).
O. C. 1325 T *b*.

D. 367. The brain of a Grisly Bear (*Ursus ferox*).
O. C. 1325 T *d*.

D. 368. The brain of a Syrian Bear (*Ursus syriacus*).
O. C. 1325 T *a*.
Presented by Dr. Buckland.

D. 369. A cast of the cranial cavity of *Ailuropus melanoleucus*.

The brain itself could not have afforded a better demonstration of the arrangement of the typically Arctoid pseudosylvian, suprasylvian, orbital, corono-lateral, ansate, crucial and precrucial sulci. The lesser degree of macrosmatism resulting in the attenuation of the olfactory bulbs and peduncles prepares us for the condition we find in the Sea-Bear (*Otaria*).

Suborder PINNIPEDIA.

Family *OTARIIDÆ.*

D. 370. The brain of a "Sea-Bear" (*Otaria gillespii*) (♂), in which the two cerebral hemispheres have been separated from the rest of the brain.

[The interpretation of the sulci of the Pinnipeds given in these accounts will be found to be utterly at variance with those of Turner and Kükenthal and Ziehen (or Flatau and Jacobsohn, who follow the latter). This is no place to discuss the grounds for the views presented, but if the reader carefully examines, in the order named, the brains of *Ursus maritimus*, *Ursus labiatus* (specimen D. 365) [or *Meles meles*], *Otaria*, *Odobænus*, and *Phoca*, the writer feels assured that no further advocacy of his views will be necessary to convince the reader of their essential accuracy.]

"The brain of the Sea-Bear is very instructive, for it supplies what would otherwise be a 'missing-link' of much importance between the brain of the Seals and that of ordinary land Carnivora. In the first place it is intermediate in general form. It is less rounded than in the Seals, but differs from that of ordinary Carnivora by being almost as broad in front as it is behind" (Mivart, *op. cit.*). These illuminating remarks of Mivart will be seen to have a much wider application than even their author intended, for the resemblance between the plan of the sulci in *Otaria* and *Ursus* is so very striking, even in the arrangement of small and apparently unimportant features, that there can be no question as to the identity of the two series of sulci.

The olfactory bulb [lacking in this specimen] is large for a Pinniped Carnivore [compare the cast of the cranial cavity, D. 371]. It is borne on a long peduncle, which extends from the region of the tuberculum olfactorium forward on the base and then upward on the anterior surface almost to the antero-dorsal angle or apex of the hemisphere (fig. 160). It is lodged in a deep sagittal olfactory sulcus.

Fig. 160. (×$\frac{1}{3}$.)

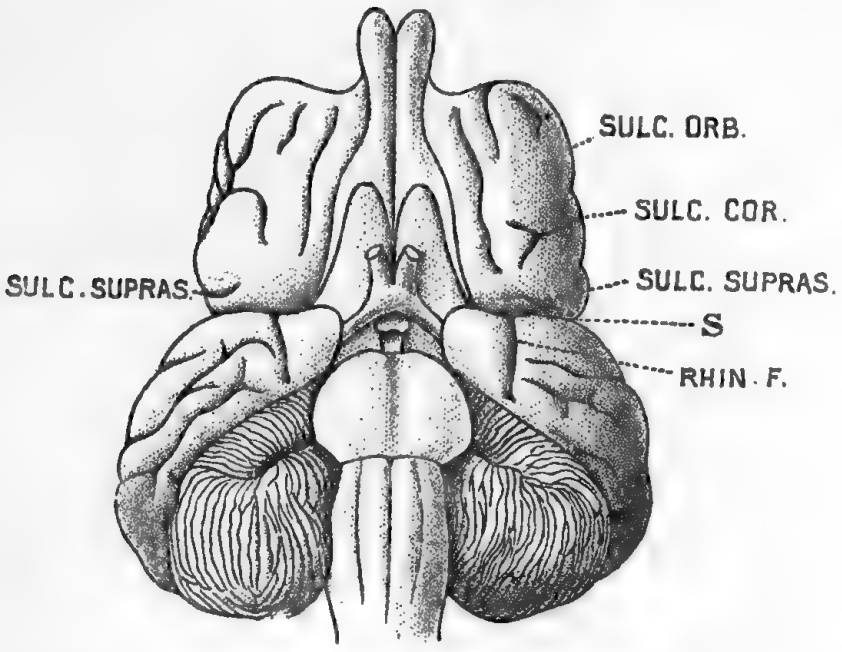

Parallel to and coextensive with the latter there is an orbital (presylvian) sulcus, which does not join the rhinal fissure (fig. 160). A comparison of this with the human orbital (so-called triradiate) will make clear to the reader why the term "orbital" has been employed in these notes throughout the whole mammalian series in place of the more customary "presylvian."

The "Sylvian fissure" is distinctly Ursine. It begins on the ventral surface of the brain in a distinct vallecula Sylvii caused by the flexure of the small pyriform lobe (fig. 160): it ascends with a slight inclination backward.

The clue to the complete understanding of the brain of the Seals is afforded by the study of the Bear's brain. It will be noticed in the latter that the first arcuate gyrus has been completely submerged in the "Sylvian fissure," and there is a strongly-marked tendency for the anterior limb of the second arcuate gyrus to sink into the same great gulf. In some Bears and in the Badger this may actually occur. And in *Otaria* and the Seals the tendency becomes more distinctly pronounced; in other words, the anterior limb of the second arcuate gyrus becomes depressed and partially overlapped by the third arcuate gyrus. As a result we find a great vertical depression on the lateral aspect of the brain (fig. 161) in which the "Ursine Sylvian fissure" and the suprasylvian sulcus are seen separated by a narrow strip of submerged second arcuate gyrus. The suprasylvian sulcus emerges from the apex of this great depression and, after giving off a minor ansate sulcus, proceeds obliquely upward and backward to end between the two pieces of the forked upper end of the postsylvian (posterior suprasylvian) sulcus. This Sylvio-suprasylvian complex may be regarded as analogous to the Sylvian fissure of Human Anatomy (*vide infra*).

Fig. 161. ($\times\frac{2}{3}$.)

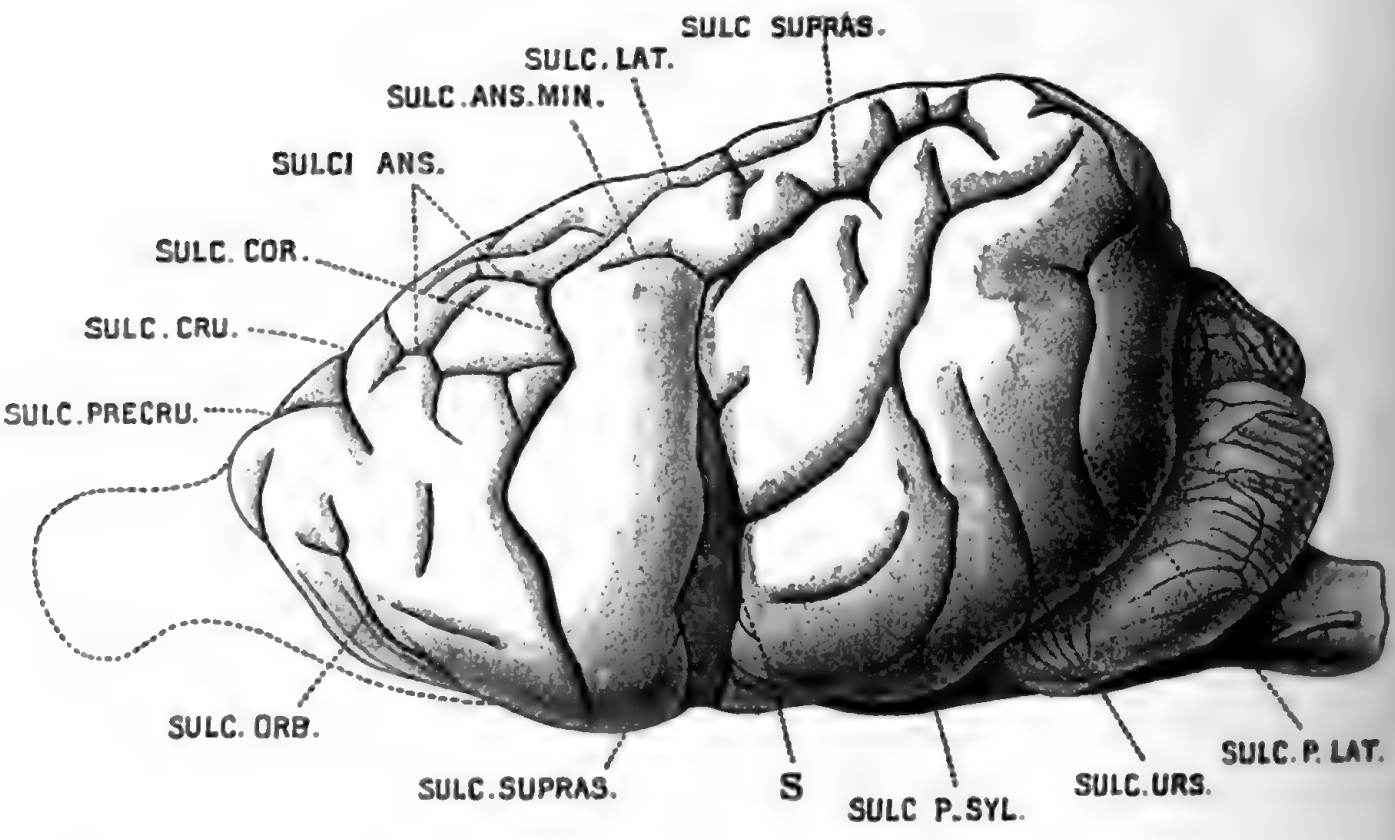

The postsylvian sulcus is not joined to the suprasylvian (figs. 161 & 162); its lower extremity bends forward (fig. 161) almost as far as the Sylvian fissure. Several shallow oblique sulci extend across the broad gyrus which separates the postsylvian sulcus and the Sylvian fissure.

The great corono-lateral sulcus is parallel to and co-extensive with the suprasylvian sulcus, from which it is separated by a broad gyrus. A large ansate sulcus and several smaller branches spring from the angle of junction of the coronal and lateral sulci. This region is further complicated by irregular compensatory ansate sulci. A short oblique sulcus (fig. 162, A) is found on the gyrus separating the lateral from the postlateral sulcus. The latter is very well-developed (fig. 161). An exceedingly deep entolateral sulcus is found (fig. 162) near the posterior third of the mesial edge of the hemisphere. Posteriorly it is prolonged into a sulcus which is placed exactly on the caudo-lateral edge of the hemisphere [and is hence not

Fig. 162. (×$\frac{2}{3}$.)

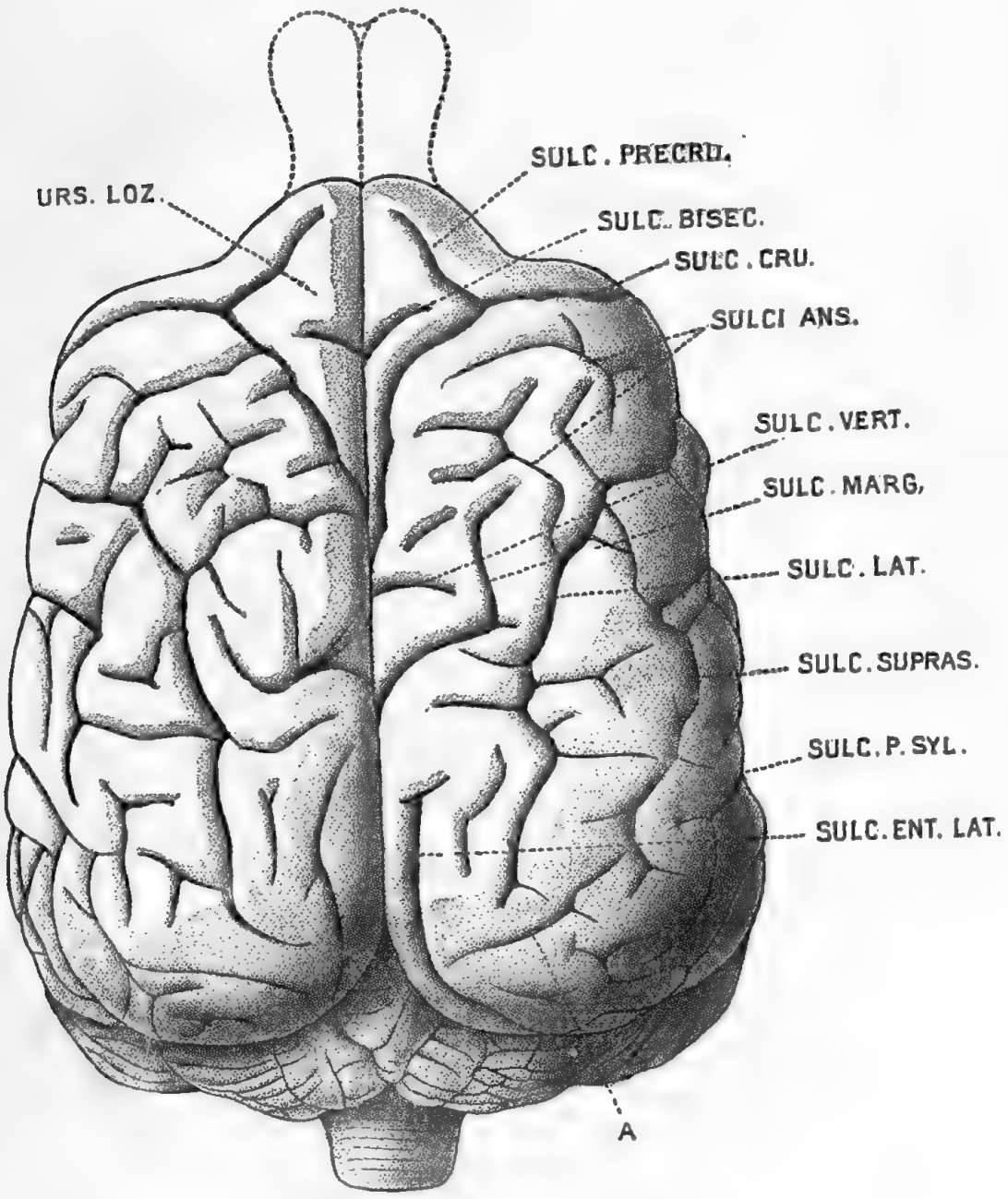

visible in the figures]. This undoubtedly represents the paracalcarine sulcus of the Bears (*vide supra*). This conjoint entolateral-paracalcarine sulcus is as much as 2 cm. deep in parts of its course. This may be partly due to the fact that the paracaudal sulci of the Bear's brain are not present here. As in the Bear's brain, the posterior rhinal fissure ends upon the ventral surface of the hemisphere, *i. e.* does not extend backward on to the mesial surface. Behind its extremity we find in *Otaria* a well-developed representative of the peculiar sulcus distinguished by the name "ursinus" in the Bear. In fact this sulcus is even larger than it is in the Bear's brain, and extends upward on the lateral surface between the postsylvian and postlateral sulci (fig. 161).

Fig. 163. (×$\frac{2}{3}$.)

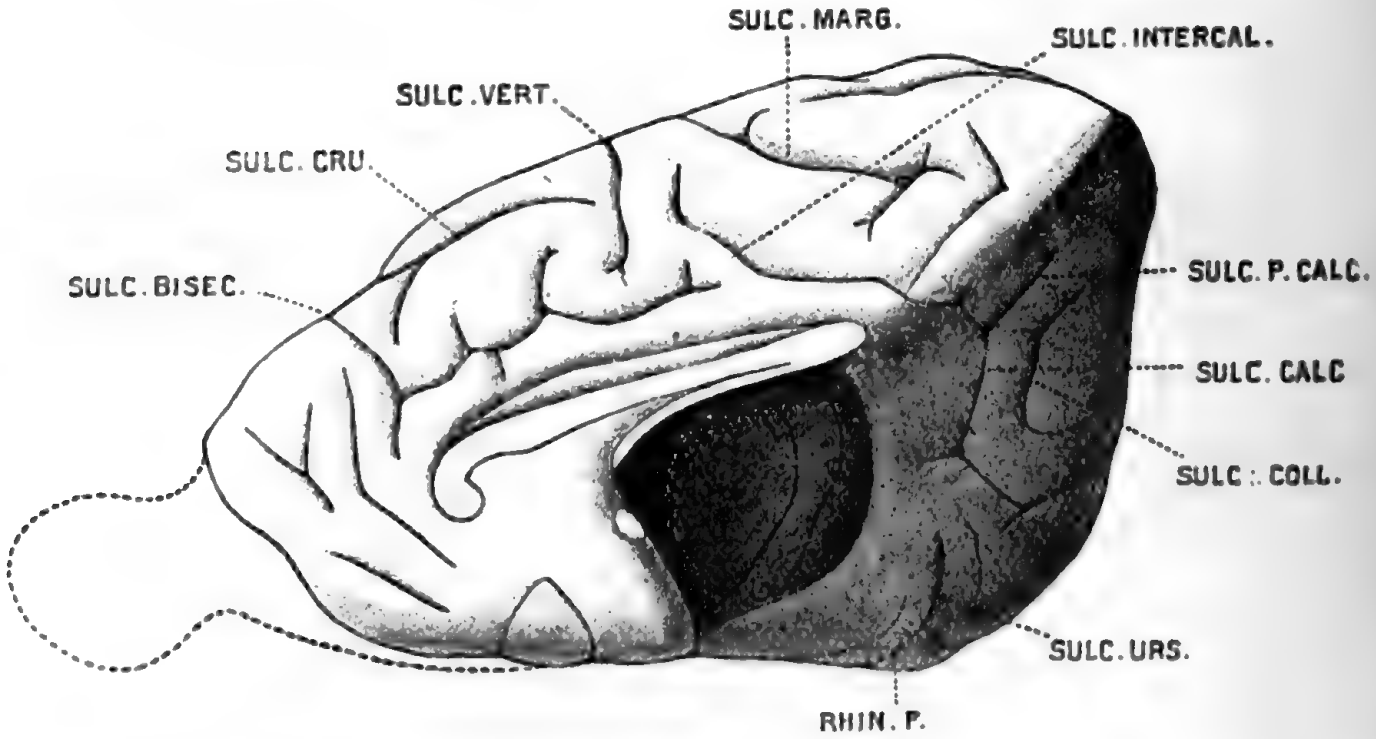

The calcarine sulcus is very deep and its forward continuation (intercalary) is oblique and very short (fig. 163). There is a deep retrocalcarine branch (SULC. P. CALC.) of the calcarine. There is a small collateral sulcus, analogous to but not strictly homologous with the human collateral (*vide infra*).

There is a typically Ursine crucial sulcus (fig. 162) with large precrucial branches, and consequently the "Ursine lozenge" of Mivart is very large and distinct.

Those peculiar sulci which were distinguished by the names "vertical" and "bisector" in the Bear's brain are present in the same forms in this brain (figs. 162 & 163).

There is a great oblique marginal sulcus of Owen ("suprasplenial" of other authors) parallel to the intercalary sulcus (fig. 163); it crosses on to the dorsal surface, where it pursues a considerable course (fig. 162).

The cerebral hemispheres overlap the cerebellum to a much greater extent in this brain than is the case in the Bear.

In structure the cerebellum, like that of the Bears, presents the usual Carnivore features. O. C. 1325 v e

J. Murie, Trans. Zool. Soc., vol. viii. 1874, p. 517.

D. 371. A cast of the cranial cavity of a Sea-Bear (*Otaria jubata*).

D. 372. The brain of a Walrus (*Odobænus* [*Trichechus*] *rosmarus*).

The cerebral hemispheres are short and very broad, especially in the postsylvian region. They overlap the cerebellum to a much smaller extent than in *Otaria*; and the great caudo-dorsal extension of the hemispheres, which is chiefly responsible for this in the "Sea-Bear," is not developed to nearly the same degree in the Walrus. On the other hand, the lateral caudo-ventral region of the hemisphere is widely extended laterally, so as to partly overlap the cerebellum.

The elongated olfactory peduncles are arranged as in *Otaria* and all the Seals; but, as the cast of the cranial cavity shows, the olfactory bulbs are relatively very small. The broad anterior perforated spot, the flattened remains of the olfactory tubercle, and the pyriform lobe resemble the corresponding parts in *Otaria*.

The sulci are described in the account of the next specimen. O. C. 1325 x.

W. Turner, 'Challenger' Reports, vol. xxvi. 1887, p. 102.

D. 373. The right cerebral hemisphere of a Walrus (*Odobænus* [*Trichechus*] *rosmarus*) (figs. 164, 165, 166, & 167).

The sulci of this hemisphere, in spite of the difference of its shape and consequently of the mechanical factors during growth, conform essentially to the same plan as those of *Otaria*. This leads us to an interpretation of the sulci which is utterly at variance with the views propounded by

Ziehen and other writers on the brains of the Seals. It also differs in many respects from Sir William Turner's interpretation. The anomalous Bear's brain (D. 365) and that of *Otaria* form the two links which connect the Bear's brain with those of the Walrus and Seals, and give the clue which leads us to adopt the views here set forth.

Fig. 164. (× ⅔.)

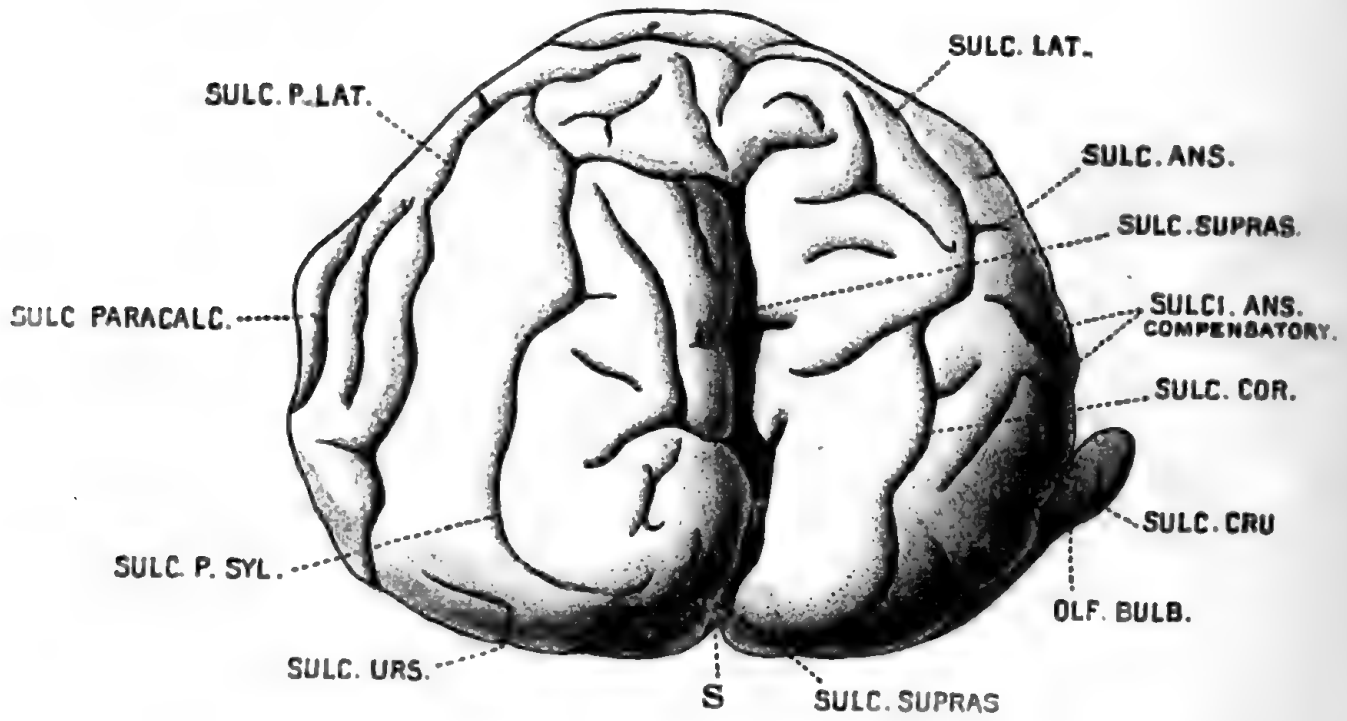

Fig. 165. (× ⅔.)

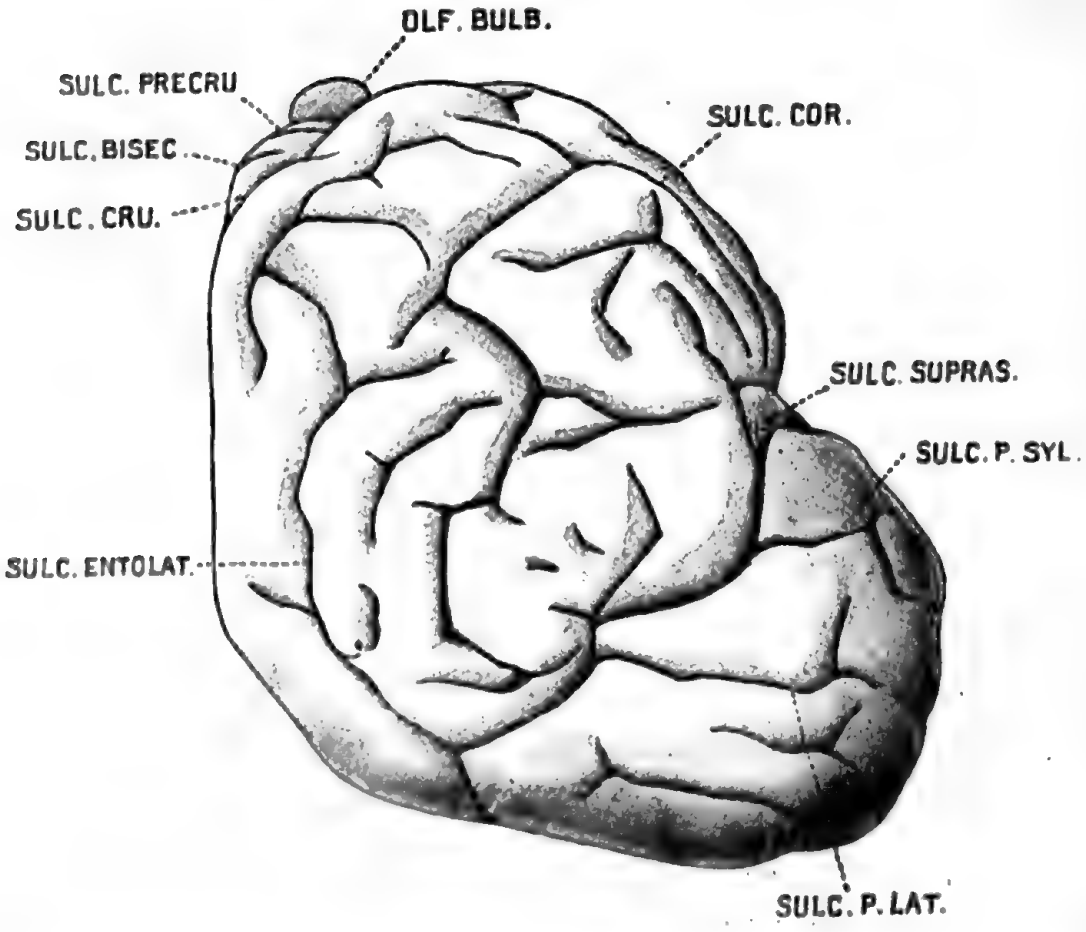

The orbital sulcus, like that of *Otaria*, lies on the basal surface of the frontal region parallel to the olfactory peduncle (fig. 166). Its anterior extremity is hidden by the olfactory peduncle; but it is placed in front of the olfactory sulcus, which does not extend the whole length of the peduncle.

There is a large crucial sulcus, as in *Otaria*, but it is placed on the anterior rather than the dorsal surface. It joins the intercalary sulcus on the mesial surface (fig. 167). There is a large and very deep precrucial sulcus freely opening into the crucial. And the "Ursine lozenge" is bisected as it is in *Otaria* and the Bears.

Fig. 166. (× $\frac{2}{3}$.)

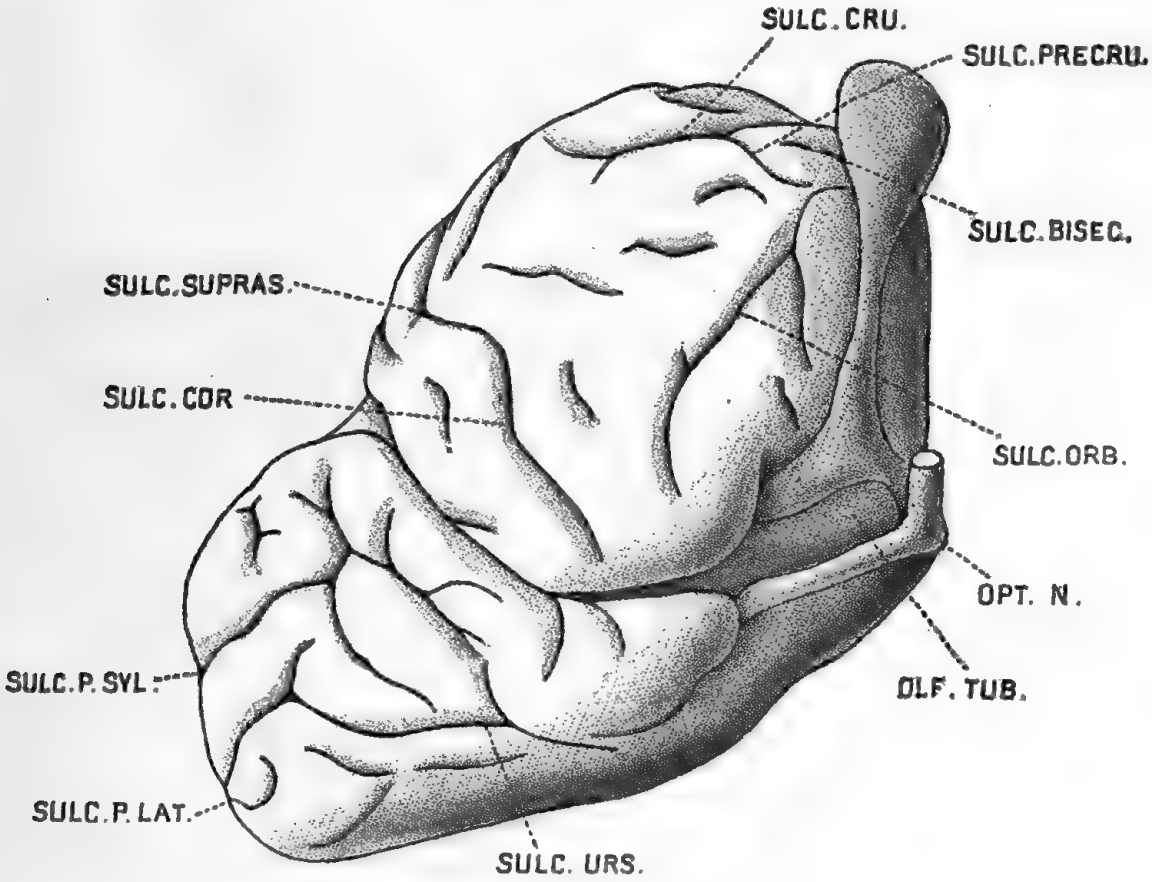

Fig. 167. (× $\frac{2}{3}$.)

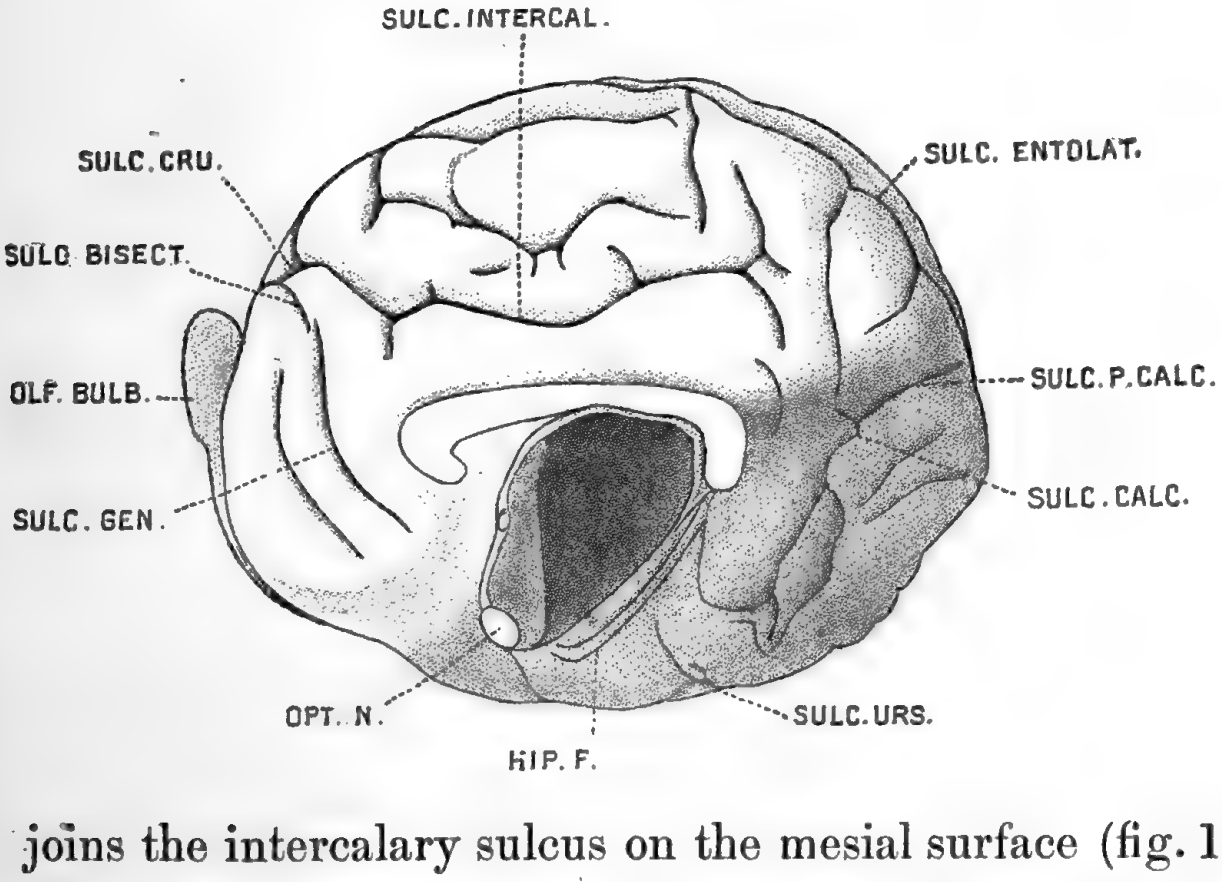

The features of the Sylvian region essentially agree with those of *Otaria* (figs. 164 & 166). We can, however, recognise in the submerged area more definite traces of the ectosylvian sulci than in *Otaria*. They are found in a position analogous to those of the Bear (D. 360).

The anterior limb of the suprasylvian ("ectosylvian" of Ziehen) sulcus is submerged, and can be exposed only by drawing forward the anterior lip of the Sylvian fissure (fig. 164). It emerges at the apex of the Sylvian fissure, and, after giving off a short vertical branch, bends backward for about an inch, and then passes freely into continuity with the vertical postsylvian; the latter pursues a course exactly like that of *Otaria* (compare figs. 161 & 164).

A large vertical branch proceeds from the junction of the suprasylvian and postsylvian sulci.

As in *Otaria*, the region between the postsylvian and the pseudosylvian sulci is much broken up by a series of oblique sulci.

The great vertical coronal sulcus passes freely into the lateral sulcus. The latter is not joined to the large vertical postlateral sulcus. There is a great oblique sulcus between the crucial and the lateral sulci; it corresponds to the dorsal prolongation of the marginal sulcus in *Otaria*, but is to be regarded also as a compensatory ansate. The ansate sulcus is very small, and, as we have seen in the Bear's brain, we should expect to find a large compensatory series of sulci in this situation.

We find a deep entolateral (or paracalcarine) sulcus, as in *Otaria* and the Ursidæ. Its lower part is represented by a separate sulcus, parallel to the postlateral on the cranial surface.

There is a well-defined "Ursine sulcus," which is prolonged laterally between the postsylvian and postlateral as in *Otaria*.

There is a great, deep, vertical calcarine, which becomes forked at its ventral extremity; in other words, the compensatory calcarine (analogous to the Primate collateral) sulcus opens into it.

There is a postcalcarine branch, as in *Otaria*.

The calcarine is separated from the intercalary merely by a submerged gyrus. There is a shallow marginal sulcus, in addition to the compensatory ansate.

There are rostral and genual sulci. The latter is separated from the sulcus which bisects the Ursine lozenge, merely by a submerged gyrus.

Ziehen, Anat. Anzeiger, Bd. v. 1890, p. 692.

D. 374. A cast of the cranial cavity of a Walrus (*Odobœnus* [*Trichechus*] *rosmarus*). [In duplicate.]

Family *PHOCIDÆ.*

D. 375. The brain of a fœtal Common Seal (*Phoca vitulina*).

The shape of the hemispheres of the Common Seal differs most markedly from that of *Otaria* and *Odobœnus.*

[This account is based not on this specimen but on a damaged specimen in the Stores.]

There is no great indentation of the lateral contour in the Sylvian region as in *Otaria* and *Odobœnus.* The hemispheres present an elliptical appearance when viewed from above and an ovoid form in profile. The anterior pole is blunt and rounded, the posterior pole is prolonged backward to cover the cerebellum and carries with it a diverticulum (posterior cornu) of the lateral ventricle.

The upper extremity of the pseudosylvian sulcus appears to bifurcate. The anterior branch is formed by the anterior vertical portion of the suprasylvian sulcus emerging from the Sylvian fissure, in the anterior lip of which it is placed as in the Walrus. This overlaps without joining the horizontal part of the suprasylvian.

The posterior limb of the bifurcation probably represents the upper part of the anterior ectosylvian sulcus or the "Ursine Sylvian fissure."

As a result of the backward growth of the hemisphere, the postsylvian sulcus is very oblique. It is joined to the horizontal arc of the suprasylvian, and is also prolonged far beyond the junction to reach the apex of the occipital pole.

The orbital and coronal sulci are arranged as in *Odobænus*. There are some fragmentary paracoronal sulci between them. The coronal joins a long, sagittal, lateral sulcus which is placed close to the mesial plane and is very deep. It extends on to the posterior pole. It is probably homodynamous with the entolateral (paracalcarine) sulcus of *Otaria*, *Odobænus*, and the Bears.

The postlateral is represented by a horizontal sulcus below the postsylvian, but the analogy is by no means exact.

There is a short, deep, crucial sulcus, the mesial branch of which is short and not joined to the intercalary. There is also a deep and well-defined precrucial branch, but it is placed wholly on the mesial surface, so that the "Ursine lozenge," although exceedingly clearly defined, is not visible upon the dorsal, or rather anterior, surface of the hemisphere.

A sulcus joined to the genual sulcus bisects this "lozenge," as in *Otaria* and some Bears.

The calcarine resembles that of *Otaria*. Its lower extremity joins a long horizontal sulcus. The small ursine sulcus is joined to the posterior rhinal fissure. The intercalary sulcus is independent both of the calcarine, genual, and crucial sulci.

The cerebellum in all the Seals conforms to the Carnivore type already described in the case of the Cat. Its shape, however, is variously moulded in the different genera by the backward growth of the hemispheres.

The flocculus and both of the paraflocculi are very large and richly foliate, without, however, losing the general resemblance in form to that of the Cat.

A large part of the dorsal surface is formed by the richly branched leaf-like lateral expansions of the second lobule of the middle lobe (see account of Cat's cerebellum). The folia of the laterai parts of the third lobule are much more numerous, and as a result have lost the regular transverse arrangement seen in the Cat. O. C. 1325 U.

Flatau & Jacobsohn, Vergl. Anat. d. Centralnervensyst. Säugethiere, 1899, p. 304.

D. 376. The left half of the brain of a Common Seal (*Phoca vitulina*).

D. 377. The right cerebral hemisphere of a Common Seal (*Phoca vitulina*), in which the whole of the lateral wall has been removed to open up the lateral ventricle.

Behind the upper extremity of the hippocampus the small posterior horn of the ventricle is seen, and a bulging (calcar avis) is visible upon the mesial surface. A glass rod has been pushed through the calcarine (so-called "splenial") sulcus to show that the calcar avis in this brain is really produced by the calcarine sulcus. This fact was first recorded by Serres (Anat. Comp. de Cerveau, Paris, 1826, t. ii. p. 470).

Fish, who (in apparent ignorance of this) rediscovered the presence of the posterior cornu, singularly failed to appreciate its important bearing upon the question of the homology of the so-called "splenial fissure," for he was doubtful whether the calcarine or the parieto-occipital sulcus should be regarded as its (splenial sulcus) Primate representative.

P. A. Fish, Journ. Comp. Neurology, 1898, p. 79.

D. 378. A cast of the cranial cavity of a Common Seal (*Phoca vitulina*).

D. 379. The brain of a Gray Seal (*Halichœrus grypus*).

This brain resembles that of the Common Seal.

O. C. 1325 U *a*.

D. 380. The brain of a Monk Seal (*Monachus albiventer*).

The general features of this brain closely resemble those of *Phoca*; but in many respects it is much more like the brains of *Odobœnus* and *Otaria* than that of *Phoca*. It is therefore of considerable value to us in bridging over what would otherwise be the very considerable gap between the families of the Pinnipedia.

The pseudosylvian, suprasylvian, and orbital sulci are like those of *Phoca*. The coronal sulcus, however, is not joined to the lateral sulcus.

In addition to the lateral sulcus there is an extremely well-developed entolateral sulcus, as in *Odobœnus* and *Otaria*; its position and extent support the contention that the lateral sulcus in *Phoca* really represents both the lateral and the entolateral sulci of these other Pinnipeds.

The dorsal part of the crucial sulcus is much more extensive than it is in *Phoca*, and the small precrucial is placed upon the dorsal surface. Hence the small "Ursine lozenge" occupies a more usual position than it does in *Phoca*. [It is only right to mention that by *Phoca* I refer more especially to the individual specimen upon which the above description is based.]

The intercalary and calcarine sulci are joined.

According to Fish, the posterior cornu of the lateral ventricle is smaller in *Monachus* than it is in *Phoca*.

O. C. 1325 v *d*.

P. A. Fish, Journ. Comp. Neurology, 1898, p. 81.

D. 381. A cast of the cranial cavity of a Sea-Leopard (*Stenorhynchus leptonyx*).

D. 382. The brain of a young Hooded Seal (*Cystophora cristata*).

This brain exhibits the features of the basal surface in a very distinct manner. Note especially the acute flexure of the pyriform lobe, which produces a deep transverse vallecula Sylvii.

Note also the large, expanded, and highly complex floccular lobes.

The olivary bodies may also be seen cropping out at the lateral edges of the pyramids. O. C. 1325 v.

D. 383. The brain of a Hooded Seal (*Cystophora cristata*).

This brain closely resembles that of the Monk Seal (D. 380), excepting that the calcarine sulcus does not join the intercalary but overlaps it obliquely, as in *Phoca*.

As in all Pinnipedia, there is a well-developed "Ursine lozenge" of Mivart. O. C. 1325 v *b*.

D. 384. The brain of a Hooded Seal (*Cystophora cristata*), (♂). In this excellent specimen the features of the brain described in the other examples are shown with great clearness.

The "Ursine lozenge" is especially distinct and much larger than usual, the precrucial sulci being unusually great. The coronal sulcus is joined to the lateral.

Almost the whole of the anterior vertical limb of the suprasylvian fissure can be seen in the anterior lip of the "Sylvian fissure."

The cranial nerves are well demonstrated in this specimen. They conform to the usual mammalian type. The large seventh and eighth pairs are especially prominent.

O. C. 1325 v *a*.

D. 385. A cast of the cranial cavity of a Hooded Seal (*Cystophora cristata*).

D. 386. A cast of the cranial cavity of an Elephant-Seal (*Macrorhinus leoninus*).

The extraordinary shape of the hemispheres produced by the pronounced lateral divergence of their caudal extremities is well shown.

Turner, 'Challenger' Reports, "Seals," p. 92.

ORDER UNGULATA.

Suborder HYRACOIDEA.

D. 387. The brain of a Hyrax (*Procavia capensis*), (♀), (figs. 168–170).

Fig. 168. (Nat. size.)

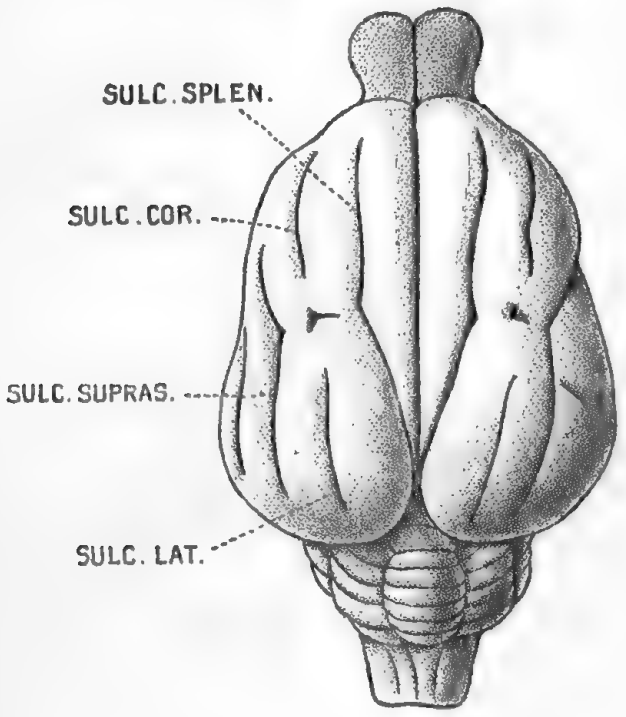

In the accounts of the brain of the Hyrax hitherto published a considerable amount of discrepancy exists, but examination shows (the writer has examined seven brains) that the features of the brain vary greatly in different specimens.

The general appearance of the brain (fig. 168) is not unlike that of a Sloth. The pattern of the sulci on the hemisphere, however, is distinctly Ungulate—though much simplified.

Thus the rhinal fissure is approximately horizontal (fig. 169): the calcarine sulcus (fig. 170) is prolonged into an intercalary sulcus which extends the whole length of the hemisphere, and is placed wholly upon the dorsal surface, such as is commonly the case among Ungulates and occurs only in *Helictis* among Carnivores; there is a well-developed suprasylvian sulcus in the form of a flattened bow, such as we find in the smaller Cervidæ and in the Tragulidæ; there is either no postsylvian sulcus or the slight notch below the suprasylvian sulcus represents a Herpestine form of this sulcus.

Fig. 169. (Nat. size.)

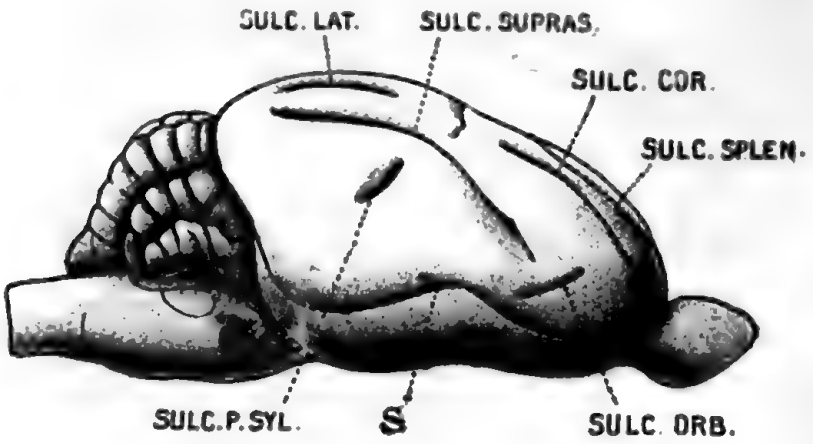

Fig. 170. (Nat. size.)

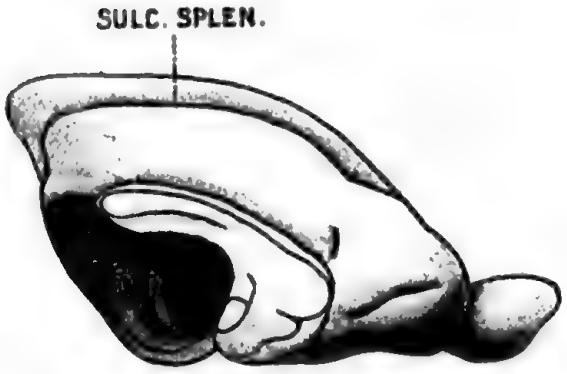

There is a small orbital (presylvian) sulcus, which does not join the rhinal fissure on the right side, but does so on the left hemisphere.

On the right hemisphere there is a very slight notch in the upper lip of the rhinal fissure, such as represents the "Sylvian fissure" in many Viverridæ. This is even more faint on the left hemisphere and is of doubtful significance. There is a short sagittal coronal and a similar lateral sulcus—both such as occur in the smaller Cervidæ and Tragulidæ. There is a small rostral sulcus.

The small cerebellum is rounded and compact, and its folia present the simple transverse arrangement found in the Capybara and other Rodents and most Ungulates.

O. C. 1330 G.

Krueg, Zeitsch. f. wiss. Zool., Bd. xxxiii. 1880, p. 648.
Turner, Journ. Anat. and Phys., vol. xxv. 1890, p. 122.

D. 388. The two cerebral hemispheres of a Hyrax (*Procavia* sp.) (fig. 171).

In these hemispheres there is a long and fairly definite sulcus (fig. 171, s), such as would by most writers be unhesitatingly branded "Sylvian" in a Carnivore. This sulcus was found in only one of seven brains examined, although in a second specimen such a groove was produced by the middle cerebral artery. On the other hand, the presence of a more definite vertical postsylvian sulcus parallel to this pseudosylvian sulcus shows that the latter is sufficiently definite to influence the adjoining cortical areas.

Fig. 171. (Nat. size.)

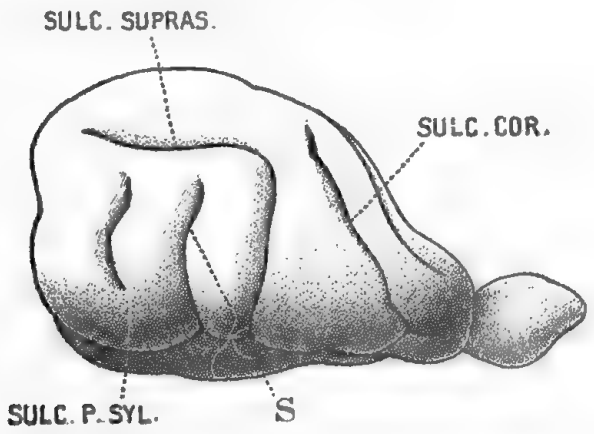

The suprasylvian sulcus is here bent at right angles and opens into the anterior rhinal fissure. There can be no doubt concerning the small postsylvian sulcus in this brain. The orbital sulcus appears to be missing. The coronal sulcus is prolonged in a peculiar manner.

A comparison of this specimen with the preceding at once explains the apparent discrepancy between the accounts of Turner (*op. cit.*) and Krueg (*op. cit.*) respectively.

D. 389. A cast of the cranial cavity of a Hyrax (*Procavia capensis*). [In duplicate.]

The olfactory bulbs project well in front of the hemispheres. In addition to the constant sulci, there is a well-developed vertical postsylvian and also a faint indication of an orbital sulcus.

Extinct Suborder AMBLYOPODA.

D. 390. A cast of the cranial cavity of *Dinoceras mirabile.*

This cast proves conclusively that the brain of this Eocene mammal, which nearly equalled the Elephant in size, was proportionately smaller than that in any other known mammal, recent or fossil, and even less than in some reptiles.

Its general appearance is not unlike that of many reptiles, and the colossal size of the olfactory bulbs leads us to infer that the diminutive cerebral hemispheres must have been almost wholly composed of pyriform lobe, tuberculum olfactorium, and hippocampus (together with the corpus striatum).

The neopallium could not have been much greater than it is in Reptiles, in which it is so insignificant that it has hitherto never been definitely described as such. It is unlikely that any rhinal fissure had yet developed, and probably the hippocampus constituted the whole of the mesial surface of the hemisphere, as it does in Reptiles.

The simple leaf-like cerebellum must have closely resembled that of the Marsupial Mole (*Notoryctes*).

Marsh, American Journ. of Sci. and Art, vol. xi. 1876, p. 165.

Suborder PROBOSCIDEA.

Family *ELEPHANTIDÆ.*

D. 391. The brain of an Asiatic Elephant (*Elephas indicus*): a female about 25 years old.

[The arrangement of the sulci in this brain is fundamentally different to that represented by Krueg (Mayer) and Flatau and Jacobsohn.]

An Elephant weighing approximately 46 times as much as a Man is provided with a brain almost four times the size of the human brain. In comparison with the brain-weights of other large Ungulates it must be regarded as a large and well-developed brain. According to the most recent studies on the question of the size of the brain, the dimensions of the cerebral hemispheres, which are chiefly responsible for the great variations in the size of the mammalian brain, are in any given Order determined largely, or even wholly, by the extent of the sensory surfaces. Thus an animal like the Elephant possessing an enormous surface-area would have a correspondingly large extent of cerebral cortex. But the degree of this cortical representation of sensory surfaces, or "cephalisation," as it is called, varies in different orders, so that, for instance, a given area of bodily surface in a Primate is represented by a much larger cortical area than the same extent of surface would be in an Ungulate. This degree of "cephalisation" has also rapidly increased, even in the same Order, within recent (geologically speaking) times. Thus the *Titanotherium*, a Miocene Perissodactyle as large as the Elephant, was provided with a brain considerably smaller than that of the Horse. On the other hand, this brain was very considerably greater than that of the Eocene *Dinoceras*. It is not improbable that the enormous extent of the neopallium in the Elephant—proportionately much greater than in other Ungulates—becomes necessary to such an immense animal which lives in the open, because such a creature is naturally exposed to greater risks of pursuit &c. than a smaller animal, and needs to display greater cunning to avoid extermination. Hence the "organ of associative memory," the neopallium, becomes of vital importance, and becomes, for an Ungulate, disproportionately great.

The posterior parts of the large cerebral hemispheres have expanded laterally rather than longitudinally, and hence the enormous cerebellum remains almost wholly uncovered—a fact to which an altogether undue importance is usually attached as an index of cerebral greatness. The anterior part of the hemispheres, however, remains narrow and pointed, as in most Mammals.

Fig. 172. (× $\frac{3}{7}$.)

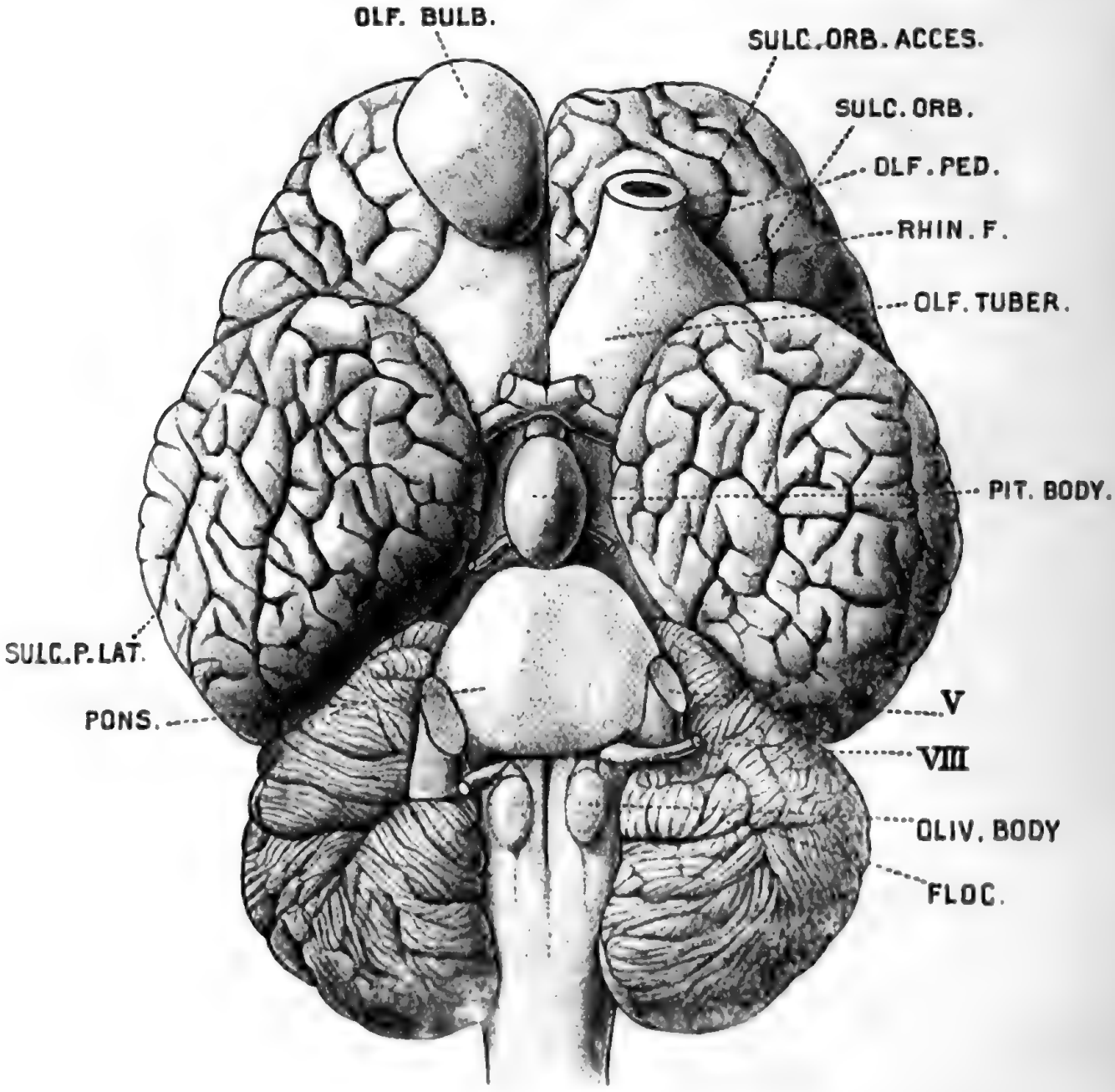

The cerebellum increases *pari passu* with the cerebrum, and, in spite of the fact that the organ is built up essentially on the Ungulate plan, it comes to assume a striking general resemblance to the human cerebellum. The floccular lobes, of course, do not share in this greatness. The pons Varolii also assumes an appearance closely resembling the Human pons, although it is not yet quite large enough to completely hide the trapezoid bodies. The development of large olivary bodies still further increases the resemblance of the bulbar region to that of the brain of Man, but they differ in being placed some distance to the caudal side of the pons.

Fig. 173.

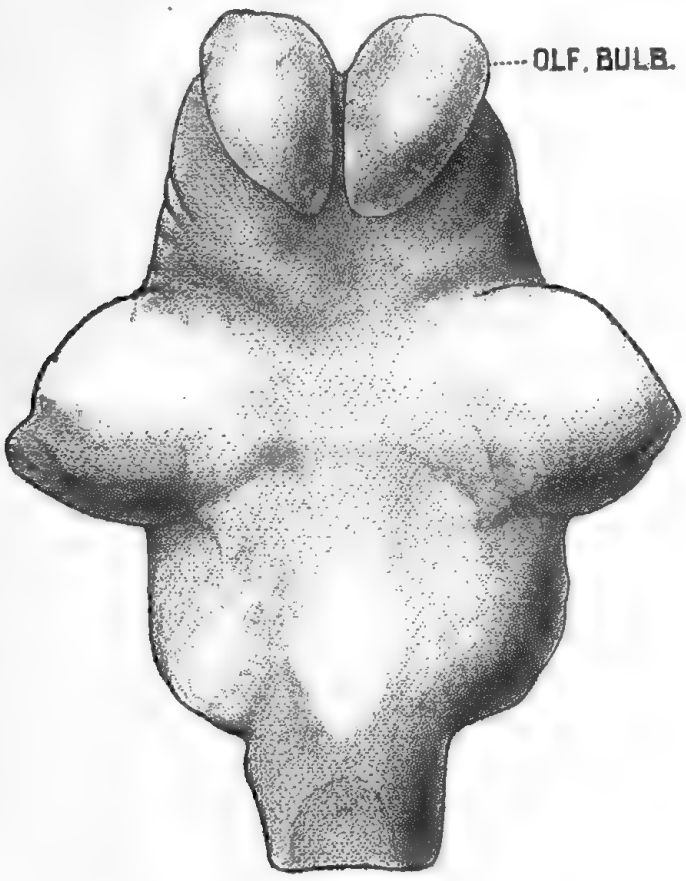

Fig. 174. (× $\frac{2}{7}$.)

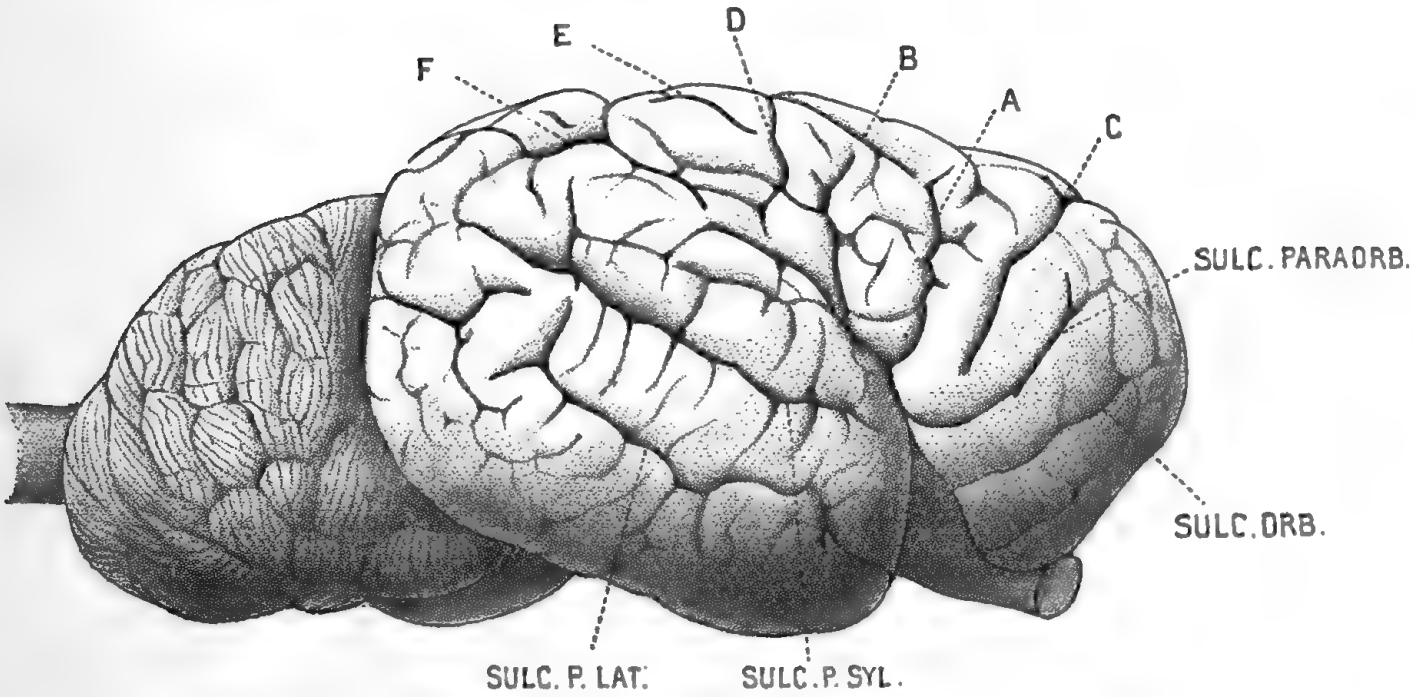

There is a large, flattened, olfactory bulb (the exact size and shape of which is seen to better advantage in the cranial cast, fig. 173). A broad olfactory peduncle leads backward to a huge flattened olfactory tubercle (fig. 172); but the pyriform lobe, which must be of considerable extent, is so buried in the deep cleft of the "Sylvian fissure" that it cannot be satisfactorily seen. These regions of the brain show a considerable resemblance to the corresponding parts of the Tapir's brain.

The extension downward (ventrally) and forward of that part of the hemisphere which lies behind the tuberculum olfactorium gives rise to a great ventral boss distantly resembling the temporal lobe of the human brain (figs. 173 & 174). This is separated from the anterior parts of the hemisphere by a great gulf, which may for convenience be termed the "Sylvian fissure." This is extraordinarily deep, and consists of a deep vallecula extending upward and backward for a considerable distance *. The sulcus which probably represents the "Sylvian fissure" of other Ungulates is placed in this deep vallecula. [In this specimen the surface of the brain is in an excellent state of preservation, but the areas buried in the pseudosylvian sulcus are soft and utterly destroyed. It is thus impossible to accurately interpret this region. And the only existing accounts do not help us in this matter.]

Fig. 175.

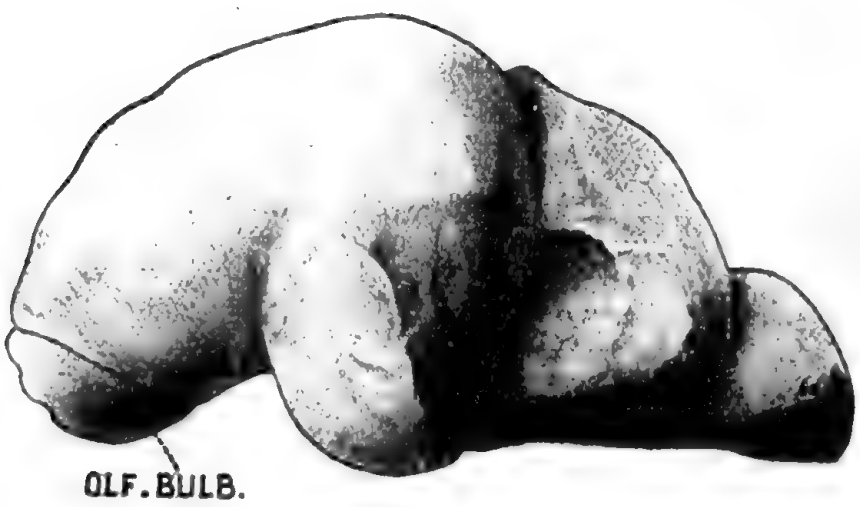

The orbital (presylvian) sulcus is placed chiefly upon the ventral surface, and appears, at least on the left side, to open into the clearly-defined rhinal fissure.

Bearing in mind the exceedingly irregular manner in which such stable sulci as the suprasylvian, postsylvian,

---

* In this respect it differs most markedly from the condition represented by Krueg and Flatau and Jacobsohn.

lateral, and coronal, become broken up and supplemented by irregular and unstable sulci in other large Ungulates, it becomes a matter of the greatest difficulty to even recognise these chief sulci in the Elephant's brain. There can be little doubt as to the identity of the postsylvian sulcus, which is so obliquely placed as to be almost horizontal (fig. 174). This is in marked contrast to the observations of Krueg on the Asiatic Elephant, and Flatau and Jacobsohn on the African Elephant, in both of which this sulcus is represented as vertical.

Fig. 176.

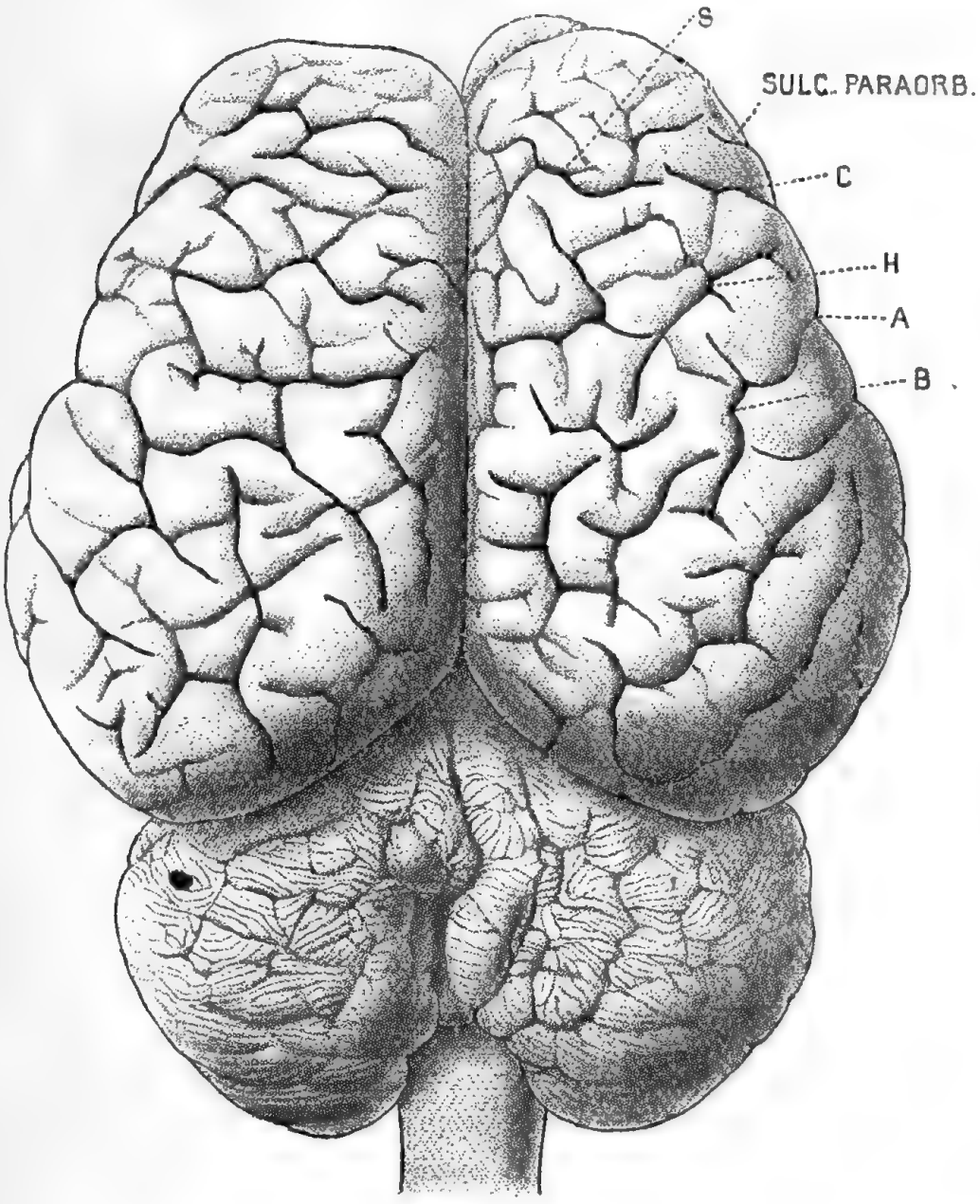

The sulcus below and parallel to it is probably the postlateral sulcus (fig. 174).

The suprasylvian sulcus proper is broken up and rendered complex by numerous branches, some of which seem (but probably do not actually do so) to join the "Sylvian fissure." The coronal sulcus is probably the deep, almost vertical, sulcus in front of the suprasylvian. The "lateral" series of sulci is represented by a group of short, irregular, and richly branched sulci between the suprasylvian sulcus and the mesial edge of the hemisphere *.

Fig. 177.

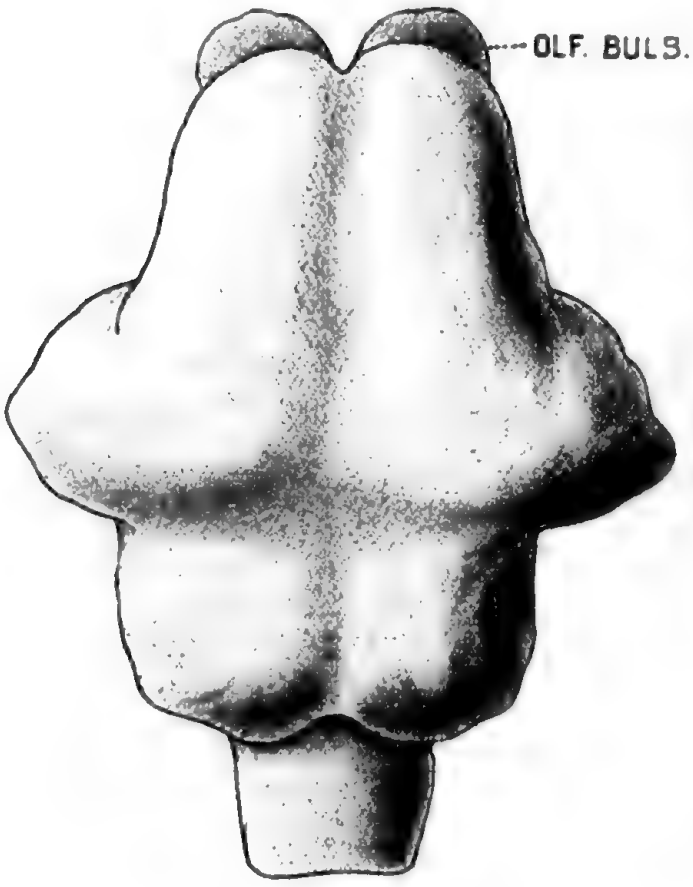

Concerning the mesial aspect of the hemisphere nothing can be said with certainty. O. C. 1331 A.

Krueg, Zeitsch. f. wiss. Zool., Bd. xxxiii. 1880, p. 652.

Flatau & Jacobsohn, Centralnervensyst. d. Säugethiere, 1899, pp. 423 & 435.

---

* In the absence of any developmental data, it is quite impossible to satisfactorily solve the problem of interpreting the involved tangle of short, branching, and intertwining sulci in the Elephant's brain. The homologies suggested above are merely those which seem most likely. I have therefore inserted three illustrations of this brain, which have been drawn from photographs so as to be quite accurate; and, as such a huge mass of soft tissue is specially liable to distortion, a drawing of a cast of the cranial cavity has been placed alongside each to show the true shape of the brain.

If we compare the brain of the Elephant with those of such Ungulates as the Tapir (figs. 179 & 180), and especially the Hippopotamus (figs. 185 & 186), we shall gain a much more accurate conception of the meaning of the Proboscidean pattern of sulci than a study of the Elephant's brain alone could afford.

In the brain of the Hippopotamus (fig. 185) the suprasylvian sulcus (which presents a close resemblance to the complex of the sulci A and B of the

D. 392. A cast of the cranial cavity of an Indian Elephant (*Elephas indicus*).

This shows that the enormous brain of the Elephant has very much the same form as that of the Yak (*Poëphagus grunniens*), but the caudal broadening and the frontal narrowing of the hemispheres is much exaggerated.

Extinct Suborder TYPOTHERIA.

D. 393. A cast of the cranial cavity of *Typotherium cristatum*.

In this cast the horizontal rhinal fissure of the Ungulates can be recognised. There is a deep impression in the "Sylvian region," produced apparently by a suprasylvian sulcus, analogous to that of *Myrmecophaga*, and the hemispheres are considerably expanded behind it. As a whole, the brain is not unlike that of a Chevrotain.

It has a small rounded cerebellum such as *Procavia* and *Hydrochœrus* present.

Gervais, Journn. de Zool., t. i. 1872, p. 430.

Elephant's brain [fig. 174]) is separated from the irregularly Y-shaped postsylvian sulcus by an oblique sulcus (fig. 185, E), in a manner similar to the separation of the sulcus B in the Elephant from the long, oblique, Y-shaped postsylvian by the sulci E and F (fig. 174). The lateral and entolateral sulci become exceedingly irregular in many Ungulates (compare the Tapir's brain, fig. 180) by the development of accessory branches, and in the Elephant the continuity of the main sulcus becomes broken, so that instead of a long, well-defined, lateral and entolateral sulcus, we find a very complicated pattern formed by short, deep, irregular sulci. In the Tapir the coronal sulcus (fig. 180) has become so much shifted from the sagittal direction, which it usually has in the Ungulata, that it is more nearly transverse. In the Hippopotamus the main coronal sulcus is still sagittal (fig. 186), but it is provided with numerous transverse rami. In addition there is in this brain a transverse sulcus (figs. 185 & 186, C) parallel to and compensatory to the suprasylvian sulcus. In the Elephant's brain we find in the region where we should seek for the coronal sulcus no trace of any sagittally directed furrows, but there are two deep transverse sulci (figs. 174 & 176, C & H), which must be regarded as representatives of the coronal sulcus of the Tapir and the sulcus C of the Hippopotamus respectively. Between the sulcus C and the orbital sulcus there is a deep, long, paraorbital sulcus, such as we find in almost all Ungulates.

Suborder PERISSODACTYLA.

Family *TAPIRIDÆ.*

D. 394. The brain of an American Tapir (*Tapirus terrestris*), (♀).

In this large and highly macrosmatic brain the typical features of those parts of the cerebral hemispheres which are most intimately concerned with olfactory functions are shown in an exceedingly clear manner. On the mesial surface (fig. 178) the large supracallosal vestiges of the hippocampus may be distinctly seen in front of the genu of the corpus callosum passing into continuity with the precommissural area and the olfactory peduncle. Posteriorly they are prolonged into an enormous subsplenial hippocampal flexure, the limits and subdivisions of which are demonstated in an unusually clear manner. The large plump anterior portion (fascia dentata) is distinctly marked off from the posterior portion (*hippocampus nudus*) by a definite sulcus; and the latter is separated from the neopallium by an equally distinct groove or "sulcus limitans." The structure which I have called "hippocampus nudus" is merely an exposed part of the hippocampus, and is variously known as "Balkenwindung" (Zuckerkandl) and "gyrus Andreæ Retzii" (Gustav Retzius).

Fig. 178. (× $\frac{2}{3}$.)

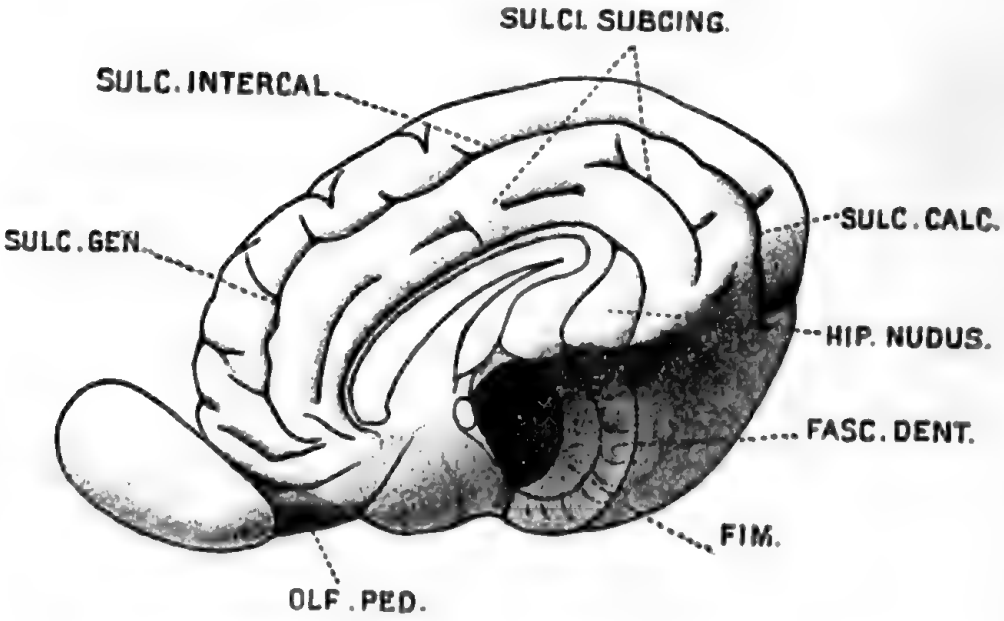

The features of the olfactory bulb, tuberculum olfactorium, and pyriform lobe are also shown very clearly. The arrangement of the rhinal fissure, which separates the latter from the neopallium, is peculiar. The anterior and posterior rhinal fissures do not join (fig. 179), and appear to pursue a very considerable course parallel to one another in such a manner that the forward extension of the posterior rhinal fissure lies in the neopallium (and may be joined to the orbital sulcus), and the caudal extension of the anterior rhinal fissure lies in the pyriform lobe. This arrangement may be compared to that found in the Aardvark.

The furrow usually called "Sylvian fissure" in the Ungulata cannot be strictly regarded as the exact representative of any of the various forms of "Sylvian fissure" (so-called) of the Carnivora nor of the true (Primate) Sylvian fissure. It may be caused by factors analogous to those which produce the similarly-named "fissure" in the Carnivora, and hence it is convenient to retain the name; but only with the distinct reservation that no strict homology is thereby implied. Holl has shown that the sulcus usually called "Sylvian" in the Ungulata more nearly represents a complex of two sulci, representing the ectosylvian of Carnivores, the so-called "Sylvian fissure" of the Carnivore being represented by a very insignificant furrow. But I have here retained the conventional nomenclature.

Fig. 179. (× $\frac{2}{3}$.)

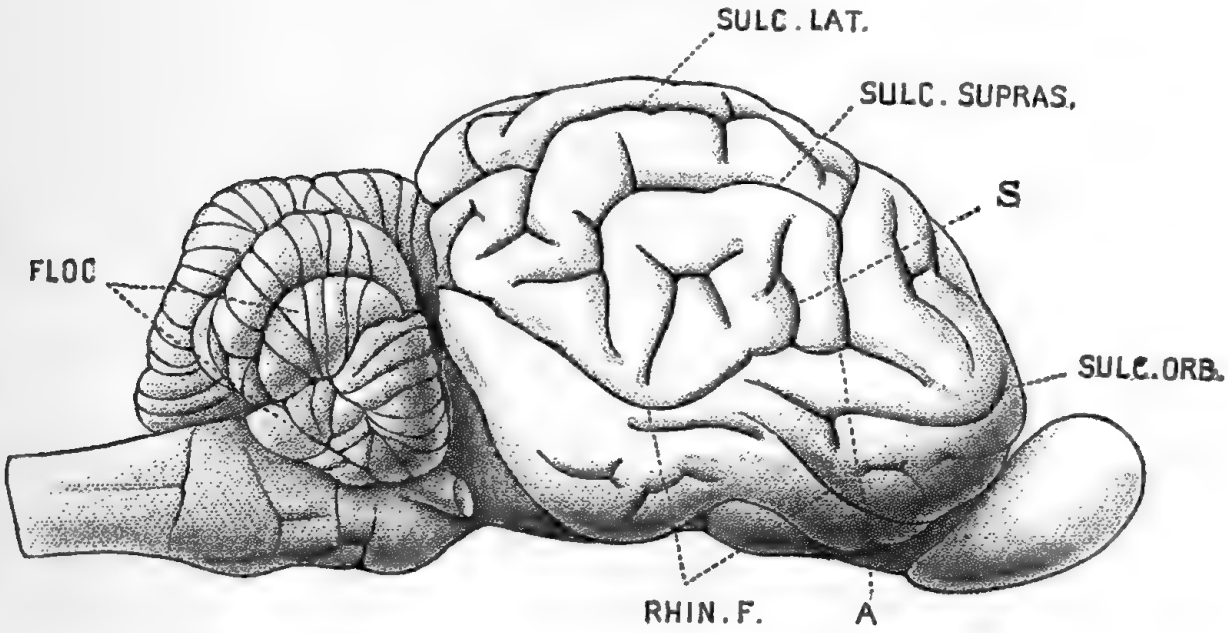

In the brain of the Tapir the "Sylvian fissure" is represented by a short deep sulcus (fig. 179) ascending vertically from the cephalic prolongation of the posterior rhinal fissure for less than half an inch. The posterior lip of this "fissure" is a large operculum covering a depressed area which is continuous with a narrow, uncovered, depressed area above the posterior part of the orbital sulcus. The latter area is limited above by an operculum, the horizontal limiting sulcus of which (fig. 179, A) appears to join the "Sylvian fissure." There is no feline pseudosylvian sulcus.

There is an inverted-**U**-shaped suprasylvian arc (conjoint supra- and postsylvian sulci), which appears to join the above-mentioned horizontal limb (A) of the Sylvian complex. In reality a submerged gyrus separates the two sulci.

The posterior part of the suprasylvian arc is formed of a vertical limb (postsylvian sulcus), as in most Carnivores. It will be seen, however, to give off a short horizontal posterior ramus, which is a very characteristic Ungulate feature.

The Ungulate lateral sulcus is generally oblique (as it is in this case), so that its anterior extremity is nearer the mesial plane than the posterior, and it is not joined to the coronal sulcus. There is an entolateral sulcus of complicated shape (fig. 180). The coronal sulcus is also placed very obliquely, as it is in many early Tertiary Ungulates, such as *Titanotherium*.

The orbital sulcus is like that of the Carnivora. There are also compensatory orbital sulci (fig. 179). Most of the sulci of the hemisphere have numerous offshoots, so that the appearance of its surface is very complicated.

In the left hemisphere (fig. 178) the conjoint calcarine and intercalary (splenial) sulci are united with the genual to form a complete cingular arc. On the right side the genual does not join the intercalary sulcus. Midway between the cingular complex there is a series of shallow sulci which may be called the "subcingular sulci."

In spite of its large size, the cerebellum exhibits exceedingly simple features. The floccular lobe is very large, and instead of being formed chiefly by two regular horizontal paraflocular bands as in the Carnivora, it consists of a great cake-like mass of very large irregular folia arranged like those of the Sloths. The lateral parts of the interfloccular regions of the cerebellum are not markedly expanded as they are in the Carnivora, but are made up of a simple arrangement of transverse folia. O. C. 1330 C.

Fig. 180. (× $\frac{2}{3}$.)

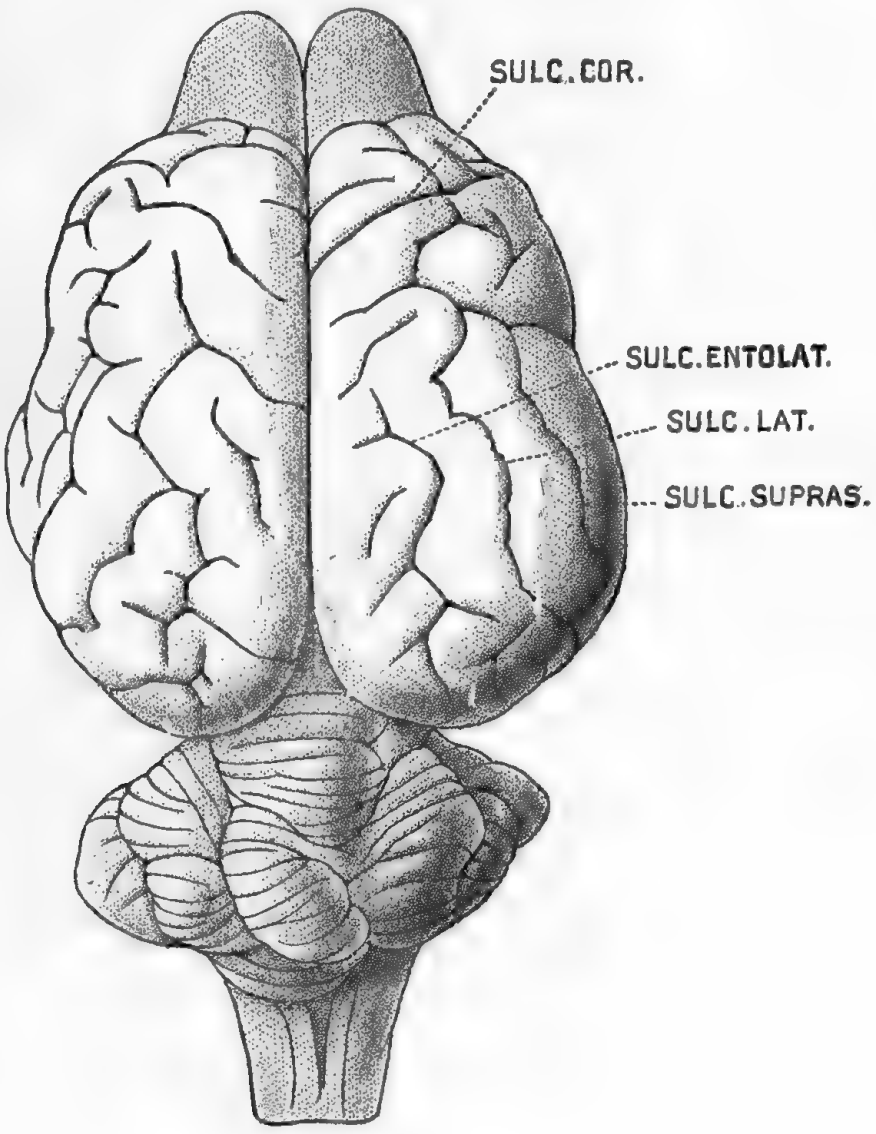

Krueg, Zeitsch. f. wiss. Zool., Bd. xxxi. 1878, p. 326.
Holl, Archiv f. Anat. u. Phys., (Anat. Abth.) 1900, p. 329.

D. 395. The cast of the cranial cavity of an American Tapir (*Tapirus americanus*).

This shows the enormous flattened olfactory bulbs, like those of the Elephant.

D. 396. The brain of a Baird's Tapir (*Tapirus bairdi*), (♂ juv.).
O. C. 1330 D.
Presented by the Zoological Society.

D. 397. The brain of an Asiatic Tapir (*Tapirus indicus*).

In this brain the lips of the main sulci have been separated. The opercular nature of the perisylvian cortex is well shown.

The posterior horizontal limb of the suprasylvian sulcus is well developed and more like that of other Ungulates.

O. C. 1330 B *a*.

D. 398. The brain of a Tapir (*Tapirus* sp.) in which the arachnoid and pia mater have been left *in situ* on the right side.

O. C. 1330 B.

Family *RHINOCEROTIDÆ*.

D. 399. The brain of an Indian Rhinoceros (*Rhinoceros unicornis*).

This brain resembles that of the Horse in size and structure. The cerebral hemispheres, however, are narrower in front and broader behind than those of the Horse.

The pyriform lobe presents the peculiar features seen in the Equidæ, and to a less extent in the Tapiridæ.

The Sylvian region is like that of the Horse.

The coronal, lateral, suprasylvian, and orbital sulci are like those of the Tapir, but enormously more complicated by lateral branches and compensatory sulci. O. C. 1330 E.

Krueg, Zeitsch. f. wiss. Zool., Bd. xxxi. 1878, p. 327.
Holl, Archiv. f. Anat. 1900, p. 328.

D. 400. The brain of a Sumatran Rhinoceros (*Dicerorhinus sumatrensis*), (♀).

Although the Sumatran Rhinoceros is smaller than the Indian species, the brain is even more richly supplied with secondary sulci, so that the surface of the hemisphere presents an exceedingly complicated pattern of enteriform gyri. The fundamental plan, however, is the same as that of the Tapir. O. C. 1330 F.

Presented by the Zoological Society.

Garrod, Trans. Zool. Soc., vol. x. 1877, p. 411.

D. 401. The cast of the cranial cavity of a Sumatran Rhinoceros (*Dicerorhinus sumatrensis*).

Family *EQUIDÆ.*

D. 402. The brain of a Horse (*Equus caballus*).

The Horse is about six times as big as a Man; but in spite of this fact its brain weighs less than one-half as much as the human brain.

In structure the brain may be regarded as a larger and correspondingly more complicated Tapir's brain. The cerebral hemispheres are relatively less macrosmatic than the latter, and consequently only a very small area of the great kidney-shaped lateral aspect of the hemisphere of the Horse is formed of pyriform lobe.

The "Sylvian fissure" is essentially of the same nature as that of the Tapir, but there are usually two or more compensatory sulci parallel to the chief "fissure," which is also relatively very short. The irregular **H**-shaped sulcus found in the Tapir's brain (fig. 179) between the "Sylvian fissure" and the postsylvian sulcus is here simplified and prolonged to form part of an irregular arcuate sulcus like the ectosylvian of the Cynoidea. It is not, however, homologous to the latter, for, as Holl has shown, the "Sylvian fissure" of the Horse is really formed by the ectosylvian sulci.

Then again the "anterior horizontal limb of the Sylvian complex" is prolonged to form an enormous sulcus parallel to and much longer than the orbital sulcus.

The posterior horizontal ramus of the suprasylvian arc is greatly elongated and gives off numerous branches. The postsylvian sulcus is also large, and the great quadrilateral area between it and the latter sulcus is rendered exceedingly complicated by numerous irregular sulci.

In addition to the typical lateral sulcus there are large ecto- and entolateral sulci. On the mesial surface there is a complete cingular arc (conjoint calcarine, intercalary, and genual sulci), as in the Tapir. There is also a complete subcingular arc (the so-called "sublimbic" sulcus of Guldberg).

Numerous secondary sulci, not present in the Tapir's brain, have now made their appearance. On the whole, they are analogous to those found in the Camel's brain (*vide infra*).

There is a peculiar, large, elongated, olfactory bulb, which projects upwards and forwards free from the hemisphere.

The cerebellum is relatively simple. It presents a large, cake-like, floccular lobe, which Flatau and Jacobsohn loosely term the "tonsil." O. C. 1330 A *b*.

Presented by H. Power, Esq.

Flatau and Jacobsohn, Vergl. Anat. d. Centralnervensyst. 1899, p. 405.

Bradley, Journ. Anat. & Phys., vol. xxxiii. 1899, p. 215.

D. 403. Entire brain of a Horse (*Equus caballus*). O. C. 1329.

Hunterian.

D. 404. A cast of the cranial cavity of a Horse (*Equus caballus*).

D. 405. The brain of an Ass (*Equus asinus*). O. C. 1330 A *c*.

Presented by H. Power, Esq.

Krueg, Zeitschr. wiss. Zool., Bd. xxxi. p. 328.

D. 406. Brain of an Ass (*Equus asinus*) having the lateral portion of the left hemisphere and of the cerebellum removed. O. C. 1330.

Hunterian.

D. 407. The brain of an Onager (*Equus onager*), (♀).

O. C. 1330 A *a*.

Suborder ARTIODACTYLA.

Family *SUIDÆ*.

D. 408. The brain of a Diminutive Pig (*Sus salvanius*), (♀).

The brain in this Family, which includes the Pigs and the Wart-Hogs, is distinguishable from that of any other Artiodactyle animal by one or two well-marked characters, the most striking of which is the blending of the coronal with the intercalary (splenial) sulcus. Behind the coronal sulcus there is generally an equally characteristic second sulcus parallel to it joining the intercalary to an offshoot of the suprasylvian sulcus. This sulcus is seen to best advantage in the Common Pig and is not complete in this Diminutive Pig.

In the Pigs also the anterior and posterior opercula of the "Sylvian fissure" are so well developed that the latter appears to spring from the rhinal fissure (fig. 181) as in the Carnivora. It presents, however, essentially the same arrangement as other Ungulates.

The suprasylvian and ectosylvian sulci may be compared to those of the Tapir (*vide supra*). According to Holl, however, the homologue of the ectosylvian sulcus of the Carnivora is not to be sought in that which topographically resembles it here, but in the sulci, the opercular lips of which form the pseudosylvian sulcus.

Fig. 181. (× $\frac{2}{3}$.)

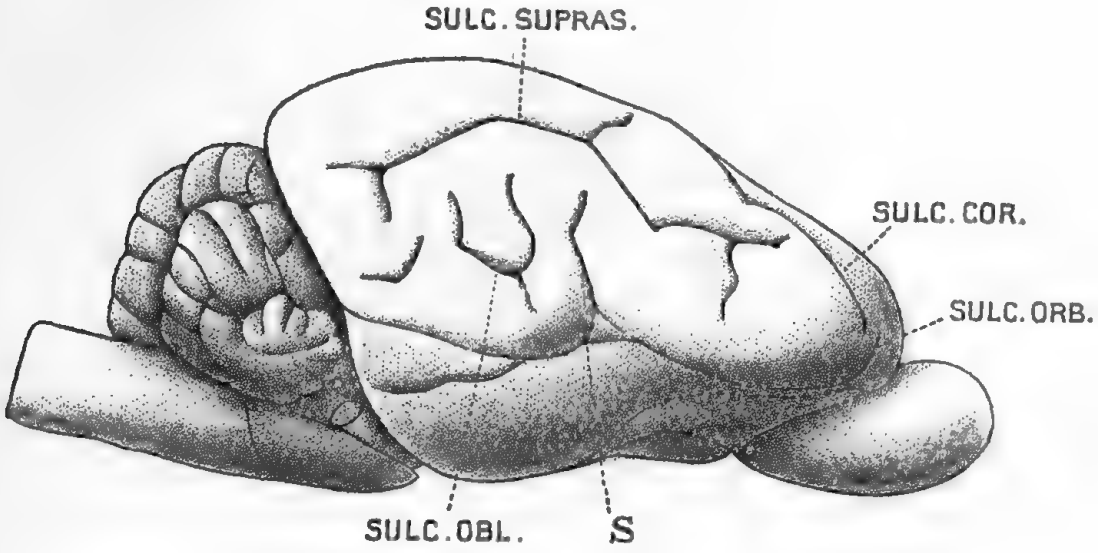

The orbital (presylvian) sulcus is placed very far forward and springs from the rhinal fissure.

As is usual among Ungulates, the rhinal fissure is horizontal. O. C. 1328 N.

Garson, Proc. Zool. Soc. 1883, p. 416.

For general remarks on the Pig's brain, see Garrod, Trans. Zool. Soc. vol. xi. 1879, p. 13, and also Holl, Archiv f. Anat. 1900, p. 298.

D. 409. The brain of a Corean Pig (*Sus scrofa*). O. C. 1328 o.

D. 410. The brain of a Pig (*Sus scrofa*).

The features distinctive of the Pig Family mentioned in the description of specimen D. 408 are seen in a much more pronounced and typical form here. Observe the junction of the coronal and so-called "splenial" sulci; the connecting-link from the latter to the suprasylvian; the definite post-sylvian sulcus, usually absent or very small in the Cotylophora; and the apparent origin of the "Sylvian fissure" from the rhinal, whereas in the Cotylophora this so-called "fissure" usually ends below in two sulci which pursue a course parallel to the rhinal fissure. O. C. 1328 I.

Flatau and Jacobsohn, *op. cit.* 1899, p. 384.

D. 411. A cast of the cranial cavity of *Sus scrofa*. [In duplicate.]

D. 412. The brain of a Pallas's Wart-Hog (*Phacochœrus æthiopicus*) (figs. 182, 183, 184).

In most respects the brain of the Wart-Hog resembles that of the Pigs, but it exhibits some peculiar features.

Fig. 182. (× $\frac{2}{3}$.)

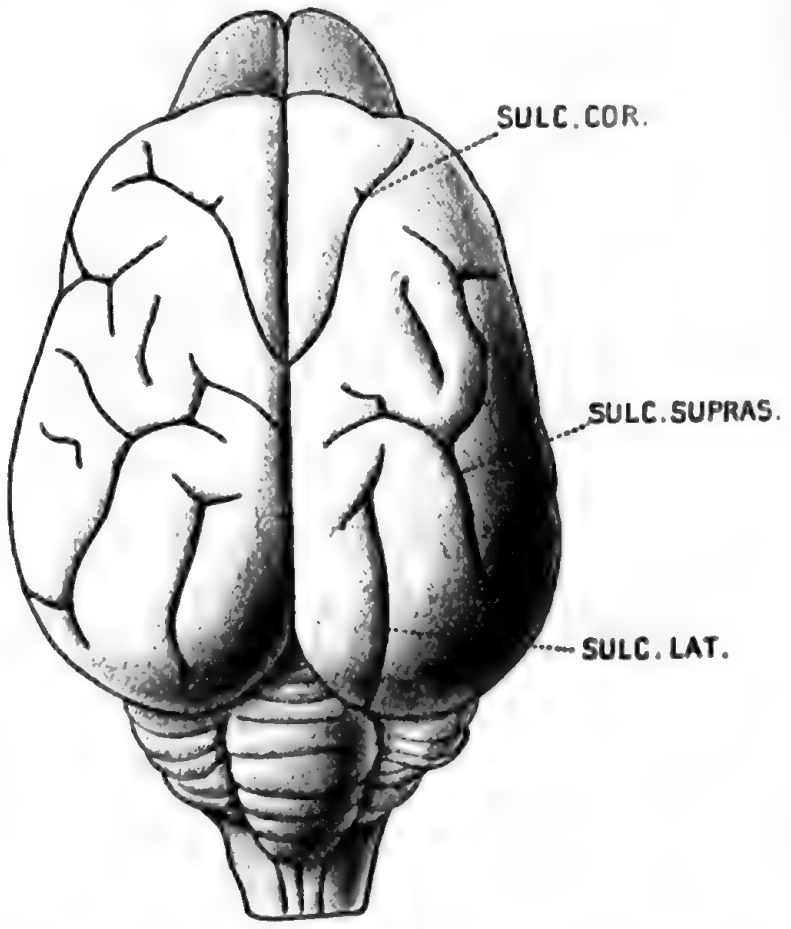

As in the Pig's brain, the orbital sulcus is placed very far forward; it does not really join the rhinal fissure, but is separated from it by a narrow strip of submerged cortex. The apparent posterior prolongation of the orbital sulcus inclines obliquely upward away from the rhinal fissure (fig. 184), and finally ends in the position where we should expect to find the "Sylvian fissure." The operculum which forms its anterior (upper) lip meets a slighter posterior operculum, so as to form a pseudosylvian sulcus of the Ungulate type (fig. 184, s). On the left hemisphere there is no other feature which could be called "Sylvian fissure";

Fig. 183. (× $\frac{2}{3}$.)

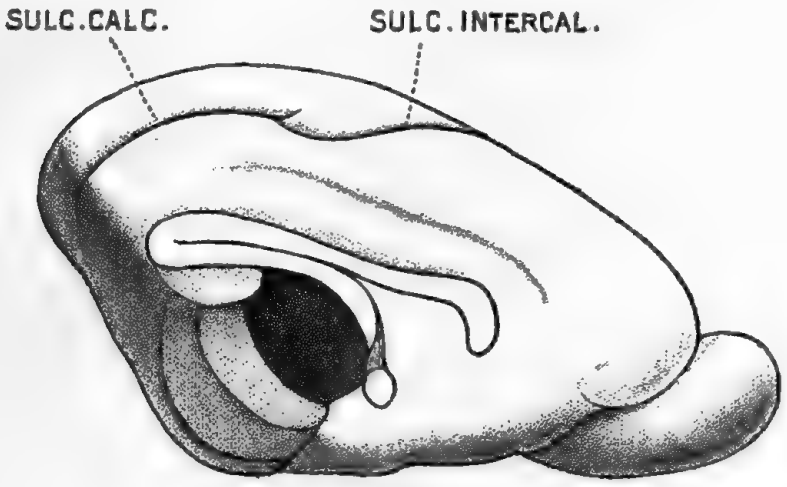

Fig. 184. (× $\frac{2}{3}$.)

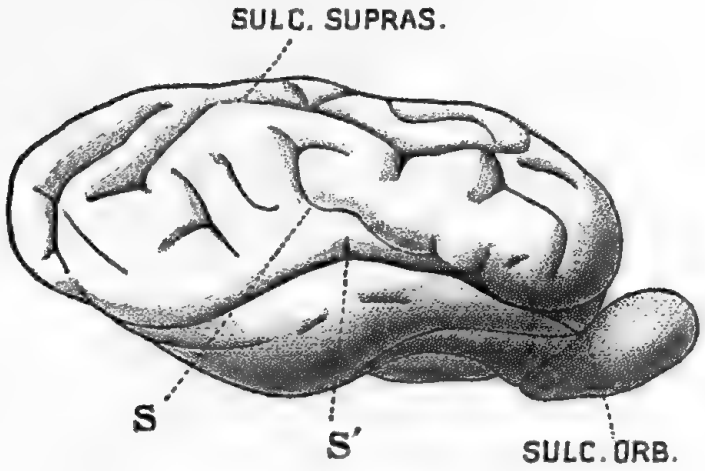

but on the right side (fig. 184) there is a very short deep notch (s′) above the rhinal fissure, the exact analogue of which is perhaps seen in the brain of the Ox (*vide infra*), or in the pseudosylvian sulcus of Carnivores.

O. C. 1328 K.

D. 413. The brain of an Ælian's Wart-Hog (*Phacochœrus africanus*).

The Sylvian region of this brain exhibits interesting variations of the condition found in the last specimen. On the left hemisphere the sulcus which emerges from the rhinal fissure forms a complex more like the ectosylvian than the pseudosylvian of Carnivores; and the pit-like depression above the rhinal fissure, noted on the right hemisphere of the last specimen, has formed a definite "pseudosylvian fissure."

This confirms the view of Holl that the Ungulate pseudosylvian sulcus is formed by the homologues of the ectosylvian sulci of Carnivores.

This is but one more example of the morphological instability of the so-called "Sylvian fissure," of which the Carnivora and especially the Ungulata afford so many examples. O. C. 1328 K *a*.

Family *Dicotylidæ*.

D. 414. The brain of a Collared Peccary (*Tayassu tajaçu*), (♀).

According to Garrod (Trans. Zool. Soc. vol. xi. 1879, p. 13) the brain of *Tayassu* does not resemble that of the true Swine so closely as Krueg suggests. The arrangement of the orbital sulcus is like that seen in the Wart-Hog; and the so-called "Sylvian fissure," which is here very insignificant, finds its closest analogue in *Phacochærus*. The postsylvian sulcus is quite wanting.

There is a complete cingular arc of fused calcarine, intercalary, and genual sulci, as in the Tapir. This is joined (on the right side only) to the coronal sulcus, but is not prolonged into the latter, as is the case in the Swine family. There is a cephalic prolongation of the lateral sulcus midway between the coronal and suprasylvian sulci. There is also a well-defined entolateral sulcus.

O. C. 1328 M.

Krueg, Zeitsch. f. wiss. Zool., Bd. xxxi. 1878, p. 323.

D. 415. The brain of a Collared Peccary (*Tayassu tajaçu*), (♂).

In this smaller specimen the "Sylvian fissure" is more pronounced.

The sulcus between the coronal and suprasylvian sulci is much shorter. O. C. 1328 M *a*.

D. 416. The brain of a Collared Peccary (*Tayassu tajaçu*).

No "Sylvian fissure" can be seen, but the upper lip of the rhinal fissure is much puckered by numerous small sulci, especially on the right hemisphere. O. C. 1328 M *b*.

Family *HIPPOPOTAMIDÆ.*

D. 417. The brain of a new born Hippopotamus (*Hippopotamus amphibius*). O. C. 1328 L.

D. 418. The brain of a Hippopotamus (*Hippopotamus amphibius*), (♂), (figs. 185 & 186).

In comparison with the dimensions of its body the Hippopotamus has a remarkably small brain. Thus the brain is smaller than that of the Horse, in spite of the fact that the Horse is about one-fifth the weight of the Hippopotamus: an Elephant of approximately the same size as a Hippopotamus has a brain more than five times as large.

Fig. 185. ($\times\frac{2}{3}$.)

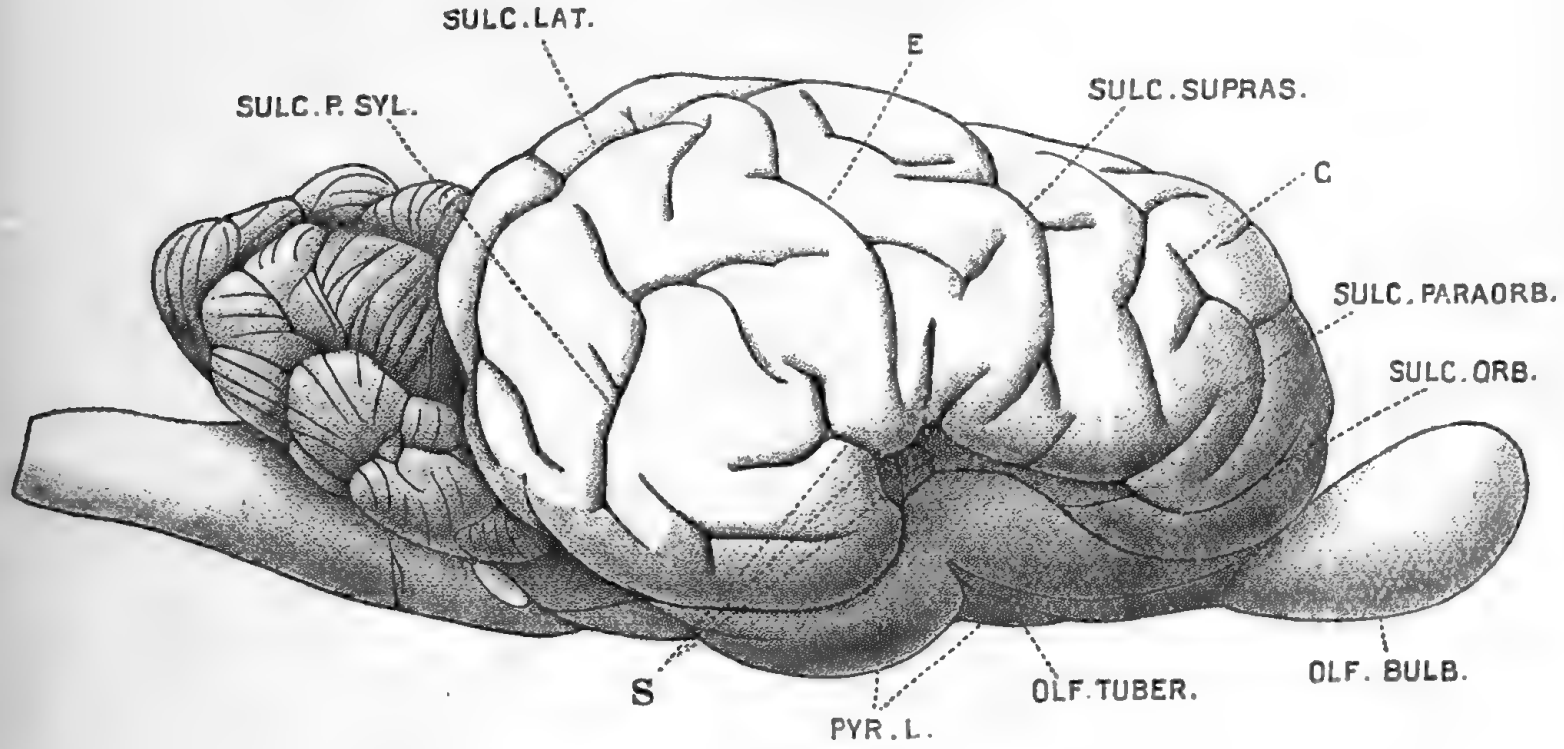

This points to the conclusion, which is supported by the general evidence of Comparative Anatomy, that the Hippopotamus is an instance of the persistence of a primitive small-brained mammal in virtue of the fact that it has maintained itself in the fierce struggle for existence simply by pursuing an eminently safe and retired mode of life. The cunning and alertness of the mammal living in the open thus cease to have that vital importance which implies one or other of the only alternatives—a large brain or extinction (Max Weber, Kon. Ak. v. Wetens. t. Amsterd. 1896).

The hemispheres exhibit a comparative paucity of sulci, which are certainly no more abundant than in the brain of the Ox and are much fewer and simpler than in that of the Giraffe.

The Sylvian region is modelled upon the same general plan as that of the Horse and Camel. The horizontal limiting sulcus of the Sylvian depression is prolonged forward into a short paraorbital sulcus which appears to be joined to the orbital sulcus (fig. 185).

Fig. 186. ($\times \frac{2}{3}$.)

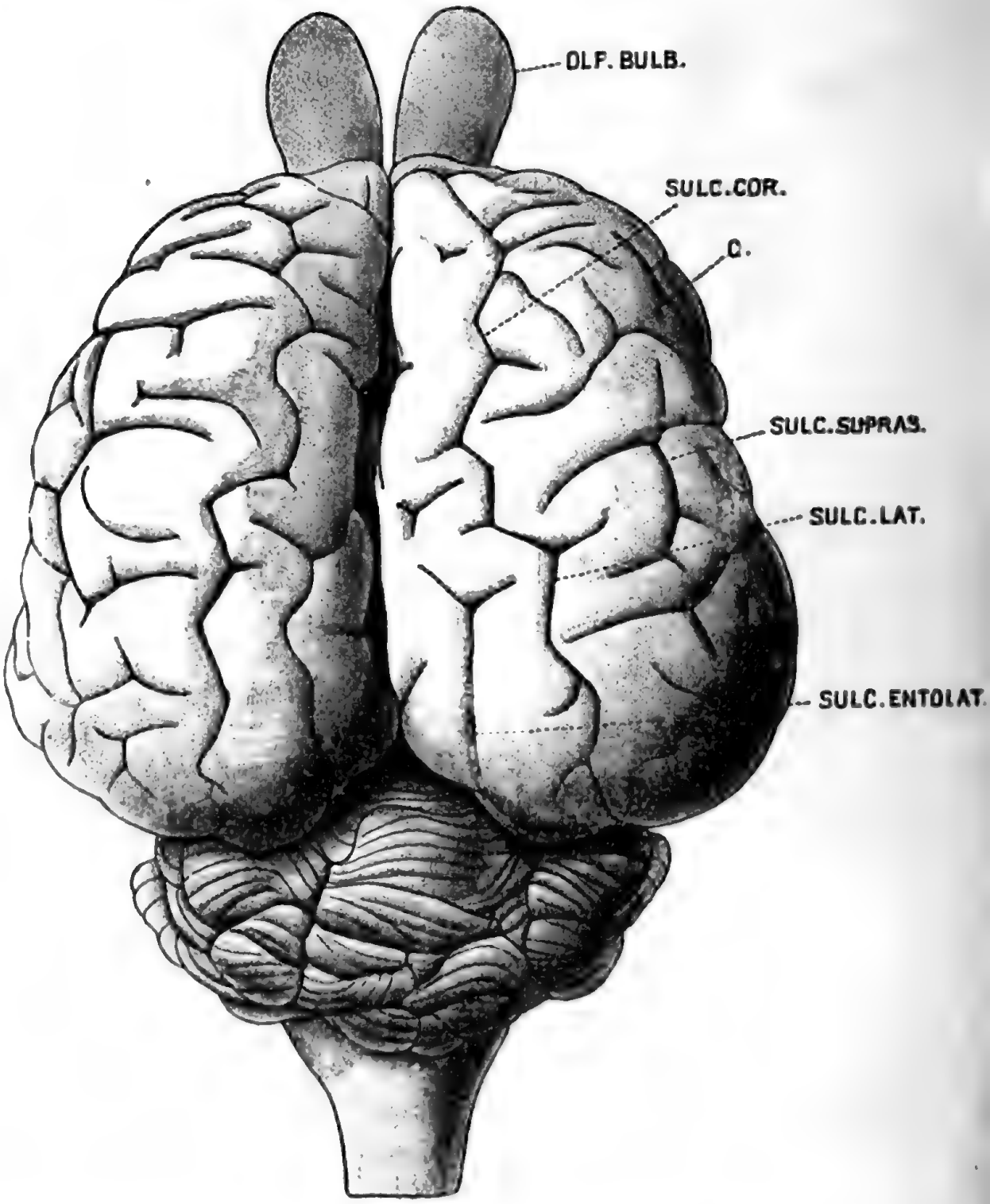

On the right hemisphere the lateral and coronal sulci are fused to form one great sagittal complex extending the whole length of the hemisphere. According to Garrod, "no other Ungulate has these sulci joined, but they are almost so in the Camels, Giraffe, *Dicotyles*, and Pig," as they are also on the left hemisphere of this specimen. The common occurrence of this phenomenon in other Orders indicates the probability of its being a primitive character.

The suprasylvian sulcus is represented by a relatively short transverse arc which is separated from the postsylvian sulcus by an oblique sulcus (fig. 185, E). There is a well-defined entolateral sulcus. There is also a complete cingular arc, as in the Horse and the Tapir.

"Looked at generally, the brain of the Hippopotamus is evidently very different from that of the genus *Sus* and its nearest allies. In the great breadth and complicatedness of the [third arcuate gyrus of Leuret] it most resembles the Camels and the Giraffe, from the form of which it strikingly differs in the much less 'pronation' [inward rotation] of the hemisphere. On the whole, it stands very much by itself" (Garrod). O. C. 1328 L *a*.

Garrod, Trans. Zool. Soc., vol. xi. 1879, p. 16.

D. 419. A cast of the cranial cavity of a Hippopotamus (*Hippopotamus amphibius*).

Family *CAMELIDÆ.*

D. 420. The brain of an Arabian Camel (*Camelus dromedarius*).

In general appearance and size the brain of the Camel resembles that of the Horse; and this resemblance is also found to obtain to a very considerable extent in the arrangement of the sulci of the cerebral hemisphere. The anterior rhinal fissure has disappeared except in its most posterior part, but nevertheless the line of demarcation between pyriform lobe and neopallium is quite obvious. The posterior rhinal fissure is also exceedingly shallow and is not joined to the anterior rhinal.

The posterior end of the anterior rhinal fissure is very deep and is prolonged upward and backward for a short distance in the neopallium as the posterior limiting sulcus of the Sylvian depression: this depression is partially overlapped above by an operculum, the horizontal limiting sulcus of which is parallel to the rhinal fissure. This operculum is deeply incised by several sulci, of which the most posterior corresponds to that which in many Ungulates is called the "Sylvian fissure." The horizontal limiting sulcus is joined in front to a great oblique paraorbital sulcus, as in the Horse's brain.

The orbital sulcus is in front of and parallel to the latter: it is deep and long and does not join the rhinal fissure, or, to be strictly accurate, does not reach the situation where the rhinal fissure should be found.

There is an exceedingly deep sagittal suprasylvian sulcus placed very high up on the dorsal surface; it gives off numerous offshoots. There is a very deep, short, irregular sulcus between it and the paraorbital sulcus, which may represent either the diagonal sulcus or a part of the suprasylvian sulcus itself. There is a long vertical postsylvian sulcus of irregular shape, which is separated from the suprasylvian by a broad gyrus.

In the broad cortical area between the Sylvian region and the suprasylvian sulcus there is an irregular ectosylvian arc, which is of the same nature as, but far more complicated than, that of the Horse *.

The deep, sagittal, coronal sulcus is separated from the long, deep, lateral sulcus merely by a narrow gyrus.

The exceedingly deep complex of calcarine and intercalary sulci (so-called "splenial") is prolonged obliquely upward and forward on to the dorsal surface, without joining the genual sulcus as in the Horse's brain. In many cases there is a small posterior cornu of the lateral ventricle into which the calcarine sulcus pushes a slight bulging or calcar avis.

There is an interesting grouping of sulci around the calcarine strongly suggestive of the arrangement which becomes fixed in the Human brain as the postcalcarine (posterior calcarine), parieto-occipital, and collateral sulci.

O. C. 1338 c.

Krueg. Zeitsch. f. wiss. Zool., Bd. xxxi. 1878, p. 322.

---

* Holl (Arch. f. Anat. u. Phys., Anat. Abth. 1900) calls this sulcus "obliquus," and regards the ectosylvian as the constituents of the pseudo-sylvian sulcus.

D. 421. The brain of a Bactrian Camel (*Camelus bactrianus*), (♀).

This brain closely resembles that of the Arabian Camel.
O. C. 1328 G *a*.

D. 422. The cast of the cranial cavity of a Bactrian Camel (*Camelus bactrianus*).

D. 423. The brain of a Llama (*Lama glama*).

A smaller, much simplified, Camel's brain. O. C. 1328 H.

Family *TRAGULIDÆ*.

D. 424. The brain of a Chevrotain (*Tragulus* sp.).

"The brain of *Tragulus* as far as its surface-marking is concerned is a simplified miniature of the Cervidæ" (Flower).

There is an elongated, deep, suprasylvian sulcus. But there does not appear to be any definite representative of a pseudosylvian sulcus, although the shallow vertical furrow [on the left side there are two furrows] below the suprasylvian sulcus may represent the "Sylvian fissure," so-called.

No coronal sulcus, such as Krueg describes (from Owen's figures), is present in this specimen. Nor is there any lateral sulcus, as Krueg represents; but the suprasylvian sulcus gives off a horizontal branch which may in a sense serve the same purpose as the lateral sulcus.

There is a short orbital sulcus placed very far forward in the hemisphere.

Perhaps the most peculiar feature of this brain is the position of the sulcus which a comparison with the brains of other Ungulates compels us to regard as the "splenial" complex of calcarine and intercalary sulci. It is placed almost wholly upon the dorsal surface and only reaches the mesial surface at its extreme anterior end. O. C. 1328 F.

Krueg, Zeitsch. f. wiss. Zool., Bd. xxxi. 1878, p. 315.

D. 425. The brain of a Javanese Chevrotain (*Tragulus javanicus*).

This extremely simple and highly-macrosmatic brain is of interest as exemplifying the primitive types which may occur exhibiting distinctly-Ungulate characters.

There appears to be a definite coronal sulcus quite distinct from the suprasylvian.

The posterior horizontal branch of the suprasylvian sulcus is seen to better advantage in this than in the last specimen.

In this brain, and more especially on the right side, there seems to be a definite representative of the Ungulate "Sylvian fissure." O. C. 1328 F *a*.

Presented by J. Abrahams, Esq.

D. 426. A cast of the cranial cavity of a Stanley's Chevrotain (*Tragulus stanleyanus*).

This shows the true size and shape of the olfactory bulbs. It also shows that as regards the suprasylvian sulcus and its horizontal branch this Chevrotain closely agrees with the Javan representative.

Gervais, Journal de Zoologie, t. i. 1872, p. 460.

D. 427. The brain of an African Water-Chevrotain (*Dorcatherium aquaticum*), (♀).

This brain presents a very close resemblance to that of the Chevrotain both as regards its general features and shape and also in respect of the suprasylvian and "splenial" sulci. The orbital sulcus, however, is more pronounced and approaches very close to the suprasylvian sulcus.

There is a definite short "Sylvian fissure" ascending from the rhinal fissure toward the suprasylvian sulcus.

O. C. 1328 F *b*.

D. 428. The brain of an African Water-Chevrotain, divided by mesial sagittal section, and with the right cerebral hemisphere separated from the brain-stem.

This is an excellent example of the simplest type of Ungulate brain. It clearly exhibits the characteristic relationship of the Ungulate pseudosylvian sulcus to the rhinal fissure and to the orbital sulcus. It can now be clearly seen that the pseudosylvian sulcus does not really join the rhinal fissure and is therefore not identical with the Carnivore pseudosylvian sulcus. There is no lateral sulcus, and the intercalary and suprasylvian sulci occupy their distinctively Ungulate positions on the dorsal surface of the hemisphere.

Family *Cervidæ.*

D. 429. The brain of a Musk-Deer (*Moschus moschiferus*), (♀).

This brain is like a larger and slightly more complicated edition of the Chevrotain's brain.

There is the same type of suprasylvian sulcus passing directly by a transverse connecting-link at its anterior end into a sulcus, which Krueg regards as the coronal (figs. 187 & 188).

Fig. 187. (× ⅔.)

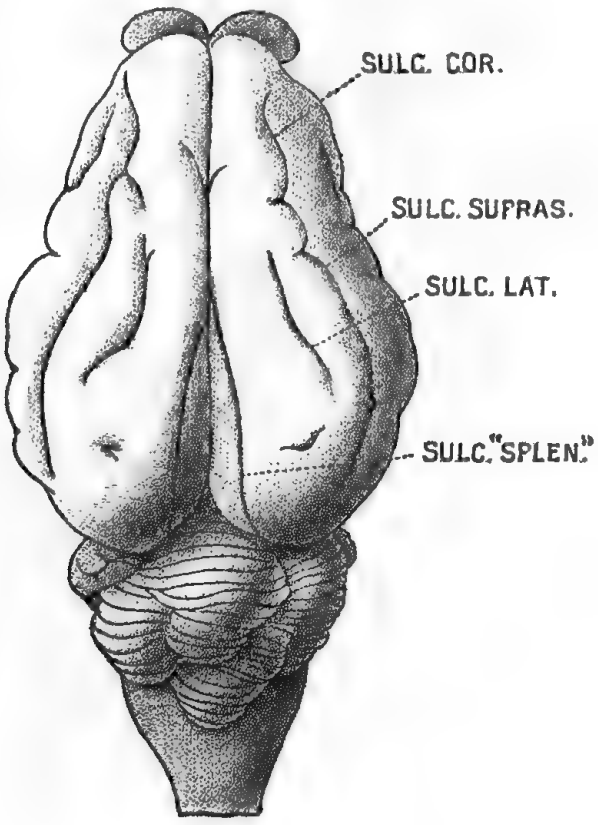

Fig. 188. (× ⅔.)

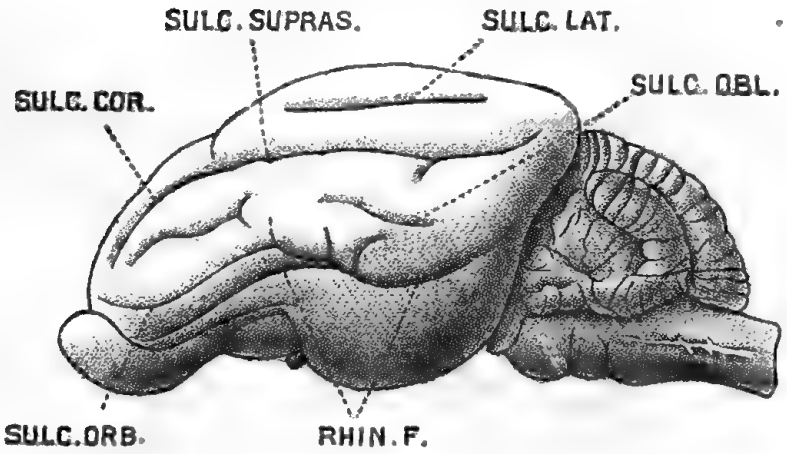

There is a very long orbital (presylvian) sulcus pursuing a course parallel to the anterior rhinal fissure; it, however, never joins the latter. The posterior half of the sulcus Krueg regards as the "processus anterior of the Sylvian fissure," but it would be less confusing to follow Holl and call it "anterior ectosylvian." It is continued into a short vertical sulcus—the pseudosylvian. From the latter a sulcus, which Krueg calls the "processus posterior of the Sylvian fissure," leads backward toward the posterior rhinal fissure. It is the posterior ectosylvian sulcus of Holl.

There is a depressed area between the rhinal fissure and these three parts of the so-called "Sylvian fissure." This is the trigonum Sylvii (Holl) and it is continuous anteriorly with the so-called "gyrus orbitalis," *i. e.*, the narrow strip of pallium between the orbital (presylvian) sulcus and the rhinal fissure (fig. 188).

Although the calcarine (splenial) sulcus can be partly seen on the dorsal surface, it is placed chiefly upon the mesial surface, as in most mammals (fig. 189). The position of this sulcus in the Ungulata seems to be determined largely by the size of the hemispheres. In the small Chevrotain it is chiefly dorsal, in the larger Musk-Deer it is on the dorso-mesial border, and in the larger Deer it is mesial.

Fig. 189. ($\times \frac{2}{3}$.)

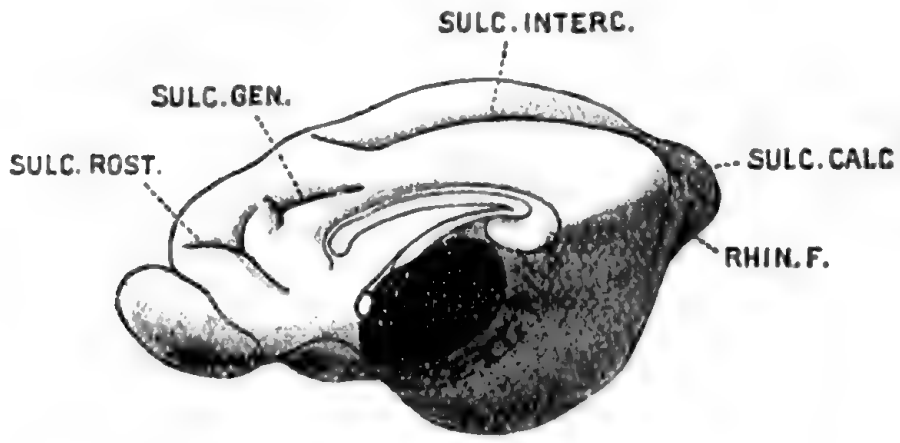

There is a well-developed lateral sulcus pursuing a course parallel to the posterior half of the suprasylvian sulcus, and there are several short sulci behind and in front of it.

There is a small genual sulcus above the anterior extremity of the corpus callosum and a rostral sulcus in front of it.

The anterior extremity of the prolongation of the calcarine (splenial) sulcus is upturned and may correspond to the crucial sulcus. A small ansate sulcus given off from the junction of the coronary and suprasylvian sulci presents the same relation to the upturned splenial as to the crucial in the Canidæ.

There is no sulcus posticus, as Krueg describes; but between the posterior rhinal fissure and the suprasylvian sulcus there are several vertical fragmentary sulci. On the left side the suprasylvian sulcus itself extends downward in this situation. There it shows that what Krueg regards as the posterior part of this latter sulcus is merely a branch or extension backward. O. C. 1328 E *c*.

Krueg, Zeitsch. f. wiss. Zool., Bd. xxxi. 1878, p. 317.

D. 430. The brain of a Musk-Deer (*Moschus moschiferus*), (♀).

This brain differs only in minor details, such as the poorer development of the ansate and lateral sulci, from the other specimen.

The sulcus posticus, which Krueg mentions in this brain, is present only in the right hemisphere as a small horizontal depression between the suprasylvian sulcus and the posterior rhinal fissure. O. C. 1328 E *i*.

D. 431. A cast of the cranial cavity of *Moschus moschiferus*.

D. 432. The brain of a Muntjac (*Cervulus muntjac*).

In spite of its much larger proportions this brain presents many resemblances to that of the Musk-Deer.

The splenial sulcus is dorsally situated during a considerable part of its course. Its anterior extremity bends outward like a crucial sulcus.

The pseudosylvian, suprasylvian, lateral, coronal, and orbital sulci conform to the same type.

There is a small diagonal sulcus and a shallow sulcus posticus of Krueg (sulcus obliquus of Holl).

O. C. 1328 E *r*.

Presented by the Zoological Society.

D. 433. The brain of a Michie's Deer (*Elaphodus michianus*), (♂).

The brain is fairly rich in sulci considering its size. It is somewhat larger than that of the Pudu ; but it closely resembles it in the arrangement of its sulci as well as in the considerable size, and especially the breadth, of the anterior part of the hemispheres. As in the Musk-Deer and the Pudu, the cephalic prolongation of the calcarine sulcus appears on the dorsal surface of the hemisphere. The brain is not unlike that of the Muntjac, but the sulci are better developed in Michie's Deer, and the anterior parts of the hemispheres are broader in the latter (Garrod).

O. C. 1328 E *s.*

Presented by the Zoological Society.

Garrod, Proc. Zool. Soc. 1876, p. 763.

D. 434. The brain of a Sambur (*Cervus aristotelis*).

This is a typical Deer's brain; it is larger and correspondingly more complicated than the brain of Michie's Deer.

There is a long vertical "pseudosylvian sulcus." Ectolateral and entolateral sulci are present. O. C. 1328 E *n.*

Presented by the Zoological Society.

D. 435. The brain of a Moluccan Deer (*Cervus moluccensis*), (♀).

This resembles the last specimen in most of its essential features. O. C. 1328 E *t.*

Presented by the Zoological Society.

D. 436. The brain of a Swamp-Deer (*Cervus duvaucelli*).

This resembles the brain of the Sambur. O. C. 1328 E *o.*

Presented by the Zoological Society.

D. 437. The brain of a new-born Axis (*Cervus axis*).

The extraordinary richness of sulci in this brain is very remarkable, when its small size is taken into account.

This is especially noteworthy in the region of the lateral sulcus, where also well-developed ecto- and entolateral sulci are found. O. C. 1328 E *l.*

Presented by the Zoological Society.

D. 438. The brain of a Red Deer (*Cervus elaphus*), (♀).

The magnitude of the vertical "pseudosylvian sulcus" of the Deer and the characteristic fusion of the coronal and suprasylvian sulci are well shown. O. C. 1328 E *f.*

Presented by Sir Victor Brooke, Bart.

D. 439. The brain of a Kashmir Stag (*Cervus cashmeerianus*), (♂).

An excellent example of the typical Deer's brain.

O. C. 1328 E *m.*

Presented by the Zoological Society.

D. 440. The brain of a Common Fallow-Deer (*Cervus dama*), (♀) (figs. 190, 191).

Fig. 190. (×$\frac{2}{3}$.)

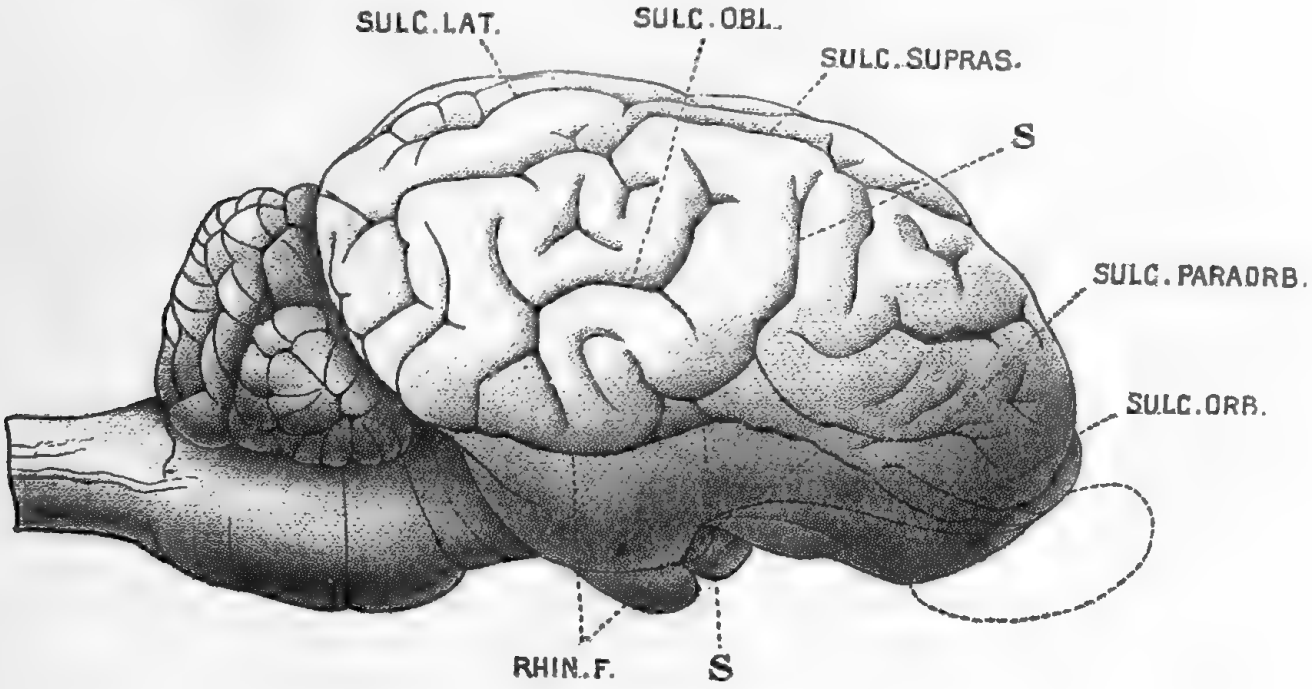

Fig. 191. (×$\frac{2}{3}$.)

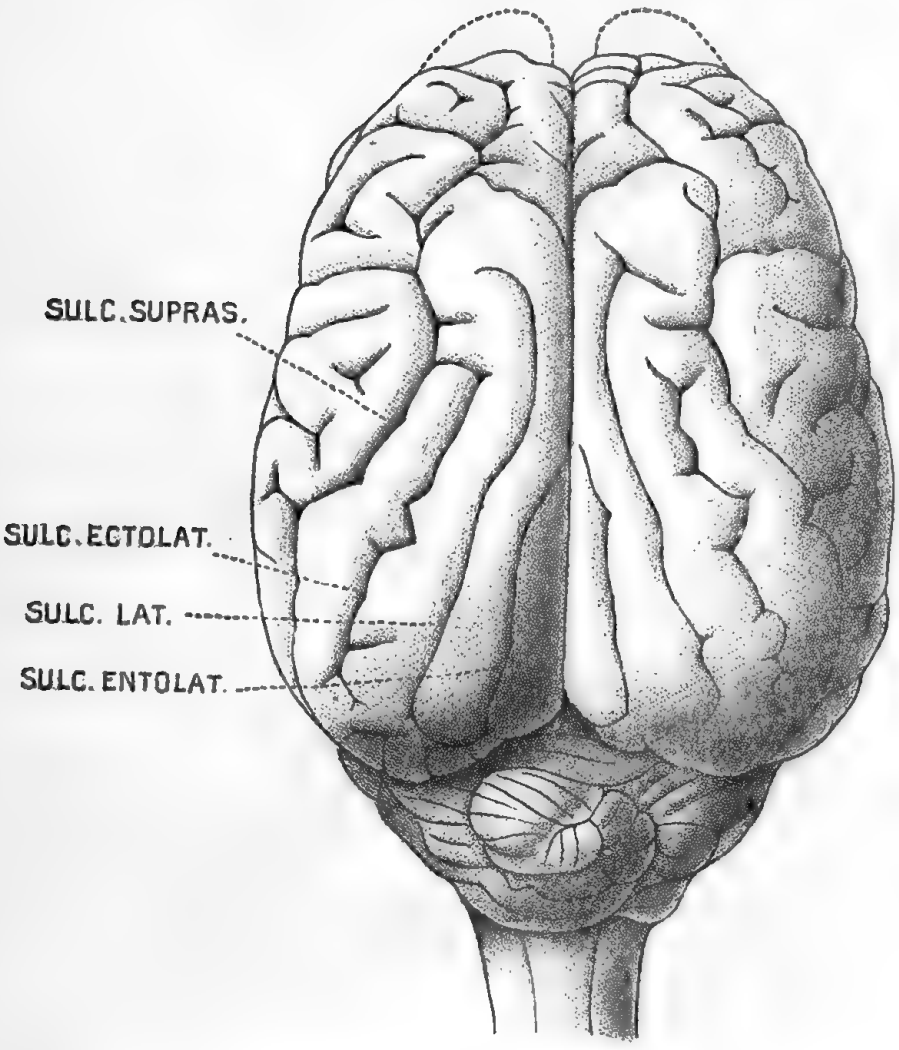

This may be taken as the type of the brain in the great Family of Deer.

The great vertical pseudosylvian sulcus (s) is formed by the meeting of the vertical parts of the two ectosylvian sulci, which diverge below to form a horizontal sulcus parallel to the rhinal fissure. The anterior ectosylvian sulcus is prolonged forward as a paraorbital sulcus, which overlaps the true orbital sulcus.

The suprasylvian arc surmounts the pseudosylvian sulcus, and is then prolonged back to the posterior margin of the hemisphere. The anterior part of the suprasylvian arc is joined to the coronal sulcus.

There is no proper postsylvian sulcus, but the great quadrilateral area between the suprasylvian sulcus and the posterior rhinal fissure is broken up by an irregular series of sulci.

There is a characteristic arrangement of lateral, ectolateral, and entolateral sulci (fig. 191).

O. C. 1328 E *d.*

Presented by Sir Victor Brooke, Bart.

D 441. A cast of the cranial cavity of an extinct Irish Deer (*Cervus giganteus*).

D. 442. The brain of a Reindeer (*Rangifer tarandus*), three weeks old.

This small specimen of the Reindeer's brain resembles such brains as that of *Odocoileus*, especially in the presylvian region, more closely than the succeeding specimens.

The diagonal sulcus is quite independent of the suprasylvian sulcus. O. C. 1328 E *h.*

D. 443. The brain of a Reindeer (*Rangifer tarandus*), (♀).

This is a highly complicated Deer's brain. If we imagine the progressive series of changes which are to be noted in a successive comparison of the brains of *Hydropotes*, *Pudu*, *Capreolus*, and *Odocoileus* to be carried a step further, an accurate conception of the Reindeer's brain will be gained.

O. C. 1328 E *g.*

Holl, Archiv f. Anat. 1900, p. 318.

D. 444. The brain of a Reindeer (*Rangifer tarandus*).

This resembles D. 442, but is considerably larger.

O. C. 1328 E.

D. 445. The brain of an Elk (*Alces machlis*), (♂).

This is a typical Deer's brain. O. C. 1328 E *q*.

Presented by the Zoological Society.

D. 446. The brain of a Roe Deer (*Capreolus caprea*), (♀).

In spite of its much greater size, this brain is only very slightly more complicated than that of the Chinese Water-Deer, which it resembles.

The posterior descending limb of the suprasylvian sulcus has completely aborted and a horizontal sulcus has developed below the posterior horizontal ramus of the suprasylvian, which may be regarded as a compensatory sulcus.

The orbital sulcus is still placed very far forward and a paraorbital sulcus is formed by the cephalic extension of the anterior ectosylvian sulcus, which is prolonged obliquely upward and forward as a deep incision in the upper opercular lip of the anterior rhinal fissure.

The splenial complex is placed much higher than in *Hydropotes*, so that it comes to lie on the dorsal rather than the mesial surface. This is just the reverse of what we should expect after a study of the brain of other Deer, for, as a rule, the larger the brain the more mesial and the nearer the corpus callosum the position of the conjoint calcarine and intercalary sulci is.

There is a most pronounced crucial-like lateral bending of the anterior extremity of this sulcus. O. C. 1328 E *e*.

Presented by Sir Victor Brooke, Bart.

D. 447. The brain of a Chinese Water-Deer (*Hydropotes inermis*).

"In its cerebral organization *Hydropotes* approaches the genus *Capreolus* more nearly than any other Cervine form known to me" (Forbes).

In the greatly simplified arrangement of sulci in this brain, the type common to all the Deer is well exemplified.

There is a simple vertical "Sylvian fissure" (fig. 192, S.), ascending from the rhinal fissure; a long, simple, orbital (presylvian) sulcus, also springing from the latter far forward on the anterior pole; a simple semicircular suprasylvian sulcus with a short posterior descending limb and a longer posterior horizontal ramus, its anterior extremity joins the diagonal sulcus; and the extensive coronal sulcus joins the convexity of the suprasylvian arc opposite the apex of the "Sylvian fissure."

There is a short, vertical, posterior, "oblique" sulcus. The characteristically oblique lateral sulcus of the Deer is also present, and is quite independent of the coronal sulcus (fig. 193).

Fig. 192. (× $\frac{2}{3}$.)

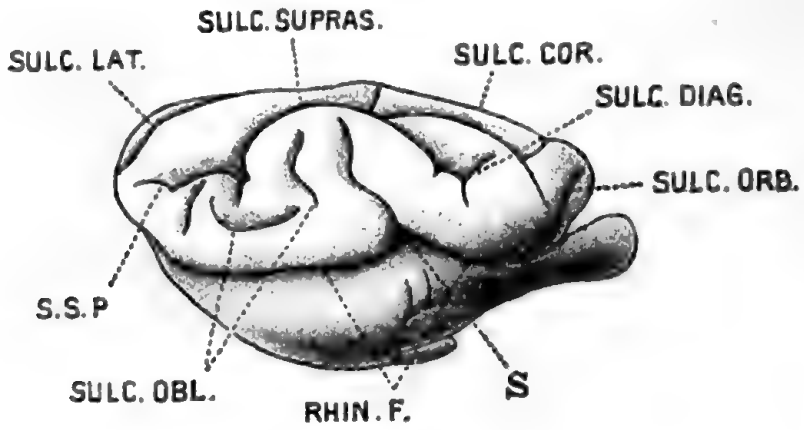

Fig. 193. (× $\frac{2}{3}$.)

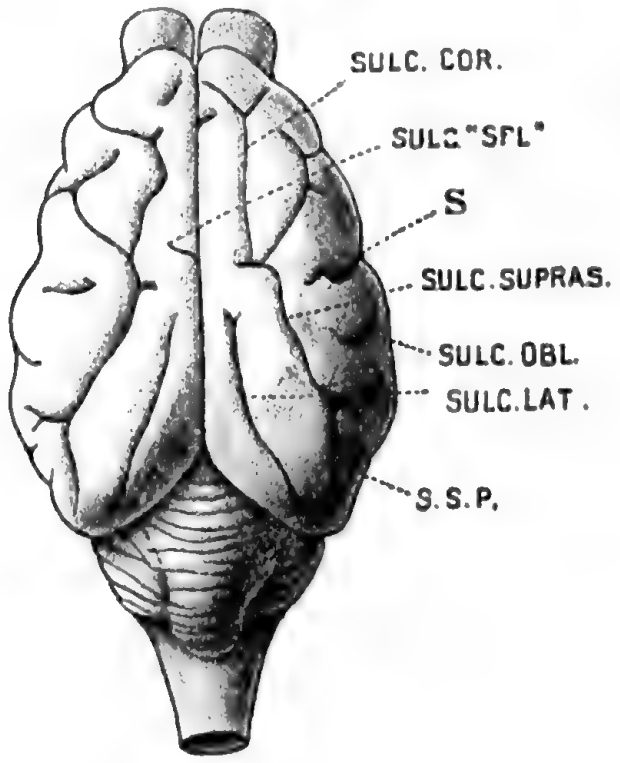

The calcarine and intercalary sulci are joined to form a typical "splenial" sulcus, the anterior extremity of which bends upward and indents the dorsal surface (SPL.), like the crucial in the Cynoidea, opposite the junction of the coronal and suprasylvian and in front of a small ansate branch of the latter.

Small independent genual and rostral sulci are present.

The cerebellum conforms to the simple transversely foliated Ungulate type. O. C. 1328 E *u.*

Forbes, Proc. Zool. Soc. 1882, p. 638.

D. 448. The brain of a Chinese Water-Deer (*Hydropotes inermis*), (♂).

This specimen shows better than the last how closely the brain conforms to the same type as that of the Musk-Deer. The pseudosylvian sulcus is longer and more complete, for the depressed area is now almost completely hidden by the downgrowth of opercular folds, especially in front of the sulcus. As a result the orbital sulcus now appears to spring far forward from the rhinal fissure.

The anterior part of the suprasylvian sulcus is prolonged beyond the junction with the coronal sulcus, and a vertical secondary sulcus (the diagonal of Krueg) has made its appearance between the coronal and suprasylvian sulci. The diagonal is not joined to the suprasylvian sulcus as it is in the last specimen.

There is a longer lateral sulcus than there is in the Musk-Deer. The splenial sulcus is now wholly mesial, probably because the brain is larger. It does not, however, extend so far forward. The genual sulcus is longer and so also is the rostral, which appears to cross the dorso-mesial margin of the hemisphere and join the coronal sulcus. O. C. 1328 E *k*.

Presented by the Zoological Society.

D. 449. The brain of a Mexican Deer (*Odocoileus mexicanus*).

This brain is a larger and correspondingly more complicated copy of that of *Capreolus*.

The true nature of the paraorbital sulcus is clearly seen.

There is no posterior descending ramus of the suprasylvian sulcus, but the posterior horizontal branch is very deep and extensive and its ventral compensatory sulcus is also extremely well developed.

Well-defined ecto- and entolateral sulci have made their appearance. O. C. 1328 E *a*.

D. 450. The brain of a Virginian Deer (*Odocoileus virginianus*).

This brain agrees with the description of *O. mexicanus*.

O. C. 1328 E *p*.

Presented by the Zoological Society.

D. 451. The brain of a Chilian Deer (*Pudu pudu*), (♂).

This brain shows features of great interest in comparison with those of *Odocoileus* and *Capreolus*. The suprarhinal operculum is poorly developed and the anterior ectosylvian sulcus forms a short, vertical, paraorbital sulcus which is joined by the true orbital.

The splenial complex lies upon the dorsal surface in a great part of its course.

This brain in other respects may be regarded as a smaller and correspondingly much simplified copy of that of *Capreolus*. O. C. 1328 E *b*.

Family *GIRAFFIDÆ*.

D. 452. The brain of a Giraffe (*Giraffa camelopardalis*).

In this brain the Sylvian and presylvian regions conform essentially to the same plan as we find in the larger Deer. There is a vertical pseudosylvian sulcus, from the lower end of which the anterior ectosylvian sulcus proceeds forwards parallel to, and a considerable distance on the dorsal side of, the anterior rhinal fissure. This ectosylvian sulcus joins the orbital sulcus anteriorly, and at the junction a large, vertical, paraorbital sulcus is formed, as in the larger Deer. The region between the anterior ectosylvian sulcus and the anterior rhinal fissure is a large depressed area marked by vertical sulci and partly hidden by a great dorsal overhanging operculum.

There is also a large operculum extending towards the rhinal fissure and overhanging the posterior ectosylvian sulcus. This is deeply incised by two radial sulci, which may be regarded as compensatory to the pseudosylvian.

There is a very deep and complete arcuate sulcus, with a large, vertical, apical process between the pseudosylvian and suprasylvian sulci.

Unlike the condition found in the Deer, the suprasylvian sulcus has a very large, vertical, posterior, descending ramus, in addition to the posterior horizontal ramus. And the compensatory sulcus is vertical in relation to the former, and not to the latter as in the Deer. The suprasylvian sulcus is not joined to the coronal, and its connection with the large, irregular, triradiate, diagonal sulcus is very doubtful.

The splenial complex is wholly mesial in position and is not connected with any crucial-like sulcus.

The cerebellum is of the usual transversely foliate Ungulate type. O. C. 1328 D *a*.

Krueg, *op. cit.* Bd. xxxi. p. 318.

D. 453. The brain of a Giraffe (*Giraffa camelopardalis*), (♂).
O C. 1328 D.

Family *ANTILOCAPRIDÆ.*

D. 454. A cast of the cranium of a Prongbuck (*Antilocapra americana*).

Family *BOVIDÆ.*

D. 455. The brain of a Gnu (*Connochætes gnu*). O. C. 1327 C *l*.

D. 456. A cast of the cranial cavity of a Gnu (*Connochætes gnu*).

D. 457. The brain of a Tora Antelope (*Bubalis tora*), (♀).

This brain closely resembles that of *Odocoileus*.
O. C. 1327 C *i*.

D. 458. A cast of the cranial cavity of a Hartebeest (*Bubalis caama*).

D. 459. The brain of a Duikerbok (*Cephalophus monticola*).

This brain is remarkable by reason of its exceeding abundance of sulci, in spite of the fact that it is of small size. Although the brain is smaller than that of *Hydropotes*, it exhibits a wealth of sulci as rich as that of the much larger *Odocoileus*.

In proportion to the size of the animal this brain is large.

The plan of its cerebral sulci and the features of the cerebellum resemble those of the Deer Family.
O. C. 1327 C *d*.

D. 460. The brain of a Duikerbok (*Cephalophus dorsalis*), (♀).

This larger brain conforms to the same type as the pygmy species. The suprarhinal operculum is notably better developed. O. C. 1327 c *e*.

D. 461. The brain of a Duikerbok (*Cephalophus maxwelli*), (♀).

See the account of the pygmy species. O. C. 1327 c *f*.

D. 462. The brain of a *Cephalophus grimmi*.

D. 463. A cast of the cranial cavity of a Duikerbok (*Cephalophus natalensis*).

D. 464. The brain of a Four-horned Antelope (*Tetraceros quadricornis*).

D. 465. A cast of the cranial cavity of the Royal Antelope (*Ourebia montana*).

D. 466. A cast of the cranial cavity of a Reitbok (*Cervicapra arundinum*).

D. 467. The brain of a Black-Buck (*Antilope cervicapra*), (♀).

This brain conforms to the same pattern as those of the Deer.

Of the three oblique furrows of the "lateral series" the mesial is the deepest and the most pronounced Instead of this being the lateral, as might be imagined, it represents an entolateral sulcus, which has attained to a greater importance at the expense of the true lateral—the intermediate of the three sulci.

There is a small, ectosylvian, arcuate sulcus, the posterior limb of which joins the Sylvian fissure, as in some of the Carnivora. O. C. 1327 c *a*.

D. 468. The brain of an Antelope (*Antilope* sp.).

Note the junction of the crucial-like prolongation of the intercalary with the coronal sulcus on the right side.

O. C. 1327 c.

D. 469. A cast of the cranial cavity of a Palla (*Æpyceros melampus*).

D. 470. A cast of the cranial cavity of a Saiga (*Saiga tatarica*).

D. 471. The brain of a Gazelle (*Gazella dorcas*).

The "lateral series" of sulci resembles that of the Black-Buck.

There is, however, no ectosylvian arc, such as we find in the latter. O. C. 1327 c *b*.

D. 472. The brain of a Gazelle (*Gazella subgutturosa*), (♀).

In this specimen it is clear that the intermediate of the "lateral series" of three sulci is the true lateral, and that the large sulcus in the last Gazelle and the Black-Buck must be an unusually pronounced entolateral.

The crucial-like prolongation of the splenial complex (calcarine and intercalary) joins the coronal sulcus.

O. C. 1327 c *c*.

D. 473. A cast of the cranial cavity of a Gazelle (*Gazella sœmmerringi*).

D. 474. A cast of the cranial cavity of a Sable Antelope (*Hippotragus equinus*).

D. 475. The brain of a Beisa (*Oryx beisa*).

This brain may be regarded as an extremely complicated form of the type found in the Gazelle and Antelope. The complications are introduced by means of numerous additional secondary sulci. O. C. 1327 c *k*.

D. 476. The brain of an Arabian Beatrix Antelope (*Oryx beatrix*).

Note the marked twisting of the mesial part of the cerebellum, which presents such a strong contrast to the symmetrical arrangement of the corresponding part in the Deer. Indications of a similar phenomenon are found even in the brain of a *Cephalophus dorsalis*. O. C. 1327 c *p*.

D. 477. A cast of the cranial cavity of the Nilghai (*Boselaphus tragocamelus*).

D. 478. The brain of a Guib (*Tragelaphus scriptus*).

The suprasylvian sulcus is placed unusually high up on the dorsal surface and pursues a sagittal course. It has

an extensive posterior horizontal and a very small posterior vertical ramus. There is a well-developed ectosylvian arc.
O. C. 1327 c *o*.

D. 479. A cast of the cranial cavity of the Harnessed Antelope (*Limnotragus spekii*).

D. 480. The brain of a Kudu (*Strepsiceros kudu*).

This may be regarded as an exceedingly complicated Guib's brain. The dorsally-placed suprasylvian sulcus is exceedingly well developed, and on the left side has a very large posterior vertical ramus. It joins the coronal and, on the right side, the crucial-like prolongations of the intercalary. There is a well-developed ectosylvian arc, with several radiating branches. O. C. 1327 c *n*.

D. 481. The brain of an Eland (*Taurotragus oryx*), (♀).

In most respects this brain resembles that of the Kudu, but is larger and more complicated. The branches of the ectosylvian are prolonged to form a great horizontal sulcus parallel to the suprasylvian.

Behind the "Sylvian fissure" there is a deep sulcus cutting obliquely into the posterior operculum from the rhinal fissure. It is probably a representative of the feline pseudosylvian sulcus. O. C. 1327 c *g*.

D. 482. Cast of the cranial cavity of a Takin (*Budorcas*).

D. 483. The right cerebral hemisphere of a Goat (*Capra hircus*), partially dissected.

There is a large vertical "Sylvian fissure" extending upward from a long horizontal sulcus—the conjoint anterior and posterior terminal sulci—which runs parallel to and some distance to the dorsal side of the rhinal fissure. The orbital (presylvian) sulcus is quite independent of the anterior terminal sulcus. These terminal sulci are analogous to the ectosylvian sulci of the Carnivora.

There is a typically Ungulate suprasylvian sulcus, with long horizontal and short vertical rami. It is not joined to the well-developed diagonal sulcus, but is connected with the coronal. The lateral sulcus is broken up into triradiate fragments anteriorly. O. C. 1327 B.

Holl, Arch. f. Anat. 1900, p. 313.

D. 484. A cast of the cranial cavity of a Goat (*Capra hircus*).

D. 485. The brain of a Goat (*Capra*), dissected to show the hippocampus in the left cerebral hemisphere. O. C. 1327 B *a*.

D. 486. The brain of a Sheep (*Ovis aries*) (figs. 194, 195, 196).

This brain clearly exhibits the typically Ungulate arrangement of the pseudosylvian, orbital, and suprasylvian sulci, as described in the Goat. The coronal, however, is not joined to the suprasylvian sulcus in this specimen.

The three accompanying diagrams explain the general disposition of the cerebral sulci. The small insignificant notch (S) above the rhinal fissure probably represents the pseudosylvian fissure of the Carnivora, whereas the much longer (S′) furrow, generally called "Sylvian fissure," is formed by the meeting of the opercular upper lips of the anterior (fig. 194, E) and posterior (F) ectosylvian sulci. It will be seen from the account of the brain in the Lemuroidea that neither the Carnivore nor the Ungulate type of pseudosylvian fissure represents the true (Primate) Sylvian fissure, which is a complex of several elements. The chief of these, and therefore the nearest homologue of

Fig. 194. (× $\frac{2}{3}$.)

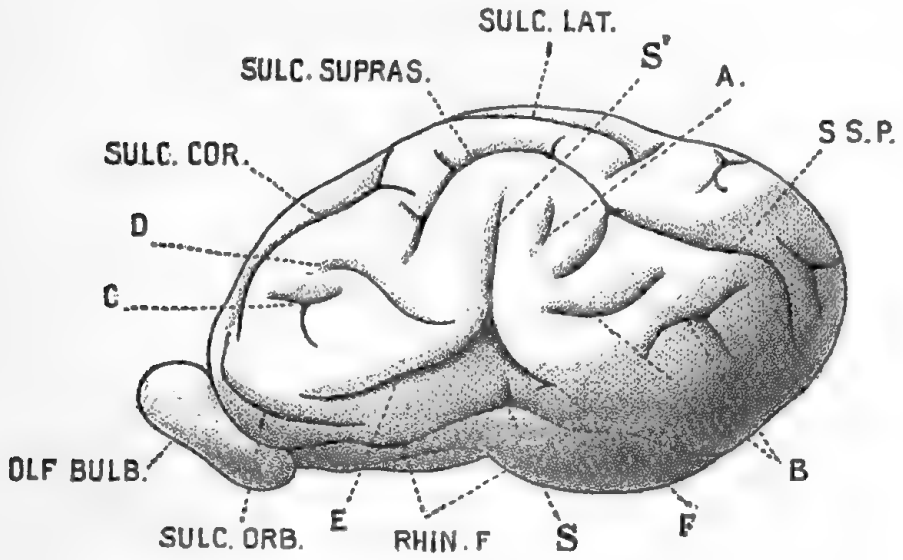

the true Sylvian fissure, is the suprasylvian fissure. The latter forms an arc around the apex of the Ungulate pseudosylvian fissure (S′) and gives off a characteristically Ungulate posterior branch (S.S.P.). Below the latter are the representatives (B) of a constant sulcus called "obliquus" by Holl. The sulcus A is distinguished as "perpendicularis." The diagonal (D) and its very constant accessory sulcus (C) are also seen (fig. 194).

Fig. 195. (× $\frac{2}{3}$.)

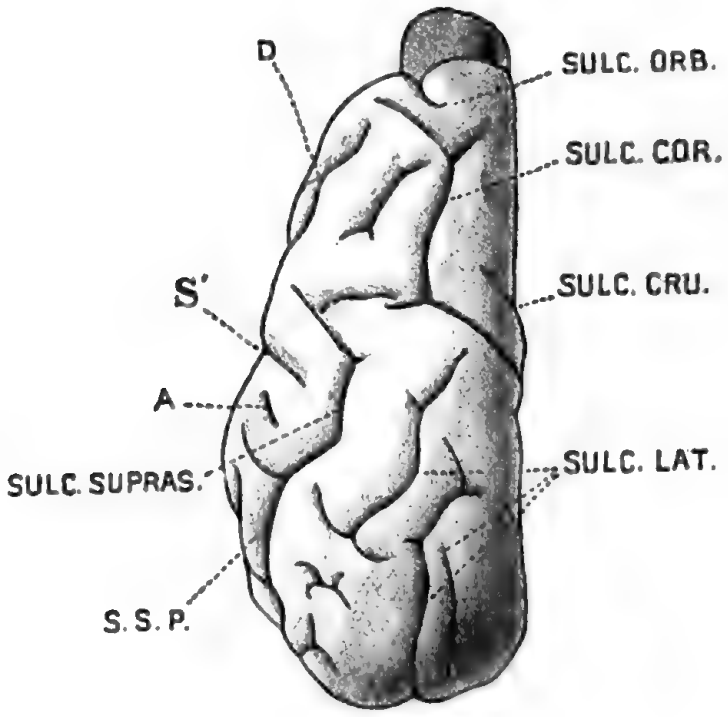

Fig. 196. (× $\frac{2}{3}$.)

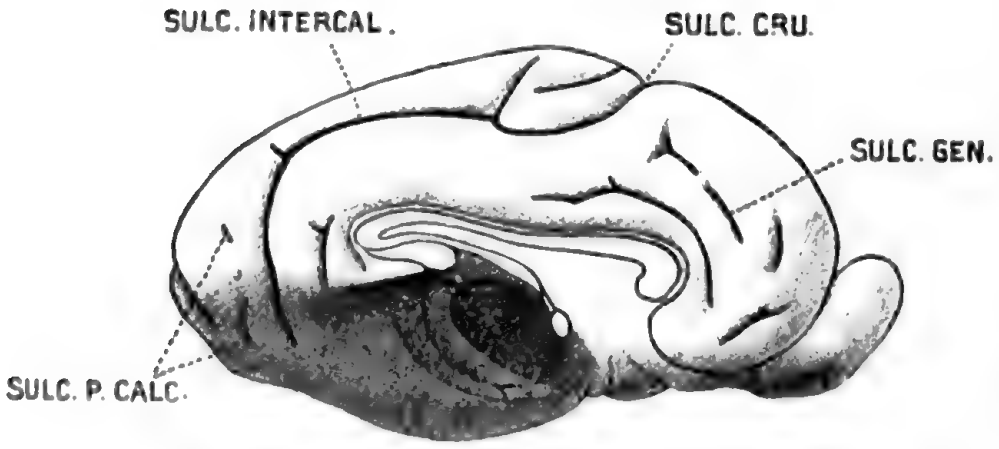

The lateral, ento- and ectolateral sulci (fig. 195, SULC. LAT.) are better developed than they are in the specimen of the Goat's brain.

The splenial complex of intercalary and calcarine sulci is seen to bend upward anteriorly in a crucial-like manner.

O. C. 1327 A *m.*

Holl, Arch. f. Anat. 1900, p. 308.

D. 487. A cast of the cranial cavity of a Sheep (*Ovis aries*).

D. 488. The left half of the brain of a Sheep (*Ovis aries*), separated by a mesial sagittal section.

The Sylvian depressed area is very well shown.

O. C. 1327 A *b*.

D. 489. The right half of the brain of a Sheep (*Ovis aries*).

The typical arrangement of sulci is well demonstrated.

The paraorbital sulcus, which is merely the upturned anterior extremity of the anterior ectosylvian sulcus, is joined to the true orbital sulcus.

The posterior ectosylvian sulcus is joined to the rhinal fissure by an accessory sulcus, which completes the caudal boundary of the Sylvian trigone and probably represents the pseudosylvian fissure of the Carnivora. O. C. 1327 A *c*.

D. 490. The brain of a Sheep (*Ovis aries*), in which the lateral ventricles have been opened and the corpora striata and hippocampi exposed. O. C. 1327 A *a*.

D. 491. The brain of a Sheep (*Ovis aries*), in which a great part of the cerebral hemispheres has been removed so as to expose the corpora striata, optic thalami, pineal body, corpora quadrigemina, and cerebellum.

The great extent of the anterior quadrigeminal bodies is shown.

The characteristic features of the typically Ungulate cerebellum—the narrowness and the simple transverse arrangement of the folia on the lateral parts of the organ—are clearly seen. The floccular lobes are exceedingly large and complicated; they form cake-like masses applied to the lateral aspect of the truncated lateral regions of the "middle lobe" of the cerebellum.

The flocculus (*sensu stricto*) is a little feather-like structure placed on the middle peduncle below the great irregular paraflocculus. O. C. 1327 A.

D. 492. The right half of the brain of a Sheep (*Ovis aries*).

The orbital (presylvian) sulcus is quite independent of the anterior ectosylvian sulcus. O. C. 1327 A *e*.

D. 493. The left half of the brain of a Sheep (*Ovis aries*).

The appearance of the mesial sagittal section of the cerebellum, the pattern of which is remarkably constant throughout the Meta- and Eutheria, is clearly shown.

O. C. 1327 A *g*.

W. Küithan, Die Entwickl. des Kleinhirn. München, 1895.

D. 494. The right cerebral hemisphere of a Sheep, dissected to expose the hippocampus. O. C. 1327 A *h*.

D. 495. Part of the left half of the brain-stem of a Sheep (*Ovis aries*).

The large size of the anterior quadrigeminal bodies in comparison with the posterior pair is shown. The tractus peduncularis transversus can be very clearly seen as a prominent strand crossing the inferior brachium from the groove between the optic thalamus and the anterior quadrigeminal bodies to reach the surface of the pes pedunculi. The mesial geniculate body lies in front of the tract; it is flattened and unobtrusive. O. C. 1327 A *i*.

D. 496. The brain of an Anoa (*Anoa depressicornis*), (♀).

The simplest and most generalised Ox-brain.

O. C. 1327 C *m*.

D. 497. The head of a fœtal Ox (*Bos taurus*) with the dorsal surface of the brain exposed *in situ*.

The simple corono-suprasylvian and lateral are the only sulci present on the dorsal surface, and the splenial complex can also be seen on the dorso-mesial edge.

The corpora quadrigemina are not yet covered by the hemispheres. O. C. 1328 A *b*.

Krueg, Zeitsch. wiss. Zool., Bd. xxxi. 1878, p. 319.

D. 498. The brain of an Ox (*Bos taurus*), from which the membranes have been only partially removed.

The brain of the Ox resembles that of the Sheep, but is more richly supplied with sulci as a result of its greater size.

A very peculiar arrangement of the "Sylvian region" is found in this specimen.

There is a large vertical Ungulate pseudosylvian sulcus placed high up on the lateral wall of the hemisphere (fig. 197, S); its lower extremity joins a short posterior ectosylvian sulcus and a long horizontal anterior ectosylvian sulcus continuous with the orbital. These ectosylvian sulci are far removed from the rhinal fissure, from which a **Y**-shaped feline pseudosylvian sulcus S′ ascends through the Sylvian depressed area, and is surrounded by a small arc formed by the two ectosylvian sulci. O. C. 1328.
Hunterian.

Fig. 197. (×⅔.)

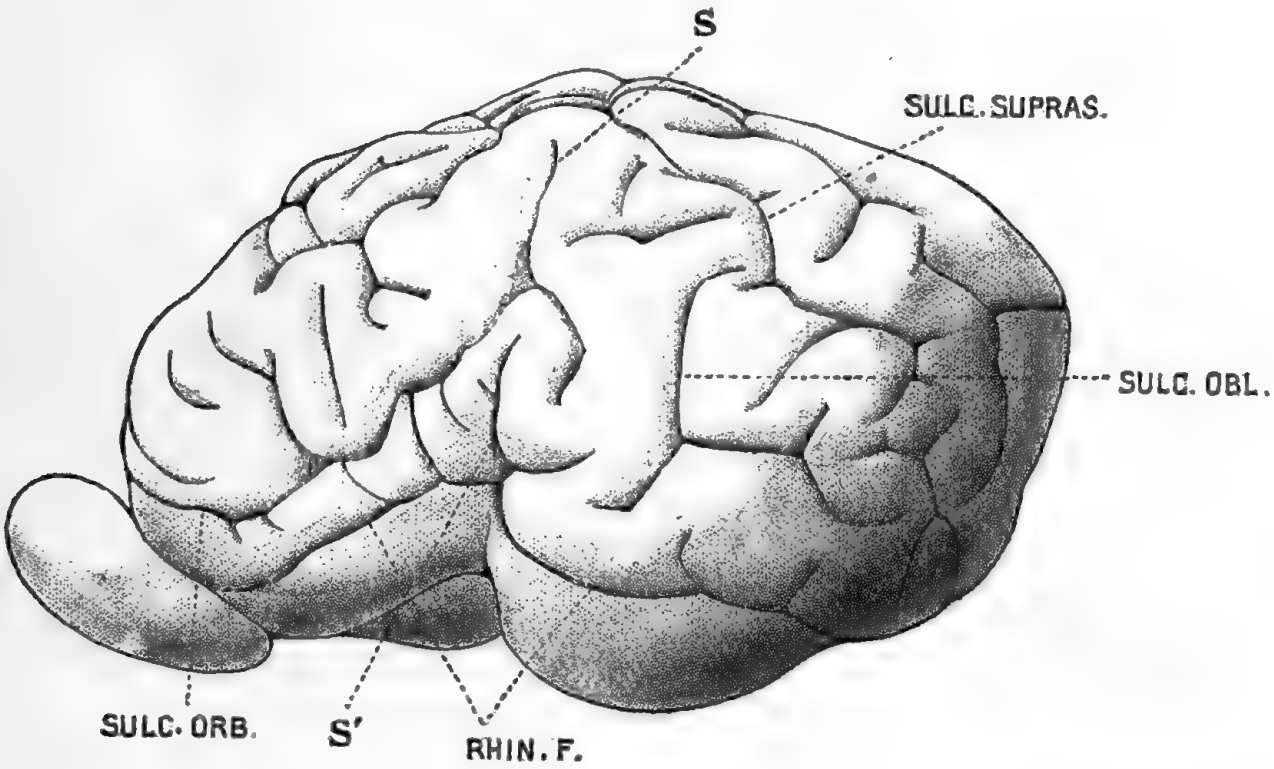

D. 499. A dissection of a brain of a Calf (*Bos taurus*), to show the relations of the optic tract. O. C. 1328 A.

D. 500. The brain of a Calf (*Bos taurus*). O. C. 1328 B *b*.

D. 501. A cast of the cranial cavity of an Ox (*Bos taurus*).

D. 502. The brain of an Indian Ox (*Bos indicus*). O. C. 1328 B *a*.

D. 503. The right half of the brain of an Indian Ox (*Bos indicus*). O. C. 1328 B.

D. 504. The brain of a Bison (*Bison europæus*).

This closely resembles the brain of the Ox.

O. C. 1328 C.

D. 505. Two casts of the cranial cavity of a Yak (*Poëphagus grunniens*).

The shape of this brain is very much like that of the Elephant.

Order SIRENIA.

D. 506. The brain of a Manatee (*Trichechus manatus*), which had been sliced in various planes by Mr. Garrod and partially built up again.

Amongst the whole series of placental mammals there is no other animal in which the brain presents features so extraordinary and so bizarre as in the Sirenia. The only parallel which can be found for the peculiar cases presented by the Manatee and the Dugong is that occasionally presented in the brains of idiots, in which the process of elaboration has ceased in the earlier months of intra-uterine life, and the organ has simply grown in size without becoming perfected in structure.

Fig. 198. ($\times \frac{2}{3}$.)

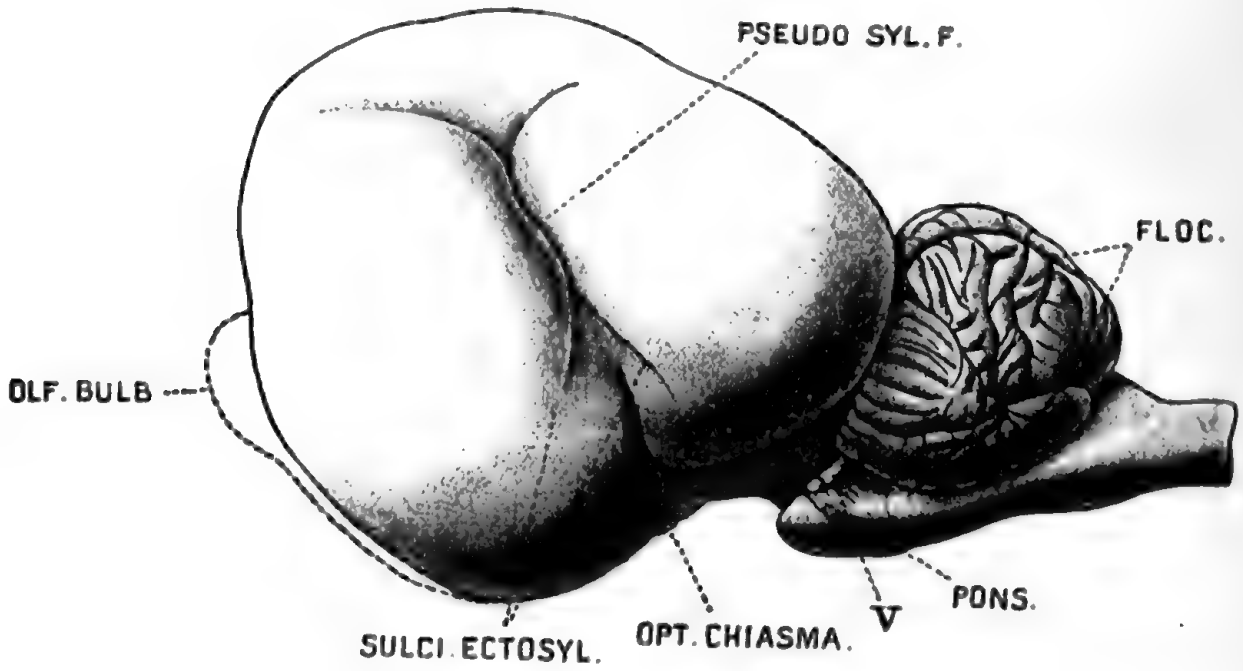

In the two species of Manatee the shape of the cerebral hemispheres varies considerably, as Beddard has shown (Proc. Zool. Soc. 1897).

The cerebral hemisphere is a large thick-walled bladder (figs. 198 & 200) with a very spacious ventricular cavity, such as is found in fœtal brains, but not usually in those of adult animals.

The lateral wall is deeply invaginated into the cavity of this ventricle (fig. 200), so as to produce a great vertical furrow on the surface (fig. 198). This "complete" sulcus is of a very different nature to the Sylvian fissure of any mammal of other Orders. In some brains this sulcus appears to bifurcate both above and below (fig. 198), but in other cases the posterior limb at the upper extremity may be a separate sulcus (? suprasylvian); and sometimes also the postero-inferior limb is wanting.

Neither of these lower limbs represents the rhinal fissure, as Beddard believes, because the situation of the rhinal fissure can be readily determined at a lower level, although the fissure itself is almost wholly aborted. The inferior bifurcation ought rather to be compared to the limiting furrows of the Sylvian depressed area, which are such constant appendages of the ventral extremity of the "Sylvian fissure" of the Ungulata. Their nearest analogues are therefore the two sulci called "ectosylvian" in the Ungulata.

Fig. 199. (×$\frac{2}{3}$.)

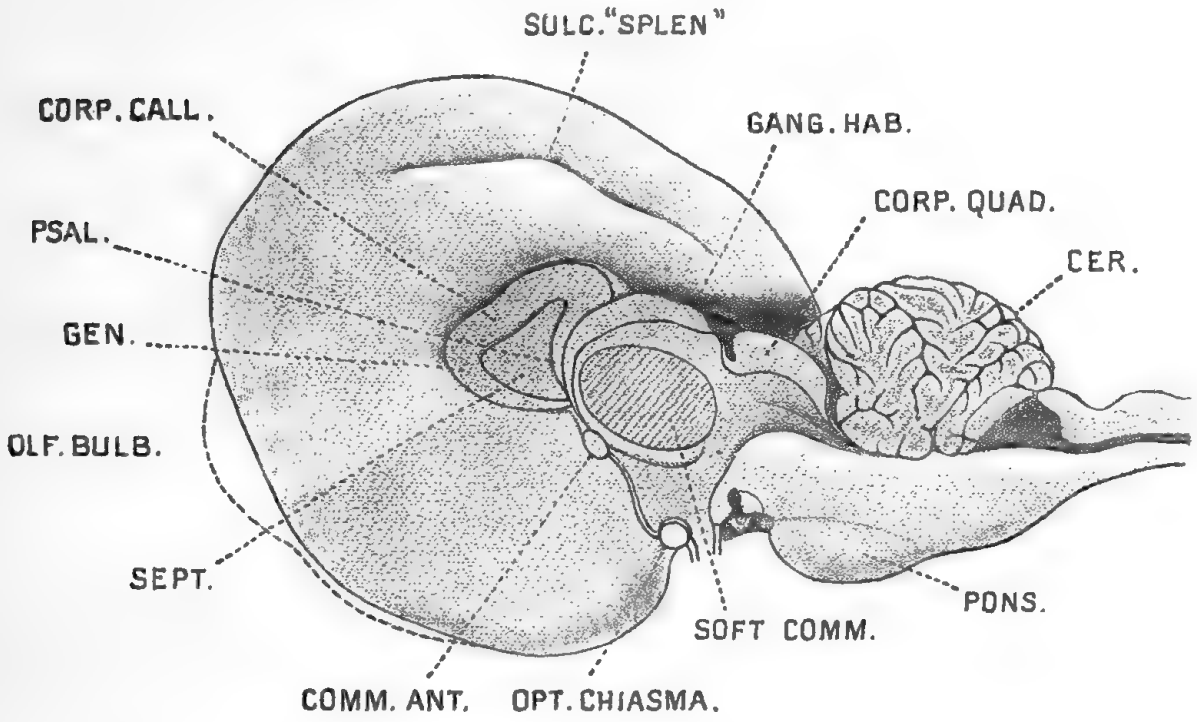

The small olfactory bulb, the flattened ribbon-like olfactory peduncle, and the ill-defined tuberculum olfactorium and pyriform lobe present no unusual features beyond their smallness (as a result of the aquatic habits of the Manatee) and the abortion of their boundary, the rhinal fissure. The hippocampus also presents the characteristic features. In one specimen of Manatee (specimen D. 507), however, I have seen a peculiar large tubercle of inverted hippocampus such as I have found elsewhere only in the primitive brain of *Orycteropus* and in the Primates. Strange to relate, this condition was present in only one of three Manatees' brains examined.

The corpus callosum is peculiarly short and small, but it has an extraordinarily complete genu (fig. 199).

Sometimes there is a deep "splenial" (conjoint calcarine and intercalary) sulcus, in other cases only one or two shallow furrows take its place.

Fig. 200. (×$\frac{2}{3}$.)

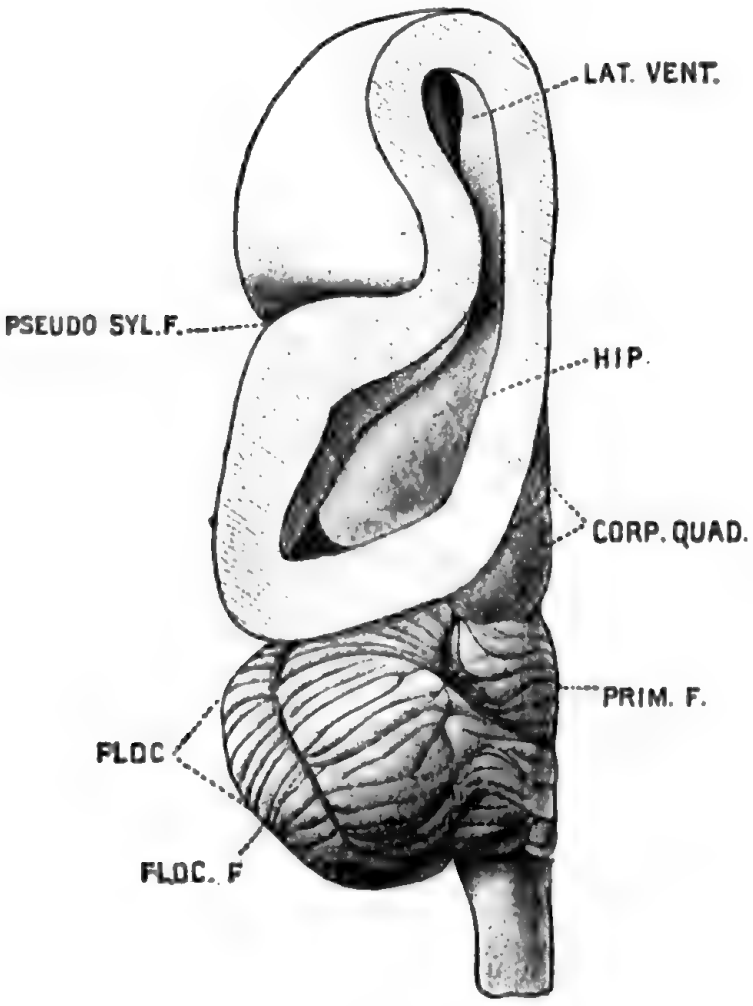

The left half of a Manatee's brain, in which the roof of the lateral ventricle has been removed by horizontal section.

The base of the brain is quite typical, which one would hardly gather from Murie's representation of it. There are small optic tracts, prominent exposed crura cerebri, a large interpeduncular body, very prominent pons, trapezium, and pyramids, and very large fifth, seventh, and eighth nerves. Contrary to the statements of Murie, these nerves are found in the positions usual in other Mammals.

Although the cerebellum conforms to the usual mammalian (and especially Ungulate) plan it presents some very peculiar features. The floccular lobes (figs. 198 & 200) can only be properly described as enormous; they consist of large, cake-like, compact masses of very complicated character forming the whole of the lateral aspects of the organ. The flocculus (*sensu stricto*) is a small foliate plump mass, quite distinct from the great parafloccular masses which form the bulk of the floccular lobe. The interfloccular mass is relatively small; its lateral portion is marked by a simple transverse pattern, as in most Ungulates; and its mesial part is reduced to extraordinarily small dimensions.

The references to somewhat unsatisfactory accounts of this brain which Murie, Chapman, and Garrod have given will be found in the recent note by Beddard, Proc. Zool. Soc. 1897, p. 52. O. C. 1331 B.

Presented by the Zoological Society.

D. 507. The lateral wall (separated by a sagittal section) of the left cerebral hemisphere of a Manatee (*Trichechus latirostris*).

The lower half of the hippocampus is exposed in the descending cornu of the lateral ventricle. The peculiar hippocampal tubercle described in the account of the last specimen is exposed at the lower end of the fascia dentata. The fimbria appears to spread out on its anterior border.

On the lateral aspect the peculiar Ungulate type of pseudosylvian sulcus is exhibited.

D. 508. A cast of the cranial cavity of a Manatee (*Trichechus senegalensis*).

D. 509. A cast of the cranial cavity of a Dugong (*Halicore dugong*).

The brain of the Dugong, as Miklucho-Maclay's account shows, closely agrees in structure with that of the Manatee.

Miklucho-Maclay, Proc. Linn. Soc. New South Wales, vol. x.

D. 510. A cast of the cranial cavity of a Rhytina.

In spite of its lowly organisation, this brain (according to Brandt) shares with the Elephant and the great Baleen

Whales the distinction of exceeding the dimensions of the Human brain (Dubois, Bull. Soc. d'Anthropol. de Paris, t. viii. 1897, p. 338).

The cerebral hemisphere in each of the three Sirenians consists of a great elliptical bladder, the lateral wall of which is deeply indented at its mid-point. The hemisphere of the Dugong is relatively much narrower and more like those of the extinct *Eotherium* and *Halitherium* than that of the Manatee. In this respect *Rhytina* occupies a position intermediate between the two living genera. The olfactory bulbs of *Halicore* are long, conical, projecting structures; those of *Trichechus* are broad flattened cakes closely applied to the anterior surface of the hemispheres; and here again *Rhytina* occupies the intermediate position. In all extinct and living Sirenians the cerebellum has the same peculiar shape.

Brandt, Mélanges Biolog., Bull. de l'Acad. Imp. des Sci. de St. Pétersbourg, t. vi. 1867, p. 364.

ORDER CETACEA.

Suborder ODONTOCETI.

Family *DELPHINIDÆ*.

D. 511. The brain of a Porpoise (*Phocæna phocæna*).

"The size of the brain differs much in the different genera of the Whale-tribe, and likewise in the different proportion it bears to the bulk of the animal. In the Porpoise, I believe, it is largest, and perhaps in that respect comes nearest to the Human.

"The size of the cerebellum in proportion to that of the cerebrum is smaller in the Human subject than in any animal with which I am acquainted. In many quadrupeds, as the Horse, Cow, &c., the disproportion in size between cerebellum and cerebrum is not great, and in this tribe it is still less, yet not so small as in the bird, &c.

"The whole brain in this tribe is compact, the anterior part of the cerebrum not projecting so far forwards as in either the

Quadruped or in the Human subject; neither is the medulla oblongata so prominent, but flat, lying in a hollow made by the two lobes of the cerebellum.

"The brain is composed of cortical and medullary substances, very distinctly marked; the cortical being, in colour, like the tubular substance of a kidney; the medullary very white. These substances are nearly in the same proportion as in the Human brain. The two lateral ventricles are large, and in those that have olfactory nerves are not continued into them as in many Quadrupeds; nor do they wind so much outwards as in the Human subject, but pass close round the posterior ends of the thalami nervorum opticorum. The thalami themselves are large; the corpora striata small; the crura of the fornix are continued around the windings of the ventricles, much as in the Human subject. The plexus choroides is attached to a strong membrane, which covers the thalami nervorum opticorum, and passes through the whole course of the ventricle, much as in the Human subject.

"The substance of the brain is more visibly fibrous [specimens D. 527 and D. 528 were prepared by Hunter to demonstrate this] than I ever saw it in any other animal, the fibres passing from the ventricle, as from a centre, to the circumference, which fibrous texture is also continued through the cortical substance. The whole brain in the Piked Whale [*Balænoptera acuto-rostrata*] weighed four pounds ten ounces.

The nerves going out from the brain, I believe, are similar to those of the Quadruped, except in the want of olfactory nerves in the genus of the Porpoise."—John Hunter, on Whales, Phil. Trans. 1787, p. 423.

O. C. 1333.
Hunterian.

D. 512. The brain of a Porpoise (*Phocœna phocœna*), (♂).
O. C. 1333 A.

D. 513. A cast of the cranial cavity of a Porpoise (*Phocœna phocœna*).

The large brain of the Porpoise is one of the smallest in the Cetacean Order, in which the organ attains to a much greater absolute size than in any other animals. In a record by Flatau and Jacobsohn the brain of a Porpoise weighed 468 grammes, being $\frac{1}{38}$th the total body-weight. Haswell has recorded a lesser brain-weight in this Order, that of *Kogia grayi*, which was 454 grammes.

The brain of the Odontoceti is peculiar in that the olfactory apparatus, which develops in the early embryo just as it does in other mammals, becomes entirely aborted before the time of birth. As a result the olfactory bulb and its peduncle completely disappear; the cortex of the tuberculum olfactorium atrophies so that a broad expanse of corpus striatum comes to the surface immediately in front of the optic chiasma on the basal surface of each hemisphere; the pyriform lobe becomes greatly reduced in size and altered in structure; the hippocampus, including the fascia dentata, and fornix become reduced to very diminutive proportions; and the anterior commissure becomes greatly attenuated, or may even disappear entirely. This abortion of the apparatus of smell is undoubtedly to be attributed to the purely aquatic habits of the Cetacea; and it is of interest because in other purely aquatic animals, such as Fish, Amphibia, and Reptiles, such a complete disappearance of the mechanism of smell cannot occur because there is no neopallium, which as a "*sensorium commune*" can make good the absence of the sense of smell.

The peculiar spherical shape of the cerebral hemisphere is to be attributed chiefly to this waning importance of the rhinencephalon.

The primitive cerebrum of all mammals consists essentially of two parts: a basal olfactory part and a dorsal neopallium. The relatively greater expansion of the latter, which the dwindling of the former must entail, naturally produces the marked ventral bending of the anterior and "temporal" poles of the hemisphere, so that when the enormous growth of the neopallium, which distinguishes this Order, occurs the hemispheres become moulded by this early bias and assume a shape which appears roughly spherical from above and kidney-shaped in profile. The "hilus" of the kidney-shape forms the "Sylvian fissure" (using this term with the reservation already adopted for the Carnivora and Ungulata).

The hemispheres in all the Cetacea become complicated in a most intricate and highly elaborate manner by the development of innumerable sulci. But the essential plan of the chief sulci of the hemisphere is a modification of the well-known plan of suprasylvian, corono-lateral, and calcarine-intercalary arcuate sulci, which divide the hemisphere into broad strips which become broken up by an extraordinarily rich supply of sulci.

The plan of these sulci is very constant in Odontoceti, so that the description of the brain of *Delphinus tursio* (*vide infra*) may be considered sufficient for the Suborder. It must, however, be remembered that, rich as the supply of sulci is in *Phocæna*, the surface of the hemisphere becomes even more broken up in the larger members of the Order.

Pari passu with the growth of the cerebral hemispheres the cerebellum also attains to very great proportions, in order, no doubt, that it may co-ordinate the activities of the enormous body, the large sensory surface of which has called into being the extensive neopallium.

The structure of the cerebellum is essentially identical with that of other large mammals.

The other parts of the brain call for little mention. It is, however, worthy of note that the olivary bodies are placed some distance to the caudal side of the large pons Varolii.

Flatau and Jacobsohn, Vergl. Anat. d. Centralnervensystems, 1899, p. 449.

D. 514. The left half of the brain of a Dolphin (*Delphinus tursio*) (♂), which has been split in the mesial sagittal plane.

O. C. 1333 H.

Presented by the Westminster Aquarium.

D. 515. The right half of the same brain.

This brain is larger and correspondingly richer in sulci than that of the Porpoise; but the structure of the two organs is essentially the same.

The so-called "Sylvian fissure" begins upon the base of the brain in a deep cleft-like vallecula Sylvii. It ascends for only a short distance upward and slightly backward (fig. 201) upon the lateral aspect. In this respect it differs most markedly from the larger Carnivora, in the brains of which (compare the Bears and Seals) the "Sylvian fissure" becomes greatly elongated. There is a much more striking resemblance to the arrangement found in the larger Ungulata (compare the Horse's and Camel's brain). For in the latter the "Sylvian fissure" becomes relatively shorter the larger the brain becomes, and it also gives off several radiating branches, just as the larger Cetacean brain gives off a group of deep radiating branches (fig. 201, S.R.), some of which actually open into the "Sylvian fissure," while others merely seem to do so.

Extending across the lateral convexity of the hemisphere there is a series of large concentric arcuate sulci, the lowermost of which surrounds the radial branches of the "Sylvian fissure."

Fig. 201. (× $\frac{4}{9}$.)

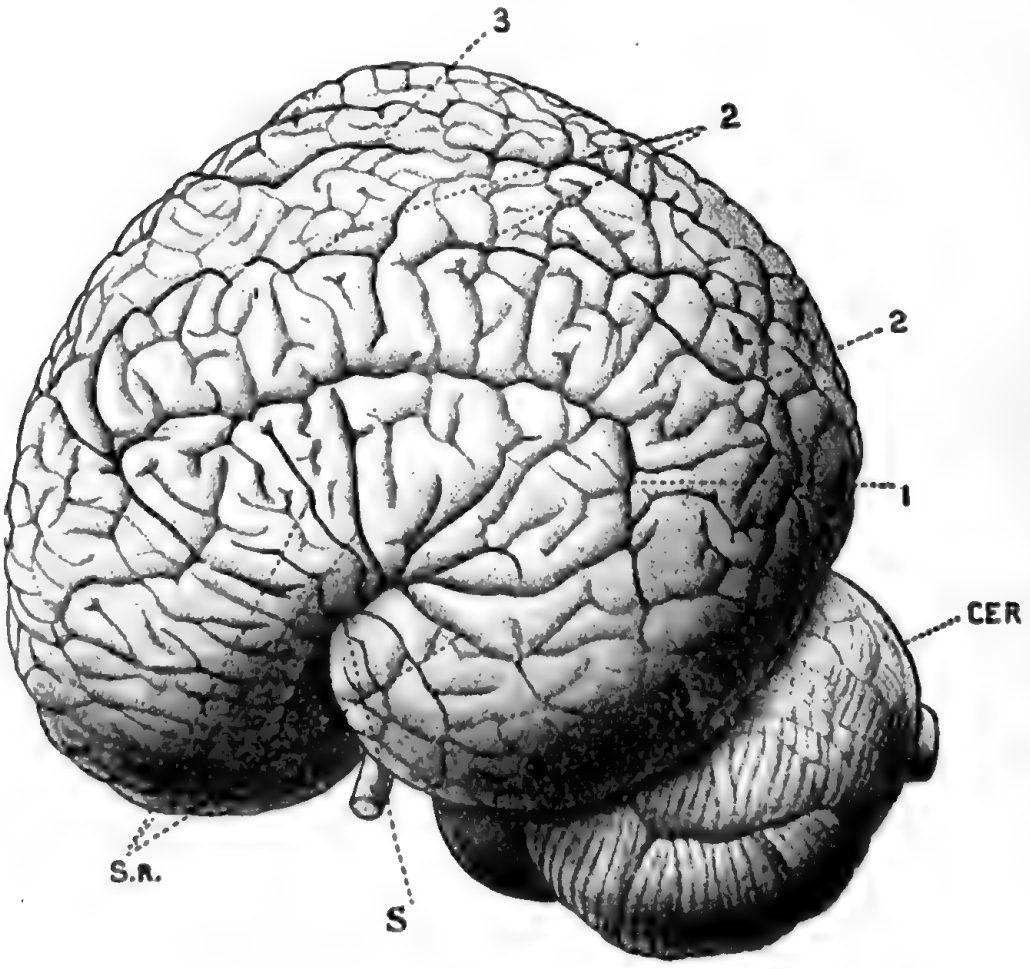

It is customary to regard these great arcs as the homologues of (i) the ectosylvian, (ii) the suprasylvian, and (iii) the corono-lateral arcuate sulci respectively from below upward (fig. 201, *1*, *2*, and *3*). If such be the case (which is hardly probable), the reservation must be made that it is unusual in the Carnivora and Ungulata to find the ectosylvian sulcus so exceptionally well developed as it is in this Cetacean, in which it so closely simulates the suprasylvian sulcus of other mammalian Orders.

On the mesial surface, which is of unusually great area, there is a sulcus (fig. 202, *5*) of extraordinary depth, which pursues most of its course on the mesial surface near the rounded dorsal margin ; both of its extremities cross on to the cranial aspect. If this sulcus does not represent the lateral it must be an unusually accentuated entolateral sulcus, such as occurs in the Seals.

The calcarine sulcus is very deep and is placed very close to the splenium of the corpus callosum. It is joined to the intercalary and genual sulci to form a complete cingular arc (fig. 202). The wide gap between the latter and sulcus *5* contains innumerable sulci, three of which are very pronounced posteriorly (fig. 202, *6*).

Fig. 202. (×$\frac{4}{9}$.)

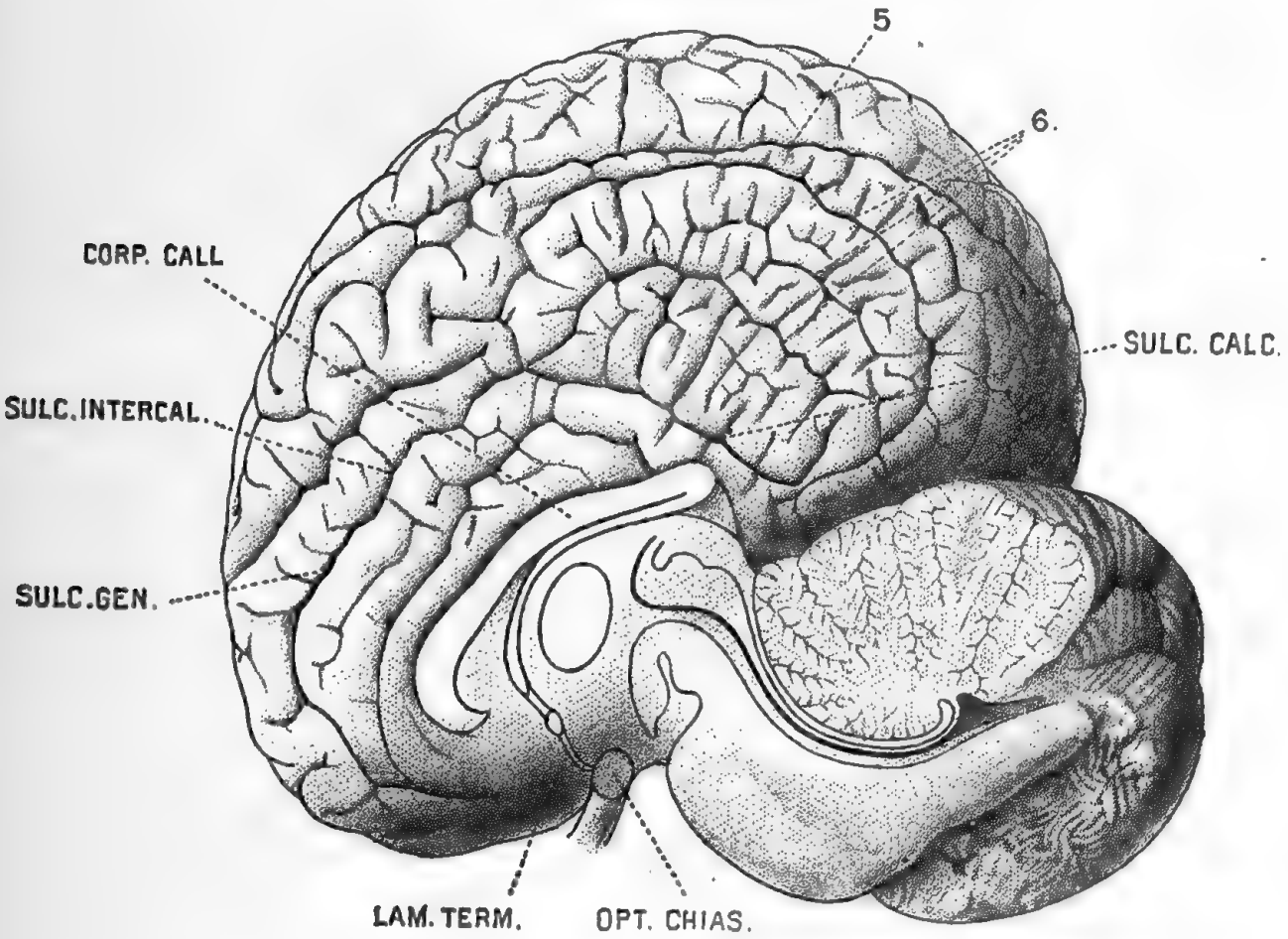

The orbital sulcus is represented by two or three relatively insignificant furrows on the basal surface. It is possible that the dwindling of the olfactory regions accounts for the insignificance of the orbital sulcus. O. C. 1333 I.

Presented by the Westminster Aquarium.

D. 516. The brain of a Dolphin (*Delphinus tursio*). O. C. 1333 E.

D. 517. The brain of a Dolphin (*Delphinus* sp.). O. C. 1333 C.

D. 518. The brain of a Dolphin (*Delphinus* sp.).
O. C. 1333 D.

D. 519. The brain of a Dolphin (*Delphinus delphis*), (♀).
O. C. 1333 G.
Presented by Matthias Dunn, Esq.

D. 520. A cast of the cranial cavity of a Beluga or White Whale (*Delphinapterus leucas*).

D. 521. The brain of a Beluga or White Whale (*Delphinapterus leucas*): from a female 9 ft. long. The fresh brain weighed 1797 grammes.

The brains of the Beluga and all the Dolphins closely resemble that of the Porpoise. O. C. 1333 F.
Presented by M. Morris, Esq.

Kükenthal and Ziehen, Denksch. d. med.-nat. Gesell. Jena, Bd. iii. 1893, p. 108.

Family *Physeteridæ*.

D. 522. A cast of the cranial cavity of a Sperm Whale (*Physeter macrocephalus*).

Suborder MYSTACOCETI.

Family *Balænidæ*.

D. 523. The brain of a Rorqual (*Balænoptera*, probably *musculus*), from which the right hemisphere has been removed.

D. 524. The right hemisphere of the same brain.

[In the absence of any definite information concerning the species of the Whale of which this is the brain, I have called it "*musculus*," because its dimensions agree to within a millimetre with those given by Guldberg for this species, whereas they differ considerably from the measurements of the other species of Rorqual as given by the same writer.]

This is the largest brain of any living animal, and yet, relatively to the size of its enormous body, it is the smallest mammalian brain. Thus, according to one record, the brain of a Common Rorqual weighed 4700 grammes and the body of the animal, approximately, 25,000 times as much.

From recent investigations as to the factors which determine the size of the brain in mammals, there can be little doubt that in any given Order of mammals *of the same geological epoch* the size of the cerebral cortex varies directly with the extent of the sensory surfaces of the body. It must, however, be borne in mind that the impressionable surfaces of the organs of the special senses have a relatively greater representation in the cortex than the general sensory areas, because the psychical importance of the olfactory, visual, and auditory impressions is greater than that of mere tactile sensibility. In the Whale the olfactory areas become reduced to insignificant proportions. The diameter of the retina of Sibbald's Whale is only 2½ times as great as that of the Porpoise (Dubois, *op. cit.* p. 356). So that, presumably, the visual area of cortex, although much larger in the Whale than in the Porpoise, is relatively much smaller in the former than in the latter. Then, again, the disproportion between the general surface areas of the Porpoise and Whale is much greater than that of the body-weight. Hence the brain of a small animal (the Porpoise) is much greater than that of a large animal (the Whale) *per unit of body-weight.*

For a given unit of sensory surface the extent of the cerebral cortex varies in different Orders, or, as Dubois puts it, "the index of cephalisation increases as the organisation of the animal becomes higher." Thus, in a series of estimations of this index, Dubois gives 2·8186 and 2·6778 as the human male and female figures respectively; for the Apes indices ranging from 0·3636 (*Macacus*) to 0·7607 (*Hylobates*); for the Carnivores from 0·2166 (*Putorius*) to 0·4413 (*Lycaon*—very old specimen); for the Ungulates from 0·2026 (*Tapir*) to 0·4573 (*Equus*), sinking in exceptional cases as low as 0·1819 (*Hippopotamus*) and rising as high as 1·2484 (*Elephas*); and finally for the Rodents from 0·0767 (*Mus*) to 0·2369 (*Hydrochœrus*). Estimating this index in the same way for *Balænoptera sibbaldi*, he calculates it at between 0·2263 and 0·2680, *i. e.* as being slightly below the average Carnivore and Ungulate status and considerably higher than the average Rodent index.

The apparently extraordinary dimensions of the Whale's brain cannot therefore be considered an unusual phenomenon, because this enormous extent of cerebral cortex to receive and "store" the impressions of such vast sensory surfaces becomes a condition of survival of the animal.

The marvellous complexity of the surface of the cerebrum is the direct result of its great size. In order, apparently, that the cerebral cortex may be efficiently nourished and at the same time be spared to as great a degree as possible the risk of vascular disturbances [such as would be produced by large vessels passing into it], its thickness does not appreciably increase in large animals. Thus Dubois quotes the following figures to show this:—In a Whale (*Hyperoodon*) cortex 2–3 mm. (Kükenthal and Ziehen), in *Bos* 2 mm., in *Lepus* 2 mm., and *Homo* 2–3 mm. Such being the case, it naturally results that the increased bulk of cortex in a large animal can only be packed by becoming thrown into an increasing number of folds, separated by a correspondingly large number of sulci. In *Balænoptera* this process is carried to a much greater extent than in any other animal.

(E. Dubois, Bull. Soc. d'Anthropologie de Paris, t. viii. 1897, p. 337.)

The presence of a diminutive olfactory bulb and peduncle is a noteworthy feature which distinguishes the Baleen Whales from the Toothed Whales, in which all the olfactory structures are wanting. [In this specimen, unfortunately, the olfactory regions are damaged.] According to Guldberg the cerebral hemispheres and the two halves of the cerebellum are asymmetrical both in shape and size in *Balænoptera musculus*, but not in the other Baleen Whales. From the measurements of this specimen there cannot be much doubt that it belongs to the species "*musculus*," and yet the asymmetry, if present, is so slight that it might easily have occurred during the preservation of such a huge mass of soft tissue.

The so-called "fissure of Sylvius" is peculiar in that it pursues a course obliquely upward and *forward* for a considerable distance (fig. 203, s). It thus presents a marked

Fig. 203. (× $\frac{1}{3}$.)

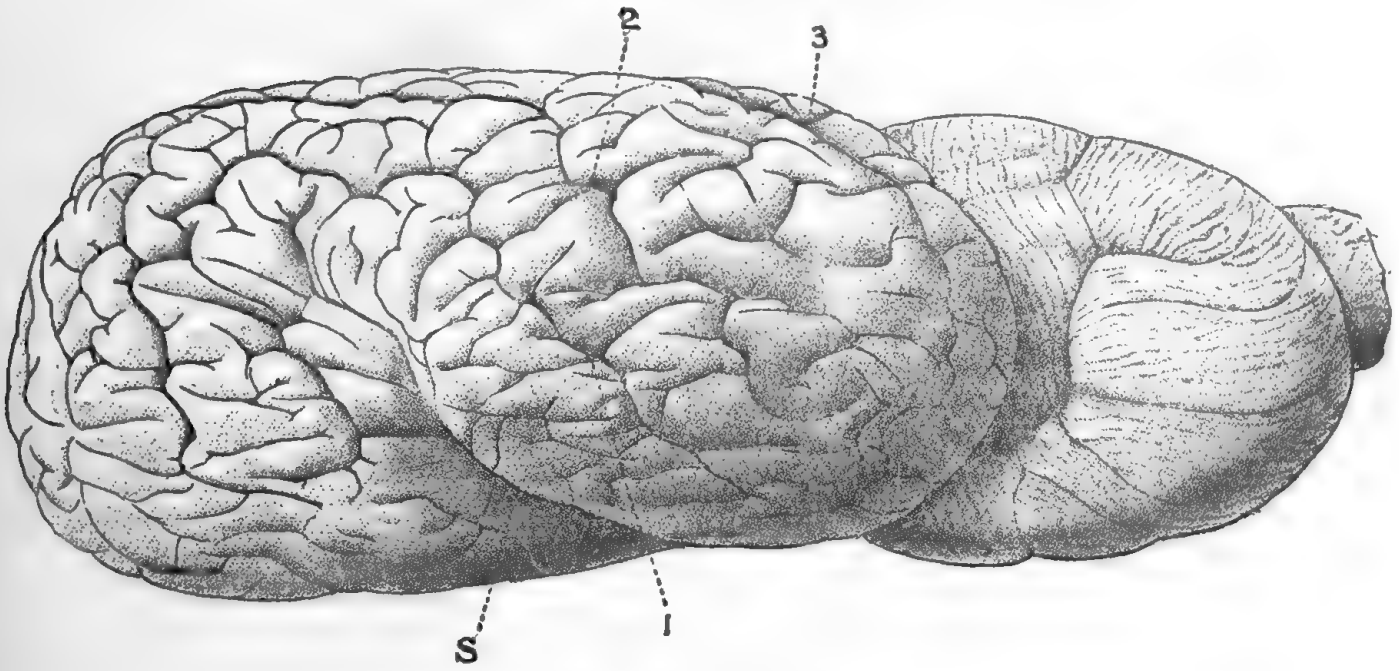

Fig. 204. (× $\frac{1}{3}$.)

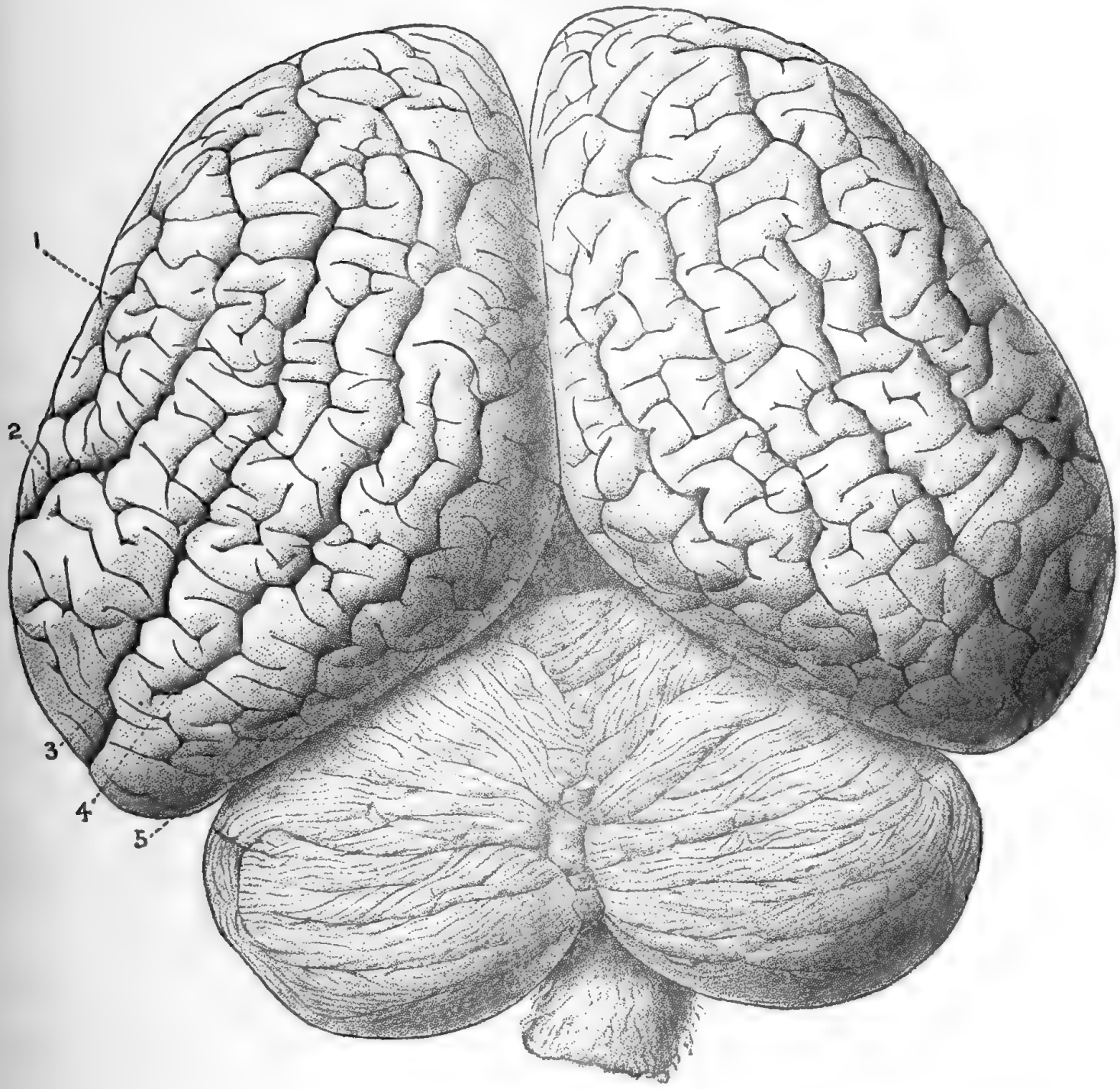

contrast to the "Sylvian fissure" of the Odontoceti. The difference is further increased by the different arrangement of the branches of the "fissure," which do not assume the peculiar radiating grouping found in the Porpoise's brain.

The chief sulci form a series of concentric arcs around the "Sylvian fissure," the lowermost of which are much more acutely flexed than is the case in the Porpoise. There is little exact information to guide us in determining the exact homologies of these five great arcs; but it is customary to call them from below upwards: (i.) the ectosylvian, (ii.) the suprasylvian, (iii.) the ectolateral, (iv.) the lateral, and (v.) the entolateral sulci, respectively (figs. 203 and 204). In the depths of the "Sylvan fissure" there is a very large submerged area, which is usually termed the "*insula*," although it cannot be regarded as the strict homologue of the human "island of Reil."

On the mesial surface the most peculiar feature is the enormous rostrum of the corpus callosum (fig. 25).

Fig. 205. (× ⅓.)

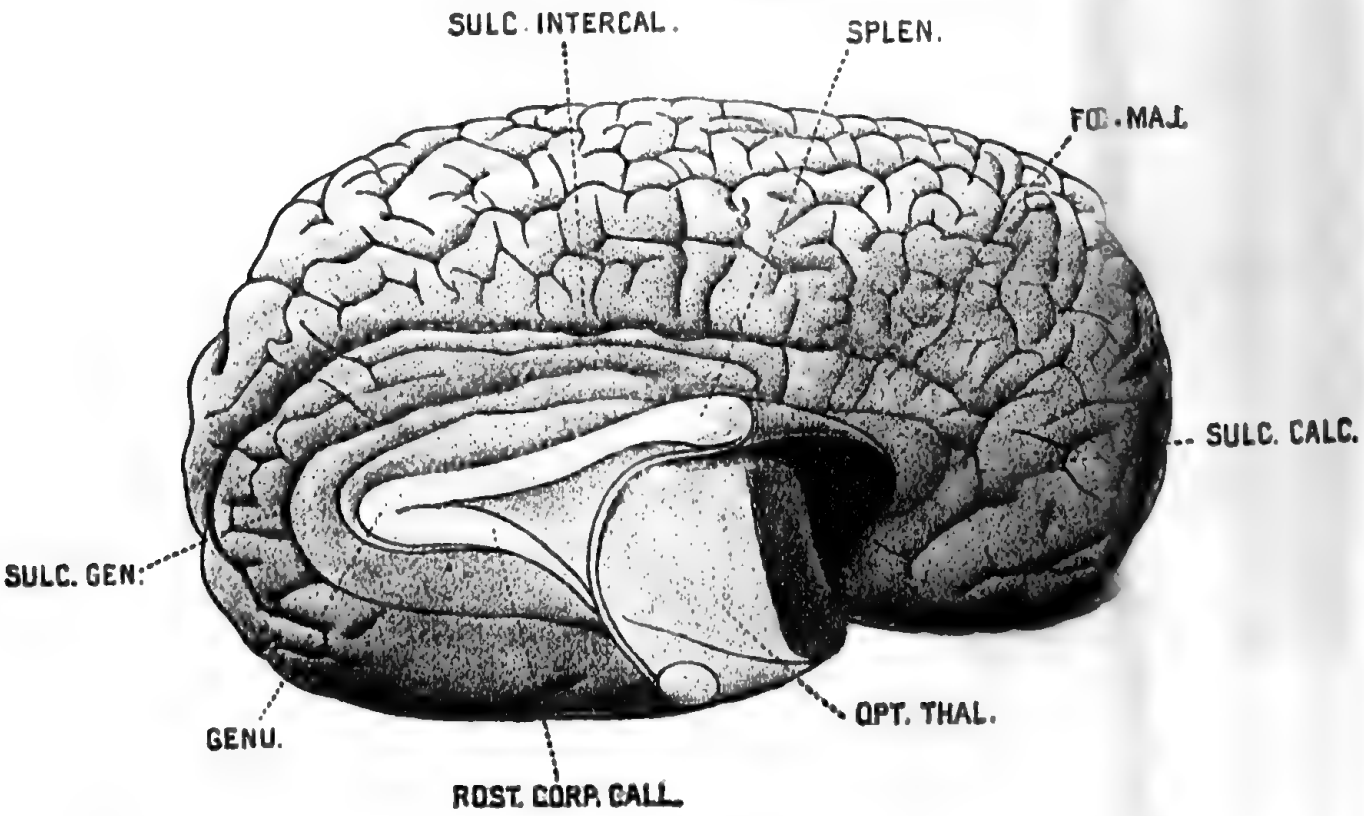

There is a very deep cingular arc formed by the united calcarine, intercalary, and what we may call the pragenual sulci (fig. 205).

Beyond this arc the irregular tangle of sulci does not permit any satisfactory analysis.

Guldberg, Forhand. Vidensk. Selsk. Christiania, 1885, p. 19.

D. 525. A cast of the cranial cavity of a young Rorqual (*Balænoptera musculus*).

D. 526 A cast of the cranial cavity of a Common Rorqual (*Balænoptera musculus*).

D. 527 A portion of the brain of a Piked Whale (*Balænoptera uto-rostrata*), "showing a fibrous texture." O. C. 1335.
Hunterian.

D. 52 A similar specimen. O. C. 1336. *Hunterian.*

These two specimens were prepared to demonstrate some emarks of Hunter's (*vide* notes, specimen D. 511).
O. C. 1337.

D. 52 A cast of the cranial cavity of an Arctic Right Whale (*Balæna mysticetus*).

D. 50. Cast of the right half of the cranial cavity of a *Megaptera*.

ORDER PRIMATES.

Suborder * PROSIMII.

Family *CHIROMYIDÆ*.

D. 31. The brain of an Aye-aye (*Daubentonia* [*Chiromys*] *madagascariensis*), divided by a mesial sagittal section (figs. 206 and 207).

Fig. 206. (Nat. size.)

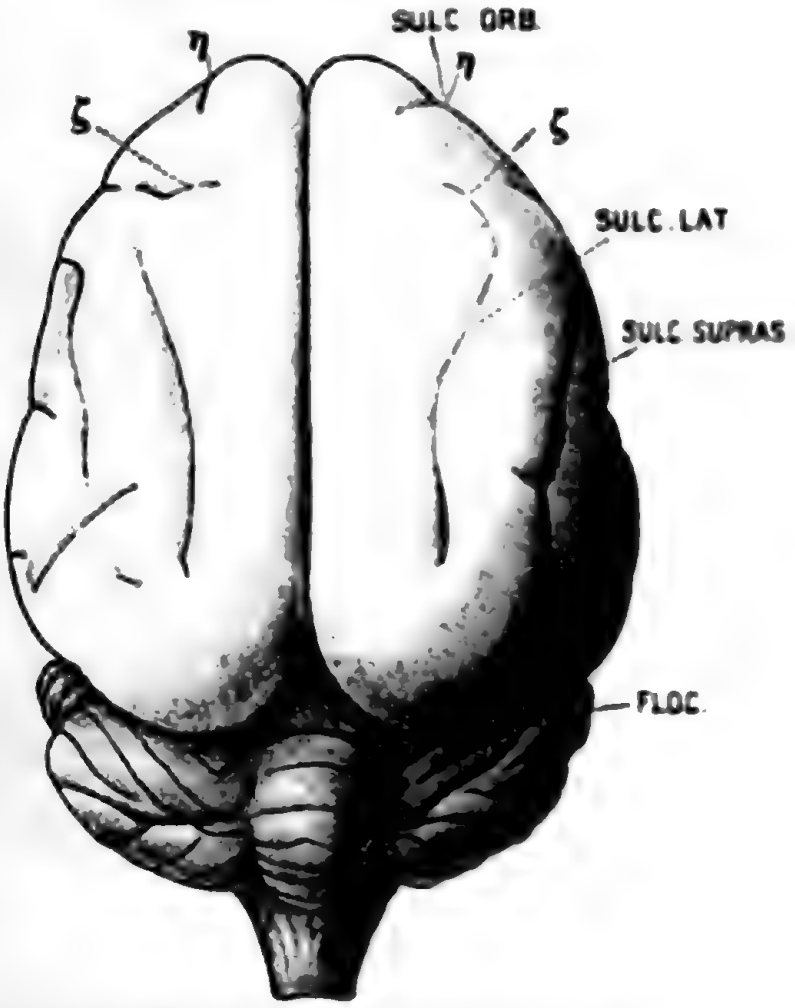

---

* See the footnote to the account of the brain of *Midas* (D. 549).

Fig. 207. (Nat. size.)

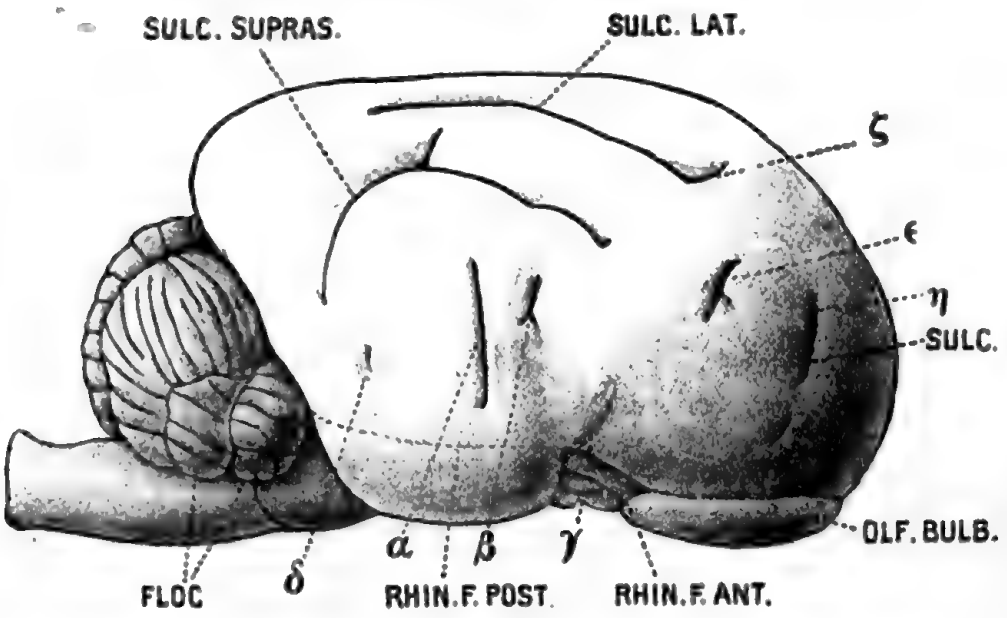

D. 532. The brain of an Aye-aye (*Daubentonia* [*Chiromys*] *madagascariensis*), split in the mesial plane and the left cerebral hemisphere separated from its half of the brain-stem (figs. 208 and 209).

Fig 208. (Nat size.)

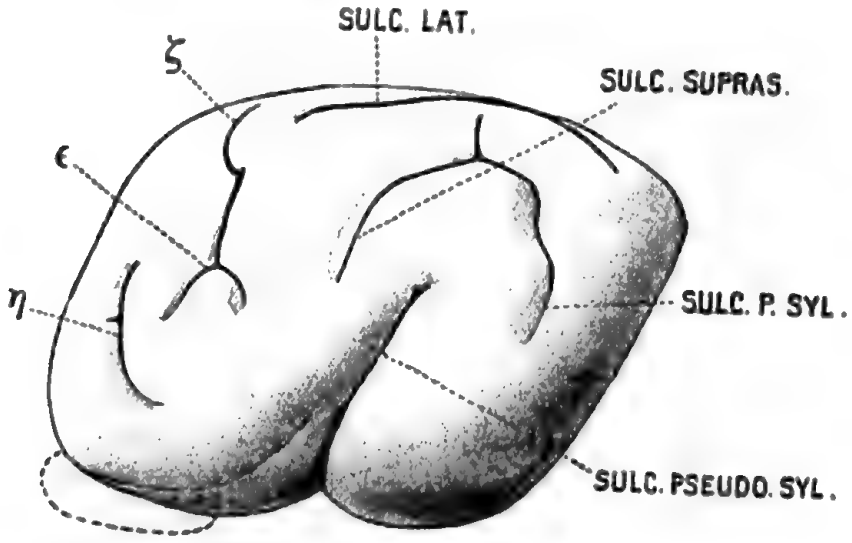

Fig. 209. (Nat. size.)

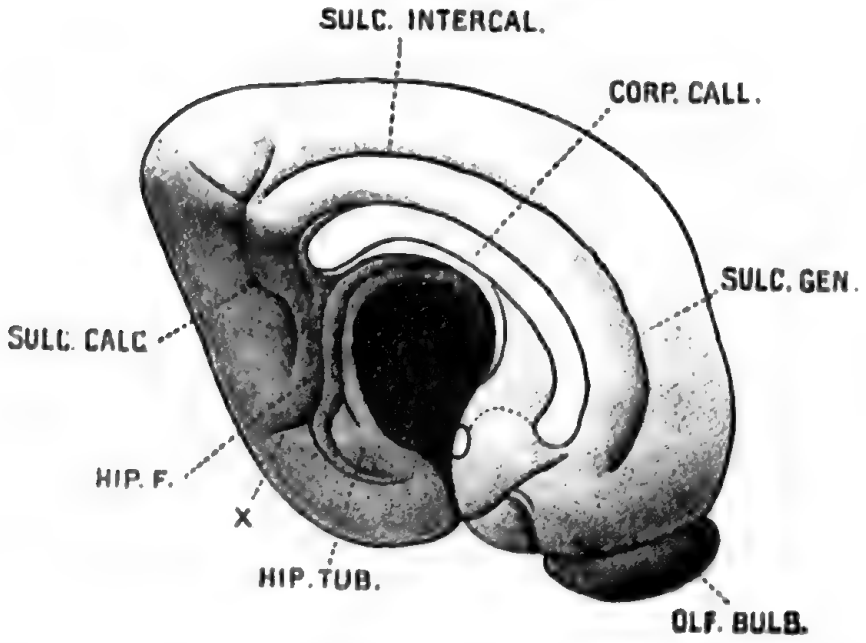

The characters of these two brains indicate the wide separation of the Aye-aye and the true Lemurs; and yet, highly specialised as the brain is in both families, that of the Aye-aye clearly exhibits features indicative of the affinity of its possessor to the Lemurs. At the same time several of the peculiarities of the brain of *Daubentonia* are unquestionably features intermediate between those of the great body of mammals and the Primates (more especially the Lemurs), and as such afford the clue to the interpretation of an exact comparison between the Primates and other mammals, which would otherwise be far less definite and sure than it is now possible to make it *.

The accounts of the Aye-aye's brain which have hitherto been published by Owen, Oudemans, and Chudzinsky, and Gervais's remarks concerning a cast of the cranial cavity, are so conflicting that one would hardly imagine that they all apply to the same species of mammal. Moreover they all seem to me to disregard the most instructive and significant features of this remarkable brain. It must, however, be admitted that the brain is subject to extreme variation in this species—a fact which emphasises the importance of those features which are constant; and fortunately the two specimens in this Collection are not unlike the only two examples of which we possess anything like an intelligible account. Specimen D. 531 might be compared with that described by Oudemans, and D. 532 with that described by Owen †.

The cerebral hemispheres completely overlap the broad, flattened olfactory bulbs, but in the caudal direction they are so short as to leave almost the whole of the cerebellum uncovered. In the latter respect they approximate to the condition found in the Carnivora and Ungulata more decidedly than do the Lemur's cerebral hemispheres.

---

[*] The fact that many of these peculiarities are undoubtedly due to retrogressive changes does not, in this particular instance, lessen their importance.

[†] I was at first inclined to believe that this old specimen, which I found only after searching through the Store-room of this Museum, had probably been stowed away there since the late Sir Richard Owen was Conservator, and might be the identical specimen described by him in the 'Transactions' of the Zoological Society. But he described and figured a dissection of his specimen, whereas this was undissected when I happened to find it. There was no note, either with the specimen or in the old manuscript catalogue, to indicate the source of this interesting brain.

The anterior poles of the hemispheres are remarkably blunt and flattened. In this respect they present a resemblance to those of the extinct Lemuroid *Megaladapis*.

The broad flattened olfactory bulbs must be considered large, even for a Prosimian brain; and the proportions of the typical olfactory tubercles and pyriform lobes are in accord with this fact. The rhinal fissure is clearly defined in its anterior part; but it becomes obliterated behind the vallecula Sylvii, so that there is no clearly defined line of demarcation between the caudal part of the pyriform lobe and the neopallium (fig. 207).

There is a relatively large corpus callosum with a plump splenium and a well-formed genu, which is linked to the anterior commissure by a delicate rostrum.

The lower extremity of the hippocampal formation exhibits that peculiar swelling of inverted hippocampus (fig. 209, HIP.TUB.) which occurs in all the Primates, and is found so well developed elsewhere, so far as I know, only in *Orycteropus* (*vide* "The Brain in the Edentata," Trans. Linn. Soc. 1899), and sometimes in the Manatee. There is also a peculiar notch-like offshoot from the hippocampal fissure just above this "hippocampal tubercle," such as is commonly found in the brains of Lemurs (compare figs. 209 and 212, x).

The condition of the "cingular" group of sulci is particularly interesting. At a casual glance the calcarine, intercalary, and genual sulci on the separate left hemisphere (fig. 209) seem to be joined to form one long "cingular" sulcus as, for instance, in the Tapir's brain. But a close examination reveals the fact that the calcarine sulcus is separated from the intercalary-genual complex (or callosomarginal sulcus, as we may now call it), as in all other Primates. But in this instance the separation is effected only by a very narrow, partially submerged gyrus. The condition of the calcarine sulcus thus exhibited (which essentially resembles not only that found in Lemurs, but also that of the Edentate *Manis*) affords yet another demonstration of the identity of the calcarine sulcus of the Primates and the vertical posterior part of the sulcus generally called "splenial" in other mammals.

By far the most significant feature of these brains of the Aye-aye is the existence of a separate suprasylvian arc. In the Carnivora and many other mammals (e. g. *Bradypus*) the suprasylvian sulcus is joined to the postsylvian (generally known as "posterior suprasylvian") to form a "supra-sylvian arc." Such an arc is generally found in the brain of *Daubentonia*, but in that of no other Primate. In all the Lemurs and Apes the suprasylvian sulcus is separated from the postsylvian (which is then called "parallel" or "superior temporal") sulcus; and the former then *appears* to be joined to the angle of the rhinal fissure by means of a shallow depression, the nearest parallel for which is to be sought in the sulcus erroneously called "Sylvian fissure" in most mammals. The latter is not the true Sylvian fissure, but a sulcus of no morphological stability, which is probably produced as a kink in the neopallium at the site of its bending. The true Sylvian fissure is a peculiar complex of many elements, which is seen in its perfect form only in the human brain. Its fundamental constituent is the suprasylvian sulcus, and in some Lemurs the "Sylvian fissure" is the suprasylvian sulcus, pure and simple. But in most Primates the dorsal lip of the suprasylvian sulcus would seem to become opercular and tends to overlap a depressed area which is also partly covered by the forwardly extending posterior opercular lip of the pseudosylvian sulcus. According to this hypothesis, the suprasylvian sulcus of non-Primate mammals is represented in the Primates by the superior limiting sulcus of the "island of Reil," which is the fundamental constituent of the complex known as the Sylvian fissure.

The great importance attaching to the brain of *Daubentonia* lies in the fact that the suprasylvian sulcus (which a comparison at once shows to be identical with the Lemurine "Sylvian fissure") is not linked to the rhinal fissure, but is joined in most cases to the postsylvian sulcus, as it is in the Carnivora and many other mammals. An interesting parallel phenomenon is found in the brain of the Great Anteater (*Myrmecophaga jubata*). In most cases the suprasylvian sulcus of this creature is completely separated from the postsylvian and joined by that suprarhinal kink, which may be called the "pseudo-sylvian fissure," to the rhinal fissure. It is therefore the rule in *Myrmecophaga* (*vide* specimens D. 282 and D. 283) to find the suprasylvian sulcus converted into a Lemuroid Sylvian fissure. But it may happen (*vide* specimen D. 281) that the suprasylvian sulcus becomes separated from the "pseudosylvian fissure" and joined to the postsylvian. This anomalous Anteater's brain, therefore, presents exactly the same relationship to the normal Anteater's brain as the brain of the Aye-Aye does to the Lemur's.

None of the various sulci which Owen, Oudemans, and Chudzinsky have labelled "Sylvian" is the true Primate "Sylvian fissure." The morphological instability of the pseudosylvian furrow (which has also been abundantly demonstrated in the Carnivora, especially in the Viverridæ) is clearly exhibited by these two specimens. In one brain (D. 532) there is a deep, well-defined sulcus extending obliquely upward from the neighbourhood of the rhinal bend, like the pseudo-sylvian fissure of a Carnivore (fig. 208). In the other brain there is no such sulcus, its place being taken by a vertical sulcus (fig. 207, α) and several shallow depressions (β and γ). A further variation in the disposition of these regions is shown by Oudeman's specimen.

There is a simple linear "lateral" (or "intraparietal," as it is called in the Primates) sulcus (fig. 206).

The interpretation of the sulci in front of the suprasylvian sulcus presents great difficulty. If we attempt to compare them with those of the Lemur's brain, we find a most marked contrast between the two brains, such as we should hardly expect to find after noting the close similarity of the mesial surfaces of the cerebral hemispheres. If, however, we compare the brain of *Daubentonia* with that of other Mammals (such as the Cat's), there would be little hesitation in labelling the great transverse sulcus (fig. 208, ζ) in front of the lateral sulcus of one brain (D. 532) "coronal." In the other specimen (D. 531) the representative of this sulcus is broken up into two fragments, the upper of which (ζ) is joined to the lateral sulcus on the right hemisphere (figs. 206 and 207), whereas the lower remains entirely independent (fig. 207, ϵ).

Such an interpretation, however, is not wholly correct because the resemblance to the Carnivore condition is largely spurious: it is not the persistence in a Primate of the common mammalian plan of sulci, but a special combination produced by profound retrogressive changes occurring in a distinctly and characteristically-Primate brain. In most of the Lemuroidea the coronal sulcus of the Ungulates and of the more generalised members of other Orders (the conjoint proreo-coronal sulcus of the Rodentia, or the union of the separated coronal and prorean elements of the Carnivora, Edentata, and Marsupialia) persists in a practically unchanged form. In the series of retrogressive modifications which the primitive Prosimian brain must have undergone to produce the condition found in the Aye-aye, the region surrounding the coronal sulcus has suffered most change, and, as these four hemispheres abundantly show, exhibits the greatest amount of variability. The correct interpretation is a matter of extreme difficulty; but a thorough study of the Prosimian brain leads me to the opinion that the coronal sulcus becomes broken up into two irregular fragments in *Daubentonia*: the anterior of these (η) usually joins the orbital sulcus. The posterior (ϵ) exhibits great irregularity in shape and in behaviour. It may join a furrow (ζ) which probably represents the crucial sulcus of other mammals, and the result is the furrow $\epsilon + \zeta$, which I believe to be identical with the sulcus centralis of the Primates. The furrows ϵ and ζ may remain separate and ζ may be linked to the lateral sulcus (fig. 207). [These views are put forward chiefly as the result of a study of the brain in the Indrisinæ, which are the nearest relations of the Aye-aye.]

Most of the other parts of the brain conform to the type presented by the great majority of mammals. But, in accordance with the relatively large dimensions of the cerebral hemispheres, the crura cerebri and pyramidal tracts are large and prominent, as in all the Primates. Moreover a definite olivary body is present.

The tuberculum acusticum and the trapezoid body are very large.

The cerebellum conforms to the simple, common mammalian type such as is presented by *Tamanduas*, for example. The details of this common fundamental plan have been demonstrated by a series of six diagrams in the case of *Cabassous* (figs. 79, 80, 82, 83, 84, and 85). The floccular lobes are built-up on the same plan in *Daubentonia*, but the dorsal part of the paraflocculus (comp. fig. 83, PARAFLOC.D.) is much the largest part of the lobe. From the anterior part of the paraflocculus a prominent "petrosal lobule" projects into a fossa in the petrous temporal.

In comparison with the simple cerebellum of *Cabassous* there is a noteworthy expansion (fig. 206) of the region labelled "area B" in this Armadillo's brain (figs. 82 and 85). Such a development also occurs in the Anteaters, Carnivores, and many other mammals.

Considered as a whole, the brain of the Aye-aye exhibits a curious blending of many of the features of the Lemur's brain and those of most non-Primate mammals, and more especially those of the Sloths, Anteaters, and Pangolins.

Oudemans, Nat. Verh. Akad. Amsterdam, 1890, p. 26.

Chudzinsky, Bull. Soc. d'Anthrop., t. vii. 1896, p. 12.

Family *LEMURIDÆ*.

D. 533. The brain of a Ruffed Lemur (*Lemur varius*), (♀) (figs. 210, 211, 212 & 213).

The brain of the Lemurs is of great interest in that it exhibits features which undoubtedly indicate its genetic affinity to the brain of the Apes, and at the same time shows characters which allow an accurate comparison to be instituted with the organ of *Daubentonia* and of the lowlier mammalian Orders [*]. As in *Daubentonia*, the cerebellum is almost wholly uncovered in the adult.

---

[*] By this I do not mean to imply that the Lemurs, or even *Daubentonia*, are primitive types (because there is much to suggest that they are to some extent reversionary); but they certainly permit accurate comparisons to be instituted with the lowlier mammals more readily than do the Anthropoidea.

The mesial surface of the brain exhibits features—corpus callosum, hippocampus, hippocampal fissure, the bifurcated calcarine sulcus, and the separate intercalary sulcus—the almost exact parallel of which is exhibited by the brain of the Aye-aye (compare figs. 212 and 209).

Fig. 210. (Nat. size.)

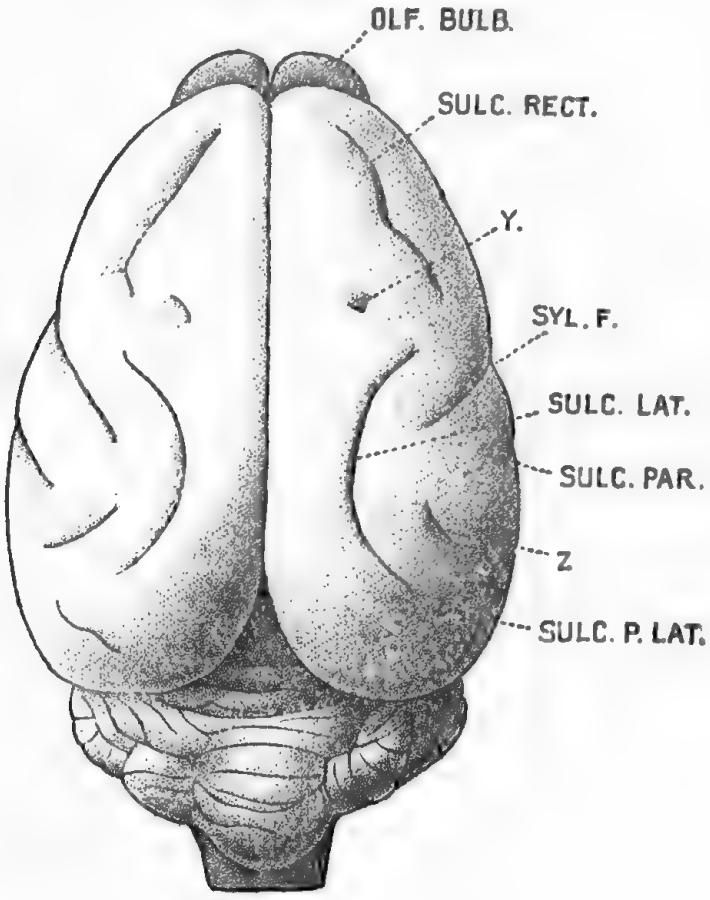

Fig. 211. (Nat. size.)

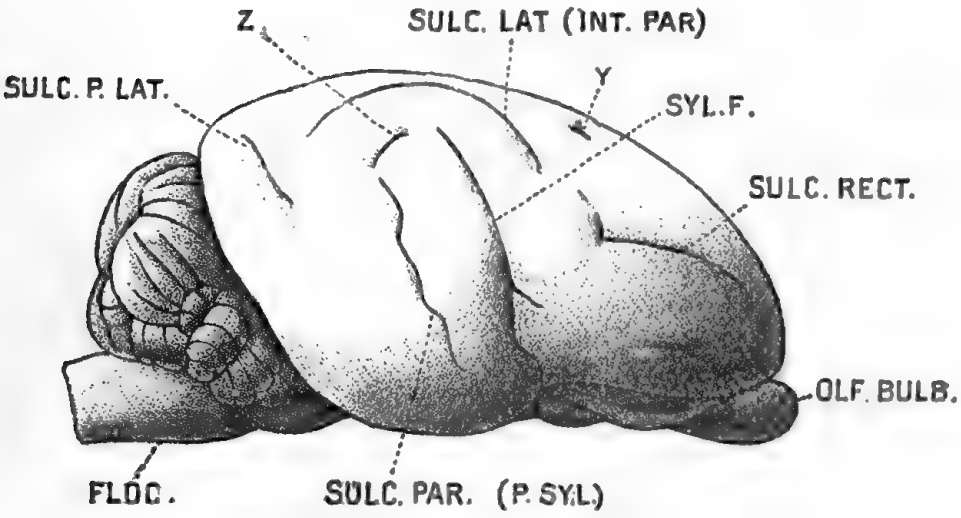

Upon the external aspect of the hemisphere there is an interesting modification of the primitive type represented by *Daubentonia* (in common with most mammals, such as the Carnivora, Ungulata, and the Sloths). In the latter the suprasylvian and postsylvian sulci are joined to form one arc, whereas in the Primates there is a complete separation of the postsylvian sulcus from the suprasylvian, and the conversion of the latter into the Primate or true Sylvian fissure. The separate postsylvian sulcus (see the left hemisphere of D. 531) is clearly the representative of the "parallel sulcus" of Human Anatomy. And the suprasylvian sulcus, which has absorbed, or become merged in, certain inconstant kinks above the bend of the rhinal fissure which in the Carnivora and Ungulata would be called "Sylvian fissure," now becomes the true "Sylvian fissure."

Fig. 212. (Nat. size.)

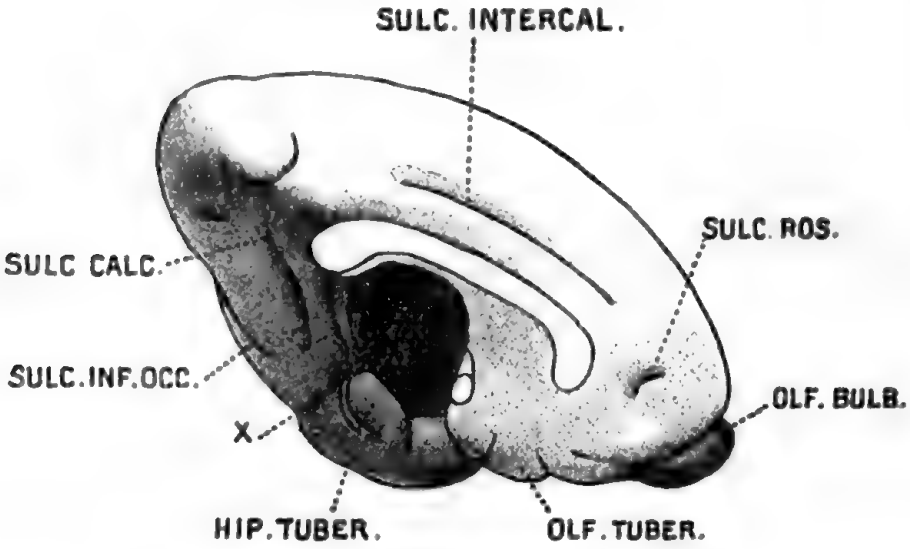

Fig. 213. (Slightly enlarged.)

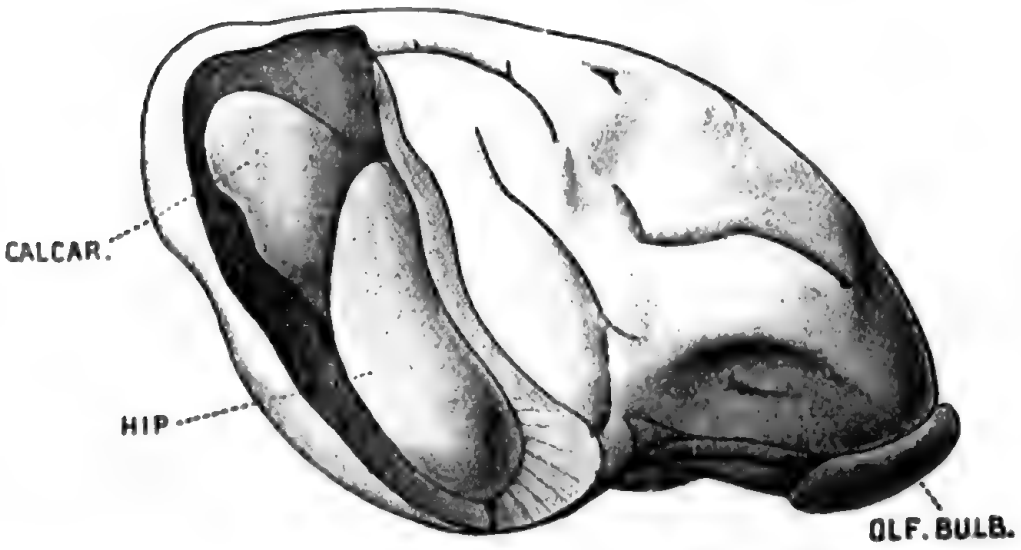

This process of blending of suprasylvian sulcus and what may be called the "feline Sylvian fissure," will be the better appreciated if the reader studies the varied analogous phenomena exhibited by *Myrmecophaga* (*vide supra*), *Dolichotis* (*vide supra*), and (in a different manner) the Seals (*vide supra*). In the case of the Lemurs the ventral parts of this Sylvian fissure may be absent so that it does not join the rhinal fissure and is practically the homologue of the suprasylvian sulcus, pure and simple (fig. 213). In other cases the lower part of the Sylvian fissure is shallow, and at the point where the shallow part ("feline Sylvian") joins the deep part (suprasylvian) the lower extremity of the suprasylvian sulcus may be seen emerging so as to cut into the anterior lip of the fissure. [It is only right to inform the reader that these views are here put forward for the first time, and are in direct conflict with the usual teaching.]

The lateral (intraparietal) sulcus forms an arc around the Sylvian fissure, as it does in *Daubentonia*. Behind it there is a small postlateral or, as we now should probably call it, "transverse occipital" sulcus.

The crucial sulcus of the Carnivora is apparently represented by a small pit on the dorsal surface (figs. 210 and 211, Y), which may perhaps be regarded as the first rudiment of the sulcus centralis (Rolandi) of the Primates*.

The intrepretation of a well-marked sagittal sulcus on the dorso-lateral aspect of the front part of the hemisphere raises a question of great difficulty. For reasons which cannot be stated in full here (but which will be apparent if the reader refers to the brains of *Procavia* and *Viverra*), this furrow (SULC. RECT.) is almost certainly the coronal.

On the other hand, it is regarded as the representative of the sulcus rectus of the Apes, which in turn is considered by Eberstaller and many others as the homologue of the sulcus frontalis medius, and by Cunningham as the sulcus frontalis inferior. If the tendencies which are to be noted in the evolution of the lowlier Primate brain continue to exercise their influence in the Anthropoidea (and in this matter they unquestionably do), there can be little doubt as to the accuracy of Cunningham's interpretation †.

---

* It is difficult to be otherwise than sceptical concerning the suggestion of this being sulcus centralis, although it occupies the position where we find the earliest rudiment of the central sulcus in the Cebidæ. The only other sulcus it can possibly be is the ramus postcentralis superior of the intraparietal sulcus. A careful study of the whole series of Primate brains, however, seems to point to the conclusion that the sulcus Y represents the upper part of the sulcus of Rolando.

† The sulcus in question probably represents the conjoint sulci rectus (inferior frontal) and arcuatus (inferior precentral) of the Apes.

In this particular brain the orbital sulcus appears to be almost, if not completely, aborted.

The right cerebral hemisphere has been dissected so as to expose the hippocampus (major) as a vertical column. Behind and above its upper end is the obverse of the calcarine sulcus, *i. e.* the calcar avis (so-called "hippocampus minor"). Nothing points the contrast between Lemurs and Apes so forcibly as a comparison of these structures with those exposed in the brain of *Hapale* (D. 553). Figures 210 and 211 represent the condition of this specimen before the dissection was made.

There is *no* posterior horn of the ventricle in the Lemur, and the dissection shown in fig. 213 was effected only by separating from the surface of the eminence labelled "calcar" a mass of adherent medullary matter.

The features of most of the other parts of the brain resemble, like those of *Daubentonia*, the type which prevails in such forms as the Edentata, Rodentia, Insectivora, and Chiroptera. O. C. 1337 A.

T. Ziehen, Arch. f. Psych., Bd. xxviii. 1896, p. 913.

D. 534. The brain of a Black-faced Lemur (*Lemur nigrifrons*).

In this brain the lateral and postlateral sulci are united to form the complete intraparietal sulcus. The anterior extremity of this sulcus is almost (and in the left hemisphere quite) confluent with the sulcus rectus.

The anterior rhinal fissure is faintly indicated, and external to it there is a small representative of the orbital (presylvian) sulcus. A small sulcus makes its appearance between the orbital sulcus and the Sylvian fissure in the brain of some Lemurs. It probably represents the fronto-orbital sulcus of the Apes and the diagonal sulcus of other mammals.

A comparison of the brains of a number of Lemurs shows a series of short sulci in the interval between the dorsal ends of the Sylvian (suprasylvian) and parallel (postsylvian) sulci. They may be joined to either of these sulci, and add further testimony to their original connection as a single suprasylvian arc, as in *Daubentonia* and most non-Primate mammals. [The specimens of *Myrmecophaga* are especially instructive in regard to this point.]

The form which the calcarine sulcus has assumed in this brain may raise some doubt whether the anterior limb of the calcarine sulcus should not be regarded as the strict homologue of the parieto-occipital sulcus of the Anthropoidea. It must be admitted that the length of the upper limb of the Y, its wide separation from the other postcalcarine limb, and its relation (on the dorsal surface) to the intraparietal sulcus (especially on the right hemisphere), closely simulate the corresponding relations of the parieto-occipital sulcus in the Apes. Its wide separation from the intercalary (calloso-marginal) sulcus serves to accentuate the likeness.

When the cerebral hemisphere begins to extend into a caudal or occipital process, as it does in the Lemurs, and to a much more pronounced degree in the Anthropoidea, the calcarine sulcus assumes an increasingly oblique position and blends with certain postcalcarine elements (which occur in most mammalian Orders). These postcalcarine elements are morphologically very unstable and inconstant in their arrangement (compare the larger Carnivores and Ungulates, and also the Apes), and tend to adapt themselves solely to the mechanical conditions which prevail. Thus in the Carnivora they are generally parallel to the calcarine, because the tendency to caudal extension is restrained : in the Primates this is not so, and the sulcus runs in the long axis of the occipital diverticulum (compare *Midas* or *Hapale*). But in many forms (compare *Manis* and *Daubentonia*) a second element, simulating the parieto-occipital of higher forms, develops to relieve the tension of the growing cortex in that region, which is accommodated in most mammals by the fusion of the calcarine and intercalary sulci. The condition found in *Daubentonia* makes it abundantly clear that this is so ; and we can have no hesitation in regarding the state of affairs in the Lemurs as essentially identical with that of the Aye-aye, however closely the former may simulate the condition sometimes found in the human brain. But just as we know that the occasional blending of parieto-occipital and calcarine sulci in the human brain is quite a secondary development, so also the series of Anthropoidean brains in this collection clearly shows that the parieto-occipital sulcus makes its first appearance in the Cebidæ as a sulcus obviously compensatory to an already Y-shaped calcarine complex. Moreover there is no parallel anywhere in the Anthropoidea for a Y-shaped complex of calcarine and parieto-occipital sulci except occasionally in the human brain. If, however, it be urged that the Lemurs are reversionary forms, which are not strictly comparable with the lowlier Apes, it remains to be explained how *Daubentonia* and *Manis* (the calcarine sulci of which are essentially identical with those of the Lemurs) came to assume the form they present *. O. C. 1337 A *b*.

W. H. Flower, Phil. Trans. vol. clii. 1862, p. 195.

D. 535. The brain of a Black-faced Lemur (*Lemur nigrifrons*), from which almost the whole of the right cerebral hemisphere and a considerable part of the left have been removed. In the left hemisphere the whole of the ventricular surface of the hippocampus [major] has been exposed, and a purely artificial posterior cornu of the lateral ventricle has been made. The latter and the calcar avis lying in it are seen to be relatively smaller than the corresponding parts in many of the Cebidæ.

The small oblique optic thalami and the typical corpora quadrigemina are exposed. On the right side, the whole extent of the large optic tract and prominent external (anterior) geniculate body are clearly demonstrated.

There is a large projecting mesial (posterior) geniculate body and a very prominent tractus peduncularis transversus.

The features of the typically simple cerebellum, which resembles that of the Viverridæ and Sloths and many other lowly mammals, stand out very distinctly.

O. C. 1337 A *c*.

Flower, Phil. Trans. vol. clii. 1862, p. 195.

---

* Further investigations (made since this was written) have convinced me that the apparent anterior limb of the Y-shaped calcarine group of sulci represents the more ventral of the two elements of which the true Simian parieto-occipital sulcus (*vide infra*) is composed.

D. 536. The brain of a Ring-tailed Lemur (*Lemur catta*), in which the left hemisphere has been separated from the rest of the brain.

The deficiency of the lower end of the Sylvian fissure is clearly shown.

The composite character of the Sylvian fissure is well-demonstrated in the left hemisphere of this specimen. The lower extremity of the suprasylvian sulcus emerges from the Sylvian complex.

The peculiar hook-like appendage of the upper extremity of the Sylvian fissure is also another reminder of the relationship of the suprasylvian (Sylvian) sulcus to the postsylvian (parallel), such as we have also seen elsewhere in *Myrmecophaga* (Edentata). O. C. 1337 A *d*.

D. 537. The brain of a young Ring-tailed Lemur (*Lemur catta*). The left cerebral hemisphere has been separated.

In this specimen there is no trace of a separate suprasylvian element in the Sylvian fissure such as the last specimen exhibited. The Sylvian is a straight, unbroken fissure passing below into a deep cleft-like vallecula Sylvii such as is found in the Apes. The upper extremity of the Sylvian fissure is not hook-like, but the short sulcus (which in the last specimen gave rise to the hook) is seen here in the interval between the upper ends of the parallel and Sylvian elements. O. C. 1337 A *a*.

Presented by J. Wiblin, Esq.

D. 538. The brain of a Mongoose-Lemur (*Lemur mongoz*).

Bristles have been inserted in the several cranial nerves.

In this brain a small sulcus, such as that tentatively called "fronto-orbital," is present. O. C. 9.

Hunterian.

D. 539. The brain of a White-faced Lemur (*Lemur albifrons*), with its left cerebral hemisphere separate.

The parallel sulcus of the left hemisphere of this brain is interesting in comparison with those of the Ring-tailed Lemur, for its upper extremity is hooked forward, *i. e.*

the intermediate sulcus, which is joined to the Sylvian in D. 536, is here joined to the parallel sulcus.

O. C. 1337 A *g*.

D. 540. Two casts of the cranial cavity of a Lemur (*Lemur macaco*).

This shows in an admirable manner the exact shape and relations of the cerebral hemispheres, olfactory bulbs, and the cerebellum. We can also distinctly see deep grooves produced by the Sylvian and posterior rhinal fissures, the intraparietal, parallel, and coronal ("rectus") sulci, and also the small sulcus tentatively called "central."

D. 541. The brain of a Great Galago (*Galago crassicaudata*), of which the left hemisphere is separate.

The rhinal and Sylvian fissures present the characteristic features.

There is a typical intraparietal sulcus, but its postlateral (transverse occipital) elements are fragmentary and separate.

The parallel sulcus is represented merely by a short shallow furrow.

There is a typical orbital sulcus and a sulcus rectus which approaches near to the intraparietal. There is no sign of a separate "central" sulcus, except a shallow depression above the sulcus rectus.

O. C. 1337 B *a*.

F. E. Beddard, Proc. Zool. Soc. 1895, p. 146.

D. 542. The brain of a Garnett's Galago (*Galago garnetti*) (figs. 214 and 215). Though only slightly smaller than the other brain of a *Galago*, this specimen exhibits in comparison with the latter a pronounced paucity of sulci. It also serves to demonstrate how great a change has taken place in the occipital regions of the brain. When compared

Fig. 214. (Nat. size.)

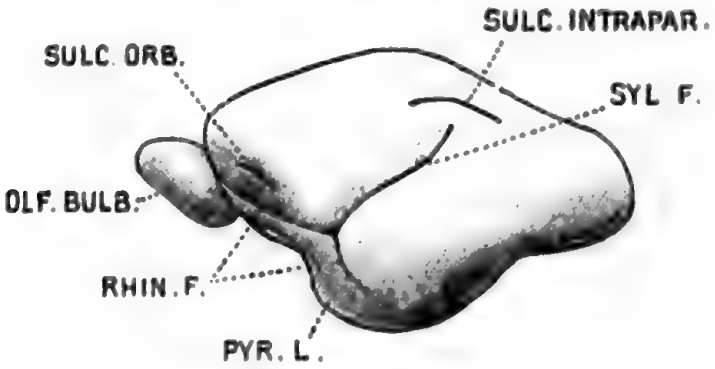

with that of *Daubentonia*, which presents a blunt occipital pole, like that of a Dog's brain, the contrast exhibited by *Galago*, in which the occipital pole approaches the condition found in the Marmosets, is very striking.

There are typically complete rhinal and Sylvian fissures, a short rectilinear intraparietal sulcus, and a short orbital sulcus alongside the anterior rhinal fissure (fig. 214). In the place of the sulcus rectus and the parallel sulcus very faint depressions are found.

Fig. 215. (Nat. size.)

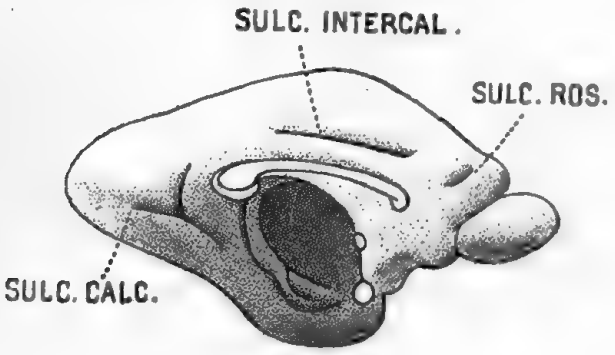

On the mesial surface the typical Lemurine calcarine and intercalary (calloso-marginal) sulci are found (fig. 215).

There is a considerable depressed area in the lower part of the Sylvian fissure. It is chiefly covered by a temporal operculum. O. C. 1337 B *b*.

Th. Ziehen, Arch. f. Psych., Bd. xxviii. 1896, p. 910.

D. 543. The brain of a Smith's Dwarf-Lemur (*Microcebus smithii*), (♀).

In this diminutive brain the sulci are few in number. On the external surface, in addition to the Sylvian fissure, there is a small sulcus rectus on the right side and a shallow depression which may be the posterior rhinal fissure (incisura temporalis of Human Anatomy).

There is a typical calcarine sulcus with the usual Lemurine dorsal bifurcation. There is neither an intercalary nor a genual sulcus.

It is interesting to compare this brain with that of the peculiar little aberrant Prosimian *Tarsius**, which possesses

---

* There is no brain of *Tarsius* in this Collection. For the opportunity of examining several excellently-preserved specimens I am indebted to Dr. Charles Hose of Borneo.

only the Sylvian fissure and the calcarine group of furrows. This fact indicates the increased morphological stability of the Sylvian and calcarine sulci in the Family Lemuridæ.

O. C. 1337 A *f.*

D. 544. A cast of the cranial cavity of an extinct sub-fossil Lemuroid (*Globilemur flacourti*).

The brain of this extinct Lemurid is much larger and its hemispheres very much richer in sulci than that of any Lemur.

Fig. 216. ($\times \frac{2}{3}$.)

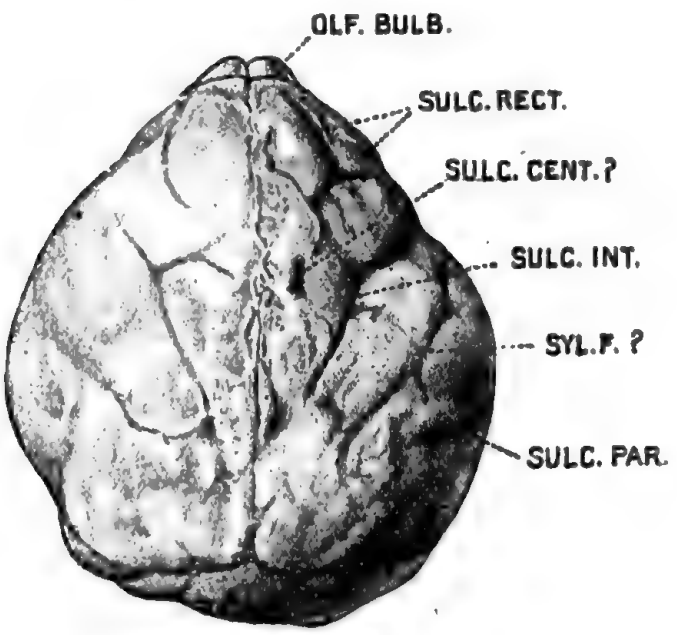

Fig. 217. ($\times \frac{2}{3}$.)

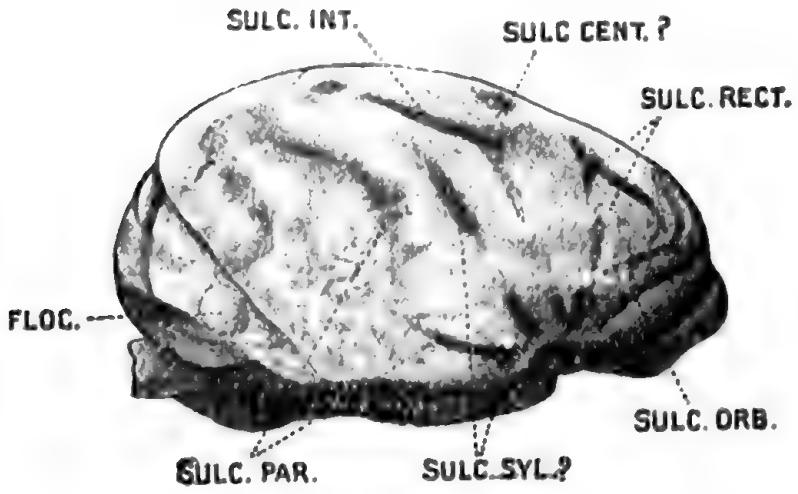

Its "form approaches most to that of the smallest members of the Family (Lemuridæ), viz. *Microcebus*, both being broad in their posterior moiety and suddenly attenuated anteriorly. . . . In the arrangement of its convolutions the fossil departs from the Lemurid and approaches the Cebidæ and the Cercopithecidæ."

It is extremely difficult to accurately determine the pattern formed by the numerous sulci which indent the neopallium. But we can certainly say that, however we interpret such sulci as can be mapped out (figs. 216 and 217), their arrangement differs considerably from that of the Lemurs and Apes. In the accompanying drawings, a tentative interpretation of the sulci is attempted.

Dr. Forsyth Major, Proc. Roy. Soc. vol. lxii. 1898, p. 46.

D. 545. A cast of the cranial cavity of an extinct Lemuroid (*Megaladapis madagascariensis*).

The general appearance of this brain is not unlike that of *Daubentonia*, but the olfactory bulbs appear to be borne on long stalks, a part only of which is represented in this cast as a prominent rostrum.

Fig. 218. (× $\frac{2}{3}$.)

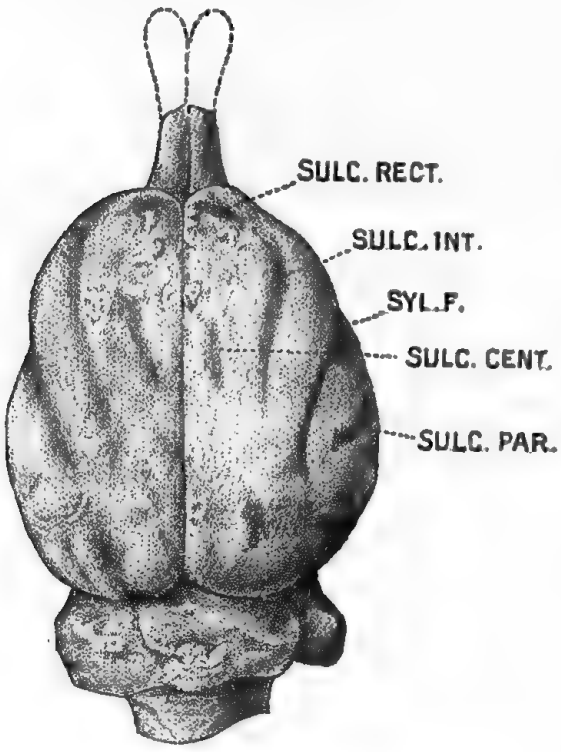

Fig. 219. (× $\frac{2}{3}$.)

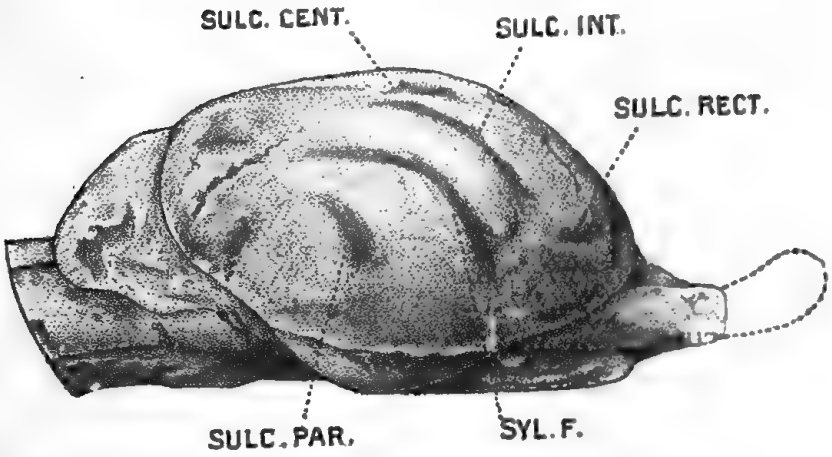

As Dr. Forsyth Major has clearly and decisively demonstrated, the optic nerves enter the cranium in a situation extraordinarily far forward. The pattern formed by the cerebral sulci, however, closely follows that of the other Lemuridæ.

These peculiar modifications are the result of retrogressive changes which occur partly in the ontogeny of every individual, as a result of which the brain becomes actually smaller in the adult than it is in the young animal.

Forsyth Major, Proc. Roy. Soc. vol. lxii. 1898, p. 47.

D. 546. The brain of a Slender Loris (*Loris gracilis*).

This brain resembles that of the Lemur.

The rhinal fissure is distinct in front, but rapidly becomes indistinct on the caudal side of the vallecula Sylvii.

The usual Lemurine forms of the Sylvian fissure, the intraparietal and the parallel sulci are present. The interesting relationship between the upper extremities of the Sylvian fissure and the parallel sulcus, noted in the Lemurs proper, is also found here.

The mesial surface shows the typical Lemurine features.

Ziehen, Arch. f. Psych., Bd. xxviii. 1896, p. 908.

O. C. 1337 A *h*.

D. 547. The brain of a Potto (*Perodicticus potto*) (fig. 220).

[Although this brain is presumably that described by Ziehen (*op. cit.* 1896, p. 901), the fig. 3 of his memoir can hardly be regarded as an accurate representation of this specimen.]

Fig. 220. (Nat. size.)

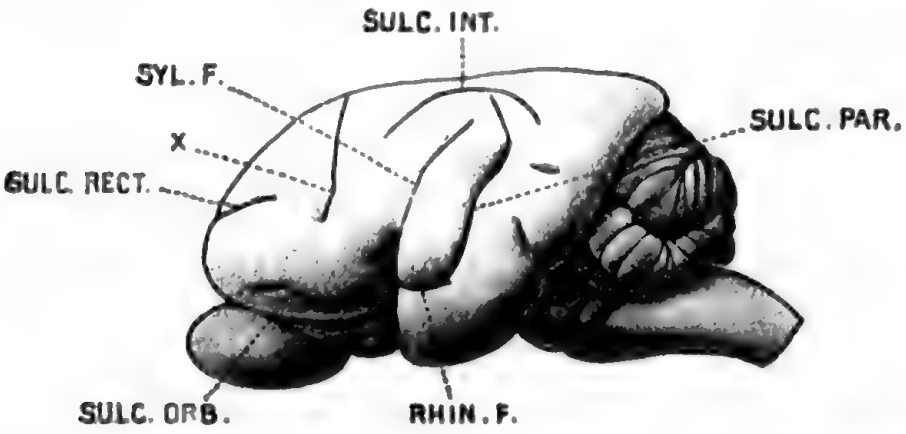

The excellent preservation of the olfactory bulb and its cerebral appendages enables us to appreciate the large [for a Primate] size of these olfactory regions of the brain, and how closely they resemble the corresponding regions in other mammalian Orders.

The rhinal fissure is very distinct and can be seen crossing the vallecula Sylvii to become the posterior rhinal. The latter soon ends near the parallel sulcus, with the lower end of which it appears to become continuous. The Sylvian fissure and the intraparietal sulcus are like those of the Lemur. The upper extremity of the parallel sulcus curves forward so as almost to join the upper end of the Sylvian fissure, as sometimes occurs in the Lemur.

There is a short arcuate sulcus rectus and, between it and the Sylvian fissure, a sulcus (x) closely resembling the central sulcus of the Anthropoidea. There is no conclusive evidence to enable us to determine the homology of this sulcus, which often makes its appearance in the Lemurs, in *Propithecus* (occasionally), and in *Daubentonia* *. There is a well-marked orbital sulcus. The lower extremity of the fascia dentata is distinctly seen on the base of the brain on each side of the tuber cinereum; and the projections of the posterior part of the pyriform lobe which Gustav Retzius calls gyrus lunaris and gyrus ambiens are very prominent. The structure which Retzius calls "gyrus lunaris" is not a cortical formation, but is merely the surface of the nucleus amygdalæ and ought to be so called.

O. C. 1337 B.

D. 548. The brain of a Javan Slow-Loris (*Nycticebus tardigradus*) (fig. 221).

Fig. 221. (Nat. size.)

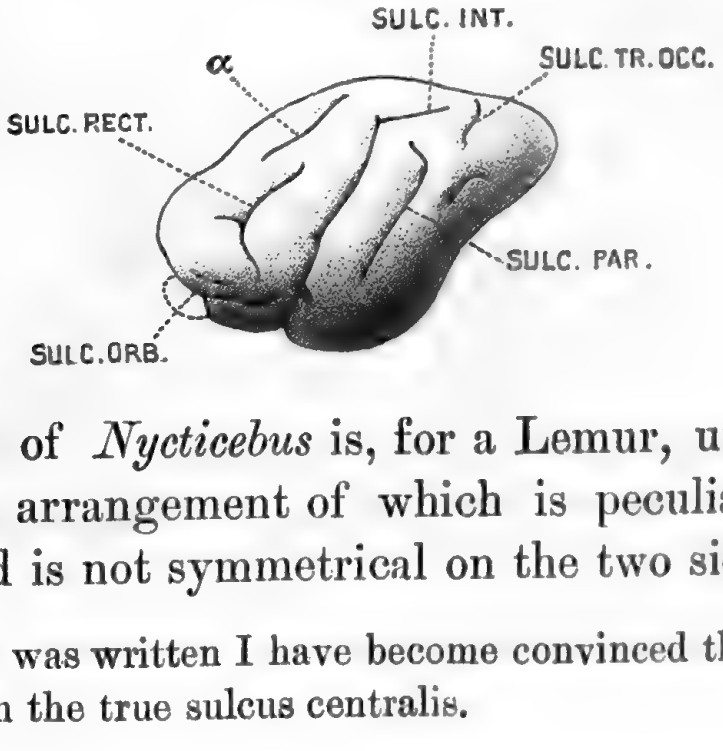

The brain of *Nycticebus* is, for a Lemur, unusually rich in sulci, the arrangement of which is peculiar in several respects, and is not symmetrical on the two sides.

* Since the above was written I have become convinced that the furrow x can be no other than the true sulcus centralis.

There is a clearly defined rhinal fissure from the bend of which the Sylvian fissure ascends obliquely. The Sylvian fissure is concurrent with the intraparietal, as in the brain of *Chrysothrix*. This "suprasylvio-lateral" fusion is of interest as a further extension of that process which results in the formation of the Sylvian fissure of the Primates by a blending of the suprasylvian and the inconstant suprarhinal kinks (pseudosylvian fissure).

There is an extensive parallel sulcus behind the Sylvio-intraparietal complex, and fragments representing an inferior temporal sulcus behind and below the parallel.

In front of the Sylvian fissure we find the following sulci in order from below upward:—the almost sagittally directed orbital close to the olfactory peduncle, a triradiate sulcus rectus, and then another sagittal sulcus (of very doubtful homology) nearer the mesial plane (fig. 221, *a*). It often happens, however, in the Apes that when the Sylvian and intraparietal elements fuse, an accessory intra-parietal sulcus makes its appearance in a position analogous to that occupied by this sulcus.

On the left hemisphere the posterior part of the intraparietal sulcus is separated from the rest. The parallel sulcus is not bifurcated as it is on the right side.

On the mesial surface the two limbs of the calcarine are so large as to simulate the parieto-occipital and post-calcarine (posterior calcarine) sulci of the Anthropoidea. There is a short intercalary sulcus and also a small and faintly marked rostral sulcus.

There is a deep notch on the ventro-caudal margin of the hemisphere (not only in this brain but in most Lemurid brains), for the true interpretation of which we must examine a series of Ape-brains. It will then be found to represent a compensatory sulcus, the place of which is taken in a higher phase of development by the collateral and inferior occipital sulci, to which in the highest Apes we may add the occipito-temporal. It cannot, however, be strictly said to represent any one of these three sulci exclusively. **O. C. 1337 B *c*.**

Th. Ziehen, Arch. f. Psych., Bd. xxviii. 1896, p. 905.

Suborder ANTHROPOIDEA.

Family *HAPALIDÆ.*

D. 549. The brain of a Pinche Monkey or Tamarin (*Midas œdipus*), (♂), (fig. 222).

With this specimen we enter on the account of the brain in that higher division of the Primates known as the Suborder Anthropoidea *. Although the brain may be smaller than that of many Lemurs, its proportions are different, inasmuch as the occipital parts of the cerebral hemispheres overlap the cerebellum to a distinctly greater extent than is the case in the brains of the Lemuroidea. This character reaches its greatest degree in a member of the Family Cebidæ, viz., in *Chrysothrix*, in which it is developed to an extent unsurpassed even in Man.

Fig. 222. (Nat. size.)

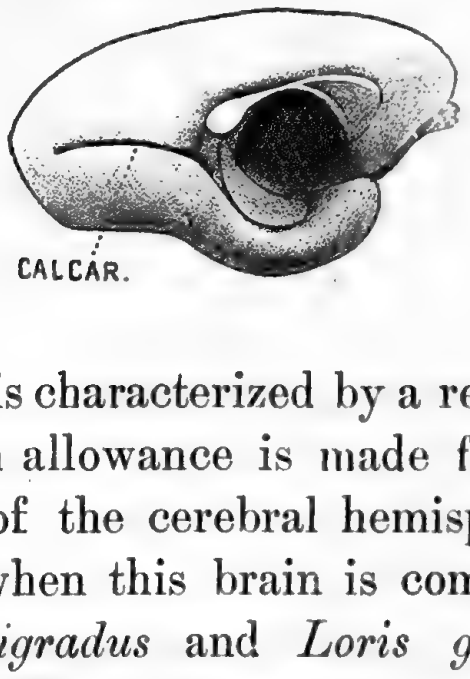

This small brain is characterized by a remarkable poverty of sulci, even when allowance is made for the absolutely small dimensions of the cerebral hemisphere, as will be better understood when this brain is compared with those of *Nycticebus tardigradus* and *Loris gracilis*, which it resembles in size. The Sylvian fissure commences below in a Sylvian vallecula which is so fissure-like that the distinction between vallecula and fissure would be unjustifiable, but for the fact that the limits of the two are marked by the postsylvian part of the rhinal fissure. The latter is

---

* The separation of the Lemuroidea from the other Primates as a separate suborder is certainly not justified by the evidence of cerebral anatomy, as there is a very close affinity between the brain-type of the Lemurs and the Cebidæ.

visible crossing the lower part of the temporal lobe very much as it does in Lemuroidea. (The posterior rhinal fissure, however, is placed relatively much nearer the mesial surface than it is in the Lemurs.)

The Sylvian fissure runs up and backwards across the hemisphere, pursuing a much more oblique course than in the Lemuroidea. In this brain there appears to be absolutely no sulcus in the position of the intraparietal of the Lemuroidea (note, however, the difference from *Hapale penicillata* in this respect); but a very faintly-marked depression is seen about the spot at which the intraparietal sulcus might be expected to give off its terminal offshoot posteriorly. The only other sulci on this surface are a short but distinct parallel sulcus and an indistinct orbital.

The hippocampal fissure presents those features which are common to all placental mammals. The calcarine sulcus is prolonged far back into the elongated occipital pole as a simple linear furrow without any trace of bifurcation.

The olfactory parts of the brain exhibit a most pronounced diminution in size when compared with the corresponding regions in the Lemurs and other mammals.

There is a noteworthy reduction in the size of the floccular lobes, and the cerebellum itself, although still simple, exhibits a greater lateral expansion. O. C. 1337 c.

For a general survey of the literature relating to the brain in the Anthropoidea, see Kükenthal and Ziehen (Jenaische Zeitsch. f. Naturwiss., Bd. xxix. 1895, p. 1).

D. 550. The brain of a Black-eared Marmoset (*Hapale penicillata*).

The description of the preceding specimen applies in almost every detail to this. A short intraparietal sulcus, however, is visible in the right hemisphere; the Sylvian fissure turns slightly backwards at its upper end; on the orbital surface there is merely a depression and no orbital sulcus, and on the mesial aspect there is a short calloso-marginal (intercalary) sulcus. The olfactory bulbs and peduncles are preserved in this specimen. The anterior part of the pyriform lobe is slender, and the anterior rhinal fissure by which it is bounded becomes much fainter as the Sylvian vallecula is approached. O. C. 1337 c *a.*

Presented by C. E. Flower, Esq.

D. 551. The brain of a Black-eared Marmoset (*Hapale penicillata*). The left hemisphere has been separated.

This is a more carefully-preserved specimen than any of the others, and not only are all parts of the brain preserved intact, but they all retain their natural shapes.

Thus the true proportions of the small ellipsoidal olfactory bulb and its exceedingly delicate ribbon-like peduncle can be appreciated. The (external) olfactory tract is very distinct (as, in fact, is the case in all Anthropoidea), pursuing its backward course in the olfactory peduncle, then skirting the lateral edge of the tuberculum olfactorium (which is still recognisable as such, in spite of its diminutive proportions), and finally disappearing in the vallecula Sylvii to reach the posterior part of the pyriform lobe. The rhinal fissure indicates the lateral boundary of the latter.

It is a peculiarity of all the Anthropoidea that these olfactory areas of the brain are greatly reduced in comparison with those of other Mammals. For in Man and Monkeys the sense of smell loses the predominant rôle which it exercises in most other (non-aquatic) Mammals. The Sylvian fissure, the simple orbital, parallel, calcarine, and the faint trace of the calloso-marginal sulci need only be mentioned. There is, however, an oblique sulcus on the ventral surface, which probably represents the collateral sulcus.

The features of the corpus callosum, the diminutive psalterium, the anterior commissure, the lamina terminalis, the optic chiasma, and the cerebellum are beautifully demonstrated in this specimen.

D. 552. The brain of a Common Marmoset (*Hapale jacchus*).

The intraparietal sulcus is absent (or possibly represented by an almost imperceptible depression in the left hemisphere); the parallel sulcus is very faint; and on the mesial aspect there is a sulcus in a corresponding position to that tentatively called inferior occipital or collateral in the Lemurs. There is also a depression in a position that might be occupied by the extreme hinder end of the calloso-marginal sulcus. O. C. 1337 c *b*.

D. 553. The brain of a Marmoset (*Hapale jacchus*) (fig. 223).

A dissection has been made in the left cerebral hemisphere to open up the descending and posterior cornua of the lateral ventricle.

Fig. 223.

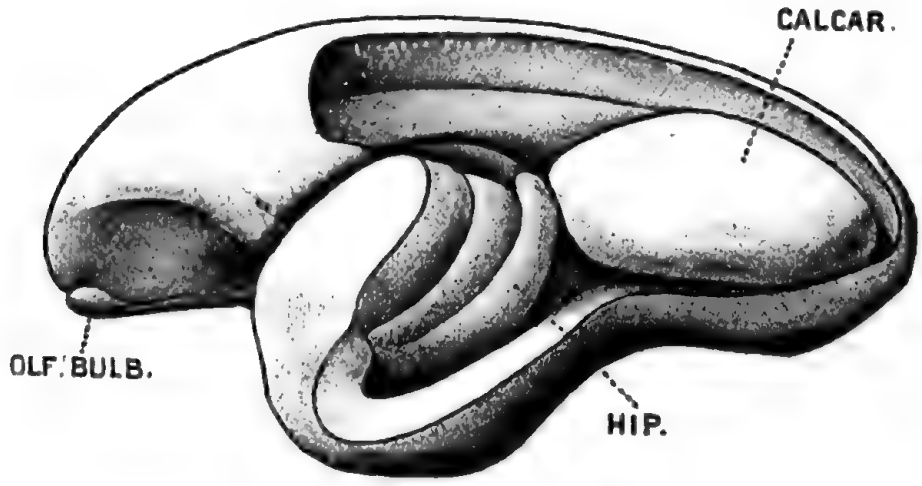

In the descending cornu the diminutive hippocampus is exposed. The posterior cornu is very extensive and is occupied by a relatively enormous swelling—calcar avis—of the mesial wall, which is produced by its indentation by the calcarine sulcus. Even if it were not inappropriate and confusing for other reasons, the term "hippocampus minor" would be singularly inapt if it were applied to the enormous broad expanse of the indented ventricular wall, which is much better called "calcar."

Although a posterior cornu of the lateral ventricle is occasionally found in other Orders, such as the Cetacea, Ungulata (*e. g.* in the Camel), and Carnivora (*e. g.* in certain Seals), it is only in the Primates, and more especially in the Suborder Anthropoidea, that it assumes the extensive proportions exhibited in this specimen.

W. H. Flower, Phil. Trans. vol. clii. 1862, p. 185.

Family *Cebidæ*.

D. 554. The brain of a Squirrel-Monkey (*Chrysothrix sciurea*), (♂); in which the left hemisphere has been separated (figs. 224, 225, 226).

Fig. 224. (Nat. size.)

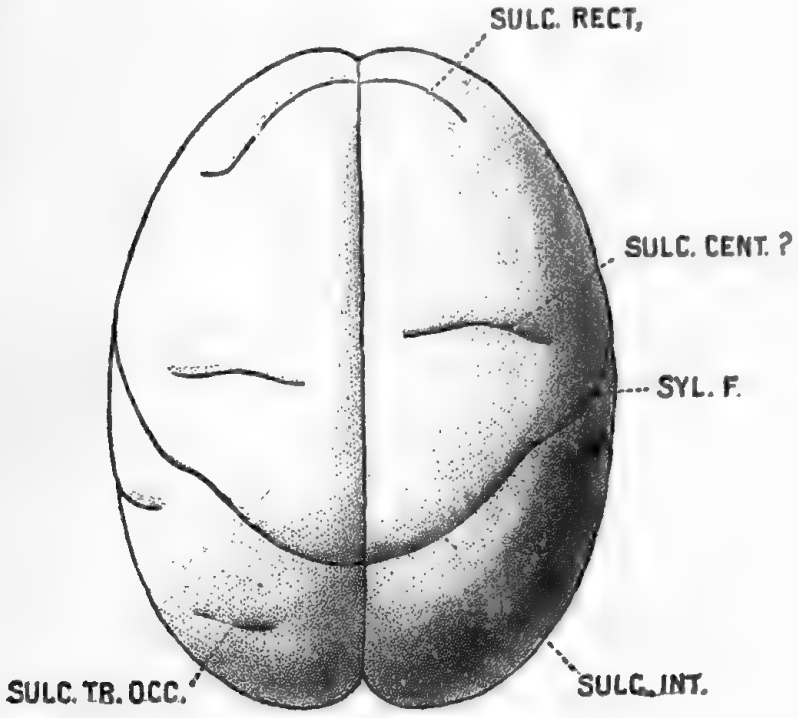

Fig. 225. (Nat. size.)

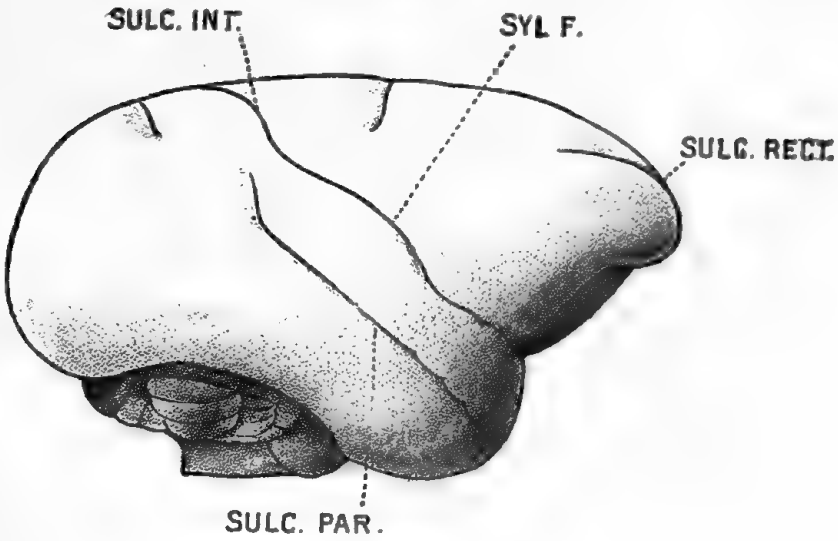

Fig. 226. (Nat. size.)

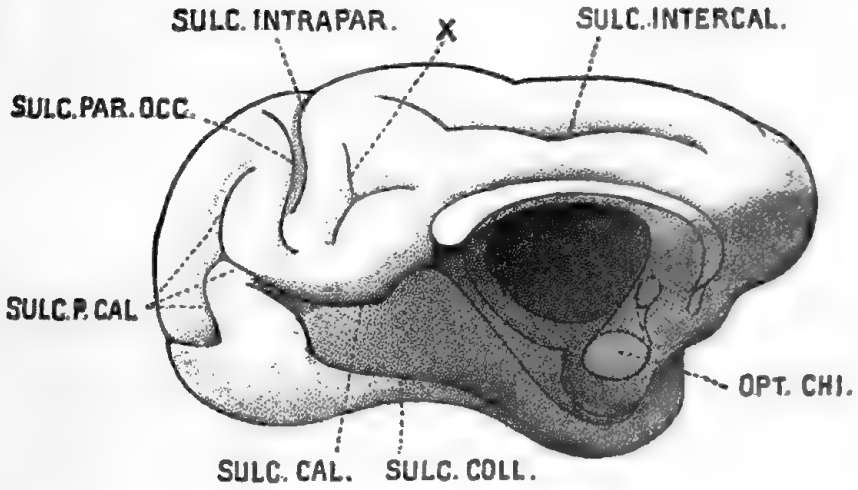

In this brain perhaps the most striking feature is the very pronounced manner in which the caudal extension of the cerebral hemisphere has taken place so as to completely cover the flattened cerebellum. The extent of this backward growth is most strikingly shown upon the mesial surface (fig. 226): almost half of the hemisphere lies behind the situation of the splenium of the corpus callosum (figs. 224 & 225).

Upon the cranial surface the Sylvian fissure will be seen to have fused with the intraparietal sulcus, as in *Nycticebus*; and the sulcus has even become prolonged on to the mesial surface (fig. 226) where it runs parallel and in close proximity to a new sulcus—the parieto-occipital of Human Anatomy. So close are these two sulci that they appear to become concurrent, but if the lips of the common cleft be separated the condition represented in fig. 226 is found *. An elongated parallel sulcus is present. In front of the Sylvio-intraparietal complex there is a short transverse sulcus on the dorsal surface (fig. 224), which may be the earliest Primate form of the central (Rolando's) sulcus. On the other hand, it may represent part of the intraparietal sulcus which has not joined the Sylvian fissure.

As a result of the pronounced caudal elongation of the hemisphere the calcarine sulcus becomes almost horizontal: it ends posteriorly by joining a great vertically transverse sulcus †, which must be regarded as analogous to the retrocalcarine sulcus of other mammalian Orders. As a result of the altered mechanical conditions, a series of new compensatory-calcarine sulci make their appearance. By reason of its altered direction, the calcarine sulcus is not extended downward to the neighbourhood of the rhinal fissure, as in most mammals, and a ventral compensatory sulcus—the "collateral" of Human Anatomy—develops to make good this defect. It appears in this case to join the calcarine, but is in reality separated from it by a submerged gyrus (fig. 226). A vertical compensatory sulcus makes its appearance on the dorsal side of the calcarine and

---

* In reality the parieto-occipital sulcus represents the fusion of two separate sulci. In this case the dorsal of these two fundamental elements is concurrent with the intraparietal sulci.

† Perhaps it would be more correct to say that it joins the stem of a T-shaped postcalcarine sulcus.

becomes the "parieto-occipital" sulcus. It is quite independent of the calcarine, but parallel to its forked caudal branches. In this brain the parieto-occipital appears to join the intraparietal sulcus, but in reality the two sulci are separated by a submerged gyrus (fig. 226).

The intercalary sulcus is here independent of all other sulci, and it is significant that its posterior extremity is turned upward. This tendency becomes much more pronounced in the higher Anthropoidea.

In the situation corresponding to that in which the calcarine-intercalary union takes place in the Carnivora and Ungulata there is a small triradiate sulcus (x), which in Human Anatomy is still often called by Broca's name "postlimbic," in spite of the fact that the hypothesis of a limbic lobe, which is implied in this name, is not now seriously entertained. We might more aptly call it the "compensatory" sulcus, in reference to its obvious rôle. It will be seen to be a very constant element throughout the Anthropoidea.

There is a small transverse occipital sulcus on the left hemisphere. And far forward on the apex of the hemisphere there is a short sagittally-directed sulcus, which may represent an early phase of the sulcus rectus.

The posterior rhinal fissure occupies a position on the ventral and not on the strictly lateral aspect of the hemisphere, whereas in the Lemurs the rhinal fissure occupies the lateral aspect of the cerebral hemisphere. (*Cf.* also with regard to this point, the cerebral hemisphere in *Nyctipithecus trivirgatus* or *Aotus felinus.*)

If the lips of the Sylvian fissure be separated, a small insula is exposed, chiefly under the larger fronto-parietal operculum. Its surface is smooth. O. C. 1337 D *a*.

D. 555. A cast of the cranial cavity of the Common Squirrel-Monkey (*Chrysothrix sciurea*).

D. 556. The brain of a Black-fronted Squirrel-Monkey (*Callithrix nigrifrons*), (♂). The left hemisphere has been separated (figs. 227 & 228).

The sulci of this brain are much simpler than those of *Chrysothrix*, and the cerebral hemispheres as a whole present a striking resemblance to those of the Lemurs in all points except the difference in shape resulting from the occipital prolongation *.

The Sylvian and intraparietal elements are here separate. The upper end of the parallel sulcus approaches the Sylvian fissure, as in many Lemurs.

There are typical sulci rectus and orbitalis.

Fig. 227. (Nat. size.)

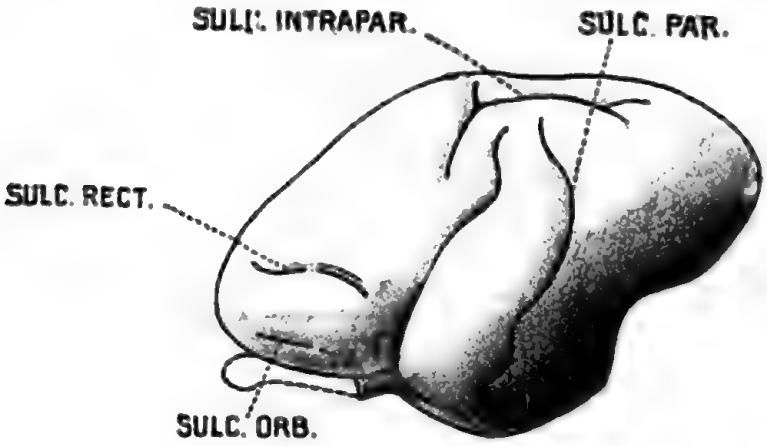

Fig. 228. (Nat. size.)

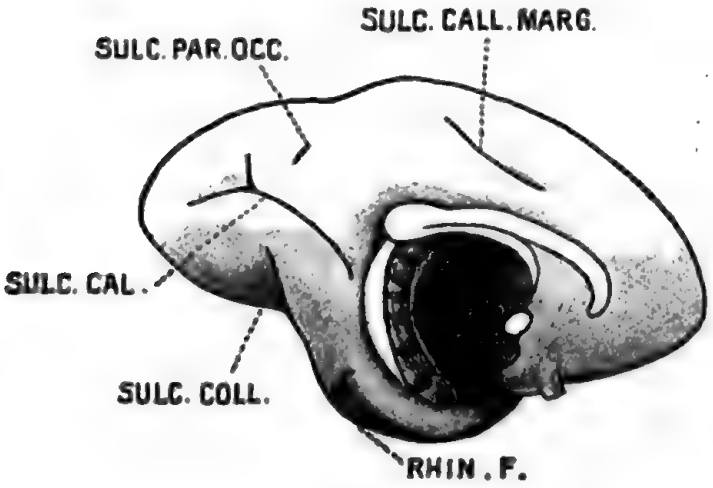

On the mesial surface the calcarine sulcus is concurrent, as in most Primates, with the retrocalcarine sulcus and the latter is markedly bifid at its posterior extremity. There is no parieto-occipital sulcus on the left hemisphere; but on the right there is a shallow groove in the position where this sulcus may make its appearance. There is a well-

---

* This likeness becomes all the more significant when it is recalled that in some of the Prosimiæ the restriction of the caudal pole is a secondary modification which occurs during ontogeny. Thus, among a number of skulls kindly lent me by Dr. Forsyth Major was one of a *Propithecus coronatus* 15 days old, from which it was evident that the cerebral hemispheres must have almost wholly covered the cerebellum.

marked oblique sulcus crossing the inferior margin of the hemisphere in the situation where a great inferior operculum is found in many Cercopithecidæ. Kükenthal and Ziehen call it "inferior occipital." But the presence of such a sulcus in this brain clearly does away with the necessity for a collateral sulcus. O. C. 1337 D *c*.

D. 557. The brain of a Masked Titi (*Callithrix brunnea*), (♂).

This specimen closely resembles the last described. If the lips of the Sylvian fissure be divaricated in either of these brains a small, smooth, submerged area or insula will be found. The anterior (fronto-parietal) is much more extensive than the posterior (temporal) operculum.

There is a short but definite central sulcus on the right hemisphere.

The manner in which the upper end of the parallel sulcus approaches the Sylvian fissure (especially in the right hemisphere) is very instructive, when we recall that in most non-Primate brains the representatives of these two sulci are united to form a suprasylvian arc.

The calcarine complex is unbranched, as in *Hapale*.

O. C. 1337 D *b*.

D. 558. The brain of an Orabassu Titi (*Callithrix moloch*).

This closely resembles the last specimen. There is, however, no central sulcus. The simple calcarine sulcus is clearly shown.

D. 559. The brain of a Three-banded Dourocoli (***Nyctipithecus*** *trivirgatus*), (♀).

The right cerebral hemisphere has been separated from the remainder of the encephalon. The left cerebral hemisphere has been dissected so as to exhibit the principal structures in the lateral ventricle ; the descending and the posterior cornua of the ventricle have been laid open, exposing, in the former, the hippocampus major and the fimbria and, in the latter which is prolonged into the overhanging occipital lobe, a large calcar avis.

The arrangement of the sulci resembles that in *Chrysothrix sciurea*, and, less closely, that in *Lemur*. The pyriform lobe is rather broader than in *Chrysothrix*, and the posterior rhinal fissure is placed very low down on the lateral convexity of the hemisphere. The principal sulcus on the lateral convexity is a combination of the Sylvian fissure with the intraparietal sulcus. (To this compound sulcus greater apparent length is given by the appearance of the Sylvian vallecula, which is a deep groove and thus differs decidedly from the shallow form of vallecula met with in Lemur-brains. Unlike the long furrow of the brain of *Chrysothrix*, it does not attain the mesial aspect.)

Anteriorly to this compound fissure the following sulci are found on the frontal part of the hemisphere, viz.: a small depression in a situation similar to that occupied in other Primate brains by the central sulcus, of which the depression is probably a rudiment: near the frontal extremity of the hemisphere is a sagitally-running shallow groove which probably represents the sulcus rectus (inferior frontal) of higher forms ; it is, however, interesting to note that it is a little more mesially placed than is usually the case with the s. rectus*: on the orbital surface of the frontal lobe is a single, sagittally-directed, distinct orbital sulcus ; and on the same surface, under the posterior part of the olfactory peduncle, is a shallow sulcus olfactorius. Behind the combined Sylvian and intraparietal fissures is a distinct parallel sulcus ; above and behind this are one or two indistinct depressions, but none can justifiably be described as genuine sulci (compare fig. 229).

The calcarine sulcus is **Y**-shaped rather than **T**-shaped, the two posterior limbs meeting at an angle of about 60°, instead of being in the same straight line. The stem of this **Y**-shaped sulcus almost reaches the hippocampal fissure. Below the calcarine is a curved collateral sulcus. There is another sulcus behind this; it is placed almost coronally, though it does not run into the calcarine. This somewhat unusual sulcus occurs in both hemispheres of this specimen of *N. trivirgatus*, but in neither of the hemispheres of the other specimen of *N. trivirgatus* (D. 560) and in none of the six hemispheres of *Aotus felinus* which were available for examination.

---

* In other words, the sulcus rectus occupies a progressively lower position in the hemisphere in the evolution of the Ape-brain ; so that it seems to be placed exceptionally high up in those forms where it first appears.

Above the calcarine there is in this specimen no trace of a parieto-occipital sulcus; further downwards, however, there is a short and obliquely-placed calloso-marginal sulcus. O. C. 1337 E.

D. 560. The brain of a Three-banded Dourocoli (*Nyctipithecus trivirgatus*). The left cerebral hemisphere has been separated.

In spite of its damaged condition this specimen has been retained because it exhibits in an especially clear manner a rhinencephalon with the typical features such as we find in mammals other than Primates and which are not usually so clearly demonstrable in the Anthropoidea.

Note the absence of central sulci. The sulcus rectus is also very poorly developed.

The dorsal limb of bifurcation of the calcarine is so diminutive that at a casual glance the sulcus resembles the unbranched condition found in the Marmosets.

D. 561. The brain of a Lemurine Dourocoli (*Aotus felinus*). The left hemisphere has been detached.

This brain resembles the preceding specimen. Note, however, that the calcarine complex presents the usual **Y**-shape. O. C. 1337 E *a*.

D. 562. The brain of a Lemurine Dourocoli (*Aotus felinus*). The left hemisphere has been separated.

This brain resembles the two previous specimens. There is, however, a small central sulcus and a very faint rudiment of a parieto-occipital sulcus. O. C. 1337 E *b*.

D. 563. The brain of a Lemurine Dourocoli (*Aotus felinus*), (♂). The left hemisphere has been detached (fig. 229).

Fig. 229. (Nat. size.)

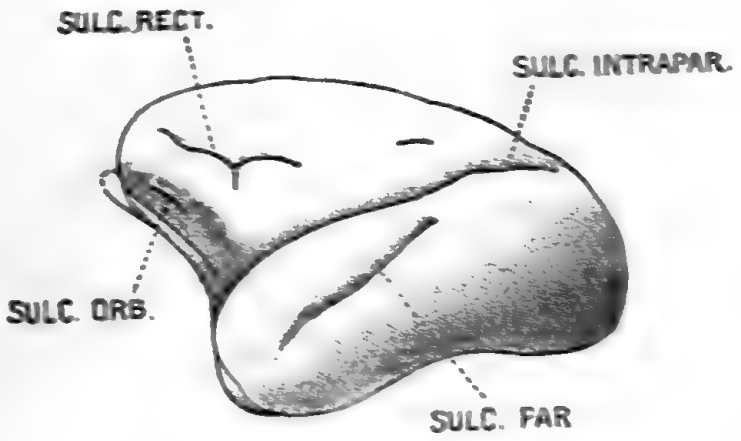

This specimen resembles the preceding. O. C. 1337 E *c*.

D. 564. The brain of a Hairy Saki (*Pithecia monachus*), (♀) (figs. 230 & 231).

The right hemisphere has been detached and dissected so as to show the general relations of the descending horn of the lateral ventricle. The posterior cornu is clearly visible.

Although the general plan is the same, there is a much richer supply of sulci than in any of the Primate brains hitherto described in this Catalogue. The sulcus rectus is deeper and has become bent. There is a deep, well-defined central sulcus. The intraparietal sulcus ends posteriorly in a bifid extremity—the transverse occipital sulcus. There is a short but deep parieto-occipital sulcus, and a well-defined, calloso-marginal sulcus. The Sylvian fissure is quite independent of the intraparietal sulcus. There is on the tentorial surface a deep sulcus, which must be regarded as the collateral.

Fig. 230. (× ⅔).

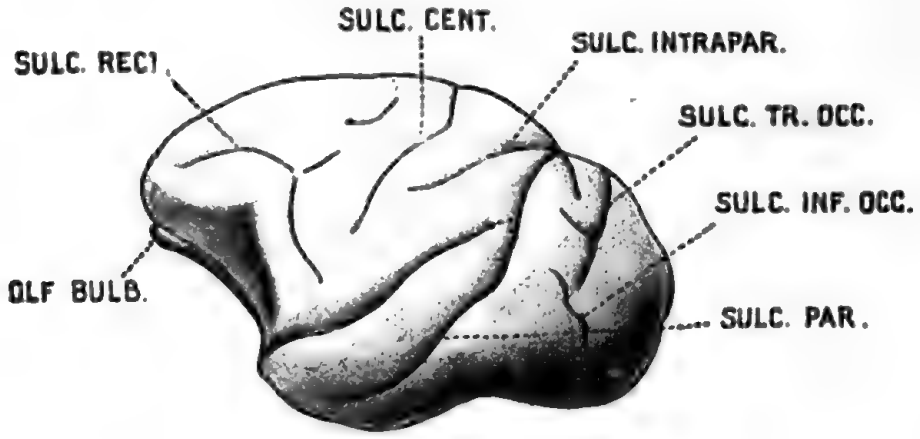

Fig. 231. (× ⅔.)

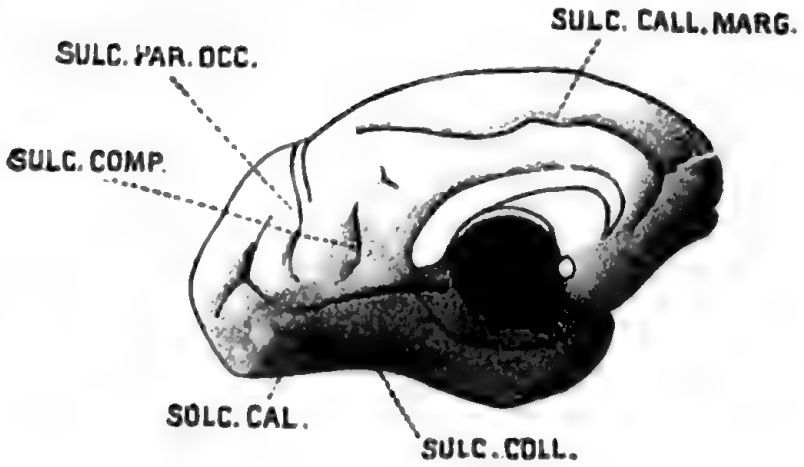

In the right hemisphere the hippocampus lying in the descending cornu and the calcar in the large roomy posterior cornu are exposed. The disproportion between the sizes of these two bodies is not so marked as it is in *Hapale*.

The cerebellum is very instructive. Its floccular lobe still retains the form exhibited by most mammals. It possesses a large projecting petrosal lobule of the paraflocculus. But these lobes appear to be very small because the rest of the cerebellum has attained such great dimensions. O. C. 1337 F.

Flower, Proc. Zool. Soc. 1862, p. 328.

D. 565. The brain of a Hairy Saki (*Pithecia monachus*). The left hemisphere has been detached.

The parieto-occipital sulcus extends further on to the dorsal aspect and produces a corresponding bend in the ramus occipitalis of the intraparietal sulcus. There is an extensive sulcus behind and parallel to the transverse occipital. It may represent the earliest phase of the Simian sulcus—the "Affenspalte" of German writers.

Below this there is a small sulcus parallel to the tentorial margin, which may represent the inferior occipital sulcus of other Apes. O. C. 1337 F *d*.

D. 566. The brain of a Black Saki (*Pithecia satanas*). The left hemisphere has been detached.

This brain is much richer in sulci. The Sylvian fissure is crossed obliquely at its upper end by the terminal portion of the elongated parallel sulcus, with which (on the left side) it is superficially continuous, though deeply it is found that the two are separated by a submerged gyrus. The intraparietal sulcus is acutely bent around the apex of the parallel sulcus; and from the angle of the former a deep furrow extends on to the mesial surface. The upper end of the parieto-occipital sulcus becomes swept, as it were, into this intraparietal cleft, so that at a superficial glance the two sulci appear to be concurrent. This furrow, which is constituted by two separate elements, represents the parieto-occipital sulcus of the highest Anthropoids. It consists of a ventral element, which is clearly compensatory to the calcarine, and a dorsal element (the "intraparietal cleft" of this paragraph).

There is an extensive Simian sulcus. It runs rather more than halfway across the hemisphere, and gives off a short branch which is directed forwards. The antero-superior extremity of a definite inferior occipital sulcus approaches very close to the lower end of the Simian sulcus. This leaves a comparatively large occipital area free from anything more than faint depressions, and in the possession of this character, these brains of *Pithecia* and those of *Brachyurus* form a strong contrast to that of *Lagothrix*.

Anteriorly to the Sylvian and intraparietal fissures there is a well-developed central sulcus and immediately in front of this another sulcus, shorter than, but having the same general direction as, the central sulcus itself. The sulcus rectus is tri-radiate (on the left hemisphere). On the orbital surface is an **H**-shaped orbital sulcus.

The calloso-marginal sulcus (prolonged forwards into a genual), the internal parieto-occipital, the **T**-shaped calcarine (with a single long collateral sulcus running superficially into it), and the hippocampal fissures occupy their usual positions (for which see, *inter alia*, especially accounts of *Alonatta* and *Lagothrix*). O. C. 1337 F *a.*

D. 567. The brain of a White-nosed Saki (*Pithecia albinasia*). The right hemisphere has been detached.

Its general appearance is remarkably similar to D. 566, but the Sylvian fissure does not quite reach the parallel sulcus even superficially. In the left hemisphere of this specimen, D. 567, as in the left hemisphere of D. 566, the connection between the two sulci is closer than that obtaining in the corresponding right hemispheres. Near the temporal pole there is a short, well-marked inferior temporal sulcus.

The sulcus seen in front of the central fissure in D. 566, and named pre-central, is here represented by two short sulci, an upper and a lower on the left side. Further forward there is a short oblique sulcus above the sulcus rectus.

Note the peculiar shape and direction of the orbital sulci. O. C. 1337 F *e.*

D. 568. The brain of a Red Uakari (*Brachyurus rubicundus*), (♀). The left hemisphere has been detached. O. C. 1337 F *c.*

D. 569. The brain of a Red Uakari (*Brachyurus rubicundus*). Both cerebral hemispheres have been detached.

This brain clearly resembles that of *Pithecia satanas* (D. 566).

The Sylvian fissure (superficially) joins the parallel sulcus on both sides.

The peculiar relation of intraparietal and parieto-occipital sulci found in *Pithecia* also occurs here.

The Simian sulcus is more rudimentary, whereas the inferior occipital is deeper and its upper lip tends to become opercular.

The sulcus rectus is plain. The orbital sulcus is **H**-shaped. O. C. 1337 F *b*.

D. 570. Cast of the cranial cavity of *Brachyurus calvus*.

D. 571. The right cerebral hemisphere of a Red Howler (*Alonatta senicula*), (♂) (figs. 232 & 233).

Fig. 232. (× $\frac{2}{3}$.)

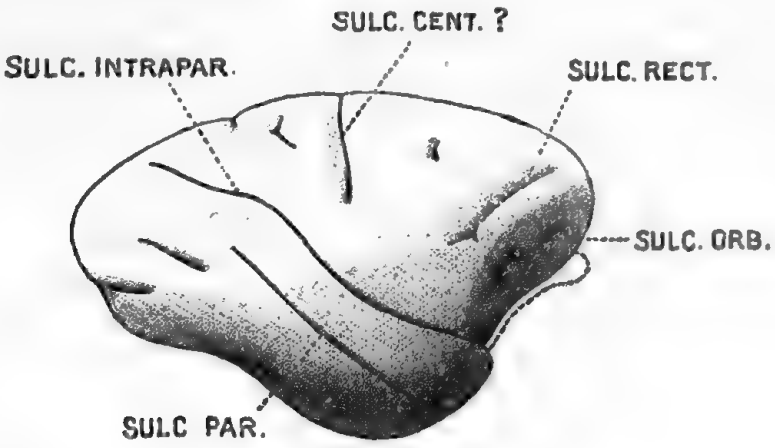

Fig. 233. (× $\frac{2}{3}$).

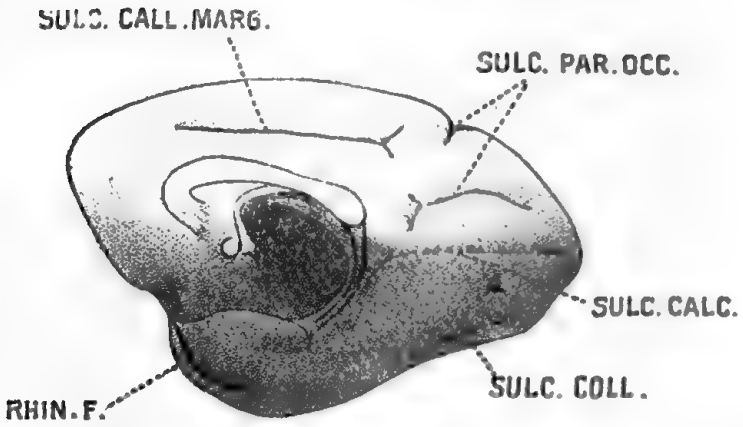

This presents some resemblance to the brain of *Nyctipithecus*.

The Sylvian fissure and the intraparietal sulcus are concurrent. There is a simple parallel sulcus, which does not approach the Sylvian fissure. Between the short central sulcus and the intraparietal element of the complex there is a short compensatory intraparietal sulcus. There is no Simian sulcus, but there are two small sulci representing the inferior occipital sulcus. There is a very deep sulcus rectus and an **H**-shaped orbital sulcus. There is a deep, straight, unbranched calcarine sulcus. The essentially calcarine-compensatory nature of the parieto-occipital sulcus is shown by the fact that as the result of the peculiarity of the calcarine sulcus, the parieto-occipital is represented chiefly by a sulcus parallel to the almost horizontal calcarine, which is merely analogous to, and cannot be homologous with, it. A slight notch in the upper margin of the hemisphere shows the usual situation of the parieto-occipital sulcus and represents the more dorsal of the two elements which go to form the parieto-occipital sulcus in Man (*vide infra*). There is a short, plain, collateral sulcus and a calloso-marginal which has no genual element. O. C. 1337 G *a*.

D. 572. The brain of a Red Howler (*Alonatta senicula*), (♂) (fig. 234).

Fig. 234. (× ⅔.)

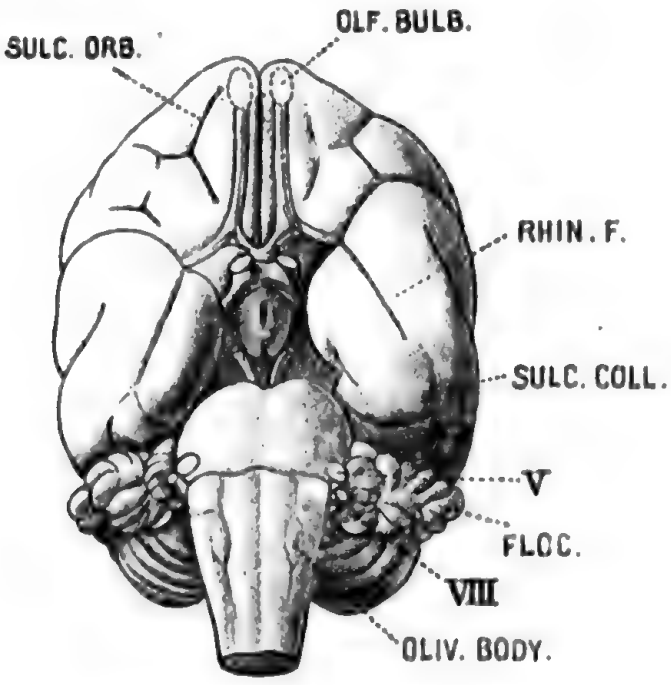

This well-preserved specimen is perfect in all parts except the olfactory bulbs, which are missing.

External to the orbital sulcus (which is triradiate on the right and simply linear on the left hemisphere) there is a small sulcus (triradiate on the right side, and on the left linear and prolonged forward into what is obviously a compensatory orbital sulcus). This small sulcus is one of the earliest forms of the fronto-orbital sulcus of the Simiidæ, which becomes in Man the anterior limiting sulcus of the island of Reil.

The Sylvian fissure becomes confluent with the simple linear intraparietal sulcus, which ends just behind the parieto-occipital sulcus.

There is a very short central sulcus, and between it and the intraparietal a small punctate ramus postcentralis superior of the intraparietal.

The simple parallel sulcus nowhere approaches the Sylvian fissure.

There is a simple arcuate sulcus rectus running parallel to the fronto-orbital margin. On the right side it gives off a small branch. In front of the mid-point of the central sulcus there is a small depression, which may possibly represent the incipient arcuate sulcus.

Behind the upper end of the parallel sulcus there is a short transverse occipital sulcus, and behind this a second small furrow (? inferior occipital sulcus). Beginning near the end of the posterior rhinal sulcus there is a deep and well-defined occipito-temporal sulcus on the tentorial surface.

The cerebellum is of great interest, because it is still sufficiently simple to permit us to recognize the principal features exhibited by the non-Primate organ, and yet the exuberant growth of its lateral parts clearly points to the human homologies of the various regions.

The most instructive parts of the organ in this specimen, however, are the floccular lobes. For this example clearly shows that this part of the cerebellum is composed in the Apes, as in other mammals, of two distinct parts or lobules —a small mesial part (surrounding the auditory nerve) being the flocculus proper, *i. e.* the part we call by that name in the human brain; and a large lateral part or paraflocculus, which dwindles to a mere vestige (flocculi secundarii of Henle) in the brain of Man. In this brain the flocculus is a narrow sagittal band of about seven rounded "folia," whereas the paraflocculus is a great projecting mass of folia arranged in a feather-like pattern. Unlike the condition found in most mammals with projecting lobules (compare *Tamanduas*), almost the whole of the paraflocculus contributes to form the so-called "petrosal lobule" in this case. O. C. 1337 G.

D. 573. The brain of a young Red Howler (*Alonatta senicula*). The left cerebral hemisphere has been separated.

The sinuous intraparietal element of the Sylvio-intraparietal complex ends in a bifid manner so as to form a small transverse occipital sulcus. There is, however, a well-developed compensatory-intraparietal sulcus behind the central and parallel to the main intraparietal element.

There is a long deep sulcus parallel to the caudal part of the "parallel" sulcus, which can only be the Simian sulcus.

There are small and faintly-marked inferior occipital, inferior temporal, and collateral sulci; and at the point toward which these three sulci converge there is a peculiar deep irregular pucker. The meaning of this is not quite clear, but it is significant that the inferior occipital may, in different brains, be confluent with either of the other two sulci. Here all three sulci are poorly developed, and this peculiar depression makes its appearance—apparently as a compensatory factor.

There is a simple linear orbital sulcus and an equally plain external compensatory-orbital, which we can now have no hesitation in calling fronto-orbital. This is the lowliest Ape in which this sulcus (which in the Man-like Apes marks the anterior boundary of the insula) has been observed.

The sulci upon the mesial aspect of these hemispheres are particularly interesting. Although the calcarine sulcus (unlike that of D. 572) has a bifid extremity, its caudal limbs are so small that they produce no mechanical disturbance. The parieto-occipital sulcus is broken up to an even greater extent than in specimen D. 571. The notch in the superior border is present only on the left hemisphere. The calloso-marginal sulcus joins the "compensatory" sulcus, and the latter is quite separate from the small detached parieto-occipital element which is found above the calcarine sulcus. Further, on the right hemisphere (in which the notch in the superior margin is absent) the latter element is more strongly marked.

This apparently hopeless confusion becomes quite intelligible if the student remembers (1) that the parieto-occipital sulcus arises merely as a furrow compensatory to the calcarine complex; (2) that in the interval between the calloso-marginal and calcarine sulci another sulcus (which I have called "compensatory") generally makes its appearance for reasons similar to those that call the parieto-occipital into being; and (3) that the relations of the "compensatory" sulcus to the calloso-marginal and calcarine sulci are determined mainly by the nature of the other compensatory sulcus, which is the parieto-occipital.

O. C. 1337 *a b*.

D. 574. Two casts of the cranial cavity of a Red Howler (*Alonatta senicula*).

D. 575. The brain of a White-cheeked Capuchin (*Cebus lunatus*): the left cerebral hemisphere has beeen separated (figs. 235, 236, 237, 238).

Fig. 235. (× $\frac{2}{3}$.)

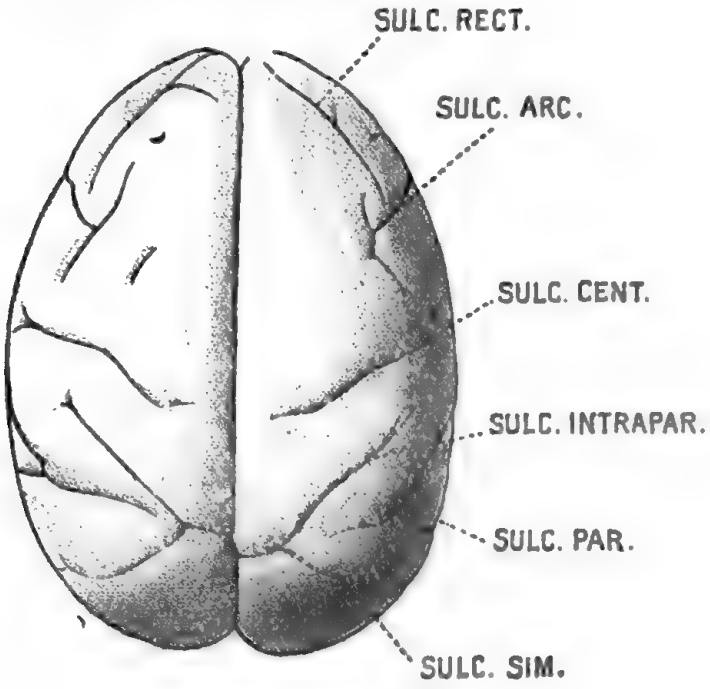

Occupying as it does a central position among the Primates, *Cebus* lends itself very favourably to a wide comparison. For while its brain has attained to a sufficiently high stage of development to permit accurate comparison with that of the large Old World Apes and Man, it is at the same time sufficiently simple to be compared with all the New World Apes, and even with the Lemurs.

The olfactory bulb and its long attenuated peduncle are well shown in this specimen. The diminutive proportions of these bodies, and also of the pyriform lobe, are common to all the Anthropoidea.

Fig. 236.

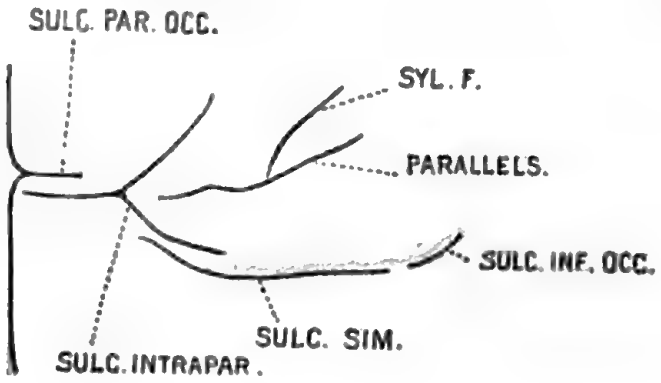

Fig. 237. (× ⅔.)

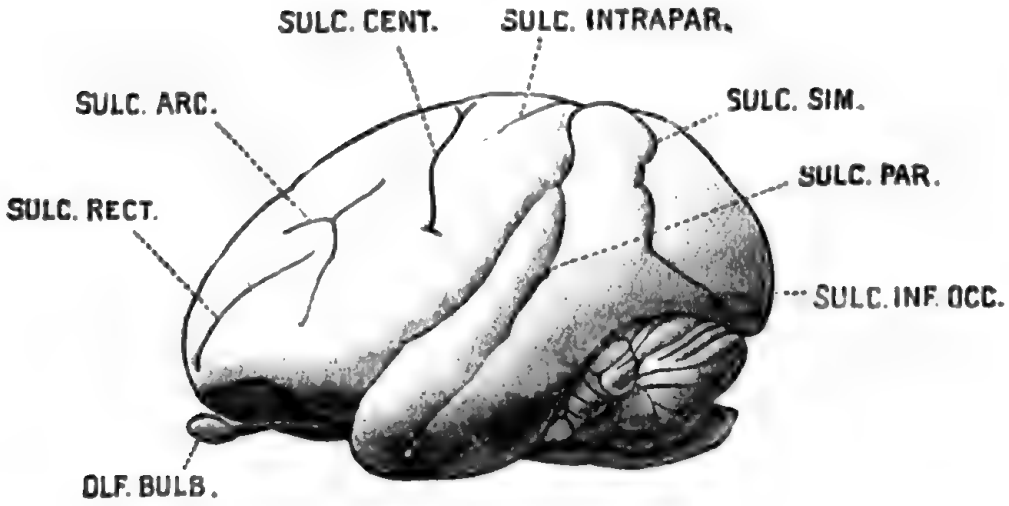

The deep long oblique Sylvian fissure begins on the base of the hemisphere in a deep vallecula Sylvii. It appears to end above by joining the parallel sulcus (fig. 237), but they are in reality separated by a submerged gyrus, beyond which the latter is prolonged for some distance (fig. 236) into the angle of the intraparietal sulcus.

The neopallium becomes folded in a most complicated manner in the neighbourhood of the caudal part of the intraparietal sulcus (fig. 236).

The intraparietal sulcus has the form of an inverted V, the anterior limb of which is about twice as long as the posterior. The sulcus is exceedingly deep in the greater part of its extent, and from its apex a deep cleft extends on to the mesial surface of the hemisphere. The depth of this cleft (which we may call the ramus parieto-occipitalis sulci intraparietalis) is expressed by its length on the mesial surface (fig. 238, x).

The parieto-occipital sulcus is swept, as it were, into the mesial part of this great cleft *. It emerges near the ventral extremity of the latter, and fuses with one of the two "compensatory" sulci. Thus a V-shaped sulcus is produced which is parallel to the calcarine sulcus and the upper part of the retrocalcarine.

At a superficial glance the Simian sulcus seems to join the posterior limb of the V-shaped intraparietal sulcus. But on separating the lips of the sulci it will be seen that the shallow Affenspalte lies entirely behind the deep intraparietal. In fact the rôle (which is assumed by the Affenspalte in many Cercopithecidæ) of relieving the tension of the expanding occipital regions is fulfilled by the operculation of the posterior lip of the ramus parieto-occipitalis sulci intraparietalis, rather than by that of the Simian sulcus.

The Affenspalte becomes much deeper, and its posterior lip slightly opercular in its lateral part. On the left hemisphere it (superficially) joins the inferior occipital sulcus, the upper lip of which is also operculated. On the right hemisphere the Simian sulcus is much more poorly developed, but its posterior lip is operculated in its whole extent. It is separated from the inferior occipital sulcus by a wide interval, and not merely by a narrow submerged gyrus, as on the left side.

There is a T-shaped calcarine complex. The long collateral sulcus is superficially joined to the retrocalcarine sulcus (fig. 238, SULC. P. CALC.).

The superior limiting sulcus of the insula (the suprasylvian sulcus of other mammals) emerges anteriorly from

---

* The parieto-occipital sulcus of Human Anatomy really consists of two separate sulci (corresponding to those just referred to as ramus parieto-occipitalis of the intraparietal and the parieto-occipital sulcus) submerged in the one cleft as in this case, but the dorsal sulcus does not join the intraparietal as it does in this brain.

the Sylvian fissure. On the left hemisphere it is linked by a shallow furrow to the orbital sulcus.

The sulcus called "rectus" in the lowlier Cebidæ is now broken up into two separate sulci:—the "rectus" (*sensu stricto*) and the "arcuatus;" corresponding respectively to the inferior frontal and the inferior precentral sulci of Human Anatomy.

Fig. 238. (× ⅔.)

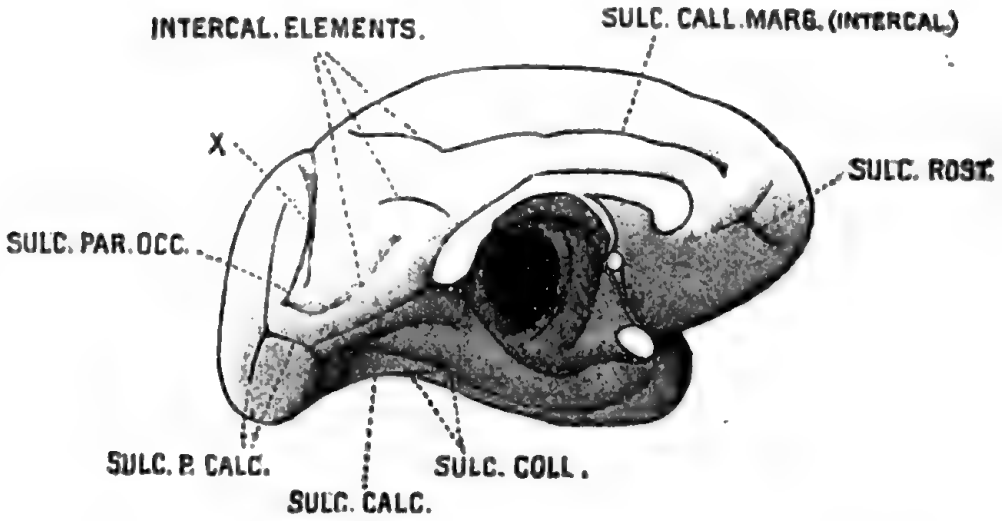

Immediately external to the typical posterior rhinal fissure there is a small inferior temporal sulcus. O. C. 1337 K *e.*

D. 576. The brain of a White-cheeked Capuchin (*Cebus lunatus*).

This specimen closely resembles the last. Upon the right hemisphere the anterior end of the superior limiting sulcus of Reil can just be seen emerging from the Sylvian fissure on to the orbital surface. O. C. 1337 K *f.*

D. 577. The brain of a White-fronted Capuchin (*Cebus albifrons*).

In this brain the Affenspalte is a simple sulcus lying some distance behind the transverse occipital ramus of the intraparietal sulcus. There is a feeble depression representing the ramus postcentralis superior of the intraparietal sulcus in the left hemisphere. O. C. 1337 K *c.*

D. 578. The brain of a White-fronted Capuchin (*Cebus albifrons*).

The region around the intraparietal sulcus is disposed like that in the two specimens of *C. lunatus*. The Simian sulcus, however, is very small on the left hemisphere, so that the whole of the intraparietal sulcus can be seen.

No part of the superior limiting sulcus is exposed.

O. C. 1337 K *a.*

D. 579. The brain of a Brown Capuchin (*Cebus fatuellus*).

The small simple Simian sulcus is separated from the transverse occipital ramus of the intraparietal by a broad exposed gyrus.

The ramus postcentralis superior of the intraparietal sulcus is wanting. O. C. 1337 K *d.*

D. 580. The brain of a Brown Capuchin (*Cebus fatuellus*).

This specimen, on the other hand, closely resembles the two brains of *C. lunatus*, especially in regard to the Affenspalte. O. C. 1337 K *g.*

D. 581. The brain of a Brown Capuchin (*Cebus fatuellus*).

O. C. 1337 K *h.*

D. 582. The brain of a White-throated Capuchin (*Cebus hypoleucus*).

This brain resembles that of *Cebus albifrons* so far as the Affenspalte is concerned. O. C. 1337 K *k.*

D. 583. The brain of a White-throated Capuchin (*Cebus hypoleucus*), (♂).

This resembles the preceding specimen. O. C. 1337 K *b.*

D. 584. The brain of a Smooth-headed Capuchin (*Cebus monachus*). The left hemisphere has been separated.

In this large series of *Cebus*-brains the features are so constant that the only variation specially noted above has been the somewhat trivial point — whether or not the posterior lip of the Simian sulcus extends forward sufficiently far to give the appearance of a fusion of the intraparietal and Simian sulci. On the right hemisphere of this specimen, the opercular lip of the Simian sulcus almost (but not quite) reaches the anterior lip of the ramus occipitalis transversus, whereas they are more widely separated on the left hemisphere. This brain therefore exhibits two interesting stages intermediate between the condition of the Affenspalte-region in the extreme types exhibited by *Cebus lunatus* (D. 575) and *C. hypoleucus* (D. 582) (D. J. Cunningham, Mem. Roy. Irish Acad. 1892, p. 222).

Note on the right hemisphere two faint depressions representing a superior frontal sulcus. O. C. 1337 K *i.*

D. 585. The brain of a *Cebus* (sp.).

The left cerebral hemisphere has been separated and the dorsal operculum of the Sylvian fissure removed to show the extent of the insula. The mesial lip of the intraparietal sulcus (in the region of its bend) has been removed to show that the parieto-occipital sulcus does not become confluent with the ramus parieto-occipitalis sulci intraparietalis, but merely cuts into its posterior wall.

On the right hemisphere the inferior lip of the Sylvian fissure has been cut away to show how the superior limiting sulcus of Reil ends anteriorly.

This is a small and correspondingly simple brain for a *Cebus*. The sulci rectus and arcuatus have fused to form a simple bow. The Simian sulcus is especially diminutive and is quite independent of the ramus transversus occipitalis of the intraparietal sulcus. O. C. 1337 K.

D. 586. The brain of a Humboldt's Woolly Monkey (*Lagothrix humboldti*), (♂), (figs. 239, 240).

Fig. 239. (× $\frac{2}{3}$.)

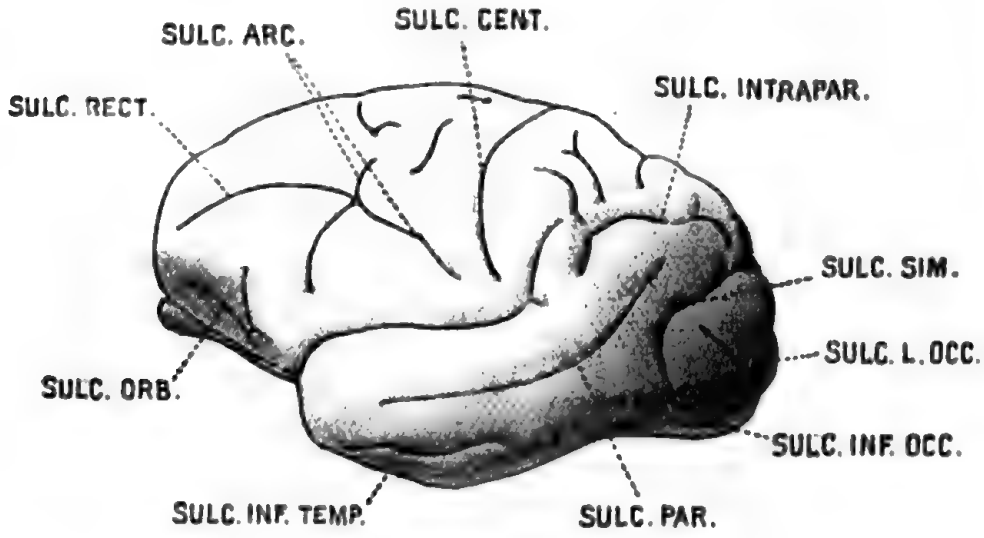

This brain still further demonstrates the extreme instability of the region of the parieto-occipital sulcus. The tension of the expanding cortex in this region of the Primate hemisphere may be relieved by the development of a deep sulcus which may be derived from the intraparietal system (as in *Cebus*, where we have seen the ramus parieto-occipitalis), or from the Simian sulcus (as in many Cercopithecidæ), or, as in this case, by a great extension and deepening of the parieto-occipital sulcus. The latter sulcus has extended far on to the dorsal surface, and has become exceedingly deep. Not only so, but its walls are rendered very irregular by numerous sulci, one of which emerges from the sulcus on the mesial surface of the left hemisphere. With the presence of this deep sulcus there is no need for a "compensatory" (Broca's "postlimbic") sulcus: and all the less so because the calloso-marginal sulcus approaches very near to the parieto-occipital sulcus. The unusually great dorsal extent of the parieto-occipital sulcus greatly disturbs the intraparietal sulcus. The latter consists of a triradiate arrangement far removed from the mesial plane. One limb of the sulcus extends between the upper ends of the Sylvian fissure and the parallel sulcus (both of which are very short). A second limb appears to join the mid-point of the Affenspalte, but in reality it runs parallel to the upper half of the latter, separated from it by a very deeply-submerged gyrus. The anterior limb of the triradiate sulcus extends above the Sylvian fissure toward the mid-point of the central gyrus. On the left hemisphere it joins the ramus postcentralis superior, which is a separate sulcus on the right side.

Fig. 240. (× $\frac{2}{3}$.)

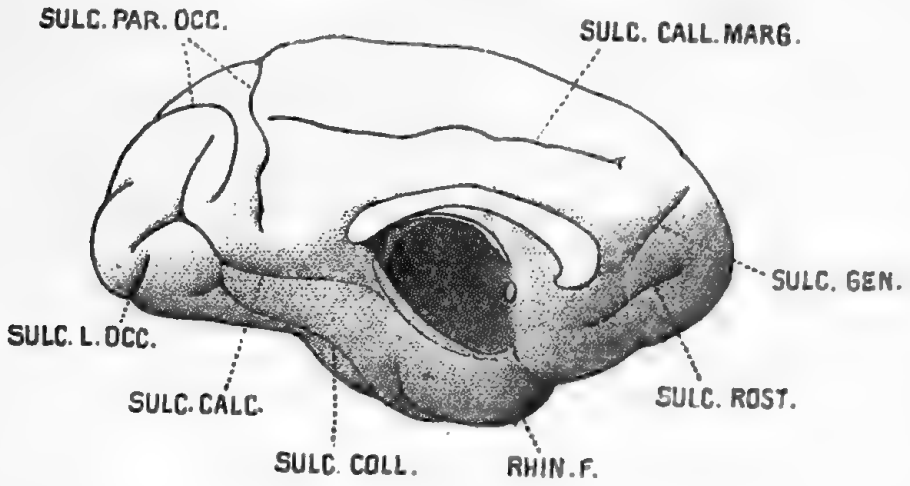

The Simian sulcus (Affenspalte) is short but very deep, and its posterior lip is slightly opercular. Behind its upper end there is a short compensatory sulcus, such as is sometimes seen in *Cebus*. The inferior occipital sulcus approaches very close to the caudal end of the collateral sulcus. An obliquely directed lateral occipital sulcus (not hitherto met with) crosses the hemisphere from the occipital pole toward the mid-point of the Simian sulcus (SULC. L. OCC.).

The collateral sulcus is represented by two deep sulci.

The sulci rectus et arcuatus are concurrent.

There is a small superior precentral sulcus.

External to the orbital sulcus there is now a definite fronto-orbital (anterior limiting) sulcus. The floccular lobes of the cerebellum, which closely resemble those of *Alonatta* (D. 572), are particularly well-demonstrated. The vermiform flocculus alongside the auditory nerve is very distinct, and the peculiar club-shaped "petrosal lobule" of the paraflocculus presents very well-marked features.

O. C. 1337 I.

D. 587. The brain of a Humboldt's Woolly Monkey (*Lagothrix humboldti*). The left hemisphere is detached.

The peculiar features of the parieto-occipital and intraparietal sulci are found here also. The posterior ramus of the triradiate intraparietal sulcus is separated from the Affenspalte by a wide gyrus, especially on the right side.

The posterior sulcus compensatory to the Simian sulcus is much larger than in the last specimen. Nevertheless the lateral occipital sulcus is well-developed. The result of this, however, is that the inferior occipital sulcus is poorly developed, but there is a compensatory deepening of the anterior segment of the collateral sulcus.

On the right hemisphere the dual nature of the conjoint sulci rectus et arcuatus is indicated by a submerged gyrus. On the left hemisphere, however, the conjoint sulci form an irregular crucial pattern.

The inferior temporal sulcus is unusually well-developed.

O. C. 1337 I *a*.

D. 588. The brain of a Black-faced Spider-Monkey (*Ateles ater*).

The condition of the parieto-occipital and intraparietal sulci is essentially identical with that just described in *Lagothrix*. But the inferior limb of the triradiate intraparietal seems, at a casual glance, to actually join the Sylvian fissure. But in reality it ends *behind* the upper extremity of the Sylvian fissure, as in *Lagothrix*, and is separated from the latter only by a deeply submerged gyrus. On the right side the ramus postcentralis superior is united to the intraparietal, but on the left side it consists of three fragments, of which only the inferior is united to the main sulcus.

The ramus occipitalis of the intraparietal is bifid and quite independent of the Simian sulcus. The latter is extensive and irregular on the right side, but is more fragmentary on the left. It is a simple sulcus, *i. e.* its posterior lip is not operculated. The lateral occipital sulcus is dislocated to such a ventral position that the inferior occipital sulcus seems to be entirely aborted.

There is a simple sulcus rectus, not joined to the sulcus arcuatus. The latter gives off a peculiar, extraordinarily long, posterior horizontal branch. Fragmentary representatives of the superior precentral and superior frontal sulci are present.

Few Apes possess such a complicated occipital region, with such a complete absence of operculation and, for its size, such a well-furrowed frontal area as *Ateles*. In these respects the comparison of *Ateles* and *Homo* is very instructive. O. C. 1337 H *e*.

Huxley, Proc. Zool. Soc. 1861, p. 247.

D. 589. The brain of a Black-faced Spider-Monkey (*Ateles ater*).

Note again the apparent continuity of Sylvian fissure and intraparietal sulcus, such as occasionally occurs in Lemurs and Apes, with the difference that here there is a submerged gyrus to indicate the line of separation of the overlapping elements. All the superior precentral elements are separate here.

The Simian sulcus is much larger and deeper here than in the last specimen. This is particularly marked on the right hemisphere, where the posterior lip of the sulcus is obviously operculated.

The caudal ramus of the arcuate sulcus is much shorter and the central sulcus correspondingly larger than in the last specimen.

The anterior end of the superior limiting sulcus of Reil is clearly exposed on the right hemisphere (compare with the Anthropoid Apes). O. C. 1337 H *f*.

D. 590. The brain of a Geoffroy's Spider-Monkey (*Ateles geoffroyi*).

This is a smaller and simpler brain than the last two.

The frontal region resembles that of specimen D. 588.

In addition to the chief parieto-occipital sulcus (which has only a short dorsal course in front of the intraparietal sulcus, where it ends in a bifid manner) there is a second, shallower, vertical accessory parieto-occipital sulcus behind the occipital part of the intraparietal sulcus. The latter is not joined by its superior post-central ramus (the chief element of which has an unusually sagittal direction). Anteriorly it appears to join the Sylvian fissure: posteriorly it dips into the Simian sulcus and its termination is thus hidden from view. O. C. 1337 H *d.*

D. 591. The brain of "*Ateles,*" species unknown: the left hemisphere has been detached. The ramus postcentralis superior of the intraparietal sulcus is triradiate and not joined to the rest.

There is a well-developed ramus occipitalis (transversus) of the intraparietal sulcus which lies in front of and parallel to the Affenspalte and behind the extensive parieto-occipital sulcus. So that the typical relations of these three sulci are demonstrated (especially on the left side) with diagrammatic clearness.

The calcarine has but very short limbs of bifurcation and seems to be joined by the parieto-occipital sulcus, as sometimes happens in the human brain but exceedingly rarely in the Apes. And the collateral sulcus is composed of inner and outer parts, of which the inner approaches, but does not quite reach, the stem of the calcarine sulcus. O. C. 1337 H *c.*

D. 592. The brain of a Long-haired Spider-Monkey (*Ateles vellerosus*). The left hemisphere has been detached. The membranes have not been removed. The backwardly-directed branch of the arcuate sulcus is detached on the right side, but on the left is continuous with the rest of the sulcus.

The superior limiting sulci of Reil (Marchand's opercular sulci) are again partially exposed. O. C. 1337 H *a.*

D. 593. The brain of a Long-haired Spider-Monkey (*Ateles vellerosus*) : young male.

The right hemisphere has been dissected from above to display the structures in the descending and posterior cornua of the lateral ventricle. The hippocampus major and the fimbriated extremity of the fornix accompanying it are well shown ; the optic thalamus and corpus striatum are also visible ; the great length of the posterior cornu of the lateral ventricle and the prominence in its wall corresponding to the calcarine sulcus, are very noteworthy features of the dissection. O. C. 1337 H.

Family *CERCOPITHECIDÆ.*

D. 594. The brain of a Bonnet Macaque (*Macacus sinicus*) : the left hemisphere has been detached.

Fig. 241. (× $\frac{2}{3}$.)

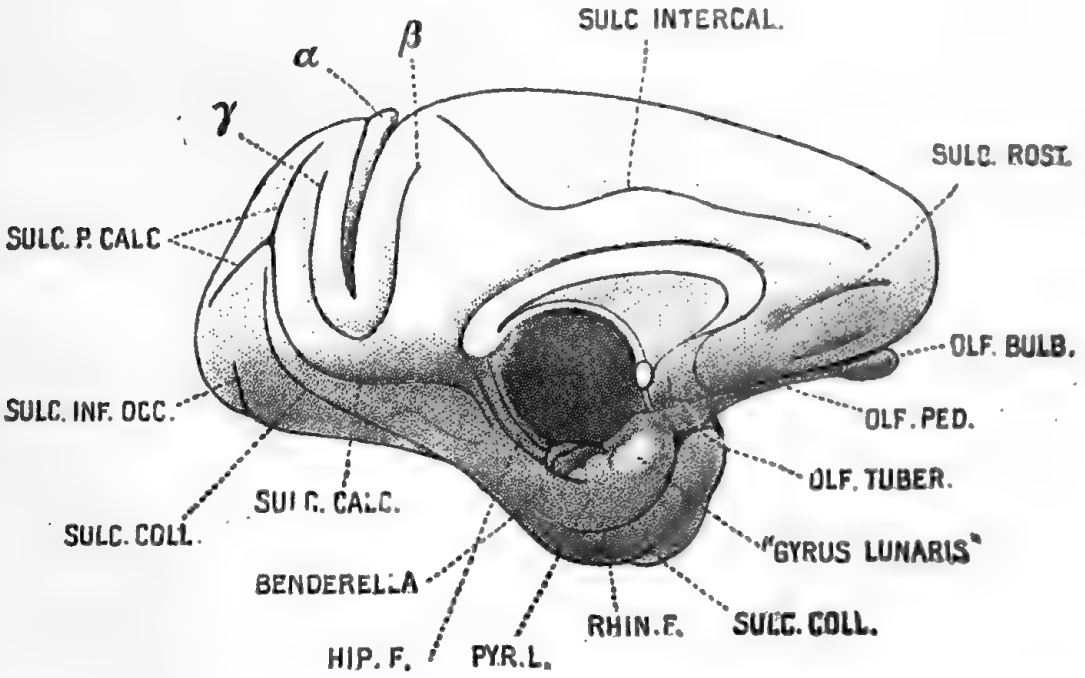

The "gyrus lunaris" of Retzius is the nucleus amygdalæ
SULC. P. CALC. refers to the retrocalcarine sulcus.

With the present specimen we enter upon the consideration of the brain among the Catarrhine Apes (Old World Monkeys).

There is a close resemblance between the brain in the larger Cebidæ and that of the Cercopithecidæ. The general form of the brain is the same in the two Families.

In spite of this identity of structure with the Cebidæ, it is useful to enter into a somewhat minute examination of a Macaque's brain, not only that we may emphasize those common mammalian features which become obscured in the Simiidæ and especially in Man, but also because the brain of *Macacus* has been so often explored by physiological methods that the homologies of its various parts thus acquire an added interest.

The olfactory bulb (which has been destroyed in this specimen) is a small ellipsoidal mass of grey matter. As a result of the great forward extension of the cerebral hemispheres in the Anthropoidea, the place of attachment of the olfactory peduncle to the hemisphere becomes removed progressively further away from the cribriform plate of the ethmoid bone, where the olfactory bulb is, as it were, moored by the olfactory nerves. The olfactory peduncle therefore becomes greatly elongated, and as a result the proportion of grey matter to white fibres (olfactory tract) becomes greatly reduced, so that the peduncle becomes a long, attenuated, white ribbon. In most Cercopithecid brains no olfactory sulcus is developed to accommodate this flattened peduncle.

Fig. 242. (× $\frac{2}{3}$.)

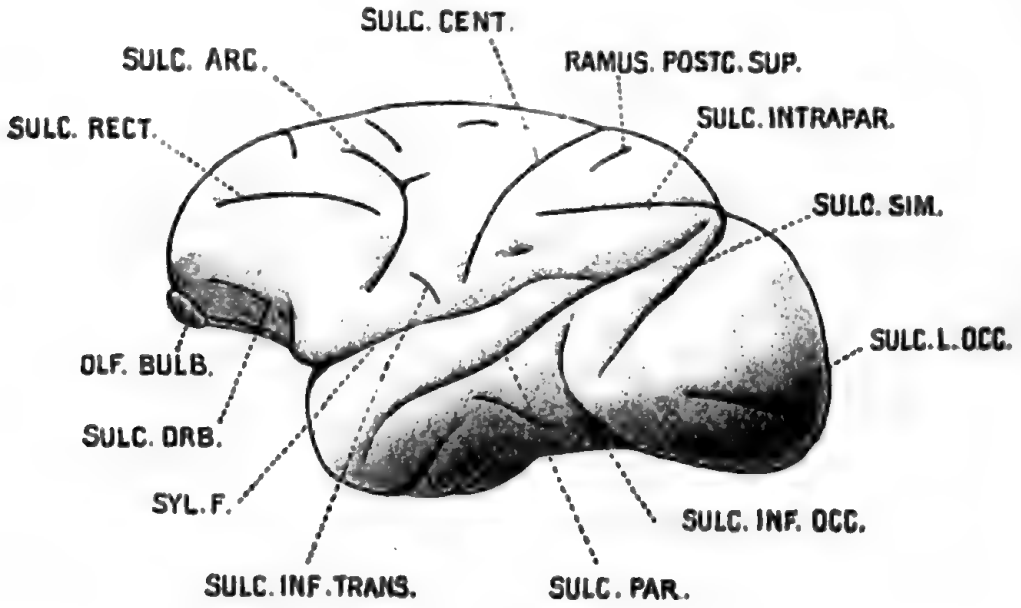

The relations of the olfactory peduncle to the tuberculum olfactorium and pyriform lobe are identical with those so clearly demonstrable, say, in the brain of a Dog or of a Sheep. The tuberculum olfactorium is still very distinct, because it has not become flattened out to the same extent as it has in the human brain. A very pronounced flexure has occurred in the pyriform lobe producing the vallecula Sylvii. The part of the pyriform lobe in front of this vallecula has become greatly reduced and would not be recognizable as such if it were not for the presence of the distinct olfactory tract extending from the olfactory peduncle to the posterior part of the lobe. The anterior rhinal fissure has vanished. The posterior rhinal fissure, however, forms a very distinct incisura temporalis, which constitutes the lateral boundary of the pyriform lobe.

The Sylvian fissure appears to begin upon the base of the brain as a lateral extension of this vallecula Sylvii of the pyriform lobe. It then extends obliquely upward and backward as a deep cleft upon the lateral aspect; its dorsal extremity almost reaches the parallel sulcus, from which it is separated by a very narrow gyrus, which is often submerged so that the Sylvian fissure appears to join the parallel sulcus in a superficial view.

If the lips of the Sylvian fissure be separated or cut away (as has been done in the right hemisphere) a large triangular depressed area—the insula *—will be found, overlapped chiefly by the dorsal (or fronto-parietal) operculum. The dorsal limiting sulcus of the insula probably represents the suprasylvian sulcus of other mammals (which in the Primates forms the chief and most stable factor in the complex called "Sylvian fissure"). When this fissure is opened up in a Macaque, the anterior extremity of this dorsal limiting sulcus will be found to extend forward into the deep surface of the operculum just external to the junction of Sylvian vallecula and fissure. In the Gibbons and higher Apes this limiting sulcus extends still further forward and becomes visible. The anterior part of the fronto-parietal operculum which borders on this upturned extremity of the limiting sulcus, meets in the human brain another lip which arises in front of the insula and forms the anterior limb (or limbs) of the Sylvian fissure. In the brains of the Macaques there is no trace of this anterior operculum (or opercula); but in this brain there is a well-defined, simple, linear

---

* It must, however, be remembered that in the Apes the anterior part of the insula is not submerged but extends forward to the fronto-orbital sulcus.

fronto-orbital sulcus between the Sylvian fissure and the triradiate orbital sulcus. When the anterior lip of this sulcus becomes opercular it forms the orbital operculum. In other words, the fronto-orbital is the anterior limiting sulcus of the island of Reil.

Upon the orbital surface we always find an orbital sulcus, which (as I have frequently insisted elsewhere in these notes) probably represents the "presylvian" sulcus of other mammals. An exceedingly variable series of compensatory-orbital sulci develope alongside the true orbital sulcus, sometimes on its mesial side, sometimes on its lateral side, and often on both sides. Frequently in this way an **H**-shaped or triradiate arrangement of sulci is formed. The external compensatory-orbital sulcus often becomes deep and well-defined (as in this case) to form the fronto-orbital sulcus.

The parallel sulcus extends beyond the Sylvian fissure at both extremities.

The intraparietal (lateral) sulcus arches around the apex of the parallel. Its bifurcated caudal extremity—the transverse occipital sulcus—is hidden under that peculiar occipital operculum, the outgrowth of which produces that great cleft known as the "Affenspalte" or "Simian sulcus." [On the left hemisphere the operculum has been cut away so as to show the transverse occipital sulcus.]

Occupying the same relation to the intraparietal sulcus as the ansate does to the lateral sulcus in the Carnivora, we often find in the Cercopithecidæ a small ramus postcentralis superior of the intraparietal sulcus. This is very poorly developed, especially on the right side, in this specimen.

There is a typical central sulcus.

There is a plain sagittal sulcus rectus (the inferior frontal sulcus) and a typical sulcus arcuatus (inferior precentral).

Above the sulcus arcuatus there are two small depressions representing the superior frontal sulcus. Below the central sulcus there is a small plain sulcus, which Eberstaller calls "inferior transverse."

The inferior occipital sulcus is an elongated furrow the upper lip of which is markedly opercular. It skirts the ventro-lateral margin and then bends upward in front so as either to superficially join the Affenspalte or, as in this case, to end between the lower end of the latter and the parallel sulcus.

Two fragmentary sulci, generally regarded as inferior temporal, are found in the triangle formed by the parallel, inferior occipital, and collateral sulci. There is also a shallow horizontal sulcus on the cranial aspect of the occipital pole, corresponding to that called "lateral occipital" in the Cebidæ.

On the mesial surface we find the deep calcarine sulcus placed almost horizontally and passing without any line of demarcation into the stem of the **T**-shaped retro-calcarine sulcus. The collateral sulcus begins in the inferior angle of the **T** and, after an extensive course along the inferior margin, ends in close proximity to the rhinal fissure (fig. 241).

The parieto-occipital, being essentially a compensatory sulcus, exhibits extreme variation. We may find a simple deep incision (α) in the dorso-mesial angle of the hemisphere opposite the apex of the occipital arc of the intraparietal, which it joins. This fundamental sulcus may be surrounded by a **U**-shaped arc ($\beta+\gamma$) on the mesial surface, the posterior limb (γ) of which is essentially "parieto-occipital," whereas the anterior limb (β) really belongs to the intercalary series—being the "compensatory" or so-called "post-limbic" sulcus of Broca. The fundamental sulcus (α) in this case is exactly analogous to that which was named ramus parieto-occipitalis sulci intraparietalis in *Cebus* (*vide supra*). The anterior limb (β) of the **U**-shaped compensatory sulcus is often separated as a distinct "compensatory" element. While all this variety bears out the fundamentally compensatory nature of the sulcus, it renders a concise definition of the parieto-occipital sulcus impossible *.

A glance at the illustration (fig. 241) or at the mesial surface of the brain of any Ape, will at once show how the majority of the (posterior) mesial sulci are essentially

---

* The human parieto-occipital sulcus consists of the representatives of the sulci a and γ, the intervening area being submerged so that the two sulci appear to form one cleft.

compensatory to the calcarine sulcus, around which they are grouped in such a peculiar manner.

There is always a well-developed intercalary (calloso-marginal) sulcus with an upturned caudal extremity. And generally there is a small separate rostral sulcus.

In proportion to the size of the cerebral hemispheres, the other regions of the brain seem very diminutive in the Apes. This is very striking in the case of the quadrigeminal and geniculate bodies, and even more so as regards the corpora mammillaria and interpeduncular body. Even the cerebellum appears to be very small in the Apes, although its actual size—in comparison with that of the body—is great. The pons Varolii is relatively broad, but not sufficiently so to hide the trapezoid body, which is in the Cercopithecidæ quite as distinct as it is in the Carnivora. The pyramidal tracts are relatively very large and prominent. And the olivary body is very distinct.

The cerebellum in the Apes is very different in shape from that of other mammals because it becomes moulded to the configuration of the cerebral hemispheres which overlap it. Structurally it does not differ much from the organ in other mammals. But the relative size of the floccular lobe has become greatly reduced, although not nearly to such a marked extent as it is in *Homo*, *Anthropopithecus*, and *Simia*. It is noteworthy that the lateral lobule of the floccular lobe, *i. e.* the paraflocculus, is still larger than the mesial lobe (flocculus) and is provided with a projecting pedunculated appendage—the petrosal lobule—as is the case in many lowlier mammals. O. C. 1338 C *g*.

D. 595. The brain of a new-born Bengal Macaque (*Macacus rhesus*). The left hemisphere has been detached.

The intraparietal sulcus gives off (in each hemisphere) a short branch towards the upper margin of the hemisphere. Such a short branch is probably a representative of part, and *not* of the whole of the ramus postcentralis superior of the intraparietal sulcus, for its direction is not that taken by the isolated subdivision of the latter. Otherwise the specimen presents characters wholly in agreement with those of D. 594. O. C. 1338 c *b*.

D. 596. The brain of a Bengal Macaque (*Macacus rhesus*).

This is a much better specimen than D. 594, which it closely resembles.

The gyrus separating the sulcus γ (see fig. 241) from that labelled α is very narrow and deeply submerged, so that the former appears to be concurrent with the latter, *i. e.* to be a branch of the intraparietal. O. C. 1338 c *c*.

D. 597. Two casts of the cranial cavity of a Rhesus Monkey (*Macacus rhesus*).

Unlike most casts of the cranial cavity, this shows no trace of the cerebral sulci but a good impression of the meningeal vessels and of the sutures separating the cranial bones.

D. 598. The brain and part of the skull of a fœtal Crab-eating Macaque (*Macacus cynomolgus*).

There has been an injection into the membranes.

A horizontal section opens the lateral ventricles (most of the corpus callosum has been removed, but a slight bridge still remains) and exposes the corpora striata, optic thalami, and the hippocampi in the descending cornua. O. C. 1338 c *e*.

D. 599. The brain of a Crab-eating Macaque (*Macacus cynomolgus*), (♀). O. C. 1338 c *d*.

D. 600. The brain of a Crab-eating Macaque (*Macacus cynomolgus*), The left hemisphere has been detached from the remainder of the encephalon.

The collateral is represented by two sulci in the left hemisphere, but by one only in the right hemisphere.

The fronto-orbital sulcus is especially well-developed.
O. C. 1338 c *f*.

D. 601. Two casts of the cranial cavity of a Crab-eating Macaque (*Macacus cynomolgus*).

D. 602. The brain of a Lion-tailed Macaque (*Macacus silenus*) in which the left hemisphere has been detached.

The opercular fold at the lower margin of the occipital lobe is particularly well developed and the hinder end of the collateral sulcus runs under it. Otherwise the conformation of this brain agrees with that of D. 594. O. C. 1338 *h*.

D. 603. The brain of a Lion-tailed Macaque (*Macacus silenus*).
O. C. 1338 C *a*.

D. 604. The brain of a Barbary Macaque or Magot (*Macacus inuus*), (♂). The left hemisphere has been detached.

On both sides the Sylvian fissure is separated from the parallel sulcus by an exposed gyrus. Just above the posterior end of the Sylvian is a small linear accessory furrow in the left hemisphere. O. C. 1338 C *i*.

D. 605. The brain of a Himalayan Macaque (*Macacus erythræus*).

This is an exceedingly well-preserved specimen. The left hemisphere has been divided into several portions by a series of horizontal sections. An opercular growth has taken place in the upper lip of the inferior occipital sulcus. Such an operculum is suggested feebly by most specimens of *Macacus*, but here it has carried a fold of cortex downwards and has folded it almost over on to the mesial aspect. This operculum, combined with the normally-developed one at the "Affenspalte," confers a striking appearance on this specimen.

D. 606. The brain of a Sooty Mangabey (*Cercocebus fuliginosus*): the left hemisphere has been detached.

This specimen closely resembles the brain of a *Macacus*. It is noteworthy that in the right hemisphere the arcuate sulcus sends off a posterior branch which reaches the central sulcus. Cunningham has pointed out that in the Mangabeys the transverse occipital ramus of the intraparietal sulcus may become concurrent with the "Affenspalte" (Memoirs Roy. Irish Acad. 1892, p. 229). O. C. 1338 D.

D. 607. The brain of a Sooty Mangabey (*Cercocebus fuliginosus*), (♀). The left hemisphere has been detached.

There is a well-developed lateral occipital sulcus.
O. C. 1338 D *a*.

D. 608. The brain of a Sooty Mangabey (*Cercocebus fuliginosus*), (♀), from which the left hemisphere has been detached.

This specimen closely resembles the *Macacus*-brain.
O. C. 1338 D *b*.

D. 609. The brain of a White-collared Mangabey (*Cercocebus collaris*), (♀): the left hemisphere has been detached.

There is no important difference from the foregoing or from the *Macacus*-brains. The opercular fold in the lower margin of the occipital lobe of the right side is very extensive, stretching forward into the temporal region; it is also deep, so much so that the collateral sulcus is represented by two short sinuous sulci only, there being presumably no call for the greater amount of surface they would provide if better developed.

There is a slight tendency among these *Cercocebus*-hemispheres to irregularity (more so than in *Macacus*) in the arrangement of the collateral sulcus. O. C. 1338 D *c*.

D. 610. The brain of a Diana Guenon (*Cercopithecus diana*), (♀): the left hemisphere has been detached.

The differences from *Macacus* (and also from *Cercocebus*) are insignificant, being attributable to the smaller size of the brains in the present genus. The arcuate sulcus gives no posterior branch in the right hemisphere and only a very short one in the left. On the mesial aspect the collateral sulcus is seen to be represented by three isolated sulci the posterior of which appears to spring from the calcarine.

O. C. 1338 E.

D. 611. The brain of a Diana Guenon (*Cercopithecus diana*): the left hemisphere has been detached. The floccular lobes are well preserved. There are three sulci in the collateral group of the left hemisphere, two in the right hemisphere.

O. C. 1338 E *m*.

D. 612. The brain of a Lesser White-nosed Guenon (*Cercopithecus petaurista*), (♀): the left hemisphere has been detached.

There is a slight irregularity in the collateral sulcus, which in each hemisphere is represented by two sulci.

O. C. 1338 E *a*.

D. 613. The brain of a Lesser White-nosed Guenon (*Cercopithecus petaurista*), (♂): the left hemisphere has been detached.

O. C. 1338 E *a a*.

D. 614. The brain of a Lesser White-nosed Guenon (*Cercopithecus petaurista*) : the left hemisphere has been detached.
O. C. 1338 E *a b*.

D. 615. The brain of a *Cercopithecus* (sp.) : the left hemisphere has been detached. O. C. 1338 E *b*.

D. 616. The brain of a Grivet Monkey (*Cercopithecus sabæus*), (♀): the left hemisphere has been separated from the rest of the brain. O. C. 1338 E *f*.
Presented by C. E. Flower, Esq.

D. 617. The brain of a Grivet Monkey (*Cercopithecus sabæus*), (♀). O. C. 1338 E *g*.

D. 618. The brain of a Vervet Guenon (*Cercopithecus lalandii*) : the left hemisphere has been detached from the remainder of the encephalon.

The Sylvian fissure does not join the parallel in the left hemisphere, and only does so very superficially in the right hemisphere. O. C. 1338 E *h*.

D. 619. The brain of a Patas Guenon (*Cercopithecus ruber*), (♀): the left hemisphere has been detached.

The orbital surface of the left hemisphere bears three sagittally-directed sulci, the outermost being represented by a depression only, in the right hemisphere. O. C. 1338 E *i*.

D. 620. Brain of the Hocheur Guenon (*Cercopithecus nictitans*). The left hemisphere has been detached. O. C. 1338 E *n*.

D. 621. The brain of a Campbell's Guenon (*Cercopithecus campbelli*), (♂).

Notice a deep sagittally-directed sulcus on the occipital lobe. O. C. 1338 E *k*.

D. 622. The brain of a Green Guenon (*Cercopithecus callitrichus*), (♀).

The left hemisphere has been detached from the remainder of the encephalon. O. C. 1338 E *l*.

D. 623. The brain of a Malbrouck Guenon (*Cercopithecus cynosurus*): the left hemisphere has been detached. O. C. 1338 E *o*.

D. 624. The brain of a Malbrouck Guenon (*Cercopithecus cynosurus*): the left hemisphere has been detached.

Both brains conform precisely to the typical arrangement.

O. C. 1338 E *p.*

D. 625. The brain of a Yellow Baboon (*Papio babuin*), (♂): the left hemisphere has been separated.

This is a very much larger brain than that of any of the Primates yet considered. The cerebral hemispheres are also proportionately longer than in the other genera.

In accordance with its greater extent, the surface of the hemispheres is more richly furrowed than in the smaller Cercopithecidæ, but its pattern is essentially the same.

The Sylvian fissure is separated from the parallel sulcus throughout by a wide exposed gyrus. The parallel sulcus is prolonged far beyond the Sylvian, and its apex is encircled by the ramus horizontalis of the intraparietal sulcus. The latter splits and forms a transverse occipital sulcus, but, unlike the condition found in the Apes hitherto considered, the mesial limb of the transverse occipital cuts deeply into the mesial wall of the hemisphere, so that it represents (functionally) the sulcus α of *Macacus* (*vide supra*). Such being the case, it is not surprising to find that the parieto-occipital sulcus (which in a superficial view of the left hemisphere seems to join the intraparietal element) cuts into the anterior wall (and not the posterior, as in the higher Cebidæ and in the Macaques) of the intraparietal ramus. On the right side the parieto-occipital sulcus lies wholly in front of the ramus intraparietalis. On both sides the former sulcus appears to join the calcarine, but a submerged gyrus separates them*.

There is a well-developed occipital operculum, which has been partially removed on the right side in order to expose the transverse occipital sulcus. No proper operculum is formed by the upper lip of the horizontal inferior occipital sulcus.

Three horizontal sulci, representing the transverse

---

* By parieto-occipital sulcus is meant that labelled γ in *Macacus*, which, as explained above, does not strictly represent the parieto-occipital sulcus of Human Anatomy.

occipital sulcus, are found in the triangle partially formed by the Simian sulcus and the inferior occipital sulcus.

There is a very rudimentary superior postcentral sulcus. In addition to the typical sulcus rectus and sulcus arcuatus there is a small "inferior transverse" sulcus of Eberstaller (between the lower ends of the latter and the central sulcus) and a small "diagonal" sulcus (in front of the lower end of the arcuate sulcus) *.

An irregular series of small furrows represents the superior precentral and superior frontal sulci. Simple orbital and fronto-orbital sulci are present.

The floccular lobes of the cerebellum are still very large and retain those features common to most mammals. The flocculus consists of a narrow band of small folia encircling the eighth nerve. The paraflocculus consists of a much larger and broader band surrounding the flocculus. Its mesial lobule lies in front of (and without minute examination is indistinguishable from) the flocculus. From the antero-lateral part of the paraflocculus projects a small, though widely salient, "petrosal lobule." But in contrast to the condition found in the Cebidæ and many Cercopithecidæ, the "petrosal lobule" constitutes a very small part of the paraflocculus.

As this is a larger brain than that of any Ape yet considered, it affords an excellent demonstration of the great increase in size and prominence of the olivary bodies and pyramidal tracts. Although the pons has become very broad, the large trapezoid bodies are still uncovered, as in lowlier mammals. O. C. 1338 A *a*.

D. 626. The brain of a Yellow Baboon (*Papio babuin*), (♂). The left hemisphere is separate.

In the presence of a deep long collateral sulcus (such as we shall see in specimen D. 627) the occipito-temporal almost completely disappears as a separate sulcus, and the inferior occipital sulcus becomes smaller.

In the right hemisphere both the lateral and mesial olfactory tracts are unusually clearly shown. O. C. 1338 A *f*.

---

* This sulcus, called "diagonalis" by Eberstaller, is not the furrow called by this name in other Mammals by Krueg. The latter, in all probability, becomes the fronto-orbital in Primates.

D. 627. The brain of a Chacma Baboon (*Papio porcarius*), (♂). The left hemisphere has been detached. [The right hemisphere has been damaged by a horizontal saw-cut.]

There is an exceptionally well-developed anterior limiting sulcus of Reil or, as it is more generally known, fronto-orbital sulcus. External to this there is a short deep sulcus [best seen on the right hemisphere] just in front of the exposed end of the superior limiting sulcus of Reil, that emerges from the Sylvian fissure. This is of great interest because it indicates that extension of the surface in this region which in a slightly higher phase of development leads to the formation of an operculum. An examination of the series of brains of Anthropoid Apes shows that this operculum is often formed by the upper lip of a small sulcus in this position, which is not part of either the superior (Marchand's "opercular") or the anterior (fronto-orbital) limiting sulcus.

The collateral sulcus is unusually extensive, its caudal end almost joining the calcarine sulcus, and its anterior end overlapping the rhinal fissure. There is, therefore, no separate occipito-temporal sulcus such as we find in the brain of some Baboons.

On the left hemisphere there are small superior precentral and superior frontal sulci of diagrammatic simplicity. O. C. 1338 A.

[For fuller information concerning this brain, see D. J. Cunningham, Mem. Roy. Irish Acad. vol. iii. 1892, p. 282.]

D. 628. The brain of a Chacma Baboon (*Papio porcarius*). The left cerebral hemisphere has been separated.

The peculiarly extensive collateral sulcus of the preceding specimen is exactly reproduced here also.

On the left hemisphere, the opercular lip of the Simian sulcus has been pulled backward sufficiently far to show that the relations of the intraparietal sulcus and that which we may now call "parieto-occipital" are essentially the same as those described in specimen D. 630 (*vide infra*). O. C. 1338 A *i*.

D. 629. The cerebellum, medulla oblongata, &c., of an Arabian Baboon (*Papio hamadryas*), (♂).

The floccular lobe of the left side is well preserved.

O. C. 1338 A *b*.

D. 630. The left cerebral hemisphere of the same brain.

This is a smaller hemisphere, and the sulci are slightly less complex than in the preceding examples (D. 626).

The anterior part of the collateral is separated from the posterior part, and is prolonged backward as an occipito-parietal sulcus to join the inferior occipital. O. C. 1338 A *c*.

D. 631. The brain of a Guinea Baboon (*Papio sphinx*). The two cerebral hemispheres have been detached.

This specimen affords two more interesting variations in the ever-changing area around the parieto-occipital sulcus.

In a superficial view of the mesial aspect of the right hemisphere there appears to be a Y-shaped combination of parieto-occipital and calcarine elements. If, however, the lips of the sulci be drawn asunder, the parieto-occipital is found to be separated from the calcarine sulcus by a narrow, deeply-submerged gyrus; and the apparent parieto-occipital sulcus consists of two distinct sulci, which are seen as such on the left hemisphere widely separated by a broad gyrus. On the right side, however, the two sulci are separated by a submerged gyrus, and, after comparison with the last specimen, there can be no doubt that the anterior sulcus (that which appears to join the calcarine) corresponds to the element hitherto called "parieto-occipital," whereas the deeper and more extensive posterior sulcus (compare the left hemisphere) is unquestionably identical with that distinguished as the "ramus parieto-occipitalis sulci intraparietalis." But the importance of this specimen depends upon the fact that upon the right hemisphere the latter sulcus is separated from the intraparietal sulcus by a small, exposed, arcuate gyrus, which can be no other than that called arcus occipitalis in Human Anatomy. Essentially the same condition is found on the left hemisphere, but the arcus occipitalis is submerged.

There can be no doubt that the parieto-occipital sulcus of Man is represented not merely by the sulcus so named in the last specimen and other Apes, but also by the second element distinguished as "ramus parieto-occipitalis sulci intraparietalis."

The caudal extremity of the intraparietal sulcus ends without bifurcating under cover of the occipital operculum, but does not reach the bottom of the Simian sulcus.

In the right hemisphere the collateral series is represented by two long deep sulci. Below the calcarine there is the true collateral sulcus, the posterior end of which is separated from the calcarine by a submerged gyrus. Occupying a more lateral position there is a second longer and deeper sulcus of the same series, which must now be called the inferior (or third) temporal or the occipito-temporal sulcus. Posteriorly this appears to join the very long inferior occipital sulcus at about its mid-point, but there is a narrow submerged gyrus between them. The anterior end of the inferior occipital is separated from the Simian sulcus by a partially submerged gyrus, and its caudal end is prolonged far back on to the mesial surface almost as far as the calcarine sulcus.

On the left hemisphere the inferior occipital is a very short sulcus, the mid-point of which is joined by a vertical furrow to the mid-point of the occipito-temporal sulcus. The posterior half of the latter therefore takes the place of the posterior (mesial) prolongation of the inferior occipital sulcus on the right side. O. C. 1338 A *e*.

D. 632. The brain of a Gelada Baboon (*Papio gelada*), (♀). This brain is much smaller than those of most Baboons, and hence the surface is less complicated.

There is a collateral sulcus like that of the last specimen, but the inferior occipital sulcus is placed lower, and is greatly prolonged to form a sulcus parallel to and almost coextensive with the collateral. O. C. 1338 A *g*.

D. 633. The brain of a Drill (*Papio leucophæus*).

This is a relatively small and simple brain, which exhibits the characteristic features of the Baboon's brain particularly

clearly. This is especially so in the region of the hind brain, where an admirable demonstration is afforded of the relations of the pyramidal tracts, olivary bodies, trapezoid bodies, eighth nerves, and the three parts of the floccular lobes—the mesial paraflocculus in front, the flocculus behind it, and the large lateral paraflocculus, which is placed behind the rest. Although the floccular lobes do not seem to be damaged, there is no projecting "petrosal lobule."
O. C. 1338 A *h*.

D. 634. Two casts of the cranial cavity of a Drill (*Papio leucophæus*).

D. 635. The brain of a young female hybrid between a male Macaque (*Macacus cynomolgus*) and a female Baboon (*Papio mormon*). From the Zoological Gardens, 1880.

This brain is indistinguishable from that of a Macaque. In that region of the brain—around the parieto-occipital sulcus—where alone noteworthy distinctive features are found in the two genera, this brain exhibits the typical features of the Macaque.

The influence of the male parent has therefore been clearly predominant in determining the features of the brain in this instance. O. C. 1338 B *b*.

D. 636. The brain of a Hanuman Langur or Entellus Monkey (*Semnopithecus entellus*), (♂). The left hemisphere has been separated.

The seven brains representative of the genus *Semnopithecus* in this Collection are of varying sizes, some larger and some smaller than those of the genus *Macacus*, but on the average they are rather larger than the latter. On the other hand, they are much smaller than those of the genus *Papio*, and accordingly the pattern formed by the sulci of the cerebral hemisphere is somewhat simpler than that found in the Baboons.

The parieto-occipital sulcus and the representative of that called "ramus parieto-occipitalis" of the intraparietal in the Macaques have now become confluent (although slight irregularities exist in the depths of the sulcus to indicate its dual nature in the Baboons and lowlier Apes). The resulting single sulcus is obviously the parieto-occipital sulcus of Man. It is a simple linear sulcus, the lower end of which is separated from the calcarine by a submerged gyrus (as in the human brain) ; its upper extremity is surrounded by a broad arcus occipitalis which separates it completely from the intraparietal sulcus. As occasionally happens in the genus *Papio*, the occipital operculum is not extensive enough to hide the arcus occipitalis or the parieto-occipital sulcus.

The inferior occipital operculum (*i. e.* the dorsal lip of the inferior occipital sulcus) is much less developed than it is in *Macacus*. In other respects the brain closely resembles that of *Macacus*, with the exception that the calcarine sulcus is not bifid. O. C. 1338 F.

D. 637. The brain of an Entellus Monkey (*Semnopithecus entellus*), (♀). The left hemisphere has been separated.

This closely resembles the preceding specimen. The sulcus arcuatus is, however, triradiate in this case.

The collateral series of sulci vary in the two brains in the same way as we have already noted in *Papio*.

O. C. 1338 F *a*.

Presented by P. L. Sclater, Esq.

D. 638. The brain of an Entellus Monkey (*Semnopithecus entellus*).

This old specimen exhibits the same arrangement of sulci as the preceding.

In spite of its damaged condition it shows the relations of the flocculus, paraflocculus, and the projecting " petrosal lobule " better than the more recent specimens.

O. C. 1338 F *b*.

D. 639. The brain of an Entellus Monkey (*Semnopithecus entellus*). The left hemisphere has been separated.

In these hemispheres the arcus occipitalis has become submerged under the occipital operculum, so that, at a superficial glance, the Simian and the parieto-occipital sulci seem to be confluent.

The lips of the Sylvian fissure have been separated on the right hemisphere so as to expose the anterior end of the superior limiting sulcus of Reil.

The petrosal lobule of the floccular lobe is more distinctly demonstrable. O. C. 1338 F *c.*

D. 640. The brain of an Entellus Monkey (*Semnopithecus entellus*). The left hemisphere has been separated.

Unlike the condition found in all the other Entellus Monkeys, the calcarine sulcus presents the bifurcated form more usual in the Cercopithecidæ. The cerebellum and floccular lobes are better preserved in this specimen.

O. C. 1338 F *d.*

D. 641. Two casts of the cranial cavity of an Entellus Monkey (*Semnopithecus entellus*).

D. 642. The brain of a Purple-faced Langur (*Semnopithecus leucoprymnus*). The left hemisphere has been detached.

This is a much smaller brain than those of many other Langurs.

The lower opercular lip of the Sylvian fissure has been removed in the left hemisphere, so as to expose the insula and its superior limiting sulcus.

The inferior occipital sulcus has dwindled to most insignificant proportions, and unless the student examines a large series of brains he will hardly recognize in the little arc around the lower end of the Simian sulcus the representative of the deep operculated infra-occipital sulcus of the Macaques. O. C. 1338 F *e.*

D. 643. The brain of a Purple-faced Langur (*Semnopithecus leucoprymnus*). The left hemisphere has been separated.

This is a well-preserved typical Langur's brain. The features of the floccular lobe are very clearly shown here.

If the Simian sulcus be opened up in a series of brains of this genus, the transverse occipital sulcus will be found in many cases to be confluent with it, as it is here.

O. C. 1338 F *f.*

Family *Simiidæ*.

D. 644. The brain of a Hoolock Gibbon (*Hylobates hoolock*), (♀). The left cerebral hemisphere has been separated (figs. 243, 244).

Fig. 243. (× $\frac{2}{3}$.)

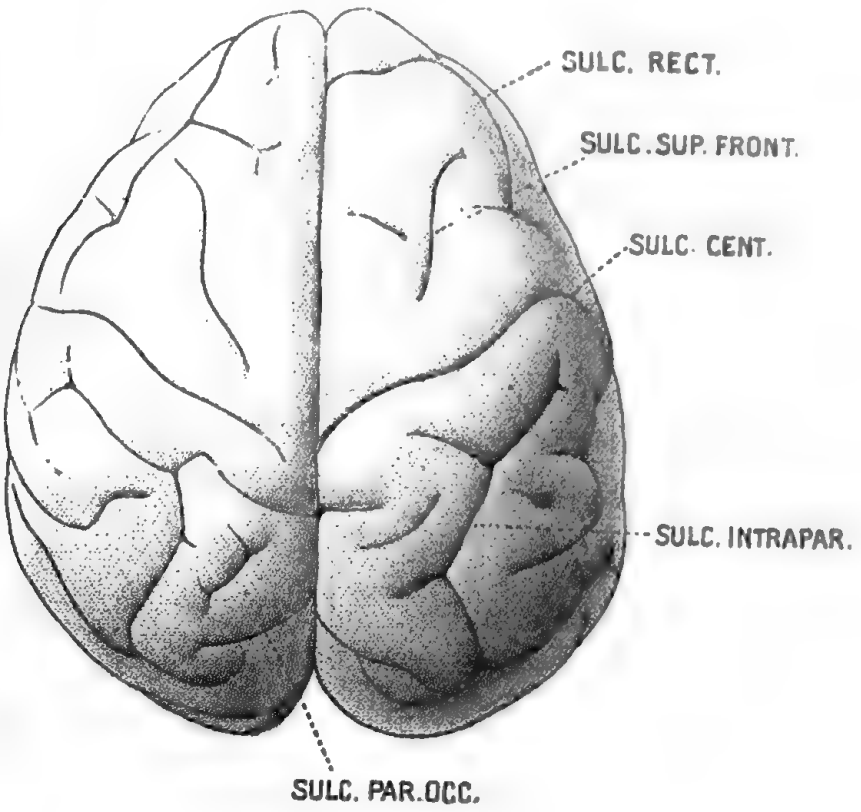

Fig. 244. (× $\frac{2}{3}$.)

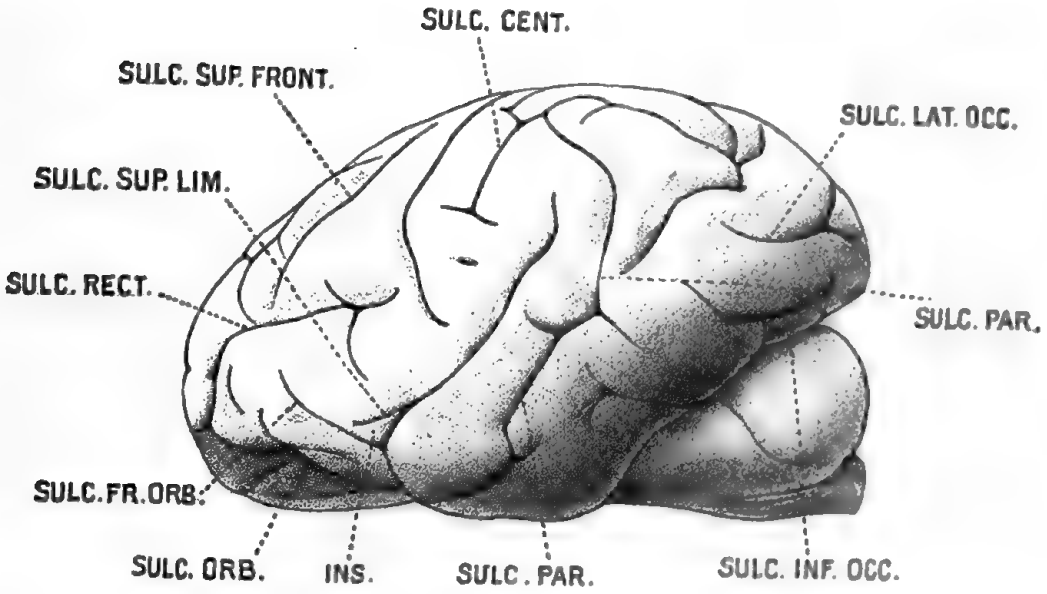

The brain is of special interest in the Gibbons, because it presents many features which may be regarded as intermediate between those of the Anthropoid and other Apes.

The series of modifications which would be necessary to convert the brain of a *Macacus* into that of a *Semnopithecus* are carried a stage further in the case of *Hylobates*.

The parieto-occipital sulcus is now a simple sulcus with external (dorsal) extent almost as great as its internal portion. It is separated from the intraparietal and Simian sulci by a wide gyrus on the left hemisphere. On the right hemisphere, the Simian sulcus curves forward so as almost to reach the parieto-occipital sulcus.

The calcarine sulcus presents upon the left hemisphere the usual bifid form common to most Apes, whereas upon the left side it is plain and undivided, as in most *Semnopitheci*. The occipital operculum is smaller even than it is in the Langur-family, and the inferior occipital sulcus is reduced to a mere vestige, which is triradiate on the left hemisphere.

The lateral occipital sulcus, which is well developed in *Semnopithecus* in comparison with other Apes, is even better developed in this brain. It is a deeply-incised **Y**-shaped sulcus, the two limbs of the **Y** embracing the caudal end of the calcarine sulcus.

The sulci rectus and arcuatus are concurrent, as they are in many of the lower Apes.

But the most characteristic feature of the brain in the Gibbons is the condition of the insular region, which distinguishes this brain from that of all mammals except the Anthropoid Apes. The fronto-orbital sulcus is especially well-developed (see the left hemisphere), and now constitutes the anterior limit of the exposed part of the insula, the dorsal boundary of which has been mapped out by the superior limiting (Marchand's "opercular") sulcus, which has emerged from the Sylvian fissure to a much greater extent than in any of the lowlier Apes. O. C. 1338 G *a*.

D. 645. The brain of a Gibbon (*Hylobates lar*). The left hemisphere has been separated.

This is a smaller and somewhat simpler brain than the above.

The calcarine sulcus is unbranched on both hemispheres. The ramus postcentralis superior of the intraparietal (which is very well developed and united to the main sulcus in the last specimen) is a mere disconnected depression. The two-limbed sulcus formed by the union of the superior precentral and superior frontal sulcus explains the significance of the obliquely-placed sulcus in the preceding specimen. The orbital sulcus is simply linear, instead of being irregularly triradiate, as in the last specimen.

The other sulci do not essentially differ. In both brains the collateral is represented by two sulci, the anterior of which overlaps the posterior laterally, and thus relieves the tension of the growing cortex, which in other hemispheres is relieved by a special sulcus—the occipito-temporal. O. C. 1338 G.

D. 646. The brain of a White-cheeked Gibbon (*Hylobates leucogenys*), (♂). The left cerebral hemisphere has been separated.

The cerebral hemispheres of this brain are much larger and richer in sulci than those of the other two Gibbons' brains.

A peculiar appearance is produced in the occipital region by the parieto-occipital sulcus (after crossing on to the dorsal surface) being prolonged (superficially) backward for some distance so as to form a **V**-shaped pattern with an analogous backward extension of the Simian sulcus. The two sulci, however, do not join. This peculiar appearance seems to be the result of a very pronounced broadening of the anterior limb of the gyrus called arcus occipitalis, which has pushed back, so to speak, the occipital operculum and the mesial end of the Simian sulcus, and driven the diminutive posterior limb of the arcus under cover of the mesial lip of the peculiar sagittally-directed part of the parieto-occipital sulcus. As a further result, the bifid extremity of the intraparietal sulcus, which forms the transverse occipital sulcus, not only lies far in front of the Simian sulcus and operculum, but also in front of the bent parieto-occipital sulcus.

The complexity of the intraparietal series of sulci is still further increased not only by the ramus postcentralis but by several other additional rami.

The inferior occipital sulcus is present as a short deep furrow, and is joined on the right hemisphere to the posterior element of the middle temporal sulcus. The occipito-temporal sulcus is very long and deep, its extension having taken place at the expense of the collateral sulcus. On the left hemisphere the little inferior occipital sulcus is linked to the occipito-temporal sulcus, just as occurs in the corresponding hemisphere of the Guinea Baboon (D. 631).

The calcarine sulcus has two long diverging caudal limbs, as well as several accessory sulci surrounding it.

The superior frontal sulcus is exceptionally well-developed.

But by far the most interesting and important feature of this brain is the condition of the anterior insular region. On the right side, this region does not markedly differ from that already described in the case of the Hoolock Gibbon (D. 644). But in the left hemisphere the fronto-orbital sulcus is very deep (as it also is on the right side), and the superior limiting sulcus is prolonged forward so as almost to reach the fronto-orbital (in fact, on casual examination it appears to do so): moreover, the dorsal lip of the superior limiting sulcus has become opercular, so that the anterior insular region is not only almost completely surrounded by sulci, but is also depressed below the level of the surrounding areas. Thus a condition is produced which finds a close parallel in the developing human brain. (Compare Cunningham's observations on the analogous phenomena in the Chimpanzee's brain, Journ. Anat. & Phys. vol. xxxii. 1898, pp. 11 *et seq.*)

Fig. 245. (× $\frac{2}{3}$.)

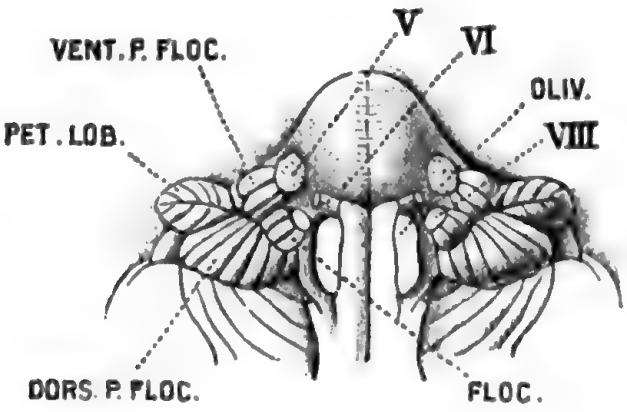

The trapezium, although covered by the pons to a much greater extent than in *Papio,* is still distinct laterally.

The floccular lobe resembles that of the Cercopithecidæ, and is relatively much larger than it is in the Anthropoid

Apes. It consists of a small mesially-placed flocculus, consisting of a series of simple folia grouped around the auditory nerve, and a very large external paraflocculus. The latter consists of the usual two parts, viz., a dorsal (lateral) paraflocculus composed of broad flattened folia, and a ventral (mesial) paraflocculus composed of narrower folia. From the angle of junction of dorsal and ventral lobules a large strongly-projecting feather-like group of parafloccular folia projects to form the pedunculated petrosal lobule (fig. 245). O. C. 1338 a *b*.

D. 647. Two casts of the cranial cavity of a Siamang (*Hylobates syndactylus*), (♂).

D. 648. The left cerebral hemisphere and the rest of the brain of a young Mias or Orang-Outang (*Simia satyrus*).

In comparison with those of other Apes the brains of the Anthropoids are characterized by their greater absolute dimensions. The cerebral hemispheres are fuller and more rounded than those of *Hylobates*, and especially so in the frontal region. There is, however, a very pronounced rostration of the orbital region resulting in the formation of a most prominent keel. The floccular lobes of the cerebellum (and more especially the paraflocculus) undergo a noteworthy reduction in size. The trapezoid bodies become covered by the pons to a much greater extent than is the case in other Apes; and also, partly, as a result of the increasing breadth of the pons, the large olivary bodies now extend as far as the latter body.

But by far the most important changes are found in the cerebral hemispheres, the surfaces of which are much more extensive, and consequently much more richly supplied with sulci than is the case in lower Apes.

The anterior insular region presents features such as have been already described in the Gibbons. The fronto-orbital (anterior limiting) sulcus is deep and very long, extending across the orbital margin so as almost to meet the inferior precentral (arcuate) sulcus. The exposed portion of the superior limiting (opercular) sulcus is also deep and long, but is still separated from the fronto-orbital by a broad gyrus. The upper lip of this sulcus is the more prominent, an indication of its conversion into an operculum in a higher phase of development.

The Sylvian fissure has a T-shaped caudal extremity. The long central (Rolando's) sulcus has a slight genu: it does not attain to the mesial surface.

The inferior precentral (arcuate sulcus) is a deep irregularly-triradriate sulcus, the inferior limb of which is superficially joined to the Sylvian sulcus by the inferior transverse sulcus. The gyrus which separates these sulci is wholly submerged on the left, and only partially so on the right hemisphere. In calling this sulcus "arcuate" it must be borne in mind that in the earliest phase of its history (curiously reproduced again in the Gibbons) the arcuate and straight (rectus) sulci are one, and later this single sulcus becomes broken up into the two distinct elements, which acquire a very questionable individuality, so that one must not imagine that the sulci called respectively arcuatus and rectus in a higher Ape correspond exactly to those similarly named in the Macaques and Capuchin Monkeys, even if it be admitted that the complex of the two sulci in the Anthropoid represents the two elements of the lower Apes. At the same time it often happens in the case of the Anthropoid Apes, and even in Man, that the exact forms of arcuate (inferior precentral) and straight (inferior frontal) sulci which occur in *Macacus* and *Cebus* may be developed.

In the case under consideration, I am inclined to believe that the sulcus arcuatus has become deeper and longer at the expense of the sulcus rectus, which is a diminutive element (triradiate on the left, arcuate on the right side) in the position where the sulcus fronto-marginalis of Wernicke is found in the human brain.

On the right hemisphere it is joined to the irregularly linear orbital sulcus, the posterior part of which is also linked to the fronto-orbital by a transverse sulcus.

This somewhat lengthy digression has been introduced in order to render intelligible the status of a sulcus which makes its appearance external to the anterior extremity of the sulcus rectus, to which it is obviously compensatory.

It is the sulcus frontalis medius, and is seen in its primitive and typical form on the left hemisphere of *Hylobates leucogenys* (D. 646), and also on the left hemisphere of this Orang just above the triradriate sulcus, which, with a reservation, has been called "rectus." Yet on the right hemisphere the function of this sulcus frontalis medius has obviously been taken partly by the sulcus frontalis inferior (rectus) and partly by the anterior end of the superior frontal. The extensive, deep, superior precentral and superior frontal sulci are united to form a triradiate pattern, and are arranged with quite diagrammatic simplicity.

Between the superior frontal sulcus and the mesial edge there are two small shallow sulci, which can only represent a "sulcus frontalis mesialis," which, so Cunningham believes, "never occurs in the cerebral hemisphere of the Apes" (Mem. Roy. Irish Acad. 1892, p. 296).

The parieto-occipital sulcus is very deeply and irregularly incised, and if its lips be separated (or even without doing so in the right hemisphere) the dual composition of the sulcus (which was explained in the case of *Papio*) is rendered evident. The sulcus has a much greater dorsal extent (see especially the left hemisphere) than in any of the Cercopithecidæ. The elongated arcus occipitalis is wholly exposed on the left hemisphere, so that it has the appearance of having pushed back the occipital operculum. On the right side, however, the posterior limb of the arcus is hidden under the operculum.

In the right hemisphere there is an ideally complete intraparietal sulcus, with a very long ramus postcentralis superior and ramus occipitalis transversus, which is concurrent with the Simian sulcus. There are in addition compensatory sulci parallel to and on both sides of the ramus horizontalis and in front of the ramus postcentralis inferior.

On the left hemisphere, the intraparietal sulcus presents a condition such as often occurs in Man, but never (so far as I am aware) in lower Apes. The ramus postcentralis superior, and not the inferior, is joined to the ramus horizontalis.

The upper end of the parallel sulcus forms a hook-like arch around the bifid Sylvian, such as sometimes happens in the Baboons.

There is a very long and complete linear collateral sulcus. The calcarine sulcus is parallel to the parieto-occipital, and the two are separated throughout by an exposed gyrus.

The inferior occipital sulcus is very small, but the posterior element of the occipito-temporal sulcus is deepened and lengthened in compensation, and ends posteriorly in a horizontal sulcus below and parallel to the typical **Y**-shaped lateral occipital sulcus. On the left hemisphere there is a shallow compensatory sulcus both above and below the latter.

The anterior separate portion of the occipito-temporal sulcus is parallel to the anterior half of the collateral, and is deepened at the expense of the inferior (middle) temporal sulcus, the anterior portion of which consequently disappears on the left side. The posterior part of the inferior (middle) temporal sulcus is prolonged on to the tentorial surface between the anterior part of the occipito-temporal and inferior occipital sulci. On the mesial surface there are typical calloso-marginal and rostral sulci.

The whole of the ventral surface of the brain-stem closely resembles that of a very small human brain. The optic and auditory nerves are, however, proportionately much larger than in Man. A very small area of the trapezium seems to be exposed just to the outer side of the sixth nerve.

The floccular lobe presents a very marked contrast to that of the Gibbon and all the Cercopithecidæ and Cebidæ. It is relatively very much smaller, and the shrinkage affects almost wholly the paraflocculus, which becomes reduced to very small proportions, so that none of its folia project to form a "petrosal lobule." In this specimen the paraflocculus is even so reduced as to be completely hidden under the flocculus, like the flocculi secundarii of Henle in the human brain.

The enormous lateral expansion of the main mass of the cerebellum has resulted in the formation of an organ exactly like a small human cerebellum.

O. C. 1338 H a* & H a.

D. 649. The brain of a nearly adult female Orang-Outang (*Simia satyrus*).

This excellent specimen admirably demonstrates the high vaulting and rotundity of the hemispheres and the great extent of the prominent orbital keel and consequent excavation of the orbital surface.

The floccular lobe of the cerebellum is distinctly larger than that of the last specimen ; the difference in size appears to chiefly affect the paraflocculus, which is much the larger of the two lobules, and is also exposed, as in the lower Apes.

On the right cerebral hemisphere there is a peculiar arrangement of the superior limiting sulcus of Reil, which seems to end in a **T**-piece so as to simulate the **Y**-shaped disposition of the anterior rami of the human Sylvian fissure. A short branch of the fronto-orbital sulcus affords a further indication of the closing-in of the anterior insular area.

By its irregular mode of union with the oblique sulcus the arcuate contributes to the formation of a very irregular and asymmetrical pattern. The inferior frontal ("rectus") sulcus is simple and well-developed on each hemisphere.

The upper frontal region is occupied by such an irregular group of scattered, disjointed sulci that it is impossible to say which are superior or middle frontal elements.

There is a typical (Primate) intraparietal sulcus. The ramus postcentralis superior is separate on both sides : it is particularly well developed on the right side, but broken up into four irregular fragments on the left.

The Sylvian fissure has a bifid extremity on both sides. But the hooked extremity of the parallel sulcus is not nearly so complete as in the last specimen.

The broad plump arcus occipitalis is wholly exposed on both sides.

The occipital operculum is now quite small.

O. C. 1338 H.

D. 650. The brain of an Orang-Outang (*Simia satyrus*). The left hemisphere has been detached.

This specimen is especially interesting because all the sulci are gaping as a result of the treatment of the brain during preservation. This enables us to see at a glance the real condition of the various sulci, and not merely the surface-pattern.

The floccular lobes are very small, as in D. 648, and practically reduced to flocculus (*sensu stricto*), as in the human brain. On the mesial aspect of the right hemisphere the septum lucidum and fornix of the *left* side are displayed, and in that portion of the section just above the mammillary bodies is seen a white ascending streak, which is the mammillo-thalamic tract (Vicq d'Azyr's). In the section of the crus the substantia nigra is clearly seen. On the mesial aspect of the left hemisphere, the head of the nucleus caudatus is seen bulging into the anterior cornu of the lateral ventricle. The gaping sulci afford an exceptional opportunity of studying the true relations of these important features of the brain.

The submerged posterior part of the insula is visible, and its relation to the uncovered anterior part (which is partly mapped out by the fronto-orbital and superior limiting sulci) is clearly demonstrated. The relation of the inferior transverse sulcus of Eberstaller to the Sylvian fissure is admirably shown.

There is a simple and easily-understood grouping of the inferior precentral (arcuate), inferior frontal ("rectus"), superior precentral (*vide* right hemisphere), and superior and middle frontal sulci.

There is a typical intraparietal sulcus. The occipital region is disposed as in the last specimen. The small inferior occipital sulcus is fused to the lower end of the Simian sulcus. But it is functionally represented by a deep occipito-temporal sulcus, the anterior end of which is joined to the posterior element of the inferior (middle) temporal series.

The collateral sulcus is represented by two parallel furrows.

D. 651. The brain of an Orang-Outang (*Simia satyrus*). The left hemisphere has been separated.

The irregular pattern formed by the sulci in the left frontal area is essentially identical with that of specimen

D. 649. That of the right side, however, probably gives the clue to the interpretation of all the other brains. A very well-developed inferior transverse sulcus appears to unite (superficially) the Sylvian fissure to a very extensive arcuate sulcus, which has now altogether dissociated itself from the sulcus rectus, and has become so far extended mesially as to usurp the place of the anterior part of the superior frontal sulcus. The sulcus rectus also is now represented by two irregularly branched sulci, the posterior of which is in other brains joined to the arcuate.

The lower end of the fronto-orbital sulcus bends backward into the Sylvian fissure in a peculiar manner on both hemispheres, and particularly so on the left side.

The occipital operculum is much better developed in this than in most Orang's brains, so as to almost completely cover the submerged arcus occipitalis (which has been exposed on the left hemisphere by drawing apart the lips of the Simian sulcus).

The calcarine sulcus is unbranched. In the right hemisphere there is an extensive accessory calloso-marginal sulcus parallel to the main sulcus, below which it is placed.

A small paraflocculus may be seen emerging at the outer side of the flocculus.

D. 652. The brain of an Orang-Outang (*Simia satyrus*).

In spite of the large number of Orang's brains in this Collection, this small and damaged specimen has been added because it exhibits some unusual features.

The exposed part of the superior limiting (Marchand's "opercular") sulcus is so diminutive that the anterior insular region is hardly more distinctly delimited than in the larger Cercopithecidæ.

The left fronto-orbital sulcus is small, whereas the right is long and **Y**-shaped.

There is an unusually complete superior frontal sulcus in both hemispheres.

It is peculiar how frequent is the union of the inferior transverse ("diagonal," according to Cunningham) and arcuate sulci on the right, and not on the left hemisphere. On the left hemisphere the sulci arcuatus and rectus are quite independent of the great vertical sulcus (so peculiar to the Orang), which I am inclined to regard as a separate posterior element of the "rectus," in spite of the fact that in most brains of *Simia* it is joined not to the straight but to the arcuate sulcus.

The arcus occipitalis is wholly submerged on both sides.

After studying a series of intermediate forms, I am persuaded to regard that sulcus, which we would unhesitatingly call "inferior occipital" if we compared this specimen directly with a Macaque's brain, as the occipito-temporal, which has become so deepened at the expense of the inferior occipital, that the latter has become reduced to an altogether insignificant furrow.

The shape of the corpus callosum and septum lucidum are most admirably demonstrated.

Presented by Professor John Marshall.

D. 653. The brain of a small Orang-Outang (*Simia morio*). The left hemisphere has been detached.

In this alone of all the Orang-brains the posterior end of the Sylvian fissure is not bifurcated. Here again the arcuate sulcus and posterior element of the "rectus" present that peculiar relationship, which seems to be so characteristic of the Orangs (compare D. 651 and D. 649). And in the right hemisphere again the arcuate sulcus is prolonged into the position of the superior frontal, and is also superficially linked to the Sylvian fissure by the inferior transverse sulcus (Cunningham calls it "diagonal" in the case of the Orang; Mem. Roy. Irish Acad. 1890, p. 294), as in the corresponding hemisphere of D. 651.

The union of orbital and inferior frontal (rectus) sulci is again found here in both hemispheres.

The calcarine sulcus is unbranched, as in *Alonatta* and *Ateles*, but some of the postcalcarine elements exist as independent sulci.

The arcus occipitalis is wholly uncovered on the left, and almost completely hidden by the occipital operculum on the right hemisphere.

Although the general appearance of the anterior insular region presents very striking contrasts in this series of Orang-brains, close examination shows that its fundamental plan is identical in all.

D. 654. Two casts of the cranial cavity of an Orang-Outang (*Simia satyrus*).

Note the prominent orbital keel.

D. 655. Two casts of the cranial cavity of a smaller Orang-Outang (*Simia satyrus*).

D. 656. The left cerebral hemisphere of a Gorilla (*Anthropopithecus gorilla*) (figs. 246, 247, 250). O. C. 1338 I *f*.

D. 657. The remainder of the left half of the same brain.
O. C. 1338 I *f*.

D. 658. The right half of the same brain (figs. 248, 249).

This excellently preserved brain (obtained from a young male Gorilla some 33 lbs. in weight and 34 inches high) is probably by far the best specimen of its kind to be found anywhere. And, so far as the writer is aware, it has never been adequately described, although Kükenthal and Ziehen (who seem to imagine that "*Troglodytes savagii*" [the old legend on this specimen] is a Chimpanzee) and Beddard (Proc. Zool. Soc. 1899) have published brief notes concerning it.

The brain of the Gorilla is the largest found in any Ape, and (so far as this large collection of Anthropoid brains is concerned) presents a much stronger resemblance to the human brain than does that of any other Ape. According to Keith, there is a very marked difference in the cranial capacity of the two sexes (Proc. Zool. Soc. 1899, p. 299).

In general shape the brains of the three great Anthropoid Apes exhibit a strong resemblance. This is best shown by the casts of the cranial cavity. The hemispheres of the Orang present a more exaggerated oval outline, when viewed from above, than do those of either of the two Anthropopitheci; and of the latter the frontal regions of the Gorilla are fuller and less Cercopithecoid than those of the Chimpanzee. On the whole the shape of the Gorilla's brain approximates nearest to that of Man, whereas that of the Orang most resembles the lower Ape-form.

Each of the three types is provided with a prominent orbital keel, which is probably slightly more pronounced in the Orang's brain than in that of the other genus *.

Fig. 246. ($\times \frac{2}{3}$.)

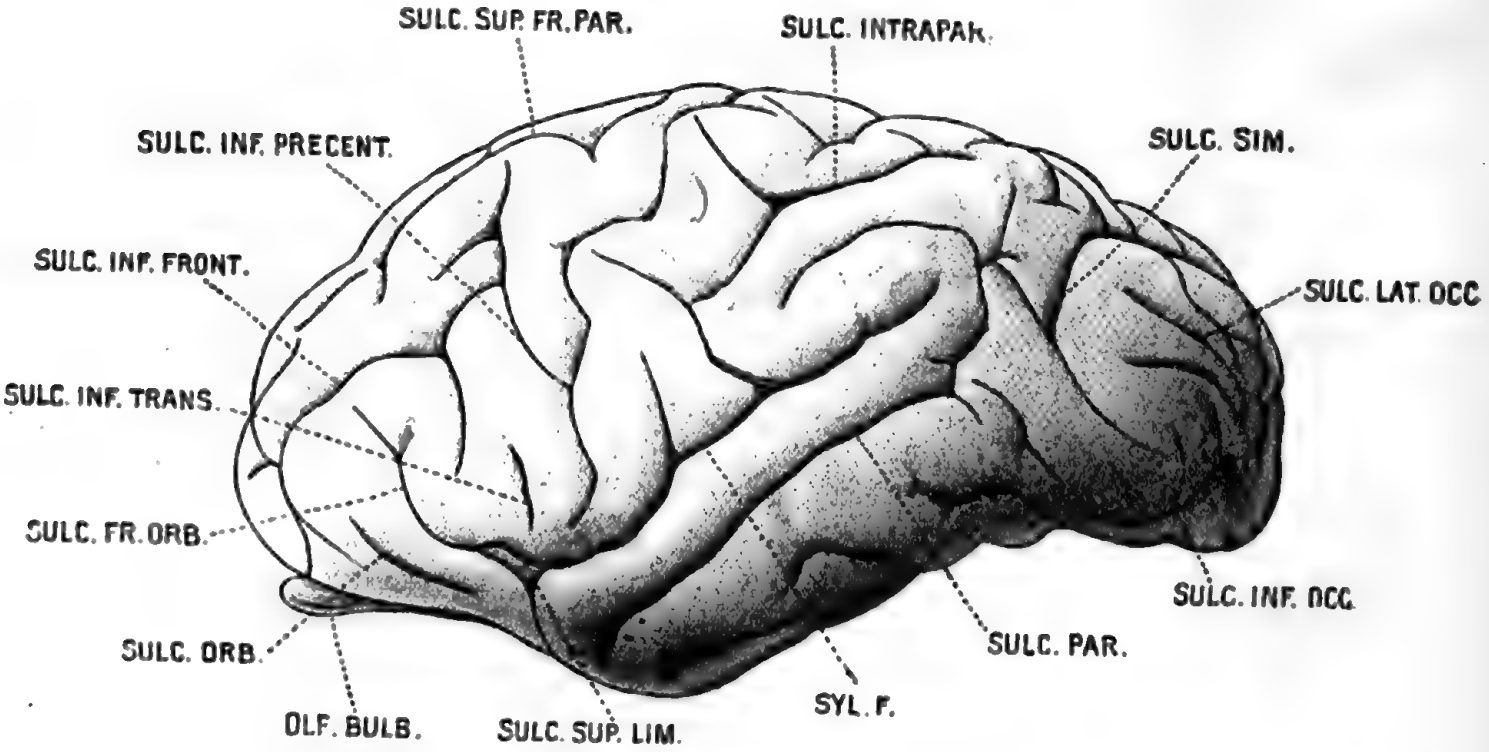

As in the Orang and Chimpanzee, there is a very wide range of variation in the arrangement of the different parts of the brain, especially in those regions in which the human brain differs from the Simian †.

Upon the base of the brain the posterior rhinal fissure is retained in its entirety with a diagrammatic clearness, which is rarely seen in Man (although I have often seen

---

* In the literature of this subject many erroneous statements will be found in regard to this point.

† In order that the student should not draw erroneous conclusions as to the nature of the brain in the Anthropoid Apes from the examination of solitary specimens, the Museum Committee has generously acceded to my request that a valuable set of Anthropoid brains be purchased from the Zoological Gardens. Thus a series of specimens, which is probably unique in its completeness, is available for comparison. For it is the apparently fortuitous variations in the Anthropoid Apes which point the way or the possibility of human evolution.

it in the Soudanese races). In this way the demarcation between the neopallium and the pyriform lobe is as distinct as it is in the Cercopithecidæ and in the macrosmatic Mammalia. To the student of Human Anatomy, who is taught to unite this part of the pyriform lobe with

Fig. 247. (× $\frac{2}{3}$.)

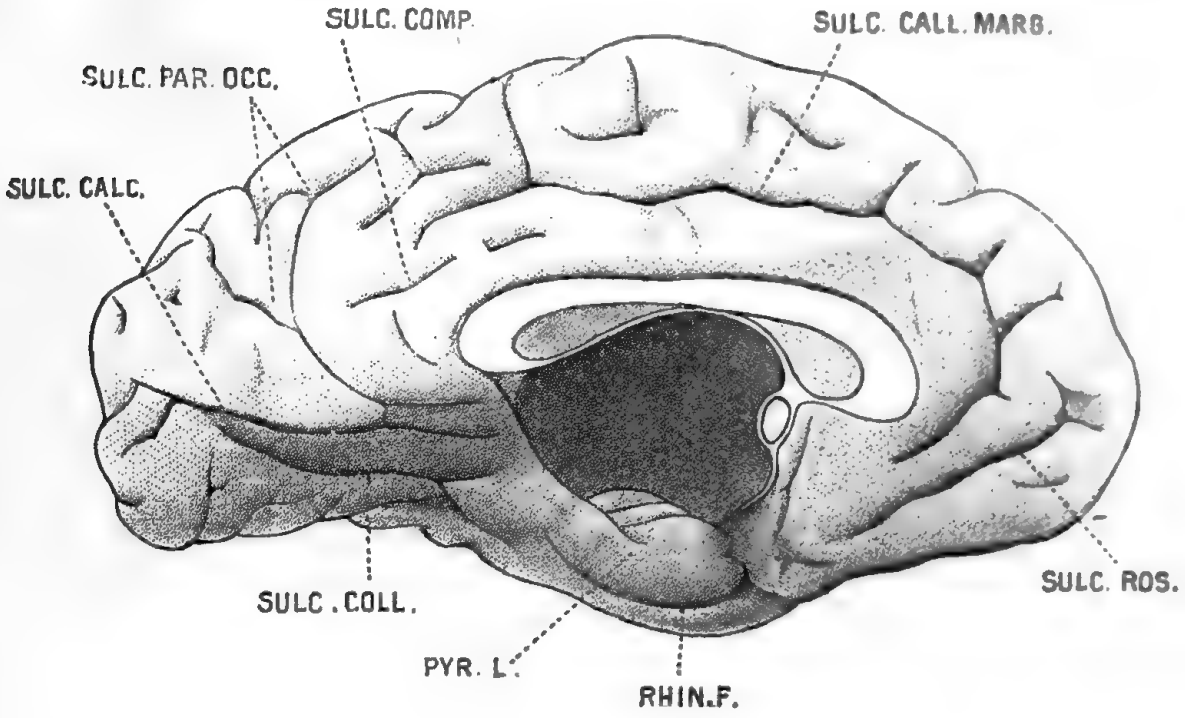

Fig. 248. (× $\frac{2}{3}$.)

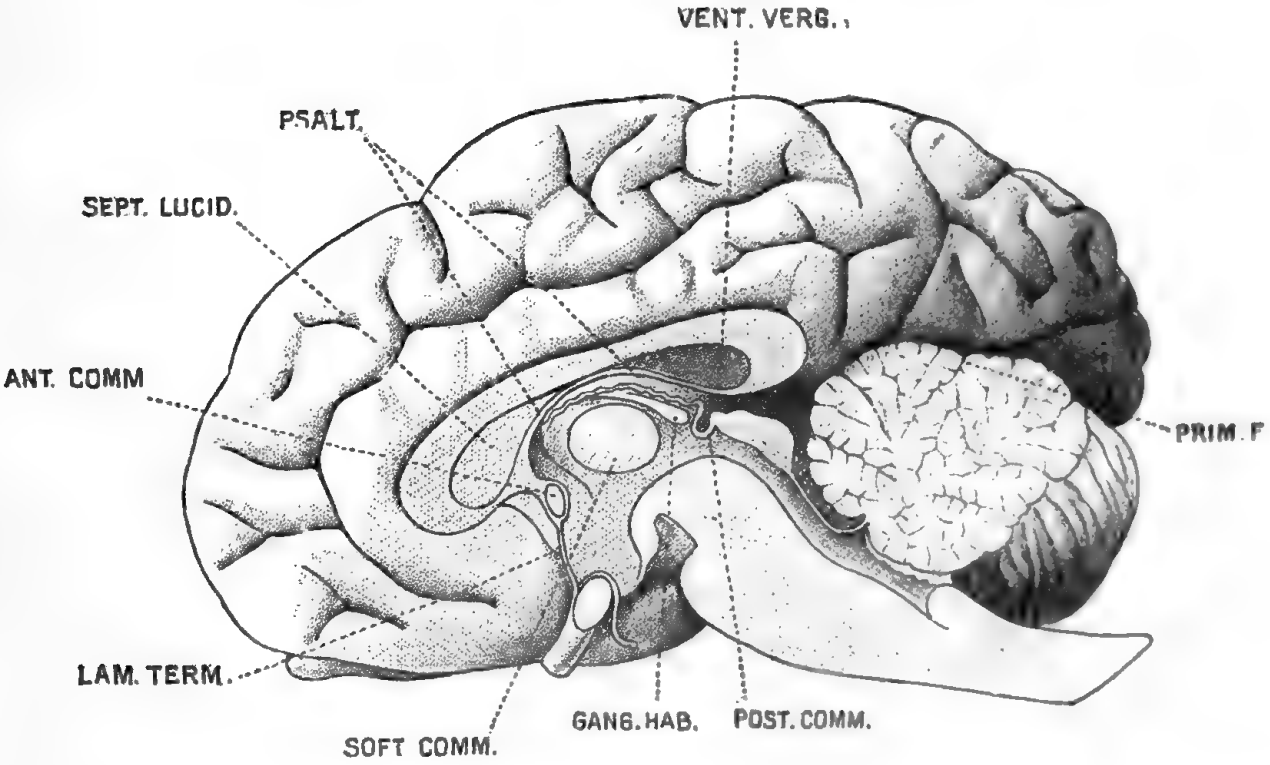

a strip of neopallium (and sometimes, also, with the uncus which is partly hippocampal) and call the heterogeneous collection "uncinate gyrus," or, even by the more confused designation, "hippocampal gyrus," this specimen is particularly instructive, because it resembles the human brain so closely that he can see at a glance how far the rhinal fissure and the pyriform lobe extend (figs. 249 and 250).

There is a deep vallecula Sylvii, which leads into the stem of the Sylvian fissure. The latter is clearly formed in this interesting specimen by the meeting of two definite opercula, temporal and orbital respectively, as in the human brain. As these opercula extend laterally they diverge from one another so as to expose a small triangular depressed area of insula (fig. 250). In this specimen one can see at a glance that the fronto-orbital sulcus (the anterior lip of which is so markedly opercular) is really the anterior limiting sulcus of the insula. And the dorsal operculum is also so complete that the forward prolongation of the superior limiting (Marchand's "opercular") sulcus appears to join the anterior limiting sulcus *. That this close resemblance to the human condition is not the rule in the

Fig. 249. (× ⅗.)

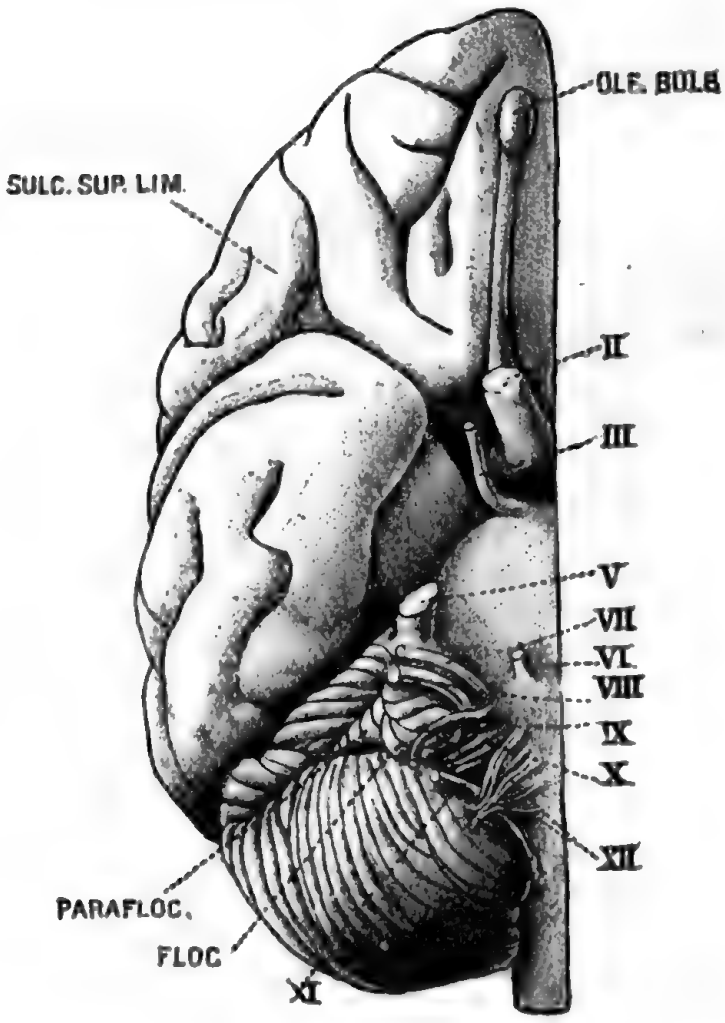

---

* It is interesting to note that the superior limiting sulcus does not actually join the fronto-orbital even in this extreme case, the two sulci being separated by a submerged gyrus. Thus we cannot speak of anterior limbs of the Sylvian fissure in the Anthropoids.

Gorilla is shown by the other six hemispheres, in all of which the superior limiting sulcus is separated by an *exposed* gyrus from the anterior limiting sulcus; and neither sulcus possesses a markedly opercular lip. In six out of the eight hemispheres the mesial end of the fronto-orbital sulcus appears to join the stem of the Sylvian fissure; in the other brain the orbital region is damaged, but probably its fronto-orbital sulci were always separated from the Sylvian.

Fig. 250. (× ⅔.)

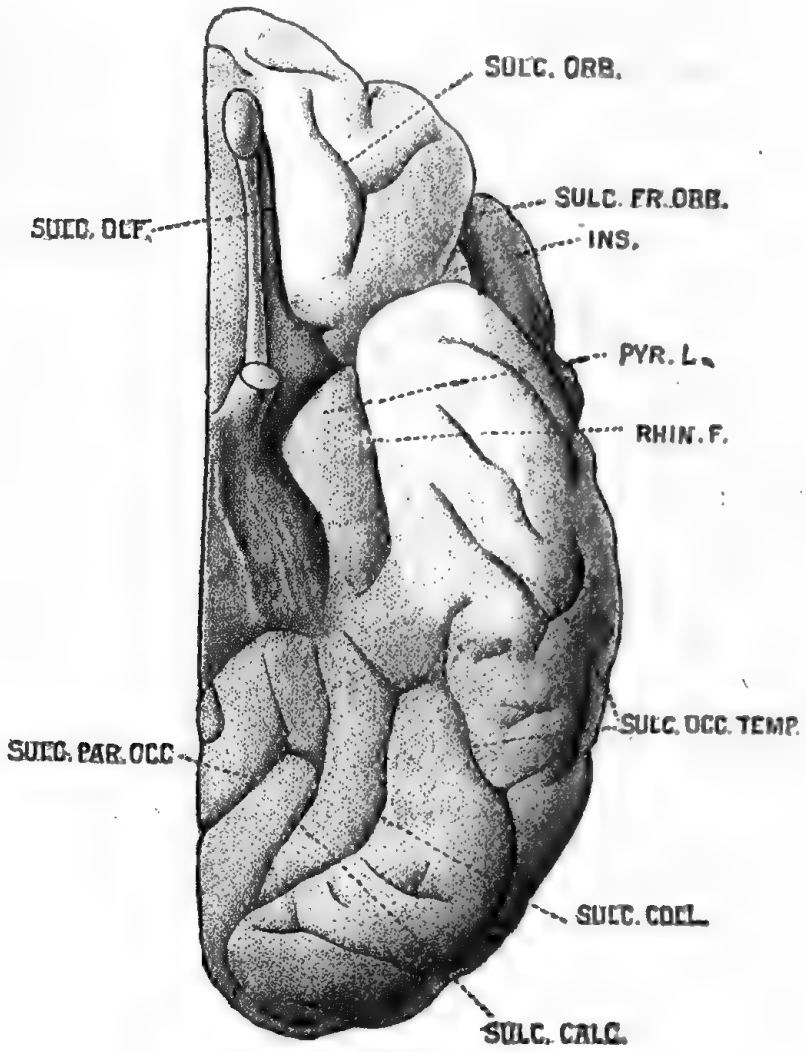

In contrast to the conditions found in the human brain, it is noteworthy that the fronto-orbital sulcus is very long.

The orbital sulcus is seen on the right hemisphere in its primitive state as a long, deep, simple linear sulcus. It pursues a course parallel to the fronto-orbital sulcus. To its mesial side there is an unimportant secondary orbital sulcus, which is joined to the main sulcus on the left hemisphere, to form a triradiate sulcus such as is often found in the human brain. If a large series of human brains be examined (because this sulcus is exceedingly variable), it will be found that the fundamental plan of the orbital sulcus (which is that often called "presylvian" in other mammals) is that exhibited on the right hemisphere of this Gorilla's brain. In the other three Gorilla-brains, different variants of this plan of orbital are exhibited.

The peculiar bifurcation of the termination of the Sylvian fissure, which is such a constant feature of the Orang's brain, is very poorly developed on the right hemisphere of this, and even less distinctly in the two hemispheres of specimen D. 659. The central sulcus exhibits a very distinct genu.

On the right hemisphere there is a typical primitive sulcus arcuatus (inferior precentral) such as the Apes exhibit. There is a long bow-shaped sulcus rectus, which joins the mesial accessory-orbital sulcus in front. A short branch of the "straight" sulcus passes between the dorsal ends of the orbital and fronto-orbital sulci. On the left hemisphere, the oblique upper limb of the arcuate seems considerably curtailed and its lower end passes (superficially) into the central sulcus. Moreover, the upper part of the sulcus is linked by a short deep branch to the sulcus rectus. If the reader compares this specimen with those of the Orang and notes the relations of the sulci to the fronto-orbital sulcus, he cannot fail to understand why the anterior limb of that peculiar H-shaped frontal system of furrows, which is so characteristic of the Orang, was called (in these notes) the posterior part of the "sulcus rectus" (the inferior frontal of Human Anatomy). On the left hemisphere a small cephalic element of the "rectus" series has become separated to form a fronto-marginal sulcus of Wernicke. In both hemispheres, the superior precentral and superior frontal sulci are arranged with a simplicity and regularity which is quite diagrammatic.

On the left hemisphere there is a short "sulcus frontalis medius," placed very far forward between the anterior ends of the superior and inferior frontal sulci. On the right hemisphere there is a short, almost coronal sulcus in the same region.

When we recall how constant in the Orang's brain is the presence of an inferior transverse sulcus (superficially) joined to the Sylvian sulcus, it is worthy of note that it is absent, at any rate as a separate element, in all the eight hemispheres of the Gorilla. There is a small diagonal sulcus of Eberstaller on both hemispheres, and the lower end of the central (Rolando's) sulcus is curved forward into such a position that it would relieve the tension of the expanding cortex which expends itself in the Orang in the formation of the inferior transverse sulcus.

The parallel sulcus is prolonged into a very extensive hook around the end of the Sylvian fissure on the left hemisphere. On the right hemisphere the recurved portion of the "hook" is a separate triradiate sulcus. The deep, richly-branched intraparietal sulcus extends around these sulci. Its lower extemity is linked (superficially) to the Sylvian fissure by a deep, oblique sulcus, the free end of which extends towards and seems to accentuate the bend in the central sulcus. The very irregular and unsymmetrical ramus postcentralis superior is not joined to the intraparietal; but the latter gives off deep branches (two on the right and one on the left side) alongside the chief element of the ramus. Posteriorly the intraparietal sulcus dips into the Simian sulcus (Affenspalte) and is hidden under the occipital operculum. The apparent bifid mesial extremity of the Affenspalte may represent the transverse occipital sulcus.

The arcus occipitalis is very large and wholly exposed, the mesial end of the occipital operculum having been pushed completely outward and backward.

There is a typical, obliquely placed, **Y**-shaped lateral occipital sulcus in all eight hemispheres.

The occipital operculum is bounded by an almost hemispherical Affenspalte, both the superior (mesial) and inferior (lateral) extremities of which are about 1 cm. distant from the dorso-mesial and tentorial borders respectively.

The calcarine sulcus (of the left hemishere, in which alone it is wholly exposed) is an unbranched furrow of which the anterior half (calcarine *sensu stricto*) is much deeper than the posterior half (retrocalcarine). The caudal extremity of the latter bends almost at right angles and ends near the inferior limb of the Y-shaped lateral occipital sulcus.

At the bend of the retrocalcarine a second postcalcarine sulcus appears to emerge from the former and then run parallel to and on the dorsal side of it. It is separated from the ventral postcalcarine by a gyrus which is submerged at its anterior end. The dorsal postcalcarine sulcus is much shallower and more widely separated from the calcarine complex on the right side.

The parieto-occipital sulcus is a deep and well-defined sulcus on the right hemisphere, and there are also several small accessory sulci. On the left hemisphere the sulcus is represented by three sulci of varying depths. The meaning of these separate sulci will be best appreciated if the reader refers to the account of the Baboon's brain. There is, first, a deep irregular notch in the upper margin of the hemisphere, which represents the sulcus distinguished as the ramus parieto-occipitalis (sulci intraparietalis) in the larger Cercopithecidæ. There is a very deep sulcus on the mesial surface, which begins above in front of the last-described element and ends near and parallel to the calcarine sulcus, to which it is joined by a shallow connecting furrow. Then there is a third shallower furrow making (on the surface) a Y-shaped pattern with the last. The two limbs of the Y are separated from the first ("ramus par.-occ. s. intrap.") element by a plump arcuate gyrus. If the other Gorilla-brains be examined, further variations of the calcarine and parieto-occipital systems will be found. Thus in specimen D. 659 the calcarine complex is T-shaped in both hemispheres; in specimen D. 660 the calcarine and retrocalcarine unite at an obtuse angle and small compensatory sulci surround the latter. All this shows that the true calcarine (Cunningham's "anterior calcarine") is the only stable element in the calcarine series and the retrocalcarine (Cunningham's "posterior calcarine") series is extremely variable, although the chief sulcus is always concurrent with the calcarine.

The parieto-occipital series, being essentially of the nature of compensatory sulci, is even more variable. In specimen D. 659 the state of affairs is essentially identical with the left hemisphere of this individual (D. 656), but the sulcus around which the partially submerged arcus occipitalis is arranged *seems* to join the posterior limb of the **Y**-shaped arrangement of the other two elements; and a branch of the intraparietal cuts into and thereby complicates the arcus occipitalis. In D. 660 there seems to be a long, simple, vertical, parieto-occipital sulcus cutting deeply and transversely into the hemisphere: its dorsal limb is surrounded by a broad extensive simple arcus occipitalis. A peculiar sulcus, however, emerges from the dorsal part of the parieto-occipital sulcus and pursues a sagittal course backward.

There is on the left hemisphere of this individual (D. 656) a simple collateral sulcus, beginning below the bend in the postcalcarine, from which it is separated by a partially submerged gyrus, and ending immediately below the anterior end of the calcarine. It is linked to the posterior element of the occipito-temporal sulcus, which is very deep. It crosses on to the external surface and fulfils the function of the inferior occipital sulcus of other Apes. Its anterior segment is separate and deepened at the expense of the inferior occipital. There is a very complete calloso-marginal sulcus. But it is peculiar that in all these hemispheres of the Gorilla the sulcus is prolonged much further back than the neighbourhood of the upper end of the central sulcus (where it usually ends in the human brain). The sulcus, however, which represents its caudal part in the human subject, has all the appearance in the left hemisphere (also in the right hemisphere of specimen D. 660 and in both sides in D. 659) of being merely a vertical branch of the sulcus and in the right hemisphere is quite separate from it.

In the left hemisphere of specimen D. 660 the manner in which these variations are brought into line with the human condition is shown. The form of the "compensatory" (Broca's "postlimbic") varies with the form of the calloso-marginal. It is best developed as a large triradiate figure in the right hemisphere of this specimen.

This brain affords an admirable demonstration of the mesial structures—corpus callosum, fornix, septum lucidum, anterior commissure, lamina terminalis, and the large optic chiasma. The anterior commissure is slightly larger than in the human brain and the optic tracts are considerably greater.

It is of interest to note the presence of a large ventricle of Verga under the posterior part of the corpus callosum—an anomaly occasionally found in the human brain.

The other structures exposed in the mesial section closely resemble the corresponding features of the human brain. They are here shown exceptionally clearly. Note especially the foramen of Monro, the soft commissure, the ganglion habenulæ, the posterior commissure, the smooth lateral wall of the third ventricle, the optic recess, the remains of the embryonic optic diverticulum just above the optic chiasma, the aqueduct of Sylvius and the fourth ventricle. [The description of all these structures found in text-books of Human Anatomy applies equally here.]

The cerebellum has now assumed a close likeness to the human organ. The floccular lobe, however, is still larger than it is in most human brains, although it is subject to extreme variation in Man as in the Anthropoid Apes. The floccular lobe, which is best seen on the left side, is composed of two distinct lobules each attached by its own stalk. Of these, the mesial is much the larger and plumper of the two and is composed of three separate groups of folia (three or four in each group), the separate stalks of which unite into a common peduncle. The lateral lobule is much smaller and is almost hidden by the mesial lobule. Two or three of its folia may, however, be seen emerging in the great horizontal fissure external to the mesial lobule.

There can be no doubt that the lateral lobule represents the flocculi secundarii of Man, and these may correspond to the paraflocculus (although much fuller developmental evidence than Stroud [Journ. Comp. Neur. 1895] adduces is necessary to prove the identity).

In appearance the other parts of the brain exposed in these specimens closely resemble the corresponding regions in the human brain. The olivary body is now in contact with the lower border of the pons. To the naked eye no trapezoid body is apparent, although it seems to be partially exposed in specimen D. 661 (left side).

The mesial geniculate body seems to be much more prominent than it is in Man—a prominence possibly associated with the larger size of the auditory nerve.

Beddard (Proc. Zool. Soc. 1899, p. 65), in a memoir based upon these four specimens and one other, gives a list of the literature of the Gorilla-brain. His figures 1, 2 and 4 represent this specimen.

[In drawing up a comparison between the brains of the Chimpanzee and Gorilla, Kükenthal and Ziehen place this specimen (formerly labelled "*Troglodytes savagii*") among the Chimpanzees, and state that they have had no opportunity of studying the brain of a Gorilla! Jenaische Zeitschr. f. Naturwiss., Bd. xxix. 1894.] O. C. 1338 *I e.*

D. 659. The brain of a Gorilla (*Anthropopithecus gorilla*), subdivided by a mesial sagittal section.

In this brain we find the usual Anthropoid arrangement of the anterior insular region, instead of the more human disposition presented by the preceding specimen. The superior limiting (Marchand's "opercular") sulcus emerges from the Sylvian fissure and approaches without even appearing to join the long fronto-orbital (anterior limiting) sulcus. Nor are the lips of these sulci opercular as in that specimen. In other words, the condition found in this specimen is that which is usual in the three great Anthropoids. Unlike the arrangement in the last specimen, the sulci arcuatus and rectus are here blended to form a single sulcus, as in the Gibbons. The superior frontal and superior precentral sulci resemble those of the previous specimen, except that they are less regular. There are also a few small furrows which can only represent the sulcus frontalis mesialis, which Cunningham regards as distinctively human.

The parallel sulcus resembles that of the last specimen, as also does the intraparietal excepting the fusion with its ramus postcentralis superior on the left side.

The mesial portion of the Simian sulcus seems to have been pushed backward into a peculiar **V**-shape by the expanding arcus occipitalis, which is still partially submerged.

In this brain there seems to be a definite inferior occipital sulcus which is joined to the parallel sulcus.

There is no ventricle of Verga in this specimen.

Beddard, Proc. Zool. Soc. 1899, p. 71, fig. 5.

D. 660. The brain of a Gorilla, cut in mesial sagittal section.

The condition of the insular region in this is essentially the same as in the preceding specimen. But more of the insula and much more of the superior limiting sulcus are exposed. Nor does the mesial extremity of the fronto-orbital (anterior limiting) sulcus become hidden by the temporal pole, so that the insula can be seen passing into continuity with the locus perforatus. The superior limiting sulcus gives off a deep, short branch cutting into the insula on each hemisphere.

The two great **T**-shaped complexes of inferior precentral and inferior frontal sulci and superior precentral and superior frontal sulci respectively are disposed with diagrammatic simplicity, especially on the right hemisphere.

The other sulci of this brain agree in arrangement with those of the last specimen. The intraparietal sulcus, however, is joined to its ramus postcentralis superior on both sides ; and a series of compensatory intraparietal sulci are found which are not exactly comparable to those of the other brains.

Beddard, *op. cit.* p. 73, fig. 7.

D. 661. The brain of a Gorilla (*Anthropopithecus gorilla*).

The insular region resembles that of specimen D. 659.

The inferior precentral and inferior frontal sulci are fused. The superior frontal sulcus is subdivided into two parts of which the posterior is joined to the superior precentral and also (on the right side) to the inferior frontal.

The intraparietal sulcus resembles that of the last specimen.

In the foregoing accounts it was suggested that there was some reason to regard the lateral sulcus of Carnivores as the intraparietal, the ansate as its ramus postcentralis superior, and the crucial as the representative of the central (Rolando's) sulcus. Such being the case, it is not altogether surprising to find in two mammals, which possess brains of approximately the same size, although they have diverged so widely as the Bear and the Gorilla, that this central region of the hemispheres has retained some resemblance, even though the frontal and occipital poles have become so vastly altered. Even if it be partly fortuitous, there can be no question of the essential identity of the chief features of these regions say in specimen D. 365 (Bear) and this Gorilla's brain. Even the peculiar curves of the crucial (central) sulcus and its relations to the precrucial (precentral), to the ansate (ramus postcentralis) and lateral (intraparietal) are curiously reproduced in each hemisphere.

The paraflocculi are equal to the flocculi in size and are freely exposed.

Beddard, *op. cit.* p. 72, fig. 6.

D. 662. Two casts of the cranial cavity of a young Gorilla (*Anthropopithecus gorilla*).

D. 663. Two casts of the cranial cavity of an adult Gorilla (*Anthropopithecus gorilla*).

These are of interest as showing the exact shape and especially the degree of rostration of the cerebral hemispheres.

D. 664. The brain of a Chimpanzee (*Anthropopithecus troglodytes*), (♂).

Apart from the difference in size there is little to distinguish the brain of the Chimpanzee from that of the Gorilla. If, however, the four specimens of Gorilla-brains in this Collection be compared with the ten specimens of Chimpanzee-brains, it will be noticed that the Simian cleft or Affenspalte is much more complete and Cercopithecoid in the Chimpanzee than it is in the Gorilla. At the same time, one must not hastily conclude that the Gorilla's brain is therefore more like the human than is that of the Chimpanzee, for, as specimens D. 666 & D. 667 show, the brain of the latter may resemble that of Man quite as closely as any Gorilla-brain. Those most competent to express an opinion, regard the Chimpanzee as the nearest relative of Man. Still the fact remains that the series of Gorilla-brains in this Collection is certainly nearer the human type than is the series of Chimpanzee-brains.

I have so far referred only to the region of the "Affenspalte," because in all other parts there seems to be a close agreement in the brains of the two species.

The insular region is just as variable as it is in the other Anthropoids. In the left hemisphere of this specimen, we find the simple short exposed superior limiting sulcus, approaching the fronto-orbital just as it does in the Gibbon. On the left hemisphere, however, the exposed part of the superior limiting sulcus is much longer (so that at a casual glance it seems to join the fronto-orbital sulcus) and its upper lip is markedly opercular.

The right inferior precentral sulcus is very long and approaches very close to the caudal end of the superior frontal, and, to a great extent, usurps the place of the superior precentral which is represented merely by the short bifid caudal process of the superior frontal sulcus. The long typical inferior frontal sulcus is joined to the inferior precentral.

On the left side, the inferior precentral is joined to the ventral extremity of the central (Rolando's) sulcus. The inferior frontal is not so long as on the right side, the cephalic extremity being separated as a fronto-marginal sulcus of Wernicke. Thus we have a curious reproduction of what we may call the "Orang condition," such as we have also seen in the left hemisphere of a Gorilla-brain (D. 656). The middle frontal gyrus is broken up by irregularly-placed sulci, but none of these can be strictly called the middle frontal sulcus.

Behind the sinuous central sulcus there is a typical intraparietal complex, all the four constituent parts of which are united. It passes posteriorly under cover of a much more complete occipital operculum than any of the eight Gorilla-hemispheres presents, and then joins the transverse occipital sulcus which (as the right side, in which the operculum has been cut away, shows) does not exactly coincide with the bottom of the Simian cleft ("Affenspalte").

A comparison of the dissected and the undissected halves of this specimen shows how extensive an operculum is present, and how complete the Simian sulcus is in this Chimpanzee. In marked contrast to the condition found in the Gorilla, the dorsal part of the parieto-occipital sulcus is altogether covered by the operculum (see the right side).

Fig. 251. (× $\frac{2}{3}$.)

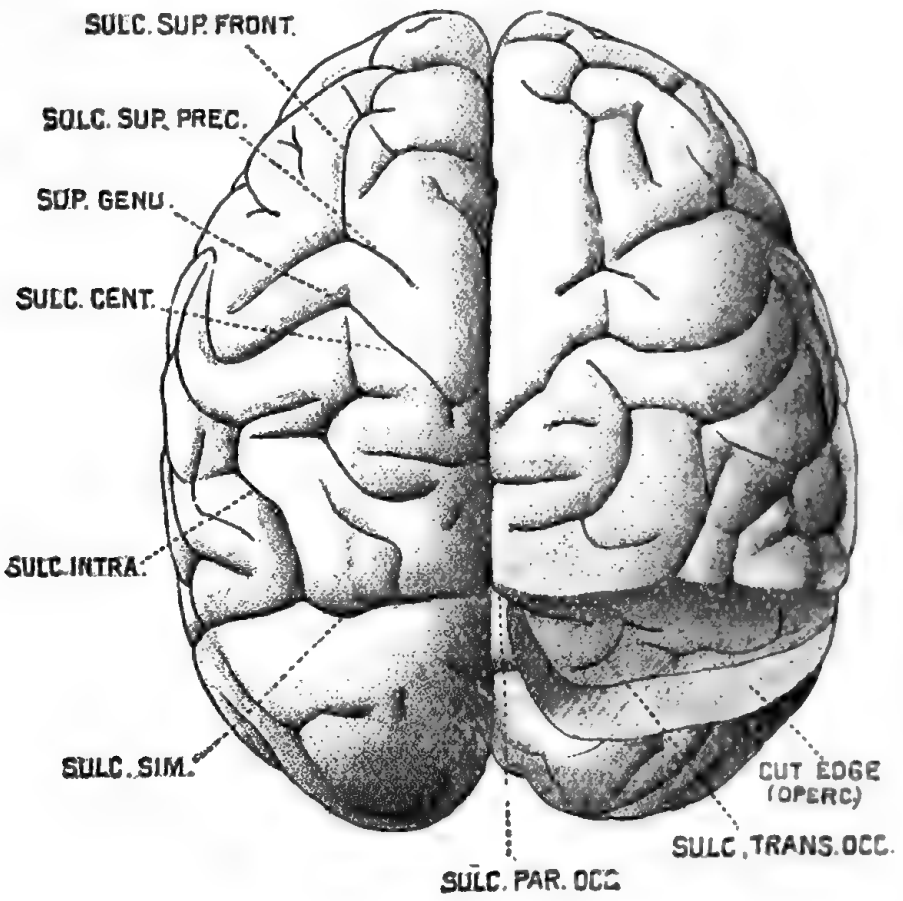

The parallel sulcus is partially hooked around the bifid extremity of the Sylvian fissure on the right side, but not so completely on the left hemisphere.

The posterior element of the inferior temporal sulcus is prolonged backward into a very deep sulcus skirting the ventral border of the occipital region. A similar disposition is found in the Gorilla.

The area lying behind the "Affenspalte" seems to be much poorer in sulci than is that of the Gorilla. The lateral occipital sulcus has lost the typical **Y**-shape, and is an irregularly arcuate shallow sulcus.

The lateral lobule of the floccular lobe (*i. e.* the paraflocculus) is quite as large as the flocculus and is wholly exposed. O. C. 1338 I *c.*

Benham, Quart. Journ. Micr. Sci., vol. xxxvii. p. 47.

D. 665. The left cerebral hemisphere and the rest of the brain of a Chimpanzee (*Anthropopithecus troglodytes*), (♀).

The anterior insular region conforms to the usual Anthropoid type.

There is a well-marked inferior transverse sulcus such as always occurs in the Orang, but rarely in the Gorilla.

There is a typically united, triradiate complex of sulci rectus and arcuatus; but it is difficult to say whether the upper part of the precentral limb (which is separate and H-shaped on the right side, but linear and concurrent on the left) ought to be regarded as part of the superior or inferior precentral.

Again, there is an extensive occipital operculum hiding the arcus occipitalis and the parieto-occipital sulcus. The Affenspalte extends as far as the mesial edge. Unlike the condition found in the last specimen, there is a typical deep, Y-shaped lateral occipital sulcus.

There is a very deep and long inferior occipital sulcus, but it is questionable whether it can be homologised with the sulcus so-called in the Cercopithecidæ or with the occipito-temporal sulcus. There is an unusually well-developed inferior (middle) temporal sulcus.

The calcarine complex presents the typical T-shaped "tail-piece." If the lips of the sulcus be separated, a submerged gyrus will be found at about its mid-point imperfectly separating the calcarine and retrocalcarine elements, as in the human brain.

In the left hemisphere the parieto-occipital sulcus is represented by the two distinct sulci (hidden in one great furrow) such as we have seen in the Baboons. But in the right hemisphere, the functions of a parieto-occipital sulcus are only partially fulfilled by the wholly mesial sulcal complex of that name; for a deep cleft, formed by an irregular apical branch of the intraparietal sulcus, buried deeply in the unusually extensive mesial prolongation of the Simian sulcus is chiefly instrumental in accommodating the expanding cortex in this region. This Cercopithecoid arrangement affords a striking contrast to the condition found in the Gorilla and in Man. There is a typical calloso-marginal sulcus.

The floccular lobe seems to conform to the usual human pattern. It is composed of a plump oval mass of folia which completely hides the flattened diminutive paraflocculus. O. C. 1338 I *a*; 1338 I *a* *.

D. 666. The brain of a Chimpanzee (*Anthropopithecus troglodytes*), which has been subdivided by a mesial sagittal section. The arteries have been injected.

In this specimen the anterior insular area is depressed and the limiting sulci almost meet. It is of interest to note that the relations of branches of the middle cerebral artery to this insula and its diminutive opercula are identical with those in the human brain.

A short sulcus proceeding backward from the fronto-orbital toward the superior limiting sulcus is of interest as an indication of the expansion of the cortex in this region, which leads to such marked results in the human brain.

There is a remarkably close agreement between the features of these cerebral hemispheres and those of D. 664.

The structures cut in the mesial sagittal section are exceedingly clearly shown. They closely resemble the corresponding human structures.

The inferior transverse sulcus is present in a different form in the two hemispheres. In the left hemisphere there is a complete precentral sulcus. Further evidence of the variability of the calcarine and parieto-occipital sulci is afforded by this specimen, but the variations are not new, parallel instances having been described in the Gorilla and Orang (*vide supra*).

D. 667. The brain of a Chimpanzee (*Anthropopithecus troglodytes*).

This somewhat imperfectly-preserved specimen is retained in the Museum because it exhibits a very interesting and rare condition of the insular region. The superior limiting sulcus (on both sides) passes forward and actually joins the fronto-orbital sulcus so as to *completely* map out the anterior insular region. It is the normal state in Man.

In the left hemisphere the superior and inferior precentral sulci are confluent. O. C. 1338 I.

Presented by W. E. Leach, Esq.

D. 668. The brain of a young female Chimpanzee (*Anthropopithecus troglodytes*).

The left cerebral hemisphere has been separated.

This is a small and in some respects simple brain. On the right hemisphere the insular region presents the simplest and most primitive Anthropoid type, *i. e.* the lips of the superior limiting and the fronto-orbital sulci are not opercular and the sulci are widely separated. On the left hemisphere, the sulci approach so close that they almost meet (at a casual glance they appear to join); and there is a faintly marked tendency to operculation.

The extent of the occipital operculum and the freedom of the exposed surface of the occipital area from any other sulci except the plain linear inferior occipital, are quite Cercopithecoid characteristics. On the left hemisphere the occipital operculum has been cut away, and the wide separation of the transverse occipital sulcus from the bottom of the "Affenspalte" is thus demonstrated in a much more decisive fashion than is the case in D. 664. In this brain the parieto-occipital series is represented by the parieto-occipital sulcus proper, a shallow sulcus behind it, and especially by the deep mesial limb of the transversal occipital sulcus.

In front of the tortuous central sulcus there are typical superior and inferior precentral sulci. The latter is fused to the inferior frontal sulcus, which (in the right hemisphere) gives off a peculiar mesial transverse branch. A sulcus frontalis medius is (superficially) joined both to this sulcus and also to the inferior precentral. O. C. 1338 I *d.*

D. 669. The brain of a Chimpanzee (*Anthropopithecus troglodytes*).

This specimen is of interest as a demonstration of the manner in which the three great Anthropoid types of brain merge indefinitely one into the other.

If the insular region be carefully studied, it will be found to conform essentially to the most primitive Anthropoid type already defined. But the unusual direction of the superior limiting sulcus gives the insula the ill-defined appearance which is sometimes seen in the Orang's brain.

Then again, although the occipital operculum is better developed than it is in most Gorillas and Orangs, it shows signs of retrogression in comparison with the other Chimpanzee's brains; and as this involves the mesial end of the operculum a condition not unlike the much more pronounced dwindling in the Gorilla's brain is produced. Still the institution of this comparison tends rather to emphasize the primitive Cercopithecoid features of the occipital operculum as being a most decisive characteristic of the Chimpanzee among the Anthropoidea, or at least in the two species of Anthropopitheci.

Note the large size of the lobule, which appears to be the paraflocculus.

D. 670. The brain of a Chimpanzee (*Anthropopithecus troglodytes*).

This small and simply convoluted brain is retained chiefly because it exhibits another interesting arrangement of the insular region.

At a casual glance, the depressed left anterior insular area appears to be completely delimited by a blending of superior and anterior (fronto-orbital) limiting sulci; but as a matter of fact the superior limiting sulcus is not complete, and a horizontal branch from the fronto-orbital sulcus, which is separated from the superior limiting sulcus by a narrow gyrus, completes the delimitation of the insula. In spite of the markedly different appearance of the right insula, essentially the same arrangement occurs. The superior limiting sulcus, however, is much longer and more oblique, and the branch of the fronto-orbital sulcus is hidden by the gyrus, which forces its way to the surface between it and the superior limiting sulcus.

The right side of this brain affords a clear demonstration of yet another variety of the [illegible] lobe. It is undivided into flocculus and paraflocculus in such a manner that the former completely overlaps the latter, although in this case the two lobules are of approximately the same size. O. C. 1338 1*b*.

D. 671. The brain of a Chimpanzee (*Anthropopithecus troglodytes*).

In spite of the fact that this excellently preserved specimen has been badly injured by saw-cuts in the occipital region, it has been mounted because of the interest attaching to its insular and occipital regions.

The remarks made concerning the insulæ of the last specimen apply to the corresponding regions of the two respective hemispheres of this specimen. But the chief interest here is the instructive demonstration of opercular formation. The dorsal operculum of the anterior insular area is being formed in spite of the fact that the superior limiting sulcus is incomplete. This is especially well shown on the left side.

The marked dwindling of the mesial extremity of the occipital operculum forms a most pronounced contrast to the condition met with in all the other Chimpanzee's brains in this Collection. It shows that we cannot rely in every case upon this character to distinguish a Chimpanzee from a Gorilla or even an Orang (*cfr.* specimen D. 649).

The floccular lobe is very interesting. The paraflocculus and flocculus being clearly distinguished not only by position but also by shape in a manner quite unusual in the Anthropoid Apes. *Presented by Prof. J. Marshall.*

D. 672. The brain of a Chimpanzee (*Anthropopithecus troglodytes*).

A considerable part of the right cerebral hemisphere has been removed by dissection in order to expose the whole insula ; and the left hemisphere has been cut horizontally in order to show the relationship of the insula to the claustrum and the lenticular nucleus. This section has been made in order that it may be compared with specimen D. 728, which is a corresponding section of the human brain.

A similar section was made by Prof. D. J. Cunningham to show that the anterior exposed part of the insula in the Anthropoid Apes presents the same relation to the claustrum and lenticular nucleus as the human insula does.

Figs. 252. (× ⅔.)

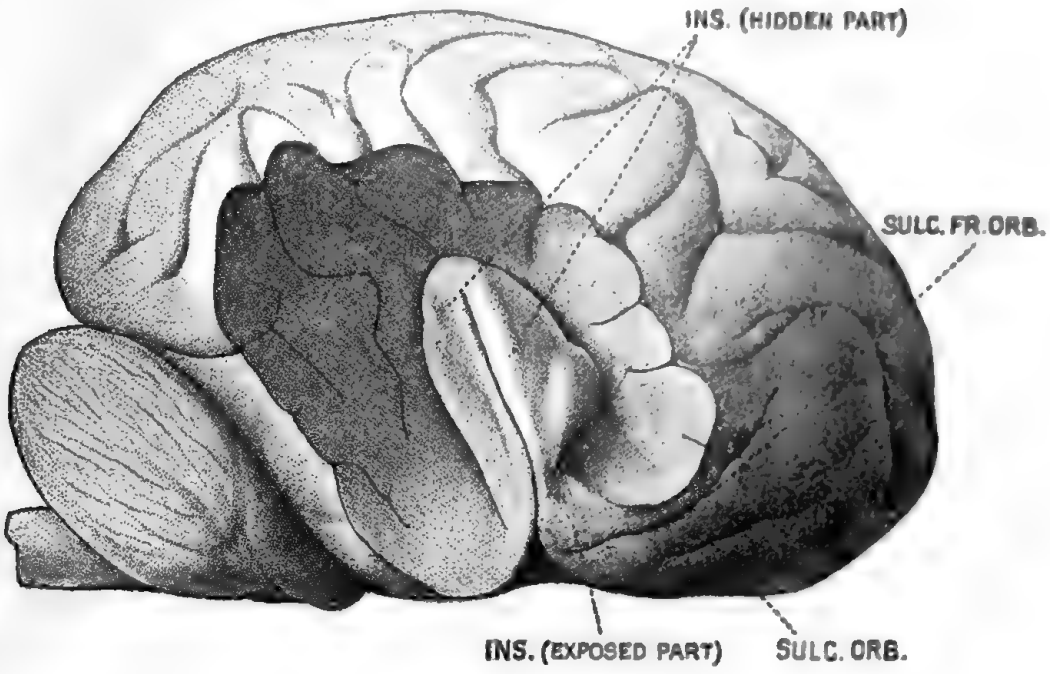

D. J. Cunningham, Journ. of Anat. & Phys., vol. xxxii. 1898, p. 11.

D. 673. Two casts of the cranial cavity of a Chimpanzee (*Anthropopithecus troglodytes*).

D. 674. Two casts of the cranial cavity of a smaller Chimpanzee (*Anthropopithecus troglodytes*).

Family *HOMINIDÆ*.

D. 675. The brain of an early human fœtus (about 2 months ?) *in situ* in the head, showing the post-mortem wrinkling of the thin neopallium, which is generally regarded (probably erroneously) as a system of "transitory fissures."

The roof of the right hemisphere has been removed so that the corpus striatum can be seen in the lateral ventricle.

The corpora quadrigemina are exposed.

The cerebellum exhibits an interesting phase, for it consists of two primitive laterally placed rudiments united across the middle line by a narrow bridge.

[Wax models of this and the following five specimens are in Guy's Hospital Museum.] O. C. 1341 A.

Presented by John Hilton, Esq.

Hochstetter, Bibliotheca Medica A: Heft 2, 1898.

D. 676. The whole central nervous system of a human fœtus, somewhat older than the last specimen.

The brain is partially divided by a mesial sagittal section.

The pyriform lobe is recognisable as an acutely-bent band fringing the locus perforatus anticus, ending posteriorly in a swollen extremity on the temporal pole.

External to it we see a slight depression on the lateral wall of the hemisphere, representing the fossa Sylvii, the dorsal limit of which is marked by a faint furrow—the superior limiting sulcus (suprasylvian sulcus of other mammals).

On the mesial surface of each hemisphere there is a deep irregular furrow resulting from post-mortem softening of the thin-walled hemisphere, and its consequent collapse. This was until recently supposed to be a real sulcus—sulcus arcuatus ("Bogenfurche" of German writers), but Hochstetter has recently shown it to be a post-mortem change.

Note that the cerebellar bridge is broader than in the last specimen, but that the lateral masses are still much plumper than the mesial bridge. O. C. 1341 B.

Presented by John Hilton, Esq.

Gustav Retzius, "Das Menschenhirn," 1896.

D. 677. The body of a human fœtus (older than last specimen), dissected to show the whole central nervous system *in situ.*

The fossa Sylvii is now much deeper and its superior and inferior limiting sulci quite definite.

On the mesial wall of the hemisphere the calcarine sulcus has now made its appearance.

The cerebellar bridge is now complete and two fissures (in addition to the limiting fissure of the floccular lobe) have now developed. They are the primary fissure (usually called "preclival") and the secondary fissure (usually called "prepyramidal").

In the spinal cord the cervical and lumbar enlargements are now apparent. O. C. 1341 C.

Presented by John Hilton, Esq.

D. 678. A human fœtal brain (of about the same age as the last specimen) lying *in situ* in the head. A great part of the lateral wall of the left hemisphere has been removed so as to show the corpus striatum, hippocampus and choroid plexus in the lateral ventricle. It also shows the relation of the fossa Sylvii to the corpus striatum.

Most of the ridges on the mesial wall are the obverse of those post-mortem puckerings called "transitory fissures." The most caudal of them, however, is not of this nature but is the calcar avis produced by the calcarine sulcus.

O. C. 1341 D.

Presented by John Hilton, Esq.

D. 679. The central nervous system of a slightly older human embryo, dissected to show the lateral ventricles.

On the right side the whole of the hippocampus is exposed, whereas on the left side it is hidden by the choroid plexus.

The calcarine sulcus is well shown on the left side.

On the base of the hemisphere note the acutely flexed pyriform lobe.

The cerebellum is now rich in fissures in the mesial region, but only a few of them have yet extended laterally.

O. C. 1341 E.

Presented by John Hilton, Esq.

D. 680. The brain of a later human fœtus. The left hemisphere has been separated.

The posterior part of the Sylvian fissure is now taking form. The superior limiting sulcus of Reil can be distinctly seen.

The form of calcarine sulcus is somewhat unusual, for it appears to be prolonged into an extraordinarily precocious parieto-occipital sulcus.

The cerebellum is now well-fissured. O. C. 1341 F.

Presented by John Hilton, Esq.

D. 681. The right hemisphere of the brain of a seven months' female fœtus, hardened in chromic acid.

On the mesial surface of this hemisphere the vestiges of the supra-callosal hippocampus (*vide* account of Marsupial brain) are very clearly seen in the callosal sulcus, especially near the splenium of the corpus callosum. The calcarine and parieto-occipital sulci appear to be united to form a **Y**-shaped figure; but, as we have seen in the Apes, so also in the developing human brain the parieto-occipital sulcus is usually quite independent of and altogether subsidiary to the calcarine sulcus. The retrocalcarine sulcus—the cross of the **T**—is widely separated from the calcarine. The collateral sulcus is represented by very faintly-marked depressions, but the occipito-temporal sulcus is present as two deep sulci. The calloso-marginal and rostral sulci are well developed.

Fig. 253. (× $\frac{2}{3}$.)

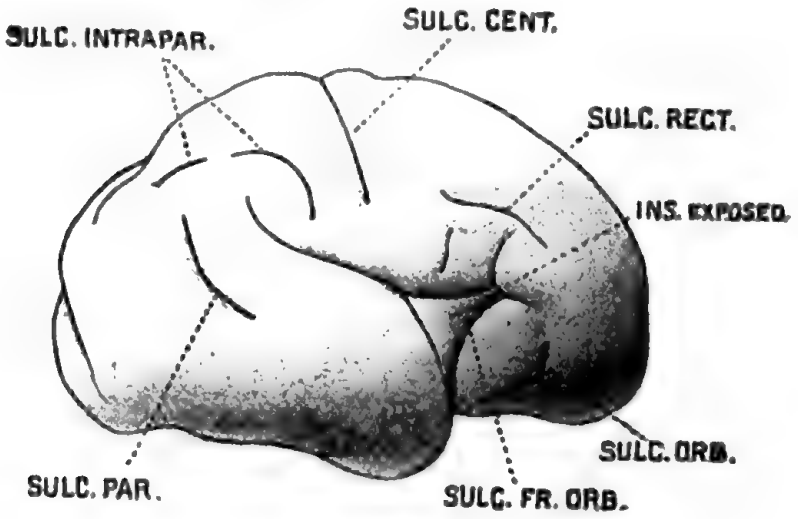

The orbital sulcus is fully formed.

The Sylvian fissure is in an interesting stage of development. The fronto-parietal, temporal and orbital opercula surround a triangular Sylvian fossa. [Unfortunately the anterior part of the specimen is damaged so that the frontal operculum cannot be seen.] The sulcus rectus (inferior frontal) is already developed. The central is a simple (and single) straight linear sulcus.

The intraparietal system is represented by short shallow sulci representing the ramus postcentralis inferior and ramus horizontalis, and very faintly-marked depressions representing the ramus postcentralis superior and ramus occipitalis.

The parallel is a very short sulcus. O. C. 1341 G.

Presented by S. G. Shattock, Esq.

D. J. Cunningham, Royal Irish Acad. Memoirs, Nos. 6 & 7 (1892).

D. 682. The left hemisphere of a human fœtus shortly before birth.

D. 683. The brain of a Microcephalic male Idiot, twenty-two years of age. He was 4 feet 8½ inches in height.

When first removed from the body, the brain weighed 12½ ounces (355 grms.). (In adult human males of a stature of 65 inches and under, the weight of the brain averages 46·95 ounces [1315 grms.].) The extreme length of the median curve of the hemispheres was 120 mm. The cerebellum projected 20 mm. beyond the occipital lobe.

After preservation in spirit the median curve of the frontal lobe from its anterior pole to the fissure of Rolando measures 76 mm., the parietal lobe 37 mm., and the occipital lobe from the parieto-occipital fissure to its posterior pole 7 mm.; there is therefore a marked deficiency of the occipital lobes, which do not nearly cover the cerebellum. The anterior inferior portion of the central lobe or island of Reil is exposed on the surface of the hemisphere, and is only slightly below the level of the frontal cortex. The exposure of this part of the island of Reil is due to the deficiency of the frontal and orbital opercula which cover the central lobe in the healthy adult human brain. The fronto-orbital sulcus bounds the exposed part of the insula anteriorly ; above, it is limited by the superior limiting sulcus or lower free border of the third frontal convolution. On the right side of the brain the temporal and the parieto-frontal opercula have been removed so as to expose the whole of the external surface of the island of Reil. If the central lobe of this brain is compared with that of a healthy adult human cerebrum, or that of the Chimpanzee (see specimen D. 673), it will be seen how small and ill-developed the island of Reil is in this microcephalic cerebrum. The marked deficiency in the weight of this human cerebrum, its defective orbital and fronto-parietal opercula, together with the anatomical characteristics of the island of Reil, place it among brains of the Simian type.

With the exception of the remarkable imperfections in this brain above referred to, its various external fissures and convolutions, although simple in character, do not differ essentially from those of the average adult human cerebrum.

The individual to whom this brain belonged is reported to have been a well-behaved lad when left alone, though mischievous; but under provocation was passionate and uncontrolled. He was called, from his appearance (*i. e.*, large coarse features and long arms), "The Monkey boy," and knew those who treated him well, following them about like a dog, with a peculiar gait. He was incapable of articulate speech, but expressed his wants by noises and signs. Music had a great attraction for him and he could imitate the actions of playing the violin or trumpet. He liked to be taken notice of by visitors, and, when asked, would show off certain tricks he had learnt, as, for instance, imitating the action of playing cricket. His habits were dirty at times.

D. 684. A cast of the brain of a Microcephalic Idiot.

D. 685. The brain of C. Babbage, Esq., F.R.S., a distinguished mathematician and inventor. The brain (with the pia mater) weighed 49½ ozs. (1406 grms.) immediately after removal. O. C. 1339 A *a*.

A full description of the human brain does not come within the scope of this Catalogue. This the student will find in text-books of Human Anatomy.

It would perhaps be more in keeping with the intentions of the founder of this Museum, who brought together such specimens as would throw any light upon the structure of Man, to briefly summarise such facts revealed in studying this collection of Vertebrate brains as help to explain the complicated anatomy of the human brain.

The human brain is by no means the largest known to us. The Elephant and the Great Whales possess much larger organs, and even the extinct Sirenian *Rhytina* was provided with a brain of larger absolute dimensions than that of Man. In the case of these huge animals the enormous mass of the brain is probably to be explained by the fact that the increase in size of the surface of the body necessitates a corresponding growth of the neopallium (to which the great proportions are chiefly due), which is the ultimate receptive-organ for sensory impressions.

In the case of the human brain, however, the Anthropoid Apes (which approach near to Man in bodily dimensions) afford us a criterion as to the amount of neopallium which may be regarded as "necessary" (in the Family Simiidæ) for the reception of impressions coming from such an extent of sensory surface as Man possesses. When it is remembered that the largest Ape's brain is approximately half the size of the smallest normal human brain, and the average Gorilla's brain only about one third (approximately) the weight of the average European's brain, it will then be understood how great an area of neopallium (to which the disproportionate size of the human and Anthropoid brains is chiefly due) Man possesses over and above the needs of the average member of the Simiidæ, to serve as the physical basis (so to speak) of an associative memory of immeasurably greater potentialities (for storing and comparing sensory impressions) than that of any other animal. The feature, therefore, which distinguishes the human from all other brains is the relatively enormous size of the neopallium in comparison with the minimum which the forces of natural selection have made a condition of survival in a member of the Simiidæ *.

The neopallium assumes important functions and becomes a condition of survival for the first time in the Mammalia, and in each successive epoch it has become incumbent upon every mammal either, on the one hand, to adopt some eminently safe mode of life or some special protective apparatus to avoid extinction, or, on the other hand, to "cultivate" a larger neopallium, which, as the organ of associative

---

* I use the term "neopallium" (Journ. Anat. and Phys. vol. xxxv. 1901, p. 431) because the other parts of the pallium, *i. e.* the hippocampus and pyriform lobe, do not share in this increase.

memory, would enable it to acquire the cunning and skill to evade danger and yet adequately attend to its needs. In many of the Eocene Mammalia (*cf.* the cranial cast of *Dinoceras*) the neopallium is reduced to such diminutive proportions that the brain resembles the reptilian type; and in each successive generation the neopallium becomes larger or the creature, in self-defence, is compelled to adopt some safe form of life. The *Hippopotamus* and the Sirenia are examples of mammals which have not kept pace in the fierce race for neopallial supremacy but survive by adopting habits of life which are eminently safe. The condition of the human brain represents the other extreme. Here the neopallium has attained its maximum development, and its possessor has not had to seek refuge either in a retired mode of life or by any protective specialisations of structure either for offence or defence, but has attained the dominant position in the animal kingdom, whilst retaining much of the generalised structural features of a primitive mammal.

This expansion of the neopallium is general and not restricted to any localised areas. Thus we cannot say that the greatness of the human neopallium is to be wholly attributed to a growth of the frontal or of the parietal or of the occipital areas, as various writers have maintained; because all parts exhibit distinct evidences of extension. But some regions exhibit the effects of this general expansion more decisively than others, and many writers have assumed (quite erroneously, I believe) that such effects are to be attributed to localised growth *. Thus there are very noteworthy evidences of growth in the region around the insula in the human brain, but this is probably for the most part an expression of the general extension in a region which lends itself to a clear demonstration of any increase.

In the early mammals the olfactory areas form by far the greater part of the cerebral hemisphere, which is not surprising when it is recalled that the forebrain is in the primitive brain essentially an appendage, so to speak, of the smell-apparatus. When the cerebral hemisphere comes to occupy such a dominant position in the brain it is perhaps not unnatural to find that the sense of smell is the most influential and the chief source of information to the animal; or perhaps it would be more accurate to say that the olfactory sense, which conveys general information to the animal such as no other sense can bring concerning its prey (whether near or far, hidden or

---

* There is no doubt that localised hypertrophies do occur, but the fundamental distinction of the human brain is the *general* expansion of the whole neopallium.

exposed), is much the most serviceable of all the avenues of information to the lowly mammal leading a terrestrial life and therefore becomes predominant; and its particular domain—the forebrain—becomes the ruling portion of the nervous system.

This early predominance of the sense of smell persists in most mammals (unless an aquatic mode of life interferes and deposes it: compare the Cetacea, Sirenia, and Pinnipedia for example) even though a large neopallium develops to receive visual, auditory, tactile, and other impressions pouring into the forebrain. In the Anthropoidea alone of non-aquatic mammals the olfactory regions undergo an absolute (and not only relative, as in the Carnivora and Ungulata) dwindling, which is equally shared by the human brain, in common with those of the other Simiidæ, the Cercopithecidæ, and the Cebidæ. But all the parts of the rhinencephalon, which are so distinct in macrosmatic mammals, can also be recognised in the human brain. The small ellipsoidal olfactory bulb is moored, so to speak, on the cribriform plate of the ethmoid bone by the olfactory nerves so that, as the place of attachment of the olfactory peduncle to the expanding cerebral hemisphere becomes removed (as a result of the forward extension of the hemisphere) progressively farther and farther backward, the peduncle becomes greatly stretched and elongated. And as this stretching involves the grey matter without lessening the number of nerve-fibres in the olfactory tract, the peduncle becomes practically what it is usually called, *i. e.* the olfactory "tract." The tuberculum olfactorium becomes greatly reduced and at the same time flattened, so that it is not easy to draw a line of demarcation between it and the anterior perforated space. The anterior rhinal fissure, which is present in the early human fœtus vanishes (almost, if not altogether) in the adult. Part of the posterior rhinal fissure is always present as the "incisura temporalis," and sometimes (D. 710), especially in some of the non-European races, the whole of the posterior rhinal fissure is retained in that typical form which we find in the Anthropoid Apes. When this occurs we can easily recognise the caudal limits of the pyriform lobe, which otherwise becomes confused with the neopallium.

The hippocampal fissure is of a peculiarly consistent nature, and is found in all mammalian brains from *Ornithorhynchus* to *Homo*. The rhinal fissure is equally *sui generis* and almost as constant as the hippocampal. A few small mammals, such as *Notoryctes*, *Chlamydophorus*, *Chrysochloris*, and some small Chiroptera, have no rhinal fissure.

Of the sulci perhaps the most constant is the calcarine, which is found in the Marsupials (both Poly- and Diprotodont), in the larger Chiroptera, *Galeopithecus*, (but not in any true Insectivore, nor, strange to relate, Rodent, so far as I am aware), and in all the Edentates, Carnivores, Ungulates, Cetaceans, and Primates. This wide distribution of the calcarine sulcus is not generally admitted, for most writers regard the calcar avis and the calcarine sulcus as the special prerogative of the Primates or even Anthropoidea, and in the celebrated controversy of 1864 the late Professor Owen strove to prove that it was confined to the human brain. It is, however, the most primitive (it may, however, first appear at the same time as the orbital and suprasylvian sulci) and widely prevalent neopallial sulcus in the Mammalia. It makes its appearance in most mammals (soon after the hippocampal and rhinal fissures have developed) as a short oblique sulcus behind the splenium of the corpus callosum (or in the corresponding situation in Marsupials), and hence it is commonly called "splenial" (Krueg) in non-Primate Orders, in which its true nature has not been properly recognised hitherto*.

Its subsequent history varies greatly in different Orders. In the Carnivora, Ungulata, Chiroptera, and many other mammals the sulcus becomes concurrent with another element of vastly less morphological importance, which I have called the "intercalary" sulcus. The calcarine-intercalary complex forms the "splenial sulcus" of these brains.

In most mammals, with the exception of the Primates, the tension of the growing cortex in the infracalcarine region is relieved by the downward extension of the calcarine sulcus to the neighbourhood of the rhinal fissure.

In the Anteaters, Sloths, Pangolins, Lemurs, and Apes the calcarine sulcus always remains separate from the intercalary sulcus, and the latter joins with the genual sulcus in the Primates to form the callosomarginal sulcus.

In many Carnivores and Ungulates (and in large mammals generally) one or more deep sulci make their appearance behind the calcarine sulcus, and in most cases one of these, which we may call the "retrocalcarine" sulcus, is deeper and more constant than the others and often joins the calcarine sulcus. This is seen to advantage in the brain of the Lion, Tiger, or Seal among Carnivores, or in the Horse, Camel, or Ox among Ungulates. This retrocalcarine sulcus is obviously of very minor morphological importance in comparison with

---

* Meynert and Ziehen have called the splenial sulcus "calcarine" in some Carnivores, without indicating any valid reasons for their views. They have attempted to extend its supposed homologies to the Anthropoid pattern so far as to utterly discredit any value that may attach to their recognition of its calcarine nature.

the true calcarine sulcus, and this is shown by its adaptability to the varying mechanical conditions prevalent in different Orders *. In the Primates both the retrocalcarine (Cunningham's "posterior calcarine") and the true calcarine (Cunningham's "anterior calcarine") sulci tend, as a result of the occipital extension of the hemisphere, to become horizontal and in most cases become concurrent. In the more rapidly expanding human brain it often happens that the two sulci do not exactly meet, as they generally do in the Apes. Cunningham is thus led to the belief that the human brain differs from the Simian brain in possessing a rétrocalcarine sulcus; but there can be little doubt that the so-called "calcarine" sulcus of the Apes is really a fusion of the retrocalcarine and true calcarine sulci, and therefore does not materially differ from the human calcarine complex. If the caudal extremity of this "calcarine complex" be studied in the Apes it will be found to be exceedingly variable and unstable, so that one cannot regard it as part of the true calcarine, which is an exceedingly stable sulcus.

By true "calcarine sulcus" I mean that depression which corresponds to or produces the calcar avis. As Flower long ago pointed out (Phil. Trans. 1862, p. 198, footnote), the presence of a posterior cornu of the lateral ventricle is not necessary for the existence of a calcar avis. Thus we find a free calcar in many hemispheres (those of *Orycteropus*, *Thylacinus*, *Pteropus*, for example) in which there is no posterior cornu. But in most mammals the calcar becomes hidden by a great mass of fibres (compare most Carnivores and Ungulates), and cannot therefore be said to exist as a projection *in the ventricle*; and yet in many large Carnivores (*Phoca* for instance) and Ungulates (*Camelus*) a small posterior cornu of the lateral ventricle makes its appearance, and with it a typical calcar again becomes exposed as in the Primates.

It would be strange indeed if the most constant and stable sulcus of the mesial surface of the hemisphere of most mammals should entirely disappear in the Primates, to be replaced by another sulcus presenting identical relations to the lateral ventricle and a similar developmental history, but without being homologous. There is an overwhelming mass of evidence to show that the vertical part of the sulcus generally called "splenial" is the direct homologue of the calcárine sulcus of the Primates.

---

* At the same time the fact that it develops in the midst of the region in which Vicq d'Azyr's stripe occurs in the Primates, and which represents the visual "centre," lends a special interest to this sulcus, which obviously accommodates the expanding visual cortex.

In many mammals (such as the Lion) the tension of the growing infracalcarine neopallium is relieved chiefly by the downward extension of the calcarine sulcus toward the posterior rhinal fissure, but also partly by certain irregular and inconstant compensatory sulci behind and parallel to this extension. In the Primates, however, the calcarine sulcus becomes very obliquely placed, not only because the occipital region of the hemisphere becomes caudally extended above the cerebellum, but also because the elongating corpus callosum pushes back, as it were, the pericalcarine neopallium; and as a result of this obliquity the sulcus cannot be prolonged towards the rhinal fissure, as happens in the Carnivora and Ungulata, so that the compensatory sulcus, which is known as the "collateral" sulcus, attains a greatly enhanced importance, and fulfils the rôle of the ventral extension of the calcarine sulcus.

A study of the variable collateral sulcus in the brain of Man and the Apes clearly shows its compensatory-calcarine nature.

Another result of the occipital prolongation of the hemisphere is that the calcarine sulcus becomes widely separated from the intercalary (calloso-marginal) sulcus, to which it is joined in most mammals. The stages in this separation are well shown by comparing, say, the brain of a typical Carnivore with those of *Daubentonia* and the Lemurs. As the result of this separation a new set of mechanical conditions prevail in the area between the calcarine and the calloso-marginal sulci; and, to further complicate matters, the arcuate sulcus formed on the dorso-lateral aspect of the hemisphere by the lateral and post-lateral sulci (*i. e.* the intraparietal and its ramus occipitalis transversus respectively) becomes more and more acutely flexed as the occipital prolongation occurs, so that in the Cebidæ the sharp-pointed apex of the **V**-shaped sulcus so-formed extends toward this region of the mesial wall, which is, for the reasons just mentioned, already in a state of "unstable equilibrium," so to speak. As the result two sulci (which may, however, be concurrent) are formed:—(*a*) a ventral compensatory-calcarine parallel to the calcarine and the dorsal limb of the postcalcarine sulcus, and (*b*) a vertical sulcus cutting into the dorsal edge of the hemisphere. The latter appears to relieve the tension of the extending surface in a region which is obviously influenced by the proximity of the "apex" of the intraparietal sulcus. In some cases (e. g. *Chrysothrix*, D. 554) this sulcus *b* may be joined to the intraparietal, but in most Apes it is independent of it. The two sulci *a* and *b* usually overlap, and in most cases the intervening gyrus becomes submerged so that the two elements appear to form one furrow, which is the "parieto-occipital sulcus." The latter, therefore, is a complex of two (and often three) new elements; it makes its appearance for the first time in the Anthropoidea in the region between the phylogenetically old calcarine and intraparietal sulci, which are the common heritage of the Meta- and Eutheria. This account will explain the extreme variability of the parieto-occipital sulci in the human brain.

There is yet another remnant in the Primate-brain of the calcarine-intercalary junction (which occurs in so many mammals) in the form of a short sulcus above and behind the splenium, which I have called "compensatory" (instead of Broca's misleading title "postlimbic").

The Sylvian fissure in its complete form is found only in the human brain, and even in Man it is often imperfect. It is really a great cleft upon the ventro-lateral aspect of the hemisphere formed by the meeting of the peripheral opercular lips of three sulci, which are quite distinct in origin and in their phylogenetic history. The most stable of these three sulci, and therefore that which takes the chief share in the development of the Sylvian fissure, is that called "suprasylvian" in most mammals. The second is an unstable sulcus analogous to the pseudosylvian sulcus (that which is commonly called the "Sylvian fissure") of the Carnivora and many other mammals. And the third sulcus is the fronto-orbital.

The suprasylvian sulcus is one of the most primitive and constant in the Mammalian series. It is the earliest neopallial sulcus to make its appearance on the external surface of the hemisphere in the course of the development of the Carnivore, Ungulate, and (according to the old observations of Pouchet) Edentate brain, synchronising in this respect with the calcarine sulcus on the mesial surface. Even if its identification is not altogether sure in the Marsupialia (see the accounts of *Thylacinus*, *Macropus*, and *Phascolomys*), we know that it is a most stable sulcus in the Edentata, Rodentia, Carnivora, and Ungulata. In many Mammals it is joined to the less stable post-sylvian ("posterior suprasylvian" of most writers) sulcus, which we call "parallel" in the Anthropoidea. In the Great Anteater, however, it usually becomes separated from the latter and joined to a pseudosylvian sulcus to form a Sylvian fissure, not unlike that found in the Lemuroidea. It is significant that in the only case in six hemispheres of *Myrmecophaga* where this junction does not take place, it should also happen that the suprasylvian sulcus is joined to the postsylvian, as in the Carnivora. In *Daubentonia* the suprasylvian sulcus is always separate from the pseudosylvian, and is generally joined to the postsylvian sulcus. In the Family Lemuridæ the suprasylvian sulcus is always (or practically always) separated from the parallel (postsylvian) sulcus, but numerous fragmentary sulci, and a backwardly-directed hook at the upper end of the suprasylvian (Sylvian) sulcus, or a forwardly-directed hook to the postsylvian (parallel) sulcus, serve to remind us of the old link between these two sulci, which has been broken.

The lower end of the suprasylvian sulcus in the Lemurs overlaps the upper part of a pseudosylvian sulcus (of the feline type), the gyrus between the two sulci becomes submerged, and the resulting sulcus we now call the "Sylvian fissure." The lower end of the suprasylvian sulcus can be seen in many Prosimian hemispheres emerging from the front of the "Sylvian complex" a short distance above the rhinal fissure.

In the Apes the submerged area increases in extent and is called the "insula." It is hidden by two opercula; and a comparison of a large series of Ape-brains seems to clearly demonstrate that the dorsal limiting sulcus of the insula is no other than the suprasylvian sulcus.

In no brain does this sulcus extend so far (in the ventral direction) as the rhinal fissure. In many of the larger Apes it emerges slightly and cuts into the anterior lip of the Sylvian fissure. In *Hylobates*, *Simia*, and the *Anthropopitheci* it extends forward upon the surface so as almost to reach the fronto-orbital sulcus.

The early history of the latter sulcus is not satisfactorily known. It is present in an exceedingly well-developed condition in all the Simiidæ, and in a less obtrusive form in many of the larger Apes: but, on the other hand, it is absent in many of the Cebidæ and Cercopithecidæ. Such being the case, it is very surprising to sometimes find in the Lemurs a small sulcus, which can be no other than the fronto-orbital. It is impossible to say with any degree of probability whether this sulcus is represented beyond the limits of the Primates. The diagonal sulcus of the Carnivora, Ungulata, Edentata (*Bradypus*, *Myrmecophaga*) occupies a position analogous to that of the fronto-orbital in the Primates.

In the Anthropoid Apes there is a pronounced tendency for the anterior lip of this (fronto-orbital) sulcus to become opercular and to extend backward over the insula, the anterior limit of which is marked out by the sulcus itself.

This process of operculation may be carried very far even in *Hylobates*, *Simia*, and *Anthropopithecus troglodytes*; and in one specimen of *Anthropopithecus gorilla* (D. 656) a very close though spurious imitation of the human condition of this region is attained.

In the human brain this process of operculation generally leads to the complete covering of the insula. The anterior lip of the fronto-orbital (or, as we may now call it, anterior limiting sulcus of Reil) grows backward to meet the temporal operculum, and thus gives rise to the "stem" of the Sylvian fissure. The dorsal lip of the forward extension of the superior limiting sulcus grows down to meet the temporal operculum (thus forming the anterior part of the posterior limb of the Sylvian fissure) and also the orbital operculum (which is the anterior operculated lip of the fronto-orbital sulcus). The latter meeting gives rise to the anterior limb of the Sylvian fissure. It often happens, however, that the expanding cortex in the neighbourhood of the meeting place of the anterior and superior limiting sulci becomes accommodated by the formation of an additional operculum—the frontal. As the result two anterior limbs of the Sylvian fissure (instead of one) are produced.

It follows from this account that a complete Sylvian fissure exists only in the human brain, and that the so-called Sylvian fissure of even the Anthropoid Apes lacks properly-constituted anterior limbs, a small part of the posterior limb, and generally also the "stem" of the complete sulcus.

The full development of the opercula leads to the abortion of the upper part of the fronto-orbital sulcus in the human brain.

The lateral, post-lateral, and ansate sulci of the Carnivora and other Mammalian Orders become in the Primates the intraparietal, transverse occipital, and ramus postcentralis superior respectively. It is a moot point whether the coronal sulcus, which is so constant and precocious, in the Carnivora, Ungulata, and Edentata, forms the ramus postcentralis inferior of the intraparietal system. The evidence seems to point to the sulcus rectus and the lower part of the central sulcus as being the real derivatives of this furrow.

In most Apes the region lying behind the transverse occipital sulcus undergoes a peculiar modification leading to the formation of a great operculum from the posterior lip of a new sulcus, called Simian or, as the Germans say, "Affenspalte." This does not usually occur in the human brain, probably because the cortical areas around the transverse occipital sulcus undergo a greater expansion than is the case in the Apes.

I have seen, however, in the brain of an Egyptian fellah a small indubitable Simian sulcus like that of the Gorilla. It was separated by a considerable interval from the mesial plane.

It thus happens that this region of the human brain more closely resembles the condition found in many of the larger Cebidæ (in which the opercular formation has either not begun or is only just commencing) than that of the Anthropoid Apes. Of the latter the brain of the Gorilla approaches the human condition much more nearly than does that either of the Chimpanzee or Orang. It must be remembered, however, that the "occipital" and "insular" regions exhibit an extraordinary amount of variation in each of the Simiidæ; the average condition of these two changing areas is much nearer the human type in the Gorilla than in either of the other great Apes.

Of the other sulci of the human brain (besides those already discussed) the only ones which can be called "old" in the phylogenetic sense are the orbital and possibly the inferior frontal sulci.

The orbital sulcus is probably one of the most primitive furrows in the neopallium, if not the earliest. It is the only sulcus found in the most generalised mammals, *Erinaceus* and *Perameles*. It is a very constant and precocious sulcus in all the Carnivora, Ungulata, Edentata, Cetacea, and many Rodents and *Galeopithecus*. Most writers call it "presylvian" in all these non-Primate orders, but there can be little doubt as to its homology with the orbital sulcus, although, so far as I am aware, such an interpretation has never hitherto been suggested. But it would be strange if this (the most widespread and constant) sulcus of the neopallium should not be represented in the Primates, and there is no other furrow of sufficient constancy in the pararhinal region to represent the presylvian sulcus of other mammals. If moreover we compare such brains as those of *Dolichotis* (Rodent), *Galeopithecus* (Insectivore), *Bradypus* (Edentate), and *Phascolomys* (Marsupial) with the Lemur's, it is clear that the "presylvian" sulcus of the former can be represented in the Prosimiæ only by the orbital or the fronto-orbital sulcus. Of these the former is not only by far the more constant of the two sulci, but it is also that which occupies the same position and relationship to the rhinal fissure as the "presylvian." A comparison of *Galago* and *Dolichotis* shows this.

If again we compare the behaviour of the orbital sulcus in the larger Ungulates (*e. g.*, the Camel, Horse, and Ox) and Carnivores (*e. g.*, the Seals), we shall find that as the hemisphere increases in magnitude (and more especially if at the same time it becomes more microsmatic) the "presylvian" sulcus becomes relegated to a position alongside the anterior rhinal fissure exactly analogous to that occupied by the orbital sulcus in the Gorilla's brain. In Man the simple linear orbital sulcus becomes complicated by numerous side branches so as to form triradiate, H-shaped or other patterns; but if a large number of human brains be examined, the orbital sulcus will be found to consist in a very considerable proportion of these cases of a single deep linear sulcus, the apparent branches of which are mere shallow furrows of little importance. Not unfrequently this sulcus joins a small anterior rhinal fissure—thus completing the resemblance to the junction of the "presylvian" sulcus with the rhinal in the Carnivora and others.

The coronal sulcus of the non-Primate mammals may be represented in the inferior frontal and the inferior precentral sulci of Man. One of the earliest sulci to make its appearance in the developing Carnivore and Ungulate brain is the coronal. In the Carnivores it often joins the lateral sulcus, in many Ungulates it is linked to the suprasylvian, in the Pig-family it is united with the intercalary sulcus. In the Primates the so-called sulcus rectus exhibits a similar precocity, and occupies a position not unlike that of the coronal in the Ungulates and the primitive Viverrine Carnivores. It becomes split up in the Cebidæ and Cercopithecidæ into two parts, the sulcus rectus (*sensu stricto*) and the sulcus arcuatus. The former develops into the inferior frontal and the latter into the inferior precentral sulcus.

The problem of the exact interpretation of the central (Rolando's) sulcus presents many difficulties. There can be no doubt whatever as to the homology of the mammalian lateral with the intraparietal sulcus of the Primates, and the interpretation of the ansate as the ramus postcentralis superior is almost as sure. We find in the Carnivora and the Primates respectively a deep and important sulcus bearing the same relations to the ansate and lateral sulci. In the former we call it "crucial" and in the latter "central"; the solution thus naturally suggested is that the central sulcus of the Primates represents the crucial sulcus of the Carnivora. Such a view has often been propounded before, and has in several instances been discarded for no valid reason. Thus it has been urged (with a singular disregard for the facts of the case) that the crucial sulcus "belongs to the mesial wall," in spite of the patent evidence afforded by the Arctoid Carnivora that when the crucial sulcus becomes dissociated from the intercalary sulcus it often lies *wholly* on the dorsal surface of the hemisphere (see the brain of the Bears, the Glutton, and in fact most of the Arctoidea).

If we study the forms assumed by the crucial sulcus in the large Carnivores (such as the Bears and Seals) and by the central sulcus in the large Apes (Simiidæ), we cannot fail to be struck with a striking parallelism, which could only be produced by the operation of similar factors in the two cases. Moreover, the earliest phases of the development of the central sulcus in the Lemurs are similar to the first rudiments of the crucial sulcus in the Viverridæ.

Physiological evidence (which, however, in such matters is notoriously misleading) does not altogether support such an homology. In the

Anthropoidea the central sulcus sharply marks the exact caudal limit of the area of excitable cortex, whereas in the Carnivora (so the physiologists tell us) the crucial sulcus lies in the midst of the excitable area.

If we admit the homology of the central and crucial sulci we shall (by comparison with the behaviour of the latter) find an explanation of many features of the former. According to such an hypothesis a glance at a Bear's brain will at once make intelligible the meaning of the superior genu, the caudal bend in the mesial extremity, and the tendency of the central sulcus in the Anthropoid Apes and Man to extend on to the mesial surface in front of the upturned end of the calloso-marginal sulcus.

In the features of its central sulcus (the relative positions of the genua and the behaviour of the mesial extremity of the sulcus) the *Anthropopitheci* approach much nearer to Man than does the Orang or any other Ape *.

The human brain is distinguished from those of the Apes by the abundance of sulci between these stable and constant elements.

The superior frontal and especially the middle frontal sulci are much better developed than in the Apes, and innumerable sulci develop in connection with these. The inferior transverse sulcus (so constant in the Simiidæ and larger Cercopithecidæ) is longer and deeper; and the diagonal sulcus, rarely or never seen in a well-developed form in the Apes, is now almost constantly present as a deep, extensive sulcus, lying between the anterior ascending limb of the Sylvian and the inferior precentral sulcus.

The parietal area is notably much more variable and much richer in secondary sulci than it is in the Apes.

In the temporo-occipital region the "Affenspalte" of the Apes has disappeared, and the depth and extent of the dorsal end of the parallel, the transverse occipital and lateral occipital sulci are correspondingly increased. The inferior occipital, inferior temporal, occipito-temporal, and collateral sulci are usually all present in a well-developed form. In the Apes the deepening and lengthening of any one of these sulci involved a dwindling of its neighbour—a highly developed occipito-temporal sulcus often led to the abortion of the inferior temporal, the disappearance of the anterior end of the collateral, or the curtailment

---

* As the result of further investigations since the above was written, I have come to the conclusion that the crucial sulcus represents the dorsal part of the central sulcus and that the ventral part of the latter is formed either from or at the expense of (mechanically) the caudal extremity of the coronal sulcus.

of the inferior occipital or *vice versa*; but in the human brain there is room for all these unstable and mutually compensatory sulci to exist in a well-developed form side by side.

The expansion of the neopallium has far-reaching effects upon other regions of the nervous system: the fibre systems connected with it become more bulky, the cerebellum becomes larger, its middle peduncle—the pons—becomes so broad that it completely covers the trapezoid bodies and extends down to the inferior olives. In innumerable ways the whole nervous system is profoundly influenced and modified in structure as the result, directly or indirectly, of the attainment of the neopallium to the height of its perfection.

D. 686. A human brain, presumably British. O C. 1339 A *b*.

D. 687. A human brain, presumably British. O. C. 1339 A.

D. 688. The right half of a brain, presumably British.
O. C. 1339 D.

D. 689. The left half of the same brain. O. C. 1339 D′.

D. 690. The left cerebral hemisphere of a man, hardened in dilute nitric acid and then dried.
Prepared and presented by S. G. Shattock, Esq.

D. 691. Fragment of a human left cerebral hemisphere from a Prehistoric burial place at El Amrah, Upper Egypt.
Presented by Prof. G. Elliot Smith.

D. 692. A cast of the interior of the Neanderthal skull.
Presented by Professor Huxley.
Huxley, "Man's Place in Nature," p. 168.

D. 693. A cast of the frontal region of the cranial cavity of the "Gibraltar" skull—a palæolithic cranium, remarkable for the low retreating forehead, found in the brecciated talus of a quarry behind "Forbes' Battery" under the north front of the Rock of Gibraltar. (See Osteol. Series, 371.)
Presented by N. C. Macnamara, Esq.

D. 694. Two casts of the cranial cavity of a "European."

D. 695. A cast of the cavity of Dean Swift's skull.

D. 696. Two casts of the cranial cavity of a Chinaman.

D. 697. Two casts of the cranial cavity of a Tartar (male).

This is so extraordinarily broad that the outline is almost circular.

D. 698. Two casts of the cranial cavity of a Turk.

This also is very broad.

D. 699. A human brain labelled "New Zealand." O. C. 1339 B.

D. 700. Two casts of the cranial cavity of a Maori (male).

D. 701. Two casts of the cranial cavity of an Australian (male).

D. 702. Two casts of the cranial cavity of an Australian (male).

D. 703. Two casts of the cranial cavity of an Australian (male).

The first two of these casts (D. 701, D. 702) are remarkable by reason of their extreme narrowness, especially in the frontal region. The third (D. 703), however, is quite broad.

D. 704. A cast of the interior of a narrow skull.

This cast was made, at the instance of the late Professor Huxley, from a skull (probably of an Australian) to contrast with that of a Tartar (specimen D. 697) so as to demonstrate the extreme variations in the form of the cranial cavity, and consequently of the brain, in different races of mankind. *Presented by Professor Huxley.*

Huxley, Journ. of Anat. & Phys. vol. i. 1867, p. 60.

D. 705. A cast of the cranial cavity of a Papuan.

D. 706. The brain of a young female "Bushman," from which the left cerebral hemisphere has been removed.

This specimen has been described in detail by Professor John Marshall (Phil. Trans. 1864, pp. 501–525). He pointed out the relative simplicity of the sulci and the proportionate scarcity of secondary sulci when compared with the European brain, and came to the conclusion that these phenomena could not be wholly attributed to the sex of the individual but constituted definite evidence of the racial inferiority of the Bushmen.

At the same time one is bound to add to Marshall's remarks, that those parts of the brain which we know to have been markedly modified during the short recent phases of human evolution (such, for example, as the insular region and the areas around the parieto-occipital and calcarine sulci) show little if any sign of inferiority in comparison with the European brain. O. C. 1339 B *a*.

D. 707. The left cerebral hemisphere belonging to the previous specimen. O. C. 1339 B *b*.

D. 708. The brain of a Bushman. O. C. 1339 B *bb*.
Presented by Professor John Marshall.

D. 709. Two casts of the cranial cavity of a Bushman.

D. 710. The brain of a Zulu (♂ æt. 22 yrs.). O. C. 1339 B *c*.
Presented by Dr. W. H. Allchin.

D. 711. Two casts of the cranial cavity of an "African."

D. 712. Two pairs of casts of the cranial cavities of Negroes.

D. 713. Casts of two preparations made by Prof. D. J. Cunningham to demonstrate the cranio-cerebral topographical relations.

Cunningham, Memoirs Royal Irish Acad. vol. vii.

D. 714. Coloured cast of the human calvarium, showing the relations of the cerebral sulci to the bony sutures.
Prepared by Professor P. Broca of Paris.

D. 715. A coronal section of the human head passing through the genu corporis callosi. O. C. 1339 C.

D. 716. A similar section passing through the rostrum corporis callosi and opening up the anterior cornua of the lateral ventricles. O. C. 1339 C *a*.

D. 717. A similar section passing through the splenium corporis callosi.

It exposes the upper part of the descending cornu of the lateral ventricle and also the floor of the fourth ventricle.

O. C. 1339 C *b*.

D. 718. A similar section cutting the cerebellum at its maximum breadth. O. C. 1339 C *c*.

D. 719. A similar section passing through the occipital poles of the hemispheres. O. C. 1339 C *d*.

D. 720. The pons Varolii, medulla oblongata, and cerebellum of a human brain.

The medulla oblongata has been dissected by Mr. Swan in order to show the pyramidal decussation.

O. C. 1339 E 16.

D. 721. A sagittal section through the lateral mass of the human cerebellum.

This shows the dentate nucleus lying in the medulla.

O. C. 1339 E 18.

D. 722. A dissection to show the nerve-fibres collecting from all parts of the cerebral hemisphere to form the pes pedunculi.

O. C. 1339 E 10.

D. 723. A similar specimen. O. C. 1339 E 11.

D. 724. A dissection of the human medulla oblongata to show the pyramidal decussation. O. C. 1339 D 36.

D. 725. A preparation of the human optic thalami, mid-brain, pons, and medulla oblongata in which a bristle has been passed from the 3rd to the 4th ventricle through the aqueduct of Sylvius.

D. 726. A dissection to show the behaviour of the fibres of the corpus callosum, in the cerebral hemispheres: mesial view.

O. C. 1339 D 7.

D. 727. A specimen showing the relations of the corpus callosum to the cerebral hemispheres from above. O. C. 1339 D 8.

D. 728. A horizontal section of the human brain mounted by Mr. Greenwood, of Leeds, in glycerine jelly (Miall's process).

If this specimen be compared with the section made in a corresponding plane through the left cerebral hemisphere of a Chimpanzee (D. 672), a striking demonstration is afforded of the contrast between the human insula (which is wholly covered) and the Anthropoid island of Reil (which is partially exposed on the surface).

Presented by C. G. Wheelhouse, Esq.

D. J. Cunningham, Journ. Anat. & Phys., vol. xxxii., 1898, p. 11.

Membranes of the Brain.

The brain is enveloped by at least two distinct sheaths of connective tissue, which serve for its protection and support and give passage to its blood-vessels and lymphatics. The innermost sheath (pia mater, or in lower Vertebrates where two sheaths only are present, the combined rudiment of the pia and arachnoid) is closely applied to its surface, and follows accurately all the brain contours and conveys into its substance blood-vessels and lymphatics. The outermost sheath (dura mater) is a modification of the periosteum, and in some cases (*e. g.* Mammalia) forms a single sheet with it, but is more generally separated into periosteal and dural layers by a zone of looser tissue. In Teleosts this interdural space is frequently very extensive, and is occupied by a very delicate trabecular connective tissue containing a gelatinous substance or fat. The dura mater is separated from the underlying layer or layers by a subdural lymph-space. This in the higher groups is a relatively narrow and almost continuous cavity, but in Elasmobranchs and Reptiles is large and is occupied by a delicate trabecular tissue. In Birds and Mammals there is interposed between the pia and dura mater a third layer (arachnoid) which is nothing but the outer parts of the pia separated off by the increase and confluence of lymph-spaces. The subarachnoid space thus formed is traversed by numerous trabeculæ and is filled with cerebro-spinal fluid. In the Mammalia processes of the arachnoid (glandulæ Pacchioni) protrude between the fibres of the dura into the cavities of the venous sinuses, and, apparently, by allowing the cerebro-spinal fluid to escape into the veins, ensure an adjustment of the pressure in and around the cerebro-spinal axis, when the flow of blood to those organs is increased.

The surfaces of all three sheaths are covered by a pavement epithelium.

D. 729. The head of a Sea Bream (*Pagellus centronotus*) in sagittal section. The brain occupies only the ventral parts of the spaceous cranial cavity ; it is enveloped above by a deep layer of fat lodged in the subdural space.

Preserved in 5 per cent. formol.

D. 730. A portion of the vascular covering, or pia mater, of the brain of a Goose (*Anser ferus*). The internal surface is smooth like the external, corresponding to the smooth unconvoluted surface of the brain which it invests. The vessels are injected showing their ramifications upon the membrane. O. C. 1342. *Hunterian.*

D. 731. The cranial roof of a Dog (*Canis familiaris* var. *borealis*) showing two sheet-like processes of the dura mater or outer covering of the brain. One—the falx—projects downwards in the sagittal plane, and in its natural position lies between the dorsal parts of the two hemispheres. The other—the tentorium—is attached transversely to the hinder margin of the falx ; it stretches across the posterior part of the cranial cavity and is inserted between the cerebrum and cerebellum.

In the Carnivora extensive ossification occurs within the tentorial membrane. In this specimen part of the membrane has been reflected to show the bony tentorium beneath. O. C. 1346 A.

D. 732. A portion of the dura mater of an Elephant (*Elephas indicus*) showing the union of the falx and tentorium. The dura is of considerable thickness, and can be separated into three layers, of which the outer and inner are firm and compact, the intermediate zone being of looser texture, and containing venous sinuses.

D. 733. The choroid plexus of a Porpoise (*Phocæna phocæna*).

The choroid plexuses are pleated invaginations of the anterior and posterior tela choroidea into the lateral and fourth ventricles of the brain. They consist of highly vascular pia mater covered on its inner surface by the columnar epithelium that lines the brain cavities. They are mainly concerned in the production of the cerebrospinal fluid. O. C. 1334. *Hunterian.*

D. 734. The choroid plexus of a Piked Whale (*Balænoptera acuto-rostrata*). O. C. 1337. *Hunterian.*

D. 735. The head of a small American Monkey (*Callithrix* sp.) from which the calvarium has been removed, leaving the external surface of the dura mater exposed to view. The outer parts of the dura are closely applied to the cranial bones and form their periosteum. The arteries have been injected. O. C. 1345 A.

D. 736. A vertical section of the head of a young child, showing the processes of the dura mater that project into the cranial cavity and support the several regions of the brain. These are: the falx cerebri—an extensive sagittal partition between the upper parts of the hemispheres; the tentorium, crossing the hinder part of the cranial cavity in a transverse and obliquely horizontal direction and situated between the cerebrum and cerebellum; and the falx cerebelli, a small sagittal partition lying between the hemispheres of the cerebellum. The transit of the cranial nerves through the dura mater at the base of the cranium is also shown. The proximal ends of the straight and superior longitudinal sinuses have been exposed by the section, and a black bristle has been inserted into the superior longitudinal sinus. Black bristles have been inserted into the optic foramen and into the cavity of the nose. O. C. 1344 A.

D. 737. The dura mater removed from the dorsal parts of a human brain, showing the falx cerebri and the parts of the tentorium in connection with it. The straight sinus and proximal parts of the lateral sinuses have been opened from below, the walls of the former being kept apart by a black bristle. Other bristles have been inserted between the layers of the falx cerebri and into a cavity beside the superior longitudinal sinus, the cut end of which is situated just posterior to the right lateral sinus. A similar opening can also be seen upon the left side. In this specimen the arteries are injected. O. C. 1344. *Hunterian.*

D. 738. A portion of the dura mater from the dorsal parts of a Human cranium. Its fibrous nature is clearly shown. The superior longitudinal sinus has been laid open to show a number of "glandulæ Pacchioni"—irregular outgrowths of the arachnoid membrane, through which the cerebrospinal fluid contained in the sub-arachnoid space can exude into the blood.

The two layers of the dura mater have been separated and a portion of the external layer removed from one side. O. C. 1345. *Hunterian.*

D. 739. The brain of a Human Female covered by the pia mater and arachnoid membranes. O. C. 1339. *Hunterian.*

D. 740. A portion of the pia mater with the arachnoid membrane adhering to it, from one of the cerebral hemispheres of a Human brain. The pia mater is thrown into a series of folds, that pass between the convolutions of the brain, and support the blood-vessels in their progress to the deeper parts. The villous character of the inner surface of this membrane is produced by the minute vessels which, adhering to the pia mater, have been torn from the cerebral substance. The arachnoid membrane is extended smoothly over the external surface of the pia mater, attached to it by numerous delicate laminæ and trabeculæ, but is not reflected with it into the sulci of the hemisphere. The arteries in this specimen have been minutely injected. The external surface of the arachnoid membrane is smooth and is separated by a slight cavity from the dura mater. O. C. 1343. *Hunterian.*

Blood-vessels of the Brain.

D. 741. The head of a Dog-fish (*Acanthias vulgaris*) showing, from the ventral surface, the arteries of the brain and their connection with the carotids. Two carotid arteries arise on either side from the efferent vessel of the first demibranch —an anterior carotid or hyoidean artery and a posterior carotid. The posterior carotid divides at the hinder border of the orbit into an external and an internal trunk ; the latter enters the cranial cavity and passes across it in the perichondrium below the hypophysis, to form a connection with the internal branch of the opposite hyoidean artery. The hyoidean artery gives off in the orbit an external (ophthalmic) and an internal branch. The latter divides into (i.) the above-mentioned connection with the posterior carotid artery, and (ii.) a trunk that breaks up into anterior and posterior cerebral arteries, the first of which supplies the cerebrum and olfactory bulbs, and the second, the rest of the brain by branches to its dorsal and ventral surface. The latter unite upon the ventral surface of the medulla oblongata, to form a median (myelonic) artery continued backward along the spinal cord.

Parker, Phil. Trans. vol. clxxvii. 1886, p. 690.

D. 742. The brain of a Turtle (*Chelone mydas*) with the arterial blood-vessels injected. The cut ends of the internal carotids can be seen on either side of the infundibulum. Each divides on the base of the brain into two branches, one of which runs forwards and branches out over the cerebrum and olfactory bulbs. The other passes backwards and shortly unites with its fellow at the base of the medulla to form the basilar artery, but gives off before this union two large branches to the optic lobes and cerebellum.

O. C. 1313 c.

D. 743. The brain of a Goose (*Anser ferus*) with the arteries injected. Bristles have been inserted into the ruptured end of the left olfactory bulb and into the roots of the chief cranial nerves.

O. C. 1320.

Hunterian.

D. 744. The brain and the upper part of the spinal cord of a Lion (*Felis leo*) with the arteries injected.

In this beautiful preparation, the origin of the chief arteries of the brain and a great part of their distribution are clearly shown. The essential points of the arterial arrangement are comparable to the condition found in Man. Anterior, middle, and posterior cerebral arteries can be distinguished arising in much the usual places from the circle of Willis. Upon the right side the posterior cerebral artery consists of two separate trunks.

The superior cerebellar artery arises by two roots on the left side, one from the basilar artery, the other from the posterior arm of the circle of Willis.

The anterior (ventral) and inferior (posterior) cerebellar arteries form branches of a common trunk.

The lateral parts of the circle of Willis are very strongly developed. O. C. 1326.
Hunterian.

D. 745. The brain of a Sheep (*Ovis aries*) with the arteries injected. In this specimen the origin of the anterior and middle cerebral arteries from the circle of Willis is more plainly visible than in the preceding specimen. The posterior cerebral and superior cerebellar arteries are represented by a number of small vessels that arise from the hinder part of the circle of Willis and from the anterior end of the basilar artery. The lateral parts of the circle of Willis are remarkably stout, as in the Lion (D. 744). Bristles have been inserted into the various cranial nerves. O. C. 1327.
Hunterian.

D. 746. The brain and the upper part of the spinal cord of a Porpoise (*Phocæna phocæna*), injected. O. C. 1332.
Hunterian.

D. 747. The basilar artery of a Rorqual (*Balænoptera* sp.).
O. C. 939 H *a*.

D. 748. The main arteries of the human brain, injected, isolated, and spread out on a flat surface. The anterior communicating artery is abnormally long and slender.

SPINAL CORD.

The spinal cord is a direct backward continuation of the medulla oblongata. It extends for a variable distance towards the tail, being in lower forms coextensive with the vertebral column, but in the higher showing a more or less marked shortening in relation to it. In the latter case, a degenerate vestige of the hinder end of the cord is still present in the posterior parts of the neural canal, surrounded by a bundle of spinal nerve-roots (cauda equina). Extreme shortening of the cord occurs in isolated cases in widely separated groups (*Diodon*, *Erinaceus*).

In transverse section, the cord is usually oval or circular, rarely flattened and ribbon-like (*Cyclostomi*) or quadrangular (Rays). The central canal is lined by an ependyma and surrounded by a layer of grey matter.

In many fishes there is no definite boundary between the grey and white matter, but in most cases it is clearly defined and has in transverse section the form of a St. Andrew's cross.

In the lower groups, where the sense-organs of the skin are mainly innervated by certain cranial nerves, the dorsal (sensory) horns of grey matter are relatively very weak. Ganglion-cells occur chiefly in the ventral (motor) horns, evenly distributed throughout their length. The presence of limbs, if of sufficient size and activity to require nerves markedly larger than those of the trunk, is accompanied by a swelling of the cord due to an increase in the number of nerve-elements at the point of origin of the limb-nerves. In a similar way, any other increased nerve-supply occasions a corresponding local thickening of the cord: (*e. g.*, Gurnard, tactile pectoral fin-rays. *Gymnotus*, electric organ). Conversely, diminished nerve-supply, as in the thoracic region in the Chelonia, is accompanied by diminution in the size of the cord.

The cord is more or less extensively united by tracts to the different regions of the brain. In lowly forms this connection is comparatively slight, being restricted mainly to the ventral tracts (fasciculi longitudinales posteriores) and fillet. Hence in these the cord is far more independent of the brain in its actions than in higher vertebrates in which tracts from the cortex, cerebellum, and other parts of the brain form the greater part of its white matter.

In most bony fishes, Ganoids, Dipnoi, and larval Amphibians, the ventral (motor) tracts contain a pair of giant nerve-fibres (Mauthner's fibres) which arise from a pair of giant cells in the neighbourhood of the acoustic nucleus. They cross in the floor of the medulla and at the hinder end of the cord break up and enter the motor nerves of the tail-fin. A number of somewhat similar fibres (Müller's fibres) occur in the ventral tracts of the cord in Cyclostomi. In many Fishes a number of remarkable giant ganglion-cells are found in the dorsal fissure, usually at the anterior end of the cord; their axis cylinders apparently run in some cases forwards, in others backwards, and form connections either with the dorsal roots of the spinal nerves or with the sensory branches of the trigeminal. The development of these elements has been noticed to be particularly strong in fish with special epidermal sensory processes (*Lophius*, *Batrachus tau*). Whether these cells are homologous wherever they occur, and what their exact relations may be to similar cells that form a transient nervous system in Elasmobranch embryos, is still a matter of doubt.

Fig. 254.

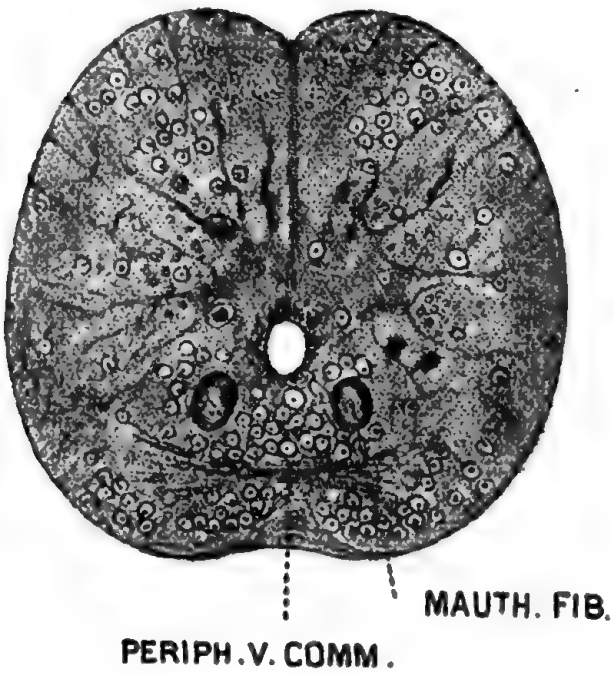

PISCES.

CYCLOSTOMI.

D. 749. Two pieces of the trunk of a Sea-Lamprey (*Petromyzon marinus*) with the cord exposed from above in one, and in transverse section in the other, to show its dorso-ventrally flattened, ribbon-like form. The grey matter of the cord surrounds the central canal and has the same outline in cross-section as the cord itself. In the white matter are a number of large fibres (Müller's fibres). The cord occupies only a small part of the neural canal, and is surrounded by two fibrous sheaths—an outer dura mater attached here and there by trabeculæ to the fibrous walls of the canal, and a delicate pia mater close to the cord. Between the two there is a large subdural space occupied by loose trabecular tissue. In the upper specimen, the cord is seen in transverse section situated near the floor of the neural canal and surrounded by a mass of subdural tissue. In the lower specimen the two sheaths have been slit along the dorsal mid-line, and black paper has been inserted beneath them. A red rod has been placed beneath the posterior part of the cord.

ELASMOBRANCHII.

D. 750. A section of the head and vertebral column of a Skate (*Raia batis*), in which the cerebro-spinal axis has been laid bare by the removal of the posterior walls of the cranial and spinal cavities. The spinal cord is continued to the caudal end of the vertebral column, regularly and very gradually decreasing in size. The dorsal roots of the spinal nerves can be seen arising from the dorso-lateral borders of the cord at regular intervals and passing diagonally backwards to their point of exit from the neural canal, their direction becoming more and more oblique towards the hinder end of the body. In the anterior region the dorsal roots occur at more frequent intervals than further back, and here perforate the continuous cartilaginous walls of the neural canal. When separate vertebral arches are differentiated (about 80 mm. behind the skull) a dorsal root perforates each of the interdorsalia. A number of the anterior spinal nerves converge as they pass outwards to form the cervical and brachial plexuses. The parts have been finely injected. O. C. 1347. *Hunterian.*

D. 751. A similar specimen of the anterior part of the spinal cord of a Skate (*Raia batis*). The cord is surrounded by a large subdural space. O. C. 1347 C.

D. 752. A portion of the spinal cord of a Skate (*Raia batis*) exposed within the neural canal from above. Upon the left side, the passage of the dorsal roots of the spinal nerves through the interdorsalia is shown upon the section surface, and in a similar way upon the right side that of the motor (ventral) roots at a lower level through the dorsalia. The dorsal and ventral roots emerge from the cord in the same transverse plane, but pass through the neural arches at different levels, the ventral root perforating a dorsalium and the dorsal root the succeeding interdorsalium. The increasing obliquity of the nerve-roots, towards the lower end of the specimen, in their passage to the walls of the neural canal is very clearly shown. O. C. 1347 D.

TELEOSTEA.

D. 753. The posterior end of the vertebral column of a Cod (*Gadus morrhua*), showing from above the hinder portion of the spinal cord. Before reaching the extremity of the vertebral column it swells to form a large pear-shaped terminal ganglion, from the hinder end of which a delicate terminal filament is given off. A similar enlargement is found in many bony fish. O. C. 1347 F.

D. 754. The cranium and vertebral column of a Fishing Frog (*Lophius piscatorius*), from which the dorsal parts have been removed to expose the brain and spinal cord *in situ.*

The anterior end of the cord, where it passes into the medulla, is much enlarged and shows upon the dorsal surface a pair of pyriform prominences, abruptly swollen in front and gradually decreasing to the normal level of the cord behind. The nerves that arise from this region of the cord are stouter than the rest of the spinal nerves. In minute structure, these eminences agree with the metameric enlargements at the anterior end of the cord in the Gurnards. In both cases they are due to an increase in the dorsal horns of the grey matter of the cord corresponding to an increase in the development of the sensory roots of the anterior spinal nerves. The cleft between the two prominences is occupied by a mass of giant ganglion-cells, whose axis cylinders have been traced to the roots of the trigeminal. They are probably connected with the innervation of the epidermal processes upon the head of the fish. The cord rapidly diminishes in size posteriorly, until upon a level with the 3rd or 4th vertebra it is represented by a delicate thread lying in the centre of a "cauda equina" formed by the roots of the posterior spinal nerves. The actual posterior limit of this terminal filament is not very clear in the specimen, but it apparently stops at some distance from the extremity of the tail. The filament is indicated by bristles and black paper placed beneath it.

Another example of the spinal cord of this fish is shown in D. 100. O. C. 1347 E.

Fritsch, Arch. f. Mikr. Anat., Bd. xxvii. 1886, p. 13.

D. 755. A Gurnard (*Trigla hirundo*) with the brain and spinal cord exposed from above. The cord is remarkable for a series of five pairs of rounded eminences upon its dorsal surface close behind the medulla. The first two pairs are relatively insignificant, but the last three are large and of about equal size. The eminences consist of grey matter with a superficial layer of small ganglion-cells. Like the sensory cranial nerve-nuclei, which they much resemble in structure, they are formed by a great development of the grey matter of the anterior horns, arising in response to a demand for increased nerve-supply. They give origin to the dorsal roots of the three anterior pairs of spinal nerves. These (especially the roots of the 3rd pair) are of great size and supply the free digitiform rays of the pectoral fins.

Ussow, Arch. Biol. t. iii. 1882, p. 608.

AMPHIBIA.

D. 756. A *Menobranchus lateralis* with the brain and spinal cord exposed from above. The cord, like that of a fish, extends to the tip of the tail gradually decreasing in size. It shows no appreciable thickening at the points of origin of the limb-nerves.

D. 757. A Common Toad (*Bufo vulgaris*) with the brain and spinal cord exposed from above. The cord is much shortened relative to the vertebral column It rapidly tapers to form, on a level with the fifth vertebra, a filum terminale that extends into the urostyle and is surrounded at its proximal end by a cauda equina formed by the posterior nerve-roots. Brachial and crural swellings are distinguishable, separated by a short narrower segment of the cord.

REPTILIA.

D. 758. A Monitor Lizard (*Varanus indicus*) with the brain and spinal cord exposed from the dorsal aspect. The cord is cylindrical and except for the brachial and crural enlargements, is of about equal calibre from its anterior extremity to the root of the tail. From this point to its termination at the tip of the tail it rapidly diminishes in size. The brachial and crural enlargements are of quite moderate dimensions. As in all other cases where they occur, they are mainly due to an enlargement of the ventral horns of grey matter, occasioned by the increased motor nerve-supply necessary for the limbs. The cord completely fills the neural canal. O. C. 1349 A.

D. 759. The spinal cord of some large Reptile, apparently a Snake, showing the gradual diminution of the cord to its caudal extremity. There are no indications of brachial or crural enlargements. O. C. 1351. *Hunterian.*

D. 760. The tail of a Python (*Python* sp.) showing the spinal cord *in situ* from above. As in *Varanus,* the cord extends to the tip of the tail gradually diminishing in size. It fills the cavity of the neural canal. O. C. 1349 B.

D. 761. Parts of the cranium and neck of a young Crocodile with the brain and cervical part of the spinal cord exposed from above. The cord is surrounded by two protective membranes—the dura mater which has been divided along the dorsal mid-line and turned to either side, and a delicate pia mater closely investing the cord and carrying the blood-vessels. Between the two sheaths is a subdural lymph-space. The arteries of the pia mater have been injected. The entrance of the dorsal roots of the spinal nerves into the cord by several spreading rootlets is clearly seen through the transparent pia mater. The brain has been preserved to show its comparatively small size in relation to the spinal cord. The right tympanic membrane and columella auris are also shown. O. C. 1348. *Hunterian.*

D. 762. The hinder part of the spinal cord of a young Crocodile, isolated. This is apparently the rest of the cord shown in the preceding specimen. It has been cut off at the anterior end of the brachial enlargement (the posterior limit of the previous specimen) and its arteries have been injected. The brachial and crural enlargements are of moderate development. Behind the latter, the cord rapidly diminishes to form the caudal segment. The extreme caudal end has been removed. The cord is enveloped by the pia mater, and in places also by the dura. O. C. 1349. *Hunterian.*

D. 763. The brain and spinal cord of a Tortoise (*Testudo græca*). This specimen is a striking example of the correlation that occurs between the size of the different regions of the central nervous system and the activity of the parts innervated by them. In the Tortoises movements are mainly restricted to the head, neck, tail, and limbs, the trunk region being rendered immotile by the development of the carapace. In consequence of the absence of the greater part of the usual muscles and integumentary sense-organs from this immotile region, the cord and spinal nerves are here remarkably slender. In its other parts (cervical and caudal regions and limb swellings) the cord shows a considerable state of development.

D. 764. Part of the spinal cord of a Turtle (*Chelone mydas*) invested in its protective membranes. Parts of the dura mater have been removed, exposing the underlying pia mater and the subdural space. The slenderness of the cord relative to the distance between the origins of the spinal nerve-roots is well shown. O. C. 1350. *Hunterian.*

AVES.

D. 765. A part of the spinal cord from the neck of an Ostrich (*Struthio camelus*). The protecting membranes have been reflected from the dorsal surface of the cord, showing the longitudinal dorsal fissure extending down to the dorsal grey commissure. In one part the two halves of the cord have been thrust apart, rupturing this commissure and exposing the central canal. Upon the ventral surface of the cord the dura mater has in part been preserved. It is folded back to expose the origins of the dorsal and ventral roots of a pair of spinal nerves. The dorsal root is the larger of the two and enters the cord by several well-defined rootlets. O. C. 1352. *Hunterian.*

D. 766. A smaller portion of the cervical region of the spinal cord of an Ostrich (*Struthio camelus*). The dura mater has been removed. In the posterior part of the specimen the right dorsal column of the cord has been cut away to show the depth of the dorsal longitudinal fissure. A black bristle has been inserted into the central canal. The roots of a pair of spinal nerves are shown in detail. The dorsal root breaks up before entering the cord into nine or ten rootlets, whose several points of entrance into the cord lie in a straight line, some 15 mm. in length, upon its lateral border. The ventral root rises from the cord near the mid-ventral line by three main rootlets. The dorsal and ventral roots run for some distance (20 mm.) before uniting. At the point of union lies the large ganglion of the dorsal root. O. C. 1353. *Hunterian.*

D. 767. A portion of the thoracic segment of the spinal cord of an Ostrich (*Struthio camelus*) with the dura mater partly removed. O. C. 1354. *Hunterian.*

D. 768. The sacral and caudal parts of the spinal cord of an Ostrich, showing the enlargement which takes place at the point of origin of the nerves for the hind limbs, and the lateral separation of the posterior columns of the cord at this part, leaving an interspace—the "sinus rhomboidalis." The cavity of this space in Birds is filled by a cellular mass derived apparently from the ependyma of the central canal. The following is the original description of this preparation:—"The part of the medulla which lies in the loins and tail of an Ostrich. That part which lies in the loins is considerably larger than those which belonged to the neck and back; and then it becomes pretty fast smaller to the tail. This swelling in the loins is owing, perhaps, to this bird having such large thighs and legs; and when we consider that this bird, having such small wings, must have the whole progressive motion performed by the legs, and the legs are therefore longer in proportion to the size of the bird than in birds in common, we must see why the medulla ought to be large at this part in this bird." O. C. 1355. *Hunterian.*

D. 769. The hinder part of the crural swelling and the caudal part of the spinal cord of an Ostrich, with the membranes partially reflected showing, upon the ventral surface, the origins of some of the motor roots of the nerves to the legs. The dorsal longitudinal fissure is shown in the caudal part. There is never in Birds a cauda equina due to the shortening of the spinal cord in relation to the vertebral column. O. C. 1356. *Hunterian.*

D. 770. The attenuated caudal prolongation of the spinal cord of an Ostrich. O. C. 1357. *Hunterian.*

D. 771. The brain and spinal cord of a Partridge (*Perdix rufa*) exposed *in situ* from above. This specimen shows clearly the relative proportions of the different regions of the cord: the long cylindrical cervical segment; the fusiform swelling at the origin of the brachial plexus; the relatively short thoracic portion; the crural swelling, with its open rhomboid fossa; and the rapid diminution of the cord behind the sacrum. The cord almost completely fills the cavity of the neural canal. O. C. 1358. *Hunterian.*

MAMMALIA.

MONOTREMATA.

D. 772. The brain and spinal cord of a Duck-billed Platypus (*Ornithorhynchus paradoxus*) exposed from above. The cord extends into the tail, gradually diminishing in size as it passes backwards. The brachial and crural enlargements are but slightly marked. O. C. 1358 A.

D. 773. A similar specimen of the brain and spinal cord of a Spiny Ant-eater (*Tachyglossus* [*Echidna*] *aculeatus*). The cord is remarkably stout and terminates in the thoracic region, at a point about a third of the distance from the brachial plexus to the sacrum. From the medulla to within two centimetres of its termination it is of great size and of about equal calibre, but then rapidly comes to a point and ends in a filum terminale amidst the bundle of backwardly directed nerve-roots that constitutes the cauda equina. The branching rootlets of the sensory roots of the spinal nerves are well shown, particularly in the brachial region. There is no marked swelling of the cord at this point. O. C. 1358 B.

INSECTIVORA.

D. 774. A Hedgehog (*Erinaceus europæus*) with the brain and spinal cord exposed from above. The spinal cord, as in *Tachyglossus*, is remarkably short. It extends, of about the same calibre, from the medulla to the level of the third rib, and from this point rapidly diminishes in size, until on a level with the fifth rib it is replaced by a delicate terminal filament, which forms the central strand of the cauda equina.

In this specimen the brachial plexuses have been dissected. O. C. 1372 B.

EDENTATA.

D. 775. The brain and spinal cord of an Armadillo (*Dasypus* sp.), isolated. The cervical part of the cord is of considerable thickness and scarcely swells at all at the point of origin of the brachial nerves. Between the brachial and lumbo-sacral plexuses, the cord is somewhat reduced in size and is slightly flattened from above downwards. The crural swelling is of great length and not sharply defined. The cord is replaced posteriorly by a terminal filament and a cauda equina. O. C. 1358 E.

D. 776. A similar specimen of the brain and spinal cord of a Two-toed Sloth (*Cholœpus didactylus*). In its general proportions this cord differs considerably from that of *Dasypus*, owing partly to the greater length of the thoracic region of the vertebral column and the consequent backward shifting of the lumbo-sacral plexus and crural enlargement, and partly to the greater development of the limbs accompanied by a corresponding prominence of the limb-swellings. The thoracic part of the cord is relatively very slender. The crural swelling tapers abruptly behind to form the terminal filament.

In this specimen the nerve-roots, particularly in the cervical and brachial regions, are very distinct. On either side, a bristle has been passed along the cord between the dorsal and ventral roots to demonstrate their division, towards the cord, into numerous delicate rootlets. The ganglia on the dorsal roots are in many cases very clear. O. C. 1358 D.

CARNIVORA.

D. 777. The hinder part of the spinal cord of a Lion (*Felis leo*), injected. The dura mater has been divided along the dorsal mid-line and reflected to either side, exposing the sub-dural lymph-space and the delicate inner sheath of the cord composed of arachnoid and vascular pia mater. Behind the crural swelling, the cord rapidly diminishes and gives place to a cauda equina. The main nerve-roots that form the cauda lie in the specimen somewhat apart, and thus display very clearly the terminal part of the cord dwindling rapidly to a filament and giving off on either side delicate nerve-roots of diminishing size. At the anterior extremity of the specimen the subdural lymph-space is relatively small, but it gradually increases as the cord tapers and forms a capacious cavity in which the proximal parts of the cauda equina lie free. O. C. 1373. *Hunterian.*

D. 778. The hinder part of the spinal cord of a young Lion (*Felis leo*), injected. The dura mater has been removed from the dorsal surface, showing very clearly the division of the dorsal roots of the spinal nerves into radiating rootlets before their entrance into the cord. It should be noticed that the shortening of the cord in relation to the vertebral column (indicated by the backward passage of the nerve-roots towards the intervertebral foramina) is not apparent until about the middle of the crural swelling. The relations of the dura mater and subdural space to the cord and proximal parts of the cauda equina are very clear.
O. C. 1374. *Hunterian.*

D. 779. The brain and spinal cord of a Coati-mundi (*Nasua narica*). The dura mater has been removed from the dorsal surface. The cervical part of the cord, as in *Dasypus*, is little, if at all, smaller than the brachial swelling. The crural swelling is very long and tapers gradually towards the tail, forming a cauda equina in which the components are closely compacted together. O. C. 1374 B.

D. 780. The isolated brain and spinal cord of a Badger (*Meles meles*). The cord is enveloped in its membranes. Posteriorly it terminates in a cauda equina. O. C. 1374 A.

UNGULATA.

D. 781. "The lower part of the medulla spinalis of a Fawn (*Cervus dama*) with the dura mater turned off from one side, to show the origins of the nerves arising from the medulla, and that the cauda equina is formed by the nerves after they have passed through the dura mater, as in the Porpesse; but here it may be observed that after they have perforated the dura mater they do not run so obliquely downwards [backwards], and therefore the cauda is not so perfect."

The crural swelling merges very gradually into the rest of the cord in front. In the interspaces between the nerves the arachnoid forms a series of lateral connections with the dura mater—the external attachments of a longitudinal ligament (l. denticulatum) by which the cord is suspended in the centre of the neural canal.

O. C. 1365. *Hunterian.*

D. 782. The spinal cord of a Giraffe (*Giraffa camelopardalis*) The dura mater has been removed except around the nerve-roots. In the cervical region the nerves are widely separated, but their tributary rootlets arise from so large an area of the cord that the last rootlet of one nerve-root arises almost on the same level as the first of the succeeding root. The rootlets of the second cervical nerve are indicated on the right side by the insertion of a black rod between the sensory and motor series. The brachial and crural swellings are slightly developed. O. C. 1365 A.

D. 783. The spinal cord of a Calf (*Bos taurus*). The dura mater has been longitudinally divided above and below and reflected to either side. By this means the subdural space and nerve-roots are well shown, as well as a series of processes of the pia mater and arachnoid (ligamentum denticulatum), by which these membranes are laterally united to the dura in the intervals between each pair of spinal nerves.

The arachnoid also accompanies the rootlets of the spinal nerve-roots, and is at these points clearly distinguishable from the underlying pia mater.

In front of the crural swelling the cord has been folded upon itself, and in this part the dura mater has not been cut. The brachial and crural swellings merge very gradually

into the rest of the cord, and are thus not very definite although in fact well developed. O. C. 1364 B.
Presented by J. Holm, Esq.

D. 784. Part of the spinal cord of a Calf (*Bos taurus*). The dura mater, except around the nerve-roots, and the arachnoid and pia mater of the left side have been removed. The arteries of the pia mater have been injected. The ventral longitudinal furrow, occupied by a lamina of pia mater, and the lateral dorsal furrows at the entrance of the rootlets of the dorsal roots of the spinal nerves are also clearly shown. O. C. 1365 B.

D. 785. A portion of the spinal cord of an Ox (*Bos taurus*) stripped of its membranes. Parts of the dorsal and ventral columns have been partially torn away and teased at their free ends to show their ready cleavage in a longitudinal direction, in accordance with the course of their component fibres. O. C. 1365 F.

D. 786. The terminal portion of the spinal cord of a Calf (*Bos taurus*) stripped of its membranes, and showing the ventral longitudinal fissure and the passage of the cord into the filum terminale. O. C. 1365 G.

D. 787. The posterior cervical and anterior thoracic regions of the spinal cord of an Elephant (*Elephas indicus*).

The dura mater and arachnoid have been reflected from the dorsal surface, showing the loose subarachnoid tissue and, at the cut margin of the membranes, the slit-like subdural space. The rootlets of the dorsal roots of the spinal nerves are very strongly developed at the brachial swelling, and form an almost continuous series on either side. O. C. 1368. *Hunterian.*

D. 788. Part of the thoracic region of the spinal cord of an Elephant (*Elephas indicus*). The dorsal and ventral roots of the spinal nerves are very dissimilar in their mode of connection with the cord. The dorsal roots enter the cord abruptly by a few large and distinct rootlets; the ventral rootlets take their origin from a more extended area, and are numerous and small, converging and uniting to form several fasciculi before they finally pass through the dura mater. The arachnoid membrane can be seen at the cut edge of the dura, separated from it by a narrow subdural space. The much larger space between the arachnoid and pia mater is occupied by laminar and trabecular subarachnoid tissue. On either side a stout ligament (l. denticulatum) runs longitudinally within this tissue between the dorsal and ventral nerve-roots. In each interspace between the nerves it bends outwards towards the arachnoid and unites with it, and with the dura mater.

O. C. 1369. *Hunterian.*

D. 789. The posterior end of the spinal cord of the same Elephant, showing the crural enlargement and the origin of the cauda equina. The dura has been removed from the ventral surface. Where the cord gives place to the cauda equina the dura lies at some distance from it, and encloses within its general cavity a considerable length of the nerve-roots that form the cauda. The median spinal artery is shown within the pia mater in the ventral mid-line.

O. C. 1370. *Hunterian.*

D. 790. Part of the spinal cord of an Elephant from the lumbo-sacral region. The dura mater is removed from both dorsal and ventral surfaces, showing the origins of the nerves. The specimen is suspended by the ligamentum denticulatum. A small portion of the pia mater is reflected from the dorsal surface of the cord, showing the lamina that projects from its inner surface into the dorsal longitudinal fissure. The corresponding lamina in the ventral fissure is seen upon the upper sectional surface. A portion of the dorsal columns of the cord has been removed at the lower end of the specimen, showing the fibrils of the dorsal roots passing a little way into the substance of the cord. A bristle has been placed beneath them on the left side.

O. C. 1371. *Hunterian.*

CETACEA.

"The medulla spinalis is much smaller in proportion to the size of the body than in the human species, but still bears some proportion to the quantity of brain; for in the Porpoise, where the brain is largest, the medulla spinalis is largest; yet this did not hold good in the Spermaceti Whale, the size of the medulla spinalis appearing to be proportionately larger than the brain, which was small when compared to the size of the animal .... The dura mater .... where it covers the medulla spinalis, differs from all the quadrupeds I am acquainted with, inclosing the medulla closely, and the nerves immediately passing out through it at the lower part, as they do at the upper, so that the cauda equina, as it forms, is on the outside of the dura mater."—HUNTER, "Observations on the Structure and Œconomy of Whales," *Phil. Trans.* vol. lxxvii. 1787, p. 424.

D. 791. The hinder part of the brain and the spinal cord of a Porpoise (*Phocœna phocœna*).

"The dura mater is removed from about one half of the breadth of the posterior surface [on the left side] through its whole length to expose the medulla. It is not so loose as in the Human subject, but incloses the medulla very tightly. It goes no further than to the lower end of the medullary substance; so that it does not inclose the cauda equina beyond that termination, as in the Human subject or Monkey. The nerves go out of this sheath immediately, through the whole length of the medulla; so there is no cauda equina on the inside of the dura mater either above or below the termination of the medullary substance. The cauda equina is therefore on the outside of the sheath of the dura mater."

Although in a sense the strands of the cauda equina and the distal parts of the other nerve-roots may be said to lie outside the dura, if by that we mean the common dural investment of the cord, yet each root from its emergence from this common investment to its exit from the neural canal is covered by a reflexion of the dura, and thus in fact lies within it. The cervical region of the cord is remarkably short. The nerves in this part are consequently aggregated together, the hindermost arising from a fairly pronounced brachial swelling. The shortening of the cord in relation to the vertebral column is indicated by the gradually increasing obliquity of the nerve-roots towards the hinder end. Although there are no functional hind limbs, the posterior part of the cord shows a well marked swelling, due to the great nerve-supply necessary for the tail. There is a strongly developed cauda equina, the component strands of which are more or less tortuous. This condition has been thought to be " due to the great freedom of movement and flexibility possessed by the caudal portion of the animal " (Cunningham, p. 212). O. C. 1359.

D. J. Cunningham, Jour. Anat. & Phys., vol. xi. 1877, p. 209.

D. 792. The spinal cord of a Porpoise (*Phocæna phocæna*), injected. The dura mater has been removed from the dorsal surface. O. C. 1360. *Hunterian.*

D. 793. The cervical portion of the spinal cord of a Dolphin (*Delphinus tursio*), showing the origins of the eight cervical and first thoracic pairs of nerves. The dura mater has been removed from the ventral surface, and has been longitudinally divided upon the dorsal surface and reflected to either side to show the underlying membranes. The arachnoid is distinguished by a white bristle inserted between it and the pia. The roots of the first four cervical nerves are very oblique. O. C. 1361. *Hunterian.*

D. 794. A transverse section through the thoracic region of the spinal cord of the same Dolphin, showing on the section surface the central canal and the infolding of the pia mater into the ventral longitudinal fissure. The membranes of the cord have been treated as in the preceding specimen. O. C. 1362. *Hunterian.*

D. 795. Part of the spinal cord of a Piked Whale (*Balænoptera acuto-rostrata*) showing the rootlets of the spinal nerve-roots. O. C. 1363. *Hunterian.*

D. 796. The posterior part of the spinal cord of the same Whale, from the dorsal surface of which the left half of the thick dura mater has been removed, showing that it forms a comparatively close investment to the cord, as in the Porpoise (D. 791), and that the long separate roots of the posterior nerves, that compose the cauda equina, are external to the common dura mater investment of the cord, although each is covered by an independent sheath derived from that investment. O. C. 1364. *Hunterian.*

PRIMATES.

D. 797. "Part of the brain, and the whole medulla spinalis of a common Monkey. The dura mater is in part removed from the front [ventral] part, and exposes the cauda equina, which is inclosed in that membrane. There is little or no difference between these parts in this animal and the human subject, only that the dura mater is not so large in proportion to the size of the medulla." The brachial and crural swellings are well shown. O. C. 1375. *Hunterian.*

D. 798. The cerebellum, medulla oblongata, and spinal cord of a young Orang-Outang (*Simia satyrus*) exposed from the dorsal aspect. The proximal parts of the first pair of ribs have been left to mark the limit of the cervical region of the cord. The brachial swelling is strongly pronounced. The large size of the nerves arising from it is well shown, and the abrupt termination of their dorsal roots in the lateral dorsal furrow of the cord. Behind the cervical region the nerve-roots take a very oblique backward course and on a level with the second lumbar vertebra form the cauda equina. The lumbo-sacral swelling is very slight.

The ganglia upon the dorsal nerve-roots can be clearly seen; in the cervical region they lie upon the roots in the intervertebral canals, but further back are situated within the neural canal before the nerve passes between the vertebræ. O. C. 1375 B.

Presented by Sir Victor Horsley.

Figueiredo-Rodriques, Arch. Mikr. Anat., Bd. lix. 1901, p. 417.

D. 799. The spinal cord of a young Gorilla (*Anthropopithecus gorilla*) with the dura mater removed, and the constituent nerve-roots of the cauda equina separated to either side to show the filum terminale.

In its general features the cord resembles that of Man.

O. C. 1375 A.

Waldeyer, Abhandl. Akad. Wiss. Berlin, 1888, p. 61.

D. 800. The vertebral column and spinal cord of an infant, including the thoracic and lumbo-sacral regions. The vertebral column and dura mater have been divided by a sagittal section and spread apart, exposing the cord. In places the ligamentum denticulatum can be seen, binding the arachnoid membrane to the dura in the interspaces between the nerves. Upon the right side the arachnoid has been stretched away from the pia mater, and shows very clearly. A great part of the cauda equina lies within the common dura mater sheath. Several of the arteries have been injected. O. C. 1378 A.

Mus. Heaviside.

D. 801. The medulla oblongata and spinal cord of Man. The dura mater and arachnoid membrane have been sagittally divided and spread to either side, thus extending the nerve-roots and showing clearly the subarachnoid tissue and the ligamentum denticulatum. The brachial and crural swellings, the cauda equina and terminal filament are well shown. The gradually increasing obliquity of the course of the spinal nerve-roots towards the hinder end of the cord is very striking, and affords an indication of the shortening of the cord relative to the vertebral column. O. C. 1376 B.

Presented by J. Holm, Esq.

D. 802. "Nearly the whole length of the medulla spinalis, with the cauda equina, of the Human subject. The dura mater is in part removed to show the medulla and the going out of the nerves through that membrane." The arachnoid membrane is well shown upon the ventral surface.

O. C. 1376. *Hunterian.*

D. 803. "The termination of the medulla spinalis with the nerves cut off, which formed the cauda equina, excepting the last nerve, which arises from the very termination of the medulla. It shows that the medulla is lengthened out in the form of a nerve, and, as it were, continued into the last nerve."

The "last nerve" of the above description is the degenerate remains of the hinder part of the cord (filum terminale), and consists mainly of connective tissue and a few medullated nerve-fibres. At its anterior end there are vestiges of the central canal and grey matter. O. C. 1377.

Hunterian.

D. 804. A portion of the spinal cord of Man, showing the roots of the spinal nerves and the relations of the protective membranes to the cord. A strip of dura mater has been left attached to the nerve-roots on the right side. Close beneath it upon the ventral surface, but separated from it by a narrow subdural space, is the delicate arachnoid membrane. The pia mater adheres closely to the cord; it has been removed from the left half of the specimen; its cut edge can be seen between the termination of the nerve-roots and the ventral fissure. Within the fissure lies a lamina of pia mater. The dorsal and ventral nerve-roots, as in the Elephant and other mammals, arise from the cord in a characteristic manner—the dorsal roots enter the cord abruptly in the dorso-lateral fissure by a few stout rootlets; the ventral leave it by more numerous branching rootlets that emerge at slightly different distances from the ventral mid-line. O. C. 1378 F.

D. 805. A similar specimen showing the origin of two pairs of spinal nerve-roots. The dura mater has been removed and the spinal ganglia dissected on the right side.

O. C. 1378 C.

Membranes of the Spinal Cord.

D. 806. A section of the vertebral column, with the spinal cord and its membranes, of a Basking Shark (*Selache maxima*). The neural canal is lined by a thin fibrous membrane—the outer, perichondrial layer of the dura mater. The space between this layer and the cord is occupied by loose trabecular tissue forming the deeper parts of the dura, and giving support to a network of blood-vessels. The cord is surrounded by a close-fitting pia mater.

D. 807. Part of the spinal cord of a Calf (*Bos taurus*). The dura mater has been removed except at the sides of the upper part of the specimen. Upon the ventral surface of the cord the arachnoid membrane has been longitudinally divided and reflected, exposing the pia mater closely adherent to the cord. The cut edge of the pia can be seen on either side of the ventral longitudinal fissure at the upper end of the specimen. O. C. 1365 c.

D. 808. A portion of the spinal cord of Man. The dura mater has been removed from the dorsal and ventral surfaces, exposing the subdural space and arachnoid membrane.
O. C. 1378 b.

ABBREVIATIONS USED IN FIGURES OF VERTEBRATE CENTRAL NERVOUS SYSTEM.

ACOU. TUB., acoustic tubercle.
ALV., alveus of the hippocampus.
ANT. COMM., anterior commissure (Fishes).
ANT. QUAD. CORP., anterior corpora quadrigemina.
ANT. WING, anterior wing of valvula cerebelli (*Mormyrus*).
AQUA. SYL., Aqueduct of Sylvius.
AREA PRECOM., precommissural area.
AREA TEGMEN., tegmental area.
AREA A, B, C., see page 211.
BL. CORP., blood corpuscles.
BL. V., blood-vessel.
CALCAR., calcar avis (calcarine sulcus in fig. 222).
CAP. EXT., external capsule.
CAP. INT., internal capsule.
CER. *or* CEREBEL., cerebellum.
CER. HEM., cerebral hemispheres.
COMM. ANT. *or* COMM. A., anterior commissure (Mammals).
COMM. D., dorsal or hippocampal commissure.
COMM. MOL. *or* SOFT COMM., commissura mollis.
COMM. SUP., superior commissure.
COMM. V., ventral *or* true anterior commissure.
CORP. CALL., corpus callosum.
CORP. GEN. ANT., corpus geniculatum anterior.
CORP. GEN. POST. *or* CORP. GEN., corpus geniculatum posterior.
CORP. INTERPED., INTER., INTERP., *or* GANGL. INTER., corpus interpedunculare.
CORP. MAM., corpus mammillare.
CORP. PARATERM., paraterminal body.
CORP. PIN., pineal body.
CORP. PIT., pituitary body.
CORP. QUAD., corpora quadrigemina.
CORP. ST., CORP. STR., CORP. STRI., *or* C. STR., corpus striatum.
CRUS CER., crus cerebri.
DORS. P. FLOC., dorsal paraflocculus.
DORS. SAC., dorsal sac.
ECTOSYL., ectosylvian arc.

EPEND., ependyma.
EPIPH., epiphysis.
EPISTRI., epistriatum.
FASC. ABERR., fasciculus aberrans.
FASC. DENT., fascia dentata.
FASC. LONG., fasciculus longitudinalis posterior.
FI. *or* FIM., fimbria.
1st ARCU. GYR., first arcuate gyrus of Leuret.
FLOC., floccular lobe of cerebellum.
FLOC., (in figs. 77, 83, 84, 85, 92, 106, 112, 116, 245, 249), flocculus (*sensu stricto*).
FLOC. F., floccular fissure.
FORC. MAJ., forceps major.
FOR. LAB. INF., passage from the infundibulum into the lobus inferior.
FOR. MONR., Foramen of Monro.
4TH VENT., fourth ventricle.
F. PRIM., primary fissure of cerebellum.
F. SECUND., secondary fissure of cerebellum.
GANG. HAB., ganglia habenulæ.
GANG. INTER., *or* CORP. INTER., corpus interpedunculare.
GEN. *or* GENU, genu of corpus callosum.
HEM., cerebral hemisphere.
HIP., hippocampus.
HIP. F., hippocampal fissure.
HIP. INV., inverted hippocampus.
HIP. NUDUS, hippocampus nudus.
HIP. TUB., *or* TUBER., hippocampal tubercle.
HIP. VEST., vestiges of the hippocampal arc.
INF., *or* INFUN., infundibulum.
INS., insula.
ISTH., isthmus.
LAM. TERM., lamina terminalis.
LAT. VENT., lateral ventricle.
LOB. ANT., anterior lobe of cerebellum.
LOB. CENT., middle lobe of cerebellum.
LOB. FAC., lobus facialis.
LOB. IMPAR, lobus impar.
LOB. INF., lobus inferior.
LOB. LIN. LAT., lobus lineæ lateralis.
LOB. OPT., optic lobes.
LOB. POST., lobus posterior of cerebellum.
LOB. VAG., lobus vagi.
LOC. PERFOR. *or* PERF., locus perforatus.
LONG. ZONE, longitudinal zones of cerebellum in lower vertebrates.
MARG. (POST. CALL.), marginal sulcus.

MAUTH. FIB., Mauthner's fibres.
MED., medulla oblongata.
MED. AUR., medullary auricles.
MED. OB. *or* OBL., medulla oblongata.
MESEN., mesencephalon.
MID. WING., middle or lateral wing of valvular cerebelli of *Mormyrus.*
MONRO FOR., Foramen of Monro.
N. AMYGD., nucleus amygdalæ.
NEOPAL., neopallium.
NEUROP., neuropile.
NON-HIP. PAL., non-hippocampal pallium.
NUC. V,, nucleus quinti.
NUC. X., nucleus vagi.
OLF. BULB., olfactory bulb.
OLF. PED., olfactory peduncle.
OLF. N., olfactory nerve.
OLF. TR., (lower vertebrates) olfactory peduncle.
OLF. TR., (mammals) olfactory tract, " external olfactory root."
OLF. TR. TUBER., tubercle of the olfactory tract.
OLF. TUBER. *or* TUB., tuberculum olfactorium.
OLF. VENT., ventricle of olfactory bulb.
OLIV. *or* OLIV. BODY, olivary body.
OPERC., occipital operculum.
OPT. CHIASMA., OPT. CHIAS., *or* OPT. CHI., optic chiasma.
OPT. LOB., lobus opticus.
OPT. N., optic nerve.
OPT. THAL., optic thalamus.
OPT. TR., optic tract.
PALL., pallium.
PARAFLOC., paraflocculus.
PARAFLOC. D., & V., paraflocculus dorsalis and ventralis.
PARALLEL S., parallel sulcus.
PARAPHY., paraphysis.
PARATERM., paraterminal body.
PAR. STALK., parietal stalk.
PED. OLF., olfactory peduncle.
PERIPH. V. COMM., peripheral ventral commissure of spinal cord.
PET. LOB., petrosal lobule of the paraflocculus.
PINEAL, pineal body.
PIT. BODY, pituitary body.
PONS. *or* PONS. VAROL., pons Varolii.
POST. COMM., posterior commissure.
POST. QUAD. CORP., posterior corpora quadrigemina.
POST. WING, posterior wing of valvula cerebelli of *Mormyrus.*

PRECOM. AREA., precommissural area.

PRIM. F., primary (preclival) fissure of cerebellum.

PSAL. *or* PSALT., psalterium (hippocampal commissure).

PSAL. V., PSAL. D., psalterium ventrale and dorsale.

PSEUDO SYL. F., pseudosylvian fissure (Sirenia).

PYR., pyramids.

PYRAMID, pyramid of cerebellum.

PYR. L., pyriform lobe.

PYR. L. ANT., PYR. L. POST., anterior and posterior parts of pyriform lobe.

RAMUS POST. SUP., ramus postcentralis superior of intraparietal sulcus.

RHIN. F., rhinal fissure.

RHIN. F. ANT., anterior rhinal fissure.

RHIN. F. POST., posterior rhinal fissure.

ROOT VALV. CER., root of the valvula cerebelli.

ROST. CORP. CALL., rostrum of corpus callosum.

SAC. INF., saccus infundibuli.

SAC. VASC., saccus vasculosus.

SECUN. F., secondary fissure of the cerebellum.

2ND GYR., second arcuate gyrus of Leuret.

SEPT. *or* SEPT. LUCID., septum lucidum.

SOFT. COMM. *or* COMM. MOL., soft commissure.

SPLEN. *or* SPL., splenium of corpus callosum.

S. S. P., posterior branch of the supra-sylvian sulcus.

SUP. GENU, superior genu of the central sulcus.

S., S'., *or* SYL. F., the various modifications of the Sylvian and pseudosylvian fissures.

SYL. ECTOS. COMP., sylvio-ectosylvian complex.

SYL. SUPRAS. COM., sylvio-suprasylvian complex (true Sylvian fissure).

SULC. ANS., ansate sulcus.

SULC. ANS. MIN., minor ansate sulcus.

SULC. ARC., sulcus arcuatus.

SULC. BISECT. *or* SULC. BISEC., bisector sulcus.

SULC. CALC. *or* CAL., calcarine sulcus.

SULC. CALL. MARG., calloso-marginal sulcus.

SULC. CENT., central (Rolando's) sulcus.

SULC. COLL., collateral sulcus.

SULC. COMP., compensatory sulcus.

SULC. COR., coronary sulcus.

SULC. COR. LAT., *or* COR. L., corono-lateral sulcus.

SULC. CR. *or* CRU., crucial sulcus.

SULC. DIAG., diagonal sulcus.

SULC. ECTOLAT., ectolateral sulcus.

SULC. ECTOSYL., posterior ectosylvian sulcus (fig. 135), and ectosylvian arc.

SULC. ECTOS. A., SULC. ECTOS. P., anterior and posterior ectosylvian sulci.
SULC. ENTOLAT., ENT. LAT., *or* ENT. L., entolateral sulcus.
SULC. EPISTRI., epistriatic invagination (Reptiles).
SULC. FR. ORB., fronto-orbital sulcus.
SULC. GEN., genual sulcus.
SULC. INF. FRONT., inferior frontal sulcus.
SULC. INF. OCC., inferior occipital sulcus.
SULC. INF. PRECENT., sulcus arcuatus (inferior precentral).
SULC. INF. TEMP., inferior temporal sulcus.
SULC. INF. TRANS., inferior transverse sulcus.
SULC. INT., intraparietal sulcus.
SULC. INTER. *or* INTERCAL., intercalary sulcus.
SULC. INTRA. *or* INTRAPAR., intraparietal sulcus.
SULC. LAT. *or* SULC. LAT. (INT. PAR.), lateral (intraparietal) sulcus.
SULC. LAT. P., post-lateral sulcus.
SULC. L. OCC. *or* LAT. OCC., lateral occipital sulcus.
SULC. LIM. PALL., sulcus limitans pallii.
SULC. MARG., marginal sulcus.
SULC. OBL., oblique sulcus.
SULC. OCC. TEMP., occipito-temporal sulcus.
SULC. OLF., sulcus olfactorius.
SULC. ORB., orbital (presylvian) sulcus.
SULC. ORB. ACCES., accessory orbital sulcus.
SULC. PAR. *or* PAR. (P. SYL.), parallel sulcus.
SULC. PARACALC., paracalcarine sulcus.
SULC. PARACAUD. *or* SULC. P. CAUD., paracaudal sulci.
SULC. PARAM., paramedial sulcus.
SULC. PARAORB., paraorbital sulcus.
SULC. PAR. OCC., parieto-occipital sulcus.
SULC. P. CALC., post- *or* retro-calcarine sulcus.
SULC. P. LAT., post-lateral sulcus.
SULC. POST. RHIN., posterior rhinal fissure.
SULC. POSTS., post-sylvian sulcus.
SULC. PRECRU., precrucial sulcus.
SULC. PROR., prorean sulcus.
SULC. P. SYL., post-sylvian sulcus.
SULC. PSEUDO SYL., pseudosylvian sulcus.
SULC. RECT., sulcus rectus.
SULC. ROS., *or* ROST., rostral sulcus.
SULC. SIM., Simian sulcus.
SULC. SPLEN., splenial sulcus (intercalary prolongation of calcarine).
SULCI SUBCING., subcingular sulci.
SULC. SUP. FRONT., superior frontal sulcus.
SULC. SUP. LIM., superior limiting (Marchand's opercular) sulcus.

SULC. SUP. PREC., superior precentral sulcus.
SULC. SUPRAS., suprasylvian sulcus.
SULC. TR. OCC., transverse occipital sulcus.
SULC. URS., Ursine sulcus.
SULC. VERT., vertical sulcus.
TÆN. THAL., tænia thalami.
TECT. OPT., tectum opticum.
TELA *or* TEL. CHOR., tela choroidea.
THAL., thalamencephalon.
THAL. STRI. JUNC., junction of striatum and thalamus.
THIRD VENT. *or* 3RD VENT., third ventricle.
TORUS LONGI., torus longitudinalis.
TOR. SEMICIRC., torus semicircularis.
TRAP., trapezium.
TUB. ACOUST., acoustic tubercle.
TUB. CIN., tuber cinereum.
TUBER. V., tuberculum quinti.
TUB. OLF. TR., tubercle of the olfactory tract.
URS. LOZ., Ursine lozenge.
VALL. SYL., Vallecula Sylvii.
V. CEREB. MAG., vena cerebralis magna.
VALV. CER., valvula cerebelli.
VENT. CER., cerebral ventricle.
VEL. MED., velum medullare.
VENT. P. FLOC., ventral paraflocculus.
VENT. III., third ventricle.
VENT. VERG., Ventricle of Verga.
II. III. V. VI. VII. VIII. IX. X. XI. XII., roots of the cranial nerves.
V. M., motor root of V.

For letters A B C etc., $\alpha\,\beta\,\gamma$ etc., see text, except the following, in figs. 78, 90, 105:—F. D., fascia dentata; FI., fimbria; G., genu of corpus callosum; H. F., hippocampal fissure; IF. IH., inverted hippocampus; L. T., lamina terminalis; PS. V., PS. D., dorsal and ventral psalterium.

INDEX TO COMPARATIVE ANATOMY OF MAMMALIAN BRAIN.

[*The figures in italics refer to statements in the general summary.*]

PRINTED BY TAYLOR AND FRANCIS, RED LION COURT, FLEET STREET.

59777 Museum. Zool
Author Royal College of Surgeons of England. Morph
R
Title Descriptive and illustrated catalogue of the
physiological series. vol.2.

University of Toronto
Library

DO NOT
REMOVE
THE
CARD
FROM
THIS
POCKET

Acme Library Card Pocket
LOWE-MARTIN CO. LIMITED