Nat. Hist.

# DEVELOPMENT AND GROWTH OF THE RATTLE OF RATTLESNAKES

ARNOLD A. ZIMMERMANN

AND

CLIFFORD H. POPE

FIELDIANA: ZOOLOGY
VOLUME 32, NUMBER 6
*Published by*
CHICAGO NATURAL HISTORY MUSEUM
MARCH 29, 1948

# DEVELOPMENT AND GROWTH OF THE RATTLE OF RATTLESNAKES

ARNOLD A. ZIMMERMANN
*Professor of Anatomy, College of Medicine*
*University of Illinois*

AND

CLIFFORD H. POPE
*Curator of Amphibians and Reptiles*
*Chicago Natural History Museum*

FIELDIANA: ZOOLOGY
VOLUME 32, NUMBER 6
*Published by*
CHICAGO NATURAL HISTORY MUSEUM
MARCH 29, 1948

PRINTED IN THE UNITED STATES OF AMERICA
BY CHICAGO NATURAL HISTORY MUSEUM PRESS

# CONTENTS

## INTRODUCTION AND LITERATURE

The rattle of rattlesnakes is a unique structure found only on the New World pit-vipers (Crotalidae) of the genera *Crotalus* and *Sistrurus*. Although this structure has been discussed in scientific literature for more than two hundred years, there is still no adequate account of its remarkable method of development and growth.

In 1940 Dr. L. M. Klauber, the noted authority on rattlesnakes, published a 62-page paper carefully describing the rattle and discussing its growth and every aspect of its natural history. Because he used neither histological techniques nor x-ray photography, Klauber's account of growth failed to clarify the confusion that already existed. His valuable paper is recommended to all who are interested in other aspects than growth; it is especially useful for the mechanical interpretation of the rattle's structure and action. Since his paper includes an extensive bibliography with 145 titles, we have given only a brief one.

There has been a vast amount of speculation on the function of the rattle. Klauber (1940) discussed the various theories and concluded that only the "warning theory" is reasonable. One cannot doubt that the rattle is used to frighten intruders, and its sound, therefore, may be compared with the growl of a wolf or the snarl of a tiger. Any mechanism that helps the animal to avoid physical struggle may be assumed to have selective value. We prefer to call the sounding of the rattle a bluffing rather than a warning reaction, since obviously the snake is merely trying to avoid damage to itself.

Certainly it is of special interest that the deaf rattler protects itself by vibrations for which it has no sensory perception. This reptilian bluffing is more appropriately directed against intrusions by "higher" warm-blooded enemies with an acute sense of hearing.

The most notable description of the rattle's form and growth was given as early as 1857 by Joh. Czermak, who studied scant material of *Crotalus durissus terrificus*. Many modern German handbooks of comparative anatomy (see Bolk and others, 1939) still quote Czermak and reproduce some of his diagrams. Leuckart (1855) had previously made some observations on this structure. He had noticed, for instance, that a rattle evidently is not present at birth;

there is merely a simple horny covering with a direct transition to the scales of the skin. He had assumed that only three caudalmost vertebrae were fused into a single flattened skeletal end-piece or style.

Czermak corrected this point, after having counted seven or eight full-grown elements in the "end-body of the vertebral column," as he called the style. However, he realized that differences might be due to age or to species. Czermak compared this conical, bilaterally flattened style and its two rounded, more or less separate points to a simple exostosis. He correctly observed that the vertebral canal continues into the end-body and that it has rudiments of intervertebral foramina "so that the spinal cord undoubtedly extends also into the end-body." Obviously he had prepared the caudal end of the vertebral column by maceration, as he also observed the vascular canal below the centra and stated that "it probably contains blood vessels."

Czermak recognized three main muscular masses associated with the tail vertebrae: two dorso-lateral masses and one inferior mass, each of which is subdivided into several strands and layers. He noticed that this strongly developed musculature terminates at the base of the style and produces the rapid vibrations of the caudalmost vertebral column and of the end-body. The movements are transmitted to the rattle, "whose individual segments vibrate and glide on each other—whereby a very peculiar, hissing sound results." Czermak observed the thickened skin covering the end-body, from which each separate unit of the rattle is produced. He also noticed that a deep furrow, covered by the last scales, separates the end-body from the rest of the tail.

The connective tissue of the end-body was described by him as a "spongy, whitish mass, but relatively firm, consisting of interwoven fibers." He even made microscopic sections, evidently hand-made razor cuts, and described ramified pigment cells everywhere within the whitish connective tissue stroma and particularly toward the surface, where some pigment cells mingle with "roundish compact cells, so that the outermost layer of the cutis appears dark." He actually observed pigment cells between the epidermal cells of the cutis, an observation that our histological preparations have fully confirmed some ninety years later. Besides pigment cells and collagenous fibers, Czermak noted in the stroma of the end-body numerous nerves and bloodvessels and an apparent absence of elastic fibers.

Our own observations show that Czermak was a thorough and astute observer, considering the little material and the simple technique at his disposal.

This pioneer, however, went beyond the direct observations of facts and attempted, "partly with certainty, partly with probability," to deduce the mode of formation of the rattle. In this mixture of fact and fancy, of good observation and old-fashioned "logical" deductions he failed. Parts of his explanation are such that a clear picture can scarcely be obtained.

Nevertheless, much information was gained from the two specimens at his disposal. "Both were," he pointed out, "in that phase of development of the rattle, where the youngest or basal element of the rattle had just been fully formed and was lying directly adjacent, cap-like, to the thickened skin of the end-body." The following points in Czermak's description are in agreement with our own findings: Each segment is formed as an epidermal cap or covering of the thickened skin over the end-body. The segment is separated later, like the stratum corneum of the remainder of the epidermis, from the substratum. Each segment must be the exact mold of that skin thickening. Differences in size and form of the segments must be closely correlated with differences in the epidermal covering of the end-body occurring during growth of the animal and during the successive steps in the development of the rattle. Recent segments cannot be mere duplications in form and size of earlier ones. The new segments would burst open the older ones. They form, instead, a partly telescoped row of cap-like segments. A new lobe must be added to the proximal segment, this addition taking place in the furrow covered by the last scales.

In his attempt to explain the shift and changes in form and size of the epidermal thickening over the end-body, Czermak is vague and his assumptions are difficult to follow. This part of his explanation is pure speculation. He believed himself to have "correctly sketched, in general, the mode of formation of the rattle in Crotalus and to have discovered a new and interesting developmental process." Czermak was aware that detailed observations of various steps in this complicated growth process "are left to later, more extensive studies." He specifically pointed out the need for finding and exactly determining the several suggested (theoretical) stages in the development of the rattle, for a study of the process of keratinization and for determining whether a new segment is being formed with each molting. In spite of many deficiencies, Czermak's stimulating paper pointed the way for our own investigation.

## ACKNOWLEDGMENTS

This paper could not have been written without the generous cooperation of the Department of Anatomy, College of Medicine of the University of Illinois, and the Department of Zoology of Chicago Natural History Museum. We are indebted to the following administrators of these institutions: Dr. O. F. Kampmeier, Head of the Department of Anatomy; Colonel Clifford C. Gregg, Director of Chicago Natural History Museum; and Mr. Karl P. Schmidt, Chief Curator of its Department of Zoology.

We are grateful for assistance received from many other sources. Dr. L. M. Klauber, Mr. D. Dwight Davis, Dr. Rainer Zangerl, and Mr. Leon L. Walters gave welcome advice and criticism. Technical work was done by Miss Jane Bostrom and Mrs. Dorothy Foss at the University of Illinois and at Chicago Natural History Museum. Miss Norma Lockwood, also of the Museum, and Miss Nancy Joy and Miss Zelma Oser of the Illustration Studios, College of Medicine, University of Illinois, gave expert assistance in the preparation of many illustrations from original camera lucida drawings made by the senior author. The technical difficulties in obtaining good x-ray negatives and appropriate enlargements for measuring purposes were overcome with the skillful help of Messrs. Arthur L. Hesse (x-rays) and Lawrence A. Toriello (photography), both of the College of Medicine of the University of Illinois. Living or freshly preserved snakes were supplied by Messrs. J. E. Johnson, Richard C. Snyder, Ross Allen, and R. Marlin Perkins and the Lincoln Park Zoo, Chicago. The rattlesnake from which we obtained an x-ray record of one complete molting cycle was lent to us by the Chicago Zoological Society through the courtesy and cooperation of Director Robert Bean, Mr. Robert Snedigar, and Mr. Emil J. Rokosky.

## MATERIAL AND METHODS

Our material was of three kinds: (1) Tails selected by careful examination of hundreds of preserved rattlesnakes in the study collection of Chicago Natural History Museum. These were not suitable for histological work. (2) Well-preserved, fresh tails secured especially for us. These, fixed in formalin, were suitable for histological study. (3) The living adult specimen of *Crotalus atrox* studied by means of x-ray photography throughout one molting cycle.

The species studied were the Texas and Florida diamond-backs (*Crotalus atrox* and *C. adamanteus*); the timber rattlesnake (*Crotalus* *horridus horridus*); the prairie and Pacific rattlers (*Crotalus viridis viridis* and *C. viridis oreganus*); and the massasauga (*Sistrurus catenatus catenatus*). The living Texas diamond-back studied by means of the x-ray came from New Mexico, although it was reared in a zoo; the other specimens of this species were from Texas, except a series of live juveniles of unknown origin. The Florida diamond-backs came from Alabama. The timber rattlers were caught in Wisconsin, the prairie and Pacific rattlesnakes in Nebraska and southern California, respectively, the massasaugas in Wisconsin and in the Chicago region.

The preserved tails were examined macroscopically as well as microscopically. Camera lucida drawings were made of all important specimens before they were dissected or sectioned. Gross dissection and hand sectioning aided considerably in the early stages of the work. Alizarine staining of bone and clearing by a modified Spalteholtz method was done on many specimens. X-ray photography helped in working out details of growth of the rattle and of structural relationships of the bony style. Tails were bisected longitudinally before they were embedded and sectioned. Decalcification of the bony structures within severed tail-ends was effected by immersion in 2 per cent nitric acid for twelve hours. The slow embedding in celloidin was accomplished by routine technique.

The sections were made at 25, 30, and 40 microns, stained routinely with Delafield's hematoxylin and eosin and mounted in Canada balsam. It might have been preferable to embed the young tail material in one piece instead of first slicing it in half. Yet there were compensating advantages: we gained, before embedding, mid-sagittal orientation-views as well as better penetration of celloidin. Although preparing snake material for microscopic study was a novel experience to us, reptilian scales and hornified elements of the rattle did not present special difficulties.

Investigation of rattle-accretion in the living, adult diamond-back was accomplished by taking a series of x-ray photographs throughout a molting cycle. We found ourselves confronted with the difficult problem of proper exposure for structures of very different radiopacity. According to the chemical analysis by C. E. White, given by Klauber (op. cit.), the mineral ash content of the rattle is only 2.53 per cent. The style and the vertebrae, however, have a high degree of mineralization, and even the rattlesnake skin contains almost four times as much mineral ash as the rattle itself. The large, muscular masses within the tail, and the connective tissue in the end-body also produced surprisingly strong shadows in the x-ray negatives.

This high differential between strong and very slight radiopacity further necessitated special manipulation by the photographer in making the enlarged positive prints. For measurements of growth changes and for good reproductions in printing it was desirable to obtain two- and four-fold enlargements. We used the special Kodak x-ray film, Industrial type M. This fine-grained, slow-exposure film gave satisfactory results.

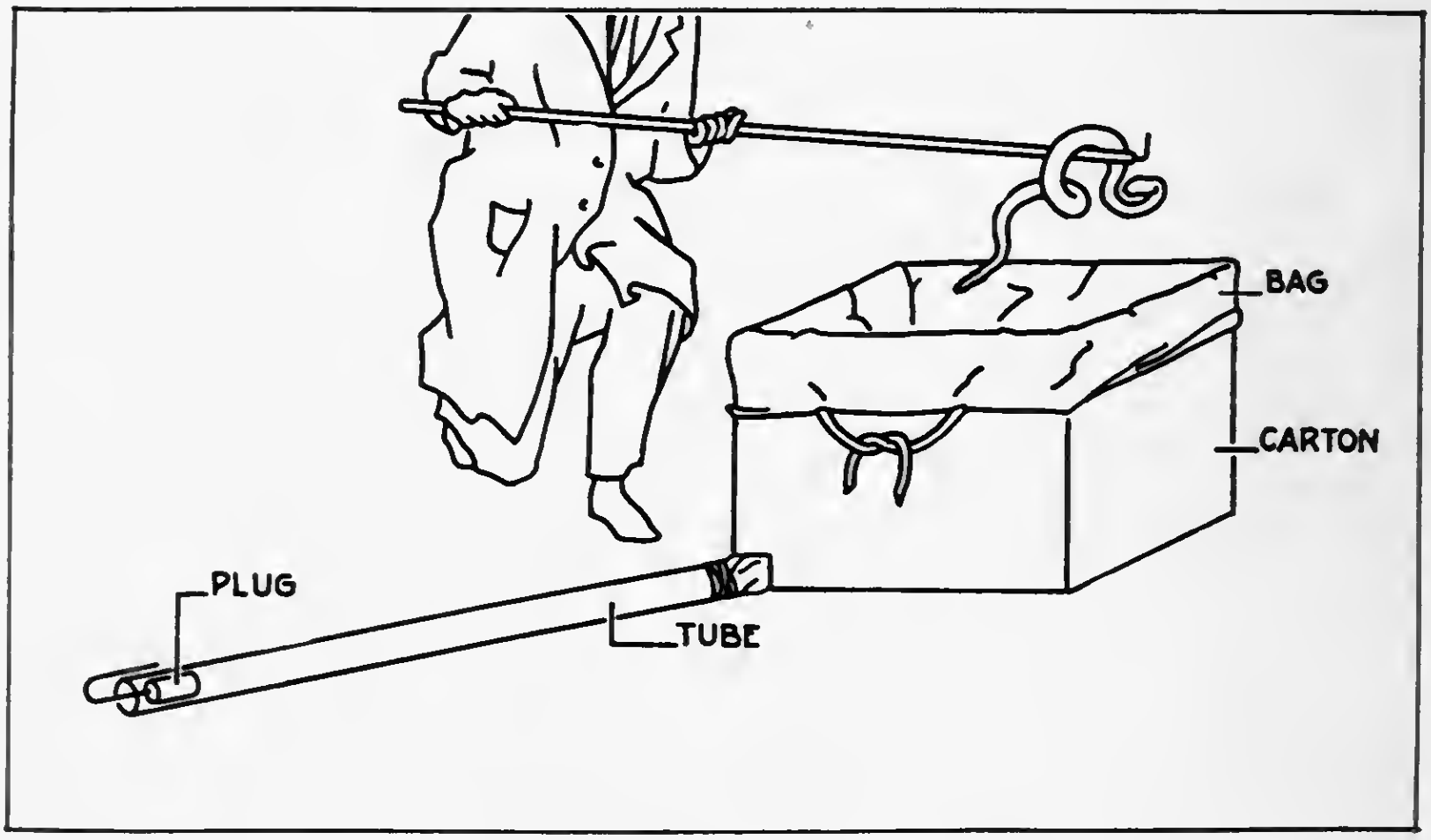

FIG. 57. A diagram of the equipment needed in getting the live Texas diamond-back (*Crotalus atrox*) into a tube preparatory to making an x-ray exposure of its tail. The snake was coaxed from a bag, supported by a carton, into a 5-foot tube made of rolled sheets of cellulose acetate. The tube was then detached from the bag and the snake safely carried to the x-ray table.

A novel method was used in bringing the living rattlesnake to the x-ray table (fig. 57). The basic piece of equipment was a five-foot tube made by rolling to a suitable bore several sheets of cellulose acetate and holding them in position by rubber bands. One end of this strong, transparent tube was closed by a loosely fitting, movable stopper controlled by a piece of wire; the other end remained open. We then placed a tapering sack in a carton so that the mouth of the sack, held open by having its border turned outward over the rim of the box, could be quickly closed by pulling a loop of string. One bottom corner of the sack had a small hole into which the open end of the tube, after being passed from the outside through a corresponding hole in one corner of the box, was fastened by adhesive tape. The snake was gently hooked and dropped into the sack, which was easily closed by tightening the loop of string. Sack and tube were then pulled out of the box together.

Although it was usually easy to coax the snake from the sack into the tube, patience was ever necessary, because an aroused snake will bite through a sack. Once the snake had crawled in, the tube was separated from the sack, and the snake safely carried to the x-ray table. The stopper allowed us to keep the snake from crawling too far into the tube; fortunately the reptile seldom tried to back out, but any effort of that kind was readily controlled. On the x-ray table the forward end of the tube was covered with leaded rubber pads to darken and steady it. The x-ray exposures of the live tail were made at a target distance of 30 inches with 32,000 V. and 30 m.a., and best results were obtained with an exposure time of seven seconds. Fine-grained Industrial type M Kodak films were used in order to obtain satisfactory enlargements from the negatives. The latter were developed for eight minutes at 65° F.

To release the snake we merely removed the stopper and quickly placed that end of the tube in the cage. The snake then slowly crawled out. During a period of three months we made thirty-two exposures of this adult rattler with little difficulty or danger. Moreover, the valuable reptile was not in the least harmed.

## ANATOMY OF THE FULLY DEVELOPED RATTLE

The general anatomical features of the rattle, well known to herpetologists, have been described by previous authors. Klauber's (1940) comprehensive paper on this structure makes a detailed description by us unnecessary. He gives an adequate terminology, and lays emphasis on structural features from the point of view of mechanics. However, in view of our frequent references to the rattle as a whole, it seems advisable to discuss and illustrate certain aspects of gross structure.

Figure 58 shows the complete rattle of a relatively young Pacific rattlesnake (*Crotalus viridis oreganus*) with seven articulated units or segments, which are partially telescoped into each other like a column of hats. The snake measured 765 mm. from snout to vent. The same rattle is also shown disarticulated, the characteristic shapes and proportions of the individual segments thereby becoming visible in detail. Each segment was drawn by camera lucida, with the apex

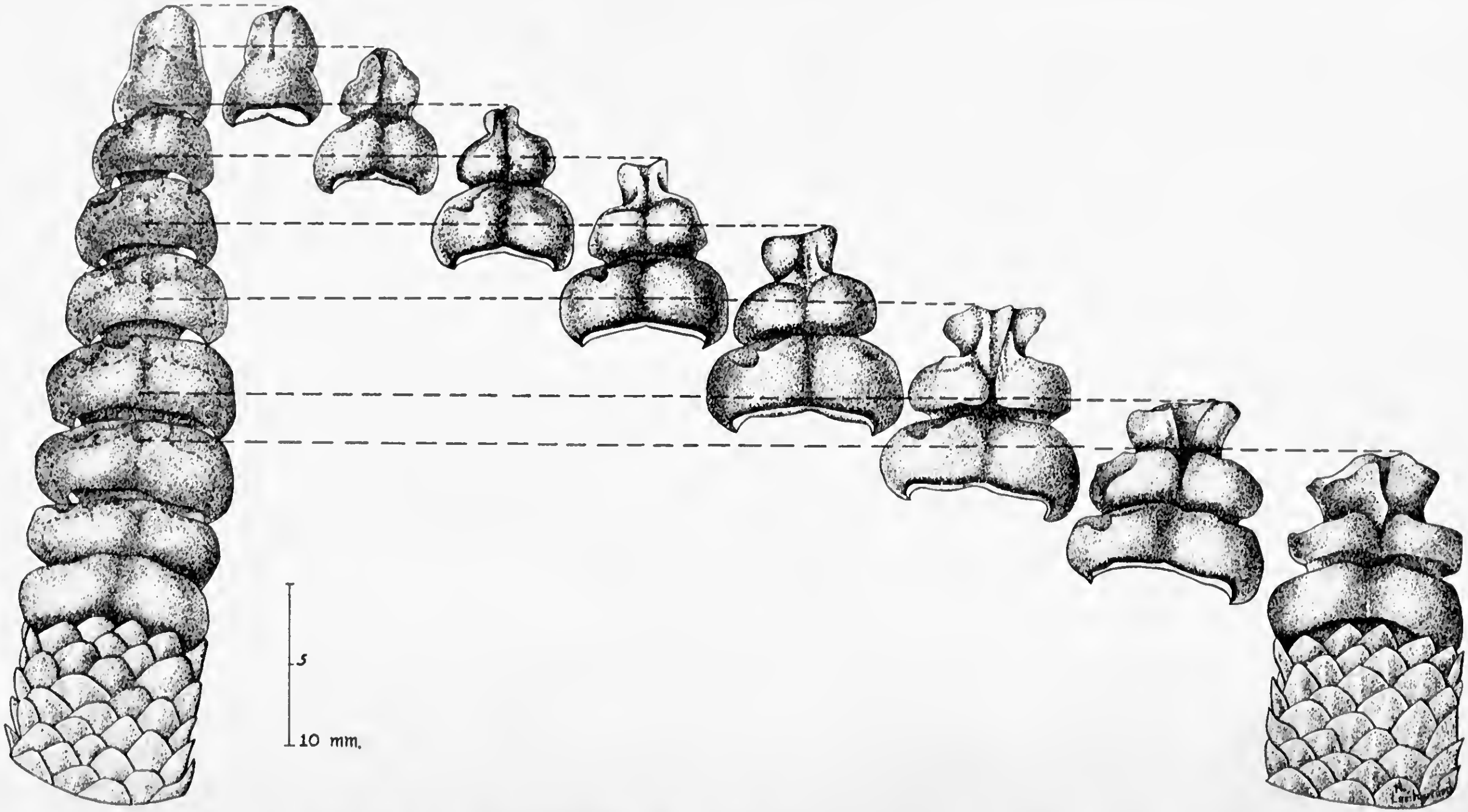

FIG. 58. Camera lucida tracings of the complete rattle of a relatively young Pacific rattlesnake (*Crotalus viridis oreganus*). The rattle is shown as a whole, as well as in its disarticulated form. Dotted lines connect tips of the same segments. Note the progressive enlargement of all segments and the marked change in form of the distal lobe.

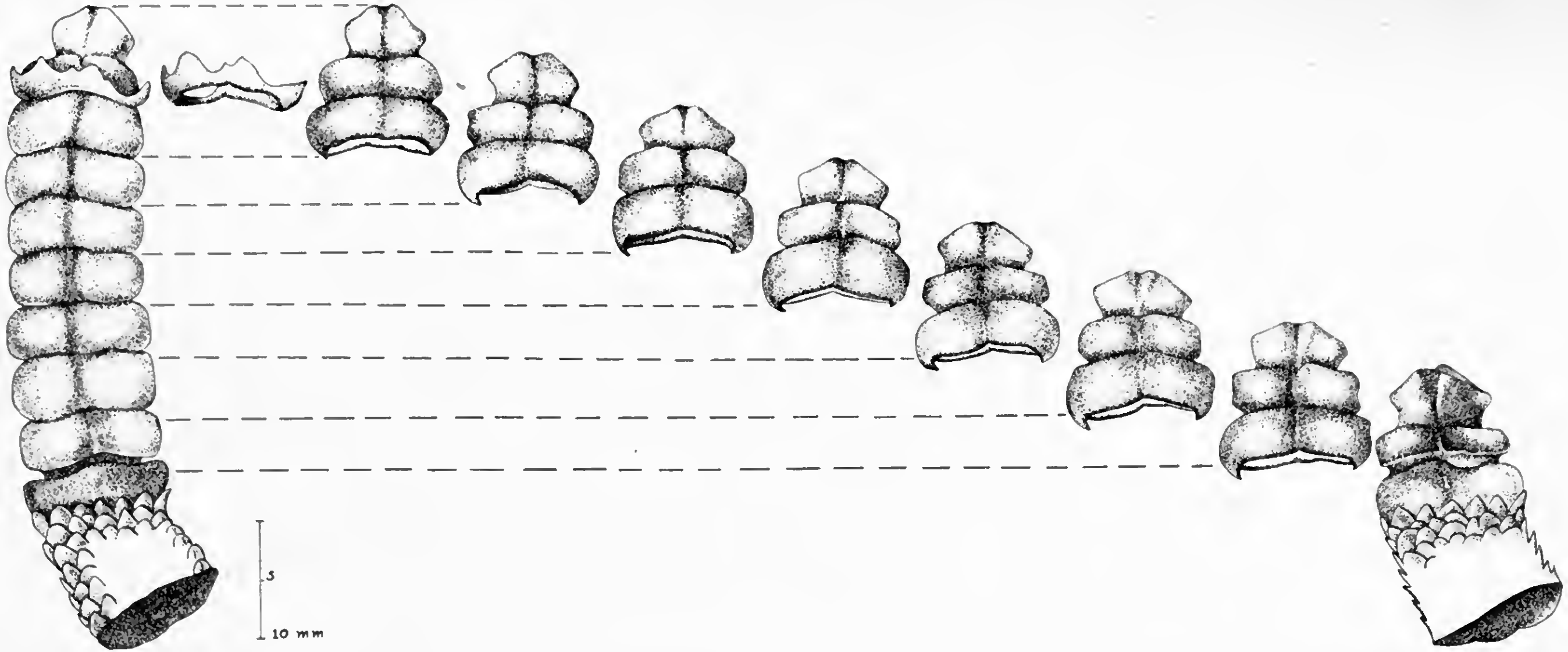

FIG. 59. Camera lucida tracings of the incomplete rattle of an old Pacific rattlesnake (*Crotalus viridis oreganus*). The rattle is shown as a whole, as well as in its disarticulated form. The segments vary little in size or shape, as the end-body evidently had reached adult dimensions. The rattle, therefore, is not tapering.

at the level that it occupied in the rattle. Eight hornified segments are thus seen in a staggered arrangement from the oldest and terminal segment or button to the youngest and largest unit. The latter is most proximal and lies directly caudal to the last scales. This youngest horny segment intimately caps the subjacent tissues of the end-body, which consists essentially of living epidermis, derma, connective tissue, and the bony style.

Differences in size among the successive segments are readily recognized. The total length of the button, in the specimen under discussion, was 6 mm., whereas the length of the most proximal segment was 10 mm. The greatest width in the dorso-ventral direction was 6.2 mm. for the button and 12 mm. for the proximal segment. All segments are about as wide as long. The total length of the rattle before its disarticulation was 4 cm.

There are striking differences in shape between the segments. The larger proximal units consist of three distinct lobes. They may be termed conveniently (*a*) the basal or proximal lobe, (*b*) the middle lobe, and (*c*) the distal or terminal lobe. The last one shows a more pronounced lateral longitudinal groove than the other two. The button consists of only two lobes, which correspond to the distal and middle ones of the other segments.

In young snakes the distal lobe of successive segments shows a characteristic change in shape and a relative increase in size. The rattle from a mature specimen of *Crotalus viridis oreganus* is illustrated in one piece as well as in its disarticulated form (fig. 59). Obviously, a number of distal segments had been lost, and the retained portion of the rattle does not allow an estimate of the age of that snake, which measured 725 mm. from snout to vent. A detailed comparison of the disarticulated segments reveals but little change in size or shape among them, the distal lobes in particular being nearly alike. Evidently the snake was a fully grown specimen. The over-all length of the retained portion of the rattle was 4.3 cm. It was composed of nine segments with an average length of 1 cm. and a dorso-ventral width in the proximal lobe of 1.2 cm. The living end-body obviously had reached adult dimensions before the latest segments of the rattle were formed over its core. A comparison of figures 58 and 59 clearly shows these differences between the segments of young and old rattles.

Unquestionably the differences in size and shape of the successive segments are due to differences in size and shape of the living end-body. The younger the snake the smaller the end-body that constitutes the mold or "matrix" for a segment forming over it. Details of developmental processes involved will be described subsequently.

It is clear that differences between distal and proximal segments of the same rattle are not due to a secondary reduction in size after they have been formed. There is no evidence that drying or other external influences were responsible for the smaller size of the segments that were established earlier. The button remains as it was when first separated from its matrix. The gradual increase in size of successive segments merely reflects the normal growth of the snake.

A degree of asymmetry has long been known to exist between the dorsal and ventral halves of the segments. This asymmetry keeps the end of the rattle from drooping, a condition that would probably interfere with sound production.

In the complete, articulated rattle only the proximal lobe of each segment and the original button are visible. Since one proximal lobe is added to the growing rattle at each molt, the number of molts can be ascertained by counting the proximal lobes. Adult snakes rarely carry complete rattles and the number of segments, therefore, indicates age little or no better than does size of the snake.

## GROWTH CHANGES IN THE END-BODY OF A LIVING TEXAS DIAMOND-BACK

*(Observed by Means of X-ray Photographs)*

To supplement our gross studies of the rattle and to obtain confirmation of certain histological findings we used the x-ray technique on a live snake. From March 25 to June 24, 1946, we obtained thirty-two x-ray exposures from a specimen of *Crotalus atrox.*

The snake measured forty-eight inches (exclusive of the rattle) and weighed 4¼ pounds. It was in excellent condition, having grown to maturity in the Zoo of the Chicago Zoological Society at Brookfield, Illinois, during the past 7½ years. It was kept at relatively constant temperatures (72° to 76° F.) and fed on freshly killed rats. This valuable reptile passed through one molting cycle while under our observation and was safely handled by the method described on page 362.

The pertinent features of growth in the end-body are portrayed in the positive prints from selected x-ray negatives (figs. 60–62). The first print of this series shows the condition of the end-body and the style on March 25, 1946, four days after we took the animal to our laboratory. At that time we failed to detect any outward signs of an approaching molt or of new growth in the sulcus. The x-ray negatives, however, furnished unmistakable evidence of such phenomena.

This March 25 exposure shows the tail from the right side. The faint outlines of the ten free segments (the rattle itself) are seen in their normal relationships to each other and to the end-body. Since they are previously established segments they are not further considered. The features of especial interest concern the end-body only. It consists of three well-differentiated lobes whose connective tissue stroma is outlined by a moderately dense x-ray shadow. In the specimen the distal lobe extended 5.5 mm. beyond the end of the style. This feature is the most significant sign of the approaching molt. Soft tissues of the end-body begin to extend beyond the style only at the termination of the long latent period. This extension characterizes, indeed, the relatively short pre-molting period of accretion.

The basal projections of the style lie not in the proximal lobe but deep to the caudalmost scales. This is the site of the widened sulcus in which new growth takes place. It must be emphasized that during this accretion period, as at all other times, two main features of the anatomy of the tail remain fixed: (1) the plane of articulation between style and caudalmost vertebra; (2) the number of caudal vertebrae and the relative length of the muscular portion of the tail. Growth in the sulcus, therefore, never encroaches upon the tail itself but leads to the only other possible effect: a caudad shift of soft tissues over the style.

The total length of the style, measured on its dorsal side, remained constant throughout the period of observation. A new basal lobe was formed in approximately fourteen days, a period that we designate as the actual growth phase or period of accretion. The first such period lasted from about March 20 to April 5 and the second from June 12 to June 24. On April 13 and again on July 2 the molts were shed. During these periods of accretion the end-body grew longer by the addition of a fourth distinct lobe in the sulcus.

Synchronously with this growth of the end-body there occurs the caudad displacement or shift of the whole rattle. This is a natural consequence of the pre-existing articulation of the last free segment with the distal and middle lobes of the end-body. When these two lobes shift caudad the whole rattle moves with them.

Up to the time of the actual molting there is no discrepancy between the caudad shift of the end-body and that of the keratinized epithelium covering it. In other words, there is no evidence in support of Klauber's assumption of a "sort of wave action in the corrugations of the material constituting the tissues of the lobes, relative to the surface skin and the bones beneath." (Op. cit.) There merely occurs a flow or shift of the end-body as a whole over the style.

Figure 60, *c*, illustrates the size and the relationship of the end-body to the style near the climax of the period of accretion. A comparison with figure 60, *a*, shows that in the earlier stage the style extended well into the distal lobe of the end-body, whereas in the later stage that lobe lay entirely beyond the style. The maximal distance (6 mm.) between the tip of the style and the tip of the end-body had been attained. This difference clearly is not due to resorption of the tips of the style, which, as already stated, retains a constant length, but to a caudad displacement of the connective tissue of the end-body.

It is equally clear, however, that resorption of soft tissues in the end-body itself must follow as a further sequence in the molting cycle. Otherwise, the end-body would become larger with each period of accretion. From the three-lobed condition the end-body accrued to a four-lobed one between March 20 and April 5 and the process was repeated between June 12 and June 24. If no reduction took place the end-body would become five-lobed in the next growth period, and the segments would become successively larger and more complex. Instead, they remain constant in form and in their relationship to each other.

The resorption phenomena in the end-body are synchronous with the molt and continue for a short time thereafter. Seventy-two hours elapsed between the last exposure made prior to molting and that obtained just afterward. The resorption of parts of the end-body was complete at the end of that interval. In contrast to accretion, which lasts for about fourteen days, resorption is relatively short and occurs mainly during the actual process of molting.

The x-ray exposure shown in figure 61, *b*, was obtained soon after the snake had molted. A comparison with the exposure made prior to this (fig. 61, *a*) reveals striking differences in the end-body: From a transient four-lobed condition it has changed to a three-lobed post-molting one by the full resorption of the distal lobe. The previous middle lobe thereby became the new distal lobe. Its connective tissue core, likewise, was reduced and now lies immediately over the

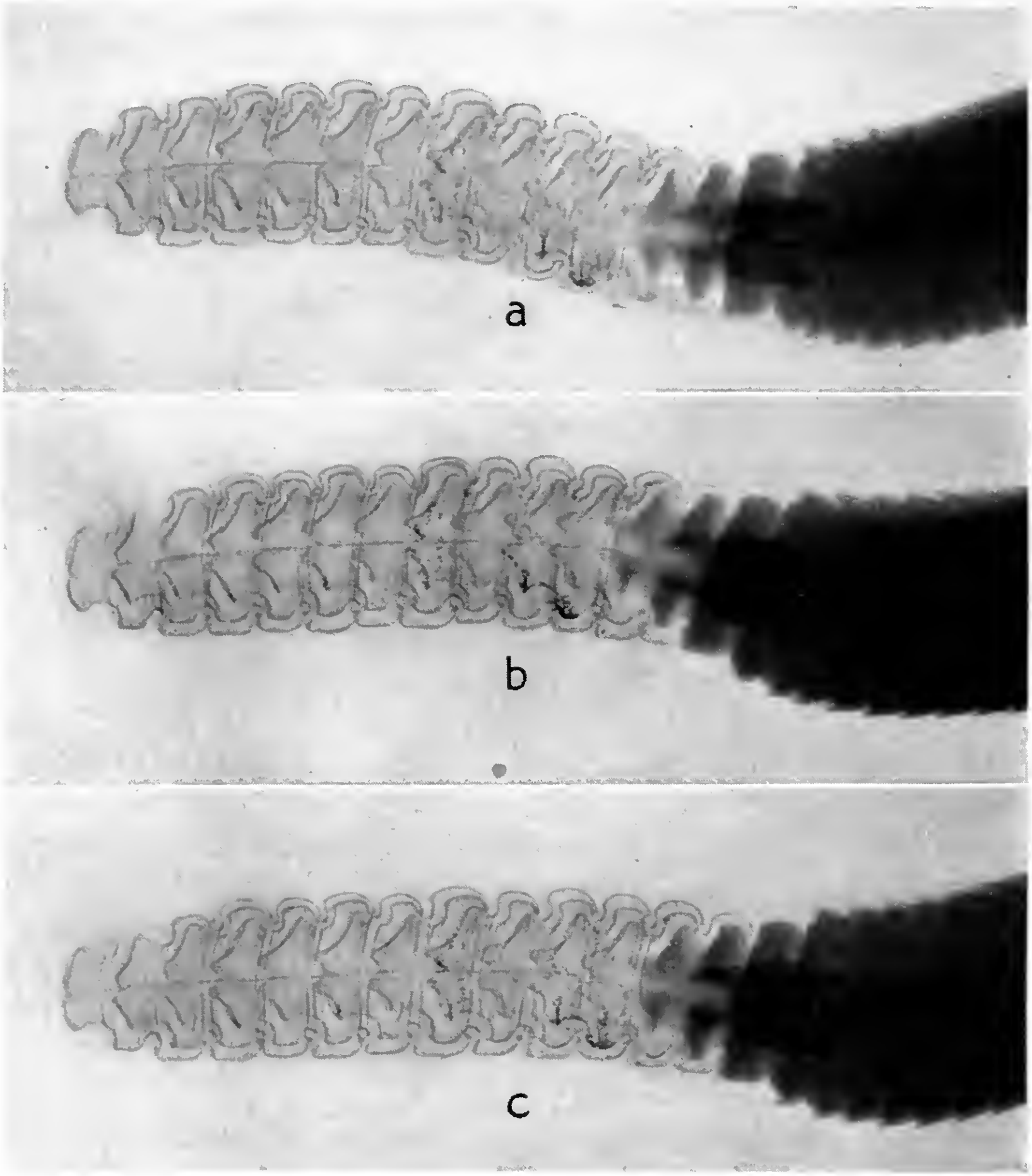

Fig. 60. Positive prints of x-ray photographs of the tail of a living adult Texas diamond-back (*Crotalus atrox*). Dates of exposure: (*a*) March 25; (*b*) April 5; (*c*) April 8. These photographs portray the period of accretion. The base of the style lies in the new basal lobe beneath the last scales. The distal lobe extends from 5 to 6 mm. beyond the tip of the style.

distal tips of the style. This is the characteristic relationship of the distal lobe to the style during the entire latent period, which follows. In other words the previous second lobe has become the new distal lobe in position and shape.

Resorption involves the connective tissue only, and it is evident that the epithelial covering remains intact as the living stratum profundum on the rapidly shrinking lobe. In contrast, the stratum

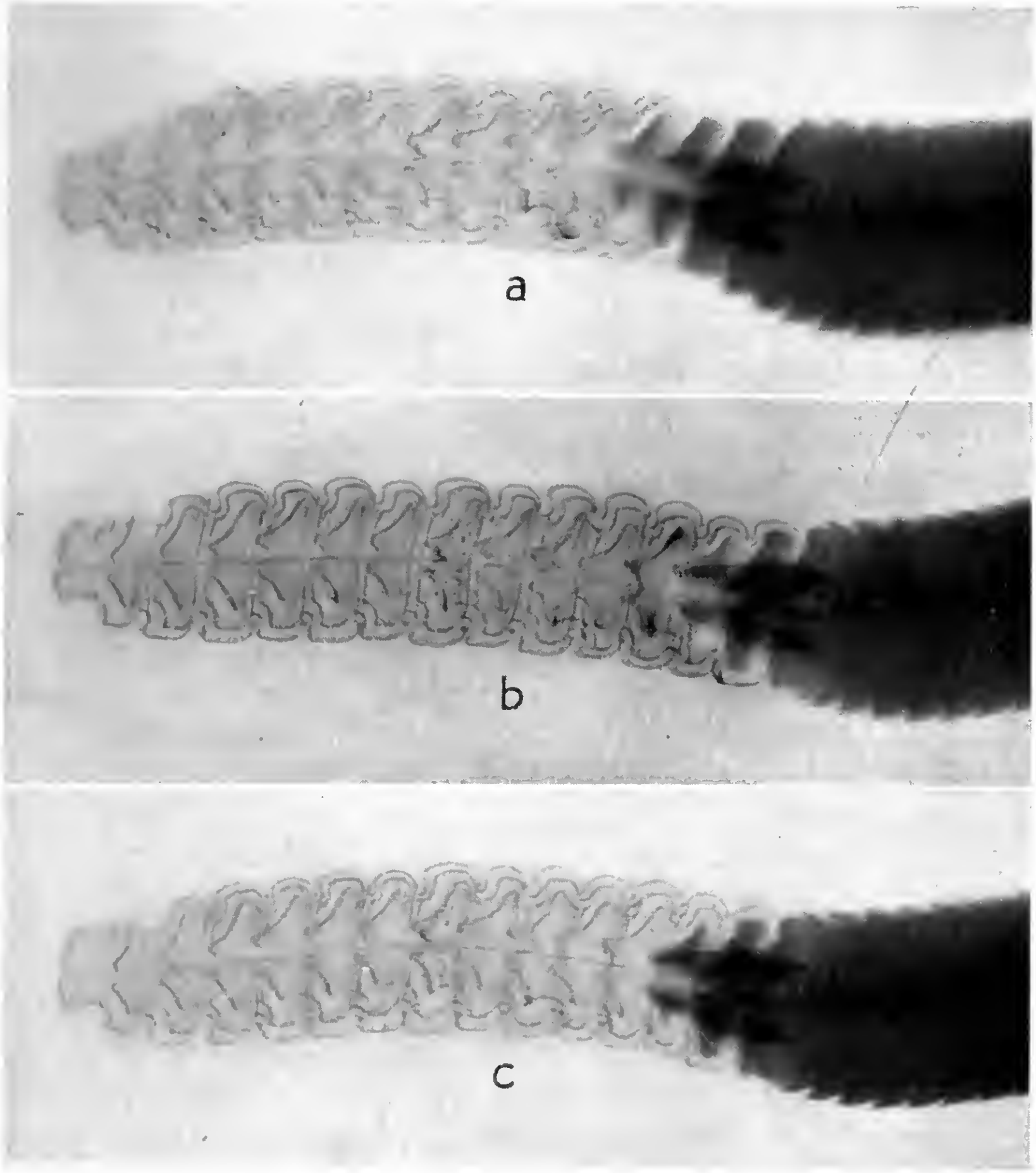

FIG. 61. Continuation of the series shown in figure 60. Dates of exposure: (*a*) April 12; (*b*) April 15; (*c*) April 22. *a*, the climax of the accretion period ends; *b*, the full resorption of the end-body, the stratum corneum remaining behind as a new segment of the rattle; *c*, the relation of the end-body to the style at the onset of the latent period. Molting occurred between the two stages shown in *a* and *b*.

corneum becomes detached and remains behind to constitute the new horny segment of the rattle. It is a replica of the distal three lobes of the transient four-lobed end-body.

There is a diminishing degree of resorption from the distal to the proximal lobes of the end-body. Measurements of the dorsoventral diameters of the stroma in the various lobes were taken on the x-ray negatives, which gave practically the natural dimensions in the living specimen. The differences in the pre- and post-molting conditions are summarized in the following table:

DORSO-VENTRAL DIMENSIONS OF CORRESPONDING LOBES OF END-BODY BEFORE AND AFTER RESORPTION

| End-body after accretion (April 8) mm. | | End-body after resorption (April 15) mm. | |
|---|---|---|---|
| 11.5 | Distal lobe | .... | Lobe resorbed |
| 13.0 | Middle lobe | 10.5 | New distal lobe |
| 13.3 | Basal lobe | 13.8 | New middle lobe |
| 16.0 | New basal lobe | 15.0 | New basal lobe |

If the dorso-ventral diameters of the lobes in the pre-molting condition and the same diameters of the newly formed horny segment are compared they prove to be nearly the same. The newly detached horny segment, therefore, reflects the shape and size of the distal three lobes of the pre-molting end-body.

The resorption of the living soft tissues in the end-body is of primary importance in the disengagement of the newly formed segment of the rattle from its matrix, and in re-shaping the end-body for the next growth period. There is definitely no flow or longitudinal displacement of soft tissues within the epidermal covering and the newly forming horny segment. Instead, there is a withdrawal or shrinkage after the soft tissues of the end-body with the rattle have moved caudad. Before resorption takes place, the stratum corneum of the newly forming horny segment, which is about to become a functional part of the rattle, cannot be identified in the x-ray negatives. After the resorption, the new horny segment is clearly defined inasmuch as three lobes of the end-body have sufficiently withdrawn to leave a clear space between the new horny segment and the living tissues. That condition is illustrated in figure 61, *b*. Before molting, the rattle consisted of eleven horny segments and a four-lobed end-body; immediately after molting, of twelve horny segments and a three-lobed end-body.

The size and morphological features of the end-body as newly established during the active process of molting remained essentially the same during the following two months (April 15–June 12, 1946). This long phase of little or no change is the latent period. The second molting cycle was then initiated by a new growth period. This second period of accretion lasted from June 12 to June 24. At the latter date a four-lobed end-body characteristic of the pre-molting condition had again developed, and actual molting followed on July 2.

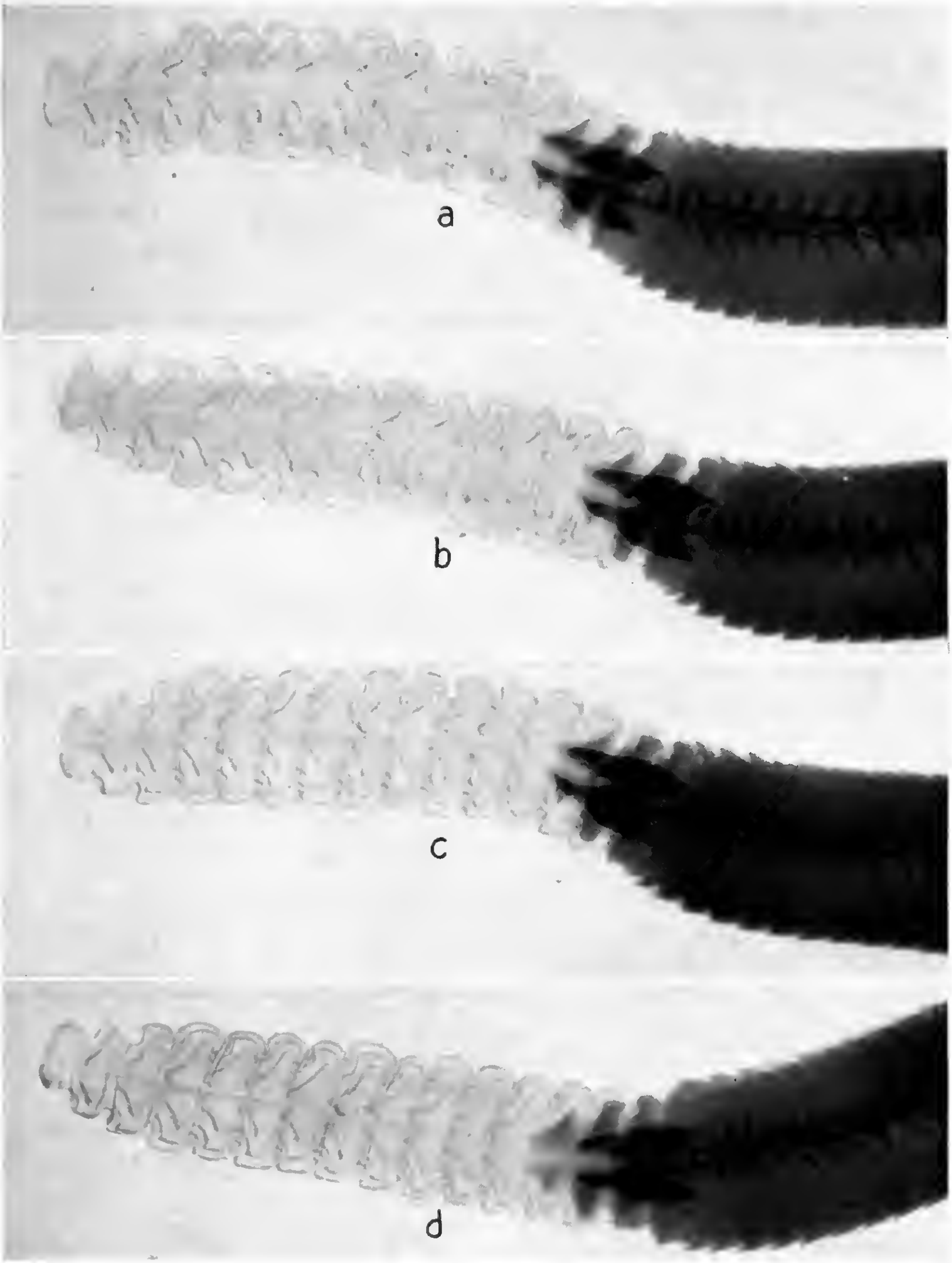

FIG. 62. Completion of the series shown in figures 60 and 61. Dates of exposure: (*a*) May 1; (*b*) May 14; (*c*) May 27; (*d*) June 24. Exposures *a–c* illustrate the relationship of the end-body to the style throughout the relatively long latent period. In *d* the caudad shift of the soft tissues beyond the style and the proximal growth of a new basal lobe have again occurred; *d* represents a new period of accretion. The second molt occurred on July 2.

Figures 61, *c*, and 62, *a–c*, illustrate the condition of the end-body and rattle during the latent period from April 19 to June 12. Figure 62, *d*, shows the pre-molting condition as a result of the second period of accretion. The anatomical features of the stage represented by this figure are comparable to those in figure 60, *b*, except that one segment had been added to the rattle. The interval between these two comparable x-ray exposures was seventy-six days and the addition of another segment to the rattle was imminent. Based on the dates of shedding of these successive molts the cycle was completed in eighty or eighty-one days. The table (p. 375) summarizes the x-ray findings and correlates them with the observed external conditions of the snake.

## DEVELOPMENT OF THE SHAKER OR STYLE

The caudalmost vertebrae of rattlesnakes fuse to form the shaker or style. This fusion takes place at different developmental stages in different species. In *Sistrurus catenatus,* for instance, fusion occurs postnatally, whereas in *Crotalus atrox* and *C. adamanteus* the consolidation of the last vertebrae is well advanced in late embryos.

The style was recognized in adult snakes as early as 1855 by Leuckart, and described, as stated above, by Czermak (1857), who named it the "end-body of the vertebral column." He compared it with a simple exostosis in the form of "a single, conical, bilaterally flattened piece with two rounded, more or less separate points" and believed it to be composed of seven or eight vertebral elements. He noticed that the vertebral canal continues far into this bony structure and that it is provided with vestiges of intervertebral foramina.

Garman (1888) stated that the caudal vertebral column in embryos of rattlesnakes (specifically *Sistrurus catenatus*) is "similar to that of other ophidians at the same stage: each vertebra is distinct, movable." But he believed that later additions occur whereby the end of the vertebral column becomes markedly changed. Shortly after birth "the hinder seven or eight of the vertebrae are seen to have coalesced into a single mass, showing a disposition to expand so as to obliterate the processes and lines of demarcation of the bones of which it is composed, but which are still plainly indicated. This composite bone may be called the shaker."

Garman further stated that because of the expansion of the style and the thickening of the skin "the muscles between the bone and

### Record of Molting Cycle of Captive Texas Diamond-back

| Date | Stage of cycle | Remarks |
|---|---|---|
| March 20. | Growth phase or period of accretion already begun | No exposure yet made; new lobe probably began to develop at about this time. Snake is kept at constant temperature (76° F.). |
| March 25. | Period of accretion continues | First exposure shows new basal lobe well under way, but external examination reveals no change; cornea clear. See fig. 60, *a*. |
| March 30. | Period of accretion continues | Cornea clear. |
| April 1. | Period of accretion continues | Exposure and external examination show new basal lobe well developed; cornea cloudy. |
| April 3. | Period of accretion continues | Exposure and external examination show new basal lobe approaching maximum development; cornea very cloudy. |
| April 5. | Period of accretion continues | Exposure and external examination show new basal lobe at about maximum development; cornea very cloudy. See fig. 60, *b*. |
| April 8. | Period of accretion reaches climax | Exposure and external examination show little or no discernible change in new basal lobe; cornea has cleared. See fig. 60, *c*. |
| April 10. | Period of accretion still at climax | Exposure and external examination reveal no further change; cornea clear. |
| April 12. | Period of accretion ended, period of resorption beginning | Looseness of molt shows that ecdysis is imminent; cornea clear. See fig. 61, *a*. |
| April 13. | Period of resorption continues | Molt found in cage; segment being added to rattle; cornea clear. |
| April 15. | Period of resorption ended, latent period begun | Segment, now a functional part of rattle, contains only remnants of the rapidly disappearing stratum intermedium; cornea clear. See fig. 61, *b*. |
| April 19–June 12 | Latent period continues | Exposures made on and between these dates were identical with that of April 15 except that remnants of the stratum intermedium were no longer evident; cornea clear. See figs. 61, *c*, and 62, *a–c*. |
| June 24. | Period of accretion well advanced | New basal lobe had developed to a phase comparable to that shown in exposure of April 1, indicating completion of the 83-day cycle; cornea slightly cloudy. |
| July 2. | Period of resorption under way | Molt occurs, completing cycle of 80 days based on April 12 ecdysis. |

the skin are on the way to disappear." Our own observations on the youngest postnatal stages do not confirm this view. There is no evidence that muscle tissues ever extend farther caudad than the base of the developing style.

Garman's figures obviously are diagrammatic and unconvincing. We doubt that his material and technique were adequate for the study of early stages.

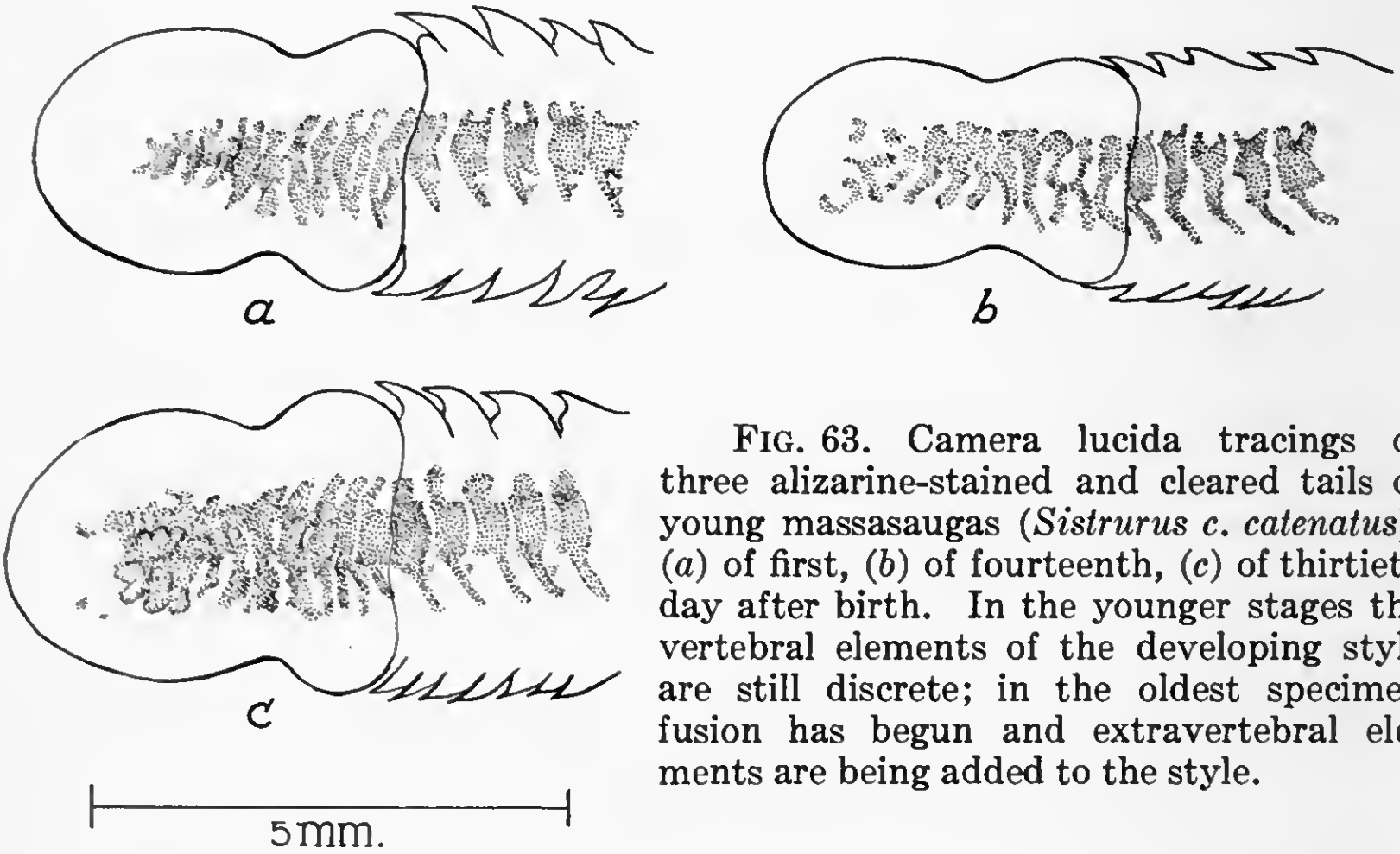

FIG. 63. Camera lucida tracings of three alizarine-stained and cleared tails of young massasaugas (*Sistrurus c. catenatus*): (*a*) of first, (*b*) of fourteenth, (*c*) of thirtieth day after birth. In the younger stages the vertebral elements of the developing style are still discrete; in the oldest specimen fusion has begun and extravertebral elements are being added to the style.

We have studied the development of the style in numerous specimens of *Sistrurus catenatus* and of the *Crotalus atrox-adamanteus* group, using the method of selective staining with alizarine followed by clearing. The material varied in age and size from tails of late embryos to those of fully grown snakes.

Our observations on the development of the style were most instructive in *Sistrurus catenatus* because in that species coalescence of terminal vertebrae takes place postnatally and our material was ample. A brood was born at the Museum, and specimens were killed at intervals: one on the first, one on the fourteenth and a third on the thirtieth day after birth. These young snakes were 218 mm., 211 mm. and 246 mm. long, respectively, and their buttons measured from 3.7 to 3.9 mm. in length. The average length of the fully formed button in this species being 5 mm., it is evident that the end-bodies of these young specimens had not yet attained their full size. Neither had a stratum corneum become detached from the young epidermis. Further growth, therefore, takes place in the end-body between birth and the time of detachment of the keratinized button.

Figure 63, *a*, shows that on the first postnatal day separate vertebral elements are present in the axis of the end-body. Nine, possibly ten such units can be counted. Their contours are not sharply defined since they are in transition from the blastemal to cartilaginous and early bony stages. The caudalmost element is very small and the entire group tapers. In our preparation the caudal artery was seen to extend into the end-body.

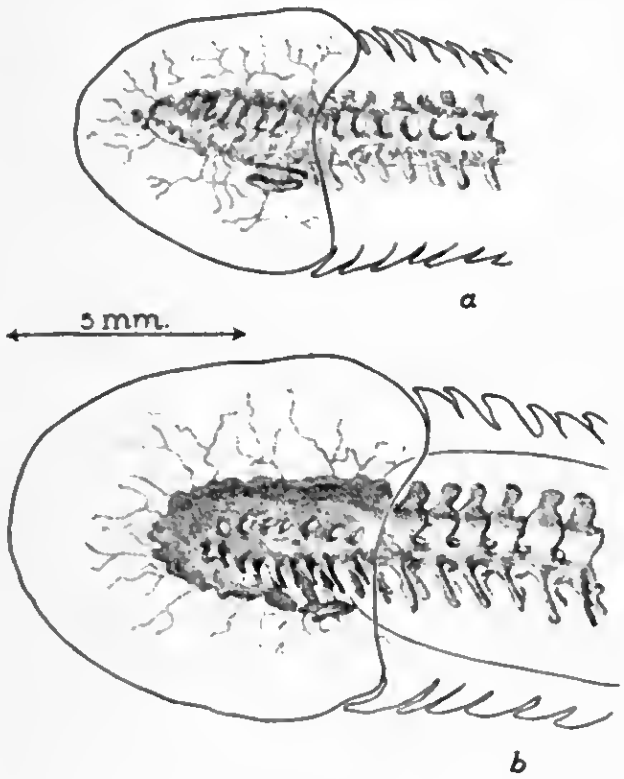

FIG. 64. Camera lucida tracings of the alizarine-stained and cleared tails of (*a*) the advanced embryo of a Texas diamond-back (*Crotalus atrox*), (*b*) the advanced embryo of a Florida diamond-back (*C. adamanteus*). The original intervertebral foramina are recognizable, and longitudinal trabeculae are developing on the ventral side of the style.

During the first fourteen days of postnatal life little progress in the establishment of a shaker or style is evident (fig. 63, *b*). There is no marked degree of fusion among the caudalmost vertebrae, but osteogenic foci appear in the connective tissue surrounding the very tip of the vertebral column. These secondary additions produce nodular, irregular trabeculae, which change the previously tapering end of the vertebral column to a broader and somewhat fan-shaped mass.

The results of this change are more pronounced in the specimen one month old (fig. 63, *c*), but vertebrae within the end-body are still discrete. Fusion has begun distally between the caudalmost vertebral units and the secondary bony contributions from the surrounding connective tissue. Further osseous nodules are developing even beyond this fused portion of the young style.

The other material at our disposal for this part of the study included embryos and early postnatal stages of *Crotalus atrox* and

*C. adamanteus.* We stained and cleared the tail ends of two embryos of *Crotalus atrox* (260 and 265 mm. in total length) and of one late embryo of *C. adamanteus* that was obtained from within its amniotic sac (total length 380 mm.).

The formation of the style in these late embryos of *Crotalus* was more advanced than that in postnatal *Sistrurus,* a considerable fusion of eight to ten terminal vertebrae having taken place within the end-body (fig. 64, *a* and *b*). The original intervertebral foramina are easily recognizable in the illustration and betray the segmental portion of the style.

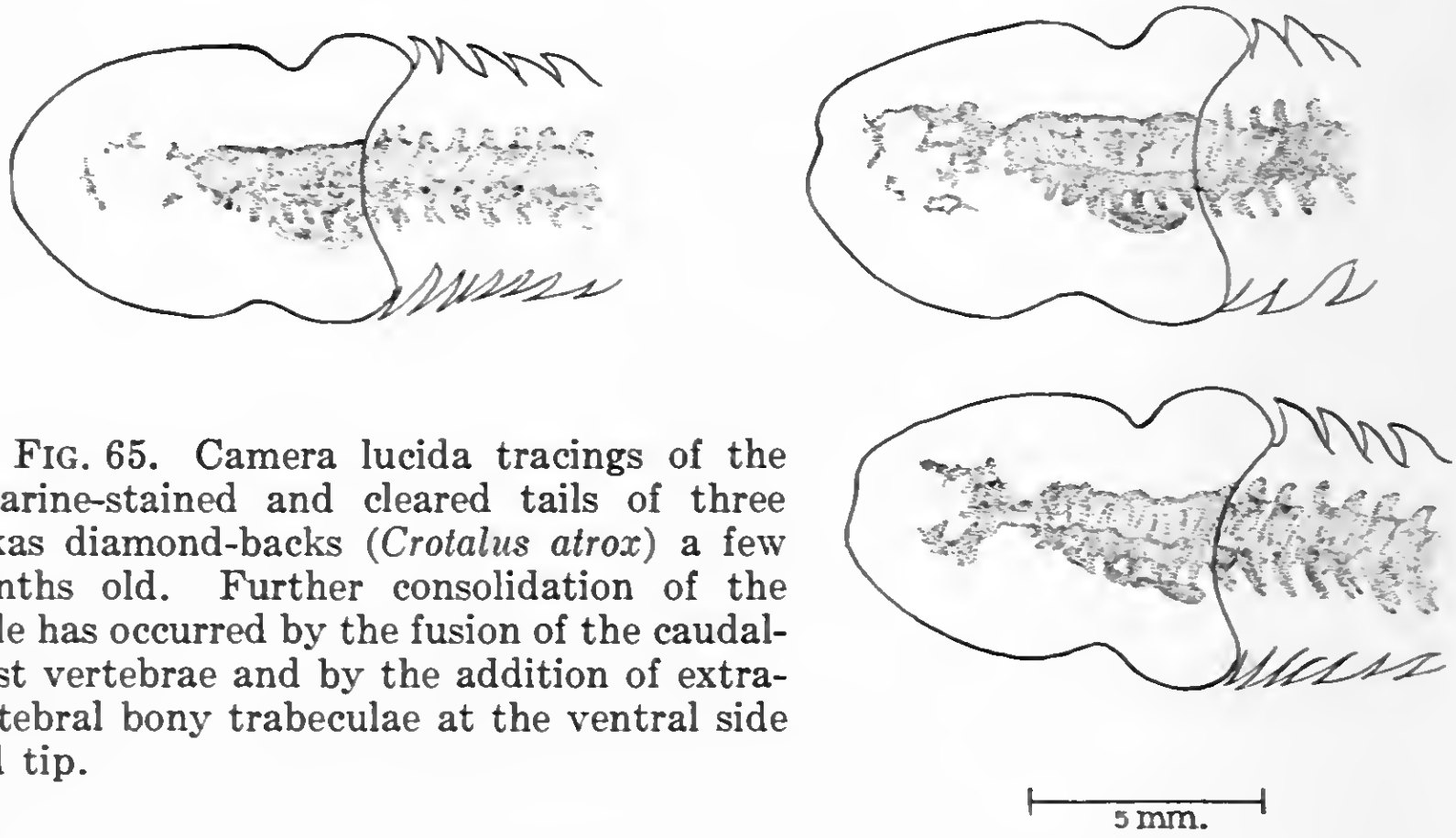

FIG. 65. Camera lucida tracings of the alizarine-stained and cleared tails of three Texas diamond-backs (*Crotalus atrox*) a few months old. Further consolidation of the style has occurred by the fusion of the caudalmost vertebrae and by the addition of extravertebral bony trabeculae at the ventral side and tip.

There are indications of extravertebral additions by osteogenic centers near the tip. Furthermore, a pair of longitudinal trabeculae develops on the ventral proximal side of the young style. Numerous fine bloodvessels radiate from the style into the connective tissue of the end-body. They are evidently the terminal branches of the caudal artery.

The next older stage studied was represented by postnatal specimens of *Crotalus atrox.* They were killed in October when a few months old. Their average total length was 333 mm. Three specimens of the twenty studied in this group are illustrated above (fig. 65).

The end-bodies at this stage are definitely covered by a stratum corneum that is detached or ready to be detached as the button. Its length ranged from 7.1 mm. to 8.0 mm. in the cleared preparations illustrated. The style has further developed by fusion of previously discrete vertebral and extravertebral elements. The end-prongs are forming from distalmost bony trabeculae arising in connective tissue and the pair of ventral longitudinal bars gradually extend distad. When well developed they look like runners on a sled. They strengthen the ventral margin of the style. There are minor variations in the degree of consolidation of the various elements of the style in specimens of about the same age. But the general form and the structural characteristics of the style are attained within a few months after birth.

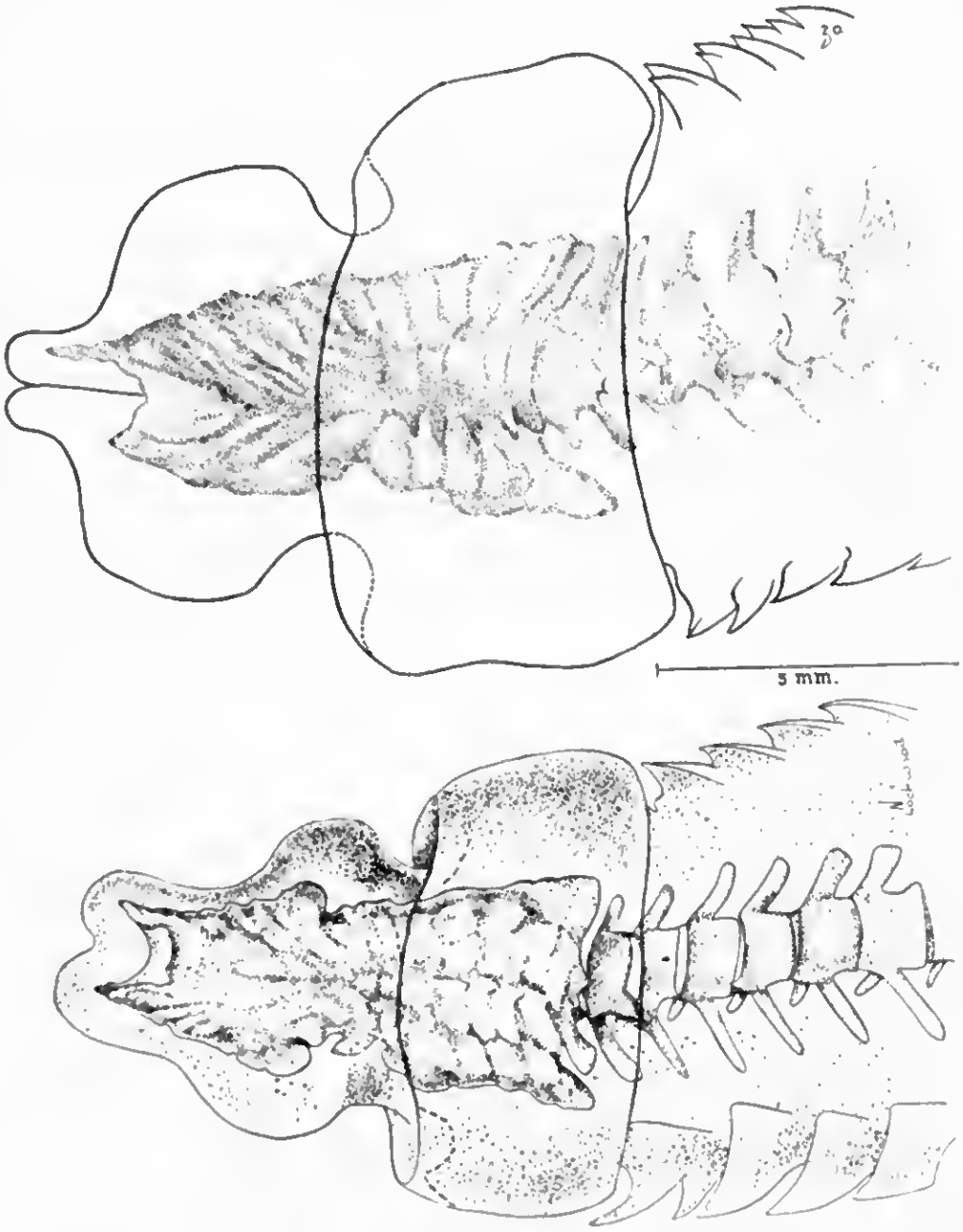

FIG. 66. Camera lucida tracings of the alizarine-stained and cleared tails of two young Texas diamond-backs (*Crotalus atrox*). The segmental origin of the proximal portion of the style is still recognizable. The extravertebral part of the style extends into the distal lobe.

Figure 66 shows the tails of two older specimens of *Crotalus atrox*, 455 mm. and 550 mm. in total length. The end-body of the smaller snake was 9.4 mm. long and 7.6 mm. wide at the basal lobe; that of the larger 10.4 mm. long and 10 mm. wide. In both specimens the segmental origin of the proximal portion of the style is indicated by successively overlapping bony ridges and trabeculae betraying the forms of various bodies and apophyses of former vertebrae; distally no such segmental arrangement is discernible.

The proximal portion of the style extends into the middle lobe. This is consistent with our observation on other material that the spinal cord terminates within this lobe. The portion of the style derived by extravertebral ossification, therefore, occupies the remainder of the middle lobe and extends somewhat into the distal one.

The styles of fully grown specimens shown in figures 67 and 68 belonged to snakes (*Crotalus atrox*) 835 mm. and 1,000 mm. in total length. The long axes of their end-bodies measured 12 mm. and 16 mm., respectively. The distinction between the originally segmental and the non-segmental distal portions is less apparent in old than in young snakes. Yet even in the largest specimens the style is not a compact bony end-piece of the vertebral column. Structurally, young and old styles are highly trabeculated, with fairly smooth ventral and dorsal margins. Between the bony trabeculae there are relatively large marrow spaces. From the style emerge eight or nine segmentally arranged nerves, which course into the soft tissues of the end-body. These nerves evidently are sensory as there is no muscle within the end-body needing motor supply and small ganglia are recognizable at their roots, just outside the vestigial intervertebral foramina of the style. The dorsal and ventral muscular masses of the tail are inserted on the corresponding proximal prongs of the style. The rapid vibrations caused by muscular action are

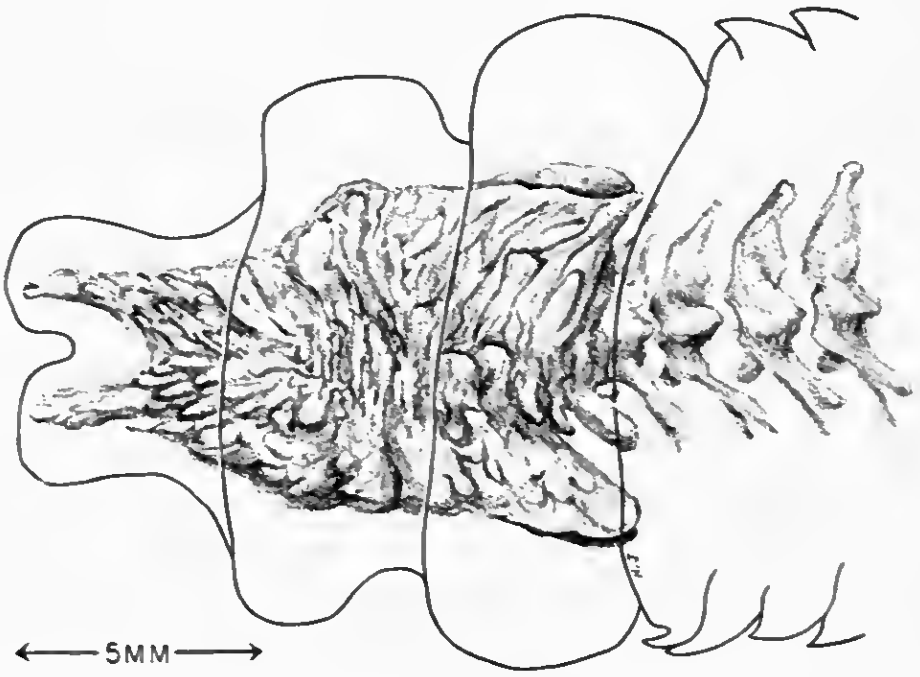

FIG. 67. Camera lucida tracing of the style and the caudalmost vertebrae of an adult Texas diamond-back (*Crotalus atrox*). The highly trabeculated structure of the style is evident.

secondarily transmitted to the rattle, the proximal segment of which caps the soft tissues of the end-body.

## DEVELOPMENT OF THE RATTLE IN YOUNG OF THE FLORIDA DIAMOND-BACK

The histological study of the development of the first segment with three lobes was a main object of the study. Previous workers, failing to consider such details, merely speculated with the help of theories and mechanistic schemes.

We used nine selected specimens of *Crotalus adamanteus* that had been preserved shortly after birth. One specimen of this series had a rattle consisting of a button and two segments, the youngest of these segments having just been established. The other specimens had only a button with a first segment in various stages of development. Six of these specimens were studied histologically after the tail ends had been embedded in celloidin and sectioned with the microtome.

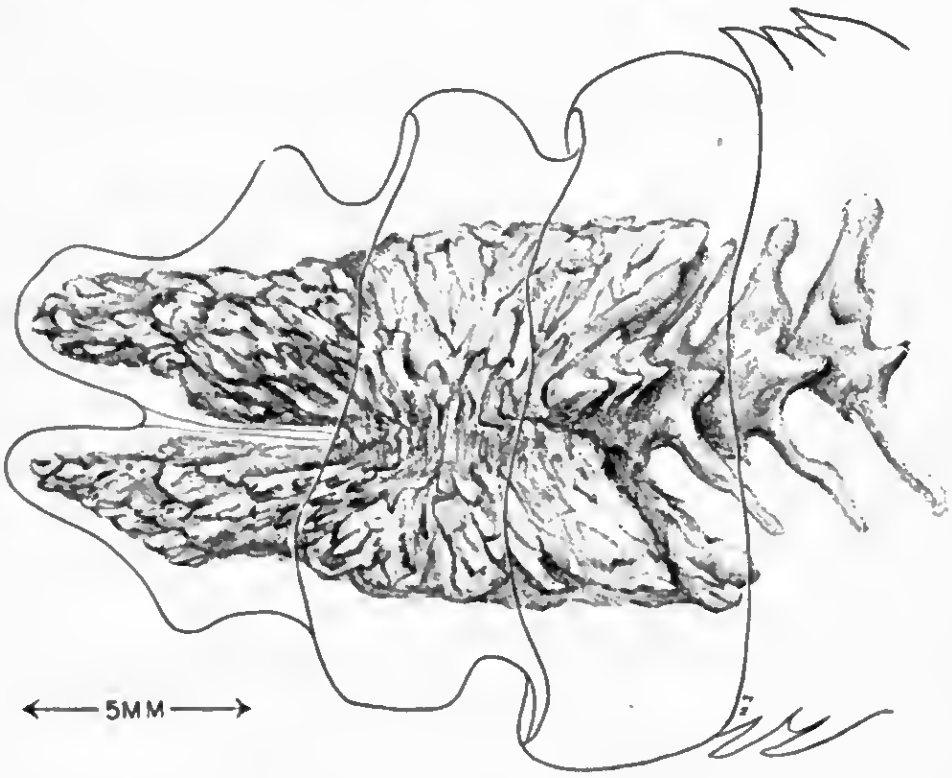

FIG. 68. Camera lucida tracing of the style and the caudalmost vertebrae of an old Texas diamond-back (*Crotalus atrox*).

### Morphological Features

The average length of the severed tail ends was 15 mm. and that of their buttons was 7.4 mm. The average dorso-ventral diameter at the proximal lobe of the button was 6 mm.

Figure 69, A–D, shows lateral views of four specimens of this series. The original drawings were made with hand lens and camera lucida, before decalcification and embedding. The broad lateral margins of the caudal plates indicate the ventral sides. Each button has two lobes, which are separated by a transverse groove, and there is a narrow longitudinal furrow on each side of the button. The characteristic asymmetry of the button is readily seen, the ventral side of the proximal lobe extending consistently farther caudad than the dorsal side. This indicates either an earlier differentiation or a faster rate of growth of the ventral side of that lobe.

In figure 69 the specimens are arranged in the order of development, A representing the earliest and D the latest stage in the development of the first segment. Outwardly, no marked features indicate such development, but close examination reveals two important steps in the development of the new segment of the rattle, one of resorption and one of accretion.

The feature of resorption is visible through the translucent button. Even though the detached stratum corneum constituting the button is heavily pigmented in *Crotalus adamanteus*, a shrinkage of the inner core or end-body is easily detected, particularly with the help of the binocular dissecting microscope. The progressive degree of that shrinkage of the underlying end-body away from the horny button is indicated in the figures by a broken line representing the contour of the end-body.

The horny button becomes detached from the underlying epidermis that gave it origin as the keratinized stratum corneum. There is no expansion or change in form of the button after its detachment; its invariable measurements in successive stages make this fact evident.

Measurements were also taken of the distance between the caudalmost tips of the button and of the end-body within. The distances between these points were 0.3 mm., 1.4 mm., 1.2 mm., and 1.7 mm. for the successive stages portrayed (fig. 69).

In the latest stage shown the reduction of the end-body within the button appears to be almost one-fourth of the length of the button (1.7 mm. within the button of a total length of 7.2 mm.).

However, the processes involved in this lack of conformity between the button and the caudalmost extension of the end-body are not clearly shown by our material. The obvious reduction is independent of the growth proximal to the button. This growth establishes a new basal lobe and causes a slow caudad dislocation of the end-body over the bony style.

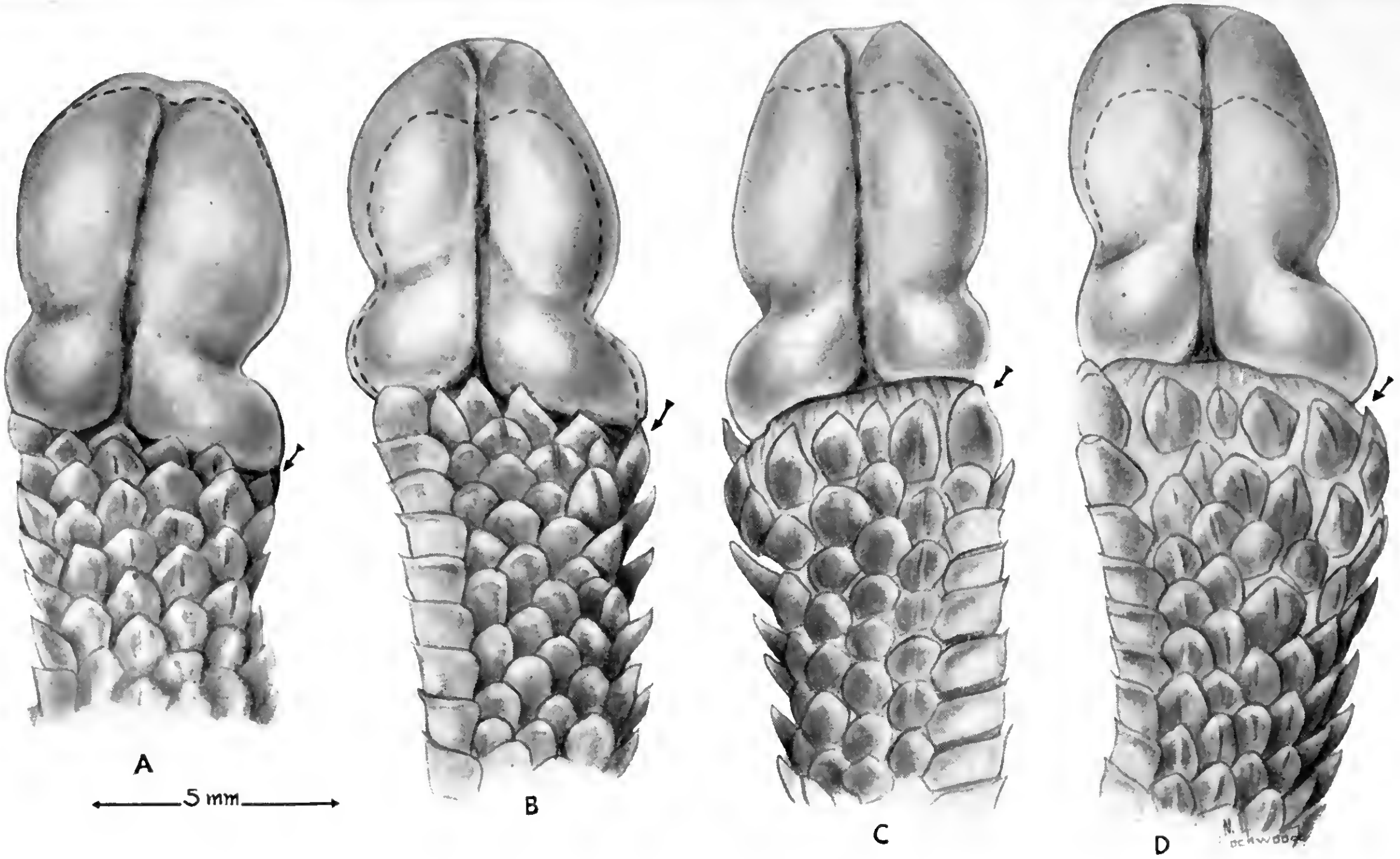

FIG. 69. Lateral views of tails with button of young Florida diamond-backs (*Crotalus adamanteus*). The caudal plates indicate the ventral side. The degree of resorption of the end-body within the translucent buttons is indicated by a broken line. Growth in the sulcus (arrows) separates the caudalmost scales. This spreading is most advanced in D, which represents the pre-molting stage.

This feature of growth or accretion is detectable in figure 69, B–D, immediately proximal to the button. Beneath the caudalmost scales there arises a swelling in the region of the epidermal sulcus between the button and the last scales. By the relatively rapid expansion of the newly forming lobe the caudalmost scales themselves become separated from each other, their displacement being in a longitudinal as well as in a transverse direction. Their intersquamal folds become erased or reduced by stretching.

In figure 69, A, the scales are seen to be closely imbricated, whereas in D the scales of the last two rows are spread apart and the intersquamal epidermis is visible. This spreading makes it possible to ascertain whether a rattlesnake of any age is in the pre-molting stage when growth of a new basal lobe occurs. We used this sign of growth in checking over numerous preserved specimens in the study collection of Chicago Natural History Museum. The sign, always betraying proximal accretion of the rattle, is an indication of imminent molting as valid as is the clouding of the cornea.

The stretched epidermis and the unimbricated scales, just proximal to the button, involve only that layer of the skin that forms the molt. The caudal end of the molt is always attached to the button, or, subsequently, to the horny segment about to be freed. The area of attachment lies in the first transverse groove of the new but still functionless basal segment. Consequently, the molt temporarily hides the developing proximal bulge.

A comparison of figure 69, D, and figure 70 shows that similar conditions prevail in very young and in mature specimens of different species. Figure 70 was drawn from a specimen of the prairie rattlesnake, *Crotalus viridis viridis*. It shows the tail end of a grown snake in the pre-molting stage. The functional horny segments of the rattle have been removed and the proximal segment has been cut open lengthwise. One-half of this segment is covered by the attached molt, whereas the other half has been freed of its molt in order to expose the new basal lobe and the closely imbricated caudalmost scales.

Further features are illustrated by figure 71, A–D, which was drawn from longitudinal sections, made previous to embedding, of the same specimens shown in figure 69, A–D. The figures with identical letters portray the same specimens (only in the case of D are they viewed from the same side). They were drawn with identical magnifications. Three of the sections are slightly parasagittal but B and D show midsagittal sections. The extension of the spinal cord into the end-body is clearly seen; it ends in the distal lobe within the fused vertebral elements of the style.

In these hand-made sections the connective tissue of the end-body had the characteristic white appearance with a bluish tinge caused, mainly, by the interspersed pigment cells. As the sections were unstained, the detail features and contours of the various tissues are merely suggested.

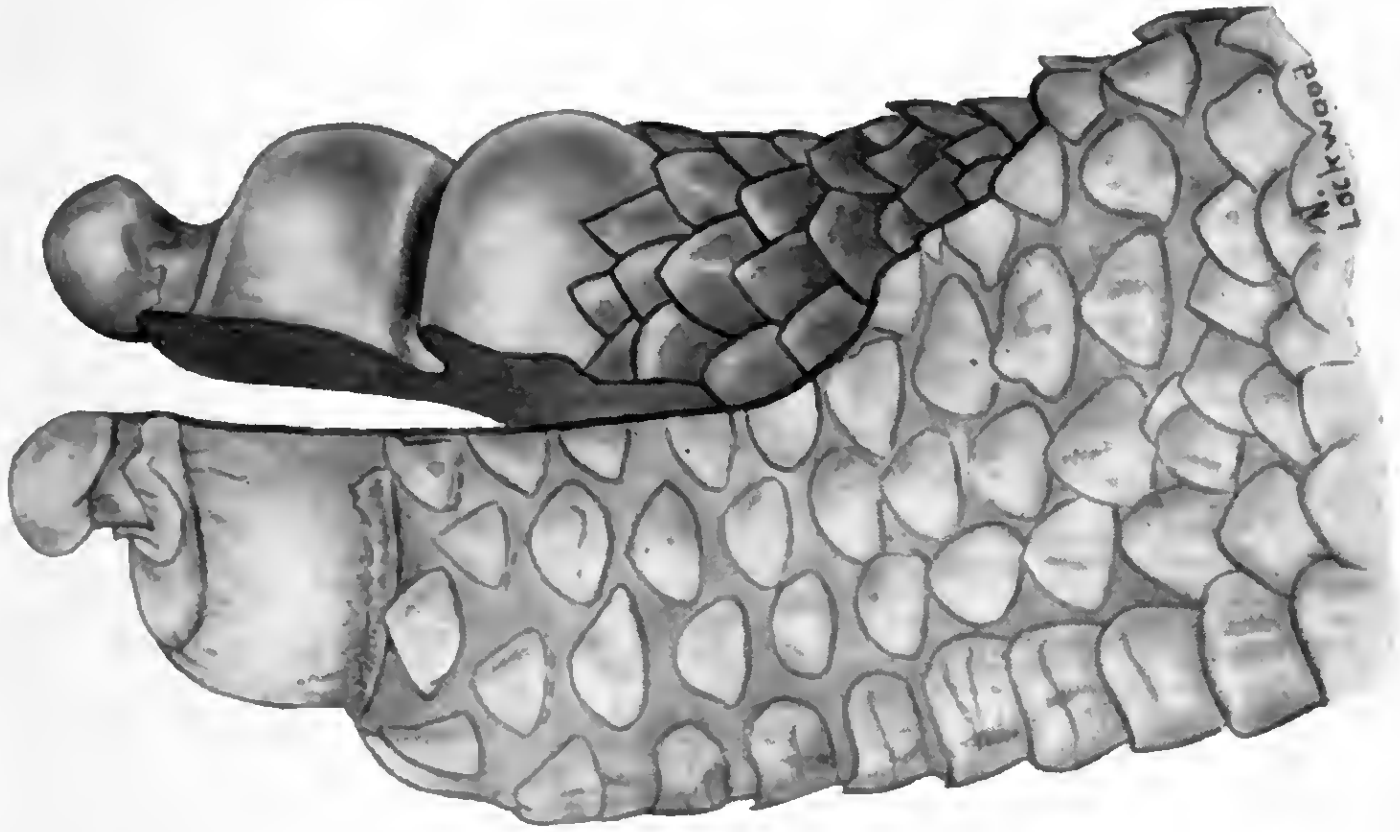

FIG. 70. The tail of an adult prairie rattlesnake (*Crotalus v. viridis*) in premolting stage. The functional segments of the rattle have been removed and the end-body has been bisected longitudinally. The molt still covers the ventral half of the newly formed basal lobe. Compare the widely separated scales of the molt with the closely imbricated scales of the half from which the molt has been removed.

The significant features in these figures are the sectional views of the developing proximal lobe in the first rattle segment. The region of special interest in each section is indicated by an arrow. In A it merely marks the epidermal groove between the last scales and the button. In B the formerly narrow sulcus had widened but is still partly covered by the caudal plates and scales. This widened groove indicates earliest growth in a newly forming lobe. In C a young basal lobe is present in the identical location of the previously widened groove, immediately proximal to the base of the button. The new lobe is still narrow and covered by the future molt. In D, finally, the newly added basal lobe of the first segment is well formed, though still covered by the molt.

In all figures, the ventral and dorso-lateral muscular masses may be seen extending caudad as far as the sulcus. This caudal musculature does not extend into the end-body proper at any stage of development. The several muscular bundles insert upon the base of the style, which lies in the same transverse plane as the base of the proximal lobe.

In D the space between the button and the end-body is shown to be occupied by a peculiarly spongy tissue. It has signs of degeneration, such as vacuolization and formation of irregular strands. This tissue, derived from the stratum intermedium between two succeeding generations of the stratum corneum, is destined ultimately to disappear. Further details of this process are considered in the following paragraphs.

## Histological Features

The histological studies of growth in the developing rattle dealt with the following main aspects of the problem:

1) *Histology of the end-body:* the connective tissue core; the epithelium and its relation to the detached button; the process of keratinization; the coalesced terminal segments of the vertebral column (style); the extension of the spinal cord into the end-body.
2) *Phenomena of degeneration and of resorption:* degeneration of the stratum intermedium between successive generations of the stratum corneum; bone resorption in the style; changes in the connective tissue of the end-body.
3) *Phenomena of accretion:* evidences of new growth in the sulcus between the last scales and the end-body; the formation of a new proximal lobe.

### Histology of the End-Body

A general orientation of the young end-body and its relation to the button are shown (fig. 72, A and B) in the sections of a Florida diamond-back (*Crotalus adamanteus*) not more than a few months old. The original drawings were made as camera lucida tracings from horizontal longitudinal sections, at a 20-fold magnification. Figure 72, A, shows a section through the spinal cord. It is dorsal to that shown in figure 72, B, which passes through the caudalmost vertebrae and the style. The procoelous vertebral bodies and their articulations can be readily identified (fig. 72, B). The ganglia of the caudalmost spinal nerves are also shown.

The major portion of the connective tissue of the end-body consists of densely interlaced collagenous fibers. They form a tough

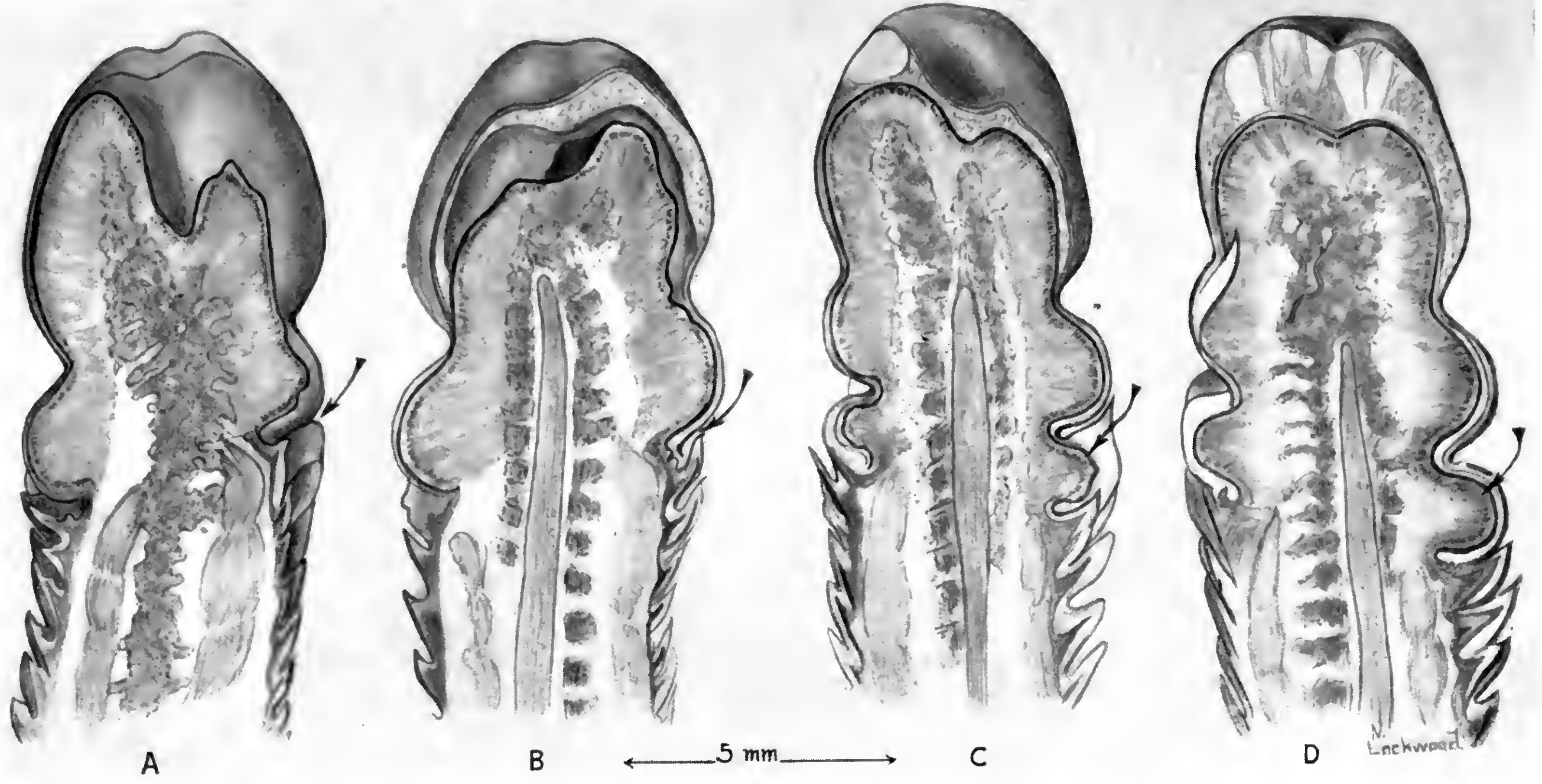

FIG. 71. Sagittal sections of the tails of young Florida diamond-backs (*Crotalus adamanteus*) illustrated in figure 69. The arrows indicate the sulcus (A) and the newly forming basal lobe (B–D). Histological features are merely suggested. The space between the button and the end-body is occupied by a spongy mass of the degenerating stratum intermedium.

felt-work, intermingled with numerous pigment cells. This connective tissue bed is well provided with bloodvessels that emerge from the style as the last branches of the caudal artery and vein. The nerve supply in the connective tissue of the end-body is also rich. The terminal branches of nerves emerge from between the fused segments of the style. From seven to eight segmentally arranged pairs were identified within the end-body proper. Their distribution appears limited primarily to the connective tissue and skin of the proximal lobe; only traces of nerve fibers were identified in the distal lobe. However, no silver preparations were made. The difference in the number and size of nerves supplying the two lobes of the end-body, nevertheless, is striking. The relative paucity of nerves in the distal lobe may be related to the resorption phenomena that this lobe suffers during the development of the rattle.

The density of the connective tissue in the end-body is not homogeneous. It is more uniform in the distal lobe where the collagenous fibers are evenly interlaced. A distinction between the derma of the skin and the underlying connective tissue of this lobe cannot be made, whereas a definite dermic zone is easily identified in the proximal lobe. Here the subcutaneous connective tissue shows distinct zones. Surrounding the style there is a layer of coarse collagenous fibers that form an open-meshed network with interfibrous spaces. Farther peripherally, this tissue is connected to the derma by a much finer connective tissue zone with greater homogeneity; coarse fiber bundles are lacking and there are no conspicuous interstitial spaces. The coarse open-meshed zone of connective tissue in the proximal lobe gives the impression of a fluid cushion around the style. This arrangement may be related to rapid growth changes that occur in the nearby sulcus and produce a shift of soft tissues in the end-body over the stationary style. Further consideration of this caudal displacement is given in the account of our x-ray studies.

Pigment cells are numerous throughout the connective tissue of the end-body. They are star-shaped, with numerous long processes containing brown pigment granules. They are most numerous in the derma directly beneath the basal layer of the epidermis, often lying adjacent to the adventitia of small bloodvessels. In many instances pigment cells were observed in the process of migrating from the derma to the epidermis. Such migrated pigment cells are located between the cells of the deeper layers of the squamous stratified epithelium. Furthermore, both the detached button and the new

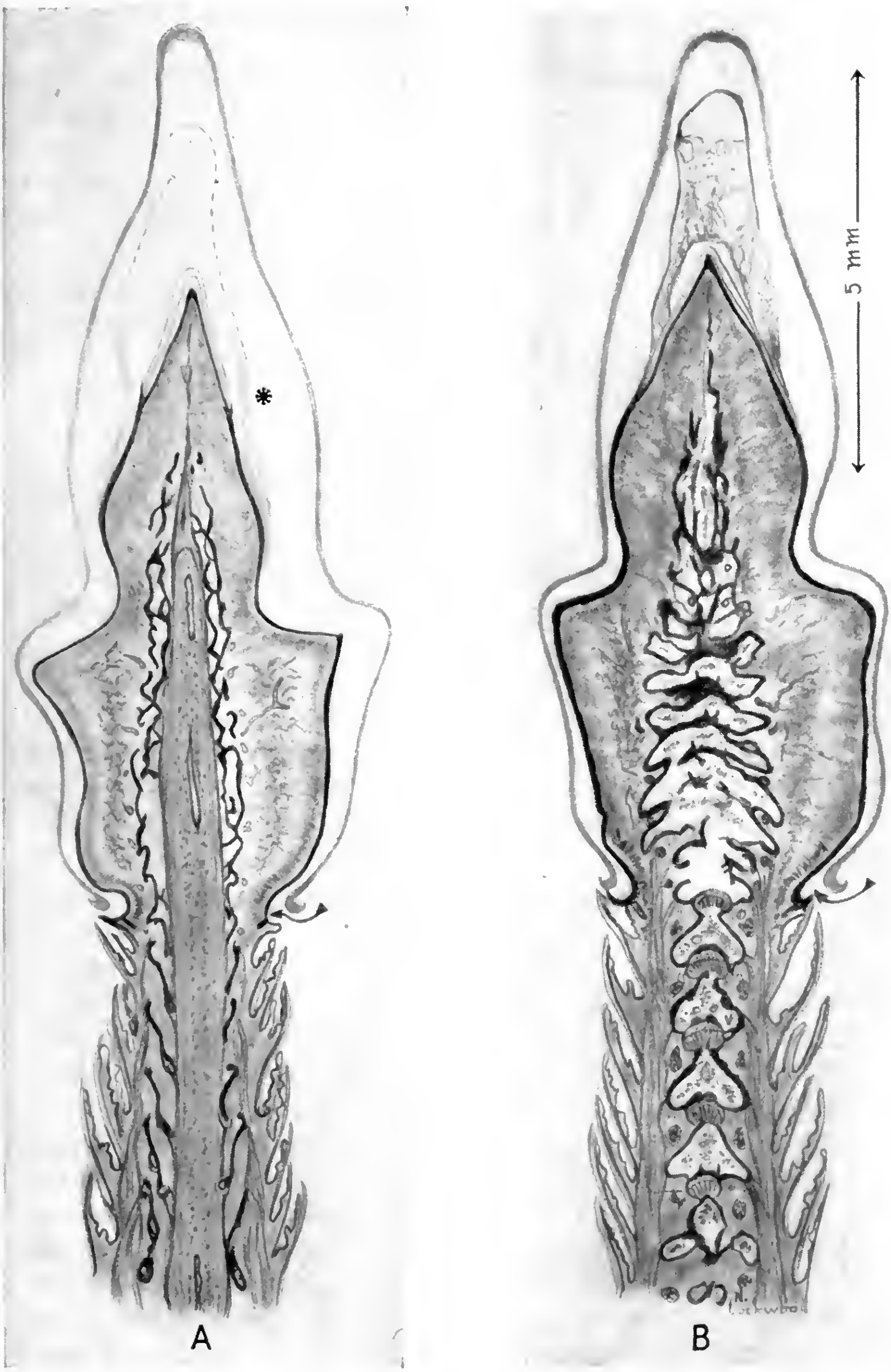

FIG. 72. Horizontal longitudinal sections of the tail of a young Florida diamondback (*Crotalus adamanteus*): A, the termination of the spinal cord within the end-body; B (ventral to A), the caudalmost vertebrae, style, and termination of lateral muscle masses. At the tip of the end-body, between the button and the newly forming stratum corneum, lies the degenerating stratum intermedium. Arrows indicate the sulcus; the asterisk (*) refers to the details shown in figure 73.

stratum corneum adjacent to the end-body contain characteristic pigment deposits that in their mottled arrangement betray an origin from infiltrated chromatophores.

The epidermis investing the end-body consists of squamous stratified epithelium. Unfortunately, there is little uniformity in the histological nomenclature and in the interpretation of the various layers of the skin in Squamata. The same layers have been variously designated, some discrepancies being due, undoubtedly, to differences between genera or species.

The following description is based primarily on observations of the epidermis in the young specimens of *Crotalus adamanteus* already referred to. The detached button consists exclusively of a stratum corneum (horny layer) and constitutes the first unit of the rattle (figs. 69, 71, and 72). It is fully keratinized with variable amounts of pigment granules deposited within the horny substance. The latter has a natural orange-yellow color and is refractory to acid or basic stains (eosin and hematoxylin). With the exception of the pigment granules in it, the button is virtually an anucleated homogeneous layer. Traces of degenerated nuclei of once living cells are found infrequently. In the thickened and reverted proximal margin of the button there usually are a number of eosinophile granulocytes that migrated into the outer stratum corneum before its detachment, and died there.

The process of keratinization is of special interest. In the epidermis of the end-body one recognizes a deeply staining basal layer (stratum basale) of columnar or cuboidal cells. It is the germinative layer (stratum germinativum) from which all other epithelial cells are derived. In young specimens of *Crotalus* the basal layer of the end-body is overlain by six to ten layers of polygonal or slightly squamous cells, which may be referred to as a stratum spinosum. Together, the stratum basale and the stratum spinosum constitute the stratum profundum. There is no trace of keratinization in this layer. In figure 72, A and B, however, a new generation of a stratum corneum covers the very tip of the distal lobe of the end-body. No such layer is present over the proximal lobe or over proximal portions of the distal lobe. Therefore, the process of keratinization does not occur simultaneously in the outer layer of the entire epidermis covering the end-body but progresses from its tip to the sulcus. There exists a narrow zone of epidermis in which an intensely staining stratum granulosum can be identified (fig. 73). In the specimen portrayed it lies around the middle of the distal lobe and shows an abrupt transition into the yellow, fully keratinized stratum corneum of the new generation. The deeply staining granules of keratohyalin, characteristic of the stratum granulosum, apparently are transformed into eleidin abruptly and in this narrow zone only, which gradually extends proximad over the end-body. Evidently there is a gradient in the progress of keratinization. The transition between keratohyalin and eleidin strikingly resembles that in the nail bed of a human fetal finger. Our selected material supplies no evidence for the rate of progress of the keratinization from the tip to the base of a newly forming horny segment.

Keratinization begins over the distal tip of the future three-lobed end-body before a new basal lobe becomes established. During the development of later segments, keratinization of the new stratum corneum occurs in the final phase of the resorptive process, which immediately follows formation of a new basal lobe.

The difference in these events becomes clear when one considers that within the two-lobed button the distal lobe of the end-body is not being resorbed to a considerable degree. If it were, there could not result a three-lobed end-body by the addition of a new basal lobe. The end-body within the button, therefore, remains essentially two-lobed and keratinization of its new stratum corneum can begin before new growth is under way in the terminal sulcus.

An additional feature is characteristic of this zone of keratinization. Only a narrow cell layer immediately above the stratum profundum differentiates into a stratum granulosum. The cell layers above the latter quickly acquire entirely different characteristics. They fail to accumulate keratohyalin granules but rapidly show pronounced vacuolization. These outer layers in the thickened band of cell proliferation become the stratum intermedium. It is the outermost of the new generation of epidermal layers and provides the zone of detachment of the old stratum corneum from the living epidermis. Distal to the band of keratinization the stratum intermedium suffers such extensive vacuolization that its original epithelial nature is virtually erased.

Here then, is an outer zone in the epidermal epithelium that shows no trace of keratinization. It becomes detached from the underlying stratum granulosum. In snakes with only a button it expands into a spongy mass of spherical cells. This peculiar tissue approximately fills the space between the old horny layer and the newly forming one. In distal, older portions of the vacuolated stratum intermedium many cell boundaries are lost. Through coalescence of cell spaces larger "vacuoles" are formed (see fig. 72, B). Further degeneration of the stratum intermedium reduces it to mere strands of former cell walls with still larger spaces between them. Pycnotic nuclei are numerous in the older portions. This tissue, shown macroscopically (fig. 71, D), is little more than a temporary "filler" between the horny button and the new generation of a stratum corneum covering the end-body. In preparations obtained by standard histological techniques the vacuoles of such a tissue appear empty and the tissue looks much like a foam. It is more likely, however, that the vacuoles were fluid-filled before dehydration with alcohols. Probably this is the jelly-like tissue noticed by Klauber. Eventually it disappears, presumably by desiccation.

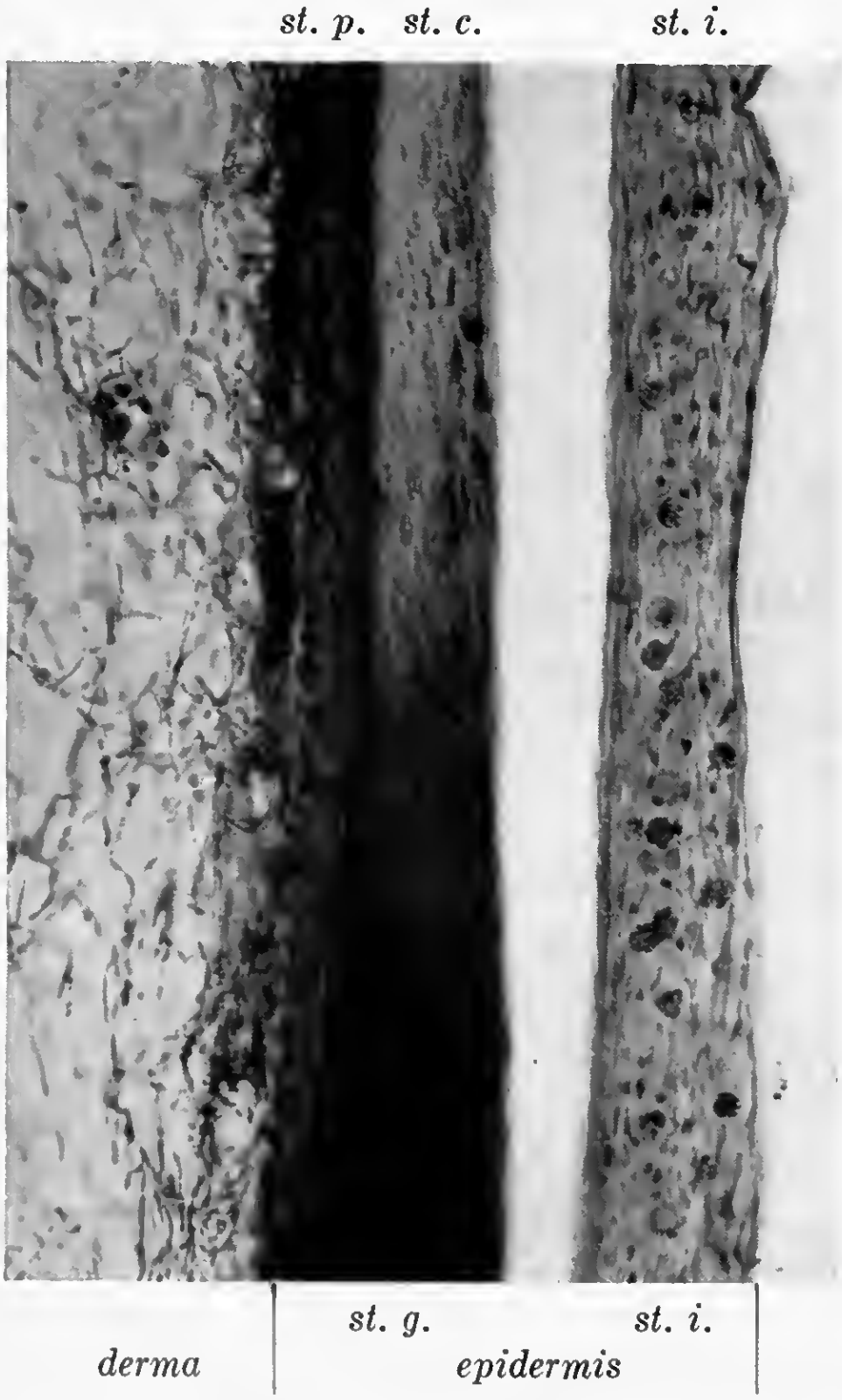

FIG. 73. Photomicrograph of the epidermis and the derma of a young Florida diamondback (*Crotalus adamanteus*) in the area marked by an asterisk (*) in figure 72, A.

This illustration shows the transition from stratum granulosum (*st. g.*) to stratum corneum (*st. c.*) of the newly forming horny segment. The stratum intermedium (*st. i.*) contains numerous granulocytes; *st. p.* is the stratum profundum of the epidermis.

In the process of degeneration the stratum intermedium suffers an invasion of numerous leucocytes. These cells are eosinophile granulocytes, the white cells in the blood of reptiles. They invade the connective tissue of the end-body directly from their site of origin in the bone marrow of the style. These round or ovoid cells are two or three times the size of nucleated erythrocytes in the same species. Their nuclei usually are eccentric and the cytoplasm contains refractile eosinophile granules.

Figure 73 is a photomicrograph of the dermal and epidermal layers in the zone of keratinization. A number of eosinophile granulocytes are seen in the stratum intermedium of the epidermis. Unquestionably, they are functionally related to the rapid degeneration of that layer. Their possible role will be referred to below.

The caudalmost extension of the vertebral column into the end-body is clearly illustrated (fig. 72, A and B). The last articulated vertebra reaches a plane passing through the sulcus. Distal to that plane the successive elements of the caudal vertebral column are fused to form the style. The segmental origin of the style is still discernible through paired lateral projections and through the segmental arrangement of the caudalmost nerves that appear from within the style. In young specimens of *Crotalus* the style extends nearly to the tip of the end-body. Its caudalmost portion consists mainly of longitudinal trabeculae.

The style in these young specimens is not a dense bony mass, but, as already indicated, contains marrow spaces. Connective tissue lies between the delicate spicules or trabeculae of the distal part of the style; ossification begins proximally. The development of the style was described in a preceding section.

The caudalmost extension of the spinal cord (figs. 71, B–D, and 72, A) reaches into the distal lobe of the end-body, lying within the larger portion of the style. The meningeal investments, particularly a layer of connective tissue that corresponds to the mammalian dura mater, extend farther caudad than the spinal cord. A conspicuous fibrous strand in the nature of a dural filum reaches the tip of the end-body. This midsagittal region of the end-body shows the interesting histological features of osteoclastic activity considered below.

### Phenomena of Degeneration and of Resorption

The earliest signs of tissue degeneration and of resorption appear in the end-body of the specimens of *Crotalus adamanteus* not more than a few months old.

The degenerative changes in the epidermis concern the stratum intermedium, which comes to lie between the old and new generations of the stratum corneum. The invasion of this layer by a great number of eosinophile granulocytes was previously indicated (fig. 73). The presence of such conspicuous cells of non-epithelial origin within an obviously degenerating layer of the epidermis deserves further consideration. The relatively large leucocytes apparently remain alive for a considerable time after infiltrating this epidermal layer. The fact that their cytoplasm and nuclei retain their stainability even in the caudalmost portions of the vacuolated stratum intermedium is good evidence of such viability.

What is the function of these cells in the process of ecdysis? This study cannot give direct proof for a specific function but it supplies circumstantial evidence that eosinophile granulocytes are concerned with degenerative processes within the stratum intermedium. The functions of eosinophile granulocytes in reptiles might well be the same as in man and mammals. Eosinophile leucocytes in the stratum intermedium, therefore, may be concerned with the elaboration of proteolytic enzymes (Naegeli, 1923). Hence, we believe that the jelly-like vacuolated nature of the degenerating stratum intermedium is the result of protein-dissolving properties of the invading eosinophile leucocytes.

The distribution of numerous eosinophile granulocytes is by no means limited to the stratum intermedium over the distal lobe of the end-body. These leucocytes are equally numerous and presumably equally important in the delamination processes that occur in the epithelium of the sulcus at the time of formation of a new proximal lobe. They are likewise encountered in the derma, in the epidermis, and even in the detaching molt at the caudalmost intersquamal folds.

It would appear, therefore, that the dehiscence between two layers of the stratified squamous epithelium does not occur simply by a progressive hornification of the outermost cell-layers or by simple physical factors such as drying and subsequent delamination. The timing in the events leading to the development of such a relatively intricate structure as the keratinized rattle evidently is prepared and controlled by special histological events. The appearance of large numbers of eosinophile granulocytes in zones of intraepithelial delamination undoubtedly constitutes one such controlling factor.

An explanation seems necessary for the spatial relationship between the horny button and the epithelium over the proximal lobe of the end-body, as portrayed (fig. 72, A and B). It was pointed out above that no stratum intermedium exists between these two layers in the region concerned. Yet in the figures the stratum corneum of the button is detached from the proximal lobe. We believe this to be an artifact, due probably to some degree of shrinkage of the end-body.

In vertebrates, the eosinophile granulocytes are derived from the myeloid tissue in the marrow spaces of the skeleton. The marrow of the style and of the articulated vertebrae contains, indeed, large numbers of eosinophile myelocytes. In reptiles, as in birds, granulopoiesis and erythropoiesis are distinct from each other within the myeloid tissue. Granulopoiesis, that is, the development of granular leucocytes from myelocytes, occurs outside the bloodvessels in the marrow, whereas the erythrocytes arise by an intravascular process of cell proliferation. Figure 74 illustrates the characteristic type of eosinophile myelocyte that constitutes the ancestral cell-forms of eosinophile granulocytes. The cells portrayed are ovoid or polygonal and have a slightly basophile cytoplasm. The nucleus usually is excentrically located; it stains a dull blue and has no nucleolus but contains a few indistinct chromatin granules. It is larger but less dense than the nucleus of erythrocytes. The cytoplasm contains relatively coarse eosinophile granules that usually are accumulated in a limited area of the cell. In the fully developed and migrated eosinophile leucocyte, these granules occupy the entire cytoplasm.

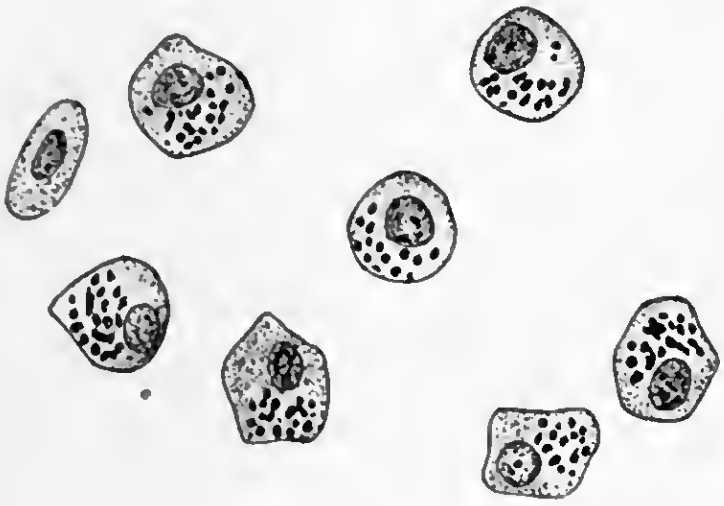

FIG. 74. Eosinophile myelocytes of the bone marrow in the style and vertebrae of a young Florida diamond-back (*Crotalus adamanteus*).

The diameter of the eosinophile myelocytes varies from 10 to 12 microns. Because of their round or polygonal shape they appear considerably larger than the highly ellipsoid erythrocytes, although the latter's longitudinal diameter measures about 10 or 11 microns.

Bone resorption occurs within the tip of the end-body distal to the termination of the spinal cord. High power observation of the mid-axis of connective tissue revealed the presence of osteoclasts. The length of the distal lobe of the end-body shown in figure 72 measured 4 mm., the caudalmost tip devoid of trabeculae only 2 mm. Within this terminal zone, bone resorption extends through 1,200 microns. Here lie the meningeal filum and the last branches of the caudal artery and vein. A high power field of this area is shown in figure 75, A, originally drawn by camera lucida at a magnification of 600 times. A number of multinucleated giant cells, readily identified as osteoclasts, lie in a group, interspersed in the axial connective tissue between the caudalmost bloodvessels. In some sections as many as twenty-two osteoclasts were counted within a length of 1.2 mm. of caudal tissue.

The shape and size of these giant cells vary greatly, in part because in any section mere fragments of the voluminous cell-bodies may be encountered. Some of the cells measure 40–50 by 20 microns. A whole cell or a fragment naturally shows a variable number of nuclei, but from eight to ten nuclei were frequently observed. The nuclei, characteristically, appear empty, vesicular, with a single nucleolus. The cytoplasm of these osteoclasts is non-granular and stains slightly purple with ordinary H and E stain. The cells are stellate, their margins provided with processes that may be of considerable length. These osteoclasts are strikingly like those of mammals and man. Some osteoclasts are shown at a larger scale (fig. 75, B) and in association with an isolated bony trabecula.

It is evident that a degree of bone resorption occurs at the distal end of the young style and is part of the final shaping that involves loss of its attenuated tip. This process of regression precedes the development of a new proximal lobe. No comparable bone resorption takes place during the formation of subsequent segments. Furthermore, the sequence of events here is the reverse of that observed in x-ray exposures of the growing adult rattle. There, resorption of the distal lobe follows accretion, as a temporary four-lobed end-body becomes reduced to a three-lobed structure. In contrast, the main event in the establishment of the very first three-lobed segment consists in the addition of a third lobe to the slightly reduced two-lobed end-body within the button.

It is evident (see fig. 72, A and B) that the end-body became reduced in size after the button had been formed over it. Even if a small degree of shrinkage is accepted as an artifact there remains a considerable space between the distal lobe and the tip of the button. The distal lobe previously was the direct mold for the button. Therefore, some regression must have taken place. This may have been due partly to a resorption of tissue fluids, which might explain the

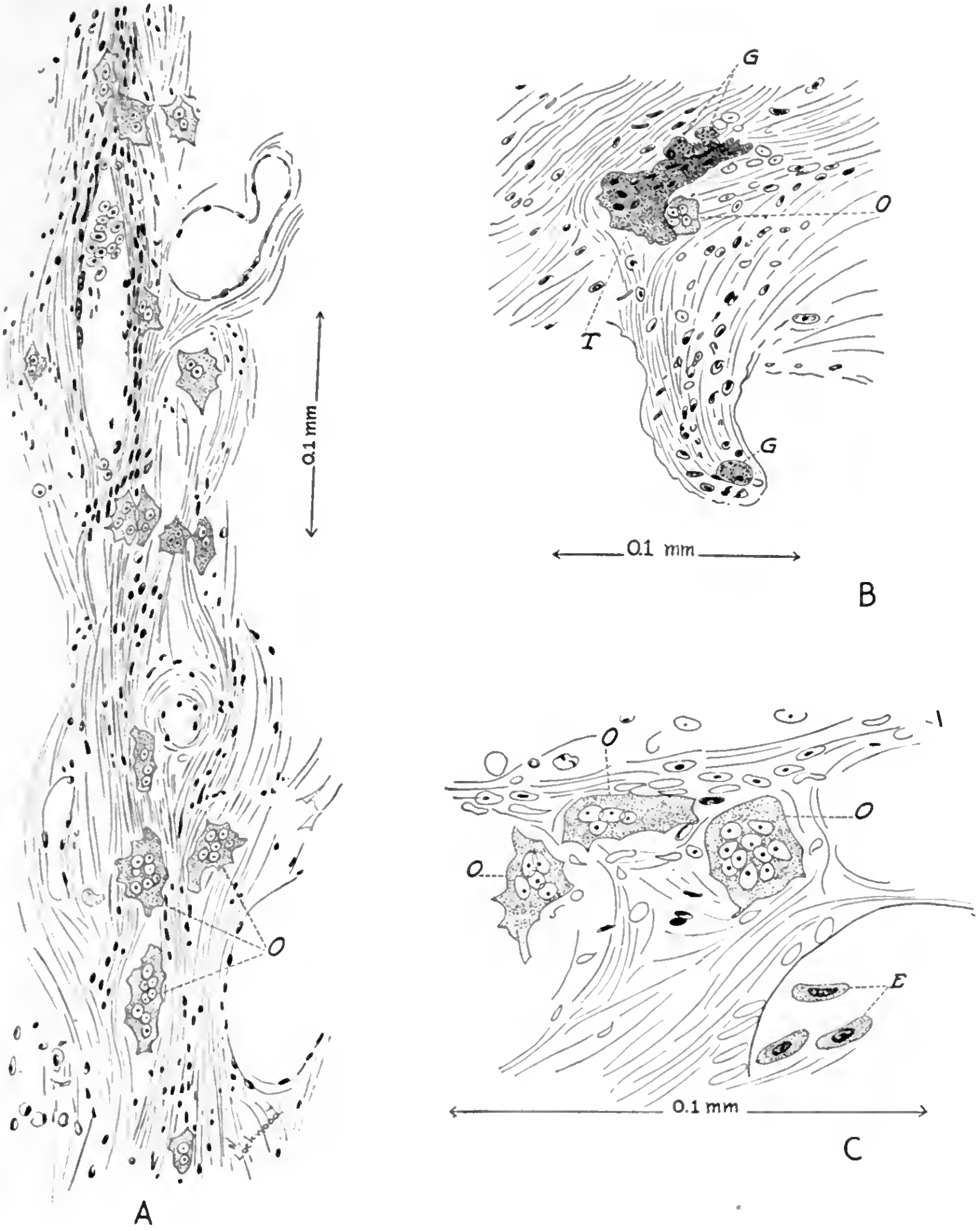

FIG. 75. Osteoclasts (*O*) or multinucleated giant cells within the end-body of a Florida diamond-back (*Crotalus adamanteus*): A, in the long axis of the distal lobe, just beyond the terminal tip of the style; B, a single osteoclast (*O*) and several granulocytes (*G*) adjacent to the bony trabecula of the style; C, three osteoclasts (*O*) and, for comparison, three erythrocytes (*E*) situated near a resorbed bone spicule.

denser aspect of the connective tissue of the distal lobe as compared with that in the proximal one.

Reduction of the underlying connective tissue in all probability precedes bone resorption and is the earliest sign in the chain of events that lead to the reduction in size of the living core within the button. The essential phenomena are: (1) reduction of the connective tissue in the distal lobe beneath the keratinized button; (2) bone resorption in the tip of the style; (3) degeneration of the stratum intermedium between the old and the new generations of the stratum corneum.

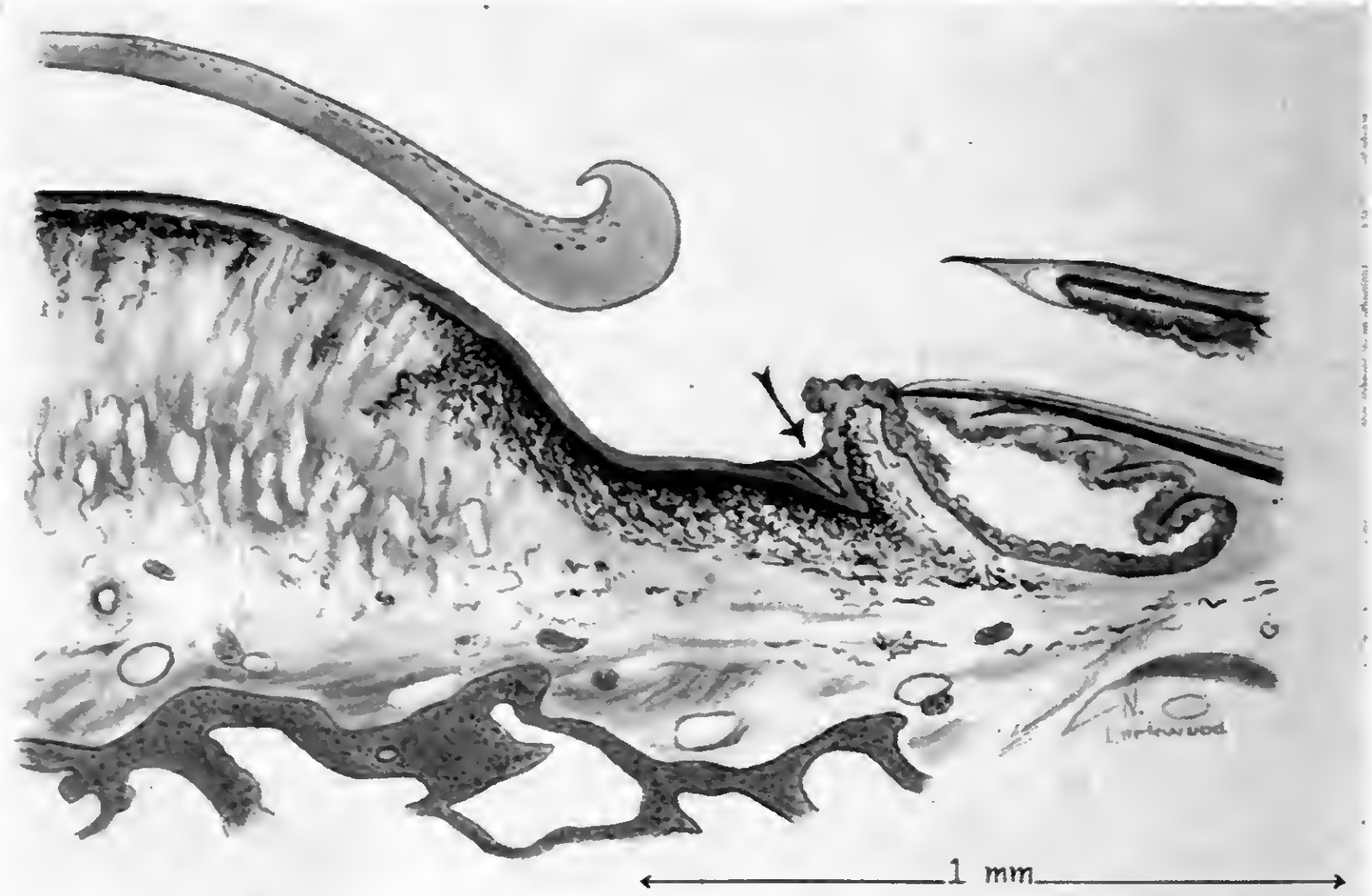

Fig. 76. Histological details in the sulcus of the section shown in figure 72, A. The thickened proximal margin of the button overlies the sulcus. The arrow marks the beginning of an epithelial invagination, earliest sign of a newly developing basal lobe.

### Phenomena of Accretion

We have already shown that the first three-lobed end-body is formed by the addition of a new proximal lobe, and that growth succeeds resorption in the distal portions of the young end-body within the button. Figures 69, B, and 72, A, show distal resorption under way when no noticeable accretion is evident in the sulcus. Soon, however, relatively rapid growth processes do take place in the sulcus. The general morphologic aspects were described in a previous chapter and illustrated by figures 69 and 71. It should be emphasized that most active growth of this region occurs in the pre-molting stage and that the newly forming proximal lobe remains hidden beneath the caudalmost portion of the molt. The molt is engaged in the sulcus by its constricted end, which fits the sulcus like a collar.

Histologically, the earliest and most important features of accretion occur in the epidermis. The basic process is a simple epithelial invagination in the sulcus beneath the proximal border of the button. When a new lobe begins to develop, the ingrowing epithelial lamina extends obliquely forward (see fig. 76, an enlargement of the area indicated by an arrow in fig. 72, A). The thickened and reverted margin of the horny button is seen to overlie the sulcus, the width of which measures approximately 300 microns. The arrow (fig. 76) marks the beginning of an epithelial invagination. The ingrowing lamina lies adjacent to the last subsquamal fold. The overlying tips of the last scales may be noted farther proximad.

The epidermis lining the sulcus is a relatively thin, deeply staining squamous stratified epithelium. It consists essentially of the stratum profundum. Unquestionably the deepest layer is in an active period of proliferation, although the dense accumulation of pigment cells prevented the detection of mitotic figures. The chromatophores represent a characteristic feature of the growth zone in the sulcus; they form here the darkest area in the derma and crowd directly against the deepest cell layer of the epidermis.

Our sections of young end-bodies further show that differentiation and growth on the ventral side of the sulcus precedes that on the dorsal. We observed repeatedly that the epithelial lamina separating a newly forming third lobe from the last scales was present on the ventral side, whereas dorsally the second lobe was still growing by expansion. This difference obviously is the cause for the dorsoventral asymmetry of the end-body and of the rattle as a whole.

The histological features of the developing basal lobe in further advanced stages are illustrated in young specimens of the timber rattlesnake (*Crotalus horridus;* figs. 77 and 78), which measured, respectively, 366 and 373 mm. in total length. At the time of death the cornea of the smaller one was clear, that of the larger slightly milky. The histological findings confirm the fact established long ago by reptile keepers, that clouding of the cornea precedes molting.

The newly forming basal lobe is the result of two growth processes (see fig. 77): the invagination of the epithelial lamina directly caudal to the last scales, and the vigorous expansion of the fibrous connective tissue immediately distal to that lamina. The former process prepares a new surface epithelium beneath which the growing connective tissue produces the bulging new lobe. Characteristically, the expanding connective tissue is rich in chromatophores that crowd beneath the basal layer of the covering epithelium. In the younger stage (fig. 77) the total width of the base of the newly forming lobe is 0.9 mm. and its height approximately 0.6 mm.

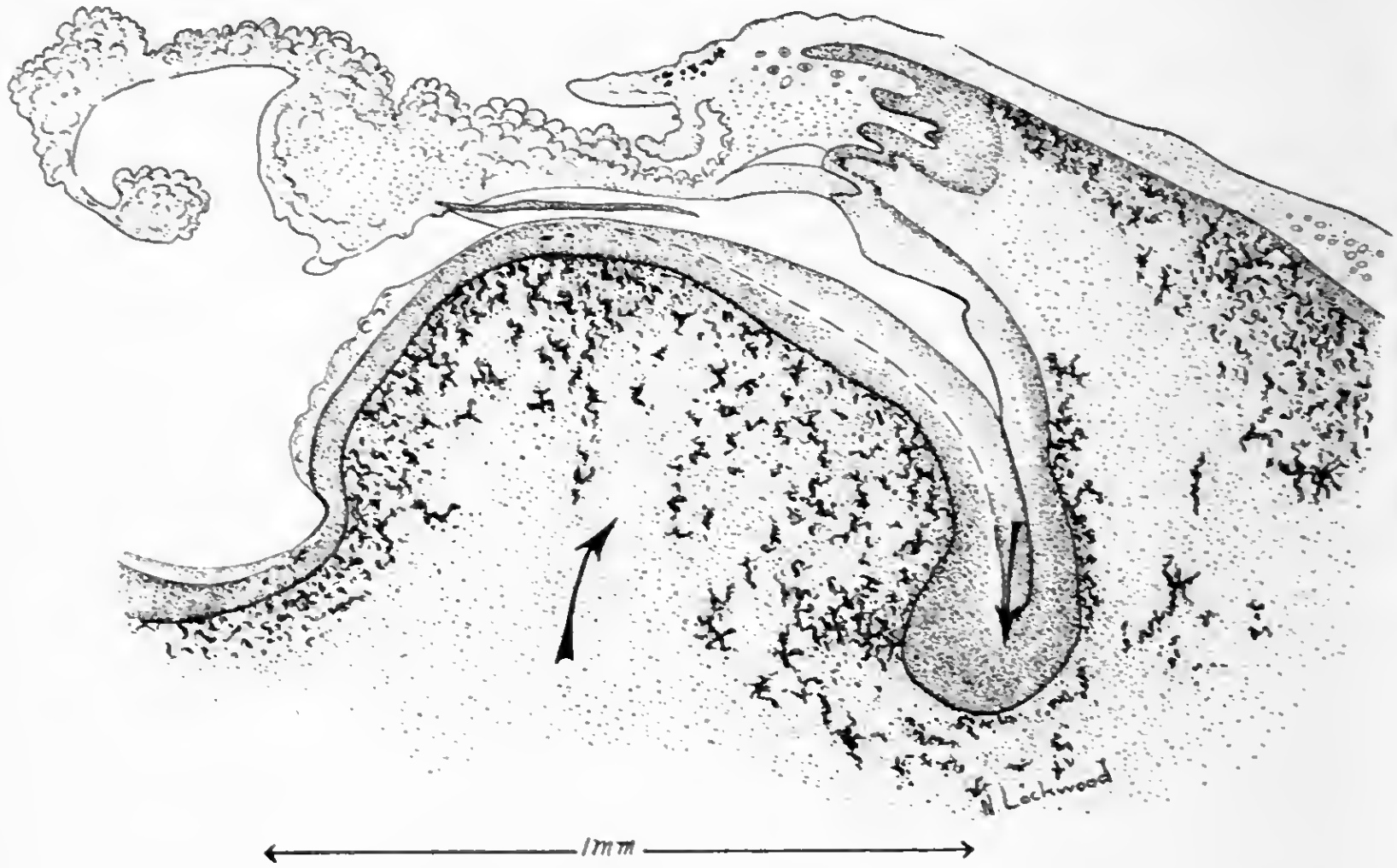

FIG. 77. Cross section of a newly forming basal lobe in a young timber rattlesnake (*Crotalus h. horridus*). The opposite directions of the invaginating epithelial lamina and of the bulging connective tissue of the new lobe are indicated by arrows. The expanding lobe is rich in chromatophores.

The epithelial ingrowth is bulbous at its deepest point, where proliferation appears to be most active. This point lies close to the caudal insertion of the dorsal musculature on the base of the style.

A clear delamination within this epithelial ingrowth has not occurred at this early stage but signs of that process are unmistakable. The epithelium covering the young lobe is relatively thick (about 100 microns) and consists mainly of a stratum profundum. Its layers stain intensely blue with hematoxylin. The outer layer of this young epidermis stains lightly with eosin, and includes many cells of the squamous type. Chromatophores and eosinophile granulocytes, two interesting cell types foreign to the epidermis proper, begin to migrate into the multilayered epithelium.

Eosinophile granulocytes invade the epidermis from the subjacent connective tissue, where they can be observed in groups. Their presence further confirms our opinion that delamination within the epidermis, which here must occur in order to establish a lumen of the newly forming sulcus, is not merely a physical process of fissuration between cell layers, but is initiated by the highly probable proteolytic action of these leucocytes.

The newly forming lobe is covered by the terminal portions of the future molt, which is also invaded by numerous eosinophile leucocytes that penetrate it in groups from the derma of the subsquamal folds. Leucocytic activity appears definitely related to the process of ecdysis.

At a more advanced stage in the development of a new lobe (fig. 78) the epithelial lamina separating the future basal lobe from the last scales had grown deeper and, correspondingly, the developing lobe had attained greater height (1.5 mm.). The base of the lobe is still relatively narrow (1.2 mm.). Individual variability may account for the differences in the shape of the new lobe of the specimens illustrated and described. Pigmentation of the dermic portions of the lobe is heavy. In the epithelial lamina a stratum granulosum represents the preparatory stage of keratinization. As compared with the conditions described for the smaller specimen (fig. 77), the leucocytes here are more numerous in the connective tissue adjacent to the invaginating lamina. They are likewise aggregated in clusters. Some of these granulocytes had penetrated the stratum germinativum of the epidermal ingrowth. They are also invading the future molt from the connective tissue of the subsquamal folds on the under surface of the last scales.

Very few leucocytes are present within the growing basal lobe itself. This is well supplied with bloodvessels that radiate toward the periphery, and some of the arterioles are accompanied by small nerves. These vessels and nerves are terminal branches emerging from the interior of the style.

Longitudinal sections of the specimen in the later pre-molting stage show interesting differences in the distribution of leucocytes through the distal and middle lobes. Resorption in the style and in the connective tissue of the soft parts had preceded the formation of a new lobe. On the ventral side of the end-body the connective tissue of the distal and middle lobes is rich in intercellular fluid (edema). The small bloodvessels stain poorly and some appear ruptured. Associated with these apparently degenerating vessels one again finds groups of eosinophile granulocytes.

On the dorsal side, in contrast, where growth changes lag, the connective tissue is dense, with few signs of an edematous condition. This is particularly apparent in the middle lobe. Here, the connective tissue contains large numbers of leucocytes that apparently have not begun their proteolytic activity.

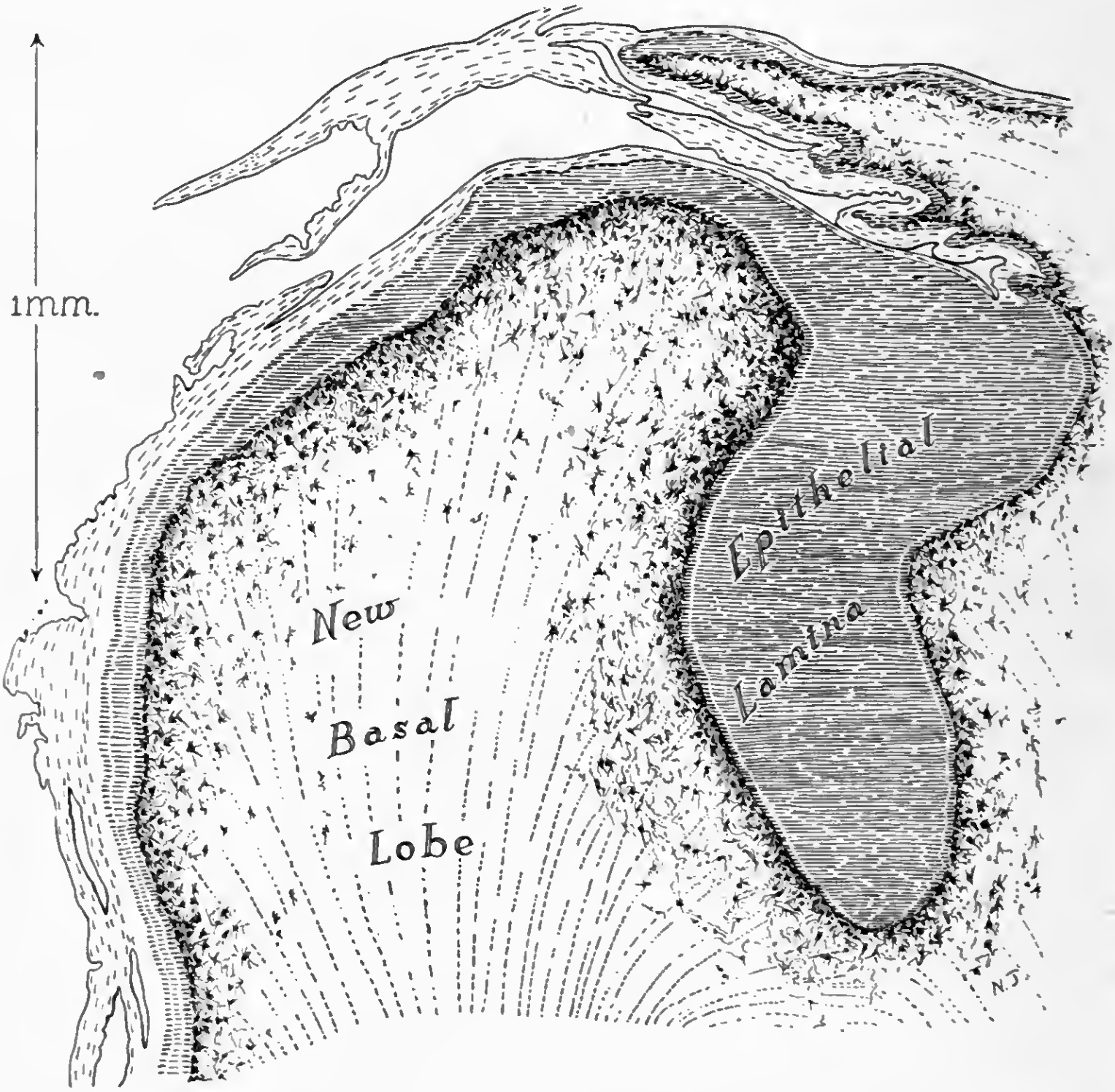

Fig. 78. Cross section of a farther advanced basal lobe of a young timber rattlesnake (*Crotalus h. horridus*). The epithelial lamina of the sulcus is deeper but still solid; delamination occurs later. The new basal lobe is richly vascular. Chromatophores form a dense layer directly beneath the stratum germinativum.

The absence of leucocytes in a newly growing lobe, their scarcity in the ventral portions of the end-body that have already degenerated to an edematous condition, and, finally, their predominance in the dorsal regions that subsequently undergo similar degenerative changes, make it highly probable that eosinophile leucocytes are concerned with such atrophic changes. Most likely their activity in producing a proteolytic enzyme leads to a partial hydration of a previously dense and tough fibrous end-body.

A thick stratum granulosum is present in any portion of the epidermis where hornification soon follows. In unstained sections that layer appears opaque and white; it stains deep blue, indicating probably an acid condition of the cells that contain keratohyalin granules.

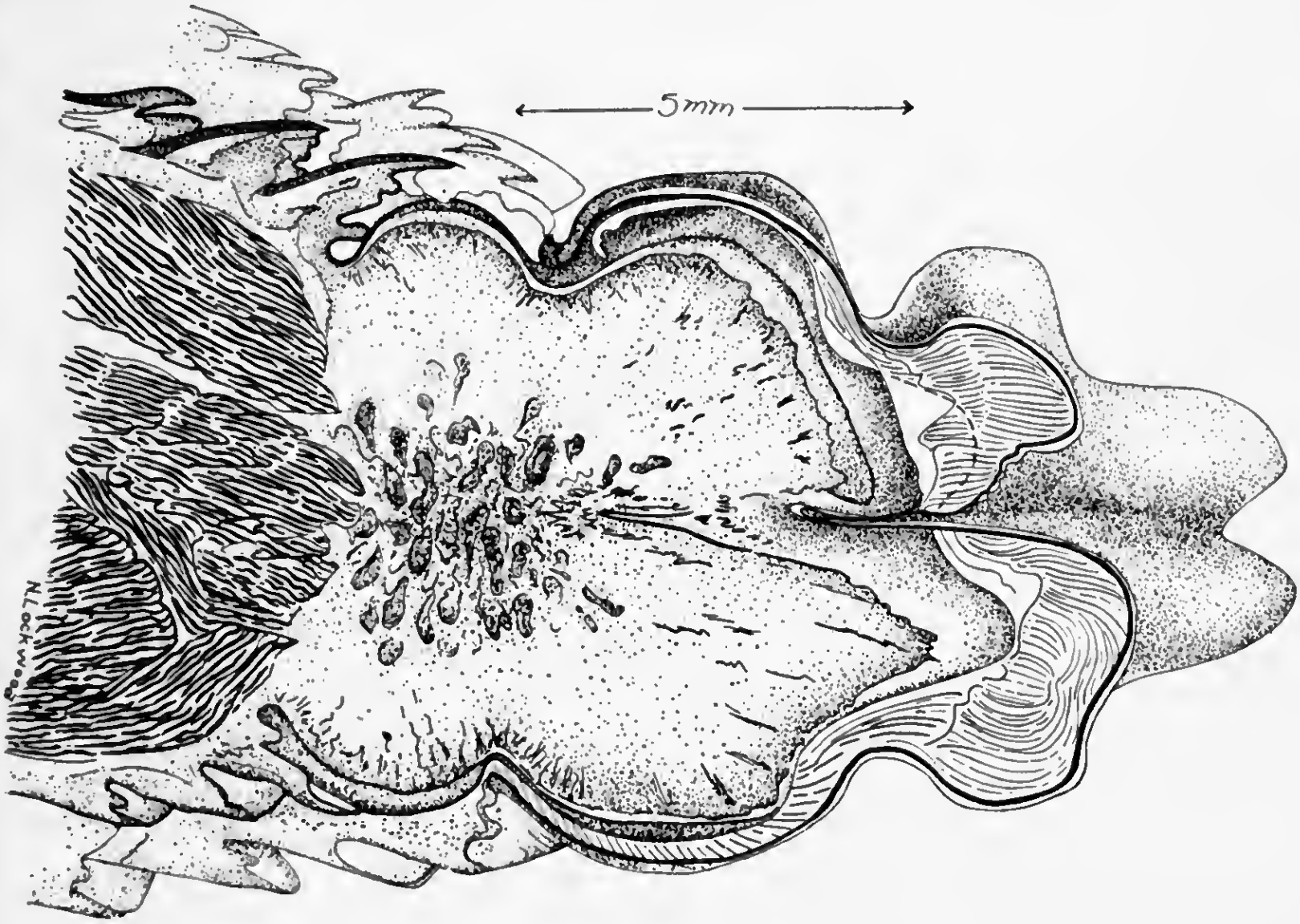

FIG. 79. Parasagittal, longitudinal section of the tail of an adult massasauga (*Sistrurus c. catenatus*). The snake was in the late accretion period and the molt still covers the newly formed basal lobe. The space between the last formed horny segment of the rattle and the end-body was filled with a spongy stratum intermedium.

## GROWTH OF THE RATTLE IN THE MASSASAUGA

In order to compare growth of the rattle in *Crotalus* with growth in the other genus of rattlesnakes we studied the end-body in *Sistrurus catenatus*. Our comparative study of histological sections failed to reveal any basic differences in mode of rattle formation. The foregoing description of histological features in *Crotalus*, therefore, holds in the main for *Sistrurus*.

Figure 79 shows the morphological aspects, in parasagittal longitudinal section, of the tail end of an adult *Sistrurus* from which the free elements of the rattle had been removed. The snake had a total length of 685 mm. When the animal was killed the corneae were clear and the skin was peeling. The figure reveals a new basal lobe largely established. It is covered by the molt still attached to the proximal margin of the last-formed segment. At the time of fixation a new generation of stratum corneum had already been formed as the outermost layer of the epidermis covering the end-body. The interval between the two generations of stratum corneum was filled with a spongy stratum intermedium. The specimen, therefore, was definitely in the late accretion phase.

The following histological features were observed in sections of the same material: (1) Some degree of osteolysis on the trabeculae of the style is evident. This affects the periphery of the main portion of the style rather than the tips. The free ends of such trabeculae appear to lose their affinity for stains, probably through demineralization of the ossein. Eosinophile granulocytes and osteoclasts were observed in the adjacent tissues. Such bone resorption is relatively insignificant in comparison with that seen in very young specimens of *Crotalus* and described in the preceding section. That the style as a whole is not appreciably affected by resorption in adult specimens is further proved by our x-ray findings on the live *Crotalus atrox;* (2) the connective tissue of the distal lobe, and to a lesser extent of the middle lobe of the end-body, was edematous and infiltrated by numerous leucocytes, which had also invaded the vacuolated stratum intermedium; (3) the dominant cellular elements in the bone marrow of the caudalmost vertebrae and in the style were eosinophile myelocytes, the precursors of the eosinophile leucocytes; (4) the deepest layers of the epidermis over the end-body were being invaded by the pigmented processes of numerous chromatophores from the subjacent derma. As there was no stratum granulosum, keratinization of a new stratum corneum evidently had not begun.

Two younger specimens of *Sistrurus catenatus* were likewise studied histologically. One was in the latent stage. The other was in the pre-molting or accretion phase, showing a thick stratum granulosum as a characteristic feature of the epidermis during this period, which comes late in the cycle.

A representative section of this end-body in the latent stage (see fig. 80, A) is slightly parasagittal and does not reveal the caudalmost extension of the spinal cord. (In other sections of the same specimen the spinal cord terminates well within the style just distal to the groove between the proximal and middle lobes.) The trabeculated

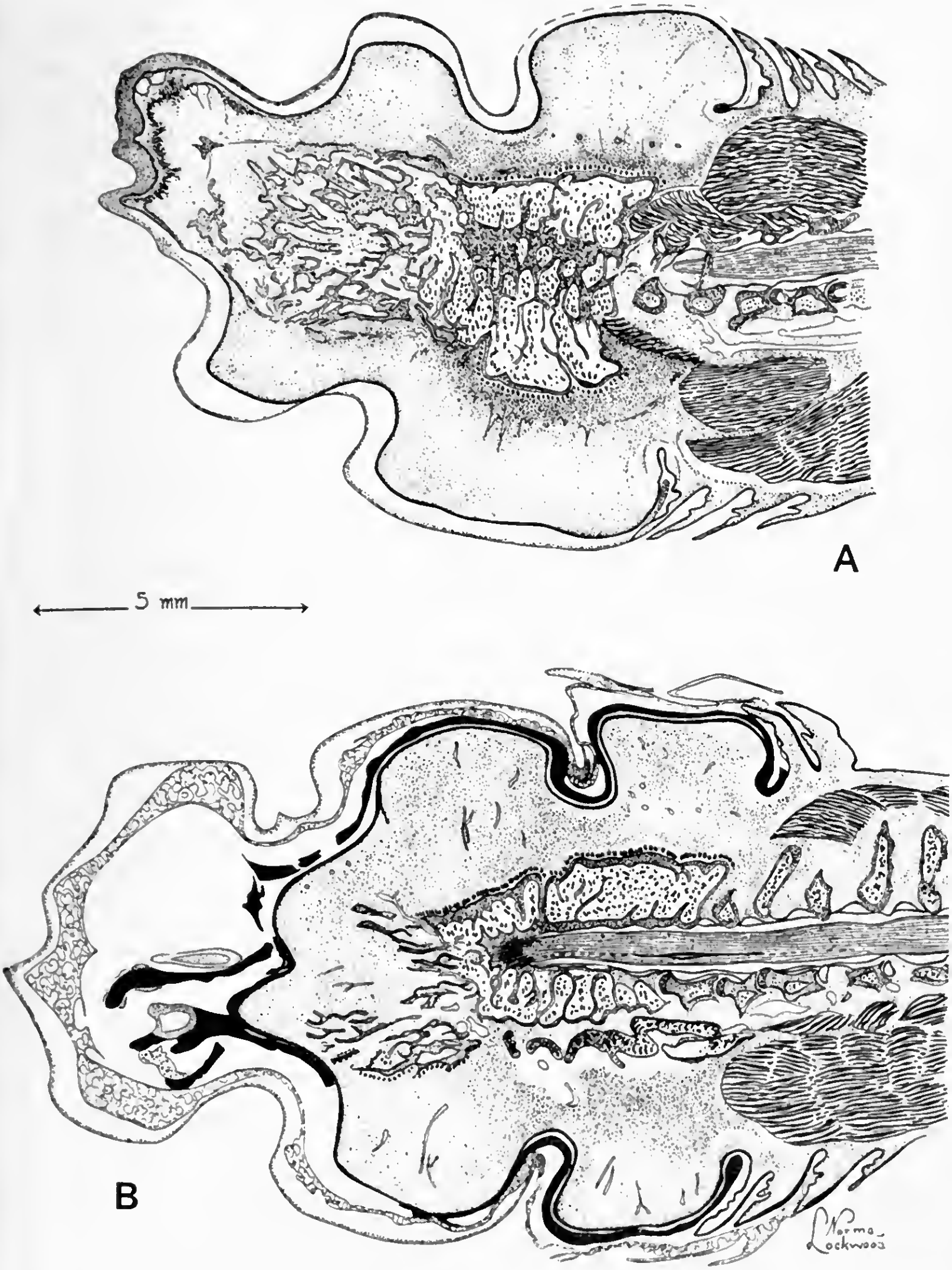

FIG. 80. Representative longitudinal sections of the end-body of two massasaugas (*Sistrurus c. catenatus*): A, in the latent period; B, in the accretion phase. In A the stratum corneum is seen as the outer layer of the relatively thin epidermis of the end-body. (Its partial detachment is an artifact.) In B the epidermis has thickened. Its characteristics are a well-developed stratum granulosum (heavy black layer) and a degenerating stratum intermedium. The stratum granulosum becomes the immediate mold for the new horny segment.

nature of the style and its marrow spaces, the caudal termination of the muscular masses, and the relative position of the last articulated vertebra with respect to the sulcus are indicated in the figure. The detachment of the stratum corneum obviously is an artifact, due most likely to shrinkage of the soft parts in the end-body during preparation. An epithelial ingrowth at the sulcus may be noticed. It is undercutting the basal lobe and provides the earliest indication of the future widening of the sulcus.

There is evidence of bone growth on the periphery of the proximal portion of the style. This osseous framework of the end-body naturally will increase in size with the rapid growth of the snake. In the section, a fairly continuous single row of osteoblasts lies adjacent to the margins of the style. In the distal portions bone growth is much less marked.

Figure 80, B, shows a midsagittal section through the end-body of the specimen in the pre-molting stage. The caudal termination of the spinal cord within the style and the course of the caudal artery adjacent to its ventral surface are evident. The formation of a new basal lobe was well under way at the time of fixation. In section, the lobe measures 3 mm. in width on the ventral side. Osteogenetic processes are identified by numerous osteoblasts that line the dorsal margin of the style in an almost continuous layer. Similar growth is noticeable also along the trabeculae in the distal portions of the style. Appositional bone growth, therefore, appears fairly active in the late accretion period.

In the pre-molting stage the stratum intermedium between the old stratum corneum and the newly formed thick stratum granulosum shows advanced degeneration by its highly vacuolar condition. Eosinophile leucocytes within that layer have largely disappeared. Near the sulcus and in the attached molt they are still numerous and stain well. The connective tissue stroma of the soft parts in the end-body shows no evidence of edema nor are there any signs of pronounced infiltration by eosinophile leucocytes.

The most striking histological feature of the pre-molting stage is the thick stratum granulosum of the epidermis. In the section illustrated (fig. 80, B) this layer had been broken by fixation. During the pre-molting phase the epidermis always is markedly thickened over the end-body and appears white before embedding. Its stratum granulosum is the immediate mold for the new horny layer of the rattle segment, which differentiates during the final phase of the active period. In the section shown, there is no sign of that final keratinizing process. If it preceded the maturation of the new basal lobe, the new horny segment would prematurely imprison the connective tissue of the end-body and successive rattle segments, necessarily, would become smaller.

## SUMMARY

The development and growth of the rattle of the rattlesnake has never before been adequately investigated. Having abundant material and modern histological and x-ray technique at our disposal, we have undertaken such an investigation.

Although the gross anatomy of the functional rattle had been described by Klauber and others, we have illustrated a young, tapering rattle and an old non-tapering one to show exactly how the segments, each with three lobes, are interlocked, and to point out certain differences due to age. After the relationship of one horny segment to another is understood, the functional part of the rattle may be disregarded and attention focused on the living tip of the tail where actual development and growth take place. This tip, the end-body, consists of (1) a bony core formed largely by the coalescence of several terminal vertebrae and known as the style or shaker; (2) fibrous connective tissue; (3) epidermis. The shape of the end-body is like that of a segment. The end-body forms and molds the successive segments, which become detached from it synchronously with the sloughing of the molt, an event that takes place from two to four times a year.

If the end-body as the living mold of each segment remained constant in shape and in its relationship to the last-formed segment, the successive units of the rattle obviously would be arranged one inside the other. The horny segments are not nested but extend in a linear series, the two proximal lobes of one capping the two distal lobes of the next younger. The manner by which the segments assume this special alignment had never been fully explained. Just how does the basal lobe of each segment come to be exposed? It is obvious that a shift of some sort takes place during the formation of each segment.

This shift occurs as follows: First, a fourth lobe is temporarily added to the end-body. This new element is formed just proximal to the third or basal lobe. This growth dislocates caudad the last horny segment and all preceding ones a distance equal to the length of the new lobe. Second, the four-lobed condition of the end-body

is suddenly reduced by resorption mainly of the distal lobe. This re-establishes a three-lobed end-body but leaves behind the just-detached stratum corneum, which itself becomes the latest segment of the rattle. Thus there is growth at the base of the end-body followed by reduction of its tip. The sequence of the histological phenomena is the key to the problem. The caudad dislocation of a single functional segment and thereby of the whole rattle is fully accounted for without invoking wave-action in soft tissues, slipping of one horny segment partly off another, or any of the fanciful theories that have been advanced.

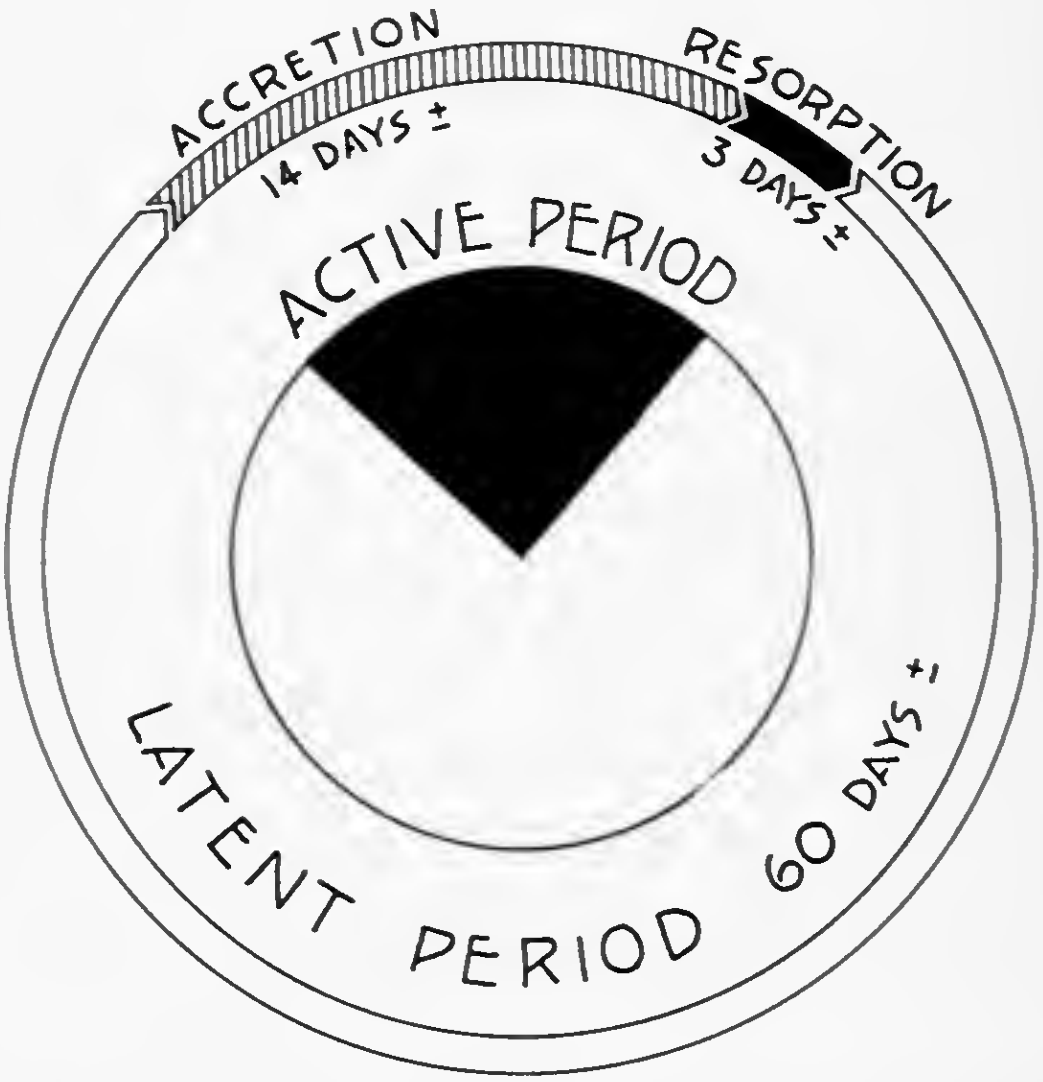

FIG. 81. Diagram of the molting cycle of a Texas diamond-back (*Crotalus atrox*) illustrating the relative duration of latent and active periods. Within the period of resorption the molt is cast and a new segment is added to the rattle.

There is a modicum of truth in the statement of early herpetologists that the segment of a rattle is nothing but a little of the molt left on the end of the tail. That out-moded statement is useful only in emphasizing the relation between the molt and a new rattle segment: As the molt is released from the body as a whole the newly keratinized segment being added to the functional rattle is released from the end-body. The intimate relationship between molting and segment formation is thus evident. In the newly forming rattle segment the epidermal layers, which are truly homologous to the molt, consist of the stratum corneum, which is retained, and of the stratum intermedium, which degenerates.

In order further to elucidate this relationship we periodically x-rayed the tail of a living Texas diamond-back throughout one molting cycle. The complete cycle observed may be divided into three periods: a long quiescent or latent period, a much shorter one of active growth or accretion, and a brief one of resorption and ecdysis. The approximate duration of each is indicated by the diagram (fig. 81).

Individual and species variation in the duration of a cycle as well as in its parts is to be expected; age, season, temperature, and probably nutrition will have their effects.

Important histological changes that take place in the end-body during each molting cycle concern the connective tissue and the epidermis. The bony core or style, once formed, shows no characteristic periodic changes.

During the latent period the connective tissue remains unchanged, but when accretion begins, new connective tissue forms the bulk of the developing fourth lobe. The expansion of this lobe forces the soft tissues of the end-body caudad along the style. Then, during resorption, a drastic reduction of connective tissue takes place in the distal and, to a limited extent, in the median parts of the end-body. Just prior to resorption, the connective tissue becomes edematous and there is infiltration by a great number of leucocytes derived from the marrow of the style. Their presence appears to be functionally related to resorption. This process is comparable to the reduction of the tail in a metamorphosing tadpole except that, in the amphibian, resorption is complete, and no keratinized shell, shaped like the original tail, is left behind.

The degenerative or absorptive changes that take place in the epidermis of the end-body chiefly concern the stratum intermedium. This cell layer is invaded by great numbers of eosinophile granulocytes, which are large leucocytes. They appear to advance the processes of resorption by proteolytic action. This degeneration allows a new generation of stratum corneum to become widely separated from the older generation as the remaining layers of the epidermis follow the rapidly shrinking connective tissue to its new position. The stratum intermedium temporarily becomes a jelly-like mass; its cells are highly vacuolated and, taken as a whole, lose the characteristics of a squamous layer. The stratum intermedium later dries out, the old generation of keratinized stratum corneum becoming free as a newly functional segment of the rattle. X-ray photographs reveal remnants of this intermediate layer between successive segments; evidently it contains traces of mineral salts.

The deeper layers of the epidermis and its supporting connective tissue are continuous with the similar elements of the new basal lobe and with them form an end-body that will lie dormant throughout the latent period just beginning. Keratinization of the new stratum corneum over this young end-body takes place immediately. It begins at the tip of the distal lobe and progresses toward the basal lobe. In tails covered by the loose molt, ready to be shed, the new generation of stratum corneum of the end-body is firmer at the tip than on the basal lobe.

The initiation of growth of the new basal lobe in the sulcus is a process of simple epithelial invagination. Active cell proliferation occurs in the deepest epidermal layer, the stratum profundum, and the resulting ingrowing lamina extends obliquely forward. A concomitant feature of this process is the dense accumulation of pigment cells or chromatophores that crowd upon the stratum profundum and prevent detection of mitotic figures. This activity is hidden beneath the caudalmost scales, which soon will be cast off as part of the molt. The swelling of the growing lobe, produced by rapidly proliferating connective tissue, noticeably stretches the skin and spreads the overlying scales apart several days before the molt is shed.

The significant events of development of the rattle take place in the late embryo and during the first few postnatal months; thereafter the segments merely become larger as the snake grows. Development in the three species investigated, the Florida and the Texas diamond-backs and the massasauga, is essentially similar except for an interesting temporal difference: In the massasauga, fusion of the caudalmost vertebrae to form the style occurs after birth, whereas in the Florida and Texas diamond-backs fusion is well-advanced in late embryos. The tail of the massasauga, therefore, is more primitive in showing at birth less differentiation. This is in agreement with several other characters of *Crotalus* and *Sistrurus.*

The style of both species is formed chiefly by coalescence of the terminal caudal vertebrae, about nine of them being involved. Certain extravertebral additions occur: a few nodular trabeculae from osteogenic foci in the tip of the end-body distal to the vertebrae, and a pair of elongate trabeculae on the ventral side near the base of the developing style. In young snakes the origin of the proximal portion of the style is betrayed by regularly overlapping ridges and trabeculae suggestive of the segmental arrangement of the vertebrae; in old snakes the style becomes relatively homogeneous. The muscles that vibrate the rattle are inserted in the base of the style, the last normal vertebra articulating with it and acting as the pivot of vibration.

In newborn rattlesnakes the outer covering of the end-body is a stratum corneum soon to be detached as the keratinized button. This simple structure terminates every complete rattle and has only two lobes, both poorly defined. The first two segments that follow the button are intermediate in structure between it and later three-lobed units of the rattle.

There are two interesting differences between the earliest postnatal growth processes of the end-body and later ones: (1) the stratum corneum of the first segment succeeding the button is keratinized before rather than immediately after the formation of a basal lobe; (2) bone resorption occurs at the distal tip of the style only during the initial molting cycle.

## REFERENCES

BOLK, L., GÖPPERT, E., KALLIUS, E. AND LUBOSCH, W. [EDITORS]
1931. Handbuch der vergleichenden Anatomie der Wirbeltiere. **1**, pp. 375–448. Berlin.

CZERMAK, JOH. N.
1857. Ueber den schallerzeugenden Apparat von *Crotalus*. Zeitschr. wiss. Zool., **8**, pp. 294–302.

GARMAN, SAMUEL
1888. The rattle of the rattlesnake. Bull. Mus. Comp. Zool., **13**, pp. 259–268, 2 pls.

KLAUBER, L. M.
1940. A statistical study of the rattlesnakes. Part V: The rattle. Occ. Pap. San Diego Soc. Nat. Hist., No. 6, pp. 1–63, figs. 47–63.
Contains an annotated bibliography of 145 titles.

NAEGELI, OTTO
1923. Blutkrankheiten und Blutdiagnostik. Lehrbuch der morphologischen Hämatologie. 4th ed. Leipzig.

ZIMMERMANN, A. A., AND POPE, C. H.
1946. The development of the rattle in rattlesnakes. Anat. Rec., **94**, p. 65. [Abstract.]

# INDEX