


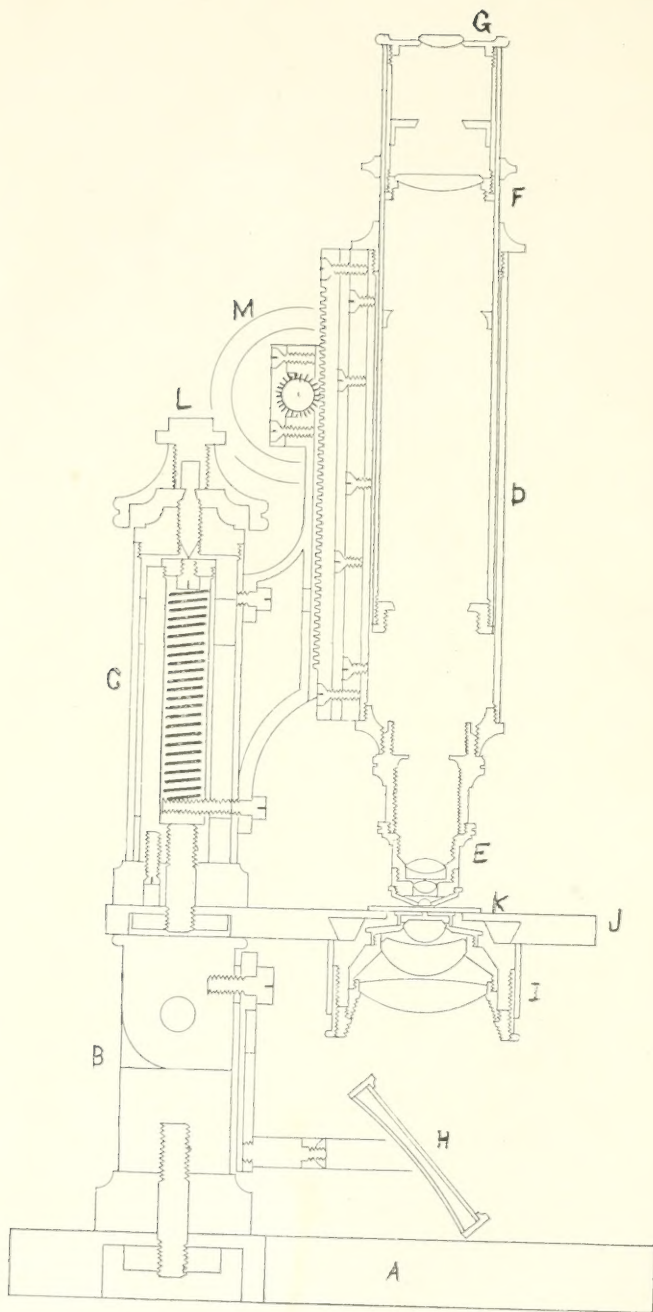
UNIVERSITY OF TORONTO



3 1761 00831831 3



Digitized by the Internet Archive
in 2008 with funding from
Microsoft Corporation



MEDIUM CONTINENTAL, THREE-FIFTHS ACTUAL SIZE.

Bausch and Lomb Optical Company.

A, base or foot; B, pillar; C, arm, in it the spring for the fine adjustment; D, body; E, objective; F, draw-tube; G, eye-piece or ocular; H, mirror; I, sub-stage condenser; J, stage; K, slide; L, fine adjustment; M, coarse adjustment.

DIRECTIONS

FOR WORK IN THE

HISTOLOGICAL LABORATORY


MORE ESPECIALLY ARRANGED FOR THE USE OF
CLASSES IN THE UNIVERSITY OF MICHIGAN

G. CARL HUBER, M. D.

Assistant Professor of Histology and Embryology

SECOND EDITION.

GEORGE WAHR
PUBLISHER AND BOOKSELLER
ANN ARBOR, MICHIGAN



COPYRIGHTED
GEO. WAHR
1895

QM
555
H 86
1895

PREFACE TO THE SECOND EDITION.

The subject matter of the first part of these laboratory notes has been almost entirely rewritten; the lessons have been rearranged; some few of the exercises outlined in the first edition, have been replaced by others, and many new ones added. The course, as now outlined, covers the essentials of normal histology.

The second part has been amplified, and many new methods added.

I wish to thank my assistant, Dr. Alfred B. Olsen, for aid rendered in proof reading and other assistance given.

Ann Arbor, June, 1895.

G. CARL HUBER.

PREFACE TO THE FIRST EDITION.

The following pages have been prepared with the hope that they may serve as a guide and a help to the students doing work in the Histological Laboratory. In the very brief description that is given of the tissues to be studied, I have bornⁱⁿ mind that the students entering on this work will have had a course of lectures on Histology. The aim of the notes is therefore not to *supplant*, but rather to *supplement* the text-books on this subject.

Drawings are to be made of nearly all the preparations examined. There is no better way for the student to obtain a correct and a lasting impression of the tissues to be studied than by carefully sketching what he sees under the microscope. The drawings are to be made in the laboratory. A few methods for hardening, macerating, embedding, and staining tissues are given; such as have proved themselves to be most reliable have been selected. Anyone familiar with the methods here given can without difficulty employ any he may find recorded in the works on microscopical technic.

I am indebted to the Bausch & Lomb Optical Company for sectional diagram of their Model microscope; to Mr. S. P. Budgett for the drawings of the two wood cuts. I also wish to acknowledge the help received in the arrangement of lessons, from Schäffer's Essentials of Histology.

G. C. H.

SUPPLIES.

The student before entering on his work should supply himself with the following outfit:—

One gross of slides.

Cover glasses. One oz. of No. 2 $\frac{3}{4}$ inch squares.

Two dozen No. 2 $\frac{3}{4}$ inch circles.

One dozen No. 2 1 in. by $\frac{3}{4}$ or $\frac{7}{8}$ inch.

Slide boxes.

Drawing pencil and blender. Two droppers. Two teasing needles.

Section lifter. Two camel's-hair brushes.

Four solid watch crystals. A pair of cover glass forceps.

A section knife (a razor flat on one side will answer).

A tube of Canada balsam. Slide labels.

BOOKS OF REFERENCE.

HISTOLOGY.

Piersol.—Normal Histology.

Toldt.—Lehrbuch der Gewebelehre.

Behrens, Kossel, Schiefferdecker.—Die Gewebe des Menschlichen Körpers.

Kölliker.—Handbuch der Gewebelehre des Menschen.

Schwalbe.—Lehrbuch der Anatomie der Sinnesorgane.

Cadiat.—Traité d'Anatomie Générale.

Quain.—Elements of Anatomy. Vol. I. Part II. General Anatomy or Histology, by Prof. Schäffer.

Orth.—Normale Histologie.

Stöhr.—Lehrbuch der Histologie.

MICROSCOPICAL TECHNIC.

Lee.—The Microtometist's Vade-Mecum.

Whitman.—Methods of Microscopical Anatomy and Embryology.

Behrens.—Tabellen zum Gebrauch bei mikroskopischen Arbeiten.

Ranvier.—Traité technique d'Histologie.

Boehm and Oppel.—Taschenbuch der mikroskopischen Technik.

Friedlander-Eberth.—Mikroskopische Technik zum Gebrauch bei Medicinischen und pathologisch-anatomischen Untersuchungen.

Kahlden.—Technik der histologischen Untersuchung pathologisch-anatomischer Präparate.

Rawitz.—Leitfaden der histologischen Untersuchungen.

Behrens, Kossel, Schiefferdecker.—Vol. I.

LESSON I.

CELL AND CELL DIVISION.

(a) Plant Cells.

From one of the layers of an onion remove with forceps a small strip of the film which covers its inner surface. Spread out this membrane on a slide in a drop of water, and cover with a cover glass. Use the low power. In studying an unstained preparation, it is best to employ one of the smaller openings in the diaphragm, thus cutting off all unnecessary light.

Observe the large cells, oblong or nearly rectangular in shape, each surrounded by a distinct cell membrane. Notice the round or oval nucleus with one or more nucleoli. Carefully elevate the cover glass at one edge, and add a drop or two of Lugol's solution or tincture of iodine, and again replace the cover slip. In a few moments the cells will assume a yellowish-brown color. Their structure can now be made out more easily. Sketch a number of the cells as seen under both low and high power, after they have been stained.

(b) Karyokinesis in Plant Cells.

Young and growing onion roots were hardened in Fleming's solution, embedded in paraffin, longitudinal sections cut and fixed to cover glasses, and stained in safranin. Come to the table with a small drop of Canada balsam on your slide, and the section will be mounted for you. m/

Under the low power it will be noticed that some of the nuclei are stained deeper than others. Examine these under high power. Usually they will show some one of the several stages of mitotic cell division. Observe the difference in structure between a resting nucleus and one in the spirem stage. In the former a chromatic network will be seen, in the latter the chromosom~~at~~ can be clearly es

made out. Search for cells showing the nucleus in the monaster, metakinetic, and diaster stages. Sketch a resting nucleus, and the various stages of division seen in your section.

(c) Large Animal Cells.

The ovary of a very young chicken was hardened in a saturated aqueous solution of bichloride of mercury, stained *en masse* in borax carmine, embedded in paraffin, and sectioned.

All paraffin sections are to be mounted in the following way:—Bring to the distributing table a slide on which a thin layer of albumen fixative (equal parts of white of egg and glycerine) has been spread. The paraffin section will then be fixed to the slide. Then hold the slide over a gas flame until the paraffin *begins* to melt, next drop a few drops of turpentine on the section, and at the same time rock the slide backward and forward until the paraffin has been dissolved. Wipe away the excess of turpentine, add a small drop of balsam, and cover with a cover glass.

Study under low power. Observe the large round cells, some of which show a relatively large nucleus. Sketch several as seen under low power.

(d) Karyokinesis in Animal Cells.

m The testes of a salamander are to be removed from the animal during the month of June. They were cut into small pieces, hardened in Flemming's or Hermann's solution, embedded in paraffin, very thin sections cut and fixed to cover glasses, and stained either in safranin and light grün or Haidenhain's iron-lack-hæmatoxylin and acid fuchsin. After staining, the sections were dehydrated, passed through oil of bergamot into xylol, from which they are mounted. Come to the table with a small drop of balsam on your slide.

Study the section first under low power, and you will observe that the cells are arranged in larger and smaller nests. Under high power groups of cells in mitotic cell division are often met with. All the cells in such a group usually present about the same stage of division. Search the section thoroughly until all the stages have been seen and sketched.

(e) **Cells Showing Nucleus and Accessory Nucleus (Nebenkernel).**

Small pieces of a guinea pig's testis were hardened in the following mixture:

Osmic acid, 2% solution	2 parts.
Platinum chloride, 2% solution	3 “
Mercuric chloride, saturated aqueous sol.	5 “

They are hardened for 24 hours, embedded in paraffin, sectioned and fixed to cover glasses, stained in iron-lack-haematoxylin (Haidenhain's), dehydrated, cleared in oil of bergamot, and passed into xylol. Come to the table with a small drop of balsam on your slide.

Search for tubules showing the last stages of the development of the spermatozoa. In the cells forming the walls of the seminiferous tubules, the accessory nucleus is stained deeply black, the nucleus a bluish-gray color. Sketch several of the cells showing this structure.

DRAWINGS FOR LESSON I.

DRAWINGS FOR LESSON I.

LESSON II.

BLOOD.

(a) Fresh Human Blood.

Obtain a drop of blood by pricking a carefully cleaned finger with a steel pen, one of the prongs of which has been broken off; quickly mount the drop on a slide, and examine with the high power.

Observe that most of the red cells are arranged in rouleaux, and between these now and then a white corpuscle is seen. If your drop was small, some of the red corpuscles found in the peripheral part of the preparation will appear crenated.

(b) Fresh Human Blood with Normal Salt.

Obtain a very small drop of blood as above directed, mix it on the slide with a drop of normal salt solution, and cover.

The smaller number of corpuscles will allow of a more careful study of their size and shape. Observe that the red appear as biconcave circular discs, and are a little smaller than the majority of the white. Some of the red will soon be crenated. Make a drawing of a number of the red cells as seen on "the flat," and a few seen on the edge (profile).

(c) Human Blood Stained in Hæmatoxylin and Eosin.

A small drop of blood was spread between two clean square cover glasses (No. 1, $\frac{3}{4}$ in.); the cover glasses were then quickly drawn apart, and the thin film of blood allowed to dry. The cover glass with the blood was then placed for 1 to 24 hours in a solution composed of 3 parts of ether and 1 of absolute alcohol which fixes the blood, it was next stained for 15 to 20 minutes in Boehmer's hæmatoxylin, and for 5 minutes in a 1% solution of eosin, washed in flowing water and dried between filter paper. Mount on a small drop of balsam.

All nuclei are stained with the hæmatoxylin, the protoplasm with the eosin. Eosinophile granules are also stained red; the other granules are not stained.

On examining with high power the following varieties of cells will be seen in the preparation:

(1) Red blood cells stained in eosin.

(2) Small lymphocytes, in size a little larger than the red blood corpuscles, with a relatively large nucleus stained quite deeply by the hæmatoxylin, and only a narrow border of protoplasm.

(3) Large mononuclear cells showing a much larger border of protoplasm, and a nucleus which usually stains quite faintly.

(4) Transitional form with a horseshoe-shaped nucleus. These develop from the large mononuclear.

(5) Polynuclear cells, with a lobulated nucleus, which usually stains quite deeply. They develop from the transitional forms, and form about 70 to 75 % of the white blood cells.

(6) Eosinophile polynuclear cells, with lobulated nucleus, and eosinophile granules in the protoplasm.

Make a sketch of each of the above varieties.

(d) Human Blood Stained in Ehrlich's Neutrophile Stain.

Blood was spread and fixed as in (c) of this lesson, was then stained in Ehrlich's neutrophile stain for half an hour, washed in flowing water, dried between filter paper, and are to be mounted on balsam.

The red blood corpuscles are stained a reddish-brown, all nuclei green, neutrophile granules in the protoplasm of polynuclear cells a reddish-purple, and eosinophile granules red. Study under high power, and the corpuscles named in (c) will be seen. Look carefully for the neutrophile granules in polynuclear cells. They are not found in lymphocytes nor in the mononuclear cells, and only in the latter stages of the transitional forms.

(e) Amphibian Blood Stained in Hæmatoxylin and Eosin.

The heart of a frog was opened, and a small drop of blood placed on a cover glass, quickly covered with another cover glass,

and the two covers drawn apart, next fixed in ether and alcohol, stained in hæmatoxylin and eosin, washed and dried. Mount in balsam.

Study under high power. The red blood corpuscles are oval, somewhat flattened and nucleated. When seen in profile they show a slight convexity in the center. Observe the white corpuscles which are smaller than the red. Sketch several red, and the several forms of the white met with.

(f) Pigeon Blood Stained in Hæmatoxylin and Eosin.

One of the toes of a pigeon was amputated. From the flowing blood a small drop was caught on the cover glass, spread, fixed, and stained in hæmatoxylin and eosin. Mount in balsam.

The red cells are oval, somewhat flattened, and nucleated. Observe the white cells. Sketch red and white corpuscles.

(g) Amœboid Movement in White Blood Cells of a Frog.

A small quantity of blood obtained from the heart of a frog is mixed with a drop of normal salt solution and covered with a slip. To prevent evaporation while examining, the cover glass is fixed by means of two or three drops of melted paraffin, so placed, that after congealing, one-half of the drop will rest on the slide, the other on the edge of the cover; the sealing is then completed by means of a camel's-hair brush which has been dipped in vaseline and drawn about the edge of the cover.

In examining this preparation be very careful not to bring the end of the objective in contact with the vaseline on the slide. Search the specimen until you find a white blood cell of somewhat irregular shape; place it in the center of the field, and make a drawing of it as it presents itself to you at this time; at intervals of one or two minutes carefully repeat the sketching until about ten sketches have been made. You will no doubt see that the cell in question has changed its shape a number of times, pseudopodia may have been thrown out and again withdrawn, etc.

DRAWINGS FOR LESSON II.

LESSON III.

BLOOD (Concluded).

(a) Fibrin.

Place a *large* drop of blood on the slide, allow it to clot partially; cover with a cover slip. Wash gently with a current of water until nearly all the red blood cells have been washed out. Run a few drops of a 1% solution of methylene blue under the cover glass.

Examine with high power. Small glistening fibrillæ woven into a network will be seen; these are fibrin filaments. The nuclei of the white blood cells will be stained blue.

(b) Teichmann's Crystals, Hæmin Crystals, Chloride of Hæmatin.

Several weeks ago the blood of a mammal was allowed to flow on a piece of cloth. Cut out a small piece of the cloth with a portion of the blood-stain on it. Tease it on a slide in a few drops of normal salt, and set it aside until some of the stain soaks out into the solution. In case the normal salt begins to evaporate add now and then a drop of the solution in order to keep the teased fibres well soaked. When some of the blood has been dissolved by the salt solution, remove the cloth fibres, and set the slide away to evaporate. If care be taken *not to get the slide too hot*, the evaporation can be hastened by holding the slide over a gas flame. When the evaporation has been completed, scrape what is left on the slide into a small mass, and add one or two drops of glacial acetic acid, cover with a cover glass, and heat over a flame until bubbles form. Continue the heating till the acid has evaporated. Run a drop of water under the cover glass, and examine for Teichmann's crystals. If present, the cover glass may be removed, dried, and mounted on balsam.

Study under high power. The crystals are seen in the form of rhombic plates or rhombic rods of a brownish-red color.

(c) Teichmann's Crystals from Pigeon's Blood.

Prepare as (b) of this lesson.

The crystals will be of the same form and size as those made from mammalian blood. Teichmann's crystals can be obtained from *blood* stains no matter how old, hence their presence is often of value in medico-legal cases. Remember that the fact that Teichmann's crystals can be obtained from a stain only shows the presence of blood and nothing more; they can be obtained from the hæmoglobin of any red blood cell.

(d) Detection of Red Blood Cells in a Dry Clot of Mammalian Blood.

Take a small portion of a dry clot, place it on a slide, and cover it with several drops of a 33% solution of potassium hydrate. After the clot has become somewhat softened, break it up into as small pieces as possible with your teasing needles, and cover with a cover glass. Set it aside for 5 to 10 minutes, then gently tap the cover glass with a teasing needle.

Examine to see whether any of the corpuscles are free; if so, determine their shape and size; if not set aside awhile and try again.

(e) Detection of Red Blood Corpuscles in a Dry Clot of Pigeon's Blood.

Prepare as (d) of this lesson.

Search for the oval red blood cells; you may be able to make out a nucleus in them.

DRAWINGS FOR LESSON III.

DRAWINGS FOR LESSON III.

LESSON IV.

EPITHELIUM.

(a) Pavement Epithelium, Isolated Cells.

Scrape the inside of the cheek with a clean slide or the edge of a knife, mount in a drop of saliva, and cover with a slip.

Study under high power, and make use of one of the smaller openings in the diaphragm. Observe the large flat cells with oval or rounded nuclei showing now and then a few granules in the protoplasm. You will also see the salivary corpuscles, leucocytes which have wandered through the oral epithelium. They are slightly swollen by the imbibition of water.

(b) Isolated Pavement Epithelial cells Stained in Hæmatoxylin and Eosin.

Tease some scrapings from the inside of the cheek on a cover glass, dry the preparation (after teasing) over the flame, stain for 15 minutes in Boehmer's hæmatoxylin, wash in flowing water, stain in eosin for 5 minutes, again wash in water, and dry the preparation between two filter papers. Mount in balsam.

The nuclei are stained blue, the protoplasm red. Sketch a number of the epithelial cells and salivary corpuscles as seen under the high power.

(c) Cutaneous Epithelium from a Frog's Epidermis.

If a frog is imprisoned for some time in a jar containing a small quantity of water, portions of the epidermis are from time to time shed, and are found floating in the water. These thin membranes were washed, stained in Boehmer's hæmatoxylin, dehydrated in alcohol, and are now in oil of cloves. To mount, place the tissue on a clean slide, remove excess of oil, add a drop of Canada balsam, and cover with a slip.

This preparation gives you a surface view of stratified pavement epithelium. Observe the flat nucleated cells, cemented together by a small amount of intercellular cement substance. Sketch a small portion of the field as seen under the high power.

(d) Cross Section of Stratified Pavement Epithelium.

A small portion of the soft palate or the œsophagus was hardened in a saturated aqueous solution of mercuric chloride or absolute alcohol, stained in borax or alum carmine, embedded in paraffin, and sectioned. Mount in balsam.

Observe the several layers of epithelial cells, and their change in shape as they are traced outwards. In the lowest layer, the cells are columnar, in the following polygonal, while in the outermost layers they are flattened. Notice the change in the shape and structure of the nuclei of the cells of the different layers. Sketch as seen under high power.

(e) Isolated Transitional Epithelial Cells Stained in Hæmatoxylin and Eosin.

The bladder of a large dog was distended with 33% alcohol before removing, the urethra was tied. The bladder was then placed in 33% alcohol, where it remained 24 hours. It was then cut into small pieces. Scrape the epithelial surface of one of the small pieces, place the scraping on a cover glass, and tease thoroughly. After teasing dry the preparation over a flame. Stain in hæmatoxylin and eosin, and mount on balsam.

Examine under high power. Cells of various shapes will be seen. Some are large flat scales with one or two nuclei; others are pear-shaped, spindle-shaped, or triangular. The pelvis of the kidney, the ureter, and the bladder, are lined with transitional epithelium. Sketch the several forms of epithelial cells found.

(f) Cross Section of Transitional Epithelium.

Small pieces of the bladder of a dog were hardened in absolute alcohol, stained for 24 hours in Delafield's hæmatoxylin (one part of the stain to ten parts of distilled water), embedded in paraffin, and sectioned. Fix to the slide with albumen fixative, and mount in balsam.

Study under high power. The cells of the upper layer (free border) are large flat scales with a smooth free edge. The lower border is often slightly pitted, these depressions receiving the cells of the next lower layer. These large cells have one or two nuclei. The cells of the second layer are pear-shaped or irregularly columnar. The cells of the deeper layer are triangular or spindle-shaped, and fit in between the cells of the second layer. Sketch a portion of the epithelium.

DRAWINGS FOR LESSON IV.

DRAWINGS FOR LESSON IV.

LESSON V.

EPITHELIUM (Concluded).

(a) Isolated Columnar Epithelial Cells.

The small intestine of a cat was opened, and macerated for 24 to 48 hours in 33% alcohol. Tease a small portion of the mucous membrane in gum glycerine.

Study under high power, and use one of the smaller openings in the diaphragm. Observe the shape of the cells, position and shape of nucleus, and the striated border. Sketch as seen under high power.

(b) Isolated Columnar Cells Stained in Hæmatoxylin.

Tease very thoroughly a small portion of the above on a cover glass. Dry over the flame, stain in hæmatoxylin, and mount on balsam.

Observe the columnar cells, the faintly striated protoplasm, the cuticular border, and the structure of the nucleus. Sketch a few of the cells as seen under high power.

(c) Cross Section of Simple Columnar Epithelium.

The small intestine of a cat was cut open, pinned out on a cork, hardened in absolute alcohol, stained in Delafield's hæmatoxylin, and embedded in paraffin. Cross sections of the villi were made. Fix to slide and mount in balsam.

Under low power you will observe many small, nearly round or oval patches of tissue. When one of these is studied under high power, it will be found to be surrounded by a single layer of columnar cells cemented together by a small amount of intercellular cement substance. In the intercellular cement a leucocyte is now and then found. Sketch as seen under high power.

(d) Goblet Cells Stained in Hæmatoxylin and Eosin.

The large intestine of a cat was macerated in 33% alcohol 24 to 48 hours. Tease a small portion of the epithelium on a cover glass, dry over the flame, and stain in hæmatoxylin and eosin. Mount in balsam.

Study under high power. Some of the cells observed are ordinary columnar cells; others are distended with mucinogen, the nucleus being pressed down into the lower part of the cell; these are the goblet cells. Sketch several as seen under high power.

(e) Isolated Ciliated Columnar Cells Stained in Hæmatoxylin and Eosin.

The trachea of a cat was macerated in 33% alcohol. Tease a portion of the epithelium on a cover glass, and stain in hæmatoxylin and eosin. Mount in balsam.

Study under high power. Observe that the majority of the cells are columnar in shape, possessing an oval nucleus. Notice particularly the clusters of fine short hairs adhering to the free end of some of the columnar cells. A few goblet cells may be found. Sketch as seen under high power.

(f) Cross-Section of Stratified Ciliated Columnar Epithelium.

The respiratory mucous membrane of a dog's nose was hardened in mercuric chloride, stained in Delafield's hæmatoxylin, embedded in paraffin, and sectioned. Mount in balsam.

Study under high power. This epithelium is composed of three layers of cells, the free cells being ciliated. Sketch a portion of epithelial border.

DRAWINGS FOR LESSON V.

DRAWINGS FOR LESSON V.

LESSON VI.

FIBROUS CONNECTIVE TISSUE.

(a) Fibrils of White Fibrous Connective Tissue.

One of the small tendons of a rat's tail is to be placed on a clean and dry slide. Place a small piece of filter paper (about $\frac{1}{4}$ in. square) moistened in normal salt over the middle part of the tendon; quickly spread out the ends of the tendon with your teasing needles. The spread-out ends will dry and fix the tendon to the slide. Tease the middle portion in normal salt, and cover with a slip.

Study under high power. Observe the very fine fibrillæ, often slightly wavy. Notice that they neither branch nor anastomose. Add a few drops of a 1% solution of acetic acid. This causes the fibrils to swell up and become homogeneous. Sketch as seen before acetic acid is added.

(b) Fibrils of Yellow Elastic Connective Tissue.

Tease a small portion of the elastic tissue taken from the ligamentum nuchæ of an ox in normal salt solution.

Observe the fibrils of yellow elastic tissue. They are highly refractive, branch and anastomose, and the broken ends curl back. Run a few drops of the acetic acid solution under the cover glass, and notice that the yellow elastic fibrils are not affected by it.

(c) Stained Yellow Elastic Tissue.

Small pieces of ligamentum nuchæ were macerated for 3 to 4 days in a 1% solution of acetic acid, stained for several days in a 1% aqueous solution of acid fuchsin, thoroughly washed in flowing water, and placed in glycerine. Tease in gum glycerine.

The stained fibrils will be easily made out. Sketch under high power.

(d) **Areolar Connective Tissue.**

A small portion taken from the subcutaneous tissue of a young cat is placed on a dry slide, the edges are drawn out and made to adhere to the slide by allowing them to dry, while the center is kept moist by breathing upon it. In this way a thin film is obtained. Place a drop of normal salt on a cover glass and invert it over the center of the film.

Examine under high power, using one of the smaller openings of the diaphragm. Observe the bundles of white fibrous tissue, composed of elementary fibrils, crossing the field in every direction, and forming a felted network. On and between these bundles, yellow elastic fibres will be seen. They have a more definite outline, and branch and anastomose. Search for connective tissue cells.

Carefully elevate the cover glass, and add a drop of 1% solution of acetic acid.

In a few moments the bundles of white fibrous tissue will swell and appear homogeneous, while the unaffected yellow elastic fibres will stand out boldly; the nuclei of the fixed connective tissue cells can now be more clearly seen. Sketch a bundle of white fibrous connective tissue, some yellow elastic fibres, and a number of the connective tissue cells.

(e) **Cell Spaces in Areolar Connective Tissue.**

A small piece of areolar connective tissue was removed from a young animal, spread out on a dry, clean slide, immersed for 15 minutes in a 1% solution of silver nitrate, rinsed in water, placed in 95% alcohol, and exposed to direct sunlight. The sunlight reduces the silver nitrate giving the tissue a brown color. It was then removed from the slide, hardened in alcohol, and cleared in oil of bergamot. Mount in balsam.

Study under high power. The ground substance of the tissue is stained brown, and the irregular, branched, and often anastomosing cell spaces are left unstained, and thus are clearly seen. Sketch.

(f) **Tendon.**

Tendons taken from the tail of a rat were suspended in alum carmine for 24 hours. Tease in gum glycerine.

The tendon fasciculi are somewhat swollen; between them rows of tendon cells which have taken the red color will be distinctly seen; they are oblong or square in shape, with the nucleus usually at one end. Sketch two fasciculi with the intervening cells.

(g) Cross-Section of Tendon.

The skin covering the tail of a rat was removed, the tail cut in small pieces, fixed in a saturated aqueous solution of mercuric chloride, washed in water, hardened in alcohol, decalcified in a 1% solution of hydrochloric acid, stained in borax carmine, embedded in paraffin, and cross-sectioned. Fix to the slide and mount in balsam.

Examine first under low power. Four small tendons will be seen in cross section. Place one of these in the field, and examine under high power. Observe that the tendon is surrounded by an areolar connective tissue sheath. The ends of the tendon fasciculi are seen in cross section. Notice the tendon corpuscles between the fasciculi; they usually have a triangular body with long processes. They are stained more deeply than the fibrous tissue. Sketch as seen under high power.

DRAWINGS FOR LESSON VI.

DRAWINGS FOR LESSON VI.

LESSON VII.

CONNECTIVE TISSUE (Concluded).

(a) Cross-Section of Ligamentum Nuchæ.

Small pieces of the ligamentum nuchæ of an ox were hardened in picric acid, stained in borax carmine, embedded in paraffin, and sectioned. Fix to the slide and mount.

The cut ends of the yellow elastic fibres have an irregular angular shape. They are grouped into larger or smaller bundles. These bundles are separated from each other by a small amount of white fibrous tissue. Here and there a connective tissue cell between the yellow elastic fibres is to be noticed. Sketch as seen under high power.

(b) Longitudinal Section of Ligamentum Nuchæ.

The section was prepared as above, and longitudinal sections made. Fix to the slide and mount in balsam.

Observe the anastomosing fibres of yellow elastic tissue. Sketch as seen under high power.

(c) Embryonic Connective Tissue.

The umbilical cord of a human fœtus was hardened in a saturated aqueous solution of mercuric chloride, stained in Delafield's hæmatoxylin, embedded in paraffin, and sectioned. Fix to the slide and mount in balsam.

The umbilical vessels will be seen occupying the central part of the section. In this section, however, the connective tissue is to receive special attention. Observe the branched connective tissue cells with their long processes. The cells are separated by a large amount of a granular, intercellular ground substance, in which fine connective tissue fibrils, as well as the highly refractive elastic fibres, may be seen. Make a sketch as seen under high power.

(d) Fat Cells.

The mesentery of a cat was spread on a large glass slide, hardened for 48 hours in 95% alcohol, stained in hæmatoxylin, washed in water, dehydrated, and cleared in oil of bergamot. A small portion including an arteriole is cut off with scissors, transferred to the slide, and mounted in balsam.

Study first under low power, and observe the large, clear, round or oval, cells, arranged in rows or small groups on either side of the small vessels. Under high power a nucleus is now and then made out. A network of capillaries embracing the fat cells is often observed. Sketch as seen under low power.

(e) Section of Adipose Tissue.

A small portion of the skin was hardened in absolute alcohol, stained in borax carmine, embedded in paraffin, and sectioned. Fix to the slide and mount.

Study under low power. Notice the groups of fat cells, lobules of fat, separated by bundles of fibrous connective tissue. Sketch as seen under low power.

(f) Endothelial Cells.

A 1% solution of silver nitrate was injected into the peritoneal cavity of a frog. After 15 minutes the intestines with the attached mesentery were removed, pinned out on a small piece of cork, placed into 95% alcohol, and exposed to the sunlight until it assumed a brown color. After dehydration the tissue was cleared in oil of bergamot. Mount in balsam.

Study under high power, and observe that the silver is deposited in the intercellular cement substance, a delicate black line surrounding and outlining each cell. Now and then the protoplasm and nuclei are stained a light brown. Sketch as seen under high power.

DRAWINGS FOR LESSON VII.

DRAWINGS FOR LESSON VII.

LESSON VIII.
CARTILAGE.

(a) Hyaline, Fresh.

Thin sections are removed from the articular surface of a frog's femur by a sharp razor. Mount in normal salt solution.

Examine under high power, using one of the smaller openings in the diaphragm. Observe the round or oval cartilage cells, each surrounded by a capsule, and possessing a large spherical or oval nucleus. The cells are often found in groups of 2, 4 or more, and are in small spaces (the lacunæ) in the homogeneous, intercellular ground substance, the matrix.

(b) Hyaline Cartilage, Stained.

The head of a femur of a cat was divided into several pieces; these were hardened in a saturated aqueous solution of mercuric chloride, decalcified in a 1% solution of hydrochloric acid, stained in borax carmine, embedded in paraffin, and cross-sections made.

Study first under low power. Observe the hyaline cartilage surrounding the cancellated bone. In the deeper portion of the cartilage, the matrix is granular; this is a narrow zone of calcified cartilage. Sketch the section as seen under low power.

(c) Elastic Fibro-Cartilage.

The epiglottis of a dog was hardened in alcohol, embedded in celloidin, stained in hæmatoxylin, and counter-stained in a 1% aqueous solution of acid fuchsin.

Study under low power. The nuclei of the cartilage cells are stained with the hæmatoxylin. An interlacing network of yellow elastic fibres stained red by the acid fuchsin will be seen in the ground substance. Sketch as seen under high power.

(d) **White Fibro-Cartilage.**

Small pieces of the intervertebral discs of a calf were hardened in a saturated aqueous solution of picric acid, washed in alcohol, stained in picro-carmin, embedded in paraffin, and sectioned.

Study under high power. The intercellular matrix is composed largely of white fibrous tissue stained yellow in the picric acid. Between these bundles are found cartilage cells, enclosed in a capsule, and often surrounded by a narrow zone of hyaline matrix. Sketch as seen under high power.

DRAWINGS FOR LESSON VIII.



DRAWINGS FOR LESSON VIII.

DRAWINGS FOR LESSON VIII.

LESSON IX.

BONE.

(a) Cross-Section of Bone.

From a thoroughly macerated and dried bone a thin cross-section is removed from the shaft by means of a fine saw. This is ground between two hones until it becomes very thin and transparent, care being taken to keep the stones well moistened with water, and not to use too much pressure. The section is now washed, first in distilled water, and then in alcohol. This is best done by means of a fine camel's-hair brush, using a deep watch crystal. In order to determine whether your section is clean, mount it in a drop of alcohol, and examine under the microscope. The Haversian canals and the lacunæ must be free from sand, as they will be if the section is well washed. If clean, dry between two filter papers. A dry bone section must be mounted in hard balsam. To prepare this, place a large drop of balsam on a slide, and another on a cover glass. Heat both over the flame for a few moments, and then set aside to cool. When ready the touch of a needle will make a dimple in the balsam. Then place the bone section on the balsam and cover with the prepared cover slip. Gently press the cover with a needle until the layers of balsam fuse.

Examine under low power. Observe that in a Haversian system the bone lamellæ are concentrically arranged about the Haversian canal. Note the bone lacunæ between the lamellæ; these communicate with one another by means of the fine canaliculi. Look for the interstitial and circumferential lamellæ. Sketch several Haversian systems as seen under low power.

(b) Longitudinal Section of Bone.

A thin longitudinal section is made from the shaft of a bone by means of a fine saw. Grind and wash as above. Dry and mount in hard balsam.

Study under low power, and observe the anastomosing Haversian canals. The bone lamellæ and lacunæ are arranged parallel to them. Sketch under low power.

(c) Cross-Section of Decalcified Bone.

A portion of the shaft of a small bone was hardened in a saturated aqueous solution of mercuric chloride, decalcified in 1% hydrochloric acid, stained in Delafield's hæmatoxylin, washed in acid alcohol for several hours, dehydrated, embedded in paraffin, and sectioned. Fix to the slide and mount.

Study under high power. Observe the Haversian canals; each contains one or more capillaries or small arterioles in section. The lamellæ are arranged around the canals concentrically; between these are the lacunæ; and in each lacuna a bone cell. The canaliculi are not well shown. The periosteum is composed chiefly of fibrous tissue. On the inner surface of the periosteum will be seen one or more layers of short, irregularly cuboidal cells, the osteoblasts. Sketch under high power.

(d) Longitudinal Section of Decalcified Bone.

This was prepared the same as the cross-section. Mount in balsam.

Study under high power. The Haversian canals and lamellæ are seen in longitudinal section; between two lamellæ is a row of lacunæ containing bone cells. Sketch as seen under high power.

DRAWINGS FOR LESSON IX.

DRAWINGS FOR LESSON IX.

LESSON X.

CANCELLED BONE, DEVELOPING BONE, AND BONE MARROW.

(a) Cancellated Bone.

The head of a long bone taken from a young animal was divided into small pieces, hardened in mercuric chloride, decalcified in a 1% solution of hydrochloric acid, stained in Delafield's hæmatoxylin, embedded in paraffin, and sectioned. Sections were fixed to cover glasses, and counter-stained in eosin, dehydrated, and cleared in oil of bergamot. Mount in balsam.

Study first under low power. Observe the network of trabeculæ. The spaces bounded by them are filled with marrow cells. Under high power a layer of osteoblasts is often seen lining the spaces. Fragments of calcified cartilage, taking the stain more deeply, may be seen in the trabeculæ. Sketch as seen under high power.

(b) Developing Bone.

One of the developing bones removed from a fœtal limb was hardened and decalcified in micro-sulphuric acid, embedded in celloidin, sectioned, and stained in hæmatoxylin and eosin. Sections are now in oil of bergamot, and are to be mounted in balsam.

Study first under low power. If the section comes from the center of the bone it will show the following areas, named in order as they present themselves when the section is moved from the articular surface toward the middle of the shaft, where ossification is most advanced:—

- (1) Area of articular cartilage.
- (2) Area of flattened cartilage cells, arranged in rows.
- (3) Area of enlarged cartilage cells. Calcification may have taken place in the matrix between the rows.
- (4) Area of ossification. Osseous substance is being deposited by the osteoblasts on the calcified trabeculæ of the cartilage. Small arterioles and capillaries surrounded

by marrow cells are found in the spaces between the trabeculae (the primary marrow spaces). The periosteal bone is being formed, and is well marked off from the endochondral bone. Sketch under low power, showing in your drawing the several areas mentioned above.

(c) **Red Marrow.**

A small portion of red marrow taken from the femur of a guinea pig was placed on a cover glass and covered by another cover glass; the two were then pressed together and quickly drawn apart. They were then hardened for 24 hours in a solution of three parts ether and one of absolute alcohol, and stained in hæmatoxylin and eosin. Mount in balsam.

Study under high power. Find and sketch the following cells:—

- (1) Mononuclear giant cell.
- (2) Polynuclear giant cell; the nucleus may be lobulated, s-shaped, or in the form of a ring.
- (3) Nucleated red corpuscle; the spherical nucleus takes the stain very freely.
- (4) Erythroblasts; a little larger than the red blood cells, and containing none or very little hæmoglobin.
- (5) Polynuclear, transitional, and mononuclear white blood cells, and perhaps a few lymphocytes.
- (6) Myelocytes or red marrow cells, mononuclear and a little larger than the white blood cells.

DRAWINGS FOR LESSON X.

DRAWINGS FOR LESSON X.

LESSON XI.

MUSCLE.

(a) Fresh Striped Muscle.

Tease a small shred of muscle taken from the leg of a frog in normal salt solution.

Study first under low power. Observe the long cylindrical fibres showing a transverse striation. Move the the slide about and you will find broken fibres, the broken ends of which are often united by the sarcolemma. Cause a few drops of a 1% solution of acetic acid to flow under the cover glass, and in a few moments the muscle nuclei will be seen. Make a sketch showing the sarcolemma; also a small segment of a muscle fibre showing muscle nuclei as seen under high power.

(b) Teased and Stained Striped Muscle.

Small pieces of a striped muscle were macerated for about 24 hours in Sihler's macerating fluid, then transferred to glycerine for several hours, and stained in Sihler's hæmatoxylin for several days. Tease carefully in gum glycerine.

Study under low power. The cross striations are very clearly seen, also the muscle nuclei. Sketch as seen under low power.

(c) Branched Striped Muscle Fibres.

The posterior free end of a frog's tongue was macerated for several hours in M. Schultz's mixture, and stained in hæmatoxylin. Tease a small portion in gum glycerine.

When a voluntary muscle fibre is inserted into a mucous membrane or the epidermis, the end so inserted is often branched. This preparation, if you have teased it carefully, will show you these branched fibres. Sketch under high power.

(d) Cross-Section of Voluntary Muscle.

One of the small muscles of a mammal was hardened in a saturated aqueous solution of mercuric chloride, stained in borax carmine, embedded in paraffin, and cross-sectioned. Fix to the slide, and mount in balsam.

Study first under low power. Observe the endomysium and perimysium. Under high power note the structure of the muscle fibres and the areas of Cohnheim. Observe the position of the muscle nuclei. Sketch under high power.

(e) Longitudinal Section of Injected Striped Muscle.

The arteries of one of the extremities of a dog were injected with a Berlin blue gelatine mass; the tissue was then hardened in alcohol; stained in alum carmine; embedded in paraffin, and sections cut parallel to the course of the fibres. Fix to the slide, and mount in balsam.

Study under low power. The muscle fibres are stained with the alum carmine. Between and over the fibres are tortuous blue threads, the injected capillaries, forming an anastomosing network. Sketch as seen under low power.

(f) Cross-Section of Tongue.

The tongue of a cat was hardened in absolute alcohol, stained in Delafield's hæmatoxylin, embedded in paraffin, fixed to cover glasses, and counter-stained in eosin. Mount in balsam.

Study first under low power. Notice the striped muscle fibres cut transversely, longitudinally, and obliquely. The structure of the muscle fibres will be more clearly made out under high power. The nuclei are stained blue, the muscle substance red. Sketch under low power.

DRAWINGS FOR LESSON XI.

DRAWINGS FOR LESSON XL.

LESSON XII.

MUSCLE (Concluded).

(a) Nerve-Ending in Voluntary Muscle.

Small pieces of the intercostal muscles of a snake (the intercostal or any other short muscle of a small mammal may be used) were placed for 10 to 15 minutes in filtered lemon juice, then hastily washed in distilled water, transferred to a 1% gold chloride solution for 15 to 20 minutes, again washed in water, and placed in 20% formic acid solution where they remained (protected from the light) 24 to 48 hours. Tease in glycerine.

Study first under low power, and search for a nerve fibre terminating in an end plate. The nerve fibre and the branched ending have a purplish color, the muscle a reddish purple. Sketch under high power.

(b) Isolated Heart Muscle Cells.

Small pieces of the cardiac muscle of a dog were macerated in a 30% solution of caustic potash for 15 minutes; the maceration was then interrupted by placing the tissue in a saturated aqueous solution of potassium acetate. Tease in gum glycerine.

Observe the short oblong cells, one end usually branched. The cells show a cross and longitudinal striation, and possess one, occasionally two, oval nuclei. Draw several as seen under high power.

(c) Section of Heart Muscle.

A small piece taken from the ventricle of a dog's heart was hardened in a saturated aqueous solution of mercuric chloride, stained in Delafield's hæmatoxylin, embedded in paraffin, and sectioned. Fix to slide, and mount in balsam.

Study under high power. Note how the cells are cemented into fibres, and these into anastomosing bundles. In cross sections of the muscle the nuclei are seen occupying the center of the cells. Sketch as seen under high power.

(d) Teased Involuntary Muscle.

The muscular coat of the small intestine of a cat was macerated for 15 minutes in a 30% solution of caustic potash, then placed in a saturated solution of acetate of potash. Tease in gun glycerine.

Observe the long, fusiform or spindle-shaped cells with rod-shaped nuclei. The protoplasm often shows a longitudinal striation. Sketch several under high power.

(e) Section of Involuntary Muscle.

The muscular coat of the small intestine of a cat was hardened in absolute alcohol, stained in Delafield's hæmatoxylin, embedded in paraffin, and sectioned. Fix and mount in balsam.

The fibres in the longitudinal coat will appear in cross section; note that they vary in size, and only a few are nucleated (many cross sections can be made of a single cell, but very few of them will pass through the nucleus). The circular layer is cut in the direction of the longitudinal axis of the cells. Sketch under high power a portion of both coats.

DRAWINGS FOR LESSON XII.

DRAWINGS FOR LESSON XII.

LESSON XIII.

PERIPHERAL NERVES.

(a) Fresh Medullated Nerve.

Tease a piece from the sciatic nerve of a frog in normal salt solution. Before covering arrange the fibres as straight as possible.

Examine under high power, employing one of the smaller openings in the diaphragm. Observe the axis cylinder, seen as a light band passing down through the center of the fibre. It is surrounded by a thin glistening layer usually of a light green color, the medullary sheath; around this is the neurilemma. Find the nodes of Ranvier; search for the nucleus of an internodal segment. Some of the fibres may show the segments of Lantermann.

(b) Medullated Nerve Fibres Stained in Osmic Acid.

The sciatic of a frog was fixed for 24 hours in a 1% solution of osmic acid. Tease very carefully in gum glycerine.

Examine under high power. The medullary sheath is stained deeply black by the osmic acid. The nodes of Ranvier are very clearly seen in this preparation.

(c) Medullated Nerve Fibres Stained in Hæmatoxylin.

A small cerebro-spinal nerve was hardened in a saturated aqueous solution of picric acid for 48 hours, washed for several days in 70% alcohol, teased, and stained in Boehmer's hæmatoxylin for about one hour. Tease thoroughly in gum glycerine.

Study under high power. The axis cylinder appears as a deeply stained cord passing through the center of the fibre. The medullary substance has a reticulated appearance. The internodal nuclei are also stained. Sketch as seen under high power.

(d) Non-Medullated Nerve Fibres Stained in Hæmatoxylin.

The splanchnic nerves of a dog were hardened in picric acid, and stained in Boehmer's hæmatoxylin. Tease in gum glycerine.

Examine under high power. The great majority of the fibres are non-medullated, i. e., possess no medullary sheath, and hence showing no nodes of Ranvier. Numerous nuclei will be seen, often giving the fibre a beaded appearance. Sketch under high power.

(e) Cross-Section of a Nerve Trunk Hardened in Osmic Acid.

The sciatic of a frog was hardened in a 1% solution of osmic acid saturated with picric acid for 24 hours, washed in 70% alcohol for 2 days, embedded in paraffin, and sectioned. Fix to the slide and mount in balsam.

Study under high power. The medullary sheath is stained black, and the axis cylinder a grayish-black. Now and then fine granules can be seen in the axis cylinder; these are the ends of the primitive fibrillae. Sketch under high power.

(f) Cross-Section of a Nerve Trunk Stained in Anilin Blue and Safranin.

The posterior tibial nerve (human) was hardened for several weeks in Müller's fluid, dehydrated, embedded in paraffin, and sectioned. The sections were fixed to cover glasses, stained in anilin blue and safranin, dehydrated, and cleared in oil of bergamot and xylol.

The axis cylinders are stained blue, the myelin orange, and the nuclei red. Study under low power. Note that the funiculi are held together by a loose connective tissue, the epineurium; in it groups of fat cells and the blood vessels of the nerve trunk are found. Each funiculus is surrounded by a dense connective tissue sheath, the perineurium; this shows a lamellar structure. The nerve fibres in cross section should be studied under high power. Between the nerve fibres of a funiculus a small amount of connective tissue is seen, the endoneurium. Draw under low power a number of funiculi, and the surrounding

perineurium and epineurium; and under high power a small portion of a funiculus showing the fibres in cross section.

**(g) Longitudinal Section of a Nerve Trunk
Stained in Anilin Blue and Safranin.**

The section was prepared as above, and the reaction to the stain is the same as in the cross section.

Study and sketch as seen under high power.

DRAWINGS FOR LESSON XIII.

DRAWINGS FOR LESSON XIII.

LESSON XIV.

NERVE CELLS.

(a) Nerve Cells from Spinal Cord.

The gray matter was dissected from the cervical cord of an ox, macerated for several days in a very weak solution of chromic acid (1-15,000), and was then stained in lithium carmine. Tease very carefully in gum glycerine, controlling the results under the low power. Aim to isolate the cells from the surrounding tissue. The worth of this preparation will depend very largely on the care with which it is teased.

Examine under high power, and observe the large branching nerve cells; try to make out the axis cylinder process. Sketch several cells under this power.

(b) Nerve Cells from the Spinal Cord Stained in Methylene Blue.

The gray matter was dissected from a spinal cord, and crushed between two cover glasses, these are then drawn apart, and set aside to dry. Stain for 30 minutes in a 1% methylene blue solution, wash in water, and dry between filter paper. When thoroughly dry mount the preparation in balsam.

Study the preparation under high power. A few nerve cells will be found. Observe the relatively large nucleus with its prominent nucleolus; also the spongioblastic network in the cell body. Sketch as seen under high power.

(c) Spinal Cord Stained after Golgi's Method.

The spinal cord of an embryo or young mammal was divided into small pieces, placed for 2 or 3 days in a solution composed of 1 part of a 1% solution of osmic acid and 4 parts of a 3% solution of potassium bichromate, then in a $\frac{1}{4}$ % solution of silver nitrate for about an hour, finally in a $\frac{3}{4}$ % solution of the same salt in which they remained for 2 to 4 days, then surrounded with paraffin, and sectioned. The sections were cut into 95% alcohol, transferred to

creosote for 15 minutes, and then into turpentine. Transfer a section to the slide, remove as much of the turpentine as possible, *cover with a large drop of balsam, and heat the slide over the flame for several minutes. Cover with a warm cover glass, and set aside to cool.*

Study under high power. Only a few of the nerve cells are stained (a brownish black), but these are usually brought out very clearly. The protoplasmic processes are seen branching and rebranching, and the axis cylinder process may now and then be traced through several fields of the microscope. This process gives off only a few small branches. A few neuroglia cells may also be stained; they have a small body from which many fine processes radiate. Sketch nerve and neuroglia cells as seen under high power.

(d) Brain Cortex Stained after Golgi's Method.

These sections were stained according to the above mentioned method. Mount in the same way as the spinal cord section.

Study under high power. The cortical cells have a triangle-shaped body; an axis cylinder process is given off from the base, which passes down into the white substance; the protoplasmic processes are large, especially the one given off from the apex. Sketch a number of the cells as seen under high power.

(e) Cerebellum Stained after Golgi's Method.

The section was stained as above; mount in hard balsam as directed.

Study first under low power, and search for Purkinje's cells. These are often very beautifully stained. They have an oval or pear-shaped body, from the lower end of which an axis cylinder process is given off, and from the other end a large protoplasmic process which usually divides into two or three branches and these divide and redivide until a complicated system of branches is formed. A few of the nerve cells in the granular layer and some of the basket cells may also be stained. Sketch the cells under high power.

(f) Posterior Root Ganglion Stained in Osmic Acid.

The posterior root ganglion of a small mammal was hardened in Hermann's solution, embedded in paraffin, and sectioned longitudinally. Fix the section to the slide, and mount in balsam.

Study under low power. Observe that the fibrous capsule around the ganglion is continuous with the epineurium of the in-coming and out-going nerve trunk. The nerve fibres are stained black. The nerve trunk breaks up into several smaller bundles after it enters the ganglion. Between these bundles may be seen groups of ganglion cells, round or oval in shape, with prominent nuclei and nucleoli. They are stained a faint brown color. The cells are surrounded by a nucleated capsule. Sketch the ganglion under low power.

(g) Posterior Root Ganglion Stained in Hæmatoxylin.

The posterior root ganglion of a dog was hardened in mercuric chloride, stained in Delafield's hæmatoxylin, embedded in paraffin, and sectioned longitudinally. Fix to the slide, and mount in balsam.

Study first under low power, and observe the structure as described for (f) of this lesson. Sketch a number of the cells with the intervening nerve fibres as seen under high power.

DRAWINGS FOR LESSON XIV.

DRAWINGS FOR LESSON XIV.

LESSON XV.

SPINAL CORD, CEREBELLUM, AND
CEREBRUM.

(a) Spinal Cord with Anterior and Posterior
Roots.

A segment of the cervical cord of a cat with the anterior and posterior roots of the two sides (to a point a short distance beyond their junction) was removed and hardened in mercuric chloride. To insure the hardening of the roots in a plane so that the cord and roots on both sides might be cut in one section, the following device was made use of: An opening large enough to admit the cord was made in a card; one end of the cord segment was pushed through this opening, and the roots were spread out on the card to which they adhered. The preparation was then placed in mercuric chloride. After hardening it was stained *en masse* in borax carmine for several days, embedded in paraffin, and sectioned. Fix to the slide, and mount in balsam.

Study under low power. Observe the anterior and posterior roots in connection with the anterior and posterior horns of the gray matter. Sketch under low power.

(b) Section of Spinal Cord Stained in Weigert's
Hæmatoxylin.

A human cord was hardened in Müller's fluid, embedded in celloidin, stained in Weigert's hæmatoxylin, dehydrated, and cleared in carbol-xylol. Place section on slide, wipe away excess of clearing fluid, and mount in balsam.

Study under low power. The cord is nearly divided into two symmetrical halves by two fissures, the anterior and posterior median fissures, the latter is really only a connective tissue septum. In each half of the cord the gray matter, which in this section has a yellowish-brown color, appears in the form of a crescent. The convex borders of the two crescents are opposed to each other. The anterior horns of gray matter are broader and shorter,

and do not come so near to the surface as the posterior. The two crescents are united by an anterior white, and a posterior gray, commissure, between which is found the central canal. In the gray matter a very fine network of fibres is seen. This is composed of medullated fibres, branches of nerve cells, and neuroglia tissue. The nerve cells are usually found in small groups, those in the anterior horn are larger and more numerous. The white matter, stained a bluish black, surrounds the gray. It is composed of medullated nerve fibres seen in cross section. Between these fibres a small amount of neuroglia tissue is observed. Sketch the cord in outline as seen under low power, and sketch portions of the gray matter of the anterior horn and white matter as seen under high power.

(c) Cerebellum.

Small pieces of the cerebellum were hardened in mercuric chloride, stained in Delafield's hæmatoxylin, embedded in paraffin, and sectioned at right angles to the small folds. Fix to the slide and mount in balsam.

Under high power the gray matter shows the following layers in cross-section:—

(1) An outer molecular layer, composed largely of neuroglial tissue, and containing a few small ganglion cells.

(2) Between the above stratum and the third a single layer of Purkinje's cells is found. From the base of these cells an axis cylinder process is given off; from the opposite pole one or two protoplasmic processes, these extending into the molecular layer and there dividing and redividing, until the process has the appearance of a deer's antlers.

(3) The granular layer, composed largely of round and spindle-shaped cells possessing comparatively large nuclei, so that in the section very little but the nuclei will be seen. The axis cylinder processes of Purkinje's cells pass through this layer, become medullated, and are lost in the white substance making up the central portion of the fold. Sketch the cortex under high power.

(d) Cerebral Cortex.

Small pieces of cerebral cortex were hardened in mercuric chloride, stained in Delafield's hæmatoxylin, embedded in paraffin,

and sectioned at right angles to the surface. Fix and mount in balsam.

Under high power the following structure will be seen:—

(1) The outer or molecular layer, composed largely of neuroglial tissue. In it are a few small nerve cells and a thin stratum of fine medullated fibres, running parallel to the surface just under the pia mater.

(2 and 3) Layer of small and large pyramidal cells. In the former layer the cells are small and close together; in the latter they are larger and farther apart. There is, however, no distinct boundary line between the two layers.

(4) A layer of small cells, some of which are pyramidal, others spindle-shaped, still others multipolar.

Sketch a portion of the cortex under high power.

(e) Cerebral Cortex Stained with Weigert's Hæmatoxylin.

Small pieces of the human cortex were hardened in Müller's fluid, embedded in celloidin, sectioned at right angles to the surface, stained in Weigert's hæmatoxylin, dehydrated, and cleared in carbol-xylol. Wipe away excess of clearing fluid, and mount in balsam. The nerve fibres are stained a bluish-black, all other elements (except the red blood cells) a yellowish brown.

Study under low power. "The nerve fibres entering the gray cortex are arranged in bundles, from which arise networks variously arranged and situated. The radiating bundles proceed as such through about half the entire thickness of the cortex; beyond this level they rapidly separate into the component fibres which take their way between the ganglion cells." (Piersol.) Sketch a portion of the cortex as seen under low power.

DRAWINGS FOR LESSON XV.

DRAWINGS FOR LESSON XV.

DRAWINGS FOR LESSON XV.

LESSON XVI.

BLOOD VESSELS.

(a) Capillaries.

The thoracic aorta of a rat or guinea pig was injected with a 1% solution of silver nitrate. After 20 to 30 minutes the mesentery was removed, pinned out on flat corks, placed in 95% alcohol, in which the tissue was exposed to direct sunlight. In a few minutes the tissue turns a brownish color. It was then dehydrated, cleared in oil of bergamot, and cut into small pieces. Mount in balsam.

Study under high power. Small capillaries and arterioles, the endothelial cells of which are outlined by brownish-black lines, will be seen. Sketch a number of the capillaries under high power.

(b) Small Arterioles.

The mesentery of a cat was pinned out on a cork, hardened in alcohol, stained in Delafield's hæmatoxylin, dehydrated, and cleared in oil of bergamot. Mount in balsam.

Study under high power. Look for arterioles consisting of an endothelial coat, and a media composed of a single or double layer of non-striated muscle cells, about which there is a thin layer of fibrous tissue. Search for capillaries, in which the nuclei of the endothelial cells are stained. Sketch an arteriole and capillary as seen under high power.

(c) Artery and Vein.

The posterior tibial artery and vein (human) were hardened in mercuric chloride or alcohol, stained in borax carmine or Delafield's hæmatoxylin, embedded in paraffin, and cross-sectioned. Fix to the slide and mount in balsam.

Study first under low power. In the wall of the artery three coats are seen,—

(1) An inner coat, the tunica intima, which consists of a single layer of endothelial cells lining the lumen of the vessel, a thin stratum of sub-endothelial connective tissue, and a stratum of elastic tissue, the elastic intima or fenestrated membrane of Henle.

(2) The middle coat, tunica media, composed largely of circularly disposed bundles of non-stripped muscle tissue; between these thin films of elastic tissue, seen in cross section as wavy lines, are found.

(3) The outer coat, tunica adventitia, consists of bundles of white fibrous tissue felted into a dense network. Between these bundles a few elastic fibres are seen. This coat is continuous with the surrounding connective tissue.

The wall of the vein is not so thick. Three coats are seen, resembling in structure the ones seen in the artery. In the intima of the vein the elastic tissue is not so prominent; in the tunica media there is relatively less muscle; the bundles of muscle are separated by white fibrous tissue. The adventitia is thicker than the corresponding coat of the artery. This section also shows in section a number of small arteries and veins in the fibrous tissue surrounding the larger vessels.

Sketch a segment of the arterial wall, also of the venous wall, and sketch a small artery, all under low power.

(d) **Aorta.**

Small pieces of the aorta were hardened in alcohol, stained in borax carmine, embedded in paraffin, and cross-sectioned. Fix and mount in balsam.

The media is relatively thick, and is composed of alternating layers of non-stripped muscle and yellow elastic tissue. The majority of the non-stripped muscle cells are arranged transversely, some few longitudinally. The adventitia is a relatively thin coat, composed largely of white fibrous tissue, together with a few elastic and non-stripped muscle fibres. The intima is composed of endothelial cells, elastic, and white fibrous tissue. Sketch a portion of the wall under high power.

DRAWINGS FOR LESSON XVI.

DRAWINGS FOR LESSON XVI.

LESSON XVII.

**SIMPLE ADENOID TISSUE. THYMUS,
LYMPH GLAND, AND SPLEEN.**

(a) Simple or Diffuse Adenoid Tissue.

A portion of the vermiform appendix of a rabbit was hardened in absolute alcohol, stained in borax carmine, embedded in paraffin, and cross-sectioned. Fix to the slide, and mount in balsam.

Examine under high power. The mucosa and submucosa form a continuous zone of adenoid tissue. The mass of round cells are so closely packed that they cover up the adenoid reticulum in which they are found. Sketch as seen under high power.

(b) Tonsil.

The tonsil of a dog was hardened in mercuric chloride, stained in Delafield's hæmatoxylin, embedded in paraffin, and sectioned. Fix and mount in balsam.

Study first under low power. Under the stratified pavement epithelium are found a number of round or oval nodules of adenoid tissue embedded in diffuse adenoid tissue. They are more or less completely separated from the surrounding tissue by a fibrous tissue envelope. Under high power it will be noticed that in many places cells from the adenoid tissue have wandered into the epithelium, often to such an extent that it is difficult to recognize the epithelial cells. One or more small mucous glands are often seen in sections of the tonsil. Sketch under low power.

(c) Thymus Gland.

The thymus gland of a new-born mammal was hardened in mercuric chloride, stained in Delafield's hæmatoxylin, embedded in paraffin, and sectioned. Fix and mount in balsam.

Study under low power. The gland is divided into

lobules which are surrounded by fibrous tissue, from which septa pass into the lobules and divide them into secondary lobules. The secondary lobules are composed of adenoid tissue. This is denser and stains more deeply in the periphery of the lobules forming the cortical zone; the less dense center forms the medullary portion. In the medullary portion are found the concentric corpuscles of Hassall. They are the remains of the entodermal epithelial tissue of which the gland was composed in its early development.

(d) Compound Lymph Gland.

A lymph gland was hardened in mercuric chloride, stained in Delafield's hæmatoxylin, embedded in paraffin, and sectioned. Sections were fixed to cover glasses, counter-stained in eosin, dehydrated, and cleared in oil of bergamot and xylol. Mount on a drop of balsam.

Examine first under low power. Observe the capsule, from which trabeculæ pass into the gland, dividing its outer or cortical portion into comparatively large compartments, in which the cortical nodules of adenoid tissue are found. On entering the medulla the trabeculæ divide and anastomose; the network so formed has small meshes in which are found the medullary cylinders of adenoid tissue. The adenoid tissue is composed of a reticular framework and cells.

“The cortical follicles and the medullary cylinders do not completely fill out the compartments made for them by the capsule and trabeculæ respectively, but a narrow peripheral zone of each compartment is left free, this is a lymph sinus.” (Klein.) The lymph sinuses form an anastomosing system. Sketch a portion of the gland under low power.

(e) Reticulum of Adenoid Tissue.

A lymph gland was hardened in alcohol, and cut on the freezing microtome. The sections were stained in Boehmer's hæmatoxylin. They were then transferred to a test-tube half full of distilled water, in which they were carefully shaken for 10 or 15 minutes. In this way many of the lymph cells are shaken out of the reticulum. Mount in gum glycerine.

Examine under high power, using one of the smaller openings in the diaphragm. A reticulum of very fine

fibrils will be seen. Fixed connective tissue cells are often found on the network. Sketch under this power.

(f) Lymph Cells.

Cover glasses were drawn over the freshly cut surface of a lymph gland, and fixed in a solution of 3 parts ether and 1 part absolute alcohol for $\frac{1}{2}$ hour. Stain in hæmatoxylin for 15 minutes, wash in water, counter-stain in eosin for 5 minutes, again wash in water, and dry between filter paper. Mount in balsam.

Study under high power. The greater proportion of the cells seen have the shape and structure of the lymphocytes found in the blood. A few mononuclear and polynuclear cells will also be found. Sketch under high power.

(g) Spleen.

Small pieces from the spleen of a dog were hardened in mercuric chloride, stained in borax carmine, embedded in paraffin, and sectioned. Fix to the slide, and mount in balsam.

Observe the capsule composed of connective tissue and non-stripped muscle cells. From the capsule trabeculae pass into the gland, branching and forming an anastomosing network; their structure is similar to that of the capsule. Within the capsule two kinds of tissue are found, the Malpighian corpuscles and the splenic pulp. The former are composed of adenoid tissue, and are usually found surrounding the vessels. In the pulp a framework of fine fibrils and cells is found, in the meshes of which red and white blood cells are seen. Sketch a portion under high power.

(h) Cover Glass Preparation of Splenic Pulp.

Cover glasses were drawn over the freshly cut surface of a spleen, and fixed in ether-alcohol solution for 1 hour. Stain in hæmatoxylin and eosin as (f) of this lesson, and mount on balsam.

Study under high power. Many red blood cells stained with the eosin, and the various forms of white blood cells, will be seen. Of the white blood cells the mononuclear are found in much larger proportion than in circulating blood. Sketch the cells as seen under high power.

DRAWINGS FOR LESSON XVII.

DRAWINGS FOR LESSON XVII.

DRAWINGS FOR LESSON XVII.

LESSON XVIII.

SKIN AND APPENDAGES.

(a) Macerated Epidermis.

A small piece of skin was macerated for several days in $\frac{1}{4}\%$ solution of acetic acid. The epidermis was then carefully lifted from the dermis, rinsed in water, hardened in alcohol, stained in borax carmine, and cleared in oil of bergamot. Mount in balsam, taking care to mount it in such a way that the under surface of the epidermis is uppermost.

Study under low power. Observe the depressions in the under surface of the epidermis into which the papillæ of the true skin fit. Note their number and arrangement. Sketch under low power.

(b) Preparation of the Dermis.

The skin was macerated as above, and the epidermis removed. The dermis was hardened in alcohol, stained in borax carmine, embedded in paraffin, and sectioned.

Study under low power. This section is given to show the papillæ of the true skin. In many of these a capillary network can be made out. Sketch a number of the papillæ under low power.

(c) Cross-Section of Human Skin.

A small piece of skin removed from the plantar surface of the foot or palmar surface of the hand was hardened in 10% nitric acid for 24 hours, then in Müller's fluid for two weeks, stained in Delafield's hæmatoxylin, embedded in paraffin, sectioned, fixed to cover glasses, counter-stained in 1% acid fuchsin, dehydrated, and cleared in oil of bergamot and xylol. Mount in balsam.

This section is to be studied first under low power, and the general arrangement of the tissues observed. In the epidermis the following layers are found, named in order from within, outward:—

(1) *Stratum Malpighii* (*rete mucosa*), composed of stratified pavement epithelium.

(2) *Stratum granulosum*, a narrow layer of cells which contain kerato-hyalin granules (*Waldeyer*) in their protoplasm.

(3) *Stratum lucidum*, composed of horny cells the outlines of which are very indistinct.

(4) *Stratum corneum*, the thick outer layer.

Observe also the twisted portion of the sudoriferous glands passing through the epidermis.

In the *cutis vera* an outer denser portion, the papillary layer, is observed. This is composed of closely interwoven bundles of white fibrous tissue, between which a small amount of elastic tissue is found. This layer is beset with papillæ. In the deeper portion of the *corium*, the reticular layer, the bundles of fibrous tissue are loosely woven. In the large open meshes groups of fat cells and the secreting portion of the sweat glands are found. Some of the preparations may show a *Vater-Pacini* corpuscle in section.

Sketch the several layers of the epidermis and the dermis as seen under low power.

(d) **Cross-Section of the Scalp.**

A portion of the scalp was hardened in *Müller's fluid*, embedded in celloidin, sectioned, and stained in *hæmatoxylin* and *eosin*. The sections are in oil, and are to be mounted in balsam.

In this section special attention is to be given to the study of the hair and its follicle. An attempt was made to cut them longitudinally. Examine first under low power, and observe the several layers of the follicle, the sebaceous gland seen in connection with it, and the *arrectores pili*. Sketch under this power.

(e) **Tangential Section of the Scalp.**

This tissue was prepared as the cross-section. Mount in balsam.

In this section the hair follicles are seen in cross-section. Study under high power.

Each follicle shows the following layers, named in order from without, in:—

In the dermal coat,

- (1) A longitudinal fibrous layer.
- (2) A circular fibrous layer.
- (3) Glassy layer.

In the epidermal coat,

- (1) Outer root sheath (rete mucosa).
- (2) Henle's layer.
- (3) Huxley's layer.
- (4) Cuticle of the shaft.

Sketch a follicle as seen under high power.

DRAWINGS FOR LESSON XVIII.

DRAWINGS FOR LESSON XVIII.

LESSON XIX.

THE DIGESTIVE TRACT.

(a) Cross-Section of Human Lip.

Pieces of the lip of a child were hardened in mercuric chloride, stained in Delafield's hæmatoxylin, embedded in paraffin, and cross-sectioned. Fix to the slide and mount.

Study under low power. Observe that the outer surface of the lip is covered with a thin epidermis resting on a dermis in which many hair follicles, sebaceous and sweat glands are found. The inner surface of the lip is covered with a mucous membrane consisting of stratified pavement epithelium and a fibrous mucosa. In the submucous tissue, and in the deeper parts of the mucosa, are often found quite large mucous glands which empty on the inner side of the lip. Between the epidermal and mucous surfaces striped muscle, fibrous, and adipose tissue is found. Often one or more quite large blood vessels and nerve trunks are seen. Sketch under low power.

(b) Section of the Tongue Showing Filiform Papillæ.

The tip of the tongue of a cat was hardened in mercuric chloride, stained in Delafield's hæmatoxylin, embedded in paraffin, and longitudinal sections cut. Fix to the slide, and mount in balsam.

Study under low power. The papillæ are found on the dorsal surface. The mucosa is thrown into conical projections, the primary papillæ, on which several secondary papillæ are often seen. The papillæ are covered with stratified pavement epithelium, which on the outer surface has a smooth free border. Sketch several papillæ under high power.

(c) **Section of Tongue showing Fungiform Papillæ.**

Portions from the posterior part of a dog's tongue, known to contain fungiform papillæ, were hardened in mercuric chloride, stained in Delafield's hæmatoxylin, embedded in paraffin, and sectioned at right angles to the long axis of the tongue. The sections were fixed to cover glasses and counter-stained in eosin, dehydrated, and cleared in oil of bergamot and xylol. Mount on balsam.

Study first under low power. Search for the broad conical projections of the mucosa, composed of a rather dense fibrous tissue on which many secondary papillæ are seen. They are covered with stratified pavement epithelium. Many filliform papillæ will also be seen in this section. Observe the arrangement of the muscle fibres. The preparation will also show arteries, veins, and nerves in section. Sketch one fungiform papilla as seen under high power.

(d) **Taste Buds.**

The papilla foliata of a rabbit was hardened in mercuric chloride, stained in Delafield's hæmatoxylin, embedded in paraffin, and sectioned at right angles to the transverse ridges seen on the papilla. Mount in balsam.

The taste buds are embedded in the epithelium lining the furrows between the ridges. In the muscular and connective tissue below the papilla foliata small serous glands will be seen in section. Sketch two ridges with the intervening furrow and taste buds as seen under high power.

(e) **Mucous and Serous Salivary Glands.**

Small pieces taken from the submaxillary and parotid glands of a dog were hardened in mercuric chloride, pieces of each gland embedded side by side in paraffin (so that one section will pass through both glands), and sectioned. The sections were then fixed to cover glasses, stained in Haidenhain's iron-lack-hæmatoxylin, dehydrated, and cleared in oil of bergamot and xylol. Thus on each cover glass are sections of both submaxillary and parotid glands. Mount in balsam.

Study first under low power. The less deeply stained section is the mucous (submaxillary) gland. Both glands have the same general structure. The acini are grouped into lobules which are held together by a loose fibrous tis-

sue. The acini of the mucous glands are larger than those of the serous glands. Study the structure of the acini under high power.

In the *mucous glands* the acini are surrounded by a *membrana propria* which is nearly filled with clear mucous cells stained a steel-gray. The nuclei are in the peripheral part of the cells. Many of the acini will show a crescent of more deeply stained cells, the demilunes of Heidenhain, lying between the mucous cells and the *membrana propria*. The ducts are regularly round or oval with relatively large lumina. They are lined by a single layer of columnar cells with striated protoplasm.

The acini of the *serous glands* also have a limiting *membrana propria*. They are lined by cuboidal or polyhedral cells with the nuclei near the center of the cells. They often have a granular protoplasm. The structure of the ducts is the same as in the mucous glands.

Sketch a duct and a number of acini surrounding it, from both mucous and serous glands as seen under high power.

(f) Mucous and Serous Salivary Glands Stained in Delafield's Hæmatoxylin.

Pieces of the submaxillary and parotid glands of a dog were hardened in mercuric chloride, stained in Delafield's hæmatoxylin, and a piece of each gland embedded side by side in a block of paraffin, and sectioned. Fix to the slide and mount in balsam.

The structure seen in (e) will again be observed.

(g) Mucous and Serous Salivary Glands Stained in Borax Carmine.

Pieces from the submaxillary and parotid glands of a dog were hardened in absolute alcohol, stained in borax carmine, pieces of each gland embedded as above, and sectioned. Fix and mount.

The last two preparations are given to the student to show the structure of mucous and serous glands as shown by hæmatoxylin and carmine stains to facilitate their recognition in sections to be given later on in the work.

DRAWINGS FOR LESSON XIX.

DRAWINGS FOR LESSON XIX.

DRAWINGS FOR LESSON XIX.

LESSON XX.

DIGESTIVE TRACT (Continued).

(a) Longitudinal Section of Hard Tooth.

By means of a fine saw a longitudinal section is cut from a tooth (incisors or canines best). Grind this on an emery wheel as thin as possible, and then between two hones until it becomes quite transparent. Care must be taken to grind it evenly; keep the hones well moistened with water. Wash thoroughly, first in water, then in alcohol; then dry the section between filter paper. Mount in hard balsam.

Study the preparation first under low power, observing the shape and size of the pulp cavity, and the relative proportion of the dentine, cement, and enamel. The structure of these parts is then to be studied under high power. In the enamel note the enamel prisms; in the dentine the dentinal tubules radiating from the pulp cavity, and in its peripheral portion, the interglobular spaces. The cement shows the structure of bone; very seldom, however, are Haversian canals found. Sketch under low power.

(b) Cross-Section of Decalcified Tooth.

The canine of a young cat was extracted, the pulp cavity opened from above, and hardened in 50 parts of a saturated aqueous solution of mercuric chloride and 3 parts of formalin, for 2 days. It was then washed in flowing water for 12 hours, and decalcified in 20 parts of formic acid, 3 parts of glacial acetic acid, and 30 parts of distilled water. It was again washed in water, dehydrated, embedded in paraffin, and cross-sectioned. The sections were fixed to cover glasses, stained in hæmatoxylin and eosin, dehydrated, and cleared in oil of bergamot and xylol. Mount in balsam.

Study under high power. The preparation is given to demonstrate the structure of the pulp. Observe the loose connective tissue, consisting of a few fibrils and branched connective tissue cells. A layer of odontoblasts bounds the pulp. These cells have a column-shaped body; from

this two branches are given off, pulpal processes communicating with the branched cells of the pulp, and tubular processes which enter the dentinal tubules. Sketch under high power a portion of the pulp with odontoblasts and a segment of the adjacent dentine.

(c) Developing Tooth Showing the Enamel Organ.

A cat embryo about an inch in length was hardened in mercuric chloride. The head was removed and stained in Delafield's hæmatoxylin, embedded in paraffin, and cross-sections of the face made. Fix and mount in balsam.

Study first under low power. The preparation shows the nasal cavities, separated from each other by the nasal septum, and separated from the oral cavity by the roof of the mouth. From the floor of the mouth there projects a broad fold, the tongue. In the developing lower jaw will be seen the enamel organs, a little to the side of the tongue; also, at a point just above, in the developing upper jaw. Study one of the enamel organs under high power. It has the shape of a shallow bowl, and is in connection with the epithelium lining the mouth cavity by a narrow stalk. The enamel organ is developed from this epithelium. The embryonic connective tissue under the enamel organ shows a denser structure, and much more cell proliferation than the surrounding connective tissue; it constitutes the dental papilla. Sketch the section in outline as seen under low power, and one of the enamel organs and dental papillæ as seen under high power.

(d) Developing Tooth Showing Formation of Dentine and Enamel.

The head of an embryo cat (about 4 to 5 inches long) was hardened in picro-sulphuric acid, stained in Delafield's hæmatoxylin, embedded in paraffin, cross-sections of the face made, fixed to cover glasses, counter-stained in eosin, dehydrated, and cleared in oil of bergamot and xylol. Mount on balsam.

Study first under low power. The same general structure will be recognized in this section as in (c) of this lesson. Study one of the developing teeth under high power. In the enamel organ three kinds of cells can be

made out. The lower layer consists of very regular, tall, columnar cells, the enamel cells. These cells are engaged in depositing the enamel, consisting of prisms of a structureless substance. Above the enamel cells are found 2 to 3 layers of short columnar or polyhedral cells. Then there is a layer of varying thickness composed of highly metamorphosed epithelial cells, seen in the form of flattened plates or fibres, or spindle-shaped or star-shaped cells. This layer constitutes the enamel pulp. The outer layer is composed of two or three rows of flattened, irregular cells in connection with the epithelium lining the mouth cavity.

In the dental papilla the cells of the peripheral part have assumed a very regular arrangement, and are columnar in shape. They constitute the layer of odontoblasts, and are engaged in the deposition of dentine. The dentine is quite deeply stained in eosin in this section. In it fine canals can be made out, into which the processes of the odontoblasts extend. The remaining portion of the dental papilla shows the structure of embryonic connective tissue. Make an outline sketch of the section as shown under low power, and of one of the developing teeth as seen under high power.

DRAWINGS FOR LESSON XX.

DRAWINGS FOR LESSON XX.

DRAWINGS FOR LESSON XX.

LESSON XXI.

DIGESTIVE TRACT (Concluded).

(a) Œsophagus.

The œsophagus of a dog was hardened in alcohol, stained in borax carmine, embedded in paraffin, and cross-sectioned. Fix to the slide, and mount in balsam.

Study first under low power, and notice the stratified pavement epithelium resting on a papillated mucosa, which is limited externally by a muscularis mucosa. Then follows the submucosa, a fibrous tissue coat containing the larger vessels. Mucous glands may be seen in this stratum. Next is a muscular coat composed of inner circular and outer longitudinal bundles. If the section is from the upper third of the œsophagus, the muscular tissue is largely of the striped variety, below this, non-striped. Sketch a segment of the wall as seen under low power.

(b) Junction of the Œsophagus and Cardiac End of the Stomach.

A portion of the alimentary canal, including the lower end of the œsophagus and cardiac end of the stomach, was removed, pinned out on a flat cord, and hardened in absolute alcohol. A small piece including the œsophagus and cardiac end of the stomach was cut out, stained in borax carmine, embedded in paraffin, and sectioned. Fix to the slide, and mount in balsam.

Study under low power. The œsophageal portion of the section shows the structure seen in preparation (a) of this lesson: the epithelial lining is stratified pavement which ends abruptly at the termination of the œsophagus. Large mucous glands are usually found in the mucosa and submucosa. In the dog a layer of striped muscle fibres, which extends as a thin sheath outside of the non-striped

muscle to the end of the œsophagus, passes for a short distance on to the wall of the stomach. The portion of the section coming from the stomach is lined by a single layer of columnar cells. A few imperfectly formed peptic glands are also seen. Sketch the portion of the section showing the junction of the stratified pavement and the single layer of columnar epithelium with the underlying mucosa, as seen under low power.

(c) Cardiac End of the Stomach.

Pieces from the cardiac end of the stomach of a dog were hardened in absolute alcohol, embedded in paraffin, and sectioned. The sections were fixed to cover glasses, and stained in the Ehrlich-Biondi triple stain, dehydrated, and cleared in oil of bergamot and xylol. Mount on balsam.

Study first under low power. Observe the mucosa with the cardiac glands, the muscularis mucosa, the fibrous submucosa with the larger vessels, the muscular coat composed of two or three layers of non-striped muscle, and the peritoneal coat. Under high power the finer details are made out. The peptic glands are simple or branched tubular glands, with short neck and comparatively long secreting tubules. In the latter two kinds of cells are found, the central, chief, or peptic cells, stained a faint green color, and the parietal or oxyntic cells of Langley, of oval shape and stained a reddish tinge.

This section, and the sections of the pyloric end of the stomach and of the small and large intestines are to be sketched side by side in the spaces outlined for you on two of the pages reserved for the drawings of this lesson. The sketches are to be so made that the muscularis mucosa of each of the four sections falls on the dotted line running across the pages. The relative thicknesses of the several coats should be shown as accurately as possible. Sketch under low power.

(d) Pyloric End of the Stomach.

The tissue was taken from the pyloric end of a dog's stomach, hardened in alcohol, stained in borax carmine, and embedded in paraffin. Mount in balsam.

Observe that in the pyloric glands the duct is longer, the secreting tubule correspondingly shorter, and lined by only one kind of cells, these resembling the chief cells in the cardiac glands. The section may show small masses of adenoid-tissue in the deeper portion of the mucosa. Sketch as above directed.

(e) Section of the Pyloric End of the Stomach and Small Intestine, Showing Brunner's Glands.

A piece of the intestinal canal, including the junction of the pyloric end of the stomach and the small intestine, was removed from a cat, pinned out on a flat cork, hardened in absolute alcohol, stained in borax carmine, embedded in paraffin, and so cut as to include both pyloric end and small intestine in the section. Fix to the slide, and mount in balsam.

Study under low power. The portion of the section from the pyloric end will show the structure above described. In the portion from the small intestine, observe the villi and the crypts of Lieberkühn in the mucosa, and Brunner's glands in the submucosa. The latter are compound tubular glands with the secreting tubules in the submucosa. They are grouped about the ends of the long ducts which pass up through the muscularis mucosa and mucosa, opening in the depressions between the villi. In the cat the secretion of these glands is mucous. Sketch a portion of the small intestine showing Brunner's glands as seen under low power.

(f) Small Intestine.

Small pieces from the small intestine of a dog were hardened in mercuric chloride, stained in Delafield's hæmatoxylin, embedded in paraffin, and cross-sectioned. Fix sections to the slide, and mount in balsam.

Study first under low power: Note the villi, conical projections of the mucosa, covered by a single layer of columnar cells. Observe the chyle vessel in the center of each villus. In the mucosa are found many tubular glands, the crypts of Lieberkühn, coming to the surface between the villi. The mucosa is bounded below by a muscularis mucosa composed of two or three layers of non-

striped muscle cells. Beneath this coat is a loose fibro-elastic coat, the submucosa, in which several quite large arteries and veins will be seen in section. The muscle coat is composed of an inner circular and an outer longitudinal layer of non-striped muscle tissue. The serous coat is seen as a thin layer of fibrous tissue, covered on the outer surface by a layer of endothelial cells. Sketch the section by the side of the drawing of the pyloric end of the stomach.

(g) Small Intestine Showing Peyer's Patch.

A piece of the small intestine known to contain a Peyer's patch was hardened in mercuric chloride, stained in Delafield's hæmatoxylin, embedded in paraffin, and sectioned. Fix and mount in balsam.

Study under low power. Observe the several nodules of simple adenoid tissue in the mucosa and submucosa, pushing aside the crypts of Lieberkühn, and often coming up under the epithelial lining of the intestine and causing an elevation of the epithelial layer. Sketch a portion of the intestine showing a lymph nodule as seen under low power.

(h) Injected Small Intestine.

The mesenteric artery of a cat was injected with gelatine-carminé, hardened in alcohol, stained in Delafield's hæmatoxylin, embedded in paraffin, and cross-sectioned. Fix and mount in balsam.

Use low power. Note the arrangement of the injected vessels in the muscular coat, in the submucosa, about the crypts of Lieberkühn, and in the villi. Sketch a portion of the wall under low power.

(i) Large Intestine.

Pieces of the large intestine of a dog were hardened in alcohol, stained in borax carminé, embedded in paraffin, and sectioned. Fix to the slide, and mount in balsam.

Notice that in the large intestine no villi are found. Simple tubular glands, the crypts of Lieberkühn, are observed. They are placed vertically in the mucosa, and are lined by a single layer of short columnar cells, the great majority of these appearing as goblet cells. Sketch by the side of the small intestine as above directed.

(j) Pancreas.

The pancreas of a dog was hardened in mercuric chloride, stained in Delafield's hæmatoxylin, embedded in paraffin, and sectioned. Fix sections to the slide, and mount in balsam.

Study first under low power. The structure of the pancreas is in many ways similar to that of a serous salivary gland. Note the inner granular zone in the cells lining the alveoli; the nucleus is found in the outer zone. Sketch several alveoli as seen under high power.

DRAWINGS FOR LESSON XXI.

DRAWINGS FOR LESSON XXI.

CARDIAC END OF STOMACH.

PYLORIC END OF STOMACH.

DRAWINGS FOR LESSON XXI.

SMALL INTESTINE.

LARGE INTESTINE.



DRAWINGS FOR LESSON XXI.

LESSON XXII.

LIVER, TRACHEA, LUNG, AND THYROID.

(a) Liver Cells.

Small pieces from the liver of a cat were macerated for 24 hours in Ranvier's alcohol, and for 2 hours in 0.5% osmic acid. Tease in gum glycerine.

Study under high power. The liver cells are polyhedral in form, and possess a distinct intracellular network. Fat globules, stained black, may be seen in the cells. As a rule a single spherical nucleus is found. Sketch several as seen under high power.

(b) Injected and Stained Liver.

The liver of a pig was injected through the portal vein with Berlin blue, hardened in alcohol, stained in borax carmine, embedded in paraffin, and sectioned. Fix and mount in balsam.

Study under high power. Note that the gland is composed of lobules, and injected interlobular branches of the portal vein are seen between them. From these interlobular vessels capillaries pass into the lobule and unite in an intralobular vessel, this emptying into a sublobular vein. The liver cells appear arranged in columns between the capillaries. Sketch two of the lobules, showing the arrangement of blood vessels and liver cells as seen under low power.

(c) Human Liver.

Small pieces of a human liver were hardened in mercuric chloride, embedded in paraffin, and sectioned. The paraffin was removed from the sections with xylol; they were then stained in hæmatoxylin and eosin, dehydrated, and cleared in oil of bergamot. Mount in balsam. Study first under low power.

In the human liver the hepatic lobules are separated one from the other by only a very small amount of inter-

lobular connective tissue. The intralobular vein is quite easily made out in the center of each lobule; from this the cords of liver cells radiate in the form of irregular anastomosing columns, between which the open capillaries, often containing a few red blood cells deeply stained in eosin, can be seen. Here and there a bile duct, lined by a single layer of cubical or short columnar cells, will be seen in the interlobular connective tissue. Sketch a portion of the section, including a bile duct, as seen under high power.

(d) Liver with Bile Capillaries Stained According to Oppel's Method.

Small pieces of the liver were hardened in a solution of potassium bichromate and osmic acid (Ramon y Cajal) for three days, then transferred to a $\frac{3}{4}$ % solution of silver nitrate, in which they remained for several days. The sections are in turpentine; mount in hard balsam.

The bile capillaries are stained black. Two sections are given, one from the liver of an embryo rat, in this the compound tubular character of the gland is easily made out; the second from the liver of a young kitten, showing an apparent network of bile capillaries between the liver cells. Sketch a portion of each section as seen under high power.

(e) Trachea.

Small pieces from the trachea of a young cat were hardened in mercuric chloride, stained in Delafield's hæmatoxylin, embedded in paraffin, and sectioned. Fix and mount in balsam.

Study under high power. The trachea is lined by stratified ciliated columnar epithelium resting on a mucosa of loose fibro-elastic tissue, in the outer portion of which the elastic fibres form a well-marked layer. The fibrous submucosa contains the mucous tracheal glands. In the external fibrous coat is found the hoop of hyaline cartilage. Between the ends of the cartilage the outer layer is composed of fibrous and non-striped muscle tissue. Sketch a segment of the trachea as seen under high power.

(f) Lung.

The lung of a cat was distended with absolute alcohol before opening the chest cavity; after ligating the trachea the lung was

carefully removed, and suspended for several days in alcohol, then divided into small pieces, stained in borax carmine or Delafield's hæmatoxylin, embedded in paraffin, and sectioned. Fix to the slide, and mount in balsam.

Study first under low power, and notice the bronchi, blood vessels, and alveoli. The sections of the large bronchi show a lining of stratified ciliated columnar epithelium resting on a fibrous mucosa, in which small mucous glands may be observed. Next, there is a band of non-stripped muscle tissue, outside of which cartilage plates may be seen in cross-section. The small bronchi are lined by a single layer of ciliated columnar cells, and the cartilaginous plates are wanting. Try and make out the capillaries between the alveoli; a few blood cells may be seen in them. Sketch a segment from the wall of a large bronchus; also a small bronchiole with a few of the surrounding alveoli, as seen under high power.

(g) **Thyroid Gland.**

A piece of the thyroid gland of a dog was hardened in mercuric chloride, embedded in paraffin, sectioned, and fixed to cover glasses. The sections were then stained in hæmatoxylin and eosin, dehydrated, and cleared in oil of bergamot and xylol. Mount on balsam.

Study first under low power. The gland is surrounded by a fibrous capsule. Oval or round alveoli, lined by a single layer of cubical cells, are seen. The alveoli are filled with a substance which stains deeply in eosin. Sketch several alveoli under high power.

DRAWINGS FOR LESSON XXII.

DRAWINGS FOR LESSON XXII.

DRAWINGS FOR LESSON XXII.

LESSON XXIII.

KIDNEY, ADRENAL, AND PROSTATE.

(a) Isolated Tubules of Kidney.

Pieces from the kidney of a small mammal were macerated for 24 hours in a 30 % solution of hydrochloric acid, and washed for $\frac{1}{2}$ hour in flowing water. Tease very carefully in gum glycerine.

Different portions of the tubules will be seen in the field. Sketch a Malpighian corpuscle, a convoluted tubule, and a loop of Henle, under low power.

(b) Longitudinal Section of a Small Kidney.

The kidney of a young rat or other small mammal was hardened in mercuric chloride, stained in Delafield's hæmatoxylin, and longitudinal sections cut. The sections were fixed to cover glasses and counter-stained in eosin, dehydrated, and cleared in oil of bergamot and xylol. Mount on balsam.

Study first under low power. In this preparation only one Malpighian pyramid is seen. In the medullary portion the tubules have a more or less straight direction, radiating from the apex toward the base of the Malpighian pyramid. In the cortex are observed bundles of straight collecting tubules arranged in the form of pyramids (the pyramids of Ferrein or medullary rays), the bases of which rest on the base of the Malpighian pyramid. Between the medullary rays is found the labyrinth of the kidney, composed of Malpighian corpuscles, proximal and distal convoluted tubules, and spiral and zigzag portions of the uriniferous tubules. Study the form and structure of the epithelium lining the different portions of the uriniferous tubules under high power. Make an outline sketch of the section as seen under low power.

(c) Injected Kidney.

The kidney of a dog was injected with Berlin blue through the renal artery, hardened in alcohol, stained in borax carmine, and embedded in paraffin. Fix and mount in balsam.

Study under low power, observing the injected interlobular arteries. Note the glomeruli with their afferent and efferent vessels, the capillary network about the convoluted tubules, and the straight capillaries of the medulla. Sketch a portion of the cortex and medulla seen under low power.

(d) Human Kidney.

A human kidney was cut transversely into flat pieces about $\frac{1}{8}$ of an inch thick, hardened in mercuric chloride, embedded in paraffin, and sectioned. The sections were fixed to cover glasses, stained in hæmatoxylin and eosin, dehydrated, and cleared in oil of bergamot and xylol. Mount on balsam.

Study under low power. Observe the relatively thick capsule of fibrous tissue, and a narrow zone of convoluted tubules just below the capsule, in which no Malpighian corpuscles are found. Locate the medullary rays of the cortex; between these are the portions of the uriniferous tubules constituting the labyrinth of the kidney. Note the scarcity of the connective tissue between the tubules; also the interlobular vessels passing up between the medullary rays. In the medullary portion the collecting tubules converge toward the apex of the Malpighian pyramid. The largest ones near the apex of the pyramid are known as the tubules of Bellini. Between the straight collecting tubules, capillaries often filled with blood are to be looked for. Sketch a portion of the cortex and of the medulla as seen under high power, reproducing as accurately as possible the character of the epithelium lining the different parts of the uriniferous tubules.

(e) Suprarenal Body.

The suprarenal body of a guinea pig was hardened in mercuric chloride, stained in Delafield's hæmatoxylin, embedded in paraffin, and sectioned. Fix and mount in balsam.

Study first under low power. Observe the fibrous capsule from which septa pass into the gland. The gland

tissue is arranged in an outer more deeply stained border, the cortical zone, and a central portion, the medulla. In the cortex the granular cells are arranged in small groups in its peripheral portion; this is called the glomerular zone. Then comes a broad area, in which the cells are arranged in quite regular columns, the fascicular zone. Finally there is a third stratum next to the medulla in which anastomosing strands of cells are made out; this is the reticular zone. In the medulla are to be seen cords of irregular, pigmented cells, between which large vascular spaces are found. Sketch a band through the cortex and medulla as seen under high power.

(f) Prostate.

The prostate of a dog was divided transversely into several pieces, hardened in mercuric chloride, stained in Delafield's hæmatoxylin, and sectioned. The sections were fixed to cover glasses, and counter-stained in eosin, dehydrated, and cleared in oil of bergamot and xylol. Mount on balsam.

Study first under low power. The capsule of the prostate is made up largely of non-striped muscle tissue and a small amount of fibrous tissue. From the capsule fibromuscular trabeculæ pass toward the urethral canal, forming a framework for the glandular structure. The glands are compound tubular. The secreting tubules are lined by a single layer of short columnar cells. The gland ducts which empty into the urethra are relatively large, and lined for a distance with transitional epithelium. In the outer portion of the prostate, and here and there in the trabeculæ between the glands, smaller or larger sympathetic ganglia are to be seen. The prostatic urethra is lined by transitional epithelium. Sketch about $\frac{1}{4}$ of the section as seen under low power, and a portion of one of the glands as seen under high power.

DRAWINGS FOR LESSON XXIII.

DRAWINGS FOR LESSON XXIII.

DRAWINGS FOR LESSON XXIII.

LESSON XXIV.

MALE AND FEMALE ORGANS OF REPRODUCTION.

(a) Testis.

The testis of a dog was divided transversely into thin pieces, hardened in mercuric chloride, stained in Delafield's hæmatoxylin, embedded in paraffin, and sectioned. Fix to slide, and mount in balsam.

Use the low power. The section is given to show the general structure of the gland. Observe the fibrous tissue capsule, the tunica albuginea, surrounding the gland. From this septa pass into the parenchyma, and form a framework for the seminiferous tubules. These are seen cut in cross and oblique section. They are lined by several layers of epithelial cells. Some are filled with spermatozoa. Off to one side of the testis is seen the epididymis. The round or oval twisted tube as seen in cross section is lined by a layer of stratified ciliated columnar epithelium. The wall is composed of a fibrous mucosa; outside of this is a layer of non-stripped muscle tissue. Near the epididymis is the vas deferens. It shows a relatively broad outer wall of non-stripped muscle tissue, the majority of the cells of which are arranged transversely. The narrow fibrous mucosa is lined by stratified ciliated columnar epithelium.

Sketch a portion of the testis under low power, and a tubule of the epididymis and the vas deferens as seen under high power.

(b) Section of the Testis Showing Spermato-genesis.

Very small pieces of a guinea pig's testis were hardened for 24 hours in a solution composed of two parts of 2% osmic acid, three parts of 2% platinum chloride, and five parts of a saturated aqueous solution of mercuric chloride. They were then

washed for a few hours in flowing water, embedded in paraffin, sectioned, fixed to cover glasses, stained in Heidenhain's iron-lack-haematoxylin, counter-stained in a saturated aqueous solution of acid fuchsin, washed, dehydrated, and cleared in oil of bergamot and xylol. Mount on balsam.

Study under high power. On moving the section about you will observe that the variously cut seminiferous tubules show different stages of development. Within the tunica propria of a resting tubule are seen several layers of cells, in the outermost of which are found the spermatogones (parent cells), and the lower portion of the supporting cells of Sertoli. Then comes a layer of quite large cells, the spermatocytes (mother cells), descendants of the spermatogones. Lining the lumen of the tubules are found several layers of small cells, the spermatoblasts (daughter cells). The mother cells dividing by indirect cell division give rise to the small inner cells; from these the spermatozoa are developed. Search for a tubule showing the fusion of the spermatoblasts with the supporting cells of Sertoli. Other tubules will show the successive steps in the development of the spermatozoa in these cells until they are found free in the lumen of the tubule. Observe especially the change undergone by the accessory nucleus during the development of the spermatoblasts into the spermatozoa. In the spermatoblast the accessory nucleus is seen as a relative large ball stained black in this preparation; it is situated on one side of the nucleus. As development begins the accessory nucleus becomes demilunar in shape and applies itself to the nucleus. It then assumes a triangular shape, and finally becomes the head cap of the fully developed spermatozoa. Sketch portions of 3 or 4 tubules showing the several stages of spermatogenesis, as seen under high power.

(c) Ovary.

The ovary of a rabbit or cat was hardened in mercuric chloride, stained in Delafield's haematoxylin, embedded in paraffin, and sectioned. Fix and mount in balsam.

Study first under low power. The ovary is covered by a single layer of germinal epithelium. It consists of a medullary portion, in which large vessels are found, sur-

rounded by a cortical portion containing Graafian follicles seen in different stages of development. The framework or stroma is composed of fibrous and non-stripped muscle tissue. A fully developed Graafian follicle consists of a dense surrounding stroma; it is lined by the membrana granulosa composed of several layers of small cells; in one portion of the follicle this lining is thickened to form the discus proligerus; in this discus the ovum is embedded. The cavity of the follicle is filled by the liquor folliculi. Other follicles in different stages of development will also be observed; in some the ovum is surrounded by only a single layer of cells; in others by several layers, while in still others the cavity of the follicle may just be forming. The section may show a portion of a corpus luteum. If this is well developed, it will consist of a mass of quite large cells with relatively small nuclei, between which a network of capillaries will be seen. Sketch several Graafian follicles showing different stages of development, and a portion of the corpus luteum if present, as seen under high power.

(d) Uterus.

A human uterus was divided into small pieces, hardened in mercuric chloride, stained in Delafield's hæmatoxylin, embedded in paraffin, and cross sections of the wall made. Fix to the slide, and mount in balsam.

Study first under low power. The uterus will show mucous, muscular, and serous coats. The mucosa is composed of loose fibrous tissue, and is covered by a layer of ciliated columnar cells. In it are found the uterine glands, simple or branched tubules lined by a layer of ciliated columnar cells. The next coat is composed of non-stripped muscle tissue. Fibrous tissue is found between the muscle bundles, also relatively large vessels. Sketch a portion of the wall as seen under low power.

(e) Vagina.

The vagina of a dog was hardened in absolute alcohol, stained in borax carmine, embedded in paraffin, and sectioned. Fix to the slide, and mount in balsam.

Use the high power. The vagina has three coats, an inner mucous, composed of stratified pavement epithelium

and a fibrous mucosa; next is the muscular coat, composed of an inner circular, and an outer longitudinal layer of non-stripped muscle cells; lastly an outer fibro-elastic coat. Sketch under high power.

(f) Mammary Gland.

Small pieces taken from the mammary gland of a nursing bitch were hardened in mercuric chloride, stained in Delafield's hæmatoxylin, embedded in paraffin, and sectioned. The sections were fixed to cover glasses, counter-stained in eosin, dehydrated, and cleared in oil of bergamot and xylol. Mount on Balsam.

Study first under low power. Observe the acini of the gland united into small lobules by fibrous tissue. Under high power it will be seen that the acini are limited by a membrana propria, and lined by a single layer of cubical or polyhedral cells. In the protoplasm of these cells, fat droplets, varying in size, are often seen. The nucleus is in the outer part of the cell. The lumen of the acinus is quite large, and often contains granules, droplets of fat, and fragments of epithelium. Sketch a number of acini under high power.

DRAWINGS FOR LESSON XXIV.

DRAWINGS FOR LESSON XXIV.

DRAWINGS FOR LESSON XXIV.

LESSON XXV.

**EYE, EAR, AND OLFACTORY MUCOUS
MEMBRANE.**

**(a) Section of the Anterior Quadrant of the Eye-
ball.**

The anterior half of a human eye was hardened in Müller's fluid. After hardening, the lens was removed, and a quadrant including a portion of the cornea and sclerotic and ciliary region cut out, stained in Delafield's hæmatoxylin, embedded in paraffin, and sectioned. Fix and mount in balsam.

Study first under low power. The cornea is composed of 5 layers, named in order from before backward, as follows:—

(1) Stratified pavement epithelium.

(2) Bowman's layer, or the anterior homogeneous lamella.

(3) Substantia propria, the thickest of the several coats, composed of bundles of white fibrous tissue arranged in layers, between which the corneal corpuscles are found.

(4) The posterior elastic or Descemet's membrane.

(5) The endothelium of the anterior chamber.

In the sclera the bundles of white fibrous tissue are densely woven, and are continuous with the fibrous tissue bundles of the substantia propria of the cornea, but are not so regularly arranged. Observe the canal of Schlemm as seen in cross-section in the sclero-corneal junction. Of the middle layer, the iris, ciliary body, and anterior portion of the choroid are included in this section. The iris is covered anteriorly by a layer of cells continuous with the ones found on the posterior surface of the cornea. The stroma is a loose fibrous tissue in which pigmented and unpigmented branched cells and many vessels are found. The iris is covered posteriorly by a double layer of deeply pig-

mented cells, the pars iridis retinae. The fibres of the sphincter of the iris are seen in cross-section near its free edge and posterior surface. Observe the ligamentum pectinatum, composed of trabeculae of fibrous tissue uniting the ciliary body to the outer coat at the sclero-corneal junction. The spaces between the trabeculae of this ligament communicate with the anterior chamber, and are known as Fontana's spaces.

The ciliary body is a very much thickened portion of the middle coat; it is continuous anteriorly with the iris, and posteriorly with the choroid. It is composed of meridionally placed folds, the ciliary processes, and the ciliary muscle. The meridional fibres of this muscle have their origin from the wall of the canal of Schlemm and the adjacent fibrous tissue, extending backward to the anterior portion of the choroid (the tensor choroidae), and into the ciliary body. The equatorial or circular fibres of Müller are observed in cross section near the base of the iris. The ciliary body and processes are covered by a double layer of pigmented cells, the pars ciliaris retinae. Only a small portion of the choroid is seen in this section. Note how vascular it is. In the stroma many branched and pigmented connective tissue cells are seen.

Notice how the coats of the retina are quite abruptly reduced to a double layer of cells at the ora serata, continuing over the ciliary body and posterior surface of the iris as the pars ciliaris retinae and pars iridis retinae. Observe the suspensory ligament of the lens, composed of homogeneous fibres, these seemingly arising from the apices of the ciliary processes, and passing from these to the equator of the lens, some uniting with the capsule of the lens on its anterior, others on its posterior surface.

Draw this preparation as seen under low power.

(b) Lens Fibres.

A lens was macerated for several days in $\frac{1}{2}$ % solution of hydrochloric acid. Tease and mount in gum glycerine.

Examine under high power. Sketch several of the fibres, as seen under this power.

(c) Retina.

The posterior half of a human eye was hardened in mercuric chloride. Small pieces of the retina were removed, stained in Delafield's hæmatoxylin, embedded in paraffin, and sectioned. Fix to the slide, and mount in balsam.

Use high power. The following layers are made out, named in order from before backward:—

- (1) Internal limiting membrane.
- (2) Layer of nerve fibres.
- (3) Layer of ganglion cells.
- (4) Inner granular or molecular layer.
- (5) Inner nuclear layer.
- (6) Outer granular or molecular layer.
- (7) Outer nuclear layer.
- (8) Outer limiting membrane.
- (9) Layer of rods and cones.

(10) Layer of pigment cells; this layer often remains attached to the choroid, and may therefore not be seen in your section.

Sketch under high power.

(d) Optic Papilla.

The posterior part of a human eye was hardened in Müller's fluid. The optic papilla with a small portion of the posterior wall and entering optic nerve was removed, stained in Delafield's hæmatoxylin, embedded in paraffin, and sectioned. Fix and mount in balsam.

Study first under low power. Note the dural and arachnoidal sheaths of the optic nerve. They are continuous with the sclerotic. The optic nerve fibres passing through the lamina cribrosa and bending over and spreading out to form the layer of nerve fibres of the retina, are to be observed. Notice the excavation in the optic papilla. The nerve fibres of the retina are on the anterior surface; the rods and cones point toward the sclerotic. The section may show the artery centralis retinæ in longitudinal, and some of its branches in cross or oblique, section. Sketch under low power.

(e) Cochlea of a Guinea Pig.

The cochlea of a guinea pig was hardened in Flemming's solution, decalcified in 1 % chromic acid, and embedded in celloidin.

The sections were cut in a direction parallel to the long axis, stained in hæmatoxylin and acid fuchsin, and are now in oil of bergamot. Mount in balsam.

The cochlear canals were opened on one side so that the hardening fluid might penetrate more easily. Study first under low power. Observe the bony axis or modeolus about which the cochlear canal is spirally wound. Sections of it are seen on either side of the modeolus. The cochlear canal is divided into two portions by the lamina spiralis, a bony crest attached to the modeolar wall of the canal, and the basilar membrane extending from the lamina spiralis to the ligamentum spiralis. The upper portion of the canal is the scala vestibuli, the lower the scala tympani; they are lined by endothelial cells. A triangular canal, the cochlear duct or scala media, is cut off from the scala vestibuli by Reissner's membrane. In the cochlear duct resting on the basilar membrane is found the organ of Corti, in which the following parts are to be distinguished: The pillars of Corti, arranged in the form of an arch; the inner and the three or four outer hair cells; Deiter's cells supporting the outer hair cells; peripheral to the organ of Corti are Hensen's cells, in these fat granules are found in the guinea pig. Note the membrana tectoria resting on the organ of Corti. Observe the spiral ganglion in the lamina spiralis; from this nerve fibres pass toward the organ of Corti, and make connection with the hair cells. They may be seen passing through the tunnel of Corti.

Sketch under low power the entire section, also under high power a cochlear duct with the organ of Corti.

(f) Olfactory Membrane (Teased).

The olfactory membrane of a dog was fixed and macerated in $\frac{1}{2}$ % osmic acid. Place a small piece of the macerated tissue on a slide and cover with a few drops of methylene blue, allow it to stain for several minutes, then wash away the excess of stain with distilled water, add a drop of gum glycerine, tease, and mount.

Study under high power, and search for olfactory and sustentacular cells. Sketch a number of the cells as seen under this power.

(g) Olfactory Membrane (Section).

The mucous membrane was removed from the septum of a rabbit's nose, hardened in mercuric chloride, stained in Delafield's hæmatoxylin, embedded in paraffin, and sectioned. Fix to the slide, and mount in balsam.

This preparation shows olfactory and respiratory mucous membrane. The epithelium covering the latter is stratified ciliated columnar. In the regio olfactoria the two kinds of cells studied in the teased preparation will be observed. In the mucosa, which is composed of loose fibrous tissue, Bowman's glands will be seen in section. Sketch under high power.

DRAWINGS FOR LESSON XXV.

DRAWINGS FOR LESSON XXV.

DRAWINGS FOR LESSON XXV.

METHODS FOR LABORATORY WORK.

Methods for Macerating Fresh Tissues.

Ranvier's Alcohol.

Place small pieces of the tissue to be macerated in 33 % alcohol, in which they remain from 12 to 24 hours; then transfer them to a 0.25 % osmic acid solution for two to four hours. They can now be teased.

This method is very useful for macerating epithelial tissue; for instance, the cells lining the intestinal canal or the trachea, for isolating the cells of the liver, etc.

Caustic Potash Solution.

Make a 30 % aqueous solution of KOH. Small pieces are placed in this solution for 15 to 20 minutes. The maceration is then interrupted by transferring the tissue to a saturated aqueous solution of acetate of potash (it takes about 60 parts of the acetate of potash to saturate 40 parts of water), to which a few drops of glacial acetic acid have been added (the author adds five to six drops to 25 c. c. of the saturated solution). In about 30 minutes the tissue is ready for teasing; it can, however, be kept a long time, several months, in the acetate of potash.

This method is used for macerating non-stripped and heart muscle, also epithelial cells.

Hydrochloric Acid.

A 30 % aqueous solution is used; in it the tissues remain for 12 to 24 hours, and are then washed in flowing water for half an hour, when they are ready to be teased. HCl is especially useful for isolating the tubules of the kidney.

Nitric Acid (Gage).

A 30 % aqueous solution is used; small pieces of the tissue remain in the fluid about 24 hours, and are then thoroughly washed in water.

Striped muscle fibres are well macerated by this method.

Sulphuric Acid (M. Schultz and Ranvier).

Place the tissue to be macerated on the slide, add a few drops of strong sulphuric acid, and cover with a cover glass. In a few moments the cells can be separated by gently tapping or pressing with a needle the top of the cover glass.

Useful for macerating hair, nail, and horny epidermis.

Schultze's Mixture.

One or two grams of crystals of chlorate of potash are mixed with a little HNO_3 , only enough acid being used to make a thick pastè. In this the tissue to be macerated is embedded for two or three hours, at the end of which time the tissue may be removed to a slide and teased. If it does not tease easily, embed again in the paste, repeating at intervals of about thirty minutes, until it teases readily.

This method brings out nicely the branched muscle fibres. A frog's tongue may be used.

Osmic Acid.

A 1.0 % aqueous solution of osmic acid is very useful for macerating retina, olfactory membrane, etc. The tissues remain in the fluid from 24 to 48 hours, and may then be teased.

Macerated tissues are to be teased and mounted in glycerine, glycerine gelatin, or gum glycerine.

The *glycerine gelatin* may be prepared after Fol's formula:

Water,	42 c. c.
Glycerine,	38 c. c.
Gelatin,	7 grms.
Carbolic acid,	1 gram.

Cut the gelatin in small pieces, place the small pieces into a clean beaker, and add the water. Warm over a

water-bath until the gelatin melts, then add the glycerine while stirring with a clean glass rod, and finally add the carbolic acid. Filter through a hot flannel.

The *gum glycerine* may be prepared according to Farant's formula :

Glycerine,	50 c. c.
Water,	50 c. c.
Gum Arabic (powder),	50 grms.
Arsenious acid,	1 gm.

Dissolve the arsenious acid in the water. Place the gum arabic in a glass mortar and mix it with the water, then add the glycerine. Filter through a wet filter paper or through fine muslin.

Methods for Hardening and Fixing Tissues.

Alcohol.

When possible to cut the tissue into small pieces about one quarter to one-half inch cube, it is best to place them at once into 95% alcohol; here they remain for four or five days, and are then transferred to absolute alcohol for 24 to 48 hours. It is always well to place a layer of absorbent cotton in the hardening jar to prevent the tissues from resting on the bottom. The fluid can then more readily touch all surfaces of the tissue to be hardened. Gland tissue, such as salivary glands and pancreas, also the intestinal canal, are well hardened by this method. Kahlden states that this method is especially useful when the tissues are to be examined for bacteria.

Bichloride of Mercury Solution.

Make a saturated aqueous solution of bichloride of mercury. This is most easily done by dissolving 80 to 100 grms. of the salt in a liter of hot distilled water, and setting this supersaturated solution aside to cool. The excess will then precipitate out, and the cold saturated solution can then be decanted.

Only *small* or *thin pieces*, not thicker than $\frac{1}{8}$ th of an inch should be placed into this hardening fluid. They remain in the solution for 12 to 24 hours, are then thoroughly washed in flowing water for 12 to 24 hours, transferred to 70% alcohol for 24 hours, and 95% alcohol for another day. This is one of the very best of hardening fluids, and can be used to advantage for hardening all glands, mucous membranes, muscle, etc. It is especially useful for hardening pathological tissues. Almost any staining fluid may be used after it.

Mercuric Chloride and Formalin.

The author has used to good advantage the following solution :

Saturated aqueous solution of bichloride of mercury 100 parts
 Formalin 4 parts.

In this solution the tissues remain for 24 to 48 hours, are then washed in flowing water for 24 hours, and the hardening is completed in 70% (24 hours.) and 95% alcohol. It is useful for hardening teeth, developing teeth, developing bone, etc.

Mercuric Chloride and Picric Acid Solution (Rabl).

Saturated aqueous sol. of mercuric chloride 1 part.
 Saturated aqueous sol. of picric acid - 1 part.
 Distilled water - - - - - 2 parts.

This is excellent for hardening mammalian embryos. The tissues remain in the fluid 8 to 12 hours, are then transferred to 70% alcohol until the picric acid is washed out of the tissue; the hardening is completed in 95% alcohol.

Mueller's Fluid (Heinrich Müller).

The fluid is made after the following formula :

Potassium bichromate 2.5 parts.
 Sodium sulphate 1 part.
 Water 100 parts.

The potassium bichromate and sodium sulphate are to be ground in a mortar. They dissolve quickly if the water is heated. A large quantity of the fluid may be kept on hand as it does not deteriorate by standing. Müller's fluid is especially to be recommended when large pieces are to be hardened, but it must be remembered that the hardening takes place very slowly. Pieces of about an inch cube harden in 2 to 4 weeks, of two inches cube 1 to months, and larger masses proportionately longer; a human brain for instance needs to be in the fluid from 6 to 8 months. *Always use a large quantity of the fluid, and change whenever it becomes turbid.* Weigert recommends that the jar containing the tissue to be hardened, especially if it be the central nervous system, be kept in a warm oven at a temperature of 30° to 40° C.; a spinal cord may in this way be

hardened in 1 to 2 weeks. After hardening in Müller's fluid the tissues need to be well washed in flowing water for several hours. They are then placed into 75 % alcohol for 2 or 3 days, and into 95 % for 4 to 6 days; they are now ready for cutting. Hans Virchow* recommends that the preparation be transferred from Müller's fluid into 96 % alcohol; the tissues must, however, be kept in the dark.

This method is especially useful for hardening the central nervous system, and when necessary to harden large masses, entire organs, tumors, etc. It is not used to advantage when the finer structure of cells is desired.

Nitric Acid (Benda).

Benda recommends a 10% solution; in this the tissues remain from 24 to 48 hours, are then transferred to Müller's fluid for 1 or 2 weeks, thoroughly washed in flowing water for several hours; and the hardening completed in graded alcohol. This method gives good results when it is desired to harden an entire eye; the HNO_3 fixes the tissues, and it can then be placed into Müller's fluid without collapsing.

The skin and scalp are also well hardened after this method.

Picric Acid.

A saturated aqueous solution is kept on hand. Always filter before using. The tissue needs to be cut into small blocks; they remain in the fluid for 1 to 3 days, are then rinsed in water, and placed in 80% alcohol, which must be changed as often as it becomes yellow; as soon as none or very little of the acid is given off, place in 95% alcohol. Peripheral nerves, vessels, elastic cartilage, and fibro-cartilage are well hardened in this way. Fœtal bones are decalcified.

Flemming's Solution.

One of the best of hardening solutions is a mixture of chromic, osmic, and acetic acid in the following proportions:

* Quoted by Rawitz — Leitfaden, Histologischer Untersuchungen.



Osmic acid (2% aqueous sol.)	. 4 parts.
Chromic acid (1% aqueous sol.)	. 15 parts.
Glacial acetic acid	. 1 part.

The solution may be kept on hand in a well-stoppered bottle. Tissues must be in small pieces, one dimension of which ought not to be more than one-twelfth or one-eighth of an inch. The chromic acid might penetrate larger pieces, the osmic might not. The tissues remain in the solution about 24 hours, are then thoroughly washed in flowing water, and the hardening completed in graded alcohol. This solution is largely used in hardening tissues for cell division, and for bringing out the finer details in the structure of the protoplasm and nucleus. Unless the tissues are well washed it is often hard to stain them.

Hermann's Solution.

Hermann uses in place of the chromic acid in Flemming's solution a 1% aqueous solution of platinum chloride, the formula reading as follows:

Platinum chloride (1% aqueous sol.)	15 parts.
Osmic acid (2% aqueous sol.)	. 2-4 parts.
Glacial acetic acid	. 1 part.

The pieces need to be small; they remain in the solution for 24 to 48 hours, are then washed in water, and hardened in graded alcohol. Hermann's fluid is used with good results in hardening for karyokinesis, spermatogenesis, etc.

Solution of Platinum Chloride, Osmic Acid, and Mercuric Chloride.

The author has found the following solution a very good fixative:

Platinum chloride (2% aqueous sol.)	3 parts.
Osmic acid (2% aqueous sol.)	. 2 parts.
Mercuric chloride (sat. aqueous sol.)	5 parts.

It is especially useful for hardening the testes of mammalia. Very small pieces are to be hardened for about 24 hours, are then thoroughly washed in flowing water for 12 hours, and the hardening completed in graded alcohol. In testes hardened in this solution, the accessory nucleus is very clearly seen in nearly every cell; its change in shape until it forms the "head cap" of the fully developed spermatozoa can easily be traced.

Methods for Decalcifying Tissues.

Kahlden* gives the following general directions to be observed when decalcifying:—

(1) The tissues must first be well hardened in alcohol or Müller's fluid.

(2) A large quantity of the decalcifying fluid needs to be used, and changed frequently.

(3) After decalcification the tissues must be thoroughly washed in flowing water for several days.

(4) They are again hardened in graded alcohol, after which they are ready for cutting.

Nitric and Hydrochloric Acid.

Use the following proportions:

Nitric acid (10% aqueous solution) 1 part.

Hydrochloric acid (1% aqueous solution) 1 part.

The decalcification is quite rapid, the fluid needs to be changed every second or third day. The tissues are from time to time taken from the fluid and tested by pushing a needle into the bone, and if it enters easily and without grating, the decalcification may be considered complete. They are then washed in flowing water, and hardened in graded alcohol.

Ebner's Decalcifying Fluid.

The following formula is taken from Behren's Tabellen:

Sodium chloride	2.5 grms.
Water	100.0 c.c.
Alcohol	500.0 c.c.
Hydrochloric acid	2.5 c.c.

*Technik der Histologischen Untersuchung pathologisch-anatomischer Präparate. Third edition, page 13.

This solution decalcifies very slowly, but without injury to the tissues. Large quantities (10 to 20 times the bulk of the tissue) need to be used, and one or two c.c. of hydrochloric acid are daily added to the fluid until decalcification is complete. Wash very thoroughly in flowing water, and harden in graded alcohol.

Haug's Chrom-Osmium Solution.

Osmic acid (1% aqueous solution)	10 c.c.
Chromic acid (1% aqueous solution)	25 c.c.
Water	60 c.c.

Useful for decalcifying the cochlea; it acts very slowly. Wash in flowing water, and harden in alcohol.

***Lepkowski's Method.**

Small pieces of tooth or bone are placed in the following solution:

Chloride of gold (1% aqueous solution)	6 parts.
Formic acid	3 parts.

The tissues are decalcified in two or three days. The chloride of gold is deposited in the dentinal tubules or canaliculi, so that the tissue will be both stained and decalcified at the same time.

*Anatomischer Anzeiger, 1892.

Impregnation of Tissues.

Silver Nitrate.

This is used for staining the endothelial membranes lining blood-vessels and serous cavities. An albumenate of silver is formed with the intercellular cement between the endothelial cells; the silver is reduced on exposing to sunlight. A 1% aqueous solution of the silver nitrate is used. In making a preparation of an endothelial membrane, the peritoneum of a frog may be selected. Make a small opening through the abdominal wall of a frog near the sternum, inject 10 to 20 c.c. of the 1% solution of silver nitrate; while injecting, the abdomen is gently kneaded, so that the fluid may be well distributed in the abdominal cavity. In 15 to 20 minutes the abdomen is opened, the intestinal canal with the mesentery is removed, the latter (without removing from the intestines) is pinned out on a cork board, is now immersed, preparation side up, in 80% alcohol (it will be necessary to fix small lead weights to the cork to bring it under the alcohol), and placed in the sunlight; as soon as the tissue shows a brown color it is ready for study. It may be mounted in gum glycerine or balsam.

Another method is to carefully remove the peritoneum, pleura, or pericardial sack, and spread out on a clean, dry slide, to which the tissue will adhere quite firmly if set aside for a few moments. The slide with the tissue on it may then be placed in the silver nitrate solution and treated as above. Connective tissue, when stained in silver nitrate to show the cell spaces, may be prepared in the same way. If it is desired to mount the tissue in balsam, it may,

after the reduction of the silver has taken place, be dehydrated in absolute alcohol, cleared in oil of bergamot, and mounted in balsam.

SILVER NITRATE AND BICHROMATE OF POTASH METHOD (Golgi, Ramon y Cajal, and Lenhossek).

This is a method used for staining nerve cells and their processes both in the central and peripheral nervous system. The formulæ here given are taken from Lenhossek's *Reprint in Fortschritte der Medicin*, August and September, 1892.

Golgi's Slow Method.

Small pieces of brain or spinal cord are hardened in a 2% solution of bichromate of potassium from 20 to 30 days; are then, without washing, transferred to a $\frac{1}{2}$ % solution of silver nitrate, in which they remain from 24 to 48 hours; or in place of the silver, a 5% solution of bichloride of mercury may be used; in this they remain from 2 to 4 weeks.

The Mixed Golgi Method.

The tissues to be hardened and stained are placed in a large quantity (20 to 30 times the bulk of the tissues used) of the following solution:

Bichromate of potassium	. (1% aqueous sol.)	8 parts.
Osmic acid	. (1% aqueous sol.)	1 part.

In this they remain four or five days; are then transferred to 0.75% solution of silver nitrate for 24 to 30 hours.

Rapid Method (Ramon y Cajal).

The following solution is now largely used:

Bichromate of potassium	(3 to 5% sol.)	4 parts.
Osmic acid	(1% aqueous sol.)	1 part.

If it is desired to stain neuroglia cells, allow the tissues to remain in the solution 2 or 3 days; if nerve cells, 3 to 5 days; if nerve fibres and collateral branches, 5 to 7 days. They are then transferred to a 1% aqueous solution of silver nitrate, in which they remain from 24 to 36 hours. Lenhossek adds one drop of formic acid to 200 c. c. of the silver solution.

These methods give the best results when embryonic tissues, or tissues taken from newly born or young animals, are employed.

Often when the methods above noted do not give good results at the first trial, they may with success be repeated on the same tissue. If after the tissues have been 2 or 3 days in the silver nitrate, the trial sections (free-hand sections cut from the blocks, mounted and examined in 95% alcohol) show no staining, they may again be placed in the bichromate of potassium solution for several days, and then again into silver. Good results follow a second and even the third trial.

Sections are cut into 95 % alcohol; they may be made either free-hand or, after surrounding with paraffin or embedding in celloidin, cut with the microtome. From the alcohol, sections are placed for 15 minutes into creosote then washed from 3 to 5 minutes in oil of turpentine, out of which they are taken and arranged on the slide. The excess of oil of turpentine is removed with filter paper, and the sections are covered with balsam. The slide is now *carefully* heated over an alcohol flame, until the balsam becomes so thick that on cooling, it at once hardens (3 to 5 minutes of careful heating are required, allow no bubbles to form); while the balsam is yet warm cover with a cover glass which has been passed through the flame several times; after cooling, the preparation is ready for study. Mounted in this way, Golgi preparations *do not fade*.*

Gold Chloride (Ranvier's Lemon Juice Method).

This method is especially useful for staining the nerve-ending in voluntary muscle.

Place small pieces of a short muscle (intercostal of a snake or guinea pig) in filtered lemon juice for 10 to 15 minutes (or until the tissue becomes transparent), wash hastily in distilled water and transfer the tissue to a 1% solution of chloride of gold, in which they remain for 15 to 20 minutes. The tissue is then again hastily washed in

* Huber. Anatomischer Anzeiger. VII Jahrgang (1892), No. 18.

distilled water, and placed in a 20% solution of formic acid, in which they remain in the dark for 24 to 48 hours. Tease a small portion of the muscle in glycerine, and if the motor endings are stained, transfer the tissue to glycerine. Tease and mount in glycerine.

Methods for Injecting.

When it is desired to bring out prominently the relation between the blood vessels and the other elements of a tissue or an organ, it is necessary to inject the vessel. This is best done by means of substances which are fluid when warm, but harden on cooling. Gelatin, which has been colored with some dye, is usually employed. The directions for making two such injecting masses are here given. Much experience is required to inject successfully; too much space would be required to go fully into the methods used. They are demonstrated in the *course on methods*.

Carmine Gelatin (Gerlach).

The formula is taken from Behren's Tabellen.

Carmine	10 grms.	}	I.
Ammonium hydrate	1 c. c.		
Water	8 c. c.		
Gelatin	12 grms.	}	II.
Water	16 c. c.		

The gelatin is cut into fine pieces, placed in an evaporating dish, and the water added; in this the pieces soak about 12 hours. The gelatin is then dissolved over a water-bath. To solution II, add solution I (which is prepared by dissolving the carmine in the ammonium hydrate and water over a water-bath), slowly, while constantly stirring. The mass is now alkaline, and unless neutralized would stain the blood vessels and surrounding tissue. The neutralization is accomplished by means of glacial acetic acid, which is added drop by drop until no ammonia is detected by the sense of smell, stirring well after every drop.

It will also be noticed that the mass changes its color, becoming a brighter red. If the mass becomes too acid it appears granular if a drop is examined under the microscope; in this state it is not entirely useless, but the resulting injection is never so good as when the mass is neutral.

Before using, the mass must be strained through a piece of flannel which has been dipped in hot water. The canula, syringe, and animal must be kept warm during the injection. If the entire animal is to be injected, the canula is to be tied into the arch of the aorta, through the left ventricle; if a single organ, the canula is tied into its main artery. As soon as the injection mass appears in the accompanying vein, this vein is firmly tied. After the tissues have been fully injected, the animal or organ is set aside in a cold place until the injection congeals, the tissues are then removed, cut into small pieces, and hardened in alcohol. These may, before embedding, be stained in Delafield's hæmatoxylin.

Berlin Blue Mass (Harting, as given by Rawitz).

One part of oxalic acid is "rubbed up" in a glass mortar; to this is added one part of Berlin blue, and, while constantly stirring, 12 parts of water. To an equal quantity of warm gelatin solution (made as above directed) add the Berlin blue solution slowly, continually stirring. Filter through a piece of flannel before using.

Inject while the solution is warm. After the tissues are cold, harden in alcohol. The tissues may be stained in alum or borax carmine.

Methods for Embedding and Cutting Sections.

Free Hand Cutting.

It is usually necessary to surround the tissues to be cut with some material, which gives no resistance to, and does not injure the knife, at the same time is firm enough to give support. Pathologists have for a long time used small strips of amyloid liver which had been hardened in alcohol or Müller's fluid. If these can not be obtained, pig's or calf's liver will answer. Elder-pith is also used. The little blocks of liver tissue, or the elder-pith rods, are divided into two parts, between which the tissue to be cut is placed. It can now be firmly held between the thumb and the index finger of the left hand. A razor, which is flat on one side (the under while in use), is employed. Its upper surface is well covered with 80% alcohol. Try to make the section with one continuous cut, resting the blade of the knife on the index finger. Sections which answer for purposes of orientation can easily be made in this way. They are, however, not to be compared with the ones that can be cut with the microtome when the tissues are properly embedded.

Embedding Tissues.

A great many methods for embedding tissues are in use, the principle involved is the same in all. In the one case the tissues are permeated with substances that are fluid when warm and become hard enough to cut on cooling; in others again, the embedding mass hardens, on the evaporation of a solvent which was used to bring them to a fluid state. The methods for embedding in celloidin, in

paraffin, and in a solution of gum arabic (for the freezing microtome) are here given. It is deemed beyond the scope of these notes to go into the methods for *cutting sections*; they will be taught in the laboratory.

Embedding for Cutting with the Freezing Microtome.

To prepare the tissues for cutting on the freezing microtome, remove the alcohol from the hardened tissues by allowing them to remain in water about eight hours, then transfer to a solution of gum arabic (the solution should be about as thick as syrup). It is made by dissolving the gum arabic in hot water, and straining through a cloth; cool before using. In about six hours they are permeated with the gum arabic and are ready for freezing. Sections need to be cut into warm distilled water, which removes the gum arabic. Before staining or placing in alcohol they must again be washed in distilled water.

Celloidin or Collodium Embedding.*

A *stock solution* of celloidin or collodium is kept on hand. This is made by adding celloidin or collodium to a mixture of equal parts of absolute alcohol and ether until a thick solution is obtained. The stock solution needs to be kept in a well-stoppered bottle, as it thickens on the evaporation of the alcohol and ether. The steps for embedding tissues are the following:—

(1) From the 95% alcohol the tissues are placed into absolute for 24 to 48 hours.

(2) Into a mixture of *equal parts* of absolute alcohol and ether from 1 to 2 days.

(3) Into a *thin solution of celloidin*, consisting of one part of the stock solution and two parts of the alcohol and ether mixture (equal parts); in this they remain, according to the size of the pieces embedded, from 2 or 3 days to as many weeks.

(4) Into the stock solution for an equal length of time. The tissues are ready for further treatment as soon

* The methods for embedding in celloidin and collodium are the same, and the results seem to the author equally good; collodium is cheaper. The steps here given for the one will answer for the other.

as they are thoroughly permeated with the celloidin; no definite time can be fixed for this. Loose tissues, such as lung, are permeated in 3 or 4 days; skin in 2 or 3 weeks; brain or spinal cord, especially if the pieces are large, in 3 to 6 weeks.

As soon as permeation seems complete, some of the stock solution is poured into a flat glass dish (enough to cover well the tissues to be embedded), into this the tissues are brought, and if several pieces are to be embedded, they are to be so arranged that a small area of celloidin (one-fourth of an inch wide) surrounds each piece. The dish is now covered with a glass plate, and placed under a bell-jar. The alcohol and ether evaporate very slowly, as this goes on the celloidin hardens. In case the glass plate fits tightly, push it to one side, thus leaving a small space uncovered. Several days are required for the celloidin to become hard. As soon as the mass is so *firm* that it can not be indented with the finger, it is removed from the glass dish. It can now be cut into a square block containing the tissue; or into several, if a number of pieces were embedded. These celloidin blocks are to be fixed to small cylinders of hard wood. The diameter of the wooden blocks should be a little larger than the celloidin block, and about one-half an inch long. This is done by immersing one end of the wooden cylinder in the stock solution; a layer of celloidin is in this way spread over one end of the cylinder of wood. The celloidin block is, after having been immersed in equal parts of alcohol and ether for about 5 minutes, pressed against the layer of celloidin on the wooden block, and then placed under a bell-jar for about an hour. It is then transferred to 70% alcohol for several hours, at the end of which time it is ready for cutting.

When cutting sections of a tissue embedded in celloidin, the knife should be moistened with 80% alcohol; sections are cut into weak alcohol or distilled water. The celloidin blocks, even after they are fixed to the wooden cylinders, may be kept for a long time in 70% alcohol.

The celloidin method is now very largely used; it is especially useful for cutting sections of the central nerv-

ous system, of an entire eye, or tissues or organs containing much fibrous tissue. It may be used whenever not very thin sections (less than 10 μ . to 15 μ .) are required. The celloidin or collodium need not be removed before staining or mounting; and unless the aniline dyes are used for coloring, very little stain is taken by the celloidin. The sections need to be *cleared* in oil of bergamot, as the oil of cloves dissolves the celloidin. The following method for staining and mounting celloidin sections *in series*, is recommended by Weigert:—*

(1) A clean glass plate is covered with a thin layer of a solution of collodium; this is to be spread out as evenly as possible over the entire surface. The plate is now placed on edge, and the collodium allowed to dry, care being taken to keep the dust from it.

(2) A section is placed on a strip of "closet paper," near one end. Succeeding sections, as soon as cut, are placed to the right of it. They are removed from the knife to the strip of paper, by holding the paper extended under the knife, and slipping the section onto it. To keep the sections from drying, the strip of paper is, after the removal of every section, placed in a flat dish, in which several layers of filter paper, have been spread out and thoroughly saturated with 80% alcohol. On each strip of paper is arranged only one row of sections; the strips are kept in the dish in the order used.

(3) As soon as a number of strips have been covered with sections, they are arranged, sections downward, on the layer of collodium above described, and gently pressed to it. The strips of the paper can now be removed, the sections adhering to the layer of collodium. Several layers of filter paper are now pressed over the sections, in this way removing as much of the alcohol as possible.

(4) Before the sections have time to dry a layer of the collodium solution is poured over them, equally distributed, and allowed to dry. As soon as dry the plate may be placed into 80% alcohol, where it may be kept, or

* Taken from Rawitz Leitfaden der histologischen Untersuchungen. Page 37.

into the stain; the layer of collodium containing the sections then separates from the glass plate, and it can be treated as a single section.

Paraffin Embedding.

Undoubtedly the paraffin method of embedding is of all methods the most satisfactory for general work in histology, embryology, and pathology. Only very few tissues met with, can not to advantage be embedded in this way. Exceedingly thin sections can be cut when the tissues are properly embedded in paraffin, and as the paraffin is always removed from sections before staining, it has none of the disadvantages of the celloidin method. The tissues after thorough dehydration are placed for a longer or shorter time into a fluid which mixes readily with alcohol on the one hand and is a good solvent for paraffin on the other hand. The method used in this laboratory is briefly as follows:—

(1) The tissues are thoroughly dehydrated in absolute alcohol. This takes from 2 to 24 hours, depending on the size of the pieces, the density of the tissue and the extent of dehydration before placing in absolute alcohol.

(2) The tissues are then transferred to toluol or xylol (chloroform, turpentine, or oil of origanum may be used) for 4 to 24 hours. Toluol is preferred as it mixes very readily with absolute alcohol and is one of the very best solvents of paraffin. In case the tissues are not thoroughly dehydrated before placing in the toluol or xylol, these fluids become milky and the tissue should then be again transferred to absolute alcohol until the dehydration is complete.

(3) The tissues are then placed into melted *soft paraffin* in which they remain for 1 to 12 hours, again depending on the size of the piece of tissue to be embedded, its density, etc. Soft paraffin has a melting point of about 38° to 42° C. The cup, jar, or bottle containing this paraffin is kept in a warm oven, the temperature of which can be regulated; it should not exceed 50° to 52° C. If delicate tissues, embryos, etc., are to be embedded, it is well to add from time to time a few small pieces of unmelted soft

paraffin to the toluol or xylol containing the tissue to be embedded; the dish or bottle containing said tissue can at this time be placed in the warm oven. In this way the change from the toluol or xylol to the melted soft paraffin can be made very gradual, and there will be less danger of causing any shrinkage in the tissue.

(4) From the soft paraffin, the tissues are transferred to melted *hard paraffin*, which is usually a mixture of equal parts of soft paraffin and a paraffin with a melting point of about 52° to 55° C., and answers very well for ordinary room or laboratory temperature. During the summer months, it may be necessary to use two parts of the paraffin with 55° C. melting point, and only one of the soft, and in very warm weather even less of the soft.

In very warm weather the author has often used the following mixture with success:

Soft paraffin	. . .	1 part by weight.
Hard paraffin	. . .	4 parts " "
Spermaceti	. . .	1 part " "

In the hard paraffin the tissues remain from 2 to 24 hours, of course in the warm oven. It is essential that the melted paraffins while in use for embedding should be at

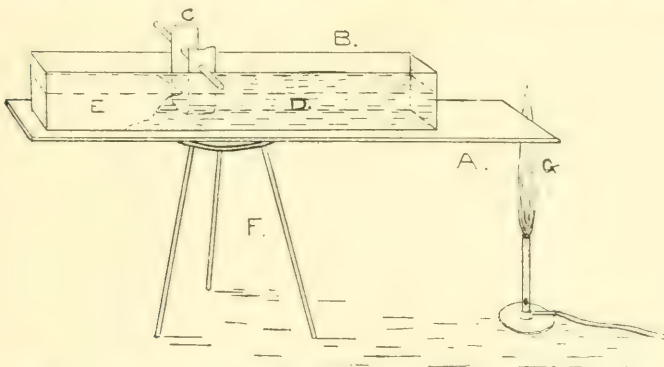


Fig. I. Simple paraffin bath; A, copper plate; B, paraffin tray; C, loop of filter paper; D, area of melted paraffin; E, area of unmelted paraffin; F, tripod; G, flame.

a constant temperature; this can easily be done when a water-bath with temperature regulator, such as is found in most laboratories, is at hand. A very simple apparatus, and one that meets the requirements quite well, is shown

in Fig. I. It consists of a tripod (F); a copper plate (A) about fifteen inches long, five inches wide, and one-eighth to three-sixteenths of an inch thick; and two tin trays (B) (only one is shown in the diagram); these are ten inches long, two wide, and three deep. They are partly filled with paraffin; the one with soft, the other with the hard. If an alcohol lamp or a Bunsen burner be so placed that the end of the flame (G) touches one end of the copper plate, as shown in diagram, and the trays containing the hard and soft paraffin be placed on the copper plate toward the end away from the flame, it will be found that after a short time, fifteen to thirty minutes, the paraffin in the end of the trays near the flame will be melted while in the other end it is yet hard, by reason of the fact that the flame end of the copper plate has a higher temperature than the opposite end. With a little patience the trays may be so adjusted, by moving them toward or away from the flame, that about half of the paraffin will be melted, the rest not. As shown in the diagram, D represents the area of melted paraffin, E of the unmelted. It of course stands to reason, that if the two trays be placed side by side on the copper plate, the one containing the hard paraffin needs to be nearer the flame than the one containing the soft, to obtain in each an area of melted and unmelted paraffin. In either tray, the area of unmelted paraffin acts as a thermometer, the adjoining melted paraffin must have a temperature, which, when expressed in degrees, is about the melting point of the paraffin in question; about 40° C. for the soft, 50° C. for the hard. It is not advisable to allow the tissues to rest on the bottom of the tray. A loop can easily be made with a strip of filter paper about two inches wide; this is supported from a wire or glass rod, and allowed to hang in the area of melted, near the edge of the unmelted paraffin, C in the figure. The tissues are placed on the filter paper.

When the tissues are thoroughly permeated with the hard paraffin, a rectangular trough is made with two metallic L's, resting on a glass plate, and filled with melted hard paraffin. Into this the tissue is placed by means of a pair of small forceps, which before using were warmed in a

flame. The piece of tissue is placed in one end, and so arranged that the plane in which it is to be cut, is at right angles to the long axis of the trough. The paraffin is now allowed to cool, and as soon as a film forms over it, the trough is placed in cold water; this quickly congeals the paraffin. The metallic L's are removed; the paraffin block can now be taken from the glass plate, and is ready for cutting. The knife used for cutting paraffin sections must be dry, and if perfectly embedded very thin sections can be cut, thinner than when embedded, after any other method.

Before mounting or staining paraffin sections it is always necessary to remove the paraffin. Before doing this it is advisable to fix the section to the slide or cover glass by means of one of the many methods now in use. Sections stuck to slide or cover can then be stained without in the least destroying the relation of the elements of the tissue. The contents of tubules, of small cysts or spaces do not fall out during the process of staining and mounting.

Of the many methods used for fixing sections to slide or cover glass, the following have been found by the author to be most reliable. It must be remembered that sections will not stick well unless the slide or cover glass is thoroughly clean. In this laboratory they are cleaned by placing the slides or cover glasses in strong sulphuric acid for 10 to 15 minutes, then wash thoroughly in flowing water, next place them for a few minutes in glacial acetic acid, again wash in flowing water until all the acid has been removed, pour off the water, and add 95% alcohol, from which the slides or covers are wiped with a clean piece of old linen.

Albumen Fixative (Mayer).

The albumen fixative consists of equal parts of white of egg and glycerine. It is prepared by chopping the white of an egg with a pair of scissors, then straining it through muslin or linen; it is now mixed with an equal quantity of glycerine. The glycerine and white of egg are to be thoroughly mixed by stirring with a glass rod, and filtered.

A small drop of the albumen fixative is placed on a slide, and spread in a *very thin* layer with a clean glass rod, or better, with a dry and clean finger. The section is now placed on the albumen fixative, and pressed to the slide. If the section is *stained*, the paraffin is melted by holding the slide or cover glass over an alcohol flame, or by placing them on a water bath, until the paraffin begins to melt; then cover with a few drops of oil of turpentine, which dissolves the paraffin; remove excess of oil with filter paper, and mount in balsam. If it is desired to stain the sections after they are fixed to the slide or cover glass, the following steps are taken to remove the paraffin:—

1. Heat quickly over the flame until the paraffin begins to melt.
2. Place the slide or cover glass into toluol or xylol until the paraffin is dissolved.
3. Transfer to absolute alcohol for 3 to 5 minutes; this removes the toluol or xylol.
4. Transfer to 95% alcohol for 5 minutes.
5. Transfer to 70% alcohol for several minutes.
6. Remove alcohol by placing slide or cover into distilled water. Sections can now be stained.

It is often quite difficult to remove folds from paraffin sections (especially if sections are large) before fixing to the slide or cover glass with albumen fixative; the author has used with success this simple method;

An evaporating dish is partly filled with distilled water; on this the sections are placed. The water is now slowly heated by holding the evaporating dish over an alcohol flame. It will be noticed that as the temperature of the water is raised, the paraffin in and about the sections begins to soften, and the sections spread out over the surface of the water. The water is heated until all folds are obliterated. Care should be taken not to get the water hot enough to melt the paraffin. A slide or cover glass, on which a thin layer of the albumen fixative is spread, is now passed under one of the sections; on it the section is caught and withdrawn from the water. Allow all the water to evaporate, this usually takes 8 to 12 hours, at the

end of which time the paraffin may be removed as above described. This method is very useful for mounting serial sections.

Gaule's 50% Alcohol Method.

A few drops of 50% alcohol are placed on a slide or cover glass; on this the sections are placed. As the alcohol evaporates, the sections are fixed to the slide or cover; 12 to 24 hours are required, and it is best to place them in a warm oven at a temperature of 40° C. The paraffin is removed in the same manner as when sections are fixed with albumen fixative. The slide or cover must be very clean, even then the sections are often loosened while the paraffin is being removed. Sections from alcohol or sublimate hardened tissues seem to be most firmly fixed.

Dextrin Method of Fixing Sections.

This method is to be recommended for class purposes, where 30 to 50 or even more preparations have to be stained in section.

The following two solutions are kept on hand:—

Sol. No. 1.

A solution of equal parts of white sugar and	
boiling distilled water	300 c. c.
A solution made with equal parts of dextrin	
and distilled water	100 c. c.
Absolute alcohol	200 c. c.

Mix the sugar and dextrin solutions in a mortar, and add very slowly, while constantly stirring, the absolute alcohol. Filter through fine muslin, and keep in a wide-mouthed bottle. Place in the cork a broad camel's-hair brush.

Sol. No. 2.

℥ / Photocollin (dry) or good celloidin or gun	
cotton	10 grms.
Absolute alcohol	100 c. c.
Ether	500 c. c.

The sections to be stained are cut in paraffin, and arranged on a piece of paper. A clean glassplate is coated

with a thin layer of the dextrin solution. The paraffin sections are then arranged in rows on the layer of dextrin, and pressed against the plate with the finger. The plate with the sections fixed to it is now placed in the warm oven, the temperature of which should not exceed 40° C., where it remains from 4 to 24 hours. The plate is then taken from the warm oven, warmed over a flame until the paraffin about the sections begins to melt, and transferred to a tray containing xylol or toluol, where it remains until the paraffin is dissolved. It is then transferred to a tray containing 95% alcohol. In the course of a few minutes the plate is taken out, and the alcohol drained off. The sections are now covered with a thin layer of solution No. 2, after which the plate is set aside until the photoxolyn or celloidin dries. The plate can now be placed in the stain (Boehmer's hæmatoxylin and eosin for instance). After staining, washing, and dehydrating, the sections are cleared in oil of origanum. It should be stated that in the stains or in the water used for washing off the stains, the thin layer of photoxolyn or celloidin, to which the sections adhere, separates from the glass plate; the film may then be taken up from two sides, and transferred from one solution to another, until cleared in the oil of origanum. With a small pair of scissors the sections can now be cut out, and mounted in balsam.

Methods for Staining.



It has long been known that when properly hardened tissues are subjected to the action of coloring matters, certain elements of the tissues, even certain parts of the cells, show greater affinity for the stain than others. This *selective action* noticed in so many stains, warrants the place they hold in histological technic. Of the great number in use, a few of the most trustworthy, and such as can be most easily made and used, are here given.

HÆMATOXYLIN SOLUTIONS.

Boehmer's Solution.

This solution is one of the best in use, and is made after the following formula:—

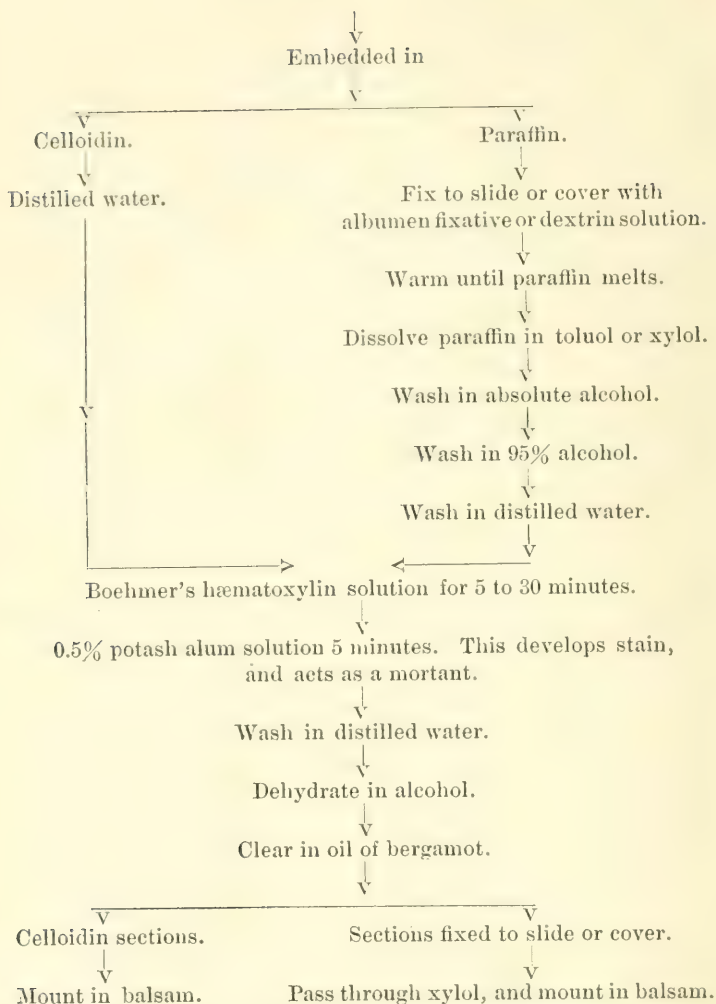
Hæmatoxylin crystals	1 gm.)	} sol. I.
Absolute alcohol	10 c. c.)	
Potash alum	10 grms.)	} sol. II.
Distilled water	200 c. c.)	

The crystals of hæmatoxylin are dissolved in the absolute alcohol, and kept in a well-stoppered bottle for 24 hours (solution I).

The alum is dissolved in warm distilled water, and allowed to cool, keeping it free from dust (solution II). Add solution one to solution two, stir, and keep in an open dish for about a week; filter, and the solution is ready for use.

The tissues must be stained in section; the steps are as follows:—

The tissues may be hardened in Müller's fluid, alcohol, mercuric chloride, picric acid, nitric acid, etc., are



Ehrlich's Haematoxylin Solution.

This solution can be kept for a long time, it seems to improve with age.

Hæmatoxylin crystals,	2 grms.
Absolute alcohol,	20 c. c.
Glycerine,	100 c. c.
Distilled water,	100 c. c.
Absolute alcohol,	80 c. c.
Glacial acetic acid,	10 c. c.
Potash alum to saturation.		

Mix the distilled water, the glycerine, and 80 c. c. of the absolute alcohol, and the 10 c. c. of glacial acetic acid. Dissolve the hæmatoxylin crystals in 20 c. c. of absolute alcohol, add to the above solution, and shake well for several minutes.

The solution so obtained should have a reddish color, and is now to be saturated with the alum; filter at the end of 24 hours.

Ehrlich's hæmatoxylin needs to mature from 1 to 2 months before it can be used. Steps for staining are as follows:—

1. Sections remain in the stain from 10 to 30 minutes (they do not easily overstain).

2. Wash in distilled water, dehydrate, clear in oil of cloves or bergamot, and mount in balsam.

Delafield's Hæmatoxylin Solution.

The formula is taken from Behren's Tabellen.

Hæmatoxylin crystals,	4 grms.
Absolute alcohol,	25 c. c.
Ammonium alum,	52 grms.
Distilled water,	400 c. c.
Glycerine,	100 c. c.
Methyl alcohol,	100 c. c.

The hæmatoxylin crystals are dissolved in the absolute alcohol, the alum in the hot water; as soon as the alum solution cools, add the hæmatoxylin solution. Allow to stand in a wide vessel from 3 to 4 days, filter, and add the glycerine and methyl alcohol.

This hæmatoxylin solution is generally used for staining tissues *en masse*. Before using, dilute the stain 5 to 10 times with distilled water. The tissues, which may be hardened in Müller's fluid, mercuric chloride, picric acid, alcohol, or Flemming's or Hermann's solution, remain in the

stain for 24 to 48 hours, are then rinsed in distilled water, and placed in an acid alcohol wash—

Alcohol (70%)----- 100 c. c.
and hydrochloric acid----- 3 to 5 drops,

for 3 to 6 hours. They are then washed in flowing water for 1 to 2 hours, dehydrated, and embedded in paraffin or celloidin. Embryos are very well stained by this method.

Heidenhain's Hæmatoxylin Solution.

Tissues need to be hardened in alcohol, and stained *en masse*. Gland tissues are well stained by this method. Small pieces of the tissue are placed in a 1% aqueous solution of hæmatoxylin crystals, where they remain for 8 to 12 hours. They are then transferred to a 1% aqueous solution of bichromate of potash for 12 to 18 hours; in this solution the tissues become jet black. Embed in paraffin.

Heidenhain's Iron-Lack-Hæmatoxylin Solution.

The tissues are to be hardened in alcohol, mercuric chloride, Flemming's or Hermann's solution, or in the osmium, platinum chloride, and mercuric chloride mixture suggested by the author. They are then embedded in paraffin. The sections must be cut very thin. These are fixed to cover glasses with albumen fixative, which is best done by floating the sections on warm distilled water, and drawing them upon a cover smeared with a thin layer of the fixative.

The steps are as follows:—

Remove paraffin from sections,
↓
Place cover glass with sections fixed to it in a 3% aqueous solution of ammonium sulphate of iron for 1 to 3 hours.
↓
Rinse in distilled water for a few minutes.
↓
Place sections into a saturated aqueous solution of hæmatoxylin crystals for 1 to 3 hours.
↓
Rinse in distilled water.

↓
Wash in the ammonium sulphate of iron solution until the black clouds cease to be given off; the section should now have a bluish-gray color.

↓
Rinse in distilled water.

↓
Dehydrate.

↓
Clear in oil of bergamot.

↓
Pass through xylol.

↓
Mount in balsam.

In sections stained in iron-lack-hæmatoxylin, the details of the nuclear structure, as also the accessory nucleus, are very clearly brought out.

Weigert's Hæmatoxylin Solution.

This is used for staining the central nervous system. The tissues need to be hardened in Müller's fluid, are then transferred without washing into alcohol, and embedded in celloidin. The celloidin block is placed in the following solution for 24 to 48 hours:—

Acetate of copper (saturated aqueous solution) } equal parts.
Distilled water }

The block is then washed in 70% alcohol for 24 hours, and may then be sectioned. (If desired the sections may first be cut, and then placed in the above solution of acetate of copper for 24 hours, and washed for several hours in 70% alcohol.) Sections are now stained in Weigert's hæmatoxylin solution:

Hæmatoxylin crystals,	1 gm.
Absolute alcohol,	10 c. c.
Lithium carbonate,	1.2 grms.
Distilled water,	100 c. c.

The hæmatoxylin crystals are dissolved in the absolute alcohol, the lithium carbonate in the water; mix the two solutions. The sections remain in the stain 12 to 24

hours, are then washed in Weigert's differentiating fluid;

Borax,	2 grms.
Potassium ferricyanide,	2.5 grms.
Distilled water,	100 c. c.

The sections remain in the differentiating fluid until the gray matter has a brownish-yellow, and the white a bluish-black color. Sections are then washed in tap water for several hours, dehydrated in alcohol, and cleared in the following clearing fluid (Weigert's):—

Carbolic acid crystals	1 part.
Xylol	3 parts.

The sections may then be mounted in balsam.

This method has been variously modified; two such modifications are here given.

Pal's Method.

Prepare and cut sections as for Weigert's stain. Stain in Weigert's hæmatoxylin solution, after staining wash the sections in water to which a trace of lithium carbonate has been added. The sections are then placed in a $\frac{1}{4}\%$ aqueous solution of permanganate of potash in which they remain 20 to 30 seconds, are then rinsed in distilled water, and differentiated in the following solution:—

Oxalic acid	1 gm.
Potassium sulphite (K_2SO_3)	1 gm.
Distilled water	200 c. c.

They remain in this solution for $\frac{1}{2}$ to 1 minute, or until the gray matter has assumed a yellowish color, are then washed in water, dehydrated, cleared in Weigert's clearing fluid, and mounted in balsam.

Benda's Method.

Benda's modification is usually followed in this laboratory.

Harden tissues in Müller's fluid.



Embed in celloidin.



Sections are placed for 12 to 24 hours in the following solution:

Liquor ferri ter sulphatis	1 part.
Distilled water	2 parts.

↓
Rinse thoroughly in two tap waters and one distilled water.

↓
Stain for 24 hours in—

Hæmatoxylin crystals	. . .	1 gm.
Absolute alcohol	. . .	10 c. c.
Distilled water	. . .	90 c. c.

↓
Wash sections in tap water for 10 to 15 min.

↓
Place in 0.25% aqueous solution of permanganate of potash until the gray matter begins to stand out (1 to 15 minutes).

↓
Wash in distilled water.

↓
Differentiate in the following solution—

Hydric sulphite	. . .	about 5 to 10 c. c.
Distilled water	. . .	100 c. c.

until the gray matter has a light yellow color.

↓
Wash in tap water for 1 to 2 hours.

↓
Rinse sections in distilled water.

↓
Double stain in alum carmine for 1 to 1½ hours, wash in distilled water.

↓
Dehydrate.

↓
Clear in Weigert's clearing fluid.

↓
Mount in balsam.

If sections have been kept for some time in alcohol, it is advisable to place them for 24 hours in Müller's fluid, from which they are *rinsed* in distilled water, and stained after any one of the above three methods.

CARMINE STAINS.

Carmine has for many years held a prominent place among the stains used for coloring tissue. It is especially useful for staining them in bulk.

Grenacher's Borax Carmine Solution.

Carmine (No. 40).	3 grms.
Borax	4 grms.
Distilled water	100 c. c.
Alcohol (70%)	100 c. c.

The carmine and borax are dissolved in warm distilled water, allowed to cool, after which the alcohol is added; at the end of 48 hours, the solution is filtered; the filtrate must stand for several weeks before using. Tissues hardened in alcohol or bichloride of mercury are stained well after this method. The pieces remain in the stains from 24 to 48 hours, are then washed in an *acid alcohol wash* (6 to 8 drops of HCl to 100 c. c. of 70% alcohol) from 6 to 24 hours, and then in 70% alcohol for two hours, dehydrated, and embedded in celloidin or paraffin.

Grenacher's Alum Carmine Solution.

Carmine (No. 40),	1 gm.
Potash alum,	3-5 grms.
Distilled water,	100 c. c.

Add the alum and carmine to the water; place over a flame, and bring the water to the boiling point; allow to boil 15 minutes. As soon as the solution is cold, filter, and it will be ready for use. Tissues hardened in the chrome salts, alcohol, or bichloride of mercury, are well stained in this solution; stain *en masse*. The pieces remain in the stain from 24 to 48 hours (even longer if they are large), are then washed for several hours in flowing water, dehydrated, and embedded in paraffin or celloidin.

Orth's Lithium Carmine Solution.

Carmine,	2.5 grms.
Lithium carbonate,	1.2 grms.
Distilled water,	100 c. c.

The carmine and lithium carbonate are dissolved in warm water; allow to cool, and filter. Sections remain in

the stain 10 to 15 minutes, are then washed in acid alcohol or in 70% alcohol to which a few crystals of picric acid have been added; remove acid by transferring sections to 70% alcohol. Dehydrate, clear in oil of bergamot, and mount in balsam.

Orth's Picro-Lithium Carmine Solution.

To three parts of the above lithium carmine solution add one part of a saturated aqueous solution of picric acid. Sections stain in 10 to 20 minutes. Wash in 70% alcohol to which a few crystals of picric acid have been added.

ANILINE DYES.

It would lead far beyond the scope of this guide, to mention even very briefly, the various aniline dyes that have found their way into microscopical technic. The certainty and ease with which many of the microorganisms are stained by them, has made them very useful in bacteriological work. Their use, as staining agents for tissues, dates back to 1863, at which time Waldeyer and Frey made use of one of the fuchsins for staining tissues. Since that time an ever increasing number of these dyes has been tried, and recommended by various investigators. The few here mentioned have proved themselves most useful in the hands of the author.

Ehrlich classifies all aniline dyes, as basic, neutral, or acid. In a general way we may say that the basic dyes, such as *methylene blue*, *methyl green*, *gentian violet*, *methyl violet*, *Bismark brown*, *safranin*, etc. are to be used when it is desired to stain the nucleus, while the acid aniline dyes, such as *eosin*, *orange G*, *acid fuchsin*, *lichtgrün*, *aurantia*, and *nigrosin* are generally used for staining the protoplasm of cells.

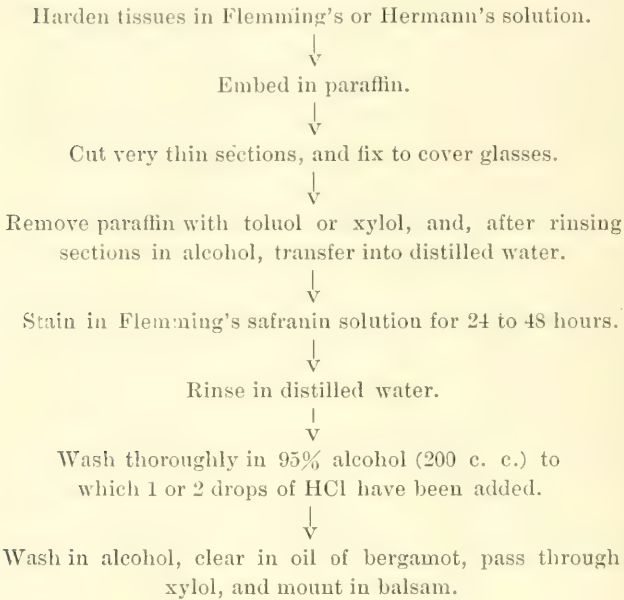
Almost all aniline stains are readily soluble in alcohol or water, and, as they stain very deeply and quickly, only dilute solutions (0.5 to 1%) are recommended. The majority of the basic stains give the best results when combined with *aniline water*, but as nearly all stain diffusely, the sections need to be thoroughly washed in water, alcohol, or acidulated alcohol before mounting.

Flemming's Safranin Solution.

Safranin	1 grm.
Absolute alcohol	10 c. c.
Aniline water	90 c. c.

The aniline water is prepared by shaking 5 to 8 c. c. of aniline oil with 100 c. c. of distilled water, and filtering through a *wet* filter paper. Dissolve the safranin in aniline water, and add the alcohol. Filter before using.

The steps for staining are as follows:—



In tissues hardened and stained in the above way, the chromatic network of the nucleus is well stained; this method is largely used for staining cells in process of division.

Gentian Violet Solution (Ehrlich and Bizzozero), Taken from Lee's *Vade Mecum*.

Gentian violet	1 part.
Alcohol	15 parts.
Aniline oil	3 parts.
Distilled water	80 parts.

Mix the aniline oil with water, and filter through *wet* filter paper. Dissolve gentian violet in aniline water, and add the alcohol.

The steps of the method are as follows:—

The tissues are hardened in Flemming's or Hermann's solution.

↓

Embed in paraffin, section, and fix sections to cover glasses; remove paraffin from sections, and bring them into distilled water.

↓

Stain in the above solution for 10 to 15 hours.

↓

Rinse in alcohol.

↓

Wash in 1% aqueous sol. of chromic acid 30 seconds.

↓

Wash in alcohol for a few seconds.

↓

Again bring into 1% aqueous sol. of chromic acid 30 seconds.

↓

Wash in alcohol for 30 to 40 seconds.

↓

Clear in oil of cloves; the oil needs to be changed once or twice, as much of the stain is given off in it.

Sections remain in the oil until no more stain is given off.

↓

Pass through xylol, and mount in balsam.

Tissues hardened in alcohol need to be stained only 10 to 15 minutes; the after treatment is the same as above given.

This method brings out clearly nuclear structure and karyokinetic figures.

Methylene blue, methyl violet, methyl green, and Bismark Brown, may be made up as 1% solutions in about 15% alcohol. The tissues hardened in alcohol and mercuric chloride will be stained in 10 to 15 minutes; tissues hard-

ened in Flemming's or Hermann's solution in as many hours.

Wash sections thoroughly in alcohol, and mount in balsam.

As the acid aniline dyes are generally used for counter-staining, they will be described under the head of double and triple stains.

DOUBLE STAINING.

When certain colors are combined in a solution, or used one after the other in staining, it has been found that some elements of the tissues to be stained are colored by one of the dyes used, while others show greater affinity for other dyes. This fact is made use of in combining dyes for double and triple staining.

Hæmatoxylin and Eosin or Acid Fuchsin.

The eosin solution used for double staining is made after the following formula:—

Eosin 1 gm.

Alcohol (60%) 100 c. c.

The acid fuchsin solution—

Acid fuchsin 1 to 2 grms.

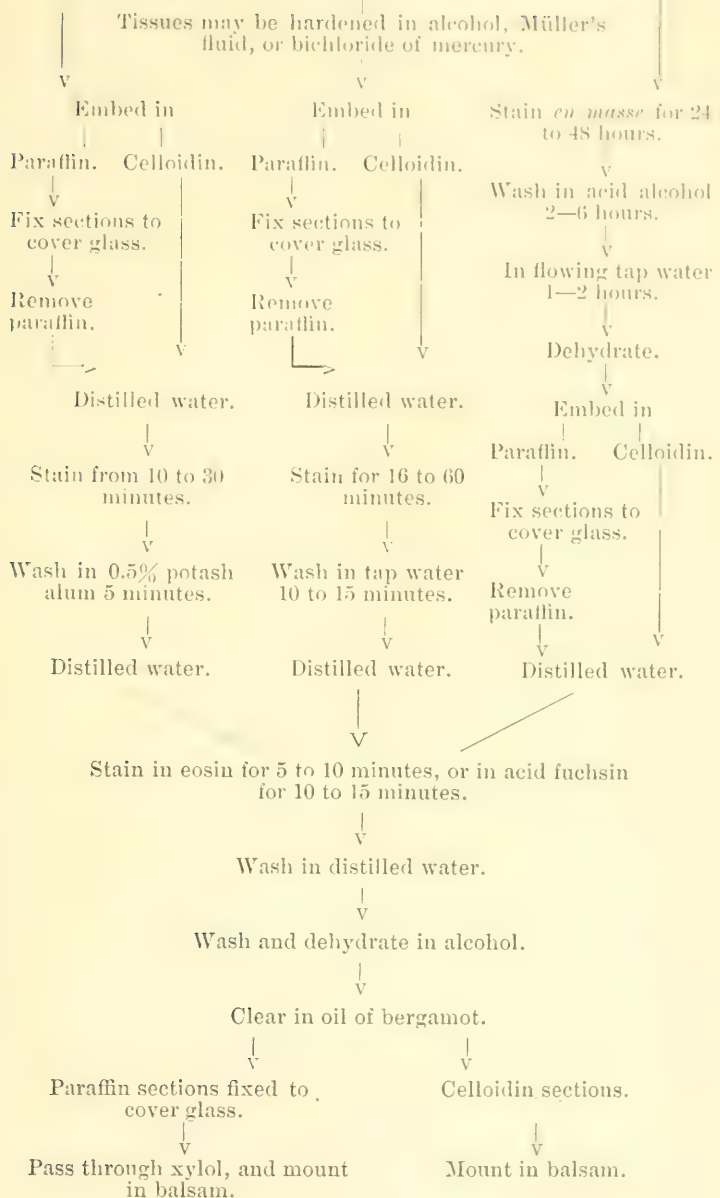
Distilled water 100 c. c.

The steps for staining are as follows:—

Boehmer's
Hæmatoxylin.

Ehrlich's
Hæmatoxylin.

Delafield's
Hæmatoxylin.



Orange G and Hæmatoxylin (Rawitz).

The tissues should be hardened in absolute alcohol, mercuric chloride, or picric acid.

↓

Embed in paraffin, and fix sections to cover glass.

↓

Remove paraffin, and bring sections into distilled water.

↓

Stain in a saturated aqueous solution of Orange G (filtered) for about 24 hours.

↓

Rinse in distilled water.

↓

Stain in Boehmer's hæmatoxylin solution for about 5 minutes.

↓

Wash in distilled water.

↓

Dehydrate in alcohol.

↓

Clear in oil of bergamot.

↓

Pass through xylol, and mount in balsam.

This is certainly one of the best of double stains, especially for glandular tissues. The nuclei are stained with the hæmatoxylin, the protoplasm with orange G.

Safranin and Lichtgruen (Benda).

Tissues hardened in Flemming's or Hermann's solution are embedded in paraffin, and sections fixed to the cover glass. Remove paraffin, and bring sections into distilled water.

Stain for about 24 hours in the following safranin solution:—

Safranin	1	gram.
Aniline water	90	c. c.
Absolute alcohol	10	c. c.

Sections are then washed in absolute alcohol for 30 seconds, and in a 1% alcohol solution of lichtgrün for 15 to 45 seconds, again washed in absolute alcohol, cleared in oil of bergamot, passed through xylol, and mounted in balsam.

When the stain is properly managed, the chromatic network of the nucleus and the chromosomal of dividing cells are stained red, the protoplasm green. 25

Nigrosin and Eosin.

This method is useful for staining sections of the central nervous system. Sections are stained for one hour in a 1% solution of nigrosin, are then washed in distilled water for several minutes; they are then placed in a 1% solution of eosin in which they remain from 3 to 5 minutes.

Wash first in 70% alcohol, then in 95% until no stain is given off from the section. Clear in oil of bergamot, and mount in balsam.

Aniline Blue and Safranin (Stroebe).

This method is especially to be recommended for staining peripheral nerves. The method as here outlined is slightly modified from that given by Stroebe.

The peripheral nerves are hardened in Müller's fluid, embedded in paraffin, and cut longitudinally or transversely. Sections are fixed to cover glasses, the paraffin removed, and carried through alcohol into distilled water.

1. Sections are then stained for 1 to 5 hours in a saturated aqueous solution of aniline blue (Grübler's wasserlösliches anilin blau).

2. They are then rinsed in distilled water.

3. Decolorize in an alkali alcohol wash, which is prepared by dissolving 1 gm. of caustic potash in 100 c. c. of absolute alcohol, and filtering. Just before using, about 30 drops of this solution are added to 30 c. c. of absolute alcohol. On placing the sections into the wash, they lose their blue color, and assume a reddish-brown tinge, at the same time reddish-brown waves are given off from the preparation. The bleaching is continued until the reddish-brown clouds cease to be given off, usually about 1 to 2 minutes.

4. The sections are now transferred to distilled water, in which the sections again assume a blue color, of a much lighter hue, however. In the distilled water the sections remain about 10 minutes.

5. Counter-stain in a saturated aqueous solution of safranin for about 30 minutes.

6. Rinse in distilled water.

7. Wash, and dehydrate quickly in 95% and absolute alcohol.

8. Clear in oil of bergamot, pass sections through xylol, and mount in balsam.

The axis cylinders are all stained blue, the myelin a yellowish-red or orange color, and all nuclei red.

Carmine and Aniline Blue (Duval).

Tissues are stained in borax carmine in the usual way, are then embedded in paraffin, sectioned, and sections fixed to cover glasses. Remove paraffin from sections, and bring them into absolute alcohol.

Stain for 10 to 20 minutes in—

Aniline blue, saturated alcohol solution 10 drops.

Absolute alcohol 10 c. c.

Wash, and clear sections in turpentine, pass through xylol, and mount in balsam.

The central nervous system is well stained after this method; the tissues may be hardened in bichloride of mercury. The connective tissue elements are stained blue, the nerve cells and axis cylinders a reddish-violet.

Borax Carmine and Indigo Carmine (Norris and Shakespeare, taken from Böhm and Oppel's *Taschenbuch der mikroskopischen Technik*).

Sol. A. Grind in a mortar.

Carmine 2 grms.

Borax 8 grms.

Distilled water 130 c. c.

Allow to stand for 24 hours, then filter.

Sol. B. Rub up in mortar.

Indigo carmine 8 grms.

Borax 8 grms.

Distilled water 130 c. c.

Allow to stand for 24 hours, then filter.

Before using, mix equal parts of sol. A and B. Stain tissues for 20 minutes, wash in a concentrated aqueous sol. of oxalic acid, rinse in absolute alcohol, dehydrate, and mount in balsam.

- Tissues may be hardened in Müller's fluid, thoroughly washed in water, and embedded in celloidin.

^ RIPLE STAINING. T

The formula here given was first recommended by Ehrlich, and used by him for staining blood preparations. Biondi and Heidenhain have slightly modified it, to make it more suitable for section staining.

Acid fuchsin (sat. aqueous sol.)	.	20 parts.
Methyl green (sat. aqueous sol.)	.	50 parts.
Orange G (sat. aqueous sol.)	.	100 parts.

The acid fuchsin and orange G are mixed, the methyl green is slowly added while constantly stirring. The stain should not be filtered, and needs to be diluted with distilled water 40 to 60 times before using.

Steps for staining are as follows:—

Harden tissues in absolute alcohol or bichloride of mercury.

↓

Embed in paraffin.

↓

Fix sections to cover glasses.

↓

Remove paraffin, and bring sections into distilled water.

↓

Stain for 4 to 24 hours.

↓

Rinse in distilled water.

↓

Wash thoroughly in alcohol.

↓

Dehydrate, and clear in oil of bergamot.

↓

Pass through xylol, and mount in balsam.

Grübler of Leipzig sells the stain in the form of a powder. A 1% aqueous solution is made of the powder, but before using, it is necessary to add 6 to 10 drops of a sat. aqueous sol. of acid fuchsin. Use as above directed.

The nuclei are stained a bluish-green, the protoplasm a reddish-purple, fibrous connective tissue fuchsin-red, and the red blood cells orange.

Methods for Preparing and Staining Blood Preparations.

The steps for obtaining blood preparations are as follows:—Arrange on a piece of filter paper a number of carefully cleaned cover glasses; these must be very thin, extra number one. Ehrlich washes the cover glasses first in strong sulphuric acid, rinses in water, and places them for a few moments in glacial acetic acid; they are then washed in flowing water until all the acid is removed, transferred to 95% alcohol, from which they are taken and wiped. Unless the cover glasses are thin and clean, no good preparation can be made. The finger is pricked with a steel pen, one of the prongs of which has been broken off. From the flowing blood a very small drop is caught on the cover glass, near its edge, and the glass quickly placed, blood side downward, on another cover glass, care being taken to cover this second cover glass only about half. The blood will be seen to spread out between the two covers. Quickly draw one cover glass from the other; a thin layer of blood will in this way be spread on both slips. Ten to twenty preparations are to be made in this way, and placed, blood side up, on the filter paper before you, and allowed to dry. Before staining, the preparations need to be fixed. This is done by one of the following two methods. You may harden the preparations in—

Ether	3 parts.
Absolute alcohol	1 part.

In this solution they remain for 1 to 24 hours, are then set aside for a few moments until the ether and alcohol evaporates, when they are ready for staining.

Ehrlich recommends the fixing of the preparations by heat. He suggests a very simple apparatus, shown in Fig. II, by means of which the blood may be fixed.

It consists of a copper plate about 15 inches long, 4 wide, and $\frac{1}{8}$ inch thick. The copper plate is heated at one end by means of an alcohol or gas flame. If then, at the

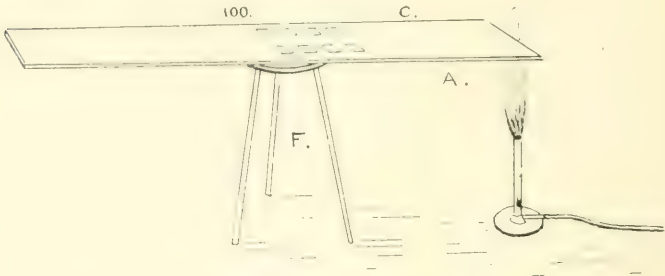


Fig. II. Plate for heating blood preparations. A, copper plate; C, blood preparations; F, tripod.

end of 15 minutes a glass rod which has been dipped into water be passed over the plate, beginning at the end away from the flame, a place is reached where the water begins to boil; this region of the copper plate is looked upon as having a temperature of 100° C.; it is represented by a dotted line in the diagram. The blood preparations (C) are placed on the plate (blood side up) between the flame and this imaginary line (nearer the latter), and heated for a time varying with the stain to be used.

The blood of any vertebrate may be spread and fixed as above directed. When desired to make preparations from fish, amphibian, or reptilian blood, the blood is most easily obtained from the heart. This, after exposure, is nipped with a pair of scissors, a small drop of the flowing blood is picked up on the end of a clean glass rod, quickly transferred to cover glass, and spread in the usual way, Bird's blood is readily obtained from one of the toes, which, after anaesthetizing the animal, may be cut or partially amputated; a small drop is taken from the flowing blood, and spread. Preparations of *red bone marrow*, of the *spleen*, or of *lymph glands* may also be prepared after this method. Very small pieces of the tissue are placed between two

cover glasses and crushed, after which procedure the covers are quickly drawn apart; or the cover glasses may be drawn over the freshly cut surface of the tissue. These preparations may after fixing be stained after any one of the following methods:—

Hæmatoxylin and Eosin Stain.

The preparations are fixed for about 1 hour in ether and alcohol or are exposed to a temperature of 100° to 110° C. for about 45 to 60 minutes, stained in Boehmer's hæmatoxylin for 20 to 30 minutes, washed in flowing water, counter-stained in eosin for 5 minutes, again washed, and *quickly* dried between filter paper. Mount in balsam.

All nuclei are stained blue, protoplasm and eosinophile granules red. The other granules are not stained.

Ehrlich's Neutrophile Mixture—

Orange G (saturated aqueous solution),	130-135 c. c.
Acid fuchsin (saturated aqueous solution),	80-165 c. c.
Methyl green (saturated aqueous solution),	125 c. c.
Distilled water,	300 c. c.
Alcohol (absolute),	200 c. c.
Glycerine,	100 c. c.

Mix orange G, acid fuchsin, water, and absolute alcohol in a bottle, add slowly and while shaking the methyl green. The glycerine is then added. For staining in Ehrlich's neutrophile mixture, the preparations need to be hardened in ether and alcohol for about one hour, or fixed at a temperature of 100° to 110° C. for 15 to 30 minutes. Float the preparation on a small quantity of the stain for about 15 minutes, wash in flowing water, dry between several filter papers, and mount in balsam. The red corpuscles should have a reddish-brown color (brick color), all nuclei green, the eosinophile granules red, and the neutrophile granules violet-red.

Chenzinski's Stain.

Methylene blue (saturated aqueous solution),	40 parts.
Eosin (1% sol. in 70% alcohol),	20 parts.
Distilled water,	30 parts.
Glycerine,	10 parts.

The eosin, distilled water, and glycerine are mixed in a bottle; the methylene blue is added slowly while shaking. Preparations need to be fixed from 1 to 1½ hours at a temperature of 120° C. or in ether and alcohol for 1 to 2 hours. They remain in the stain for 24 hours in the warm oven at a temperature of 40° C. Wash quickly in flowing water, dry between filter paper, and mount in balsam. The red corpuscles and the eosinophile granules are stained red, all nuclei blue.

Ehrlich's Triacid Glycerine Mixture.

Aurantia,	2 grms.
Eosin	3 grms.
Nigrosin,	5 grms.
Glycerine,	40 c. c.

The glycerine is divided into three parts, to each is added one of the above stains, and each needs to be ground in a mortar for several hours. The three glycerine solutions are then mixed, and exposed to a temperature of 60° C. for two weeks. The stain is then ready for use, and if well made amply repays all the trouble taken in making it. It will keep for a long time, and should be of a syrupy consistency. The blood preparations need to be fixed at a temperature of 130° to 140° C. for 1 to 3 hours. A small quantity of the stain is spread out in a flat dish; on this the preparations are placed, they remain in the warm oven (40° C.) for 24 hours; are then washed in flowing water, dried between filter paper, and mounted in balsam. The red blood cells are stained yellow, all nuclei black, the eosinophile granules red, other granules are not stained.

Ehrlich's Methylene Blue Solution.—This is employed for staining basophile cells (Mastzellen of Ehrlich).

Methylene blue (saturated alcoholic solution),	1 part.
Distilled water,	2 parts.

Preparations are fixed at a temperature of 110° C. for 30 minutes. Stain for 15 minutes. Wash quickly in flowing water, dry between filter paper, and mount in balsam. All nuclei are stained blue, and *only* the basophile granules, which also take a blue color, are stained.

The methods here given are especially useful for studying the blood clinically, and can not be too warmly recommended.

COUNTING BLOOD CELLS.

The instrument now generally used for this purpose is the *Thoma-Zeiss hæmacytometer*. This apparatus consists of two parts, pipettes by means of which the blood is diluted 100 times, when counting red, or 10 times when white blood cells are to be counted: and a glass slide, on which there is a small well of known depth, the bottom of the well being divided off into small squares. The pipette used when counting the red cells, consists of a capillary tube, near the middle of which there is an ampullar enlargement. This is so graduated that the cubical contents of the capillary tube is just one-hundredth part of the cubical contents of the ampulla. The blood to be examined is drawn into the capillary tube, to a line marked 1 (just below the ampulla), the end of the pipette is then inserted into the diluting fluid, and this is sucked up until the diluted blood reaches a line marked 101 (just above the ampulla). The pipette is then carefully shaken to mix thoroughly the blood and the diluting fluid.

Either of the following two solutions may be used for diluting the blood:—

Hayem's Solution.

Bichloride of mercury,	0.5	gram.
Sodium chloride,	1.0	gram.
Sodium sulphate,	5.0	grms.
Distilled water	200.0	c. c.

Toison's Fluid (as given by Kahlden).

Methyl violet 5 B,	0.025	grms.
Neutral glycerine,	30.0	c. c.
Distilled water,	80.0	c. c.

Mix methyl violet in glycerine and the distilled water; to this solution is added

Sodium chloride (C. P.),	1.0	grms.
Sodium sulphate (C. P.),	8.0	grms.
Distilled water,	80.0	c. c.

Filter, and the solution will be ready for use. The white blood cells are stained violet, and may thus be counted with the red.

The diluting fluid contained in the capillary tube is then blown out, and a small drop of the diluted blood is placed on the centre of the small glass disc. This small disc is surrounded by a ring of glass, cemented to the slide. The glass ring is 0.1 m. m. thicker than the glass disc. When this small moist chamber is covered with a thick cover glass, we have a layer of blood 0.1 m. m. deep between the disc and the cover glass. On the upper surface of the small glass disc (on which the drop of diluted blood was placed) there are marked off 400 small squares. The sides of the small squares are $\frac{1}{20}$ of 1 m. m. long. It will be seen that the layer of blood over each of the squares would have a cubical contents of—

$$\frac{1}{40000} \text{ of a c. m. m. } \left(\frac{1}{20} \times \frac{1}{20} \times \frac{1}{20} = \frac{1}{4000} \right).$$

The hæmacytometer slide is now placed on the stage of the microscope, where it should remain undisturbed for several minutes before counting. The red blood cells in 25 to 50 squares are then counted. To ascertain the number of red cells in a cubic millimeter the following formula may be useful:—

$$\frac{4000 \left\{ \begin{array}{l} \text{Each cube of blood counted} \\ \text{has a cubical contents of} \\ \frac{1}{1000} \text{ c. m. m.,} \end{array} \right\} \times d \left\{ \begin{array}{l} \text{The dilution of the} \\ \text{blood, which} \\ \text{would be 100,} \end{array} \right\} \times n \left\{ \begin{array}{l} \text{The number} \\ \text{of red cells} \\ \text{counted,} \end{array} \right\}}{n \text{ sq (The number of squares counted)}}$$

The number of red
blood cells in
1 c. m. m.

Or ascertain the average of the red blood cells in the squares counted, and multiply this number by 400,000.

In case it is desired to count only the white blood corpuscles, a $\frac{1}{3}$ % sol. of glacial acetic acid is used for diluting the blood. This solution bleaches the red cells, and brings out clearly the white corpuscles.

The blood is diluted only 10 times, using for this purpose, the Thoma-Zeiss pipette for counting white corpuscles. The formula then reads as follows:

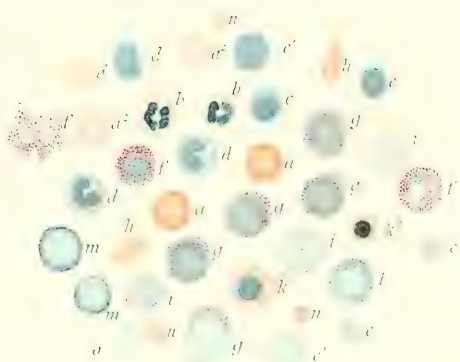
$$4000 \times d (10) \times n \left\{ \begin{array}{l} \text{The number of white} \\ \text{blood corpuscles} \\ \text{counted.} \end{array} \right\} \frac{\text{The number of white}}{\text{blood cells found in}} \\ \text{n sq (Number of squares counted).} \quad \text{cubic millimeter.}$$

Or multiply the average number of white corpuscles in each square by 40,000.

PLATE I.—Blood Elements.

- a.* Red blood cells, Erythrocytes, stained in Ehrlich's neutrophile mixture.
- a¹-a².* Red blood cells stained in eosin-methylen blue.
- u.* Microcytes.
- h.* Poikilocyte.
- k¹-k².* Nucleated red blood cells.
-
- b.* Polynuclear white blood cells, stained in eosin-methylen blue.
- i.* Polynuclear white blood cells, stained in Ehrlich's neutrophile mixture.
- d.* Transitional white blood cells.
- e¹.* Mononuclear white blood cell.
- e-c* Lymphocytes.
- f.* Eosinophile white blood cells.
- g.* Myelocytes, stained in Ehrlich's neutrophile mixture.
- m.* Myelocytes stained in methylen blue.
- l.* Basophile white blood cell.
- o.* Blood plaques or blood plates.

PLATE I.



MEMORANDA.

MEMORANDA.

ERRATA.

Wherever *Fleming* appears, read *Flemming*.

Wherever *Haidenhain* appears, read *Heidenhain*.

Page 41, seventh line from bottom, for *Schultz's* read *Schultz's*.

Page 174, read $\frac{1}{4000}$ of a c. m. m. ($\frac{1}{20} \times \frac{1}{20} \times \frac{1}{10} = \frac{1}{4000}$) instead of ($\frac{1}{20} \times \frac{1}{20} \times \frac{1}{10} = \frac{1}{400}$).

INDEX.

	Page
Accessory nucleus,	11
Adenoid tissue,	67
" " reticulum,	68
Adipose tissue,	56
Albumen fixative,	141
Alcohol, Ranvier's, for macerating tissue,	125
" 95%, for hardening tissues,	178
Alum carmine,	178
Amœboid movement of white blood cells,	7
Aniline blue and carmine, double stain,	166
" " " safranin, " " 	165
Aniline dyes,	159
" " acid,	159
" " basic,	159
" " solubility of,	159
Aniline water,	160
Aorta,	64
Arterioles,	63
Artery,	63
BENDA'S hardening fluid,	130
Benda's modified Weigert's hæmatoxylin,	156
Berlin blue injection mass,	139
Bichloride of mercury for hardening,	128
Bile capillaries,	98
Bismark brown,	161
Blood, amphibian,	6
" human,	5, 6
" pigeon,	7
" stain, detection of,	10
Blood cells, counting of,	173
Blood preparations, hardening methods,	169, 170
" " stains;	171
Chenzinski's,	171
Ehrlich's methylene blue,	172
" neutrophile,	171
" triacid,	172
Hæmatoxylin and eosin,	171
Boehmer's hæmatoxylin,	151
Bone,	33

Bone, cancellated,	37
“ decalcified,	34
“ developing,	37
“ marrow,	38
Borax carmine,	158
“ “ and indigo carmine, double stain,	166
Brain,	58
Brunner's glands,	91
CAPILLARIES,	63
Carmine gelatin injection mass,	138
Carmine stains;	158
alum carmine,	158
borax carmine,	158
lithium carmine,	158
picro-lithium carmine,	159
Cartilage,	29
“ elastic fibro-,	29
“ hyaline,	29
“ white fibrous,	30
Caustic potash, for macerating tissues,	125
Cells, animal,	2
“ plant,	1
Cerebellum,	58
“ Golgi stained,	54
Cerebrum, Golgi stained,	54
“ Weigert stained,	59
Chenzinski's blood stain,	171
Ciliary body,	116
Cleaning cover glasses and slides,	147
Cochlea,	117
Connective tissue,	21
“ “ areolar,	22
“ “ cell spaces,	22
“ “ embryonic,	25
“ “ white fibrous,	21
“ “ yellow elastic,	21
Cornea,	115
Corpus luteum,	111
Corti, organ of,	118
Counting blood cells,	173
Cutting sections;	
celloidin sections,	142
free hand sections,	140
freezing method,	141
paraffin sections,	147
DECALCIFYING methods,	132
Ebner's	132
Haug's	133

INDEX.

	187
Lepkowski's,	133
nitric and hydrochloric acid,	132
Delafield's hæmatoxylin,	151
Dermis,	73
Dextrin method of fixing sections to slide or cover,	149
Double staining,	162
aniline blue and carmine,	166
aniline blue and safranin,	165
borax carmine and indigo carmine,	166
hæmatoxylin and acid fuchsin,	163
hæmatoxylin and eosin,	163
hæmatoxylin and orange G,	164
Ebner's decalcifying fluid,	132
Ehrlich's hæmatoxylin,	152
" methylene blue <i>mastzellen</i> stain,	172
" neutrophile stain,	171
" triacid stain,	171
Ehrlich-Biondi triple stain,	167
Ehrlich and Bizzozero's gentian violet sol.,	160
Embedding tissues,	140
celloidin or collodium,	141
gum arabic,	141
paraffin,	144
Endothelium,	26
Epidymis, <i>male</i> ,	73
Epididymis,	109
Epithelium,	13
" ciliated, teased,	18
" " section of,	18
" columnar, teased,	17
" " section of,	17
" stratified pavement, teased,	13
" " " section of,	14
" transitional, teased,	14
" " " section of,	14
Eye,	115
Fat cells,	26
Fibrin,	9
Filiform papillæ,	77
Fixing sections to slide or cover glass, methods of,	147
albumen fixative,	147
dextrin method,	149
Gaule's method,	149
Huber's method,	148
Flemming's hardening solution,	150
Flemming's safranin solution,	160
Fungiform papillæ,	78


GAULE'S method of fixing sections to slide or cover,	149
Gentian violet solution,	160
Goblet cells,	18
Gold chloride, Ranvier's method,	136
Golgi method,	135
HEMACYTOMETER,	173
Hematoxylin solution,	151
Hematoxylin stains,	151
Boehmer's solution,	151
Benda's method,	156
DeLafield's solution,	153
Ehrlich's solution,	152
Heidenhain's hæmatoxylin stain,	154
Heidenhain's iron-lack-hæmatoxylin,	154
Pal's method,	156
Weigert's hæmatoxylin,	155
Hematoxylin and acid fuchsin, double stain,	162, 163
" " eosin, double stain,	162, 163
Hematoxylin and eosin, blood stain,	171
" " Orange G,	164
Hæmin crystals,	9
Hair,	74
Hair follicle,	74, 75
Hardening methods,	128
alcohol, 95%,	128
Benda's method,	130
bichloride of mercury,	128
Flemming's solution,	130
Hermann's solution,	131
Huber's solution,	131
Müller's fluid,	129
mercuric chloride,	128
mercuric chloride and formalin,	129
mercuric chloride and picric acid,	129
nitric acid,	130
picric acid,	130
Rabl's solution,	129
Haug's chrom-osmium sol. for decalcifying,	133
Hayem's solution,	173
Heidenhain's hæmatoxylin,	154
" iron-lack-hæmatoxylin,	154
Hermann's solution,	131
Huber's method of fixing sections to slide or cover,	148
" hardening solution,	131
Hydrochloric acid for macerating,	125
IMPREGNATION of tissues,	134
gold chloride, Ranvier's method,	136
Golgi's method,	135

Ramon y Cajal's method,	135
silver nitrate,	131
Injecting tissues,	
Berlin blue mass,	139
carmine gelatin,	138
Intestine, large,	92
" small,	91, 92
KARYOKINESIS in animal cells,	2
" " plant cells,	1
Kidney,	103
" tubules of,	103
" human,	101
LARGE intestine,	92
Lens,	116
Lepkowski's decalcifying fluid,	133
Ligamentum nuchæ,	25
Lip,	77
Lithium carmine,	158
Liver,	97
" cells,	97
" of pig,	97
" of man,	97
Lung,	98
Lymph cells,	69
" gland,	68
MAMMARY gland,	112
Macerating tissues, methods of,	125
alcohol, Ranvier's,	125
caustic potash,	125
hydrochloric acid,	125
nitric acid,	126
osmic acid,	126
Schultze's mixture,	126
sulphuric acid,	126
Mercuric chloride,	128
" " and formalin,	129
" " and picric acid,	129
Methylene blue,	161
Methyl green,	161
Methyl violet,	161
Mitosis, animal cells,	2
" plant cells,	1
Müller's fluid,	129
Muscle,	41
" branched striped,	41
" heart muscle,	45
" involuntary,	46


Muscle, nerve-ending in striped muscle,	45
" striped, voluntary,	41, 42
Nerve cells,	51
" " of brain cortex,	51
" " of cerebellum,	51
" " of posterior root ganglion,	55
" " of spinal cord,	73
Nerve fibres,	51
" " medullated,	44
" " non-medullated,	54
Nerve trunk,	50, 51
Nitric acid,	120
" " for hardening,	120
Nitric and hydrochloric acid,	127
ŒSOPHAGUS,	90
" and cardiac end of stomach,	90
Olfactory mucous membrane, section,	119
" " " teased,	118
Optic papilla,	117
Osmic acid,	116
Ovary,	110
PAL'S modified Weigert's method,	156
Pancreas,	113
Paraffin, hard,	145
" soft,	144
Peptic glands,	90
Picric acid for hardening,	129
Picro-lithium carmine,	159
Prostate,	165
RAMON Y CAJAL'S method,	163
Removing paraffin from paraffin sections preparatory to staining,	148
Retina,	117
SAFRANIN solution,	160
Salivary gland, mucous,	78
" " serous,	78
Scalp,	74
Schlemm, canal of,	116
Schultze's mixture,	126
Serial celloidin sections, Weigert's method,	143
Silver nitrate,	131
Skin, human,	73
Small intestine,	91, 92
Spermatogenesis,	169
Spinal cord,	57
" " with anterior and posterior roots,	57
" " Golgi stained,	53

INDEX

Spinal Cord, Weigert stained,	62
Spleen,	62
" pulp,	62
Spreading blood on cover glasses,	162
Staining sections,	151
Stomach, cardiac end,	90
" pyloric end,	90
Sulphuric acid for macerating,	126
Suprarenal body,	101
TASTE buds,	78
Teichmann's crystals,	2
Tendon,	22, 23
Testis,	109
Thyroid gland,	99
Thymus gland,	67
Toison's solution,	173
Tonsil,	67
Tooth,	83
" decalcified,	83
" developing,	84
Trachea,	98
Triple staining,	167
UTERUS,	111
VAGINA,	111
Vas deferens,	109
Veins,	63
WEIGERT'S hæmatoxylin,	155
White blood cells,	6







41

PLEASE DO NOT REMOVE
CARDS OR SLIPS FROM THIS POCKET

UNIVERSITY OF TORONTO LIBRARY

QM Huber, Gotthelf Carl
555 Directions for work in the
H86 histological laboratory
1895

BioMed

