


EM 100-100



BOSTON
MEDICAL LIBRARY
8 THE FENWAY

Joshua C. Hubbard -




THE
ELEMENTS OF EMBRYOLOGY.



THE
ELEMENTS OF EMBRYOLOGY

BY

M. FOSTER, M.A., M.D., LL.D., F.R.S.,

FELLOW OF AND PRÆLECTOR IN PHYSIOLOGY IN TRINITY COLLEGE, CAMBRIDGE,

AND THE LATE

FRANCIS M. BALFOUR, M.A., LL.D., F.R.S.,

FELLOW OF TRINITY COLLEGE, CAMBRIDGE,
AND PROFESSOR OF ANIMAL MORPHOLOGY IN THE UNIVERSITY.

SECOND EDITION REVISED.

EDITED BY

ADAM SEDGWICK, M.A.,

FELLOW AND ASSISTANT LECTURER OF TRINITY COLLEGE, CAMBRIDGE,

AND

WALTER HEAPE,

DEMONSTRATOR IN THE MORPHOLOGICAL LABORATORY OF THE UNIVERSITY
OF CAMBRIDGE.

London:
MACMILLAN AND CO.

1883

[*The Right of Translation is reserved.*]

P. MAY 1824

20120

Cambridge :

PRINTED BY C. J. CLAY, M.A. & SON,
AT THE UNIVERSITY PRESS.

3. L. H.

PREFACE TO THE SECOND EDITION.

WHEN this little work first appeared, it was put forward as a Part I, to be followed by other Parts. That plan was however soon abandoned. Nevertheless the volume seemed to have a place of its own; and my dear lost friend undertook to prepare a second edition, intending to add some account of the development of the Mammal with a view of making the work an elementary introduction to vertebrate embryology more particularly suited for medical students. He was occupied with the task at the time of his sad death; and indeed a melancholy interest is attached to some of the sheets, by the fact that he had taken them to Switzerland with him, on that fatal journey.

All the first part up to p. 160 he had passed for press; and he had further revised up to about p. 202. The whole of the rest of the volume has been under-

taken by Mr Adam Sedgwick and Mr Walter Heape. They have attempted to carry out as far as possible what we believe to have been Balfour's views, and trust that the public will judge leniently of their efforts to perform a difficult task. I have myself been able to do no more than offer general advice from time to time; and though it has not been thought advisable to change the title, the merits as well as the responsibilities of the latter part of the work must rest with them.

M. FOSTER.

TRINITY COLLEGE,
CAMBRIDGE,
March, 1883.

TABLE OF CONTENTS.

PART I. THE HISTORY OF THE CHICK.

CHAPTER I.

THE STRUCTURE OF THE HEN'S EGG, AND THE CHANGES WHICH TAKE
PLACE UP TO THE BEGINNING OF INCUBATION . pp. 1—24.

The shell and shell-membrane, 1—3. The albumen, 3. The vitelline membrane, 4. The yolk, 5—7. Area opaca, 7. Area pellucida, 8. The structure of the blastoderm, 7—10. Recapitulation, 10. The ovarian ovum, 11—15. The descent of the ovum along the oviduct, 15—17. Impregnation, 17. Segmentation, 18—24.

CHAPTER II.

BRIEF SUMMARY OF THE WHOLE HISTORY OF INCUBATION,
pp. 25—47.

The embryo is formed in the area pellucida, 25. The germinal layers, 25, 26. The extension of the blastoderm over the yolk, 26. The vascular area, 27. The head-fold, 27—36. The tail-fold, 37. The lateral folds, 37. The yolk-sac, 37. The alimentary canal, 39. The neural tube, 39, 40. The body-cavity, 41. The somatopleure, 41. The splanchnopleure, 42. The stalk of the yolk-sac, 42, 43. The amnion, 43—46. The allantois, 46, 47.

CHAPTER III.

THE CHANGES WHICH TAKE PLACE DURING THE FIRST DAY OF INCUBATION	pp. 48—76.
---	------------

Variations in the progress of development, 48, 49. The embryonic shield, 49. Formation of hypoblast, 51. The germinal wall, 52. The primitive streak, 52—54. Formation of primitive streak mesoblast, 54, 55. Hypoblastic mesoblast, 55. Primitive groove, 56, 57. The notochord, 59—62. The medullary groove, 62, 63. Amnion, 63. The changes taking place in the three layers, 63—66. The germinal wall, 65, 66. The increase of the head-fold, 66. The closure of the medullary canal, 66, 67. The cleavage of the mesoblast; formation of splanchnopleure and somatopleure, 68. The vertebral and lateral plates, 69. The mesoblastic somites, 70. The sinus rhomboidalis, 71. The neurenteric passage, 71—74. Formation of the vascular area, 74, 75. Recapitulation, 75, 76.

CHAPTER IV.

THE CHANGES WHICH TAKE PLACE DURING THE FIRST HALF OF THE SECOND DAY	pp. 77—95.
--	------------

Increasing distinctness and prominence of embryo, 77. The first cerebral vesicle, 78, 79. The auditory pits, 81. Increase in number of mesoblastic somites, 81. The fore-gut, 82. The heart, 82—89. The vascular system, 89—94. Formation of blood-vessels, 92—94. The rudiment of the Wolffian duct, 94. Summary, 94, 95.

CHAPTER V.

THE CHANGES WHICH TAKE PLACE DURING THE SECOND HALF OF THE SECOND DAY	pp. 96—108.
---	-------------

Increasing prominence of the embryo; the tail-fold and lateral folds, 96. Continued closure of medullary canal, 96—98. *The brain*, 98—101. The optic vesicles, 98. The second and third cerebral vesicles, 100. The cerebral hemispheres, 100. First appearance of cranial nerves, 100, 101. The notochord, 101. The cranial flexure, 101. The auditory vesicle, 101. Increase of curvature of heart, 101,

102. Auricular appendages, 102. *Vascular System*, 102—106. Commencement of circulation, 102. The primitive aortæ and first pair of aortic arches, 102, 103. The vitelline vessels and sinus terminalis, 103, 104. The course of the circulation, 105. The second and third pairs of aortic arches, 105, 106. The Wolffian duct and first appearance of Wolffian body, 106. The growth of the amnion, 107. The first appearance of the allantois, 107. Summary, 107, 108.

CHAPTER VI.

THE CHANGES WHICH TAKE PLACE DURING THE THIRD DAY,

pp. 109—194.

The diminution of the albumen, 109. The spreading of the opaque and vascular areas, 109, 110. The vascular area, 110—113. The continued folding-in of the embryo, 113. The increase of the amnion, 113. The change in position of the embryo, 113—116. The curvature of the body, 116. The cranial flexure, 116, 117. *The brain*, 117—123. Growth of the vesicle of the cerebral hemispheres, 117. The lateral ventricles, 117. The vesicle of the 3rd ventricle or thalamencephalon, 117. The rudiment of the pineal gland, 117, 118. The infundibulum, 119. The stomodæum, 119. The pituitary body, 119—121. Changes in the mid-brain, the corpora bigemina, crura cerebri and iter, 121. Changes in the hind-brain, the medulla, cerebellum, 4th ventricle, 121, 122. Changes in the neural canal, 122, 123. *The cranial and spinal nerves*, 123—132. The neural band, 123—126. The fifth, seventh, ninth and tenth cranial nerves, 126, 127. Later development of cranial nerves, 127—129. The spinal nerves, 129. The shifting of point of attachment of nerves, 131. Anterior roots, 131. *The eye*, 137—156. The first changes in the optic vesicles, 132, 133. The secondary optic vesicle and development of the lens, 134—137. The choroidal fissure, 137—140. The choroid, sclerotic and cornea, 140, 141. The further development of the optic vesicle, 141. The ora serrata, 142. The iris, 142. Pigment epithelium of choroid, 142. The ciliary processes, uvea, ciliary muscle and ligamentum pectinatum, 144. The histological changes in the retina, 144—146. Optic nerve, 146, 147. The choroid fissure, 147. The pecten, 148. The histological changes in the lens, 149, 150. The vitreous humour, 150. The cornea, 150—153. The aqueous humour, 153. Summary of the development of the eye, 154, 155. The eyelids, 155. The lacrymal glands and duct, 155, 156. *The organ of hearing*, 156—161. Closure

of the auditory involution, 157. The otic vesicle, 157. The membranous labyrinth, 158, 159. The osseous labyrinth, 159, 160. Comparison of ear with eye, 160, 161. The organ of smell, 161, 162. The olfactory lobes and nerves, 162. *The visceral arches and visceral clefts*, 162—167. Superior maxillary, and fronto-nasal processes, 164, 165. Fate of first visceral cleft, 165, 166. The meatus auditorius externus, 166. The tympanic membrane, 166. The Eustachian tube and tympanic cavity, 165, 166. The fenestra ovalis and rotunda, 166. The columella, 166, 167. *The vascular system*, 167—170. The aortic arches, 167. Changes in the heart, 167, 168. The venous system, 169, 170. The meatus venosus, cardinal veins and ductus Cuvieri, 169, 170. *The alimentary canal*, 171—185. Folding in of the splanchnopleure, tail-fold, 171, 172. The mesentery, 172, 173. Oesophagus and stomach, 173. The intestine, 174. The postanal gut, neurenteric canal and proctodæum, 174—176. The lungs, 176—178. The liver, 178—181. The pancreas, 181. The thyroid body, 181, 182. The spleen, 182. The growth and blood-vessels of the allantois, 182—184. *The mesoblast*, 185—193. The muscle-plates, 186—189. The intermediate cell-mass and Wolffian body, 189—193. A typical Wolffian tubule, 193. Change of position of Wolffian duct, 193. Summary, 193, 194.

CHAPTER VII.

THE CHANGES WHICH TAKE PLACE ON THE FOURTH DAY, pp. 195—231.

Appearance on opening the egg, 195. Growth of amnion, 195, 196. The vitelline duct, 196. Increase of cranial flexure and tail-fold, 196—198. The first appearance of the limbs, 198. The growth of the brain, 200. The face, 202. Changes in the nasal pits, 202. The stomodæum and mouth, 202, 203. The cranial nerves, 203. *Changes in the mesoblastic somites*, 204—212. The membranous vertebral column, 205. The secondary segmentation of the vertebral column and formation of the permanent vertebræ, 205—207. Recapitulation, 207, 208. The changes in the notochord, 208—211. Ossification of vertebræ, 209, 210. The changes in the muscle plates, 211, 212. Wolffian body and duct, 212—214. The Müllerian duct, 214—218. The kidney and ureter, 218—220. The ovaries and testes, 220—223. Fate of the embryonic urinogenital organs, 223, 224. Changes in the arterial system, 224—226. Changes in the venous system; veins of the liver, 226—229. Changes in the heart; the ventricular septum, 229, 230. Summary, 230, 231.

CHAPTER VIII.

THE CHANGES WHICH TAKE PLACE ON THE FIFTH DAY, pp. 232—274.

Appearance on opening the egg, 232. The changes in the limbs, 233, 234. The pectoral and pelvic girdles; the ribs and sternum, 234, 235. *The development of the skull*, 235—246. The cranium, 235. The parachordals and notochord, 237, 238. The trabeculæ, 239—241. The sense capsules, 241, 242. Membrane and cartilage bones, 242. Skeleton of visceral arches, 242—245. Table of bones, 246. The changes in the face, 246—251. The posterior nares, 251. Changes in the spinal cord; its histological differentiation, 251—254. The central canal; and the posterior and anterior fissures, 254—256. Changes in the heart, 256—264. Septum in the bulbus and semilunar valves, 257—259. The cardiac valves, 262. The foramen ovale and Eustachian valve, 262—264. The pericardial and pleural cavities, 264—269. Histological differentiation and the fate of the three primary layers, 269—273. Summary, 273, 274.

CHAPTER IX.

FROM THE SIXTH DAY TO THE END OF INCUBATION, pp. 275—303.

The appearance of distinct avian characters, 275. The foetal appendages during the 6th and 7th days, 276—278. During the 8th, 9th and 10th days, 278. From the 11th to the 16th days, 278, 279. From the 16th day onwards, 279, 280. Changes in the general form of the embryo during the 6th and 7th days, 280—282. During the 8th—10th days, 282. From the 11th day onwards, 282. Feathers, 282. Nails, 283. Ossification, 283. Changes in the venous system before and after the commencement of pulmonary respiration, 283—289. Changes in the arterial system, the modification of the aortic arches, 289—297. Summary of the chief phases of the circulation, 297—303. Hatching, 303.

PART II. THE HISTORY OF THE MAMMALIAN EMBRYO.

INTRODUCTION, pp. 307, 308.

CHAPTER X.

GENERAL DEVELOPMENT OF THE EMBRYO . . . pp. 309—341.

The ovarian ovum, 309, 310. The egg-membranes, 310. Maturation and impregnation, 310—312. Segmentation, 312—314. The blastodermic vesicle, 314—316. The formation of the layers, 316—320. The primitive streak and groove, 319, 320. The medullary groove, 320, 321. The mesoblast, 321—325. The notochord, 325, 326. The rudiment of the neurenteric canal, 326. Recapitulation, 326. The vascular area, 326. General growth of the embryo, 327—334. The human embryo, 335—341. Embryos of guinea-pig, etc. with so-called inversion of the layers, 341.

CHAPTER XI.

EMBRYONIC MEMBRANES AND YOLK-SAC . . . pp. 342—364.

The typical development of the embryonic membranes, 342—352. Vascular area of rabbit, 343—346. The yolk-sac or umbilical vesicle; amnion, 343. The subzonal membrane, 346. Attachment of blastodermic vesicle to uterine walls, 347. The formation of the chorion, 348. Mesoblast and blood-supply of the allantois, 348, 349. The placenta, 349, 350. The fate of the embryonic membranes, 350—352. Deciduate and non-deciduate type of placenta, 352. *Comparative history of the mammalian fetal membranes*, 352—359. Fœtal membranes of Monotremata and Marsupialia, 352. The discoidal placenta, 353, 354. The metadiscoidal placenta, 354—358. The zonary placenta, 358, 359. The diffuse and polycotyledonary placenta, 359. Comparative histology of the placenta, 359—363. Evolution of the placenta, 364.

CHAPTER XII.

THE DEVELOPMENT OF THE ORGANS IN MAMMALIA, pp. 365—422.

The organs derived from the epiblast, 365—400. Hairs, 365. Glands, 366. The hind-brain, 367—370. The mid-brain, 370, 371. General development of fore-brain, 371. Thalamencephalon, 371—376. Pituitary body, 372, 373. Pineal gland, 373—376. Cerebral hemispheres, 376—385. The olfactory lobes, 385. Histogenesis of brain, 385—387. The eyes, 387—390. Choroid slit, membrana capsulo-pupillaris and arteria centralis retinae, 389. The auditory organ, 390—397. Accessory auditory structures, 397—399. The nasal organ, and organ of Jacobson, 399. Cranial and spinal nerves; sympathetic system, 400.

Organs derived from the mesoblast, 400—417. The vertebral column, 400, 401. The skull, 401. The visceral arches, 402. Mandibular and hyoid arches; malleus, incus, and stapes, 403—405. Ribs; sternum; pectoral and pelvic girdles, 405. Skeleton of the limbs, 406. Body-cavity; pericardial, pleural cavities and diaphragm, 406.

The vascular system, 406—413. The heart, 406, 407. The arterial system, 407—409. The venous system, 409—413. The supra-renal bodies, 413, 414. The urinogenital organs, 414—417. Wolffian duct and body; kidney; ovary and testis, 414, 415. Genital cord, 415. Urinogenital sinus and external generative organs, 415—417.

Alimentary canal and its appendages, 417—422. Splanchnic mesoblast and mesentery, 419, 420. Stomodæum, 420, 421. Hard and soft palate, 420, 421. Teeth, 421. Proctodæum, 422.

APPENDIX . . . pp. 423—471.

Incubators, 423—425. Hardening reagents, 425—428. Staining reagents, 428—432. Imbedding, 432—434. Cutting sections, 434, 435. Mounting sections, 436. Preservation of embryos as a whole, 436, 437.

Practical directions for obtaining and studying chick embryos, 437—460. Examination of a 36—48 hours embryo, 437—444. Of an embryo of about 48—50 hours, 444—447. Of an embryo at the end of the 3rd day, 447—451. Of an embryo of the 4th day, 451—453. Of a blastoderm of 20 hours, 453—456. Of an unincubated blastoderm, 457. Of the process of segmentation, 458. Of the later changes of the embryo, 459. Of the development of blood-vessels, 459, 460.

Practical directions for obtaining and studying Mammalian embryos, 460—471. Animals and breeding, 460, 461. Examination and treatment of segmenting ova, 461—464. Of the blastodermic vesicle, 72—90 hours, 465. Of the blastodermic vesicle of 7 days, 465, 466. Of an 8 days embryo, 466—468. Of an embryo of 8 days 12 hours, 468, 469. Of the foetal membranes of an embryo of 14 days, 469, 470.


NOTE A. Automatic microtome, 471.

NOTE B. New method of mounting sections, 471.

PART I.

THE HISTORY OF THE CHICK.

100-100-100
100-100-100
100-100-100



CHAPTER I.

THE STRUCTURE OF THE HEN'S EGG, AND THE CHANGES WHICH TAKE PLACE UP TO THE BEGINNING OF INCUBATION.

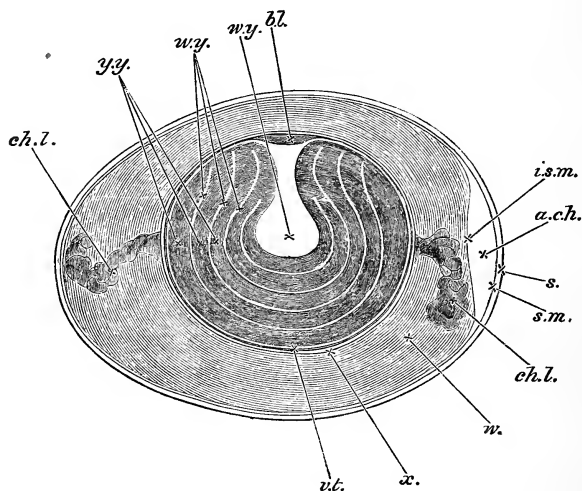
IN a hen's egg quite newly laid we meet with the following structures. Most external is the *shell* (Fig. 1, s.), composed of an organic basis, impregnated with calcic salts. It is sufficiently porous to allow of the interchange of gases between its interior and the external air, and thus the chemical processes of respiration, feeble at first, but gradually increasing in intensity, are carried on during the whole period of incubation.

It is formed of two layers, both of which may contain pigment. The inner layer is by far the thickest, and is perforated by vertical canals which open freely on its inner aspect. Superficially these canals appear to be closed by the extremely thin outer layer. They are probably of some importance in facilitating the penetration of air through the shell.

Lining the shell, is the *shell-membrane*, which is double, being made up of two layers: an outer thicker

(Fig. 1, *s. m.*), and an inner thinner one (*i. s. m.*). Both of these layers consist of several laminæ of felted fibres of various sizes, intermediate in nature between connective and elastic fibres.

FIG. 1.



DIAGRAMMATIC SECTION OF AN UNINCUBATED FOWL'S EGG
(modified from Allen Thomson).

bl. blastoderm. *w. y.* white yolk. This consists of a central flask-shaped mass and a number of layers arranged concentrically around this. *y. y.* yellow yolk. *v. t.* vitelline membrane. *x.* layer of more fluid albumen immediately surrounding the yolk. *w.* albumen consisting of alternate denser and more fluid layers. *ch. l.* chalaza. *a. ch.* air-chamber at the broad end of the egg. This chamber is merely a space left between the two layers of the shell-membrane. *i. s. m.* internal layer of shell-membrane. *s. m.* external layer of shell-membrane. *s.* shell.

Over the greater part of the egg the two layers of the shell-membrane remain permanently in close apposition; but at the broad end they tend to separate, and thus to develop between them a space into which air finds its way. This air-chamber, as it is called, is not to be found in perfectly fresh eggs, but makes its appearance in eggs which have been kept for some time, whether incubated or not, and gradually increases in size, as the white of the egg shrinks in bulk from evaporation.

Immediately beneath the shell-membrane is the *white of the egg* or albumen (Fig. 1, *w.*), which is, chemically speaking, a mixture of various forms of proteid material, with fatty, extractive, and saline bodies. The outer part of the white, especially in eggs which are not perfectly fresh, is more fluid than that nearer the yolk.

Its average composition may be taken as

12.0 p. c. proteid matter,

1.5 p. c. fat and extractives,

5 p. c. saline matter, chiefly sodic and potassic chlorides,
with phosphates and sulphates,

86.0 p. c. water.

The white of the egg when boiled shews in section alternate concentric layers of a transparent and of a finely granular opaque material. In the natural condition, the layers corresponding to these opaque layers are composed of more fluid albumen, while those corresponding to the transparent layers are less fluid, and consist of networks of fibres, containing fluid in their meshes. The innermost layer, however, immediately surrounding the yolk (Fig. 1, *x.*), is of the more fluid finely granular kind.

In eggs which have been hardened a spiral arrangement of the white may be observed, and it is possible to

tear off laminæ in a spiral direction from left to right, from the broad to the narrow end of the egg.

Two twisted cords called the *chalazæ* (Fig. 1, *ch. l.*), composed of coiled membranous layers of denser albumen, run from the two extremities of the egg to the opposite portions of the yolk. Their inner extremities expand and merge into a layer of denser albumen surrounding the fluid layer next the yolk. Their outer extremities are free, and do not quite reach the outer layer of the white. Thus they cannot serve to suspend the yolk, although they may help to keep it in position, by acting as elastic pads. The interior of each chalaza presents the appearance of a succession of opaque white knots; hence the name *chalazæ* (hailstones).

The yolk is enclosed in the *vitelline membrane* (Fig. 1, *v. t.*), a transparent somewhat elastic membrane easily thrown into creases and wrinkles. It might almost be called structureless, but under a high power a fine fibrillation is visible, and a transverse section has a dotted or punctuated appearance; it is probably therefore composed of fibrils. Its affinities are with elastic connective tissue.

The whole space within the vitelline membrane is occupied by the *yolk*. To the naked eye this appears tolerably uniform throughout, except at one particular point of its surface, at which may be seen, lying immediately under the vitelline membrane, a small white disc, about 4 mm. in diameter. This is the *blastoderm*, or *cicatricula*.

A tolerably typical *cicatricula* in a fecundated egg will shew an outer white rim of some little breadth, and within that a circular transparent area, in the centre of

which, again, there is an opacity, varying in appearance, sometimes homogeneous, and sometimes dotted.

The disc is always found to be uppermost whatever be the position of the egg, provided there is no restraint to the rotation of the yolk. The explanation of this is to be sought for in the lighter specific gravity of that portion of the yolk which is in the neighbourhood of the disc, and the phenomenon is not in any way due to the action of the chalazæ.

A section of the yolk of a hard-boiled egg will shew that it is not perfectly uniform throughout, but that there is a portion of it having the form of a flask, with a funnel-shaped neck, which, when the egg is boiled, does not become so solid as the rest of the yolk, but remains more or less fluid.

The expanded neck of this flask-shaped space is situated immediately underneath the disc, while its bulbous enlargement is about in the middle of the yolk. We shall return to it directly.

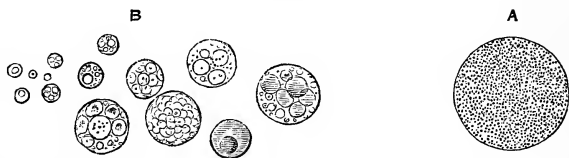The great mass of the yolk is composed of what is known as the *yellow yolk* (Fig. 1, *y. y.*). This consists of spheres (Fig. 2, *A.*) of from 25μ to $100\mu^1$ in diameter filled with numerous minute highly refractive granules; these spheres are very delicate and easily destroyed by crushing. When boiled or otherwise hardened *in situ*, they assume a polyhedral form, from mutual pressure. The granules they contain seem to be of an albuminous nature, as they are insoluble in ether or alcohol.

Chemically speaking the yolk is characterized by the presence in large quantities of a proteid matter, having many affinities with globulin, and called *vitellin*. This exists in peculiar associa-

¹ $\mu = .001$ mm.

tion with the remarkable body *Lecithin*. (Compare Hoppe-Seyler, *Hdb. Phys. Chem. Anal.*) Other fatty bodies, colouring matters, extractives (and, according to Dareste, starch in small quantities), &c. are also present. Miescher (Hoppe-Seyler, *Chem. Untersuch.* p. 502) states that a considerable quantity of *nuclein* may be obtained from the yolk, probably from the spherules of the white yolk.

FIG. 2.



- A. Yellow yolk-sphere filled with fine granules. The outline of the sphere has been rendered too bold.
- B. White yolk-spheres and spherules of various sizes and presenting different appearances. (It is very difficult in a woodcut to give a satisfactory representation of these peculiar structures.)

The yellow yolk, thus forming the great mass of the entire yolk, is clothed externally by a thin layer of a different material, known as the *white yolk*, which at the edge of the blastoderm passes underneath the disc, and becoming thicker at this spot forms, as it were, a bed on which the blastoderm rests. Immediately under the middle of the blastoderm this bed of white yolk is connected, by a narrow neck, with a central mass of similar material, lying in the middle of the yolk (Fig. 1, *w. y.*). When boiled, or otherwise hardened, the white yolk does not become so solid as the yellow yolk; hence the appearances to be seen in sections of the hardened yolk. The upper expanded extremity of this neck of

white yolk is generally known as the "nucleus of Pander."

Concentric to the outer enveloping layer of white yolk there are within the yolk other inner layers of the same substance, which cause sections of the hardened yolk to appear to be composed of alternate concentric thicker laminae of darker (yellow) yolk, and thinner laminae of lighter (white) yolk (Fig. 1, *w, y.*).

The microscopical characters of the white yolk elements are very different from those of the yellow yolk. It is composed of vesicles (Fig. 2, *B.*) for the most part smaller than those of the yellow yolk (4μ — 75μ), with a highly refractive body, often as small as 1μ , in the interior of each; and also of larger spheres, each of which contains a number of spherules, similar to the smaller spheres.

Another feature of the white yolk, according to His, is that in the region of the blastoderm it contains numerous large vacuoles filled with fluid; they are sufficiently large to be seen with the naked eye, but do not seem to be present in the ripe ovarian ovum.

It is now necessary to return to the *blastoderm*. In this, as we have already said, the naked eye can distinguish an opaque white rim surrounding a more transparent central area, in the middle of which again is a white spot of variable appearance. In an unfecundated cicatricula the white disc is simply marked with a number of irregular clear spaces, there being no proper division into a transparent centre and an opaque rim.

The opaque rim is the commencement of what we shall henceforward speak of as the *area opaca*; the central transparent portion is in the same way the

beginning of the *area pellucida*. In the part corresponding to the *area opaca* the blastoderm rests immediately on the white yolk; underneath the *area pellucida* is a shallow space containing a nearly clear fluid, to the presence of which the central transparency seems to be due. The white spot in the middle of the *area pellucida* appears to be the nucleus of Pander shining through.

Vertical sections of the blastoderm shew that it is formed of two layers. The upper of these two layers is composed, see Fig. 3, *ep*, of a single row of cells, with their long axes arranged vertically, adhering together so as to form a distinct membrane, the edge of which rests upon the white yolk. After staining with silver nitrate, this membrane viewed from above shews a mosaic of uniform polygonal cells.

Each cell is composed of granular protoplasm filled with highly refractive globules; and in each an oval nucleus may be distinguished. They are of a nearly uniform size (about 9μ) over the opaque and the pellucid areas.

The under layer (Fig. 3, *l*), is composed of cells which vary considerably in diameter; but even the smaller cells of this layer are larger than the cells of the upper layer. They are spherical, and so filled with granules and highly refractive globules, that a nucleus can rarely be seen in them: in the larger cells these globules are identical with the smaller white yolk spheres.

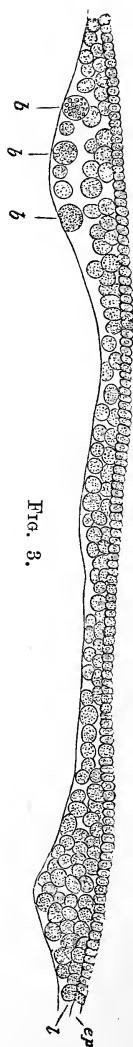
The cells of this layer do not form a distinct membrane like the cells of the upper layer, but lie as a somewhat irregular network of cells between the upper layer and the bed of white yolk on which the blastoderm

rests. The lowest are generally the largest. The layer is thicker at the periphery than at the centre: and rests on a bed of white yolk, from which it is in parts separated by a more or less developed cavity, containing probably fluid yolk matter about to be absorbed. In the bed of white yolk nuclei are present, which are destined to become the nuclei of cells about to join the lower layer of the blastoderm. These nuclei are generally more numerous in the neighbourhood of the thickened periphery of the blastoderm than elsewhere. Amongst the lower layer cells are to be found

FIG. 3.

SECTION OF A BLASTODERM OF A FOWL'S EGG
AT THE COMMENCEMENT OF INCUBATION.

The thin but complete upper layer *ep* composed of columnar cells rests on the incomplete lower layer *l*, composed of larger and more granular cells. The lower layer is thicker in some places than in others, and is especially thick at the periphery. The line below the under layer marks the upper surface of the white yolk. The larger so-called formative cells are seen at *b*, lying on the white yolk. The figure does not take in quite the whole breadth of the blastoderm; but the reader must understand that both to the right hand and the left *ep* is continued farther than *l*, so that at the extreme edge it rests directly on the white yolk.



peculiar large spherical bodies, which superficially resemble the larger cells around them, and have been called formative cells. Their real nature is still very doubtful, and though some are no doubt true cells, others are perhaps only nutritive masses of yolk.

The opacity of the peripheral part of the blastoderm is in a large measure due to the collection of the lower layer cells in this region, and the thickening, so caused, appears to be more pronounced for a small arc which subsequently constitutes the hinder border of the area pellucida.

Over nearly the whole of the blastoderm the upper layer rests on the under layer. At the circumference however the upper layer stretches for a short distance beyond the under layer, and here consequently rests directly on the white yolk.

To recapitulate:—In the normal unincubated hen's egg we recognize the blastoderm, consisting of a complete upper layer of smaller nucleated granular cells and a more or less incomplete under layer of larger cells, filled with larger granules; in these lower cells nuclei are rarely visible. The thin flat disc so formed rests, at the uppermost part of the entire yolk, on a bed of white yolk, and a peripheral thickening of the lower layer causes the appearance in the blastodermic disc of an area opaca and an area pellucida. The great mass of the entire yolk consists of the so-called yellow yolk composed of granular spheres. The white yolk is composed of smaller spheres of peculiar structure, and exists, in small part, as a thin coating around, and as thin concentric laminæ in the substance of the yellow yolk, but chiefly in the

form of a flask-shaped mass in the interior of the yolk, the upper somewhat expanded top of the neck of which forms the bed on which the blastoderm rests. The whole yolk is invested with the vitelline membrane, this again with the white; and the whole is covered with two shell-membranes and a shell.

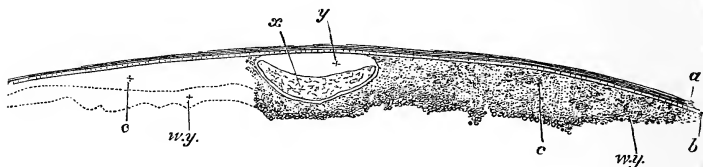
Such an egg has however undergone most important changes while still within the body of the hen; and in order to understand the nature of the structures which have just been described, it will be necessary to trace briefly the history of the egg from the stage when it exists as a so-called ovarian ovum in the ovary of a hen up to the time when it is laid.

In birds the left ovary alone is found in the adult; and is attached by the *mesovarium* to the dorsal wall of the abdominal cavity, on the left side of the vertebral column. It consists of a mass of vascular stroma in which the ova are imbedded, is covered superficially by a layer of epithelium, continuous with the epithelial lining of the peritoneal cavity. The appearance of the ovary varies greatly according to the age of the individual. In the mature and sexually active females it is almost wholly formed of pedunculated and highly vascular capsules of various sizes, each containing a more or less developed ovum; in the young animal however it is much more compact, owing to the absence of advanced ova.

If one of the largest capsules of the ovary of a hen which is laying regularly be opened, it will be found to contain a nearly spherical (or more correctly, ellipsoidal with but slightly unequal axes) yellow body enclosed in a delicate membrane. This is the ovarian ovum or egg.

Examined with care the ovum, which is tolerably uniform in appearance, will be found to be marked at one spot (generally facing the stalk of the capsule and forming the pole of the shorter axis of the ovum) by a small disc differing in appearance from the rest of the ovum. This disc which is known as the *germinal* disc or *discus*

FIG. 4.



SECTION THROUGH THE GERMINAL DISC OF THE RIPE OVARIAN OVUM OF A FOWL WHILE YET ENCLOSED IN ITS CAPSULE.

- a.* Connective-tissue capsule of the ovum. *b.* follicular epithelium, at the surface of which nearest the ovum lies the vitelline membrane. *c.* granular material of the germinal disc, which becomes converted into the blastoderm. (This is not very well represented in the woodcut. In sections which have been hardened in chromic acid it consists of fine granules.) *w. y.* white yolk, which passes insensibly into the fine granular material of the disc. *x.* germinal vesicle enclosed in a distinct membrane, but shrivelled up by the action of the chromic acid. *y.* space originally completely filled up by the germinal vesicle, before the latter was shrivelled up by the action of the chromic acid.

proligerus, consists of a lenticular mass of protoplasm (Fig. 4, *c*), imbedded in which is a globular or ellipsoidal body (Fig. 4, *x*), about 310μ in diameter, called the *germinal vesicle*. This has a delicate wall, and its contents are clear and fluid in the fresh state, but become granular upon the addition of reagents.

The rest of the ovum is known as the yolk. This consists of two elements, the white yolk- and the yellow yolk-spheres, which are distributed respectively very much in the same way as in the laid egg, the yellow yolk forming the main mass of the ovum, and the white yolk being gathered underneath and around the disc (Fig. 4, *w. y.*), and also forming a flask-shaped mass in the interior. The delicate membrane surrounding the whole is the *vitelline membrane*.

The youngest ova in the ovary of a fowl, in common with those of all other animals, present the characters of a simple cell. Such a cell is diagrammatically represented in Fig. 5.

It is seen to consist of a naked protoplasmic body containing in its interior a nucleus—the germinal vesicle—which in its turn envelopes a nucleolus—constituting what is known as the *germinal spot*. Such young ova are enclosed in a capsule of epithelium, named the follicle or follicular membrane, and are irregularly scattered in the stroma of the ovary.

FIG. 5.

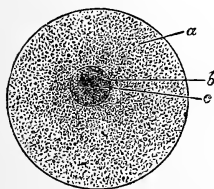


DIAGRAM OF THE OVUM. (From Gegenbaur.)

a. Granular protoplasm. *b.* Nucleus (germinal vesicle). *c.* Nucleolus (germinal spot).

The difference between such an immature ovum and the ripe ovum just described is very great, but throughout its growth the ovum retains the characters of a cell, so that the mature ovarian ovum, equally with the youngest ovum in the ovary, is a single cell.

The most striking changes which takes place in the

course of the maturation of the ovum concern the body of the cell rather than the germinal vesicle. As the body grows in size a number of granules make their appearance in its interior. These granules are formed by the inherent activity of the protoplasm, which is itself nourished, in a large measure at any rate, by the cells of the follicle. The outermost layer of the protoplasm remains free from these granules. As the ovum grows older the granules become larger, first of all in the centre, and subsequently at the periphery, and take the form of white yolk-spherules. The greater part of them become at a later stage converted into yellow yolk-spheres, while a portion of them, situated in the position of the white yolk of the ripe ovum, retain their original characters.

The germinal vesicle, which in the youngest ova is situated centrally or subcentrally, travels in the course of the growth of the ovum towards the periphery, and the protoplasm immediately surrounding it remains relatively free from yolk granules, and so constitutes the germinal disc. In the younger ova there is but a single germinal spot in the germinal vesicle, but as the ova enlarge several accessory germinal spots make their appearance, while in the ripe ovum it seems doubtful whether there is any longer a trace of a germinal spot.

The cells of the follicular epithelium are at first arranged in a single row, but at a later stage become two or more rows deep: they undergo however a nearly complete atrophy in the ripe ovum. Around the follicular epithelium there is present a *membrana propria*, and in the later stages of the growth of the

ovum this is in its turn embraced by a highly vascular connective-tissue capsule.

The youngest ova are, as has already been stated, quite naked. In ova of about 1.5 mm. the superficial layer of the ovum becomes converted into a radiately striated membrane called the *zona radiata*. At a later period a second membrane, placed between the *zona radiata* and the cells of the follicle, makes its appearance, but its mode of origin is still unknown. As the ovum approaches maturity the *zona radiata* disappears, and in the ripe ovum the second membrane, which has already been spoken of as the vitelline membrane, alone remains.

From what has just been stated it follows that in an egg which has been laid the yolk alone constitutes the true ovum. The white and the shell are in fact accessory structures formed during the passage of the ovum down the oviduct.

When the ovarian ovum is ripe and about to be discharged from the ovary, its capsule is clasped by the open infundibulum of the oviduct. The capsule then bursts, and the ovum escapes into the oviduct, its longer axis corresponding with the long axis of the oviduct, the germinal disc therefore being to one side.

In describing the changes which take place in the oviduct, it will be convenient, following the order previously adopted, to treat first of all of the formation of the accessory parts of the egg. These are secreted by the glandular walls of the oviduct. This organ therefore requires some description. It may be said to consist of four parts:—1st. The dilated infundibulum

with an abdominal opening. 2nd. A long tubular portion—the oviduct proper—opening by a narrow neck or isthmus into the 3rd portion, which is much dilated, and has been called the uterus; the 4th part is somewhat narrow, and leads from the uterus into the cloaca. The whole of the mucous membrane lining the oviduct is largely ciliated.

The accessory parts of the egg are entirely formed in the 2nd and 3rd portions. The layer of albumen which immediately surrounds the yolk is first deposited; the chalazæ are next formed. Their spiral character and the less distinctly marked spiral arrangement of the whole albumen is brought about by the motion of the egg along the spiral ridges into which the interior of the second or tubular portion of the oviduct is thrown. The spirals of the two chalazæ are in different directions. This is probably produced by their peripheral ends remaining fixed while the yolk to which their central ends are attached is caused to rotate by the contractions of the oviduct. During the formation of the chalazæ the rest of the albumen is also deposited; and finally the shell-membrane is formed in the narrow neck of the 2nd portion, by the fibrillation of the most external layer of albumen. The egg passes through the 2nd portion in little more than 3 hours. In the 3rd portion the shell is formed. The mucous membrane of this part is raised into numerous flattened folds, like large villi, containing follicular glands. From these a thick white fluid is poured out, which soon forms a kind of covering to the egg, in which the inorganic particles are deposited. In this portion of the oviduct the egg remains from 12 to 18

hours, during which time the shell acquires its normal consistency. At the time of laying it is expelled from the uterus by violent muscular contractions, and passes with its narrow end downwards along the remainder of the oviduct, to reach the exterior.

Impregnation. This process occurs in the upper portion of the oviduct; the spermatozoa being found actively moving in a fluid which is there contained.

We have as yet, as far as the fowl is concerned, no direct observations concerning the changes preceding and following upon impregnation; nor indeed concerning the actual nature of the act of impregnation.

In other types however these processes have been followed with considerable care, and the result has been to shew that prior to impregnation a division of the ovum takes place into two very unequal parts. The smaller of these parts is known as the *polar body*, and plays no further part in the development. In the course of the division of the ovum into these two parts the germinal vesicle also divides, and one part of it enters the polar body, while a portion remains in the larger segment which continues to be called the ovum, and is there known as the *female pronucleus*. Impregnation has been found to consist essentially in the entrance of a single spermatozoon into the ovum, followed by the fusion of the two. The spermatozoon itself is to be regarded as a cell, the head of which corresponds to the nucleus. When the spermatozoon enters the ovum the substance forming its tail becomes mingled with the protoplasm of the latter, but the head enlarges and constitutes a distinct body called the *male pronucleus*, which travels towards and finally fuses with

the female pronucleus to constitute the nucleus of the impregnated ovum.

Segmentation. There follows upon the impregnation a remarkable process known as the segmentation. The process consists essentially in the division of the impregnated ovum by a series of successive segmentations into a number of cells, of which the whole of the cells of the future animal are the direct descendants. In the majority of instances this process results in the division of the whole ovum into cells; but in cases of ova where there is a large amount of food yolk, only that part of the ovum in which the protoplasm is but slightly loaded with food material, and which we have already described as the germinal disc, becomes so divided. The remainder of the ovum constitutes a food reservoir for the use of the developing embryo and is known as the food yolk. The segmentation in such ova, of which that of the fowl is one of the best known examples, is described as being partial or meroblastic¹.

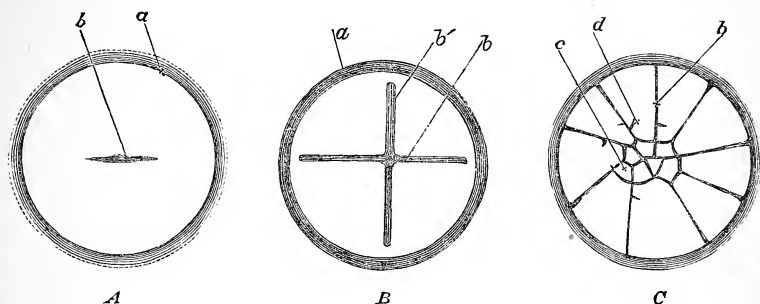
In order to understand the process of segmentation in the fowl's ovum it must be borne in mind that the germinal disc is not sharply separated from the remainder of the ovum, but that the two graduate insensibly into each other.

The segmentation commences in the lower part of the oviduct, shortly before the shell has begun to be formed.

Viewed from above, a furrow is seen to make its

¹ For a fuller account of the relation between holoblastic and meroblastic segmentation the reader is referred to the treatise on Comparative Embryology by Balfour, Vol. I. chapter iii.

FIG. 6.



SURFACE VIEWS OF THE EARLY STAGES OF THE SEGMENTATION
IN A FOWL'S EGG. (*A* and *C* after Coste.)

A represents the earliest stage. The first furrow (*b*) has begun to make its appearance in the centre of the germinal disc, whose periphery is marked by the line *a*. In *B*, the first furrow is completed nearly across the disc, and a second similar furrow at right angles to the first has appeared. The disc thus becomes divided somewhat irregularly into quadrants by four (half) furrows. In a later stage (*C*) the meridian furrows *b* have increased in number, from four, as in *B*, to nine, and cross furrows have also made their appearance. The disc is thus cut up into small central (*c*) and larger peripheral (*d*) segments. Several new cross furrows are seen just beginning, as *ex. gr.* close to the end of the line of reference *d*.

appearance, running across the germinal disc, though not for the whole breadth, and dividing it into two halves (Fig. 6, *A*). This primary furrow is succeeded by a second at right angles to itself. The surface thus becomes divided into four segments or quadrants (Fig. 6, *B*).

The second furrow cuts the first somewhat excentrically.

The first four furrows do not extend through the whole thickness of the germinal disc, and the four segments marked out by them are not separated from the disc on their lower aspect.

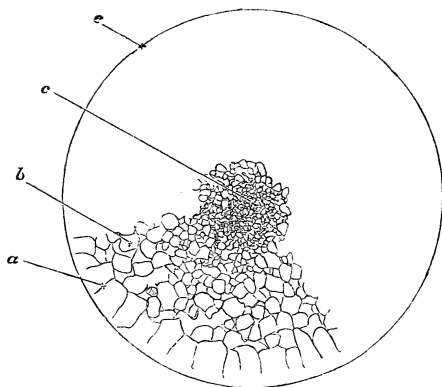
Each of these is again bisected by radiating furrows, and thus the number of segments is increased from four to eight (it may be seven or nine). The central portion of each segment is then, by a cross furrow, cut off from the peripheral portion, giving rise to the appearance of a number of central smaller segments, surrounded by more external elongated segments (Fig. 6, *C*).

The excentricity in the arrangement of the segments is moreover still preserved, the smaller segments being situated nearer one side of the germinal disc. The excentricity of the segmentation gives to the segmenting germinal disc a bilateral symmetry, but the relation between the axis of symmetry of the segmenting germinal disc and the long axis of the embryo is not known.

Division of the segments now proceeds rapidly by means of furrows running in various directions. And it is important to note that the central segments divide more rapidly than the peripheral, and consequently become at once smaller and more numerous (Fig. 7).

Meanwhile sections of the hardened blastoderm teach us that segmentation is not confined to the surface, but extends through the mass of the blastoderm; they shew us moreover that division takes place by means of not only vertical, but also horizontal furrows, *i.e.* furrows parallel to the surface of the disc (Fig. 8).

FIG. 7.



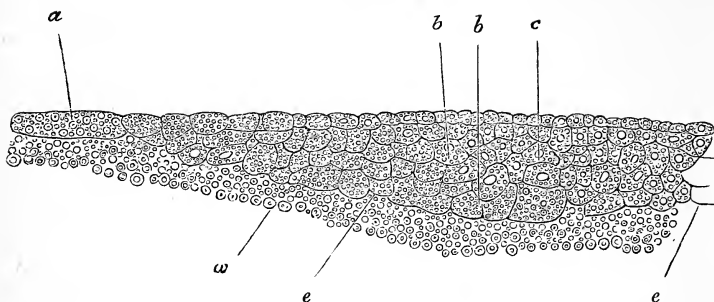
SURFACE VIEW OF THE GERMINAL DISC OF A HEN'S EGG
DURING THE LATER STAGES OF SEGMENTATION.
(Chromic Acid Preparation.)

At *c* in the centre of the disc the segmentation masses are very small and numerous. At *b*, nearer the edge, they are larger and fewer; while those at the extreme margin *a* are largest and fewest of all. It will be noticed that the radiating furrows marking off the segments *a* do not reach to the extreme margin *e* of the disc.

The drawing is completed in one quadrant only; it will of course be understood that the whole circle ought to be filled up in a precisely similar manner.

In this way, by repeated division or segmentation, the original germinal disc is cut up into a large number of small rounded masses of protoplasm, which are smallest in the centre, and increase in size towards the periphery. The segments lying uppermost are moreover smaller than those beneath, and thus the establishment of the two layers of the blastoderm is foreshadowed.

FIG. 8.



SECTION OF THE GERMINAL DISC OF A FOWL DURING THE
LATER STAGES OF SEGMENTATION.

The section, which represents rather more than half the breadth of the blastoderm (the middle line being shewn at *c*), shews that the upper and central parts of the disc segment faster than those below and towards the periphery. At the periphery the segments are still very large. One of the larger segments is shewn at *a*. In the majority of segments a nucleus can be seen; and it seems probable that a nucleus is present in all. Most of the segments are filled with highly refracting spherules, but these are more numerous in some cells (especially the larger cells near the yolk) than in others. In the central part of the blastoderm the upper cells have commenced to form a distinct layer.

a. large peripheral cell. *b*. larger cells of the lower parts of the blastoderm. *c*. middle line of blastoderm. *e*. edge of the blastoderm adjoining the white yolk. *w*. white yolk.

In the later stages of segmentation not only do the first-formed segments become further divided, but segmentation also extends into the remainder of the germinal disc.

The behaviour of the nucleus during the segmentation has not been satisfactorily followed, but there is,

from the analogy of other forms, no doubt that in the formation of the first two segments the original nucleus, formed by the fusion of the male and female pronuclei, becomes divided, and that a fresh division of the nucleus takes place with the formation of each fresh segment. Nuclei make their appearance moreover in the part of the ovum immediately below that in which the segmentation has already taken place; these are in all probability also derived from the primitive nucleus. The substance round some of these nuclei rises up in the form of papillæ, which are subsequently constricted off and set free as supplementary segmentation masses; while some of the nuclei remain and form the nuclei already spoken of as existing in the bed of white yolk below the blastoderm in the unincubated egg.

Between the segmented germinal disc, which we may now call the blastoderm, and the bed of white yolk on which it rests, a space containing fluid makes its appearance.

As development proceeds, segmentation reaches its limits in the centre, but continues at the periphery, and thus eventually the masses at the periphery become of the same size as those in the centre.

The distinction however between an upper and a lower layer becomes more and more obvious.

The masses of the upper layer arrange themselves, side by side, with their long axes vertical; their nuclei become very distinct. In fact they form a membrane of columnar nucleated cells.

The masses of the lower layer, remaining larger than those of the upper layer, continue markedly granular and round, and form rather a close irregular network

than a distinct membrane. Their nuclei are not readily visible.

At the time when the segmentation-spheres in the centre are smaller than those at the periphery, and those above are also smaller than those below, a few large spherical masses, probably containing each one of the nuclei already spoken of, arise by a process of segmentation from the bed of white yolk, and rest directly on the white yolk at the bottom of the shallow cavity below the mass of segmentation-spheres. They contain either numerous small spherules, or fine granules; the spherules precisely resembling the smaller spheres of white yolk. These loose spherical masses form the majority of the *formative cells* already spoken of.

Thus the original germinal disc of the ovarian ovum becomes, by the process of segmentation, converted into the blastoderm of the laid egg with its upper layer of columnar nucleated cells, and its lower layer of irregularly disposed cells, accompanied by a few stray "formative" cells lying loose in the cavity below.

CHAPTER II.

A BRIEF SUMMARY OF THE WHOLE HISTORY OF INCUBATION.

STEP by step the simple two-layered blastoderm described in the previous chapter is converted into the complex organism of the chick. The details of the many changes through which this end is reached will perhaps be rendered more intelligible if we prefix to the special history of them a brief summary of the general course of events from the beginning to the end of incubation.

In the first place, it is to be borne in mind that the embryo itself is formed in the area pellucida, and in the area pellucida alone. The area opaca in no part enters directly into the body of the chick; the structures to which it gives rise are to be regarded as appendages, which sooner or later disappear.

Germinal layers. The blastoderm at starting consists of two layers. Very soon a third layer makes its appearance between the other two. These three layers, known as the germinal layers, the establishment of which is a fact of fundamental importance in the history of the embryo, are called respectively the upper, middle and lower layers, or *epiblast*, *mesoblast* and *hypoblast*. Of

these the epiblast and hypoblast constitute the primary layers.

Three similar germinal layers are found in the embryos of all vertebrate and most invertebrate forms, and their history is one of the most important parts of comparative embryology.

The epiblast gives rise to the epidermis, the central and peripheral parts of the nervous system, and to the most important parts of the organs of special sense. The hypoblast is essentially the secretory layer, and furnishes the whole epithelial lining of the alimentary tract and its glands, with the exception of part of the mouth and anus which are lined by the epiblast and are spoken of by embryologists as the *stomodæum* and *proctodæum*. Finally the mesoblast is a source from which the whole of the vascular system, the muscular and skeletal system, and the connective tissue of all parts of the body, are developed. It gives in fact origin to the connective-tissue basis both of the skin and of the mucous membrane of the alimentary tract, and to all the structures lying between these two with the exceptions already indicated. It is more especially to be noted that it gives rise to the excretory organs and generative glands.

Formation of the embryo. The blastoderm which at first, as we have seen, lies like a watch-glass over the cavity below, its margin resting on the circular germinal wall of white yolk, spreads, as a thin circular sheet, over the yolk, immediately under the vitelline membrane. Increasing uniformly at all points of its circumference, the blastodermic expansion covers more and more of the yolk, and at last, reaching the opposite pole, completely envelopes it. Thus the whole yolk, instead of being

enclosed as formerly by the vitelline membrane alone, comes to be also enclosed in a bag formed by the blastoderm.

It is not however until quite a late period that the complete closing in at the opposite pole takes place; in fact the extension of the blastoderm must be thought of as going on during the first seven days of incubation.

Both the area opaca and the area pellucida share in this enlargement, but the area opaca increases much more rapidly than the area pellucida, and plays the principal part in encompassing the yolk.

The mesoblast, in that part of the area opaca which is nearest to the area pellucida, becomes the seat of peculiar changes, which result in the formation of blood-vessels. Hence this part of the area opaca is called the *vascular area*.

The embryo itself may be said to be formed by a folding off the central portion of the area pellucida from the rest of the blastoderm. At first the area pellucida is quite flat, or, inasmuch as it forms part of the circumference of the yolk, slightly but uniformly curved. Very soon, however, there appears at a certain spot a semi-lunar groove, at first small, but gradually increasing in depth and extent; this groove, which is represented in section in the diagram (Fig. 9, *A*), breaks the uniformity of the level of the area pellucida. It may be spoken of as a tucking in of a small portion of the blastoderm in the form of a crescent. When viewed from above, it presents itself as a curved line (the hinder of the two concentric curved lines in front of *A* in Fig. 22), which marks the hind margin of the groove, the depression itself being hidden.

FIG. 9.

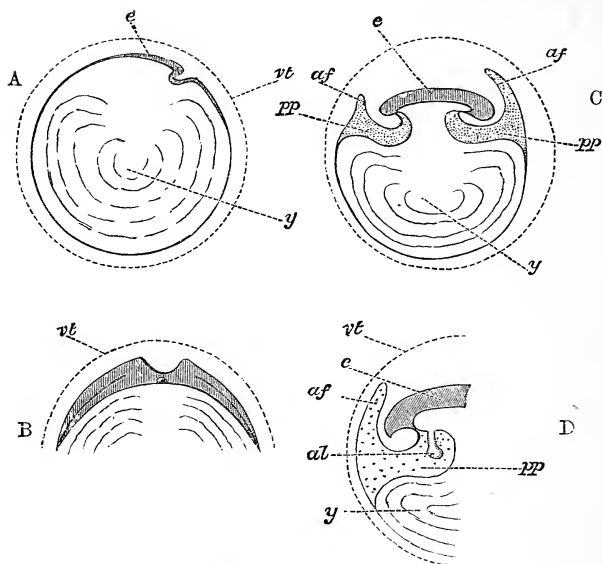


Fig. 9, *A* to *N* forms a series of purely diagrammatic representations introduced to facilitate the comprehension of the manner in which the body of the embryo is formed, and of the various relations of the yolk-sac, amnion and allantois.

In all *vt* is the vitelline membrane, placed, for convenience sake, at some distance from its contents, and represented as persisting in the later stages; in the actual egg it is in direct contact with the blastoderm (or yolk), and early ceases to have a separate existence. In all *e* indicates the embryo, *pp* the general pleuro-peritoneal space, *af* the folds of the amnion proper; *ae* or *ac* the cavity holding the liquor amnii; *al* the allantois; *a'* the alimentary canal; *y* or *ys* the yolk or yolk-sac.

A, which may be considered as a vertical section taken longitudinally along the axis of the embryo, represents the relations of the parts of the egg at the time of the first appearance of the head-fold, seen on the right-hand side of the blastoderm *e*. The

blastoderm is spreading both behind (to the left hand in the figure), and in front (to right hand) of the head-fold, its limits being indicated by the shading and thickening for a certain distance of the margin of the yolk *y*. As yet there is no fold on the left side of *e* corresponding to the head-fold on the right.

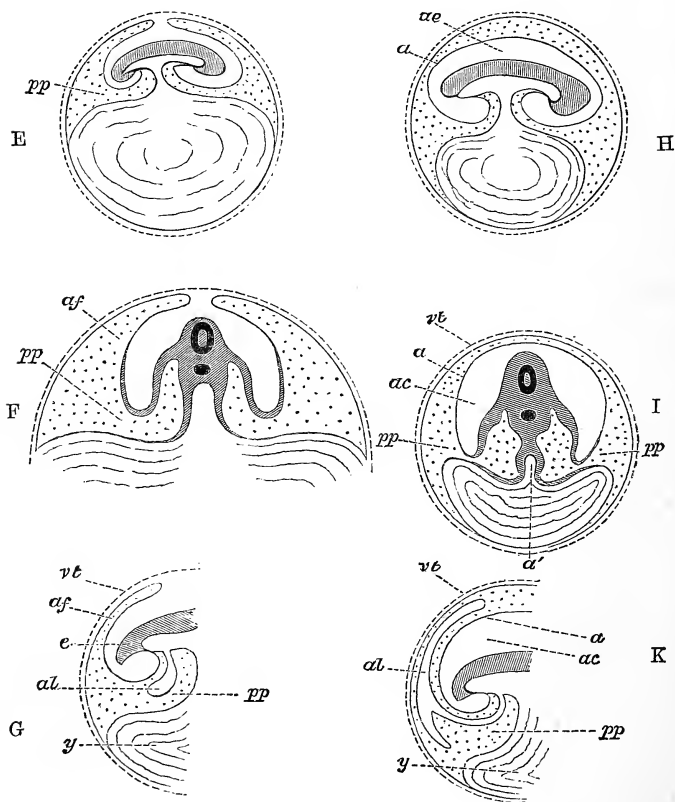
B is a vertical transverse section of the same period drawn for convenience sake on a larger scale (it should have been made flatter and less curved). It shews that the blastoderm (vertically shaded) is extending laterally as well as fore and aft, in fact in all directions ; but there are no lateral folds, and therefore no lateral limits to the body of the embryo as distinguished from the blastoderm.

Incidentally it shews the formation of the medullary groove by the rising up of the laminæ dorsales. Beneath the section of the groove is seen the rudiment of the notochord. On either side a line indicates the cleavage of the mesoblast just commencing.

In *C*, which represents a vertical longitudinal section of later date, both head-fold (on the right) and tail-fold (on the left) have advanced considerably. The alimentary canal is therefore closed in, both in front and behind, but is in the middle still widely open to the yolk *y* below. Though the axial parts of the embryo have become thickened by growth, the body-walls are still thin ; in them however is seen the cleavage of the mesoblast, and the divergence of the somatopleure and splanchnopleure. The splanchnopleure both at the head and at the tail is folded in to a greater extent than the somatopleure, and forms the still wide splanchnic stalk. At the end of the stalk, which is as yet short, it bends outwards again and spreads over the surface of the yolk. The somatopleure, folded in less than the splanchnopleure to form the wider somatic stalk, sooner bends round and runs outwards again. At a little distance from both the head and the tail it is raised up into a fold, *af*, *af*, that in front of the head being the highest. These are the amniotic folds. Descending from either fold, it speedily joins the splanchnopleure again, and the two, once more united into an uncleft membrane, extend some way downwards over the yolk, the limit or outer margin of the opaque area not being shewn. All the space between the somatopleure and the splanchnopleure, *pp*, is shaded with dots. Close

to the body this space may be called the pleuroperitoneal cavity ; but outside the body it runs up into either amniotic fold, and also extends some little way over the yolk.

D represents the tail end at about the same stage on a more enlarged scale, in order to illustrate the position of the allantois *al* (which was for the sake of simplicity omitted in *C*), shewn as a bud from the splanchnopleure, stretching downwards into the pleuroperitoneal cavity *pp*. The dotted area representing as before the



whole space between the splanchnopleure and the somatopleure, it is evident that a way is open for the allantois to extend from its present position into the space between the two limbs of the amniotic fold *af*.

E, also a longitudinal section, represents a stage still farther advanced. Both splanchnic and somatic stalks are much narrowed, especially the former, the cavity of the alimentary canal being now connected with the cavity of the yolk-sack by a mere canal. The folds of the amnion are spreading over the top of the embryo and nearly meet. Each fold consists of two walls or limbs, the space between which (dotted) is as before merely a part of the space between the somatopleure and splanchnopleure. Between these arched amniotic folds and the body of the embryo is a space not as yet entirely closed in.

F represents on a different scale a transverse section of *E* taken through the middle of the splanchnic stalk. The dark ring in the body of the embryo shews the position of the neural canal, below which is a black spot, marking the notochord. On either side of the notochord the divergence of somatopleure and splanchnopleure is obvious. The splanchnopleure, more or less thickened, is somewhat bent in towards the middle line, but the two sides do not unite, the alimentary canal being as yet open below at this spot; after converging somewhat they diverge again and run outwards over the yolk. The somatopleure, folded in to some extent to form the body-walls, soon bends outwards again, and is almost immediately raised up into the lateral folds of the amnion *af*. The continuity of the pleuroperitoneal cavity within the body with the interior of the amniotic fold outside the body is evident; both cavities are dotted.

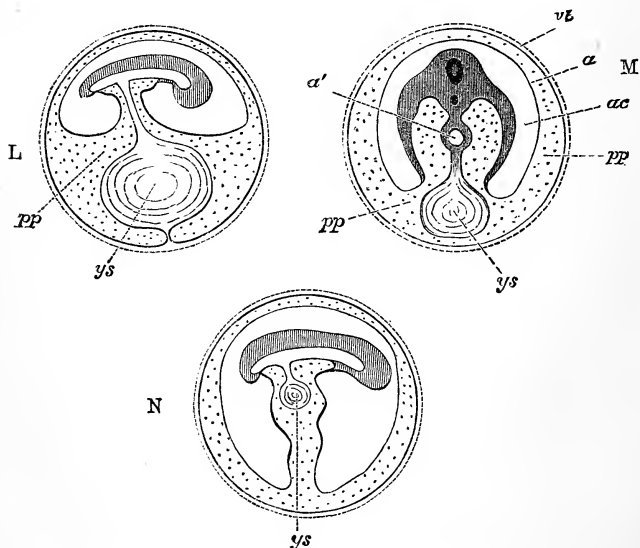
G, which corresponds to *D* at a later stage, is introduced to shew the manner in which the allantois, now a distinctly hollow body, whose cavity is continuous with that of the alimentary canal, becomes directed towards the amniotic fold.

In *H* a longitudinal, and *I* a transverse section of later date, great changes have taken place. The several folds of the amnion have met and coalesced above the body of the embryo. The inner limbs of the several folds have united into a single membrane (*a*), which encloses a space (*ae* or *ac*) round the embryo. This mem-

brane (α) is the amnion proper, and the cavity within it, *i.e.* between it and the embryo, is the cavity of the amnion containing the liquor amnii. The allantois is omitted for the sake of simplicity.

It will be seen that the amnion α now forms in every direction the termination of the somatopleure; the peripheral portions of the somatopleure, the united outer or descending limbs of the folds af in *C*, *D*, *F*, *G* having been cut adrift, and now forming an independent continuous membrane, the *serous membrane*, immediately underneath the vitelline membrane.

In *I* the splanchnopleure is seen converging to complete the closure of the alimentary canal α' even at the stalk (elsewhere the canal has of course long been closed in), and then spreading outwards as before over the yolk. The point at which it unites with the somatopleure, marking the extreme limit of the cleavage of the mesoblast, is now much nearer the lower pole of the diminished yolk.



As a result of these several changes, a great increase in the dotted space has taken place. It is now possible to pass from the actual peritoneal cavity within the body, on the one hand round a great portion of the circumference of the yolk, and on the other hand above the amnion *a*, in the space between it and the serous envelope.

Into this space the allantois is seen spreading in *K* at *al*.

In *L* the splanchnopleure has completely invested the yolk-sac, but at the lower pole of the yolk is still continuous with that peripheral remnant of the somatopleure now called the serous membrane. In other words, the cleavage of the mesoblast has been carried all round the yolk (*ys*) except just at the lower pole.

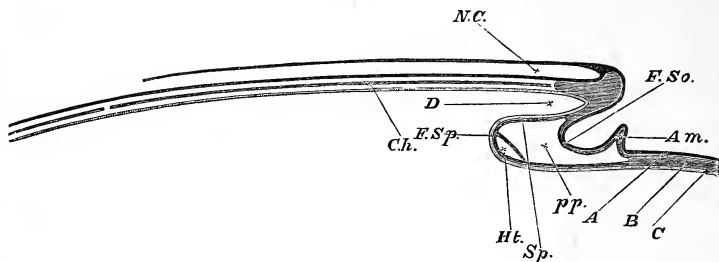
In *M* the cleavage has been carried through the pole itself; the peripheral portion of the splanchnopleure forms a complete investment of the yolk, quite unconnected with the peripheral portion of the somatopleure, which now exists as a continuous membrane lining the interior of the shell. The yolk-sac (*ys*) is therefore quite loose in the pleuroperitoneal cavity, being connected only with the alimentary canal (*a'*) by a solid pedicle.

Lastly, in *N* the yolk-sac (*ys*) is shewn being withdrawn into the cavity of the body of the embryo. The allantois is as before, for the sake of simplicity, omitted; its pedicle would of course lie by the side of *ys* in the somatic stalk marked by the usual dotted shading.

It may be repeated that the above are diagrams, the various spaces being shewn distended, whereas in many of them in the actual egg the walls have collapsed, and are in near juxtaposition.

In a vertical longitudinal section carried through the middle line, we may recognize the following parts (Fig. 9, *A*, or on a larger scale Fig. 10, which also shews details which need not be considered now). Beginning at what will become the posterior extremity of the embryo (the left-hand side of the figure in each case), and following the surface of the blastoderm forwards (to the right in the

FIG. 10.



DIAGRAMMATIC LONGITUDINAL SECTION THROUGH THE AXIS OF
AN EMBRYO.

The section is supposed to be made at a time when the head-fold has commenced but the tail-fold has not yet appeared.

F. So. fold of the somatopleure.

F. Sp. fold of the splanchnopleure.

The line of reference *F. So.* is placed in the lower bay, outside the embryo. The line of *D* is placed in the upper bay inside the embryo; this will remain as the alimentary canal. Both folds (*F. So.*, *F. Sp.*) are parts of the head-fold, and are to be thought of as continually travelling onwards (to the left) as development proceeds.

pp. space between somatopleure and splanchnopleure: pleuro-peritoneal cavity.

Am. commencing (head) fold of the amnion.

A fuller explanation is given under Fig. 29.

figures), the level is maintained for some distance, and then there is a sudden descent, the blastoderm bending round and pursuing a precisely opposite direction to its previous one, running backwards instead of forwards, for some distance. It soon, however, turns round again, and once more running forward, with a gentle ascent, regains the original level. As seen in section, then, the blastoderm at this spot may be said to be folded up in the

form of the letter **2**. This fold we shall always speak of as the *head-fold*. In it we may recognize two limbs: an upper limb in which the curve is directed forwards, and its bay, opening backwards, is *underneath* the blastoderm, *i.e.* as we shall see, *inside* the embryo (Fig. 10. *D*); and an under limb in which the curve is directed backwards, and its bay, opening forwards, is *above* the blastoderm, *i.e.* *outside* the embryo. If an **2** like the above, made of some elastic material, were stretched laterally, the effect would be to make both limbs longer and proportionally narrower, and their bays, instead of being shallow cups, would become more tubular. Such a result is in part arrived at by the growth of the blastoderm; the upper limb of the **2** is continually growing forward (but, unlike the stretched elastic model, increases in all its dimensions at the same time), and the lower limb is as continually lengthening backwards; and thus both upper and lower bays become longer and longer. This we shall hereafter speak of as the *traveling backwards of the head-fold*.

The two bays do not however both become tubular. The section we have been speaking of is supposed to be taken vertically along a line, which will afterwards become the axis of the embryo; and the lower bay of the **2** is a section of the crescentic groove mentioned above, in its middle or deepest part. On either side of the middle line the groove gradually becomes shallower. Hence in sections taken on either side of the middle line or axis of the embryo (above or below the plane of the figures), the groove would appear the less marked the farther the section from the middle line, and at a certain distance would disappear altogether. It must be

remembered that the groove is at first crescent-shaped, with the concavity of the crescent turned towards what will be the hind end of the embryo (Fig. 22). As the whole head-fold is carried farther and farther back, the horns of the crescent are more and more drawn in towards the middle line, the groove becoming first semicircular, then horse-shoe-shaped. In other words, the head-fold, instead of being a simple fold running straight backwards, becomes a curved fold with a central portion in front running backwards, and two side portions running in towards the middle line. The effect of this is that the upper bay of the \mathcal{Z} (that within the embryo) gets closed in at the sides as well as in the front, and thus speedily becomes tubular. The under bay of the \mathcal{Z} (that outside the embryo) remains of course open at the sides as in front, and forms a sort of horse-shoe-shaped ditch surrounding the front end of the embryo.

We have dwelt thus at length on the formation of the head-fold, because, unless its characters are fairly grasped, much difficulty may be found in understanding many events in the history of the chick. The reader will perhaps find the matter easier to comprehend if he makes for himself a rough model, which he easily can do by spreading a cloth out flat to represent the blastoderm, placing one hand underneath it, to mark the axis of the embryo, and then tucking in the cloth from above under the tips of his fingers. The fingers, covered with the cloth and slightly projecting from the level of the rest of the cloth, will represent the head, in front of which will be the semicircular or horse-shoe-shaped groove of the head-fold.

At its first appearance the whole \mathcal{Z} may be spoken

of as the head-fold, but later on it will be found convenient to restrict the name chiefly to the lower limb of the \mathcal{Z} .

Some time after the appearance of the head-fold, an altogether similar but at first less conspicuous fold makes its appearance, at a point which will become the posterior end of the embryo. This fold, which travels forwards just as the head-fold travels backwards, is the *tail-fold* (Fig. 9, *C*).

In addition, between the head- and the tail-fold two lateral folds appear, one on either side. These are simpler in character than either head-fold or tail-fold, inasmuch as they are nearly straight folds directed inwards towards the axis of the body (Fig. 8, *F*), and not complicated by being crescentic in form. Otherwise they are exactly similar, and in fact are formed by the continuations of the head- and tail-folds respectively.

As these several folds become more and more developed, the head-fold travelling backwards, the tail-fold forwards, and the lateral folds inwards, they tend to unite in the middle point; and thus give rise more and more distinctly to the appearance of a small tubular sac seated upon, and connected, by a continually-narrowing hollow stalk, with that larger sac which is formed by the extension of the rest of the blastoderm over the whole yolk.

The smaller sac we may call the "embryonic sac," the larger one "the yolk-sac." As incubation proceeds, the smaller sac (Fig. 9) gets larger and larger at the expense of the yolk-sac (the contents of the latter being gradually assimilated by nutritive processes into the tissues forming the growing walls of the former, not

directly transferred from one cavity into the other). Within a day or two of the hatching of the chick, at a time when the yolk-sac is still of some considerable size, or at least has not yet dwindled away altogether, and the development of the embryonic sac is nearly complete, the yolk-sac (Fig. 9, *N*) is slipped into the body of the embryo, so that ultimately the embryonic sac alone remains.

The embryo, then, is formed by a folding-off of a portion of the blastoderm from the yolk-sac. The general outline of the embryo is due to the direction and shape of the several folds which share in its formation; these, while preserving a nearly perfect bilateral symmetry, present marked differences at the two ends of the embryo. Hence from the very first there is no difficulty in distinguishing the end which will be the head from that which will be the tail.

In addition to this, the tubular sac of the embryo, while everywhere gradually acquiring thicker and thicker walls, undergoes at various points, through local activities of growth in the form of thickenings, ridges, buds or other processes, many modifications of the outline conferred upon it by the constituent folds. Thus bud-like processes start out from the trunk to form the rudiments of the limbs, and similar thickenings and ridges give rise to the jaws and other parts of the face. By the unequal development of these outgrowths the body of the chick is gradually moulded into its proper outward shape.

Were the changes which take place of this class only, the result would be a tubular sac of somewhat complicated outline, but still a simple tubular sac. Such

a simple sac might perhaps be roughly taken to represent the body of many an invertebrate animal ; but the typical structure of a bird or other vertebrate animal is widely different. It may very briefly be described as follows.

First there is, above, a canal running lengthways along the body, in which are lodged the brain and spinal cord. Below this neural tube is an axis represented by the bodies of the vertebræ and their continuation forwards in the structures which form the base of the skull. Underneath this, again, is another tube closed in above by the axis, and on the sides and below by the body-walls. Enclosed in this second tube, and suspended from the axis, is a third tube, consisting of the alimentary canal with its appendages (liver, pancreas, lungs, &c., which are fundamentally mere diverticula from one simple canal). The cavity of the outer tube, which also contains the heart and other parts of the vascular system, is the general body cavity ; it consists of a thoracic or pleural, and an abdominal or peritoneal section ; these two parts are, however, from their mode of origin, portions of one and the same tube. Thus a transverse section of a vertebrate animal always shews the same fundamental structure : above a single tube, below a double tube, the latter consisting of one tube enclosed within another, the inner being the alimentary canal, the outer the general cavity of the body. Into such a triple tube the simple tubular embryonic sac of the chick is converted by a series of changes of a remarkable character.

The upper or neural tube is formed in the following way. At a very early period the upper layer of the

blastoderm or epiblast in the region which will become the embryo, is raised up into two ridges or folds, which run parallel to each other at a short distance on either side of what will be the long axis of the embryo, and thus leave between them a shallow longitudinal groove (Fig. 9, *B*, also Figs. 21, *m.c*). As these ridges, which bear the name of *medullary folds*, increase in height they arch over towards each other, and eventually meet and coalesce in the middle line, thus converting the groove into a canal, which at the same time becomes closed at either end (Fig. 8, *F. I*, also Fig. 34. *Mc*). The cavity so formed is the cavity of the neural tube, and eventually becomes the cerebro-spinal canal. Its walls are wholly formed of epiblast.

The lower double tube, that of the alimentary canal, and of the general cavity of the body, is formed in an entirely different way. It is, broadly speaking, the result of the junction and coalescence of the fundamental embryonic folds, the head-fold, tail-fold, and lateral folds; in a certain sense the cavity of the body is the cavity of the tubular sac described in the last paragraph.

But it is obvious that a tubular sac formed by the folding-in of a single sheet of tissue, such as we have hitherto considered the blastoderm to be, must be a simple tubular sac possessing a single cavity only. The blastoderm however does not long remain a single sheet, but speedily becomes a double sheet of such a kind that, when folded in, it gives rise to a double tube.

Very early the blastoderm becomes thickened in the region of the embryo, the thickening being chiefly due

to an increase in the middle layer or mesoblast, while at the same time it becomes split or cleft horizontally over the greater part of its extent into two leaves, an upper leaf and a lower leaf. In the neighbourhood of the axis of the body, beneath the neural tube, this cleavage is absent (Fig. 9, *B*; also Figs. 24, 34), in fact, it begins at some little distance on either side of the axis and spreads thence into the periphery in all directions. It is along the mesoblast that the cleavage takes place, the upper part of the mesoblast uniting with epiblast to form the upper leaf, and the lower part with the hypoblast to form the lower leaf.

In the fundamental folds both leaves are involved, both leaves are folded downwards and inwards, both leaves tend to meet in the middle below; but the lower leaf is folded in more rapidly, and thus diverges from the upper leaf, a space being gradually developed between them (Fig. 9). In course of time the several folds of the lower leaf meet and unite to form an inner tube quite independently of the upper leaf, whose own folds in turn meet and unite to form an outer tube separated from the inner one by an intervening space. The inner tube which from its mode of formation is clearly lined by hypoblast is the alimentary canal which is subsequently perforated at both ends to form the mouth and anus; the walls of the outer tube are the walls of the body; and the space between the two tubes is the general *body* or *pleuroperitoneal cavity*.

Hence the upper (or outer) leaf of the blastoderm, from its giving rise to the body-walls, is called the *somatopleure*¹; the lower (or inner) leaf, from its form-

¹ *Soma*, body, *pleuron*, side.

ing the alimentary canal and its tributary viscera, the *splanchnopleure*¹.

This horizontal splitting of the blastoderm into a somatopleure and a splanchnopleure, which we shall hereafter speak of as *the cleavage of the mesoblast*, is not confined to the region of the embryo, but gradually extends over the whole of the yolk-sac. Hence in the later days of incubation the yolk-sac comes to have two distinct coats, an inner splanchnopleuric and an outer somatopleuric, separable from each other all over the sac. We have seen that, owing to the manner of its formation, the 'embryonic sac' is connected with the 'yolk-sac' by a continually narrowing hollow stalk; but this stalk must, like the embryonic sac itself, be a double stalk, and consist of a smaller inner stalk within a larger outer one, Fig. 9, *E, H*. The folds of the splanchnopleure, as they tend to meet and unite in the middle line below, give rise to a continually narrowing hollow stalk of their own, a *splanchnic stalk*, by means of which the walls of the alimentary canal are continuous with the splanchnopleuric investment of the yolk-sac, and the interior of that canal is continuous with the cavity inside the yolk-sac. In the same way the folds of the somatopleure form a similar stalk of their own, a *somatic stalk*, by means of which the body-walls of the chick are continuous (for some time; the continuity, as we shall see, being eventually broken by the development of the amnion) with the somatopleuric investment of the yolk-sac; and the pleuroperitoneal cavity of the

¹ *Splanchnon*, viscus, *pleuron*, side.

body of the chick is continuous with the narrow space between the two investments of the yolk-sac.

At a comparatively early period the canal of the splanchnic stalk becomes obliterated, so that the material of the yolk can no longer pass directly into the alimentary cavity, but has to find its way into the body of the chick by absorption through the blood-vessels. The somatic stalk, on the other hand, remains widely open for a much longer time; but the somatic shell of the yolk-sac never undergoes that thickening which takes place in the somatic walls of the embryo itself; on the contrary, it remains thin and insignificant. When, accordingly, in the last days of incubation the greatly diminished yolk-sac with its splanchnic investment is withdrawn into the rapidly enlarging abdominal cavity of the embryo, the walls of the abdomen close in and unite, without any regard to the shrivelled, emptied somatopleuric investment of the yolk-sac, which is cast off as no longer of any use. (Fig. 9. Compare the series.)

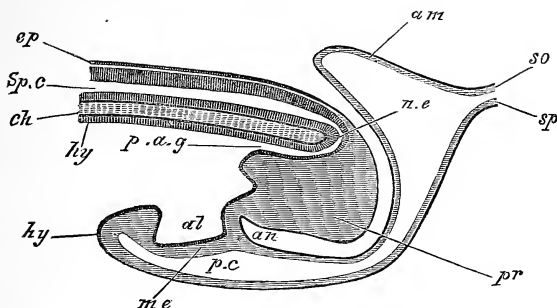
The Amnion. Very closely connected with the cleavage of the mesoblast and the division into somatopleure and splanchnopleure, is the formation of the *amnion*, all mention of which was, for the sake of simplicity, purposely omitted in the description just given.

The amnion is a peculiar membrane enveloping the embryo, which takes its origin from certain folds of the somatopleure, and of the somatopleure only, in the following way.

At a time when the cleavage of the mesoblast has somewhat advanced, there appears, a little way in front

of the semilunar head-fold, a second fold (Fig. 22, also Fig. 9, *C*.), running more or less parallel or rather concentric with the first, and not unlike it in general appearance, though differing widely from it in nature. In the head-fold the whole thickness of the blastoderm is involved; in it both somatopleure and splanchnopleure (where they exist, *i.e.* where the mesoblast is cleft) take part. This second fold, on the contrary, is limited entirely to the somatopleure. Compare Figs. 9 and 10. In front of the head-fold, and therefore altogether in front of the body of the embryo, the somatopleure is a very thin membrane, consisting only of epiblast and a very thin layer of mesoblast; and the fold we are speaking of is, in consequence, itself thin and delicate. Rising up as a semilunar fold with its concavity directed towards the embryo (Fig. 9, *C*, *af*.), as it increases in height it is gradually drawn backwards over the developing head of the embryo. The fold thus covering the head is in due time accompanied by similar folds of the somatopleure starting at some little distance behind the tail, and at some little distance from the sides (Fig. 9, *C*, *D*, *E*, *F*, and Fig. 11 *am*.). In this way the embryo becomes surrounded by a series of folds of thin somatopleure, which form a continuous wall all round it. All are drawn gradually over the body of the embryo, and at last meet and completely coalesce (Fig. 9, *H*, *I*), all traces of their junction being removed. Beneath these united folds there is therefore a cavity, within which the embryo lies (Fig. 9, *H*, *ae*). This cavity is the cavity of the amnion. The folds which we have been describing are those which form the amnion.

FIG. 11.



DIAGRAMMATIC LONGITUDINAL SECTION THROUGH THE POSTERIOR END OF AN EMBRYO BIRD, AT THE TIME OF THE FORMATION OF THE ALLANTOIS.

ep. epiblast; *Sp.c.* spinal canal; *ch.* notochord; *n.e.* neurenteric canal; *hy.* hypoblast; *p.a.g.* postanal gut; *pr.* remains of primitive streak folded in on the ventral side; *al.* allantois; *me.* mesoblast; *an.* point where anus will be formed; *p.c.* perivisceral cavity; *am.* amnion; *so.* somatopleure; *sp.* splanchnopleure.

Each fold, of course, necessarily consists of two limbs, both limbs consisting of epiblast and a very thin layer of mesoblast; but in one limb the epiblast looks towards the embryo, while in the other it looks away from it. The space between the two limbs of the fold, as can easily be seen in Figs. 9 and 11, is really part of the space between the somatopleure and splanchnopleure; it is therefore continuous with the general space, part of which afterwards becomes the pleuro-peritoneal cavity of the body, shaded with dots in figure 9 and marked (*pp*). It is thus possible to pass from the cavity between the two limbs of each

fold of the amnion into the cavity which surrounds the alimentary canal. When the several folds meet and coalesce together above the embryo, they unite in such a way that all their inner limbs go to form a continuous inner membrane or sac, and all their outer limbs a similarly continuous outer membrane or sac. The inner membrane thus built up forms a completely closed sac round the body of the embryo, and is called the amniotic sac, or *amnion proper* (Fig. 9, *H, I, &c. a.*), and the fluid which it afterwards contains is called the amniotic fluid, or *liquor amnii*. The space between the inner and outer sac, being formed by the united cavities of the several folds, is, from the mode of its formation, simply a part of the general cavity found everywhere between somatopleure and splanchnopleure. The outer sac over the embryo lies close under the vitelline membrane, while its periphery is gradually extended over the yolk as the somatopleuric investment of the yolk-sac described in the preceding paragraph. It constitutes the false amnion while the membrane of which it forms a part is frequently known as the *serous membrane*.

The Allantois. If the mode of origin of these two sacs (the inner or true amnion, and the outer or false amnion, as Baer called it) and their relations to the embryo be borne in mind, the reader will have no difficulty in understanding the course taken in its growth by an important organ, the *allantois*, of which we shall hereafter have to speak more in detail.

The allantois is essentially a diverticulum of the alimentary tract, into which it opens immediately in front of the anus. It at first (Fig. 11, *al*) forms a

flattened sac projecting into the pleuroperitoneal cavity, the walls of the sac being formed of a layer of splanchnic mesoblast lined by hypoblast.

It grows forwards in the peritoneal cavity until it reaches the stalk connecting the embryo with the yolk-sac, and thence very rapidly pushes its way into the space between the true and false amniotic sacs (Fig. 9, *G*, *K*). Curving over the embryo, it comes to lie above the embryo and the amnion proper, separated from the shell (and vitelline membrane) by nothing more than the thin false amnion. In this position it becomes highly vascular, and performs the functions of a respiratory organ. It is evident that though now placed quite outside the embryo, the space in which it lies is a continuation of that peritoneal cavity in which it took its origin.

It is only necessary to add, that the serous membrane, including the false amnion, either coalesces with the vitelline membrane, in contact with which it lies, or else replaces it; and in the later days of incubation was called by the older embryologists the chorion—a name however which we shall not adopt.

CHAPTER III.

THE CHANGES WHICH TAKE PLACE DURING THE FIRST DAY OF INCUBATION.

DURING the descent of the egg along the oviduct, where it is exposed to a temperature of about 40° C., the germinal disc, as we have seen, undergoes important changes. When the egg is laid and becomes cold these changes all but entirely cease, and the blastoderm remains inactive until, under the influence of the higher temperature of natural or artificial incubation, the vital activities of the germ are brought back into play, the arrested changes go on again, and usher in the series of events which we have now to describe in detail.

The condition of the blastoderm at the time when the egg is laid is not exactly the same in all eggs; in some the changes being farther advanced than in others, though the differences of course are slight. In some eggs, especially in warm weather, changes of the same kind as those caused by actual incubation may take place, to a certain extent, in the interval between laying and incubation; lastly, in all eggs, both under natural and especially under artificial incubation, the

dates of the several changes are, within the limits of some hours, very uncertain, particularly in the first few days; one egg being found, for example, at 36 hours in the same stage as another at 24 or 30 hours, or a third at 40 or 48 hours. When we speak therefore of any event as taking place at any given hour or part of any given day, we are to be understood as meaning that such an event will generally be found to have taken place at about that time. We introduce exact dates for the convenience of description.

The changes which take place during the first day will be most easily considered under several periods.

From the 1st to about the 8th hour.—During this period the blastoderm, when viewed from above, is found to have increased in size. The pellucid area, which at the best is but obscurely marked in the unin-cubated egg, becomes very distinct (the central opacity having disappeared), and contrasts strongly with the opaque area, which has even still more increased both in distinctness and size.

For the first few hours both the pellucid and opaque areas remain approximately circular, and the most important change, besides increase in size and greater distinctness which can be observed in them, is a slight ill-defined opacity or loss of transparency, which makes its appearance in the hinder half of the pellucid area. This is known as the *embryonic shield*.

Slight as are the changes which can at this stage be seen from surface views, sections taken from hardened specimens bring to light many most important changes in the nature and arrangement of the constituent cells.

FIG. 12.

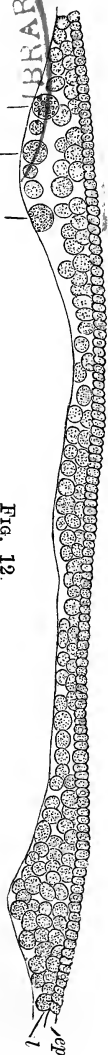
SECTION OF A BLASTODERM OF A FOWL'S EGG
AT THE COMMENCEMENT OF INCUBATION.

The thin but complete upper layer *ep* composed of columnar cells rests on the incomplete lower layer *l*, composed of larger and more granular cells. The lower layer is thicker in some places than in others, and is especially thick at the periphery. The line below the under layer marks the upper surface of the white yolk. The larger so-called formative cells are seen at *b*, lying on the white yolk. The figure does not take in quite the whole breadth of the blastoderm; but the reader must understand that both to the right hand and the left *ep* is continued farther than *l*, so that at the extreme edge it rests directly on the white yolk.

It will be remembered that the blastoderm in the unincubated egg is composed of two layers, an upper (Fig. 12, *ep*) and an under layer; that the upper is a coherent membrane of columnar nucleated cells, but that the lower one (Fig. 12, *l*) is formed of an irregular network of larger cells in which the nuclei are with difficulty visible; and that in addition to this there are certain still larger cells, called 'formative cells' (Fig. 12, *b*), lying at the bottom of the segmentation-cavity.

Under the influence of incubation changes take place very rapidly, which

Fig. 12.



MAY 2 - 1924 50

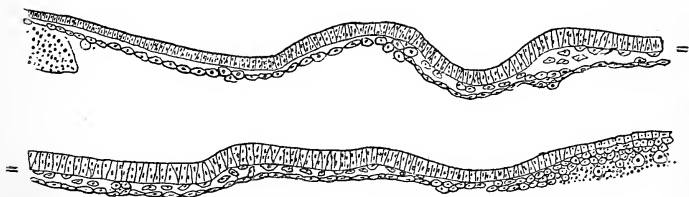
LIBRARY

result in the formation of the three layers of the blastoderm.

The upper layer, which is the *epiblast* already spoken of (Fig. 13), takes *at first* but little share in these changes.

In the lower layer, however, certain of the cells begin to get flattened horizontally, their granules become less numerous, and the nucleus becomes distinct; the cells so altered cohere together and form a membrane. The membrane thus formed, which is first completed in

FIG. 13.



TRANSVERSE SECTION THROUGH THE BLASTODERM OF A CHICK
BEFORE THE APPEARANCE OF THE PRIMITIVE STREAK.

The epiblast is represented somewhat diagrammatically. The hyphens shew the points of junction of the two halves of the section. The hypoblast is already constituted as a membrane of flattened cells, and a number of scattered cells are seen between it and the epiblast.

the centre of the pellucid area, constitutes the *hypoblast*. Between the hypoblastic membrane and the epiblast there remain a number of scattered cells (Fig. 13) which cannot however be said to form a definite layer altogether distinct from the hypoblast. They are almost entirely confined to the posterior part of the area pellucida, and

give rise to the opacity of that part, which we have spoken of as the embryonic shield.

At the edge of the area pellucida the hypoblast becomes continuous with a thickened rim of material, underlying the epiblast, and derived from the original thickened edge of the blastoderm and the subjacent yolk. It is mainly formed of yolk granules, with a varying number of cells and nuclei imbedded in it. It is known as the *germinal wall*, and is spoken of more in detail on pp. 65 and 66.

The epiblast is the *Hornblatt* (corneal layer), and the hypoblast the *Darmdrüsenblatt* (epithelial glandular layer) of the Germans, while those parts of the mesoblast which take part in the formation of the somatopleure and splanchnopleure correspond respectively to the *Haut-muskel-platte* and *Darm-faser-platte*.

All blood-vessels arise in the mesoblast. Hence the *vascular* layer of the older writers falls entirely within the mesoblast.

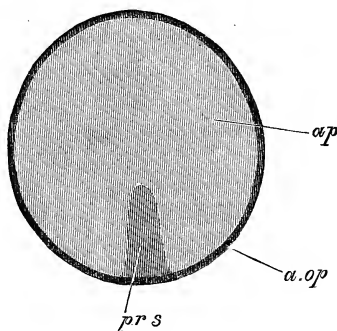
The *serous layer* of the old authors includes the whole of the epiblast, but also comprises a certain portion of mesoblast; for they speak of all the organs of animal life (skin, bones, muscle, &c.) as being formed out of the serous layer, whereas the epiblast proper gives rise only to the epidermis and to certain parts of the nervous system. In the same way their *mucous layer* corresponds to the hypoblast with so much of the mesoblast as takes part in the formation of the organs of organic life. Their *vascular layer* therefore answers to a part only of the mesoblast viz. that part in which blood-vessels are especially developed.

From the 8th to the 12th hour. The changes which next take place result in the complete differentiation of the embryonic layers, a process which is intimately connected with the formation of a structure known as the primitive streak. The full meaning of the

latter structure, and its relation to the embryo, can however only be understood by comparison with the development of the lower forms of vertebrate life.

It will be remembered that in surface views of the unincubated blastoderm a small arc, at what we stated to be the posterior end, close to the junction between the area opaca and the area pellucida is distinguished by its more opaque appearance. In the surface view the primitive streak appears as a linear opacity, which gradually grows forwards from the middle of this arc till it reaches about one-third of the diameter of the

FIG. 14.



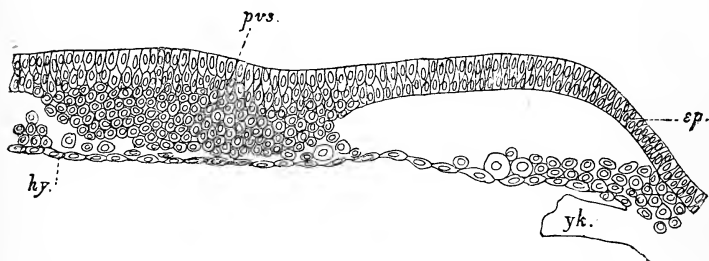
AREA PELLUCIDA OF A VERY YOUNG BLASTODERM OF A CHICK, SHEWING THE PRIMITIVE STREAK SHORTLY AFTER ITS FIRST APPEARANCE.

pr.s. primitive streak ; *ap.* area pellucida ; *a.op.* area opaca.

area pellucida. During the formation of the primitive streak the embryonic shield grows fainter and finally vanishes. When definitely established the primitive streak has the appearance diagrammatically represented in Fig. 14.

Sections at this stage throw a very important light on the nature and mode of origin of the primitive streak. In the region in front of it the blastoderm is still formed of two layers only, but in the region of the streak itself the structure of the blastoderm is greatly altered. The most important features in it are represented in Fig. 15. This figure shews that the median

FIG. 15.



TRANSVERSE SECTION THROUGH A BLASTODERM OF ABOUT THE AGE REPRESENTED IN FIG. 14, SHEWING THE FIRST DIFFERENTIATION OF THE PRIMITIVE STREAK.

The section passes through about the middle of the primitive streak.

pvs. primitive streak ; *ep.* epiblast ; *hy.* hypoblast ; *yk.* yolk of the germinal wall.

portion of the blastoderm has become very much thickened (thus producing the opacity of the primitive streak), and that this thickening is caused by a proliferation of rounded cells from the epiblast. In the very young primitive streak, of which Fig. 15 is a section, the rounded cells are still continuous throughout with the epiblast, but they form nevertheless the rudiment of the greater part of a sheet of mesoblast, which will soon arise in this region.

In addition to the cells clearly derived from the epiblast, there are certain other cells (Fig. 15), closely adjoining the hypoblast; these are derivatives of the cells, interposed between the epiblast and hypoblast, which gave rise to the appearance of the embryonic shield during the previous stage. In our opinion these cells also have a share in forming the future mesoblast.

It thus appears that the primitive streak is essentially a linear proliferation of epiblast cells; the cells produced being destined to give rise to the mesoblast. This proliferation first commences at the hinder end of the area pellucida, and thence proceeds forwards.

While the primitive streak is being established, the epiblast becomes two or more rows of cells deep in the region of the area pellucida.

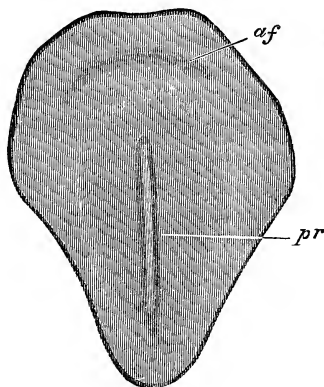
Soon after this, the hitherto circular pellucid area becomes oval (the opaque area remaining circular). The oval is, with remarkable regularity, so placed that its long axis forms a right angle, or very nearly a right angle, with the long axis of the egg itself. Its narrow end corresponds with the future hind end of the embryo. If an egg be placed with its broad end to the right hand of the observer, the head of the embryo will in nearly all cases be found pointing away from him.

The 12th to the 16th hour. The primitive streak at its first appearance is shadowy and ill-defined; gradually however it becomes more distinct; and during the same period the pellucid area rapidly increases in size, and from being oval becomes pear-shaped (Fig. 16). The primitive streak grows even more rapidly than the pellucid area; so that by the 16th hour it is not only

absolutely, but also relatively to the pellucid area, longer than it was at the 12th hour.

It finally occupies about two-thirds of the length of the area pellucida; but its hinder end in many instances appears to stop short of the posterior border of the area pellucida (Fig. 16). The median line of the

FIG. 16.



SURFACE VIEW OF THE AREA PELLUCIDA OF A CHICK'S BLASTODERM SHORTLY AFTER THE FORMATION OF THE PRIMITIVE GROOVE.

pr. primitive streak with primitive groove ;

af. amniotic fold.

The darker shading round the primitive streak shews the extension of the mesoblast.

primitive streak becomes marked by a shallow furrow running along its axis. In fresh specimens, viewed with transmitted light, this furrow appears as a linear transparency, but in hardened specimens seen under reflected light may be distinctly recognized as a narrow groove,

the bottom of which, being thinner than the sides, appears more transparent when viewed with transmitted light. It is known as the *primitive groove*. Its depth and the extent of its development are subject to great variations.

During these changes in external appearance there grow from the edges of the cord of cells constituting the primitive streak two lateral wings of mesoblast cells, which gradually extend till they reach the sides of the area pellucida (Fig. 17). The two wings of mesoblast meet along the line of the primitive streak, where they still remain attached to the epiblast. During this period many sections through the primitive streak give an impression of the mesoblast being involuted along the lips of a groove. The hypoblast below the primitive streak is always quite independent of the mesoblast above, though much more closely attached to it in the median line than at the sides. The part of the mesoblast, which we believe to be derived from the primitive lower layer cells, can generally be distinctly traced. In many cases, especially at the front end of the primitive streak, it forms, as in Fig. 17, a distinct layer of stellate cells, quite unlike the rounded cells of the mesoblastic involution of the primitive streak.

In the region in front of the primitive streak, where the first trace of the embryo will shortly appear, the layers at first undergo no important changes, except that the hypoblast becomes somewhat thicker. Soon, however, as shewn in longitudinal section in Fig. 18, the hypoblast along the axial line becomes continuous behind with the front end of the primitive streak. Thus at this point, which is the future hind end of the

Fig. 17.

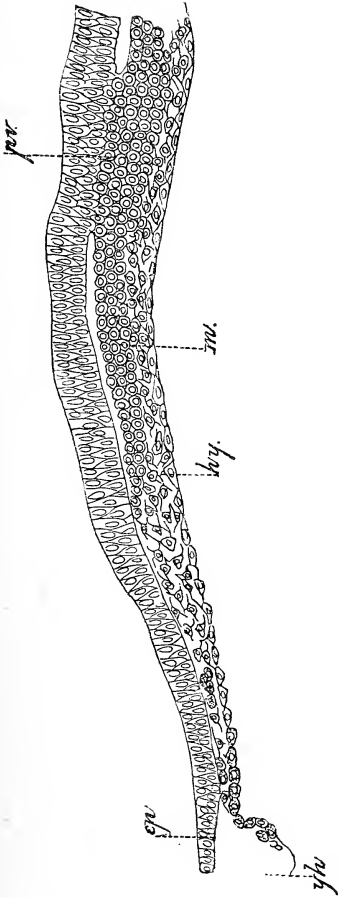


Fig. 18.

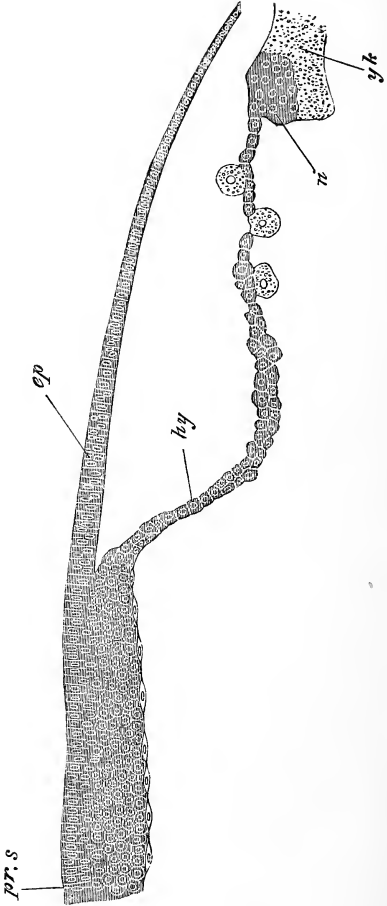


FIG. 17.

TRANSVERSE SECTION THROUGH THE FRONT END OF THE PRIMITIVE STREAK OF A BLASTODERM OF THE SAME AGE AS FIG. 16.

pv. primitive groove; *m.* mesoblast; *ep.* epiblast; *hy.* hypoblast; *yh.* yolk of germinal wall.

FIG. 18.

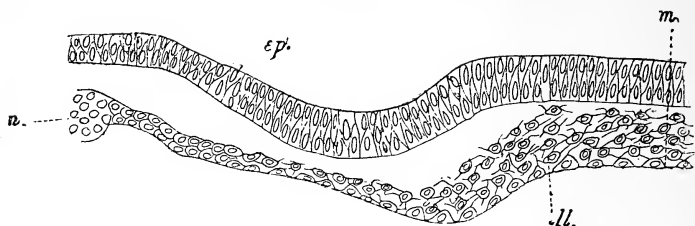
LONGITUDINAL SECTION THROUGH THE AXIAL LINE OF THE PRIMITIVE STREAK, AND THE PART OF THE BLASTODERM IN FRONT OF IT, OF THE BLASTODERM OF A CHICK SOMEWHAT YOUNGER THAN FIG. 19.

pr.s. primitive streak; *ep.* epiblast; *hy.* hypoblast of region in front of primitive streak; *n.* nuclei; *yk.* yolk of germinal wall.

embryo, the mesoblast, the epiblast, and the hypoblast all unite together.

From the 16th to the 20th hours. At about the 16th hour, in blastoderms of the stage represented in Fig. 16, an important change takes place in the constitution of the primitive hypoblast in front of the primitive streak. The rounded cells, of which it is at first composed (Fig. 18), break up into (1) a layer formed of a single row of more or less flattened elements below—the hypoblast proper—and (2) into a layer formed of several rows of stellate elements, between the hypoblast and the epiblast—the mesoblast (Fig. 19 *m*). A separation between these two layers is at first hardly apparent, and before it has become at all well marked, especially in the median line, an axial opaque line makes its appearance in surface views, continued forwards from the front end of the primitive streak, but stopping short at a semicircular

FIG. 19.



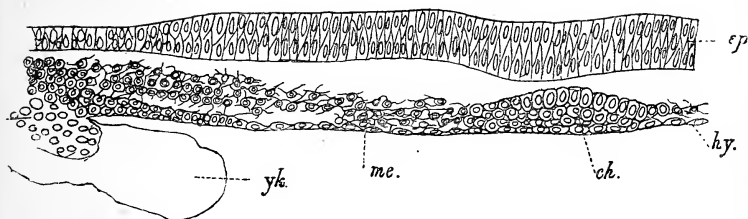
TRANSVERSE SECTION THROUGH THE EMBRYONIC REGION OF THE BLASTODERM OF A CHICK SHORTLY PRIOR TO THE FORMATION OF THE MEDULLARY GROOVE AND NOTOCHORD.

m. median line of the section ; *ep.* epiblast ; *ll.* lower layer cells (primitive hypoblast) not yet completely differentiated into mesoblast and hypoblast ; *n.* nuclei.

fold—the future head-fold—near the front end of the area pellucida. In section (Fig. 20) this opaque line is seen to be due to a special concentration of cells in the form of a cord. This cord is the commencement of an extremely important structure found in all vertebrate embryos, which is known as the notochord (*ch*). In most instances the commencing notochord remains attached to the hypoblast, after the mesoblast has at the sides become quite detached (*vide* Fig. 20), but in other cases the notochord appears to become differentiated in the already separated layer of mesoblast. In all cases *the notochord and the hypoblast below it unite with the front end of the primitive streak*; with which also the two lateral plates of mesoblast become continuous.

From what has just been said it is clear that in the region of the embryo the mesoblast originates as two lateral plates split off from the primitive hypoblast, and

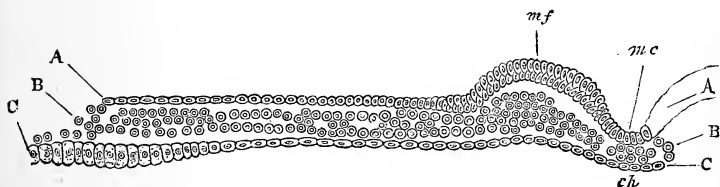
FIG. 20.



TRANSVERSE SECTION THROUGH THE EMBRYONIC REGION OF THE BLASTODERM OF A CHICK AT THE TIME OF THE FORMATION OF THE NOTOCHORD, BUT BEFORE THE APPEARANCE OF THE MEDULLARY GROOVE.

ep. epiblast; *hy.* hypoblast; *ch.* notochord; *me.* mesoblast; *yk.* yolk of germinal wall.

FIG. 21.



TRANSVERSE SECTION OF A BLASTODERM INCUBATED FOR 18 HOURS.

The section passes through the medullary groove *mc.*, at some distance behind its front end.

A. Epiblast. B. Mesoblast. C. Hypoblast.

m.c. medullary groove; *m.f.* medullary fold; *ch.* notochord.

that the notochord originates simultaneously with the mesoblast, with which it is at first continuous, as a median plate similarly of hypoblastic origin.

Kölliker¹ holds that the mesoblast of the region of the embryo is derived from a forward growth from the primitive streak. 'There is no theoretical objection to this view, and we think it would be impossible to shew for certain by sections whether or no there is a growth such as he describes; but such sections as that represented in Fig. 19 (and we have series of such sections from several embryos) appear to us to be conclusive in favour of the view that the mesoblast of the region of the embryo is to a large extent derived from a differentiation of the primitive hypoblast. The mesoblast of the primitive streak forms in part the vascular structures found in the area pellucida, and probably also in part the mesoblast of the allantois.

The differentiation of the embryo may be said to commence with the formation of the notochord and the lateral plates of mesoblast. Very shortly after the formation of these parts, the axial part of the epiblast above the notochord and in front of the primitive streak, being here somewhat thicker than in the lateral parts, becomes differentiated into a distinct medullary plate, the sides of which form two folds known as the medullary folds, enclosing between them a groove known as the *medullary groove*. The medullary plate itself constitutes that portion of the epiblast which gives rise to the central nervous system.

Between the 18th to the 20th hour the medullary groove, with its medullary folds or laminæ dorsales, is fully established. It then presents the appearance, towards the hinder extremity of the embryo, of a shallow

¹ *Entwick. d. Menschen u. höheren Thiere*. Leipzig, 1879.

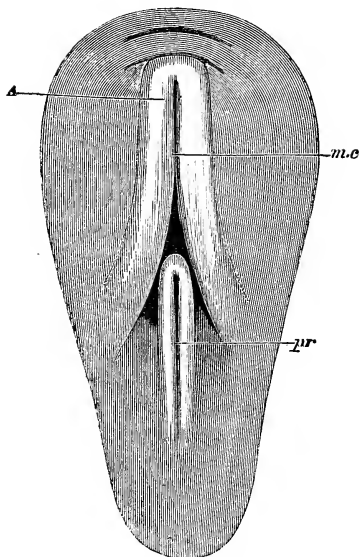
groove with sloping diverging walls, which embrace between them the front end of the primitive streak. Passing forwards towards what will become the head of the embryo the groove becomes narrower and deeper with steeper walls. On reaching the head-fold (Fig. 22), which continually becomes more and more prominent, the medullary folds curve round and meet each other in the middle line, so as to form a somewhat rounded end to the groove. In front therefore the canal does not become lost by the gradual flattening and divergence of its walls, as is the case behind, but has a definite termination, the limit being marked by the head-fold.

In front of the head-fold, quite out of the region of the medullary folds, there is usually another small fold formed earlier than the head-fold, which is the beginning of the *amnion* (Fig. 22).

The appearance of the embryo and its relation to the surrounding parts are somewhat diagrammatically represented in Fig. 22. The primitive streak now ends with an anterior swelling (not represented in the figure), and is usually somewhat unsymmetrical. In most cases its axis is more nearly continuous with the left, or rarely the right, medullary fold than with the medullary groove. In sections its front end appears as a ridge on one side or rarely in the middle of the floor of the wide medullary groove.

The general structure of the developing embryo at the present stage is best understood from such a section as that represented in Fig. 21. The medullary groove (*m. c.*) lined by thickened epiblast is seen in the median line of the section. Below it is placed the notochord (*ch*), which at this stage is a mere rod of cells, and on each

FIG. 22.



SURFACE VIEW OF THE PELLUCID AREA OF A BLASTODERM OF
18 HOURS.

None of the opaque area is shewn, the pear-shaped outline indicating the limits of the pellucid area.

At the hinder part of the area is seen the primitive groove *pr.*, with its nearly parallel walls, fading away behind, but curving round and meeting in front so as to form a distinct anterior termination to the groove, about half way up the pellucid area.

Above the primitive groove is seen the medullary groove *m.c.*, with the medullary folds *A*. These diverging behind, slope away on either side of the primitive groove, while in front they curve round and meet each other close upon a curved line which represents the head-fold.

The second curved line in front of and concentric with the first is the commencing fold of the amnion.

side are situated the mesoblastic plates (B). The hypoblast forms a continuous and nearly flat layer below.

While the changes just described have been occurring in the area pellucida, the growth of the area opaca has also progressed actively. The epiblast has greatly extended itself, and important changes have taken place in the constitution of the germinal wall already spoken of.

The mesoblast and hypoblast of the area opaca do not arise by simple extension of the corresponding layers of the area pellucida; but the whole of the hypoblast of the area opaca, and a large portion of the mesoblast, and possibly even some of the epiblast, take their origin from the peculiar material which forms the germinal wall and which is continuous with the hypoblast at the edge of the area opaca (*vide* figs. 15, 17, 18, 19, 20).

The exact nature of this material has been the subject of many controversies. Into these controversies it is not our purpose to enter, but subjoined are the results of our own examination. The germinal wall first consists, as already mentioned, of the lower cells of the thickened edge of the blastoderm, and of the subjacent yolk material with nuclei. During the period before the formation of the primitive streak the epiblast appears to extend itself over the yolk, partly at the expense of the cells of the germinal wall, and possibly even of cells formed around the nuclei in this part. The cells of the germinal wall, which are at first well separated from the yolk below, become gradually absorbed in the growth of the hypoblast, and the remaining cells and yolk then become mingled together, and constitute a compound structure, continuous at its inner border with the hypoblast. This structure is the germinal wall usually so described. It is mainly formed of yolk granules with numerous nuclei, and a somewhat variable number of rather large cells imbedded

amongst them. The nuclei, some of which are probably enclosed by a definite cell body, typically form a special layer immediately below the epiblast. A special mass of nuclei (*vide* Figs. 18 and 20, *n*) is usually present at the junction of the hypoblast with the germinal wall.

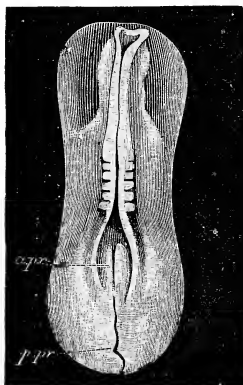
The germinal wall retains the characters just enumerated till near the close of the first day of incubation. One function of its cells appears to be the absorption of yolk material for the growth of the embryo.

The chief events then of the second period of the first day are the appearance of the medullary folds and groove, the formation of the notochord and lateral plates of mesoblast, the beginning of the head-fold and amnion, and the histological changes taking place in the several layers.

From the 20th to the 24th hour. A view of the embryo during this period is given in Fig. 23. The head-fold enlarges rapidly, the crescentic groove becoming deeper, while at the same time the overhanging margin of the groove (the upper limb of the S), rises up above the level of the blastoderm; in fact, the formation of the head of the embryo may now be said to have definitely begun.

The medullary folds, increasing in size in every dimension, but especially in height, lean over from either side towards the middle line, and thus tend more and more to roof in the medullary canal, especially near the head. About the end of the first day they come into direct contact in the region which will afterwards become the brain, though they do not as yet coalesce. In this way a tubular canal is formed. This is the *medullary* or *neural canal* (Fig. 23, Fig. 24,

FIG. 23.



DORSAL VIEW OF THE HARDENED AREA PELLUCIDA OF A CHICK WITH FIVE MESOBLASTIC SOMITES. THE MEDULLARY FOLDS HAVE MET FOR PART OF THEIR EXTENT, BUT HAVE NOT UNITED.

a.pr. anterior part of the primitive streak ; *p.pr.* posterior part of the primitive streak.

Mc.). It is not completely closed in till a period considerably later than the one we are considering.

Meanwhile important changes are taking place in the axial portions of the mesoblast, which lie on each side of the notochord beneath the medullary folds.

In an embryo of the middle period of this day, examined with transmitted light, the notochord is seen at the bottom of the medullary groove between the medullary folds, as a transparent line shining through the floor of the groove when the embryo is viewed from above. On either side of the notochord the body of the embryo appears somewhat opaque,

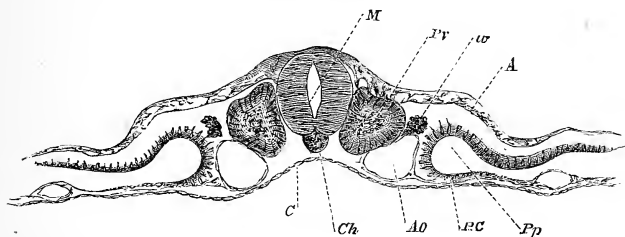
owing to the thickness of the medullary folds; as these folds slope away outwards on either side, so the opacity gradually fades away in the pellucid area. There is present at the sides no sharp line of demarcation between the body of the embryo and the rest of the area; nor will there be any till the lateral folds make their appearance; and transverse vertical sections shew (Fig. 21) that there is no break in the mesoblast, from the notochord to the margin of the pellucid area, but only a gradual thinning.

During the latter period of the day, however, the plates of mesoblast on either side of the notochord begin to be split horizontally into two layers, the one of which attaching itself to the epiblast, forms with it the *somatopleure* (shewn for a somewhat later stage in Fig. 24), while the other, attaching itself to the hypoblast, forms with it the *splanchnopleure*. By the separation of these two layers from each other, a cavity (*Pp*), containing fluid only, and more conspicuous in certain parts of the embryo than in others, is developed. This cavity is the beginning of that great serous cavity of the body which afterwards becomes divided into separate cavities. We shall speak of it as the *pleuro-peritoneal cavity*.

This cleavage into somatopleure and splanchnopleure extends close up to the walls of the medullary canal, but close to the medullary canal a central or axial portion of each plate becomes marked off by a slight constriction from the peripheral (Fig. 24), and receives the name of *vertebral plate*, the more external mesoblast being called the *lateral plate*. The cavity between the two layers of the lateral plate rapidly

enlarges, while that in the vertebral plate remains in the condition of a mere split.

FIG. 24.



TRANSVERSE SECTION THROUGH THE DORSAL REGION OF AN EMBRYO OF THE SECOND DAY (copied from His), introduced here to illustrate the formation of the mesoblastic somitis, and the cleavage of the mesoblast.

M. medullary canal; *Pv.* mesoblastic somite; *w.* rudiment of Wolffian duct; *A.* epiblast; *C.* hypoblast; *Ch.* notochord; *Ao.* aorta; *BC.* splanchnopleure.

At first each vertebral plate is not only unbroken along its length, but also continuous at its outer edge with the upper and lower layers of the lateral plate of the same side. Very soon, however, clear transverse lines are seen, in surface views (Fig. 23), stretching inwards across each vertebral plate from the edge of the lateral plate towards the notochord; while a transparent longitudinal line makes its appearance on either side of the notochord along the line of junction of the lateral with the vertebral plate.

The transverse lines are caused by the formation of vertical clefts, that is to say, narrow spaces containing nothing but clear fluid; and sections shew that they

are due to breaches of continuity in the mesoblast only, the epiblast and hypoblast having no share in the matter.

Thus each vertebral plate appears in surface views to be cut up into a series of square plots, bounded by transparent lines (Fig. 23). Each square plot is the surface of a corresponding cubical mass (Fig. 24, *Pv.*). The two such cubical masses first formed, lying one on each side of the notochord, beneath and a little to the outside of the medullary folds, are the first pair of mesoblastic somites¹.

The mesoblastic somites form the basis out of which the voluntary muscles of the trunk and the bodies of the vertebræ are formed.

The first somite rises close to the anterior extremity of the primitive streak, but the next is stated to arise in front of this, so that the first-formed somite corresponds to the second permanent vertebra. The region of the embryo in front of the second formed somite—at first the largest part of the whole embryo—is the cephalic region (Fig. 23). The somites following the second are formed in regular succession from before backwards, out of the unsegmented mesoblast of the posterior end of the embryo, which rapidly grows in length to supply the necessary material. With the growth of the embryo the primitive streak is continually carried back, the lengthening of the embryo always taking place between the front end of the primitive streak and the last somite; and during this

¹ These bodies are frequently called *protovertebræ*, but we shall employ for them the term mesoblastic somites.

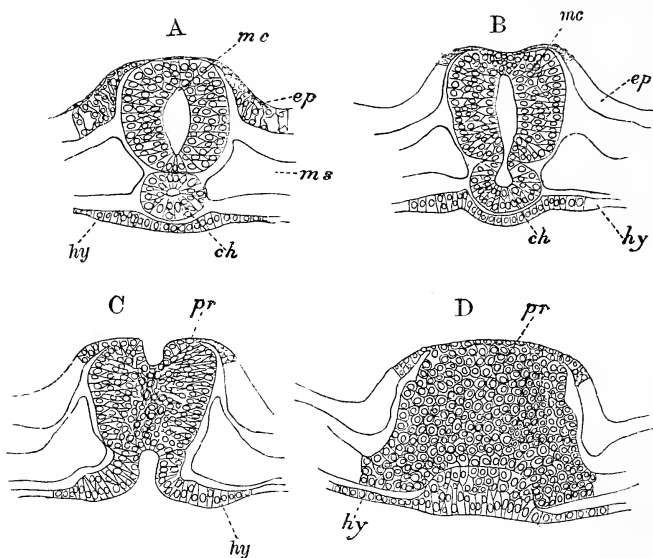
process the primitive streak undergoes important changes both in itself and in its relation to the embryo. Its anterior thicker part, which is embraced by the diverging medullary folds, soon becomes distinguished in structure from the posterior part, and is placed symmetrically in relation to the axis of the embryo, (Fig. 23 *a.pr*); at the same time the medullary folds, which at first simply diverge on each side of the primitive streak, bend in again and meet behind so as completely to enclose this front part of the primitive streak. The region, where the medullary folds diverge, is known as the sinus rhomboidalis of the embryo bird, though it has no connection with the similarly named structure in the adult.

This is a convenient place to notice remarkable appearances which present themselves close to the junction of the neural plate and the primitive streak. These are temporary passages leading from the hinder end of the neural groove or tube into the alimentary canal. They vary somewhat in different species of birds, and it is possible that in some species there may be several openings of the kind, which appear one after the other and then close again. They were first discovered by Gasser, and are spoken of as the *neurenteric* passages or canals¹. In all cases, with some doubtful exceptions, they lead round the posterior end of the notochord, or through the point where the notochord falls into the primitive streak.

The largest of these passages is present in the embryo duck with twenty-six mesoblastic somites, and is represented in the series of sections (Fig. 25). The passage leads obliquely backwards and ventralwards from the hind end of the neural tube

¹ "Die Primitivstreifen bei Vögelembryonen." *Schrift. d. Gesell. z. Beförd. d. Gesamten Naturwiss. zu Marburg*. Vol. II. Supplement I. 1879.

FIG. 25.



FOUR TRANSVERSE SECTIONS THROUGH THE NEURENTERIC PASSAGE AND ADJOINING PARTS IN A DUCK EMBRYO WITH TWENTY-SIX MESOBLASTIC SOMITES.

A. Section in front of the neurenteric canal, shewing a lumen in the notochord.

B. Section through the passage from the medullary canal into the notochord.

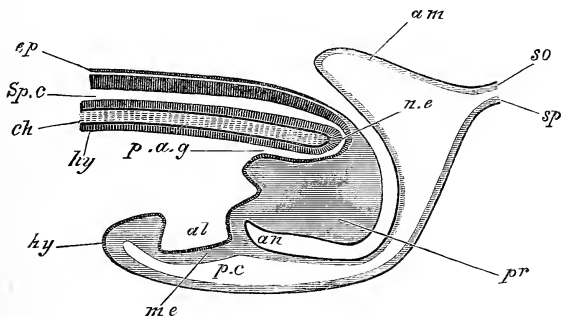
C. Section shewing the hypoblastic opening of the neurenteric canal, and the groove on the surface of the primitive streak, which opens in front into the medullary canal.

D. Primitive streak immediately behind the opening of the neurenteric passage.

mc. medullary canal ; *ep.* epiblast ; *hy.* hypoblast ; *ch.* notochord ; *pr.* primitive streak.

into the notochord, where the latter joins the primitive streak (B). A narrow diverticulum from this passage is continued forwards for a short distance along the axis of the notochord (A, *ch*). After traversing the notochord, the passage is continued into a hypoblastic diverticulum, which opens ventrally into the future lumen of the alimentary tract (C). Shortly behind the point where the neurenteric passage communicates with the neural tube the latter structure opens dorsally, and a groove on the surface of the primitive streak is continued backwards from it for a short distance (C). The first part of this passage to appear is the hypoblastic diverticulum above mentioned.

FIG. 26.



DIAGRAMMATIC LONGITUDINAL SECTION THROUGH THE POSTERIOR END OF AN EMBRYO BIRD AT THE TIME OF THE FORMATION OF THE ALLANTOIS.

ep. epiblast ; *Sp.c.* spinal canal ; *ch.* notochord ; *n.e.* neurenteric canal ; *hy.* hypoblast ; *p.a.g.* post-anal gut ; *pr.* remains of primitive streak folded in on the ventral side ; *al.* allantois ; *me.* mesoblast ; *an.* point where anus will be formed ; *p.c.* perivisceral cavity ; *am.* amnion ; *so.* somatopleure ; *sp.* splanchopleure.

In the chick we have found in some cases an incomplete passage prior to the formation of the first somite. At a later stage

there is a perforation on the floor of the neural canal, which is not so marked as those in the goose or duck, and never results in a complete continuity between the neural and alimentary tracts; but simply leads from the floor of the neural canal into the tissues of the tail-swelling, and thence into a cavity in the posterior part of the notochord. The hinder diverticulum of the neural canal along the line of the primitive groove is, moreover, very considerable in the chick, and is not so soon obliterated as in the goose. The incomplete passage in the chick arises at a period when about twelve somites are present. The third passage is formed in the chick during the third day of incubation.

The anterior part of the primitive streak becomes converted into the tail-swelling; the groove of the posterior part gradually shallows and finally disappears. The hinder part itself atrophies from behind forwards, and in the course of the folding off of the embryo from the yolk the part of the blastoderm where it was placed becomes folded in, so as to form part of the ventral wall of the embryo. The apparent hinder part of the primitive streak is therefore in reality ventral and anterior in relation to the embryo.

Since the commencement of incubation the area opaca has been spreading outwards over the surface of the yolk, and by the end of the first day has reached about the diameter of a sixpence. It appears more or less mottled over the greater part of its extent, but this is more particularly the case with the portion lying next to the pellucid area; so much so, that around the pellucid area an inner ring of the opaque area may be distinguished from the rest by the difference of its aspect.

The mottled appearance of this inner ring is due to changes taking place in the mesoblast above the germinal wall—changes which eventually result in the forma-

tion of what is called the *vascular area*, the outer border of which marks the extreme limit to which the mesoblast extends.

The changes then which occur during the first day may thus be briefly summarized:

(1) The hypoblast is formed as a continuous layer of plate-like cells from the lower layer of the segmentation spheres.

(2) The primitive streak is formed in the hinder part of the area pellucida as a linear proliferation of epiblast cells. These cells spread out as a layer on each side of the primitive streak, and form part of the mesoblast.

(3) The primitive groove is formed along the axis of the primitive streak.

(4) The pellucid area becomes pear-shaped, the broad end corresponding with the future head of the embryo. Its long axis lies at right angles to the long axis of the egg.

(5) The medullary plate with the medullary groove makes its appearance in front of the primitive groove.

(6) The primitive hypoblast in the region of the medullary plate gives rise to an axial rod of cells forming the notochord, and to two lateral plates of mesoblast. The innermost stratum of the primitive layer forms the permanent hypoblast.

(7) The development of the head-fold gives rise to the first definite appearance of the head.

(8) The medullary folds rise up and meet first in the region of the mid-brain to form the neural tube.

(9) By the cleavage of the mesoblast, the somatopleure separates from the splanchnopleure.

(10) One or more pairs of mesoblastic somites make their appearance in the vertebral portion of the mesoblastic plates.

(11) The first trace of the amnion appears in front of the head-fold.

(12) The vascular area begins to be distinguished from the rest of the opaque area.

CHAPTER IV.

THE CHANGES WHICH TAKE PLACE DURING THE FIRST HALF OF THE SECOND DAY.

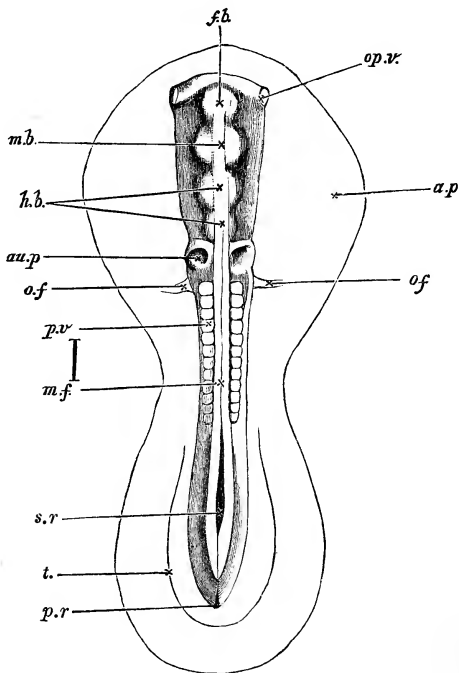
General development. In attempting to remove the blastoderm from an egg which has undergone from 30 to 36 hours' incubation, the observer cannot fail to notice a marked change in the consistency of the blastodermic structures. The excessive delicacy and softness of texture which rendered the extraction of an 18 or 20 hours' blastoderm so difficult, has given place to a considerable amount of firmness; the outlines of the embryo and its appendages are much bolder and more distinct; and the whole blastoderm can be removed from the egg with much greater ease.

In the embryo itself viewed from above one of the features which first attracts attention is the progress in the head-fold (Fig. 27). The upper limb or head has become much more prominent, while the lower groove is not only proportionately deeper, but is also being carried back beneath the body of the embryo.

The medullary folds are closing rapidly. In the region of the head they have quite coalesced, a slight notch in the middle line at the extreme front marking

for some little time their line of junction (Fig. 23). The open medullary groove of the first day has thus become converted into a tube, the neural canal, closed in front, but as yet open behind. Even before the

FIG. 27.



EMBRYO OF THE CHICK BETWEEN THIRTY AND THIRTY-SIX HOURS,
VIEWED FROM ABOVE AS AN OPAQUE OBJECT.
(Chromic acid preparation.)

f.b. front-brain ; *m.b.* mid-brain ; *h.b.* hind-brain ; *op.v.* optic vesicle ; *au.p.* auditory pit ; *o.f.* vitelline vein ; *p.v.* mesoblastic somite ; *m.f.* line of junction of the medullary folds above the

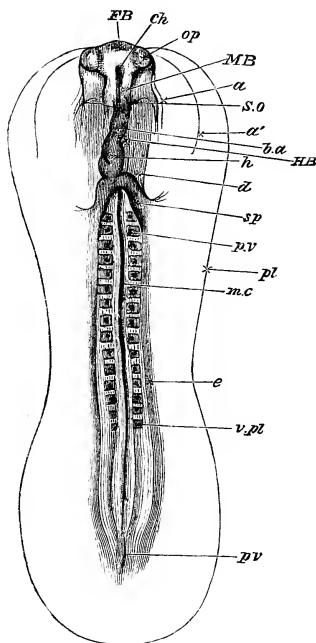
medullary canal; *s.r.* sinus rhomboidalis; *t.* tail-fold; *p.r.* remains of primitive groove (not satisfactorily represented); *a.p.* area pellucida.

The line to the side between *p.v.* and *m.f.* represents the true length of the embryo.

The fiddle-shaped outline indicates the margin of the pellucid area. The head, which reaches as far back as *o.f.*, is distinctly marked off; but neither the somatopleuric nor splanchnopleuric folds are shewn in the figure; the latter diverge at the level of *o.f.*, the former considerably nearer the front, somewhere between the lines *m.b.* and *h.b.* The optic vesicles *op.v.* are seen bulging out beneath the superficial epiblast. The heart lying underneath the opaque body cannot be seen. The tail-fold *t.* is just indicated; no distinct lateral folds are as yet visible in the region midway between head and tail. At *m.f.* the line of junction between the medullary folds is still visible, being lost forwards over the cerebral vesicles, while behind may be seen the remains of the sinus rhomboidalis, *s.r.*

medullary folds coalesce completely in the cephalic region, the front end of the neural canal dilates into a small bulb, whose cavity remains continuous with the rest of the canal, and whose walls are similarly formed of epiblast. This bulb is known as the *first cerebral vesicle*, Fig. 27, *f.b.*, and makes its appearance in the early hours of the second day. From its sides two lateral processes almost at once grow out: they are known as the *optic vesicles* (Fig. 27, *op.v.*), and their history will be dealt with at length somewhat later. Behind the first cerebral vesicle a second and a third soon make their appearance; they are successively formed very shortly after the first vesicle; but the consideration of them may be conveniently reserved to a later period. At the level of the hind end of the

FIG. 28.



AN EMBRYO CHICK OF ABOUT THIRTY-SIX HOURS, VIEWED
FROM BELOW AS A TRANSPARENT OBJECT.

FB. the fore-brain or first cerebral vesicle, projecting from the sides of which are seen the optic vesicles, *op*. A definite head is now constituted, the backward limit of the somatopleure fold being indicated by the faint line *S.O.* Around the head are seen the two limbs of the amniotic head-fold: one, the true amnion *a*, closely enveloping the head, the other, the false amnion *a'*, at some distance from it. The head is seen to project beyond the anterior limit of the pellucid area.

The splanchnopleure folds extend as far back as *sp*. Along its diverging limbs are seen the conspicuous venous roots of

the vitelline veins, uniting to form the heart *h*, already established by the coalescence of two lateral halves which, continuing forward as the bulbus arteriosus *b.a.*, is lost in the substance of the head just in front of the somatopleure fold.

HB. hind-brain; *MB.* mid-brain; *p.v.* and *v.pl.* mesoblastic somites; *ch.* front end of notochord; *mc.* posterior part of notochord; *e.* parietal mesoblast; *pl.* outline of area pellucida; *pv.* primitive streak.

head two shallow pits are visible. They constitute the first rudiments of the organ of hearing, and are known as the *auditory pits* (Fig. 27, *au.p.*).

The number of mesoblastic somites increases rapidly by a continued segmentation of the vertebral plates of mesoblast. The four or five pairs formed during the first day have by the middle of the second increased to as many as fifteen. The addition takes place from before backwards; and the hindermost one is for some time placed nearly on a level with the boundary between the hind end of the trunk of the embryo, and the front end of the primitive streak. For some time the already formed somites do not increase in size, so that at first the embryo clearly elongates by additions to its hinder end.

Immediately behind the level of the last mesoblastic somite there is placed an enlargement of the unclosed portion of the medullary canal. This enlargement is the sinus rhomboidalis already spoken of. It is shewn in Fig. 23. On its floor is placed the front end of the primitive streak. It is a purely embryonic structure which disappears during the second day.

In a former chapter it was pointed out (p. 27) that the embryo is virtually formed by a folding

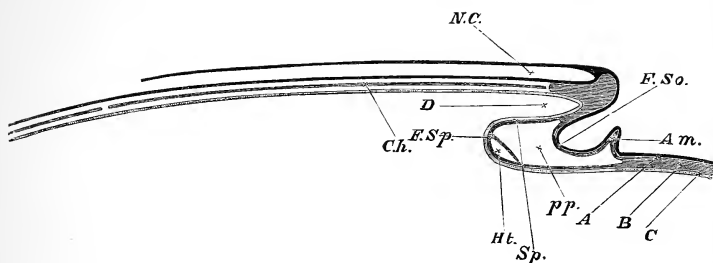
or tucking in of a limited portion of the blastoderm, first at the anterior extremity, and afterwards at the posterior extremity and at the sides. One of the results of this doubling up of the blastoderm to form the head is the appearance, below the anterior extremity of the medullary tube, of a short canal, ending blindly in front, but open widely behind (Fig. 29, *D*), a *cul de sac*, in fact, lined with hypoblast and reaching from the extreme front of the embryo to the point where the splanchnopleuric leaf of the head-fold (Fig. 29, *F. Sp*) turns back on itself. This *cul de sac*, which of course becomes longer and longer the farther back the head-fold is carried, is the rudiment of the *front end of the alimentary canal*, the fore-gut, as it might be called. In transverse section it appears to be flattened horizontally, and also bent, so as to have its convex surface looking downwards (Fig. 30, *al*). At first the anterior end is quite blind, there being no mouth as yet; the formation of this at a subsequent date will be described later on.

At the end of the first half of the second day the head-fold has not proceeded very far backwards, and its limits can easily be seen in the fresh embryo both from above and from below (Fig. 28).

The heart. It is in the head-fold that the formation of the *heart* takes place, its mode of origin being connected with that cleavage of the mesoblast and consequent formation of splanchnopleure and somatopleure of which we have already spoken.

At the extreme end of the embryo (Fig. 29), where the blastoderm begins to be folded back, the mesoblast is never cleft, and here consequently there is neither somatopleure nor splanchnopleure; but at a point a

FIG. 29.



DIAGRAMMATIC LONGITUDINAL SECTION THROUGH THE AXIS OF
AN EMBRYO.

The section is supposed to be made at a time when the head-fold has commenced but the tail-fold has not yet appeared.

N.C. neural canal, closed in front but as yet open behind. *Ch.* notochord. The section being taken in the middle line, the protovertebræ are of course not shewn. In front of the notochord is seen a mass of uncleft mesoblast, which will eventually form part of the skull. *D.* the commencing foregut or front part of the alimentary canal. *F. So.* Somatopleure, raised up in its peripheral portion into the amniotic fold *Am.* *Sp.* Splanchnopleure. At *Sp.* it forms the under wall of the foregut; at *F. Sp.* it is turning round and about to run forward. Just at its turning point the cavity of the heart *Ht.* is being developed in its mesoblast. *pp.* pleuroperitoneal cavity. *A* epiblast, *B* mesoblast, *C* hypoblast, indicated in the rest of the figure by differences in the shading. At the part where these three lines of reference end the mesoblast is as yet uncleft.

very little further back, close under the blind end of the foregut, the cleavage (at the stage of which we are speaking) begins, and the somatopleure, *F. So.*, and splanchnopleure, *F. Sp.* diverge from each other. They

thus enclose between them a cavity, *pp*, which rapidly increases behind by reason of the fact that the fold of the splanchnopleure is carried on towards the hinder extremity of the embryo considerably in advance of that of the somatopleure. Both folds, after running a certain distance towards the hind end of the embryo, are turned round again, and then course once more forwards over the yolk-sac. As they thus return (the somatopleure having meanwhile given off the fold of the amnion, *Am.*), they are united again to form the uncleft blastodermic investment of the yolk-sac. In this way the cavity arising from their separation is closed below.

It is in this cavity, which from its mode of formation the reader will recognise as a part (and indeed at this epoch it constitutes the greater part) of the general pleuroperitoneal cavity, that the heart is formed.

This makes its appearance at the under surface and hind end of the foregut, just where the splanchnopleure folds turn round to pursue a forward course (Fig. 29, *Ht.*); and by the end of the first half of the second day (Fig. 28, *h*) has acquired somewhat the form of a flask with a slight bend to the right. At its anterior end a slight swelling marks the future *bulbus arteriosus*; and a bulging behind indicates the position of the *auricles*. It is hollow, and its cavity opens behind into two vessels called the *vitelline* veins (Figs. 27, *o.f.* and 28 *sp.*), which pass outwards in the folds of the splanchnopleure at nearly right angles to the axis of the embryo. The anterior extremity of the heart is connected with the two aortæ.

The heart, including both its muscular wall and its

epitheloid lining, is developed out of the splanchnic mesoblast on the ventral side of the throat. But since the first commencements of the heart make their appearance prior to the formation of the throat, the development of this organ is somewhat complicated; and in order to gain a clear conception of the manner in which it takes place the topography of the region where it is formed needs to be very distinctly understood.

In the region where the heart is about to appear, the splanchnopleure is continually being folded in on either side, and these lateral folds are progressively meeting and uniting in the middle line to form the under or ventral wall of the foregut. At any given moment these folds will be found to have completely united in the middle line along a certain distance measured from the point in front where the cleavage of the mesoblast (*i.e.* the separation into somatopleure and splanchnopleure) begins, to a particular point farther back. They will here be found to be diverging from the point where they were united, and not only diverging laterally each from the middle line, but also both turning so as to run in a forward direction to regain the surface of the yolk and rejoin the somatopleure, Fig. 29. In a transverse section taken behind this extreme point of union, or point of divergence, as we may call it, the splanchnopleure on either side when traced downwards from the axis of the embryo may be seen to bend in towards the middle so as to approach its fellow, and then to run rapidly outwards, Fig. 31, *B*. A longitudinal section shews that it runs forwards also at the same time, Fig. 29. A section through the very point of

divergence shews the two folds meeting in the middle line and then separating again, so as to form something like the letter *x*, with the upper limbs converging, and the lower limbs diverging. In a section taken in front of the point of divergence, the lower diverging limbs of the *x* have disappeared altogether; nothing is left but the upper limbs, which, completely united in the middle line, form the under-wall of the foregut.

As development proceeds, what we have called the point of divergence is continually being carried farther and farther back, so that the distance between it and the point where the somatopleure and splanchnopleure separate from each other in front, *i.e.* the length of the foregut, is continually increasing.

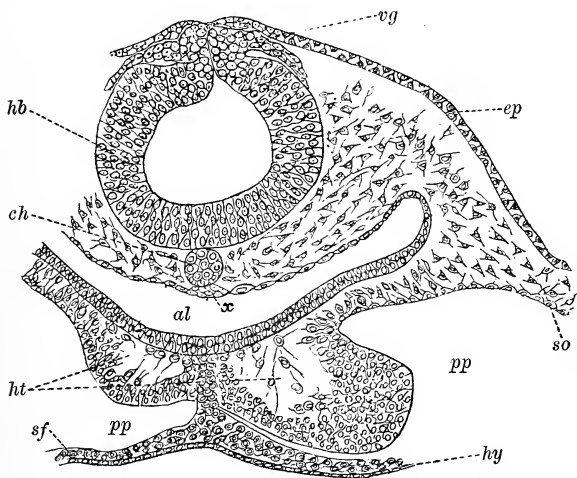
In the chick, as we have already stated, the heart commences to be formed in a region where the folds of the splanchnopleure have not yet united to form the ventral wall of the throat, and appears in the form of two thickenings of the mesoblast of the splanchnopleure, along the diverging folds, *i.e.* along the lower limbs of the *x*, just behind the point of divergence. These thickenings are continued into each other by a similar thickening of the mesoblast extending through the point of divergence itself.

The heart has thus at first the form of an inverted V, and consists of two independent cords of splanchnic mesoblast which meet in front, without however uniting. As the folding-in of the splanchnopleure is continued backwards the two diverging halves of the heart are gradually brought together. Thus very soon the developing heart has the form of an inverted Y, consisting of an

unpaired portion in front and two diverging limbs behind. The unpaired portion is the true heart, while the diverging limbs are the vitelline veins already spoken of (Fig. 28, *sp*). While the changes just spoken of have been taking place in the external form of the heart, its internal parts have also become differentiated.

A cavity is formed in each of the halves of the heart before even they have coalesced. Each of these cavities has at first the form of an irregular space

FIG. 30.



TRANSVERSE SECTION THROUGH THE POSTERIOR PART OF THE HEAD OF AN EMBRYO CHICK OF THIRTY HOURS.

hb. hind-brain; *vg.* vagus nerve; *ep.* epiblast; *ch.* notochord; *x.* thickening of hypoblast (possibly a rudiment of the sub-notochordal rod); *al.* throat; *ht.* heart; *pp.* body cavity; *so.* somatic mesoblast; *sf.* splanchnic mesoblast; *hy.* hypoblast.

between the splanchnic mesoblast and the wall of the throat (Fig. 30, *ht.*). During their formation (Fig. 30), a thin layer of mesoblast remains in contact with the hypoblast, but connected with the main mass of the mesoblast of the heart by protoplasmic processes. A second layer next becomes split from the main mass of mesoblast, being still connected with the first layer by the above-mentioned protoplasmic processes. These two layers unite to form a tube which constitutes the epithelioid lining of the heart; the lumen of this tube is the cavity of the heart, and soon loses the protoplasmic trabeculæ which at first traverse it. The cavity of the heart may thus be described as being formed by a hollowing out of the splanchnic mesoblast. Some of the central cells of the original thickenings probably become blood-corpuscles.

The thick outer part of the cords of splanchnic mesoblast which form the heart become the muscular walls and peritoneal covering of this organ. The muscular wall of each division of the heart has at first the form of a half tube widely open on its dorsal aspect, that is towards the hypoblast of the gut (Fig. 30 and 32). After the two halves of the heart have coalesced in the manner already explained, the muscular walls grow in towards the middle line on the dorsal side until they meet each other and coalesce, thus forming a complete tube as shewn diagrammatically in Fig. 31, A. They remain, however, at first continuous with the splanchnic mesoblast surrounding the throat, thus forming a provisional mesentery—the mesocardium—attaching the heart to the ventral wall of the throat. The epithelioid tubes formed in the two halves of the heart remain for

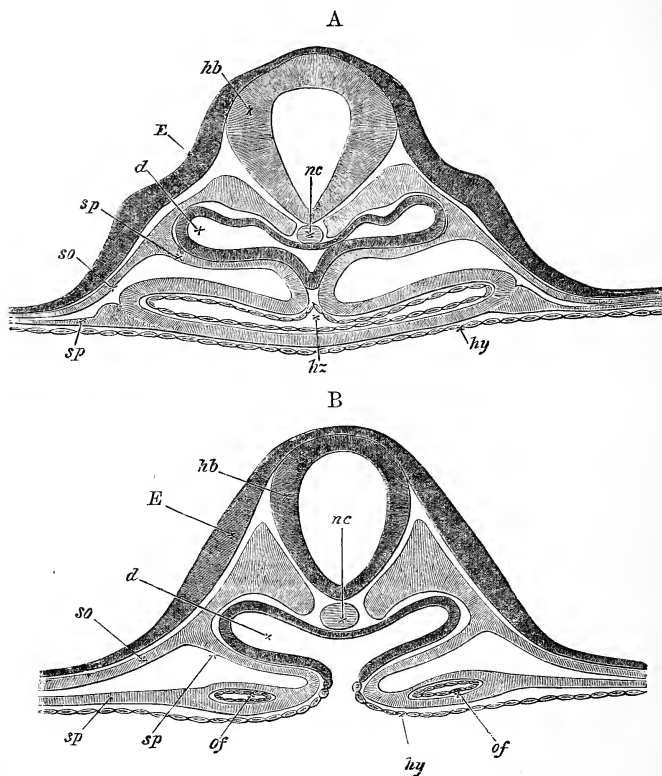
some time separate, and cause the cavity of the heart to be divided into two tubes even after its two halves have to all appearance completely coalesced¹.

Soon after its formation the heart begins to beat; its at first slow and rare pulsations beginning at the venous and passing on to the arterial end. It is of some interest to note that its functional activity commences long before the cells of which it is composed shew any distinct differentiation into muscular or nervous elements.

Vascular system. To provide channels for the fluid thus pressed by the contractions of the heart, a system of tubes has made its appearance in the mesoblast both of the embryo itself and of the vascular and pellucid areas. In front the single tube of the bulbus arteriosus bifurcates into two *primitive aortæ*, each of which bending round the front end of the foregut, passes from its under to its upper side, the two forming together a sort of incomplete arterial collar imbedded in the mesoblast of the gut. Arrived at the upper side of the gut, they turn sharply round, and run separate but parallel to each other backwards towards the tail, in the mesoblast on each side of the notochord immediately under the mesoblastic somites (Figs. 32, 40, 34, 40). About half way to the hinder extremity each gives off at right angles to the axis of the embryo a large branch, the *vitelline artery* (Fig. 36, *Of, A.*), which, passing outwards, is distributed over the pellucid and vascular areas, the main trunk of each aorta passing on with greatly diminished calibre towards the tail, in which it becomes lost.

¹ This is not shewn in the diagram, Fig. 31, A.

FIG. 31.



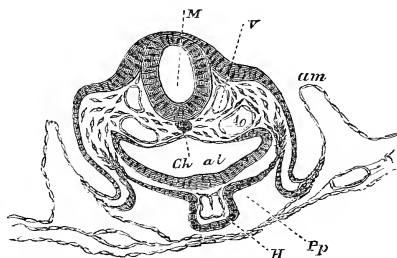
TWO DIAGRAMMATIC SECTIONS OF A THIRTY-SIX HOURS' EMBRYO
 ILLUSTRATING THE STRUCTURE OF THE HEART SHORTLY
 AFTER ITS FORMATION. *A* IS THE ANTERIOR SECTION.

hb. hind brain ; *nc.* notochord ; *E.* epiblast ; *so.* somatopleure ;
sp. splanchopleure ; *d.* alimentary canal ; *hy.* hypoblast ;
hz. (in *A*) heart ; *of.* vitelline vein.

In *A* the two halves of the heart have coalesced to form an
 unpaired tube suspended from the ventral wall of the throat.

In *B* are seen in the diverging folds of the splanchnopleure the two vitelline veins (*of*) which will shortly unite to form the ductus venosus.

FIG. 32.



TRANSVERSE SECTION OF AN EMBRYO AT THE END OF THE SECOND DAY PASSING THROUGH THE REGION OF THE BULBUS ARTERIOSUS. (Copied from His.)

M. medullary canal in the region of the hind brain; *V.* anterior cardinal vein; *Ao.* Aorta; *Ch.* Notochord; *al.* alimentary canal; *H.* Heart (bulbus arteriosus); *Pp.* Pleuroperitoneal cavity; *am.* amnion.

In the vascular and pellucid areas, the formation of vascular channels with a subsequent differentiation into arteries, capillaries and veins, is proceeding rapidly. Blood-corpuscles too are being formed in considerable numbers. The mottled yellow vascular area becomes covered with red patches consisting of aggregations of blood-corpuscles, often spoken of as blood-islands.

Round the extreme margin of the vascular area and nearly completely encircling it, is seen a thin red line, the *sinus* or *vena terminalis* (Fig. 36, *Sv.*). This will soon increase in size and importance.

From the vascular and pellucid area several large channels are seen to unite and form two large trunks,

one on either side, which running along the splanchnopleure folds at nearly right angles to the axis of the embryo, unite at the "point of divergence" to join the venous end of the heart. These are the vitelline veins spoken of above.

Both vessels and corpuscles are formed entirely from the cells of the mesoblast; and in the regions where the mesoblast is cleft, are at first observed exclusively in the splanchnopleure. Ultimately of course they are found in the mesoblast everywhere.

In the pellucid area, where the formation of the blood-vessels may be most easily observed, a number of mesoblastic cells are seen to send out processes (Fig. 33). These processes unite, and by their union a protoplasmic network is formed containing nuclei at the points from which the processes started. The nuclei, which as a rule are much elongated and contain large oval nucleoli, increase very rapidly by division, and thus form groups of nuclei at the, so to speak, nodal points of the network. Several nuclei may also be seen here and there in the processes themselves. The network being completed, these groups, by continued division of the nuclei, increase rapidly in size; the protoplasm around them acquires a red colour, and the whole mass breaks up into blood-corpuscles (Fig. 33, *b.c.*) The protoplasm on the outside of each group, as well as that of the uniting processes, remains granular, and together with the nuclei in it forms the walls of the blood-vessels. A plasma is secreted by the walls, and in this the blood-corpuscles float freely.

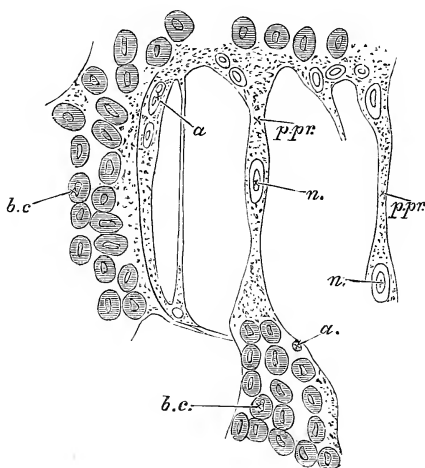
Each nodal point is thus transformed into a more or less rounded mass of blood-corpuscles floating in plasma but enveloped by a layer of nucleated protoplasm, the several groups being united by strands of nucleated protoplasm. These uniting strands rapidly increase in thickness; new processes are also continually being formed; and thus the network is kept close and thickset while the area is increasing in size.

By changes similar to those which took place in the nodal

points, blood-corpuscles make their appearance in the processes also, the central portions of which become at the same time liquefied.

By the continued widening of the connecting processes and solution of their central portions, accompanied by a corresponding increase in the enveloping nucleated cells, the original proto-

FIG. 33.



SURFACE VIEW FROM BELOW OF A SMALL PORTION OF THE POSTERIOR END OF THE PELLUCID AREA OF A THIRTY-SIX HOURS' CHICK. To illustrate the formation of the blood-capillaries and blood-corpuscles, magnified 400 diameters.

b.c. Blood-corpuscles at a nodal point, already beginning to acquire a red colour. They are enclosed in a layer of protoplasm, in the outermost part of which are found nuclei, *α*. These nuclei subsequently become the nuclei of the cells forming the walls of the vessels. The nodal groups are united by protoplasmic processes (*p.pr.*), also containing nuclei with large nucleoli (*n*).

plasmic network is converted into a system of communicating tubes, the canals of which contain blood-corpuscles and plasma, and the walls of which are formed of flattened nucleated cells.

The blood-corpuscles pass freely from the nodal points into the hollow processes, and thus the network of protoplasm becomes a network of blood-vessels, the nuclei of the corpuscles and of the walls of which have been, by separate paths of development, derived from the nuclei of the original protoplasm.

The formation of the corpuscles does not proceed equally rapidly or to the same extent in all parts of the blastoderm. By far the greater part are formed in the vascular area, but some arise in the pellucid area, especially in the hinder part. In the front of the pellucid area the processes are longer and the network accordingly more open; the corpuscles also are both later in appearing and less numerous when formed.

Assuming the truth of the above account, it is evident that the blood-vessels of the yolk-sack of the chick do not arise as spaces or channels between adjacent cells of the mesoblast, but are hollowed out in the communicating protoplasmic substance of the cells themselves. The larger vessels of the trunk are however probably formed as spaces between the cells, much as is the case with the heart.

Wolffian duct. About this period there may be seen in transverse sections, taken through the embryo in the region of the seventh to the eleventh somite a small group of cells (Fig. 34, *W. d*) projecting on either side from the mass of uncleft mesoblast on the outside of the mesoblastic somites, into the somewhat triangular space bounded by the epiblast above, the upper and outer angle of the mesoblastic somite on the inside, and the somatic mesoblast on the outside.

This group of cells is the section of a longitudinal ridge, the rudiment of the *Wolffian duct* or primitive duct of the excretory system; while the mass of cells

from which it springs is known as the *intermediate cell mass*. We shall return to them immediately.

Summary. The most important changes then which take place during the first half of the second day are, the closure of the medullary folds, especially in the anterior part, and the dilatation of the canal so formed into the first cerebral vesicle; the establishment of a certain number of mesoblastic somites; the elevation of the head from the plane of the blastoderm; the formation of the tubular heart and of the great blood-vessels; and the appearance of the rudiment of the Wolffian duct.

It is important to remember that the embryo of which we are now speaking is simply a part of the whole germinal membrane, which is gradually spreading over the surface of the yolk. It is important also to bear in mind that all that part of the embryo which is in front of the foremost somite corresponds to the future head, and the rest to the neck, body and tail. During this period the head occupies about a third of the whole length of the embryo.

CHAPTER V.

THE CHANGES WHICH TAKE PLACE DURING THE SECOND HALF OF THE SECOND DAY.

ONE important feature of this stage is the rapid increase in the process of the folding-off of the embryo from the plane of the germ, and its consequent conversion into a distinct tubular cavity. At the beginning of the second day, the head alone projected from the rest of the germ, the remainder of the embryo being simply a part of a flat blastoderm, nearly completely level from the front mesoblastic somite to the hind edge of the pellucid area. At this epoch, however, a *tail-fold* makes its appearance, elevating the tail above the level of the blastoderm in the same way that the head was elevated. *Lateral folds* also, one on either side, soon begin to be very obvious. By the progress of these, together with the rapid backward extension of the head-fold and the slower forward extension of the tail-fold, the body of the embryo becomes more and more distinctly raised up and marked off from the rest of the blastoderm.

The medullary canal closes up rapidly. The wide sinus rhomboidalis becomes a narrow fusiform space,

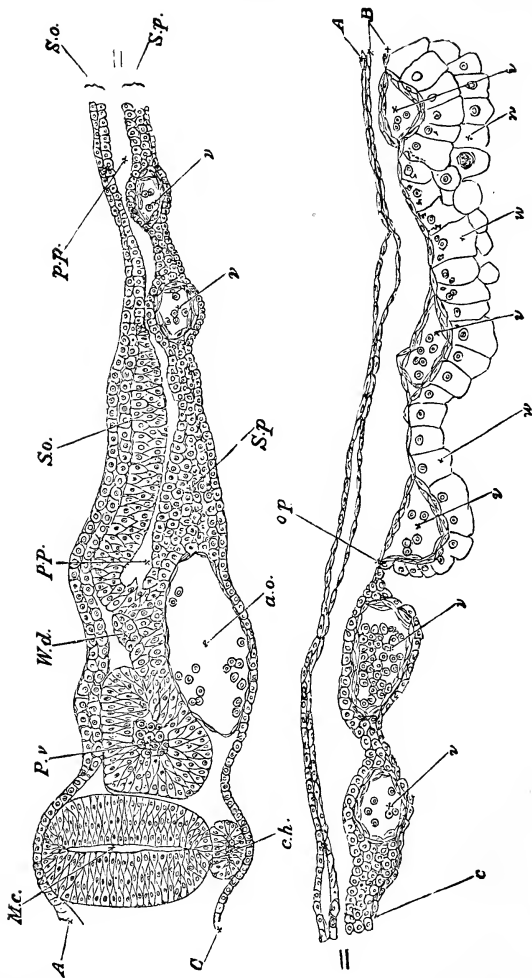
and at the end of this period is entirely roofed over. The conversion of the original medullary groove into a closed tube is thus completed.

The brain. In the region of the head most important changes now take place. We saw that at the beginning of this day the front end of the medullary canal was dilated into a bulb, the first cerebral vesicle, which by budding off two lateral vesicles became converted into three vesicles: a median one connected by short hollow stalks with a lateral one on either side. The lateral vesicles known as the *optic vesicles* (Fig. 27, *op. v.*, Fig. 35, *a*), become converted into parts of the eyes; the median one still retains the name of the first cerebral vesicle.

The original vesicle being primarily an involution of the epiblast, the walls of all three vesicles are formed of epiblast; all three vesicles are in addition covered over with the common epiblastic investment which will eventually become the epidermis of the skin of the head. Between this superficial epiblast and the involuted epiblast of the vesicles, there exists a certain quantity of mesoblast to serve as the material out of which will be formed the dermis of the scalp, the skull, and other parts of the head. At this epoch, however, the mesoblast is found chiefly underneath the several vesicles (Fig. 30). A small quantity may in section be seen at the sides; but at the top the epidermic epiblast is either in close contact with the involuted epiblast of the cerebral and optic vesicles or separated from it by fluid alone, there being as yet in this region between the two no cellular elements representing the mesoblast.

The constrictions marking off the optic vesicles also

FIG. 34.



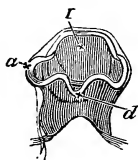
TRANSVERSE SECTION THROUGH THE DORSAL REGION OF AN
EMBRYO OF 45 HOURS.

A. epiblast. *B.* mesoblast. *C.* hypoblast consisting of a single row of flattened cells. *M.c.* medullary canal. *P.v.* mesoblastic somite. *W.d.* Wolffian duct. *S.o.* Somatopleure. *S.p.* Splanchnopleure. *p.p.* pleuroperitoneal cavity. *c.h.* notochord. *a.o.* dorsal aorta. *v.* blood-vessels of the yolk-sac. *o.p.* line of junction between opaque and pellucid areas; *w.* palisade-like yolk spheres which constitute the germinal wall.

Only one-half of the section is represented in the figure—if completed it would be bilaterally symmetrical about the line of the medullary canal.

take place of course beneath the common epiblastic investment, which is not involved in them. As a consequence, though easily seen in the transparent fresh

FIG. 35.



HEAD OF A CHICK AT THE END OF THE SECOND DAY VIEWED FROM BELOW AS A TRANSPARENT OBJECT.

(Copied from Huxley).

I. first cerebral vesicle. *a.* optic vesicle. *d.* infundibulum.

The specimen shews the formation of the optic vesicles (*a*), as outgrowths from the 1st cerebral vesicle or vesicle of the 3rd ventricle, so that the optic vesicles and vesicle of the 3rd ventricle at first freely communicated with each other, and also the growth of the lower wall of the vesicle of the 3rd ventricle into a process which becomes the infundibulum (*d*).

embryo (Fig. 28), they are but slightly indicated in hardened specimens (Fig. 27).

When an embryo of the early part of the second day is examined as a transparent object, that portion of the medullary canal which lies immediately behind the first cerebral vesicle is seen to be conical in shape, with its walls thrown into a number of wrinkles. These wrinkles may vary a good deal in appearance, and shift from time to time, but eventually, before the close of the second day, after the formation of the optical vesicles, settle down into two constrictions, one separating the first cerebral vesicle from that part of the medullary canal which is immediately behind it, and the other separating this second portion from a third. So that instead of there being one cerebral vesicle only, as at the commencement of the second day, there is now, in addition to the optic vesicles, a series of three, one behind the other: a *second* and *third cerebral vesicle* have been added to the *first* (Fig. 27, *mb*, *hb*). They may be also called the "fore brain," the "mid brain," and the "hind brain," for into these parts will they eventually be developed.

The optic vesicles, lying underneath the epiblast, towards the end of the day are turned back and pressed somewhat backwards and downwards against the sides of the first cerebral vesicle or fore brain, an elongation of their stalks permitting this movement to take place. The whole head becomes in consequence somewhat thicker and rounder.

Before the end of the day the fore brain elongates anteriorly. The part so established is not at first separate from that behind, but it is nevertheless the first

unpaired commencement of two vesicles which develop into the *cerebral hemispheres*; but up to the end of the day it is still very small and inconspicuous.

Early on the second day the commencements of several of the cranial nerves make their appearance as outgrowths of the (Fig. 30, *vg*) roof of the mid and hind brains, but their development, together with that of the spinal nerves, will be dealt with in the next chapter.

The notochord. The notochord, whose origin was described in the account of the first day, is during the whole of the second day a very conspicuous object. It is seen as a transparent rod, somewhat elliptical in section (Fig. 34, *ch*), lying immediately underneath the medullary canal for the greater part of its length, and reaching forward in front as far as below the hind border of the first cerebral vesicle.

Cranial flexure. Round the anterior termination of the notochord, the medullary canal, which up to the present time has remained perfectly straight, towards the end of the day begins to curve. The front portion of the canal, *i.e.* the fore-brain with its optic and cerebral vesicles, becomes slightly bent downwards, so as to form a rounded obtuse angle with the rest of the embryo. This is the commencement of the so-called *cranial flexure* and is, mechanically speaking, a consequence of the more rapid growth of the dorsal wall of the anterior part of the brain as compared with that of the ventral.

Auditory vesicle. Lastly, as far as the head is concerned, the epiblastic plates forming the rudiments of the auditory vesicles become converted into deep pits

opening one on each side of the hind-brain (Fig. 27, *au. p*).

Heart. We left the heart as a fusiform body slightly bent to the right, attached to the under wall of the foregut by the mesocardium. The curvature now increases so much that the heart becomes almost ω -shaped, the venous portion being drawn up towards the head so as to lie somewhat above (dorsal to) and behind the arterial portion. (It would perhaps be more correct to say that the free intermediate portion is by its own growth bent downwards, backwards, and somewhat to the right, while the venous root of the heart is at the same time continually being lengthened by the carrying back of that "point of divergence" of the splanchnopleure folds which marks the union of the vitelline veins into a single venous trunk.) The heart then has at this time two bends, the one, the venous bend, the right-hand curve of the ω ; the other, the arterial bend, the left-hand curve of the ω . The venous bend which, as we have said, is placed above and somewhat behind the arterial bend, becomes marked by two bulgings, one on either side. These are the rudiments of the *auricles*, or rather of the *auricular appendages*. The ascending limb of the arterial bend soon becomes conspicuous as the *bulbus arteriosus*, while the rounded point of the bend itself will hereafter grow into the *ventricles*.

Vascular system. The blood-vessels, whose origin during the first half of this day has been already described, become during the latter part of the day so connected as to form a complete system, through which a definite circulation of the blood is now for the first

time (consequently some little while after the commencement of the heart's pulsation) carried on.

The two *primitive aortæ* have already been described as encircling the foregut, and then passing along the body of the embryo immediately beneath the mesoblastic somites on each side of the notochord. They are shewn in Figs. 32 *A.o.* and 34 *a.o* in section as two large rounded spaces lined with flattened cells. At first they run as two distinct canals along the whole length of the embryo; but, after a short time, unite at some little distance behind the head into a single trunk, which lies in the middle line of the body immediately below the notochord (Fig. 57). Lower down, nearer the tail, this single primitive trunk again divides into two *aortæ*, which, getting smaller and smaller, are finally lost in the small blood-vessels of the tail. At this epoch, therefore, there are *two aortic* arches springing from the bulbus arteriosus, and uniting above the alimentary canal in the back of the embryo to form the single dorsal aorta, which travelling backwards in the median line divides near the tail into two main branches. From each of the two primitive *aortæ*, or from each of the two branches into which the single aorta divides, there is given off on either side a large branch. These have been already spoken of as the *vitelline arteries*. At this stage they are so large that by far the greater part of the blood passing down the aorta finds its way into them, and a small remnant only pursues a straight course into the continuations of the aorta towards the tail.

Each vitelline artery leaving the aorta at nearly right angles (at a point some little way behind the

backward limit of the splanchnopleure fold which is forming the alimentary canal), runs outwards beneath the mesoblastic somites in the lower range of the mesoblast, close to the hypoblast. Consequently, when in its course outwards it reaches the point where the mesoblast is cleft to form the somatopleure and splanchnopleure, it attaches itself to the latter. Travelling along this, and dividing rapidly into branches, it reaches the vascular area in whose network of small vessels (and also to a certain extent in the similar small vessels of the pellucid area) it finally loses itself.

The terminations of the vitelline arteries in the vascular and pellucid areas are further connected with the heart in two different ways. From the network of capillaries, as we may call them, a number of veins take their origin, and finally unite into two main trunks, the vitelline veins. These have already been described as running along the folds of the splanchnopleure to form the venous roots of the heart. Their course is consequently more or less parallel to that of the vitelline arteries, but at some little distance nearer the head, inasmuch as the arteries run in that part of the splanchnopleure which has not yet been folded in to form the alimentary canal. Besides forming the direct roots of the *vitelline veins*, the terminations of the vitelline arteries in the vascular area are also connected with the *sinus terminalis* spoken of above as running almost completely round, and forming the outer margin of the vascular area. This (Fig. 36, *ST*), may be best described as composed of two semicircular canals, which nearly meet at points opposite the head and opposite the tail, thus all but encircling the vascular area between them. At the

point opposite the head the end of each semicircle is connected with vessels (Fig. 36), which run straight in towards the heart along the fold of the splanchnopleure, and join the right and left vitelline veins. At the point opposite the tail there is at this stage no such definite connection. At the two sides, midway between their head and tail ends, the two semicircles are especially connected with the vitelline arteries.

The circulation of the blood then during the latter half of the second day may be described as follows. The blood brought by the vitelline veins falls into the twisted cavity of the heart, and is driven thence through the bulbus arteriosus and aortic arches into the aorta. From the aorta, by far the greater part of the blood flows into the vitelline arteries, only a small remnant passing on into the caudal terminations. From the capillary net-work of the vascular and pellucid areas into which the vitelline arteries discharge their contents, part of the blood is gathered up at once into the lateral or direct trunks of the vitelline veins. Part however goes into the middle region of each lateral half of the sinus terminalis, and there divides on each side into two streams. One stream, and that the larger one, flows in a forward direction until it reaches the point opposite the head, thence it returns by the veins spoken of above, straight to the vitelline trunks. The other stream flows backward, and becomes lost at the point opposite to the tail. This is the condition of things during the second day; it becomes considerably changed on the succeeding day.

At the time that the heart first begins to beat the capillary system of the vascular and pellucid areas is

not yet completed; and the fluid which is at first driven by the heart contains, according to most observers, very few corpuscles.

At the close of the second day the single pair of aortic arches into which the bulbus arteriosus divides is found to be accompanied by a *second pair*, formed in the same way as the first, and occupying a position a little behind it. Sometimes even a *third pair* is added. Of these aortic arches we shall have to speak more fully later on.

Wolffian duct. During the latter half of the second day the Wolffian duct to which we have already alluded becomes fully established, while the first traces of the embryonic excretory organs or kidneys, known as the Wolffian bodies, make their appearance. The development of the latter will be dealt with in the history of the third day, but the history of the duct itself may conveniently be completed here.

The first trace of it is visible in an embryo Chick with eight somites, as a ridge projecting from the intermediate cell mass towards the epiblast in the region of the seventh somite. In the course of further development it continues to constitute such a ridge as far as the eleventh somite (Fig. 34 *Wd.*), but from this point it grows backwards by the division of its cells, as a free column in the space between the epiblast and mesoblast. In an embryo with fourteen somites of about the stage represented in fig. 28 a small lumen has appeared in its middle part, and in front it is connected with rudimentary Wolffian tubules, which develop in continuity with it. In the succeeding stages the lumen of the duct gradually extends backwards and forwards,

and the duct itself also passes inwards relatively to the epiblast (fig. 43 *wd*). Its hind end elongates till it comes into connection with, and opens on the fourth day into the cloacal section of the hind-gut.

The amnion and allantois. The amnion, especially the anterior or head fold, advances in growth very rapidly during the second day, and at the close of the day completely covers the head and neck of the embryo; so much so that it is necessary to tear or remove it when the head has to be examined in hardened opaque specimens. The tail and lateral folds of the amnion, though still progressing, lag considerably behind the head-fold.

The side-folds eventually meet in the median dorsal line, and their coalescence proceeds backwards from the head-fold in a linear direction, till there is only a small opening left over the tail of the embryo. This finally becomes closed early on the third day.

In Figs. 32 and 43 *am*. the folds of the amnion are shewn before they have coalesced. After the coalescence of the folds of the amnion above the embryo the two limbs of which each is formed become, as already explained in chapter II., separate from each other: the inner, forming a special investment of the embryo, and constituting the amnion proper (Fig. 65), the outer attaching itself to the vitelline membrane and becoming the serous envelope.

The development of the allantois commences during the second day, but since it is mainly completed during the third day we need not dwell upon it further in this place.

Summary. The chief events, then, which occur during the second half of the second day are as follow:—

1. The second and third cerebral vesicles make their appearance behind the first.

2. The optic vesicles spring as hollow buds from the lateral, and the unpaired commencement of the cerebral hemispheres from the front, portions of the first cerebral vesicle.

3. The auditory plate becomes converted into a pit, opening at the side of the hind-brain or third cerebral vesicle.

4. The first indications of the cranial flexure become visible.

5. The head-fold, and especially the splanchnopleure moiety, advances rapidly backwards; the head of the embryo is in consequence more definitely formed. The tail-fold also becomes distinct.

6. The curvature of the heart increases; the first rudiments of the auricles appear.

7. The circulation of the yolk-sac is established.

8. The amnion grows rapidly, and the allantois commences to be formed.

CHAPTER VI.

THE CHANGES WHICH TAKE PLACE DURING THE THIRD DAY.

OF all days in the history of the chick within the egg this perhaps is the most eventful; the rudiments of so many important organs now first make their appearance.

In many instances we shall trace the history of these organs beyond the third day of incubation, in order to give the reader a complete view of their development.

On opening an egg on the third day the first thing which attracts notice is the diminution of the white of the egg. This seems to be one of the consequences of the functional activity of the newly-established vascular area whose blood-vessels are engaged either in directly absorbing the white or, as is more probable, in absorbing the yolk, which is in turn replenished at the expense of the white. The absorption, once begun, goes on so actively that, by the end of the day, the decrease of the white is very striking.

The blastoderm has now spread over about half the yolk, the extreme margin of the opaque area reach-

ing about half-way towards the pole of the yolk opposite to the embryo.

The vascular area, though still increasing, is much smaller than the total opaque area, being in average-sized eggs about as large as a florin. Still smaller than the vascular area is the pellucid area in the centre of which lies the rapidly growing embryo.

During the third day the vascular area is not only a means for providing the embryo with nourishment from the yolk, but also, inasmuch as by the diminution of the white it is brought close under the shell and therefore fully exposed to the influence of the atmosphere, serves as the chief organ of respiration.

This in fact is the period at which the vascular area may be said to be in the stage of its most complete development; for though it will afterwards become larger, it will at the same time become less definite and relatively less important. We may therefore, before we proceed, add a few words to the description of it given in the last chapter.

The blood leaving the body of the embryo by the vitelline arteries (Fig. 36, *R. Of. A.*, *L. Of. A.*) is carried to the small vessels and capillaries of the vascular area, a small portion only being appropriated by the pellucid area.

From the vascular area part of the blood returns directly to the heart by the main lateral trunks of the vitelline veins, *R. Of.*, *L. Of.* During the second day these venous trunks joined the body of the embryo considerably in front of, that is, nearer the head than, the corresponding arterial ones. Towards the end of the third day, owing to the continued lengthening of

FIG. 36.

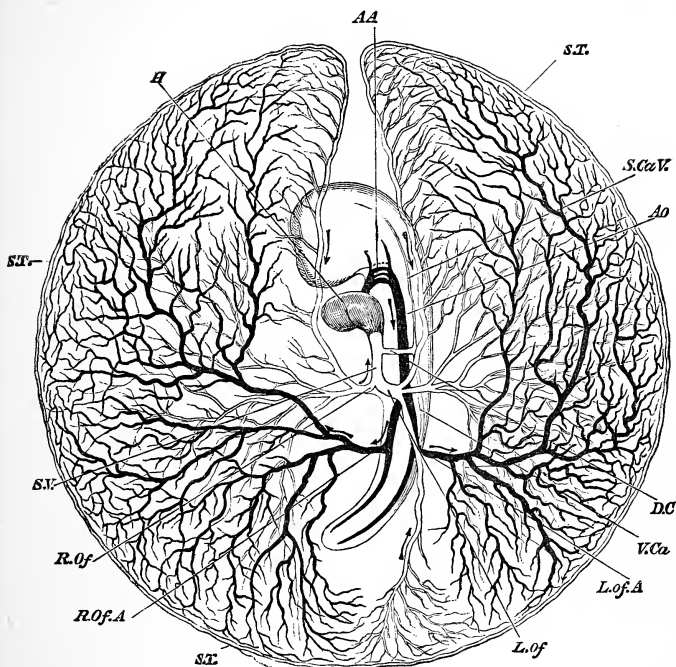


DIAGRAM OF THE CIRCULATION OF THE YOLK-SACK AT THE END OF THE THIRD DAY OF INCUBATION.

H. heart. *AA.* the second, third and fourth aortic arches ; the first has become obliterated in its median portion, but is continued at its proximal end as the external carotid, and at its distal end as the internal carotid. *AO.* dorsal aorta. *L. Of. A.* left vitelline artery. *R. Of. A.* right vitelline artery. *S. T.* sinus terminalis. *L. Of.* left vitelline vein. *R. Of.* right vitelline vein. *S. V.* sinus venosus. *D. C.* ductus Cuvieri. *S. Ca. V.* superior cardinal or jugular vein. *V. Ca.* inferior cardinal vein. The veins are marked in

outline and the arteries are made black. The whole blastoderm has been removed from the egg and is supposed to be viewed from below. Hence the left is seen on the right, and *vice versa*.

the heart, the veins and arteries run not only parallel to each other, but almost in the same line, the points at which they respectively join and leave the body being nearly at the same distance from the head.

The rest of the blood brought by the vitelline arteries finds its way into the lateral portions of the sinus terminalis, *S.T.*, and there divides on each side into two streams. Of these, the two which, one on each side, flow backward, meet at a point about opposite to the tail of the embryo, and are conveyed along a distinct vein which, running straight forward parallel to the axis of the embryo, empties itself into the left vitelline vein. The two forward streams reaching the gap in the front part of the sinus terminalis fall into either one, or in some cases two veins, which run straight backward parallel to the axis of the embryo, and so reach the roots of the heart. When one such vein only is present, it joins the left vitelline trunk; where there are two they join the left and right vitelline trunks respectively. The left vein is always considerably larger than the right; and the latter when present rapidly gets smaller and speedily disappears.

The chief differences, then, between the peripheral circulation of the second and of the third day are due to the greater prominence of the sinus terminalis and the more complete arrangements for returning the blood from it to the heart. After this day, although the vascular area will go on increasing in size until it finally

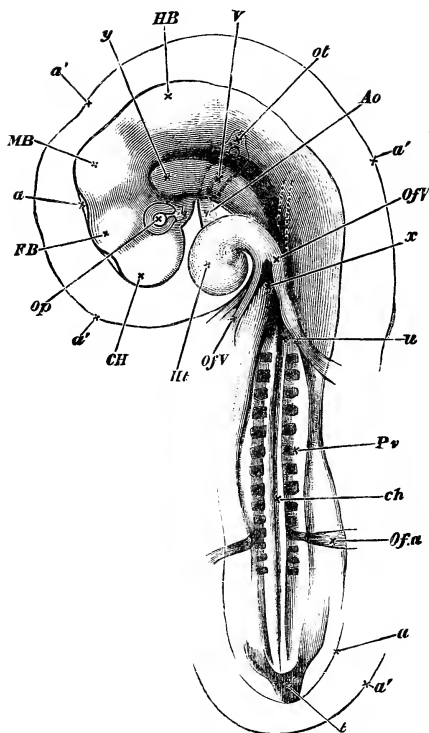
all but encompasses the yolk, the prominence of the sinus terminalis will become less and less in proportion as the respiratory work of the vascular area is shifted on to the allantois, and its activities confined to absorbing nutritive matter from the yolk.

The folding-in of the embryo makes great progress during this day. Both head and tail have become most distinct, and the side folds which are to constitute the lateral walls have advanced so rapidly that the embryo is now a *bonâ fide* tubular sac, connected with the rest of the yolk by a broad stalk. This stalk, as was explained in Chap. II, is double, and consists of an inner splanchnic stalk continuous with the alimentary canal, which is now a tube closed at both ends and open to the stalk along its middle third only, and an outer somatic stalk continuous with the body-walls of the embryo, which have not closed nearly to the same extent as the walls of the alimentary canal. (Compare Fig. 9, *A* and *B*, which may be taken as diagrammatic representations of longitudinal and transverse sections of an embryo of this period.)

The embryo is almost completely covered by the amnion. Early in this day the several amniotic folds will have met and completely coalesced along a line over the back of the embryo in the manner already explained in the last chapter.

During this day a most remarkable change takes place in the position of the embryo. Up to this time it has been lying symmetrically upon the yolk with the part which will be its mouth directed straight downwards. It now turns round so as to lie on its left side.

FIG. 37.



CHICK OF THE THIRD DAY (FIFTY-FOUR HOURS) VIEWED FROM UNDERNEATH AS A TRANSPARENT OBJECT.

- a'*. the outer amniotic fold or false amnion. This is very conspicuous around the head, but may also be seen at the tail.
- a*. the true amnion, very closely enveloping the head, and here seen only between the projections of the several cerebral vesicles. It may also be traced at the tail.

In the embryo of which this is a drawing, the head-fold of the amnion reached a little farther backward than the reference *u*,

but its limit could not be distinctly seen through the body of the embryo. The prominence of the false amnion at the head is apt to puzzle the student; but if he bears in mind the fact, which could not well be shewn in Fig. 9, that the whole amniotic fold, both the true and the false limb, is tucked in underneath the head, the matter will on reflection become intelligible.

C. H. cerebral hemisphere. *F. B.* thalamencephalon or vesicle of the third ventricle. *M. B.* mid-brain. *H. B.* hind-brain. *Op.* optic vesicle. *Ot.* otic vesicle. *Of V.* vitelline veins forming the venous roots of the heart. The trunk on the right hand (left trunk when the embryo is viewed in its natural position from above) receives a large branch, shewn by dotted lines, coming from the anterior portion of the sinus terminalis. *Ht.* the heart, now completely twisted on itself. *Ao.* the bulbus arteriosus, the three aortic arches being dimly seen stretching from it across the throat, and uniting into the aorta, still more dimly seen as a curved dark line running along the body. The other curved dark line by its side, ending near the reference *y*, is the notochord *ch.*

About opposite the line of reference *x* the aorta divides into two trunks, which, running in the line of the somewhat opaque mesoblastic somites on either side, are not clearly seen. Their branches however, *Ofa*, the vitelline arteries, are conspicuous and are seen to curve round the commencing side folds.

Pv. mesoblastic somites. Below the level of the vitelline arteries the vertebral plates are but imperfectly cut up into mesoblastic somites, and lower down still, not at all.

x is placed at the "point of divergence" of the splanchnopleure folds. The blind foregut begins here and extends about up to *y*. *x* therefore marks the present hind limit of the splanchnopleure folds. The limit of the more transparent somatopleure folds is not shewn.

It will be of course understood that all the body of the embryo above the level of the reference *x*, is seen through the portion of the yolk-sac (vascular and pellucid area), which has been removed

with the embryo from the egg, as well as through the double amniotic fold.

We may repeat that, the view being from below, whatever is described in the natural position as being to the right here appears to be left, and *vice versa*.

This important change of position at first affects only the head (Fig. 37), but subsequently extends also to the trunk. It is not usually completed till the fourth day. At the same time the left vitelline vein, the one on the side on which the embryo comes to lie, grows very much larger than the right, which henceforward gradually dwindles and finally disappears.

Coincidentally with the change of position the whole embryo begins to be curved on itself in a slightly spiral manner. This *curvature of the body* becomes still more marked on the fourth day, Fig. 67.

In the head very important changes take place. One of these is the *cranial flexure*, Figs. 37, 38. This (which must not be confounded with the curvature of the body just referred to) we have already seen was commenced in the course of the second day, by the bending downwards of the head round a point which may be considered as the extreme end either of the notochord or of the alimentary canal.

The flexure progresses rapidly, the front-brain being more and more folded down till, at the end of the third day, it is no longer the first vesicle or fore-brain, but the second cerebral vesicle or mid-brain, which occupies the extreme front of the long axis of the embryo. In fact a straight line through the long axis of the embryo would now pass through the mid-brain instead of, as at the beginning of the second day, through the fore-brain,

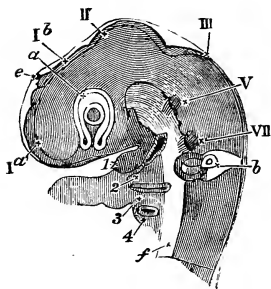
so completely has the front end of the neural canal been folded over the end of the notochord. The commencement of this cranial flexure gives the body of an embryo of the third day somewhat the appearance of a retort, the head of the embryo corresponding to the bulb. On the fourth day the flexure is still greater than on the third, but on the fifth and succeeding days it becomes less obvious, owing to the filling up of the parts of the skull.

The brain. The vesicle of the cerebral hemispheres, which on the second day began to grow out from the front of the fore-brain, increases rapidly in size during the third day, growing out laterally, so as to form two vesicles, so much so that by the end of the day it (Fig. 37, *CH*, Fig. 38) is as large or larger than the original vesicle from which it sprang, and forms the most conspicuous part of the brain. In its growth it pushes aside the optic vesicles, and thus contributes largely to the roundness which the head is now acquiring. Each lateral vesicle possesses a cavity, which afterwards becomes one of the *lateral ventricles*. These cavities are continuous behind with the cavity of the fore-brain.

Owing to the development of the cerebral vesicle the original fore-brain no longer occupies the front position (Fig. 37, *FB*, Fig. 38, *Ib*), and ceases to be the conspicuous object that it was. Inasmuch as its walls will hereafter be developed into the parts surrounding the so-called third ventricle of the brain, we shall henceforward speak of it as *the vesicle of the third ventricle*, or thalamencephalon.

On the summit of the thalamencephalon there may now be seen a small conical projection, the rudiment of

FIG. 38.



HEAD OF A CHICK OF THE THIRD DAY VIEWED SIDEWAYS AS A TRANSPARENT OBJECT. (From Huxley.)

I *a*. the vesicle of the cerebral hemisphere. I *b*. the vesicle of the third ventricle (the original fore-brain); at its summit is seen the projection of the pineal gland *e*.

Below this portion of the brain is seen, in optical section, the optic vesicle *a* already involuted with its thick inner and thinner outer wall (the letter *a* is placed on the junction of the two, the primary cavity being almost obliterated). In the centre of the vesicle lies the lens, the shaded portion being the expression of its cavity. Below the lens between the two limbs of the horse-shoe is the choroidal fissure.

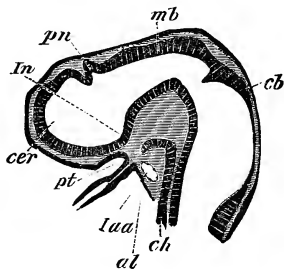
II. the mid-brain. III. the hind-brain. V. the rudiments of the fifth cranial nerve, VII. of the seventh. Below the seventh nerve is seen the auditory vesicle *b*. The head having been subjected to pressure, the vesicle appears somewhat distorted as if squeezed out of place. The orifice is not yet quite closed up.

1, the inferior maxillary process of the first visceral or mandibular fold. Below, and to the right of this, is seen the first visceral cleft, below that again the second visceral fold (2), and lower down the third (3) and fourth (4) visceral folds. In front of the folds (*i.e.* to the left) is seen the arterial end of the heart, the aortic arches being buried in their respective visceral folds.

f. represents the mesoblast of the base of the brain and spinal cord.

the *pineal gland* (Fig. 38, *e*), while the centre of the floor is produced into a funnel-shaped process, the *infundibulum* (Fig. 39, *In*), which, stretching towards the

FIG. 39.



LONGITUDINAL SECTION THROUGH THE BRAIN OF A YOUNG
PRISTIURUS EMBRYO.

cer. commencement of cerebral hemisphere; *pn.* pineal gland; *In.* infundibulum; *pt.* ingrowth of mouth to form the pituitary body; *mb.* mid-brain; *cb.* cerebellum; *ch.* notochord; *al.* alimentary tract; *Iaa.* artery of mandibular arch.

extreme end of the oral invagination or *stomodæum*, joins a diverticulum of this which becomes the *pituitary body*.

The development of the pituitary body or hypophysis cerebri has been the subject of considerable controversy amongst embryologists, and it is only within the last few years that its origin from the oral epithelium has been satisfactorily established.

In the course of cranial flexure the epiblast on the under side of the head becomes tucked in between the blind end of the throat and the base of the brain. The part so tucked in constitutes a kind of bay, and forms the *stomodæum* or primitive buccal cavity already spoken of. The blind end of this bay becomes produced as a papilliform diverticulum which may be called the pituitary diverticulum. It is represented as it appears in a

lower vertebrate embryo (Elasmobranch) in Fig. 39, but is in all important respects exactly similar in the chick. Very shortly after the pituitary diverticulum becomes first established the boundary wall between the stomodæum and the throat becomes perforated, and the limits of the stomodæum obliterated, so that the pituitary diverticulum looks as if it had arisen from the hypoblast. During the third day of incubation the front part of the notochord becomes bent downward, and, ending in a somewhat enlarged extremity, comes in contact with the termination of the pituitary diverticulum. The mesoblast around increases and grows up, in front of the notochord and behind the vesicle of the third ventricle, to form the posterior clinoid process. The base of the vesicle of the third ventricle at the same time grows downwards towards the pituitary diverticulum, and forms what is known as the infundibulum. On the fourth day the mesoblastic tissue around the notochord increases in quantity, and the end of the notochord, though still bent downwards, recedes a little from the termination of the pituitary diverticulum, which is still a triangular space with a wide opening into the alimentary canal.

On the fifth day, the opening of the pituitary diverticulum into the alimentary canal has become narrowed, and around the whole diverticulum an investment of mesoblast-cells has appeared. Behind it the clinoid process has become cartilaginous, while to the sides and in front it is enclosed by the trabeculæ. At this stage, in fact, we have a diverticulum from the alimentary canal passing through the base of skull to the infundibulum.

On the seventh day the communication between the cavity of the diverticulum and that of the throat has become still narrower. The diverticulum is all but converted into a vesicle, and its epiblastic walls have commenced to send out into the mesoblastic investment solid processes. The infundibulum now appears as a narrow process from the base of the vesicle of the third ventricle, which approaches, but does not unite with, the pituitary vesicle.

By the tenth day the opening of the pituitary vesicle into the throat becomes almost obliterated, and the lumen of the vesicle itself very much diminished. The body consists of anastomosing cords of epiblast-cells, the mesoblast between

which has already commenced to become vascular. The cords or masses of epiblast cells are surrounded by a delicate membrana propria, and a few of them possess a small lumen. The infundibulum has increased in length. The relative positions of the pituitary body and infundibulum are shewn in the figure of the brain in Chapter VIII.

On the twelfth day the communication between the pituitary vesicle and the throat is entirely obliterated, but a solid cord of cells still connects the two. The vessels of the pia mater of the vesicle of the third ventricle have become connected with the pituitary body, and the infundibulum has grown down along its posterior border.

In the later stages all connection is lost between the pituitary body and the throat, and the former becomes attached to the elongated *processus infundibuli*.

The real nature of the pituitary body is still extremely obscure, but it is not improbably the remnant of a glandular structure which may have opened into the mouth in primitive vertebrate forms, but which has ceased to have a function in existing vertebrates¹.

Beyond an increase in size, which it shares with nearly all parts of the embryo, and the change of position to which we have already referred, the mid-brain undergoes no great alteration during the third day. Its roof will ultimately become developed into the *corpora bigemina* or optic lobes, its floor will form the *crura cerebri*, and its cavity will be reduced to the narrow canal known as the *iter a tertio ad quartum ventriculū*.

In the hind-brain, or third cerebral vesicle, that part which lies nearest to the mid-brain, is during

¹ Wilhelm Müller *Ueber die Entwicklung und Bau der Hypophysis und des Processus Infundibuli Cerebri*. *Jenaische Zeitschrift*, Bd. VI. 1871, and V. von Mihalkovics, *Wirbelsaite u. Hirnanhang*, *Archiv f. mikr. Anat.* Vol. XI. 1875.

the third day marked off from the rest by a slight constriction. This distinction, which becomes much more evident later on by a thickening of the walls and roof of the front portion, separates the hind-brain into the *cerebellum* in front, and the *medulla oblongata* behind (Figs. 38 and 39). While the walls of the cerebellar portion of the hind-brain become very much thickened as well at the roof as at the floor and sides, the roof of the posterior or medulla oblongata portion thins out into a mere membrane, forming a delicate covering to the cavity of the vesicle (Fig. 40, IV), which here becoming broad and shallow with greatly thickened floor and sides, is known as the *fourth ventricle*, subsequently overhung by the largely developed posterior portion of the cerebellum.

The third day, therefore, marks the differentiation of the brain into five distinct parts: the cerebral hemispheres, the central masses round the third ventricle, the corpora bigemina or optic lobes, the cerebellum and the medulla oblongata; the original cavity of the neural canal at the same time passing from its temporary division of three single cavities into the permanent arrangement of a series of connected ventricles, viz. the lateral ventricles, the third ventricle, the iter (with a prolongation into the optic lobe on each side), and the fourth ventricle.

At the same time that the outward external shape of the brain is thus being moulded, internal changes are taking place in the whole neural canal. These are best seen in sections.

At its first formation, the section of the cavity of the neural canal is round, or nearly so.

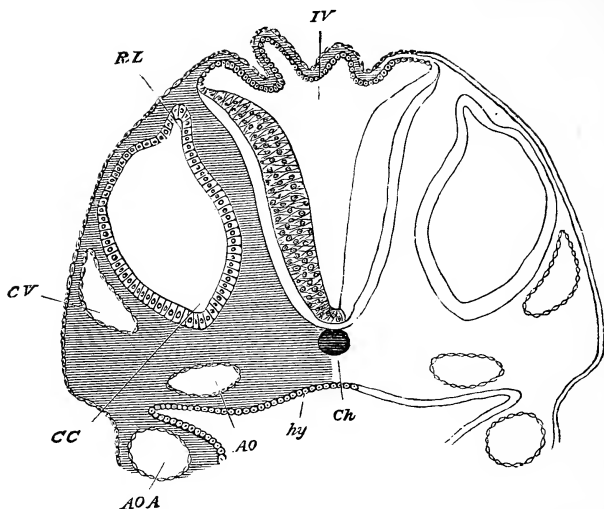
About this time, however, the lining of involuted epiblast along the length of the whole spinal cord becomes very much thickened at each side, while increasing but little at the mid-points above and below. The result of this is that the cavity as seen in section (Figs. 64 and 65), instead of being circular, has become a narrow vertical slit, almost completely filled in on each side.

In the region of the brain the thickening of the lining epiblast follows a somewhat different course. While almost everywhere the sides and floor of the canal are greatly thickened, the roof in the region of the various ventricles, especially of the third and fourth, becomes excessively thin, so as to form a membrane reduced to almost a single layer of cells. (Fig. 40, IV.)

Cranial and spinal nerves. A most important event which takes place during the second and third days, is the formation of the cranial and spinal nerves. Till within a comparatively recent period embryologists were nearly unanimous in believing that the peripheral nerves originated from the mesoblast at the sides of the brain and spinal cord. This view has now however been definitely disproved, and it has been established that both the cranial and spinal nerves take their origin as outgrowths of the central nervous system.

The cranial nerves are the first to be developed and arise before the complete closure of the neural groove. They are formed as paired outgrowths of a continuous band known as the neural band, composed of two laminæ, which connects the dorsal edges of the incompletely closed neural canal with the external epiblast. This mode of development will best be understood by

FIG. 40.



SECTION THROUGH THE HIND-BRAIN OF A CHICK AT THE END OF THE THIRD DAY OF INCUBATION.

IV. Fourth ventricle. The section shews the very thin roof and thicker sides of the ventricle.

Ch. Notochord—(diagrammatic shading).

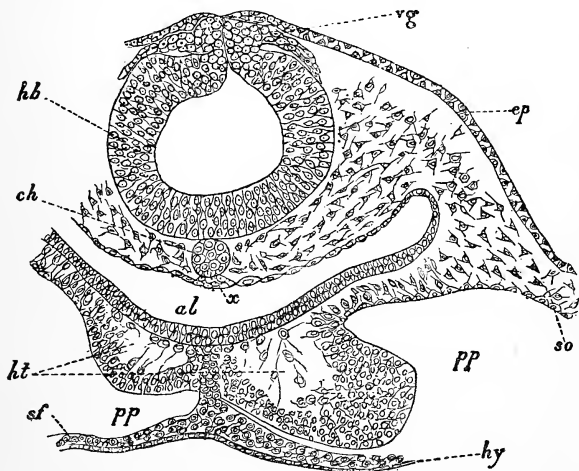
CV. Anterior cardinal or jugular vein.

CC. Involute auditory vesicle. *CC* points to the end which will form the cochlear canal. *RL.* Recessus labyrinthi. *hy.* hypoblast lining the alimentary canal. *hy* is itself placed in the cavity of the alimentary canal, in that part of the canal which will become the throat. The ventral (anterior) wall of the canal is not shewn in the section, but on each side are seen portions of a pair of visceral arches. In each arch is seen the section of the aortic arch *AOA* belonging to the visceral arch. The vessel thus cut through is running upwards towards the head, being about to join the dorsal aorta *AO*. Had the section been nearer the head, and carried through the plane at which the aortic arch curves

round the alimentary canal to reach the mesoblast above it, *AOA* and *AO* would have formed one continuous curved space. In sections lower down in the back the two aortæ, *AO*, one on each side, would be found fused into one median canal.

an examination of Fig. 41, where the two roots of the vagus nerve (*vg*) are shewn growing out from the neural band. Shortly after this stage the neural band becomes separated from the external epiblast, and constitutes

FIG. 41.



TRANSVERSE SECTION THROUGH THE POSTERIOR PART OF THE
HEAD OF AN EMBRYO CHICK OF THIRTY HOURS.

hb. hind-brain; *vg.* vagus nerve; *ep.* epiblast; *ch.* notochord; *x.* thickening of hypoblast (possibly a rudiment of the sub-notochordal rod); *al.* throat; *ht.* heart; *pp.* body cavity; *so.* somatic mesoblast; *sf.* splanchnic mesoblast; *hy.* hypoblast.

a crest attached to the roof of the brain, while its two laminæ become fused.

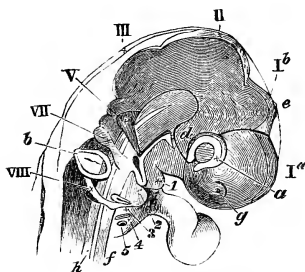
Anteriorly, the neural crest extends as far as the roof of the mid-brain. The pairs of nerves which undoubtedly grow out from it are the fifth pair, the seventh and auditory (as a single root), the glosso-pharyngeal and the various elements of the vagus (as a single root).

After the roots of these nerves have become established, the crest connecting them becomes partially obliterated. The roots themselves grow centrifugally, and eventually give rise to the whole of each of the cranial nerves. Each complete root develops a ganglionic enlargement near its base, and (with the exception of the third nerve) is distributed to one of the visceral arches, of which we shall say more hereafter. The primitive attachment of the nerves is to the roof of the brain, but in most instances this attachment is replaced by a secondary attachment to the sides or floor.

The rudiments of four cranial nerves, of which two lie in front of and two behind the auditory vesicle, are easily seen during the third day at the sides of the hind-brain. They form a series of four small opaque masses, somewhat pearshaped, with the stalk directed away from the middle line.

The most anterior of these is the rudiment of the fifth nerve (Figs. 42 and 67, V). Its narrowed outer portion or stalk divides into two bands or nerves. Of these one passing towards the eye terminates at present in the immediate neighbourhood of that organ. The other branch (the rudiment of the inferior maxillary

FIG. 42.



HEAD OF AN EMBRYO CHICK OF THE THIRD DAY (SEVENTY-FIVE HOURS) VIEWED SIDEWAYS AS A TRANSPARENT OBJECT. (From Huxley.)

Ia. cerebral hemispheres. *Ib.* vesicle of the third ventricle. *II.* mid-brain. *III.* hind-brain. *g.* nasal pit. *a.* optic vesicle. *b.* otic vesicle. *d.* infundibulum. *e.* pineal body. *h.* notochord. *V.* fifth nerve. *VII.* seventh nerve. *VIII.* united glossopharyngeal and pneumogastric nerves. *1, 2, 3, 4, 5* the five visceral folds.

branch of the fifth nerve) is distributed to the first visceral arch.

The second mass (Figs. 42 and 67, *VII*) is the rudiment of the seventh, or facial nerve, and of the auditory nerve. It is the nerve of the second visceral arch.

The two masses behind the auditory vesicle represent the glossopharyngeal and pneumogastric nerves (Fig. 42, *VIII*, Fig. 67, *G. Ph.* and *Pg.*). At first united, they subsequently become separate. The glossopharyngeal supplies the third arch, and the pneumogastric the fourth and succeeding arches.

The later development of the cranial nerves has only been partially worked out, and we will confine ourselves here to a very

brief statement of some of the main results arrived at. The outgrowth for the vagus nerve supplies in the embryo the fourth and succeeding visceral arches, and from what we know of it in the lower vertebrate types, we may conclude that it is a compound nerve, composed of as many primitively distinct nerves as there are branches to the visceral arches.

The glossopharyngeal nerve is the nerve supplying the third visceral arch, the homologue of the first branchial arch of Fishes. The development of the hypoglossal nerve is not known, but it is perhaps the anterior root of a spinal nerve. The spinal accessory nerve has still smaller claims than the hypoglossal to be regarded as a true cranial nerve. The primitively single root of the seventh auditory nerves divides almost at once into two branches. The anterior of these pursues a straight course to the hyoid arch and forms the rudiment of the facial nerve, Fig. 67, VII; the second of the two, which is the rudiment of the auditory nerve, develops a ganglionic enlargement, and, turning backwards, closely hugs the ventral wall of the auditory involution. The sixth nerve appears to arise later than the seventh nerve from the ventral part of the hind-brain, and has no ganglion near its root.

Shortly after its development the root of the fifth nerve shifts so as to be attached about half-way down the side of the brain. A large ganglion is developed close to the root, which becomes the Gasserian ganglion. The main branch of the nerve grows into the mandibular arch (Fig. 67), maintaining towards it similar relations to those of the nerves behind it to their respective arches.

An important branch becomes early developed which is directed straight towards the eye (Fig. 67), near which it meets and unites with the third nerve, where the ciliary ganglion is developed. This branch is usually called the ophthalmic branch of the fifth nerve, and may perhaps represent an independent nerve.

Later than these two branches there is developed a third branch, passing the upper process of the first visceral arch. It forms the superior maxillary branch of the adult.

Nothing is known with reference to the development of the fourth nerve.

The history of the third nerve is still imperfectly known. There is developed early on the second day from the neural crest, on the roof of the mid-brain, an outgrowth on each side, very similar to the rudiment of the posterior nerves. This outgrowth is believed by Marshall to be the third nerve, but it must be borne in mind that there is no direct evidence on the point, the fate of the outgrowth in question not having been satisfactorily followed.

At a very considerably later period a nerve may be found *springing from the floor of the mid-brain*, which is undoubtedly the third nerve. If identical with the outgrowth just spoken of, it must have shifted its attachment from the roof to the floor of the brain.

The nerve when it springs from the floor of the brain runs directly backwards till it terminates in the ciliary ganglion, from which two branches to the eye-muscles are given off.

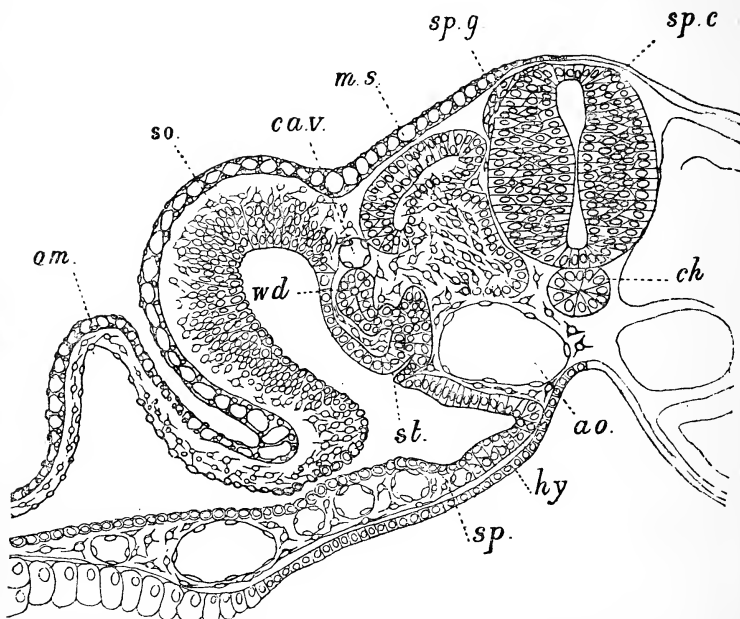
[A. Marshall. "The development of the cranial nerves in the Chick." *Quart. Journal of Microscop. Science*, Vol. XVIII.]

In the case of the spinal nerves the posterior roots originate as outgrowths of a series of median processes of cells, which make their appearance on the dorsal side of the spinal cord. The outgrowths, symmetrically placed on each side, soon take a pyriform aspect, and apply themselves to the walls of the spinal cord. They are represented as they appear in birds in Fig. 43, *sp. g.*, and as they appear in a lower vertebrate form in Fig. 44.

The original attachment of the nerve-rudiment to the medullary wall is not permanent. It becomes, in fact, very soon either extremely delicate or absolutely interrupted.

The nerve-rudiment now becomes divided into three parts, (1) a proximal rounded portion; (2) an enlarged middle portion, forming the rudiment of a ganglion; (3) a distal portion, forming the commencement of the nerve. The proximal portion may very soon be observed to be

FIG. 43.



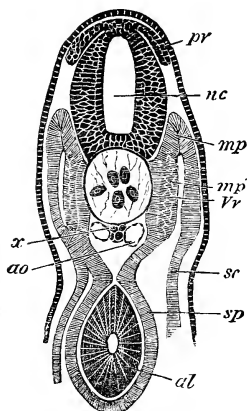
TRANSVERSE SECTION THROUGH THE TRUNK OF A DUCK EMBRYO
WITH ABOUT TWENTY-FOUR MESOBLASTIC SOMITES.

am. amnion; *so.* somatopleure; *sp.* splanchnopleure; *wd.* Wolffian duct; *st.* segmental tube; *ca.v.* cardinal vein; *ms.* muscle-plate; *sp.g.* spinal ganglion; *sp.c.* spinal cord; *ch.* notochord; *ao.* aorta; *hy.* hypoblast.

united with the side of the spinal cord at a very considerable distance from its original point of origin. It is moreover attached, not by its extremity, but by its side.

The above points, which are much more easily studied in some of the lower vertebrate forms than in Birds, are illustrated by the subjoined section of an Elasmobranch embryo, Fig. 45.

FIG. 44.



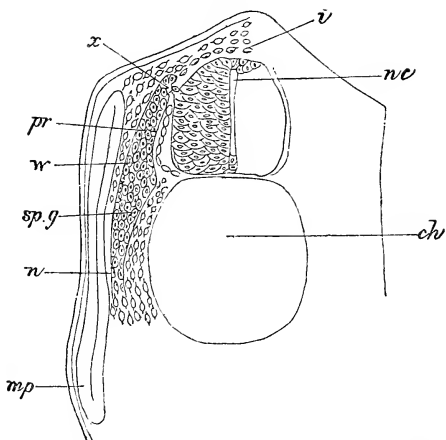
TRANSVERSE SECTION THROUGH THE TRUNK OF A YOUNG EMBRYO
OF A DOG-FISH.

nc. neural canal; *pr.* posterior root of spinal nerve; *x.* sub-notochordal rod; *ao.* aorta; *sc.* somatic mesoblast; *sp.* splanchnic mesoblast; *mp.* muscle-plate; *mp'.* portion of muscle-plate converted into muscle; *Vv.* portion of the vertebral plate which will give rise to the vertebral bodies; *al.* alimentary tract.

It is extremely difficult to decide whether the permanent attachment of the posterior nerve-roots to the spinal cord is entirely a new formation, or merely due to the shifting of the original point of attachment. We are inclined to adopt the former view.

The origin of the anterior roots of the spinal nerves has not as yet been satisfactorily made out in Birds; but it appears probable that they grow from the ventral corner of the spinal cord, considerably later than the posterior roots, as a number of strands for each nerve,

FIG. 45.



SECTION THROUGH THE DORSAL REGION OF AN EMBRYO DOG-FISH.

pr. posterior root; *sp.g.* spinal ganglion; *n.* nerve; *x.* attachment of ganglion to spinal cord; *nc.* neural canal; *mp.* muscle-plate; *ch.* notochord; *i.* investment of spinal cord.

which subsequently join the posterior roots below the ganglia. The shape of the root of a completely formed spinal nerve, as it appears in an embryo of the fourth day, is represented in Fig. 68.

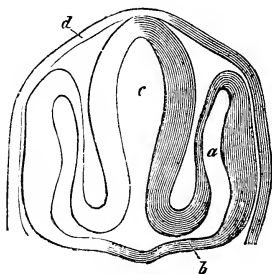
The Eye. In the preceding chapter we saw how the first cerebral vesicle, by means of lateral outgrowths followed by constrictions, gave rise to the optic vesicles. These and the parts surrounding them undergo on the third day changes which result in the formation of the *eyeball*.

At their first appearance the optic vesicles stand out at nearly right angles to the long axis of the embryo (Fig. 27), and the stalks which connect them

with the fore-brain are short and wide. The constrictions which give rise to the stalks take place chiefly from above downwards, and also somewhat inwards and backwards. Thus from the first the vesicles appear to spring from the under part of the fore-brain.

These stalks soon become comparatively narrow, and constitute the rudiments of the optic nerves (Fig. 46 *b*). The constriction to which the stalk or optic

FIG. 46.



SECTION THROUGH THE HEAD OF AN EMBRYO TELEOSTEAN, TO SHEW THE FORMATION OF THE OPTIC VESICLES, ETC. (From Gegenbaur; after Schenk.)

c. fore-brain; *a.* optic vesicle; *b.* stalk of optic vesicle; *d.* epidermis.

nerve is due takes place obliquely downwards and backwards, so that the optic nerves open into the base of the front part of the thalamencephalon (Fig. 46 *b*).

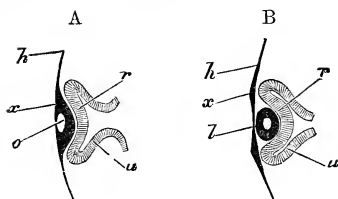
While these changes have been going on in the optic stalks, development has also proceeded in the region of the vesicles themselves, and given rise to the rudiments of the retina, lens, vitreous humour, and other parts of the eye.

Towards the end of the second day the external or superficial epiblast which covers, and is in all but immediate contact with, the most projecting portion of the optic vesicle, becomes thickened. This thickened portion is then driven inwards in the form of a shallow open pit with thick walls (Fig. 47 A, *o*), carrying before it the front wall (*r*) of the optic vesicle. To such an extent does this involution of the superficial epiblast take place, that the front wall of the optic vesicle is pushed close up to the hind wall, and the cavity of the vesicle becomes almost obliterated (Fig. 47, *B*).

The bulb of the optic vesicle is thus converted into a cup with double walls, containing in its cavity the portion of involuted epiblast. This cup, in order to distinguish its cavity from that of the original optic vesicle, is generally called the *secondary optic vesicle*. We may, for the sake of brevity, speak of it as the *optic cup*; in reality it never is a vesicle, since it always remains widely open in front. Of its double walls the inner or anterior (Fig. 47 *B*, *r*) is formed from the front portion, the outer or posterior (Fig. 47 *B*, *u*) from the hind portion of the wall of the primary optic vesicle. The inner or anterior (*r*), which very speedily becomes thicker than the other, is converted into the retina; in the outer or posterior (*u*), which remains thin, pigment is eventually deposited, and it ultimately becomes the tessellated pigment-layer of the choroid.

By the closure of its mouth the pit of involuted epiblast becomes a completely closed sac with thick walls and a small central cavity (Fig. 47 *B*, *l*). At the same time it breaks away from the external epi-

FIG. 47.



DIAGRAMMATIC SECTIONS ILLUSTRATING THE FORMATION OF THE EYE. (After Remak.)

In *A*, the thin superficial epiblast *h* is seen to be thickened at *x*, in front of the optic vesicle, and involuted so as to form a pit *o*, the mouth of which has already begun to close in. Owing to this involution, which forms the rudiment of the lens, the optic vesicle is doubled in, its front portion *r* being pushed against the back portion *u*, and the original cavity of the vesicle thus reduced in size. The stalk of the vesicle is shewn as still broad.

In *B*, the optic vesicle is still further doubled in so as to form a cup with a posterior wall *u* and an anterior wall *r*. In the hollow of this cup lies the lens *l*, now completely detached from the superficial epiblast *x*. Its cavity is still shewn. The cavity of the stalk of the optic vesicle is already much narrowed.

blast, which forms a continuous layer in front of it, all traces of the original opening being lost. There is thus left lying in the cup of the secondary optic vesicle, an isolated elliptical mass of epiblast. This is the rudiment of the *lens*. The small cavity within it speedily becomes still less by the thickening of the walls, especially of the hinder one.

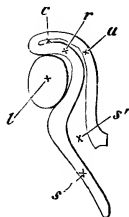At its first appearance the lens is in immediate contact with the anterior wall of the secondary optic vesicle (Fig. 47 *B*). In a short time, however, the lens

is seen to lie in the mouth of the cup (Fig. 50 A), a space (*vh*) (which is occupied by the vitreous humour) making its appearance between the lens and anterior wall of the vesicle.

In order to understand how this space is developed, the position of the optic vesicle and the relations of its stalk must be borne in mind.

The vesicle lies at the side of the head, and its stalk is directed downwards, inwards and backwards. The stalk in fact slants away from the vesicle. Hence when the involution of the lens takes place, the direction in which the front wall of the vesicle is pushed in is not in a line with the axis of the stalk, as for simplicity's sake has been represented in the diagram Fig. 47, but forms an obtuse angle with that axis, after the manner of Fig. 48, where *s'* represents the cavity

FIG. 48.



DIAGRAMMATIC SECTION OF THE EYE AND THE OPTIC NERVE
AT AN EARLY STAGE (from Lieberkühn),

to shew the lens *l* occupying the whole hollow of the optic cup, the inclination of the stalk *s* to the optic cup, and the continuity of the cavity of the stalk *s'* with that of the primary vesicle *c*; *r*, anterior, *u* posterior wall of the optic cup.

of the stalk leading away from the almost obliterated cavity of the primary vesicle.

Fig. 48 represents the early stage at which the lens fills the whole cup of the secondary vesicle. The subsequent state of affairs is brought about through the growth of the walls of the cup taking place more rapidly than that of the lens. But this growth or this dilatation does not take place equally in all parts of the cup. The walls of the cup rise up all round except that part of the circumference of the cup which adjoins the stalk. While elsewhere the walls increase rapidly in height, carrying so to speak the lens with them, at this spot, which in the natural position of the eye is on its under surface, there is no growth: the wall is here imperfect, and a gap is left. Through this gap, which afterwards receives the name of the *choroidal fissure*, a way is open from the mesoblastic tissue surrounding the optic vesicle and stalk into the interior of the cavity of the cup.

From the manner of its formation the gap or fissure is evidently in a line with the axis of the optic stalk, and in order to be seen must be looked for on the under surface of the optic vesicle. In this position it is readily recognized in the transparent embryo of the third day, Figs. 37 and 48.

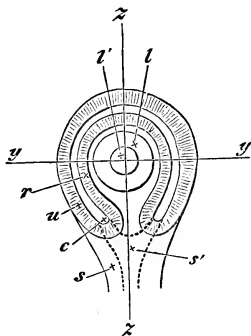
Bearing in mind these relations of the gap to the optic stalk, the reader will understand how sections of the optic vesicle at this stage present very different appearances according to the plane in which the sections are taken.

When the head of the chick is viewed from underneath as a transparent object the eye presents very

much the appearance represented in the diagram Fig. 49.

A section of such an eye taken along the line y , perpendicular to the plane of the paper, would give a figure corresponding to that of Fig. 50 A. The lens, the cavity and double walls of the secondary vesicle, and the remains of the primary cavity, would all be repre-

FIG. 49.



DIAGRAMMATIC REPRESENTATION OF THE EYE OF THE CHICK OF ABOUT THE THIRD DAY AS SEEN WHEN THE HEAD IS VIEWED FROM UNDERNEATH AS A TRANSPARENT OBJECT.

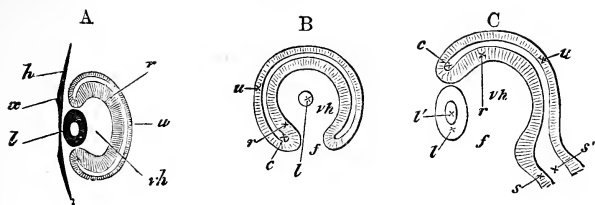
l the lens, l' the cavity of the lens, lying in the hollow of the optic cup.

r the anterior, u the posterior wall of the optic cup, c the cavity of the primary optic vesicle, now nearly obliterated. By inadvertence u has been drawn thicker than r , it should have been thinner throughout.

s the stalk of the optic cup with s' its cavity, at a lower level than the cup itself and therefore out of focus; the dotted line indicates the continuity of the cavity of the stalk with that of the primary vesicle.

The line z, z , through which the section shewn in Fig. 50 C is supposed to be taken, passes through the choroidal fissure.

FIG. 50.



- A. Diagrammatic section taken perpendicular to the plane of the paper, along the line y, y , Fig. 49. The stalk is not seen, the section falling quite out of its region. vh , hollow of optic cup filled with vitreous humour; other letters as in Fig. 47 B.
- B. Section taken parallel to the plane of paper through Fig. 49, so far behind the front surface of the eye as to shave off a small portion of the posterior surface of the lens l , but so far in front as not to be carried at all through the stalk. Letters as before; f , the choroidal fissure.
- C. Section along the line z, z , perpendicular to the plane of the paper, to shew the choroidal fissure f , and the continuity of the cavity of the optic stalk with that of the primary optic vesicle. Had this section been taken a little to either side of the line z, z , the wall of the optic cup would have extended up to the lens below as well as above. Letters as above.

sented (the superficial epiblast of the head would also be shewn); but there would be nothing seen of either the stalk or the fissure. If on the other hand the section were taken in a plane parallel to the plane of the paper, at some distance above the level of the stalk, some such figure would be gained as that shewn in Fig. 50 B. Here the fissure f is obvious, and the communication of the cavity vh of the secondary vesicle with the outside of the eye evident; the section of course would not go through the superficial epiblast.

Lastly, a section, taken perpendicular to the plane of the paper along the line *z*, *i.e.* through the fissure itself, would present the appearances of Fig. 50 C, where the wall of the vesicle is entirely wanting in the region of the fissure marked by the position of the letter *f*. The external epiblast has been omitted in the figure.

The fissure such as we have described it exists for a short time only. Its lips come into contact, and unite (in the neighbourhood of the lens, directly, but in the neighbourhood of the stalk, by the intervention of a structure which we shall describe presently), and thus the cup-like cavity of the secondary optic vesicle is furnished with a complete wall all round. The interior of the cavity is filled by the vitreous humour, a clear fluid in which are a few scattered cells.

With reference to the above description, two points require to be noticed. Firstly it is extremely doubtful whether the invagination of the secondary optic vesicle is to be viewed as an actual mechanical result of the ingrowth of the lens. Secondly it seems probable that the choroid fissure is not simply due to a deficiency in the growth of part of the walls of the secondary optic cup, but is partly due to a more complicated inequality of growth resulting in a doubling up of the primary vesicle from the side along the line of the fissure, at the same time that the lens is being thrust in in front. In Mammalia, the doubling up involves the optic stalk, which becomes flattened (whereby its original cavity is obliterated) and then folded in on itself, so as to embrace a new central cavity continuous with the cavity of the vitreous humour.

During the changes in the optic vesicle just described, the surrounding mesoblast takes on the characters of a distinct investment, whereby the outline of

the eyeball is definitely formed. The internal portions of this investment, nearest to the retina, become the *choroid* (i.e. the *chorio-capillaris*, and the *lamina fusca*, the pigment epithelium, as we have seen, being derived from the epiblastic optic cup), and pigment is subsequently deposited in it. The remaining external portion of the investment forms the *sclerotic*.

The complete differentiation of these two coats of the eye does not however take place till a late period.

In front of the optic cup the mesoblastic investment grows forwards, between the lens and the superficial epiblast, and so gives rise to the substance of the cornea; the epiblast supplying only the anterior epithelium.

We may now proceed to give some further details with reference to the histological differentiation of the parts, whose general development has been dealt with in the preceding pages.

The histological condition of the eye in its earliest stages is very simple. Both the epiblast forming the walls of the optic vesicle, and the superficial layer which is thickened to become the lens, are composed of simple columnar cells. The surrounding mesoblast is made up of cells whose protoplasm is more or less branched and irregular. These simple elements are gradually modified into the complicated tissues of the adult eye, the changes undergone being most marked in the cases of the retina, the optic nerve, and the lens with its appendages.

The optic vesicle. We left the original cavity of the primary optic vesicle as a nearly obliterated space

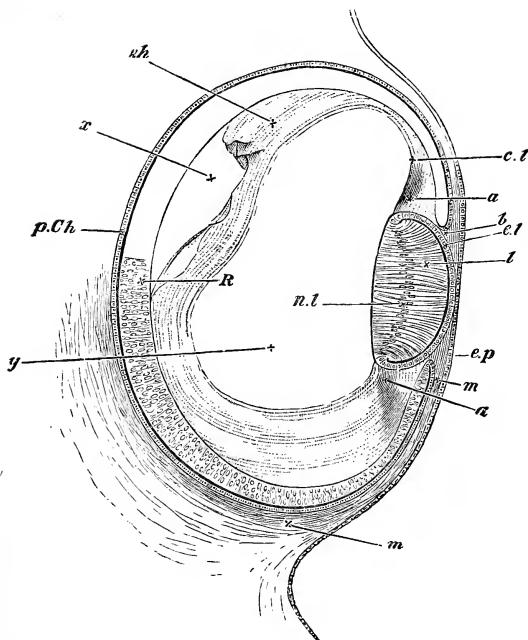
between the two walls of the optic cup. By the end of the third day the obliteration is complete, and the two walls are in immediate contact.

The inner or anterior wall is, from the first, thicker than the outer or posterior; and over the greater part of the cup this contrast increases with the growth of the eye, the anterior wall becoming markedly thicker and undergoing changes of which we shall have to speak directly (Fig. 51).

In the front portion however, along, so to speak, the lip of the cup, anterior to a line which afterwards becomes the ora serrata, both layers not only cease to take part in the increased thickening, accompanied by peculiar histological changes, which the rest of the cup is undergoing, but also completely coalesce together. Thus a hind portion or true retina is marked off from a front portion.

The front portion, accompanied by the choroid which immediately overlays it, is, behind the lens, thrown into folds, the ciliary ridges; while further forward it bends in between the lens and the cornea to form the iris. The original wide opening of the optic cup is thus narrowed to a smaller orifice, the pupil; and the lens, which before lay in the open mouth, is now inclosed in the cavity of the cup. While in the hind portion of the cup, or retina proper, no deposit of black pigment takes place in the layer formed out of the inner or anterior wall of the vesicle, in the front portion we are speaking of, pigment is largely deposited throughout both layers, so that eventually this portion seems to become nothing more than a forward prolongation of the pigment-epithelium of the choroid.

FIG. 51.



SECTION OF THE EYE OF CHICK AT THE FOURTH DAY.

ep. superficial epiblast of the side of the head.

R. true retina : anterior wall of the optic cup. *p. Ch.* pigment-epithelium of the choroid : posterior wall of the optic cup. *b* is placed at the extreme lip of the optic cup at what will become the margin of the iris.

l. the lens. The hind wall, the nuclei of whose elongated cells are shewn at *nl.*, now forms nearly the whole mass of the lens, the front wall being reduced to a layer of flattened cells *el.*

m. the mesoblast surrounding the optic cup and about to form the choroid and sclerotic. It is seen to pass forward between the lip of the optic cup and the superficial epiblast.

Filling up a large part of the hollow of the optic cup is seen a hyaline mass forming the hyaloid membrane and the coagulum of the vitreous humour. In the neighbourhood of the lens it seems to be continuous as at *c* with the tissue *a*, which in turn is continuous with the mesoblast *m*, and appears to be the rudiment of the capsule of the lens and suspensory ligament.

Thus while the hind moiety of the optic cup becomes the retina proper, including the choroid-pigment in which the rods and cones are imbedded, the front moiety is converted into the ciliary portion of the retina, covering the ciliary processes, and into the uvea of the iris; the bodies of the ciliary processes and the substance of the iris, their vessels, muscles, connective tissue and ramified pigment, being derived from the mesoblastic choroid. The margin of the pupil marks the extreme lip of the optic vesicle, where the outer or posterior wall turns round to join the inner or anterior.

The ciliary muscle and the ligamentum pectinatum are both derived from the mesoblast between the cornea and the iris.

The retina. At first, as we have said, the two walls of the optic cup do not greatly differ in thickness. On the third day the outer or posterior becomes much thinner than the inner or anterior, and by the middle of the fourth day is reduced to a single layer of flattened cells (Fig. 51, *p. Ch.*). At about the 80th hour its cells commence to receive a deposit of pigment, and eventually form the so-called pigmentary epithelium of the choroid; from them no part of the true retina (or no other part of the retina, if the pigment-layer in question be supposed to belong more truly to the retina than to the choroid) is derived.

On the fourth day, the inner (anterior) wall of the optic cup (Fig. 51, *R*) is perfectly uniform in structure, being composed of elongated somewhat spindle-shaped cells, with distinct nuclei. On its external (posterior) surface a distinct cuticular membrane, the *membrana limitans externa*, early appears.

As the wall increases in thickness, its cells multiply rapidly, so that it soon appears to be several cells thick: each cell being however probably continued through the whole thickness of the layer. The wall at this stage corresponds closely in its structure with the brain, of which it may properly be looked upon as part. According to the usual view, which is not however fully supported by recent observations, the retina becomes divided in its subsequent growth into (1) an outer part, corresponding morphologically to the epithelial lining of the cerebro-spinal canal, composed of what may be called the visual cells of the eye, *i. e.* the cells forming the outer granular (nuclear) layer and the rods and cones attached to them; and (2) an inner portion consisting of the inner granular (nuclear) layer, the inner molecular layer, the ganglionic layer and the layer of nerve-fibres corresponding morphologically to the substance of the brain and spinal cord.

The actual development of the retina is not thoroughly understood. According to the usual statements (Kölliker¹) the layer of ganglion cells and the inner molecular layer are first differentiated, while the remaining cells give rise to the rest of the retina proper, and are bounded externally by the *membrana limitans externa*. On the inner side of the ganglionic layer the stratum of nerve-fibres is also very early established. The rods

¹ *Entwick. d. Menschen, etc.*, 1879.

and cones are formed as prolongations or cuticularizations of the cells which eventually form the outer granular layer. The layer of cells external to the molecular layer is not divided till comparatively late into the inner and outer granular (nuclear) layers, and the interposed outer molecular layer.

Löwe¹ has recently written an elaborate paper on this subject in which he arrives at very different results from Kölliker and other observers.

According to him only the outer limbs of the rods and cones, which he holds to be metamorphosed cells, correspond to the epithelial layer of the brain.

The changes described above are confined to that portion of the retina which lies behind the ora serrata. In front of this both walls of the cup coalesce as we have said into a cellular layer in which a deposit of pigment takes place.

At a very early period a membrane appears on the side of the retina adjoining the vitreous humour. This membrane is the hyaloid membrane. It is formed at a time when there is no trace of mesoblastic structures in the cavity of the vitreous humour, and must therefore be regarded as a cuticular deposit of the cells of the optic cup.

The optic nerve. The optic nerves are derived, as we have said, from the at first hollow stalks of the optic vesicles. Their cavities gradually become obliterated by a thickening of the walls, the obliteration proceeding from the retinal end inwards towards the brain. While the proximal ends of the optic stalks are still hollow, the rudiments of the optic chiasma are formed at the roots of the stalks, the fibres of the one stalk growing over into the attachment of the other. The decussation of the fibres would appear

¹ *Archiv für mikr. Anat.* Vol. xv.

to be complete. The fibres arise in the remainder of the nerves somewhat later. At first the optic nerve is equally continuous with both walls of the optic cup; as must of necessity be the case, since the interval which primarily exists between the two walls is continuous with the cavity of the stalk. When the cavity within the optic nerve vanishes, and the fibres of the optic nerve appear, all connection between the outer wall of the optic cup and the optic nerve disappears, and the optic nerve simply perforates the outer wall, remaining continuous with the inner one.

The choroid fissure. During the third day of incubation there passes in through the choroid slit a vascular loop, which no doubt supplies the transuded material for the growth of the vitreous humour. Up to the fifth day this vascular loop is the only structure passing through the choroid slit. On this day however a new structure appears, which remains permanently through life, and is known as the pecten. It consists of a lamellar process of the mesoblast cells round the eye, passing through the choroid slit near the optic nerve, and enveloping part of the afferent branch of the vascular loop above mentioned. The proximal part of the free edge of the pecten is somewhat swollen, and sections through this part have a club-shaped form. On the sixth day the choroid slit becomes rapidly closed, so that at the end of the sixth day it is reduced to a mere seam. There are however two parts of this seam where the edges of the optic cup have not coalesced. The proximal of these adjoins the optic nerve, and permits the passage of the pecten, and at a later period of the optic nerve; and the second or distal

one is placed near the ciliary edge of the slit, and is traversed by the efferent branch of the above-mentioned vascular loop. This vessel soon atrophies, and with it the distal opening in the choroid slit completely vanishes. In some varieties of domestic Fowl (Lieberkühn) the opening however persists. The seam which marks the original site of the choroid slit is at first conspicuous by the absence of pigment, and at a later period by the deep colour of its pigment. Finally, a little after the ninth day, no trace of it is to be seen.

Up to the eighth day the pecten remains as a simple lamina; by the tenth or twelfth day it begins to be folded or rather puckered, and by the seventeenth or eighteenth day it is richly pigmented, and the puckerings have become nearly as numerous as in the adult, there being in all seventeen or eighteen. The pecten is now almost entirely composed of vascular coils, which are supported by a sparse pigmented connective tissue; and in the adult the pecten is still extremely vascular. The original artery which became enveloped at the formation of the pecten continues, when the latter becomes vascular, to supply it with blood. The vein is practically a fresh development after the atrophy of the distal portion of the primitive vascular loop of the vitreous humour.

There are no true retinal blood-vessels.

The permanent opening in the choroid fissure for the pecten is intimately related to the entrance of the optic nerve into the eyeball; the fibres of the optic nerve passing in at the inner border of the pecten, coursing along its sides to its outer border, and radi-

ating from it as from a centre to all parts of the retina.

The lens. This when first formed is somewhat elliptical in section with a small central cavity of a similar shape, the front and hind walls being of nearly equal thickness, each consisting of a single layer of elongated columnar cells.

In the subsequent growth of the lens, the development of the hind wall is of a precisely opposite character to that of the front wall. The hind wall becomes much thicker, and tends to obliterate the central cavity by becoming convex on its front surface. At the same time its cells, still remaining as a single layer, become elongated and fibre-like. The front wall on the contrary becomes thinner and thinner and its cells more and more flattened and pavement-like.

These modes of growth continue until at the end of the fourth day, as shewn in Fig. 51, the convex hind wall *l* comes into absolute contact with the front wall *el* and the cavity is thus entirely obliterated. The cells of the hind wall have by this time become veritable fibres, which, when seen in section, appear to be arranged nearly parallel to the optic axis, their nuclei *nl* being seen in a row along their middle. The front wall, somewhat thickened at either side where it becomes continuous with the hind wall, is now a single layer of flattened cells separating the hind wall of the lens, or as we may now say the lens itself, from the front limb of the lens-capsule; of this it becomes the epithelium.

The subsequent changes undergone consist chiefly in the continued elongation and multiplication of the lens-fibres, with the partial disappearance of their nuclei.

During their multiplication they become arranged in the manner characteristic of the adult lens.

The lens capsule is probably formed as a cuticular membrane deposited by the epithelial cells of the lens. But it should be stated that many embryologists regard it as a product of the mesoblast.

The vitreous humour. The vitreous humour is a mesoblastic product, entering the cavity of the optic cup by the choroid slit just spoken of. It is nourished by the vascular ingrowths through the choroid slit. Its exact nature has been much disputed. It arises as a kind of transudation, but frequently however contains blood-corpuscles and embryonic mesoblastic cells. It is therefore intermediate in its character between ordinary intercellular substance, and the fluids contained in serous cavities.

The integral parts of the eye in front of the lens are the cornea, the aqueous humour, and the iris. The development of the latter has already been sufficiently described in connection with the retina, and there remain to be dealt with the cornea, and the cavity containing the aqueous humour.

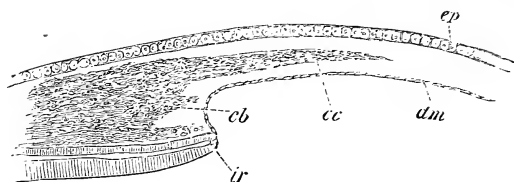
The cornea. The cornea is formed by the coalescence of two structures, viz. the epithelium of the cornea and the cornea proper. The former is directly derived from the external epiblast, which covers the eye after the invagination of the lens. The latter is formed in a somewhat remarkable manner, first clearly made out by Kessler.

When the lens is completely separated from the epidermis the central part of its outer wall remains directly

in contact with the epidermis (future corneal epithelium). At its edge there is a small ring-shaped space bounded by the outer skin, the lens and the edge of the optic cup. There appears, at about the time when the cavity of the lens is completely obliterated, a structureless layer external to the above ring-like space and immediately adjoining the inner face of the epidermis. This layer, which forms the commencement of the cornea proper, at first only forms a ring at the border of the lens, thickest at its outer edge, and gradually thinning away towards the centre. It soon however becomes broader, and finally forms a continuous stratum of considerable thickness, interposed between the external skin and the lens. As soon as this stratum has reached a certain thickness, a layer of flattened cells grows in along its inner side from the mesoblast surrounding the optic cup (Fig. 52, *dm*). This layer is the epithelioid layer of the membrane of Descemet¹. After it has become completely established, the mesoblast around the edge of the cornea becomes divided into two strata; an inner one (Fig. 52 *cb*) destined to form the mesoblastic tissue of the iris already described, and an outer one (Fig. 52 *cc*) adjoining the epidermis. The outer stratum gives rise to the corneal corpuscles, which are the only constituents of the cornea not yet developed. The corneal corpuscles make their way

¹ It appears possible that Lieberkühn may be right in stating that the epithelium of Descemet's membrane grows in between the lens and the epiblast before the formation of the cornea proper, and that Kessler's account, given above, may on this point require correction. From the structure of the eye in some of the lower forms it seems probable that Descemet's membrane is continuous with the choroid.

FIG. 52.



SECTION THROUGH THE EYE OF A FOWL ON THE EIGHTH DAY OF DEVELOPMENT, TO SHEW THE IRIS AND CORNEA IN THE PROCESS OF FORMATION. (After Kessler.)

ep. epiblastic epithelium of cornea ; *cc.* corneal corpuscles growing into the structureless matrix of the cornea ; *dm.* Descemet's membrane ; *ir.* iris ; *cb.* mesoblast of the iris (this reference letter points a little too high).

The space between the layers *dm.* and *ep.* is filled with the structureless matrix of the cornea.

through the structureless corneal layer, and divide it into two strata, one adjoining the epiblast, and the other adjoining the inner epithelium. The two strata become gradually thinner as the corpuscles invade a larger and larger portion of their substance, and finally the outermost portion of each alone remains to form above and below the membrana elastica anterior and posterior (Descemet's membrane) of the cornea. The corneal corpuscles, which have grown in from the sides, thus form a layer which becomes continually thicker, and gives rise to the main substance of the cornea.

Whether the increase in the thickness of the layer is due to the immigration of fresh corpuscles, or to the division of those already there, is not clear. After the

cellular elements have made their way into the cornea, the latter becomes continuous at its edge with the mesoblast which forms the sclerotic.

The derivation of the original structureless layer of the cornea is still uncertain. Kessler derives it from the epiblast, but it appears more probable that Kölliker¹ is right in regarding it as derived from the mesoblast. The grounds for this view are, (1) the fact of its growth inwards from the border of the mesoblast round the edge of the eye, (2) the peculiar relations between it and the corneal corpuscles at a later period. This view would receive still further support if a layer of mesoblast between the lens and the epiblast were really present as believed by Lieberkühn. It must however be admitted that the objections to Kessler's view of its epiblastic nature are rather *a priori* than founded on definite observation.

The observations of Kessler, which have been mainly followed in the above account, are strongly opposed by Lieberkühn and other observers, and are not entirely accepted by Kölliker. It is however especially on the development of these parts in Mammalia (to be spoken of in the sequel) that the above authors found their objections.

The aqueous humour. The cavity for the aqueous humour has its origin in the ring-shaped space round the front of the lens, which, as already mentioned, is bounded by the external skin, the edge of the optic cup, and the lens. By the formation of the cornea this space is shut off from the external skin, and on the appearance of the epithelioid layer of Descemet's membrane a continuous cavity is developed between the cornea and the lens. This cavity enlarges and

¹ L. Kessler, *Zur Entwick. d. Auges d. Wirbelthiere*. Leipzig, 1874. N. Lieberkühn, "Beiträge z. Anat. d. embryonalen Auges," *Archiv f. Anat. u. Phys.*, 1879. Kölliker, *Entwick. d. Menschen, etc.* Leipzig, 1879.

receives its final form upon the full development of the iris.

Summary. We may briefly recapitulate the main facts in the development of the eye as follows.

The eye commences as a lateral outgrowth of the fore-brain, in the form of a stalked vesicle.

The stalk, becoming narrowed and subsequently solid, is converted into the optic nerve.

An involution of the superficial epiblast over the front of the optic vesicle, in the form first of a pit, then of a closed sac with thick walls, and lastly, of a solid rounded mass (the small central cavity being entirely obliterated by the thickening of the hind wall), gives rise to the lens. Coincidentally with this involution of the lens, the optic vesicle is doubled up on itself, and its cavity obliterated; thus a secondary optic vesicle or optic cup with a thick anterior and a thin posterior wall is produced. As a result of the manner in which the doubling up takes place, or of the mode of growth afterwards, the cup of the secondary optic vesicle is at first imperfect along its under surface, where a gap, the choroidal fissure, exists for some little time, but subsequently closes up.

The mesoblast in which the eye is imbedded gathers itself together around the optic cup into a distinct investment, of which the internal layers become the choroid, the external the sclerotic. An ingrowth of this investment between the front surface of the lens and the superficial epiblast furnishes the body of the cornea, the epiblast itself remaining as the anterior corneal epithelium.

The mesoblast entering on the under side through

the choroidal fissure gives rise to the vitreous humour, while at a later stage a definite process of this mesoblast becomes the pecten.

Of the walls of the optic cup, the thinner outer (posterior) wall becomes, behind the line of the ora serrata, the pigment-epithelium of the choroid, while the thicker inner (anterior) wall supplies all the elements of the retina, including the rods and cones which grow out from it into the pigment-epithelium.

In front of the line of the ora serrata, both walls of the optic cup, quite thin and wholly fused together, give rise to the pigment-epithelium of the ciliary processes and iris, the bodies of both these organs being formed from the mesoblastic investment.

Accessory Organs connected with the Eye.

Eyelids. The most important accessory structures connected with the eye are the eyelids. They are developed as simple folds of the integument with a mesoblastic prolongation between their two laminæ. They are three in number, viz. an upper and lower, and a lateral one—the nictitating membrane—springing from the inner or anterior border of the eye. Their inner face is lined by a prolongation of conjunctiva, which is the modified epiblast covering the cornea and part of the sclerotic.

The Lacrymal glands and Lacrymal duct.

The lacrymal glands are formed as solid ingrowths of the conjunctival epithelium. They appear on the eighth day of incubation.

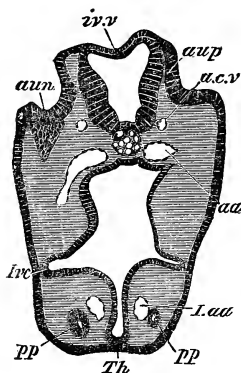
The lacrymal duct begins as a solid ridge of the epidermis, projecting inwards along the line of the so-called lacrymal groove, from the eye to the nasal pit.

At the end of the sixth day this ridge begins to be separated from the epidermis, remaining however united with it on the inner side of the lower eyelid.

After it has become free, it forms a solid cord, the lower end of which unites with the wall of the nasal cavity. The cord so formed gives rise directly to the whole of the duct proper and to the lower branch of the collecting tube. The upper branch of the collecting tube is formed as an outgrowth from it. A lumen begins to be formed in it on the twelfth day of incubation, and first appears at the nasal end. It arises as a space amongst the cells of the cord, but is not due to an absorption of the central cells¹.

Organ of hearing. During the second day the *ear* first made its appearance on either side of the hind-brain as an involution of the external epiblast, thrust down into the mass of mesoblast rapidly developing between the epiblast of the skin and that of the neural

FIG. 53.



SECTION THROUGH THE HEAD OF AN ELASMOBRANCH EMBRYO,
AT THE LEVEL OF THE AUDITORY INVOLUTION.

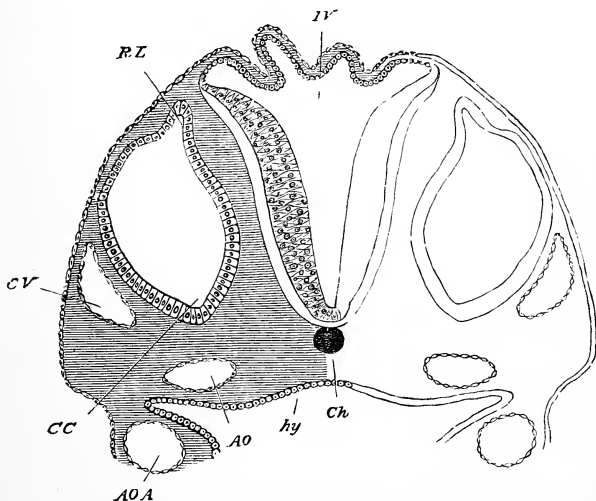
aup. auditory pit; *aun.* ganglion of auditory nerve; *iv.v.* roof of fourth ventricle; *a.c.v.* anterior cardinal vein; *aa.* aorta;

¹ G. Born: "Die Nasenhöhlen u. Thränennasengang d. amnioten Wirbelthiere, I. Lacertilia II. Aves." *Morphologisches Jahrbuch*, Vol. v., 1879.

l.aa. aortic trunk of mandibular arch; *pp.* head cavity of mandibular arch; *lvc.* alimentary pouch which will form the first visceral cleft; *Th.* rudiment of thyroid body.

canal (Fig. 27, *au. p.*). It then had the form of a shallow pit with a widely open mouth, similar in form to that shewn for an embryo dog-fish in Fig. 53, *au. p.* Before the end of the third day, its mouth closes up and all signs of the opening are obliterated. The pit thus becomes converted into a closed vesicle, lined with epiblast, and surrounded by mesoblast. This vesicle is the *otic vesicle*, whose cavity rapidly enlarges while its walls become thickened (Fig. 54, *CC*).

FIG. 54.



SECTION THROUGH THE HIND-BRAIN OF A CHICK AT THE END OF THE THIRD DAY OF INCUBATION.

IV. Fourth ventricle. The section shews the very thin roof and thicker sides of the ventricle.

Ch. Notochord—(diagrammatic shading).

CV. Anterior cardinal or jugular vein.

CC. Involuted auditory vesicle. *CC* points to the end which will form the cochlear canal. *RL.* Recessus labyrinthi. *hy.* hypoblast lining the alimentary canal. *hy* is itself placed in the cavity of the alimentary canal, in that part of the canal which will become the throat. The lower (anterior) wall of the canal is not shewn in the section, but on each side are seen portions of a pair of visceral arches. In each arch is seen the section of the aortic arch *AOA* belonging to the visceral arch. The vessel thus cut through is running upwards towards the head, being about to join the dorsal aorta *AO*. Had the section been nearer the head, and carried through the plane at which the aortic arch curves round the alimentary canal to reach the mesoblast above it, *AOA* and *AO* would have formed one continuous curved space. In sections lower down in the back the two aorta, *AO*, one on either side, would be found fused into one median canal.

The changes by which this simple otic vesicle is converted into the complicated system of parts known as the internal ear, have been much more completely worked out for Mammals than for Birds. We shall therefore reserve a full account of them for a later portion of this work. Meanwhile a brief statement of the essential nature of the changes may be useful; and will be most conveniently introduced here.

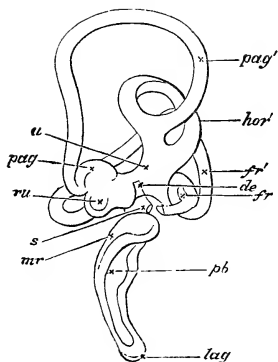
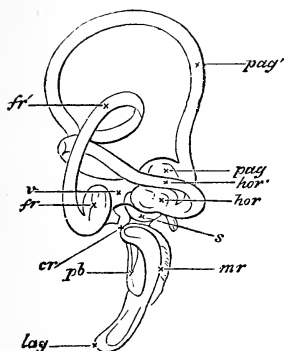
The internal ear consists essentially of an inner *membranous labyrinth* lying loosely in and only partially attached to an outer *osseous labyrinth*.

The membranous labyrinth (Fig. 55) consists of two parts: (1) the *vestibule*, with which are connected three pairs of semicircular canals, *pag'*, *fr'*, *hor'*, and a long narrow hollow process, the *aqueductus* or *recessus vesti-*

A.

FIG. 55.

B.



TWO VIEWS OF THE MEMBRANOUS LABYRINTH OF COLUMBA DOMESTICA (copied from Hasse).

A, from the exterior, B, from the interior.

hor'. horizontal semicircular canal, *hor*. ampulla of ditto, *pag'*. posterior vertical semicircular canal, *pag*. ampulla of ditto, *fr'*. anterior vertical semicircular canal, *fr*. ampulla of ditto, *u*. utricle, *ru*. recessus utriculi, *v*. the connecting tube between the ampulla of the anterior vertical semicircular canal and the utricle, *de*. ductus endolymphaticus (recessus vestibuli), *s*. sacculus hemisphericus, *cr*. canalis reuniens, *lag*. lagena, *mr*. membrane of Reissner, *pb*. Basilar membrane.

buli, and (2) the *ductus cochlearis*, which in birds is a flask-shaped cavity slightly bent on itself, the dilated end of which is called the *lagena*. The several parts of each of these cavities freely communicate, and the two are joined together by a narrow canal, the canalis reuniens, *cr*.

The osseous labyrinth has a corresponding form, and may be similarly divided into parts: into a bony vestibule, with its bony semicircular canals and recessus

vestibuli, and into a bony cochlea; but the junction between the cochlea and the bony vestibule is much wider than the membranous canalis reuniens.

The cavity of the osseous cochlea is partially divided lengthways by the ductus cochlearis into a scala tympani and a scala vestibuli, which do not however extend to the lagena.

The auditory nerve, piercing the osseous labyrinth in various points, is distributed in the walls of the membranous labyrinth.

All these complicated structures are derived from the simple primary otic vesicle and the surrounding mesoblast by changes in its form and differentiation of its walls. All the epiblast of the vesicle goes to form the epithelium of the membranous labyrinth, whose cavity, filled with endolymph, represents the original cavity which was first open to the surface but subsequently covered in. It gradually attains its curiously twisted form by a series of peculiar processes of unequal growth in the, at first, simple walls of the vesicle. The corium of the membranous labyrinth, and all the tissues of the osseous labyrinth, are developed out of the mesoblastic investment of the vesicle. The space between the osseous and membranous labyrinths, including the scala vestibuli and scala tympani, may be regarded as essentially a series of lymphatic cavities hollowed out in the mesoblast.

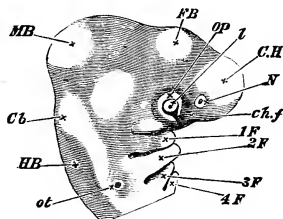
It will be seen then that the ear, while resembling the eye in so far as the peculiar structures in which the sensory nerve in each case terminates are formed of involuted epiblast, differs from it inasmuch as it arises by an independent involution of the superficial epiblast,

whereas the eye is a constricted portion of the general involution which gives rise to the central nervous system.

The origin of the auditory nerve has already been described. It is shewn in close contact with the walls of the auditory pit in Fig. 53.

Organ of Smell. The organ of smell makes its appearance during the third day, as two depressions or pits, on the under surface of the head, a little in front of the eye (Fig. 56, *N*).

FIG. 56.



HEAD OF AN EMBRYO CHICK OF THE THIRD DAY VIEWED
SIDEWAYS AS AN OPAQUE OBJECT.

(Chromic acid preparation.)

C.H. Cerebral hemispheres. *F.B.* Vesicle of third ventricle.

M.B. Mid-brain. *CB.* Cerebellum. *H.B.* Medulla oblongata.

N. Nasal pit. *ot.* otic vesicle in the stage of a pit with the opening not yet closed up. *op.* Optic vesicle, with *l.* lens and *ch.f.* choroidal fissure. The superficial epiblast moulds itself to the form of the optic vesicle and the lens; hence the choroidal fissure, though formed entirely underneath the superficial epiblast, is distinctly visible from the outside.

1 F. The first visceral fold; above it is seen a slight indication of the superior maxillary process.

2, 3, 4 F. Second, third and fourth visceral folds, with the visceral clefts between them.

Like the lens and the labyrinth of the ear, they are formed from the external epiblast; unlike them they are never closed up.

The olfactory nerves arise as outgrowths of the front end of the cerebral hemispheres, before any trace of a special division of the brain, forming an olfactory lobe, has become established. Their peripheral extremities unite with the walls of the olfactory pits during the third day. The olfactory lobes arise as outgrowths of the cerebral hemispheres on the seventh day of incubation.

Visceral Arches and Visceral Clefts. It must be borne in mind that, especially in the early stages of development, owing to the very unequal growth of different parts, the relative position of the various structures is continually shifting. This is very well seen in the instance of the heart. At its first appearance, the heart is lodged immediately beneath the extreme front of the alimentary canal, so far forwards as to underlie that portion of the medullary canal which will form the brain. It is, in fact, at that epoch a part of the head. From that early position it gradually recedes farther and farther backward, until, at the end of the third day, a considerable interval is observed between it and the actual head. In other words, a distinct neck has been formed, in which most important changes take place.

The neck is distinguished from the trunk in which the heart now lies by the important feature that in it there is no cleavage of the mesoblast into somatopleure and splanchnopleure, and consequently no pleuroperitoneal cavity. In passing from the exterior into the ali-

mentary canal, the three layers of the blastoderm are successively traversed, without any breach of continuity, save such as is caused by the cavities of the blood-vessels. In this neck, so constituted, there appear on the third day certain fissures or clefts, the *visceral* or *branchial clefts*. These are real clefts or slits passing right through the walls of the throat, and are placed in series on either side across the axis of the alimentary canal, lying not quite at right angles to that axis and parallel to each other, but converging somewhat to the middle of the throat in front (Fig. 56). Viewed from the outside in either fresh or preserved embryos they are not very distinctly seen to be clefts; but when they are seen from within, after laying open the throat, their characters as elongated oval slits can easily be recognised.

Four in number on either side, the most anterior is the first to be formed, the other three following in succession. Their formation takes place from within outwards. The hypoblast is pushed outwards as a pouch, which grows till it meets the epiblast, which is then broken through, while the hypoblast forms a junction with the epiblast at the outside of the throat.

No sooner has a cleft been formed than its anterior border (*i.e.* the border nearer the head) becomes raised into a thick lip or fold, the *visceral* or *branchial fold*. Each cleft has its own fold on its anterior border, and in addition the posterior border of the fourth or last visceral cleft is raised into a similar fold. There are thus *five* visceral folds to *four* visceral clefts (Fig. 56). The last two folds however, and especially the last, are not nearly so thick and prominent as the other three, the second

being the broadest and most conspicuous of all. The first fold meets, or nearly meets, its fellow in the middle line in front, but the second falls short of reaching the middle line, and the third, fourth and fifth do so in an increasing degree. Thus in front views of the neck a triangular space with its apex directed towards the head is observed between the ends of the several folds.

Into this space the pleuroperitoneal cavity extends, the somatopleure separating from the splanchnopleure along the ends of the folds; and it is here that the aorta plunges into the mesoblast of the body.

The visceral clefts and arches to a large extent disappear in the adult, and constitute examples of an interesting class of embryonic organs, whose presence is only to be explained by the fact that, in the ancestors of the types in which they are now developed in the embryo, they performed an important function in the adult. The visceral arches and clefts are in fact the homologues of the branchial arches and branchial clefts of Fishes, which continue to be formed in the embryos of the higher vertebrate types, although they have ceased to serve as organs of respiration. The skeletal structures developed in the visceral arches persist as the jaw-bones and hyoid bone, but the clefts, with the exception of the first, become obliterated.

Of the history of the skeletal elements we shall speak in detail hereafter; meanwhile we may briefly deal with the general history of these parts.

The first fold on either side, increasing rapidly in size and prominence, does not, like the others, remain single, but sends off in the course of the third day a branch or bud-like process from its anterior edge. This

branch, starting from near the dorsal beginning of the fold, runs ventralwards and forwards, tending to meet the corresponding branch from the fold on the other side, at a point in the middle line nearer the front of the head than the junction of the main folds. The two branches do not quite meet, being separated by a median process, which at the same time grows down from the extreme front of the head, and against which they abut. Between the main folds, which are directed somewhat backwards and the branches which slant forwards, a somewhat lozenge-shaped space is developed which, as the folds become more and more prominent, grows deeper and deeper. In the main folds are developed the mandibles, and in the branches the *superior maxillæ*: the lozenge-shaped cavity between them is the cavity of the mouth, and the descending process which helps to complete the upper margin of this cavity is called, from the parts which will be formed out of it, the *fronto-nasal process*.

Part of the mesoblast of the two succeeding pairs of visceral folds is transformed into the hyoid bone, which will be best considered in connection with the development of the skull. The two last arches disappear without giving rise to any permanent structures.

With the exception of the first the visceral clefts become obliterated at an early stage of embryonic life; but the first persists, although it loses all trace of its original branchial function and becomes intimately connected with the organ of hearing, of which in fact it forms a most essential part, becoming converted into the Eustachian tube and tympanic cavity. The outer opening and the outer part also of the cleft become

obliterated at an early date, but from the inner part of the cleft a diverticulum is given off towards the exterior, which becomes the tympanic cavity. The inner part of the cleft itself forms the Eustachian tube, while its mouth forms the oral aperture of this tube.

The meatus auditorius externus first appears as a shallow depression at the region where the closure of the first visceral cleft takes place. It is in part formed by the tissue surrounding this depression growing up in the form of a wall, but the blind end of the meatus also becomes actually pushed in towards the tympanic cavity.

The tympanic membrane is derived from the tissue which separates the meatus auditorius externus from the tympanic cavity. This tissue is obviously constituted of an hypoblastic epithelium on its inner aspect, an epiblastic epithelium on its outer aspect, and a layer of mesoblast between them, and these three layers give rise to the three layers of which this membrane is formed in the adult. During the greater part of foetal life it is relatively very thick, and presents a structure bearing but little resemblance to that in the adult.

The tympanic cavity is bounded on its inner aspect by the osseous investment of the internal ear, but at two points, known as the fenestra ovalis and fenestra rotunda, the bone is deficient and its place is taken by a membrane.

These two fenestræ appear early, and are probably formed by the nonchondrification of a small area of the embryonic cartilage. The upper of the two, or fenestra ovalis, contains the base of a bone, known as the columella. The main part of the columella is

formed of a stalk which is held by Parker to be derived from part of the skeleton of the visceral arches, while the base, forming the stapes, appears to be an independent formation.

The stalk of the columella extends to the tympanic membrane; its outer end becoming imbedded in this membrane, and serving to transmit the vibrations of the membrane to the fluid in the internal ear.

Vascular system. By the end of the second day three pairs of aortic arches had been established in connection with the heart. When the visceral folds and clefts are formed, a definite arrangement between them and the aortic arches is always observed. The first visceral cleft runs between the first and second aortic arches. Consequently the first aortic arch runs in the first visceral fold, and the second in the second. In the same way, the second visceral cleft lies between the second and third aortic arches, the third aortic arch running in the third visceral fold. Each aortic arch runs in the thickened mesoblast of the corresponding fold.

Arrived at the dorsal surface of the alimentary canal, these arches unite at acute angles to form a common trunk, the dorsal aorta (Fig. 57, *A.O.*), which runs along the back immediately under the notochord. The length of this common single trunk is not great, as it soon divides into two main branches, each of which, after giving off the large vitelline artery, *Of.A.*, pursues its course with diminished calibre to the tail, where it is finally lost in the capillaries of that part.

The heart is now completely doubled up on itself. Its mode of curvature is apparently somewhat complicated. Starting from the point of junction of the vitel-

FIG 57.

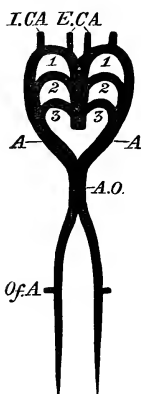


DIAGRAM OF THE ARTERIAL CIRCULATION ON THE
THIRD DAY.

- 1, 2, 3. The first three pairs of aortic arches. *A*. The vessel formed by the junction of the three pairs of arches. *A.O.* Dorsal aorta formed by the junction of the two branches *A* and *A*; it quickly divides again into two branches which pass down one on each side of the notochord. From each of these is given off a large branch *Of.A.*, the vitelline artery. *E.CA*, *I.CA*, external and internal carotid arteries.

line veins (Fig. 37, *Ht*), there is first a slight curvature towards the left; this is followed by a turn to the right, and then the heart is completely bent on itself, so that afterwards it pursues a course directed from behind quite straight forwards (except perhaps for a little inclination to the left) to the point where the aortic arches branch off. In this way, as shewn in section in Fig. 59, *A*, the end of the bulbus arteriosus (*v*) comes to lie just underneath (or in front of according to the position of

the embryo) that part which has already been marked off by the lateral bulgings as the auricular portion (*au*).

That part of the heart which is turned to the right, including the point of doubling up, is the ventricular portion, and is even at this stage separated from the auricular portion by a slight neck. This external constriction corresponds to an internal narrowing of the lumen of the heart, and marks the position of the future *canalis auricularis*.

The ventricular portion is, on the other hand, likewise separated by a fainter constriction from the anterior continuation of the heart which forms the bulbus arteriosus. The projecting part where the doubling takes place is at this stage still quite round; we shall see that later on it becomes pointed and forms the apex of the heart.

The whole venous portion of the heart (if we may so speak of it, though of course at this stage blood of the same quality passes right along the whole cardiac canal) lies in a plane which is more dorsal than the arterial portion. The point at which the venous roots of the heart, *i.e.* the two vitelline trunks, unite into a single canal, is on this day carried farther and farther away from the heart itself. By the end of the day there is a considerable distance between the auricular portion of the actual heart and the point where the venous roots separate, each to pursue its course along the splanchnopleure-fold of its own side. This distance is traversed by a single venous trunk, of which the portion close to the auricles is called the *sinus venosus*, and the more distant the *ductus venosus*. We shall give to the whole trunk the name used by the older observers, the *meatus venosus*.

Small arteries to various parts of the body are now being given off by the aorta and its branches. The capillaries in which these end are gathered into veins which unite to form two main trunks on either side, the *cardinal veins*, anterior and posterior (Fig. 36, Fig. 58

FIG. 58.

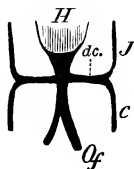


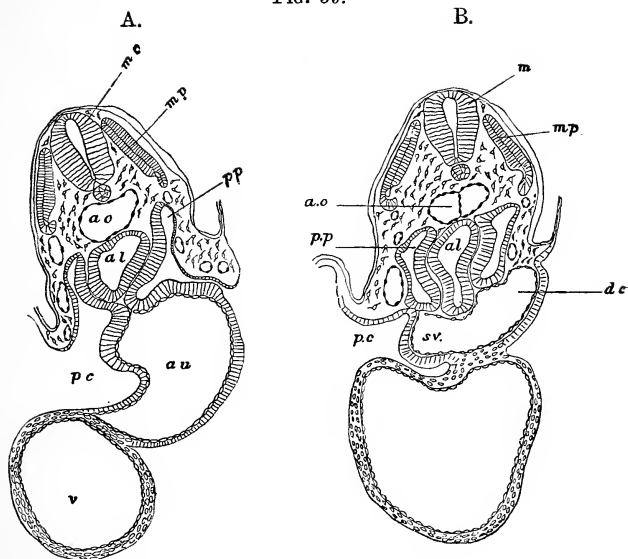
DIAGRAM OF THE VENOUS CIRCULATION ON THE
THIRD DAY.

H. Heart. *J.* Jugular or anterior cardinal vein. *C.* Inferior or posterior cardinal vein. *Of.* Vitelline vein. *dc.* Ductus Cuvieri.

J and *C*), which run parallel to the long axis of the body in the upper part of the mesoblast, a little external to the mesoblastic somites. These veins, which do not attain to any great importance till well on in the third day, unite opposite to the heart, on each side, into a short common trunk at right angles to themselves. The two short trunks thus formed, which bear the name of *ductus Cuvieri* (Fig. 36, Fig. 58, *dc*), running ventralwards and then transversely straight inwards towards the middle line fall into the sinus venosus.

The two ductus Cuvieri pass from the heart to the body walls in a special horizontal mesentery, whose formation and function we shall return to in speaking of the formation of the pericardial cavity. The position of one of them is shewn in section in Fig. 59 B, *dc*.

FIG. 59.



TRANSVERSE SECTIONS THROUGH A CHICK EMBRYO WITH TWENTY-ONE MESOBLASTIC SOMITES TO SHEW THE FORMATION OF THE PERICARDIAL CAVITY, A. BEING THE ANTERIOR SECTION.

pp. body cavity ; *pc.* pericardial cavity ; *al.* alimentary cavity ; *au.* auricle ; *v.* ventricle ; *sv.* sinus venosus ; *dc.* ductus Cuvieri ; *ao.* aorta ; *mp.* muscle-plate ; *mc.* medullary cord.

The alimentary canal. As we stated above, the folding in of the splanchnopleure to form the alimentary canal is proceeding with great rapidity, the tail-fold as well as the head-fold contributing largely to this result.

The formation of the tail-fold is very similar to that of the head-fold. The tail is a solid, somewhat curved, blunt cone of mesoblast, immediately coated with the

superficial epiblast except at the upper surface (corresponding to the back of the embryo), where lies the pointed termination of the neural tube.

So rapid is the closure of the splanchnopleure both in front and behind, that two of the three parts into which the digestive tract may be divided, are brought, on this day, to the condition of complete tubes.

The first division, including the region from the mouth to the duodenum, is completely folded in by the end of the day; so likewise is the third division comprising the large intestine and the cloaca. The middle division, corresponding to the future small intestine, still remains quite open to the yolk-sac below.

The attachment of the newly formed alimentary canal to the body above is at first very broad, and only a thin stratum of mesoblast separates the hypoblast of the canal from the notochord and mesoblastic somites; even that may be absent under the notochord. During the third day, however, along such portions of the canal as have become regularly enclosed, *i.e.* the hinder division and the posterior moiety of the anterior division, the mesoblastic attachment becomes narrower and (in a vertical direction) longer, the canal appearing to be drawn more ventralwards (or according to the position of the embryo forwards), away from the vertebral column.

In what may be regarded as the pleural division of the general pleuroperitoneal space, along that part of the alimentary canal which will form the œsophagus, this withdrawal is very slight (Fig. 59), but it is very marked in the peritoneal space. Here such parts of the digestive canal as are formed come to be suspended from the body above by a narrow flattened band of mesoblas-

tic tissue which reaches from the neighbourhood of the notochord, and becomes continuous with the mesoblastic coating which wraps round the hypoblast of the canal. This flattened band is the *mesentery*, shewn commencing in Fig. 65, and much more advanced in Fig. 68, *M*. It is covered on either side by a layer of flat cells forming the epithelioid lining of the peritoneal membrane, while its interior is composed of indifferent tissue.

The front division of the digestive tract consists of three parts. The most anterior part, the *œsophagus*, still ending blindly in front reaches back as far as the level of the hind end of the heart; and is divided into two regions, viz. an anterior region, characterized by the presence of the visceral clefts, whose development has already been dealt with, and a posterior region without such clefts.

Its transverse section, which up to the end of the second day was somewhat crescent-shaped, with the convexity downwards, becomes on this day more nearly circular. Close to its hinder limit, the lungs (Fig. 60, *lg*), of whose formation we shall speak directly, take their origin.

The portion of the digestive canal which succeeds the *œsophagus*, becomes towards the close of the third day somewhat dilated (Fig. 60, *St*); the region of the *stomach* is thus indicated.

The hinder or pyloric end of the stomach is separated by a very small interval from the point where the complete closing in of the alimentary canal ceases, and where the splanchnopleure-folds spread out over the yolk. This short tract is nevertheless clearly marked out as

FIG. 60.

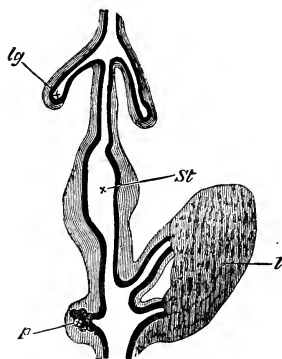


DIAGRAM OF A PORTION OF THE DIGESTIVE TRACT OF A
CHICK UPON THE FOURTH DAY.

(Copied from Götte.)

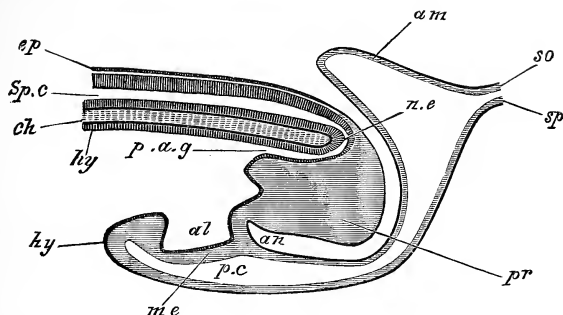
The black inner line represents the hypoblast, the outer shading the mesoblast. *lg.* lung-diverticulum with expanded termination, forming the primary lung-vesicle. *St.* stomach. *z.* two hepatic diverticula with their terminations united by cords of hypoblast cells. *p.* diverticulum of the pancreas with the vesicular diverticula coming from it.

the duodenum by the fact that from it, as we shall presently point out, the rudiments of the ducts of the liver and pancreas are beginning to be formed.

The posterior division of the digestive tract, corresponding to the great intestine and cloaca, is from its very first formation nearly circular in section and of a larger bore than the œsophagus.

During part of the third day the hinder end of this section of the gut is in communication with the neural tube by the neurenteric canal already spoken of (Fig. 61, *ne*). The communication between the two tubes

FIG. 61.



DIAGRAMMATIC LONGITUDINAL SECTION THROUGH THE POSTERIOR END OF AN EMBRYO BIRD, AT THE TIME OF THE FORMATION ON THE ALLANTOIS.

ep. epiblast; *Sp.c.* spinal canal; *ch.* notochord; *n.e.* neurenteric canal; *hy.* hypoblast; *p.a.g.* postanal gut; *pr.* remains of primitive streak folded in on the ventral side; *al.* allantois; *me.* mesoblast; *an.* point where anus will be formed; *p.c.* perivisceral cavity; *am.* amnion; *so.* somatopleure; *sp.* splanchnopleure.

does not last long, but even after its rupture there remains a portion of the canal continuous with the gut; this, however, constitutes a purely embryonic and transient section of the alimentary canal, and is known as the postanal gut. Immediately in front of it is a deep infolding of the epiblast, which nearly meets the hypoblast (Fig. 61, *an*) and forms the rudiment of the anus and of the outer section of the cloaca into which the bursa Fabricii opens in the adult. It is known to embryologists as the *proctodæum*, but does not open into the alimentary tract till considerably later. The

section of the alimentary tract immediately in front of the postanal gut is somewhat enlarged, and becomes the inner section of the adult cloaca receiving the urinary and genital ducts. The allantois, to whose development we shall return directly, opens into it ventrally.

It is to be noted that the two sections of the cloaca of adult birds have a different origin. The inner section being part of the primitive alimentary tract and lined by hypoblast; the outer being part of an involution of the outer skin and lined by epiblast.

The lungs are in their origin essentially buds or processes from the primitive œsophagus.

At a point immediately behind the region of the visceral clefts the cavity of the alimentary canal becomes compressed laterally, and at the same time constricted in the middle so that its transverse section (Fig. 62, 1) is somewhat hourglass-shaped, and shews an upper or dorsal chamber *d*, joining on to a lower or ventral chamber *l* by a short narrow neck.

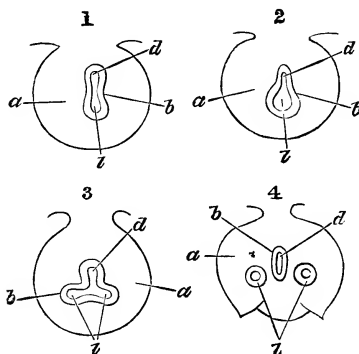
The hinder end of the lower tube enlarges (Fig. 62, 2), and then becomes partially divided into two lobes (Fig. 62, 3). All these parts at first freely communicate, but the two lobes behind, partly by their own growth, and partly by a process of constriction, soon become isolated posteriorly (Fig. 60, *lg*); while in front they open into the lower chamber of the œsophagus.

By a continuation forwards of the process of constriction the lower chamber of the œsophagus, carrying with it the two lobes above mentioned, becomes gradually transformed into an independent tube, opening in front by a narrow slit-like aperture into the œsophagus. The single tube in front is the rudiment of the trachea

and larynx, while the two diverticula behind (Fig. 60, *lg*) become the bronchial tubes and lungs.

While the above changes are taking place in the hypoblastic walls of the alimentary tract, the splanchnic

FIG. 62.



FOUR DIAGRAMS ILLUSTRATING THE FORMATION OF THE LUNGS. (After Götte.)

a. mesoblast ; *b.* hypoblast ; *d.* cavity of digestive canal ; *l.* cavity of the pulmonary diverticulum.

In (1) the digestive canal has commenced to be constricted into a dorsal and ventral canal ; the former the true alimentary canal, the latter the pulmonary tube ; the two tubes communicate with each other in the centre.

In (2) the ventral (pulmonary) tube has become expanded.

In (3) the expanded portion of the tube has become constricted into two tubes, still communicating with each other and with the digestive canal.

In (4) these are completely separated from each other and from the digestive canal, and the mesoblast has also begun to exhibit externally changes corresponding to the internal changes which have been going on.

mesoblast surrounding these structures becomes very much thickened; but otherwise bears no marks of the internal changes which are going on, so that the above formation of the lungs and trachea cannot be seen from the surface. As the paired diverticula of the lungs grow backwards, the mesoblast around them takes however the form of two lobes, into which they gradually bore their way.

The further development of the lungs is, at first, essentially similar to that of a racemose gland. From each primitive diverticulum numerous branches are given off. These branches, which are mainly confined to the dorsal and lateral parts, penetrate into the surrounding mesoblast and continue to give rise to secondary and tertiary branches. At right angles to the finest of these the arborescent branches so characteristic of the avian lung are given off. In the mesoblast around them numerous capillaries make their appearance.

The air sacs, which form such important adjuncts of the avian lungs, are the dilated extremities of the primary pulmonary diverticula and of their main branches.

The whole pulmonary structure is therefore the result of the growth by budding of a system of branched hypoblastic tubes in the midst of a mass of mesoblastic tissue, the hypoblastic elements giving rise to the epithelium of the tubes and the mesoblast providing the elastic, muscular, cartilaginous, connective and other tissues of the tracheal and bronchial walls.

The liver is the first formed chylopoietic appendage of the digestive canal, and arises between the 55th and

60th hour as a couple of diverticula one from either side of the duodenum immediately behind the stomach (Fig. 60, *l*). These diverticula are of course lined by hypoblast. The right one is, in all cases, from the first longer, but of smaller diameter than the left. Situated a little behind the heart, they embrace between them the two vitelline veins forming the roots of the meatus venosus.

The diverticula soon give rise to numerous hollow branches or processes, which extend into the surrounding mesoblast.

Towards the end of the third day there may further be observed in the greatly thickened mesoblastic investment of either diverticulum a number of cylindrical solid cords of hypoblast which are apparently outgrowths from the hypoblast of the branches of the diverticula. These cylinders rapidly increase in number, apparently by a process of sprouting, and their somewhat swollen peripheral extremities come into contact and unite. And thus, about the ninetieth hour, a sort of network of solid thick strings of hypoblastic cells is formed, the mesoblast in the meshes of the network becoming at the same time largely converted into blood-vessels. Each diverticulum becomes in this way surrounded by a thick mass composed partly of solid cylinders, and to a less extent of hollow processes, continuous with the cylinders on the one hand, and the main diverticulum on the other, all knit together with commencing blood-vessels and unchanged mesoblastic tissue. Between the two masses runs the now fused roots of the meatus venosus with which the blood-vessels in each mass are connected.

Early on the fourth day each mass sends out ventral to the meatus venosus a solid projection of hypoblastic cylinders towards its fellow, that from the left side being much the longest. The two projections unite and form a long solid wedge, which passes obliquely down from the right (or from the embryo lying on its left side, the upper) mass to the left (or lower) one. In this new wedge may be seen the same arrangement of a network of hypoblastic cylinders filled in with vascular mesoblast as in the rest of the liver. The two original diverticula with their investing masses represent respectively the right and left lobes of the liver, and the wedge-like bridge connecting them is the middle lobe.

During the fourth and fifth days the growth of the solid, lobed liver thus formed is very considerable; the hypoblastic cylinders multiply rapidly, and the network formed by them becomes very close, the meshes containing little more than blood-vessels. The hollow processes of the diverticula also ramify widely, each branch being composed of a lining of hypoblast enveloped in a coating of spindle-shaped mesoblastic cells. The blood-vessels are in direct connection with the meatus venosus—have become, in fact, branches of it. It may soon be observed, that in those vessels which are connected with the posterior part of the liver (Fig. 74), the stream of blood is directed from the meatus venosus into the network of the liver. In those connected with the anterior part the reverse is the case; here the blood flows from the liver into the meatus venosus. The thick network of solid cylinders represents the hepatic parenchyma of the adult liver, while the hollow processes of the diverticula are the rudiments of the biliary ducts; and we may suppose

each solid cylinder to represent a duct with its lumen almost, but perhaps not quite, completely obliterated.

During the fifth day, a special sac or pouch is developed from the right primary diverticulum. This pouch, consisting of an inner coat of hypoblast, and an outer of mesoblast, is the rudiment of the gall-bladder.

The Pancreas arises nearly at the same time as the liver in the form of an almost solid outgrowth from the dorsal side of the intestine nearly opposite but slightly behind the hepatic outgrowths (Fig. 60, *p*). Its blind end becomes somewhat enlarged and from it numerous diverticula grow out into the passive splanchnic mesoblast.

As the ductules grow longer and become branched, vascular processes grow in between them, and the whole forms a compact glandular body in the mesentery on the dorsal side of the alimentary tract. The primitive outgrowth elongates and assumes the character of a duct.

On the sixth day a new similar outgrowth from the duodenum takes place between the primary diverticulum and the stomach. This, which ultimately coalesces with its predecessor, gives rise to the second duct, and forms a considerable part of the adult pancreas. A third duct is formed at a much later period.

The Thyroid body. The thyroid body arises at the end of the second or beginning of the third day as an outgrowth from the hypoblast of the ventral wall of the throat opposite the point of origin of the anterior aortic arch. It has at first the form of a groove extending forwards up to the future mouth, and in its front part extending ventrally to the epiblast. It has not been made out whether the whole groove becomes converted into the permanent thyroid. By the fourth day it becomes a solid mass of cells, and by the fifth ceases to be connected

with the epithelium of the throat, becoming at the same time bilobed. By the seventh day it has travelled somewhat backwards, and the two lobes have completely separated from each other. By the ninth day the whole is invested by a capsule of connective tissue, which sends in septa dividing it into a number of lobes or solid masses of cells, and by the sixteenth day its two lobes are composed of a number of follicles, each with a 'membrana propria,' and separated from each other by septa of connective tissue, much as in the adult¹.

The spleen. Although the spleen cannot be reckoned amongst the glands of the alimentary tract its development may conveniently be dealt with here. It is formed shortly after the first appearance of the pancreas, as a thickening of the mesentery of the stomach (mesogastrium) and is therefore entirely a mesoblastic structure. The mass of mesoblast which forms the spleen becomes early separated by a groove on the one side from the pancreas and on the other from the mesentery. Some of its cells become elongated, and send out processes which, uniting with like processes from other cells, form the trabecular system. From the remainder of the tissue are derived the cells of the spleen pulp, which frequently contain more than one nucleus. Especial accumulations of these take place at a later period to form the so-called Malpighian corpuscles of the spleen.

The Allantois. We have already had occasion to point out that the allantois is essentially a diverticulum of the alimentary tract into which it opens immediately in front of the anus. Its walls are formed of vascular splanchnic mesoblast, within which is a lining of hypoblast. It becomes a conspicuous object on the third day of incubation, but its first development takes place at an earlier period, and is intimately connected with the formation of the posterior section of the gut.

At the time of the folding in of the hinder end of

¹ Müller *Ueber die Entwicklung der Schilddrüse*. Jenaische Zeitschrift, 1871.

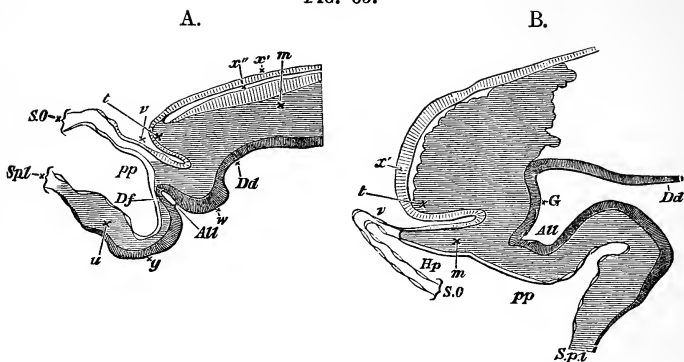
the gut the splitting of the mesoblast into somatopleure and splanchnopleure has extended up to the border of the hinder division of the primitive streak. The ventral wall of what we have already termed the postanal section of the alimentary tract is formed by the primitive streak. Immediately in front of this is the involution which forms the proctodæum; while the wall of the hindgut in front of the proctodæum owes its origin to a folding in of the splanchnopleure.

The allantois first appears as a narrow diverticulum formed by a special fold of the splanchnopleure just in front of the proctodæum. This protuberance arises, however, before the splanchnopleure has begun to be tucked in so as to form the ventral wall of the hindgut; and it then forms a diverticulum (Fig. 63 A, *All*) the open end of which is directed forward, while its blind end points somewhat dorsalwards and towards the peritoneal space behind the embryo.

As the hindgut becomes folded in the allantois shifts its position, and forms (Figs. 63 B and 61) a rather wide vesicle lying immediately ventral to the hind end of the digestive canal, with which it communicates freely by a still considerable opening; its blind end projects into the pleuroperitoneal cavity below.

Still later the allantois grows forward, and becomes a large spherical vesicle, still however remaining connected with the cloaca by a narrow canal which forms its neck or stalk (Fig. 9 G, *al*). From the first the allantois lies in the pleuroperitoneal cavity. In this cavity it grows forwards till it reaches the front limit of the hindgut, where the splanchnopleure turns back to enclose the yolk-sac. It does not during the third

FIG. 63.



TWO LONGITUDINAL SECTIONS OF THE TAIL-END OF AN EMBRYO CHICK TO SHEW THE ORIGIN OF THE ALLANTOIS. A AT THE BEGINNING OF THE THIRD DAY; B AT THE MIDDLE OF THE THIRD DAY. (After Dobrynin.)

t. the tail; *m.* the mesoblast; *x'.* the epiblast; *x''.* the neural canal; *Dd.* the dorsal wall of the hindgut; *SO.* somatopleure; *Spl.* splanchnopleure; *u.* the mesoblast of the splanchnopleure carrying the vessels of the yolk-sac; *pp.* pleuroperitoneal cavity; *Df.* the epithelium lining the pleuroperitoneal cavity; *All.* the commencing allantois; *w.* projection formed by anterior and posterior divisions of the primitive streak; *y.* hypoblast which will form the ventral wall of the hindgut; *v.* anal invagination (proctodæum); *G.* cloaca.

day project beyond this point; but on the fourth day begins to pass out beyond the body of the chick, along the as yet wide space between the splanchnic and somatic stalks of the embryo, on its way to the space between the external and internal folds of the amnion, which it will be remembered, is directly continuous with the pleuroperitoneal cavity (Fig. 9 K). In this space it

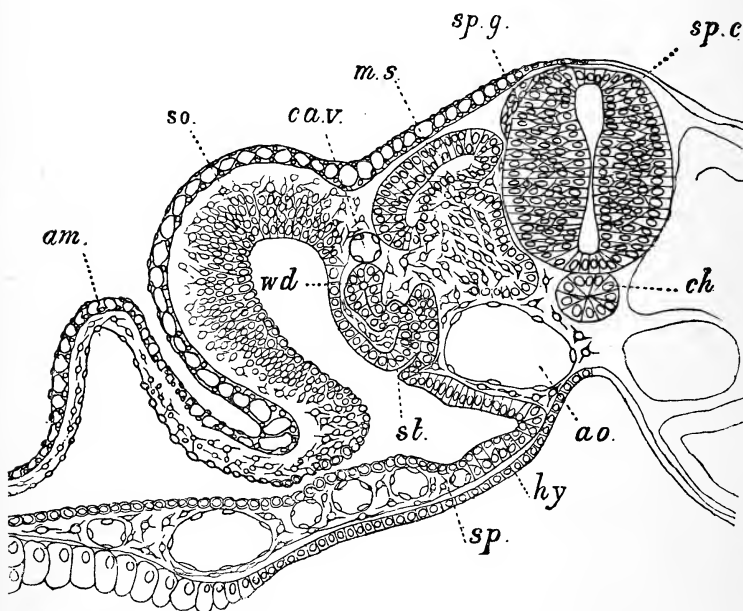
eventually spreads out over the whole body of the chick. On the first half of the fourth day the vesicle is still very small, and its growth is not very rapid. Its mesoblast wall still remains very thick. In the latter half of the day its growth becomes very rapid, and it forms a very conspicuous object in a chick of that date (Fig. 67, *Al*). At the same time its blood-vessels become important. It receives its supply of blood from two branches of the aorta known as the allantoic arteries, and the blood is brought back from it by two allantoic veins which run along in the body walls, and after uniting into a single trunk fall into the vitelline vein close behind the liver.

Mesoblast of the trunk. Coincidentally with the appearance of these several rudiments of important organs in the more or less modified splanchnopleure-folds, the solid trunk of the embryo is undergoing marked changes.

When we compare a transverse section taken through say the middle of the trunk at the end of the third day (Fig. 65), with a similar one of the second day (Fig. 34), or even the commencement of the third day (Fig. 64), we are struck with the great increase of depth (from dorsal to ventral surface) in proportion to breadth. This is partly due to the slope of the side walls of the body having become much steeper, as a direct result of the rapidly progressing folding off of the embryo from the yolk-sac. But it is also brought about by the great changes both of shape and structure which are taking place in the mesoblastic somites, as well as by the development of a mass of tissue between the notochord and the hypoblast of the alimentary canal.

It will be remembered that the horizontal splitting of the mesoblast into somatic and splanchnic layers extends at first to the dorsal summit of the vertebral plates, but after the formation of the somites the split

FIG. 64.



TRANSVERSE SECTION THROUGH THE TRUNK OF A DUCK EMBRYO WITH ABOUT TWENTY-FOUR MESOBLASTIC SOMITES.

am. amnion; *so.* somatopleure; *sp.* splanchnopleure; *wd.* Wolfian duct; *st.* segmental tube; *ca.v.* cardinal vein; *ms.* muscle-plate; *sp.g.* spinal ganglion; *sp.c.* spinal cord; *ch.* notochord; *ao.* aorta; *hy.* hypoblast.

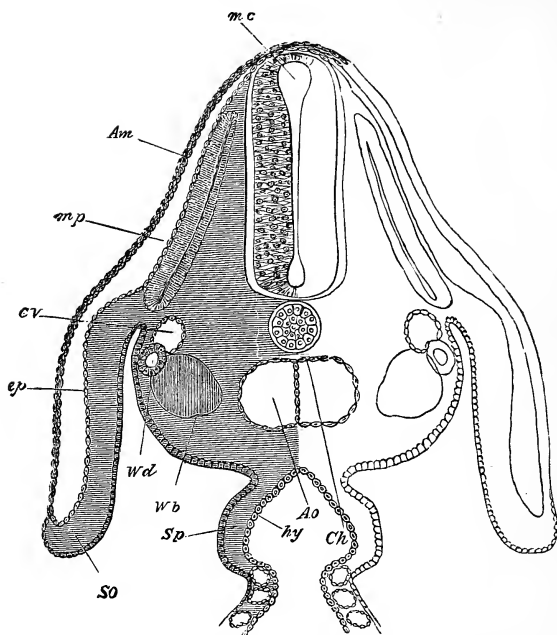
between the somatic and splanchnic layers becomes to a large extent obliterated, though in the anterior somites

it appears in part to persist. The somites on the second day, as seen in a transverse section (Fig. 34, *P.v*), are somewhat quadrilateral in form but broader than they are deep.

Each at that time consists of a somewhat thick cortex of radiating rather granular columnar cells, enclosing a small kernel of spherical cells. They are not, as may be seen in the above figure, completely separated from the ventral (or rather at this period lateral) parts of the mesoblastic plate, and the dorsal and outer layer of the cortex of the somites is continuous with the somatic layer of mesoblast, the remainder of the cortex, with the central kernel, being continuous with the splanchnic layer. Towards the end of the second and beginning of the third day the dorsal and outer layer of the cortex, together probably with some of the central cells of the kernel, becomes separated off as a special plate. From this plate, which is shewn in the act of being formed in Fig. 64, *ms*, the greater part of the voluntary muscular system of the trunk is developed. When once formed the muscle-plates have in surface views a somewhat oblong form, and consist of two layers, an inner and an outer, which enclose between them an almost obliterated central cavity (Fig. 65, *mp*). No sooner is the muscle-plate formed than the middle portion of the inner layer becomes converted into longitudinal muscles. The central space in the muscle-plates is clearly a remnant of the *vertebral portion of the body cavity*, which, though it wholly or partially disappears in a previous stage, reappears again on the formation of the muscle-plate.

It is especially interesting to note that the first

FIG. 65.



SECTION THROUGH THE DORSAL REGION OF AN EMBRYO CHICK
AT THE END OF THE THIRD DAY.

Am. amnion. *m.p.* muscle-plate. *C. V.* cardinal vein. *Ao.* dorsal aorta. The section passes through the point where the dorsal aorta is just commencing to divide into two branches. *Ch.* notochord. *W. d.* Wolffian duct. *W. b.* commencing differentiation of the mesoblast cells to form the Wolffian body. *ep.* epiblast. *SO.* somatopleure. *Sp.* splanchnopleure. *hy.* hypoblast. The section passes through the point where the digestive canal communicates with the yolk-sac, and is consequently still open below.

This section should be compared with the section through the dorsal region of an embryo at the commencement of the third

day (Fig. 64). The chief differences between them arise from the great increase in the space (now filled with mesoblast-cells) between the notochord and the hypoblast. In addition to this we have in the later section the completely formed amnion, the separation of the muscle-plate from the mesoblastic somites, the formation of the Wolffian body, etc.

The mesoblast including the Wolffian body and the muscle-plate (*m.p.*) is represented in a purely diagrammatic manner. The amnion, of which only the inner limb or true amnion is represented in the figure, is seen to be composed of epiblast and a layer of mesoblast; though in contact with the body above the top of the medullary canal, it does not in any way coalesce with it, as might be concluded from the figure.

formed muscles in embryo birds have an arrangement like that which is permanent in fishes; being longitudinal in direction, and divided into segments.

The remainder of the somites, after the formation of the muscle-plates, is of very considerable bulk; the cells of the cortex belonging to them lose their distinctive characters, and their major part becomes converted, in a manner which will be more particularly described in a future chapter, into the bodies of the permanent vertebræ.

We may merely add here that each of these bodies sends a process inwards ventral to the medullary cord, and that the processes from each pair of these bodies envelope between them the notochord.

The intermediate cell-mass and the Wolffian body. In a transverse section of a 45 hours' embryo a considerable mass of cells may be seen collected between the mesoblastic somites and the point where the divergence into somatopleure and splanchnopleure begins (Fig. 34, just below *W.d.*). This mass of cells, which we have already

spoken of as the *intermediate cell-mass*, is at first indistinguishable from the cells lining the inner end of the body cavity; but on the third day, a special peritoneal lining of epithelioid cells is developed which is more or less sharply marked off from the adjoining part of the intermediate cell-mass. This latter now also passes without any very sharp line of demarcation into the mesoblastic somite itself; and as the folding in of the side wall progresses, the mass of cells in this position increases in size and grows in between the notochord and the hypoblast, but does not accumulate to a sufficient extent to separate them widely until the end of the third or beginning of the fourth day.

The fusion between the intermediate cell-mass and the inner portions of the somites becomes so complete on the third day that it is almost impossible to say which of the cells in the neighbourhood of the notochord are derived from the somites and which form the intermediate cell-mass. It seems almost certain however that the cells which form the immediate investment of the notochord really belong to the somites.

The intermediate cell-mass is of special importance to the embryologist, in that the excretory and generative systems are developed from it.

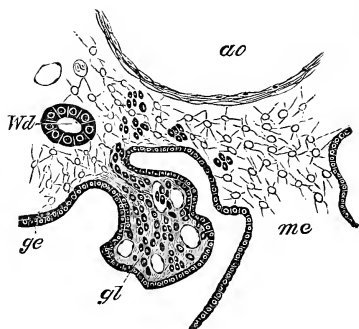
We have already described (p. 106) the development of the Wolffian duct, and we have now to deal with the Wolffian body which is, as the reader has no doubt gathered, the embryonic excretory organ.

The structure of the fully developed Wolffian body is fundamentally similar to that of the permanent kidneys, and consists essentially of convoluted tubules, commencing in Malpighian bodies with vascular glomeruli, and opening into the duct.

The tubules of the Wolffian body are developed independently of the Wolffian duct, and are derived from the intermediate cell-mass, shewn in Fig. 34, between the upper end of the body-cavity and the mesoblastic somite. In the chick the mode of development of this mass into the segmental tubules is different in the regions in front of and behind about the sixteenth segment. In front of about the sixteenth segment special parts of the intermediate cell-mass remain attached to the peritoneal epithelium, on this layer becoming differentiated; there being several such parts to each segment. The parts of the intermediate cell-mass attached to the peritoneal epithelium become converted into S-shaped cords (Fig. 64 *st*) which soon unite with the Wolffian duct (*wd*), and constitute the primitive Wolffian tubules. Into the commencement of each of these cords the lumen of the body-cavity is for a short distance prolonged, so that this part constitutes a rudimentary peritoneal funnel leading from the body-cavity into the lumen of the Wolffian tubule.

In the foremost Wolffian tubules, which never reach a very complete development, the peritoneal funnels widen considerably. The section of the tube adjoining the wide peritoneal funnel becomes partially invaginated by the formation of a vascular ingrowth known as a glomerulus, and this glomerulus soon grows to such an extent as to project through the peritoneal funnel, the neck of which it completely fills, into the body-cavity (Fig. 66, *gl*). There is thus formed a series of glomeruli belonging to the anterior Wolffian tubuli projecting freely into the body-cavity. These glomeruli with their tubuli become however early aborted.

FIG. 66.



SECTION THROUGH THE EXTERNAL GLOMERULUS OF ONE OF THE ANTERIOR SEGMENTAL TUBES OF AN EMBRYO CHICK OF ABOUT 100 HOURS.

gl. glomerulus ; *ge.* peritoneal epithelium ; *Wd.* Wolffian duct ; *ao.* aorta ; *me.* mesentery.

The Wolffian tubule, and the connection between the external and internal parts of the glomerulus are not shewn in this figure.

In the case of the remaining tubules developed from the S-shaped cords, the attachment to the peritoneal epithelium is very soon lost. The cords acquire a lumen, and open into the Wolffian duct. Their blind extremities constitute the commencements of Malpighian bodies.

In the posterior part of the Wolffian body of the chick the intermediate cell-mass becomes very early detached from the peritoneal epithelium, and at a considerably later period breaks up into oval vesicles, which elongate into Wolffian tubules. In addition to the primary tubules, whose development has just been described, secondary and tertiary tubules are formed on the dorsal side of the primary tubules. They are

differentiated out of the mesoblast of the intermediate cell-mass and open independently into the Wolffian duct.

A tubule of the Wolffian body typically consists of the following parts, (1) a section carrying the peritoneal opening, and known as the peritoneal funnel, (2) a dilated vesicle into which this opens, (3) a coiled tubulus proceeding from (2), and terminating in (4) a wider portion opening into the Wolffian duct.

In the chick, the peritoneal funnel is only found in the most anterior tubules and soon atrophies; it is not developed in the tubules of the posterior part of the Wolffian body. Region No. 4 also is not clearly marked off from region No. 3. One part of the wall of the dilated vesicle (2) is invaginated by a bunch of capillaries and gives rise to the Malpighian body.

In consequence of the continual folding in of the somatopleure and especially of the splanchnopleure, as well as owing to the changes taking place in the mesoblastic somites, the Wolffian duct undergoes on the third day a remarkable change of position. Instead of lying, as on the second day, immediately under the epiblast (Fig. 34, *W.d.*), it is soon found to have apparently descended into the middle of the intermediate cell-mass (Fig. 64, *w.d.*) and at the end of the third day occupies a still lower position and even projects somewhat towards the pleuroperitoneal cavity. (Fig. 65, *W.d.*)

The chief events then which take place on the third day are as follows:

1. The turning over of the embryo so that it now lies on its left side.

2. The cranial flexure round the anterior extremity of the notochord.

3. The completion of the circulation of the yolk-sac; the increased curvature of the heart, and the demarcation of its several parts; the appearance of new aortic arches, and of the cardinal veins.

4. The formation of four visceral clefts and five visceral arches.

5. The involution to form the lens, and the formation of the secondary optic vesicle.

6. The closing in of the otic vesicle.

7. The formation of the nasal pits.

8. The appearance of the vesicles of the cerebral hemispheres; the separation of the hind-brain into cerebellum and medulla oblongata.

9. The definite establishment of the cranial and spinal nerves as outgrowths of the central nervous system.

10. The completion of the fore-gut and of the hind-gut; the division of the former into œsophagus, stomach and duodenum, of the latter into large intestine and cloaca.

11. The formation of the lungs from a diverticulum of the alimentary canal immediately in front of the stomach.

12. The formation of the liver and pancreas: the former as two diverticula from the duodenum, which subsequently become united by nearly solid outgrowths; the latter as a single diverticulum also from the duodenum.

13. The changes in the mesoblastic somites and the appearance of the muscle-plates.

14. The definite formation of the Wolffian bodies and the change in position of the Wolffian duct.

CHAPTER VII.

THE CHANGES WHICH TAKE PLACE DURING THE FOURTH DAY.

ON opening an egg in the middle or towards the end of the fourth day, a number of points in which progress has been made since the third day are at once apparent. In the first place, the general growth of the embryo has been very rapid, so that its size is very much greater than on the previous day. In the second place, the white of the egg has still further diminished, the embryo lying almost in immediate contact with the shell membrane.

The germinal membrane embraces more than half the yolk, and the vascular area is about as large as a halfpenny.

Corresponding to the increased size of the embryo, there is a great increase in the quantity of blood circulating in the vascular area as a whole, though the sinus terminalis is already less distinct than it was.

The amnion becomes increasingly conspicuous. It is now seen as a distinct covering obscuring to a certain extent the view of the body of the chick beneath, and

all traces of the junction of its folds are by this time lost. As yet there is very little fluid in the amniotic sac proper, so that the true amnion lies close upon the embryo.

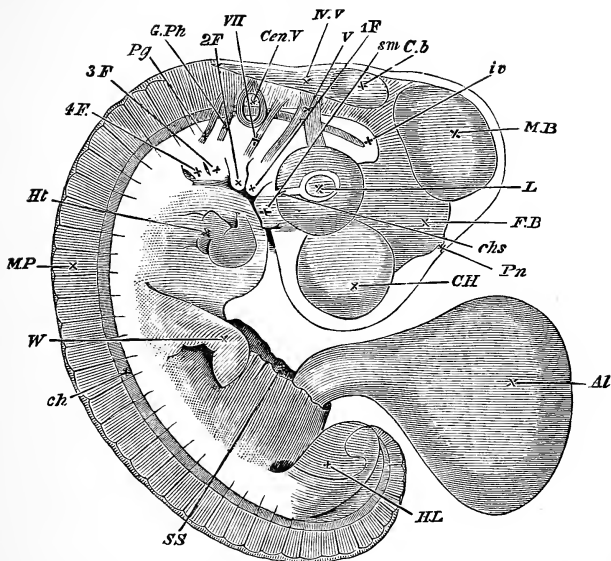
The folding off of the embryo from the yolk sac has made great progress. The splanchnic stalk, which on the third day was still tolerably wide, inasmuch as about one third of the total length of the alimentary canal was as yet quite open to the yolk sac below, now becomes so much constricted by the progressive closing in of the splanchnopleure folds, that the alimentary canal may be said to be connected with the yolk sac by a very narrow neck only. This remnant of the splanchnic stalk we may now call the *vitelline duct*; though narrow, it is as yet quite open, affording still free communication between the inside of the yolk sac and the interior of the alimentary canal.

The somatic stalk, though narrowing somewhat, is much wider than the splanchnic stalk, so that a considerable ring-shaped space exists between the two.

Another very prominent feature is the increase in the cranial flexure. During the third day, the axis of the front part of the head was about at right angles to the long axis of the body; the whole embryo being still somewhat retort-shaped. On this day, however, the flexure has so much increased that the angle between the long axis of the body and that of the front segment of the head is an acute one.

The tail-fold, which commenced to be noticeable during the third day, has during this day increased very much, and the somewhat curved tail (Fig. 67) forms quite a conspicuous feature of the embryo. The general

FIG. 67.



EMBRYO AT THE END OF THE FOURTH DAY SEEN AS
A TRANSPARENT OBJECT.

The amnion has been completely removed, the cut end of the somatic stalk is shewn at *S.S.* with the allantois (*Al.*) protruding from it.

C.H. cerebral hemisphere. *F.B.* fore-brain or vesicle of the third ventricle (thalamencephalon) with the pineal gland (*Pn.*) projecting from its summit. *M.B.* mid-brain. *Cb.* cerebellum. *IV.V.* fourth ventricle. *L.* lens. *chs.* choroid slit. Owing to the growth of the optic cup the two layers of which it is composed cannot any longer be seen from the surface; the posterior surface of the choroid layer alone is visible. *Cen. V.* auditory vesicle. *sm.* superior maxillary process. *1F*, *2F*, etc. first, second, third and fourth visceral folds. *V.* fifth nerve sending one branch to the eye, the ophthalmic branch, and

another to the first visceral arch. *VII.* seventh nerve passing to the second visceral arch. *G.Ph.* glossopharyngeal nerve passing towards the third visceral arch. *Pg.* pneumogastric nerve passing towards the fourth visceral arch. *iv.* investing mass (basilar plate). No attempt has been made in the figure to indicate the position of the dorsal wall of the throat, which cannot be easily made out in the living embryo. *ch.* notochord. The front end of this cannot be seen in the living embryo. It does not end however as shewn in the figure, but takes a sudden bend downwards and then terminates in a point. *Ht.* heart seen through the walls of the chest. *M.P.* muscle-plates. *W.* wing. *H.L.* hind limb. Beneath the hind limb is seen the curved tail.

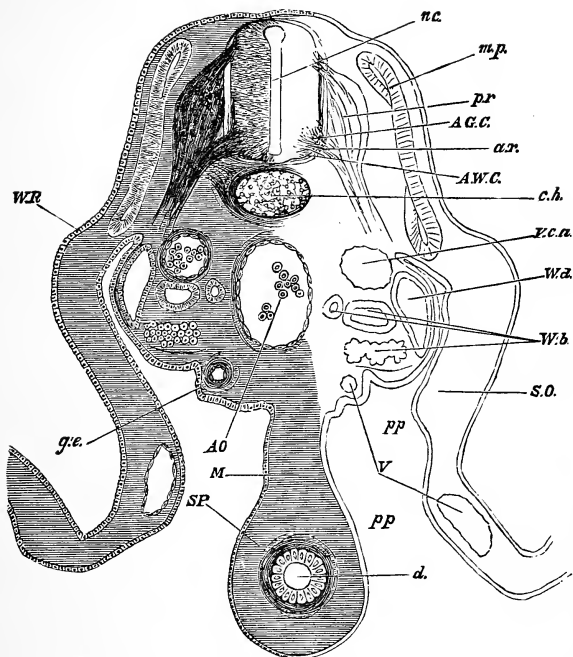
curvature of the body has also gone on increasing, and as the result of these various flexures, the embryo has become somewhat spirally curled up on itself (Fig. 67).

The distinct appearance of the limbs must be reckoned as one of the most important events of the fourth day.

Owing to the continued greater increase of depth than of breadth, the body of the embryo appears in section (Fig. 68) higher and relatively narrower than even on the third day, and the muscle-plates, instead of simply slanting downwards, come to be nearly vertical in position. Not far from the line which marks their lower ends, the somatopleure, almost immediately after it diverges from the splanchnopleure, is raised up (Fig. 68, *W.R.*) into a low rounded ridge which runs along nearly the whole length of the embryo from the neck to the tail.

It is on this ridge, which is known as the Wolffian ridge, that the limbs first appear as flattened conical buds projecting outwards. They seem to be local de-

FIG. 68.



SECTION THROUGH THE LUMBAR REGION OF AN EMBRYO AT
THE END OF THE FOURTH DAY.

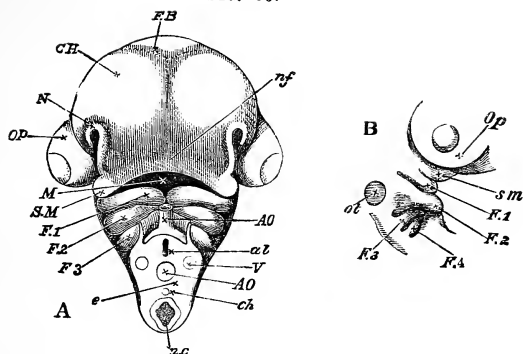
n.c. neural canal. *p.r.* posterior root of spinal nerve with ganglion. *a.r.* anterior root of spinal nerve. *A.G.C.* anterior grey column of spinal cord. *A.W.C.* anterior white column of spinal cord just commencing to be formed, and not very distinctly marked in the figure. *m.p.* muscle-plate. *ch.* notochord. *W.R.* Wolffian ridge. *A.O.* dorsal aorta. *V.c.a.* posterior cardinal vein. *W.d.* Wolffian duct. *W.b.* Wolffian body, consisting of tubules and Malpighian corpuscles. One of the latter is represented on each side. *g.e.* germinal

epithelium. *d.* alimentary canal. *M.* commencing mesentery. *S.O.* somatopleure. *S.P.* splanchnopleure. *V.* blood-vessels. *pp.* pleuroperitoneal cavity.

velopments of the ridge, the rest of which becomes less and less prominent as they increase in size. Each bud, roughly triangular in section, consists of somewhat dense mesoblast covered by epiblast which on the summit is thickened into a sort of cap. The front limbs or wings (Fig. 67) arise just behind the level of the heart, and the hind limbs in the immediate vicinity of the tail. The first traces of them can be seen towards the end of the third, but they do not become conspicuous till the fourth day, by the end of which the two pairs may be already distinguished by their different shapes. The front limbs are the narrowest and longest, the hind limbs being comparatively short and broad. Both are flattened from above downwards and become more so as their growth continues.

In the head, the vesicles of the cerebral hemispheres are rapidly increasing in size, their growth being enormous as compared with that of the thalamencephalon or vesicle of the third ventricle. The mid-brain is now, as compared to the other parts of the brain, larger than at any other epoch, and an indistinct median furrow on its upper surface indicates its division into two lateral halves. The great increase of the mesoblastic contents of the secondary optic vesicle or involuted retinal cup causes the two eyeballs to project largely from the sides of the head (Fig. 69, *Op*). The mass of mesoblast which invests all the various parts of the brain, is not only growing rapidly below and at the sides, but is also undergoing developments which result in the formation

FIG. 69.



A. HEAD OF AN EMBRYO CHICK OF THE FOURTH DAY VIEWED FROM BELOW AS AN OPAQUE OBJECT. (Chromic acid preparation.)

C.H. cerebral hemispheres. *F.B.* vesicle of the third ventricle or thalamencephalon. *Op.* eyeball. *nf.* naso-frontal process. *M.* cavity of mouth. *S.M.* superior maxillary process of *F. 1*, the first visceral fold (mandibular arch). *F. 2*, *F. 3* second and third visceral arches. *N.* nasal pit.

In order to gain the view here given the neck was cut across between the third and fourth visceral folds. In the section *e* thus made are seen the alimentary canal *al*, the neural canal *n.c.*, the notochord *ch.*, the dorsal aorta *AO.*, and the jugular veins *V.* *Ao.* bulbus arteriosus.

In the drawing the nasal groove has been rather exaggerated in its upper part. On the other hand the lower and shallower part of the groove where it runs between the superior maxillary process *S.M.* and the broad naso-frontal process has not been satisfactorily rendered. Hence the end of the superior maxillary process seems to join the inner and not, as described in the text, the outer margin of the nasal groove. A few hours later the separation of the two would have been very visible.

B. The same seen sideways, to shew the visceral folds. *ot.* otic vesicle. Remaining letters as before.

of the primitive skull. All these events, added to the cranial flexure spoken of above, give to the anterior extremity of the embryo a shape which it becomes more and more easy to recognize as that of a head.

Meanwhile the face is also being changed. The two nasal pits were on the third day shallow depressions complete all round. As the pits deepen on the fourth day by the growth upwards of a rim round them, a deficiency or break in the ridge may be observed on that side of it turned towards the mouth; which constitutes a kind of shallow groove (Fig. 69 *N*) directed obliquely downwards towards the cavity of the mouth. The fronto-nasal process or median ridge (Fig. 69, *nf*), which on the third day rose up between the superficial projections caused by the bulging anterior extremities of the vesicles of the cerebral hemispheres, and on the fourth day becomes increasingly prominent, separates the two grooves from each other, and helps to form the inner wall of each of them, while the depth of the groove also becomes increased by the prolongation along its inner side of the rim surrounding the nasal pit. Abutting on the outer side of each groove near the mouth and so helping to form the outer wall of each, lie the ends of the superior maxillary processes of the first visceral arch (Fig. 69 *B*, *SM*), which like the fronto-nasal process are increasing in size. By their continued growth, the groove is more and more deepened, and leading as it does from the nasal pit to the cavity of the mouth, may already be recognized as the rudiment of the passage of the posterior nares.

During the latter half of the fourth day there appears at the bottom of the deep lozenge-shaped cavity

of the stomodæum or primitive buccal cavity, in the now thin wall dividing it from the alimentary canal, a longitudinal, or according to Götte a vertical slit which, soon becoming a wide opening, places the two cavities in complete communication.

The cavity of the mouth, being, it will be remembered, formed partly by depression, partly by the growth of the surrounding folds, is lined entirely with epiblast, from which the epithelium of its surface and of its various glands is derived. In this respect, as Remak pointed out, it differs from all the rest of the alimentary canal, whose whole epithelium is formed out of hypoblast.

By the side of the hind-brain the cerebellum, through the increased thickening of its upper walls, is becoming more and more distinct from the medulla oblongata; while both in front and behind the auditory vesicle, in which the rudiments of the cochlea and recessus vestibuli are already visible, the cranial ganglia and nerves are acquiring increased distinctness and size. They may be very plainly seen when the head of the fresh embryo is subjected to pressure.

The foremost is the fifth cranial nerve (Fig. 67, *V.*) with its Gasserian ganglion; it lies a little way behind the anterior extremity of the notochord immediately below the cerebellum. Next to this comes the seventh nerve (Fig. 67, *VII.*), starting just in front of the ear-vesicle, and extending far downwards towards the second visceral arch. The two nerves which lie behind the ear-vesicle are now obviously separate from each other; the front one is the glossopharyngeal (Fig. 67, *G.Ph.*), and the hinder one already shews itself to be the pneumogastric (Fig. 67, *Pg.*).

The mesoblastic somites, which by the continued differentiation of the axial mesoblast at the tail end of the embryo have increased in number from thirty to forty, undergo during this day changes of great importance. Since these changes are intimately connected with the subsequent development of the vertebral column, it will perhaps be more convenient to describe briefly here the whole series of events through which the somites become converted into the permanent structures to which they give rise, though many of the changes do not take place till a much later date than the fourth day.

The separation of the muscle-plates (p. 187) left the remainder of each somite as a somewhat triangular mass lying between the neural canal and notochord on the inside, and the muscle-plate and intermediate cell-mass on the outside (Fig. 64). Already on the third day (Fig. 65) the upper angle of this triangle grows upwards, between its muscle-plate and the neural canal, and meeting its fellow in the middle line above, forms a roof of mesoblast over the neural canal, between it and the superficial epiblast. At about the same time, the inner and lower angle of the triangle grows inwards towards the notochord, and passing both below it (between it and the aorta) and above it (between it and the neural canal), meets a similar growth from its fellow somite of the other side, and thus completely invests the notochord with a coat of mesoblast, which, as seen in Fig. 68, is at first much thicker on the under than on the upper side.

Both neural canal and notochord are thus furnished from neck to tail with a complete investment of meso-

blast, still marked, however, by the transparent lines indicating the fore and aft limits of the several somites. This mesoblastic investment is sometimes spoken of as the "membranous" vertebral column.

The portions of the somites thus forming the primary vertebræ or membranous vertebral column are converted into the permanent vertebræ; but their conversion is complicated by a remarkable new or secondary segmentation of the whole vertebral column.

On the fourth day, the transparent lines marking the fore and aft limits of the somites are still distinctly visible. On the fifth day, however, they disappear, so that the whole vertebral column becomes fused into a homogeneous mass whose division into vertebræ is only indicated by the series of ganglia. This fusion, which does not extend to the muscle-plates in which the primary lines of division still remain visible, is quickly followed by a fresh segmentation, the resulting segments being the rudiments of the *permanent* vertebræ. The new segmentation, however, does not follow the lines of the segmentation of the muscle-plates, but is so effected that the centres of the vertebral bodies are opposite the septa between the muscle-plates.

The explanation of this character in the segmentation is not difficult to find. The primary segmentation of the body is that of the muscle-plates, which were present in the primitive forms in which vertebræ had not appeared. As soon however as the notochordal sheath was required to be strong as well as flexible, it necessarily became divided into a series of segments.

The condition under which the lateral muscles can best cause the flexure of the vertebral column is clearly that each muscle-plate shall be capable of acting on two vertebræ; and this condition can only be fulfilled when the muscle-segments are oppo-

site the intervals between the vertebræ. For this reason, when the vertebræ became formed, their centres were opposite not the middle of the muscle-plates but the inter-muscular septa.

These considerations fully explain the characters of the secondary segmentation of the vertebral column. On the other hand the primary segmentation of the vertebral rudiments is clearly a remnant of a condition when no vertebral bodies were present; and has no greater morphological significance than the fact that the cells of the vertebræ were derived from the segmented muscle-plates, and then became fused into a continuous sheath around the notochord and nervous axis; till finally they became in still higher forms differentiated into vertebræ and their arches.

By these changes this remarkable result is brought about, that each permanent vertebra is formed out of portions of two consecutive mesoblastic somites. Thus, for instance, the tenth permanent vertebra is formed out of the hind portion of the tenth somite, and the front portion of the eleventh somite.

The new segmentation is associated with or rather is caused by histological changes. At the time when the fusion takes place, the mesoblast, which in the form of processes from the somites surrounds and invests the notochord, has not only increased in mass but also has become cartilaginous, so that, as Gegenbaur¹ points out, there is present for a short period on the fifth day a continuous and unsegmented cartilaginous investment of the notochord.

This cartilaginous tube does not however long remain uniform. At a series of points corresponding in number to the original somites it becomes connected

¹ *Untersuchung zur vergleichenden Anatomie der Wirbelsäule bei Amphibien und Reptilien*, Leipzig, 1862.

with a number of cartilaginous arches which appear in the mesoblastic investment of the neural canal. These arches, which thus roof in the neural canal, are the cartilaginous precursors of the osseous vertebral arches. We further find that the portions of the cartilaginous tube from which the arches spring come to differ histologically from the portions between them not connected with arches: they are clearer and their cells are less closely packed. There is however at this period no distinct segmentation of the cartilaginous tube, but merely a want of uniformity in its composition.

The clearer portions, from which the arches spring, form *the bodies of the vertebræ*, the segments between them the *intervertebral regions* of the column.

On the fifth day a division takes place of each of the *intervertebral* segments into two parts, which respectively attach themselves to the contiguous vertebral regions. A part of each intervertebral region, immediately adjoining the notochord, does not however undergo this division, and afterwards gives rise to the ligamentum suspensorium.

This fresh segmentation is not well marked, if indeed it takes place at all in the sacral region.

To recapitulate:—the original somites lying side by side along the notochord, after giving off the muscle-plates, grow around, and by fusing together completely invest, with mesoblast, both neural canal and notochord.

This investment, of which by reason of its greater growth the original bodies of the somites now seem to be only an outlying part, becomes cartilaginous in such a way that while the notochord becomes surrounded with a thick tube of cartilage bearing no signs of segmenta-

tion, but having the ganglia lodged on its exterior at intervals, the neural canal is covered in with a series of cartilaginous arches, connected to each other by ordinary mesoblastic tissue only, but passing at their bases directly into the cartilaginous tube around the notochord.

By a process of histological differentiation the cartilaginous tube is divided into vertebral and intervertebral portions, the vertebral portions corresponding to the arches over the neural canal. Fresh lines of segmentation then appear in the intervertebral portions, dividing each of them into two parts, of which one attaches itself to the vertebra in front and the other to the vertebra behind.

The notochord. Meanwhile from the fourth to the sixth day important changes take place in the notochord itself.

On its first appearance the notochord was, as we have seen, composed of somewhat radiately arranged but otherwise perfectly typical mesoblast-cells.

On the third day some of the central cells become vacuolated, while the peripheral cells are still normal. The vacuolated cells exhibit around the vacuole a peripheral layer of granular protoplasm in which the nucleus lies embedded, whilst the vacuoles themselves are filled with a perfectly clear and transparent material, which in an unaltered condition is probably fluid. Towards the end of the day the notochord acquires a delicate structureless sheath which is no doubt a product of its peripheral cells.

On the fourth day all the cells become vacuolated with the exception of a single layer of flattened cells at the periphery. The vacuoles go on enlarging until

on the sixth day the vacuoles in each cell have so much increased at the expense of the protoplasm that only a very thin layer of the latter is left at the circumference of the cell, at one part of which, where there is generally more protoplasm than elsewhere, the starved remains of a nucleus may generally be detected. Thus the whole notochord becomes transformed into a spongy reticulum, the meshes of which correspond to the vacuoles of the cells and the septa to the remains of their cell-walls.

The notochord is on the sixth day at the maximum of its development, the change which it henceforward undergoes being of a retrograde character.

From the seventh day onward, it is at various points encroached upon by its investment. Constrictions are thus produced which first make their appearance in the intervertebral portions of the sacral region. In the cervical region, according to Gegenbaur, the intervertebral portions are not constricted till the ninth day, though in the vertebral portions of the lower cervical vertebræ constrictions are visible as early as the seventh day. By the ninth and tenth days, however, all the intervertebral portions have become distinctly constricted, and at the same time in each vertebral portion there have also appeared two constrictions giving rise to a central and to two terminal enlargements. In the space therefore corresponding to each vertebra and its appropriate intervertebral portion, there are in all three constrictions and three enlargements.

On the twelfth day the ossification of the bodies of the vertebræ commences. The first vertebra to ossify is the second or third cervical, and the ossification gradu-

ally extends backwards. It does not commence in the arches till somewhat later. For each arch there are two centres of ossification, one on each side.

The notochord persists for the greater part of foetal life and even into post-foetal life. The larger vertebral portions are often the first completely to vanish. They would seem in many cases at any rate (Gegenbaur) to be converted into cartilage and so form an integral part of the permanent vertebræ. Rudiments of the intervertebral portions of the notochord may long be detected in the ligamenta suspensoria.

We may remind the reader that in the adult bird we find between each of the vertebræ of a neck and back a cartilaginous disc—the meniscus—which is pierced in the centre. These discs are thick at the circumference but thin off to a fine edge round the central hole. Owing to the shape of these discs there are left between each pair of vertebræ two cavities, which only communicate through the central aperture of the meniscus. Through this central aperture there passes a band called the ‘ligamentum suspensorium,’ connecting the two vertebræ.

In the tail the menisci are replaced by bodies known as the ‘annuli fibrosi,’ which precisely resemble the similarly named bodies in mammals. They differ from the menisci in being attached over their whole surface to the ends of the vertebral bodies, so that the cavities between the menisci and the vertebræ do not exist. They are pierced however by a body corresponding with the ligamentum suspensorium and known as the ‘nucleus pulposus.’

In the intervertebral regions the chorda, soon after the commencement of ossification, entirely disappears. The cartilage around it however becomes converted (in the region of the neck) into the ligamentum suspensorium, which unites the two vertebræ between which it is placed.

In the tail the cartilage becomes the nucleus pulposus, which corresponds exactly to the ‘ligamentum suspensorium’ of the neck and back.

Shortly after the formation of the *ligamentum suspensorium* the remaining cartilage of the intervertebral segments is converted into the meniscus between each two *vertebræ*, and in the tail into the *annulus fibrosus*. Both are absent in the *sacrum*.

Muscle-plates. We shall conclude our account of the mesoblastic somites by describing the changes which take place in the muscle-plates.

In the chick these are somewhat complicated, and have not been fully worked out.

On the third day the muscle-plates end opposite the point where the mesoblast becomes split into *somatopleure* and *splanchnopleure*. On the fourth day however (Fig. 68 *mp.*) they extend a certain distance into the side walls of the body beyond the point of the division into *somatopleure* and *splanchnopleure*.

Into what muscles of the trunk they become converted has been somewhat disputed. Some embryologists have stated that they only form the muscles of the back. We have, however, little doubt that all the episkeletal muscles, to use Professor Huxley's term (*Vertebrates*, p. 46), are their products; a view also adopted by Professors Huxley and Kölliker.

The development of the subvertebral system of muscles (*hyposkeletal* of Huxley) has not been worked out, but on the whole there is reason to believe that it is derived from the muscle-plates. Kölliker, Huxley and other embryologists believe however that these muscles are independent of the muscle-plates in their origin.

Whether the muscle of the diaphragm is to be placed in the same category as the *hyposkeletal* muscles has not been made out.

It is probable that the cutaneous muscles of the trunk are derived from the cells given off from the muscle-plates. Kölliker however believes that they have an independent origin.

The limb-muscles, both extrinsic and intrinsic, are in certain fishes (Elasmobranchii), derived from the muscle-plates, and a similar origin has been observed in Lacertilia and Amphibia.

In the Chick and other higher Vertebrata on the other hand the entrance of the muscle-plates into the limbs has not been made out (Kölliker). It seems therefore probable that by an embryological modification, of which instances are so frequent, the cells which give rise to the muscles of the limbs in the higher Vertebrata can no longer be traced into a direct connection with the muscle-plates.

At first, as is clear from their mode of origin, the muscle-plates correspond in number with the protovertebræ, and this condition is permanent in the lower vertebrates, such as fishes, where we find that the lateral muscle is divided by septa into a series of segments corresponding in number with the vertebræ.

Wolffian body or mesonephros. Of all the events of the fourth day, none perhaps are more important than those by which the rudiments of the complex urinary and generative systems are added to the simple Wolffian duct and body, which up to that time are the sole representatives of both systems.

We saw that the duct arose on the second day (pp. 94, 106) as a solid ridge which subsequently became a tube, lying immediately underneath the epiblast above the intermediate cell-mass, close against the upper and outer angles of the somites, and reaching from about opposite to the seventh somite away to the hinder end of the embryo.

At first the duct occupies a position immediately underneath the superficial epiblast, but very soon after its formation the growth of the somites and the changes which take place in the intermediate cell-mass, together

with the general folding in of the body, cause it to appear to change its place and travel downwards (p. 193). While the shifting is going on, the cells lining the upper end of the pleuroperitoneal cavity (the kind of bay which, as seen in sections, is formed by the divergence of the somatopleure and splanchnopleure) become columnar, and constitute a distinct epithelium. This epithelium, which is clearly shewn in Fig. 64, and is also indicated in Fig. 65, is often called the *germinal epithelium*, because some of its cells subsequently take part in the formation of the ovary. Soon after the appearance of the germinal epithelium, the intermediate cell-mass increases in size and begins to grow outwards into the pleuroperitoneal cavity, as a rounded projection which lies with its dorsal surface towards the somatopleure, and its ventral surface towards the splanchnopleure, but is in either case separated from these layers by a narrow chink. The Wolffian duct (Figs. 65, 68, *Wd*) travels down, and finally before the end of the third day is found in the upper part of this projection, near that face of it which is turned towards the somatopleure.

The tubules of the anterior part of the Wolffian body have by the end of the fourth day almost entirely disappeared; but the tubules of that part of the Wolffian body which is found behind the 16th segment undergo a further development.

Each increases in size especially that portion which proceeds from the Malpighian body and is known as the coiled tubulus (region No. 3, see p. 193). This becomes much elongated and twisted. As a consequence of this increase in size the intermediate cell-mass comes to project more and more into the pleuroperitoneal cavity.

The large size of the hinder part of the Wolffian body as compared with that of the anterior part is due to the presence of the dorsally placed secondary tubules, whose development was mentioned on p. 192. These are more numerous in the posterior than in the anterior part of the Wolffian body. At the hind end of the Wolffian body there are as many as four to each primary tubule.

The tubules, which from their contorted course are in sections (Figs. 68, 71) seen cut at various angles, possess an epithelium which is thicker than that of the Wolffian duct. From this difference it is generally easy to distinguish the sections of the tubules from those of the duct. The glomeruli of the Malpighian bodies are in sections of hardened embryos usually filled with blood-corpuscles.

Towards the hind end of the embryo, the projection of the intermediate cell-mass spoken of above becomes smaller and smaller, and the Wolffian duct is thus brought nearer to the splanchnopleure, and in the region of the hind-gut comes to lie close to the walls of the alimentary canal. On the fourth day, the two ducts meet and open into two horns, into which the side-walls of the recently formed cloaca are at that time produced, one on either side.

As we shall afterwards see, the ducts of the permanent kidneys and Müller's duct also fall into these two horns of the cloaca.

The Wolffian bodies thus constituted perform the offices of kidneys for the greater part of embryonic life. In the chick they disappear before birth; but in most of the Ichthyopsida they remain for life as the permanent kidneys.

Müllerian duct. After the establishment of the

Wolffian body there is formed in both sexes a duct, which in the female becomes the oviduct, but which in the male is functionless and usually disappears. This duct, in spite of certain peculiarities in its development, is without doubt homologous with the Müllerian duct of the Ichthyopsida.

The first rudiment of the Müllerian duct appears at the end of the fourth day, as three successive open involutions of the peritoneal epithelium, connected together by more or less well-defined ridge-like thickenings of the epithelium. It takes its origin from the layer of thickened peritoneal epithelium situated near the dorsal angle of the body-cavity, close to the Wolffian duct, and some considerable distance behind the front end of the Wolffian duct.

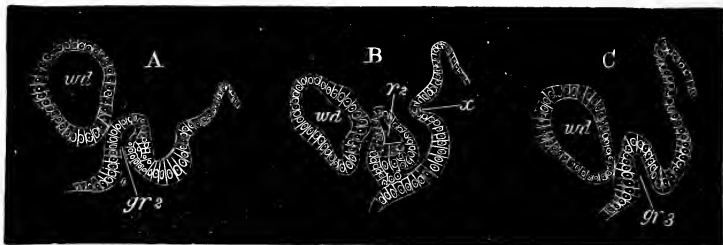
In a slightly later stage the ridges connecting the grooves become partially constricted off from the peritoneal epithelium, and develop a lumen. The condition of the structure at this stage is illustrated by Fig. 70, representing three transverse sections through two grooves, and through the ridge connecting them.

The Müllerian duct may in fact now be described as a short but slightly convoluted duct, opening into the body-cavity by three groove-like apertures, and continued for a short distance behind the last of these.

In an embryo not very much older than the one last described the two posterior apertures vanish and the anterior opening alone remains as the permanent opening of the Müllerian duct.

The position of these openings in relation to the Wolffian body is shewn in Fig. 71, which probably passes through a region between two of the peritoneal openings.

FIG. 70.



SECTIONS SHEWING TWO OF THE PERITONEAL INVAGINATIONS WHICH GIVE RISE TO THE ANTERIOR PART OF THE MÜLLERIAN DUCT (PRONEPHROS).

A is the 11th section of the series.

B „ 15th „ „

C „ 18th „ „

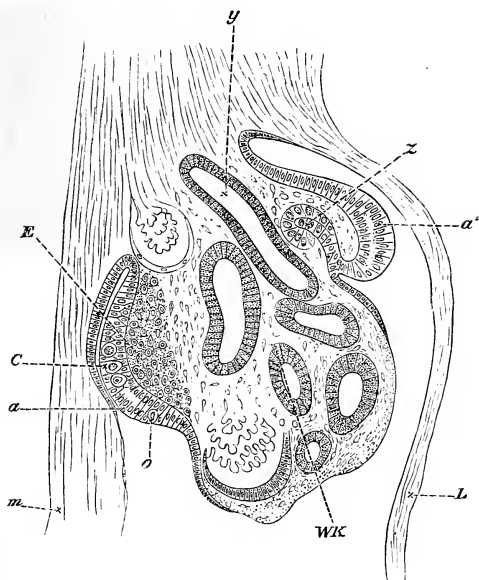
gr 2 second groove. *gr 3* third groove. *r 2* second ridge. *wd.* Wolffian duct.

As long as the openings persist, the Müllerian duct consists merely of a very small rudiment, continuous with the hindermost of them, and its solid extremity appears to unite with the walls of the Wolffian duct.

After the closure of the two hinder openings the Müllerian duct commences to grow rapidly backwards, and for the first part of its subsequent course it appears to be split off as a solid rod from the outer or ventral wall of the Wolffian duct (Fig. 72). Into this rod the lumen, present in its front part, subsequently extends. Its mode of development in front is thus precisely similar to that of the Müllerian duct in *Elasmobranchii* and *Amphibia*.

This mode of development only occurs however in the anterior part of the duct. In the posterior part of

FIG. 71.

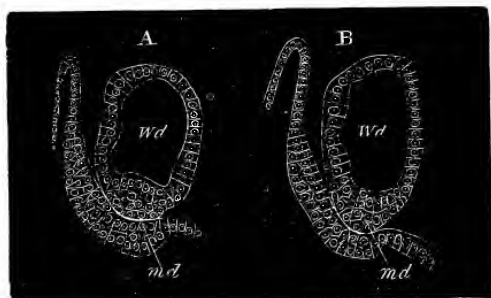


SECTION OF THE INTERMEDIATE CELL-MASS ON THE FOURTH DAY. (From Waldeyer.) Magnified 160 times.

m. mesentery. *L.* somatopleure. *α'*. portion of the germinal epithelium from which the involution to form the duct of Müller (*z*) takes place. *α*. thickened portion of the germinal epithelium in which the primitive ova *C* and *o* are lying. *E.* modified mesoblast which will form the stroma of the ovary. *WK.* Wolffian body. *y.* Wolffian duct.

its course its growing point lies in a bay formed by the outer wall of the Wolffian duct, but does not become definitely attached to that duct. It seems however possible that, although not actually split off from the

FIG. 72.



TWO SECTIONS SHEWING THE JUNCTION OF THE TERMINAL SOLID PORTION OF THE MÜLLERIAN DUCT WITH THE WOLFFIAN DUCT.

In A the terminal portion of the duct is quite distinct; in B it has united with the walls of the Wolffian duct.

md. Müllerian duct. *wd.* Wolffian duct.

walls of the Wolffian duct, it may grow backwards from cells derived from that duct.

The Müllerian duct finally reaches the cloaca though it does not in the female for a long time open into it, and in the male never does so.

The anterior part of the commencing Müllerian duct with its three openings into the body-cavity is probably homologous with the head kidney or pronephros of the Ichthyopsida.

Permanent kidney or metanephros. Between the 80th and 100th hour of incubation, the permanent kidneys begin to make their appearance, and as is the case with the Wolffian bodies, the first portion of them to appear is their duct. Near its posterior extremity the Wolffian duct becomes expanded, and from the expanded portion a diverticulum is constricted off which in a

transverse section lies dorsal to the original duct, and the blind end of which points forwards, that is, towards the head of the chick. This is the duct of the permanent kidney or ureter. At first the ureter and the Wolffian duct open by a common trunk into the cloaca, but this state of things lasts for a short time only, and by the sixth day the two ducts have independent openings.

The ureter thus beginning as an outgrowth from the Wolffian duct grows forwards, and extends along the outer side of a mass of mesoblastic tissue which lies mainly behind, but somewhat overlaps the dorsal aspect of, the Wolffian body.

This mass of mesoblastic cells may be called the metanephric blastema. It is derived from the intermediate cell-mass of the region reaching from about the thirty-first to the thirty-fourth somite. It is at first continuous with, and indistinguishable in structure from, the portion of the intermediate cell-mass of the region immediately in front of it, which breaks up into Wolffian tubules. The metanephric blastema remains however quite passive during the formation of the Wolffian tubules in the adjoining blastema; and on the formation of the ureter breaks off from the Wolffian body in front, and, growing forwards and dorsalwards, becomes connected with the inner side of the ureter in the position just described.

In the subsequent development of the kidney collecting tubes grow out from the ureter, and become continuous with masses of cells of the metanephric blastema, which then differentiate themselves into the kidney tubules.

The formation of the kidneys takes place before the end of the seventh day, but they do not become of functional importance till considerably later.

From their mode of development it clearly follows that the permanent kidneys are merely parts of the same system as the Wolffian bodies, and that, their separation from these is an occurrence of a *purely secondary importance*.

The generative ridge. Before describing the subsequent fate of the Wolffian and Müllerian ducts, it will be necessary to give an account of the formation of the true sexual glands, the ovaries and testes.

At the first appearance of the projection from the intermediate cell-mass, which we may now call the *genital ridge*, a columnar character is not only visible in the layer of cells covering the nascent ridge itself along its whole length, but may also be traced for some little distance outwards on either side of the ridge in the cells lining the most median portions of both somatopleure and splanchnopleure. Passing outwards along these layers, the columnar cells gradually give place to a flat tessellated epithelium. As the ridge continues to increase and project, the columnar character becomes more and more restricted to cells covering the ridge itself, over which at the same time it becomes more distinct. On the outer side of the ridge, that is on the side which looks towards the somatopleure, the epithelium undergoes, as we have seen, an involution to form the commencement of the duct of Müller, and for some little time retains in the immediate neighbourhood of that duct its columnar character (Fig. 71, *a'*), though eventually losing it.

The median portion of the ridge is occupied by the projection of the Wolffian body, and here the epithelium rapidly becomes flattened.

On the inside of the ridge however, that is on the side looking towards the splanchnopleure, the epithelium not only retains its columnar character, but grows several cells deep (Fig. 71, *a*), while at the same time the mesoblast (*E*) underlying it becomes thickened. In this way, owing partly to the increasing thickness of the epithelium, and partly to the accumulation of mesoblast beneath it, a slight eminence is formed, which when viewed from below, after opening the abdominal cavity, appears in direct light as a fusiform white patch or streak, in its early stages extending along the whole length of the Wolffian body and genital ridge, but subsequently restricted to its anterior portion. Its appearance under these circumstances has been well described by Von Baer.

This 'sexual eminence' is present in the early stages of both sexes. In both the epithelium consists of several layers of short cylindrical cells, a few of which are conspicuous on account of their size and their possessing a highly refractive oval nucleus of considerable bulk; in both, the underlying thickened mesoblast consists—as indeed at this epoch it does generally in all parts of the body—of spindle-shaped cells.

The larger conspicuous cells of the epithelium, which appear to have quite a common origin with their fellow cells and to arise from them by direct differentiation, and which are seen at the first in male as well as female embryos, are the *primordial ova* or *primitive germinal cells* (Fig. 71; *o*). Thus in quite early

stages it is impossible to detect the one sex from the other.

The ovary. In the female the primordial ova enlarge and become more numerous, the whole epithelium growing thicker and more prominent, and the spindle-shaped cells of the underlying mesoblast also increase rapidly and thus form the stroma of the ovary. The primordial ova after undergoing some further changes, into which it is not within the scope of this work to enter, become surrounded by a number of the ordinary epithelium cells. These form a distinct layer, the follicular epithelium, round the ovum. After a time there appear numerous vascular ingrowths from the stroma, which penetrate through all parts of the germinal epithelium and break it up into a sponge-like structure formed of trabeculæ of germinal epithelium interpenetrated by vascular strands of stroma. The trabeculæ of the germinal epithelium form the egg-tubes of Pflüger.

In this way each ovum becomes invested by a capsule of vascular connective tissue lined internally by a layer of epithelium; the whole constituting a *Graafian follicle*.

The large nucleus of the primordial ovum becomes the germinal vesicle, while the ovum itself remains as the true ovum; this subsequently becomes enlarged by the addition of a quantity of yolk derived from a differentiation of its protoplasm.

The testis. The first traces of the testes are found in the dorsal and inner side of the intermediate cell-mass, and appear about the sixth day. From the first they differ from the rudimentary ovaries, by coming into

somewhat close connection with the Wolffian bodies; but occupy about the same limits from before backwards. The mesoblast in the position we have mentioned begins to become somewhat modified, and by the eighth day the testis is divided by septa of connective tissue into a number of groups of cells; which are the commencing tubuli seminiferi. By the sixteenth day the cells of the tubuli have become larger and acquired a distinctly epithelial character.

The history of the primordial cells in the male has not been so thoroughly worked out as in the female. The spermatozoa appear to arise by the division of the primitive ova (present, as we have stated, in the early stages of both sexes), which probably migrate into the adjacent stroma, accompanied by some of the indifferent epithelial cells. Here the primitive germinal cells increase in number and give rise to the cells lining the secretory tubules of the testes.

Outgrowths from the Malpighian bodies of the Wolffian body appear to be developed, which extend into the testis and come into connection with the true seminiferous stroma.

It is evident from the above account that the male and female generative products are homodynamous, but the consideration of the development of the products in the two sexes shows that a single spermatozoon is not equivalent to an ovum, but rather *that the whole of the spermatozoa derived from a primordial ovum are together equivalent to one ovum.*

We have now described the origin of all the parts which form the urinary and sexual systems, both of the embryo and adult. It merely remains to speak briefly

of the changes, which on the attainment of the adult condition take place in the parts described.

The Wolffian body, according to Waldeyer, may be said to consist of a sexual and urinary part, which can, he states, be easily distinguished in the just-hatched chick. The sexual part becomes in the cock the after-testes or *coni vasculosi*, and consists of tubules which lose themselves in the seminiferous tubules. In the hen it forms part of the *epoophoron*¹ of Waldeyer, and is composed of well-developed tubes without pigment. The urinary part forms in both sexes a small rudiment, consisting of blindly ending tubes with yellow pigment; it is most conspicuous in the hen. This rudiment has been called by Waldeyer *parepididymis* in the male and *paroophoron* in the female.

The Wolffian duct remains as the *vas deferens* in the male. In the female it becomes atrophied and nearly disappears.

The duct of Müller on the right side (that on the left side with the corresponding ovary generally disappearing) remains in the female as the oviduct. In the male it is almost entirely obliterated on both sides.

Vascular system. We may return to the changes which are taking place in the circulation.

On the fourth day, the point at which the dorsal aorta divides into two branches is carried much further back towards the tail.

A short way beyond the point of bifurcation, each vessel gives off a branch to the newly-formed allantois.

¹ This is also called *parovarium* (His), and *Rosenmüller's organ*.

It is not, however, till the second half of the fourth day, when the allantois grows rapidly, that these *allantoic*, or, as they are sometimes called, umbilical, arteries acquire any importance, if indeed they are present before.

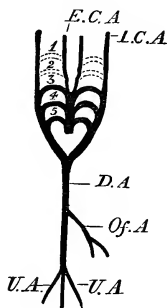
The vitelline arteries are before the end of the day given off from the undivided aortic trunk as a single but quickly bifurcating vessel, the left of the two branches into which it divides being much larger than the right.

During this day, the arterial arch running in the first visceral fold becomes obliterated, the obliteration being accompanied by the appearance of a new (fourth) arch running in the fourth visceral fold on either side.

The second pair of arterial arches also becomes nearly (if not entirely) obliterated; but a new pair of arches is developed in the last (fifth) visceral fold, behind the last visceral cleft; so that there are still three pairs of arterial arches, which however now run in the third, fourth and fifth visceral folds, the last of these being as yet small. If we reckon in the slight remains of the second pair of arches we may consider that there are in all four pairs of arches. When the first and second arches are obliterated, it is only the central portion of each arch on either side which absolutely disappears. The ventral portion connected with the bulbus arteriosus, and the dorsal portion which joins the dorsal aorta, both remain, and are both carried straight forward towards the head. The ventral portions of both first and second arches unite on each side to form a branch, the external carotid (Fig. 73, *E.C.A.*),

which runs straight up from the bulbus arteriosus to the head.

FIG. 73.



STATE OF ARTERIAL CIRCULATION ON THE FIFTH OR SIXTH DAY.

E.C.A. external carotid. *I.C.A.* internal carotid. *D.A.* dorsal aorta. *Of.A.* vitelline artery. *U.A.* allantoic arteries.

In the same way the dorsal portions form a branch, the internal carotid, which takes its origin from the dorsal or far end of the third arch.

In the venous system important changes also occur.

As the liver in the course of its formation wraps round the common trunk of the vitelline veins, or meatus venosus, it may be said to divide that vessel into two parts: into a part nearer the heart which is called the *sinus venosus* (Fig. 74, *S.V.*), and into a part surrounded by the liver which is called the *ductus venosus*. Beyond, *i.e.* behind the liver, the ductus venosus is directly continuous with the vitelline veins, or, as we may now say, vein, for the right trunk has become so small as to appear a mere branch of the left (Fig. 74, *Of.*).

FIG. 74.

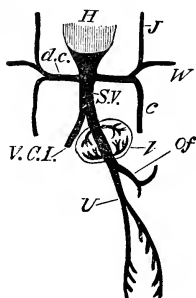


DIAGRAM OF THE VENOUS CIRCULATION AT THE COMMENCEMENT OF THE FIFTH DAY.

H. heart. *d.c.* ductus Cuvieri. Into the ductus Cuvieri of each side fall *J.* the jugular vein or superior cardinal vein, *W.* the vein from the wing, and *c.* the inferior cardinal vein. *S.V.* sinus venosus. *Of.* vitelline vein. *U.* allantoic vein, which at this stage gives off branches to the body-walls. *V.C.I.* vena cava inferior. *l.* liver.

The hepatic circulation, which was commenced on the third day, becomes completely established. Those branches which come off from the ductus venosus soon after its entrance between the liver lobes carry blood into the substance of the liver and are called *venæ advehentes*, while those which join the ductus venosus shortly before it leaves the liver (*i.e.* nearer the heart) carry blood away from the hepatic substance into the ductus and are called *venæ revehentes*. As a result of this arrangement there is a choice of paths for the blood in passing from the vitelline vein to the sinus venosus; it may pass through the capillary network of the liver, going in by the *venæ advehentes* and

coming back again by the *venæ revehentes*, or it may go straight through the *ductus venosus* without passing at all into the substance of the liver.

As the alimentary canal by its continued closing in becomes on the fourth day more and more distinct from the yolk-sac, it gradually acquires veins of its own, the *mesenteric veins*, which first appear as small branches of the vitelline vein, though eventually, owing to the change in the relative size and importance of the yolk-sac and intestine, the latter seems to be a branch of one of the former.

Corresponding to the increase in the size of the head, the superior cardinal veins (Fig. 74, *J.*) become larger and more important and are joined by the wing veins (*W.*). As before, they form the *ductus Cuvieri* (*d.c.*) by joining with the inferior cardinal veins (*c.*).

The latter are now largely developed, they seem to take origin from the Wolffian bodies, and their size and importance is in direct proportion to the prominence of these bodies. They might be called the veins of the Wolffian bodies.

As the kidneys begin to be formed a new single median vein makes its appearance, running from them forwards, beneath the vertebral column, to fall into the *sinus venosus* (Fig. 74, *V.C.I.*). This is the *vena cava inferior*.

As the lungs are being formed the pulmonary veins also make their appearance and become connected with the left side of the auricular division of the heart.

The blood carried to the allantois by the allantoic arteries is brought back by two veins, which very soon after their appearance unite, close to the allantois, into

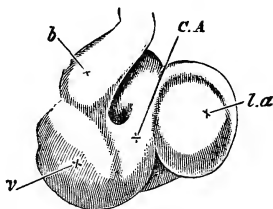
a single trunk, the *allantoic* vein, which, running along the splanchnopleure, falls into the vitelline vein (Fig. 74, *U*).

Meanwhile the heart is undergoing considerable changes. Though the whole organ still exhibits a marked curvature to the right, the ventricular portion becomes directed more distinctly ventralwards, forming a blunted cone whose apex will eventually become the apex of the adult heart.

The concave (or dorsal) walls of the ventricles become much thicker, as did the convex or ventral walls on the third day.

Well-marked constrictions now separate the ventricles from the bulbus arteriosus on the one hand, and from the auricles on the other. The latter constriction is very distinct, and receives the name of *canalis auricularis* (Fig. 75, *C.A.*); the former, sometimes called the *fretum Halleri*, is far less conspicuous.

FIG. 75.



HEART OF A CHICK ON THE FOURTH DAY OF INCUBATION
VIEWED FROM THE VENTRAL SURFACE.

l.a. left auricular appendage. *C.A.* canalis auricularis. *v.* ventricle. *b.* bulbus arteriosus.

The most important event is perhaps the formation of the *ventricular septum*. This, which commenced on the third day as a crescentric ridge or fold springing from the convex or ventral side of the rounded ventricular portion of the heart, now grows rapidly across the ventricular cavity towards the concave or dorsal side. It thus forms an incomplete longitudinal partition, extending from the *canalis auricularis* to the commencement of the *bulbus arteriosus*, and dividing the twisted ventricular tube into two somewhat curved canals, one more to the left and above, the other to the right and below. These communicate freely with each other, above the free edge of the partition, along its whole length.

Externally the ventricular portion as yet shews no sign of the division into two parts.

The *bulbus arteriosus* (Fig. 75, *b.*) has increased in size, and is now very conspicuous.

The venous end of the heart is placed still more dorsal, and to the left of the arterial end; its walls are beginning to become thicker.

The auricles are nearly if not quite as far forward as the ventricles, and the auricular appendages (Fig. 75, *l.a.*), which were visible even on the third day, are exceedingly prominent, giving a strongly marked external appearance of a division of the auricular portion of the heart into two chambers; but Von Baer was unable to detect at this date any internal auricular septum.

The chief events then of the fourth day are:—

- (1) The increase of the cranial and body flexure.

- (2) The increase in the tail-fold.
- (3) The formation of the limbs as local thickenings of the Wolffian ridge.
- (4) The formation of the olfactory grooves.
- (5) The absorption of the partition between the mouth and the throat.
- (6) The vacuolation of the cells of the notochord.
- (7) The formation of the ureter.
- (8) The formation of the duct of Müller.
- (9) The appearance of the primitive ova in the germinal epithelium.
- (10) The development of a fifth pair of arterial arches, and the obliteration of the first, and partial obliteration of the second pair.
- (11) The development of the 'canalis auricularis,' the growth of the septum of the ventricles and of the auricular appendages.

CHAPTER VIII.

THE CHANGES WHICH TAKE PLACE ON THE FIFTH DAY.

ON opening an egg about the middle of the fifth day, the observer's attention is not arrested by any new features; but he notices that the progress of development, which was so rapid during the later half of the fourth day, is being continued with undiminished vigour.

The allantois, which on the fourth day began to project from the pleuroperitoneal cavity, has grown very rapidly, and now stretches away from the somatic stalk far over the right side of the embryo (which it will be remembered is lying on its left side) in the cavity between the two amniotic folds (Fig. 9, *K*). It is very vascular, and already serves as the chief organ of respiration.

The blastoderm has spread over the whole of the yolk-sac, and the yolk is thus completely enclosed in a bag whose walls however are excessively delicate and easily torn. The vascular area extends over about two-thirds of the yolk.

The splanchnic stalk or vitelline duct has now reached its greatest narrowness; it has become a solid

cord, and will undergo no further change till near the time of hatching. The space between it and the somatic stalk is still considerable, though the latter is narrower than it was on the fourth day.

The embryo remains excessively curved, so much so indeed that the head and the tail are nearly in contact.

The limbs have increased, especially in length; in each a distinction is now apparent between the more cylindrical stalk and the flattened terminal expansion; and the cartilaginous precursors of the several bones have already become visible.

The fore and hind limbs are still exceedingly alike, and in both the stalk is already beginning to be bent about its middle to form the elbow and knee respectively.

The angles of both knee and elbow are in the first instance alike directed outwards and somewhat backwards. By the eighth day, however, the elbow has come to look directly backwards and the knee forwards. In consequence of this change, the digits of the fore limb point directly forwards, those of the hind limb directly backwards. This state of things is altered by a subsequent rotation of the hand and foot on the arm and leg, so that by the tenth day the toes are directed straight forwards, and the digits of the wing backwards and somewhat ventralwards, the elbow and knee almost touching each other.

While these changes are taking place the differences between wing and foot become more and more distinct. The cartilages of the digits appear on the fifth day as streaks in the broad flat terminal expansions, from the

even curved edge of which they do not project. On the sixth or seventh day the three digits of the wing (the median being the longest) and the four (or in some fowls five) digits of the foot may be distinguished, and on the eighth or ninth day these begin to project from the edge of the expanded foot and wing, the substance of which, thin and more or less transparent, remains for some time as a kind of web between them. By the tenth day the fore and hind extremities, save for the absence of feathers and nails, are already veritable wings and feet.

Within the mesoblast of the limbs a continuous blastema becomes formed, which constitutes the first trace of the skeleton of the limb. The corresponding elements of the two limbs, viz. the humerus and femur, radius and tibia, ulna and fibula, carpal and tarsal bones, metacarpals and metatarsals, and phalanges, become differentiated within this, by the conversion of definite regions into cartilage, which probably are at first united. These cartilaginous elements subsequently ossify.

The pectoral girdle. The scapulo-coracoid elements of the shoulder girdle are formed as a pair of cartilaginous plates, one on each side of the body. The dorsal half of each plate ossifies as the scapula, the ventral as the coracoid. The clavicles are probably membrane bones.

The pelvic girdle is derived from a pair of cartilaginous plates, one on each side. Each of them is developed in continuity with the femur of its side. The dorsal half of each plate ossifies as the ilium; the ventral half becomes prolonged into two processes, the anterior of which ossifies as the pubis, the posterior at the ischium.

Ribs and sternum. The ribs appear to arise as cartilaginous bars in the connective tissue of the body

walls. They are placed opposite the intervals between the muscle-plates, and are developed independently of the vertebræ, with the transverse processes of which they subsequently become closely united by fibrous tissue.

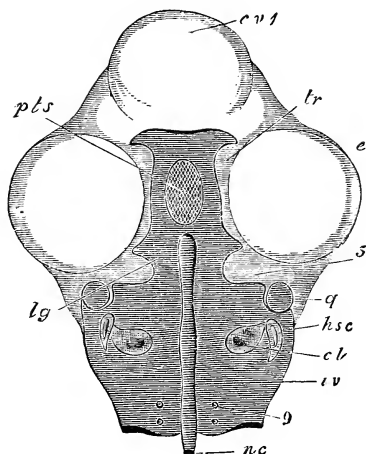
The sternum appears to be formed from the fusion of the ventral extremities of a certain number of the ribs. The extremities of the ribs unite with each other from before backwards, and thus give rise to two cartilaginous bands. These bands become segmented off from the ribs with which they are at first continuous, and subsequently fuse in the median ventral line to form the unpaired sternum.

The skull. Two distinct sets of elements enter into the composition of the avian skull. These are (1) the cranium proper, (2) the skeleton of the visceral arches.

The cranium. As we mentioned in the last chapter, the formation of the primitive cranium commenced upon the fourth day. This primitive cranium, in its earliest stage, inasmuch as it is composed of condensed but otherwise only slightly differentiated mesoblast, may be spoken of as the membranous cranium. On the sixth day true hyaline cartilage makes its appearance as a differentiation within the membranous cranium. The cartilaginous cranium is composed of the following parts.

(1) A pair of cartilaginous plates placed on each side of the cephalic section of the notochord, and known as the *parachordals* (Fig. 76, *iv.*). These plates, together with the notochord (*nc.*) enclosed between them, form a floor for the hind- and mid-brain. The continuous plate, formed by them and the notochord, is known as the *basilar plate*.

FIG. 76.



VIEW FROM ABOVE OF THE PARACHORDALS AND OF THE TRABECULÆ ON THE FIFTH DAY OF INCUBATION. (From Parker.)

In order to shew this the whole of the upper portion of the head has been sliced away. The cartilaginous portions of the skull are marked with the *dark* horizontal shading.

c.v. 1. cerebral vesicles (sliced off). *e.* eye. *nc.* notochord. *iv.* parachordal. 9. foramen for the exit of the ninth nerve. *cl.* cochlea. *h.s.c.* horizontal semi-circular canal. *q.* quadrate. 5. notch for the passage of the fifth nerve. *lg.* expanded anterior end of the parachordals. *pt.s.* pituitary space. *tr.* trabeculæ. The reference line *tr* has accidentally been made to end a little short of the cartilage.

(2) A pair of bars forming the floor for the fore-brain, and known as the *trabeculæ* (*tr.*). These bars are continued forward from the parachordals, with which, in the chick, they are from the first continuous. United

behind where they embrace the front end of the notochord, they diverge anteriorly for some little distance and then bend in again in such a way as to enclose a space—the pituitary space. In front of this space they again unite and extend forwards into the nasal region.

(3) The cartilaginous capsules of the sense organs. Of these the auditory and olfactory capsules unite more or less intimately with the cranial walls, while the optic capsules, forming the sclerotics, remain distinct.

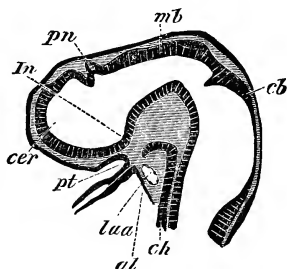
The parachordals and notochord. The first of these sets of elements, viz. the parachordals and notochord, forming together the basilar plate, is an unsegmented continuation of the axial tissue of the vertebral column. It forms the floor for that section of the brain which belongs to the primitive postoral part of the head, and its extension is roughly that of the basioccipital of the adult skull.

Laterally it encloses the auditory sacs (Fig. 76), the tissue surrounding these (forming the so-called ‘periotic capsules’) is in the chick never separate from the basilar plate. In front it becomes narrowed, and at the same time excavated so as to form a notch on each side (Fig. 76, 5) through which the fifth nerve passes; and in front of this it again becomes expanded.

In order to render our subsequent account more intelligible, we may briefly anticipate the fate of the basilar plate. Behind it grows upwards on both sides, and the two outgrowths meet above so as completely to enclose the medulla oblongata, and to circumscribe a hole known as the ‘*occipital foramen*.’ And it is at this point only that the roof of the skull is at any period formed of cartilage.

It will be convenient to say a few words here with reference to the notochord in the head. It always extends along the floor of the mid- and hind-brains, but ends immediately behind the infundibulum. The front end of the notochord becomes more or less ventrally flexed in correspondence with the cranial flexure; its anterior end being in some animals (Elasmobranchii) almost bent backwards (Fig. 77).

FIG. 77.



LONGITUDINAL SECTION THROUGH THE HEAD OF A YOUNG
PRISTIURUS EMBRYO.

cer. commencement of the cerebral hemisphere. *pn.* pineal gland.
In. infundibulum. *pt.* ingrowth from mouth to form the
pituitary body. *mb.* mid-brain. *cb.* cerebellum. *ch.* noto-
chord. *al.* alimentary tract. *Iaa.* artery of mandibular
arch.

Kölliker has shewn that in the Rabbit, and a more or less similar phenomenon may also be observed in Birds, the anterior end of the notochord is united to the hypoblast of the throat in immediate contiguity with the opening of the pituitary body; but it is not clear whether this is to be looked upon as the remnant of a primitive attachment of the notochord to the hypoblast, or as a secondary attachment.

Within the basilar plate the notochord often exhibits two or more dilatations, which have been regarded by Parker and Kölliker as indicative of a segmentation of this plate; but they hardly appear to be capable of this interpretation.

The trabeculæ. The trabeculæ, so far as their mere anatomical relations are concerned, play the same part in forming the floor for the front cerebral vesicle as the parachordals for the mid- and hind-brains. They differ however from the parachordals in one important feature, viz. that, except at their hinder end, they do not embrace between them the notochord.

The notochord constitutes, as we have seen, the primitive axial skeleton of the body, and its absence in the greater part of the region of the trabeculæ would probably seem to indicate, as pointed out by Gegenbaur, that these parts, in spite of their similarity to the parachordals, have not the same morphological significance.

While this distinction between the parachordals and the trabeculæ must be admitted, there seems to be no reason against supposing that the trabeculæ may be plates developed to support the floor of the fore-brain, for the same physiological reasons that the parachordals have become formed at the sides of the notochord to support the floor of the hind-brain. By some anatomists the trabeculæ have been held to be a pair of branchial bars; but this view has now been generally given up. They have also been regarded as equivalent to a complete pair of neural arches enveloping the front end of the brain. The primitive extension of the base of the fore-brain through the pituitary space is an argument, not without force, which has been appealed to in support of this view.

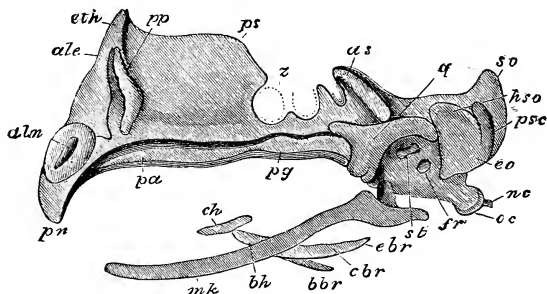
In the majority of the lower forms the trabeculæ arise quite independently of the parachordals, though the two sets of elements soon unite; while in Birds (Fig. 76) and Mammals the parachordals and trabeculæ are formed as a continuous whole. The junction be-

tween the trabeculæ and parachordals becomes marked by a cartilaginous ridge known as the posterior clinoid.

The trabeculæ are somewhat lyre-shaped, meeting in front and behind, and leaving a large pituitary space between their middle parts (Fig. 76). Into this space there primitively projects the whole base of the fore-brain, but the space itself gradually becomes narrowed, till it usually contains only the pituitary body. The carotid arteries pass through it in the embryo; but it ceases to be perforated in the adult. The trabeculæ soon unite together, both in front and behind, and form a complete plate underneath the fore-brain, ending in two horns in the interior of the fronto-nasal process. A special vertical growth of this plate in the region of the orbit forms the *interorbital plate* (Fig. 78, *ps.*), on the upper surface of which the front part of the brain rests. The trabecular floor of the brain does not long remain simple. Its sides grow vertically upwards, forming a lateral wall for the brain, in which two regions may be distinguished, viz. an *alisphenoidal* region (Fig. 78, *as.*) behind, growing out from what is known as the *basisphenoidal* region of the primitive trabeculæ, and an *orbitosphenoidal* region in front growing out from the *presphenoidal* region of the trabeculæ. These plates form at first on each side a continuous lateral wall of the cranium. At the front end of the brain they are continued inwards, and more or less completely separate the true cranial cavity from the nasal region in front. The region of the trabeculæ in front of the brain is the *ethmoidal* region; it forms the anterior boundary of the cranial cavity. The basal part of this region forms an internasal plate, from which an

internasal septum, continuous behind with the inter-orbital septum, grows up (Fig. 78); while the lateral

FIG. 78.



SIDE VIEW OF THE CARTILAGINOUS CRANIUM OF A FOWL ON THE SEVENTH DAY OF INCUBATION. (After Parker.)

pn. prenasal cartilage. *aln.* alinasal cartilage. *ale.* aliethmoid; immediately below this is the aliseptal cartilage. *eth.* ethmoid. *pp.* pars plana. *ps.* presphenoid or inter-orbital. *pa.* palatine. *pg.* pterygoid. *z.* optic nerve. *as.* alisphenoid. *q.* quadrate. *st.* stapes. *fr.* fenestra rotunda. *hso.* horizontal semicircular canal. *psc.* posterior vertical semicircular canal: both the anterior and the posterior semicircular canals are seen shining through the cartilage. *so.* supra-occipital. *eo.* exoccipital. *oc.* occipital condyle. *nc.* notochord. *mk.* Meckel's cartilage. *ch.* cerato-hyal. *bh.* basi-hyal. *cbr.* and *ebr.* cerato-branchial. *bbr.* basibranchial.

part is known as the *lateral ethmoid* region, which is always perforated for the passage of the olfactory nerve.

The sense capsules. The most important of these is the auditory capsule, which, as we have seen, fuses intimately with the lateral walls of the skull. In front there is usually a cleft separating it from the alisphen-

noid region of the skull, through which the third division of the fifth nerve passes out. This cleft becomes narrowed to a small foramen. The sclerotic is free, but profoundly modifies the region of the cranium near which it is placed. The nasal investment is developed in continuity, and is closely united, with the ethmoid region.

The cartilaginous cranium, the development of which has been thus briefly traced, persists in the adult without even the addition of membrane bones in certain fishes, *e.g.* the Elasmobranchii. In the Sela-chioid Ganoids it is also found in the adult, but is covered over by membrane bones. In all other types it is invariably present in the embryo, but becomes in the adult more or less replaced by osseous tissue.

The bones in the adult skull may be divided roughly into two categories according to their origin.

(1) *Cartilage bones, i.e.* ossifications in the primitive cartilaginous cranium.

(2) *Membrane bones, i.e.* ossifications in membrane without any cartilaginous precursors.

The names which have been given to the various parts of the cartilaginous cranium in the above account are derived from the names given to the bones appearing in the respective regions in the more developed skull.

The skeleton of the visceral arches. The visceral arches were all originally branchial in function. They supported the walls between successive branchial clefts.

The first arch (mandibular) has in all living forms lost its branchial function, and its bar has become converted into a supporting skeleton for the jaws.

The second arch (hyoid), with its contained bar, though retaining in some forms (Elasmobranchii) its branchial function, has in most acquired additional functions, and has undergone in consequence various peculiar modifications.

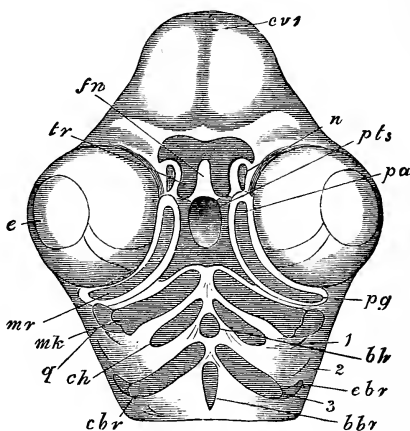
The succeeding arches and their contained bars retain their branchial function in Pisces and some Amphibia, but are secondarily modified and largely aborted in the abbranchiate forms.

The ordinary visceral arches in the chick are, as we have seen, sufficiently obvious, while as yet their mesoblast is quite undifferentiated; but in the three anterior of them rods of cartilage are subsequently developed and begin to make their appearance about the fifth day.

The first arch (mandibular), it will be remembered, budded off a process called the superior maxillary process. The whole arch, therefore, comes to consist of two parts, viz. a superior and an inferior maxillary process; it is in the latter of these that the cartilaginous rod on each side is developed. The membranous tissue in the superior maxillary process is called, from its subsequent fate, the *pterygo-palatine* bar, and is in the chick ossified directly without the intervention of cartilage. In the inferior maxillary process two developments of cartilage take place, a proximal and a distal. The proximal cartilage is situated (Figs. 76 and 79, *q*.) at the side of the periotic capsule, but is not united with it. It is known as the *quadrate*, and in the early stage is merely a small knob of cartilage. The quadrate cartilage ossifies as the quadrate bone, and supplies the permanent articulation for the lower jaw. The distal rod is called

Meckel's cartilage (Fig. 79, *mk.*); it soon becomes covered by investing (membrane) bones which form the mandible; and its proximal end ossifies as the *articulare*.

FIG. 79.



VIEW FROM BELOW OF THE PAIRED APPENDAGES OF THE SKULL OF A FOWL ON THE FIFTH DAY OF INCUBATION. (From Parker.)

cv. 1. cerebral vesicles. *e.* eye. *fn.* fronto-nasal process. *n.* nasal pit. *tr.* trabeculae. *pts.* pituitary space. *mr.* superior maxillary process. *pg.* pterygoid. *pa.* palatine. *q.* quadrate. *mk.* Meckel's cartilage. *ch.* cerato-hyal. *bh.* basi-hyal. *cbr.* ceratobranchial. *ebr.* proximal portion of the cartilage in the third visceral arch. *bbr.* basibranchial. 1. first visceral cleft. 2. second visceral cleft. 3. third visceral arch.

In the next arch, usually called the second visceral or hyoid arch, there is a very small development of cartilage. This consists of a central azygos piece, the

'basi-hyal' (Fig. 79, *bh.*), and two rods, one on each side, the 'cerato-hyals' (Fig. 79, *ch.*).

In the third arch, which corresponds with the first branchial arch of the Ichthyopsida, there is on each side a large distal cartilaginous rod (Fig. 79, *cbr.*), the 'cerato-branchial,' and a smaller proximal piece (Fig. 79, *ebr.*); between the two arches lies an undefined mass (Fig. 79, *bbr.*), the 'basibranchial.' In the arches behind this one there is in the bird no development of cartilage.

The lower part of the hyoid arch, including the basi-hyal, unites with the remnants of the arch behind to form the hyoid bone of the adult.

The fenestra ovalis and fenestra rotunda appear on the seventh day as spaces in the side walls of the periotic cartilage. The former is filled up by a small piece of cartilage, the *stapes* (Fig. 78, *st.*), which in the adult forms part of the columella (see pp. 166, 167).

The columella is believed by Huxley and Parker to represent the independently developed dorsal element of the hyoid, together with the stapes with which it has become united.

For further details of the development of the skull we must refer the student to Professor Parker's *Memoir upon the Development of the Skull of the Common Fowl* (*Gallus domesticus*), *Phil. Trans.*, 1866, Vol. CLVI., pt. 1, and to the chapter on the Bird's skull in the *Morphology of the Skull*, by Professor Parker and Mr Bettany.

We shall conclude this account by giving a table of those bones which are preformed in cartilage, and of the purely splint or membrane bones.

Parts of the bird's skull which are either preformed in cartilage or remain cartilaginous.

Formed from the parachordal cartilages and their upgrowths around the foramen magnum.—Supraoccipital. Exoccipital. Basioccipital.

Formed in the periotic cartilage.—Epiotic. Prootic. Opisthotic.

Formed from the trabeculæ and their upgrowths.—Alisphenoid. Basisphenoid. Orbitosphenoid. Presphenoid. Ethmoid. Septum nasi, turbinals, prenasal and nasal cartilages.

Articulare and quadrate belonging to the first visceral arch. Skeleton of the second and third visceral arches and stapes.

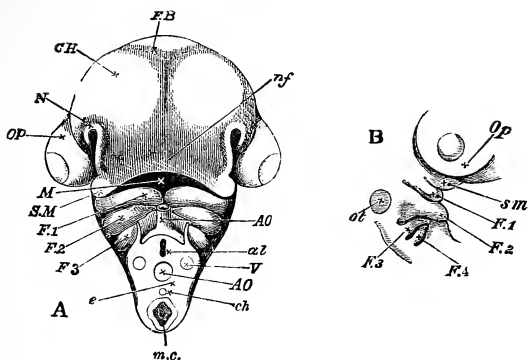
Splint-bones not preformed in cartilage.

Parietals. Squamosals. Frontals. Lacrymals. Nasals. Premaxillæ. Maxillæ. Maxillo-palatines. Vomer. Jugals. Quadrato-jugals. Dentary and bones of mandible. Basi-temporal and rostrum. Pterygoid and palatine (superior maxillary process).

The face. Closely connected with the development of the skull is the formation of the parts of the face.

After the appearance of the nasal grooves on the fourth day the mouth (Fig. 80, *M.*) appears as a deep depression inclosed by five processes. Its lower border is entirely formed by the two inferior maxillary processes (Fig. 80, *F. 1*), at its sides lie the two superior maxillary processes *S. M.*, while above it is bounded by the fronto-nasal process *nf*.

FIG. 80.



A. HEAD OF EMBRYO CHICK OF THE FOURTH DAY VIEWED FROM BELOW AS AN OPAQUE OBJECT. (Chromic acid preparation.)

C.H. cerebral hemispheres. *FB.* vesicle of the third ventricle. *Op.* eyeball. *nf.* naso-frontal process. *M.* cavity of mouth. *S.M.* superior maxillary process of *F. 1*, the first visceral fold (mandibular arch). *F. 2*, *F. 3*, second and third visceral folds. *N.* nasal pit.

In order to gain the view here given the neck was cut across between the third and fourth visceral folds. In the section *e* thus made, are seen the alimentary canal *al* with its collapsed walls, the neural canal *m.c.*, the notochord *ch.*, the dorsal aorta *AO.*, and the jugular veins *V.*

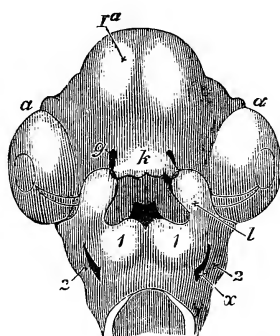
B. The same seen sideways, to shew the visceral folds. Letters as before.

After a while the outer angles of the fronto-nasal process, enclosing the expanded termination of the trabeculae, project somewhat outwards on each side, giving the end of the process a rather bilobed appearance. These projecting portions of the fronto-nasal process form on each side the inner margins of the rapidly

deepening nasal grooves, and are sometimes spoken of as the *inner nasal processes*. The outer margin of each nasal groove is raised up into a projection frequently spoken of as the *outer nasal process*, which runs downwards to join the superior maxillary process, from which however it is separated by a shallow depression. This depression, which runs nearly horizontally outwards towards the eyeball, is known as the lacrymal groove (see p. 155).

On the fifth day the inner nasal processes, or lower and outer corners of the fronto-nasal process, arching over, unite on each side with the superior maxillary processes. (Compare Fig. 81, which, however, is a view of the head of a chick of the sixth day.) In this way each nasal groove is converted into a canal, which leads

FIG. 81.



HEAD OF A CHICK AT THE SIXTH DAY FROM BELOW. (From Huxley.)

la. cerebral vesicles. *a.* eye, in which the remains of the choroid slit can still be seen. *g.* nasal pits. *k.* fronto-nasal process. *l.* superior maxillary process. *1.* inferior maxillary process

or first visceral arch. 2. second visceral arch. *x.* first visceral cleft between the first and second visceral arches.

The cavity of the mouth is seen enclosed by the fronto-nasal process, the superior maxillary processes and the first pair of visceral arches. At the back of it is seen the opening leading into the throat. The nasal grooves leading from the nasal pits to the mouth are already closed over and converted into canals.

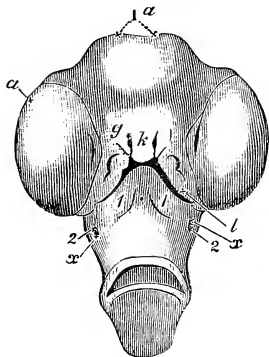
from the nasal pit above, into the cavity of the mouth below, and places the two in direct communication. This canal, whose lining consists of epiblast, is the rudiment of the nasal labyrinth.

By the seventh day (Fig. 82), not only is the union of the superior maxillary and fronto-nasal processes completed, and the upper boundary of the mouth thus definitely constituted, but these parts begin to grow rapidly forward, thus deepening the mouth and giving rise to the appearance of a nose or beak (Fig. 82), which, though yet blunt, is still distinct. The whole of the lower boundary of the buccal cavity is formed by the inferior maxillary processes.

As we have before mentioned (p. 240), cartilage succeeded by bone is developed in the fronto-nasal process; the pterygo-palatine osseous bar (membranous ossification) in the superior maxillary process; Meckel's cartilage the main part of which atrophies, the proximal end only ossifying as the articulare, and the quadrate succeeded by bone in the inferior maxillary process; the other bones which form the boundaries of the mouth in the adult are developed later after all external trace of these parts as separate processes has disappeared.

At first the mouth is a simple cavity into which the nasal canals open directly. When however the various

FIG. 82.



HEAD OF A CHICK OF THE SEVENTH DAY FROM BELOW. (From Huxley.)

la. cerebral vesicles. *α.* eye. *g.* nasal pits. *k.* fronto-nasal process. *l.* superior maxillary process. *1.* first visceral arch. *2.* second visceral arch. *x.* first visceral cleft.

The external opening of the mouth has become much constricted, but it is still enclosed by the fronto-nasal process and superior maxillary processes above, and by the inferior maxillary processes (first pair of visceral arches) below.

The superior maxillary processes have united with the fronto-nasal process, along the whole length of the latter, with the exception of a small space in front, where a narrow angular opening is left between the two.

processes unite together to form the upper boundary of the mouth, each superior maxillary process sends inwards a lateral bud. These buds become flattened and form horizontal plates which stretch more and more inward towards the middle line. There they finally meet, and by their union, which is effected first in front and thence extends backwards, constitute a horizontal

plate stretching right across the mouth and dividing it into two cavities—an upper and a lower one.

In the front part of the mouth their union is quite complete, so that here there is no communication between the two cavities. Behind, however, the partition is not a complete one, so that the two divisions of the buccal cavity communicate at the back of the mouth. The external opening of the mouth passes into the lower of these two cavities, which may therefore be called the mouth proper. Into the upper chamber the nasal ducts open; it may be called the respiratory chamber, and forms the commencement of the chamber of the nose. In birds generally the upper nasal cavity becomes subsequently divided by a median partition into two chambers, which communicate with the back of the mouth by separate apertures, the posterior nares. The original openings of the nasal pits remain as the nostrils.

The spinal cord.—On this day important changes take place in the spinal cord; and a brief history of the development of this organ may fitly be introduced here.

At the beginning of the third day the cavity of the neural canal is still of considerable width, and when examined in vertical section its sides may be seen to be nearly parallel, though perhaps approximating to each other more below than above.

The exact shape varies according to the region of the body from which the section is taken.

The epiblast walls are at this time composed of radiately arranged columnar cells. The cells are much elongated, but somewhat irregular; and it is very

difficult in sections to make out their individual boundaries. They contain granular oval nuclei in which a nucleolus can almost always be seen. The walls of the canal are both anteriorly and posteriorly considerably thinner in the median plane than in the middle.

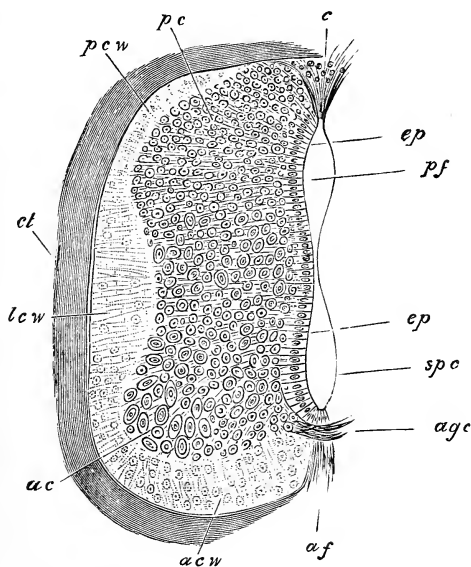
Towards the end of the third day changes take place in the shape of the cavity. In the lumbar region its vertical section becomes more elongated, and at the same time very narrow in the middle while expanded at each end into a somewhat bulbous enlargement, producing an hour-glass appearance (Fig. 65). Its walls however still preserve the same histological characters as before.

On the fourth day (Fig. 68) coincidently with the appearance of the spinal nerves, important changes may be observed in the hitherto undifferentiated epiblastic walls, which result in its differentiation into (1) the epithelium of the central canal, (2) the grey matter of the cord, and (3) the external coating of white matter.

The white matter is apparently the result of a differentiation of the outermost parts of the superficial cells of the cord into longitudinal nerve-fibres, which remain for a long period without a medullary sheath. These fibres appear in transverse sections as small dots. The white matter forms a transparent investment of the grey matter; it arises as four patches, viz. an anterior and a posterior white column on each side, which lie on a level with the origin of the anterior and posterior nerve-roots. It is always, at first, a layer of extreme tenuity, but rapidly increases in thickness in the sub-

sequent stages, and extends so as gradually to cover the whole cord (Fig. 83).

FIG. 83.



SECTION THROUGH THE SPINAL CORD OF A SEVEN DAYS' CHICK.

pcw. dorsal white column. *lcw.* lateral white column. *acw.* ventral white column. *c.* dorsal tissue filling up the part where the dorsal fissure will be formed. *pc.* dorsal grey cornu. *ac.* anterior grey cornu. *ep.* epithelial cells. *agc.* anterior commissure. *pf.* dorsal part of spinal canal. *spc.* ventral part of spinal canal. *af.* anterior fissure.

The grey matter and the central epithelium are formed by a differentiation of the main mass of the walls of the medullary canal. The outer cells lose their

epithelial-like arrangement, and, becoming prolonged into fibres, give rise to the grey matter, while the innermost cells retain their primitive arrangement, and constitute the epithelium of the canal. The process of formation of the grey matter would appear to proceed from without inwards, so that some of the cells which have, on the formation of the grey matter, an epithelial-like arrangement, subsequently become converted into true nerve-cells.

The central epithelium of the nervous system probably corresponds with the so-called epidermic layer of the epiblast.

The grey matter soon becomes prolonged dorsally and ventrally into the posterior and anterior horns. Its fibres may especially be traced in two directions:—(1) round the anterior end of the spinal canal, immediately outside its epithelium and so to the grey matter on the opposite side, forming in this way an anterior grey commissure, through which a decussation of the fibres from the opposite sides is effected: (2) dorsalwards along the outside of the lateral walls of the canal.

There is at this period (fourth day) no trace of the ventral or dorsal fissure, and the shape of the central canal is not very different from what it was at an earlier period. This condition of the spinal cord is especially instructive as it is very nearly that which is permanent in *Amphioxus*.

The next event of importance is the formation of the ventral or anterior fissure. This begins on the fifth day and owes its origin to a downgrowth of the anterior horns of the cord on each side of the middle line. The two downgrowths enclose between them a some-

what linear space—the anterior fissure—which increases in depth in the succeeding stages (Fig. 83, *af*).

The dorsal or posterior fissure is formed at a later period (about the seventh day) than the anterior, and accompanies the atrophy of the dorsal section of the embryonically large canal of the spinal cord. The exact mode of its formation appears to be still involved in some obscurity.

It seems probable, though further investigations on the point are still required, that the dorsal fissure is a direct result of the atrophy of the dorsal part of the central canal of the spinal cord. The walls of this coalesce dorsally, and the coalescence gradually extends inwards, so as finally to reduce the central canal to a minute tube, formed of the ventral part of the original canal. The epithelial wall formed by the coalesced walls on the dorsal side of the canal is gradually absorbed.

The epithelium of the central canal, at the period when its atrophy commences, is not covered dorsally either by grey or white matter, so that, with the gradual reduction of the dorsal part of the canal and the absorption of the epithelial wall formed by the fusion of its two sides, a fissure between the two halves of the spinal cord becomes formed. This fissure is the posterior or dorsal fissure. In the process of its formation the white matter of the dorsal horns becomes prolonged so as to line its walls; and shortly after its formation the dorsal grey commissure makes its appearance; this is not improbably derived from part of the epithelium of the original central canal.

Meanwhile an alteration is taking place in the external outline of the cord. From being, as on the fourth and fifth days, oval in section, it becomes, chiefly through the increase of the white matter, much more nearly circular.

By the end of the seventh day the following im-

portant parts of the cord have been definitely established:

(1) The anterior and posterior fissures.

(2) The anterior and posterior horns of grey matter.

(3) The anterior, posterior and lateral columns of white matter.

(4) The spinal canal.

As yet, however, the grey masses of the two sides of the cord only communicate by the anterior grey commissure, and the white columns of opposite sides do not communicate at all. The grey matter, moreover, still far preponderates over the white matter in quantity.

By the ninth day the posterior fissure is fully formed, and the posterior grey commissure has also appeared.

In the centre of the sacral enlargement this commissure is absent, and the posterior columns at a later period separate widely and form the 'sinus rhomboidalis,' which is not, as has been sometimes stated, the remains of the primitive 'sinus rhomboidalis' visible during the second day.

The anterior white columns have much increased on this day, and now form the sides of the already deep anterior fissure. The anterior white commissure does not however appear till somewhat later.

The heart. The fifth day may perhaps be taken as marking a most important epoch in the history of the heart. The changes which take place on that and on the sixth day, added to those previously undergone,

transform the simple tube of the early days of incubation into an almost completely formed heart.

The venous end of the heart, though still lying somewhat to the left and dorsal, is now placed as far forwards as the arterial end, the whole organ appearing to be drawn together. The ventricular septum is complete.

The apex of the ventricles becomes more and more pointed. In the auricular portion a small longitudinal fold appears as the rudiment of the auricular septum, while in the *canalis auricularis*, which is now at its greatest length, there is also to be seen a commencing transverse partition tending to separate the cavity of the auricles from those of the ventricles.

About the 106th hour, a septum begins to make its appearance in the *bulbus arteriosus* in the form of a longitudinal fold, which according to Tonge (*Proc. of Royal Soc.* 1868) starts, not (as Von Baer thought) at the end of the *bulbus* nearest to, but at that farthest removed from, the heart. It takes origin from the wall of the *bulbus* between the fifth and fourth pairs of arches and grows backwards in such a manner as to divide the *bulbus* into two channels, one of which leads from the heart to the fourth and third pair of arches and the other to the fifth pair. The free edge of the septum is somewhat V-shaped, so that its two legs as it were project backwards towards the heart, further than its central portion; and this shape of the free edge is maintained during the whole period of its growth. Its course backwards is not straight but spiral, and thus the two channels into which it divides the *bulbus arteriosus* wind spirally the one over the

other. The existence of the septum can only be ascertained at this stage by dissection or by sections, there being as yet no external signs of the division.

At the time when the septum is first formed, the opening of the bulbus arteriosus into the ventricles is narrow or slit-like, apparently in order to prevent the flow of the blood back into the heart. Soon after the appearance of the septum, however, semilunar valves (Tonge, *loc. cit.*) are developed from the wall of that portion of the bulbus which lies between the free edge of the septum and the cavity of the ventricles.

These arise as six solid outgrowths of the wall arranged in pairs, a ventral, a dorsal, and an outer pair, one valve of each pair belonging to the one and the other to the other of the two main divisions of the bulbus which are now being established.

The ventral and the dorsal pairs of valves are the first to appear: the former as two small prominences separated from each other by a narrow groove, the latter as a single shallow ridge, in the centre of which is a prominence indicating the point where the ridge will subsequently become divided into two. The outer pair of valves appear opposite each other, at a considerably later period, between the ends of the other pair of valves on each side.

As the septum grows backwards towards the heart, it finally reaches the position of these valves. One of its legs then passes between the two ventral valves, and the other unites with the prominence on the dorsal valve-ridge. At the same time the growth of all the parts causes the valves to appear to approach the heart and thus to be placed quite at the top of the ventricular

cavities. The free edge of the septum of the bulbus now fuses with the ventricular septum, and thus the division of the bulbus into two separate channels, each provided with three valves, and each communicating with a separate side of the heart, is complete, the position of the valves not being very different from what it is in the adult heart.

That division of the bulbus which opens into the fifth pair of arches is the one which communicates with the right ventricle, while that which opens into the third and fourth pairs communicates with the left ventricle (vide Fig. 93). The former becomes the pulmonary artery, the latter the commencement of the systemic aorta.

The external constriction actually dividing the bulbus into two vessels does not begin to appear till the septum has extended some way back towards the heart.

The semilunar valves become pocketed at a period considerably later than their first formation (from the 147th to the 165th hour) in the order of their appearance.

Towards the end of the fifth and in the course of the sixth day further important changes take place in the heart.

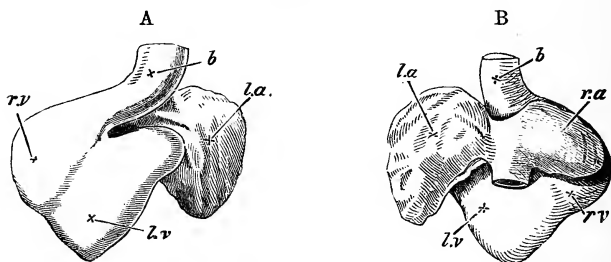
The venous end with its two very conspicuous auricular appendages, comes to be situated more dorsal to the arterial end, though it still turns rather towards the left. The venous portion of the heart undergoes on the sixth day, or even near to the end of the fifth, such a development of the muscular fibres of its walls that the *canalis auricularis* becomes almost entirely concealed. The point of the heart is now directed

nearly backwards (*i.e.* towards the tail), but also a little ventralwards.

An alteration takes place during the sixth day in the relative position of the parts of the ventricular division of the heart. The right ventricle is now turned towards the abdominal surface, and also winds to a certain extent round the left ventricle. It will be remembered that on the fourth day the right ventricle was placed dorsal to the left.

The right ventricle is now also the smaller of the two, and the constriction which divides it from the left ventricle does not extend to the apex of the heart (Fig. 84). It has, however, a very marked bulge towards the right.

FIG. 84.



TWO VIEWS OF THE HEART OF A CHICK UPON THE FIFTH DAY OF INCUBATION.

A. from the ventral, B. from the dorsal side.

l.a. left auricular appendage. *r.a.* right auricular appendage.
r.v. right ventricle. *l.v.* left ventricle. *b.* bulbus arteriosus.

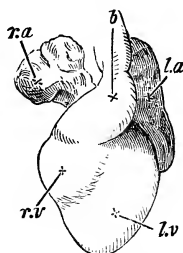
At first the bulbus arteriosus appeared to come off chiefly from the left ventricle; during the fifth day, and still more on the sixth, it appears to come from the

right chamber. This is caused by the canal from the right ventricle into the bulbus arteriosus passing towards the left, and on the ventral side, so as entirely to conceal the origin of the canal from the left chamber of the heart. On the seventh day the bulbus arteriosus appears to come less markedly from the right side of the heart.

All these changes, however, of position of the bulbus arteriosus only affect it externally; during the whole time the two chambers of the heart open respectively into the two divisions of the bulbus arteriosus. The swelling of the bulbus is much less marked on the seventh day than it was before.

At the end of the sixth day, and even on the fifth day (Figs. 84, 85), the appearance of the heart itself,

FIG. 85.



HEART OF A CHICK UPON THE SIXTH DAY OF INCUBATION,
FROM THE VENTRAL SURFACE.

l.a. left auricular appendage. *r.a.* right auricular appendage.
r.v. right ventricle. *l.v.* left ventricle. *b.* bulbus arteriosus.

without reference to the vessels which come from it, is not very dissimilar from that which it presents when adult.

The original curvature to the right now forms the apex of the ventricles, and the two auricular appendages are placed at the anterior extremity of the heart.

The most noticeable difference (in the ventral view) is the still externally undivided condition of the bulbus arteriosus.

The subsequent changes which the heart undergoes are concerned more with its internal structure than with its external shape. Indeed, during the next three days, viz. the eighth, ninth, and tenth, the external form of the heart remains nearly unaltered.

In the auricular portion, however, the septum which commenced on the fifth day becomes now more conspicuous. It is placed vertically, and arises from the ventral wall; commencing at the canalis auricularis and proceeding backwards, it does not as yet reach the opening into the sinus venosus.

The blood from the sinus, or, as we may call it, the inferior vena cava, enters the heart obliquely from the right, so that it has a tendency to flow towards the left auricle of the heart, which is at this time the larger of the two.

The valves between the ventricles and auricles are now well developed, and it is about this time that the division of the bulbus arteriosus into the aorta and pulmonary artery becomes visible on the exterior.

By the eleventh or thirteenth day the right auricle has become as large as the left, and the auricular septum much more complete, though there is still a small opening, the *foramen ovale*, by which the two cavities communicate with each other. Through this foramen the greater part of the blood of the vena cava inferior,

which is now joined just at its entrance into the heart by the right vena cava superior, is directed into the left auricle. The left vena cava superior enters the right auricle independently; between it and the inferior vena cava is a small valve which directs its blood entirely into the right auricle.

On the sixteenth day the right vena cava superior, when viewed from the exterior, still appears to join the inferior vena cava before entering the heart; from the interior however the two can now be seen to be separated by a valve. This valve, called the 'Eustachian valve,' extends to the opening of the left vena cava superior, and into it the valve which in the earlier stage separated the left superior and inferior venæ cavæ has apparently become merged. There is also on the left side of the opening of the inferior cava a membrane stretching over the foramen ovale, and serving as a valve for that orifice. The blood from the inferior cava still passes chiefly into the left auricle through the foramen ovale, while the blood from the other two venæ cavæ now falls into the right auricle, being prevented from entering the left chamber by the Eustachian valve.

Hence, since at this period also the blood from the left ventricle passes to a great extent to the anterior portion of the body, there is a species of double-circulation going on. The greater part of the blood from the allantois entering the left auricle from the inferior vena cava passes into the left ventricle and is thence sent chiefly to the head and anterior extremities through the third and fourth arches; from these it is brought back through the right auricle to the right ventricle, from

whence through the fifth arch it is returned along the aorta to the allantois.

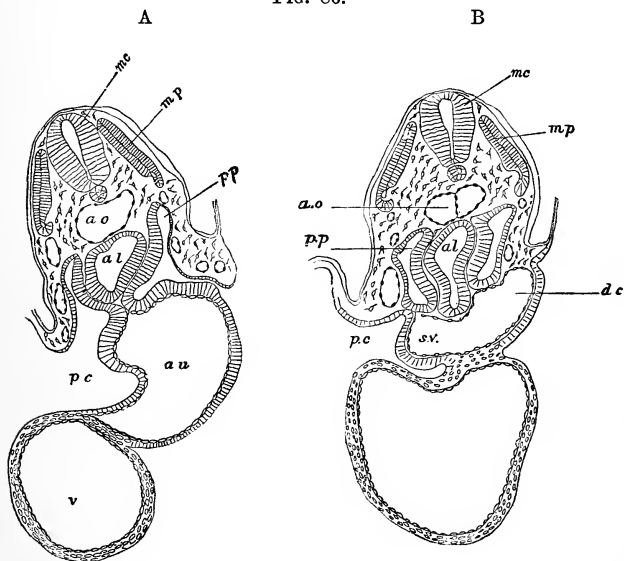
From the seventeenth to the nineteenth day the right auricle becomes larger than the left. The large Eustachian valve still prevents the blood from the superior cavæ from entering the left auricle, while it conducts the blood from the inferior vena cava into that chamber through the foramen ovale. The entrance of the inferior vena cava is however further removed than it was from the foramen ovale, and the increased flow of blood from the lungs prevents all the blood of the inferior cava from entering into the left auricle. At the same time the valve of the foramen ovale prevents the blood in the left auricle from entering the right auricle.

During the period from the seventh day onwards the apex of the heart becomes more marked, the arterial roots are more entirely separated and the various septa completed, so that when the foramen ovale is closed and the blood of the inferior vena cava thereby entirely confined to the right auricle, the heart has practically acquired its adult condition.

The pericardial and pleural cavities. The heart at first lies in the general body cavity attached to the ventral wall of the gut by a mesocardium (Fig. 86, A), but the part of the body cavity containing it afterwards becomes separated off as a distinct cavity known as the pericardial cavity. It is formed in the following way. When the two ductus Cuvieri leading transversely from the sinus venosus to the cardinal veins become developed (p. 170), a horizontal septum is formed to support them, stretching across from the splanchnic to the so-

matic side of the body cavity, dividing the body cavity for a short distance in this region into a dorsal section, (formed of a right and a left division) constituting the true body cavity (Fig. 86 B, *p.p*), and a ventral section (Fig. 86, B, *p.c.*), the pericardial cavity. The two parts of the body cavity thus formed are at first in free communication both in front of and behind this septum. The

FIG. 86.

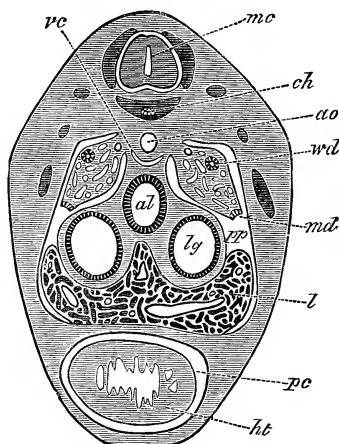


TRANSVERSE SECTIONS THROUGH A CHICK EMBRYO WITH TWENTY-ONE MESOBLASTIC SOMITES TO SHEW THE FORMATION OF THE PERICARDIAL CAVITY, A. BEING THE ANTERIOR SECTION.

pp. body cavity. *pc.* pericardial cavity. *al.* alimentary cavity. *au.* auricle. *v.* ventricle. *sv.* sinus venosus. *dc.* ductus Cuvieri. *ao.* aorta. *mp.* muscle-plate. *mc.* medullary cord.

septum however is soon continued forwards so as completely to separate the ventral *pericardial* and the dorsal *body* cavity in front, the pericardial cavity extending considerably further forwards than the body cavity.

FIG. 87.



SECTION THROUGH THE CARDIAC REGION OF AN EMBRYO OF *LACERTA MURALIS* OF 9 M.M. TO SHEW THE MODE OF FORMATION OF THE PERICARDIAL CAVITY.

ht. heart. *pc.* pericardial cavity. *al.* alimentary tract. *lg.* lung.
l. liver. *pp.* body cavity. *md.* open end of Müllerian duct.
wd. Wolffian duct. *vc.* vena cava inferior. *ao.* aorta. *ch.*
 notochord. *mc.* medullary cord.

Since the horizontal septum, by its mode of origin, is necessarily attached to the ventral side of the gut, the dorsal part of the primitive body space is, as we have already mentioned, divided into two halves by a median vertical septum formed of the gut and its

mesentery (Fig. 86, B). Posteriorly the horizontal septum grows in a slightly ventral direction along the under surface of the liver (Fig. 87), till it meets the abdominal wall of the body at the insertion of the falciform ligament, and thus completely shuts off the pericardial cavity from the body cavity. The horizontal septum forms, as is obvious from the above description, the dorsal wall of the pericardial cavity.

After the completion of this separation the right and left sections of the body cavity, dorsal to the pericardial cavity, rapidly become larger and receive the lungs which soon sprout out from the throat.

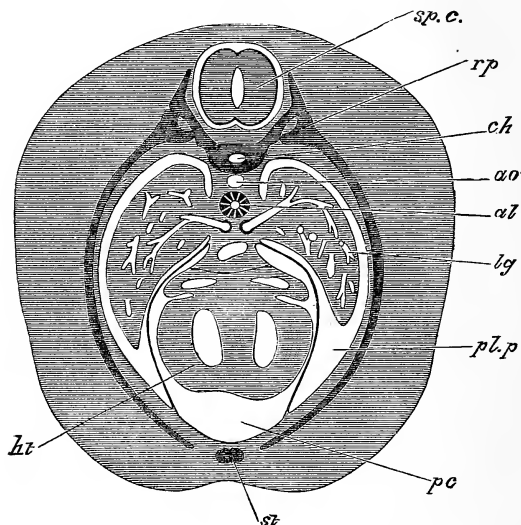
The diverticula which form the lungs grow out into splanchnic mesoblast, in front of the body cavity, but as they grow they extend into the two anterior compartments of the body cavity, each attached by its mesentery to the mesentery of the gut (Fig. 87, *lg.*). They soon moreover extend beyond the posterior limit of the pericardium into the undivided body cavity behind.

To understand the further changes in the pericardial cavity it is necessary to bear in mind its relations to the adjoining parts. It lies at this period completely ventral to the two anterior prolongations of the body cavity containing the lungs. Its dorsal wall is attached to the gut, and is continuous with the mesentery of the gut passing to the dorsal abdominal wall, forming the posterior mediastinum of human anatomy.

The changes which next ensue consist essentially in the enlargement of the sections of the body cavity dorsal to the pericardial cavity. This enlargement takes place partly by the elongation of the posterior mediastinum, but still more by the two divisions of the

body cavity which contain the lungs extending themselves ventrally round the outside of the pericardial cavity. This process is illustrated by Fig. 88, taken

FIG. 88.



SECTION THROUGH AN ADVANCED EMBRYO OF A RABBIT TO SHEW HOW THE PERICARDIAL CAVITY BECOMES SURROUNDED BY THE PLEURAL CAVITIES.

ht. heart. *pc.* pericardial cavity. *pl.p.* pleural cavity. *lg.* lung.
al. alimentary tract. *ao.* dorsal aorta. *ch.* notochord. *rp.*
 rib. *st.* sternum. *sp.c.* spinal cord.

from an embryo rabbit. The two dorsal sections of the body cavity (*pl.p.*) finally extend so as completely to envelope the pericardial cavity (*pc.*), remaining however separated from each other below by a lamina extending from the ventral wall of the pericardial cavity

to the body wall, which forms the anterior mediastinum of human anatomy.

By these changes the pericardial cavity is converted into a closed bag, completely surrounded at its sides by the two lateral halves of the body cavity, which were primitively placed dorsally to it. These two sections of the body cavity, which in the chick remain in free communication with the undivided peritoneal cavity behind, may, from the fact of their containing the lungs, be called the *pleural cavities*.

Histological differentiation. The fifth day may also be taken as marking the epoch at which histological differentiation first becomes distinctly established and begins to make great progress.

It is of course true that long before this date, even from the earliest hours, the cells in each of the three fundamental layers have ceased to be everywhere alike. Nevertheless the changes undergone by the several cells have been few and slight. The cells of epiblastic origin, both those going to form the epidermis and those included in the neural involution, are up to this time simple more or less columnar cells; they may be seen here elongated, there oval, and in another spot spheroidal; here closely packed, with scanty protoplasm, there scattered, with each nucleus well surrounded by cell-substance; but wherever they are found they may still be recognized as cells of a distinctly epithelial character. So also with the cells of hypoblastic origin, whether simply lining the alimentary canal or taking part in the formation of the compound glands. Even in the mesoblast, which undergoes far more changes than either of the other layers, not only increasing more rapidly in

bulk but also serving as the mother tissue for a far greater number of organs, the alterations in the individual cells¹ are, till near upon the fifth day, insignificant. Up to this time the mesoblast may be spoken of as consisting for the most part of little more than indifferent tissue:—of nuclei imbedded in a protoplasmic cell-substance. In one spot the nuclei are closely packed together, and the cell-substance scanty and compact; at another the nuclei are scattered about with spindle-shaped masses of protoplasm attached to each, and there is a large development either of intercellular spaces or of intracellular vacuoles filled with clear fluid. The protoplasm differs in various places, chiefly in being more or less granular, and less or more transparent, having as yet undergone but slight chemical transformation. Up to this epoch (with the exception of the early differentiated blood and muscles of the muscle plates) there are no distinct *tissues*, and the rudiments of the various organs are simply marked out by greater or less condensation of the simple mesoblastic substance.

From the fifth day onwards, however, histological differentiation takes place rapidly, and it soon becomes possible to speak of this or that part as being composed of muscular, or cartilaginous, or connective, &c. tissue. It is not within the scope of the present work to treat in detail of these histogenetic changes, for information concerning which we would refer the reader to histological treatises. We have already had occasion to refer

¹ With the exception of the cells of the middle part of the inner layer of the muscle-plates, which we have seen become converted into longitudinal muscles on the third day (p. 187).

incidentally to many of the earliest histological events, and shall content ourselves by giving a brief summary of the derivation of the tissues of the adult animal from the three primary layers of the blastoderm.

The epiblast or upper layer of many embryologists forms primarily two very important parts of the body, viz. the central nervous system and the epidermis.

It is from the involuted epiblast of the neural tube that the whole of the grey and white matter of the brain and spinal cord appears to be developed, the simple columnar cells of the epiblast being apparently directly transformed into the characteristic multipolar nerve-cells. The whole of the sympathetic¹ nervous system and the peripheral nervous elements of the body, including both the spinal and cranial nerves and ganglia, are epiblastic in origin.

The epithelium (ciliated in the young animal) lining the *canalis centralis* of the spinal cord, together with that lining the ventricles of the brain, all which cavities and canals are, as we have seen, derivatives of the primary neural canal, is the undifferentiated remnant of the primitive epiblast.

The epiblast, as we have said, also forms the epidermis, not however the dermis, which is of mesoblastic origin. The line of junction between the epiblast and the mesoblast coincides with that between the epidermis

¹ The details of the development of the sympathetic system have only been imperfectly worked out in the chick. We propose deferring our account of what is known on this head to the second part of this work dealing with the Mammalia. We may here state, however, that the whole of the chain of the sympathetic ganglia is developed in continuity with the outgrowths from the wall of the neural tube which give rise to the spinal nerves.

and the dermis. From the epiblast are formed all such tegumentary organs or parts of organs as are epidermic in nature.

In addition to these, the epiblast plays an important part in the formation of the organs of special sense.

According to their mode of formation these organs may be arranged into two divisions. In the first come the cases where the sensory expansion of the organ of special sense is derived from the involuted epiblast of the medullary canal. To this class belongs the retina, including the epithelial pigment of the choroid, which is formed from the original optic vesicle budded out from the fore-brain.

To the second class belong the epithelial expansions of the membranous labyrinth of the ear and the cavity of the nose, which are formed by involution from the superficial epiblast covering the external surface of the embryo. These accordingly have no primary connection with the brain. We may also fairly suppose that the 'taste bulbs' and the nervous cells, which have lately been described as present in the epidermis, are also structures formed from the epiblast.

In addition to these we have the crystalline lens formed of involuted epiblast, and the cavity of the mouth and anus lined by it. The pituitary body is also epiblastic in origin. These are the most important parts which are derived from the epiblast.

From the hypoblast are derived the epithelium of the digestive canal, the epithelium of the trachea, bronchial tubes and air cells, the cylindrical epithelium of the ducts of the liver, pancreas and other glands of the alimentary canal, as well as the hepatic cells con-

stituting the parenchyma of the liver, developed, as we have seen, from the hypoblast cylinders given off around the primary hepatic diverticula.

Homologous, probably with the hepatic cells, and equally of hypoblastic origin, are the more spheroidal 'secreting cells' of the pancreas and other glands. The epithelium of the salivary glands, though these so exactly resemble the pancreas, is of epiblastic origin, inasmuch as the cavity of the mouth (p. 119) is entirely lined by epiblast.

The hypoblast lines the allantois, and the notochord also is an hypoblastic product.

From the mesoblast are formed all the remaining parts of the body. The muscles, the bones, the connective tissue and the vessels, both arteries, veins, capillaries and lymphatics, with their appropriate epithelium, are entirely formed from the mesoblast.

The generative and urinary organs are also derived from the mesoblast. It is worthy of notice that their epithelium, though resembling the hypoblastic epithelium of the alimentary canal, is undoubtedly mesoblastic.

From the mesoblast lastly are derived all the muscular, connective and vascular elements, as well of the alimentary canal and its appendages as of the skin and the tegumentary organs. Just as it is only the epidermic moiety of the latter which is derived from the epiblast, so it is only the epithelium of the former which comes from the hypoblast.

The important events then which characterize the fifth day are :—

1. The growth of the allantois.

2. The appearance of the knee and elbow, and of the cartilages which precede the bones of the digits and limbs.

3. The formation of the primitive cartilaginous cranium, more especially of the investing mass and the trabeculæ, and the appearance of rods of cartilage in the visceral arches.

4. The developments of the parts of the face: the closing in of the nasal passages by the nasal processes.

5. A large development of grey matter in the spinal cord as the anterior and posterior cornua; considerable growth both of the anterior and posterior white columns, and the commencement of the anterior and posterior fissures.

6. The appearance of the auricular septum, of a septum in the bulbus arteriosus, and of the semilunar valves.

7. The establishment of the several tissues.

CHAPTER IX.

FROM THE SIXTH DAY TO THE END OF INCUBATION.

THE sixth day marks a new epoch in the development of the chick, for distinctly avian characters then first make their appearance.

Striking and numerous as are the features, which render the class Aves one of the most easily recognizable in the whole animal kingdom, the embryo of a bird does not materially differ in its early phases from that of a reptile or a mammal, even in the points of structure which are most distinctively avian. It may, it is true, be possible to infer, even at a comparatively early stage, from some subsidiary tokens, whether any given embryo belongs to this class or that (and indeed the same inference may be drawn from the ovum itself); but up to a certain date it is impossible to point out, in the embryo of the fowl, the presence of features which may be taken as broadly characteristic of an avian organization. This absence of any distinctive avian differentiation lasts in the chick roughly speaking till the commencement of the sixth day.

We do not mean that on the sixth day all the organs suddenly commence to exhibit peculiarities which mark them as avian. There are no strongly marked breaks in the history of development; its course is perfectly gradual, and one stage passes continuously into the next. The sixth and seventh days do however mark the commencement of the period in which the specialization of the bird begins to be apparent. Then for the first time there become visible the main features of the characteristic manus and pes; the crop and the intestinal cæca make their appearance; the stomach takes on the form of a gizzard; the nose begins to develop into a beak; and the commencing bones of the skull arrange themselves after an avian type. Into these details we do not propose to enter, and shall therefore treat the history of the remaining days with great brevity.

We will first speak of the FETAL APPENDAGES.

On the sixth and seventh days these exhibit changes which are hardly less important than the events of previous days.

The amnion at its complete closure on the fourth day very closely invested the body of the chick; the true cavity of the amnion was at that time therefore very small. On the fifth day fluid begins to collect in the cavity, and raises the membrane of the amnion to some distance from the embryo. The cavity becomes still larger by the sixth day, and on the seventh day is of very considerable dimensions, the fluid increasing with it. On the sixth day Von Baer observed movements of the embryo, chiefly of the limbs; he attributes them to the stimulation of the cold air on opening the egg.

By the seventh day very obvious movements begin to appear in the amnion itself; slow vermicular contractions creep rythmically over it. The amnion in fact begins to pulsate slowly and rythmically, and by its pulsation the embryo is rocked to and fro in the egg. This pulsation is due probably to the contraction of involuntary muscular fibres, which seem to be present in the attenuated portion of the mesoblast, forming part of the amniotic fold. (Cf. Chap. II. p. 45.) Similar movements are also seen in the allantois at a considerably later period.

The growth of the allantois has been very rapid, and it forms a flattened bag, covering the right side of the embryo and rapidly spreading out in all directions, between the primitive folds of the amnion, that is between the amnion proper and the false amnion (serous membrane). It is filled with fluid, so that in spite of its flattened form its opposite walls are distinctly separated from each other.

The vascular area has become still further extended than on the previous day, but with a corresponding loss in the definite character of its blood-vessels. The sinus terminalis has indeed by the end of the seventh day lost all its previous distinctness, and the vessels which brought back the blood from it to the heart are no longer to be seen.

Both the vitelline arteries and veins now pass to and from the body of the chick as single trunks, assuming more and more the appearance of being merely branches of the mesenteric vessels.

The yolk is still more fluid than on the previous day, and its bulk has (according to Von Baer) increased.

This can only be due to its absorbing the white of the egg, which indeed is diminishing rapidly.

During the eighth, ninth, and tenth days the amnion does not undergo any very important changes. Its cavity is still filled with fluid, and on the eighth day its pulsations are at their height, henceforward diminishing in intensity.

The splitting of the mesoblast has now extended to the outer limit of the vascular area, viz. over about three quarters of the yolk-sac. The somatopleure at this point is continuous (as can be easily seen by reference to Fig. 9) with the original outer fold of the amnion.

It thus comes about that the further splitting of the mesoblast merely enlarges the cavity in which the allantois lies. The growth of this organ keeps pace with that of the cavity in which it is placed. Spread out over the greater part of the yolk-sac as a flattened bag filled with fluid, it now serves as the chief organ of respiration.

Hence it is very vascular, the vessels on that side of the bag which is turned to the serous membrane and shell being especially large and numerous.

The yolk now begins to diminish rapidly in bulk. The yolk-sac becomes flaccid, and on the eleventh day is thrown into a series of internal folds, abundantly supplied with blood-vessels. By this means the surface of absorption is largely increased, and the yolk is more and more rapidly taken up by the blood-vessels, and in a partially assimilated condition transferred to the body of the embryo.

By the eleventh day the abdominal parietes though

still much looser and less firm than the walls of the chest may be said to be definitely established, and the loops of intestine, which have hitherto been hanging down into the somatic stalk, are henceforward confined within the cavity of the abdomen. The body of the embryo is therefore completed; but it still remains connected with its various appendages by a narrow somatic umbilicus, in which run the stalk of the allantois and the solid cord suspending the yolk-sac.

The cleavage of the mesoblast still progressing, the yolk is completely invested by the (splanchnopleuric) yolk-sac except at the pole opposite to the embryo, where for some little time a small portion remains unenclosed; at this spot the diminished white of the egg adheres as a dense viscid plug.

The allantois meanwhile spreads out rapidly, and lies over the embryo close under the shell, being separated from the shell membrane by nothing more than an attenuated membrane, the serous membrane, formed out of the outer primitive fold of the amnion and the remains of the vitelline membrane. With this serous membrane the allantois partially coalesces, and in opening an egg at the later stages of incubation, unless care be taken the allantois is in danger of being torn in the removal of the shell membrane. As the allantois increases in size and importance, the allantoic vessels are correspondingly developed. They are very conspicuous when the egg is opened, the pulsations of the allantoic arteries at once attracting attention.

On about the sixteenth day, the white having entirely disappeared, the cleavage of the mesoblast is carried right over the pole of the yolk opposite the

embryo, and is thus completed (Fig. 9). The yolk-sac now, like the allantois which closely wraps it all round, lies loose in a space bounded outside the body by the serous membrane, and continuous with the pleuro-peritoneal cavity of the body of the embryo. Deposits of urates now become abundant in the allantoic fluid.

The loose and flaccid walls of the abdomen enclose a space which the empty intestines are far from filling, and on the nineteenth day the yolk-sac, diminished greatly in bulk but still of some considerable size, is withdrawn through the somatic stalk into the abdominal cavity, which it largely distends. Outside the embryo there remains nothing now but the highly vascular allantois and the practically bloodless serous membrane and amnion. The amnion, whose fluid during the later days of incubation rapidly diminishes, is continuous at the umbilicus with the body-walls of the embryo. The serous membrane (or outer primitive amniotic fold) is by the completion of the cleavage of the mesoblast and the invagination of the yolk-sac, entirely separated from the embryo. The cavity of the allantois by means of its stalk passing through the umbilicus is of course continuous with the cloaca.

In the EMBRYO itself a few general points only deserve notice.

By the sixth or seventh day the flexure of the body has become less marked, so that the head does not lie so near to the tail as on the previous days; at the same time a more distinct neck makes its appearance.

Though the head is still disproportionately large, its growth ceases to be greater than that of the body.

Up to this period the walls of the somatic stalk have remained thin and flaccid, almost membranous in fact, the heart appearing to hang loosely out of the body of the embryo. About this time however the stalk, especially in front, rapidly narrows and its mesoblast becomes thickened. In this way the heart and the other thoracic viscera are enclosed by definite firm chest walls, along the sides of which the ribs grow forwards and in front of which the cartilaginous rudiments of the sternum appear.

The abdominal walls are also being formed, but not to the same extent, and the stalk of the allantois still passes out from the peritoneal cavity between the somatic and the splanchnic stalks.

In the brain one of the most marked features is the growth of the cerebral hemispheres. The median division between these has in front increased in depth, so that the lateral ventricles are continued forwards as two divergent horns, while backwards they are also continued as similar divergent horns separated from one another by the vesicle of the third ventricle.

We propose to treat more fully of the development of the brain in the second part of this work, the importance of the mammalian brain rendering it undesirable to go too much into the details of the brain of the bird.

All the visceral clefts are closed by the seventh day. It will be remembered that the inner part of the first cleft persists as the Eustachian tube (p. 166).

The structures which surround the mouth are beginning to become avian in form, though the features are as yet not very distinctly marked.

The tongue has appeared on the floor of the mouth as a bud of mesoblast covered by epiblast.

During the eighth, ninth, and tenth days the embryo grows very rapidly, the head being still especially large, and at the same time becoming more round, the mid-brain not being so prominent.

From the eleventh day onwards the embryo successively puts on characters which are not only avian, but even distinctive of the genus, species and variety.

So early as the ninth or tenth day the sacs containing the feathers begin to protrude from the surface of the skin as papillæ, especially prominent at first along the middle line of the back from the neck to the rump, and over the thighs, the sacs of the tail feathers being very conspicuous. On the thirteenth day these sacs, generally distributed over the body, and acquiring the length of a quarter of an inch or more, appear to the naked eye as feathers, the thin walls of the sacs allowing their contents, now coloured according to the variety of the bird, to shine through. They are still however closed sacs, and indeed remain such even on the nineteenth day, when many of them are an inch in length.

Feathers are epidermal structures. They arise from an induration of the epidermis of papillæ containing a vascular core.

On the eighth day a chalky-looking patch is observable on the tip of the nose. This by the twelfth day has become developed into a horny but still soft beak.

On the thirteenth day, nails are visible at the extremities, and scales on the remaining portions of the

toes. These on the sixteenth day become harder and more horny, as does also the beak.

Nails are developed on special regions of the epidermis, known as the primitive nail beds. They are formed by the cornification of a layer of cells which makes its appearance between the horny and mucous layers of the epidermis. The distal border of the nail soon becomes free, and the further growth is effected by additions to the under side and attached extremity of the nail.

By the thirteenth day the cartilaginous skeleton is completed and the various muscles of the body can be made out with tolerable clearness.

Ossification begins according to Von Baer on the eighth or ninth day by small deposits in the tibia, in the metacarpal bones of the hind-limb, and in the scapula. On the eleventh or twelfth day a multitude of points of ossification make their appearance in the limbs, in the scapular and pelvic arches, in the ribs, in the bodies of the cervical and dorsal vertebræ and in the bones of the head, the centres of ossification of the vertebral arches not being found till the thirteenth day.

The events which we have thus briefly narrated are accompanied by **important changes in the arterial and venous systems.**

The condition of the venous system at about the end of the third day was fully described in Chap. VI. p. 170, and the changes which have taken place between that date and the latter days of incubation may be seen by comparing the diagram Fig. 58 with the diagrams Figs. 89 and 90.

On the third day, nearly the whole of the venous blood from the body of the embryo was carried back to

the heart by two main venous trunks, the superior (Fig. 58, *J*) and inferior (Fig. 58, *C*) cardinal veins, joining on each side to form the short transverse ductus Cuvieri, both which in turn united with the sinus venosus close to the heart. As the head and neck continue to enlarge and the wings become developed, the single superior cardinal or jugular vein, as it is usually called (Figs. 89, 90, *J*), of each side, is joined by two new veins: the

FIG. 89.




DIAGRAM OF THE VENOUS CIRCULATION AT THE COMMENCEMENT OF THE FIFTH DAY.

H. heart. *d.c.* ductus Cuvieri. Into the ductus Cuvieri of each side fall *J.* the jugular vein, *W.* the vein from the wing and *C.* the inferior cardinal vein. *S.V.* sinus venosus. *Of.* vitelline vein. *U.* allantoic vein, which at this stage gives off branches to the body-walls. *V.C.I.* inferior vena cava. *l.* liver.

vertebral vein (*Su. J. V.*), bringing back blood from the head and neck, and the vein from the wing (*W*).

The inferior cardinal veins have their roots in the Wolffian bodies; they become developed, *pari passu*,

with those organs, and may be called the veins of the Wolffian bodies. On the third day they are the only veins which bring the blood back from the hinder part of the body of the embryo.

About the fourth or fifth day, however, a new single venous trunk, the vena cava inferior (Fig. 89, *V.C.I.*), makes its appearance in the middle line, in a plane more dorsal than that of the cardinal veins. This, starting from the sinus venosus not far from the heart, is on the fifth day a short trunk running backward in the middle line below the aorta, and speedily losing itself in the tissues above the Wolffian bodies. When the kidneys are formed it receives blood from them, and thenceforward enlarging rapidly eventually becomes the channel by which the greater part of the blood from the hind limbs and the hinder part of the body finds its way to the heart. In proportion as this vena cava inferior increases in size, and the Wolffian bodies give place to the permanent kidneys, the posterior cardinal veins diminish. The blood originally coming to the posterior cardinals from the posterior part of the spinal cord and trunk is transported into two posterior vertebral veins; which are placed dorsal to the heads of the ribs and join the anterior vertebral veins. With the appearance of these veins the anterior part of the posterior cardinals disappears.

At its first appearance the vena cava inferior may be considered as a branch of the trunk which we have called the sinus venosus, but as development proceeds, and the vena cava becomes larger and larger, the sinus venosus assumes more and more the appearance of being merely the cardiac termination of the vena cava, and

the ductus venosus from the liver may now be said to join the vena cava instead of being prolonged into the sinus.

While this growth of the vena cava is going on, the points at which the ductus Cuvieri enter into the sinus venosus are drawn in towards the heart itself, and finally these trunks fall directly and separately into the auricular cavities, and are henceforward known as the right and left vena cava superior (Fig. 90, *V.S.R.*, *V.S.L.*). There

FIG. 90.

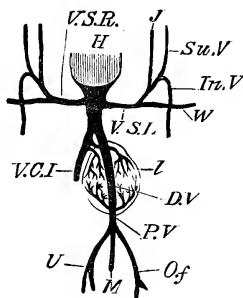


DIAGRAM OF THE VENOUS CIRCULATION DURING THE LATER DAYS OF INCUBATION.

H. heart. *V.S.R.* right vena cava superior. *V.S.L.* left vena cava superior. The two venæ cavæ superiores are the original 'ductus Cuvieri,' they still open into the sinus venosus and not independently into the heart. *J.* jugular vein. *Su.V.* superior vertebral vein. *In.V.* inferior vertebral vein. *W.* vein for the wing. *V.C.I.* vena cava inferior, which receives most of the blood from the inferior extremities, etc. *D.V.* ductus venosus. *P.V.* portal vein. *M.* a vein bringing blood from the intestines into the portal vein. *Of.* vitelline vein. *U.* allantoic vein. The three last mentioned veins unite together to form the portal vein. *l.* liver.

The remnants of the inferior cardinal veins are not shewn.

are therefore, when these changes have been effected, three separate channels, with their respective orifices, by which the blood of the body is brought back to the heart, viz. the right and left superior and the inferior *venæ cavæ*.

While the auricular septum is as yet unformed, the blood from these veins falls into both auricles, perhaps more into the left than into the right. As the septum however grows up, the three vessels become connected with the right auricle only while the left receives the two pulmonary veins coming from the lungs. (Compare Chap. VII. p. 228).

On the third day the course of the vessels from the yolk-sac is very simple. The two vitelline veins, of which the right is already the smaller, form the *meatus venosus* from which, as it passes through the liver on its way to the heart, are given off the two sets of *venæ advehentes* and *venæ revehentes*.

With the appearance of the allantois on the fourth day, a new feature is introduced. From the *meatus venosus*, a short distance behind the liver, there is given off a vein which quickly divides into two branches. These, running along the ventral side of the body from the walls of which they receive some amount of blood, pass to the allantois. They are the allantoic or umbilical veins. The single vein which they unite to form becomes, by reason of the rapid growth of the allantois, very long; and hence it is perhaps better to speak of it as the allantoic vein (Fig. 90, *U*). The right branch soon diminishes in size and finally disappears. Meanwhile the left on reaching the allantois bifurcates; and, its two branches becoming large and conspicuous, there

still appear to be two main allantoic veins uniting at a short distance from the allantois to form the single long allantoic vein. At its first appearance the allantoic vein seems to be but a small branch of the vitelline, but as the allantois grows rapidly, and the yolk-sac dwindles, this state of things is reversed, and the less conspicuous vitelline appears as a branch of the larger allantoic.

On the third day the blood returning from the walls of the intestine is insignificant in amount. As however the intestine becomes more and more developed, it acquires a distinct venous system, and the blood sent to it by branches of the aorta is returned by veins which form a trunk, the *mesenteric vein* (Fig. 90, *M*), falling into the vitelline vein at its junction with the allantoic vein.

These three great veins in fact, viz. the vitelline, the allantoic, and the mesenteric, form a large common trunk which enters at once into the liver, and which we may now call the portal vein (Fig. 90, *P.V.*). This, at its entrance into the liver, partly breaks up into the *venæ advehentes*, and partly continues as the ductus venosus straight through the liver, emerging from which it joins the vena cava inferior. Before the establishment of the vena cava inferior, the *venæ revehentes*, carrying back the blood which circulates through the hepatic capillaries, joined the ductus venosus close to its exit from the liver (Fig. 89). By the time however that the vena cava has become a large and important vessel it is found that the *venæ revehentes* or as we may now call them the *hepatic veins* have shifted their embouchment and now fall directly into that vein, the

ductus venosus making a separate junction rather higher up (Fig. 90).

This state of things continues with but slight changes till near the end of incubation, when the chick begins to breathe the air in the air-chamber of the shell, and respiration is no longer carried on by the allantois. Blood then ceases to flow along the allantoic vessels; they become obliterated. The vitelline vein, which as the yolk becomes gradually absorbed proportionately diminishes in size and importance, comes to appear as a mere branch of the portal vein. The ductus venosus becomes closed, remaining often as a mere ligament; and hence the whole of the blood coming through the portal vein flows into the substance of the liver, and so by the two hepatic veins into the vena cava (Fig. 91, *HP*).

Previous to these changes one of the veins passing from the rectum into the vena cava has given off a branch which effects a junction with one of the mesenteric veins. This now forms a somewhat conspicuous connecting branch between the systems of the vena cava and the portal vein (Fig. 91, *Cy. M.*).

All three venæ cavæ now fall exclusively into the right auricle, and by the closure of the foramen ovale the blood flowing through them is entirely shut off from the left auricle, into which passes the blood from the two pulmonary veins (Fig. 91, *L. V.*).

Such is the history of the veins in the chick. As will be seen in the second part of this work, the course of events in the mammal, though in the main similar, differs in some unimportant respects.

It remains for us to speak of the changes which

FIG. 91.

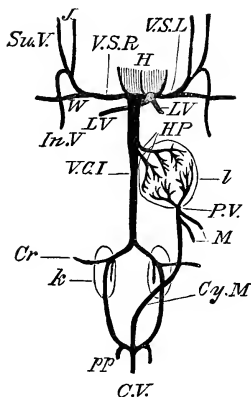
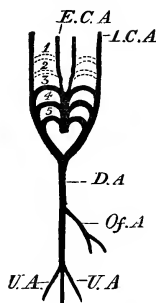


DIAGRAM OF THE VENOUS CIRCULATION OF THE CHICK AFTER THE COMMENCEMENT OF RESPIRATION BY MEANS OF THE LUNGS.

W. wing vein. J. jugular vein. Su.V. superior vertebral vein. In.V. inferior vertebral vein. These unite together on each side to form the corresponding superior vena cava. L.V. pulmonary veins. V.C.I. vena cava inferior. H.P. hepatic veins. P.V. portal vein. M. mesenteric veins. Cy.M. connecting vessel between the branches of the portal vein and the system of the vena cava inferior. It is called the coccygeo-mesenteric vein, and unites the cross branch connecting the two hypogastrics with the mesenteric vein. The ductus venosus has become obliterated. The three venæ cavæ fall independently into the right auricle and the pulmonary veins into the left auricle. Cr. crural vein. k. kidney. l. liver. pp. hypogastric veins. C.V. caudal vein.

have in the meantime been taking place in the arterial system. The condition of things which exists on the fifth or sixth day is shewn in the diagram (Fig. 92).

FIG. 92.



STATE OF ARTERIAL CIRCULATION ON THE FIFTH OR SIXTH DAY.

E.C.A. external carotid. *I.C.A.* internal carotid. *D.A.* dorsal aorta. *Of.A.* vitelline artery. *U.A.* allantoic artery.

We have already seen (Chap. VII. p. 225) that of the three aortic arches which make their appearance on the third day, the first two disappear: the first on the fourth, the second on the fifth day; but that their disappearance is accompanied by the formation behind them of two new aortic arches, the fourth and the fifth. Thus there are generally three, never more than three, pairs of aortic arches present and functional at one time.

This statement needs some limitation; for according to Von Baer there are four arches present both on the fourth and fifth days. In the case of the fourth day a slight remnant of the first pair of arches still persists when the fourth pair is already formed; and on the fifth day the second pair has not entirely disappeared when the fifth pair is formed. In both of these cases however the first pair of arches of the four is only present for a very short time, and then is so diminished in size as to be of no importance.

The first pair of arches, before it entirely disappears, sends off on each side two branches towards the head. Of these, one forms the direct continuation of the bulbus arteriosus in a straight line from the point where the first aortic arch leaves it; primarily distributed to the tongue and inferior maxillary region, it becomes the *external carotid* (Fig. 92, *E.C.A.*). The other, starting from the point where the aortic arch of each side joins its fellow, dorsal to the alimentary canal, to form the dorsal aorta, is primarily distributed to the brain, and becomes the *internal carotid* (Fig. 92, *I.C.A.*).

When the first arch disappears, the external carotid arteries still remain as the anterior continuations of the bulbus arteriosus. And since the dorsal trunks uniting the distal ends of the first and second arches do not become obliterated at the time when the first pair of arches disappears, the internal carotids remain as branches springing from the distal ends of the second pair of arches; they are supplied with blood from that pair, the stream in which flows chiefly towards the head instead of backwards towards the dorsal aorta, as is the case with the succeeding arches. When the second pair of arches is obliterated, the connecting branch with the next arch is again left, and thus the internal carotids appear as branches from the distal ends of the third pair of arches.

On the third day the dorsal aorta does not for any distance remain single in its backward course along the body, but soon divides into two trunks which run one on either side of the middle line of the body. These two trunks, as development proceeds, gradually unite along their whole length, and there is thus formed a

single median aorta terminating behind in the caudal artery (Figs. 92, 94). The arteries to the kidneys, hind limbs, etc. are developed as branches of this aorta.

As the allantois grows rapidly and becomes an important respiratory organ, the allantoic or umbilical arteries increase in size. As a general, though apparently not invariable rule, the right allantoic artery gets gradually smaller and soon disappears.

The vitelline artery (*Of. A.*) now leaves the aorta as a *single* but quickly bifurcating trunk, which at the end of the fifth day is still very large.

By the fifth day the ventricular portion of the heart (compare Chap. VII. p. 257) is completely divided into two chambers. The bulbus arteriosus is also divided by a septum into two channels, one of which communicates with the right ventricle of the heart and the other with the left.

One result of this arrangement is that all the blood which passes to the anterior extremity of the body comes from the left ventricle of the heart.

At about the seventh day an entire separation begins to take place between the arterial roots which come respectively from the right and left chambers of the heart. The root from the right chamber (Fig. 93) remains connected with the fifth pair of arches. The root from the left ventricle is connected with the third and fourth pairs of arches.

The lower part of the body still receives blood from both the right and left ventricles, since the blood which enters the fifth arch still flows into the common dorsal aorta. As the lungs however increase in size, a communication is set up between them and the fifth pair of

FIG. 93.

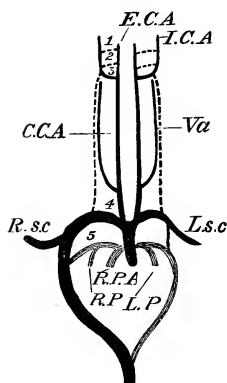


DIAGRAM OF THE CONDITION OF THE ARCHES OF THE AORTA
TOWARDS THE CLOSE OF INCUBATION.

1, 2, 3, 4, 5. the several aortic arches. *E.C.A.* external carotid. *I.C.A.* internal carotid. *C.C.A.* common carotid. *V.a.* vertebral artery. *R.sc.* right subclavian. *L.sc.* left subclavian. *R.P.*, *L.P.* right and left pulmonary arteries. *R.P.A.* right arterial root or division of the bulbus arteriosus, or pulmonary artery; the left root or division, constituting the aorta, is seen by its side. The system of the fifth arch is in lighter shading. The dotted lines shew the portions of the arches which have been obliterated.

arches in the shape of two vessels which, springing one from the arch of each side, grow downwards towards the lungs. At first small and narrow, these pulmonary arteries, for such they are, grow rapidly larger and larger, so that more and more of the blood from the right ventricle is carried to the lungs.

At the same time the connection between the third and fourth pairs of arches on each side grows weaker; so

that less and less of the blood which flows along the third pair of arches is able to pass backwards to the hind end of the body.

The fourth arch of the right side now becomes the most important of all the arches; and nearly the whole of the blood supplying the hinder parts of the body passes through it. It is this arch which remains as the permanent aortic arch of the adult; and it is important to notice that the arch which forms the great dorsal aorta in birds is the fourth on the right side, and not as in mammals the fourth on the left side. The fourth arch of the left side in birds, after giving off the subclavian, is continued as an exceedingly small and unimportant vessel to join the fourth right arch. It is soon obliterated.

In consequence of these changes the condition of the aortic arches during the latter days of incubation, before respiration by the lungs has commenced, is as follows (Fig. 93).

The first and second arches are completely obliterated. The third arch on each side is continued at its dorsal end as the internal carotid, *I.C.A.*, the connection between it and the fourth arch having become entirely obliterated. From its ventral end as the direct continuation of the trunk which originally supplied the first and second arches the external carotid, *E.C.A.*, is given off. Each pair of carotids arises therefore from a common trunk—the common carotid (*C.C.A.*). Each of these trunks gives off near its proximal end a branch, the vertebral artery (*V.a.*).

The common carotid on the right side comes off from the fourth arch of the right side (the arch of the

dorsal aorta), and is not as yet connected with the right subclavian, *R.sc.* The common carotid of the left side comes off from the fourth arch of the left side; but since this arch becomes the left subclavian, *L.sc.* (the connection between the fourth and fifth left arches being obliterated), the portion of the trunk between the fourth arch and the bulbus arteriosus (or as it must now be called the common aortic root) is called the left innominate artery.

The fourth arch of the right side forms the commencement of the great dorsal aorta, and gives off the right subclavian (*R.sc.*) just before it is joined by the fifth arch.

The fifth arch of each side gives off branches (*R.P.*, *L.P.*) to the lungs; their distal continuations, by which these arches are connected with the systemic circulation, though much reduced, are not obliterated.

The final changes undergone by the arterial system after the commencement of the pulmonary respiration consist chiefly in the complete separation of the pulmonary and systemic circulations. As the branches to the lungs become stronger and stronger, less and less blood from the right ventricle enters into the dorsal aorta; and the connecting vessels become smaller and smaller.

Each of these fifth arches from the right ventricle may therefore be considered at about the sixteenth or eighteenth day as divided into two parts, an inner part which connects the heart with the lung, and an outer part which still connects the arch with the main dorsal aorta. As these outer parts become smaller they receive the name of the 'ductus or canales Botalli' or

‘ductus arteriosi.’ The one on the right side is short; that on the left side is much longer and narrower.

When respiration commences the blood ceases to pass through these canals, which either remain as mere ligaments or else become absorbed altogether. By this means, the foramen ovale becoming at the same time closed, a complete double circulation is established. All the blood from the right ventricle passes into the lungs, and all that from the left ventricle into the body at large.

Two other changes take place about the same time in the aortic branches. That portion of the right fourth or aortic arch which lies between the origin of the right subclavian and the common carotid becomes shortened, and is finally swallowed up in such a fashion that the right subclavian (Fig. 94, *R. sc.*) comes off from the right common carotid, a very short trunk being formed by the union of the two to serve as the right innominate artery.

At the same time, corresponding to the increase in the length of the neck, the common carotids are very greatly lengthened. They lie close together in the neck, and in many birds actually unite to form a common trunk.

It will of course be understood that with the disappearance of the allantois and the absorption of the yolk, the allantoic and vitelline arteries also disappear.

It may perhaps be of advantage to the reader if we here briefly summarize the condition of the circulation at its four most important epochs; viz. on the third day, on the fifth day, during the later days of incubation before respiration by the lungs has commenced,

FIG. 94.

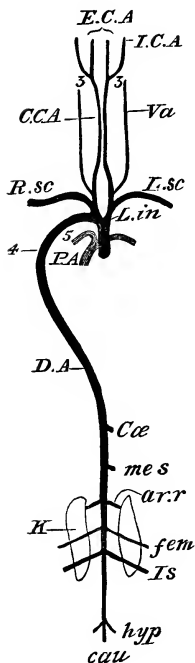


DIAGRAM OF THE ARTERIAL SYSTEM OF THE ADULT FOWL.

P.A. root of pulmonary artery. *L.in.* left innominate artery. *D.A.* dorsal aorta. *Cæ.* caeliac arteries. *mes.* mesenteric artery. *ar.r.* renal arteries. *fem.* femoral arteries. *Is.* ischiatic arteries. *hyp.* hypogastric arteries. *cau.* caudal artery. The other letters as in Fig. 93.

and after the chick has begun to breathe by the lungs.

On the third day the circulation is of an exceedingly simple character.

The heart is to all intents and purposes a simple twisted tube marked off by constrictions into a series of three consecutive chambers. The blood coming from the venous radicles passes through the heart and then through the three pairs of arterial arches.

From these it is collected into the great dorsal aorta. Upon this dividing into two branches, the stream of blood passes down on each side of the notochord along the body, and thence out by the vitelline arteries, which distribute it to the yolk-sac.

In the yolk-sac it partly passes into the sinus terminalis and so into the fore and aft trunks, partly directly into the lateral trunks, of the vitelline veins. In both cases it is brought back to the two venous radicles and so to the heart.

On this day the blood is aërated in the capillaries of the yolk-sac.

On the fifth or sixth day the two auricles are present though having a common cavity. The septum of the ventricles is nearly complete, so that the blood on entering the ventricles from the auricles is divided into two streams. These two streams pass respectively from the right and left chambers of the heart into the two divisions of the bulbus arteriosus. The blood from the right ventricle passes into the fifth pair of arches and that from the left ventricle into the third and fourth pairs of arches.

From the anterior parts the blood is brought back by the anterior cardinal or jugular veins; from the hinder parts of the body, chiefly by the cardinal veins, but also in part by the now commencing vena cava inferior.

The blood from the yolk-sac and allantois, together with a small quantity from the intestine, is collected into the portal vein, and by that vessel carried to the liver. Here it becomes divided into two streams, part flowing directly by the ductus venosus into the sinus venosus, and the remainder passing through the capillaries of the liver, being brought back to the ductus venosus by the hepatic veins.

During this period the blood is aerated both by the allantois and yolk-sac, but as yet chiefly by the latter.

At a somewhat late period of incubation the blood from the ventricles passes into two entirely distinct roots. The one of these, that from the right chamber, sends the blood to the fifth pair of arches; passing through which the greater part of the blood flows into the dorsal aorta, a small portion only finding its way into the lungs through the as yet unimportant pulmonary arteries.

Through the other aortic root, viz. that from the left ventricle, the blood flows into the third and fourth pairs of arches. That part of the blood which flows into the third pair, passes almost entirely to the head and upper extremities by the external and internal carotids; that which flows into the right arch of the fourth pair is chiefly brought to the dorsal aorta, but some of it passes to the right wing; that, on the contrary, which goes into the left fourth arch is for the most part sent to the left wing, a small part only reaching the dorsal aorta. There is still a mixture of the blood from the two chambers of the heart, so that the blood in the dorsal aorta is composed partly of blood from the left, and partly from the right chambers.

The blood of the upper (anterior) end of the body comes entirely from the left ventricle.

The blood of the dorsal aorta passes to the yolk-sac and allantois, and to all the hinder parts of the body. It is brought back from the yolk-sac, from the allantois, and to a certain extent from the intestines, by the portal vein, part of the blood from which passes to the inferior vena cava by the direct course (ductus venosus), and part indirectly by the more circuitous course of the capillaries of the liver and hepatic veins.

The blood from the generative and urinary organs, and from the hinder extremities, is brought back to the heart by the vena cava inferior; that from the upper extremities and head by the jugular, vertebral and wing veins into the two venæ cavæ of the right and left side, and so to the heart. Of these three venæ cavæ, the right superior and the inferior join the auricle by a common entrance, but the left superior has an entrance of its own. All of these open into the cavity of the right auricle, but the opening of the inferior vena cava is so directed (vide Chap. VIII. p. 263) that the blood carried by this vessel flows chiefly through the foramen ovale into the left auricle. The blood from the two superior venæ cavæ enters the right auricle only. Now the blood of the inferior vena cava has been partly aërated by the allantois; and, since it is this blood which passing through the left auricle and ventricle is distributed to the third aortic arch, unmixed by any blood from the right ventricle (the mixture with the blood from the fifth arch reaching only as far as the fourth arch), it happens that the blood which flows to the anterior extremities

and head is more aërated than that in any other part of the body.

From the anterior extremities the blood is to a great extent returned by the left superior cava, and goes into the right auricle, whence, by the right ventricle, it is distributed through the fifth pair of arches over the body, after joining the more aërated blood passing through the fourth pair of arches.

The blood from the lungs is brought back by two small veins into the left auricle.

The characteristics of the circulation at this time are that the blood is aërated by the allantois, and that there is a partial double circulation. (Vide Chap. VIII. p. 263.)

As soon as respiration commences the canals leading to the dorsal aorta from the fifth pair of arches, which communicate only with the right ventricle, become closed. The blood passing along the fifth arch now flows only into the lungs, through the pulmonary arteries. The blood from the left ventricle owing to the cessation of the circulation of the yolk-sac and of the allantois is distributed exclusively to the body of the chick, from whence it is all brought back into the right auricle by the three now independently opening venæ cavæ.

The portal veins henceforward receive blood from the intestines only, and the ductus venosus is obliterated, so that all the blood of the portal vein passes through the capillaries of the liver.

The partition between the auricles is rendered complete by the closure of the foramen ovale; into the right auricle the veins of the body enter, and into the left the pulmonary veins.

There is thus a completely double circulation formed, in which all the blood of the left ventricle is arterial, and all the blood of the right ventricle venous, and there is at no part of the circulation a mixture of venous and arterial blood.

As early as the sixth day movements, as we have said, may be seen in the limbs of the embryo upon opening the egg. We may conclude that after this epoch spontaneous movements occur from time to time in the unopened egg. They cannot however be of any great extent until the fourteenth day, for up to this time the embryo retains the position in which it was first formed, viz. with its body at right angles to the long axis of the egg.

On the fourteenth day a definite change of position takes place; the chick moves so as to lie lengthways in the egg, with its beak touching the chorion and shell membrane where they form the inner wall of the rapidly increasing air-chamber at the broad end (Chap. I. p. 3).

On the twentieth day or thereabouts the beak is thrust through these membranes, and the bird begins to breathe the air contained in the chamber. Thereupon the pulmonary circulation becomes functionally active, and at the same time blood ceases to flow through the umbilical arteries. The allantois shrivels up, the umbilicus becomes completely closed, and the chick piercing the shell at the broad end of the egg with repeated blows of its beak, casts off the dried remains of allantois, amnion and chorion, and steps out into the world.

PART II.

THE HISTORY OF THE MAMMALIAN
EMBRYO.

INTRODUCTION.

THE most important difference between the development of Mammalia and Aves depends upon the amount and distribution of the food-yolk in the ovum. In birds, as we have seen (Ch. I.), the ovum is large and the greater part of it so heavily charged with food-yolk that it is unable to segment. The segmentation is confined to one small portion, the germinal disc, the protoplasm of which is less burdened with food-yolk than that of the remainder of the ovum. Such partial segmentation is known as *meroblastic*.

In Mammals, on the other hand, the ovum is small¹, and contains but a slight amount of food-yolk; the little there is being distributed uniformly throughout. In consequence of this the *whole* ovum is able to segment; the segmentation therefore belongs to the *holoblastic* type. This fundamental difference in the constitution of the ovum of Birds and Mammals is accompanied not only by differences in the segmentation but also by important differences, as we shall see, in the stages of development which immediately follow segmentation. Finally, in

¹ The human ovarian ovum is $\frac{1}{125}$ to $\frac{1}{150}$ of an inch in diameter.

birds, as we have seen, the nutrition of the developing embryo is entirely effected at the expense of the food-yolk and albumen with which the ovum was charged in the ovary and oviduct respectively, and the eggs leave the parent very soon after the close of segmentation. In the Mammalia the absence of sufficient food-yolk necessitates the existence of some other source of nutriment for the embryo, and that source is mainly the maternal blood.

The development of Mammalia may be divided into two periods: 1. the development within the uterus; 2. the development after birth.

In all the higher Mammalia the second period is very unimportant, as compared with the first; for the young are born in a condition closely resembling that of the adult of the species to which they belong. The development during the first period takes place in the uterus of the mother, and nutriment passes from the maternal blood to that of the embryo by means of a structure, to be described in detail hereafter, known as the placenta. This difference between the development of Birds and Mammals may be briefly expressed by saying that the former are *oviparous*, while the latter are *viviparous*.

The source of nutriment during the second period is the Mammary glands. In certain of the lower Mammalia (Marsupials) the young are born in a very immature condition, and become attached by their mouths to the nipples of these glands. They are carried about, usually in a special pouch (marsupium) by the mother, and undergo in this position the greater part of the remainder of their development.

CHAPTER X.

GENERAL DEVELOPMENT OF THE EMBRYO.

THERE is a close agreement in the history of the development of the embryo of the various kinds of Mammals. We may therefore take one, the Rabbit, as a type. There are without doubt considerable variations to be met with in the early development even of species nearly allied to the Rabbit, but at present the true value of these variations is not understood, and they need not concern us here.

The ovarian ovum. Mammals possess two ovaries situated in the body cavity, one on either side of the vertebral column immediately posterior to the kidneys. They are somewhat flattened irregularly oval bodies, a portion of the surface being generally raised into protuberances due to projecting follicles.

In an early stage of development the follicle in the mammalian ovary is similar to that of the fowl, and is formed of flat cells derived from the germinal cells adjoining the ovum. As development proceeds however it becomes remarkably modified. These flat cells surrounding the ovum become columnar and then one or two layers deep. Later they become thicker on one side of the ovum than on the other, and there appears

in the thickened mass a cavity which gradually becomes more and more distended and filled with an albuminous fluid.

As the cavity enlarges, the ovum, around which are several layers of cells, forms a prominence projecting into it. The follicle cells are known as the *membrana granulosa*, and the projection in which the ovum lies as the *discus* or *cumulus proligerus*. The whole structure with its tunic is known as the *Graafian follicle*.

If the ovary of a mature female during the breeding season be examined, certain of the protuberances on its surface may be seen to be considerably larger than others; they are more transparent than their fellows and their outer covering appears more tense; these are *Graafian follicles* containing nearly or quite ripe ova. Upon piercing one of these follicles with a needle-point the ovum contained therein spirts forth together with a not inconsiderable amount of clear fluid.

Egg Membranes. The ovum is surrounded by a radiately striated membrane, the *zona radiata*, internal to which in the nearly ripe egg a delicate membrane has been shown, by Ed. v. Beneden, to exist. The cells of the *discus* are supported upon an irregular granular membrane external to the *zona radiata*. This membrane is more or less distinctly separated from the *zona*, and the mode of its development renders it probable that it is the remnant of the first formed membrane in the young ovum and is therefore the *vitelline membrane*.

Maturation and impregnation of the ovum. As the ovum placed in the *Graafian follicle* approaches maturity the *germinal vesicle* assumes an excentric

position and undergoes a series of changes which have not been fully worked out, but which probably are of the same nature as those which have been observed in other types (p. 17). The result of the changes is the formation of one or more polar bodies, and the nucleus of the mature ovum (female pronucleus).

At certain periods one or more follicles containing a ripe ovum burst¹, and their contents are received by the fimbriated extremity of the Fallopian tube which appears according to Hensen to clasp the ovary at the time. The follicle after the exit of the ovum becomes filled with blood and remains as a conspicuous object on the surface of the ovary for some days. It becomes eventually a corpus luteum. The ovum travels slowly down the Fallopian tube. It is still invested by the zona radiata, and in the rabbit an albuminous envelope is formed around it in its passage downwards. Impregnation takes place in the upper part of the Fallopian tube, and is shortly followed by the segmentation, which is remarkable amongst the Amniota for being complete².

The entrance of the spermatozoon into the ovum and its subsequent fate have not been observed. Van Beneden describes in the rabbit the formation of the first segmentation nucleus (i.e. the nucleus of the ovum after fertilization) from two nuclei, one peripheral and the other ventral, and deduces from his observations

¹ So far as is known there is no relation between the bursting of the follicle and the act of coition.

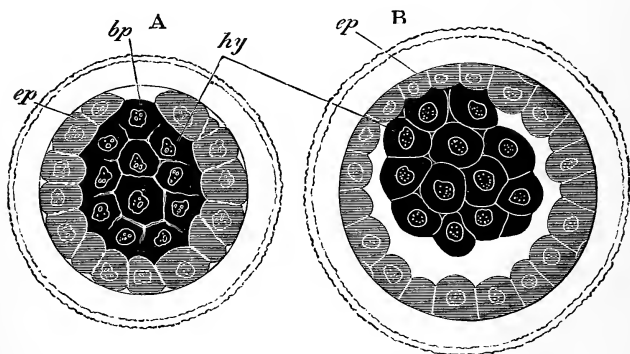
² It is stated by Bischoff that shortly after impregnation, and before the commencement of the segmentation, the ova of the rabbit and guinea-pig are covered with cilia and exhibit the phenomenon of rotation. This has not been noticed by other observers.

that the peripheral nucleus was derived from the sper-matic element.

Segmentation. The process of segmentation occupies in the rabbit about 72 hours; but the time of this and all other stages of development varies considerably in different animals.

The details of segmentation in the rabbit are differently described by various observers; but at the close of segmentation the ovum appears undoubtedly to be composed of an outer layer of cubical hyaline cells, almost entirely surrounding an inner mass of highly granular rounded or polygonal cells.

FIG. 95.



OPTICAL SECTIONS OF A RABBIT'S OVUM AT TWO STAGES CLOSELY FOLLOWING UPON THE SEGMENTATION.

(After E. van Beneden.)

ep. outer layer; *hy.* inner mass; *bp.* Van Beneden's blastopore.

The shading of the outer and inner layers is diagrammatic.

In a small circular area however the inner mass of cells remains exposed at the surface (Fig. 95, A). This

exposed spot may for convenience be called with v. Beneden the blastopore, though, as will be seen by the account given of the subsequent development, it in no way corresponds with the blastopore of other vertebrate ova.

In the following account of the segmentation of the rabbit's ovum, v. Beneden's description is followed as far as the details are concerned, his nomenclature is however not adhered to¹.

According to v. Beneden the ovum first divides into two nearly equal spheres, of which one is slightly larger and more transparent than the other. The larger sphere and its products will be spoken of as the outer spheres, and the smaller one and its products as the inner spheres, in accordance with their different destinations.

Both the spheres are soon divided into two, and each of the four so formed into two again; and thus a stage with eight spheres ensues. At the moment of their first separation these spheres are spherical, and arranged in two layers, one of them formed of the four outer, and the other of the four inner spheres. This position is not long retained, for one of the inner spheres passes to the centre; and the whole ovum again takes a spherical form.

In the next phase of segmentation each of the four outer spheres divides into two, and the ovum thus becomes constituted of twelve spheres, eight outer and four inner. The outer spheres have now become markedly smaller than the inner.

The four inner spheres next divide giving rise, together with the eight outer spheres, to sixteen spheres in all; which are nearly uniform in size. Of the eight inner spheres four soon pass to the centre, while the eight now superficial outer spheres form a kind of cup partially enclosing the inner spheres. The outer spheres now divide in their turn, giving rise to sixteen

¹ The cells spoken of as the outer layer correspond to Van Beneden's epiblast, whilst those cells spoken of as the inner correspond to his primitive hypoblast.

spheres which largely enclose the inner spheres. The segmentation of both outer and inner spheres continues, and in the course of it the outer spheres spread further and further over the inner, so that at the close of segmentation the inner spheres constitute a central solid mass almost entirely surrounded by the outer spheres. In a small circular area however the inner mass of spheres remain for some time exposed at the surface (Fig. 95 A).

The blastodermic vesicle. After its segmentation the ovum passes into the uterus. The outer cells soon grow over the blastopore and thus form a complete superficial layer. A series of changes next take place which result in the formation of what has been called the *blastodermic vesicle*.

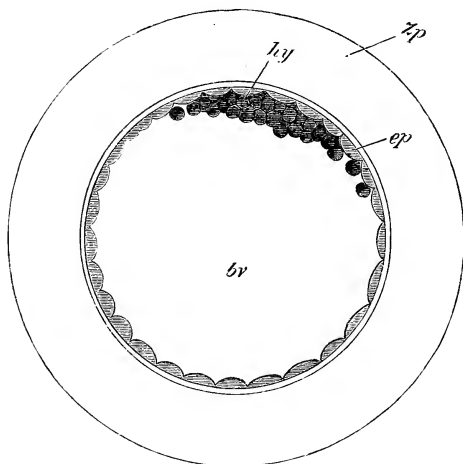
These changes commence with the appearance of a narrow cavity between the outer and inner layers, which extends so as completely to separate them except in the region adjoining the original site of the blastopore (Fig. 95 B)¹. The cavity so formed rapidly enlarges, and with it the ovum also; so that this soon takes the form of a thin walled vesicle with a large central cavity. This vesicle is the blastodermic vesicle. The greater part of its walls are formed of a single row of flattened outer layer cells; while the inner mass of cells forms a small lens-shaped mass attached to the inner side of the outer layer (Fig. 96).

Although by this stage, which occurs in the rabbit between seventy and ninety hours after impregnation, the blastodermic vesicle has by no means attained its greatest dimensions, it has nevertheless grown from

¹ Van Beneden regards it as probable that the blastopore is situated somewhat excentrically in relation to the area of attachment of the inner mass to the outer layer.

about 0.09 mm.—the size of the ovum at the close segmentation—to about 0.28 in diameter. It is enclosed by the zona radiata and the albuminous layer

FIG. 96.



RABBIT'S OVUM BETWEEN 70—90 HOURS AFTER IMPREGNATION.

(After E. van Beneden.)

bv. cavity of blastodermic vesicle (yolk-sac); *ep.* outer layer;
hy. inner mass; *Zp.* albuminous envelope.

around it. The blastodermic vesicle continues to enlarge rapidly, and during the process the inner mass undergoes important changes. It spreads out on the inner side of the outer layer and at the same time loses its lens-like form and becomes flattened. The central

part of it remains however thicker, and is constituted of two rows of cells, while the peripheral part, the outer boundary of which is irregular, is formed of an imperfect layer of amœboid cells which continually spread further and further beneath the outer layer. The central thickening of the inner layer forms an opaque circular spot on the blastoderm, which constitutes the commencement of the *embryonic area*.

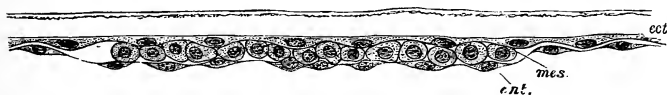The formation of the layers. The history of the stages immediately following, from about the commencement of the fifth day to the seventh day, when a primitive streak makes its appearance, is not perfectly understood, and has been interpreted very differently by various observers. The following account must therefore be considered as a tentative one.

About five days after impregnation the cells of the inner mass in the embryonic area become divided into two distinct strata, an upper stratum of rounded cells adjoining the flattened outer layer and a lower stratum of flattened cells. This lower stratum is the true hypoblast (Fig. 97). At the edge of the embryonic area the hypoblast is continuous with a peripheral ring of the amœboid cells of the earlier stage, which now form, except at the edge of the ring, a continuous layer of flattened cells in contact with the outer layer. During the sixth day the middle layer becomes fused with the outer layer, and gives rise to a layer of cells which are columnar and are arranged in the rabbit in a single row (Fig. 98). They form together the true epiblast of the embryonic area.

At this stage therefore the embryonic area, which is circular, is formed throughout of two single layers of

cells, a columnar epiblast and a layer of flattened hypoblast.

FIG. 97.

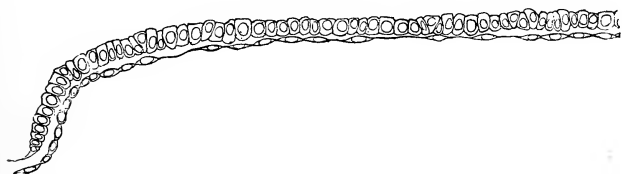


SECTION THROUGH THE NEARLY CIRCULAR EMBRYONIC AREA OF
A RABBIT OVUM OF SIX DAYS.

(From Allen Thomson, after E. van Beneden.)

ect. upper layer; *mes.* middle layer; *ent.* true hypoblast.

FIG. 98.



SECTION THROUGH THE BLASTODERM OF A RABBIT ON THE
SEVENTH DAY: TAKEN IN FRONT OF THE PRIMITIVE
STREAK.


Half of the area is represented.

Towards the end of the sixth day the embryonic area of the rabbit, which has hitherto been round, becomes oval.

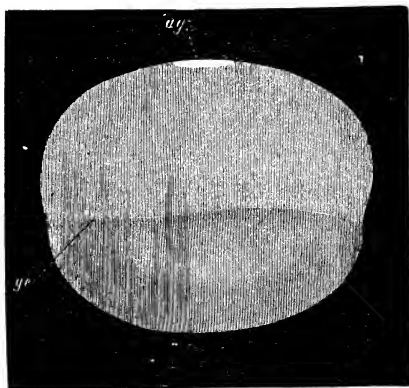
A diagrammatic view of the whole blastodermic vesicle at about the beginning of the seventh day is given in Fig. 99. The embryonic area is represented in white. The line *ge* in B shows the extension of the hypoblast round the inside of the vesicle. The blas-

FIG. 99.

A.



B.



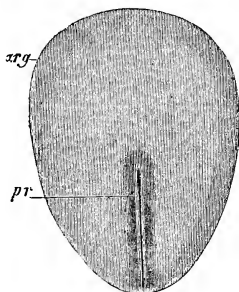
VIEWS OF THE BLASTODERMIC VESICLE OF A RABBIT ON THE SEVENTH DAY WITHOUT THE ZONA. A. from above, B. from the side. (From Kölliker.)

ag. embryonic area ; *ge.* boundary of the hypoblast.

totodermic vesicle is therefore formed of three areas, (1) the embryonic area with two layers, a columnar epiblast and flat hypoblast; (2) the region around the embryonic area where the walls of the vesicle are formed of flattened epiblast¹ and of hypoblast; (3) the area beyond this again where the vesicle is formed of flattened epiblast¹ only.

The changes which next take place begin with the formation of a primitive streak, homologous with, and in most respects similar to, the primitive streak in Birds.

FIG. 100.



EMBRYONIC AREA OF AN EIGHT DAYS' RABBIT.

(After Kölliker.)

arg. embryonic area ; *pr.* primitive streak.

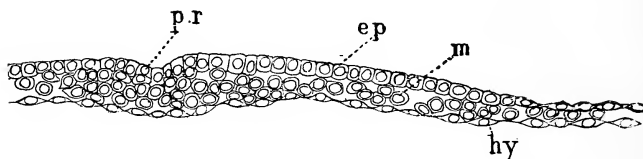
The formation of the streak is preceded by that of a dark spot near the middle of the blastoderm, forming the nodal point of Hensen. This spot subsequently constitutes the front end of the primitive streak.

Early on the seventh day the embryonic area becomes pyriform, and at its posterior and narrower end

¹ The epiblast of the blastodermic vesicle beyond the embryonic area is formed of the outer layer only.

the primitive streak makes its appearance; it is due to a proliferation of rounded cells from the epiblast.

FIG. 101.



SECTION THROUGH AN OVAL BLASTODERM OF A RABBIT ON THE SEVENTH DAY. THE LENGTH OF THE AREA WAS ABOUT 1.2 MM. AND ITS BREADTH ABOUT .86 MM.

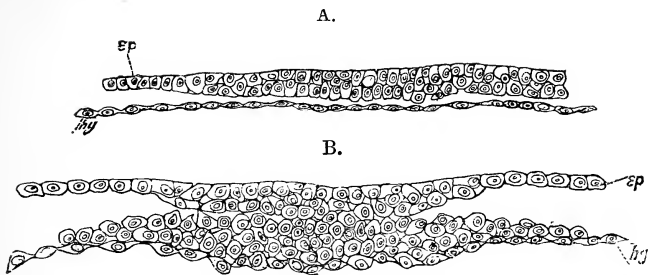
Through the front part of the primitive streak; *ep.* epiblast; *m.* mesoblast; *hy.* hypoblast; *pr.* primitive streak.

These cells give rise to a part of the mesoblastic layer of the embryo, and may be termed from their origin the primitive streak mesoblast.

During the seventh day the primitive streak becomes a more pronounced structure (Fig. 101), the mesoblast in its neighbourhood increases in quantity, while an axial groove (Fig. 100)—the primitive groove—is formed on its upper surface.

The formation of the medullary groove. In the part of the embryonic area in front of the primitive streak there arise during the eighth day two folds bounding a shallow median groove, which meet in front, but diverge behind, and enclose between them the foremost end of the primitive streak (Fig. 103). These folds are the medullary folds and they constitute the first definite traces of the embryo. The medullary plate bounded by them rapidly grows in length, the primitive streak always remaining at its hinder end. While the

FIG. 102.



TWO TRANSVERSE SECTIONS THROUGH THE EMBRYONIC AREA
OF AN EMBRYO RABBIT OF SEVEN DAYS.

The embryo has nearly the appearance represented in Fig. 100.

A. is taken through the anterior part of the embryonic area. It represents about half the breadth of the area, and there is no trace of a medullary groove or of the mesoblast.

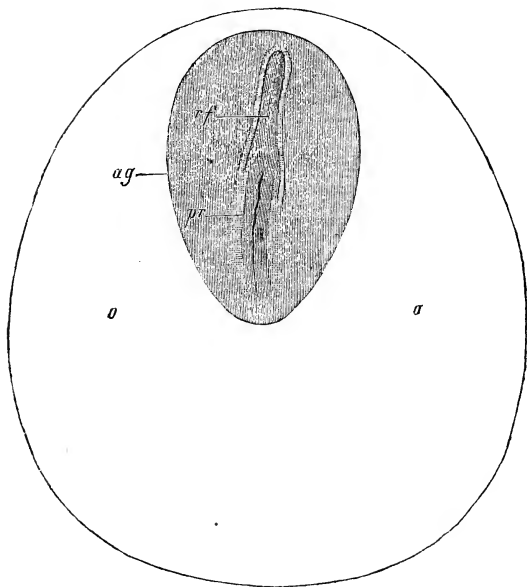
B. is taken through the posterior part of the primitive streak.

ep. epiblast ; *hy.* hypoblast.

lateral epiblast is formed of several rows of cells, that of the medullary plate is at first formed of but a single row (Fig. 104, *mg*).

The mesoblast and notochord. The mesoblast in mammalia has, as in the chick, a double origin, and the details of its development appear to resemble essentially those in the chick. It arises (1) from the epiblast of the primitive streak ; this has been already described ; (2) from the primitive hypoblast in front and at the sides of the primitive streak. The latter is known as hypoblastic mesoblast, and as in the chick appears to originate as two lateral plates split off from the primitive hypoblast. These two plates are at first continuous

FIG. 103.



EMBRYONIC AREA OF A SEVEN DAYS' EMBRYO RABBIT.
(From Kölliker.)

o. place of future area vasculosa ; *rf.* medullary groove ; *pr.* primitive streak ; *ag.* embryonic area.

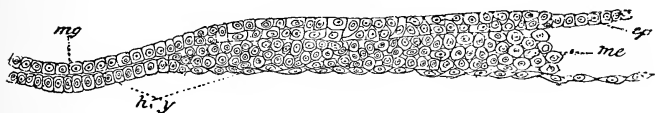In the region *o.* a layer of mesoblast has already grown ; there are however as yet no signs of blood-vessels in it.

This mesoblast is derived from the mesoblast of the primitive streak (Kölliker).

in the axial line with the primitive hypoblast. When the medullary groove is formed the lateral bands of mesoblast become separate from the axial hypoblast and give rise to two independent lateral plates of mesoblast

(Fig. 104). The axial band of hypoblast eventually gives rise to the notochord.

FIG. 104.



TRANSVERSE SECTION THROUGH AN EMBRYO RABBIT OF EIGHT DAYS.

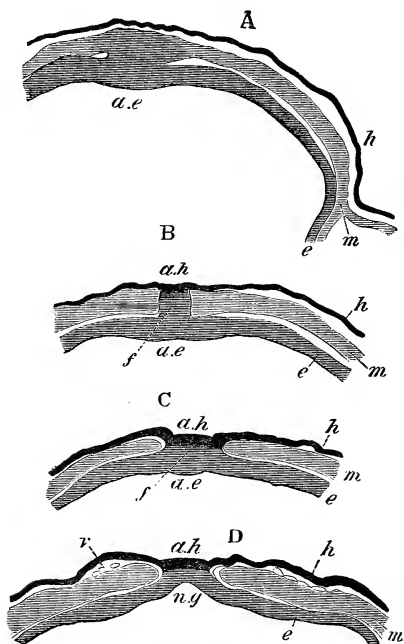
ep. epiblast ; *me.* mesoblast ; *hy.* hypoblast ; *mg.* medullary groove.

The mesoblastic elements from these two sources, though at first characterised by the difference in the appearance of their cells (Fig. 102, B), those of the primitive streak mesoblast being more rounded, soon become blended and indistinguishable from one another; so that it is difficult to say to what parts of the fully formed mesoblast they severally contribute.

In tracing the changes which take place in the relations of the layers, while passing from the region of the embryo to that of the primitive streak, it will be convenient to follow the account given by Schäfer for the guinea-pig, which on this point is far fuller and more satisfactory than that of other observers. In doing so we shall leave out of consideration the fact that the layers in the guinea-pig are inverted. Fig. 105 represents a series of sections through this part in the guinea-pig. The anterior section (D) passes through the medullary groove near its hinder end. The commencement of the primitive streak is marked by a slight prominence on the floor of the medullary groove between the two diverg-

ing medullary folds (Fig. 105 C, *ae*). Where this prominence becomes first apparent the epiblast and hypoblast

FIG. 105.



A SERIES OF TRANSVERSE SECTIONS THROUGH THE JUNCTION OF THE PRIMITIVE STREAK AND MEDULLARY GROOVE OF A YOUNG GUINEA-PIG. (After Schäfer.)

A. is the posterior section.

e. epiblast; *m.* mesoblast; *h.* hypoblast; *ae.* axial epiblast of the primitive streak; *ah.* axial hypoblast attached in B. and C. to the epiblast at the rudimentary blastopore; *ng.* medullary groove; *f.* rudimentary blastopore.

are united together. The mesoblast plates at the two sides remain in the meantime quite free. Slightly further back, but before the primitive groove is reached, the epiblast and hypoblast are connected together by a cord of cells (Fig. 105 B, *f*), which in the section next following becomes detached from the hypoblast and forms a solid keel projecting from the epiblast. In the following section the hitherto independent mesoblast plates become united with this keel (Fig. 105 A); and in the posterior sections, through the part of the primitive streak with the primitive groove, the epiblast and mesoblast continue to be united in the axial line, but the hypoblast remains distinct. These peculiar relations may shortly be described by saying that in the axial line the hypoblast becomes *united with the epiblast at the posterior end of the embryo*; and that the cells which connect the hypoblast and epiblast are posteriorly continuous with the fused epiblast and mesoblast of the primitive streak, the hypoblast in the region of the primitive streak having become distinct from the other layers.

The notochord. The thickened axial portion of the hypoblast in the region of the embryo becomes separated, as we have already pointed out, from the lateral parts as the notochord.

Very shortly after the formation of the notochord, the hypoblast grows in from the two sides, and becomes quite continuous across the middle line. The formation of the notochord takes place from before backwards; and at the hinder end of the embryo it is continued into the mass of cells which forms the axis of the primitive streak, becoming therefore at this point continuous

with the epiblast. The notochord in fact behaves exactly as did the axial hypoblast in the earlier stage.

The peculiar relations just mentioned are precisely similar to those we have already described in the chick (p. 60). They receive their explanation by comparison with the lower types.

The cells which form the junction between the epiblast and the axial hypoblast constitute in the lower types the front wall of a passage perforating the blastoderm and leading from the exterior into the alimentary canal. This passage is the vertebrate blastopore.

In the chick we have seen (p. 72) this passage is present at a certain stage of development as the neurenteric canal ; and in the duck at a still earlier stage. It is also present at an early stage in the mole.

The presence of this blastopore renders it clear that the blastopore discovered by Ed. van Beneden cannot have the meaning he assigned to it in comparing it with the blastopore of the frog.

To recapitulate. At the stage we have now reached the three layers are definitely established.

The epiblast is derived partly from the outer layer of segmentation spheres and partly from the larger proportion of those segmentation spheres which constitute the inner mass. The hypoblast arises from the few remaining cells of the inner mass ; while the mesoblast has its origin partially from the epiblast of the primitive streak and partially from the hypoblast cells anterior to the primitive streak.

During the period in which these changes have been taking place, the rudiments of a vascular area become formed, and while as Kölliker has shewn, the mesoblast of this portion is to some extent derived from the mesoblast of the primitive streak, it is possible that a portion of it owes its origin to hypoblastic mesoblast.

General growth of the embryo. We have seen that the blastodermic vesicle becomes divided at an early stage of development into an embryonic area, and a non-embryonic portion. The embryonic area gives rise to the whole of the body of the embryo, while the non-embryonic part forms an appendage known as the umbilical vesicle, which becomes gradually folded off from the embryo, and has precisely the relations of the yolk-sac of the chick. It is almost certain that the Mammalia are descended from ancestors, the embryos of which had large yolk-sacs, but that the yolk has become reduced in quantity owing to the nutriment received from the wall of the uterus taking the place of that originally supplied by the yolk. A rudiment of the yolk-sac being thus retained in the umbilical vesicle, this structure may be called indifferently umbilical vesicle or yolk-sac.

The yolk which fills the yolk-sac in Birds is replaced in Mammals by a coagulable fluid; while the gradual extension of the hypoblast round the wall of the blastodermic vesicle, which has already been described, is of the same nature as the growth of the hypoblast round the yolk-sac in Birds.

The whole embryonic area would seem to be employed in the formation of the body of the embryo. Its long axis has no very definite relation to that of the blastodermic vesicle. The first external trace of the embryo to appear is the medullary plate, bounded by the medullary folds, and occupying at first the anterior half of the embryonic area (Fig. 103). The two medullary folds diverge behind and enclose the front end of the primitive streak. As the embryo elongates the

medullary folds nearly meet behind and so cut off the front portion of the primitive streak, which then appears as a projection in the hind end of the medullary groove. At the hind end of the medullary groove (mole) a deep pit perforates its floor and enters the mass of mesoblast cells lying below. The pit is a rudiment of the blastopore (described on p. 326) which has been enclosed by the medullary folds.

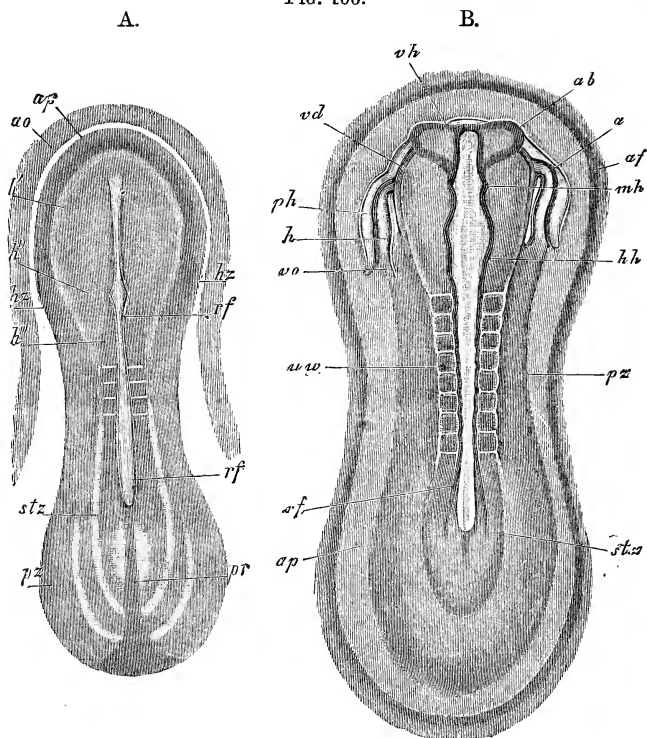
Henceforward the general course of development is very similar to that in the chick and so will be only briefly described. The special features in the development of particular organs will be described later. In an embryo rabbit, eight days after impregnation, the medullary groove is about 1.80 mm. in length. At this stage a division may be clearly seen in the lateral plates of mesoblast into a vertebral zone adjoining the embryo and a more peripheral lateral zone; and in the vertebral zone indications of two somites, about 0.37 mm. from the hinder end of the embryo, become apparent. The foremost of these somites marks the junction, or very nearly so, of the cephalic region and trunk. The small size of the latter as compared with the former is very striking, but is characteristic of Vertebrates generally. The trunk gradually elongates relatively to the head, by the addition behind of fresh somites. The embryo has not yet begun to be folded off from the yolk-sac.

In a slightly older embryo of nine days there appears (Hensen, Kölliker) round the embryonic area a delicate clear ring which is narrower in front than behind (Fig. 106 A. *ap*). This ring is regarded by these authors as representing the peripheral part of the area pellucida of

Birds, which does not become converted into the body of the embryo. Outside the area pellucida, an area vasculosa has become very well defined. In the embryo itself (Fig. 106 A) the disproportion between head and trunk is less marked than before; the medullary plate dilates anteriorly to form a spatula-shaped cephalic enlargement; and three or four somites are established. In the lateral parts of the mesoblast of the head there may be seen on each side a tube-like structure (*hz*). Each of these is part of the heart, which arises as two independent tubes. The remains of the primitive streak (*pr*) are still present behind the medullary groove.

In somewhat older embryos (Fig. 106 B) with about eight somites, in which the trunk considerably exceeds the head in length, the first distinct traces of the folding off of the head end of the embryo become apparent, and somewhat later a fold also appears at the hind end. In the formation of the hind end of the embryo the primitive streak gives rise to a tail swelling and to part of the ventral wall of the post-anal gut. In the region of the head the rudiments of the heart (*h*) are far more definite. The medullary groove is still open for its whole length, but in the head it exhibits a series of well-marked dilatations. The foremost of these (*vh*) is the rudiment of the fore-brain from the sides of which there project the two optic vesicles (*ab*); the next is the mid-brain (*mh*) and the last is the hind-brain (*hh*), which is again divided into smaller lobes by successive constrictions. The medullary groove behind the region of the somites dilates into an embryonic sinus rhomboidalis like that of the bird. Traces of the

FIG. 106.



EMBRYO RABBITS OF ABOUT NINE DAYS FROM THE DORSAL SIDE.
(From Kölliker.)

A. magnified 22 times, and B. 21 times.

ap. area pellucida; *rf.* medullary groove; *h'*. medullary plate in the region of the future fore-brain; *h''*. medullary plate in the region of the future mid-brain; *vh.* fore-brain; *ab.* optic vesicle; *mh.* mid-brain; *hh.* and *h'''*. hind-brain; *uw.* mesoblastic somite; *stz.* vertebral zone; *pz.* lateral zone; *hz.* and *h.* heart; *ph.* pericardial section of body-cavity; *vo.* vitelline vein; *af.* amnion fold.

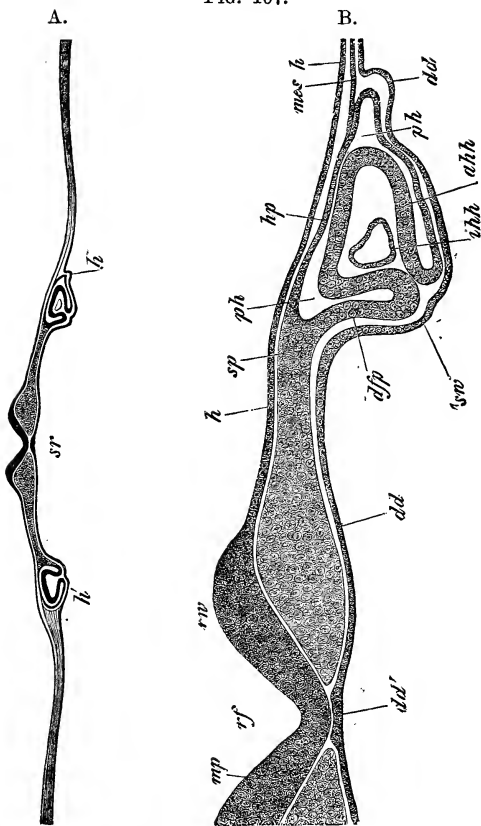
amnion (*af*) are now apparent both in front of and behind the embryo.

The structure of the head and the formation of the heart at this age are illustrated in Fig. 107. The widely open medullary groove (*rf*) is shewn in the centre. Below it the hypoblast is thickened to form the notochord *dd'*; and at the sides are seen the two tubes, which, on the folding-in of the fore-gut, give rise to the unpaired heart¹. Each of these is formed of an outer muscular tube of splanchnic mesoblast (*ahh*), not quite closed towards the hypoblast, and an inner epithelioid layer (*ihh*); and is placed in a special section of the body cavity (*ph*), which afterwards forms the pericardial cavity.

Before the ninth day is completed great external changes are usually effected. The medullary groove becomes closed for its whole length with the exception of a small posterior portion. The closure commences, as in Birds, in the region of the mid-brain. Anteriorly the folding-off of the embryo proceeds so far that the head becomes quite free, and a considerable portion of the throat, ending blindly in front, becomes established. In the course of this folding the, at first widely separated, halves of the heart are brought together, coalesce on the ventral side of the throat, and so give rise to a median undivided heart. The fold at the tail end of the embryo progresses considerably, and during its advance the allantois is formed in the same way as in Birds. The somites increase in number to about twelve. The amniotic folds nearly meet above the embryo.

¹ The details of the development of the heart are described below (ch. xii.).

FIG. 107.



TRANSVERSE SECTION THROUGH THE HEAD OF A RABBIT OF THE SAME AGE AS FIG. 106 B. (From Kölliker.)

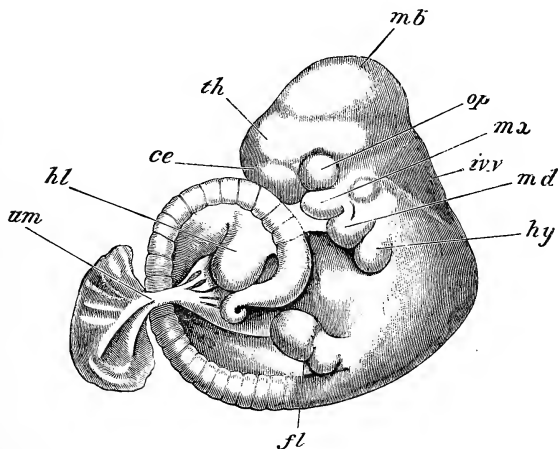
B. is a more highly magnified representation of part of A.

rf. medullary groove ; *mp.* medullary plate ; *rw.* medullary fold ; *h.* epiblast ; *dd.* hypoblast ; *dd'.* notochordal thickening of hypoblast ; *sp.* undivided mesoblast ; *hp.* somatic mesoblast ;

dfp. splanchnic mesoblast; *ph.* pericardial section of body-cavity; *ahh.* muscular wall of heart; *ihh.* epithelioid layer of heart; *mes.* lateral undivided mesoblast; *sw.* fold of hypoblast which will form the ventral wall of the pharynx; *sr.* commencing throat.

The later stages in the development proceed in the main in the same manner as in the Bird. The cranial flexure soon becomes very marked, the mid-brain forming the end of the long axis of the embryo (Fig. 108). The sense organs have the usual development. Under the fore-brain appears an epiblastic involution giving

FIG. 108.

ADVANCED EMBRYO OF A RABBIT (ABOUT TWELVE DAYS)¹.

mb. mid-brain; *th.* thalamencephalon; *ce.* cerebral hemisphere; *op.* eye; *iv.v.* fourth ventricle; *mx.* maxillary process; *md.* mandibular arch; *hy.* hyoid arch; *fl.* fore-limb; *hl.* hind-limb; *um.* umbilical stalk.

¹ This figure was drawn by Mr Weldon.

rise both to the mouth and to the pituitary body. Behind the mouth are three well marked pairs of visceral arches. The first of these is the mandibular arch (Fig. 108 *md*), which meets its fellow in the middle line, and forms the posterior boundary of the mouth. It sends forward on each side a superior maxillary process (*mx*) which partially forms the anterior margin of the mouth. Behind the mandibular arch are present a well-developed hyoid (*hy*) and a first branchial arch (not shewn in Fig. 108). There are four clefts, as in the chick, but the fourth is not bounded behind by a definite arch. Only the first of these clefts persists as the tympanic cavity and Eustachian tube.

At the time when the cranial flexure appears, the body also develops a sharp flexure immediately behind the head, which is thus bent forwards upon the posterior straight part of the body (Fig. 108). The amount of this flexure varies somewhat in different forms. It is very marked in the dog (Bischoff). At a later period, and in some species even before the stage figured, the tail end of the body also becomes bent (Fig. 108), so that the whole dorsal side assumes a convex curvature, and the head and tail become closely approximated. In most cases the embryo, on the development of the tail, assumes a more or less definite spiral curvature (Fig. 108). With the more complete development of the lower wall of the body the ventral flexure partially disappears, but remains more or less persistent till near the close of intra-uterine life. The limbs are formed as simple buds in the same manner as in Birds. The buds of the hind-limbs are directed somewhat forwards, and those of the fore-limb backwards.

The human embryo. Our knowledge as to the early development of the human embryo is in an unsatisfactory state. The positive facts we know are comparatively few, and it is not possible to construct from them a history of the development which is capable of satisfactory comparison with that in other forms, unless all the early embryos known are to be regarded as abnormal. The most remarkable feature in the development, which was first clearly brought to light by Allen Thomson in 1839, is the very early appearance of branched villi. In the last few years several ova, even younger than those described by Allen Thomson, have been met with, which exhibit this peculiarity.

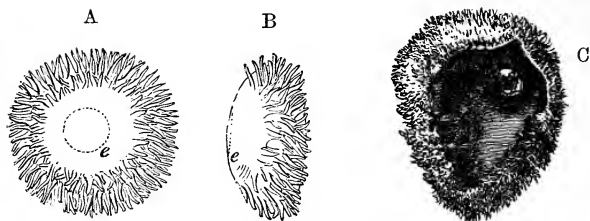
The best preserved of these ova is one described by Reichert¹. This ovum, though probably not more than thirteen days old, was completely enclosed by a decidua reflexa. It had (Fig. 109 A and B) a flattened oval form, measuring in its two diameters 5.5 mm. and 3.5 mm. The edge was covered with branched villi, while in the centre of each of the flattened surfaces there was a spot free from villi. On the surface adjoining the uterine wall was a darker area (*e*) formed of two layers of cells. Nothing certain has been made out about the structure of ova of this age.

The villi, which at first leave the flattened poles free, seem soon to extend first over one of the flat sides and finally over the whole ovum (Fig. 109 C).

Unless the two-layered region of Reichert's ovum is the embryonic area, nothing which can clearly be identified as an embryo has been detected in these

¹ Abhandlungen der Königl. Akad. d. Wiss. zu Berlin, 1873.

FIG. 109.



THE HUMAN OVA DURING EARLY STAGES OF DEVELOPMENT.

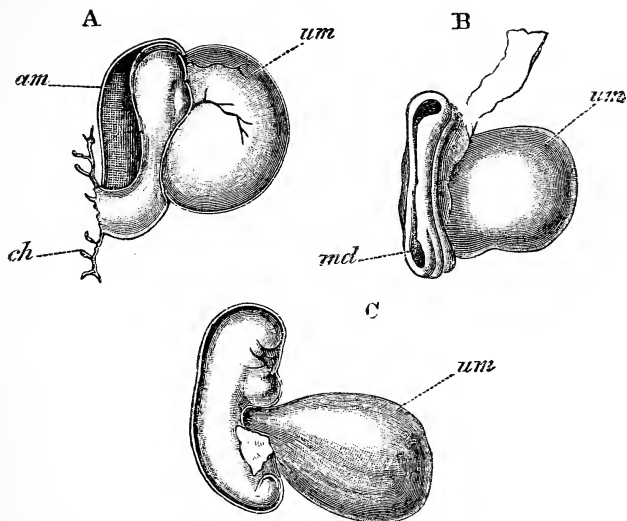
(From Quain's *Anatomy*.)

- A. and B. Front and side view of an ovum figured by Reichert, supposed to be about thirteen days. *e.* embryonic area.
- C. An ovum of about four or five weeks shewing the general structure of the ovum before the formation of the placenta. Part of the wall of the ovum is removed to shew the embryo *in situ*. (After Allen Thomson.)

early ova. In an ovum described by Breus, and in one described long ago by Wharton-Jones, a mass found in the interior of the ovum may perhaps be interpreted (His) as the remains of the yolk. It is, however, very probable that all the early ova so far obtained are more or less pathological.

The youngest ovum with a distinct embryo is one described by His. This ovum, which is diagrammatically represented in Fig. 111 in longitudinal section, had the form of an oval vesicle completely covered by villi, being about 8.5 mm. and 5.5 mm. in its two diameters, and flatter on one side than on the other. An embryo with a yolk-sac was attached to the inner side of the flatter wall of the vesicle by a stalk, which must be regarded as the allantoic stalk; the embryo

FIG. 110.



THREE EARLY HUMAN EMBRYOS. (Copied from His.)

A. Side view of an early embryo described by His.

B. Embryo of about 12—14 days described by Allen Thomson.

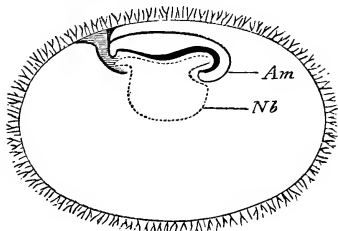
C. Young embryo described by His.

am. amnion ; *md.* medullary groove ; *um.* umbilical vesicle ;
ch. chorion, to which the embryo is attached by a stalk.

and yolk-sac filled up but a very small part of the whole cavity of the vesicle.

The embryo, which was probably not quite normal (Fig. 110 A), was very imperfectly developed; a medullary plate was hardly indicated, and, though the mesoblast was unsegmented, the head fold, separating the embryo from the yolk-sac (*um*), was already in-

FIG. 111.



DIAGRAMMATIC LONGITUDINAL SECTION OF THE OVUM TO WHICH THE EMBRYO (FIG. 110 A.) BELONGED. (After His.)

am. amnion; *Nb.* umbilical vesicle.

dicated. The amnion (*am*) was completely formed, and vitelline vessels had made their appearance.

Two embryos described by Allen Thomson are but slightly older than the above embryo of His. Both of them probably belong to the first fortnight of pregnancy. In both cases the embryo was more or less folded off from the yolk-sac, and in one of them the medullary groove was still widely open, except in the region of the neck (Fig. 110 B). The allantoic stalk, if present, was not clearly made out, and the condition of the amnion was also not fully studied. The smaller of the two ova was just 6 mm. in its largest diameter, and was nearly completely covered with simple villi, more developed on one side than on the other.

In a somewhat later period, about the stage of a chick at the end of the second day, the medullary folds are completely closed, the region of the brain already marked, and the cranial flexure commencing. The mesoblast is divided up into numerous somites, and the mandibular and first two branchial arches are indicated.

The embryo is still but incompletely folded off from the yolk-sac below.

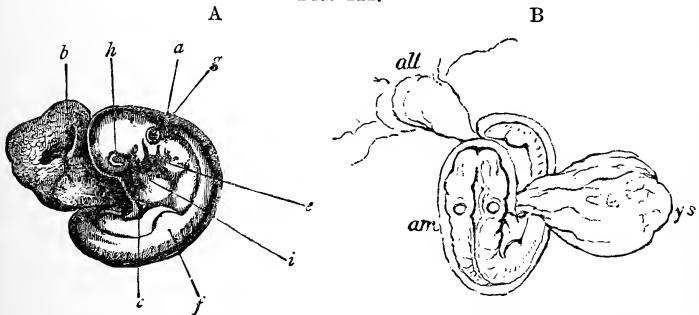
In a still older stage the cranial flexure becomes still more pronounced, placing the mid-brain at the end of the long axis of the body. The body also begins to be ventrally curved (Fig. 110 C).

Externally human embryos at this age are characterized by the small size of the anterior end of the head.

The flexure goes on gradually increasing, and in the third week of pregnancy in embryos of about 4 mm. the limbs make their appearance.

The embryo at this stage (Fig. 112), which is about

FIG. 112.



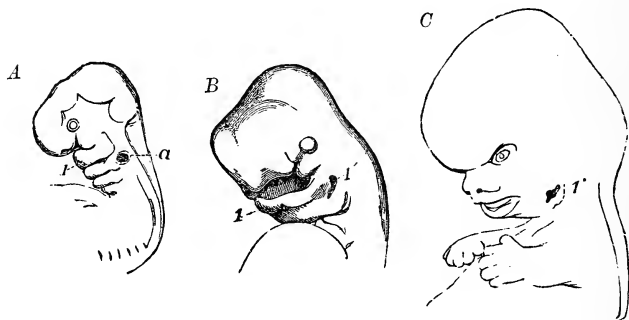
TWO VIEWS OF A HUMAN EMBRYO OF BETWEEN THE THIRD AND FOURTH WEEK.

- A. Side view. (From Kölliker; after Allen Thomson.) *a.* amnion; *b.* umbilical vesicle; *c.* mandibular arch; *e.* hyoid arch; *f.* commencing anterior limb; *g.* primitive auditory vesicle; *h.* eye; *i.* heart.
- B. Dorsal view to shew the attachment of the dilated allantoic stalk to the chorion. (From a sketch by Allen Thomson.) *am.* amnion; *all.* allantois; *ys.* yolk-sac.

equivalent to that of a chick on the fourth day, resembles in almost every respect the normal embryos of the Amniota. The cranial flexure is as pronounced as usual, and the cerebral region has now fully the normal size. The whole body soon becomes flexed ventrally, and also somewhat spirally. The yolk-sac (B; *ys*) forms a small spherical appendage with a long wide stalk, and the embryo is attached by an allantoic stalk with a slight swelling, probably indicating the presence of a small hypoblastic diverticulum, to the inner face of the chorion.

A detailed history of the further development of the human embryo does not fall within the province of

FIG. 113.



FIGURES SHEWING THE EARLY CHANGES IN THE FORM OF THE HUMAN HEAD. (From Quain's *Anatomy*.)

- A. Head of an embryo of about four weeks. (After Allen Thomson.)
- B. Head of an embryo of about six weeks. (After Ecker.)
- C. Head of an embryo of about nine weeks.

1. mandibular arch ; 1'. persistent part of hyomandibular cleft ;
a. auditory vesicle.

this work; while the later changes in the embryonic membranes will be dealt with in the next chapter. For the changes which take place on the formation of the face we may refer the reader to Fig. 113. For a full discussion as to the relation between the human embryos just described and those of other Mammals, we refer the reader to the *Comp. Embryology*, Vol. II. p. 224 et seq.

The guinea pig, rat and mouse present a peculiar method of development, the details of which are not entirely understood, and we do not propose to examine them here. Suffice it to say that the mode of development gives rise to the so-called inversion of the layers; so called because the outer layer of the embryonic vesicle appeared to the older observers to be formed of hypoblast and the embryonic epiblast to be enclosed *within*.

CHAPTER XI.

EMBRYONIC MEMBRANES AND YOLK-SAC.

IN the Mammalia the early stages in the development of the embryonic membranes are nearly the same as in Aves; but during the later stages the allantois enters into peculiar relations with the uterine walls, and the two, together with the interposed portion of the subzonal membrane or false amnion (the nature of which will be presently described), give rise to a very characteristic Mammalian organ—the placenta—into the structure of which it will be necessary to enter at some length. The embryonic membranes vary so considerably in the different forms that it will be advantageous to commence with a description of their development in an ideal case.

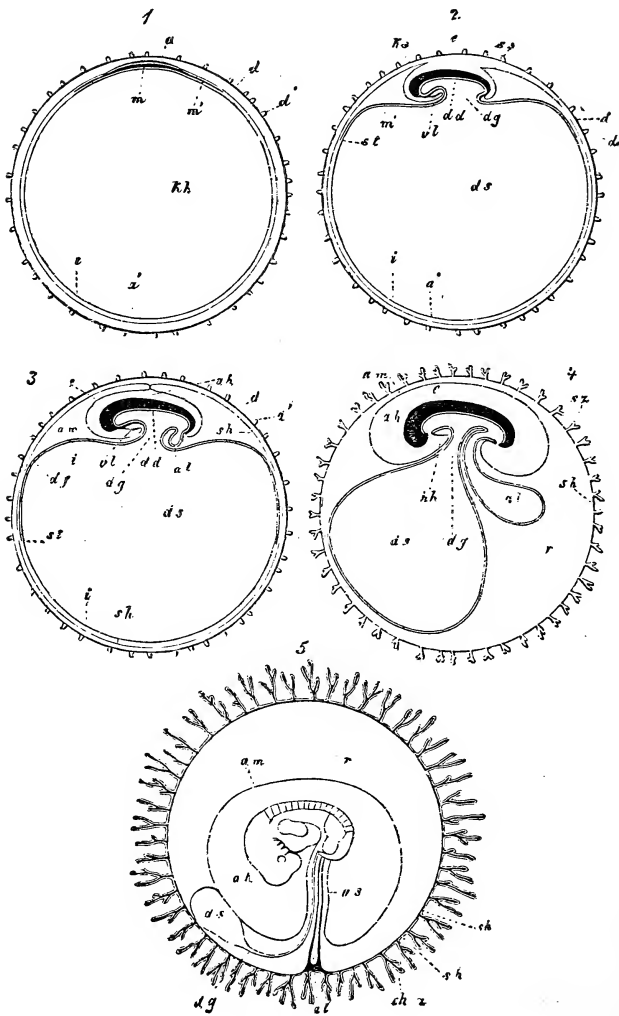
We may commence with a blastodermic vesicle closely invested by the delicate remnant of the zona radiata at the stage in which the medullary groove is already established. Around the embryonic area a layer of mesoblast would have extended for a certain distance; so as to give rise to an area vasculosa, in which however the blood-vessels would not have become definitely

established. Such a vesicle is represented diagrammatically in Fig. 114, 1. Somewhat later the embryo begins to be folded off first in front and then behind (Fig. 114, 2). These folds result in a constriction separating the embryo and the yolk-sac (*ds*), or as it is called in Mammalian embryology, the *umbilical vesicle*. The splitting of the mesoblast into a splanchnic and a somatic layer has taken place, and at the front and hind end of the embryo a fold (*ks*) of the somatic mesoblast and epiblast begins to rise up and grow over the head and tail of the embryo. These two folds form the commencement of the amnion. The head and tail folds of the amnion are continued round the two sides of the embryo till they meet and unite into a continuous fold. This fold grows gradually upwards, but before it has completely enveloped the embryo the blood-vessels of the area vasculosa become fully developed. They are arranged in a manner not very different from that in the chick.

The following is a brief account of their arrangement in the rabbit:—

The outer boundary of the area, which is continually extending further and further round the umbilical vesicle, is marked by a venous sinus terminalis (Fig. 114, *st*). The area is not, as in the chick, a nearly complete circle, but is in front divided by a deep indentation extending inwards to the level of the heart. In consequence of this indentation the sinus terminalis ends in front in two branches, which bend inwards and fall directly into the main vitelline veins. The blood is brought from the dorsal aortæ by a series of lateral vitelline arteries, and not by a single pair as in the chick. These arteries break up into a more deeply situated arterial network, from which the blood is continued partly into the sinus terminalis, and partly into a superficial venous

FIG. 114.



FIVE DIAGRAMMATIC FIGURES ILLUSTRATING THE FORMATION OF THE FOETAL MEMBRANES OF A MAMMAL. (From Kölliker.)

In 1, 2, 3, 4 the embryo is represented in longitudinal section.

1. Ovum with zona pellucida, blastodermic vesicle, and embryonic area.

2. Ovum with commencing formation of umbilical vesicle and amnion.

3. Ovum with amnion about to close, and commencing allantois.

4. Ovum with villous subzonal membrane, larger allantois, and mouth and anus.

5. Ovum in which the mesoblast of the allantois has extended round the inner surface of the subzonal membrane and united with it to form the chorion. The cavity of the allantois is aborted. This fig. is a diagram of an early human ovum.

z. zona radiata; *z'* and *sz.* processes of zona; *sh.* subzonal membrane, outer fold of amnion, false amnion; *ch.* chorion; *ch. z.* chorionic villi; *am.* amnion; *ks.* head-fold of amnion; *ss.* tail-fold of amnion; *a.* epiblast of embryo; *a'.* epiblast of non-embryonic part of the blastodermic vesicle; *m.* embryonic mesoblast; *m'.* non-embryonic mesoblast; *df.* area vasculosa; *st.* sinus terminalis; *dd.* embryonic hypoblast; *i.* non-embryonic hypoblast; *kh.* cavity of blastodermic vesicle, the greater part of which becomes the cavity of umbilical vesicle *ds.*; *dg.* stalk of umbilical vesicle; *al.* allantois; *e.* embryo; *r.* space between chorion and amnion containing albuminous fluid; *vl.* ventral body wall; *hh.* pericardial cavity.

network. The hinder end of the heart is continued into two vitelline veins, each of which divides into an anterior and a posterior branch. The anterior branch is a limb of the sinus terminalis, and the posterior and smaller branch is continued towards the hind part of the sinus, near which it ends. On its way it receives, on its outer side, numerous branches from the venous network. The venous network connects by its anastomoses, the posterior branch of the vitelline vein and the sinus terminalis.

Shortly after the establishment of the circulation of the yolk-sac the folds of the amnion meet and coalesce above the embryo (Fig. 114, 3 and 4, *am*). After this the inner or true amnion becomes severed from the outer or false amnion, though the two sometimes remain connected by a narrow stalk. The space between the true and false amnion is a continuation of the body cavity. The true amnion consists of a layer of epiblastic epithelium and generally also of somatic mesoblast, while the false amnion consists as a rule of epiblast only; though it is possible that in some cases (the rabbit?) the mesoblast may be continued along its inner face.

Before the two limbs of the amnion are completely severed the epiblast of the umbilical vesicle becomes separated from the subjacent mesoblast and hypoblast of the vesicle (Fig. 114, 3), and, together with the false amnion (*sh*) with which it is continuous, forms a complete lining for the inner face of the zona radiata. The space between this membrane and the umbilical vesicle with the attached embryo is obviously continuous with the body cavity (*vide* Figs. 114, 4 and 115). To this membrane Turner has given the appropriate name of *sub-zonal membrane*: by Von Baer it was called the serous

envelope. It soon fuses with the zona radiata, or at any rate the zona ceases to be distinguishable.

While the above changes have been taking place the whole blastodermic vesicle, still enclosed in the zona, has become attached to the walls of the uterus. In the case of the typical uterus with two tubular horns, the position of each embryo, when there are several, is marked by a swelling in the walls of the uterus, preparatory to the changes in the wall which take place on the formation of the placenta. In the region of each swelling the zona around the blastodermic vesicle is closely embraced in a ring-like fashion by the epithelium of the uterine wall. The whole vesicle assumes an oval form, and it lies in the uterus with its two ends free. The embryonic area is placed close to the mesometric attachment of the uterus. In many cases peculiar processes or villi grow out from the ovum (Fig. 114, 4, *sz*) which fit into the folds of the uterine epithelium. The nature of these processes requires further elucidation, but in some instances they appear to proceed from the zona (rabbit) and in other instances from the subzonal membrane (dog). In any case the attachment between the blastodermic vesicle and the uterine wall becomes so close at the time when the body of the embryo is first formed out of the embryonic area, that it is hardly possible to separate them without laceration; and at this period—from the 8th to the 9th day in the rabbit—it requires the greatest care to remove the ovum from the uterus without injury. It will be understood of course that the attachment above described is at first purely superficial and not vascular.

During the changes above described as taking place in the amnion, the allantois grows out from the hind-gut as a vesicle lined by hypoblast, but covered externally by a layer of splanchnic mesoblast (Fig. 114, 3 and 4, *al*)¹. It soon becomes a flat sac, projecting into the now largely developed space between the subzonal membrane and the amnion, on the dorsal side of the embryo (Fig. 115, *ALC*). In some cases it extends so as to cover the whole inner surface of the subzonal membrane; in other cases again its extension is much more limited. Its lumen may be retained or may become nearly or wholly aborted. A fusion takes place between the subzonal membrane and the adjoining mesoblastic wall of the allantois, and the two together give rise to a secondary membrane round the ovum known as the *chorion*. Since however the allantois does not always come in contact with the whole inner surface of the subzonal membrane the term chorion is apt to be somewhat vague; in the rabbit, for instance, a considerable part of the so-called chorion is formed by a fusion of the wall of the yolk-sac with the subzonal membrane (Fig. 116). The region of the chorion which gives rise to the placenta may in such cases be distinguished as the true chorion from the remaining part which will be called the false chorion.

The mesoblast of the allantois, especially that part of it which assists in forming the chorion, becomes highly vascular; the blood being brought to it by two allantoic arteries continued from the terminal bifur-

¹ The hypoblastic element in the allantois is sometimes very much reduced, so that the allantois may be mainly formed of a vascular layer of mesoblast.

FIG. 115.

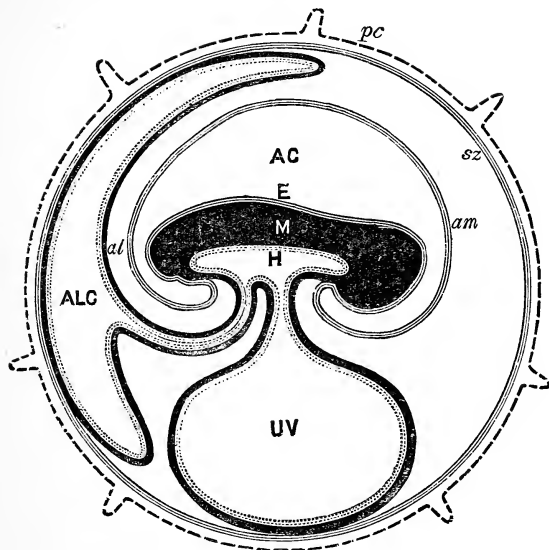


DIAGRAM OF THE FŒTAL MEMBRANES OF A MAMMAL. (From Turner.)

Structures which either are or have been at an earlier period of development continuous with each other are represented by the same character of shading.

pc. zona with villi; *sz.* subzonal membrane; *E.* epiblast of embryo; *am.* amnion; *AC.* amniotic cavity; *M.* mesoblast of embryo; *H.* hypoblast of embryo; *UV.* umbilical vesicle; *al.* allantois; *ALC.* allantoic cavity.

cation of the dorsal aorta, and returned to the body by one, or rarely two, allantoic veins, which join the vitelline veins from the yolk-sac. From the outer surface of the true chorion (Fig. 114, 5, *ch. z.*, 116) villi grow out and fit into crypts or depressions which have in the

meantime made their appearance in the walls of the uterus¹. The villi of the chorion are covered by an epithelium derived from the subzonal membrane, and are provided with a connective-tissue core containing an artery and vein and a capillary plexus connecting them. In most cases they assume a more or less arborescent form, and have a distribution on the surface of the chorion varying characteristically in different species. The walls of the crypts into which the villi are fitted also become highly vascular, and a nutritive fluid passes from the maternal vessels of the placenta to the foetal vessels by a process of diffusion; while there is probably also a secretion by the epithelial lining of the walls of the crypts, which becomes absorbed by the vessels of the foetal villi. The above maternal and foetal structures constitute together the organ known as the placenta. The maternal portion consists essentially of the vascular crypts in the uterine walls, and the foetal portion of more or less arborescent villi of the true chorion fitting into these crypts.

While the placenta is being developed the folding off of the embryo from the yolk-sac becomes more complete; and the yolk-sac remains connected with the ileal region of the intestine by a narrow stalk, the vitelline duct (Fig. 114, 4 and 5 and Fig. 115), consisting of the same tissues as the yolk-sac, viz. hypoblast and splanchnic mesoblast. While the true splanchnic stalk

¹ These crypts have no connection with the openings of glands in the walls of the uterus. They are believed by Ercolani to be formed to a large extent by a regeneration of the lining tissue of the uterine walls.

of the yolk-sac is becoming narrow, a somatic stalk connecting the amnion with the walls of the embryo is also formed, and closely envelopes the stalk both of the allantois and the yolk-sac. The somatic stalk together with its contents is known as the *umbilical cord*. The mesoblast of the somatopleuric layer of the cord develops into a kind of gelatinous tissue which cements together the whole of the contents. The allantoic arteries in the cord wind in a spiral manner round the allantoic vein. The yolk-sac in many cases atrophies completely before the close of intra-uterine life, but in other cases it, like the other embryonic membranes, is not removed till birth. The intra-embryonic portion of the allantoic stalk gives rise to two structures, viz. to (1) the urinary bladder formed by a dilatation of its proximal extremity, and to (2) a cord known as the urachus connecting the bladder with the wall of the body at the umbilicus. The urachus, in cases where the cavity of the allantois persists till birth, remains as an open passage connecting the intra- and extra-embryonic parts of the allantois. In other cases it gradually closes, and becomes nearly solid before birth, though a delicate but interrupted lumen would appear to persist in it. It eventually gives rise to the ligamentum vesicæ medium.

At birth the foetal membranes, including the foetal portion of the placenta, are shed; but in many forms the interlocking of the foetal villi with the uterine crypts is so close that the uterine mucous membrane is carried away with the foetal part of the placenta. It thus comes about that in some placentæ the maternal and foetal parts simply separate from each other at birth,

and that in others the two remain intimately locked together, and both are shed together as the after-birth. These two forms of placenta are distinguished as *non-deciduate* and *deciduate*, but no sharp line can be drawn between the two types. Moreover, a larger part of the uterine mucous membrane than that actually entering into the maternal part of the placenta is often shed in the deciduate Mammalia, and in the non-deciduate Mammalia it is probable that the mucous membrane (not including vascular parts) of the maternal placenta is either shed or absorbed.

Comparative history of the Mammalian foetal membranes.

Two groups of Mammalia—the Monotremata and the Marsupialia—are believed not to be provided with a true placenta. Nothing is known of the arrangement of the foetal membranes in the former group of animals (Monotremata). In the latter (Marsupialia) the yolk-sac is large and vascular, and is, according to Owen, attached to the subzonal membrane. The allantois on the other hand is but small, and is not attached to the subzonal membrane; it possesses however a vascular supply.

Observations have hitherto been very limited with regard to the foetal membranes of this group of animals, but it appears highly probable that both the yolk-sac and the allantois receive nutriment from the walls of the uterus.

All Mammalia other than the Monotremata and Marsupialia have a true allantoic placenta. The pla-

centa presents a great variety of forms, and we propose first to treat the most important of these in succession, and then to give a general exposition of their mutual affinities.

The discoidal placenta is found in the Rodentia, Insectivora, and Cheiroptera. The Rabbit may be taken as an example of this type of placenta.

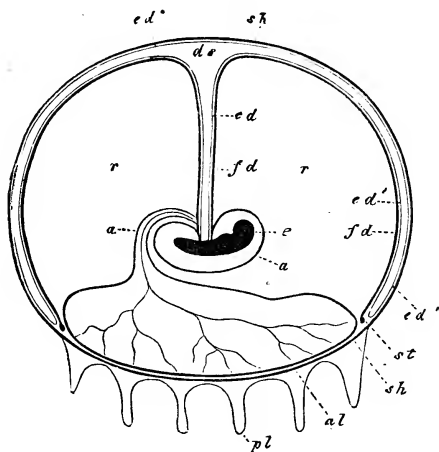
The Rabbit. In the pregnant female Rabbit several ova are generally found in each horn of the uterus. The general condition of the foetal-membranes at the time of their full development is shewn in Fig. 116.

The embryo is surrounded by the amnion, which is comparatively small. The yolk-sac (*ds*) is large and attached to the embryo by a long stalk. It has the form of a flattened sac closely applied to about two-thirds of the surface of the subzonal membrane. The outer wall of this sac, adjoining the subzonal membrane, is formed of hypoblast only; but the inner wall is covered by the mesoblast of the area vasculosa, as indicated by the thick black line (*fd*). The vascular area is bordered by the sinus terminalis (*st*). In an earlier stage of development the yolk-sac had not the compressed form represented in the figure. It is, however, remarkable that the vascular area never extends over the whole yolk-sac; but the inner vascular wall of the yolk-sac fuses with the outer wall, and with the subzonal membrane, and so forms a false chorion, which receives its blood supply from the yolk-sac. This part of the chorion does not develop vascular villi.

The allantois (*al*) is a simple vascular sac with a large cavity. Part of its wall is applied to the subzonal membrane, and gives rise to the true chorion from which there project numerous vascular villi. These fit into corresponding uterine crypts. It seems probable, from Bischoff's and Kölliker's observations, that the subzonal membrane in the area of the placenta becomes attached, by means of villi, to the uterine wall even before its fusion with the allantois. In the later periods of gestation the intermingling of the maternal and foetal parts of the placenta becomes very

close, and the placenta is truly deciduate. The cavity of the allantois persists till birth. Between the yolk-sac, the allantois, and the embryo, there is left a large cavity filled with an albuminous fluid.

FIG. 116.



DIAGRAMMATIC LONGITUDINAL SECTION OF A RABBIT'S OVUM AT AN ADVANCED STAGE OF PREGNANCY. (From Kölliker after Bischoff.)

e. embryo; *a.* amnion; *u.* urachus; *al.* allantois with blood-vessels; *sh.* sub-zonal membrane; *pl.* placental villi; *fd.* vascular layer of yolk-sac; *ed.* hypoblastic layer of yolk-sac; *ed'.* inner portion of hypoblast, and *ed''.* outer portion of hypoblast lining the compressed cavity of the yolk-sac; *ds.* cavity of yolk-sac; *st.* sinus terminalis; *r.* space filled with fluid between the amnion, the allantois and the yolk-sac.

The metadiscoidal type of placenta is found in Man and the Apes. The placenta of Man may be conveniently taken as an example of this type.

Man. The early stages in the development of the foetal membranes in the human embryo have not been satisfactorily observed; but it is known that the ovum, shortly after its entrance into the uterus, becomes attached to the uterine wall, which in the meantime has undergone considerable preparatory changes. A fold of the uterine wall appears to grow round the blastodermic vesicle, and to form a complete capsule for it, but the exact mode of formation of this capsule is a matter of inference and not of observation. During the first fortnight of pregnancy villi grow out, over the whole surface of the ovum. The further history of the early stages is extremely obscure: what is known with reference to it will be found on p. 335 et seq.; we will here take up the history at about the fourth week.

At this stage a complete chorion has become formed, and is probably derived from a growth of the mesoblast of the allantois (unaccompanied by the hypoblast) round the whole inner surface of the subzonal membrane. From the whole surface of the chorion there project branched vascular processes, covered by an epithelium. The allantois is without a cavity, but a hypoblastic epithelium is present in the allantoic stalk, though not forming a continuous tube. The blood-vessels of the chorion are derived from the usual allantoic arteries and vein. The general condition of the embryo and of its membranes at this period is shewn diagrammatically in Fig. 114, 5. Around the embryo is seen the amnion, already separated by a considerable interval from the embryo. The yolk-sac is shewn at *ds*. Relatively to the other parts it is considerably smaller than it was at an earlier stage. The allantoic stalk is shewn at *al*. Both it and the stalk of the yolk-sac are enveloped by the amnion, *am*. The chorion with its vascular processes surrounds the whole embryo.

It may be noted that the condition of the chorion at this stage is very similar to that of the normal diffused type of placenta, described in the sequel.

While the above changes are taking place in the embryonic membranes, the blastodermic vesicle greatly increases in size, and forms a considerable projection from the upper wall of the uterus. Three regions of the uterine wall, in relation to the

blastodermic vesicle, are usually distinguished; and since the superficial parts of all of these are thrown off with the after-birth, each of them is called a decidua. They are represented at a somewhat later stage in Fig. 117. There is (1) the part of the wall reflected over the blastodermic vesicle, called the *decidua reflexa* (*dr*); (2) the part of the wall forming the area round which the reflexa is inserted, called the *decidua serotina* (*ds*); (3) the general wall of the uterus, not related to the embryo, called the *decidua vera* (*du*).

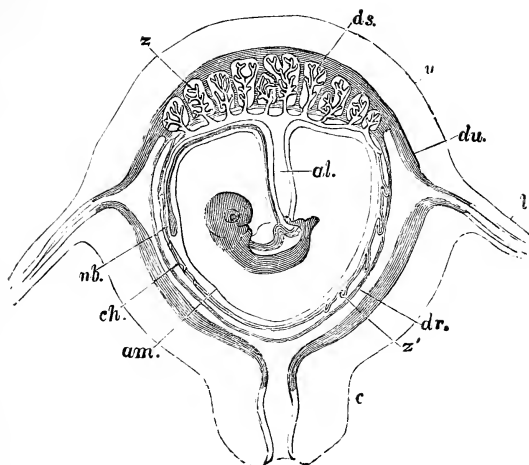
The decidua reflexa and serotina together envelop the chorion (Fig. 114. 5), the processes of which fit into crypts in them. At this period both of them are highly and nearly uniformly vascular. The general cavity of the uterus is to a large extent obliterated by the ovum, but still persists as a space filled with mucus, between the decidua reflexa and the decidua vera.

The changes which ensue from this period onwards are fully known. The amnion continues to dilate (its cavity being tensely filled with amniotic fluid) till it comes very close to the chorion (Fig. 117, *am*); from which, however, it remains separated by a layer of gelatinous tissue. The villi of the chorion in the region covered by the decidua reflexa, gradually cease to be vascular, and partially atrophy, but in the region in contact with the decidua serotina increase and become more vascular and more arborescent (Fig. 117, *z*). The former region becomes known as the *chorion læve*, and the latter as the *chorion frondosum*. The chorion frondosum, together with the decidua serotina, gives rise to the placenta.

The umbilical vesicle (Fig. 117, *nb*), although it becomes greatly reduced in size and flattened, persists in a recognisable form till the time of birth.

The decidua reflexa, by the disappearance of the vessels in the chorion læve, becomes non-vascular. Its tissue and that of the decidua vera undergo changes which we do not propose to describe here; it ultimately fuses on the one hand with the chorion, and on the other with the decidua vera. The membrane resulting from its fusion with the latter structure becomes thinner and thinner as pregnancy advances, and is reduced to a thin layer at the time of birth.

FIG. 117.



DIAGRAMMATIC SECTION OF PREGNANT HUMAN UTERUS WITH
CONTAINED FŒTUS. (From Huxley after Longet.)

al. allantoic stalk; *nb.* umbilical vesicle; *am.* amnion; *ch.* chorion; *ds.* decidua serotina; *du.* decidua vera; *dr.* decidua reflexa; *l.* fallopian tube; *c.* cervix uteri; *u.* uterus; *z.* foetal villi of true placenta; *z'.* villi of non-placental part of chorion.

The placenta has a somewhat discoidal form, with a slightly convex uterine surface and a concave embryonic surface. At its edge it is continuous both with the decidua reflexa and decidua vera. Near the centre of the embryonic surface is implanted the umbilical cord. As has already been mentioned, the placenta is formed of the decidua serotina and the foetal villi of the chorion frondosum. The foetal and maternal tissues are far more closely united than in the placenta of the rabbit. The villi of the chorion, which were originally comparatively simple, become more and more complicated, and assume an extremely arborescent form. At birth the whole placenta, together with the fused de-

cidua vera, and reflexa, with which it is continuous, is shed; and the blood-vessels thus ruptured are closed by the contraction of the uterine walls.

The metadiscoidal placenta of Man and Apes and the discoidal placenta of the Rabbit are usually classified by anatomists as *discoidal* placenta, but it must be borne in mind that they differ very widely.

In the Rabbit there is a dorsal placenta, which is co-extensive with the area of contact between the allantois and the subzonal membrane, while the yolk-sac adheres to a large part of the subzonal membrane. In Apes and Man the allantois spreads over the whole inner surface of the subzonal membrane; the placenta is on the ventral side of the embryo, and occupies only a small part of the surface of the allantois.

Zonary placenta. Another form of deciduate placenta is known as the zonary. This form of placenta occupies a broad zone of the chorion, leaving the two poles free. It is found in the Carnivora, Hyrax, Elephas, and Orycteropus.

In the Dog, which may be taken as a type, there is a large vascular yolk-sac formed in the usual way, which does not however fuse with the chorion. It has at first an oval shape, and persists till birth. The allantois first grows out on the dorsal side of the embryo, where it coalesces with the subzonal membrane, over a small discoidal area, and *there is thus formed a rudimentary discoidal placenta* closely resembling that of the Rabbit.

The area of adhesion between the outer part of the allantois and subzonal membrane gradually spreads over the whole interior of the subzonal membrane, and vascular villi are formed over the whole area of adhesion except at the two extreme poles of the ovum.

With the full growth of the allantois there is formed a broad placental zone, with numerous branched villi fitting into corresponding pits which are not true glands but special develop-

ments of the uterine surface. The maternal and foetal structures become closely interlocked and highly vascular; and at birth a large part of the maternal part is carried away with the placenta; some of it however still remains attached to the muscular wall of the uterus. The zone of the placenta diminishes greatly in proportion to the chorion as the latter elongates, and at the full time the breadth of the zone is not more than about one-fifth of the whole length of the chorion.

At the edge of the placental zone there is a very small portion of the uterine mucous membrane reflected over the non-placental part of the chorion, so as to form a small reflexa analogous with the reflexa in Man.

The most important of the remaining types of placenta are the **diffuse** and the **polycotyledonary**, and these placentæ are for the most part non-deciduate. In the diffuse placenta, found in the Horse, Pig, Lemurs, etc., the allantois completely envelopes the embryo, and villi are formed on all parts of the chorion, excepting over a small area at the two poles.

In the polycotyledonary placenta, which is characteristic of the Ruminantia, the allantois grows round the whole inner surface of the subzonal membrane; the placental villi are however not uniformly distributed, but collected into patches or *cotyledons*, which form as it were so many small placentæ. The foetal villi of these patches fit into corresponding pits in thickened patches of the wall of the uterus.

Comparative histology of the Placenta.

It does not fall within the province of this work to treat from a histological standpoint the changes which take place in the uterine walls during pregnancy. It will, however, be convenient to place before the reader

a short statement of the relations between the maternal and foetal tissues in the different varieties of placenta.

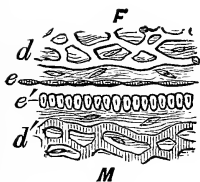
The simplest known condition of the placenta is that found in the pig (Fig. 118 II.). The papilla-like foetal villi fit into the maternal crypts. The villi (*v*) are formed of a connective tissue core with capillaries, and are covered by a layer of very flat epithelium (*e*) derived from the subzonal membrane. The maternal crypts are lined by the uterine epithelium (*e'*), immediately below which is a capillary plexus. The maternal and foetal vessels are here separated by a double epithelial layer. The same general arrangement holds good in the diffused placentæ of other forms, and in the polycotyledonary placenta of the Ruminantia, but the foetal villi in the latter (III.) acquire an arborescent form. The maternal vessels retain the form of capillaries.

In the deciduate placenta a much more complicated arrangement is usually found. In the typical zonary placenta of the fox and cat (IV. and V.), the maternal tissue is broken up into a complete trabecular meshwork, and in the interior of the trabeculæ there run dilated maternal capillaries (*d'*). The trabeculæ are covered by a more or less columnar uterine epithelium (*e'*), and are in contact on every side with foetal villi. The capillaries of the foetal villi preserve their normal size, and the villi are covered by a flat epithelial layer (*e*).

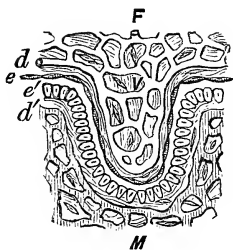
In the Sloth (VI.) which has a discoidal placenta the maternal capillaries become still more dilated, and the epithelium covering them is formed of very flat polygonal cells.

FIG. 118.

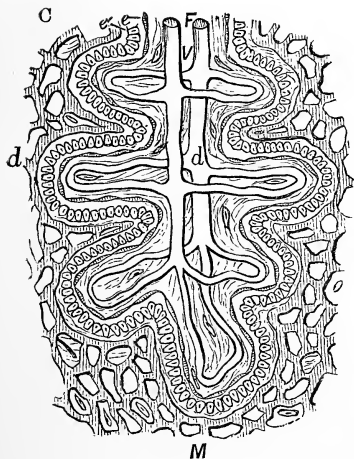
I.



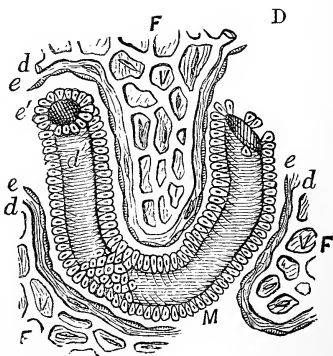
II.



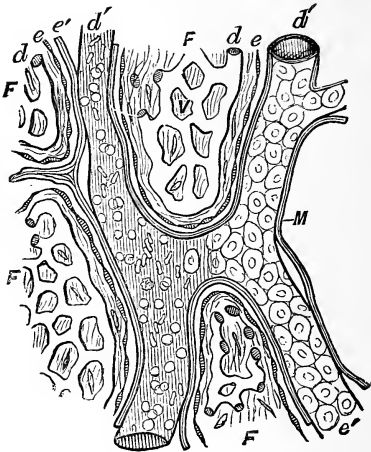
III.



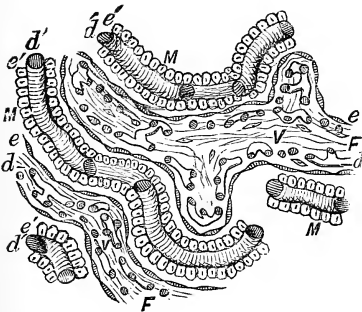
IV.



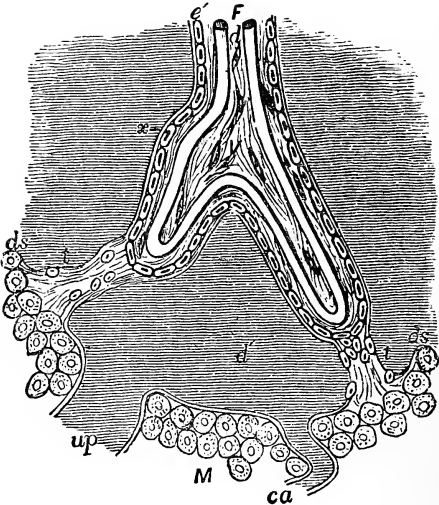
VI.



V.



VII.



DIAGRAMMATIC REPRESENTATIONS OF THE MINUTE STRUCTURE OF THE PLACENTA. (From Turner.)

F. the foetal; *M.* the maternal placenta; *e.* epithelium of chorion; *e'.* epithelium of maternal placenta; *d.* foetal blood-vessels; *d'.* maternal blood-vessels; *v.* villus.

I. Placenta in its most generalized form. II. Structure of placenta of a Pig. III. Of a Cow. IV. Of a Fox. V. Of a Cat.

VI. Structure of placenta of a Sloth. On the right side of the figure the flat maternal epithelial cells are shewn *in situ*. On the left side they are removed, and the dilated maternal vessel with its blood-corpuscles is exposed.

VII. Structure of Human placenta. In addition to the letters already referred to, *ds.* represents the decidua serotina of the placenta; *t, t.* trabeculae of serotina passing to the foetal villi; *ca.* curling artery; *up.* utero-placental vein; *x.* a prolongation of maternal tissue on the exterior of the villus outside the cellular layer *e'*, which may represent either the endothelium of the maternal blood-vessel or delicate connective tissue belonging to the serotina, or both. The layer *e'* represents maternal cells derived from the serotina. The layer of foetal epithelium cannot be seen on the villi of the fully-formed human placenta.

In the human placenta (VII.), as in that of Apes, the greatest modification is found. Here the maternal vessels have completely lost their capillary form, and have become expanded into large freely communicating sinuses (*d'*). In these sinuses the foetal villi hang for the most part freely, though occasionally attached to their walls by strands of tissue (*t*). In the late stages of foetal life there is only one epithelial layer (*e'*) between the maternal and foetal vessels, which closely invests the foetal villi, but is part of the uterine tissue. In the foetal villi the vessels retain their capillary form.

Evolution of the placenta. Excluding the marsupials whose placentation is not really known, the arrangement of the foetal membranes of the Rabbit is the most primitive observed. In this type the allantois and yolk-sac both function in obtaining nutriment from the mother; and the former occupies only a small discoidal area of the subzonal membrane. In all higher types the allantois gradually spreads out over the whole inner surface of the subzonal membrane and its importance increases; while that of the yolk-sac as a nutritive organ decreases. In the *diffuse* type of placenta simple villi are present over nearly the whole surface of the chorion. In the remaining types the villi become more complicated and restricted to a smaller area (meta-discoidal, zonary, &c.) of the chorion; though in the early stages they are more scattered and simpler, in some cases occupying nearly the whole surface of the chorion. It therefore seems probable that the placenta of Man has been derived not directly from the discoidal placenta of the Rabbit, but from the diffuse placenta such as is seen in the Lemurs, etc., and that generally the zonary, cotyledonary, &c. types of placenta have been derived from the diffuse by a concentration and increase in the complexity of the foetal villi.

CHAPTER XII.

THE DEVELOPMENT OF THE ORGANS IN MAMMALIA.

IN chap. X. we have described the early stages and general development of the mammalian embryo. In the present chapter we propose to examine the formation of such mammalian organs as differ in their development from those of the chick. This will not be a work of any considerable extent, as in all essential points the development of the organs in the two groups is the same. They will be classified according to the germinal layers from which they originate.

THE ORGANS DERIVED FROM THE EPIBLAST.

Hairs are formed in solid processes of the deep (Malpighian) layer of the epidermis, which project into the subjacent dermis. The hair itself arises from a cornification of the cells of the axis of one of the above processes; and is invested by a sheath similarly formed from the more superficial epidermic cells. A small papilla of the dermis grows into the inner end of the epidermic process when the hair is first formed. The

first trace of the hair appears close to this papilla, but soon increases in length, and when the end of the hair projects from the surface, the original solid process of the epidermis becomes converted into an open pit, the lumen of which is filled by the root of the hair.

The development of nails has been already described on p. 283.

Glands. The secretory part of the various glandular structures belonging to the skin is invariably formed from the epidermis. In Mammalia it appears that these glands are always formed as solid ingrowths of the Malpighian layer. The ends of these ingrowths dilate to form the true glandular part of the organs, while the stalks connecting the glandular portions with the surface form the ducts. In the case of the sweat-glands the lumen of the duct becomes first established; its formation is inaugurated by the appearance of the cuticle, and appears first at the inner end of the duct and thence extends outwards. In the sebaceous glands the first secretion is formed by a fatty modification of the whole of the central cells of the gland.

The muscular layer of the secreting part of the sweat-glands is said to be formed from a modification of the deeper layer of the epidermic cells.

The mammary glands arise in essentially the same manner as the other glands of the skin. The glands of each side are formed as a solid bud of the Malpighian layer of the epidermis. From this bud processes sprout out, each of which gives rise to one of the numerous glands of which the whole organ is formed.

The central nervous system.

The development of the spinal cord in Mammals differs in no important respects from that of the chick, and we have nothing to add to the account we have already given of its general development and histogenesis in that animal. The development of the brain however will be described at greater length, and some additional facts relative to the development of the Avian brain will be mentioned.

The first differentiation of the brain takes place in Mammalia before the closure of the medullary folds, and results as in the chick in the formation of the three cerebral vesicles, the fore-, mid- and hind-brain (Fig. 106, B). A cranial flexure precisely resembling that of the chick soon makes its appearance.

The hind brain early becomes divided into two regions, the rudimentary medulla oblongata and cerebellum.

The posterior section, the medulla, undergoes changes of a somewhat complicated character. In the first place its roof becomes very much extended and thinned out. At the raphe, where the two lateral halves of the brain originally united, a separation, as it were, takes place, and the two sides of the brain become pushed apart, remaining united by only a very thin layer of nervous matter, consisting of a single row of flattened cells (Fig. 40). As a result of this peculiar growth in the brain, the roots of the nerves of the two sides, which were originally in contact at the dorsal summit of the brain, become carried away from one another, and appear to rise at the sides of the brain.

The thin roof of the fourth ventricle thus formed is somewhat rhomboidal in shape.

At a later period the blood-vessels of the pia mater form a rich plexus over the anterior part of this thin roof which becomes at the same time somewhat folded. The whole structure is known as the *tela vasculosa* or *choroid plexus of the fourth ventricle* (Fig. 119, *chd* 4). The floor of the whole hind-brain becomes thickened, and there very soon appears on its outer surface a layer of longitudinal non-medullated nerve-fibres, similar to those which first appear on the spinal cord (p. 252). They are continuous with a similar layer of fibres on the floor of the mid-brain, where they constitute the *crura cerebri*. On the ventral floor of the fourth ventricle is a shallow continuation of the anterior fissure of the spinal cord.

Subsequently to the longitudinal fibres already spoken of, there develop first the olivary bodies of the ventral side of the medulla, and at a still later period the pyramids. The fasciculi teretes in the cavity of the fourth ventricle are developed shortly before the pyramids.

When the hind-brain becomes divided into two regions the roof of the anterior part does not become thinned out like that of the posterior, but on the contrary, becomes somewhat thickened and forms a band-like structure roofing over the anterior part of the fourth ventricle (Fig. 39 *cb*).

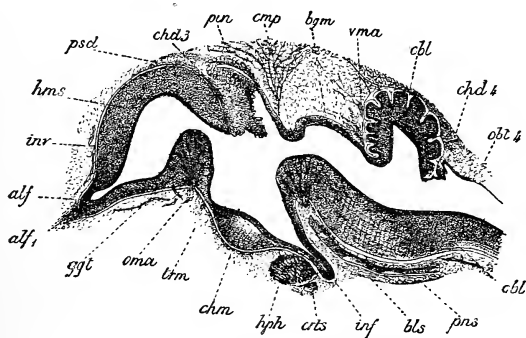
This is a rudiment of the cerebellum, and in all Craniate Vertebrates it at first presents this simple structure and insignificant size.

In Birds the cerebellum attains a very considerable development (Fig. 119 *cbl*), consisting of a folded central

lobe with an arbor vitæ, into which the fourth ventricle is prolonged. There are two small lateral lobes, apparently equivalent to the flocculi.

In Mammalia the cerebellum attains a still greater development. The median lobe or vermiform process

FIG. 119.



LONGITUDINAL SECTION THROUGH THE BRAIN OF A CHICK OF TEN DAYS. (After Mihalkovics.)

hms. cerebral hemispheres; *alf.* olfactory lobe; *alf₁*, olfactory nerve; *ggt.* corpus striatum; *oma.* anterior commissure; *chd 3.* choroid plexus of the third ventricle; *pin.* pineal gland; *cmp.* posterior commissure; *trm.* lamina terminalis; *chm.* optic chiasma; *inf.* infundibulum; *hph.* pituitary body; *bgm.* commissure of Sylvius (roof of iter a tertio ad quartum ventriculum); *vma.* velum medullæ anterius (valve of Vieussens); *cbl.* cerebellum; *chd 4.* choroid plexus of the fourth ventricle; *obt 4.* roof of fourth ventricle; *obl.* medulla oblongata; *pns.* commissural part of medulla; *inv.* sheath of brain; *bls.* basilar artery; *crt.* internal carotid.

is first developed. In the higher Mammalia the lateral parts constituting the hemispheres of the cerebellum become formed as swellings at the sides at a considerably later period; these are hardly developed in the Monotremata and Marsupialia.

The cerebellum is connected with the roof of the mid-brain in front and with the choroid plexus of the fourth ventricle behind by delicate membranous structures, known as the velum medullæ anterius (valve of Vieussens) (Fig. 119 *uma*) and the velum medullæ posterius.

The pons Varolii is formed on the ventral side of the floor of the cerebellar region as a bundle of transverse fibres at about the same time as the olivary bodies. It is represented in Birds by a small number of transverse fibres on the floor of the hind-brain immediately below the cerebellum.

The mid-brain. The changes undergone by the mid-brain are simpler than those of any other part of the brain. It forms, on the appearance of the cranial flexure, *an unpaired vesicle* with a vaulted roof and curved floor, at the front end of the long axis of the body (Fig. 67, *MB*). It is at this period in Mammalia as well as in Aves relatively much larger than in the adult: its cavity is known as the *iter a tertio ad quartum ventriculum* or *aqueductus Sylvii*.

The roof of the mid-brain is sharply constricted off from the divisions of the brain in front of and behind it, but these constrictions do not extend to the floor.

In Mammalia the roof and sides give rise to two pairs of prominences, the corpora quadrigemina.

These prominences, which are simply thickenings not containing any prolongations of the iter, become

first visible on the appearance of an oblique transverse furrow, by which the whole mid-brain is divided into an anterior and posterior portion. The anterior portion is further divided by a longitudinal furrow into the two anterior tubercles (nates); but it is not until later on that the posterior portion is similarly divided longitudinally into the two posterior tubercles (testes).

The floor of the mid-brain, bounded posteriorly by the pons Varolii, becomes developed and thickened into the crura cerebri. The corpora geniculata interna also belong to this division of the brain.

Fore-brain. The early development of the fore-brain in Mammals is the same as in the chick. It forms at first a single vesicle without a trace of separate divisions, but very early buds off the optic vesicles, whose history is described with that of the eye. The anterior part becomes prolonged and at the same time somewhat dilated. At first there is no sharp boundary between the primitive fore-brain and its anterior prolongation, but there shortly appears a constriction which passes from above obliquely forwards and downwards.

Of these two divisions the posterior becomes the thalamencephalon, while the anterior and larger division forms the rudiment of the cerebral hemispheres (Fig. 39 *cer*) and olfactory lobes. For a considerable period this rudiment remains perfectly simple, and exhibits no signs, either externally or internally, of a longitudinal constriction dividing it into two lobes.

The thalamencephalon forms at first a simple vesicle, the walls of which are of a nearly uniform thickness and formed of the usual spindle-shaped cells.

The cavity it contains is known as the third ventricle. Anteriorly it opens widely into the cerebral rudiment, and posteriorly into the ventricle of the mid-brain. The opening into the cerebral rudiment becomes the foramen of Monro.

For convenience of description we may divide the thalamencephalon into three regions, viz. (1) the floor, (2) the sides, and (3) the roof.

The floor becomes divided into two parts: an anterior part, giving origin to the optic nerves, in which is formed the optic chiasma; and a posterior part, which becomes produced into a prominence at first inconspicuous—the rudiment of the infundibulum (Fig. 39 *In*). This comes in contact with the involution from the mouth which gives rise to the pituitary body (Fig. 39 *pt*).

In Birds, although there is a close connection between the pituitary body and the infundibulum, there is no actual fusion of the two. In Mammalia the case is different. The part of the infundibulum which lies at the hinder end of the pituitary body is at first a simple finger-like process of the brain (Fig. 120 *inf*); but its end becomes swollen, and the lumen in this part becomes obliterated. Its cells, originally similar to those of the other parts of the nervous system, and even containing differentiated nerve-fibres, partly atrophy and partly assume an indifferent form, while at the same time there grow in amongst them numerous vascular and connective-tissue elements. The process of the infundibulum thus metamorphosed becomes inseparably connected with the true pituitary body, of which it is usually described as the posterior lobe.

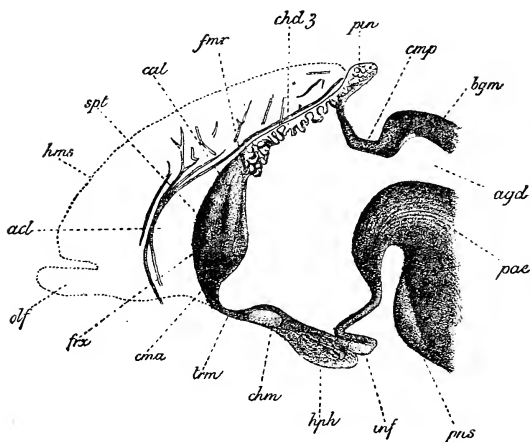
In the later stages of development the unchanged portion of the infundibulum becomes gradually prolonged and forms an elongated diverticulum of the third ventricle, the apex of which is in contact with the pituitary body (Fig. 120 *hph*).

The posterior part of the primitive infundibulum becomes the corpus albicans, which is double in Man and the higher Apes; the ventral part of the posterior wall forms the tuber cinereum. Laterally, at the junction of the optic thalami and infundibulum, there are continued some of the fibres of the crura cerebri, which are probably derived from the walls of the infundibulum.

The sides of the thalamencephalon become very early thickened to form the optic thalami, which constitute the most important section of the thalamencephalon. These are separated on their inner aspect from the infundibular region by a somewhat S-shaped groove, known as the sulcus of Monro, which ends in the foramen of Monro. They also become secondarily united by a transverse commissure, the grey or middle commissure, which passes across the cavity of the third ventricle.

The roof undergoes more complicated changes. It becomes divided, on the appearance of the pineal gland as a small papilliform outgrowth (the development of which is dealt with below), into two regions—a longer anterior in front of the pineal gland, and a shorter posterior. The anterior region becomes at an early period excessively thin, and at a later period, when the roof of the thalamencephalon is shortened by the approach of the cerebral hemispheres to the mid-brain, it becomes (*vide* Fig. 120 *chd* 3) considerably folded, while at the same time a vascular plexus is formed in the pia mater

FIG. 120.



LONGITUDINAL VERTICAL SECTION THROUGH THE ANTERIOR PART OF THE BRAIN OF AN EMBRYO RABBIT OF FOUR CENTIMETRES. (After Mihalkovics.)

The section passes through the median line so that the cerebral hemispheres are not cut; their position is however indicated in outline.

spt. septum lucidum formed by the coalescence of the inner walls of part of the cerebral hemispheres; *cma.* anterior commissure; *frx.* vertical pillars of the fornix; *cal.* genu of corpus callosum; *trm.* lamina terminalis; *hms.* cerebral hemispheres; *olf.* olfactory lobes; *acl.* artery of corpus callosum; *fmr.* position of foramen of Monro; *chd. 3.* choroid plexus of third ventricle; *pin.* pineal gland; *cmp.* posterior commissure; *bgm.* lamina uniting the lobes of the mid-brain; *chm.* optic chiasma; *hph.* pituitary body; *inf.* infundibulum; *pns.* pons Varolii; *pde.* cerebral peduncles; *agd.* iter a tertio ad quartum ventriculum.

above it. On the accomplishment of these changes it is known as the tela choroidea of the third ventricle.

In the roof of the third ventricle behind the pineal gland there appear transverse commissural fibres, forming a structure known as the posterior commissure, which connects together the two optic thalami.

The most remarkable organ in the roof of the thalamencephalon is the pineal gland, which is developed as a hollow papilliform outgrowth of the roof, and is at first composed of cells similar to those of the other parts of the central nervous system (Fig. 120 *pin*). It is directed backwards over the hinder portion of the roof of the thalamencephalon.

In Birds (p. 116) the primitive outgrowth to form the pineal gland becomes deeply indented by vascular connective-tissue ingrowths, so that it assumes a dendritic structure (Fig. 119 *pin*). The proximal extremity attached to the roof of the thalamencephalon soon becomes solid and forms a special section, known as the infra-pineal process. The central lumen of the free part of the gland finally atrophies, but the branches still remain hollow. The infra-pineal process becomes reduced to a narrow stalk, connecting the branched portion of the body with the brain.

In Mammalia the development of the pineal gland is generally similar to that of Birds. The original outgrowth becomes branched, but the follicles or lobes to which the branching gives rise eventually become solid (Fig. 120 *pin*). An infra-pineal process is developed comparatively late, and is not sharply separated from the roof of the brain.

No satisfactory suggestions have yet been offered as

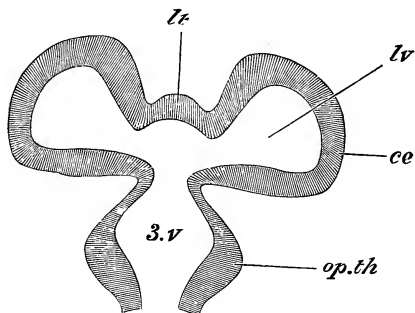
to the nature of the pineal gland. It appears to possess in all forms an epithelial structure, but, except at the base of the stalk (infra-pineal process) in Mammalia, in the wall of which there are nerve-fibres, no nervous structures are present in it in the adult state.

The cerebral hemispheres. It will be convenient to treat separately the development of the cerebral hemispheres proper, and that of the olfactory lobes.

In the cerebral rudiment two parts may be distinguished, viz. the floor and the roof. The former gives rise to the ganglia at the base of the hemispheres, the corpora striata, the latter to the hemispheres proper.

The first change which takes place consists in the roof growing out into two lobes, between which a shallow median constriction makes its appearance (Fig. 121).

FIG. 121.



DIAGRAMMATIC LONGITUDINAL HORIZONTAL SECTION THROUGH THE FORE-BRAIN.

3.v. third ventricle ; lv. lateral ventricle ; lt. lamina terminalis ; ce. cerebral hemisphere ; op.th. optic thalamus.

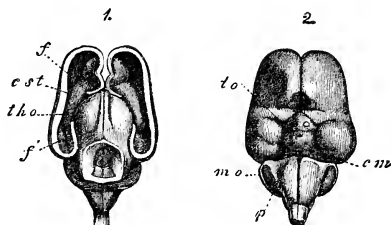
The two lobes thus formed are the rudiments of the two hemispheres. The cavity of each of them opens by a widish aperture into a cavity at the base of the cerebral rudiment, which again opens directly into the cavity of the third ventricle (3 *v*). The Y-shaped aperture thus formed, which leads from the cerebral hemispheres into the third ventricle, is the *foramen of Monro*. The cavity (*lv*) in each of the rudimentary hemispheres is a lateral ventricle. The part of the cerebrum which lies between the two hemispheres, and passes forwards from the roof of the third ventricle round the end of the brain to the optic chiasma below, is the rudiment of the lamina terminalis (Figs. 121 *lt* and 123 *trm*). Up to this point the development of the cerebrum is similar in all Vertebrata, and in some forms it practically does not proceed much further.

The cerebral hemispheres undergo in Mammalia the most complicated development. The primitive unpaired cerebral rudiment becomes, as in lower Vertebrates, bilobed, and at the same time divided by the ingrowth of a septum of connective tissue into two distinct hemispheres (Figs. 125 and 124 *f* and 122 *1*). From this septum is formed the *falx cerebri* and other parts.

The hemispheres contain at first very large cavities, communicating by a wide foramen of Monro with the third ventricle (Fig. 124). They grow rapidly in size, and extend, *especially backwards*, and gradually cover the thalamencephalon and the mid-brain (Fig. 122 *1, f*). The foramen of Monro becomes very much narrowed and reduced to a mere slit.

The walls are at first nearly uniformly thick, but

FIG. 122.



BRAIN OF A THREE MONTHS' HUMAN EMBRYO : NATURAL SIZE.
(From Kölliker.)

1. From above with the dorsal part of hemispheres and mid-brain removed ; 2. From below. *f.* anterior part of cut wall of the hemisphere ; *f'.* cornu ammonis ; *tho.* optic thalamus ; *est.* corpus striatum ; *to.* optic tract ; *cm.* corpora mammillaria ; *p.* pons Varolii.

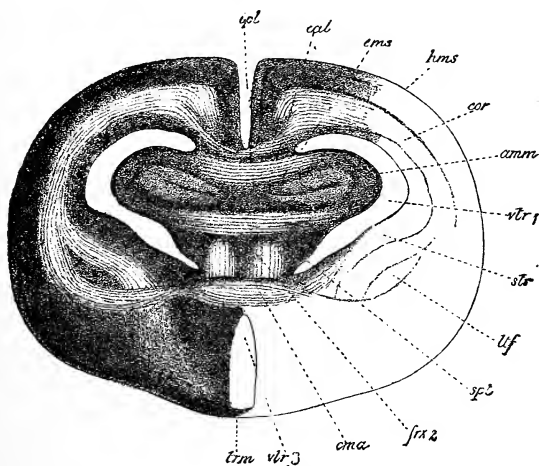
the floor becomes thickened on each side, and gives rise to the corpus striatum (Figs. 124 and 125 *st*). The corpus striatum projects upwards into each lateral ventricle, and gives to this a somewhat semilunar form, the two horns of which constitute the permanent anterior and descending cornua of the lateral ventricles (Fig. 126 *st*).

With the further growth of the hemisphere the corpus striatum loses its primitive relations to the descending cornu. The reduction in size of the foramen of Monro above mentioned is, to a large extent, caused by the growth of the corpora striata.

The corpora striata are united at their posterior border with the optic thalami. In the later stages of development the area of contact between these two pairs of ganglia increases to a large extent (Fig. 125),

and the boundary between them becomes somewhat obscure, so that the sharp distinction which exists in the embryo between the thalamencephalon and cerebral hemispheres becomes lost.

FIG. 123.



TRANSVERSE SECTION THROUGH THE BRAIN OF A RABBIT OF FIVE CENTIMETRES. (After Mihalkovics.)

The section passes through nearly the posterior border of the septum lucidum, immediately in front of the foramen of Monro.

hms. cerebral hemispheres; *cal.* corpus callosum; *amm.* cornu ammonis (hippocampus major); *cms.* superior commissure of the cornu ammonis; *spt.* septum lucidum; *frx 2.* anterior pillars of the fornix; *ama.* anterior commissure; *trm.* lamina terminalis; *str.* corpus striatum; *luf.* nucleus lenticularis of corpus striatum; *vtr 1.* lateral ventricle; *vtr 3.* third ventricle; *ipl.* slit between cerebral hemispheres.

The outer wall of the hemispheres gradually thickens, while the inner wall becomes thinner. In the latter, two curved folds, projecting towards the interior of the lateral ventricle, become formed. These folds extend from the foramen of Monro along nearly the whole of what afterwards becomes the descending cornu of the lateral ventricle. The upper fold becomes the hippocampus major (cornu ammonis) (Figs. 123 *amm*, 124 and 125 *h*, and 126 *am*).

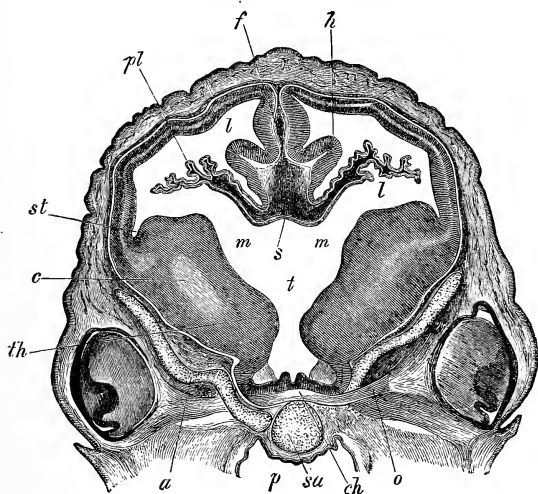
The wall of the lower fold becomes very thin, and a vascular plexus, derived from the connective-tissue septum between the hemispheres, and similar to that of the roof of the third ventricle, is formed outside it. It constitutes a fold projecting into the cavity of the lateral ventricle, and together with the vascular connective tissue in it gives rise to the choroid plexus of the lateral ventricle (Figs. 124 and 125 *pl*).

It is clear from the above description that a marginal fissure leading into the cavity of the lateral ventricle does not exist in the sense often implied in works on human anatomy, since the epithelium covering the choroid plexus, and forming the true wall of the brain, is a continuous membrane. The *epithelium* of the choroid plexus of the lateral ventricle is quite independent of that of the choroid plexus of the third ventricle, though at the foramen of Monro the roof of the third ventricle is of course continuous with the inner wall of the lateral ventricle (Fig. 124 *s*). The *vascular elements* of the two plexuses form however a continuous structure.

The most characteristic parts of the Mammalian cerebrum are the commissures connecting the two

hemispheres. These commissures are (1) the anterior commissure, (2) the fornix, and (3) the corpus callosum, the two latter being peculiar to Mammalia.

FIG. 124.



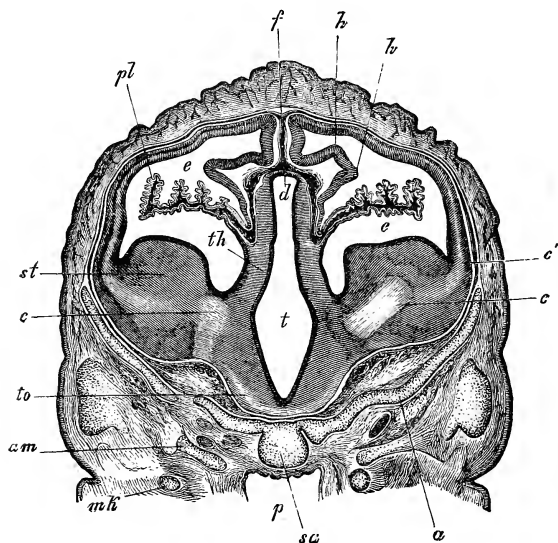
TRANSVERSE SECTION THROUGH THE BRAIN OF A SHEEP'S EMBRYO OF 2.7 CM. IN LENGTH. (From Kölliker.)

The section passes through the level of the foramen of Monro.

st. corpus striatum; *m.* foramen of Monro; *t.* third ventricle; *pl.* choroid plexus of lateral ventricle; *f.* falx cerebri; *th.* anterior part of optic thalamus; *ch.* optic chiasma; *o.* optic nerve; *c.* fibres of the cerebral peduncles; *h.* cornu ammonis; *p.* pharynx; *sa.* pre-sphenoid bone; *a.* orbito-sphenoid bone; *s.* points to part of the roof of the brain at the junction between the roof of the third ventricle and the lamina terminalis; *l.* lateral ventricle.

By the fusion of the inner walls of the hemispheres in front of the lamina terminalis a solid septum is formed, continuous behind with the lamina terminalis,

FIG. 125.



TRANSVERSE SECTION THROUGH THE BRAIN OF A SHEEP'S EMBRYO OF 2.7 CM. IN LENGTH. (From Kölliker.)

The section is taken a short distance behind the section represented in Fig. 124, and passes through the posterior part of the hemispheres and the third ventricle.

st. corpus striatum; *th.* optic thalamus; *to.* optic tract; *t.* third ventricle; *d.* roof of third ventricle; *e.* fibres of cerebral peduncles; *c'.* divergence of these fibres into the walls of the hemispheres; *e.* lateral ventricle with choroid plexus *pl*; *h.* cornu ammonis; *f.* primitive falx; *am.* alisphenoid; *a.* orbito-sphenoid; *sa.* presphenoid; *p.* pharynx; *mk.* Meckel's cartilage.

and below with the corpora striata (Figs. 120 and 123 *spt*). It is by a series of differentiations within this septum, the greater part of which gives rise to the septum lucidum, that the above commissures originate. In Man there is a closed cavity left in the septum known as the fifth ventricle, which has however no communication with the true ventricles of the brain.

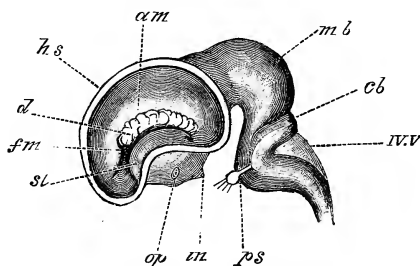
In this septum there become first formed, below and behind, the transverse fibres of the anterior commissure (Fig. 120 and Fig. 123 *cma*), while above and behind these the vertical fibres of the fornix are developed (Fig. 120 and Fig. 123 *frx* 2). The vertical fibres meet above the foramen of Monro, and thence diverge backwards, as the posterior pillars, to lose themselves in the cornu ammonis (Fig. 123 *amm*). Ventrally they are continued, as the descending or anterior pillars of the fornix, into the corpus albicans, and thence into the optic thalami¹.

The corpus callosum is not formed till after the anterior commissure and fornix. It arises in the upper part of the septum formed by the fusion of the lateral walls of the hemispheres (Figs. 120 and 123 *cal*), and at first only its curved anterior portion—the genu or rostrum—is developed. This portion is alone found in Monotremes and Marsupials. The posterior portion, which is present in all the Monodelphia, is gradually formed as the hemispheres are prolonged further backwards.

¹ Recent observations tend to show that the anterior pillars of the fornix end in the corpus albicans; and that the fibres running from the latter into the optic thalami are independent of the anterior pillars.

Primitively the Mammalian cerebrum, like that of the lower Vertebrata, is quite smooth. In some of the Mammalia, *Monotremata*, *Insectivora*, etc., this condition is retained nearly throughout life, while in the majority of Mammalia a more or less complicated system of fissures

FIG. 126.



LATERAL VIEW OF THE BRAIN OF A CALF EMBRYO OF 5 CM.
(After Mihalkovics.)

The outer wall of the hemisphere is removed, so as to give a view of the interior of the left lateral ventricle.

hs. cut wall of hemisphere; *st.* corpus striatum; *am.* hippocampus major (cornu ammonis); *d.* choroid plexus of lateral ventricle; *fm.* foramen of Monro; *op.* optic tract; *in.* infundibulum; *mb.* mid-brain; *cb.* cerebellum; *IV.V.* roof of fourth ventricle; *ps.* pons Varolii, close to which is the fifth nerve with Gasserian ganglion.

is developed on the surface. The most important, and first formed, of these is the Sylvian fissure. It arises at the time when the hemispheres, owing to their growth in front of and behind the corpora striata have assumed somewhat the form of a bean. At the root of the hemispheres—the hilus of the bean—there is formed a

shallow depression which constitutes the first trace of the Sylvian fissure. The part of the brain lying in this fissure is known as the island of Reil.

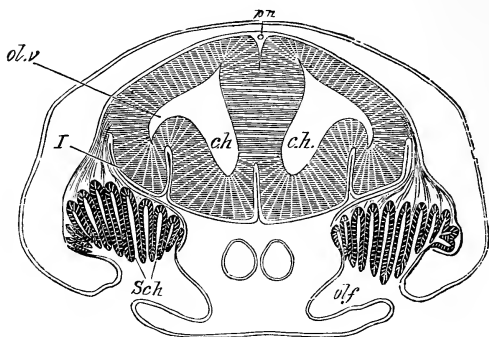
The fissures of the cerebrum may be divided into two classes; (1) the *primitive*, (2) the *secondary* fissures. The primitive fissures are the first to appear; they owe their origin to a folding of the entire wall of the cerebral vesicles. Many of them are transient structures and early disappear. The most important of those which persist are the hippocampal, the parieto-occipital, the calcarine (in Man and Apes) sulci and the Sylvian fissures. The secondary fissures appear later, and are due to folds which implicate the cortex of the hemispheres only.

The olfactory lobes. The olfactory lobes, or rhinencephala, are secondary outgrowths of the cerebral hemispheres, and contain prolongations of the lateral ventricles, which may however be closed in the adult state; they arise at a fairly early stage of development from the under and anterior part of the hemispheres (Fig. 127).

Histogenetic changes. The walls of the brain are at first very thin and, like those of the spinal cord, are formed of a number of ranges of spindle-shaped cells. In the floor of the hind- and mid-brain a superficial layer of delicate nerve-fibres is formed at an early period. This layer appears at first on the floor and sides of the hind-brain, and almost immediately afterwards on the floor and the sides of the mid-brain. The cells internal to the nerve-fibres become differentiated into an innermost epithelial layer lining the cavities of the ventricles, and an outer layer of grey matter.

The similarity of the primitive arrangement and

FIG. 127.



SECTION THROUGH THE BRAIN AND OLFACTORY ORGAN OF AN
EMBRYO OF SCYLLIUM.

ch. cerebral hemispheres; *ol.v.* olfactory vesicle; *olf.* olfactory pit; *Sch.* Schneiderian folds; *I.* olfactory nerve (the reference line has been accidentally carried through the nerve so as to appear to indicate the brain); *pn.* anterior prolongation of pineal gland.

histological characters of the parts of the brain behind the cerebral hemispheres to those of the spinal cord is very conclusively shewn by the examination of any good series of sections. In both brain and spinal cord the white matter forms a cap on the ventral and lateral parts some considerable time before it extends to the dorsal surface. In the medulla oblongata the white matter does not eventually extend to the roof owing to the peculiar degeneration which that part undergoes.

In the case of the fore-brain the walls of the hemispheres become first divided (Kölliker) into a superficial thinner layer of rounded elements, and a deeper and thicker epithelial layer, and between these the fibres of

the crura cerebri soon interpose themselves. At a slightly later period a thin superficial layer of white matter, homologous with that of the remainder of the brain, becomes established.

The inner layer, together with the fibres from the crura cerebri, gives rise to the major part of the white matter of the hemispheres and to the epithelium lining the lateral ventricles.

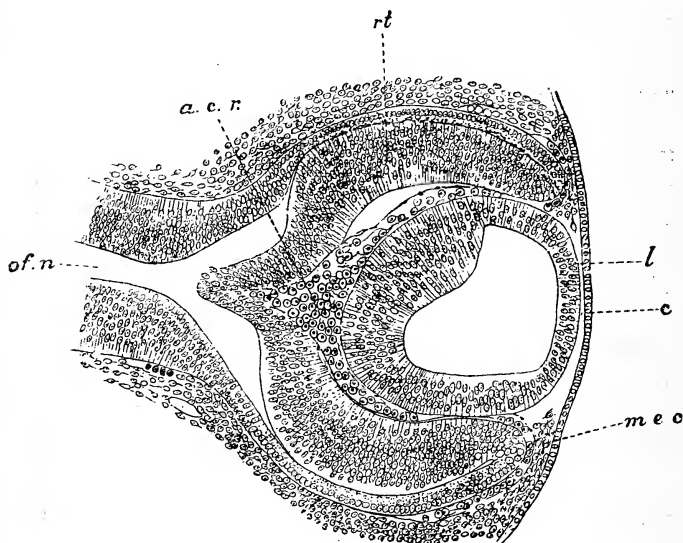
The outer layer of rounded cells becomes divided into (1) a superficial part with comparatively few cells, which, together with its coating of white matter, forms the outer part of the grey matter, and (2) a deeper layer with numerous cells, which forms the main mass of the grey matter of the cortex.

The eyes. The development of the Mammalian eye is essentially similar to that of the chick (ch. VI.) There are however two features in its development which deserve mention. These are (1) the immense foetal development of the blood-vessels of the vitreous humour and the presence in the embryo of a vascular membrane surrounding the lens, known as the *membrana capsulo-pupillaris*, (2) the absence of any structure comparable to the pecten, and the presence of the arteria centralis retinae.

In the invagination of the lens (rabbit) a thin layer of mesoblast is carried before it, and is thus transported into the cavity of the vitreous humour. In the folding in of the optic vesicle which accompanies the formation of the lens the optic nerve is included, and on the development of the cavity of the vitreous humour an artery, running in the fold of the optic nerve, passes through the choroid slit into the

cavity of the vitreous humour (Fig. 128 *acr*). The sides of the optic nerve subsequently bend over, and completely envelope this artery, which then gives off

FIG. 128.



SECTION THROUGH THE EYE OF A RABBIT EMBRYO OF ABOUT
TWELVE DAYS.

c. epithelium of cornea; *l.* lens; *mec.* mesoblast growing in from the side to form the cornea; *rt.* retina; *a.c.r.* arteria centralis retinae; *of.n.* optic nerve.

The figure shews (1) the absence at this stage of mesoblast between the lens and the epiblast; the interval between the two has however been made too great; (2) the arteria centralis retinae forming the vascular capsule of the lens and continuous with vascular structures round the edges of the optic cup.

branches to the retina, and becomes known as the *arteria centralis retinae*. It is homologous with the arterial limb of the vascular loop projecting into the vitreous humour in Birds.

Before becoming enveloped in the optic nerve this artery is continued through the vitreous humour (Fig. 128), and when it comes in close proximity to the lens it divides into a number of radiating branches, which pass round the edge of the lens, and form a vascular sheath which is prolonged so as to cover the anterior wall of the lens. In front of the lens they anastomose with vessels, coming from the iris, many of which are venous, and the whole of the blood from the *arteria centralis* is carried away by these veins. The vascular sheath surrounding the lens is the *membrana capsulo-pupillaris*. The posterior part of it is either formed simply by branches of the *arteria centralis*, or out of the mesoblast cells involuted with the lens. The anterior part of the vascular sheath is however enclosed in a very delicate membrane, the *membrana pupillaris*, continuous at the sides with the membrane of Descemet.

The *membrana capsulo-pupillaris* is simply a provisional embryonic structure, subserving the nutrition of the lens.

In many forms, in addition to the vessels of the vascular capsule round the lens, there arise from the *arteria centralis retinae*, just after its exit from the optic nerve, provisional vascular branches which extend themselves in the posterior part of the vitreous humour. Near the ciliary end of the vitreous humour they anastomose with the vessels of the *membrana capsulo-pupillaris*.

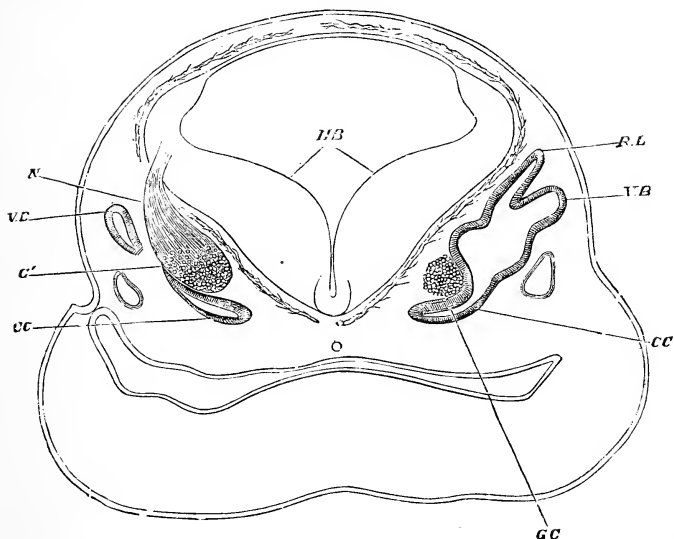
The choroid slit closes very early, and is not perforated by any structure homologous with the pecten. The only part of the slit which can be said to remain open is that in which the optic nerve is involved; in the centre of the latter is situated the arteria centralis retinae as explained above. From this artery there grow out the vessels to supply the retina, which however are distinct from the provisional vessels of the vitreous humour just described, the blood being returned from them by veins accompanying the arteries. On the atrophy of the provisional vessels the whole of the blood of the arteria centralis passes into the retina.

Of the cornea, aqueous humour, eyelids and lacrymal duct no mention need here be made, the account given in Part I. being applicable equally to mammalian embryos.

The auditory organ. In Mammals, as we have seen to be the case in the chick (chap. VI.), the auditory vesicle is at first nearly spherical, and is imbedded in the mesoblast at the side of the hind-brain. It soon becomes triangular in section, with the apex of the triangle pointing inwards and downwards. This apex gradually elongates to form the rudiment of the cochlear canal and sacculus hemisphericus (Fig. 129, *CC*). At the same time the recessus labyrinthi (*R.L*) becomes distinctly marked, and the outer wall of the main body of the vesicle grows out into two protuberances, which form the rudiments of the vertical semicircular canals (*V.B*). In the lower forms (Fig. 132) the cochlear process hardly reaches a higher stage of development than that found at this stage in Mammalia.

The parts of the auditory labyrinth thus established soon increase in distinctness (Fig. 130); the cochlear

FIG. 129.



TRANSVERSE SECTION OF THE HEAD OF A FETAL SHEEP
(16 MM. IN LENGTH) IN THE REGION OF THE HIND-BRAIN.
(After Böttcher.)

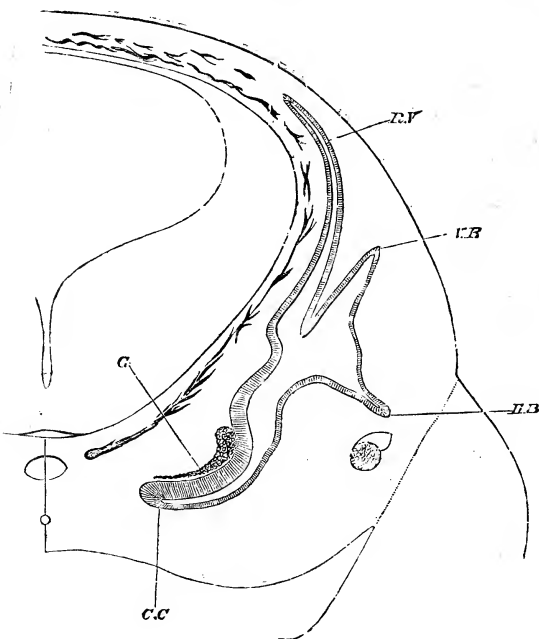
HB. the hind-brain. The section is somewhat oblique, hence while on the right side the connections of the recessus vestibuli *R.L.*, and of the commencing vertical semicircular canal *V.B.*, and of the ductus cochlearis *CC.*, with the cavity of the primary otic vesicle are seen : on the left side, only the extreme end of the ductus cochlearis *CC*, and of the semicircular canal *V.B.* are shewn.

Lying close to the inner side of the otic vesicle is seen the cochlear ganglion *GC* ; on the left side the auditory nerve *G'* and its connection *N* with the hind-brain are also shewn.

Below the otic vesicle on either side lies the jugular vein.

canal (*CC*) becomes longer and curved; its inner and concave surface being lined by a thick layer of columnar epiblast. The recessus labyrinthi also increases in length, and just below the point where the bulgings to form the vertical semicircular canals are situated, there is formed a fresh protuberance for the horizontal semi-

FIG. 130.



SECTION OF THE HEAD OF A FETAL SHEEP 20 MM. IN LENGTH. (After Böttcher.)

R.V. recessus labyrinthi; *V.B.* vertical semicircular canal; *H.B.* horizontal semicircular canal; *C.C.* cochlear canal; *G.* cochlear ganglion.

circular canal. At the same time the central parts of the walls of the flat bulgings of the vertical canals grow together, obliterating this part of the lumen, but leaving a canal round the periphery; and, on the absorption of their central parts, each of the original simple bulgings of the wall of the vesicle becomes converted into a true semicircular canal, opening at its two extremities into the auditory vesicle. The vertical canals are first established and then the horizontal canal.

Shortly after the formation of the rudiment of the horizontal semicircular canal a slight protuberance becomes apparent on the inner commencement of the cochlear canal. A constriction arises on each side of the protuberance, converting it into a prominent hemispherical projection, the *sacculus hemisphericus* (Fig. 131 *SR*).

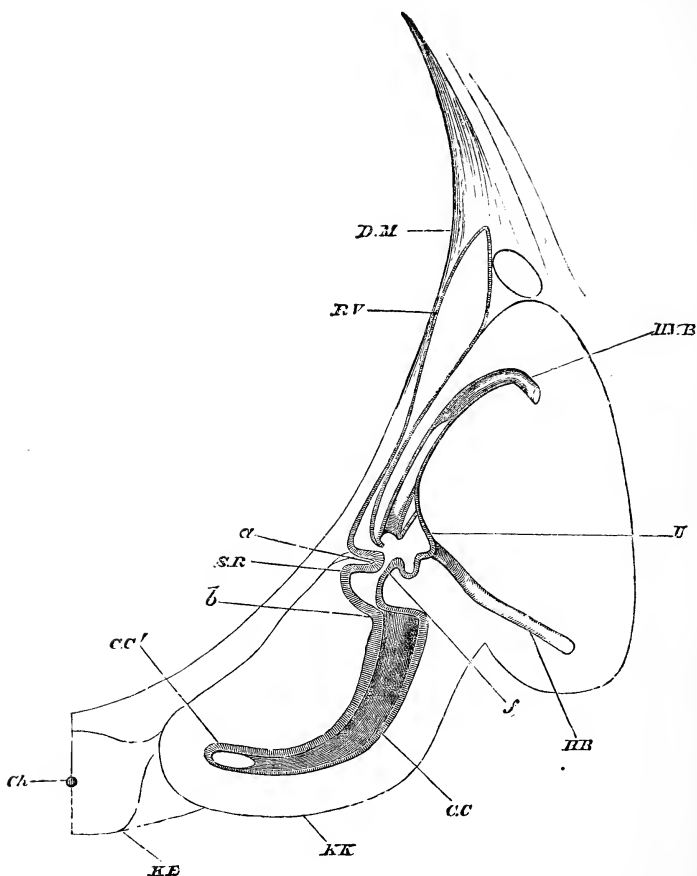
The constrictions are so deep that the sacculus is only connected with the cochlear canal on the one hand, and with the general cavity of the auditory vesicle on the other, by, in each case, a narrow short canal. The former of these canals (Fig. 131 *b*) is known as the *canalis reuniens*.

At this stage we may call the remaining cavity of the original otic vesicle, into which all the above parts open, *the utriculus*.

Soon after the formation of the *sacculus hemisphericus*, the cochlear canal and the semicircular canals become invested with cartilage. The *recessus labyrinthi* remains however still enclosed in undifferentiated meso-blast.

Between the cartilage and the parts which it surrounds there remains a certain amount of indifferent

FIG. 131.



SECTION THROUGH THE INTERNAL EAR OF AN EMBRYONIC SHEEP 28 MM. IN LENGTH. (After Böttcher.)

D.M. dura mater; *R.V.* recessus labyrinthi; *H.V.B.* posterior vertical semicircular canal; *U.* utricle; *H.B.* horizontal

semicircular canal; *b.* canalis reuniens; *a.* constriction by means of which the sacculus hemisphericus *S.R.* is formed; *f.* narrowed opening between sacculus hemisphericus and utriculus; *C.C.* cochlea; *C.C.¹* lumen of cochlea; *K.K.* cartilaginous capsule of cochlea; *K.B.* basilar plate; *Ch.* notochord.

connective tissue, which is more abundant around the cochlear canal than around the semicircular canals.

As soon as they have acquired a distinct connective-tissue coat, the semicircular canals begin to be dilated at one of their terminations to form the ampullæ. At about the same time a constriction appears opposite the mouth of the recessus labyrinthi, which causes its opening to be divided into two branches—one towards the utriculus and the other towards the sacculus hemisphericus; and the relations of the parts become so altered that communication between the sacculus and utriculus can only take place through the mouth of the recessus labyrinthi (Fig. 132).

When the cochlear canal has come to consist of two and a half coils, the thickened epithelium which lines the lower surface of the canal forms a double ridge from which the *organ of Corti* is subsequently developed. Above the ridge there appears a delicate cuticular membrane, the *membrane of Corti* or *membrana tectoria*.

The epithelial walls of the utricle, the saccule, the recessus labyrinthi, the semicircular canals, and the cochlear canal constitute together the highly complicated product of the original auditory vesicle. The whole structure forms a closed cavity, the various parts of which are in free communication. In the adult the

fluid present in this cavity is known as the *endolymph*.

In the mesoblast lying between these parts and the cartilage, which at this period envelopes them, lymphatic spaces become established, which are partially developed in the Sauropsida, but become in Mammals very important structures.

They consist in Mammals partly of a space surrounding the utricle and saccule and called the vestibule, into which open spaces surrounding the semicircular canals, and partly of two very definite channels, which largely embrace between them the cochlear canal. The latter channels form the *scala vestibuli* on the upper side of the cochlear canal and the *scala tympani* on the lower. The *scala vestibuli* is in free communication with the lymphatic cavity surrounding the utricle and saccule, and opens at the apex of the cochlea into the *scala tympani*. The latter ends blindly at the fenestra rotunda.

The fluid contained in the two *scalæ*, and in the remaining lymphatic cavities of the auditory labyrinth, is known as *perilymph*.

The cavities just spoken of are formed by an absorption of parts of the embryonic mucous tissue between the perichondrium and the walls of the membranous labyrinth.

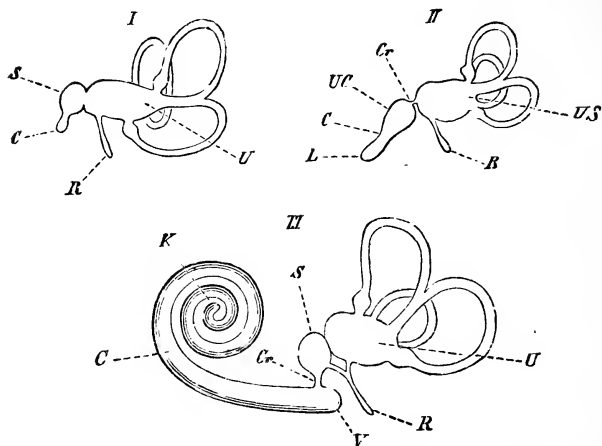
The *scala vestibuli* is formed before the *scala tympani*, and both *scalæ* begin to be developed at the basal end of the cochlea: the cavity of each is continually being carried forwards towards the apex of the cochlear canal by a progressive absorption of the mesoblast. At first both *scalæ* are somewhat narrow, but they soon increase in size and distinctness.

The cochlear canal, which is often known as the scala media of the cochlea, becomes compressed on the formation of the scalæ so as to be triangular in section, with the base of the triangle outwards. This base is only separated from the surrounding cartilage by a narrow strip of firm mesoblast, which becomes the *stria vascularis*, etc. At the angle opposite the base the cochlear canal is joined to the cartilage by a narrow isthmus of firm material, which contains nerves and vessels. This isthmus subsequently forms the *lamina spiralis*, separating the scala vestibuli from the scala tympani.

The scala vestibuli lies on the upper border of the cochlear canal, and is separated from it by a very thin layer of mesoblast, bordered on the cochlear aspect by flat epiblast cells. This membrane is called the *membrane of Reissner*. The scala tympani is separated from the cochlear canal by a thicker sheet of mesoblast, called the *basilar membrane*, which supports the organ of Corti and the epithelium adjoining it. The upper extremity of the cochlear canal ends in a blind extremity called the *cupola*, to which the two scalæ do not for some time extend. This condition is permanent in Birds, where the cupola is represented by a structure known as the lagena (Fig. 132, II. L). Subsequently the two scalæ join at the extremity of the cochlear canal; the point of the cupola still however remains in contact with the bone, which has now replaced the cartilage, but at a still later period the scala vestibuli, growing further round, separates the cupola from the adjoining osseous tissue.

Accessory auditory structures. The development of the Eustachian tube, tympanic cavity, tympanic

FIG. 132.



DIAGRAMS OF THE MEMBRANOUS LABYRINTH. (From Gegenbaur.)

I. Fish.

II. Bird.

III. Mammal.

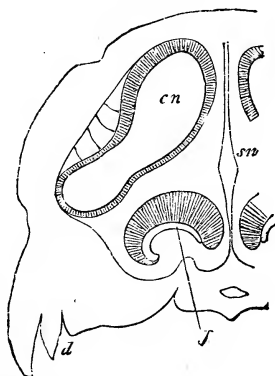
U. utricle; *S.* saccule; *US.* utriculus and saccule; *Cr.* canalis reuniens; *R.* recessus labyrinthi; *UC.* commencement of cochlea; *C.* cochlear canal; *L.* lagena; *K.* cupola at apex of cochlear canal; *V.* caecal sac of the vestibulum of the cochlear canal.

membrane and external auditory meatus resembles that in Birds (p. 166). As in Birds two membranous fenestræ, the fenestra ovalis and rotunda, in the bony inner wall of the tympanic cavity are formed. The fenestra ovalis opens into the vestibule, and is in immediate contiguity with the walls of the utricle, while the fenestra rotunda adjoins the scala tympani. In place of the columella of Birds, three ossicles, the malleus, incus and stapes reach across the tympanic cavity from the tympanic membrane

to the fenestra ovalis. These ossicles, which arise mainly from the mandibular and hyoid arches (*vide* p. 403), are at first imbedded in the connective tissue in the neighbourhood of the tympanic cavity, but on the full development of this cavity, become apparently placed within it, though really enveloped in the mucous membrane lining it.

Nasal organ. In Mammalia the general formation of the anterior and posterior nares is the same as in Birds; but an outgrowth from the inner side of the canal between the two openings arises at an early period; and becoming separate from the posterior nares and provided with a special opening into the mouth, forms the *organ of Jacobson*. The general relations of this organ when fully formed are shewn in Fig. 133.

FIG. 133.



SECTION THROUGH THE NASAL CAVITY AND JACOBSON'S ORGAN.
(From Gegenbaur.)

sn. septum nasi ; *cn.* nasal cavity ; *J.* Jacobson's organ ; *d.* edge of upper jaw.

The development of the cranial and spinal nerves in Mammals is as far as is known essentially the same as in the chick, for an account of which see p. 123 *et seq.*

Sympathetic nervous system. The development of the sympathetic system of both Aves and Mammalia has not been thoroughly worked out. There is however but little doubt that in Mammalia the main portion arises in continuity with the posterior spinal ganglia.

The later history of the sympathetic system is intimately bound up with that of the so-called supra-renal bodies, the medullary part of which is, as we shall see below, derived from the peripheral part of the sympathetic system.

THE ORGANS DERIVED FROM MESOBLAST.

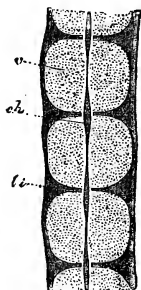
The vertebral column. The early development of the perichordal cartilaginous tube and rudimentary neural arches is almost the same in Mammals as in Birds. The differentiation into vertebral and intervertebral regions is the same in both groups; but instead of becoming divided as in Birds into two segments attached to two adjoining vertebræ, the intervertebral regions become in Mammals wholly converted into the intervertebral ligaments (Fig. 135 *li*). There are three centres of ossification for each vertebra, two in the arch and one in the centrum.

The fate of the notochord is in important respects different from that in Birds. It is first constricted in the *centres of the vertebrae* (Fig. 134) and disappears there shortly after the beginning of ossification; while in

the intervertebral regions it remains relatively unconstricted (Figs. 134 and 135 c) and after undergoing certain histological changes remains through life as part of the nucleus pulposus in the axis of the intervertebral ligaments. There is also a slight swelling of the notochord near the two extremities of each vertebra (Fig. 135 c' and c'').

In the persistent vertebral constriction of the notochord Mammals retain a more primitive and piscine mode of formation of the vertebral column than the majority either of the Reptilia or Amphibia.

FIG. 134.

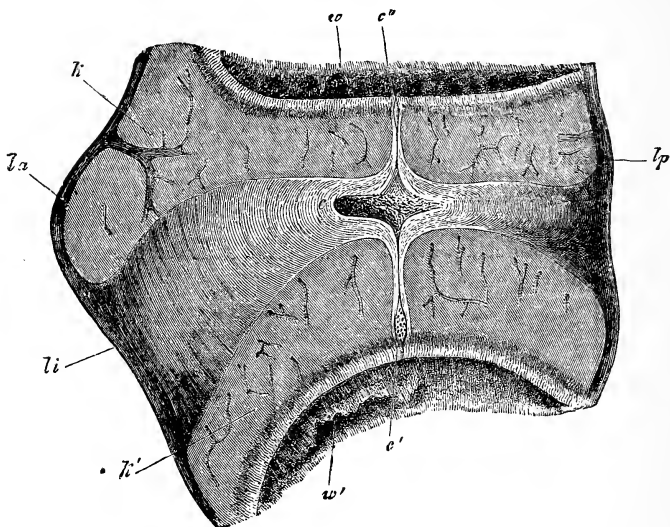


LONGITUDINAL SECTION THROUGH THE VERTEBRAL COLUMN OF AN EIGHT WEEKS' HUMAN EMBRYO IN THE THORACIC REGION. (From Kölliker.)

v. cartilaginous vertebral body; li. intervertebral ligament;
ch. notochord.

The skull. Excepting in the absence of the interorbital plate, the early development of the Mammalian *cranium* resembles in all essential points that of Aves, to our account of which on p. 235 et seq. we refer the reader.

FIG. 135.



LONGITUDINAL SECTION THROUGH THE INTERVERTEBRAL LIGAMENT AND ADJACENT PARTS OF TWO VERTEBRÆ FROM THE THORACIC REGION OF AN ADVANCED EMBRYO OF A SHEEP. (From Kölliker.)

la. ligamentum longitudinale anterius ; *lp.* ligamentum long. posterius ; *li.* ligamentum intervertebrale ; *k, k'.* epiphysis of vertebra ; *w. and w'.* anterior and posterior vertebræ ; *c.* intervertebral dilatation of notochord ; *c' and c''.* vertebral dilatation of notochord.

The early changes in the development of the visceral arches and clefts have already been described, but the later changes undergone by the skeletal elements of the first two visceral arches are sufficiently striking to need a special description.

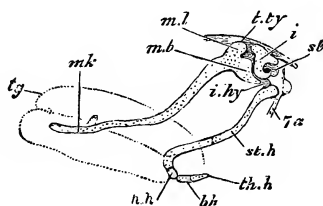
The skeletal bars of both the hyoid and mandibular arches develop at first more completely than in any of the other types above Fishes; they are articulated to each other above, while the pterygo-palatine bar is quite distinct.

The main features of the subsequent development are undisputed, with the exception of that of the upper end of the hyoid, which is still controverted. The following is Parker's account for the Fig.

The mandibular and hyoid arches are at first very similar, their dorsal ends being somewhat incurved, and articulating together.

In a somewhat later stage (Fig. 136) the upper end of the mandibular bar (*mb*), without becoming segmented

FIG. 136.



EMBRYO PIG, AN INCH AND A THIRD LONG; SIDE VIEW OF MANDIBULAR AND HYOID ARCHES. THE MAIN HYOID ARCH IS SEEN AS DISPLACED BACKWARDS AFTER SEGMENTATION FROM THE INCUS. (From Parker.)

tg. tongue; *mk.* Meckelian cartilage; *ml.* body of malleus; *mb.* manubrium or handle of the malleus; *t.ty.* tegmen tympani; *i.* incus; *st.* stapes; *i.hy.* interhyal ligament; *st.h.* stylohyal cartilage; *h.h.* hypohyal; *b.h.* basibranchial; *th.h.* rudiment of first branchial arch; *7a.* facial nerve.

from the ventral part, becomes distinctly swollen, and clearly corresponds to the quadrate region of other types. The ventral part of the bar constitutes Meckel's cartilage (*mk*).

The hyoid arch has in the meantime become segmented into two parts, an upper part (*i*), which eventually becomes one of the small bones of the ear—the *incus*—and a lower part which remains as the *anterior cornu* of the *hyoid* (*st.h*). The two parts continue to be connected by a ligament.

The incus is articulated with the quadrate end of the mandibular arch, and its rounded head comes in contact with the stapes (Fig. 136, *st*) which is segmented from the fenestra ovalis.

According to some authors the stapes is independently formed from mesoblast cells surrounding a branch of the internal carotid artery.

The main arch of the hyoid becomes divided into a hypohyal (*h.h*) below and a stylohyal (*st.h*) above, and also becomes articulated with the basal element of the arch behind (*bh*).

In the course of further development the Meckelian part of the mandibular arch becomes enveloped in a superficial ossification forming the dentary. Its upper end, adjoining the quadrate region, becomes calcified and then absorbed, and its lower, with the exception of the extreme point, is ossified and subsequently incorporated in the dentary.

The quadrate region remains relatively stationary in growth as compared with the adjacent parts of the skull, and finally ossifies to form the *malleus*. The processus

gracilis of the malleus is the primitive continuation into Meckel's cartilage.

The malleus and incus are at first embedded in the connective tissue adjoining the tympanic cavity, which with the Eustachian tube is the persistent remains of the hyomandibular cleft; and externally to them a bone known as the tympanic bone becomes developed so that they become placed between the tympanic bone and the periotic capsule. In late foetal life they become transported completely within the tympanic cavity, though covered by a reflection of the tympanic mucous membrane.

The dorsal end of the part of the hyoid separated from the incus becomes ossified as the tympano-hyal, and is anchylosed with the adjacent parts of the periotic capsule. The middle part of the bar just outside the skull forms the stylo-hyal (styloid process in man) which is attached by ligament to the anterior cornu of the hyoid (cerato-hyal). The tympanic membrane and external auditory meatus develop as in the chick (p. 166).

The ribs and sternum appear to develop in Mammals as in Birds (p. 234).

The pectoral girdle, as in Birds (p. 234), arises as a continuous plate of cartilage, the coracoid element of which is however much reduced.

The clavicle in Man is provided with a central axis of cartilage, and its mode of ossification is intermediate between that of a true cartilage bone and a membrane bone.

The pelvic girdle is formed in cartilage as in Birds, but in Man at any rate the pubic part of the cartilage is formed independently of the remainder. There are the usual three centres of ossification, which unite eventually into a single bone—the innominate bone. The pubis and ischium of each side unite ventrally, so as completely to enclose the obturator foramen.

The skeleton of the limbs develops so far as is known as in Birds, from a continuous mesoblastic blastema, within which the corresponding cartilaginous elements of the limbs become differentiated.

The body cavity. The development of the body cavity and its subsequent division into pericardial pleural and peritoneal cavities is precisely the same in Mammalia as in Aves (p. 264 et seq.). But in Mammalia a further change takes place, in that by the formation of a vertical partition across the body cavity, known as the diaphragm, the pleural cavities, containing the lungs, become isolated from the remainder of the body or peritoneal cavity. As shewn by their development the so-called pleuræ or pleural sacs are simply the peritoneal linings of the anterior divisions of the body cavity, shut off from the remainder of the body cavity by the diaphragm.

The vascular system.

The heart. The two tubes out of which the heart is formed appear at the sides of the cephalic plates, opposite the region of the mid- and hind-brain (Fig. 107). They arise at a time when the lateral folds which form the ventral wall of the throat are only just becoming visible. Each half of the heart originates in the same way as in the chick; and the layer of the splanchnic mesoblast, which forms the muscular wall for each part (*ahh*), has at first the form of a half tube open below to the hypoblast.

On the formation of the lateral folds of the splanchnic walls, the two halves of the heart become carried inwards

and downwards, and eventually meet on the ventral side of the throat. For a short time they here remain distinct, but soon coalesce into a single tube.

In Birds, it will be remembered, the heart at first has the form of two tubes, which however are in contact in front. It arises at a time when the formation of the throat is very much more advanced than in Mammalia; when in fact the ventral wall of the throat is established as far back as the front end of the heart.

In the lower types the heart does not appear till the ventral wall of the throat is completely established, and it has from the first the form of a single tube.

It is therefore probable that the formation of the heart as two cavities is a secondary mode of development, which has been brought about by variations in the period of the closing in of the wall of the throat.

The later development of the heart is in the main similar to that of the chick (p. 256 et seq.).

The arterial system. The early stages of the arterial system of Mammalia are similar to those in Birds. Five arterial arches are formed, the three posterior of which wholly or in part persist in the adult.

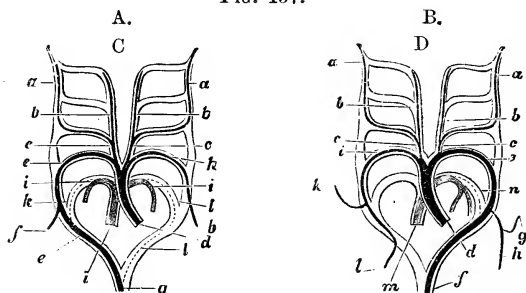
The bulbus arteriosus is divided into two (fig. 137 B), but the *left fourth arch (e)*, instead of, as in Birds, the right, is that continuous with the dorsal aorta, and the right fourth arch (*i*) is only continued into the right vertebral and right subclavian arteries.

The fifth pair of arches which is continuous with one of the divisions of the bulbus arteriosus gives origin to the two pulmonary arteries. Both these however are derived from the arch on one side, viz. the left (fig. 137 B); whereas in Birds, one pulmonary artery comes from the left and the other from the right fifth arch (fig. 137 A).

The ductus Botalli of the fifth arch (known in Man as the ductus arteriosus) of the side on which the pulmonary arteries are formed, may remain (*e.g.* in Man) as a solid cord connecting the common stem of the pulmonary aorta with the systemic aorta.

The diagram, Fig. 137, copied from Rathke, shews at a glance the character of the metamorphosis the arterial arches undergo in Birds and Mammals.

FIG. 137.



DIAGRAMS ILLUSTRATING THE METAMORPHOSIS OF THE ARTERIAL ARCHES IN A BIRD A. AND A MAMMAL B.

(From Mivart after Rathke.)

- A. *a.* internal carotid ; *b.* external carotid ; *c.* common carotid ; *d.* systemic aorta ; *e.* fourth arch of right side (root of dorsal aorta) ; *f.* right subclavian ; *g.* dorsal aorta ; *h.* left subclavian (fourth arch of left side) ; *i.* pulmonary artery ; *k.* and *l.* right and left ductus Botalli of pulmonary arteries.
- B. *a.* internal carotid ; *b.* external carotid ; *c.* common carotid ; *d.* systemic aorta ; *e.* fourth arch of left side (root of dorsal aorta) ; *f.* dorsal aorta ; *g.* left vertebral artery ; *h.* left subclavian artery ; *i.* right subclavian (fourth arch of right side) ; *k.* right vertebral ; *l.* continuation of right subclavian ; *m.* pulmonary artery ; *n.* ductus Botalli of pulmonary artery.

In some Mammals both subclavians spring from a trunk common to them and the carotids (*arteria anonyma*); or as in Man and some other Mammals, the left one arises from the systemic aorta just beyond the carotids. Various further modifications in the origin of the subclavians are found in Mammalia, but they need not be specified in detail. The vertebral arteries arise in close connection with the subclavians, whereas in Birds they arise from the common carotids.

The venous system. In Mammals the same venous trunks are developed in the embryo as in Birds (Fig. 138 A). The anterior cardinals or external jugulars form the primitive veins of the anterior part of the body, and the internal jugulars and anterior vertebrals are subsequently formed. The subclavians (Fig. 138 A, s), developed on the formation of the anterior limbs, also pour their blood into these primitive trunks. In the lower Mammalia (Monotremata, Marsupialia, Insectivora, some Rodentia, etc.) the two ductus Cuvieri remain as the two superior venæ cavæ, but more usually an anastomosis arises between the right and left innominate veins, and eventually the whole of the blood of the left superior cava is carried to the right side, and there is left only a single superior cava (Fig. 138 B and C). A small rudiment of the left superior cava remains however as the *sinus coronarius* and receives the *coronary vein* from the heart (Figs. 138 C, *cor* and 139 *cs*).

The posterior cardinal veins form at first the only veins receiving the blood from the posterior part of the trunk and kidneys; and on the development of the hind limbs receive the blood from them also.

An unpaired vena cava inferior becomes eventually

FIG. 138.

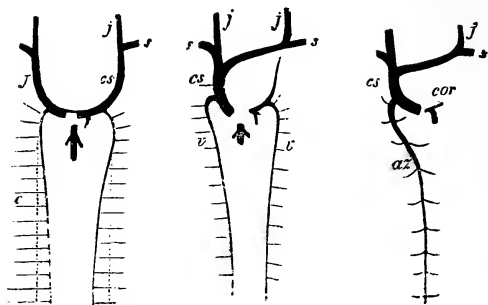


DIAGRAM OF THE DEVELOPMENT OF THE PAIRED VENOUS SYSTEM OF MAMMALS (MAN). (From Gegenbaur.)

j. jugular vein ; *cs.* vena cava superior ; *s.* subclavian veins ; *c.* posterior cardinal vein ; *v.* vertebral vein ; *az.* azygos vein ; *cor.* coronary vein.

A. Stage in which the cardinal veins have already disappeared. Their position is indicated by dotted lines.

B. Later stage when the blood from the left jugular vein is carried into the right to form the single vena cava superior ; a remnant of the left superior cava being however still left.

C. Stage after the left vertebral vein has disappeared ; the right vertebral remaining as the azygos vein. The coronary vein remains as the last remnant of the left superior vena cava.

developed, and gradually carries off a larger and larger portion of the blood originally returned by the posterior cardinals. It unites with the common stem of the allantoic and vitelline veins in front of the liver.

At a later period a pair of trunks is established bringing the blood from the posterior part of the cardinal veins and the crural veins directly into the vena cava

inferior (Fig. 139, *il*). These vessels, whose development has not been adequately investigated, form the common

FIG. 139.

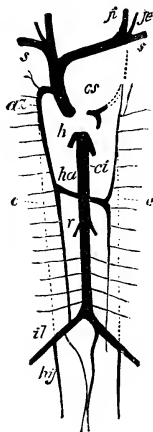


DIAGRAM OF THE CHIEF VENOUS TRUNKS OF MAN.

(From Gegenbaur.)

- cs.* coronary sinus ; *s.* subclavian vein ; *ji.* internal jugular ;
je. external jugular ; *az.* azygos vein ; *ha.* hemiazygos vein ;
c. dotted line shewing previous position of cardinal veins ;
ci. vena cava inferior ; *r.* renal veins ; *il.* iliac ; *hy.* hypogastric veins ; *h.* hepatic veins.

The dotted lines shew the position of embryonic vessels aborted in the adult.

iliac veins, while the posterior ends of the cardinal veins which join them become the hypogastric veins (Fig. 139 *hy*).

Posterior vertebral veins, similar to those of Birds, are established in connection with the intercostal and

lumbar veins, and unite anteriorly with the front part of the posterior cardinal veins (Fig. 138 A).

Upon the formation of the posterior vertebral veins, and upon the inferior vena cava becoming more important, the middle part of the posterior cardinals becomes completely aborted (Fig. 139 *c*), the anterior and posterior parts still persisting, the former as the continuations of the posterior vertebrals into the anterior vena cava (*az*), the latter as the hypogastric veins (*hy*).

Though in a few Mammalia both the posterior vertebrals persist, a transverse connection is usually established between them, and the one (the right), becoming the more important, constitutes the azygos vein (Fig. 139 *az*), the persisting part of the left forming the hemiazygos vein (*ha*).

The remainder of the venous system is formed in the embryo by the vitelline and allantoic veins, the former being eventually joined by the mesenteric vein so as to constitute the portal vein.

The vitelline vein is the first part of this system established, and divides near the heart into two veins bringing back the blood from the yolk-sac (umbilical vesicle). The right vein soon however aborts.

The allantoic (anterior abdominal) veins are originally paired. They are developed very early, and at first course along the still widely open somatic walls of the body, and fall into the single vitelline trunk in front. The right allantoic vein disappears before long, and the common trunk formed by the junction of the vitelline and allantoic veins becomes considerably elongated. This trunk is soon enveloped by the liver, and later in its passage through, gives off branches to, and also

receives branches from this organ near its anterior exit. The main trunk is however never completely aborted, as in the embryos of other types, but remains as the *ductus venosus Arantii*.

With the development of the placenta the allantoic vein becomes the main source of the ductus venosus, and the vitelline or portal vein, as it may perhaps be now conveniently called, ceases to join it directly, but falls into one of its branches in the liver.

The vena cava inferior joins the continuation of the ductus venosus in front of the liver, and, as it becomes more important, it receives directly the hepatic veins which originally brought back blood into the ductus venosus. The ductus venosus becomes moreover merely a small branch of the vena cava.

At the close of foetal life the allantoic vein becomes obliterated up to its place of entrance into the liver; the ductus venosus becomes a solid cord—the so-called round ligament—and the whole of the venous blood is brought to the liver by the portal vein.

Owing to the allantoic (anterior abdominal) vein having merely a foetal existence an anastomosis between the iliac veins and the portal system by means of the anterior abdominal vein is not established.

The supra-renal bodies. These are paired bodies lying anterior to the kidneys and are formed of two parts, (1) a cortical and (2) a medullary portion. They first appear in the Rabbit on the 12th or 13th day of gestation, and arise as masses of mesoblast cells lying between the aorta and the mesentery and to one side of the former. On the 14th day they are well marked, and lying dorsal to them is another mass of cells which

is found to be continuous with the sympathetic nervous system.

On the 16th day processes from the sympathetic mass enter the mesoblastic tissue and become transformed into the medullary portion of the adult suprarenal; while the mesoblastic tissue gives rise to the cortical layer.

The urinogenital organs.

The history of these organs in Mammalia, excepting so far as concerns the lower parts of the urinogenital ducts, is the same as in the Chick.

The **Wolffian body and duct** first appear, and are followed by the **Müllerian duct** and the **kidney**. The exact method of development of the latter structures has not been followed so completely as in the Chick; and it is not known whether the peculiar structures found at the anterior end of the commencing Müllerian duct in Aves occur in Mammalia.

The history of the **generative glands** is essentially the same as in the Chick.

Outgrowths from a certain number of Malpighian bodies in the Wolffian body are developed along the base of the testis, and enter into connection with the seminiferous stroma. It is not certain to what parts of the testicular tubuli they give rise, but they probably form at any rate the *vasa recta* and *rete vasculosum*. Similarly intrusions from the Malpighian bodies make their way into the ovary of the female, and give rise to cords of tissue which may persist throughout life.

The **vasa efferentia** (*coni vasculosi*) appear to be derived from the glandular tubes of part of the Wolffian

body. The Wolffian duct itself becomes in the male the **vas deferens** and the convoluted canal of the **epididymis**; the latter structure except the head being entirely derived from the Wolffian duct.

The functionless remains of the embryonic organs described for the chick (p. 224) are found also in mammals.

The Müllerian ducts persist in the female as the Fallopian tubes and uterus.

The lower parts of the urinogenital ducts are somewhat further modified in the Mammalia than the Chick.

The genital cord. The lower part of the Wolffian ducts becomes enveloped in both sexes in a special cord of tissue, known as the genital cord (Fig. 140 *gc*), within the lower part of which the Müllerian ducts are also enclosed. In the male the Müllerian ducts in this cord atrophy, except at their distal end where they unite to form the uterus masculinus. The Wolffian ducts, after becoming the vasa deferentia, remain for some time enclosed in the common cord but afterwards separate from each other. The seminal vesicles are outgrowths of the vasa deferentia.

In the female the Wolffian ducts within the genital cord atrophy, though rudiments of them are for a long time visible or even permanently persistent. The lower parts of the Müllerian ducts unite to form the vagina and body of the uterus while the upper become the horns of the uterus and the Fallopian tubes. The junction commences in the middle and extends forwards and backwards; the stage with a median junction being retained permanently in Marsupials.

The urinogenital sinus and external generative organs. The dorsal part of the cloaca with the alimen-

tary tract becomes partially constricted off from the ventral, which then forms a urinogenital sinus (Fig. 140 *ug*). In the course of development the urinogenital

FIG. 140.

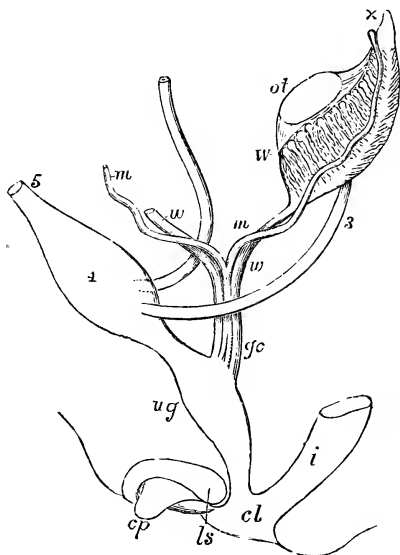


DIAGRAM OF THE URINOGENITAL ORGANS OF A MAMMAL AT AN EARLY STAGE. (After Allen Thomson; from Quain's *Anatomy*.)

The parts are seen chiefly in profile, but the Müllerian and Wolffian ducts are seen from the front.

3. ureter; 4. urinary bladder; 5. urachus; *ot.* genital ridge (ovary or testis); *W.* left Wolffian body; *x.* part at apex from which coni vasculosi are afterwards developed; *w.* Wolffian duct; *m.* Müllerian duct; *gc.* genital cord consisting of Wolffian and Müllerian ducts bound up in a common sheath; *i.* rectum; *ug.* urinogenital sinus; *cp.* elevation which becomes the clitoris or penis; *ls.* ridge from which the labia majora or scrotum are developed.

sinus becomes, in all Mammalia but the Ornithodelphia, completely separated from the intestinal cloaca, and the two parts obtain separate external openings. The ureters (Fig. 140, 3) open higher up than the other ducts into the stalk of the allantois which here dilates to form the bladder. That part of the stalk which connects the bladder with the ventral wall of the body constitutes the urachus, and loses its lumen before the close of embryonic life. The part of the stalk of the allantois below the openings of the ureters narrows to form the urethra, which opens together with the Wolffian and Müllerian ducts into the urogenital cloaca.

In front of the urogenital cloaca there is formed a genital prominence (Fig. 140 *cp*) with a groove continued from the urinogenital opening, and on each side a genital fold (*ls*). In the male the sides of the groove on the prominence coalesce together, embracing between them the opening of the urinogenital cloaca, and the prominence itself gives rise to the penis, along which the common urinogenital passage is continued. The two genital folds unite from behind forwards to form the scrotum.

In the female the groove on the genital prominence gradually disappears, and the prominence remains as the clitoris, which is therefore the homologue of the penis: the two genital folds form the labia majora. The urethra and vagina open independently into the common urogenital sinus.

THE ALIMENTARY CANAL AND ITS APPENDAGES.

It is convenient to introduce into our account of the organs derived from the hypoblast, a short account of

certain organs connected with the alimentary canal such as the mesentery, stomodæum, etc., which are not hypoblastic in origin.

The origin of the hypoblast, and the process of folding by which the cavity of the mesenteron is established have already been described. The mesenteron may be considered under three heads.

1. *The anterior or respiratory division of the mesenteron.* The pharynx, thyroid body, Eustachian tube, tympanic cavity, cesophagus, trachea, bronchi, lungs and stomach are developed from this portion, and their development in the Mammal so closely resembles that in the Chick that it is unnecessary for us to add to the account we have already given in the earlier part of this work.

This section of the alimentary canal, as in the Chick, is distinguished in the embryo by the fact that its walls send out a series of paired diverticula which meet the skin, and, after perforation has been effected at the regions of contact, form the visceral clefts.

2. *The middle division of the mesenteron*, from which the liver and pancreas are developed, as in the Chick, forms the intestinal and cloacal region and is at first a straight tube. It remains for some time connected with the yolk sack.

The Cloaca appears as a dilatation of the mesenteron which receives, as in Aves, the opening of the allantois almost as soon as the posterior section of the alimentary tract is established. The eventual changes which it undergoes have already been dealt with in connection with the urinogenital organs.

The intestine. The posterior part of this becomes

enlarged to form the large intestine, while the anterior portion becoming very much elongated and coiled forms the small intestine, and moreover gives rise anteriorly to the **liver** and **pancreas**.

From the large intestine close to its junction with the small intestine an outgrowth is developed, the proximal part of which enlarges to form the *cæcum*, while the distal portion in Man forms the *vermiform appendix*.

3. *The postanal division of the mesenteron* atrophies at an early period of embryonic life. In the Chick and lower types it communicates for a short time with the hind end of the neural canal.

Splanchnic mesoblast and mesentery. The mesenteron consists at first of a simple hypoblastic tube, which however becomes enveloped by a layer of splanchnic mesoblast. This layer, which is not at first continued over the dorsal side of the mesenteron, gradually grows in, and interposes itself between the hypoblast of the mesenteron, and the organs above. At the same time it becomes differentiated into two layers, viz. an outer epithelioid layer which gives rise to part of the peritoneal epithelium, and an inner layer of undifferentiated cells which in time becomes converted into the connective tissue and muscular walls of the mesenteron. The connective tissue layers are first formed, while of the muscular layers the circular is the first to make its appearance.

Coincidentally with the differentiation of these layers the connective tissue stratum of the peritoneum becomes established.

The mesentery is developed as in the Chick (p. 172). In the thoracic region it is hardly if at all developed.

The primitive simplicity in the arrangement of the mesentery is usually afterwards replaced by a more complicated disposition, owing to the subsequent elongation and consequent convolution of the intestine and stomach.

The layer of peritoneal epithelium on the ventral side of the stomach is continued over the liver, and after embracing the liver, becomes attached to the ventral abdominal wall. Thus in the region of the liver the body-cavity is divided into two halves by a membrane, the two sides of which are covered by the peritoneal epithelium, and which encloses the stomach dorsally and the liver ventrally. The part of the membrane between the stomach and liver is narrow, and constitutes a kind of mesentery suspending the liver from the stomach: it is known to human anatomists as the *lesser omentum*.

The part of the membrane connecting the liver with the anterior abdominal wall constitutes the *falciform* or *suspensory ligament of the liver*. It arises by a secondary fusion, and is not a remnant of a primitive ventral mesentery (*vide* p. 264).

The mesentery of the stomach, or mesogastrium, enlarges in Mammalia to form a peculiar sack known as the *greater omentum*.

The stomodæum. The anterior section of the permanent alimentary tract is formed, as in the Chick, by an invagination of epiblast, constituting a more or less considerable pit, with its inner wall in contact with the blind anterior extremity of the mesenteron.

From the epiblastic lining of this pit are developed the pituitary body and the salivary as well as the other buccal glands.

FIG. 141.

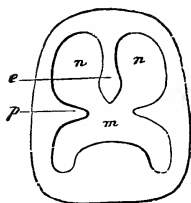


DIAGRAM SHEWING THE DIVISION OF THE PRIMITIVE BUCCAL CAVITY INTO THE RESPIRATORY SECTION ABOVE AND THE TRUE MOUTH BELOW. (From Gegenbaur.)

p. palatine plate of superior maxillary process; *m.* permanent mouth; *n.* posterior part of nasal passage; *e.* internasal septum.

A palate grows inwards from each of the superior maxillary processes (Fig. 141), which, meeting in the middle line, form a horizontal septum dividing the front part of the stomodæum into a dorsal respiratory section, containing the opening of the posterior nares, and a ventral cavity forming the permanent mouth. These two divisions open into a common cavity behind. This septum on the development within it of an osseous plate constitutes the hard palate. A posterior prolongation in which no osseous plate is formed constitutes the soft palate. An internasal septum (Fig. 141 *e*) may more or less completely divide the dorsal cavity into two canals, continuous respectively with the two nasal cavities.

The teeth are special products of the oral mucous membrane. They are formed from two distinct organs, viz. an epithelial cap and a connective tissue papilla,

which according to most authors give rise to the enamel and dentine respectively.

The proctodæum. The cloacal section of the alimentary canal is placed in communication with the exterior by means of a shallow epiblastic invagination constituting the proctodæum.

APPENDIX.

PRACTICAL INSTRUCTIONS FOR STUDYING THE DEVELOPMENT OF THE CHICK.

I. A. Incubators.

OF all incubators, the natural one, *i.e.* the hen, is in some respects the best. The number of eggs which fail to develop is fewer than with an artificial incubator, and the development of monstrosities is rarer. A good sitter will continue to sit for thirty or more days at least, even though the eggs are daily being changed. She should never be allowed to want for water, and should be well supplied according to her appetite with soft food. It is best to place the food at some little distance from the eggs, in order that the hen may leave the eggs when feeding. She will sit most persistently in a warm, quiet, somewhat darkened spot. When an egg is placed under her, the date should be marked on it, in order that the duration of its incubation may be exactly known. When the egg is intended to remain for some time, *e.g.* for seven days or more, the mark should be bold and distinct, otherwise it will be rubbed off.

On the whole however we have found it more convenient to use a good artificial incubator. We have ourselves used with success two different incubators. One made by the Cambridge Scientific Instrument Company, and the other by Wiesnegg of 64, Rue Gay-Lussac, Paris (Fig. 65 in his catalogue for 1881). We have had the longest experience with the former, and have found it work exceedingly well: having been able to hatch chicks without more attention than now and then turning over the eggs.

Both these incubators consist essentially of a large water-bath fitted with a gas regulator. They are both perfectly automatic and when once regulated require no further attention.

The temperature within the incubator should be maintained at from 37° to 40°C. A rise above 40° is fatal; but it may be allowed to descend to 35° or in the young stages lower, without doing any further harm than to delay the development.

The products of the combustion of the gas should be kept as much as possible from the eggs, while *a supply of fresh air and of moisture is essential.*

Tolerably satisfactory results may be obtained with an ordinary chemical double-jacketed drying water-bath, thoroughly covered in with a thick coat of cotton wool and flannel baize, and heated by a very small gas-jet. If the vessel be filled with hot water, and allowed to cool down to 40° or thereabouts, before the eggs are introduced, a very small gas flame will be sufficient to maintain the requisite temperature. A small pin-hole-nozzle, giving with ordinary pressure an exceeding narrow jet of flame about two inches high, is the most convenient. By turning the gas off or on, so as to reduce or increase the height

of the jet as required, a very steady mean temperature may be maintained.

In the absence of gas, a patent night-light placed at a proper distance below the bath may be made to answer very well. When a body of water, once raised to the necessary temperature, is thoroughly surrounded with non-conducting material, a very slight constant amount of heat will supply all the loss.

B. *On preparing sections of the embryo.*

1. HARDENING.

a. Picric acid.

We find this reagent the most satisfactory for hardening the chick and in most instances mammalian embryos.

Kleinenberg's solution of picric acid is the best.

With 100 parts of water, make a cold saturated solution of picric acid; add to this two parts of concentrated sulphuric acid or nitric acid: filter and add to the filtrate three times its bulk of water.

In this solution of picric acid¹ the embryo must be placed and left for from 2—5 hours. It should then be washed in alcohol of 30 p.c. and placed in alcohol 50 p.c. for *one* hour. From this it must be removed into alcohol of 70 p.c. in which it should be left until all the picric acid is extracted; to facilitate this the 70 p.c. alcohol should be frequently changed: when free from picric the embryo

¹ It is sometimes advantageous to add to this solution of picric acid as much pure kreasote as it will dissolve (*vide* Kleinenberg, "Development of Earthworm," *Quarterly Journal of Mic. Sci.* 1879).

should be placed in 90 p.c. alcohol and kept there until required for further use.

N.B. Hardened embryos should always be kept in 90 p.c. spirit and only placed in absolute before imbedding, or staining with haematoxylin.

Some histologists prefer to keep hardened tissues in alcohol 70 p.c.

b. **Corrosive sublimate.**

Place the embryo in a large quantity of a saturated aqueous solution of corrosive sublimate to which a few drops of glacial acetic acid have been added, and allow it to remain for half-an-hour¹. It is necessary thoroughly to extract the corrosive sublimate from the cells of the embryo; to accomplish this, wash it thoroughly with water for from 10 minutes to 3 hours according to the size of the object. The washing may be limited to frequent changes of water or the embryo may be placed in a vessel through which a continuous stream of water is kept running. When all the sublimate is removed, place it in 50 p.c. alcohol acidulated with nitric acid (half-a-dozen drops of acid to a 4 oz. bottle of spirit) for five minutes. The preservation of the embryo is completed by treating it with 70 p.c. alcohol for twenty-four hours and then keeping it in 90 p.c. alcohol. We have not found that corrosive sublimate gives such good results as picric acid in the case of chicks and mammalian embryos.

¹ If there is only a small quantity of acetic acid mixed with the sublimate, a prolonged immersion will do the embryo no harm.

c. **Osmic acid.**

Osmic acid is a difficult reagent to use, but when properly applied it gives most excellent results.

It should be used as a weak solution ($\cdot 1$ to $\cdot 5$ p.c.). The object should be left in it until it has acquired a *light* brown tint. The stronger the solution the less time is required for the production of this tint. It should then be removed and placed in picro-carmin, which arrests the action of the osmic and stains the embryo. The time required for the picro-carmin staining must be determined by practice. From the picro-carmin the object must be washed in 70 p.c. spirit; and then placed in 90, or may be preserved directly in glycerine.

If it is desired to use other staining agents (borax-carmin is good for some preparations), the object must be removed from osmic into water or weak spirit, thence through 50 into 70 p.c., stained, and passed through 70 to 90 p.c. spirit.

- d. After using osmic it is well in some cases (mammalian segmenting ova) to place the object in Müller's fluid for 2 or 3 days, after which it may be preserved in glycerine or spirit.

Müller's fluid is made by dissolving 25 grms. of bichromate of potash and 10 grms. of sodic sulphate in 1000 cc. of water.

e. **With chromic acid.**

The embryo must be immersed in a solution of the strength of $\cdot 1$ p.c. for 24 hours. From this it should be removed and placed in a stronger

solution (.3 p.c.) for another 24 hours. If it then appears sufficiently hard, it may be at once placed in alcohol of 70 p.c., in which it should remain for one day, and then be transferred to alcohol of 90 p.c.

f. Absolute alcohol has also been employed as a hardening reagent, but is by no means so good as the reagents recommended above.

The object of these so-called hardening reagents is to kill the tissues with the greatest possible rapidity without thereby destroying them. The subsequent treatment with alcohol completes the hardening which is only commenced by these reagents.

There is room for the exercise of considerable skill in the use of alcohol, and this skill can only be acquired by experience. A few general rules may however be laid down.

- (1) Tissues should not, generally, be changed from water or an aqueous solution of the first hardening reagent into an alcoholic solution of too great strength, nor should the successive solutions of alcohol used differ too much in strength. The distortion produced by the violence and inequality of the diffusion currents is thus diminished. This general rule should be remembered in transferring tissues from alcohol to the staining agents and vice versa.
- (2) The tissues should not be left too long (more than one or two hours) in alcoholic solutions containing less than 70 p.c. of alcohol.
- (3) They should not be kept in absolute alcohol longer than is necessary to dehydrate them (see B. 1, p. 426). The alcoholic solutions we generally use contain 30, 50, 70, 90 p.c. of alcohol.

2. STAINING.

In most cases it will be found of advantage to stain the embryo. The best method of doing

this is to stain the embryo as a whole, rather than to stain the individual sections after they have been cut.

We have found hæmatoxylin and borax-carminc the best reagents for staining embryos as a whole.

a. **With hæmatoxylin.**

The best solution of hæmatoxylin, one for which we are indebted to Kleinenberg, is made in the following way.

- (1) Make a saturated solution of crystallized calcium chloride in 70 p.c. alcohol, and add alum to saturation.
- (2) Make also a saturated solution of alum in 70 p.c. alcohol, and add 1 to 2 in the proportion of 1 : 8.
- (3) To the mixture of 1 and 2 add a *few* drops of a saturated solution of hæmatoxylin in absolute alcohol.
- (4) It is often the case that hæmatoxylin solution prepared in this way has not the proper purple tint; but a red tint. This is due to acidity of the materials used. The proper colour can be obtained by treating it with some alkaline solution. We have found it convenient to use for this purpose a saturated solution of sodium bi-carbonate in 70 p.c. spirit. (The exact amount must be determined by experiment, as it depends upon the amount of acid present.)

The embryo should be placed for some hours in absolute alcohol, before staining with hæ-

matoxylin, and should be removed directly from absolute into the hæmatoxylin.

The time required for staining varies with the size of the object and the strength of the staining fluid. Hæmatoxylin will not stain if the embryo is not quite free from acid.

If the embryo is stained too dark, it should be treated with a solution of 70 p.c. alcohol acidulated with nitric acid ($\cdot 25$ p.c. of acid) until the excess of staining is removed; and in all cases the hæmatoxylin staining is improved by treating the embryo with acidulated 70 p.c. alcohol.

After staining the embryo must be well washed in 70 and placed in 90 p.c. spirit.

b. **With borax-carmine.**

Make an aqueous solution of 2 to 3 p.c. carmine and 4 p.c. borax, by heating: add an equal volume of 70 p.c. alcohol, and let the mixture stand for thirty-six hours; after which carefully filter.

Stain the object thoroughly by leaving it in this solution for one or even two days; it will attain a dull maroon colour: transfer it then to acidulated alcohol (see *a*) until it becomes a bright red, and afterwards keep it as before in 90 p.c. alcohol.

This staining solution permeates more thoroughly and uniformly a large object than does hæmatoxylin: therefore when a four or five day chick is to be stained, borax-carmin is the best staining reagent to use. Embryos that have been preserved in corrosive sublimate will be

found to stain more thoroughly in this than in the hæmatoxylin solution.

c. **With carmine.**

Beale's carmine or some alcoholic solution is the best. Into this the embryo may be removed directly from 90 p.c. alcohol, left for 24 hours, and then placed again in alcohol until required.

d. **With picro-carmine.**

This reagent is useful as will be seen later for staining mammalian segmenting ova and very young blastoderms; it is used with the greatest success after hardening in osmic acid.

There are several methods of making picro-carmine, the following is the simplest, and we have found it answer our purpose fairly well.

To a solution made up of 1 grm. of carmine 4 cc. of liquor ammonia and 200 cc. of distilled water add 5 grms. of picric acid; agitate the mixture for some minutes, and then decant, leaving the excess of acid.

The decanted fluid must remain for several days, being stirred up from time to time; eventually evaporated to dryness in a shallow vessel, and to every 2 grms. of the residue add 100 cc. of distilled water.

e. **With alum carmine.**

To make it, boil a strong aqueous solution of ammonia-alum with excess of carmine for 10 to 20 minutes, filter, and dilute the filtrate until it contains from 1 to 5 p.c. of alum. Add a few drops of carbolic acid to prevent the growth of fungus.

Well hardened tissues may be left in this aqueous solution for 24 hours. It is especially good for staining nuclei; as a rule the staining is not diffuse, but it is necessary after staining to treat with acid alcohol (see *a*).

3. IMBEDDING AND CUTTING SECTIONS.

It is not possible to obtain satisfactory sections of embryos without employing some method of imbedding, and using a microtome. Many imbedding solutions and methods of cutting sections have been used, but we find the following far superior to any other. It combines several advantages; in the first place it renders it comparatively easy to obtain, what is so essential, a complete *consecutive series* of sections of the embryo; and secondly, all the sections when mounted are in the same relative position; and the various parts of each section retain their normal position with regard to each other.

a. Imbedding.

The substance we prefer for imbedding is paraffin. As will be seen below it is necessary to have at hand paraffins of various melting points, according to the temperature of the room at the time when the sections are cut.

It will be found most convenient to obtain paraffins of the highest and lowest melting points and to mix them together as experience dictates.

Place the stained embryo in absolute alcohol until completely dehydrated (two hours is sufficient for small embryos): and when ready

to imbed soak it in turpentine¹ until it is completely saturated: and transfer it thence *with as little turpentine as possible* to a dish of melted paraffin.

In cases of very delicate tissues, it is better to use chloroform instead of turpentine. The chloroform should be carefully added by means of a pipette to the absolute alcohol in which the tissue is placed. The chloroform sinks to the bottom of the bottle or tube and the embryo, which at first lies at the junction of the two liquids, gradually sinks into the chloroform. When this is accomplished, remove *all* the absolute with a pipette and add pieces of solid paraffin to the chloroform. Gently warm this on a water bath till all the chloroform is driven off; then imbed in the usual way.

Care must be taken that no more heat is used than is necessary to melt the paraffin; for this purpose the paraffin should be warmed over a water bath the temperature of which is kept constant (from 50 to 60°C. but not more than 60°C.).

A paraffin melting at 44°C. is of the proper consistency for cutting when the temperature of the room is 15°C. (60°F).

With care a porcelain evaporating dish and a gas flame may be made to answer, but the student is advised not to imbed without a water bath.

The embryo may be left in the paraffin two, three or more hours, after which it is imbedded by placing it along with the melted paraffin in either a box made by bending up the sides and folding in the corners of a piece of stiff paper, or what is better, a box formed by two L-shaped

¹ If the alcohol is not quite absolute kreasote should be used instead of turpentine.

pieces of lead, placed on a glass slide in such a manner as to enclose a space. The latter is preferable because the object can be placed in any position required with great ease by moving it with a hot needle, and the whole can be cooled rapidly. It is advisable, at any rate at first, to arrange the embryo so as to cut it into transverse sections.

When cool a block of paraffin is formed, in the midst of which is the embryo.

Other imbedding agents have been used. The best of these are, (1) pure cocoa butter; (2) a mixture of spermaceti and castor oil or cocoa butter (4 parts of the former to one of the latter). With these imbedding substances, it is generally necessary to moisten the razor, either with olive oil or turpentine and ribbons of sections cannot be made (see *b*).

b. **Cutting sections.**

When the imbedding block is cold pare away the edges, then gradually slice it away until the end of the embryo is near the surface, and place it in a microtome.

The microtome we are most accustomed to is a 'sliding microtome' made by Jung of Heidelberg; it gives excellent results. Recently however Messrs Caldwell and Threlfall have designed an automatic microtome which has been used with success at the Cambridge Morphological Laboratory and promises to effect a great saving of time and trouble in cutting sections (vide p. 471 and *Proceedings of the Cambridge Phil. Soc.* 1883). A convenient small microtome is one made by Zeiss of Jena (also by the Cambridge Scientific Instrument Company), in which the object is fixed and by means of a finely divided screw

raised through a hole in a glass plate, across which a razor held in the hand is pushed. We will briefly describe the method of manipulation for the small microtome, it will be found easily applicable to Jung's sliding microtome.

The paraffin block is pared in such a manner that the edge nearest to the operator and that opposite to him are parallel. A dry razor is then pushed upon the glass plate over the hole through which the block of paraffin projects upwards, and a section cut which remains upon the razor. Care must be taken that the edge of the razor is parallel to the parallel edges of the paraffin block. The block having been raised by the screw, a second section is made in the same way and on the same part of the razor as the first; in consequence of which, the first section will be pushed backwards by the second. Similarly each new section pushes backwards those already made; and a ribbon of sections formed which, *if the paraffin is of the right consistency*, will adhere firmly together.

Experience must teach the manipulator how to mix the paraffin in such a manner that it is neither too hard nor too soft; if it is too hard, the sections will not adhere together and will curl up on the razor, if too soft they will stick to the razor and be found to be creased. When it is not possible to keep the temperature of the room constant it will be found convenient to use a hard paraffin, and when necessary to raise the temperature by means of a lamp.

The paraffin should completely surround the embryo and fill up all the spaces within it.

c. **Mounting sections.**

When the sections are cut, place them in rows on a slide prepared in the following manner. Make a solution of white shellac in kreasote by heating, and let it be of the consistency of glycerine, or slightly more fluid. With a camel's hair-brush paint a very thin and uniform layer of this gum over the slide which must be clean and *dry*, and while the gum is wet place the sections in rows upon it. Now place the slide on a water bath which is heated up to the melting point of the paraffin. The sections sink down into the thin layer of shellac and kreasote, the kreasote slowly evaporates and the shellac becoming hard fixes the section in the position in which it was placed on the slide. When the kreasote has been evaporated, pour turpentine carefully upon the slide, this dissolves the paraffin and clears the sections which may at once be mounted in canada balsam.

A turpentine or chloroform solution of canada balsam should be used.

This method of cutting ribbons of sections was first introduced by Mr Caldwell, to whom we are also indebted for the account given above for mounting sections (vide Note B, p. 471). The latter however is a modification and improvement of Dr Giesbrecht's method. (*Zoologischer Anzeiger* No. 92, 1881.)

C. *Preservation of the embryo as a whole.*

Chick embryos of the first or second day may be easily preserved whole as microscopic objects. For this purpose, the embryo, which has been preserved

in the ordinary way (B, *a*) should be stained *slightly*, dehydrated, soaked in oil of cloves until transparent and mounted in balsam.

Whole embryos of a later date cannot be satisfactorily preserved as microscopic objects.

PRACTICAL DIRECTIONS FOR OBTAINING AND STUDYING CHICK EMBRYOS.

II. Examination of a 36 to 48 hours' embryo.

The student will find it by far the best plan to begin with the study of an embryo of this date. The manipulation is not difficult; and the details of structure are sufficiently simple to allow them to be readily grasped. Earlier embryos are troublesome to manage until some experience has been gained; and the details of later ones are so many as to render it undesirable to begin with them.

A. *Opening the Egg.*

Take the egg warm from the hen or the incubator, and place it (it does not matter in what position, since the blastoderm will at this stage always be found at the uppermost part of the egg) in a small basin large enough to allow the egg to be covered with fluid. It is of advantage, but not necessary, to place at the bottom of the basin a mould, *e.g.* a flat piece of lead with a concavity on the upper surface, in which the egg may rest securely without rolling. Pour into the basin so much of a .75 per cent. solution of sodium chloride warmed to 38°C. as will cover the egg completely. With a sharp tap break through the shell at the broad end over the air-chamber, and let out as much air as has already been gathered there. Unless this is done,

the presence of air in the air-chamber will cause the broad end to tilt up. At this date there will be very little air, but in eggs of longer incubation, inconvenience will be felt unless this plan be adopted.

Instead of being broken with a blow, the shell may be filed through at one point, and the opening enlarged with the forceps; but a little practice will enable the student to use the former and easier method without doing damage.

With a blunt pair of forceps, remove the shell carefully bit by bit, leaving the shell-membrane behind; begin at the hole made at the broad end, and work over the upper part until about a third or half of the shell has been removed.

Then with a finer pair of forceps remove the shell-membrane; it will readily come away in strips, torn across the long axis of the egg in a somewhat spiral fashion. The yolk and embryo will now come into view.

It is the practice of some simply to break the egg across and pour the yolk and white together into a basin, very much as the housewife does. We feel sure, however, that the extra trouble of the method we have given will be more than repaid by the results.

During this time, and indeed during the whole period of the examination of the embryo *in situ*, the basin and its contents must be maintained, either by renewal of the salt solution, or by the basin being placed on a sand-bath, at about 38°C.

B. *Examination of the blastoderm in situ.*

This may be done with the naked eye, or with a simple lens of low power. Observe :—

1. Lying across the long axis of the egg, the *pellucid area*, in the middle of which the *embryo* may be obscurely seen as a white streak.
2. The mottled *vascular area*, with the blood-vessels just beginning to be formed.
3. The *opaque area* spreading over the yolk with the changes in the yolk around its periphery.
4. (With a simple lens), the contractions of the heart; perhaps the outlines of the head of the embryo may be detected.

C. *Removal of the embryo.*

Plunge one blade of a sharp fine pair of scissors through the blastoderm, just outside the outer margin of the vascular area, and rapidly carry the incision completely round until the circle is complete, avoid as much as possible any agitation of the liquid in the basin.

With a little trouble, the excised blastoderm may now be floated into a watch-glass, care being taken to keep it as flat as possible. With a pair of forceps or with a needle, aided by gentle shaking, remove the piece of vitelline membrane covering the blastoderm.

If any yolk adheres to the blastoderm, it may with a little gentle agitation easily be washed off. Sometimes it is of advantage to suck up the yolk with a glass syringe, replacing the fluid removed with clean (.75 p.c.) salt solution.

The blastoderm should now be removed from the watch-glass to a microscopic glass slide; since it is difficult in the former to prevent the edges of the blastoderm from curling up.

The transference may easily be effected, if both the watch-glass and slide are plunged into a basin of clean warm salt solution. With a little care, the blastoderm can then be floated from the one to the other, and the glass slide, having the blastoderm with its upper surface uppermost spread flat upon it, very gently raised out of the liquid.

A thin ring of putty may now be placed round the blastoderm, a small quantity of salt solution gently poured within the ring, and the whole covered with a glass slide, which may be pressed down until it is sufficiently close to the embryo. The presence of any air-bubbles must of course be avoided.

Provided care be otherwise taken to keep the embryo well covered with liquid, the putty ring and the coverslip may be dispensed with. They are often inconvenient, as when the embryo has to be turned upside down.

The object is now ready for examination with a simple lens or with a compound microscope of low objective. It is by far the best for the student to begin at least with the simple lens. In order that everything may be seen at its best, the slide should be kept warmed to about 38°, by being placed on a hot stage.

D. *Surface view of the transparent embryo
from above.*

The chief points to be observed are :

1. The *head-fold*.
2. The indications of the *amnion*; especially the *false amnion*, or outer amniotic fold.

3. The *neural tube*: the line of coalescence of the medullary folds, the *first cerebral vesicle*, the commencing *optic vesicles*, the indications of the *second and third cerebral vesicles*, the as yet open medullary folds at the tail end.
4. The *heart* seen dimly through the neural tube; note its pulsation if present.
5. The *fold of the somatopleure* anterior to the heart (generally very faintly shewn).
6. The *fold of the splanchnopleure* (more distinctly seen): the *vitelline veins*.
7. The *mesoblastic somites*.
8. Indications of the *vitelline arteries*.
9. The as yet barely formed *tail-fold*.
10. The commencing *blood-vessels* in the pellucid and vascular areas.

E. *Surface view of the transparent embryo from below.*

The coverslip must now be removed and the glass slide again immersed in a vessel of clean salt solution. By gently seizing the extreme edge of the opaque area with a pair of forceps, no difficulty will be found in so floating the blastoderm, as to turn it upside down, and thus to replace it on the slide with the under surface uppermost.

The points which most deserve attention in this view, are :—

1. The *heart*: its position, its union with the vitelline veins, its arterial end.

2. The *fold of the splachnopleure* marking the hind limit of the gut; the vitelline veins running along its wings.
3. The *mesoblastic somites* on each side of the neural canal behind the heart; farther back still, the vertebral plates not divided into somites.

F. *The examination of the embryo as an opaque object.*

This should never be omitted. Many points in the transparent embryo only become intelligible after the examination of it as an opaque object.

Having removed the putty ring and coverslip, if previously used, allow the blastoderm so far to become dry, that its edge adheres to the glass slide. Care must of course be taken that the embryo itself does not become at all dry. Place the glass slide with the blastoderm extended flat on it, in a shallow vessel containing a solution of picric acid (I. B.).

If the blastoderm be simply immersed by itself in the picric acid solution, the edges of the opaque area will curl up and hide much of the embryo. The method suggested above prevents these inconveniences.

The embryo thus hardened and rendered opaque by immersion in the acid (a stay of 2 to 3 hours in the solution will be sufficient) may be removed to a watch-glass, containing either some of the solution, or plain water, and examined with a simple lens, under a strong direct light. The compound microscope will be found not nearly so advantageous for this purpose as the simple lens. A piece of black paper placed under the watch-glass, will throw up the lights and

shadows of the embryo, with benefit. The watch-glass should have a flat bottom; or a shallow flat glass cell should be used instead.

a. Looking at the embryo from above, observe:—

1. The *head-fold*; the head distinctly projecting from the plane of the blastoderm, and formed chiefly by the forebrain and optic vesicles.
2. The elevation of the medullary canal, and the indications of the side walls of the embryo.
3. The indications of the tail.
4. The *Amnion* partly covering the head. Tear it open with needles. Observe its two folds.

b. Having turned the blastoderm upside down, observe the following points, looking at the embryo from below.

1. The hinder limit of the splanchnopleure in the head-fold, marking the hind limits of the *fore-gut*. The opaque folds now conceal the head almost entirely from view.
2. The commencing tail-fold, and the shallow boat-shaped cavity (of the alimentary canal) between it and the head-fold.

The student should not fail to make sketches of the embryo, both as a transparent, and as an opaque object, seen from below as well as from above. These sketches will be of great service to him when he comes to study the sections of the same embryo.

G. *The following transverse sections will perhaps be the most instructive.*

Manipulation as in I. B. 3.

1. Through the optic vesicles, shewing the optic stalks.
2. Through the hind-brain, shewing the auditory sacs.
3. Through the middle of the heart, shewing its relations to the splanchnopleure and alimentary canal.
4. Through the point of divergence of the splanchnopleure folds, shewing the venous roots of the heart.
5. Through the dorsal region, shewing the medullary canal, mesoblastic somites and commencing cleavage of the mesoblast.
6. Through a point where the medullary canal is still open, shewing the mode in which its closing takes place.

Longitudinal sections should also be made and compared with the transverse sections.

III. Examination of an Embryo of about 48—50 hours.

- A. *Opening the egg*—as in II. A.
- B. *Examination of the blastoderm in situ.*

Observe

1. The *form of the embryo*, which is much more distinct than at the earlier stage.
2. The *beating of the heart*.
3. The general features of the *circulation*.

C. *Removal of the Embryo from the yolk, as in*
II. C.

D. *Surface view of the transparent embryo from*
above.

Notice :—

1. *General form of the embryo.*
 - a. Commencing *cranial flexure*.
 - b. The *tail* and *side folds*.
2. *Amnion*. Notice the inner and outer (false amnion) limbs and remove them with a needle. When the amnion has been removed the features of the embryo will be much more clearly visible.
3. *The organs of sense.*
 - a. *Eye*. Formation of the *lens* already nearly completed.
 - b. *Auditory involution*, now a deep sac with a narrow opening to the exterior.
4. *The brain.*
 - a. The vesicles of the *fore-, mid-, and hind-brain*.
 - b. The *cerebral vesicle*.
 - c. The cranial flexure taking place at the mid-brain.

E. *Transparent embryo from below.*

Manipulation as in II. E.

Notice :—

1. The increase of the *head-folds* of the somatopleure and splanchnopleure, especially the latter, and the commencement of these folds at the tail.

2. The now ω -shaped *heart*; for further particulars vide Chap. IV.
3. The commencing 1st and 2nd *visceral clefts* and the *aortic arches*.
4. The *circulation of the yolk sac*, vide Fig. 36. Make out all the points there shewn and ascertain by examination that what have been called the veins and arteries in that figure, are truly such.

F. *The embryo as an opaque object.*

Treatment as in II. F.

FROM ABOVE :

Observe the *amnion*, which is a very conspicuous object, and remove it with needles if not done previously. The *external form of the brain* and the *auditory sac* appear very distinctly.

FROM BELOW :

Observe the nature of the *head- and tail-folds*, which are much more easily understood from the opaque than from the transparent embryos.

Observe also the *alimentary canal*, the widely open *hind* end of the *fore-gut*, and the *front* end of the as yet very short *hind-gut*.

G. *Sections.*

Manipulation as in I. B. 3.

The more important sections to be observed, are

1. Through optic lobes, shewing :
 - a. The formation of the lens.
 - b. The involution of the primary optic vesicle.
 - c. The constriction, especially from above, of the optic stalk.

2. Through auditory sac, shewing :
 - a. Auditory sac still open.
 - b. The thin roof and thick sides of the hind-brain.
 - c. Notochord.
 - d. Heart.
 - e. Closed alimentary canal.
3. Through dorsal region, shewing the general appearance of a section of an embryo at this stage, which should be compared with a similar section of the earlier stage.

It shews :

- a. The commencement of the side folds ; the alimentary canal still however open below.
- b. The Wolffian duct lying close under the epiblast on the outside of the mesoblastic somites.
- c. The notochord with the aortæ on each side.

IV. Examination of an Embryo at the end of the third day.

- A. *Opening the egg*, as in II. A.
- B. *Examination of the blastoderm in situ*.

Observe :—

1. The great increase of the *vascular area* both in size and distinctness. The circulation is now better seen *in situ* than after the blastoderm has been removed.
2. That the embryo now lies completely on its *left side* and that it is only connected with the yolk-sac by a somewhat broad stalk.

C. *Removal of the embryo.* See II. C.

It is now unnecessary to remove the whole of the blastoderm with the embryo; indeed it is better to cut away the vascular area unless it is wanted for examination.

D. *Surface view of the transparent embryo.*

Since the embryo now lies on its side we shall not have to speak of the view from above and below. The views from the two sides differ chiefly as to the appearance of the heart.

The embryo (freed from the blastoderm and the amnion) is to be floated on to a glass slide in the usual way. It is necessary to protect it while under examination, with a coverslip, which must not be allowed to compress it. To avoid this, we have found it a good plan to support the coverslip at one end only, since by moving it about when thus supported, a greater or less amount of pressure can be applied at will to the object.

The details which can at this stage be seen in a transparent embryo are very numerous and we recommend the student to try and verify everything shewn in Fig. 37. Amongst the more important and obvious points to be noticed are

1. The increase of the *cranial flexure* and the *body-flexure*.
2. The condition of the *brain*. The mid-brain now forms the most anterior point of the head.

The fore-brain consists of the inconspicuous vesicle of the third ventricle and the two large cerebral lobes.

The hind-brain consists of a front portion, the cerebellum with a thickened roof; and a hinder portion, the fourth ventricle with a very thin and delicate roof.

3. *Organs of sense.*

The *eye* especially is now in a very good state to observe. The student may refer to Fig. 51, and the description there given.

The *ear-vesicle* will be seen either just closing or completely closed.

4. In the region of the heart attention must also be paid to :

a. The *visceral clefts*.

b. The *investing-mass*, i.e. the growth of mesoblast taking place around the end of the notochord.

c. The condition of the *heart*.

5. In the region of the body the chief points to be observed are :

a. The increase in the number of the *somites*.

b. The *Wolffian duct*, which can be seen as a streak along the outer side of the hinder somites.

c. The *allantois*, which is now a small vesicle lying between the folds of the somatopleure and splanchnopleure at the hind end of the body, but as yet hardly projects beyond the body cavity.

E. *The embryo as an opaque object.*

Preparation as in II. F.

The general form of the embryo can be very satisfactorily seen when it is hardened and examined as an opaque object; but the most important points to be

made out at this stage in the hardened specimens are those connected with the visceral clefts and folds and the mouth.

If the amnion has not been removed it will be necessary to pick it completely away with needles. Without further preparation a view of the visceral folds and clefts may be obtained from the side; but a far more instructive view is that from below, in order to gain which the following method may be adopted.

Pour a small quantity of melted black wax (made by mixing together lampblack and melted wax) into a watch-glass, using just enough to cover the bottom of the glass. While still soft make a small depression in the wax with the rounded end of a pen-holder or handle of a paint-brush and allow the wax to cool. In the meantime cut off the head of the hardened embryo by a sharp clean transverse incision carried just behind the visceral clefts, transfer it to the watch-glass and cover it with water or spirit. By a little manipulation the head of the embryo may now be shifted into the small depression in the wax, and thus be made to assume any required position. It should then be examined with a simple lens under a strong reflected light, and a drawing made of it.

When the head is placed in the proper position, the following points may easily be seen.

1. The *opening of the mouth* bounded below by the *first pair of visceral folds*, and commencing to be enclosed above by the now very small buds which are the rudiments of the *superior maxillary processes*. Compare Fig. 56.

2. The *second and third visceral arches and clefts*.
3. The *nasal pits*.

F. *Sections*. Manipulation as in I. B. 3.

The most important sections are :—

1. Through the eyes in the three planes, *vide* Fig. 50, A. B. C.
2. Through the auditory sac.
3. Through the dorsal region, shewing the general changes which have taken place.

Amongst these, notice

- a. The *changes of the mesoblastic somites*: the commencing formation of the *muscle-plates*.
- b. The position of the Wolffian duct and the formation of the *germinal epithelium*.
- c. The *aortæ* and the *cardinal veins*.
- d. The great increase in depth and relative diminution in breadth of the section.

V. *Examination of an Embryo of the Fourth Day*.

A. *Opening the egg*, as in II. A.

Great care will be required not to injure the embryo, which now lies close to the shell-membrane.

B. *Examination in situ*. Observe:—

1. The now conspicuous *amnion*.
2. The *allantois*, a small, and as yet hardly vascular vesicle, beginning to project from the embryo into the space between the true and the false amnion.
3. The rapidly narrowing *somatic stalk*.

C. *Removal of the embryo*, as in II. C. and IV. C.

The remarks made in the latter place apply with still greater force to an embryo of the fourth and succeeding days.

D. *Surface view of the transparent embryo*. For manipulation, *vide* IV. D.

The points to be observed are :—

1. The formation of the *fifth, seventh, and ninth cranial nerves*.

To observe these, a small amount of pressure is advantageous.

2. The formation of the *fourth visceral cleft*, and the increase in size of the superior maxillary process.
3. The formation of the *nasal pits and grooves*.
4. The great relative growth of the *cerebral lobes* and the formation of the *pineal gland* from the roof of the vesicle of the third ventricle.
5. The great increase in the *investing mass*.
6. The formation and growth of the *muscle-plates*, which can now be easily seen from the exterior.
7. The *allantois*. Make out its position and mode of opening into the alimentary canal.

E. *The embryo as an opaque object*. Manipulation as II. F. For mode of examination *vide* IV. E.

The view of the mouth from underneath, shewing the nasal pit and grooves, the superior and inferior maxillary processes and the other visceral folds and clefts, is very instructive at this stage. Compare Fig. 69.

F. *Sections.* Manipulation as in I. B. 3.

The most important sections are,

1. Through the *eyes*.
2. Transverse section immediately behind the visceral arches, shewing the origin of the *lungs*.
3. Transverse section just in front of the umbilical stalk, shewing the origin of the *liver*.
4. Transverse section at about the centre of the dorsal region, to shew the *general features* of the fourth day. Compare Fig. 68.

Amongst the points to be noticed in this section, are

- a.* Muscle-plates.
 - b.* Spinal nerves and ganglia.
 - c.* Wolffian duct and bodies.
 - d.* Müller's duct.
 - e.* Mesentery.
 - f.* Commencing changes in the spinal cord.
5. Section passing through the opening of the allantois into the alimentary canal.

For the points to be observed in embryos of the **fifth and sixth days**, the student must consult the chapters devoted to those days.

In the hardened specimens, especial attention should be paid to the changes which take place in the parts forming the boundaries of the mouth.

VI. **Examination of a Blastoderm of 20 hours.**

- A. *Opening the egg*, as in II. A.
- B. *Examination in situ*.

It will not be found possible to make out anything very satisfactory from the examination of a blasto-

derm *in situ* at this age. The student will however not fail to notice the *halones*, which can be seen forming concentric rings round the blastoderm.

C. *Removal of the embryo.*

Two methods of hardening can be adopted at this age. One of these involves the removal of the blastoderm from the yolk, as in II. C. In the other case, the yolk is hardened as a whole. If the latter method be employed, the embryo cannot be viewed as a transparent object.

In the cases where the blastoderm is removed from the yolk, the manipulation is similar to that described under II. C, with the exception of more care being required in freeing the blastoderm from the vitelline membrane.

D. *Surface view transparent, from above.*

Observe :—

1. The *medullary groove* between the two *medullary folds*, whose hind ends diverge to enclose between them the end of the *primitive groove*.
2. The *head-fold* at the end of the medullary groove.
3. The one or two pairs of *mesoblastic somites* flanking the medullary groove.
4. The *notochord* as an opaque streak along the floor of the medullary groove.

E. *Surface view transparent, from below.*

Same points to be seen as from above, but less clearly.

F. *Embryo as an opaque object.*

As an opaque object, whether the embryo is hardened *in situ* or after being removed from the yolk, the same points are to be seen as when it is viewed as a transparent object, with the exception of the notochord and mesoblastic somites (*vide* D). The various grooves and folds are however seen with far greater clearness.

G. *Sections.*

Two methods of hardening may be employed ; (1) with the embryo *in situ*, (2) after it has been removed.

To harden the blastoderm *in situ* the yolk must be hardened as a whole. After opening the egg either leave the yolk in the egg-shell or pour it out into a Berlin capsule ; in any case freeing it as much as possible from the white, and taking especial care to remove the more adherent layer of white which immediately surrounds the yolk.

Place it in picric acid or a weak solution of chromic acid (first of .1 p.c. and then of .5 p.c.) with the blastoderm uppermost and leave it in that position for two or three days.

Care must be taken that the yolk does not roll about ; the blastoderm must not be allowed to alter its position : otherwise it may be hard to find it when everything has become opaque. If at the end of the *second* day the blastoderm is not sufficiently hard, the strength of the solution, if chromic acid be used, should be increased and the specimen left in it for another day.

After it has become hardened by the acid, the yolk should be washed with water and treated suc-

cessively with weak and strong spirit, *vide* I. B. After it has been in the strong spirit (90 p.c.) for two days, the vitelline membrane may be safely peeled off and the blastoderm and embryo will be found *in situ*. The portion of the yolk containing them must then be sliced off with a sharp razor, and placed in absolute alcohol.

The staining, &c. may be effected in the ordinary way.

If osmic acid, which we believe will be found serviceable for these early stages, is employed, it will be necessary to remove the blastoderm from the yolk before treating it with the reagent.

The following transverse sections are the most important at this stage :

1. Through the medullary groove, shewing
 - a. The *medullary folds* with the thickened mesoblast.
 - b. The *notochord* under the medullary groove.
 - c. The commencing *cleavage of the mesoblast*.
2. Through the region where the medullary folds diverge, to enclose the end of the primitive groove, shewing the greatly increased width of the medullary groove, but otherwise no real alteration in the arrangement of the parts.
3. Through the front end of the primitive groove with the so-called axis cord underneath it, while on each side of it are still to be seen the medullary folds.
4. Through the primitive groove behind this point, shewing the typical characters of the primitive groove.

VII. Examination of an unincubated Blastoderm.

A. *Opening the egg.* Vide II. A.

B. *Examination of the blastoderm in situ.*

Observe the central white spot and the peripheral more transparent portion of the blastoderm and the halones around it.

C. *Removal of the blastoderm.* Vide VI. C.

With the unincubated blastoderm still greater care is required in removal than with the 20 hours' blastoderm, and there is no special advantage in doing so unless it is intended to harden it with osmic acid.

D. *Surface view transparent from above.*

Observe the absence of the central opacity.

E. *Surface view transparent from underneath.*

Nothing further to be observed than from above.

F. *As an opaque object.*

There is nothing to be learnt from this.

G. *Sections.*

Manipulation as in VI. G.

The sections shew

a. The distinct *epiblast*.

b. The *lower layer* cells not as yet differentiated into *mesoblast* and *hypoblast*.

c. The thickened edge of the blastoderm.

d. The *segmentation cavity* and *formative cells*.

VIII. Examination of the process of Segmentation.

To observe the process of segmentation it will be found necessary to kill a number of hens which are laying regularly. The best hens lay once every 24 hours, and by observing the time they usually lay (and they generally lay pretty regularly about the same time), a fair guess may be made beforehand as to the time the egg has been in the oviduct. By this means a series of eggs at the various stages of segmentation may usually be obtained without a great unnecessary sacrifice of hens. For making sections, the yolk must in all cases be hardened as a whole, which may be done as recommended in VI. G. Chromic acid is an excellent reagent for this and it will be found very easy to make good sections.

In the sections especial attention should be paid,

1. To the first appearance of nuclei in the segments, and their character.
2. To the appearance of the horizontal furrows.
3. As to whether new segments continue to be formed outside the limits of the germinal disc, or whether the fresh segmentation merely concerns the already formed segments.
4. In the later stages, to the smaller central and larger peripheral segments, both containing nuclei.

For surface views, the germinal disc, either fresh or after it has been hardened, can be used. In both cases it should be examined by a strong reflected light. The chief point to be noticed is the more rapid segmentation of the central than of the peripheral spheres.

IX. Examination of the later changes of the Embryo.

For the later stages, and especially for the development of the skull and the vascular system of the body of the chick, it will be found necessary to dissect the embryo. This can be done either with the fresh embryo or more advantageously with embryos which have been preserved in spirit.

If the embryos are placed while still living into spirit a natural injection may be obtained. And such an injection is the best for following out the arrangement of the blood-vessels.

Sections of course will be available for study, especially when combined with dissections.

X. Study of the development of the Blood-vessels.

Observations on this subject must be made with blastoderms of between 30—40 hours. These are to be removed from the egg, in the usual way (*vide* II. A. and C.), spread out over a glass slip and examined from below, *vide* II. E.

The blastoderm when under examination must be protected by a coverslip with the usual precautions against pressure and evaporation, and a hot stage must also be employed.

Fresh objects so prepared require to be examined with a considerable magnifying power (400 to 800 diameters). From a series of specimens between 30 and 40 hours old all the points we have mentioned in Chapter IV. p. 92, can without much difficulty be observed.

Especial attention should be paid in the earlier specimens to the masses of nuclei enveloped in protoplasm and connected with each other by proto-

plasmic processes; and in the later stages to the breaking up of these masses into blood corpuscles and the conversion of the protoplasmic processes into capillaries, with cellular walls.

Blastoderms treated in the following ways may be used to corroborate the observations made on the fresh ones.

With gold chloride.

Immerse the blastoderm in gold chloride (.5 p.c.) for one minute and then wash with distilled water and mount in glycerine and examine.

By this method of preparation, the nuclei and protoplasmic processes are rendered more distinct, without the whole being rendered too opaque for observation.

The blastoderm after the application of the gold chloride should become a pale straw colour; if it becomes in the least purple, the reagent has been applied for too long a time.

With potassium bichromate.

Immerse in a 1 p.c. solution for one day and then mount in glycerine.

With osmic acid.

Immerse in a .5 p.c. solution for half an hour and then in absolute alcohol for a day, and finally mount in glycerine.

PRACTICAL DIRECTIONS FOR OBTAINING AND STUDYING
MAMMALIAN EMBRYOS.

XI. **Animals and breeding.**

For class work the Rabbit is the most convenient animal from which to obtain embryos, it will breed

freely in the early spring months of the year and will give ample opportunity for the student to observe the exact time when the female is covered. A number of does should be kept together in a large pen, and two or three bucks in separate small cages also placed within the pen ; at the period of heat, the doe should be temporarily placed with the buck and the exact time of copulation noted, the age of the embryo being calculated from that hour.

XII. Examination of segmenting ova.

It will be well to mention here that although a doe may have been satisfactorily covered, embryos are not always obtained from her. A superficial examination of the ovaries will determine whether or no fertilized ova are present. If ova have been recently dehisced from the ovary, the Graafian follicles from which they were discharged will be found to be of a distinctly red colour. In case no such 'corpora lutea' as they are called are present further search is useless.

A. *To obtain ova from 1 to 60 hours old.*

Cut open the abdomen from pubis to sternum, and from the pubis round the thigh of each side, and turn back the flaps of the body wall so formed. Remove the viscera and observe below (dorsal) the single median vagina, from the anterior end of which the uterine horns diverge.

Observe at the anterior end of each uterine horn a small much coiled tube, the oviduct (Fallopian tube) near the anterior end of which a little below the kidney lies the ovary. Cut out the uterus and oviduct together and lay them in a small dissecting

dish. Carefully stretch out the oviduct by cutting the tissue which binds it, and separating it from the uterus, taking care to obtain its whole length, lay it upon a glass slide.

With the aid of a lens it is frequently possible to distinguish the ovum or ova, through the wall of the oviduct. In this case cut a transverse slit into the lumen of the duct with a fine pair of scissors a little to one side of an ovum; press with a needle upon the oviduct on the other side of the ovum, which will glide out through the slit, and can be with ease transported upon the point of a small scalpel, or what is better spear-headed needle. In case the ovum cannot be distinguished in the oviduct by superficial observation, the latter must be slit up with a fine pair of scissors, when it will easily be seen with the aid of an ordinary dissecting lens.

B. *Treatment of the ovum.*

The ovum may be examined fresh in salt solution, it is however more instructive when preserved and stained in the following manner.

- a. Immerse it in a $\frac{1}{5}$ p.c. solution of osmic acid for 5 or even 10 minutes, transfer it thence to the picrocarmine solution described above (I). After staining the ovum should then be washed in distilled water and placed in a weak solution of glycerine in a watch-glass—half glycerine, half water. It should be allowed to remain thus under a bell jar for several days (7 to 14 or longer) in a warm room until the water has evaporated. By this means shrinkage and distortion are avoided, the glycerine becoming

very gradually more and more dense. It should be mounted in glycerine in which 1 p.c. formic acid has been mixed to prevent fungoid growths. Care must be taken that there is no pressure upon the ovum this being insured by the insertion of a couple of slips of paper one on each side of the ovum under the cover glass.

- b. Another method of preservation is used, but does not appear to us so successful as the one already described. It consists of an immersion of the ovum for 5 minutes in $\frac{1}{5}$ to $\frac{1}{2}$ p.c. osmic acid, subsequent treatment with Müller's fluid for two or three days, and finally mounting in glycerine.

C. *Examination of the ovum.*

The most instructive stages to observe are ova of

- a. 18 hours old, when four segmentation spheres will be observed.
- b. 36 hours old when the segmentation is more advanced and the spheres numerous.

The chief points to be noted are :—

1. The number and size of the segmentation spheres ; in each of which, when treated as described in B. a., a large deeply stained nucleus will be visible. The spheres themselves are also stained slightly.
2. The presence of one or two polar bodies on the outer side of the segments in ova of not more than 48 hours old: these also are slightly stained.
3. The zona radiata immediately surrounding the segments, and
4. The thick albuminous coat, marked with concentric rings.

D. *The fully segmented ovum. 70 hours old.*

The fully segmented ovum is found in the uterus at its anterior end close to the place where the oviduct opens into the uterus.

To obtain this stage the uterus must be slit open and examined carefully with a dissecting lens: the ovum will be seen as a somewhat opaque spot on the glistening moist mucous epithelium of the uterus.

It may be treated in the manner described under B. *a.*, but the segments being closely pressed together their outlines are not rendered distinct by this method. A more advantageous mode of treatment is the following: wash the ovum rapidly in distilled water, and place it in a 1 p.c. solution of silver nitrate for about 3 minutes: then expose it to the light in a dish of distilled water until it be tinged a brown colour.

The brown colour is due to the reduction of the silver, which takes place chiefly in the cement substance between the cells and thus defines very exactly their size and shape. The ovum may now be treated with glycerine and mounted as described in B.

The points to be observed are :—

1. The division of the segmentation spheres into the layers—an outer layer of cubical hyaline cells, and an inner of rounded granular cells.
2. The blastopore of van Beneden.
3. The presence of a thin layer of mucous outside the concentrically ringed albuminous coat of the ovum.

XIII. Examination of the blastodermic vesicle, 72—90 hours.

- A. *To obtain the embryo see XII. D.*
- B. *Prepare the ovum either as in XII. B. or D.
or in picric acid see I. B. 1.*
- C. *Surface view, or in section see I. B. 3.*

Observe :—

1. The great increase in size of the ovum and the reduction in the thickness of the membranes.
2. The flattened layer of outer cells enclosing a cavity.
3. The rounded cells of the inner mass attached as a lens-shaped mass to one side of the vesicle.

XIV. Examination of a blastodermic vesicle of 7 days, in which the embryonic area and primitive streak are present.

- A. *To obtain the embryo.*

On opening the body cavity the uterus will be found to be uniformly swollen and very vascular.

Remove the uterus and open it carefully with fine scissors along the free, non-mesometric edge, taking care to keep the point of the scissors within the uterus close against its wall.

Observe

1. The oval thin-walled vesicles lying at intervals on the walls of the uterus.
2. The presence of the pyriform embryonic area, at the posterior end of which is seen the primitive streak.

3. The commencement of the area vasculosa around the hind end of the area. This is seen better after treatment with picric acid.

B. *Treatment and Examination of the embryo.*

- a. Preserve the vesicle in picric see I. B. 1. Stain in haematoxylin, cut out the embryonic area, leaving a considerable margin, imbed and cut into sections.
- b. In transverse sections observe :—
 1. At the anterior end of the area the single row of columnar epiblast and the single row of flattened hypoblast cells.
 2. Immediately in front of the primitive streak between these two layers a few irregularly shaped mesoblast cells.
 3. Through the middle of the primitive streak,
 - a. Several layers of rounded mesoblast cells attached to, and continuous with, the epiblast in the middle line, and stretching out laterally beyond the edge of the area.
 - b. A single layer of flattened hypoblast.
 4. The epiblast outside the embryonic area in the form of flattened cells and, except in the region around the primitive streak, overlying a layer of flattened hypoblast.

XV. **Examination of an eight days' embryo.**

A. *To obtain the embryo.*

The uterus will be found here and there to be swollen. In these swellings the embryos lie; and

owing to the fact that the wall of the embryonic vesicle is exceedingly thin, and attached to the uterine wall, they are very difficult to obtain whole.

Cut the uterus transversely on each side of the swellings and pin the pieces so obtained slightly stretched out in small dissecting dishes. Cover the tissue with picric acid solution and allow it to remain untouched for an hour. Then with two pairs of fine pointed forceps carefully tear the uterus longitudinally, slightly to one side of the median line of the free side. This operation will necessarily take some time, for but a small portion should be done at once, the picric acid being allowed time to penetrate into that part of the uterus which has been most recently torn open.

With care, however, the student will be able to open completely the swelling and will observe within the thin walled vesicle. Great care must also be exercised in freeing the vesicle from the uterus.

This dissection should be performed with the aid of a dissecting lens. In case the embryonic vesicle is burst it will still be possible to extract the embryonic area which lies on the mesometric side of the uterus; the area itself is not attached to the uterine walls.

B. *Examination of surface view.*

Observe:

1. The increased size of the embryonic area.
2. In the anterior region the medullary folds; diverging behind and enclosing between them,
3. The primitive streak.
4. The area opaca now completely surrounding the embryo.

C. *Examination of sections.*

Prepare and cut into transverse sections as advised in XIV. B.

Notice

1. In the sections of the anterior region,
 - a. The lateral epiblast composed of several layers of columnar cells.
 - b. The epiblast in the median line one layer thick and in the form of a groove (medullary groove).
 - c. The lateral plates of mesoblast.
 - d. The flattened lateral hypoblast, and columnar hypoblast underlying medullary groove (notochord).
2. In sections through the anterior end of the primitive streak.
Note the continuation of the epiblast, mesoblast and hypoblast in the middle line.
3. In sections through the posterior end of the area the same points to be seen as in XIV. B. b. 3.

XVI. **Examination of an embryo about 8 days 12 hours.**

A. *Manipulation as in XV. A.*

B. In surface view observe (cf. Fig. 106) :

1. Area pellucida surrounding embryo, outside which is the well marked area vasculosa.
2. Widely open neural canal, at anterior end dilated, and partially divided into the three primary vesicles of the brain : note the optic vesicles. At the posterior end, the sinus rhomboidalis.
3. The mesoblastic somites, 4 to 8.

4. The two lateral tubes of the heart, and the commencement of the two vitelline veins.
5. The rudiment of the primitive streak.
6. The commencing head and tail folds.
7. The commencing folds of the amnion.
Compare Fig. 106.

XVII. Examination of the foetal membranes of an embryo of 14 days.

A. *To obtain the embryo, with its membranes.*

Manipulate as in XV. A. only dissect under salt solution instead of picric acid.

B. *Observe before removing the embryo from the uterus ;*

1. The attachment of the vesicle to the mesometric side of the uterus over a discoidal area, the placental area.
2. The position and form of the placenta.

C. *Remove the embryo with its membranes intact,* and observe :

1. the vascular yolk sac, extending completely round the chorion with the exception of a comparatively small area where
2. the allantois is situated. The vascularity of the allantois. The foetal villi projecting into the maternal placental tissue.

D. *Separate the membranes from one another without tearing them,*

and notice :

1. The embryo surrounded by the amnion.
2. The allantois ; its position dorsal to the embryo ; its attachment to the chorion ; its circulation.
3. The flattened yolk sac, ventral to the embryo ; its long stalk ; its circulation.
4. The heart.

E. *The embryo in surface view.*

The points to be observed are

1. The cranial and body flexure, the spiral curvature of the hinder portion of the body.
2. The vesicles of the brain : cerebral hemispheres, fore-brain, mid-brain and hind-brain.
3. The eye, and the ear.
4. The heart.
5. The visceral arches and clefts.
6. The fore and hind limbs, and the tail.

NOTE A.

Since writing the account of section-cutting on p. 434, we have obtained more experience as to the practical working of Messrs. Caldwell and Threlfall's microtome there mentioned. We find that it cuts more accurately and better than any other microtome with which we are acquainted, and can confidently recommend it to investigators and teachers with large classes. In the Cambridge Laboratory, it is driven by a small water engine and will cut at a rate of 500 a minute, without detriment to the sections.

NOTE B.

Mr Threlfall, of Caius College, has recently elaborated a method of mounting sections which in our opinion has many important advantages over the shellac method. It is as follows. Make a solution of pure india-rubber in benzine or chloroform. Spread a thin film of this on a clean glass slide, and allow it to dry. Arrange the sections on the film; melt the paraffin; allow the slide to cool, then immerse the slide for a moment in benzoline (liquid paraffin), which dissolves the paraffin, and mount in balsam. The chief advantages of this method are that the sections do not adhere to the india-rubber until warmed, and they can be stained after they are fixed on the slide if necessary. For the latter purpose, wash the benzoline away with absolute alcohol; treat with weaker alcohol; stain; return to absolute; clear with oil of cloves or kreasote, and mount in balsam (vide *Zoologischer Anzeiger*, 1883).

INDEX.

A

- Abdominal wall of chick, 281
 Air-chamber, 3
 Albumen: composition of, 3;
 arrangement of, in hen's egg,
 3; formation of, in hen, 16;
 fate of, in hen's egg, 109; of
 incubated egg, 185
 Alimentary canal of chick, 28—33,
 39; of third day and append-
 ages of, 171—185; mammalia,
 417—421
 Alisphenoid region of chick, 240,
 246
 Allantoic arteries: of chick, 225,
 293, 298; in mammals, 348,
 410—413
 Allantoic veins of chick, 228, 287,
 290; of mammals, 342
 Allantoic stalk, 351
 Allantois: of chick, 28—33, 46
 —47, 107, 182—185, 277, 280;
 as a means of respiration, 232;
 pulsation of, 277; of rabbit, for-
 mation of, 331, 353; of human
 embryo, 336—340, 355—358;
 of mammalia, structure of, 348;
 of marsupials, 352; of dog, 358
 Alum carmine, to make and use,
 431
 Amnion: of chick, 28—33, 43—46,
 63, 107, 195; of third day, 113,
 276—280; pulsation of, 277,
 278; false, of chick, 46; of
 rabbit, 330, 353; of human
 embryo, 338—340; of mam-
 malia, 343; structure of mam-
 malian, 346; of dog, 358
 Amphioxus, spinal cord of, 254
 Annuli fibrosi of birds, 210
 Anterior commissure of cerebral
 hemisphere, mammalia, 381
 Aorta of chick, 224, 292, 298;
 of mammals, 407
 Aortæ of chick of second day,
 89, 103
 Aortic arches of chick, 103, 106,
 167; of fourth day, 225, 291—
 298
 Apes' placenta, 355; histology of,
 363; derivation of, 364
 Aqueductus vestibuli of chick,
 158
 Aqueductus sylvii (*see iter.*)
 Aqueous humour: of chick, 153—
 154; of mammalia, 390
 Arbor vitæ of birds, 369
 Area opaca of chick, 7, 49, 195;
 mesoblast of, 65; hypoblast of,
 65; vascular portion of, 74—75,
 110; of third day, 109
 Area pellucida: of chick, 8, 49, 55;
 of third day, 110; of mammals,
 328
 Area vasculosa: of mammalia,
 formation of, 342; circulation
 of, 343—346
 Arteria centralis retinæ of mam-
 malia, 387—390
 Arterial system: of chick, 224—
 226, 291—303; mammalia, 407
 —409
 Arterial arches, mammalia, 407

Articulare of chick, 244
 Attachment of ovum in uterus, 347
 Auditory capsule of chick, 241
 Auditory pits of chick, 81, 101
 Auricles of chick, 84, 102, 229, 259, 262
 Auricular: appendages of chick of second day, 102; septum of chick, 257
 Avian characteristics, 275
 Azygos vein, mammalia, 412

B

Basi-hyal chick, 245
 Basilar: plate, 235—238; membrane, mammalia, 397
 Basi-occipital region of chick, 237
 Basi-sphenoid of chick, 240, 246
 Basi-temporal bone, chick, 246
 Beak of chick, 249; formation of, 282
 Biliary ducts of chick, 180—181
 Birds, oviparous, 308
 Bladder: derivation of, in mammals, 351; mammalian, 417
 Blastoderm of chick, 4; structure of, in unincubated hen's egg, 7—10; area pellucida of, 8; formative cells of, 23, 24; extension of, 26, 27; lateral folds of, 37; head fold of, 27, 37; tail fold of, 29, 37; vascular area of, 27; hypoblast of, 51; germinal wall of, 52; epiblast, 55; of third day, 109, 110
 Blastoderm of mammal, formation of layers of, 314—325; vascular area of, 326; pellucid area of, 328; head and tail folds, 329
 Blastodermic vesicle, 314—316, 319; outer layer of, 314; inner mass of, 314; to examine, 465
 Blastopore of mammalian ovum (van Beneden's), 314; of chick and mammals, see neurenteric canal

Blood islands of vascular area of chick, 91
 Blood corpuscles of chick, formation of, 92—94
 Blood-vessels: of area opaca of chick, formation of, 92—94; development of, practical directions for study of, 459, 460
 Body cavity: of chick, 39; formation of, 40, 41; posterior mediastinum of, 267; of mammalia, 406
 Body flexure of chick, 196; on third day, 116
 Body flexure: in rabbit, 334; in dog, 334; of human embryo, 239—240
 Borax carmine, to make and use, 430
 Brain: of chick, 117—123, 281; of mammalia, 367—387; divisions of, 367; hind brain, 367—370; mid brain, 370, 371; fore brain, 371—385; histogeny of, 385—387
 Branchial clefts and arches (*see* Visceral)
 Breeding mammals for study, 460
 Bronchi, mammalian, 418
 Bronchial tubes of chick, 177
 Bulbus arteriosus of chick, 84, 225, 229, 257; septum of, 257, 259, 260—262; of mammalia, 407

C

Cæcum, mammalia, 419
 Canales Botalli (*see* Ductus Botalli)
 Canalis auricularis of chick, 257, 259
 Canalis reuniens, 160; auricularis of chick, 169, 229; reuniens of ear of mammalia, 393—398
 Cardinal veins: of chick, 170; 284—285; anterior and posterior of mammalia, 409—413
 Carmine, 431
 Carnivora, placenta of, 358

- Carotid: common artery of chick, 295, 298; external and internal artery, 292, 295; of bird and mammal, 408
- Carpus of chick, 234
- Cartilage bones, 242; of skull of chick, 246
- Cerato-hyals of chick, 245
- Cerebellum: of chick, 122, 203, 368—370; of mammalia, 367—370; ventricle of, 368; choroid plexus of, 368; pyramids, and olivary bodies of, 368; arbor vitæ, flocculi of, 369; pons varolii of, 369, 370; velum medullæ ant. 370
- Cerebral hemispheres: of chick, 117; of mammalia, 376—385; ventricles of, 377; lamina terminalis, 377; corpus striatum, 378; commissures of, 381—383; septum lucidum, 383; fissures of, 384—385
- Cerebral vesicles of chick, 200; of second day, 79, 100
- Cerebro-spinal canal in chick, 40
- Cerebrum of mammalia, monotremata, insectivora, 384
- Chalazæ, 4
- Cheiroptera, placenta of, 353
- Chest wall, of chick, 281
- Chorion: of hen's egg, 47; of mammal, true and false, 348; of rabbit, true and false, 353; of human ovum, 355—358; of dog, 358
- Chorion læve, 356—358
- Chorion frondosum, 356—358
- Chorionic villi of mammal, 349
- Choroid coat of eye, of chick, 141
- Choroid plexuses of mammalia, 368, 380
- Choroidal fissure of chick, 136—141, 147—149; of mammalia, 387
- Chromic acid, 427—428
- Cicatricula, 4
- Ciliary: ganglion of chick, 128; ridges of chick, 142; muscles, 144
- Circulation: in chick of second day, 105; of third day, 110—113; of chick, later stages, 263—264
- Circulatory system of chick, résumé, 298—303
- Clavicle: man, 405; of chick, 234
- Clinoid ridge, posterior, chick, 240
- Clitoris, mammalia, 417
- Cloaca of chick, 174; mammalia, 418
- Cochlea of chick, 203
- Cochlear canal, mammalia, 390—398
- Cock, coni-vasculosi, parepididymis and vas deferens of, 224
- Columella of chick, 166, 245
- Commissures of spinal cord, 253, 256
- Coni-vasculosi of cock, 224
- Cornea of chick, 150—153; of mammalia, 390
- Cornu ammonis, (*see* Hippoc. major)
- Coracoid of chick, 234
- Coronary vein, mammalia, 409—413
- Corpora bigemina of chick, 121
- Corpora mammillaria, 378
- Corpora quadrigemina of mammalia, 370; geniculata, 371
- Corpus albicans, 373
- Corpus callosum: mammalia, 381; rostrum of, 383; of marsupials, 383; of monotremes, 383
- Corpus luteum, 311
- Corpus striatum, mammalia, 378
- Corrosive sublimate, how to use, 426
- Cotyledonary placenta, derivation of, 364
- Cotyledons, 359
- Cranial flexure: of chick, 116, 196; of second day, 101; of rabbit, 333; of human embryo, 338
- Cranial nerves: of chick, 123—129, 203; of second day, 101; development of, 127—129; of mammalia, 400
- Cranium of chick, 235—242;

cartilaginous, 242; cartilage bones of, 242; membrane bones of, 242

Cranium, mammalia, 401

Crura cerebri, 371

Crypts of placenta, 360—363

Cumulus proligerus, 310

Cupola, 397, 398

D

Decidua: of human placenta, 356; reflexa in human, 356—358; vera, 356—358; serotina, 356—358; reflexa in dog, 359

Deciduate placenta, 352; histology of, 360

Dentary bones, 246

Dentine, mammalia, 421

DESCMET'S membrane, chick, 151

Diaphragm, muscles of, 211; mammalia, 406

Diffuse placenta, 359; histology of, 360

Discoidal placenta, 353

Dog, placenta of, relation with placenta of rabbit, 358

Dorsal aorta of chick, 167

Ductus arteriosus, man, 408

Ductus cochlearis of chick, 159

Ductus Botalli of chick, 287, 289, 296; of mammalia, 408

Ductus Cuvieri of chick, 170, 228, 284

Ductus venosus of chick, 169, 226; of mammalia, 413

Duodenum of chick, 172—174

E

Ear: of chick, 156—161; of mammalia, 390—397; accessory structures of, 397—399

Egg tubes of Pflüger, 222

Egg membranes of mammal, 310

Egg, to open, 437, 438

Elephas, placenta of, 358

Embryo of chick: directions for examining, 439—459; of 36—48 hours, 437—444; of 48 to 50 hours, 444—447; of third

day, 447—451; of fourth day, 451—453; of 20 hours, 453—456; before incubation, 457; segmentation, 458; blood-vessels of, 459

Embryo of mammals: directions for examination of, 461—470; of segmenting ova, 1—72 hours, 461—464; of blastodermic vesicle of, 72—90 hours, 465; of 7 days, 465; of 8 days, 466; of 8 days 12 hours, 468; of 14 days, 469; of foetal membranes, 469

Embryonic area of rabbit, 317; composition of, 317

Embryonic membranes: in mammalia, ideal type, 342—352; yolk sac of, 345—351; amnion of, 345—351; allantois of, 345—351; zona radiata of, 345; serous membrane of, 345; chorion of, 345; shedding of, at birth, 351; monotremata, 352; marsupialia, 352; rodentia, 353, 354; insectivora, 353; chiroptera, 353; man and apes, 355—358; carnivora, 358; hyrax, 358; elephas, 358; orycteropus, 358, horse, 359; pig, 359; lemurs, 359

Embryonic sac in chick, 37—38

Embryonic shield of chick, 49, 52—54

Enamel, 421

Endolymph, mammalia, 396

Epiblast: formation of, in chick, 25, 26; derivation of, 26; of rabbit embryo, 316; histological differentiation of, in chick, 271; epidermis, 271; nervous system, 271; sense organs, 272; mouth, 272; anus, 272; pituitary body, 272; salivary glands, 273; of blastoderm from 8th to 12th hour, 55

Epididymis, mammalia, 415

Epitotic of chick, 246

Epithelioid lining of heart of chick, 88

Epithelium of throat of chick, 182

Epoophoron, of hen, 224
 Ethmoid: region, chick, 240;
 lateral, 241; bone, chick, 246
 Eustachian tube: of chick, 165;
 of rabbit, 334; of mammalia,
 397—418
 Eustachian valve: of heart of
 chick, 263—4
 External auditory meatus of mam-
 malia, 398
 External carotid artery, chick, 225
 Eye; of chick, 200; development
 of, 132—155; of mammalia,
 387—390
 Eyelids, of chick, 155; of mam-
 malia, 390

F

Face of chick, 246; of human
 embryo, 340
 Facial nerve (*see* Seventh)
 Falciform ligament, mammalia,
 420
 Fallopian tubes, mammalia, 415
 False amnion of chick, 46
 Falx cerebri mammalia, 377
 Fasciculi teretes, 368
 Feathers, formation of, 282
 Female pronucleus, 17
 Femur, chick, 234
 Fenestra ovalis, of chick, 166, 245;
 mammalia, 398
 Fenestra rotunda of chick, 166,
 245; mammalia, 398
 Fibula, chick, 234
 Fifth nerve of chick, 126—129,
 203
 Fifth ventricle of man, 383
 First cerebral vesicle of chick,
 second day, 97
 Fissures of spinal cord, 254
 Flocculi of cerebellum of birds, 369
 Foetal appendages: of chick, 276—
 280; amnion, 276—278; allan-
 tois, 277; yolk-sac, 277; mem-
 branes of mammal, to examine,
 469
 Folding-off of embryo chick, 113,
 196
 Follicle, ovarian, 12—15

Foramen ovale: of heart of chick,
 262, 264, 289, 297, 302
 Foramen of MONRO, 372
 Forebrain: of chick, 100; of rab-
 bit, 329; of mammalia, 371—
 385; optic vesicles of, 387—390;
 thalamencephalon, 371—376;
 cerebral hemispheres, 376—
 385; olfactory lobes, 385
 Foregut of chick, formation of,
 81—82
 Formation of the layers in mam-
 mals, 314—325
 Formative cells, 23—24
 Fornix, mammalia, 381; pillars
 of, 383
 Fourth ventricle, chick, 122;
 mammalia, 368
 Fourth nerve, chick, 128
 Fretum Halleri, chick, 229
 Frontal bones, chick, 246
 Fronto nasal process, chick, 165,
 202, 246

G

Gall-bladder of chick, 181
 Gasserian ganglion, chick, 128
 Generative glands: of chick, 220—
 224; of mammalia, 414—415
 Generative organs, external, mam-
 malia, 415—417
 Genital cord, mammalia, 415
 Genital ridge, chick, 220
 Germ cells, primitive, of chick,
 221
 Germinal disc of chick, 12
 Germinal epithelium, 213
 Germinal layers of chick, 26
 Germinal vesicle of chick, 12
 Germinal wall, 52; structure of,
 65—66; function of, 66
 Glomeruli of kidney of chick,
 214
 Glands, epidermic, of mammalia,
 366
 Glomerulus of Wolffian body of
 chick, 191
 Glossopharyngeal nerve (*see* Ninth
 nerve)
 Gold chloride, 460

Graafian follicle, chick, 222, 310
 Grey matter, of spinal cord of chick, 253; of brain of mammalia, 387
 Growth of embryo of chick, 70
 Guinea-pig, structure of blastoderm of, 323; relation of embryonic layers of, 323; inversion of the layers in, 341

H

- Hæmatoxylin, to make and use, 429
 Hairs, 365
 Hardening reagents, 425—428; picric acid, 425; corrosive sublimate, 426; osmic acid; 427; chromic acid, 427; absolute alcohol, 428; the necessity of, 428
 Head of chick, 200; of rabbit, 331
 Headfold of chick, 27—29, 33—37; 16 to 20 hours, 60; 20 to 24 hours, 66; of second day, 77; of mammal, 329
 Heart of chick, 229—230, 256—264; formation of, 82—89, 102; beating of, on second day, 89; of third day, 167; auricles, 259—262; ventricles, 260—262; auricular septum, 257—262; ventricular septum, 257; canalis reuniens, 257—259; bulbus arteriosus, 257—262; foramen ovale, 262—264; Eustachian valve, 263—264; circulation in, 263—264; structure of, 287—289, 293—297; résumé of, 299—303
 Heart of mammals, 329; structure of, 331; formation of, 406; comparison of, with birds, 407
 Hemiazzygos vein, mammalia, 412
 Hen: formation of albumen in, 16; ovarian follicle of, 12—15; mesovarium of, 11; ovary of, 11; ovarian ovum of, 11, 15; oviduct of, 15; epooophoron, paroophoron and oviduct, 224
 Hen's egg, albumen of, 3, 16; blastoderm, 7—10, 26, 27; chalazæ, 4; cicatricula, 4; impregnation of, 17; laying of, 17; polar bodies of, 17; segmentation of, 18—24; vitelline membrane of, 4, 13—15; yolk of, 4—7; chorion of, 47; shell of, 1, 16; irregular development of, 48, 49; segmentation, cavity of, 50
 Hepatic cylinders of chick, 179; circulation of chick, 227; veins, 288—290
 Hind brain: of chick, 100; of rabbit, 329; of mammals, and birds, 367—370; medulla of, 367; cerebellum of, 367—370
 Hippo-campus major, mammalia, 380
 Hippo-campal fissure of cerebrum of mammalia, 385
 Histological differentiation, in chick, 269—273; of epiblast, 269, 271; of hypoblast, 269; of mesoblast, 269
 Histology of placenta, 359
 Holoblastic segmentation, 307
 Human embryo: villi of, 335; early stages of, 335; allantois of, 336—340; yolk-sac of, 336—340; medullary plate of, 337; amnion of, 338—340; cranial flexure of, 338—340; limbs of, 339; body flexure of, 339—340; face of, 340; relation of, with other mammals, 341; placenta of, 355
 Human ovum, size of, 307
 Human placenta, histology of, 363; derivation of, 364
 Humerus, chick, 234
 Hyaloid membrane, chick, 144, 146
 Hyoid arch of chick, 243—245; of rabbit, 334; of mammalia, 403—404
 Hyoid bone of chick, 245
 Hypoblast of chick: formation of, 25, 51, 59; derivation of, 26; of area opaca, 65; histological

differentiation of, 269; of digestive canal, 272; of respiratory ducts, 272; of allantois, 273; notochordal, 273
 Hypoblast of rabbit embryo, 316, 321, 417
 Hypoblastic mesoblast of chick, 59—62; of mammal, 321
 Hypogastric veins: chick, 289; mammalia, 411—413
 Hypohyal, mammalia, 403
 Hypophysis cerebri (*see* Pituitary body)
 Hyrax, placenta of, 358

I

Ileum, chick, 234
 Iliac veins, mammalia, 411—413
 Imbedding, methods of, 432—434
 Impregnation of hen's egg, 17; of ovum of mammal, 310—312
 Incubators, makers of, and how to manage, 423
 Incus, mammalia, 398, 404
 Inferior cardinal veins, chick, 228
 Infundibulum: chick, 119—121; ventricle of, 373; tubercinereum of, 373; of mammalia, 372; of birds, 372
 Inner mass of segmented ovum, 314; of blastodermic vesicle, 314
 Innominate artery of chick, 296—8
 Insectivora, placenta of, 353
 Intercostal veins, mammalia, 411—413
 Interhyal ligament, 403
 Intermediate cell mass of chick, 95, 189, 190
 Internal carotid artery, chick, 225
 Inter-nasal plate, chick, 240
 Inter-orbital plate of chick, 240
 Intervertebral ligaments, mammalia, 400
 Intervertebral regions, chick, 207, 209
 Intestine, mammalia, 419
 Inversion of the layers, 341

Ischium, chick, 234
 Island of Reil, 385
 Iter a tertio ad quartum ventriculum, 121, 370

J

Jugal bones, chick, 246
 Jugular vein, 284—290

K

Kidney: of chick, 218—220; tubules of, 219; of mammalia, 414

L

Labia majora, mammalia, 416
 Lacrymal bones, chick, 246; ducts, chick, 155, 156; glands, chick, 155, 156; groove, chick, 248; duct, mammalia, 390
 Lagna, chick, 159; birds, 397, 398
 Lamina, dorsalis of chick, 29, 62
 Lamina spiralis, mammalia, 397
 Lamina terminalis, mammalia, 377
 Large intestine of chick, 174
 Larynx of chick, 177
 Lateral folds of blastoderm of chick, 37; of chick of second day, 96
 Lateral plates of mesoblast, 68
 Lateral ventricles of chick, 117; of mammalia, 377; cornua of, 378
 Laying of eggs, 17
 Lecithin, 6
 Legs of chick, 200
 Lens, chick, formation of, 134, 149
 Ligamenta suspensoria, of birds, 210
 Ligamentum, pectinatum, 144; vesicæ medium, 351
 Ligamentum longitudinale anterius and posterius, mammalia, 402

Limbs, of chick, 198—200, 233;
of rabbit, 334; of human em-
bryo, 339; mammalia, 406
Liver of chick, 178—181; mam-
malia, 419
Lumbar veins, mammalia, 412—
413
Lungs of chick, 176—178, 267;
mammalia, 418

M

Male pronucleus, 17
Malleus, 398, 404
Malpighian corpuscles, chick, 182;
bodies of chick, 190
Mammalia, two periods of develop-
ment, 308; viviparous, 308
Mammary glands, 366; a source
of nutriment for the embryo,
308
Man (*see* Human embryo)
Mandible, chick, 246
Mandibular arch, chick, 242—
244; maxillary process of,
chick, 243; rabbit, 334; mam-
malia, 403—404
Manubrium of malleus, 403
Marsupialia, foetal membranes of,
352
Marsupium, 308
Maturation of ovum of mammal,
310
Maxilla bones, chick, 246
Maxilla-palatine bones, chick, 246
Maxillary, processes of mandibu-
lar arch of chick, 243
Meatus auditorius externus, of
chick, 166; of mammal, 397
Meatus venosus, of chick, 169,
287
Meckelian cartilage, chick, 244;
mammalia, 403
Medulla oblongata, of chick, 122;
of mammalia, 367
Medullary canal, of chick, 40, 62,
96
Medullary folds, of chick, 40, 62,
66, 77, 97; of mammal, 327
Medullary groove, of chick, 29,
62—65; of rabbit, 320, 321;
of man, 338; closure of, in
mammal, 327—331
Medullary plate, of chick, 62; of
rabbit, 320; of man, 338
Membrana capsulo pupillaris of
mammalia, 387—389
Membrana limitans externa, 145;
granulosa, 310
Membrana propria of follicles,
chick, 182
Membrane: of shell of hen's egg,
1; serous, of chick, 32—41;
vitelline of hen's egg, 13—15
Membrane bones, 242; of skull,
chick, 246
Membrane of Reissner, mamma-
lia, 397
Membrane of Descemet, 389
Membrane of Corti, and tectoria
mammalia, 395
Membranous labyrinth, chick,
158
Meniscus of birds, 210
Meroblastic segmentation, 18
Mesenteric veins of chick, 228,
288—290
Mesentery, of chick, 173; mam-
malia, 419—20
Mesoblast: derivatives of, in chick,
25—26; of primitive streak of
chick, 54, 57; derived from
lower layer cells in chick, 55,
57, 59; of area opaca in chick,
65; splitting of, in chick, 68; of
trunk of embryo chick, 185—
189; histological differentiation
of, in chick, 269; of primitive
streak of rabbit, 320; of mam-
mal, double origin of, 321—
323; vertebral zone of, 328;
lateral zone of, 328; somites
of, 328
Mesoblastic somites, formation of
in chick, 70; of chick, 81, 185—
187, 204—208
Mesocardium of chick, 88; forma-
tion of, 264
Mesogastrium, chick, 182
Mesonephros of chick, 212

Mesovarium of fowl, 11
 Metacarpus, chick, 234
 Metadiscoidal placenta, histology of, 362; derivation of, 364
 Metamorphosis of arterial arches, bird and mammalia, 408
 Metanephros (*see* Kidney)
 Metanephric blastema, of chick, 219
 Microtomes, and makers of, 434—435; 471
 Mid brain: of chick, 100, 200; of rabbit, 329; of mammalia, 370 371; ventricle of, 370; nates and testes of, 371; corpora geniculata, and crura cerebri of, 371
 Monotremata, foetal membranes of, 352
 Mouse, inversion of the layers in, 341
 Mouth, chick, 249, 281; of rabbit, formation of, 334
 Müllerian duct: chick, 214—218; mammalia, 414—415
 Muscle plates of chick, 187—189, 204—208, 211; segmentation of, 212
 Muscles: hyposkeletal, chick, 211; episkeletal, chick, 211; cutaneous, chick, 211; extrinsic and intrinsic of limb, chick, 212
 Muscular walls of heart of chick, 88

N

Nails, of chick, 283
 Nares: posterior, chick, 251; anterior and posterior, of mammalia, 399
 Nasal capsule, chick, 242; cartilages, chick, 246; bones, chick, 246; groove, chick, 246; processes of chick, inner, 248; outer, 248; labyrinth, chick, 249—51
 Nasal organ (*see* Olfactory organ)
 Nasal pits, of birds, 71; chick, 202
 Nates of mammalia, 371

Nerves, of chick of second day, 101; of mammalia, 400
 Nervous system of mammalia, 367—400
 Neural band, chick, 123; crest, 126
 Neural canal of chick, 31—39, 66; second and third day, 122; development of, 251—256
 Neurenteric canal, of chick, 71—74, 175; mammalia, 399; of mole, 326, 328
 Ninth nerve, chick, 126—129, 203
 Node of Hensen, 319
 Non-deciduate placenta, 352
 Nose, chick, 249
 Nostrils, chick, 251
 Notochord: of chick, 29, 60—62, 208—210, 237—238; of second day, 101; sheath of chick, 208; of mammal, 323, 400; formation of, 325
 Nuclei, 16
 Nucleolus, 13
 Nucleus, 13
 Nucleus of Pander, 7
 Nucleus pulposus, of birds, 210, 401
 Nutrition of mammalian embryo: 308; by means of placenta, 350

O

Occipital: supra-, basi-, ex-, of chick, 246; foramen, chick, 237
 Oesophagus of chick, 173; mammalia, 418
 Olfactory organ of chick, 161; nerve of chick, 162; grooves, chick, 202; lobes of mammalia, 385
 Ovary bodies, 368
 Omentum, mammalia, lesser, 420; greater, 420
 Opisthotic of chick, 246
 Optic vesicles: of chick of second day, 79, 97; chick, 133—134; formation of, 141—144; of rabbit, 329

Optic lobes, chick, 121
 Optic nerves, chick, 133, 146
 Optic cup, 134
 Optic chiasma, chick, 147; mammalia, 372
 Optic thalami of mammalia, 373
 Orbitosphenoid, 246
 Orbitosphenoidal region, chick, 240
 Organ of Corti, mammalia, 395
 Organ of Jacobson, mammalia, 399
 Orycteropus, placenta of, 358
 Osmic acid, how to use, 427
 Osseous labyrinth, chick, 158
 Otic vesicle, chick, 157
 Outer layer, of blastodermic vesicle, 314
 Ova, primordial, of chick, 221
 Ovarian follicle: of hen, 12—15; mammal, 309
 Ovarian ovum: of hen, 11—15; of mammals, 309
 Ovary: of adult hen, 11; of chick, 222; of mammals, 309; follicles of, 309; corpus luteum of, 311.
 Oviduct of adult hen, 15; of chick, 224
 Oviparous animals, 308
 Ovum: of birds and mammals compared, 307; of mammal—in follicle, 309; membranes of, 310; maturation and impregnation of, 310—312; polar bodies of, 311; segmentation of, 312—314; blastopore of (Beneden), 314

P

Palate, mammalia, 420, 421
 Palatine bones, chick, 246
 Pancreas: of chick, 181; mammalia, 419
 Pander, nucleus of, 7.
 Parachordals, chick, 235—238
 Paraffin, 432—434
 Parepididymis of cock, 224
 Parietal bones of chick, 246
 Parieto-occipital fissure of cerebrum of man and apes, 385
 PARKER on the fowl's skull, 245
 Paroophoron of hen, 224
 Pecten, chick, 147
 Pectoral girdle, chick, 234; mammalia, 405
 Pelvic girdle, chick, 234; mammalia, 405
 Penis, mammalia, 417
 Pericardial cavity, chick, development of, 264—269; of rabbit, 331; mammalia, 406
 Perilymph, mammalia, 396
 Periotic capsules, chick, 237
 Peritoneal covering of heart of chick, 88; cavity, mammalia, 406
 Peritoneum, mammalia, 419—420
 PFLUGER, egg tubes, 222
 Phalanges, chick, 234
 Pharynx, mammalia, 418
 Picric acid, how to use, 425
 Picro-carmin, to make and use, 431
 Pig, placenta, histology of, 360
 Pineal glands, chick, 117—119; of mammalia and birds, 373—376
 Pituitary body: chick, 119—121; rabbit, 334; of birds, 372; mammalia, 372, 420
 Pituitary space, chick, 240
 Placenta: 342; discoidal, deciduate, type of, 353, 354; metadiscoidal, type of, 354—358; decidua of, 356; chorion laeve of, 356—358; chorion frondosum of, 356—358; comparison of, 358; zonary type of, 358; diffuse form, 359; polycotyledonary form, 359; histology of, 359—363; evolution of, 364; of sloth, 360.
 Pleural cavity, chick, development of, 264—269; mammalia, 406
 Pleuroperitoneal space of chick, 28—33, 84; formation of, 40, 41, 68
 Pneumogastric nerve (*see* Tenth nerve)

Polar bodies, 17; of ova of mammals, 311
 Polycotyledonary placenta, 359; histology of, 360
 Pons Varolii of birds, 369; of mammals, 370
 Position of embryo chick of third and fourth days, 113—116
 Postanal gut, of chick, 175; of rabbit, relation of, to primitive streak, 329
 Posterior nares, chick, 202
 Potassium bichromate, 460
 Premaxilla bones, chick, 246
 Prenasal bones of chick, 246
 Presphenoid region, chick, 240—246
 Primitive groove of chick, 56; of rabbit, 320
 Primitive streak of chick, 52—62; of chick from 20 to 24 hours, 70; of rabbit, 319
 Processus infundibuli, chick, 121
 Proctodæum of chick, 175; of mammal, 422
 Pronephros, 218
 Pronucleus, female, 17; male, 17
 Protoic, chick, 246
 Protovertebræ (*see* Mesoblastic somites)
 Pterygo-palatine bar, chick, 243
 Pterygoid bones, chick, 246
 Pubis, chick, 234
 Pulmonary veins of chick, 228, 289—290
 Pulmonary arteries of chick, 294—298; mammalia, 407
 Pupil, chick, 142
 Pyramids of cerebellum, 368

Q

Quadrato-jugal bones, 246
 Quadrate, chick, 243

R

Rabbit embryo, growth of, 327—334; placenta of, 353
 Radius, chick, 234

Rat, inversion of the layers in, 341
 Recessus labyrinthi, mammalia, 390—398
 Recessus vestibuli (*see* Aqueductus vestibuli) chick, 203
 Respiration of chick, 303; of third day, 110
 Rete vasculosum, mammalia, 414
 Retina, chick, 142, 144—146
 Ribs, chick, 234; mammalia, 405
 Rodentia, placenta of, 353
 Rods and cones of retina, chick, 146
 Rostrum, chick, 246
 Ruminants' placenta, histology of, 360

V

Sacculus hemisphericus, mammalia, 390—398
 Salivary glands, mammalia, 420
 Scala media (*see* Cochlear canal)
 Scala tympani, mammalia, 395—397
 Scala vestibuli, mammalia, 395—397
 Scapula of chick, 234
 Sclerotic coat of eye of chick, 141
 Sclerotic capsules, mammalia, 405
 Scrotum, mammalia, 416
 Sebaceous glands, 366
 Secondary optic vesicle (*see* Optic cup)
 Sections, method of cutting, 434—436; mounting of, 436
 Segmentation: of hen's egg, 18—24; meroblastic, 18; of mammalian ovum, 312—314; of hen's egg to observe, 458; of mammalian ovum to observe, 461
 Semicircular canal: of chick, 158; mammalia, 390—398
 Semi-lunar valves, chick, 258
 Sense capsules of chick, 211—212
 Septum lucidum, mammalia, 383
 Septum-nasi, chick, 246
 Serous membrane of chick, 32—41

- Serous envelope of chick, 107;
of mammals, 346
- Seventh nerve of chick, 127—129,
203
- Shell-membrane of chick, 1
- Shell of hen's egg, 1; formation
of, 16
- Shield, embryonic, of chick, 49
- Sinus rhomboidalis: of embryo
chick, 71, 81; of rabbit, 329
- Sinus terminalis, of chick of
second day, 91, 104; in rabbit,
343
- Sinus venosus of chick, 169, 226,
285—290
- Skeleton of limb, chick, 234
- Skull of chick, 235—251; cartilage
and membrane bones of, 246;
of mammalia, 401—405
- Sloth, placenta, histology of, 360
- Somatic stalk of chick, 29—42;
of mammals, 351
- Somatopleure of chick, 29—33;
formation of, 40—41, 68
- Spermatozoa of chick, 223
- Spinal nerves: of chick, 123; de-
velopment of, 129—132; of
mammalia, 400
- Spinal cord of chick: develop-
ment of, 251—256; white mat-
ter of, 252; grey matter of,
253; canal of, 252—256; epi-
thelium of, 251, 252; anterior
grey commissure of, 256; an-
terior fissure of, 254—256;
dorsal fissure of, 255—256;
posterior grey commissure of,
256; sinus rhomboidalis of,
256; anterior columns of, 256;
posterior columns of, 256;
lateral columns of, 256; an-
terior white commissure of,
256; posterior white commis-
sure of, 256
- Splanchnic stalk of chick, 29—
42, 232
- Splanchnopleure of chick, 29—
33; formation of, 40—42, 68
- Spleen of chick, 182
- Splint bones of chick, 246
- Squamosal bones of chick, 246
- Staining reagents, 428—432; hæ-
matoxylin, 429; borax carmine,
430; carmine, 431; picro-car-
mine, 431; alum carmine, 431
- Stapes, of chick, 245; mammalia,
398, 404
- Sternum of chick, 235; of mam-
malia, 405
- Stomach of chick, 173; mam-
malia, 418
- Stomodæum, of chick, 119, 203;
mammalia, 420
- Stria vascularis, mammalia, 397
- Subclavian arteries of chick, 296
—298, of mammalia, 409
- Subclavian veins, mammalia, 409
—413
- Sulcus of Monro, 373
- Superior maxilla of chick, 165;
maxillary processes of chick,
202; of rabbit, 334
- Superior cardinal veins of chick,
228
- Supra-renal bodies, mammalia,
structure of, 413; relation of,
with sympathetic nervous sys-
tem, 414
- Subzonal membrane of mammal,
346
- Sylvian fissure, mammalia, 384,
385
- Sympathetic nervous system of
mammalia, 400
- Sweat-glands, 366
- T.
- Tail-fold of chick, 29—37, 196;
of second day, 96; of mammal,
329
- Tail-swelling of chick, 74
- Tarsus of chick, 234
- Teeth, mammalia, 421
- Tela choroidea, 375
- Tenth nerve of chick, 125, 127—
129, 203
- Testis of chick, 222, 371
- Thalamencephalon: of chick,
117; of mammalia, 371—376;
ventricle of, 372; floor of, 372,

373; sides of, 373; roof of, 374—376
 Third nerve of chick, 129
 Third ventricle of mammalia, 372
 Throat of rabbit, formation of, 331
 Thyroid body, of chick, 181; mammalia, 418
 Tibia of chick, 234
 Tongue of chick, 282
 Trabeculæ of chick, 236, 239—241
 Trachea of chick, 176, 177; mammalia, 418
 Tuber cinereum, 373
 Turbinal bones of chick, 246
 Tympanic cavity of chick, 166; membrane of chick, 166; cavity of mammalia, 397, 418; membrane of mammalia, 397

U.

Ulna, of chick, 234
 Umbilical, arteries (*see* Allantoic); veins (*see* Allantoic veins); vesicle of mammals (*see* Yolk-sac); stalk of chick of third day, 113; cord, 351
 Urachus, 351
 Ureter of chick, 219; mammalia, 417
 Urethra, mammalia, 417
 Urinogenital organs of mammalia, 414—417; sinus of mammalia, 415—417
 Uterine crypts, 350
 Uterus, mammalia, 415
 Utriculus of mammalia, 393—398
 Uvea of iris, chick, 144

V.

Valve of Vieussens, of birds, 369; of mammals, 370
 Vagina mammalia, 415
 Vagus nerve (*see* Tenth nerve)
 Vasa efferentia and recta mammalia, 414
 Vascular system of chick, 224—230; of second day, 89—94, 102

—106; of third day, 167—170; mammalia, 406—413
 Vascular area: of blastoderm of chick, 27; of third day, 110—113; of rabbit's ovum, formation of, 326
 Vas deferens: of cock, 224; mammalia, 415
 Velum medullæ antierius (*see* Valve of Vieussens); posterius, 370
 Vermiform appendix, mammalia, 419
 Vena cava, inferior, of chick, 228, 285—290; mammalia, 409—413
 Venæ cavæ, superior, of chick, 286—290; of mammalia, 409—413
 Venæ advehentes of chick, 227, 287—289; revehentes of chick, 227, 287—289
 Vena terminalis (*see* Sinus terminalis)
 Venous system: of chick, 226—229, 283—290, 301—303; mammalia, 409—413
 Ventricles of brain of chick of second day, 102; of mammals, 117, 121—122; of chick, 229
 Ventricular septum, chick, 230, 257
 Vertebrae of chick, primary, 205—208; permanent, 205—208; bodies of, 207—209
 Vertebral arches, osseous, of chick, 207, 210; mammalia, 409
 Vertebral artery of chick, 295—298
 Vertebral column, of chick, 205—208; membranous, 205—208; secondary segmentation of, 205—208; explanation of do., 205—206; of mammalia, early development, ossification of, 400, 401
 Vertebrate animal, general structure of, 39
 Vesicle of third ventricle (*see* Thalamencephalon)

Vessels of placenta, 360—363
 Vestibule, chick, 158
 Villi: of human ovum, 335; of zona in dog, 347; of subzonal membrane of rabbit, 347; of chorion of mammal, 349; of placenta, 360—363
 Visceral arches, 245; of rabbit, 334
 Visceral arches of chick, 162—167; of rabbit, 334; of mammalia, 402
 Visceral clefts: of chick, 162—167, 281; closure of do., 164; of rabbit, 334; of mammalia, 402, 418
 Visceral folds of chick, 163
 Visceral skeleton of chick, 242—246
 Visceral vein of chick, 284—290; of mammalia, 409—413
 Vitellin, 5
 Vitelline arteries: of chick, 167, 293—298, 225; of second day, 89, 103
 Vitelline duct of chick, 196, 232; of mammals, 350
 Vitelline membrane, 4; of hen's egg, 13—15; of mammal, 310
 Vitelline veins of chick, 84, 226, 288—290; of second day, 92, 104; in rabbit, 343; of mammalia, 410—413
 Vitreous humour of chick, 140, 150

Viviparous animals, 308
 Vomer of chick, 246

W


White matter: of spinal cord of chick, 252; of brain of mammalia, 386—387
 Wings of chick, 200
 Wolfian body: of chick, 190—193; of mammalia, 414; of chick of second day, 106
 Wolfian duct of chick, 190, 213; of second day, 94—95, 106; of mammalia, 414
 Wolfian ridge of chick, 198
 Wolfian tubules of chick, 106, 191—193, 213

Y

Yolk of hen's egg, 4—7; arrangement of, 6; structure of, 5
 Yolk-sac: of chick, 28—37, 277—280; of mammals, 327; of marsupials, 352; of rabbit, 353; of human ovum, 355—358; of dog, 358

Z

Zona radiata, 310; of chick, 15
 Zonary placenta: histology of, 360; derivation of, 364



260
int-

