

1917  
K59

Kingman

The Epiphysial Structures of Acanthias



THE EPIPHYSIAL STRUCTURES OF ACANTHIAS

BY

ROBERT HILLS KINGMAN  
A. B. Washburn College, 1913.

---

THESIS

Submitted in Partial Fulfillment of the Requirements for the

Degree of

MASTER OF ARTS

IN ZOOLOGY


IN

THE GRADUATE SCHOOL

OF THE

UNIVERSITY OF ILLINOIS

1917



1917  
K59

UNIVERSITY OF ILLINOIS  
THE GRADUATE SCHOOL

May 31 1917

6 Feb. 18 Ciley

I HEREBY RECOMMEND THAT THE THESIS PREPARED UNDER MY SUPER-  
VISION BY Robert Hills Kingman

ENTITLED The Epiphyseal Structures of  
Acanthias

BE ACCEPTED AS FULFILLING THIS PART OF THE REQUIREMENTS FOR THE  
DEGREE OF Master of Arts

J. Kingsley  
In Charge of Thesis  
James M. ...  
Head of Department

Recommendation concurred in:\*

\_\_\_\_\_  
\_\_\_\_\_  
\_\_\_\_\_

} Committee  
on  
Final Examination\*

\*Required for doctor's degree but not for master's.

UNIVERSITY OF ILLINOIS

CHAMPAIGN, ILLINOIS

LIBRARY OF THE UNIVERSITY OF ILLINOIS  
CHAMPAIGN, ILLINOIS  
DATE \_\_\_\_\_  
BY \_\_\_\_\_



1952

Table of Contents.

\* \* \*

I. Title	- - - - -	1.
II. Recommendation	- - - - -	ii.
III. Table of Contents	- - - - -	iii.
IV. Introduction	- - - - -	1.
V. Methods and Materials	- - -	4.
VI. Morphology	- - - - -	5.
VII. Discussion	- - - - -	20.
VIII. Conclusions	- - - - -	25.
IX. Bibliography	- - - - -	27.
X. Explanation of Plates.	- -	29.
XI. Plates	- - - - -	33.





## THE EPIPHYSIAL STRUCTURES OF ACANTHIAS.

\* \* \* \* \*

The discovery by Spencer ('86) that there is a third eye in Sphenodon was one of the most striking announcements of that decade, and it immediately inaugurated a large amount of investigation on similar structures in other vertebrates. One of the early results of these studies was the recognition that there are two of these diencephalic evaginations, that either of them might develop into an eye-like organ, and that the third eye of Sphenodon is not, as Spencer had regarded it, as the homologue of the pinealis of man, but arises in front of it and hence the organ in Sphenodon is usually called the parietal organ or eye, while the name pinealis is properly reserved for the structures, whether eye-like or not, which arise farther back on the roof of the diencephalon.

Since Gaupp ('98) has summarized the work done in the last century, when most of the morphology of these organs was made out, it is not necessary to enumerate the groups which have a parietal and which a pineal organ. It is not out of place, however, to epitomize the work done on the pinealis of the Elasmobranchs, as that structure forms the basis of the present dissertation.

So far as I am aware Ehlers ('78) was the first to recognize the pineal vesicle in any Elasmobranch. He described it in both Acanthias and Raja, but only its grosser features as he used no refined histological methods. Farther, he had no suspicion of its eye-like character, as he wrote eight years before Spencer,

Digitized by the Internet Archive  
in 2013

<http://archive.org/details/epiphysialstruct00king>

and the parts are so modified, at least in *Acanthias*, that one would hardly think of an eye in connection with them. The same applies to the work of Cattie ('81), three years later, who studied the pinealis in several genera belonging both to the Selachoid and the Batoid groups. These two are at variance on several points as will be pointed out below. To them we owe practically all that is known of the structure of the adult pinealis in Elasmobranchs.

The development was touched upon by Balfour<sup>U</sup><sub>A</sub> ('77), in his classic monograph, but he gave few details, though he traced the structure until it became imbedded in the roof of the skull. There is almost equally little in Van Wijhe's paper ('82), on the mesoderm of the head. Locy, however, has several articles which discuss the development ('93, '94, '95), but carries his studies with any considerable detail only through the early stages, as he was more concerned with the thesis that there were the rudiments of several pairs of visual or sensory structures in the medullary plate, even before its closure to form the neural tube. He believed that both parietal organ and pinealis were homonomous structures and that each was primitively paired, but that only one of a pair ever developed, the other degenerating and disappearing.

To Minot ('01) we owe the first consecutive account of the development in any Elasmobranch, and his results, as far as they go, are confirmed in main, in the present paper. Minot discusses the several epiphysial structures as they appear in *Acanthias* - paraphysis, velum transversum, parietal arch (his post-velar arch), and pinealis, carrying his studies to the point where the parietal arch had vanished and the pinealis had assumed a form readily comparable with the adult.



In Scammon's Normentafeln (II) of Acanthias there are scattered notes of the condition of the epiphysial structures, but from the character of his work there can be expected no detailed account of them. So far as I know there has been no other embryological work in these structures in any Elasmobranch.



### Material and Methods.

The material for these studies was collected by Professor Kingsley at South Harpswell, Maine, but most of them with no idea of following out the development of the epiphysial structures, but as illustrating Elasmobranch development. Most of them were killed with corrosive acetic or with Zenker's fluid, were sectioned in the usual manner, and were stained, some with borax carmine, some with alum cochineal, and some with Delafield's haemotoxylin. In some cases there were no exact statements on the slides as to the exact length of the specimen, an omission due usually to the fact that the specimen was imperfect, or, to apparent shrinkage in the reagents. There are, however, a number of series which were put up for special nerve studies. These are mostly larger embryos and the later stages up to the fullgrown dog fish. Most of these were prepared by Ranson's modification of Cajal's silver impregnation. Many of these show the nerve fibers in the clearest manner, but the fact that these materials were plunged at once into absolute alcohol has caused shrinkage in parts which interferes with the clear vision of many structural details.

The study of this material was begun some years ago by Doctor Kingsley, who made a number of drawings and several models of the roof of the 'twixt brain region. He also had the advantage of studying the material collected by Dr. H. V. Neal, some of which is incorporated in the present paper. All of this material the notes, drawings, and models were turned over to me, and the following paper is the result.





### Morphology.

In the early development of the epiphysial organs, if the measurements can be depended upon, there is not a close correlation between body length and the stage of these organs. Thus I find a specimen labeled 12 mm. which is more advanced in this respect than another, stated to be 13 mm. long. This will explain some of the discrepancies in the following account.

In a 10 mm. embryo, a total mount, the diencephalon is clearly marked off from the telencephalic portion of the primitive fore-brain. Its anterior portion, the post-velar arch of Minot ('01) lies just behind the scarcely indicated velar fold, while at the posterior limits of the diencephalon the posterior commissural region is more strongly developed, projecting as a slight transverse ridge into the cavity of the brain. (Fig.1). Between these two landmarks the roof of the brain is much thicker than it is in the paraphysial region just in front of the velum. As yet the roof shows no sign of later differentiation into parietal and pineal arches.

In a total mount, labeled 13 mm., the diencephalic roof is slightly thinner about half way between its anterior and posterior boundaries, than in front of or behind this line. This is the earliest indication I have seen of the differentiation of the two epiphysial structures, and the line between them is far more marked on the inner than the external surfaces (Fig. 2). The posterior commissure now dips more deeply into the cavity of the brain, while the internal velar ridge is more pronounced than before.


The changes in an embryo, said to be 12 mm. long, are not great. Externally parietal (post-velar arch) and pineal arches



are hardly differentiated, but in optical sections the boundary between the two is thinner than before, while there are slight excavations in the roof corresponding to the two arches (Fig.3).

In sagittal sections of a 12.5 mm. embryo, the division between tel- and diencephalon is more marked by a further ingrowth of the velar fold (Fig.4), while a similar development of the posterior commissure emphasises the contrast between the 'twixt and the mid brains. Between these limits the two arches are as evident on the external as internal surface. The roof shows a thickening between the two arches, the anlage of the superior commissure. The paraphysial arch, in front of the velar fold, is more prominent than in the 12 mm. stage. The parietal and pineal arches are decidedly arcuate as seen in sagittal sections, but they are, in reality two transverse projections of the dorsal surface of the diencephalon.

In an embryo 15 mm. long (Fig.5) the velar fold has extended still farther into the cavity of the brain. Between the two walls of this fold mesenchymatous cells are found which have migrated in from the region above. The paraphysial arch has become more pronounced and its apex more acute as a result of the backward growth of the telencephalon. Whether this is the normal condition is somewhat doubtful, as somewhat older stages do not show this condition. The parietal and pineal arches are almost equally prominent, and they show no indication of a paired condition. The posterior commissure has become more thickened and shows the beginning of the commissural fibers traversing it from side to side in the ectoglea layer. The fibers of the superior commissure have not yet appeared. The epiphysial arch is in contact with the dorsal surface of the posterior commissure. The region of the posterior commissure



is thickest dorsally, and from it there is a marked thickening on the inner surface of the diencephalon which extends ventrally and anteriorly, meeting a similar elevation on the inner surface, the two uniting and extending downward on the lateral wall of the diencephalon, gradually fading out at about the level of the inferior margin of the velum transversum.

In sections of an embryo said to be 26 mm. long (about equivalent to text figure 13 of Scammon '11) the diencephalic region is relatively shortened by the farther ingrowth of the posterior commissure and the velum and the great increase of di- and mesencephalic regions (Fig. 6). The pineal outgrowth is now far more prominent and is vesicular in character, the neck of the outgrowth being somewhat narrowed and actually smaller than in the last stage. There is no marked change in the posterior commissure, and the superior commissure shows no further differentiation.

In an embryo slightly more advanced in other respects than the last (Fig. 7) the pineal outgrowths has become more vesicular and is more strongly marked off from the parietal arch by the greater development on the inner surface of the superior commissure. The velum, now a strong fold of the dorsal surface, extends farther into the brain, and shows a differentiation of its anterior and posterior walls, the posterior being much thinner than the other. Mesenchyme cells, as yet few in number, lie between the two layers of this fold. The paraphysial arch is a dorsal continuation of the anterior wall of the velum and no sharp line can be drawn between velar and paraphysial parts. But in front the paraphysial parts are sharply marked off from the rest of the telencephalon by a transverse groove on the outer surface of the cerebral regions.



In an embryo (Neal M-D) between 18 and 20 mm. long (about equivalent to text figure 15 or 16 of Scammon), sagittal sections show an interesting fact in that the internal lateral extensions of the posterior arch are unequally developed on the two sides, the left being much thicker than the right, and associated with this (possibly correlated with it) the pinealis shows a marked tendency towards the right side of the brain. Dorsal to lateral thickenings noted in the 15 mm. embryo the cavity of the brain extends laterally into each half of the parietal arch, these extensions of course communicating in the median line with the third ventricle. From this it is evident that the parietal arch is median, or bilaterally symmetrical.

In a 23 mm. embryo (transverse section) (Fig. 11 and 12) the distal end of the pineal outgrowth is decidedly asymmetrical, lying on the right side of the median line, while the base of the structure, while still on the right side, is much nearer the median line.

Sagittal sections of a 27 mm. embryo (Fig. 8) show the diencephalon relatively shortened by the continued growth of the other parts of the brain. The velum has grown farther downward and its posterior wall is much the thinner of the two, while at the origin of the velum from the roof of the brain the two walls are closely approximated to each other. Below this region the two walls are separated by the mesenchyme, which is slightly more plentiful than was found in the embryo shown in figure 7. The superior commissures now show transverse commissural fibers, and superior and posterior commissures are now relatively and actually closer to each other so that the opening into the lumen of the





pineal outgrowth which lies between the two is narrower than before. The posterior commissure has increased very materially in size. The anterior limit of the paraphysial arch is now indicated by a sudden narrowing of the posterior dorsal surface of the telencephalon, the arch itself curving backward and downward and gradually passing into the anterior wall of the velum.

In another 27 mm. embryo there is a farther development of the epiphysial parts. The parietal arch has almost entirely disappeared as a distinct structure, its anterior and posterior walls being nearly in contact, the anterior being the dorsal part of the posterior wall of the velum, while the posterior side of the parietal evagination forms the anterior side of the superior commissure. The pinealis now is more vesicular with a narrow stalk and the axis of the whole is vertical. The posterior wall of the pinealis rests against the posterior commissure, while immediately in front of the outgrowth is the posterior wall of the paraphysis which bends slightly backward over the remnants of the parietal arch. The pineal outgrowth is flattened in the antero-posterior direction. The anterior boundry of the paraphysis is marked as before by the same groove in the roof, but this is now sharper and more pronounced than before.

In embryos 30 mm. long (Fig. 9) there is a little advance over the 27 mm. stage. The most noticeable change is the plication of the posterior wall of the velum transversum, the first step in the formation of the chorioid plexus. The pinealis is still vesicular without any sharp differentiation into vesicle and stalk.

In transverse sections of a 33 mm. embryo (Fig. 13) the anterior wall of the velum transversum has its lateral parts



plicated, these folds marking the postero-ventral limit of the paraphysis. Into these and the folds on the posterior surface, blood vessels now enter and blood corpuscles occur here and there. The distal end of the pinealis is clearly to the right of the median line, but the point of attachment to the roof of the diencephalon is almost if not quite in the sagittal plane.

Immediately below the median portion of the posterior commissural fibers the ependymal cells of the roof are modified so that the inner portion contains few nuclei but is composed of faint fibers which project down to the edge of the brain cavity. The area which has its ependymal cells thus modified is slightly thinner than the rest of the brain wall to form the future subcommissural fossa. This modified region is the subcommissural organ and is represented, not as separate strip laterally located, but as the entire area in median line of the brain. The lateral edges are, however, more strikingly modified than is the median region.

The next embryo in order is without indication of its length. It was considerably larger than 33 mm. and less than the next to be described (60 mm.). The wall of the velum transversum are now largely converted into telae chorioideae, and the accompanying blood vessels are more extensively developed. There is a noticeable increase in the superior commissure, both in size and in the number of fibers which it contains. The tip of the pinealis now overhangs the superior commissure and it is, as before, to the right of the median line but its point of attachment is still nearly median. It is slightly differentiated into a distal enlargement which is about twice as thick as the proximal stalk.



The lining cells of the brain beneath the fibers of the posterior commissure have now elongated, the early stage of the so-called subcommissural organ. The subcommissural organ is found below the posterior commissure in a short longitudinal depression, the subcommissural fossa, which possesses a median groove and two lateral grooves, the latter grooves are wider. The lining of these grooves and part of the edge of the median one is elongated epithelial cells which compose the subcommissural organ.

A 60 mm. *Acanthias* is cut in transverse sections, and the changes are such as to require a more extended description. The pinealis has elongated and its distal end lies above the bottom of the longitudinal fissure and shows three regions, the attachment to the roof of the diencephalon, the stalk, and the distal vesicle.

The vesicle (Gaupp's pars craniale) is imbedded in the connective tissue which stretches across the wide epiphysial foramen (Grace Wells 1917) in the roof of the chondrocranium. In transverse section it is somewhat triangular, the flattened base being directed upwards and the other two sides passing into the stalk. The distal side is slightly lenticular in section, the cells with spherical nuclei radiating from a center, the whole forming a lens, covered externally by corium and skin. The lateral or retinal walls are composed of elongate cells with oval nuclei, their inner ends being pointed or conical and projecting some distance into the lumen of the vesicle (Fig. 10). At this stage there is no pigment in the eye or in the surrounding skin. Outside of these cells is a layer of fibers, limited externally by connective tissue. In view of what is found in *Acanthias* at a later stage, and what occurs in other pineales, I have been inclined to



regard these fibers as nervous, although I have no material preserved with any distinctive nerve-stain.


The stalk (partie mediane of Cattie '82, pars intermedia of Gaupp '97) is cylindrical at the distal end where it connects with the vesicle. It is hollow throughout but flattened dorso-ventrally, and continues backwards and downwards between the cerebral hemispheres, its ventral surface resting on the paraphysis.

The stalk is connected with the right side of the brain roof, the median line of which is readily determined by the groove in the middle of the superior commissure as noted by Minot ('01). The divergence at the point of attachment is slight but still decidedly recognizable. On the inner dorsal surface of the diencephalon the ependyma immediately posterior to the base of the pinealis shows the modification of the cells to form the sub-commissural organ somewhat advanced over the proceeding stage.

The parietal or post velar arch has been completely lost as a distinct structure and is represented by the space between the superior commissure and the posterior wall of the velum. The velum itself is now wholly chorioidal in character and extends down far into the third ventricle. The paraphysis is thin-walled throughout and passes abruptly into the cerebrum in front and without any sharp line of demarcation into the tela chorioidea behind.

The following description is from a series of 75 sections of an early "pup" in which the brain measured 14.5 mm. in total length. As this was removed from the head, the pineal vesicle was lacking.

The subcommissural organ, which was very small in the





earlier stages, now spreads on the surface of the brain as an elongate oval, the major axis of which does not coincide with the major axis of the brain, but oblique, its anterior end being a little to the right of the median line. The pit in the mesencephalic and diencephalic roof where this organ lies, is deepest anteriorly where the cavity is connected with the lumen of the pineal stalk, and just in front of this the anterior border of the groove is almost vertical. On the anterior side and on the whole of the left side the groove passes gradually into the rest of the wall of the brain, but on the posterior, and the posterior part of the right side the subcommissural region is margined by a sharp crest, which, viewed from below, slightly overhangs the groove. (In a later "pup" there is a similar crest on both sides posteriorly). Between the crest and the subcommissural fossa there is a narrow groove into which the columnar epithelium characterising the subcommissural organ extends. The opening between the subcommissural fossa and the recessus subpineal, (Sargent '04) (or the lumen of the pineal stalk) is nearly circular. Just inside of the opening is a semicircular groove, the basipinealis groove, its concavity directed anteriorly, and its lateral horns are continued inside the stalk as the lateral parts of the lumen. Between this groove and the subcommissural fossa is a prominent ridge with rounded ventral margin, which descends from the dorsal or posterior wall of the base of the pineal stalk.

The stalk is surrounded by a layer of loose connective tissue continuous with the dura mater of the rest of the brain - the pia mater is pierced by the stalk and surrounds the median portion while the distal end is surrounded by the dura mater which



forms the lining of the skull. In the distal part of the stalk the nerve fibers run parallel to the axis of the stalk (Fig. 28), but near the proximal end their course is different as will be described below. Inside of this nerve fiber layer and lining the lumen of the stalk is a layer of nucleated cells, (continuous with the ependyma of the brain) which varies in thickness with the diameter of the stalk. Thus near the distal end there is but a single layer of these cells, while at the base the layer is five or six cells in thickness (Fig. 21). The cells which immediately border the lumen are produced internally into fine, thread-like projections, thicker at the base and tapering as they extend into the lumen. In the distal part of the stalk the lumen is almost entirely filled with these filaments, while near the base the tangle which they produce is much looser, and more of the lumen is free from them.

In the distal part of the stalk the nerve fibers are almost equally distributed in all sides of the wall, but near the union of the stalk with the roof of the brain the number of fibers in the lateral parts is greater than on the dorsal or ventral sides, although the median dorsal tract contains more fibers than the ventro-lateral parts.

These fibers can be traced fairly well in sagittal sections of the stalk itself, but near its union with the diencephalic roof many of them take an oblique course so that it is practically impossible to follow any single fiber. As far as they could be distinguished, the following is their distribution in this region, the conclusions being drawn by the position of separate bundles in successive sections.



The fibers of the lateral regions of the stalk, on reaching the roof region, may be grouped roughly into anterior (or ventral) and posterior (or dorsal) groups. Of these the anterior fibers bend anteriorly in the roof and pass obliquely to the habenular ganglion of the same side where they become associated with a group of ganglion cells (Fig. 14). Similarly, the more dorsal fibers proceed backward to enter the posterior commissure, passing just lateral to the margin of the subcommissural organ, and ventral to all of the ganglionic cells of the region. Still another group from the lateral regions pass outwards and backwards along the margin of the subcommissural organ to the ventral surface of the posterior commissure (Fig. 30). In the case of the fibers of the dorsal (posterior) side of the stalk a marked decussation is plainly seen in some sections, fibers from the right side of the stalk passing to the left side of the diencephalic roof and vice versa (Fig. 29). After this decussation the fibers pass back to the region of the posterior commissure, but there they become confused with fibers coming from other parts.

The subcommissural organ at this stage consists of two bands of columnar cells along the margin of the fossa in the roof. From these cells fiber-like processes project into the lumen of the ventricle.

In a somewhat larger "pup", in which the brain was 16.5mm. long, the attachment of the epiphysis was on the right side of the diencephalon, the asymmetry noticeable on both outer and inner surfaces of the brain. The fossa of the subcommissural organ is relatively shorter and proportionately narrower than before. The fossa is deepest anteriorly where it continues into the recessus



subpinealis (Fig. 27). It is roughly divided into right and left halves by a median furrow which is a backward continuation of the lumen of the stalk. To the left of this groove the fossa forms a more shallow pit. On the dorsal surface of the brain, almost directly above this shallow pit is a small projection to the left of the base of the epiphysal stalk (Fig. 26). In its general appearance it recalls the earlier stages of the pinealis, but I have no evidence, other than this, of its morphological importance.

As in the last stage the stalk is flattened dorso-ventrally at, and near the base, but farther out it becomes more nearly cylindrical, especially near the distal end. Its lumen is filled with a network of fine fibers as in younger stages (Fig. 21). The same fibers were observed in the same places in the stalk as before, but on account of the different method of preparation, these could not be traced as well and it is impossible to say anything regarding their decussation or termination.

The pineal vesicle is the expanded distal end of the stalk. Its cavity is continuous with that of the stalk. Viewed from above it is somewhat oval in outline, the transverse diameter being much greater than the sagittal. In sagittal sections it is obliquely triangular (Fig. 20) with dorsal, ventral and posterior walls, the connection of its cavity with the lumen of the stalk being between the posterior and the ventral walls.

Transverse sections (Fig. 16) show that the dorsal wall is smooth externally where it lies immediately beneath the corium of the top of the head; but the inner surface is thrown into a series of longitudinal folds or thickenings, the number of which varies in different parts of the organ. The cells composing this





wall are columnar, long in the fold, and nuclei placed in the deeper ends of the cells, close to the internal surface, following the ridge and depression very closely.

Sagittal sections through the middle ridge (Fig. 20) give a lenticular outline to the thickened area, which is bounded in front and behind, but more especially in the latter region, by a distinct groove. In the more lateral thickenings (Figs. 18 & 20) there are still traces of the lenticular outline, but this is not marked as near the middle of the vesicle, while the posterior groove is much wider, which is, possibly, in part the result of the fact that the plane of the section passes near the margin of the structure.

On the ventral wall of the vesicle much the same conditions occur (Figs. 16 & 20) as in the dorsal. There are similar ridges projecting internally, formed in general of similar columnar cells, and (Fig. 20) having the same lenticular outline, though the latter is not so pronounced as in the dorsal wall. At either side of the median line this lenticular outline is lost (Figs. 17 & 18) because of the plane in which the sections are cut.

The posterior wall is formed by a strong transverse ridge, just above the beginning of the lumen of the stalk. This is best seen in median sections (Fig. 20), but it is still recognizable farther to the side (Figs. 17 & 18).

A noticeable feature is the irregularity of the inner surface of the vesicle, the result of the position of some of the lining cells, which here and there appear as if about to be cast off into the cavity (Figs. 17 & 18). These cells resemble in several respects the "mucous" cells which Dendy ('10) describes



in the lens region of the pinealis of *Sphenodon*, and which arise from the lenticular area to form the "vitreous body".

The external part of the wall of the vesicles contains very few nuclei, but immediately beneath the corium and the connective tissue are fibers, which probably are nerve fibers, though in none of the Ransom-Cajal material did they take the characteristic nerve impregnation. These fibers, in favorable transverse sections, are seen to pass into the bases of the ridges.

Interpreting the pinealis of *Acanthias* in the terms of the pineal and parietal eye of the other vertebrates, the dorsal wall would correspond to the lens, the ventral and posterior wall would be the retinal region. The difficulties of this interpretation are: (1) The distribution of what are apparently nerve fibers on the dorsal or lenticular surface of the eye; (2) The failure to recognize any distinctly receptor apparatus (rods and cones) in the retinal areas (except in younger 60 mm. stage the cone-like cells might be receptors, corresponding to Dendy's "sense cells", 1910, p.267); (3) The failure to find a connection of the nerve fibers with the cells in the ventral and posterior wall of the vesicle, which should be retinal in character.


On the other hand, the well defined nerve fibers in the stalk in this, and other stages, and the distribution of these to the superior and posterior commissural regions and the neighboring ganglion cells, all indicate that the pineal vesicle is sensory in character although this does not necessarily preclude its having other functions.



There are apparently some change in structure of the pineal vesicle between the "pup" and the adult. The inner surface of the vesicle is not thrown into such ridges as in the earlier stages and the posterior wall, so evident before, has flattened out and slopes gradually into the stalk as did the ventral wall in the "pup".

The retinal and lens regions are not as sharply shown in these sections because the sections do not pass longitudinally with the furrows of the vesicle. Notwithstanding these ridges are narrower than those present in the "pup" and are seen to pass down into the lumen of the stalk, the nerve fibers in the deeper portion of the ridge and the nuclei close to the lumen of the vesicle.

The lumen of the vesicle contains a considerable amount of coagulum, which, in places is clear and homogeneous, but in places there are varying amounts of a darkly staining bodies, around which are lines closely simulating cell walls. That these are true cells I am unable to say with certainty, but they have every appearance of being such. This interpretation is in accord with what Denty finds in the parietal eye of *Sphenodon*. These he claims are sloughed from the region of the lens, pass into the cavity of the vesicle and there form what he calls the vitreous body, though he, at the same time, calls these cells "mucous cells". In the stalk of the adult eye there are similar nuclei collected in the center of the lumen (Fig. 25) while the inner surface of the stalk was irregular, with processes, with processes extending toward the center nuclei; but whether these processes of the lining cells actually are connected in life with the central nuclei, I am unable to determine.



## Discussion.

Ehlers ('78) describes the pinealis as hollow throughout, Cattie ('81) says, "J'ai trouve la glande pinealis partout massive, excepte dans as partie la plus proximale". The present work confirms Ehlers' view that the pinealis is a hollow vesicle, stalk and all, and its cavity in connection with the ventricle of the brain. Gaupp ('97) accepts Cattie's view on the subject. Cattie's misconception regarding this point can be easily explained, when we consider that the vesicle as well as the stalk contains a coagulum or network of fibers, partially or completely filling the lumen. This coagulum when stained with haemotoxylin is homogeneous with pseudopodia-like projections, while in silver nitrate preparations (Ranson-Cajal method) it forms a granular network similar to the intercellular (?) substance of the stalk.

Minot, describing the superior commissural region in an embryo 70 mm. long says, "Around the superior commissure, - - - there is also a considerable accumulation of differentiated nervous tissue, indicated in the figure by shading with lines. This material does not extend across from side to side but is interrupted by a deep narrow cleft in the morphological median plane - - - as can be readily observed in transverse and frontal sections of this and earlier stages". He then says in describing the pineal region shown in a sagittal section of a 70 mm. embryo, "The section figured passes through the mouth of the epiphysis but does not pass through the cleft mentioned - - -". Although Minot does not explicitly state that the pinealin is median, he gives that impression; this statement could be interpreted to mean that in his material the pinealis is not strictly median but to one side of the median line.






No one, I believe, has found the pinealis of *Acanthias* to the right of the median line, and described it as such, prior to the present description.

Minot mentions the presence of blood vessels in the velum transversum in the 86 mm. embryo, but gives no account in earlier stages of the presence of blood vessels or any substance from which the blood vessels could be formed.

Comparing the present findings in *Acanthias* with the *Cystostomes* we see that *Petromyzon*, according to Scott and Abhorn, is very different from *Acanthias*. Scott describes the primary vesicle as a median diverticulum from the brain. A second diverticulum appears later (Scott knows not how) and the primary and secondary pineal vesicles lie to the left of the median line of the brain. After metamorphosis the characters of these parts are essentially the same, the pineal stalk becomes elongated and attached to the left habenular ganglion.

In *Geotria*, Dendy ('07) finds that the posterior vesicle (his pineal organ or right parietal organ) is on the right of the median line, while the anterior vesicle or parapineal organ is to the left. The nerve connections were traced to: "(1) The epithelium of the ependymal groove (both directly and possibly also by fibers which pass through the posterior commissure), (2) With the right habenular ganglion and, (3) With the right bundle of Meynert". Comparing this with the nerve connections in *Acanthias* the first point is the same in *Acanthias* as *Geotria*. The nerve fibers were not traced with certainty to either habenular ganglion, but as far as they could be followed they were taking a direction as if to enter both of these ganglia. The third connection, that to the



right bundle of Meynert, was not definitely determined.


Among the Ganoids we see that there is a striking asymmetry. In *Amia*, Hill ('94) finds the "posterior epiphysial vesicle or epiphysis" in a 10 mm. embryo, "attached by a narrow short stalk to the roof of the thalamencephalon in the median plane and between the posterior and superior commissure. Its middle point lies a little to the right of the median plane between the posterior and superior commissure". In *Amia* and *Polypterus*, Sargent figures, in sagittal sections, the "epiphysial decussation" at the base of the pinealis, but does not describe it in his text.

In Teleosts, Hill ('94) finds in *Salmo* and *Catostoma* the posterior epiphysial vesicle "lies a trifle to the right of the median line of the brain", while the anterior epiphysial vesicle lies to the left of the median plane of the brain. In *Stizostedion* and *Tepoms*, however, he finds that the posterior vesicle lies in the median plane while the anterior vesicle "lies just to the left of the median plane".

Sargent ('04) shows figure of epiphysial decussation in *Amiurus nebulosus* but because of the nature of the article does not describe it in detail.

In the Dipnoi, Beaugard ('81), Huxley ('76) and Burckhardt ('92) say nothing about its being on the right or left side, although Burckhardt shows a figure with it in the median line in *Ceratodus*. In *Protopterus*, Bing and Burckhardt ('05) fail to mention or figure the position of these structures.

Dendy ('10) together with other writers strongly support the bilateral theory of the pineal organs; which supposes the two pineal vesicles to be derived from a pair of diverticula of the



brain which arise from the same transverse region. The four criteria that Deny<sup>d</sup> uses to determine this character are: (1) The position of the parietal and pineal organ to the right or left of the median line, (2) The identical structure of the two vesicles, (3) The nerve connections of these vesicles with the corresponding members of the Habenular ganglion-pair, (4) The marked asymmetry in point of size of the two habenular ganglia and the exact correspondence of the bundles of Meynert to the unequal development of the two pineal sense organs with which they are respectively connected.

Of these four criteria the first is the only one that applies to *Acanthias* as the pineal vesicle in the adult lies to the right of the median line while the early parietal vesicle is median. In the early embryological stages both the parietal and pineal vesicles are symmetrically placed, median and unpaired organs. The second point that of identical structure does not apply in the least as the parietal vesicle is rudimentary in the later stages while the pinealis is more distinctly eye-like. The nerve connections of the two vesicles with the habenular ganglion elements is not easily applied as apparently the nerves from the pinealis connect with both habenular ganglia. The fourth criterion the correspondence in size of the habenular ganglion elements to the degree of development of the parietal and pineal eyes is not applicable because the habenular ganglion elements are almost equal while the pineal and parietal elements are very different.

It might be argued that since the habenular ganglia are nearly alike in size and since there is a decussation of nerve fibers in the proximal end of the pineal stalk that the parietal



and pineal vesicles have become fused (a decussation of nerve fibers from the right and left epiphysial vesicles is described by Cameron ('04) in the Teleosts where the fibers continue to the opposite elements of the habenular ganglion from which they originate. This argument as far as I can see has no foundation as the early embryonic stages show clearly that the parietal and pineal arches are entirely separated.





### Conclusions.

In early stages of *Acanthias* two transverse arches are developed in the diencephalic roof, an anterior or parietal arch and a posterior pineal arch.

The pinealis is entirely derived from the posterior arch, the parietal or post-velar arch making no contributions to it.

With farther development the pineal arch gives rise to an eye-like structure while the parietal arch gradually becomes lost in the tissue between the superior commissure and the velum transversum.

In the early stages neither arch shows any more indication of being a paired structure than does any other part of the brain roof. In later stages, however, the base of the pineal stalk is attached a little to the right of the median line, and this, with a correlated asymmetry of some other parts lends a little support to the view that the epiphysial organs were originally paired. There is no evidence that the existing pinealis is derived by the fusion of paired organs.

The structure of the wall of the terminal vesicle is such that, without the knowledge of the pinealis and parietal organ in other forms, this would not probably be regarded as a modified eye.

Distinct nerve fibers run from the vesicle through the stalk to the roof of the mid-brain where they are distributed to different parts, some going to the superior commissure and the associated habenular ganglion, some going to the region of the posterior commissure, while some on the dorsal (morphologically posterior) side of the stalk undergo a decussation before entering




the region of the posterior commissure.

The nervous connections, though not traced into discrete cells of the terminal vesicle, are such as to render it almost certain that the pinealis is sensory, but there is nothing found which militates against its having other functions.




## Bibliography.

- Balfour, F. M. 1878. A monograph on the development of the Elasmobranch fishes. London.
- Cattie, J. 1881. Recherches sur la grande pineale (epiphysis cerebri) des Plagiostomes, des Ganoides et des Teleosteens Archives de Biologie, Vol. 3.
- Beauregard, 1881. Encephale et nerfs craniens du *Ceratodus forsteri*. Journal de l'Anatomie et de la Physiologie.
- Bing, R. and Burckhardt, R. 1905. Das Centralnervensystem von *Ceratodus forsteri*. Jena.
- Burckhardt, R. 1892. Das Centralnervensystem von *Protopterus annectans*. Berlin.
- Dendy, A. 1907. On the parietal sense organs and associated structures in the New Zealand lamprey (*Geotria australis*). Quart. Jour. Micr. Sci., Vol. 51.
- Dendy, A. 1910. On the structure, development and morphological interpretations of the pineal organs and adjacent parts of the brain in tuatara (*Sphenodon punctatus*). Philos. Trans. of Royal Soc., Vol. 201.
- Ehlers, E. 1878. Die Epiphyse am Gehirn der Plagiostomen. Zeitsch. Wiss. Zool., Vol. 30, Supplement.
- Gaupp, E. 1897. Zirbel, Parietalorgan und Paraphysis. Ergebn. Anat. u. Entwickl., Vol. 7.
- Hill, C. 1894. The epiphysis of Teleosts and *Amia*. Jour. Morph. Vol. 9.
- Huxley, 1876. On *Ceratodus forsteri*. Proceedings of the Scientific meeting of the Zoological Society of London.



- Locy, W. A. 1893. The derivation of the pineal eye. *Anat. Anz.*, Vol. 9.
- Locy, W. A. 1894. The optic vesicle of Elasmobranchs and their serial relation to other structures in the cephalic plate. *Jour. Morph.*, Vol. 9.
- Locy, W. A. 1895. Contributions to the structure and development of the Vertebrate head. *Jour. Morph.*, Vol. 11.
- Minot, C. S. 1901. On the morphology of the pineal region, based upon its development in *Acanthias*. *American Jour. of Anatomy*, Vol. 1.
- Sargent, P. E. 1904. The optic reflex apparatus of Vertebrates for short circuit transmission of motor reflexes through the Reissner's fibers: Its morphology ontogeny, phylogeny, and its function. Part I, The fish-like Vertebrates. *Bull. Mus. Comp. Zoology*, Vol. 45.
- Scammon, R. E. 1911. Normmentafeln zur Entwicklungsgeschichte des Wirbelthiere. Jena.
- Scott, W. B. 1887. Notes on the development of *Petromyzon*. *Jour. Morph.*, Vol. 1.
- Spencer, W. B. 1887. On the presence and structure of the pineal eye in *Lacertilia*. *Quart. Jour. Micr. Soc.*, Vol. 2.
- Van Wijhe. 1882. Über die Mesodermsegmente und die Entwicklungsgeschichte der Nerven des Selachierkopfes. *Verhand. K. Akad Amsterdam*, Vol. 22.
- Wells, G. 1917. The skull of *Acanthias vulgaris*. *Jour. of Morph.*, Vol. 28.






## Explanation of Figures.

\* \* \* \* \*

p.c. - posterior commissure.  
v.tr. - velum transversum.  
pi. - pinealis.  
p. - parietal organ.  
pa. - paraphysis.  
s.c. - superior commissure.  
n.b. - mid brain.  
f.b. - fore brain.  
ch.p. - choroid plexus.  
p.s. - pineal stalk.  
n.f. - nerve fibers.  
s.c.f. - subcommissural fossa.  
ct. - connective tissue.  
co. - coagulum.  
n. - nucleus of sense cells.  
ep. - epidermis.  
cor. - corium.  
car. - cartilage.  
b.v. - blood vessels.  
p.p. - parietal plug.  
n.f.l. - nerve fiber layer.  
l.r. - lenticular region.  
n.c. - nuclei in coagulum.  
b.p.g. - basi-pineal groove.  
pr. - prominence.  
p.v. - pineal vesicle.




r.f.b. - roof of fore brain.

t.ch. - tela choroidea.

\* \* \* \* \*

Plate I.

- Figure 1.- Optical section of 10.25 mm. embryo. X 73.
- Figure 2.- Optical section of 13. mm. embryo. X73.
- Figure 3.- Optical section of 12 mm. embryo. X 73.
- Figure 4.- Sagittal section of 12.5 embryo. X 73.
- Figure 5.- Sagittal section of 15 mm. embryo. X 73.
- Figure 6.- Sagittal section of 26 mm. embryo. X 73.
- Figure 7.- Sagittal section, length not recorded. X 46.
- Figure 8.- Sagittal section 27 mm. embryo (not quite sagittal through posterior commissure). X 46.
- Figure 9.- Sagittal section 30 mm. embryo. X 46.
- Figure 10.- Section of retinal region of 60 mm. embryo. X 230.
- Figure 11.- Transverse section of 23.5 mm. embryo through the midbrain and pineal vesicle showing distal end of pinealis to the right of the axis of the brain. X 15.
- Figure 12.- Transverse section of 23 mm. embryo through the fore-brain and midbrain passing through the base of the pinealis. X 15.
- Figure 13.- Transverse section of 33 mm. embryo through forebrain and midbrain, passing through the superior commissure and basal region. X 15.
- Figure 14.- Sagittal section of base of pinealis showing nerve connections with superior and posterior commissures. X 73.



## Plate II.

- Figure 15.- Transverse section through vesicle of pinealis in situ. X 23.
- Figure 16.- Same transverse section as figure 15. X 73.
- Figure 17.- Sagittal section through pineal vesicle through a longitudinal ridge - "pup". X 73.
- Figure 18.- Sagittal section through pineal vesicle through a longitudinal groove - "pup". X 73.
- Figure 19.- Sagittal sections through pineal vesicle showing lenticular and retinal areas - "pup". X 155.
- Figure 20.- Sagittal section through the pineal vesicle showing relation to cranial elements - "pup". X 73.
- Figure 21.- Sagittal section of portion of pineal stalk of "pup" X 155.
- Figure 22.- Not quite sagittal section through pineal vesicle of adult. X 73.
- Figure 23.- Section lateral to section shown in figure 22 of adult pineal vesicle. X 73.
- Figure 24.- Section lateral to section shown in figure 23 of adult pineal vesicle. X 73.
- Figure 25.- Section of pineal stalk. X 73.

## Plate III.

- Figure 26.- Dorsal view of wax reconstruction of proximal portion of pineal stalk showing attachment to the right (model reversed) of the median line. X46.
- Figure 27.- Ventral view of wax reconstruction showing subcommissural fossa. X 46.




Figure 28.- Reconstructed drawing from several sections through median portion of pineal stalk (pineal vesicle partially torn away) showing relation of epiphysial structures in "pup". X 34.

Figure 29.- Decussation of pineal nerves. X 230.

Figure 30.- Sagittal section to one side of the recessus sub-pinealis showing nerve connections of pinealis with posterior commissure.






PLATE 1

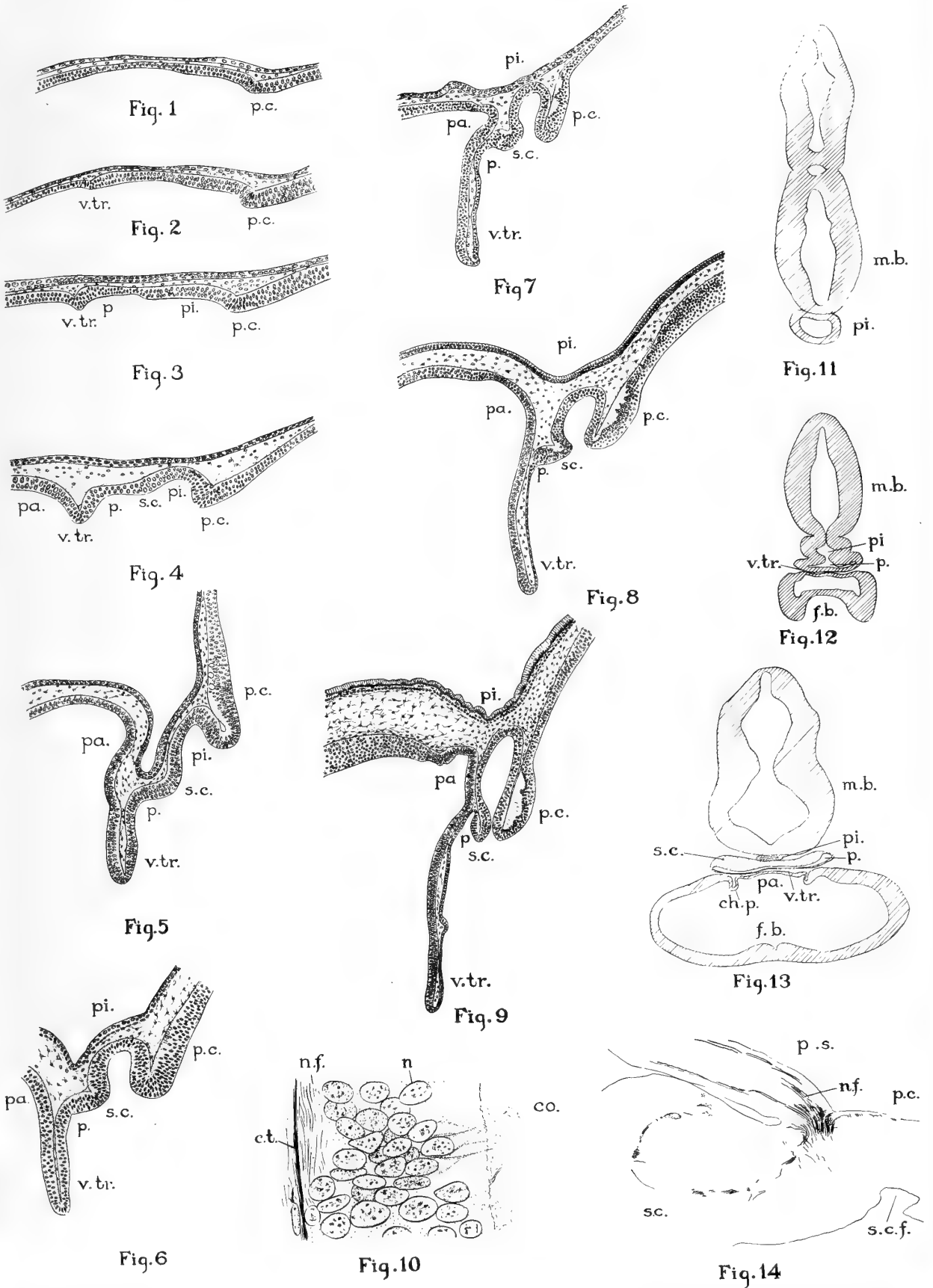




PLATE 2

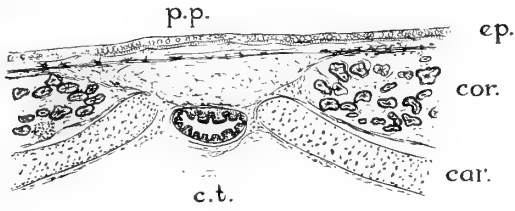


Fig. 15

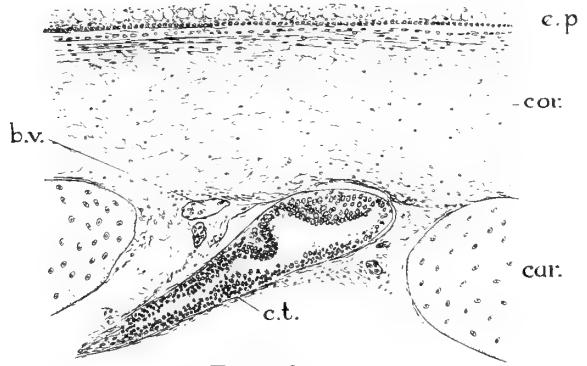


Fig. 20

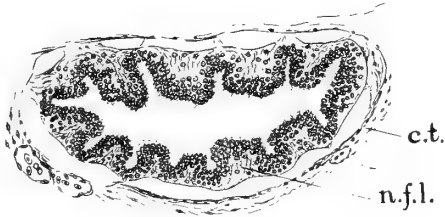


Fig. 16

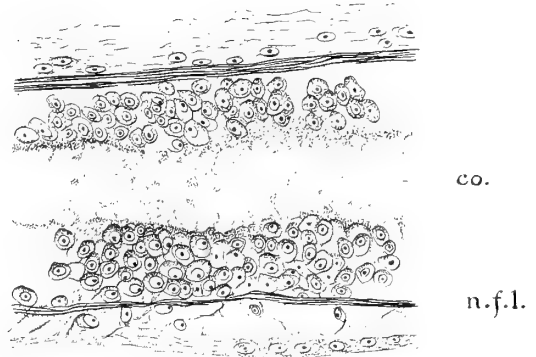


Fig. 21

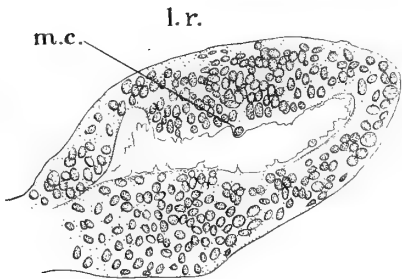


Fig. 17

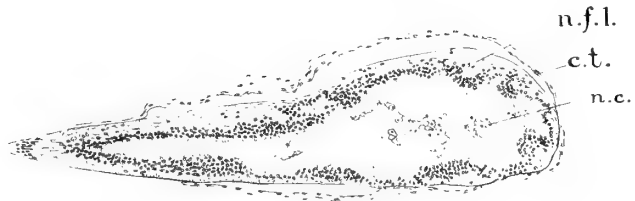

Fig. 22

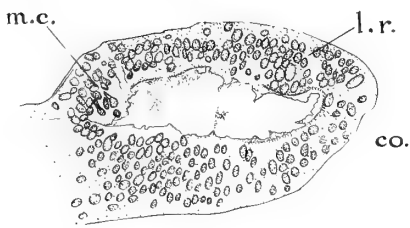


Fig. 18

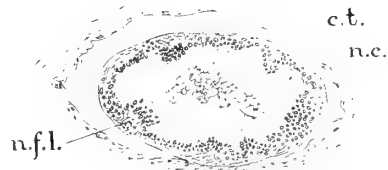


Fig. 23



Fig. 19




Fig. 24



Fig. 25



PLATE 3

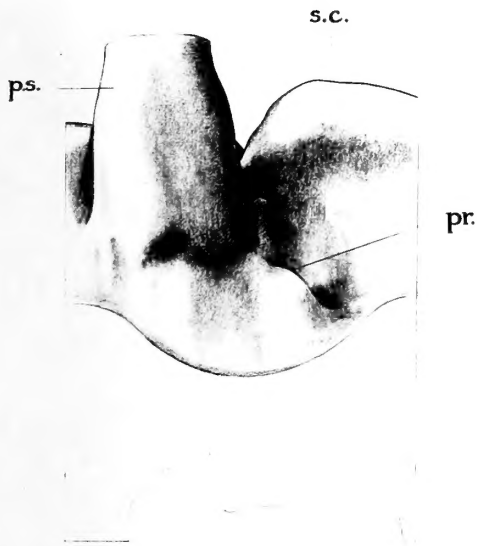


Fig. 26

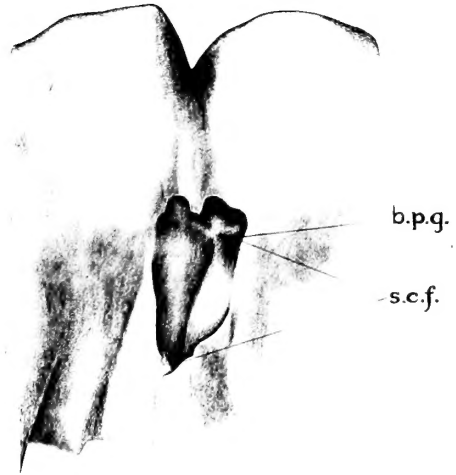


Fig. 27

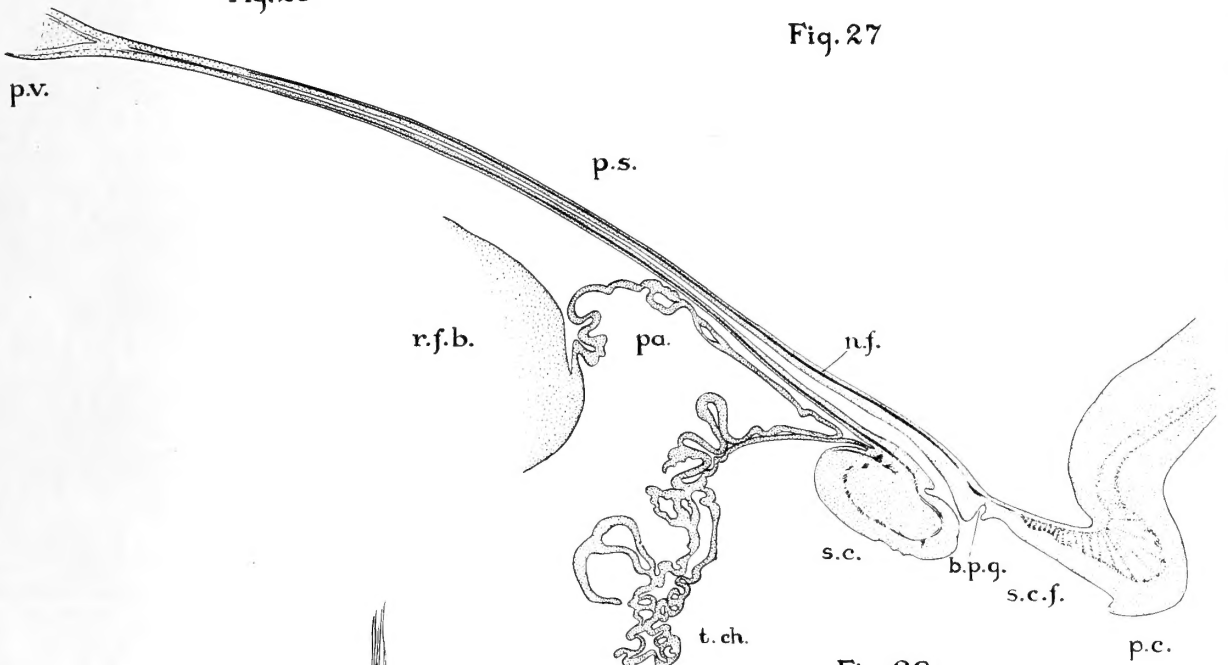


Fig. 28

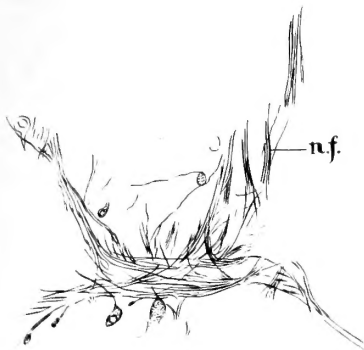


Fig. 29

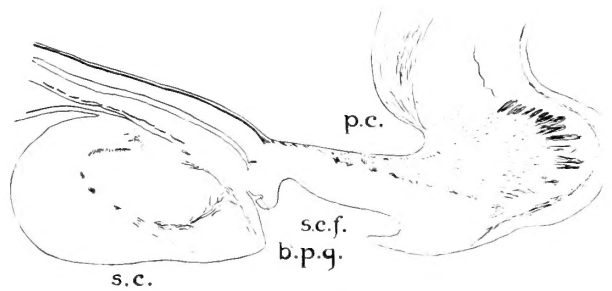


Fig. 30

LIBRARY  
OF THE  
UNIVERSITY OF ALABAMA



UNIVERSITY OF ILLINOIS-URBANA



3 0112 086832430