



JOHN A. SEAVERNS

Webster Family Library of Veterinary Medicine
Cummings School of Veterinary Medicine at
Tufts University
200 Westboro Road
North Grafton, MA 01536

VETERINARY MEDICINE SERIES

No. 17

Edited by D. M. Campbell

FISTULA OF THE WITHERS
AND POLL-EVIL

BY

Major L. A. MERILLAT, Sr., V. C., N. A.,

Editor, Department of Surgery,

AMERICAN JOURNAL OF VETERINARY MEDICINE



Published by
American Veterinary Publishing Co.,
Chicago

Copyright, 1917, by
American Veterinary Publishing Co.
Chicago

CONTENTS

FISTULA OF THE WITHERS	Page
Introduction	7
The Withers	13
Pathogenesis	37
Symptoms	57
Treatment	67
POLL-EVIL	
The Poll	105
Pathogenesis	113
Symptoms	121
Treatment	127

PREFACE

There are several reasons why a manual on this disease should be a part of the veterinary literature of the day, the chief one being that fistula of the withers is a very prevalent disease of horses and thus exacts a big toll from the horse industry. Another reason for bringing it especially to the attention of readers of veterinary literature is the deplorable fact that its treatment has never been standardized in the veterinary profession. Almost all long known and common complaints of domestic animals of a serious character are handled according to definite plans, differing only in minor details. The many conferences of our teachers of surgery in association work, and the interchange of ideas made possible by the splendid periodicals which all progressive veterinarians now read, as well as the profusion of all kinds of literature that reaches everyone, has fortunately created a standard of treatment for nearly all of the more important ailments of animals.

Not so, however, with fistula of the withers. Each seems to have his own plan of treatment and few, indeed, claim even a fair degree of

success. Some are satisfied with caustics, others with lancing and irrigations, others with bacterins, while a few of the more daring prefer radical surgery that removes the causative elements. To these plans might also be added that of those who avoid fistula of the withers entirely, because of the discredit meddlesome intervention generally brings them.

In every rural community of the Middle West the empiric finds a fruitful field for exploitation in the many chronic, loathsome, half-cured fistulæ of the withers found in the hands of owners willing to try anything after having given up in despair the various treatments that have failed.

If this book will do no more than to inspire the veterinary practitioner to approach this ailment in a matter of fact manner and to handle it according to the common laws of modern surgical procedure; and if it will discourage a continuance of the half-hearted and always unsatisfactory methods in vogue, the effort will not have been lost.

The Author.

Camp Mills, N. Y., December, 1917.

INTRODUCTION

The disease known universally among American veterinarians as fistula of the withers is described at much greater length in the following pages than has ever been done before in veterinary literature. Most of the authors of surgical subjects have dismissed this affliction with a few words, referring to it only incidentally as an occasional complication of harness galls or other forms of trauma about the crest of the neck and withers, but always without dignifying it as an entity worthy of special notice. Its frequent origin in the bursæ on the thoracic spines of the region and its development independent of any apparent injury have only recently attracted attention. In fact, there are many who still entertain the opinion that it is but a complication of a contusion inflicted by the collar, by rolling upon hard ground, by striking against a low stable beam, by rubbing against branches of trees while at the pasture, or by bites from other horses. Without ever having been able to attribute any given typical fistula of the withers to a given traumatism, the theory of traumatic origin has been indifferently accepted as ample expla-

nation of its cause. Thus years have been wasted in attacking the disease from without, giving only casual attention to the "interior" of the withers where it actually originates.

We do not insist that the names "fistulous withers" or "fistula of the withers" are even good appellatives for the disease we are about to describe. On the contrary, a name less specially pathologic in its meaning would seem more appropriate, since fistula is but a phase of the entity as a whole. The name, inappropriate as it is, we retain because among our American readers it has been consecrated by so many years of usage that a change would lead to no better understanding of our exposition or argument. We retain the name, therefore, with the full knowledge that it is appropriate only for the latter stages of the disease and that the fistulae are but insignificant parts of the total pathogeny.

Poll-evil, which we argue is but the same condition attacking the atlantal bursa, has, on the contrary, been more extensively described by writers throughout the history of modern veterinary science, and although it had been referred to always as a complication of a traumatism in the earlier days, it was the first of these two diseases to be recognized as a bursitis. It has been designated as inflammation of the

bursa of the ligamentum nuchæ and by some writers as inflammation of the ligament itself. No one has thus far been able to prove its definite cause. Like fistula of the withers, apparently for want of an explanation based on demonstrable facts, it has always been attributed to bruising of the poll.

While we do not entirely eliminate traumatism as the cause of some cases of poll-evil and some attacks of fistula of the withers, it has been our experience that when injuries are the cause, the wound or bruise is always apparent and the disease advances into the depths of the region by gradual stages from the initial focus deeper and deeper until the interior is finally attacked by the encroaching pyogenic process. In ordinary cases of both of these afflictions, the initial focus is always central, far down in the depths of the body where external violence can have but little influence. From this central location the disease as gradually advances in the outward direction in the ordinary case, as it does inward in the exceptional cases due to trauma. We have, therefore, no choice than that of describing both poll-evil and fistula of the withers as having two distinct causes, one a wound or bruise at the very surface, and the other, and commonest, as yet unknown.

The prevalence of fistula of the withers and

poll-evil we have found to be much greater in some localities than others. In some districts it is actually an equine scourge, while in others it is a rare occurrence. In southern California, for example, veterinarians seldom if ever see a typical fistula of the withers or poll-evil, while in central Illinois it is a veritable horse plague. In a recent conversation with an old horse breeder in the latter location the information was elicited that fistula was once as rare there as in California. Asked if he had any theory to advance as to the cause he seemed inclined to attribute most cases to influenza, and colt distemper, claiming that before these diseases became prevalent from the interchange of horses from shipping centers there were no cases of fistula of the withers. The rarity of shipping fever (influenza) in California, seems to add logic to these observations.

But no matter what the cause may eventually prove to be, the veterinary practitioner is today confronted with a serious disease of horses that he must endeavor to control and handle to the better satisfaction of horse breeders and the public. To fall short of meeting this requirement is one more adverse reflection on our ability to meet the demands of our growing live stock industry. To study, to experiment with, to strive to curb, and to analyze

this affliction from every angle is therefore a worthy enterprise. It is at least a problem of the rural districts of the Middle West that is neither well handled, nor, so far as we can perceive, intelligently studied.

The loss in horses in Illinois from fistulæ alone reaches into the thousands. The loss to veterinarians from their helplessness in handling the cases and the discredit this state of helplessness brings to the veterinary profession are matters to be thoughtfully considered.

The fact that the treatment of poll-evil is no longer an unsolved problem in veterinary surgery, and that this treatment, now standard for more than ten years, has proved as nearly universally successful as any surgical departure can prove, and the further fact that this ailment differs from fistula of the withers only in matters governed by the location, should, it seems to us, have spurred veterinarians to resort to similar measures for handling both. The fact that the latter is located in a more complex region and requires an operation of greater magnitude is, we believe, the only reason why no advance has been made in its treatment.

Better surgery from every angle by which good surgery is judged (anesthesia, restraint, asepsis, hemostasis and wound treatment)

will, we believe, eventually solve the problem of fistula of the withers in the same way that the much simpler operation has solved that of poll-evil.

THE WITHERS

The region of the anatomy called the withers has no well defined limits. The word "withers," therefore, while academic in hippology, is not usually found indexed in text books on anatomy. It is described as to shape in the study of types, but seldom as regards to its component parts, except in surgical anatomy—a branch of veterinary science that is as yet ill-developed. The horse judge studies the profile of the withers very carefully because the general appearance of any given horse depends a great deal upon its shape, its size and the measurements of its dimensions. The surgeon studies not only its shape and dimensions, but its constituent parts as well and their complex and disadvantageous arrangement from the surgical point of view.

It is important to note that the withers may be high, low, narrow, broad, steep, sloping, long or short, and that any two or three of these characteristics combine to determine the various types of withers of different individuals. Graphic writers in describing equine types often use such terms as sharp withers, low withers, high withers, long withers, thick

withers, muscular withers, effaced withers, prominent withers, each of which, in addition to being descriptive in the study of profile, is equally suggestive in the study of etiology of affections of these parts and their surgical treatment. Each one of these characteristics contributes to a different etiologic factor as well as a different surgical problem.

Boundaries

The withers, although having ill-defined limits, may be said, for surgical study, to extend from the crest of the neck anteriorly, to a point posteriorly, where the dorsal spines descend to the level of the back. The second dorsal spine may be selected as the uniform anterior limit, but posteriorly no line can be drawn, because some withers end abruptly toward the level of the back, while others slope gradually to a more distant posterior point between the eighth and twelfth spines. The highest point is almost universally at the fifth spine. The second dorsal spine may, therefore, be said to represent the anterior boundary, the fifth spine the summit and any point between the eighth and twelfth dorsal spines the posterior boundary. In the downward direction, the withers may be said to descend to the bodies of the vertebrae mesially and to the distal border of the scapu-

lar cartilage, (cartilage of prolongation) laterally. With these boundaries as a point of departure, each structure comprising the withers might be studied *per se*, but from the surgical point of view its study *en masse* is of first importance.

Component Parts

The withers are composed of skin, fascia, muscles, ligaments, cartilage, bones, blood vessels, lymphatics and nerves. These are combined in a very complex and exceedingly disadvantageous manner, since *in situ* they form a pyramid whose base is loosely arranged while the summit is dense. The summit of the withers, under the skin, is composed of hard ligamentous structures fixed firmly to the underlying bones. From this point, the layers of which the region is constituted separate from each other in the downward direction, permitting thereby a ready filtration of pus into constantly deeper and more inaccessible fortresses, and constituting a favorable field for the fruitful development and undisturbed sojourn of inflammatory processes of a chronic character. The base of the pyramid is bounded laterally and ventrally by bones (the scapulæ and bodies of the dorsal vertebræ) while anteriorly and posteriorly its component structures extend

without change of arrangement into the neck and back. Thus pus within the withers after filtering downward finds its only exit by traveling first in either of these two directions, and ultimately to the surface of the body at points remote from the seat of development. It is this complex arrangement that affords the impregnable intrenchment of pathological products and that is responsible for the refractory character, the extreme seriousness and the unvarying chronicity of the disease known as fistula of the withers.

The Skin

The skin covering the withers possesses nothing unusual except the thickness of the subcutem along the median line anteriorly where the heavy connective tissue of the mane begins. Posterior to the summit of the withers the skin is of normal thickness, but is separable only with difficulty from the aponeurosis of the fleshy panniculus whose fixed attachment is at the level of the fourth or fifth spine. Very often, however, the skin is the seat of scars supervening harness and collar injuries which fuse it into the underlying ligaments, fascia or muscles as the location may determine.

Panniculus Carnosis (Cutaneous Muscle)

This muscular structure is a prominent feature of the withers in that its chief attachment

is to the summit. Along the region of the withers its fibers, unlike those of any other part of the body, are vertical, extending downward to the proximal border of the scapular cartilage, where they find another fixed attachment. It is fused with and in fact may be regarded a part of the superficial fascia. As a structure to incise for invasions into the withers it may be so considered. Beneath the superficial fascia is another aponeurotic layer whose fibers are so arranged as to cross those of the trapezius beneath at right angles. This layer is of no special surgical importance. It is found only in a careful dissection of the region and is in no way influential in guiding pathological processes nor in shaping surgical procedure.

The Trapezius

The trapezius, excluding the fascia just mentioned, is the third layer of the withers and is really the first of the anatomical structures that must be reckoned with in the study of fistula. It is a triangular membranous muscle with its base upward running along the withers where its aponeurosis is attached to the supraspinous ligament along the withers and to the ligamentum nuchæ in the cervical region, extending in all from the axis to the tenth dorsal vertebra. This triangular sheet-like structure

is bisected vertically with a central aponeurosis that is attached ventrally to the tuber spinæ of the scapula. The anterior part is the trapezius cervicalis and the posterior the trapezius thoracalis.

The Roof of the Withers

Together with the skin, the fascia and the panniculus carnosus, the trapezius muscles may be regarded as the "roof of the withers."

It is under this roof that typical fistulæ of the withers develop and beneath which the atypical (traumatic) fistulæ burrow in directions of resistance less than that afforded by its dense, aponeurotic character.

Rhomboideus Thoracalis

The rhomboideus thoracalis extends from the spinous processes of the second, third, fourth, fifth, sixth and seventh dorsal vertebræ in a downward and outward direction to the mesial face of the scapular cartilage. It constitutes a thick, heavy curtain forming a "second or inner roof of the withers." Compared with the structures of a building, it might be said to be a curtain, sagging slightly in the middle, that extends from the comb of the roof to a point on the wall just beneath the plate beam. It is very loosely attached to the

mesial face of the trapezius laterally and to the longissimus dorsi ventrally and spinalis dorsi mesially and ventrally. Secondary abscesses of fistulæ of the withers said to be located "under the scapula" are in reality located under this muscle, resting upon the longissimus dorsi but without any obstacle against the filtration of pus further down than under the upper part of the serratus dorsi. Pus seldom goes to a lower level because the latter muscle is attached firmly to the costal surface and above to the mesial face of the scapula, forming a space having a firm floor but without anterior and posterior walls.

Rhomboideus Cervicalis

The rhomboideus cervicalis is the forward elongation of the thoracalis, extending toward the head along the ligamentum nuchæ as far forward as the axis. Its insertion is the anterior part of the mesial face of the cartilage of prolongation. Its surgical importance lies in the fact that its ventral margin just in front of the scapula affords a point of invasion into the seat of a typical fistula (Fig. 2). It is also so closely related to the ligamentum nuchæ that it seldom escapes attack from the morbid process, and when heedlessly sacrificed in resecting the ligamentum nuchæ a pronounced de-

formation of the crest of the neck (ewe-neck) results. It may be said to reinforce the "roof of the withers" anteriorly.

Other Structures Important Surgically

The splenius and the *serratus cervicis* are related to, in fact occupy, the anterior part of the withers. They lie immediately below the *rhomboideus cervicalis* and beneath the *trapezius cervicalis*. Their upper margins are related to the former. Just in front of the cartilage of prolongation they are very loosely attached to the *rhomboideus* and thus afford the portal for surgical invasion above referred to. They are thick, tuberos curtain-like muscles forming the bulk of the crest of the neck and on account of their thickness prevent facile direct invasion to the bottom of pus cavities which are usually located below this margin at the level of the second dorsal spine. These two thick muscles, in short, form the lower part of the lateral walls of the pus cavity in fistula of the withers. The treatment of fistula of the withers would be a lesser problem if the pus cavity could be drained over the dorsal margin of these muscles instead of through them.

The longissimus dorsi. The *longissimus dorsi* at the withers occupies the space between the

rhomboideus and the complexus and spinatus. These three muscles may be said for descriptive purposes to fill in the angular space formed by the ribs and vertebral spines.

Structures of Lesser Surgical Importance

The complexus anteriorly and the spinalis dorsi posteriorly have no especial surgical significance, except that the former lies closely attached both to the lamellar and the funicular portions of the ligamentum nuchæ and the latter to the spines of the vertebra and are therefore implicated in disease processes, and besides being just two more structures to form channels for the burrowing of pus they in no way govern the course of surgical operations. In fact pus cavities that have formed beneath these muscles are inaccessible and disease of the structures between them (bones posteriorly and the lamellar portion of the ligamentum nuchæ anteriorly) usually constitutes an incurable condition.

Viewed as a Whole

The muscles of the withers viewed with the purpose of standardizing surgical procedure against fistula may be compared to an irregularly-shaped covered trough containing a longitudinal partition. Anteriorly the trough is walled by the splenius and the serratus cer-

vicis, posteriorly by the serratus thoracis and the scapular cartilage. Its floor is formed by the longissimus dorsi and its roof by the trapezius and rhomboideus. The central partition is constituted of the dorsal spines, spinalis dorsi posteriorly and the lamellar portion of the ligamentum nuchæ covered with the complexus anteriorly. The bottom of the trough which must be reached for effectual drainage can be penetrated only with difficulty and the risk of inviting complications in structures not previously implicated. Furthermore, these muscles being in constant use in locomotion, respiratory acts and movements of the neck, tend to encourage the burrowing of pus into still more inaccessible recesses.

Thus we find the musculature of primal importance in any study of fistula of the withers. It bounds initial abscess cavities in places difficult of access for drainage, they move upon each other and favor the distribution of purulent products into new fields, where secondary abscesses are formed, and it exhibits a remarkable trend toward fibrosis under the influence of the chronic inflammation of adjacent parts.

The Ligaments

The ligaments implicated in fistula of the withers are the ligamentum nuchæ and the

supraspinous ligament, each of which is but a continuation of the other; the dorsoscapular; and the interspinous ligaments, which curtain off the spaces between the spinous processes.

The ligamentum nuchæ is a strong, powerful apparatus composed of yellow elastic tissue and divided into two distinct parts: the *funicular* portion and the *lamellar* portion. The former which is of especial importance in fistula of the withers and poll-evil, extends from the occipital bone anteriorly to the summit of the withers posteriorly where it becomes white fibrous tissue and is continued over the spines of the sacrum as the posterior part of the supraspinous ligament. It is composed of two lateral halves each of which is heavy and flattened at the withers but gradually becoming round and somewhat smaller toward the occipital crest to which it is attached to the occipital protuberance. Two bursæ are found associated with this structure—one at the atlas and the other in the dorsal region. The *atlantal bursa* is the seat of poll-evil while the *dorsal* or *supraspinous bursa* is the location of typical fistula of the withers. The atlantal lies between the ligament and the dorsal surface of the atlas. The dorsal bursa is usually over the third dorsal spine but sometimes extends backward as far as the crest, that is, over

the fourth and the fifth spines, and often as far forward as the second. It is at the level of the second dorsal spine where the causative center of most of the cases of fistula of the withers that we have examined carefully, were located.

An important point to remember about the funicular portion of the ligamentum nuchæ is its wide expansion posteriorly. Approaching the crest of the withers it extends in the outward and downward direction five to six inches, partly enveloping the rhomboideus and trapezius. This expanded portion is often the cause of recurrence of fistula after the main portion has been removed.

It is surmounted along its course by the "pad of the mane" a structure composed of elastic fibers interspersed with adipose tissue. It is most abundant in the middle of the cervical region and is best developed in stallions of the draft breeds.

The funicular portion is a sheet-like partition dividing the superior cervical muscles into halves. It is composed of two layers attached loosely to one another by areolar tissue, and each layer is composed of two parts, anterior and posterior. The anterior part is thick and strong, attached to the funicular portion above and to the cervical spinous proc-

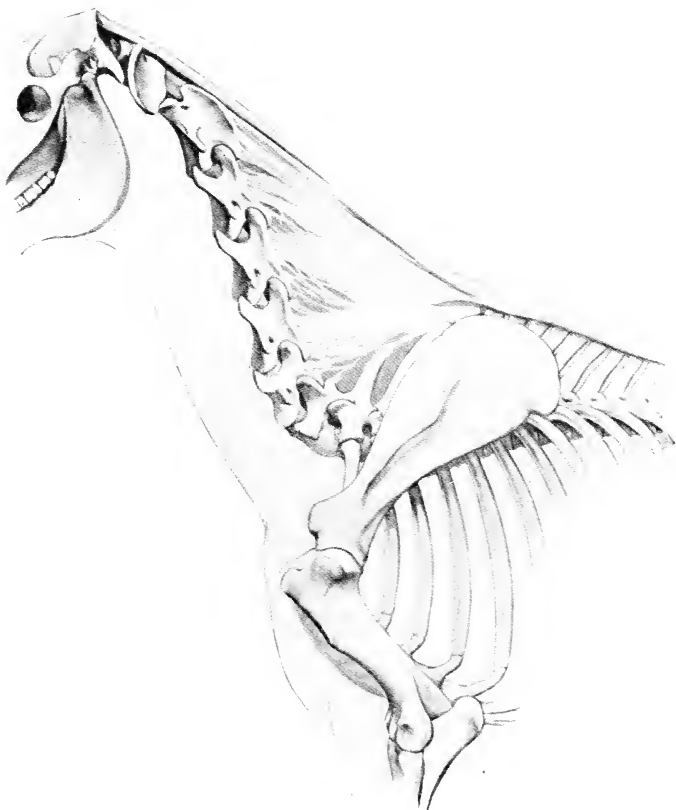

FIG. 1—LIGAMENTUM NUCHE OF HORSE.

Note particularly the relation of the funicular portion of the ligamentum nuche to the atlas and to the spines of the thoracic vertebrae. Also the arrangement of the lamellar portion. (After Sisson.)

esses below. The posterior part is attached to the second and third dorsal spines and extends in the form of several digitations forward and downward where its brush-like fibers reach the spines of the fifth and sixth cervical segments. The fibers of the ligament are more spare than in the anterior part and sometimes do not even reach the sixth vertebra. Between the anterior and the posterior parts is a space of considerable dimensions which especially in horses of good flesh contains a mass of fatty tissue. This opening is at the level of the extremity of the second dorsal spinous process and is the seat of typical fistula of the withers. It is the space where the sacculation of fistula begins.

The supraspinous ligament is a structure composed of white fibrous tissue and extends along the dorsal region to the sacrum. It is the continuation of the ligamentum nuchæ posteriorly. A careful dissection of this structure fails to show that it begins as an independent structure, as its fibers although they change in structure from yellow elastic to white fibrous tissue, are simply continuations of each other. From the surgical standpoint the supraspinous ligament and the ligamentum nuchæ must be regarded as a single apparatus which changes in the character of its tissue at the crest of the withers. Over the crest it is a very thick, dense

structure and along its whole course backward it is attached firmly to the summits of the spines.

The interspinous ligaments are thin membranous structures connecting the spines to one another and completely filling in the space between them from the bodies to the supraspinous ligament above, and thus completing a perfect partition between the two halves of the withers

The dorso-scapular ligament is a reflection of the superficial fascia. It is a thick aponeurosis attached dorsally to the crest of the withers and passing outward and downward under the rhomboideus to the scapula and giving off layers which pass between the underlying muscles—the longissimus and spinalis. At the crest it is really the aponeurotic origin of both the rhomboideus thoracalis and the splenius.

The importance of these ligaments in fistula of the withers lies in the fact that they are implicated in the disease more commonly than the other component parts. Lying adjacent to the initial seat of the inflammatory process, and being but poorly nourished structures, they fall an easy prey to microbial products, becoming riddled with necrotic areas and thus preventing cicatrization of contiguous abscess

cavities. In poll-evil it is the anterior part of the funicular portion of the ligamentum nuchæ that prevents healing, while in fistula of the withers it is the posterior end or its ligamentous continuation—the supraspinous ligament—that is implicated.

Cartilages of the Withers

The cartilaginous tissue included among the component parts of the withers is found in the scapular cartilage (cartilage of prolongation) and in the semi-cartilaginous summits of the dorsal spines.

The scapular cartilage which is attached to the vertebral border of the scapula is a wide expanse of hyaline cartilage about two inches wide extending from the cervical to the dorsal angle. It is thick at the attachment to the bone but becomes thin toward its vertebral border which presents an evenly rounded profile. Its mesial relations are the rhomboideus and the serratus ventralis and its lateral the trapezius and the attachment of the panniculus carnosus. To these muscles it is intimately related, being in fact imbedded in them. It forms the lateral wall of many of the secondary abscesses of fistula and its cervical angle and sometimes its vertebral border becomes implicated in the disease. By becoming divested of

its muscular attachments and perichondrium it plays the role of a foreign body and thus perpetuates secondary fistulous tracts, which, on account of the movement to and fro are very slow to cicatrize, even after the necrotic parts have been extirpated.

Cartilage is found on the spinous processes of the third, fourth, fifth, sixth and seventh spines, but is most abundant on the fifth and sixth. To this cartilage is fused the fibers of the supraspinous ligament. When the ligament detaches from disease the cartilaginous ends lie bare and being soft often induce surgeons to indulge in reckless curetting when no such procedure is indicated. Protruding like stumps into the bottom of the abscess cavity and being slow to separate from the viable bone beneath, these cartilaginous summits are exceedingly instrumental in delaying cicatrization and a prolific source of recurrences.

Bones

The bones of the withers are the spinous processes of the dorsal vertebræ from the second to the point posteriorly where they reach the level of the back. They incline backward. They are thin at the anterior border, thick posteriorly and expanded dorsally to receive the attachment of the supraspinous ligament.

They increase in length from the first to the crest (the fifth) and then gradually diminish to the twelfth. Those immediately over the crest exhibit the cartilaginous ends above mentioned. The increase in length is not symmetrical, the second being almost twice as long as the first.

They are connected to one another by the interspinous ligaments which complete an impervious partition between the two lateral halves of the withers. Laterally they are covered with the spinalis and longissimus dorsi muscles.

The spinous processes rank high in importance in the study of fistula of the withers. The initial pathological process of typical fistulæ is usually seated on the second and third segments. The cyst which constitutes the first pathological change is attached to them and when opened often exposes their cartilaginous summits. In traumatic fistulæ originating from superficial wounds, these processes often become the seat of a stubborn osteitis that descends into the cancellated tissue, sometimes as far down as the bodies of the vertebræ, creating very chronic if not always incurable conditions.

The student of surgical anatomy should remember their length at the different points,

their cartilaginous summits, their backward direction, their connecting media and the contiguous musculature.

Blood Vessels

The withers receives its blood supply chiefly from two sources: the *dorsal* and the *deep cervical* arteries. Both are direct radicals of the brachial arteries, or more correctly speaking, the left one arises from the left brachial artery and the right one from that part of the same vessel on the right side while it still bears the name brachiocephalic artery. The origin of both is within the thorax. The dorsal enters the region of the withers through the second intercostal space and the deep cervical, through the first. Both of them leave the thorax near the bodies of the vertebræ. Their extra-thoracic distribution alone interests us, in surgery of the withers.

Extra-thoracic distribution of the dorsal artery. After emerging from the thorax through the second intercostal space it passes under the longissimus dorsi in an upward and backward direction, soon dividing into several branches. The largest anterior branch passes forward and upward under the splenius; extending branches anastomose with the deep cervical or are lost in the deep muscles of

the cervical region. The posterior branches pass upward between the dorso-scapular ligament and the rhomboideus and thence to the superficial muscles and skin. These radicals are normally small vessels, but in old fistulæ they are often enlarged into arteries of a formidable capacity. The main trunk lying deeply in the base of the withers is seldom exposed in surgical operations. The variation in the distribution of these branches and especially the enlargement of some of them under the influence of disease make the study of the blood supply of the withers somewhat unsatisfactory from the surgical standpoint. There is always a pronounced difference in the amount of bleeding produced from incisions of exactly the same kind.

The extra-thoracic distribution of the deep cervical artery.—Emerging from the first intercostal space, it passes upward and forward between the lamellar portion of the ligamentum nuchæ and the complexus. Its destination is the region of the poll where it anastomoses with branches of the occipital. Along its course along the neck it exhibits free communications with the vertebral and supplies by lateral branches the lateral cervical muscles. These lateral branches of the deep cervical which enter the splenius and serratus

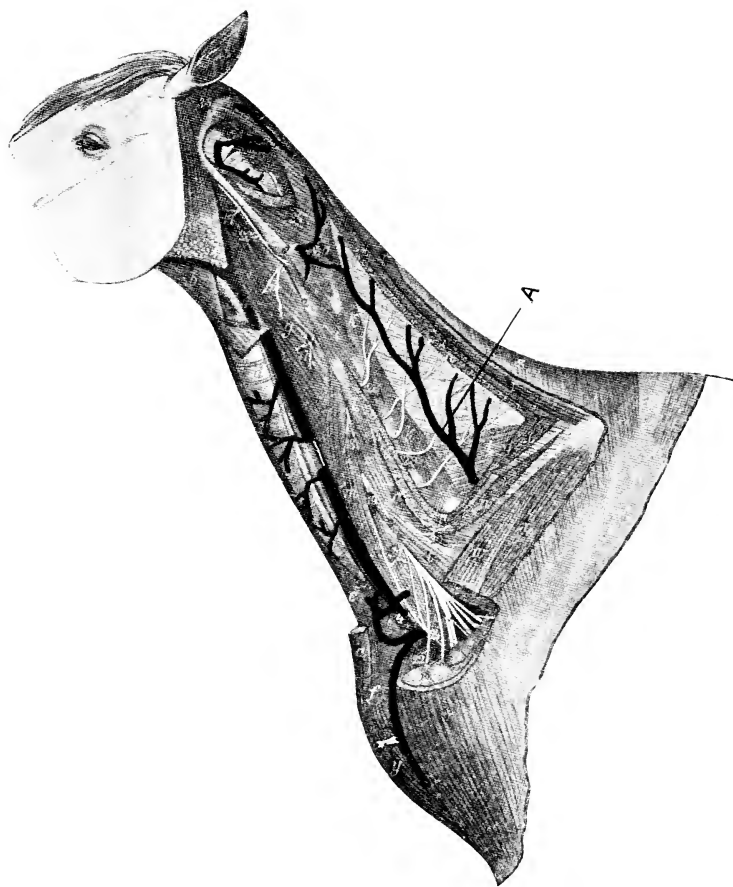


FIG. 2.—DEEP DISSECTION OF NECK OF HORSE.
A. Deep Cervical Artery. (After Sisson.)

cervicis in the region of fistula of the withers are often enlarged into vessels of considerable dimensions.

The vertebral artery.—The vertebral artery which emerges from the thorax in front of the first rib passes between the longus colli and the scalenus, and thence along the vertebral column through the foramina transversaria. At the axis it anastomoses with the occipital and along its course supplies numerous branches to the musculature, of both the dorsal and ventral cervical regions. The former anastomoses freely with branches of the deep cervical.

This artery is of no great importance in surgery of the withers on account of its deep, protected location. That its branches are capable of undergoing enlargement must, however, be considered in operations invading the region of the vertebral column, as for example in attempts to establish a drainage of abscess cavities resting on the bodies of the vertebræ (cervical fistula).

The Nerves

The nerves of the withers are both cranial and spinal. Sensation is supplied by the dorsal branches of the thoracic and cervical spinal nerves while the motor supply is derived not only from those mixed nerves but also from

the spinal accessory—the eleventh cranial—nerve.

The spinal nerves are seldom exposed to view in surgery of the withers and as they have a promiscuous distribution, loss of motor power is never observed from incision of the trunks or their ramuli.

The spinal accessory being the chief motor supply of the trapezius and lying in a superficial position may be incised in making reckless vertical incision over the lateral surface of the scapula below the scapular cartilage. Its division while not attended with any pronounced harm is inadvisable on the general grounds that large muscular areas should not be unnerved.

The Lymphatic System of the Withers

This may be said to include the *intercostal* nodes of this region and the *prescapular* nodes, together with their afferent vessels.

The intercostal nodes are located at the intercostal spaces at each side of the vertebræ, and they receive vessels arising chiefly in and among the dorsal muscles. They are small in the normal state but in fistula of the withers they become larger and may even suppurate or become the initial seat of a secondary pleuritis,

The afferent vessels empty directly into the thoracic duct.

The prescapular glands receive afferent vessels from the skin of the anterior part of the withers and also from the superficial muscles of the neck. The afferent vessels lead to the posterior cervical nodes and thence to the thoracic duct.

PATHOGENESIS

There are two kinds of fistulæ of the withers. One is the *typical* or idiopathic form and the other is the *atypical, traumatic* or *symptomatic* form. The first or typical has its origin in the development of a serous sac or cyst under the ligamentum nuchæ at the level of the second or third dorsal spines, while the second or atypical is caused by an external wound that serves as a portal of entrance for microorganisms. In the first stages these two forms differ very materially in every respect but in the final stage they are alike in that both of them cause disease of the ligamentum nuchæ or its backward extension (the supraspinous ligament) and sometimes the spines of the vertebræ themselves. In short, each form finally plays the same havoc upon these structures, although they have an entirely different pathology at the beginning. Fistula of the withers in the final stage might be properly called *necrosis of the ligamentum nuchæ* or of the supraspinous ligament according to its cephalo-caudal location. In the typical form it is the ligamentum nuchæ that is chiefly affected while the traumatic form, being

usually due to harness bruises, reflects more upon that part of the region occupied by the supraspinous ligament. The disease progresses in many cases from one to the other of these two structures by extension of the disease process in one direction or the other according to the initial seat. That is to say, a fistula beginning in a cyst at the level of the second dorsal spine may attack the ligamentum nuchæ above that level and then travel backward into the supraspinous ligament, while on the other hand a harness bruise may cause a disease of the supraspinous ligament at the level of the saddle seat that will travel forward into the ligamentum nuchæ. In fact, all old cases have this dual involvement and often the spines beneath are found necrotic.

The Typical Form

To make our study more comprehensive we shall divide the development of this form of fistula into three stages, namely: The *saccular* stage, the *phlegmonous* stage and the *fistulous* stage.

1. *Saccular Stage.* This is the initial one. It has its origin in the accumulation of serosity upon or adjacent to one of the dorsal spines, usually the second. Beginning with this collection of serum, which is sero-fibrinous in

character, it gradually enlarges into a cyst of larger and larger dimensions until it becomes clinical by bulging at the surface of the base of the neck or at a point of least resistance adjacent thereto. The sac is at first very small and without any well developed limiting membrane but as it becomes larger the tissues react to the encroachment by forming a firm connective tissue layer around it and at the same time fibrin and cells attach themselves to the inner wall and thus pave it with a smooth carpet that completes a firm encapsulation of the liquid contents. *The amount of connective tissue contained in the encapsulating structure varies with the chronicity of the process. In old, slowly forming cases the fibrous elements may form in large quantities, encroaching upon the capacity of the sac internally and gradually bulging exteriorly until the lesion is in fact more fibrous than cystic. Thus we have the large fistulae of the withers in which fibrosis is the dominating feature.* This sac is uniformly related to one of the dorsal spines, usually the second, but sometimes the third and in rare cases the fourth or even the fifth. We have never seen a typical fistula of the withers originate farther back. Those located on the summit or further back are always of the other variety (traumatic or atypical). The point of

predilection of typical fistula of the withers is stubbornly anterior to the summit of the withers—in the space where the spines decline abruptly into the cervical region.

The sac forms slowly and without apparent pain or discomfort to the patient. We have found ample evidence post-mortem in subjects that have died from other causes that cysts of this character sojourn here without attracting attention. They are too small to bulge externally and cause no distress that would attract one's attention to them. These hidden cysts are sometimes the size of an egg and sometimes as large as a base ball, and when old are so well encapsulated as to prevent further development. Thus cysts may never develop into fistulæ or, in other words, the saccular stage may never advance into the fistulous stage. The process is arrested by encapsulation and later the fluid content is reabsorbed, leaving no trace of its previous existence. The resulting cicatricial tissue is lost in its connective environment. *This process of arrested development, encapsulation and reabsorption occurs also in clinical cases.* Or in other words, a clinical case of fistula of the withers in the saccular stage that has never been exposed to extraneous microorganisms may disappear spontaneously. It is thus that

liniments and blisters applied to them often are credited with curative properties when, in fact, it was an inherent influence that operated to that end.

The duration of this stage has been very difficult for us to determine. We believe, however, that it is very irregular, that some cases develop very rapidly into clinical cases while others remain almost dormant for months, some disappearing entirely and some bulging slowly toward the surface.

It is these slowly forming ones that develop so much fibrous tissue and thus change the entire aspect of the condition from *cyst to neoplasm*. This occurrence seems almost sufficient reason to include in the classification a third form of fistula of the withers—the fibrous form—if the reader were not familiar with the remarkable aptitude of horse-flesh to form fibrous tissue from continued irritation. Edema, pressure, foreign body, feebly virulent infection, cold abscess, granuloma and other tumors in the flesh of horses cause the formation of great volumes of fibrous tissue unlike that of any other animal. It is thus that a slowly forming fistula beginning in the depths of the neck becomes the underlying cause of the formation of new tissue in such abundance

as is seen in some cases of fistula long before infection has entered into the situation.

Summarizing the condition during the sacular stage we find a sac containing a sero-fibrinous, sterile exudate, that may be large and surrounded by a thin capsule or small and enclosed in a very thick mass of connective tissue. Between these two extremes we find the intermediate varieties—for example, one the size of a child's head containing a quart of fluid and encapsulated with a fibrous envelope one inch in thickness; another the size of a football with only a very thin wall; and finally, a rare case with a very insignificant cavity surrounded with a great volume of connective tissue. Pathologically all of these are similar, they differ only in the relative quantities of the different elements entering into their constituent parts.

During this stage fistula is a benign disease. It is not as yet infectious. There is no systematic disorder. The patient suffers no apparent inconvenience. Its general health is undisturbed.

Until now the process belongs to an order of pathological conditions no more understood than the growth of tumors. In fact, it resembles tumor and cyst formation in all respects. It is but cellular activity around a

fluid-containing cavity with the formation of new tissue influenced by an unknown stimulus. Henceforth, however, a change occurs; it passes into another entirely different stage through the intrusion of pyogenic microorganisms into the cavity.

2. *Phlegmonous Stage.* This is the second step in the development toward a real fistulous condition. Inasmuch as there is no positive information about the thoroughfare through which infection occurs we shall only venture an opinion that it is through the blood stream or lymph channels that the microbes reach their goal. There is, of course, the possibility that cutaneous bruises from the collar may afford an entrance avenue, but the fact that suppuration occurs in animals that have never been in harness and could not reasonably have sustained contusions of sufficient severity to cause subcutaneous infection, least of all, a still deeper infection within the cavity without any surface inflammation, leaves no doubt that at least a great majority of fistulæ become infected *from within*. We have observed fistulæ develop rapidly from the saccular to the phlegmonous stage following influenza, especially complicated influenza. In fact, fistula of the withers might with all reason be included as one of the sequelæ of influenza. The large

number of remounts that develop this complication after attacks of shipping fever confirms our observation of twenty-five years of city practice in this connection. *The saccular stage of the disease affords a fertile field for the localization of the microbes in the germ-ridden body of the influenza patient.*

Once infected the patient falls sick and is henceforth in the siege of an enfeebling disease. The temperature rises to 102 degrees to 104 degrees Fahrenheit; depression is pronounced and movements of the body are painful. Often the patient grunts as in pleurisy from the pain of turning the body. When these symptoms occur before there is any conspicuous surface swelling, there is indeed danger of overlooking the cause of the patient's indisposition. Ordinarily the withers are hot, tumefied, radiating and painful on one or both sides.

The course of this stage will depend upon the virulence of the infection, the fertility of the field afforded by the saccular stage, and the natural resistance of the patient. If the sac is small and well encapsulated and the infection feebly virulent, the process may be slow and even go on almost unnoticed, all of the while causing the formation of more fibrous tissue and making its inroad of destruction into the poorly nourished ligamentum nuchæ and ad-

jacent structures, coming to the surface very slowly. It is, in fact, a cold abscess. Some months may elapse after infection has occurred before the abscess points at the surface, but all of the while pathological changes are taking place within. More connective tissue is formed and the necrosis of the ligament is extending forward and backward from the seat of the abscess which was originally the cyst. Soaked in this infected environment the dorsal spines become involved and separate from the soft structures attached to them, sometimes standing out stump-like into the cavity until sequestration occurs. Slowly the pus finds an exit at the surface of the body after burrowing here and there in different directions. The exit aperture is not uniformly located. It may sometimes appear at the summit of the enlargement, but more often it is more remote, the pus having traveled between the different layers of fascia and muscular tissue of this complex region to places far removed from the initial hot-bed. We once traced a fistulous tract from the lumbar region forward along the longissimus dorsi, under the scapula to the level of the second dorsal vertebra. Other cases burrow backward under the cervical angle of the scapula and point at the highest point of the withers, leaving one to suppose that this is the original

seat of the trouble as in the traumatic forms. This likelihood of fistulæ to point at or near one side of the summit has misled many a practitioner away from the actual seat of the causative center. In short, the existence of the aperture in a posterior location is no indication that the case is not a typical one centered at the usual place, under the ligament at the level of the second dorsal spine. The aperture may come at different very remote points that are often deceptive.

The average case is more acute. Given one with a sac containing a quart of fluid with a thin capsule and infected with virulent microbes that produce an acute inflammatory process, a channel is soon dissolved directly to the surface. Often pointing occurs long before there is much damage done to either the ligament and bones and if proper treatment were instituted, these might never become seriously involved. A cure could be effected without disturbing them. The cyst is developed, becomes infected and bursts at the surface without having done much damage. This is the most favorable of all the fistulæ of the withers to treat surgically. On the contrary, if the process is slow and there is delay in pointing, and if no treatment is instituted to relieve matters, the disease slowly but surely encroaches into the adjacent struc-

tures and thus creates a less favorable condition.

The duration of this stage like the former one is variable. If the infection is acute and the cyst wall thin, the abscess may ripen and burst in a few days, while on the other hand if less virulent and incarcerated in a thick wall, pointing may be delayed for weeks and even months. When the abscess has once found a surface exit and has discharged its contents, the disease has passed into an entirely different stage, and for a time the systemic condition improves.

3. *Fistulous Stage.* This is fistula of the withers. Heretofore the condition was fistula only in name, now it is a reality. Heretofore the course of the disease was guided solely by internal influences, now it is exposed also to secondary infections from without. It does not matter whether the pointing was spontaneous or whether an aperture was made artificially, we now have to deal with a deep-seated cavity that communicates freely with the outside where reinfection will continue to occur, and to make matters still worse the drainage is seldom good enough to evacuate the contents entirely. By remaining full of pus the cavity becomes a fertile field for microbial growth and cicatrizes very slowly. The pus-soaked walls of the cavity becoming carpeted with undulating indol-

ent granulations that encroach slowly on its capacity and without always showing any tendency to complete the process of cicatrization because they must sprout largely from a poorly nourished matrix (the ligament) which now dies in foci here and there, and then sojourns only as a foreign agent to perpetuate the process indefinitely. The ligament, contrary to the generally accepted conclusion, is never found entirely dead, except in very old and exceptional cases; it undergoes only focal necrosis at different spots, retaining enough vitality to delay sequestration, and all of the while sprouting out with indolent granulations over its viable zones. The granulations are incapable of maturing into scar tissue because of the dead zones protruding here and there among them and because they are poorly nourished. Thus we must not suppose when we say that fistula of the withers is due to necrosis of the ligamentum nuchæ, that the ligament is immediately dead and that as a dead object perpetuates the disease right from the beginning. Fistula on the contrary is due to the slowly dying process of the ligament, to its stubborn viability rather than to its death. Once dead, however, and separated from the living part, the cavity will cicatrize as soon as the slough is removed, encysted or dissolved, pro-

viding there are no secondary cavities that do not drain.

During the fistulous stage of the disease we must reckon, therefore, with a slowly dying ligament, exfoliation of the ends of the spines, the secondary pus due to the burrowing of pus into adjacent spaces and the fibrosis that continues to encroach upon the surrounding musculature. It is plain that these constitute a combination of very inimical conditions. There is also in addition to these, a chronic septicemia that slowly but surely undermines the general health and manifestly reduces the patient's vitality. The tracts leading from pus cavities to the surface apertures, to still further complicate matters, close up by cicatrization from time to time and thus pen up the pus again until it has burrowed out a new channel. During this occurrence the patient is again sick as in the phlegmonous stage, exhibiting pain, distress in movement, fever and general malaise. Each attack of this kind leaves the patient more enfeebled and still further damages the withers by forming new tracts, more fibrous tissue and sometimes new secondary cavities. The disease ends in one of two ways: the common one is emaciation and death, and the other is chronic fistula, discharging limited amounts of pus for several years. Rare cases heal up spontan-

ously. Often the death follows an operation postponed too long, postponed until the patient is too weak to stand the ordeal of the extensive intervention needed to cope with the neglected condition.

The location of the secondary pus cavities is varied. Backward between the scapular cartilage and the dorsal spines as far back as the caudal angle of the scapula and under the rhomboideus, is a favorite location. Another place where pus commonly gathers is in the space under the scapula just above the insertion of the serratus thoracalis, and sometimes this same cavity is diverted also under this muscle and then extends downward over the costal surface as far down as the sternum. The most serious secondary cavity, however, is the one that seats itself in the cervical region on the bodies of the vertebrae on one or both sides of the lamellar portion of the ligamentum nuchæ. This one constitutes what has been called *cervical fistula*, a condition due to implication of the ligament anteriorly. When a large area of the lamellar portion is involved the neck tumefies on both sides and one or more tracts form to the surface, often as far forward as the middle third of the cervical region. This is one of the most hopeless terminations of fistula of the withers as the affected center is inaccessible to

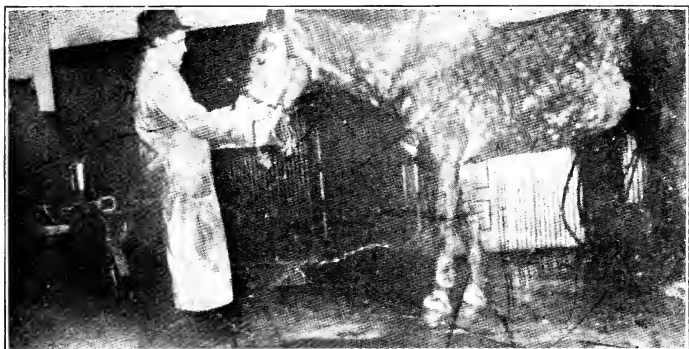


FIG. 3.—A PRONOUNCED FISTULA OF THE WITHERS.

any form of effectual treatment. The affected area of ligament is too extensive to extirpate and drainage apertures cannot be made nor maintained to any advantage. In short, cervical fistula is an incurable, hopeless condition.

Still another location is the bodies of the dorsal vertebræ between the scapulæ. Here the pus follows the spines downward and seats itself at an inaccessible place for drainage.

The Atypical Form

By atypical fistulæ we refer to those of strictly traumatic origin. They supervene saddle, harness and collar sores and cutaneous contusions of various kinds, especially those due to a hard, continuous pressure or deep pressure. Most of them begin as a pressure gangrene of a small zone of the skin, the subcutem and the underlying ligament. The microbial floræ of these lesions are the usual horde of staphylococci and bacilli that ordinarily infect wounds of horses. In one specimen taken from our clinic, Prof. Herzog isolated the *Bacillus necrophorus* in addition to the others. The ligament once attacked is slowly invaded farther and farther along its course and the underlying spines become implicated. That is, the disease once seated becomes progressive,

because the cavity, pointing upward, does not drain and the pus-soaked dead elements of the ligament remaining stubbornly attached to the living, favor the gradual onward march of the process of destruction. Those originating posteriorly travel forward into the ligamentum nuchæ under the connective tissue of the mane and thus seat themselves at just the same point as the atypical form, the chief difference being the amount of bone involvement, which in the atypical form is always more pronounced than in the other. Beginning at the highest point of the withers from a serious pressure necrosis from the harness, this form is more prone to travel downward into the spines, oftentimes attacking two or more of them with an acute destructive osteitis that travels down toward the bodies of the vertebræ casting off sequestra and fusing them together with a mass of connective tissue that is very slow to reconnect itself to the surrounding integuments, even after the pathological process has otherwise terminated.

The disease is most common in horses whose withers are thin of flesh from hard work and privation. The vitality thus reduced is a dominating etiological factor. The enfeebled tissue becomes the prey of the virulent infection introduced through and harbored by the harness

sore. The local dry gangrene called *sitfast* at the level of the collar seat is one of the commonest causes as well as the initial lesion of the very gravest of fistulæ of this kind. Here the thick, folded, hair-clothed skin and also the thick pad of connective tissue underlying the mane first undergo gangrene from collar pressure. Some of these sitfasts involve only the skin (superficial sitfast), others invade into the connective tissue and still others entirely through it, exposing the ligamentum nuchæ beneath. From this exposure the process marches on along the course of the ligament and there sows the seed of a chronic state precisely the same as fistula from other causes, and requiring the same remedial measures. In fact, it is our experience that fistulæ of this origin are the most stubborn of all.

Once seated in the ligament and bones, atypical fistula is identical with the one having its origin in a pre-existing cyst (typical fistula) and will henceforth undergo the same course of successive abscess and tract formation. Abscesses form, burrow to the surface, discharge for a time, heal up, gather again and burst at another point, and this chain of events may recur indefinitely. During the formation of a new abscess there is local pain, distressed movements, fever and a general indisposition just

the same as during the abscess formation of the typical form. There is, however, never as much fibrous tissue formed as in the other variety. Although the environs of the tracts and abscess are surrounded by fibrous tissue it is never so abundant. Voluminous fibrosis is an attribute only of slowly forming typical fistula.

The secondary pus cavities of atypical fistula are more superficial than those of the typical kind, particularly during the early stages. These are often subcutaneous, sometimes just under the superficial fascia and at other times simply under the trapezius, but later when the disease has become more deeply seated and has traveled anteriorly along the ligament, they may be found in the same deep locations as in the typical forms. On the other hand, it might be said here that these superficial abscesses do not occur except in the atypical ones, except when lancing or other improperly directed treatment causes them.

The differences pathologically between these two forms might be summarized as follows:

1. Typical fistulæ originate in sterile cysts located on or adjacent to the second dorsal spine.

2. The cause of typical fistulæ is unknown, and the influence under which the cyst develops

a well defined limiting wall is likewise not understood. It simulates tumor formation.

3. Typical fistulae develop deep secondary abscess during the early phase of the phlegmonous stage, while atypical ones develop these only in the later stages. The early abscess cavities of the latter are superficial.

4. Fibrosis, that is, the formation of fibrous tissue is more pronounced in the typical form and is never voluminous in the other.

5. Bone involvement is more certain and always more extensive in the atypical forms.

6. The toxemia is more pronounced in the early stages of the typical form, but in later stages both are alike in this connection.

SYMPTOMS

The initial stage of typical fistula of the withers develops unnoticed. As long as the cyst located in its mesial position is not large enough to bulge to the exterior of the body on one side or the other and before it has become infected with pyogenic microorganisms, there are no symptoms that would attract attention to the developing disorder of the region. Everything is normal in appearance and the patient suffers no apparent discomfort. Yet there is this initial stage of fistula of the withers to reckon with. How long the trouble is developing at the center before there is any change in the profile of the region is not known. The fact, however, that we find on post-mortem examinations accumulations of a serous fluid at the level of the second dorsal spine varying from small sacs the size of an egg to that of a base ball enclosed in a feebly developed sac, in animals that were never suspected of having any such a condition and which died from other causes, is ample evidence that the disease exists a long time before the symptoms begin to appear. Finally, however, the region begins to enlarge, first on one side and then on the other.

In rare cases both sides bulge simultaneously. The bulging may take the form of a circumscribed spherical protrusion or it may be diffuse, extending evenly forward over the base of the neck and backward over the withers with its crest opposite the cephalic angle of the scapula or slightly forward from that point. When both sides bulge from a diffuse enlargement, the withers may appear enormous in width and elevation, sometimes to the extent of making the patient seem top-heavy. If the cavity is not artificially evacuated, nor otherwise molested, the enlargement may remain unchanged indefinitely. We have in mind cases remaining in the sacular stage for more than two years with no other changes pathologically than that of becoming less fluctuant from the development of its fibrous encapsulation, and not infrequently we have seen them disappear entirely. There is no way to predict accurately when any given case will suppurate.

Finally, the great majority of cases pass into the phlegmonous stage; that is, they become inflamed from the invasion of microorganisms. This event is announced by local pain, radiating lines extending from the crest of the enlargement, indisposition to move, grunting, fever and general depression. Cases that become infected before the cyst is large enough to bulge

out the neck may prove puzzling in the absence of any pathognomic symptom.

Then again we must differentiate (before suppuration unmasks the character of the ailment) fistula from other enlargements and growths in the region. Sarcomata and melanosis may localize on the withers, and unless taken into account there is some danger of error in diagnosis. The former is, however, rare and the latter is seen only in white horses. A black work horse, submitted to the writer by Dr. D. M. Campbell, exhibiting a voluminous enlargement of the withers that had every resemblance of the fibrosis of fistula, was found after an unsuccessful operation to be affected with a very large, deeply rooted sarcoma extending downward into the thorax and affecting nearly the whole of one lung in addition to involving all of the structures about the withers. And again, the author once submitted a twelve-year-old horse, just turning white, to an operation for fistula only to find that the bulging was due to a melanotic tumor the size of a cocoanut, located in the splenius.

It is also important to judge carefully recent swellings of the base of the neck and of the withers, as these might be mistaken for fistula. Horses frequently sustain severe contusions in this region, exhibiting either fluctuant or firm

swellings that are not easy to differentiate from the saccular and phlegmonous conditions associated with the graver state preceding the fistulous stage. Subcutaneous and subfascial sanguinous sacs and hemotomata complicated or uncomplicated with infection, are the most misleading of these lesions for which fistulæ might be mistaken. The differentiation can never be made with certainty until the behavior of the swelling is noted, both before and after evacuating the contents. In fistula such swellings accentuate; in the others they subside, either with or without lancing. Besides they are always diffuse whereas the fistulæ presents a spherical swelling in almost every instance.

Although acute diseases running short courses, malignant edema and other erysipelatous inflammations when attacking the withers may at first mislead the diagnostician, these are recognized by their acuteness and rapid advancement into adjacent regions and the serious concomitant toxemia.

The early symptoms of the atypical form are likewise very often misleading. That any given harness sore will or will not end favorably is not always easy to determine. What might at first seem like a simple enough harness sore may finally prove to be the initial phase of a bad fistula. On the other hand, a badly in-

flamed back may heal promptly. It is, therefore, advisable to withhold an opinion about the seriousness of harness sores until the behavior of the swelling and of the discharge can be noted. As a rule, however, a sore that exposes the ligament, and especially if the pain on palpation is excruciating and extends along the back some distance from it, is one to be viewed with suspicion. Painful subacute diffuse swellings extending forward over the summit of the withers are likewise incriminating. Both of these circumstances indicate an extensive involvement of the ligament and underlying bones right from the beginning that is pretty sure to lead to a chronic inflammation of these structures far beyond the original focus—the harness sore.

Sitfast of the collar seat, on the contrary, develops into fistula without these threatening external manifestations, and even without any perceptible pain. It causes fistula by rooting through the connective tissue of the mane into the ligament almost unnoticed. It is only when sequestration begins or when extirpation is attempted that the depth and the seriousness are determined.

During this first stage of atypical fistula—which in this case is the phlegmonous stage—the patient is not stricken with illness as during

the same stage of the typical form. The trouble is thus far more like simple superficial abscess and is not attended with any serious toxemia. The toxins escape through the wound, whereas in the typical form they are pent up and absorbed. It is only during the development of secondary abscesses that any serious systemic indisposition is ever observed.

The symptoms of the fistulous stage. Fistula once a reality and beyond the developmental stage produces a clinical picture well known to everyone having had any experience with horses. Its exposition, if not also its description, might seem unnecessary for the average reader, so well known are the manifestations of this fell and loathsome disease.

It might be said for information of the novice that any chronic discharge of pus from or about the withers is fistula of the withers. It may be from a single aperture and unassociated with swelling or it may be from two or more apertures with voluminous enlargement of the region on one or on both sides. The apertures may be located posteriorly, medially or anteriorly, on or near the median line or laterally at any point about the neck or shoulders. The most anterior location at which apertures are found is the middle cervical region and the most posterior location is the

acnestis. These two extremes are, however, rare ones. Most of the apertures are found on or about the level of the withers and base of the neck. Ventrally pus sometimes burrows subcutaneously over the lateral face of the scapula and points at the level of the shoulder joint and more commonly a few inches above that level. The amount of pus discharged varies with the size of the cavity. After lancing, after the first spontaneous bursting or after a secondary abscess has been evacuated artificially or otherwise, the discharge is sometimes very copious, overrunning the sides of the body as far down as the foot and by desiccating encrusts itself thickly over the whole shoulder region and forearm. The discharge finally moderates and may even cease entirely pending the formation of a new abscess and new aperture often on the opposite side or at some remote location on the same side, causing the same loathsome condition all over again.

In the meantime the patient loses flesh and is unthrifty in general appearance. The coat is dull and uncouth, the ribs and skeletal angles become visible, and the reduced vitality becomes more apparent. It is only the patient that is well groomed, well fed and well attended as to its infirmity that remains in good condition. The neglected subject sinks rapidly

into a still lower state of depression and may even die from chronic septicæmia. Operated on in this enfeebled state fatalities are of common occurrence.

The profile of the withers during the course of the fistulous stage varies in different cases. Some are tumefied on one side, some on both, usually from fibrosis but also from common inflammatory swellings which subside with each pointing of the abscess. Each aperture leaves a tell-tale scar and a denuded zone beneath where the discharges have destroyed the hair follicles. Where caustics, strong blisters or strong chemical irrigations have been employed this marring is still more pronounced (see Fig. 4).

Where the disease was left to run its own course, or was treated by only palliative measures, the withers, neck and shoulders are left riddled with these indelible blemishes, and often through extensive sloughing of the ligamentum nuchæ the neck drops down in front of the withers into a permanent deformity (ewe-neck).

In other cases the spines at the summit of the withers having lost their ligamentous covering protrude beneath the imperfectly regenerated integument and thereafter become the seat of sores from the harness and saddle that are diffi-

cult to heal. At the sides of the neck just in front of the cephalic angle of the scapula the permanently enlarged musculature covered with denuded skin likewise chafes from the collar and thus proves a constant annoyance. Marred and sore-ridden, the subject is unsalable and ofttimes almost useless.

TREATMENT

The assertion that all fistulæ of the withers might, to the best advantage, be submitted to a uniform (standard) method of treatment is a paradox. It is a paradox because such a statement at first thought apparently false is after all entirely true, as the treatment needs to vary only in regard to its details. The same general principles of management and treatment may be laid down for all of them, no matter from what source they originate, the course they may have taken, or the stage in which they are found when submitted for the surgeon's deliberation.

That certain fistulæ of the withers do sometimes yield to lateral lancements and irrigations is not denied, but that the great majority surely but slowly develop into grave, enfeebling, incurable and often fatal afflictions in spite of such treatment is equally true.

It is, therefore, evident that prompt treatment of the radical sort is indicated at an early stage and before the infections of extraneous origin have done a widespread damage to the ligaments, bones and muscles, and before pus has burrowed into the inaccessible recesses of this complex region.

It does not matter whether the condition has been caused by an abrasion or has originated in a cyst of the dorsal bursa, procrastination is inadvisable.

We have found, however, in the cases of typical fistulæ that the evacuation of the contents of the sac one week before the radical operation is performed, is good practice, because it fortifies the tissues against post-operative infections of a grave character. Where strict aseptic conditions are maintained in the operation and the patient has skillful after-care, this precaution is not as essential as when careless methods prevail or when the after-care must be consigned to untrained hands.

It is, therefore, recommended, as a routine measure in field practice, to lance the cyst, evacuate the liquid and flocculent contents and then submit the sac to casual irrigations one week to ten days before operating.

In the case of old fistulæ originating as cysts and which have become infected from any source or in the traumatic variety having either superficial or deep pus accumulations, lancing one week before operating is likewise helpful in that surgical shock is modified and there is less soiling of the surgical wound with pus during the operation.

These suggestions need not be laid down as

absolute laws, but it is advisable to follow them where it is desired to take advantage of every helpful influence. They are most important in subjects enfeebled from hard work or privation and when from any cause a clean operation and good after-care cannot be carried out.

External applications such as liniments and blisters we do not recommend. They only complicate matters by irritating the skin and encrusting it with dried excretions difficult to remove in preparing the field for operation later, and so far as we have been able to determine they do not in any way influence the course of the disease within. Occasional cases abort in the cystic stage but this trend is spontaneous and is not hastened by local applications, and it is by no means certain that the decrease in the size of the enlargement is permanent. Our observations indicate that at least some of these rare cases recur and finally burst to the surface.

As regards the application of caustic chemical substances into the tracts we doubt if there is any charlatanry, ancient, medieval or modern, that savors more of cruelty and malpractice. The caustics—arsenic, copper sulphate, lye, corrosive sublimate, caustic lime, zinc chlorid, etc., after dissolving in the albuminous secretions overflow the surface of the body,

cause severe pain, prolonged discomfort and permanent blemish. Often large patches of integument slough away (Fig. 4).

The only beneficial effect of caustics is the widening of the aperture and tract for drainage and since this can be accomplished better and without discomfort by other means the one argument in their favor loses force.

The treatment of fistula of the withers which in our hands has given the best results is prompt, thorough, surgical intervention. Our operation of choice and which is hereinafter described consists of a median line incision extending from the crest of the withers forwards six to twelve inches and downward through the skin, the pad of the mane and then between the two halves of the ligamentum nuchæ into the space beneath lying over the summits of the second and third thoracic vertebræ. This is followed by a resection of such parts of the ligamentum nuchæ as are thought to be harmful and then by making lateral drainage apertures from the bottom of the cavity to the surface of the cervical region into which a perforated drainage tube is inserted.

Radical Operation for Fistula of the Withers

Preparation.—As the procedure is one of some magnitude, attended with all of the dan-

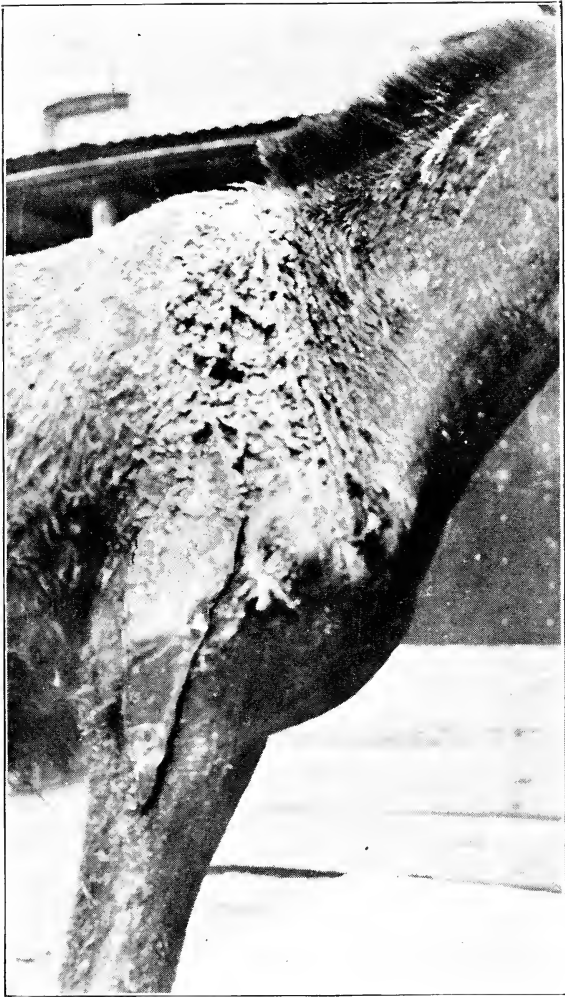

FIG. 4.—EFFECTS OF THE USE OF CAUSTICS.

This mule was treated for a typical fistula of the withers by the injection of concentrated lye. Discharge from the wound occasioned sloughing of the skin over large areas.

gers of major operations, it is essential to investigate carefully into the patient's physical condition. Weak, emaciated, enfeebled subjects should be given a preparatory treatment that will tend to build them up in strength and vigor. This may consist in evacuating and irrigating large abscesses, cleaning them up over the soiled shoulders, grooming the body, good feeding and any general good care that will improve the health. The week or two required for such preparatory treatment is not lost, since the improved health before the operation will shorten the duration of the period of post-operative convalescence, and will reduce the rate of mortality which in enfeebled subjects is bound to be high on account of shock and the magnitude of the invading wound. Large wounds cannot be made in the bodies of an animal with impunity; in enfeebled subjects they are positively disastrous. Infections run riot in them and without effectual resistance toxemias are fatal. We, therefore, advise against the operation in subjects not physically fit to stand the ordeal.

Dieting is also essential as a preparatory step, as no animal may be safely cast and submitted to a severe surgical operation with its alimentary canal filled with ingesta. This is especially the case with subjects to be anesthe-

tized, with chloroform or narcotized with chloral.

Preparation of the Field.—Scraping off the dried pus encrusted over the shoulders, washing the skin with soap and hot water must precede the attention to the field itself, as otherwise no effectual cleansing of the withers for surgical work would be effectual. Preferably this should be done on the day preceding the operation, and to prevent further soiling the shoulders might be annointed with vaseline.

The hair over the withers and on each side, down no less than ten inches, is clipped and if possible shaved. The mane is clipped off well forward over the seat of the collar and the remaining mane is braided to prevent its tufts from dangling into the wound as well as to keep it free from pus during the after-treatment.

A good ablution with brisk friction of mercuric chlorid in the dilution of not less than one part to five hundred is much the best preparatory disinfection of the skin along the line of incision. The field might in addition be painted with tincture of iodine. Shaving the mane hairs especially on the neck where the skin is folded transversely is difficult and very tedious as the folds are closed while the head is erect and as a painstaking shaving process pro-

longs the duration of decumbency we have in our recent operations been satisfied with clipping. By using the curved scissors these coarse hairs, even those between the folds can be trimmed away. In order to conserve the subject's strength by shortening the duration of the operation proper it is, however, preferable that all of this cleaning up process and disinfection be done in the standing position. By standing upon an elevation in a place where the patient's movements can be controlled and by twitching the nose, a more thorough cleaning can be given in the standing position than after the animal has been cast. When the body lies flat on the mat, ground or even the operating table, the sides of the withers are less accessible for clipping and washing, and besides when this is postponed until the subject is down, the ground under and about the withers becomes a disagreeable place to occupy while operating.

Anesthesia.—Chloroform anesthesia is much the best, although narcosis with chloral hydrate administered no less than one hour before casting will answer when the retinue lacks a satisfactory anesthetist.

For this purpose we administer *per os*, preferably as a drench twelve drams of chloral dissolved in one quart of warm water. Cannabis indica intravenously, chloral in the peritoneal

cavity or morphin hypodermically may be substituted, but in our hands these agents have been greater disappointments as surgical narcotics than chloral hydrate, which, given as above described on an empty stomach, always produces some measure of blunted sensibility that facilitates the control of the patient if it does nothing more.

When chloroform anesthesia is used, everything is made ready before it is administered in order to shorten the duration of unconsciousness to the minimum.

Restraint.—The standing position even with the best stocks is by no means an adequate restraint for effectual work. The lunging subject is in danger of injury and the movements of the neck prevent accuracy of technic. The standing position answers well enough for lateral incisions, such as may be required to evacuate abscesses preparatory to the operation, but when the center of the withers must be invaded for the purpose of resecting a necrotic ligament or of perforating the cervical muscles for drainage, the control must be complete—perfect.

The preferable method is rope restraint, with all fours folded securely under the body. The collar part of the rope must pass from breast

to back instead of encircling the neck. The collar seat must be free from obstacles because the incision crosses it and besides a rope encircling the base of the neck would interfere with making the lateral apertures for drainage. A rope whose collar is large enough to drop under the sternum while its backward part will rest in the middle of the back is best adapted for the purpose, as it leaves the withers unobstructed. The two free ends of the rope encircle the pasterns of the hind legs and then pass forward into the collar. When the horse is down the hind legs are drawn into a securely flexed position. The fore legs are tied securely, flexed with straps or preferably with cords. Thus secured the body of the anesthetized or narcotized subject can be rolled into the ventral position where it can be blocked with sacks or held by several assistants. The operator standing on the right side is now in a splendid position to proceed.

On the operating table which brings the body up to a position comfortable enough to invade the withers mesially there is the objection that the under side is not very accessible for making the lateral apertures. Although this objection can be overcome by rolling the head and neck downward and backward there is by no means the same opportunity to perforate the cervical

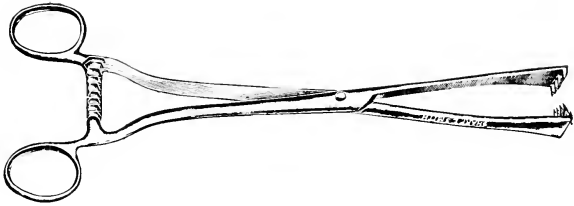


Fig. 5.—Tumor forceps of a serviceable pattern for fistula operation. The style of the jaws in tumor forceps is a matter that should be carefully noted in purchasing such an instrument. For instance, some vulsellum forceps are so designed that the incomplete curve of the jaws together with their slender and weak construction makes them too delicate for much veterinary surgical work. The instrument illustrated above is designed so that with them a firm grasp of tissues is possible and a secure hold is insured.




FIG. 6.—DRAINAGE TUBE AND INSERTER.

By means of the drainage tube inserter it is possible to introduce a rubber drainage tube with a minimum of invasion of sound tissue. This, in many cases, is an important factor, as it prevents needless contamination of uninvaded parts, limits the area of infected tissue and possible resultant complications and greatly facilitates the execution of this part of the technic. Hemorrhage is reduced to a minimum, operations are completed with dispatch and, therefore, with less danger of surgical shock when these appliances are employed.

muscles as when the subject is tied in ropes and rolled into the ventral position.

Instruments Required.—A good strong and well sharpened scalpel; a probe pointed bistoury, two large tumor forceps, an assortment of hemostats, a drainage tube inserter, a perforated rubber drainage hose, a large needle threaded with strong material. There will be needed in addition to the usual basins for antiseptics, a separate basin containing an abundance of oakum, which is to be used for packing the cavity immediately after the operation has been completed. We use clean oakum soaked in a strong solution of mercuric chlorid for this purpose and with this we place the threaded needle to prevent its thread from becoming entangled among the instruments while operating.

A yard of muslin or burlap will also be needed to cover the withers as a protection against soiling after the patient is returned to the stable.

Technic.—Standing on the side of the patient now rolled in the ventral position, facing toward its head, the operator plunges the scalpel deeply into the middle of the neck at a point varying from six inches to twelve inches in front of the crest of the withers, and then draws it backward as far as the crest—the

full depth of the blade. The variation in length of the incision is necessitated by the difference in the size of the patient, in the thickness of the skin and underlying pad, and also by the size of the tumefaction. In a small horse, for example, having only a small rounded sac bulging at one side, an incision six inches long will be found ample, while in a large "meaty-necked" draft horse having an enormous swelling it must be at least twelve inches long. Otherwise the walls of the wound cannot be parted enough to give a good access to the bottom of the cavity for inspection and for resection of diseased parts of the ligament. We aim in the first stroke of the knife to incise the skin and underlying pad from end to end, that is, from the point decided upon anteriorly to the crest of the withers. For descriptive purposes this may be designated the *first step* of the operation.

In the *second step* each of the edges of this large wound is grasped deeply with the tumor forceps. An assistant should hold one of the forceps and the operator the other. By drawing the wound apart with some force the bleeding now spurting from many small vessels is immediately controlled and after widening it out, a good view of the bottom is obtained for the next incision. The scalpel is now plunged

between the two halves of the funnicular portion of the ligamentum nuchæ into the loose tissue beneath and drawn backward again the full length of the wound. This opens the central cavity which in typical fistulæ is uniformly located at the level of the second thoracic spine.

The *third step*. Blood is now hurriedly wiped out, the forceps are drawn upon with force to reduce the flow and the large spurters are snapped up in hemostats. It is not, however, advisable to devote much time to this hemostasia unless efforts at its control promise to be promptly effectual, since futile attempts delay the work and add to the blood loss. If the operation antedates the formation of pus, that is, if the contents are still sero-fibrinous, there is no occasion for doing anything else than that of now inserting the drainage tube, while on the other hand, if there is pus and the ligament is found more or less riddled with disease, resection of the diseased parts is now undertaken. In very old cases it is entirely removed, in more recent cases its mesial parts are sliced off. In this step we also in many cases endeavor to resect the wall of the sac, or as much of it as is accessible for hurried removal, leaving the ligament untouched. This, of course, is possible only where the sac is small and on

account of age has a well defined limiting wall. It is often possible in many cases to resect the sac and then heal up the wound under aseptic conditions without drainage. More often, however, the region is invaded with infection of long duration and exhibits necrotic areas which must be removed. For example, if the ligament is found carpeted with undulated granulations and is seen to exhibit necrotic spots or is riddled with pus tracts, it should be entirely removed. The resection is effected by cutting it off anteriorly, grasping the end with a tumor forceps and then dissecting it in the backward direction to the posterior commissure of the wound. This is done on both sides or only on one side according to the condition in which the ligament is found. When not too firmly fixed into the adjacent connecting tissue it can often be torn out with the tumor forceps.

The bones beneath are left severely alone. Trimming with bone forceps or curette is not recommended. Spontaneous exfoliation is depended upon exclusively. We have found that meddling with the spinous processes is a harmful practice. The exposed curetted ends become open channels for the descent of new and deeper inflammatory processes, when later during the healing they are constantly soaked in

pus. Necrotic ends sooner or later, without interference, separate from the viable bone, and then leave it carpeted with granulations which now cicatrize with the rest of the wound. We are, therefore, unequivocally opposed to the removal of bone tissue other than the already well-loosened sequestra, which are sometimes found floating in the cavity or feebly attached *in situ*.

The *fourth step* is the insertion of the drainage tube. This is done with the drainage tube inserter. (Fig. 3.)

Armed with the tube the point of the inserter is placed at the bottom of the cavity and then pushed out laterally in the downward direction through the splenius and serratus cervicis muscles to the surface. The skin must be incised as the point of the inserter bulges it out as its point is not sharp enough to penetrate it unassisted by an incision. When inserted on the one side the inserter is passed into the other end of the tube and pushed through the same place on the opposite side. This places the tube across the bottom of the cavity and out to each side of the neck. (Fig. 4.)

When the operation is prolonged for any cause and the blood loss has been great, we postpone the insertion of the tube until the

second day, at which time it is inserted in the standing position.

It is advisable in passing tubes through this thick musculature to keep the neck in a nor-

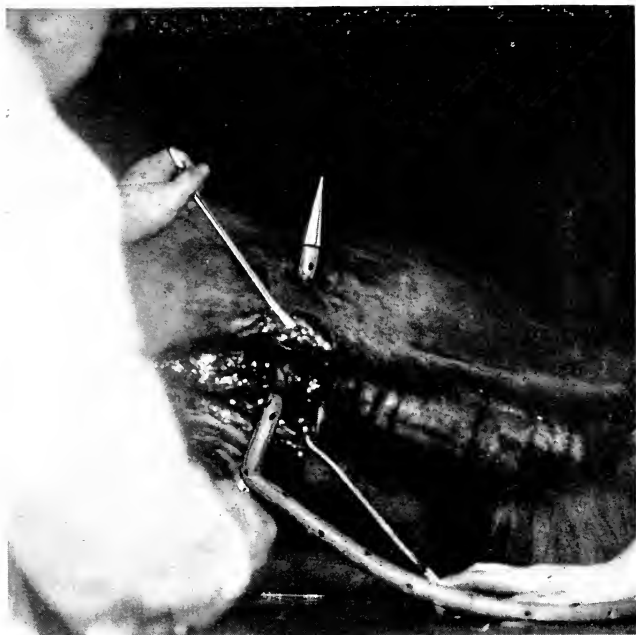


FIG. 7.—INSERTING THE DRAINAGE TUBE.

mal position. Otherwise the tube will be in a strained position.

The *fifth step* is that of packing and suturing the cavity. For this we use sterilized anti-septic oakum. We prepare the oakum already

arranged in wads of different sizes so that it can be packed into the recesses piece by piece where it will press directly upon the bleeding vessels and thus arrest the hemorrhage at once. If indifference is displayed in this connection, the bleeding may force its way between the

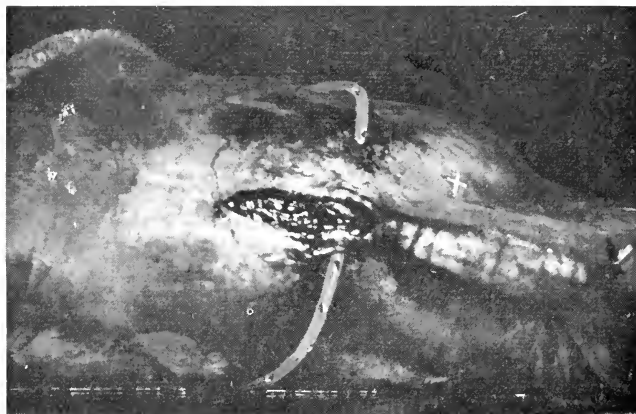


FIG. 8.—THE DRAINAGE TUBE INSERTED.

This shows the position of the drainage tube in an atypical case of fistula before the wound is sutured. In typical fistula the tube would be inserted more anterior, making its exit at the point marked X.

layers of the surrounding tissues. Once well packed the wound is closed with sutures deeply inserted into each lip. The wound must be closed tight to prevent any further blood loss.

Dressing. When the patient rises to its feet, its body is washed free of all blood accumula-

tions, and rubbed as dry as possible. We then cover the withers with a layer of cotton or gauze and hold it in place with a muslin or burlap sheet tied down with cords encircling the breast and the girth. The patient is now ready for the stall.

After-care. At the end of twenty-four hours




FIG. 9.—THE DRAINAGE TUBE AFTER THE WOUND HAS BEEN SUTURED, TYPICAL FISTULA.

the sutures are removed and the packing lifted out carefully. There is at this time still some danger of bleeding if the interior of the cavity is harshly handled. We, therefore, advise that no attempt be made to clean out the blood clots attached here and there about the cavity until the end of forty-eight hours, but that we content ourselves with a second packing of oakum

or gauze soaked in mercuric chlorid solution and bound down with the withers bandage. At the end of forty-eight hours we give the whole cavity a good cleaning under strict aseptic precautions, removing the blood clots attached to the tissue completely. The cavity is now sprinkled with iodoform and then filled up with

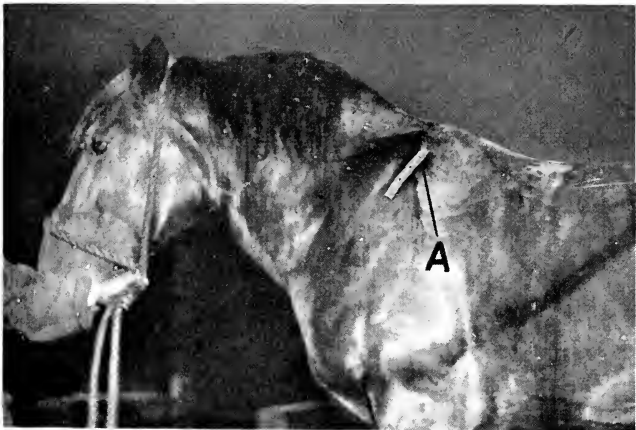


FIG. 10.—THE DRAINAGE TUBE AFTER THE WOUND HAS BEEN SUTURED, ATYPICAL FISTULA.

a mixture consisting of iodoform five per cent and boric acid ninety-five per cent and the withers protected again with clean cotton and the bandage.

In cases where the wound has not been soiled during the operation a daily renewal of the antiseptic powder after wiping out the old will

answer for the after-care, but where the cavity was found badly infected or in instances where the operation was not a perfectly clean one, it is essential that the powder be renewed no less frequently than three times a day for the first four days. By attending with great care to this large wound, the discharges will not be abundant, but when the whole area of exposed flesh is allowed to become contaminated the issue is copious. It is, therefore, important to pay strict attention to the wound, treating it skillfully during the first four days. After four days there is less danger of grave infections gaining any headway in the wound as the tissues are then better protected against microbial invasion.

The drainage tube is managed much like a seton. We fasten a spike across one end and then pull it through from the other end and give the holes and lumen a good cleaning. A stylet is needed to dislodge the dried pus that chokes it. By bending it about, cleaning its holes and ramming a stylet through its lumen and then rinsing it well with a strong antiseptic solution, it can be kept perfectly clean and open. The next day the same manner of handling is repeated except that it is drawn to the opposite side.

Cases having an osseous complication should

be watched more carefully. They must not be allowed to close above before sequestration is complete and the bone is in condition to cicatrize with the rest of the wound. It is here that recurrences occur. Stumps of bare vertebrae are covered by scar tissue and cause a re-accumulation of pus which will require subsequent attention if not a second operation of equal magnitude.

During the healing of the wound its walls are scrutinized daily for shreds of ligament that are becoming surrounded with granulations before detaching from their viable continuation. It often happens that large sloughs of ligamentous or new-formed fibrous tissue appear here and there about the cavity as cicatrization proceeds. These delay healing and should be removed as soon as possible.

At the end of five weeks we usually dispense with the tube and apply such simple astringents as a two per cent solution of zinc sulphate or common white lotion. At this time horses may be worked with breast harness but collar pressure directly upon the region is not admissible until after three months have elapsed.

Modifications

Large subcutaneous or subfascial abscesses are evacuated at dependent points and drain-

age apertures maintained as long as there is any issue from them. When the discharge continues to be profuse, attempt should be made to locate the cause. The main cavity has not been drained. If located in an inaccessible place, as for example upon the cervical vertebræ (cervical fistula) or along the thoracic vertebræ under the longissimus dorsi, spinalis or complexus, it may not be possible to give helpful assistance. These secondary abscesses are the result of improper treatment or neglect. They seldom if ever complicate a well directed operation followed by faithful after-care.

In the case of atypical fistula arising from wounds of the back or crest, the operation is much the same except that the incision is made more posteriorly (Fig. 10).

It is, however, never advisable to make such a median line incision on a thin horse having a prominent, sharp withers, as the wound lips will sag down below the level of the vertebræ and produce a condition that will heal very slowly and imperfectly. In draft horses with thick, low withers there is less danger from this standpoint. The fleshy surrounding affords ample protection against protrusion of the crest above the level of the wound edges.

Special Remarks

Objections have been raised against the use of drainage tubes in the treatment of fistula on the grounds that they are difficult to keep open. This objection we are sure comes from those who have not persevered in their use. A tube long enough to cross the neck and protrude no less than eight inches on each side is very easily cleaned without removing it entirely, as described above, and after it has established a good tract for itself it can be taken out entirely for cleaning and can be easily reinserted. It is essential that a tube be composed of strong material, strong enough to resist the pressure upon it. It must not collapse. A soft tube is worthless. When the strong muscles through which it passes press upon it, its usefulness for drainage is destroyed. We, therefore, recommend a strong reinforced rubber hose which we perforate with a harness punch (Fig. 6.)

To prevent drainage tubes from coming out we arm each end with a common twenty penny nail passed across at right angles. A meat skewer or common round stick will also answer the same purpose.

It seems important to emphasize here the worthlessness of mere incisions through thick muscles as drainage apertures. A collapsed

aperture through muscle tissue does not drain in the surgical sense. Such an aperture *leaks* pus but does *not* drain the cavity dry enough to serve the purpose for which drainage is needed. It does not matter how many drainage incisions are made through muscle tissue, the cavity would still overflow unless the apertures are held wide open with a tube. The same may be said of setons. While pus is absorbed by them (in very limited quantities) they do not empty the cavity and are, therefore, worthless. To heal a wound as large as the one required to expose the diseased part of a fistula of the withers, it is essential that it be kept free from accumulations of its secretions.

Accidents and Sequelae

Septicemia is the commonest sequel of the operation. It is predisposed by enfeebled states of the patients but can often be traced to badly directed surgical work. Failure to obey the common laws of modern surgery as regards asepsis is always disastrous in operations of this magnitude, and since this one is performed often in a pus ridden region, dirty internally and externally, and must often be done where conditions are none too favorable, the operation exacts its full toll of fatality

from septicemia, even in the most vigorous subjects.

The prevention lies in making the best of the situation by using sterilized instruments, cleaning the hands well, packing the wound with a safe wadding and then protecting it thereafter until the danger of a grave infection has passed. It is also very essential to remove the packing material at the end of twenty-four hours so that the blood supply of the tissues pressed upon by the tight packing will be restored to the walls of the wound. A packing of doubtful purity wadded tightly into a wound as large as this one is indeed a hazard. It weakens the tissues and besides impregnates them with infections.

Malignant Edema

We have had cases of malignant edema follow operations where the directions given about the removal of the packing were not carried out. To let a packing sojourn forty-eight hours in a large wound always invites anaërobic infections of this character. In fistulæ of the withers it is positively disastrous. There is danger from this disease even after apparently clean operations because the condition created is so favorable. The prompt removal of the packing at the end of twenty-four hours

and the re-application of a well soaked anti-septic pack is universally preventive.

Hemorrhage

The blood loss, always considerable, often reaches the danger point when large radicals of the nutrient arteries are divided and the closing up of the wound is in some way delayed. We depend more upon hasty work and prompt closure of the cavity to limit the blood loss than upon ligation or forcep hemostasia. Often when blood is gushing from some part of the wound in a threatening manner and a forcep cannot be snapped upon it promptly we pack the bleeding place with a hard wad of oakum and let an assistant hold it down tight with a long blunt instrument while the work proceeds without further hindrance. While cognizant of the fact that this is not a display of the best surgery, it has always seemed impossible for us to make any headway in the direction of systematic hemostasia in these operations and we have come to the conclusion that less blood is lost by hurrying through the work and then depending upon the packing to prevent any further loss.

In exceptionally large withers, infiltrated with an abundance of newly formed fibrous tissue, the wound is of such magnitude that in

spite of care the loss of blood assumes dangerous proportions. And while fatalities from this cause are not usual, the weakened state produced by excessive bleeding operates with other influences against the general welfare of the patient during the first few days of convalescence.

Recurrence

When the withers tumefy again after the wound has been healed for some time or when it does not heal in the usual time, it is evident that some necrotic ligament or bone still remains. These may have been overlooked in the operation or else the disease may have advanced into adjacent places. We have found that most of our recurrences are due to healing of the wound before the spines have cast off the sequestra. A second operation of lesser magnitude often reveals a loosened segment which on removal is followed by prompt cicatrization. When this is not found to be the cause a new operation the same as the first may be required.

Complications

The complications arising from fistula of the withers independent of those caused entirely by operations and other remedial measures which will be considered under the head of "se-

quels and accident" are: Acute septicemia, chronic septicemia, pneumonia, pleurisy and paralysis.

1. *Septicemia*. As already mentioned under the chapter on pathogenesis, there is a toxemia associated with every case of fistula. The only exception is during the sacular stage of the typical form. After infection has entered, the situation is only a question of how badly the patient is affected by this complication. Some patients resist this systemic complication better than others, but after a fistula has become chronic and has drained the patient's vitality by copious discharges of pus for a long while, impregnation of the organism with toxic products and bacteria occurs to a greater or less extent in every case. Death from acute septicemia, except after operations, is rare, but clinical chronic septicemia is a very common occurrence. It is this complication that most undermines the health of all cases and which causes the emaciation and general enfeeblement already referred to. And while the complication is an insidious one, deaths occur therefrom quite often. We have found secondary abscess of the lungs and of the spleen in animals that have died from fistula. As a source of focal infection fistulae of the with-

ers is by far the best example we have in domestic animal pathology. Its symptoms are seen in the unthrifty and enfeebled state of the patient and in its susceptibility to other diseases, particularly to new infections after



FIG. 11.—A COMPLICATED CASE OF FISTULA AND POLL-EVIL.

operations, and to pneumonia—the common form of dissolution of so many diseases.

Pneumonia

The pneumonia arising as a complication of fistula of the withers occurs chiefly in old debilitated subjects or in younger animals reduced to a state of general enfeeblement from neglect and exposure. It is sometimes also metastatic—abscess of the lungs—the infection is carried from the purulent hot bed to the pulmonary

capillaries where the lung tissue falls an easy prey to the subsequent pyogenesis. We have found the lungs riddled with abscesses in affected horses that have died from fistula.

Pleurisy

The pleura is occasionally attacked with an inflammatory process arising from its continuity with the affected musculature surrounding it. The deep secondary abscesses which burrow down to the bodies of the vertebræ and then descend over the costal surface are the influential factors in this connection. At first circumscribed, the inflammation soon extends over a wider surface until the subject is affected with a diffuse fatal sero-fibrinous pleuritis. Figure 11 illustrates a case affected both with poll-evil and fistulæ of the withers. The subject was seven years and a fair type of delivery wagon horse weighing eleven hundred and fifty pounds. It was first attacked with poll-evil, but before this was submitted for treatment the withers were already tumefied with a phlegmonous enlargement. The poll-evil was submitted to the radical operation and promptly cured after thirty days. During this period of convalescence from the poll-evil operation, the withers pointed and discharged a copious quantity of pus on the right side ad-

jaacent to the cervical angle of the scapula. The patient was not relieved from this evacuation but on the contrary remained indisposed, refusing to move about except when urged, and at each movement grunted with agony. The respirations at first only slightly accelerated became gradually faster during the succeeding three weeks, at which time several gallons of exudate were aspirated from the right side of the thorax. The patient's condition became gradually worse and at six weeks following the evacuation of the withers it died from a re-filling of the pleural sacs. The post mortem examination of the carcass showed clearly a case of pleurisy beginning along the dorsal region extending with a gradual lessening intensity in the downward direction over the thoracic parietes, beginning at the intercostal lymph nodes, which were found enlarged.

Paralysis

Nervous involvement is less likely to complicate fistula of the withers than poll-evil, because the spinal cord of the dorsal region is better protected against encroachment from extending pyogenic processes. We have nevertheless observed cases in which death due to *spinitis* arising from extension of the disease into the neural canal. The patients al-

ready weakened from the disease and also from general neglect weakened in the hind quarters and after exhibiting a progressive paralytic state, were finally found unable to rise, dying in delirium after some days of decumbency.

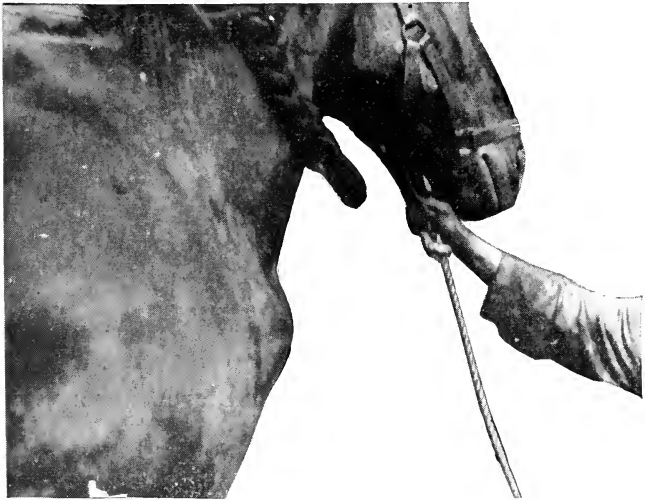

FIG. 12.—COLD ABSCESS OF THE PRESCAPULAR LYMPH NODES.
FOLLOWING FISTULA OF THE WITHERS.

Cold Abscess of the Prescapular Lymph Nodes

The adjacent lymph nodes may suppurate during or following fistula of the withers as shown in case of a draft horse (Fig. 14). After recovering from an operation for a fistula of the withers and before having been put to work a pronounced enlargement developed at

the shoulder. This proved to be a typical cold abscess involving these lymph nodes.

Fistula Caused From Collar Sitfasts

There is a type of fistula that differs somewhat from those just described. It is located in front of the generally accepted limits of the withers proper, and it exhibits certain etiologic, pathologic and clinical differences that call for a special description and which require different methods of management.

This injury starts as a cutaneous collar lesion. It begins as a pressure necrosis of the skin alone but later involves first the pad of the mane and then the funicular portion of the ligamentum nuchæ and even extends downward into the lamellar portion, creating a very troublesome condition to treat.

When observed in the early stage of development, the seat of the collar at the level of the mane where the thick skin is folded transversely into several deep undulations, is found to contain a black, smooth, hairless, leather-like, circular zone of insensitive integument that is loosened slightly from the viable skin all around its circumference, but which can not be lifted off. It is attached and although some time is given for it to separate, no such an event occurs. It remains stubbornly attached. At

first there is no swelling and the patient displays little discomfort, but later when the dead tissues begin to putrefy and impregnate the adjacent tissues with infections or serve as an avenue of entrance into them, the subject becomes unfit to work with a collar, a certain amount of discharge begins to appear around its borders, and the subjacent musculature becomes swollen or bulges from the swollen ligaments within. Soon the slough which is a large cone-shaped mass of skin and pad detaches itself and can then be removed by blunt dissection, leaving a deep well whose bottom is the ligamentum nuchæ. Treated as an open wound the cavity often closes up with nothing more harmful than a slight deformity of the neck which will vary according to the size of the slough removed.

Many cases, however, do not behave so well. Cicatrization of the cavity leaves a small fistulous tract that runs down to and often under the ligamentum nuchæ, and which in spite of local treatment continues to discharge considerable pus. The sides of the neck along the ligament bulge slightly in both the forward and the downward directions. *This is fistula from sitfast.* Later if no relief is given the lamellar portion becomes involved, at first only slightly but later over a wider and wider zone until the

whole lower third of the cervical region is hard and tumefied. Abscesses may point well forward along the neck and as far down as the level of the vertebræ. *This is cervical fistula*, a type that may also result from either the typical or the atypical types previously described.

The treatment of fistula from sitfast should begin with prevention. That is to say, the sitfast should be properly managed. It is an error to allow even the smallest superficial sitfast to sojourn on the neck unchecked. The veterinarian should recommend prompt extirpation and give warning about the serious state that may develop from careless treatment thereafter. The sitfast should be extirpated down into the sound, unaffected tissues, no matter how far it may extend, and the subject must be removed from service or worked with a breast collar. To leave any part of the dead tissue in the cavity or to subject the neck to continued injury by working the patient with a collar will encourage the development of chronic fistula and the attendant results. We therefore advise that all sitfasts be managed with this end in view, that the patient be submitted to a proper operation and the wound treated as it should be after the operation. The extirpation of deep sitfasts and the application of caustic into the cavity in our hands have not

been found to be good practice. We have depended upon the completeness of the extirpation as the main treatment, and in order to properly carry out this plan we have found it necessary to place the patients in the recumbent position with the neck well stretched downward to expose the field to the best advantage. Attempts to extirpate sitfasts of this character in the standing position end in failure to remove all of the dead elements. With the head elevated, the skin folded, the patient lunging about and the blood masking the view, it is never possible to work accurately, and a misdirected or incomplete extirpation is the result.

By placing the patient on the operating table or down on the ground with ropes, the neck can be drawn downward, the parts cleaned, the blood well baled and the whole mass of dead and unviable tissues can be cut away. Prompt healing will then follow.

Once the fistula has formed it will be necessary to operate promptly to prevent the spread of the advancing inflammation into the lamellar portion of the ligament.

We cast the patient clean and shave the neck and then make an incision no less than eight inches long in the median line through the skin, pad of the mane and down between the

two halves of the ligament. Widening the wound with the tumor forceps we then resect as much of the ligament as is thought to be diseased, making sure that the lowest limits of the disease have been reached. In the average case, not yet encroaching into the lamellar portion, the bottom of the cavity is found just under the funicular portion of the ligament.

The wound is treated without drainage by smothering it well with boric acid and iodoform until cicatrization is well advanced.

POLL-EVIL

The Poll

The poll or nape of the neck of quadrupeds having a long highly mobile neck and large head is an important region. Although less complicated from the anatomical standpoint than the withers it is nevertheless composed of a great many separate anatomical structures and although more shallow than the withers its relations to the large nerve centers makes affections of the poll more or less dreaded from the view point of disease and of surgery. The structures involved in poll-evil are contiguous to the coverings of the spinal cord in the atlanto-axoid space, to the occipito-atlantoid articulation and finally to the meninges and the brain. It is plain that no chronic pathological process so serious as poll-evil can sojourn unchecked without sooner or later implicating some of these structures if not all of them. The surgical anatomy of the withers does not include a trochoid articulation and its relations to the spinal cord are more remote.

The surgical anatomy of the poll includes, the skin, the pad of the mane, the atlas, the

axis, the occipital crest, the occipito-atlantoid articulation the atlanto-axoid ligament, the spinal cord, the funicular portion of the ligamentum nuchæ, the musculature, the blood supply, the anterior end of the spinal cord the meninges, the medulla oblongata, the spinal accessory nerve, and the first two spinal nerves.

The skin of the central line of the poll is thick and inseparable from the thick pad of the mane lying immediately beneath it. On the sides of the mane it is thin, somewhat delicate in texture, but possesses nothing out of the ordinary to describe. On the sides, the borders of the wing of the axis can be felt through it. Elsewhere the outlines of the bones can be palpated through it. In old cases of poll-evil it is riddled with perforations and often it contains scars of previous perforations.

The pad of the mane at the poll is very heavy especially in the draft breeds of horses, often exceeding two inches in thickness. In the lighter breeds as for example the thoroughbreds it is thin and in some subjects it does not exist. The pad here like that at the base of the neck is composed of elastic tissue and fat matted into a very firm structure homogeneous in appearance, and always very vascular.

The atlas, or first cervical vertebra possesses

none of the characteristics of vertebræ in general. It articulates by means of diarthrodial articulations with the occipital condyles anteriorly and with the odontoid process of the axis posteriorly. Its wide expansive dorsal surface gives attachment to the muscles to which it is related.

Its wings which extend downward and outward become gradually thinner and thicken again into a roughed heavy border. Each one is perforated with a large foramen which gives passage to the occipital artery, in its course from the carotid to the region of the poll.

The whole dorsal face is a smooth expanse interrupted only by a slight median elevation representing the superior spinous process.

The dorsal surface of the atlas is important in poll-evil because it sooner or later becomes affected with periosteitis and osteitis on account of its close relations to the disease process in and about the ligamentum nuchæ. It serves as a floor for the abscess cavity from which it is often separated only by a carpet of granulation tissue attached to the periosteum.

The axis or second cervical vertebra may be said to be the posterior boundary of the poll-evil process. It is seldom itself involved in disease. Its crest or superior spinous process stands above the level of the axis where it serves

as a pillar for the ligamentum nuchæ to bridge over the space between it and the nuchal (occipital) crest. The ligamentum nuchæ is, however, attached to it only by the lamellar portion, which at this point is very thick.

The nuchal (occipital) crest is a process of the occipital bone extending upward to give attachment to the ligamentum nuchæ and to the muscles of the poll. It has a rough border and a somewhat concave posterior face which is depressed at one point on each side of the median line to receive each half of the ligament. Its upper outlines determine the profile of the space between the ears.

The compact tissue of the occipital crest is dense and hard particularly along the summit. The cells of the cancellated tissue are large and the plates separating them are thin and therefore easily permeated with inflammatory processes. Although the occipital crest is not encroached upon by disease in poll-evil itself, it sometimes becomes affected by a chronic osteitis from chiseling into it to effect drainage as recommended by Williams.

The atlanto-axoid ligament covers the gap intervening dorsally between the anterior portions of the axis and the posterior part of the atlas. This space is about an inch and a half to two inches long and about an inch wide, be-

neath which lies the spinal cord unprotected by bony covering. Above the intervertebral ligament there is a thick musculature and the funicular portion of the ligamentum nuchæ.

The occipito-atlantoid articulation is a diarthrosis whose large capsular ligament is arranged to include both occipital condyles. It is protected superiorly by muscles which also separate it from the ligament laterally.

The atlantoid bursa—the initial seat of almost all poll-evils—lies between the ligamentum nuchæ and the dorsal arch of the atlas. This bursa has no connection with the articulation.

The spinal cord is exposed in two places to both the disease and the operation against poll-evil. It is, however, in the atlanto-axoid space that it is most likely to be encroached upon. The musculature covering it in the atlanto-axoid space or the intervertebral ligament, is usually the floor of the abscess cavity but sometimes these structures are degenerated and perforated in a downward direction until first the meninges and later the cord becomes involved. The cord exposure in the space is about one and a half to two inches. The cord must also be thought of when packing wound cavities with hemostatic packs because its covering is compressible and considerable spinal pressure

may be caused by wadding the cavity too tight.

The other place through which the spinal cord becomes exposed is at the occipito-atlanto-oid articulation. Here it is attacked by encroaching disease after the capsule of the joint has been invaded.

The ligamentum nuchæ is a powerful, elastic apparatus, the principal function of which is to assist the extensor muscles of the head and neck. It extends from the occipital bone to the withers, where it is directly continuous with the supraspinous ligament. It consists of two parts, funicular and lamellar.

The funicular part arises from the external occipital protuberance and the fossa below it and is inserted into the summits of the vertebral spines at the withers.—*Sisson*.

It is between the funicular portion of this ligament and the dorsal arch of the atlas that the bursa (supra-atloid) lies. At the pole the funicular part consists of two bands closely attached to each other. The lamellar portion of the ligamentum nuchæ is not attached to the atlas, but begins at the axis to which a very thick and strong digitation is attached.

Obliquus Capitis Anterior. This is a short, flat and nearly square muscle, having tendinous intersections. It originates from the anterior edge and ventral surface of the wing of

the atlas inserts to the parmastoid process nuchal (occipital) crest and the mastoid process.

Obliquus Capitis Posterior (Posticus). This muscle lies upon the dorsolateral aspect of the atlas and axis. It is broad, flat, thick and fleshy. Its origin is from the side of the spine and the posterior articular process of the axis. It inserts to the dorsal surface of the wing of the atlas. Its function is chiefly to rotate the atlas, and by this means, the head.

Rectus Capitis Dorsalis Major. This muscle originates from the edge of the spinous process of the axis and inserts to the occipital bone, below the tendon of insertion of the complexus. It is in contact with the ligamentum nuchæ.

Rectus Capitis Dorsalis Minor. This is a small muscle which lies under the rectus capitis dorsalis major. It originates from the dorsal surface of the atlas and inserts to the occipital bone beneath the point of insertion of the last named muscle. It is lateral to the cordiform portion of the ligamentum nuchæ.

Rectus Capitis Ventralis (Anticus) Major. This, the long flexor muscle of the head has its origin posteriorly from the transverse processes of the third, fourth and fifth cervical verte-

brae. It inserts to tubercles which occur at the junction of the basilar part of the occipital bone with the body of the sphenoid. These muscles (the pair) may be said to form a roof for a part of the pharynx.

The blood supply of the poll is from three sources: The occipital, the superior cervical and the vertebral arteries. The first named is, however, the chief one. It is a radical of the carotid and passes to the region of the poll through the large foramen in the wing of the atlas. Its branches anastomose with the other two. The branches are numerous and often through the influence of the disease become greatly enlarged. In the operation for poll-evil the incision being a standard one, made irrespective of blood vessels, there is nothing of importance to say about avoiding them, except that lateral invasion into the region of the alar foramen through which the occipital passes must be made cautiously. In short, no especial effort except this one, is ever made to avoid arteries.

The nerve supply is of no especial importance. It is derived from the spinal accessory and the first two spinal nerves, none of which is ever seen in the operation, nor is a solution on the continuity of their branches attended with any observable harm.

PATHOGENESIS

Poll-evil, like fistula of the withers, we divide into two classes: typical and atypical. By typical poll-evil we mean those cases that develop independent of any known cause in the atlantoid bursa, just as fistula of the withers so frequently develops in the dorsal bursa. By atypical poll-evil—a rare entity—we designate those that originate from abrasions or wounds. The former invade outward while the latter invade inward from the initial seat.

The course of all typical poll-evil we divide into three stages: the saccular stage, the phlegmonous stage and the fistulous stage, as in fistula of the withers.

The *saccular stage* begins in the form of a distension of the atlantoid bursa with a sero-fibrinous fluid that is sterile and whose influence causes the formation of a well defined membranous wall composed of a cellular internal face fortified by fibrous tissue. As the lesion becomes older the fibrous tissue becomes more abundant, sometimes amounting to an extensive fibrosis of the surrounding musculature. The sac may bulge on one or both sides and may be small or large enough to conspicu-

ously deform the region. Being imbedded under firm tissues, it is often hard to the touch, fluctuating only after pushing its way to the surface on the side of the ligamentum nuchæ and pad of the mane. Evacuating the contents of the sac during this stage yields an amber colored fluid carrying coagulated detritus containing no bacteria.

This sac may sojourn indefinitely and may even for a time seem to disappear entirely, only to reappear subsequently.

Evacuation and careful attention to the tract and cavity may sometimes end the process by slow cicatrization. Thus sometimes a poll-evil is cured without a radical operation. In most cases, however, the invasion of the tract and cavity with extraneous microbes ends in chronic fistula.

The phlegmonous stage. In the usual course of events the saccular stage ends in infection of the cavity. The manner in which microörganism gains access to the cavity is not known, but the frequency with which poll-evil is associated with strangles and influenza has led us to believe that these diseases play an important role in its etiology; the affected atlantoid bursa serving as a focus of localization for microörganisms contained in the blood after these diseases.

During this stage the patient becomes sick and severely hindered in the movements of the head. It becomes manifestly opisthotonic in attitude, and develops a body temperature of from two to three degrees above normal. The poll becomes progressively more painful to the touch and the sides of the neck are streaked with radiating lines.

The Fistulous Stage

Either by lancing or by spontaneous ripping and bursting of the abscess this stage sooner or later passes into the stage of chronic discharge—fistula. If the infection is not a virulent one the development is very slow—cold abscess—and fibrosis becomes a prominent feature of the process. That is to say, if the accumulating pus is not released the process reacts upon the surroundings in some way that causes the muscular elements to become fibrous.

The fistulous and the phelgmonous stages are of course influenced by microörganism. These exert a more or less destructive influence upon the ligamentum nuchæ, which is in the center of the theater of attack. Once this fibro-elastic structure has been damaged it acts as the underlying cause of subsequent pathologic processes. Riddled with perforations, shredded with bundles of its fibers which remain

stubbornly attached, and carpeted here and there with dormant granulations it prevents cicatrization of the abscess cavity. It is this stubborn viability of the ligamentum nuchæ that is responsible for the chronicity of poll-evil.

This stage, like that of fistula of the withers, continues indefinitely, healing at one place and bursting at another and all of the while transforming the muscles into fibrous tissue. The inflammatory process extends into the periosteum of the atlas, into the capsule of the occipito-atlantoid articulation, into the meninges and brain, into the neural canal and into the spinal cord, producing the variety of complications for which poll-evil is known.

An old poll-evil left to sojourn unmolested or one indifferently treated usually exhibits the following morbid states: a tumefied poll, one or more apertures discharging pus, scars of previous apertures, encrustations of dried pus matted into the mane and surrounding hairs, extended head from fibrous ankylosis of the occipito-atlantoid articulation and a wabbling gait that becomes more and more accentuated until the patient is unable to rise. Sectioned, the poll is found to have been transformed into a mass of hard, fibrous tissue, which fuses all of the component structures in-

to one homogenous mass. This mass is riddled with tracts and under the now unrecognizable ligamentum nuchæ is an abscess cavity almost closed by granulation tissue. The surface of the atlas is rough from destruction of its periosteum and it may be studded by numerous vegetations of bony growths. There is found sometimes a shredded condition of parts of the ligament, parts that have partly loosened from necrosis. In some cases, usually in aged horses, the ligament is permeated with calcareous deposits, each of which is well incarcerated with connective tissue elements.

Atypical Poll-Evil

The atypical poll-evil begins with a halter abrasion of some kind of wound that gives admission to pyogenic microorganisms. It is at first a subcutaneous abscess, and if carbuncular in character may give rise to all of the symptoms of a typical poll-evil in the phlegmonous stage. This form will differ from the typical form in that cicatrization will follow evacuation of its pus and general slough. If deep and the slough should be attached to the ligamentum nuchæ a chronic poll-evil having all of the characteristics of the other, the typical kind, will supervene. In this case the ligament is at-

tacked from without. Its dorsal face is attacked first, while in the other, the under part at the atlantal bursa, is attacked before the upper part becomes involved.

This form of fistula can only be recognized as such at the early stage, for once spread deeply into the poll it has no differentiating qualities.

Etiology

The cause of poll-evil, like that of fistula of the withers, is by no means settled. The academic explanation (traumatism) that seems to have satisfied all past writers on the subject entirely lacks confirmation. Wherever this subject is discussed verbally or in literature the matter of etiology is always indifferently passed over as if it is a settled fact that poll-evil is a traumatism. No one seems to have ever questioned seriously the theory of traumatic origin in spite of the fact that no one seems to have ever actually traced a typical poll-evil to any definite traumatism. The truth seems to be that traumatism plays no part whatever in its cause. Except in the rare case that originates with a wound of the poll it is plain that we must seek farther for a reasonable theory of cause. It is our opinion that the cause is unknown, that the serous sac that starts it develops under influences we cannot

explain at the present time. We believe, however, that infectious diseases such as influenza or strangles play an important role in the course if not also in the original cause. Where influenza is rampant so will poll-evil and fistula of the withers be found rampant. We are, however, not today justified as laying this down as an absolute law, as subsequent investigations no doubt may show that its cause is more specific.

SYMPTOMS

Typical poll-evil is first seen as a slight bulging of one or both sides of the poll. There are at first no manifestations of pain either on palpation or in movements of the head. Later as the phlegmonous stage begins the movements of the head become painful and palpations annoy the patient. Some will oppose any attempt to touch the region. Before the abscess points there are radiating lines along the sides of the neck. The head is held extended, lateral movements are painful and the whole body is turned stiffly, as if the whole axial skeleton were ankylosed.

Later the abscess points and discharges its contents over the sides of the neck. The aperture may then discharge a limited quantity of pus for weeks that keeps the region continually soiled and irritated. The aperture will finally close gradually as the discharges become less abundant, but this will eventually be followed by the forming of another abscess, which will behave in the same manner as the preceding one, and so the condition proceeds. While these abscesses and tracts are forming, the musculature involved becomes considerably elevat-

ed above the surrounding level. The head, at first extended from the pain of the forming abscesses, gradually becomes fixed in the extended position from fibrous ankylosis of the region. An animal affected with poll-evil has a characteristic attitude simulating the opisthotonos of tetanus.

Poll-evil that becomes infected before there is any enlargement of the region must be diagnosed sometimes entirely from this attitude and from the pain produced by manipulating the head.

Rare cases cause epileptiform seizures when the head is moved about manually or in working. In such instances when local evidence is entirely lacking because of the depth of the infected focus it may not be an easy matter to arrive at a diagnosis.

The development of poll-evil is always gradual, although it may often assume considerable proportions before attracting attention. The mane and forelock shelter the region so effectually in some animals that the enlargement develops unnoticed until discharges appear. These cases are, however, rare, as the pain and the position of the head which precede the discharge are usually pronounced enough to attract attention.

The average poll-evil when submitted to the

veterinarian is either found as an enlargement on one or both sides of the poll or else as a suppurative condition that matts the hairs of the mane and soils the region with dried pus.

As the disease progresses the patient becomes distinctly unthrifty in appearance and loses flesh. Locomotion is slow. The patient gropes about and trots only when urged. Feeding from the bottom of the manger and grazing is painful.

Later, as nervous complications develop, the hind quarters wobble inordinately and rising becomes more and more difficult. Finally the failing subject, unable to stand, dies from decubital complications, if it is not sooner killed to end its misery.

Complications

Paralysis.—The most serious complication is paralysis due to advancement of the inflammatory process into the meninges, the cord and even the brain itself. The invasion is usually at the atlanto-axoid space, but sometimes occurs through the occipito-atlantoid articulation. When these nervous structures become involved early in the progress of the disease, the case is not necessarily a hopeless one because of the nerve involvement, since an operation which evacuates the pus externally may turn

the tide of the inflammatory process towards resolution. On the other hand, if nervous complications develop as a phase of later stages, the case is always hopeless. The practitioner is warned against operating upon such cases, because the operation is always blamed for the unfavorable termination, and in fact rightly so, since the advancement of the process into the cord and brain is accentuated rather than retarded by surgical treatment at this stage of the development. And besides, patients thus stricken are unable to withstand the enfeebling influence of such a major operation.

Involvement of the Occipito-Atlantoid Articulation.—Lying adjacent to the initial focus of the disease, this joint very often becomes infected within its capsular ligament at an early stage. As a rule, however, this complication features later stages, the joint becoming involved gradually through the medium of the atlas. The periosteum and then the bone, soaked with pus develop chronic inflammation that advances into the joint through the articular cartilage. When this occurs it is only a matter of weeks before serious results ensue through involvement of the meninges. The subject thus affected is in sore straits from the severe pain it suffers, especially in moving the head.

This complication is one of the common causes of recurrences and failures of operative treatment. It is incurable and if known to exist should be regarded as a contra-indication of the radical operation now universally recommended for poll-evil.

Secondary Abscesses.—Although there are fewer recesses and lamellar spaces for pus to burrow into about the poll than there are about the withers, there are, nevertheless, places where pus will escape from the immediate region of the seat of poll-evil and cause secondary abscesses. The common one that occurs both before and after operating, localized at some point of the neck along the ligamentum nuchæ. We have observed cases in which tracts extended down the ligament as far as the base of the neck, the route followed being the space between the cervical muscles and the lamellar portion of the ligaments just under the funicular portion. Most of these abscesses, however, localize at the level of the axis, where they sometimes produce a stubborn condition to handle by implicating the lamellar portion of the ligament at that point.

Another focus of abscess formation is the space between the anterior part of the wing of the atlas and the styloid process of the occipital. This complication is disclosed at the

time of the operation. After the ligament has been removed, a sound can sometimes be passed downward five or six inches before it touches the bottom of the cavity.

Chronic Septicemia co-exists to a certain extent in all bad cases of poll-evil. It is, however, less serious than in fistula of the withers, since the region is smaller.

TREATMENT

No time should be lost in submitting a poll-evil to radical treatment. The new case should be lanced and the cavities irrigated with antiseptics for a week or ten days and then promptly operated upon. There will be nothing gained by waiting longer, as the older the case the more it will have damaged the structures of the region and thus the more difficult it will be to cure. In cases found in the phlegmonous stage and before the abscess has burst we also recommend lancing and irrigations as preparatory treatment.

Subjects having unmistakable involvement of the occipito-atlantoid articulation and all those already showing nervous complications should be left severely alone and pronounced incurable. Weak subjects that do not exhibit sufficient strength to withstand a major operation should likewise be left alone. These might, however, be submitted to a restorative treatment until it is thought advisable to interfere further.

The Radical Operation for Poll-Evil

Restraint.—No attempt should ever be made to operate in the standing position, no matter

how tractable the patient may seem. Operations performed in the standing position under some form of narcosis always turn out to be very unsurgical exhibitions. The patient should be cast with ropes or else placed upon an operating table. The latter is much the best because of the elevated position of the head. On the floor or ground the field is not so accessible and must be elevated by blocking the neck and head up in some way to bring it where the surgeon can work. Chloroformed, the patient can be handled better than under narcosis. When rope restraint is used chloroform should really be administered because it is difficult to control the sweeping movements of the head of a partially anesthetized subject down on the ground. Our plan in field work is to clean up the poll well while the subject is standing, cast with ropes, administer chloroform and then block up the neck and poll with a tightly filled sac of straw. This sac may be bound to the neck and head with cords, one around the middle of the cervical region and one around the head just below the eyes. Thus tied the blocking will stay in place when the neck and head move. This form of blocking is particularly essential when the operation is done on the ground under narcosis. It is important that the sac be well filled, otherwise it will flatten down and do

no good. For this purpose we also use when available two or three buggy or automobile seat cushions.

The head should be maintained at about its normal angle with the neck. Extreme extension or flexion is undesirable.

The patient should lie on its right side. Although this is not mandatory, the surgeon finds that it is easier to cut backward with the right hand when the patient is thus positioned.

Incision. First Step.—The scalpel is pushed carefully downward, with its cutting surface backward, just behind the occipital crest in the very middle of the neck, until it either enters the bursa or is blocked by the occipital bone. Its blade should be buried about four inches in the average case. It is then drawn backward, maintaining this depth, about eight inches. If a longer incision is decided upon it is best to make it more shallow posteriorly because of the danger of invading the neural canal. If a short bladed scalpel is used several strokes will be required. Blood will flow copiously from many sources, but no attempt is made to control it either by ligation or forceps. It is our experience that more blood is lost when the operation is stopped to make these attempts at hemostasia. We, however, grasp

each edge of the wound with a tumor forceps give one to the assistant and hold the other in the left hand. By drawing hard on these the

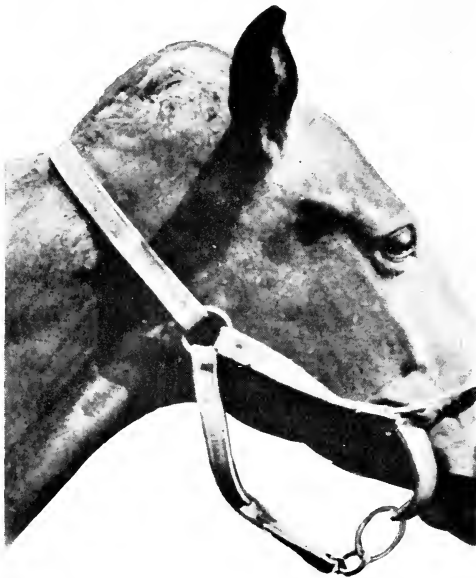

FIG. 13.—POLL EVIL SHOWING DEFORMITY DUE TO THE TREATMENT WITH CAUSTICS.

bleeding will be controlled to some extent.

Separating the ligament from the occipital Crest. Second Step.—This to us is the most

important part of the operation, as it supplies the first "landmark" for the subsequent resection. Those who ignore this step will find it



FIG. 14.—A RECURRENT CASE AFTER TEMPORIZING TREATMENT.

Note the scars from lateral incisions through which drainage had been attempted.

difficult to locate the ligament and will often abandon the work without having accomplished

the main object—the resection of the ligament.

In this step we lay the scalpel aside and take up the probe-pointed bistoury. We first pass the index finger of the right hand under the ligament right at the crest and using the finger as a guide pass the bistoury under it, cutting outward and upward. The ligament through its extreme elasticity will contract backwards as fast as it is cut and thus reveal itself to the operator. That is, the end will come right out into the foreground after contracting backward an inch or more. We then grasp the end with a tumor forcep and dissect it in the backward direction as it is drawn upon with the forcep. Over the region most badly damaged by disease it will be found so fused with the other connective elements that it can not be said to be a distinct structure. We attempt to take away as much of this connective tissue as is thought prudent as the dissection proceeds backward. The dissection is continued along the whole length of the incision or until the sound part of the ligament is reached posteriorly. We know when the sound part is reached by its elasticity. When the section now held in the forcep is drawn back and forth the ligament it seen to stretch easily. Here it is cut off.

The attention is now directed to the other

side, as this removes only one-half of the ligament. The operation must be repeated in the same way on the opposite side. Allowance must be made for a possible sectioning of the ligament into two unequal parts when the first

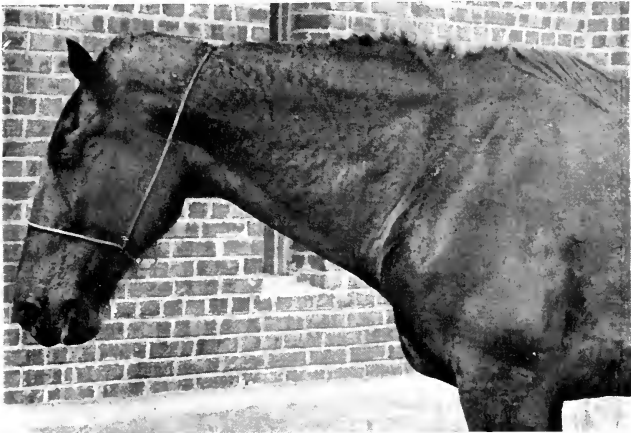

FIG. 15.—THE OPERATION COMPLETED.

Note that the operative wound is packed so tightly that the poll appears swollen even more than before the operation. Note also the enlargement of the lymphatics of the neck, due to the absorption of toxic materials from the suppurating area.

incision was made. That is to say, when the scalpel was drawn backward in making the incision it may not have traveled exactly between the two lateral halves of the ligament and thus has left more to be removed from

one side than from the other. Sometimes in misdirected plunges of the scalpel into the poll the ligament may all be left on one side, sometimes two-thirds is on one side and one-third on the other, etc. And again, if the incision was not made straight there may be more ligament anteriorly than posteriorly on a given side. These are points to keep in mind at all times. The point is to remove all of it along the affected zone, but no more than is necessary posteriorly.

Packing and Suturing. Third Step.—The wound is now wadded with a hemostatic pack of oakum and sutured securely. We make no attempt to wad the cavity so very tight posteriorly on account of the danger of spinal pressure, although it must be well filled. The object in making a safe hemostatic pack for poll-evil is to distribute the pressure evenly over the whole cavity. That is, severe pressure from hard lumps of the oakum must be avoided, especially at the posterior end of the wound. When the patient is standing again the poll and bloody neck are washed off with liberal ablutions of water and then the poll is covered with a layer of oakum or cotton soaked in mercuric chlorid solution and this is held in place with a hood made from muslin or common bur-lap.

After-care.—At the end of twenty-four hours the sutures are removed and the packing carefully lifted out. Harsh handling will cause bleeding and should be avoided at this early moment after the operation. We simply fill the cavity with a cotton wadding dripping with mercuric chlorid solution and replace the hood for another twenty-four hours before attempting any systemic after-treatment.

The subsequent after-care consists of smothering the wound secretions by the application of abundance of boric acid and iodoform in the proportion of 95 to 5. This should be applied three times a day for the first five days and later twice and still later once a day.

Healing is usually complete in forty days.

Accidents and Sequelae

Hemorrhage is a common enough accident of poll-evil. Always copious, it assumes serious proportions when the operation is in any way delayed. When the anesthesia or the restraint miscarries serious blood losses always occur. Secondary hemorrhage is rare except when the cavity is too harshly handled when the packing is first removed.

The hemostasia of poll-evil operations lies in:

1. Stretching the wound apart forcibly

with the tumor forcep as soon as the incision is made.

2. Performing the operation without delay.

3. Packing the wound with an even pressure with oakum securely retained with sutures.

4. Avoiding harsh handling until at least forty-eight hours have elapsed.

Paralysis.—We have had animals become entirely paralyzed after poll-evil operations, due to having attempted to cure incurable cases already having nervous complications, but aside from those it is always possible, when due care is not taken to properly attend to such a large wound adjacent to the neural canal, for the inflammatory process to invade through the muscles covering the atlanto-axoid space and produce trouble that did not previously exist. Then again, undue pressure of a lumpy hemostatic pack is always a hazard. By avoiding operations on subjects exhibiting a wobbly gait, carefully packing the wound and then properly caring for it afterward there is little danger from this complication.

Slough of the Distal Stump of the Ligament Nuchae.—Failure of the wound to heal at the posterior commissure is due always to a slough of the stump of the ligament. Sometimes the slough is small and at other times it

is large. This sequel is manifested in two ways. In some cases the wound heals everywhere except at the posterior end, where a small fistulous tract remains. Probed it is found to be deep. If forceps are introduced the slough can usually be taken hold of and drawn out. Sometimes the aperture must first be enlarged.

The other manifestation is the appearance of a new phlegmonous condition on each side of the neck just behind and below the posterior end of the wound. The abscess is sometimes threatening and unless properly handled may end in a new fistulous condition quite difficult to handle. The first sign of such a complication, which usually occurs at about thirty-five to forty days after the operation, must be met by making an incision at the posterior end of the old wound downward into the abscess cavity, where a slough of the stump of the ligament is always awaiting removal.

It is our practice to make a careful examination of the wound at the end of thirty days with a view of determining whether or not such a slough exists, and to remove it if found.

Recurrences and Failures

The failures from the radical operation for poll-evil are almost always due to procrastina-

tion. The disease being left to effect incurable damage to the bones, particularly to the occipito-atloid articulation, can not be cured entirely by simply resecting the ligament. Where the ligament is removed early failures are negligible. Recurrences are due to sloughs of the distal stump referred to above or to failure to remove all of the ligament.

By avoiding old incurable cases, by resorting to effectual restraint and anesthesia, by operating deliberately and without delay, by attending skillfully to the wound and by keeping in mind the slough of the distal stump, the radical operation for poll-evil is attended with a few failures. It should be a routine measure with every veterinary practitioner.

And what is writ is writ;

Would that it were worthier.—Homer.

THE END

Webster Family Library of Veterinary Medicine
Cummings School of Veterinary Medicine at
Tufts University
200 Westboro Road

