




3 1761 06706864 3

UNIV. OF
TORONTO
LIBRARY





HAND-ATLAS

OF

HUMAN ANATOMY

BY
WERNER SPALTEHOLZ
EXTRAORDINARY PROFESSOR OF ANATOMY IN THE UNIVERSITY AT LEIPZIG

EDITED AND TRANSLATED FROM THE FOURTH GERMAN EDITION
BY

LEWELLYS F. BARKER

PROFESSOR OF THE PRINCIPLES AND PRACTICE OF MEDICINE, JOHNS HOPKINS UNIVERSITY, BALTIMORE
FORMERLY PROFESSOR OF ANATOMY IN THE UNIVERSITY OF CHICAGO AND RUSH MEDICAL COLLEGE

WITH A PREFACE

BY

FRANKLIN P. MALL

PROFESSOR OF ANATOMY IN THE JOHNS HOPKINS UNIVERSITY AT BALTIMORE

SECOND EDITION IN ENGLISH

VOL. II.

REGIONS, MUSCLES, FASCLE, HEART, BLOOD-VESSELS

PHILADELPHIA AND LONDON
J. B. LIPPINCOTT COMPANY

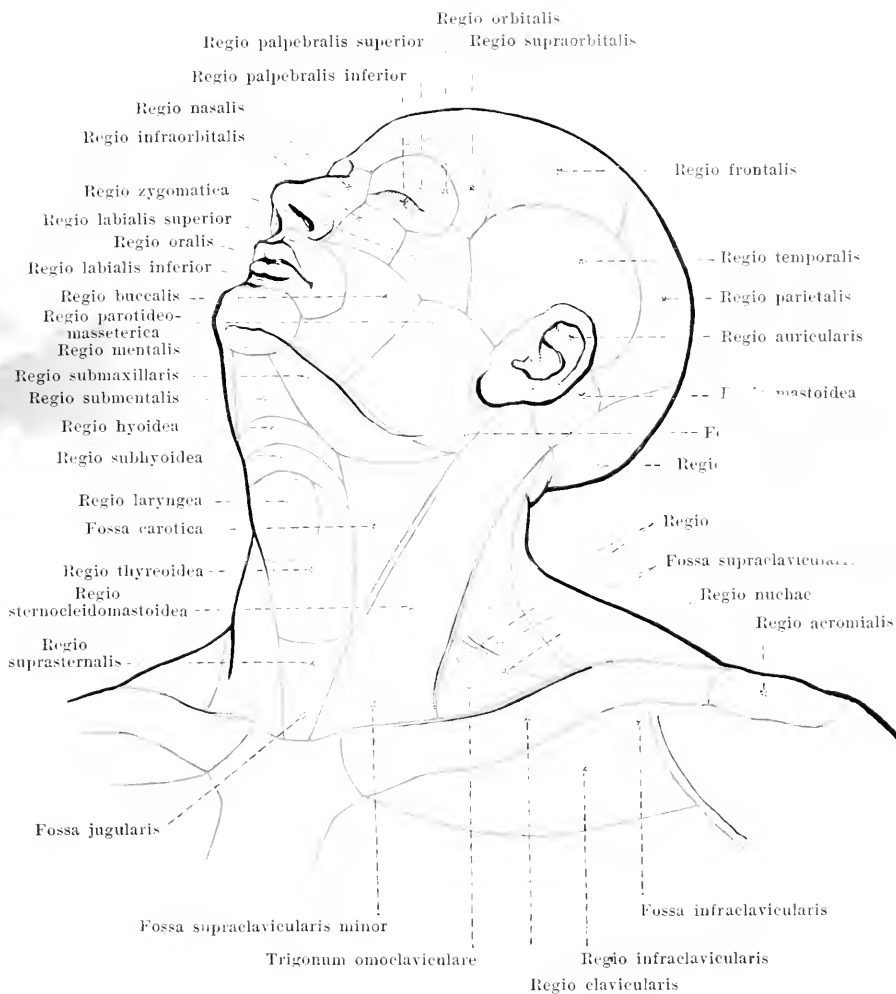
8444
29/10/07

ALL RIGHTS RESERVED

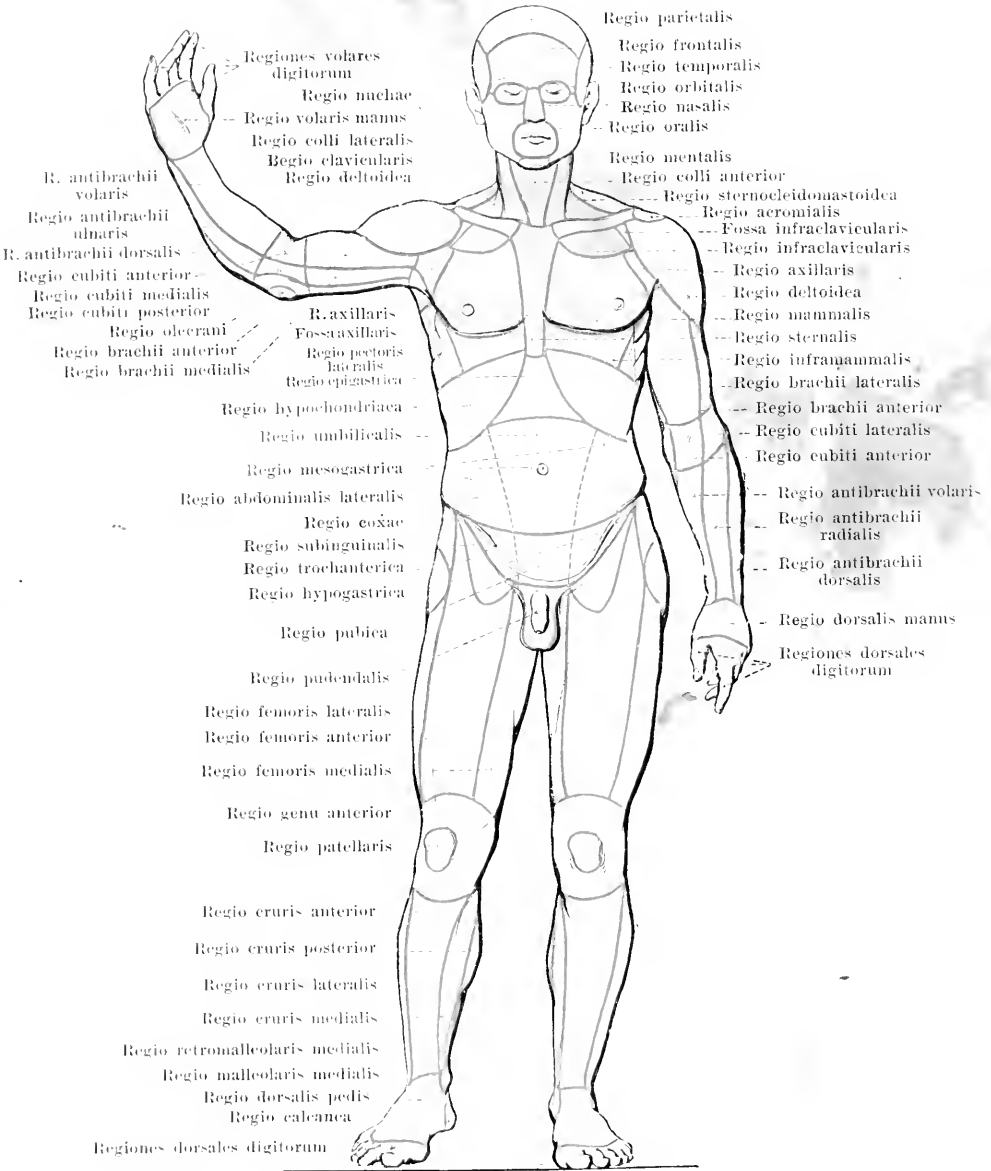
II.

REGIONS, MUSCLES, FASCIÆ,
HEART, BLOOD-VESSELS.

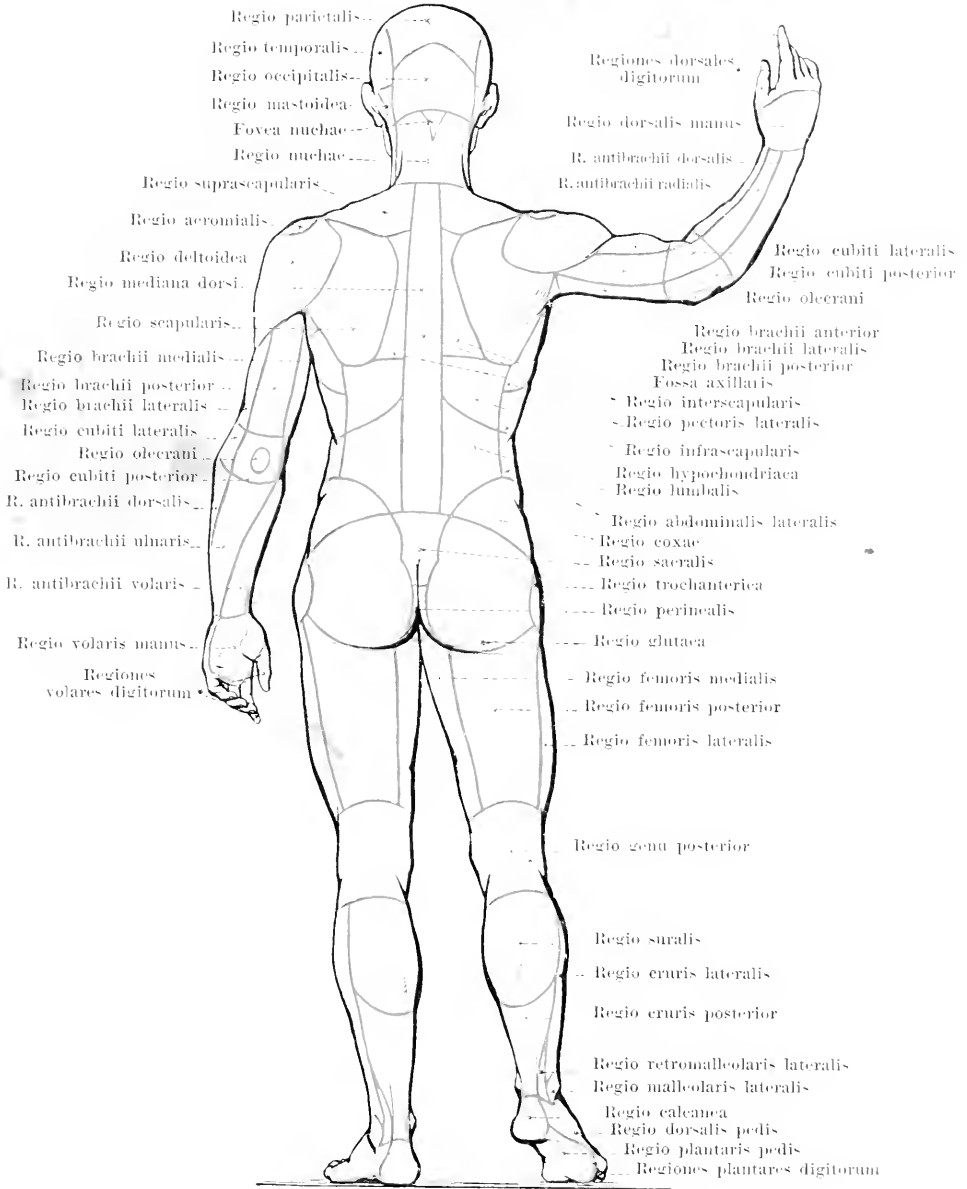
Digitized by the Internet Archive
in 2007 with funding from
Microsoft Corporation



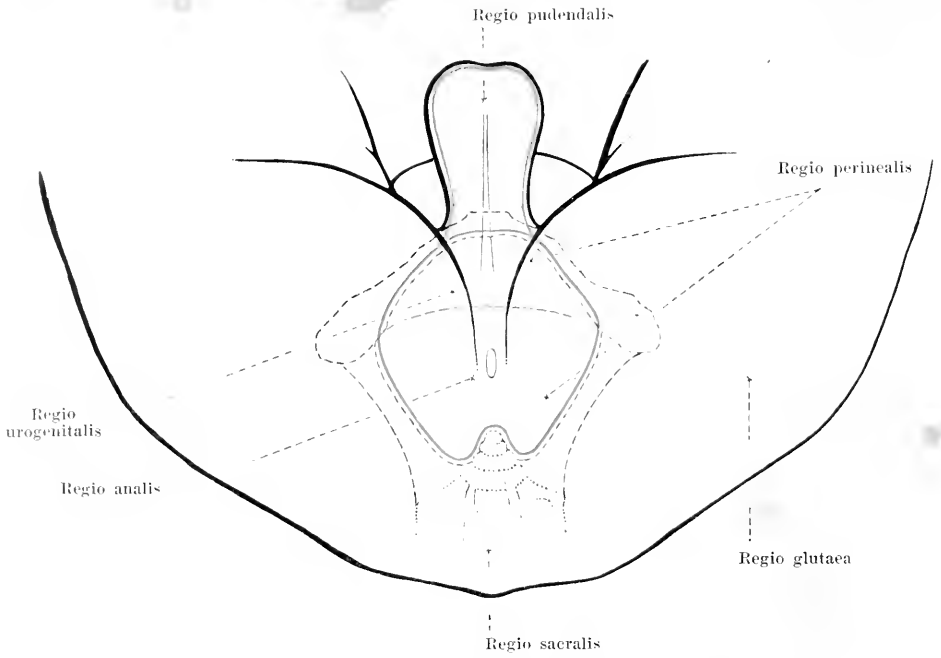
281. Regions of the head and neck.



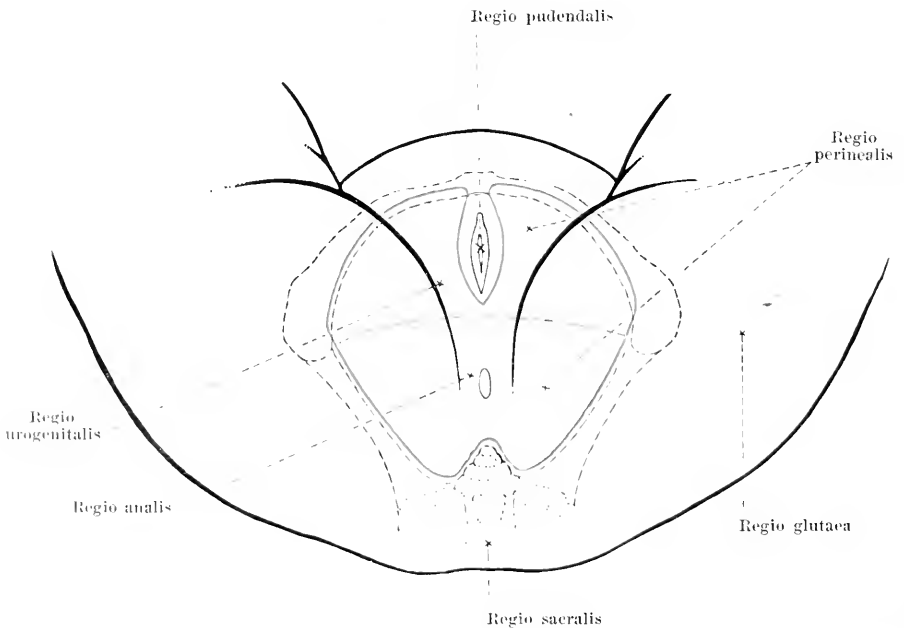
282. Regions of the body, viewed from in front.



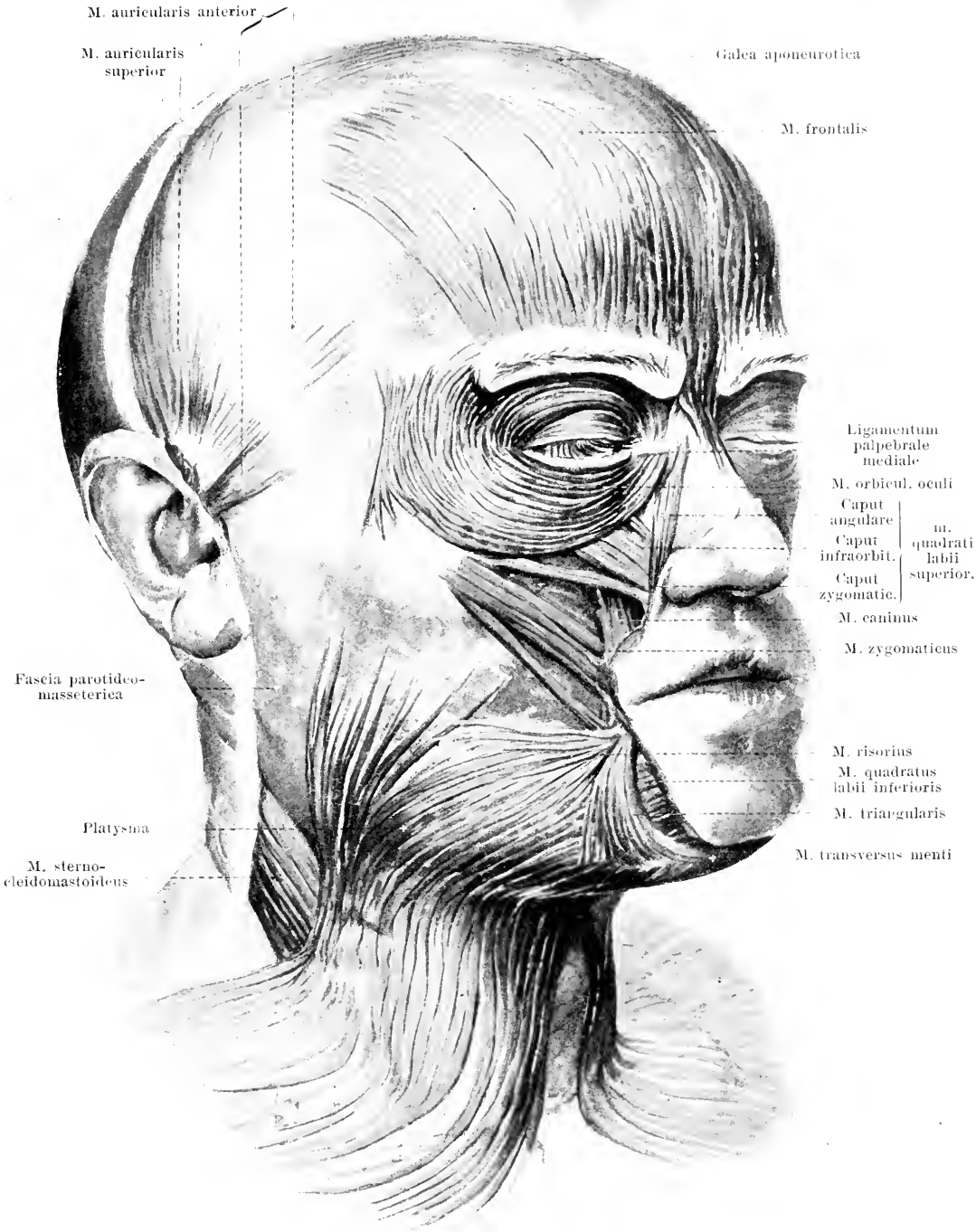
283. Regions of the body, viewed from behind.



284. Regions of the male perineum.



285. Regions of the female perineum.



M. auricularis anterior

M. auricularis superior

Galea aponeurotica

M. frontalis

Ligamentum palpebrale mediale

M. orbicul. oculi

Caput	m.	quadrati labii superior.
Caput infraorbit.		
Caput zygomatic.		

M. caninus

M. zygomaticus

Fascia parotideo-masseterica

Platysma

M. risorius

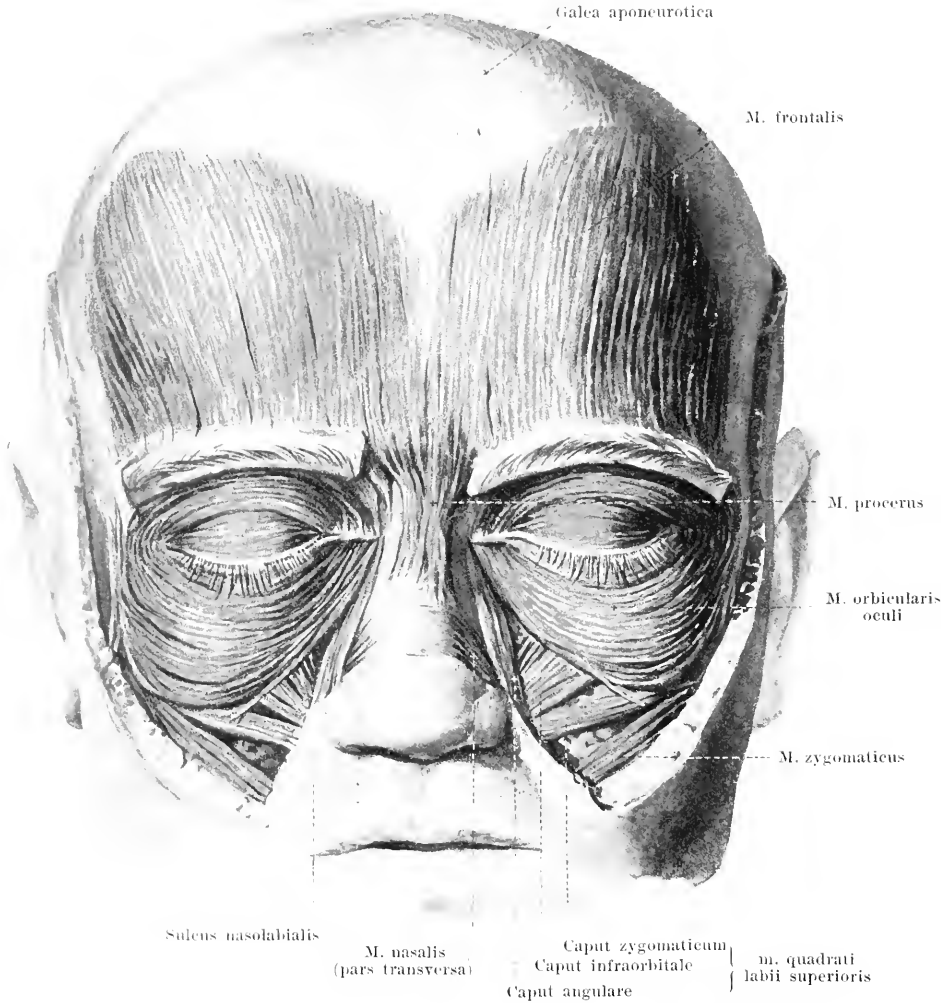
M. quadratus labii inferioris

M. triangularis

M. sterno-cleidomastoideus

M. transversus menti

286. Muscles of the head and face, viewed somewhat from the right.



287. Muscles of the head and face, viewed from in front.

Musculus epicranicus. Form: flat, broad. Position: covers the roof of the skull.

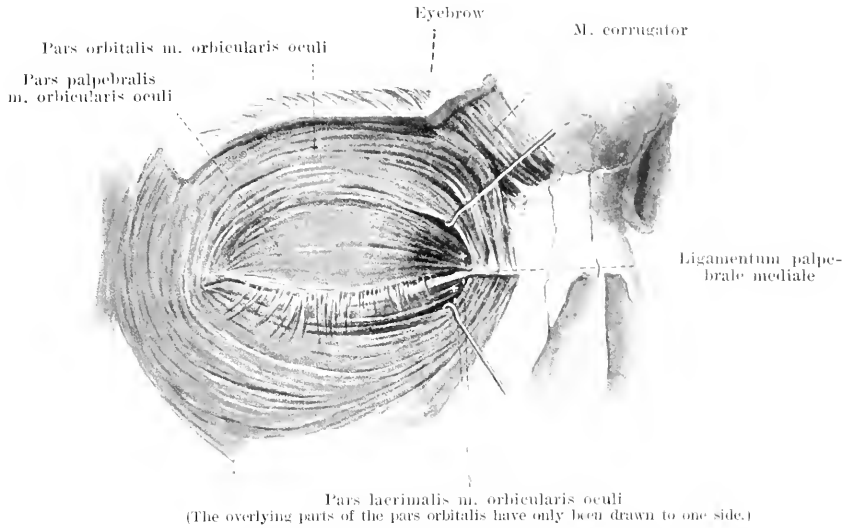
Posterior part, fleshy: **m. occipitalis** (see Fig. 296). Origin: lineae nuchae suprae oss. occipitalis. Insertion: galea aponeurotica. Action: draws the galea backward.

Middle portion, tendinous: **galea aponeurotica**, large flat tendon inserted between m. occipitalis and m. frontalis; loosely and movably united with the periosteum, very firmly connected with the cutis.

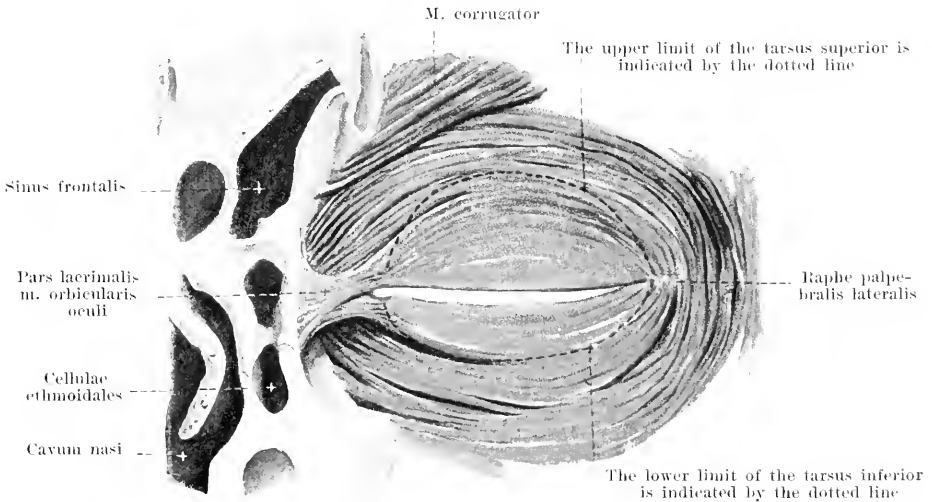
Anterior portion, fleshy: **m. frontalis** (see also Fig. 286). Origin: galea aponeurotica. Insertion: skin of the eyebrows, ossu nasalia (latter portion called **m. procerus**). Action: draws eyebrows upward, wrinkles forehead transversely; moves galea aponeurotica.

Innervation: n. facialis.

M. quadratus labii superioris (see also Fig. 286). Form: flat, triangular. Position: lateral from the nose; origins partly covered by m. orbicularis oculi. *Caput angulare.* Origin: proc. frontalis maxillae. Insertion: skin of the ala nasi and of the sulcus nasolabialis. *Caput infraorbitale.* Origin: margo infraorbitalis. Insertion: sulcus nasolabialis. *Caput zygomaticum.* Origin: facies malaris oss. zygomatici. Insertion: sulcus nasolabialis. Action: draws ala nasi and upper lip outward and upward, widens nasal opening and deepens the sulcus nasolabialis. Innervation: n. facialis.

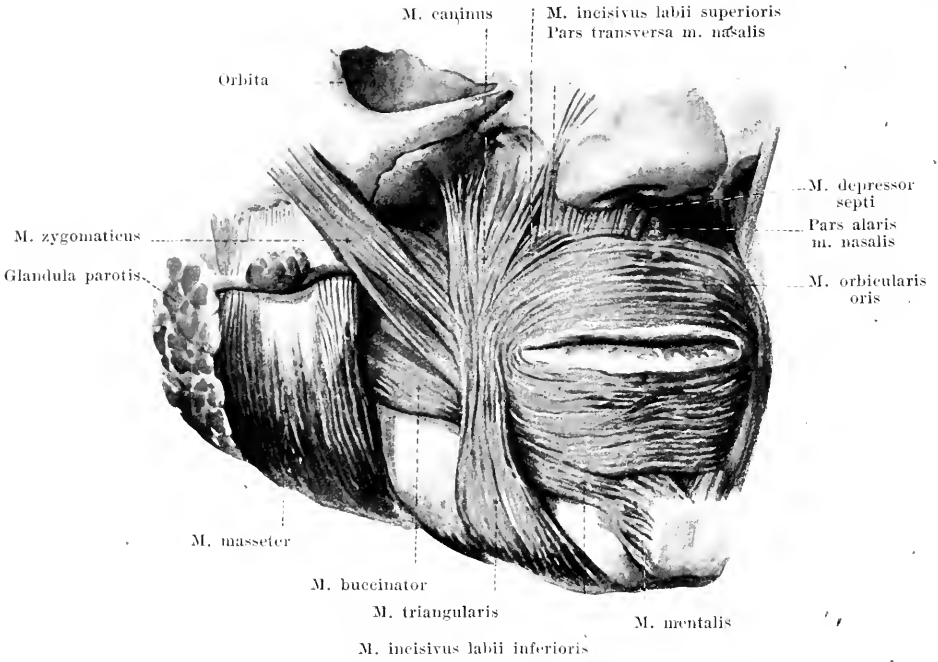


288. Muscles of the right eyelid, viewed from in front.



289. Muscles of the right eyelid, viewed from behind.

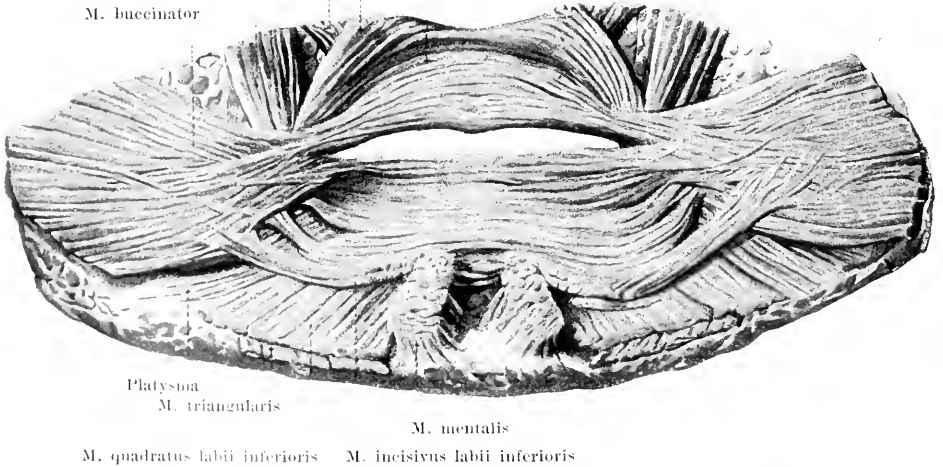
M. orbicularis oculi (see also Figs. 286 and 257). Form: flat, elliptical. Position: in the eyelids and at their periphery. *Pars orbitalis*. Origin: pars nasalis oss. frontalis, crista lacrimalis anterior maxillae, anterior limb of the lig. palpebrale mediale; the fibres surround the eyelids in flat, concentric arches and interweave with one another lateralward from the external angle of the eye or go to a thin, horizontal band of connective tissue (*Raphe palpebralis lateralis*) which extends from the external angle of the eye to the lateral margin of the orbit. Action: draws the eyebrow downward, the skin of the cheek upward; helps to close the lids. *Pars lacrimalis* [Hörneri]. Origin: crista lacrimalis posterior oss. lacrimalis; it runs lateralward behind the tear-sac to the medial angle of the eye and spreads out thin within the lids corresponding in extent to about that of the tarsi. In the lids it forms the *pars palpebralis*. Action: widens tear-sac, closes eyelids. Innervation: n. facialis.



290. Muscles of the region of the mouth, viewed somewhat from the right side.

(Platysma, mm. risorius, quadrati and orbicularis oculi have been removed.)

- M. quadratus labii superioris M. incisivus labii superioris
- M. caninus M. orbicularis oris
- M. buccinator



291. Muscles of the region of the mouth, viewed from behind.

(The tissues about the mouth have been loosened from their bony substratum and the muscles have been dissected out from the posterior surface.)

M. corrugator (see Figs. 288—289). Form: flat, narrow. Position: near the root of the nose, extending upward and lateralward. Origin: pars nasalis oss. frontalis. Insertion: skin of the eyebrow. Action: causes longitudinal folds at the side of the root of the nose. Innervation: n. facialis.

M. nasalis. Form: flat, triangular. Position: lateralward from and below the ala nasi, partly covered by the m. quadratus labii superioris.

Pars transversa. Origin: jugum alveolare of the upper canine tooth. Insertion: to the dorsum of the nose spreading out by a thin tendon to the muscle of the other side.

Pars alaris. Origin: jugum alveolare of the upper lateral incisor tooth. Insertion: lateral and lower margin of the ala nasi.

Action: draws ala nasi downward, narrows nasal opening. Innervation: n. facialis.

M. depressor septi. Form: flat, quadrangular. Position: below the nose, just medianward from the preceding muscle. Origin: jugum alveolare of the upper medial incisor tooth. Insertion: septum nasi. Action: draws nasal septum downward, narrows nasal openings. Innervation: n. facialis.

M. risorius (see Fig. 286). Form: flat, triangular; very variable. Position: lateral from the angle of the mouth, upon the platysma. Origin: fascia parotidomasseterica. Insertion: unites at the angle of the mouth, or somewhat below it, with the m. triangularis. Action: helps to draw the angle of the mouth lateralward; causes dimple. Innervation: n. facialis.

M. zygomaticus (see also Fig. 286). Form: oblong, flat-cylindrical. Position: lateralward from and above the angle of the mouth. Origin: facies malaris oss. zygomatici. Insertion: skin of the angle of the mouth; some of the fibres go over into the m. orbicularis oris. Action: draws the angle of the mouth lateralward and upward. Innervation: n. facialis.

M. caninus (see also Fig. 286). Form: flat, triangular. Position: in the fossa canina covered by the m. quadratus labii superioris; comes to the surface between the latter and the m. zygomaticus. Origin: fossa canina. Insertion: with converging fibres, partly to the skin of the angle of the mouth; partly the fibres go over arch-like into the lower lip. Action: draws the angle of the mouth upward; the muscles of the two sides together lift the lower lip and help to close the mouth. Innervation: n. facialis.

M. triangularis (see also Figs. 286 and 297). Form: flat, triangular. Position: below the angle of the mouth; covers the foramen mentale. Origin: just above the basis mandibulae below the foramen mentale. Insertion: with converging fibres to the angle of the mouth and, in largest part, arch-like into the upper lip. Single bundles sometimes connect the muscles of the two sides below the chin; they lie upon the platysma as the **m. transversus menti** (see Fig. 297). Action: draws the angle of the mouth downward; the muscles of the two sides together draw the upper lip down and help to close the mouth. Innervation: n. facialis.

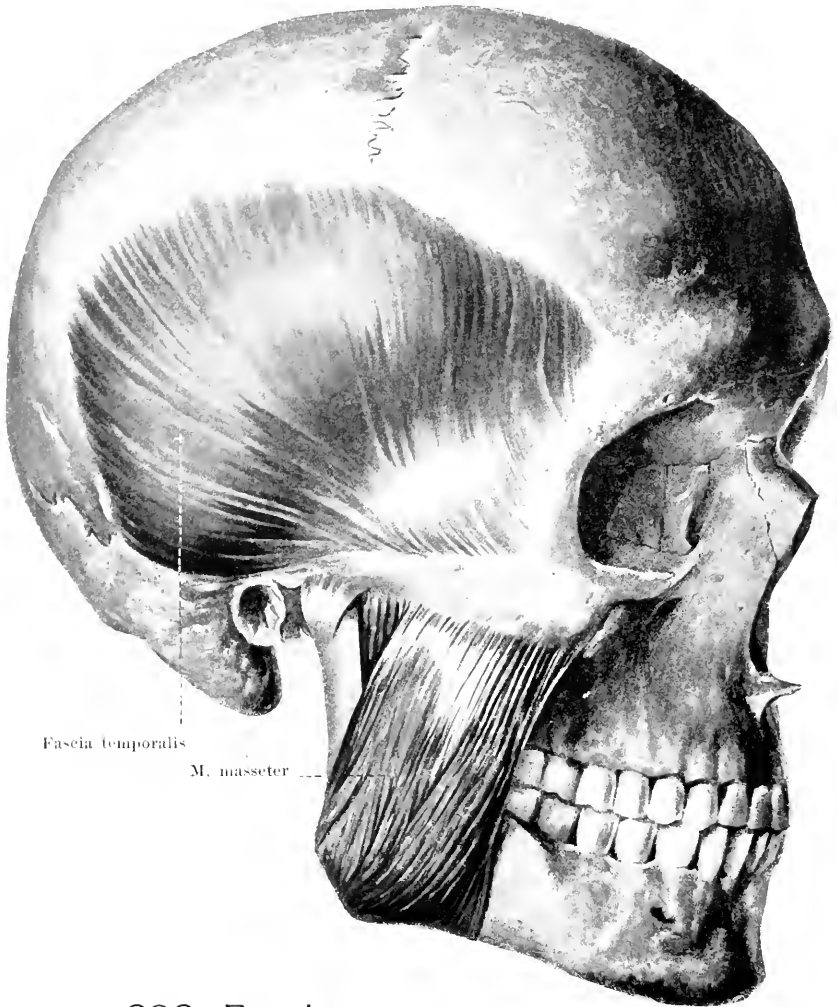
M. quadratus labii inferioris (see also Figs. 286 and 297). Form: flat, quadrangular. Position: below the lateral part of the mouth opening, for the most part covered by the m. triangularis. Origin: the upper part is a direct continuation of the platysma, the lower part arises from the basis mandibulae. Insertion: skin of lower lip. Action: draws the lower lip lateralward and downward. Innervation: n. facialis.

M. incisivus labii superioris (see also Fig. 293). Form: flat, triangular, narrow. Position: above the angle of the mouth, covered by the m. quadratus labii superioris, at the upper margin of the m. orbicularis oris. Origin: jugum alveolare of the upper canine tooth. Insertion: arch-like to the angle of the mouth, interwoven there with the other muscles. Action: draws the angle of the mouth medianward and upward. Innervation: n. facialis.

M. incisivus labii inferioris (see also Fig. 293). Form: flat, quadrangular, narrow. Position: below the angle of the mouth, covered by the m. quadratus labii inferioris, at the lower margin of the m. orbicularis oris. Origin: jugum alveolare of the lower lateral incisor tooth. Insertion: to the lower margin of the m. orbicularis oris, interweaving with it. Action: draws the angle of the mouth medianward. Innervation: n. facialis.

M. orbicularis oris, a muscle-plate situated in the lips which owes its formation to the fact that the muscles going to the mouth opening, at the angles of the mouth, partly radiate out into the upper or lower lip. The fibres run in the lips for the most part transversely, at the angles of the mouth also arch-like between the two lips and are attached in part to the external skin. In this way a sort of ring muscle is formed. Action: if it contracts alone it closes the mouth and points it. Innervation: n. facialis.

M. mentalis. Form: thick, cylindrical, short. Position: on the chin. Origin: jugum alveolare of the lower medial incisor tooth. Insertion: obliquely downward into the skin of the chin. Action: lifts the skin of the chin and wrinkles it. Innervation: n. facialis.

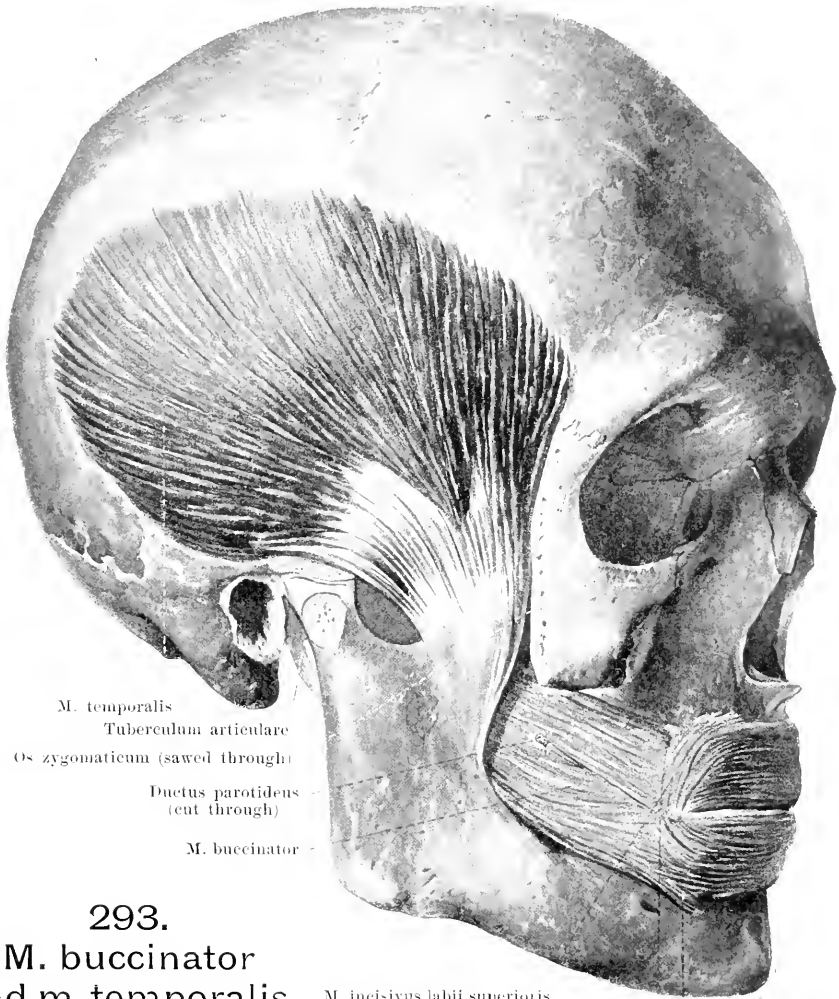


292. Fascia temporalis and m. masseter, viewed from the right side.

Fascia parotideomasseterica (see Fig. 256) covers the lateral (and medial) surface of the glandula parotis as a thick membrane, the m. masseter as a thinner membrane, and becomes lost medianward below the m. zygomaticus, platysma and m. risorius.

Fascia temporalis, very dense, covers the fossa temporalis externally, arises from the linea temporalis superior, divides below into two layers, separated usually by fat, and goes to the medial and lateral surface of the arcus zygomaticus and the os zygomaticum.

M. masseter. Form: flat, quadrangular, thick. Position: immediately upon the lateral surface of the ramus mandibulae; behind partly covered over by the glandula parotis; in front and below covered by the platysma. It consists of two layers which are separated from one another distinctly behind only; the external layer is the longer and broader. Origin: external layer: anterior and middle part of the arcus zygomaticus (tendon of origin jagged, reaching far downward); internal layer: middle and posterior part of the arcus zygomaticus. Insertion: external layer: obliquely backward and downward to the lateral surface of the angulus mandibulae and its periphery; internal layer: downward and somewhat forward to the lateral surface of the ramus mandibulae. Action: lifts the lower jaw. Innervation: n. massetericus (V. 3).



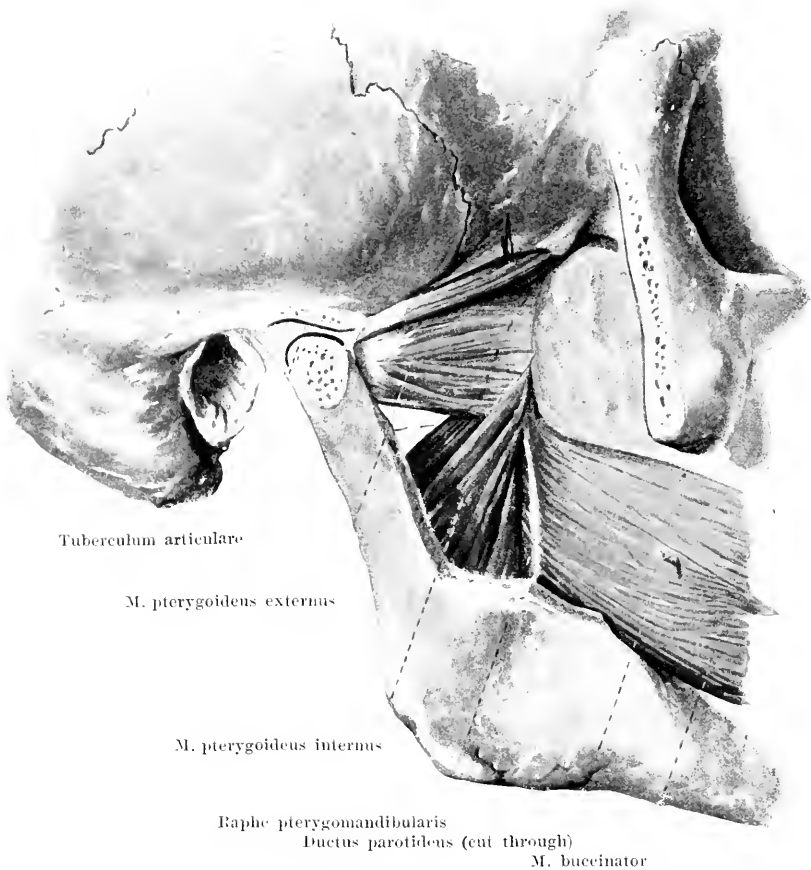
293.
M. buccinator
 and **m. temporalis**,
 viewed from the right side.

M. incisivus labii superioris
 Mm. zygomaticus, caninus, triangularis
 (cut through) M. incisivus
 labii inferioris

(The arcus zygomaticus has been sawed away at its origins, the joint of the lower jaw having been opened at the same time.)

M. temporalis. Form: flat, triangular, broad and thin above, narrow and thick below. Position: covered by the fascia temporalis and the arcus zygomaticus; it fills up the fossa temporalis completely. Origin: the whole extent of the fossa temporalis and medial surface of the fascia temporalis. Insertion: the anterior fibres run vertically, the posterior almost horizontally and markedly curved; all the fibres converge to the processus coronoideus mandibulae and descend deep to its medial surface. The tendon reaches in a jagged form as far as half the height of the muscle on its lateral surface. Action: lifts the lower jaw and draws it somewhat backward. Innervation: nn. temporales profundi (V. 3).

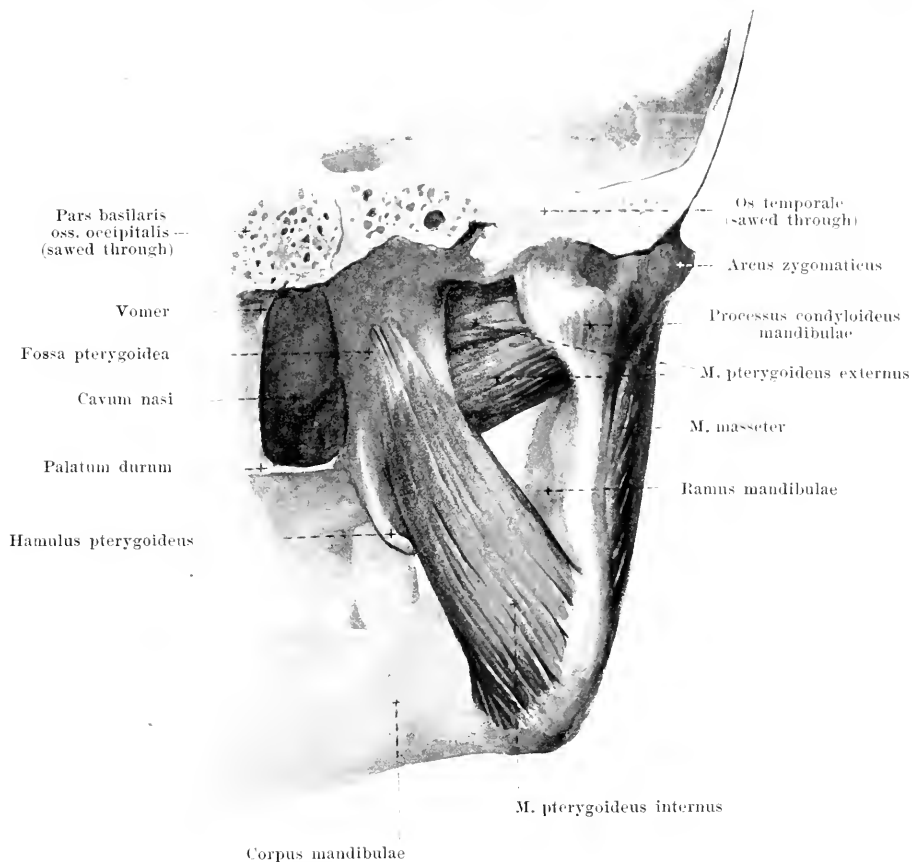
Fascia buccopharyngea, very thin, covers the lateral surface of the m. buccinator; it becomes lost in front at the angle of the mouth, is stretched out as a denser cord between the hamulus pterygoideus and the posterior end of the crista buccinatoria [mandibulae] as the *raphe pterygomandibularis* (see Fig. 294) and goes over behind upon the outer surface of the muscles of the throat.



294. Mm. pterygoidei of the right side, external view.

(The arcus zygomaticus has been removed as in Fig. 293; the processus coronoideus and an adjacent piece of bone have been chiselled out of the ramus mandibulae.)

M. buccinator (see also Figs. 290, 294 and 293). Form: flat, oblong-quadrangular, thin. Position: beneath all the other muscles of the mouth like a transverse, curved band; close to the mucous membrane of the cheeks and lips, along the rows of teeth. Origin: raphe pterygomandibularis, lateral surface of the processus alveolaris maxillae and the crista buccinatoria (or corresponding portion) of the lower jaw bone. The fibres run partly parallel, partly they decussate into the upper and lower lip at the angles of the mouth and there go over into the fibres of the muscles of the other side. In the lips it forms the deepest layer of the m. orbicularis oris. Action: it draws the angle of the mouth lateralward, closes the mouth opening, presses the lips and cheeks upon the teeth. Innervation: n. facialis.

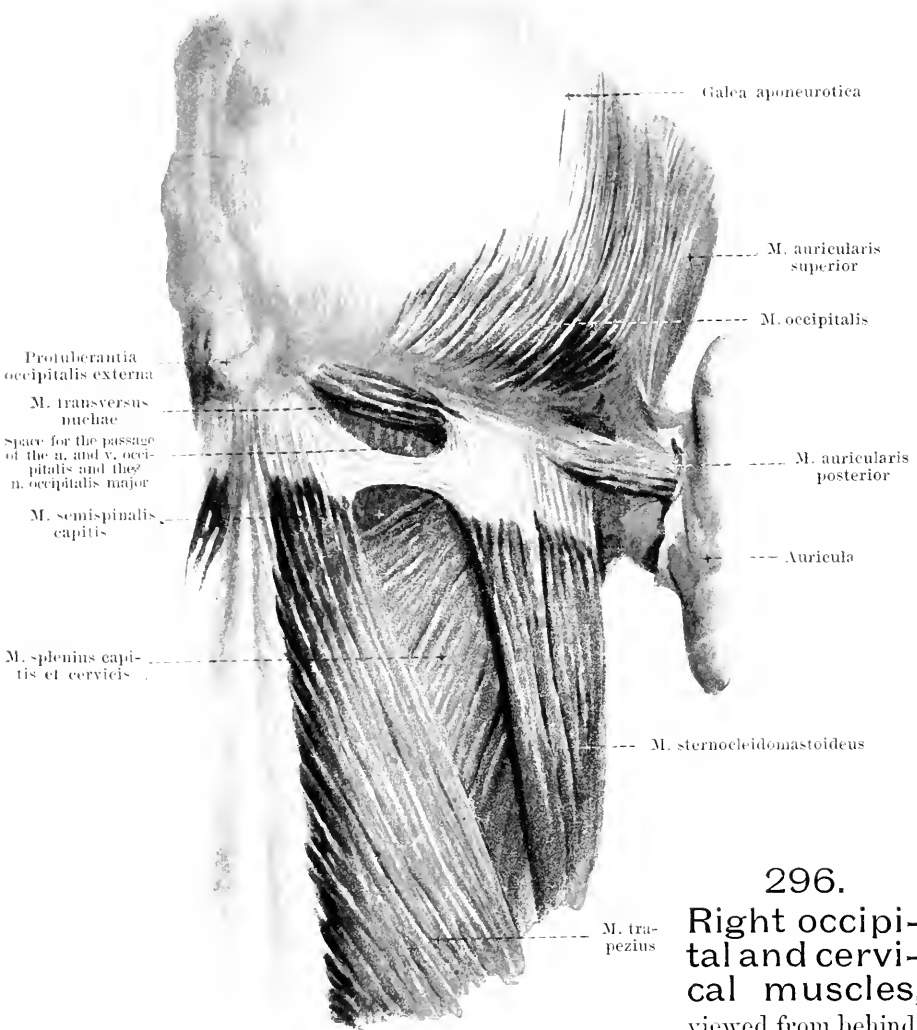


295. Muscles of mastication on right side, viewed from behind and somewhat medianward.

(The posterior half of the skull has been removed.)

M. pterygoideus externus (see also Fig. 294). *Form*: triangular, thick. *Position*: in the fossa infratemporalis, covered lateralward by the m. temporalis, arcus zygomaticus and m. masseter. *Origin*: by two heads; upper head: flat, from the crista infratemporalis and the facies infratemporalis of the great wing of the sphenoid; lower head: rounded, partly from the lamina lateralis proc. pterygoidei and from the processus pyramidalis oss. palatini, partly from the tuber maxillare. *Insertion*: the fibres run converging backward and lateralward to the fovea pterygoidea proc. condyloidei mandibulae, partly also to the anterior surface of the capsula articularis and of the discus articularis of the joint of the lower jaw. *Action*: draws the mandibula forward, the proc. condyloideus and discus articularis under the tuberculum articulare; when it acts on one side alone it draws it somewhat toward the other half of the body. *Innervation*: pterygoideus externus (V. 3).

M. pterygoideus internus (see also Fig. 294). *Form*: oblong-quadrangular, thick. *Position*: on the medial side of the lower jaw, in a direction similar to that of the m. masseter; it is covered lateralward partly by the m. pterygoideus externus, m. temporalis, ramus mandibulae and m. masseter. *Origin*: fossa pterygoidea, by a small part also (lateralward from the m. pterygoideus externus) from the corpus maxillae. *Insertion*: by parallel fibres downward, backward and somewhat lateralward to the medial surface of the angulus mandibulae and its neighbourhood. *Action*: lifts the lower jaw; when it acts on one side only it draws the jaw toward the opposite side of the body. *Innervation*: n. pterygoideus internus (V. 3).



296.

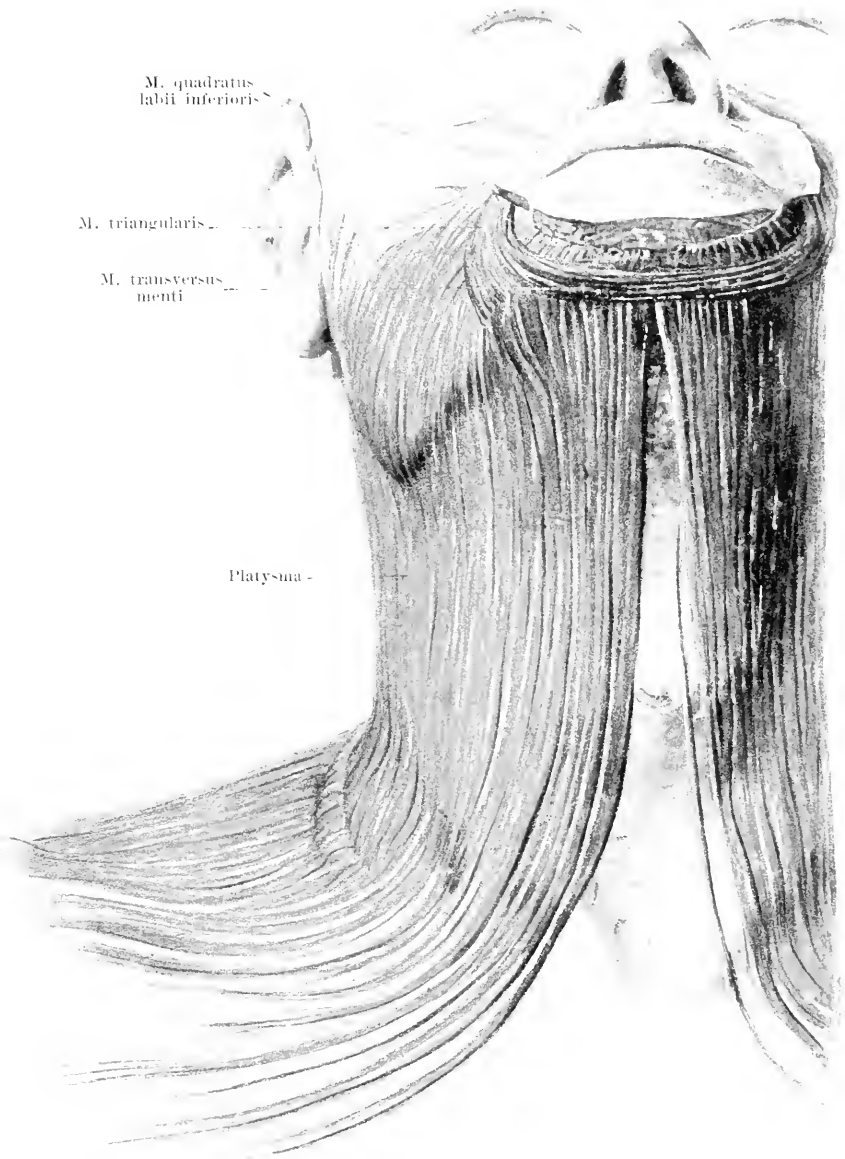
Right occipital and cervical muscles, viewed from behind.

M. auricularis anterior (O. T. attrahens aurem) (see Fig. 286). Form: flat, triangular. Position: in front of and above the ear. Origin: galea aponeurotica. Insertion: to the anterior end of the helix auriculæ. Action: it draws the auricle forward and upward. Innervation: n. facialis.

M. auricularis superior (O. T. attollens aurem) (see also Fig. 286). Form: flat, triangular. Position: above the ear. Origin: galea aponeurotica. Insertion: narrow, to the eminentia fossæ triangularis auriculæ. Action: it draws the auricle upward. Innervation: n. facialis.

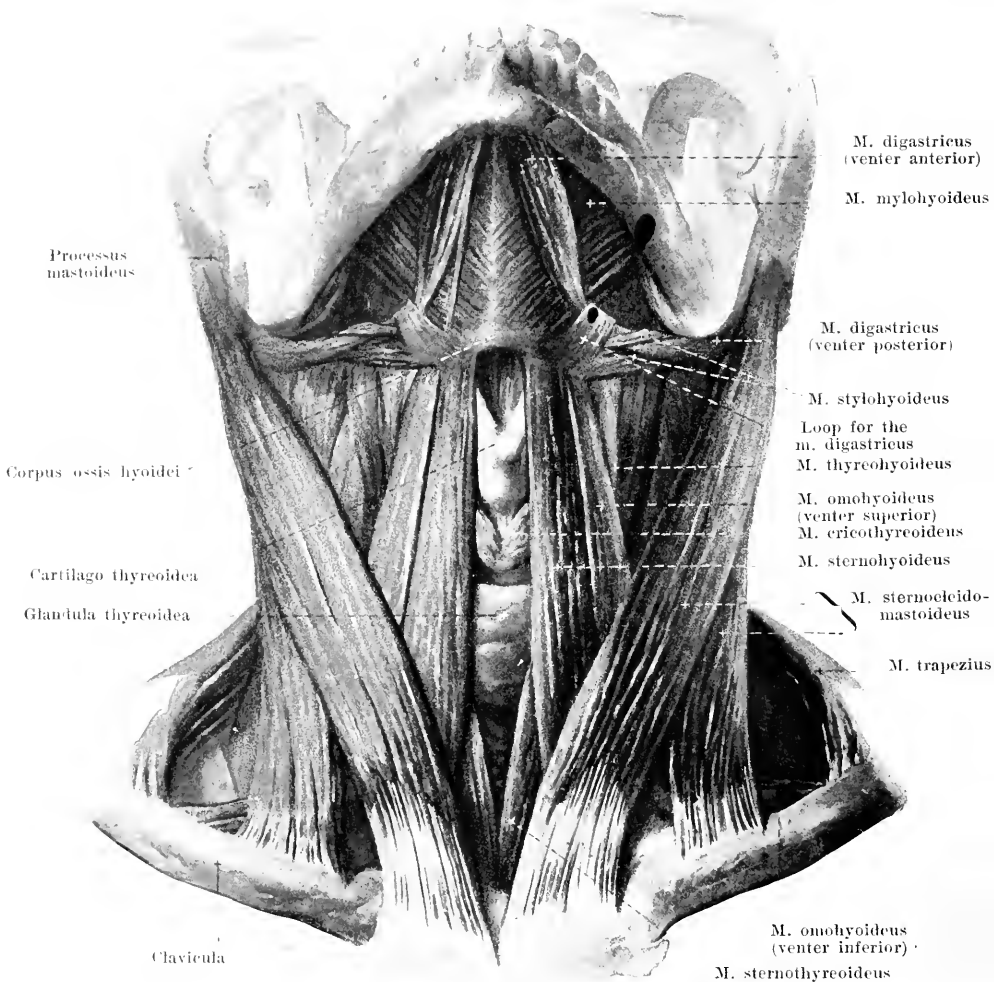
M. auricularis posterior (O. T. retrahens aurem). Form: oblong-quadrangular, single or divided. Position: behind the ear. Origin: pars mastoidea oss. temporalis, upon the tendon of the m. sternocleidomastoideus. Insertion: with parallel fibers to the eminentia conchæ auriculæ. Action: it draws the auricle backward and upward. Innervation: n. auricularis posterior (VII).

M. transversus nuchæ, inconstant. Form: oblong-quadrangular. Position: it lies superficially upon the linea nuchæ superior, in the same layer as the mm. trapezius and sternocleidomastoideus. Origin: protuberantia occipitalis externa. Insertion: tendon of the m. sternocleidomastoideus.



297. Right platysma, viewed from in front.

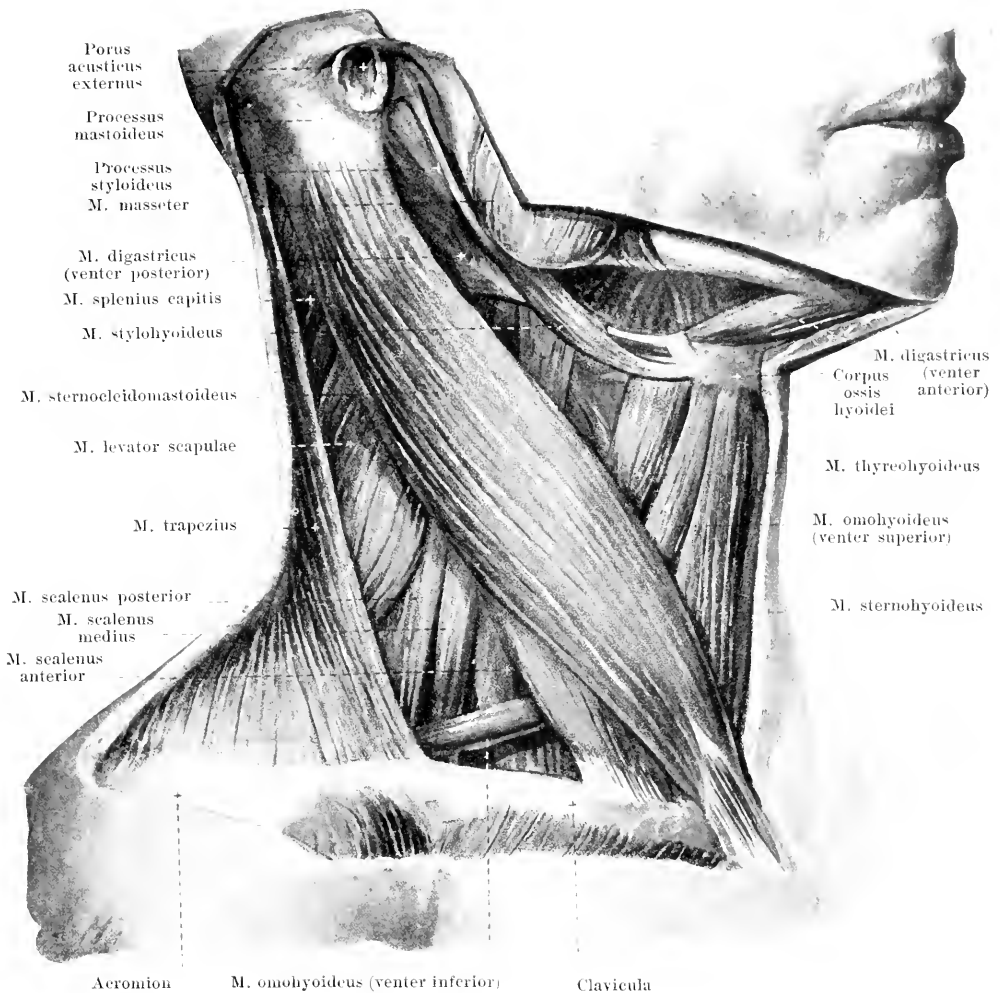
Platysma (see also Figs. 286 and 294). **Form:** oblong-quadrangular, thin, very large. **Position:** just beneath the skin in the clavicular region, in the neck and in the lower part of the face. **Origin:** fascia pectoralis. **Insertion:** the fibers run parallel, medianward and upward: the posterior fibers radiate out upon the fascia parotidomasseterica, the anterior go partly to the angle of the mouth, partly into the m. quadratus labii inferioris, partly to the basis mandibulae. Below the chin the fibers of the two sides often decussate. **Action:** it lifts the skin of the neck from the subjacent tissue; it draws the angle of the mouth to the side and downward. **Innervation:** ramus colli n. facialis.



298. Muscles of the neck, (2nd layer), viewed from in front.

(The head has been bent backward; the platysma has been removed.)

M. sternocleidomastoideus (see also Figs. 296 and 299). Form: long, flat-cylindrical, strong. Position: on the lateral and anterior surface of the neck, covered in its lower half by the platysma. Origin: by two heads; medial head: by a long tendon from the anterior surface of the manubrium sterni, partly covering the articulatio sternoclavicularis; lateral head: by a short tendon from the upper surface of the sternal extremity of the clavicle. Between the two heads there is usually a triangular space, which is broader below, and which corresponds to the fossa supraclavicularis minor (see Fig. 281). Insertion: the lateral head passes under the medial; the two unite at about the middle of the neck and go obliquely upward, backward and lateralward to become attached by a short tendon to the lateral surface of the processus mastoideus and to the linea nuchae suprema. Action: the muscle of one side acting alone turns the head to the opposite side and the face at the same time upward; the muscles of the two sides acting together draw the head obliquely forward and downward, or, if the head be fixed, they elevate the clavicle and sternum (and with them also the thorax). Innervation: n. accessorius.



299. Muscles of the neck (2nd layer), viewed from the right side.

(The platysma has been removed.)

M. digastricus (see also Figs. 298 and 301). Form: two rounded bellies, *venter posterior* and *venter anterior*, with a long intermediate tendon. Position: below, behind and medianward from the mandibula. The venter posterior arises in the incisura mastoidea oss. temporalis and goes over in front and below into an intermediate tendon, which is fastened by a loop-like strip of the fascia colli to the corpus oss. hyoidei; the venter anterior arises from this intermediate tendon and usually also from the corpus oss. hyoidei and goes to the fossa digastrica mandibulae. Action: when the hyoid bone is fixed, it depresses the lower jaw; when the lower jaw is fixed, it draws the hyoid bone upward. Innervation: *venter posterior*: r. digastricus n. facialis; *venter anterior*: n. mylohyoideus (V. 3).

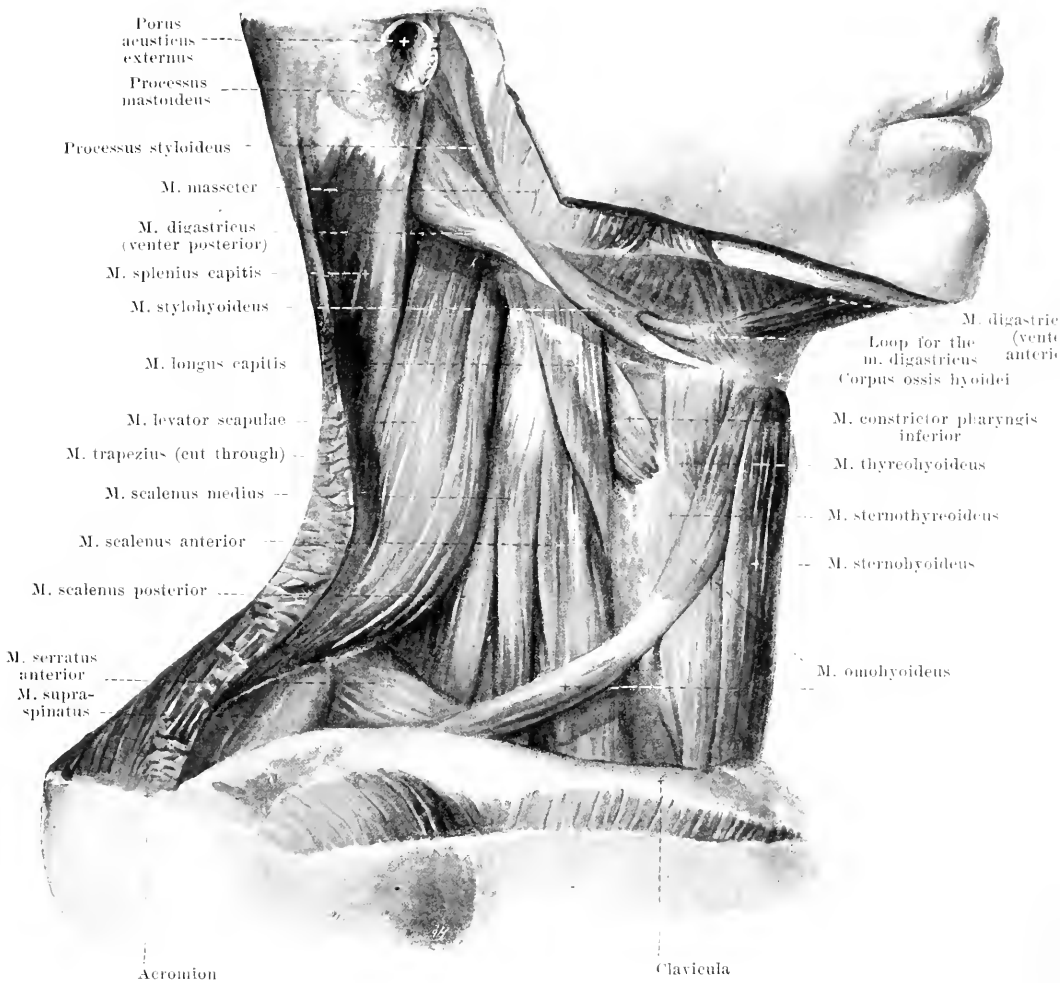
M. stylohyoideus (see also Figs. 298, 300 and 301). Form: flat, oblong, thin. Position: behind and below the mandibula, just in front of and above the posterior belly of the m. digastricus. Origin: processus styloideus. Insertion: forward, downward and medianward to the corpus oss. hyoidei; in the neighborhood of its insertion it surrounds the m. digastricus by two limbs. Action: it draws the hyoid bone backward and upward. Innervation: r. stylohyoideus n. facialis.



300. Muscles of the neck (3rd layer), viewed from in front.

(Like Fig. 298; in addition however the mm. sternocleidomastoidei, trapezii and digastrici have been removed; the right clavicle has been sawed through close to the sternum and removed.)

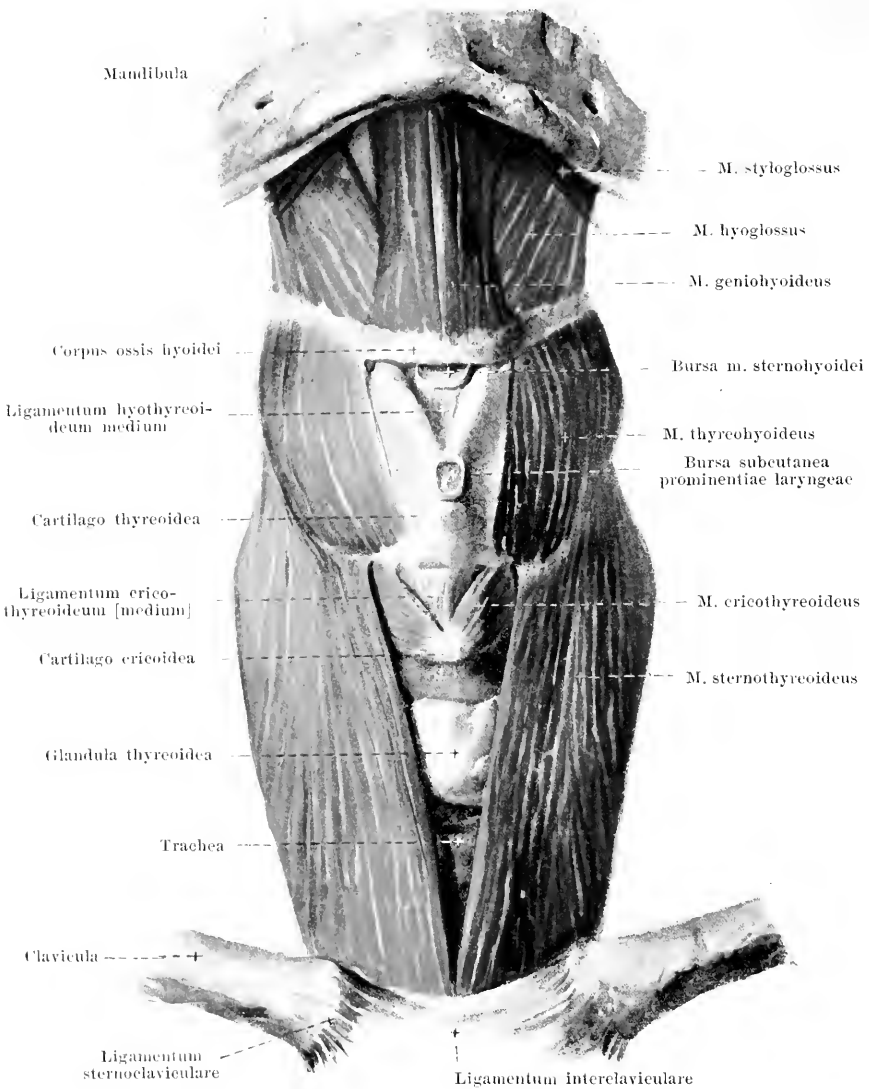
M. omohyoideus (see also Figs. 298, 299 and 301). *Form*: flat, narrow, long; divided by an intermediate tendon into two bellies, *venter inferior* and *venter superior*. *Position*: on the lateral and anterior surface of the neck, covered behind by the clavicle and the m. trapezius, in the middle by the m. sternocleidomastoideus. The intermediate tendon is ensheathed in the fascia colli and united with the anterior wall of the v. jugularis interna. *Origin*: margo superior scapulae and lig. transversum scapulae superius. *Insertion*: runs in front of the mm. scaleni forward and upward to the intermediate tendon and thence, bends upward to the corpus oss. hyoidei, where it lies laterally from the m. sternohyoideus and in front of the m. thyrohyoideus. *Action*: it draws the hyoid bone downward and makes the fascia colli tense. *Innervation*: r. descendens n. hypoglossi.



301. Muscles of the neck (3rd layer), viewed from the right side.

(The platysma, m. sternocleidomastoideus and the anterior part of the m. trapezius have been removed.)

M. sternohyoideus (see also Figs. 295—300). Form: flat, oblong-quadrangular, thin. Position: on the anterior surface of the neck in front of the larynx and the trachea, covered above by the platysma only, below by the m. sternocleidomastoideus; the muscles of the two sides approach very close to each other and sometimes even touch in the median line. Origin: posterior surface of the manubrium sterni, of the articulatio sternoclavicularis and of the first costal cartilage (see Fig. 313). Insertion: the fibers run parallel to one another upward, at first also somewhat medianward, and go to the corpus oss. hyoidei (*bursa m. sternohyoidei*, see Fig. 302 and p. 257). Action: it draws the hyoid bone downward. Innervation: r. descendens n. hypoglossi.



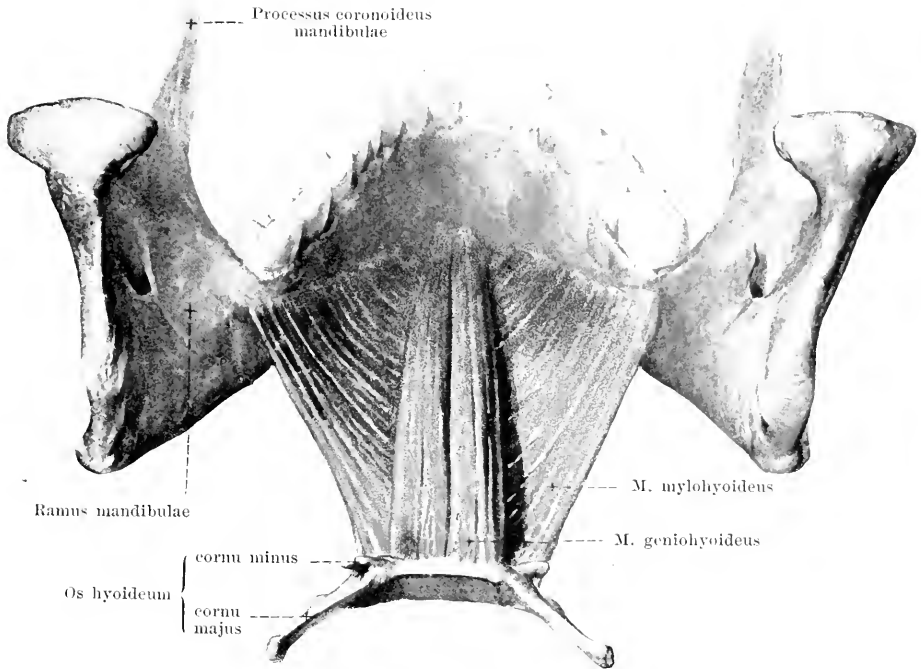
302. Muscles of the hyoid bone

(deep layer), viewed from in front.

(The mm. sternohyoidei, omohyoidei, digastrici and mylohyoideus have been removed.)

M. sternothyreoideus (see also Figs. 298, 300 and 301). Form: flat, oblong-quadrangular, very thin. Position: on the anterior surface of the neck, close to the glandula thyreoidea, covered by the mm. omohyoideus and sternohyoideus. Origin: posterior surface of the manubrium sterni and of the first costal cartilage (see Fig. 313). Insertion: upward and lateralward to the lamina cartilaginosa thyreoidea (linea obliqua); single fibers go over immediately into the m. thyreochoideus. Action: it draws the cartilago thyreoidea downward. Innervation: r. descendens n. hypoglossi.

M. thyreochoideus (see also Figs. 298—301). Form: flat, quadrangular, very thin. Position: on the anterior surface of the neck, close to the cartilago thyreoidea, covered by the m. omohyoideus. Origin: lamina cartilaginosa thyreoidea (linea obliqua) (see also above). Insertion: corpus and cornu majus oss. hyoidei (bursa m. thyreochoidei, see p. 257). Action: draws the hyoid bone closer to the cartilago thyreoidea and *vice versa*. Innervation: r. thyreochoideus n. hypoglossi.



303. Muscles of the floor of the mouth, viewed from behind and above.

(The muscles of the tongue have been completely removed.)

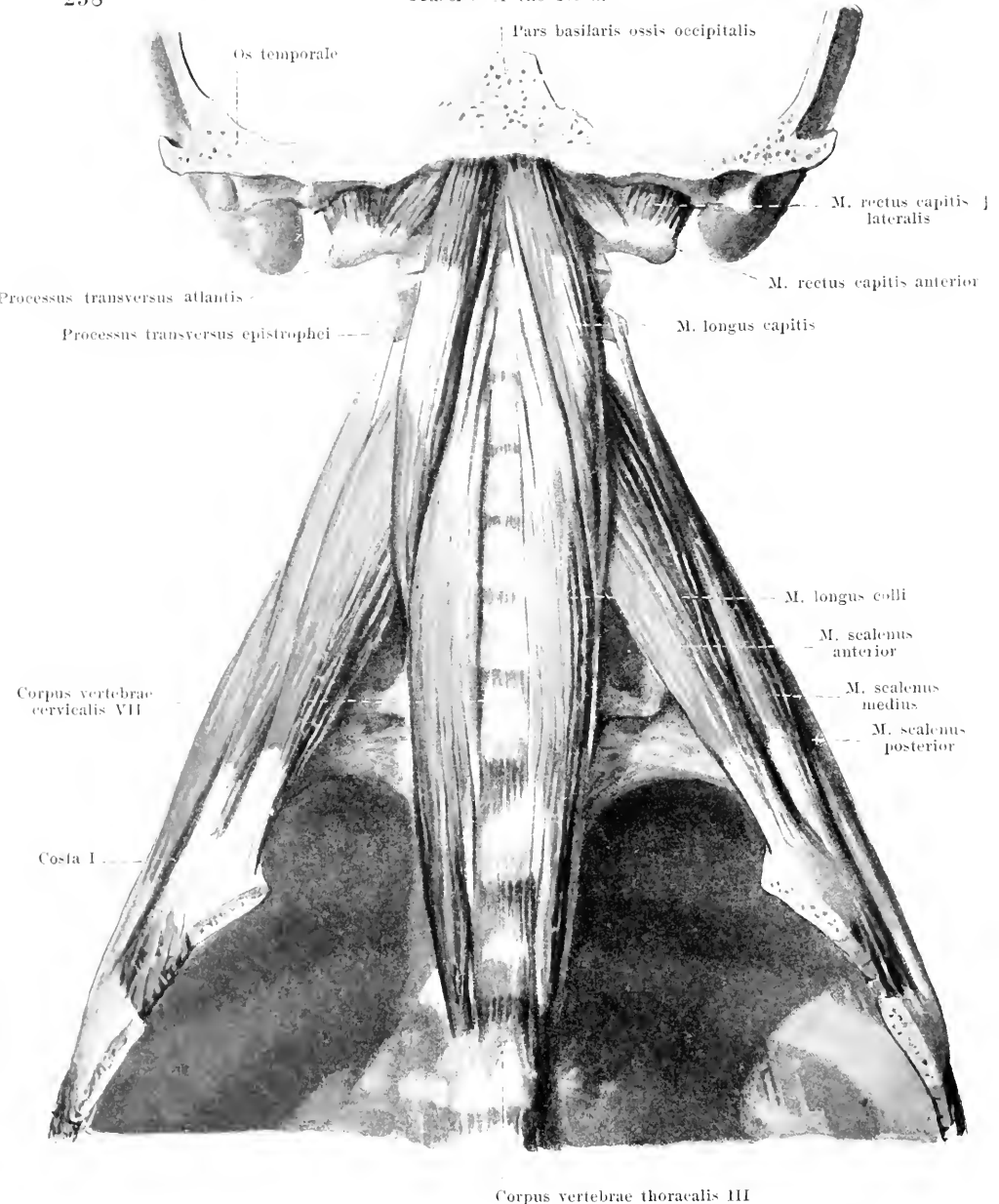
M. mylohyoideus (see also Figs. 295 and 300), unpaired. Form: flat, quadrangular, broad, above, hollowed out, like a trough. Position: stretches between the lower jaw and the hyoid bone and thus forms the floor of the mouth; immediately adjacent to its lower surface lies the anterior belly of the m. digastricus. Origin: lineae mylohyoideae mandibulae. Insertion: the fibers run parallel to one another on each side, backward, downward and medianward and are attached for the most part to a medially situated connective-tissue raphe; the posterior fibers go to the anterior surface of the corpus oss. hyoidei. Action: when the hyoid bone is fixed, it depresses the lower jaw; when the lower jaw is fixed, it draws the hyoid bone forward and upward. Innervation: n. mylohyoideus (V. 3).

M. geniomylohyoideus (see also Fig. 302). Form: flat-cylindrical, oblong. Position: on the upper (buccal) side of the m. mylohyoideus, completely hidden by it from below; the mm. geniomyloidei of the two sides are immediately adjacent to one another in the median plane. Origin: by a short tendon from the spina mentalis mandibulae. Insertion: the fibers, diverging a little, extend to the anterior surface of the corpus oss. hyoidei. Action: when the hyoid bone is fixed, it depresses the lower jaw; when the lower jaw is fixed, it draws the hyoid bone forward and upward. Innervation: n. hypoglossus.

Bursa [mucosa] subcutanea prominentiae laryngeae (see Fig. 302), often absent, usually found only in men and only in older individuals; it is unpaired and lies in the subcutaneous tissue in front of the upper part of the thyroid cartilage.

Bursa m. sternohyoidei (see Fig. 302), almost constant, is better developed in the male than in the female and lies, if unpaired, in the median plane or, if paired, close to the median plane upon the lig. hyothyroideum medium, between it on the one hand and the m. sternohyoideus and the fascia colli on the other; it extends upward behind the hyoid bone.

Bursa m. thyroehyoidei (not shown in the drawing), still more constant than the preceding, lies below the cornu majus oss. hyoidei, upon the membrana hyothyroidea, between it and the upper end of the m. thyroehyoideus.

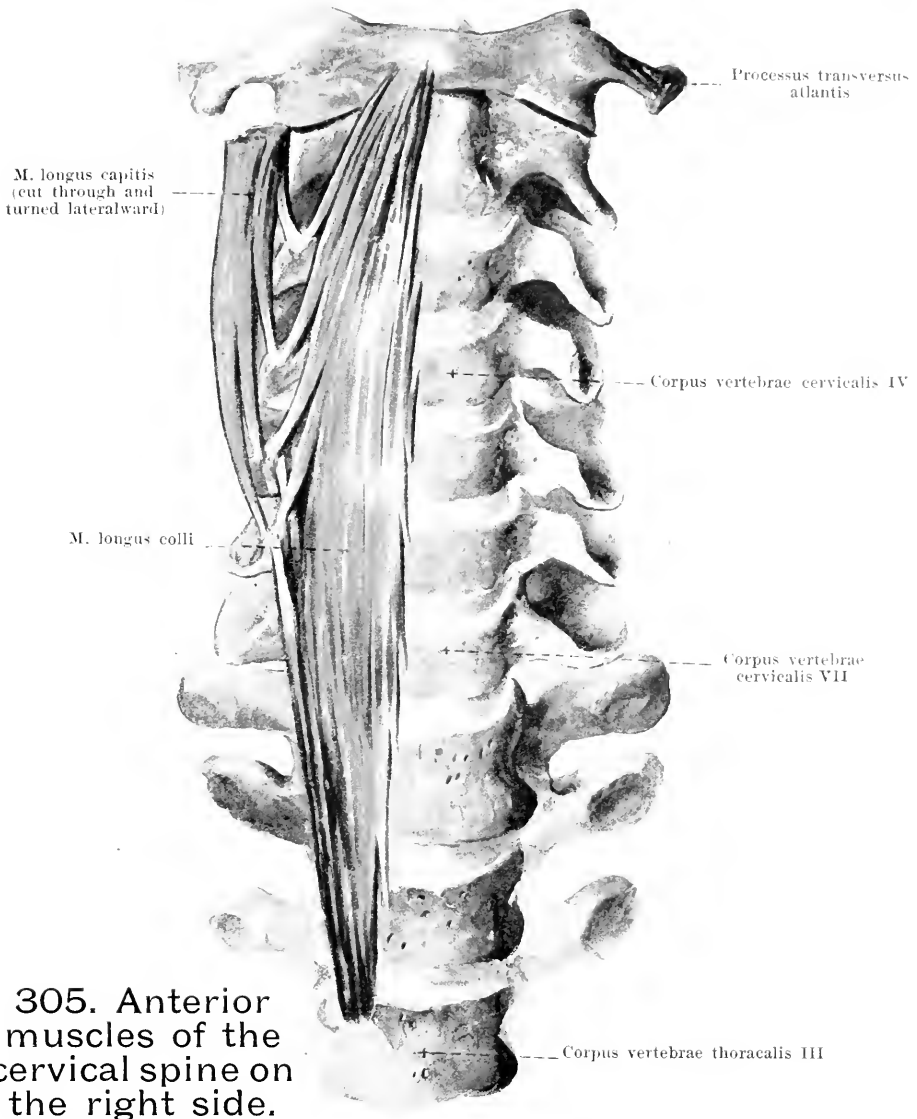


304. Deep muscles of the neck, viewed from in front.

(The sternum and the anterior ends of the ribs with their muscles have been removed.)

M. rectus capitis lateralis. Form: flat, short. Position: in front of the articulatio atlanto-occipitalis. Origin: proc. transversus atlantis. Insertion: inferior surface of the proc. jugularis oss. occipit. Action: bends head to the side. Innervation: direct branch of the plexus cervicalis.

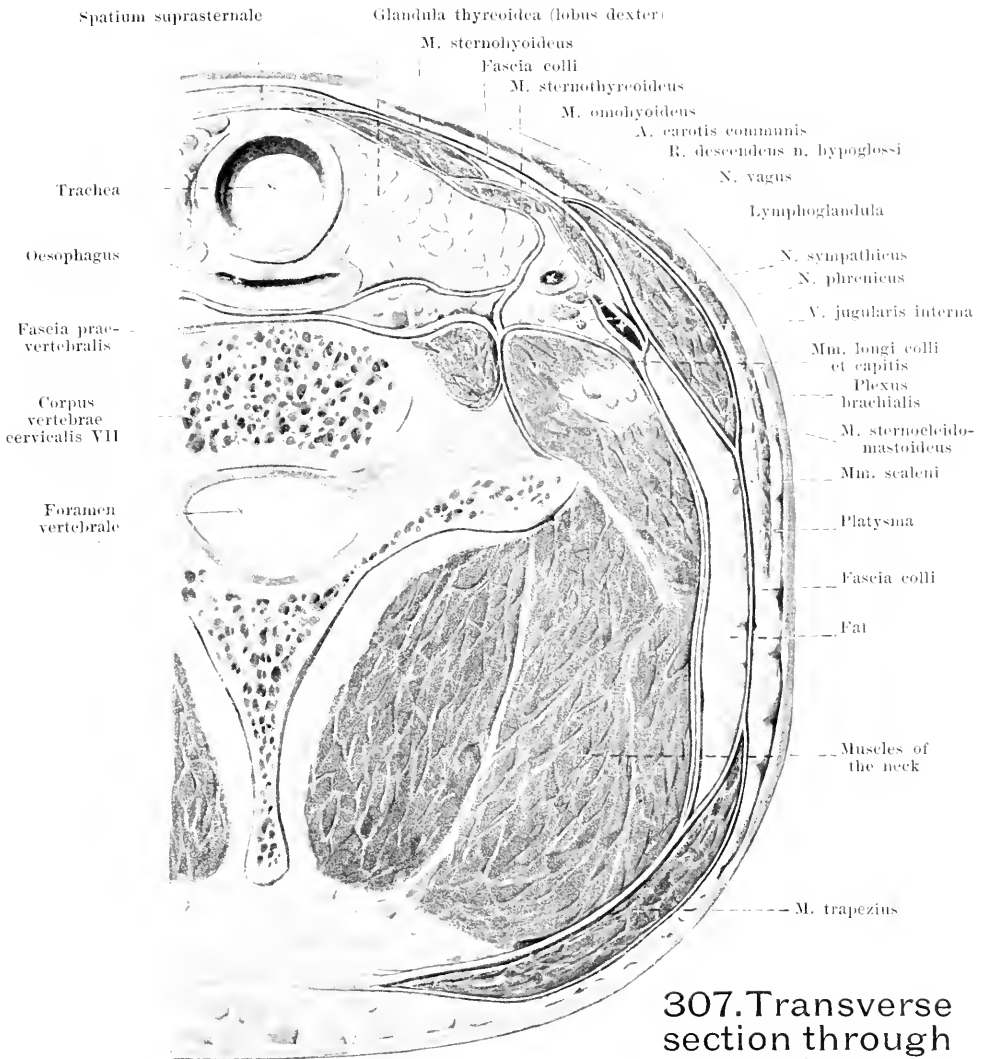
M. rectus capitis anterior (O. T. rectus capitis anticus minor). Form: flat, short. Position: in front of the articulatio atlantooccipitalis. Origin: massa lateralis and proc. transversus atlantis. Insertion: pars basilaris oss. occipit. Action: bends head forward. Innervation: direct branch of the plexus cervicalis.



305. Anterior muscles of the cervical spine on the right side.

M. longus capitis (*O. T. rectus capitis anticus major*) (see also Figs. 300, 301, 304). *Form*: flat, oblong-triangular. *Position*: just in front of the upper end of the cervical spine and in front of the membrana atlantooccipitalis anterior. *Origin*: tubercula anteriora of the transverse processes of the 3rd—6th cervical vertebra. *Insertion*: upward and medianward to the pars basilaris oss. occipitalis. *Action*: bends the head forward. *Innervation*: direct branch of the plexus cervicalis.

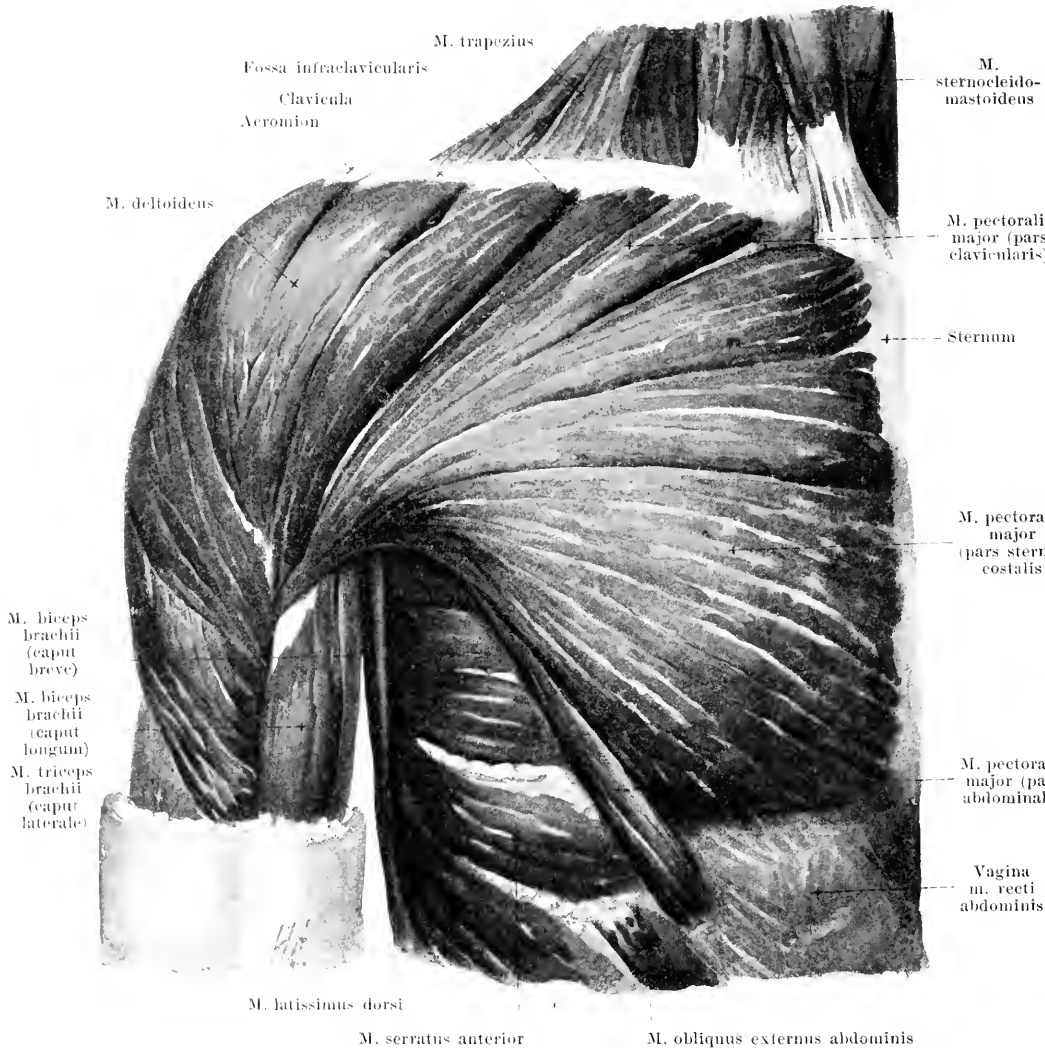
M. longus colli (see also Fig. 304). *Form*: flat, oblong-triangular, broadest in the middle. *Position*: close to the anterior surface of the cervical spine, in the groove between the bodies and transverse processes of the vertebrae; it is partially covered above by the m. longus capitis. Two portions. *Inferior, medial*: from the bodies of the 3rd thoracic to the 5th cervical vertebra, goes to the bodies of the 5th—2nd cervical vertebra and to the anterior tubercles of the transverse processes of the 6th and 5th cervical vertebra; *superior, lateral portion*: from the anterior tubercles of the transverse processes of the 6th—3rd cervical vertebra, goes to the tuberculum anterius atlantis. *Action*: bends the cervical spine forward and lateralward. *Innervation*: direct branches of the cervical and brachial plexuses.



307. Transverse section through the neck, at the level of the uppermost cartilages of the trachea, viewed from above (after Fr. Merkel).

The **fascia praevertebralis** is a thin but strong membrane which covers the anterior surface of the cervical spine and the deep muscles of the neck; part of it descends with these into the thorax, part extends upon the outer surface of the mm. scaleni and of the thorax; it covers directly all the muscles represented in Fig. 304.

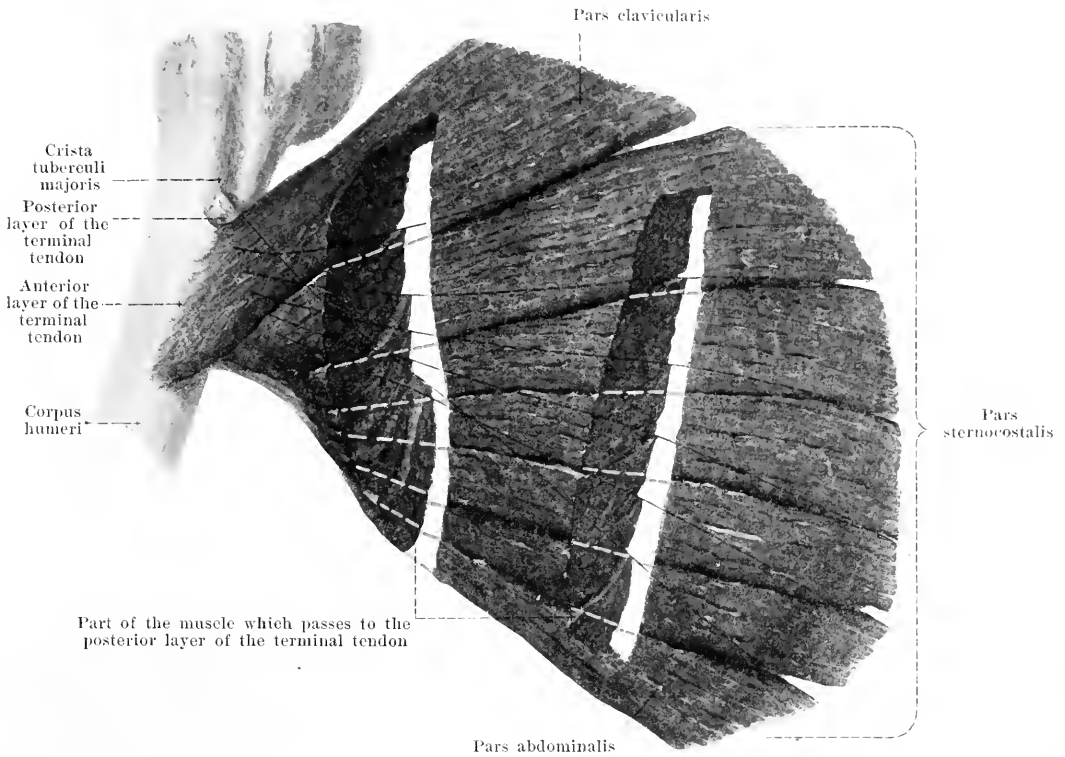
The **fascia colli** extends as a strong membrane from the hyoid bone to the sternum and clavicle in front of the larynx, laryngeal muscles and trachea. It is attached to the sternum by two leaves, which enclose the *spatium suprasternale* and its fatty contents. Laterally it extends above in front of the m. omohyoideus and past it as far as the anterior surface of the bundle of blood vessels, where it becomes lost; it forms a sheath for the intermediate tendon and the venter inferior of the m. omohyoideus. Behind, it becomes thinner and passes below the m. sternocleidomastoideus, upon the fat which helps to fill up the lateral cervical triangle, and below the m. trapezius to the lig. nuchae; the external surface of the mm. sternocleidomastoideus and trapezius is covered only by delicate muscle-fascia.



308. Muscles of the right side of the chest, viewed from in front.

(The platysma has been removed.)

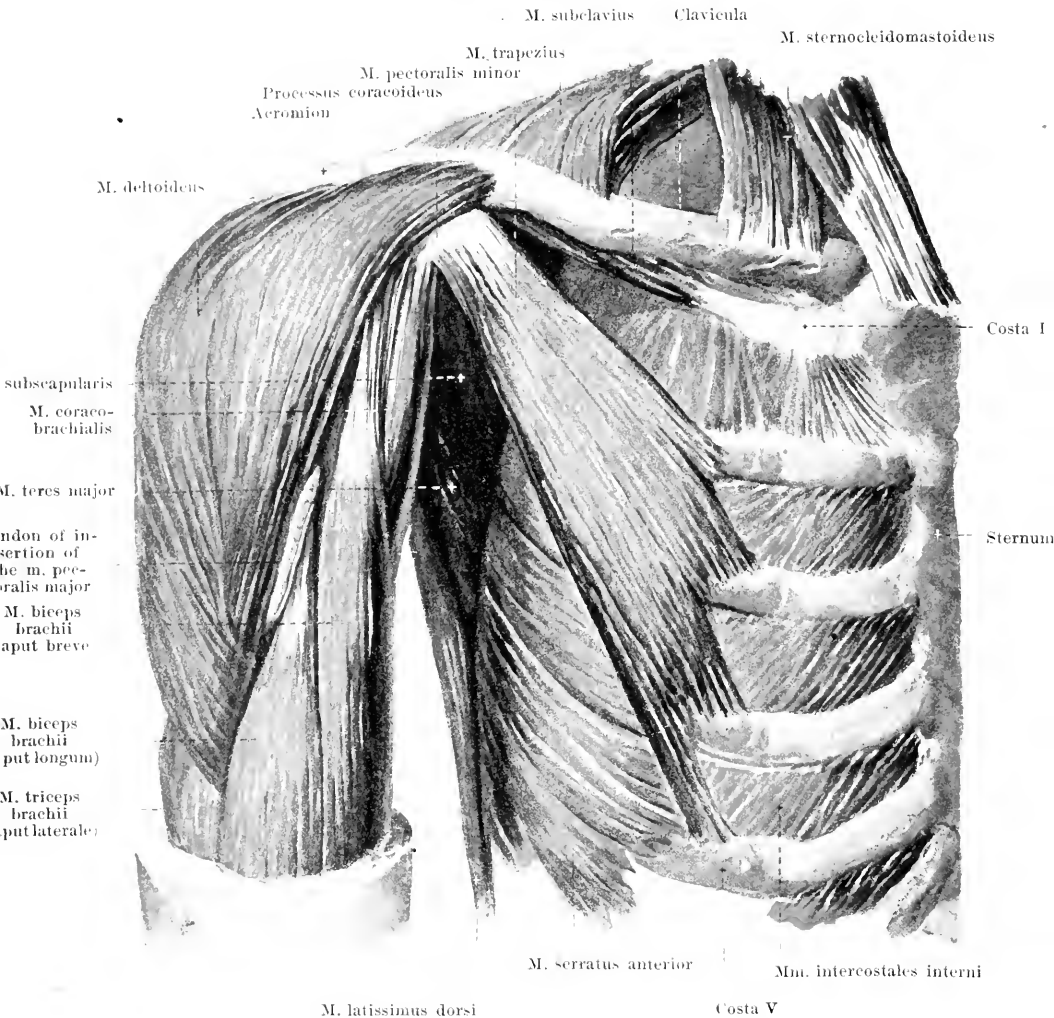
M. pectoralis major (see also Figs. 309, 316, 317 and 343). Form: flat, quadrangular, broad, thick. Position: on each side it passes out from the median plane to the anterior surface of the thorax and of the axilla, above it is partly covered by the platysma. Origin: medial half of the clavicle (*pars clavicularis*), anterior surface of the sternum, and of the second to the seventh costal cartilage (*pars sternocostalis*) and the anterior leaf of the vagina m. recti abdominis (*pars abdominalis*). Insertion: see p. 263.



309. Right *m. pectoralis major*, viewed from in front, semi-schematically.

(Two strips have been cut out of the muscle. The dotted black lines indicate the course of the upper, posterior margins of the muscle bundles, the dotted red lines that of the lower, anterior margins.)

M. pectoralis major (continued). Insertion: the fibers converge, lateralward to the crista tuberculi majoris of the humerus. The fibers of the pars sternocostalis and of the pars abdominalis pass, at the lower margin of the tendinous attachment, to the posterior surface of the same and thence to the bone, without altering their direction, so that the fibers which arise lowest down are inserted highest up; the tendon of insertion, accordingly, looks as though it were rolled up at its lower margin and consists of two layers, one anterior, thick (formed chiefly by the pars clavicularis), and one posterior, thin (pertaining especially to the pars sternocostalis and pars abdominalis); these layers are continuous below but can be separated from above (see Fig. 310). Between the posterior surface of the terminal tendon and the anterior surface of the caput longum *m. bicipitis brachii* there often lies an oblong bursal sack, **bursa m. pectoralis majoris** (see Fig. 346). Action: it draws the upper arm medianward and forward, and rotates it inward. Innervation: nn. thoracales anteriores.

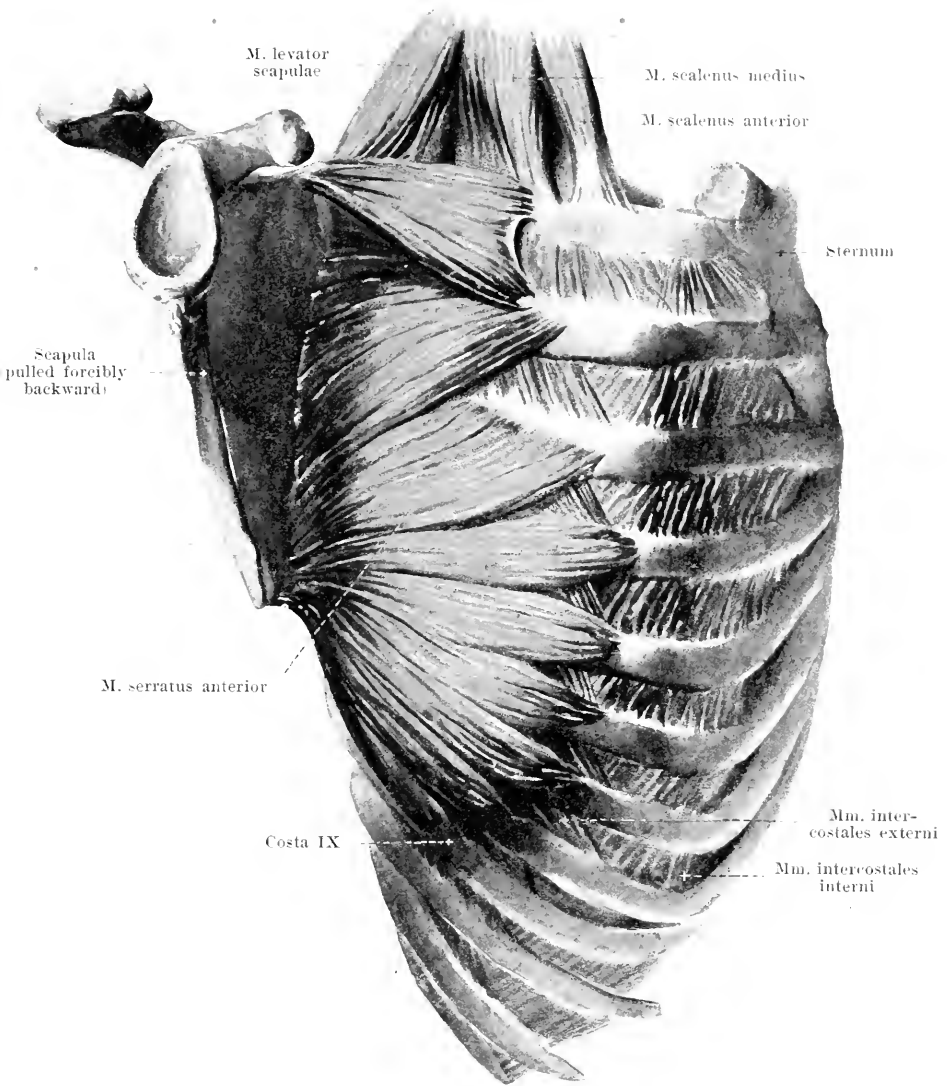


310. Muscles of the right side of the chest (2nd layer), viewed from in front.

(The platysma and the m. pectoralis major have been removed.)

M. pectoralis minor. Form: flat, oblong-triangular. Position: on the anterior surface of the thorax and of the axilla, covered by the m. pectoralis major. Origin: by four or three digitations from the anterior surface of the 2nd or 3rd—5th rib. Insertion: the fibers converge upward and lateralward to go by a short tendon to the proc. coracoideus scapulae. Action: it draws the lateral angle of the scapula downward and forward; when the shoulder blade is fixed it elevates the ribs to which it is attached. Innervation: nn. thoracales anteriores.

M. subclavius. Form: flat-cylindrical, narrow, short. Position: hidden between the clavicle and the 1st rib, covered by the platysma, the clavicle and the m. pectoralis major. Origin: tendinous, from the anterior surface of the 1st costal cartilage, just lateralward from the lig. costoclavicular. Insertion: obliquely lateralward and upward to the inferior surface of the clavicle. Action: it draws the clavicle downward and forward. Innervation: n. subclavius.

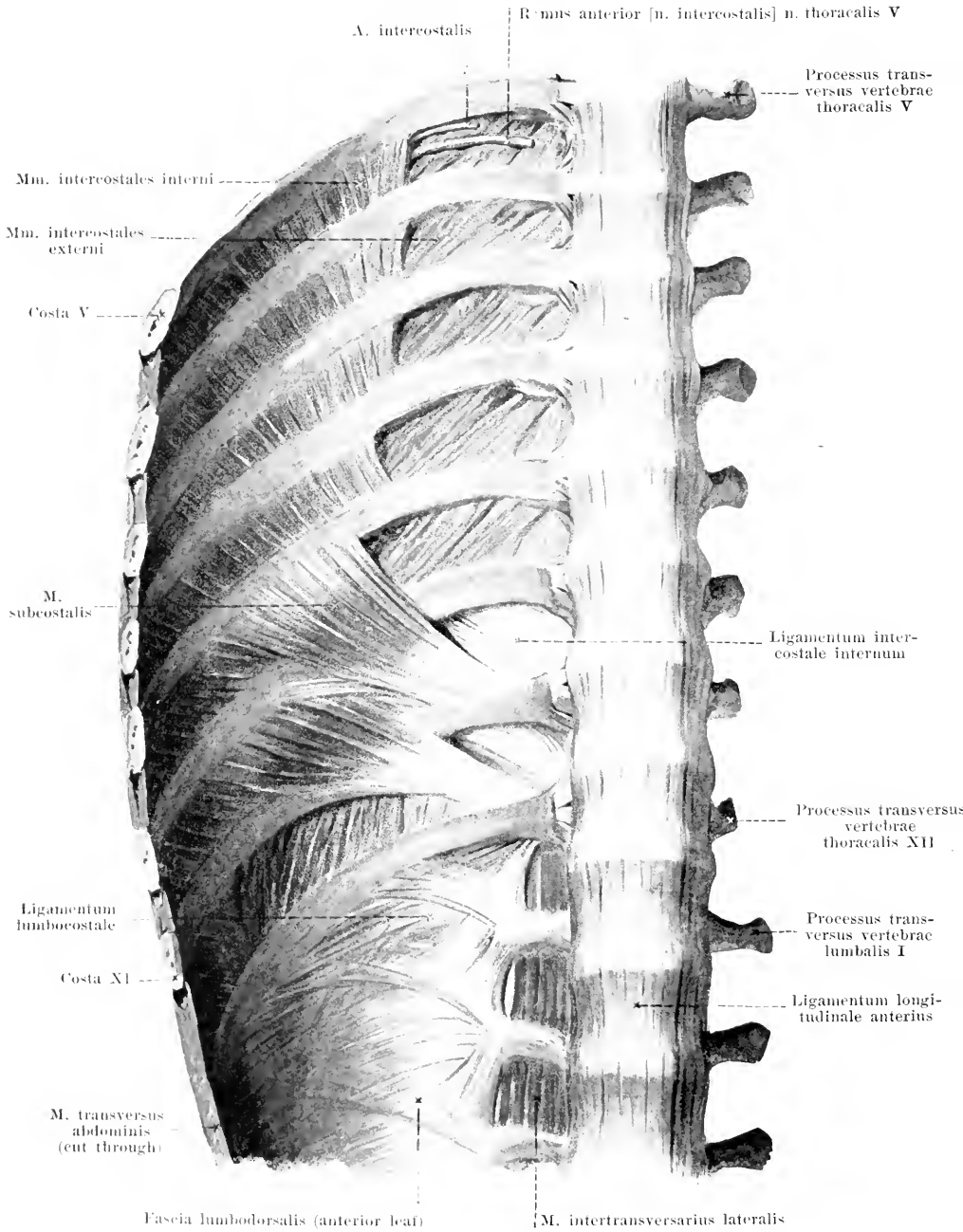


311. Right m. serratus anterior,

viewed from the side and somewhat from in front.

(The mm. pectorales as well as the muscles of the anterior and posterior scapular fossae have been removed; the clavicle has also been removed and the scapula drawn forcibly backward.)

[Text see p. 267.]



312. Right posterior wall of thorax with muscles, viewed from in front.

(Diaphragma, m. psoas and m. quadratus lumborum have been removed.)

M. serratus anterior (O. T. serratus magnus) (see Figs. 308, 310, 311, 316, 317 and 343). Form: flat, quadrangular. Position: on the lateral and posterior wall of the thorax, close to the ribs and *mm. intercostales*, covered in front and above by the *mm. pectorales*, behind by the *m. subscapularis*, by the scapula and its posterior muscles as well as by the *m. latissimus dorsi*: lateralward and below, with its 4—5 inferior digitations, just beneath the skin. Origin: by 9—10 fleshy digitations from the 8—9 uppermost ribs (by 2 digitations from the 2nd rib); also from a tendinous arch between 1st and 2nd rib. Insertion: uppermost 2 digitations (from 1st and 2nd rib) converging to the *angulus medialis scapulae*; 3rd digitation (from 2nd rib) runs diverging to the *margo vertebralis*; 4th—10th digitations (from 3rd—9th rib) extend converging to the *angulus inferior*: the latter portion is the strongest. The fibers run as a whole curved so as to be convex and to follow exactly the curvature of the wall of the thorax. Action: it presses the scapula to the thorax, draws it forward and lateralward, acting with especial power upon the *angulus inferior*; at the same time it rotates the scapula so that the *angulus lateralis* is elevated. Innervation: *n. thoracalis longus*.

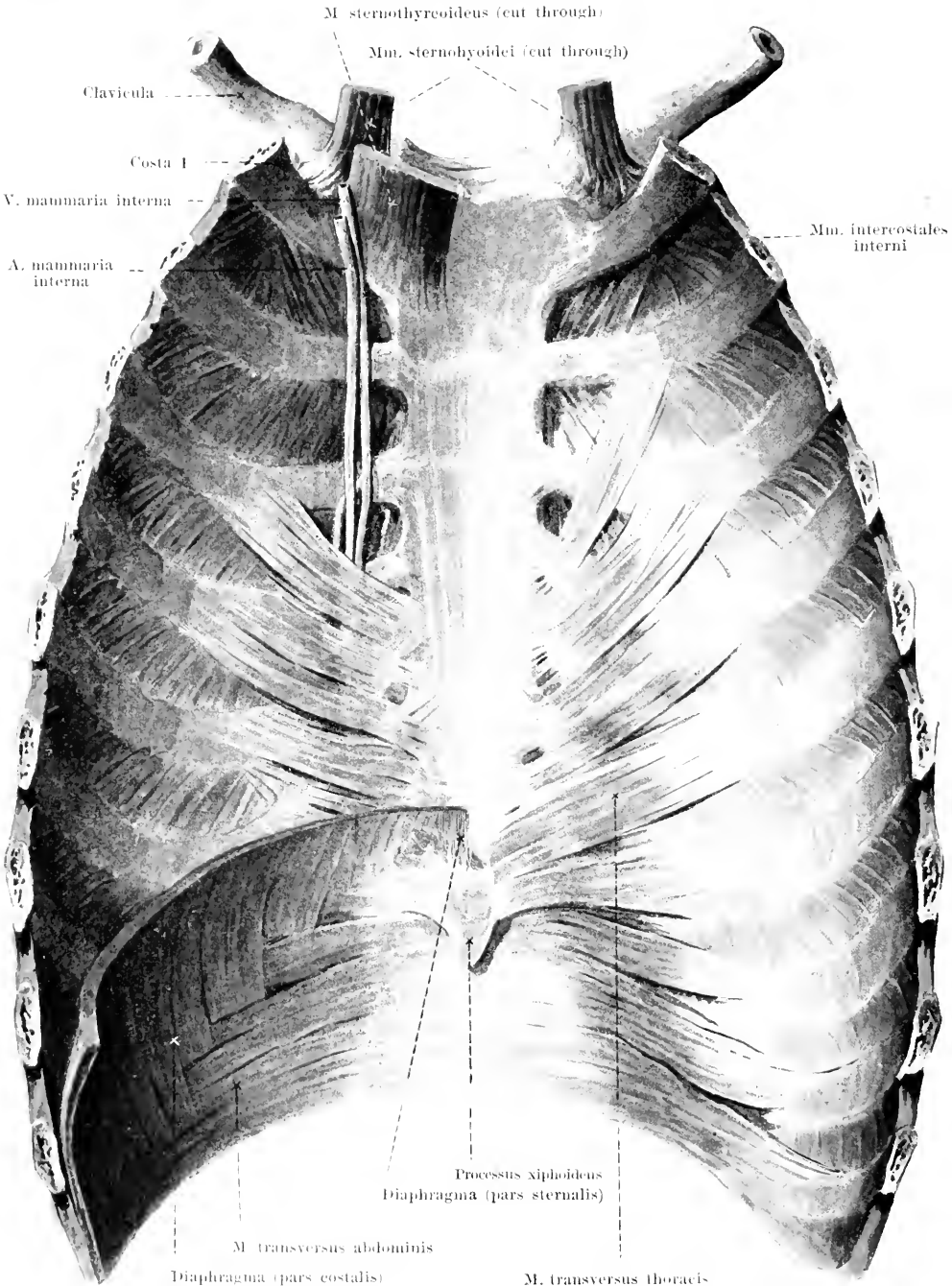
Mm. intercostales externi (see also Figs. 311, 319 and 336). Form: flat, short, thin. Position: in the intercostal spaces, from the tubercles of the ribs on, to about the lateral ends of the costal cartilages; behind they are continuous with the *mm. levatores costarum*. Origin: lower margin of each rib, external from the *sulcus costae*. Insertion: the fibers run parallel downward and sternalward to the upper margin of the next rib below. Medianward from the anterior end running in the same direction are glistening tendinous bands of connective tissue (*ligamenta intercostalia externa*, not shown in the figure). Action: muscles of inspiration. Innervation: *rami anteriores* [*nn. intercostales*] of the *nn. thoracales I—XI*.

Mm. intercostales interni (see also Figs. 310, 311, 313 and 321). Form: flat, short, thin. Position: in the intercostal spaces from the region of the angles of the ribs to the sternum: they lie more internally than the *mm. intercostales externi*, and are accordingly covered by the latter externally as far as the lateral ends of the costal cartilages; between the costal cartilages they are covered only by the *ligg. intercostalia externa*; behind they leave the anterior surface of the *mm. intercostales externi* free medianward from the angles of the ribs. Origin: inferior margin of each rib, internally from the *sulcus costae*. Insertion: the fibers run parallel downward and vertebralward to the upper margin of the next rib below. Action: the portions extending between the *ossa costalia* are muscles of expiration: those bundles running between the costal cartilages, *mm. intercartilaginei*, act like the *mm. intercostales externi*. Innervation: *rami anteriores* [*nn. intercostales*] of the *nn. thoracales I—XI*.

The *ligamenta intercostalia interna* are thin bands of connective tissue which are situated, partly in front on the inner side of the *mm. intercostales interni*, in connection with the *m. transversus thoracis* (not shown in figure), partly behind on the anterior surface of the *mm. intercostales externi* in connection with the *mm. intercostales interni* and the *mm. subcostales*.

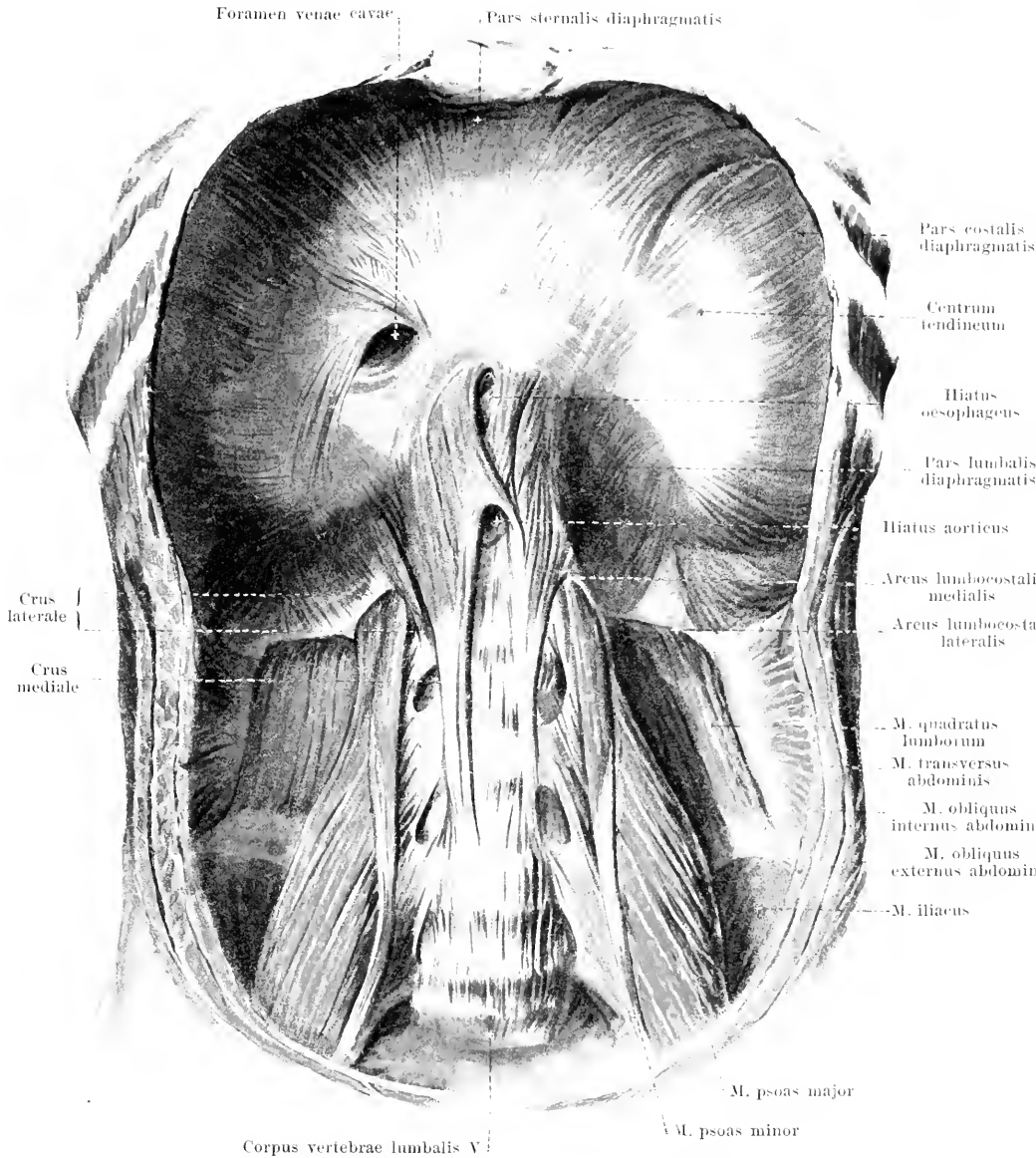
Mm. subcostales, very variable. Form: flat, triangular, very thin. Position: on the internal surface of the ribs, usually only of the lower ribs, in the region of the *anguli costarum*. Origin: from the inner surface of the ribs. Insertion: the fibers run like those of the *mm. intercostales interni*, but jump over one or two ribs. Action: muscles of expiration. Innervation: *rami anteriores* [*nn. intercostales*] of the corresponding *nn. thoracales*.

M. transversus thoracis (see Fig. 313). Form: flat, quadrangular, very thin. Position: directly upon the posterior surface of the anterior thoracic wall, below close to the diaphragm and bounding the *m. transversus abdominis*. Origin: posterior surface of the *corpus sterni* and of the *proc. xiphoideus*. Insertion: obliquely upward and lateralward to the 3rd (or also 2nd)—6th rib. Action: it draws the ribs downward on expiration. Innervation: *rami anteriores* [*nn. intercostales*] of the *nn. thoracales III* (or *II*)—*VI*.



313. Anterior wall of thorax with muscles, viewed from behind.

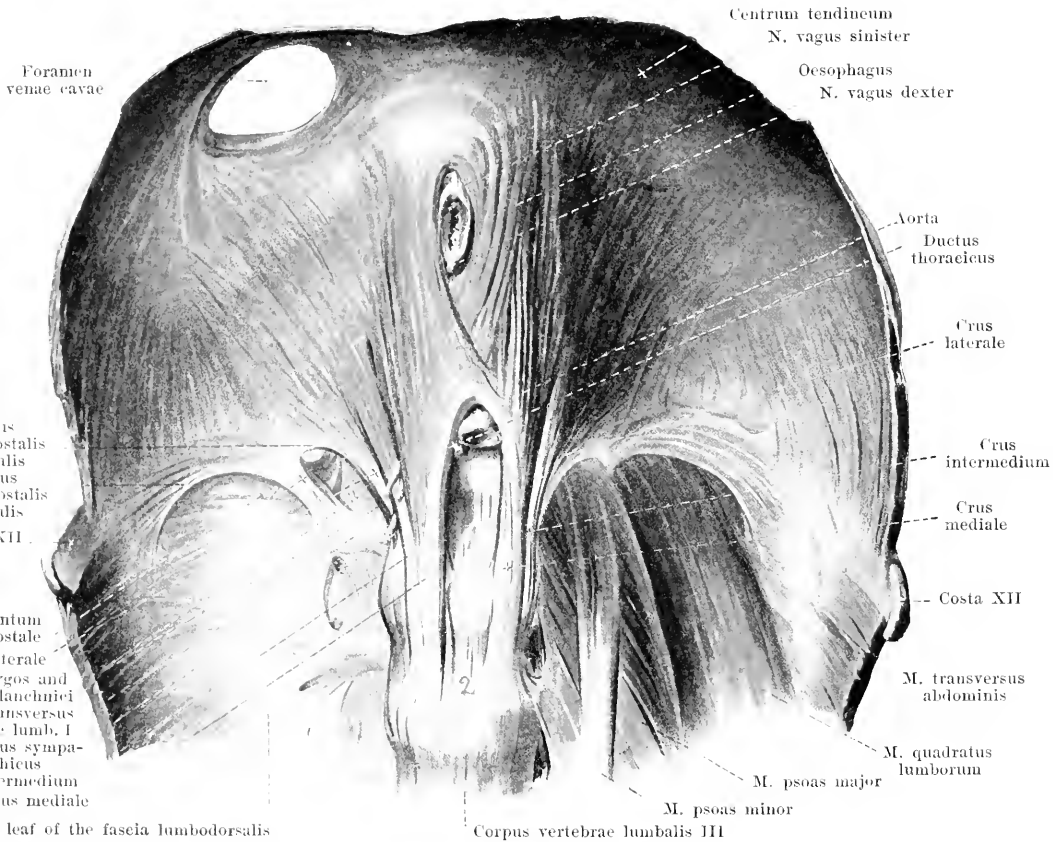
(On the right side the fibres of origin of the diaphragm have been removed.) [Text see p. 267.]



314. Diaphragm, viewed from below and in front.

(The muscles of the chest have been removed, the abdominal muscles have been cut through transversely.)

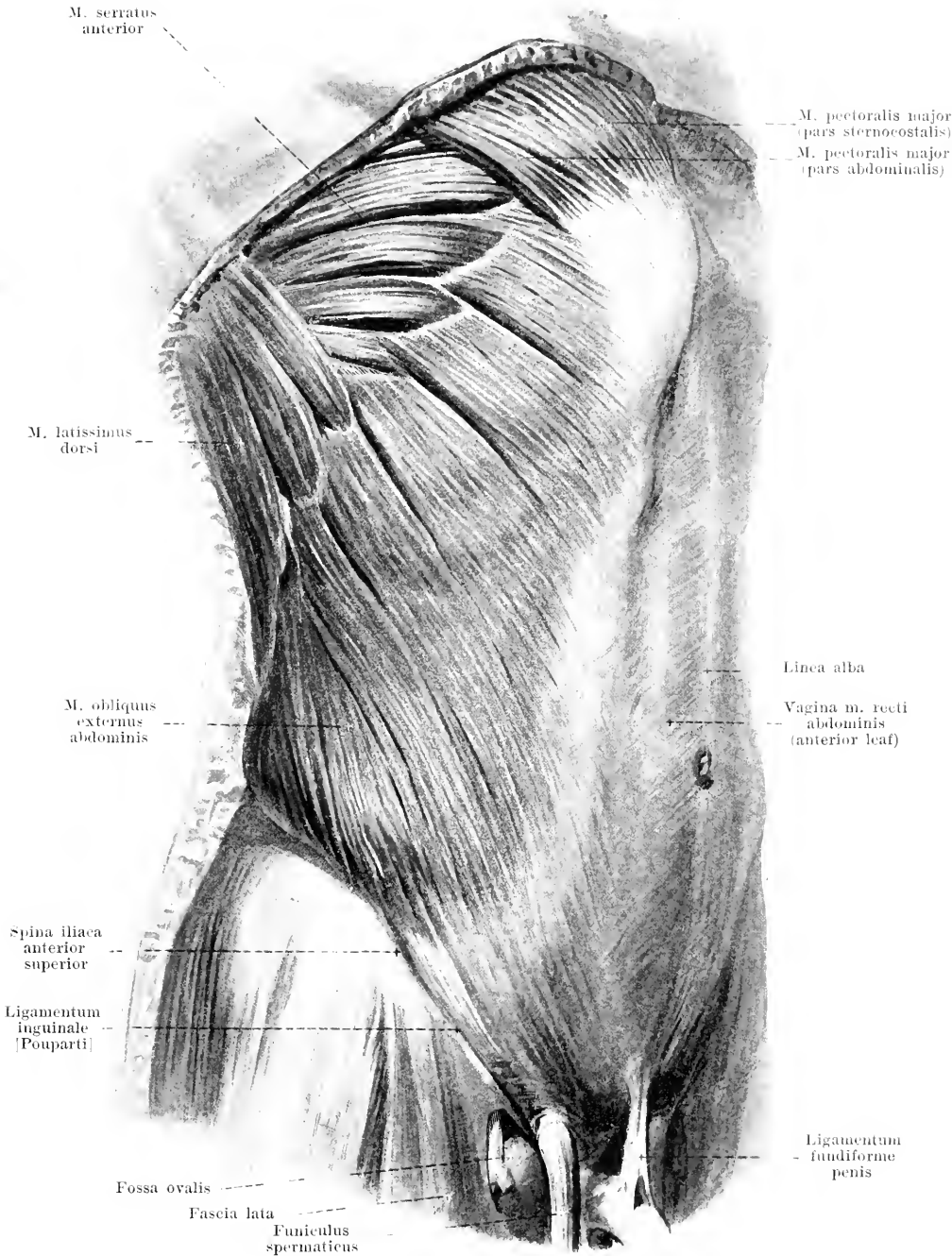
Diaphragma (*diaphragm*) (see also Figs. 313 and 315). **Form and position:** flat, broad, kidney-shaped, tendinous in the middle (*centrum tendineum*), otherwise fleshy; it is stretched out transversely between the abdominal and thoracic cavities; it bulges into the thorax, being convex above, markedly so lateralward, less so in the middle, so that to the right and to the left there arises a cupola-like elevation, those of the two sides being separated by a shallow median depression: in the adult on moderate expiration the right cupola reaches to close below the costocartilaginous junction of the 4th rib, the left cupola to just above the costocartilaginous junction of the 5th rib (see Fig. 410). **Origin:** from the posterior surface of the proc. xiphoideus sterni (*pars sternalis*), from the internal surface of the anterior ends of the 7th—12th rib (*pars costalis*) and from the lumbar vertebrae (*pars lumbalis*).



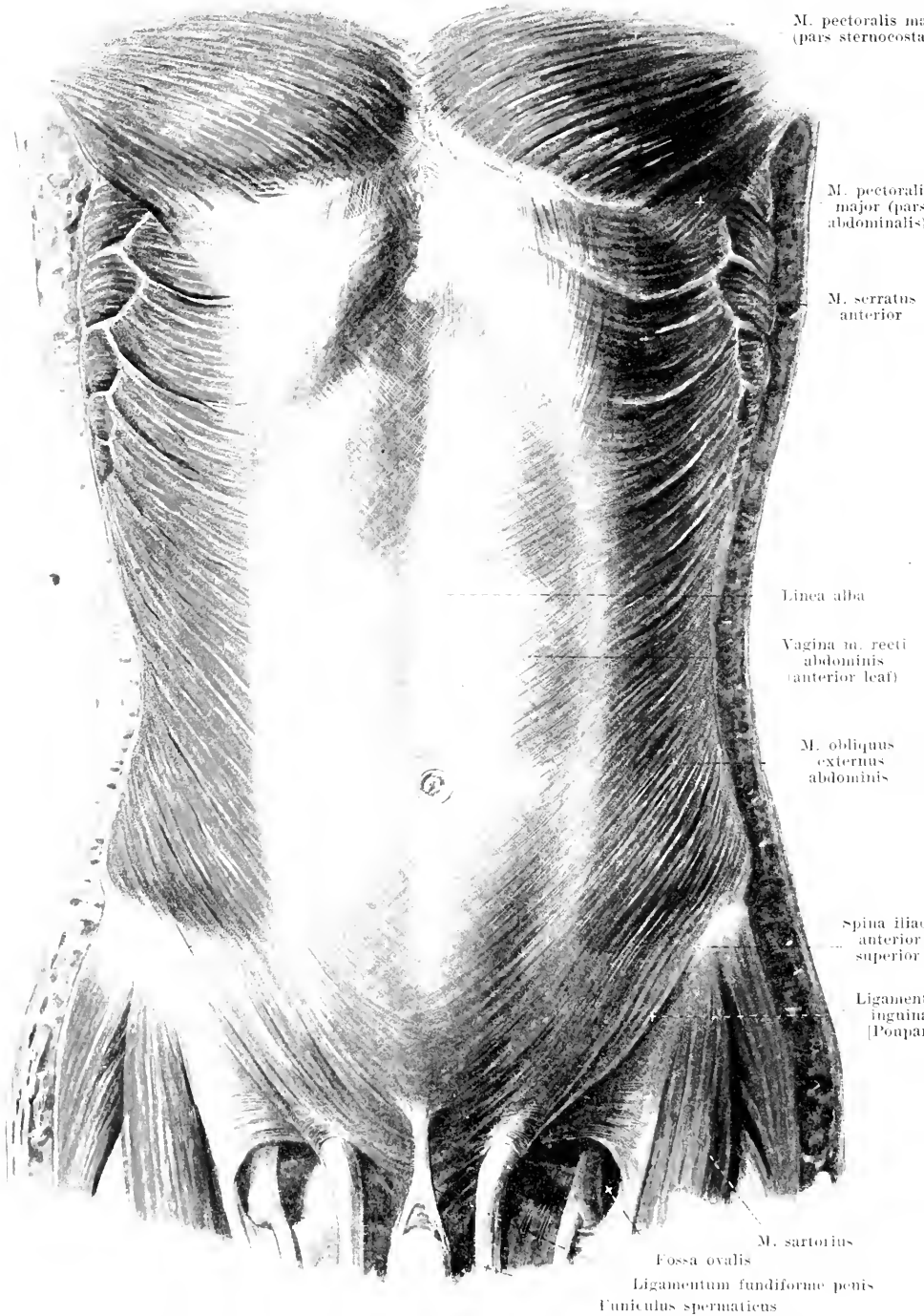
315. Diaphragm, pars lumbalis, viewed from below and in front.

(The diaphragm has been separated from the upper ribs and from the sternum and drawn somewhat upward; on the right the *mm. psoas* and *quadratus lumborum* have been removed.)

Diaphragma (continued). The *pars lumbalis* arises from the *lig. longitudinale anterius* and is divided on each side by perforating vessels and nerves (somewhat variably) into three *crura*: *crus mediale* from the anterior surface of the 3rd and 4th, *crus intermedium*, narrow, from the anterior surface of the 2nd and 3rd, *crus laterale*, from the lateral surface of the 2nd (or 1st) lumbar vertebral body and from a strip of fascia which extends thence in front of the *m. psoas* to the transverse process of the 1st lumbar vertebra (*arcus lumbocostalis medialis* [Halleri]). A second strip of fascia, between the point last mentioned and the 12th rib (*arcus lumbocostalis lateralis* [Halleri]), forms a bridge over the *m. quadratus lumborum* and serves chiefly to give origin also to muscle fibers; it is not rare to find a triangular space in the muscle over it. The *crura mediale* of the two sides diverge somewhat above and in front and leave between them and the spine an oblong space, the *hiatus aorticus* (for the aorta and ductus thoracicus), which is closed above by a small tendinous arch. Over this, the right *crus mediale* divides into two bundles which enclose a slit which reaches almost to the *centrum tendineum*, the *hiatus oesophageus* (for the oesophagus and the *nn. vagi*); the left *crus mediale* sends only a few corresponding fibers to the right. Between the *crus mediale* and the *crus intermedium* run usually the *v. azygos* (or *hemiazygos*) and the *nn. splanchnici*; between the *crus intermedium* and the *crus laterale* runs the *truncus sympathicus*. Insertion: on all sides radially to the *centrum tendineum* (O. T. central tendon), which has the shape of a clover-leaf and consists of interwoven tendon bundles. In its right half lies the *foramen venae cavae*, quadrangular rounded (for the *v. cava inferior* and the *rami phrenicoabdominales n. phrenici dextri*). Action: it enlarges the thoracic cavity; the cupolae descend markedly, the *centrum tendineum* descends less. Innervation: *nn. phrenici* and the *rami anteriores* [*nn. intercostales*] of the *nn. thoracales* VII—XII (especially VII, VIII and XI)

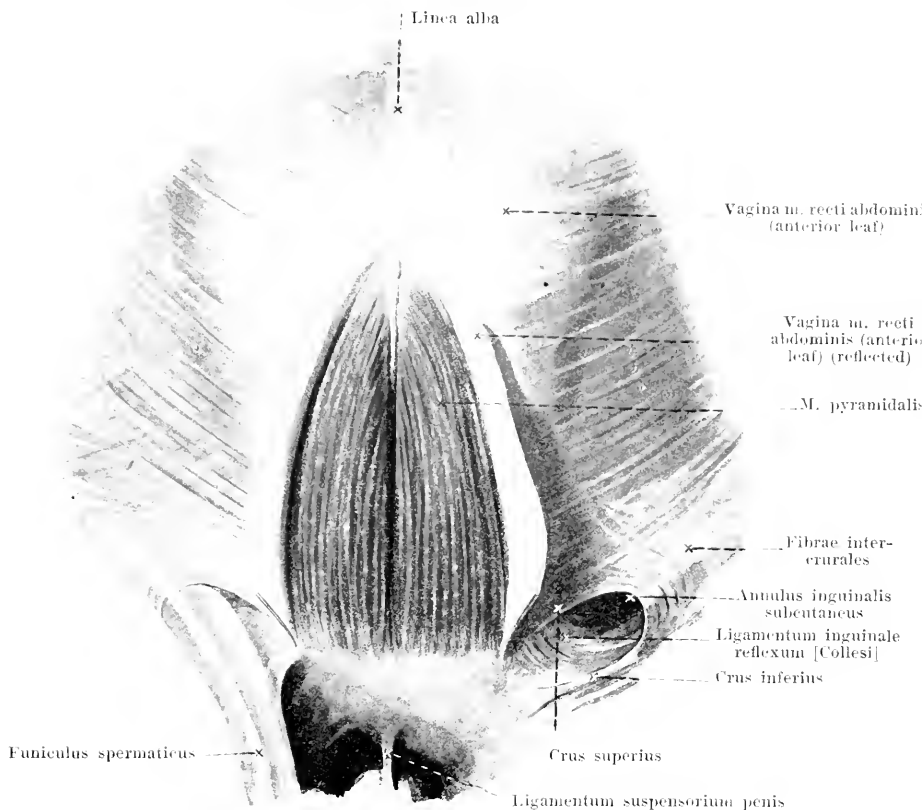


316. Muscles of the abdomen, viewed from the right side. [Text see p. 273.]



317. Muscles of the abdomen, viewed from in front.

[Text see p. 273.]

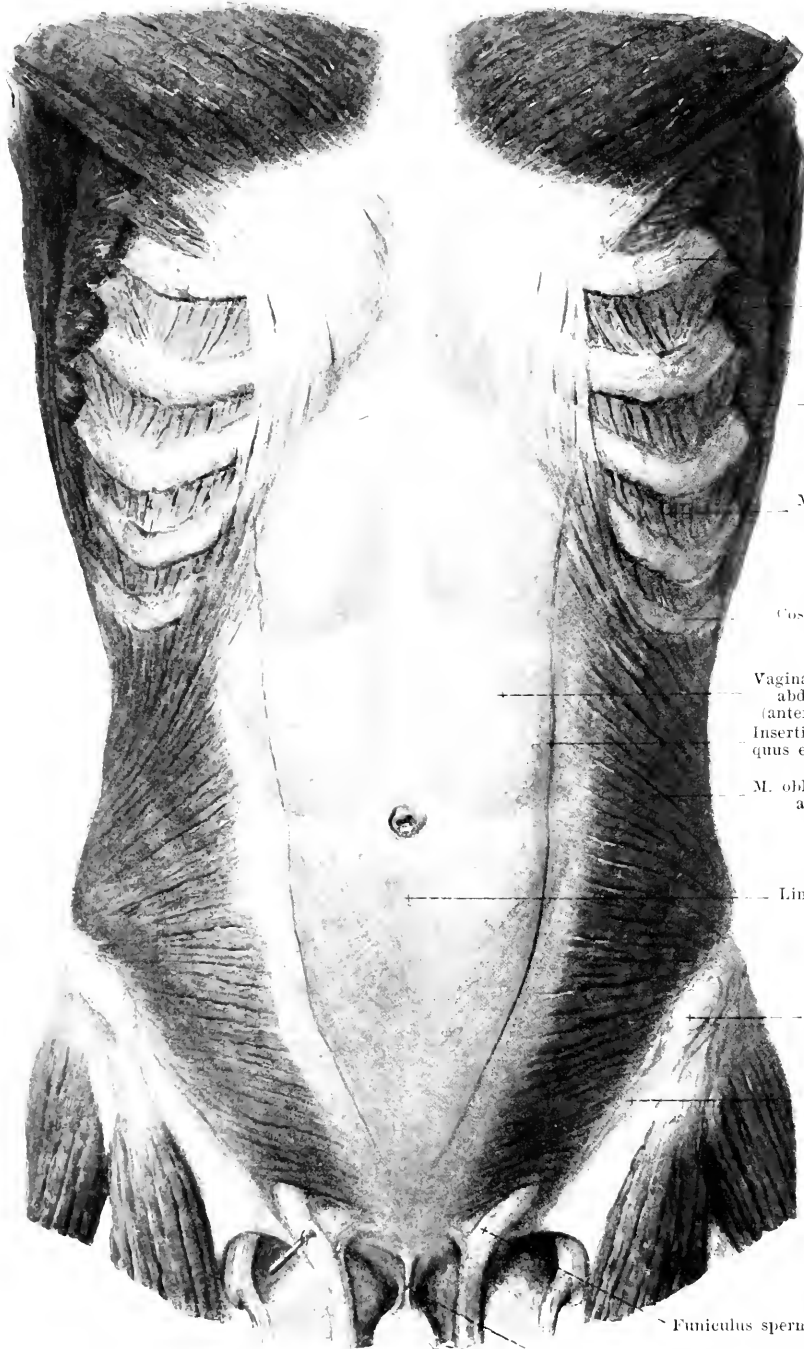


318. *Mm. pyramidales*, viewed from in front.

(The anterior leaf of the sheath of the rectus has been partially dissected off and reflected.)

M. obliquus externus abdominis (see also Figs. 316, 317, 329 and 331). Form: flat, quadrangular, broad, much longer in front than behind. Position: on the anterior and lateral surface of the abdominal and inferior thoracic region. Origin: by 8 fleshy digitations from the outer surface of the 5th—12th rib; the uppermost digitation is usually covered by the pars abdominalis m. pectoralis majoris (see Fig. 319); the 5 upper digitations are inserted between the digitations of the m. serratus anterior; the 3 lower between those of the m. latissimus dorsi. Insertion: the upper fibers run more transversely, the lower more obliquely, forward and downward. The largest, upper part goes over medianward into a broad, tendinous sheath which runs in front of the m. rectus abdominis and helps to form the anterior leaf of the vagina m. recti abdominis (see p. 279); the next lower muscle bundles pass obliquely to the *ligamentum inguinale [Poupart]* (O. T. Poupart's ligament) (see p. 280) and leave medianward an open space (*annulus inguinalis subcutaneus*) (see p. 280) for the passage of the funiculus spermaticus; the muscle fibers arising farthest back are attached in fleshy masses to the external lip of the iliac crest. Action: it draws the thorax downward, bends the spinal column forward and toward the same side and rotates it toward the other side; when the thorax is fixed it elevates the pelvis. Innervation: rami anteriores [nn. intercostales] of the nn. thoracales VIII—XII and the nn. iliohypogastricus and ilioinguinalis.

M. pyramidalis, inconstant. Form: flat, oblong-triangular. Position: close to the median plane above the symphysis pubis, in front of the m. rectus abdominis, in a duplicature of the anterior leaf of the vagina m. recti abdominis. Origin: anterior surface of the ramus superior ossis pubis and of the symphysis ossium pubis. Insertion: the fibers run upward and medianward to the linea alba. Action: it tightens the linea alba in the upright position and gives rise to the median groove below the navel when the abdominal muscles are relaxed. Innervation: r. anterior [n. intercostalis] of the n. thoracalis XII.



M. pectoralis major (pars sternocostalis)

1st digitation of the m. obliquus externus abdominis

Costa VI

M. serratus anterior

M. latissimus dorsi

Mm. intercostales externi

Mm. intercostales interni

Costa X

Vagina m. recti abdominis (anterior leaf)

Insertion of the m. obliquus externus abdominis

M. obliquus internus abdominis

Linea alba

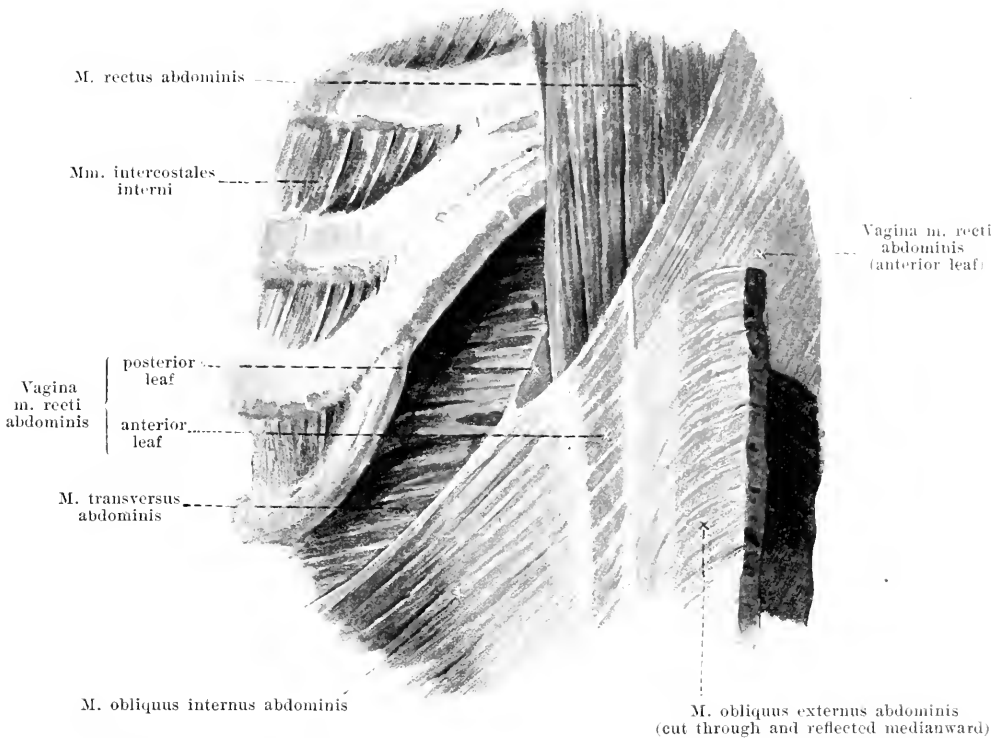
Spina iliaca anterior superior

Ligamentum inguinale [Poupart]

Funiculus spermaticus

Ligamentum suspensorium penis

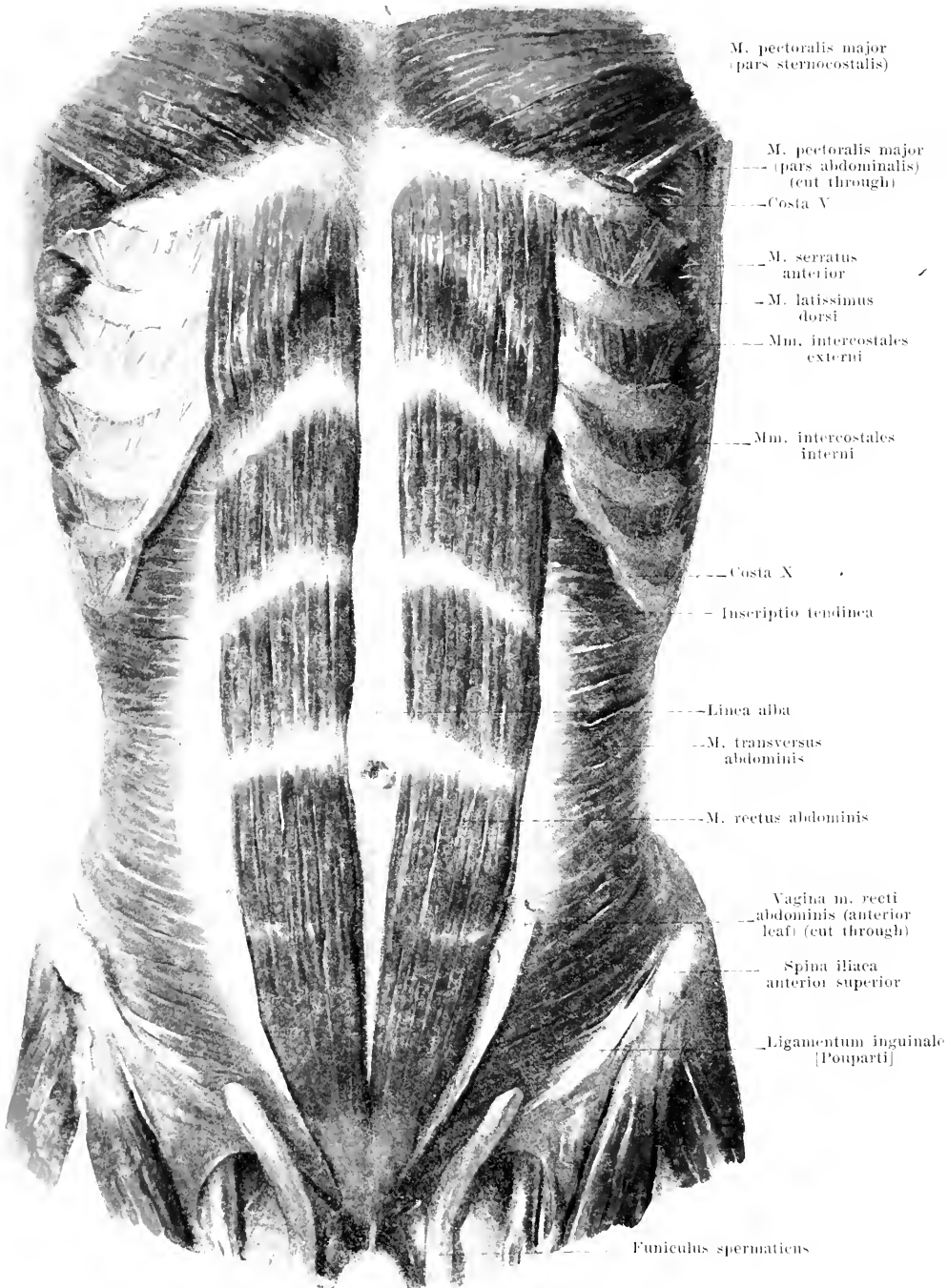
319. Muscles of the abdomen (2nd layer), viewed from in front. [Text see p. 275.]



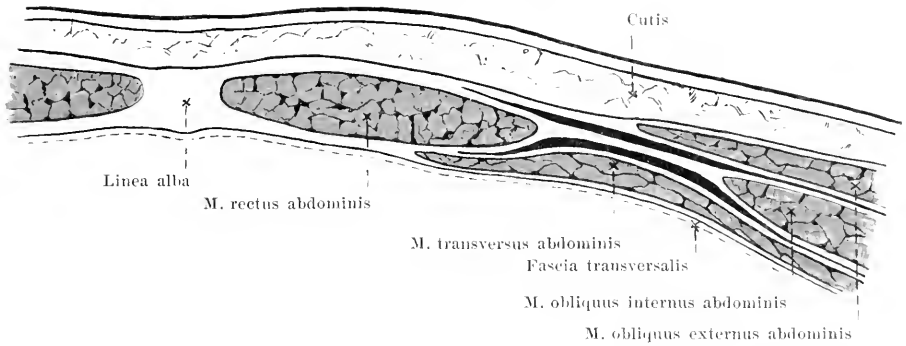
320. Transition of the tendon of the right *m. obliquus internus abdominis* into the sheath of the rectus.

(The *m. obliquus externus abdominis* has been completely removed above; below, it has been cut through and reflected; the *m. obliquus internus abdominis* has been separated at its upper border from the costal cartilages; the anterior leaf of the sheath of the rectus has been removed in the upper portion.)

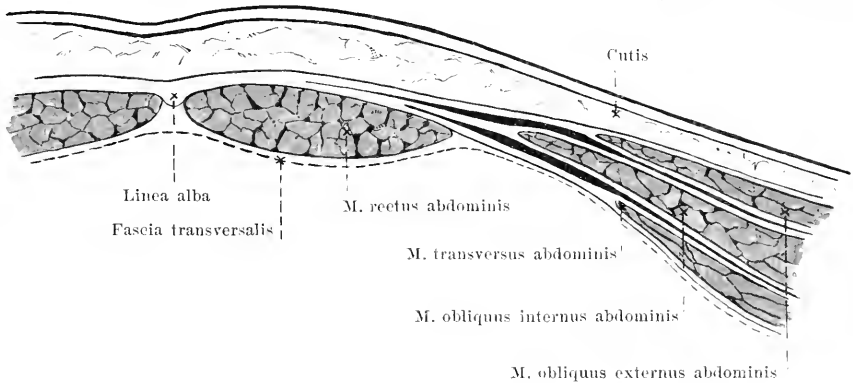
M. obliquus internus abdominis (see also Figs. 319, 331 and 332). Form: flat, quadrangular, broad, in front considerably longer than behind. Position: on the anterior and lateral surface of the abdomen, completely covered by the *m. obliquus externus abdominis*. Origin: posterior surface of the combined leaves of the fascia lumbodorsalis (see p. 288), linea intermedia of the iliac crest, lateral two thirds of the lig. inguinale. Insertion: the most posterior fibers pass upward and forward to the inferior margins of the 10th—12th rib. The other fibers coming from the iliac crest diverge and pass medianward so that the uppermost run parallel to the ends of the costal cartilages (connected with them only by loose tissue), the lowermost run transversely; the fibers from the lig. inguinale are somewhat curved as they run downward. All the muscle bundles not fastened to the ribs go over, lateralward from the *m. rectus*, along a curved line, into a tendinous plate. This divides in its upper two thirds into two lamellae, of which one passes in front of, the other behind, the *m. rectus abdominis* to go to the median plane and there form the basis for the corresponding leaf of the *vagina m. recti abdominis* (O. T. sheath of the rectus) (see also Fig. 322 and p. 279). In the lower third, all the fibers run in front of the *m. rectus abdominis* (see also Fig. 323 and p. 279); the posterior leaf of the rectal sheath is lacking here; its lower margin is curved so as to be concave and is called the *linea semicircularis [Douglasi]* (see Fig. 324). The lower margin of the muscle forms in part the upper margin of the inguinal canal (see p. 281); in addition the *m. cremaster* goes off from it (see p. 281). Action: it draws the thorax downward, bends the spinal column forward and toward the same side, rotates it toward the same side; when the thorax is fixed it elevates the pelvis. Innervation: rami anteriores [nn. intercostales] of the nn. thoracales VIII—XII and the nn. iliopogastricus and iliopigastrius.



321. Mm. recti abdominis, viewed from in front. [Text see p. 277.]

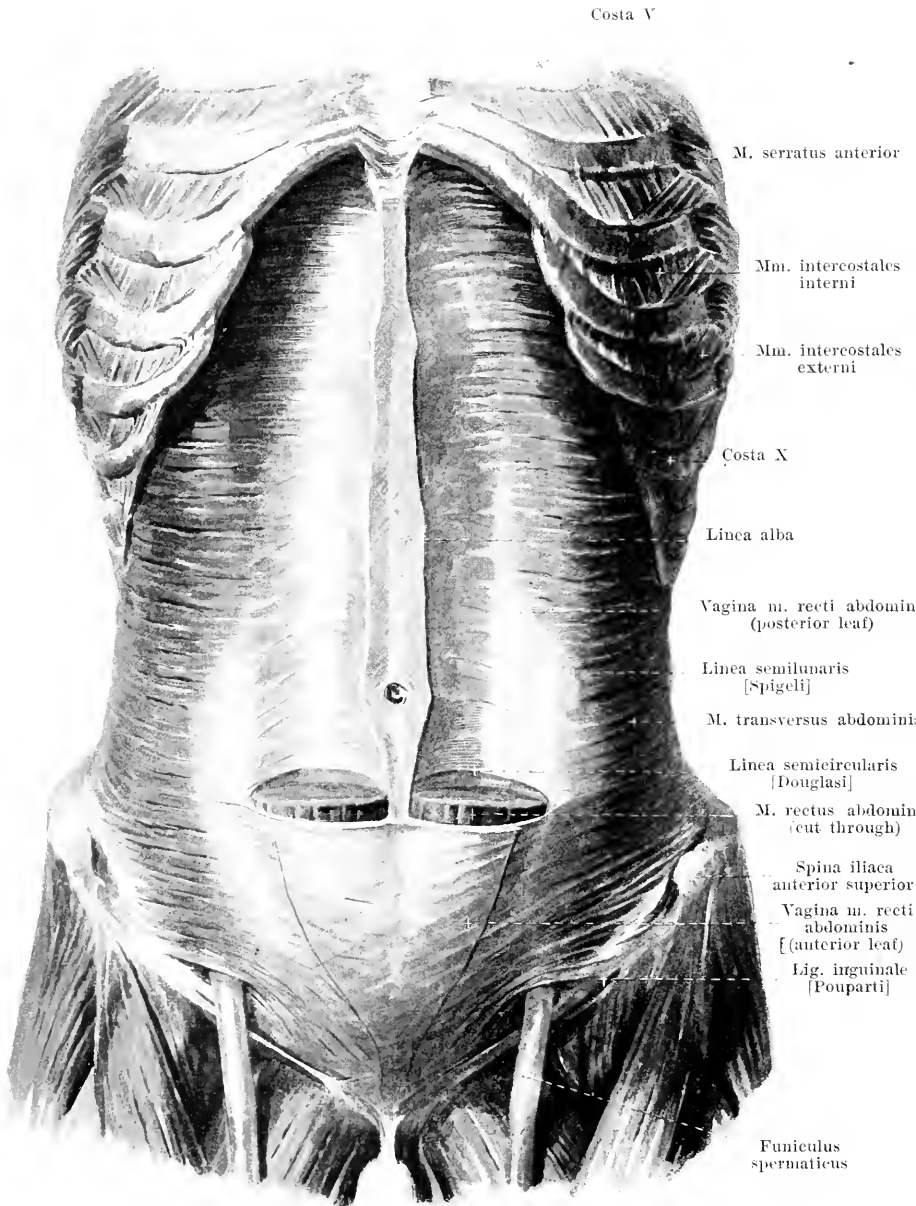


322. Transverse section through the abdominal wall above the linea semicircularis [Douglasi] (after W. Braune).



323. Transverse section through the abdominal wall below the linea semicircularis [Douglasi] (after W. Braune).

M. rectus abdominis (see Figs. 321 and 324). Form: flat, oblong-quadrangular, above broader and thinner, below narrower and thicker. Position: on the anterior surface of the abdomen close to the linea alba. In front it is covered by the anterior leaf of the vagina m. recti abdominis; behind it lies in its upper two thirds on the posterior leaf of the vagina m. recti, in the lower third directly upon the fascia transversalis. Origin: anterior surface of the 5th—7th costal cartilage, of the proc. xiphoideus and of the lig. costoxiphoideum. Insertion: its fibres run downward, parallel to one another, close to the linea alba. In its upper half it is interrupted by three intercalated tendons, *inscriptiones tendineae*: the uppermost, usually incomplete, corresponds approximately to the inferior margin of the thorax, the lowermost runs transversely at the level of the navel, and the middle one, between these two, in the same direction; these intermediate tendons often do not go entirely through the thickness of the muscle; they are very intimately connected with the anterior leaf, but loosely with the posterior leaf of the rectal sheath. The number and extent of these tendons varies; usually there is an incomplete one below the navel at the level of the linea semicircularis [Douglasi]. Below, the muscle fibres converge and are attached by a strong flat tendon to the ramus superior oss. pubis and to the anterior surface of the symphysis ossium pubis; the fibres of the tendons are very much interwoven. Action: it draws the thorax downward and bends the spinal column forward; when the thorax is fixed it elevates the pelvis. Single sections of the muscle can contract separately. Innervation: rami anteriores [nn. intercostales] of the nn. thoracales V—XII.



324. Muscles of the abdomen (3rd layer), viewed from in front.

(Mm. obliqui abdominis have been completely removed. The m. rectus abdominis and the anterior leaf of its sheath have been removed on each side in their upper two thirds.)

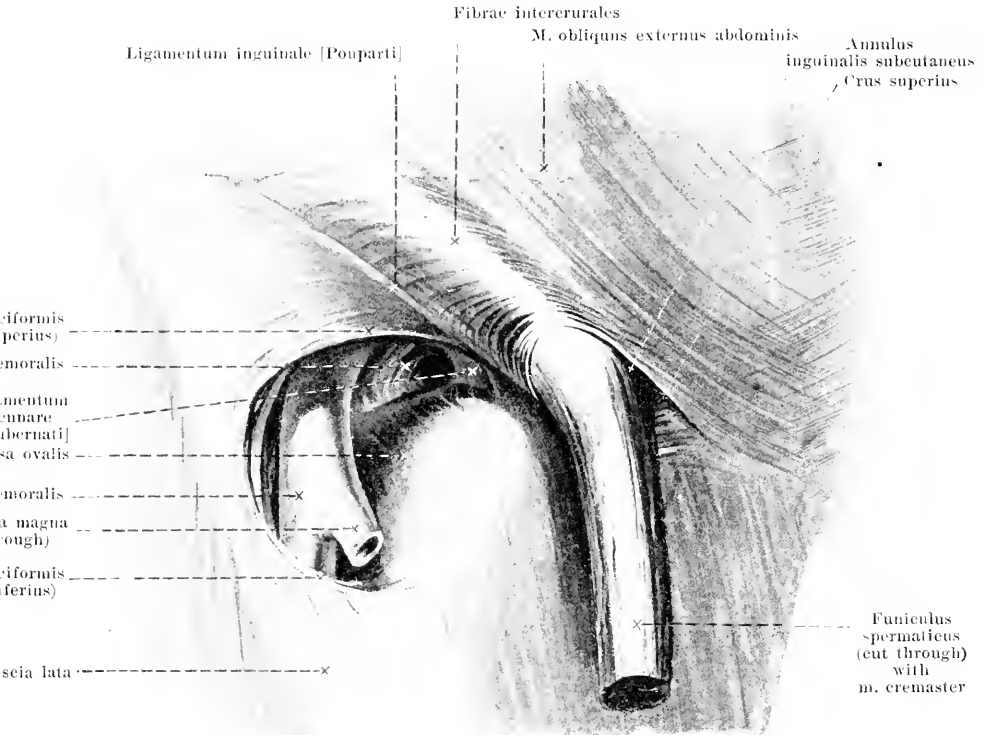
M. transversus abdominis (see also Figs. 313, 321 and 332). Form: flat, quadrangular, broad, much longer in front than behind. Position: on the anterior and lateral surface of the abdomen, completely covered by the mm. obliqui abdominis, partly also by the m. rectus abdominis. Origin: from the internal surface of the 6th—12th costal cartilage, from the union of the two leaves of the fascia lumbodorsalis (see Figs. 332 and 333), from the internal lip of the iliac crest and from the lateral two thirds of the lig. inguinale. Insertion: the fibers are parallel, run transversely forward and go over into a tendon plate along a line which is concave medianward (*linea semilunaris [Spigeli]*). This tendon plate (see also Figs. 322 and 323) runs, in its upper two thirds, behind the m. rectus abdominis and strengthens the posterior leaf of the sheath of the rectus; in the lower third, where there is no posterior leaf of the rectal sheath, it goes in front of the m. rectus abdominis and fuses with the anterior leaf of the rectal sheath. The lowermost fibers arch downward and help to form the posterior wall of the inguinal canal (see pag. 252); they are attached partly to the upper surface of the pubis, partly to the lig. inguinale. Action: it pulls the ribs downward and diminishes the size of the abdominal cavity. Innervation: rami anteriores [nn. intercostales] of the nn. thoracales VII—XII as well as the nn. iliohypogastricus and ilioinguinalis.

Vagina m. recti abdominis (*sheath of the rectus*) (see also Figs. 317, 319, 320, 322 and 323) consists on each side of two broad tendinous leaves, which cover, directly, the anterior and posterior surfaces of the m. rectus abdominis and which are formed by the tendons of the mm. obliqui et transversus abdominis; medianward both leaves meet those of the other side in the linea alba. The anterior leaf covers the whole anterior surface of the m. rectus and is firmly fused with its inscriptiones tendineae. It is very thin above and there serves to give origin to the pars abdominalis of the m. pectoralis major; it becomes stronger lower down and consists of interwoven fibers. In its upper two thirds it is formed by the anterior leaf of the tendon of the m. obliquus internus, with which is fused the tendon of the m. obliquus externus (see Fig. 322), in its lower third by the union of the tendons of the mm. obliqui and of the mm. transversus abdominis (see Fig. 323). The posterior leaf is much shorter, begins on the costal cartilages at the angulus infrasternalis and ends, more or less sharply, somewhat below the navel in a margin, the *linea semicircularis [Douglasi]*, which is concave below and stretches out lateralward from the linea alba; it consists of the transverse tendinous fibers of the posterior leaf of the tendon of the m. obliquus internus abdominis and those of the m. transversus abdominis.

Linea alba (see also Figs. 317, 318 and 321—323) is a tough connective tissue strip which extends in the median plane between the mm. recti abdominis from the proc. xyphoideus to the symphysis ossium pubis. Below the proc. xyphoideus it gradually broadens, being about twice as wide at the level of the navel as it is higher up, and again narrows below the navel to a thin cord which is attached behind the tendons of the mm. recti abdominis to the lig. pubicum superius by means of a triangular expansion (*adnunculum lineae albae*) (see Fig. 325). The sheath of the rectus is attached to the linea alba; indeed it forms it, in a way, through the union of the two leaves of the right side with the two leaves of the left. Approximately in its middle and about at the level of the body of the 4th lumbar vertebra the linea alba contains the navel, *umbilicus*.

Ligamentum fundiforme penis (O. T. suspensory ligament) (see Figs. 316 and 317) (in the male) is a broad band, consisting essentially of elastic fibers; it arises, above the symphysis ossium pubis, from the anterior surface of the vagina m. recti and the linea alba as well as from the fascia superficialis abdominis. It surrounds the penis like a loop by means of its two limbs and often radiates out into the scrotum.

Ligamentum fundiforme clitoridis (O. T. suspensory ligament) (see also Fig. 675) (in the female) corresponds to the ligament just mentioned in the male.

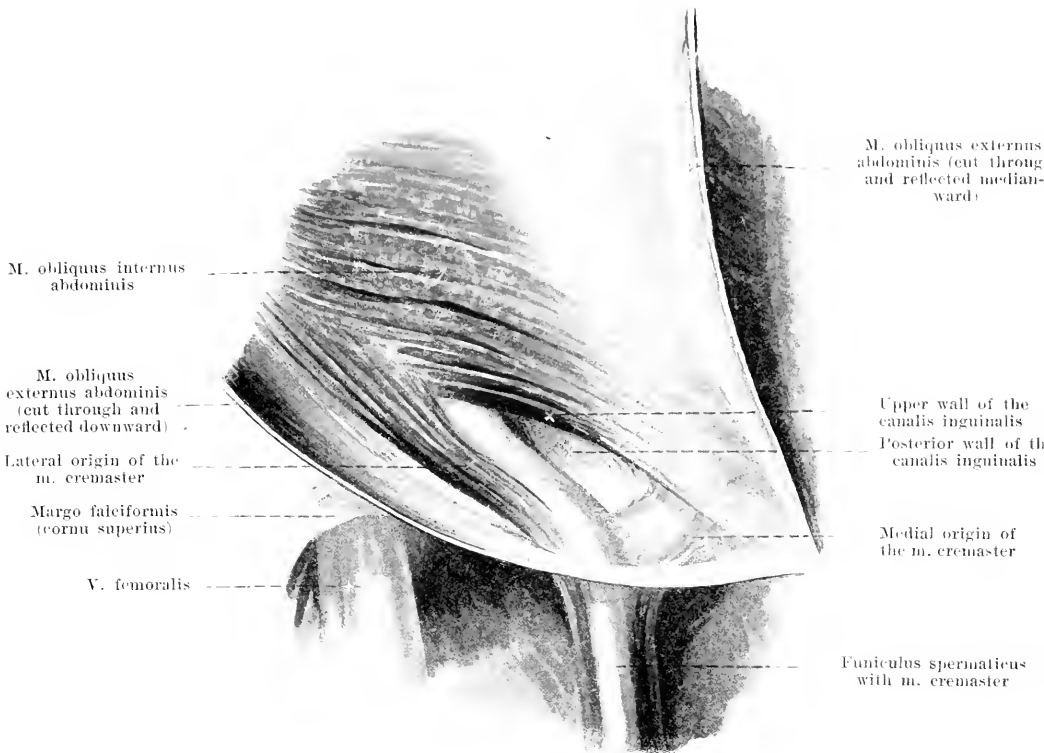


325. Right anterior abdominal ring and fossa ovalis in the male.

Ligamentum inguinale [Pouparti] (O. T. *Poupart's ligament*) (see also Figs. 316, 317, 324, 328, 370 and 376) is a powerful, flatly rounded tendon, which extends from the spina iliaca anterior superior to the tuberculum pubicum. To its upper margin are attached the tendinous fibers of the m. obliquus externus, and from it arise part of the fibers of the m. obliquus internus and m. transversus abdominis; to its lower margin the fascia lata is attached and this causes a convex downward bulging of the ligament. Medianward the ligament does not end at the tuberculum pubicum alone but also sends diverging fibers to the pecten ossis pubis; the latter insertion is a small triangular ligament, *ligamentum lacunare [Gubernati]* (O. T. *Gimbernati's ligament*) (see also Figs. 328 and 370), which bounds the annulus femoralis (see p. 325) with its lateral concave margin, and fused with the fascia pectinea, extends obliquely backward and upward.

Canalis inguinalis (inguinal canal) (see also Figs. 326—328) is a cylindrical space filled up by the funiculus spermaticus in the male, by the lig. teres uteri in the female; it perforates the lowermost portion of the abdominal muscles obliquely from behind and above, forward, downward and medianward. The canal has two openings, one posterior, *annulus inguinalis abdominalis* (O. T. *internal abdominal ring*), and one anterior, *annulus inguinalis subcutaneus* (O. T. *external abdominal ring*), and (somewhat schematically) four walls, one anterior, one inferior, one superior, one posterior.

The *annulus inguinalis subcutaneus* (see also Fig. 318) lies somewhat laterally from and a little above the tuberculum pubicum. It is formed by the separation of the lowermost fibers of the tendon of the m. obliquus externus from one another giving rise to an acute-angled space, which is bounded below by fibers which go to the tuberculum pubicum (*crus inferius*, O. T. *external pillar*), above by fibers which run to the anterior surface of the symphysis ossium pubis (*crus superius*, O. T. *internal pillar*); the larger lateral portion of the space is filled up by curved fibers which run transversely, *fibrae intercolumnares* (O. T. *intercolumnar fascia*, external spermatic fascia). These fibers leave as a free opening only a small space, convex laterally, which will permit the passage of the tip of the index finger.



326. Right inguinal canal in the male (2nd layer), viewed from in front.

(The *m. obliquus externus abdominis* has been cut through and reflected partly medianward and partly downward. The spermatic cord has been pressed somewhat downward within the inguinal canal.)

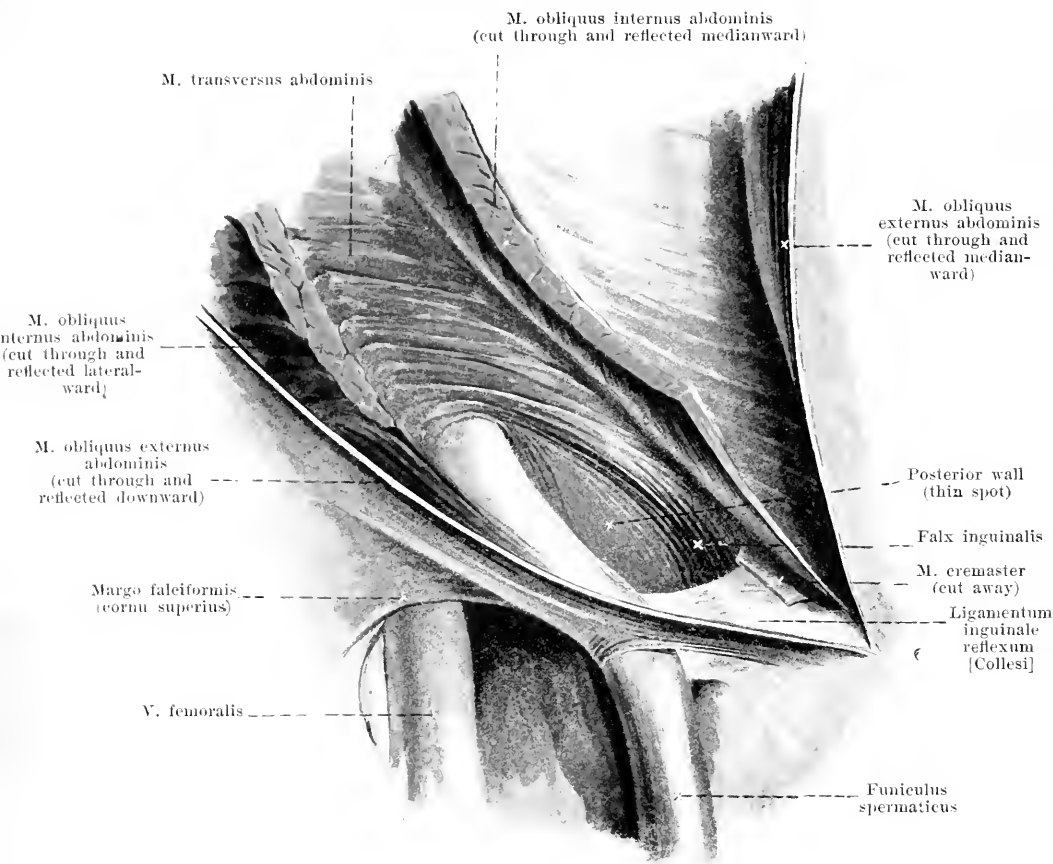
Canalis inguinalis (continued).

Anterior wall: formed by the tendon plate of the *m. obliquus externus abdominis*, and also by the *fibrae intercrurales*.

Lower wall: *m. obliquus externus*; the *lig. inguinale* [Poupart] and the fibrous bands of the *crus inferius* immediately adjacent do not extend in their medial portion in a straight line to the *tuberculum pubicum* but are curved somewhat downward so that they form a groove open above for the spermatic cord.

Upper wall: *m. obliquus internus*; the lowermost fibers of this muscle, arising from the *lig. inguinale*, extend in curves medianward and downward, forming lateralward the muscular, narrow, upper wall of the inguinal canal and going over medianward into the anterior layer of the sheath of the rectus; this medial part has its lower insertion sometimes farther lateralward and then passes close in front of and along with the *falx inguinalis* to the upper surface of the *os pubis*.

M. cremaster (see also Figs. 325 and 652) (in the male) is a portion separated from the lower margin of the *m. obliquus internus*. It arises by a thick lateral bundle from the upper margin of the *lig. inguinale* and by a weak, medial bundle from the anterior layer of the sheath of the rectus; the former lies on the lateral, the latter on the medial surface of the spermatic cord; both pass with the spermatic cord through the subcutaneous opening of the inguinal canal, spread out in common upon the *tunica vaginalis communis* of the testis and epididymis, and surround it like a loop. **Action:** it elevates the testis. **Innervation:** *n. spermaticus externus*. — In the female this muscle consists of only a few fibers which go to the *lig. teres uteri*.

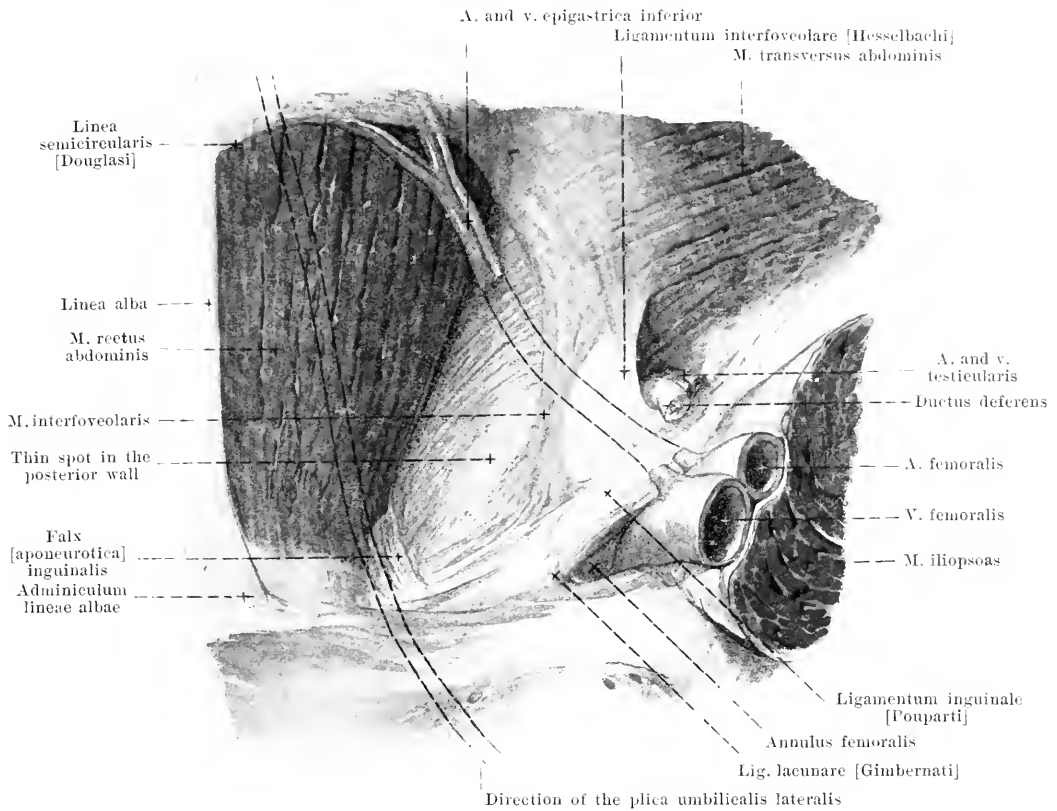


327. Right inguinal canal in the male (3rd layer), viewed from in front.

(The mm. obliqui abdominis have been cut through above the inguinal canal and reflected medianward and lateralward. The spermatic cord has been pressed somewhat downward within the inguinal canal.)

Canalis inguinalis (continued). Posterior wall (see also Fig. 325): m. transversus: the lowermost fibers of the m. transversus arch downward on the median side of the posterior abdominal ring, spread out in a divergent manner and become attached medianward to the upper surface of the os pubis, lateralward to the upper margin of the lig. inguinale. The triangular plate thus arising forms the posterior wall of the inguinal canal and varies in strength at different places. Medianward it contains a strip of strong tendinous fibers, *falx [aponurotica] inguinalis*, which extends from above downward and medianward to the upper surface of the pubis, and becomes firmly attached by its medial border to the tendon of the m. rectus; in front it is not rarely covered and strengthened by fibers of the m. obliquus internus (see p. 281). In the lowermost portion of this strip there are also fibers which extend from the lateral margin of the m. rectus abdominis, in curves, downward and lateralward (see Fig. 325); not seldom they are more powerful than the others. The lateral part of the posterior wall is strengthened by the lig. interfoveolare (see p. 283).

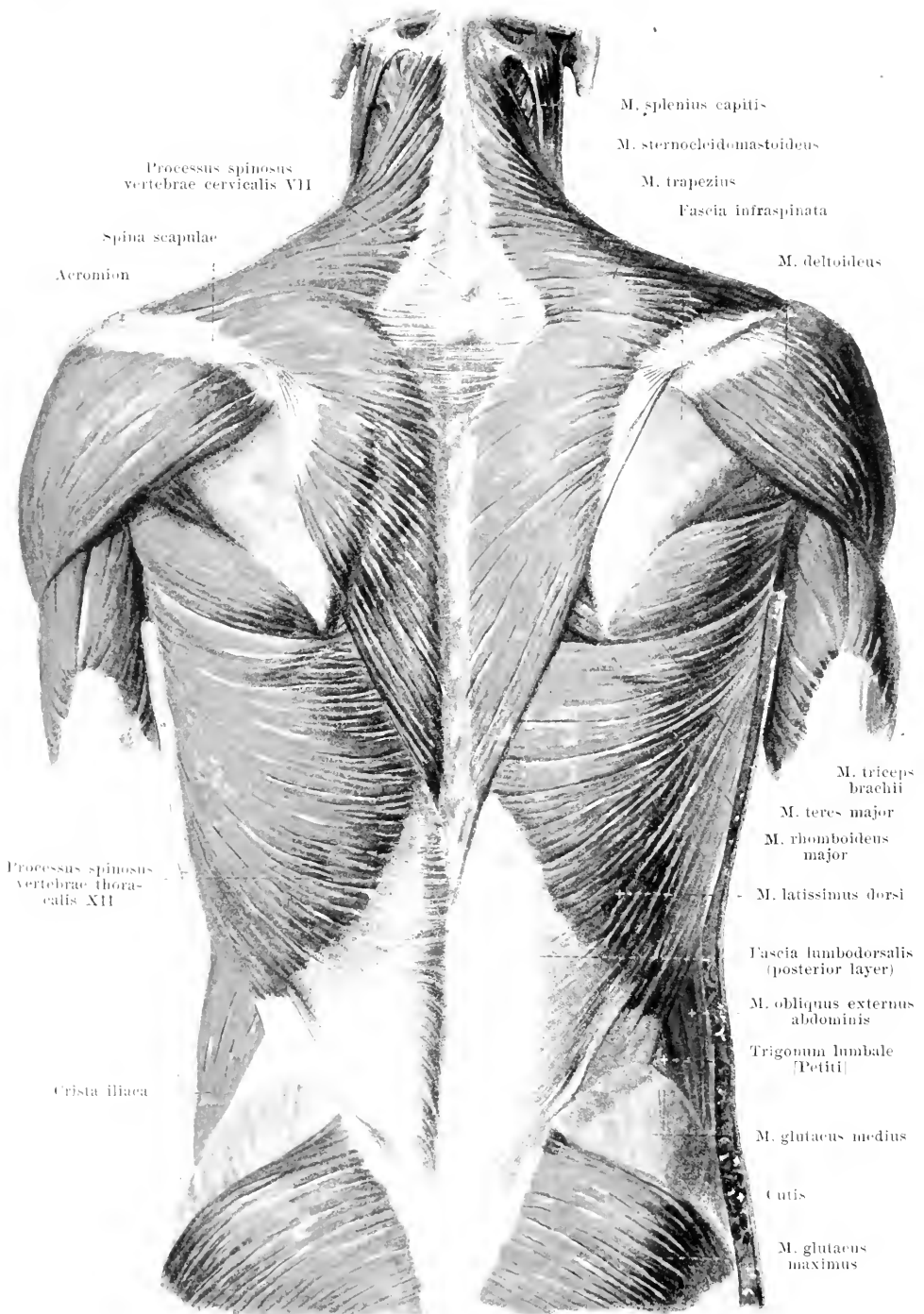
The *ligamentum inguinale reflexum [Collesi]* (see also Fig. 318) is a thin band of fibers, one finger broad, which comes into view medial from the annulus inguinalis subcutaneus, between the two crura. It extends from the medial end of the lig. inguinale and lig. lacunare obliquely upward and medianward behind the crus superius to the anterior layer of the sheath of the rectus and in so doing lies partly in front of the lowermost portion of the falx inguinalis.



328. Posterior wall of the right inguinal canal in the male, viewed from behind.

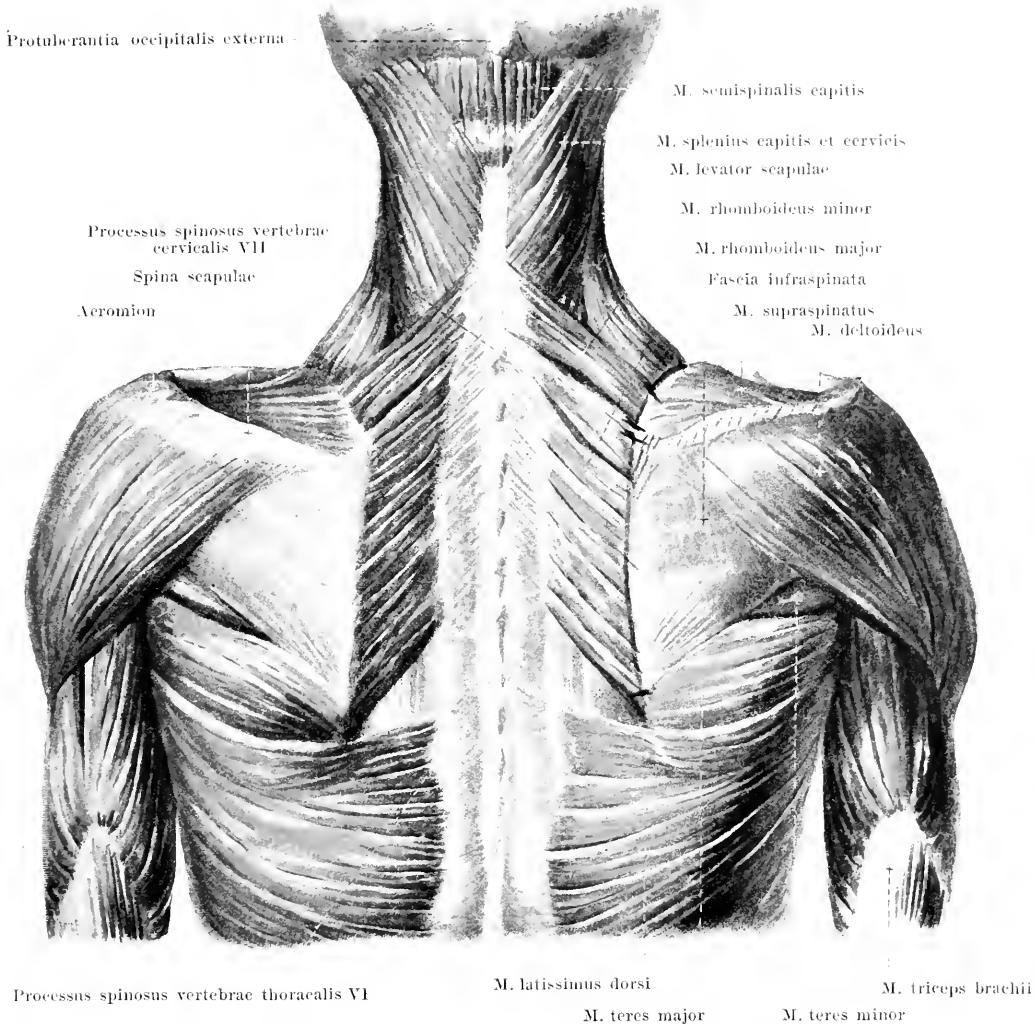
Canalis inguinalis (continued). Posterior wall (continued): The lateral part of the plate connected with the m. transversus, which forms the posterior wall (see p. 252) is strengthened by a band of fibers markedly concave lateralward and upward, the *ligamentum interfoveolare* [Hesselbachi]. This lies just in front of the a. epigastrica. It consists of fibers which bend directly downward from the m. transversus and of those which go off behind the same further up; both kinds of fibers extend downward, bend around chiefly lateralward and upward, partly also medianward and downward to the inner surface of the lig. inguinale and fuse with it. The falx inguinalis and the lig. interfoveolare vary greatly in strength and breadth. The thinner spot, situated between the two, which lies directly behind the subcutaneous abdominal ring, is broad, when they are narrow, and vice versa; it contains always single tendon fibers of the m. transversus, consists otherwise of irregularly and loosely arranged fibers, and is perforated by the a. spermatica externa and the n. spermaticus externus. On the posterior surface of the posterior wall there often run a few bundles of muscle fibers, *m. interfoveolaris*, either directly behind the lig. interfoveolare, or somewhat more medianward; they arise like a fan behind the m. transversus (sometimes also from it) and extend downward to the posterior surface of the lig. inguinale and the lig. lacunare.

The *annulus inguinalis abdominalis* (O. T. internal abdominal ring) lies somewhat medianward above the middle of the lig. inguinale, is bounded medianward and below by the lig. interfoveolare and flattens out gradually lateralward and upward.



329. Broad muscles of the back, viewed from behind.

[Text see pp. 285 and 286.]

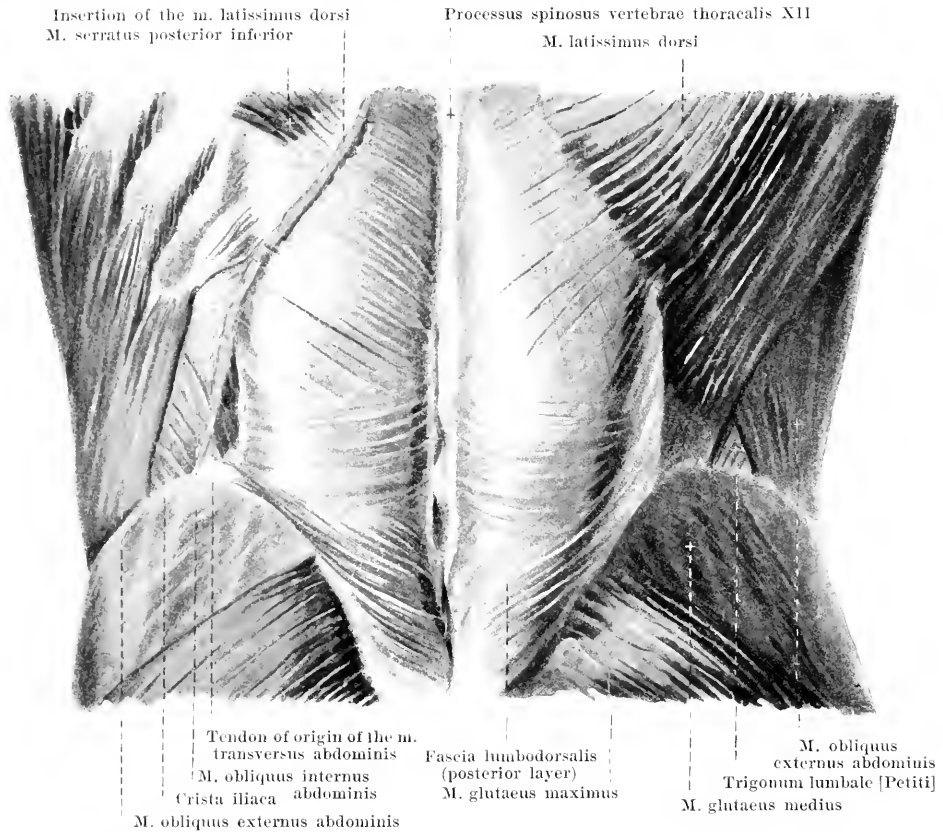


330. Broad muscles of the back

(2nd layer), viewed from behind.

(The mm. trapezii et sternocleidomastoidei have been removed.) [Text see also pp. 286—287.]

M. trapezius (see Fig. 329). **Form:** flat, triangular, broad. **Position:** in the neck and upper part of the back, just beneath the skin. **Origin** (see also Fig. 296): tendinous from the linea nuchae superior, protuberantia occipitalis externa, lig. nuchae and lig. supraspinale as far as the 12th thoracic vertebra; the tendon fibers are connected with those of the other side, are longer in the neighborhood of the vertebra prominens, and there form, on each side, a triangular area. **Insertion:** the upper fibers extend obliquely downward and forward to the acromial extremity of the clavicle; the middle fibers transversely to the acromion and to the spine of the scapula; the lower fibers converge downward and lateralward to become attached by a small, triangular, flat tendon to the inferior angle of the scapula. **Action:** it draws the shoulder-blade toward the spine and upward; when the shoulder-blade is displaced lateralward, the angulus lateralis upward; when the shoulder-blade is fixed, it draws the head backward and laterally along with the face, somewhat toward the other side. **Innervation:** r. ext. c. n. accessorii and a branch of the plexus cervicalis.

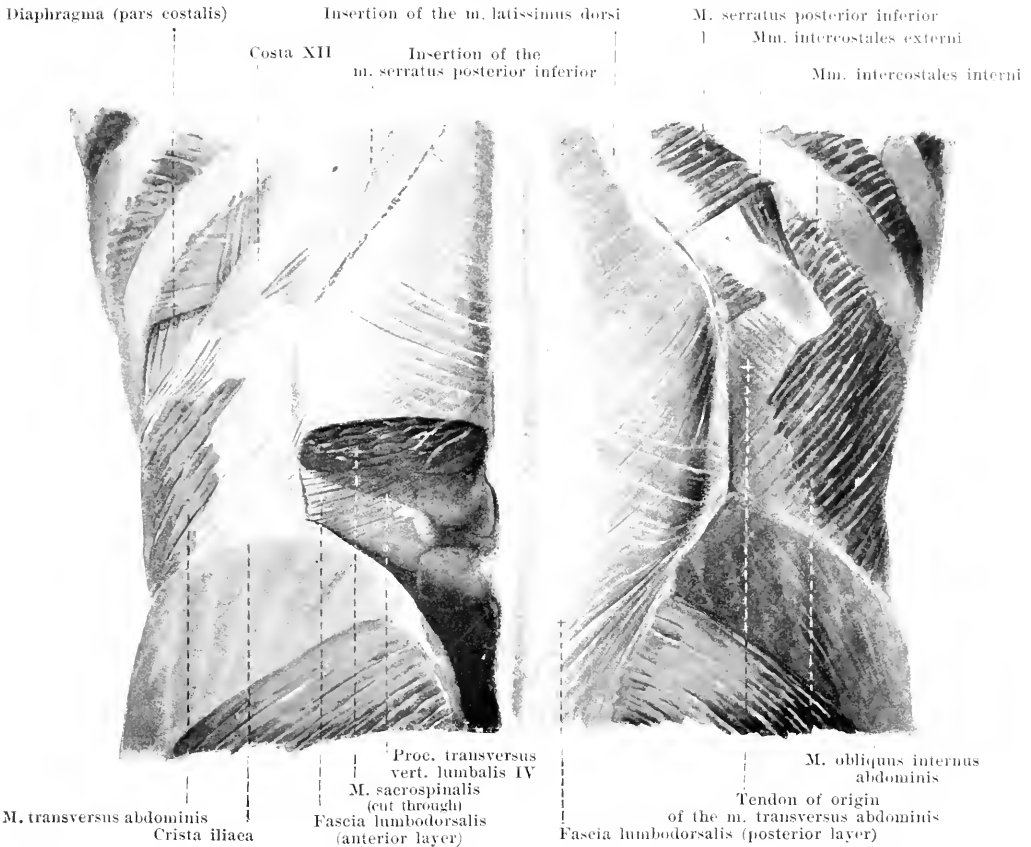


331. Muscles of the lumbar region (1st layer), viewed from behind. (On the left the *m. latissimus dorsi* has been removed.) [Text see also pp. 257 and 288.]

M. latissimus dorsi (see also Figs. 316, 329, 330 and 343). Form: flat, triangular, thin. Position: in the lower part of the back and lateral region of the thorax, being partly covered above by the *m. trapezius*. Origin: tendinous from the posterior layer of the fascia lumbodorsalis, from the proc. spinosus of the 6th thoracic vertebra on downward, from the crista iliaca and, by three or four fleshy digitations, from the external surface of the three or four lowermost ribs. Insertion: the fibers run, converging, lateralward, the upper fibers more transversely, the lower almost straight upward; they lie on the lateral wall of the thorax close to the *m. serratus anterior*, fuse with the lower margin of the *m. teres major*, wind around it to its anterior surface and become attached by a flat tendon to the crista tuberculi minoris humeri. Between these two muscles, in this situation, lies the *bursa m. latissimi dorsi* (see Fig. 345). Action: it draws the arm medianward and backward; it draws the shoulder-blade medianward and downward. Innervation: n. thoracodorsalis.

M. rhomboidens major (see Figs. 329 and 330). Form: flat, quadrangular. Position: upper part of the back, covered by the *m. trapezius*. Origin: tendinous from spinous processes and interspinal ligaments of the 1st—4th thoracic vertebra. Insertion: the fibres run parallel downward and lateralward to the margo vertebralis scapulae. Action: it draws the shoulder-blade medianward and upward and rotates it at the same time so that the *angulus inferior scapulae* is turned medianward. Innervation: n. dorsalis scapulae.

M. rhomboidens minor (see Fig. 330), often only indistinctly separable from the preceding muscle. Form: flat, oblong-quadrangular. Position: directly on the upper margin of the preceding muscle. Origin: tendinous from the lig. nuchae and the spinous processes of the two lower cervical vertebrae. Insertion: like that of the preceding muscle, just above the same. Action and innervation: same as for the preceding muscle.



332. Muscles of the lumbar region (2nd layer), viewed from behind.

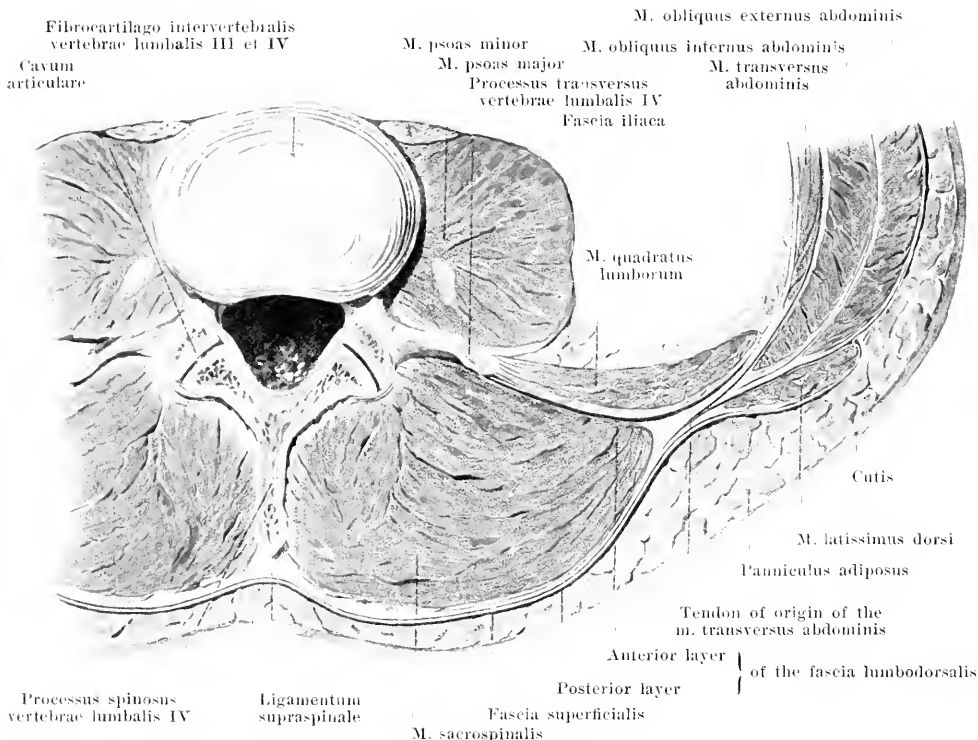
(The mm. latissimus dorsi and obliquus externus abdominis have been removed on both sides; on the left side the mm. obliquus internus abdominis and serratus posterior inferior have also been removed.)

[Text see also p. 255.]

M. levator scapulae (O. T. levator anguli scapulae) (see Figs. 299—301 and 330). Form: flatly rounded, oblong. Position: on the lateral surface of the neck, covered by the mm. sternocleidomastoideus and trapezius, in front coming in contact with the m. scalenus posterior, behind with the m. splenius capitis et cervicis. Origin: by four tendinous processus from the posterior tubercles of the transverse processes of the 1st—4th cervical vertebra (see Figs. 306 and 335). Insertion: the fibers run parallel downward, backward and lateralward to the margo vertebralis scapulae. Action: it draws the shoulder-blade medianward and upward and rotates it so that the angulus inferior is turned medianward; when the shoulder-blade is fixed, it bends the cervical portion of the spine to the same side and rotates it somewhat. Innervation: n. dorsalis scapulae.

Trigonum lumbale [Petiti] (O. T. Petit's triangle) (see Fig. 331), a triangular thinner spot of the posterior abdominal wall, varying in size; below it is bounded by the crista iliaca, lateralward by the posterior margin of the m. obliquus externus abdominis, medianward by the lateral margin of the m. latissimus dorsi. In this triangle the muscle fibers of the m. obliquus internus are visible; in front of them lies the tendon of origin of the m. transversus abdominis and of the m. quadratus lumborum.

Fascia nuchae (not represented in the figure) is a thin membrane of connective tissue which lies just beneath the mm. trapezius and rhomboidei; it goes off from the inferior surface of the squama occipitalis, covers the mm. splenii capitis et cervicis and semispinalis capitis, is connected medianward with the lig. nuchae, is continued in front into the fascia colli and goes over below at the m. serratus posterior superior into the fascia lumbodorsalis.



333. Transverse section through the muscles of the lumbar region, (after W. Braune).

The **fascia lumbodorsalis** consists of two layers.

The posterior layer (see also Figs. 329, 331, 332 and 334) lies just below the mm. trapezius, rhomboidei and latissimus dorsi on the posterior surface of the m. sacrospinalis, is thin at its beginning at the m. serratus posterior superior, where it is continuous with the fascia nuchae (see p. 257), forms a sheath below for the m. serratus posterior inferior and, becoming stronger, descends as far as the coccygeal region; on its way it is fused medianward with the spinous processes and supraspinal ligament of the thoracic and lumbar vertebrae and with the crista sacralis media; below, it fuses with the posterior ligaments of the sacrum and with the crista iliaca, lateralward with the anguli costarum and, below the ribs, between them and the crista iliaca, with the anterior layer. It consists above of transverse, below of oblique crossing fibers, which represent in part the immediate continuation of the mm. serratus posterior inferior and latissimus dorsi arising from the fascia.

The anterior layer (see also Figs. 312, 315, 332 and 340) is thinner, lies in front of the m. sacrospinalis, behind the mm. quadratus lumborum and psoas major and extends only from the 12th rib to the crista iliaca, being fastened to both. It arises by four processes from the transverse processes of the 1st—4th lumbar vertebra, is connected below with the lig. ilio-lumbale and contains, above, powerful curved fibrous bands which extend from the 1st and 2nd lumbar vertebra to the 12th rib, the *ligamentum lumbocostale* (see Figs. 312, 315 and 316). The fibers of the anterior layer run essentially transversely, unite lateral from the m. sacrospinalis with the fibers of the posterior layer and thus together form the tendon of origin of the m. transversus abdominis; the m. obliquus internus abdominis arises in part from the posterior surface of the combined layers.

334. Broad muscles of the back (3rd layer, viewed from behind.

(The shoulder-blades and the muscles going to them have been removed.)

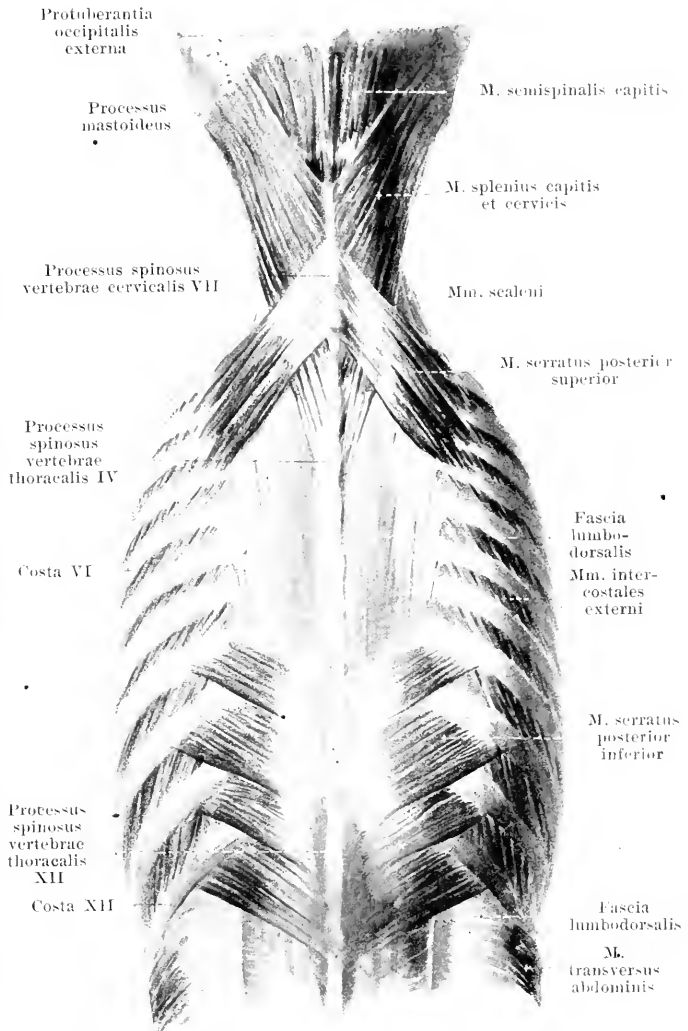
M. serratus posterior superior (O. T. serratus posticus superior). Form: flat, quadrangular, very thin. Position: upper part of the back, covered by the *mm. rhomboidei*. Origin: by a flat tendon from the *lig. nuchae* or the spinous processes of the 6th and 7th cervical and 1st and 2nd thoracic vertebrae. Insertion: the fibers run parallel, obliquely lateralward and downward and terminate by four fleshy digitations on the 2nd—5th rib. Action: it elevates these ribs. Innervation: rami anteriores [*nn. intercostales*] of the *nn. thoracales* I—IV.

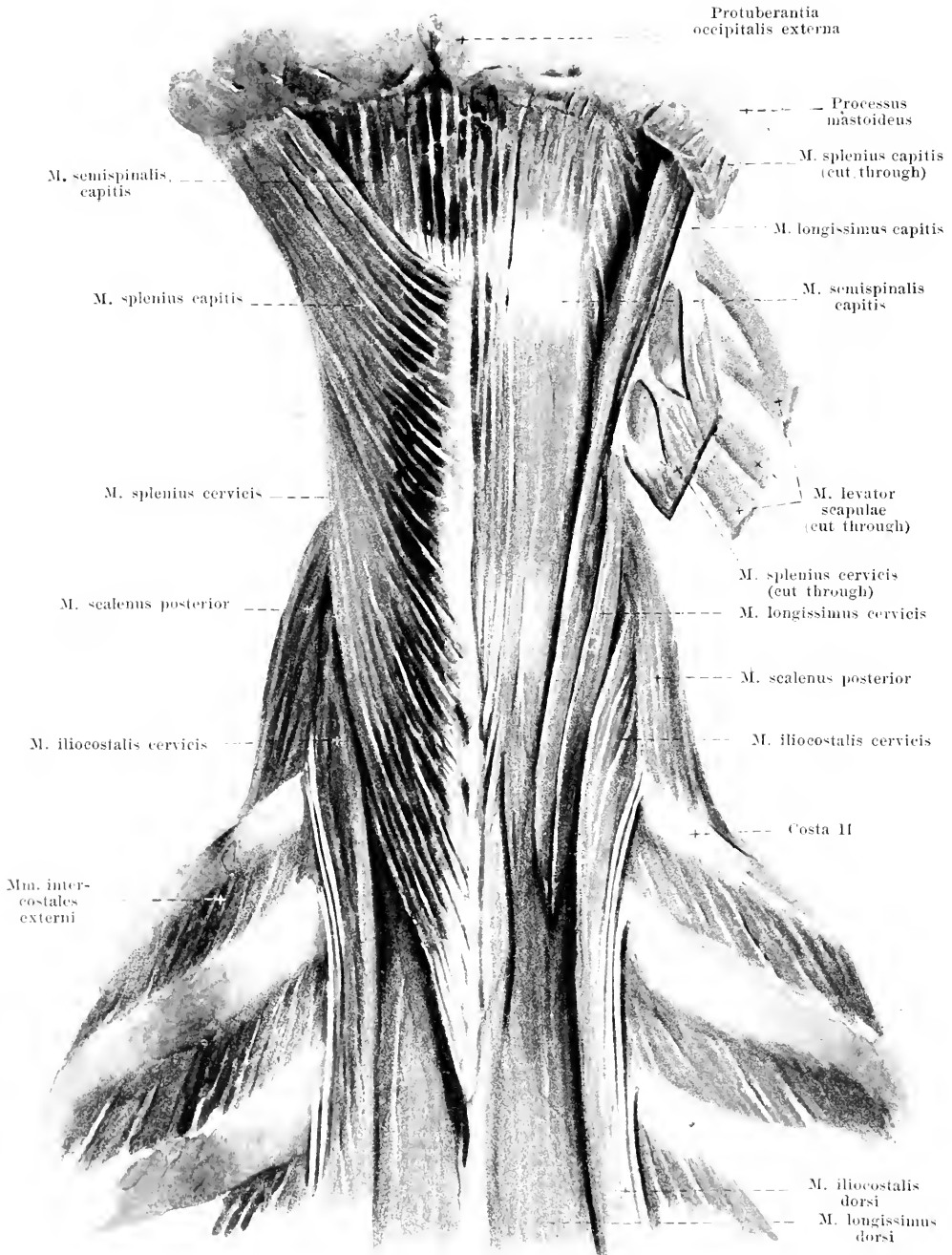
M. serratus posterior inferior (O. T. serratus posticus inferior) (see also Fig. 331). Form: flat, quadrangular, very thin. Position: lower part of the back, covered by the *m. latissimus dorsi* and partly also by the *m. trapezius*. Origin: posterior layer of the fascia lumbodorsalis in the region of the 10th—12th thoracic and the 1st and 2nd lumbar vertebrae. Insertion: the fibers run parallel obliquely lateralward and upward and terminate by four fleshy digitations on the 9th—12th rib. Action: it draws these ribs downward and outward; it contracts on inspiration. Innervation: rami anteriores [*nn. intercostales*] of the *nn. thoracales* IX—XII.

M. splenius capitis (see also Figs. 296, 301, 330 and 335). Form: flat, oblong-quadrangular, thick. Position: in the neck, partly covered by the *mm. trapezius* and *sternocleidomastoideus*, *serratus posterior superior* and *rhomboides*. Origin: *lig. nuchae*

at the level of the 3rd—7th cervical vertebra as well as from the spinous processes of the 1st and 2nd thoracic vertebrae. Insertion: the fibers converge somewhat and pass upward lateralward by a thick, short tendon to the *proc. mastoideus* and to the *linea nuchae superior oss. occipitalis*. Action: it rotates the head so that the face is turned upward and toward the same side; the muscles of the two sides together bend the head backward. Innervation: rami laterales of the rami posteriores of the *nn. cervicales* II—VIII.

M. splenius cervicis (O. T. splenius colli) (see Figs. 296, 330 and 335). Form: flat, oblong-quadrangular, narrow. Position: it forms in a way a continuation downward of the preceding muscle and is often indistinctly separable from it. Origin: *proc. spinosi* and *ligg. interspinalia* of the 3rd—6th thoracic vertebra. Insertion: by 2—3 processes to the *tubercula posteriora* of the *proc. transversi* of the 2—3 uppermost cervical vertebrae. Action: it bends the neck backward and lateralward and rotates the atlas like the preceding muscle rotates the head. Innervation: like that of the preceding muscle.





335. Muscles of the neck (left: 2nd layer, right: 3rd layer), viewed from behind.

(On both sides the mm. trapezius, sternocleidomastoideus and levator scapulae have been removed, on the right side the mm. splenii have also been removed.) [Text see p. 289 and 291—293.]

336. Long muscles of the back (1st layer), viewed from behind. (On the right side the m. iliocostalis has been pulled lateralward, on the left side it has been reflected.) [Text see also pp. 292 and 293.]

M. sacrospinalis (O. T. erector spinae) (see also Figs. 332, 333 and 337—340. Form: triangular-prismatic, long. Position: on each side along the median plane from the sacral region to the neck. Origin: fleshy in the depth, otherwise by long tendons from the crista iliaca, posterior surface of the sacrum, spinous processes of the lumbar vertebrae, inner surface of the fascia lumbodorsalis. The mass of fibers is divisible in the lumbar region into three separate muscles: m. iliocostalis, m. longissimus and m. spinalis.

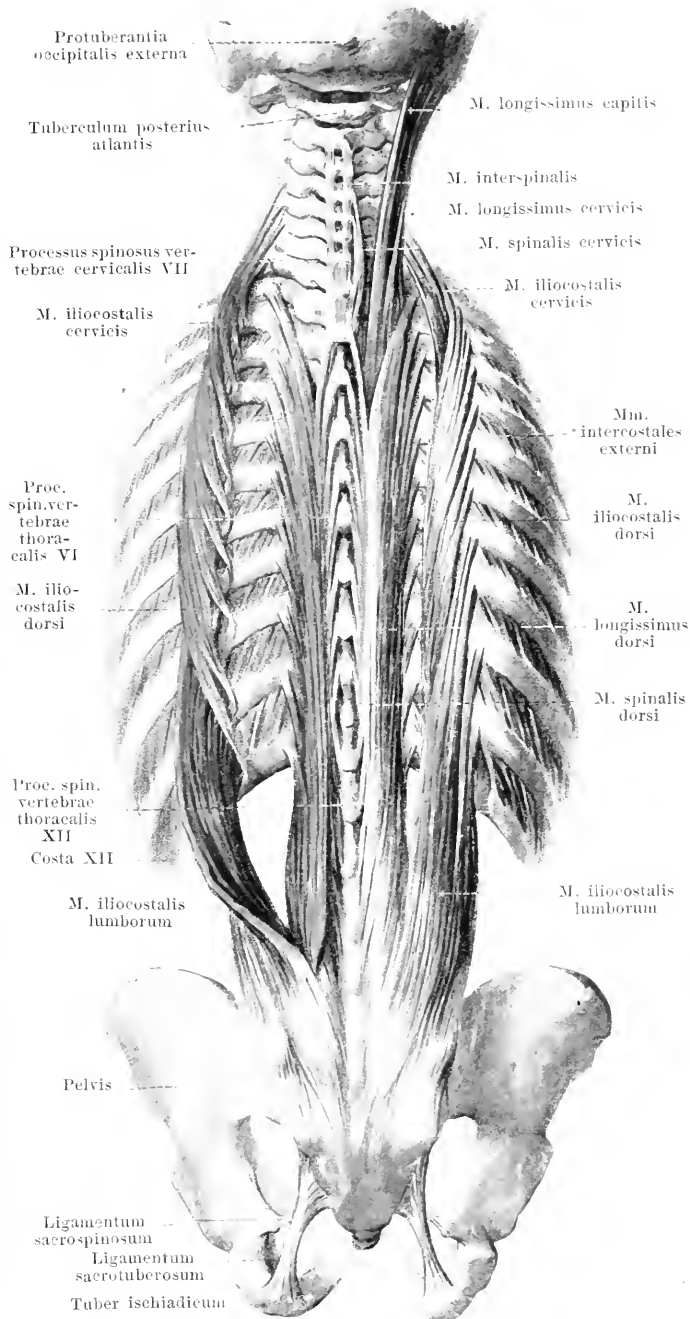
M. iliocostalis (O. T. external division of erector spinae), farthest lateralward, extends between the ribs or their homologues.

M. iliocostalis lumborum (O. T. sacrolumbalis). Insertion: by nine processes, the lower ones fleshy, the upper ones thin and tendinous, to the angles of the 12th—4th rib. Action: it can depress the ribs.

M. iliocostalis dorsi (O. T. accessory to the iliocostal). Origin: covered by the preceding, it arises by six fleshy digitations from the angles of the 12th—7th rib. Insertion: by eight thin tendons to the angles of the 7th to 1st rib and the transverse process of the 7th cervical vertebra.

M. iliocostalis cervicis (O. T. cervicalis ascendens) (see also Fig. 335). Position: it is bounded in front by the m. scalenus posterior, lateralward by the m. levator scapulae, medianward by the mm. splenius and longissimus cervicis. Origin: covered by the preceding muscle, it arises by 4—6 fleshy processes from the angles of the 6th—3rd (2nd or 1st) rib. Insertion: by three narrow tendons to the transverse processes of the 6th—4th cervical vertebra. Action: it bends the neck backward and toward the same side; it can elevate the ribs.

Action of the whole m. iliocostalis: it bends the spinal column backward and toward the same side. Innervation: rami laterales of the rami posteriores of the nn. cervicales III—VIII, thoracales I—XII and lumbalis I.



338. Short muscles of the back (1st layer), viewed from behind.

(The *m. semispinalis capitis* has been removed on the left side.)

M. spinalis (O. T. inner division of erector spinae) (see Fig. 336), very thin, forms the medial part of the *m. sacrospinalis* and extends between spinous processes.

M. spinalis dorsi. Origin: tendinous from the two uppermost lumbar and the two (or three) lowermost thoracic vertebrae, intimately fused with the *m. longissimus*. Insertion: tendinous to the thoracic vertebrae from the 9th (or 8th) to the 2nd inclusive; one vertebra (10th or 9th) is passed over without attachment.

M. spinalis cervicis (O. T. *spinalis colli*), very variable. Origin: two uppermost thoracic and two lowermost cervical vertebrae. Insertion: 4th to 2nd cervical vertebra.

Action: they extend the spinal column. Innervation: rami mediales of the rami posteriores of the nn. cervicales III—VIII and thoracales I—XII.

M. spinalis capitis see under *m. semispinalis capitis*.

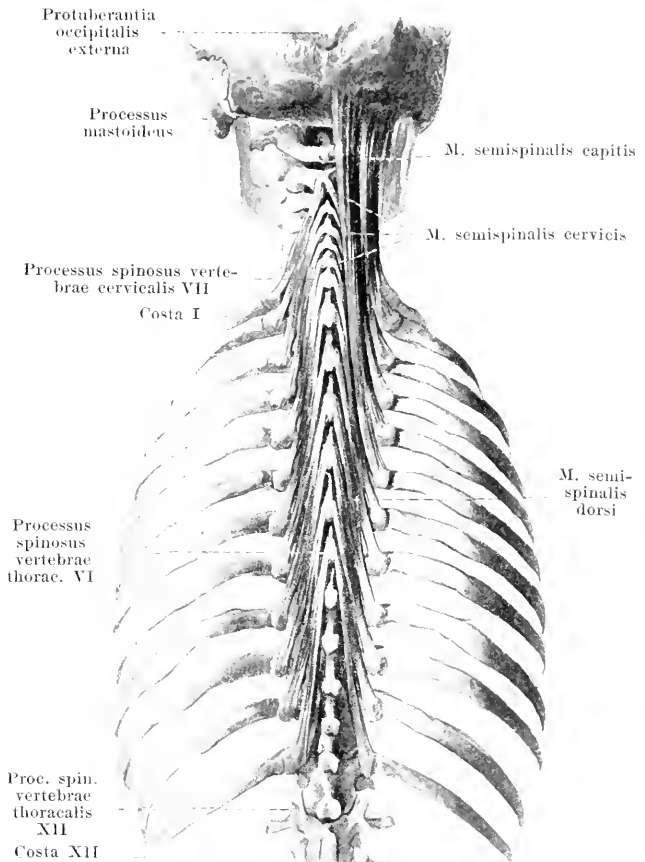
M. semispinalis (see also Fig. 337) is the superficial and most vertical layer of the fiber masses, which, running obliquely upward from the procc. transversi to the procc. spinosi, fills up the groove between the procc. spinosi and transversi as a triangular prismatic cord; the fibers pass over more than four vertebral bodies before becoming attached. The muscle is absent in the lumbar region.

M. semispinalis dorsi. Origin: procc. transversi of the six lower thoracic vertebrae. Insertion: procc. spinosi of the six upper thoracic and two lower cervical vertebrae.

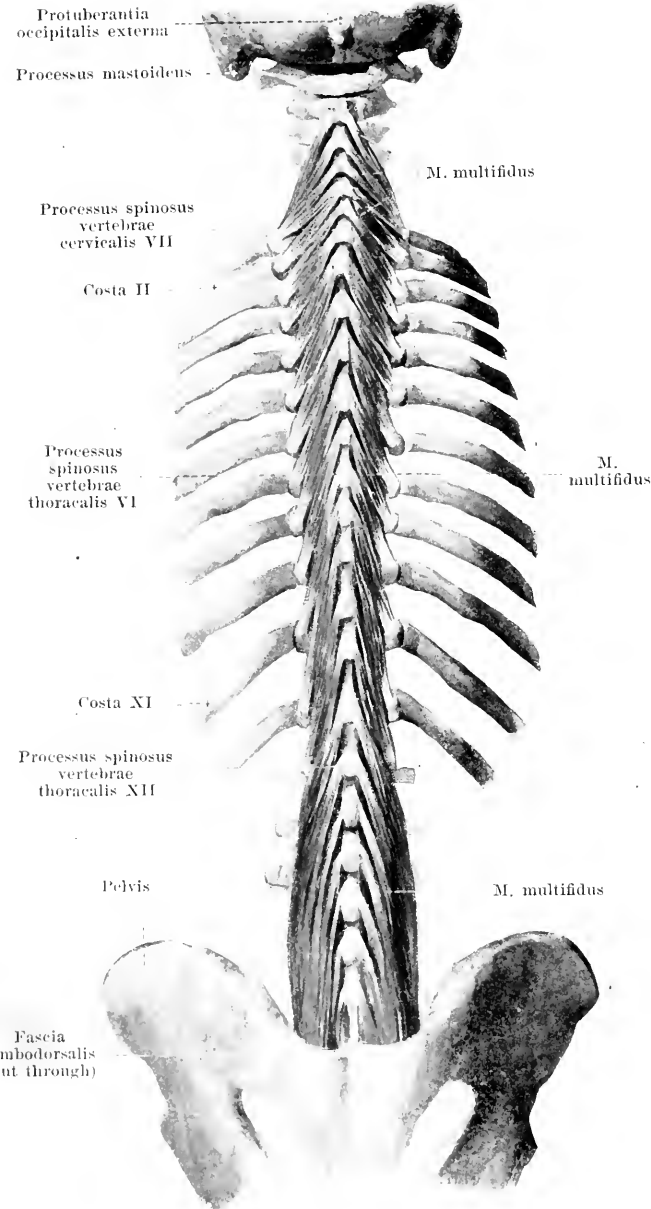
M. semispinalis cervicis (O. T. *semispinalis colli*). Origin: procc. transversi of the six upper thoracic vertebrae. Insertion: procc. spinosi of the 5th—2nd cervical vertebrae. Action: they bend the spinal column backward and rotate it toward the opposite side.

M. semispinalis capitis (O. T. *complexus*) (see also Figs. 296 and 335). Form: flat, oblong-quadrangular, thick. Position: bounded medianward by the lig. nuchae, lateralward by the *m. longissimus capitis*, covered in large part by the nn. splenii and trapezius. Origin: procc. transversi of the six upper thoracic vertebrae, procc. transversi et articulares of the 3—4 lower cervical vertebrae and procc. spinosi of the uppermost thoracic and lowermost cervical vertebrae. The fibers coming from the procc. spinosi are sometimes separated so as to form an independent muscle, the *m. spinalis capitis*. Insertion: the fibers run parallel upward and somewhat medianward to the under surface of the squama occipitalis; they are interrupted, especially medianward, by one or several jagged intermediate tendons. Action: it draws the head backward and raises the face toward the other side.

Innervation: rami mediales of the rami posteriores of the nn. cervicales II—VIII and thoracales I—XII.



339. Short muscles of the back

(2nd layer), viewed from behind.

M. multifidus (see also Fig. 337) is the second layer of the muscular mass extending from the procc. transversi to the procc. spinosi obliquely upward; it lies in the back and neck just below the m. semispinalis, in the lumbar region just below the m. longissimus dorsi; its fibers bridge over from two to four vertebral bodies. **Origins:** posterior surface of the sacrum, procc. mamillares and accessorii of the lumbar vertebrae, procc. transversi of the thoracic vertebrae and procc. articulares of the 7th—4th cervical vertebra. **Insertions:** procc. spinosi of the lumbar, thoracic and cervical vertebrae (with the exception of the atlas). **Action:** it bends the spinal column backward and rotates it toward the opposite side (it bends the lumbar spine backward only, without rotating it). **Innervation:** rami mediales of the rami posteriores of the nn. cervicales III—VIII, thoracales I—XII and lumbales I—V.

The **mm. rotatores** (see Fig. 340) form the third, deepest layer of the fiber masses going obliquely upward from the procc. transversi to the procc. spinosi; they are completely hidden by the m. multifidus. They consist of single, narrow, thin muscle bands.

Mm. rotatores longi bridge over one vertebra.

Mm. rotatores breves go to the next vertebra above.

Both go to the root of the procc. spinosi or to the arcus vertebrae, are present from the sacrum as far as the 2nd cervical vertebra and, below, run nearly vertically, above, more transversely. **Action and innervation:** same as for the m. multifidus.

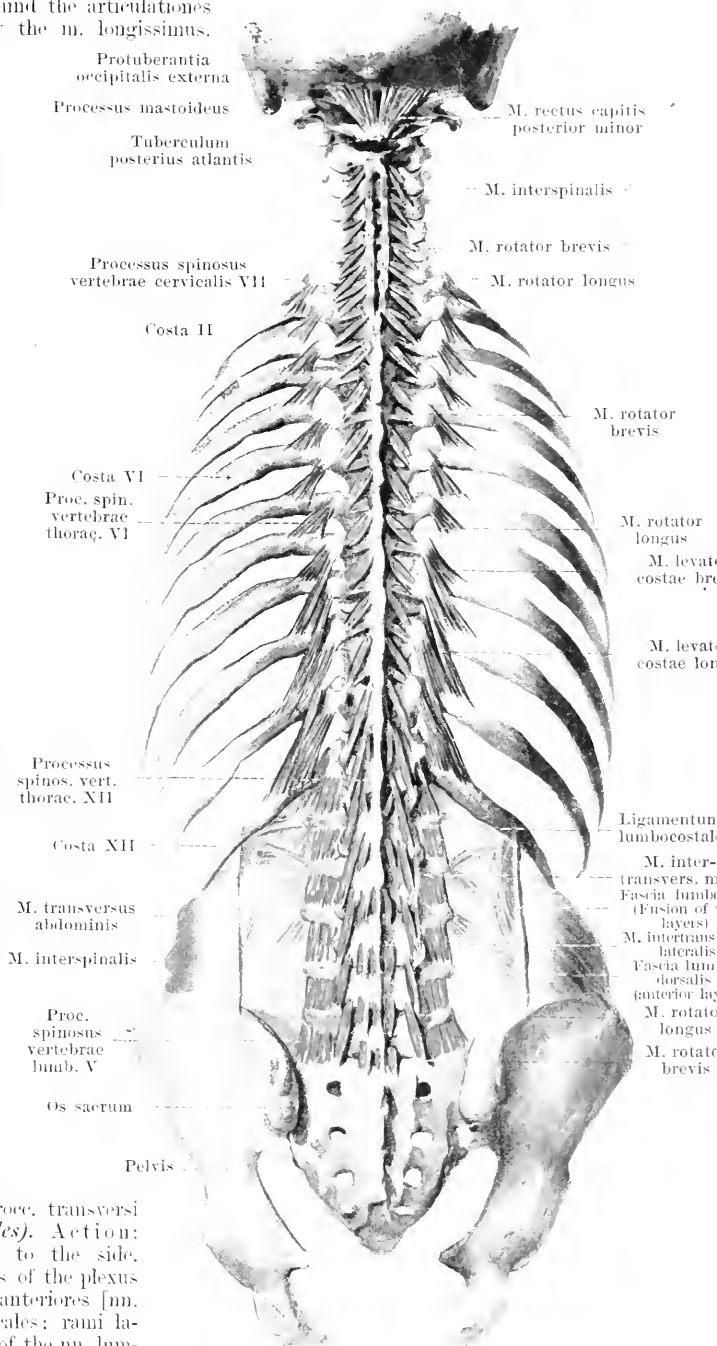
340. Short muscles of the back (3rd layer), viewed from behind.

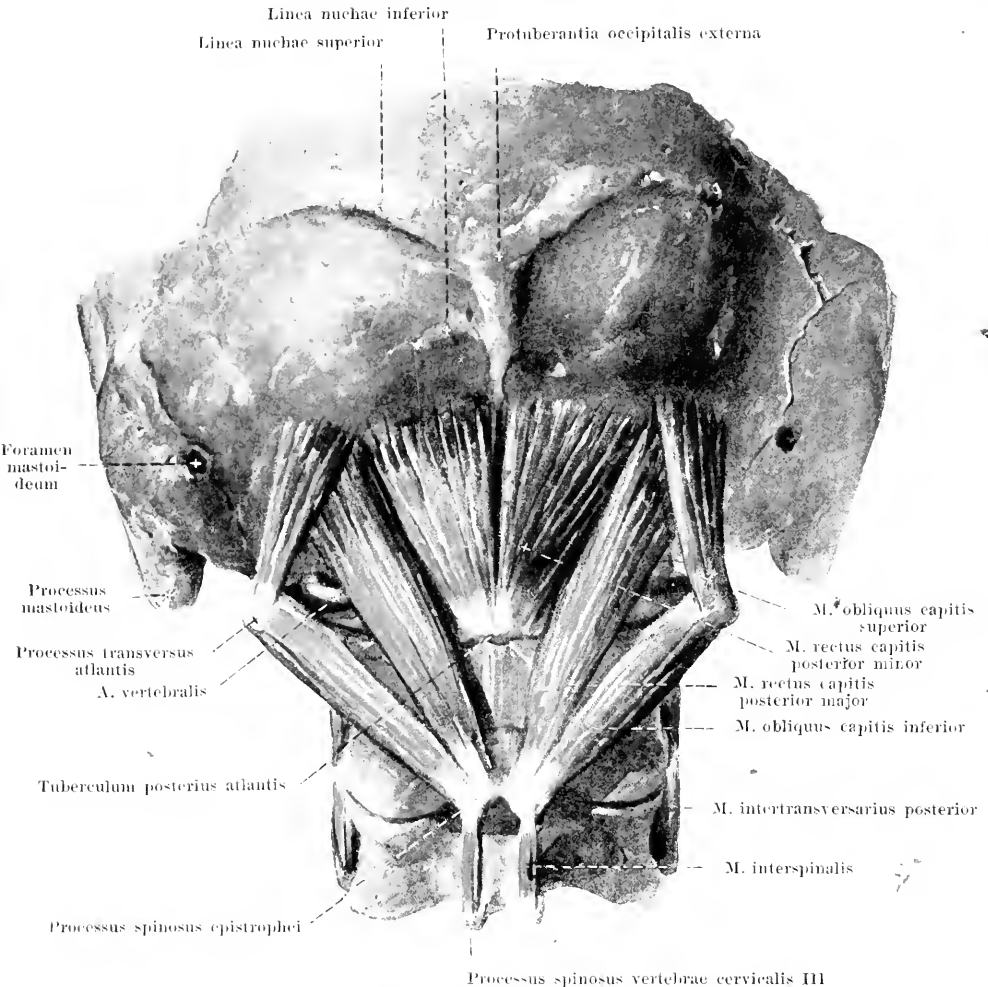
Mm. levatores costarum. Form: flat, triangular, thin. Position: behind the articulationes costotransversariae, covered by the m. longissimus.

Origin: procc. transversi of the 7th cervical and 1st—11th thoracic vertebra. Insertion: lateralward and downward to the next rib below (*mm. levatores costarum breves*); in the 3—4 lower intercostal spaces also to the next rib but one below (*mm. levatores costarum longi*). They are directly adjacent to the mm. intercostales externi. Action: they extend the spinal column, incline it toward the same, and rotate it toward the opposite side. Innervation: ramus posterior of the n. cervicalis VIII and rami anteriores [nn. intercostales] of the nn. thoracales I—XI.

Mm. interspinales, short bundles between every two neighboring spinous processes; from the epistropheus to the sacrum. They are often double on the cervical vertebrae, are usually absent from the thoracic vertebrae but very powerful on the lumbar vertebrae. Action: they bend the spinal column backward. Innervation: rami mediales of the rami posteriores of the nn. cervicales III—VIII, thoracales I—XII and lumbales I—V.

Mm. intertransversarii (O.T. intertransversales), short bundles between every two neighboring transverse processes. They are usually absent from the thoracic vertebrae. They are double on the cervical vertebrae, extending between adjacent tubercula anteriora (*mm. intertransversarii anteriores*) and also between adjacent tubercula posteriora (*mm. intertransversarii posteriores*). They are double also on the lumbar vertebrae extending between the procc. mammillares (*mm. intertransversarii mediales*) and between the procc. transversi (*mm. intertransversarii laterales*). Action: they bend the spinal column to the side. Innervation: direct branches of the plexus cervicalis and brachialis; rami anteriores [nn. intercostales] of the nn. thoracales; rami laterales of the rami posteriores of the nn. lumbales I—V.





341. Short muscles of the neck, viewed from behind and below.

M. rectus capitis posterior major (O. T. *rectus capitis posticus major*). Form: flat, oblong-triangular. Position: immediately upon the vertebrae. Origin: proc. spinosus epistrophei. Insertion: slightly diverging, upward and lateralward to the inferior surface of the squama occipitalis. Action: it draws the head backward, and rotates it toward the same side. Innervation: ramus posterior of the n. suboccipitalis.

M. rectus capitis posterior minor (O. T. *rectus capitis posticus minor*) (see also Fig. 340). Form: flat, triangular. Position: immediately upon the membrana atlantoccipitalis posterior, reaching as far as the median plane; lateralward it is partially covered by the preceding muscle. Origin: tuberculum posterius atlantis. Insertion: slightly diverging, upward to the inferior surface of the squama occipitalis. Action: it draws the head backward. Innervation: ramus posterior of the n. suboccipitalis.

M. obliquus capitis superior. Form: flat, oblong-triangular. Position: lateralward and backward from the articulatio atlantoccipitalis. Origin: proc. transversus atlantis. Insertion: slightly diverging, obliquely upward and medianward to the inferior surface of the squama occipitalis. Action: it draws the head backward. Innervation: ramus posterior of the n. suboccipitalis.

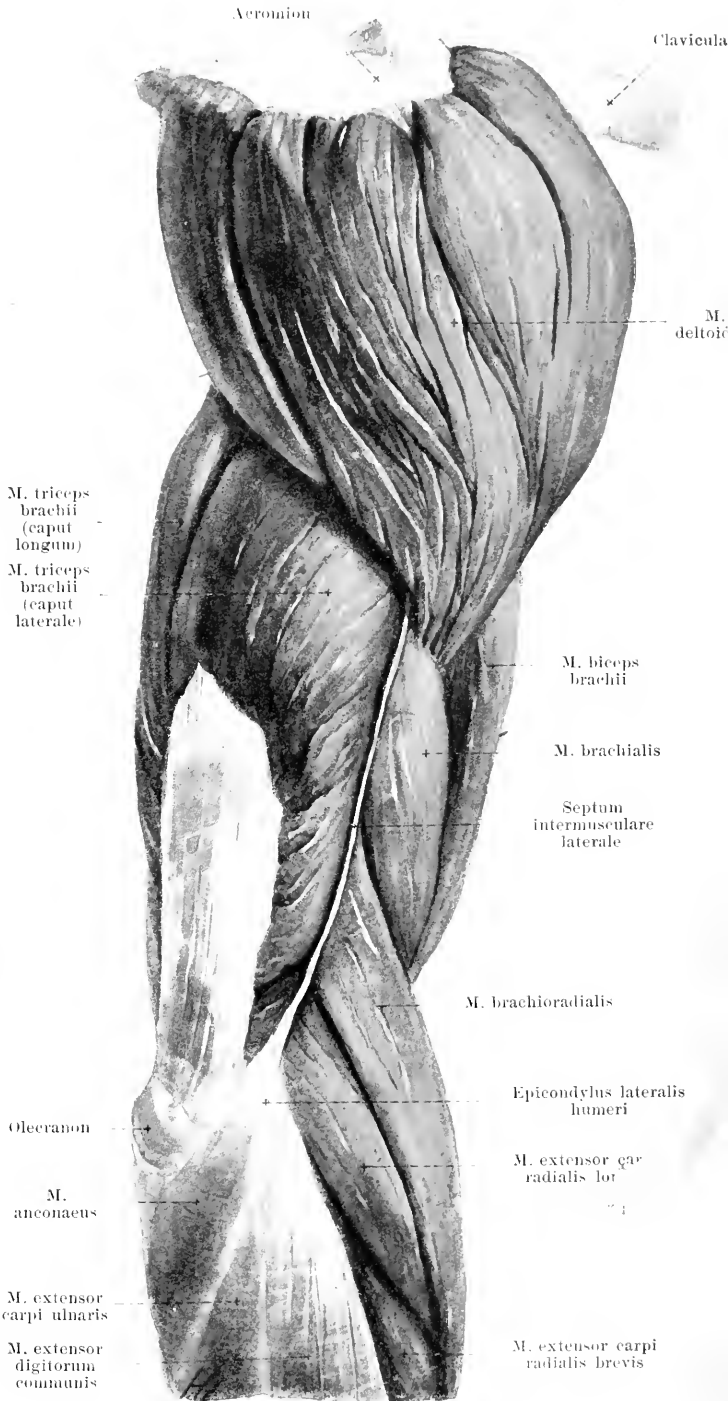
M. obliquus capitis inferior. Form: flat, oblong. Position: immediately upon the vertebrae. Origin: proc. spinosus epistrophei. Insertion: lateralward and upward to the proc. transversus atlantis. Action: it rotates the atlas and the head toward the same side. Innervation: ramus posterior of the n. suboccipitalis.

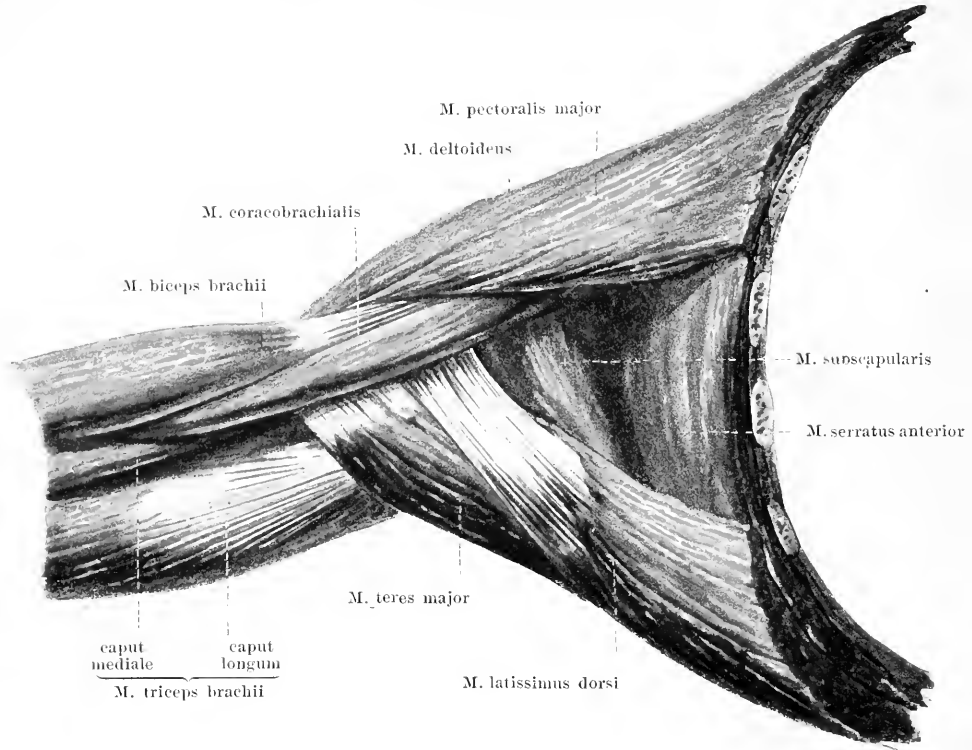
342. Muscles of the right upper arm,

viewed from the lateral side.

M. deltoideus (see also Figs. 308, 310, 329, 330, 343, 347 and 349). Form: flat, triangular, bent so as to be markedly troughlike, thicker in the middle than at the borders. Position: just beneath the skin; it forms the fleshy projection of the shoulder. Origin: fleshy from the extremitas acromialis claviculae and the acromion, tendinous from the spina scapulae, connected with the fascia infraspinata. Insertion: the anterior and posterior fibers run in almost a straight line downward and lateralward, the middle fibers curve downward over the tuberculum majus humeri (*bursa subdeltoidea* see Fig. 345); the middle part of the muscle presents a markedly pinnate appearance; all the fibers converge to the tuberositas deltoidea humeri, lateralward and below the insertion of the m. pectoralis major. Action: it lifts the upper arm lateralward in the shoulder joint. Innervation: n. axillaris.

Bursa subcutanea acromialis (see Fig. 349), often present, just beneath the skin, on the upper surface of the acromion.

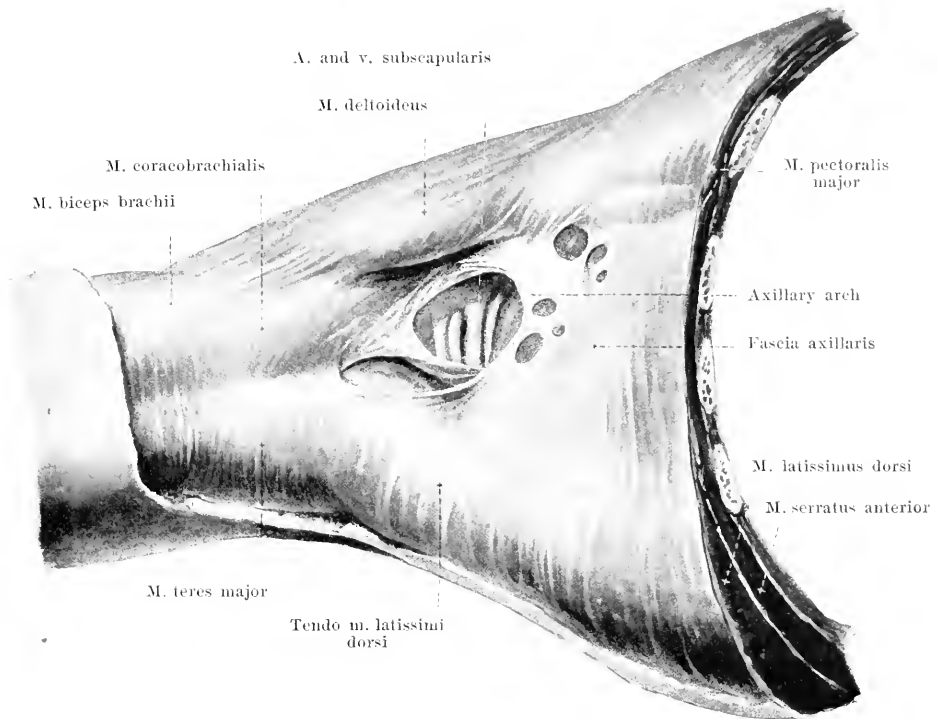




343. Muscles of the right axilla, viewed from below.

(The upper arm has been lifted to the horizontal plane.)

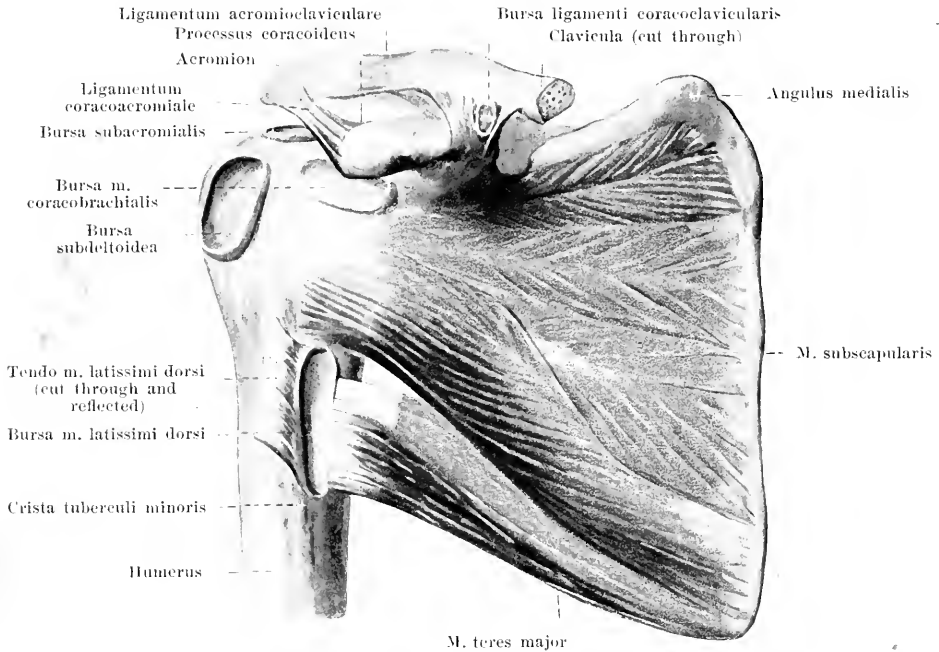
The **axilla**, when the upper arm is maintained in the horizontal plane, has the shape of a three-sided pyramid, the apex of which lies above, below the clavicle, and the base of which corresponds to the lower wall, covered only by skin and fascia. This inferior wall is bounded in front by the *m. pectoralis major*, behind by the *mm. latissimus dorsi* and *teres major*, medianward by the *m. serratus anterior*. The anterior wall is formed by the *mm. pectoralis major* and *pectoralis minor*, the posterior wall by the *mm. latissimus dorsi*, *teres major* and *m. subscapularis*, the medial wall by the *m. serratus anterior*. Along the angle between the anterior and posterior wall lies the *m. coracobrachialis*; in the groove behind the latter, between it and the muscles of the posterior wall, run the vessels and nerves. The axilla is filled with blood vessels, lymph vessels, lymph glands, nerves, and masses of fat.



• 344. Fasciae of the right axilla, viewed from below.

(The drawing corresponds to Fig. 343: the upper arm is in the horizontal plane.)

Axilla (continued). The anterior surface of the *m. pectoralis major* is covered over by the thin *fascia pectoralis*. This is more powerful lateralward and extends, from the lower margin of the muscle to the lower margin of the *mm. latissimus dorsi* and *teres major*, transversely across the axilla to form the *fascia axillaris*. The latter is multiply perforated and presents usually a more powerful, curved, fibrous band, the *axillary arch*, which varies much in form and curvature, not infrequently contains muscle fibers and extends from the region of the tendon of the *m. pectoralis major* to that of the *m. latissimus dorsi*: it is manifoldly connected with these tendons. The *fascia axillaris* goes over behind into the thin fascia of the *mm. latissimus dorsi* and *teres major*, in front into the thin covering of the *m. deltoideus* and lateralward into the somewhat stronger *fascia brachii*. This forms a sheath for the whole muscular mass of the upper arm and sends on each side a stronger strip to the *margo medialis* and the *margo lateralis humeri*, the *septum intermusculare mediale* (O. T. internal intermuscular septum) and the *septum intermusculare laterale* (O. T. external intermuscular septum), the former passing medianward and the latter lateralward between the *m. triceps brachii* on the one hand and all the other muscles of the upper arm on the other. The medial septum (see Figs. 348 and 353) lies immediately behind the insertion of the *m. coracobrachialis*, behind the *mm. brachialis* and *pronator teres* and in front of the *caput mediale m. tricipitis brachii*. The lateral septum (see Figs. 342 and 351) begins behind the insertion of the *m. deltoideus* and runs behind the *mm. brachialis*, *brachioradialis*, *extensor carpi radialis longus*, in front of the *caput laterale* and *caput mediale* of the *m. triceps brachii*. The muscles mentioned arise in part from these septa.



345. Muscles of the right shoulder-blade, viewed from in front.

M. subscapularis (see also Figs. 343 and 347). Form: flat, triangular. Position: behind the *m. serratus anterior*; it fills up the fossa subscapularis and passes immediately in front of the shoulder joint. Origin: facies costalis scapulae and fascia subscapularis (see below), very penniform. Insertion: the fibers converge upward and lateralward and are attached by a short powerful tendon to the tuberculum minus and crista tuberculi minoris of the humerus; on the posterior surface they are fused with the capsula articularis humeri; there the *bursa m. subscapularis* is found (see p. 180 and Fig. 346). Action: it draws the arm medianward and rolls it inward. Innervation: *nn. subscapulares*.

The fascia subscapularis (not shown in drawing) covers the anterior surface of the *m. subscapularis*, is connected lateralward with the continuation of the fascia brachii, which covers the *m. coracobrachialis* (see also Fig. 344).

M. teres major (see also Figs. 329, 330, 343 and 346—351). Form: flat-cylindrical. Position: at the margo axillaris of the shoulder-blade, in front covered by the tendon of the *m. latissimus dorsi*, behind and lateralward partly by the *m. latissimus dorsi*, partly by the *m. deltoideus* and *caput longum m. tricipitis brachii*. Origin: facies dorsalis of the angulus inferior scapulae. Insertion: the fibers run parallel upward and lateralward and are attached by a strong tendon to the crista tuberculi minoris. There, between the tendon and the bone, lies the *bursa m. teretis majoris* (not shown in drawing). Action: it draws the arm medianward and backward. Innervation: *nn. subscapulares*.

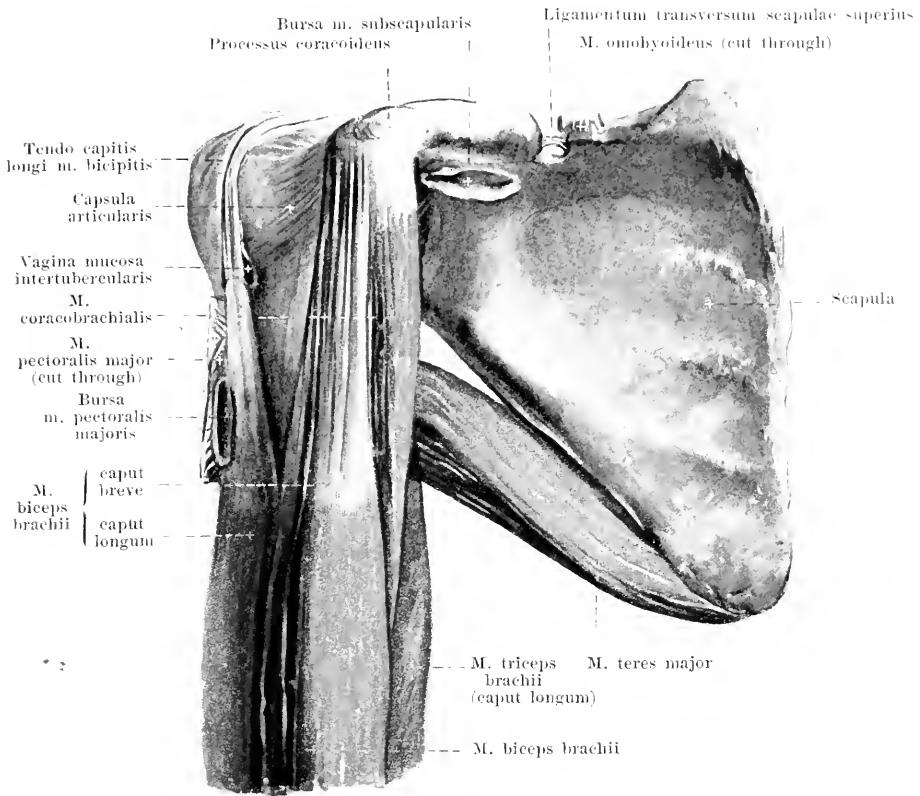
Bursa ligamenti coracoclavicularis, small, often present, between the lig. trapezoidum and the lig. conoideum of the lig. coracoacromiale.

Bursa subacromialis, large, almost constant, between the acromion and the lig. coracoacromiale on the one hand and the capsula articularis of the shoulder joint and the *m. supraspinatus* on the other. It often communicates with the following bursa.

Bursa subdeltoidea, large, almost constant, between the *m. deltoideus* and the tuberculum majus humeri, often communicating with the preceding bursa.

Bursa m. coracobrachialis, of moderate size, almost constant, situated in front of the upper part of the tendon of the *m. subscapularis*, between it, the *proc. coracoideus* and the tendon of the *m. coracobrachialis*.

Bursa m. latissimi dorsi, fairly large, oblong, constant, between the tendon of the *m. latissimus dorsi* and that of the *m. teres major*.



346. Muscles on the anterior surface of the right shoulder joint, viewed from in front.

(The clavícula, mm. deltoideus, pectoralis major and subscapularis have been removed.)

Bursa m. pectoralis majoris see p. 263.

M. biceps brachii (see also Figs. 308, 310, 342, 343, 347 and 348). Form: rounded, spindle-shaped, thick. Position: on the anterior surface of the upper arm; above, at its origin, it is covered by the mm. pectoralis major and deltoideus. Origin: by two heads. *Caput longum*: from the tuberositas supraglenoidalis scapulae and from the labrum glenoidale by a long, thin tendon, which extends first lateralward within the cavity of the shoulder joint, then curves markedly downward in the sulcus intertubercularis (see also Fig. 231) and is accompanied in its course by a prolongation of the joint-capsule, the *vagina mucosa intertubercularis* (see also p. 180). *Caput breve*: by a narrow, flat, shorter tendon from the proc. coracoideus, at first fused with the m. coracobrachialis. Insertion: both heads extend downward and unite to form a spindle-shaped muscle-belly, the fibers of which, a little above the elbow joint, go over for the most part into a flatly rounded, thick tendon, partly, also, into a superficial thin tendinous plate. The latter, *lucertus fibrosus* (O. T. semilunar fascia), runs obliquely medianward and downward in front of the m. pronator teres and becomes lost in the fascia antibrachii; the tendon proper, bending into the depth, becomes attached to the tuberositas radii (*bursa bicipitoradialis* and *bursa cubitalis interossea* see Fig. 348). Action: it lifts the upper arm forward, flexes the fore-arm and supinates it, especially, when it is flexed. Innervation: n. musculocutaneus.

Processus coracoideus

Clavicula (cut through)

Angulus
medialis scapulae

M. deltoideus

Margo
vertebralis
scapulaeM. sub-
scapularisM. coraco-
brachialisCaput breve
m. bicipitis
brachii

M. teres major

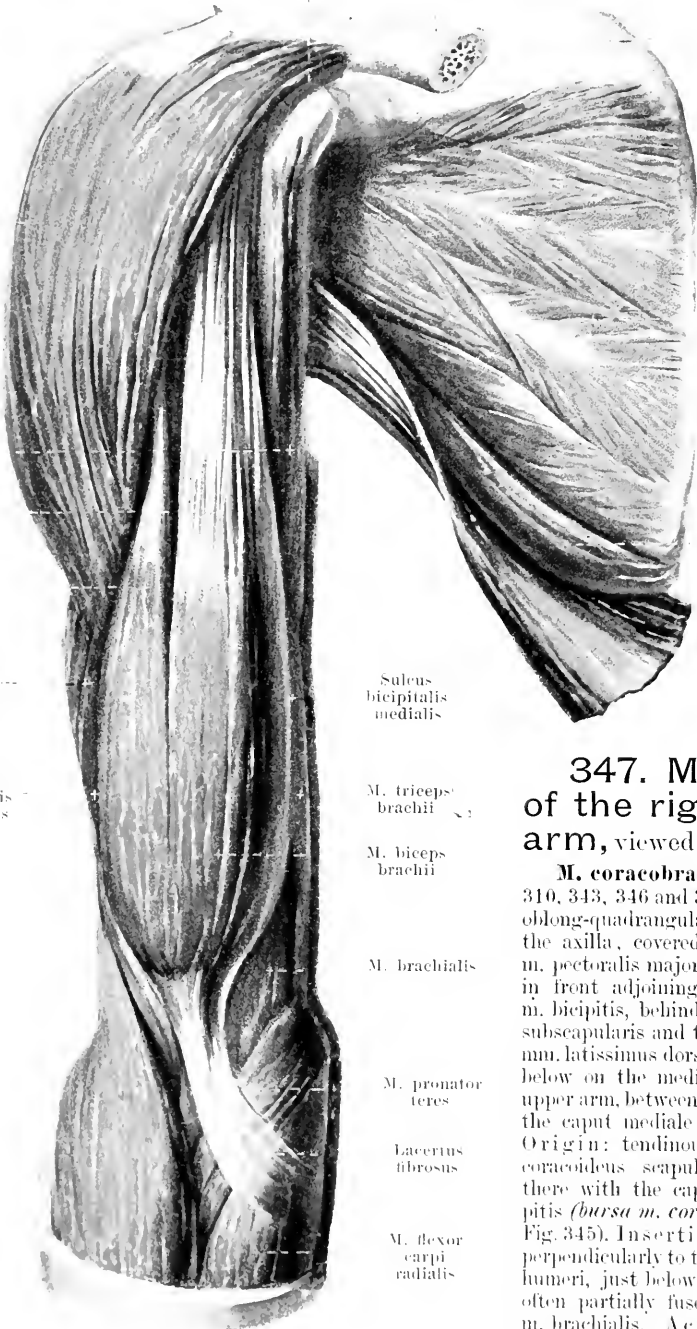
Caput longum
m. bicipitis
brachiiM. latissimus
dorsiM. triceps
brachiiSuleus
bicipitalis
medialisSuleus
bicipitalis
lateralisM. triceps
brachii

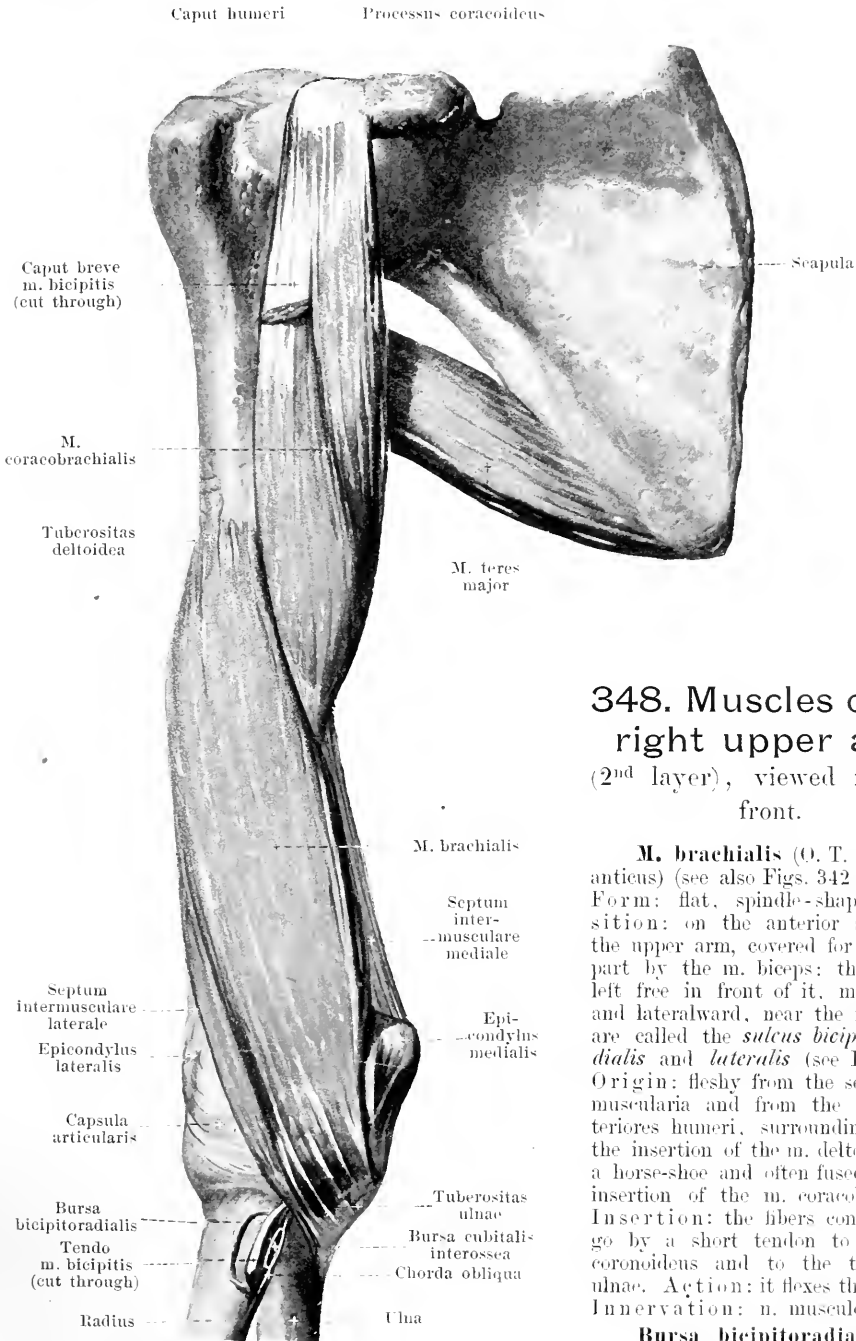
347. Muscles of the right upper arm, viewed from in front.

M. biceps
brachii

M. coracobrachialis (see Figs. 310, 343, 346 and 348). Form: flat, oblong-quadrangular. Position: in the axilla, covered in front by the m. pectoralis major, lateralward and in front adjoining the caput breve m. bicipitis, behind adjoining the m. subscapularis and the tendons of the mm. latissimus dorsi and teres major; below on the medial surface of the upper arm, between the m. biceps and the caput mediale of the m. triceps. Origin: tendinous from the proc. coracoideus scapulae, being fused there with the caput breve m. bicipitis (*bursa m. coracobrachialis* see Fig. 345). Insertion: the fibers run perpendicularly to the margo medialis humeri, just below its middle, being often partially fused there with the m. brachialis. Action: it lifts the upper arm forward. Innervation: n. musculocutaneus.

M. brachialis

M. pronator
teresEccertus
fibrosusM. flexor
carpi
radialisM.
brachioradialis

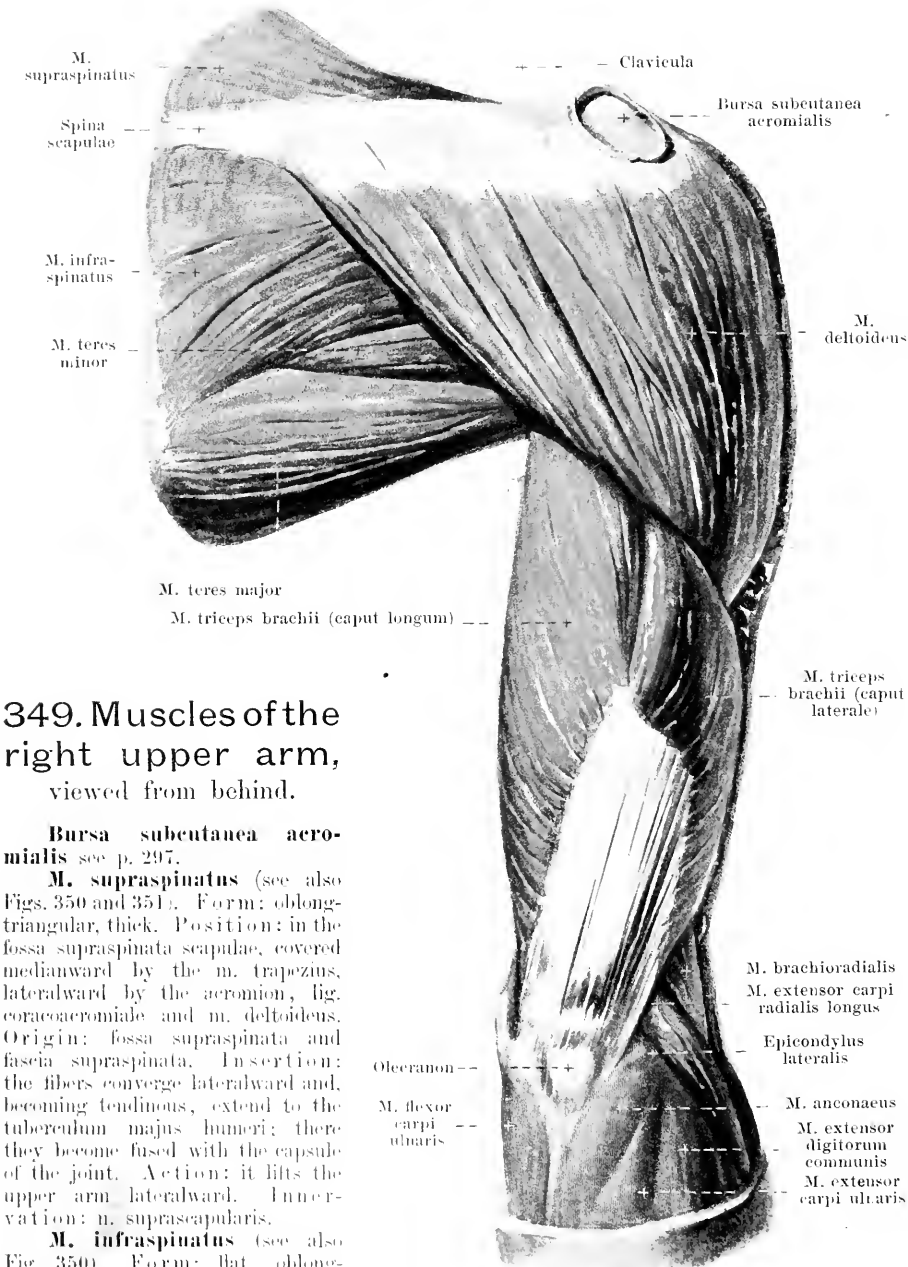


348. Muscles of the right upper arm (2nd layer), viewed from in front.

M. brachialis (O. T. brachialis anticus) (see also Figs. 342 and 347). Form: flat, spindle-shaped. Position: on the anterior surface of the upper arm, covered for the most part by the m. biceps: the grooves left free in front of it, medianward and lateralward, near the m. biceps, are called the *sulcus bicipitalis medialis* and *lateralis* (see Fig. 347). Origin: fleshy from the septa intermuscularia and from the facies anteriores humeri, surrounding, above, the insertion of the m. deltoideus like a horse-shoe and often fused with the insertion of the m. coracobrachialis. Insertion: the fibers converge and go by a short tendon to the proc. coronoideus and to the tuberositas ulnae. Action: it flexes the forearm. Innervation: n. musculocutaneus.

Bursa bicipitoradialis, constant: between the tuberositas radii and the tendon of the m. biceps.

Bursa cubitalis interossea, often present in later life; adjoining, lateralward, the tendon of the m. biceps, medianward, the ulna and chorda obliqua, behind, the m. supinator.

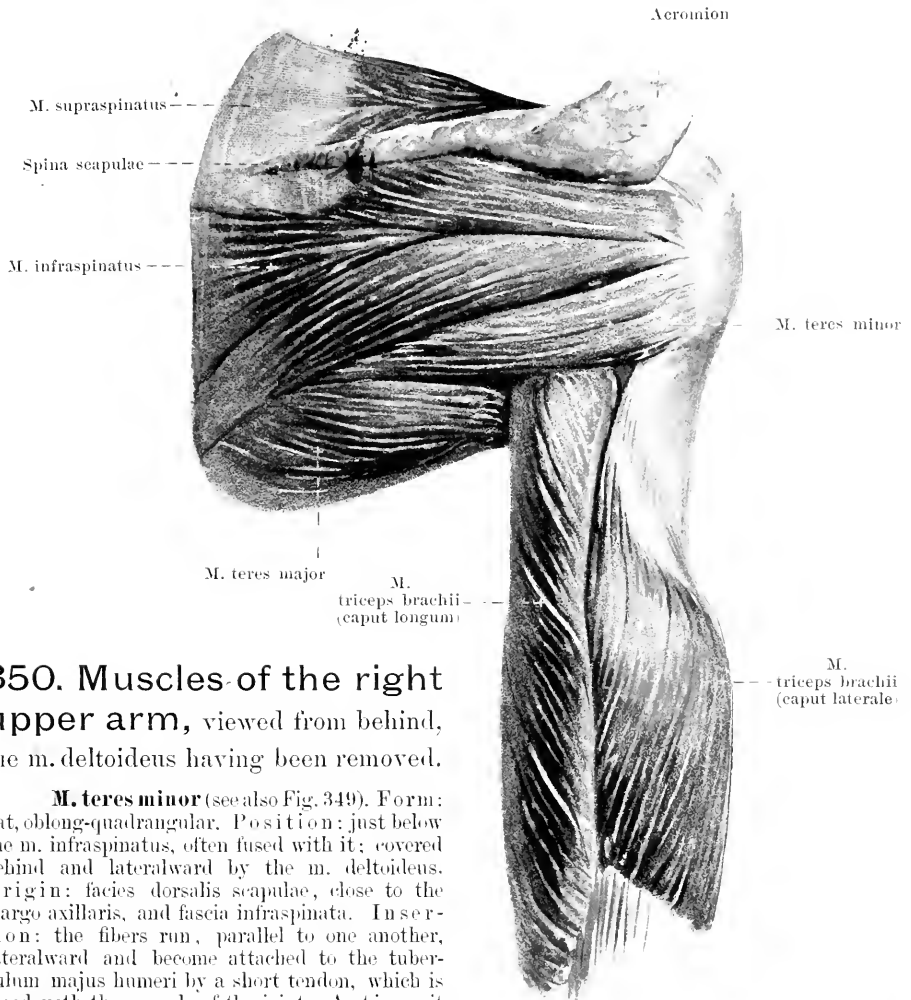


349. Muscles of the right upper arm, viewed from behind.

Bursa subcutanea acromialis see p. 297.

M. supraspinatus (see also Figs. 350 and 351). Form: oblong-triangular, thick. Position: in the fossa supraspinata scapulae, covered medianward by the m. trapezius, lateralward by the acromion, lig. coracoacromiale and m. deltoideus. Origin: fossa supraspinata and fascia supraspinata. Insertion: the fibers converge lateralward and, becoming tendinous, extend to the tuberculum majus humeri; there they become fused with the capsule of the joint. Action: it lifts the upper arm lateralward. Innervation: n. suprascapularis.

M. infraspinatus (see also Fig. 350). Form: flat, oblong-triangular, thick. Position: in the fossa infraspinata scapulae, partially covered medianward by the m. trapezius, lateralward by the m. deltoideus. Origin: fossa infraspinata and fascia infraspinata. Insertion: the fibers converge as they pass lateralward to become inserted by a strong tendon at the tuberculum majus humeri (*bursa m. infraspinati* see Fig. 351); they are there fused with the capsule of the joint. Action: it rolls the upper arm outward. Innervation: n. suprascapularis.



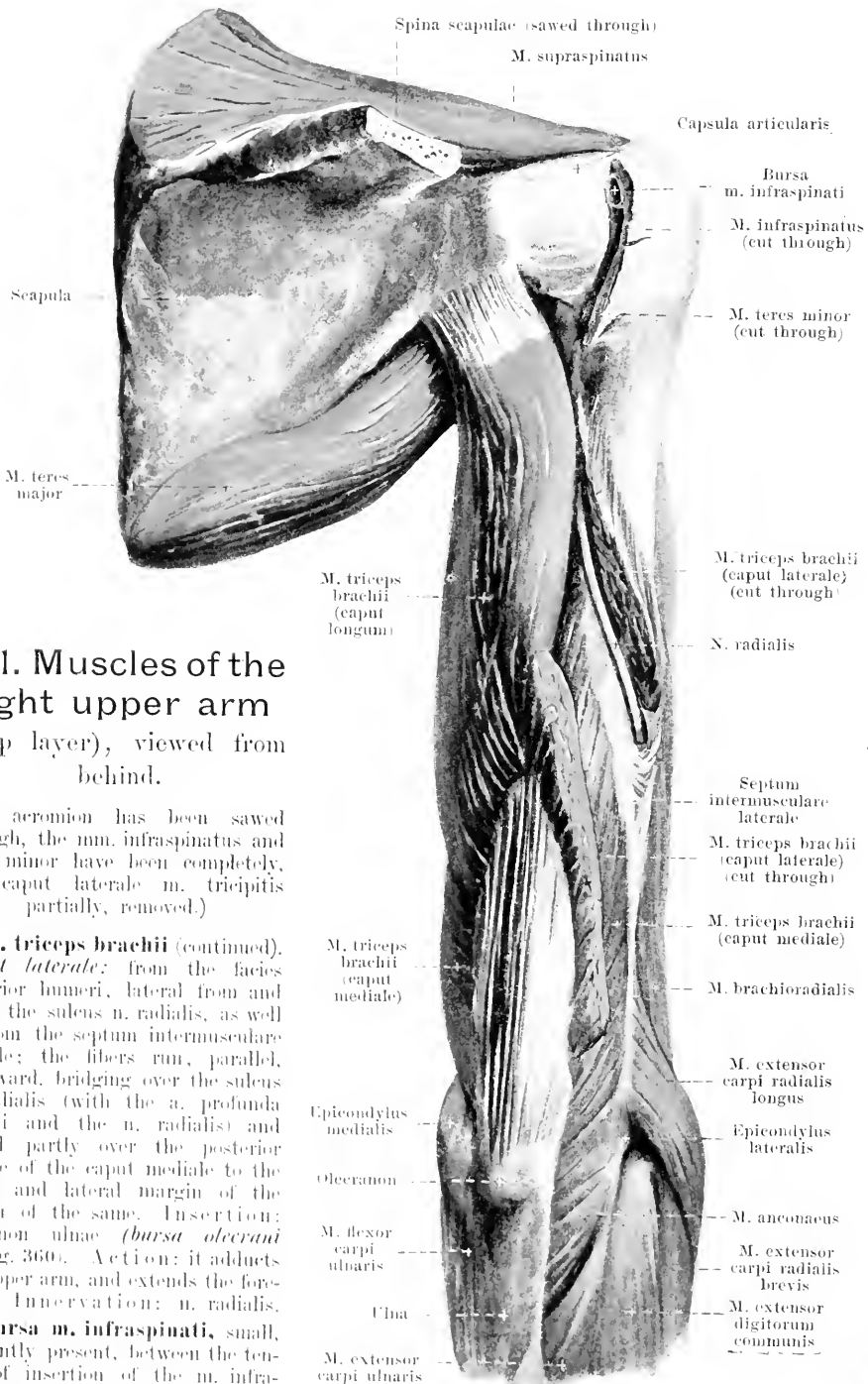
350. Muscles of the right upper arm, viewed from behind, the m. deltoideus having been removed.

M. teres minor (see also Fig. 349). *Form*: flat, oblong-quadrangular. *Position*: just below the m. infraspinatus, often fused with it; covered behind and lateralward by the m. deltoideus. *Origin*: facies dorsalis scapulae, close to the margo axillaris, and fascia infraspinata. *Insertion*: the fibers run, parallel to one another, lateralward and become attached to the tuberculum majus humeri by a short tendon, which is fused with the capsule of the joint. *Action*: it rolls the upper arm outward. *Innervation*: n. axillaris.

Fascia supraspinata (not shown in drawing) is a fascia, distinctly striated medianward, which covers the m. supraspinatus; it is fused medianward with the margo superior, the margo vertebralis and the spina scapulae and, lateralward, becomes lost.

The **fascia infraspinata** (see Figs. 329 and 330) is attached to the margo vertebralis and to the spina scapulae, is stronger medianward, covers the mm. infraspinatus and teres minor and becomes lost lateralward below the m. deltoideus.

M. triceps brachii (see also Figs. 342, 343, 349 and 351). *Form*: flatly rounded, oblong-quadrangular. *Position*: it occupies the whole posterior surface of the upper arm. *Origin*: by three heads. *Caput longum*: by a flat tendon from the tuberositas infraglenoidalis scapulae; it runs downward between the mm. teres minor and teres major, the fibers being parallel, is partly covered above by the m. deltoideus and overlaps the caput mediale, in part, from behind and medianward; below it is attached to the medial border of the tendon of the caput mediale. *Caput mediale*: from the facies posterior humeri, medial to and below the sulcus n. radialis, as well as from the septa intermuscularia mediale et laterale; the fibers reach, below close to the m. anconeus and run, converging somewhat, to a large quadrangular flat tendon, which begins in the middle of the upper arm (continued on p. 306).



351. Muscles of the right upper arm (deep layer), viewed from behind.

(The acromion has been sawed through, the m. infraspinatus and teres minor have been completely, the caput laterale m. tricipitis partially, removed.)

M. triceps brachii (continued). *Caput laterale*: from the facies posterior humeri, lateral from and above the sulcus n. radialis, as well as from the septum intermusculare laterale; the fibers run, parallel, downward, bridging over the sulcus n. radialis (with the a. profunda brachii and the n. radialis) and extend partly over the posterior surface of the caput mediale to the upper and lateral margin of the tendon of the same. Insertion: olecranon ulnae (*bursa olecrani* see Fig. 360). Action: it adducts the upper arm, and extends the forearm. Innervation: n. radialis.

Bursa m. infraspinati, small, frequently present, between the tendon of insertion of the m. infraspinatus and the capsule of the joint.

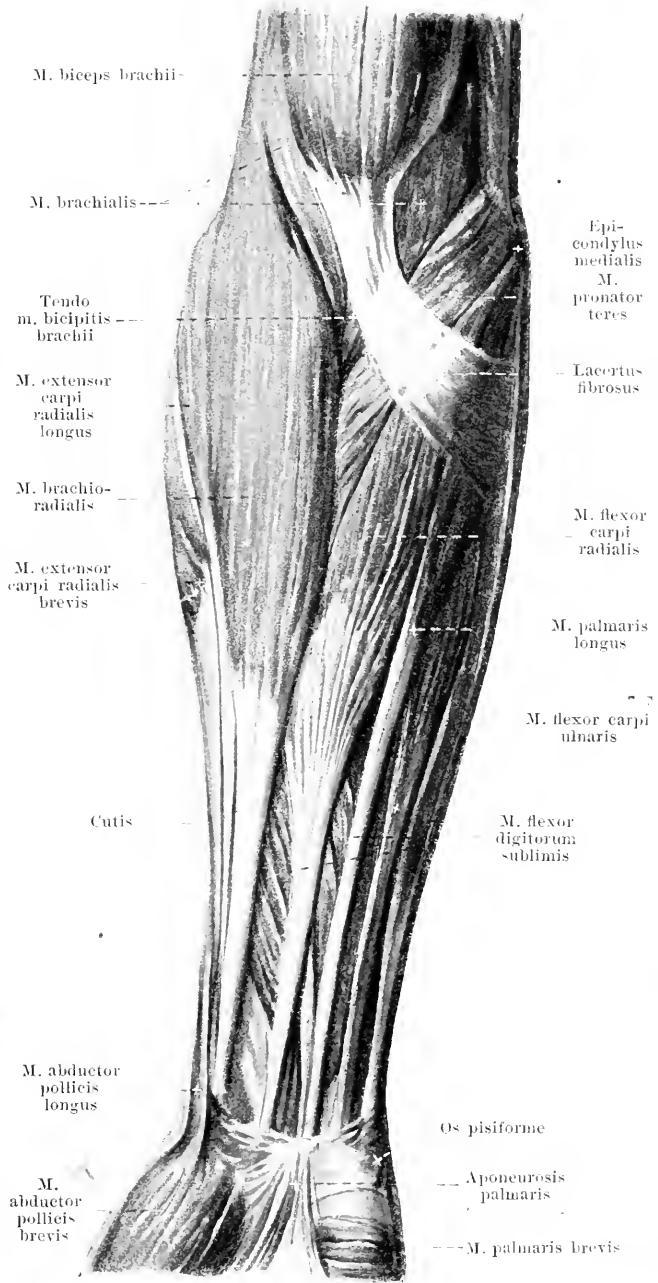
352. Muscles of the right forearm,

viewed from in front.

M. brachioradialis (O. T. *supinator longus*) (see also Figs. 353, 357 and 358). Form: flat, in the shape of a long spindle. Position: superficial on the lateral surface of the upper arm and the volar surface of the forearm. Origin: margo lateralis humeri and septum intermusculare laterale. Insertion: above, it runs between the m. triceps and the m. brachialis; below, it is bounded behind by the m. extensor carpi radialis longus, ulnarward by the mm. pronator teres and flexor carpi radialis and becomes attached by a long, thin, flat tendon above the proc. styloideus radii. Action: it flexes the forearm and brings the hand into a position midway between pronation and supination. Innervation: n. radialis.

M. palmaris longus (see also Fig. 362) (is frequently absent). Form: spindle-shaped, narrow. Position: superficial on the volar surface of the forearm. Origin: epicondylus medialis humeri and fascia anti-brachii, fused with its neighbors. Insertion: it extends above between the mm. flexor carpi radialis and flexor digitorum sublimis, then downward and radialward upon the latter and goes over by a long, thin tendon, in front of the lig. carpi transversum, into the aponeurosis palmaris. Action: it makes the aponeurosis palmaris tense and flexes the hand. Innervation: n. medianus.

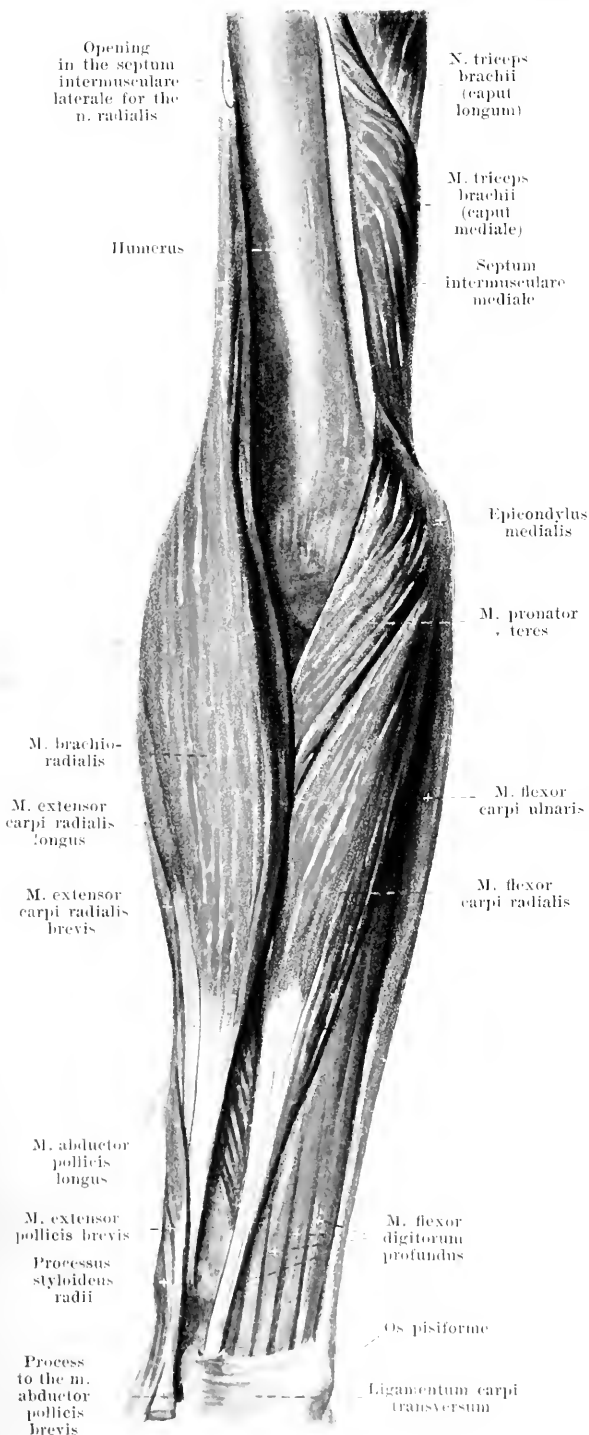
M. pronator teres (O. T. *pronator radii teres*) (see also Figs. 353 and 355). Form: oblong-quadrangular. Position: flexure of the elbow and volar surface of the forearm. Origin: partly from the septum intermusculare mediale and the epicondylus medialis humeri (*caput humerale*), partly from the proc. coronoideus ulnae (*caput ulnare*); the two heads are usually separated by the n. medianus. Insertion: the fibers run, parallel, obliquely radialward and downward to become attached by a short tendon to the facies volaris and lateralis radii. Action: it pronates the forearm and flexes it. Innervation: n. medianus.



353. Muscles of the right forearm,

viewed from in front.

(The *mm. biceps, brachialis, palmaris longus* and *flexor digitorum sublimis* have been removed.)



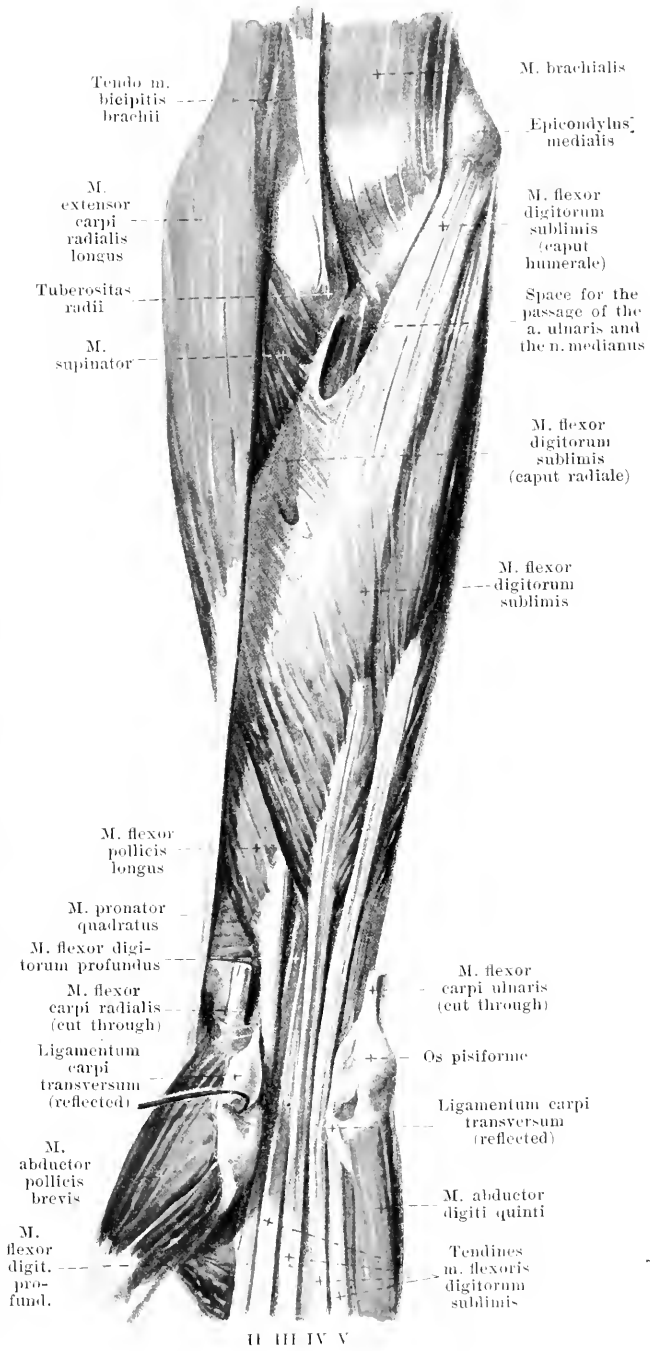
M. flexor carpi radialis (see also Fig. 352). Form: flat, oblong-spindle-shaped. Position: superficial on the volar surface of the forearm. Origin: epicondylus medialis humeri and fascia antibrachii, fused with its neighbors. Insertion: the fibers go, at first diverging, between *mm. pronator teres* and *palmaris longus*, radialward and downward, then converge and run by a long, powerful tendon between the *mm. brachioradialis* and *palmaris longus* to the hand, where the tendon, covered by the *lig. carpi transversum*, lies in the groove of the *os multangulum majus*; finally, covered by the tendon of the *m. flexor pollicis longus*, it goes to the basis *oss. metacarpalis II* and *III* (see Fig. 355). In the hand, the **bursa m. flexoris carpi radialis** (see Fig. 366) lies between the bone and the tendon. Action: it flexes the hand and pronates the forearm. Innervation: *n. medianus*.

M. flexor carpi ulnaris (see also Figs. 352, 355, 355 and 360). Form: flat, oblong-triangular; above it forms, with its anterior surface, a groove, in which lies the ulnar part of the *m. flexor digitorum profundus*. Position: superficial on the ulnar margin of the forearm. Origin: partly from the epicondylus medialis humeri and from the fascia antibrachii, fused with its neighbors (*caput humerale*), partly by a long, flat, thin tendon from the posterior surface of the olecranon and from the *margo dorsalis ulnae* (*caput ulnare*). Insertion: it runs downward, coming in contact radialward with the *m. flexor digitorum sublimis* and is attached by a long, powerful tendon to the *os pisiforme*; the **bursa m. flexoris carpi ulnaris** (not shown in figure) is frequently to be found there. Action: it flexes and adducts the hand. Innervation: *n. ulnaris*.

354. Muscles of the right forearm (2nd layer), viewed from in front.

(The mm. brachioradialis, pronator teres, flexor carpi radialis, palmaris longus and flexor carpi ulnaris have been removed; the lig. carpi transversum has been cut through.)

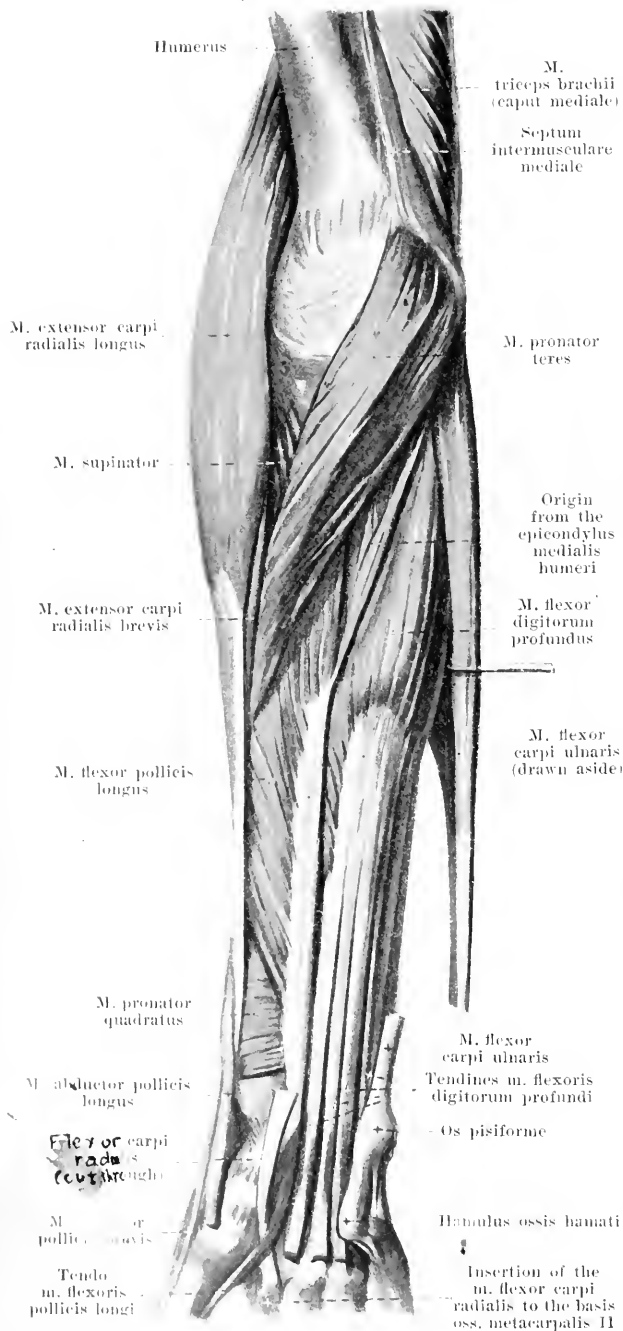
M. flexor digitorum sublimis (see also Fig. 352). Form: flat, spindle-shaped. Position: on the volar surface of the forearm; above, it is covered by the mm. brachioradialis, pronator teres, flexor carpi radialis, palmaris longus and flexor carpi ulnaris; below, it lies between the mm. flexores carpi radialis et ulnaris, coming to the surface and overlapped only by the m. palmaris longus. Origin: partly from the epicondylus medialis humeri and from the proe. coronoideus ulnae, fused with its neighbors (*caput humerale*), partly from the facies volaris radii (*caput radiale*) and, between, from a tendinous arch, which bridges over the a. ulnaris and the n. medianus. Insertion: the fibers converge downward to form four, different, widely separated muscle-bellies, from the distal ends of which emerge four flat, long tendons; these extend, so that those destined for the 3rd and 4th finger lie superficially, beneath the lig. carpi transversum to the hand; thence all diverge to the volar surfaces of the 2nd–5th finger (see Figs. 363 and 364). On the volar surface of the first phalanx each tendon divides into two halves, which surround the corresponding tendon of the m. flexor digitorum profundus (*chiasma tendinum*); the two halves unite again behind the same on the volar surface of the base of the second phalanx, where they become attached. Action: it flexes the 2nd phalanx of the 2nd–5th finger. Innervation: n. medianus.



355. Muscles of the right forearm (3rd layer),

viewed from in front.

(The mm. biceps, brachialis, brachioradialis, flexor carpi radialis, palmaris longus and flexor digitorum sublimis have been removed; the lig. carpi transversum has also been removed.)



M. flexor digitorum profundus (see also Figs. 353, 354 and 356). Form: flat, spindle-shaped. Position: on the volar surface of the forearm, directly upon the ulna and m. pronator quadratus; completely covered by the mm. pronator teres, flexor carpi radialis, palmaris longus, flexor digitorum sublimis and flexor carpi ulnaris. Origin: facies volaris and medialis ulnae and membrana interossea antibrachii. Insertion: the fibers run parallel downward; from the muscle belly, from the middle of the forearm on, go off four long, flat tendons, which go beneath and along with the tendons of the m. flexor sublimis, under the lig. carpi transversum to the hollow of the hand and thence to the 2nd—5th finger; each tendon runs, at the level of the 1st phalanx, between the halves of the chiasma tendinum of the corresponding tendon of the m. flexor sublimis to the base of the 3rd phalanx (see Fig. 364). Action: it flexes the 2nd and 3rd phalanx of the 2nd—5th finger. Innervation: ulnar half (for the 4th and 5th finger): n. ulnaris; radial half (for the 2nd and 3rd finger): n. interosseus volaris of the n. medianus.

M. flexor pollicis longus (see also Figs. 354 and 356). Form: flat, oblong-triangular. Position: on the volar surface of the forearm, immediately upon the radius and the m. pronator quadratus; covered by the mm. pronator teres, brachioradialis, flexor carpi radialis and flexor digitorum sublimis. Origin: facies volaris radii and usually, by a thin bundle, from the epicondylus medialis humeri. Insertion: the fibers run to a long tendon beginning ulnarward; this extends, along with the tendons of

the mm. flexores digitorum, below the lig. carpi transversum to the hand, then in the groove of the m. flexor pollicis brevis to the base of the 2nd phalanx of the thumb (see Fig. 364). Action: it flexes the 2nd phalanx of the thumb. Innervation: n. interosseus volaris of the n. medianus.

356. Muscles of the right forearm

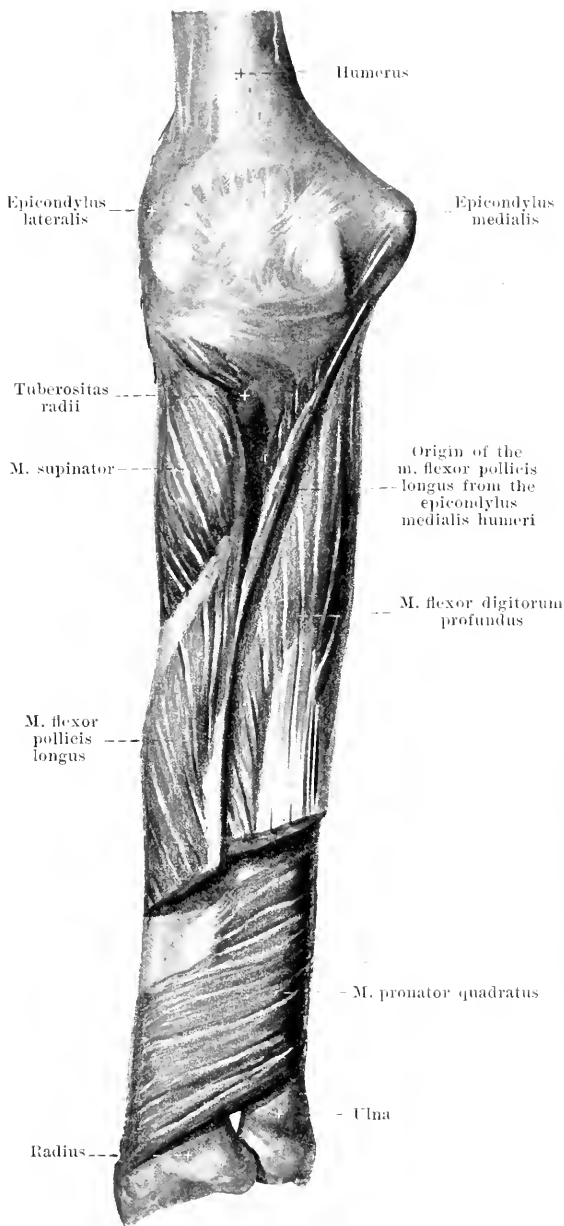
(4th layer), viewed from in front.

(The mm. flexor digitorum profundus and flexor pollicis longus have been partially, all the more superficial muscles completely, removed.)

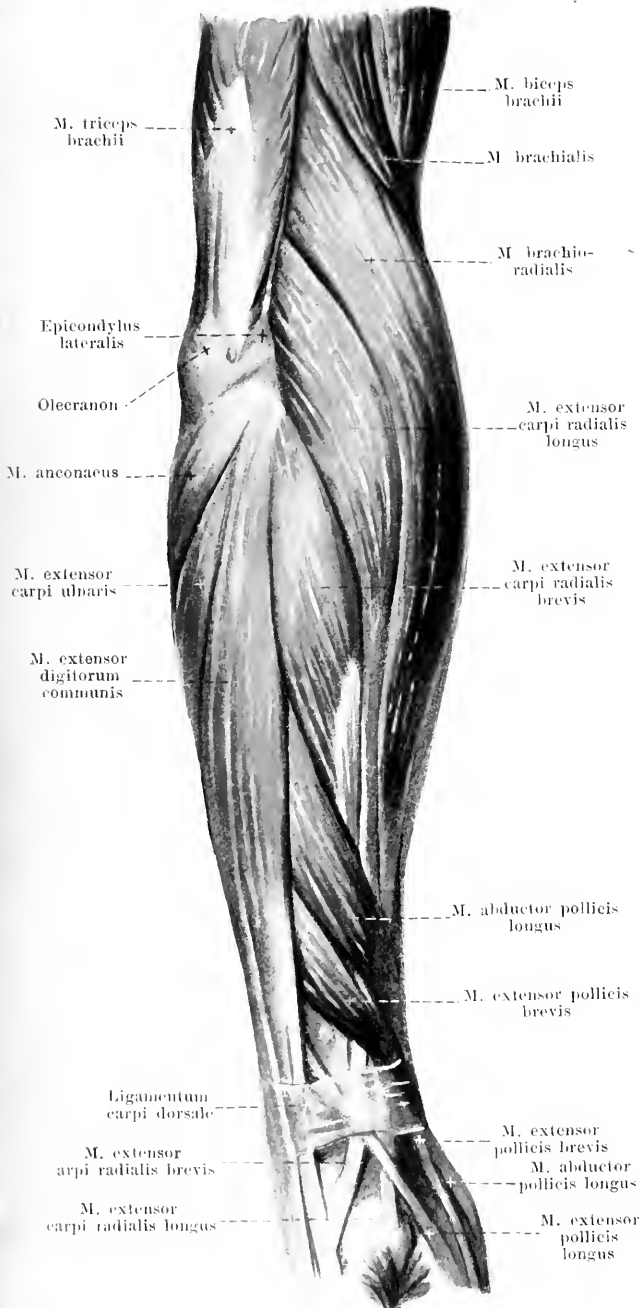
M. pronator quadratus (see also Fig. 354). **Form:** flat, quadrangular. **Position:** on the volar surface of the forearm near the wrist, immediately upon the radius, the ulna and the membrana interossea; covered by all the flexor muscles going to the hand. **Origin:** facies volaris ulnae. **Insertion:** the fibers run parallel, radialward and downward to the facies volaris radii. **Action:** it pronates the forearm. **Innervation:** n. interosseus volaris of the n. medianus.

M. supinator (O. T. supinator brevis) (see also Figs. 354, 355, 359 and 360). **Form:** flat, triangular. **Position:** close below the elbow joint on the volar, radial and dorsal surface of the forearm, immediately upon the radius, covered by the mm. brachioradialis, extensores carpi and anconaeus. **Origin:** epicondylus lateralis humeri, lig. collaterale radiale of the elbow joint and crista m. supinatoris ulnae. **Insertion:** the fibers run obliquely downward to the facies dorsalis, lateralis and volaris of the radius, partially surrounding this bone in a curve. **Action:** it supinates the forearm. **Innervation:** ramus profundus n. radialis.

M. extensor carpi radialis longus (O. T. extensor carpi radialis longior) (see Figs. 352—355, 357—359 and 361). **Form:** flat, oblong - spindle-shaped. **Position:** usually superficial on the radial side of the forearm, bounded in front by the m. brachioradialis, behind by the m. extensor carpi radialis brevis. **Origin:** septum intermusculare laterale, margo lateralis and epicondylus lateralis humeri. **Insertion:** the fibers run downward and converge in the middle of the forearm to form a long, flat tendon, which extends upon the facies lateralis radii (there partly covered by the mm. abductor pollicis longus and extensor pollicis brevis) under the lig. carpi dorsale (through its second compartment) to the dorsal surface of the basis oss. metacarpalis II; at the wrist the tendon of the m. extensor pollicis longus crosses over it. **Action:** it flexes the forearm, extends and abducts the hand. **Innervation:** ramus profundus n. radialis.



357. Muscles of the right forearm, viewed from the radial side.



M. extensor carpi radialis brevis (see also Figs. 352, 358 and 359). Form: spindle-shaped. Position: usually superficial on the radial side of the forearm, coming in contact in front with the m. extensor carpi radialis longus, behind with the m. extensor digitorum communis. Origin: epicondylus lateralis humeri and fascia antibrachii, fused with its neighbors. Insertion: the fibers go downward and converge, becoming attached in the middle of the forearm to a flat, long tendon which goes close behind that of the m. extensor carpi radialis longus through the second compartment of the lig. carpi dorsale to the dorsal surface of the basis oss. metacarpalis III; there, between the tendon and the bone, lies the **bursa m. extensoris carpi radialis brevis** (see Fig. 360), rarely absent. The tendon is partially crossed over by the same muscles as is that of the m. extensor carpi radialis longus (see also Fig. 361). Action: it extends the hand. Innervation: ramus profundus n. radialis.

M. extensor digitorum communis (see also Figs. 358 and 361). Form: oblong-spindleshaped. Position: superficial on the back of the forearm, radialward bounded by the m. extensor carpi radialis brevis, ulnarward by the m. extensor carpi ulnaris. Origin: epicondylus lateralis humeri and fascia antibrachii, fused with its neighbors. Insertion: the fibers run parallel downward and in the middle of the forearm become separated into four single bellies. Each of these goes over into a long, flat tendon; these pass together through the fourth compartment of the lig. carpi dorsale and then diverge to go to the dorsal surface of the first phalanx of the 2nd—5th finger; each becomes attached by three processes, one in the middle going to the base of the second phalanx and two at the side converging in front and going to the base of the third. The four tendons are connected with one another upon the ossa metacarpalia by means of three oblique bands, *junctionae*

tendinum. Each tendon presents a triangular expansion upon the first phalanx to which become attached mm. lumbricales and interossei (see Fig. 368). Action: it extends the hand and the 2nd—5th finger. Innervation: ramus profundus n. radialis.

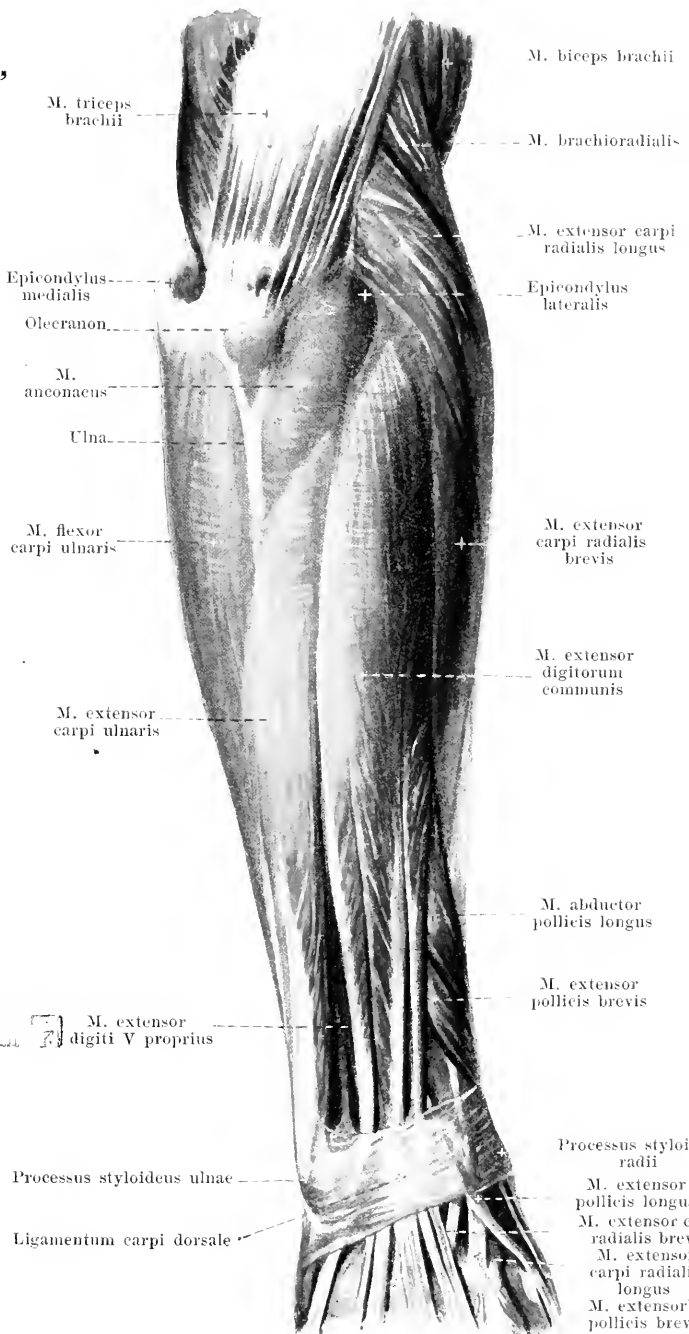
358. Muscles of the right forearm, viewed from behind.

M. extensor digiti quinti proprius (O. T. extensor minimi digiti). Form: oblong-spindle-shaped, narrow. Position: immediately on the ulnar side of the preceding muscle, fused with it above. Origin: in common with the preceding muscle. Insertion: the long, thin tendon runs through the fifth compartment of the lig. carpi dorsale and fuses on the back of the hand with the tendon going to the little finger from the m. extensor digitorum communis (see also Fig. 361). Action: it extends the 5th finger. Innervation: ramus profundus n. radialis.

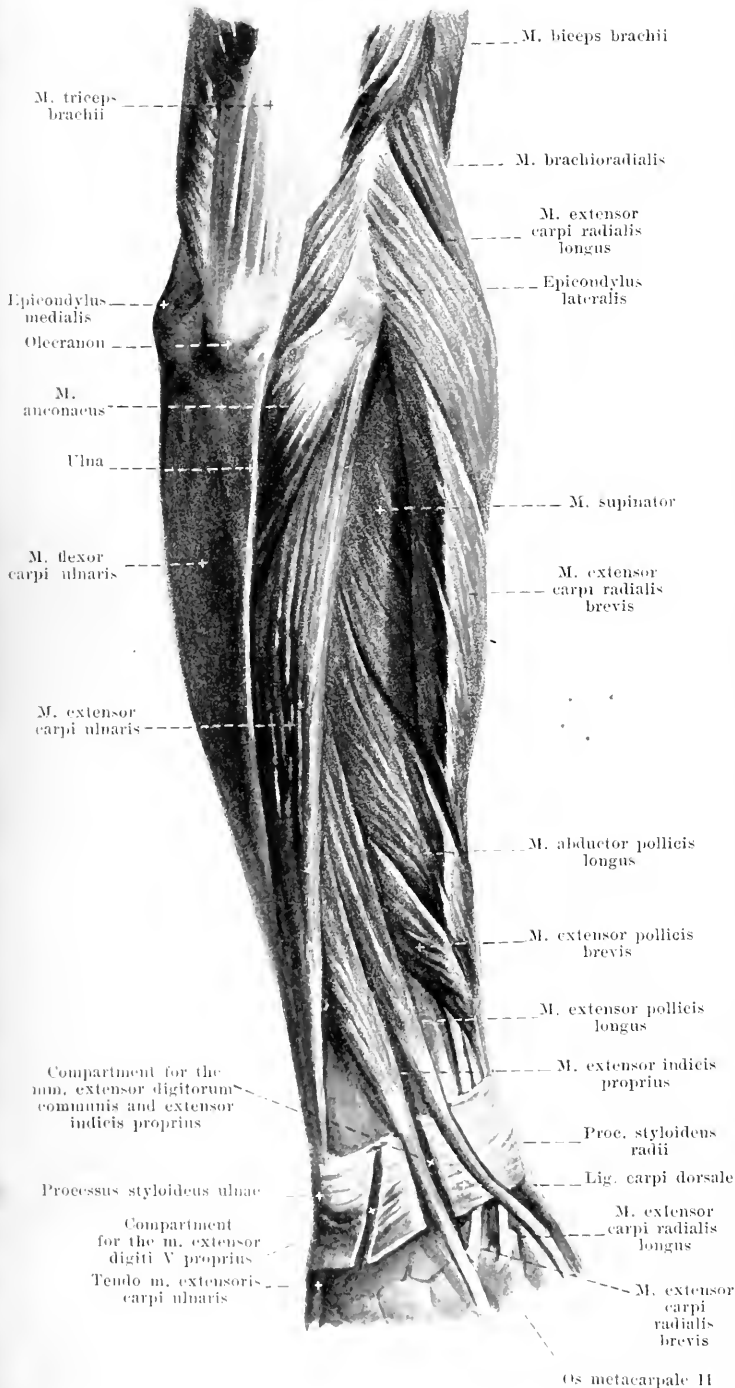
M. anconaeus (see also Figs. 351, 357, 359 and 360). Form: flat, triangular. Position: superficial on the back of the forearm, hidden by the fascia antibrachii, above immediately adjacent to the caput mediale of the m. triceps, radialward bounded by the m. extensor carpi ulnaris, ulnarward by the ulna. Origin: epicondylus lateralis humeri. Insertion: the fibers diverge to the facies dorsalis ulnae. Action: it extends the forearm. Innervation: n. radialis.

M. extensor carpi ulnaris (see also Figs. 357, 359 and 361). Form: flat, oblong-spindle-shaped. Position: superficial on the back of the forearm, radialward bounded by the m. extensor digitorum communis and the m. extensor digiti V proprius, ulnarward above by the m. anconaeus, below by the ulna. Origin: epicondylus lateralis humeri, lig. collateral-radiale of the elbow joint and fascia antibrachii, fused with its neighbors; also by a thin, tendinous leaf from the facies dorsalis ulnae. Insertion: the fibers run ulnarward and downward to the facies dorsalis ulnae and upon this go over into a long tendon, which runs through the sixth compartment of the

lig. carpi dorsale to the basis oss. metacarpalis V. Action: it extends and adducts the hand. Innervation: ramus profundus n. radialis.



Processus styloideus radii
M. extensor pollicis longus
M. extensor carpi radialis brevis
M. extensor carpi radialis longus
M. extensor pollicis brevis



359. Muscles of the right forearm,

viewed from behind.

(The m. extensor digitorum communis has been removed.)

M. abductor pollicis longus (O. T. extensor ossis metacarpi pollicis) (see also Figs. 352, 357, 358, 360, 361 and 363). Form: flat, spindle-shaped. Position: on the posterior and radial side of the forearm; behind immediately upon the membrana interossea and the radius, covered by the mm. extensor carpi ulnaris and extensor digitorum communis; radialward superficial passing over the mm. extensores carpi radiales. Origin: facies dorsalis ulnae, membrana interossea and facies dorsalis radii. Insertion: the fibers converge radialward and downward to form a flat tendon, which, at the radial side of the forearm, goes between the mm. extensores carpi radiales and flexor carpi radialis through the first compartment of the lig. carpi dorsale, partly to the m. abductor pollicis brevis, partly to the basis oss. metacarpalis I. Action: it opposes the thumb to the other fingers and abducts the hand. Innervation: ramus profundus n. radialis.

M. extensor pollicis brevis (O. T. extensor primi internodii pollicis) (see also Figs. 355, 357, 358, 360 and 361). Form: spindle-shaped. Position: just distalward from the preceding muscle. Origin: membrana interossea and facies dorsalis radii. Insertion: it runs exactly as does the preceding muscle and, close to it, goes upon the back of the os metacarpale I to the base of the first phalanx of the thumb. Action: it abducts the thumb and extends the first phalanx of the same. Innervation: ramus profundus n. radialis.

360. Muscles of the right forearm (deep layer),

viewed from behind.

(The mm. extensores carpi, digitorum communis and digiti V proprius have been removed.)

M. extensor pollicis longus (O. T. extensor secundi internodii pollicis) (see also Figs. 357—359 and 361). Form: long-spindle-shaped. Position: ulnarward from and behind the two preceding muscles, immediately upon the ulna and radius, covered by the same muscles as are they. Origin: facies dorsalis ulnae and membrana interossea. Insertion: the fibers go over into a long tendon, which passes obliquely behind the tendons of the mm. extensores carpi radiales through the third compartment of the lig. carpi dorsale and then to the base of the second phalanx of the thumb, partly also fused with the tendon of the m. extensor pollicis brevis. Action: it extends the thumb and draws it backward. Innervation: ramus profundus n. radialis.

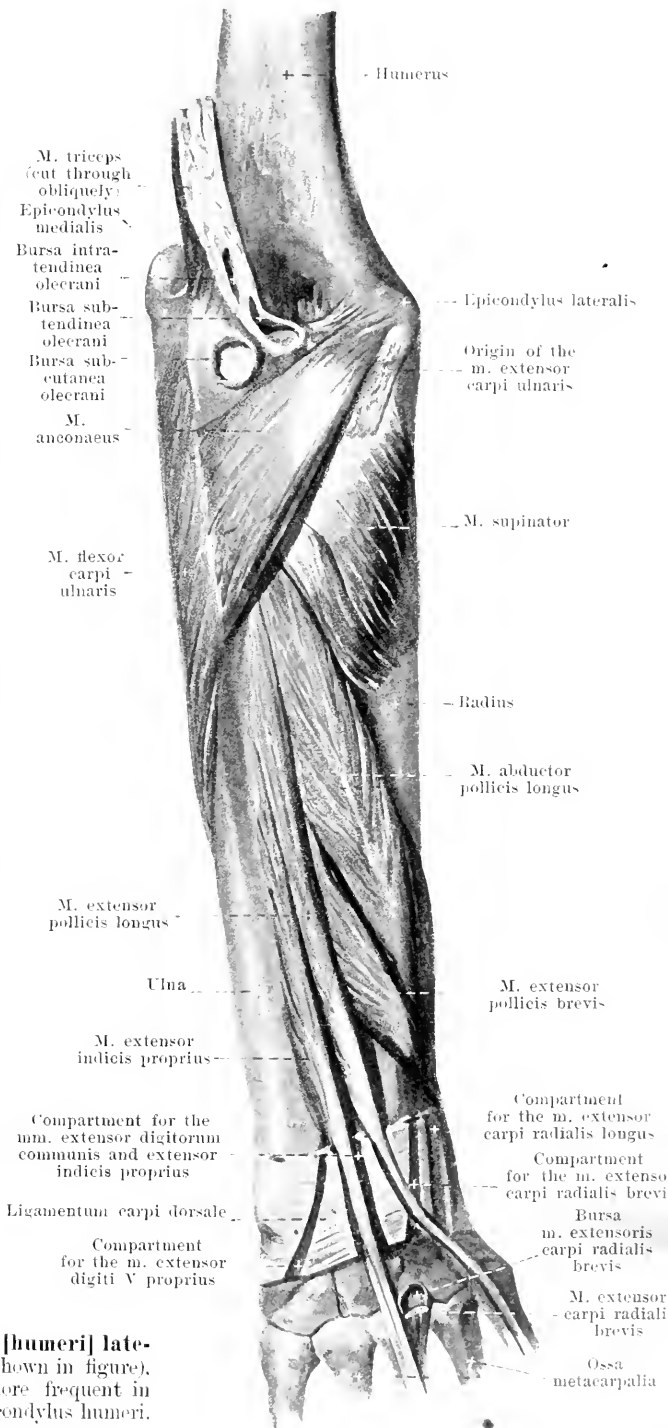
M. extensor indicis proprius (O. T. extensor indicis) (see also Fig. 359). Form: oblong-spindle-shaped. Position: ulnarward from and behind the preceding muscle, immediately upon the ulna, covered by the mm. extensor digiti V proprius, extensor digitorum communis and extensor carpi ulnaris. Origin: facies dorsalis ulnae and membrana interossea. Insertion: the fibers converge to form a flat tendon which goes in common with the tendons of the m. extensor digitorum communis through the fourth compartment of the lig. carpi dorsale and then fuses with the tendon of this muscle that goes to the index finger. Action: it extends the index finger. Innervation: n. interosseus dorsalis of the n. radialis.

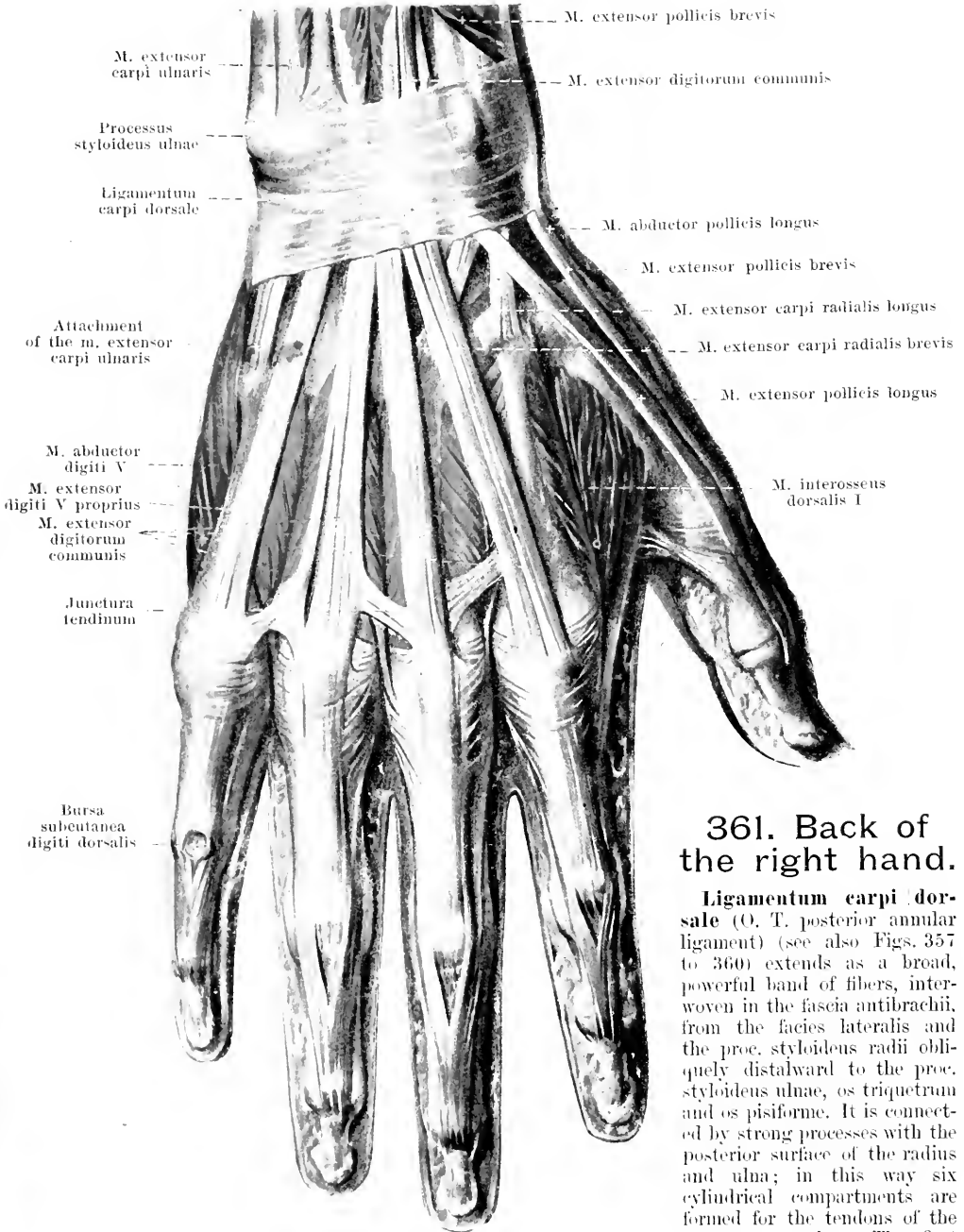
Bursa subcutanea olecrani, very frequent, upon the olecranon.

Bursa intratendinea olecrani, very frequent, in the tendon of the m. triceps.

Bursa subtendinea olecrani, occasional, in front of the tendon of the m. triceps.

Bursae subcutaneae epicondyli [humeri] lateralis et epicondyli medialis (not shown in figure), the former occasional, the latter more frequent in the adult, upon the corresponding epicondylus humeri.



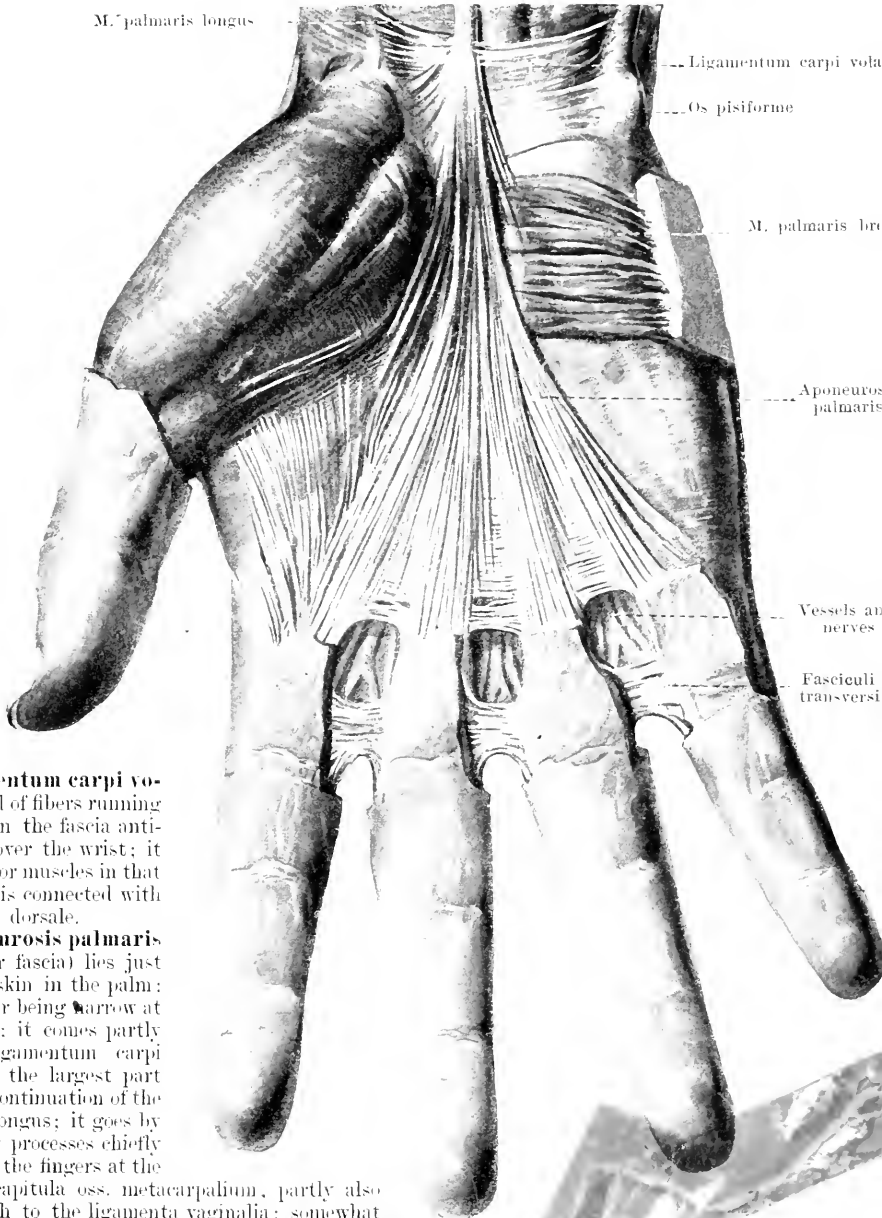


361. Back of the right hand.

Ligamentum carpi dorsale (O. T. posterior annular ligament) (see also Figs. 357 to 360) extends as a broad, powerful band of fibers, interwoven in the fascia antibrachii, from the facies lateralis and the proc. styloideus radii obliquely distalward to the proc. styloideus ulnae, os triquetrum and os pisiforme. It is connected by strong processes with the posterior surface of the radius and ulna; in this way six cylindrical compartments are formed for the tendons of the extensor muscles. The first compartment (numbered from

the radial side) is for the mm. abductor pollicis longus and extensor pollicis brevis, the second for the mm. extensores carpi radiales, the third, obliquely behind the second, for the m. extensor pollicis longus, the fourth for the mm. extensor digitorum communis and extensor indicis proprius, the fifth for the m. extensor digiti V proprius, the sixth for the m. extensor carpi ulnaris.

362. Fascia of the right palm.

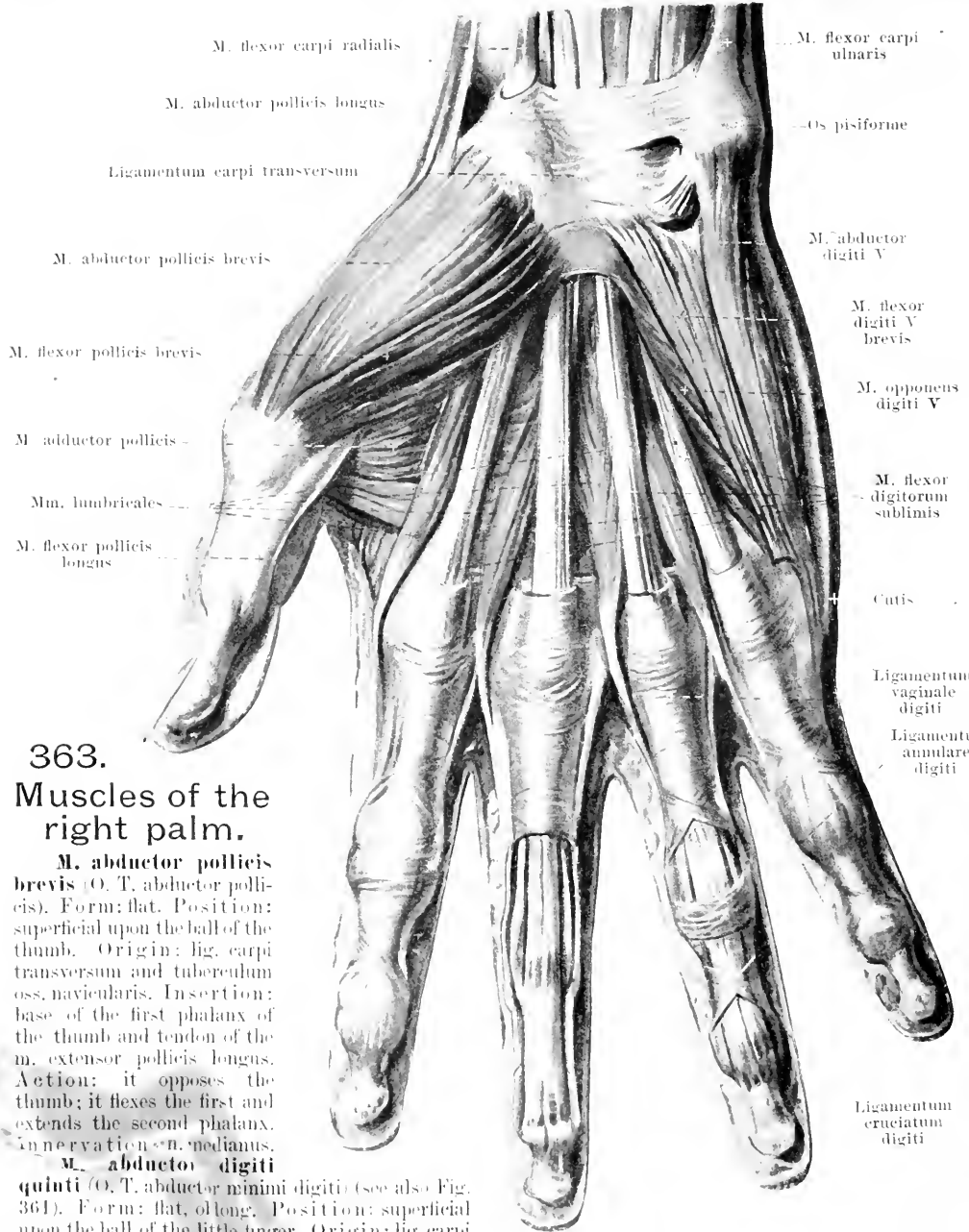


The **ligamentum carpi volare** is a band of fibers running transversely in the fascia anti-brachii just over the wrist; it covers the flexor muscles in that situation and is connected with the lig. carpi dorsale.

The **aponeurosis palmaris** (O. T. palmar fascia) lies just beneath the skin in the palm; it is triangular being narrow at its beginning; it comes partly from the ligamentum carpi transversum, the largest part of it being a continuation of the m. palmaris longus; it goes by five diverging processes chiefly to the skin of the fingers at the level of the capitula oss. metacarpalium, partly also into the depth to the ligamenta vaginalia; somewhat distalward from this insertion *fascioli transversi* are stretched out just beneath the skin between every two fingers from the 2nd—5th finger; they are also partially connected with one another. The thenar and hypothenar eminences are covered only by thin fascia. Upon the hypothenar eminence there lies in addition the

M. palmaris brevis, flat, quadrangular. Origin: ulnar margin of the aponeurosis palmaris. Insertion: to the skin at the ulnar margin of the hand. Action: it wrinkles the skin, and deepens the hollow of the hand. Innervation: ramus superficialis of the *radialis volaris manus n. ulnaris*.

Lig. carpi transversum (O. T. anterior annular ligament) (see also Figs. 363—365) is a tough fibrous band which extends transversely between the eminentiæ carpi and the adjacent ligaments; it bridges over the sulcus carpi (see p. 107).

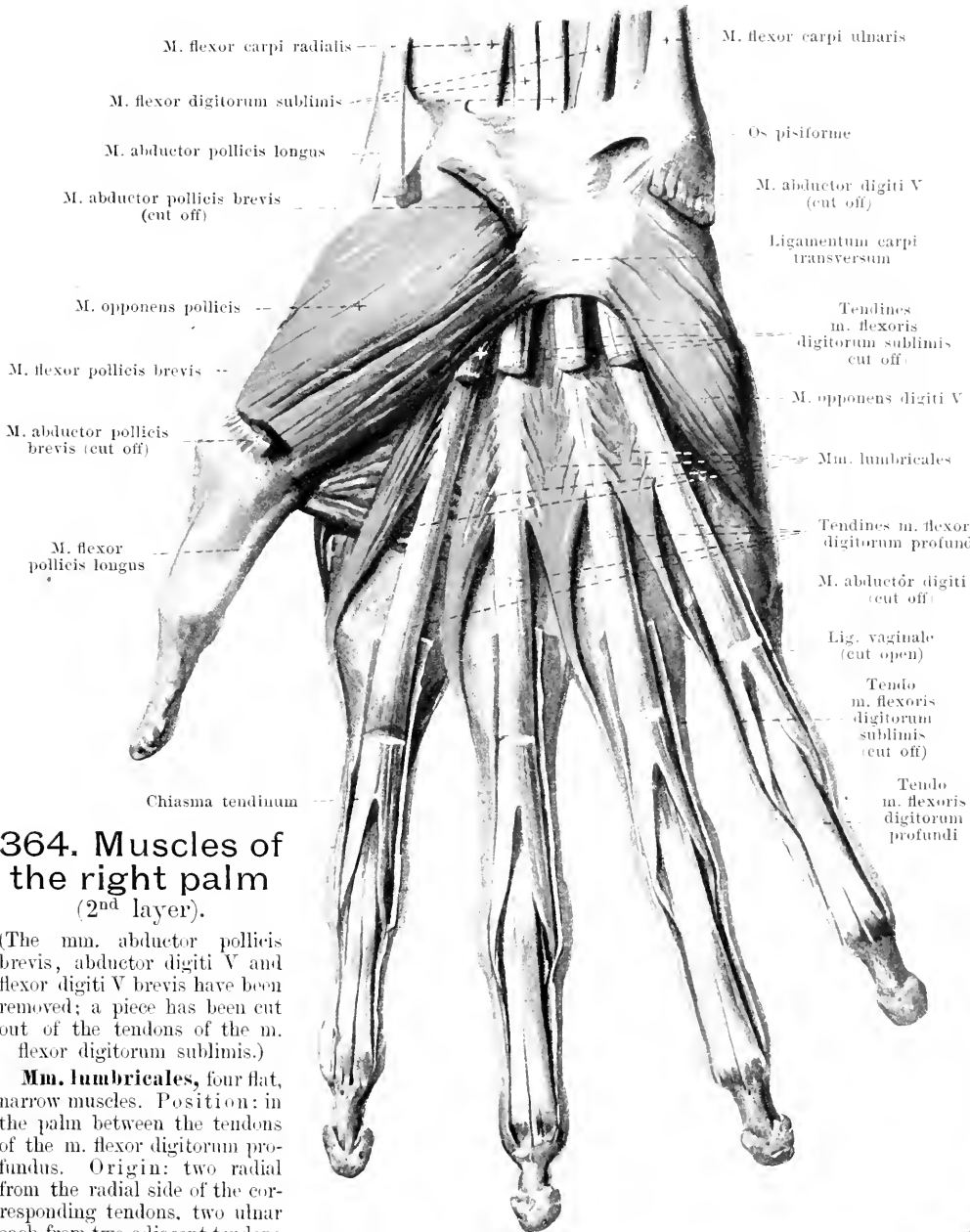


363.
Muscles of the right palm.

M. abductor pollicis brevis (O. T. abductor pollicis). Form: flat. Position: superficial upon the ball of the thumb. Origin: lig. carpi transversum and tuberculum oss. navicularis. Insertion: base of the first phalanx of the thumb and tendon of the m. extensor pollicis longus. Action: it opposes the thumb; it flexes the first and extends the second phalanx. Innervation: n. medianus.

M. abductor digiti quinti (O. T. abductor minimi digiti) (see also Fig. 361). Form: flat, oblong. Position: superficial upon the ball of the little finger. Origin: lig. carpi transversum and oss. pisiforme. Insertion: base of the first phalanx of the 5th finger and to its extensor tendons. Action: it abducts the 5th finger and extends its 2nd and 3rd phalanx. Innervation: ramus profundus of the ramus volaris manus n. ulnaris.

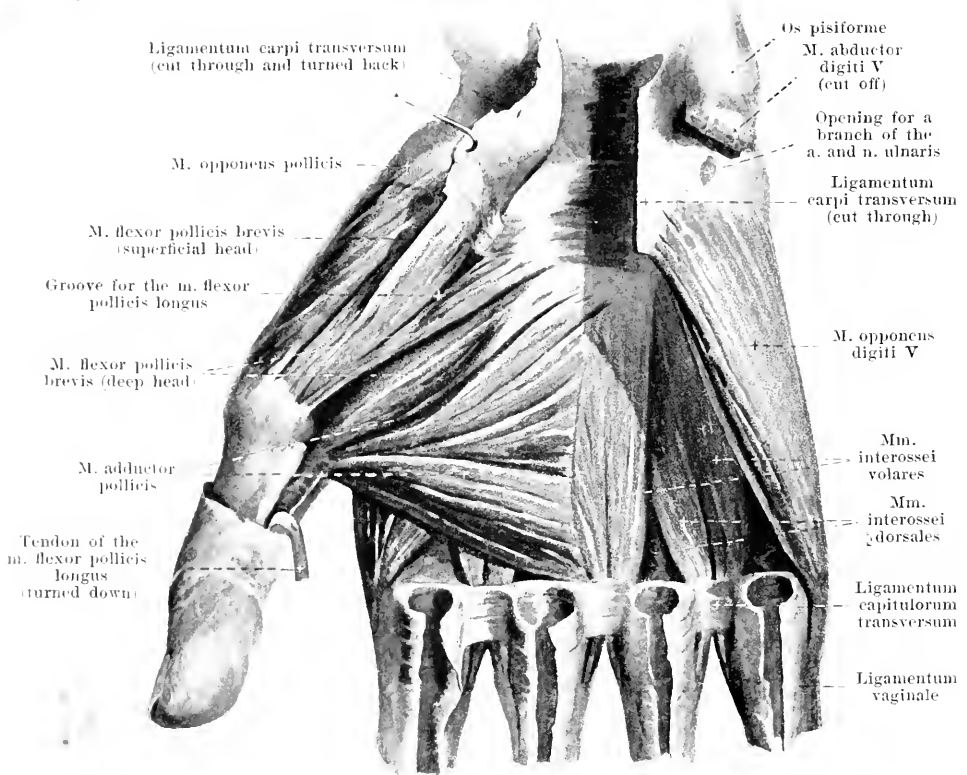
M. flexor digiti quinti brevis (O. T. flexor brevis minimi digiti) (frequently absent). Form: flat, oblong. Position: superficial, on the radial side of the preceding muscle. Orig.: lig. carpi transversum and hamulus oss. hamuli. Insertion: base of the first phalanx of the 5th finger. Action: it flexes the first phalanx of the little finger and abducts it. Innervation: like that of the preceding muscle.



364. Muscles of the right palm (2nd layer).

(The *mm. abductor pollicis brevis*, *abductor digiti V* and *flexor digiti V brevis* have been removed; a piece has been cut out of the tendons of the *m. flexor digitorum sublimis*.)

Mm. lumbricales, four flat, narrow muscles. **Position:** in the palm between the tendons of the *m. flexor digitorum profundus*. **Origin:** two radial from the radial side of the corresponding tendons, two ulnar each from two adjacent tendons of the *m. flexor digitorum profundus*. **Insertion:** the fibers converge to form narrow tendons which run on the radial side of the 2nd—5th finger, volarward from the lig. capitulum transversum (see Fig. 241), to the posterior surface of the first phalanx and to the triangular expansions of the tendons of the *m. extensor digitorum communis* (see Fig. 361). The tendon of the third muscle is frequently locked and sends also a process to the ulnar margin of the 3rd finger. **Action:** they flex the first and extend the second and third phalanx of the 2nd—5th finger. **Innervation:** 2(—3) radial from the *n. medianus*, 2(—1) ulnar from the *ramus profundus* of the *ramus volaris manus n. ulnaris*.



365. Deep muscles of the ball of the right thumb.

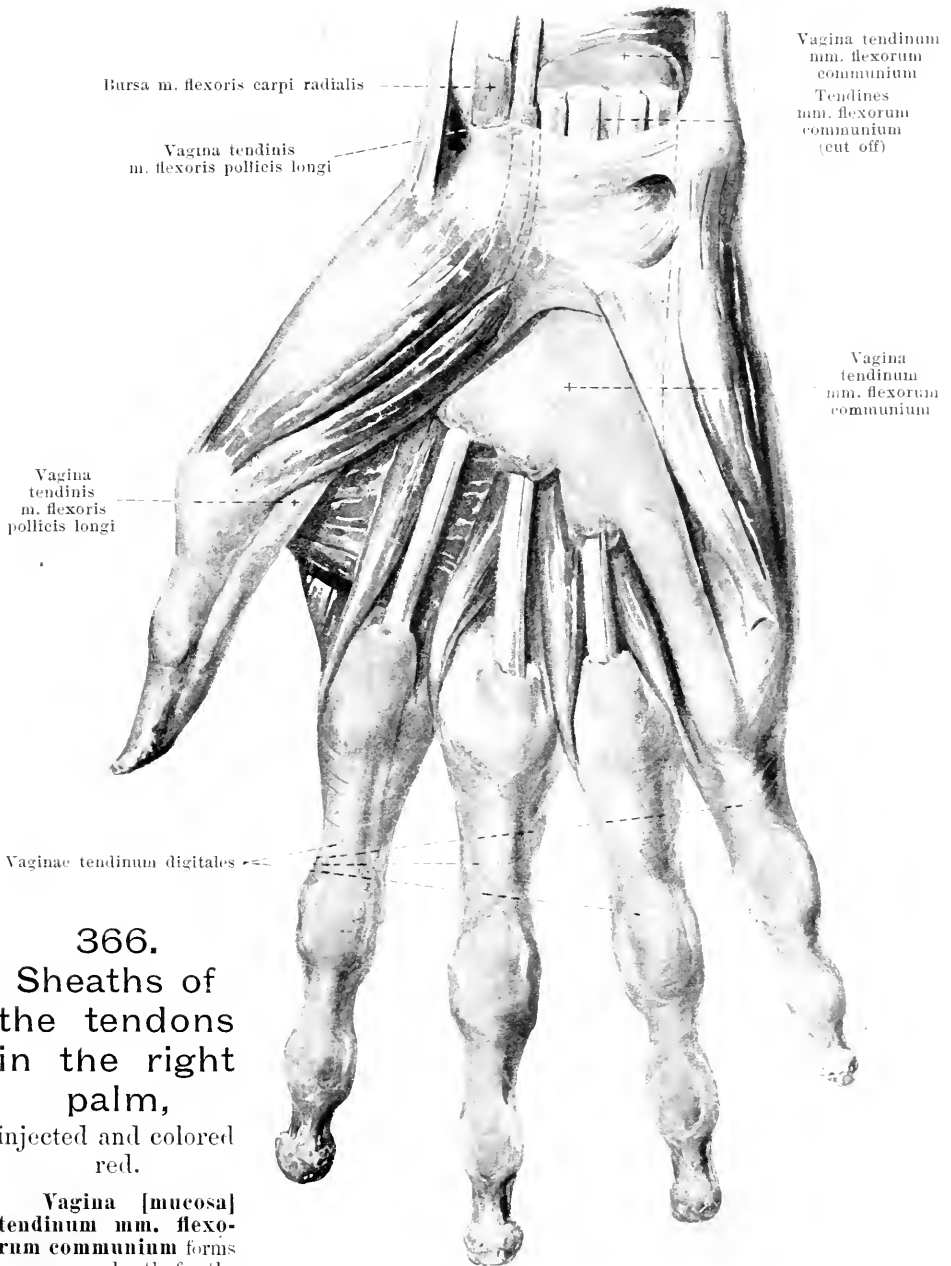
(The *mm. flexores digitorum*, *flexor pollicis longus*, *abductor pollicis brevis*, *abductor digiti V* and *flexor digiti V brevis* have been removed; the *lig. carpi transversum* has been cut through.)

M. opponens pollicis (see also Fig. 364). Form: flat, oblong-quadrangular. Position: in the ball of the thumb, almost completely covered by the *m. abductor pollicis brevis*. Origin: *lig. carpi transversum* and *tuberculum oss. multanguli majoris*. Insertion: *corpus* and *capitulum oss. metacarpalis I*. Action: it opposes the thumb to the other fingers. Innervation: *n. medianus*.

M. flexor pollicis brevis (see also Figs. 363 and 364). Form: oblong-quadrangular. Position: ulnar margin of the ball of the thumb, in the depth, bounded radialward by the *m. opponens pollicis*, ulnarward by the *m. adductor pollicis*. Origin: by two heads; superficial head: *lig. carpi transversum*; deep head: *ossa multangula, capitulum, metacarpale II*. Insertion: superficial head to the radial sesamoid bone, deep head by two divisions (one narrower, radial and one thicker, ulnar) to the radial and ulnar sesamoid bones, both also to the base of the first phalanx of the thumb and partly to the tendon of the *m. extensor pollicis longus*. Between the two heads is a groove for the tendon of the *m. flexor pollicis longus*. Action: it flexes the first and extends the second phalanx of the thumb. Innervation: superficial portions by the *n. medianus*, deep by the *ramus profundus* of the *ramus volaris manus n. ulnaris*.

M. adductor pollicis (see also Figs. 363 and 364). Form: flat, triangular. Position: in the depth of the palm, immediately upon the bones and the *mm. interossei*; covered by the tendons of the *mm. flexores digitorum*, being bounded radialward by the preceding muscle. Origin: *os metacarpale III*. Insertion: *ulnar sesamoid bone, base of the first phalanx of the thumb* and tendon of the *m. extensor pollicis longus*. Action: it adducts the thumb and opposes it to the other fingers; it extends the second phalanx of the thumb. Innervation: *ramus profundus* of the *ramus volaris manus n. ulnaris*.

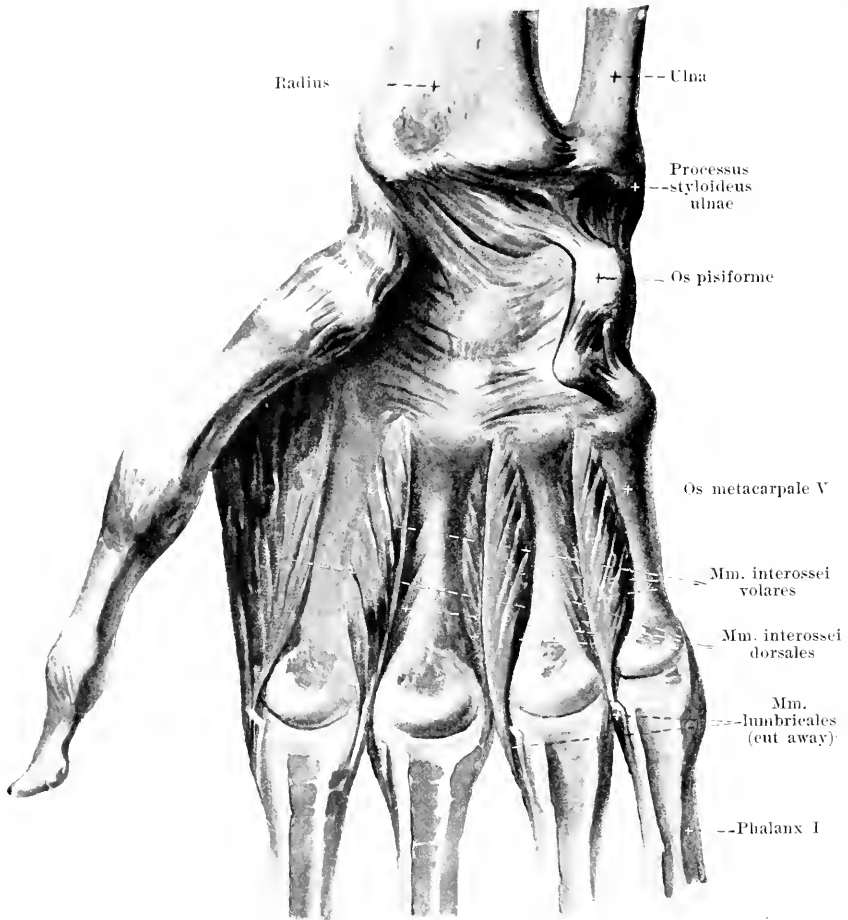
M. opponens digiti quinti (O. T. *opponens minimi digiti*) (see also Figs. 363 and 364). Form: flat, oblong-quadrangular. Position: in the ball of the little finger, almost completely covered by the *mm. abductor digiti V*, and *flexor digiti V brevis*. Origin: *lig. carpi transversum* and *hamulus oss. hamati*. Insertion: *corpus* and *capitulum oss. metacarpalis V*. Action: it draws the fifth finger toward the thumb. Innervation: *ramus profundus* of the *ramus volaris manus n. ulnaris*.



366.
**Sheaths of
 the tendons
 in the right
 palm,**
 injected and colored
 red.

Vagina [mucosa] tendinum mm. flexorum communium forms a common sheath for the tendons of the mm. flexores digitorum communes; it begins a little above the lig. carpi transversum and ends in the middle of the palm; very often a special sheath entirely or partially separated from the main sheath is to be found, radialward, for the tendon of the index finger (see also p. 322).

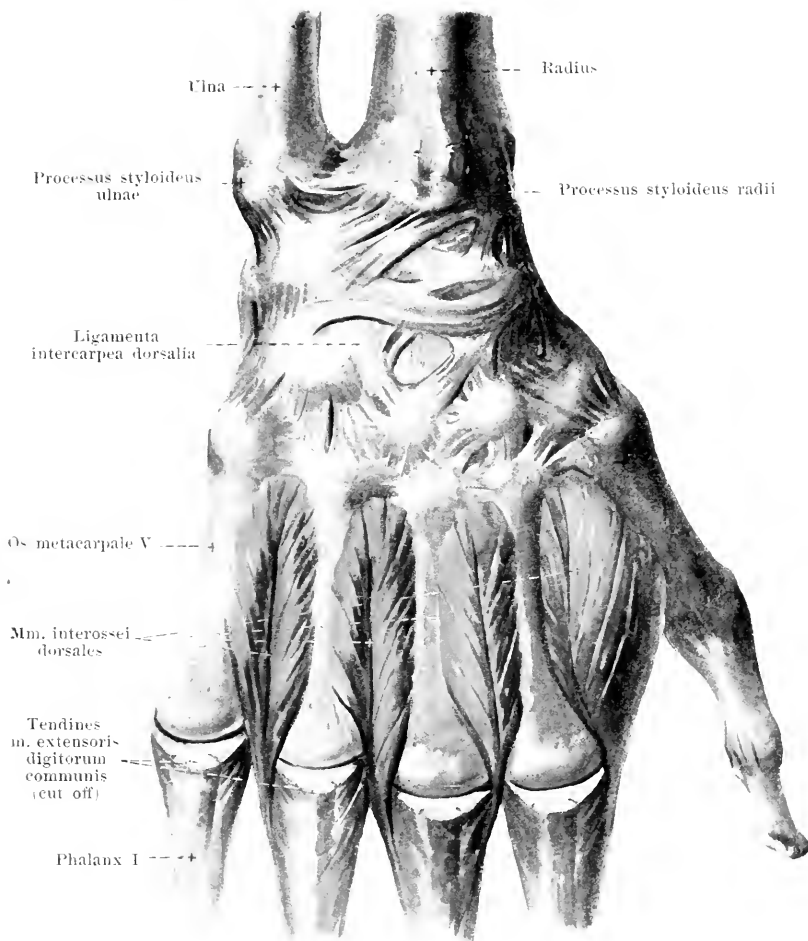
Vagina tendinis m. flexoris pollicis longi accompanies the tendon of the m. flexor pollicis longus from the upper margin of the lig. carpi transversum as far as the second phalanx; it frequently communicates with the preceding sheath.



367. Mm. interossei volares manus dextrae.

The *vaginae tendinum digitales* (see Fig. 366) are four long sheaths, which on the volar surface of the 2nd—5th finger from the region of the capitulum oss. metacarpalis on, surround the tendons of the mm. flexores digitorum communes in common as far as the third phalanx; that of the 5th finger is connected in the adult with the vagina tendinum mm. flexorum communium. Each of these tendinous sheaths for the fingers is attached, for some distance, by a connective tissue sheath, *ligamentum vaginale*, firmly to the underlying bones and ligaments (see also Fig. 241); in this sheath strong bands of fibers run, partly transversely, partly obliquely and crossed, *ligamenta annularia* and *ligamenta cruciata digitorum manus* (see Fig. 363).

Mm. interossei volares (O. T. palmar interossei), three flat, triangular, small muscles. **Position:** in the depth of the palm, in the interspaces between the ossa metacarpalia II—V, covered by all the other muscles of the palm. **Origin:** on the lateral surfaces of the ossa metacarpalia — the first on the ulnar surface of the 2nd bone, the second and third on the radial surfaces of the 4th and 5th (see also Fig. 150). **Insertion:** each of the narrow tendons goes dorsalward from the lig. capitulum transversum (see Fig. 241) on the same side of the finger to the back of the first phalanx and to the triangular expansion of the corresponding tendon of the m. extensor digitorum communis (see Fig. 361). **Action:** they draw the 2nd, 4th and 5th fingers toward the middle finger, flex the first phalanx and extend the second and third phalanx of the 2nd, 4th and 5th finger. **Innervation:** ramus profundus of the ramus volaris manus n. ulnaris.

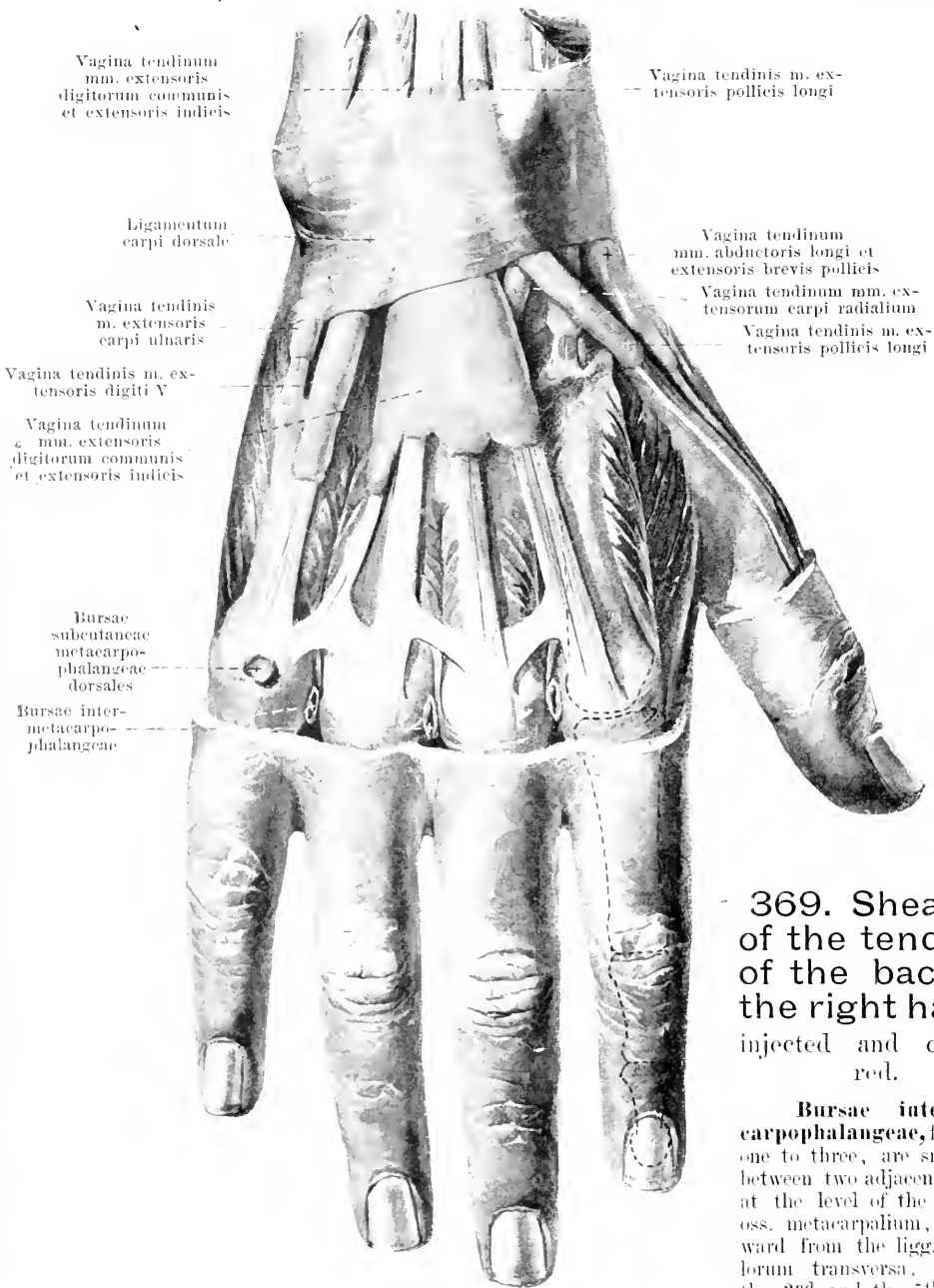

368. *Mm. interossei dorsales manus dextrae.*

Mm. interossei dorsales (see also Figs. 361 and 367), four flat triangular, penniform, small muscles. **Position:** in the interspaces between the ossa metacarpalia, nearer the back of the hand. **Origin:** each comes from the neighboring surfaces of the ossa metacarpalia (see also Fig. 151). **Insertion:** each of the narrow tendons runs dorsalward from the lig. capitulorum transversum (see Fig. 241) — the first and second each on the radial side of the 2nd and 3rd finger, the third and fourth each on the ulnar side of the 3rd and 4th finger, to the back of the first phalanx and to the triangular expansion of the corresponding tendon of the *m. extensor digitorum communis* (see also Fig. 361). **Action:** the first and second draw the 2nd and 3rd finger radialward, the third and fourth draw the 3rd and 4th finger ulnarward; all flex the first phalanx and extend the second and third phalanx of the 2nd—4th finger. **Innervation:** ramus profundus of the ramus volaris manus n. ulnaris.

Vagina tendinum *mm. abductoris longi et extensoris brevis pollicis*, vagina tendinum *mm. extensorum carpi radialis*, vagina tendinis *m. extensoris pollicis longi* (communicating constantly with the preceding), vagina tendinis *m. extensoris digiti quinti* and vagina tendinis *m. extensoris carpi ulnaris* (see Fig. 369) surround their corresponding tendons at the lig. carpi dorsale and for varying distances below it.

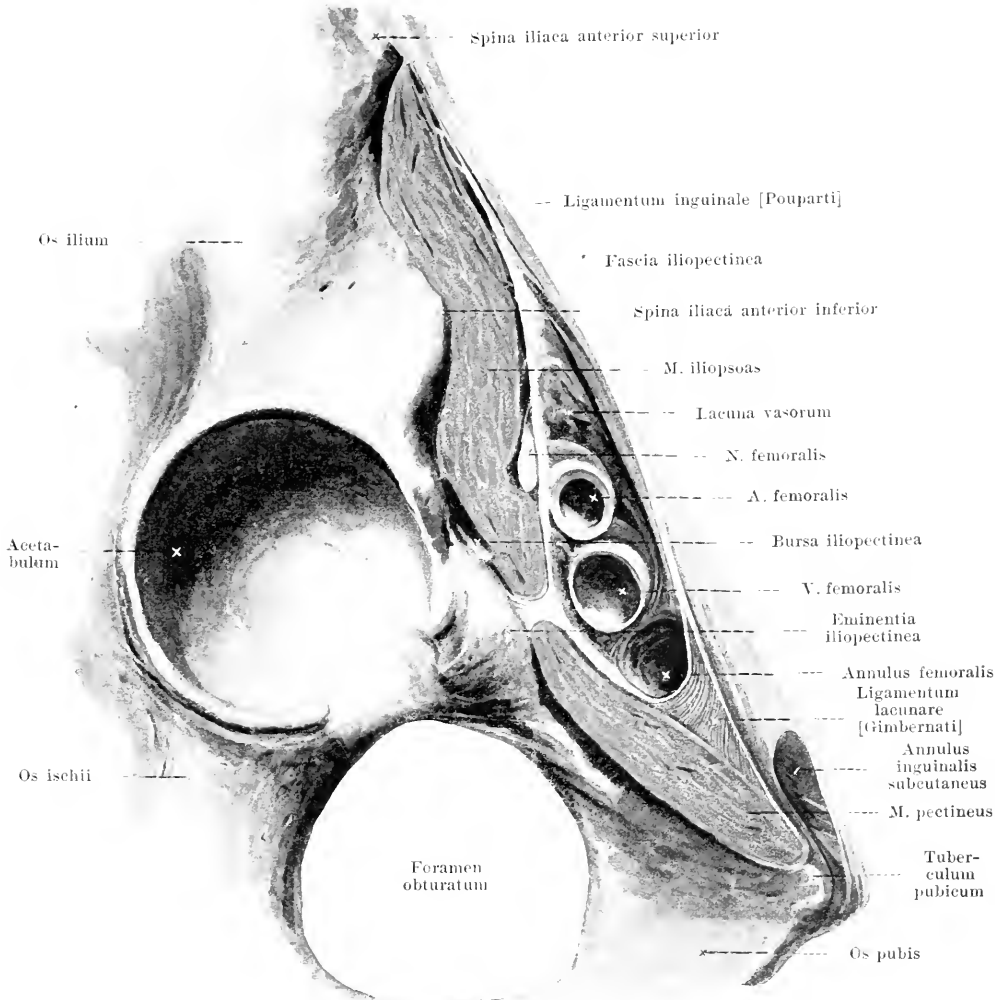
Vagina tendinum *mm. extensoris digitorum communis et extensoris indicis* (see Fig. 369) forms a sheath for the tendons of these muscles in common as far as the middle of the ossa metacarpalia.



369. Sheaths of the tendons of the back of the right hand, injected and colored red.

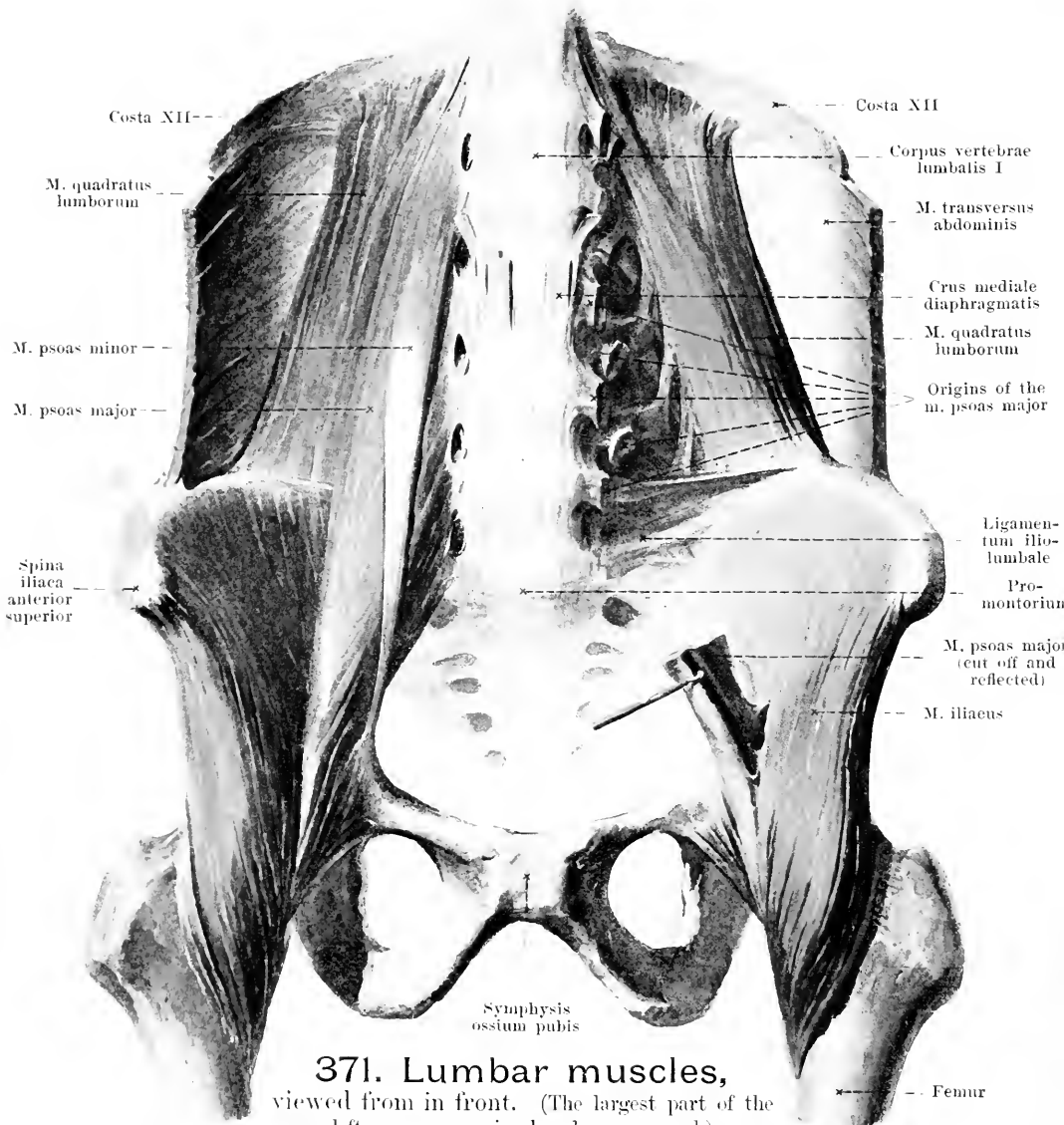
Bursae intermetacarpophalangeae, frequent, one to three, are small, lie between two adjacent fingers at the level of the capitula oss. metacarpalium, dorsalward from the ligg. capitulorum transversa, between the 2nd and the 5th finger.

Bursae subcutaneae metacarpophalangeae dorsales are occasionally present and then usually only on the 5th finger. **Bursae subcutaneae digitorum dorsales** (see Fig. 361), just beneath the skin on the back of the articulationes digitorum, usually small, occurring constantly or almost constantly on the first finger joints (between the first and the second phalanx), occasionally on the second joint of the 2nd and 4th finger.



370. Section through the muscles of the right inguinal region, parallel to and directly under the lig. inguinale [Poupartii].

Fascia iliaca (see also Fig. 372). It covers the entire free surface of the m. iliopsoas, begins above on the bodies of the lumbar vertebrae and on the crista iliaca, is strongest below, and passes over medianward into the fascia pelvis. Below the lateral portion of the lig. inguinale [Poupartii] it extends downward with the m. iliopsoas, is attached lateralward to the spina iliaca anterior superior and to the lig. inguinale, medianward to the eminentia iliopectinea and is named, from this point on, the *fascia iliopectinea*. This divides the space under the lig. inguinale into two compartments, a lateral, *lacuna musculorum*, for the m. iliopsoas and n. femoralis, and a medial, *lacuna vasorum*; the latter contains lateralward the a. femoralis, medianward the v. femoralis and, between the latter and the lateral concave edge of lig. lacunare [Gimbernati], the *annulus femoralis*, which is closed by the fascia transversalis (*septum femorale* [Cloqueti]) and serves for the passage of lymph vessels. Below the lig. inguinale the fascia iliopectinea covers the floor of the fossa iliopectinea and forms at the same time the deep layer of the fascia lata (see also p. 330).

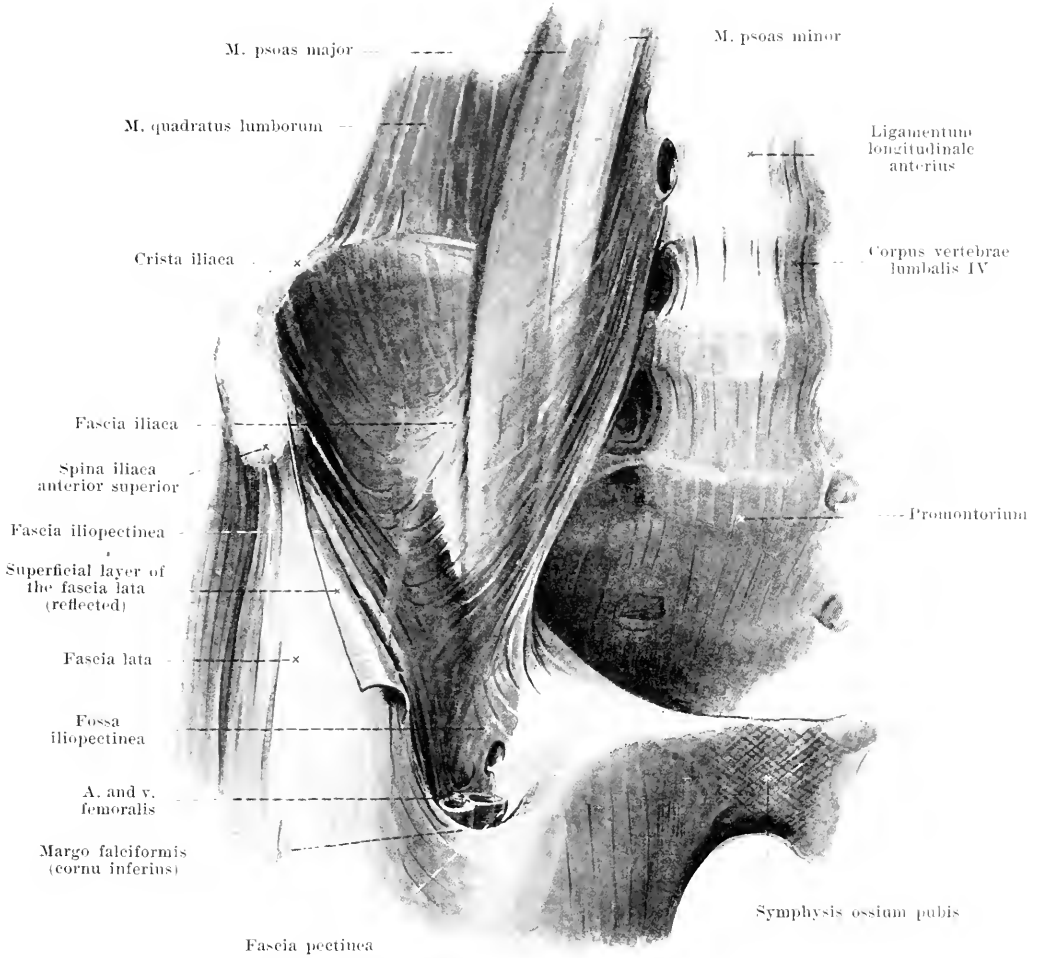


371. Lumbar muscles,
viewed from in front. (The largest part of the
left m. psoas major has been removed.)

M. quadratus lumborum (see also Figs. 314, 315 and 333). Form: flat, oblong-quadrangular. Position: posterior wall of the peritoneal cavity, directly in front of the anterior layer of the fascia lumbodorsalis, covered partly in front by the m. psoas major. Two, often slightly separated, layers. *Anterior layer.* Origin: procc. transversi of the 5th—2nd lumbar vertebra. Insertion: inferior border of the 12th rib and the body of the 12th thoracic vertebra. *Posterior layer.* Origin: labium internum cristae iliaceae and lig. iliolumbale. Insertion: inferior margin of 12th rib and procc. transversi of the 4th—1st lumbar vertebra. Action: it draws the last rib downward; it bends the lumbar spine lateralward. Innervation: rami musculares plexus lumbalis.

M. iliopsoas consists of *m. psoas minor*, *m. psoas major* and *m. iliacus*.

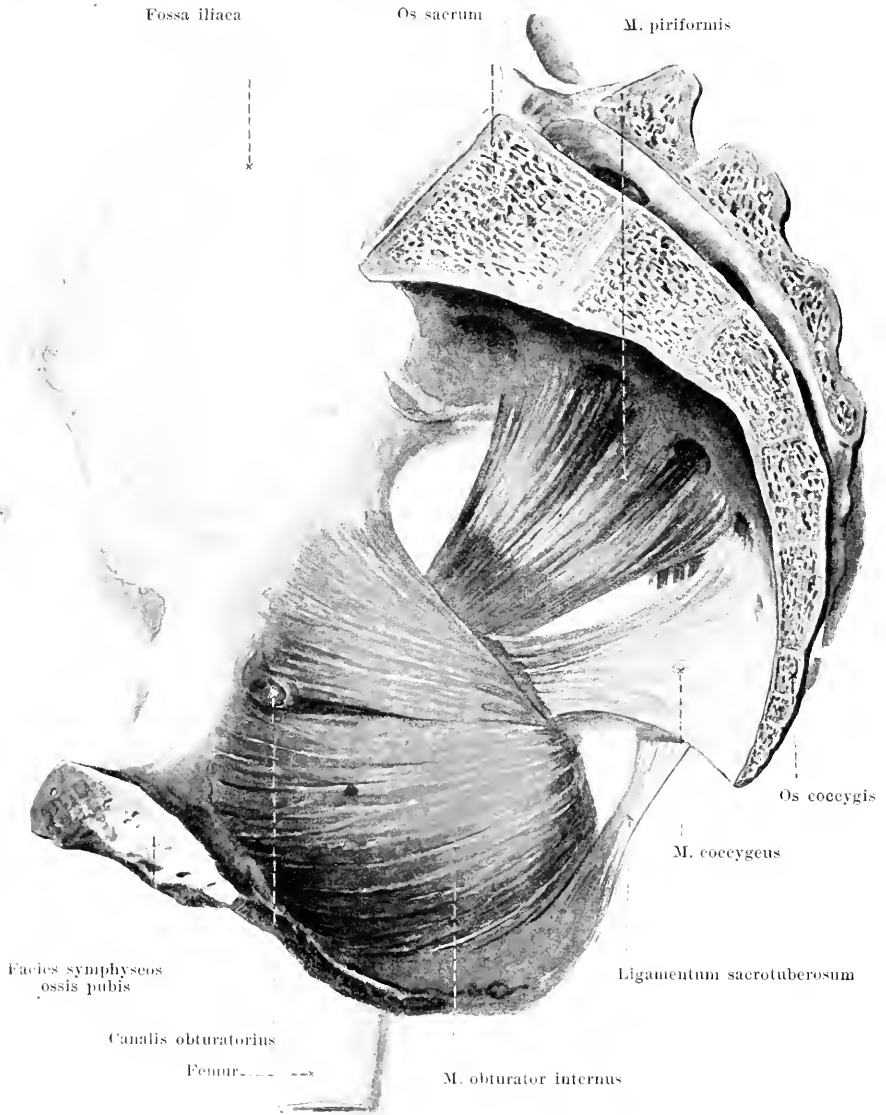
M. psoas minor (see also Figs. 314, 315 and 333), variable. Form: flat, long, narrow. Position: directly in front of the m. psoas major. Origin: lateral surface of the bodies of the 12th thoracic and 1st lumbar vertebra. Insertion: fascia iliaca. Action: it bends the lumbar spine lateralward and makes the fascia iliaca tense. Innervation: rami musculares plexus lumbalis.



372. Fascia iliaca dextra. [Text see p. 325 and 330.]

M. psoas major (see Figs. 314, 315, 333, 370, 371 and 376). Form: round, oblong-triangular. Position: posterior wall of the peritoneal cavity, directly in front of the mm. quadratus lumborum and iliacus, just lateral from the lumbar vertebrae and the apertura pelvis superior. Origin: lateral surfaces of the bodies and intervertebral discs of the 12th thoracic to the 5th lumbar vertebra as well as the procc. transversi of the lumbar vertebrae. Insertion: converging downward, forward and lateralward and with a narrow tendon to the trochanter minor femoris. Action: it bends the lumbar spine lateralward, flexes the thigh, and rotates it somewhat outward or, when the latter is fixed, it bends the pelvis and the body forward. Innervation: rami musculares plexus lumbalis.

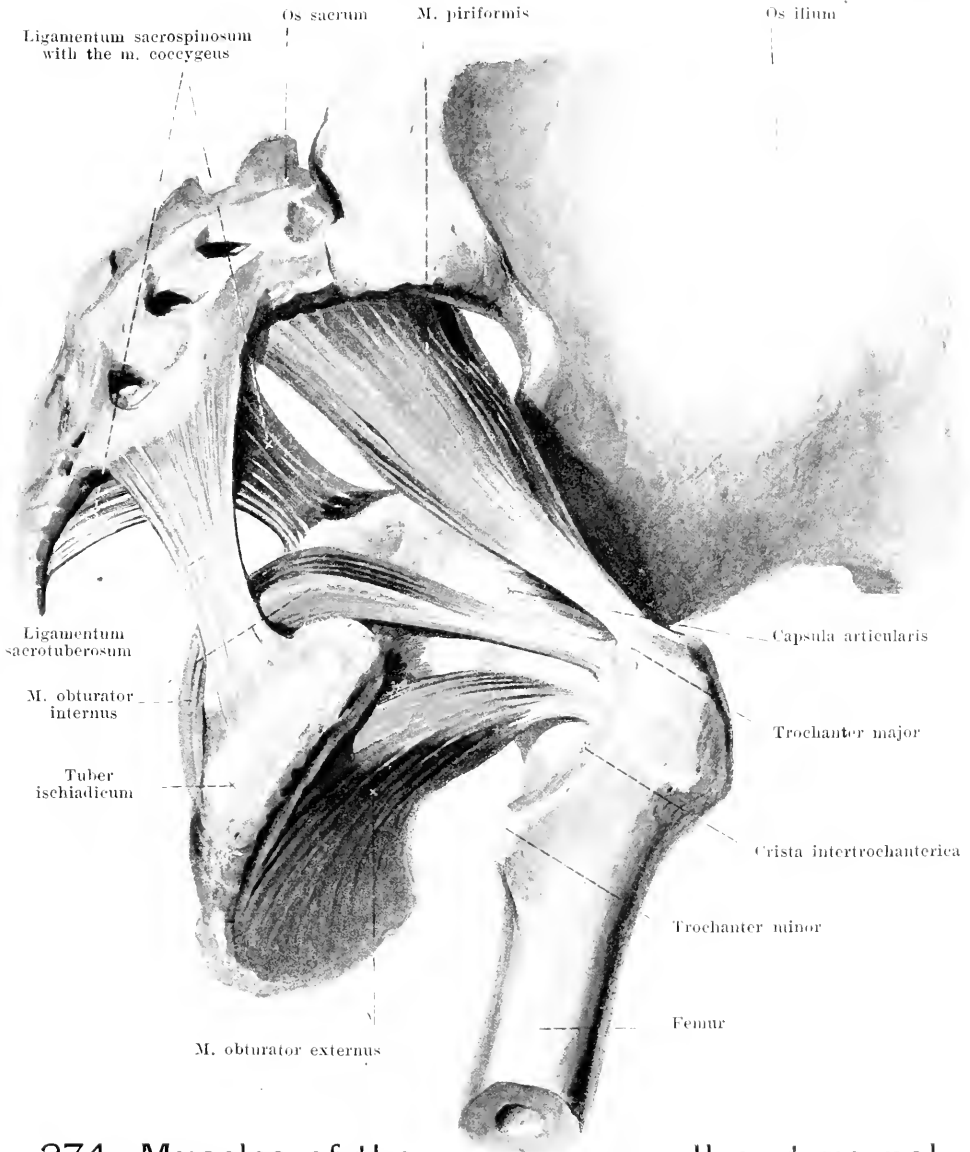
M. iliacus (see also Figs. 314, 370, 371 and 376). Form: flat, triangular. Position: in the fossa iliaca and anterior to the hip-joint, covered medianward by the m. psoas major. Origin: fossa iliaca, spina iliaca anterior superior and inferior: the latter origin (see Fig. 377) is also designated as the third head of the m. iliopsoas. Insertion: the fibers converge downward in front of the hip-joint (*bursa iliopectinea* see Fig. 377), then backward in common with the m. psoas major to the trochanter minor femoris (*bursa iliaca subtendinea* see Fig. 378). Action: it flexes the thigh and rotates it somewhat outward or, when this is fixed, it draws the pelvis, together with the body, forward. Innervation: rami musculares n. femoralis.



373. Muscles of the true pelvis on the right side, viewed from within.

M. obturator internus (see also Figs. 374 and 385). Form: flat, triangular. Position: in the small or true pelvis, on its lateral wall and close behind the hip-joint. Origin: medial surface of the os coxae and of the membrana obturatoria. Insertion: the fibers converge to the incisura ischiadica minor; there they bend lateralward (*bursa m. obturatoris interni* see Fig. 386) at a right angle and becoming tendinous pass between the two mm. gemelli to the fossa trochanterica femoris. Action: it rotates the thigh outward. Innervation: n. tibialis.

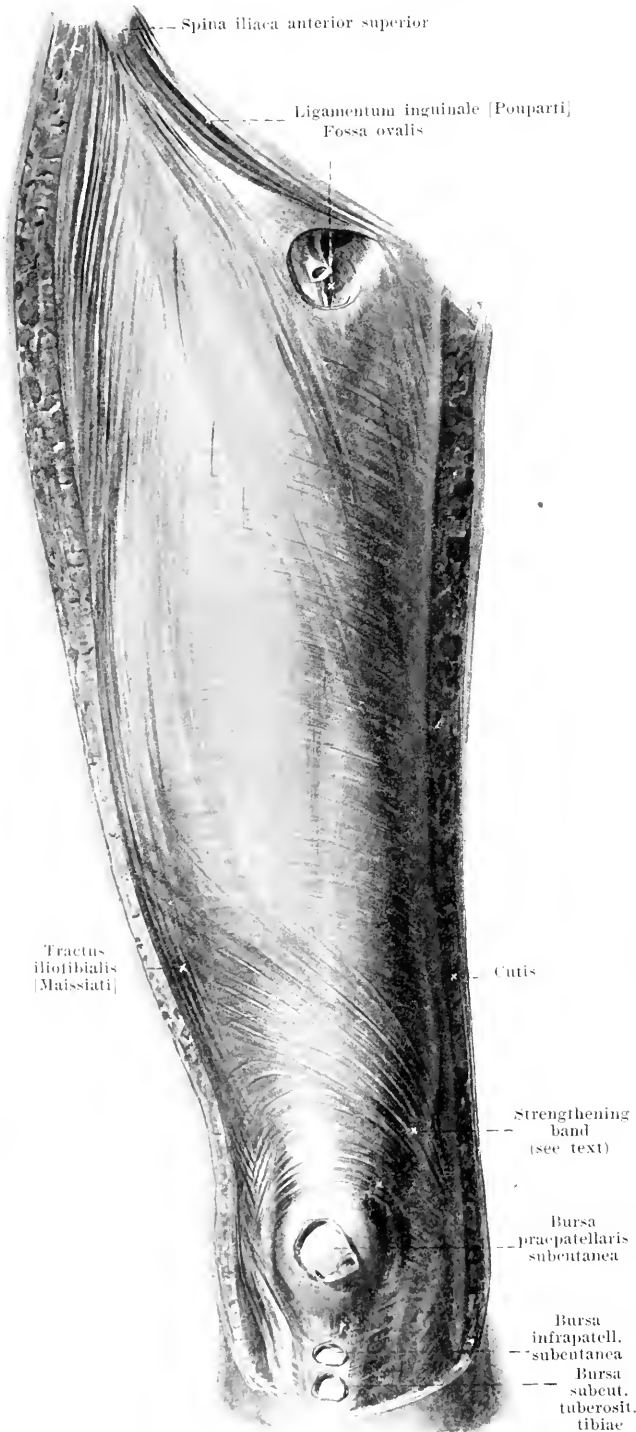
M. coccygeus (see also Figs. 374, 670 and 671). Form: quadrangular, thin. Position: on the anterior surface of the lig. sacrospinosum, forming with it a common mass of variable composition (see p. 194); it projects beyond it, especially below. Origin: spina ischiadica. Insertion: lateral edge of lower sacral and upper coccygeal vertebrae. Innervation: branches of the plexus pudendus.



374. Muscles of the small or true pelvis on the right side, viewed from without and below.

M. obturator externus (see also Figs. 375—380). Form: triangular, thick. Position: anterior surface of the small pelvis and beneath the hip-joint. Origin: anterior surface of the os coxae and of the membrana obturatoria. Insertion: converging lateralward to the fossa trochanterica femoris. Action: it rotates the thigh outward. Innervation: n. obturatorius.

M. piriformis (see also Figs. 373, 385 and 386). Form: flatly rounded, triangular. Position: behind the hip-joint. Origin: facies pelvina oss. sacri. Insertion: the fibers run, converging, through the foramen ischiadicum majus lateralward to the tip of the trochanter major femoris (*bursa m. piriformis* see Fig. 386). Action: it rotates the thigh outward and extends it somewhat backward and lateralward. Innervation: rami musculares plexus sacralis.



375.

Fascia of the right thigh, viewed from in front.

Fascia lata [anterior half] (see also Figs. 325 and 372) covers the free surface of the muscles of the thigh and is stronger lateralward and above. From near the knee a fibrous process runs upward and lateralward; a furrow in the skin corresponds to this when the knee is extended and the muscles are relaxed. The fascia also forms a sheath for the m. sartorius behind and divides above into a deep and a superficial layer. The deep layer covers the *fossa iliopectinea*. This (see Figs. 372 and 376) possesses a triangular entrance, comes in relation above with the lig. inguinale and ends below under the m. sartorius; lateralward it is bounded by the m. iliopsoas, medianward by the m. pectineus; above it is continued into the lacuna vasorum. It is the lateral part of the larger, triangular, *trigonum femorale* [*fossa Scarpae major*] (O. T. Scarpa's triangle), which is limited above by the lig. inguinale, laterally by the m. sartorius, and medianly by the medial edge of the m. adductor longus. Lateralward the deep layer is identical with the *fascia iliopectinea* (see p. 325), and medianward, upon the m. pectineus, it is called the *fascia pectinea*. The superficial layer partially covers the fossa iliopectinea and passes from the upper edge of the m. sartorius to the lower edge of the lig. inguinale. It ends medianward with a concave edge, *margo falciformis* (O. T. falciform ligament) which arises below from the fascia pectinea (*cornu inferius*), is often indistinctly outlined in its middle portion and, above (*cornu superius*), runs medianward to the lig. inguinale and the lig. lacunare.

376.

Muscles of the right thigh, viewed from in front.

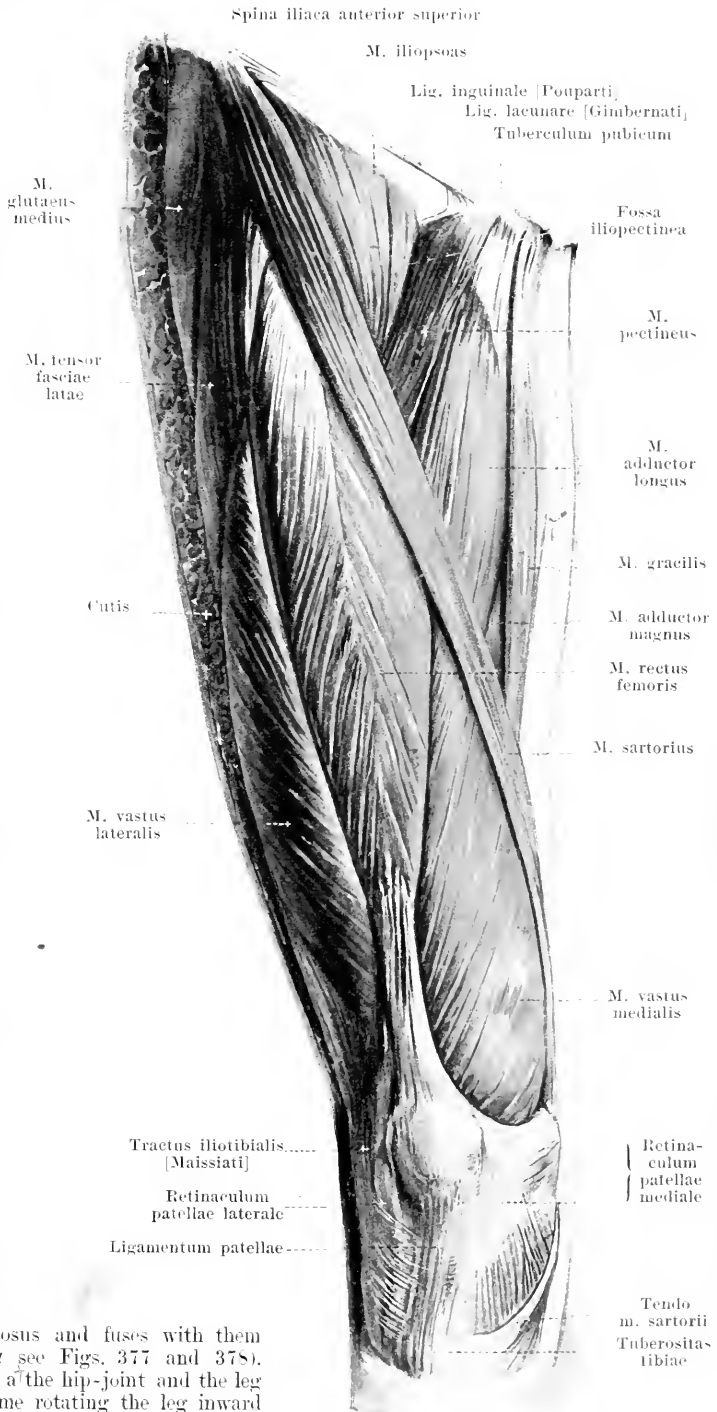
Fascia lata (continued). The fossa bounded by the margo falciformis is called the *fossa ovalis*; it is covered by the *fascia cribrosa*, a deep layer of the fascia superficialis which extends from the margo falciformis to the fascia pectinea and presents openings for lymph glands and vessels. The space from the annulus femoralis as far as the entrance to the fossa ovalis is called also the *cavitas femoralis*.

Bursae praepatellares see p. 214.

Bursa infrapatellaris subcutanea (see Fig. 375), frequently present, just beneath the skin, in front of the lig. patellae.

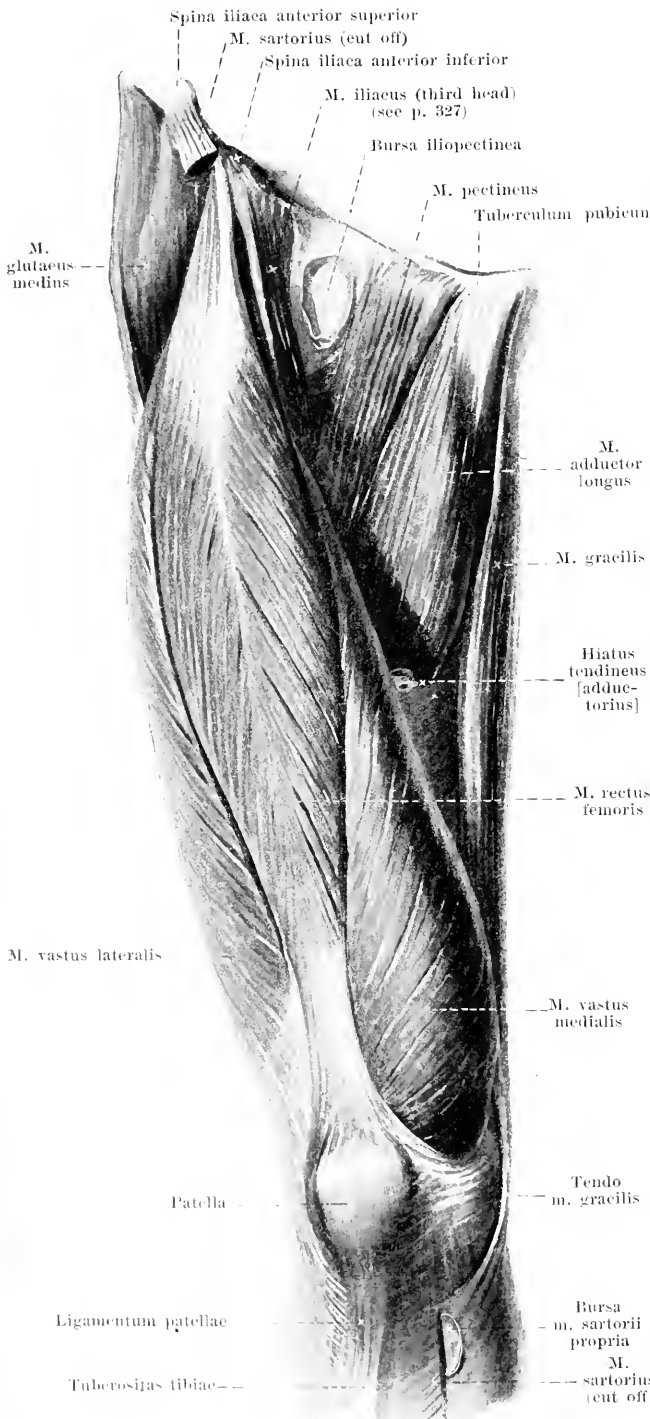
Bursa subcutanea tuberositatis tibiae (see Fig. 375), frequently present, in front of the tuberositas tibiae.

M. sartorius (see also Fig. 385). Form: flat, narrow, very long. Position: superficial, in a long spiral above on the anterior, below on the medial surface of the thigh. Origin: by a short tendon from the spina iliaca anterior superior. Insertion: the fibers run parallel, at first medianward and downward in front of the m. iliopsoas and in front of the groove between the m. quadriceps and the adductors, then downward medial from the m. vastus medialis in front of the m. vastus lateralis in front of the m. gracilis, then behind the epicondylus medialis, and thence obliquely forward with a flat, diverging tendon to the tuberositas tibiae and fascia cruris; the tendon covers the insertions of the mm. gracilis and semitendinosus and fuses with them (*bursa m. sartorii propria* see Figs. 377 and 378). Action: it flexes the thigh at the hip-joint and the leg at the knee, at the same time rotating the leg inward and the flexed thigh outward. Innervation: n. femoralis.



377. Muscles of the right thigh, viewed from in front.

(The mm. sartorius and tensor fasciae latae have been completely, the m. iliopsoas, for the most part, removed.)



Bursa iliopectinea (see also Fig. 370), constant, large, between the m. iliopsoas and the lig. iliofemorale; it is frequently connected with the cavity of the hip-joint.

M. pectineus (see also Figs. 370 and 376). Form: flat, oblong-quadrangular. Position: medial from and below the hip-joint, bounded lateralward by the m. iliopsoas, medianward by the m. adductor longus, behind by the mm. adductor brevis and obturator externus. Origin: from the ramus superior oss. pubis, pecten oss. pubis and ligamentum pubicum superius (see p. 197). Insertion: parallel downward, lateralward and backward to the linea pectinea femoris (*bursa m. pectinei* see Fig. 378). Action: it adducts and flexes the thigh, and rotates it outward. Innervation: n. femoralis.

M. gracilis (see also Figs. 376, 384, 386 and 388). Form: flat, long, thin. Position: superficial, on the medial surface of the thigh, medianward from the mm. adductores; behind it is bounded by the m. semimembranosus. Origin: by a broad tendon from the ramus inferior oss. pubis. Insertion: parallel downward, behind the epicondylus medialis femoris and thence forward by a thin tendon to the tuberositas tibiae, just below the tendon of the m. sartorius (*bursa anserina* see p. 378). Action: it adducts the thigh, flexes the leg and rotates it inward. Innervation: ramus anterior n. obturatorii.

378. Muscles of the right thigh, viewed from in front.

(The mm. sartorius, tensor fasciae latae, pectineus and gracilis have been removed; the knee joint has been opened on the medial side.)

M. quadriceps femoris, consists of four muscles, which are more or less distinctly separated above, but inseparably united at their insertion: *m. rectus femoris*, *m. vastus lateralis*, *m. vastus intermedius* and *m. vastus medialis*.

M. rectus femoris (see also Figs. 376 and 377). Form: spindle-shaped, thick, penniform. Position: on the anterior surface of the thigh, covered above by the *m. sartorius*, otherwise superficial. Origin: tendinous, partly from the spina iliaca anterior inferior, partly arch-like above the acetabulum (*bursa m. recti femoris* see Fig. 379). In sert.: the fibers diverge from the middle downward, where its flat tendon goes over above the patella into the common tendon. Action: it flexes the thigh and extends the leg. Innervation: n. femoralis.

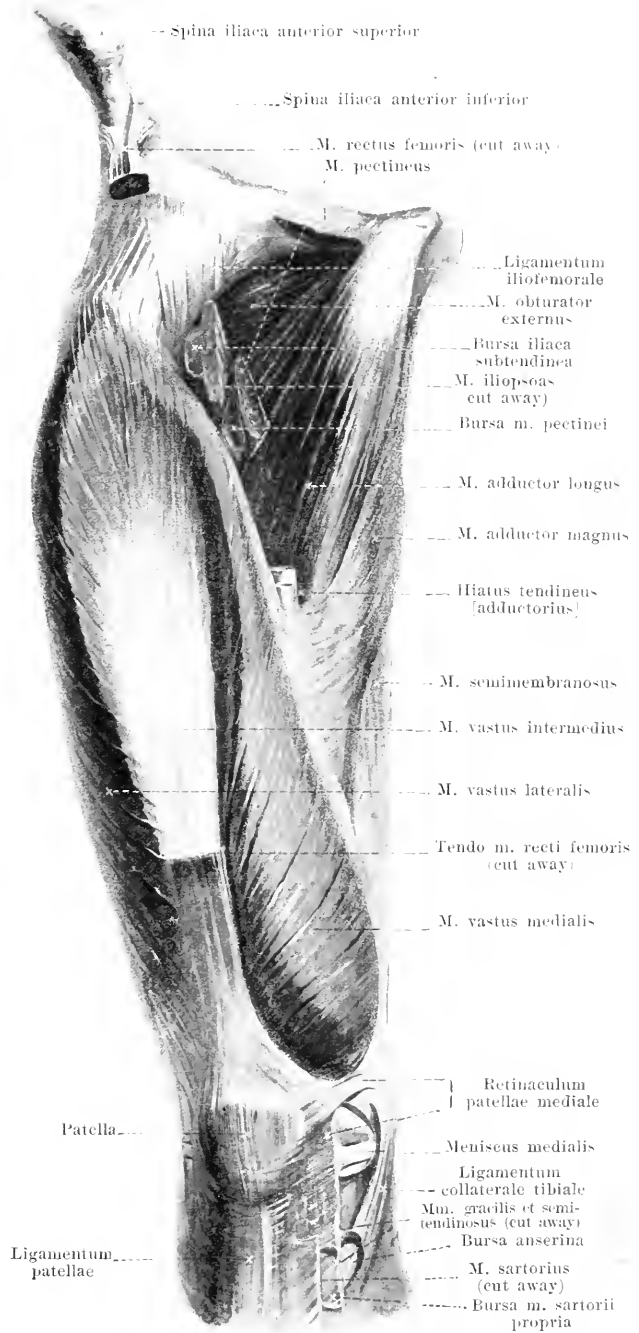
M. adductor longus (see also Figs. 376 and 377). Form: flat, oblong-triangular, thick. Position: on the anterior surface of the thigh, bounded laterally by the *m. pectineus*, medianly by the *m. gracilis*, behind by the mm. adductores brevis et magnus; in front, below, it is covered by the *m. sartorius*. Origin: by a thick tendon from the anterior surface of the ramus superior oss. pubis. In sert.: diverging downward and lateralward to the labium mediale of the linea aspera femoris. Action: it adducts and flexes the thigh and rotates it outward. Innervation: ramus anterior n. obturatorii.

Bursa iliaca subtendinea, very frequently present, between the *m. iliopsoas* and the trochanter minor.

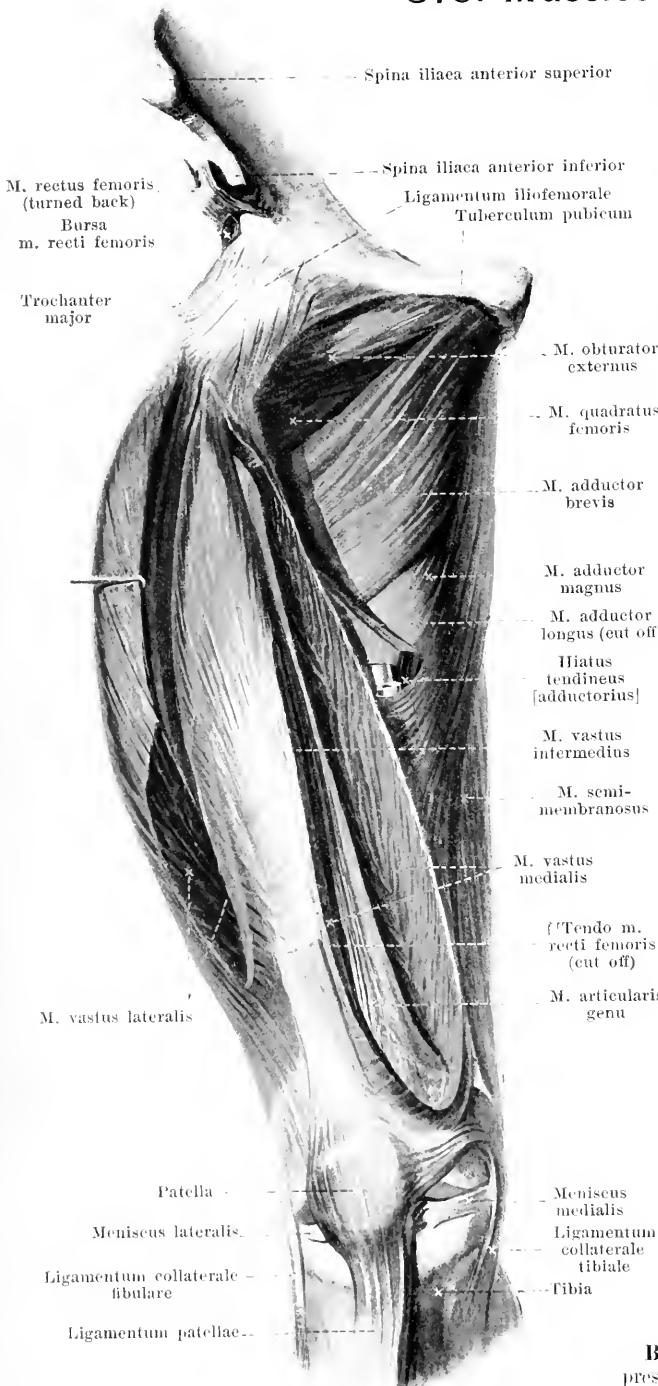
Bursa m. pectinei, very frequently present, between the *m. pectineus* and *m. iliopsoas*, just below the trochanter minor.

Bursa m. sartorii propria (see also Fig. 377), between the tendon of the *m. sartorius* and the tendons of the mm. gracilis and semimembranosus; not rarely connected with the

Bursa anserina, constant, large, between the tendons of the mm. gracilis and semitendinosus and the tibia.



379. Muscles of the right thigh, viewed from in front.



(Like Fig. 378; in addition the m. adductor longus has been entirely, the mm. vasti medialis et lateralis have been partially removed; the knee-joint has been opened.)

M. adductor brevis. Form: triangular, thick. Position: in front covered by the mm. adductor longus and pectineus, above adjoining the m. obturator externus, behind the m. adductor minimus. Origin: anterior surface of the rami ossis pubis. Insertion: diverging downward and lateralward to the labium mediale of the linea aspera femoris. Action: it adducts and flexes the thigh and rotates it outward. Innervation: ramus anterior n. obturatorii.

M. adductor minimus (O. T. upper portion of adductor magnus) (see Figs. 380 and 385—387). Form: triangular, thick. Position: behind the preceding, bounded above by the m. obturator externus and quadratus femoris, below by the m. adductor magnus, behind by the latter and the m. gluteus maximus. Origin: anterior surface of the rami inferiores ossis pubis and ossis ischii. Insertion: diverging lateralward and downward to the labium mediale of the linea aspera femoris. Action: it adducts and flexes the thigh and rotates it outward. Innervation: ramus posterior n. obturatorii.

M. adductor magnus (see Figs. 376, 378, 380, 381, 386 and 387). Form: triangular, thick. Position: on the medial side of the thigh, in front covered by the mm. adductores brevis et longus and sartorius, bounded above and in front by the m. adductor minimus, medianward by the m. gracilis and posteriorly by the mm. semimembranosus, semitendinosus and biceps. Origin: anterior surface of the ramus inferior oss. ischii and tuber ischiadicum. Insertion: the anterior fibers diverge lateralward and downward to the labium mediale of the linea aspera femoris (see also p. 336), the posterior fibers converge downward to a thick tendon, which runs to the epicondylus medialis. Action: it adducts the thigh. Innervation: ramus posterior n. obturatorii and n. tibialis.

Bursa m. recti femoris, frequently present, between the tendon of origin of the m. rectus femoris and the acetabulum.

380. Muscles of the right thigh, viewed from in front.

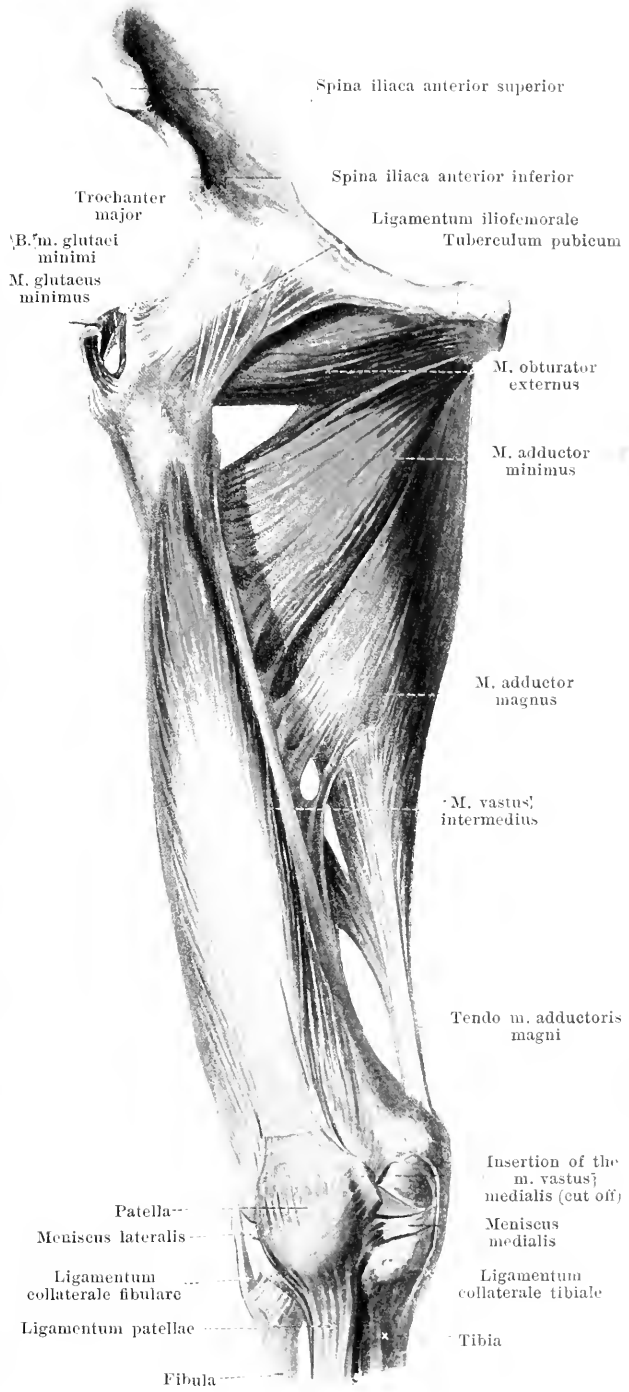
(The muscles have been removed with the exception of the *mm.* obturator externus, *adductores minimus et magnus* and *vastus intermedius*.)

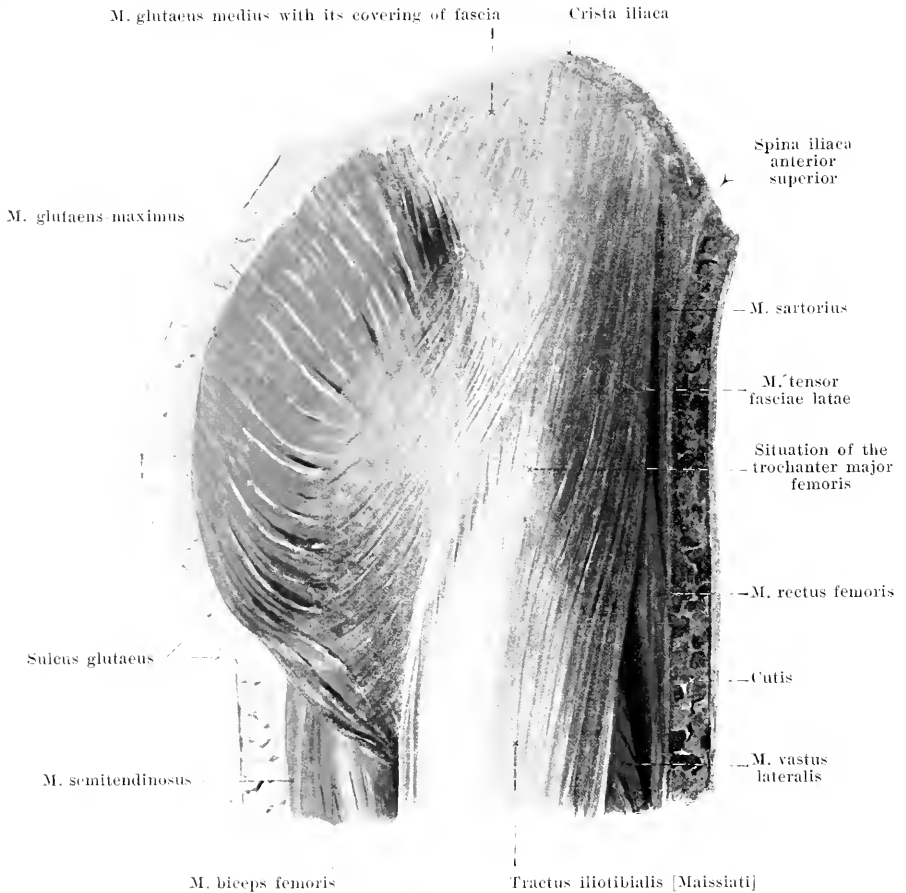
M. vastus intermedius (O. T. *crureus*) (see also Figs. 378 and 379). **Form:** flat, oblong. **Position:** on the anterior side of the thigh, directly upon the bone; in front covered by the *m. rectus femoris*; at the sides covered over by the *mm.* *vasti medialis et lateralis*, being fused with them. **Origin:** anterior surface of the *corpus femoris*. **Insertion:** the fibers run parallel downward, covered in front by a thin, flat tendon, and go, above the patella, into the common tendon (see p. 336).

M. articularis genu (O. T. *subcrureus*) (see Figs. 379, 390 and 392) forms, in a sense, the deepest layer of the preceding muscle. **Form:** flat, thin. **Position:** directly upon the lower third of the femur, covered by the preceding muscle. **Origin:** anterior surface of the *corpus femoris*. **Insertion:** upper and lateral surface of the capsule of the knee-joint. **Action:** it makes this capsule tense.

M. vastus lateralis (O. T. *vastus externus*) (see Figs. 376—379, 387 and 389). **Form:** flat, spindle-shaped, thick. **Position:** on the lateral surface of the thigh, chiefly superficial, covered only by the *m. tensor fasciæ latae* and the *tractus iliotibialis*, bounded behind by the *m. biceps femoris*. **Origin:** *linea intertrochanterica*, lateral surface of the *trochanter major* and *labium laterale* of the *linea aspera femoris*. **Insertion:** the fibers run parallel, in a curve, medianward and downward and are attached partly to the *m. vastus intermedius*, partly, above and lateralward from the patella, to the common tendon (see p. 336).

Bursa m. glutei minimi, almost constant, fairly large, between the tendon of the *m. gluteus minimus* and the *trochanter major femoris*.



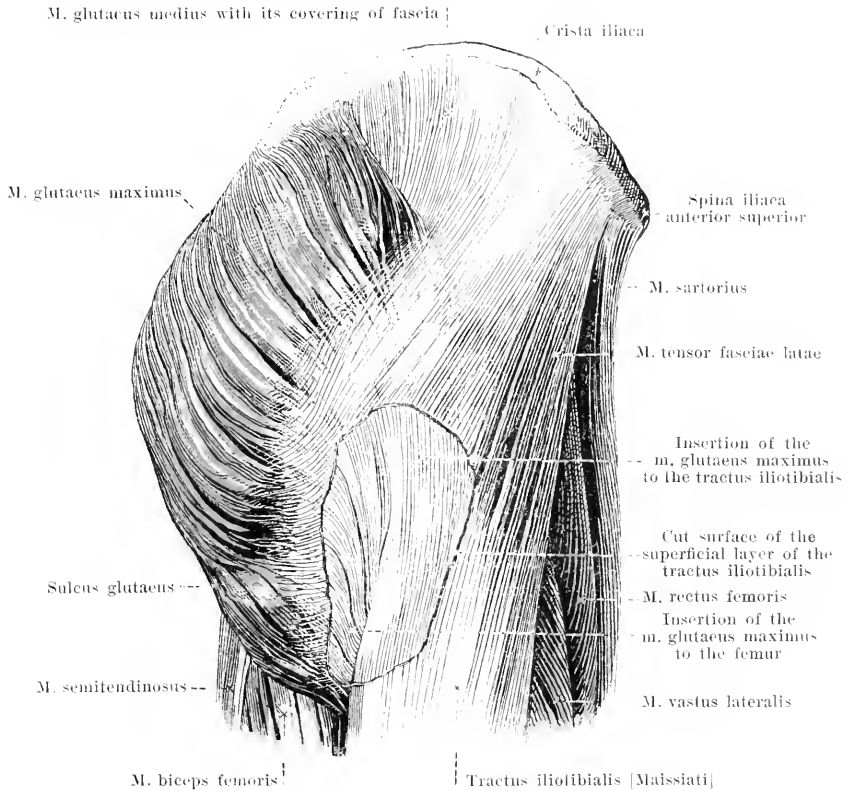


381. External muscles of the right hip, viewed from the lateral surface.

M. vastus medialis (O. T. vastus internus) (see Figs. 376—379, 387 and 388). Form: flat, spindle-shaped, thick. Position: on the medial and anterior surface of the thigh: covered at its origin by the m. sartorius; otherwise superficial; comes into contact behind with the mm. adductores longus et magnus. Origin: labium mediale lineae asperae femoris. Insertion: the fibers go, parallel, in a curve, lateralward and downward, partly to the m. vastus intermedius, partly, above and medianward from the patella, to the common tendon. From the anterior surface of the m. adductor magnus, approximately from the lower margin of the m. adductor longus on, a tendinous plate goes to the medial surface of the m. vastus medialis: this bridges over a triangular vascular canal, which extends obliquely backward and downward, the *canalis adductorius* [Hunter] (O. T. Hunter's canal), the anterior entrance to which is called the *hiatus tendineus* [adductorius].

The common tendon of the m. quadriceps femoris is attached to the upper and to the lateral margins of the patella and partly goes over in front of it, directly into the lig. patellae. Some of the tendon fibers of the mm. vastus medialis and vastus lateralis run however downward beside the patella to the anterior surface of the condyli tibiae and thus form the *retinacula patellae mediale et laterale* (see Figs. 376 and 388), of which the medial one is the broader and the more distinct: to these are also to be added other ligamentous bands which extend from the epicondylus forward to the patella and into which also bands of muscle are inserted.

Action of the mm. vasti: they extend the leg. Innervation of the same: n. femoralis.



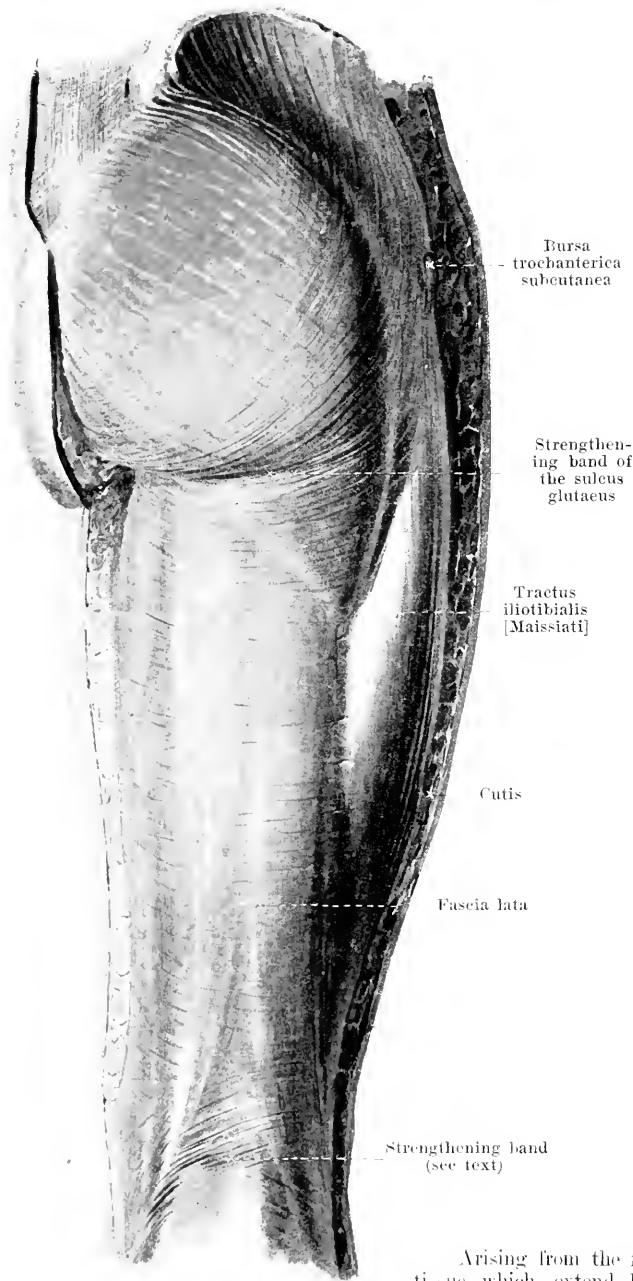
382. External muscles of the right hip, viewed from the lateral surface.

(In order to show the varying mode of attachment of the *m. glutaeus maximus*, a piece has been cut out of the superficial layer of the tractus iliobtibialis and the deeper layer has been dissected out.)

M. tensor fasciae latae (*O. T. tensor vaginae femoris*) (see also Figs. 376 and 381). **Form:** flat, oblong-quadrangular, thick. **Position:** on the lateral surface of the hip, just beneath the skin; bounded in front by the *mm. sartorius* and *rectus femoris*, medianward and behind by the *m. glutaeus medius*. **Origin:** tendinous from the spina iliaca anterior superior and from the fascia lata. **Insertion:** the fibers run parallel downward and go over, at the junction of the upper with the middle third of the thigh, into the tractus iliobtibialis [Maissiat] (iliotibial band). The muscle is covered on its lateral surface by a thin fascia, on its medial surface by a thicker layer of fascia; these can be looked upon as a superficial and a deep layer of the fascia lata. **Action:** it makes the fascia lata tense, especially the tractus iliobtibialis; it flexes the thigh and rotates it somewhat inward. **Innervation:** *n. glutaeus superior*.

M. glutaeus maximus (see also Figs. 329, 381, 384, 385 and 387). **Form:** flat, quadrangular, very thick. **Position:** just beneath the skin of the buttock, the fleshy basis of which it forms. **Origin:** lateral surface of the ala oss. ilium behind the linea glutaea posterior, the posterior surface of the sacrum and coccyx and their ligaments, the *ligg. sacro-iliaca posteriora* and the *lig. sacrotuberosum*. **Insertion:** the fibers run, nearly parallel, lateralward and downward; those of the upper portion go, in the form of a broad tendon, over the lateral surface of the trochanter major femoris (*b. trochanterica m. glutaei maximi* see Figs. 385—387 and p. 343), curve downward and pass over into the deep layer of the tractus iliobtibialis, hidden by the superficial layers of the same; the fibers of the lower portion are attached by a thick, flat tendon to the tuberositas glutaea femoris (*bursae glutaeofemorales* see Figs. 386 and 387, and p. 343). **Action:** it extends the thigh backward and rotates it somewhat outward. **Innervation:** *n. glutaeus inferior*.

383. Fascia of the right thigh, viewed from behind.



Fascia lata (posterior half) (see also Figs. 381, 382 and 389) is, upon the posterior surface of the m. gluteus maximus, in general thin; distalward it is somewhat thicker. Interwoven in the fascia, along the lateral surface, from the lower end of the m. tensor fasciae latae, on, is a broad, thick, glistening, tendinous strip of parallel fibers, the *tractus iliobibialis* [Maissiat] (O. T. iliobibial band), which is attached below to the condylus lateralis tibiae. This strip consists above (see Fig. 382) of a deep layer, which is the direct continuation of the tendinous fibers of the m. gluteus maximus, and of a superficial layer, which consists partly of tendinous fibers of the m. tensor fasciae latae, partly of fibers which descend from the thick fascial covering of the m. gluteus medius. From the latter region comes also a thicker, flat bundle which crosses the insertion of the m. gluteus maximus and extends in a curve from above downward and medianward to the tuber ischiadicum. This strand, cutting deep into the muscle, corresponds to the *sulcus gluteus* (O. T. gluteal groove), which is visible as a furrow, running transversely in the skin when the m. gluteus maximus is relaxed. A less marked strengthening band, in the popliteal space, extends from above and lateralward downward and medianward and corresponds also to a similarly directed furrow in the skin.

Arising from the fascia lata are septa of connective tissue which extend between the individual muscles and groups of muscles; the strongest of these pass behind the origins of the mm. vastus medialis and vastus lateralis to the labium mediale and labium laterale of the linea aspera femoris, forming the *septum intermusculare [femoris] mediale* and *septum intermusculare [femoris] laterale* (see Fig. 387); they serve partly for the attachment of the neighboring muscles.

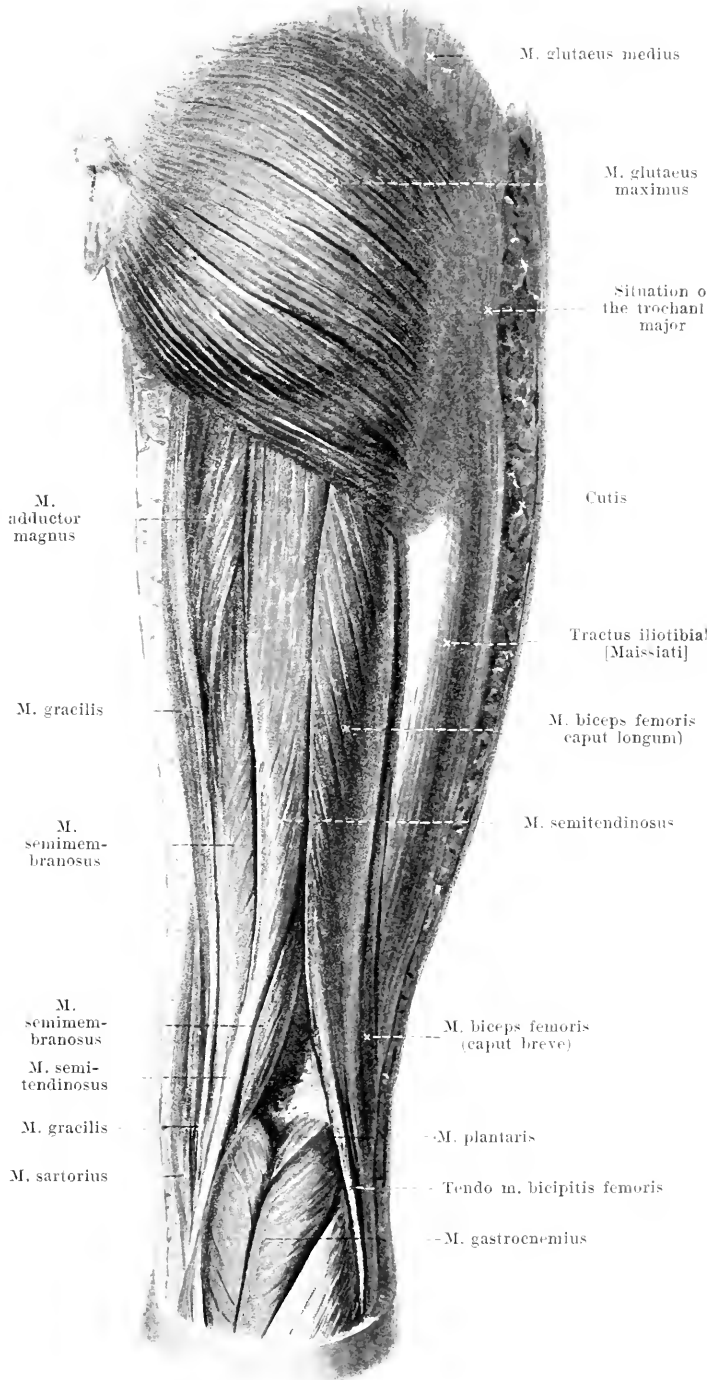
Bursa trochanterica subcutanea, frequently present, small, just beneath the skin, upon the lateral surface of the trochanter major.

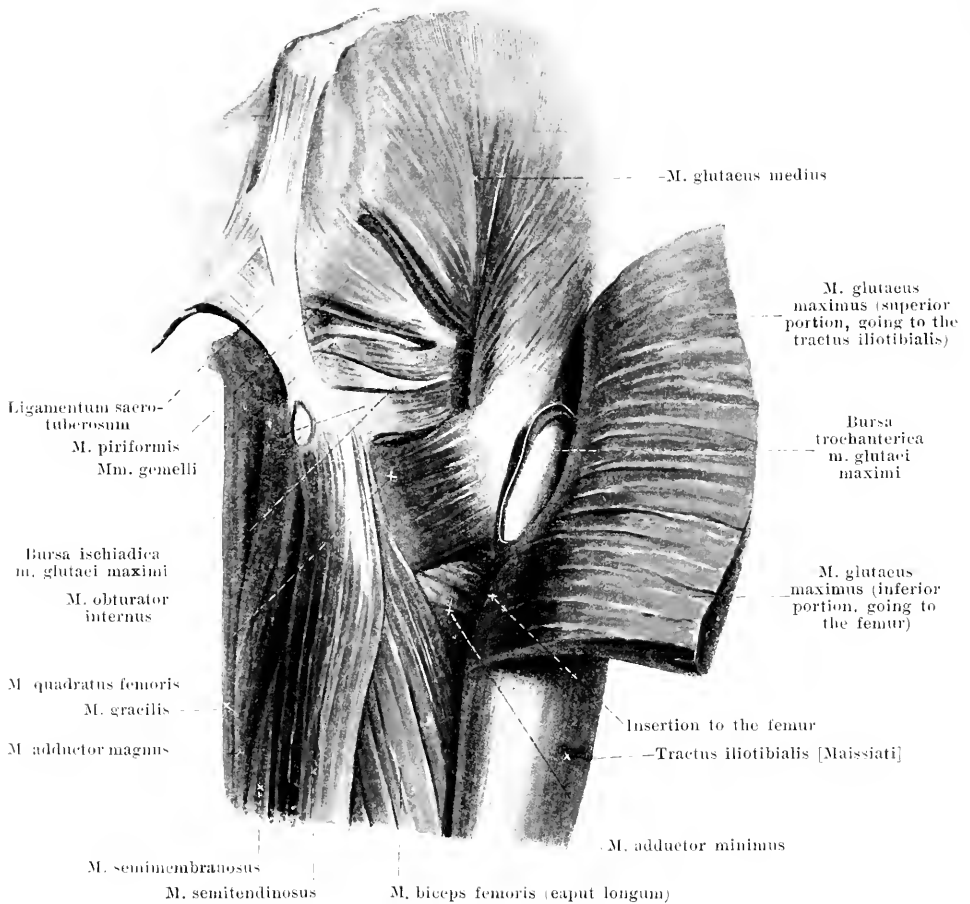
384.

Muscles of the right thigh, viewed from behind.

M. semitendinosus (see also Figs. 385 and 388). Form: triangular, long, tapering below. Position: on the posterior surface of the thigh; behind, in large part, superficial, covered only above by the m. gluteus maximus; lateralward it is bounded by the caput longum m. bicipitis, medianward by the mm. adductor magnus and semimembranosus, in front by the m. adductor magnus. Origin: tendinous from the tuber ischiadicum, in common with the caput longum m. bicipitis (*bursa m. bicipitis femoris superior* see Fig. 386 and p. 343). Insertion: it runs converging downward, then lies with a long tendon in a furrow of the m. semimembranosus and extends from there behind the tendon of the m. gracilis and in common with it, in a curve, forward to the tuberositas tibiae (see m. sartorius p. 331) (*bursa anserina* see Fig. 378). Action: it extends the thigh backward, flexes the leg and rotates it at the same time inward. Innervation: n. tibialis.

M. semimembranosus (see also Figs. 379, 385, 386 and 388). Form: flat, oblong-quadrangular. Position: on the posterior surface of the thigh; below, partly just beneath the skin, otherwise covered by the m. semitendinosus; lateralward below it is bounded by the m. biceps, in front by the mm. quadratus femoris, adductor magnus and gracilis. Origin: by a flat, long, strong tendon from the tuber ischiadicum (*bursa m. bicipitis femoris superior* see Fig. 386 and p. 343). (Continued on p. 340.)



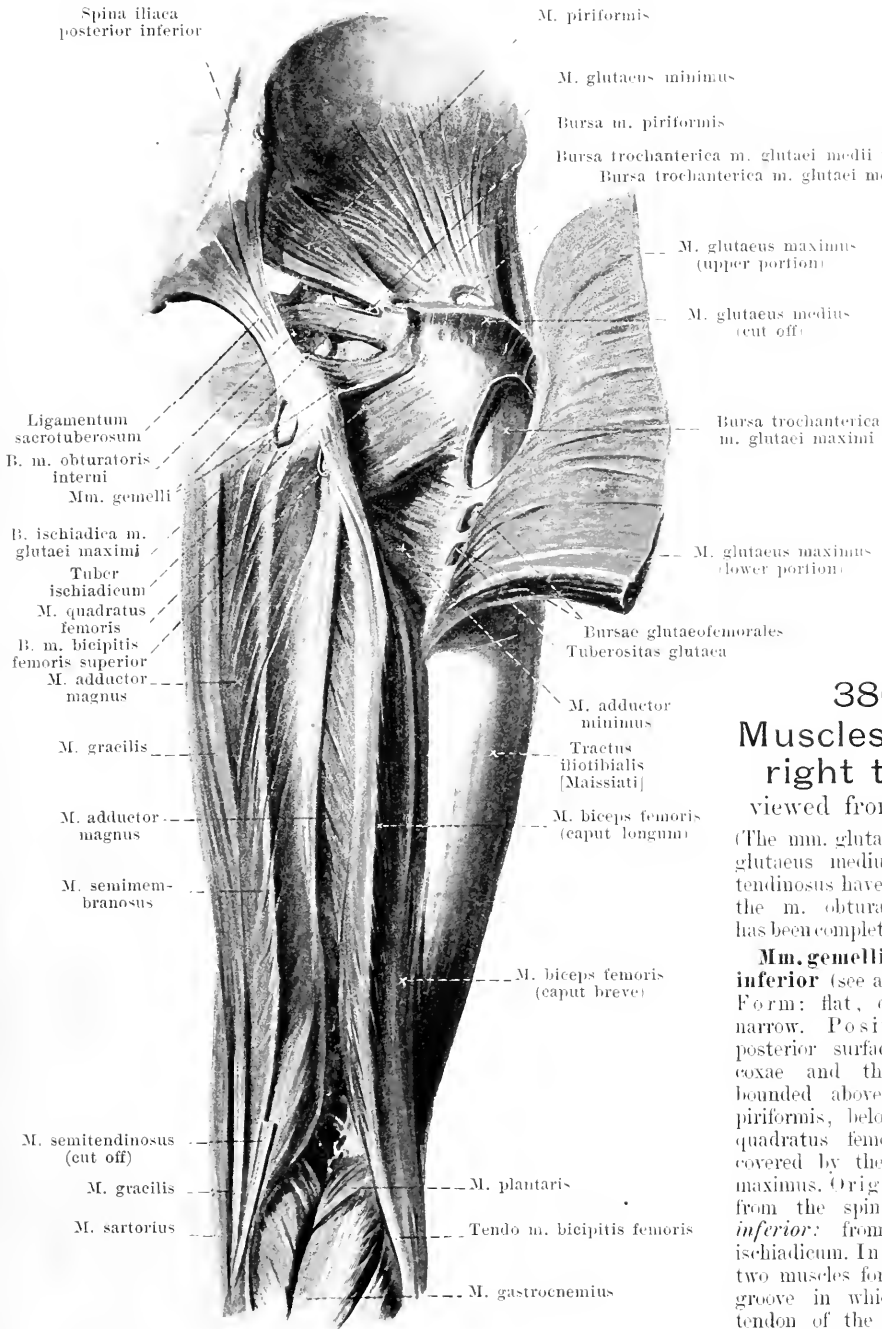


385. Muscles of the right buttock (2nd layer, viewed from behind.

(The *m. glutaecus maximus* has been cut through and reflected lateradward.)

M. semimembranosus (continued). **Insertion:** the tendon reaches downward on the lateral surface of the muscle as far as its lower half; from its medial surface fibers go medianward and downward to a tendinous strip, which begins in the upper half, runs downward on the medial surface and goes, behind the epicondylus medialis femoris between the tendons of the *mm. gracilis* and *semitendinosus* (see Fig. 388), to the condylus medialis tibiae; it is there partly attached to the bone, in part it bends around into the *lig. popliteum obliquum* and in part it goes over into that portion of the fascia cruris which covers the posterior surface of the *m. popliteus* (see Fig. 258) (*bursa m. semimembranosii* see Figs. 387, 393, 394 and 396 and p. 345). **Action:** it extends the thigh backward and flexes the leg. **Innervation:** *n. fibialis*.

M. glutaecus medius (see also Figs. 329, 376, 377, 381, 382 and 384). **Form:** flat, triangular, thick. **Position:** on the lateral surface of the hip; in its upper and lateral parts superficial, covered only by the fascia lata, which is here very thick; in front it is overlapped by the *m. tensor fasciae latae*, behind by the *m. glutaecus maximus*, being bounded medianward by the *m. glutaecus minimus*. **Origin:** lateral surface of the ala oss. ilium, between the linea glutaeca anterior and posterior; fascia lata. **Insertion:** the fibers converge downward and become attached by a short tendon to the lateral surface of the trochanter major, near its apex (*bursa trochantericae m. glutaeci medii* see Fig. 386 and p. 343). **Action:** it abducts the thigh. **Innervation:** *n. glutaecus superior*.

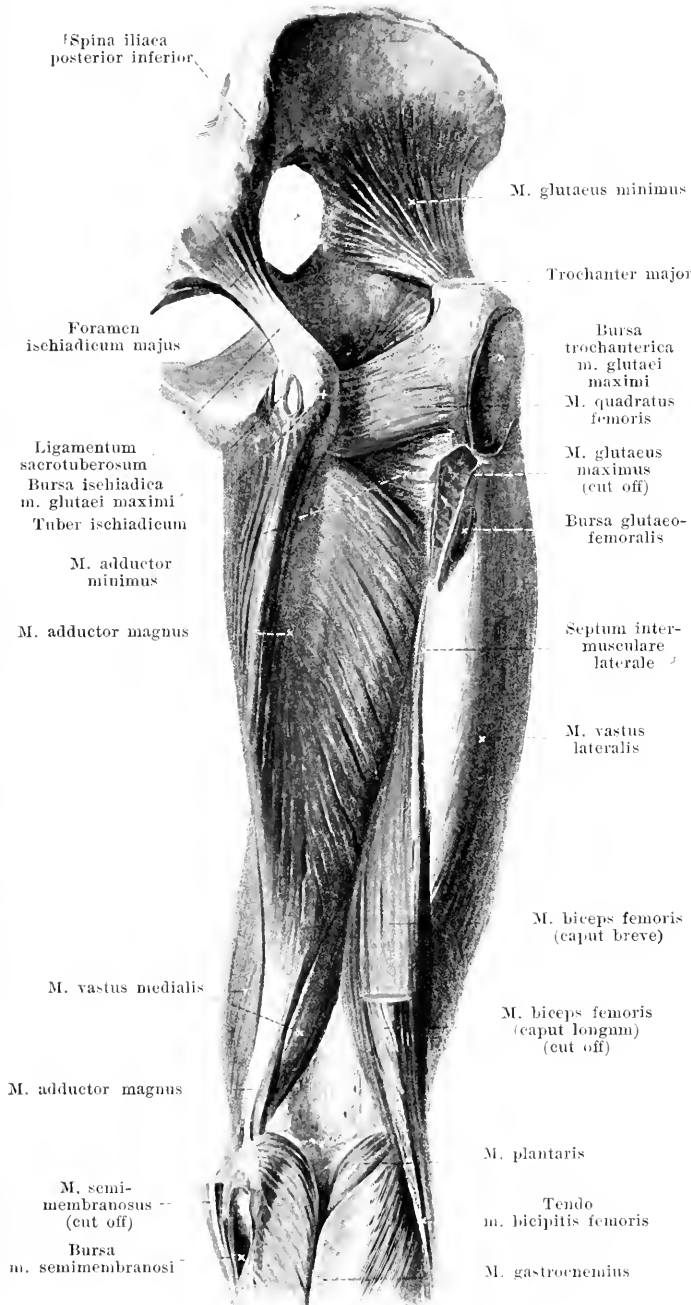


386.
Muscles of the right thigh,
 viewed from behind.

(The mm. gluteus maximus, gluteus medius and semitendinosus have been largely, the m. obturator internus has been completely, removed.)

Mm. gemelli superior et inferior (see also Fig. 385).
Form: flat, quadrangular, narrow. **Position:** on the posterior surface of the os coxae and the hip joint, bounded above by the m. piriformis, below by the m. quadratus femoris, behind covered by the m. gluteus maximus. **Origin:** *superior:* from the spina ischiadica; *inferior:* from the tuber ischiadicum. **Insertion:** the two muscles form together a groove in which runs the tendon of the m. obturator internus (*b. m. obturatoris interni* see p. 343); the fibers

run, parallel, lateralward partly to the tendon of the m. obturator internus, partly with this to the fossa trochanterica femoris. **Action:** they rotate the thigh outward. **Innervation:** n. tibialis.



387.

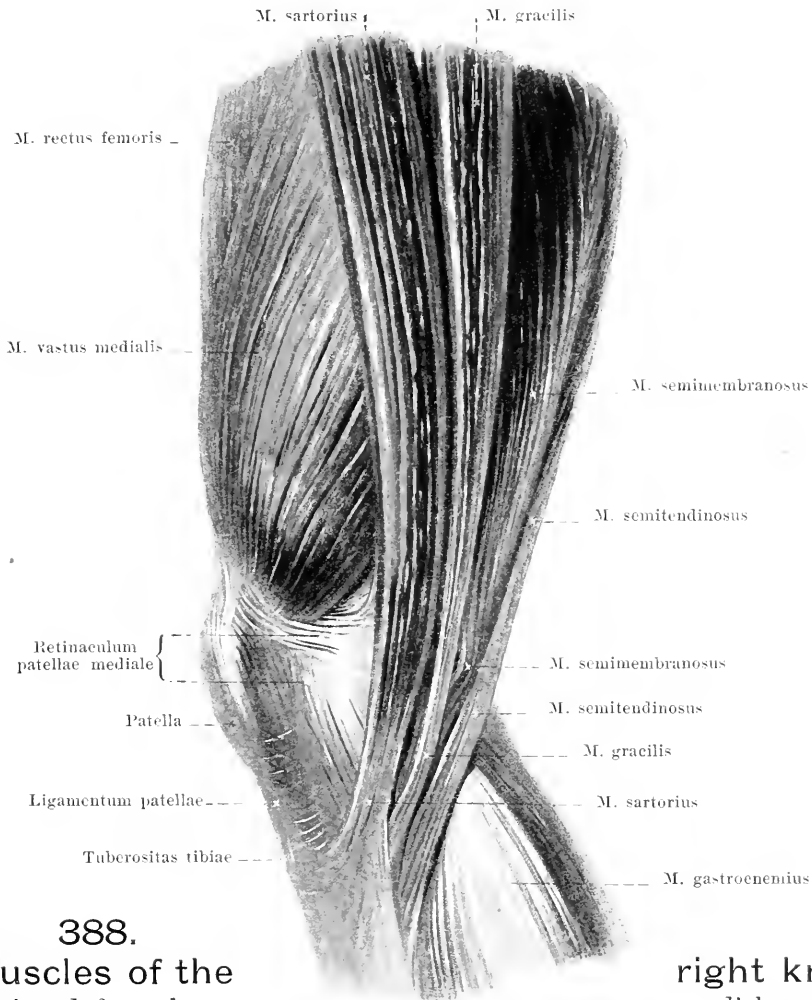
Muscles of the right thigh, viewed from behind.

(The mm. glutei maximus et medius, piriformis, obturator internus, gemelli, semitendinosus and semimembranosus, as well as the caput longum m. bicipitis, have been removed.)

M. gluteus minimus (see also Figs. 380 and 386). Form: flat, triangular. Position: on the lateral surface of the hip, just above the hip-joint; covered by the m. gluteus medius, in front partly fused with it; bounded in front by the mm. rectus femoris and tensor fasciae latae, behind by the m. piriformis. Origin: lateral surface of the ala oss. ilium between the linea glutea anterior and inferior. Insertion: the fibers converge downward and lateralward and go with a strong tendon to the anterior surface of the trochanter major femoris (*b. trochanterica m. glutei minimi* see Fig. 380). Action: it abducts the thigh. Innervation: n. gluteus superior.

M. quadratus femoris (see also Figs. 379, 385 and 386). Form: flat, quadrangular. Position: behind and below the hip-joint, bounded in front by the m. obturator externus, below by the m. adductor minimus, behind by the mm. semimembranosus, biceps and gluteus maximus, above by the m. gemellus inferior. Origin: tuber ischiadicum. Insertion: the fibers run parallel lateralward to the crista intertrochanterica femoris. Action: it rotates the thigh outward. Innervation: n. tibialis.

Bursa ischiadica m. glutei maximi (see also Figs. 385 and 386) very frequently present; upon the posterior surface of the tuber ischiadicum and of the origins of the mm. biceps and semitendinosus, between these and the m. gluteus maximus.



388.
Muscles of the
viewed from the

right knee,
medial surface.

Bursa trochanterica m. glutaeci maximi (see Fig. 385—387), constant, very large, upon the posterior and lateral surface of the trochanter major as well as upon the origin of the m. vastus lateralis. between these and the upper portion of the m. glutaecus maximus.

Bursae glutaecofemorales (see Figs. 386 and 387), constant, two or three small bursae below the preceding; partly lateral, partly medial from the attachment of the m. glutaecus maximus to the femur.

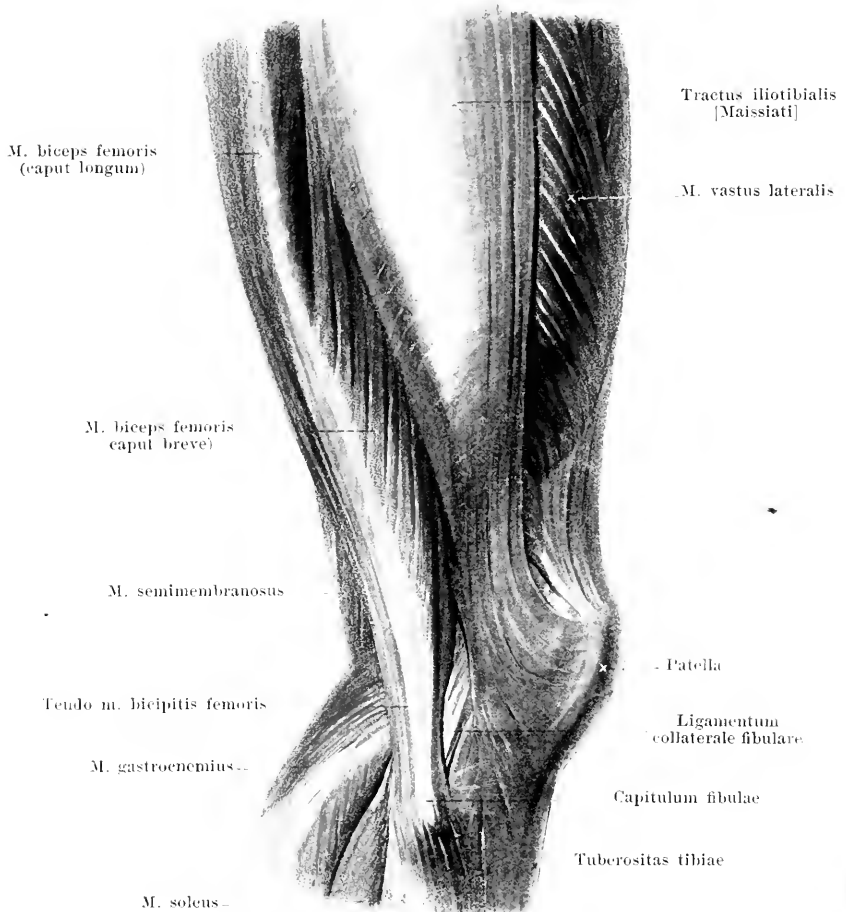
Bursa trochanterica m. glutaeci medii anterior (see Fig. 386), constant, sometimes double; between the tendon of the m. glutaecus medius and the apex of the trochanter major.

Bursa trochanterica m. glutaeci medii posterior (see Fig. 386), very frequently present, between the tendon of the m. glutaecus medius and the tendon of the m. piriformis.

Bursa m. piriformis (see Fig. 386), frequently present, in front of and below the tendon of the m. piriformis, between it, the bone and the m. gemellus superior.

Bursa m. obturatoris interni (see Fig. 386), constant, between the incisura ischiadica minor and the m. obturator internus; it is very often continued into the groove formed by the mm. gemelli, for which it forms a lining; the latter part is very rarely independent.

Bursa m. bicipitis femoris superior (see Fig. 386), inconstant, between the tendons of the mm. biceps and semitendinosus on the one hand and the tendon of the m. semimembranosus on the other.



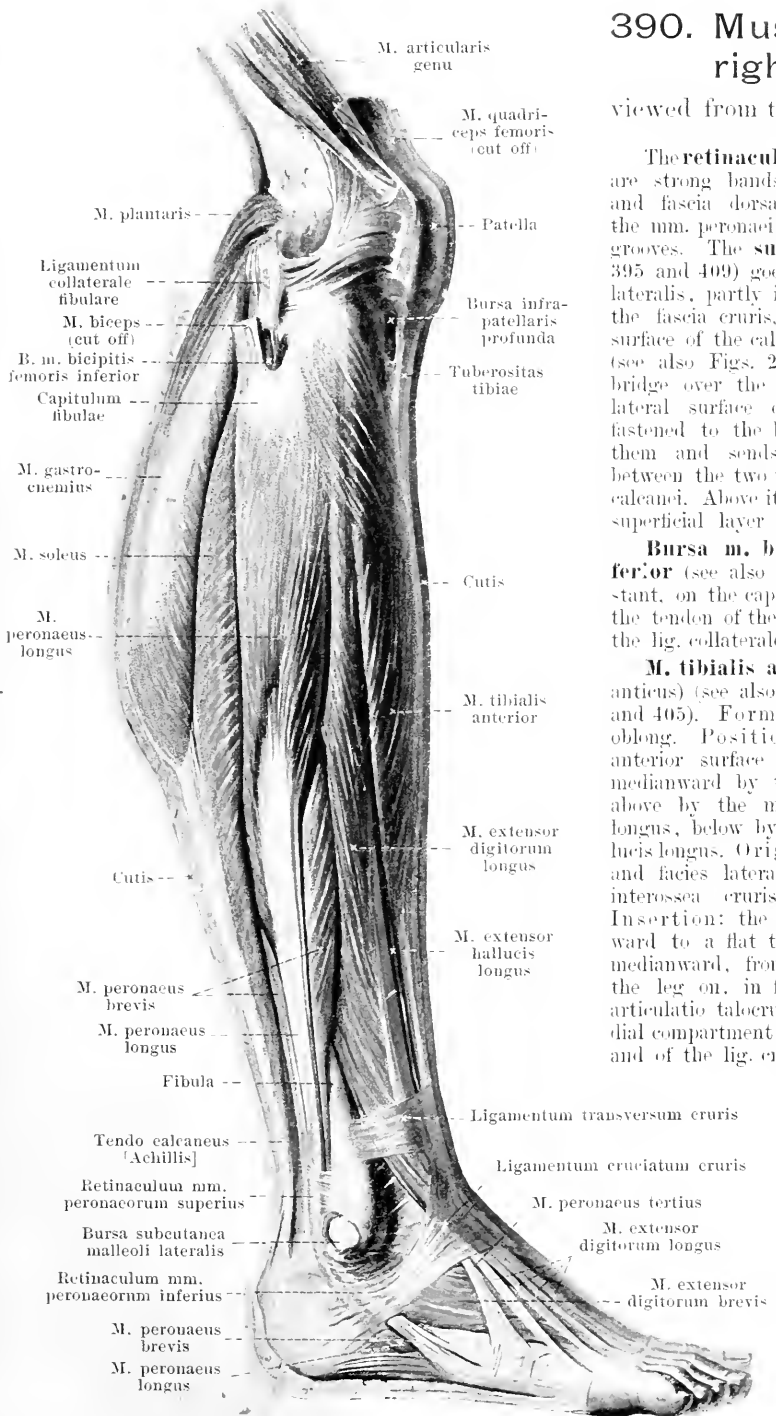
389. Muscles of the right knee, viewed from the lateral surface.

(The fascia lata with the exception of the tractus iliotibialis has been removed.)

M. biceps femoris (see also Figs. 384—387). Form: triangular-prismatic, long with two heads. Position: on the posterior surface of the thigh, chiefly superficial, covered only above by the *m. glutaeus maximus*; bounded medianward by the *mm. semitendinosus* and *semimembranosus*, lateralward by the *m. vastus lateralis*, in front by the *mm. quadratus femoris* and *adductor magnus*. Origin: *caput longum*: by a short, strong tendon from the tuber ischiadicum, in common with the *m. semitendinosus* (*bursa m. bicipitis femoris superior* see Fig. 386 and p. 343); the tendon is continued on the medial surface of the muscle as far as its inferior half; from it muscle fibers run out lateralward and downward to a tendon which begins on the lateral surface in the upper half of the muscle; *caput breve*: fleshy, from the labium laterale of the linea aspera femoris; the fibers go backward and downward to the tendon of the *caput longum*. Insertion: the lowermost, common part extends downward behind the epicondylus lateralis femoris (*b. bicipitogastrocnemialis* see Fig. 393) and goes by a strong, rounded tendon to the capitulum fibulae; in so doing it spans the lig. collaterale fibulare from behind and lateralward by two limbs (*bursa m. bicipitis femoris inferior* see Figs. 390 and 391). Action: it extends the thigh backward and rotates it outward; it flexes the leg and rotates it outward. Innervation: *caput longum*: n. tibialis; *caput breve*: n. peroneus communis.

390. Muscles of the right leg,

viewed from the lateral surface.

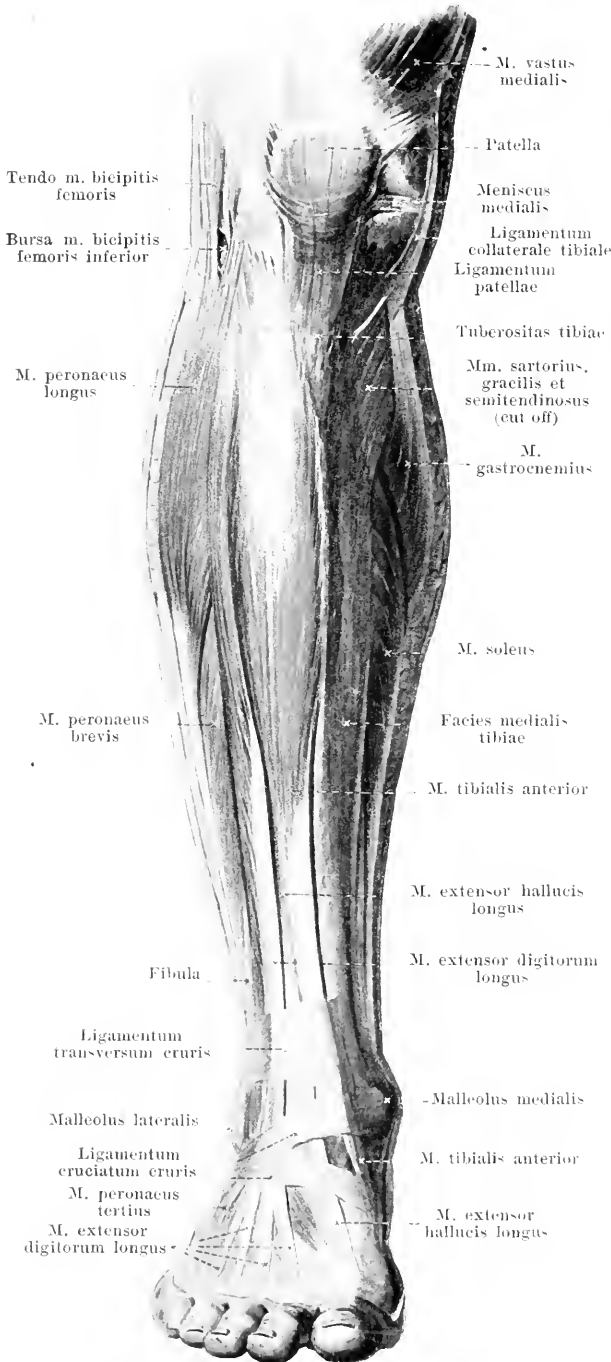


The **retinacula mm. peronaeorum** are strong bands of the fascia cruris and fascia dorsalis pedis which hold the mm. peronaei firmly in their bony grooves. The **superius** (see Figs. 393, 395 and 409) goes, from the malleolus lateralis, partly into the deep layer of the fascia cruris, partly to the lateral surface of the calcaneus. The **inferius** (see also Figs. 264 and 409) forms a bridge over the mm. peronaei on the lateral surface of the calcaneus, is fastened to the bone above and below them and sends a septum in front between the two to the proc. trochlearis calcanei. Above it is connected with the superficial layer of the lig. cruciatum.

Bursa m. bicipitis femoris inferior (see also Fig. 391), almost constant, on the capitulum fibulae between the tendon of the m. biceps femoris and the lig. collaterale fibulae.

M. tibialis anterior (O. T. tibialis anticus) (see also Figs. 391, 401, 402 and 405). Form: triangular-prismatic, oblong. Position: superficial on the anterior surface of the leg; bounded medianward by the tibia, lateralward above by the m. extensor digitorum longus, below by the m. extensor hallucis longus. Origin: condylus lateralis and facies lateralis tibiae, membrana interossea cruris and fascia cruris. Insertion: the fibers converge downward to a flat tendon, which extends medianward, from the lower third of the leg on, in front of the tibia and articulo talocruralis through the medial compartment of the lig. transversum and of the lig. cruciatum cruris, to the plantar surface of the os cuneiforme I (*b. subtendinea m. tibialis anterioris* see Figs. 402 and 406) and to the plantar surface of the basis oss. metatarsalis I (see also Fig. 268). Action: it flexes the foot dorsalward. Innervation: n. peronaeus profundus.

391. Muscles of the right leg, viewed from in front.



M. extensor digitorum longus
(see also Figs. 390, 401 and 402).
Form: flat, oblong. Position: just beneath the skin, on the lateral surface of the leg; bounded medianward above by the m. tibialis anterior, below by the m. extensor hallucis longus, lateralward above by the m. peroneus longus, below by the m. peroneus brevis. Origin: fleshy, from the condylus lateralis tibiae, capitulum and crista anterior fibulae, septum intermusculare anterius [fibulare], membrana interossea cruris and the inner surface of the fascia cruris. Insertion: the fibers extend downward and forward to a tendon beginning medianward in the middle of the leg, which runs, through the lateral compartment of the lig. transversum and of the lig. cruciatum cruris, forward and downward and becomes subdivided into five tendons; of these, the four medial tendons diverge to the heads of the ossa metatarsalia II—V, unite at the 2nd—4th toe with the corresponding tendons of the m. extensor digitorum brevis, pass forward upon the dorsal surface of the phalanges of the toes, and each becomes attached by a middle process to the second, and by two lateral processes to the third, phalanx. Upon the first phalanx each tendon forms, as in the fingers (see p. 312), a triangular expansion, into the lateral processes of which the mm. lumbricales and interossei are inserted. The fifth tendon, that situated farthest lateralward, and the muscle belonging to it, usually incompletely separated above, namely the **m. peroneus tertius** (see also Figs. 390, 401 and 409) extends to the dorsal surface of the os metatarsale V. Action: it flexes the foot dorsalward, lifts the lateral margin of the foot, and draws the 2nd—5th toe dorsalward. Innervation: n. peroneus profundus.

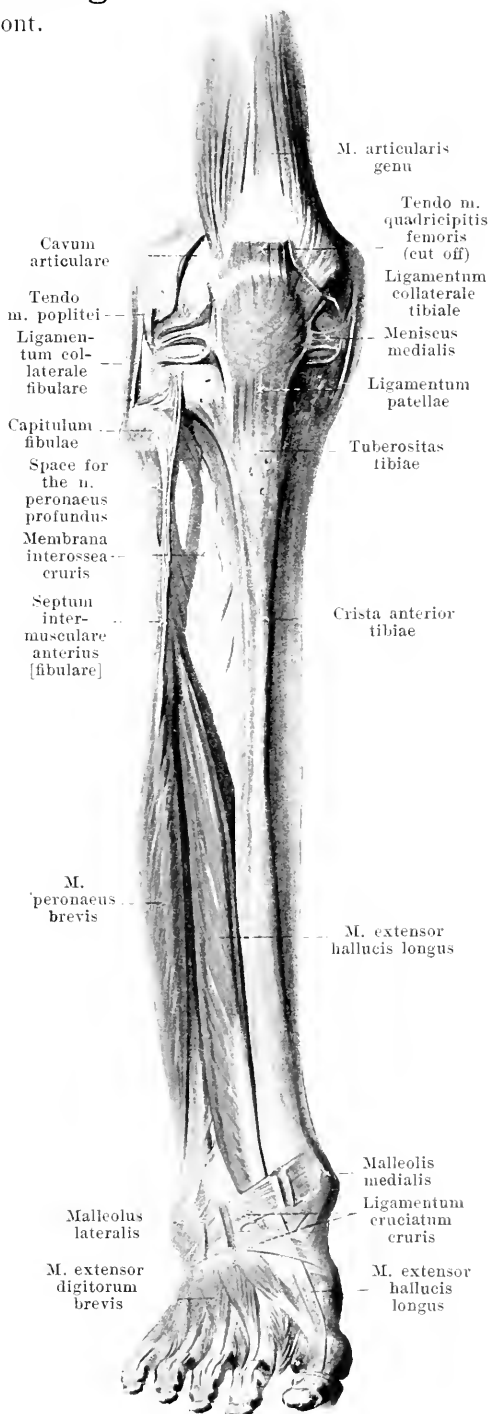
392. Muscles of the right leg

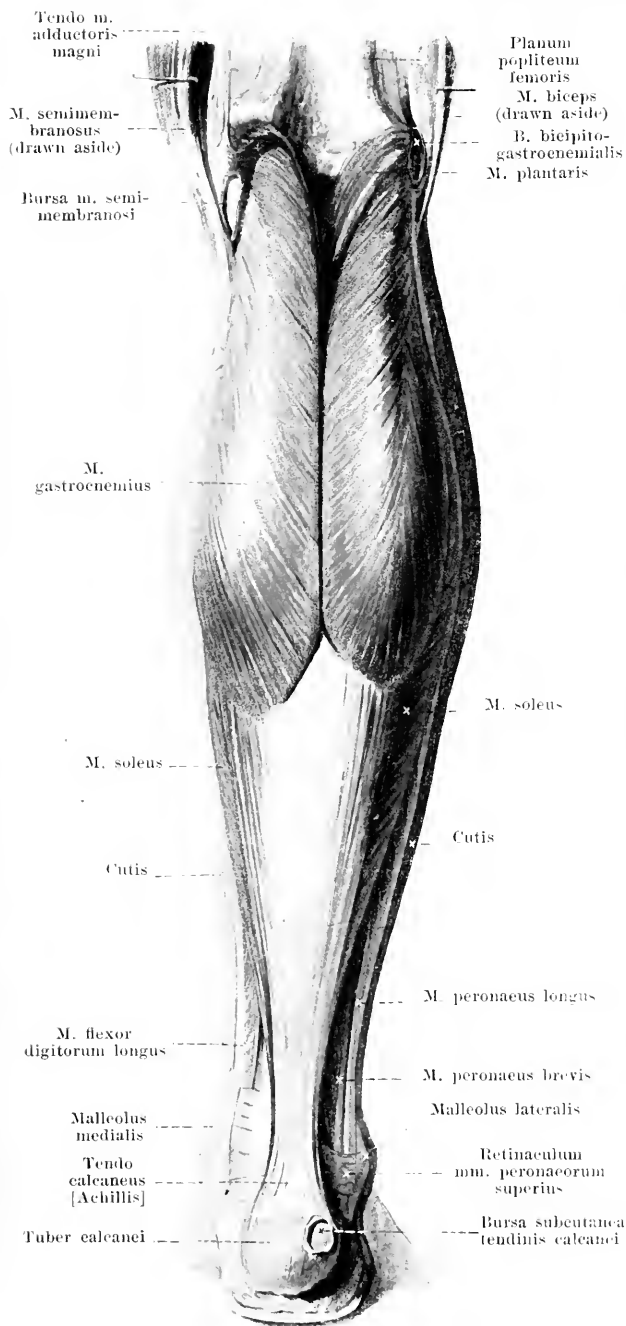
(2nd layer), viewed from in front.

(The mm. tibialis anterior, extensor digitorum longus, and peroneus longus have been removed; the lig. cruciatum cruris has been partially cut open.)

M. extensor hallucis longus (O. T. extensor proprius hallucis) (see also Figs. 390, 391, 401, 402 and 405). Form: flat, oblong. Position: on the anterior surface of the leg, below just beneath the skin, above overlapped by its two neighbors: bounded lateralward by the m. extensor digitorum longus, medianward by the m. tibialis anterior. Origin: membrana interossea cruris and facies medialis fibulae. Insertion: the fibers run parallel forward and downward to a flat tendon beginning medianward in the inferior third; this extends through the lateral compartment of the lig. transversum and through the middle compartment of the lig. cruciatum cruris, forward and medianward to the dorsal surface of the os metatarsale I and, after partial union with the tendon of the m. extensor hallucis brevis, to the base of the second phalanx of the great toe; with the first phalanx it is connected by short bands. Action: it flexes the foot dorsalward, it elevates the medial margin of the foot, it extends the first toe dorsalward. Innervation: n. peroneus profundus.

The **fascia cruris** covers the free surface of the muscles of the leg. It is connected at the knee with the fascia lata, is stronger on the anterior surface above than below and, near the ankle-joint, is strengthened by a broad band of transverse fibers, the **ligamentum transversum cruris** (O. T. broad part of anterior annular ligament) (see Figs. 391, 401 and 402). This is attached at its ends to the fibula and tibia and is divided, by a septum going to the tibia, into two compartments: one medial for the m. tibialis anterior, one lateral for the mm. extensor hallucis longus and extensor digitorum longus; the lower margin of the ligament is connected medianward with the upper medial limb of the lig. cruciatum cruris. On the back of the leg the fascia covers not only the m. triceps surae from behind, but also, passing in front of it, covers the mm. flexores longi and tibialis posterior: it thus forms a superficial and a deep layer. Medianward, upon the facies medialis tibiae, the fascia is fused with the periosteum. Lateralward it sends a strip to the fibula, in front of and behind the mm. peronei, **septum intermusculare anterius [fibulare]** and **septum intermusculare posterius [fibulare]** (see also Fig. 396), form which the muscles arise in part.





393. Muscles of the right leg, viewed from behind.

M. triceps surae, consists of two muscles, *m. gastrocnemius* and *m. soleus*, which are separated at their origins, but are inserted by means of a common tendon, *tendo calcaneus* [*Achillis*], into the posterior surface of the tuber calcanei (*b. tendinis calcanei* [*Achillis*] see Fig. 395).

M. gastrocnemius (see also Figs. 258, 384, 388—391). Form: flat, long, with two heads. Position: superficial on the back of the leg; it forms the main mass of the calf. Origin: tendinous, from the planum popliteum femoris, fused with the capsule of the joint; *caput laterale*: above the condylus lateralis (*b. m. gastrocnemii lateralis* see Fig. 395); it frequently contains a small sesamoid cartilage; *caput mediale*: above the condylus medialis (*b. m. gastrocnemii medialis* see Fig. 394). Insertion: fibers for each head arise also from a tendinous strip lying on the surface; they diverge below to form a broad tendon, which begins high up on the anterior surface of the muscle, becomes narrower and thicker below and goes over into the tendo calcaneus; the two heads converge, from their origins on, downward and are separated below only by a narrow groove; the belly of the medial head extends somewhat farther distalward. Action: it flexes the foot plantarward and supinates it. Innervation: n. tibialis.

Bursa m. semimembranosi, constant, double: one between the *m. semimembranosus* and *caput mediale m. gastrocnemii*, in front coming in contact with the capsule of the joint (it very frequently communicates with the joint cavity); the other, between the tendon of the *m. semimembranosus* and the condylus medialis tibiae (see Fig. 396).

Bursa bicipitogastrocnemialis, very rare, between the tendon of the *m. biceps* on the one side, the *caput laterale m. gastrocnemii* and *m. plantaris* on the other side; it is bounded medianward and behind by the n. peroneus communis.

Bursa subcutanea calcanea (not illustrated), constant, in the sole of the foot, just beneath the skin on the inferior surface of the tuber calcanei.

Bursa subcutanea tendinis calcanei [*Achillis*] (see also Fig. 409), frequently present on the posterior surface of the tuber calcanei.

394. Muscles of the right leg (2nd layer), viewed from behind.

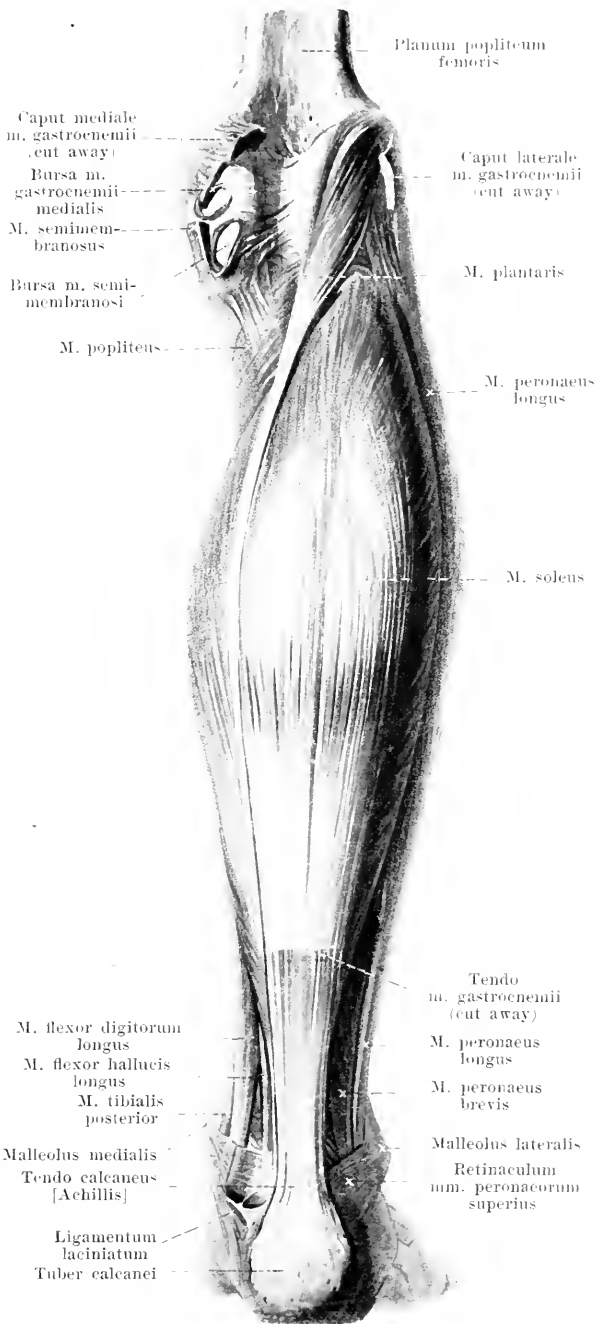
(The *m. gastrocnemius* has been removed.)

M. soleus (see also Figs. 389 to 391 and 393). Form: flat, spindle-shaped, thick. Position: on the posterior side of the leg, almost completely covered by the *m. gastrocnemius*, bounded above by the *m. popliteus*. Origin: from the capitulum and facies posterior fibulae, linea poplitea tibiae and from a tendinous arch between the two. Insertion: backward and downward to a broad superficial tendinous strip, which becomes narrower and thicker below and goes over into the tendo calcaneus. Action: it flexes the foot plantarward and supinates it. Innervation: n. tibialis.

M. plantaris (see also Figs. 384, 390 and 393). Form: flat, short-spindleshaped. Position: on the back of the leg, bounded lateradward by the caput laterale *m. gastrocnemii*, in front by the capsule of the joint and the *m. popliteus*. Origin: planum popliteum femoris above the condylus lateralis, fused with the capsule of the joint. Insertion: medianward and downward to a long, narrow tendon which passes upon the posterior surface of the *m. soleus*, in front of the *m. gastrocnemius*, on the medial side of the tendon of the latter and goes over into the tendo calcaneus; in addition some fibers go to the fascia. Action: like the *m. gastrocnemius*; it makes the fascia tense. Innervation: n. tibialis.

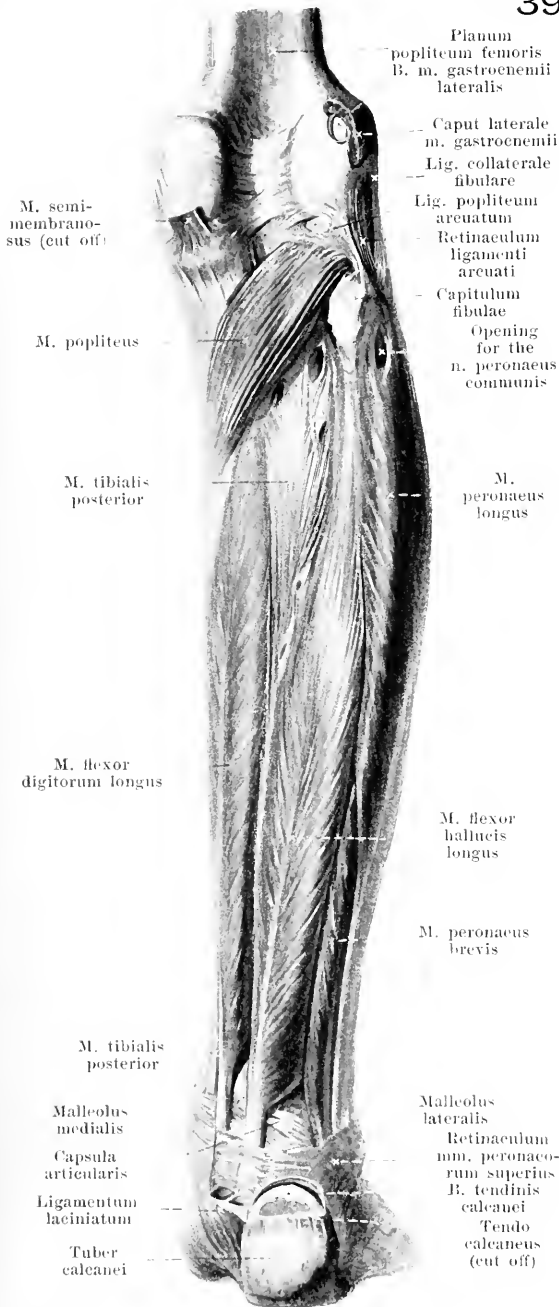
M. popliteus (see also Figs. 258, 261, 392, 395 and 396). Form: flat, triangular. Position: on the back of the knee-joint and of the tibia, covered by the *mm. plantaris* and *gastrocnemius*, bounded below by the *m. soleus*. Origin: by a narrow tendon from the epicondylus lateralis femoris (*b. m. poplitei* see Figs. 261 and 396), in addition by a fleshy origin from the lig. popliteum arcuatum. Insertion: diverging medianward and downward to the facies posterior tibiae. Action: it flexes the leg and rotates it inward. Innervation: n. tibialis.

Bursa m. gastrocnemii medialis, almost constant, between the uppermost part of the capsule of the knee-joint, the femur and the caput mediale *m. gastrocnemii*; it very frequently communicates with the cavity of the knee-joint.



395. Muscles of the right leg (3rd layer), viewed from behind.

(The mm. gastrocnemius, plantaris and soleus have been removed.)



M. flexor digitorum longus (see also Figs. 393, 399, 400, 405 and 406). **Form:** flat, oblong, penniform. **Position:** on the back of the tibia and of the m. tibialis posterior, bounded laterally by this muscle and by the m. flexor hallucis longus, covered by the m. soleus. **Origin:** facies posterior tibiae and the deep layer of the fascia cruris (see p. 347). **Insertion:** obliquely downward to a tendinous strip, which goes over above the malleolus into a rounded tendon; this extends, behind and below the tendon of the m. tibialis posterior, medianward near the sulcus m. flexor hallucis longi of the talus and at the medial margin of the sustentaculum tali of the calcaneus (see p. 141) to the sole of the foot, being held fast by the deep layer of the lig. laciniatum (see also Figs. 265 and 269). It then crosses, plantarward, the tendon of the m. flexor hallucis longus, receives from it a tendinous bundle and breaks up into four diverging tendons; these go to the 2nd—5th toe, perforate the tendons of the m. flexor digitorum brevis and become fastened to the base of the 3rd phalanx. The tendon is covered on the medial border of the foot by the m. abductor hallucis, in the sole plantarward by the m. flexor digitorum brevis. **Action:** it flexes the foot plantarward and supinates it; it draws the 3rd phalanx of the 2nd—5th toe plantarward. **Innervation:** n. tibialis.

M. flexor hallucis longus (see also Figs. 394, 399, 400 and 405—407). **Form:** rounded, oblong, penniform. **Position:** on the posterior surface of the fibula and of the m. tibialis posterior; it is bounded medianward by the m. flexor digitorum longus, lateralward by the mm. peronei, covered by the m. soleus. **Origin:** facies posterior fibulae, septum intermusculare posterius and the deep layer of the fascia cruris (see p. 347). **Insertion:** the fibers converge downward to a tendinous strip. Behind the malleolus medialis begins the rounded tendon, which goes in the sulcus m. flexoris hallucis longi of the talus and calcaneus, held in position by the deep layer of the lig. laciniatum (see also Figs. 265 and 269), behind the tendon of the m. flexor digitorum longus, to the sole of the foot. There it crosses dorsalward the tendon of the latter muscle, gives off a process to it, which goes especially to the tendon bundle for the 2nd toe and extends between the bellies of the m. flexor hallucis brevis to the base of the 2nd phalanx of the 1st toe. At the margin of the foot it is covered by the m. abductor

hallucis, in the sole plantarward in part by the m. flexor digitorum brevis. **Action:** it flexes the foot plantarward and supinates it; it draws the 1st and 2nd toe plantarward. **Innervation:** n. tibialis.

Bursa m. gastrocnemii lateralis, often present between the uppermost part of the capsule of the knee-joint and the caput laterale m. gastrocnemii; it frequently communicates with the cavity of the joint.

396. Muscles of the right leg

(4th layer), viewed from behind.

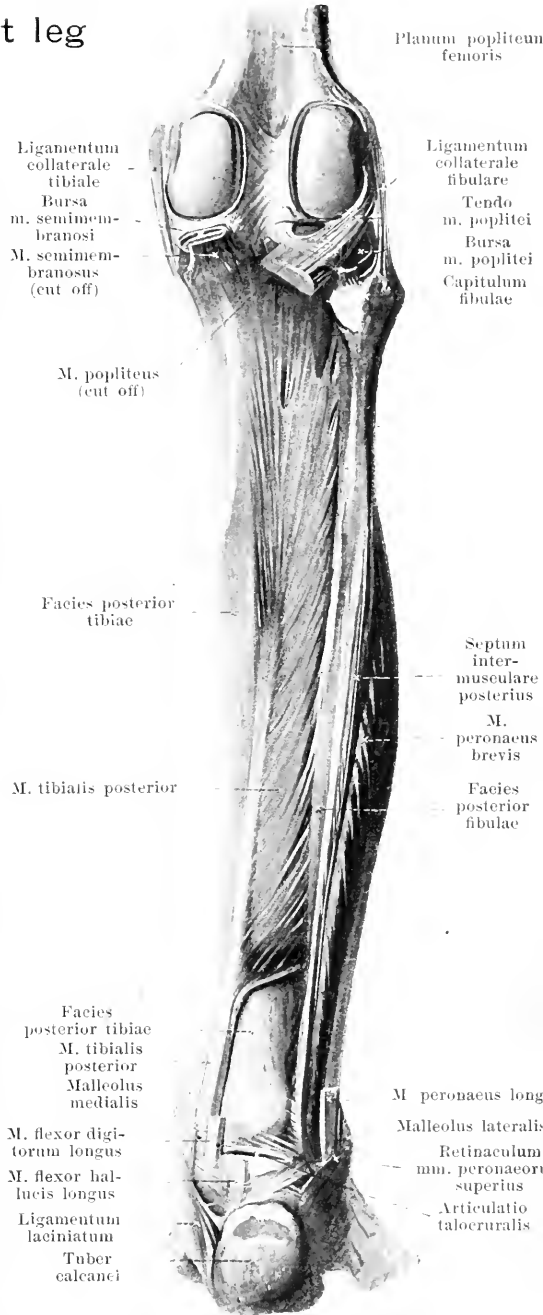
(All the muscles have been removed with the exception of the mm. tibialis posterior and peroneus brevis.)

M. peroneus longus (see Figs. 390, 391, 393—395, 400, 407 and 409). Form: flat, oblong, penniform. Position: superficial on the lateral surface of the leg, above upon the fibula, below upon the m. peroneus brevis; bounded in front by the m. extensor digitorum longus, behind by the m. soleus. Origin: capitulum and facies lateralis fibulae, fascia cruris and septa intermuscularia [fibularia]. Insertion: the fibers go obliquely downward to a tendinous strip; the flat tendon extends downward at first on the lateral, then on the posterior surface of the m. peroneus brevis in a curve behind and below the malleolus lateralis, upon the lig. calcaneofibulare to the sulcus m. peronei [longi] of the calcaneus and is held in place by the retinacula mm. peroneorum (see p. 345); thence it runs in the sulcus m. peronei [longi] upon the tuberositas oss. cuboidei to the sole of the foot and there, covered plantarward by all the muscles and by the lig. plantare longum, it goes obliquely forward to the medial border of the foot; it is attached to the os cuneiforme I and os metatarsale I (see Fig. 265). In front of the tuberositas oss. cuboidei it often contains a sesamoid cartilage, rarely a sesamoid bone. Action: it flexes the foot plantarward and pronates it. Innervation: n. peroneus superficialis.

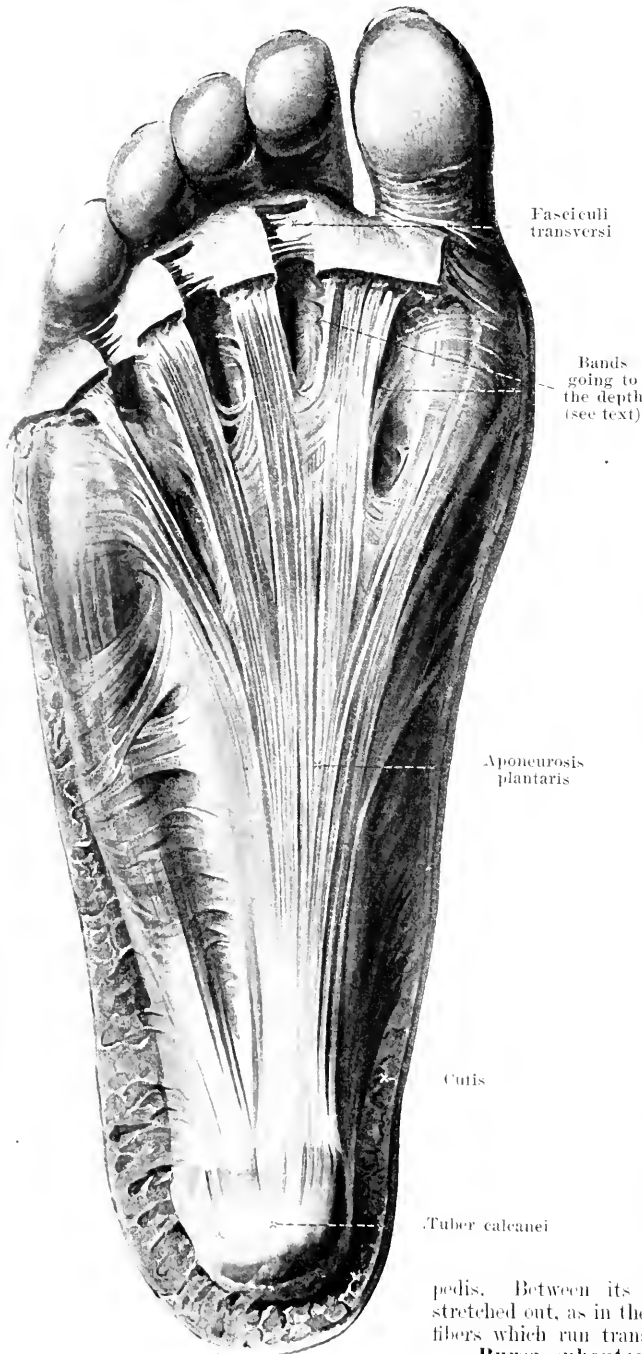
M. tibialis posterior (see also Figs. 395 and 405—407). Form: flat, oblong, penniform. Position: directly upon the posterior surface of the bones of the leg and of the membrana interossea cruris, above between the mm. flexor digitorum longus and flexor hallucis longus, covered below by these, above and below also by the m. soleus. Origin: facies posterior tibiae, membrana interossea cruris and facies medialis fibulae. Insertion: the fibers run obliquely downward to a tendinous strip situated on the medial margin; the round tendon, going out of it above the malleolus medialis, extends, directly upon the tibia in front of the m. flexor digitorum longus, downward and medianward to the sulcus malleolaris tibiae. It is there held in place by the lig. laciniatum, goes in a curve to the medial side of the ligg. talotibiale posterius and calcaneo-tibiale, thence on the medial and inferior surface of the lig. calcaneonaviculare plantare to the sole of the foot and, lying directly upon the bones and ligaments, it sends strong processes to the tuberositas oss. navicularis and to the os cuneiforme I, and feebler processes to the ossa cuneiformia II and III, metatarsalia II, III, IV and cuboideum (see also Figs. 203 and 265). Action: it flexes the foot plantarward and supinates it. Innervation: n. tibialis.

Bursa m. poplitei (see also Fig. 261) see p. 214.

Bursa tendinis calcanei [Achillis] (see Fig. 395), constantly present, large, between the posterior surface of the tuber calcanei and the tendo calcaneus [Achillis].



397. Fascia of the sole of the right foot.



M. peroneus brevis (see Figs. 390—396, 401, 402 and 409). Form: flat, oblong, penniform. Position: on the lateral side of the leg upon the fibula, partly superficial, partly covered by the m. peroneus longus; bounded in front by the mm. extensor digitorum longus and peroneus tertius, behind by the m. flexor hallucis longus. Origin: facies lateralis fibulae and septa intermuscularia [fibularia]. Insertion: the fibers converge downward to a tendinous strip; the muscle extends medianward and in front of the tendon of the m. peroneus longus, in a curve behind and below the malleolus lateralis (in a groove on the same) and then forward, directly upon the lig. calcaneofibulare and above the proc. trochlearis calcanei; it is held in place by the retinacula mm. peroneorum; thence the rounded tendon goes downward and forward to the tuberositas oss. metatarsalis V; it gives off, usually, also a process to the tendon of the m. extensor digitorum longus going to the little toe. Action: it flexes the foot plantarward and pronates it. Innervation: n. peroneus superficialis.

The **aponeurosis plantaris** is a thick layer of glistening tendinous fibers just beneath the skin; it covers the inferior surface of the muscles of the sole of the foot. It begins at the tuber calcanei, extends forward, diverging, with five processes, and there becomes attached partly to the skin beneath the heads of the ossa metatarsalia, but especially by means of bundles branching off into the depth to go to the ligg. vaginalia. It is strongest in the middle and feebler over the muscles of the great toe and of the little toe; it sends tough septa into the depth near the m. flexor digitorum brevis; otherwise it is connected behind with the fascia cruris and at the sides with the fascia dorsalis

pedis. Between its cutaneous insertions, there are stretched out, as in the hand (see p. 317), three bands of fibers which run transversely, the *fasciculi transversi*.

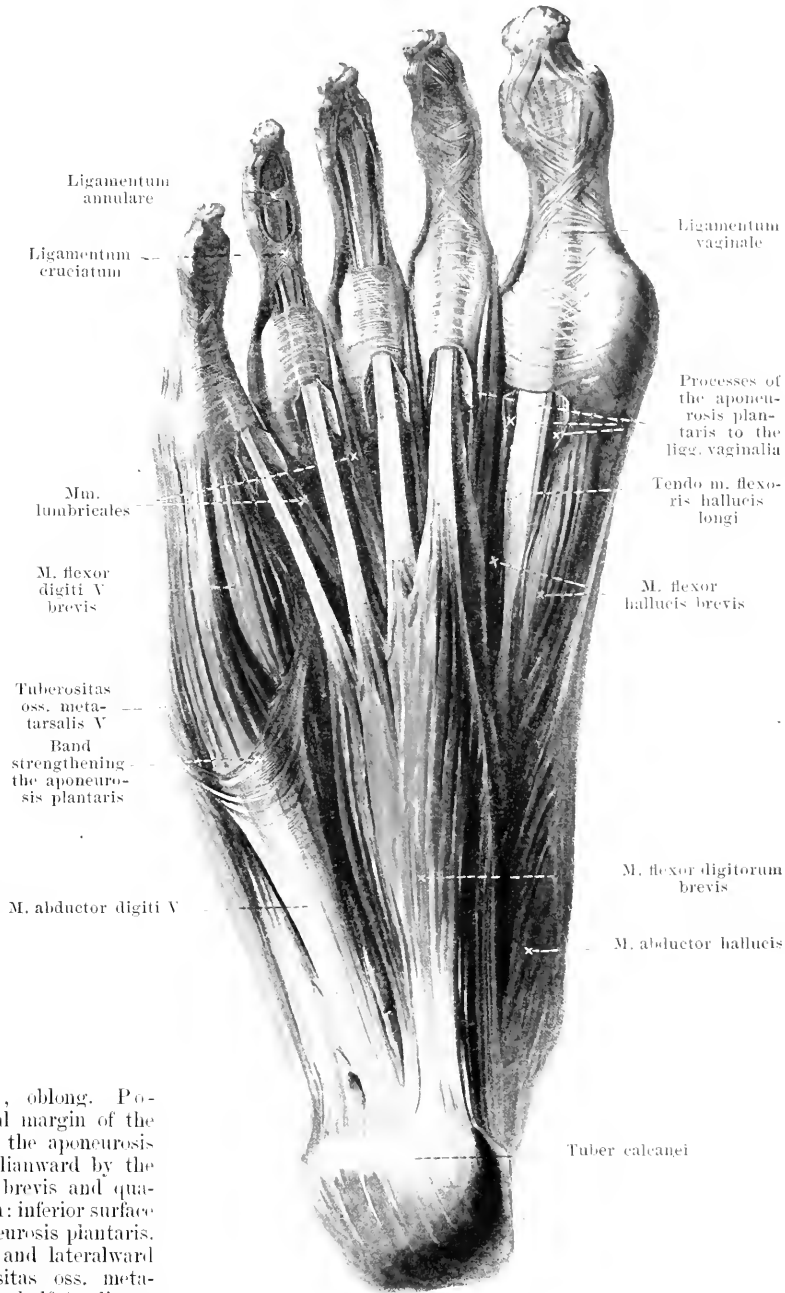
Bursa subcutanea calcanea see p. 348.

398. Muscles of the sole of the right foot.

M. flexor digitorum brevis (see also Figs. 399 and 400).
 Form: oblong-quadrangular, thick. Position: in the sole of the foot, covered only by the aponeurosis plantaris; bounded medianward by the m. abductor hallucis, lateralward by the m. abductor digiti V, dorsalward by the m. quadratus plantae and tendo m. flexoris digitorum longi. Origin: processus medialis tuberculi calcanei and aponeurosis plantaris. Insertion: the fibers diverge in front into four muscular bellies and flat tendons which go to the 2nd—5th toe; the tendons subdivide at the level of the first phalanx into two processes, permitting the corresponding tendons of the m. flexor digitorum longus to pass through between them, and become attached to the second phalanx. Action: it draws the second phalanx of the 2nd—5th toe plantarward. Innervation: n. plantaris medialis.

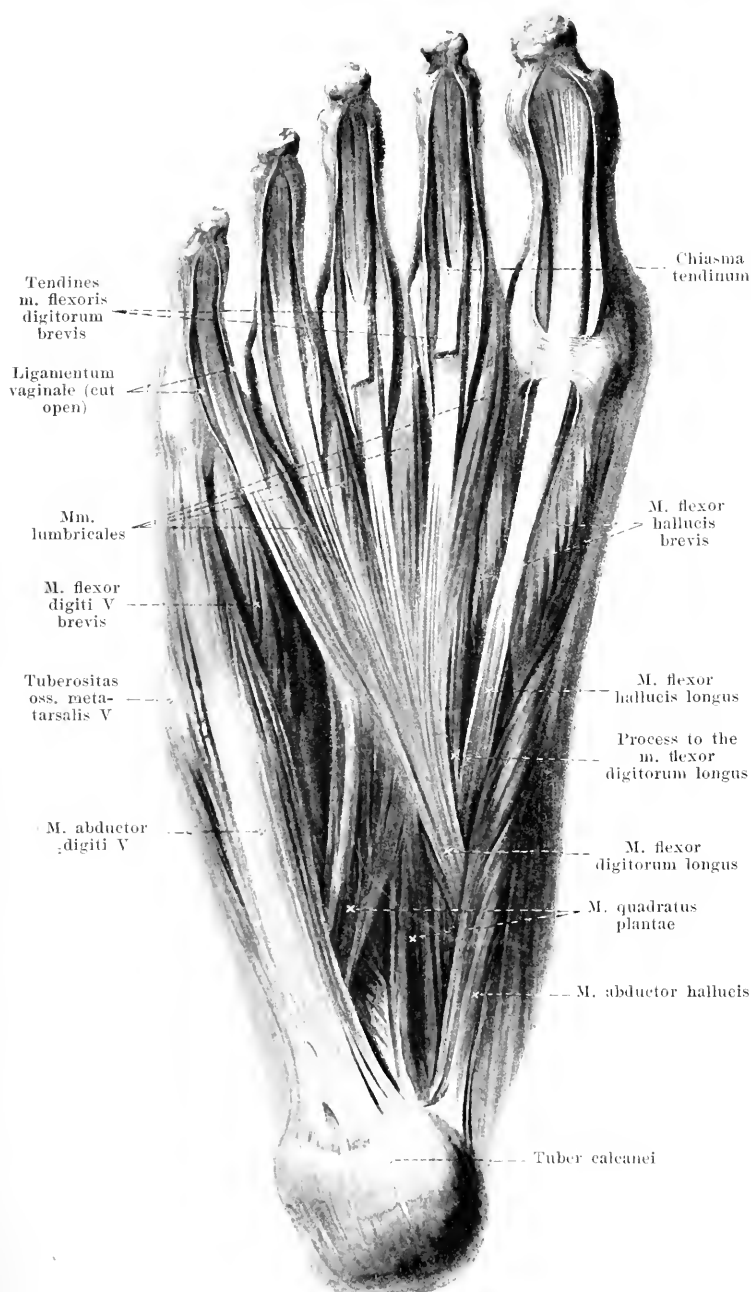
M. abductor digiti quinti (O. T. abductor minimi digiti) (see also Figs. 399, 402 and 409).

Form: flatly rounded, oblong. Position: on the lateral margin of the foot, covered only by the aponeurosis plantaris, bounded medianward by the mm. flexor digitorum brevis and quadratus plantae. Origin: inferior surface of the calcaneus, aponeurosis plantaris. Insertion: forward and lateralward partly to the tuberositas oss. metatarsalis V, partly by a half-tendinous insertion to the base of the first phalanx of the 5th toe. Action: it draws the first phalanx of the little toe lateralward and plantarward. Innervation: n. plantaris lateralis.



399. Muscles of the sole of the right foot (2nd layer).

(The m. flexor digitorum brevis has been removed.)



M. quadratus plantae (O. T. accessorius or flexor accessorius digitorum pedis) (see also Fig. 400). Form: flat, quadrangular. Position: in the sole of the foot, bounded plantarward by the m. flexor digitorum brevis, dorsalward by the lig. plantare longum and caput obliquum m. adductoris hallucis, lateralward by the m. abductor digiti V. Origin: by two processes from the inferior and medial surfaces of the calcaneus. Insertion: forward to the lateral margin of the tendon of the m. flexor digitorum longus. Action: it draws the third phalanx of the 2nd—5th toe plantarward. Innervation: n. plantaris lateralis.

Mm. lumbricales, four. Form: spindle-shaped, narrow. Position: between the terminal tendons of the m. flexor digitorum longus, bounded plantarward by the m. flexor digitorum brevis, dorsalward by the mm. adductor hallucis and interossei. Origin: partly from the medial margin, partly from the opposed margins of the tendons of the m. flexor digitorum longus. Insertion: small tendons extend forward, plantarward from the ligg. capitulorum [oss. metatars.] transversa, and go over, at the medial surface of the first phalanx of the 2nd—5th toe, into the triangular expansions of the tendons of the mm. extensores digitorum (as in the hand, see p. 319). Action: they flex the first phalanx of the 2nd to the 5th toe, and extend the second and third phalanx; they

draw the first phalanx medianward. Innervation: one medial muscle: n. plantaris medialis; three lateral: n. plantaris lateralis.

400. Muscles of the sole of the right foot (3rd layer).

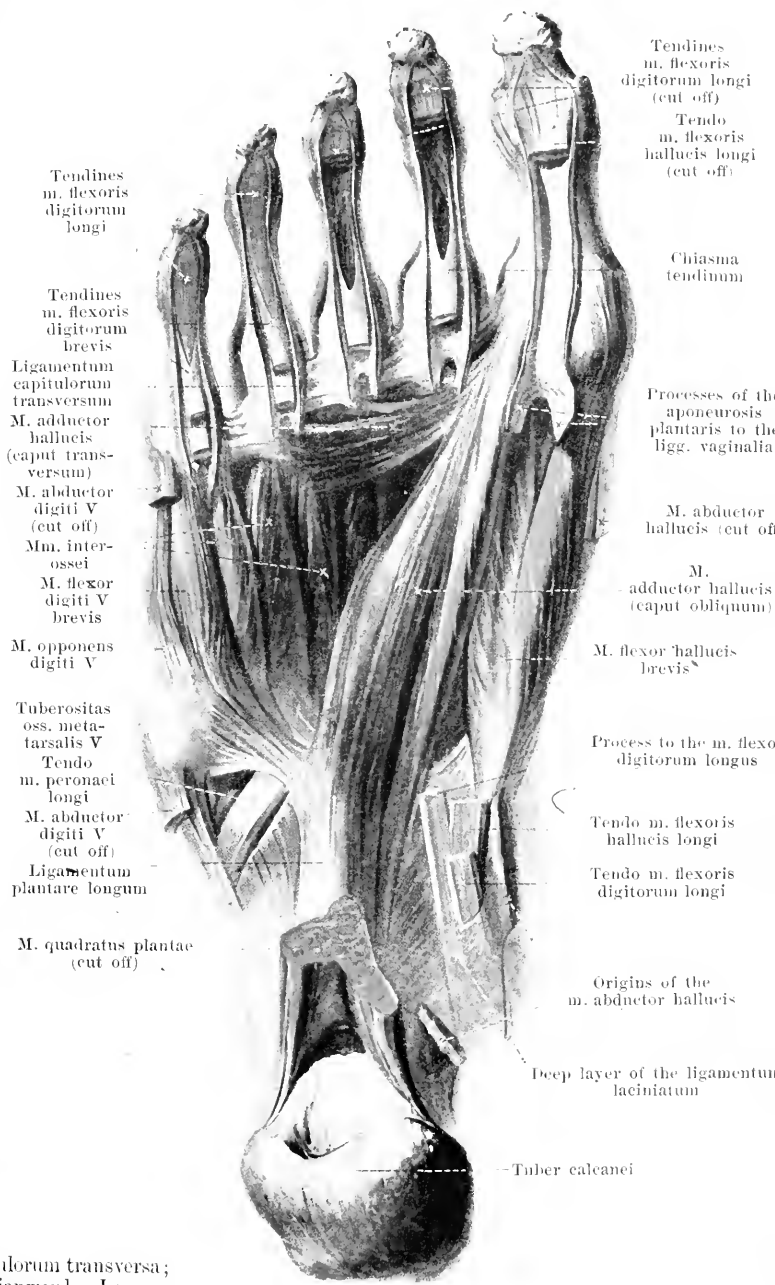
(The mm. flexores digitorum, abductor hallucis and abductor digiti V have been removed.)

M. flexor hallucis

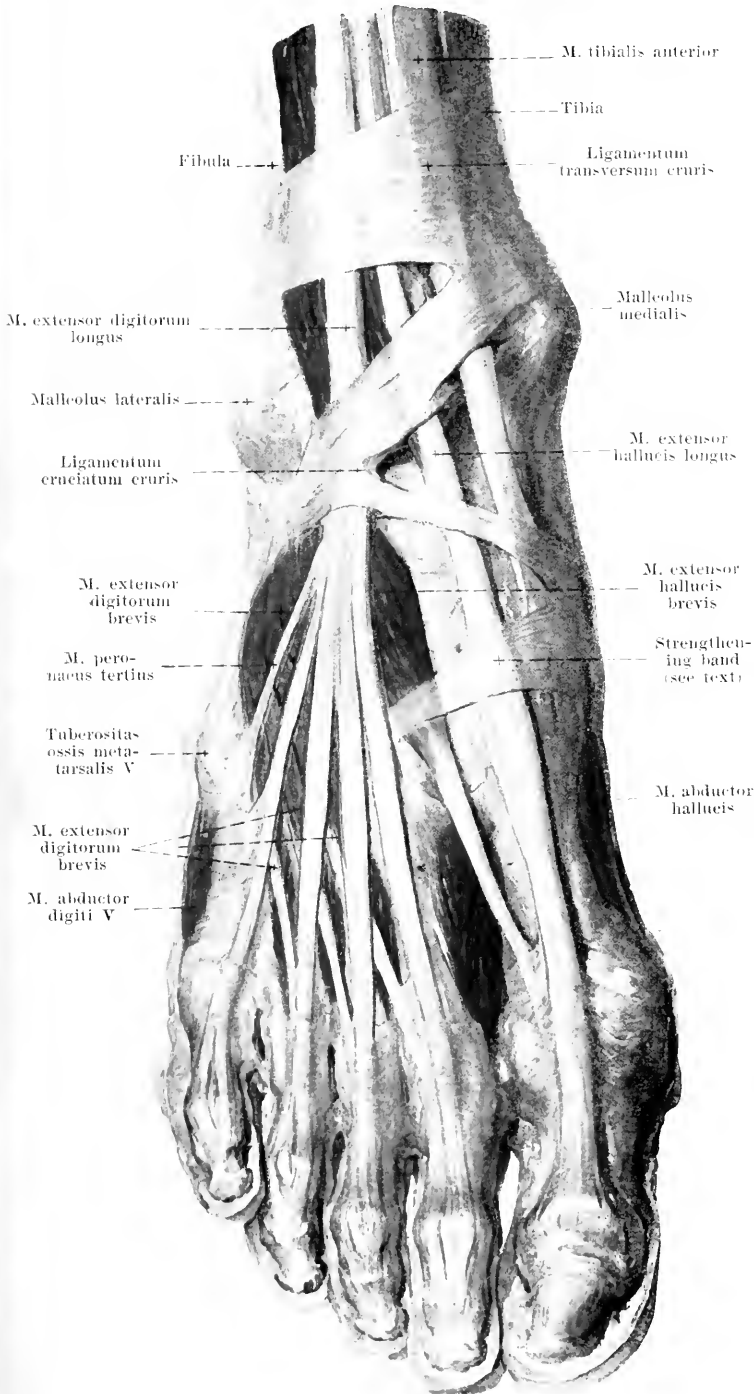
brevis (see also Figs. 398, 399 and 404). Form: oblong. Position: in the sole of the foot, partly superficial, behind and medianward covered by the m. abductor hallucis, lateralward partly fused with the caput obliquum m. adductor hallucis. Origin: plantar surface of the ossa cuneiformia I—III and lig. calcaneocuboideum plantare. Insertion: it forms two diverging rounded bellies which, becoming tendinous, run to the two sesamoid bones and to the base of the first phalanx of the great toe; in a groove between the two bellies lies the tendon of the m. flexor hallucis longus. Action: it draws the great toe plantarward. Innervation: medial belly: n. plantaris medialis; lateral belly: n. plantaris lateralis.

M. adductor hal-

lucis (see also Fig. 404). Form: two heads. Position: in the sole of the foot, bounded dorsalward by the mm. interossei, plantarward by the mm. flexores digitorum. Origin: *caput obliquum*: bases of the ossa metatarsalia II to IV, os cuneiforme III, os cuboideum and lig. plantare longum; the fibers converge to a rounded belly, which is fused medianward with the m. flexor hallucis brevis; *caput transversum*: capsular ligaments of the articulationes metatarsophalangeae II—V and ligg. capitulorum transversa; the fibers converge medianward. Insertion: the two heads become inserted into the lateral sesamoid bone and the base of the 1st first phalanx of the great toe. Action: it draws the great toe plantarward and lateralward. Innervation: n. plantaris lateralis.



401. Muscles of the back of the right foot.



The **fascia dorsalis pedis** is stretched out in the form of a membrane, for the most part thin, over the tendons and muscles of the back of the foot: above it is connected with the fascia cruris, at the sides with the aponeurosis plantaris. Intwoven in it, at the junction of the foot with the leg, is situated the powerful *ligamentum cruciatum cruris* (O. T. lower part of anterior annular ligament) (see also Figs. 392, 402, 405 and 409). This usually has the shape of a Y. Its lateral, strongest limb consists of two layers, of which the more superficial arises on the lateral surface of the calcaneus (connected with the retinaculum mm. peroneorum inferius), the deep one arising in the sinus tarsi. Both extend medianward, the former in front of, the latter behind the tendons of the m. extensor digitorum longus, unite on the medial side of the same and divide, then, into two medial limbs. The inferior medial, more delicate, limb runs in front of the tendons of the mm. extensor hallucis longus and tibialis anterior to the os naviculare and os cuneiforme I. The superior medial, stronger limb goes to the anterior surface of the malleolus medialis (see also fascia cruris p. 347); it consists likewise of two layers, which run in front of and behind the mm. extensor hallucis longus and tibialis anterior; the main mass of fibers usually runs in front of the m. extensor hallucis longus and behind the m. tibialis anterior. Going off from the medial surface of the os cuneiforme I and os metatarsale I is a curved strengthening band of fibers which passes in front of the mm. extensores hallucis to the basis oss. metatarsalis II.

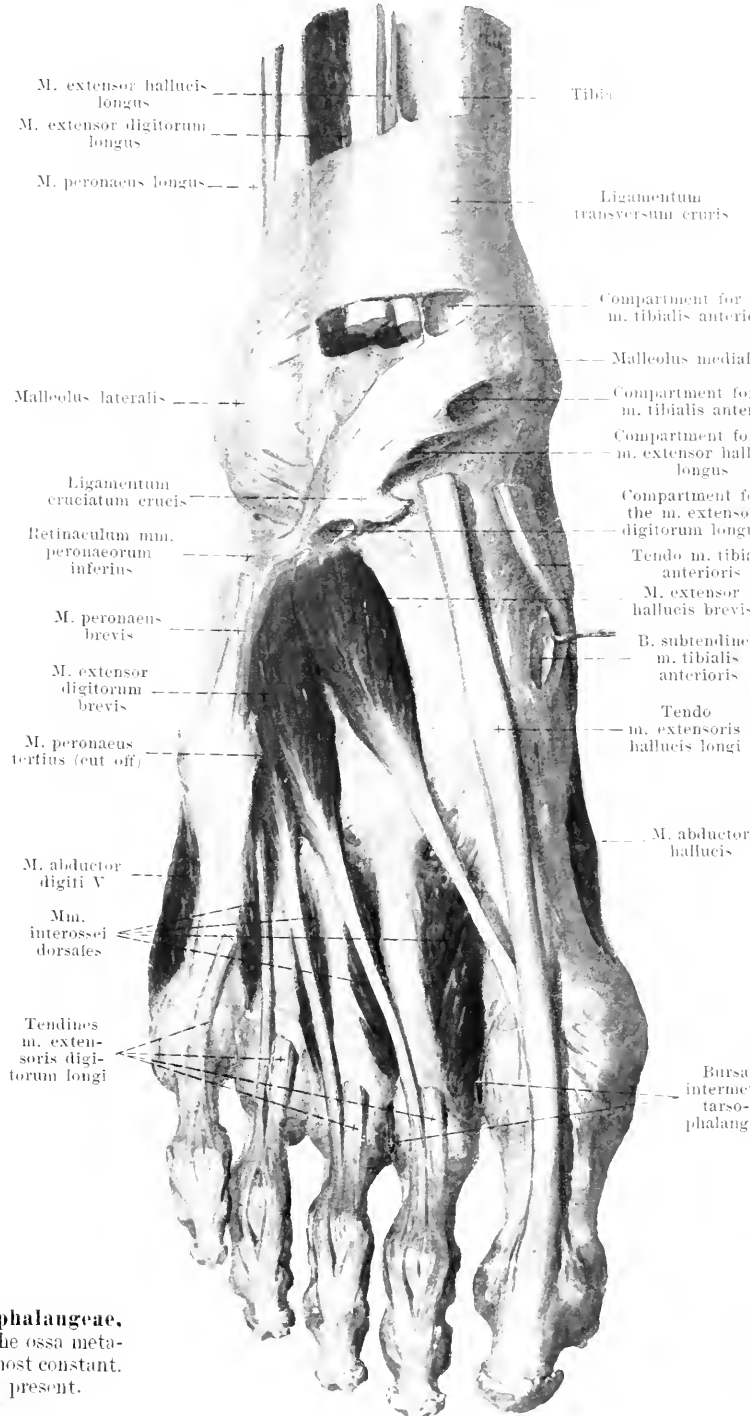
402. Muscles of the back of the right foot (2nd layer.)

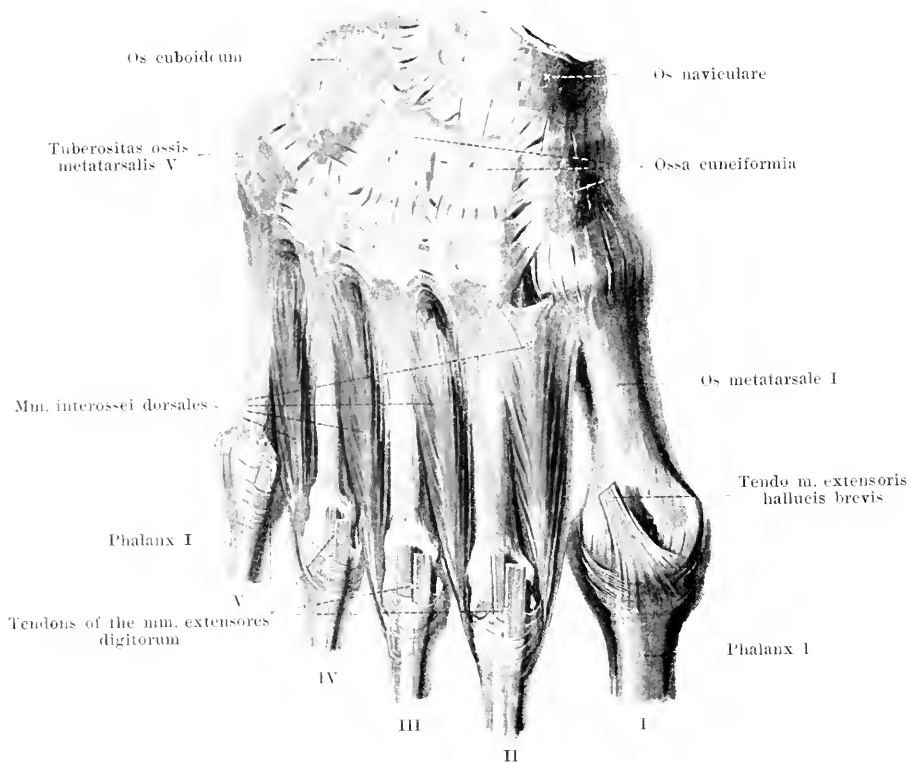
(The mm. tibialis anterior and extensores longi as well as the inferior limb of the lig. cruciatum cruris have been removed.)

M. extensor digitorum brevis (see also Figs. 390, 401 and 409). **Form:** flat, triangular. **Position:** upon the back of the foot, directly upon the bone, partly covered by the tendons of the m. extensor digitorum longus. **Origin:** lateral and superior surface of the corpus calcanei, in front of the entrance into the sinus tarsi, covered by the lateral limb of the lig. cruciatum cruris. **Insertion:** the fibers diverge forward and form four small muscular bellies, which, upon the ossa metatarsalia, go over into flat, delicate tendons. Of these, the three lateral run to the first phalanx of the 2nd—4th toe, fuse with the corresponding tendons of the m. extensor digitorum longus and go with the latter to the second and third phalanx. The medial, strongest tendon, along with the muscle belonging to it, is given a special name, being called the **m. extensor hallucis brevis**; it extends obliquely medianward and becomes attached partly to the base of the first phalanx of the great toe; partly it becomes united with the tendon of the m. extensor hallucis longus. **Action:** it draws the 1st—4th toe dorsalward and lateralward. **Innervation:** n. peroneus profundus.

Bursa subtendinea m. tibialis anterioris (see also Fig. 406), very frequently present between the medial surface of the os cuneiforme I and the tendon of the m. tibialis anterior.

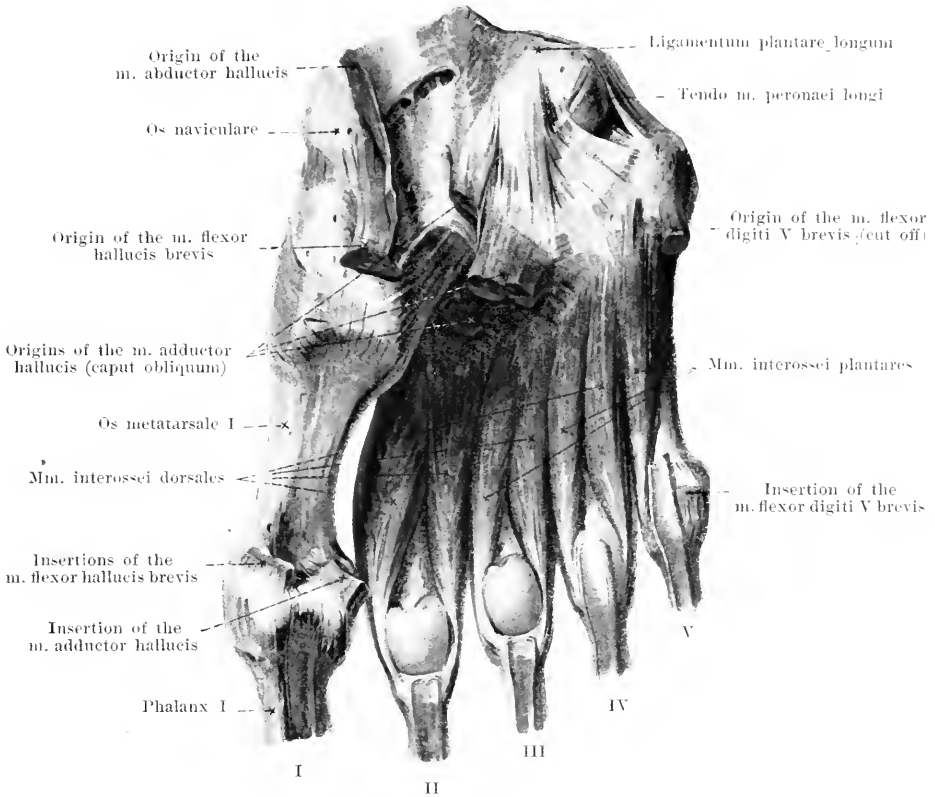
Bursae intermetatarsophalangeae, four, between the heads of the ossa metatarsalia: the three medial almost constant, the fourth only occasionally present.





403. *Mm. interossei dorsales pedis dextri*, viewed from the dorsal surface of the foot.

Mm. interossei dorsales (see also Fig. 404). four. Form: oblong-triangular, penniform, small. Position: in the interspaces between the ossa metatarsalia, projecting somewhat plantarward; covered dorsalward by all the muscles of the back of the foot, plantarward by all the muscles of the sole of the foot. Origin: from the adjacent sides of each pair of ossa metatarsalia. Insertion: the fibers of each muscle run converging forward to a small tendon; this extends dorsalward from the lig. capitulorum [oss. metatars.] transversum to the dorsal surface of the first phalanx and goes over into the triangular expansion of the tendons of the *mm. extensores digitorum* situated there. The tendon of the first (most medially situated) muscle runs on the medial side of the 2nd toe, while the tendons of the second to the fourth muscle lie on the lateral surface of the 2nd—4th toe. Action: the first draws the 2nd toe medianward, the others draw the 2nd—4th toe lateralward; all flex the first phalanx and extend the second and third of these toes. Innervation: n. plantaris lateralis.

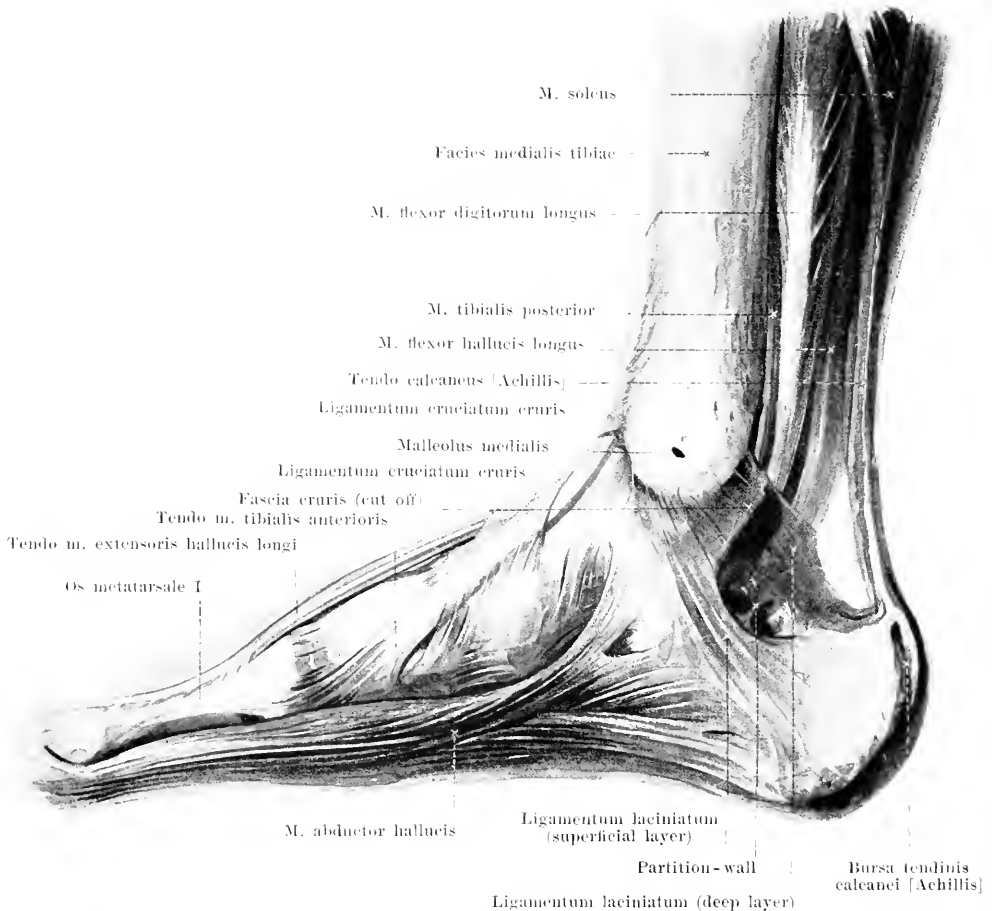


404. Mm. interossei pedis dextri, viewed from the plantar surface.

M. flexor digiti quinti brevis (O. T. flexor brevis minimi digiti pedis) (see also Figs. 398—400). **Form:** rounded, narrow, small. **Position:** in the sole of the foot, on the plantar surface of the os metatarsale V, partly covered plantarward by the m. abductor digiti V, otherwise only by the aponeurosis plantaris. **Origin:** basis oss. metatarsalis V and lig. plantare longum. **Insertion:** the fibers run converging forward and, becoming tendinous, go to the base of the first phalanx of the little toe. **Action:** it draws the 1st phalanx of the little toe plantarward and lateralward. **Innervation:** n. plantaris lateralis.

M. opponens digiti quinti (see Figs. 400 and 409). **Form:** flat, triangular, small. **Position:** directly upon the plantar surface of the os metatarsale V, covered plantarward by the m. abductor digiti V, bounded medianward by the m. flexor digiti V. **Origin:** lig. plantare longum, fused with the m. flexor digiti V brevis. **Insertion:** the fibers run lateralward and forward to the os metatarsale V. **Action:** it draws the little toe plantarward and medianward. **Innervation:** n. plantaris lateralis.

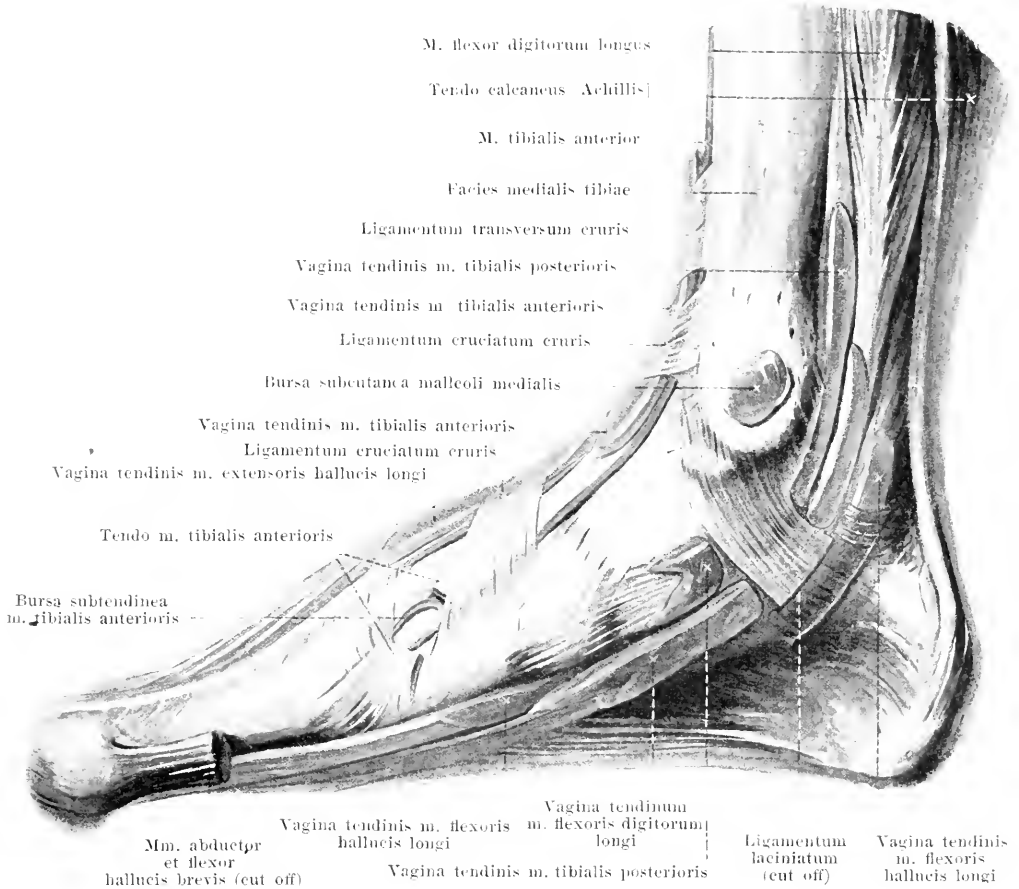
Mm. interossei plantares, three. **Form:** oblong-spindleshaped, small. **Position:** in the interspaces between the ossa metatarsalia II—V, plantarward from the mm. interossei dorsales; projecting somewhat toward the sole of the foot and covered there by all the muscles of the sole of the foot. **Origin:** from the medial surface of the ossa metatarsalia III—V. **Insertion:** the fibers of each muscle go, converging, forward to a narrow tendon, which (like the tendons of the mm. interossei dorsales, see p. 358) go to the back of the first phalanx and to the tendons of the mm. extensores digitorum. The three muscles run on the medial side of the 3rd—5th toe. **Action:** they draw the 3rd—5th toe medianward, flex the first phalanx of each and extend their second and third phalanges. **Innervation:** n. plantaris lateralis.



405. Muscles of the right foot, viewed from the medial surface.

M. abductor hallucis (see also Figs. 398—401 and 404). Form: flat, oblong-triangular. Position: superficial on the medial margin of the sole of the foot; bounded lateralward by the mm. flexor digitorum brevis and flexor hallucis brevis. Origin: medial surface of the tuber calcanei, superficial layer of the lig. laciniatum and malleolus medialis; also from the tuberositas oss. navicularis and the plantar surface of the os cuneiforme I. Insertion: the fibers converge to a tendinous strip, lying in the muscle, which goes over into a flat strong tendon; this is fused in front with the medial belly of the m. flexor hallucis brevis and goes to the medial sesamoid bone and to the base of the first phalanx of the great toe. Action: it draws the first phalanx of the great toe medianward and plantarward. Innervation: n. plantaris medialis.

Ligamentum laciniatum (O. T. internal annular ligament) (see also Figs. 268, 394, 395, 400, 406 and 407) is a strengthening band in the lower part of the fascia cruris, below and behind the malleolus medialis. It goes off from the posterior and inferior margins of the malleolus medialis, covers the tendon of the m. tibialis posterior and becomes attached to the subjacent bone; it then divides into two layers. The superficial layer is stretched out from there to the medial surface of the tuber calcanei and goes over above into the superficial layer of the fascia cruris, frequently with a sharp concave margin, sometimes without sharp limit (continued on p. 361).



406. Bursae and sheaths of tendons of the right foot, injected (sheaths of tendons stained red), viewed from the medial surface.

(The mm. abductor hallucis and flexor hallucis brevis have been removed.)

Ligamentum laciniatum (continued). The deep layer passes just behind the tendons of the mm. flexor digitorum longus and flexor hallucis longus to the medial surface of the calcaneus, is firmly attached to the margins of the corresponding bony grooves and holds the tendons firmly upon the bones; it reaches above as far as the malleolus and is continuous with the deep layer of the fascia cruris. Between the two layers is a canal for the aa., vv. and mm. plantares: a septum, rarely absent, separates the medial branches from the lateral.

Bursa subcutanea malleoli medialis (see also Fig. 405), frequently present, upon the malleolus medialis.

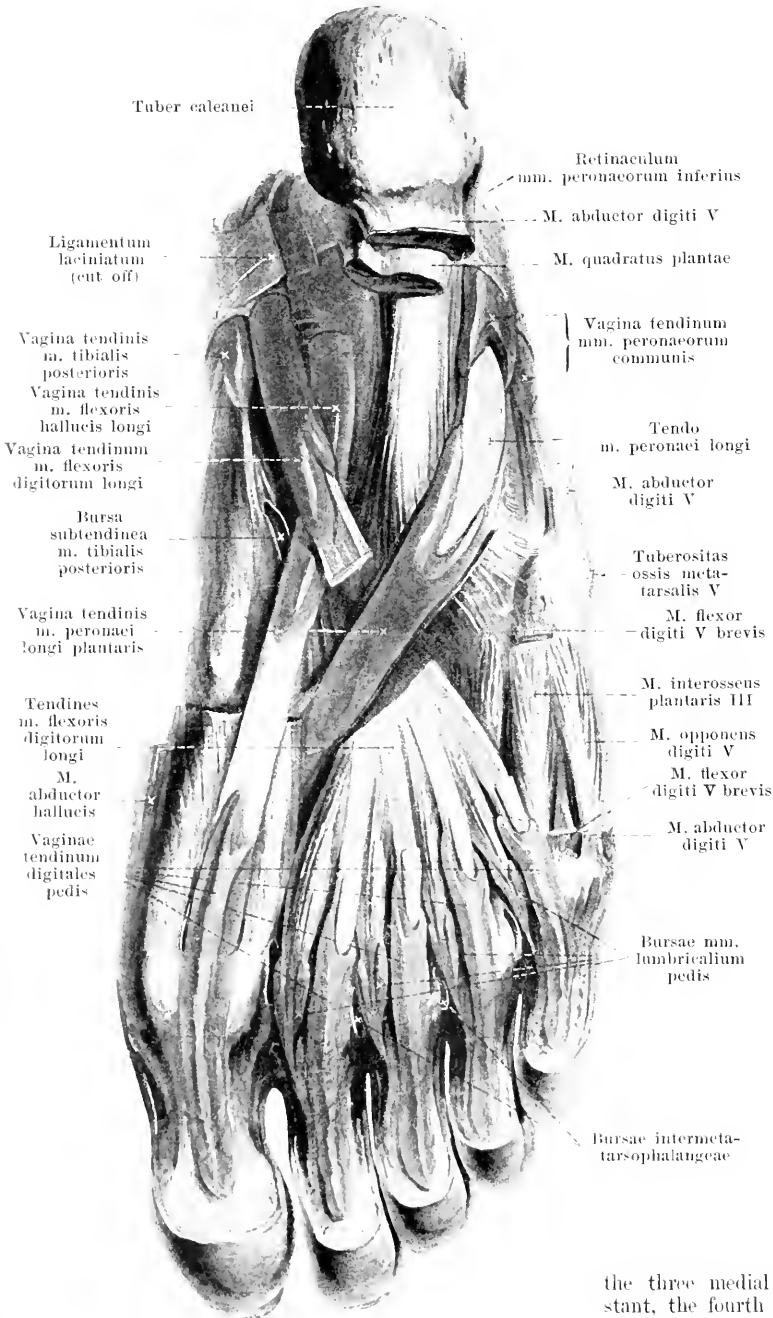
Vagina tendinis m. tibialis posterioris (see also Fig. 407) begins over the medial malleolus and ends at the os naviculare; it frequently communicates above with the following.

Vagina tendinum m. flexoris digitorum pedis longi (see also Fig. 407), begins below the preceding and ends in the sole of the foot, at the point where its tendon crosses that of the m. flexor hallucis longus, below the os naviculare; above it communicates sometimes with the preceding sheath, below sometimes with the following.

Vagina tendinis m. flexoris hallucis longi (see also Fig. 407) begins below the preceding and ends at or in front of the point where the tendon of the m. flexor digitorum longus is crossed, below the os naviculare; there it sometimes communicates with the preceding.

407. Bursae and sheaths of tendons of the sole of the right foot, injected; sheaths of tendons stained red.

(The short muscles of the 1st and 2nd layer have been for the most part removed.)



Bursa subtendinea m. tibialis posterioris, frequently present, oblong-troughshaped, between the lateral tendinous process of the m. tibialis posterior (see Fig. 265) on one side, the ossa naviculare and cuneiforme II on the other side.

Vagina tendinis m. peronei longi plantaris begins at the sulcus m. peronei [longi] of the os cuboideum and ends at about the medial margin of the lig. plantare longum; it communicates only rarely with the vagina tendinum mm. peroneorum communis.

Vaginae tendinum digitales pedis, five, one on the volar surface of each toe; they begin behind, at the great toe in the neighborhood of the base, on the other toes in the neighborhood of the heads of the ossa metatarsalia, and terminate near the terminal phalanx; they are surrounded like those in the fingers (see p. 322) by the ligg. vaginalia with the ligg. cruciata and annularia; they never communicate with the sheaths which lie more proximalward.

Bursae mm. lumbricalium pedis, four, lying on the anterior extremities of the mm. lumbricales, between them and the ligg. capitulorum [oss. metatars.] transversa;

the three medial bursae are almost constant, the fourth occurs in half the cases.

408. Bursae and sheaths of tendons of the back of the right foot, injected; sheaths of tendons stained red.

Vagina tendinis m. tibialis anterioris (see also Fig. 406)

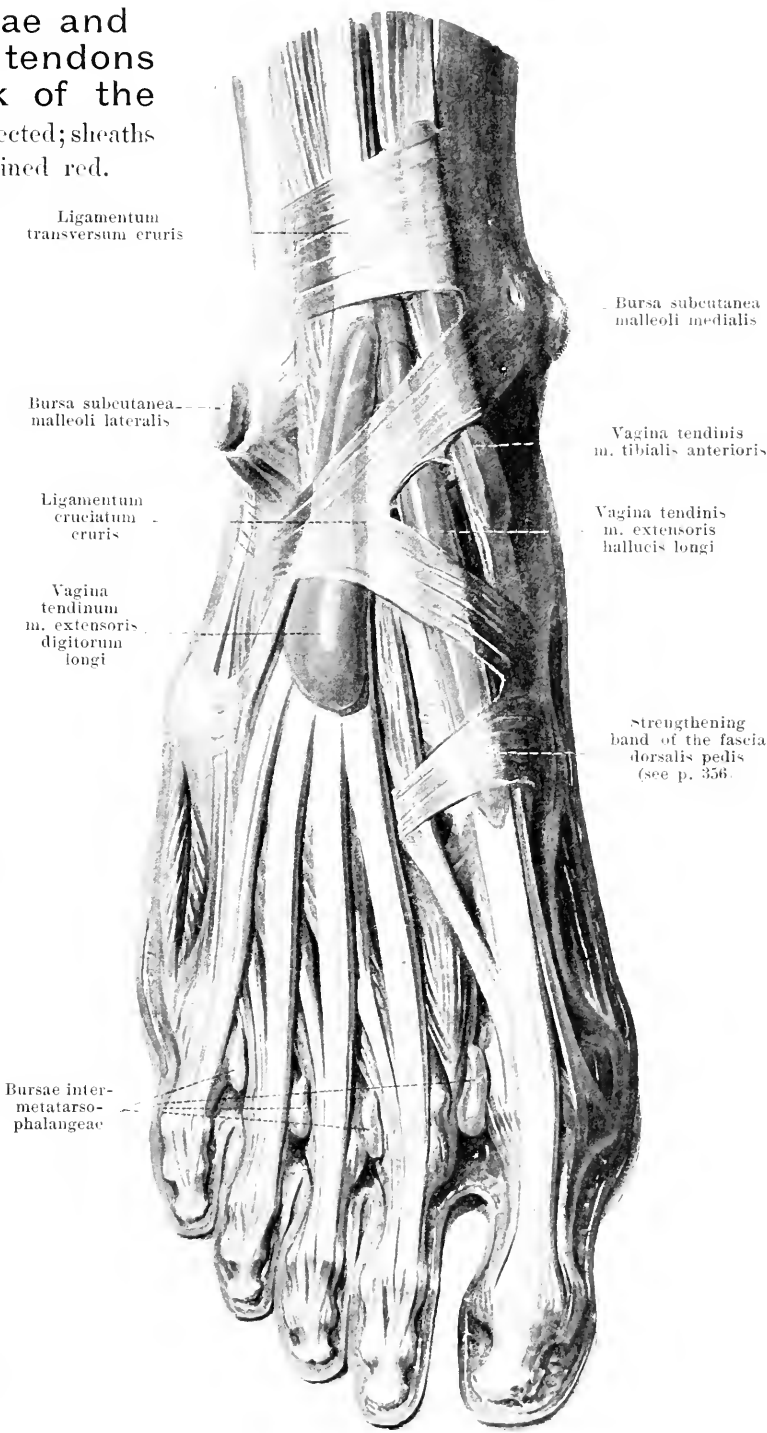
begins somewhat above the lig. transversum cruris and ends usually somewhat above the articulation talonavicularis.

Vagina tendinis m. extensoris hallucis longi (see also Fig. 406)

begins as the most deeply situated of the anterior tendon sheaths, below the lig. transversum cruris and ends farthest forward in the region of the articulation tarsometatarsae of the great toe, distalward from the strengthening band situated there (see p. 356); the distal end often has the appearance of being pinched off.

Vagina tendinum m. extensorum digitorum pedis longi (see also Fig. 409)

forms a sheath for the tendons of the m. extensor digitorum longus and of the m. peroneus III; it begins somewhat above the preceding below the lig. transversum cruris and ends over the middle of the os cuneiforme III.



Ligamentum transversum cruris

Bursa subcutanea malleoli lateralis

Ligamentum cruciatum cruris

Vagina tendinum m. extensoris digitorum longi

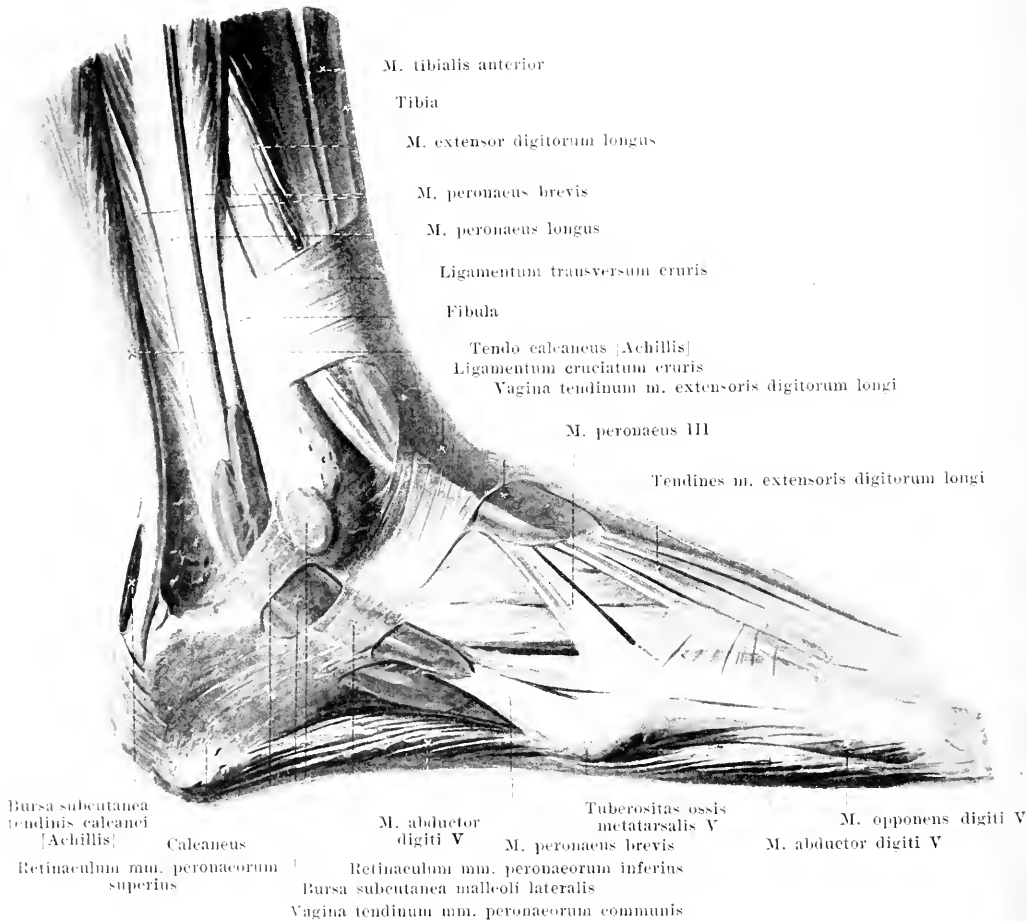
Bursa subcutanea malleoli medialis

Vagina tendinis m. tibialis anterioris

Vagina tendinis m. extensoris hallucis longi

Strengthening band of the fascia dorsalis pedis (see p. 356)

Bursae intermetatarsophalangeae

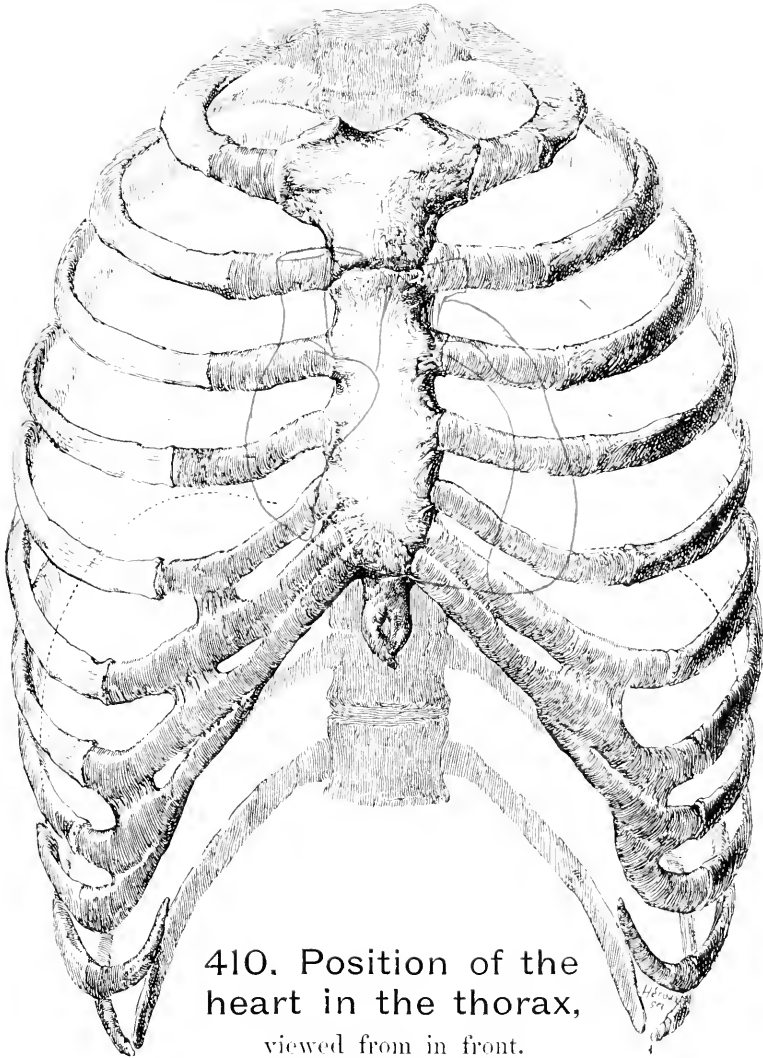


409. Bursae and sheaths of tendons of the right foot,

injected (sheaths of tendons stained red), viewed from the lateral surface.

Bursa subcutanea malleoli lateralis (see also Figs. 390 and 408), very frequently present, upon the malleolus lateralis.

Vagina tendinum mm. peronaeorum communis (see also Fig. 407), surrounds the tendons of the mm. peronaei and bifurcates, at its proximal end for a shorter, at its distal end for a longer, distance into two parts, one for each tendon. It begins above the malleolus lateralis and ends at the beginning of the tuberositas oss. cuboidei; it communicates there only rarely with the vagina tendinis m. peronaei longi plantaris.

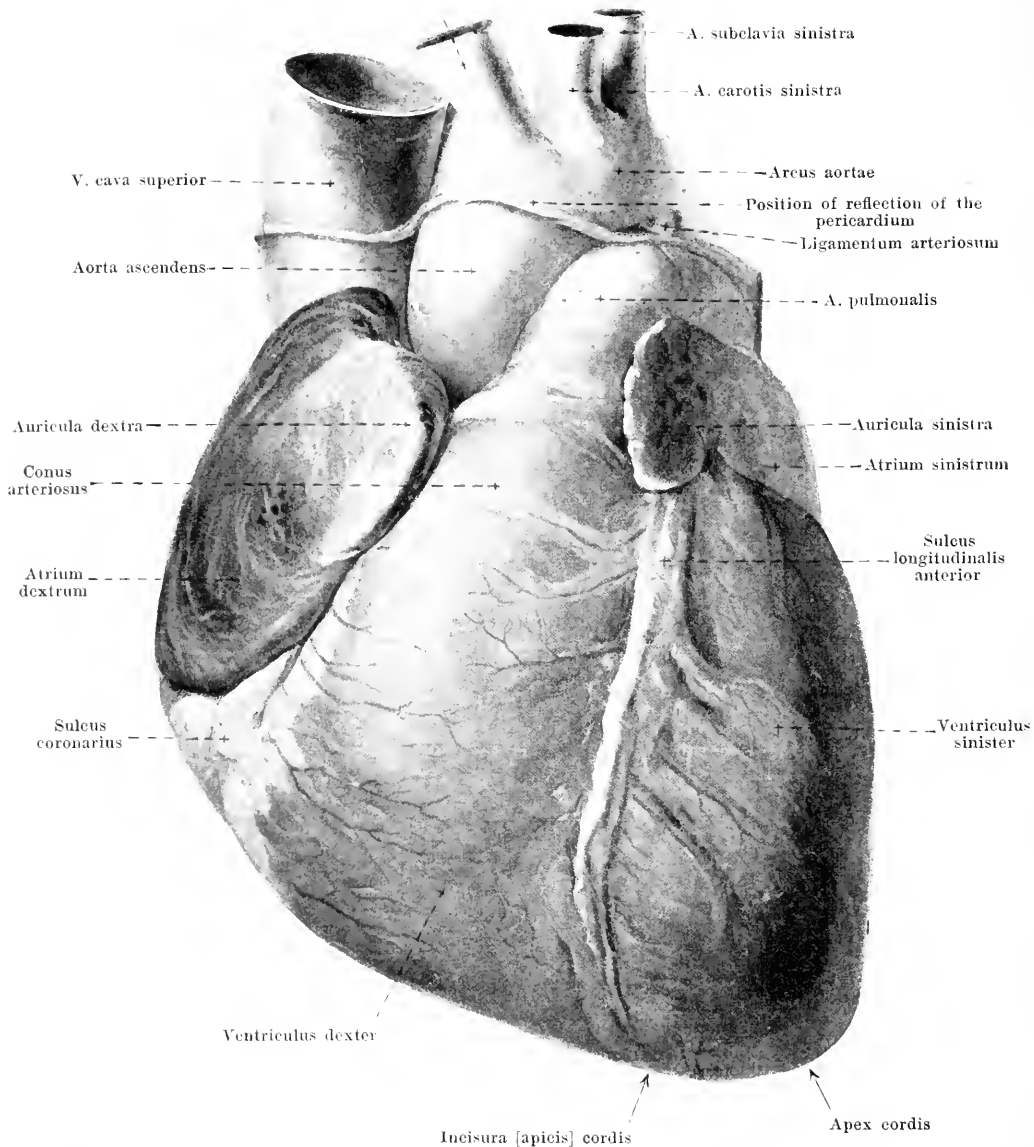


410. Position of the heart in the thorax, viewed from in front.

(The level of the diaphragm on moderate expiration is shown by the black dotted line; the outlines of the heart are indicated in red.) — (In part after W. Braune.)

The **heart (cor)** is an almost wedge-shaped, hollow, muscular body. It lies asymmetrical to the median plane in the thorax, so that the smaller part belongs to the right half of the body and the larger part of it to the left. The *basis cordis* (*base of the heart*) formed by the atria is directed backward and somewhat to the right, the *apex cordis* (*apex of the heart*) (belonging to the left ventricle alone) looks forward and to the left and comes into direct contact with the wall of the thorax in the 5th intercostal space, somewhat medial from the costocartilaginous junction. The *ostium arteriosum dextrum* (O. T. pulmonary orifice) lies usually at the sternal end of the 3rd left intercostal space, or behind the 3rd costal cartilage; the *ostium arteriosum sinistrum* (O. T. aortic orifice) lies, somewhat more medianward and downward, close below the middle of the left half of the sternum at the level of the 3rd intercostal space. The middle point of the *ostium venosum dextrum* (O. T. right auriculoventricular opening) lies behind the right half of the sternum at the level of the sternal end of the 4th intercostal space; the *ostium venosum sinistrum* (O. T. left auriculoventricular opening) lies behind the sternal end of the 3rd left intercostal space.

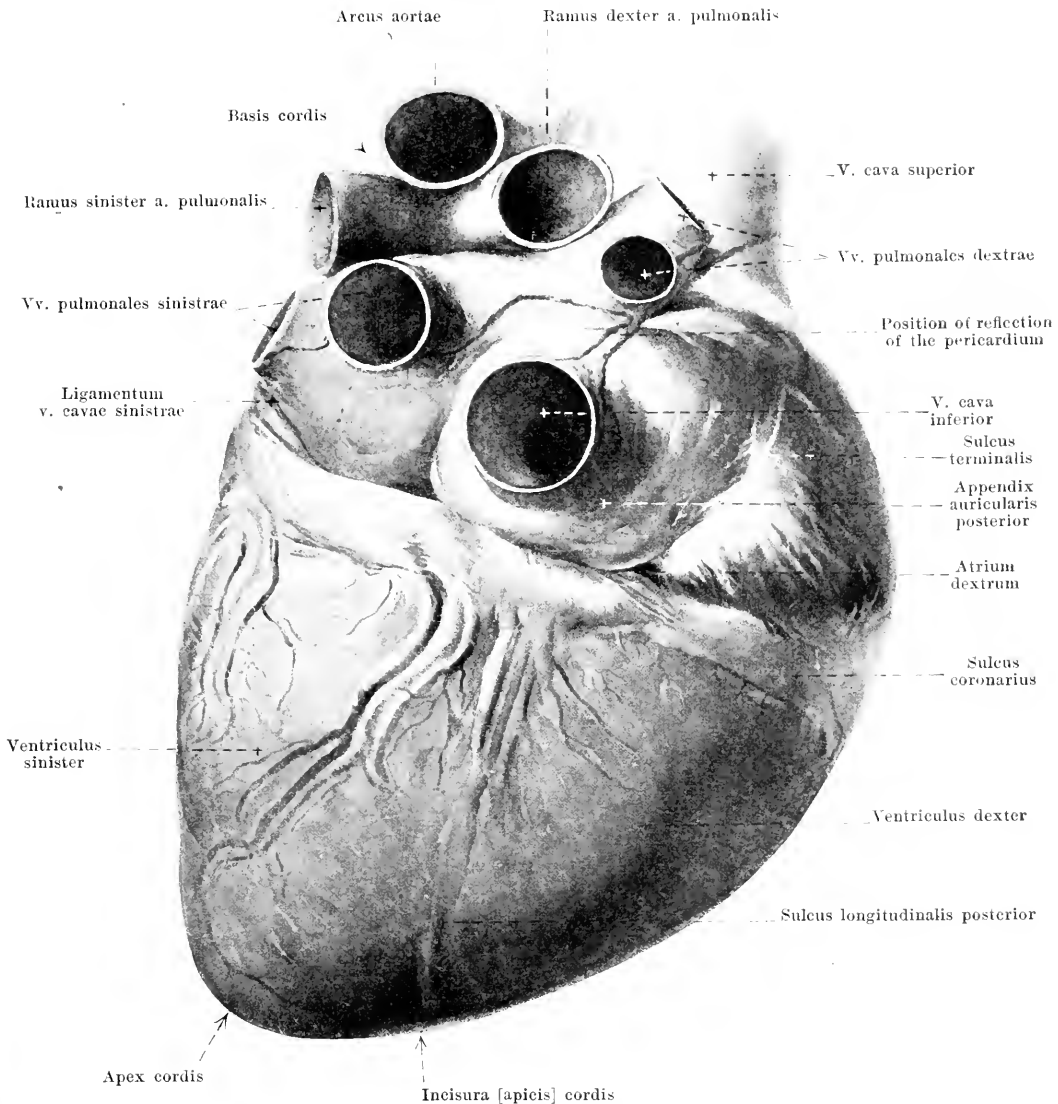
A. anonyma



411. The heart, moderately distended, viewed from above and in front.

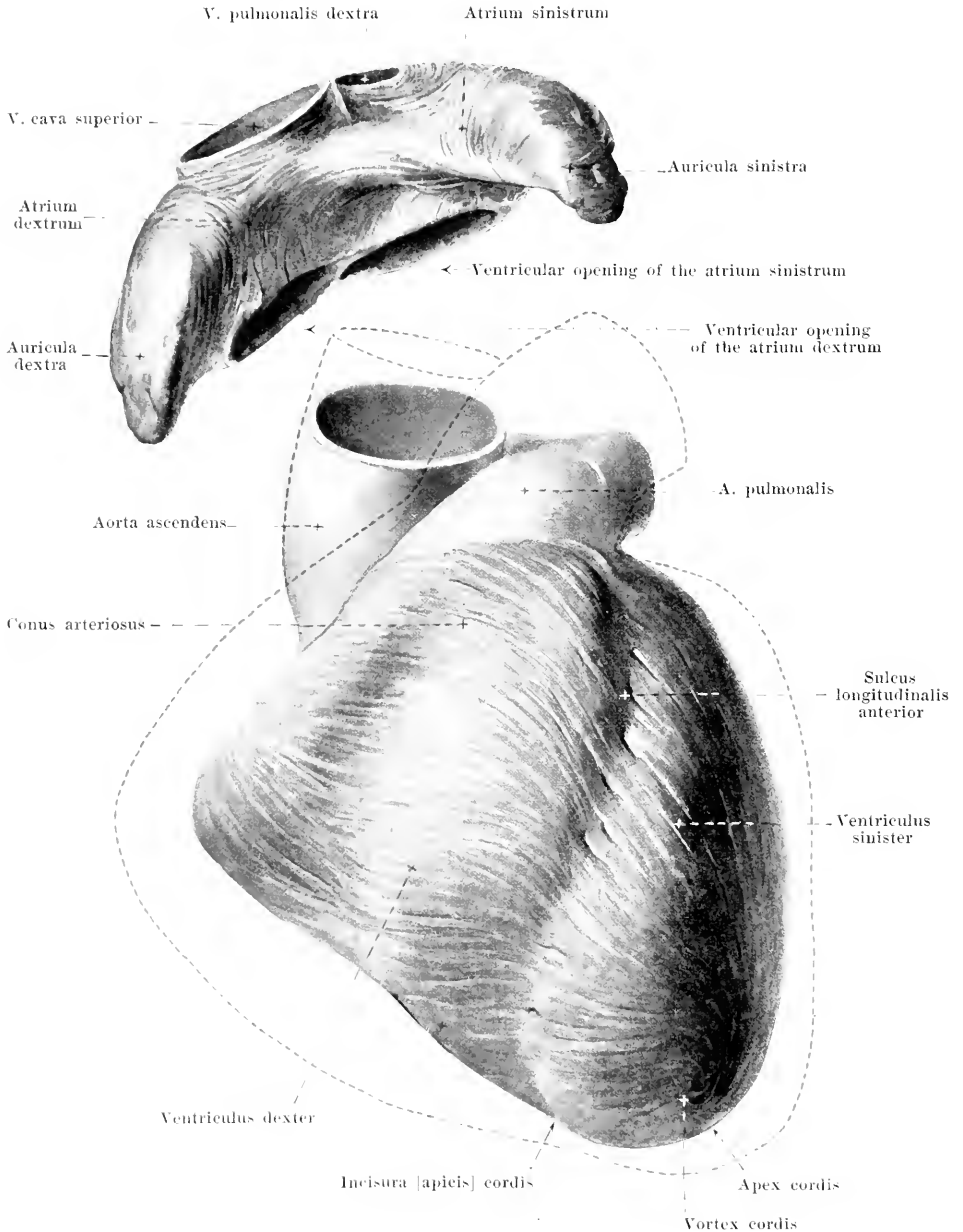
(*Facies sternocostalis.*)

The **heart** is intercalated as a pressure pump in the circulatory system and consists of two *fore-chambers*, *atrium dextrum* (O. T. right auricle) and *atrium sinistrum* (O. T. left auricle) and of two *ventricles*, *ventriculus dexter* (*right ventricle*) and *ventriculus sinister* (*left ventricle*). It presents for examination an inferior, almost plane surface, lying upon the diaphragm, the *facies diaphragmatica* (O. T. posterior surface) and a markedly curved surface looking upward and forward, the *facies sternocostalis* (O. T. anterior surface): the latter lies partly just behind the sternum and behind the anterior ends of the 3rd to the 6th pair of ribs, in part it is overlapped by the margins of the lungs.



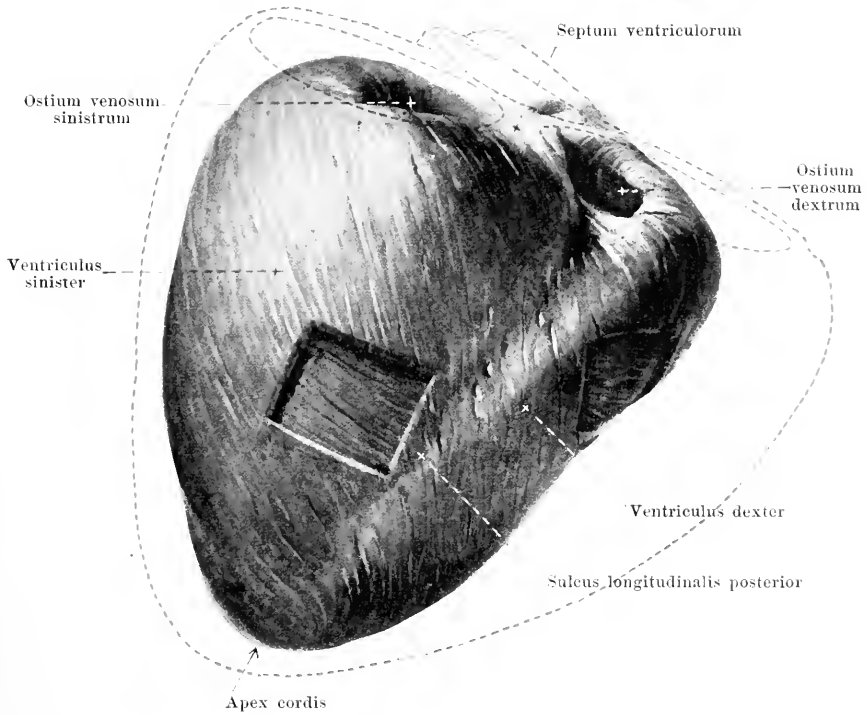
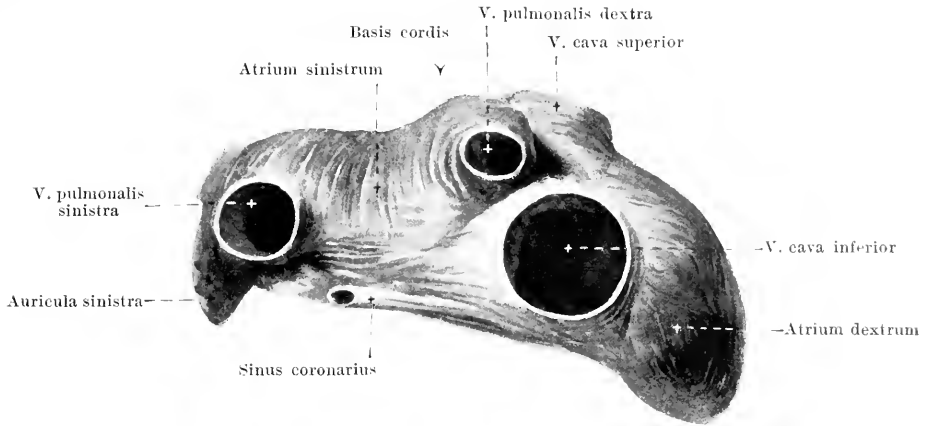
412. The heart, moderately distended, viewed from below.
(*Facies diaphragmatica.*)

The **heart**: the fore-chambers or atria are separated from the ventricles by a groove, the *sulcus coronarius* (O. T. auriculoventricular groove) which is usually filled up with blood-vessels and fat: it runs nearly perpendicular to the long axis drawn from the apex to the middle of the base and is in part hidden on the sternocostal surface by the beginning of the a. pulmonalis and aorta. The *sulcus longitudinalis posterior* (O. T. posterior interventricular groove) runs fairly straight on the inferior surface, corresponding to the septum between the two ventricles; the *sulcus longitudinalis anterior* (O. T. anterior interventricular groove) runs on the upper surface, twisted so as to be somewhat S-shaped from the base toward the apex. The latter sulcus begins, covered by the left auricle (O. T. auricular appendix), on the left side of the a. pulmonalis and meets the former at the right of the apex of the heart in a shallow groove, the *incisura [apicis] cordis*.



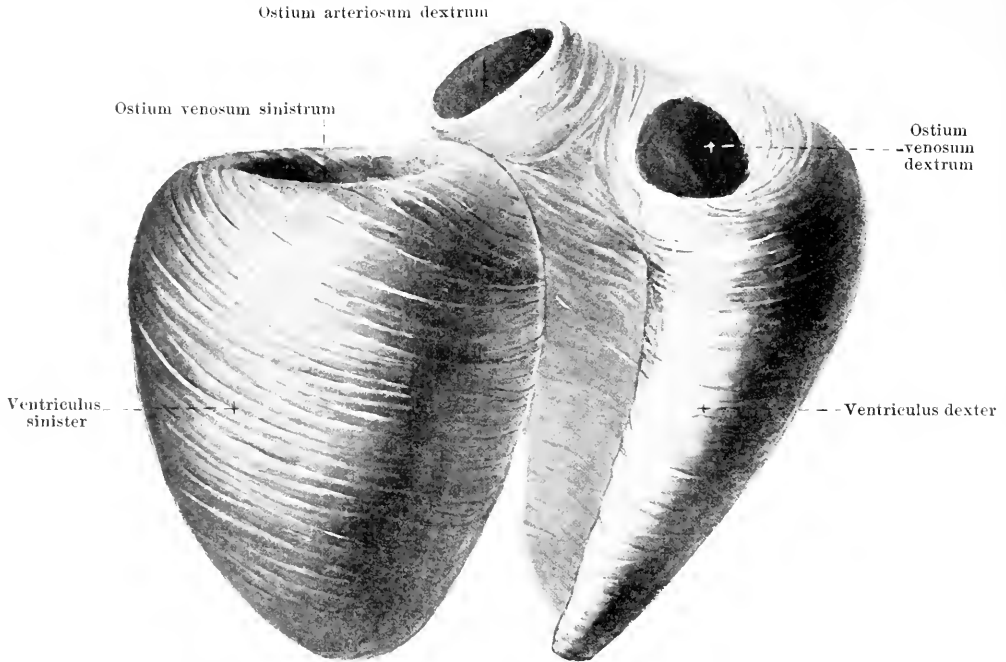413. Superficial muscle layer of a maximally contracted heart, viewed from above and in front.

(The fore-chambers or atria have been dissected off. The outlines of the dilated ventricles of the heart are indicated in red, the position of the ostium arteriosum sinistrum being assumed to be fixed. [Text see pp. 370, 371 and 373.]



414. Superficial muscle layer of a maximally contracted heart, viewed from below.

(The fore-chambers or atria have been dissected off. Two windows have been cut into the superficial muscle layer in order to show the deeper bands of fibers. The outlines of the dilated ventricles of the heart are indicated in red, the position of the ostium arteriosum sinistrum being assumed to be fixed. [Text see pp. 370, 371 and 373.]



415. The musculature of the ventricles of the heart, dissected free from one another; drawn apart; viewed from below.

Somewhat schematically represented.

(On the right the superficial muscle layer is shown, on the left the middle layer is represented.)

The **heart** is covered on its outer surface by the visceral layer of the pericardium, the *epicardium*, on its inner surface by the *endocardium*: the main mass of the wall is formed of muscle, the *myocardium* (see Fig. 421).

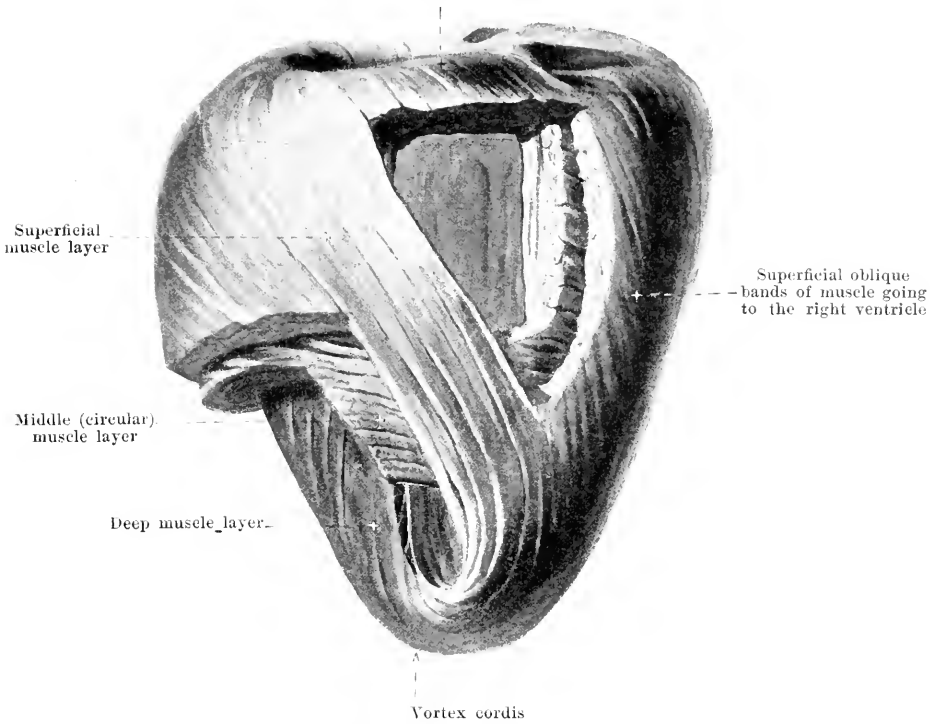
The **musculature***) of the *fore-chambers*, or atria (O. T. auricles) (see Figs. 413 and 414) is very thin and irregular. On the posterior and especially on the anterior surface fibers go transversely from the wall of one atrium to that of the other: otherwise the fibers run chiefly in rings around the mouths of the veins and around the points of origin of the auricles (O. T. auricular appendices); in the auricles themselves the fibers are irregularly arranged. In addition, fibers go over into the radial fiber layer of the valvulae tricuspidalis and bicuspidalis. In the right atrium another, inner muscle layer, the *mm. pectinati* (see p. 376), exists. Between the musculature of the atria and that of the ventricles of the heart there is in general no connection.

The **musculature** of the *ventricles* (see also Figs. 413 and 414, 416—419) is common in its most superficial layers, but otherwise separated. The most superficial layer of muscle (see Figs. 413 and 414) runs obliquely, in front from the right and above to the left and downward, behind from the left and above to the right and downward: the fibers can be followed in their course, behind partly as far as the *annulus fibrosus sinister*, otherwise, however, they cannot be distinguished, for long distances, from the other bands of muscle.

The **musculature** of the *right ventricle* (see also Figs. 420 and 424) is thin and presents in general two layers. The portion containing the ostium venosum presents, especially distinctly in the distended heart, an external, thin, connected layer and an internal, thicker layer arranged in the form of a network. In the *external* layer the fibers run, in the main, obliquely, behind from the left and above to the right and downward and come partly from the *annulus fibrosus dexter* (see p. 373), partly from the upper surface of the left ventricle, partly from the *annulus fibrosus sinister* (see p. 373), partly from the septum; in front they go partly to the upper surface of the left ventricle, partly into the septum; following upon these oblique fibers are fibers running more or less transversely. (Continued on p. 371.)

*) In the description of the musculature (pp. 370 and 371) the heart is thought as being placed with the base upward, the *facies diaphragmatica* backward and the apex downward.

Fibers arising from the
annulus fibrosus sinister and going to the right ventricle

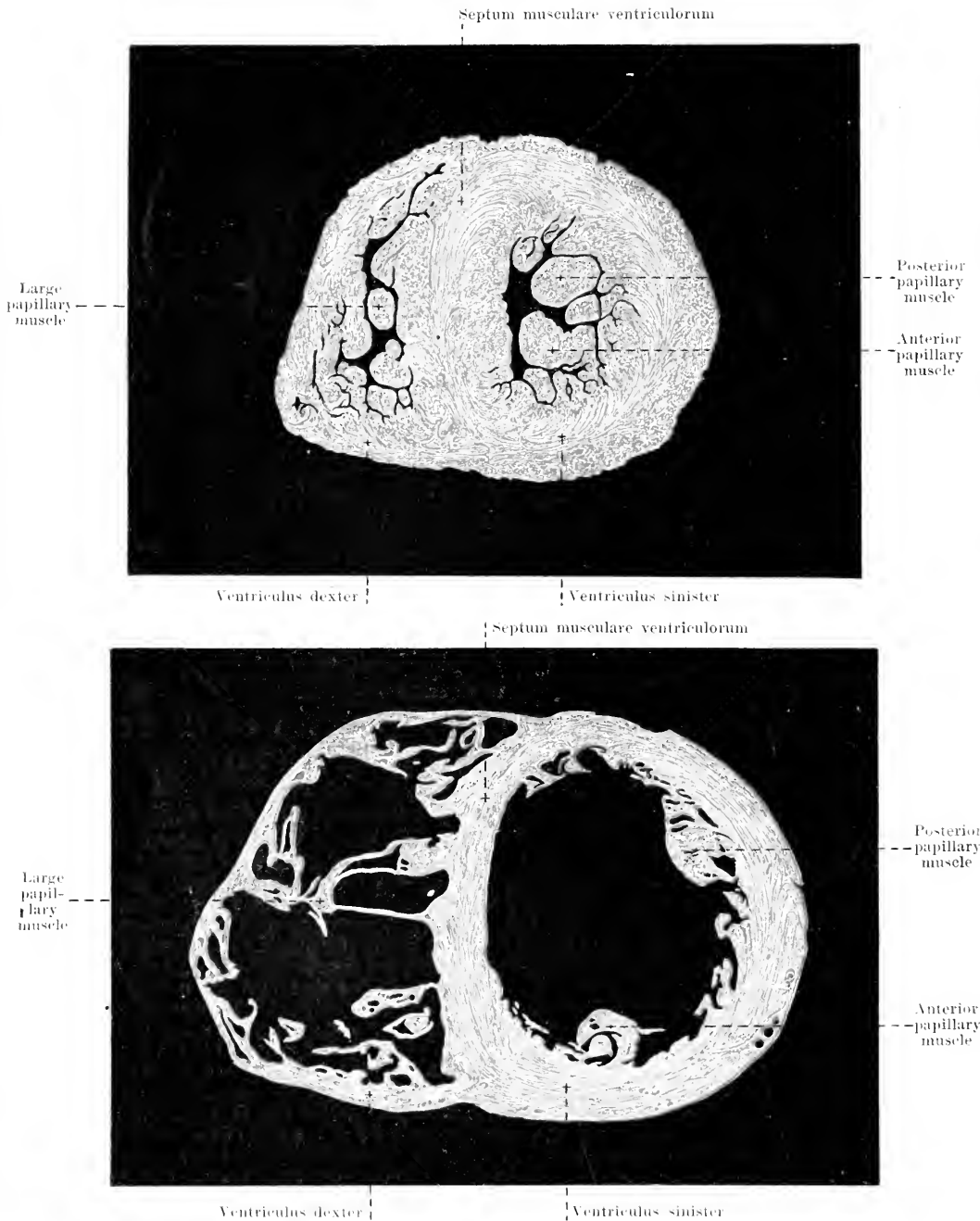


416. Course of the principal layers of muscle of the left ventricle of the heart, viewed from below. Partly schematic.

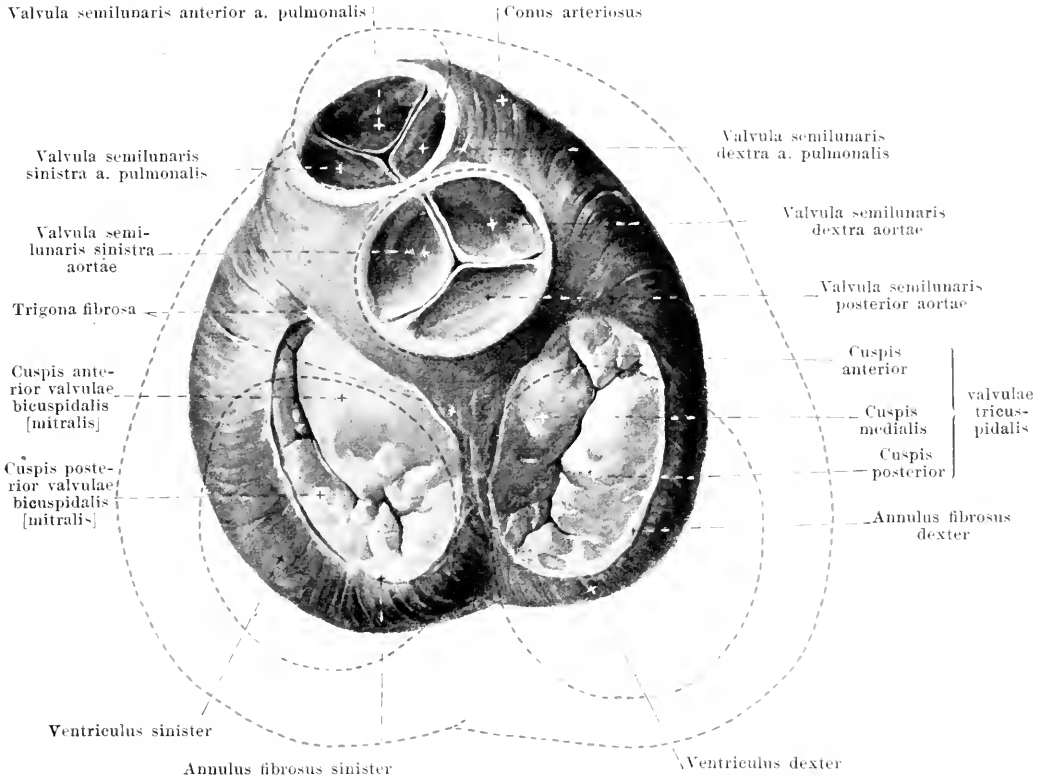
(Parts of the wall of the heart have been removed above and on the left side below.)

Musculature of the *right ventricle* (continued). The *inner* layer is formed of short bands of fibers which arise partly at the upper margin of the septum, go toward the apex, turn at varying levels toward the external wall and run upward in this again, in part to end as the musculi papillares, in part to reach the annulus fibrosus as *trabeculae carneae*; between these columns are others which are stretched out transversely. The conus arteriosus possesses an external layer of circular muscle and an internal longitudinal layer at right angles to it; the latter forms longitudinal ridges in the contracted heart.

The **musculature** of the *left ventricle* is much thicker than that of the right and is divisible into three layers of fibers, which, however, are not sharply separable from one another. The *superficial* layer is thin; its fibers arise at the annulus fibrosus sinister (see p. 373) or at the ostium arteriosum sinistrum and run (the superficial more steeply than the deeper fibers) in front from the right and above downward and to the left, for the most part to the apex of the heart to form the *vortex cordis*; there they bend around into the interior and form the deep innermost layer of muscle. The thick, *middle* layer (see Fig. 415) consists of fiber bands which form closed circles, run essentially perpendicular to the axis of the heart, on the outer surface however also a little obliquely, in front from the right and above to the left and downward; on the inner surface they are arranged in the reverse direction; in their course the bands of fibers are manifoldly interwoven with one another. The *deep*, innermost layer is the continuation of the fiber bands of the superficial layer entering into the vortex cordis. Its fibers are arranged in gentle spiral turns but nearly parallel to the long axis of the ventricle and end either in the papillary muscles or at the annulus fibrosus sinister and at the ostium arteriosum sinistrum. As the *trabeculae carneae* they form, in general, numerous longitudinal ridges, of varying thickness, which are connected with one another by thinner transverse beams; only the septum below the ostium arteriosum is entirely smooth.



417 and 418. Cross-sections of two hearts between the upper and middle third of the ventricles, perpendicular to the long axis. The upper heart has been fixed in systole, the lower in diastole. (After L. Köhl.)



419. Base of the contracted ventricles, after removal of the fore-chambers or atria. The valves are closed.

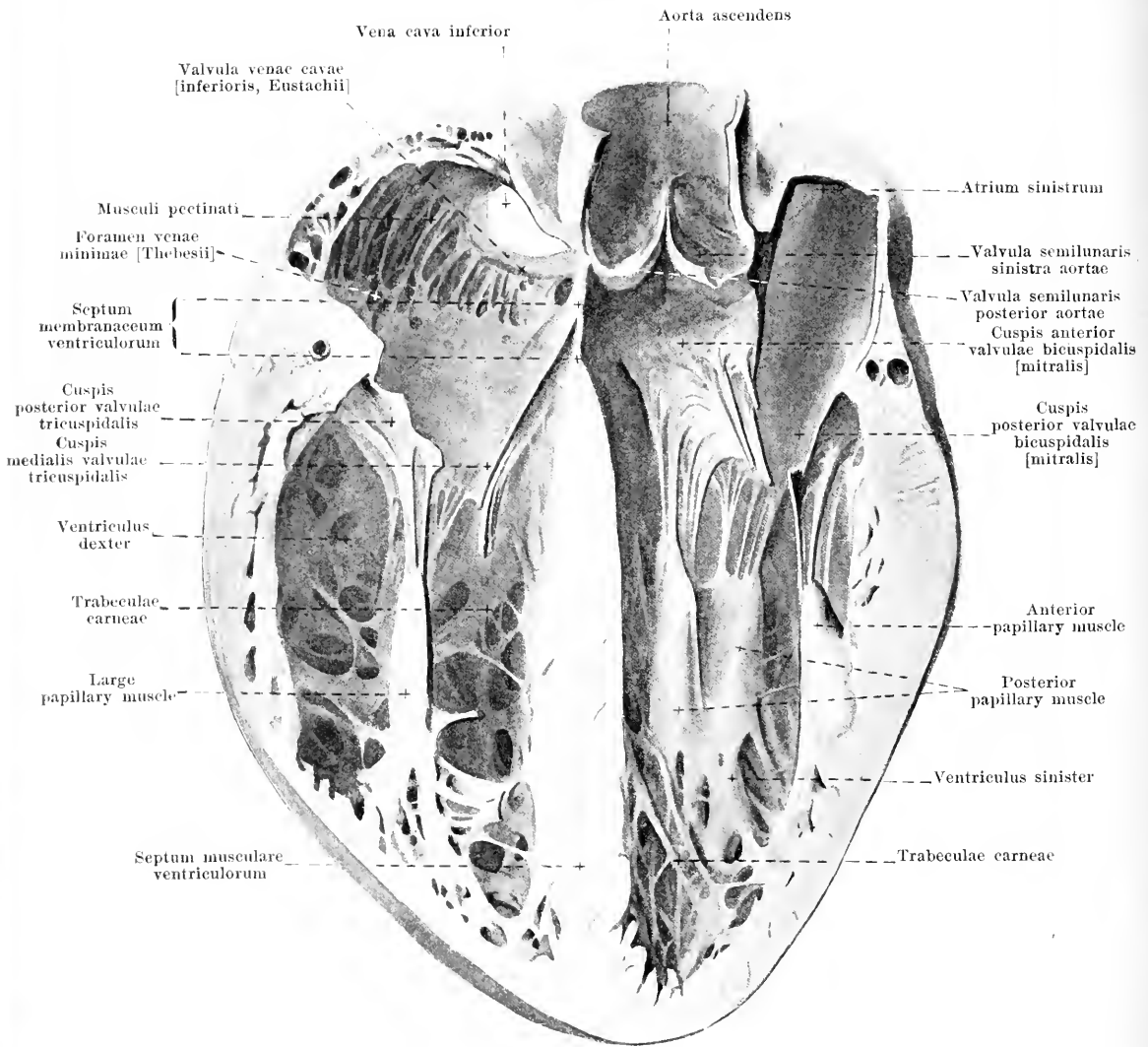
(The outlines of the distended ventricles are indicated in red, the position of the ostium arteriosum sinistrum being assumed to be fixed.)

The **annuli fibrosi** are dense, narrow bands of connective tissue, which surround the ostia venosa at the base of the ventricles. They serve for the attachment of the muscular fibers of the atria and of the ventricles, and from them arise in largest part the valvulae tricuspidalis and bicuspidalis. The right surrounds the ostium venosum dextrum in the form of an oval closed ring. The left is horseshoe-shaped surrounding the right, posterior and left sides of the ostium venosum sinistrum; it begins right and left at the root of the aorta in a nodular thickening on either side, the *trigona fibrosa*; between these the anterior cusp of the valvula bicuspidalis arises directly from the membranous wall of the root of the aorta.

The **differences between the contracted and dilated ventricles** are as follows (see also Figs. 413, 414, 417 and 418):

In the *dilated ventricles* the diameter of the base is nearly the same as that of the long axis; the form approaches that of a hemisphere. The conus arteriosus projects markedly, the lower surface bulging much less than the upper, the ostia venosa and arteriosa are large, the cavities of the ventricles are wide open; the trabeculae carneae extend partly through the lumen of the ventricles, and the musculi papillares stand out partly free in the ventricular cavities.

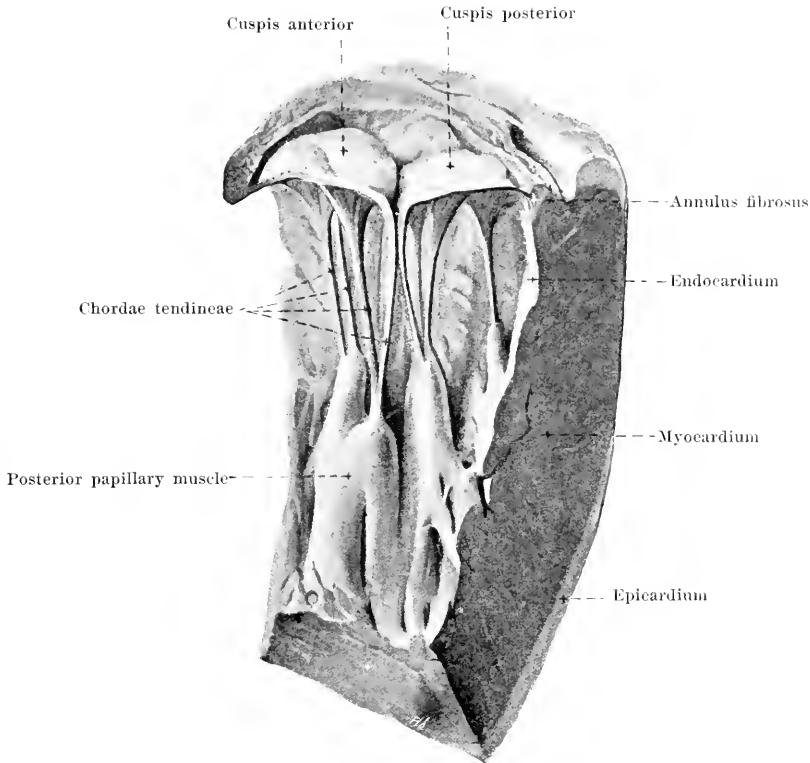
On maximal *contraction of the ventricles*, the diameter of the base is markedly shortened, while that of the long axis diminishes only slightly; the form is wedge-shaped. The conus arteriosus shortens and sinks in; the facies diaphragmatica is slightly flattened, the sulcus longitudinalis anterior has a more marked spiral twist, the ostia venosa are markedly diminished in size, the ostia arteriosa less markedly, the cavities of the ventricles are represented only by a slit (with the exception of a space situated above the apices of the papillary muscles); the trabeculae carneae and the musculi papillares lie close to the walls and form ridge-like projections.



420. Transverse section through a distended heart approximately parallel to the facies diaphragmatica.

(Inferior half of the section, viewed from above.)

The **septum ventriculorum** (*interventricular septum*) (see also Figs. 415, 417 and 418) separates the two ventricles from one another completely. It is muscular in by far its largest part (*septum musculare ventriculorum*), is formed by a corresponding portion of the musculature of each of the two ventricles and can be divided into its two components only by artificial means. On contraction it thickens and the distance between the two sulci longitudinales diminishes. The *septum membranaceum ventriculorum* (O. T. undefended space) is a small area of pure connective tissue situated just between and in front of the opposed margins of the valvulae semilunares dextra et posterior aortae (see also Fig. 426); its right surface is divided into two parts by the cuspis medialis valvulae tricuspidalis arising from it; the posterior part looks into the right atrium, the anterior into the right ventricle.

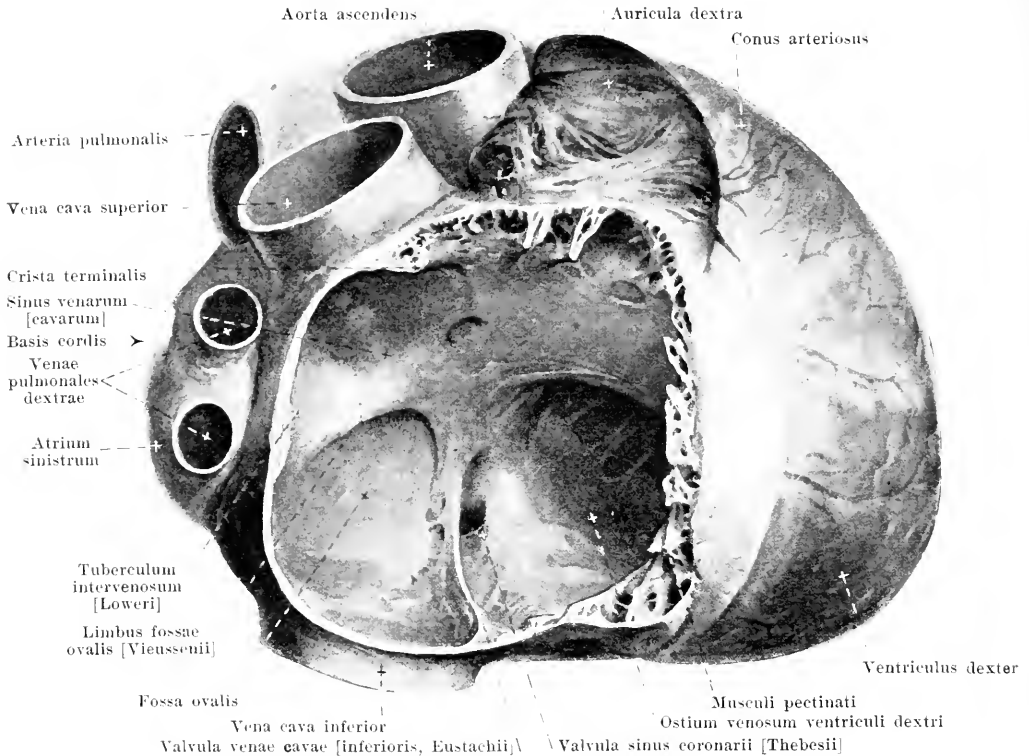


421. Transverse section through the valvula bicuspidalis [mitralis]. The valve is set.

(Inferior half, viewed from above.)

The **musculi papillares** (*papillary muscles*) (see also Figs. 417, 418, 420, 424 and 425) are more or less isolated, bluntly wedge-shaped elevations of the internal muscular layer of the ventricles. They vary much in size and in different hearts present considerable differences in appearance. From the tip of each muscle there go off one or several tendinous threads (*chordae tendineae*) of variable strength, which become attached partly to the free margins (*chordae tend.* of the I order), partly to the ventricular surface (*chordae tend.* of the II order) of the cusps of the valves guarding the ostia venosa; the insertion is in the form of a triangular flat expansion. Each papillary muscle gives off chordae usually to two adjacent cusps. In addition other tendinous threads (*chordae tend.* of the III order) arise directly from the musculature of the ventricles and become attached in the same way also to the ventricular surface of the cusps of the valves. The chordae tendineae are of unequal length and are so arranged that the valve is set when they are all put upon the stretch, and vice versa.

The *valvula tricuspidalis* and *valvula bicuspidalis [mitralis]* (see also Figs. 419 and 420) consists each of a tube-like membrane, which is attached to the annulus fibrosus (also partly to the wall of the root of the aorta on the left side) and is divided at its free margin by deep incisures into large sails or cusps (*cuspides*) and by less deep incisures into variably developed, smaller, intermediary cusps. They are covered on both sides by endocardium and in their peripheral halves contain circular and radial muscle fibers which are connected with the musculature of the fore-chambers or atria. At the end of the diastole of the ventricles, the central portions of the atrial surfaces of the cusps become applied to one another (the valves become set); the closure is water-tight and during the systole becomes gradually ever more complete, since the ostia venosa are markedly diminished in size and thus ever larger sections of the cusps of the valves are applied to one another.

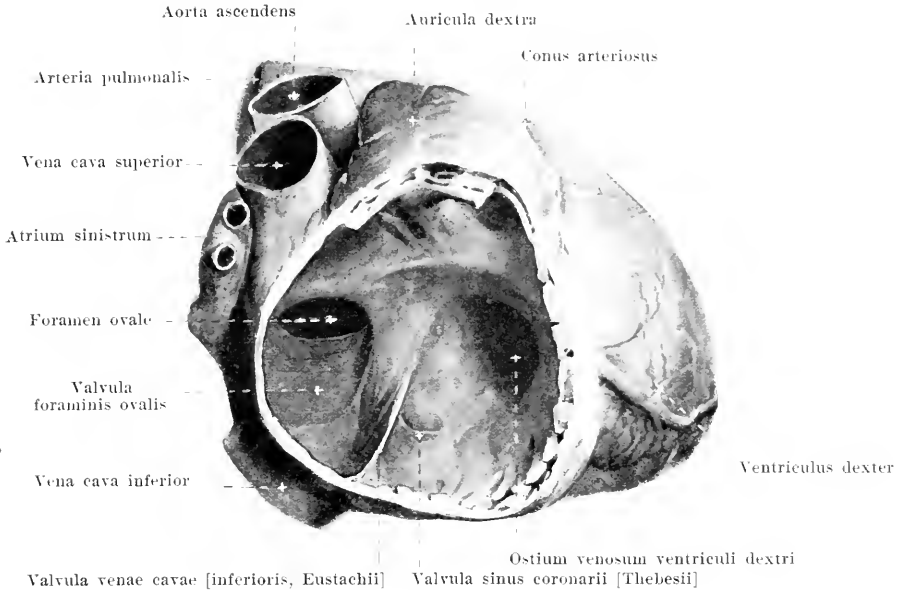


422. Right fore-chamber (*atrium dextrum*)

of a markedly distended adult heart, viewed from the right.

(A part of the wall of the atrium has been removed.)

The **atrium dextrum** (*right fore-chamber*, O. T. right auricle) (see also Figs. 411—414 and 420) is of the shape of an irregular short cylinder. A groove, variably developed, running perpendicularly over the posterior external surface, the *sulcus terminalis atrii dextri*, and a ridge on the corresponding spot of the inner wall, the *crista terminalis*, mark off a posterior, medial portion, the *sinus venarum [cavarum]* which is derived from a part of the sinus reuniens of the embryonic heart (see also p. 384). It contains in its lower and upper walls the mouths of the v. cava superior and inferior and in general has smooth walls. Between the opening of the v. cava inferior and the sulcus coronarius to the left of the sulcus terminalis there is often visible on its outer surface an irregular lumpy projection (*appendix auricularis posterior*). The posterior wall of the sinus is bounded partly by the atrium sinistrum, being slightly shoved forward by the same and presents there a transverse ridge, the *tuberculum intervenosum [Loweri]* (O. T. tubercle of Lower). The left wall is formed by the *septum atriorum* (O. T. interauricular septum), which consists partly of muscle, partly (*pars membranacea septi atriorum*) of pure connective tissue. The latter spot lies in the lower part of the wall, is somewhat deepened (*fossa ovalis*) and is surrounded in front and above by a strong ridge of muscle (*limbus fossae ovalis [Vicussenii]*). Starting at the anterior limb of the limbus, and arising from the inferior wall, is a thin, often partially perforated, fold of connective tissue which surrounds the mouth of the v. cava inferior from in front and sometimes also from the right (*valvula venae caevae [inferioris, Eustachii]*) (O. T. Eustachian valve). Just in front of it, in the angle between the inferior, left and anterior walls, lies the mouth of the sinus coronarius; it is only imperfectly closed from below by the sickle-shaped *valvula sinus coronarii [Thebesii]* (O. T. coronary valve or valve of Thebesius), which is often perforated. The anterior wall of the atrium contains the ostium venosum of the right ventricle. The right wall presents numerous muscular ridges projecting on the inner surface (*musculi pectinati*) (see also Fig. 420); these arise from the *crista terminalis* and extend approximately in the direction of the long axis of the heart as far as the sulcus coronarius; between them the wall is translucent when the heart is distended.



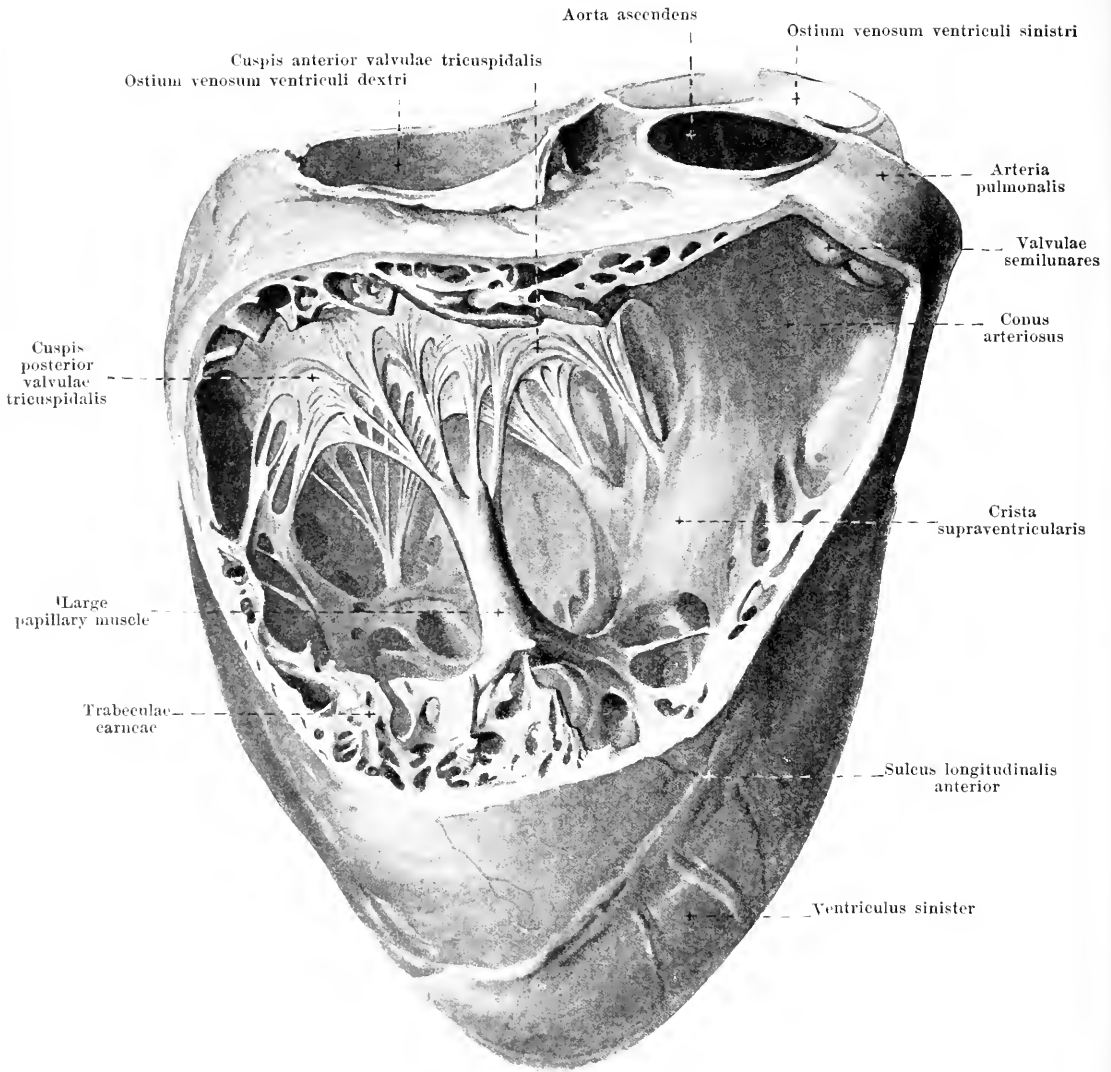
423. Right fore-chamber (*atrium dextrum*) of a foetal heart (8th month), viewed from the right.

(A part of the wall of the atrium has been removed. Magnification: 2:1.)

From the upper wall of the **atrium dextrum** projects the bluntly wedge-shaped *auricula dextra* (*right auricle of the heart*) (O. T. right auricular appendix). It curves around the first portion of the aorta ascendens to the left, is notched above and below but otherwise smooth: it presents inside numerous irregular crossing muscular columns, *trabeculae carneae*.

During fetal life the two atria communicate with one another through an opening, the *foramen ovale* situated at the spot which later is the fossa ovalis. At its margin in front and above it is surrounded by a horseshoe-shaped, powerful band of muscle, which later becomes the limbus fossae ovalis, and behind and below it is bounded by the concave margin of the *valvula foraminis ovalis*, which rises as a thin connective tissue plate from behind and below and projects, groove-like, into the left atrium. Just after birth, as soon as the pressure in the left atrium becomes higher than in the right, this valve is pressed upon the limbus and fuses with it almost completely, often, however, leaving a small slit open. The *valvula foraminis ovalis* becomes accordingly later the floor of the fossa ovalis; the anterior concave margin of the valve is often retained and is visible inside the left atrium on the septal surface.

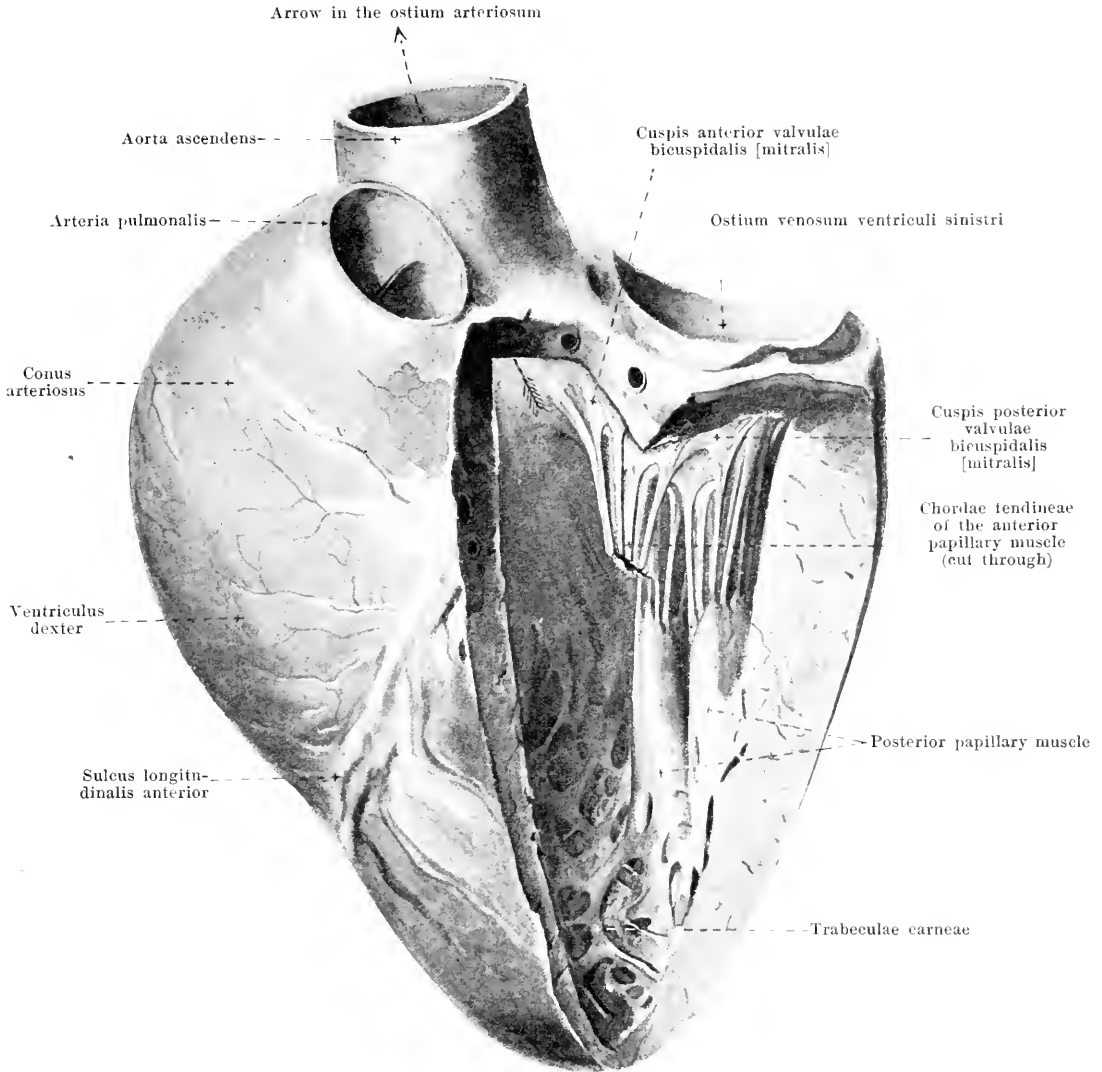
The **ventriculus dexter** (*right ventricle*) (see Figs. 411—415, 417—420 and 424) has the shape of a wedge: its left concave surface is attached to the right side of the left ventricle: its apex does not reach the apex of the heart. The base of the wedge is hidden by the attachment of the right atrium: the inferior, the right and the superior anterior surfaces lie free: the latter goes very gradually over into the *arteria pulmonalis* and, in the distended heart, projects markedly convexly forward (*conus arteriosus*). On the inside, marking off the *conus arteriosus* from the venous portion of the ventricle, is a muscular projection (*crista supraventricularis*) which extends, arch-like, from the base over the septum toward the apex and then to the right to the superior anterior wall and becomes lost in the roots of the large papillary muscle. The venous portion presents at the septum a fairly smooth wall, but elsewhere very many *trabeculae carneae* (see p. 371). The *ostium venosum* can be closed by the *valvula tricuspidalis* (*tricuspid valve*); this presents (see Fig. 419) a large cusp adjoining the interventricular septum (*cusps medialis*), further a small *cusps anterior* corresponding about to the *conus arteriosus*, a large *cusps posterior* turned toward the right free wall, and, usually, between the *cusps medialis* and *cusps posterior* an additional small intermediary cusp.



424. Right ventricle (*ventriculus dexter*) of a markedly distended heart, viewed from the right and above.

(The largest part of the right and anterior wall has been removed; the atria have been removed.)

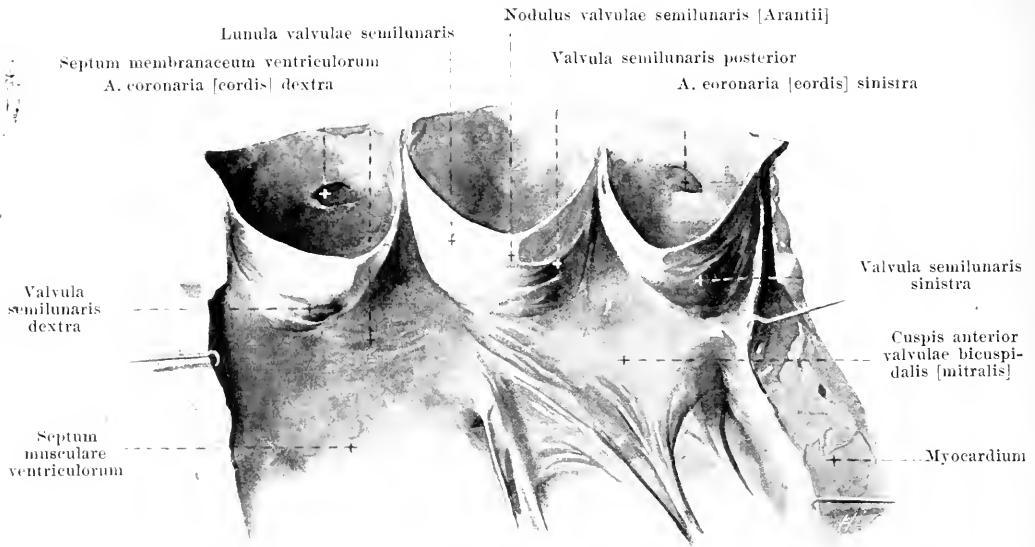
Ventriculus dexter (continued): the chordae tendineae of the anterior and posterior cusps come from a large papillary muscle which stands up free from among the trabeculae carnae at the junction of the conus arteriosus with the venous portion; besides this there is usually one smaller papillary muscle between the septum and the inferior wall, as well as a very small one on the septum just below the crista supraventricularis; the medial cusp receives many chordae directly from the septum itself. The conus arteriosus is more tubular, has a fairly smooth wall and goes over through the *ostium arteriosum* into the a. pulmonalis; at the entrance to the latter are situated the *valvulae semilunares arteriae pulmonalis anterior, dextra, sinistra* (semilunar valves of the pulmonary artery) (see p. 380).



425. Left ventricle (*ventriculus sinister*) of a distended heart, viewed from in front and somewhat from the left.

(The anterior wall has been almost entirely removed, the left wall partially; the atria have been cut away. An arrow has been introduced into the ostium arteriosum.) (Text see p. 350.)

The **atrium sinistrum** (*left fore-chamber*), (O. T. left auricle) (see Figs. 411—414 and 427) is wedge-shaped, broad behind, narrower in front. At the junction of the posterior with the lateral surfaces, right and left, lie the openings of the *venae pulmonales*. The right wall, formed partly by the *septum atriorum*, shows frequently the concave margin of the *valvula foraminis ovalis* (see p. 377). The anterior wall contains the ostium venosum ventriculi sinistri. From the junction of the right with the superior wall goes off the zigzag curved *auricula sinistra* (*left auricle of the heart*), (O. T. left auricular appendix) which curves around the a. pulmonalis from the left and reaches as far as its anterior surface. This left auricle contains inside it numerous interlacing *trabeculae carnae*; otherwise the wall of the atrium is smooth inside.



426. Valvulae semilunares aortae, opened up.

(The left ventricle and the aorta have been opened by a cut passing between the right and the left valve; the walls have been spread apart.)

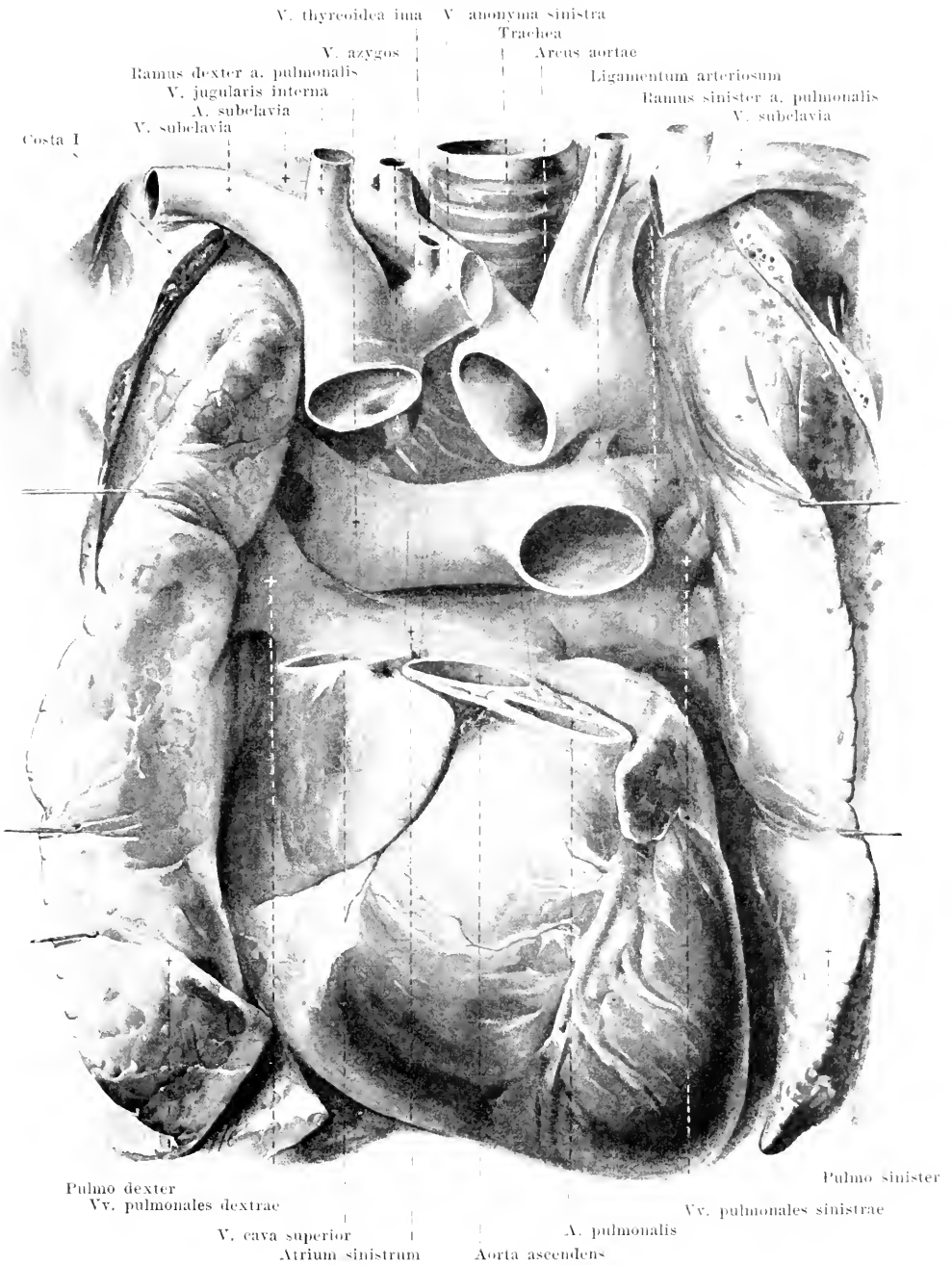
The **ventriculus sinister** (*left ventricle*) (see Figs. 411—421 and 425) has the shape of an egg, the large end of which is directed toward the right and backward and contains the ostia venosum et arteriosum; the other end forms the apex of the heart. As regards the inner surface see also p. 374. The *ostium venosum* is guarded by the *valvula bicuspidalis [mitralis]* (*bicuspid* or *mitral valve*). This consists of two large cusps and usually two small intermediary cusps: of the larger cusps, the *cusps posterior*, situated to the left and behind, arises from the annulus fibrosus sinister; the *cusps anterior*, situated to the right and in front, comes however only partially from the annulus fibrosus sinister, having its origin chiefly from that connective tissue portion of the root of the aorta which extends between the trigona fibrosa, so that the ventricular surface of this cusp goes over directly into this part of the wall of the aorta (see also Figs. 420 and 125). The chordae tendineae come from two papillary muscles, each of which can in turn be divided into several wedges; both muscles are developed from the left wall and correspond in their position approximately to the intermediary cusps. The *ostium arteriosum* contains the *valvulae semilunares aortae dextra, sinistra, posterior*; the posterior portion of the left valve and the posterior valve arise from the membranous part of the root of the aorta.

Each **valvula semilunaris** presents just below the middle of its concave free margin a small nodular thickening, *nodulus valvulae semilunaris [Arantii]*, and on both sides of this, near the margin, a sickle-shaped, thinner portion, *lunula valvulae semilunaris*, by means of which it lies against the neighboring valve.

The small or **pulmonary circulation** consists of the a. pulmonalis, the vv. pulmonales and their branches.

The **a. pulmonalis** (see Figs. 411—413, 427, 628 and 629) extends on the left side of the aorta ascendens obliquely to the left and backward and divides below the arcus aortae into a *ramus dexter* and a *ramus sinister*. The former goes below the arcus aortae behind the aorta ascendens and v. cava superior, in front of the bronchus dexter to the hilus of the right lung; the r. sinister runs in front of the bronchus sinister and the aorta thoracalis to the left lung. In the prolongation of the main stem a band of elastic connective tissue, the *ligamentum arteriosum*, extends to the concave anterior wall of the end of the arcus aortae.

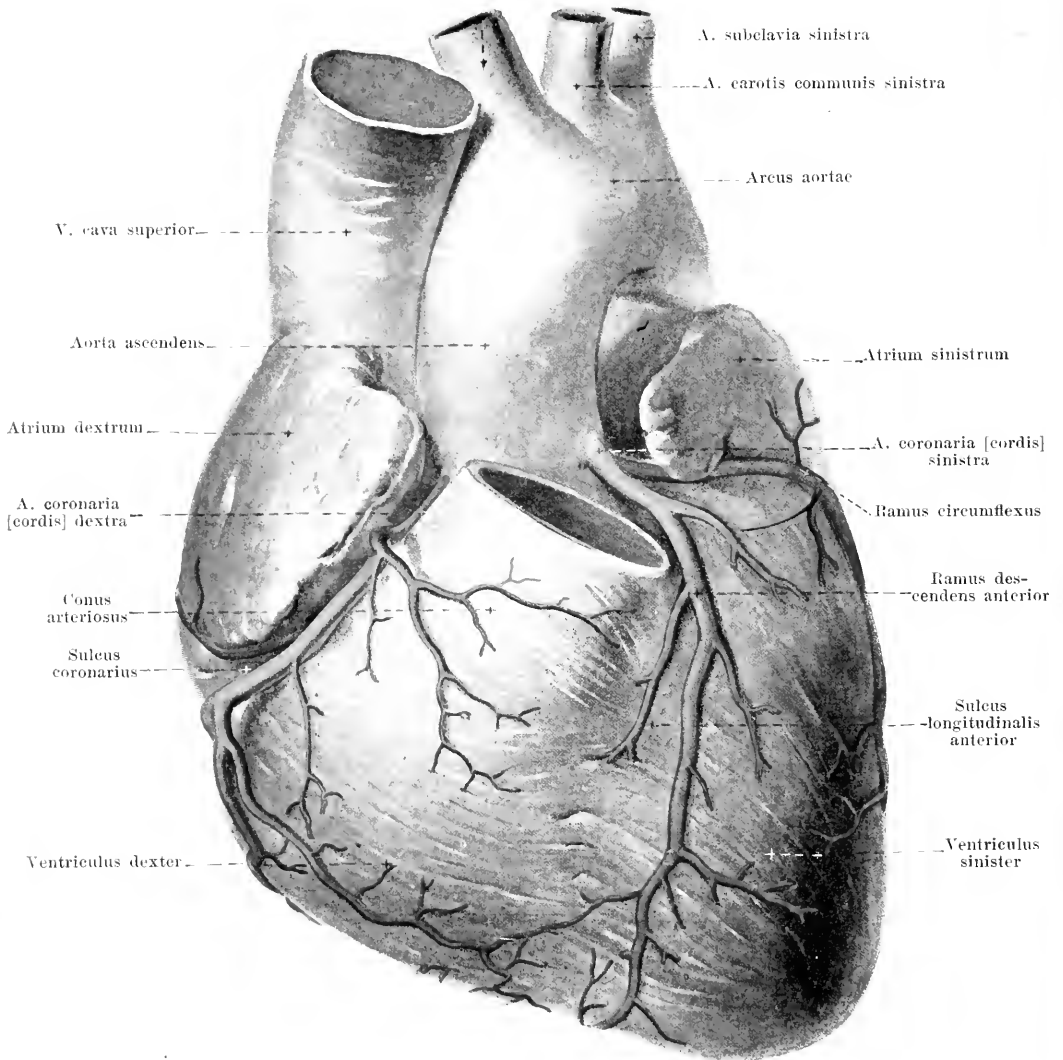
The **vv. pulmonales** (see Figs. 427, 619, 620, 628 and 629) come from the hilus pulmonalis on each side and open into the atrium sinistrum. They run on both sides in front of the main branches of the a. pulmonalis and in front of the bronchi; in addition the right veins go behind the v. cava superior and the atrium dextrum, the left in front of the aorta thoracalis.



427. Position of the heart and great vessels,
 viewed from in front.

(Pieces have been cut out of the v. cava superior, aorta and a. pulmonalis; the heart has been turned downward, so that the apex looks downward.)

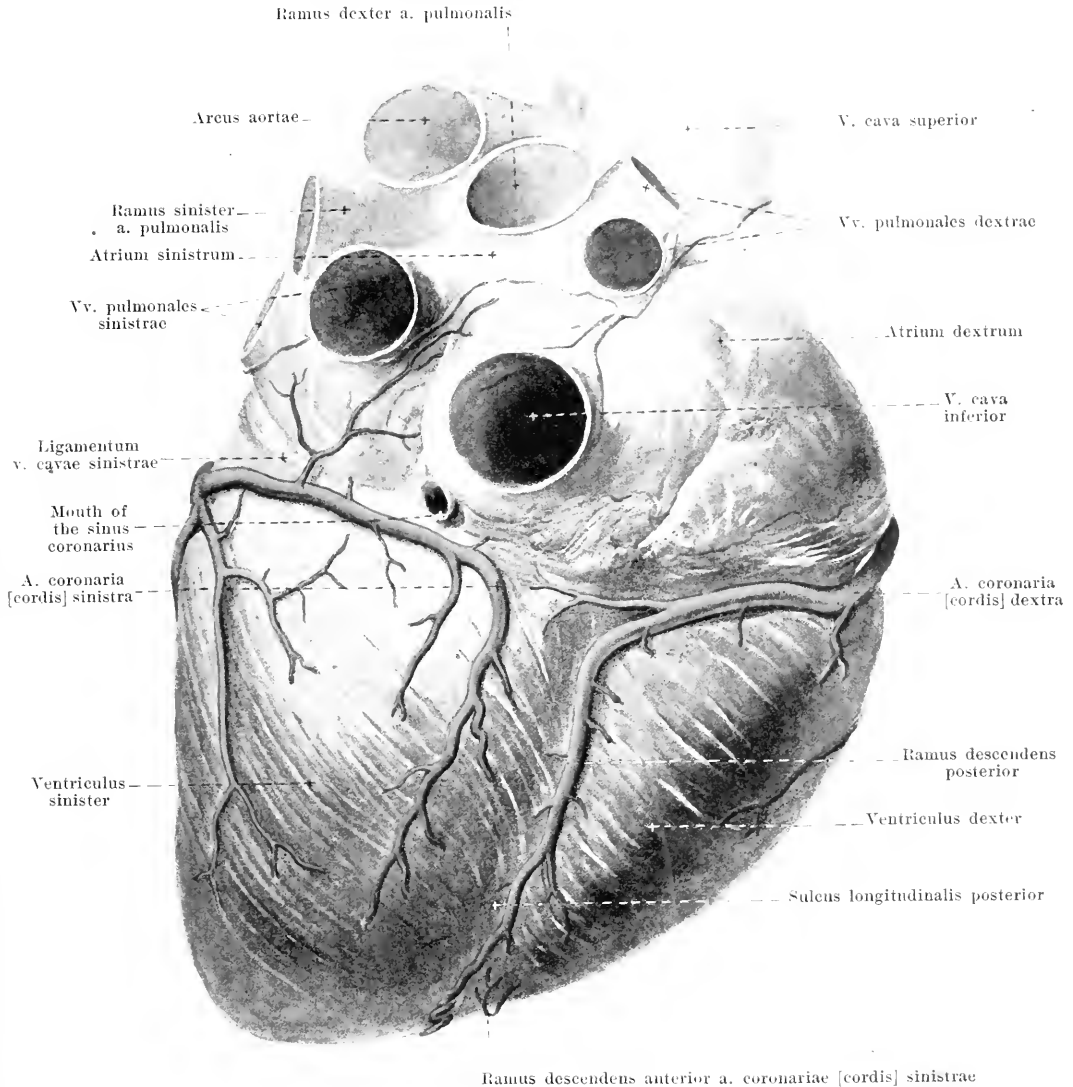
A. anonyma



428. The arteries of the heart, viewed from above and in front.

(The ostium arteriosum dextrum and the a. pulmonalis have been removed.)

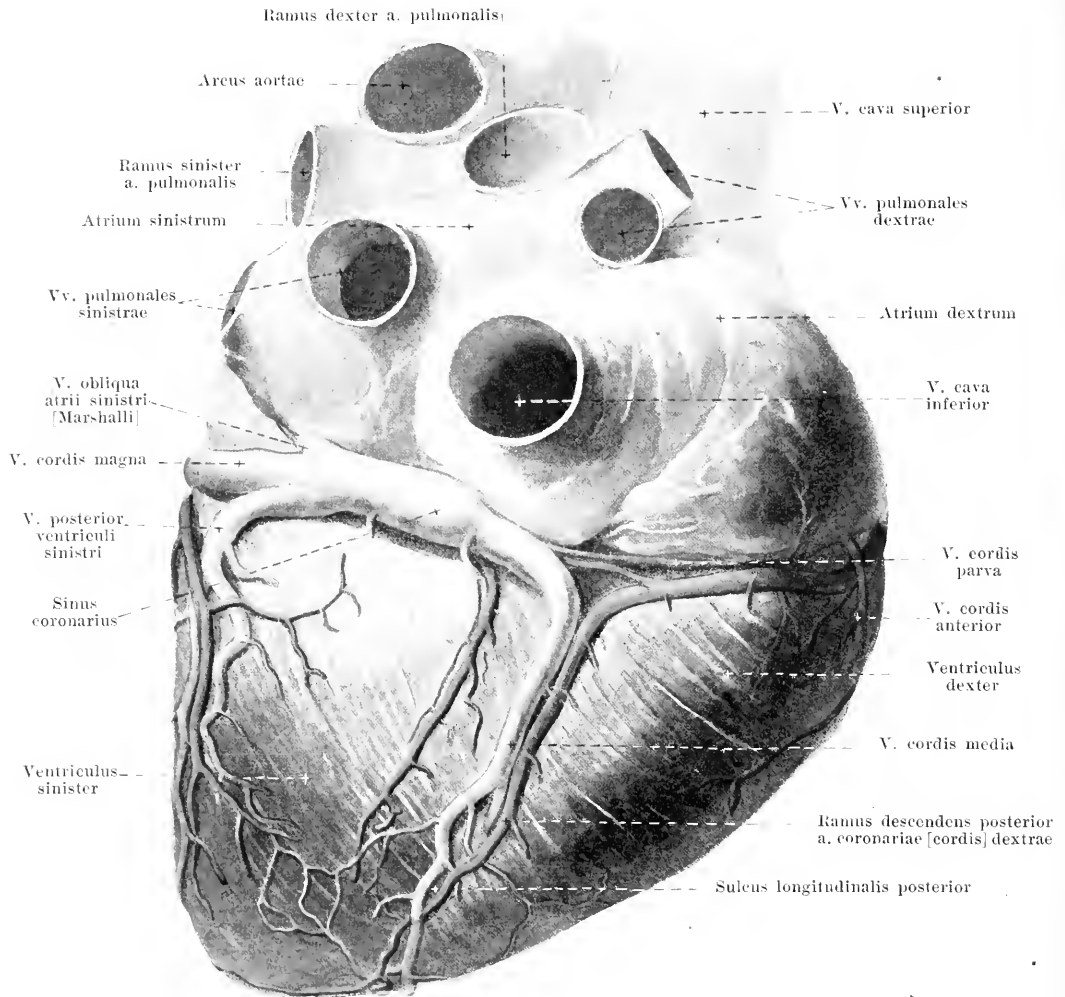
The **a. coronaria [cordis] dextra** (right coronary artery) (see also Fig. 429) arises in the right sinus aortae [Valsalvae] (see Figs. 426 and 433), runs at first between the right auricle and the conus arteriosus, then in the sulcus coronarius first to the right and then upon the facies diaphragmatica to the left; finally it bends around into the sulcus longitudinalis posterior and, as the *ramus descendens posterior*, arrives close to the apex of the heart. It gives off large branches to the right ventricle, small branches to the right atrium and (from the *r. descendens posterior*) to the left ventricle.



429. The arteries of the heart, viewed from below.

The **a. coronaria [cordis] sinistra** (left coronary artery) (see also Fig. 425) arises from the left sinus aortae [Valsalvae] (see Figs. 426 and 433), is usually larger than the right, and divides just after its origin into two branches. The *ramus descendens anterior* extends at first behind the a. pulmonalis, then to the left from it, covered by the left auricle, to the sulcus longitudinalis anterior, in which it runs as far as the incisura [apicis] cordis, usually going over to a certain extent upon the facies diaphragmatica; it gives off larger branches to the septum ventriculorum and the left ventricle and smaller branches the right ventricle. The *ramus circumflexus*, hidden below the left auricle, goes in the sulcus coronarius first to the left, then upon the facies diaphragmatica to the right and does not reach the sulcus longitudinalis posterior: it gives off larger branches to the left ventricle and smaller ones to the left atrium.

Both aa. coronariae anastomose manifoldly with one another by means of minute branches (larger than capillaries), usually inside the muscle, more rarely on the surface just beneath the epicardium.



430. The veins of the heart, viewed from below.

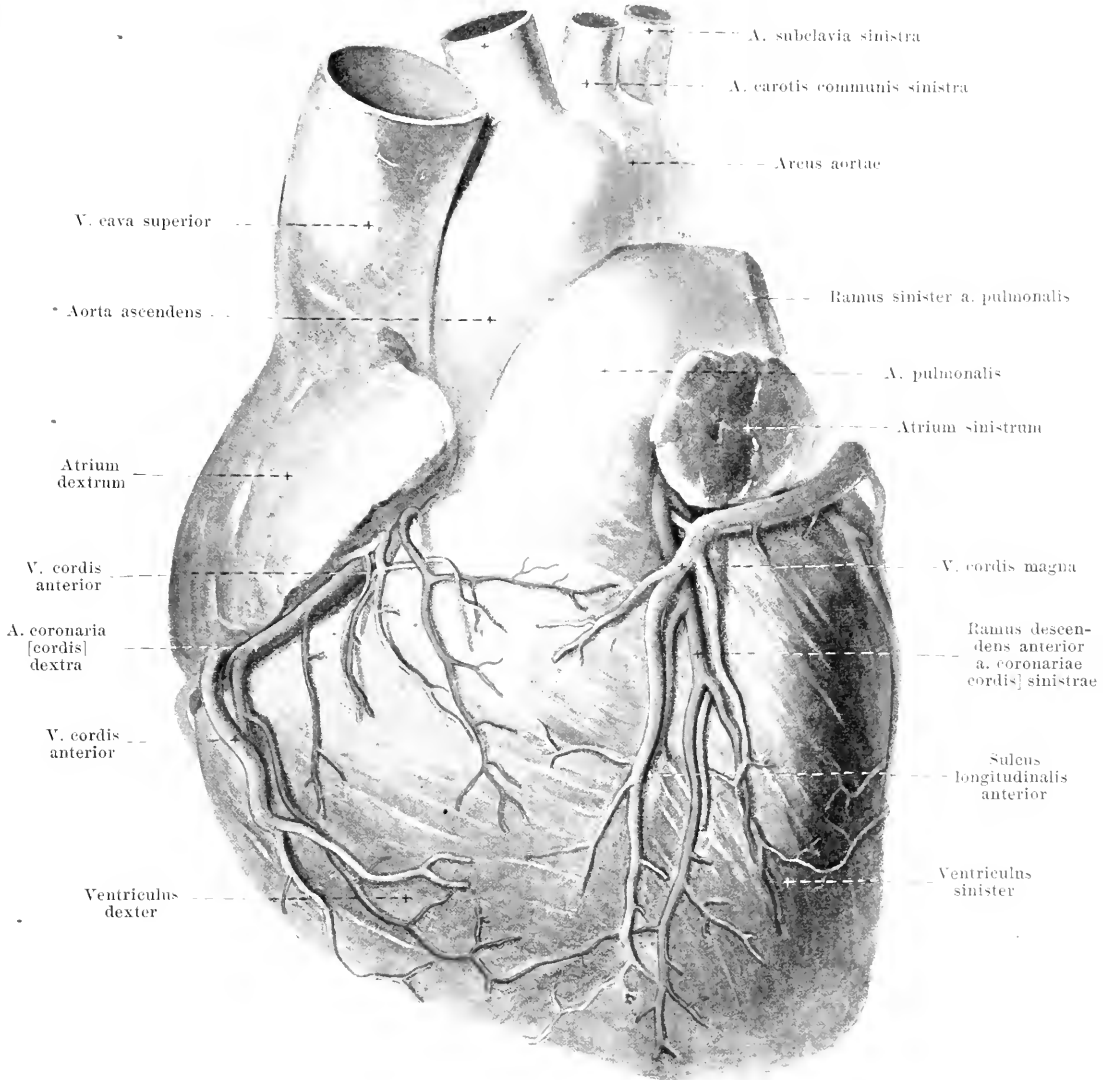
Most of the **veins of the heart** open into the *sinus coronarius*. This lies in the lower part of the sulcus coronarius, extends to the left as far as the opening of the *v. obliqua atrii sinistri* [Marshalli] and opens at the right into the right atrium (see Fig. 422); it arises from one part of the embryonic sinus reuniens (see also p. 376) and, as such, possesses cross-striped (cardiac) muscle-fibers. The veins opening into the sinus are partly closed at their mouths by valves, which, elsewhere, are absent. All the veins of the heart anastomose with one another.

The *v. cordis parva* opens from the right into the sinus; it runs in the sulcus coronarius and comes partly from the right ventricle, partly from the right atrium.

The *v. cordis media* extends in the sulcus longitudinalis posterior from the apex of the heart to the base; it receives its branches from both ventricles and opens from the right into the sinus.

The *v. obliqua atrii sinistri* [Marshalli] (O. T. oblique vein of Marshall) runs downward as a small branch on the left side of the left atrium in front of the pulmonary veins giving rise to a more or less distinct fold of the epicardium (*lig. venae cavae sinistrae*) (see Fig. 412); it opens from the left into the sinus and is a remnant of the embryonic *v. cava sinistra*.

A. anonyma



431. The veins of the heart, viewed from above and in front.

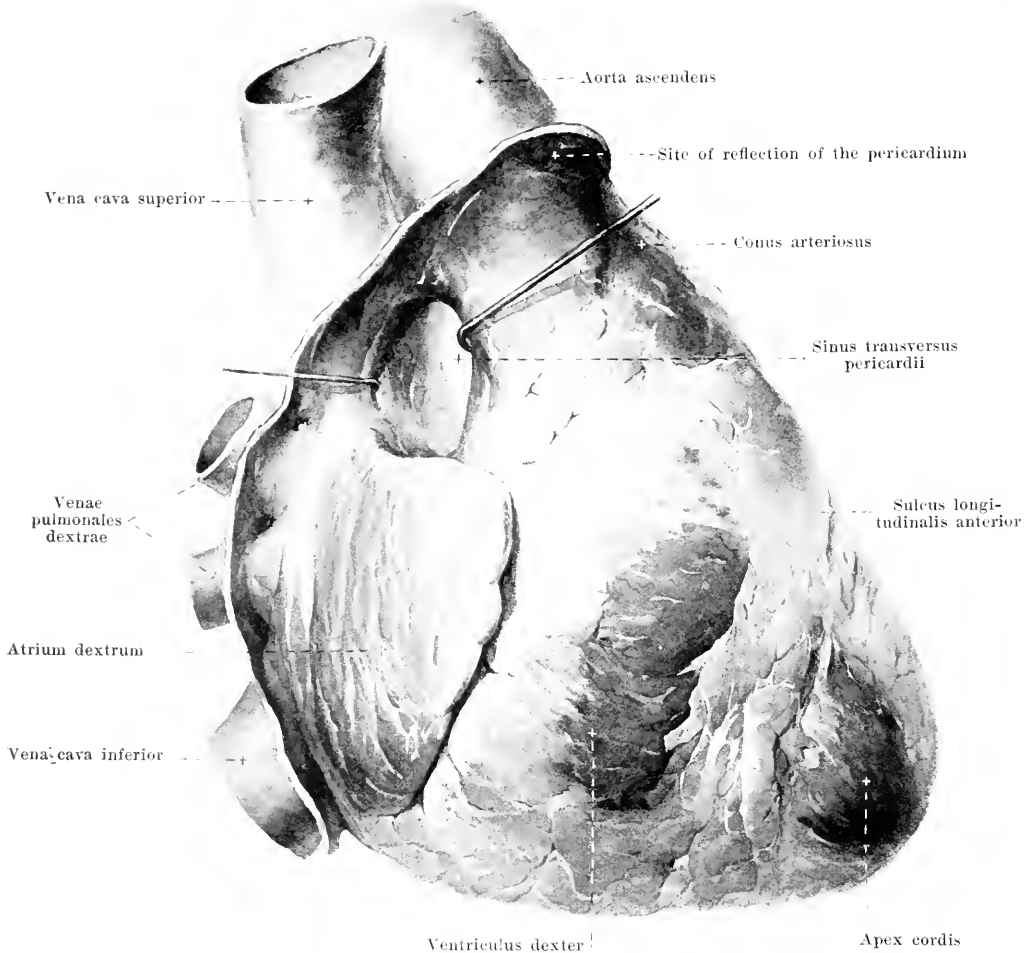
The **veins of the heart** (continued) (see also Fig. 430).

The *v. posterior ventriculi sinistri*, on the left side of the heart, receives branches from the left ventricle and opens into the *v. cordis magna* or into the sinus coronarius.

The *v. cordis magna* arises at the apex of the heart, runs at first in the sulcus longitudinalis anterior toward the base, then in the sulcus coronarius around the left surface to the sinus coronarius; it collects its blood partly from the right, but chiefly from the left ventricle.

The *vv. cordis anteriores*, varying in number, upon the right ventricle, open at the sulcus directly into the right atrium.

The *vv. cordis minimae* open directly into the cavities of the right and left heart by means of the *foramina venarum minimarum* [*Thebesii*] (see Fig. 420).

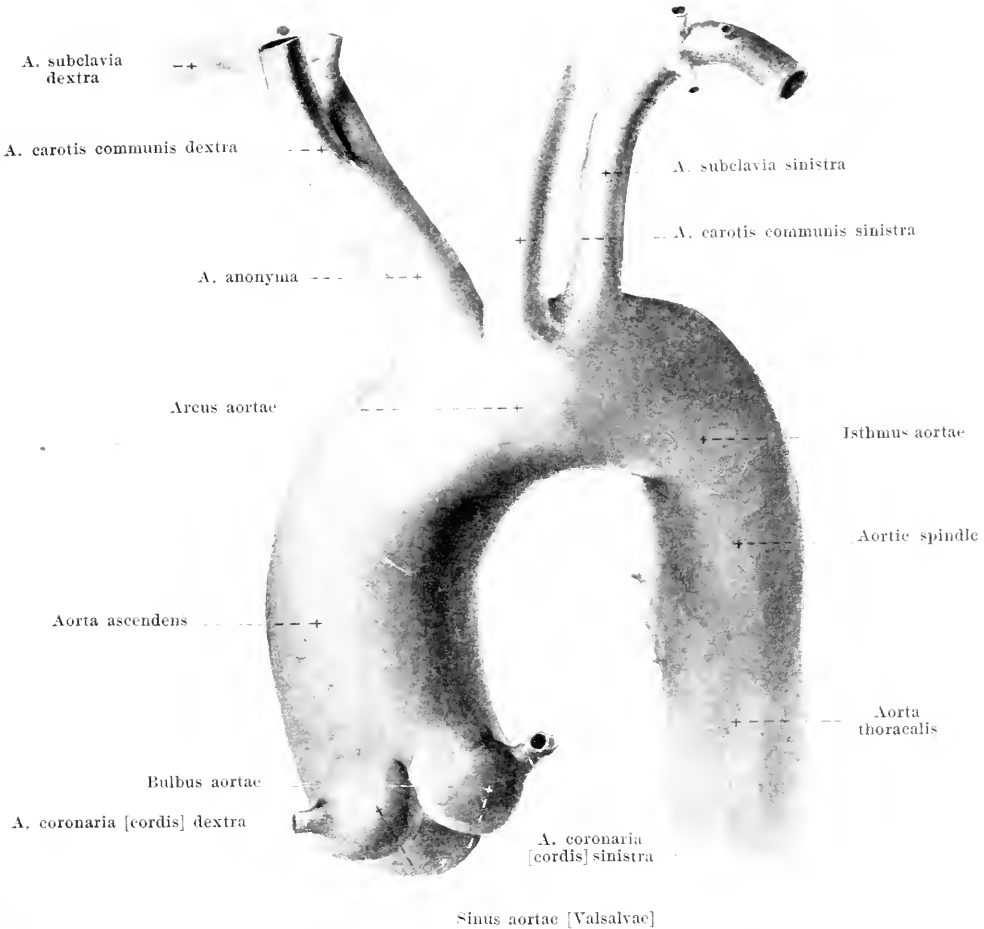


432. The heart, *viewed from the right and in front*, showing the place where the pericardium is reflected.

(The large arteries have been drawn away somewhat from the atria.)

The **pericardium** (see also Figs. 626—631) is a serous sack, closed on all sides, which presents a visceral layer, the *epicardium*, firmly attached to the heart muscle, and a parietal layer. Between the two layers is a small slit-like space in which are contained several grams of a clear, serous fluid, the *liquor pericardii*.

The *epicardium* (see also Figs. 411 and 412) covers completely the free surface of the ventricles of the heart and contains deposits of fat of variable size along the vessels. The atria are also covered on their free surface in large part by the epicardium, only the posterior surface of the left and a narrow strip of the right atrium remaining free from it; the v. cava superior is covered by it for a distance of one little finger's breadth; the v. cava inferior and vv. pulmonales are covered by it only at the point where they open into the heart. The a. pulmonalis and aorta ascendens are connected with one another by connective tissue, are covered in common by the epicardium and are separated from the anterior wall of the atria by a slit, the *sinus transversus pericardii*, which is closed above and below but open to the right and to the left. The epicardium is reflected into the parietal layer of the pericardium along the junction between the aorta ascendens and the arcus aortae, as well as over the bifurcation of the a. pulmonalis.



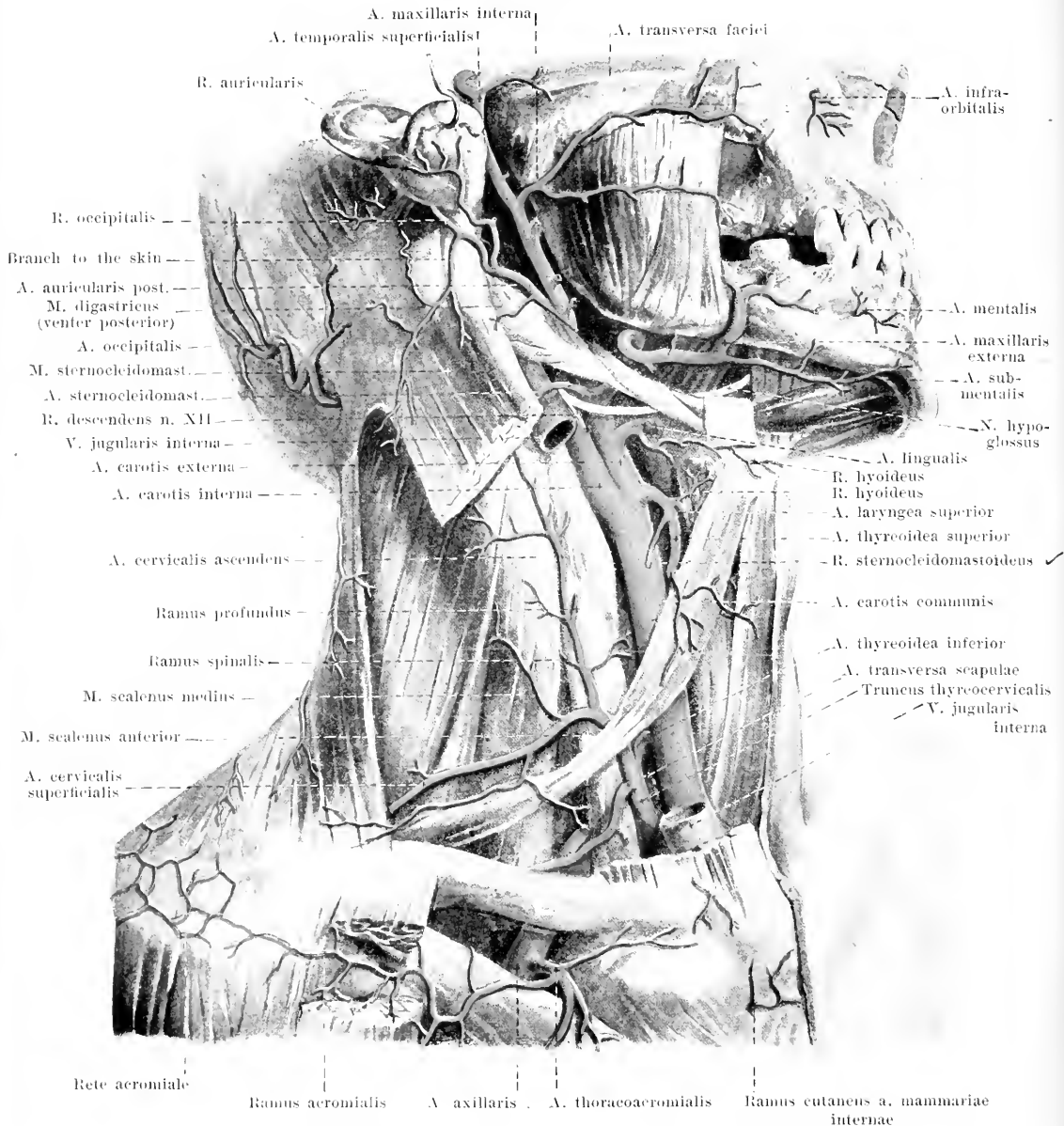
433. Aortic arch with its branches, viewed from the left and in front.

(After a plaster mould.)

The *parietal layer* of the **pericardium** (see Figs. 432, 626—631) is fused, on its lower surface, firmly with the diaphragm, on the posterior surface loosely with the oesophagus and the aorta thoracalis; to the right and left it is intimately united with the pleura pericardiaca. In front it is partly covered by the thymus and loosely connected with it; it lies in part just behind the corpus sterni and is fastened to it by several powerful, tendinous bands of fibers, the *ligamenta sternopericardiaca* (not illustrated), as well as by loose connective tissue.

The **aorta** runs, from the ostium arteriosum sinistrum, at first, upward (*aorta ascendens*); it then bends around backward (*arcus aortae*), and goes finally downward, above, in front of the thoracic spine (*aorta thoracalis*), below, in front of the lumbar spine (*aorta abdominalis*). It ends in front of the 4th lumbar vertebra, a little below the navel.

The beginning of the **aorta ascendens** (see also Figs. 410, 411, 427 and 428) lies behind that of the a. pulmonalis and presents a flask-like swelling (*bulbus aortae*) with three smaller bulgings (*sinus aortae [Valsalvae]*), of which each corresponds to one valvula semilunaris aortae. Thence the aorta passes upward and turns only a little to the right and forward; it lies behind the right auricle of the heart and behind the corpus sterni, on the right side of the a. pulmonalis and on the left side of the v. cava superior; behind, it adjoins the left atrium and the ramus dexter a. pulmonalis. The only larger branches given off by it are the two *aa. coronariae [cordis]* (see also Figs. 425 and 429).



434. Superficial arteries of the neck, viewed from the right and somewhat from in front.

(The head is bent somewhat backward; the parotid gland has been completely removed; the mm. pectoralis major, sternocleidomastoideus and the muscles of the face have been partially removed.)

The **arcus aortae** (*aortic arch*) (see Figs. 427, 433, 629 and 630) arches upward, being convex from before backward, and at the same time somewhat to the left, crossing the point of division of the a. pulmonalis and the bronchus sinister; on the right it lies upon the trachea just above its bifurcation, below it ends on the left side of the body of the 4th thoracic vertebra.

At the junction of the *arcus aortae* with the *aorta thoracalis* there is frequently a constriction, the *isthmus aortae*, and, just beyond this, an oblong expansion, the *aortic spindle* (see Fig. 433). Both formations are especially well marked when the vessel is much curved.

From the upper wall of the aortic arch go off: *a. anonyma*, *a. carotis communis sinistra* and *a. subclavia sinistra*.

A. anonyma (innominate artery) (see Figs. 427 and 429) runs obliquely in front of the trachea from the left and below to the right and upward, covered in front by the *venae anonymae*; it divides behind the articulo sternoclavicularis dextra into the *a. carotis communis dextra* and the *a. subclavia dextra*.

A. carotis communis (common carotid artery) (see also Figs. 435, 441 and 449) runs behind the articulo sternoclavicularis, at first on the right somewhat further forward, on the lateral surface of the trachea, then behind the lobe of the thyroid gland, in front of the *mm. scaleni* and *longus colli*, upward and somewhat backward and divides near the *cornu superius* of the cartilago thyroidea into the *a. carotis externa* and the *a. carotis interna*. It is accompanied in front and lateralward by the *v. jugularis interna*, behind by the *n. vagus*, and is partially covered by the *mm. sternothyroideus*, *sternocleidomastoideus* and *omohyoideus*.

A. carotis externa (external carotid artery) (see also Figs. 438, 439 and 441) passes almost straight upward, partly covered by the *venter posterior* of the *m. digastricus* and by the *m. stylohyoideus*, runs along the posterior margin of the ramus of the lower jaw on its medial surface, surrounded on all sides by the *glandula parotis*, and divides at the *collum mandibulae* into its two terminal branches: *a. temporalis superficialis* and *a. maxillaris interna*. It is partly covered by the *v. facialis communis* and by the *n. hypoglossus*. Branches:

1. **A. thyroidea superior** (superior thyroid artery) (see also Figs. 435, 441 and 449), arises from the anterior wall of the point of division, sometimes even somewhat more deeply; runs in a curve forward and downward to the upper end of the lateral lobe of the thyroid gland, covered partly by the *venter superior* of the *m. omohyoideus*. Branches:

a) *Ramus hyoideus* upward to the hyoid bone.

b) *Ramus sternocleidomastoideus* lateralward and downward to the *m. sternocleidomast.*

c) *A. laryngea superior* perforates the *membrana hyothyroidea*, being covered by the *m. thyrohyoideus*, and anastomoses on the lateral surface of the laryngeal muscles with the *a. laryngea inferior* (*a. thyroidea inferior*) and with a branch of d).

d) *Ramus cricothyroideus* runs just in front of the *m. cricothyroideus* and the *lig. cricothyroideum* medianward; it anastomoses with that of the other side.

e) and f) *Ramus anterior* and *ramus posterior*, to the anterior and posterior surface of the *glandula thyroidea*; both break up into numerous *rami glandulares* (to the gland).

2. **A. lingualis** (lingual artery) (see also Figs. 435 and 441), goes off, at the level of the greater *cornu* of the hyoid bone, from the anterior wall, extends in a curve upward upon the *m. constrictor pharyngis medius*, then, parallel to and above the hyoid bone, forward upon the *m. longitudinalis inferior* and the *m. genioglossus*, covered by the *m. hyoglossus*. Branches:

a) *Ramus hyoideus* downward to the lateral surface of the hyoid bone.

b) *Rami dorsales linguae*, double or single, on the medial surface of the *m. hyoglossus*, upward to the region of the root of the tongue and the tonsil.

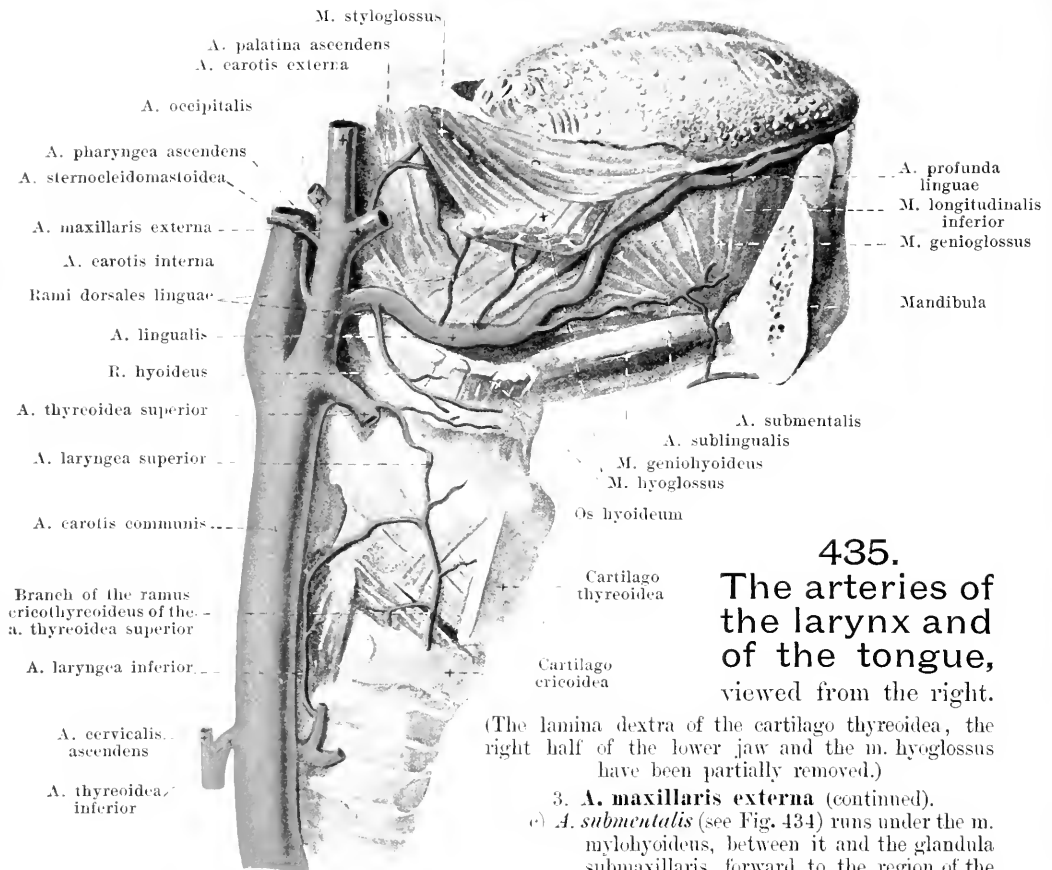
c) *A. sublingualis* arises at the anterior border of the *m. hyoglossus*, runs between the *m. mylohyoideus* and the *m. genioglossus* below the *glandula sublingualis* forward, supplies the floor of the mouth and the gums of the anterior teeth; it anastomoses through the *m. mylohyoideus* with the *a. submentalis*.

d) *A. profunda linguae* (O. T. *ramine artery*), very tortuous, runs upward and forward between the *m. longitudinalis inferior* and the *m. genioglossus*; it anastomoses above the *frenulum linguae* with that of the other side.

3. **A. maxillaris externa** (external maxillary artery) (O. T. *facial artery*) (see also Figs. 436 and 441) arises, close above the *a. lingualis*, from the anterior wall, covered by the *venter posterior* of the *m. digastricus* and by the *m. stylohyoideus*; it runs forward in a curve on the medial and upper surface of the *glandula submaxillaris*, between it and the lower jaw, then bends around the *basis mandibulae* at the anterior margin of the *m. masseter* and passes, very tortuous, upon the *mm. buccinator* and *caninus* to the side of the nose. In the face it is covered by the *platysma*, *mm. risorius*, *zygomatikus* and *quadratus labii superioris*. Branches:

a) *A. palatina ascendens* (O. T. *ascending or anterior palatine artery*) (see Fig. 441) arises near the origin of the vessel (frequently from the *a. carotis externa* or *a. pharyngea ascendens*), runs upward upon the *m. stylopharyngeus*, then between this muscle and the *m. styloglossus*, then upon the *m. constrictor pharyngis superior* to the medial surface of the *m. tensor veli palatini*; it supplies the soft palate and the pharynx.

b) *Ramus tonsillaris* (see Fig. 441), frequently a branch of a), runs upon the *m. constrictor pharyngis superior* to the *tonsilla palatina* and to the soft palate.



435.

The arteries of the larynx and of the tongue, viewed from the right.

(The lamina dextera of the cartilago thyroidea, the right half of the lower jaw and the m. hyoglossus have been partially removed.)

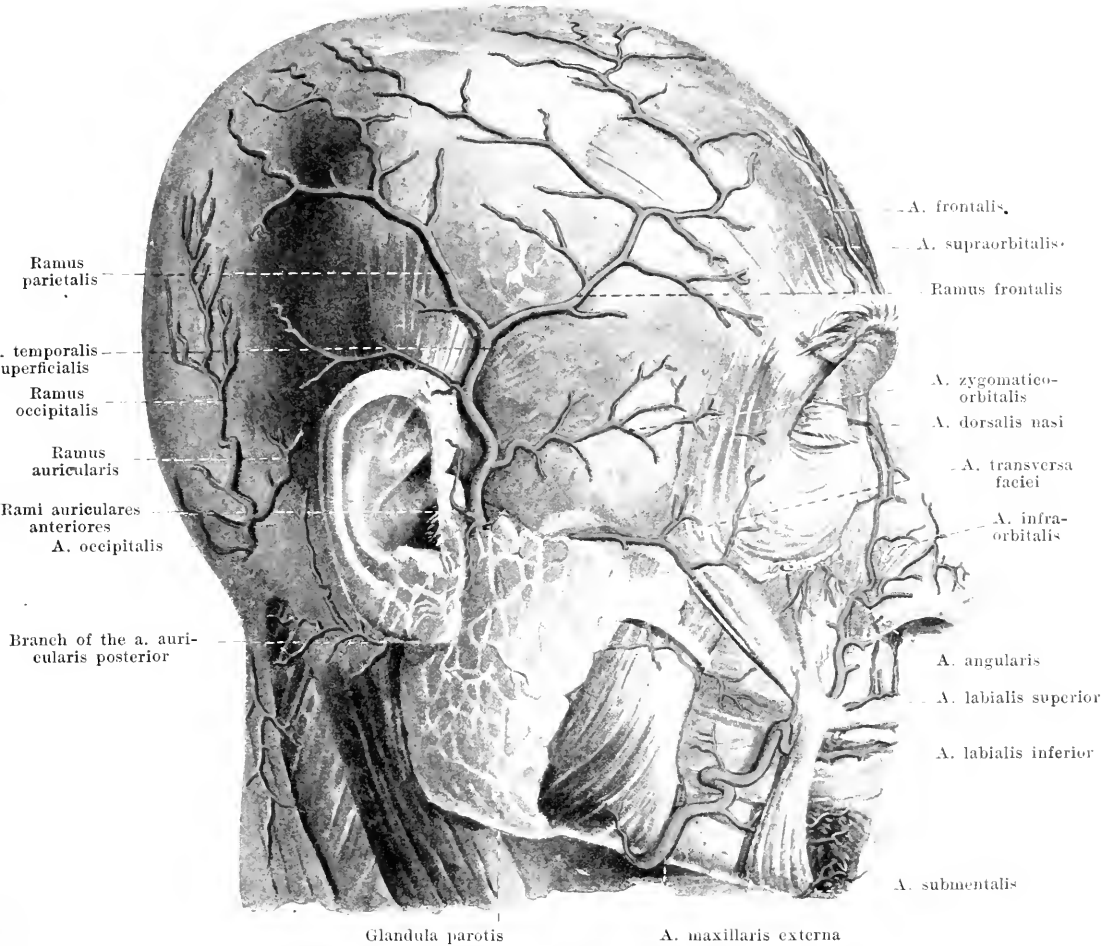
3. *A. maxillaris externa* (continued).

c) *A. submental* (see Fig. 434) runs under the m. mylohyoideus, between it and the glandula submaxillaris, forward to the region of the chin; it anastomoses with the a. sublingualis.

- d) *Rami glandulares*, arising partly from c), to the glandula submaxillaris.
 e) *A. labialis inferior* (O. T. inferior coronary artery) (see Fig. 436) arises below the angle of the mouth, runs medianward in the lower lip in the m. orbicularis oris, close to the mucous membrane, and forms a broad anastomosis with that of the other side.
 f) *A. labialis superior* (O. T. superior coronary artery) (see Fig. 436) arises at the angle of the mouth, runs in the upper lip like e) in the lower; branches to the nasal septum.
 g) *A. angularis* (see Fig. 436), the terminal branch, ascends almost vertically along the lateral margin of the nose and anastomoses with the a. dorsalis nasi (from the a. ophthalmica).

4. *A. temporalis superficialis* (superficial temporal artery) (see Figs. 434, 436—438) ascends behind the proc. condyloideus mandibulae, in front of the tragus, over the root of the zygoma; it is covered at first by the glandula parotis, and then, very tortuous, lies upon the fascia temporalis; it divides above the ear into its two terminal branches. Branches:

- a) *Rami parotidei*, in part also directly from the a. carotis externa, to the parotid gland.
 b) *A. transversa faciei* (O. T. transverse facial artery), runs forward to the cheek directly upon the m. masseter, just below the zygoma, covered behind by the parotid gland.
 c) *Rami auriculares anteriores*, 3—4, to the auricle and to the external auditory canal.
 d) *A. temporalis media* (medial temporal artery) (see Fig. 438) perforates the fascia temporalis just above the root of the zygoma, runs upward in the sulcus a. temporalis mediae of the temporal bone and is distributed in the m. temporalis.
 e) *A. zygomatico-orbitalis*, above the zygoma, to the upper margin of the orbit.
 f) *Ramus frontalis* (O. T. anterior terminal branch), is tortuous and extends first forward and upward, then backward upon the m. epicranii.
 g) *Ramus parietalis* (O. T. posterior terminal branch), tortuous, backward and upward. f) and g) form a rich anastomotic network with one another, with the aa. frontales and occipitales.



436. Superficial arteries of the face, viewed from the right.

(The platysma, m. risorius and m. quadratus labii superioris have been removed.)

5. **A. sternocleidomastoidea** (see Fig. 434) arises, at the same level as the a. maxillaris externa, from the posterior wall and goes in a curve, in front of the n. hypoglossus and the v. jugularis interna, lateralward and downward to the m. sternocleidomastoideus.

6. **A. occipitalis** (see Fig. 438), somewhat above the previous artery, from the posterior wall, runs at first upward upon the v. jugularis interna, covered by the venter posterior of the m. digastricus; then it goes backward in the sulcus a. occipitalis between the m. rectus capitis lateralis and the m. longissimus capitis, then between the m. semispinalis capitis and the m. splenius capitis; finally it bends upward and arrives between the insertions of the mm. trapezius and sternocleidomastoideus at the linea nuchae superior upon the m. epicranius. Branches:

- a) *Rami musculares* to the m. sternocleidomast. and neighboring muscles; among these
- aa) *Ramus descendens*, downward between the mm. splenius capitis and semispinalis capitis.
- b) *Ramus mastoideus* through the foramen mastoideum to the dura mater (see also Fig. 439).
- c) *Ramus auricularis* obliquely upward and forward toward the ear.
- d) *Rami occipitales*, very tortuous, upward: those of the two sides anastomose with one another and with the a. temporalis superficialis. A small branch, the *ramus meningeus*, goes through the foramen parietale to the dura mater.

7. **A. auricularis posterior** (posterior auricular artery) (see Figs. 434 and 438), above 6) from the posterior wall, runs, covered by the glandula parotis, on the upper margin of the venter post. m. digastrici, upward and in front of the proe. mastoideus behind the ear. Branches:

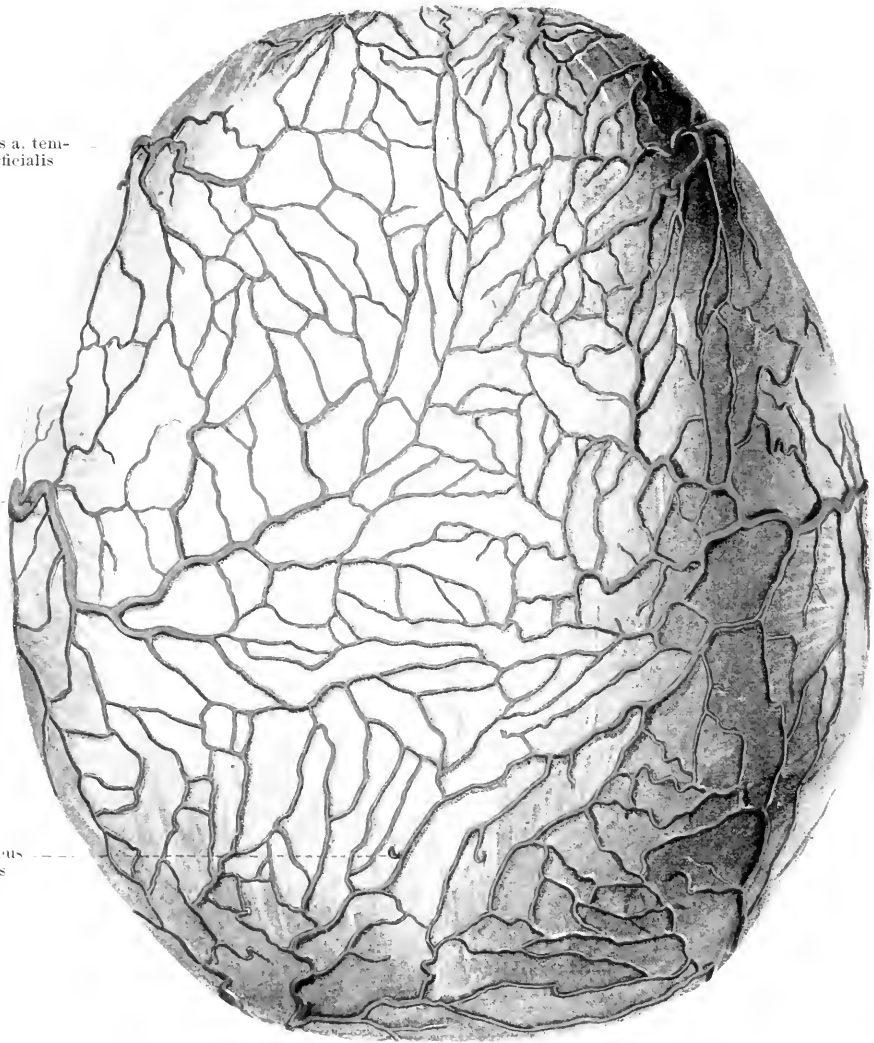
A. supraorbitalis

A. frontalis

Ramus frontalis a. temporalis superficialis

Ramus parietalis a. temporalis superficialis

Ramus meningeus a. occipitalis



Rami occipitales a. occipitalis

437. Arteries of the roof of the skull, viewed from above.

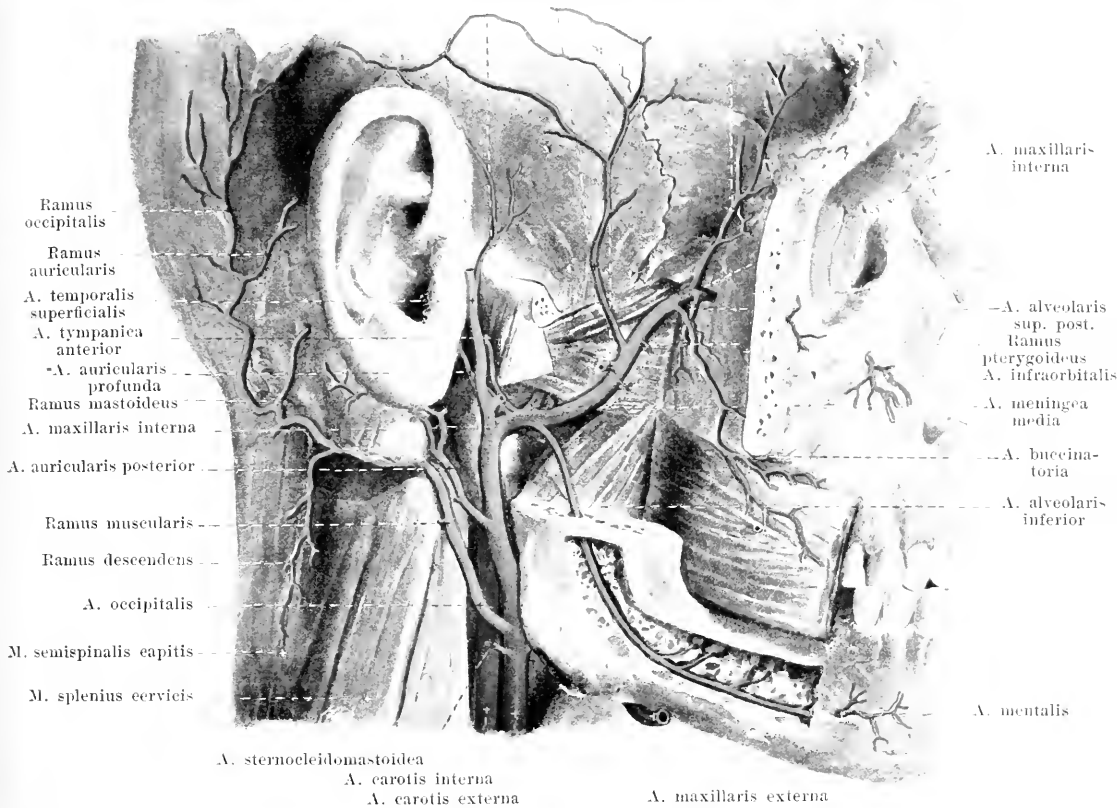
- a) *A. stylomastoidea* (see Figs. 441 and 442) goes through the foramen stylomastoideum into the canalis facialis, there gives off branches backward to the cellulae mastoideae (*rami mastoidei*), forward to the m. stapedius (*ramus stapedius*) and through the canaliculus chordae tympani into the middle ear (*a. tympanica posterior*); it anastomoses at the hiatus canalis facialis with the ramus petrosus superficialis (from the a. meningea media).
- b) *Ramus auricularis* (O. T. anterior terminal branch) to the medial surface of the external ear, and partly, perforating it, to the lateral surface of the same.
- c) *Ramus occipitalis* (O. T. posterior terminal branch) behind the ear, upward; it anastomoses with the a. occipitalis and the a. temporalis superficialis.

A. temporalis profunda posterior

A. masseterica

A. temporalis media

A. temporalis profunda anterior



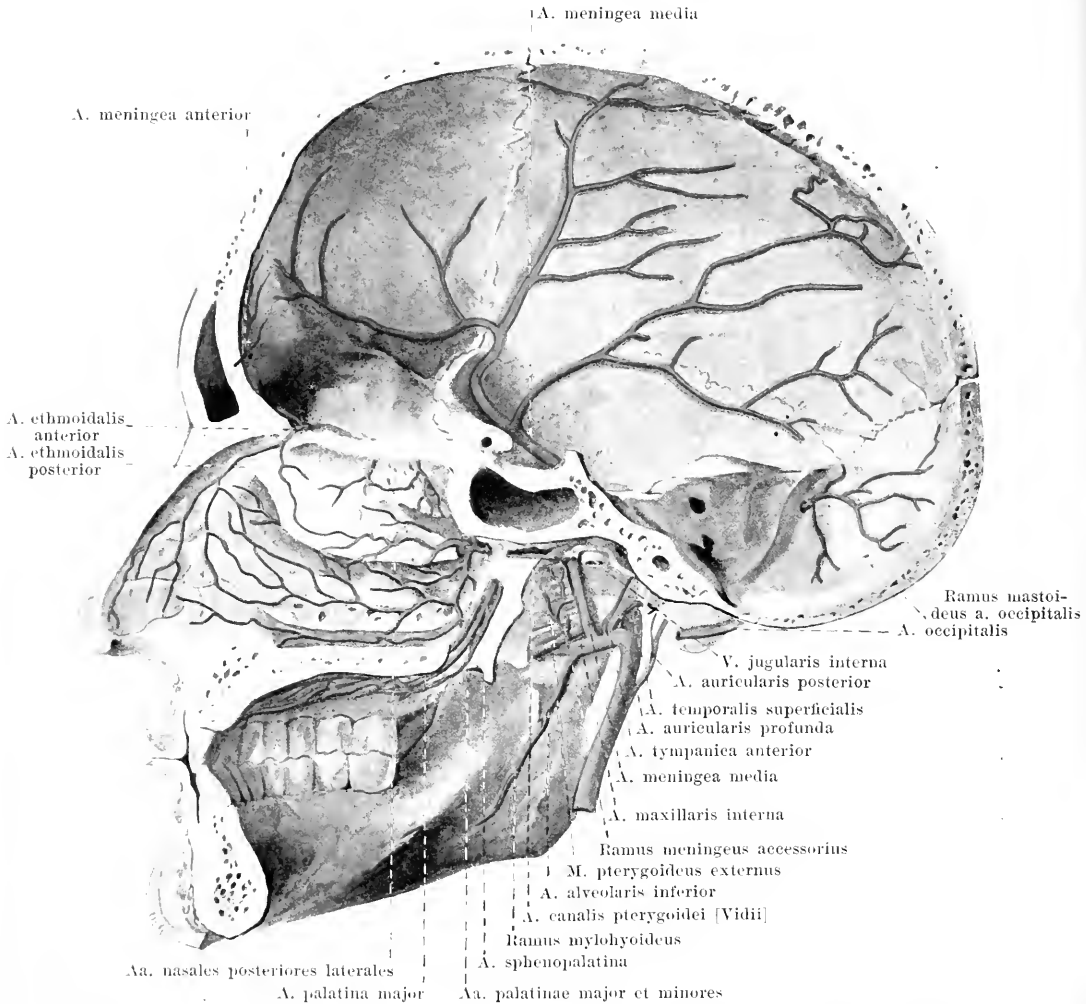
438. Deep arteries of the face, viewed from the right.

(The parotid gland has been entirely removed, the zygoma, the ramus of the lower jaw and the muscles of the lower jaw have been partially removed [see Fig. 294]; the canalis mandibulae has been chiselled open in a part of its course.)

S. A. maxillaris interna (internal maxillary artery) (see also Figs. 439—441) runs forward on the medial surface of the collum mandibulae (1st portion), then, tortuous, forward and upward, usually on the lateral surface of the m. pterygoideus externus between it and the m. temporalis (2nd portion) to the fossa pterygopalatina, in which (3rd portion) it divides into its terminal branches. Not infrequently it lies on the medial surface of the m. pterygoideus externus and arrives between the two heads of this muscle into the fossa pterygopalatina. Branches:

1st portion:

- A. auricularis profunda* backward to the joint of the jaw, auditory canal, and tympanic membrane.
- A. tympanica anterior* upward through the fissura petrotympanica [Glaseri] into the middle ear (see also Fig. 442).
- A. alveolaris inferior* (O. T. mandibular or inferior dental artery) runs downward and forward between the ramus mandibulae and the m. pterygoideus internus to the foramen mandibulare; it passes through the canalis mandibulae, giving off branches to the roots of the teeth, gums and bone.
- Ramus mylohyoideus* goes off before the entrance of the artery into the canalis mandibulae and runs, in the sulcus mylohyoideus, forward and downward.
- A. mentalis* leaves the canal through the foramen mentale and goes to the chin.



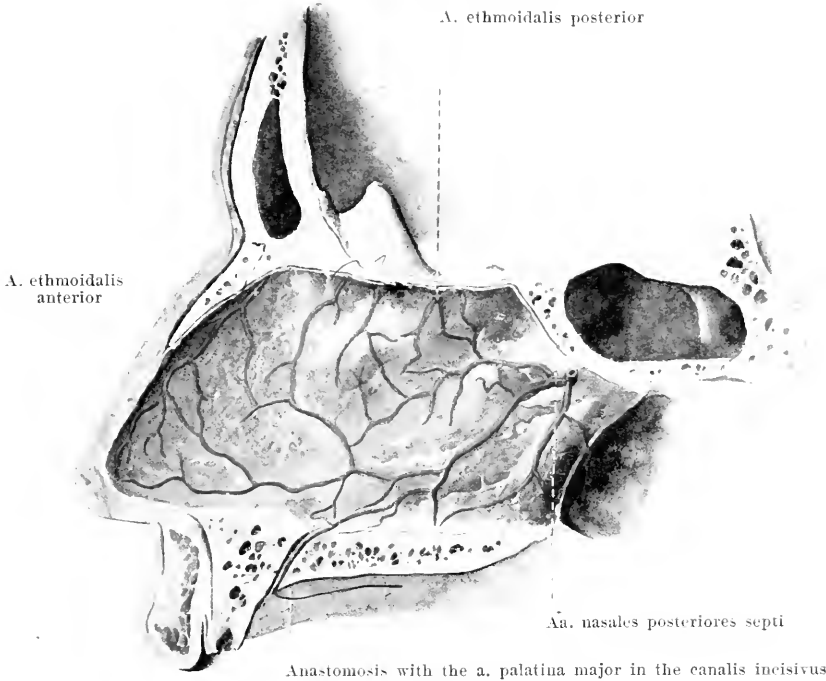
439. Arteries of the skull and of the nasal cavity, right half, viewed from within.

(The canalis pterygoideus and the canales palatini have been partly chiselled open.)

S. **A. maxillaris interna** (see also Figs. 435, 440 and 441) (continued):

2nd portion:

- d) **A. meningea media** (middle meningeal artery) bends under the m. pterygoideus externus upon its medial surface, passes upward to the foramen spinosum and is distributed inside the skull, at first imbedded in the sulci arteriosi of the sphenoid bone and the parietal bone, to the dura mater of the frontal, temporal and parietal region. Branches:
 - da) **Ramus meningeus accessorius** goes off outside the skull, often directly from the a. maxillaris interna, to the mm. pterygoidei, tuba auditiva and its neighborhood.
 - db) **Ramus petrosus superficialis** (O. T. petrosal branch) (see Fig. 442) arises just above the foramen spinosum, runs lateralward and backward to the hiatus canalis facialis and anastomoses there with the a. stylomastoidea (from the a. auricularis posterior).
 - dc) **A. tympanica superior** (see Fig. 442) arises like the preceding branch, goes through the apertura superior canaliculi tympanici and canaliculus tympanicus into the middle ear and upon the promontorium.
 - de) **A. masseterica** goes lateralward through the incisura mandibulae to the m. masseter.



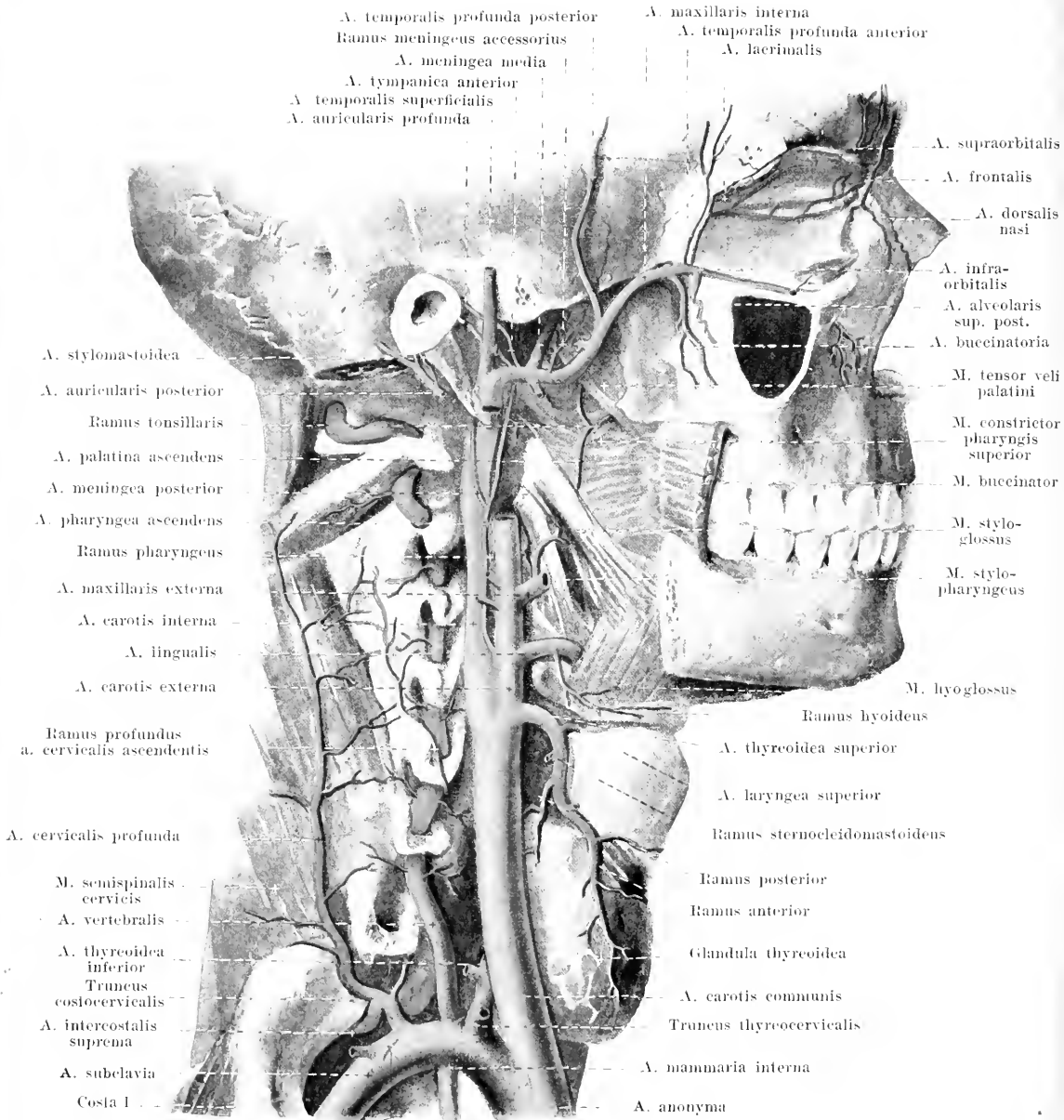
440. Arteries of the nasal septum, viewed from the left.

S. *A. maxillaris interna* (see also Figs. 435, 439 and 441) (continued).

- f) *Aa. temporales profundae posterior et anterior* (posterior and anterior deep temporal arteries) upward in the m. temporalis, the posterior close upon the squama temporalis, the anterior upon the ala magna ossis sphenoidalis.
 - g) *Rami pterygoidei*, varying in number, often from f) or h), to the mm. pterygoidei.
 - h) *A. buccinatoria* (O. T. buccal branch), downward and forward to the m. buccinator, for muscles of the face, mucous membrane of the mouth and gums of the upper jaw.
 - i) *A. alveolaris superior posterior* (posterior dental or alveolar branch) arises near the fossa pterygopalatina, forward and downward, passes through the foramina alveolaria maxillae in the canales alveolares to the sinus maxillaris, upper molar teeth and their gums.
- 3rd portion:
- k) *A. infraorbitalis*, forward through the fissura orbitalis inf. to the sulcus and canalis infraorbitalis, gives off branches to the orbital contents, and also the *aa. alveolares superiores anteriores* (O. T. anterior dental branch) in the canales alveolares to the anterior teeth and their gums: terminal branches through the foramen infraorbitale to the face.
 - l) *A. palatina descendens* (O. T. posterior or descending palatine branch) passes downward to the canalis pterygopalatinus. Above it gives off the *a. canalis pterygoidei* [*Vidiani*] (O. T. Vidian artery) which goes through the canalis pterygoideus backward to the roof of the pharynx. Below it divides into the *aa. palatinae minores et major*, which run through the canales palatini and emerge from the foramina palatina minora et majus; the minor branches go to the soft palate and its surroundings, the major branch goes to the inferior surface of the hard palate as far forward as the gums.
 - m) *A. sphenopalatina* (O. T. sphenopalatine or nasopalatine artery), through the foramen sphenopalatinum into the nose; it supplies the lateral wall of the nose and the pharynx by means of the *aa. nasales posteriores laterales*, runs at the inferior surface of the body of the sphenoid to the nasal septum and breaks up into the *aa. nasales posteriores septi* which anastomose in the canalis incisivus with the a. palatina major.

9. *A. pharyngea ascendens* (ascending pharyngeal artery) (see Figs. 441 and 442) from the posterior surface, near the a. lingualis, ascends, at first between the a. carotis externa and interna, then in front of the latter between it and the lateral wall of the pharynx, medial from the mm. styloglossus and stylopharyngeus, as far as the base of the skull. Branches:

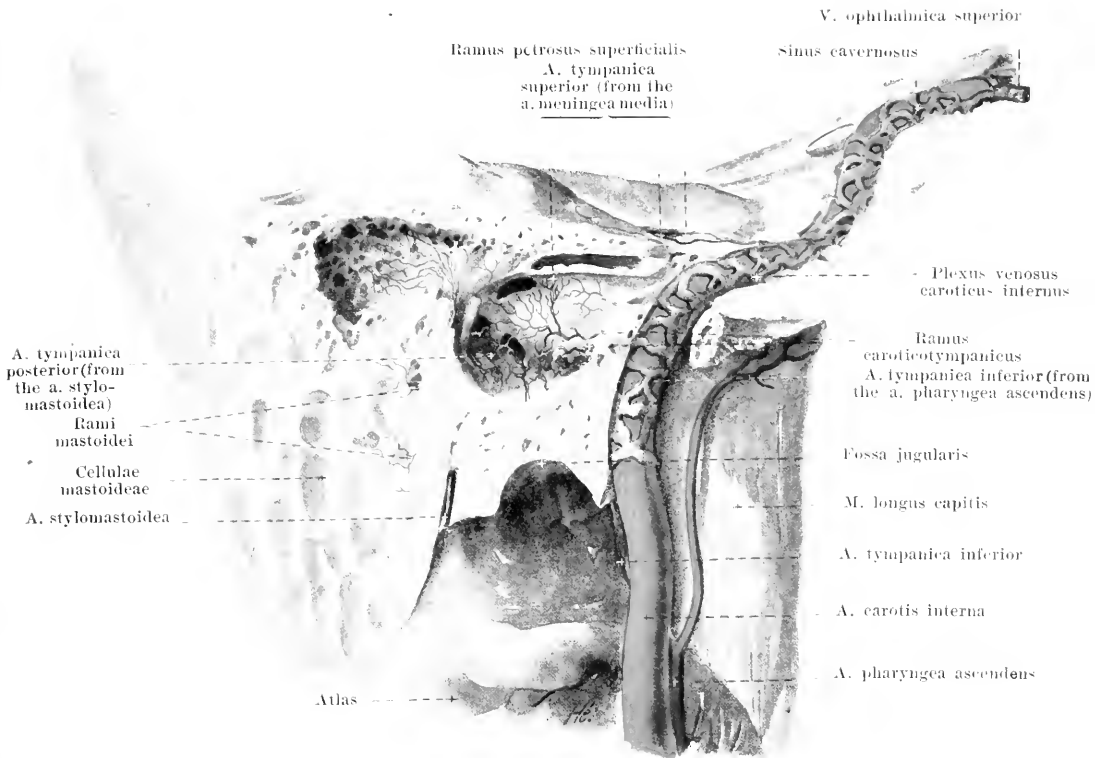
- a) *Rami pharyngei*, 2—3, partly descending, partly ascending, to the pharynx and palate.



441. Deep arteries of the neck, viewed from the right.

(The muscles of the neck and face have been in large part removed; the bones of the face have been partially removed.)

- b) *A. meningea posterior* ascends upon the lateral surface of the a. carotis interna and goes through the foramen jugulare to the dura mater (see Fig. 447).
 c) *A. tympanica inferior* (see Fig. 442) passes through the fossula petrosa and the canaliculus tympanicus into the middle ear and upon the promontorium.



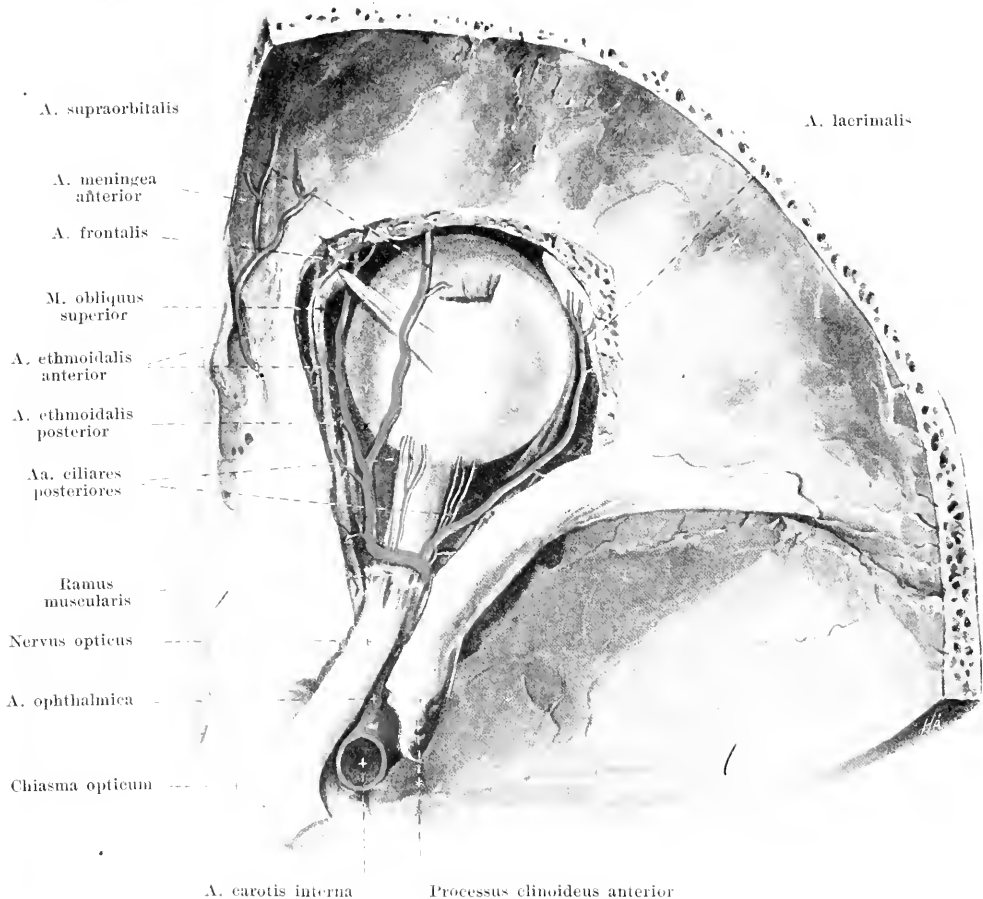
442. A. carotis interna and the middle ear, viewed from the right.

(The temporal bone has been cut open and drawn as in Fig. 11; the plexus venosus caroticus internus has been introduced after N. Rüdinger. Magnification : 3 : 2.)

A. carotis interna (*internal carotid artery*) (see also Figs. 434, 441, 443 and 445), curved slightly like the letter **S**, runs in front of the *mm. longus colli* and *longus capitis* to the base of the skull, bounded medianward by the lateral wall of the pharynx; lateralward and behind, it adjoins the *v. jugularis interna*; in front and lateralward it adjoins below the *a. carotis externa*, above the *glandula parotis* and the *mm. styloglossus* and *stylopharyngens*; the latter muscles separate it from the *a. carotis externa*. It then enters the *canalis caroticus*, and passes through it going first upward, then horizontally medianward and forward, runs through the *foramen lacerum* in a groove of the *fibrocartilago basalis*, turns upward and goes, slightly curved, in the *sulcus caroticus* of the body of the sphenoid bone to a position below the *processus clinoidens anterior*; there it bends sharply backward and upward, medial from the *proc. clinoidens anterior* and behind the *foramen opticum*, perforates the *dura mater* and breaks up into its terminal branches lateral from the *chiasma opticum*, below the *substantia perforata anterior*. Inside the *canalis caroticus* it is surrounded by the *plexus venosus caroticus internus*, in the *sulcus caroticus* by the *sinus cavernosus* (see also Fig. 452). In the neck it gives off no branches, in the *canalis caroticus* it gives off the *ramus caroticotympanicus*, in the *sinus cavernosus* small branches to the surrounding parts and during its course behind the *foramen opticum*, from the convexity of its last curve, the *a. ophthalmica*.

1. **Ramus caroticotympanicus** (O. T. *tympanic branch*), a fine branch which passes through one of the *canaliculi caroticotympanici* to the mucous membrane of the middle ear.

2. **A. ophthalmica** (see Fig. 443), at the lateral inferior surface of the *n. opticus*, goes through the *foramen opticum* into the orbit, then bends somewhat upward and passes transversely over the *n. opticus*, between it and the *m. rectus superior*, to the junction of the medial with the upper wall of the orbit; there it passes, below the *m. obliquus superior*, forward and divides between the *trochlea* and the *ligamentum palpebrale mediale* into its terminal branches: *aa. palpebrales mediales, dorsalis nasi* and *frontalis*. Branches:

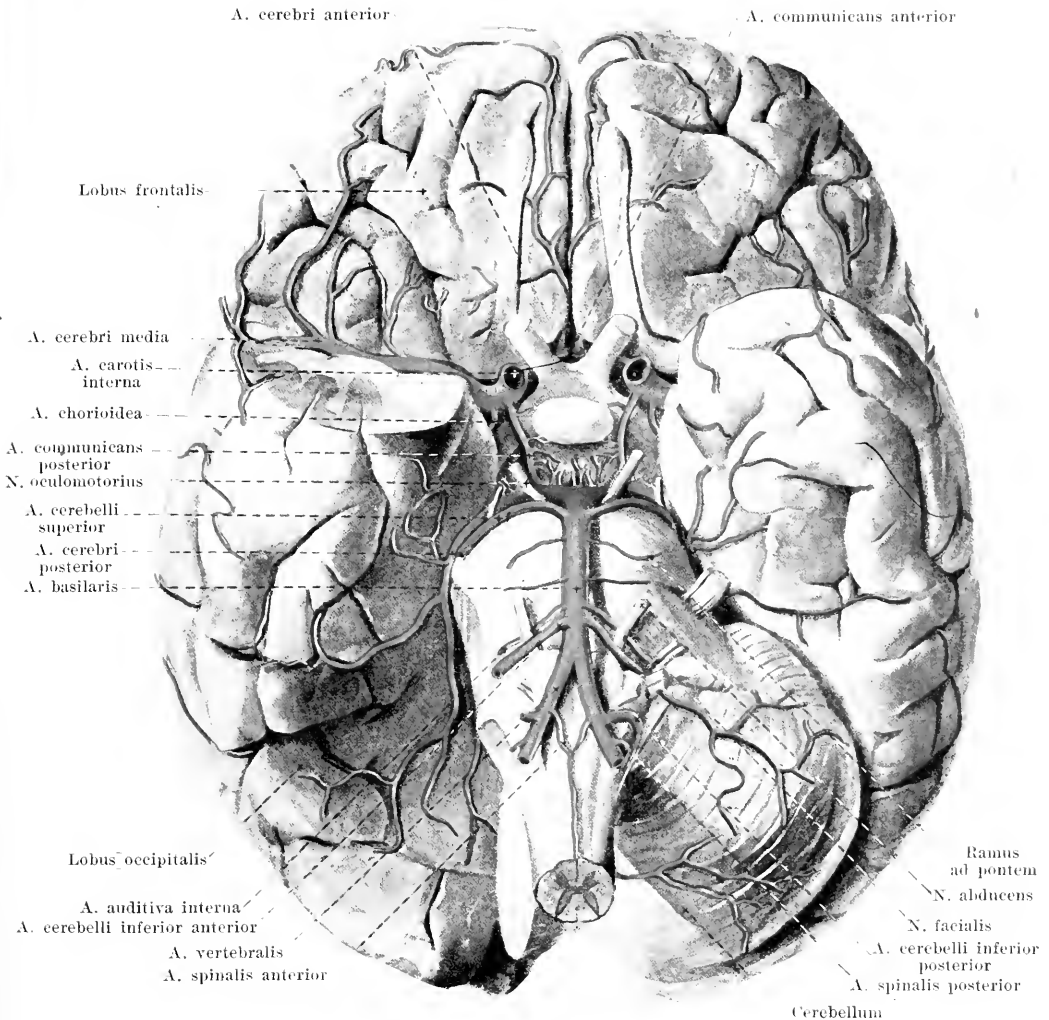


443. Arteries of the right orbit, viewed from above.
Magnification: 10:7.

(The bony roof and the contents of the orbit have been partially removed.)

2. A. ophthalmica (continued):

- a) *A. centralis retinae* (central artery of the retina) (not illustrated) often arises in common with c), perforates the medial inferior surface of the sheath of the optic nerve and passes in the axis of the same to the retina.
- b) *A. lacrimalis* (lacrimal artery) runs forward over the m. rectus lateralis at the lateral wall of the orbit; it gives off several aa. ciliares posteriores, and small branches into the foramen zygomaticoorbitale, perforates the lacrimal gland, supplies it and ends at the lateral angle of the eye in *aa. palpebrales laterales*, one for each eyelid.
- c) *Aa. ciliares posteriores breves et longae* (short and long posterior ciliary arteries), 4—6, partly from neighboring branches, divide manifoldly, perforate the sclera in the neighborhood of the n. opticus and are distributed in the tunica vasculosa oculi.
- d) *Rami musculares*, partly from neighboring branches, several in number, among them frequently one large, lateral, superior and one medial, inferior to the eye muscles.
- e) *Aa. ciliares anteriores* (see Eye) arise usually from the anterior ends of the rami musculares, run forward in the tendons of the eye muscles and pass partly upon the sclera to the margin of the cornea (*aa. episclerales*), partly to the conjunctiva (*aa. conjunctivales anteriores*), partly perforating the sclera to the m. ciliaris.
- f) *A. supraorbitalis* (see also Figs. 436, 437 and 441) passes just below the roof of the orbit to the foramen supraorbitale and through this to the forehead.
- g) *A. ethmoidalis posterior* (see also Figs. 439 and 440) through the foramen ethmoidale post. to the posterior ethmoidal cells and to the posterior superior part of the nasal cavity.

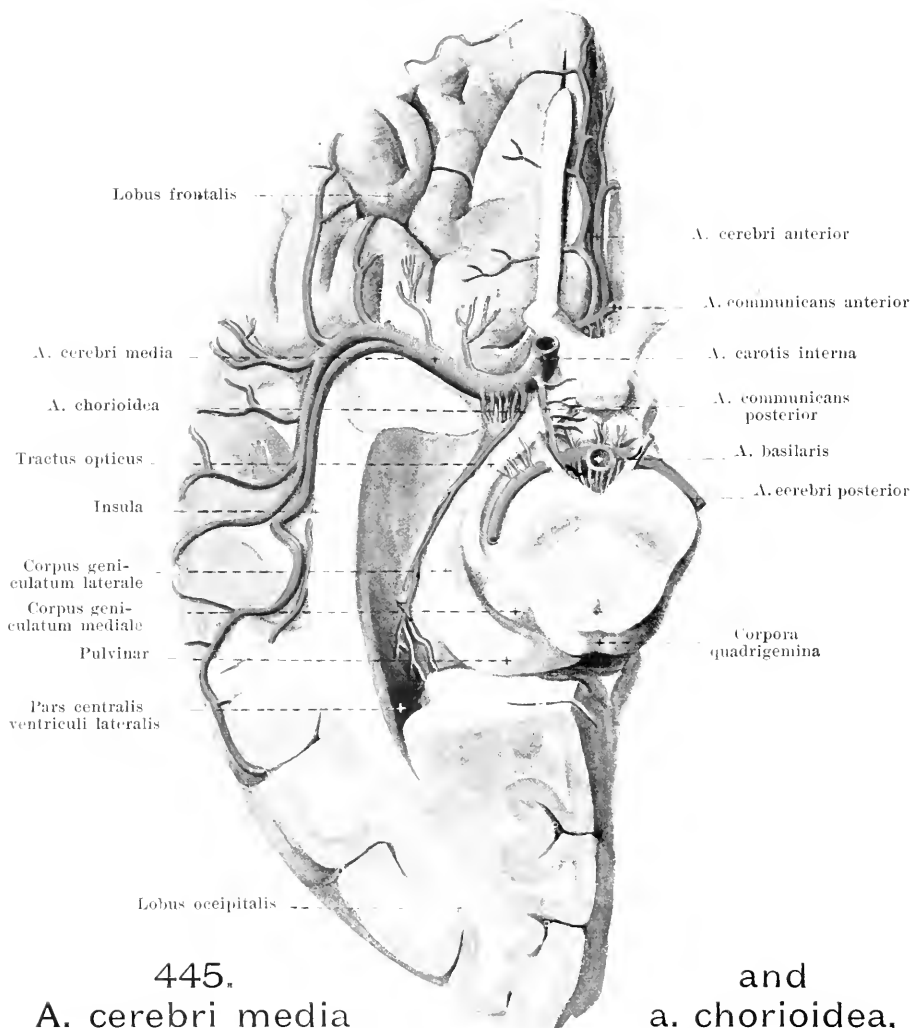


444. Arteries of the base of the brain.

(The pole of the right temporal lobe and the right side of the cerebellum have been cut away.)

2. *A. ophthalmica* (continued).

- h) *A. ethmoidalis anterior* (see Figs. 439, 440 and 443) passes through the foramen ethmoidale arterius upon the lamina cribrosa, there gives off the *a. meningea anterior* upward to the dura mater, then perforates the lamina cribrosa and supplies the anterior part of the wall of the nasal cavity.
- i) *Aa. palpebrales mediales* (not illustrated), one in each eyelid lateralward; they form by anastomosis of each medial artery with one *a. palpebralis lateralis* (from the *a. lacrimalis*), the *arcus tarseus superior* and *inferior*, situated near the free margin of the eyelid, in front of the tarsus. They give off fine branches to the conjunctiva (*aa. conjunctivales posteriores*).
- k) *A. dorsalis nasi* (O. T. nasal branch) (see Figs. 436 and 441) perforates the m. orbicularis oculi above the ligamentum palpebrale mediale, passes downward and anastomoses with the *a. angularis* (from the *a. maxillaris externa*).
- l) *A. frontalis* (see Figs. 436, 437, 441 and 443) goes through the incisura frontalis to the forehead and supplies the muscles and skin in that situation.



445.
A. cerebri media

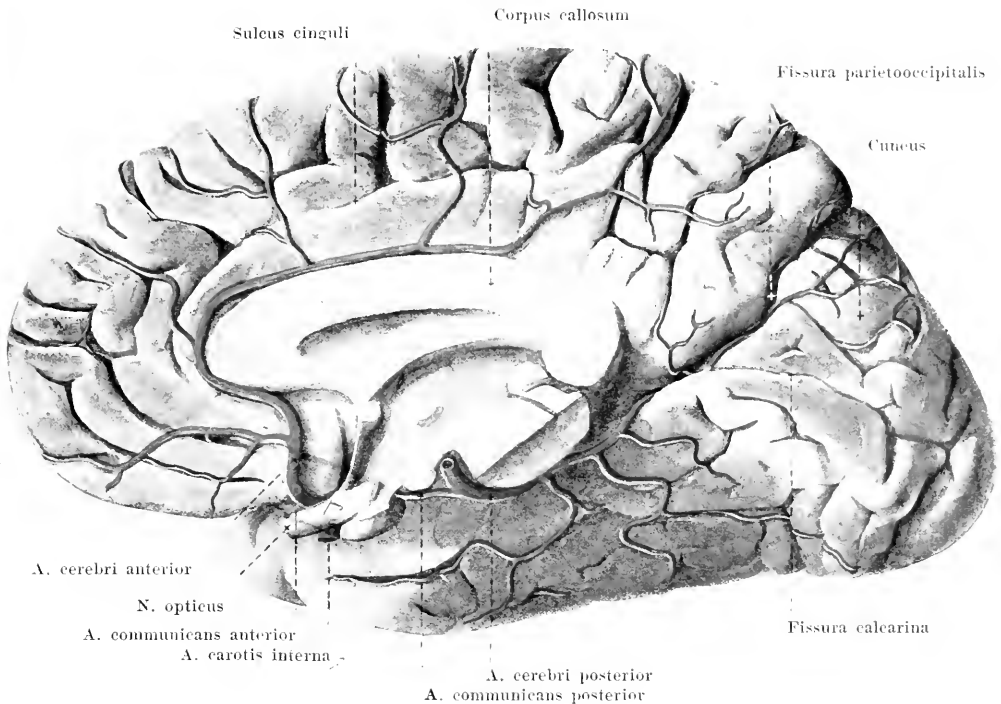
and
a. chorioidea,

on the right side, viewed from below.

(The temporal lobe and the occipital lobe have been removed to open up the cornu inferius ventriculi lateralis and to permit the fossa cerebri lateralis [Sylvii] to come into view; the cerebellum and the pons have been cut off just in front of their anterior margin.)

3. **A. communicans posterior** (posterior communicating artery) (see also Figs. 444, 446—448) passes backward over the sinus cavernosus, below the tractus opticus and the pedunculus cerebri, lateralward from the tuber cinereum and the corpus mamillare, gives off small branches to the parts named and opens into the a. cerebri posterior (from the a. vertebralis).

4. **A. cerebri anterior** (see also Figs. 444, 446—448) runs medianward above the n. opticus, sends branches to the cerebral ganglia through the substantia perforata anterior and to the chiasma opticum, approaches closely the vessel of the same name of the other side and forms a broad anastomosis with it by means of the *a. communicans anterior*. It next goes into the fissura longitudinalis cerebri forming a loop upward around the anterior surface of the genu corporis callosi, lying directly upon it, and passes backward upon the corpus callosum. It supplies the corpus callosum, the medial surface of the frontal and parietal lobes almost as far as the fissura parietooccipitalis, the gyrus rectus, the lobus olfactorius, the gyri orbitales as far as the medial limb of the sulci orbitales and the gyri frontales superior et medius.

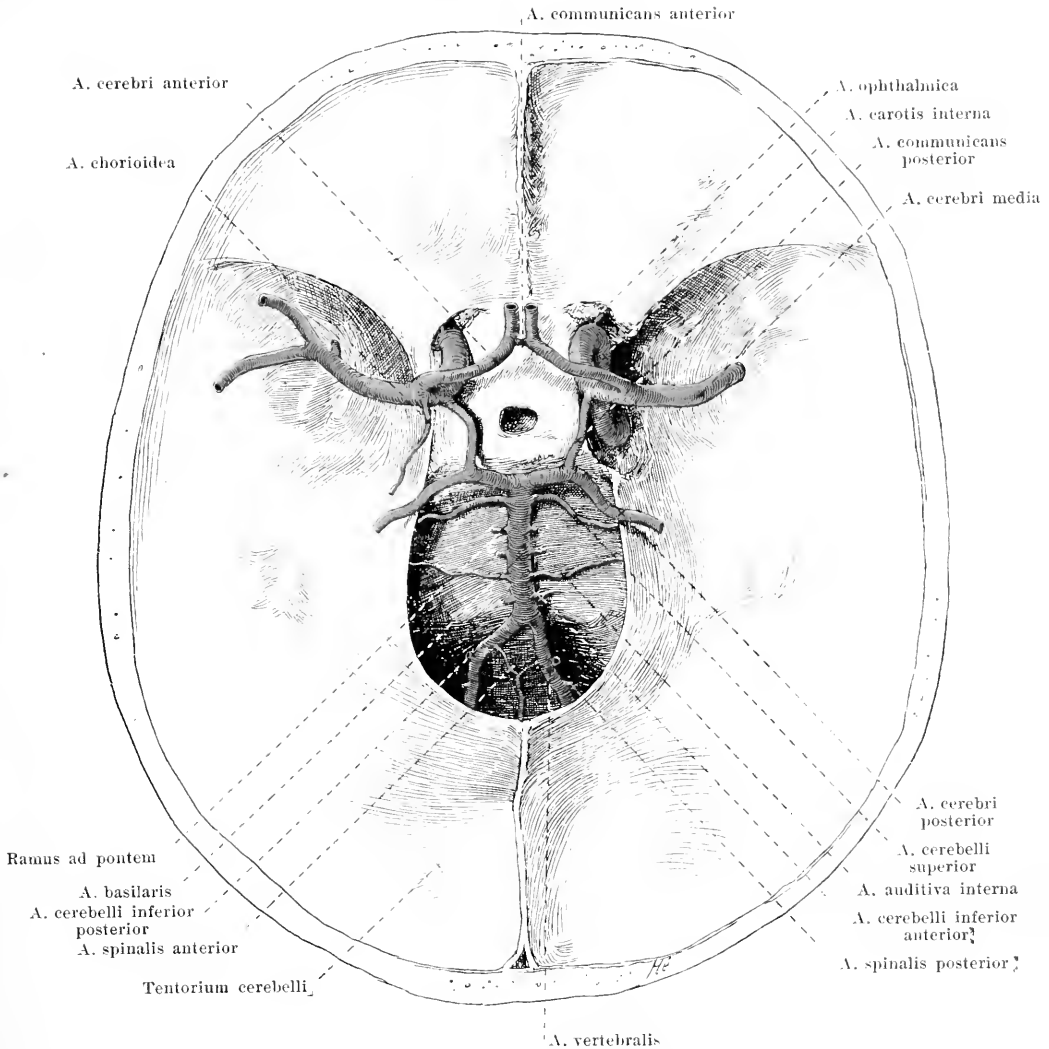


446. Arteries of the medial surface of the right cerebral hemisphere.

5. **A. chorioidea** (O. T. anterior chorioid artery) (see Figs. 444 and 445), delicate, goes between the tractus opticus and the gyrus hippocampi backward and lateralward to the cornu inferius of the lateral ventricle and breaks up in the plexus chorioideus ventriculi lateralis into branches; it sends besides small branches to the surrounding parts.

6. **A. cerebri media** (middle cerebral artery) (see Figs. 444, 445, 447 and 448) runs lateralward to the fossa cerebri lateralis [Sylvii] and in this to the lateral surface of the frontal, parietal and temporal lobe; it supplies the island and the gyri frontalis inferior, centrales anterior et posterior, the lobuli parietales superior et anterior, the gyri supramarginalis, angularis and temporalis superior.

A. subclavia (see Figs. 427, 434, 441 and 449) arises on the right side from the a. anonyma, on the left side directly from the arch of the aorta (see p. 389); the right is therefore shorter than the left, which ascends at first behind the v. anonyma sinistra, on the left side of the trachea. The artery runs on each side lateralward in a curve over the pleural cupula and over the first rib, being convex upward. In front it is bounded at first by the v. subclavia, then by the m. scalenus anterior, behind by the m. scalenus medius and comes to lie in the triangular space between these two muscles in the sulcus subclaviae of the first rib. From there on it goes, in the depth of the fossa supraclavicularis major, downward and lateralward to the axilla, behind and below the middle of the clavicle; it is covered by lymph glands and adipose tissue and is bounded in front by the v. subclavia and the a. transversa scapulae, behind and above by the plexus brachialis. From the lower margin of the m. subclavius on, its continuation is called the a. axillaris. Arising from it medianward from the m. scalenus anterior are the following branches: a. vertebralis, a. mammaria interna and the truncus thyrocervicalis, which again divides in a variable manner into the a. thyreoidea inferior, a. cervicalis ascendens, a. cervicalis superficialis and a. transversa scapulae; behind the m. scalenus anterior the truncus costocervicalis is given off, which divides into the a. intercostalis suprema and the a. cervicalis profunda; in the space between the mm. scaleni the a. transversa colli arises.



448. Arteries of the base of the brain in their relation to the skull after removal of the brain; viewed from above.

(On the right side the a. carotis interna has been exposed in its course in the sinus cavernosus.)

1. **A. vertebralis** (continued) (see also Figs. 444—446):

- c) *A. spinalis posterior*, delicate, bends around the lateral margin of the medulla oblongata and runs downward, forming anastomoses with that of the other side, in the sulcus lateralis posterior of the spinal cord, in front of and lateralward from the posterior roots; it unites with branches of the rami spinales of the a. vertebralis, aa. intercostales, lumbales and sacrales laterales and supplies the spinal cord and its membranes.
- d) *A. spinalis anterior*, delicate, unites with the artery of the opposite side at the upper end of the spinal cord and runs downward, unpaired, in front of the fissura mediana anterior as far as the filum terminale; like the preceding artery it receives a variable number of branches of the rami spinales, and supplies the spinal cord and its membranes.
- e) *A. cerebelli inferior posterior* (posterior inferior cerebellar artery) turns backward to the posterior part of the inferior surface of the cerebellum; it gives off branches to the plexus chorioideus ventriculi quarti.

1. **A. vertebralis** (continued) see Figs. 441—445):Branches of the **a. basilaris**:

- f) *A. cerebelli inferior anterior*, paired, runs lateralward to the anterior surface of the cerebellum.
- g) *A. auditiva interna* (O. T. internal auditory artery) goes lateralward to the nn. facialis and acusticus and with these into the meatus acusticus internus; it supplies the internal ear by means of a delicate branch.
- h) *Rami ad pontem* (O. T. transverse [or pontal arteries], numerous small branches, to the substance of the pons.
- i) *A. cerebelli superior*, paired, arises shortly before the terminal subdivision, extends, at the anterior margin of the pons, lateralward and backward, forms a loop around the pedunculus cerebri so as to arrive upon the upper surface of the cerebellum and supplies mainly this region; it gives off branches to the plexus chorioideus ventriculi tertii.
- k) *A. cerebri posterior* (posterior cerebral artery), paired, at first parallel to the preceding artery, separated from it by the n. ocnomotorius and further lateralward by the tentorium cerebelli; it goes at the anterior margin of the pons around the pedunculus cerebri to the inferior surface of the occipital lobe. It gives off branches through the substantia perforata posterior to the cerebral ganglia, branches to the cerebral peduncles and to the plexus chorioideus ventriculi lateralis and supplies the whole occipital lobe and the temporal lobe with the exception of the gyrus temporalis superior.

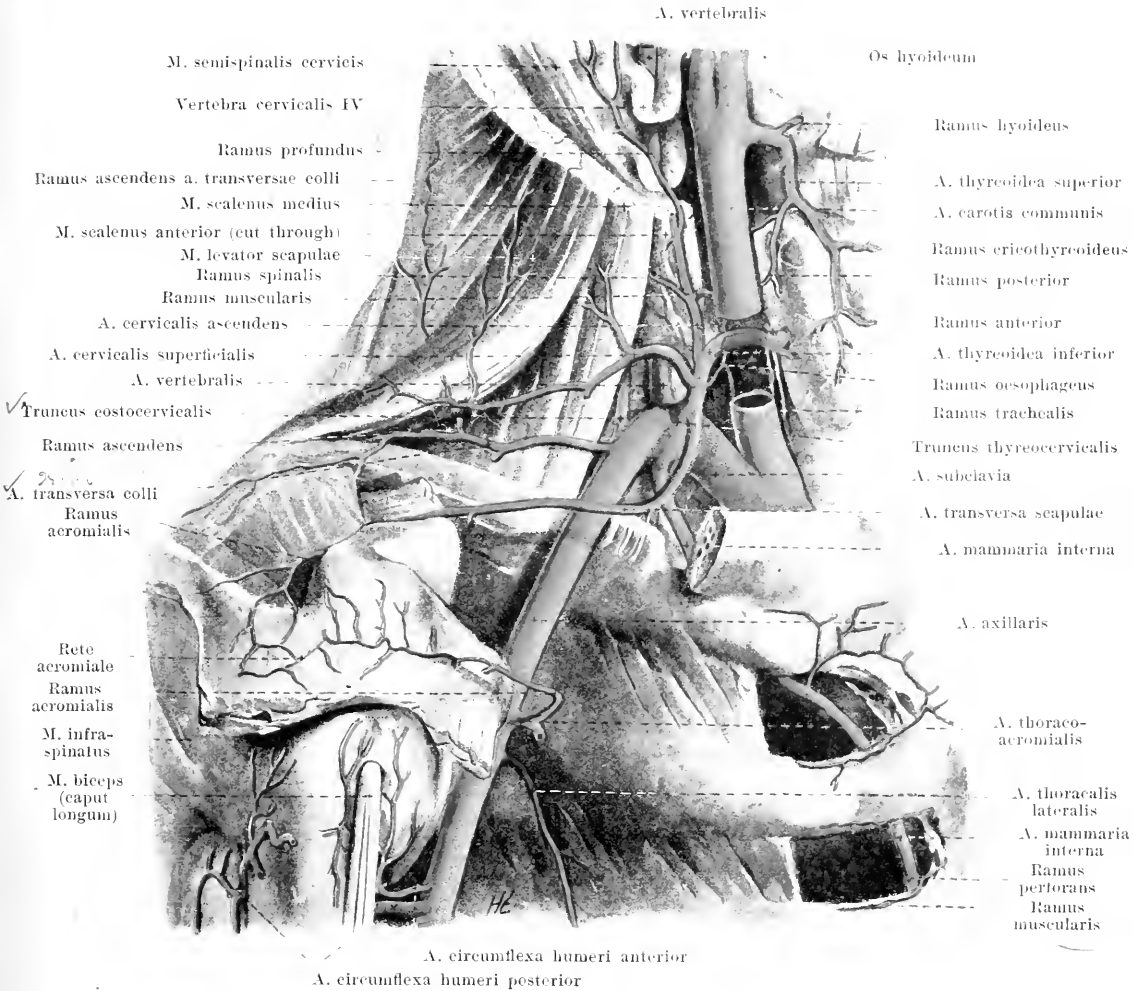
The a. cerebri posterior receives near its origin the a. communicans posterior (from the a. carotis interna); in this way arises the *circulus arteriosus [Willisi]* (O. T. circle of Willis) which lies over the sella turcica and the diaphragma sellae and surrounds the chiasma opticum, the tuber cinereum and the corpora mamillaria.

2. **Truncus thyreoecervicalis** (O. T. the thyroid axis) (see also Fig. 434), arises from the anterior wall of the a. subclavia; it divides in a somewhat variable manner into the following branches:

- a) *A. thyreoidea inferior*, runs, in front of the m. scalenus anterior, at first upward and then bends behind the a. carotis communis medianward and forward to the posterior surface of the glandula thyroidea, into which it penetrates by means of its *rami glandulares*; it gives off on its way the *rami pharyngei, oesophagei tracheales*, as well as the *a. laryngea inferior* (see Fig. 435), which goes below the m. crico-pharyngeus into the larynx and anastomoses upon the lateral surface of the internal laryngeal muscles with the a. laryngea superior (from the a. thyroidea superior).
- b) *A. cervicalis ascendens*, ascends upon the origins of the mm. scaleni and levator scapulae, at first medianward from the n. phrenicus, behind the v. jugularis interna often going as far upward as the base of the skull; it gives off below several *rami spiruales* into the foramina intervertebralia as well as *rami musculares* to the surrounding muscles; one of the latter branches, *ramus profundus* (see also Fig. 441), runs between the transverse processes of the 4th and 5th cervical vertebra backward to the deep muscles of the neck; it can take the place of the a. cervicalis profunda.
- c) *A. cervicalis superficialis*, goes behind the m. omohyoideus transversely through the fossa supraclavicularis major, in front of the mm. scaleni, levator scapulae and plexus brachialis, becomes hidden beneath the m. trapezius and supplies this and adjacent muscles.
- d) *A. transversa scapulae* (O. T. suprascapular or transversalis humeri) (see also Fig. 452), bends downward and forward, in front of the m. scalenus anterior, to the posterior surface of the clavicle and runs along this bone over the lig. transversum scapulae superius to the fossa suprascapularis; it then runs behind the collum scapulae in front of the lig. transversum scapulae inferius to the fossa infraspinata, and there forms a broad anastomosis with the a. circumflexa scapulae. Near the incisura scapulae arises the *ramus acromialis*, which goes through the m. trapezius to the rete acromiale.

3. **A. mammaria interna** (internal mammary artery) (see also Fig. 450) goes from the inferior wall of the a. subclavia medianward and downward behind the v. subclavia directly upon the pleura and then vertically downward just behind the cartilages of the 1th—7th rib. It runs nearly parallel to the lateral margin of the sternum, is separated from it, increasing from above downward, one to two cm. and is covered behind by the pleura and by the m. transversus thoracis. In the region of the 6th intercostal space it divides into its two terminal branches: *a. musculophrenica* and *a. epigastrica superior*. Branches:

- a) *Aa. mediastinales anteriores*, delicate branches, backward to the structures lying in the spatium mediastinale anterius.
- b) *Aa. thymicae* (not illustrated), partly from neighboring vessels, backward to the thymus.
- c) *Rami bronchiales* (not illustrated), to the lower end of the trachea and the bronchi; often absent.
- d) *A. pericardiacophrenica*, with the n. phrenicus in front of the root of the lung on the pericardium downward to the diaphragm; it supplies the pericardium and the diaphragm.



449. A. subclavia dextra, viewed from the right.

(Most of the clavicle has been removed, as have been the muscles attached to the clavicle, the m. scalenus anterior and the mm. pectorales and deltoideus.)

3. A. mammaria interna (continued) (see also Fig. 450):

- e) *Rami sternales*, medianward to the posterior surface of the sternum; there they form a network of anastomoses with the vessels of the same name of the other side.
- f) *Rami perforantes*, 6—7, the uppermost usually between the two heads of the m. sternocleidomastoideus (see Fig. 434), the others through forward the uppermost 6 intercostal spaces. They supply the m. pectoralis major and the skin of the front of the chest (*rami musculares, rami cutanei*). Among the latter that which comes from the 2nd intercostal space is usually very large, bends downward to the mamma and supplies it by means of the *rami mammarii*. The branch perforating the 6th intercostal space is also large and supplies the skin in front of the m. rectus abdominis as far as the navel.
- g) *Rami intercostales*, two for each intercostal space, arise separately or in common. They run lateralward in the six upper intercostal spaces close to the ribs, supply the muscles and the pleura and anastomose with the aa. intercostales. The branch running at the lower margin of each rib is the larger.

3. **A. mammaria interna** (continued):

- b) *A. musculophrenica*, extends behind the cartilages of the 7th—10th (or 11th) rib, just over the origins of the pars costalis of the diaphragm, lateralward and downward; it gives off *rami intercostales* for the 7th—10th (or 11th) intercostal space and is distributed also in the diaphragm and in the abdominal muscles.
- i) *A. epigastrica superior*, passes between the processus xiphoides and the 7th costal cartilage forward into the substance of the m. rectus abdominis, runs downward in this and anastomoses in the region of the navel with the a. epigastrica inferior; it gives off several small branches which go forward to the skin in the neighborhood of the navel.

4. **Truncus costocervicalis** (see also Figs. 441 and 461), from the posterior wall, divides after a short, upward course into two terminal branches:

- a) *A. cervicalis profunda* (deep cervical artery), backward between the 1st rib and the proc. transversus of the 7th cervical vertebra, runs upon the m. semispinalis cervicis as far as the epistropheus. It supplies the muscles of the neck and, by a descending branch, the long muscles of the back; several branches into the intervertebral foramina.
- b) *A. intercostalis suprema* (first intercostal artery) bends downward and backward in front of the neck of the first rib to the 1st intercostal space and also usually in front of the neck of the 2nd rib to the 2nd intercostal space. It gives off *rami posteriores* to the muscles and skin of the back and *rami spinuales* into the foramina intervertebralia; in these branches and in its further course it behaves quite like the aa. intercostales (see p. 419).

5. **A. transversa colli** (O. T. transverse cervical artery or transversalis colli) (see Figs. 449 and 452), from the upper wall of the a. subclavia, runs among the branches of the plexus brachialis, directly upon the lateral surface of the m. scalenus medius, lateralward and backward and divides beneath the m. levator scapulae into its two terminal branches. It gives off a branch to the fossa supraspinata and supplies the muscles in the neighborhood of the same.

- a) *Ramus ascendens*, extends upward between the m. levator scapulae and the mm. splenii in the neck to supply these muscles.
- b) *Ramus descendens*, passes downward between the mm. rhomboidei and the m. serratus posterior superior along the margo vertebralis of the scapula; it supplies these and the adjacent muscles and sends branches to the skin.

A. axillaris (*axillary artery*) (see Figs. 434, 449 and 451) runs distalward from the lower margin of the m. subclavius along the lateral angle of the axilla; it is covered at first by the proc. coracoideus, then lies in the groove behind the m. coracobrachialis and is bounded behind by the mm. subscapularis, latissimus dorsi and teres major, medianward by the m. serratus anterior. Superficially (in front and medianward) it is covered by the v. axillaris; on the lateral, posterior and inferior and partially also on the anterior surface it is directly surrounded by the long branches of the plexus brachialis. From the lower margin of the m. pectoralis major on, its continuation is called the *a. brachialis*. Besides small branches to the m. subscapularis, *rami subscapulares*, it gives off the following branches:

1. **A. thoracalis suprema** (O. T. superior thoracic artery) (not illustrated) arises behind the m. subclavius and runs downward, partly in front of and partly behind the m. pectoralis minor to the muscles of the chest; it is usually absent and substituted by a branch of the a. thoracoacromialis.

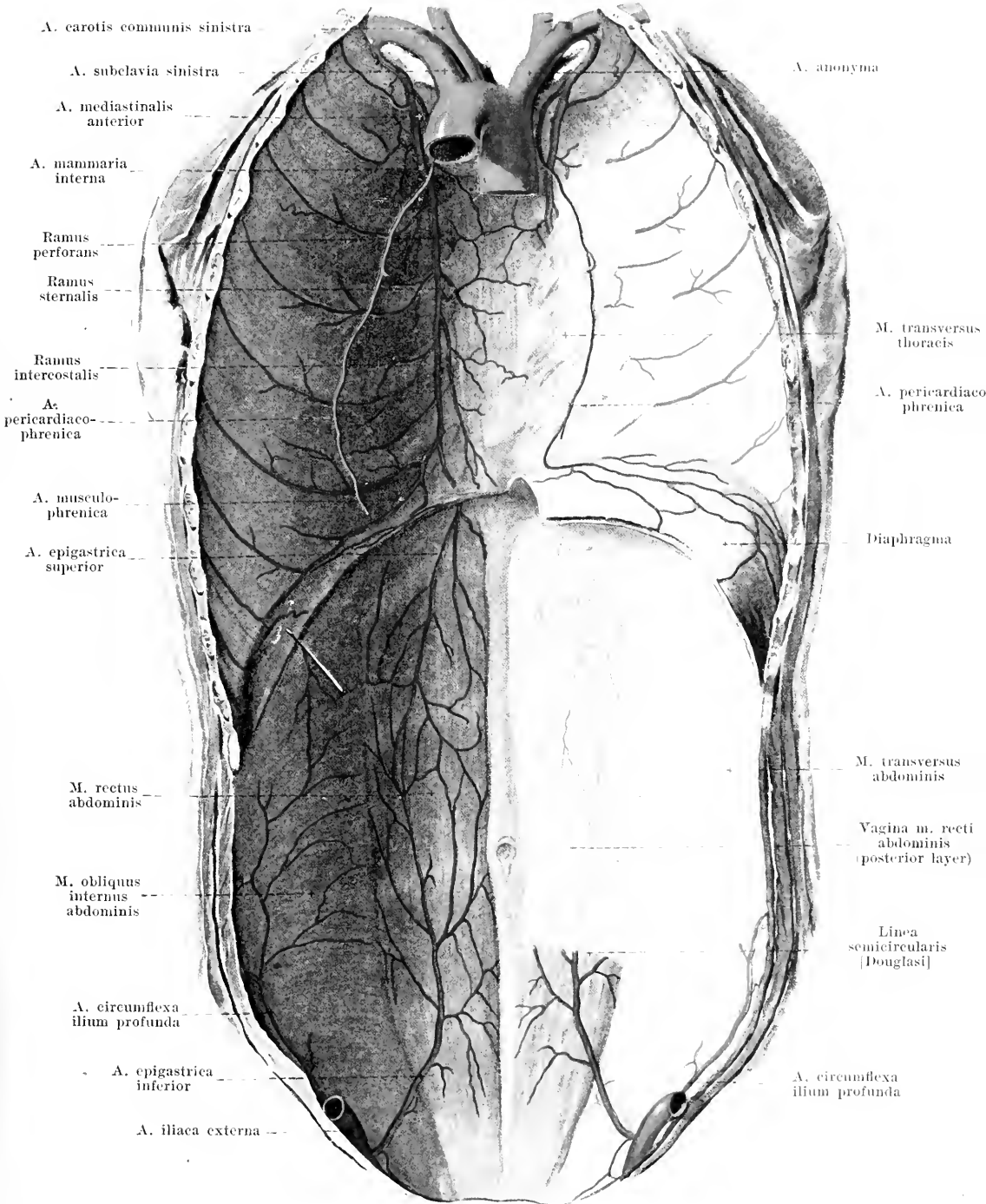
2. **A. thoracoacromialis** (O. T. acromiothoracic or thoracic axis) (see Figs. 434, 449 and 451) arises at the upper margin of the m. pectoralis minor and ends in *rami pectorales* between the muscles of the chest. Branches:

- a) *Ramus acromialis*, transversely beneath the mm. pectoralis major and deltoideus, in front of the proc. coracoideus, lateralward, supplies these muscles, perforates the m. deltoideus and ends in the *rete acromiale*, situated upon the upper surface of the acromion.
- b) *Ramus deltoideus* goes downward in the slit between the mm. pectoralis major and deltoideus; it supplies especially the latter muscle and the skin over it.

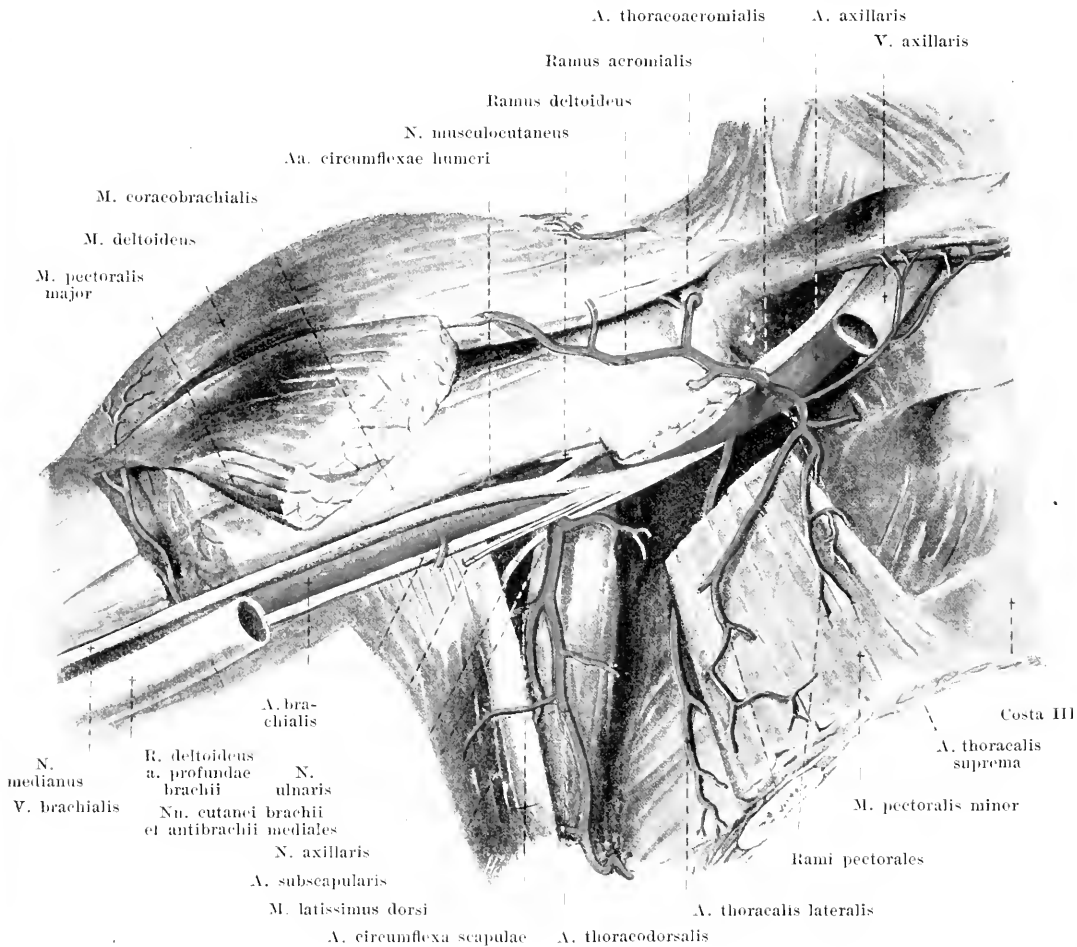
3. **A. thoracalis lateralis** (O. T. long thoracic artery) (see Fig. 449 and 451) arises behind the m. pectoralis minor and runs upon the m. serratus anterior downward as far as the 5th or 6th intercostal space; it supplies especially the m. serratus anterior. Several branches (*rami mammarii externi*) go through the m. pectoralis major to the skin of the mammary region.

4. **A. subscapularis** (see Figs. 451 and 452), arises at the lower margin of the m. subscapularis, goes downward and soon divides into two terminal branches:

- a) *A. circumflexa scapulae* (O. T. dorsalis scapulae), bends backward between the mm. subscapularis and teres major and then, medial from the caput longum of the m. triceps, goes upward, partly in front of, partly behind the m. teres minor, into the fossa infraspinata. It supplies the neighboring muscles and skin and anastomoses freely with the a. transversa scapulae.
- b) *A. thoracodorsalis*, between the mm. latissimus dorsi and serratus anterior along the margo axillaris scapulae downward and backward, supplies the neighboring muscles and skin.



450. Arteries of the anterior wall of the trunk, viewed from behind.
 (The aa. epigastricae are drawn upon the surface of the m. rectus abdominis.)

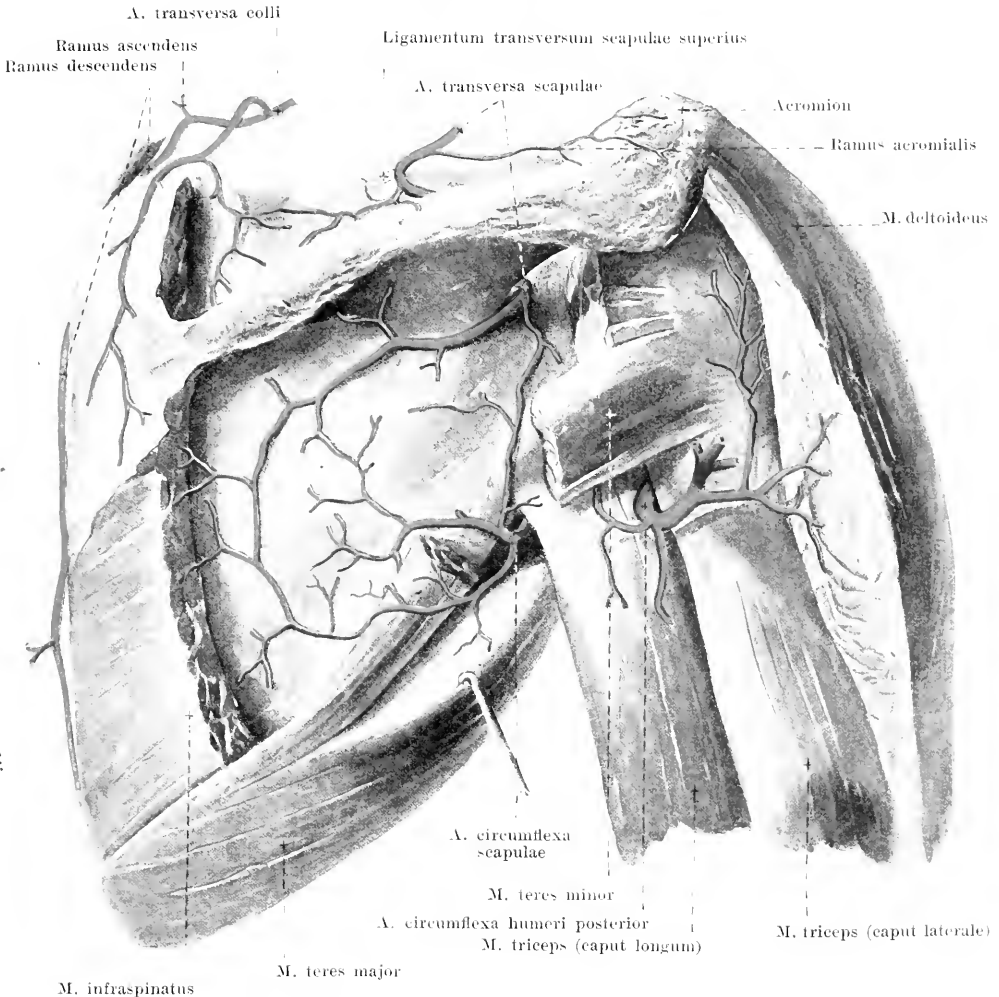


451. Arteries of the right axilla, viewed from in front.

(The arm is lifted, the *m. pectoralis major* has been completely, the *m. pectoralis minor* partially, removed.)

5. **A. circumflexa humeri anterior** (O. T. anterior circumflex artery) (see Fig. 449) goes, directly on the anterior surface of the collum chirurgicum humeri, covered by all the muscles, first lateralward, then backward. It supplies these muscles, the shoulder joint and by means of 1-2 branches (*aa. nutritivae humeri*) the superior epiphysis.

6. **A. circumflexa humeri posterior** (O. T. posterior circumflex artery) (see Figs. 449, 452 and 454) arises at the same level as the preceding artery, sometimes in common with it, passes backward through the space between the humerus, *mm. teretes* and *caput longum m. tricipitis* and surrounds the collum chirurgicum from behind and lateralward, lying always upon the bone and covered by all the muscles. It supplies these muscles, the shoulder joint and the skin over the *m. deltoideus*; it usually gives off two branches (*aa. nutritivae humeri*) to the superior epiphysis of the humerus.



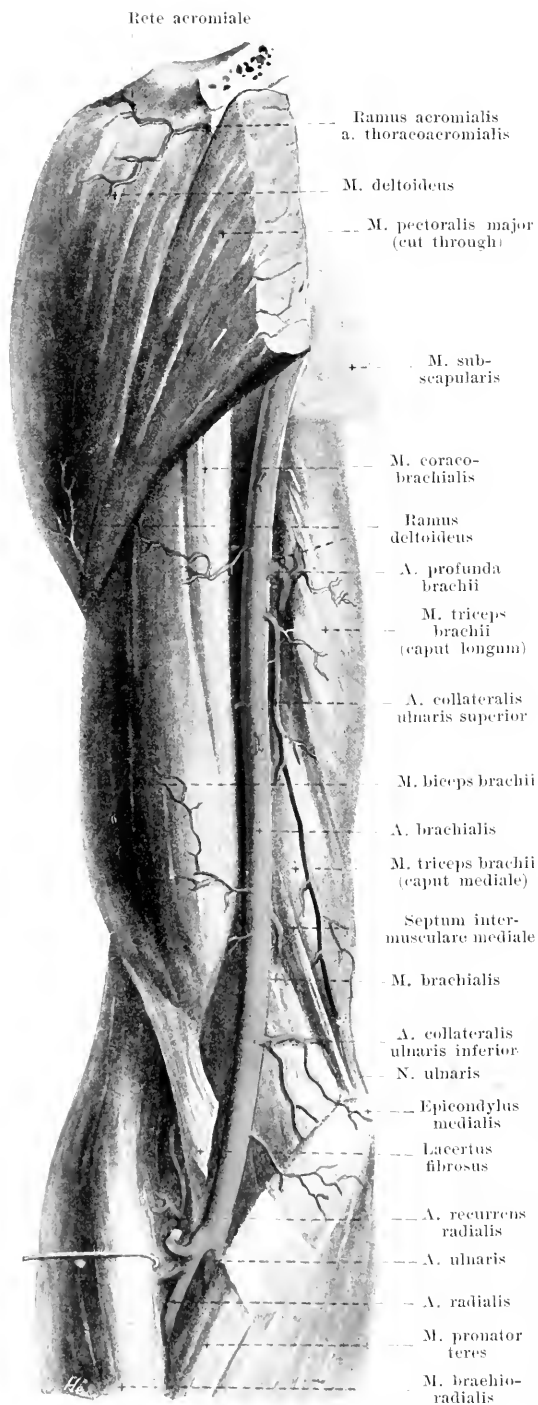
452. Arteries of the right shoulder blade, viewed from behind.

(The mm. supraspinatus, infraspinatus, teres minor and deltoideus have been partially removed.)

A. brachialis (*brachial artery*) (see Figs. 451, 453, 455 and 456) extends from the inferior margin of the m. pectoralis major onward, at first just behind the m. coracobrachialis, in front of the caput longum and caput mediale of the m. triceps, then in the sulcus bicipitalis medialis almost straight downward; it then passes upon the m. brachialis, covered by the lacertus fibrosus, to the depth of the elbow, there to divide at the level of the proc. coronoideus ulnae into the *a. radialis* and the *a. ulnaris*. Superficial to it medianward and in front of it run the vv. brachiales; on its lateral anterior surface above descends the n. medianus, which, however, above the elbow passes in front of the artery to its medial side; on its medial, posterior surface above, lie the n. ulnaris and radialis; these, however, soon diverge from it. Besides several small branches to the neighboring muscles and skin, it gives off the following:

1. **A. profunda brachii** (O. T. superior profunda artery) (see Figs. 453 and 454), arises from the upper portion of the vessel, bends backward and downward and follows a spiral course along with the n. radialis in the sulcus n. radialis around the posterior surface of the humerus downward and lateralward; in its course it runs between the origins of the caput laterale and mediale m. tricipitis and is covered by the former. Branches:

453. Arteries of the right upper arm, viewed from in front.



1. *A. profunda brachii* (continued) (see also Fig. 454):

a) *Ramus deltoideus* (see also Fig. 451), goes off immediately below the origin of the artery or arises from the a. brachialis or from the a. collateralis ulnaris superior; it runs lateralward, transversely over the anterior surface of the humerus, covered by the mm. coracobrachialis and biceps, to the m. deltoideus and gives off branches to these and to the m. brachialis.

b) *A. collateralis media*, runs downward in the substance of the caput mediale of the m. triceps and sometimes reaches the rete articulare cubiti, which it then helps to form.

c) *A. collateralis radialis* (O. T. articular branch of the superior profunda), appears somewhat below the middle of the upper arm between the caput laterale and the caput mediale of the m. triceps (with the n. cutaneus antibrachii dorsalis of the n. radialis), runs just behind the septum intermusculare laterale as far as the epicondylus lateralis and there opens into the rete articulare cubiti. It supplies the neighboring muscles, the skin over the m. triceps and partly also that over the mm. brachialis and biceps.

d) *A. nutritia humeri* (not illustrated), arises sometimes also from a muscular branch or from the a. brachialis itself; it passes through the canalis nutriticus to the bone and marrow of the diaphysis.

2. *A. collateralis ulnaris superior* (O. T. inferior profunda artery) (see also Figs. 454—456), arises usually a little below the preceding artery, runs downward with the n. ulnaris on the medial surface of the caput mediale m. tricipitis (behind the septum intermusculare mediale) and enters into the rete articulare cubiti near the olecranon. It supplies the neighboring muscles and skin.

3. *A. collateralis ulnaris inferior* (O. T. anastomotica magna artery) (see also Figs. 454—457), goes off somewhat above the epicondylus medialis humeri, runs medianward in front of the m. brachialis, perforates the septum intermusculare mediale, bends directly upon the bone backward and lateralward and enters into the rete articulare cubiti; it gives off branches to the adjacent muscles.

454. Arteries of the right upper arm, viewed from behind.

(The *m. triceps* has been partially removed, the other muscles of the upper arm have been completely removed.)

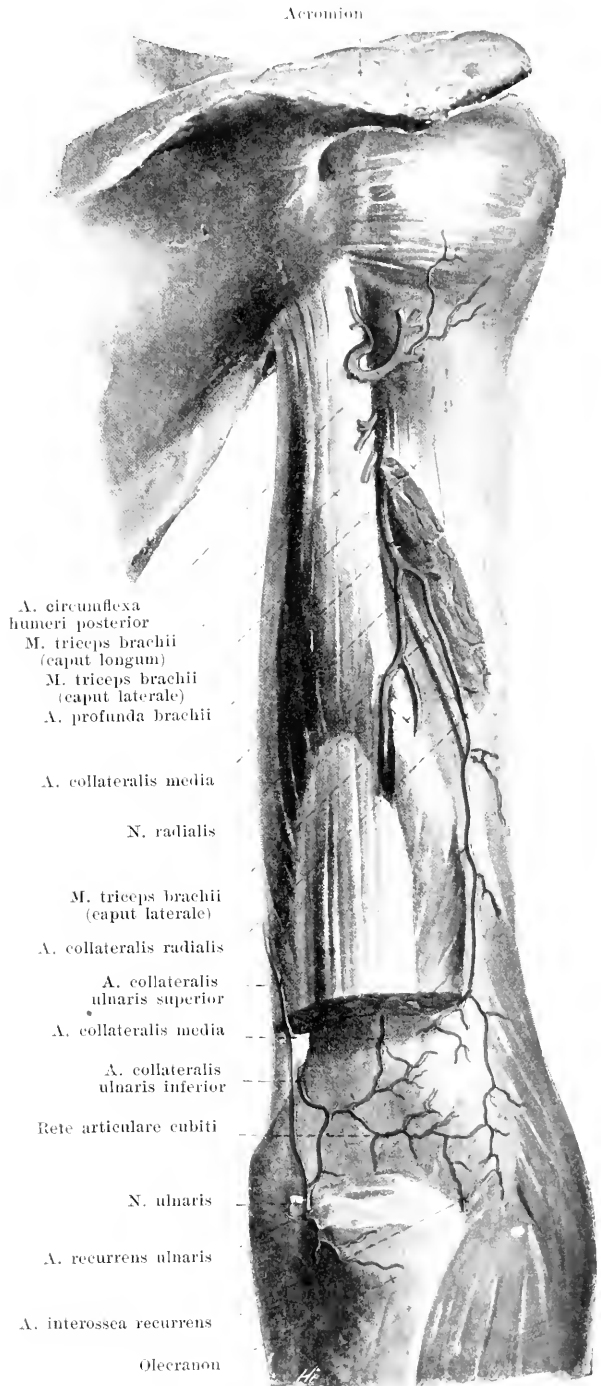
A. radialis (*radial artery*)

(see also Figs. 453, 455—460), extends radialward, slightly curved, upon the *m. supinator* and then runs almost straight to the wrist between the *m. brachioradialis* on one side, the *mm. pronator teres, flexor carpi radialis* and *flexor digitorum sublimis* on the other side; it is covered over in its upper portion by the margin of the *m. brachioradialis* and, below, lies free, covered only by the *fascia antibrachii*; above it lies, in its course, upon the insertion of the *m. pronator teres*, below upon the *mm. flexor pollicis longus* and *pronator quadratus*, and is accompanied on its radial side by the *ramus superficialis n. radialis*. Distalward from the *proc. styloideus radii* it bends to the back of the hand, covered by the tendons of the *mm. abductor pollicis longus* and *extensor pollicis brevis*, then runs distalward beneath the tendons of the *m. extensor pollicis longus*, passes between the bases of the *ossa metacarpalia I* and *II* into the palm and ends in the *arcus volaris profundus*. Branches:

1. **A. recurrens radialis** (*radial recurrent artery*) (see Fig. 456) goes off directly after the artery arises, bends upward and backward like a hook along the *n. radialis* directly upon the *m. supinator*; it supplies the adjacent muscles and the skin lying over them and sends off a branch beneath the origin of the *m. brachioradialis* through the *septum intermusculare laterale* backward into the *rete articulare cubiti* (see Fig. 457).

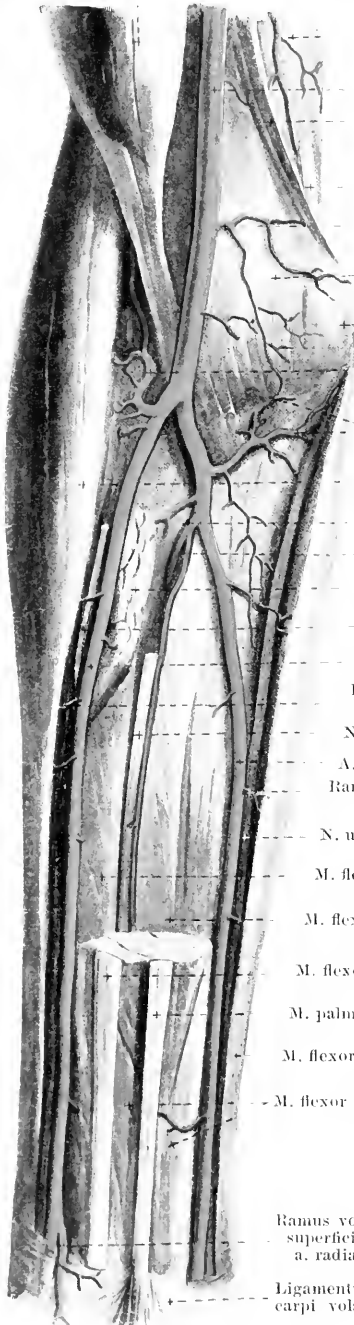
2. **Rami musculares** (see Fig. 455) in the forearm, numerous, to the adjacent muscles and to the skin.

3. **Ramus volaris superficialis** (*superficial volar branch*) (see Fig. 459), arises at the level of the *proc. styloideus radii*, runs distalward upon or partly between the bundles of the *m. abductor pollicis brevis*, otherwise covered only by the thin fascia of the ball of the thumb, and goes over usually in the form of a curve into the *arcus volaris superficialis*. It gives off branches to the muscles and skin of the thumb.



455. Arteries of the right forearm, viewed from in front, 1st layer.

M. biceps brachii



A. collateralis ulnaris superior

M. triceps brachii
(caput mediale)

A. brachialis

Septum intermusculare
mediale

N. ulnaris

A. collateralis
ulnaris inferior

M. brachialis

Epicondylus medialis
humeri

A. recurrens radialis

Aa. recurrentes
ulnares

M. brachioradialis

A. interossea
communis

A. mediana

M. pronator teres

Ramus superficialis
n. radialis

A. radialis

Ramus muscularis
a. radialis

N. medianus

A. ulnaris

Ramus muscularis
a. ulnaris

N. ulnaris

M. flexor pollicis longus

M. flexor digitorum profundus

M. flexor carpi radialis

M. palmaris longus

M. flexor carpi ulnaris

M. flexor digitorum sublimis

Ramus volaris
superficialis
a. radialisLigamentum
carpi volare

(The mm. pronator teres, palmaris longus, flexor carpi radialis and flexor digitorum sublimis have been partially removed from their origins on.)

4. **Ramus carpeus volaris** (O. T. anterior radial carpal) (see Figs. 456 and 160), delicate, goes ulnarward at the distal margin of the m. pronator quadratus, directly upon the bone; it helps to form the *rete carpi volare*.

5. **Ramus carpeus dorsalis** (O. T. posterior radial carpal) (see Figs. 457 and 458), arises from the portion of the artery situated in the back of the hand, extends ulnarward directly upon the bones and ligaments and helps to form the *rete carpi dorsale*.

6. **A. metacarpea dorsalis I** (O. T. dorsalis indicis or dorsal artery of the first finger) (see Fig. 458), goes off shortly before the passage of the artery through the m. interosseus dorsalis I, divides soon afterward and supplies the adjacent margins of the index finger (as far as the second phalanx) and thumb. A small branch to the radial margin of the thumb usually arises separately.

A. ulnaris (*ulnar artery*) (see also Figs. 453, 456—160) goes into the depth at the upper margin of the m. pronator teres and then turns ulnarward beneath this as well as beneath the mm. flexor carpi radialis and flexor digitorum sublimis, directly upon the m. flexor digitorum profundus; it then runs along the volar margin of the m. flexor carpi ulnaris, between it and the mm. flexores digitorum sublimis et profundus to the wrist. It is hidden in its course beneath the margins of the neighboring muscles, is accompanied ulnarward for part of the way by the n. ulnaris and rests upon the m. flexor digitorum profundus. In the hand it runs beneath the lig. carpi volare, then upon the lig. carpi transversum on the radial side of the os pisiforme and ends in the arcus volaris superficialis. Branches:

1. **Aa. recurrentes ulnares** (ulnar recurrent arteries) (see also Fig. 454) single or in a common trunk from the beginning of the artery; they run in a recurrent direction, that is, proximalward; one runs usually upon the anterior surface of the m. brachialis towards the a. collateralis ulnaris inferior, the other runs backward between the origins of the mm. flexor carpi radialis and flexor digitorum sublimis to the sulcus n. ulnaris of the epicondylus medialis humeri and there enters into the *rete articulare cubiti*. It supplies the surrounding muscles and skin.

2. **Rami musculares**, in the forearm, numerous branches, to the surrounding muscles and to the skin.

456. Arteries of the right forearm,

viewed from in front, 2nd layer.

(The mm. brachioradialis, pronator teres, flexor carpi radialis and flexores digitorum sublimis et profundus have been removed.)

3. **Ramus carpeus volaris** (O. T. anterior ulnar carpal) (see also Fig. 460), usually double, delicate, goes radialward in the neighborhood of the wrist, directly upon the bone, to the *rete carpi volare*.

4. **Ramus carpeus dorsalis** (O. T. posterior ulnar carpal) (see Figs. 457, 458 and 460) runs, directly upon the bone, around the ulna to the back of the hand and to the *rete carpi dorsale*.

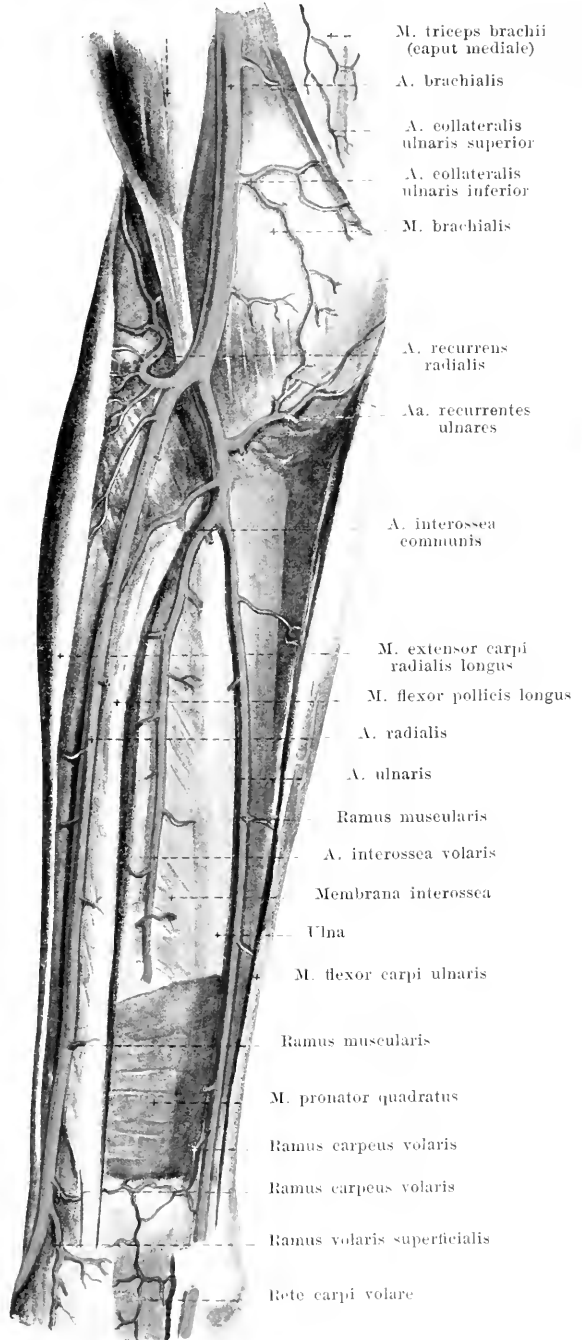
5. **Ramus volaris profundus** (O. T. deep ulnar artery) (see Figs. 459 and 460) arises close to the os pisiforme, goes into the depth between the origins of the mm. flexor digiti V brevis and abductor digiti V and helps to form the *arcus volaris profundus*; it gives off small branches to the muscles of the ball of the little finger. From this branch, or from the stem of the a. ulnaris itself, an artery passes beneath the m. palmaris brevis upon the muscles of the ball of the little finger (giving branches to these and to the skin) to the ulnar margin of the 5th finger.

6. **A. interossea communis** (common interosseous artery) (see also Fig. 455) goes off a little below the tuberositas radii and divides immediately into two branches:

a) **A. interossea volaris** (O. T. anterior interosseous artery) runs distalward directly upon the volar surface of the membrana interossea, covered by the m. flexor digitorum profundus; it supplies the muscles of the volar surface and sends a series of branches through the membrane to the muscles of the posterior surface; it also sends branches to the radius and ulna. It reaches the dorsal surface of the membrana interossea at the upper margin of the m. pronator quadratus and runs distalward upon it to the *rete carpi dorsale* (see Figs. 457 and 458); a small branch remains upon the volar surface and goes to the *rete carpi volare* (see also Fig. 460). Branch:

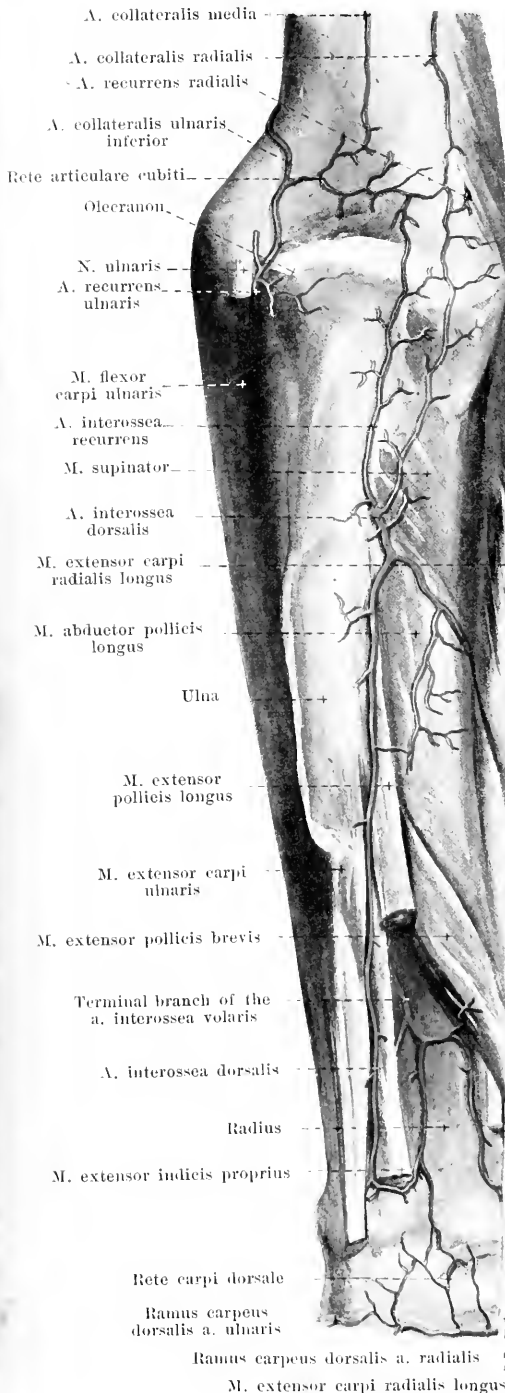
aa) **A. mediana** (O. T. median artery or arteria comes nervi mediani) (see Fig. 455), comes off from the first portion of the artery, is slender and accompanies the n. medianus distalward, finally to reach the palm.

M. biceps brachii



457. Arteries of the right forearm, viewed from behind.

(The *m. extensor digitorum communis* has been completely removed, the *mm. extensores carpi, indicis proprius, digiti V proprius* partially.)

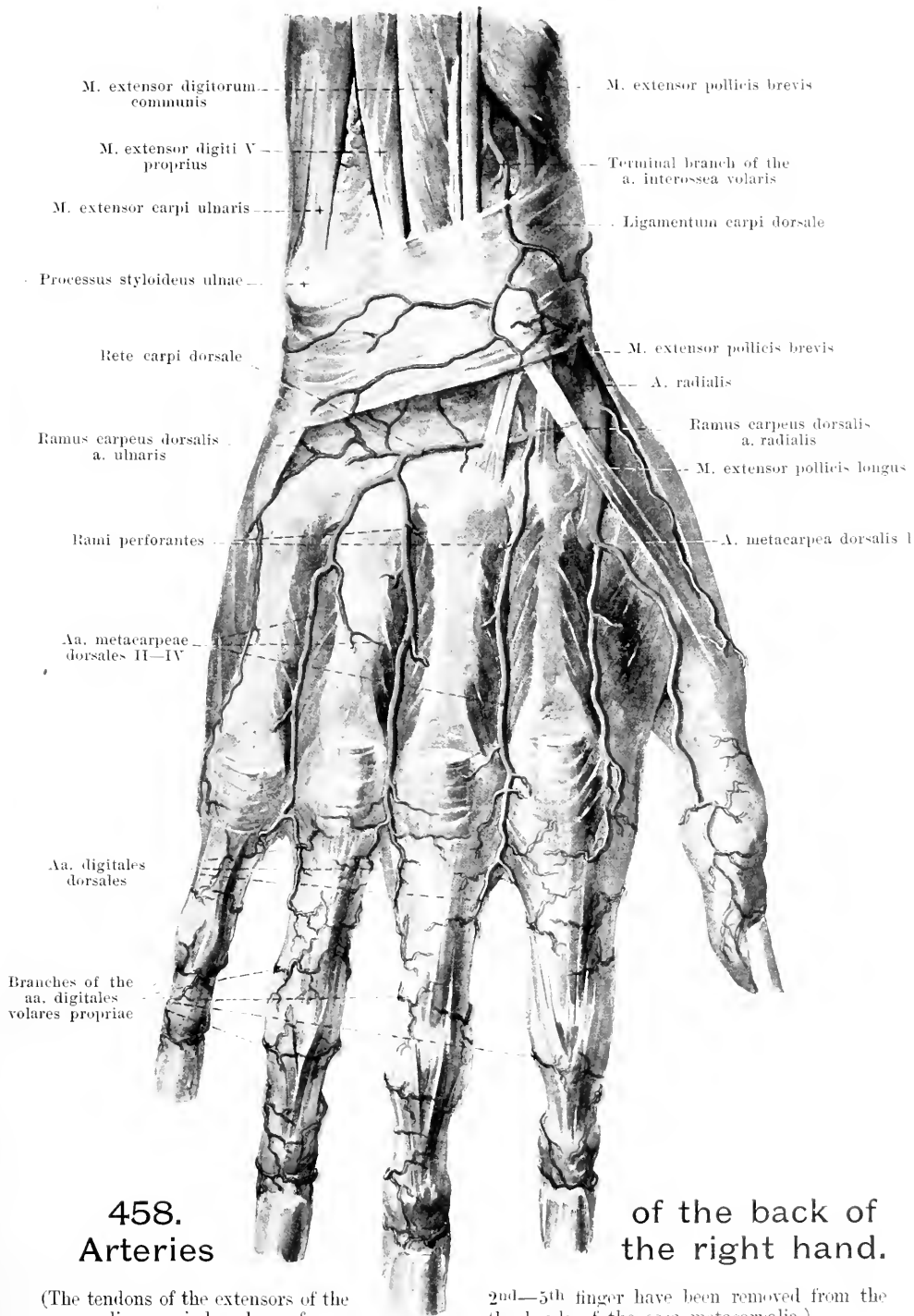
6. *A. interossea communis* (continued):

- b) *A. interossea dorsalis* (O. T. posterior interosseus artery), perforates the *membrana interossea* a little below the *chorda obliqua*, appears at the lower margin of the origin of the *m. supinator* and then runs almost straight distalward upon the ulnar origins of the *mm. abductor pollicis longus, extensor pollicis longus* and *extensor indicis proprius*. It is distributed to the adjacent muscles and skin and ends in the *rete carpi dorsale*. Branch:
- bb) *A. interossea recurrens* (O. T. interosseus recurrent or posterior interosseus recurrent), runs upward upon or near the *m. supinator* (covered by the *m. anconaeus*), gives off branches to both muscles and to the skin covering them and goes to the *rete articulare cubiti*.

Rete articulare cubiti (see also Fig. 454)

is a wide vascular network, situated especially on the dorsal surface of the elbow joint, in part more superficially upon the olecranon and the tendon of the *m. triceps*, in part deeper between this tendon, the humerus and the elbow joint. Opening into it from above are the *aa. collaterales ulnares superior et inferior, collateralis media* and *collateralis radialis*, from below large branches from the posterior *a. recurrens ulnaris* and the *a. interossea recurrens* and small branches from the *a. recurrens radialis*. A little above the capsule of the joint there is usually a large, transverse anastomosis, which is fed especially by the *a. collateralis ulnaris inferior*. Branches go off from the network to the surrounding bones, joints, muscles and skin.

Rete carpi dorsale (O. T. posterior carpal rete) (see also Fig. 458), lies upon the back of the wrist and is arranged in two layers: one more superficial, consisting of finer vessels, upon the *lig. carpi dorsale* and one deeper, directly upon the ligaments and bones of the wrist. The rete is formed by the *rami carpei dorsales* of the *a. radialis* and of the *a. ulnaris*, as well as by the terminal branches of the *aa. interossee volaris et dorsalis*. From the deep part of the network arise 3 *aa. metacarpeae dorsales* (O. T. dorsal interosseus arteries), which run distalward upon the *mm. interossei dorsales II, III et IV*, one upon each, each dividing at the level of the heads of the *ossa metacarpalia* into 2 *aa. digitales dorsales* (dorsal digital arteries) for the adjacent margins of the 2nd to the 5th finger. The latter vessels are short and end in the region of the first joint of the finger. A vessel arises usually directly from the network for the ulnar margin of the little finger. The *aa. metacarpeae dorsales* receive the *rami perforantes* of the *aa. metacarpeae volares*.

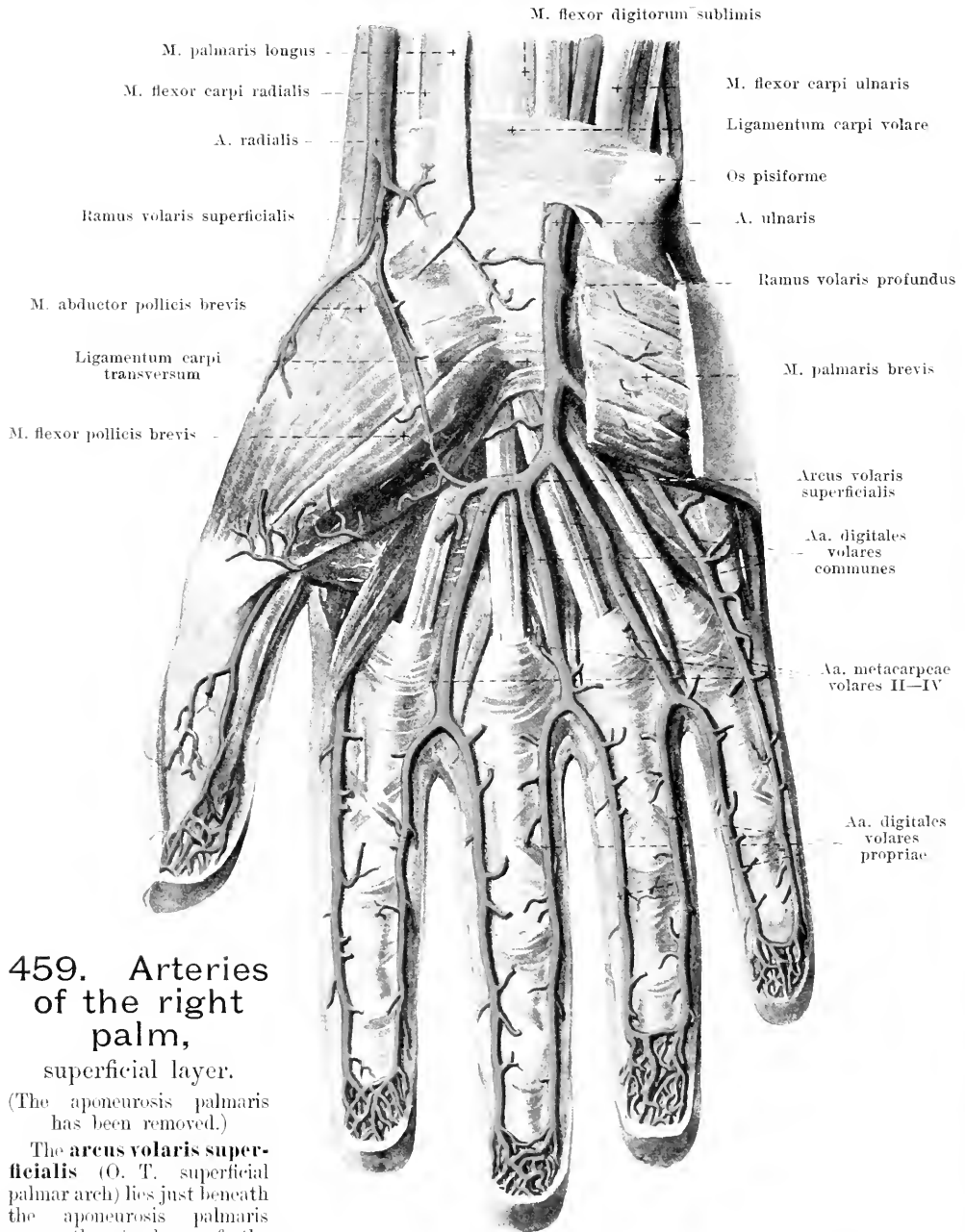


458.
Arteries

of the back of
the right hand.

(The tendons of the extensors of the lig. carpi dorsale as far as

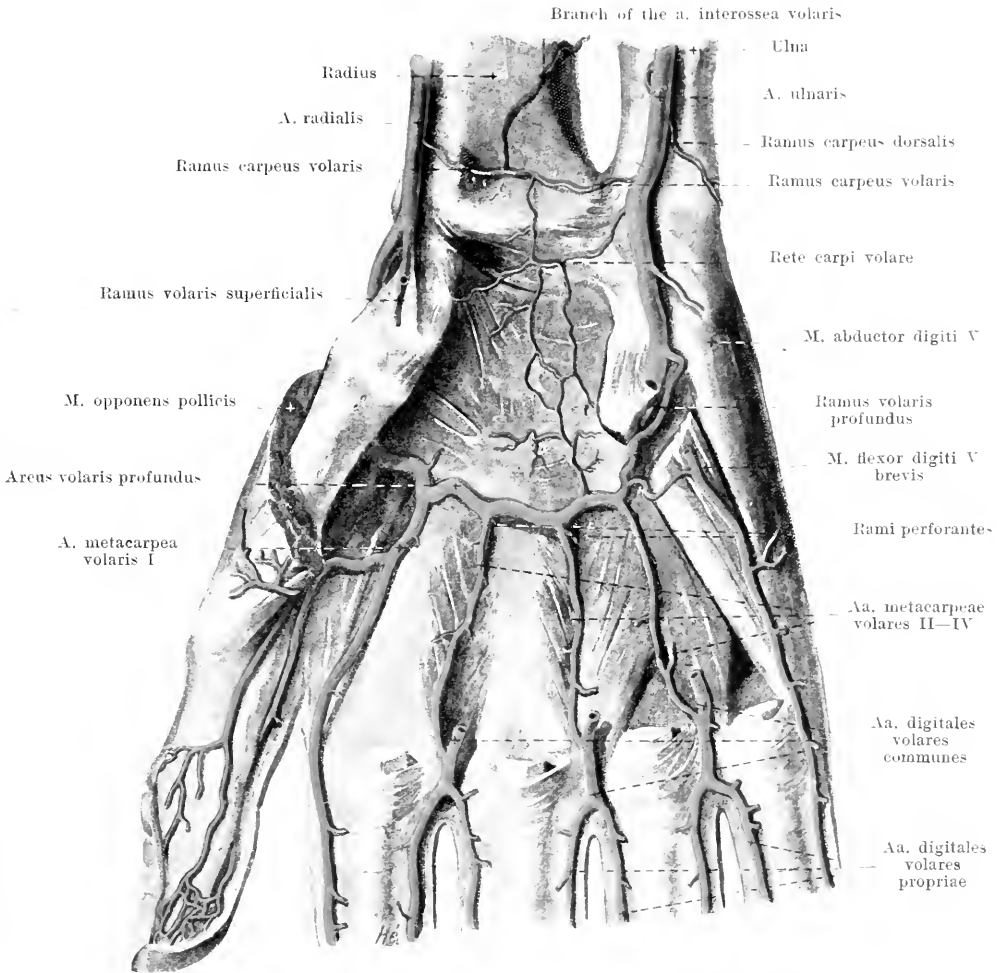
2nd—5th finger have been removed from the the heads of the ossa metacarpalia.)



459. Arteries of the right palm, superficial layer.

(The aponeurosis palmaris has been removed.)

The **arcus volaris superficialis** (O. T. superficial palmar arch) lies just beneath the aponeurosis palmaris upon the tendons of the *m. flexor digitorum sublimis*; its convexity is directed distalward. It is formed chiefly by the termination of the *a. ulnaris*, which unites usually with the delicate *ramus volaris superficialis* of the *a. radialis*. It gives off small branches to the surrounding muscles and skin as well as three *aa. digitales volares communes* (O. T. palmar digital arteries), which extend distalward upon the 2nd–4th *m. lumbricalis*, receive the *aa. metacarpeae volares II–IV* (see also Fig. 460) and divide at the metacarpophalangeal joints, each into two *aa. digitales volares propriae* (O. T. collateral digital arteries) for the adjacent surfaces of the 2nd–5th finger.



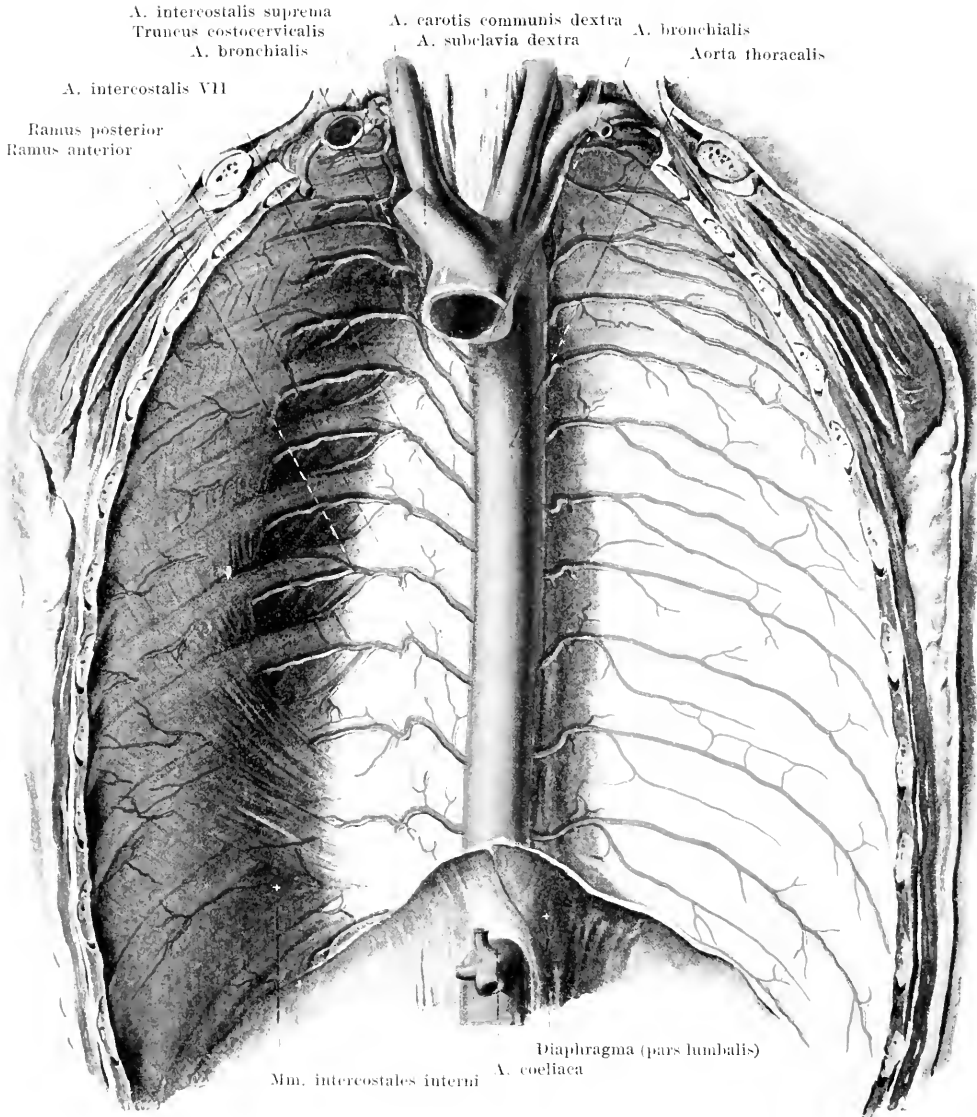
460. Arteries of the right palm, deep layer.

(All the structures have been removed with the exception of the *mm. interossei*, the muscles of the ball of the little finger and the insertions of the *mm. opponens pollicis* and *flexor pollicis brevis*.)

The *aa. digitales volares propriae* (see also Fig. 459) supply the volar surfaces and, from the region of the first joint of the finger on, also the dorsal surfaces of the fingers.

The **arcus volaris profundus** (O. T. deep palmar arch) lies directly upon the proximal ends of the *ossa metacarpha* and the *mm. interossei*, covered by the tendons of all the flexors of the fingers and by the *m. adductor pollicis*. It forms a flatter curve than the superficial arch; its convexity looks distalward. In its formation is chiefly concerned the termination of the *a. radialis*, which anastomoses with the *ramus volaris profundus* of the *a. ulnaris*. Proximalward it gives off branches to the *rete carpi volare*, distalward four *aa. metacarpeae volares* (O. T. *principes pollicis*, *radialis indicis* and *palmar interosseeae* arteries) which run upon the *mm. interossei*. The first goes to the two margins of the thumb and to the radial margin of the index finger. The 2nd, 3rd and 4th artery gives off, close to its origin, a *ramus perforans*, which passes through the *mm. interossei* to the corresponding *a. metacarpea dorsalis*; the arteries finally anastomose, close to the heads of the *ossa metacarpha*, with the *aa. digitales volares communes*.

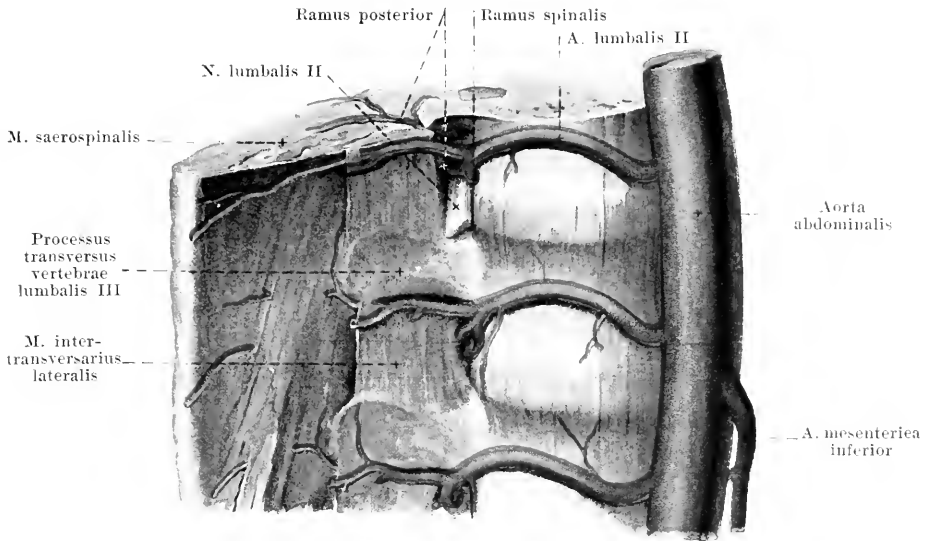
The **rete carpi volare** (O. T. anterior carpal rete) (see also Fig. 456) lies directly upon the volar surface of the wrist and consists of several fine branches from the *a. interossea volaris*, from the *rami carpei volares* of the *aa. radialis* and *ulnaris* and from the *arcus volaris profundus*.



461. Aorta thoracalis, viewed from in front.

(On the left side the mm. intercostales interni and subcostales have been removed; the diaphragm has been cut away at its origins.)

The **aorta thoracalis** (thoracic aorta) (see also Figs. 556, 629—631) runs, from the left side of the body of the 4th thoracic vertebra on, downward and somewhat to the right and passes in front of the lower margin of the 12th thoracic vertebra, a little to the left of the median plane, through the hiatus aorticus of the diaphragm and there goes over into the aorta abdominalis. On the left side it is directly adjacent to the v. hemiazygos and is covered by the pleura mediastinalis (and is accordingly in direct contact with the cavum pleurae); on the right side it adjoins the ductus thoracicus and the v. azygos, above also the oesophagus, which further down lies on its anterior surface; in front it comes into relation also with the bronchus sinister and with the pericardium in the region of the left atrium. It gives off branches to the thoracic viscera, **rami viscerales**, and to the walls of the thorax, **rami parietales**.



462. Branches of the arteriae lumbales dextrae.

(A piece of the lumbar spine with its muscles, viewed from the right and somewhat from above.)

A. Rami viscerales: 1. **Aa. bronchiales** (see Fig. 464). 2—3, from the anterior wall of the first part of the vessel, very frequently (especially on the right side) from the a. intercostalis III. They go forward to the right and left bronchus and along with these into the lungs.

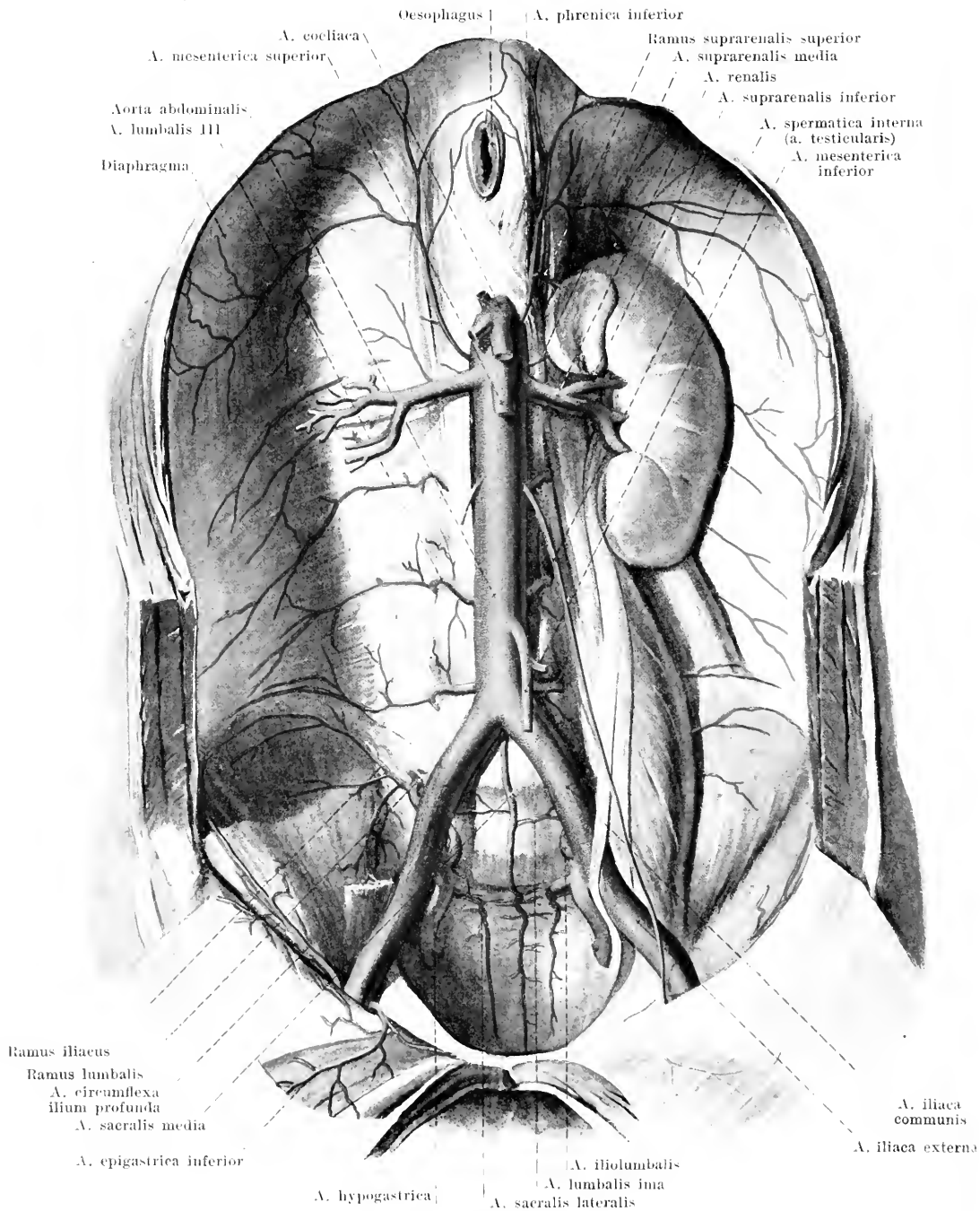
2. **Aa. oesophageae** (not illustrated), 3—7, from the anterior wall at different levels, forward and to the right to the oesophagus; the lowermost anastomoses with the a. gastrica sinistra.

3. **Rami pericardiaci** (not illustrated), delicate, to the posterior wall of the pericardium.

4. **Rami mediastinales** (not illustrated), arising partly in common with the preceding, slender, going to the contents of the spatium mediastinale posterius; the lowermost spread out also upon the pars lumbalis of the diaphragm as the *aa. phrenicae superiores* (not illustrated).

B. Rami parietales: Aa. intercostales (see also Fig. 461), from the posterior wall of the vessel, ten on each side for the 3rd—11th intercostal space and the lower margin of 12th rib. The upper arteries run upward in a recurrent direction, the lower ones more horizontally; those on the right side are the longer. All of them lie upon the lig. longitudinale arterius, behind the n. sympathicus and behind the v. azygos or hemiazygos, the right also behind the oesophagus and behind the ductus thoracicus. Each arrives at the lower margin of a capitulum costae and there divides.

- a) *Ramus posterior* gives off a *ramus spinalis*, which goes through the foramen intervertebrale into the canalis vertebralis to the spinal cord and its surroundings. It then goes backward, medianward from the lig. costotransversarium arterius, gives off *rami musculares*, and divides into two branches. One of these runs between the mm. semispinalis and longissimus, appears between two proce. spinosi and turns lateralward to the skin (*ramus cutaneus medialis*); the other lies between the mm. longissimus and iliocostalis and goes often (especially in the lower segments) also to the skin (*ramus cutaneus lateralis*).
- b) *Ramus anterior* runs forward in the spatium intercostale beneath the v. intercostalis (see p. 455), at first covered only by the fascia endothoracica and the pleura, then also by the mm. intercostales interni or the m. subcostalis; it gives off a branch to the upper margin of the next lower rib and also many *rami musculares*. In front it anastomoses with the corresponding ramus intercostalis of the a. mammaria interna. In the region of the digitations of origin of the m. obliquus abdominis externus *rami cutanei laterales [pectorales et abdominales]* (not illustrated) go, some backward (*ramus posterior*) to the lateral, some forward (*ramus anterior*) to the anterior wall of the trunk; small *rami mammarii laterales* go from the latter to the mammary gland. Only in the 4th—6th intercostal space, as a rule, small branches pass to the skin medial from the nipple (*rami cutanei anteriores [pectorales et abdominales]*) (not illustrated) and some to the mammary gland (*rami mammarii mediales*).



463. Aorta abdominalis, viewed from in front.

(On the right side the kidney and the mm. psoas and quadratus lumborum have been removed.)

The **aorta abdominalis** (see also Figs. 499 and 633) runs downward on the anterior surface of the lumbar vertebrae, a little to the left of the median plane. It is directly covered in front by the corpus pancreatis, the pars inferior duodeni and the peritoneum, lies on the left side of the v. cava inferior and divides in front of the lower margin of the 4th lumbar vertebra into the aa. iliaca communes dextra et sinistra. Its branches are divisible into **rami parietales** (to the walls of the abdomen) and **rami viscerales** (to the abdominal viscera).

A. Rami parietales:

1. **A. phrenica inferior**, paired, arises in front of the 12th thoracic vertebra, separated from, or in common with, that of the other side, goes upward, forward and lateralward on the inferior surface of the pars lumbalis diaphragmatis (on the right side behind the foramen venae cavae) and helps to supply the diaphragm. Branches:

a) *Rami suprarenales superiores*, from the first part of the artery, to the adrenal.

2. **Aa. lumbales I—IV** (O. T. lumbar arteries) (see also Fig. 462), paired, go off, usually at a right angle, from the posterior wall, one in front of in body of each of the 1st—4th lumbar vertebrae; they run backward on the lateral surface of the same, covered by the crura diaphragmatis and the origins of the m. psoas major, and pass through the m. quadratus lumborum to the muscles and to the skin of the lateral wall of the abdomen. Each gives off one branch:

a) *Ramus posterior*, corresponds exactly to the r. posterior of an a. intercostalis (see p. 419); it gives off a *ramus spinalis* and goes to the muscles and skin of the lumbar region.

3. **A. sacralis media** (middle sacral artery) (see also Figs. 470 and 471), unpaired, from the posterior wall of the aorta a little above the bifurcation, extends downward, somewhat tortuous, in the median plane in front of the 5th lumbar vertebra, sacrum and coccyx. It gives off branches to the neighboring bones, muscles, nerves and to the rectum and ends in a vascular skin, the *glomus coccygeum* (not illustrated), situated beneath the tip of the coccyx. Branch:

a) *A. lumbalis ima* runs lateralward and downward, one on each side, upon the body of the 5th lumbar vertebra to the mm. psoas major and iliacus.

B. Rami viscerales:

1. **A. suprarenalis media** (middle suprarenal artery), paired, arises a little below the a. coeliaca and runs directly in front of the crus mediale diaphragmatis to the adrenal.

2. **A. renalis** (renal artery), paired, arises nearly at a right angle at the level of the 1st lumbar vertebra (or somewhat lower), runs transversely in front of the crus mediale diaphragmatis (on the right side behind the v. cava inferior) behind the v. renalis and sends its branches in front of and behind the pelvis of the kidney to the substance of the kidney (see also Fig. 638). Variations in the origin and number of the renal arteries are frequent. Each, by means of small branches to the tunica adiposa of the kidney, anastomoses with the aa. phrenica inferior, lumbales, suprarenales, spermaticae internae and mesentericae. Each gives off also:

a) *A. suprarenalis inferior* to the adrenal.

3. **A. spermatica interna** (O. T. spermatic artery) (see also Figs. 464 and 465), paired, arises, at an acute angle, at the level of the 2nd lumbar vertebra, runs downward, lateralward and forward (on the right side in front of the v. cava inferior) upon the mm. psoas major and minor, in front of the ureter, behind the peritoneum, gives off in its course fine branches to the tunica adiposa of the kidney, to the ureter and to the lymph glands and approaches the lateral margin of the pelvic inlet. Thence it is distributed differently in the two sexes.

In the male, as the *a. testicularis* (see also Figs. 467, 499 and 650) it goes upon the m. psoas major, in front of the a. and v. iliaca externa to the annulus inguinalis abdominalis and, surrounded by the plexus pampiniformis, in the spermatic cord to the epididymis and testicle.

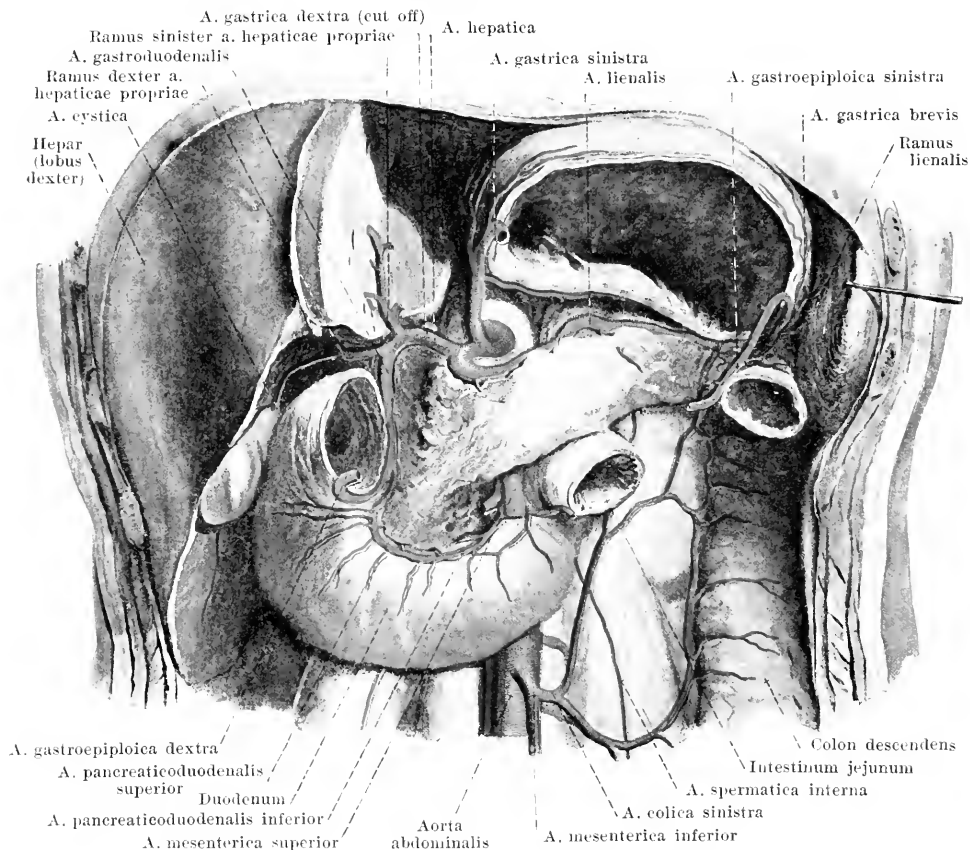
In the female, as the *a. ovarica* (see Figs. 471, 472 and 503) it crosses the a. and v. iliaca externa, nearly in front of the ureter, enters into the lig. suspensorium ovarii, surrounded by the plexus pampiniformis, runs along the anterior margin (margo mesovaricus) of the ovary, gives off branches to it and forms a broad anastomosis with the ramus ovarii of the a. uterina.

4. **A. coeliaca** (O. T. coeliac axis) (see also Fig. 464), unpaired, from the anterior wall between the 12th thoracic and the 1st lumbar vertebra, is short, and divides at the upper margin of the corpus pancreatis into three branches.

a) *A. gastrica sinistra* (O. T. gastric or coronary artery) (see Figs. 464 and 465), bends forward and upward in the plica gastropancreatica to the right side of the cardia and runs in the omentum minus, along the curvatura minor of the stomach, to the right and downward. Small branches to the oesophagus (*rami oesophagei*), larger ones to the anterior and posterior walls of the stomach and to the omentum minus.

b) *A. hepatica* (hepatic artery) (see Figs. 464 and 465) runs upon the right crus mediale diaphragmatis at the upper margin of the pancreas behind and below the vestibulum bursae omentalis to the left posterior surface of the pylorus. Branches:

ba) *A. gastrica dextra* (O. T. pyloric artery) arises at the pylorus and runs between the layers of the omentum minus along the curvatura minor to the left; it unites with the a. gastrica sinistra and gives off branches to the anterior and posterior walls of the stomach.



464. Arteries of the abdominal viscera, deepest layer, viewed from in front.

(The left lobe of the liver, the largest part of the stomach, the small intestines and the colon transversum have been removed; the peritoneum has been, in large extent, dissected off.)

- bb) *A. hepatica propria* ascends between the layers of the lig. hepatoduodenale, to the left of the ductus choledochus and in front of the v. portae (see Fig. 497), to the porta hepatis and there divides into a *ramus dexter* (O. T. right terminal branch) to the right half and a *ramus sinister* (O. T. left terminal branch) to the left half of the liver (see also Fig. 581). The former gives off the *a. cystica* to the gall bladder.
- bc) *A. gastroduodenalis* (gastroduodenal artery) runs downward to the left of and behind the pars superior duodeni and divides into two branches:
- a) *A. pancreaticoduodenalis superior* extends downward and to the left on the concave side of the pars descendens and pars inferior duodeni, between it and the caput pancreatis, unites with the *a. pancreaticoduodenalis inferior* and supplies, with its *rami pancreatici*, the caput pancreatis, and with its *rami duodenales*, the duodenum.
 - β) *A. gastroepiploica dextra* (right gastroepiploic artery) arrives at the lower surface of the pars superior duodeni between the two anterior layers of the omentum majus, runs to the left along the curvatura major of the stomach and unites with the *a. gastroepiploica sinistra*. It gives branches to the anterior and posterior walls of the stomach, as well as *rami epiploici* to the great omentum.
 - c) *A. lienalis* (O. T. splenic artery) bends to the left and extends to the left at the upper margin of the pancreas or behind it, as well as behind the bursa omentalis, in front of the left adrenal and kidney, in a tortuous course to the hilus of the spleen. Branches (see p. 424):

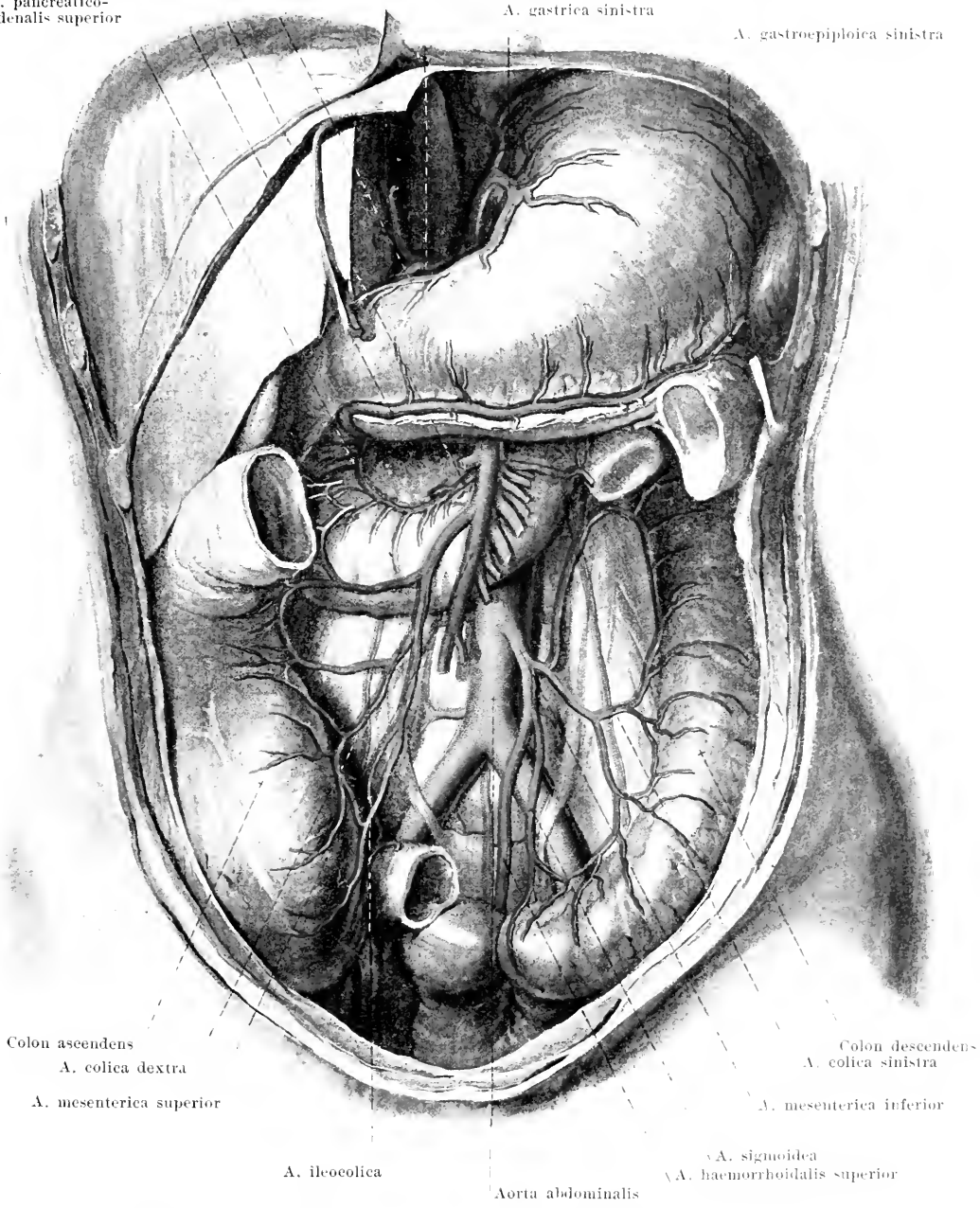
A. pancreaticoduodenalis inferior
 A. gastroepiploica dextra
 A. pancreaticoduodenalis superior

A. gastrica dextra

A. hepatica

A. gastrica sinistra

A. gastroepiploica sinistra



Colon ascendens
 A. colica dextra
 A. mesenterica superior

Colon descendens
 A. colica sinistra
 A. mesenterica inferior

A. ileocolica

Aorta abdominalis

A. sigmoidea
 A. haemorrhoidalis superior

465. Arteries of the abdominal viscera, more superficial layer, viewed from in front.

(The left lobe of the liver, the small intestines and the colon transversum have been removed; the mesenterium and mesocolon have been dissected off.)

- ca) *Rami pancreatici*, numerous, to the corpus and to the cauda pancreatis.
 cb) *A. gastroepiploica sinistra* (left gastroepiploic artery) (see also Fig. 465) runs forward in the lig. gastrolienale, goes to the right, between the two anterior layers of the omentum majus, along the *curvatura major* of the stomach, and unites with the *a. gastroepiploica dextra*; its branches are like those of the latter artery.
 cc) *Aa. gastricae breves* (*vasa brevia*) (see Fig. 464), in the lig. gastrolienale to the *fundus ventriculi*.
 cd) *Rami lienales* from the hilus to the substance of the spleen (see Fig. 586).

5. **A. mesenterica superior** (superior mesenteric artery) (see also Figs. 463—465, 498 and 584), unpaired, arises just below the *a. coeliaca*, separated from it by the *v. lienalis*, in front of the 1st lumbar vertebra; it goes downward at first behind the *caput pancreatis*, then passes through the *incisura pancreatis* in the groove on the anterior surface of the *processus uncinatus* and in front of the *pars inferior duodeni* between the layers of the mesenterium and runs in a curve, slightly convex to the left and forward, as far as the first portion of the large intestine.

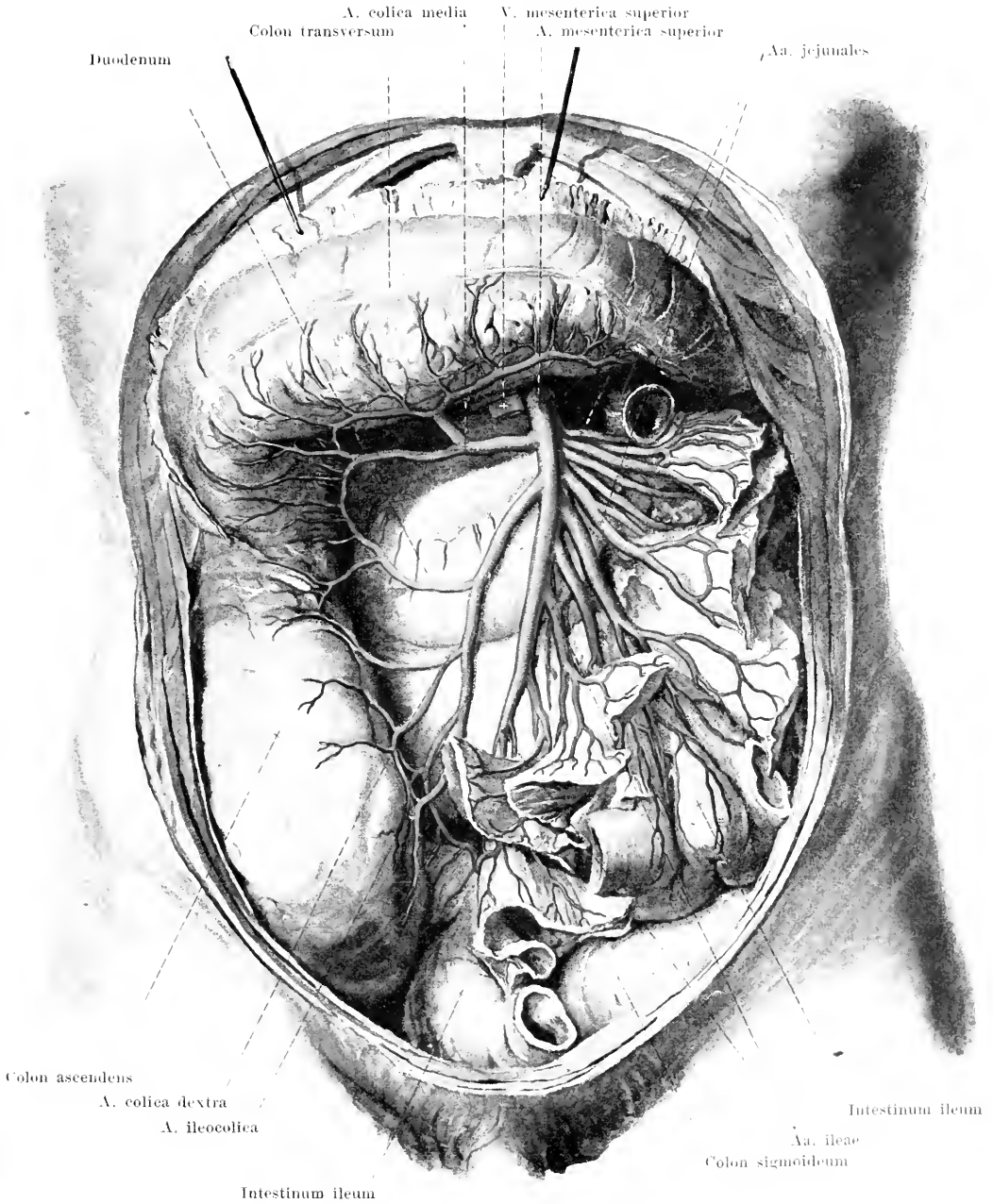
- a) *A. pancreaticoduodenalis inferior* (see Fig. 464) goes off from the right side, runs to the right on the concave surface of the *pars inferior duodeni* between it and the pancreas, supplies both organs and unites with the *a. pancreaticoduodenalis superior*.
 b) *Aa. intestinales* (O. T. *vasa intestini tenuis*), about sixteen, from the convexity of the arch, pass between the layers of the mesenterium to the loops of the jejunum (*aa. jejunales*) and ileum (*aa. ileae*). Each artery bifurcates and forms arch-like anastomoses with the branches of neighboring vessels; the branches arising from these form further anastomoses and so on until two to five series of anastomoses follow upon one another (see Fig. 496). From the last numerous branches of nearly equal size and almost equidistant from one another go to the small intestine. Small branches go also to the contents of the mesentery. The last *a. ilea* unites with the *a. ileocolica*.
 c) *A. ileocolica*, from the right side, runs behind the peritoneum to the right and downward to the end of the small and beginning of the large intestine, anastomoses with the last *a. ilea* and with the *a. colica dextra*. A small branch, the *a. appendicularis* (not indicated), goes behind the ileum to the vermiform process.
 d) *A. colica dextra* (right colic artery), from the right side, very often a branch of the preceding artery, goes to the right behind the peritoneum to the colon ascendens; it anastomoses with the *a. ileocolica* and with the *a. colica media*.
 e) *A. colica media* (middle colic artery), from the right side, in front of the pancreas; it extends to the right and forward in the *mesocolon transversum* to the colon transversum; it anastomoses with the *a. colica dextra* and with the *a. colica sinistra*.

6. **A. mesenterica inferior** (see Figs. 462—465), unpaired, arises between the 3rd and 4th lumbar vertebra and runs downward and to the left, beneath the peritoneum. Branches:

- a) *A. colica sinistra* (left colic artery), beneath the peritoneum to the left to the colon descendens; it anastomoses with the *a. colica media* and with the *aa. sigmoideae*.
 b) *Aa. sigmoideae*, often single, run downward and to the left to the colon sigmoideum; they anastomose with the *a. colica sinistra* and with the *a. haemorrhoidalis superior*.
 c) *A. haemorrhoidalis superior* (see also Figs. 470 and 471) bends downward in front of the *a. and v. iliaca communis sinistra* and in front of the promontorium and goes downward between the two layers of the mesorectum, in front of the sacrum and behind the rectum, and then divides into two branches, which run right and left to the *intestinum rectum*; it anastomoses above with the *aa. sigmoideae*, below with the *aa. haemorrhoidales mediae* (from the *a. hypogastrica*).

A. iliaca communis (iliac artery) (see also Figs. 463, 467, 468, 470, 471 and 499) paired, goes downward, lateralward and forward, slightly curved, in front of the bodies of the 4th and 5th lumbar vertebra at the medial margin of the *m. psoas major*; it is covered by peritoneum and runs, on the left side, behind the ureter and the *a. haemorrhoidalis superior*. It lies in front of and somewhat to the left of the *v. iliaca communis*. It divides in front of the *articulatio sacroiliaca* into the **a. hypogastrica** and the **a. iliaca externa**.

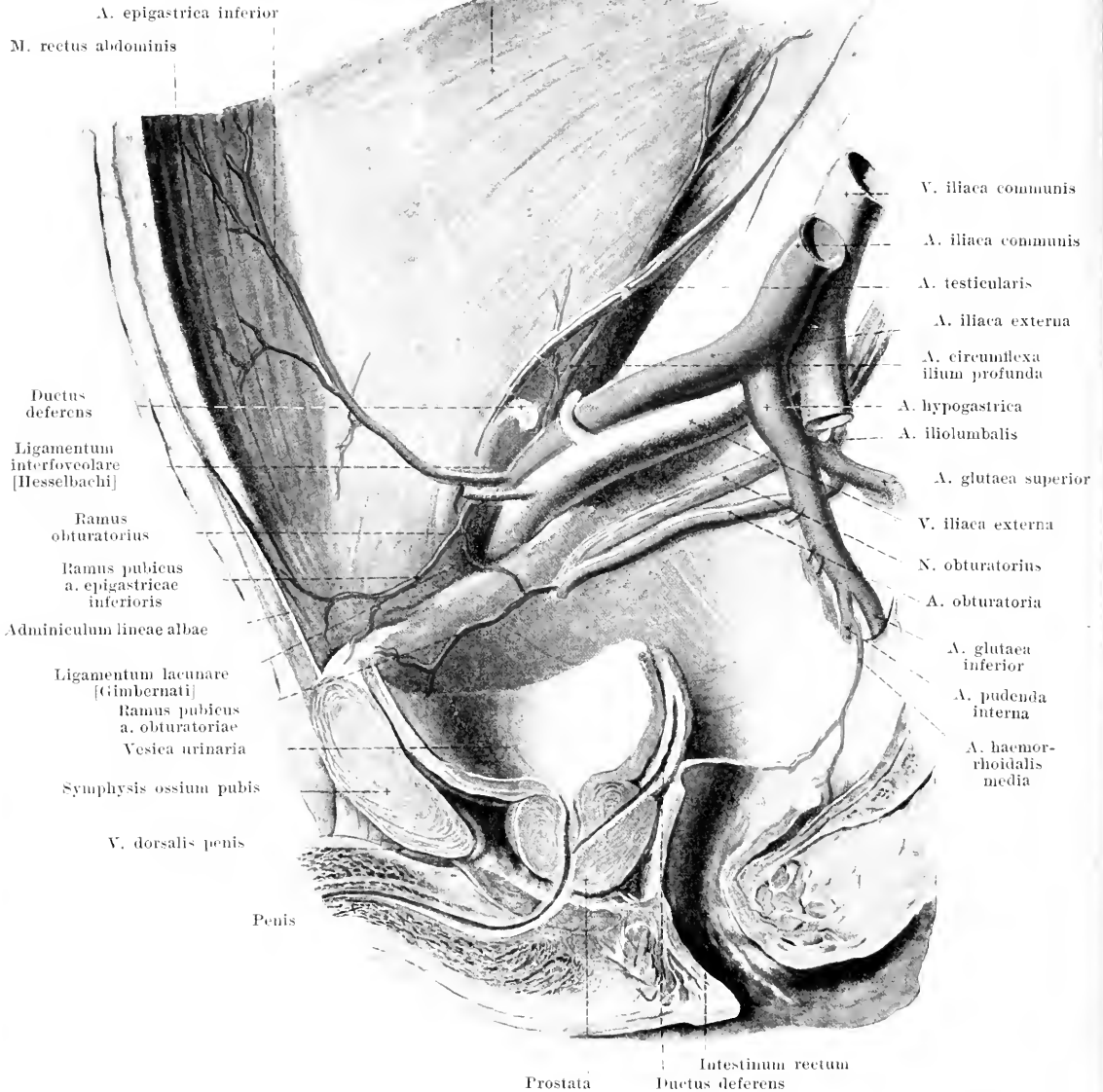
A. hypogastrica (see Figs. 463, 467, 468, 470 and 471) turns downward and somewhat backward into the small pelvis and divides, after a short course, usually into a posterior and an anterior branch. The posterior branch bends markedly backward to the upper part of the *foramen ischiadicum majus* (above the *m. piriformis*), gives off the *aa. ilioumbalis, obturatoria* and *sacralis lateralis* and ends as the *a. glutaea superior*. The anterior branch runs in front of the *m. piriformis* to the inferior portion of the *foramen ischiadicum majus*, gives off the *aa. umbilicalis* (or *aa. vesicales superiores*), *vesicalis inferior*, *deferentialis* (in the male), *uterina* (in the female) and *haemorrhoidalis media* and bifurcates into the *aa. glutaea inferior* and *pubenda interna*. The subdivisions of the posterior branch (and the *a. glutaea inferior*) go chiefly to the walls of the pelvis as **rami parietales**, those of the anterior branch (with the exception of the *a. glutaea inferior*) chiefly to the viscera as **rami viscerales**.



466. Branches of the a. mesenterica superior, viewed from in front.

(The small intestine has been cut away at the mesentery with the exception of two loops, the transverse colon has been drawn upward, the great omentum cut off, and the mesentery reflected to the left. The mesentery and mesocolon have been partially dissected away.)

M. transversus abdominis

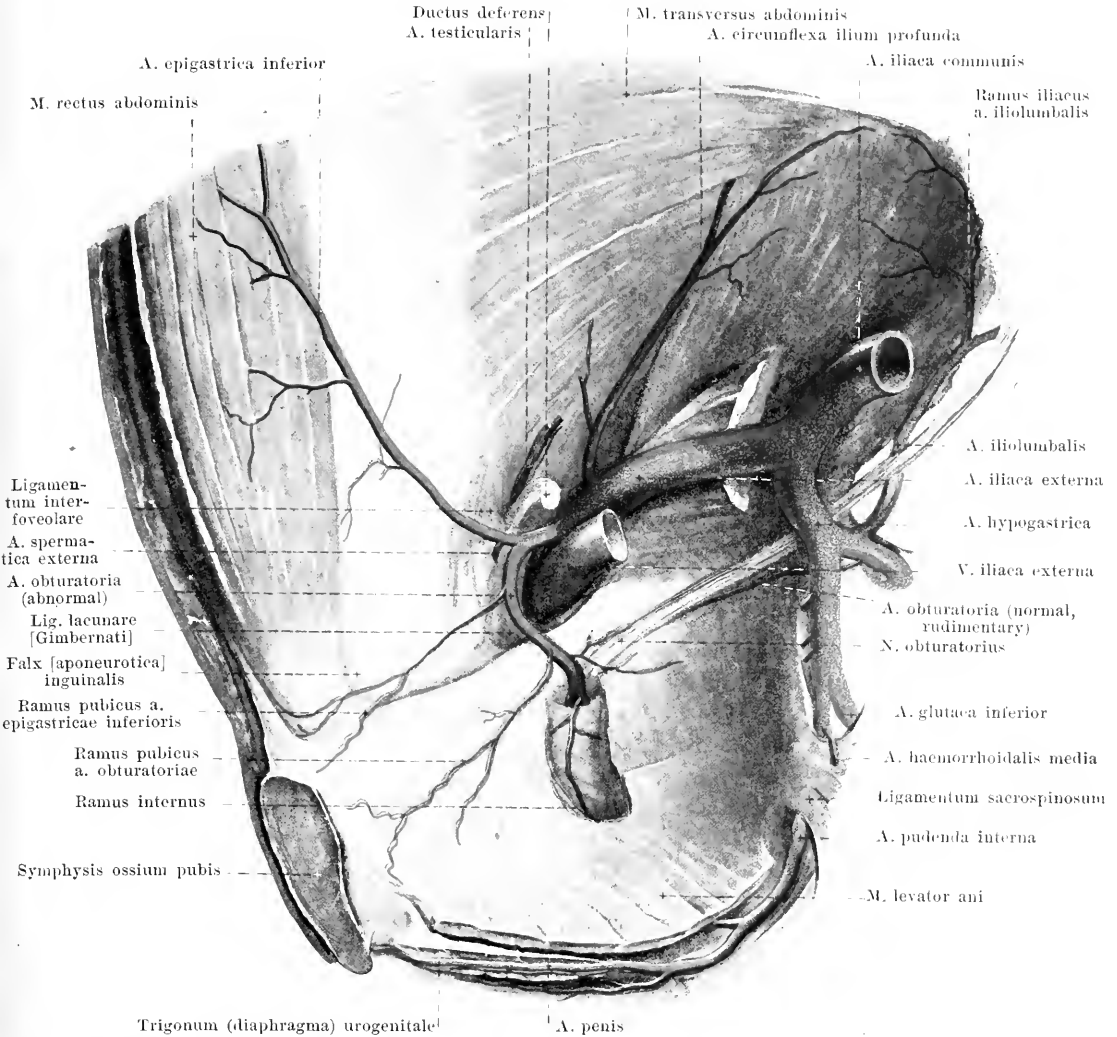


467. Right a. obturatoria and a. epigastrica inferior, in the male, viewed from the left.

A. Rami parietales:

1. **A. iliolumbalis** (O. T. iliolumbar artery) (see also Figs. 463 and 465) turns lateralward and upward behind the n. obturatorius, between the basis ossis sacri and the m. psoas major, and divides into two branches:

- Ramus lumbalis* corresponds to the ramus posterior of an a. lumbalis (see Fig. 462) and gives off a *ramus spinalis* to the spinal canal: it supplies the neighboring muscles and skin.
- Ramus iliacus* runs behind the m. psoas major along the crista iliaca, gives off branches to the bones and muscles: it unites with the a. circumflexa ilium profunda.



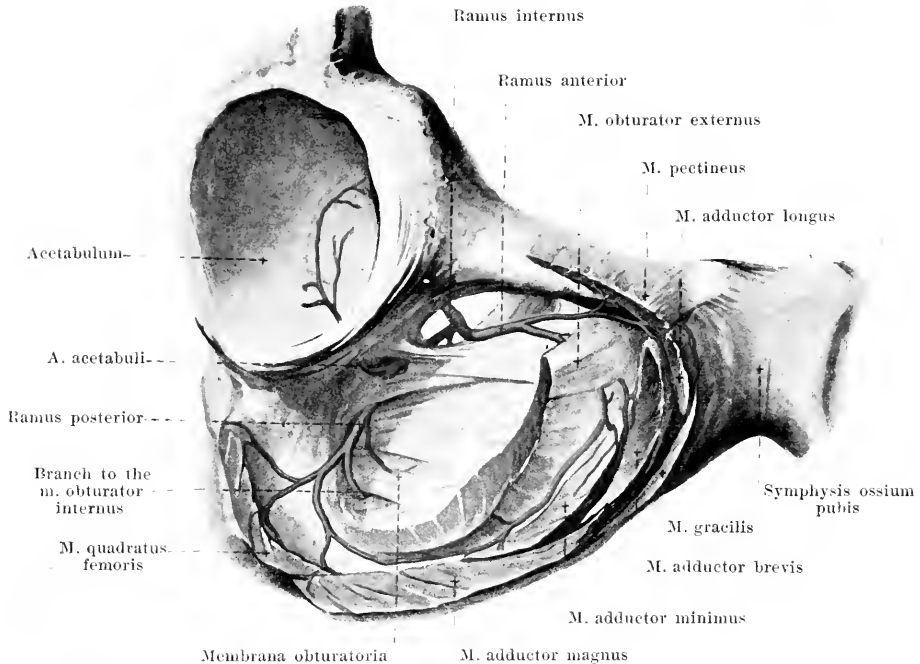
468. Abnormal a. obturatoria dextra in the male.

(A window has been cut out of the mm. obturator internus and levator ani.)

2. **A. sacralis lateralis** (lateral sacral artery) (see Fig. 463) downward, single or double, upon the facies pelvina of the sacrum, gives off *rami spinales* through the foramina sacralia into the canalis sacralis, and branches to the muscles and to the skin of the back.

3. **A. obturatoria** (obturator artery) (see also Figs. 467, 469—471 and 476), frequently arising from the anterior branch, extends forward and downward beneath the linea terminalis of the pelvis and beneath the n. obturatorius to the canalis obturatorius, inside which it divides into its terminal branches. In the pelvis, small branches to its surroundings, as well as:

- a) *Ramus pubicus*. This runs medianward on the posterior surface of the ramus superior ossis pubis and anastomoses on the upper surface of the lig. lacunare [Gimbernati] with the ramus obturatorius of the a. epigastrica inferior. By this anastomosis the a. obturatoria arises in about one-third of the cases from the a. epigastrica; it lies in half of these cases upon the lig. lacunare or upon the septum femorale, in the other half, lateralward from the annulus femoralis.
- b) *Ramus internus*, medial from the membrana obturatoria, downward to the ischium.



469. Terminal branches of the a. obturatoria dextra, viewed from in front and from the right.

(The muscles of the thigh have been cut off short at their origin.)

3. A. obturatoria (continued). Terminal branches:

c) *Ramus posterior*, goes downward in the membrana obturatoria at the posterior margin of the foramen obturatum to the anterior surface of the ramus superior ossis ischii, and gives off, as it goes, the *a. acetabuli*, which passes through the incisura acetabuli to the hip joint; it also gives off branches which pass through the membrane to the m. obturator externus, and sends its terminal branches in part forward upon the origin of the m. obturator externus, in part backward especially to the ischium.

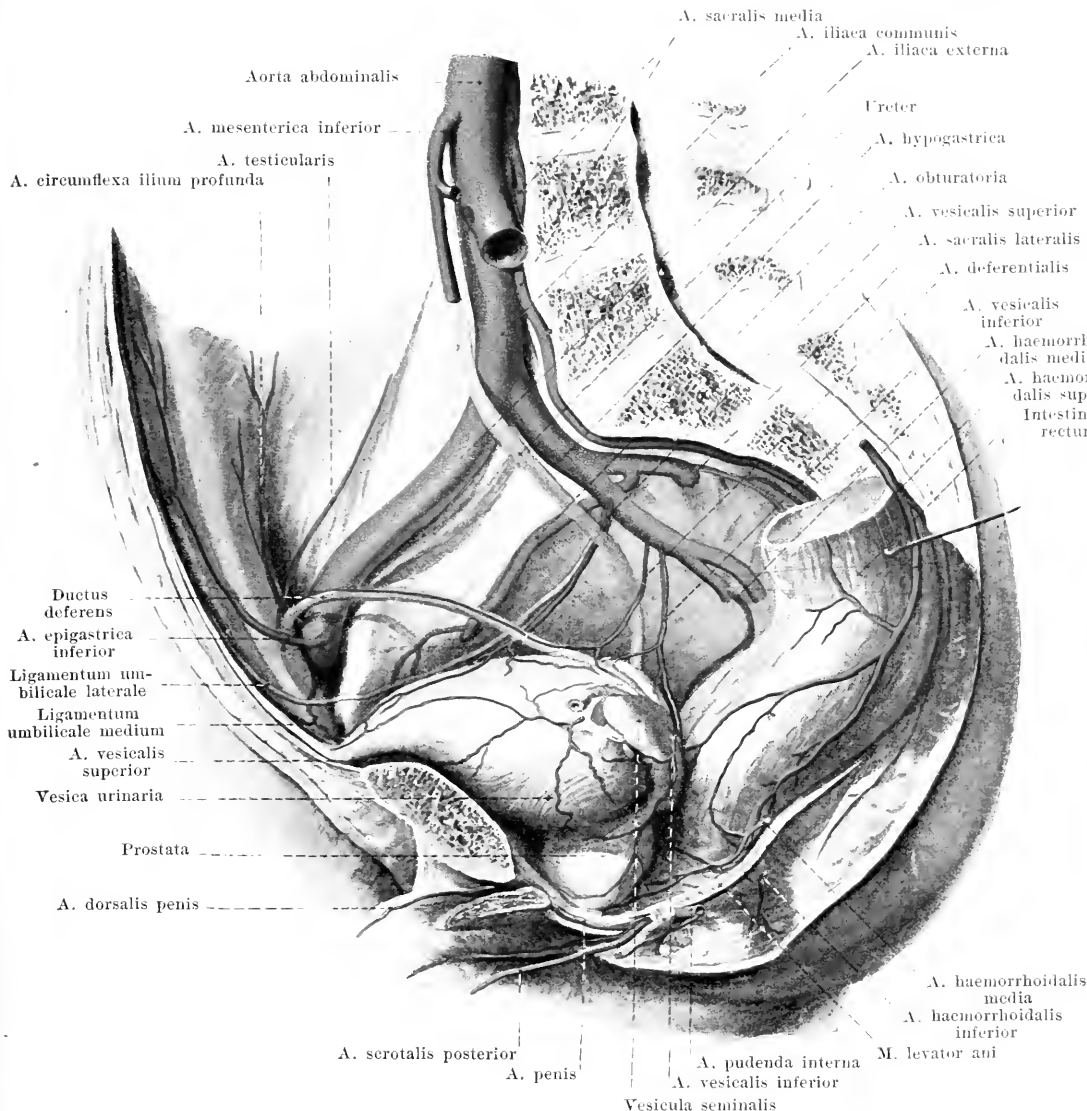
d) *Ramus anterior*, forward upon the external surface of the membrane and then, partly through, partly in front of the m. obturator externus, toward the preceding artery.

4. **A. glutea superior** (gluteal artery) (see Figs. 467, 470 and 477) goes backward through the upper part of the foramen ischiadicum majus, above the m. piriformis, gives small branches to the surrounding muscles and bones and divides into a superficial branch, which goes downward between the mm. gluteus maximus and medius, and into a deep branch, which runs forward between the mm. gluteus minimus and medius. This latter branch divides into a *ramus superior* along the upper margin of the m. gluteus minimus and into a *ramus inferior* in the substance of the m. gluteus medius. It gives off, also, branches to the skin covering the region.

5. **A. glutea inferior** (see Figs. 467, 470 and 477) runs backward and downward between the lower margin of the m. piriformis and the lig. sacrospiniosum through the lower part of the foramen ischiadicum majus to the anterior surface of the m. gluteus maximus. It supplies especially this muscle, its neighbors and the skin covering that region and gives off a fine *a. comitans n. ischiadici* which goes downward to the n. ischiadicus.

B. Rami viscerales.

1. **A. umbilicalis** (O. T. hypogastric artery) (see Figs. 470, 471, 510 and 511) present in its full development only before birth, runs in a curve, on the inner wall of the small pelvis, forward and upward to the anterior abdominal wall, arrives on this behind the lateral margin of the tendon of the m. rectus abdominis and then goes, beneath the peritoneum in the plica umbilicalis lateralis, to the navel (see also Figs. 328 and 599). It gives off the *aa. vesicales superiores* to the upper part of the bladder. After birth only the beginning of the artery and the branches to the bladder remain open, the largest part of the vessel becomes obliterated to form the *ligamentum umbilicale laterale* (O. T. lateral false ligament).



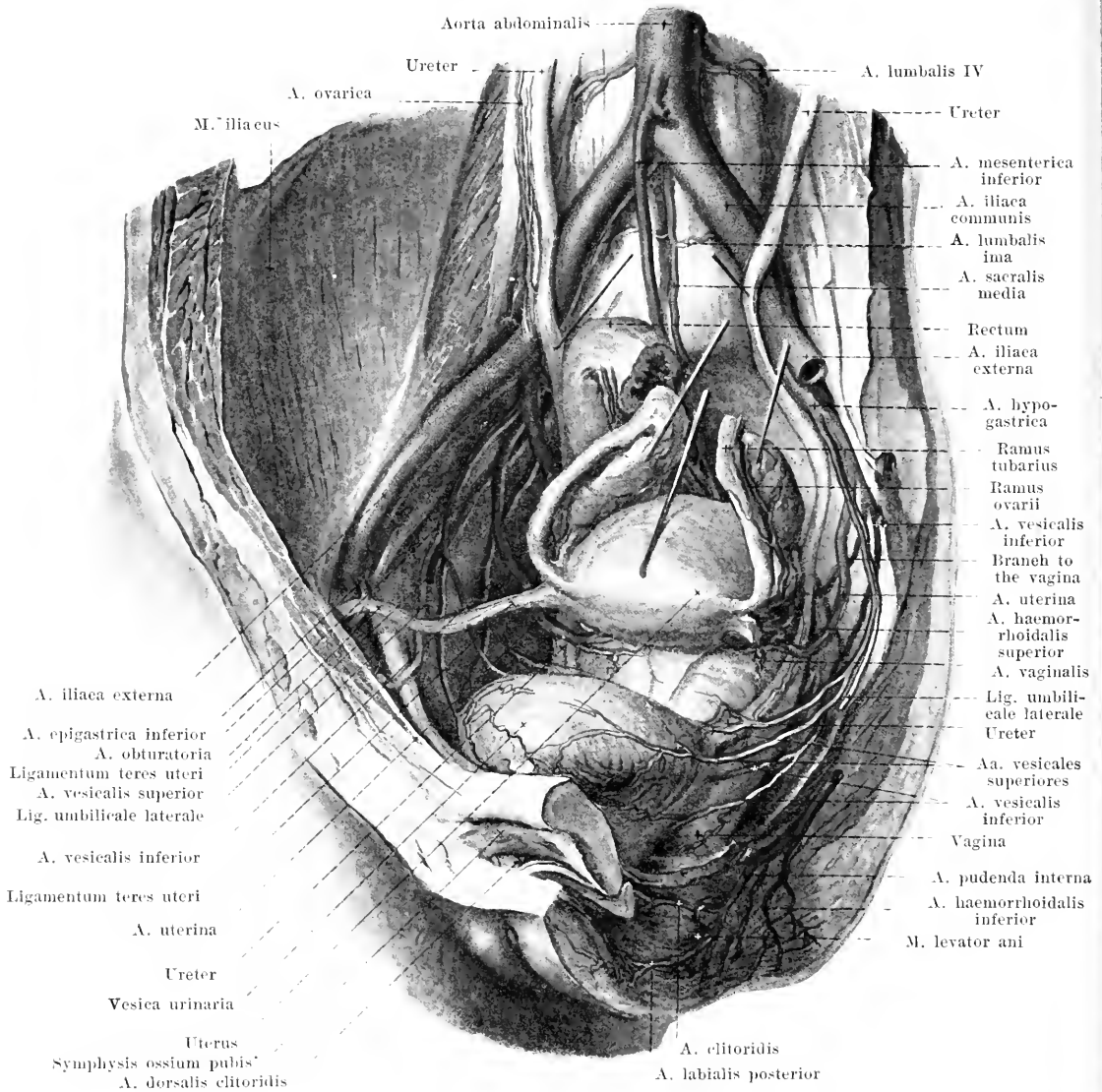
470. Arteries of the male pelvis, viewed from the left.

(The rectum has been drawn somewhat to the left, the peritoneum has been removed.)

2. **A. deferentialis** (O. T. artery of the vas deferens) (present only in the male), frequently arising from the preceding artery or from the following, passes forward and downward to the ductus deferens, there divides, one part going downward as far as the vesicula seminalis, the other upward to the inguinal canal and thence to the epididymis; it anastomoses there with the a. testicularis.

3. **A. vesicalis inferior** (see also Figs. 471 and 472) goes downward to the fundus vesicae; it goes also in the male to the vesicula seminalis and the prostate, in the female to the vagina.

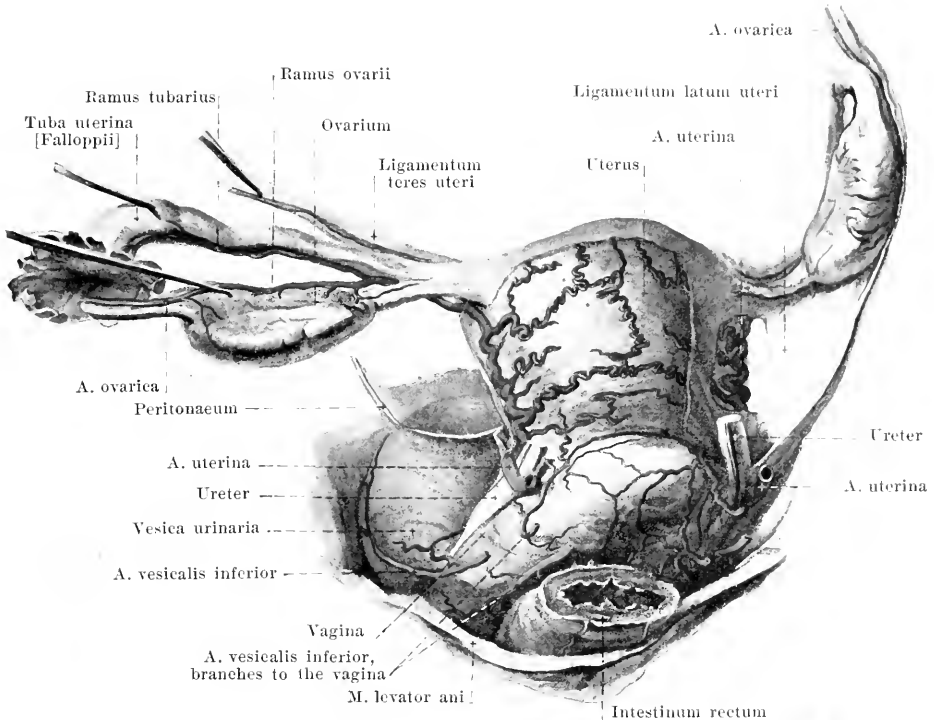
4. **A. haemorrhoidalis media** (middle haemorrhoidal artery) (see also Fig. 467) comes frequently from the a. pudenda interna and runs over the m. coccygeus and m. levator ani, downward and medianward to the rectum and to the surrounding muscles; it gives off branches to the vesiculae seminales and to the prostate in the male, to the vagina in the female.



471. Arteries of the female pelvis, viewed somewhat from the left.

(The organs have been partly drawn out of their position; the peritoneum has been removed.)

5. **A. uterina** (uterine artery) (present only in the female) (see also Fig. 472) goes forward beneath the peritoneum at first on the inner wall of the small pelvis, then turns medianward, runs through the parametrium obliquely forward in front of the ureter to the cervix uteri and there gives off the *a. vaginalis*, which runs downward on the lateral wall of the vagina. The uterine artery then runs along the *margo lateralis uteri*, following a very tortuous course between the layers of the *ligamentum latum uteri*, as far as the *fundus uteri* and sends off numerous corkscrew-like, tortuous branches to the anterior and posterior surfaces of the uterus, anastomosing with one another and with those of the other side; it ends in a branch which runs in the *ligamentum latum* partly to the *ligamentum teres uteri* and to the *tuba uterina* (*ramus tubarius*), partly to the ovary (*ramus ovarii*); the latter branch runs along the *margo mesovariicus* of the ovary and forms a broad anastomosis with the *a. ovarica*.

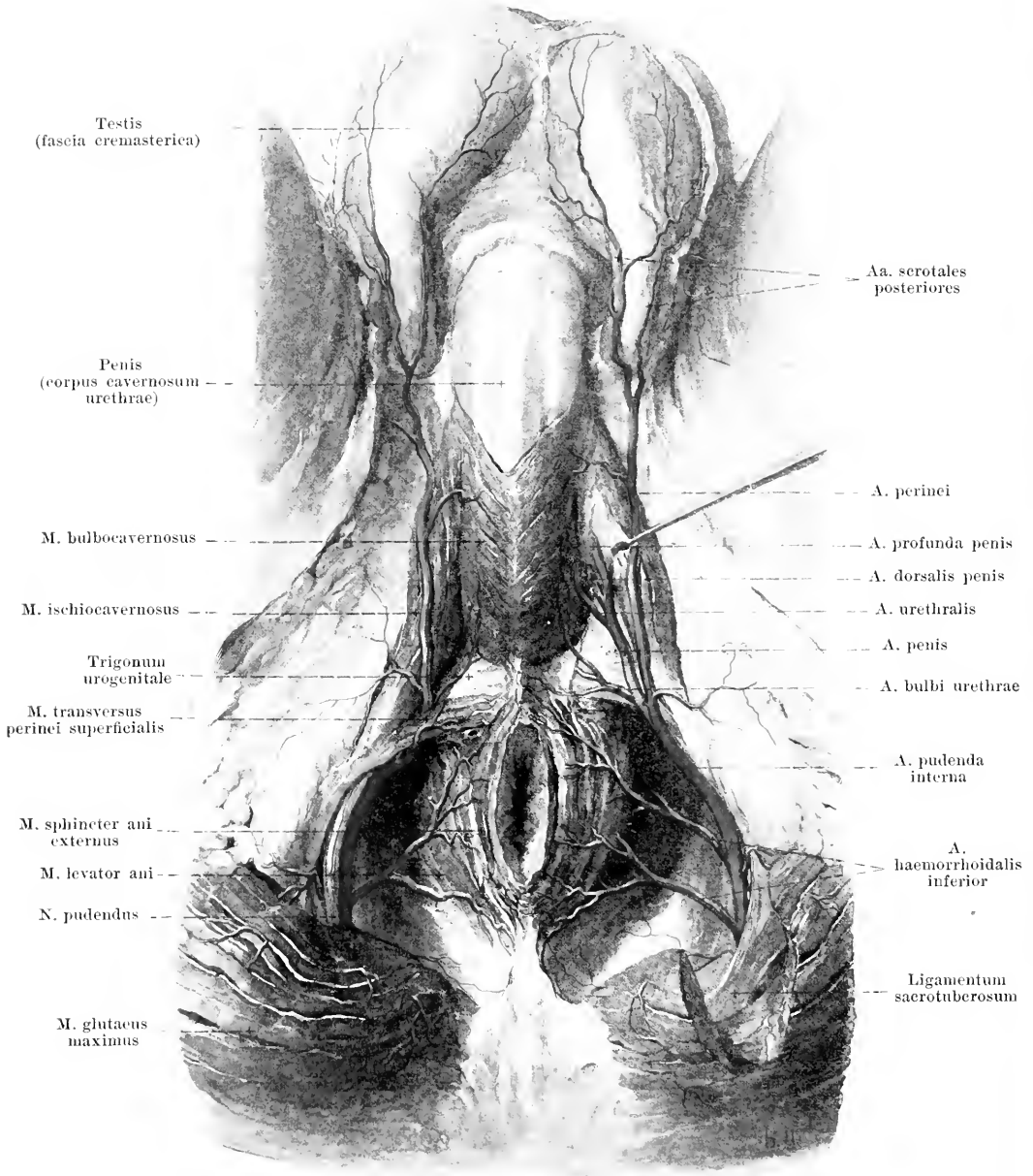


472. Arteries of the uterus and surrounding structures, viewed from behind and somewhat from the left.

(On the left side the ovary, the Fallopian tube and the ligamentum teres uteri have been displaced from their normal position.)

6. *A. pudenda interna* (see Figs. 465, 473 and 474) goes downward at the lower margin of the *m. piriformis* behind the *lig. sacrospinosum*, lies on the medial surface of the *tuber ischiadicum* and passes forward, in the form of a curve, upon this and on the medial surface of the *ramus inferior ossis ischii*; in its course it runs somewhat above the *processus falciformis* and is covered by the *fascia obturatoria*; close behind the *m. transversus perinei superficialis* it divides into the *a. perinei* and the *a. penis* (or *a. clitoridis*). It always gives off small branches to the surrounding muscles and nerves, and often, also, the *a. haemorrhoidalis media*.

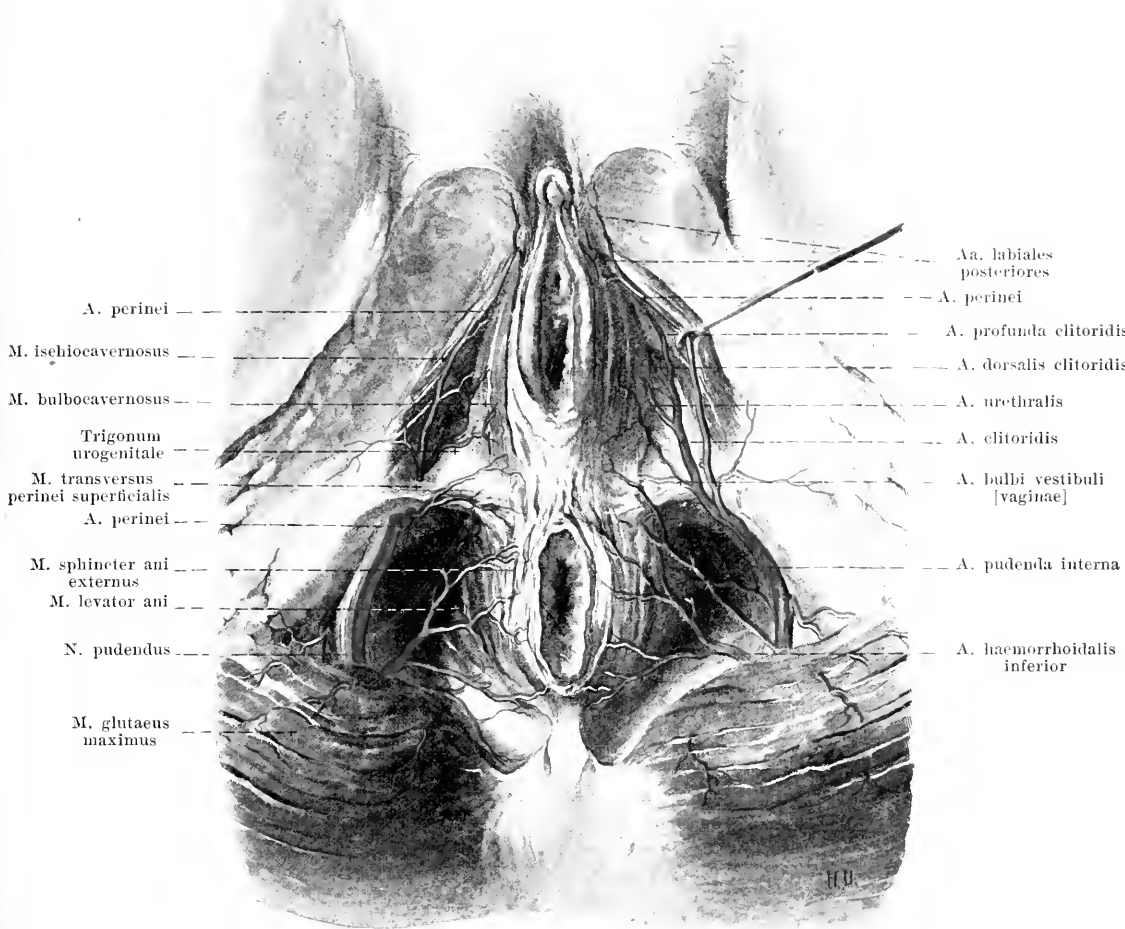
- 1) *A. haemorrhoidalis inferior* (O. T. external or inferior haemorrhoidal artery) (see Figs. 473 and 474) usually double or triple. It runs, transversely medianward through the fat of the *fossa ischiorectalis*, being fairly superficial, to the fat, muscles and skin about the anus.
- 2) *A. perinei* (O. T. superficial, perineal artery) (see Figs. 473 and 474) extends, over or under the *m. transversus perinei superficialis*, forward and medianward; it is superficial, being covered only by the *fascia superficialis perinei*; it goes in the male to the posterior surface and to the septum of the *scrotum* by means of the *aa. scrotales posteriores*, in the female into the *labium majus* and *labium minus* by means of the *aa. labiales posteriores*. It also gives off small branches to the superficial muscles of the perineum.
- 3a) *A. penis* (in the male only) (see Figs. 465, 473, 655, 673 and 677) runs forward, in the direction of the main stem, close to the *ramus inferior ossis pubis*, within the *trigonum (diaphragma) urogenitale* until it lies below the *lig. arcuatum pubis* where it is continued directly into the *a. dorsalis penis*. Branches:
 - aa) *A. bulbi urethrae* (O. T. artery of the bulb) (see Fig. 473) goes off at the posterior margin of the *trigonum urogenitale* and runs medianward and forward to the *bulbus urethrae* and to the neighboring muscles.
 - ab) *A. urethralis* (see Fig. 473) forward and medianward to the *corpus cavernosum urethrae*.



473. Arteries of the male perineum.

(On the left side the dissection shows the *m. transversus perinei profundus*; the *crus penis* has been drawn aside.)

a) *A. profunda penis* arises close under the *ligamentum arcuatum pubis*, penetrates the *corpus cavernosum penis* on its medial surface and runs in it partly backward, partly forward close to the *septum penis* (see also Fig. 659) as far as its tip; its branches anastomose with one another and with those of the opposite side.



474. Arteries of the female perineum.

(Dissection similar that of Fig. 473; the crus clitoridis has been drawn aside.)

- ad) *A. dorsalis penis* (see Figs. 470, 473, 475 and 659) goes near the lig. suspensorium penis to the dorsum penis and in its medial groove, on each side near the unpaired *v. dorsalis penis*, as far as the glans; it gives branches to the skin, to the corpora cavernosa penis et urethrae and especially to the glans penis.
- 3b) *A. clitoridis* (present only in the female) is comparable in its course to the *a. penis*; it gives off the *a. bulbi vestibuli [vaginae]* to the perineal muscles, the vagina and the bulbus vestibuli, the *a. urethralis* to the latter and to the vestibulum vaginae, and the *a. profunda clitoridis* to the crus clitoridis; the *a. dorsalis clitoridis* runs upon the clitoris to the glans clitoridis, praeputium clitoridis and labia minora.

A. iliaca externa (external iliac artery) (see Figs. 463, 467, 468, 470, 471, 476, 499, 500 and 503) downward, lateralward and forward on the medial, anterior surface of the *m. psoas major*; it runs first forward, then lateralward from the *v. iliaca externa*, in front of the fascia iliaca and behind the peritonaeum; on the right side the anterior and medial surface of its initial portion is crossed by the ureter. It goes through the lacuna vasorum beneath the lig. inguinale (see Fig. 370) and from there on is called the *a. femoralis*. Branches:

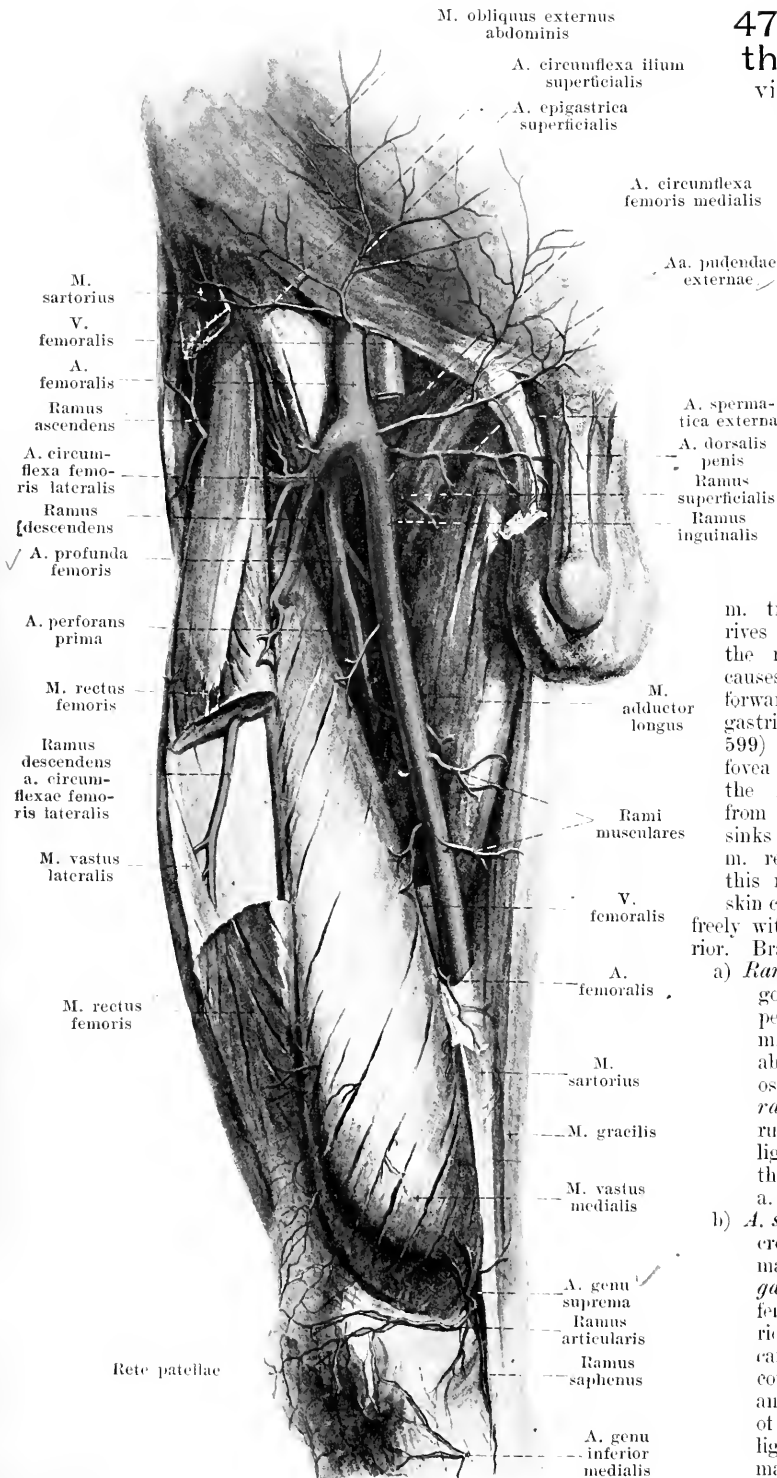
475. Arteries of the right thigh, viewed from in front, superficial layer.

(The m. sartorius has been for the most part removed and a piece has been cut out of the m. rectus femoris.)

1. **A. epigastrica inferior** (O. T. deep epigastric artery) (see Figs. 450, 467, 468 and 470) arises just above the lig. inguinale and runs in a curve, first obliquely medianward, then vertically upward. In its course it lies at first behind the lig. inguinale and lig. interfoveolare, medial from the annulus inguinalis abdominalis and, then, passing behind the tendon of the

m. transversus abdominis arrives at the posterior surface of the m. rectus abdominis. It causes the peritonaeum to bulge forward to form the plica epigastrica (see also Figs. 328 and 599) and thus separates the fovea inguinalis medialis and the fovea inguinalis lateralis from each other. Finally, it sinks into the substance of the m. rectus abdominis, supplies this muscle and a part of the skin covering it, and anastomoses freely with the a. epigastrica superior. Branches:

- a) **Ramus pubicus** (see Fig. 467) goes medianward behind the pelvic attachment of the m. transversus abdominis just above the ramus superior ossis pubis and gives off the **ramus obturatorius**, which runs downward behind the lig. lacunare [Gimbernati] to the ramus pubicus of the a. obturatoria (see p. 427).
- b) **A. spermatica externa** (O. T. cremasteric branch) (in the male) (see Fig. 468), **a. ligamenti teretis uteri** (in the female), perforates the posterior wall of the inguinal canal, enters the spermatic cord or the lig. teres uteri and spreads out in the tunics of the testicle, or in the lig. teres and in the labia majora.



476. Arteries of the right thigh, viewed from in front, deep layer.

(The *mm. sartorius*, *tensor fasciae latae*, *rectus femoris*, *pectineus*, *adductor longus* and *gracilis* have been removed.)

2. **A. circumflexa ilium profunda** (deep circumflex iliac artery) (see also Figs. 463, 467 and 468) arises behind or below the *lig. inguinale*, passes lateralward and upward in the groove between the *mm. transversus abdominis* and *iliacus*, gives off small branches to the neighboring muscles, as well as one larger branch upward between the *mm. transversus* and *obliquus internus abdominis* (see Fig. 450) and extends backward along the *crista iliaca*; it anastomoses with the *r. iliacus a. iliolumbalis*.

A. femoralis (femoral artery) (see also Fig. 475) follows a fairly straight course, in the groove between the *mm. pectineus* and *adductores* on the one hand, the *m. iliopsoas* and *m. vastus medialis* on the other, downward and medianward and finally through the *canalis adductorius* (O. T. Hunter's canal). It lies upon the deep layer of the fascia lata and is covered, from the inferior angle of the *trigonum femorale* on, by the *m. sartorius*. Above, it lies lateralward from the *v. femoralis*, further down, it lies in front of the same (see also Fig. 505). Branches:-

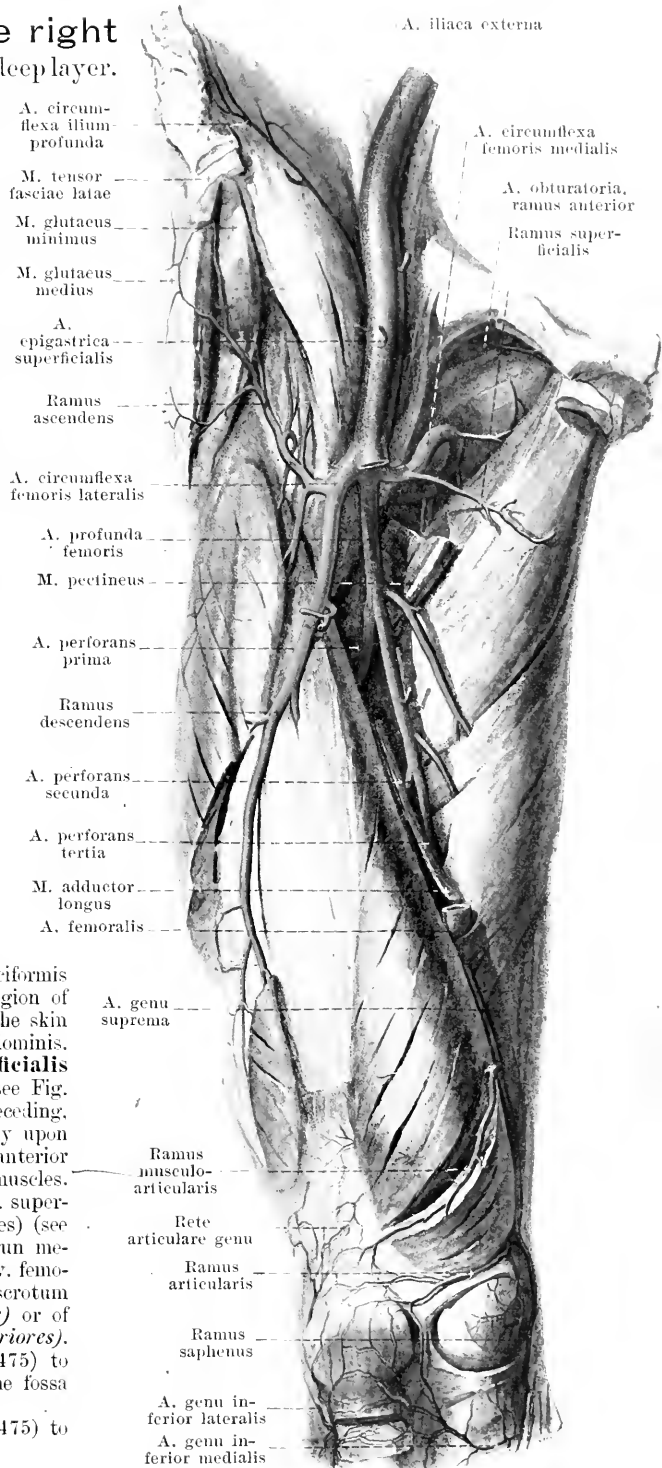
1) **A. epigastrica superficialis** (superficial epigastric artery) (see Fig. 475) arises just below the *lig. inguinale*, perforates the *margo falciformis* and runs upward as far as the region of the navel; it gives off branches to the skin and to the *m. obliquus externus abdominis*.

2) **A. circumflexa ilium superficialis** (superficial circumflex iliac artery) (see Fig. 475), frequently a branch of the preceding, goes lateralward, usually superficially upon the fascia lata, to the *spina iliaca anterior superior* and supplies the skin and muscles.

3) **Aa. pudendae externae** (O. T. superficial and deep external pudic arteries) (see Fig. 475), usually two in number, run medianward, in front of and behind the *v. femoralis*, to the anterior surface of the scrotum and penis (*aa. scrotales anteriores*) or of the labia majora (*aa. labiales anteriores*).

4) **Rami inguinales** (see Fig. 475) to the lymph glands and muscles of the fossa iliopectinea.

5) **Rami musculares** (see Fig. 475) to the neighboring muscles and skin.



477.

Arteries of the right thigh, viewed from behind.

(The m. gluteus maximus has been reflected inward, the mm. gluteus medius, quadratus femoris and caput longum m. bicipitis have been partially removed.)

6) **A. genu suprema** (O. T. anastomotica magna) (see Fig. 476) goes off in the canalis adductorius, perforates its anterior medial wall, runs downward between it and the m. sartorius behind the epicondylus medialis and finally accompanies the n. saphenus for a variable distance (*ramus saphenus*). It gives off *rami musculares*, as well as a *ramus musculo-articularis* (O. T. deep branch) in the m. vastus medialis and *rami articularis* (O. T. superficial branch) below the same to the rete articulare genu.

7) **A. profunda femoris** (O. T. profunda or deep femoral artery) (see also Figs. 475 and 476) arises in the fossa ilipectinea and descends behind the f. femoralis. It lies in front of the mm. iliopsoas, pectineus and adductor brevis, covered by the m. adductor longus, and ends as the a. perforans tertia. Branches:

a) **A. circumflexa femoris medialis** (O. T. internal circumflex artery) goes off near the origin and runs medianward behind the a. and v. femoralis. Branches:

aa) **Ramus superficialis**, in front of the m. pectineus, medianward between the mm. adductores longus and brevis.

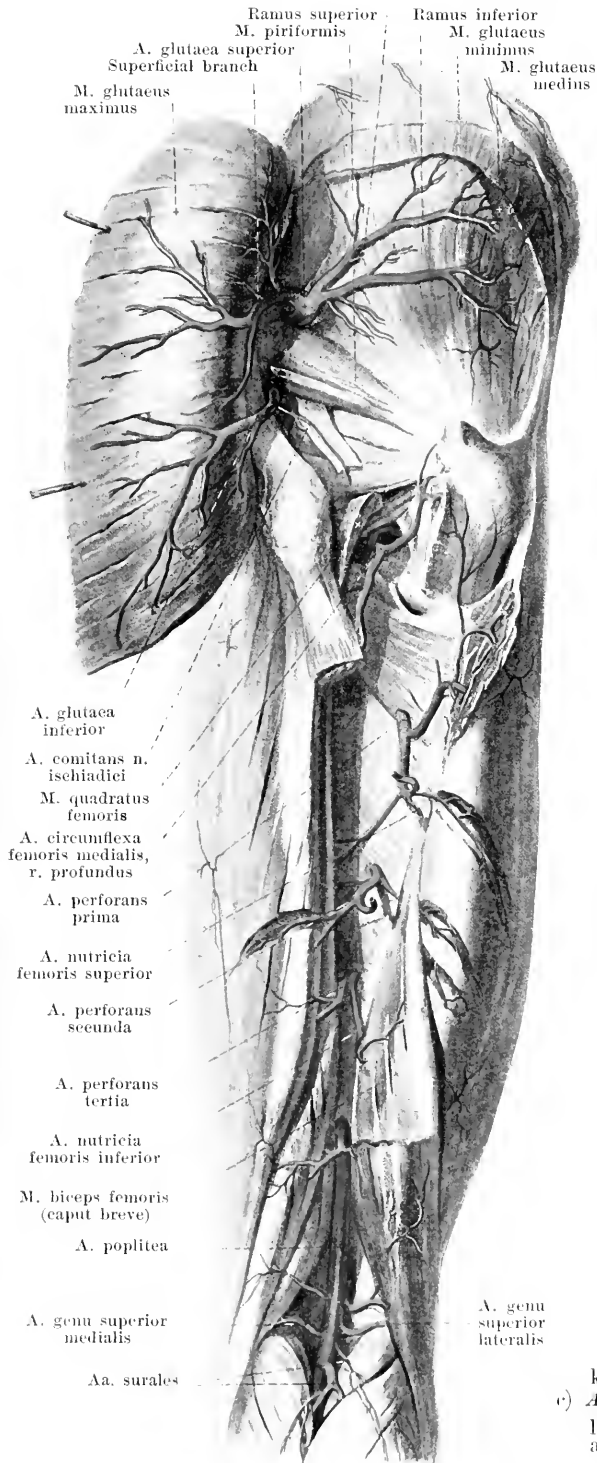
ab) **Ramus profundus**, a larger branch, bends upward, passes backward between the mm. iliopsoas and pectineus and, below the m. obturator externus, to the anterior surface of the m. quadratus femoris. It sends branches to the hip joint and divides into a branch ascending to the fossa trochanterica, and a branch descending behind the adductor muscles; it supplies the neighboring muscles and skin.

b) **A. circumflexa femoris lateralis** (O. T. external circumflex artery) lateralward in front of the m. iliacus. Branches:

ba) **Ramus ascendens**, goes upward and lateralward beneath the m. rectus femoris to the mm. glutei and tensor fasciae latae and to the fossa trochanterica.

bb) **Ramus descendens**, a larger branch, downward and lateralward beneath the m. rectus femoris between the mm. vasti intermedii and lateralis almost to the knee; it also gives off branches to the skin.

c) **A. perforans prima** (O. T. superior or first perforating artery) perforates the adductors at the lower margin of the m. pectineus:



478. Arteries of the right leg, viewed from behind.

(The muscles of the thigh with the exception of the *m. adductor magnus* have been completely removed; the *mm. gastrocnemius*, *plantaris*, *soleus* and *flexor hallucis longus* have been partially removed.)

- d) *A. perforans secunda* (see Figs. 476 and 477) perforates the adductors at the lower margin of the *m. adductor brevis*;
- e) *A. perforans tertia* (see Figs. 476 and 477) perforates them somewhat above the hiatus tendineus. All three *aa. perforans* supply the adductors and the muscles and skin of the posterior surface.

The *a. nutritia femoris* is usually single and given off by the *a. perforans II*; more rarely it is double (*superior* and *inferior*) and then comes from the *aa. perforans I* and *III*.

A. poplitea (popliteal artery) (see also Fig. 477) runs downward, from the end of the canalis adductorius on, upon the planum popliteum femoris, upon the capsula articularis of the knee joint, upon the posterior surface of the *m. popliteus* and in front of the tendinous arch between the origins of the *m. soleus* and divides just below the latter into the *a. tibialis posterior* and the *a. tibialis anterior*. In its course it is covered above by the *m. semimembranosus*; in the popliteal space, behind and somewhat lateralward, by the *v. poplitea* and (behind this) is overlapped by the *n. tibialis*; below, it is hidden beneath the *mm. gastrocnemius* and *plantaris*. Branches:

1) **A. genu superior lateralis** (O. T. superior external articular artery) (see also Fig. 479) goes, above the condylus lateralis femoris, directly upon the bone to the *rete articulare genu*.

2) **A. genu superior medialis** (O. T. superior internal articular artery), like the preceding, above the condylus medialis femoris.

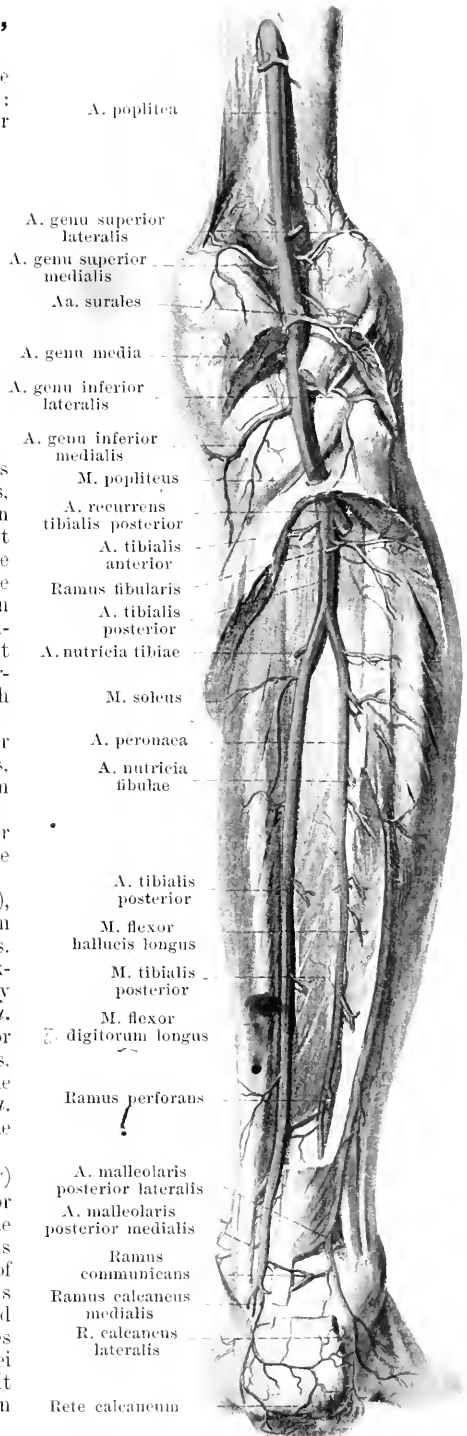
3) **A. genu media** (O. T. azygos articular artery), perforates the capsule above the lig. popliteum obliquum and goes to the ligg. cruciata and to the synovial folds.

4) **A. genu inferior lateralis** (O. T. inferior external articular artery) (see also Fig. 479) goes, directly upon the meniscus lateralis, to the *rete articulare genu*.

5) **A. genu inferior medialis** (O. T. inferior internal articular artery) (see also Fig. 476) goes, below the condylus medialis tibiae, covered by the lig. collaterale tibiale, to the *rete articulare genu*.

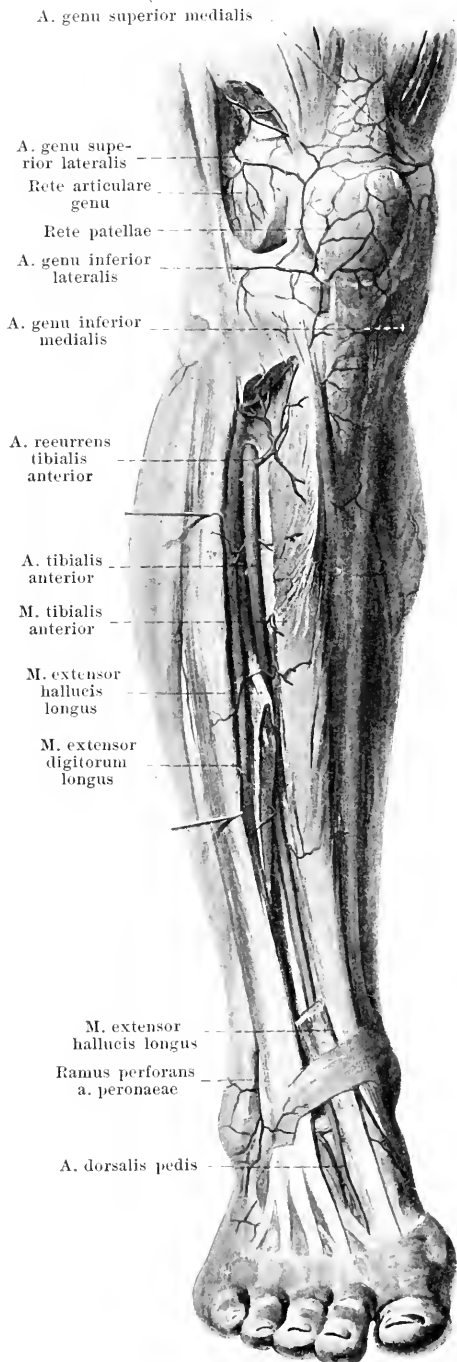
6) **Aa. surales**, several, sometimes from one trunk, to the *m. triceps surae* and to the skin.

A. tibialis posterior (posterior tibial artery) extends downward and medianward upon the posterior surface of the *m. tibialis posterior*, covered above by the *m. triceps surae* only, below by the *m. flexor hallucis longus* also. Below, it runs between the tendons of the *mm. flexor digitorum longus* and *flexor hallucis longus* upon the deep layer of the fascia cruris and of the lig. laciniatum, curved forward, and divides between the malleolus medialis and the tuber calcanei into the *aa. plantares medialis* and *lateralis*. It gives off branches to the muscles and to the skin and, in addition, the following:



479. Arteries of the right leg, viewed from in front.

(The *mm. tibialis anterior* and *extensor hallucis longus* have been partially removed.)



1) **Ramus fibularis** (see Fig. 478) extends lateralward toward the collum fibulae to the *mm. soleus* and *peroneus longus*.

2) **A. peronaea** (peroneal artery) (see Fig. 478) arises just below the collum fibulae and runs downward on the posterior surface of the *m. tibialis posterior*, between it and the *m. flexor hallucis longus*, near the fibula; below, it lies upon the posterior surface of the tibia or the *membrana interossea cruris* and breaks up behind the ankle joint into the *rami calcanei laterales* (O. T. external calcaneal arteries) which go to the *rete calcaneum* and its neighborhood. Numerous branches to the muscles, and further:

- a) **A. nutritia fibulae** (see Fig. 478) into the *canalis nutriticius fibulae*.
- b) **Ramus perforans** (O. T. anterior peroneal artery) (see also Figs. 478 and 480) perforates the *membrana interossea* just above the syndesmosis tibiofibularis, unites with the *a. malleolaris anterior lateralis* and helps to form the *rete malleolare laterale* and the *rete calcaneum*.
- c) **A. malleolaris posterior lateralis** (see Fig. 478), directly upon the fibula, to the *rete malleolare laterale*.
- d) **Ramus communicans** (see Fig. 478), upon the posterior surface of the tibia, just above the ankle joint, to the *a. tibialis posterior*.

3) **A. nutritia tibiae** (see Fig. 478) into the *canalis nutriticius tibiae*.

4) **A. malleolaris posterior medialis** (O. T. internal malleolar branch) (see Fig. 478), directly upon the tibia to the *rete malleolare mediale*.

5) **Rami calcanei mediales** (O. T. internal calcaneal branches) (see Figs. 478 and 481) form, with the *rami calcanei laterales*, the *rete calcaneum*, which is situated superficially upon the *tuber calcanei*, as well as upon the surrounding muscles and tendons.

A. tibialis anterior (anterior tibial artery) goes forward above the *membrana interossea cruris* and directly downward upon its anterior surface. Above, it lies between the *m. tibialis anterior* and the *m. extensor digitorum longus*; below, between the former muscle and the *m. extensor hallucis longus*. Farther down, it is situated upon the anterior surface of the tibia and of the capsule of the upper joint of the ankle, as well as behind the *m. extensor hallucis longus* and behind the deep layer of the *lig. cruciatum* and there becomes continuous with the *a. dorsalis pedis*. It gives off numerous branches to the muscles and skin, and further:

1) **A. recurrens tibialis posterior** (posterior tibial recurrent artery) (see Fig. 478) which comes off at the beginning of the artery, extends, behind the fibula, to the *articulatio tibiofibularis*. It is often absent.

2) **A. recurrens tibialis anterior** (anterior tibial recurrent artery) upward, upon the anterior surface of the *condylus lateralis tibiae*, to the *rete articulare genu*, which is spread out partly upon the bones and ligaments of the knee joint, partly upon the tendon of the *m. quadriceps femoris*, upon the *lig. patellae* and upon the *patella* itself (*rete patellae*).

480. Arteries of the back of the right foot.

3. *A. malleolaris anterior lateralis*

(O. T. external malleolar artery) to the malleolus lateralis, unites with the ramus perforans of the *a. peronea* and helps to form the *rete malleolare laterale* upon the lateral malleolus and its neighborhood.

4. *A. malleolaris anterior medialis*

(O. T. internal malleolar artery) goes to the malleolus medialis and helps to form the *rete malleolare mediale*, situated there.

A. dorsalis pedis (see also Fig.

469) extends forward, upon the ligaments and bones of the back of the foot, between the mm. extensor hallucis longus and extensor hallucis brevis and breaks up between the proximal ends of the ossa metatarsalia I and II into the *ramus plantaris profundus* and the *a. metatarsa dorsalis I*. Branches:

1. **Aa. tarseae mediales** (O. T. internal tarsal artery), 2—3, run upon the bones and ligaments to the medial border of the foot and help to form the *rete malleolare mediale*.

2. **A. tarsea lateralis** (O. T. external tarsal artery) lateralward and forward upon the bones and ligaments, covered by the m. extensor digitorum brevis, toward the basis ossis metatarsalis V, unites there with the lateral end of the *a. arcuata*. Branches which anastomose with one another and, with branches of the *a. dorsalis pedis* and *a. arcuata*, form the *rete dorsale pedis*.

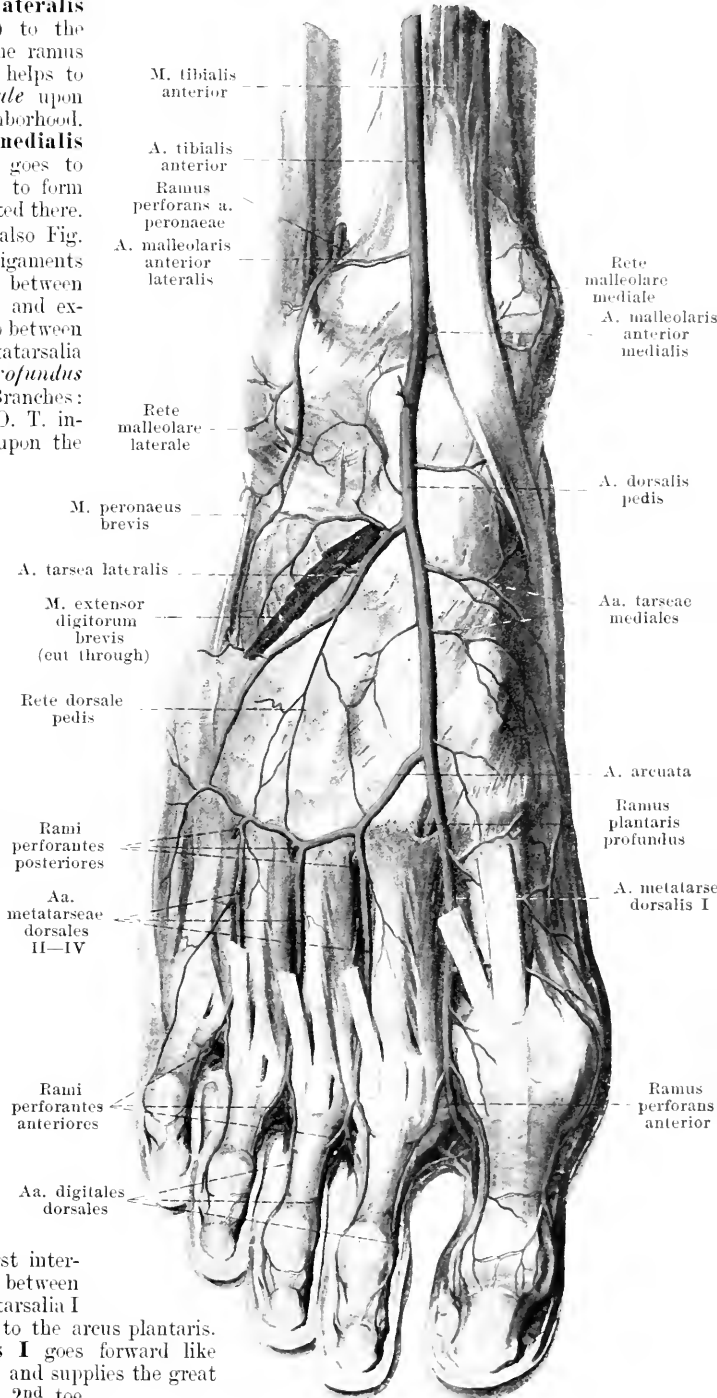
3. **A. arcuata** (O. T. metatarsal artery) lateralward directly upon the proximal ends of the ossa metatarsalia unites with the *a. tarsea lateralis*. Branches:

a) **Aa. metatarsae dorsales II to IV** (O. T. tarsal interosseous arteries) run forward upon the 2nd—4th m. interosseus dorsalis and each divides into two *aa. digitales dorsales* (dorsal digital arteries) behaving just as do the arteries to the fingers. Larger *rami perforantes posteriores* and smaller, inconstant *anteriores* between the bases (or between the heads) of the ossa metatarsalia, to go to the *aa. metatarsae plantares*.

4. **Ramus plantaris profundus**

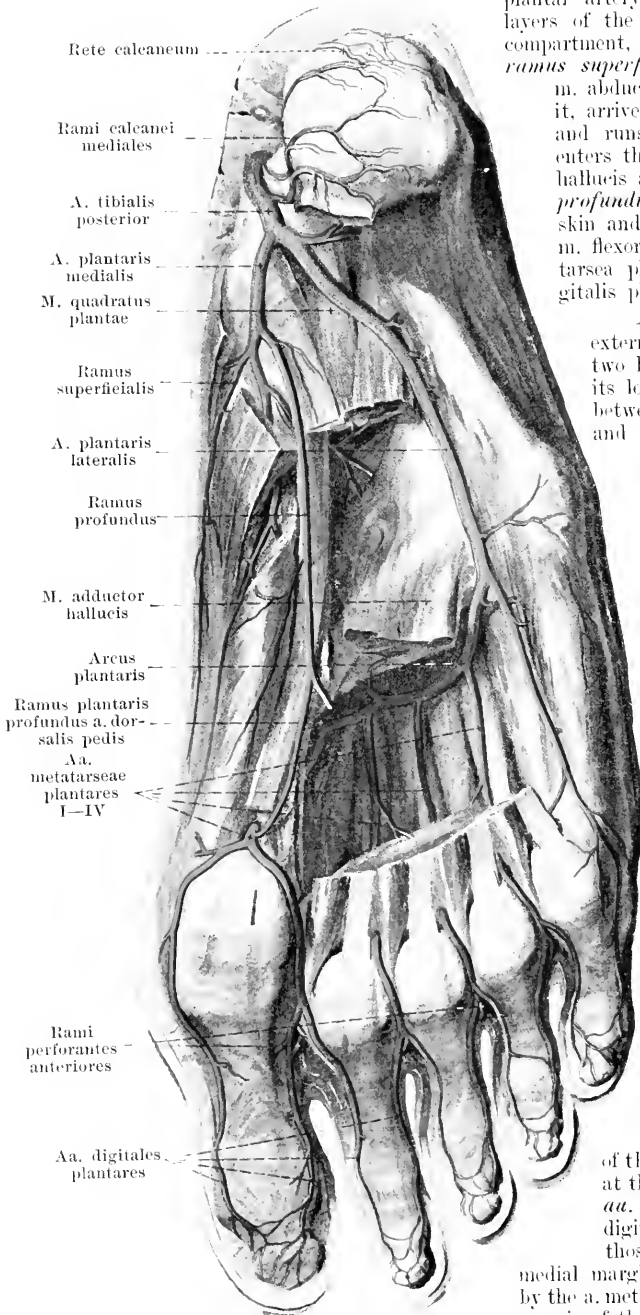
(O. T. communicating, first interosseus perforating or plantar artery) between the proximal ends of the ossa metatarsalia I and II, into the sole of the foot, to the *arcus plantaris*.

5. **A. metatarsa dorsalis I** goes forward like the other *aa. metatarsae dorsales* and supplies the great toe and the medial surface of the 2nd toe.



481. Arteries of the sole of the right foot.

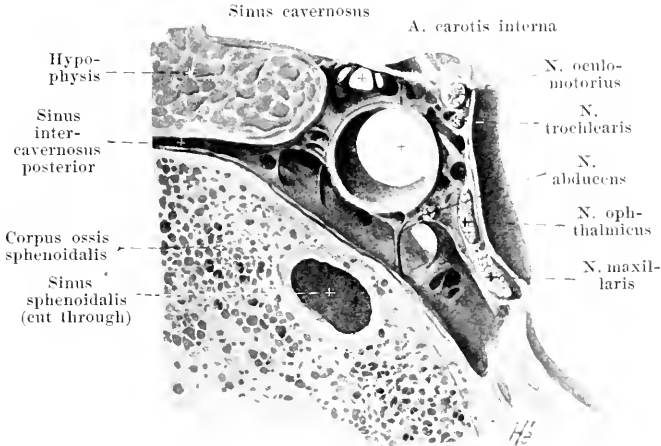
(The muscles have, for the most part, been removed.)



A. plantaris medialis (O. T. internal plantar artery) goes forward, between the two layers of the lig. laciniatum (through its upper compartment, see p. 361), and there gives off the *ramus superficialis*, which passes through the m. abductor hallucis, giving off branches to it, arrives at the medial margin of the foot and runs as far as the great toe. It then enters the groove between the mm. abductor hallucis and flexor digitorum brevis (*ramus profundus*), supplies these muscles and the skin and goes, between the two bellies of the m. flexor hallucis brevis, into the a. metatarsa plantaris I or into the medial a. digitalis plantaris of the great toe.

A. plantaris lateralis (O. T. external plantar artery) runs, between the two layers of the lig. laciniatum (through its lower compartment see p. 361), then between the mm. flexor digitorum brevis and quadratus plantae, forward and lateralward towards the basis ossis metatarsalis V; there it lies more superficially, between the mm. quadratus plantae and flexor digiti V and bends around medianward into the arcus plantaris. It gives off branches to the neighboring bones, ligaments, muscles and skin.

The **arcus plantaris** lies directly beneath the proximal ends of the 2nd to the 4th metacarpal bone and beneath the mm. interossei, between them and the caput obliquum of the m. adductor hallucis, being more superficial lateralward than medianward. It diminishes in calibre from the lateral toward the medial margin of the foot, arises, lateralward, directly from the a. plantaris lateralis and unites medianward, between the ossa metatarsalia I and II, with the ramus plantaris profundus of the a. dorsalis pedis. It gives off recurrent branches to the bones and muscles; running forward from it are the 4 *aa. metatarsae plantares* (O. T. digital or plantar digital arteries). Each of these passes forward between two metacarpal bones, receives the rami perforantes of the aa. metatarsae dorsales and divides at the bases of the first phalanges into the *aa. digitales plantares* (O. T. collateral digital arteries), which behave just as do those to the fingers. The artery for the medial margin of the great toe is usually given off by the a. metatarsa plantaris I; that for the lateral margin of the little toe arises usually as a separate artery from the end of the a. plantaris lateralis.



482. Frontal section through the right sinus cavernosus, viewed from behind. Magnification 5:2.

The **sinus durae matris** (*sinuses of the dura mater*) are venous canals which run, chiefly, between the separated layers of the dura mater and lie at the same time in corresponding bony grooves. They stand open on section and are devoid of valves; the sinus sagittalis superior and cavernosus are crossed in a network-like manner by bands of connective tissue. They receive the *vv. cerebri, meningeae, diploicae* (partially), *auditiuae internae* and the *v. ophthalmicae*.

1. **Sinus transversus** (O. T. lateral sinus) (see Figs. 483 and 484), paired, collects most of the blood from the skull cavity. It begins on each side at the protuberantia occipitalis interna, communicating with that of the other side by an opening of variable size; it is usually larger on the right than on the left side and runs curved lateralward in the sulcus transversus of the occipital bone and of the parietal bone, in the attached margin of the tentorium cerebelli. Thence, it goes tortuous medianward and downward, in the sulcus sigmoideus of the temporal bone and in the sulcus transversus of the pars lateralis oss. occipitalis, to the foramen jugulare to become continuous there with the upper end of the *v. jugularis interna*. In the region of the tentorium cerebelli it is triangular-prismatic in shape, elsewhere semi-cylindrical.

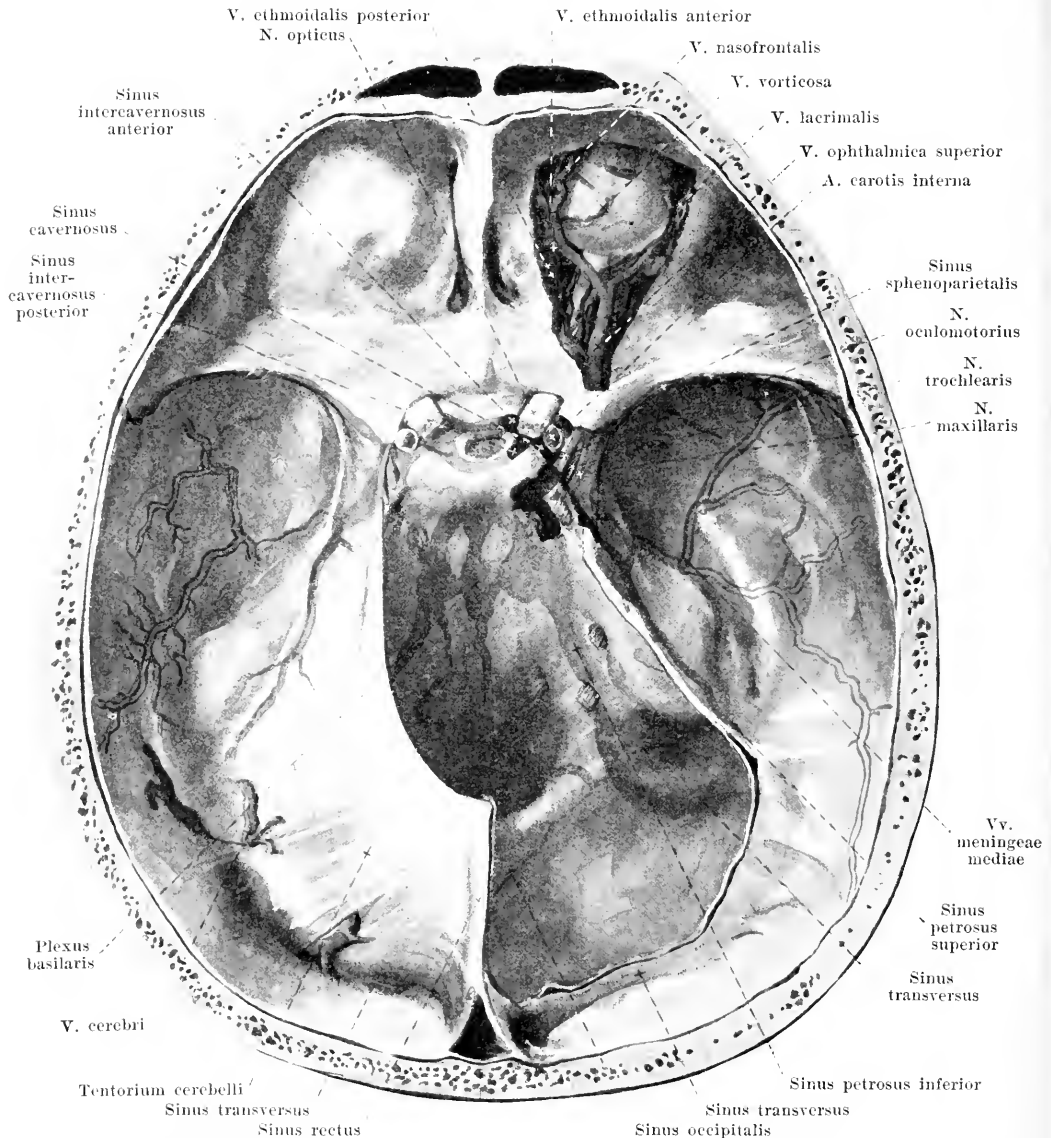
2. **Sinus sagittalis superior** (O. T. superior longitudinal sinus) (see Figs. 483 and 484), unpaired, extends from before backward, in a curve, in the attached margin of the falx cerebri near the crista frontalis and in the sulcus sagittalis of the frontal bone, of the parietal bones and of the occipital bone and opens into the sinus transversus (usually into the right). It is triangular in transverse section. The sinus anastomoses with the following.

3. **Sinus sagittalis inferior** (O. T. inferior longitudinal sinus) (see Figs. 483 and 484), unpaired, from before backward in the free margin of the falx cerebri into the sinus rectus.

4. **Sinus rectus** (straight sinus) (see Figs. 483 and 484), unpaired, goes as a triangular canal, at the point of attachment of the falx cerebri to the tentorium cerebelli, from in front and above, backward and downward and opens into the sinus transversus (usually into the left).

5. **Sinus occipitalis** (see Figs. 483 and 484), unpaired or paired, begins at the protuberantia occipitalis interna and goes downward, close to the median plane, in the attached margin of the falx cerebelli. Above, it begins at the spot where the sinus transversus, the sinus sagittalis superior and the sinus rectus meet (*confluentium sinuum*). Below, it bifurcates, turns lateralward and forward on both sides above the foramen occipitale magnum and enters the sinus transversus, close to the foramen jugulare. It anastomoses with the plexus venosi vertebrales interni and varies much in the degree of its development.

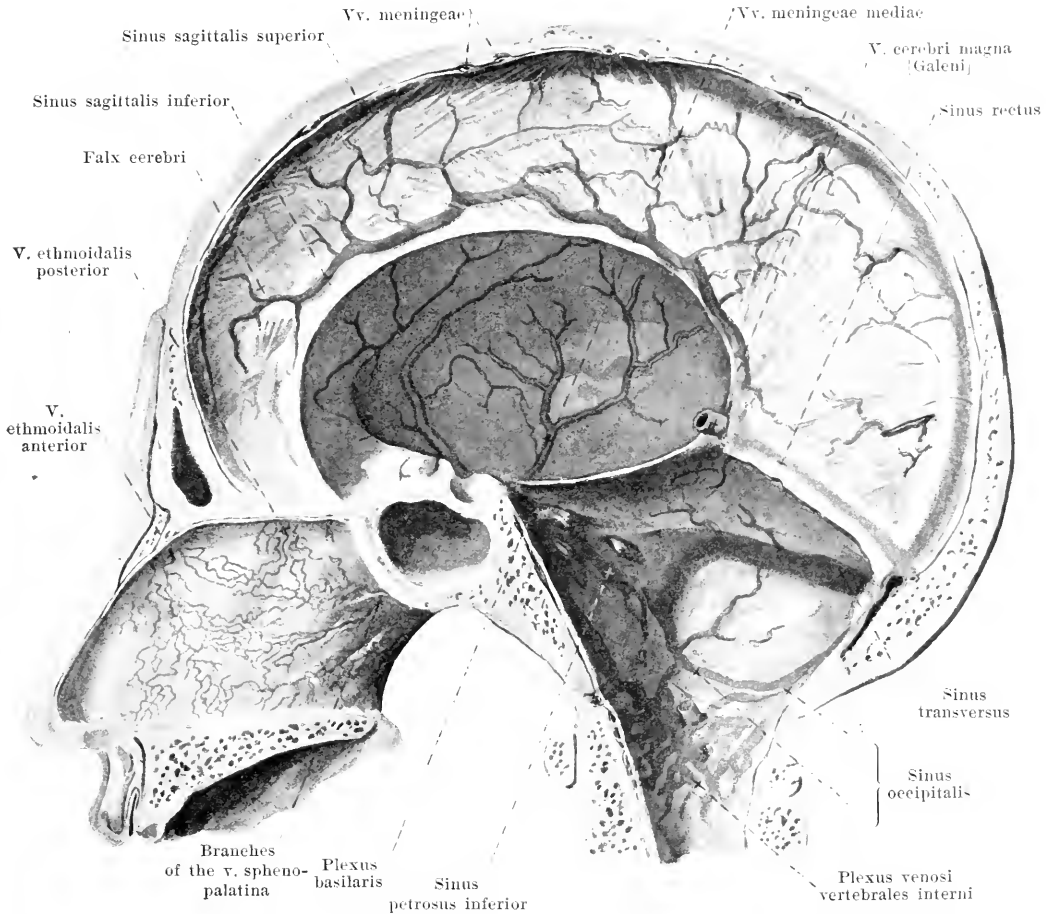
6. **Sinus cavernosus** (see also Figs. 442, 483 and 484), paired, is an irregular space, which is situated, on each side, near the sella turcica and the corpus oss. sphenoidalis. It is bounded above and lateralward by that part of the dura mater which is stretched out between the proc. clinoides anterior and the dorsum sellae and the apex of the pyramis oss. temporalis and goes over into the tentorium cerebelli; it surrounds, in addition, the *a. carotis interna*, the *n. abducens* and the *plexus caroticus internus*. Tributaries:



483. Sinus durae matris, viewed from above.

(The right orbit and sinus cavernosus have been opened; the tentorium has been cut away.)

- a) *V. ophthalmica superior* (superior ophthalmic vein) (see also Fig. 488), devoid of valves, corresponds only approximately to the *a. ophthalmica*, which possesses, in addition, two delicate accompanying veins. It anastomoses freely above the *lig. palpebrale mediale* by its anterior extremity (*v. nasofrontalis*) (see Figs. 487 and 488) with the *v. angularis* (of the *v. facialis anterior*), runs backward near the *m. obliquus superior*, then lateralward between the *n. opticus* and the *m. rectus superior*, finally backward through the *fissura orbitalis superior* into the *sinus cavernosus*. Medianward, it sends an anastomosis to the *v. ophthalmica inferior*. It receives the *vv. ethmoidales anterior et posterior*, *v. lacrimalis*, *vv. musculares* and the veins of the *bulbus oculi* and of the eyelids (see Sense Organs: the *v. centralis retinae* opens into the *sinus cavernosus*).

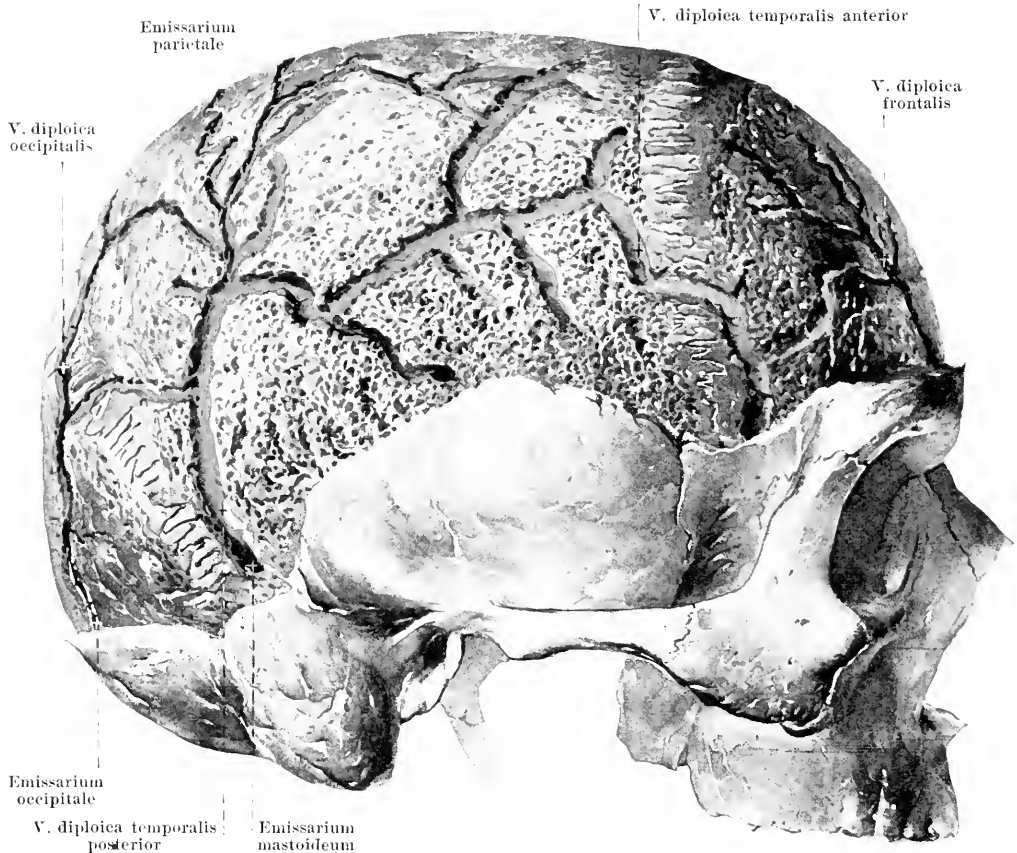


484. Sinus durae matris of the right half of the skull, viewed from the left.

- b) *V. ophthalmica inferior* (see Fig. 485), devoid of valves, arises from the veins of the tear-sac, of the eyelids, &c., in the anterior part of the orbit, between the medial and inferior wall; it runs in the inferior part of the orbit and divides into two branches. One branch goes backward through the fissura orbitalis superior into the sinus cavernosus; the other passes lateralward through the fissura orbitalis inferior and opens into the ramus profundus of the *v. facialis anterior*. It receives *vv. musculares* and veins of the bulbus oculi and anastomoses medianward with the *v. ophthalmica superior*.
- c) *Sinus sphenoparietalis* (see Fig. 483), paired, begins on each side a little behind the sutura coronalis on the parietal bone in a bony groove or in a bony canal, turns medianward beneath the ala parva ossis sphenoidalis and enters the anterior end of the sinus cavernosus. It receives usually one *v. meningea media*, *vv. cerebri inferiores* (from the fissura cerebri lateralis [Sylvii]), as well as the *v. ophthalmomeningea*, and often, also, the *v. diploica temporalis anterior*.

7. and 8. **Sinus intercavernosus anterior** and **sinus intercavernosus posterior** (see Fig. 483), unpaired, run in front of, behind and partly also beneath the hypophysis and unite the two sinus transversus with each other. They form, with these, the **sinus circularis**.

9. **Sinus petrosus superior** (superior petrosal sinus) (see Fig. 483), paired, goes lateralward and backward on each side, from the posterior part of the sinus cavernosus in the sulcus petrosus superior of the temporal bone and in the attached margin of the tentorium cerebelli, to the sulcus sigmoideus and into the sinus transversus.



485. Venae diploicae, viewed from the right.

(The lamina externa of the roof of the skull has been filed off.)

10. **Sinus petrosus inferior** (inferior petrosal sinus) (see Figs. 483 and 484), paired, extends lateralward and downward on each side from the posterior, inferior portion of the sinus cavernosus in the sulcus petrosus inferior of the occipital and temporal bones to the foramen jugulare and runs downward through its most anterior subdivision; it opens, either in the foramen jugulare or below it, into the bulbus v. jugularis superior.

11. **Plexus basilaris** (see Figs. 483 and 484), unpaired, lies as a plexus upon the clivus and is connected above, on both sides, with the sinus cavernosus and the sinus petrosus inferior, below, at the foramen occipitale magnum, with the plexus venosi vertebrales interni.

Vv. cerebri collect the blood partly from the surface, partly from the interior of the brain and open into sinus durae matris (see Neurology); they possess no valves.

Vv. meningeae (see Figs. 483 and 484), stand open, are devoid of valves, are numerous in the dura mater encephali, are connected above with the sinus sagittalis superior and anastomose manifoldly with one another. They accompany the stems of the corresponding arteries, there being usually two veins to one artery, and open into a neighboring sinus. The *vv. meningeae mediae*, usually two in number, run near the a. meningea media, are connected with the sinus sphenoparietalis and the rete foraminis ovalis, extend downward through the foramen spinosum and open into the plexus pterygoideus.

Vv. auditivae internae (not illustrated) come from the internal ear through the meatus acusticus internus and open into the sinus transversus or the sinus petrosus inferior.

Venae diploicae (see Fig. 485) are thin-walled tubes, which lie in the flat *canales diploici* [*Brescheti*] in the substance of the bones of the roof of the skull. They have no valves: they are arranged in the form of a network and are very variable. The main stems run from above downward and are connected at their extremities by openings (*emissaria*) with the external veins of the skull or with the sinus durae matris or (usually) with both at the same time.

- 1) *V. diploica frontalis* opens into the v. supraorbitalis and the sinus sagittalis superior.
- 2) *V. diploica temporalis anterior* into a v. temporalis profunda and the sinus sphenoparietalis.
- 3) *V. diploica temporalis posterior* (O. T. external parietal or posterior temporal diploic vein) extends from the emissarium parietale to the emissarium mastoideum.
- 4) *V. diploica occipitalis* opens into the emissarium occipitale.

Emissarium parietale, in the foramen parietale, unites the sinus sagittalis superior with the superficial veins of the skull; its valves permit a flow in an outward direction only.

Emissarium mastoideum, in the foramen mastoideum, unites the sinus transversus with the v. auricularis posterior or with the v. occipitalis or with the beginning of the v. jugularis externa.

Emissarium occipitale, at the level of the protuberantiae occipitales, opens usually either internally into a sinus transversus or into the confluens sinuum or externally into the v. occipitalis, often into both.

Emissarium condyloideum (not illustrated), in the canalis condyloideus, unites the sinus transversus and the plexus venosi vertebrales externi.

Plexus venosus caroticus internus (see Fig. 442) surrounds the a. carotis interna in the canalis caroticus in the form of a network, is connected above with the sinus cavernosus, receives veins from the cavum tympani and opens below into the v. jugularis interna.

Rete foraminis ovalis (not illustrated) in the foramen ovale from the sinus cavernosus to the plexus pterygoideus; it is often connected above with the vv. meningee mediae.

Rete canalis hypoglossi (not illustrated) in the canalis hypoglossi from the sinus occipitalis and from the plexus venosi vertebrales interni to the sinus petrosus inferior.

Vena cava superior (see Figs. 411, 427, 486 and 495), unpaired, free from valves, arises behind the first right costal cartilage by the union of the **vv. anonymae dextra et sinistra** and extends downward, and curved moderately convex toward the right, in front of the root of the right lung and of the right side of the aorta ascendens, to the right atrium. It is bounded in front by the thymus and on the right by the right lung; it is covered above on its right side by the pleura mediastinalis, below by the visceral layer of the pericardium. In the upper part of its course the *v. azygos* (see p. 456) opens into it from behind.

V. anonyma (O. T. innominate vein) (see also Figs. 427, 486 and 495) is formed behind the articulatio sternoclavicularis and in front of the a. subclavia by the union of the **v. jugularis interna**, **v. subclavia** and **v. jugularis externa**; the latter opens usually into the v. subclavia. The right vein is bounded on the right by the right lung and runs vertically downward; the left, distinctly longer, extends to the right and downward, behind the manubrium sterni and the thymus, directly over the arcus aortae, in front of the aa. subclavia sinistra, carotis communis sinistra and anonyma. Both veins are devoid of valves. Branches:

1. **Vv. thyroideae inferiores** (inferior thyreoid veins) (see Fig. 486) from the *plexus thyreoides impar*. This lies partly in front of the lower margin of the isthmus glandulae thyroideae, in part it surrounds the beginning of the trachea like a ring; it anastomoses with the vv. thyroideae superiores of both sides and receives, behind, the *vv. tracheales*, the *vv. oesophageae* and the *v. laryngea inferior* (corresponding to the arteries of the same names). Three veins usually go off from the plexus: a right vein opens at the angle of junction of the v. anonymae or into the v. anonyma dextra or into the v. jugularis interna dextra, a left vein into the v. anonyma sinistra and a *v. thyroidea ima*, running downward in front of the trachea, into the v. anonyma sinistra.

2. **V. mammaria interna** (internal mammary vein) (see Figs. 313 and 486) corresponds almost exactly to the artery of the same name. Arising from the union of the 2 *vv. epigastricae superiores* (rich in valves) and the *vv. musculophrenicae* it is double in the region of the m. transversus thoracis; above the latter it is single and situated medial from the artery. It receives (with the vv. musculophrenicae) the anterior extremities of the 9 (—10) superior *vv. intercostales* (see p. 455), which have valves at their mouths, further the *rami perforantes*, which have valves (especially marked in the 1st or 2nd intercostal space), as well as *rami sternales* from the networks which are situated upon both surfaces of the sternum, and in which there are several large transverse connections between the trunks of the two sides, sometimes especially one such on the anterior surface of the processus xiphoideus.

3. **Vv. phrenicae superiores** (not illustrated), possess valves, are double, and correspond to the a. pericardiacophrenica.

4. **Vv. thymicae, pericardiacae, mediastinales anteriores, bronchiales anteriores** (not illustrated) from the viscera of the thorax, open separately or partially in common.

5. **V. vertebralis** (see Fig. 488) corresponds to the cervical part of the a. vertebralis, on the lateral side of which it extends downward from the foramen magnum through the foramina transversaria of the 1st—6th (often —7th) cervical vertebra. It begins in the plexus venosi vertebrales, anastomoses with the v. occipitalis and receives branches from the spinal canal, from the deep muscles of the neck and from the plexus vertebrales externi. It stands open and has valves at its mouth. Branch:

- a) **V. cervicalis profunda** (see Fig. 486) corresponds approximately to the a. cervicalis profunda, begins near the back of the head in the plexus vertebralis posterior and runs downward behind or in front of the m. semispinalis cervicis; it goes forward beneath the proc. transversus of the 7th cervical vertebra into the v. vertebralis. There are valves at its mouth.

V. jugularis interna (internal jugular vein) (see also Fig. 489) corresponds together with the v. jugularis externa to the a. carotis communis. It arises as the direct continuation of the sinus transversus in the lateral compartment of the foramen jugulare with a swelling, the *bulbus v. jugularis superior*, above runs downward behind the a. carotis interna on the lateral wall of the pharynx, becomes displaced gradually to the lateral side first of the a. carotis interna, then of the a. carotis communis and extends downward, close to the latter, to the v. anonyma. A little above its termination it presents a spindle-shaped dilatation, the *bulbus v. jugularis inferior*, which is closed above by a single or double valve. Otherwise it is devoid of valves. Branches:

1. **Sinus durae matris** see pp. 441—444.

2. **V. canaliculi cochleae** (not illustrated) comes from the cochlea (see Organ of Hearing) through the canaliculus cochleae and opens into the bulbus v. jugularis superior.

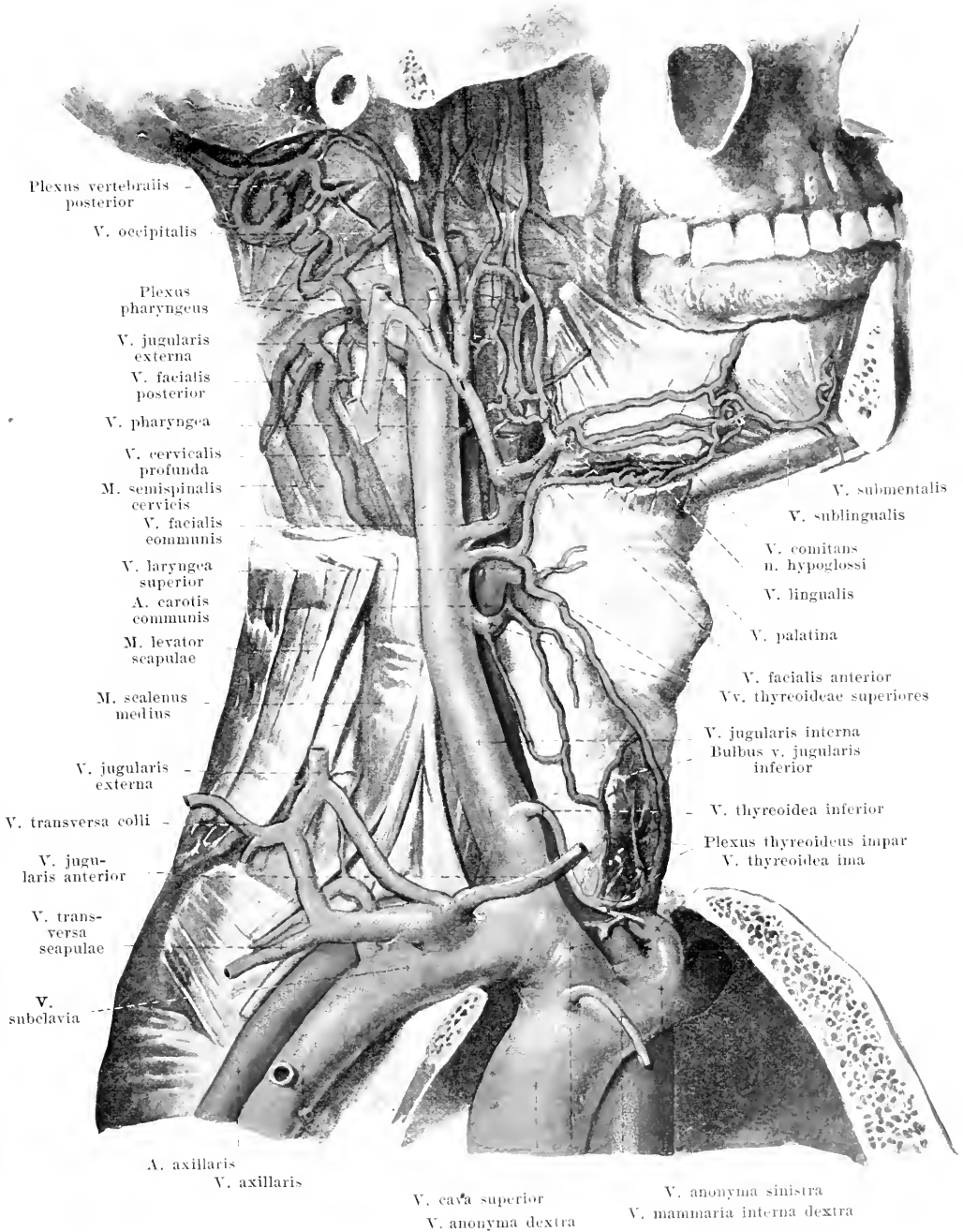
3. **Vv. pharyngeae** vary in number and come at different levels from the *plexus pharyngeus* which covers the outer surface of the pharynx and receives branches from the deep muscles of the pharynx, from the tuba auditiva, the palate and the dura mater (*v. meningea*, corresponding to the a. meningea posterior), as well as the *v. canalis pterygoidei* [Vidii] (from the canalis pterygoideus); it is connected with the neighboring veins. The inferior vv. pharyngeae may open also into other branches of the v. jugularis interna. They are all devoid of valves.

4. **V. lingualis** (lingual vein) (see also Fig. 489) runs backward at first exactly as does the a. lingualis, later, however, on the lateral surface of the m. hyoglossus; it receives a large *v. sublingualis* and the *vv. dorsales linguae*. The a. lingualis is accompanied medial from the m. hyoglossus by small veins, which together with the *v. comitans n. hypoglossi* open into the v. lingualis. All branches of the lingual vein possess valves; the vein communicates with the vv. pharyngeae and the v. thyroidea superior; it opens sometimes into a v. facialis.

5. **Vv. thyroideae superiores** (superior thyroid veins) (see also Fig. 489), usually two, accompanying the artery only in part: one opens far below, the other above, in the neighborhood of the a. thyroidea superior. The latter receives a *v. sternocleidomastoidea* and the *v. laryngea superior* (corresponding to the a. laryngea superior), which may also open into the v. facialis communis, and frequently the whole vein opens into the v. facialis communis. These veins possess valves.

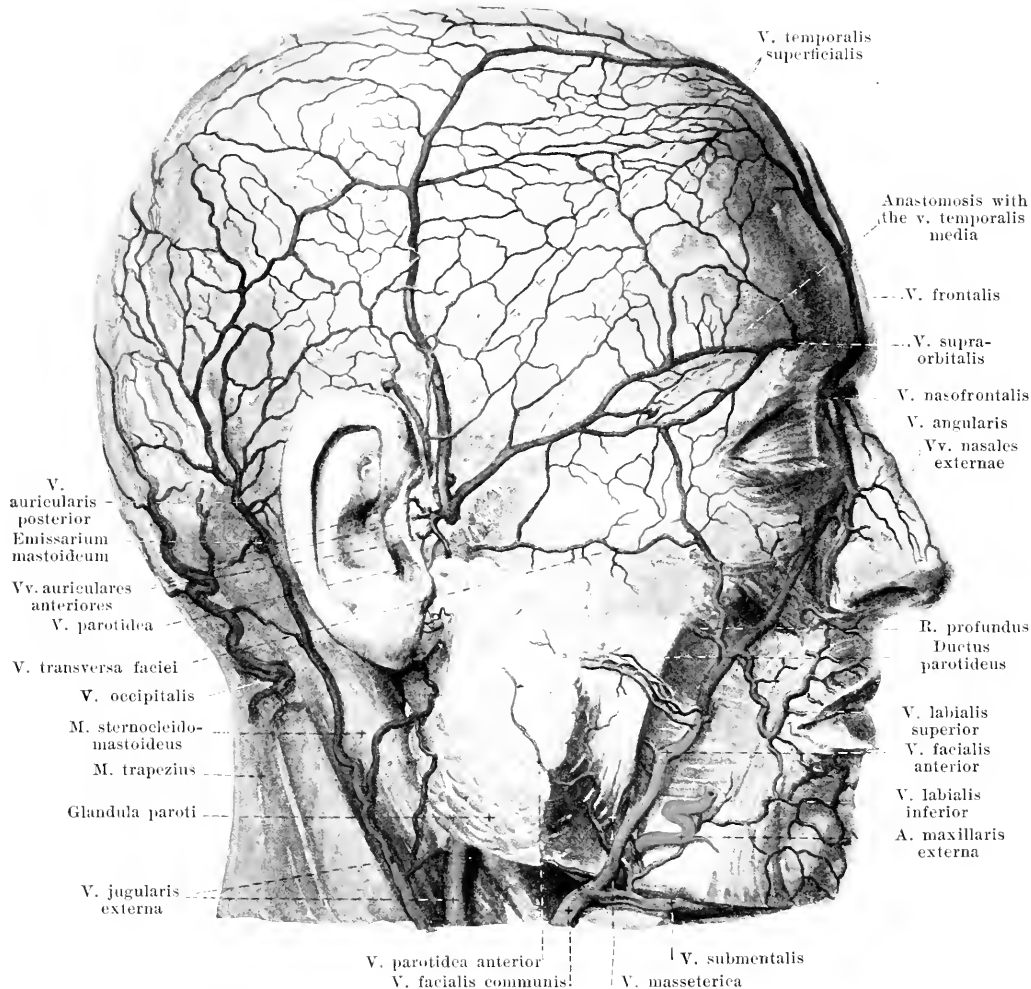
6. **V. facialis communis** (see also Figs. 488 and 489) arises beneath the angle of the lower jaw, from the *vv. faciales anterior* and *posterior*, which may also open separately into the v. jugularis interna. It runs downward and backward, covered only by the platysma, crosses the a. carotis externa and terminates at the level of the hyoid bone. It has no valves. Branches:

- a) **V. facialis anterior** (see also Figs. 487—489) corresponds in its course to that of the a. maxillaris externa, which itself possesses in addition two small accompanying veins; it is a little tortuous and runs usually behind the artery and in part more superficially, covered only by the m. zygomaticus and platysma, from the root of the nose to the angle of the lower jaw. It arises superficially at the medial angle of the eye as the *v. angularis*, formed by the *vv. frontalis* (usually unpaired, and then very frequently opening into the left v. angularis), *supraorbitalis* (runs transversely medianward partly beneath the m. orbicularis oculi over the margo supraorbitalis, anastomoses with the vv. temporales superficialis and media) and *nasofrontalis* (see p. 442); in front of the root of the nose it forms a broad union with the vein of the other side. Above, it receives further: the *vv. palpebrales superiores, nasales externae, palpebrales inferiores* and *labialis superior*, besides the *ramus profundus*; this is formed in the fossa infratemporalis by the *vv. alveolares superiores* (corresponding to the arteries of the same name) and by branches of the plexus pterygoideus, and receives one branch of the v. ophthalmica inferior; it runs forward upon the facies infratemporalis maxillae and terminates below the arcus zygomaticus. Farther down enter the *v. labialis inferior*, *vv. massetericae* and *vv. parotideae anteriores*. Beneath the lower jaw it receives further the large *v. submental*, which is connected with the v. sublingualis and v. jugularis anterior as well as one *v. palatina*, which corresponds to the a. palatina ascendens. All the branches of the vein possess efficient valves at their mouths; the main trunk also contains such valves at the level of the ductus parotideus.



486. Deep veins of the neck, viewed from the right.

(The muscles of the neck and face have been in large part removed; the bones of the face have been partially removed.)

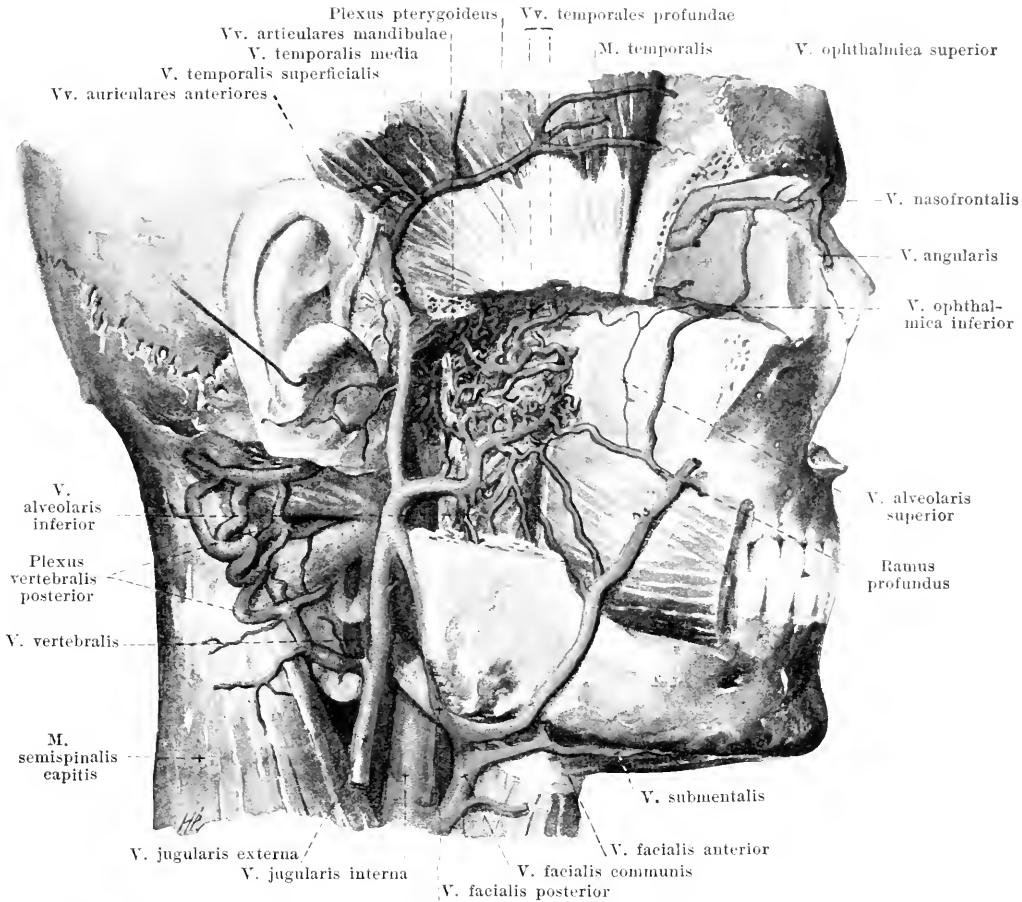


487. Superficial veins of the face, viewed from the right.

(With partial use of a preparation by W. Braune.)

(Below the zygoma, the subcutaneous fat and a part of the muscles have been removed.)

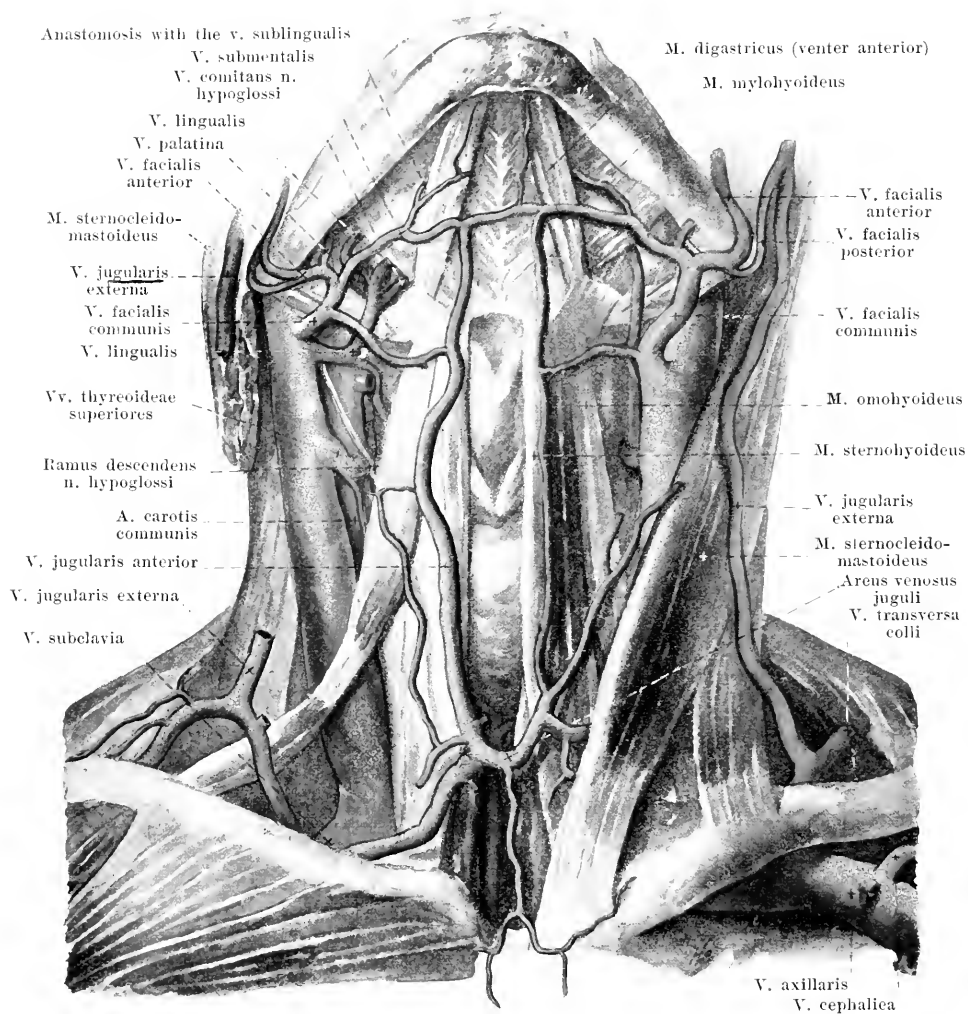
- b) *V. facialis posterior* (see also Figs. 486 and 488) arises superficially in front of the ear through the union of the vv. temporales, runs downward in the substance of the glandula parotis behind the ramus mandibulae and lateral from the carotis externa and bends obliquely forward below the angulus mandibulae, over or under the m. digastricus, to the v. facialis communis. It gives off a large branch at a variable level to the v. jugularis externa. It receives:
- ba) *V. temporalis superficialis*, from the superficial plexus of the roof of the skull, runs downward behind the trunk of the artery. It possesses a valve in front of the ear.
- bb) *V. temporalis media* runs transversely backward, deviating from the artery, in the m. temporalis, anastomoses at the lateral angle of the eye with the superficial veins, in the muscle with the vv. temporales profundae and perforates the fascia temporalis over the root of the zygoma. It possesses valves.
- bc) *Vv. auriculares anteriores*, from the lateral surface of the external ear.
- bd) *Vv. parotideae posteriores*, from the glandula parotis.



488. Deep veins of the face, viewed from the right.

(The bones and muscles have been removed as in Fig. 438.)

- be) *Vv. articulares mandibulae*, from a plexus surrounding the joint of the jaw, which also receives the *vv. tympanicæ* (not illustrated) (through the fissura petrotympanica [Glaseri] from the middle ear) and veins from the external auditory passage and drum membrane and is connected with the plexus pterygoideus.
- bf) *V. stylomastoidea* (not illustrated), corresponding to the artery of the same name, anastomoses at the hiatus canalis facialis with the *vv. meningeæ mediae*.
- bg) *V. transversa faciei* (transverse facial vein), frequently double, corresponds to the artery of the same name.
- bh) *Plexus pterygoideus* extends from the fossa pterygopalatina as far as the collum mandibulae and lies, with wider vessels, on both sides of the *m. pterygoideus externus*, with narrower vessels, also on the medial surface of the *m. pterygoideus internus* and on the membranous wall of the tuba auditiva; it forms a sheath for the *a. maxillaris interna*. It receives: the *v. sphenopalatina* (from the nasal cavity through the foramen sphenopalatinum), the *vv. meningeæ mediae* (see p. 444), the *vv. temporales profundæ* (from the *m. temporalis*, in which it forms a plexus with branches of the *v. temporalis media*), the *vv. massetericæ*, *v. alveolaris inferior* (the latter two corresponding to the arteries of the same names) and the *rete foraminis ovalis* (see p. 445). It anastomoses with the *vv. articulares mandibulae* and with the plexus pharyngeus and empties in part through the ramus profundus *v. facialis anterioris*, especially however through two valve-bearing vessels, which accompany the *a. maxillaris interna*, into the *v. facialis posterior*.



489. Veins of the neck, viewed from in front.

(On the right the *m. sternocleidomastoideus*, on the left the *m. pectoralis major*, has been removed.)

V. jugularis externa (external jugular vein) (see also Figs. 486—488) arises below the ear by two roots; the anterior, frequently the larger, comes from the *v. facialis posterior* (see p. 448), the posterior arises behind the ear. It crosses the *m. sternocleidomastoideus* obliquely, covered by the *platysma*, goes into the depth and opens usually into the *v. subclavia*, generally with the *v. jugularis anterior*. Valves at its mouth and in its middle. Branches:

1. **V. occipitalis** corresponds to the artery. It opens partly into the preceding vein, partly doubled, accompanies the artery to the *v. jugularis interna*; it anastomoses with the *plexus vertebralis posterior*.

2. **V. auricularis posterior** from the superficial plexus behind the ear.

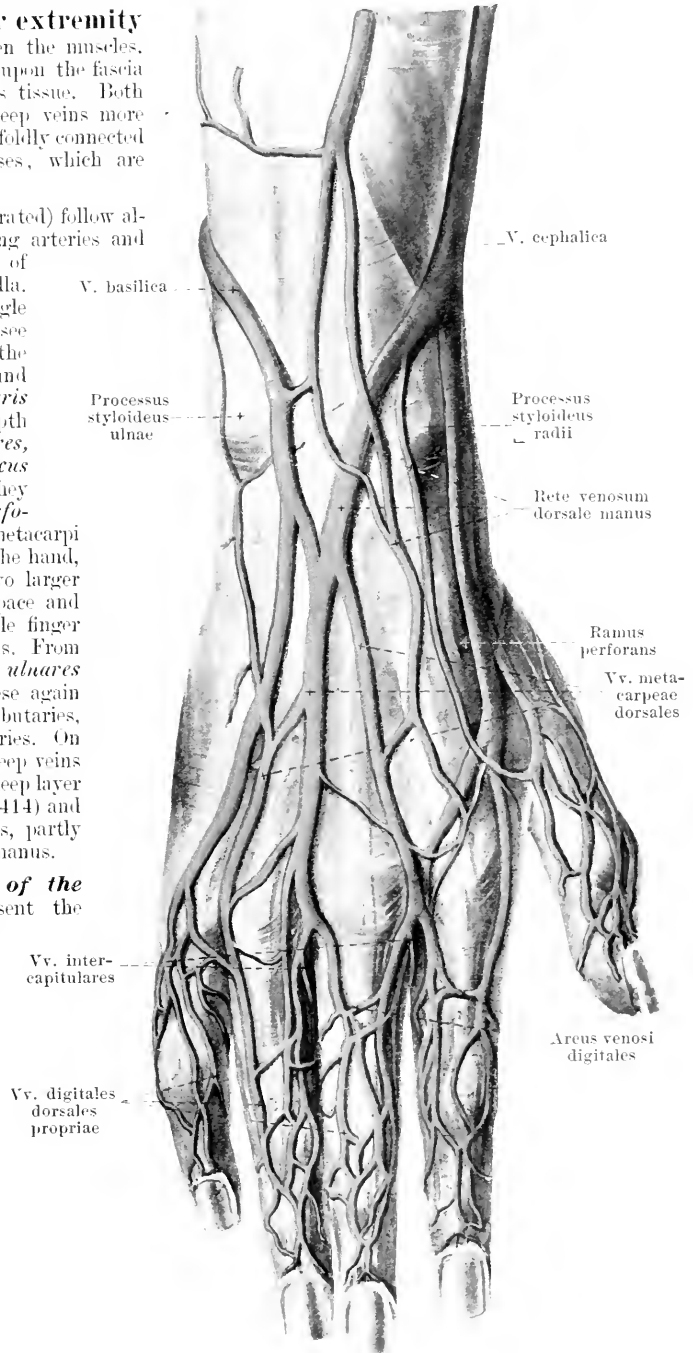
3. **V. jugularis anterior**, downward from the chin upon the *mm. mylohyoideus* and *sternohyoideus*, extends lateralward below the origins of the *m. sternocleidomastoideus* to the *v. jugularis externa* or the *v. subclavia*. It anastomoses with the adjacent veins, and, by the large *arcus venosus juguli*, below the *glandula thyroidea* with the vein of the opposite side. More rarely instead of this vein only an unpaired median trunk (*v. mediana colli*) is present.

490. Superficial veins of the back of the right hand. (Partly after W. Braune.)

The **veins of the upper extremity** run partly in the depth between the muscles, partly in plexuses, superficially, upon the fascia superficialis, in the subcutaneous tissue. Both possess numerous valves, the deep veins more than the superficial, and are manifoldly connected with one another by anastomoses, which are devoid of valves.

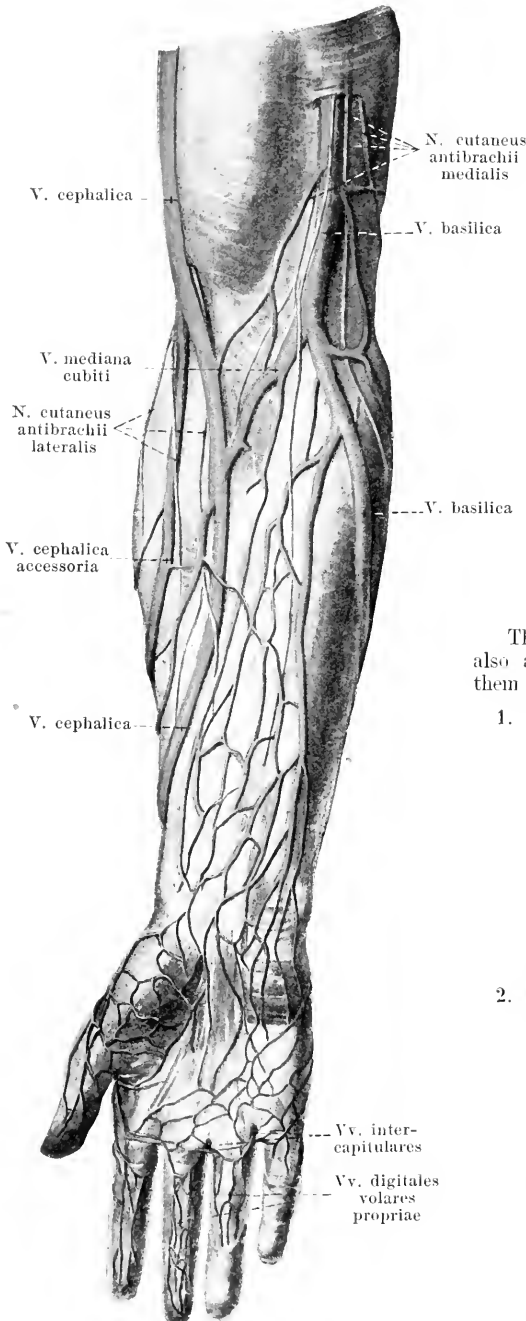
The **deep veins** (not illustrated) follow almost exclusively the corresponding arteries and are double, with the exception of those in the fingers and in the axilla. In the **palm** they begin as single *vv. digitales volares propriae* (see Fig. 491), which unite to form the *vv. digitales volares communes* and go into the double *arcus volaris venosus superficialis*. In the depth run the *vv. metacarpeae volares*, which open into the double *arcus volaris venosus profundus*; they send in addition several *rami perforantes* into the spatia interossea metacarpi to the deep veins of the back of the hand, several smaller and regularly two larger veins into the 1st metacarpal space and through the muscles of the little finger to the rete venosum dorsale manus. From the palmar arch arise the *vv. ulnares* and *vv. radiales* and from these again the *vv. brachiales* with their tributaries, corresponding exactly to the arteries. On the **back of the hand** the deep veins accompany, as small vessels, the deep layer of the rete carpi dorsale (see p. 414) and empty partly into the *vv. radiales*, partly into the rete venosum dorsale manus.

The **superficial veins of the back of the hand** represent the chief canals of outflow for the skin. They begin upon the phalanges of the fingers in a plexus, which permits of the recognition of longitudinal trunks, *vv. digitales dorsales propriae*, and each terminates on the first phalanx in the *arcus venosus digitalis* which is concave proximalward. From the union of every pair of these arches, arise four larger *vv. metacarpeae dorsales*; these form the *rete venosum dorsale manus*, the meshes of which are elongated in the direction of the long axis of the limb.



491. Superficial veins of the right forearm, viewed from in front.

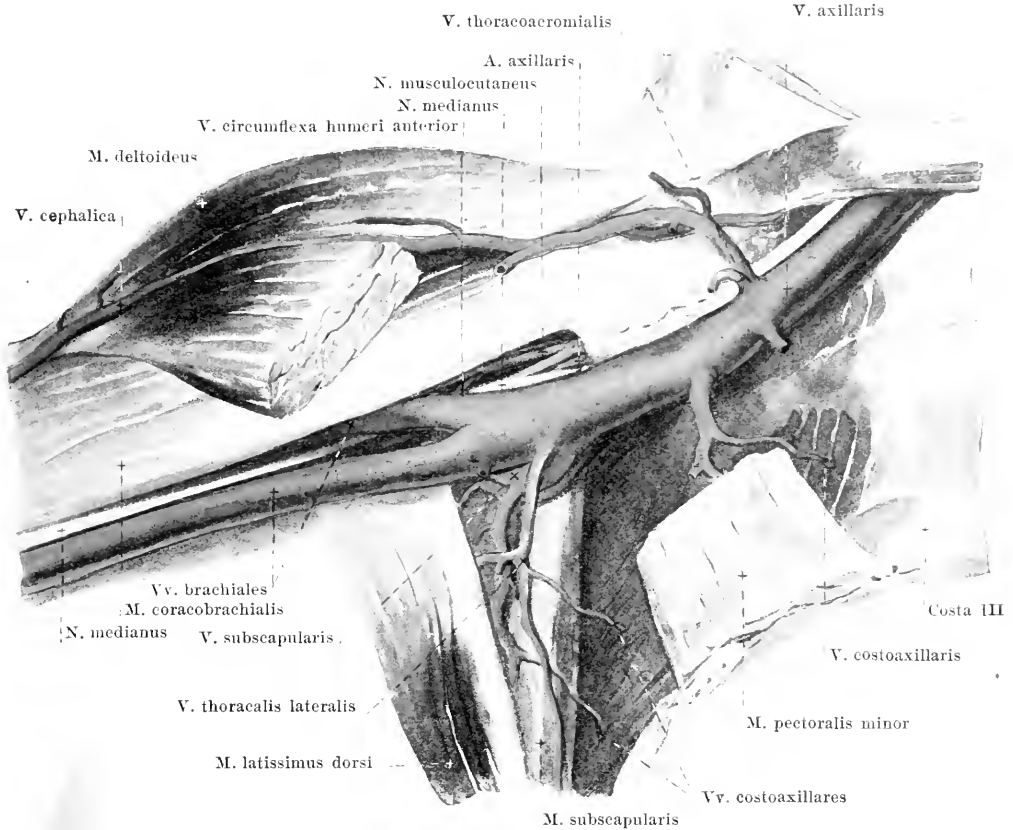
(Palm after W. Braune.)



The **superficial veins of the palm** are much finer than those of the back of the hand. They begin upon the phalanges in a plexus in which one can make out more or less distinctly the *vv. digitales volares propriae* and out of which most of the blood is conducted to the posterior surface through several vessels at the lateral margins of the fingers. Similarly the *vv. intercapitulares* (see also Fig. 490) conduct blood into the spaces between the fingers from the volar to the dorsal vessels. The superficial network of the palm lies upon the aponeurosis palmaris and upon the fascia of the thenar and hypothenar eminences; in the latter two places the network is somewhat closer. Proximalward it goes over into the plexus in the forearm.

The **superficial veins of the forearm** are also arranged in the form of a plexus. Among them two are usually very distinct:

1. *V. basilica* (see also Fig. 490) begins upon the back of the hand, frequently as the continuation of the *v. metacarpea dorsalis IV*, loops around the ulnar side of the forearm to its volar surface and runs on this as far as the elbow, then in the sulcus bicipitalis medialis along the upper arm as far as its middle third. There it perforates the fascia, goes still some distance upward and unites sooner or later with one of the (more delicate) *vv. brachiales*.
2. *V. cephalica* (see also Fig. 490) arises on the back of the hand, often especially from the *v. metacarpea dorsalis I*, winds around the radial side of the forearm to its volar surface and extends on this as far as the elbow; thence it goes upward in the sulcus bicipitalis lateralis and (in a duplicature of the fascia brachii) in the groove between the *mn. pectoralis major* and *deltoideus*, sinks into the depth just below the clavicle and after union with a *v. thoracoacromialis* empties into the *v. axillaris* (see also Fig. 492). Sometimes a second longitudinal vessel is situated lateralward on the forearm, the *v. cephalica accessoria*, which opens into the main vein.



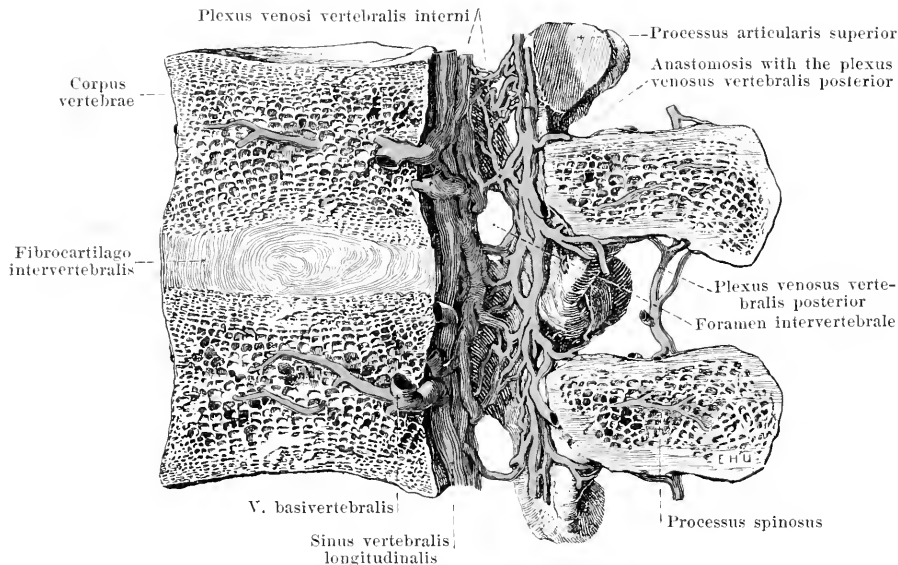
492. Veins of the right axilla, viewed from in front.

(Arrangement as in Fig. 451.)

- 3) *V. mediana cubiti* (see Fig. 491) is a connecting branch, which usually leads obliquely upward in the flexure of the elbow from the *v. cephalica* to the *v. basilica* and, lateralward from the *lacertus fibrosus*, anastomoses freely with the deep veins.

In other cases (not illustrated) a vein (*v. mediana antibrachii*) goes upward upon the middle of the volar surface of the forearm, bifurcates in the flexure of the elbow and goes partly to the *v. basilica* (as a *v. mediana basilica*), partly to the *v. cephalica* (as *v. mediana cephalica*). There is always, however, even then, free anastomosis with the deep veins of the elbow.

V. axillaris (*axillary vein*) (see also Fig. 456) arises usually at the lower margin of the *m. pectoralis major* by the union of the two *vv. brachiales* and extends as far as the clavicle on the medial and anterior surface of the artery, which is also accompanied directly by small veins. Its branches correspond to those of the artery. The **v. thoracalis lateralis** receives the **v. thoracopigastica** (see Fig. 504), which extends subcutaneously upward from the *v. femoralis* or from the *v. epigastrica superficialis* on the anterior and lateral surface of the trunk. Into this or into the neighboring veins empty the **vv. costoaxillares**, which, in the upper 6–7 intercostal spaces, carry the blood from the middle portions of the *vv. intercostales* (see p. 455) to the axilla. The *v. axillaris* and its branches are richly provided with valves.

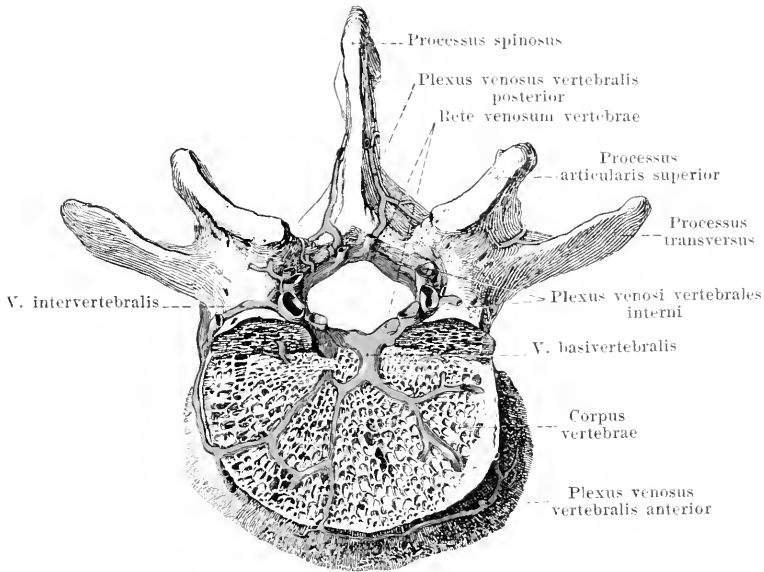


493. Spinal veins, seen in a median section, viewed from the left.

V. subclavia (subclavian vein) (see Fig. 486) is the name of the continuation of the *v. axillaris* from the lower margin of the *m. subclavius* on. It accompanies the *a. subclavia* on its anterior and inferior surface and crosses the first rib in front of the *m. scalenus anterior*. Behind the articulation sternoclavicularis it helps to form the *v. anonyma*. It has valves at its beginning and at its termination. In addition to it some small veins directly accompany the *a. subclavia*. Tributaries (besides the *v. jugularis externa*):

1. and 2. **V. transversa scapulae** and **v. transversa colli** (see Figs. 486 and 489) near the corresponding arteries, unite usually to form one stem, which frequently opens into the *v. jugularis externa*. They carry valves at their mouths.

Veins of the spinal column. In the *canalis vertebralis*, between the two layers of the *dura mater spinalis*, lie close venous plexuses, **plexus venosi vertebralis interni**, the tributaries of which come partly from the vertebrae, partly from the spinal cord. These plexuses (see also Fig. 494) extend chiefly in the longitudinal direction from the *foramen occipitale magnum* to almost as far as the tip of the sacrum and permit the recognition of four trunks, two anterior and two posterior. The *anterior* lie upon the posterior surface of the bodies of the vertebrae and of the intervertebral disks on each side lateral from the *lig. longitudinale posterius*; they consist of several large veins, running very close together, which anastomose manifoldly with one another, possess a lumen which stands open especially in the cervical and thoracic part and are accordingly also called the *sinus vertebralis longitudinales*. The *posterior* plexuses are situated on both sides on the anterior surface of the *arcus vertebrarum* and of the *ligamenta flava* and anastomose through spaces in the latter with the *plexus externi posteriores*; they are more delicate and less numerous and form more irregular, wider networks. The anterior plexuses are united with one another on the posterior surface of each vertebral body by transverse trunks, which run between the *periosteum* and the *lig. longitudinale posterius* and there receive the *vv. basivertebralis*. The latter (see also Fig. 494) extend radially in the vertebral body toward the middle of the posterior surface and open there in common or separately, being provided at the mouth with valves; in front they anastomose through the bones with the *plexus externi anteriores*. The posterior plexuses are connected with one another by branches arranged in the form of a network; with the anterior they are connected by numerous shorter vessels which are present especially on the medial side of each *radix arcus vertebrae* and leave free only the upper part of the *foramen intervertebrale*. Through the connecting branches of the different plexuses with one another arise the more or less distinct vascular rings, *retia venosa vertebrarum*, one at the level of each vertebra. The upper end of the plexus surrounds the *foramen occipitale magnum* like a wreath (see Fig. 484), is connected with the *sinus occipitalis*, *plexus basilaris* and *rete canalis hypoglossi* and empties into the *v. vertebralis*. In the *canalis sacralis* the vessels become smaller, the plexuses become looser and empty through the *foramina sacralia* into the *vv. sacrales*.



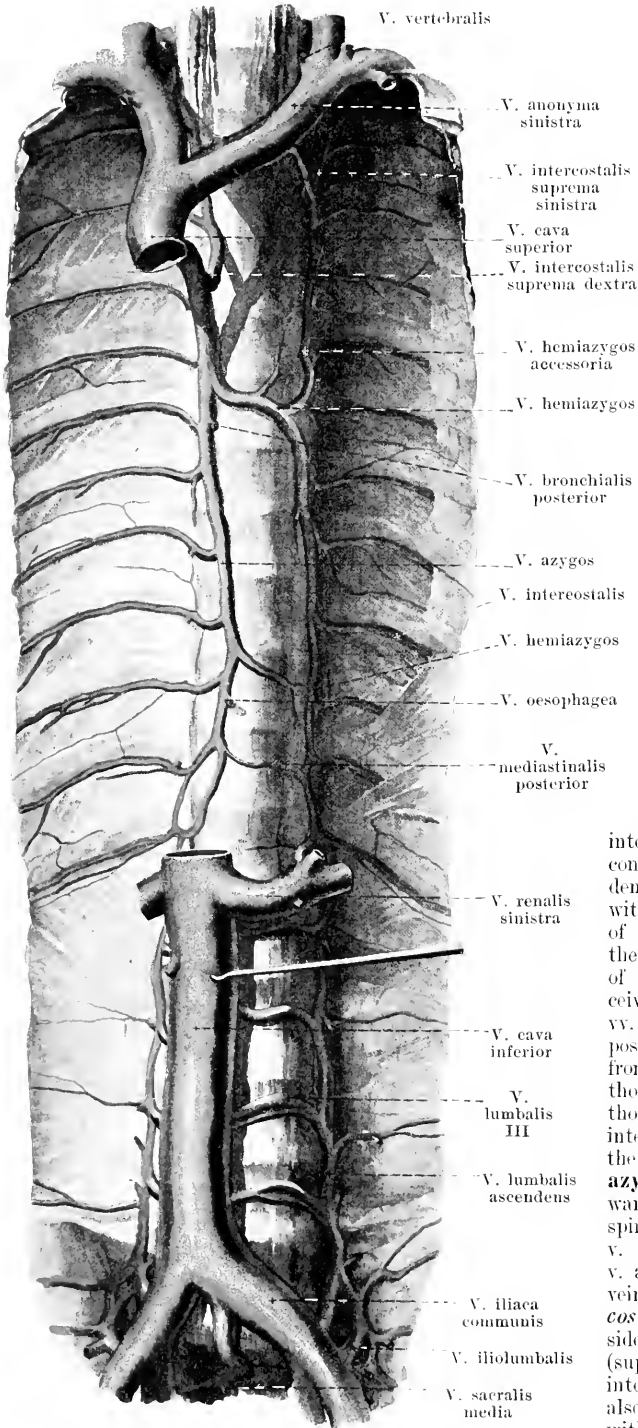
494. Spinal veins in a horizontal section, viewed from above.

(Only the body of the vertebra has been cut through.)

Plexus venosi vertebrales externi (see also Fig. 493) lie on the external surface of the spinal column and are divisible into anterior, smaller plexuses and posterior, larger plexuses. The *plexus venosi vertebrales anteriores* are best developed in the cervical spine and there lie upon the bodies of the vertebrae and upon the *mm. longi capitis et colli*; they receive tributaries from the muscles and from the bodies of the vertebrae and are connected lateralward with the *vv. intervertebrales* and with the following plexuses. The *plexus venosi vertebrales posteriores* lie in part directly upon the posterior surface of the vertebral arches, processes and ligaments, in part between the short muscles of the back. They are best developed in the cervical portion (see also Figs. 486 and 488) and are connected there especially with the *v. occipitalis*, *v. vertebralis* and *v. cervicalis profunda*; besides, they anastomose through spaces in the ligamenta flava with the plexus interni and unite in front with the plexus anteriores and with the *vv. intervertebrales*.

Vv. intervertebrales accompany the *mm. spinales* in the foramina intervertebralia and lie chiefly in plexuses on their anterior surfaces. They receive the *vv. spinuales* (from the spinal cord), which bear valves at their openings and are connected with the plexus vertebrales interni and externi representing their channels of outflow; they have valves where they terminate in the neck in the *v. vertebralis*, or in the trunk in the *vv. intercostales*, *lumbales* or *sacrales laterales*.

The ***vv. intercostales*** (see Fig. 495), situated usually singly at the lower margin of a rib in the sulcus costae, close to and above the artery, increase evenly in diameter from above downward. The upper 9 (—10) form venous circles which empty their contents partly sternalward into the *vv. mammaria interna* and *musculophrenicae* (see p. 445), partly vertebralward into the system of the *v. azygos*; at their mouths they carry valves correspondingly directed; from their middle portions they send off branches in the 1st—6th (or 7th) intercostal spaces to the axilla (*vv. costoaaxillares*) (see p. 453). The lower 2—3 *vv. intercostales* have no outflow forward and receive tributaries, supplied with valves, from the diaphragm and from the abdominal muscles. Veins of smaller diameter and inconstant in length are to be found also at the upper margin of each rib; they are manifestly connected with the others. Each *v. intercostalis* receives a *ramus posterior* near the bodies of the vertebrae, which is larger than it is itself and which runs near the *ramus posterior* of the *a. intercostalis*; into this flow tributary vessels from the skin and from the muscles of the back, as well as the *ramus spinalis*, which, as a continuation of the *vv. intervertebrales* (*vide supra*), collects the blood from the spinal column and its contents.



495. Vena azygos, viewed from in front.

(The diaphragm and the lumbar muscles have been removed.)

V. azygos, unpaired, begins as a continuation of the *v. lumbalis ascendens dextra* (see p. 460), between the right *crus mediale* and *crus intermedium* of the diaphragm, ascends in the *spatium mediastinale posterius* on the right side of the vertebral bodies, and in its course lies in front of the *aa. intercostales*, to the right of the *aorta thoracalis* and of the *ductus thoracicus* and behind the *oesophagus*. At the level of the 5th or 4th thoracic vertebra it bends forward over the root of the right lung and opens into the *v. cava superior* (see also Figs. 427 and 628). In this latter portion of its course it usually possesses valves, which, however, are not efficient. It receives the nine lowermost *vv. intercostales* of the right side, as well as the *vv. oesophageae*, *vv. bronchiales posteriores* and *vv. mediastinales posteriores* (from the corresponding organs) (not illustrated), besides the **v. hemiazygos**. The latter (see also Fig. 629) begins, unpaired, between the left *crus mediale* and *crus*

intermedium of the diaphragm as the continuation of the *v. lumbalis ascendens sinistra*, but is also connected with the *v. renalis sinistra*. Devoid of valves, it extends upward, behind the *aorta thoracalis*, on the left side of the bodies of the vertebrae, receives several *vv. intercostales sinistralae*, *vv. oesophageae* and *vv. mediastinales posteriores*, and bends to the right in front of one of the inferior or middle thoracic vertebrae behind the *ductus thoracicus* to go to the *v. azygos*. The intercostal veins, next higher up on the left side, empty into a **v. hemiazygos accessoria**, which goes downward on the left side of the thoracic spine and empties either into the *v. hemiazygos* or directly into the *v. azygos*. The 3—4 upper intercostal veins open on each side into a *v. intercostalis suprema*, which on the right side usually opens into the *v. azygos* (supplied with valves), on the left side into the *v. hemiazygos*, but in addition also communicates above on each side with the *v. anonyma*.

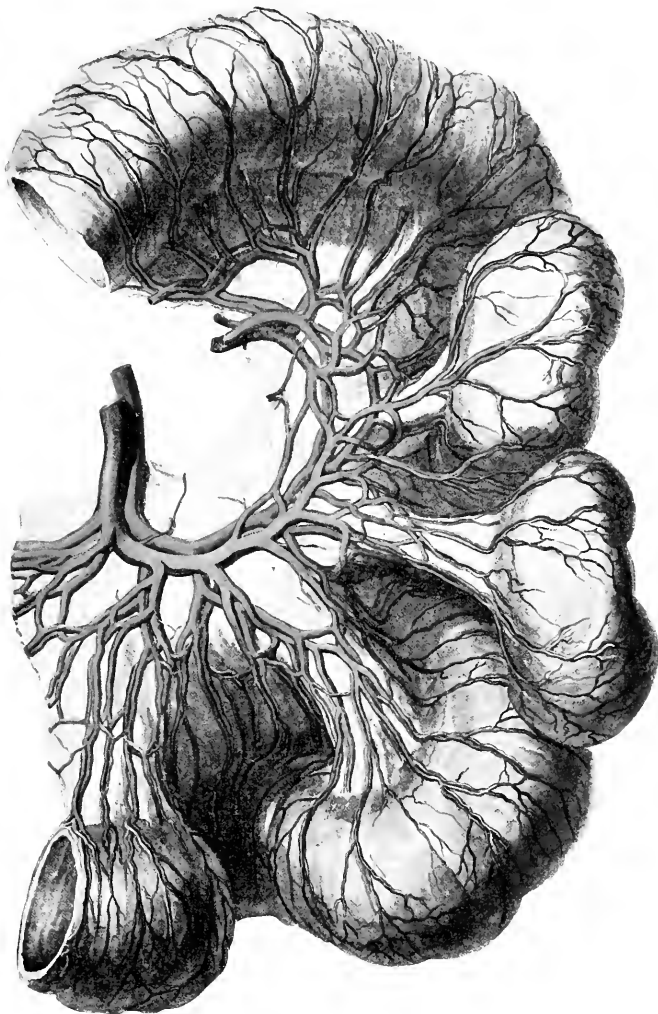
496. Arteries and veins of a piece of small intestine.

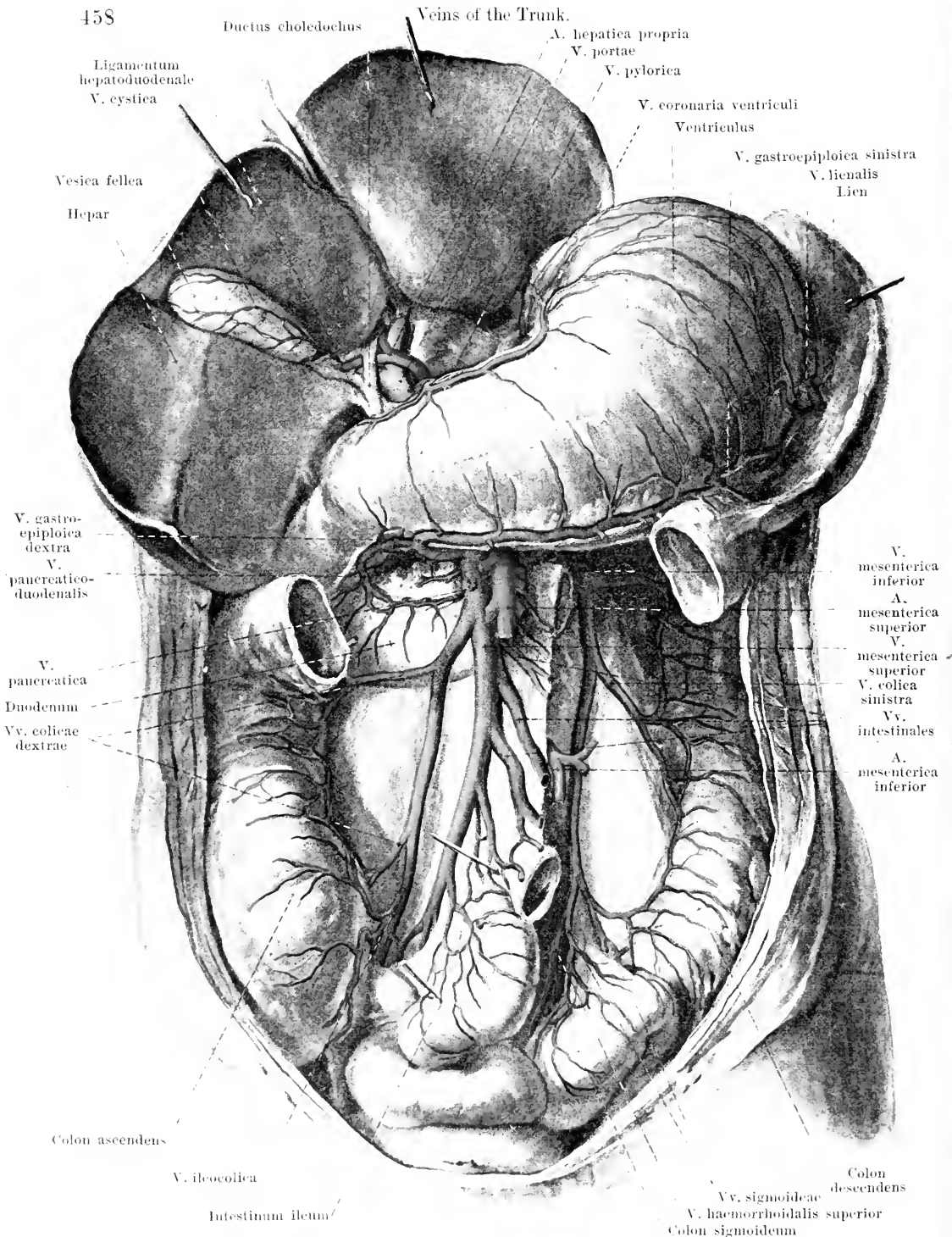
The **vena portae** (*portal vein*) (see Figs. 497 and 498) collects the blood from the whole digestive tube from the cardia on as far as the *m. levator ani*, from the pancreas, the gall bladder and the spleen. Its trunk arises behind the *caput pancreatis*, on the left and posterior surface of the *pars superior duodeni*, from the union of the *v. mesenterica superior* and the *v. lienalis*; it is 2—3 cm long and runs upward in the *lig. hepatoduodenale*, behind the *a. hepatica* and the hepatic and biliary ducts, to the *porta hepatis*; there it divides into a right and left branch one for each half of the liver. Its roots follow, in general, the branches of the arteries of the same name and are supplied with valves only in their finer subdivisions immediately after their exit from the wall of the stomach and intestine.

1. **V. mesenterica superior** (see Figs. 497 and 498) runs on the right side of the *a. mesenterica superior* arises from numerous *vv. intestinales* (from the small intestine), from the *v. ileocolica*, *vv. colicae dextrae*, *v. pancreaticoduodenalis*, *vv. duodenales*, *vv. pancreaticae*, *v. colica media* and *v. gastroepiploica dextra*. The intestinal veins anastomose with one another very much as the arteries do but more frequently.

2. **V. mesenterica inferior** (see Figs. 497 and 498) collects its blood from the *v. haemorrhoidalis superior*, the *vv. sigmoideae* and the *v. colica sinistra*. Its peripheral course agrees with that of the *a. mesenterica inferior*; its trunk however separates from this and goes in a curved direction upward and to the right behind the peritoneum (frequently in the *plica duodenojejunalis*) and behind the pancreas; it usually opens into the *v. lienalis*, frequently into the *v. mesenterica superior*, sometimes at the point of junction of the two.

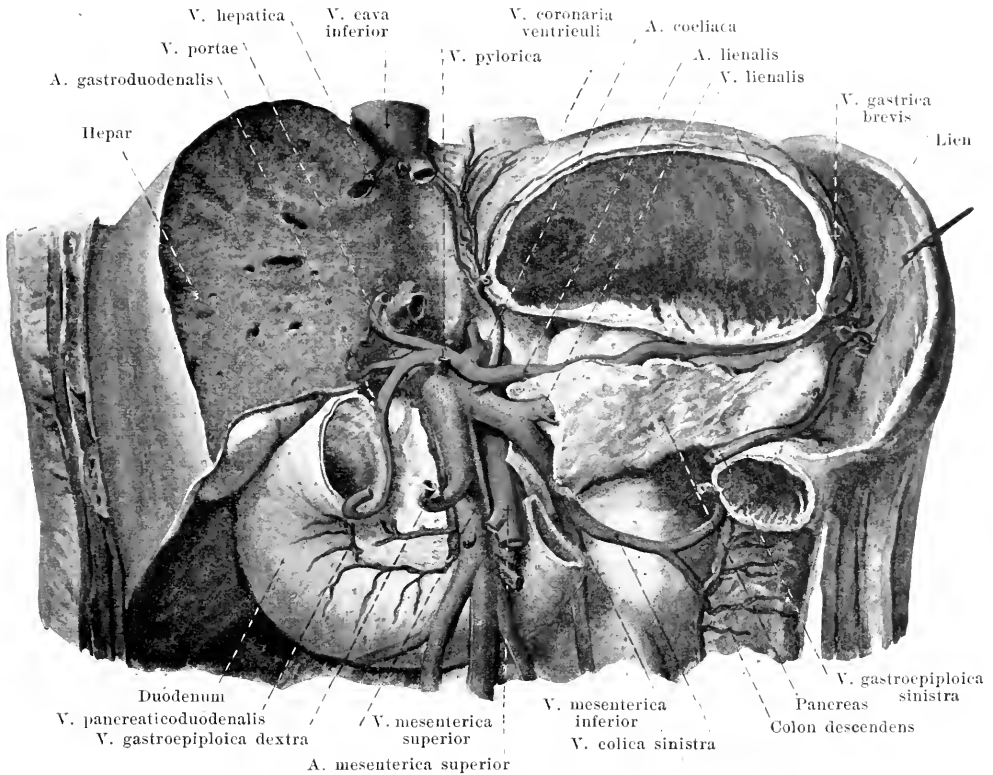
3. **V. lienalis** (see Figs. 497 and 498) is formed by the union of the veins of the spleen with the *v. gastroepiploica sinistra* and with the *vv. gastricae breves*; it runs from the left to the right beneath the *a. lienalis* and behind the pancreas, and in its course receives several pancreatic veins.





497. Tributaries of the portal vein.

(The transverse colon and the small intestine have been partially removed; the liver has been drawn upward.)



498. Trunk of the portal vein.

(The stomach, liver and pancreas have been partially, the small intestine and the transverse colon completely, removed.)

4. **V. coronaria ventriculi** (see also Fig. 497) runs from the right to the left along the curvatura minor of the stomach, anastomoses at the pylorus with the v. pylorica, at the cardia with the oesophageal veins and opens near the a. gastrica sinistra into the trunk of the v. portae or the v. lienalis.

5. **V. pylorica** (see also Fig. 497), more delicate than the preceding, extends from the left to the right near the a. gastrica dextra at the curvatura minor of the stomach, anastomoses with the preceding vein and opens at the pylorus into the stem of the v. portae.

6. **V. cystica** (see Fig. 497) from the gall bladder, opens into the stem or the right branch of the portal vein.

The **accessory portal veins** (not illustrated) are small vessels which arise in the folds of the peritoneum connected with the liver or which come from the stomach and pass either into the stem of the portal vein or directly into the substance of the liver.

The **anastomoses of the portal** with the vv. cavae are regularly present as follows:

- 1) At the cardia of the stomach between the v. coronaria ventriculi (v. portae) and the oesophageal veins (v. azygos);
- 2) at the rectum in the plexus haemorrhoidales between the v. haemorrhoidalis superior (v. mesenterica inferior) and the vv. haemorrhoidales mediae et inferiores (vv. hypogastricae);
- 3) *vv. parumbilicales* [Sappeyi] (not illustrated), 4—5 small vessels, which are connected in the neighborhood of the navel with the superficial veins and with the vv. epigastricae inferiores, extend near the lig. teres hepatis to the liver and empty usually directly into its substance. The largest anastomoses also with the left v. epigastrica superior. One of these veins is said to be the remains of the v. umbilicalis. They are supplied with valves; the current is directed toward the liver.

V. cava inferior (see also Fig. 633) arises by the union of the vv. iliacae communes in front of the intervertebral disk between the 4th and 5th lumbar vertebra behind the first portion of the a. iliaca communis dextra somewhat to the right of the median plane. From there on, it ascends at first in front of the bodies of the lumbar vertebrae and in front of the origins of the right m. psoas major, then in front of the a. renalis dextra and in front of the right crura diaphragmatis and at the same time somewhat to the right and forward, goes through the foramen venae cavae of the diaphragm and, curved somewhat forward, opens into the right atrium of the heart. In its course it lies on the right side of the aorta abdominalis and is covered in front by the peritonaeum, by the pars inferior duodeni and by the caput pancreatis; above, it is embedded in the fossa venae cavae of the liver and firmly fused with it, so that only its posterior wall lies partly free (see Fig. 581). It is devoid of valves. Its branches are divisible into **radices parietales** (from the walls of the peritoneal cavity) and **radices viscerales** (from the abdominal viscera).

A. Radices parietales:

1. **V. phrenica inferior**, paired, corresponds to the a. phrenica inferior and opens at the foramen venae cavae.

2. **Vv. lumbales** (see also Figs. 495 and 500), on each side 4—5, run close to and over the aa. lumbales, correspond to the vv. intercostales (see p. 453) and receive tributaries from the muscles and from the skin of the back, from the plexuses of the spine and from the abdominal muscles. They possess (insufficient) valves, run medianward upon the lateral and anterior surface of the bodies of the vertebrae (those of the left side behind the aorta) and open into the posterior wall of the v. cava. The vv. lumbales are united on each side with one another by means of longitudinal anastomoses which are situated behind the m. psoas major in front of the roots of the procc. transversi. The sum of these anastomoses forms on each side a vessel running vertically, the *v. lumbalis ascendens*, which is connected below with the v. iliolumbalis and frequently with the v. iliaca communis, above however is continued on the right side directly into the v. azygos, on the left side into the v. hemiazygos (see p. 456); each anastomoses usually with the a. renalis of the same side.

B. Radices viscerales:

1. **Vv. hepaticae** (see also Fig. 580), 2—3 large trunks, collect the blood which is led to the capillary system of the liver through the a. hepatica propria and v. portae; they leave the liver in the uppermost part of the fossa venae cavae and open into the v. cava just below the diaphragm. The right v. hepatica, largest, carries the blood from the right lobe of the liver, the middle, smallest vein from the lobi caudatus [Spigeli] and quadratus, the left from the left lobe of the liver. Several small vv. hepaticae open in the fossa venae cavae, below the large ones, directly into the v. cava inferior. Valves are only rarely present at the mouths of the large veins.

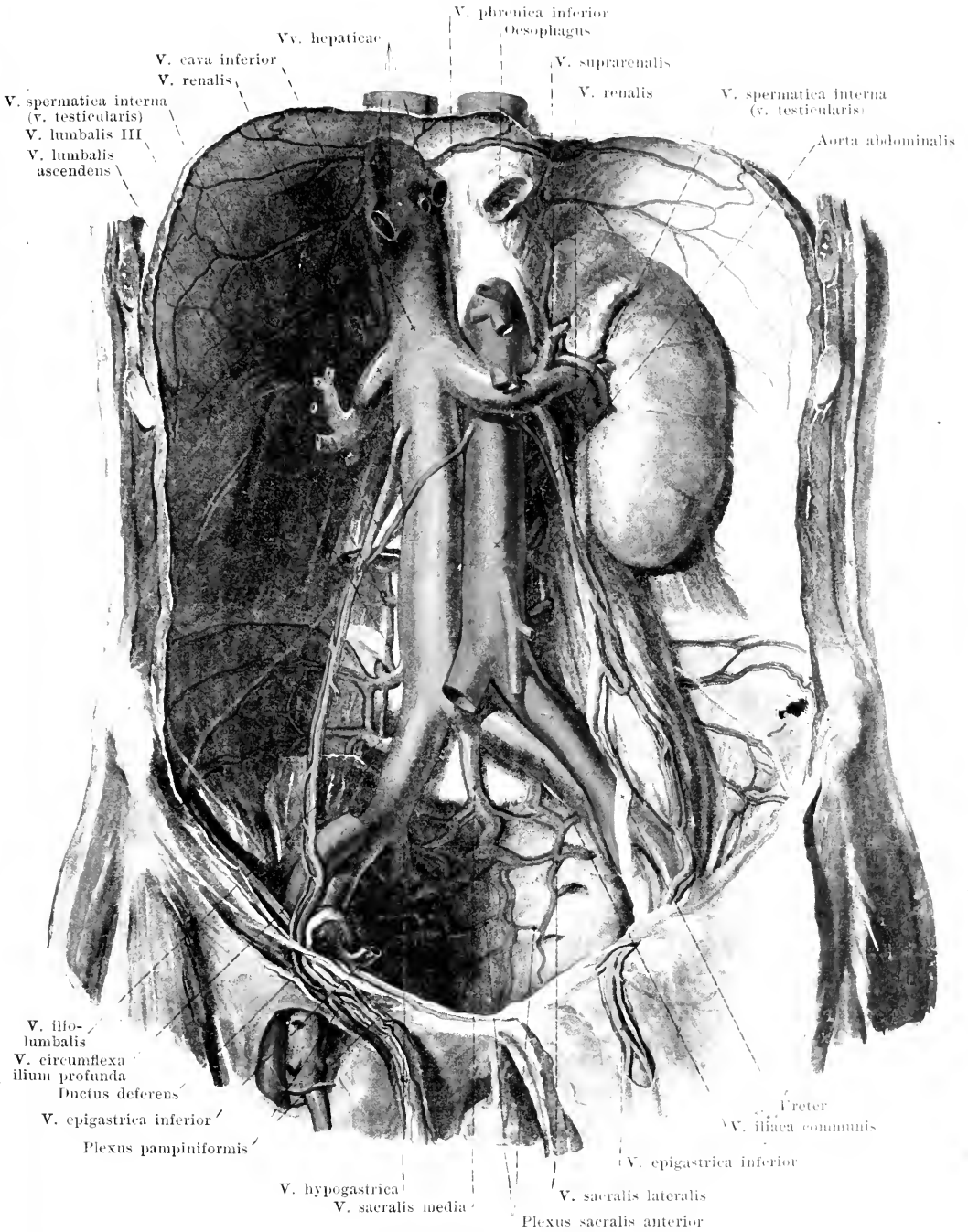
2. **V. renalis** (renal vein) (see also Fig. 633), paired, arises by the fusion of from three to five branches near the hilus renalis, runs medianward and at the same time somewhat upward at the level of the 2nd lumbar vertebra in front of the a. renalis and opens into the lateral wall of the v. cava. The left v. renalis is somewhat the larger and longer; it lies usually in front of the aorta just beneath the origin of the a. mesenterica superior. It receives tributaries from the capsula adiposa of the kidney and from the ureter; the left v. renalis receives also usually the v. spermatica sinistra. In addition the left vein anastomoses very frequently with the v. hemiazygos and the v. lumbalis ascendens, the right with the latter only. The vv. renales rarely possess valves at their mouths.

3. **V. suprarenalis** (suprarenal vein) (see also Fig. 639), paired, comes from the anterior surface of the adrenal and opens on the right side usually into the v. cava; on the left side into the v. renalis. It is devoid of valves.

4. **V. spermatica** (spermatic vein) (see also Figs. 500, 502 and 503), paired, accompanies the a. spermatica interna directly and is separated from it only at its termination. It consists of from 2 to 3 anastomosing vessels which surround the artery like a plexus, receive branches from the ureter, from the peritonaeum and from the capsula adiposa of the kidney and unite finally to form a single trunk. The right vein opens obliquely into the anterior wall of the v. cava and there possesses efficient valves, the left goes almost at a right angle into the inferior wall of the v. renalis sinistra. The beginning of the vein is different in the two sexes.

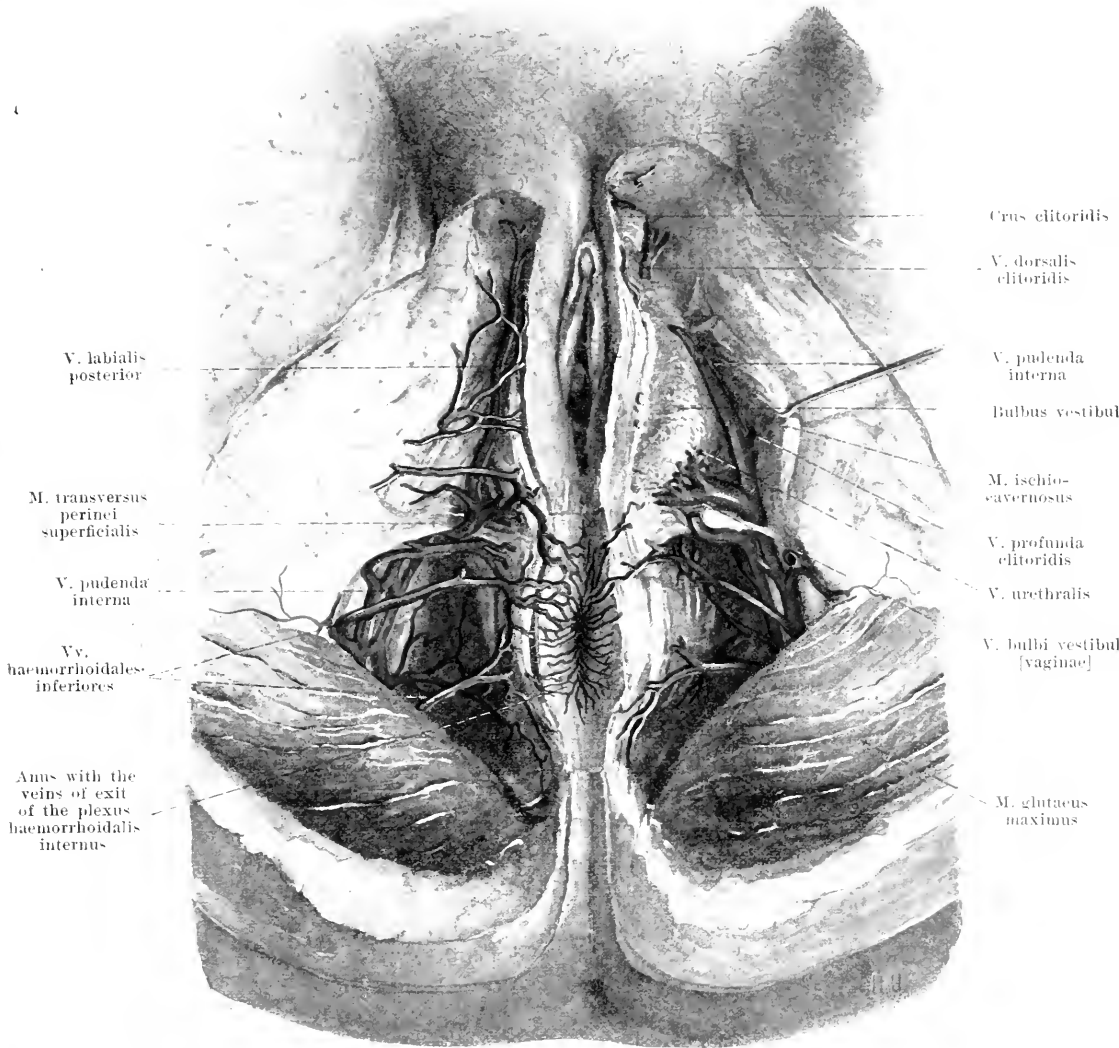
In the male, *v. testicularis*, it begins with numerous branches at the posterior margin of the testicle and epididymis (see also Fig. 650), forms a close plexus (*plexus pampiniformis*) around the artery inside the funiculus spermaticus and extends, with this, through the canalis inguinalis. Outside the inguinal canal it usually possesses (insufficient) valves.

In the female, *v. ovarica*, it arises partly from numerous vessels, which leave the ovary at its hilus, partly from broad anastomoses with the upper ends of the vv. uterinae; in addition it receives some branches from the lig. teres uteri and from the tuba uterina. All these branches, anastomosing, form a close plexus (*plexus pampiniformis*) around the artery, inside the lig. suspensorium ovarii and are devoid of valves.



499. Vena cava inferior in the male, viewed from in front.
 (On the right side the kidney has been removed, a piece of the m. psoas and of the a. iliaca communis has been cut out; on the left side the abdominal wall has been reflected downward.)

Spalteholz, Atlas.



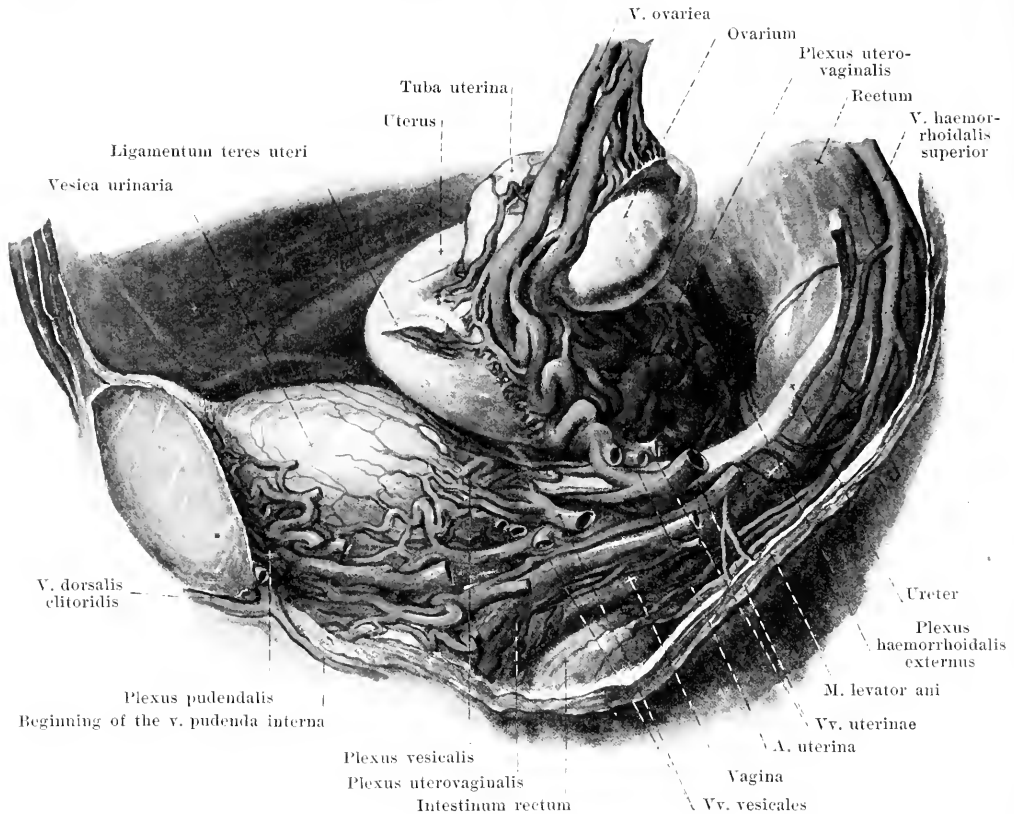
501. Veins of the female perineum (see Fig. 471).

V. iliaca communis (*common iliac vein*) (see Fig. 499), paired, devoid of valves, behind and to the right of the artery, arises from the **v. hypogastrica** and the **v. iliaca externa**. It frequently anastomoses with the *v. lumbalis ascendens*. Branch of the left vein:

1. **V. sacralis media** (middle sacral vein), unpaired, often double below, near the *a. sacralis media*, forms with branches of the *vv. sacrales laterales* the *plexus sacralis anterior* (see p. 466); it is connected with the *plexus haemorrhoidalis externus* and *vesicalis*.

V. hypogastrica (*hypogastric vein*) (see Fig. 500) lies directly behind the *a. hypogastrica*. Its branches possess valves only outside the pelvis. Branches:

V. pudenda interna (O. T. internal pudic vein) (see also Figs. 500 and 503) begins below the symphysis ossium pubis with an anastomosis from the *v. dorsalis penis* (*clitoridis*) and receives the *vv. profundae penis* (*clitoridis*), *vv. urethrales*, *vv. bulbi urethrae* (*bulbi vestibuli* [*vaginae*]), *vv. scrotales* (*labiales*) *posteriores* and *vv. haemorrhoidales inferiores*; the latter are connected with the *plexus haemorrhoidales*. All the branches correspond to the arteries of the same name. The vein is for the most part double and accompanies the artery.



502. Veins of the female pelvic organs, viewed from the left.

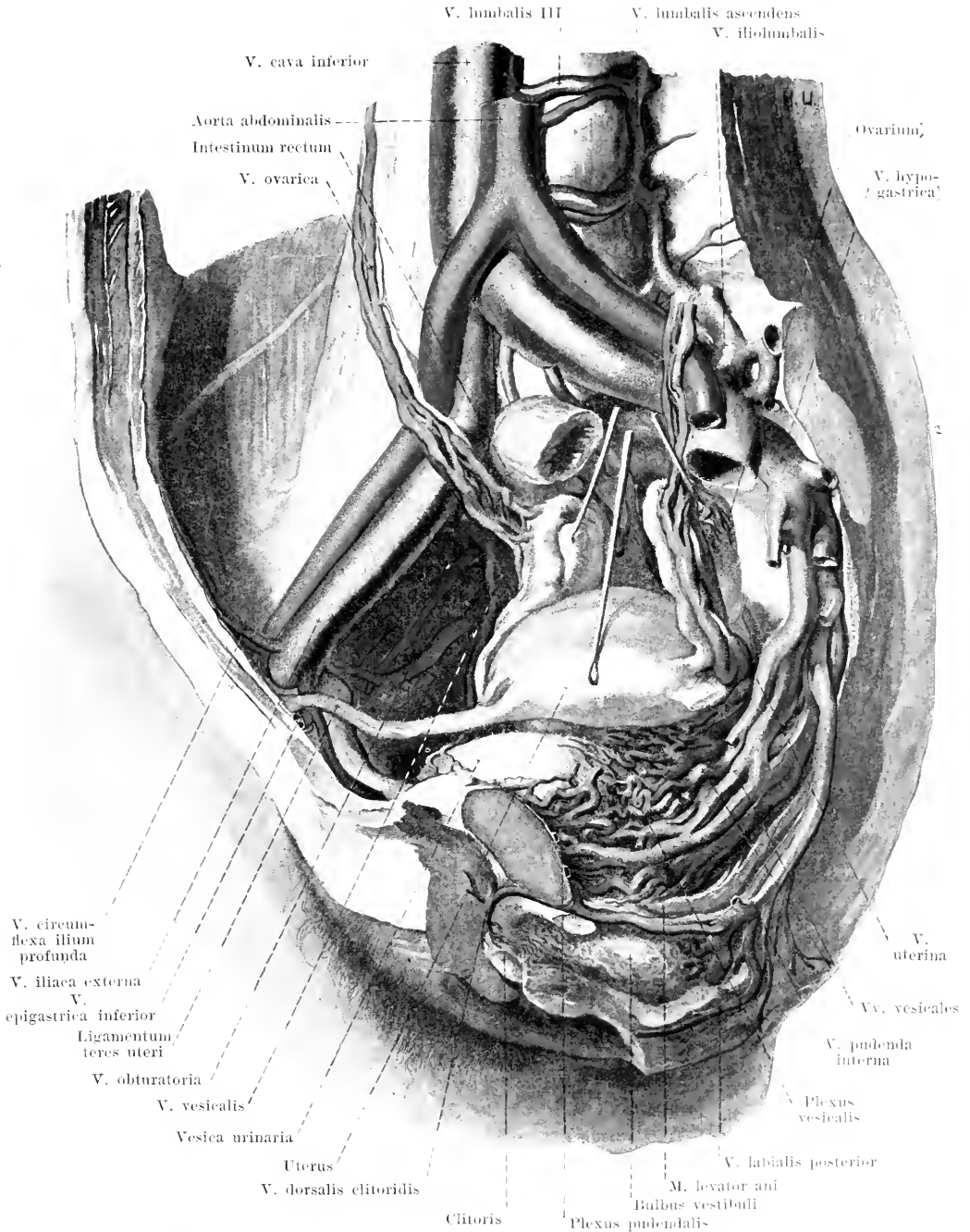
(The superficial layers of the venous plexuses [see Fig. 503] have been removed; the peritonaeum has been for the most part removed.)

2. **Plexus haemorrhoidalis internus** (see Figs. 501 and 576) in the tela submucosa of the rectum, with ampulla-like dilatations in the region of the annulus haemorrhoidalis, empties partly into a delicate superficial network at the anus, partly by means of numerous perforating branches into the **plexus haemorrhoidalis externus** (see also Fig. 500) situated upon the external surface of the tunica muscularis. From the latter arise the *v. haemorrhoidalis superior* (to the *v. mesenterica inferior* of the *v. portae*), the *rr. haemorrhoidales mediae*, paired, which receive branches from the bladder, prostate and seminal vesicles (uterus and vagina) (to the *v. hypogastrica*) and the *rr. haemorrhoidales inferiores*, paired, from the neighborhood of the anus (to the *v. pudenda interna*); in addition branches go to the *v. sacralis media*.

3. **Plexus vesicalis** (see also Figs. 500, 503 and 677) surrounds the lower part of the bladder and the basis prostatae lateralward and behind, is connected with the following plexus and is emptied on each side by means of several *rr. vesicales*.

4. **Plexus pudendalis** (see also Figs. 500 and 503) lies behind and over the lig. arcuatum pubis, in front of the prostate and bladder (in the male, the bladder and urethra in the female), receives the main trunk of the unpaired *v. dorsalis penis (clitoridis)* (see also Fig. 656), which runs between the lig. arcuatum pubis and the lig. transversum pelvis, is connected with the *v. pudenda interna* and with the plexus vesicalis and empties partly into the *v. vesicales*, partly directly into the *v. hypogastrica*.

5. **Plexus uterovaginalis** (in the female) extends over the walls of the vagina and as an especially close plexus along the *margo lateralis* of the uterus, where it partly fills up the parametrium and surrounds the ureter. It is connected in front with the plexus pudendalis and haemorrhoidalis externus and empties on each side chiefly through the large *rr. uterinae*, which surround the *a. uterina* and form broad anastomoses with the plexus pampiniformis of the *v. ovarica*.



503. Veins of the female pelvis, right half, viewed from the left and somewhat in front.

(The ovaries and uterus have been drawn out of their position; the peritoneum has been largely removed; the ureters have been removed.)

6. **V. iliolumbalis** (see Figs. 495, 499 and 500), in part double, accompanies the a. iliolumbalis and often opens into the v. iliaca communis. It receives the vv. intervertebrales (see p. 455), muscular veins and sometimes the v. lumbalis V, anastomoses with the vv. lumbalis ascendens, circumflexa ilium profunda and sacrales laterales and possesses many valves.

7. **Vv. sacrales laterales** (see Fig. 499), usually double, run near the a. sacralis lateralis and open into the v. hypogastrica or into a branch of the same. Their branches form, with those of the v. sacralis media, the *plexus sacralis anterior* upon the facies pelvina of the sacrum.

8. **V. obturatoria** (see Figs. 500 and 503) near the a. obturatoria; its branches are usually doubled; it forms a broad anastomosis with the v. iliaca externa, and sometimes opens into this. Its branches anastomose freely with the v. circumflexa femoris medialis.

9. **V. glutaea superior** (see Fig. 506) accompanies the a. glutaea superior; its branches are usually doubled. At its entrance into the pelvis its walls stand open and it possesses valves. Behind the m. piriformis it anastomoses with the v. glutaea inferior.

10. **V. glutaea inferior** (see Fig. 506), near the a. glutaea inferior; its branches, usually doubled, accompany the branches of the latter. It receives a large branch from the n. ischiadicus and anastomoses on the m. quadratus femoris by means of very wide vessels with the v. circumflexa femoris medialis and with the uppermost v. perforans of the vv. profundae femoris.

V. iliaca externa (*external iliac vein*) (see Figs. 499, 500 and 505) begins as the continuation of the v. femoralis behind the lig. inguinale, on the medial side of the a. iliaca externa and, as it ascends, becomes displaced behind the artery. It receives a broad anastomosis from the v. obturatoria and frequently possesses one (usually insufficient) valve. Branches:

1. **V. epigastrica inferior** (see Figs. 499, 500 and 505), usually doubled, accompanies the a. epigastrica inferior. It anastomoses with the vv. epigastricae superiores and behind the ramus superior ossis pubis with the v. obturatoria; in addition it receives the vv. parumbilicales, as well as the vv. *spermaticeae externae* (not illustrated) from the funiculus spermaticus and branches from the vv. cutaneae abdominis. Below the navel it possesses numerous valves.

2. **V. circumflexa ilium profunda** (see Figs. 499, 500, 503 and 505), double in most of its course, surrounds the a. circumflexa ilium profunda like a plexus and often opens into the v. epigastrica inferior; in so doing it crosses the a. iliaca externa on its anterior or posterior surface. It anastomoses with the v. iliolumbalis and is supplied with valves.

V. femoralis (*femoral vein*) (see Fig. 505) is the continuation of the vv. popliteae from the lower end of the canalis adductorius [Hunteri] on. In this canal it lies behind the a. femoralis and somewhat lateralward from it; further up it runs for the most part exactly behind the artery, and arrives finally on the medial side of the artery in the fossa iliopectinea. In its lower portion two vv. *comitantes* also run close to the artery. It possesses usually 4-5 pairs of valves. Branches:

1. **V. epigastrica superficialis** (see also Fig. 508) is situated in the subcutaneous tissue and carries the blood downward from the lower half of the anterior abdominal wall. It opens in the fossa ovalis separately or, united with neighboring veins, into the v. femoralis or into the v. saphena magna and possesses valves which conduct downward.

2. **V. circumflexa ilium superficialis** (see Fig. 508), sometimes doubled for part of its course, close to the corresponding artery in the subcutaneous tissue, opening either independently or in common with the v. epigastrica superficialis. It is supplied with valves.

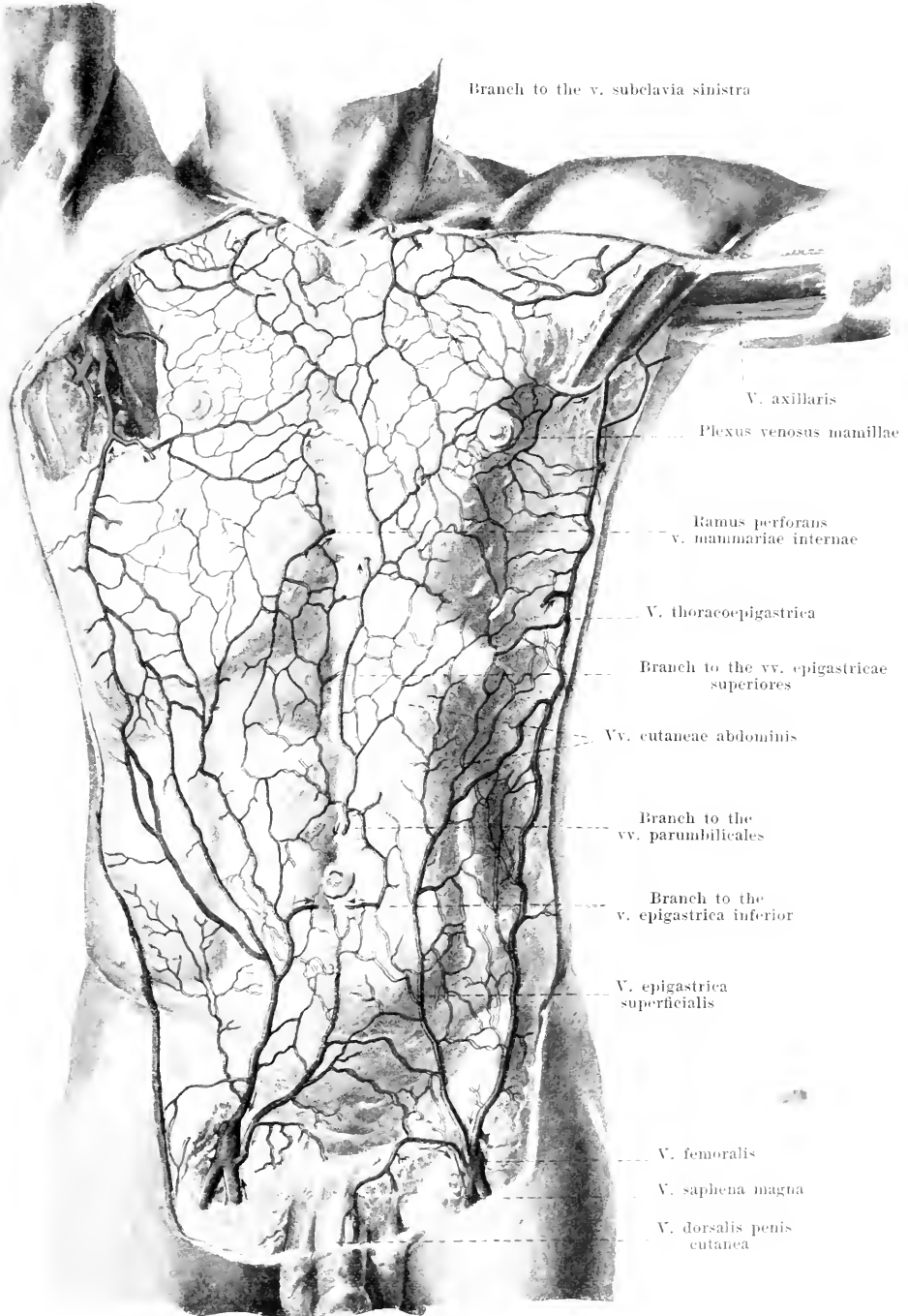
3. **V. thoracoepigastrica**, single or doubled for long distances, extends, on the anterior or lateral wall of the trunk, in the subcutaneous tissue, from the axilla as far as the fossa ovalis. Its middle portion is devoid of valves, in its upper part valves direct the blood upward to the axilla, in its lower part downward to the fossa ovalis. Above, the vein opens into the v. thoracalis lateralis (see p. 453), below it goes either separately or united with the v. epigastrica superficialis into the v. femoralis.

4. **Vv. pudendae externae** (see also Fig. 508), near the aa. pudendae externae, frequently flow into the v. saphena magna; they receive branches from the skin of the abdomen, from the scrotum (or the labia majora), vv. *scrotules (labiales) anteriores*, and from the penis (or the clitoris), v. *dorsalis penis (clitoridis) cutanea*; the latter runs unpaired or doubled upon the fascia penis as far as the symphysis pubis and there bends lateralward.

(Continuation see p. 468.)

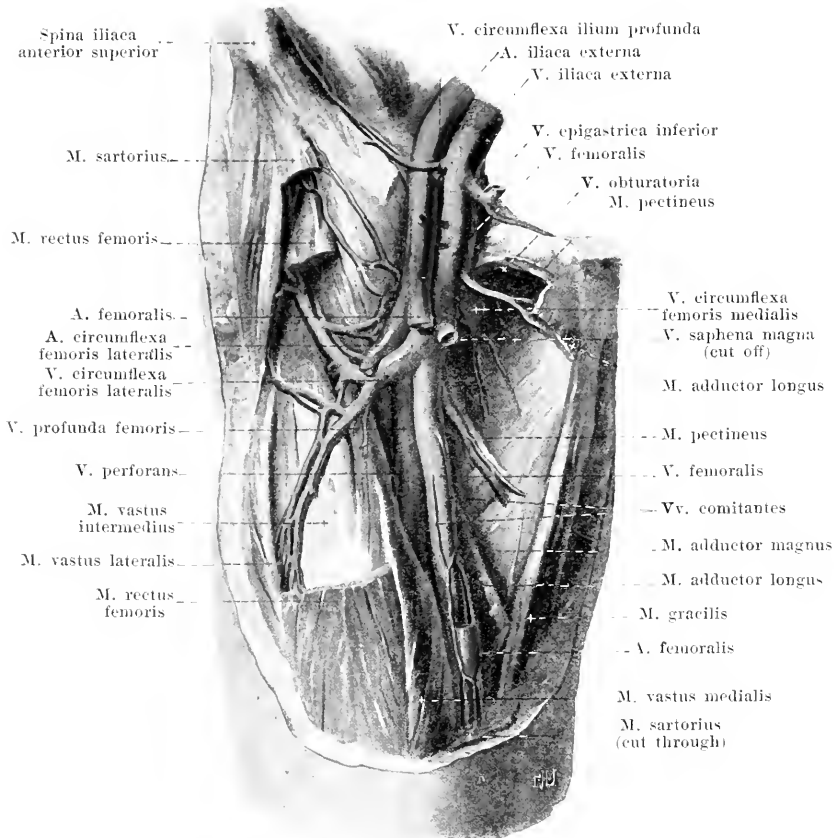
Vv. cutaneae abdominis et pectoris form, in the subcutaneous tissue of the abdominal and thoracic wall, a network of vessels, supplied with valves, from which the blood is led away on each side 1st by superficial vessels to the neck, to the axilla (v. thoracoepigastrica) and to the fossa ovalis (*vide supra*), 2nd by deep, perforating vessels to the thoracic cavity (to the vv. mammaria interna and intercostales), to the peritoneal cavity (vv. parumbilicales) and to the veins of the anterior abdominal wall (vv. epigastricae superiores et inferior).

In the neighborhood of the papilla mammae the vv. cutaneae form a wreath of vessels of uneven caliber, the *plexus venosus mamillarum*.



504. Superficial veins of the trunk,
viewed from in front (after W. Braune).

(The arrows indicate the way in which the current is directed by the valves.)



505. V. femoralis dextra, viewed from in front.

(The lig. inguinale and the mm. sartorius, rectus femoris, pectineus and adductor longus have been entirely or partially removed; a piece has been cut out of the a. femoralis.)

V. femoralis (continued):

5. V. saphena magna (see p. 471).

6. V. profunda femoris accompanies the a. profunda femoris and possesses several pairs of valves. Branches:

- Vv. perforantes* (see also Fig. 506), partly doubled, arise on the posterior surface of the m. adductor magnus and communicate freely there by longitudinal anastomoses with one another, with the vv. glutaea inferior, circumflexa femoris medialis and with the v. poplitea; they then perforate the mm. adductores near the aa. perforantes.
- Vv. circumflexae femoris mediales* (see also Fig. 506) run near the corresponding arteries and anastomose freely behind, on the m. quadratus femoris, with the vv. glutaea inferior and perforans I, in front with the v. obturatoria. They are supplied with valves.
- Vv. circumflexae femoris laterales*, supplied with valves, accompany the a. circumflexa femoris lateralis and anastomose with the preceding and with the v. glutaea inferior.

V. poplitea (popliteal vein) (see Fig. 506) arises from the union of the vv. tibiales and runs just behind the a. poplitea, in its distal part at the same time somewhat medianward, in its proximal part somewhat lateralward from it. Besides, near the artery there is below a v. comitans lateralis, above a v. comitans medialis. It is supplied with valves, receives the v. saphena parva (see p. 472) and the vv. articulares genu (double near the corresponding arteries, not illustrated) and anastomoses with the lower vv. perforantes.

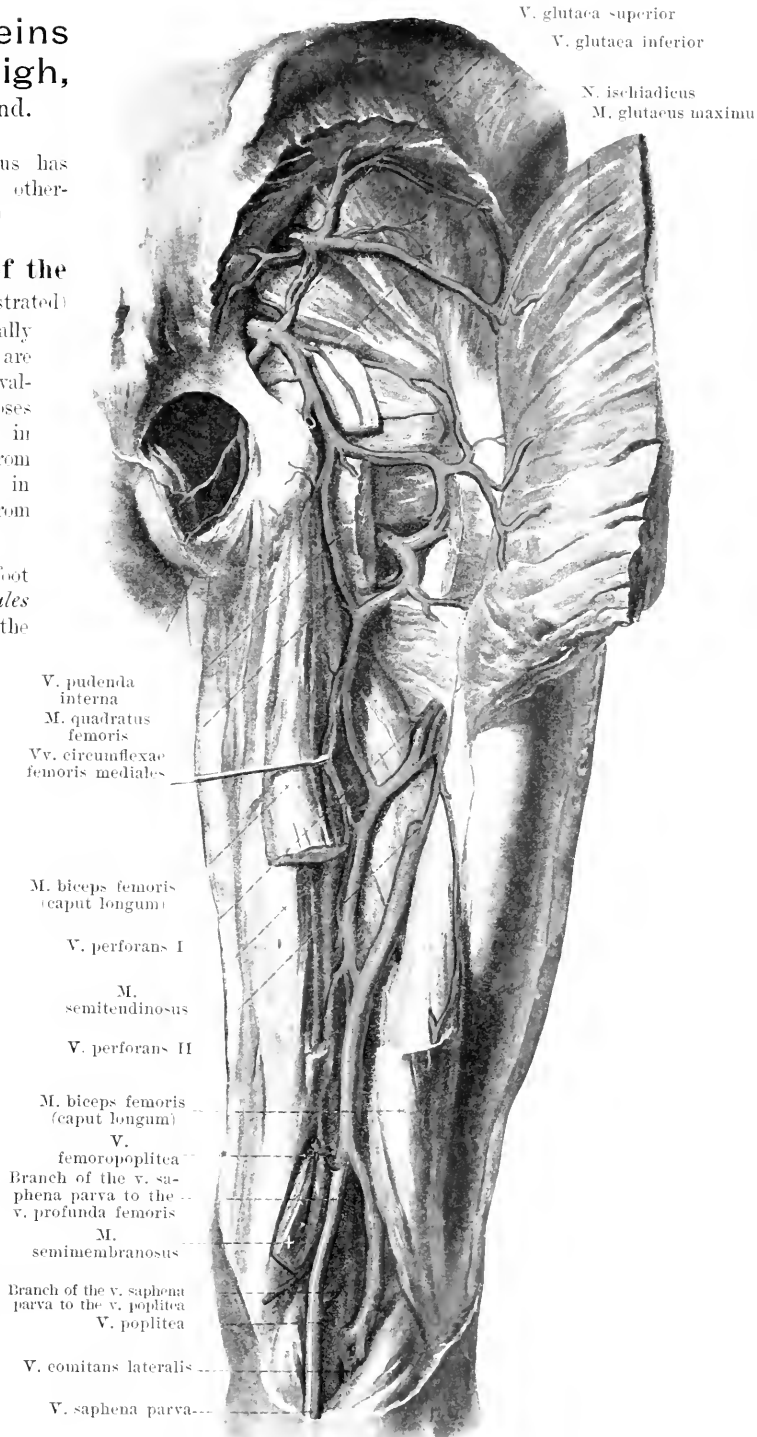
506. Deep veins of the right thigh, viewed from behind.

(The *m. gluteus maximus* has been reflected lateralward; otherwise like Fig. 477.)

The **deep veins of the foot and leg** (not illustrated) accompany the arteries, usually two to each artery, and are plentifully supplied with valves. Numerous anastomoses with the superficial veins in the foot lead the blood from the depth to the surface, in the leg (also in the thigh) from the surface to the depth.

In the sole of the foot they begin as the *vv. digitales plantares* and then form the *vv. metatarsae plantares*, which empty partly through several *rami perforantes* into the deep and the superficial veins of the back of the foot, partly into the *arcus venosus plantaris profundus*. From the latter go off the *vv. plantares laterales*, which by union with the finer *vv. plantares mediales* form the ***vv. tibiales posteriores***; in the leg the latter receive the *vv. peronaeae*. The *vv. plantares laterales* also send an anastomosis to the *v. saphena parva*, the *vv. plantares mediales* to the *v. saphena magna*.

On the back of the foot they are relatively delicate; they begin as the *vv. metatarsae dorsales pedis* and are continued into the ***vv. tibiales anteriores***.



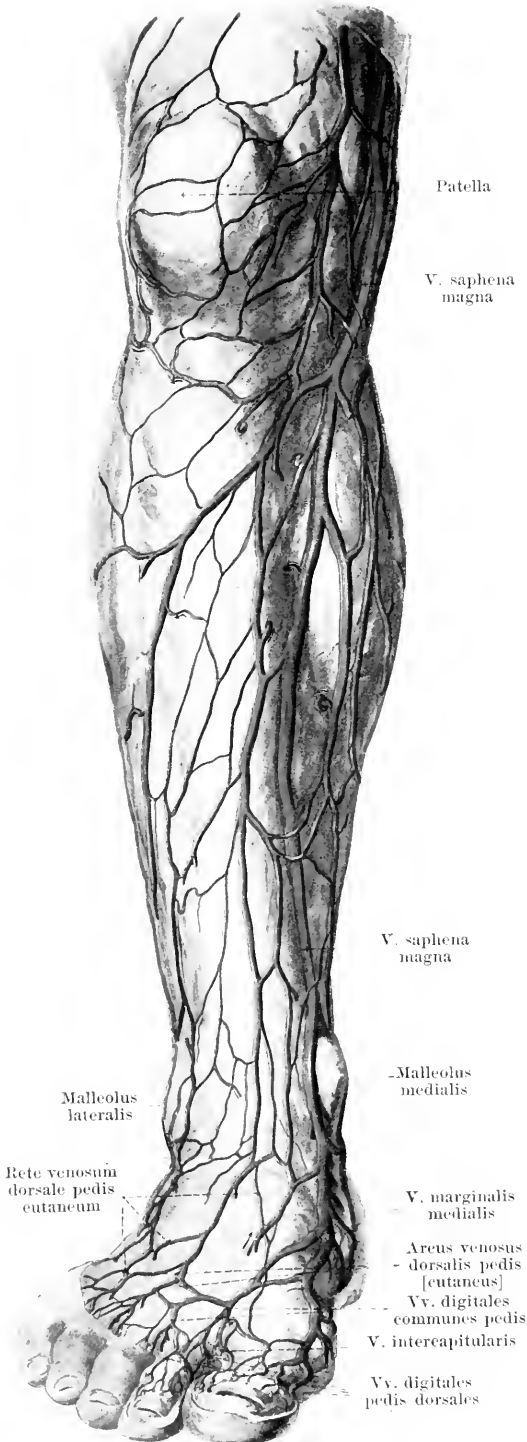
507. Superficial veins of the right leg, viewed from in front (after W. Braune).

(The arrows indicate the way the stream is directed by the valves.)

The **superficial veins of the leg** form a continuous network in the subcutaneous tissue, varying in complexity, rich in valves, and permitting the recognition in it of single larger vessels which act as the principal canals of exit. They are connected with the deep veins by numerous anastomoses (for direction of current see p. 469).

In the **sole of the foot** (not illustrated) there is a very close network (*rete venosum plantare cutaneum*), which possesses different channels of outflow. In the first place branches go to the deep veins, secondly, however, and chiefly, the blood is led away through superficial trunks around the borders of the foot to the dorsum of the foot. These pass at the medial and lateral margins of the foot into the vv. marginales medialis and lateralis of the dorsum of the foot, dorsalward over the margin of the heel toward the leg, and forward into a larger vessel (*arcus venosus plantaris cutaneus*), which runs in the toe-ball furrow at the distal margin of the fasciculi transversi aponeurosis plantaris and is continued over the medial and lateral margins of the foot into the beginnings of the vv. marginales (*vide infra*). This vascular arch receives superficial branches from the toes and sends off into the space between each two toes single or double *vv. intercapitulares* to the vv. digitales dorsales pedis.

On the **back of the foot** the veins begin at the toes as the *vv. digitales pedis dorsales*, which unite after receiving the *vv. intercapitulares* to form the short *vv. digitales communes pedis* and flow into the *arcus venosus dorsalis pedis [cutaneus]*; this is an irregular chain of anastomoses between the vv. digitales communes and the vv. marginales and lies upon the distal portion of the ossa metatarsalia. Proximalward from it lies the irregularly shaped *rete venosum dorsale pedis cutaneum*, which receives many tributaries from the depth and is continued into the anterior network of the leg. In the network, near the lateral and median margins of the foot, can be made out on each side a larger vessel, the *v. marginalis lateralis* (see Fig. 509) and the *v. marginalis medialis*, which chiefly receive tributaries from the *rete venosum plantare cutaneum*.

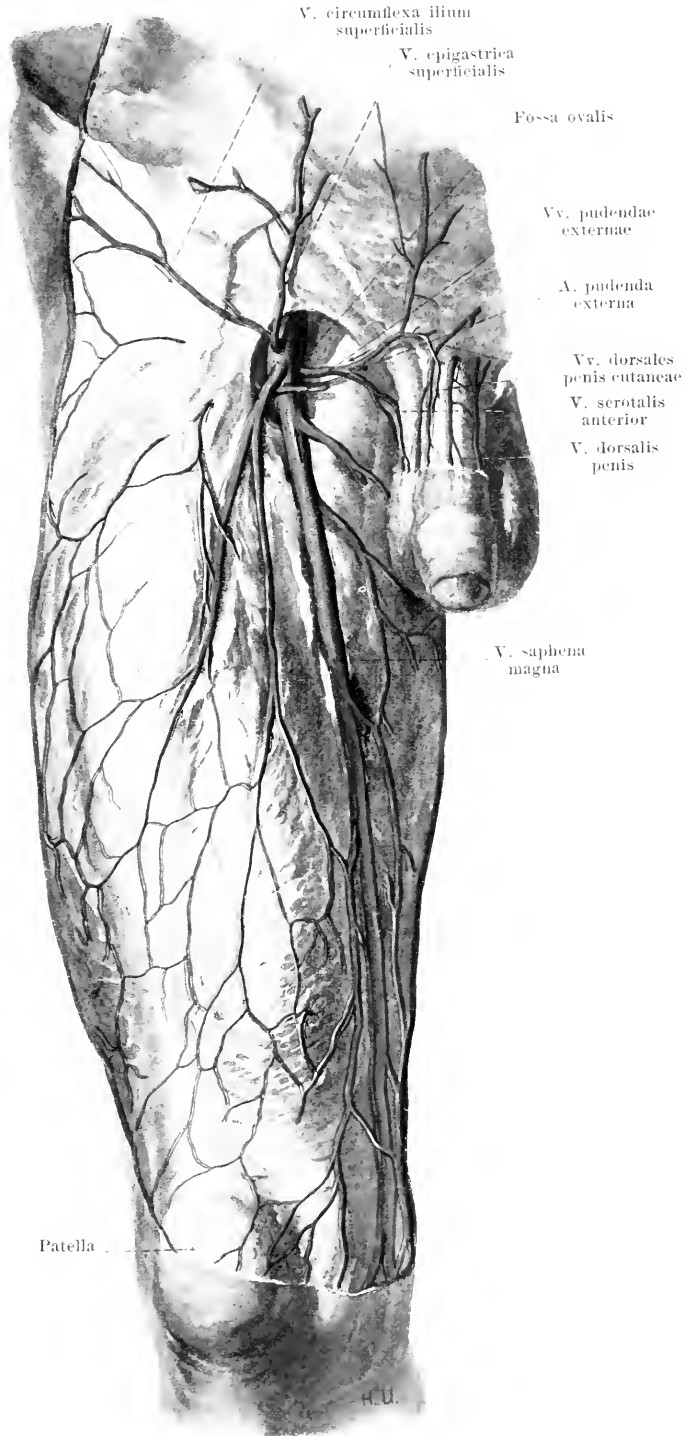


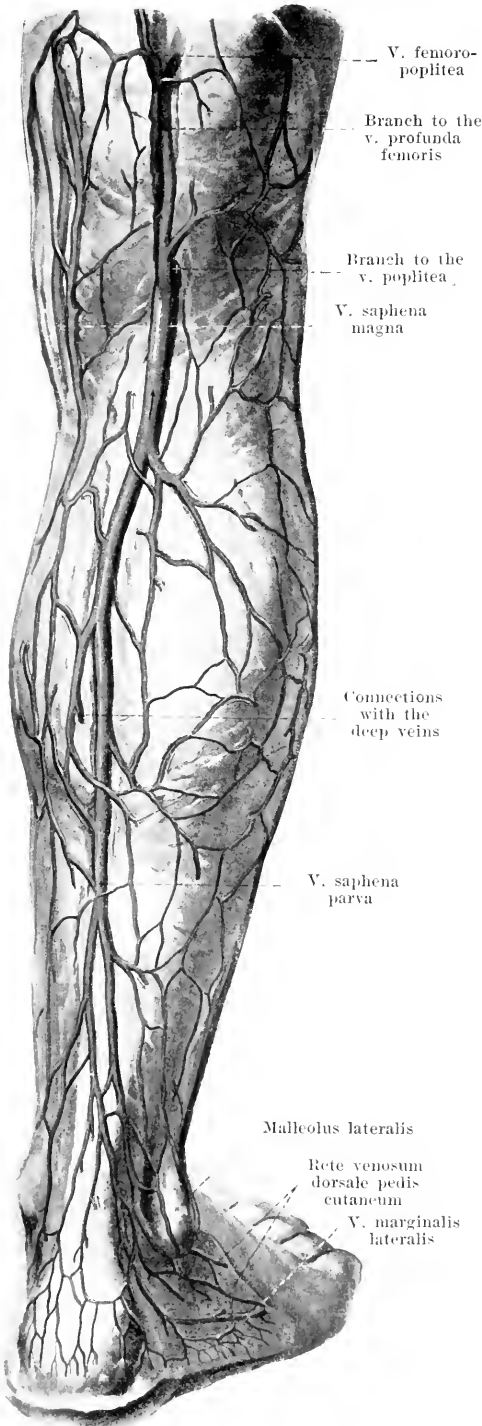
508. Superficial veins of the right thigh, viewed from in front.

(The arrows indicate the way the current is directed by the valves.)

In the plexus of superficial veins of the leg two large venous trunks stand out above the foot, the *v. saphena magna* and the *v. saphena parva*, of which the latter belongs essentially to the leg alone.

V. saphena magna (see also Figs. 505 and 507) begins in front of the medial malleolus as the continuation of the *v. marginalis medialis* and there receives superficial branches from the rete venosum plantare cutaneum and deep branches from the *vv. plantares mediales*. It then runs almost vertically upward upon the *facies medialis tibiae*, makes a slight curve behind the *condyli mediales* of the tibia and femur and then goes fairly straight but obliquely upward on the medial and anterior surface of the thigh, and enters the anterior medial wall of the *v. femoralis* in the *fossa ovalis*. In its entire course it is situated subcutaneously upon the *fascia cruris* and *fascia lata*. On its way it receives numerous branches from the superficial networks of the heel, of the leg and of the thigh, as well as veins from the tibia, and anastomoses manifoldly with the *v. saphena parva*. The superficial veins coming from the back of the thigh often form a separate trunk, the *v. saphena accessoria* (not illustrated), which accompanies the *v. saphena magna* medianward at a variable distance from it and empties into it at an inconstant level.





509.

Superficial veins of the right leg,

viewed from behind (after
W. Braune).

(The arrows indicate the way the current is directed by the valves.)

V. saphena parva (see also Fig. 506) begins behind the lateral malleolus as the continuation of the *v. marginalis lateralis* of the foot; in its formation there take part, besides superficial branches of the rete venosum plantare cutaneum, also an anastomosis from the deep *vv. plantares laterales*. It runs at first on the lateral margin, then on the posterior surface of the tendo calcaneus [Achillis]; farther up ensheathed in a duplicature of the fascia cruris, it lies in the groove between the two heads of the *m. gastrocnemius*, perforates the fascia at a variable level, sinks into the depth in the popliteal space and always bifurcates into two branches, of which one opens into the posterior wall of the *v. poplitea* and the other farther up into the beginning portion of the *v. profunda femoris*. The latter branch also receives a vessel of superficial course, running on the back of the thigh, the *v. femoropoplitea*, the contents of which flow for the most part from above downward but can also find a channel of exit by passing upward beneath the *m. gluteus maximus* into the *vv. gluteae*. The *v. saphena parva* receives in its course numerous branches from the superficial network of the heel and of the leg and anastomoses usually manifoldly with the *v. saphena magna*. It may open also into other deep veins of the thigh or into the *v. saphena magna*.

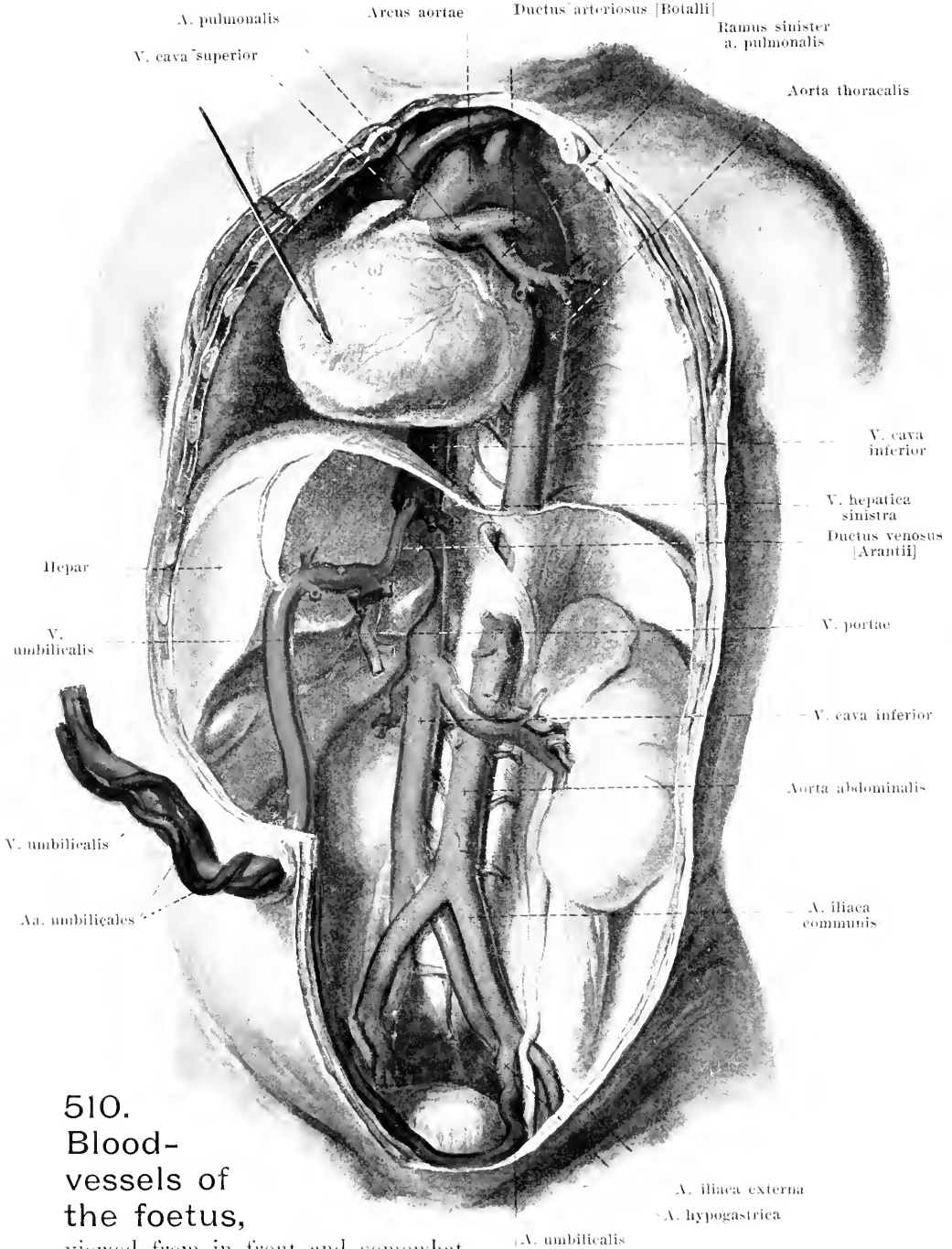
The foetal circulation.

During embryonic life the apparatus concerned in the circulation of the blood undergoes various transformations.

The arrangement which exists in the second half of pregnancy up to birth is designated the **placental circulation**. This presents the following peculiarities (see Figs. 510 and 511):

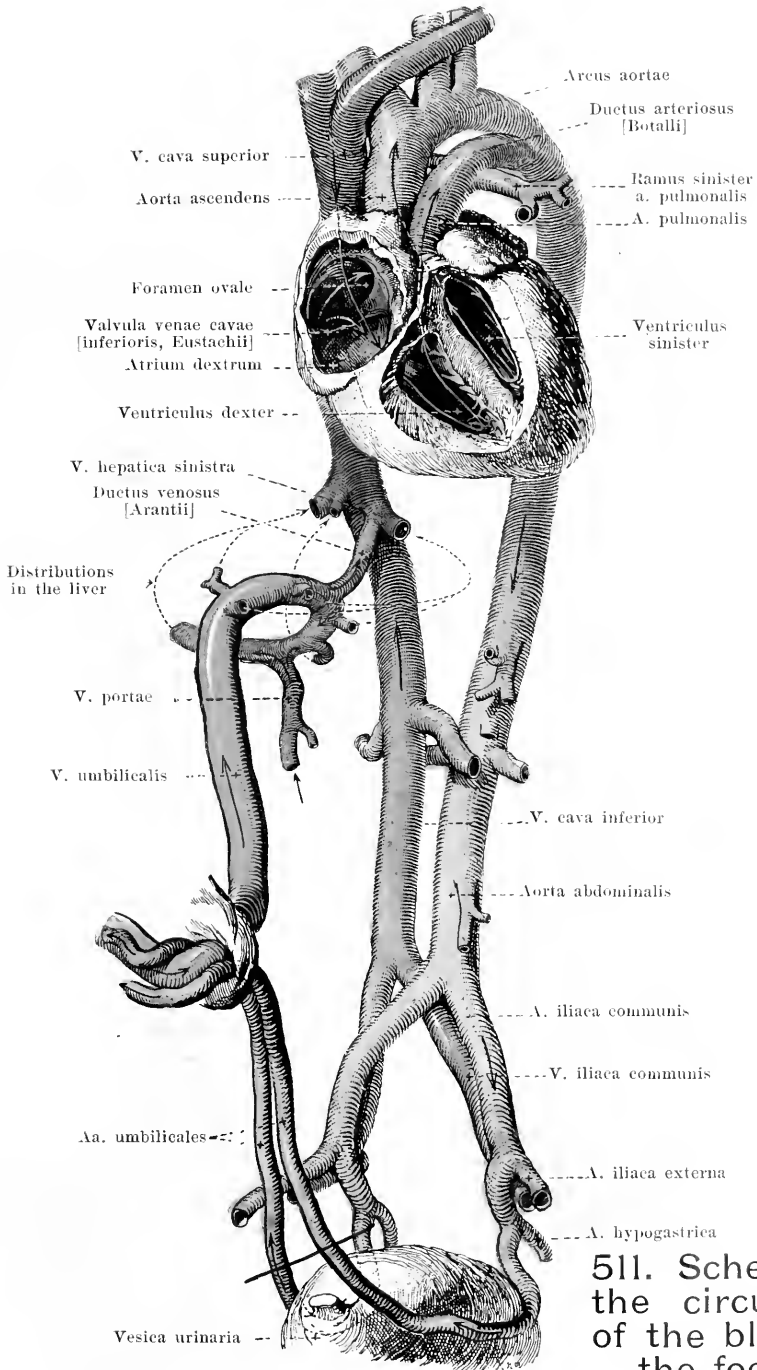
The **v. umbilicalis** (*umbilical vein*), devoid of valves, leads the blood, which has become *arterial* in the placenta, through the umbilical cord (*funiculus umbilicalis*) to the navel and thence in the free margin of the lig. falciforme hepatis to the fossa venae umbilicalis of the liver. There a part of the blood goes through direct branches to the capillary system of the liver; another part becomes mixed, in that the v. umbilicalis connects with the left branch of the v. portae, with the venous contents of the portal vein (from the stomach, intestine, pancreas and spleen) and also arrives, along with this, in the capillary system of the liver; finally, the third, smaller part runs directly to the left v. hepatica and thus to the v. cava inferior through the *ductus venosus* [*Arantii*], which is situated in the fossa ductus venosi of the liver (see also Fig. 551) and connects the v. umbilicalis with the left v. hepatica. The v. cava inferior carries mixed blood therefore on its passage through the foramen venae cavae of the diaphragm. This is composed of 1st the pure arterial contents of the ductus venosus (Arantii), 2nd the contents of the vv. hepaticae, which carry the blood away from the capillary system of the liver, and 3rd the venous contents of the v. cava inferior (especially from the renal veins, pelvic veins and those of the lower extremities). Passing through the v. cava inferior, this blood reaches the right atrium, which, in the foetus, is freely connected with the left atrium through the foramen ovale (see Fig. 423). Since the foramen ovale is situated in the direction of the current of blood arriving through the v. cava inferior, and since, in addition, the valvula venae cavae [inferioris, Eustachii] to a certain extent hinders an alteration of this direction of the current, the main mass of blood streams into the left atrium and in so doing receives and mixes with only part of the venous blood which arrives in the heart through the v. cava superior. Into the left atrium open the vv. pulmonales and their blood, which in the foetus is venous, mixes with the other contents. The so-called *mixed arterial* blood thus arising goes especially to the upper half of the body through the left ventricle, the aorta ascendens and the arcus aortae and its large branches, the aa. anonyma, carotis sinistra and subclavia sinistra; only a part comes into the aorta thoracalis.

The v. cava superior carries the venous blood from the upper half of the body and (through the v. azygos which is markedly developed in the foetus) from the wall of the trunk, to the right atrium. Thence a small part passes through the foramen ovale into the left atrium, the larger part, however, mixed with a part of the blood from the v. cava inferior and hence called *mixed venous* blood, enters the right ventricle and passes into the a. pulmonalis. The a. pulmonalis divides, in the foetus, into three branches: the rami dexter et sinister, which go to the lungs (as yet not functioning) and the *ductus arteriosus* [*Botalli*], which runs in the direction of the main trunk and enters, at the end of the arcus aortae, into the concave anterior wall of the latter. The greater part of the mixed venous blood now runs through this ductus arteriosus as far as the beginning of the aorta thoracalis; there it mixes with the residue of the mixed arterial blood coming from the end of the arcus aortae and passes through the branches of the aorta thoracalis and aorta abdominalis to the intestinal canal, to the inferior portion of the wall of the trunk and to the lower extremities, chiefly, however, through the two **aa. umbilicales** (see p. 425) into the umbilical cord and to the placenta, where it again becomes arterialized.



510.
Blood-
vessels of
the foetus,
viewed from in front and somewhat

from the left. (The abdominal and thoracic cavities have been widely opened, the lungs, the whole alimentary tract, the pancreas, the spleen, the left lobe of the liver and the serous membranes have been removed and the heart has been drawn aside to the right.) Text see p. 473.




511. Scheme of the circulation of the blood in the foetus,

viewed from in front and somewhat from the left (see Fig. 510).

(The heart is in its correct position and has been partly opened. The arrows indicate the direction of the blood current.) Text see p. 473.

Printed by Fischer & Wittig, Leipzig.





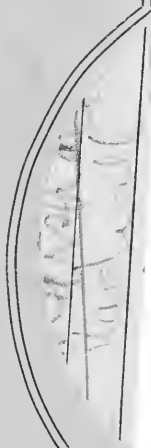J.M 12/1/44

MA
S

84441
Spalteholz, Werner
Hand-atlas of human anatomy. vol.2.

University of Toronto
Library

DO NOT
REMOVE
THE
CARD
FROM
THIS
POCKET



Acme Library Card Pocket
Under Pat. "Ref. Index File"
Made by LIBRARY BUREAU

