



3 1761 04190 7536

Digitized by the Internet Archive
in 2008 with funding from
Microsoft Corporation

HUMAN EMBRYOLOGY

BY THE SAME AUTHOR

A BIBLIOGRAPHY OF VERTEBRATE EMBRYOLOGY.

Containing over three thousand titles classified by subjects and indexed by authors. 4to. Boston, 1892. PUBLISHED AND FOR SALE BY THE BOSTON SOCIETY OF NATURAL HISTORY

HUMAN
EMBRYOLOGY

BY

CHARLES SEDGWICK MINOT

PROFESSOR OF HISTOLOGY AND HUMAN EMBRYOLOGY
HARVARD MEDICAL SCHOOL, BOSTON

FOUR HUNDRED AND SIXTY-THREE ILLUSTRATIONS

New York
THE MACMILLAN COMPANY
LONDON: MACMILLAN & CO., LTD.
1897



QM

601

M66

T897

COPYRIGHT

By CHARLES SEDGWICK MINOT

1892

TO
CARL LUDWIG
PROFESSOR OF PHYSIOLOGY
AT THE UNIVERSITY OF LEIPSIC
IN TOKEN OF
RESPECT, GRATITUDE, AND AFFECTION
THIS WORK IS DEDICATED
BY THE AUTHOR



PREFACE.

THE following attempt to present a comprehensive summary of Embryology, as it bears upon the problems of human development, is the result of ten years' labor. I have endeavored to become familiar with the principal facts by my own observation, and with the results of the principal numerous investigations, working over the material into satisfactory form. The reader will find, nevertheless, imperfections of which I am conscious, and perhaps errors, for which I must be responsible. There is probably not a page which might not be enriched with facts already recorded by investigators; certainly not a page which would not be improved by further revision. Notwithstanding these defects, I have the hope that the book will be a useful contribution toward that final and exhaustive collation of embryological facts which the future alone can give us.

I have sought to form an unbiased judgment upon each question, to accept facts of observation without regard to their supposed theoretical bearings; and to pay due attention to both Schools of Embryology, the Phylogenetic and the Anatomical, in the belief that both are justified. Whenever I have inserted a new observation or opinion, it is indicated as such by the use of the first person. In making my compilation, I have drawn constantly from the embryological manuals of Kölliker, Oskar Hertwig, Balfour and Duval; from the researches of W. His, and from the writings, especially the "Entwicklungsgeschichte der Unke," of Alexander Goette.

In regard to the technical terms, I have made certain innovations.

It seems to me important to make the number of terms as small as is compatible with clearness, and to avoid duplication. Accordingly I have discarded the words "*epiblast*, *mesoblast*, and *hypoblast*." Further it has seemed to me that, as a thorough knowledge of German is indispensable to the student of embryology, it is justifiable,

where no English equivalent is to be found, to adopt such unaltered German terms as have been fully established in embryological literature. Where there has occurred an accepted term, in English, French, or German, I have used it in preference to a Greek or Latin derivative.

Whatever merit this work may possess should be attributed to the training in scientific research which I received in Germany and France. I cannot too gratefully acknowledge the unlimited kindness shown me while a student in Leipzig under Professor Carl Ludwig and Professor Rudolph Leuckart; in Paris under Professor Léon Ranvier; and in Würzburg under Professor Carl Semper. I would also here express my gratitude to Professor Wilhelm His, to whom I am particularly indebted for his great generosity in permitting me to study his unique embryological collection in Leipzig; also to the large number of physicians, both in Europe and America, who have supplied me with material to carry on my investigations in human embryology.

CHARLES SEDGWICK MINOT.

HARVARD MEDICAL SCHOOL,
BOSTON, MASS., July 26, 1892.

TABLE OF CONTENTS.

CHAPTER	PAGE
INTRODUCTION,	1
I. The Uterus,	1
II. General Outline of Human Development,	28
PART I.	
THE GENITAL PRODUCTS.	
III. History of the Genoblasts and the Theory of Sex,	39
PART II.	
THE GERM-LAYERS.	
IV. Segmentation ; Formation of the Diaderm,	93
V. Concrecence : the Primitive Streak,	115
VI. The Mesoderm and the Cœlom,	144
VII. General Remarks on the Germ-Layers,	159
PART III.	
THE EMBRYO.	
VIII. The Medullary Groove, Notochord and Neurenteric Canals,	173
IX. Divisions of the Cœlom ; Origin of the Mesenchyma,	192
X. Origin of the Blood, Blood-Vessels and Heart,	211
XI. Origin of the Urogenital System,	230
XII. The Archenteron and the Gill Clefts,	254
XIII. The Germinal Area, the Embryo and its Appendages,	271
PART IV.	
THE FETAL APPENDAGES.	
XIV. The Chorion,	317
XV. The Amnion and Proamnion,	333
XVI. The Yolk Sack, Allantois and Umbilical Cord,	346
XVII. The Placenta,	364

PART V.

THE FŒTUS.

CHAPTER		PAGE
XVIII.	Growth and External Development of the Embryo and Fœtus,	381
XIX.	The Mesenchymal Tissues,	397
XX.	The Skeleton and Limbs,	422
XXI.	The Muscular System,	470
XXII.	The Splanchnocoel and Diaphragm,	480
XXIII.	The Urogenital System,	490
XXIV.	Transformations of the Heart and Blood-Vessels,	521
XXV.	The Epidermal System,	548
XXVI.	The Mouth Cavity and Face,	567
XXVII.	The Nervous System,	593
XXVIII.	The Sense Organs,	706
XXIX.	The Entodermal Canal,	743

LIST OF ILLUSTRATIONS.

FIG.	PAGE
1. Connective tissue of mucosa, uterus of pig,	3
2. Vertical section of the <i>mucosa corpus uteri</i> of the first day of menstruation,	5
3. Mucous membrane of a virgin uterus during the first day of menstruation,	7
4. Semi-diagrammatic outline of an antero-posterior section of the gravid uterus and ovum of five weeks,	8
5. Uterus about forty days advanced in pregnancy,	9
6. Uterus one month pregnant; outlines of the glands from a vertical section,	14
7. Uterus one month pregnant; portion of the compact layer of the decidua seen in vertical section,	15
8. Uterus one month pregnant; section of gland from cavernous layer, with the epithelium partly adherent to the walls,	16
9. Uterus one month pregnant; section of gland from cavernous layer with the epithelium loosened from the walls,	16
10. Section of the decidua serotina, near the margin of the placenta; normal uterus about seven months pregnant,	17
11. Decidual cells from the section represented in Fig. 10; stained with alum hæmatoxylin, and eosin,	18
12. Section of human decidua reflexa at two months,	20
13. Uterus twelve hours after artificial delivery at six months' pregnancy,	22
14. Section of the placental area of the uterus three weeks <i>post partum</i> ,	23
15. Vertical section through the wall of a uterus about seven months pregnant, with the fetal membranes <i>in situ</i> ,	29
16. Human embryo, 4.2 mm. long,	32
17. Embryo, 2.15 mm. long,	33
18. Diagram of an embryo of fifteen to sixteen days,	34
19. Generalized diagram of an amniote vertebrate embryo,	34
20. Generalized diagram of an amniote vertebrate embryo before the separation of the amnion,	35
21. Structure of a rat's spermatozoon,	41
22. Human spermatozoa,	42
23. Peripheral layer of the seminiferous tubule of a rat,	43
24. Column of spermatocytes from the rat,	44
25. Developing spermatoblasts of the rat,	45
26. Developing spermatozoa of a marsupial,	46
27. Human spermatoblasts, to illustrate the rupture of the membrane,	46
28. Sertoli's column, with a basal nucleolated nucleus and a cluster of developing spermatoblasts,	47

FIG.	PAGE
29. Part of a cross-section of a seminiferous tubule of a rat,	47
30. Egg of <i>Tendra zostericola</i> ,	49
31. Primary follicles from the ovary of a woman thirty-one years old, .	51
32. Ovary of cat,	52
33. Egg-cell of <i>Tengenaria domestica</i> ,	54
34. Full-grown human ovum before maturation,	56
35. Part of the ovum of a mole,	57
36. Ovum of a sea urchin, <i>Toxopneustes lividus</i> ,	58
37. Ovarion egg of hamops,	63
38. Egg of a leech (<i>nephelis</i>), three-quarters of an hour after being laid,	63
39. Ovum of <i>nephelis</i> (a leech), three hours after laying,	64
40. Ovum of a rabbit; taken from the middle of the oviduct about eighteen hours after coitus,	71
41. Anterior pole of the ovum of the petromyzon, with a spermatozoon,	72
42. Egg of <i>nephelis</i> , three hours after laying,	74
43. Ovum of <i>sagitta</i> with two pronuclei,	75
44. Two ova of the land-snail, <i>arion</i> ,	76
45. Ovum of a rabbit seventeen hours after coitus with the pronuclei about to conjugate,	76
46. Ovum of <i>Limax campestris</i> during the first cleavage,	96
47. Blastula stage of <i>Echinocardium cordatum</i> twenty hours after impregnation,	97
48. Segmentation of the egg of the common frog,	98
49. Section of the segmented ovum of axolotl,	99
50. Four stages of the segmentation of the hen's ovum,	100
51. Ovum of a flounder in transverse vertical section,	102
52. Ovum of a rabbit of twenty-four hours,	103
53. Rabbit's ovum of about seventy hours,	104
54. Ovum of a bat, <i>Vespertilis murina</i> , with four segmentation spheres,	105
55. Ovum of Virginian opossum, with four segments,	105
56. Young blastodermic vesicle of a mole,	105
57. Sections through the inner mass of the blastodermic vesicle of the mole, at three successive stages,	106
58. Ovum of a rabbit, ninety-four hours after coitus,	107
59. Diagram of a segmented mammalian ovum,	108
60. Ovum of <i>Amphioxus lanceolatus</i> during segmentation stage, with eighty-eight cells,	110
61. Section of a gastrula of <i>Toxopneustes lividus</i> ,	113
62. Diagrams of the principal modifications of the gastrula,	114
63. Longitudinal section of an early stage of the gecko,	115
64. Diagram illustrating the growth of the blastoderm and concrescence of its rim to form the primitive axis,	116
65. Diagram of concrescence in a teleostean egg,	118
66. Diagram of an elasmobranch blastoderm to illustrate the formation of the marginal groove,	119
67. Diagram of a vertebrate blastoderm a little more advanced than Fig. 96,	120
68. Ovum of axolotl,	121
69. Ovum of petromyzon in longitudinal section,	121
70. Longitudinal section of the ovum of a sturgeon after the formation of the entodermic cavity,	122
71. Formation of the blastoporic canal in <i>Lacerta muralis</i> ,	123

FIG.	PAGE
72. Hen's ovum ; incubated six hours,	124
73. Diagrammatic cross-section of a vertebrate ovum, in which con- escence is supposed to have been arrested,	126
74. Dog-fish embryo, nearly in Balfour's stage C,	126
75. Germinal area of a guinea-pig at thirteen days and twenty hours,	127
76. Diagram showing the relations of a vertebrate ovum with an em- bryo in cross-section and a large yolk,	128
77. Sections of axolotl eggs,	130
78. Area pellucida of a hen's egg, with completed primitive furrow,	131
79. Longitudinal section of the region of the primitive streak of a hen's ovum incubated six hours,	132
80. Transverse sections of a generative area, with half-formed primi- tive streak, of a hen's egg,	133
81. Transverse section of the anterior region of a fully developed primi- tive streak of a hen's ovum,	135
82. Blastodermic vesicle of a rabbit of seven days,	136
83. Transverse section of the embryonic shield of the blastodermic vesicle of a sheep,	137
84. Central portion of a sheep's blastodermic vesicle of twelve to thir- teen days,	138
85. Embryonic shield of a rabbit's ovum of five days,	139
86. Section of the primitive streak of the mole,	140
87. Blastodermic vesicle of <i>Mus sylvaticus</i> ,	142
88. Axolotl embryo ; transverse section of an early stage,	146
89. Diagrams of the embryonic area of the chick,	150
90. Diagram of the embryonic area of a chick,	150
91. The mesodermal cavities of the germinal area of a chick of the third day,	151
92. Section of a chicken embryo of about thirty-six hours,	152
93. Transverse section of an amphioxus embryo,	156
94. Amphioxus embryo,	157
95. Opossum embryo of seventy-three hours ; transverse section at the level of the heart,	173
96. Blastoderm of rabbit's ovum,	174
97. Chicken embryo with seven primitive segments,	175
98. Part of a transverse section of a young mole embryo,	176
99. Surface view of a young mole embryo,	176
100. Transverse section of a mole embryo,	176
101. Early stage of <i>Amblystoma punctatum</i> ,	177
102. Part of a transverse section of an axolotl embryo,	178
103. Transverse section of a rabbit embryo of eight days and two hours,	179
104. Part of a transverse section of an embryo of <i>Lumbricus trapezoides</i> ,	180
105. Transverse section of a mole embryo,	183
106. Longitudinal section of the head end of a mole embryo,	183
107. Rabbit embryo of 6 mm. ; median longitudinal section of the head,	185
108. Longitudinal sections of the notochord of bombinator,	186
109. Degenerating notochord tissue, from the central portion of the in- tervertebral disc of a cow's embryo,	187
110. Longitudinal section of a frog's ovum, shortly after closure of the medullary groove,	188
111. Transverse section of an embryo paroquet (<i>melopsittacus</i>) to show the anterior or true neurenteric canal,	189

FIG.	PAGE
112. Chicken embryo with one segment,	193
113. Area vasculosa and embryo with eight segments of a hen's egg,	193
114. Rabbit embryo with eight segments,	194
115. Transverse section of a pristurus embryo with fourteen segments, through the centre of the fourth segment,	194
116. Transverse section through a recently formed primitive segment of a chick with eighteen and twenty segments,	196
117. Section of a chick with about twenty segments,	198
118. Head of an embryo of <i>Torpedo ocellata</i> , in Balfour's stage J,	200
119. Longitudinal vertical section through five primitive segments of a rabbit embryo of nine days and seventeen hours,	204
120. Longitudinal horizontal section through a segment of a rabbit embryo of ten and one-half days,	205
121. Transverse section through the upper part of a myotome of a chick of about seventy hours,	206
122. Pristurus embryo with forty-five to forty-six segments,	208
123. Diagram of a cross-section of a young amphioxus,	209
124. Surface view of a small part of the vascular network of an embryo chick of two days,	212
125. Vascular anlagen of the area vasculosa of a chick of forty hours,	213
126. Section of the area vasculosa of a chick,	214
127. Corpuseles from rabbits, from acanthias, from a chick, from a human embryo,	219
128. <i>Salamandra maculosa</i> ; larva, very young; transverse section to show the formation of the coelom in the heart region,	224
129. <i>Salamandra maculosa</i> , larva with branchial arches,	225
129A. Embryo chick; section through the anlage of heart,	226
130. Chick embryo,	227
131. Diagrammatic cross-section of a vertebrate to show the fundamental relations of the urogenital system,	230
132. <i>Rana temporaria</i> . Tadpole of 12 mm. Cross-section through the pronephros,	231
133. Nephridium (or Wolffian tubule) of an acanthias embryo of 28.2 mm., seen from the caudal side; reconstructed from the sections,	236
134. Section through a Wolffian tubule of a chick with primitive segments,	238
135. Wolffian tubule of a sheep embryo of 9 mm.,	238
136. Coste's embryo of thirty-five days,	240
137. Transverse section of the Wolffian body or primitive kidney of a rabbit of thirteen days,	241
138. Longitudinal vertical section of the Wolffian body of a rabbit embryo of thirteen days,	242
139. Section through the testis of a human embryo of sixty-three to sixty-eight days,	244
140. Transverse section through an advanced embryo of a shark, <i>Scyrnus liehia</i> ; from the abdominal region (dots represent nuclei),	247
141. Section of the urogenital fold of a chick embryo of the fourth day,	248
142. Diagrammatic section of the yellow of a hen's egg at an early stage to show the relations of the archenteron to the yolk-sac,	255
143. Diagrams to illustrate the separation of the embryo from the yolk,	256
144. Cross-section of a rabbit embryo of eight days and two hours,	257

FIG.	PAGE
145. Longitudinal section of the posterior end of a sheep embryo of sixteen days,	258
146. Longitudinal median section of young chick embryo,	261
147. Transverse section of the head of a chick embryo with seven segments,	262
148. Two views of a wax model of the cavity of the pharynx of a rabbit embryo of eleven days,	264
149. Acanthias embryo of 17 mm. Horizontal section of the anterior half,	266
150. Chicken embryo of sixty-eight hours,	266
151. Acanthias of 17 mm.,	267
152. Cross-section of a branchial arch of an advanced shark embryo,	267
153. Longitudinal section of an embryo of <i>Petromyzon planeri</i> , four days old, reared at Naples,	268
154. Diagrams to indicate the fundamental relations of the archenteron,	270
155. Chicken embryo and germ area after twenty-seven hours' incubation,	272
156. Embryonic area of a rabbit of eleven days, with the placental area partly torn off,	273
157. Diagram of the circulation in a chick at the end of the third day, as seen from the under or ventral side,	274
158. Area vasculosa and embryo of a rabbit,	275
159. Transverse section of the rump of a dog-fish embryo 14 mm. long,	280
160. Section through the rump of a rabbit embryo of eight days and three hours,	282
161. Transverse section of the rump of an embryo chick of the third day,	283
162. Diagrams to illustrate His' theory of the origin of the human amnion,	285
163. Reichert's ovum. Two views engraved from the original plate,	288
164. Cross-section of Spee's embryo,	292
165. Section passing through the blastopore of Spee's embryo,	292
166. Diagram of His' embryo E: age fourteen (?) days; length about 2.3 mm.,	293
167. Thomson's second ovum,	294
168. Human embryo of thirteen to fourteen days,	295
169. Embryo of the beginning of third week,	296
170. Human embryo of 2.15 mm.; anatomy reconstructed from the sections	297
171. His' embryo L, 2.4 mm. long,	299
172. Ovum supposed to be from fifteen to eighteen days old,	301
173. Embryo supposed to be from fifteen to eighteen days old,	302
174. Fragment of the chorion of fig. 4, highly magnified,	302
175. His' embryo M,	304
176. Digestive canal of His' embryo,	305
177. Anterior wall of the pharynx of His' embryo BB, 3.2 mm. long,	305
178. W. His' embryo M,	306
179. Reconstruction of His' embryo BB, 3.2 mm. long,	306
180. Reconstruction of His' embryo,	307
181. Isolated terminal branch of a villus from the chorion of an embryo of twelve weeks,	320
182. Villous stem from a placenta of the fifth month,	320
183. Terminal villi of a placenta at full term,	320
184. Section of the chorion at three weeks,	321
185. Aborting villus from a chorion of the second month,	321
186. Placental chorion of an embryo of seven months,	324

FIG.	PAGE
187. Section of the chorionic membrane of an ovum supposed to belong to the third week,	328
188. Section of the chorionic membrane of an embryo of three weeks,	329
189. Section of the amnion and placental chorion of the fifth month,	329
190. Adenoid tissue of a villus from a placenta of four months,	330
191. Section of the amnion covering the placenta of a two months embryo,	334
192. Two sections of the placental amnion,	334
193. A natural group of nuclei from the mesoderm of the amnion of a fetus of the fifth month,	335
194. Mesodermic nuclei of the amnion of an embryo of about four months,	335
195. Surface view of the amniotic epithelium of an embryo of 144 days,	336
196. Diagram of the development of the foetal adnexa in the rabbit,	343
197. Longitudinal median section of a petromyzon larva,	346
198. Wall of the yolk-sac in the area opaca of a chick of the second day,	347
199. Section of the yolk-sac of a human embryo,	350
200. Diagram of the embryo and yolk-sac of a rabbit,	351
201. Vertical section of the wall of the yolk-sac of a rabbit embryo of thirteen days,	351
202. Diagram of an opossum embryo and its appendages,	351
203. Section of the allantois from the umbilical cord of an embryo of three months,	355
204. Diagrammatic section of the bauchstiel of a human embryo, modified from W. His,	356
205. Sections of human umbilical cords,	357
206. Connective tissue of the umbilical cord of an embryo of 21 mm.,	358
207. Connective tissue of the umbilical cord of a human embryo of about three months,	359
208. Epithelial covering of the umbilical cord of an embryo of three months,	360
209. Cross-section of an umbilical cord at term,	362
210. Placenta at full term, doubly injected by Dr. H. P. Quiney to show the distribution of the vessels upon the surface,	365
211. Placenta at full term,	367
212. Mesenchymal tissue of a villus, from a placenta of four months,	368
213. Section through a normal placenta of about seven months, <i>in situ</i> ,	370
214. Portion of an injected villus from a placenta of about five months,	371
215. Placenta of about five months; portion of a small villus,	371
216. His' embryo <i>a</i> , age probably twenty-three days,	385
217. Fol's embryo of 5.6 mm., probably twenty-five days old,	386
218. His' Embryo A, 7.5 mm. long,	387
219. Embryo of 9.8 mm.,	388
220. Embryo of about 14 mm.,	389
221. Dorsal view of an embryo of about 14 mm.,	389
222. Embryo of about thirty-five days,	390
223. His' embryo XXXIV,	391
224. Embryo of 22 mm.,	392
225. Embryo of 28 mm.,	392
226. Embryo of 32 mm.,	393
227. Embryo of 34 mm.,	393
228. Embryo of 55 mm.,	393
229. Embryo of 78 mm.,	394

FIG.	PAGE
230. Front view of the head and face of the embryo,	394
231. Embryo of about 120 mm.,	394
232. Embryo of 118 mm.,	395
233. Embryo of 155 mm.,	396
234. Mesenchyma of a chick embryo of the third day from close to the otoecyst,	399
235. Omentum of a human embryo of five months,	400
236. Parietal bone of a human embryo of fourteen weeks,	408
237. Transverse section of the mandible of a human embryo of the tenth week,	408
238. From a section of an ossifying vertebra of a human embryo of four months,	411
239. Section of a vertebra of the same embryo at right angles to the plane of fig. 238. and corresponding in level to the lower part of the bracket L, fig. 238,	412
240. Artery from the allantois of a chick, surrounded by a network of lymphatics,	414
241. Section of the spleen of a human embryo of six months,	416
242. Fat island from the skin of a human embryo of five months,	418
243. Reconstruction of the last occipital, and first two cervical vertebra of a cow embryo of 8.8 mm.,	425
244. Cross-section of the anlage of second cervical vertebra of a cow embryo of 8.8 mm.,	425
245. Longitudinal median section of the upper portion of the vertebral column of a cow embryo of 22.5 mm.,	427
246. Frontal projection of the cephalic part of a vertebral column of a cow embryo,	431
247. Embryo pig of about 16 mm.,	435
248. Embryo pig, one and one-third inch long,	436
249. Section of the anterior portion of the snout of an embryo pig,	437
250. Embryo pig, six inches long,	439
251. Chondrocranium of an insectivorous mammal (<i>Tatusia</i>),	442
252. Pectoral fin of a young embryo of <i>syellium</i> in longitudinal and horizontal section,	449
253. Scapula of a human embryo of five and one-half inches, dorsal view,	453
254. Vertical section of the ankle of a human embryo of nearly six months,	459
255. Isolated muscle fibres of a frog embryo,	471
256. A, transverse section; B, longitudinal section of muscle fibres in the neck of a human embryo of sixty-three to sixty-eight days,	472
257. Chick embryo, transverse section of the upper part of a myotome,	476
258. Transverse section of a branchial arch of a selachian embryo,	478
259. His' embryo R, 5 mm. Reconstruction to show the septum trans- versum,	480
260. Head of a rabbit embryo, with segments seen from the under side,	481
261. Rabbit embryo, eight and a half days, with eleven or twelve somites, cross-section,	482
262. Model of part of the pleural and abdominal cavities of a rat embryo at a stage corresponding to a rabbit at fifteen days,	484
263. Section of the supra-renal body of a rabbit embryo of twenty-six days,	487
264. Supra-renal capsule of a four months' human embryo,	488
265. Diagram of the indifferent stage of the urogenital system of amniota,	490

FIG.	PAGE
266. Diagram to illustrate the homologies of the sexual apparatus,	491
267. Section of the testis of a human embryo of sixty-three to sixty-eight days,	493
268. Section of the ovary of a human embryo of 7 cm.,	495
269. To illustrate the decensus testicularum,	498
270. Cross-section of the ovary and Wolffian body of a human embryo of the third month,	499
271. Cross-section of the rectum, genital cord, and allantois of a male human embryo of about two months,	502
272. Section of broad ligament of a female human embryo of four months,	504
273. Cross-section through the hind end of the left Wolffian body of a crocodile embryo of 12 mm.,	508
274. Section of a kidney, human embryo of about five months,	509
275. Semidiagrammatic figures of developing renal tubules of a mammal,	510
276. Section parallel to the medullary rays of the kidney of a human fœtus of about five months,	511
277. Cross-section of the medullary tubules of the kidney of a human embryo of about five months,	512
278. Longitudinal median section of the cloaca of a sheep embryo of 18 mm.,	517
279. Longitudinal section of the penis of a human embryo of about five months,	518
280. External genitalia, female embryo of 105 mm.,	518
281. Section of the clitoris and labia majora of a human embryo of about four and one-half months,	519
282. External genitalia of the female human fœtus at about four months,	519
283. Head of chick of thirty-eight hours, seen from the under side,	522
284. Reconstruction of the heart and veins of a human embryo of 2.15 mm.,	522
285. Endothelial heart of a human embryo of 2.15 mm.; seen from the left side,	522
286. Reconstructed side view of the endothelial heart of a human embryo of 4.2 mm.,	523
287. Model of the muscular heart of a rabbit embryo of nine to nine and one-half days, seen from the left side,	523
288. Endothelial heart of a human embryo of 5 mm.,	524
289. Inner surface of the heart of a human embryo of 10 mm.,	524
290. Section of the heart and pericardial cavity of a rabbit embryo of ten and one-half days,	526
291. Section in the frontal plane through the heart of a rabbit embryo of thirteen days,	529
292. Oblique section of the heart of a human embryo of 8.5 mm.,	530
293. Sections at different levels through the cardiac aorta of a human embryo of 11.5 mm.,	531
294. A diagram of pharynx of an amniote vertebrate,	535
295. Anterior wall of the pharynx of a human embryo of 3.2 mm. length,	536
296. Aortic system of His' embryo Bl, 4.25 mm.,	536
297. Aortic system of His' embryo Si, 12.5 mm.; seen from the front,	537
298. Aortic system of W. His' embryo Rg, 11.5 mm.,	539
299. Reconstruction of the arteries of the head and neck of a rabbit embryo at the end of the eleventh day,	540
300. His' embryo Lr (4.2 mm.). Reconstruction to show the course of the blood-vessels,	542

LIST OF ILLUSTRATIONS.

xix

FIG.	PAGE
301. Cross-section through the hinder part of His' embryo R (5 mm.),	542
302. Three diagrams to illustrate the transformation of the venous system,	543
303. Reconstruction of a human embryo (His' Bl.) of 4.25 mm.,	545
304. Reconstruction of the venous trunks and liver of His' embryo R, 5 mm.,	546
305. Reconstruction of the venous system of His' embryo Rg, 11.5 mm.,	547
306. Section of the skin of a human embryo of sixty-three to sixty-eight days,	548
307. Epidermis from the occiput of the human embryo of two and one-half months,	550
308. Section of the skin of the under side of the right second toe of four months' embryo,	551
309. Epitrichium of a human embryo of the fifth month,	552
310. Vertical section of the skin of a human embryo of the fifth month,	554
311. Longitudinal section of the nail of the great toe of a human embryo of five months,	556
312. Development of hairs in a human embryo of about seven months,	558
313. Isolated epidermis of a human embryo of five to six months,	559
314. Section of the sole of the foot of a fœtus of the fifth month, to show the sweat glands,	563
315. Development of the mammary gland in the rabbit,	564
316. Acanthias embryo of 17 mm., under side,	569
317. Blastoderm of a dog-fish, acanthias, with commencing tonrescence,	570
318. Longitudinal median section of a recently hatched larva of petromyzon,	572
319. Longitudinal section of an acanthias embryo of 13.2 mm.,	572
320. Median section of the head of a rabbit embryo of thirteen and one-half days,	573
321. His' embryo A, 7.5 mm.,	576
322. Facial region of a human embryo of 8 mm., front view,	576
323. Reconstruction of the face of His' embryo Sch,	577
324. View of the roof of the mouth of a human embryo,	578
325. Frontal section of the oral and nasal chambers of a young cow embryo,	579
326. Frontal section of the nasal and oral cavities of a human embryo of three months,	581
327. Dental papilla of a dermal tooth of an acanthias embryo of 10 cm.,	582
328. Section of the lower jaw of an acanthias embryo of 10 cm.,	582
329. Section of part of the lower jaw of a human embryo of 40 mm.,	583
330. Explanation in text,	584
331. Vertical section of a molar tooth-germ of a human embryo of 160 mm.,	585
332. Part of the enamel organ of a new-born child, incisor germ,	586
333. Odontoblasts from cow embryos. A, of 30 cm.; B, of 24 cm.,	588
334. Section of the submaxillary gland of a human embryo of sixty-three to sixty-eight days,	591
335. Reconstruction of the pharynx of a human embryo,	592
336. Chick embryo of twenty-nine hours,	594
337. Cross-section through the fore-brain and optic vesicles of a lepidosteus embryo of eight days,	595
338. Brain of embryo No. 22, p. 297.	596
339. Reconstruction of the brain of His' embryo Ko,	597
340. Reconstructed median view of the fore-brain of His' embryo Ko,	597

FIG.	PAGE
341. Brain of a human embryo of five weeks,	599
342. Hind-brain of a human embryo,	600
343. Dorsal view of the hind-brain of a human embryo of one month,	600
344. Sections through the cervical part of the medulla of a human embryo with thirteen segments,	602
345. Longitudinal horizontal section of the wall of the hind-brain of a young embryo of a lizard (<i>Anolis Sagrei</i>),	605
346. Diagrammatic section of the embryonic spinal cord,	607
347. Section of the medulla and otcocysts,	608
348. Sections through the regions 3 and 5 of the hind-brain of His' embryo,	608
349. Sections through the region 3 of the hind-brain of His' embryo A,	609
350. Four sections of the brain of a human embryo of about five weeks,	609
351. Brain of His' embryo Br. 3,	610
352. Neuroglia of the dorsal zone of the spinal cord of a human embryo of about three and one-half weeks,	613
353. Cross-section of the spinal cord of a human embryo of 14 mm., to show the neuroglia cells,	614
354. Part of a transverse section of the spinal cord of a human embryo of 23 cm.,	615
355. From a section of the medulla oblongata of His' embryo Br ³ .,	617
356. Group of motor neuroblasts and nerve fibres from a transverse section of the spinal cord of a cat embryo of 6 mm.,	618
357. Bipolar cells from a spinal ganglion of an embryo,	619
358. Transverse section of the dorsal cord and ganglion of a chick of nine days,	620
359. Isolated nerve fibres from the sciatic nerve of a sheep embryo of 150 mm.,	621
360. Part of the nerves of a human embryo of 13.8 mm.,	623
361. Cells and nuclei from the cervical region of the spinal cord of a human embryo of one hundred and sixty days,	624
362. Spinal ganglion cells from a longitudinal horizontal section of a human embryo of the tenth week,	626
363. Peripheral nervous system of a human embryo of about 10 mm.,	628
364. Transverse section of a mouse embryo of about seventeen to eighteen days through the lumbar region,	629
365. Transverse section of the sympathetic cord from the lower dorsal region of a rat embryo of about thirteen days,	631
366. Sympathetic ganglia of one side of a human embryo of the fifth month,	632
367. Transverse section through the posterior part of the mid-brain of a human embryo of five weeks,	639
368. Section of the brain of a five weeks' embryo,	640
369. Section of the brain of a five weeks' embryo,	643
370. Section of the brain of a human embryo of five weeks,	645
371. Otcocysis and nerves of a human embryo of four and one-half weeks,	647
372. Acoustic ganglia of a human embryo of two months,	647
373. Torpedo embryo of 12 mm.,	653
374. Section of the medulla oblongata of a five weeks' human embryo,	655
375. Lower end of the spinal cord of a human embryo of three months,	658
376. Section of the spinal cord of a human embryo of sixty-three to sixty-eight days,	660

FIG.	PAGE
377. Transverse section of the spinal cord from the upper dorsal region of a human embryo of six weeks,	661
378. Lower cervical cord of a human embryo of about five months,	663
379. Transverse section of the medulla oblongata of His' embryo Ru,	666
380. Transverse section of the medulla oblongata of His' embryo Mr,	667
381. Section through the medulla oblongata of His' embryo CR,	669
382. Median section of the brain of a chick embryo of about four days,	673
383. Longitudinal median section of the cerebellum of a chick of about twelve days,	673
384. Section through the cerebellum and medulla oblongata of a human embryo of one hundred and sixty days,	674
385. Section of the cerebellum of a human embryo of one hundred and sixty days,	675
386. Median section of the head of a sheep embryo of .36 mm.,	678
387. Brain, human fœtus, five months,	678
388. Part of the brain of His' embryo CR, 13.6 mm.,	679
389. Section of the thalamencephalon of an embryo of five weeks,	681
390. Section of the fore-brain of a sheep embryo of 27 mm.,	681
391. Brain of a human embryo of about three months,	683
392. Brain of a human embryo of the fourth month,	683
393. Median view of a frog's brain,	684
394. Section through the fore-brain of a fœtal guinea-pig,	685
395. Reconstruction of the brain of an embryo of about seven and one-half weeks,	686
396. Brain of a chick embryo, fourth day,	688
397. Human embryo of about four months; brain <i>in situ</i> ,	691
398. Section through the lateral wall of the cerebral hemisphere of a human embryo of four months,	694
399. View of the hemisphere of a human embryo from the early part of the third month,	695
400. Outlines of the fissure of Sylvius of human embryos at successive lunar months,	696
401. Median view of the fore-brain of a human embryo from the beginning of the third month,	696
402. Brain of human embryo of the fifth month after removal of the right hemisphere,	698
403. Right hemisphere, natural size of a fœtus of nearly seven months,	699
404. Under side of the brain of a human embryo of the fifth month,	700
405. Section of the fore-brain of a human embryo of nearly five weeks,	704
406. Horizontal section of the ciliary ganglion of a young torpedo embryo,	707
407. Reconstruction to show the cephalic ganglia of a petromyzon larva 4 mm. long,	707
408. Rabbit embryo of ten and one-half days; section of head,	711
409. Rabbit embryo of thirteen days; section of the eye,	712
410. Reconstruction from His' embryo Seh, 13.8 mm.,	713
411. Section through the iris region of the eye of a chick of thirteen days,	714
412. Rabbit embryo of ten and one-half days; section of the lens anlage,	715
413. Vertical section of the eye of a chick embryo of the third day,	715
414. Section of the distal portion of the optic nerve of a rabbit embryo of thirteen days,	718
415. Surface view of the membrana limitans externa with the developing rods and cones of a chick of fifteen to sixteen days,	720

FIG.	PAGE
416. Injected vascular membrane of the retina of the eye of a pig embryo, 16 cm. long.	721
417. Section through the iris region of the eye of a chick of thirteen days.	725
418. United eyelids of a human embryo of about four months, seen in vertical section.	726
419. Sections of human embryos showing the otoecyst; A, embryo of 2.4 mm.; B, embryo of 4 mm.. . . .	728
420. Horizontal section of the otoecyst of a chick of the third day.	729
421. Left otoecyst of a human embryo of about four weeks; A, from the inner, B, from the outer side.	729
422. Transverse section of the head of a rabbit embryo of ten and one-half days.	730
423. Left otoecyst of a human embryo of about five weeks, seen from outside and below.	730
424. Transverse section of the semicircular canal of an embryo rabbit of twenty-four days.	731
425. Left otoecyst of a human embryo of about two months.	732
426. Transverse section of scala media cochleæ of a rabbit embryo of 55 mm.. . . .	733
427. Section through Corti's organ of the lower coil of the cochleæ of a rabbit embryo of 75 mm.,	734
428. Section through the internal ear of a sheep embryo, 28 mm.,	736
429. Isolated right membranous labyrinth of human embryo of six months, seen from in front and outside.	737
430. Section through the region of the ear of a human embryo of three months.	739
431. Development of the human external ear; A, embryo of one month; B, six weeks; C, eight weeks; D, ten weeks; E, fourteen weeks.	741
432. Reconstruction of the pharyngeal region of a human embryo of 11.5 mm.,	744
433. From a section of a tonsil of a human embryo of five months.	745
434. Section through the third gill-cleft of a human embryo from the beginning of the third week.	746
435. Reconstruction of the pharyngeal region of a human embryo of 9.1 mm.,	748
436. Reconstructions to show the development of the thyroid gland in the pig; A, embryo of 15 mm.; B, of 16 mm.; C, of 20 mm.; D, of 22.5 mm.,	749
437. A, section of the thyroid gland of a human embryo of about four months; B, a single acinus, more highly magnified.	751
438. Reconstruction of His' embryo B; the head is drawn as if erected.	752
439. Transverse section of the œsophagus of a human embryo of four months.	752
440. Highly magnified view of a small portion of the epithelium of fig. 439.	753
441. Reconstruction of Fol's embryo.	753
442. Epithelium of the greater curvature of the stomach of an embryo cat of 85 mm.,	754
443. Peptic glands from the greater curvature of stomach of a human embryo from the end of the eighth lunar month.	754
444. Digestive tracts of four human embryos. A, embryo of 4.2 mm.; B, embryo of 7 mm.; C, embryo of 13.8 mm.; D, embryo of 12.5 mm.,	756

FIG.	PAGE
445. Two front views of the entodermal canal. A, embryo Sch. 1 of His'; B, His' embryo Sch. 2,	757
446. Part of the intestine of a human embryo of about six months,	758
447. Section of the small intestine of a human embryo of sixty-three to sixty-eight days,	759
448. Section of the small intestine of a human embryo of three months,	759
449. Portion of a section of the liver of an acanthias embryo of 29 mm.,	761
450. Section through the liver of a rabbit embryo of thirteen days,	763
451. Section of a rabbit embryo of thirteen days through the region of the fore limbs and liver,	764
452. Section of the pancreas of a human embryo of four months,	767
453. Two diagrams to illustrate morphological relations of the vertebrate mesentery; A, earlier; B, later condition,	768
454. Diagram to illustrate the relations of the mesentery,	768
455. Diagram of the human mesentery in its primitive relations,	769
456. Diagrams to illustrate the history of the human mesentery. A, earlier; B, later condition,	770
457. Two diagrams to illustrate the history of the mesentery; A, earlier; B, later stages,	771
458. Outline of the entodermal canal of His' embryo Lr.,	773
459. Three views of the lungs of a human embryo of 10.5 mm.,	775
460. Lungs of a human embryo of five months,	776
461. Cross-section of the bronchial tube of a human embryo of sixty- three to sixty-eight days,	777
462. Section through the lung of a human embryo of the fourth month,	777
463. Epithelium and gland of the trachea of a four months' embryo,	778



HUMAN EMBRYOLOGY.

INTRODUCTION.

CHAPTER I.

THE UTERUS.

THE uterus enters in the mammalia into such intimate relations with the embryo, that a thorough knowledge of its structure is necessary to the embryologist. The treatment of the uterus in the text-books of human anatomy is usually too brief for the requirements of embryology. These considerations make it desirable to give a somewhat detailed account of the human uterus.

The uterus is the most variable organ within normal limits of the body, both as to size and structure. The virgin uterus is about three inches long and two inches wide at the upper part, where it is broadest; it weighs about 40 grammes. At the end of pregnancy it is about ten inches long and nine wide, and weighs about 1,000 grammes. The walls of the virgin or resting uterus are tense and mainly muscular; those of the pregnant organ are more spongy in texture and extremely vascular, yet at the same time the muscular layers are greatly increased, though relatively less than the vascular layer. After a pregnancy the uterus never returns to its primitive condition, and its weight does not fall below two or three ounces; from the gradual effects of advanced age, however, and independent of pregnancy, the uterus shrinks, becomes paler in color, and harder in texture. Finally at each successive recurrence of menstruation a complete removal of the superficial part of the mucous membrane takes place by a process, which we can describe but not explain. The removal is said to commence close to the cervix or at the *os internum*, and to progress toward the fundus during the remaining days of the flow of blood. As the shape and topographical relations are sufficiently described in the standard Anatomies, we confine ourselves principally to the histology. The descriptions are arranged in the following order:

1. Muscularis.
2. Mucosa corpus uteri.
3. Mucosa cervicis.
4. Blood-vessels.
5. Lymphatics.

1. Muscular Coat.—The volume of the muscularis varies greatly with the condition of the uterus, for during pregnancy the muscles

undergo a progressive hypertrophy, which is so great that not only is there an enormous expansion corresponding to the dilatation of the uterus, but also a great thickening of the coat. The increase in volume is due—1, to the growth of the single fibres (in length from 44–68 μ to 220–560 μ); 2, it is said also by the development of new muscle cells from small granular cells. After parturition the fibres in part return to their original size, in part undergo fatty degeneration (Kölliker, "Gewebelehre," 1867, p. 566).

The disposition of the fibres is most readily elucidated in uteri near the end of gestation. Having made no original observations on this subject, I transcribe the following passage from Quain's "Anatomy": "The external layer of the muscular coat forms a thin superficial sheet immediately beneath the peritoneum, and incomplete strata situated more deeply. A large share of these fibres, beginning as longitudinal bands at the cervix, arch transversely and obliquely over the fundus and adjoining part of the body of the organ, and pass on each side into the broad ligament. Of these some at either side run toward the commencement of the round ligaments, along which they are in part prolonged to the groin; others pass off to the Fallopian tubes, and strong transverse bands from the anterior and posterior surfaces are extended into the ovarian ligaments. Other fibres run back from the cervix uteri beneath the recto-uterine folds of the peritoneum. The inner layer of the muscular coat, which is also thin, is composed of fibres which are found chiefly on the back of the uterus, and stretch over the fundus and toward the sides, running somewhat irregularly between the ramifications of the blood-vessels." On the inner boundary the mucosa is quite sharply set off from the muscularis; an erroneous contrary statement is frequent in English and American works.

It is commonly asserted that the muscular coat of the uterus is largely made up of the hypertrophied *muscularis mucosæ*. The evidence for this view is not to be found either in the anatomy or in the developmental history of the uterus, but, so far as I can ascertain, solely in the preconception that every *mucosa* must have a special muscularis to itself, as is the case in the intestine, for example. Comparative anatomy, however, is conclusive on this point; for it is not rare to find a mucosa without the special muscle layer. The true morphological relations are probably the reverse of those which have been assumed by the view here criticised; the primitive form is probably a mucosa composed of epithelium and sub-epithelial connective tissue resting on a muscular layer, as in the uterus; the secondary form, that in which other muscular fibres have been differentiated to form a special layer, the *muscularis mucosæ*.

The muscle fibres have been shown by Elischer, 76.1, to differ somewhat from the forms known in other organs. They are elongated cells, often spindle-shaped, but frequently broad and stumpy; in the pregnant uterus they are enlarged and flattened; in length they increase from 40–60 μ (virgin uterus) to 300–600 μ (uterus at term): in transverse section they are seen to be more or less distinctly polyhedral: their ends and sometimes their sides bear branching processes; they have one, sometimes two, or even more nuclei, which are usually oval, sometimes round, and usually nucleolo-

lated; the nucleolus is eccentric. The nucleus is surrounded by granular matter, which stretches out toward each end of the cell; often the granules are separated by a clear space from the nucleus. This space has been observed by various authors. Eimer has found it in several sorts of cells and gives it the name of hyaloid. It is a peculiarity of the uterus that its muscle cells vary greatly among themselves in appearance.

2. Mucosa Corporis Uteri. (A). Virginalis.—At birth the mucosa of the body of the uterus is about 0.2 mm. thick, soft, pale gray or reddish-gray; it consists of a covering ciliated cylinder epithelium and a connective-tissue layer; it is without glands, the glands not appearing usually until the third or fourth year, and developing very slowly up to the age of puberty. Wyder, **78.1**, has shown that the time of the appearance of the glands is extremely variable.

In the virgin resting uterus after puberty the mucosa is about 1 mm. in thickness. It is sharply marked off from the muscularis. The glands are tubular, often bifurcated in their lower third, round or oval in transverse section; they run more or less perpendicularly to the surface of the membrane, upon which they open; yet, strictly speaking, this is true of the glands in their upper half only, and even in that part their course is not straight but wavy. In their lower half they deviate much more, being more irregular and tortuous, the fundus curved sometimes even so much as to run parallel to the muscular layer (G. J. Engelmann, **75.1**). These differences between the upper and lower parts of the glands are accentuated during menstruation and gravidity. The glands are invaginations of the uterine epithelium, are accordingly lined by ciliated cylinder cells, and have a nucleated basement membrane (Fig. 1, *d*), formed by a layer of anastomosing connective-tissue cells (Leopold, **74.1**). Overlach, **85.1**, however, expressly denies the existence of any such membrane in the human uterus examined by him. The glands reach to, and may even slightly penetrate, the muscularis.

Between the glands is found a somewhat embryonic connective tissue, consisting of elongated cells with oval nuclei and branching

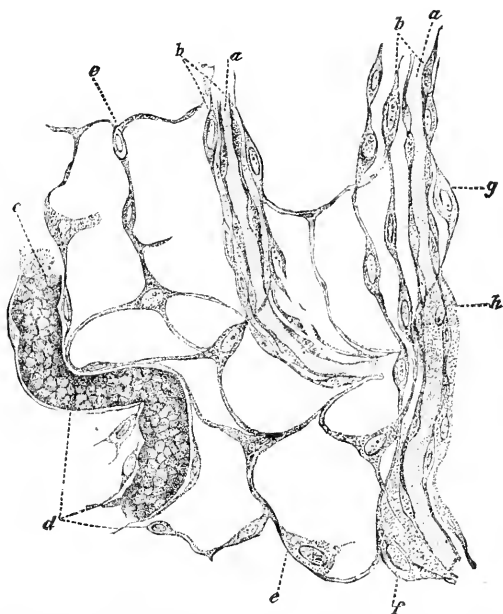


FIG. 1.—Connective tissue of mucosa, uterus of pig; *a a*, capillaries; *b b*, sheath of the same; *c*, uterine gland; *d*, gland-sheath. After Leopold.

processes, which anastomose with one another* (Fig. 1); the spaces of the cellular network communicate, according to Leopold, *l.s.c.*, with the lymphatic vessels of the muscularis and external serosa, and may therefore be regarded as lymph roots or lymph spaces. The branching spindle-cells resemble somewhat those found in the umbilical and other embryonic structures, and known under the name of mucous tissue. They tend to crowd together around the blood-vessels and glands. There do not appear to be any fibres in this layer, although some observers have so stated.

Between the spindle-cells are small, round cells, probably wandering cells (leucocytes), which vary greatly in number.

The blood-vessels enter as veins and arteries from the muscularis, and take a winding course toward the surface; the capillaries form a network around the glands and under the surface of the mucosa.

(B). Decidua Menstrualis.—The function of menstruation involves great changes in the mucosa of the body of the uterus. We distinguish three periods: 1, tumefaction of the mucosa, with accompanying structural changes, taking 5 days, or, according to Heusen, 10 days; 2, menstruation proper, about 4 days; 3, restoration of the resting mucosa, about 7 days. The times given are approximative only. The whole cycle of changes covers about 16 days; as the monthly period is about four weeks, the period of rest as thus calculated is only about 12 days.

1. TUMEFACTION.—A few days before the menstrual flow the mucosa gradually thickens; the surface becomes irregular; the openings of the glands lie in depressions. The connective-tissue cells are increased in number, and it is said by some authors in size, but the increase in size I doubt; the number of round cells increases; the glands expand and become more irregular in their course; a short time before hemorrhage begins, the blood-vessels, *especially* the capillaries and veins, become greatly distended. We must assume that the connective-tissue cells proliferate, but we have no satisfactory observations upon their division. It was formerly asserted that the menstrual decidua contains decidual cells, but in all the specimens I have studied there are none present.

2. MENSTRUATION.—When the changes just described are completed, the decidua menstrualis is fully formed, and its partial disintegration begins. The process commences with an infiltration of blood into the subepithelial tissues: this infiltration has hitherto been commonly explained as due to the rupture of the capillaries; but as no ruptures at this period have been observed, Overlach, 85.1, very justly regards this explanation as inadmissible and thinks the infiltration occurs *per diapedesin*. It lasts for a day or two, and is apparently the immediate cause of a very rapid molecular disintegration of the superficial layers of the mucosa, which in consequence are lost; the superficial blood-vessels are now exposed, and by rupturing cause the well-known hemorrhagia of menstruation; by the disappearance of its upper portion the mucosa is left without any lining epithelium, and very much (and abruptly) reduced in thickness. Its surface is formed by connective tissue and exposed

* Compare also Schmidt, Amer. Journal Obstet., Jan., 1884.

blood-vessels. The third stage is the restoration of lost parts. Signs of fatty degeneration are found during the above-mentioned disintegration. Kundrat and Engelmann, 73.1, supposed this degeneration to precede and cause the hemorrhage; but this view has not been confirmed by subsequent investigation, it having been found that the degeneration begins later than the bleeding. Overlach, 85.1, suggests that the hemorrhage is caused by the gorging of the veins and capillaries, which in its turn is caused by the contraction of the muscles of the uterus compressing the thin-walled veins. Against this view I would urge that it is not shown that marked contraction of the muscles precedes the bloody discharge, and that if it does occur it cannot be assumed that it would cause sufficient compression of the veins to produce capillary ruptures.

It is desirable to add a few words as to Williams' view, 75.1, 75.2. This author has maintained that the whole, or nearly the

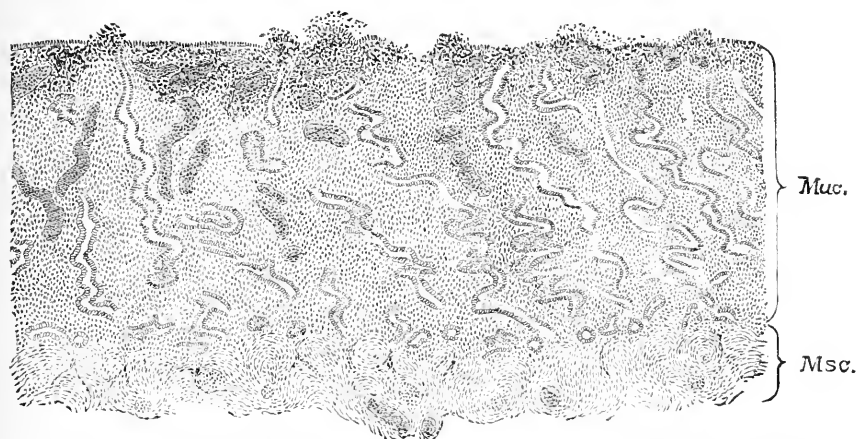


FIG. 2.—Vertical section of the *mucosa corpus uteri* of the first day of menstruation; after Leopold. *Msc.*, muscularis; *Muc.*, mucosa: the blood-vessels (shaded dark) are much distended; the glands much contorted; there is a subepithelial blood infiltration, in consequence of which the epithelium is partly lost.

whole, of the mucosa disappears from the body of the uterus during menstruation. This opinion is often cited as authoritative, especially by English and American writers, but it is now definitely known to be erroneous (Leopold, 77.1, Underhill, 75.1, *et al.*). It was based upon—1, failure to consider the effects of disease upon the uteri observed (*cf.* Wyder, 78.1, 24); 2, erroneous observations; 3, erroneous interpretations, involving a total disregard of the elementary laws of histogenesis.

Minot, 98, 413–416, describes and figures a normal virgin uterus near the close of menstruation. “The mucous membrane is from 1.1–1.3 mm. thick; its surface is irregularly tumefied; the gland openings lie for the most part in the depressions. In the cavity of the uterus there was a small blood-clot. The mucosa is sharply limited against the muscularis, Fig. 3. In transverse sections one sees that the upper fourth of the mucosa is very much broken down and disintegrated, Fig. 3, *d*; the cells stain less than those

of the deep portions of the membrane; as represented in the figure the tissue is divided into numerous more or less separate small masses; some of the blood-vessels appear torn through, but it is difficult to make sure observation." Overlach, 85.1, considers it probable that the infiltration of blood takes place by diaporesis, not by rupture of the capillaries. The superficial epithelium, *ep*, is loosened everywhere; in places fragments of it have fallen off, and in some parts it is gone altogether; it stains readily with cochineal and its nuclei color well, the epithelium differing in this respect from the underlying connective tissue, which does not stain well; the blood-vessels in the disintegrated layer are for the most part small. The deeper layer of the mucosa is dense with crowded, well-stained cells, which lie in groups separated by clearer lines; in the figure this grouping shows less plainly than in the preparation; the lighter channels are perhaps lymph vessels—a suggestion which occurs to me because in so-called "moulds" one sometimes finds similar channels crowded with leucocytes. The cells appear to be the proliferated interglandular tissue; there are very few leucocytes, so far as I can distinguish; the cells have small, oval or elongated, darkly stained nuclei, with a very small granular protoplasmatic body each; there is certainly no noticeable enlargement of the cells, but only a remarkable multiplication.

3. RESTORATION OF THE MUCOSA.—At the close of menstruation the mucosa is 2-3 mm. thick; the regeneration of the lost layers begins promptly and is completed in a variable time, probably five to ten days. The hyperæmia rapidly disappears; the extravasated blood corpuscles are partly resorbed, partly cast off; the spindle-cell network grows upward, while from the cylinder epithelium of the glands young cells grow up and produce a new epithelial covering; new subepithelial capillaries appear. The details of these changes are imperfectly known; they effect the return of the mucosa to its resting-stage.

(C). **The decidua graviditatis** is the decidua menstrualis preserved *in situ*, and considerably metamorphosed in consequence of pregnancy. The preservation is initiated by the presence of a fertilized ovum in the upper end of the Fallopian tube, as is shown for various mammals by observation, and for man by conclusive inference; and the preservation is dependent for its continuance upon the further development of the ovum *in utero*. In the very youngest gravidity yet studied (twelve days) very great alterations have occurred, and we are reduced to hypotheses to explain how these alterations are effected. The ovum at this stage is already attached to the wall of the uterus, and is completely enclosed by a special covering known as the decidual reflexa. The arrangement of the parts can also be followed in older ova, and is illustrated by the accompanying woodcut, Fig. 4, which represents a median section of a uterus about five weeks pregnant. The whole uterus is considerably enlarged; the mucosa lining the uterus is very greatly thickened; to one part of it the ovum is attached; the mucosa also rises all around the ovum, completely covering it in, so as to make a closed bag. The ovum itself is a sack, known as the chorionic vesicle, which is covered on all parts by shaggy villi, and encloses the small

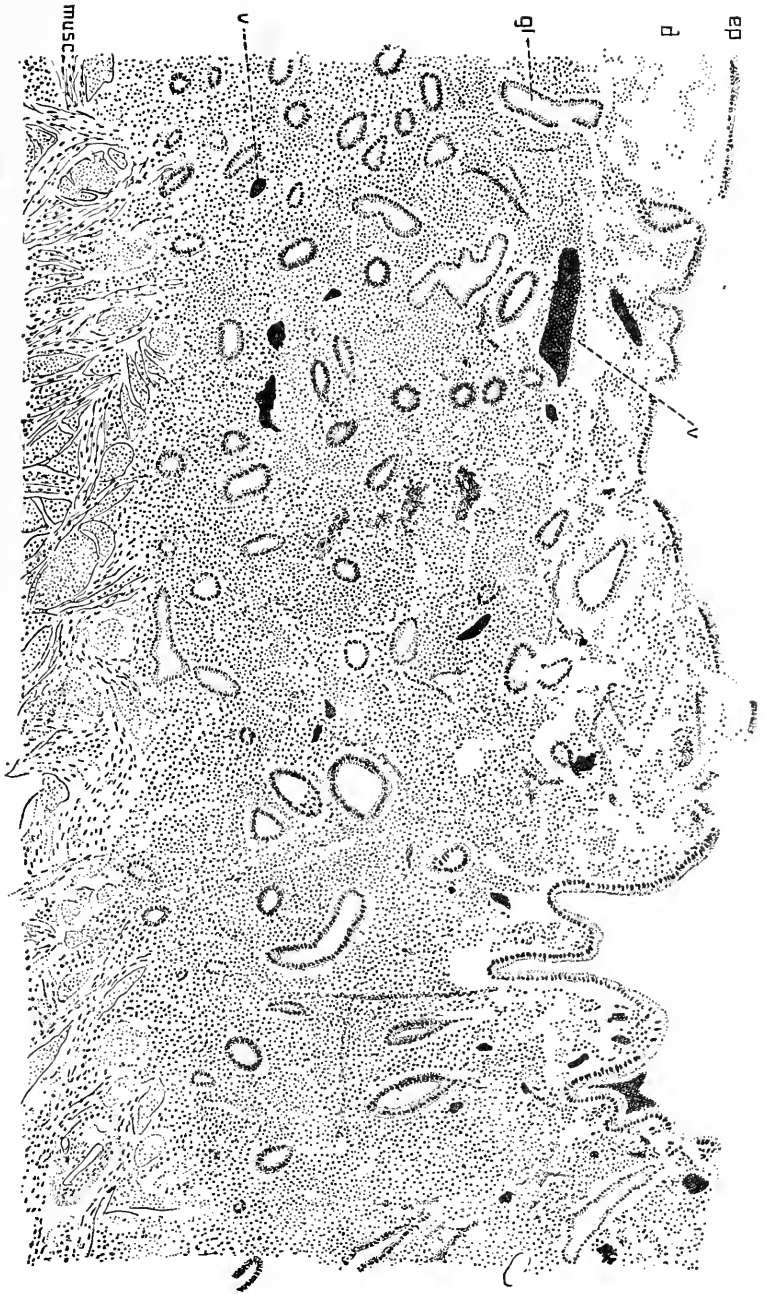

FIG. 3.—Mucous membrane of a virgin uterus during the first day of menstruation; *ep*, epithelium; *d*, disintegrated layer; *gl*, gland; *v*, blood-vessels; *musc*, muscularis. X 65 diams.

embryo in its interior; it is very important to note that only the tips of the chorionic villi come in contact with the mucosa. The mucosa, we thus learn, is divided into three parts: 1, the *decidua serotina*, the area of the uterine wall, *s s*, to which the ovum is attached; 2, the *decidua vera*, comprising all the remaining portions of the mucosa forming part of the walls of the body of the uterus; 3, the *decidua reflexa*, the arching dome of maternal tissue, *r r*,

which rises from the walls of the uterus and completely encapsules the ovum.

If the walls of the uterus are cut through and simply reflected, leaving the reflex intact, the appearances will be found essentially as in Fig. 5. The mucosa is enormously hypertrophied, and contains a great many dilated, irregular blood sinuses. From one part hangs down a large bag, the *decidua reflexa*, *D. ref.*, nearly filling the cavity of the uterus. The *reflexa* presents the same general appearance as the surface of the uterus; if the *reflexa* be opened we come upon the villous chorion of the ovum, and find as previously stated that only the tips of the villi are united with the surface of the *reflexa* or *serotina*.

To form the placenta the *serotina* and the parts of the *villi* and *chorion* connected with it (chorion frondosum of later stages) undergo synchronous hypertrophy and metamorphoses and become closely united, compare Chapter XVII.

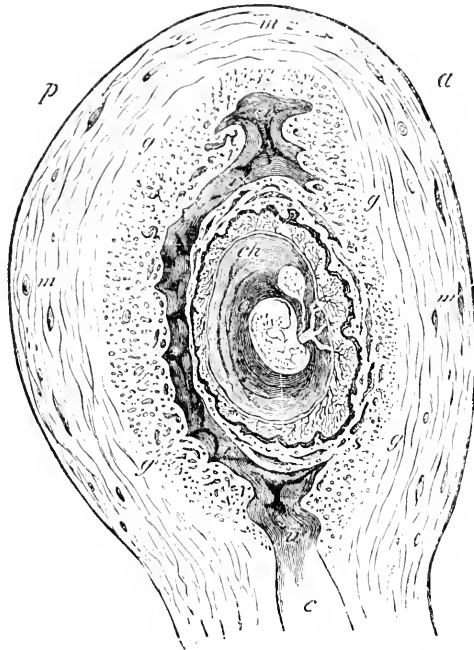


FIG. 4.—Semi-diagrammatic outline of an antero-posterior section of the gravid uterus and ovum of five weeks; *a*, anterior surface; *p*, posterior surface; *g*, inner margin of metamorphosed mucosa; *s s*, area of the *decidua serotina*;—all the parts of the mucosa adherent to the uterine walls and not included in the area of the *serotina* constitute the *decidua vera*; *ch*, chorion, within which is the embryo enclosed in the amnion, and attached to the walls of the chorion; appended to the embryo is the long-stalked yolk-sack; the chorion is covered in by the arching extension of the mucosa, which is the *decidua reflexa*, *r r*. After Allen Thompson.

In gross appearance the decidua is reddish-gray, spongy or pulpy, soft and very moist; after the fourth month it acquires, especially in the superficial layers, a duller brownish color, which subsequently becomes more marked; this coloration is due to the decidual cells. The *vera* and *serotina* are divided each into an upper or superficial more compact layer, and a deeper cavernous or spongy layer, Fig. 6; the two layers are usually of about equal thickness, but the cavernous layer sometimes encroaches upon the compact layer. After the fifth month, they are found very distinctly differentiated. The lumina of the deep layer are the cavities of the enlarged and irregu-

lar uterine glands. During the first two or three months the scattered openings of the uterine glands can still be distinguished over

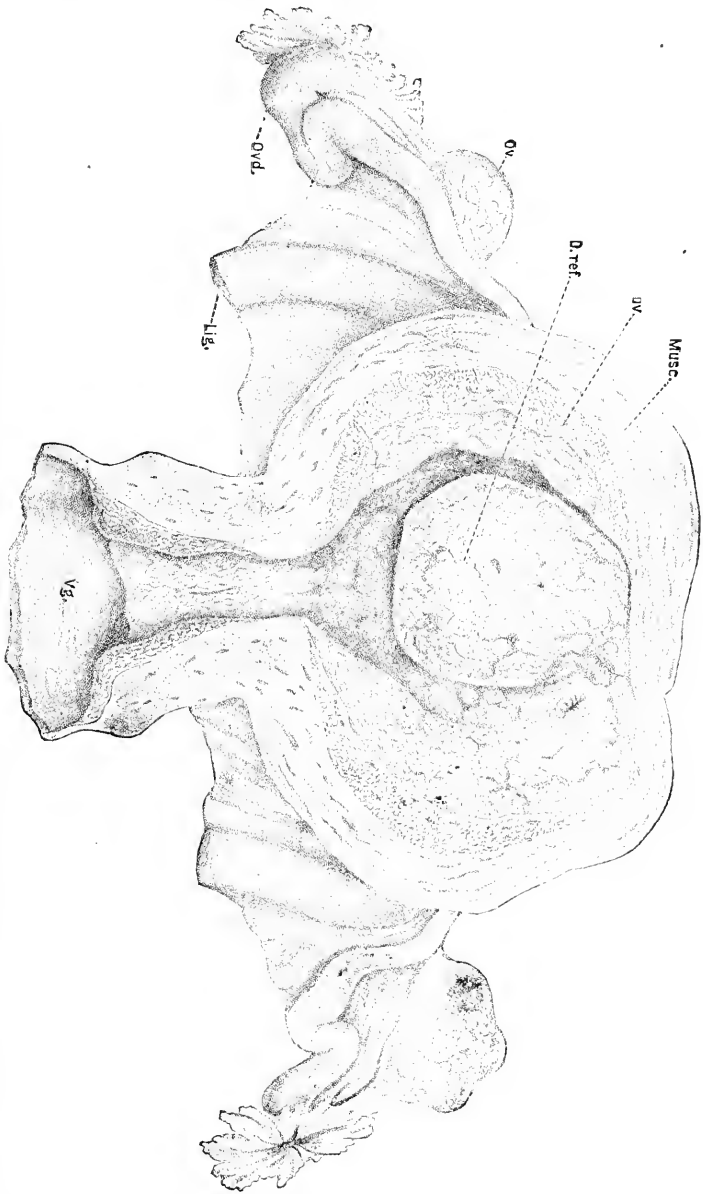


Fig. 5.—Uterus about forty days advanced in pregnancy; after Coste. *Musc.*, muscularis; *D. ver.*, decidua vera; *D. ref.*, decidua reflexa; *Ov.*, ovary; *Fallop.*, Fallopian tube; *Lig.*, round ligament; *Va.*, Vagina. The uterus has been opened by cutting through the anterior wall and reflecting the sides.

the surface alike of the vera and serotina and over *both* surfaces of the reflexa. The surfaces of the vera and reflexa, though somewhat irregular, remain more or less smooth; the inner surface of the reflexa

is more irregular, and the protuberant parts are united with the tips of the foetal chorionic villi.

The surface of the decidua serotina becomes very irregular during the progress of pregnancy. Rohr, 89. 1, has distinguished three kinds of projections in a uterus of the eighth month, viz.: 1, Hillocks, 1-4 mm. high, and with broad bases, their summits pointed, irregular or even branching; 2, columns, beginning with a slightly expanded base, narrow stalk and often enlarged ends; the columns are long and stretch up toward the chorion, which they actually reach at least in the peripheral parts of the placenta; in the central region they rise more or less vertically, but obliquely in the peripheral region; in sections of the placenta they are often cut across, and give rise then to the appearance of islands of decidual tissue in the midst of the villi; 3, septa, with wide bases rising irregularly to the height of 0.5 to 1.5 cm.; it is by these septa that the placenta is divided into the so-called cotyledons, compare Chapter XVII.

THE ORIGIN OF THE DECIDUA REFLEXA is uncertain, there being no actual observations upon its genesis. The only view which has hitherto commanded attention is the following: When the ovum attaches itself to the wall of the uterus, the mucosa (decidua) is supposed to form an annular upgrowth around it; the upgrowth continues making first a high wall, then arching over, and finally closing at the top, dome-like. I do not know with whom this hypothesis originated.

In certain rodents also there is a decidua reflexa. Selenka has shown that in them the ovum becomes completely buried in the uterine mucosa, and that the part of the mucosa covering in the ovum is converted into the reflexa as the ovum expands. In the hedgehog a reflexa is formed, according to Hübner, in a similar manner.

DISAPPEARANCE OF THE DECIDUA REFLEXA.—A very important change in the disposition of the parts takes place usually during the fifth month, viz.: the *reflexa*, which, by its own expansion, corresponding to the growth of the ovum it encloses, is pressed close against the *vera*, disappears. Its disappearance has long been known, but until recently was unexplained; it seems safe now to say that it degenerates and is resorbed, compare p. 19. In consequence of the disappearance of the reflexa the outermost layer (chorion *laeve*) of the ovum comes into direct contact with the decidua *vera*. Before the fifth month, if we cut through the uterine wall in the region of the *vera*, we come upon the decidua reflexa; after the fifth month a similar cut brings us upon the chorion of the foetus.

THE GLANDS are already dilated in the menstrual mucosa; in pregnancy the dilatation is continued, but is still chiefly confined to the deeper parts of the glands. In the same proportion as the uterus expands the deep portions of the glands become stretched in their transverse diameter and appear during the latter half of pregnancy in sections of the decidua, Fig. 10, as narrow fissures; by the fifth month the glands can no longer be traced in the upper compact layer, their ducts being obliterated. The partitions left between the glands are quite thin, Fig. 10; they carry the blood-vessels and contain spindle cells, and, it is said, also multinucleate giant-cells after the fourth month. Compare the description below of the serotina of the

eighth month. The spindle cells, as stated by Langhaus, resemble smooth muscle cells in appearance, but when isolated are seen rather to be broad, round, and flat; they ought probably to be regarded rather as true decidual cells than as merely enlarged connective-tissue cells.

The epithelium of the glands very early breaks down, as described by Minot, compare below, p. 16. The epithelial cells at first lie scattered singly in the gland cavity, although patches of them still adhere to the walls; the cells disintegrate. I have observed this degeneration in every one of a large number of specimens which I have examined of all ages up to seven months. The degree of breaking down may be said in a general way to advance with the duration of pregnancy, but even at term patches of intact epithelium and groups of single cells are always recognizable. The openings of the glands have been shown by Mogilowa, 91.1, to be closed by the growth of decidua; this fact is important, for it shows that the glands cannot discharge any secretion, and shows further that we must discard the suggestion made by Minot, 98, 426, that some of the persistent openings on the surface of the placental decidua are glandular and not vascular.

THE BLOOD-VESSELS of the mucosa are all enlarged, those in the deeper parts to a lesser degree than the superficial capillaries and veins, which are enormously dilated, forming huge, sinus-like cavities in the upper stratum of the decidua. During the latter part of pregnancy the vessels are less conspicuous. The remarkable arrangement of the blood-vessels in the decidua serotina is fully described in Chapter XVII.; it will suffice, therefore, to state now merely that the arteries and veins both open upon the surface of the decidua, so that the maternal blood circulates in the spaces between the villi of the placental chorion.

The following *changes in the blood-vessels* must be noted, beside those already mentioned in describing the gross appearances. The vessels of the *vera* and *reflexa* reach their maximum development at the end of the second month, when they begin to atrophy, preparatory to finally disappearing. Apparently in the serotina, also, the blood-vessels are reduced in volume and number toward the end of pregnancy; but this alteration needs very much to be further investigated.

GROWTH OF THE DECIDUA.—With the growth of the foetus and the consequent dilatation of the uterus, the decidua, of course, must increase rapidly in superficial extension. In fact there goes on a steady growth of the tissues, which however is not sufficient to effect the expansion of the membrane throughout the whole period of pregnancy in both superficies and thickness. The growth begins by a thickening of the mucosa within the area of the uterine wall to which the ovum is attached, so that during the third and perhaps fourth week this area (*serotina*) is the thickest portion of the decidua (Kollmann, 79.1); but the *vera* and *reflexa* also thicken, the former much the most, and soon outdo the serotina. By the end of the fifth week the reflexa measures nearly 2 mm. and the vera fully 1 cm. The absolute thickness of the serotina does not change much after this period, remaining 3 mm. or a little less up to the

end of pregnancy. On the other hand, by the eighth month the reflexa has entirely disappeared, and the vera is reduced to about 2 mm. It must be added—1, that the reflexa is thinner over the poles opposite the serotina than elsewhere, and 2, that the vera thins out toward the cervix and toward the opening of each Fallopian tube.

The decidual cells are the most striking of the histological elements of the decidua. They are *very large*, somewhat flattened, rounded, oval, or branching cells, which assume a characteristic brownish color after the fourth month; they usually have a single, often nucleolated nucleus, but sometimes two, three, or more up to thirty or forty, Fig. 11. They are exceedingly numerous and continue increasing in number up to nearly if not quite the termination of gestation. In size they vary from 0.03–0.1 mm. Kundrat and Engelmann, **73. 1**, and others maintain that the cells undergo fatty degeneration before delivery, and attribute the loosening of the placenta to the very fact of the fatty metamorphosis. This view is at best questionable, and it is even doubtful whether the fatty change is a constant phenomenon. Of the decidual cells, we notice particularly the very large ones (giant cells of Leopold), with numerous nuclei and often with branching processes; the number of nuclei varies from ten to thirty and more. These giant cells are said by Leopold, **77. 1**, to appear quite abruptly and abundantly during the fifth month. They lie at first principally in the neighborhood of the blood-vessels of the deep parts of the decidua; they do not occur in the reflexa, and are far less numerous in the vera than in the serotina. The multinucleate decidual cells are perhaps only intermediate stages in the multiplication of the uninuclear cells, each nucleus of the large cells finally separating from the parent with its share of the parent protoplasm to make a new decidual cell; if this is the case it accounts for the final disappearance of the giant cells. As regards the function of the multinucleate cells we know nothing; in the rabbit, however, the multinucleate decidual cells have a glycogenic function (see Chapter XVII.), but they differ very much in microscopic appearance from the human multinucleate cells, and perhaps differ equally in function.

The decidual cells are most abundantly crowded together in the upper or compact layer, and contribute much to give that layer its main characteristics. By the eighth month they are found to have wandered into the cellular layer of the placental chorion, as is more fully described in the chapter on the chorion, apparently finding an entrance at the edge of the placenta.

Scattered among the decidual cells may be found a number of smaller cells which are more conspicuous during the earlier months, and are usually regarded as wandering cells (leucocytes). Langhaus, **77. 1**, 110, regards the leucocytes as the parents of the decidual cells—a view I cannot accept.

THE ORIGIN of the decidual cells was long uncertain. Three views contended for acceptance: 1st, they are modified leucocytes (Hennig, Langhaus just cited above, Sinèty, **76.1**); 2d, they arise from the connective-tissue cells of the mucosa (Hegar und Maier, Leopold); 3d, they are produced by the epithelium. In favor of the first view there has never been, to my knowledge, any

evidence of importance. The second view has been definitely established by Minot, **98**, 429.

The epithelial origin was first advocated by Frommel (*Aerztliches Intelligenzblatt*, München, 1883, No. 21) for the mouse; by Overlach, **85.1**, for man. Overlach traced the decidual cells to their origin in the epithelium, but his observations are restricted to a *single* uterus with pseudo-menstruation from acute phosphorus-poisoning. In the epithelium of the cervix of the uterus in question the following developmental stages of the decidual cells were found: 1, cells with a mother nucleus and one or several, up to fifteen smaller daughter nuclei; 2, cells with a little clearer though granular protoplasm collected around the daughter nucleus (or nuclei); 3, cells in which the protoplasm about the daughter nuclei has increased and is separated by a clear vacuole-like space from the protoplasm of the parent; we have then a mother cell, much distended, with a vacuole partly filled by a daughter cell, or by several such huddled together; 4, young decidual cells, lying just under the epithelium and closely similar to the endogenous brood in the cells. The observations of A. Walker, **87.1**, on a case of abdominal pregnancy may be taken as confirming Overlach. Walker found that the peritoneal epithelium at certain points in contact with the chorion had proliferated, forming several layers of cells, presenting an obvious similarity to true decidual cells. Isolated cells of a similar character were observed in the underlying connective tissue of the peritoneum. It thus appears that the ovum may cause in other epithelia than the uterine a cell growth analogous to that described by Overlach. Walker, it must be added, maintains that in his specimen the pseudo-decidual cells also arise *in part* by metamorphosis of the connective-tissue cells. I am inclined to interpret Overlach and Walker's observations as evidence of hyperplastic degeneration, and not of the production of decidual cells.

The manner in which the true decidual cells arise is described in the next section. For a description of the fully developed cells see p. 18.

Uterus One Month Pregnant.—The specimen to be described came from a woman who committed suicide by violence. The specimen was received in very fresh condition, but the reflexa was badly torn; the embryo had been removed, and I was therefore unable to verify the age, or investigate the attachment of the villi of the chorion to the uterus. There was a beautiful *corpus luteum* in one ovary, quite similar to that figured by Dalton in his report on the *corpus luteum* in the Transactions of the American Gynecological Society for 1877, Fig. 9.

My specimen enables me to confirm in most respects Turner's accurate description of two uteri of about the same age, **79.1**, 546-548. The inner surface shows the hillocks (*Inseln*) described by Reichert in the uterus of two weeks studied by him, which have been figured by Coste in slightly older specimens, and found by Turner also, **79.1**, 540.

The four illustrations given herewith are all from sections through what I suppose to be the placental region.

There is an upper compact layer, Fig. 6, *D*, and a lower cavernous layer *D'*; the caverns being gland cavities, which appear as rounded

arcolae partly lined with epithelium, partly filled with broken-down epithelial cells. The drawing, reproduced in Fig. 6, was obtained by drawing the outlines very carefully, stippling the areas occupied

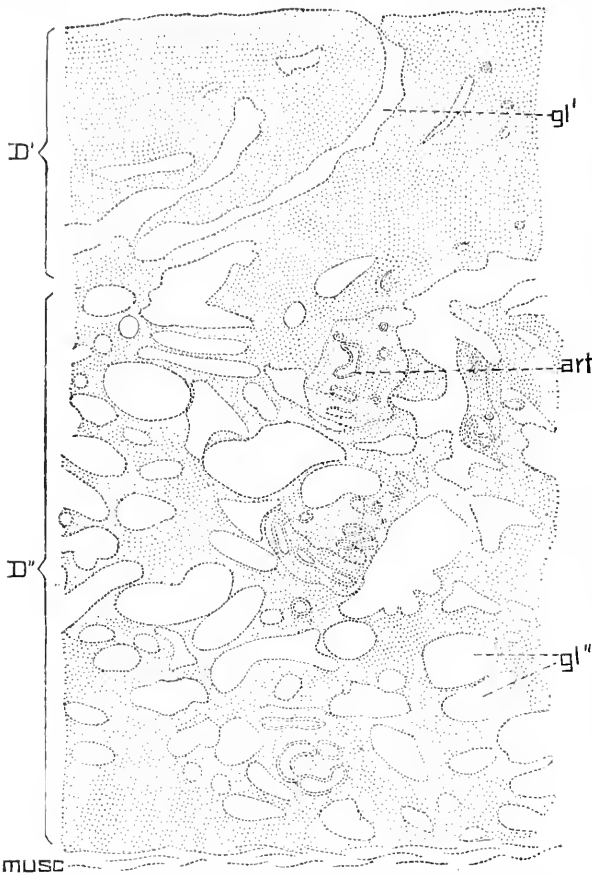


FIG. 6.—Uterus one month pregnant; outlines of the glands from a vertical section; to show the division of the mucosa into an upper compact layer *D'* and a lower cavernous layer *D''*; *gl'*, *gl''*, glands; *art*, spiral artery; *musc.*, muscularis.

by the connective tissue, representing the blood-vessels by double outlines, and omitting the glandular epithelium altogether. It will be noticed that about three-fourths of the diameter of the mucosa is occupied by the cavernous layer, *D''*.

The upper or compact layer is shown in Fig. 7. The surface is without any trace of epithelium, and is covered only by a thin fibrous and granular coagulum, *coagl*; the tissue itself consists almost exclusively of young decidual cells, *d*, *d'*, with a clear, homogeneous matrix; here and there are leucocytes, but they are nowhere numerous; the decidual cells are all quite large, with their

bodies deeply stained by the eosin; the nuclei are round, oval, or slightly irregular in shape, coarsely granular, and sharp in outline; the cells themselves, though irregular and variable in shape, are all more or less rounded with processes running off in various directions; scattered between the cells are many sections of their processes; occasionally it can be seen that two cells are connected; in fact, we have in this tissue evidently a modified embryonic or so-called anastomosing connective tissue. Now, as we know through the observations of Leopold, 77.1, which I have verified, the connective tissue of the uterine mucosa consists of anastomosing cells, and as stated in the previous section the cells are found proliferating in the menstruating uterus; we have, therefore, only to imagine the cells

enlarged with certain accompanying modifications to obtain the tissue figured in Fig. 7. There is no special formation of cells around the blood-vessels, where, according to Ercolani, the decidual tissue arises by new formation. In Turner's specimens the upper part of the compact layer was imperfectly preserved, but according to his description there appears to have been a coagulum similar to that which I have found, but thicker. In the deep part of the layer the cells are less enlarged, and when the cavernous layer is reached there occurs a rapid transition in the character of the cells, which become smaller and more fusiform, and their nuclei more elongate, smaller, and deeper stained by alum-cochineal. The gland openings upon the surface of the uterus lead into tubes, Fig. 6, *gl'*, which run slightly obliquely through the compact layer, taking a more or less nearly straight course and joining the contorted gland tubes, Fig. 6, *gl''*, of the cavernous layer. The gland ducts are completely devoid of lining epithelium, which has disappeared except for a very loose cell, occasionally found lying free in the ducts; the cells have not fallen out from the sections, but were lost before the tissue was imbedded.* The ducts then are wide tubes running nearly straight through the upper part of the decidua and bounded directly by the decidual tissue; they communicate below with the contorted cavities.

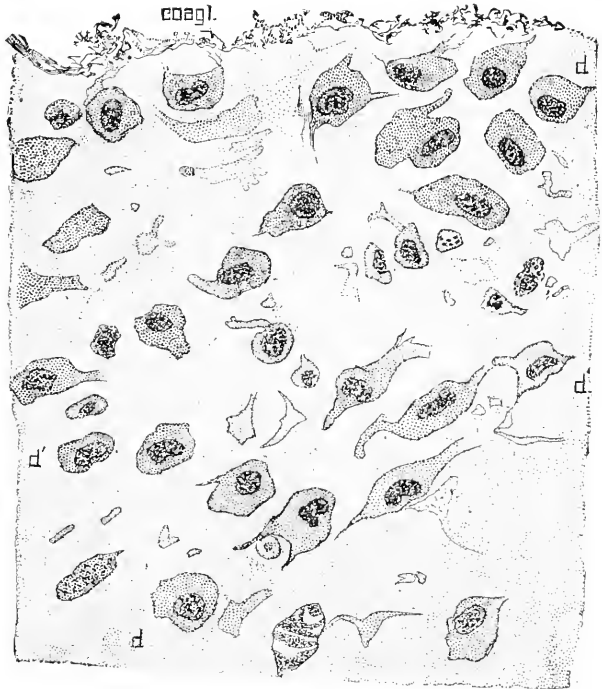


FIG. 7.—Uterus one month pregnant; portion of the compact layer of the decidua seen in vertical section; *coagl.*, coagulum upon the surface; *d*, *d'*, decidual cells. $\times 45$ diams.

The cavernous layers contain numerous spaces, the areolæ of Turner, 79.1, 547, who was uncertain as to their character, though he ascertained that many of them belong to the glandular system. In my specimen it is perfectly clear that all the larger areolæ belong to the glands, which must be extremely distorted and distended to give the shapes shown in Fig. 6. The thin

* The blocks to be cut were stained *in toto* with alum-cochineal and eosin, imbedded in paraffin, etc. The sections were fastened on the side with celloidin, to keep the parts in place.

dissepiments between the areolæ are composed of connective tissue, the long dark nuclei of which, Fig. 8, are strikingly different from those of the cells of the compact layer, Fig. 7. The areolæ present two extreme modifications and all intermediate phases between

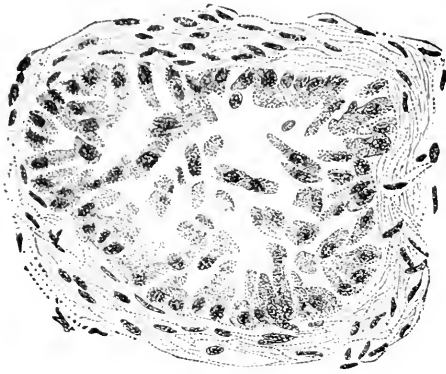


FIG. 8.—Uterus one month pregnant; section of gland from cavernous layer, with the epithelium partly adherent to the walls. $\times 445$ diams.

these two. The smaller areolæ are lined by a well-preserved cylinder epithelium, or by one in which the cells are separated by small fissures; in other areolæ the cells are a little larger, Fig. 8, each for the most part cleft from its fellows, and some of them loosened from the wall and lying free in the cavity. The other extreme is represented in Fig. 9; the size of the areolæ is much increased—compare Figs. 8 and 9—both drawn on the same scale; the epithelium is entirely loosened from the wall, and the cells lie separately

in the cavity which they fill; the cells are greatly enlarged, their bodies having three or four times the diameter of the cells in the small areolæ; they have not the cylinder shape, but are irregular in outline; their protoplasm is finely granular and stains rather lightly; the nuclei are large, rounded, granular, and with sharp outlines; they are less darkly stained than the nuclei of the epithelium of Fig. 8. The obvious interpretation of the appearances described is that

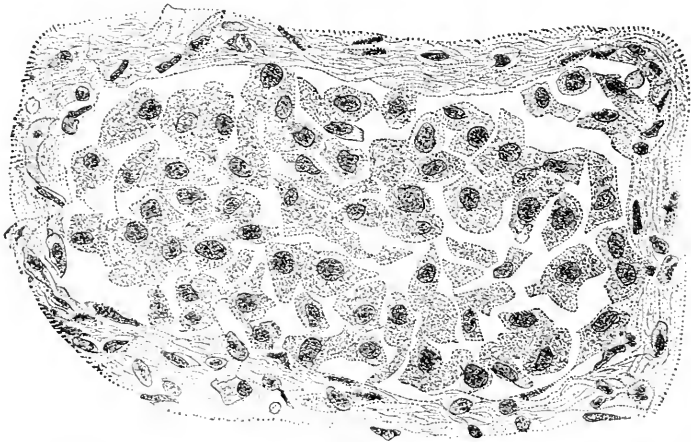


FIG. 9.—Uterus one month pregnant; section of gland from cavernous layer with the epithelium loosened from the walls. $\times 445$ diams.

the glandular epithelium is breaking down, being lost altogether from the ducts, but is still present in the deep portions of the glands; in breaking down the cells separate from one another, and then from

the wall, and falling into the gland cavity there enlarge, the cavity enlarging also. Similar appearances are also found in "moulds" of the second month; very likely they have been often observed and mistaken for pathological changes.

The blood-vessels of course lie in the dissepiments between the glands. I observed nothing to correspond with the "colossal capillaries dilated into small sinuses," mentioned by Turner, 79.1, 548. Were not these supposed capillaries gland cavities, from which the epithelium had fallen out? Occasionally the sections pass through a spiral artery, Fig. 6, *art*, which is cut again and again as it twists around in its characteristic separate column of connective tissue.

Decidua Serotina at Seven Months.—In a normal uterus about eight months pregnant I find the following relations: The serotina

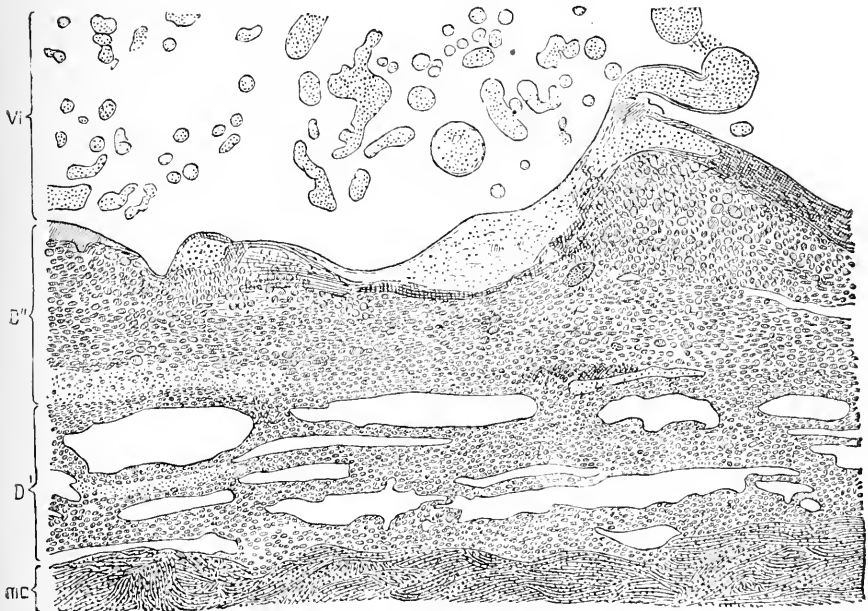


FIG. 10.—Section of the decidua serotina, near the margin of the placenta; normal uterus about seven months pregnant. *m.c.*, Muscularis; *D'*, *D''*, decidua serotina; *D'*, cavernous or spongy layer, the spaces in which are the glands; *D''*, compact layer; *V*, scattered chorionic villi; the intervillous spaces were filled with blood, which is not represented in the figure.

is about 1.5 mm. thick, and contains an enormous number of decidual cells, Fig. 10; the cavernous, *D'*, and compact layers, *D''*, are very clearly separated; the mucosa is sharply marked off from the muscularis, although scattered decidual cells have penetrated between the muscular fibres. The muscularis is about 10 mm. thick and is characterized by the presence of quite large and numerous venous thrombi, especially in the part toward the decidua. *The decidua itself contains few blood-vessels.* Upon the surface of the decidua can be distinguished a special layer of denser decidual tissue, which in many places is interrupted by the ends of the chorionic villi which

have penetrated it, as is well shown in the accompanying Figure 10. The gland cavities of the spongy layer, *D*, are long and slit-like; they are filled for the most part with fine granular matter, which stains light blue with hæmatoxylin; they also contain a little blood, and sometimes a few decidual cells. I have also seen in them a few oval bodies several times larger than any of the decidual cells, and presenting a vacuolated appearance. What these bodies are I have not ascertained; in a number of uteri over two months pregnant I have found them invariably present. In many places the glandular epithelium is perfectly distinct; its cells vary greatly in appearance, neighbors being often quite dissimilar; nearly all are cuboidal, but some are flattened out; of the former a number are small with darkly stained nuclei, but the majority of the cells are enlarged, with greatly enlarged hyaline, very refringent nuclei. There are also in many of the gland spaces isolated enlarged cells, which have detached themselves from the wall, and in some cases the detached cells nearly fill the gland cavity, very much as in Fig. 9.

The decidual cells of the cavernous layer, Fig. 10, *D*, are smaller and more crowded than most of those of the compact layer. The largest cells are scattered through the compact layer, but are most numerous toward the surface. They extend around the margin of

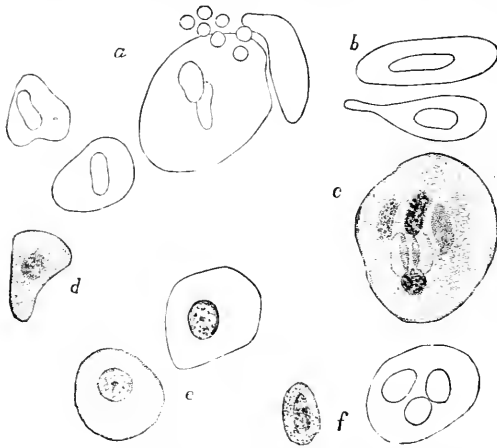


FIG. 11.—Decidual cells from the section represented in Fig. 10; stained with alum hæmatoxylin, and eosin; *a*, *b*, *d* and *f*, various forms of cells, from the serotina; *c*, giant cell, from the margin of the placenta; *e*, clear cells from the chorion. At *a*, seven blood globules have been drawn in to scale to afford a ready measure of size.

the placenta and have penetrated the chorion, in the cellular layer of which they are very numerous (compare on this point the chapter on the Chorion); the immigration has imparted to the chorionic layer in question somewhat the appearance of a decidua membrane. Misled by this peculiarity, Kölliker and others have held this layer to be maternal in origin, and accordingly have described it as a "decidua subchorialis." The error was, so far as I am aware, first definitely corrected by Langhaus, 77.1. The decidual cells exhibit great variety in their features, Fig. 11. They are nearly all oval discs, so that their outlines vary according as they are seen lying in the tissue turned one way or another; they vary greatly in size; the larger they are, the more nuclei they contain; the nuclei are usually more or less elongated; the contents of the cell granular. Some of the cells present another type, *c*; these are more nearly round, are clear and transparent; the nucleus is round, stains lightly, and contains relatively few and small chromatin granules; such cells are most numerous about the placental margin.

of the placenta and have penetrated the chorion, in the cellular layer of which they are very numerous (compare on this point the chapter on the Chorion); the immigration has imparted to the chorionic layer in question somewhat the appearance of a decidua membrane. Misled by this peculiarity, Kölliker and others have held this layer to be maternal in origin, and accordingly have described it as a "decidua subchorialis." The error was, so far as I am aware, first definitely corrected by Langhaus, 77.1. The decidual cells exhibit great variety in

Fate of the Decidua Reflexa.—The decidua reflexa is a distinct membrane up to the end, it is said, of the fifth month of gestation, and after that period it can no longer be found. Exactly at what time it disappears is not established by observation, though the fact of the disappearance has long been known, nor have we had hitherto any definite knowledge as to how it disappears, although its gradual attenuation and increasing transparency during the first four or five months have been familiar to us since the publication of Coste's magnificent atlas. The view most generally accepted has been that it fused with the decidua vera, and that accordingly the layer of decidua nearest the chorion during the latter half of pregnancy represents the decidua reflexa.

I have had opportunity to study four well-preserved normal pregnant uteri of two, three, five to six, and seven months' gestation respectively. These show that at two months the decidua reflexa is undergoing hyaline degeneration, that at three months the degeneration is considerably more advanced, and that by the sixth and seventh month the reflexa can no longer be found. These observations justify the theory that the reflexa degenerates and is completely resorbed.

I will review briefly the actual observations:

First, the reflexa at two months. It starts from the edge of the placental area with considerable thickness, which is rapidly lost, most of the reflexa being a thin membrane and the thinnest point being opposite the placenta. The examination of sections shows that the entire reflexa is undergoing degeneration, which is found to be the more advanced the more remote the part examined is from the placenta. The chorionic keve lies very near the reflexa, being separated only by chorionic villi, which are very much altered by degeneration, their ectoderm having become a hyaline tissue, which stains darkly, and their mesoderm showing clearly the partial loss of its cellular organization. In the region half-way between the base and the apex of the reflexa dome the tissue of the decidual membrane shows only vague traces of its original structure; only here and there can a distinct cell with its nucleus be made out, for most of the cells have broken down and fused into irregular masses without recognizable organization. Ramifying through the fused detritus there are two layers of so-called "fibrin," or, in other words, of a hyaline substance, which like the "canalized fibrin" of the chorion stains very deeply with the ordinary histological dyes, carmine and logwood. The fibrin is much more developed upon the inner or chorionic than upon the outer side of the reflexa. It forms on the inner side a dense network, which on the one hand fuses with the degenerated ectoderm of the chorionic villi wherever the villi are in contact with the decidua; and on the other hand ramifies more than half-way through the decidua, the ramifications being easily followed, owing to the hyaline character and deep staining of the "fibrin." Upon the outside the fibrin forms a thinner layer, and shows its network structure in many sections much less clearly. All of these points are illustrated by the accompanying figure.

In the uterus three months pregnant I find essentially the same conditions, except that the degeneration is farther advanced, since

the traces of cellular structure in the reflexa are still more vague and the fibrin is more developed. The membrane is much thinner than at two months; the thickness is about two-thirds of what it was. In the fresh specimen the membrane appeared much more transparent than before. In all the parts examined I found leucocytes present, and in the region of the reflexa near the placenta they are very numerous and conspicuous; it is natural to conclude that they are concerned in the resorption of the degenerated tissue. In a section not far from the base of the reflexa the three layers are distinct as at two months, there being a thicker inner and a thinner outer fibrin layer, while between them is a stratum in which remains of cells are seen; occasionally is an appearance which suggests a surviving decidual cell, and nearer the placenta the phantoms of cells

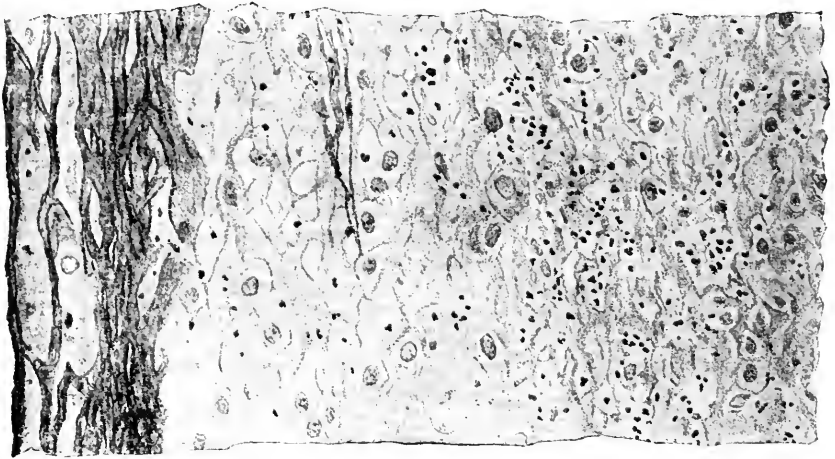


FIG. 12.—Section of human decidua reflexa at two months.

become distinctly cells, and true decidual cells can be made out. The inner fibrin layer is much denser and its meshes smaller than in the two months specimen, the trabeculae of fibrin having become thicker during the month elapsed.

Those who conceive that there is a fusion between the reflexa and vera, are forced to seek for traces of the former membrane next the chorion. They may assume either that the epithelioid layer (chorionic ectoderm) is the remnant of the decidua, which forces them to leave the fate of the chorionic epithelium unexplained, or that the upper stratum of the decidua is the reflexa which is fused with and acquired the same structure as the underlying vera. If my observations on the degeneration of the reflexa are correct, and correspond, as there is sufficient ground to believe they do, to normal conditions, then both assumptions as to the persistence of the reflexa involve the further and very improbable assumption that the degenerated tissue is removed and replaced by fully organized cellular decidual tissue. It is obviously more in accordance with our knowledge of degenerative changes to assume that the hyaline metamorphosis is necrotic and is succeeded by the disintegration and removal

of the tissue. This accounts in a satisfactory manner for the absence of the decidua reflexa during the sixth and seventh month. The relations of the membranes at this period have been well described and figured by an admirable observer, Dr. G. Leopold, whose views and one of whose drawings have been incorporated by Prof. O. Hertwig, in his "Entwicklungsgeschichte" (third edition, pp. 216-217, fig. 147). Leopold holds that the epithelioid layer is the reflexa; but what has just been said suffices, I think, to show that this view is untenable.

That the membrana decidua reflexa should degenerate and disappear no longer seems strange, since recent investigations have shown that in many placental mammals there occurs an extensive pseudo-pathological destruction of the mucosa uteri during gestation. These changes, which are best known in the rabbit (*cf.* Minot, *Biol. Centralbl.*, x., 114) vary considerably in character and are exceedingly remarkable both for their extent and for their numerous modifications, so that we need feel no surprise at the entire destruction of the decidua reflexa in man, nor at the form of the destruction being unlike the forms hitherto found in other mammals.

As to the purpose or advantage of the sacrifices of maternal tissue we are in the dark. The same is true of the causation of the degeneration, although we must regard it as the result of a reflex nervous activity. It is becoming more and more evident that the nerves have a profound influence upon organization, and it is no strained hypothesis which places the structure of the mucosa uteri under the immediate control of the nervous system.

The changes in the decidua at parturition require special description. During labor a split occurs in the decidua serotina and vera; all the parts within the split—that is, toward the chorion—are expelled, their expulsion being part of the act of delivery; the term *decidua* or *caduca* refers to the fact that the membranes are cast off; they are discharged after the fœtus, and, together with the vera and fœtal envelopes, constitute the so-called after-birth. There are thus removed the superficial portions of the vera and serotina. The split, according to Friedländer, 70.1, 73.1, usually occurs in the upper or compact layer just above the cavernous layer, leaving the surface of the uterus smooth and glistening, but the surface of the placental area is thrown into irregular hills and valleys. Sometimes the split occurs at or just below the upper limit of the cavernous layer, in which case the surface of the uterus after parturition is jagged and irregular. In rarer cases the split occurs higher up in the compact layer, leaving consequently by far the greater part of the decidua *in situ quo ante*. In all normal cases, however, more of the mucosa is lost than in menstruation, and a considerable portion is always left *in utero*; this latter portion contains the remnants of the uterine glands, and is the organ of regeneration for the entire mucosa; it has, of course, no epithelium upon its surface, which instead is formed by connective tissue and ruptured blood-vessel (and lymphatics?). The layer of vera left on the uterus is usually about 1 mm. thick; that of the serotina may be considerably less.

The post-partum regeneration of the mucosa begins very soon, but varies greatly in the rate with which it progresses, being very

rapid in vigorous, healthy women and slow in weakly women. The region of the *vera* is restored more rapidly than the placental area.

The first step is the thickening of the mucosa to about 2 mm., owing to the contraction of the uterus, which of course reduces the superficial extent without altering the volume of the mucosa. In consequence of this change also the gland spaces become rounder and

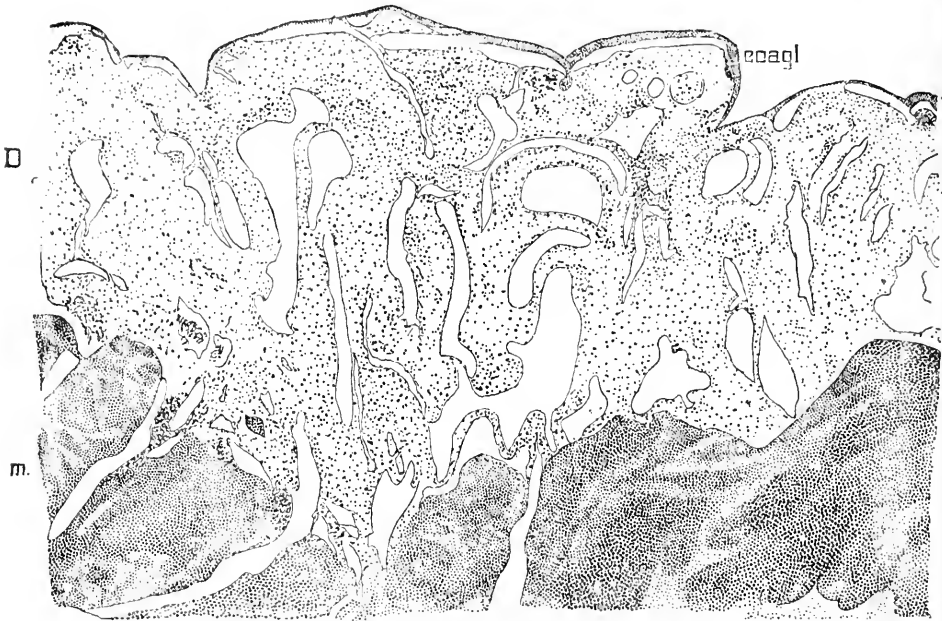


FIG. 13.—Uterus twelve hours after artificial delivery at six months pregnancy; *coagl*, blood clot; *D*, decidua; *m*, muscularis. $\times 22$ diams.

the course of the glands straighter. I will here interpolate a description of a human uterus, twelve hours after abortion, see Minot, 98, 428. The uterus was apparently normal; it was already very much contracted; the mucosa measured about 1 mm. in thickness; the surface was ragged and more or less covered with clotted blood, presenting very much the appearance so superbly figured by Coste ("Dével. corps organisés," pl. x. Espèce humaine). Vertical sections, Fig. 13, show that the surfaces of the mucosa are very uneven; on the free surface there is a thin layer of clotted blood, *coagl*; the upper or compact layer of the decidua has entirely disappeared, "leaving only the deep portion, *D*, permeated by numerous large gland spaces, between which are partitions containing the brownish and hyaline decidual cells, and a great many blood corpuscles, which lie in the tissues as well as in the blood-vessels. The presence of blood corpuscles in the tissues is probably a constant feature of the decidua post partum."

The second step is the restoration of the surface by the resorption of the blood and detritus, parallel with which advances the restoration of the glandular epithelium. These changes occupy apparently

from seven to fourteen days. The cuboidal gland cells at this time appear swollen, with indistinct intercellular boundaries; the nuclei are almost all enlarged until they nearly fill the cells; rapid cell division is going on. At this time also venous thrombi are very conspicuous, especially in the placental area, where they are found fresh and in various stages of progressing obliteration, Fig. 14. The thrombi persist for a long period (Leopold, 77.1, xii., 185).

The third step is the completion of the restoration of the glands up to their external openings, and the regrowth of the normal connective tissue of the mucosa. The resulting stage was found by Leopold, 77.1, xii., 199, to have been reached in a normal uterus three weeks after parturition. Of this specimen he gives the following description, which refers to the placental region. "As shown by the illustration (Fig. 14) the young mucosa is composed mainly of fine short spindle cells, which form the interglandular tissue. They exhibit extraordinary proliferation, and are showing themselves in numerous processes (*Zapfen*) into the musculature, but still leaving the limits of muscularis and mucosa distinct as in every non-pregnant and pregnant uterus. Secondly, between the young cells we find many blood-vessels, especially capillaries, in the neighborhood of which are collected blood corpuscles, hæmatin crystals, and pigment. Many appearances indicate the new formation of capillaries from simple cords




FIG. 14.—Section of the placental area of the uterus three weeks *post partum*. *Muc.* mucosa; *Msc.* muscularis. After Leopold.

of cells, which extend to the very surface. Thirdly, and most important, we find the young glands, which are short vertical follicles, imparting to the surface a more definite sieve-like appearance. Their cuboidal epithelium is spreading out from their mouths to recover the surface; but at this time the new epithelium is not yet completed. The mucosa is still a wounded tissue; for its complete restoration there is still lacking . . . the vascular network." The fourth step is a double one: the restoration of 1, the superficial

epithelium, which is accomplished by the spreading of the growing epithelium from the mouths of the glands, and of 2, the subepithelial network of capillaries. The completion of this, the last step in the restoration, has been observed in a normal uterus six weeks after parturition.

A very different regenerative process is stated by Duval, **90.3**, to occur in rodents; he believes that in these animals the epithelium is reproduced nearly simultaneously over the rupture surface by a direct transformation of the connective-tissue cells of the placental decidua.

4. Mucosa Cervicis Uteri.—The mucosa of the cervix has been only very imperfectly investigated. It resembles somewhat that of the body of the organ; but is distinguished *first*, by the possession of two kinds of glands, one agreeing with the utricular or uterine glands proper, the other of the "mulberry" type, there being numerous alveolar branches of the gland cavity; *second*, by the character of its lining epithelium, composed of enormous cylinder cells of many shapes, in length averaging fully 55μ (*cf.* Overlach, **85.1**, 214, 219ff.). The stratified epithelium of the vagina does not, it appears, normally extend inside the os. The utricular glands are lined by an epithelium like that of the corpus, while the epithelial cells of the "mulberry" glands resemble those lining the cervix; the latter glands are in fact strictly cervical, and apparently secrete only mucous matter; they are very likely important contributors to the plug of mucus which closes the cervix during pregnancy.

The cervix, except for this plug, remains open during gestation; it also preserves its covering epithelium, and although it becomes tumefied during gravidity, and may, as claimed by Overlach, participate in the formation of decidual cells, it never, as far as yet ascertained, forms a true deciduous membrane.

A thorough investigation of the histology of the cervix in all phases of the uterine functions would be extremely valuable.

4. Blood-Vessels.—The uterus is supplied from four arteries: two, the ovarian, running along the broad ligaments and giving each a considerable branch to the fundus; two, the uterine, derived from the internal iliacs, running to the cervix, and thence mounting by a very tortuous course toward the fundus to there join the ovarian arteries. The arteries give off very numerous branches, which take a characteristic spiral course through the muscularis, and form frequent anastomoses with one another. The arterial vessels of the uterus are further remarkable for the great development of their muscular walls, all the more striking because the muscular coat of the capillaries and veins is slightly developed.

The capillaries are wider in calibre than usual, and form specially distinct networks under the epithelium and around the glands of the mucosa. The veins are very wide, almost sinus-like, even in the resting uterus.

During and just before the menstrual flow, and still more during the first half of pregnancy, the vessels are all dilated, and it is thought by some actually increased in number; this latter opinion may be fairly doubted. The increase in the amount of blood is very obvious; indeed Rouget, **58.1**, speaks of the tissue of the uterus as erectile, but this adjective is not applicable in the anatomical

sense, as Kölliker has very properly pointed out. The vascular enlargement affects principally the capillaries and veins (Turner). It is most marked during the second and third month of pregnancy; in the fourth or fifth month the vessels begin to atrophy, and by the eighth month, as previously stated, the vessels are far less numerous; these changes require further investigation. A number of large venous sinuses remain, however, especially in the inner portion of the muscularis, and are highly characteristic of the latter half of the period of gestation.

Large thrombi normally appear in these sinuses, becoming first noticeable during the eighth month and persisting several weeks post partum. Apparently they continue to arise during the eighth and ninth months and even after delivery (Leopold). The thrombi, which were first discovered by Friedländer, 70.1, 76.1, and have been studied also by Leopold, are supposed by the latter author to be directly caused by an immigration of giant cells into the veins. Leopold further supposes, 77.1, xi., 492-500, the presence of the thrombi to cause venous congestion of the uterus. Now, if it is true, as Brown-Séquard has maintained ("Experim. Researches Applied to Physiol. and Path.," 1853, 117, and Brown-Séquard's *Journ. Physiol.*, i., 1858, 105), that carbonic acid excites toward the end of gestation uterine contractions very readily, then it is possible that the venous congestion above mentioned may be one of the proximate causes of parturition.

Additional facts in regard to the blood-vessels during pregnancy are given, pp. 23, 27.

5. Lymphatics.—Our knowledge of this subject rests principally upon the admirable memoir of Leopold, 74.1. The system begins in the intercellular spaces of the connective-tissue layer of the mucosa; in this and in the muscular layer are lymph capillaries, which communicate with the subserous (subperitoneal) network of lymphatics.

Special Physiology of the Uterus.—Our anatomical study has shown us that the most remarkable changes of the uterus during its menstrual and gestative functions are: 1, the gradual thickening of the mucosa; 2, the removal of the superficial portions of the mucosa, in the one case during the menstrual flow and in the other during labor; 3, the appearance of an enormous number of the very characteristic and peculiar decidual cells during the thickening of the mucosa. The menstrual and gravidital changes follow the same cycle, and differ from one another essentially only in two points: 1, the time occupied, and 2, the extent of the changes. In fact the alterations, though of the same character, are greater in extent and occupy a longer period during gestation than during menstruation. These considerations force us to the conclusion that the gravid uterus is passing through the menstrual cycle prolonged and intensified. The function of gestation is a direct modification of the function of menstruation, and the two are physiologically homologous. The deduction is so evident that I have been surprised not to have yet encountered it clearly enunciated in any of the authors I have consulted.

That the decidual cells perform some very important function seems to me likewise evident from their great prominence, but until

their history has been elucidated even as to details, we can hardly hope to ascertain what that function is. We may surmise that they are either organs of regeneration, or of nutrition for the embryo, or of both functions.

The cause of the formation of the decidua either in menstruation or in gestation is unknown. The presence of the *impregnated ovum* in the upper end of the Fallopian tube seems to be the cause of the arrest of the menstrual changes and the preservation of the decidua upon the uterine wall. How it produces this effect is unknown, but it is fair to assume that it takes place through the central nervous system. Experiment might demonstrate the nervous pathways followed by the irritation and the reflex, and perhaps discover a trophic centre in the cord for the uterus. That the impregnated ovum, when it exerts this influence, lies in the upper end of the oviduct quite remote from the uterus seems certain from analogy with mammals. Presumably the ovum undergoes rapid degeneration during its passage through the oviduct, and can be saved only by fertilization at the start. Lowenthal, 85.1, who shares the too frequent misapprehensions of gynæcologists in regard to the site of impregnation, and thinks in his philosophy that it is impossible for a remote ovum to exert such a marked influence on the uterus, has advanced the hypothesis that the ovum is fertilized in the uterus and affects it by direct contact. His critic, Wyhoff (*Centralbl. f. Gynæc.*, 1885, No. 26, 401), thinks impregnation may occur either at the ovary, in the Fallopian tube, or in the uterus! Such references to opinions on this subject, advanced without proper knowledge, might be readily multiplied.

But if the *decidua graviditatis* is produced by the influence of the impregnated ovum on the menstrual membrane, we have still to ask, What causes the formation of the *decidua menstrualis*? To this no answer is possible. Pflüger has advanced the theory, 65.1, that the ripening Graafian follicle exerts through the central nervous system a reflex action upon the uterus; but, inasmuch as the attempt to establish a fixed relation in time between the ripening of the follicle and menstruation failed (Leopold, 83.1), it is impossible to accept Pflüger's theory at present. That menstruation is connected with ovulation appears probable, but that ovulation has a constant casual relation to the monthly period is by no means demonstrated. The belief in the connection is favored by the fact that the operative extirpation of both ovaries usually, *but not invariably*, causes menstruation to cease. Putnam-Jacobi has advanced a theory in regard to the cause of menstruation (see *Amer. Journ. Obst.*, Apr., 1885), which is based upon singular false homologies between the ovary and uterus, and some physiological assumptions which are, I think, not admissible. Other theories, likewise not tenable in my judgment, have been advanced, but it seems undesirable to dwell upon speculative views.

The cause of the formation of the reflexa is connected with the ovum, since wherever the ovum is attached the reflexa is formed around it; how the ovum after its attachment exerts its influence, is unknown. Since the position of the ovum determines that of the reflexa it becomes the more interesting to put the question, What

determines the site of attachment of the ovum? which, unfortunately, is at present an unanswerable inquiry.

The cause of delivery is not ascertained, but has been much debated. Various suggestions have been made to explain why the decidua cleaves in two, and why the uterus contracts to expel the fœtus. Our inquiry as to the cause of birth may be resolved into two component questions: 1, What is the stimulus which causes the uterus to expel the fœtus; 2, What causes the stimulus to act at a certain period after conception, *i.e.*, what determines the duration of pregnancy? The second question I hope to discuss elsewhere.

As regards the first question, What stimulus causes delivery? it is well known that various operative procedures can excite apparently by reflex action contractions of the pregnant uterus which will result in the expulsion of the ovum. It is by taking advantage of this possibility that abortions (premature deliveries) are procured. Such stimulations as are referred to may be caused in the following ways: 1, by rupturing the amnion and allowing the amniotic fluid to escape from the uterus; 2, by the introduction of foreign bodies between the walls of the ovum and those of the uterus; 3, by mechanical irritation of various parts, especially the cervix uteri, the external genitalia, or the breasts. With these facts in mind the hypothesis is unavoidable that the normal contractions of the uterus at full term are due to reflex stimulation. Various authors have accepted this opinion and endeavored to ascertain the starting-point of the stimulation. Mauriceau sought it in the uterus having reached the limit of its expansibility; Naegele in the irritation caused by the embryo, acting like a foreign body in the uterus; Engelmann, at least partly in the degeneration of the decidual cells; Harse and others, in the accumulation of carbonic acid in the blood of the uterus. None of these views are very well founded; the two last deserve, however, a little more consideration. The fatty degeneration is not adequate, because in several instances it has been found wanting both before and immediately after birth (Simèty, 76.1, Meola, 84.1). The carbonic-acid theory is presented in its most plausible form by Leopold, and has been already stated (p. 43). To what is there said may be added that it is not shown, 1, that venous thrombi cause the venous congestion of the uterus assumed by Leopold, and 2, that such congestion would charge the uterus with sufficient carbonic acid to excite contractions in it. Compare also Spiegelberg's "Lehrbuch," 1880, p. 120.

We evidently have to do with a progressive maturation of the uterus—a series of changes we cannot explain, but which is, as already pointed out, closely similar to the series of changes during menstruation. Hence it is probable that there is a common cause for the ending of the series (the casting off of the superficial part of the mucosa *in both cases*); in the delivery there is superadded the contraction of the uterus, and for this we must see a cause also. Therefore it seems to me that it is undesirable to search for *one* cause only for the whole process of birth.

The physiology of delivery does not fall within our scope; for further information the reader is referred to Hensen's "Physiologie der Zeugung."

CHAPTER II.

GENERAL OUTLINE OF HUMAN DEVELOPMENT.

THIS chapter is designed especially for the convenience of students of medicine and biology. Advanced students will find in it little of value to them, since all the subjects it considers are more fully treated in other portions of the volume.

I. RETROGRESSIVE HISTORY OF THE FÆTUS AND ITS ENVELOPES.

Uterus Eight Months Pregnant.—If we examine a pregnant uterus at any time during the sixth to ninth month of gestation, we find essentially the same relations of the parts—the most marked difference being in the size of the uterus, which increases with the duration of gestation, to correspond to the growth of the fœtus. A description of a uterus of the eighth month after conception will suffice, therefore, for our present purpose.

Such a uterus is a large, rounded bag, with muscular walls, and measures seven or eight inches in diameter. It renders the abdomen very protuberant. Examined externally it is remarkable especially for the numerous large sinus-like blood-vessels; its surface is smooth; the texture of the walls is firm to the touch, but the walls yield to pressure, so that the position of the child can be felt. As the placenta is generally upon the dorsal side, it is usual to open the uterus by a crucial incision upon the ventral side. The walls are about one-half of an inch thick, sometimes more, sometimes less, and as soon as they are cut open we enter at once into the cavity of the uterus containing the fœtus and nearly a pint of serous liquid—the liquid is the amniotic fluid. The fœtus normally lies on one side, has the head bent forward, the arms crossed over the chest, the thighs drawn against the abdomen, and the legs crossed; it resembles closely the child at birth, but is smaller; its head is relatively to the size of the body larger; the abdomen is more protuberant, and the limbs proportionately smaller. The inner surface of the uterus is smooth and glistening; if it is touched with the finger it is found to be covered by a thin but rather tough membrane, called the amnion, which is only loosely attached. Examination of the uterine wall, where it has been cut through, shows that its thickness is formed principally by the muscular layer, which is made up by numerous laminae of fibres, between which are the large and crowded blood sinuses, similar to those distinguishable on the external surface of the uterus. About one-fifth or less of the wall inside the muscularis has a different texture and can be partly peeled off as two distinct membranes, the innermost of which is the amnion already mentioned, and the outer is the chorion united with the decidua. The amnion and chorion are appendages of the embryo; the de-

cidua is the modified mucous membrane of the uterus. The inner portion of a microscopical section through the uterine wall is shown in Fig. 15. The amnion, *am*, consists of two layers, a cubical-celled epithelium facing the embryo, and a connective-tissue stratum facing the uterus. The chorion, *Cho*, is likewise two-layered, but

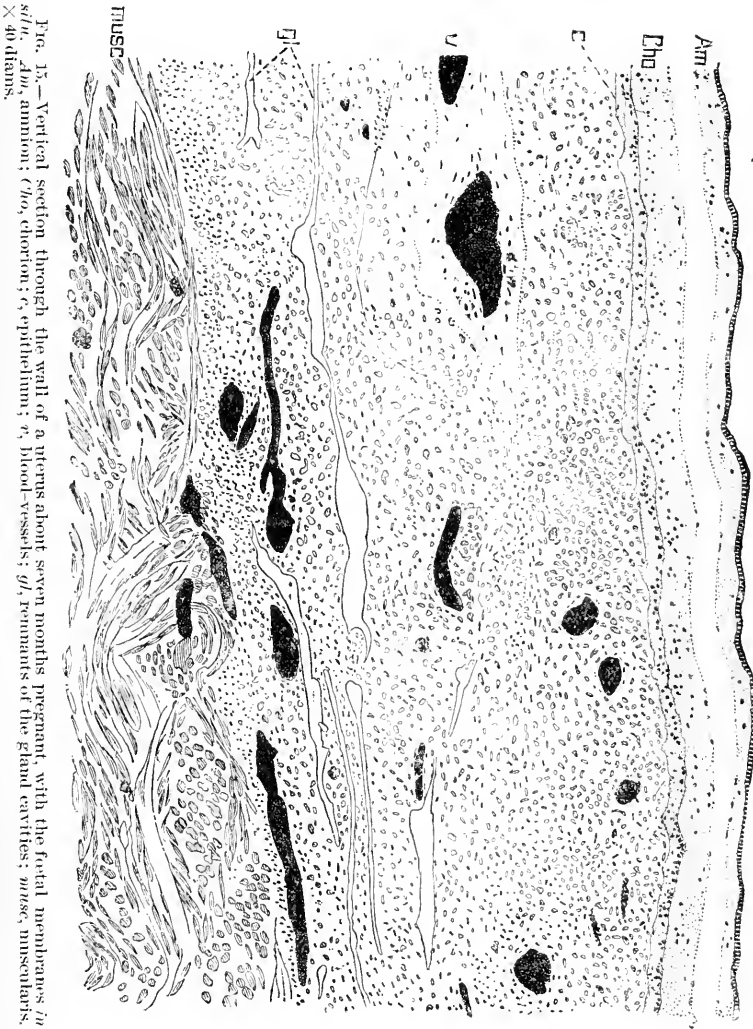


FIG. 15.—Vertical section through the wall of a uterus about seven months pregnant, with the foetal membranes in situ. *Am*, amnion; *Cho*, chorion; *c*, epithelium; *v*, blood-vessels; *gl*, remnants of the gland cavities; *musc*, muscularis. X 40 diam.

its epithelium, *c*, is next the uterus, its connective tissue next the amnion; the amnion and chorion are loosely held together by shreds and bands crossing from one membrane to the other. The decidua occupies the whole space between the chorion, *Cho*, and muscularis, *musc*; it contains blood-vessels, *v*, and remnants, *gl*, of gland cavities. Let us return to the embryo. From its abdomen there springs

a long, whitish cord, known as the umbilical cord; it is usually about one-third to one-half an inch in diameter and 40 cm. long, but its dimensions are extremely variable; it always shows a spiral twist, and contains three large blood-vessels, two arteries, and one vein, all of which can be distinguished through the translucent tissue. The distal end of the cord is attached to the wall of the uterus, usually near the middle of the dorsal side of the organ. It is easily seen that the blood-vessels of the umbilical cord radiate out from its end over the surface of the uterus underneath the amnion, branching as they go; they spread, however, only over a circumscribed area, the placental, where the wall of the uterus is very much thickened. A vertical section through the placental area shows that the amnion and chorion are widely separated from the decidua and muscularis by a spongy mass soaked with maternal blood. This mass consists of numerous trees of tissue, which spring with comparatively thick stems from the chorion and branch again and again. In these stems and branches are to be found the final ramifications of the vessels of the umbilical cord; the trees are known as chorionic or placental villi. Some of their end-twigs are very closely attached to the surface of the decidua. In the centre of the placental area the villi form a mass about three-fourths of an inch thick, but toward the edge of the area the mass gradually thins out until at the very edge the chorion and decidua come into immediate contact. The mass of villi, together with the overlying portions of the chorionic and amniotic membranes and the underlying portion of the decidua, constitutes what is known as the placenta. The decidua of the placental area is called the decidua serotina; the chorion of the placenta is known as the chorion frondosum. When birth takes place the whole *placenta* is expelled after the delivery of the child; the placenta of the obstetrician is therefore partly of foetal, partly of maternal, origin.

Uterus Three Months Pregnant.—The uterus measures about $3\frac{1}{2}$ inches in transverse diameter, and shows well-marked inlaid sinuses on its external surface. If it is opened, as before, by a crucial incision on the anterior side, its walls will be found about half an inch or more in thickness; it contains a grayish-red bag (*decidua reflexa*), which nearly fills the cavity of the uterus and incloses the embryo, so that upon opening the womb we do not encounter the foetus directly. The inner bag has a smooth surface, but shows a few small pores: it is without blood-vessels and is attached to the dorsal wall of the uterus. The inner surface of the uterus shows a rich network of blood-vessels, many of which are large, irregular sinuses. The walls are seen to consist of an outer muscular layer, and an inner decidual layer, which takes up nearly half the thickness of the wall, and is known as the *decidua vera*. As compared with the eighth-month uterus the proportion of the layers shows us that during gestation the muscular layer increases and the decidual layer diminishes in thickness. The inner bag when opened shows the large cavity in which the embryo lies, floating in amniotic fluid. The bag is formed by three very distinct membranes, of which the outermost, *decidua reflexa*, is the thickest and opaque; the two inner ones are thin and transparent; the innermost is the delicate amnion; the middle membrane is the chorion and is quite distinct from both

the amnion and reflexa; with the latter it is connected by a number of small branching villi scattered at some distance from one another over the surface; the villi adhere firmly to the reflexa by their tips. The embryo resembles a child in its general appearance; the length of the head and rump together is about eight centimetres, and the head is approximately of equal bulk to the rump. The umbilical cord is 5-7 mm. in diameter and usually about 12 centimetres long. From its distal end the blood-vessels spread out over the placental area, and around the edge of the area rises the decidua reflexa, which does not extend on to the placenta. Floating in the amniotic fluid is a pear-shaped vesicle, the yolk-sack, which is about 8 mm. in diameter; it has a fine network of blood-vessels upon its surface, and is connected at its pointed end with a long slender pedicle, the yolk-stalk, which runs to the placental end of the umbilical cord, there enters the cord itself, and runs through its entire length to its attachment to one of the coils of the intestine of the embryo. Over the whole of the placental area the chorion gives off large villous trunks, each of which has numerous branches, with ramifications of the foetal vessels; the villi fill a space about one centimetre wide between the membrane of the chorion frondosum and the surface of the uterine decidua serotina, to which the tips of some of the villi are attached. With care the villi may be separated from the decidua, which is seen, when it is thus uncovered, to be cavernous; the caverns are rounded in form and may be followed on the one hand until they connect with the blood sinuses of the uterus, and on the other until they open into the intervillous spaces, which therefore receive a direct supply of blood from the mother.

The principal difference to be noted in the relations of parts between the uterus before and that after the fifth month is in the presence or absence of the decidua reflexa as a distinct membrane. During the fourth month the reflexa stretches as the membranes expand and becomes thinner and thinner until by the end of the fourth month it is as delicate and transparent as the chorion and lies close against the wall of the uterus (decidua vera). It is probable that the decidua reflexa degenerates and is resorbed, compare p. 19.

Uterus Five Weeks Pregnant.—The relations are best shown by a median antero-posterior section, Fig. 4. The arrangement of the uterine parts is essentially the same as at three months. The mucosa uteri is changed into the decidua graviditatis. On the dorsal side from *s* to *s* is the decidua serotina of the placental area, where the villi of the chorion are fastened by their tips to the uterus. From the edge of the placental area on all sides rises the decidua reflexa, *r r*, which is much thinner than the other parts of the decidua, and which forms a closed dome over the embryo; hence when we pass through the cervix uteri, *c*, we enter, not the cavity containing the ovum, but the fissure-like space between reflexa, *r r*, and the vera, *g g*, which includes the whole of the modified mucosa of the body of the uterus, except that part to which the ovum is attached and which produces the *reflexa* and *serotina*. The vera is that portion of the decidua which is not in direct contact with the ovum. No stage of gestation earlier than the completed formation of the *reflexa* has been observed.

The embryo differs greatly from the three months' fœtus. Beginning with the envelopes we notice that the chorion is beset with well-developed villi over its entire surface, but the villi over the placental area are larger than those over the parts adjacent to the decidua reflexa. The amnion does not lie close to the chorion, but close around the embryo, leaving a wide space between the two membranes, which space, as we have seen, is subsequently obliterated by the expansion of the amnion. The embryo itself is very small and not human in appearance, and its organs are only partially differentiated. The umbilical cord is very short; the amnion springs from it at a short distance from the embryo. The yolk-stalk leaves the cord just beyond the amnion, is comparatively short, and ends in the pear-shaped yolk-sack, which is about the same size as at three months. Beyond the point where the amnion and yolk-stalk part from it, the umbilical cord continues a short distance with its blood-vessels, which ramify over the entire chorion and penetrate all the villi thereof. To produce the relations found at three months the blood-vessels and villi of the chorion must abort except over the placental area; the umbilical cord must elongate greatly; the amnion must expand until it touches the chorion, and the fœtus must grow and change.

We must now trace back the history of the embryo still farther, in order to understand the relation of the embryo to the embryonic membranes and appendages.

Ovum of Three Weeks.*—Normal human ova of this age very rarely indeed reach the embryologists, but a few have been described. The chorion forms a closed vesicle beset on all sides with crowded, clumsily-branching villi; the vesicle measures about 3 cm. in diameter; the villi are about 3 mm. long, and as yet show no regional inequality in their development. If the vesicle is opened the embryo is found within rolled up, the back being convex; it measures in its natural attitude about 44 mm. The head is bent toward the right; the caudal extremity toward the left; the head and tail are almost in contact, so that it is difficult to observe the insertion of the umbilical cord. With care this may be done, and it will then be seen that the amnion arises from the embryo,

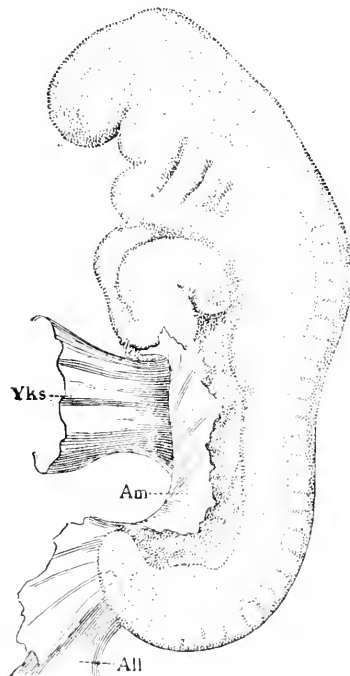


FIG. 16.—Human embryo, 4.2 mm. long (His' Lr). After W. His. Explanation in text.

and is, in fact, a prolongation of the body-wall: the amnion itself is extremely thin and lies close about the embryo. The umbilical

* For figures see Chapter XIII.

cord* unites with the abdomen; in front of it, *i.e.*, headward, is a small opening through which the stalk of the yolk-sack enters the body to unite with the intestine; it is from the edges of this opening that the amnion arises, and as the amnion passes around the umbilical cord, it may be said that the cord and the yolk-stalk both enter the body through the opening, but whereas the cord is in contact with the amnion the yolk-stalk is not. The opening may be called the umbilical foramen. The yolk-sack is pear-shaped, measures about 3 mm. in diameter, and is attached by its pointed end to a loop of the embryonic intestine. The yolk-stalk is developed by the subsequent prolongation of the pointed end of the sack.

In an embryo a little younger the relations can be more clearly recognized, Fig. 16. The embryo is nearly straight, although both head and tail are bent over ventrally. The umbilical foramen, from the edge of which the amnion arises, is very wide and long; at its tailward edge runs out the umbilical cord (*Bauchstiel*), to which the amnion is attached, and which joins the chorion a short distance from the embryo. The neck of the yolk-sack, *Yks*, is also much wider: if the sack is cut open we find its neck to be a large opening into the cavity of the intestine; in fact, the yolk-sack is an appendage of the intestinal canal, which at this stage is very simple, being hardly more than a straight tube running lengthwise; the opening between the sack and intestine may be called the vitelline foramen.

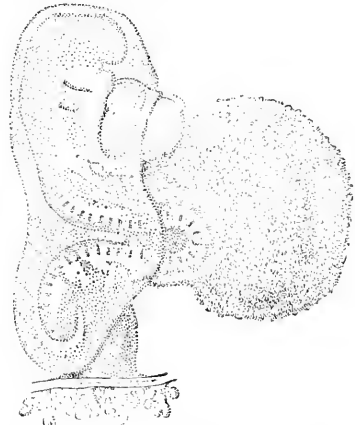


FIG. 17.—Embryo, 2.15 mm. long. After W. His' embryo Lg.

The younger the embryo the longer are—relatively to the size of the embryo—the foramen umbilicale and the foramen vitellinum, as is well shown in Fig. 17. The line of attachment of the amnion extends almost the entire length of the embryo, beginning just in front of the heart, and ending upon the umbilical cord (*Bauchstiel* or allantois-stalk), close to the chorion. The yolk-sack has also a long attachment, beginning just behind the heart, and extending nearly to the allantois stalk, which now appears to the eye very much what it is morphologically, a prolongation of the posterior extremity of the body of the embryo.

Going back still farther, we find the relations to be as represented by the accompanying diagram, Fig. 18. The embryo, *Emb*, rests upon the yolk-sack, and is scarcely longer than the umbilical foramen; the end of the embryo is prolonged posteriorly as the relatively large allantois-stalk, *Al*, by which the embryo is attached to the chorion. The amnion springs from the sides of the embryo and of its allantois stalk, and forms a closed sack over the embryo. This stage is almost the youngest in the series of known human embryos, and has been only imperfectly described.

* At this stage more properly to be called the *Bauchstiel*, see Chapter XVI.

The following generalized diagram, **Fig. 19**, of a young amniote vertebrate embryo is intended to render clear the essential relations of the embryo and its appendages. The figure represents a transverse section of the embryo, together with all the membranes. The embryo consists of an axial mass, from which runs out on each side a lamina or plate of tissue, *Som*, to form the body-wall; this plate extends beyond the embryo to form the amnion, *Am*; as the plate from one side joins that from the other, the amnion makes a closed sack over the back of the embryo. From the axial mass there run out two other plates, *Spl*, to form the walls of the intestinal canal, *In*; these plates are likewise prolonged beyond the body to form the large yolk-sack, *Yolk*, upon the top of which the em-

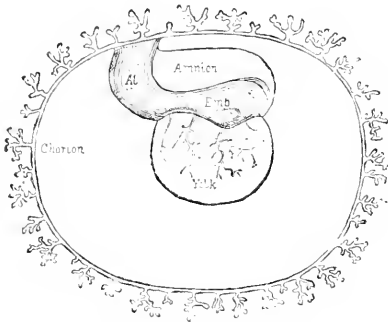


FIG. 18.—Diagram of an embryo of fifteen to sixteen days.

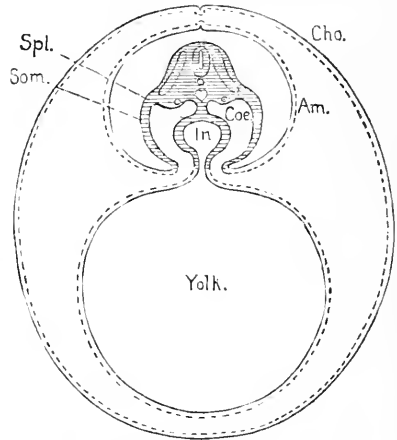


FIG. 19.—Generalized diagram of an amniote vertebrate embryo.

bryo rests. The space between the walls of the intestine and the body-walls is of course the body-cavity, *Coe*. Where the body-wall, *Som*, passes over into the amnion, *Am*, there is an opening by which the body-cavity communicates directly with the space between the amnion and yolk-sack on one side and the chorion on the other; this opening is the umbilical foramen. Similarly there is a passage by which the cavity of the intestine, *In*, communicates with that of the yolk-sack, *Yolk*; this passage is the vitelline foramen.

For our conceptions of the probable history of the human ovum up to the fourteenth day, we must rely mainly on analogy, drawn from our knowledge of the development of other mammals and of birds and reptiles. From these sources we learn that the amnion and chorion are originally portions of the same membrane, which is an extension of the body-wall of the embryo. In reality the differentiation of the amnion is quite a complex process, as is shown by the detailed history given in Chapter XV. The essential steps can be made clear, however, by a brief description. **Fig. 20** is a diagram of a stage in the development of amniota a little earlier than that shown in **Fig. 19**. Both the vitelline and umbilical foramina are much wider than in the preceding figure. The body-wall of the embryo, *Som*, passes over as before into the amnion, *Am*, but the amnion of one side does not join that of the other, but instead bends

over and is continuous with the chorion, *Cho*. Thus the amnion and chorion conjointly form a fold on each side of the embryo; if the two folds enlarge and arch over the embryo until they meet and unite by their edges the condition illustrated by the preceding diagram, Fig. 19, will be established.

Returning to the earlier condition, Fig. 20, we may say that the ovum consists of two closed vesicles united together by the axial mass of the embryo. The membrane, which forms the outer vesicle, is subdivided into three principal regions, to wit: the body-wall of the embryo, the amnion, the chorion, each having its separate history. The membrane which forms the inner vesicle is subdivided into two principal regions, to wit: the wall of the intestine and the wall of the yolk-sack, each having its separate history. It will be remembered that the posterior end of the embryo is prolonged as the allantois-stalk, by means of which it remains permanently and directly united with the chorion.

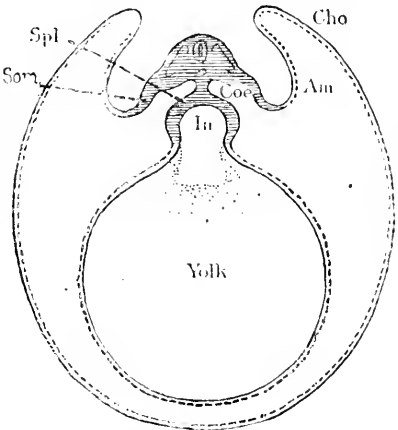


FIG. 20.—Generalized diagram of an amniote vertebrate embryo before the separation of the amnion, *Am*, and chorion, *Cho*.

It is unnecessary, for our present purpose, to follow back the earlier history step by step. Suffice it to say that in younger stages the two vesicles are represented only by one, and earlier yet there is merely a cluster of cells.

The stages of development preceding this are not to be found in the uterus, but in the Fallopian tubes. They exhibit to us merely an agglomeration of a few cells, the so-called segmented ovum. The earlier the stage the fewer the cells, until we reach the condition when there are but few cells, then two, and finally one only. This cell is the impregnated ovum, the beginning of all development, but is itself formed of two separate parts, very different in their origin and constitution, namely, the egg-cell or ovum and the spermatozoon, whose union is the act of impregnation—the beginning of a new existence.

II. PROGRESSIVE HISTORY OF THE FŒTUS AND ITS ENVELOPES.

The ovum enters the upper end of the Fallopian tube, and is there impregnated.* Very slowly it moves down the Fallopian tube, undergoing meanwhile the process of so-called segmentation, by which it is separated into a gradually increasing number of cells, that arrange themselves so as to begin the formation of the embryo and its appendages. Probably about the eighth day the ovum reaches the uterus, where it becomes adherent to the mucosa upon

*It is possible that impregnation may occur while the ovum is passing from the ovary to the fimbriate opening of the Fallopian tube.

the dorsal side of the uterus usually, and by an unknown process of agglutination. The decidua reflexa grows up around it by a process not yet observed. The amnion is differentiated from the chorion. The portion of the mucosa uteri in contact with the ovum is transformed into the decidua serotina; the remaining portion of the mucosa becomes the decidua vera. The allantois-stalk unites the embryo with the chorion, and carries the blood-vessels of the foetus to ramify upon the chorion. The embryo is enclosed by the amnion; the amnion is enclosed by the villous chorion; the chorion is enclosed by the decidua reflexa and serotina. The vesicle formed by the close adherence of the chorion to the reflexa is suspended from the wall of the uterus. The mass of tissue resulting from the union of the chorion with the serotina forms the placenta. The umbilical cord (allantois-stalk) is always attached to the placental area, and later the ramifications of the umbilical vessels are restricted to that area. During the fifth month the decidua reflexa coalesces with the decidua vera, and the space between them is of course obliterated. Finally, we find that the amnion enlarges, lays itself against the chorion, and, uniting loosely with it, becomes the innermost constituent of the vesicle enclosing the embryo.

PART I.

THE GENITAL PRODUCTS.



CHAPTER III.

THE HISTORY OF THE GENOBLASTS AND THE THEORY OF SEX.

THE term genoblast is used to designate the sexual elements. I apply it exclusively to sexual elements proper, and not to the accessory parts with which those elements are associated. The spermatozoon is a genoblast; a spermatophore is not. The egg-cell after maturation is a genoblast, but not before.

I. SPERMATOZOA.

1. Summary.—The spermatozoa of mammals are filaments consisting of a short, thick end called the head, and a very long and delicate thread called the tail. The head varies greatly in shape, according to the species; in man it is broad and thin, Fig. 22, and is widest at a little distance from the tail. The head contains chromatin, and may be colored by the usual nuclear dyes. The tail consists of three parts: 1, the *middle-piece*, which is next the head, and the thickest of the three parts; it contains an axial thread, and probably always has a *very* fine spiral thread running round it; 2, the *main-piece*; and, 3, the *end-piece*, which is not more than a line, even as seen with very high magnifying powers. The human spermatozoon is 0.055 mm. long—the head being 0.005 mm., the tail 0.050, and the *middle-piece* 0.009.

The development of the mammalian spermatozoa begins with a so-called parent or mother-cell, which lies near the outer wall of the seminiferous tubule. The mother-cell produces a number of daughter-cells, which also multiply by division; the daughter-cells break down, forming a column of matter (protoplasm), in which lie their nuclei, and at the base of which lies the nucleus of the mother-cell; the nucleus of the mother-cell and the column of matter both ultimately disappear, but exactly how is not determined; the nuclei of the daughter-cells produce each a spermatozoon. The head and tail of the future spermatozoon become visible within the nuclear membrane; the head is formed chiefly by the chromatin of the nucleus; the nuclear membrane finally ruptures, and it as well as the contents of the nucleus which have not taken part in the formation of the spermatozoon are lost. Among the lost parts is a special round body of small size, which appears in the nucleus while the spermatozoon is developing; this body may be stained by chloride of gold, but not by hæmatoxylin; its significance is unknown. The long column holding the spermatozoa together has usually been regarded as a cell, and is the supporting cell *auct.*, or Sertoli's column.

2. Spermatozoa are the essential fertilizing elements secreted by the male gland. They are minute bodies, capable of active loco-

motion, and having a characteristic form in each species. In a few instances (certain snails, etc.) there are two distinct forms of spermatozoon for a single species, but usually there is only one form, and that little variable. In a small number of animals the spermatozoa, as in the nematods, are distinctly cell-like; but in the great majority of animals, and, so far as I know, in all vertebrates, they are long and thread-like; hence their common German name, *Samenfäden*, first proposed, I think, by Kölliker.

The mammalian spermatozoa are long, slender bodies, varying considerably in configuration, but all presenting at least the following features in common: One end is thickened and is called the head; it has a strong affinity for nuclear staining fluids; this affinity must be attributed to the chromatin, which the head contains, as is shown by the history of its development; the remainder of the spermatozoon is long and slender, and constitutes the tail; the tail consists of—1, a middle part (*Mittelstück*), a little thicker than the rest, and situated next to the head; the middle part is traversed by a very fine axial thread, and ends abruptly; and, 2, a hind-piece, which, according to some writers, may be subdivided naturally into two segments, the main-piece (*Hauptstück*) and end-piece.

The spermatozoa of the various species differ in size in the proportions of the parts, and often very strikingly in the shape and structure of the head; those of the opossum are especially remarkable for being double; two apparently complete spermatozoa being united to a common plate by their heads (Selenka: "Studien über Entwicklungsgeschichte," Heft IV., p. 106). Twin spermatozoa have also been observed in the rat by Neumann, **75.1**, 313, Taf. XVII., Fig. 16, b. Compare also Max von Brunn, **84.1**, and Brock, **87.5**.

The largest known mammalian spermatozoon is perhaps that of the marsupial, *Plascogale*; the spermatozoon of this animal is 0.263 mm. long—the head, however, being only 0.013 mm. (Fürst, **87.1**, 354). The spermatozoon of the rat is 0.144 mm. long, the head 0.009, the tail 0.135, and the middle-piece 0.045 mm.

La Vallette, **71.1**, gives a synopsis concerning the forms of vertebrate spermatozoa nearly as follows: *Fish*: The spermatozoa of *Amphioxus* are threads with round heads. In *Petromyzon* the head is rod-like or egg-shaped. The teleosts generally have pin-like spermatozoa; but in the salmonidæ (Owsjannikow) the head is pointed and shaped like a heart-tip. The spermatozoa of selachians are much larger, with the head-end spindle-shaped and often spirally twisted. *Amphibia*: The head is long, generally pointed, the middle-piece short, and the tail is often provided with an undulatory membrane (Retzius, **81.1**). *Reptiles and birds*: The head is usually long, often twisted. *Mammals*: The head is more or less elongated; in ungulates the head is flattened and usually more or less egg-shaped in outline, the pointed end toward the tail. Among rodents there is considerable variety of form. In the dog the head is pear-shaped; in the hedgehog the head is truncated inferiorly, and the tail is inserted laterally. No comprehensive summary of the observed forms of spermatozoa has been made since the publication of Wagner and Leuckart's article in "Todd's Cyclopædia."

The most minutely studied mammalian spermatozoon is that of the rat, thanks especially to the patience of O. S. Jensen, whose posthumous paper, **87.1**, furnishes the basis of the ensuing description. The rat's spermatozoon measures $144\ \mu$; its head, Fig. 21, C, is a broad hook, pointed at one end and obliquely truncated at the other; from one corner of the truncated end starts the very long slender tail, which is divisible into the thicker middle-piece (*Mittelstück*, or Jensen's *Verbindungsstück*) and the thinner main-piece (*Hauptstück*). Fig. 21, A, which terminates in a short and still finer thread called the end-piece (*Endstück*). The appearance of the spermatozoon varies according to its degree of development, it not attaining full maturity until it has left the seminiferous tubule. The changes referred to affect principally the head and the middle-piece.

The head is covered, while the spermatozoon remains in the seminiferous tubules, by a membranous cap, Fig. 21, A, which subsequently disappears. The middle-piece has a spiral thread running round its outside, Fig. 21, B. The spiral thread appears soon after the rupture of the nuclear membrane, by which the developing spermatozoon is set free (*cf. infra*). The thread is at first indistinct and makes only a few turns; it rapidly becomes more distinct and the number of turns increases, until they become so numerous that in a spermatozoon taken from the vas deferens only a series of thick-set cross-lines can be distinguished; these lines have been seen by several observers and variously interpreted; the spiral may run to the right or to the left. The thread becomes loosened off by the action of glycerin (1 part) and water (4 parts), and is destroyed in one to two hours by 0.6 per cent salt solution, leaving then the axis uncovered. The thread can be stained by chloride of gold, though the axis cannot. The axis, when the spermatozoa are treated with acetic acid, often breaks up into threads (*cf. Ballowitz, 86.1*); it shows a lighter line in its centre. These observations lead Jensen to the conclusion that the axis is formed by a wall of fibrillæ surrounding a central core or cavity.

The axis does not reach quite to the head, but ends with a little knob, leaving a small, perfectly transparent space between the knob and the head, Fig. 21, C. In some spermatozoa—*e. g.*, of horse and ox—though not in those of the rat, there is a minute opening in the head called the *microporus*, and situated just opposite the knob of the axis. When the spermatozoa are stained with nuclear dyes, most of the head is colored, but the tip of the hook, which contains no chromatin, and is probably formed out of a scrap of the nuclear




Fig. 21. — Structure of a rat's spermatozoon. B, young spermatozoon, end of the middle-piece and beginning of the main-piece to show the spiral thread—greatly magnified; A, head, with part of the axial thread; C, immature spermatozoon, anterior half only. After O. S. Jensen.

membrane, remains uncolored: on the concave side of the tip a fine line can be distinguished, due, apparently, to a rod of substance. Sometimes a minute fragment of the nuclear membrane is left adherent to the lower end of the middle-piece; for the explanation of this possibility, compare the section below on development.



FIG. 22.—Human spermatozoa. A, complete spermatozoon; B, head seen from the side; C, extremity of the tail. All highly magnified. After Retzius.

The human spermatozoa are described by Retzius, **81.1**, 85, as follows: The head, seen from the flat side, appears oval, Fig. 22, A, with the front end generally tapering a little, but never pointed; the anterior half or two-thirds has a brighter and more transparent part. Seen on edge, Fig. 22, B, the head has a pointed form, with a posterior thicker, round, dark part. By adjustment of the focus it can be ascertained that the sides near the point are depressed somewhat like those of red blood corpuscles. Retzius could nowise succeed in demonstrating a special tip (Spiess) corresponding to that in the salamander, but Edw. M. Nelson (*Journ. Quekett Club*, 1889, III., 310) has observed a slender thread prolonged from the head, and also a hook at the end of the thread; these observations have been confirmed by Bardeleben, **91.1**. The latter also describes additional details of the structure of the head. The following piece (Schweigger-Seidel's *Mittelstück*) is directly united with the head by a transverse joint; there is no neck in Eimer's sense; the middle-piece is cylindrical and relatively small—about as long, or a little longer, than the head; its surface is often granular or rough, and there cling to it a few shreds of protoplasm, as has been described by several investigators; the spiral thread was long overlooked, but has been recognized and figured by K. Bardeleben,

91.1. The undulatory membrane, supposed by Gibbes, **79.1**, and W. Krause, **81.4**, to be present, was perhaps an abnormally loosened spiral thread. The *main-piece* of the tail is about half as thick as the "*Mittelstück*," gradually tapers, and ends abruptly at the beginning of the still finer and very short *end-piece*.

3. Spermatogenesis.—The seminiferous tubules are cylindrical, *i. e.*, in cross-sections they appear round; a large part of the tubule is filled with spermatozoa in various stages of development. The outer boundary is marked by a distinct line corresponding to the tunica propria, a layer of endothelial cells, with flat oval nuclei (Neumann, **75.1**, 306). Next to the tunica comes a layer which, as far as known, presents pretty much the same appearances, whatever may be the stage of development of the spermatozoa within. This layer contains two kinds of cells: *First*, the large Sertoli's columns, as they may be called, after their discoverer.* These cells are identical with Merkel's Stützzellen, La Vallette's spermatogonien, Swaen and Masquelin's cellules folliculaires. *Second*, small granular cells, vary-

* First described by Sertoli in ii. Morgagni (*cf.* Henle's Jahresberichte for 1864, p. 120). Compare Sertoli, Arch. Sci. mediche, ii., 107 (1877).

ing in appearance according to the exact stage of their development. Examined in surface views, Fig. 23 (compare also Figs. 5, 6, and 41 of Fürst's paper, 87.1), the *large cells* are seen to be mostly hexagonal in outline, to touch one another, and to pass below, *i. e.* outside, the small cells; they have large, clear, oval nuclei with sharp outlines, and usually a single well-marked nucleolus. The nuclei lie quite near the tunica propria, but in man lie farther inward, and are in this case not so near the tunica as are the small cells. Around the nucleus there lie a few highly refractile granules which may be stained by arsenic acid, and are probably fat. The small cells lie in depressions or cups of the large cells, Fig. 23, B, and when the small cells are knocked out—as sometimes happens in teasing—the partitions between the cups appear more distinctly and create a network figure, which formerly misled Von Ebner and others into describing a real network as constituting the layer. The large cells also have long columnar prolongations, as can be best seen in transverse sections of the tubules, Fig. 29; the prolongations are united with bundles of developing spermatoblasts. The *small cells* are very different; they lie over the outlines of the large cells and between their centripetal prolongations, Fig. 29; they are granular, have comparatively little protoplasm, and their nuclei are nearly spherical in shape. The nuclei vary considerably in appearance, as these cells multiply by indirect division; usually they contain a chromatin network or a coiled chromatin cord; sometimes the network is concentrated at one side of the nucleus, leaving the other side comparatively clear. At certain periods the nuclei are found in various stages of karyokinesis. The cells resulting from the division of the small cells form the packing between the inward columns of the large cells, hence in cross-sections we get alternating columns, Fig. 29.

The descendants of the small cells produce the *spermatoblasts*, and the spermatoblasts are converted into the spermatozoa. The small cells are then the parents of the spermatozoa and may be called the *parent-cells*; a great variety of names have been

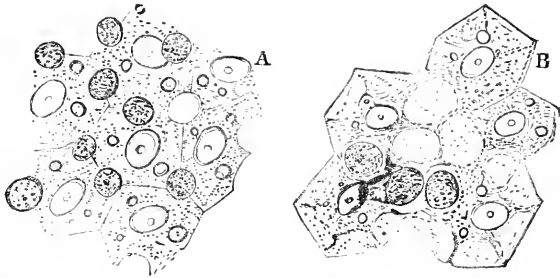


FIG. 23.—Peripheral layer of the seminiferous tubule of a rat. Two views from a teased preparation. After Neumann.

employed to designate them, such as mother-cells, spore-cells, germinative cells, Samenstammzellen, etc. The nomenclature of the small cells is very confused; those of them in process of indirect division are often smaller than the others and have been designated as the "growing cells" by H. H. Brown, 85.1, and this term has been used by other writers since. The small cells in the resting stage are called "Stammzellen" by most German writers, as an equivalent for which I have adopted *parent-cell*.

FORMATION OF THE SPERMATOBLASTS.—The parent-cells divide

and produce probably three cells, although the number has never been accurately ascertained. One cell remains as a parent-cell, and the other two are the mother-cells (*Mutterzellen*) and are well characterized by their appearance. According to Biondi, 85.1, the nucleus of the parent-cell remains and becomes like the nucleus of the large cells (Sertoli's or supporting cells). The mother-cells divide and their descendants also divide until there is produced a column of cells, Fig. 24, which stretches in a radial line from the mother-cell toward the centre of the tubule, and is packed in between the columnar centripetal prolongations of Sertoli's cells (*cf.* Figs. 24 and 29). Probably, then, although investigators are not agreed in regard to this point, the parent-cells divide in such a way that the cells resulting from the division are unlike, one of them preserving the character of the parent-cell, and the others differing from it in having a relatively larger nucleus and a finer chromatin network; the appearance of the nuclei varies, of course, according as they are in the resting or divisional (kinetic) phase.*

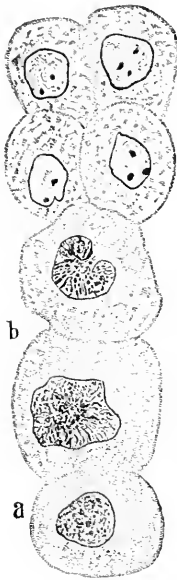


FIG. 24.—Column of spermatocytes from the rat: *a*, parent cell; *b*, mother cells. After Biondi. $\times 600$ diams.

The cell most like the original one, and which we may call still the parent-cell, lies at the outer edge of the tubule, while the others or mother-cells lie toward the centre, Fig. 24. The parent-cell, as already stated, produces at least a second and perhaps more mother-cells, so that the column grows centripetally. The column also grows by multiplication of the mother-cells, but the cells thus formed lie in the innermost part of the column; they are smaller, Fig. 24, than the first generation of (mother) cells; they have relatively large nuclei, with the chromatin gathered into two or three spots—nucleoli. We thus have a column of cells in which we can distinguish three zones: 1, the outer zone of the parent-cell; 2, the middle zone of the mother-cells; 3, the inner zone of the daughter-cells. These zones remain more or less marked for a considerable period; for, as the cells of the inner zone change into spermatoblasts, those of the middle zone change into second daughter-cells, and as the inner spermatoblasts change into spermatozoa the cells of the second zone change into spermatoblasts; the innermost zone long continues one stage ahead. The trizonal arrangement is very conspicuous in cross-sections.

The division of the mother and daughter-cells presents many peculiarities, and does not conform exactly to Flemming's well-known scheme of phases for indirect division. Attention was first directed to these peculiarities by Carnoy, in an important memoir, 85.1, and W. Flemming, 87.1, has since confirmed these discoveries, in large part, by observations on the salamander, and gives a plate of diagrams which is instructive as a facile means of comparison. La

* For figures of the karyokinetic division of the daughter-cells, see Fürst, 87. 1. Figs. 10-13.

Vallette, Niessing, **88.1**, p. 44, and others find that when the mother-cells multiply there is often a stage to be found where several nuclei (two to twelve) lie within one large cell. The multinucleate giant-cells are best found by teasing the fresh specimen. As to their place in the spermatogenetic history we possess no definite knowledge.

The spermatoblasts arise from the nuclei of the daughter-cells (spermatocytes), and not as H. H. Brown, **85.1**, and many others have, I think, erroneously believed, each out of a whole cell. Biondi, **85.1**, seems to me right in his statement that the bodies of the cells break down, or at any rate lose their boundaries, thus creating a granular protoplasmic column in which the nuclei lie. Compare also Niessing, **88.1**. The protoplasm of the parent-cell participates in these changes, hence its nucleus comes to lie at the base of the column. This nucleus has meanwhile altered its character, and become large, clear, and nucleolated. Now, these columns are the same as the large Sertoli's or supporting cells above described. By no means all writers agree with this account of the origin of Sertoli's cells, but all other explanations that I have found appear to me vague and confused, and the history of the changes here advocated is clear, and accounts for the well-established grouping of the spermatoblasts in the substance of Sertoli's column; this essential phase is explained satisfactorily by no other theory.

The nuclei congregate at the inner end of the column, and there change their character and become recognizable spermatoblasts, Figs. 25 and 29.

DEVELOPMENT OF THE SPERMATOBLASTS INTO SPERMATOZOOA.—The nuclei change into spermatozoa as follows: The chromatin is at first unequally distributed throughout the nucleus; it then in great part accumulates at the end of the nucleus toward the outer wall of the tubule; at this stage the chromatin is densest near the equator of the nucleus, where the edge of the chromatin is sharply marked, and toward the outer pole of the nucleus the chromatin is

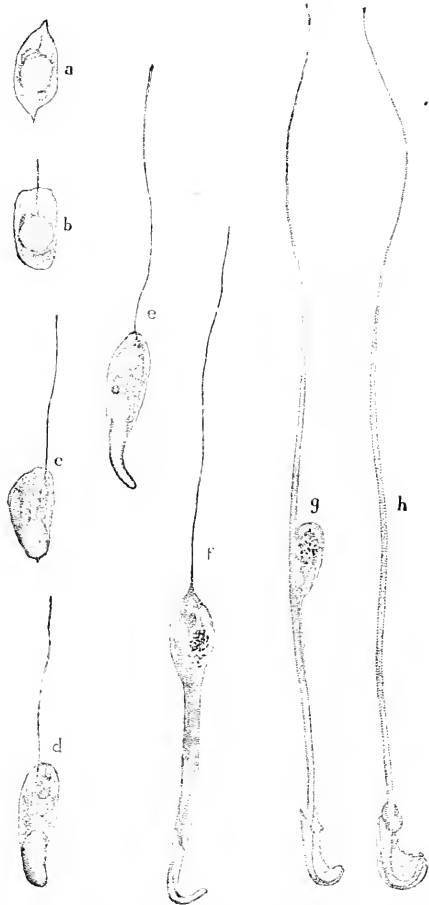


FIG. 25.—Developing spermatoblasts of the rat: *a, b, c, d, e, f, g, h*, successive stages. \times about 750 diameters. After H. H. Brown.

less condensed (Niessing, **88.1**, p. 46, Taf. I., Figs. 6, 7, and 8). It is from the equatorial plate that the future tail grows out at the start. Particles of the chromatin are said to remain in other re-

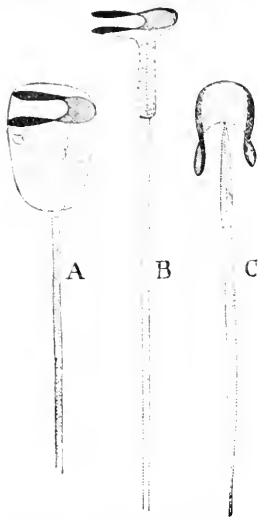


FIG. 25.—Developing spermatozoa of a marsupial: *Metachirus Quica*. A. B. C. different stages. After Fürst.

gions of the nucleus, and finally to gather together to form the small accessory corpuscle mentioned below. According to Platner, **89.2**, 131, 132, the portion of the nucleus which forms the head of the spermatozoon in pulmonate snails is homologous with his *Neubkern*. The main mass of the chromatin is concerned in the formation of the head of the spermatozoon; it is at first quite round, Fig. 25, *a* and *b*, but soon begins to alter its shape, gradually assuming the form of the spermatozoon head, Fig. 25, *c, d, e, f*. The tail appears very early as a delicate filament, growing out from the chromatin and lying entirely within the nucleus, Fig. 25, *a*, but shortly after is found to project beyond the nuclear membrane, *b*, and lengthens rapidly, *e, f, g*. The nuclear membrane is very distinct; it elongates into an oval bag, *b, c*, one end of which lies close against the chromatin, while the other surrounds part of the tail and is wide; the lengthening continues, *e, f, g*, with accompanying changes of form, best indicated by the figures; the part of the tail within the nuclear membrane becomes the middle-piece, Fig. 26, but the spiral thread is not developed until later. The accessory body may be readily seen in the rat; unlike the chromatin of the head it can be stained by chloride of gold: hence, if it is formed of chromatin at all, the chromatin must have undergone alteration. Finally, the nuclear membrane ruptures, Fig. 27, a portion of the membrane remains upon the head, and the caudal bag sometimes endures longer, Fig. 25, *g*, but at last also disappears, except that in certain cases a trace of it remains visible as a fine cross-line at the end of the middle-piece.

Fürst and others think that the axis of the tail is formed from the chromatin, and that the sheath of the axis arises from the achromatine substance of the nucleus (caryoplasma).

After the rupture of the nuclear membrane the young spermatozoa still develop a little farther. The spermatozoa are ultimately liberated, and, falling into the lumen of the tubule, pass off.

From their mode of development, it is evident that the spermatozoa necessarily lie in bundles, each bundle being held together by a Sertoli's column, Fig. 28; at first they lie at the inner end of the

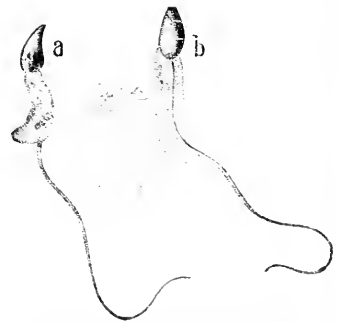


FIG. 27.—Human spermatoblasts, to illustrate the rupture of the membrane. After Wiedersperg.

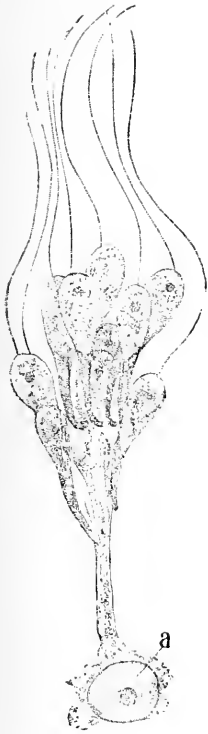

FIG. 28.—Sertoli's column, with a basal nucleolated nucleus and a cluster of developing spermatoblasts. After H. H. Brown.

tion have been detected, there is reason to suspect that the *spermatozoa* are oviparous; they are also stated to propagate by spontaneous fission, the separation taking place between the disc of the body and the caudal appendage, each of which develop the part required to form a perfect whole."

Meanwhile the investigations of Spallanzani, Wagner, Czermak, and many others gradually increased the knowledge of the forms of the spermatozoa. Dujardin was the first to consider the

column, at a considerable distance from the basal nucleus, but as the nuclei (spermatoblasts) lengthen, the heads push their way toward the base of the column, Fig. 29. Now as the development of the daughter-cells (spermatocytes) is continually progressing between Sertoli's columns, we obtain in sections the long-known, remarkable appearances shown in Fig. 29, of bundles of spermatozoa alternating with columns of proliferating cells.

4. Historical.—The seminal animalcules were, it is stated, first discovered by Ludwig Hamm, then a student at Leyden, in August, 1677. Leeuwenhoek claimed the merit of having made the discovery in November of the same year, and in 1678 Hartsoecker published an account of them, professing to have seen them as early as 1674. They were long considered to be probably parasites, and it was not until Prevost and Dumas' researches that it was definitely ascertained that the "animalcules" were the essential fertilizing element. Thus Richard Owen, in his article on "Entozoa" (1836), in Todd's "Cyclopædia," includes the spermatozoa under that head, although he writes: "It is still undetermined whether they are to be regarded as analogous to the moving filaments of the pollen of plants or as independent organisms" (Vol. II., p. 412). But just after he adds: "Although no distinct organs of genera-

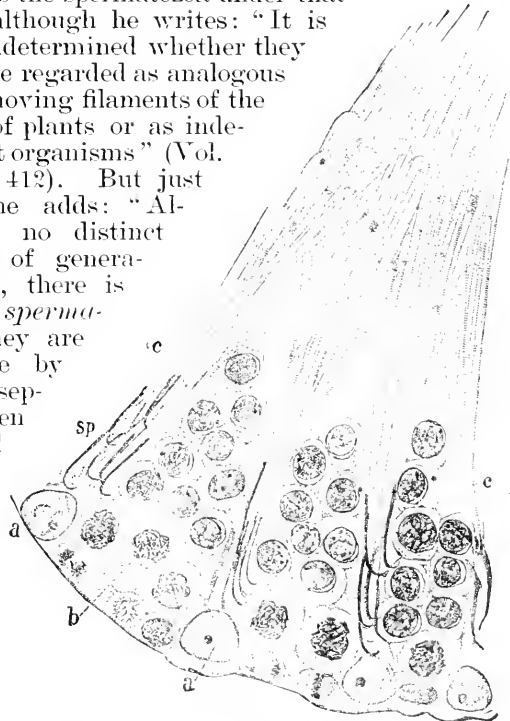


FIG. 29.—Part of a cross-section of a seminiferous tubule of a rat. \times about 750 diameters. After H. H. Brown.

spermatozoa as generated from the inner layer of the seminiferous tubules, and therefore not as parasites. The discovery of the spermatoblasts or immature spermatozoa by Von Siebold (Müller's *Archiv*, 1836 and 1843), soon confirmed by Kölliker and Reichert, marks an important step. Now follows a series of publications by which one detail after another was added to our knowledge. During the past twenty years there has been rapid progress, which may be said to have begun with Schweigger-Seidel's important memoir, 65.1, and to have made us acquainted with the minute structure of the spermatozoa, and their development. Another line of investigation was opened by O. Herwig (1875), in following up the history of the spermatozoon within the ovum after impregnation. For further historical data, see Waldeyer's address, 87.2.

II. OVA.

Definition.—The term *ovum* is employed in various senses. It is applied—1, to the cell distinguished as the ovarian cell, or *immature ovum*, out of which the female product or mature ovum is developed; 2, to the *mature ovum*, or true female spore; 3, to the mature ovum *plus* the fecundating spermatozoon united with it—that is, to the *impregnated ovum*; 4, to various stages of development of the embryo. In this article we consider only the ovum in the strict sense—namely, as the female sexual product.

Summary.—The ovum arises as a cell, which matures by a series of changes, of which the last and most striking is the expulsion of the so-called polar globules; there are many important changes which occur earlier. The genesis of the mature ovum may be conveniently divided into three arbitrary stages: (1) Differentiation of the ovic cell; (2) growth of the cell and accumulation of nutritive material in it; (3) maturation proper.

1st. The Origin of the Primitive Ova (Ureier or Ovic Cells). *—It seems to me, in the light of the recent investigations of the origin of the ova in vertebrates, safe to assert that they arise from cells of the mesothelium (peritoneal epithelium) covering the genital ridge of the embryo, the ridge giving rise to the adult ovary. On account of its function the epithelium of the genital ridge has been called the germinal epithelium (*Keimepithel*). In mammals, which alone will be here considered, according to the best authorities the *ureier* are developed as follows: Certain cells of the germinal epithelium become larger than the others; these cells are soon carried into the interior of the ovary by being included in cord-like ingrowths of the epithelium. These cords are the *Pflüger'schen Schläuche* of German writers. The primitive ova exist in multiple in the cords, but each of them early becomes surrounded by a separate envelope of epithelial cells. A little later each ovum separates from its neighbors and appears as a round cell, with a clear nucleus and distinct nucleolus, *f.* closely invested by a layer of cells smaller than itself. The young egg-cell, together with its epithelial envelope, constitutes the so-called primordial follicle (Fig. 31).

* For a full discussion of this subject see Chapter XXIII.

2d. General Growth of the Ovum and Development of the Yolk.—The modifications which occur in growing egg-cells are as follows: 1st. Change of size; the cell enlarges, it being a rule—no exception to which is, I believe, known—that the mature egg-cell is much larger than any of the other cells in the body of the parent. 2d. Change of shape; the cell usually becomes nearly or quite spherical; the shape of the egg does not necessarily remain spherical, but may be altered by external pressure, as in the uterus of *Arion* ("Hdbk.," Vol. IV., p. 7, Fig. 1815), or as when several are laid in one capsule (*Lumbricus*, *Nepheleis*, *Planaria*, etc.), or when compressed by an unyielding shell. An instance of the last-mentioned kind has been described by Repiachoff (*Z. f. wiss. Zool.*, XXX., Suppl.), who figures the egg of a European bryozoon found on eel-grass as fusiform, Fig. 30. 3d. The nucleus becomes larger, spherical, and assumes an eccentric position within the cell; the chromatin usually gathers into one nucleolus, as in mammalia; the nucleolus is large, distinct, highly refringent, easily stained, and placed eccentrically within the nucleus. The achromatic substance or protoplasm of the nucleus develops into a coarse network, which radiates irregularly from the nucleolus as a centre. 4th. The cellular network becomes very distinct; its interspaces become filled with ovoid, round or crystalline solid inclosures, which are usually, if not always, mainly of an albuminoid character. The inclosures form the part which is called the deutoplasm by Edouard van Beneden and others. The deutoplasm is the same as the yolk-substance of older writers, and is a store of nutritive material from which the protoplasm draws subsequently to support its growth. The term yolk has no very exact meaning, for it is used to designate sometimes the deutoplasm alone, sometimes the whole ovum proper, as when the segmentation of the yolk is spoken of. 5th. In all vertebrates an ovarian envelope, the *zona radiata*, is formed. 6th. It is probable that a vitelline or true cell-membrane is always formed inside the zona by the egg-cell before it reaches maturity.

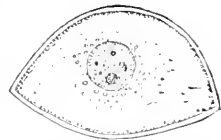


FIG. 30.—Egg of *Tendra zostericola*; after Repiachoff. Magnified.

Primordial Ovum.*—In the ovary at birth, and thereafter up to the period of the climacteric, are small egg-cells, some of which develop from time to time into mature ova. At all ages these small egg-cells together with their follicles present a constant appearance. It is currently stated in text-books that there are some seventy thousand egg-cells in the human ovary at birth; but upon what authority this assertion rests I do not know. In any case the number is very large, and it is probable that a good many of them never develop, but degenerate. These youngest egg-cells are known as the primordial ova; they lie in a layer immediately below the *albuginea* of the ovary and never in the medullary region, Fig. 32. They are slightly irregular globules, usually 50–60 μ in diameter; 48 by 54 μ , 54 by 58 μ , 64 by 68 μ , exemplify actual measurements. The protoplasm is finely and evenly granular, and consists of a uniformly

* In the ensuing account of the ovarian ovum up to its maturation, I have been guided chiefly by Nagel's article 88. 1

clear matrix (hyaloplasma) and a fine reticulum, which may be brought out by eosine staining. In birds His, **68.1**, has found "protagon" granules in the primordial ovum, and Ed. van Beneden affirms, **70.1**, that yolk-grains are present in the primordial ovum of various mammals; but in man this is not the case. The protoplasm is naked—that is, not enclosed in a cell membrane. The nucleus is round, lies in the centre of the cell, measures from 29 to 32 μ in diameter, is bounded by a very distinct membrane, and contains a round excentrically-placed nucleolus, about 9 μ in diameter. Between the nucleolus and the membrane there is a loose network of fibres, attached to both; the substance of the network is different from that of the nucleolus, as is shown by its different staining. The network was first observed by Flemming, **75.1**, in *Unio* and *Anodonta*, and has since been often observed in many species; it was first described in human ova by Trinchese (Mem. Acad. Sci. Bologna, Ser. III., T. VII.). Some of the primordial ova of very young children have no nucleolus, and in bats all of them are at first without it according to E. van Beneden. The position of the nucleolus is variable; it may lie close to the membrane of the nucleus or nearly in the centre. A peculiarity worthy of mention is that once in a great while a primordial ovum has two or even three nuclei. This occurs so very rarely that it cannot be considered as any evidence of multiplication of the ova, but only as an extremely abnormal variation (see Nagel, **88.1**, 372-375). Each primordial ovum is surrounded by a very thin epithelial envelope, Fig. 31, *f*, with scattered fusiform nuclei easily distinguished in stained specimens from the similarly shaped nuclei of the neighboring connective tissue.

The shape of the follicular nuclei has misled Schrön, **63.1**, Foulis, **76.1**, Klebs, **63.1**, and others into maintaining that the follicle is derived from the stroma-cells, instead of, as is really the case, from the germinal epithelium; Kölliker traces the origin of the follicular cells to the "*Markstränge*"; others, as, notably, Harz, **83.1**, and Sabatier, **84.2**, derive the follicular cells from the ovum. Both views must, it seems to me, be discarded (compare for details, Chapter XXIII.). The follicle forms a closed wall around the entire ovum, and not one with an opening, as certain authors have maintained. The primary follicles of mammals were first described by Barry, **38.1**, under the name of ovisacs; his observations were soon confirmed by Bischoff, **42.3**. They are now familiarly known to all histologists.

Growth of the Ovum and Primary Follicle.—The follicles remain for a long time without change, but from time to time certain ones of them develop. In a mature ovary we can find always several stages. The cause of the development of the follicles is unknown. The primary follicles are always near the surface; as they grow in size they move deeper into the stroma. The first step is the multiplication of the cells of the follicle, Fig. 31, *A*, which converts the follicle into a layer of cubical cells with the nuclei at an even height. During this change in the follicle the primordial ovum does not alter in size.

The second step is the elongation of the cells into a cubical form, with an accompanying enlargement of the ovum. The growth of

the ovum affects the protoplasm, the nucleus, and the nucleolus, all of which increase their dimensions. The follicular wall steadily increases in thickness; at first it remains single-layered, but the nuclei take their places at various levels; a little later it becomes several-layered, and then the formation of the first envelope (*zona pellucida*) around the ovum begins. Nagel, 88.1, 380-382, calls attention to the large clear cells with large nuclei, which show a distinct reticulum and one or several chromatin granules; they are found in somewhat larger follicles, but only up to the time when the yolk granules begin to form in the ovum. Nagel interprets these cells as having a nutritive function, and calls them *Nährzellen*; he offers very little evidence in favor of his view. The cells in question measure 16-21 μ , and are much smaller than the primordial ova, which they somewhat resemble in appearance. These cells have been seen by various authors, e.g., Call and Exner (Sitzber. Wien. Akad. Wiss., etc., 15 April, 1865). It is more probable that these cells have to do with the formation of the liquor of the Graafian follicle, which begins while they are present. The cells of the granulosa multiply by indirect division, as has been shown by Harz and also Flemming (*Arch. mikrosk. Anat.*, XXIV, 376-384). I have found the numerous karyokinetic figures in the follicles of the rabbit's ovary, though hardly quite as abundant as Flemming's description led me to expect. The mitoses have not been found in the first stages of follicular growth. During the growth of the follicle there is formed, as was first described by Schrön, 63.1, 419, a network of blood-vessels close around the follicle; the layer of blood-vessels constitutes the so-called *tunica vasculosa* or *theca folliculi*; the first vessel is a simple loop, which embraces the young follicle; other loops approach and unite with their fellows to form a network.

Development of the Graafian Follicle.—After the epithelium of the primary follicle has become many-layered, there appear in it rounded vacuolated spaces, which increase in size and finally become confluent, so that there is a space or fissure in the epithelium, Fig. 32, 4. This fissure divides the epithelium into two layers, an inner one immediately surrounding the ovum, and an outer one next the stroma of the ovary. Since the fissure does not extend completely around the follicle there is one place where the two layers are united, Fig. 32; the place of union, though variable in position, is always on the side of the follicle away from the surface. The fissure is filled with a serous fluid known as the *liquor folliculi*. In man and most mammals there is a single continuous fissure; but in the rabbit, and perhaps other rodents, there are often cords of cells stretching across from the outer to the inner lamina of the epithelium; the cords vary in number from two to ten; they were first described by Barry, have been beautifully figured by Coste, 47.1, *Lapin*, L. I., Fig. 2, and are

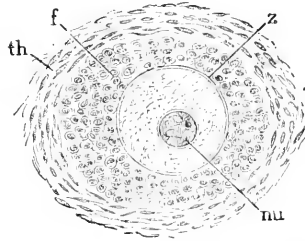


FIG. 31.—Primary follicles from the ovary of a woman, thirty-one years old: *Th.* connective-tissue layer; *f.* epithelial follicle; *z.* beginning, *zona pellucida*; *nu.* nucleus or germinative vesicle. After W. Nagel.

known as the *retinacula*. The development of the fissure changes the primary into a Graafian follicle.

The Graafian follicle is bounded by a layer of epithelium known as the *membrana granulosa*, from its appearance when examined in the fresh state; it is surrounded by a vascular layer, characterized not only by its blood-vessels, but also by the condensation of the connective tissue composing it. The follicle lies a little below the layer of primordial ova. To a part of its walls on the side away from the surface of the ovary is attached a mass of cells more or less globular in shape; this mass is known as the *discus* or *cumulus proligerus*; it encloses the ovum; the cavity between the discus and granulosa is the cavity of the follicle, and contains the liquor folliculi. The further history consists principally in growth and secondary modifications. The follicular wall and the discus increase in thickness; there is added a very thin basement membrane, Waldeyer's *mem-*

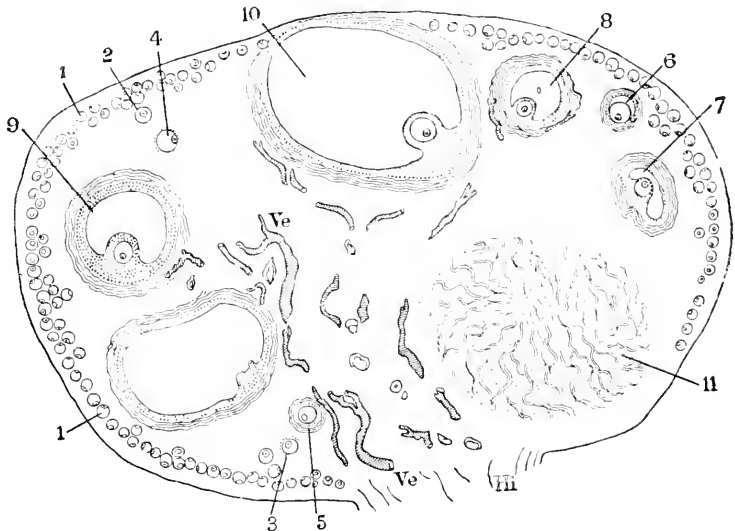


FIG. 32.—Ovary of cat: 1-11, successive stages of the ova; 1, primordial ovum; 8, 9, 10, Graafian follicles; 11, corpus luteum; Ve, blood-vessels; Hi, hilus. After Schrön.

brana propria, close around the outside of the granulosa and separating it from the tunica vasculosa; the membrana propria is said to be an endothelium derived from the connective-tissue cells of the ovary. The vascular membrane or theca folliculi becomes differentiated into an outer fibrous layer (Henle's *tunica fibrosa*) carrying the larger blood-vessels, and an inner less fibrous layer carrying the smaller blood-vessels (*tunica propria*). The distinction between the membrana propria and tunica propria should not be overlooked. The smallest blood-vessels running around the follicle from below, and minutely subdivided on its upper surface, converge toward a point near the surface of the ovary; this point is called the *stigma*, contains no blood-vessels, and marks the spot where finally the follicle is to rupture to allow the ovum to escape. The stigma, owing to

the absence of blood-vessels, is yellowish-white. In mammals and birds it is elongated and rounded in outline, but in lizards is angular (Coste, **47.1**, 160). The cells of the granulosa acquire, at least in the cow, highly characteristic forms (Lachi, **84.1**); there are, 1st, very narrow elongated cells, which stretch through the entire thickness of the layer, and present, when isolated, curious irregular forms; they have oval nuclei, about which there is usually a small amount of protoplasm; the nuclei of these cells lie in the half of the granulosa next the cavity of the follicle. 2d, cells with rounded nuclei, larger cell-bodies, and a few fine processes of irregular shapes; these cells lie between the processes of the others in the outer half of the membrane. 3d, cells that are probably immigrated leucocytes. The cells of the discus have not yet been minutely studied; those next the ovum are cylindroid, and radiate around the zona, constituting thus the so-called *corona radiata* of authors—compare Fig. 34. The cells of the outer layer of the discus are more rounded in form; it is, of course, probable that the two forms of discus-cells resemble the cells of the granulosa in actual shape.

Just before the primary follicle changes into the Graafian follicle the ovum, at least in man, has attained its full diameter, but still contains no yolk (deutoplasm). At this time there appears a clear, delicate membrane close around the ovum, separating it from the cells of the follicular wall. In the Graafian follicle this membrane steadily grows until it attains a diameter of 20–24 μ ; it is called the *zona radiata* or *pellucida*; its structure is described in the subsequent section on the full-grown egg-cell.

The first yolk-grains appear in the human species when the zona pellucida has attained a thickness of 1 μ or more, and are situated always in the centre of the egg-cell (Nagel, **88.1**, 385, 386). In other mammals they are said to appear earlier. The yolk-granules must be considered as the direct products of the vital activity of the egg-cell itself, and in my judgment there is no sufficient basis for any other view. Various hypotheses as to the origin of the yolk-grains have been advanced. Thus Waldeyer, **70.1**, has maintained that the grains are produced by the cells of the follicle, and are transferred from them across the zona into the ovum. It is not impossible that very small young granules may arise in the follicular cells and be transmitted along the fine processes by which the cells are connected through the zona radiata with the ovum, and that these granules subsequently grow within the egg-cell, as Caldwell, **87.1**, asserts is the case in monotremes and marsupials. Caldwell's statements are so aphoristic that the question must remain unsettled until more fully investigated. Lindgren, **77.1**, asserts that the cells of the granulosa immigrate through the zona to form the yolk-granules; his observations were made on ova which had already been somewhat macerated, and which had the processes of the follicular cells swollen in consequence. That the yolk-grains are produced by the gradual enlargement of small ones has been shown by Sarasin's researches on reptiles, **83.1**. He found in *Lacerta* a central area of small granules which gradually enlarge; this area (*Herd der Dotterbildung*) persists even after the embryo has appeared, and the egg increases in volume and weight after the segmentation has begun.

The characteristics of the human yolk-grain have not been accurately investigated, nor have those of any of the higher mammalia been studied carefully. In the human ova the grains are $1\ \mu$ or less in diameter; highly refringent and of various kinds. In a sheep's ova Bonnet, **84.1**, found small granules, fat-globules in considerable abundance, p. 178, and larger granules which stain with eosine, *l. c.*, p. 183. Their accumulation continues centrifugally, forcing the nucleus of the ovum to an eccentric position; when the maximum of the vitelline deposit is reached there is only a very thin layer of protoplasm around the outside of the egg-cell, Fig. 34, and a court of protoplasm around the nucleus. This disposition is particularly well shown in the ova of the monotremes and marsupials. See Caldwell, **87.1**, Pl. XXIX., Fig. 5. The cortical layer is readily distinguished in fresh ova, but in hardened specimens is quite or wholly indistinguishable. In the ovum of the placental mammalia the yolk never attains a great development; but in most vertebrates the granules gradually enlarge, and in some cases they are quite big. When they are thus developed it is easy to see that they are of various sorts. Thus in the hen's ovum there are two principal kinds of yolk-grains, the yellow and the white. The yellow grains are spheres of from $25\ \mu$ to $100\ \mu$ in diameter, filled with numerous minute, highly refractile granules; these spheres are very delicate, and easily destroyed by crushing. When boiled or otherwise hardened *in situ*, they assume a polyhedral form from mutual pressure. The white grains are vesicles, for the most part smaller ($4\ \mu$ to $7.5\ \mu$) than the spheres of the yellow yolk with a highly refractive body, often as small as $1\ \mu$ in the interior of each. There are also larger spheres, each of which contains a number of spherules similar to the smaller vesicles. The yolk-plates, or plagiostomes, which consist principally of lecithin and nuclein, are not present in the younger ova, but are present in great numbers in the full-grown ones; they are oval, barrel-shaped, or rectangular bodies, with rounded corners and edges; the surface, especially in the

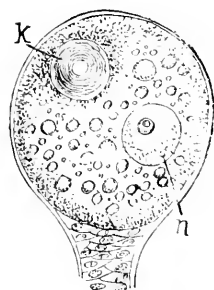


FIG. 33. — Egg-cell of *Tegenaria domestica*. *n*, nucleus; *k*, laminate yolk-nucleus After Balbiani

larger plates, shows a fine transverse striation, corresponding to the laminate structure of the grain. As no thorough comparative investigation of the yolk-granules has been made, it is not worth while to enter into further details.

Besides the yolk-grains there may also be present one or several large masses of nutritive material, such as the "oil-globules" of many teleosts, or the so-called yolk-nucleus. The "oil-globules" are produced by the liquefaction of the yolk, and are not oily. The yolk-nucleus has been described by Balbiani in the Arachnida. The eggs of some spiders contain, besides the nucleus, a second body (Fig. 33, *k*), of about the same size as the nucleus, solid, resistant, and exhibiting indications of a series of concentric laminae; this is the so-called yolk-nucleus, and is probably only a specialized form of deutoplasm, and might be compared, for instance, to the four large oil-globules described by Spengel in the eggs of *Bonellia viridis*.

A yolk-nucleus has since been recorded in the ova of various vertebrates; thus Schütz ("Ueber den Dotterkern," Diss. Inaug., Bonn, 1882) found in the ovarian ova of the pike, in September and October, a round or oval body, not sharply delimited, clear, and more homogeneous than the protoplasm, and which increased in size with the growth of the egg. A yolk-nucleus, consisting of an accumulation of larger and smaller granules, has also been observed in the frog and newt (O. Schultze, 87.1), but is apparently wanting in *Bufo* and *Bombinator* (Götte).

The amount of yolk varies in different animals very greatly, and determines, apparently, the size of the ovum. It has been observed that the process of segmentation varies according to the amount of yolk, and this has led to the arbitrary division of ova into *meroblastic* and *holoblastic* (see Segmentation of the Ovum). The yolk usually, perhaps always, leaves a peripheral layer of protoplasm free. In all vertebrate and in some invertebrate ova this layer of protoplasm is thickened, often considerably, around one pole of the ovum, which is then distinguished as the animal pole, the opposite pole being called the vegetative. These are old terms, which have come down to us from the time when the ectoderm, which is produced during segmentation, principally from the substance of the animal pole, was called the animal layer and the entoderm the vegetative layer. It is at the animal pole that the extrusion of the polar globules under normal conditions invariably takes place.

The Graafian follicle grows very much more than the ovum, until it becomes a large cyst, Fig. 32, the position of which is marked by an external protuberance on the surface of the ovary. To the deep wall of this cyst is attached the discus proligerus with the ovum, which is now nearly full grown. The stigma is at the protuberant point of the follicle, which is covered by very little ovarian tissue, so that there is a very thin wall only separating the cavity of the follicle from that of the abdomen.

The degeneration of the Graafian follicles with the contained ovum occurs normally in the ovary; but as the process has no direct interest for the embryologist, it will suffice to refer to Frommann's very admirable summary (Eulenburg's "Real. Encyclop. Heilkunde," V., 602-604).

Full-grown Ovum before Maturation.—The full-grown human ovum is distinguished among mammalian ova for the clear development and ready visibility of all its parts—a peculiarity due chiefly to the small amount of the yolk and fewness of the fat-granules it contains. Fig. 34 represents an ovum from a nearly mature Graafian follicle of a woman of thirty years: the specimen was obtained by ovariectomy and examined and drawn in the fresh state, being kept in the liquor follicle. This specimen gave the following measures: The diameter of the whole ovum, including the *zona radiata*, 165-170 μ ; thickness of the *zona*, 20-24 μ ; perivitelline fissure, 1.3 μ ; the clear outer zone of the yolk, 4-6 μ ; the protoplasmic zone, 10-21 μ ; the deutoplasm zone, 82-87 μ ; the nucleus, 25-27 μ . The *corona radiata*, *cor. r.*, exhibits the features already described. The *zona pellucida*, *Z.* shows a distinct radial striation; this is probably due to the presence of minute pore canals running through the

zona, and which, at least in early stages, give passage to processes of the cells of the corona radiata, which unite with the ovum. These processes have not yet been observed in man in an altogether satisfactory manner, and indeed Nagel, **88.1**, 402, expressly denies their existence, as well as that of the pore canals. The processes are, however,

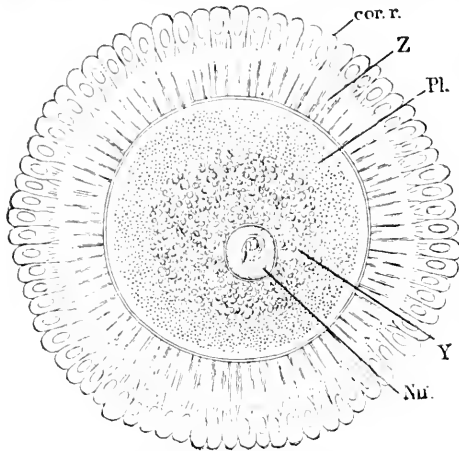


FIG. 34.—Full-grown human ovum before maturation: *cor. r.* part of the corona radiata; *Z*, zona pellucida; *Pl.* protoplasm; *Y*, yolk; *Nu.*, nucleus. After W. Nagel.

readily seen in the lower vertebrates, in the monotremes and marsupials, Caldwell, **87.1**, and have been observed in the placental mammalia, Fig. 35. Hence it seems probable that they are present in man at least while the ovum is growing, though they may be obliterated at the stage we are now considering. Several observers record "dumb-bell cells" * with the thin portion of the cell passing through the zona, and one knob lying on the outside, the other on the inside, of the zona, compare H. Virchow, **85.1**. But apparently such observations have been made solely on ova that had been somewhat macerated, and therefore the "dumb-bell cells" result probably from post-mortem changes, and cannot be interpreted as by Lindgren, **77.1**, to prove the actual normal passage of cells of the discus proligerus through the zona. The zona has no micropyle or special open channel for the entrance of the spermatozoon. For additional details, see the following section on the envelopes of the ovum.

The ovum proper is separated by a narrow fissure, *p v.*, the perivitelline space, from the zona, within which it lies free and loose, so that when a fresh specimen is examined the same side of the ovum—that containing the nucleus, which is the lightest part—is always found uppermost.

The ovum has no vitelline membrane, according to Nagel, **88.1**, 405; but in several mammals such a membrane has been described, appearing as a thin, delicate line about the time the ovum matures, Fig. 35, *v. m.* The body of the ovum may be divided into an inner kernel containing the yolk-granules and an outer protoplasmatic zone, of which the very outermost thin layer is clear, and therefore more or less differentiated from the broader, deeper layer, which is granular and constitutes most of the zone. Frommann, **89.1**, has shown that many of the granules in the ova of the sea-urchin are part of the protoplasmic reticulum; in the living egg they are incessantly changing in shape and in their connections, even disappearing and reappearing; the disappearance Frommann terms liquefaction, the reappearance a new formation. It seems to me possible that the

* Nagelzellen, Spundzellen, Zwillingszellen, or Mantelzellen of German writers.

changes seen are probably in part effects of contraction in the reticulum. The nucleus is nearly spherical, always eccentric in position, and has a nucleolus which in the fresh specimen shows amoeboid movements even at ordinary summer temperatures for several hours after removal from the ovary, Nagel, **88.1**, 407. In hardened specimens the nucleus shows its reticulum, as already described.

In certain ova there has been observed a special band of protoplasm leading from the surface of the ovum to the egg nucleus. This is found in the ovum of *Petromyzon*, having been first described and figured by Calberla, **78.1**, who, however, erroneously designated the nucleus as the female pronucleus, and interpreted it as the pathway performed for the passage of the spermatozoon—an error which Boehm has corrected by showing that the true pronucleus is formed later. As shown in the section on impregnation, p. 69, the pathway of the spermatozoon can be traced in certain amphibian ova.

Peculiar names have been applied to the nucleus and nucleolus of the ovum, and are still in general use. The nucleus was first discovered in 1830 by

Purkinje ("Symbolæ ad ovarium historiam," 1830) in birds, and by Coste (1837) in mammals, and became known as the *vesicula germinativa*, (*Purkinje'sches Bläschen*, or germinal vesicle). The nucleolus was first described in 1835 by R. Wagner, **35.1**, and became known as the germinative or

Wagnerian spot (*Wagner'scher Fleck*). It was not, however, until 1839 that Theodore Schwann for the first time interpreted the ovum as a cell; but before then the terms germinal vesicle and germinal spot had established themselves, and since then they have remained in general use.

The Envelopes of the Ovum.—The eggs of different classes, and even species of animals, are, as is well known, extremely unlike in appearance. The dissimilarity refers chiefly to size, to the character of the yolk, and the nature and number of membranes or other envelopes, by which the ovum or egg-cell proper is surrounded. Thus in the hen's egg the yolk alone represents the part corresponding to the egg-cell, while the white of the egg and the egg-shell are only secondary envelopes, the former serving to nourish, the latter to protect, the so-called *yolk*, which is the essential part, the true egg. The various envelopes which eggs ever have may be classed under four categories: *First*, a very thin and delicate one, the proper membrane of the cell itself, and which ought always to be

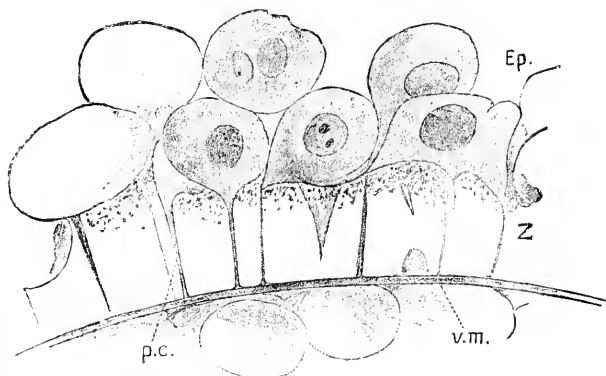


FIG. 35.—Part of the ovum of a mole: *Ep.* cells of corona radiata; *Z.* zona pellucida; *v.m.*, vitelline membrane; *p.c.* pore canals. After W. Heape

distinguished as the vitelline membrane; *second*, the ovarian envelopes, which are secreted around the egg-cell by the tissues of the ovary; *third*, the envelopes secreted by the oviduct, which may form a coating of nutritive material, or a protective shell, or both, as in the hen's egg, of which the nutritive white is secreted by the upper part, the calcareous shell by the middle part of the oviduct; *fourth*, coverings secreted by accessory glands, such as the slime in which the eggs of snails are embedded, or the tough capsules in which leeches lay their eggs. By adhering to this classification it is possible to find one's way through the labyrinth of special descriptions. It is impossible to review here the manifold variations in the ovarian coverings of animals, and we shall attempt only to describe those of the higher forms.

All vertebrate ova probably have two envelopes. *first*, a very thin inner one, the vitelline membrane proper; *second*, a thicker ovarian membrane, known as the *zona radiata* or *pellucida*. The vitelline membrane is described by Heape, in the mole, as a very thin but distinct membrane (Fig. 35, *v. m.*), immediately against the yolk, separated by a narrow space from the *zona*, it is to be regarded as a product of the ovum itself. It appears a short time before the ovum matures, and is most distinct at the time of the formation of the polar globules; its fate during segmentation has not been ascertained. The so-called vitelline membrane (*Dotterhaut*) of amphibia is really the homologue of the *zona* (Frommann). Considerable doubt in regard to the presence of this membrane in vertebrates, and especially in mammals, has been expressed by various writers, but its existence seems to me to have been sufficiently demonstrated. It was first described by Reichert in 1841, and again by H. Meyer in 1842. In recent years it has been redescribed by Ed. van Beneden, by Heape, and others. Balfour, in his "Embryology," pronounces in favor of its occurrence. The *zona radiata* (*pellucida* of C. E. v.

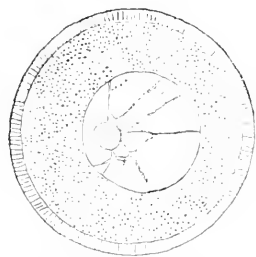


FIG. 36.—Ovum of a sea urchin, *Toxopneustes lividus*. After O. Hertwig.

Baer), Fig. 35, Z, is a membrane, usually of considerable thickness, which can be distinguished around the ovarian ovum quite early, being at first very thin, but gradually increasing in thickness until it attains in man a diameter of about $20\ \mu$ in the mature ovum. In the pig the diameter becomes 7 to $9\ \mu$; in the sheep, 7 to $12\ \mu$; in the cow, 7 to $8\ \mu$ (Schulin); in the mole, 8 to $11\ \mu$, according to Heape. In the mature ovum it is a tough, clear, glistening membrane, very resistant to acids, and soluble in alkalis only with difficulty. It is pierced by numerous radiating pores, which produce the appearance to which the term *zona radiata* refers.

These pores were first observed by Johannes Müller and Remak in fish eggs,* and they have since been observed in the ova of many other vertebrates, including several species of mammalia. It is probable that they always exist, despite the doubts expressed by Schulin, Lind-

* The homologies of the two envelopes around fish ova are somewhat uncertain, see E. L. Mark, 90 1.

gren, Von Sehlen, Nagel, and others. While the ovum is still in the ovary it is surrounded by the cells of the discus proligerus; these cells send processes through the pores of the zona (Fig. 35). It is now commonly supposed that these processes are channels of nutrition for the ovum. The zona is somewhat granular in its outer portion, next the cells of the corona. Balfour has suggested, not very plausibly, I think, that the granular portion does not belong to the zona, but represents the remains of a hypothetical primary vitelline membrane, within which the *zona* proper arose subsequently. Another very hypothetical homology is suggested by Caldwell, 87.1, who finds two membranes around the ovarian ovum of marsupials; the inner membrane resembles the zona pellucida, and is termed by Caldwell erroneously the vitelline membrane; the outer membrane is the proalbumen, which, during the passage of the ovum through the oviduct, swells up and becomes the albuminous envelope of the egg. Caldwell homologizes the inner clear layer of the zona of the placental mammals with the zona of marsupials, and the outer granular layer with the proalbumen. In *Petromyzon* (Boehm, 88.1), as in some teleosts (J. Brock, 78.1), there are two ovarian envelopes which are quite probably homologous with two envelopes found in marsupialia, but that the zona of the placentalia represents two envelopes united in one is, at least, very uncertain. It seems to me that the *zona radiata* is to be regarded as a modified intercellular substance, and that the processes going through its pores are to be homologized with the ordinary intercellular protoplasmic bridges of epithelial cells.

Heape thus describes the pores of the zona in the mole: "The radially striated appearance of the zona has long been shown to be due to a vast number of fine canals passing radially through it. The canals, I find, open on the inner side of the zona by a slightly dilated mouth, while on the outer side of the zona they communicate with the exterior by a considerably wider opening, Fig. 35. Into the external openings of these canals I have been able to trace prolongations of those cells of the discus which are immediately in contact therewith, Fig. 35, and there appears to me no room to doubt that the contents of these follicular cells are thus rendered available for the nutriment and growth of the ovum."

The term *micropyle* is used to designate a passage through the envelopes of the ovum, which serves to admit the spermatozoon. The micropyle is present in many invertebrate ova, notably in those of insects, and may have a quite complicated structure. In the vertebrates it is very rarely found, having been thus far positively demonstrated only in certain teleost eggs. Calberla, 78.1, affirmed that a micropyle was present in *Petromyzon*; but Boehm, after a later and more thorough investigation, 88.1, expressly denies its existence, Kupffer and Benecke, 78.2, having previously shown that the spermatozoa penetrated the lamprey ovum at several points. Sundry authors from time to time have asserted that a micropyle was present in the mammalian ovum, but the evidence against it seems to me conclusive.

The *corona radiata* is the name given to the envelope of cells of the discus proligerus, which adheres for a short time to the zona

radiata when the ovum is discharged from the Graafian follicle. The corona may be represented only by a few patches of cells, or may be a complete envelope; in either case the cells are entirely lost soon after the ovum begins its descent through the Fallopian tube. The egg of *Lepidosteus* has two envelopes; the outer one is homologized by Beard with the corona radiata, but E. L. Mark, 90.1, denies this homology.

The disappearance of the zona has been specially studied by Tourneux et Hermann (*C. R. Soc. Biol., Paris, 1887, p. 49*), who found that it could be distinguished in rabbits' ova of ninety-five hours, but not in those of one hundred and sixteen hours. According to Hensen the zona in guinea-pigs is ruptured, and the ovum escapes during the descent through the oviduct.

Polarity of the Ovum.—The mature egg-cell has a distinct axis, the two poles of which are unlike in character, while around the axis there is a complete radial symmetry so far as known. In my opinion the essential difference between the two poles is that the nucleus is nearer one than the other, and consequently the protoplasm of the egg-cell is more concentrated at one pole than at the other; for, as is well known, the nucleus usually has an accumulation of protoplasm around it. The eccentric position of the nucleus is, I think, probably universal. Curiously it is frequently stated that the nucleus lies in simple ova in the centre,* and the notion is prevalent that the accumulation of yolk is the cause of the eccentric position in certain ova. This notion is not quite correct; on the contrary, we must assume that the position of the nucleus causes the eccentricity of the yolk material. There is unquestionably a strong tendency for nucleus and protoplasm to keep company: thus we see when cells are connected with one another by protoplasmic bridges, a main cell-body around each nucleus. Again, within single cells, the protoplasm often forms a court around the nucleus and a looser network throughout the rest of the cell; in ova with incomplete segmentation each nucleus is imbedded in its special accumulation of protoplasm; it appears to me, accordingly, that the disposition in the egg-cell is only a special instance of a more general principle.

The eccentric position of the ovic nucleus is due to as yet unknown causes; but being given it determines the accumulation of yolk-grains at the opposite pole: it will be remembered that in the developing egg-cell the nucleus becomes eccentric before the yolk-grains appear. The amount of yolk undoubtedly affects the degree of the nuclear eccentricity. The nucleus reigns over a comparatively small territory, within which there is no, or but very little, yolk-matter developed; in all vertebrate ova the perinuclear protoplasm touches the vitelline membrane and marks externally the site of the nuclear or so-called "animal" pole. In the rest of the egg-cell the yolk-grains may be freely developed, and as they increase in number and size there is a corresponding distention of the region of the cell which they occupy. This distention may go so far that, as in the birds' ovum, the perinuclear territory is minute compared with the great bulk of the deutoplasmic territory, and consequently

* For example O. Hertwig, 1888. 1, p. 8, says "das Keimbläschen lagert gewöhnlich in der Mitte des Eies," yet his own figures correctly represent it as eccentric.

the nucleus lies far away from the centre of the ovum.* The yolk-grains centre about the pole opposite the nucleus, which might therefore be called the vitelline or deutoplasmic pole, though it is still generally known by the inappropriate name of *vegetative* pole, which has come down to us from long ago.

F. M. Balfour, in his "Comparative Embryology," divided ova into three classes, as follows: 1st, *alecithal*, without any deutoplasm; 2d, *telolecithal*, with the deutoplasm collected opposite the animal pole; 3d, *centrolecithal*, with the deutoplasm in the centre surrounded by a cortex of protoplasm. It is probable that all ova are *telolecithal* in the sense that they have a nuclear pole, and that the yolk-matter is developed away from the nuclear pole. The *alecithal* ova are those in which the nuclear eccentricity is at a minimum; the *centrolecithal* ova, which occur only among invertebrates, are likely to prove to be really telolecithal. All known vertebrate ova are telolecithal.

The polarity of the ovum dominates the process of the ripening of the egg-cell, and has a very important influence on the process of segmentation after impregnation. The extent of this domination has been thus summarized by E. L. Mark, 81.1, 515: "The migration of the germinative vesicle toward a definite point of the surface; the radial position assumed by the maturation spindles; the waves of constriction which precede the formation of the polar globules, and the inequalities in the sizes of the latter; the union of the pronuclei at a point nearer the primary than the secondary pole, and the consequently (?) eccentric position of the first segmentation spindle; the appearance of the first segmentation furrow earlier at the primary than at the opposite pole; the formation of pseudopodia-like elevations, often most conspicuous at the primary pole; the accumulation of finely granular protoplasm at the *secondary* pole after the elimination of the polar globules; and the appearance of 'polar rings' and 'ring rays' (Clepsine) at both ends of the primitive axis, are all indications of a polar differentiation of the egg."

The polarity of the ovum also evinces itself in the difference of the specific gravity of the two poles; usually, as in mammals, birds, amphibians, many fish and invertebrates, the deutoplasmic pole is heavier, and the ovum always presents the animal pole uppermost as soon as it is left free to turn; in the ripe mammalian egg the yolk has room to turn within the zona: hence when the fresh ovum is examined under the microscope, the animal pole is toward the observer and the eccentric position of the nucleus cannot be observed. In various pelagic teleost ova the animal pole is the heavier, and the embryo develops accordingly on the under side of the egg.

Maturation of the Ovum.—The term maturation is restricted by usage to the series of phenomena accompanying the expulsion of the polar globules which occurs after the egg-cell has attained its full size, and just before or just after the separation of the ovum from the ovary. A polar globule is a small, nucleated mass, extruded from a fully-grown egg-cell.

When an ovum is about to mature its nucleus moves nearer that

*J. A. Ryder has published a semi-popular discussion of nuclear displacement, 83 1.

point of the surface which may be regarded as the centre of the animal pole, and there also occurs a contraction of the vitellus. The centrifugal movement of the nucleus was first observed by Von Baer, **27.1**, 29, in the hen's egg, and has since been seen by very numerous observers and in very numerous species; it must, therefore, be considered as an unvariable phenomenon. Concerning the force which moves the nucleus we have no definite conception; for discussion of the question, see Whitman, **87.3**. The contraction of the yolk is probably also a constant phenomenon; it is apparently effected by the expulsion of fluid from the protoplasm, so that a clear space separates the zona and yolk. The observations have not been collated yet on this point, and it is impossible to state whether there is a constant rule as to the extent and epoch of the contraction.

After reaching the surface the nucleus as such disappears. This fact was known to Purkinje, **30.1**, 15, the discoverer of the nucleus, and has been shown to occur in all eggs which have been accurately examined. K. E. von Baer maintained both in 1827 and subsequently, **37.1**, 4 and 9, **37.1**, 28, 157, 297, the opinion that the disappearance of the germinal vesicle was connected with the maturation of the ovum—a conclusion which is now established beyond question. Reichert in 1846, **46.1**, 199, 205, maintained that the disappearance was the first result of impregnation, and in this error he has had several followers (A. Müller, Haeckel, Bütschli, and others). In birds the nucleus assumes a very large size, and migrates to the surface of the ovum, when it disappears as shown by Oellacher. M. Holl, **90.1**, records that in a newly hatched chick the ova measured about $14\ \mu \times 9\ \mu$, while an ovum nearly ready to leave the ovary measured $40 \times 35\ \text{mm}$; in the former the nucleus was about $9\ \mu$, in the latter $315 \times 117\ \mu$ in diameter. No polar globules have yet been observed in birds, though we must assume that they are formed.

The disappearance of the germinal vesicle is only apparent, not actual, being in reality a metamorphosis. It is probable that the first step is the discharge of nuclear fluid (*Kernsaft*) into the surrounding protoplasm. This is indicated by two appearances—1st, the shrinking of the nucleus, the outline of which becomes shrivelled; 2d, a clear space which arises around the nucleus. The shrivelling of the nucleus has been observed in several mammals (Van Beneden, Rein, Belloni, Tafani) in various vertebrates—as, for instance, in teleosts by Oellacher, **72.1**, 3, in Amphibia by O. Schultze, **87.1**, and in many invertebrates, *e.g.*, Serpula by Schenk (Sitzber. Wien. Akad. LXX. Abth. 3, 291–294, 1875), in Hydra by Klemenberg, **72.1**, 42, in Asterocanthion by Ed. van Beneden, **76.1**. The clear perinuclear space has been noticed especially in Anura by Götte, **75.1**, 20–22, and O. Schultze, **87.1**, 217. The second step is the dissolution of the membrane of the nucleus, so that the nuclear contents are brought into direct contact with, and partly mix with, the cell-plasma. Very likely this mixture of nuclear and cell substance is, as O. Schultze suggests, **87.1**, 215, one of the essential factors of maturation. The dissolution of the nuclear membrane has been found to occur in so many species that we may safely predicate it of all. We now find the contents of the nucleus lying together in the centre of the protoplasm of the animal pole. The contents themselves are altered in

character, the most noticeable change being the breaking up of the chromatin into separate granules; in mammals the formation of the granules by the cleavage of the nucleolus occurs after the nucleus has begun its migration (van Beneden, Bellonci, Tafani); in Amphibia the nucleus becomes multinucleate during the early growth of the ovum. The achromatic substance or reticulum of the nucleus appears as threads often very difficult to recognize.

The threads and granules proceed to group themselves into a spindle-shaped body, the so-called nuclear spindle (*Kernspindel*) which lies more or less nearly in the radius of the ovum and has one of its ends close to the surface of the yolk, Fig. 38, *sp.* The achromatic threads run from pole to pole of the spindle; the chromatin granules lie in the centre of the spindle in one plane and produce the appearance of a transverse band or disc (Strassburger's *Kernplatte*); each chromatin granule is associated with one of the spindle-threads. Each pointed end of the spindle lies just within

a rounded clear space, from which, and not from the end of the spindle, radiates threads in the yolk, whence results a figure like a conventional sun. The whole spindle with the two suns has been named the *amphiaster*. As amphiasters occur in connection with ordinary indirect cell-division the distinctive term *archiamphiaster* has been proposed for those concerned in the production of the polar globules. Sometimes as in *Limax*, Mark, 81.1, the astral rays are not straight, but curved as in a turbine. In amphibian ova only a portion of the granules enter into the formation of the chromatin, while the majority of them are mingled with the yolk (O. Schultze);

it is possible that this modification is connected with the large amount of yolk and will be found in other vertebrate ova. In the ova of mammals (all?) the chromatin enters into the "*Kernplatte*." The shape of the spindle varies, as does also the distribution of the granules of the nuclear plate, thus. In the guinea-pig, the ends are pointed and the threads are straight, so the outline of the spindle is like a diamond; in the bat the spindle is barrel-shaped and the threads are curved. In certain, possibly in all, cases the spindle, when first formed, lies obliquely, and subsequently becomes erect

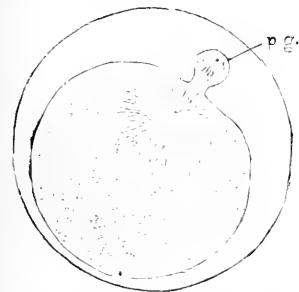


FIG. 38.—Egg of a leech (*Nephelis*), three-quarters of an hour after being laid: formation of the first polar globule, *p*, *g*. After O. Hertwig.

to the surface, as Whitman observed in the leech (Clepsine, 78.2); for further reference, see O. Schultze, 87.1, 219-221. The reason for the obliquity and the following erection is unknown.

The next changes may be followed with the help of Fig. 39. The spindle, driven by an undiscovered power, continues the centrifugal movement until it is partly extruded from the egg, as shown in the

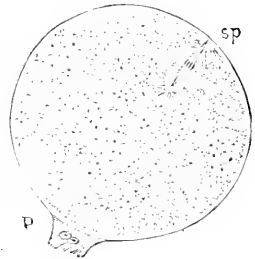


FIG. 37.—Ovarian egg of *Haemopsis* *sp.*, nuclear spindle; *p*, peduncle attaching the egg to the ovary. After O. Hertwig.

figure; the projecting end is enclosed in a distinct mass of protoplasm, *p.g.*, which is constricted around its base. The fragments of chromatin have each divided into two, and one-half of each fragment has moved toward one end, the other half toward the other end of the spindle. The half-fragments of each set move together, hence there seem to be two plates within the spindle. The translation of the groups of chromatin grains continues until they reach the ends of the spindle; the achromatic threads then break through in the middle. Thus the original nucleus, or at least part of it, has been divided. There are now two masses of nuclear substance—one in the ovum, the other in a little appendage to the ovum; this appendage is the first polar globule; its nuclear substance does not develop into a complete nucleus.

The remnants of the egg-cell nucleus within the ovum undergo further changes. Usually when the amphiastral (indirect or kinetic) division of a nucleus is over, the separated nuclear masses resume the structure of a normal resting nucleus; but in the ovum, as Platner, **89.1**, has especially noted, the nuclear remnants change directly into a second spindle, which lies as did the first within the protoplasm of the animal pole, and likewise gives rise to an amphiaster (second archiamphiaster, *zweites Richtungsspindel*). The second spindle even more clearly than the first has been observed to occupy an oblique position, as in mammals (Bellonci, **85.1**), or even parallel with the surface, as in amphibians (O. Schultze, **87.1**) and certain crustacea, Weismann and Ischikawa, **88.4**. This spindle produces a second polar globule in similar manner to the first; the globule is somewhat smaller than the first, and is at least sometimes connected both with the first globule and with the ovum. Sometimes the first globule divides into two, Fig. 39, A, and they may remain

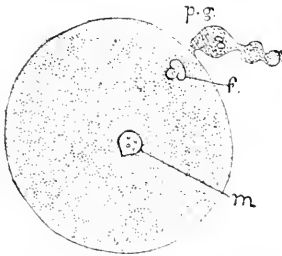


FIG. 39.—Ovum of *Nephelis* (a leech), three hours after laying: *p.g.*, polar globules; *f.*, female pronucleus; *m.*, male pronucleus. After O. Hertwig.

connected together. The connection of the globules with the yolk persists for some time, and in the case of leeches is not dissolved until segmentation begins.

The polar globules ultimately disappear—how is not exactly known. That they take no part in the further history of the ovum may be considered established: for they break off and may often be seen in mammals knocking about within the zona, while the ovum is developing after impregnation, and they then present a hyaline appearance, as if slowly degenerating.

The number of polar globules, as Weismann and Ischikawa, **87.2**, **88.4**, first explicitly demonstrated, is two. According to these authors, **88.4**, 590, two polar globules have been shown to occur in 8 species of cœlenterates, 5 of plathelminths, 6 nemathelminths, 1 zephyrean, 10 annelids, 5 echinoderms, 22 mollusks, 6 tunicates, 1 bryozoon, 15 crustaceans, 6 insects, 11 vertebrates. It can hardly be doubted that two polar globules are necessary for the complete maturation of the ovum, and that until they are formed impregnation cannot take place. On the other hand, Blochmann discovered

that in a parthenogenetic ovum there is only one polar globule formed, and Weismann and Ischikawa, **88.4**, have shown that this is true of many and presumably of all parthenogenetic ova—that is, of ova which develop without fertilization. For the theoretical consideration of the polar globules, see below.

The polar globules appear to have been seen as long ago as 1837 by Dumortier in gasteropods, and in 1840 by the elder Van Beneden, and in 1842 in the rabbit by Bischoff. Fr. Müller observed them more carefully in 1848, and detected their constant relation to the planes of segmentation, and gave them the current German name of *Richtungskörperchen*. Robin, in 1862, termed them *globules polaires*, which, translated, has become the accepted English designation. Bütschli, **76.1**, in 1876, first led the way toward a correct conception of the origin of the globules, and about the same time came the independent researches of O. Hertwig, whose able memoirs, **75.1**, **77.1**, **77.2**, **78.1**, have formed the basis of all subsequent work. These were soon followed by the investigations of Fol and many others. From these studies we possess a tolerable general conception of the origin of the polar globules, but the *comparative* study of the details and variations remains for the future.

After the formation of the second polar globule there is a small group of chromatin elements and achromatic threads, which, since they have been halved twice, represent approximately one-fourth, not of the whole egg nucleus, but of so much thereof as entered into the formation of the first polar spindle. The nuclear remnant lies close to the animal pole and in the clear protoplasm; it is the so-called *female pronucleus*, the history of which varies according to the species of animal. Three tendencies are known to affect the pronucleus—namely, to move toward a central position in the ovum; to unite with the male pronucleus as soon as that is formed out of the spermatozoon, which enters the ovum to fertilize it, and to assume the character of a membranate nucleus. As the time of the formation of the male pronucleus is variable, the other tendencies being more constant, the exact history of the female pronucleus may be said to depend principally upon the appearance of the male pronucleus. The earlier that event, the less does the female pronucleus move centripetally, and the less does it assume a nuclear form. In mammals as in echinodermis, the female pronucleus acquires a membrane, and lies, when the spermatozoon enters, near the centre. It is very much smaller than the egg nucleus (compare Figs. 36 and 39), and is remarkable for its homogeneous appearance and the absence of nucleoli. In other animals, *e.g.* Petromyzon, it is merely a cluster of granules. For further details as to the pronuclei, see the following section on impregnation.

The time when the polar globules are formed varies, and according to the animal may be before or after the egg-cell leaves the ovary. In placental mammals the maturation always begins, so far as known, in the ovary, and may be completed there, or it may go on in the Fallopian tube, as Tafani, **89.1**, 114, states is the case in white mice. Our knowledge of the maturation of the mammalian ovum is very imperfect, and rests almost exclusively upon observations on bats and rodents (rabbits, mice, rats, and guinea-pigs), and

even on these the observations are very incomplete. See Ed. van Beneden, **80.1**, Van Beneden et Julin, Rein, **83.1**, Bellonci, **85.1**, Tafani, **89.1**.

III. OVULATION.

The process of ovulation, or the discharge of the ovum from the ovary, has to be considered from both the morphological and physiological standpoint. The discharge results from structural changes in the Graafian follicle, and these changes continue after the departure of the ovum, transforming the Graafian follicle into a so-called corpus luteum. Concerning the physiology of ovulation we know almost nothing beyond the coincidence in some species of mammals of the time of the bursting of the follicle with certain periodic changes in the uterus.

Ovulational Metamorphosis of the Graafian Follicle.—The mature follicle measures some 9 by 12 millimetres, being elongated in the same direction as the ovary, but its dimensions are variable. The granulosa is very thin, and its cells show signs of a fatty degeneration. It is probable, I think, that this degeneration progresses to a considerable extent, and involves the loosening of the granulosa cells; for loose cells, granules, and fragments are found in the liquor folliculi. The cavity of the follicle is very large and filled with the fluid, which seems to be under pressure, since it spurts out with considerable force when the follicle is pricked. It is to the pressure of the liquid that Coste attributes the rupture of the follicle. Waldeyer in Stricker's "Gewebelehre," p. 571, describes a growth of the wall of the follicle, which causes it to form a series of folds which protrude into the follicle; this ingrowth produces the force that expels the ovum. Unfortunately, Waldeyer does not state on what animal his observations were made; they certainly do not apply to the human species, for there is in man no considerable growth of the follicular wall until after the rupture. The stigma becomes, meanwhile, very thin, and finally breaks through. Coste's observations, **47.1**, 172, on rabbits eight or ten hours after the coitus, showed that the rupture is not abrupt but gradual, the membranes of the follicle giving way first, and the peritoneum a little later. When the stigma breaks, the liquor folliculi, together with the ovum surrounded by the discus proligerus, escapes, and the ovulation, *sensu strictu*, is completed. The fate of the cells of the tunica granulosa is uncertain, though Benckiser, **84.1**, has shown that in the pig they disappear at the time of or soon after the rupture. I consider it probable that they are lost in man at the time the ovum escapes; it may be that they degenerate; it must be mentioned that some writers maintain that the granulosa persists and takes part in the further metamorphoses of the follicle. At the time of the rupture there occurs a hemorrhage of blood into the emptied follicle, and this blood forms a clot which fills up the entire follicle, and is known as the *corpus hemorrhagicum*. The hemorrhage may vary in amount or even be wanting altogether, as Benckiser, **84.1**, found in 8 cases out of 100 in the pig. Leopold expressly states, **83.1**, that when the follicle ruptures at the menstrual period it is always filled and distended by

blood filling it, but when the rupture occurs in the intermenstrual period the hemorrhage is small or altogether wanting; the presence of blood is therefore not indispensable to the formation of the corpus. When the follicle contains no blood it is filled with a whitish coagulum of unknown origin (Coste, **47.1**, I. 245). The coagulum, whether of blood or not, is rapidly penetrated by tissue which grows into it from the wall of the follicle, accompanied by numerous blood-vessels; the cells of this tissue have two principal forms, His, **65.2**, 186-187: *first*, spindle-shaped connective-tissue cells, which lie principally around the blood-vessels; *second*, large cells, which contain granules of a pigment, called lutein from its color; these cells are the *lutein-cells*, and are the characteristic elements of the metamorphosed clot, to the margin of which they impart a bright yellow color, whence the name corpus luteum. The ingrowing tissue is derived from the inner layer of the theca folliculi. That the blood-vessels and spindle-cells have this origin has long been the generally accepted opinion, and though the origin of the lutein-cells is under dispute it is probable that they arise exclusively from the connective-tissue cells of the theca interna, which begin to enlarge even before the follicle finally bursts, and to charge themselves with lutein granules. Certain writers attribute the origin of these cells to the granulosa either wholly (Exner and Cali) or in part (Waldeyer). Peculiar is Beulin's view in his Königsberg dissertation, 1877, that they are derived from the membrana propria folliculi. Benckiser's observations, **84.1**, prove conclusively that in the pig the lutein-cells arise exclusively from the theca interna. This view I accept for man also, not only on account of the accuracy of the observations made in support of it (see His, **65.2**, and Frommann, **86.3**), but also because specimens of my own show that there is no granulosa in the human corpus hemorrhagicum, while the young lutein-cells can be easily recognized in the fibrous tunica propria. In consequence of their site of development the lutein-cells and vessels form a band around the coagulum, and owing to its own growth this yellow band soon becomes folded. The central portion of the corpus luteum long remains distinguishable as a separate nucleus.

The exact history of the corpus luteum varies according as ovulation is followed by pregnancy or not. In the latter case the corpus is entirely resorbed in a few weeks; in the former it persists until after the birth of the child. We distinguish accordingly the corpus luteum of menstruation from the corpus luteum of pregnancy, or corpus luteum verum of authors.

The corpus luteum of menstruation begins with a blood-clot. "The more recent the date of the menstrual flow, the fresher is the clot in the cavity of a ruptured Graafian follicle, and the less change has taken place in its surrounding wall. A few days later the wall begins to be enlarged and thickened, and this enlargement within a confined space causes it to become folded upon itself in short zigzag reduplications, mainly at the deeper part of the follicle. As the process goes on the entire wall participates in the hypertrophy. Its convolutions are extended and multiplied, often in a very complicated manner. They project into the cavity of the follicle, encroach upon the central clot, and become pressed against each other, form-

ing by their coalescence a thickened, glandular-looking envelope. Previously to the rupture of a Graafian follicle its wall is a uniformly smooth, vascular membrane, not more than one-fourth of a millimetre in thickness. After the rupture, its thickness increases to one-half a millimetre; but as the foldings above described grow in number and in depth and crowd against each other laterally, the apparent thickness of the envelope thus formed becomes much greater, and may reach three or even four millimetres, especially at the deepest part of the follicle. In this way there is produced, during the intermenstrual period, a *corpus luteum*, occupying the substance of the ovary immediately beneath the superficial cicatrix which marks the site of the ruptured follicle. At this time the central clot is red and gelatinous, while the convoluted wall is of a light rosy hue, mixed with more or less of a yellowish tint. Subsequently the whole structure diminishes in size, and the convoluted wall assumes a more decided yellow" (Dalton, 78.1, p. 18).

Leopold, 83.1, distinguishes between the *typical* and *atypical* corpora, the former being those which start at the menstrual epoch and have a blood-clot, a result probably of the ovarian hyperemia, the latter beginning intermenstrually and having little or no blood. He says, *l. c.*, p. 399: "The typical corpus luteum appears on the first day as a freshly ruptured follicle, which has filled itself with blood; on the third day as an enormous blood-cavity; about the eighth day a thin cortex and a clearer nucleus are marked in the clot. From the twelfth day on, the cortex thickens and becomes folded; by the sixteenth day it becomes pale-red or yellowish. Toward the twentieth day the nucleus shrinks markedly, the cortical band becomes more and more yellow, and shoots in toward the centre in rays and narrow folds, so as to leave by the twenty-fourth to thirty-fifth day only a small, pale nucleus enclosed in a much-convoluted bright-yellow shell."

The corpus luteum of pregnancy begins in a similar manner to that of menstruation, but its growth continues. At the end of the first month its wall is convoluted, much thickened, and of a brilliant yellow color; the central clot is nearly or quite decolorized and constitutes a white or whitish firm central mass, which in nearly one case out of three has a central cavity with well-defined, smooth walls. Sometimes a few fine blood-vessels penetrate through the lutein layer. The external convoluted wall continues to grow by encroaching upon the clot or white nucleus (*corpus albicans*), and at the same time the brilliancy of the yellow color diminishes. At term the white nucleus takes up about one-third of the diameter of the corpus and is still distinctly connected with the stigma, so that the lutein wall is interrupted at one point; the corpus as a whole is somewhat smaller than at from two to six months. After delivery, resorption goes on rapidly (Dalton, 78.1).

The brilliant yellow is especially characteristic of man; in sheep the pigment is pale brown, in the cow dark orange, in the mouse brick-red, in the rabbit and pig flesh-colored. Lutein is a crystalline body, soluble in alcohol, ether, chloroform, and benzol, but of its chemical nature we have no exact knowledge.

Physiology of Ovulation.—Concerning this subject and also

concerning the functions of the corpora lutea, we possess scarcely any knowledge. We have to consider only the relation of ovulation to menstruation and coitus.

Coste, **37.1**, 454, 455, first showed that the discharge of the ova coincided with the period of heat in various animals. This was soon confirmed by Raciborski, **44.1**, and since then by numerous observers. Pouchet ("Théorie positive," etc.) attempted to prove that this is also true of the human species, the menstrual period being taken, correctly, as the equivalent of the rut. In this attempt Pouchet has had many followers, especially among gynæcologists. Coste, however, demonstrated long ago, **47.1**, 222, that the bursting of the Graafian follicles may occur before or after menstruation, though it is most apt to occur during the menses. This conclusion of Coste's has been fully confirmed by Leopold, **83.1**, who made a very careful examination of twenty-five pairs of ovaries from women whose menstrual history was accurately known.

It was Coste again, **47.1**, 183-185, who proved experimentally that coitus hastens in the rabbit the rupture of the Graafian follicles. Unfortunately he gives only two experiments, and since then they have not been repeated, so far as I am aware, either upon rabbits or other animals. But there are statements by many authors, Bary, Reichert, Hensen, **88.1**, 58, Van Beneden, **80.1**, etc., to the effect that in the rabbit after coitus during heat the follicles are found to have burst during the tenth hour.

IV. IMPREGNATION.

Impregnation is the union of the male and female elements to form a single new cell, capable of initiating by its own division a rapid succession of generations of descendent cells. The new cell is called the impregnated or fertilized ovum. The production of cells from it is called its segmentation. For the theory of the relation of the elements to one another and to cells, see the following section.

In all multicellular animals, impregnation is effected by three successive steps: 1, the bringing together of the male and female elements; 2, the entrance of the spermatozoa into the ovum and formation of the male pronucleus; 3, fusion of the pronuclei to form the segmentation nucleus. We proceed to consider these steps in their order.

1. The Bringing Together of the Sexual Elements.—This is effected in a great variety of ways, which, however, fall into two groups according as the impregnation is effected, *a*, outside the body of the mother; or, *b*, inside. The simplest manner is the discharge of the male and female elements at the same time into the water, leaving their actual contact to chance, the method of the osseous fishes for the most part and of many invertebrates. An advance is the copulation of the Anura (frogs, etc.); the male embraces the female, and, as the latter discharges the ova, ejects the sperm upon them. In the higher vertebrates the seminal fluid is transferred from the male to the female passages during coitus. The physiology of this complicated function does not fall within the scope of this work.

For a long time it was not known how the semen fertilized the ova; the problem was fruitful of fruitless speculation. The first step toward gaining actual knowledge was the discovery of the possibility of artificial fecundation by Jacobi in 1764. Spallanzani was the first to take advantage of this and to show that fecundation implied a material contact of the semen with the ova, and thus to set aside De Graaf's notion of the "aura seminalis."

But not until fifty years later did the memorable experiments of Prévost and Dumas (*Annales des Sciences Naturelles*, 1824) establish the fact that the spermatozoa are the essential factors of fertilization. Again, a little over fifty years later, Hertwig and Fol showed that one spermatozoon suffices to impregnate an ovum.

We have then to consider how the spermatozoon, after the semen has been transferred to the female, attains the ovum. They are found in mammals after copulation in the vagina and even in the uterus, but it is not clearly ascertained how they get beyond the vagina. It is probable that they travel through the female passages partly by the movements thereof, partly by their own locomotion, and enter the Fallopian tubes, though why or how is really unknown, and pass upward to meet the ovum. They are found in considerable numbers in the Fallopian tubes. The ovum meanwhile travels down the oviduct, it probably being impelled by peristaltic movements of the duct.

The meeting-point or site of impregnation in placental mammals is about one-third, perhaps one-half, way down from the fimbria to the uterus. It is remarkably constant for each species. Nothing positive is known as to the site of impregnation in man; but there is no reason to suppose, as is unfortunately often done, that the site is variable or different from that in other mammalia.

2. The Entrance of the Spermatozoon into the Ovum and Formation of the Male Pronucleus.—With our present knowledge, the assumption appears unavoidable that the ovum exerts a specific attraction upon spermatozoa of the same animal species. We observe, in fact, when artificial fecundation is employed, that the spermatozoa swarm around the ova as if held by an irresistible impulse. This phenomenon occurs with every class of animals, even in mammals, whose freshly removed ova were examined on a warm stage under the microscope (Rein, **83.1**). Stassano, **83.1**, has maintained that the eggs of echinoderms do exert such an attraction, and also a similar but less strong attraction upon the spermatozoa of allied species. But since the brothers Hertwig, **85.1**, have found by their experiments with sea-urchins that hybrid impregnation takes place more readily after the ova have been kept awhile, Stassano's view involves the further assumption that the specific nature of the attraction fades away during a few hours. Very suggestive in this connection is Pfeffer's ("Untersuch. Bot. Inst." Tübingen, Bd. I., Hft. 3, 1884) discovery that certain chemical substances may attract moving spores, etc., to definite spots. It is conceivable that the ovum may draw the spermatozoa toward itself by chemical influence, acting as an attracting stimulus.

There may be mechanical devices to facilitate the entrance of the spermatozoon; this is, perhaps, generally true of all ova with micro-

pyles serving for the passage of the spermatozoa. A careful study of such devices in the cockroach has been made by J. Dewitz, **85.1**, who found that the motions of the spermatozoa of this insect are peculiar and adapted to increase the probability of their passing through one of the micropyles of the ovum. In ova without micropyles, among which those of mammals are included, the spermatozoa may, so far as we know, penetrate any part of the envelopes.

In the rabbit (Rein, **83.1**), about ten hours after coitus, the ovum is found nearly half-way through the oviduct and surrounded by many spermatozoa—perhaps a hundred, more or less. These are all, or nearly all, in active motion, for the most part pressing their heads against the zona radiata. Several of them make their way through into the interior of the ovum. According to Hensen, **76.1**, only those spermatozoa which enter the zona along radial lines can make their way through; those which take oblique courses remain caught in the zona, Fig. 40, and may still be seen there during segmentation. As the ovum at this time is already fully matured, there is a space between the contracted yolks and the zona. In this space, as well as in the zona itself, several spermatozoa may be observed at scattered points. The female pronucleus is present, having been re-formed since the expulsion of the second polar globule from the ovum while in the ovary. One spermatozoon gets into the yolk proper, and its entrance apparently prevents the penetration of other spermatozoa—how is undetermined. The tail of the spermatozoon soon disappears, while the head enlarges, probably by the imbibition of fluid from the surrounding yolk, and thus becomes a nucleus-like body—the *male pronucleus*.

The passage of the spermatozoa through the zona was first discovered by Martin Barry in 1843, and although his statement was received with considerable hesitation by his contemporaries, it has since had competent confirmation repeatedly. Warneck (Bull. Soc. Nati., Moscou, XXIII., 90) is said to have been the first (1850) to see the two pronuclei, but their significance was not perceived. The nature of the male pronucleus was first recognized by Oskar Hertwig, who traced its genesis in the ova of echinoderms from the spermatozoon. The fact that the male pronucleus is the metamorphosed spermatozoon has since been confirmed by Selenka ("Zool. Stud.," I.): Ed. van Beneden, **83.1**; Nussbaum, **84.2**; Eberth, **84.1**; Platner, **86.1**, and others.

Although a number of the spermatozoa make their way into the perivitelline space, probably always one alone normally enters the yolk to there form a pronucleus. The best observers are agreed upon this point, and in all species the observations upon which have covered the whole series of steps in the impregnation, there has been found in normal cases always a single male pronucleus. Schneider's statements to the contrary have been definitely corrected. Bambeke,




FIG. 40.—Ovum of a Rabbit; taken from the middle of the oviduct about eighteen hours after coitus. The segmentation nucleus is already formed; the polar globules, *p*, *q*, are shown; numerous spermatozoa lie both in and within the zona. After Coste.

76.2, C. Kupffer, 82.1, and Kupffer und Benecke ("Befruchtung Nennange," 1878), have observed that several spermatozoa actually enter the yolk in batrachians and Petromyzon. Hertwig, however, found only one male pronucleus in the frog, and there has as yet been no evidence adduced that several spermatozoa are concerned in the final phases of impregnation. Fol observed that star-fish eggs are normally impregnated by one spermatozoon; but if they are exposed to the action of carbonic acid they may, while so poisoned, be impregnated by several spermatozoa, and the subsequent development in this case is abnormal; apparently each pronucleus becomes a separate centre of development.

The manner in which additional spermatozoa are excluded after the first has entered is still under discussion. In cases where there is a single micropyle, which is used for entry, it is possible that a portion of the first spermatozoon may remain to close the passage, or that in going through it sets in action some mechanism by which the opening is automatically shut. Where there are several or many micropyles, as in some insects, or where the envelopes may be pierced at any point, as in mammals, there must be some other device. Fol has maintained that this is found in the star-fish in the rapid formation of a membrane around the yolk immediately after the entrance of the first spermatozoon; but Hertwig affirms that this membrane pre-exists. Selenka (*Biolog. Centralbl.*, v., 8) describes the fertilization of the ovum of a nemertean worm; several spermatozoa enter within the vitelline membrane; the yolk contracts slowly.

After a time the two polar globules are expelled, and before they separate from the yolk one spermatozoon passes into the yolk between them; the globules then break off and are knocked about by the spermatozoa in the perivitelline space. In this case there seems to be a portal opened just long enough for one spermatozoon to enter. As the phenomenon to be explained is common to all ova, its causation is presumably fundamentally identical in all cases. Beyond this surmise our present knowledge

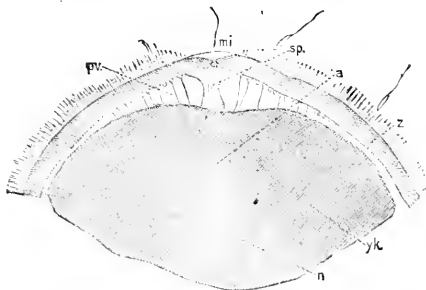


FIG. 41.—Anterior pole of the ovum of the Petromyzon, with a spermatozoon, *sp.*, entering the micropyle, *mi*; *p. v.* perivitelline space; *z.* zona pellucida; *a.* pathway to female pronucleus, *n*; *yk.*, yolk. After Calberla

does not permit us to go. The hypothesis may be suggested that the attractive power of the ovum is annulled or weakened by the formation of the male pronucleus. This hypothesis was first suggested by Minot (Buck's "Hdbk.," IV., 6), and has since been elaborated by Whitman, 87.3, 239-243.

It is probable that the tail of the spermatozoon, when that appendage exists, disappears within the yolk. In a land-snail, *Arion*, Platner, 86.1, has traced this process very clearly. Only a portion of the tail enters the yolk, but the part within acquires the property of staining readily, and so may easily be observed. He reports that the head and tail separate; only the head conjugates with the female

pronucleus, while the tail still remains distinct even after segmentation has been initiated, Fig. 44. The disappearance of the tail has been recorded by most observers. As Hertwig says (*loc. cit.*, p. 23), all these careful observations yield the assured conclusion that the head of the spermatozoon, and the head only, becomes the male pronucleus.

While the spermatozoon is passing through the ovic envelopes, active changes occur in the yolk. Of these the most constant, as well as the most obvious, is the formation of a slight protuberance on the surface of the yolk, rising up toward the spermatozoon. This protuberance may remain, as in echinoderms, until the spermatozoon meets it and by penetrating it enters the ovum, or it may retract before the spermatozoon passes through the envelopes, and even withdraw, as in *Petromyzon*, Fig. 41, so far from the advancing spermatozoon as to form into a depression on its own surface, Fig. 41. The protuberance lasts only a few moments. In *Bufo*, according to Kupffer, several spermatozoa enter the yolk and a protuberance rises toward each one, as if the yolk were actively striving to reach the male element. The protuberance always consists of fine granular protoplasm, which contains no deutoplasm, and is closely connected with the nucleus. The size of the protuberance is variable. In *Petromyzon* there is a large hummock of protoplasm, which contains the nucleus and in which both pronuclei form and unite; during these processes the protoplasm of the hummock is separated from that of the rest of the ovum by a special membrane, which disappears immediately after the pronuclear copulation. While the two pronuclei are meeting the hummock flattens out and the protoplasm forming it travels centripetally together with the pronuclei (Boehm, 88.1, 650, 651). Whether the hummock in *Petromyzon* is homologous with the much smaller protuberance in other ova I am unable to say.

The relative size of the two pronuclei varies considerably in different species, and is probably a secondary and unimportant relation. Each pronucleus when it first appears is small and gradually enlarges, apparently by the imbibition of fluids from the surrounding yolk. Now the time when the spermatozoon enters the yolk may be either after or at some stage during maturation of the ovum. If it enters early, as in *Limax* (Mark), the male pronucleus enlarges equally with the female, Fig. 42; but if late, as in the allied *Arion* (Platner), then it appears, Fig. 44, considerably smaller than the already swollen female pronucleus. O. Hertwig, in his third paper on maturation, p. 171, first gave this explanation and pointed out that in the star-fish (*Asterias*), if the impregnation is prompt, the male pronucleus becomes as large as the female, but if impregnation is delayed for four hours the male pronucleus remains much the smaller of the two. Again in *Hirudinea*, Fig. 42, many *Mollusca*, *Nematoidea*, etc., impregnation usually takes place before the formation of the polar globules is completed, and the male pronucleus is accordingly as large as the female. In *Echinus*, on the other hand, where the polar globules are formed in the ovary, the male pronucleus is always small.

Concerning the path of the male pronucleus we possess little information. O. Hertwig and Bambeke have found that in certain am-

phibian ova the spermatozoon leaves a trail (*Pigment-Strasse*) apparently by carrying along with itself some of the pigment granules from the surface of the ovum. Roux, **87.1**, has studied this path in the frog's ovum and finds that it consists of one limb, the line of penetration through the cortical layer of the ovum, which is nearly perpendicular to the ovic surface, and a second limb usually forming an angle with the first and leading directly to the female pronucleus.

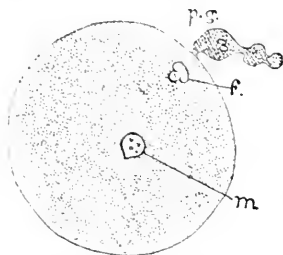


FIG. 43.—Egg of *Nephelis*, three hours after laying. *m.*, male; *f.*, female pronucleus; *p. g.*, polar globules. After O. Hertwig.

The force which draws the pronuclei together is unknown. We can only say that, as Whitman has thoughtfully expounded, **87.3**, there is a relation between the nucleus and the protoplasm of the ovum, such that the nucleus tends to take a central position. When the polar globules are formed the nucleus becomes repellant and drives

itself centrifugally; but the protoplasmic attraction remains and draws in the spermatozoon. Subsequently both pronuclei are attracted toward the centre and toward each other, and the curved routes the pronuclei often take are the resultants from these two attractions.

3. Fusion of the Pronuclei.—Each pronucleus is usually found surrounded by a space a little clearer than the rest of the yolk. Usually the yolk around this clear space presents a radiating appearance, which is known as the aster. Fig. 43; but this appearance is not constant, nor is it known how it is caused. Frommann, **89.1**, 395, states that in the egg of *Toxopneustes* the astral rays are formed by very *irregular* rows of angular granules, which may lie separately, or be strung together by fine threads, or like a row of pearls, and are irregularly connected by cross-threads. The great regularity usually pictured is purely diagrammatic. As the granules described by Frommann are part of the reticulum of the ovum, we may say that the astral figure results from the arrangement of the protoplasm. Mark, **81.1**, was unable to see it in *Limax*, and Rein, **83.1**, could not detect it in the rabbit. In *Arion*, as also in *Petromyzon*, according to Boehm, **88.1**, apparently only the male pronucleus has an aster, Fig. 44. At one time it was assumed that the pronuclei acted as centres of attraction upon the yolk, and that the asters were due to their direct influence; but since, as in *Arion*, Fig. 44, the pronucleus may move away while the aster remains behind, it follows that the relations are more complex than this assumption indicates, since the aster exhibits a certain independence of the pronucleus. This is confirmed by Flemming's observations (*loc. cit.*, p. 19), that when the asters first appear in echinoderms, the centre of radiation is not the pronucleus itself, but a clear space just alongside. Frommann, **88.1**, 396, modifies this statement by recording that the position of the centre of the male aster varies in *Toxopneustes* and may be at one side or the other of the male pronucleus or coincident with it. Boehm, **88.1**, 650, Taf. XXV., Fig. 30 *d*, notes the same peculiarity in the eggs of *Petromyzon*. These statements recall the fact that the

asters in indirect cell-division sometimes radiate from a clear spot at the tip of the spindle. Some writers have considered the aster an expression of magnetic force within the ovum—a fanciful notion without any evidence to support it.

In the rabbit, Rein, **83.1**, both pronuclei lie at first eccentrically, but they move toward each other and toward the centre, meeting, however, before the central position is attained. As they near one another, both pronuclei perform active amoeboid movements; after they meet they still continue their amoeboid movements and move together to the centre of the ovum; one of the pronuclei assumes a crescent shape and embraces the other, Fig. 45. At this time the yolk displays a radiate arrangement; from analogy with other animals it must be assumed that the two pronuclei fuse into a single nucleus, which is therefore an hermaphrodite structure, and which, after a certain period of repose, itself divides and so begins the cleavage of the yolk.

The place where the pronuclei meet varies. Apparently the female pronucleus of itself moves to the centre or near the centre of the ovum; also the male pronucleus approaches the female as speedily as possible. If now impregnation occurs early, the two pronuclei meet peripherally; if late, they meet near the centre. In the former case they move together, as in the rabbit (Rein), to a central position. The observations so far made indicate that after they meet the pronuclei both perform active amoeboid movements, which continue for several minutes. Selenka maintains that the female pronucleus sends out processes which embrace the male pronucleus, but this has not been confirmed. Finally, the two pronuclei unite, but the process of union is very obscure, never having been satisfactorily observed. Apparently the membranes of the pronuclei, where the two are in contact, are dissolved away and the contents mix. The best account known to me of the fusion of the pronuclei is that given by Boehm in his memoir, **88.1**, on *Petromyzon*. The outline of the female pronucleus is still diffuse a quarter of an hour after fertilization. The head of the spermatozoon (male pronucleus) breaks up into four, more rarely five, granules. The female pronucleus moves centripetally, and acquires a distinct membrane. The pronuclei meet, the male granules having meanwhile multiplied by division. About this time the female pronucleus also breaks up into granules. We then have a clear spot which is the centre of an astral radiation, next this a bunch of male granules (Boehm's *Spermatomeren*), and next that a bunch of female granules (Boehm's *Ocomeren*), the whole making an elongated body lying at right angles to the radius of the ovum. Three hours after fertilization the two bunches are fused together and are no longer distinguishable. Each "Merit" consists of a body containing one or two chromatin specks

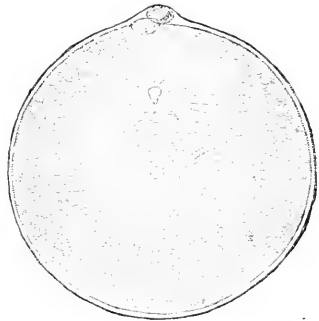


FIG. 43.—Ovum of *Sagitta* with two pronuclei. After O. Hertwig. Around each pronucleus is shown the aster.

(*Microsomen*). In the Crustacea, according to Weismann and Ischikawa, 88.4, the two pronuclei, when they meet, resemble ordinary membranate nuclei; where they come in contact with one another the membranes dissolve away and the contents of the pronuclei mingle. In *Ascaris* the process is more complicated. We may say, there-

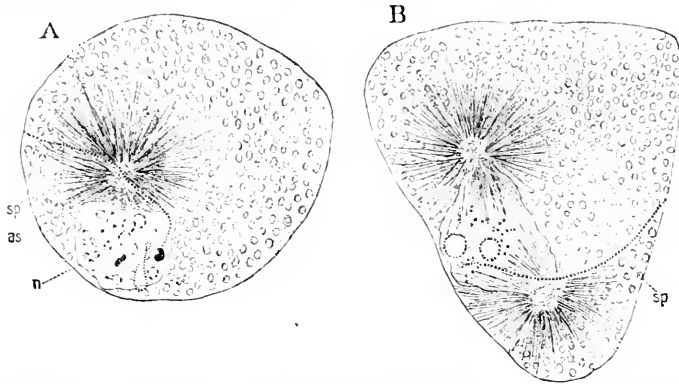


FIG. 44.—Two ova of a land-snail, *Arion*. After Platner. The ova are irregular in shape, as at this stage they are still in utero, and mutually compressed. A shows the segmentation nucleus, *n*, just formed; the two large "Karyosomen" in it are derived from the male pronucleus; the male aster still remains, *as*. B shows the commencing change of the segmentation nucleus into the first spindle. In both ova the tail, *sp*, of the spermatozoon is distinguishable.

fore, that *the fusion of the pronuclei is the essential phenomenon, and the method of the fusion is secondary in importance.*

Another point deserving mention is the rotation of the copulated nuclei. See Frommann's article on "Befruchtung" in "Eulenberg Cyclopædia," p. 568.

Now since the head of the spermatozoon is developed chiefly out of the chromatin of the nucleus of a spermatoblast, it follows that impregnation is essentially the addition of chromatin to the nucleus (female pronucleus) of the mature ovum. After the union of the pronuclei follows a period of repose, during which the yolk enlarges until it again fills or nearly fills the space within the *zona radiata*: a little room is left, which is chiefly occupied by the polar globules. The significance of the contraction of the mature and the expansion of the impregnated yolk is unknown. In certain cases the parts of the segmentation nucleus which are derived from the male pronucleus remain distinguishable. This is notably, according to Platner, the case with *Arion*. The segmentation nucleus contains a number of nucleolus-like bodies (*Karyosomen* of Platner, Fig. 44, A, *n*), with a distinct round outline, and a few granules of chromatin. These bodies are of two kinds, Fig. 44: the smaller and

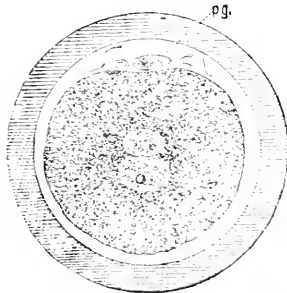


FIG. 45.—Ovum of a rabbit seventeen hours after coitus with the pronuclei about to conjugate. *pg*, polar globules; *z*, zona pellucida. After Rein

more numerous are produced by the female pronucleus, while the two larger ones arise from the division of the head of the spermatozoon.

In the later stage, when the nucleus is changing into the first segmentation spindle, Fig. 44, B, the two large male "Karyosomen" are still distinct, and have each their chromatin gathered in little particles around the periphery. Edouard van Beneden, 83.1, goes even further, stating that in *Ascaris* the chromatin from the two pronuclei can be distinguished in the nuclei of segmentation, and that when it divides, both the male and female chromatin loops divide also, so that the resulting nuclei are truly hermaphroditic.

V. THEORY OF SEX.

Sex is a term employed in two meanings, which are often confused but which it is indispensable to distinguish accurately. Originally sex was applied to the organism as a whole in recognition of the differentiation of the reproductive functions. Secondly, sex, together with the adjectives male and female, has been applied to the essential reproductive elements, spermatozoon and ovum, which it is the function of the respective sexual organisms (or organs) to produce. According to a strict biological definition, *sexuality* is the characteristic of the male and female reproductive elements, and *sex* of the individuals, in which those elements arise. A man has sex, a spermatozoon sexuality. Sexuality is primitive and essential, and sex is dependent upon it. We have to consider, 1st, the nature of sexuality: 2d, the origin of sexuality: 3d, the nature of sex.

Nature of Sexuality.—The essential facts of sexual reproduction are: That two bodies, partaking more or less plainly of the character of cells, fuse together into a single body, which seems in every known respect to be homologous with a uninucleate cell, and which undergoes a series of divisions (segmentation of the ovum) resulting in the production of an increasing number of new cells. In all the higher animals (and plants) the two bodies are obviously different. In all metazoa one body, the ovum, contains a store of nutritive material and has a special envelope of its own; the other, the spermatozoon, is small and provided with means of active locomotion: the details of their fusion, which is known as the fertilization or impregnation of the ovum, have been described.

The only hypothesis, as to the nature and mutual relations of the ovum and spermatozoon which rests, such is still my opinion, on much basis of fact is Minot's "Theory of the Genoblasts," 17.47. This hypothesis is based upon three categories of facts: 1st, Sexual reproduction is effected by the union of a male and female element, which produces a cell; this cell is, therefore, hermaphroditic, or, perhaps, one should say, asexual or neuter, since it is neither male nor female. 2d. When the cell, which gives rise to the female element matures into an ovum, it undergoes a remarkable process of unequal division, known as the extrusion of the polar globules. In other words, the cell divides into three bodies—*a*, two polar globules; *b*, a single female element. In some cases the polar globules subdivide further. 3d. When a cell divides into the male elements there remains one cell which does not form a spermatozoon. In mammals it is probable that the parent-cell divides into three cells, one of which, *b*, remains to form the base of a Sertoli's column, and

two of which, *a*, subdivide further to produce the spermatoblasts and ultimately the spermatozoa. Unfortunately our knowledge of the development of the spermatozoa is extremely unsatisfactory, no two authors agreeing, so that extreme caution is necessary. There are, however, reasons for thinking that the statements just made in regard to mammalian spermatogenesis correctly specify the essential steps, and it is probable that the essential steps are the same throughout the animal kingdom. Assuming then that the view of spermatogenesis here adopted is correct, our further deductions from the premises are almost self-evident. In the cells proper both sexes are potentially present; to produce sexual elements the cell divides into its sexual parts, the genoblasts; in the case of the egg-cell the male polar-globules are cast off, leaving the female ovum (oospore of Balfour); in the case of the sperm-cell the male spermatoblasts, which by the hypothesis of Minot are homologous with the polar globules, multiply considerably, and their descendants give rise by further specialization (in mammals of their nuclei) to the male elements, while the parent-cell, or homologue of the oospore, atrophies. In both cases the sexual cell separates into a single female element or *thelyblast*, and probably two male elements or *arsenoblasts*, which are capable of multiplication by division; but in one case it is the *thelyblast*, in the other the *arsenoblast*, which is preserved, differentiated further, and utilized. To make a complete cell there must be a union of the male and female, and this is accomplished by "impregnation of the ovum."

Minot's hypothesis is strictly morphological and offers us no insight at present into the physiological aspects of sexuality. It has been adopted by Balfour, and Ed. van Beneden, neither of whom cite Minot. Since the theory of the genoblasts was first advanced in 1877, it has been confirmed by important discoveries, especially by the series of investigations which have proven that polar globules, as stated in the section on the maturation of the ovum, occur in *all* classes of the animal kingdom, and, secondly, through the investigations on the relation of the polar globules to parthenogenesis. The general, may we not say the universal, occurrence of the formation of the polar globules as a necessary step in rendering the ovum capable of impregnation, is, of course, a very important confirmation of the theory, since the theory assumes that the production of the polar globules is *the* essential step in converting the egg-cell into an oospore or *thelyblast*.

Minot, in his original article, briefly indicated the application of his theory to parthenogenesis, and the question was more and ably discussed by Balfour in his "Comparative Embryology," I., 63-64. In his article of 1883, 47, 367, Minot is more explicit. He says: "If one assumes that the ovum becomes female by the removal of the polar globules, then it must remain asexual so long as no globules are formed. If one further assumes that no polar globules are formed in ova, which develop parthenogenetically, then these ova would remain simple cells, and their reproductive process would depend on ordinary cell-division. If the globules are developed then impregnation is an unavoidable preliminary of further development." In other words, parthenogenesis is only an extreme case of asexual repro-

duction and in nowise the development of a female element (oospore or thelyblast) without impregnation. The correctness of this view has since become extremely probable through the observations of Blochmann, **87.1**, **88.1**, of Weismann, and of Weismann and Ischikawa, **88.2**, **4**, who find that in parthenogenetic ova there is only one polar globule formed, while in eggs requiring fertilization there are two. Now by Minot's theory the cells must be hermaphroditic in order to develop, and the egg-cell becomes a thelyblast by the ejection of two polar globules; if, therefore, one polar globule is removed and the other not, the egg-cell retains part of its male constituent. The significance of the *two* polar globules has already been discussed, p. 65; Weismann's interpretation is considered in the following section on Heredity.

To my theory of the genoblasts, I feel justified in making an essential addition—namely, that sexuality is a *relation* of substances or forces, and not dependent on any special substance. The chief evidence in favor of this assumption is the fact that in all male elements the proportion of protoplasm to the nucleus is small, while in female elements (thelyblasts) it is small; and, moreover, to produce spermatozoa there is an excessive growth of the nuclei, while to produce ova there is an excessive growth of the protoplasm. It is remarkable, as Minot has demonstrated (Address, Proc. A. A. A. S., 1890), that a relative increase of protoplasm is the anatomical characteristic of senescence. The ovum resembles an old cell, the spermatozoon a young cell, and these resemblances cannot be considered fortuitous.

There is no material basis of sexuality in the sense that there is any visible male or female substance known to the biologist, nor is it probable that a male or female substance exists. The functions of life, according to our present conceptions, are not each connected with particular chemical compounds or with particular visible constituents of the cells, but rather depend upon the complex interrelations of numerous different substances, which enter into the composition of the cell. There are certain functions which are connected more intimately with one part than with another—as, for instance, contractility with the protoplasm, heredity with the nucleus; but even in these cases we cannot say that the functions in question could go on without the interplay of the other portions of the cells. The genoblasts contain nuclear substance, protoplasm, and enchylena, and we can ascertain the sex of a genoblast only by observing its history, not by any direct test. It is probable that male or female sexuality is an intracellular relation of parts, some modification of the interplay of forces within the cells, and for the present this view must hold against the opposite view that there is a male matter and a female matter.

Several interpretations of the polar globules have been advocated, which are incompatible with Minot's theory. The first of these is that of Whitman,* who, in his first article on the development of Clepsine, **78.2**, p. 48, maintains that a series of cell generations is produced by a series of divisions, and the separation of the polar

* Compare also O. Hertwig, 90. 1.

globules is merely the last of these divisions. Inasmuch as this view overlooks the fact that polar globules are part of the process of maturation and that no ovum can be impregnated until they are formed, and the further fact that the products of division (globules and oospore) are *extremely* unlike, while in ordinary divisions the two daughter-cells have close resemblance to one another—inasmuch as these fundamental facts are overlooked, it seems to me that Whitman's explanation cannot be adopted.

Allied to Whitman's view is that of Bütschli, **84.1**, who, starting from the idea of a sexual colony, such as is found in certain unicellular animals (Flagellata), considers that the tendency to form such colonies is preserved in the metazoa, and shows itself in the bundle of spermatoblasts and in a more rudimentary form in the egg-cell, forming a colony with its two polar globules. The essential objection to this view is that it overlooks the fact that the divisions of cells to produce the sexual products are divisions into *unlike* bodies, while in the sexual colonies of the Flagellata the divisions are, so far as known at present, into *like* cells.

O. Hertwig's criticisms, **90.1**, against Minot are based on the study of the differentiation of the sexual elements of *Ascaris*. He overlooks the fact that the theory of Minot depends on the origin of the sexual elements, not on their differentiation; yet nothing is known as to the *origin* of the genoblasts in *Ascaris*.

Besides the theory of sex already discussed, there are three others which must be noticed. The first of these has been advanced by Sabatier, and defended by him in a series of articles, several of which have been reprinted, making in their reprinted form the fifth volume of Sabatier's "Travaux."* Sabatier considers that the cells are neuter or hermaphroditic, agreeing in this respect with Minot, and that the casting off of the male portion converts the cell into a female element, and *vice versa*, but he goes farther than Minot in attempting to specify which parts of the cell are male and which are female. He directs attention first to the fact that in certain invertebrates there is a central mass (Bloomfield's *blastophore*), to which there are attached spermatoblasts or spermatozoa. He endeavors to prove that this is the primitive method of spermatogenesis, and concludes that the male element is peripheral, and the product of a centrifugal action. He directs attention, second, to the various products that are thrown off from the cell, which ultimately forms the ovum. Summarizing his conclusions in regard to the egg (*l. c. V.*, 202-203) he says: "If we recapitulate now the various groups of globules which are eliminated from the ovule, commencing at the asexual cell-stage of its life up to the moment when it attains the complete dignity and signification of an egg, we see that there may be:

"1st. *Globules précoces ou du début*, which become usually the elements of the follicle and give, so to speak, the first impulse to the march of the cell toward sexuality.

"2d. *Globules tardifs*, which are at times formed well before the epoch of maturity, but are eliminated at a late period, and sometimes very near the maturity. They are all formed, as are the *globules*

* "Travaux du Laboratoire de Zoologie de la Faculté des Sciences de Montpellier et de la Station Zoologique de Cette." Ire Sér., 5me vol.

précoces, by simple differentiation in the midst of the protoplasm and without karyokinetic phenomena.

“3d. Globules, which are contemporary with the period of complete maturity, and of which the elimination accentuates in the egg a very pronounced attraction for a male element coming from another cell, or even from another organism. These are the *globules de maturation parfaite*. Most of these globules result from phenomena of cellular division, and form the polar globules properly so-called.”

From this quotation it will be clear that Sabatier classes together the follicular cells surrounding the ovum, the non-cellular masses excreted from the egg-cell during its development, and the polar globules. All of these are—so he maintains—thrown off from the central ovum, hence he concludes that the female element is central and the product of a centripetal action. In brief the male element represents a centrifugal force, the female element a centripetal force.

A. Prenant has adopted a theory which is apparently a modification of Sabatier's, but until his memoir is published (*Journ. de l'Anat. et Physiol.*, 1892) discussion of his theory must be deferred.

I am unable to accept Sabatier's theory for many reasons, of which the following may be mentioned: 1st. It cannot be shown that the differentiation of the spermatozoa does occur typically at the periphery; on the contrary, in the great majority of cases, it is distinctly polar, since it takes place at the inner end of an epithelial cell. 2d. It is impossible to maintain a homology between cells and masses which are not nucleated at any period of their history, and Sabatier's views as to the maturation of the ovum oblige us to draw such an homology. 3d. Sabatier, to establish the centrifugal removals, which produce the ovum, relies largely upon the history of the *globules tardifs*, which, therefore, must by his hypothesis be male. He bases his defence largely on observations on the “testa-cells” of Ascidians, which he considers to belong under the head of *globules tardifs*; but these observations have been called in question by Fol (*Recueil Suisses Zool.*, No. 1),* so that there is doubt as to one of Sabatier's chief foundations. Now some of these globules—supposed to be male—contain no nuclear substance, yet all the sexual elements, which we know positively to be such, do contain nuclear substance.

Balbiani's theory, **79.1**, is the exact inverse of the two previously mentioned; for him every sexual element is the product of the copulation of two elements: 1st, the epithelial cells of the follicle, which are male; 2d, the *Urei*, which is always female. Balbiani has not observed any such copulation, nor has he any valid indirect evidence of it to bring forward; on the contrary, he disregards in several respects what others consider elementary principles of histology.

Nussbaum's theory appears to me valuable and suggestive. It was first advanced, so far as I know, in 1880, though similar conceptions are to be found in earlier writers. Nussbaum, **80.1**, starts with the conjugation of two similar unicellular individuals, as occurs in certain protozoa: the two individuals fuse, and after fusion

* For Sabatier's answer see same *Recueil*, No. 3.

divide into successive generations of cells. He next points out that in the higher animals all the sexual differences are secondary not only in the so-called "secondary sexual characteristics," but also in the sexual organs themselves. He then goes on to emphasize the presence of the sexual cells (*Ureier* of German authors, Hamann's *Urkeimzellen*) in the embryo, and maintains that as these both give rise to the sexual products the ovum and spermatozoon are strictly homologous cells. He writes, p. 106: "There come together during impregnation accordingly not two heterogeneous elements which complement one another and together form a whole, but rather there come together two homologous cells, of which one to facilitate conjugation is transformed into a more movable body; the other is laden with nutritive material, and is furnished with protective devices." And again, p. 113: "The differentiation of sex is not the transmission of two originally united functions to the differing descendants of a common original *Anlage*; it is rather the variation of homologous cells for the better achievement of their conjugation." The sexual elements, according to Nussbaum, are cells which are set apart for reproductive functions from the rest of the cells of the body, and there is no primary difference between male and female. He does not consider in any way the significance of the polar globules or Sertoli's columns, and therefore does not argue directly against Minot's theory. His generalization that separate cells alike in character are set apart early in embryonic development to form both the male and female elements is a very important one, and has been adopted by embryologists. Weismann accepts it and applies it to his theory of heredity, and it has received a valuable confirmation in Hamann's paper, 87.1. But this generalization leaves the question of the final differentiation of the *Ureier* into sexual elements untouched, and is not necessarily in any way in conflict with the conception of that differentiation advocated by Minot.

It seems to me, therefore, that although Minot's hypothesis cannot be proven at present, yet there is no other hypothesis of sex having nearly as strong evidence in its favor.

Origin and Objects of Sexuality.—THE ORIGIN of sexuality is involved in much obscurity. In the lowest unicellular organisms there is certainly no clear sexual differentiation, and some biologists assert that there is nothing comparable to sexual reproduction, but the observations are far too imperfect at present to justify any such assertion. The question involved is, whether sexuality is coextensive with life or not; in the latter case it is the result of evolution from asexual organisms, and is a secondary and not a primary or essential characteristic of life. The problem is, therefore, a fundamental one, but we cannot hope for its solution until our knowledge of the lowest organisms is greatly extended.

The precursor of the sexual process is undoubtedly to be found in the conjugation of two similar cells, which fuse into a single organism, as occurs in certain cryptogamous plants and among the protozoa, notably the rhizopods. In the next stage the cells which fuse together are obviously different, as in the Flagellata. If now we pass to the colonies of the Flagellata we find that certain cells only act as conjugators, and thus we approach the disposition of the mul-

ticellular animals, Metazoa, which have bodies composed of cells, certain of which produce the sexual elements, and these elements conjugate. In conjugation and impregnation alike the process is the fusion of a nucleated protoplasm with another nucleated protoplasm of different origin. In plants also, as we ascend from the lower to the higher forms, we find the differences between the conjugating bodies to increase: thus in zygophytes the conjugating cells are alike, in phanerogams the pollen and ovicell are unlike. The question arises whether the conjugation of the like or of the unlike protoplasts (or, in other words, of similar cells, or of genoblasts) gives the clew to what is essential. Is the dissimilarity of the conjugating bodies essential? If Minot's theory of the genoblasts is correct, it is probable that the dissimilarity is essential, in which case it is conceivable that when similar cells conjugate each cell contains both male and female, and the male of one saturates the female of the other, and *vice versa*. On the other hand, the whole tendency of evolution is from the simpler to the complex, and, *a priori*, it is more plausible to consider that complete sexuality is a differentiation of a simpler process rather than the mere separation of what was united in one cell. The last-mentioned conception is undoubtedly the one which would appeal to most biologists at the present time. Yet we see that the functions which exist in a cell do undergo separation, so that they become excessively predominant in certain cells; for instance, the nervous functions have been thus selected out for the superfluous endowment of certain cells, and it appears to me perfectly conceivable that male and female may be united in a unicellular organism just as completely as assimilative and nervous functions, and as these latter are differentiated, so, too, are the former.

The above considerations, and others which might be given, were it worth while to lengthen the discussion of so obscure a subject, lead me to the hypothesis *that sexuality is coextensive with life: that in protozoa* the male and female are united in each of the conjugating cells, and impregnation is double; and, finally, that in the metazoa the male and female of the cells separate to form genoblasts or true sexual elements, and impregnation is single*. It need hardly be pointed out that this hypothesis is purely tentative, and may have to be rejected altogether when we have sufficient knowledge to decide as to its validity.

THE OBJECT OF SEXUALITY is, likewise, known only by hypothesis. Three views are to be considered: its purpose is, 1st, rejuvenation; 2d, to produce variability; 3d, to check variability. 1st. The theory that the purpose of sex is to produce a young organism is very old, and is based on every-day observation; it involves, as its corollary, that organisms become old, and thereby incapable of maintaining their own existence. That sexual reproduction does produce a young organism is the universal law; it is also true that every young organism does possess certain morphological and physiological characteristics by which it may be distinguished from an old organism. When sexual reproduction occurs life pro-

*Very possibly this is not true for all protozoa for there may be protozoa with true genoblasts.

ceeds in cycles; the sexual conjugation produces a single cell, which divides again and again, until at last the process cannot proceed further; then a renewed conjugation follows and a new cycle of cell-generations ensues; in the higher animals the cells remain together as they multiply; in the protozoa the cells each lead a separate life, but in both the cell-cycle is dominant; the body of a metazoon is comparable to the *set* of individual unicellular protozoa resulting from one sexual act. In one case the cells of a cycle remain together, in the other they separate. So far, then, as it is known to occur, the sexual process is a rejuvenating one; but this does not prove that *all* living organisms require sexual rejuvenation from time to time, nor does it prove that there is no other means of rejuvenation. It may be that all cells as they divide asexually lose their growth-power, so that there comes a time when there must be a rejuvenation or restoration of the growth-power, but it is improbable that sexual reproduction is the only means to effect the necessary restoration of vitality. 2d. That the object of sex is to increase variability and so afford a wider scope for natural selection has been maintained by Weismann. At first sight the notion of the mingling of two hereditary strains of different character producing variety in the offspring seems very plausible; but the notion does not bear examination, for it renders the commencement of variability impossible, and fails to account for the divergence in the offspring of the same parents. 3d. The view that sexual reproduction checks variability has been advanced by Hatchesek, 87.1, 386, who points out that the mingling of hereditary strains tends to restore the specific norm, since in the long run the variations counterbalance one another. Galton has shown that in human stature the tendency of heredity is to restore the normal height, and the same is presumably true of other characteristics. I am strongly inclined to accept Hatchesek's theory, and to maintain with him that one result of sexual reproduction is to correct variations and so preserve the specific type.

Nature of Sex.—Sex, as we encounter it in the human species, is the result of a long evolution affecting a large number of organs—perhaps all of the organs—so as to result in characteristic differences between the male and female; but the essential difference is in the relation of the two sexes to the production of the genoblasts; the male produces the spermatozoa, the female the ova, and in this lies the whole essence of the sexual differentiation; all other distinctive morphological and physiological traits of men and women are secondary. Thus the structure and functions of the genital ducts, of the uterus, mammary glands, etc., though eminently characteristic of the sexes, in man are *not* from a biological point of view fundamental.

As we ascend the animal scale there is an increasing divergence between the sexes, owing to the increasing adaptation to the reproductive functions. It is generally believed that the primitive condition is hermaphroditic, and that the female is an individual in which the power of producing male elements is lost, and a male an individual in which the power of producing female elements is lost. In a certain sense this conception appears true, for in the embryo there is an indifferent stage in which the sexual glands are already

differentiated, but in which the future sex is unrecognizable; subsequently by unknown factors the sexual gland is converted into an ovary or a testis. In some cases, as in certain teleosts and in the snails, the sexual glands develop both ova and spermatozoa. These facts suggest that the primitive sexual gland is potentially hermaphroditic. It is to be remembered, however, that if hermaphroditism were the primitive form we should expect to find the lowest metazoa hermaphroditic; but this is not the case either with all Coelenterata or all sponges, although it is the case in some higher classes of the animal kingdom—as, for instance, the trematode worms and pulmonate gasteropods. These and other considerations have led me to the hypothesis that primitively each individual animal is sexually indifferent when young, and becomes either male or female when adult; by a secondary modification in certain forms the individual becomes both male and female. This is contrary to the prevalent opinion that the hermaphroditic condition is the primitive one.

VI. HEREDITY.

In regard to the process of hereditary transmission there are two theories, each of which appears in several modifications: 1st, the theory of pangenesis; 2d, the theory of germinal continuity. The latter does, the former does not, appear to me to conform to our present knowledge.

Pangenesis.—The theory of pangenesis was first formulated by Darwin, though it had been crudely foreshadowed by Buffon, Bonnet, and Herbert Spencer. The following quotation from Darwin's "Animals and Plants under Domestication" (Amer. edit., 1868, II., 448, 449) gives his statement of his theory: "I have now enumerated the chief facts which every one would desire to connect by some intelligible bond. This can be done, as it seems to me, if we make the following assumptions: if the first and chief one be not rejected, the others, from being supported by various physiological considerations, will not appear very improbable. It is almost universally admitted that cells or the units of the body propagate themselves by self-division or proliferation, retaining the same nature and ultimately becoming converted into the various tissues and substances of the body. But besides this means of increase I assume that cells, before their conversion into completely passive or "form-material," throw off minute granules or atoms, which circulate freely throughout the system, and when supplied with proper nutriment multiply by self-division, subsequently becoming developed into cells, like those from which they were derived. These granules, for the sake of distinctness, may be called cell-gemmules, or, as the cellular theory is not fully established, simply gemmules. They are supposed to be transmitted from the parents to the offspring, and are generally developed in the generation which immediately succeeds, but are often transmitted in a dormant state during many generations and are then developed. Their development is supposed to depend on their union with other partially developed cells or gemmules, which precede them in the regular course of growth. Why I use the term union will be seen when we discuss the direct action of

pollen on the tissues of the mother-plant. Gemmules are supposed to be thrown off by every cell or unit, not only during the adult state, but during all stages of development. Lastly, I assume that the gemmules in their dormant state have a mutual affinity for each other, leading to their aggregation either into buds or into the sexual elements. Hence, speaking strictly, it is not the reproductive elements nor the buds which generate new organisms, but the cells themselves throughout the body. These assumptions constitute the provisional hypothesis which I have called Pangenesis."

This hypothesis is the suggestion of a masterly mind, and, as a succinct and comprehensive expression of the facts of heredity, must always command admiration. But the real worth and real significance of the hypothesis have not been grasped by those who have tried to better it; its value is not in explaining, for it does not do that, but in expressing heredity in hypothetical terms, which are at once suggestive and comprehensible. Haeckel, in an amusing pamphlet,* which no competent critic can assign the slightest value to, asserted that the gemmules are rhythmical vibrations, but he gives no reasons to justify his opinion. Elsberg has also written on the subject in the Proc. Amer. Assoc. Adv. Sci., XXV., 178, and cites there earlier writings of his own.†

Brooks' modification, 76. 1, of the theory of pangenesis well deserves consideration, although the subsequent progress of biology does not lead me to think it felicitous; but we can now recognize it as a step toward Nussbaum's valuable theory of germinal continuity, and also toward Weismann's conception that sexual reproduction has for its object the maintenance of variability. Brooks' theory is advocated in his book on "Heredity" (Baltimore, 1879); he states it succinctly as follows: † "This paper proposes a modification of Darwin's hypothesis of the same name (pangenesis), removing most of its difficulties, but retaining all that is valuable. According to the hypothesis in its modified form, characteristics which are constitutional and already hereditary are transmitted by the female organism by means of the ovum; while new variations are transmitted by gemmules, which are thrown off by the varying physiological units of the body, gathered up by the testicle and transmitted to the next generation by impregnation." If this theory was tenable, there should be—to mention a single objection—little variation in individuals produced by parthenogenesis, and they ought always to be females, whereas they are sometimes males. There remains not a new theory of pangenesis, but the valuable suggestion that the maternal influence causes less variability than the paternal. I am, however, strongly disinclined to anticipate the confirmation of this suggestion, especially because the males are not more variable than the females, as we should expect. I have some extensive statistics which show

* E. Haeckel "Peregenesis der Plastidule." Berlin 1876 For some criticisms which, considering the character of this pamphlet, are very gentle. see Ray Lankester in *Nature*. July 13th. 1876. xiv 235-238

† The perusal of Elsberg's article has not enabled me to recognize anything novel except the substitution of the term plastidule for gemmule, used by Darwin, and speculations as to the composition of plastidules as if he were groping after the conception of the unicella of Nägeli, with which he was apparently unacquainted

‡ Proc Amer Assoc Sc. Buffalo 1876 p 177 abstract of a paper read before the section of natural history

that in mammals, at least, there are no essential differences between the sexes in variability. Even if Brooks' thesis should be established it would prove only that the inheritance from the mother is stronger than from the father, and there would lack reasons for his abstruse hypothesis.

The theory of pangenesis is to be resigned, not so much on account of the direct arguments against it, as on account of the accumulation of evidence in favor of the theory of germinal continuity.

Germinal Continuity.—There are various theories to be considered under this head; but they all have in common the conception that there is a formative force in organisms—that the force depends upon a special material substratum, and that some of the supply of that substratum is given by the parent to the sexual elements it produces.

The first important step toward the substitution of a new theory *vice* pangenesis was taken, so far as I am aware, by Moritz Nussbaum, whose memoirs, 80.1, 84.2, on the differentiation of sex deserve great attention. August Weismann* has adopted Nussbaum's conception and defended it with insistent energy, adding also several modifications. Nussbaum pointed out that there is noteworthy evidence in the development of various animals tending to show that the germinal cells, from which the sexual products arise, are separated off very early from the other cells of the embryo and undergo very little alteration. Hence he concluded that some of the germ substance is directly abstracted from the developing ovum and preserved without essential alteration to become, by giving rise to the sexual elements, the germ substance of another generation. Weismann insists upon the corollary that the whole nature of the animal or plant depends upon its germinal substance (*Keimplasma*), and that the reason why the offspring is like the parent is that in every genoblast some of the germinal matter is preserved unchanged. He calls this view the theory of the continuity of the germ-plasma. He follows Nussbaum also in emphasizing the fact that this theory is inconsistent with the theory of pangenesis and with the theory that parental characteristics acquired through the influence of external causes are transmissible to the offspring. On these two points Weismann's second and third papers are especially important. Nussbaum and Weismann lay great stress upon the separation of the cells of the embryo into two kinds: 1, the germ-cells, which are converted into the sexual elements; 2, the somatic-cells, which constitute the body of the organism. The germ-cells descend directly from the ovum, according to Weismann, who has carried his speculations to a great extreme, and undergo little alteration, so that they have (in suspension) the power to produce a whole organism, which the somatic-cells do not have. It is impossible to agree to this extraordinary view.

* Weismann's first paper was read before the University of Freiburg as a Prorektoratsrede, and was published in pamphlet form at Jena in 1883, 83.1. A second paper was read before the German Naturforscherversammlung in 1885, and appeared in the *Tagblatt* of that Association, it was subsequently amplified and republished, 85.1. A third paper, 86.3, was likewise addressed to the Naturforscherversammlung in 1886, and published at Jena the same year. A notice of this last is given by Kollmann, *Biol. Cbl.*, v., 673 and 70.5. At the same meeting of the Naturforscher, R. Virchow also delivered an address (see Virchow's *Arch.*, ciii., 1, 205, 413, and abstract in *Biol. Cbl.*, vi., 97, 129, 161.) in which he attacked Weismann. To Kollmann and Virchow Weismann has replied in *Biolog. Centralbl.*, vi., 38.

Minot, 70, has expressly emphasized the fact that the formative force is certainly a diffused one, as is amply proven by the processes of regeneration, by the phenomenon of duplication of parts, and by asexual reproduction, since in all these cases the formation of a part or the whole of the organism proceeds without the participation of the sexual elements. Kölliker, also, 85.1, 44-46, clearly demonstrates that a sharp division between germ-cells and somatic-cells cannot be maintained. The same position has been adopted by Whitman, 87.3, and, of course, by many others. It is to be further remembered that the cells for the different organs of the body are all set apart very early indeed, and in the case of vertebrates the germ-cells are among the very latest to become distinguishable; thus the nerve-cells, muscle-cells, notochord-cells, etc., etc., all can be seen to precede the germ-cells in their differentiation. Weismann's assumption that the germ-cells are set apart specially early is simply false; all the organs have their cells set apart early, and that too while they are in the embryonic condition; and it is not true that the germ-cells differ essentially as to their mode of origin or differentiation from the so-called somatic-cells. The early divergence of the cells according to the organs or parts they are destined for was pointed out explicitly by W. His many years ago, 74.1, 18. 19. Weismann's error consists in attributing a peculiar significance to a fact by connecting it only with the development of the sexual elements, whereas it is a fact common to all parts of the body. All, therefore, of Weismann's further speculations as to the difference between germ plasma and "histogenes plasma" are without foundation.

Nägeli was probably the first to reach the definite conception of a material basis of heredity, to which basis he gave the name of *idioplasma*. This *idioplasma* is essentially identical, it seems to me, with Weismann's Keimplasma. Nägeli's views are presented very fully in a large, abstruse, and little-studied volume, of which a useful abstract has been given by Kollmann (*Biol. Cbl.*, IV., 488, 517). Nägeli is led to the theory that there are in every living cell two substances, one of which, the *idioplasma*, alone carries on the function of hereditary transmission, while the other, the nutritive plasma (*Nährplasma*) is the seat of the remaining functions. In other words, Nägeli put forward in a definite form the theory of germinal continuity, for he assumes the formative force to reside in a specific material substratum, which reproduces and perpetuates itself, occurs throughout the organism, and, therefore, in the genital products also. The argument in support of this theory is very able, and well deserves the cordial praise which Kölliker and others have bestowed upon it.

Nägeli did not specify what constituent of the cell corresponds to his *idioplasma*. O. Hertwig, 85.1, was the first to indicate the nucleus as the organ of heredity, and this view has been ably defended by Kölliker, 85.1, Strassburger, and others. This notion rests upon the consideration of—1st, various facts which suggest that the nucleus has special control over the organization of the cell; 2d, the probability that impregnation consists essentially in the fusion of the pronuclei; 3d, the development of the spermatozoon from the nu-

cleus. That the nucleus presides over the cells is naturally suggested by the phenomena of cell-division, especially indirect division (karyokinesis, mitosis), for during the process the nucleus leads the way, and its visible alteration precedes that of the protoplasm; the astral rays both during karyokinesis and those around the pronuclei during impregnation may be interpreted as results of nuclear control. The opposite conception that the protoplasm leads has not lacked defenders (see Auerbach, Bütschli, **76.1**, Nussbaum, **86.1**, 504, and Whitman, **88.1**). I may point out that in interpreting the observations bearing upon this discussion, we must not forget that the nucleus and protoplasm are interdependent, neither being able to maintain its existence permanently without the other. "The fact," says Minot, **85**, 125, "that the visible alteration of the protoplasm in a certain rare case comes before that of the nucleus shows that the protoplasm probably has an active rôle in cell-division; but since even then its arrangement depends on the position of the nucleus, the evidence of the superiority of nuclear control is, I think, not affected." On the other hand, there are many observations, which may be interpreted as proofs, that the nuclei have a regulating power over the cells, especially as regards their division and organization. A few of these may be instanced: 1st. After a cell is formed, its nucleus enlarges first, and the cell-body follows it in growth. 2d. Kölliker, in his paper, **85.1**, on heredity (p. 29 ff.), discusses the relation of nuclei to growth very fully and ably. The great extent of his learning has enabled him to present the manifold aspects of the question more thoroughly than any other writer. His argumentation seems to me so satisfactory that it does not require the weight of his great authority to establish the conclusion that without nuclei there is no growth. Of this the most faith-compelling evidence is offered by the important experiments of Nussbaum and Gruber,* who found that when unicellular animals are artificially divided, the fragments containing nuclei continue to grow, while pieces without nuclei die off. 3d. The large unicellular Thallophytes, such as *Caulerpa* and *Codium*, become multinuclear before they attain their adult size. Further illustrations are given by Kölliker (*l. c.*, pp. 19, 20). 4th. Perhaps the most striking demonstration of the importance of the nucleus is afforded by the experimental alteration of the plane of division of the ovum. Pflüger, **83.6**, showed that the plane of the first division of the ovum is altered by tilting the ovum before the division begins, and keeping it in the same position during division: normally the plane passes through the white pole, but when the ovum is fastened in an oblique position, the plane is not in the axis of the ovum, but in the line of gravity. Born,† **84.3**, has continued these remarkable experiments, and discovered that the nucleus changes its position when the ovum is kept tilted, and that the site of the nucleus determines the plane of division of the ovum. The second and third points (the importance of the pronuclei and the nuclear origin of the

* Science, vol. vi, p. 4. See also Nussbaum's later paper in the *Archiv für mikroskop. Anat.*, xxvi, p. 485. Nussbaum also cites Fr. Schmitz's experiments on the artificial division of plants. Schmitz's paper I have not seen; it was published in 1879, in the *Festschrift der naturforschenden gesellschaft zu Halle*.


† I have not seen the original. There is an abstract in Hofmann und Schwalbe's *Jahresbericht* for 1884 p. 444.

spermatozoon) have been sufficiently elucidated in previous divisions of this chapter. Now, it is obvious, since qualities may be inherited from the father, that the nucleus alone can furnish the means of transmission from parent to offspring; and, since it can accomplish this on the paternal side, it is probable that it can do as much on the maternal side—an assumption against which no evidence has been brought forward; hence the hypothesis that *the nucleus is the organ of hereditary transmission*. For criticism of this view see J. Frenzel, 86.5, p. 89, whose arguments have been controverted by Minot, 85, 127.

We may go one step farther: Since the chromatin is the characteristic of the nucleus, and since spermatozoa in some cases consist almost exclusively of chromatin, it is probable, as maintained by Minot, 85, 127, that *chromatin is the essential factor in the function of heredity*. It is my conviction that the hypothesis of pangenesis, both in its original form and in all its subsequent modifications, has been definitely set aside. In its place we have the theory that the nature of germ, *i. e.*, of the impregnated ovum, is the same over and over again, not because there is in each case a similar collocation of gemmules or plastidules, but because the chromatin perpetuates itself so that the same kind of chromatin is found in the one generation as in the generations preceding it and following it. *The child is like the parents because its organization is regulated by not merely similar, but by some of the same, chromatin as that of the parents*. Perhaps instead of "chromatin" we ought to say, in order to avoid an unjustifiable explicitness, "nuclear substance."

The validity of this hypothesis remains for the future to decide. There is one general objection to it—that of connecting a special function with a special substance, which is against the general conception of vital functions as the resultants of interlocking activities extending throughout each cell. Compare the remarks *à propos* of the theory of sex, *ante*, p. 79. The objection is, to my mind, a real and very serious one.

PART II.
THE GERM-LAYERS.



CHAPTER IV.

SEGMENTATION FORMATION OF THE DIADERM.

THERE follows after impregnation a short pause, and then the ovum begins its process of repeated division, which is known as the "segmentation of the ovum," the term having been introduced before it was known that each "segment" is a cell. The division or cleavage (*Furchung*) of ova was described by Prevost and Dumas, 1824, and again by Rusconi, 36.1. By usage the term segmentation is restricted to the production of cells up to the period of development when the two primitive germ-layers are clearly differentiated and the first trace of organs is beginning to appear.

Segmentation Nucleus.—The impregnated ovum has a single nucleus, which is known as the segmentation nucleus, and which is formed, as stated in Chapter III., by the union of the male and female pronuclei.* It is the parent of all the nuclei subsequently found in the organism, and participates actively in the process of segmentation. It is very much smaller than the nucleus of the egg-cell before maturation; it is usually membranate and has numerous fine granules of chromatin, *microsoma*, derived from the pronuclei; in some cases the microsoma from the male pronucleus are distinguishable from those of female pronucleus (see under Impregnation, *ante*, p. 76). In the rabbit the nucleus when first formed has indistinct contours, irregular shape, and a homogeneous appearance (Ed. van Beneden, 75.1, 699); it soon enlarges, becomes regular, and acquires a distinct centrally situated nucleolus (Bischoff, 42.1, 50, Coste, 47.1, Lapin, Pl. II., Fig. 4), presumably by the gathering together of the microsoma.

The position of the nucleus is always eccentric,† so far as known, and approximately, if not exactly, the same as that of the egg-cell nucleus before maturation. Accordingly, the degree of eccentricity varies as the amount of yolk or deutoplasm, being least in alecithal and greatest in telolecithal ova. In brief, it may be said the nucleus tends to take the most central position possible with regard to the protoplasm of the ovum. The vitelline granules are not to be regarded as protoplasm, hence their accumulation may produce a one-sided distension, without, however, in the least disturbing the uniform *radial* distribution of the protoplasm. The nucleus is surrounded by protoplasm with few or no yolk-grains; in telolecithal

* Éd. van Beneden in his first paper on *Ascaris*, 83.1, affirmed that there was no real union of the pronuclei in the impregnated ova of that species; but Carnoy, 86.1, shows that Van Beneden's observations were incomplete, and Zacharias has stated, 87.1, that they are so defective as to be fundamentally erroneous in regard to important phases, and he points out that in reality the eggs of *Ascaris* offer another proof of the actual union of the pronuclei. The impregnation in this nematod has since formed the subject of numerous articles; see Van Beneden and Neyt 87.1, Carnoy 87.1, Boveri 88.1, O. Hertwig 90.1, etc.

† It is often stated that the nucleus lies *exactly* in the centre, but I have been unable to find a single observation to justify the statement.

ova the perinuclear accumulation is the court of protoplasm at the animal pole.

Period of Repose.—After the segmentation-nucleus is formed there occurs a pause, which lasts, according to observations on several invertebrates, from half to three-quarters of an hour. It is probable that a similar pause ensues in the mammalian ovum, but there are as yet no observations to show whether it occurs or not. During this period the yolk expands slightly, unless, indeed, the expansion observed is due to the influence of hardening agents,* and the monocentric radiation, which is present when the nuclei copulate, gradually fades out, and is replaced by a dicentric radiation, which marks the end of the period of repose and the commencement of the first division of the ovum.

Karyokinesis of the Ovum.—For convenience I interpolate a sketch of the process of cell-division as encountered in the ovum, based on O. Hertwig, **88.1**, 37, and C. Rabl, **84.1**. My sketch is by no means complete.

It is probable that the resting nucleus has one pole at which the connection between the reticulum of the nucleus and the surrounding protoplasm is more intimate than elsewhere, as suggested by Rabl, **89.1**. This pole is marked by a clearer spot outside the nucleus, close against it, and much smaller than it. This clear spot becomes the centre of a radiating arrangement of the protoplasm. It was, I believe, first observed by Flemming in the eggs of Echinoderms. It has been seen in *Ascaris megalocephala* by Van Beneden and Neyt, **87.1**, and by Boveri, **88.1**, in *Siredon* by Kölliker, **89.1**, and in other cases. It is now designated as the sphere of attraction,† and is seen, at least in certain phases, to contain a separate central body (centrosoma of Boveri). It is not improbable that the "sphere of attraction" is identical with the *Nebenkern* of recent German writers. In a number of instances a small part of the nucleus is seen to separate off and to lie as a distinct body, *Nebenkern*, alongside the nucleus; this body has a colorable portion, which is comparable to the "centrosoma." For an account of the scattered observations on the *Nebenkern*, together with the relation of these bodies to Gaule's so-called cytozoa, see G. Platner, **86.3**. For additional observations see Prenant, **88.1**, and Platner, **89.2**. The sphere of attraction divides, as does also its central body, and its two parts move to opposite sides of the nucleus. There thus appear two opposite accumulations of clear protoplasm, from each of which as a centre astral rays or radiating lines are formed in the cell-body. Meanwhile within the nucleus changes go on; the threads of the intranuclear network radiate out from the pole, where the sphere of attraction lies before its division, and the chromatic substance forms a number of distinct grains. When the sphere of attraction divides and its halves go asunder the nuclear substance preserves its radiating relation to each sphere, and as the membrane of the nucleus disappears during these changes the final result is the transformation of the nu-

* Van Beneden states that arsenic acid produces an artificial expansion of the ovum within the zona.

† The history and significance of the spheres of attraction, as here presented, cannot by any means be regarded as final. The observations are few, and until recently the exact history of the spheres of attraction has received no attention from investigators.

cleus into a spindle-shaped body, the points of which rest just within the clear centre of each astral system, so that the spindle stretches from one protoplasmic mass to the other. The spindle consists of fine threads extending from pole to pole and having almost no affinity for the dyes of the histologist—a peculiarity which causes them to be known as the *achromatic* threads. These threads are probably always compounded of a considerable number of exceedingly fine fibrillæ (see Rabl, **89.1**, 21, 22). The colorable substance forms a number of separate grains, each of which is united with one of the achromatic threads, and all of which lie at the same level in the centre of the spindle; when the spindle is seen from the side, the chromatine grains appear to constitute a central band or disc (Strassburger's *Kernplatte*), but when the spindle is seen endwise the separate grains are at once recognized. The shape of the grains is variable; some authors without sufficient observational proof have advanced the opinion that the grains are *always* V-shaped. The spindle, together with the polar accumulations of protoplasm and the two accompanying radiations, constitute a so-called *auphiaster*.

The domain of the radiation extends, the two protoplasmic centres move farther apart, the nuclear spindle elongates correspondingly, and the chromatin grains of the *Kernplatte* divide. Flemming maintains that the division is always lengthwise of the V-shaped grain, but this has been controverted by Carnoy. How the division occurs in the mammalian ovum is unknown. By the division, however it is effected, the number of chromatin grains is doubled; they form two sets: one set moves toward one pole, the other toward the other pole: the grains of each set keep at the same level as they move until they reach the end of the spindle, where they appear as a polar disc (Carnoy's *couronne polaire*). Next the achromatic threads of the spindle break through and are apparently drawn in toward each polar crown. There are now two nuclear masses, each near, but not at, the centre of a radiation, and each consisting of chromatin and achromatic substance. Each mass develops into a complete membranate nucleus, but the steps of this process have yet to be followed in detail in the vertebrate ovum.

The signs of division of the protoplasm usually become visible about the time the polar crowns are formed, but when the ovum contains much deutoplasm the division may be retarded. In the plane which passes through the equator of the nuclear spindle there appears a furrow on the surface of the ovum, which gradually spreads and deepens until it is a complete fissure around the cell; it cuts in deeper until at last only a thin stalk connects the two halves of the cell, and thereupon the stalk breaks and the cell is divided. There next ensues a pause, during which the astral rays of the protoplasm disappear in the daughter-cells, and the daughter-nuclei assume each the form of an ordinary resting membranate nucleus.

The external appearances of segmentation in the living ovum vary, of course, especially according to the amount and distribution of the yolk-material. The appearances in holoblastic ova with very little yolk are well exemplified by *Limax campestris*. Mark's description, **81.1**, is, nearly in his own words, as follows: In *Limax*, after impregnation, the region of the segmentation nucleus remains

more clear, but all that can be distinguished is a more or less circular, ill-defined area, which is less opaque than the surrounding portions of the vitellus. After a few moments this area grows less distinct. It finally appears elongated. Very soon this lengthening results in two light spots, which are inconspicuous at first, but which increase in size and distinctness, and presently become oval. If the outline of the egg be carefully watched, it is now seen to lengthen gradually in a direction corresponding to the line which joins the spots. As the latter enlarge the lengthening of the ovum increases, though not very conspicuously. Soon a slight flattening of the surface appears just under the polar globules; the flattening changes to a depression, Fig. 46, which grows deeper and becomes angular. A little later the furrow is seen to have extended

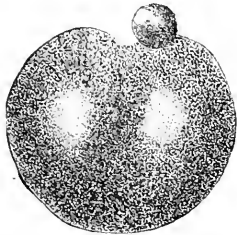


FIG. 46.—Ovum of *Limax campestris* during the first cleavage. The envelopes are not drawn in. After E. L. Mark $\times 300$ diams

around on the sides of the yolk as a shallow depression, reaching something more than half-way toward the vegetable or inferior pole, and in four or five minutes after its appearance the depression extends completely around the yolk. This annular constriction now deepens on all sides, but most rapidly at the animal pole; as it deepens it becomes narrower, almost a fissure. By the further deepening of the constriction on all sides there are formed two equal masses connected by only a slender thread of protoplasm, situated nearer the vegetable than the animal pole, and which soon becomes more attenuated and finally parts. The first cleavage

is now accomplished. Both segments undergo changes of form; they approach and flatten out against each other, and after a certain time themselves divide.

Primitive Type of Segmentation.—In the lower animals there is not found that excessive amount of deutoplasm in the ovum which is so characteristic of the vertebrates, and in their ova we have what is undoubtedly the earlier and more primitive type of segmentation. In these cases the cleavage extends, as in the egg of *Limax* (see above), through the whole of the dividing-cell. The two cells first produced are almost if not quite alike, and each of them produces two cells which are also very similar to one another; then comes a division of the four cells into eight, four of which resemble one another and differ from the remaining cells which are also similar among themselves. Four of the cells are derived chiefly from the substance of the animal pole of the ovum and are very protoplasmatic; and the other four cells are constituted out of the substance of the vegetable pole and accordingly contain most of the deutoplasm of the ovum. The eight cells form an irregular spheroid, in the centre of which there is a space between the cells; this space is known as the segmentation cavity.

The four cells of the animal pole progress in their divisions more rapidly than the four of the vegetable pole; but the latter, when the yolk matter is at a minimum, as, for instance, in echinoderms, do not lag much. From their unequal rates of division the two sets of cells come to differ more and more in size, those of the animal pole being

much the smaller. The divisions of the cells take place so that the cells form a continuous layer of epithelium, one cell thick, stretching around the enlarged central segmentation cavity, Figs. 47 and 60; the epithelium consists of a larger area of the small cells of the animal pole and a small area of the large cells of the vegetable pole. This stage of segmentation is known as the *blastula* stage; the small cells are destined to form the *ectoderm* of the embryo; the large cells the *entoderm*, the central space is the *segmentation cavity*; the line along which the two parts of the epithelium (ectoderm and entoderm) join is known as the *ectental line*.

Vertebrate Type of Segmentation.—

In the vertebrates we find that segmentation also results in two epithelia, an ectoderm and entoderm, joined at their edges, and surrounding a segmentation cavity, but the resemblance to the typical blastula is marked by changes in both ectoderm and entoderm; the vertebrate ectoderm when first fully differentiated consists of several layers of cells, and not merely of a single layer of cells, as in the primitive type of segmentation; the entoderm contains a very large amount of nutritive material (deutoplasm), and is represented either by a large mass of large cells (marsipobranchs, ganoids, amphibians) or a mass of protoplasm, not divided into cells or but partially divided into cells, and containing an enormous quantity of deutoplasm (sauropsidans and monotremes). In the higher mammals there are further modifications, described below.

The more primitive form among vertebrates is, I think, presumably that in which the entoderm consists of separate cells; for this mode of segmentation is the one which most resembles that of invertebrates, and it occurs in the lowest vertebrates, and in ova which are not excessively charged with yolk.

In the *primitive form of vertebrate segmentation*, which is preserved in the marsipobranchs, ganoids, and amphibia, there is a well-marked difference between the cells of the two poles. The following account refers especially to the frog's egg and is an adaptation of Balfour's summary ("Comp. Embryol.," l., 78, 79). The first formed furrow is vertical, it commences in the upper half of the ovum, which corresponds to the animal pole, and is characterized by the black pigment—the lower or vegetable pole being whitish. The first furrow extends rapidly through the upper, then more slowly through the lower half of the ovum, so that the divergence in the two polar rates of development is indicated already. As soon as the furrow has cleft the egg into halves, a second vertical furrow appears at right angles to the first and behaves in the same way, Fig. 48. The next furrow is at right angles to both its predecessors, and therefore parallel to the equator of the egg; but it is *much nearer the animal than the vegetative pole*. It extends rapidly around the egg and divides each of the four previous segments into two parts: *one larger with a great deal of yolk and the other smaller with*

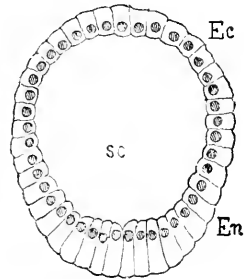


FIG. 47.—Blastula stage of *Echinocardium cordatum*, 20 hours after impregnation: Ec, ectoderm; En, entoderm; sc, segmentation cavity. After Selenka

very little yolk. The eight segments or cells have a small segmentation cavity in the centre between them. This cavity increases in size in subsequent stages, its roof being formed by the small cells further divided, and its floor by the large cells also multiplied by division, though to a less extent than the small cells. All the developmental processes progress more rapidly at the animal pole. After the equatorial furrow there follow two vertical or meridional furrows, which begin at the animal pole and divide each of its four cells into two, making eight small cells. After a short period these furrows extend to the lower pole and divide each of the large cells into two, Fig. 48, 4. The so-called *meridional* cleavages after the first and second are not true meridional cleavages, since they do not pass through the folds of the ovum, but through the poles of the cells (blastomeres), which they divide (see Rauber, *Morph. Jahrb.*, VIII., 287). A pause now ensues, after which the eight upper cells become divided by a furrow parallel to the equator, and *somewhat later* a similar furrow divides the eight lower segments. Each of the small cells is now again divided by a vertical furrow, which later divides also the corresponding large cell. The segmentation cavity

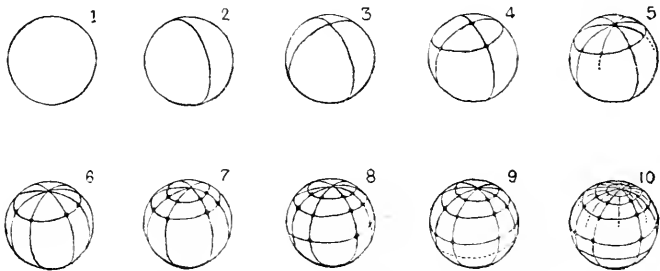
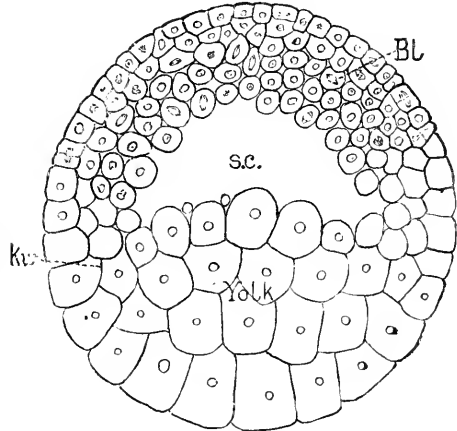


FIG. 48.—Segmentation of the egg of the common Frog

is, therefore, now bounded by 32 small and 32 large cells. After this the upper cells (ectoderm) gain more and more in number beyond the lower cells (entoderm). After the 64 segments are formed two equatorial furrows appear in the upper pole before a fresh furrow arises in the lower, making 128 ectodermal cells against only 32 entodermal. The regularity of the cleavage cannot be followed further, but the upper pole continues to undergo a more rapid segmentation than the lower. At the close of segmentation the egg forms a sphere containing an eccentric segmentation cavity, Fig. 49, *s. c.*, composed of two unequal parts, an upper arch of several layers of cells, *B1*, the primitive blastoderm of Minot or ectoderm, and a lower mass, *Yolk*, of large cells rich in protoplasm. At the edge of the mass of large cells, *kw*, there is a gradual passage in size to the cells of the blastoderm, and it appears that the small cells receive additions at the expense of the large ones; this zone corresponds to the so-called germinal wall of large vertebrate ova, and also to what we have defined as the ectental line.

The *secondary type of vertebrate segmentation* differs from the primary principally in the retarded development of the entoderm, due apparently to the increase of the yolk-matter. The yolk-granules

are, as already mentioned, found to be situated not quite exclusively, though almost so, in those parts of the ovum out of which the entodermal cells are formed. Hence, when there is a great deal of yolk the anlage of the entoderm becomes bulky, and when it segments the entodermal cells it produces are correspondingly big, as we have seen is the case in amphibian ova. On the other hand, when the amount of yolk is small, as in the primitive type of segmentation, *e.g.* echinoderms, the entodermal cells are small. In the reverse case, when the amount of yolk is exceedingly great, as in selachians, reptiles, and birds, the yolk may not divide into cells as fast as the nuclei multiply, so that it seems that the presence of the deutoplasm, though it does not affect the nuclear divisions markedly, certainly impedes very much the division of the protoplasm, and



consequently in these ova we find, at certain stages of development, a multinucleate yolk. The impediment is not encountered by the protoplasm of the animal pole, hence we see the animal pole segmenting while the yolk does not; in this case the segmentation appears confined to one portion of the ovum, and, accordingly, such ova are termed *meroblastic* in contradistinction to the *holoblastic* ova, in which the first cleavage furrow divides the whole ovum; but the difference, it must be expressly remembered, is one of degree, not of kind.

The best known example of a vertebrate meroblastic ovum is undoubtedly the hen's egg. The so-called yolk, or "yellow," is the ovum; the white and the shell are both adventitious envelopes added by the oviduct as the ovum passes down after leaving the ovary. The segmentation begins while the ovum is passing through the lower part of the oviduct, and shortly before the formation of the shell commences. If an ovum from the upper part of the oviduct be examined it is found to be surrounded with more or less white (albumen). Its animal pole is represented by a whitish disc from 2.5–3.5 mm. in diameter, and 0.30–0.35 mm. in thickness; this disc is known by many names: Formative yolk, germinal disc, cicatricula (Narbe, Hahmentritt, Keimscheibe, stratum s. discus proliferus). The animal pole consists chiefly of protoplasm, and is peculiar only in its small size compared with the whole ovum; it contains, when the ovum leaves the ovary, the egg-cell nucleus; the ovum then matures, impregnation occurs, and finally segmentation begins. Viewing the ovum from above we see the first furrow appear as a groove running across the germinal disc, though not for

FIG. 49.—Section of the segmented ovum of Axolotl: *Bl.*, blastoderm; *s. c.*, segmentation cavity; *Yolk*, yolk or entoderm; *kw.* (Keimwall), germinal wall. After Bellonci

its whole width, and dividing it into halves; this furrow is developed in accompaniment with the division of the segmentation nucleus. The primary furrow is succeeded by a second furrow nearly at right angles to the first; the surface of the germinal disc is cut up into four segments or quadrants. Fig. 50, A, which are not, however, separated from the underlying substance. The number of radiating furrows increases from four to seven or nine, when there arises a series of irregular cross-furrows, by which the central portion of each segment is cut off from the peripheral portion, giving rise to the appearance illustrated by Fig. 50, C; there are now a number of small

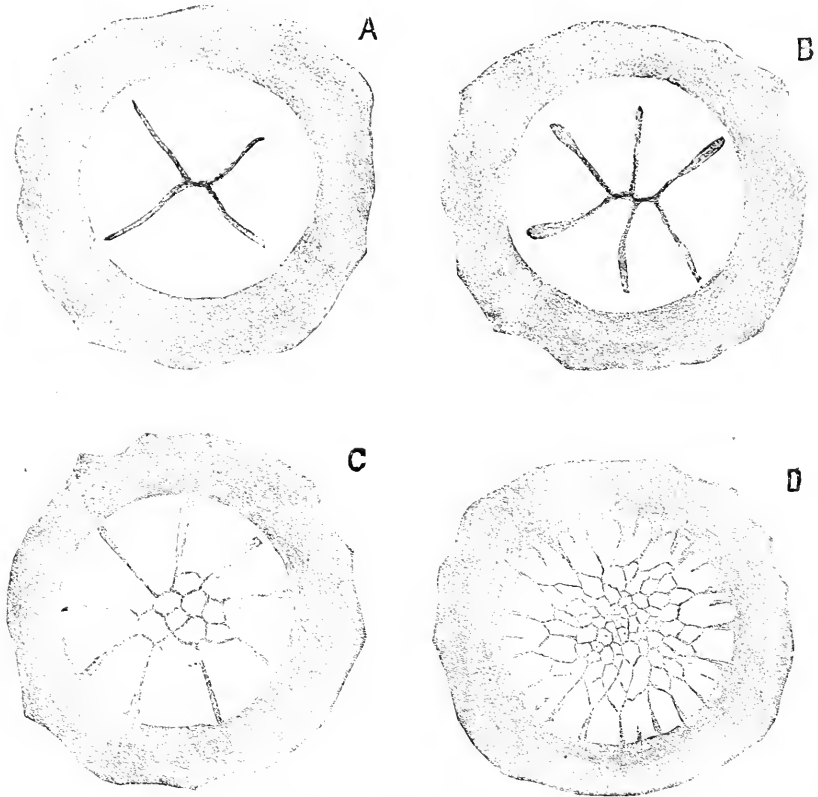


FIG. 50.—Four stages of the segmentation of the Hen's ovum. After Coste. Only the germinal disc seen from above and part of the surrounding yellow yolk are represented.

central segments surrounded by larger wedge-shaped external segments. Division of the segments now proceeds rapidly by means of furrows running in various directions. Not only are the small central segments divided into still smaller ones, D, but their number is increased also by the addition of cells cleft off from the central ends of the large peripheral segments, which are themselves subdivided by additional radiating furrows. Sections of the hardened germinal disc show that segmentation is not confined to

the surface, but extends through the protoplasmatic mass of the animal pole, there being deep-seated cleavages in planes parallel to the surface, of the ovum. According to Duval, **84.1**, when the first few small central cells are separated off, there is a small space between them and the underlying egg-substance (see Figs. 2, 3, 4, 5, and 6 of his Pl. I.), and this space he calls the segmentation cavity; but in this I think he is in error, for the cells formed below this space are incorporated in the ectoderm or primitive blastoderm; the cells referred to are those marked *in* in Fig. 8 of Duval's Pl. I. The true segmentation-cavity, as we have seen, is bounded on one side by ectoderm, on the other side by entoderm. This fundamental characteristic Duval has entirely overlooked. From the processes described there results a disc of cells, which receives peripheral additions; the border from which these additions come is known as the *segmenting zone*. The whole mass of cells derived from the germinal disc represents the ectoderm, and the segmenting zone may be homologized with the cells around the edge of the primitive blastoderm of the frog, Fig. 49, *kw*. A section through the segmented germinal disc shows the following relations: The blastoderm is a disc of cells; its upper layer is epithelioid; its lower layers consist of rounded cells more or less irregularly disposed; at its edge it merges into the yolk, which continues to produce cells; between the blastoderm and the yolk is a fissure, the segmentation cavity; the yolk under the fissure contains a few nuclei, which have each a little protoplasm about them, but do not form parts of discrete cells.

In reptiles the process of segmentation is very similar to that in birds. Our knowledge is based principally upon observations upon the eggs of the European lizards (*Lacerta agilis* and *viridis*), which have been studied by Kupffer and Benecke, **78.2**, Balfour, **79.1**, Sarasin, **83.1**, Weldon, **83.1**, and Hofmann (*Archives néerlandaises*, XVI., 1881). Hofmann gives a résumé in Brown's "Thierreich," VI., Abth. III., pp. 1877-1881. The process is very irregular, for small cells are budded off singly and in scattered clusters from the larger segments. As Strahl, **87.1**, 290, has pointed out, the blastoderm receives direct accretions from the underlying yolk, cells being separated off by horizontal cleavages. At the close of segmentation the germinal disc is converted into a membrane consisting of several layers of cells and parted from the underlying yolk by a thin space, the segmentation cavity; at its edge this membrane, the primitive blastoderm, is united with the yolk, it being immediately surrounded by a segmenting zone, from which it receives accretions. The layer of the yolk immediately under the segmentation cavity contains scattered nuclei, lying singly or in clusters; each nucleus is surrounded by protoplasm; the nuclei are not all alike; some are *very* large, round with very distinct nuclear threads; other are small and often bizarre in shape; probably the latter are budded off from the former.

In Elasmobranchs the germinal disc is thicker, and consequently the mass of cells resulting from its segmentation cuts in quite deeply into the yolk (Balfour, "Comp. Embryol," I., Fig. 46; Rückert, **85.1**, 28). Kastschenko, **88.2**, has shown that before the germinal disc is segmented into cells there are nuclei scattered through it, and he has rendered it probable, **88.1**, that these nuclei come from the seg-

mentation nucleus. It is possible that in other meroblastic vertebrates proliferation of the nuclei precedes the cleavage of the germinal disc into discrete cells. As segmentation progresses, the cells spread out into a layer which shows the same essential relations as have been described in birds and reptiles. There is the several-layered primitive blastoderm, with its edges connected with the yolk and itself overlying the segmentation cavity, the lower floor of which is formed by the multinucleate yolk, the representative of the cellular yolk-mass of the frog, Fig. 49, *Yolk*. The nuclei are confined to the layer immediately under the segmentation cavity, and this layer corresponds to the sub-germinal plate in teleost ova. Of the yolk-nuclei some are large, others are small as in reptiles; they are the *Parablastkerne* of His, the *Meroctenkerne* of Rückert.

In bony fishes also we find the same type, but modified somewhat. The process of segmentation has been very carefully studied by C. O. Whitman, 84.1, to whom I am indebted for the accompanying semi-diagrammatic figure of the segmented ovum of a flounder. The ovum is surrounded by a vitelline membrane, *z*, from which it has slightly withdrawn, notably at the upper pole, where lies the thick cap of cells constituting the blastoderm, *Bl*; in the stage represented the outer layer of cells is just beginning to assume an epithelioid character; underneath the blastoderm is the well-marked segmentation cavity, *s. c.*; everywhere at the edge of the blastoderm lies the segmenting zone, *kw*, a ring of granular protoplasm with rapidly-

dividing nuclei; the cells resulting from these divisions are added to the edge of the blastoderm, which thus enlarges peripherally. The protoplasm of the segmenting zone is prolonged inward, forming the floor of the segmentation cavity; this sheet of protoplasm, *s.g.*, is known as the *sub-germinal plate*. The segmenting zone is, of course, the homologue of the similar zone in amniote ova, or the so-called germinal wall, but it is quite sharply defined against the yolk, and therein differs from the wall in the chick, because in the latter the germinal wall merges gradually into the yolk. The process of segmentation differs from

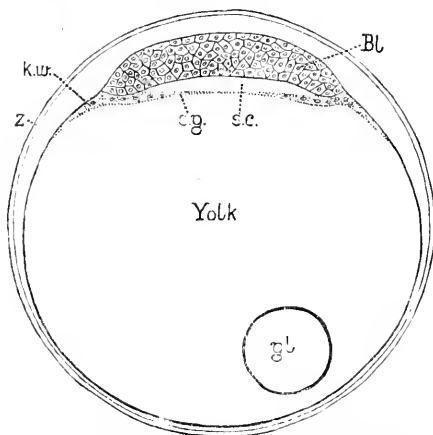


FIG. 51.—Ovum of a Flounder in transverse vertical section; semi-diagrammatic figure by Dr. C. O. Whitman. *z*, vitelline membrane (or zona?); *kw*., segmenting zone (Keimwall); *Bl*, blastoderm or primitive ectoderm; *s.c.*, segmentation cavity; *s.g.*, subgerminal plate; *gl*, oil globule of yolk.

that in elasmobranchs and sauropsida in that the cleavage of the germinal disc is strikingly regular, and further in that the whole width and thickness of the germinal disc is involved in the segmentation from the very start. The segmentation in teleosts is further interesting as affording proof that all the nuclei, as shown by Whitman's investigations, arise from the segmentation nucleus.

To summarize: In vertebrate ova with a large yolk, which does not divide into cells until segmentation is considerably advanced, the substance of the animal pole segments completely, and produces several layers of cells (the uppermost becoming epithelioid) which are the ectoderm or primitive blastoderm; the edge of the blastoderm touches the yolk, and is surrounded by a nucleated zone in which the production of cells is continuing; underneath the blastoderm is the fissure-like segmentation cavity; the floor of this cavity is formed by the unsegmented yolk (entoderm) which is furnished with scattered nuclei in the layer immediately underneath the yolk; the yolk nuclei, at least in selachians and reptiles, are of two kinds, very large ones and smaller ones, which arise probably from the large nuclei; the uninucleated layer may be termed the sub-germinal plate.

Modified Segmentation of Placental Mammals.—The lowest mammals resemble the reptiles in many respects. Among other reptilian characteristics of the monotremes we find ova of large size and rich in deutoplasm. That these ova segment in similar manner to those of reptiles and during their passage through the oviduct was first ascertained by direct observation by Caldwell in 1884, **87.1**.

In marsupials and the placental mammalia the amount of yolk-substance is greatly reduced, and the ovum is of small size. It is, therefore, holoblastic, that is to say, the cleavage planes cut through the entire cell, as in the primitive type of segmentation; but the arrangement of the cells at the close of segmentation appears to be a direct inheritance from the reptilian ancestors of the mammals.

The segmentation of the mammalian ovum was first clearly recognized by Bischoff, though it had been previously seen and misinterpreted by Barry, **38.1**, **39.1**, **40.1**; very beautiful figures of segmentation in the rabbit have been given by Coste, **47.1**. More recently observations have been published by Hensen on the rabbit, **76.1**, Van Beneden on the rabbit, **76.1**, **80.1**, Kupffer on rodents, **8.23**, Selenka on rodents, **82.1**, **83.1**, **84.1**, and opossums, **86.1**, Van Beneden and Julin on bats, **80.1**, Tafani on white mice, **89.1**. The ovum when discharged from the ovary is surrounded by the corona radiata (*cf. ante*, p. 59), which is lost when impregnation takes place. Segmentation begins when the ovum is one-half to two-thirds of the way through the oviduct. The ovum spends about seventy hours in the oviduct in the rabbit and about eight days in the dog. The first cleavage plane passes through the axis of the ovum, which is marked by the polar globules. When first formed the two segmentation spheres are oval and entirely separated from one another, but subsequently they flatten against one another and become appressed—a remarkable phenomenon, of which we possess




FIG. 52.—Ovum of a Rabbit of twenty-four hours. After Coste. The first cleavage has been completed; the two cells are appressed; above the cells lie the polar globules; numerous spermatozoa lie in and within the zona pellucida.

no explanation whatever. The second cleavage plane is also meridional.

The ovum next divides into eight and then into twelve segments, of which four are larger than the rest.

The succeeding cleavages have never been followed accurately; but from Heape's observations on the mole, **86.1**, 166, we know that the divisions progress with great irregularity, and it is probable that the commonly assumed regularity of mammalian segmentation does not exist in nature. After a time (in the rabbit about seventy hours) there is reached the stage termed *Metagastrula* by Van Beneden, **80.1**, 153-160, in accordance with his view of the homologies of this stage. The metagastrula consists of a single layer of cuboidal hyaline cells lying close against the zona pellucida, Fig. 53, *en*: the space within this layer contains an inner mass of cells, *im*, which are rounded or polygonal and densely granular. At one point the outer layer is interrupted and the space is filled by *one* of the granular segments of the inner mass, Fig. 53. The nuclei of all the cells are some-

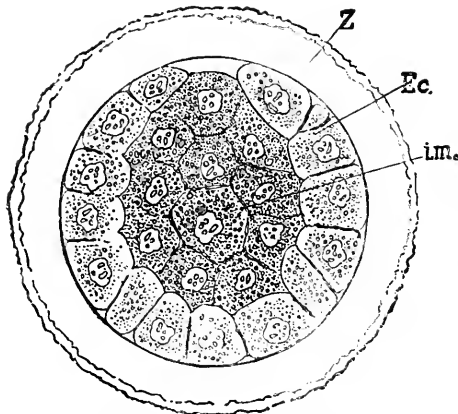


FIG. 53.—Rabbit's ovum of about seventy hours. After E. van Beneden. *z*, zona pellucida; *Ec*, ectoderm; *im*, inner mass of granular cells.

what nodulated and have several highly refractile granules each. The granules in the bodies of the cells of the outer layer are somewhat concentrated around the nucleus, leaving the cortices of the cells clear. Van Beneden, **76.1**, 28, 29, has observed that sometimes (21 ova out of 29) the first two segmentation spheres are of unequal size in the rabbit, and similar variability occurs in the mole, Heape, **86.1**, 165; Tafani, on the other hand, expressly denies its occurrence in white mice. It is, I think, very improbable that this difference, which sometimes occurs and sometimes does not, has any fundamental significance. Van Beneden, however, has maintained that the small cell gives rise in the rabbit to the inner mass of cells (see blow), which he terms the entoderm, but which must, it seems to me, be homologized with the ectoderm, as explained below. That Van Beneden is in error as to the genetic relation of the small cell to the inner mass has been demonstrated by Heape, **86.1**, 166.

The second cleavage plane is probably also meridional, and is certainly at right angles to the first, so that four similar cells are produced as in the primitive type of segmentation,* Fig. 54. These four cells are also rounded at first and probably become fitted against one another so as to produce the disposition observed by Tafani, **79.1**, 116, in mice ova at this stage. Tafani describes each cell as having the form of a three-sided pyramid with the apex at the cen-

* The distinction here made between "primitive type of segmentation" and "primitive type of vertebrate segmentation" should be borne in mind by the reader

tre of the ovum and a convex base forming part of the external surface of the yolk. That the two first cleavage planes are meridional is rendered probable by the arrangement in the four-cell stage observed by Selenka in the Virginian opossum, Fig. 55.

During all these early stages the cells (segmentation spheres) are naked, *i. e.*, without any membrane; the nuclei, when not in karyokinetic stages, are large, clear, and vesicular; the yolk-granules are small, highly refractile, and more or less nearly spherical; they show a marked tendency to lie in the cell half-way between the nucleus and the edge of the cell, or when the cells are large around the nucleus and at a little distance from it.

It is at about this stage that the ovum passes from the Fallopian tube into the uterus, where it dilates into what is known as the *blastodermic vesicle*. This dilatation is due principally to the multiplication and flattening out of the cells of the outer layer and, of course, involves the expansion and consequent thinning of the zona pellucida, compare Figs. 56 and 58. The inner mass meanwhile remains passively attached to one point on the circumference of the vesicle, Fig. 56, *i. m.* By this process the thin fissure between the inner mass and the outer layer becomes a considerable space, Fig. 59, *s. c.*, the cavity of the blastoderm or segmentation cavity (blastocoele).

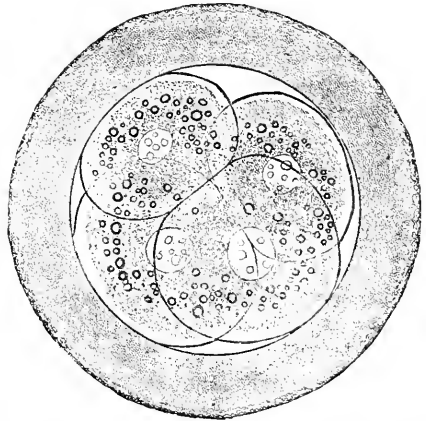


FIG. 54.—Ovum of a Bat, *Vespertilio murina*, with four segmentation spheres. After Van Beneden and Julin.

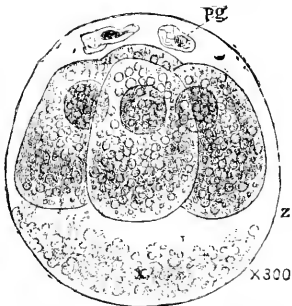


FIG. 55.—Ovum of Virginian Opossum, with four segments. After Selenka.

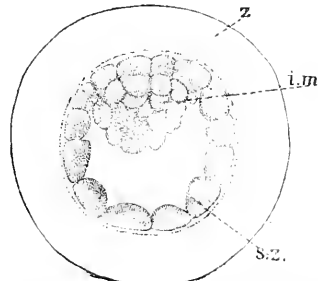


FIG. 56.—Young blastodermic vesicle of a Mole. *z.* Zona pellucida; *i. m.* inner mass of cells; *s. z.* sub-zonal layer of cells. After W. Heape.

The blastodermic vesicle continues to expand, and in the rabbit and mole there is a corresponding enlargement of the tubular uterus at the point where the vesicle is lodged. "It is clearly impossible for the delicate-walled ovum to expand in the form of a vesicle, and

distend the uterine walls by virtue of the growth of its cells; it must be, therefore, concluded that it obtains some support. This support is rendered from within. The vesicle contains a transparent

fluid, the nature of which I can only sufficiently convey to say that after treatment with alcohol a white precipitate is present in the vesicle. It is equally evident that this fluid can only have been obtained from the uterus, and that it is present within the vesicle at a very considerably greater pressure, than in the uterus itself. Such a condition is caused by means of the cells of the wall of the vesicle; they secrete the fluid within the vesicle, this function being performed against a pressure which is greater on their inner than on their outer side, exactly as the cells of the salivary glands are known to act. The uterine fluid is secreted by glands present in great numbers in the uterine tissue, and is poured through their open mouths into the cavity of the uterus. There is every probability it has nutritive qualities, since it is

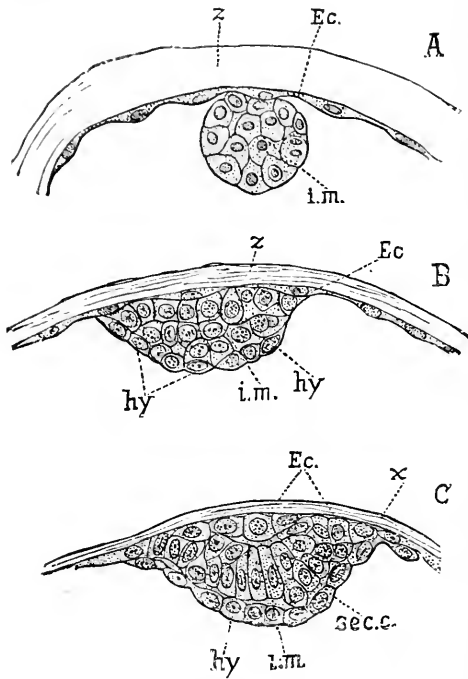


FIG. 57.—Sections through the inner mass of the blastodermic vesicle of the Mole at three successive stages. *z*, zona pellucida; *s.z.*, subzonal layer; *i.m.*, inner mass

thence taken up into the cavity of the embryonic vesicle, which eventually functions as a yolk-sac, in the walls of which embryonic blood-vessels ramify" (Heape).

The inner mass, Fig. 56, *i. m.*, does not at first grow much and retains its rounded form, becoming, at least in the mole, nearly globular, Fig. 57, A. The inner mass subsequently flattens out, becoming lens-shaped, thinner, and of larger area, Fig. 57, B. It continues spreading laterally and separates into three distinct layers. The ovum now consists of a very thin zona pellucida, Fig. 58, *z*, close against which is a single layer of thin epithelial cells, *Ec*; at one pole this layer is interrupted by a lens-shaped mass, *i. m.*, formed by three layers of cells. These three layers were first clearly described by E. van Beneden, 76.1, and have been since figured by him, 80.1; Van Beneden identified these three layers with the three permanent germ-layers which do not arise until later. Rauber, however, showed that both the outer layers enter into the formation of the ectoderm, while the inner layer is concerned in the production of the permanent entoderm; the outermost layer Rauber terms the *Deckschicht*. Lieberkühn, 79.1, and others have since then confirmed Rauber's results.

Homologies of the Mammalian Blastodermic Vesicle.—We have so little accurate information concerning the details of the formation of the blastodermic vesicle that any interpretation must be tentative. I still consider, however, the view which I brought forward in 1885, "Hdbk," I., 528, as the most satisfactory, and preferable to the similar explanation advanced independently and simultaneously by Haddon, 85.1, and reproduced by him briefly in his "Practical Embryology," 47, 48. F. Keibel, 87.1, advocated similar interpretations two years later, but without quoting Minot or Haddon. I regard the subzonal epithelium as the entoderm and the inner mass of cells as the primitive blastoderm or ectoderm; by so doing the parts can be readily and exactly homologized with the parts in the frog's ovum, as will be evident at once if the diagram, Fig. 59, of the mammalian vesicle be compared with the section of a segmented amphibian ovum, Fig. 49. The primitive blastoderm *Bl*, or ectoderm, consists of several layers of cells rich in protoplasm; below it is the large segmentation cavity, *s. c.*, relatively much larger in the mammalian than in the amphibian ovum. At its edge the primitive blastoderm joins the entoderm *Yolk*, which in amphibia is a large mass, in mammals only a single layer of cells.

Now, we know that the ancestors of the higher mammalia had ova with a large amount of deutoplasm, which in the course of evolution has been lost, so that in the ova of the placentalia there is very little yolk-material; we know further that the readiness of cellular divisions depends on the amount of yolk, hence, when the yolk is lost, we should expect to find the entoderm, which, as we have seen, is derived from the

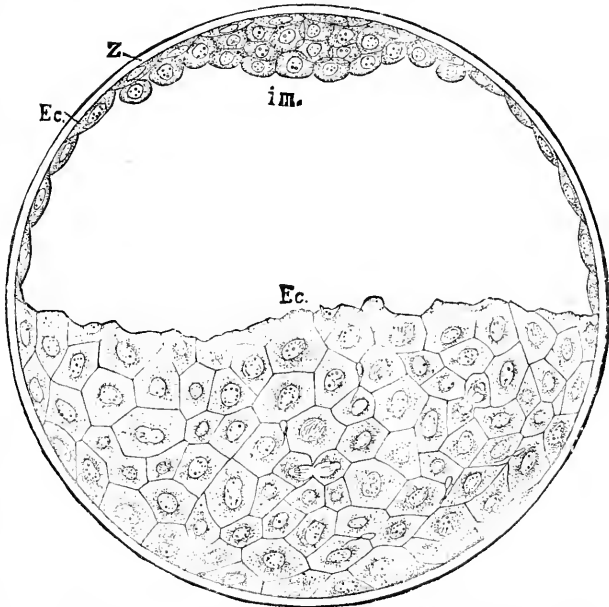


FIG. 58.—Ovum of a Rabbit, ninety four hours after coitus. After van Beneden. *En.* subzonal epithelium (entoderm); *Z.* zona pellucida; *i. m.* inner mass of cells.

vegetative substance of the ovum, to be represented by relatively small cells; if we imagine the number of entodermic cells in the frog's ovum, Fig. 49, *Yolk*, reduced, their connection with the primitive blastoderm and their character as a continuous layer being preserved, we obtain at once the characteristic arrangement of the mammalian blastodermic vesicle, Fig. 59. The homology here es-

tablished is further confirmed by the coarse network of protoplasm in the cells of the outer layer of the vesicle (Ed. van Beneden, 80.1), suggesting at once the meshes which have been emptied of their deutoplasm. Adam Sedgwick, 86.1, has shown that in the ova of *Peripatus capensis* the yolk-matter has been lost, though abundant in other species of the same genus, and the coarseness of the protoplasmic network is preserved as evidence of the granules formerly present. This observation serves to confirm the view I have suggested as to the significance of the wide-meshed reticulum of the cells of the mammalian subzonal layer, Fig. 59, *Yolk*.

The disposition of the animal pole in the ovum before segmentation also conforms to the homologies here advocated. It will be remembered, *ante*, p. 55, that the protoplasm of the animal pole extends far into the ovum and is enveloped by a cup (deutoplasm zone) of the substance of the vegetable pole. Hence, when the animal pole forms cells, they lie as an inner mass, Fig. 56, *i.m.*

If Minot's view be adopted, then the ectoderm lies within the entoderm at a certain stage of development, for the one cell

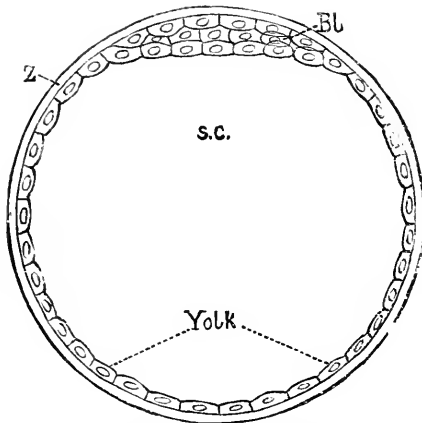


FIG. 59.—Diagram of a segmented mammalian ovum: Z, zona pellucida; Bl, primitive blastoderm; s.c., segmentation cavity; Yolk, layers of cell representing the remnant of segmented yolk.

which retains, as shown in Fig. 53, the connection of the ectoderm with the exterior is subsequently overgrown by the outer layer of cells (Van Beneden, Heape). There is, then, a complete inversion of the germ-layers in all (?) placental mammalia. In most cases the inversion is temporary; the inner mass as described above flattens out, and probably flattens out *inside* the outer epithelial layer; if this is the case then the external layer of the lens-shaped mass, Fig. 57, B and C, is really entoderm; this layer is Rauber's *Deckschicht*, which,

as already stated, usually disappears, leaving the true inner mass or permanent ectoderm to form part of the surface of the blastodermic vesicle, so that with the exception of the reduction in the dimension of the entoderm the relations are the same as in other vertebrate ova.

The inner layer of the flattened inner mass gives rise to the entoderm, and this at first sight appears to be conclusive evidence against the homology here drawn between the inner mass and the primitive ectoderm of other vertebrates. The same thing was formerly supposed to occur in the blastoderm of other vertebrates, but it is now known that the entoderm is added from another source to the under side of the primitive blastoderm or ectoderm, and though we possess no exact information whatever as to the origin of the entodermic cells under the primitive blastoderm of the mammalia, there is no reason to assume that they arise in a manner fundamentally different from that typical of other vertebrates. We may,

therefore, dismiss this objection. The origin of the entodermic cavity and its lining is described in the next chapter.

Planes of Division During Segmentation.—The plane of the first division determines those of the subsequent divisions, and also perhaps the axes of the embryo;* it is itself determined by the position of the long axis of the first amphiasier or nuclear spindle to which it is at right angles. It, therefore, is a matter of great interest to ascertain what factors determine the position of the first spindle, or, in other words, the axis of elongation of the segmentation nucleus. So far as at present known, there are two factors: 1, relation to the axis of the ovum; 2d, position of the path taken by male pronucleus to approach the female pronucleus. The axis of the ovum is fixed before impregnation; it passes through the centre of the animal and that of the vegetable pole. Usually the nuclear spindle which leads to the formation of the polar globule has its long axis coincident with that of the ovum, hence the point of exit of the polar globule marks one end of the ovic axis. *The first amphiasier or spindle is always at right angles to the ovic axis.* This, however, leaves the meridian plane undetermined. Roux, **87.1**, from a series of interesting experiments on frogs' ova, concludes that the plane is fixed by the path of the spermatozoon. So far as I know this idea was first suggested by Selenka in 1878, in his paper on "The Development of *Toxopneusters Variegatus*;" compare, also, Mark, **81.1**, p. 500. In the frog's egg the path of the male pronucleus is marked by a line of pigment, as was first described by Van Bambecke, **70.1**, 65, and has been well figured by O. Hertwig, **77.2**, Pl. V., Fig. 48. The pigment renders it easy to ascertain the position of the male road even after the first cleavage of the ovum. This Roux has done in sectioned ova, and from experiments and observations reaches this result: *The long axis of the first segmentation spindle lies in a plane, which passes through the axis of the ovum and the path of the male pronucleus.* If Roux's conclusion is confirmed, it will become of fundamental importance. Yet there must be other factors which can at least replace the male pronucleus in this special rôle, since the development of parthenogenetic ova, in which there is no male pronucleus at all, is equally determinate. It is probable that the distribution of the protoplasm is the real cause determining the position of the nucleus; thus in oval eggs the spindle lies in the direction of the long axis; it is quite probable that if the male pronucleus has the effect ascribed to it by Roux, it produces it indirectly by altering the distribution of the protoplasm within the ovum; that such alteration takes place is indicated by the occurrence of the male aster.

That the first cleavage plane is determined by relations existing in the unimpregnated ovum, has been suggested by O. Schultze in consequence of his finding the germinal vesicle lying eccentrically in the eggs of the brown frog. Schultze suggests that the first plane passes through the ovic axis and the eccentric nucleus. Roux (*Biol.*

*In certain cases, notably in birds as described above, the segmentation is irregular; and it is therefore not known yet whether the scheme of arrangement of the cleavage planes here given can be applied to all ova or not. We may say, however, that the scheme is the primitive one, from which any modifications arose phylogenetically. The best discussion is by A. Agassiz and Whitman, **84.1**, 34-41.

Cbl., VII., 420), maintains that this suggestion is set aside by his own observations cited above. For further discussion see Schultze's short note, 87.2, and Roux's rejoinder, 88.1. I think the question whether the first cleavage plane is determined by the ovum's structure or not is still an open one.

As already stated in the primitive segmentation, both invertebrate and vertebrate, the second cleavage plane is at right angles to the first and also meridional, while the third plane is at right angles to both the first and therefore equatorial. In meroblastic vertebrate ova this regularity is entirely lost.

Relation of the Segmentation Planes to the Embryonic Axis.—It has been assumed by some writers that the first cleavage plane coincided with the future median plane of the embryo. This conception is rendered extremely improbable by the fact that the segments of the ovum have been observed to migrate in various cases so as to destroy the symmetrical grouping. Miss Clapp's observations, 91.1, 499, on the toad-fish show that the median plane of the embryo may form almost any angle with the first cleavage plane.

Differentiation of the Ectoderm and Entoderm.—As already pointed out, the essential feature of segmentation is the unlikeness of the cells produced; the manifold variations in the process of segmentation depend chiefly on the amount of yolk.

Minot in 1877, 17, first established the generalization that *in all animals the ovum undergoes a total segmentation during which the cells of the ectoderm divide faster and become smaller than the cells of the entoderm*; compare Fig. 60. There are, however, a small, and I think diminishing, number of cases, where the process of segmentation is imperfectly understood, and which cannot yet be shown to conform to this generalization. "All the known variations in the process of segmentation depend merely upon: 1st, the degree of difference in size between the two sets of cells; 2d, the time when the difference appears; 3d, the mode of development, whether polar or by delamination,* either of which may or may not be accompanied by axial infolding. In Gasteropods, Planarians, "Calcispongiae, Gephyrea, Annelida, fish, birds, and Arthropods, the difference is great and appears early. In Echinoderms, most Coelenterates, some sponges, in Nematods, Amphibians, etc., it is less marked and appears later."

In most cases the entodermic cells are very decidedly larger and less numerous than those of the ectoderm. This distinction is obviously necessary on account of the mutual relations of the two primitive layers. The ectoderm has to grow around the entoderm, which it can do only by acquiring a greater superficial extension;

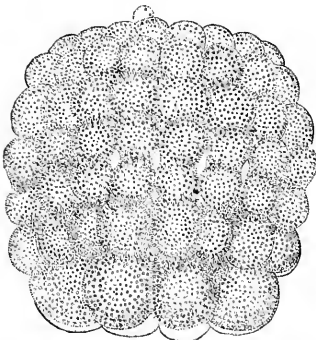


FIG. 60.—Ovum of *Amphioxus lanceolatus* during segmentation-stage, with 88 cells. $\times 280$ diams. After E. Hatschek. One pole is occupied by large entodermal, the other by smaller ectodermal cells.

* It does not occur among vertebrates.

this the ectoderm accomplishes by dividing very quickly at first into small cells. After the entoderm is fully enveloped it may then continue to grow until its superficies is much greater than that of the outer layer, within which, however, it still finds room by forming numerous folds; thus is gradually reached the condition in the higher adult animals where the intestine sometimes has an enormous surface, but is nevertheless contained in body-walls covered by ectoderm presenting much less surface. It is, therefore, only during the early stages of segmentation that we find the entoderm expanding more slowly than the ectoderm.

The terms *holoblastic* and *meroblastic* are applied to ova according to their manner of segmentation. The first is employed for those ova in which there is either very little or only a moderate amount of yolk, so that the whole of the ovum splits up into distinct masses (cells) which enter into the composition of the embryo. The second designates ova with a very large amount of yolk, so that while the protoplasm, from which the ectoderm arises, divides rapidly into distinct cells, the entodermal portion merely develops nuclei at first, with the result that while one portion of the egg is "segmenting" another portion (the entodermal) remains unsegmented, so far as the external appearances are concerned. Eggs, then, with much yolk, undergo the so-called partial segmentation; hence the adjective *meroblastic*.

Whatever the exact mode of segmentation there results always the same type of organization, to which Minot has applied the term *diaderm*; it is characterized by consisting of two plates of cells, differing in character, joined at their edge (ectental line), and surrounding a central segmentation cavity; the two plates or lamina are the two primitive germ-layers, the ectoderm and entoderm. The earliest form of the diaderm is that known as the *blastula*, as Haeckel has felicitously named the first larval form of the lower animals. In the blastula we have a simple epithelial vesicle, the cavity of which is the large segmentation cavity, Fig. 47; the epithelial layer is one cell thick and divided into two regions; one composed of smaller cells is the ectoderm. *Ec*, and the other of larger cells is the entoderm. This stage occurs with sundry modifications in a great many invertebrates. These modifications are due principally to the increase in size of the entodermic cells, which, as already pointed out, results from the increase of the yolk-matter in the ovum. Thus in many mollusks the entodermic cells are very large and at first few in number. By a still further modification the cellular yolk is replaced by a mass rich in deutoplasm, but not divided into cells, while at the same time the segmentation cavity is reduced by the invasion of the yolk-mass. In vertebrates we have the additional modification that the cells are several layers deep in the ectoderm and primitively in the entoderm also; compare the section of the axolotl's ovum, Fig. 49; in certain forms, as we have seen, the entoderm is not divided into discrete cells, but remains one mass; this is the case in Elasmobranchs and the amniota, but in the highest amniota (Placentalia) the yolk is lost and the entoderm is again represented by a single layer of cells, Fig. 59.

It seems to me evident that *the first step of development in the*

segmenting orum is the differentiation of the two germ-layers, ectoderm and entoderm, resulting in the diaderm stage. Diaderm is a term preferable to blastula, because the latter is applicable strictly only to a special larval form, while the former is a general term which refers to the essential differentiation at this stage. It is important to remark that the two layers are distinct in the diaderm or blastula stage; it is often erroneously affirmed that the blastula consists of a uniform layer of cells, part of which subsequently becomes the entoderm.

The segmentation cavity comprises the whole space between the entoderm and ectoderm; it is very early invaded by cells produced from the two primitive germ-layers. These cells are in vertebrates of many kinds and enter the segmentation cavity at various periods. It is customary to group the cells which enter early into this cavity under the common name of *mesoderm*, and to consider them as a third and distinct germ-layer. For convenience we may adopt this custom, for to a certain extent the mesoderm of authors is a separate germ-layer, but it by no means includes all the tissues which occupy the space between the two primitive germ-layers. As the space between the entoderm and ectoderm is always homologous with itself, it follows that the entire room between the epithelium (entoderm) of the digestive tract and its appendages on the one side and the epidermis on the other is homologous with the segmentation cavity.

The mesoderm of authors comprises three tissues: 1, free wandering cells (*mesamœboids*); 2, embryonic connective tissue or cells connected together by processes (*mesenchyma*); 3, epithelium, which forms two or more separate sacs. The origin of the mesoderm and the relations of the three tissues it contains are discussed in the next chapter.

The Gastrula Theory.—In invertebrates with holoblastic ova the blastula passes into a stage known as the *gastrula*. Gastrula is, properly speaking, a new name for a larval form called *planula* by older writers; but the term is now generally employed to designate an ideal embryonic stage, supposed to be common to all multicellular animals.

The blastula changes into a gastrula by a process of invagination. The entodermal area of the blastula flattens out, the ectoderm meanwhile expanding by multiplication of its cells; after flattening, the entoderm turns inward, forming at first a shallow cup, then a pit which has an opening or mouth, the rim of which is the ectental line. The larva is now a double sac, and has an external wall or ectoderm and an internal wall or entoderm; the entodermic cavity is entirely distinct from the segmentation cavity. The process of gastrulation is here described as it occurs among the lower invertebrates.

Typical gastrulæ are the free-swimming larvæ of many marine invertebrates; we may take as an example that of a sea-urchin, Fig. 61. The larva is round; at one pole it has an opening, *m*, the gastrula mouth leading into an internal cavity; as this is a free-swimming larva it is provided with long cilia for organs of locomotion; the cilia in many gastrulas are distributed over limited areas

or they may be wanting altogether. The larva consists of a double sac, a larger outer one of small epithelial cells, *ec*, the ectoderm, and a much smaller inner sac composed of larger entodermal epithelial cells, *en*; at the mouth, *m*, of the inner sac the two layers are continuous with one another; in the space between the two sacs, which corresponds to the segmentation cavity, are a few scattered cells, the first members of the mesoderm, *mes*.

The entodermal sac of the gastrula is known as the *archenteron*; other terms are also in use, *e. g.*, mid-gut, coelenteron, urdarm, etc. The opening is known as the *gastrula mouth* (archistome, urmund, etc.). The coelenterates preserve the gastrula organization throughout life, but in all higher classes

the archenteron gives rise not only to the permanent digestive tract, but also to many appendages and derivatives thereof; and, moreover, the gastrula mouth closes over, and in vertebrates the true mouth is an entirely new formation, which arises without any connection whatever, so far as known, with the gastrula mouth. By gastrulation the ectental line becomes the rim of the gastrula mouth.

A line passing through the centre of the mouth and the opposite pole of the gastrula is the so-called axis. Now, if the mouth be elongated, there would at once be a new *longitudinal axis* marked out, and the gastrula would become *bilaterally symmetrical*. If, further, the mouth is pulled out into a slit, and in the process of evolution the lips come together and unite in their middle part, the animal would still have the two ends of the original mouth left open, and would so acquire two apertures to its archenteron—one anterior to serve as mouth, and one posterior to serve as anus. This hypothesis of the conversion of a gastrula into a bilaterally symmetrical animal by the elongation of the mouth and concrescence of the lips or ectental line, was first suggested, so far as I am aware, by Rabl, **76.1**. A very perfect exemplification of the process is afforded by the developing ova of *Peripatus capensis*, as shown by Balfour, **83.1**, and Sedgwick, **85.2**, Pl. XXXII., Figs. 23-26. There are, however, serious difficulties in applying the theory to bilateral invertebrates; I am strongly inclined to think that further research will obviate these difficulties.

In certain vertebrates and annelids the concrescence of the ectental line has been clearly demonstrated, but the process is rendered by secondary modifications much more complex than that described in the preceding paragraph—the detailed account of it forms the subject of the next chapter.

The *gastrula theory* is that all metazoa have a common inherited stage of development, which follows immediately after the diaderm;

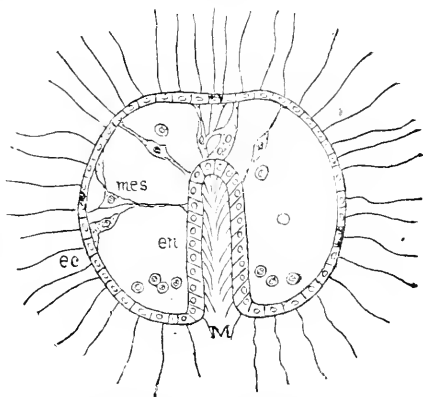


FIG. 61.—Section of a gastrula of *Toxopneustes lividus*; after Selenka. *ec*, ectoderm; *en*, entoderm; *mes*, mesoderm; *m*, mouth.

this stage is characterized by there being an outer ectodermal sac with a perforation to the edge of which is attached the entoderm, which forms a closed inner sac, the archenteron. The embryology of coelenterates teaches us that the gastrula is a secondary type, and thus the interesting problem of the origin of the gastrula is to be solved by the invertebrate embryologist (see J. P. McMurrich, 91.1, 310.)

The term gastrula was introduced by Haeckel, and is now universally used by embryologists. The discovery of the importance of the gastrula is due to the brilliant researches of Kowalewski on various invertebrates, including *Amphioxus*, then supposed to be a vertebrate. Haeckel then seized upon the idea of the gastrula and wrote an essay, 74.2, (compare also 75.1), upon it, which from its brilliant style attracted notice, and did much to direct attention to the important discovery of Kowalewski. Although Haeckel indulged his fantasy unduly and was misled into speculations which are now unheeded and almost forgotten, he did great good by starting the interest of zoologists in the right direction. By a remarkable coincidence, Lankester published an essay, 73.1, of very similar purport to Haeckel's, at about the same time.

The gastrula, like the diaderm, varies greatly, the chief modifications depending on the amount of yolk present; this is illustrated by

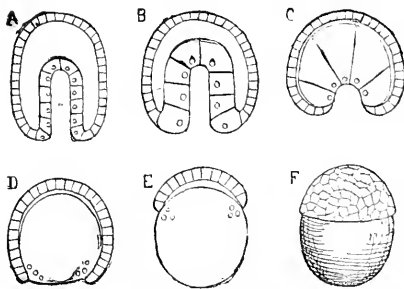


FIG. 62.—Diagrams of the Principal Modifications of the Gastrula (see text). A—E. represents sections.

the accompanying diagrams, Fig. 62; the mesoderm is intentionally omitted; A corresponds to such a larva as Fig. 61; the difference in size between the two sets of cells is slight but evident. In B, the difference is more marked, and fairly represents a gastrula of *Amphioxus*. In C, the difference is very great and corresponds to that observed in certain gastropod larvæ. In D, the inner set is no longer separated into distinct cells, although there are a number of nuclei, each of which marks the centre of a future cell; in such instances we must regard the whole inner portion as not yet transformed into a definite entodermic *cell*-layer. This figure is particularly instructive, because it shows that what we call the yolk is not something distinct from the germ, but really belongs to the inner layer of the embryo. E shows a similar egg, in which the outer set of cells has not yet grown around the yolk. F shows the same egg not in section, but seen from the outer surface in order to exhibit the cap of small cells (blastoderm) resting upon the yolk.

CHAPTER V.

CONCRESCENCE: ORIGIN OF THE PRIMITIVE STREAK AND ARCH-ENTERON.

This chapter was published in a preliminary form in the *American Naturalist*, June–August, 1890. Since then the researches of Van Beneden, 88.3, on the rabbit, and of L. Will, 89.1, 90.1, 92.1, on reptiles have cleared up many obscure points. The chief gain, as Prenant has shown in his "Embryologie," is the knowledge that probably in all, certainly in many vertebrates (excluding *Amphioxus*), the entodermal canal arises by the fusion of two cavities; one of these is the long-known notochordal or blastoporic canal, which communicates with the exterior by an opening (blastopore) at its posterior end; the other cavity is formed in the yolk immediately underneath the notochordal canal and is completely closed. Very early the partition between the two cavities disappears and they fuse, making the definite cavity of the entodermal canal. This primitive canal, from which the pharynx, lungs, and digestive organs are differentiated, is known as the *archenteron*. The relations with which we are now concerned are illustrated by Fig. 63.

I. THE LAW OF CONCRESCENCE.

Yolk Cavity.—Concerning the formation of the yolk-cavity we possess very imperfect knowledge. Undoubtedly a patient search might collate many facts from the literature of the early stages, but until such a collation shall be made and supplemented by further observations, no positive history of the yolk cavity can be given. We can say that, when the notochordal canal begins to form, there is already a large cavity under the germ and entirely surrounded by entodermal material. In elasmobranchs and Sauropsida the floor of the cavity is the yolk itself, while the roof is formed by cellular material; the cavity expands over a considerable area, but is flattened; it is completely separated from the segmentation cavity; it is designated often by the name of *sub-germinal cavity*, but unfortunately the same name is also applied to the morphologically different segmentation cavity. In Amphibia the yolk cavity has been recognized by O. Schultze; it is not large.

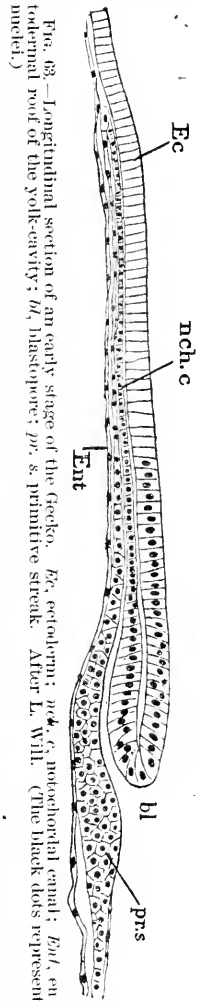


FIG. 63.—Longitudinal section of an early stage of the Gecko. Ec, ectoderm; nch.c, notochordal canal; Ent, entodermal roof of the yolk-cavity; bl, blastopore; prs, primitive streak. After L. Will. (The black dots represent nuclei.)

In mammals the yolk-cavity, as soon as the entodermic layer is fully developed—see below—comprises the so-called cavity of the two-layered blastodermic vesicle: owing to the reduction of the yolk, it is bounded wholly by a layer of cells, not partly by a mass of yolk, as in meroblastic ova, and is very large in proportion to the ovum.

Concrescence.—The passage from the stage of segmentation to the first embryonic stage is effected in vertebrates by means of certain migrations of embryonic material from lateral positions to median positions, and subsequent union in the middle line. This process of union is known as concrescence. It consists in the growing together of the two halves of the ectental line to form the structural axis of the future embryo. The process is somewhat complex, and needs therefore to be described in detail, the more so as it has still to be followed in mammals.

The accompanying diagram may assist to render clear the process of concrescence. Fig. 64. It is intended to illustrate the spreading

of the ectoderm (germinal disc, blastoderm, *auct.*) over the yolk and the simultaneous formation of the primitive axis. The whole ovum is represented as seen in projection; the proportions are such as have been suggested by the ova of flounders and frogs. Three successive stages of the expanding blastoderm are represented; the first position of the embryonic rim (ectental line) corresponds to the dotted line *a'' a''*; the concrescence reaches only to the point marked 1. The lateral margins, *S'*, which are to concresce later, still form part of the edge of the blasto-

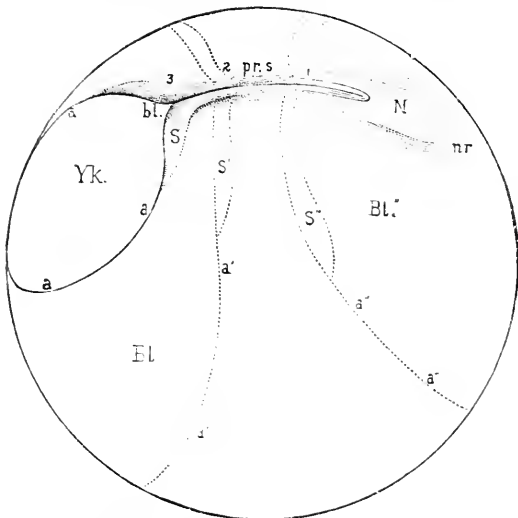


FIG. 64.—Diagram illustrating the growth of the blastoderm and concrescence of its rim to form the primitive axis. *pr. s.*, *N*, neural or medullary groove; *nr*, neural ridges; *Bl.*, blastoderm; *S*, part of the blastodermic rim, termed the *Sichel* in German; *pr. s.*, primitive axis; *bl'*, blastopore; *Yk.*, uncovered yolk. Compare also the text.

derm. At the next stage the ectoderm has grown very much and has moved its edge to *a' a'*, while the margins, *S*, have coalesced so that the primitive axis extends to 2. The extension continues, bringing the ectental line to *a a a S*, and carrying the primitive axis back to 3: behind the primitive streak a small area, *Yk*, of the yolk is still uncovered, and is homologous with, *first*, the anus of Rusconi in amphibian ova, and, *second* (in my belief), with the so-called primitive streak of the amniota. The portion of the ectental line bounding this area differs from that which is immediately concerned in the formation of the primitive streak, *S*; although it now lies behind the primitive streak, it was previously in front of it, when the

blastoderm covered only the minor portion of the ovum, see $S'' a'' a''$. Ultimately the yolk is entirely covered by the blastoderm, thus fixing the length of the primitive streak. It is essential to notice that the blastodermic rim (ectental line) divides into two portions, one, s , which forms the primitive streak, and another, $a'' a''$, which overgrows the ovum and at last closes over the yolk behind the completed primitive axis.

Historical Note.—The earliest observations on concrescence to form the embryonic axis are, so far as known to me, those of Rathke on leeches.* Nine years later Kowalewski (Mém. Acad. Sci., St. Petersburg, 7^{me} Sér., XVI., 1811) recorded its occurrence among insects. Its recognition as a vertebrate mode of development we owe to the brilliant investigations of W. His; in his first paper, 76.1, he describes very accurately and clearly the process of concrescence in the salmon; in his second paper, 77.1, he describes concrescence in the sharks, and in his third and fourth papers, 77.2, 91.2, he discusses again the general bearing of his results. Semper, in his great work on the relationship of annelids and vertebrates, 76.3, 271, was the first to make a direct comparison of the processes of concrescence in annelids, insects, and vertebrates. Unfortunately Balfour entirely failed to grasp the new conception, and by expressing himself very decidedly against it, "Comp. Embryol.," II., 306-308, led many embryologists to discredit the discovery. Whitman, 78.2, 91-94, has ably defended the comparison made by Semper (see above); Rauber, 76.2, Kollman, 85.1, Ryder, 85.5, 9, and others have added to our knowledge of the phenomenon. Duval's researches on the chick, 84.1, demonstrate concrescence there also, though the author appears unacquainted with the results of his predecessors. Minot in the article "Fœtus," in Buck's "Handbook," III., 172, 173, accepts concrescence as the typical mode of vertebrate development.

Concrescence in Bony Fishes.—At the close of segmentation the germinal disc forms a cap of cells on the yolk. The disc (primitive blastoderm) spreads over the yolk gradually; when it begins to spread its edge is already thickened; this thickened edge corresponds to the ectental line; the thickening is known as the *Randwulst*; it is also called the *blastodermic rim*, which term Ryder and others have used. When the blastoderm has spread, so as to cover perhaps a sixth or less of the surface, one point of the rim ceases † to move; consequently, as the expansion continues the edge of the disc bends in behind this point on each side, until two parts of the blastodermic rim meet as they come from opposite sides, and then grow together. This is illustrated by the accompanying diagram, Fig. 65; I is the outline of the yolk; bl is the outline of the blastoderm; a , the fixed point; the expansion of the blastoderm has brought the parts 1 1 together and they have united; the parts 2 2 are about to meet and unite; then 3 3 will meet; 4 4 and so on, until the two halves of the ectental line are brought together along their entire length; their junction marks the axis of the future embryo, and produces a longitudinal band of thicker tissue, which has long been

* Rathke and Leuckart, "Beiträge zur Entwicklungsgeschichte der Hirudineen;" Leipzig, 1802.

† Or perhaps merely moves more slowly.

known to embryologists, and may be named the *primitive axis*. The fixed point of the blastodermic rim marks the head-end of the embryo; the parts of the ectental line which grow together next behind the fixed point develop into the head, those a little farther

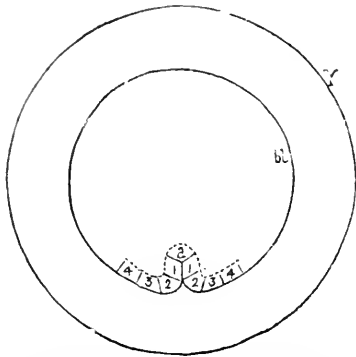


FIG. 65.—Diagram of concrescence in a Teleostean egg: Y, outline of yolk; bl, outline of blastoderm. 1 1, lateral parts already concresced; 2 2, lateral parts about to concresce; 3, 4, parts to concresce later.

back into the neck, and those farthest back into the rump and tail. The parts of the circular rim most remote from the fixed point, *a*, of course concresce last. The destiny of each portion of the ectental line is fixed before concrescence occurs. In fact in certain cases the differentiation of the tissues advances to a considerable degree in the "Randwulst" before concrescence. This is strikingly the case in Elacate, in the ova of which the myotomes (or segmental divisions of the mesoderm) appear in the embryonic rim before its concrescence (Ryder, 85.9); compare also Ryder's observations on *Belone*, 81.2. The development of the teleostean germ-layers is not yet fully

worked out. For the best history of the entoderm and mesoderm, as well also for references to conflicting authorities, see M. Kowalewski, 86.1,2, who, however, pays no heed to the law of concrescence.

That concrescence occurs in teleosts essentially as here described, seems to me evident from the figures given by W. His, 76.1, C. Kupffer, 84.1, Coste, 47.1, and others. Nevertheless the concrescence is denied by Henneguy, 88.1, H. V. Wilson, 91.1, 260, and others, but the arguments I have found against concrescence have not appeared to me valid.

In the primitive axis is a mass of cells below the ectoderm; this mass subsequently divides into mesoderm and entoderm. The entodermal cells form at first and for a considerable period a solid cord (*cf.* Balfour, "Comp. Embryol." II., 75) in which, however, a lumen appears later; this lumen I will tentatively homologize with the cavity of the notochordal canal of amniota.

Concrescence in Elasmobranchs.—Our knowledge rests mainly on the researches of His, 77.1, and his follower, Kollmann, 85.1. Fig. 66, A, is a generalized diagram of an elasmobranch ovum, representing the ectodermal disc, *Bl*, as seen from above resting upon the yolk, which is not represented in the figure. The first change noticeable in the disc after the close of segmentation is a groove running completely around its margin between it and the yolk; as the disc grows and expands the groove is no longer present along the front edge, *a a*, of the blastoderm, but only on the sides and behind. About the same time there usually appears a distinct notch, *n*, which marks the fixed point of the margin and the posterior end of the disc. If now a section be made across the line, *X Y*, the relations will be found to be essentially as represented in the diagram, Fig. 66, B; the disc rests on the yolk, *Y*, which con-

tains numerous nuclei; between the yolk and the ectoderm, *Ec*, is the segmentation cavity, *sc*; the groove is bounded above by a layer of cells, *En*, which are larger than those of the ectoderm, and have been produced by the yolk, *Vi*; sometimes there are cells lying in the segmentation cavity at this stage, the formation of the mesoderm having already begun. The essential point to note in this stage, is, as Kollmann has shown, the division of the margin of the ectodermal disc into two parts, one, *a a*, resting directly on the yolk, the other, *S*, directly continuous with a layer of entodermal cells, *B, En*, forming a little groove under the margin of the disc. The two portions of the ectental margin have entirely distinct functions, as already stated; the anterior, *a a*, is destined to grow over and cover the yolk by the extra-embryonic portion of the ectoderm; the posterior, *S*, is destined to form the primitive axis of the embryo.

Fig. 67 is similar to Fig. 66, but represents a more advanced stage. The ectodermal disc, *Bl*, is much enlarged, and its anterior grooveless margin, *a a a*, is relatively much more increased than the posterior grooved margin, *S*; the centre of the notch, Fig. 66, *n*, has remained nearly if not quite stationary, Fig. 67, *pr. s.*

while the margin, *s s*, of either side has been growing toward its fellow in the manner indicated by the arrows, and as they meet the two side-margins grow together in the median line, making a longitudinal structure. The manner and results of the concrescence of the margins from the two sides to form an axial structure become clearer in section, Fig. 67, *B*. The margin at the side, *m*, still shows the same relations as in Fig. 66, *B*; in the median line, however, the margins have met and intimately united, "so that what were originally two grooves have completely united to form a single canal, *Ent*, bounded above by entodermal cells, below by the entodermal yolk, *Vi*. This canal is the primitive entodermal cavity. Whether it represents, when first developed, merely the notochordal canal of the anniota or the fused notochordal canal and yolk cavity, we are unable to determine at present. A moment's consideration renders it evident that the canal must be open posteriorly; this opening is the blastopore, *bl*. There are some further details to be mentioned: where the ectental margins have united in

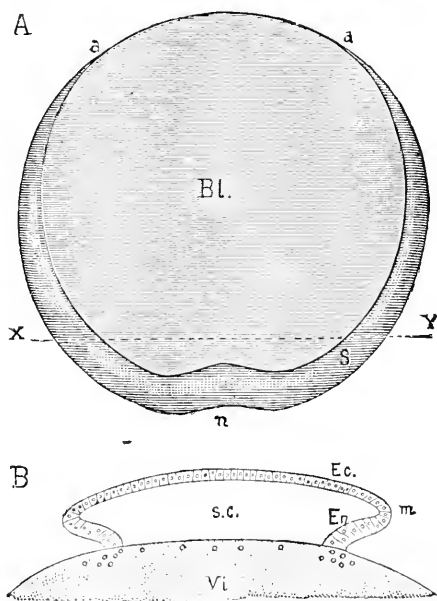


FIG. 66.—Diagram of an Elasmobranch Blastoderm to illustrate the formation of the marginal groove. A, surface-view: *Bl*, blastoderm; *a a*, anterior grooveless margin; *S* (*Sichel*), marginal groove; *n*, marginal notch; *X Y*, line of section. B, section along the line *X Y* of A. *Ec*, ectoderm; *En*, entoderm; *m*, extental line; *s.c.*, segmentation cavity; *Vi*, yolk with nuclei.

the median line there appears a lateral outgrowth, *mes*, which is the beginning of the mesoderm: in some cases this mesodermic tissue appears before the margins congregate; when viewed from the surface the mesoderm can be seen through the ectoderm, as was observed long ago; it is this faint appearance which early writers

call in anamniota the primitive streak, it being the foreshadowing of coming organization. Fig. 67, A, also shows *in front of* the primitive axis the first trace, *N*, of the central nervous system, which we shall describe later. The blastoderm is seen also to be divided already into two parts, the lighter area pellucida, *A. p.*, and the darker area opaca, *A. o.*; the latter also shows the first blood-islands. For further descriptions of these areas, see Chap. XIII.

From their observations, His, Kollmann, and others have inferred that at the anterior ectental margin, *a a a*, there are produced (from the yolk) cells, which grow in toward the embryo, and constitute part of the mesoderm and are especially concerned in

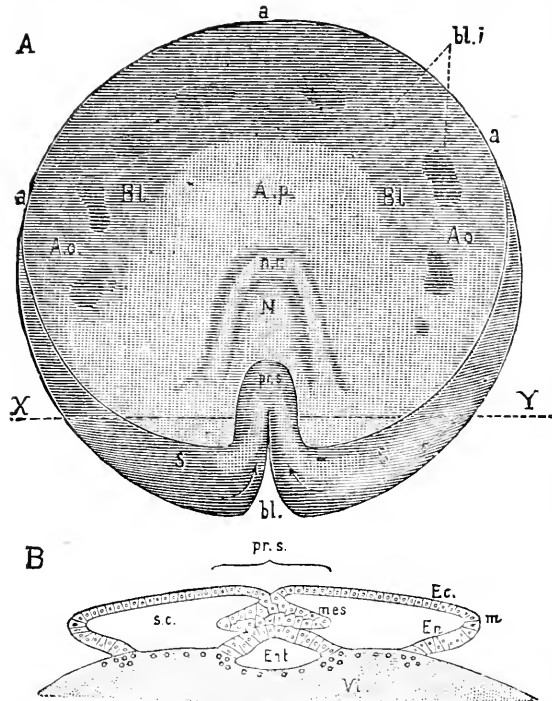


FIG. 67.—Diagram of a Vertebrate Blastoderm a little more advanced than Fig. 66: A, surface-view. B, section along the line, X Y. *Bl.*, blastoderm; *a a a*, anterior margin; *s s*, posterior margin (Siebel); *A. o.*, area opaca; *A. p.*, area pellucida; *n. r.*, neural ridges; *N*, neural or medullary groove; *pr. s.*, primitive streak; *bl.*, blastopore; *Ec.*, ectoderm; *m*, ectental margin; *En.*, entodermic cells; *V*, yolk; *mes*, mesoderm; *s. c.*, segmentation cavity.

forming the first blood, which is produced always in the extra-embryonic area. This mesoderm of peripheral origin His has named *paroblast*—a term which, unfortunately, has been employed differently by some subsequent writers. The ectoderm, entoderm, and axial mesoderm are grouped by His under the collective name of *archiblast*. This view of the double origin of the mesoderm, although it has been adopted in a modified form by the brothers Hertwig, I am unable to accept. The question is discussed in Chapter VI.

Concrescence in Marsipobranchs, Ganoids, and Amphibians.—As not only the constitution of the ovum, but also its early development, is very similar in the three classes named, we may consider them collectively in the present connection. The condition of the ovum at the close of segmentation has already been described, p. 99, and figured, Fig. 49. The ectental line is not sharply defined,

nor does there appear any groove around the edge of the blastoderm as in meroblastic ova. The small-celled ectoderm spreads over the yolk; while it is doing this a short notochordal canal appears at the hind edge of the blastoderm with a small opening to the exterior, known as the blastopore, Fig. 68, *bl*. The first indication of the canal in the frog is easily recognized, being the appearance of a curved area of pigmentation of semilunar outline amid the yolk-cells at the posterior pole; the convexity of the area is directed toward the segmentation cavity; the centre of the concavity corresponds to the dorsal lip of the blastopore (Robinson and Assheton, 91.1, 463). The canal runs forward toward the segmentation cavity, Fig. 68, *s.c.*; above and in front of the blastopore the cells have multiplied and accumulated to form the beginning of the primitive axis, *Pr*. In the lamprey there is at this stage no such axial accumulation of cells; according to Shipley the ectoderm consists of a single layer of cells, and the notochordal canal is bounded on its dorsal side by a single layer of cells also, between which and the overlying blastoderm there are no cells; the gathering of cells corresponding to the primitive axis does not arise until later. The canal, according to

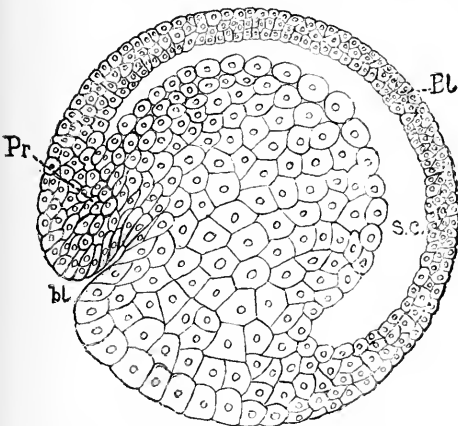


FIG. 68.—Ovum of Axolotl. After Bellonci. Longitudinal section to show the commencing formation of the primitive axis. *Pr*, *bl*, blastopore; *Bl*, blastoderm; *s.c.*, segmentation cavity.

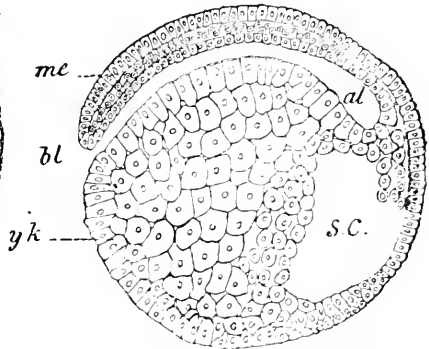


FIG. 69.—Ovum of Petromyzon in longitudinal section. After Balfour. *mc*, mesoderm of primitive axis; *bl*, blastopore; *Yk*, yolk at the anus of Rusconi; *al*, notochordal canal; *s.c.*, segmentation cavity.

O. Schultze, ultimately fuses with the yolk cavity to form the definite archenteron; it is sometimes designated as the blastoporic invagination. The canal in the same measure as the blastoderm spreads over the yolk-grooves at its hinder end away from the segmentation cavity, Fig. 69, *s.c.*, just as in elasmobranchs. A stage is soon reached in which nearly the entire length of the archenteron is formed and nearly the whole yolk is covered. There is still a blastopore which leads into the cavity, and which has moved gradually backward from its original position. Behind the blastopore lies the uncovered yolk, *Yk*, which in the frog's ovum is very conspicuous, because its whitish color contrasts with the dark color of the heavily pigmented ectoderm around it; this area of exposed yolk is the so-called *anous of Rusconi*. When the canal has completed its full length the

following disposition of the parts is found, Fig. 70: The archenteron is bounded below by the large mass of yolk-cells, *Vl*, and above by the epithelium, *Ent*, of the entoderm; its posterior end curves up to open at the blastopore, *Bl*, passing through a mass of cells, which constitute the end of the primitive streak; this portion of the archenteron is sometimes called the blastoporic canal. There is further a short prolongation, *Al*, of the cavity below the blastopore. This diverticulum has been homologized with the allantois, (see Chapter XII.). It is also very probably homologous with the more nearly spherical diverticulum found in a similar position in teleosts, and now known as Kupffer's vesicle, from having been especially studied by C. Kupffer, 66.1, 475, 68.1, who has interpreted it as the teleostean allantois. Compare D. Schwarz, 89.1, 197, Taf. XIII., Figs. 35, 37, etc. Around the blastopore is a mass of cells (primitive axis) continuous on the one side with the ectoderm, on the other with the epithelial entoderm lining the archenteron

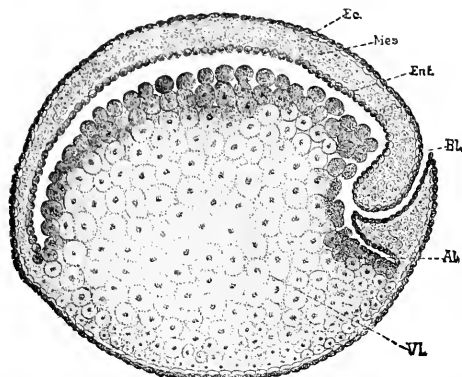


FIG. 70.—Longitudinal section of the ovum of a Sturgeon after the formation of the entodermic cavity: *Ec.* ectoderm; *Mes.* mesoderm; *Ent.* entoderm; *Bl.* blastopore; *Al.* diverticulum of the archenteron; *Vl.* yolk. After Salensky.

and, thirdly, with a sheet of cells, *Mes*, between the ectoderm, *Ec*, and entoderm, *Ent*.

The developmental phases just outlined seem to me to afford sufficient evidence of concrescence. Owing to the gradual transition between the ectoderm (blastoderm) and the entoderm (yolk-cells) there is no sharp ectental line, as in some other types. Moreover, there is no differentiation of the tissues at the blastodermic rim, but only after the cells are united in the axis; hence we cannot distinguish parts at the periphery of the blastoderm and follow their union in the primitive streak as we can in certain sharks and bony fishes. Nevertheless, we find all the essential features of concrescence; the notochordal canal and the primitive axis begin at the edge of the blastoderm and grow at their posterior end away from the segmentation cavity, and at the same rate the blastoderm overspreads the yolk.

Concrescence in Sauropsida.—The early stages in Reptilia have long been obscure. Clarke (Agassiz' "Contributions," II.), in his paper on the embryology of the turtle, mistook the commencement of the notochordal canal for the commencement of the amniotic fold. Weldon, 83.1, Kupffer, 82.1, 84.1, Strahl, 80.1, 2, 3, 82.1, 83.1, Hoffmann (Bronn's "Thierreich," VI., Abth. iii., 1892-1897), and others partly traced out the history of the canal. Will's observations, 90.1, on the development of the gecko gave the key to the history of the canal in the reptiles. In the gecko there is formed a notochordal canal, which is at first very short, but gradually lengthens out, apparently chiefly by growth at its hind or blastoporic

end, Fig. 63, *nch. c.* The end of the canal, when the germinal area is examined in surface-views, is characterized by a transverse figure or *sichel*, which is well known in reptilian embryos of all orders, and which presumably represents the portions of the *Randwulst* which are to concrease and thereby lengthen the primitive axis and the notochordal canal inclosed by the cells of the axis. Underneath the notochordal canal is a layer of entodermal cells, *Ent*, which form the roof of the yolk cavity; the figure does not show the inferior or lateral boundaries of the yolk cavity. In a little later stage, the tissue between the canal and the yolk cavity disappears and the two lumina fuse.

In other reptiles the development is similar, though obscured by the peculiarity that the anterior part of the notochordal canal opens into the yolk cavity before the posterior part is formed. In such cases there is only a short section of the canal to be observed with complete boundaries at any one stage. In reptiles then concrease can only be inferred from the presence of the "sichel" and the

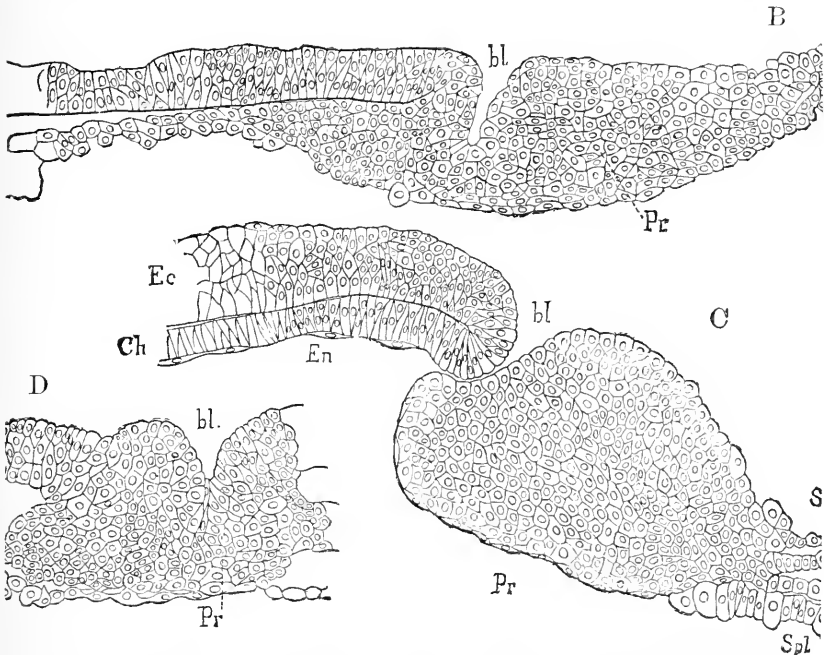


FIG. 71.—Formation of the blastoporic canal in *Lacerta muralis*. After Weldon. B, C, longitudinal sections of two successive stages of the blastoderm, which in each case has been removed from the yolk; the space under the entoderm, *En*, is the archenteric cavity. D, transverse section of the posterior part of the blastopore a little younger than C. *Ec*, ectoderm; *En*, entoderm; *Pr*, primitive streak; *bl*, blastopore; *Ch*, notochord; *mes*, mesoderm.

growth backward of the primitive axis. Fig. 71 illustrates the formation of the canal in *Lacerta*, as described and figured by W. F. R. Weldon, 83.1. *En* is the entoderm forming the roof of the yolk cavity. B shows the notochordal canal, *bl*, just beginning to form. C is a stage considerably more advanced; the anterior part of the canal has fused with the yolk cavity, and the dorsal wall of

the canal has produced the notochord, *neh*; only a short posterior end, *bl*, remains as a canal. D is a transverse action through the blastopore.

The process of concrescence in birds was partly indicated by Koller's investigations, 79.1, 82.1, and has been carefully elucidated by Duval, 84.1. The resemblance to concrescence as known in elasmobranchs is very striking. Around the edge of the blastoderm appears very early a small groove; as the blastoderm expands the front portion loses the groove; one point, the centre of the grooved margin, ceases to move, or at least moves much more slowly than the remainder of the blastodermic rim; as the expansion continues the edges of the two halves of the groove coalesce gradually behind the fixed point, thus producing the ectodermal canal in the same manner as in the sharks; cells accumulate at the same time and make behind the blastopore the so-called primitive streak. There is some uncertainty in Duval's account, as, unfortunately, at the time he wrote the existence of a yolk cavity contributing to the formation of the archenteron had not been recognized.

In birds (hen's ova) there is a further peculiarity, which is, I think, probably to be found in all amniota, namely: that portion of the edge of the ectoderm which does not share in concrescence and which corresponds to the edge of the anus of Rusconi closes over the yolk behind the primitive streak, so that the portion of the yolk which is left uncovered is remote from the embryonic area (or primitive streak). As a rare anomaly, see Whitman, 83.1, a line is visible running in the ectoderm from the hind end of the primitive

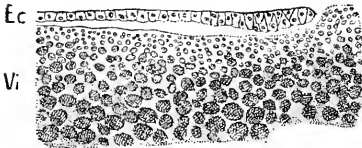


FIG. 72.—Hen's ovum: incubated six hours; anterior edge of the ectoderm resting on the yolk from a longitudinal section of the blastoderm *in situ*. After Duval.

streak to the edge of the uncovered yolk; this line is to be interpreted as evidence of the growing together of the ectoderm, behind the streak proper. The ectoderm, as it spreads over the yolk, receives no accretions from it, but accomplishes its expansion by proliferation of its own cells. Thus the uncovered yolk is bounded by the free edge of the ectoderm, Fig. 72. The area of uncovered yolk, which may be called the yolk blastopore,* is not homologous with the anus of Rusconi, from which it differs in position, being remote from instead of close (as is the anus of Rusconi) to the blastopore, for it is situated nearly opposite the embryonic area. In birds, according to Duval, 84.2, the yolk blastopore (*Dotternabel*) is never closed by ectoderm, but remains covered by the vitelline membrane only, until the mesoderm spreads over it. The growing edge of the ectoderm is somewhat thickened; it finally is reflected around the edge of the yolk blastopore, forming, as it were, a funnel, at the bottom of which is the yolk (see Duval, *l.c.*).

Concrescence in Mammals.—As shown below in the detailed history of the mammalian blastodermic vesicle, there is a fixed point (Hensen's knot) at which the formation of the primitive axis and notochordal canal begins, and from which they lengthen out back-

* Duval applies to it the name of ombilic, ombilical.

ward as they would do if formed by concrecence. The main cavity of two-layered vesicle is the yolk cavity, and with it the notochordal canal subsequently fuses, *cf. infra*. The position and history of the ectental line being absolutely unknown in mammalia, it is of course impossible to form any definite notions as to the process of concrecence in them.

Concrecence : Summary.—The evidence that concrecence is the typical means of forming the primitive streak in vertebrates is: 1, detailed and conclusive observations upon elasmobranchs, teleosts, and birds; 2, exact and extensive observations on marsipobranchs, ganoids, and amphibians, which concord with the theory of concrecence; 3, a great probability of its occurrence in reptiles, owing to the similarity of their development with that of birds; 4, a probability of its occurrence in mammals, because of the resemblance in the growth and structure of the primitive axis to that in other vertebrates. The theory seems to me inevitable that *the vertebrate primitive axis is formed by the growing together in the axial line of the future embryo of the two halves of the ectental line*.

The development of the primitive axis may be described in general terms as follows: At the close of segmentation the edge of the primitive blastoderm separates into two parts; one part (the anterior), as the ectoderm, expands, spreads over the yolk, gradually covering it with ectoderm; the other part (the posterior) forms the primitive axis; it has in its centre one fixed point; consequently, when the blastoderm expands the two halves of the posterior part of the ectental line are brought together and gradually unite (concresee) along a line running from the fixed point backward (radially as regards the blastoderm). Consequently, the segmentation cavity, which is underneath the primitive blastoderm, lies in front of the developing axis. While this goes on cells grow out from the concrecing part of the ectental line into the space between the ectoderm and entoderm (or yolk); underneath the line of junction a cavity is formed lined by entoderm; this cavity is the notochordal canal; it lengthens backward as concrecence progresses; it has, whatever its length, a small entrance, the blastopore, at its hind end; the blastopore is ultimately obliterated. The cells which grow out from the ectental line constitute the first anlage of the middle germinal layer or mesoderm, and shining through the ectoderm they produce the appearance of a whitish line, which has led to the name of primitive axis. The characteristics of the mesoderm are described in the next section. Along the line of junction there often appears a slight furrow in the ectoderm, which is known as the primitive groove.

Significance of Concrecence.—It will at once be evident that if the process of concrecence went on without the actual meeting of the two portions of the ectental line the result would be to leave the archenteron open along its entire length; the borders of the opening would be the ectental line; and this line, as we have seen, corresponds to the lips of the gastrula mouth; consequently, we should have a gastrula with an elongated mouth. This condition is illustrated by the accompanying diagram, Fig. 73. It agrees in all respects with the gastrula type; its most noteworthy peculiarities are two: first, the enormous mass of yolk accumulated in the aboral

portion of the entoderm; second, the elongation of the gastrula or archenteric cavity in a direction at right angles to the gastrula axis, *xy*. If now the lips of gastrula, Fig. 64, *s*, meet and unite we should obtain at once the vertebrate type. According to W. His' discovery, this is precisely what takes place—only the lips are brought together first at one end, where they at once unite, while behind they are widely separated; but gradually they are brought together and unite throughout their entire length.

Concrescence is, then, a modified method of uniting the lips of a greatly elongated gastrula mouth. Why this modification is established we cannot say with certainty, though we may surmise with confidence that it is consequent upon the great accumulation of yolk in vertebrate ova.

The view here adopted enables us to speak positively as to the point where we are to look in vertebrates for the homologue of the invertebrate mouth. In annelids concrescence is very well marked, whenever the ova contains much yolk; now in leeches and earthworms the ectental line does not concresce along the entire axial line,

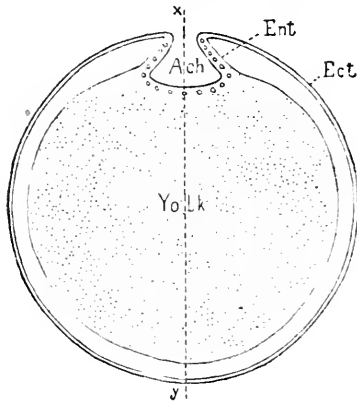


FIG. 73.—Diagrammatic cross-section of a vertebrate ovum, in which concrescence is supposed to have been arrested; *xy*, median plane; *Ach*, archenteron; *Ent*, entoderm; *Ect*, ectoderm.

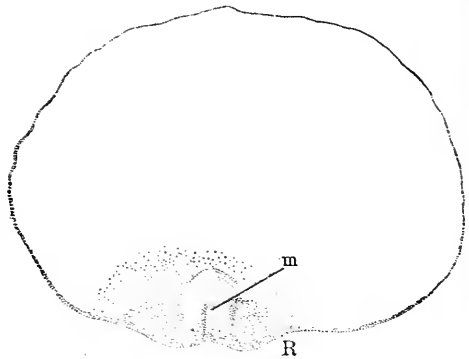


FIG. 74.—Dog-fish embryo, nearly in Balfour's stage C. *m*, position of invertebrate mouth; *R*, rim of the germinative area.

but, on the contrary, as shown by Kleinenberg and Whitman, the foremost part of the germ bands (gastrula lips) do not unite, but leave a small opening; when the permanent mouth is formed this opening is carried in and serves as the passage between the mouth cavity (Vorderdarm, stomodæum) and the archenteric cavity. The foremost part of the line of concrescence lies, according to His' observations, on fishes just where the optic outgrowths arise, Fig. 74, *m*; hence we have to search between the origins of the optic nerves for traces of the invertebrate mouths. Further reference to this question is made later in connection with the development of the nervous system.

The Notochordal Canal.—The existence of this canal was, so far as I am aware, first satisfactorily recognized by Lieberkühn, 82. 1, 84. 1, who discovered that in mammals it produces the notochord,

and by losing its lower walls fuses with the yolk cavity. The canal is a narrow tube which runs forward in the tissue of the primitive axis (Kölliker's head process); it ends blindly in front, but its posterior end communicates with the exterior by a funnel-shaped opening (the blastopore) through the ectoderm. Immediately behind the blastopore lies the accumulation of cells, termed the primitive streak in anniota, the anus of Rusconi in amphibians. The canal is lined by epithelium, which is thickened on the dorsal side to form the anlage of the notochord. At the sides the epithelium merges into cells belonging to the mesoderm.

The manner in which the canal is formed by concrecence is explained in the preceding pages, and the manner in which it fuses with the yolk cavity is described in the following section. For additional details and references see the history of the notochord in Chapter VIII.

Fusion of the Notochordal Canal and Yolk Cavity.—The fusion of these two cavities has been carefully studied in mammals and reptiles. The fusion in amphibians is briefly mentioned by O. Schulze, 88.1. In the gecko (L. Will, 90.1) and in mammals (Lieberkühn, 82.1, 84.1, Van Beneden, 88.3, and others), the canal becomes quite long, and then acquires a series of irregular openings. Fig. 75, *uch*, on its ventral side into the very large yolk cavity, which at this stage underlies the whole germinal area. The anlage of the notochord is already differentiated on the dorsal side of the canal. The ventral openings increase both in number and size until the entire canal has fused with the yolk cavity except at the hind end, where it persists for a while as the so-called blastoporic canal. The fusion occurs in guinea-pigs the fourteenth to fifteenth day, in rabbits the eighth day.

In lizards (Strahl, Kupffer) and turtles (Will) the fusion occurs in a similar manner, but sooner, so that the anterior portion of the canal has fused with the yolk cavity before the posterior portion of the canal is completed.

The union of the two cavities produces the *definitive archenteron*, which is a spacious cavity lined by entoderm, having the anlage of the notochord in its median dorsal line and opening to the exterior by the blastopore, which is situated at the caudal end of the primitive axis and the headward end of the primitive streak.

Blastopore.—The blastopore is the small opening which leads into the notochordal canal, or, after the canal has fused with the yolk cavity, leads into the archenteron. It is situated at the hind end of the primitive axis (head-process), and marks the anterior boundary of the anus of Rusconi in amphibia, or of the primitive streak, properly so-called, of anniota, Fig. 71, B.

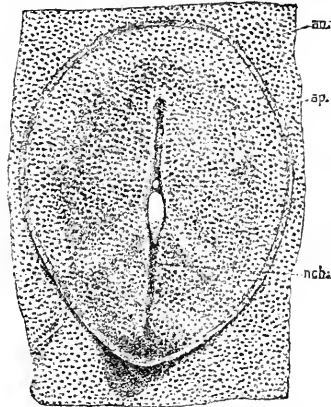


FIG. 75.—Germinal area of a Guinea-pig at thirteen days and twenty hours, seen from the under-side. After Lieberkühn. *ao*, area opaca; *ap*, area pellucida; *nch*, anlage of the notochord as a canal, with several irregular openings on the entodermic side. $\times 24$ diameters.

While the concrescence of the ectental line is going on the blastopore changes its position, being always at the end of the notochordal canal. When the canal fuses with the yolk cavity the end of the canal persists for a time as a passage at the end of the primitive axis, and this passage is sometimes designated as the blastoporic canal, see Figs. 70 and 71. The opening is finally obliterated.

The blastopore is not homologous with the gastrula mouth, but is merely a small portion thereof; in front of it the gastrula mouth is closed by concrescence; while concrescence is going on there will be a part of the gastrula mouth open behind the blastopore; when concrescence is completed the blastopore is at the end of the elongated gastrula mouth, the lips of which are united throughout the remainder of their length. The blastopore is not a fixed point, being merely the opening of the notochordal canal, and as by concrescence the canal is elongated, in precisely the same measure the blastopore travels backward.

The Meroblastic Embryo.—Considerations of practical convenience have led to the custom of distinguishing in the development

of meroblastic ova the embryonic from the extra-embryonic portions. The distinction is in reality entirely arbitrary, for the whole of the ovum is included, morphologically speaking, within the body of the embryo. Custom has led to designating the two parts as the embryo and the yolk; but the student should be careful not to allow himself to be misled by these terms. In the laboratory it is a general practice to remove the so-called "embryo" from the yolk, and in doing this the archenteric cavity loses its inferior wall, to wit: the entodermic yolk. Let the relations be represented by the accompanying diagram, Fig. 76, the embryo being drawn very much too large in proportion to the yolk, for the sake of clearness. Suppose the layers to be

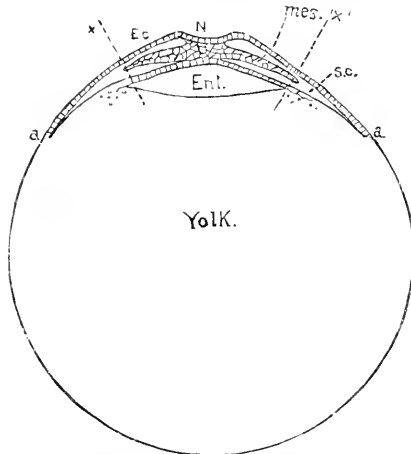


FIG. 76.—Diagram showing the relations of a vertebrate ovum with an embryo in cross-section and a large yolk. *Ec*, ectoderm; *N*, neural groove; *mes.*, mesoderm; *s.c.*, segmentation cavity; *Ent.*, archenteric cavity; *a a*, ectodermal rim, where the ectoderm is growing over the yolk.

cut through on the lines *x x'*; we could then remove the embryonic portion. This is what is actually done in practice. It is very important to understand clearly that the yolk is part of the embryo, and that our sections usually represent only a torso.

II. THE PRIMITIVE AXIS AND STREAK.

The term primitive axis is a new one, which it has seemed necessary to introduce to avoid confusion. It is nearly synonymous with the term head-process (Kölliker's *Kopffortsatz*). It is applied in *all* vertebrates to the median band of cells which runs forward from the

blastopore; the central cells of the band are entodermal* and form the epithelial wall of the notochordal canal; the lateral cells of the band contribute to the production of the mesoderm. At the blastopore the primitive axis merges into the primitive streak, *sensu strictu*, and on that account has been interpreted and described by many authors as the anterior prolongation of the primitive streak. After the ventral wall of the notochordal canal has disappeared and the canal has fused with the yolk cavity, the entire tissues of the primitive axis lie on the dorsal side of the archenteron.

The term primitive streak may be conveniently and properly restricted hereafter to the accumulation of cells lying immediately behind the blastopore. In amphibia this accumulation is known as the anus of Rusconi; it belongs to the entoderm (and later to the mesoderm also), and is very conspicuous owing to the absence of pigment in its cells. In amniota the corresponding accumulation comprises the cells in the region around the primitive groove, as described in detail below; in amniota the accumulation has the yolk cavity (later archenteron) extending under it, Fig. 71, A B, *pr*, and it is therefore not directly continuous with the yolk proper, as in amphibians.

The conceptions of the axis and streak above presented appear to me necessary consequences of our present knowledge, but until they are accepted by other embryologists, the reader must view them as largely my personal opinions, and must remember that morphologists are not yet agreed as to the nature of the primitive streak.

The Primitive Axis.—As above defined, the primitive axis is the median band of cells resulting from concrescence and overlying the definitive archenteron.

It is advisable to begin with the consideration of the arrangement as we find it in eggs of marsipobranchs, ganoids, and amphibians, since these eggs are probably more primitive in their mode of development than those of other vertebrates. The points of most importance in my judgment are illustrated in Fig. 77, A and B. In A we have a section through the middle portion of a young primitive axis of an axolotl, the axis still requiring considerable additions at its hinder end before attaining its full length; the archenteric cavity, *Ae*, is a large space bounded above by an epithelium, *En*, and below by the large mass of yolk cells, *Yk*; the two-layered ectoderm, *Ec*, everywhere bounds the section; above the archenteron and below the ectoderm lies the accumulation of cells constituting the primitive axis, *Pr*; the lateral prolongations, *Mes*, of the axis represent the commencing mesodermic outgrowths; whether the mesoderm grows out from the primitive axis and subsequently expands solely by its own proliferation, or whether it receives at its periphery accretions from the yolk cells is uncertain. I am inclined to think that the mesoderm does not receive additions from the yolk. In B we have a similar section, but of an older stage, and through the hind end of the nearly full-grown axis; the general arrangement is the same as in A; we note the following differences: the archenteric cavity is a mere slit, *Ae*; the primitive axis, *Pr*, is very thick

* Prenant ("Embryologie") regards them as ectodermal, following O. Hertwig's suggestion; the terminology in this case is largely a question of previous definition.

and composed of numerous small cells, and its lateral mesodermic expansion, *Mes*, extends farther around the ovum. In both sections we see that the cells of the primitive axis are not marked off from

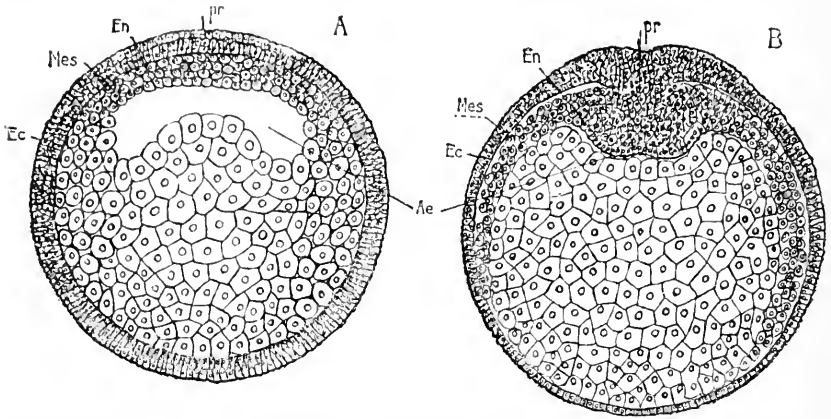


FIG. 77.—Sections of Axolotl eggs; A, frontal section somewhat anterior to the blastopore, from an egg in which the archenteron was partly formed, but the anus of Rusconi not delimited. B, frontal section of an older ovum, with well-marked but large anus of Rusconi; the section passes just in front of the blastopore. *Ec*, ectoderm; *En*, entoderm; *Mes*, mesoderm; *Ae*, archenteric cavity; *Yk*, yolk; *pr*, primitive axis. After Bellonci.

those of the adjoining entoderm. In a longitudinal section, as is illustrated by that of a sturgeon, Fig. 70, the mesoderm of the primitive axis is seen to extend far forward from the blastopore, *Bl*. The disposition of the parts and the appearance of the cells vary in the three groups we are considering, but for our purpose it is unnecessary to describe these secondary differences. The points essential to note are that the primitive axis produces chiefly mesoderm, which is accumulated along the axial line, and is thickest around the blastopore, where it joins the primitive streak, and which spreads laterally between the ectoderm and entoderm; in the axial region the mesoderm is not separated from the entoderm.

In elasmobranchs the differentiations of the axial tissues begins in the embryonic rim before concrescence takes place, so that while the type affords peculiarly conclusive evidence of concrescence, it is less convenient for the study of the primitive axis, since the hind end of the primitive axis is, as it were, divided, being continued as the embryonic rim, right and left. The degree of differentiation in the rim varies extremely: in *Pristiurus* the mesoderm grows out; in *Scyllium* the mesoderm grows out and the differentiation of the notochord begins; in *Torpedo* (Rückert, 87.1, 101) the myotomes appear in the embryonic rim before concrescence, as in *Elacate* among teleosts. The relations are further complicated by the advance in development of the axial structures while concrescence is going on, so that, as for instance in *Pristiurus*, Rabl, 89.2, 116-129, the axial notochord may be differentiated, while the mesoderm is still developing in the embryonic rim. The precocious changes in the embryonic rim demand especial attention when the origin of the mesoderm is discussed (*cf.* Chapter VI.). The ectoderm, as soon as it becomes one-layered (secondary blastoderm, see Chapter IV.), con-

sists of high-cylinder cells. As development progresses the ectoderm thins out except on either side of the axial line. The mesoderm arises from the entoderm close to the ectental line and is there quite thick, but as it stretches away it thins out. Now if it be remembered that the ectental line becomes the axial line, when concrescence occurs, it is evident that this mesodermic thickening of the entoderm is in reality an axial thickening, and when concrescence takes place it fuses with the corresponding thickening of the opposite side and constitutes an actual axial thickening or true primitive streak; but in elasmobranchs, as soon as the anterior axial structures have concresced, we find by precocious development that the notochord and medullary groove appear; now, as shown in Chapter VII., the appearance of these structures causes the division of the axial mesoderm into completely separated right and left portions. It is only by keeping the process of concrescence and the precocious development of the parts constantly in mind that we can understand the development in elasmobranchs or compare it rightly with that of other types. From what has been said it is clear that a section of the blastodermic rim from which the mesoderm was just growing out would correspond to half a section of, say, a bird's ovum, though the primitive axis, and upon comparison it will be found that all the essential relations are identical.

The primitive axis and streak of birds have been much investigated and discussed, and may be conveniently treated together. I follow in the main Duval, 78.1, 84.1, many of whose statements are confirmed by Zumstein, 87.1. Other important authorities to be consulted are Kölliker in both his text-books; His, 68.1, 77.2, 82.1, *etc.*; Koller, 82.1; Disse, 78.1, 79.1; Waldeyer, 69.1, 83.1; M. Braun, 82.3; Gasser, 77.1, 79.1; Rauber, 76.2; C. Rabl, 89.2, *et al.*

The following description applies to the hen's egg. When the egg is laid the centre of the segmented blastodisc presents a circular area of lighter color; during the first few hours of incubation this *area pellucida*, as it is called, becomes more distinct; as the *area pellucida* expands, the primitive streak appears in it eccentrically between the eighth and twelfth hour. By the sixteenth hour the primitive streak has its full length. The rate of development is extremely variable, autumn eggs developing more slowly than spring eggs; the eggs vary also individually, and are, moreover, much influenced by the tem-

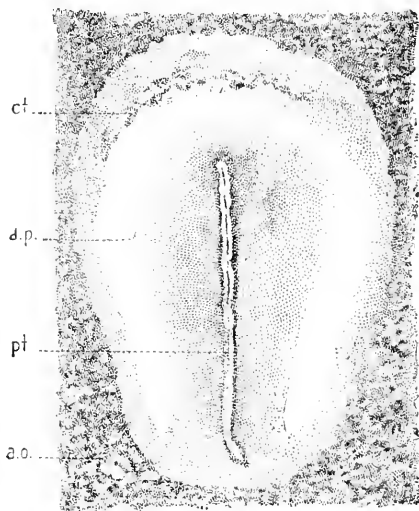


FIG. 78.—Area pellucida of a Hen's egg, with completed primitive furrow. After Duval. *a.o.*, area opaca; *ct.*, anterior crescent; *a.p.*, area pellucida; *pt.*, primitive groove. $\times 30$ diams.

perature of their incubation. For a fuller discussion of these variations see His, 68.1, 56-63. Seen from the surface the area pellucida with completed streak presents the following features, Fig. 78. The area pellucida, *a. p.*, is considerably elongated and somewhat pear-shaped, being widest at the anterior end of the primitive groove, *pt.*; this groove is well marked as a narrow and shallow furrow, which begins some distance from the anterior edge of the area and ends just before reaching the posterior edge of the area; the front end of the furrow usually bends slightly to the left, but not invariably, as Koller and Rabl have maintained, for it sometimes bends to the right or is quite straight; a line of granules is sometimes noticeable above the primitive groove; they were seen by Dursy, *l.c.*, and are called by Duval, 78.1, 15, the *filament epiaxial*—compare Gasser, 79.1. The portion of the area pellucida immediately around the primitive groove appears slightly darker than the rest. The anterior portion of the pellucida is further distinguished by the anterior crescent, *ct*, the "vordere Aussenfalte" of His, 68.1, and other German writers. The anterior crescent is a temporary appearance, due, according to Duval, to a series of folds of the entoderm, which form a curving row of shallow pockets, that, shining through, mark out the crescent. The crescent disappears a little later, and there arises nearly, if not quite, in its place a different fold, the amniotic. The similarity of position has led to the anterior crescent's being identified by some authors with the true amniotic fold.

Longitudinal and transverse sections are very instructive. We

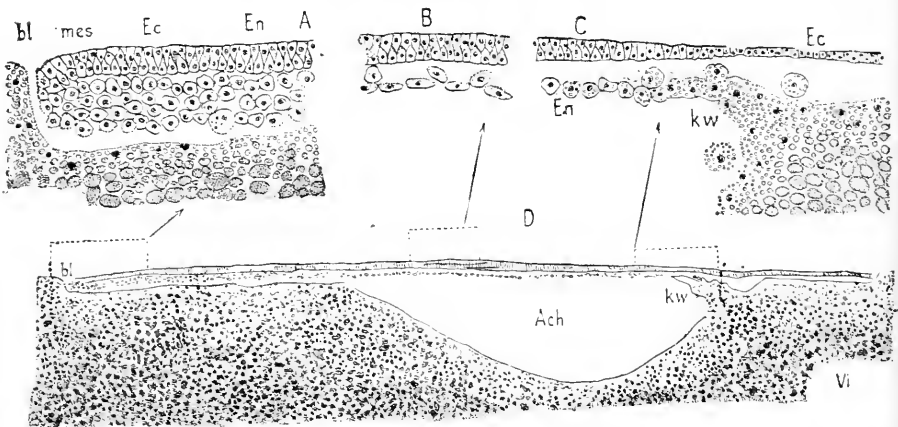


FIG. 79.—Longitudinal section of the region of the primitive streak of a Hen's ovum incubated six hours. After Duval. D, general view magnified about 40 diameters. A, B, C, details of D, with higher magnification. *Ec*, ectoderm; *mes*, mesoderm; *En*, entoderm; *bl*, Duval's "blastopore"; *kw*, germinal wall (*Keimwall*); *Ach*, archenteric cavity; *sg.c.* segmentation cavity.

begin with the examination of a *longitudinal section* of a somewhat younger stage. Later the ectoderm closes behind the primitive streak, as already stated and spreads backward over the yolk. The section shows that the yolk is not divided into cells, although nuclei are scattered through it; the nuclei are represented as black dots in

A, B, and C. The cavity of the archenteron, *Ach*,* is enlarged by the formation of a deep pit in the yolk, while the posterior half of the cavity remains a narrow fissure between the cellular entoderm, *Ent*, and the yolk; the archenteron communicates, according to Duval, with the exterior by an opening, *bl*, which he calls the blastopore; as this supposed opening is apparently at the posterior extremity of the primitive streak it cannot be the true blastopore. The entoderm is a loosely put together stratum of cells, which passes over anteriorly into a ridge of the yolk in which cells are being produced around the already accumulated nuclei; this ridge, *kw*, is the *germinal wall*. Posteriorly the cell layers are much thicker, A; the ectoderm, *Ec*, is clearly differentiated from the underlying cells, which are all more or less alike; though they represent both the entoderm and mesoderm. From this connection and from the fact that the connection between the ectoderm and mesoderm which is so well known to exist after the primitive streak has attained its full length, Duval concludes that the mesoderm arises primitively from the entoderm. *Transverse sections* afford additional information.

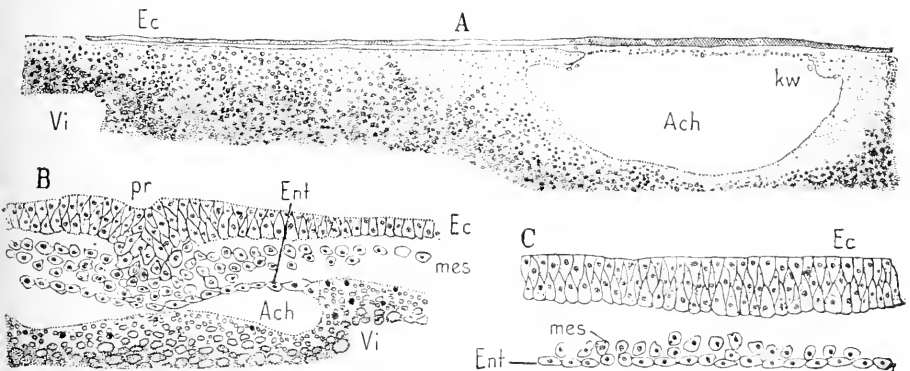


FIG. 80.—Transverse sections of a germinative area, with half-formed primitive streak, of a Hen's egg. After Duval. A, through the anterior region of the area pellucida. B, through the primitive streak. C, part of A enlarged. *Ec*, ectoderm; *mes*, mesoderm; *Ent*, entoderm; *bl*, blastopore; *kw*, germinal wall (*Keimwall*); *Ach*, archenteric cavity; *sg. c.*, segmentation cavity.

The accompanying Fig. 80 represents cross-sections of a germinal area, the primitive streak of which had attained about one-half its full length. The first section, Fig. 80, A, passes through the anterior region of the area pellucida, and therefore in front of the primitive groove; it shows the large cavern, *Ach*, of the archenteron (or yolk cavity?) hollowed out in the yolk; the entoderm, C, *Ent*, above the cavity is a thin layer of cells, connected laterally with a projecting shelf of yolk *kw* (the *bourrelet entodermo-vitellin* of Duval), which is rich in nuclei; it subsequently expands and acquires a more cellular character; this shelf is the commencement, therefore, of the *Keimwall* of German writers. Immediately above the entoderm, and intimately connected with it, are a few cells, which belong to the mesoderm, C, *mes*; the ectoderm is quite thick, C, *Ec*,

* As previously stated, Duval was unacquainted with the existence of yolk cavity; it is probable that the cavity here termed archenteric is really the yolk cavity.

and consists of high columnar cells; toward its periphery the ectoderm thins out, and its edge rests upon the yolk, with which it has no connection. In the region of the primitive streak, Fig. 80, B, there are important differences in the germ layers to note. The entodermic cavity, *Ach*, is very much smaller; the mesoderm is much thicker and in the axial region fuses with both the outer layer of cells* and the entoderm, thus forming the *Achsenstrang* (axial cord) of German writers; the mesoderm also spreads out over the yolk far beyond the archenteric cavity, and about one-third of the way from the axial line to the distal edge of the ectoderm; the ectoderm merges in the median line with the mesoderm, and presents externally a small notch, B, *pr*; corresponding to the primitive groove.

Whether at the stage from which Fig. 80 is taken the formation of the primitive axis (head-process) has fairly begun is uncertain. In slightly older stages the "head-process" is present (Kölliker, "Grundriss," 2te Aufl., 36). During these changes the archenteron (yolk cavity?) expands rapidly, the entoderm becomes very thin in the area pellucida, and passes more and more abruptly, as development progresses, into the so-called germinal wall of the area opaca; finally the ectoderm becomes thinner peripherally, so that the axial thicker part is gradually marked off more and more abruptly. Sections of a stage with the primitive groove at its maximum—a stage which is usually found toward the end of the first day of incubation—show these changes clearly. A cross-section through the area opaca in front of the area pellucida shows the thin ectoderm, the thick cellular entoderm overlying the archenteric cavity and charged with yolk granules; the entodermic nuclei are very variable in form and irregular in distribution; the cell boundaries are indistinct. There is no mesoderm. A cross-section near the front of the area pellucida likewise shows only ectoderm and entoderm; the former is a high cylinder epithelium over the area pellucida and thins out toward the opaca on each side; the latter is a thin layer over the area pellucida and passes quickly but not abruptly into the very thick yolk-bearing entoderm (or *Keimwall*) of the area opaca. Sections a short distance in front of the primitive groove show that the head-process (*Kopffortsatz*) is a forward prolongation of the primitive streak, and consists of an axial accumulation of mesodermic cells fused with the entoderm, and having broad extensions sideways to form the mesoderm between the outer and inner germ-layers; the lateral portions of the mesoderm have no connection with the other germ layers, and at its distal edge the mesoderm thins out and rests upon the entoderm of the opaca, but without being connected with it; I cannot find any satisfactory evidence that it receives any additions from the opaca entoderm, as many authors have maintained. The ectoderm in the region of the "Kopffortsatz" resembles that further forward, but it very soon shows a faint median furrow, the so-called dorsal groove (*Rückenrinne*), which is the commencement of the medullary groove (see Chapter VII.). In the anterior half of the primitive streak the relations are different from those in the "head-process." The outer layer shows the primitive groove, Fig. 81, *prg*,

* This outer layer is usually termed ectoderm, but I hold that it is not ectoderm, but the homologue of the outer layer of yolk cells in the amphibian anus of Rusconi.

and is fused with the axial cord (*Achsenstrang*) of the mesoderm; laterally the outer layer passes into the true ectoderm, *Ec*. In the posterior region of the primitive groove the connection of the mesoderm with the inner germ-layer is dissolved. Behind the primitive groove the mesoderm extends, but lies free between the ectoderm and

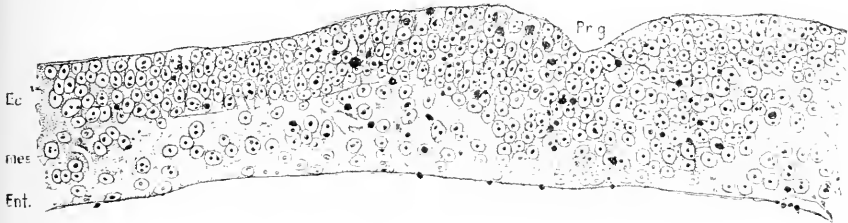


FIG. 81.—Transverse section of the anterior region of a fully-developed primitive streak of a Hen's ovum: *Ec*, ectoderm; *mes*, mesoderm; *Ent*, entoderm; *Pr. g.*, primitive groove. The large black dots represent yolk grains.

entoderm. To recapitulate: there is a long axial mesodermic thickening, which has the primitive groove over its posterior two-thirds; the thickening in front of the groove is united with the entoderm, and constitutes the primitive axis; the thickening under the front half of the groove is united with the entoderm; in the median line its external surface is freely exposed, and laterally it merges into the ectoderm; the thickening under the hind half of the groove is not united with the entoderm.

III. THE MAMMALIAN BLASTODERMIC VESICLE.

In all placental mammalia, owing presumably to the absence of the large amount of yolk present in the ova of other amniota, the early development is modified, and the germinal area instead of resting on a mass of yolk rests upon a vesicle. When the vesicle is fully developed its main cavity is lined by entodermal cells, and must be, in my opinion, homologized with the yolk cavity of other vertebrates, for it fuses with the notochordal canal to develop the definitive archenteron.

We may conveniently distinguish four stages of the vesicle, which are described below in order: 1, with one layer constituting the vesicle, except over the germinative area; 2, with two layers; 3, with primitive streak; 4, with "head-process," or primitive axis.

1. Vesicles with One Complete Layer.—After the close of segmentation we find that the inner mass becomes flattened out, and in the region it occupies we can distinguish three layers of cells, as previously described: first, counting from the outside, the thin layer of cells known as Rauber's "Deckschicht;" second, a middle layer of cylindrical cells, which becomes the ectoderm; third, an inmost layer of thin flattened cells, which belong to the entoderm; the *Deckschicht* continues round the whole vesicle as a single layer; the other layers do not so continue, compare Figs. 57 and 58. The next step in development is the formation of a second layer, which spreads out in all directions from the region of the inner mass; hence as far as the new layer reaches the blastodermic vesicle becomes two-

layered. Meanwhile the Deckschicht disappears, leaving two layers in the region of the inner mass; it is to be remarked that the Deckschicht is retained in certain rodents, undergoing special modification, as described in the section on inversion of the germ-layers.

Rabbit's Vesicle at Six Days.—The following is a summary of Ed. van Beneden's description, 80.1, 185-200. The vesicle measured 3.2 mm. in diameter; it was nearly spherical; the wall of one hemisphere consisted of one layer of cells; the other hemisphere had two layers of cells, and besides in its central portion a third layer intervening between the other two. The area with three layers Van Beneden designates as the *tache embryonnaire*; it showed no trace of the primitive streak; it was oval in outline and had one point, which the author identifies as *Hensen's knot*, where the layers adhere together closely. Transverse sections show that the outermost layer of cells is a low cylinder epithelium, which, at the edge of the area, passes into a thin epithelium, quite abruptly; it corresponds to Rauber's Deckschicht, and has been said by him to flatten out and disappear, leaving the cells underneath as the permanent outer layer of the embryonic vesicle. The cells of the innermost layer are thin and wide; they are called the hypoblast (entoderm) by Van Beneden; the cells themselves have round nuclei, around each of which is accumulated a court of granular protoplasm; the adjacent courts are connected by a coarse meshwork of protoplasmatic threads; treatment with nitrate of silver brings out the cell boundaries and divides the reticulum into polygonal areas. The cells of the present outermost layer have distinct boundaries and contain granules and long bacilliform bodies, which Van Beneden saw also in the fresh specimens and found to be constant appearances. Similar bodies are found in the germinal vesicles of sheep, and are held by Bonnet, 84.1, to be derived from the uterine milk; the rabbit

is not known to have uterine milk. The histological peculiarities of these two layers remain about the same from the fifth to the eighth day. The middle layer consists of rounded cells with numerous granules; seen from the surface their diameter is greater than that of the cells outside them, but much less than that of the cells underlying them. While we know that the middle layers are ectodermal, it is uncertain whether the inner layer is entodermal or not.

Blastocyst of the Rabbit of Seven Days.—The development is exceedingly variable, so that exact times cannot be given. The




FIG. 82.—Blastodermic vesicle of a Rabbit of seven days: *ag.* area germinativa, or embryonic shield; *ge.* line, above which the vesicle is two-layered. From Kölliker.

general appearance is illustrated by Fig. 82, from Kölliker. The vesicle figured was 4.4 mm. in length; the envelopes of the ovum are not shown, though they were still present; at the upper pole is the

small embryonic shield, corresponding in position to the region of the inner mass; it is marked out by the greater thickness of the walls of the vesicle; the developing second layer extends over more than half the vesicle, reaching to the line *ge*.

2. Blastodermic Vesicle with Two Layers.—Of this stage we have several descriptions; for the rabbit by Kölliker ("Grundriss," p. 91); Hensen, **76.1**; C. Rabl, **89.2**, 141; as well as the older accounts by Bischoff, **42.1**, and Coste, **47.1**, and the brief mention by Heape in Foster and Balfour's "Embryology," 2d edition, 316–320; for the mole by Heape, **83.1**; for the dog by Bischoff, **45.1**; for the cat by Schäfer, **76.1**; for the sheep by Bonnet, **84.1**; and for several rodents, as indicated in the section on inversion of the germ-layers, p. 141.

The two-layered stage is found in the rabbit about seven, in the sheep about thirteen, days after coitus. The dimensions for the sheep are about 4 mm. for the greatest diameter and 2.3 mm. for the lesser diameter.

The two layers form each a closed sack; the embryonic shield is well marked as a round spot, less translucent than the walls elsewhere. The outer layer has a distinctly epithelial character; in the region of the shield its cells are columnar with spherical nuclei; in the rabbit the cells are low and the nuclei lie nearly at one level; in the sheep the cells are taller and the nuclei are at various levels; in the mole (for a good figure see Heape, **83.1**, Pl. XXI., Fig. 49), and in various rodents there are several layers apparently, but perhaps in them also the epithelium is columnar, as it certainly is later. At the edge of the shield there is an abrupt change to a very thin layer, with widely expanded cells; consequently, in the region of the shield the nuclei are close set, while outside the shield they are wider apart. The change at the edge of the shield is at first less abrupt, but at the present stage is very marked. A similar difference exists in the inner layer, although its cells are very much thinned out everywhere, yet the layer is slightly thicker in the region of the shield; the nuclei of the inner layer are somewhat flattened,

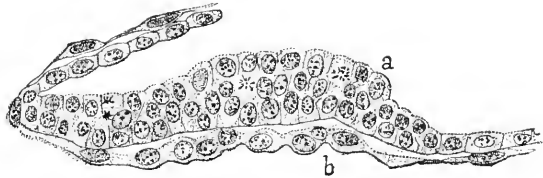


FIG. 83.—Transverse section of the embryonic shield of the blastodermic vesicle of a Sheep, thirteen days pregnant. After Bonnet. *a*, outer layer of vesicle; *b*, inner layer of vesicle.

and they are larger and farther apart than the nuclei of the outer layer—a difference which is very obvious in surface views, both during this and the next following stages. The inner layer has an epithelial character in the region of the shield, but farther away the cells move apart, and being connected by processes resemble embryonic connective tissue (Bonnet, **84.1**, 192; Hensen, **76.1**, Figs. 15 and 11, B on Taf. VII.; E. van Beneden, **80.1**). The relations are illustrated by the accompanying Fig. 83, representing the shield in the sheep at thirteen days and of a vesicle measuring 4 mm. by 2 mm.; at the left of the figure the layers are accidentally folded.

The next changes which occur are principally those of growth

both of the vesicle as a whole and of the embryonic shield, which also begins to arch up; the vesicle and shield both become oval; usually the oval shield lies lengthwise, but in the deer, as shown by Bischoff, it lies transversely of the vesicle. The size of the shield is quite nearly uniform among the placental mammals in which it has been studied, but the size of the vesicle varies extremely; especially noteworthy is the excessively rapid elongation in ungulates (pig, sheep, goat, and deer); in the sheep, for example, it trebles or sextuples its length in less than a single day after the shield appears. The next step is the appearance of a middle layer, at least in sheep (Bonnet, **84.1**, 192-196, **89.1**, 42), which shows in the fresh specimen as a slight turbidity, Fig. 84, *mes*, of the vesicular walls just outside the edge of the shield, while in the region of the shield there is no middle layer whatever. Sections show that the new layer consists of loosely scattered cells connected by anastomosing processes; it is everywhere

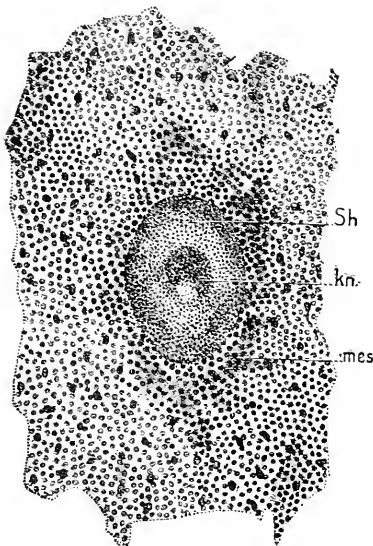


FIG. 84. — Central portion of a Sheep's blastodermic vesicle of twelve to thirteen days. *Sh*, shield; *kn*, Hensen's knot; *pr*, trace of primitive streak; *mes*, "Mesoblasthof." After Bonnet. $\times 34$ diams.

Bonnet maintains that the knot gives off cells which contribute to the formation of the middle layer. The knot marks the front end of the future primitive streak, and is the beginning of the primitive axis.

The appearances in a sheep's ovum at this stage are illustrated by Fig. 84 of a vesicle of twelve to thirteen days from a sheep; the vesicle measured 55 mm. in length by about 1.5 in breadth, but the length of the vesicle is extremely variable at this stage; the specimen had been stained to bring out the small, close-set nuclei of the outer layer and the larger, more widely set nuclei of the inner layer. The upward arching embryonic shield, *Sh*, shows Hensen's knot, *kn*; around the edge of the shield, *Sh*, the middle layer makes an irregular shadow, *mes*.

absolutely distinct from the outer layer, but merges at many points with the inner layer; from this connection Bonnet concludes that the middle layer is derived from the inner layer by what must be called a process of delamination. So far as known to me nothing analogous to this middle layer has yet been observed in other mammals. The next important step, again according to Bonnet, **81.1**, 195, is the appearance of *Hensen's knot*, which takes place while the peripheral middle layer is developing. The knot, Fig. 84, *kn*, is at first a small thickening on the under-side of the outer layer; it is situated on the middle line of the shield a little nearer one end than the other; it is distinctly separated from the inner layer, but is connected with the cells of the middle layer, which have now developed themselves in the middle region of the shield also.

A condition of the blastodermic vesicle similar to that described is figured by Coste for the rabbit, **47.1**, by Bischoff for the rabbit, **42.1**, Taf. IX., fig. 42, c, for the dog, **45.1**, Taf. III., fig. 28, B; and the gradual extension of the second layer is recorded for the mole by Heape, **83.1**. Since it is known to occur in rodents, carnivora, and insectivora, it is probably true of all placental mammals that the one-layered vesicle becomes two-layered by the outgrowth of cells from the "inner mass" found at the close of segmentation; this is the first step of development after segmentation.

RAUBER'S DECKSCHICHT has evidently great importance. It was first described by him in the rabbit, **75.2**; and was also discovered by E. van Beneden, **76.1**, who, however, made the error of considering it as the permanent ectoderm, and the true ectoderm below it as the mesoderm; this error has been amply corrected by Kölliker and is now admitted by Van Beneden (see Van Beneden and Julin, **84.1**). Its disappearance in the rabbit has also been studied by Lieberkühn, **79.1**. Balfour ("Comp. Embryol.," II., 219) from investigations on the rabbit by himself and Heape, concluded that the cells of the Desckchicht disappear by being incorporated in the true ectodermal layer becoming at the same time columnar; this view is verified by Lieberkühn, **82.1**, 400, 401. As already stated the rodent modification of the Deckschicht is discussed below, p. 141. In the rabbit the Desckchicht disappears before the second layer of cells grows completely round the vesicle.

3. Blastodermic Vesicles with Primitive Streak.—The knot of Hensen marks the front end of the primitive streak, which lengthens backward; during the same period the vesicle as a whole enlarges; in ruminants the enlargement is enormous and very rapid.* The primitive streak always lies in the long axis of the shield. The formation of the primitive axis begins with the union of Hensen's knot with the inner layer, so that at the knot all three layers are actually united—the condition originally discovered by Hensen, **76.1**, 268. The union of the knot with the inner layer spreads backward until it reaches the edge of the shield, thus generating the primitive streak. Next follows the elongation of the streak and shield, the latter becoming pointed at its hinder end. We thus have a pear-shaped shield with the primitive streak running forward from its pointed end; the anterior end of the primitive streak is somewhat enlarged and the posterior end is considerably thickened; the three layers are united along the primitive streak. Fig. 85 represents the embryonic shield of a rabbit embryo; the shield measured 1.34 mm. in length and 0.85 mm. in width; the primitive streak is a broad band, corresponding to the axial thickening, and extends about two-thirds of

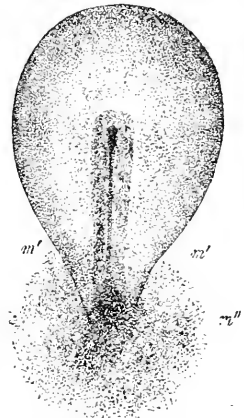


FIG. 85.—Embryonic shield of a Rabbit's ovum of five days, to show the primitive streak and the distribution of middle layer, *m' m'*. After Kölliker. $\times 28$ diams.

* Bonnet states that in the sheep the blastodermic vesicle must elongate during this period at the rate of one centimetre an hour.

the length of the shield; the mesoderm, m' , m'' , occupies a circular area around the hind end of the streak; for a similar stage in the opossum see Selenka, **86.1**, Taf. XVIII., Fig. 6; in the mole, Heape, **83.1**, Pl. XXVIII., Fig. 12; in the sheep, Bonnet, **84.1**, Taf. X., Fig. 39, 40. Cross-sections show the union of the three layers in the axis; the greater width of the streak in front (to this wide anterior end of the streak the term Hensen's knot continues to be applied); and show also the increasing thickness of the streak posteriorly. The primitive groove, which is a shallow depression of the outer layer, appears first over Hensen's knot, and thence extends gradually backward along the median line of the primitive streak.

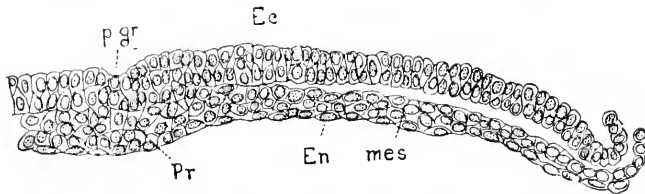


FIG. 86.—Section of the primitive streak of the Mole: *p. gr.*, primitive groove; *Ec*, ectoderm; *mes*, mesoderm; *En*, entoderm; *Pr*, primitive streak. (In sections nearer the end of the groove, *Pr* does not appear, and the inner layer is distinct, though not separated axially from the middle layer.) After Heape

A transverse section through about the middle of the streak at this stage in the mole is represented in Fig. 86, and may be considered thoroughly typical.

4. Blastodermic Vesicles with Primitive Streak and Head-Process.—In the stage we are now considering the axial thickening becomes subdivided into two parts, an anterior known as the head-process (*Kopffortsatz*), and the true primitive streak. The two are distinguished by the fact that the axial thickening in the region of the process is separated from the outer layer but fused with the inner layer, while in the region of the streak it includes, as in birds, the outer layer. Except at its anterior end, the axial thickening is not connected with the inner layer. Hence cross-sections may give us three different appearances according to the level at which they are taken.

The head-process was first distinguished, so far as I am aware, by Kölliker ("Entw.-Ges.," 1879, p. 271), also **83.1**. Lieberkühn, **82.1**, first showed that in it appears a small longitudinal canal, the walls of which form the notochord. Heape, **83.1**, discovered that the hinder end of this canal opens exteriorly in the mole, and Bonnet, **84.1**, made the same observation on sheep. Strahl describes the "process" in the rabbit incidentally in his paper on the cloaca, **86.2**; additional information is given by Bonnet, **89.1**, concerning the sheep, and by C. Rabl, **89.2**, concerning the rabbit. Especially valuable is Fr. Carius' dissertation, **88.1**. In the guinea-pig, according to Carius, after the formation of the primitive streak the middle layer grows out in *all* directions and lies free between the inner and outer layers. In front of the primitive streak the outgrowth takes place in three divisions—one median, two lateral. The median outgrowth is the head-process proper, and it becomes later

united with the inner layer, but at first lies entirely free (embryo of thirteen to fourteen days). The first indications of the formation of a canal is an alteration of form in the cells, which elongate in directions at right angles to the axis of the head-process, so that their oval nuclei are radially placed; the change begins posteriorly and progresses forward; while it is going on the anterior extremity of the head-process fuses with the inner layer. The radial cells move apart so that there arises a longitudinal canal; subsequently the canal loses its inferior wall, so that it becomes continuous as a cavity with the cavity of the vesicle formed by the inner layer; compare *ante*, p. 127. In the rabbit the head-process is also free at first, but very early unites with the inner layer, in which condition it was found by Carius, 18-19, at seven and a half days.* In the rabbit Hensen's knot presents at this stage a small depression (the front end of the primitive groove into which a small plug of tissue projects up from the underlying axial thickening (Carius' Fig. 7); Van Beneden homologizes this with the anus of Rusconi. The relations of the head-process in the sheep are very much as in the rabbit, Bonnet, 89.1, 65-67; the cells of the middle layer are at first free, as they grow forward to form the process, but subsequently are found united with the inner layer.

The head-process (*cf.* Lieberkühn), 84.1, probably always grows—as is certainly the case in the guinea-pig—at its hinder end and at the expense of the primitive streak; it is, I think, in this manner that the often-noticed shortening and final disappearance of the streak is effected. This mode of growth concords with the concrecence theory.

Homologies of the Mammalian Blastocyst.—The homologies with corresponding stages of other vertebrates are uncertain. It seems clear that the main cavity of the two-layered vesicle corresponds to the yolk cavity and that the head-process is identical with the primitive axis. But the homologies during the stages of transition from the segmented ovum to the two-layered vesicle are uncertain, and must remain so until we understand the genesis, first of the yolk cavity, second of the primitive axis. Nor can the development be clear to us until the growth of the primitive axis by concrecence is elucidated.

Inversion of the Germ-Layers in Rodents.—In many but not in all rodents the outer layer, Rauber's Deckschicht, of the embryonic shield undergoes a remarkable hypertrophy immediately after the close of segmentation proper; the Deckschicht, together with the ectoderm underlying it, becomes a plug which pushes in the other layers, thereby profoundly altering the topography of the ovum. In the mole, Heape, 83.1, the hypertrophy is not very great and the plug disappears soon, so that there is no great change; in guinea-pigs, mice, and Arvicola, the plug becomes very large and remains for a long time. The plug is very long and the ovum elongates with it, changing into an almost cylindrical vesicle (Selenka's *Keimcyl-*

*C. Rabl. 89.2, 143-145, states expressly that in the rabbit the axial thickening is not connected with the inner layer either under the head-process or under the primitive streak. He differs from other investigators in this so much that I think his preparations were probably defective; indeed, his own figures suggest at once that the inner layer has been artificially separated from the overlying one.

inder). The plug becomes hollow, and the cells corresponding to the Deckschicht become separated from those which are to form the ectoderm of the embryo. Three modifications of the hollowing out of the plug and of the separation of its two parts are known. The changes referred to are very clearly illustrated by Selenka, 84.1, Taf. XVI., in a series of comparative diagrammatic figures. In the simplest case, Fig. 87, the plug acquires a single cavity, *a*; the cells around the upper end, *Tr*, correspond to the Deckschicht and serve partly to attach the ovum to the uterine walls; the cells, *Ec*, around the lower end of the cavity become the embryonic ectoderm; all the cells around the cavity *a* are homologous with the outer layer of the embryonic shield of other mammals. The cavity *c* of the vesicle is very much reduced; the inner side of the shield, *i.e.* of the plug, is lined by an inner layer, *En*, which gives rise to the entoderm. The

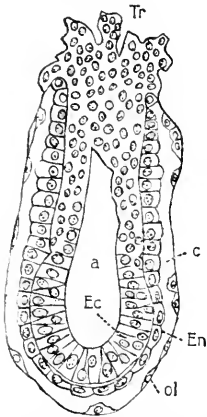


FIG. 87.—Blastodermic vesicle of *Mus sylvaticus*: *Tr*, Träger; *c*, cavity of vesicle; *En*, entoderm; *ol*, outer layer; *a*, cavity of Träger; *Ec*, ectoderm. After Selenka.

outer layer of the vesicle is very thin; it unites very closely with the walls of the uterus, and later disappears. Hence, when the uterus is opened, only the hollow plug and its covering of entoderm can be removed; as it makes a two-walled vesicle it was considered to represent by itself the two-layered stage of the blastodermic vesicle. Thus it came that Bischoff believed that in various rodents the ectoderm lies inside, the entoderm outside. Bischoff's observations, 52.1, 70.1, which were confirmed by Reichert, 62.1, are correct; but the inversion of the layers is apparent, not real. The actual homologies were not discovered until the improvements in microscopical technique enabled Selenka, 83.1, 84.1, and Kupffer, 82.3, to make sections of uteri with the ova *in situ*, and in their sections to follow the history of the outer layer. Their results have been in the main confirmed by Fraser, 83.1, and extended to another species by Biehringer, 88.1, 91.1.

In *Mus decumanus* the ectodermal cells early become a separate spherical mass, thus dividing the plug into two parts: a cavity appears in each part; these two cavities soon become confluent, and the inner layer of cells having meanwhile developed, the relations become essentially identical with those in *Mus sylvaticus*, Fig. 87. In *Mus musculus* the development is similar, but there is the additional peculiarity that the Deckschicht is regularly invaginated at first so as to form a small pit, into which uterine tissue grows. In *Arvicola* this invagination is more marked and lasts longer, but in both cases it is early obliterated.

Arvicola represents the second modification mentioned above; it has not only the invagination to distinguish it, but also the very early formation of the cavity of the plug as a fissure between the Deckschicht and the true ectodermal cells.

The guinea-pig offers the third modification and, is characterized by the early complete separation of the plug into its two parts; the Deckschicht remains at one end of the ovum and forms the Träger; it acquires an independent cavity of its own; the ectodermal portion

of the plug forms a solid spherical mass which is transported to the opposite pole of the ovum; it subsequently becomes hollowed out, presenting a space, which, as the later development shows, is the amniotic cavity. The inner layer passes from the edge of the Träger around the sphere of ectoderm; if the two parts of the plug were connected the relations of the inner layer would be the same as in *Mus sylvaticus*, Fig. 87.

The subsequent development of the rodents with inverted layers is modified in various secondary features, which it will be unnecessary for us to study. In all typical respects the embryonic development agrees with that of other mammals even as to details.

Duval, 90.2, has shown that in the rabbit the outer layer of the blastodermic vesicle degenerates and disappears, though at a much later stage than in the species just considered. Hence there is in the rabbit also potentially an inversion of the germ-layers.

Graf Spee, 89.1, 170, suggests, and I think with considerable reason, that the earliest development of the human ovum takes place by inversion of the layers. If this hypothesis is correct, it explains many of the remarkable peculiarities of the youngest human ova known at the present time.

CHAPTER VI.

THE MESODERM AND THE COELOM.*

THE morphology of the mesoderm is one of the most vexed questions of the day. Scarcely an embryologist can be found who has not published opinions on this question considerably at variance with the opinions of others. It has been maintained that the mesoderm arises from the ectoderm; that it arises from the entoderm, or from both; from neither, but from two special segmentation spheres; that it has a double origin, part coming from the blastoderm, part from the yolk, and even that there is no mesoderm.

We now know positively that in all vertebrates there is a distinct and unmistakable mesoderm, which spreads out from the primitive streak in all directions and has distinctive histological characteristics.

Two large and complex cavities appear in this mesoderm, one on each side of the median axial line. The mesodermic cells which bound these two cavities assume an epithelial arrangement, and are designated as the *mesothelium*; the cavities constitute the *coelom* or primitive body cavity; the mesothelium at various points throws off cells which compose the *mesenchyma* (embryonic connective tissue). We have, accordingly, three distinct phases to study, viz.: 1, the origin of the mesoderm; 2, formation of the coelom and mesothelium; 3, the origin of the mesenchyma. Finally, we must review the principal theories in regard to the morphological significance of the mesoderm.

I. ORIGIN OF THE MESODERM.

Mesoderm of Elasmobranchs.—In the cartilaginous fishes the mesoderm arises from the entoderm close to the ectental line. The observations of Balfour in his monograph, 78.3 (see also his works, I., 246-268), established the fact that the mesoderm appears after the two primary layers and is connected with the entoderm. This fact has since been abundantly confirmed, see Kollmann, 85.2, Swaen, 87.1, Rückert, 85.1, 87.1, Rabl, 89.2, D. Schwarz, 89.1, *et al.* These later observations, particularly those of Rückert and Rabl, have settled the exact point, or rather area, of entoderm which is mesoblastogenic. Unfortunately Rabl overlooked the phenomena of concrescence, and consequently reached conclusions as to the development of the mesoderm which I feel no hesitation in pronouncing erroneous. The mesoderm is differentiated along the embryonic rim before concrescence takes place; hence, when concrescence is partly completed, there is an axial stretch of mesoderm,

* This chapter has already been published in the *American Naturalist*, Oct., 1890, but as here reprinted has been extensively altered.

and from the hind end of this the mesoderm stretches out toward each side along the embryonic rim in connection with the entoderm, as has been described in Chapter V. We can distinguish the axial mesoderm from the lateral mesoderm; but later on, when concrescence has progressed farther, there is no lateral mesoderm, for it has become axial. Rabl, however, failed to study the later stages, and so came to consider that this temporary condition of the mesoderm signified a double origin; accordingly, he distinguishes between the "gastral" (axial) and "peristomial" (lateral) mesoderm, and makes the unsuccessful attempt to show that the "gastral" and "peristomial" mesoderms are of essentially different origin in all vertebrates. Had Rabl understood concrescence he would certainly have not fallen into these errors. There is no positive evidence that there is an evagination of the entoderm as the Hertwigs maintain can be shown in the amphibians—see below. On the contrary, the cells grow forth from the entoderm so as to constitute a sheet between the primary germ-layers. Soon the connection with the entoderm is permanently severed.

The fact that the mesoderm appears first in the embryonic rim renders it easy to make sure of its springing from the entoderm. Later, when concrescence moves the rim into the axial line, all three germ-layers are united in the primitive axis, and it becomes more difficult to decide which of the layers the mesoderm is specially connected with. To conclude: in elasmobranchs the mesoderm arises over a limited area of the entoderm near the ectental line; it separates from the entoderm apparently by a process of delamination, but the exact means of separation have yet to be investigated; it remains for a while connected with the entoderm along the embryonic axis; after its separation from the entoderm the mesoderm expands by proliferation of its own cells and receives no accretions from the yolk, so far as at present known.

Mesoderm of Teleosts.—So far as the published accounts go the middle layer of bony fishes arises as maintained by Balfour, "Comp. Embryol.," II., 74, from the entoderm. Such appears to be the significance of Ryder's observations, **84.1**, 41, of A. Goette's, **73.1**, E. Zielger's, Agassiz and Whitman's, **84.1**, and of others. For a good description, together with citations of conflicting authorities, see M. Kowalewski, **86.1**, 469-474. Apparently the blastodermic rim is turned under, and the turned-under portion yields the entoderm, and is intimately connected with the sheet of mesodermal cells, very much as in sharks; the mesoderm is several layers thick and stretches in under the ectodermal blastoderm, gradually thinning out; the cells of the middle layer are at first closely compacted.

Mesoderm of Amphibia.—Here it seems also clearly established that the mesoderm arises from the entoderm, principally along and alongside the median line, as a sheet of cells with no cavity (coelom), included between them; along the centre of the primitive axis and at the blastoporic margin the connection between the mesoderm and entoderm is both evident and intimate; see Bellonci, **84.1**, Tav. II., for figures showing this point in the axolotl, and O. Schultze, **88.1**, for similar figures of *Rana fusca*. These facts

have been recorded by so many observers that there can be little doubt or none of their entire accuracy; see the description and cuts, *ante*, p. 130. It may be considered as still uncertain whether the sheet of mesoderm receives accretions at its distal edge from the yolk cells (entodermic) upon which it rests. There usually is no sharp limit between the two, and therefore we must consider it probable that at first the mesoderm receives additions from the yolk; later on it is found divided from the vitelline cells, and after it has split off it probably grows independently. The growth of the mesoderm at first from the yolk has been found in *Petromyzon* by A. E. Shipley, **88.1**, 177, 178 (of "Studies"), although in later stages the mesoderm is severed from the yolk.

In later stages the mesoderm is wanting in the median line, and thus constitutes two masses or two lateral sheets. This bilateral division is effected by the development of the medullary groove and notochord, as described in Chapter VIII. The mesodermic connection with the entoderm is retained, but is double owing to the division. Along the median dorsal line of the archenteron runs the strip of entoderm which forms the notochord; on each side of this strip runs the line of connection between entoderm and mesoderm. The study of this *secondary* condition has led many authors into the error of ascribing a double origin to the amphibian mesoderm, and inferentially to the vertebrate mesoderm in general. This brings us to the consideration of O. Hertwig's views, which form one of the chief supports of the "Cœlomtheorie" of the brothers Hertwig. For further discussion of this theory see p. 155.

O. Hertwig, **82.1**, **83.1**, studied stages in which the notochord had appeared, and at this time, as O. Schultze, **88.1**, has shown,

the primitive relations of the layers no longer exist, but Hertwig regarded the secondary arrangements in question as primary. He found no mesoderm in the axial line above the notochord; at the edge of the notochord, where it joins the undifferentiated epithelial entoderm of the archenteron, there is on each side a groove which in cross-sections appears as a notch, Fig. 88; the notch is of variable depth, is sometimes absent, and is a temporary feature. In the neighborhood of the furrow alongside the notochord, the mesoderm is still intimately connected with the entoderm. These relations are believed by Hertwig to indicate that the mesoderm arises

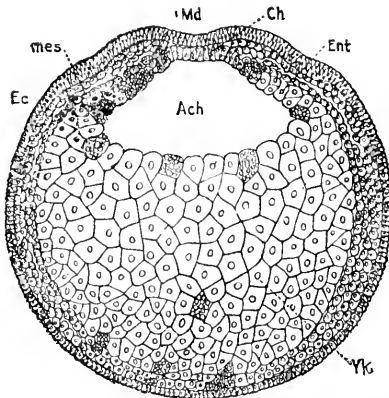


FIG. 88.—Axolotl embryo; transverse section of an early stage: *Ec*, ectoderm; *mes.*, mesoderm; *Md*, medullary groove; *Ch*, notochord; *Ent*, entoderm; *Yk*, yolk; *Ach*, archenteron. After Bellonci.

as two masses, which is not the case, and that each mass is really a diverticulum of the archenteron, the furrow being the mouth of the diverticular cavity. Hertwig's figures, **82.1**, Taf. XIII., XIV., offer the plainest representations of the mesoderm in *Triton* as paired

diverticula; but these figures* are evidently diagrammatic, and they must be termed inaccurate, I think, in the very respects which are essential to Hertwig's theory. This appears from the investigations of Goette, 75.1, Bellonci, 84.1, Bambeke, 68.1, O. Schultze, 88.1, and others. Compare also K. Lampert, 83.1. The reader may compare, for instance, Hertwig's Fig. 10, *l.c.*, Taf. XIII., with Bellonci's Fig. 11, *l.c.*, Tav. III. O. Schultze's detailed criticism, *l.c.*, 344-349, of Hertwig's account seems to me entirely justified, and I accordingly accept it as a complete disproof. This criticism shows that Hertwig's conception is based upon insufficient and erroneous observations; insufficient because he did not investigate the early condition of the mesoderm, and failed to recognize the fugitive and unessential character of the parachordal grooves; erroneous because the cavity in the mesoderm does not really communicate with that of the archenteron. There are other errors which Schultze points out and which are important. Robinson and Assheton, 91.1, 495, have also failed to verify Hertwig's statements.

We find in Amphibia at a certain stage the axial (Rabl's gastrales) and lateral (Rabl's peristomales) mesoderm. The former is in the region of the completed concrescence, the latter round the edge of the anus of Rusconi. The former is connected with the entoderm alone, the latter with the ectoderm also, since the entoderm is connected with the ectoderm around the unconcresced blastoporic rim. The connection with the ectoderm renders it possible that the middle layer receives cells from the outer layer, but there is no direct proof of this. When the concrescence is completed the mesoderm is said to sever, in the posterior axial region, its connection with the entoderm, but to retain awhile its connection with the outer germ layer. The same phenomenon recurs in the anniota. It cannot, however, be taken to signify that the middle layer originates from the ectoderm, since at an earlier stage it is clearly entodermal.

Mesoderm of Sauropsida.—We may consider reptiles and birds together, since the early history of the middle layer is very similar in the two classes.

In reptiles, so far as our present unsatisfactory knowledge enables us to judge, the mesoderm arises by delamination from the entoderm, but remains connected with it along the axial line; in front (*i.e.*, in the head-process) it is connected with the entoderm only, but posteriorly it is fused with the tissue of the primitive streak, and thereby is indirectly connected with the ectoderm. After its delamination the mesoderm expands independently of the other germ-layers except, perhaps, along the axis. That the relations are like those in birds has been shown clearly by Strahl, 83.1, and also by Weldon, 83.1, whose Figure 1 is reproduced, *ante*, Fig. 71. The intimate connection of the mesoderm with the entoderm at the blastodermic rim before concrescence is sufficiently established by Kollmann, 84.3, 403-406, though his conception that this part of the mesoderm is a separate structure, which he terms akroblast, renders it difficult to follow certain parts of his description. C. K. Hofmann may also be cited, though his account (Bromm's "Thier-

*Some of them are reproduced in Hertwig's "Lehrbuch der Entwicklungsgeschichte," ötes Capitel.

reich, Reptilien," p. 1881) is of doubtful accuracy in several respects. L. Will, 89.1, 1127, finds that in the gecko the mesoderm is united with the entoderm in the head-process, but omits to describe its exact connection with the primitive streak; the stages showing the *origin* of the mesoderm he does not mention. The processes involved will undoubtedly be understood as soon as the concrescence of the axis has been worked out—a fundamental question, which as yet not a single investigator has heeded.

In birds the exclusively entodermic origin of the mesoderm is, in my opinion, conclusively demonstrated by the researches of Duval, 84.1, 104-117; the entoderm gradually thickens by migrations of its cells over a considerable axial area; the upper stratum of this thickened area separates off as the mesoderm except that in the axial line it retains its connection with the entoderm; when concrescence takes place the two layers form the primitive axis. In the region of the primitive streak there is a single large mass of cells, Fig. 71, *Pr.*, which is continuous with all three germ-layers. Now if the homology maintained in the previous chapter be correct between the primitive streak and the anus of Rusconi, then the cells of the streak are also entodermal, and the middle germ-layer is connected in both axial regions directly only with the entoderm. After the mesoderm has separated from the entoderm except in the median line it may continue to receive accretions from the entoderm in the median line, but, as far as known, makes no peripheral additions except from its own growth. So far as heretofore observed the mesoderm receives no cells from the ectoderm.

Mesoderm of Mammals.—In this class, according to the best recent investigations, the mesoderm appears to have a distinctly twofold origin. According to Bonnet, 84.1, 196, part of the mesoderm grows out from Hensen's knot at a time when the knot is a thickening of the outer layer and has not yet acquired any connection with the inner layer; another portion is produced peripherally, Fig. 84, *mes.*, by delamination from the inner layer; the two anlagen grow toward one another and unite into one continuous mesoderm, in which all trace of the primitive double origin is obliterated. Kölliker has recorded the outgrowth of the mesoderm from Hensen's knot in the rabbit, and his statement has been confirmed by Fr. Carins, 88.1, 17. In later stages we find the relations of the layers similar to those in Sauropsida, there being a head-process with the mesoderm connected axially with the inner layer, and a primitive streak, with which the mesoderm fuses; the inner layer of the blastodermic vesicle is connected with the front part of the streak. This stage is quite well known, *cf.* Heape, 83.1, on the mole, Bonnet on the sheep, 84.1, Kölliker on the rabbit ("Grundriss"), Selenka on the opossum, 86.1, Lieberkühn, 82.1, and others, especially the very careful descriptions of the rabbit's layers by C. Rabl, 89.2.

At present it seems to me impossible to offer any satisfactory interpretation of the observed double origin of the mammalian mesoderm. The relations of the mesoderm to the primitive axis (head-process) and primitive streak are identical with those in birds and reptiles.

The Vertebrate Type of Origin of the Mesoderm.—The preceding paragraphs show that in all classes of vertebrates the

origin of the mesoderm is essentially the same, except that in some mammals it begins in two regions of the entoderm almost simultaneously. The relations in the mammals we do not understand. In the non-mammalian vertebrates the mesoderm first appears as a thickening of the entoderm over a not inconsiderable area around the concreting blastodermic rim, and it becomes separated from the entoderm by the gradual parting of the upper cells to form the true mesoderm from the lower cells or permanent entoderm; this delamination does not take place next the blastodermic rim (or—after concrecence—in the axial line); hence in the region of the primitive axis the three layers may be connected for a time; further, as the tissue of the primitive streak is at first connected with the ectoderm, the mesoderm is thereby indirectly continuous with the outer germ-layer during very early stages. It is important to note that the mesoderm arises over a considerable area during the same period; that its formation may be more or less advanced before concrecence of the rim; and that after concrecence it stretches across the axis of the embryo between the ectoderm and entoderm, thus becoming a continuous sheet or layer. This fact that the mesoderm is a single anlage needs to be specially emphasized. So far as known to me there is not a single vertebrate which has been shown to lack this stage, but on the contrary its occurrence is established for all classes and by so many observers that we may well assert that there are few facts in embryology better established. *Later* the mesoderm becomes divided in the axial line,* and consideration of this secondary condition has led to several theories of the mesoderm, which would hardly have been brought forward had their authors not neglected to take into account the earlier condition of the middle layer. Some of these theories are discussed below.

After its delamination the mesoderm is a distinct layer and grows independently, receiving no accretions from the other layers except in the axial line, where it receives cells from the entoderm and in the region of the primitive streak. The edge of the expanding sheet of mesoderm is free, as has been pointed out in the previous chapter, resting upon the yolk but not fused with it. It is therefore, it seems to me, impossible to admit that there is a peripheral ingrowth of tissues arising from the yolk and entering the mesoderm to form the blood, etc. Compare below, *Theories of the Mesoderm*, p. 153.

The primitive mesodermic cells are embryonic in character; that is, they have a large, usually nucleolated, nucleus, and very little protoplasm (Minot, 125). They are connected together by fine threads, and may lie some distance apart, then presenting an obvious resemblance to the mesenchyma of later stages. The cells become more closely compacted as development progresses, and when the coelom appears they take on a distinctly epithelial arrangement to make the mesothelium. The cells frequently contain yolk grains—in the case of Amphibia numerous and large ones. In birds the yolk grains are few, but are easily observed, Fig. 81; in mammals they are almost entirely absent.

*Mitsukuri, 91.1, has attempted to deny the views I have advanced, because in turtles the mesoderm is divided, as shown by his own observations. He has overlooked the fact that his observations refer to the secondary stage only when the medullary groove and notochord are present, and that they have no bearing on the question of the earlier and primitive condition.

Expansion of the Mesoderm.—After the mesoderm is once formed as a distinct layer without connection with the primitive layers except in the axial line, it expands independently—that is, by the proliferation of its own cells. During its early expansion the mesoderm assumes in all amniota a definite series of characteristic outlines. It is at first pear-shaped, Fig. 89, A, the anterior end being pointed; it extends a short distance only in front of the primitive streak, and is widest a little distance behind the area pellucida, *ap*. The same stage is found in mammals, see Kölliker, ("Grundriss," p. 93 and Fig. 71.) The condition in the chick at about the twentieth hour of incubation is indicated by Fig. 89, B, drawn on the same

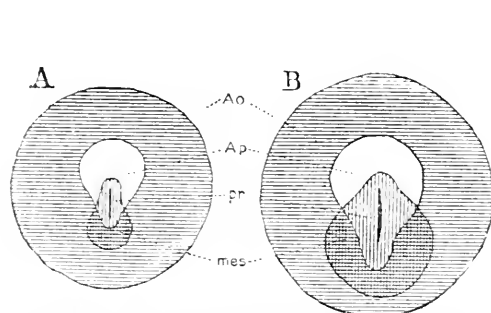


FIG. 89.—Diagrams of the embryonic area of the chick: *Ao*, area opaca; *Ap*, area pellucida; *pr*, primitive groove; *mes*, mesoderm. After Duval.

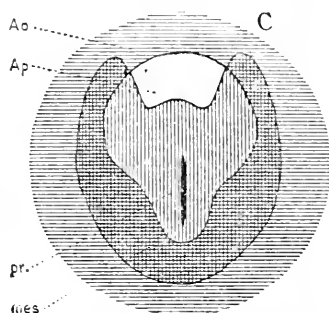


FIG. 90.—Diagram of the embryonic area of a chick: *Ao*, area opaca; *Ap*, area pellucida; *pr*, primitive groove; *mes*, mesoderm. After Duval.

scale as A, and at the close of the first day by Fig. 90. In the last mentioned figure it will be noticed that the mesoderm is expanding unequally in front, having sent out two lateral wings which leave a median space between them without mesoderm. These wings continue their growth and finally meet in front, so that in the anterior part of the area pellucida there is a small tract without any mesoderm, although there is mesoderm all around it; this tract is the *proamnion*, of which a fuller history is given in Chapter XV. The expansion does not take place by any means with the exact regularity indicated by Figs. 89, 90, but, on the contrary, in birds, as shown by Zumbstein, **87.1**, the outline of the middle layer is always irregular and more or less asymmetrical. Although there are not yet many observations available as to the outline of the growing mesoderm, yet it is probable that the preceding description is essentially correct, not merely for birds but for all amniota. It is certainly so for the rabbit, Van Beneden et Julin, **84.1**.

II. FORMATION OF THE CÆLOM AND MESOTHELIUM.

Early in the course of development there appears in the mesoderm a complex series of cavities, which very soon become united so as to form two large cavities, one on each side, which together constitute the *cœlom* or embryonic body cavity. In the adult mammal the *cœlom* is represented by the pericardial, pleural, and abdominal cavities: the *cœlom* also includes the cavities of the muscular seg-

ments (protovertebræ) and also certain tubular parts of the urogenital system. But although its subsequent changes are complex, the cœlom consists at an early stage of a pair of fissures in the mesoderm. As the cœlomatic cavities appear the cells bounding them take on a distinctly epithelial character. The mesodermic epithelium bounding the cœlom is termed the mesothelium, and it is probable—if we judge from our present imperfect knowledge—that the entire mesoderm is in all vertebrates first converted into mesothelium, before undergoing differentiation.

Only one precise account of the mode of development of the cœlom in mammals is known to me, namely, that of Bonnet, **84.1**, 202, for the sheep at about thirteen days. Around the embryo at some distance from the axis there appear a series of irregular fissures of rounded or elongated form, which may in part open on the mesodermic surface; gradually the fissures enlarge and fuse, at the same time becoming more closely bounded by the mesodermic cells; thus there arises a continuous cavity in the mesoderm which is for a time crossed by cells and cell processes; similar connections between the two leaves of the mesoderm while the cœlom is forming and their subsequent rupture have been noticed in Amphibia by B. Solger, **85.1**, 383, in Elasmobranchs by E. Ziegler, **88.1**, 383, and I find similar phases with great distinctness in the chick; meanwhile the cells, which are loosely put together, form a compact layer of epithelium bounding the cavity, which we can now designate as the *cœlom* or primitive body cavity. By similar processes the cœlom grows toward the axial region, but never penetrates it, the primitive streak and head-process never developing a median cœlom.

Albrecht Budge, **87.1**, has made a very exact study of the arrangement of the fissures in the mesoderm of the chick by means of injections of Prussian blue.* The fissures form a network of channels and by their fusion produce the cœlomatic cavities. The channels appear first around the periphery of the area vasculosa, and thence their development progresses centrifugally, but most rapidly toward the head; the channels fuse first around the head to make the amnio-cardial cœlom (*Parietalhöhle* of His); now appears a circular sinus just inside the vena terminalis; the cœlom grows back through the embryo and forms the body cavity of the rump; alongside the rump, as shown in Fig. 91, appears a network of channels, which soon fuse to create the cœlom under the lateral amniotic fold, and this unites with the cœlom of the rump, forming the completed cœlom continuous with that of the

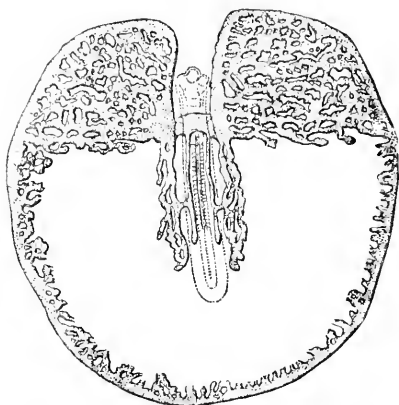


FIG. 91.—The mesodermal cavities of the germinal area of a chick of the third day, injected with Prussian blue. After A. Budge.

* The injections are made either into the amnio-cardial vesicles or into the circular fissure just inside the vena terminalis.

pericardium. The network of channels Budge regards as primary lymph spaces. Compare Chapter XIX.

Whether in all vertebrates the coelom results from the fusion of numerous small spaces or not, is not yet determined by actual observation. It is probable that it does so, and we may, therefore, say that the vertebrate coelom is what Huxley terms a schizocœle, *i.e.*, a cavity produced by splitting the mesoderm, compare p. 155. I consider it also probable that the coelom always begins to appear at a little distance from the axis of the embryo and spreads both centripetally and centrifugally.

Additional and important points in the earliest history of the coelom are treated in Chapter IX. We must add here that the coelomatic fissure divides the mesoderm on each side into an upper or outer leaf (*Hautfaserblatt*) and a lower or inner leaf (*Darmfaserblatt*), Fig. 92. The upper leaf may be called the *somatic mesoderm*, *Som*, the lower leaf the *splanchnic mesoderm*, *Spl*, as proposed by Balfour. The upper leaf lies close against the ectoderm; the two layers together form the *somatopleure* or body-wall. The lower leaf lies close against the entoderm; these two layers together

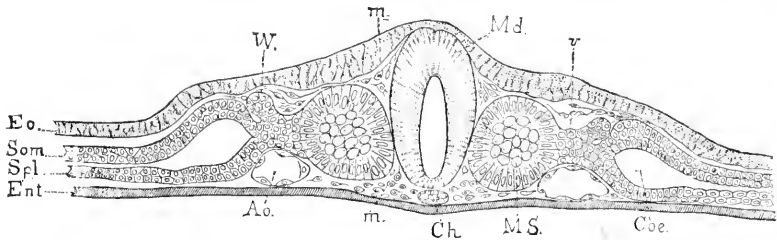


FIG. 92.—Section of a chicken embryo of about thirty-six hours: *Ec*, ectoderm; *Som*, somatic mesoderm; *Spl*, splanchnic mesoderm; *Ent*, entoderm; *W*, Wolffian duct; *m*, mesenchymal cells; *Md*, medullary groove; *v*, vein; *Co*, coelom; *MS*, primitive segment; *Ch*, notochord. After W. Waldeyer.

form the *splanchnopleure* or wall of the alimentary tract. Both the somatic leaf of mesoderm and the splanchnic consist at first solely of mesothelium, but very soon each contains mesenchyma also; the latter arises from the mesothelium; axially the two layers become continuous both with one another and with the axial mesoderm.

The morphology of the coelom is so important that it is difficult to understand why so many investigators have slurred over the question of its embryonic development. Exact observations on its first appearance and on the first stages of its expansion in various types are urgently needed, and would certainly do more than anything else to throw light on the still obscure problem of the origin of the mesoderm.

The histogenesis of the mesothelium varies somewhat in the different types. Primitively (marsobranchs, amphibians), the cells are rounded in form, contain considerable yolk, and are at first loosely aggregated, compare Fig. 88. When the coelom appears the cells become more closely appressed and so gradually assume more and more the characteristics of a cuboidal epithelium. In the amniota, on the other, hand, the mesodermal cells contain very little

yolk, Fig. 81, in which the yolk grains are shown as black dots; the cells are connected by their processes; as the cœlom develops the processes are shortened, and the cells become more closely packed, and thus gradually arrange themselves into a cuboidal mesothelium.

III. ORIGIN OF THE MESENCHYMA.

The genesis of the mesenchyma is treated in Chapter IX., as it cannot be understood without a knowledge of the development of the primitive segments. I will, therefore, merely state here the general methods of its production in order to render intelligible the following discussion of the theories of the mesoderm.

By mesenchyma we understand the whole of the mesoderm of the embryo, except the mesothelial lining of the cœlom. So far as at present demonstrated it arises solely from the mesothelium. Single cells leave the mesothelium on the side away from the cœlom; these cells remain connected with one another and with the mesothelial cells by protoplasmatic processes, but they do not lie close together as in an epithelium, so there is a considerable though variable amount of intercellular space. By the migration of the cells and their multiplication a large amount of mesodermic tissue is produced, which fills up all the room between the mesothelium and the two primary germ-layers. At first no definite distinction between the mesothelium and the mesenchyma can be established, but ultimately they become and remain distinct tissues, with divergent histories.

IV. THEORIES OF THE MESODERM.*

From the time of Von Baer's "Entwicklungsgeschichte," of which the first part appeared in 1828, until 1868, when W. His' great monograph on the chick, 68.1, was published, embryologists recognized the three layers, and regarded the mesoderm as a natural unit. His led the way to our present conception by a little-known article, 65.1, on the membranes and cavities of the body, and his monograph, 68.1, above mentioned fully established the necessity of recognizing two main groups of mesodermic tissues; accordingly he divided the mesoderm into two parts, the *archiblast* and *parablast*, corresponding respectively essentially to mesothelium and mesenchyma. Under archiblast His included not only the mesothelial tissues proper, but also the smooth or organic musculature; under parablast the mesenchymic tissue except the smooth muscle. The terms used corresponded to his theory of the origin of the two parts of the mesoderm, for he believed that the archiblast arose in the axial region and was contained in the embryo from the start, while the parablast arose peripherally and grew in toward the embryo, a conception which was perhaps suggested by the appearance of the blood-vessels, first, outside the embryo proper. Seeking still farther for the source of the supposed peripheral parablast he believed he had found it in the germinal wall. The study of the relations of the wall in the chick induced him to think that the elements of the white yolk be-

* Cf. *ante*, p. 149.

came parablast cells; moreover, the study of the hen's ovary led him to the conclusion that the white yolk was developed from the granulosa cells, and that these cells arise from leucocytes. He thus traced back the parablastic cells to maternal leucocytes. As subsequent chapters will show more fully, the granulosa cells are not leucocytes; in Chapter III. it has already been shown that the granulosa cells do not enter the ovum; the white yolk grains never become cells, for it has been proved that all nuclei of the segmenting ovum come from previous nuclei and lie in protoplasm, not in the yolk grains; and, finally, it has been shown in this chapter that the mesoderm arises as a whole, not from double sources. Professor His' views as to the origin of the parablast must be given up, but this is no reason for overlooking, as certain writers have done, the fundamental significance of the distinction drawn between the two primary groups of mesodermic tissues. Subsequent research has made only one important change necessary—namely, the transfers of smooth musculature from one group to the other. In view of this change, of the fact that parablast has been used with various other meanings, and of the unaptness of His' names—since we renounce the theory they correspond to—it will be well to use exclusively the newer terms, mesothelium and mesenchyma.

The parablast theory has been defended by His, 76.2, and modified by him, 82.1. At present he holds to the distinction originally drawn, but is inclined to withdraw his hypothesis of the origin of the parablast. A number of writers have agreed with His as to the separate peripheral development of the mesenchyma (parablast). Among these may be mentioned Rauber, 77.1, 83.4, and several authors who have dealt with the development of the blood, see Chapter X. The most important of the disciples of His is Kollmann, who, in a series of articles, 84.1, 3, 85.1, 2, has maintained the double origin of the mesoderm. Of these papers the most important is that on the "Randwulst," or germinal-wall, of the structure of which in the chick it gives an excellent description. Kollmann regards the germinal-wall not as part of the entoderm, but as a distinct organ composed of segmentation spheres, and destined to produce blood-vessels with blood, and probably also connective tissue; this peripheral anlage (*Randkeim*) he designates as *acroblast*, and the single cells derived from it he names *poronten*. Waldeyer, 83.1, has accepted the parablast theory, but with a modification by which he seeks to reconcile conflicting observations. His article is written with characteristic clearness and exhaustive mastery of the literature, and will be found especially valuable by those who wish to pursue this subject farther. Waldeyer distinguishes between the primary and secondary segmentation; the former producing the ectoderm, entoderm, and archiblastic mesoderm, the latter occurring later and giving rise to the parablast. According to Waldeyer this remnant of the ovum (which in holoblastic ova consists of cells, in meroblastic ova of egg protoplasm) has its cell division (segmentation) retarded, and the cells thus tardily produced immigrate into and between the germ-layers already developed.

The opposition to the parablast theory is the sum of numerous observations, which, as pointed out in the previous part of this chapter,

prove—it seems to me—that the mesoderm arises in all vertebrates (except mammals?) as a unit, and subsequently separates into mesothelium and mesenchyma. The leading opponent of the separate origin of the parablast is Kölliker in both his text-books (“Entwicklungsgeschichte,” etc., and “Grundriss”), and in separate articles, see especially, **84.2**, 4, and his criticism, **85.3**, of Kollmann. I agree with Kölliker that it has been sufficiently demonstrated that the “akroblast” belongs to the entoderm, and after the delamination of the mesoderm is transformed into the epithelium of the yolk-sac; for a conclusive demonstration that this is so in reptiles, see H. Strahl, **87.1**.

The *cœlom theory* of the brothers Hertwig includes a fundamental modification of the parablast theory. The main features of the cœlom theory are not original with the Hertwigs, but may be found in previous writers; nevertheless they were the first to present the theory in a complete formula and with a backing of facts, both new and collated, from others so extensive as to compel attention. In justice to E. Ray Lankester it must be stated that he is really the author of the cœlom theory, having in 1877 (**77.1**) published the hypothesis that the cœlom is derived from the archenteron, and that the mesoderm of vertebrates represents solid entodermal diverticula. It is unfortunate that the Hertwigs have not made due acknowledgment of what they owed to Lankester and others. They made a series of investigations on the germ-layers of various representatives of the animal kingdom, and presented their general results in a comprehensive article (O. and R. Hertwig, **81.1**), and O. Hertwig has again expounded the theory in his text-book of embryology. The cœlom theory consists of two parts: 1, the cœlom is formed by diverticula of the archenteron and its lining, the mesothelium, is part of the entoderm; 2, the mesenchyma consists of cells thrown off by the other germ-layers and is essentially distinct from the mesothelium. The value of this theory lay in the clearness of its formulation, thus facilitating discussion, and also in its bringing out the difference more clearly between the epithelial and the non-epithelial portions of the mesoderm. As we have seen, there is no evidence of a character to render even probable that the mesoderm of vertebrates represents archenteric diverticula, and the whole mesoderm appears as a single germ-layer, which is subsequently differentiated into mesenchyma and mesothelium. Hence, both essential parts of the cœlom theory are inapplicable to vertebrates, at least in the present state of our knowledge. For further discussion of the difficulties of the Hertwigs' theory, see Rabl, **89.2**, 198–202, also Alex. Goette, **90.1**, 18, as well as p. 146. The Hertwigs recognized the significance of the parablast and added the important rectification, which Flemmings' observations, **78.2**, had already rendered necessary, of separating the smooth muscles from the striated skeletal muscles—a separation the propriety of which was wrongly questioned by Balfour, “Comp. Embryol. II.,” 359. By this advance the two groups of mesodermal tissues became properly delimited.

C. Rabl's theory of the mesoderm is based, it seems to me, wholly upon his failure to understand the law of concrescence. That the mesoderm appears (perhaps in all vertebrates) while concrescence is

going on is well ascertained; consequently, there is an axial mesoderm (Rabl's "gastrales mesoderm") where concrescence has taken place, and a lateral mesoderm (Rabl's "peristomales mesoderm") in the part of the blastodermic rim which has not concresced. Until Rabl proves that his "peristomales" mesoderm does not become axial mesoderm in later stages his theory can have no standing. Davidoff, 90.1, 613, makes the best criticism of Rabl's theory which I have seen. Rabl's memoir brings out one point of very great importance for the elucidation of the early stages of vertebrates—namely, that the "peristomal" mesoderm, in other words, that of the blastodermic rim in selachians, and of the lips of the anus of Rusconi in amphibians, is represented in the amniota by the mesoderm of the primitive streak. If this interpretation, which is much strengthened by L. Will's researches on the gecko, 89.1, be verified, then the primitive streak is the homologue in amniota of the anus of Rusconi, and is the region where concrescence is incomplete; the head-process is then the part where concrescence is finished; this concords with the observed fact that the head-process grows at the expense of the primitive streak, as it would do if concrescence continued.

Alexander Goette's theory, 90.1, 24-33, is that the walls of the archenteron in *Amphioxus* and the true vertebrates comprise a dorsal region which develops the notochord and mesoderm, and a ventral region which develops the digestive tract. Owing to the great amount of yolk in true vertebrates the dorsal region is spread so as to lie upon the yolk, hence it is separated from the yolk or entoderm by delamination instead of forming a true evagination as in *Amphioxus*. It occurs to me that Goette's theory may be perhaps verified with the modification that the notochordal canal corresponds to his dorsal region, the yolk cavity to his ventral region of the archenteron.

Hatschek's germ-band theory offers, to my mind, the best-founded explanation of the vertebrate mesoderm, because it connects it with the mode of development of the middle layer in the annelids and other invertebrates. To understand the theory we must first consider the formation of the mesoderm in *Amphioxus*.

The ovum of *Amphioxus* is discharged from the body and impregnated externally; it is about 0.105 mm. in diameter, and, as it contains only a small amount of yolk, undergoes a holoblastic segmentation, which results in a well-marked blastula stage, Fig. 60, followed by a gastrula stage. The gastrula elongates, the blastopore remaining open at the posterior extremity. Differentiations now take place by which the ectoderm forms the axial anlage of the nervous system, and the entoderm produces the notochord

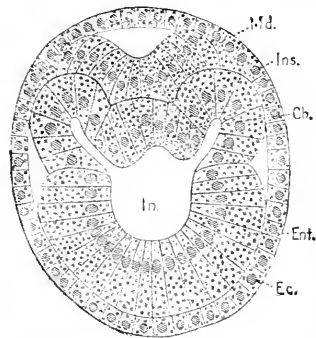


FIG. 93.—Transverse section of an *Amphioxus* embryo: *Md.* medullary plate; *Ms.* primitive segment; *Ch.* notochord; *Ent.* entoderm; *Ec.* ectoderm; *In.* archenteric cavity. After B. Hatschek.

and the mesoderm—the three processes going on simultaneously. The accompanying Fig. 93 represents a cross-section of a larva.

The ectoderm, *Ec*, everywhere bounds the section; on the dorsal side a portion of the ectoderm has been separated off to form the medullary plate, *Md*, above which is a small cavity. The cavity, *In*, of the archenteron is irregular, but symmetrical in outline; the entoderm bounding it can be separated into four parts: 1, the lower portion, which forms the permanent entoderm, *Ent*; 2, the upper median portion, which becomes the notochord, *Ch*, compare Chapter VII.; 3, 4th, two lateral portions constituting the diverticula, *Ms*; each diverticulum is a separate pouch, and as the development progresses there are formed a series of pairs of pouches, stretching on either side along the notochord; later the pouches separate altogether from the archenteron, each becoming a closed sack; the first pair of pouches, how-

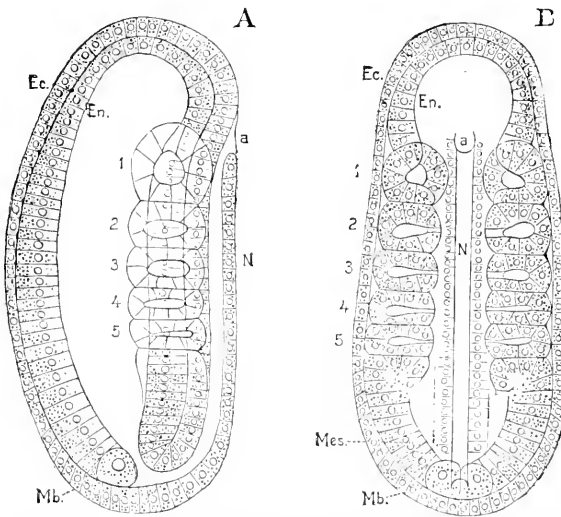


FIG. 94.—Amphioxus embryo: A, side view; B, ventral view. *Ec*, ectoderm; *En*, entoderm; *a*, neuropore; *N*, nervous system; *Mes*, mesoderm; *Mb*, mesoblast; 1-5, segments. After E. Hatschek.

ever, retain their connection for a considerable period with the archenteron, and have been described by older writers as glandular organs. The development of the pouches is, with the exception noted, most advanced anteriorly, and as we go tailward the pouches are less and less advanced in development, until, as shown in Fig. 94, they merge into the general entoderm as a band of cells, *Mes*, the last of which is the *mesoblast*, *Mb*, a large granular cell quite distinct from the remaining cells of the band or pouches. The pouches are the primitive segments (*Ursegmente*, mesoblastic somites of Balfour). In *Amphioxus*, then, the mesoderm arises from the entoderm along two lines, and is divided into paired hollow segments before it is separated from the entoderm. Some writers, especially the brothers Hertwig, think this process of development to be primitive, and that the vertebrate type is derived from it. In true vertebrates the mesoderm arises on each side, but also in the axis, and becomes two masses when the medullary groove and notochord appear; in

Amphioxus the medullary plate and notochord appear very early, and the division of the mesoderm may be due to that fact. Amphioxus is undoubtedly a lower type, but whether it really preserves the older type of development in its purity is doubtful; indeed it is probably a tunicate rather than a vertebrate.

Hatschek, in a series of brilliant investigations, has shown that in many bilaterally symmetrical invertebrates the mesoderm arises as two bands of cells, which subsequently divide into a series of closed sacks (segments), and which during their own formation terminate each in a single large posterior cell (*mesoblast*), which throws off cells to add to the mesodermal band (germ-band, *Keimstreif*). This *mesoblast*, by its appearance and position, appears to be a derivative of the entoderm. As a matter of speculation we may assume that in Amphioxus we have the germ-bands, but characterized by an exceedingly precocious segmentation. We can further assume that in vertebrates we have the germ-bands also, but that they are modified, 1, by the loss of the distinct terminal mesoblast; 2, by precocious fusion in the axial line, and 3, by extremely retarded segmentation. A great deal may undoubtedly be said in favor of these three assumptions, which together constitute that *theory of the vertebrate mesoderm*," which, of the many theories, that have been advanced, is most likely, in my opinion, to prove of permanent value.

CHAPTER VII.

GENERAL REMARKS ON THE GERM-LAYERS.

IN this chapter the general morphology and rôle of the germ-layers, the history of the theory of the germ-layers, and the laws of differentiation are briefly considered.

I. RÔLE OF THE GERM-LAYERS.

It has long been known that the bodies of embryos consist of distinct layers, which, in many cases, are separable from one another, so as to be recognized in gross as discrete membranes. It is now known that all such layers may be reduced to three primitive ones, named the ectoderm, mesoderm, and entoderm (by certain writers, epiblast, mesoblast, and hypoblast). The ectoderm is a layer of epithelium; so also is the entoderm; the mesoderm is more complex, and as we ascend the animal scale the mesoderm gradually acquires a greater predominance until in mammals nearly the whole bulk consists of mesoderm. But in spite of this change, the three layers are preserved throughout, and their essential relations are not altered, so that we are able to assert that unity of organization without which it would be impossible to accept the doctrine of evolution. The demonstration of the homologies of the germ-layers is the most important morphological generalization since the establishment of the cell-doctrine.

As the history of all the organs is given in detail in other chapters, it is unnecessary to do more here than classify the tissues and organs of the human body according to the germ-layers from which they arise. Now, in classifying organs, it is best to rank them as belonging to that layer from which their functionally essential and characteristic part is derived. Thus, although the pancreas, ovary, and spinal cord all contain connective tissue, we do not call them mesenchymal, but respectively entodermal, mesothelial, and ectodermal. The gland cells of the pancreas come from the entoderm; the ova and the Graafian follicles come from the mesothelium; the ganglion cells and nerve fibres (axis cylinders) from the ectoderm. Adopting this principle we may classify the organs of the human body as follows:

ECTODERMAL.	MESODERMAL.	ENTODERMAL.
Skin (epidermis).	1. <i>Mesothelium</i> .	Epithelium (of digestive tract).
Epidermal structures :—	Peritoncum.	Thyroid.
Hairs.	Pleurae.	Thymus.
Nails.	Pericardium.	Tonsils.
Glands :—	Urogenital.	Trachea and lungs.
Sebaceous.	Wolfian body.	Œsophagus.
Sudorific.	Kidney.	Stomach.
Salivary.	Testes.	Liver.
Mammary.	Ovary.	Pancreas.
Corneal epithelium.	Oviduct.	Intestine.
Lens of eye.	Uterus.	Yolk-sack.
Central nervous system :—	Vagina, etc.	Cæcum.
Ganglia.	Striated muscle.	Vermix.
Nerves.	2. <i>Mesenchyma</i> .	Colon.
Eye :—	Connective tissues.	Rectum.
Optic vesicle.	Blood.	Allantois :—
Optic nerve.	Blood-vessels.	(Bladder).
Olfactory organ.	Lymphatics.	Notochord.
Auditory organ.	Spleen.	
Mouth cavity :—	Smooth muscle.	
Teeth.	Fat-cells.	
Hypophysis.	Marrow.	
Anus.	Skeleton.	
Chorion :—		
Placenta.		
Amnion.		

The human body may be defined as two tubes of epithelium, one inside the other; the outer tube (epidermal or ectodermal) is very irregular in its form; the inner tube (entodermal) is much smaller in diameter, but much longer than the outer and has a number of branches (lung, pancreas, etc.), and is placed within the ectodermal tube. Between these two tubes is the very bulky mesoderm, which is divided by large cavities (abdominal and thoracic) into two main layers, one of which is closely associated with the epidermis and forms the body-wall, the somatopleure of embryologists; the other joins with the entoderm to complete the walls of the splanchnic viscera, and constitutes the splanchnopleure of embryologists. The mesoderm is permeated by two sets of cavities: 1, the heart and blood-vessels; 2, the lymphatic system. It is also differentiated into numerous tissues, muscle, tendon, bone, etc., and organs, urogenital system. The nervous system, although developed from the ectoderm, is found separated from its site of origin, and completely encased in mesoderm.

As we ascend the animal scale, we discover in all parts an increasing complexity; especially in the nervous system is this marked, but it is even more strikingly shown by the evolution of the mesoderm in relative size and differentiation. This important correspondence between the organization of the mesoderm and the degree of evolution of animals has not, to my knowledge, hitherto attracted express attention.

II. DIFFERENTIATION.

The fundamental law of embryology is that the simple precedes the complex, the general and typical the special. Each germ-layer is at

first a simple layer of cells of nearly uniform character. In order to develop out of the germ-layers the complex organs of the adult the layers have to be folded into various forms by unequal growth of their parts, and the cells composing them have to be specialized some in one way, some in another. This double process results in the differentiation of the organs. *Differentiation* may be defined as the process of change from homogeneous to heterogeneous structure, or as an increase of heterogeneity, since in living organisms there is no real homogeneity. From what has been just said it will be understood that under the present head we have to consider, 1, the laws of unequal growth; 2, the general laws of cellular differentiation, or, as it is called, histogenesis—the development of tissue.

The Relations of Surface to Mass.—However much the weight of an animal increases during its development, the ratio of the free surface to the mass alters but slightly from the ratio established when the embryo begins to take food from outside. It is only for convenience that I express this law in this precise form; in reality, about it our knowledge is scanty and our conceptions vague. According to a geometrical principle, when the bulk of a body bounded by a simple surface increases, the surface enlarges less than the mass—in the simplest case of a cube, the surface increases as the square, the mass as the cube, of the diameter. If in a cube of unit diameter one unit of surface bounds one unit of mass, then in a cube of three units diameter nine units of surface will bound twenty-seven units of mass; the proportion in the first cube is 1:1, in the second 1:3. To maintain the proper proportion in the embryo, simple enlargement is insufficient, therefore the surface increases by becoming more and more irregular. The irregularities are characteristic of each organ and part, and may be either large or microscopic. They may be conveniently grouped under two main heads—projections and invaginations.

Projections are illustrated by the limbs, filaments of the gills in fishes, the villi of the intestine, folds of the stomach in ruminants, etc. In every case the projection is covered by an epithelium and has a core of mesodermic tissue.

Invaginations exist in much more varied form and play the principal part in the differentiation of the animal body. They may be classified under four principal heads: 1, Dilatations; 2, Diverticula; 3, Glands; 4, Vesicles. *Dilatations* have considerable importance in embryology; the stomach, lungs, bladder, and uterus arise as gradual dilatations of canals or tubes of originally nearly uniform diameters. *Diverticula* in the sense of relatively large blind pouches also form important organs, such as the cæcum and appendix vermiformis, or the gall bladder; these structures arise, each as a blind outgrowth of a canal, the walls of which at a certain point rapidly grow to form the pouch. *Glands*, which are, as first shown by Johannes Müller's classic researches, only small diverticula, which end blindly and appear in an immense variety of modifications; the manifold types of glands are discussed below in a separate paragraph; they constitute the largest class of organs with which we have to deal. The glands are developed from epithelium and push their way *into* the mesoderm upon which the epithelium rests, while

in dilatations, and in diverticula, the epithelium and mesoderm expand together. *Vesicles* we call those epithelial sacs, which develop somewhat like glands by growing into the mesoderm, but the mouth of the invagination closes by the coalescence of the epithelium, thus shutting the cavity. The closed sac separates from the epithelium from which it arose, and connective tissue grows between the two; the sac may then undergo various modifications. The membranous labyrinth of the ear is developed from the ectoderm in this way, as is also the lens of the eye. We might perhaps also class the medullary canal under this head (*cf.* Chap. VIII.) if we choose to consider it as a vesicle so much lengthened that it has become a tube.

The Law of Unequal Growth.—The changing shapes of the embryo and the development of those irregularities—projections and invaginations, which preserve the proper proportion between the surface and mass of the body, both depend upon the unequal growth of the germ-layers, especially in superficies. The expansion of a germ-layer having the epithelial type of structure* may take place by three means: 1, the multiplication of the cells; 2, the flattening out of the cells; 3, enlargement of the cells. In the early stages of development the influence of the first two factors predominates; during the later stages, especially after birth, the latter. Of the three factors the first is the most important.

The unequal multiplications of the cells in all embryonic epithelia is *the* fundamental factor of development, and we see it shaping out the embryo, its organs, and the parts of organs, before histological differentiation really begins. The distinct areas and centres of growth which are necessary to develop the human body out of the germ-layers are innumerable, and their distribution, limitations, and interactions make up a large part of the subject-matter of embryology. At every turn of our studies we encounter fresh illustrations. If in a limited area of a cellular membrane there occurs a growth or expansion more rapid than in the neighboring parts, then that area is, as it were, bounded by a fixed ring, and can, therefore, find room for its own expansion only by rising above the level of the membrane; thus when in the embryonic region of the blastodermic vesicle the growth becomes more rapid, the embryo begins to rise above the level of the vesicle; when, at a certain point of the surface of the embryo, a steady and long-continued growth occurs, the limb appears, gradually lengthens out, and enlarges from a small bud at first to a complete arm or leg. If the departure takes place the other way we have an invagination produced; thus for every hair and every gland of the intestine there is a separate centre of growth.

The reason for the unequal growth is unknown. We have not even an hypothesis to offer as to why one group of cells multiplies or expands faster than another group of apparently similar cells close by in the same germ-layer. It is no real explanation to say that it is the result of heredity, for that leaves us as completely in the dark as ever as to the physiological factors at work in the developing individual.

The conception that the development of an animal depends fundamentally upon the unequal expansion and consequent foldings and

* By this limitation we exclude the mesenchyma, but not the mesothelium.

bendings of the germ-layers was first suggested by the researches of C. F. Wolff on the development of the intestine, and was more clearly recognized by Pander, who definitely asserted that the formation of the embryo is affected by foldings of the germ-layers. In recent times His has studied the problem very intently, and in his memoir on the chick, 68.1, discussed it minutely. In this memoir is to be found most of what little we know concerning embryological mechanics.

The Classification of Glands.—For a long time it has been customary to divide glands into tubular and acinous. W. Flemming, in an admirable article, 88.1, has shown that this classification as currently applied is untenable, and he proposes in its stead another, the basis of which is the branching of the glands; he makes three primary divisions: *Single glands* (Einzeldrüsen), which are unbranched; *Single branching glands* (verästelte Einzeldrüsen), with a single duct and the secretory portion branched; *Compound glands* (zusammengesetzte Drüsen), with both the ducts and the secretory portions branched. Under the first head he includes the follicles of the ovary, under the last the seminiferous tubules; but the so-called sexual glands are not, properly speaking, glands at all, since their products arise as differentiations of the cells, not as secretions; it can, I think, only perpetuate confusion to class them with the true glands. So, too, with regard to the principal organs of excretion—the lungs and the kidneys; the former can certainly not be regarded as a gland, since it produces no secretion, for the water and gases given off by the respiratory organs are not produced by the pulmonary epithelium. The kidneys have more claim to be classed with the glands, since their excretion is the direct product of the epithelium of the renal tubules; the ureter represents the duct and the secretory portions (collecting tubules) branching, thus bringing them under the second of Flemming's headings. It seems to me more convenient to give the kidneys a place apart. Under the head of compound glands Flemming ranks the liver, but inasmuch as the gland cavities (gall-capillaries) of the liver form an anastomosing system of canals, it is better to put the liver in a class by itself, especially as its development is unlike that of any other gland. For the sake of completeness we may add also the unicellular glands, such as are found in the lower vertebrates and in many invertebrates; these constitute a group by themselves, distinct from the multicellular glands. The latter may be divided into four sub-groups: Simple, Branching, Compound, Anastomosing. A *simple* gland is one consisting of a single unbranched epithelial tube, ending blindly and opening upon the epithelial surface from which the gland has been developed; a simple gland may be *tubular*, that is, a canal of approximately even diameter; or *alveolar*, that is, with the blind end somewhat dilated; or *vesicular*, that is, with the opening small, but the rest of the gland distended like a cyst. Even in the simple glands we usually find the portion of the epithelial tube near the orifice acting simply as a duct, while the deeper part alone performs the secretory office, or acts as the gland proper. The differentiation of the duct is to be regarded, generally speaking, as the earliest and most primitive specialization of a gland. A *branching* gland is a

simple gland with the addition of branching of the secretory portion proper; under this head also we have *tubular* and *alveolar* glands. A *compound* gland is a branching gland with the addition of branching of the duct. An *anastomosing* gland is a compound gland with the additional feature of the branches of the secretory portion united together so as to form a network.

If we apply this classification to the glands of man, the result may be presented in a tabular form, as follows:

GLANDS

- A. UNICELLULAR
(Found in ichthyopsida and invertebrata).
- B. MULTICELLULAR
 - 1. *Simple glands.*
 - a. *Tubular.*
 - 1. Lieberkühn's follicles.
 - 2. Peptic glands.
 - 3. Sweat glands.
 - b. *Alveolar*
Small sebaceous glands.
 - c. *Vesicular.*
(Sub-epidermal glands, amphibia).
 - 2. *Branching glands.*
 - a. *Tubular.**
 - 1. Pyloric glands.
 - 2. Brunner's glands.
 - 3. Mucous glands.
 - 4. Uterine gland.
 - b. *Alveolar.*
 - 1. Large sebaceous glands.
 - 2. Meibomian glands.
 - 3. *Compound glands.*
 - a. *Tubular*
 - 1. Salivary glands.
 - 2. Pancreas.
 - 3. Tear glands.
 - 4. Cowper's glands.
 - 5. Prostate glands.
 - b. *Alveolar.†*
Milk glands.
 - 4. *Anastomosing glands.*
Liver.

This classification cannot be regarded as final, since it is based solely on the general shape of the epithelial invagination forming the glands. We may expect in its stead a better classification, based on other and more essential characteristics. The defects of the above arrangement are serious, as is strikingly illustrated by the unnatural separation of large and small sebaceous glands. The basis of classification ought to be the phylogeny of the glands.

Histological Differentiation.—The genesis of the tissues depends upon—1, the multiplication of cells; 2d, the specialization of cells; 3d, the development of intercellular substance. The first of the factors will be discussed in a later chapter. The second and third are to be considered here.

The first tissue to appear is the epithelium of the ectoderm and

* If the kidneys be considered as glands they would come under this head, as branching tubular glands.

† If we consider the lung as a gland and the bronchi as ducts, the lung would come under this head as a compound alveolar gland.

entoderm; the second form of tissue is the mesenchyma, for the mesothelial portion of the mesoderm is also epithelium. Histological differentiation, therefore, begins with epithelium and mesenchyma; these two primitive tissues we must consider separately.

A. *Epithelium*.—In invertebrates the ectoderm and entoderm as soon as they become cellular consist each of a single row of polyhedral cells, which in the most primitive type are of equal height. The cells when viewed from the surface are always irregular in outline, usually five and six-sided, sometimes seven-sided or more, but probably never four-sided, except occasionally isolated cells, which assume that outline. When the cells are not modified by the presence of yolk, the round or nearly round nucleus lies in the centre of each cell. In every epithelial cell three axes may be distinguished, two parallel, with one perpendicular to the surface of the layer, of which the cell forms a part. In the primitive epithelium the three axes are approximately equal in length, hence the tissue is said to be composed of "cubical" (cuboidal) cells. There is very little substance between the cells, and it always remains relatively insignificant in epithelium in marked contrast to its development in the mesenchyma.

In probably all vertebrates the ectoderm and entoderm during segmentation are both several-layered, but after the close of segmentation they soon become each single-layered, as we have seen. The significance of this modification of the course of development is unknown.

The further differentiation of the epithelial germ-layers depends on—1, the formation of folds, already discussed, p. 161; 2, changes in the proportion of the cellular axes; 3, structural changes in the cells; 4, arrangement of the cells in several strata. Concerning the latter factors a few words are necessary. The horizontal axis usually remain approximately equal in length, while the perpendicular axis varies independently and to a much greater extent. That epithelial cells are primitively equiaxial may be accepted as an axiom. Yet in vertebrates there are marked departures from this type during very early stages. From the cuboidal type arise the principal modifications known as the "cylinder" epithelium and the "pavement" epithelium—names which are unfortunate. As regards the *structural differentiation*, we must distinguish between the specialization of single cells and that of groups of cells. The former is presumably the primitive form, since it predominates in cœlenterates; the later has been evolved, we must assume, by the grouping of specialized cells; but in the development of a vertebrate we see always a cluster of cells gradually differentiated from their fellows, and never the cells first specialized and then collected by migration or otherwise. Speaking generally we may say that the higher we ascend the animal scale the less specialization do we find of isolated cells, and the more of groups of cells. This noteworthy fact will, I think, be ultimately found to possess an important significance at present hidden from us. The development of *additional strata*, which is especially characteristic of the vertebrate ectoderm, is described in the chapter on the epidermis.

B. *Mesenchyma*.—The first histological differentiation of the mesenchyma in vertebrates is the separation of a certain number of

cells from all attachment to their fellows; these cells are capable of changing their site, and during further development they increase in number and variety. The first of these cells to appear are the blood-cells of the so-called blood islands. For all mesodermic cells not mechanically united to others, but capable of change of site, I have assumed that the primitive type was a cell capable of independent amœboid movements, and have proposed for them (Minot, 23, 207), the collective name of *Mesamœboids*—as a term at once appropriate and corresponding to a natural class of tissues. The mesamœboids, then, I regard as a primitive form of the cells of the mesoderm, thus implying that when amœboid cells are found in the higher metazoa we are dealing with those free mesodermic elements which have been least modified in the course of development. According to this view the wander cells and white corpuscles in vertebrates represent one of the earliest tissues of the mesoderm. As already pointed out, the essential feature of the mesenchyma is that its cells lie somewhat apart and are connected together by protoplasmatic processes running from cell to cell; the space between the cells is filled with a homogeneous, structureless, transparent substance, which is at first perhaps merely a serous fluid, and which is known as the *basal substance* (Grundsubstanz) or *matrix*. The mesenchymal matrix is the seat of numerous modifications, varying according to the special tissue formed out of the mesenchyma; each modification of the matrix is associated with the corresponding specific change of the cells.

III. HISTORY OF THE THEORY OF THE GERM-LAYERS.

The fundamental facts of the construction of the vertebrate body out of distinct layers of cells are collectively designated as the theory of the germ-layers. The theory is as important as the cell theory for the comprehension of the morphology of animals. The establishment of it is due principally to Carl Ernst von Baer, although it was first suggested half a century earlier by C. F. Wolff, and more clearly developed by Pander, from whom Von Baer drew his immediate inspiration. Since Von Baer's time numerous investigators have contributed to our knowledge of the germ-layers. If we leave out of consideration the introduction of the cell doctrine, which had a profound influence on embryology, as upon every department of biology, we may distinguish three principal steps in the acquisition of our present notions concerning the germ-layers; the first step was the recognition by Huxley that the cœlenterates are built up of two layers, and the suggestion that these two layers are homologous with the germ-layers of the higher animals; the second step was the formulation of the gastrula theory by Kowalewsky, and the third step was the discovery by His that the middle germ-layer comprises two distinct groups of tissues.


C. F. Wolff was the first investigator to recognize the embryonic germ-layers, which he did in the course of his study of the development of the digestive canal of the chick. His article was published in Latin in the "Commentaries of St. Petersburg Acad.," XII., XIII., 1768-1769, and shows that he suspected the far-reaching

significance of the observations which taught him that the intestine is evolved out of a leaf-like sheet in the embryo. Wolff's article secured very little notice from his contemporaries, nor was it until it was translated into German by the elder Meckel, and published at Halle, in 1812, that its extraordinary merit became recognized. The translation seems to have awakened the interest of Döllinger, a professor at Würzburg in the early part of this century, who, though little known by his own works, has nevertheless become distinguished through his pupils, foremost among whom are Pander and Von Baer. The former in his dissertation (Würzburg, 1817) gives a history of the metamorphosis of the hen's ovum during the first five days of incubation, and shortly after published his chief work ("Beiträge zur Entwicklungsgeschichte des Hühnchens im Eie," Würzburg, 1817), the beautiful plates of which were prepared by his friend, D'Alton. Pander distinguished in the blastoderm at first a single layer, *das Schleimblatt*, external to which, after the twelfth hour, appears the serous layer, which is thinner and more transparent, and finally, at the end of the first day, a third layer, the *Gefässschicht*, between the mucous and the serous layers. Pander appears not to have continued his embryological researches, but to have left that to his friend and fellow-student, Von Baer, who began his own studies in 1819, and continued them with some interruptions for ten years, extending them gradually to other vertebrates. In Von Baer's work we have the most profound, exhaustive, and original contribution to embryology, which has ever been made, and it is unquestionably one of the greatest achievements in the history of science. It ought to be read and pondered upon by every embryologist. The work itself was entitled "Ueber Entwicklungsgeschichte der Thiere, Beobachtung und Reflexion." Never again have observation and thought been so successfully combined in embryological work. The first part of Von Baer's "Entwicklungsgeschichte" appeared in 1828, the second part in 1837. The second part was, however, incomplete and appeared with the announcement of the publishers, stating that they had begun to print the work in 1829, and after waiting five years for manuscript had carried the printing to the 315th page, and finally, after three years more waiting, published the incomplete second part. In 1888 the missing termination of Von Baer's work was published by Stieda. It seems that Von Baer had kept it back in the hope of filling up some gaps; not succeeding in this he waited too long, and after the incomplete work had been issued, Von Baer seems to have lost his interest and to have laid aside his manuscript for the remainder of his long life. Von Baer worked out, almost as fully as was possible at this time, the genesis of all the principal organs from the germ-layers, instinctively getting at the truth as only a great genius could have done. Von Baer recognized the somatopleure, which he called *animales Blatt*, and splanchnopleure, which he called *vegetatives Blatt*, and further (as each of these Blätter consists of two layers) the animales Blatt had a *Hautschicht* (ectoderm) and a *Fleischschicht* (mesoderm), while the vegetatives Blatt had its *Schleimschicht* (entoderm) and *Gefässschicht* (mesoderm). With this generalization, and with the detail of development which he added, Von Baer


created modern embryology. It was not until after the cell doctrine was announced in 1838 by Schwann that any important progress was made; C. B. Reichert, **40.1**, **43.1**, added something to our knowledge, but the value of his work is greatly diminished by the imperfections of his observations, and still more by his errors of interpretation. Perhaps his greatest importance was in his influence upon Remak, whose masterly investigations upon the differentiation of the uniform embryonic cells into the tissues of the adult at once converted embryology into a science closely allied to histology; to Remak we owe also the recognition of the mesoderm as a unit, he having discovered that Von Baer's *Fleischschicht* and *Gefässschicht* are really parts of the same layer. There followed next a series of minor investigations by sundry authors, which, though not very numerous, nevertheless by their gradual accumulation afforded much knowledge. It is not until 1868, when His published his monograph on the chick, that anything fundamentally new was added to our notion of the germ-layers; in that work His draws the distinction between the archiblast and parablast, see p. 153.

From another side progress was being made by gathering materials by the comparative study of the germ-layers throughout the animal kingdom; here Huxley led the way by discovering the two layers which compose the body of cœlenterates—a discovery which he announced in 1849, adding at the same time the fortunate suggestion that the two layers are homologous with the two primary germ-layers of vertebrates. Four years later (1853) Allman proposed for the two layers of cœlenterates the terms *ectoderm* and *entoderm*, which have since come into general use, not only for these layers, but for the corresponding germ-layers throughout the animal kingdom. Beginning about 1845 we have a series of researches on the embryology of invertebrates, especially of marine forms. The leader in these studies was Johannes Müller, whose memoirs are classic and were published for the most part by the Berlin Academy, 1846–1854. He had numerous followers, among whom Alexander Agassiz and Metschnikoff may be mentioned. The naturalist, to whose work in this field we owe most as far as the development of the theory of the germ-layers is concerned, is Anton Kowalewsky, who, by a long series of well-known investigations accumulated a vast amount of evidence in favor of the homology of the germ-layers throughout the animal kingdom. Kowalewsky's investigations culminated in the theory that the planula, or, as it is now called, the gastrula, is the primitive embryonic type; he is the originator of the gastrula theory, an account of which has already been given, p. 112. Ernst Haeckel's two essays, **74.2**, **75.1**, contain, as already stated, exceedingly little that is really original and valuable. Lankester's two essays, **73.1**, **77.1**, are more scientific, and are also noteworthy from having furnished us with a considerable number of terms, which have since become current in embryology. Lankester's essays are further remarkable for containing the first enunciation of the cœlom theory. It will be remembered that Von Baer conceived the body cavity to be bounded by two distinct layers, the *Fleischschicht* and *Gefässschicht*; Remak showed that the cœlom is bounded by one layer only, the mesoderm; Huxley, **75.1**, p. 54, attempted to make

clear the morphology of the body cavity by distinguishing three types thereof—1, the *enterocœle* or body cavity, arising as a diverticulum of the alimentary canal, such as was then shown to be the case in the echinoderms and *Sagitta*; 2, *schizocœle*, formed by simple splitting of the mesoderm; 3, *epicœle*, formed by invagination of the outer wall of the body like the atrial chamber of *Tunicata*. Huxley suggests, p. 56, that the cœlom of vertebrates might be an epicœle. Lankester, **77.1**, maintained the opposite view, that the vertebrate cœlom is an enterocœle; for the subsequent history of Lankester's theory, especially as modified by the Hertwigs, **81.1**, see Chapter VI., p. 155.



PART III.
THE EMBRYO.



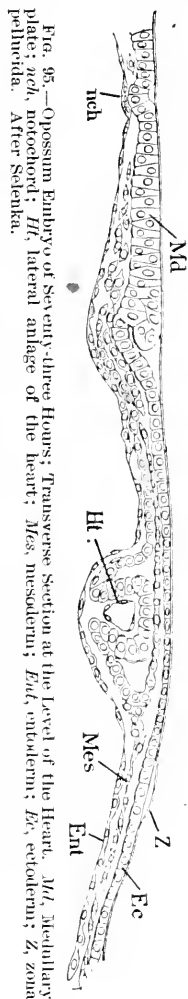
CHAPTER VIII.

THE MEDULLARY GROOVE, NOTOCHORD, AND NEURENTERIC CANALS.

IN all vertebrates there occur two primary axial structures in very early embryonic stages: one is the medullary canal, derived from the ectoderm; the other is the notochord, derived from the entoderm: as soon as these two anlagen have appeared the mesoderm disappears from the median line, and the previously continuous sheet of mesoderm becomes divided into two wings. Connected with the early history of the medullary canal and notochord are the temporary passages known as the neurenteric canals. For these reasons these three subjects are best treated together.

I. THE MEDULLARY GROOVE.

I. The Medullary Plate.—By this name we designate the central axial portion of the ectoderm, which early becomes distinguished by its greater thickness from the remaining portions of the layer and which gives rise later to the nervous system. The ectoderm of the mammalian embryonic shield and of the sauropsidan embryonic area has at first, it will be remembered, a considerable thickness, for it consists of cuboidal or low cylinder epithelial cells. The stage which follows next after the formation of the primitive axis is characterized by the gradual thinning out of the ectoderm over the peripheral portions of the shield or area, while in the neighborhood of the axial line the full diameter of the outer germ-layer is not merely retained, but is actually increased. For a time there is a gradual passage between the thicker and thinner parts, but as development progresses the demarcation rapidly becomes sharper, Fig. 95, *Md.* Soon after its formation, the medullary plate increases its thickness everywhere except along the median line, thus becoming double; the thin median part often shows a slight groove which is known as the dorsal furrow (*Rückenfurche*).* This furrow does not extend clear to the cephalic end of the plate, because there the lateral thicker bands are continuous with one another, the front end of the plate being rounded and clearly limited.



* *Rückenfurche* is also used as a synonym of medullary groove.

The medullary plate appears only in the region of the head-process in amniota, and as the process grows backward at the expense of the primitive streak the medullary plate follows, hence it is unequally developed throughout its longitudinal extent, being always more advanced headward and less advanced tailward; hence it is that while it is developing its posterior extremity is always vague and fades out into the undifferentiated ectoderm. So great is this inequality in mammals that we find the front end of the plate transformed into the medullary groove before the hind end is differentiated.

The stage of development in which there is a well-marked primitive streak and in front of it a medullary plate overlying the head-process occurs in the rabbit at the beginning of the eighth day. At its hind end the plate extends so as to partly cover the primitive streak, while in front its edges already rise slightly, so that it constitutes a minute shallow trough. For figures of a similar stage, age unknown, in the mole, see W. Heape, **83. 1**, Figs. 13 and 14. In older writers we find figures representing the medullary plate (or groove) and the primitive streak as one structure, and the dorsal furrow in the middle of the plate as the continuation of the primitive groove. To illustrate this error I present a copy, Fig. 96,

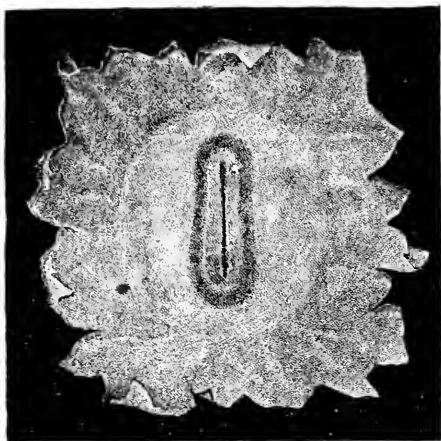


FIG. 96.—Blastoderm of Rabbit's Ovum; after Bischoff. The dorsal and primitive grooves are represented as a single continuous line.

of one of Bischoff's figures of the rabbit's ovum, in which no distinction is made between the two grooves, although in reality the dorsal groove stops in front of the primitive groove, the anterior end of which is often bent to one side.

In the Sauropsida the medullary plate is very similar to that of mammals. In both birds and lizards it can be seen that not the whole of the axial band of thicker ectoderm, but only the parts nearest the median line, share in the actual formation of the medullary groove. The differentiation is begun as in mammals by the thinning out of the ectoderm in the peripheral regions, until it becomes a thin pavement epithelium, while about the axis the cells become elongated vertically; pyramidal cells, with the apex external, alternating with those with the apex internal, thus producing a peculiar appearance on sections and causing the nuclei to form two layers; the single cells are, of course, irregular in shape. In birds and reptiles, as in mammals, the medullary plate overlies the head-process and becomes well marked off in front, while it is still being differentiated posteriorly, compare Fig. 97.

The Medullary Groove.—Almost or quite as soon as the medullary plate is formed, its edge becomes elevated in front and on each side; hence it forms an open trough, known as the medul-

lary groove, Fig. 97, *Md.gr.* During this process the medullary ectoderm increases considerably in thickness, and at the same time the nuclei multiply and lie irregularly scattered at varying heights. The ectoderm alongside the medullary plate or groove thins out still farther. Inasmuch as the development is most rapid in the

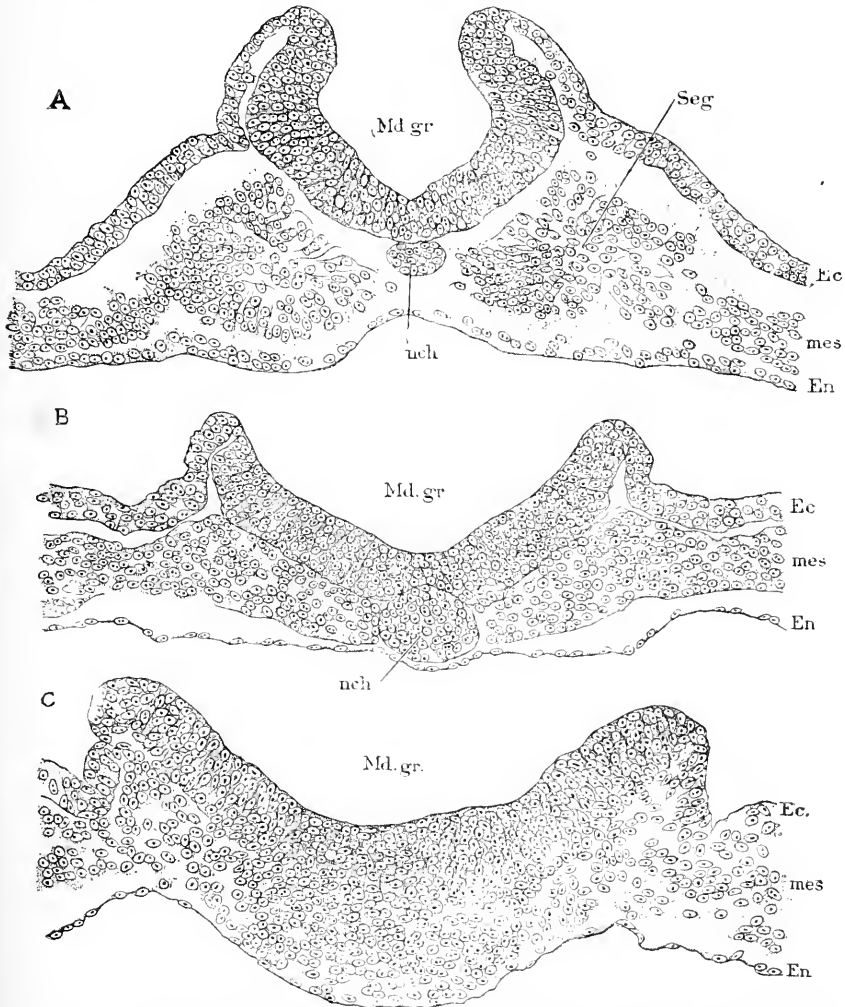


FIG. 97.—Chicken Embryo with Seven Primitive Segments (Minot Coll., Embryo A J, sections 311, 212, 172, compare Figs. 81 and 147). A, Section through one of the segments; B, section posterior to the segments; C, section just in front of the primitive streak. *Md.gr.*, medullary groove; *nch*, notochord; *Ec*, ectoderm; *mes*, mesoderm; *En*, entoderm. \times about 230 diams.

head end of the embryo, there comes a stage in which there is a well-marked medullary groove in front, a medullary plate behind that, and a primitive streak at the hind end of the embryo; but when the streak has disappeared the medullary groove is found to extend the entire length of the embryo. There is then a stage in which,

by means of a series of transverse sections, Fig. 97, of the embryo, we may study the successive steps in the development of the medullary groove. This stage is found in the rabbit at nine days; in the chick at thirty to forty hours of normal incubation.

The medullary groove gradually deepens, its sides rising higher and higher and arching more and more toward one another until the edges meet and coalesce, thus changing the groove into a tube. The process is illustrated by the series of sections through a chicken embryo with seven segments shown in Fig. 97.

In some mammals the medullary groove becomes well developed, Fig. 98, before the medullary plate

is clearly marked off by the thinning out of the ectoderm alongside of it; the groove is also much larger, Fig. 98, in proportion to the size of the embryo, Fig. 99, than is the case in the large ova of birds and reptiles. The anterior end of the groove is wide open and expanded on each side; this lateral spreading is the anlage of the optic diverticulum, Fig. 99, *op*, and is transformed later into the optic vesicle, which is an essential component of the future eye. A section through the optic grooves of a mole embryo a trifle older than Heape's stage, F, Fig. 99, is shown in Fig. 100. The medullary plate is thickened and shows a median lesser, and two lateral greater depressions; the former, *Md*, is the medullary

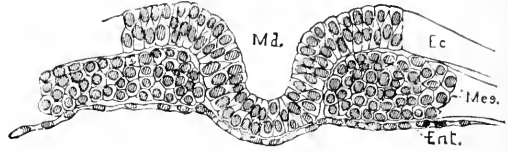


FIG. 98.—Part of a Transverse Section of a Young Mole Embryo. After Heape. *Md*, Medullary groove; *Ec*, ectoderm; *Mes*, mesoderm; *Ent*, entoderm.

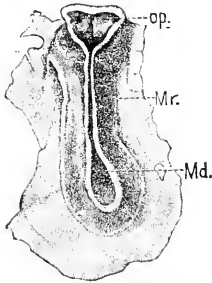


FIG. 99.—Surface View of a Young Mole Embryo (stage F, 196 mm.). After Heape. *op*, Optic diverticula; *Mr*, medullary ridge or edge of medullary groove; *Md*, medullary groove widely open.

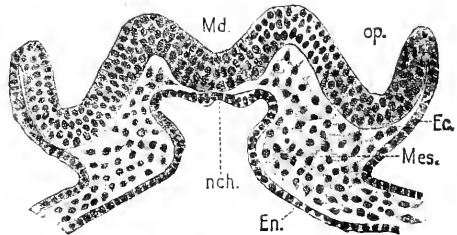


FIG. 100.—Transverse Section of a Mole Embryo (Heape's stage F). *Md*, Medullary groove proper; *op*, optic groove; *Ec*, ectoderm; *Mes*, mesoderm; *En*, entoderm; *nch*, notochord.

groove proper; the latter, *op*, do not participate in the brain formation, but in that of the eye; at the edge of the optic anlage the plate passes abruptly into the much thinner entoderm. For some distance behind the optic anlage the edges of the medullary groove are almost in contact, Fig. 99, but farther back the groove is again wide open; this widely open part is known as the *sinus rhomboidalis*, which is not to be confused with the sinus rhomboidalis of the neck, for the term is also applied to the cavity of the embryonic fourth ventricle of the brain; the sinus here described belongs to the future lumbar region. The swelling in the floor at the hind end of the sinus is caused by the mesoblast of the front end of the primitive streak.

On either side of a rabbit or opossum embryo, in a stage a little more advanced than in Fig. 99, just behind the open anterior end of the canal, there extends a longitudinal ridge corresponding to the anlage of one of the two tubes which will eventually form the heart, see Chapter XI. The lateral heart anlage of the opossum is shown in section, Fig. 95, *Ht.*

In a mole embryo, a little older than Fig. 99, the hinder portion of the medullary canal is much the same as before; anteriorly, however, development has progressed and the edges of the medullary folds have come together and partially fused at the anterior end of the embryo, owing to the more rapid growth of the sides than of the floor of the canal as pointed out above. At the extreme end, however, a pore is left. At this stage, therefore, the neural canal is still open to the exterior, both anteriorly and posteriorly. The optic grooves are now closed, and have given rise to the optic vesicles; these are shown as two bud-like vesicles projecting outward and backward and slightly downward from the front end of the neural tube; behind them the swelling of the fore-brain is discernible, while still farther backward and at the edge of the body of the embryo the two tubes of the heart are indicated. The folding off of the embryo from the yolk-sac has at this stage made some progress, and, indeed, the whole of the head of the embryo now projects freely above the blastodermic vesicle. In the next stage (H, embryo 2.2 mm.) of the mole the edges of the medullary plate have met and united, making the medullary groove in front into a canal, but the sinus rhomboidalis is still open, though beginning to close. The closure of the groove begins in the cervical region and spreads forward and more slowly backward; where the closure takes place last in front is known as the *neuroporus*; the position of the neuroporus is presumably the same in all amniota if not in all vertebrates. Van Wijhe, **84.1**, finds that in the duck the connection with the ectoderm is retained in front longest in the region of the first cerebral vesicle, and not in that of the mid-brain, so that it has nothing to do, as some have suggested, with the development of the pineal gland (epiphysis). This connection represents the final anterior closure; Van Wijhe speculates that it was an opening in the ancestors of vertebrates and terms it the anterior neuroporus.

The medullary groove of *Amphibia* has been more fully studied than that of any other class. The most complete history is that given by Alex. Goette for Bombinator, **75.1**, 158-176; see also Scott and Osborn, **79.1**, S. F. Clarke, **80.1**, Rusconi, Moquin-Tandon, **76.1**, Ecker's "Icones," Taf. XXIII., and others. In all Amphibia the medullary plate is very wide, indeed, Fig. 101, being broadest in front.

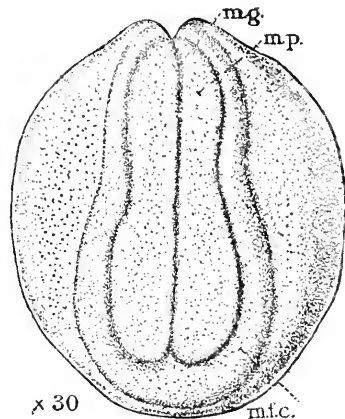


FIG. 101.—Early Stage of *Amblystoma punctatum*. *m.g.*, Median groove; *m.p.*, medullary plate; *mfc.*, cephalic portion of medullary fold. After S. F. Clarke.

Its margin is thrown up into a slight but broad ridge; when the plate closes to form a canal the surfaces of the marginal ridges grow together and the surface of the plates within the ridges becomes the surface of the central canal. In all Amphibia the central dorsal

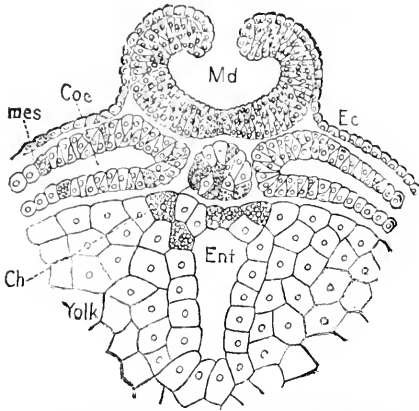


FIG. 102.—Part of a Transverse Section of an Axolotl Embryo. After Bellonci. *Mes*, Mesoderm; *coe*, coelom; *Md*, medullary groove; *Ec*, ectoderm; *Ent*, entodermal or archenteric cavity; *Ch*, notochord; *Yolk*, yolk cells. The deutoplasm is indicated in a few of the cells.

groove, *mg*, is very distinct. As the ectoderm of the amphibian ovum very early becomes distinctly two-layered, it results that in the medullary plate the two layers can be recognized from the start; the outer layer (Goette's *Deckschicht*, Balfour's epidermic stratum) of course lines the medullary cavity and alone forms the epithelium of the central canal. When the groove closes the lumen of the canal is nearly circular in section, but it soon changes into a narrow vertical slit similar to the lumen of the amniote canal. The round cavity is due to the way in which the medullary plates curl up, as shown in Fig. 102. As pointed out by Alex.

Goette, 75.1, 160, the lateral portion of the medullary plate arises by delamination, a peculiarity which has an important bearing, I think, on the discussion of the evolution of the medullary canal, see p. 179. Finally, in the Amphibia, the medullary plate extends to the middle of the blastopore, and, it is maintained by some writers, extends beyond it, so as to completely surround it. This point is recurring to in connection with the history of the anus.

The Medullary Canal.—The medullary canal, as stated, arises by the closure of the groove. The canal closes in the cervical region first, hence it has at one time two free openings; as the closure progresses the anterior region is completed, while the sinus rhomboidalis is still open; moreover, we see that the anterior end achieves considerable differentiation before the posterior end of the canal is closed. Of the entire length of the primitive canal about one-half is the anlage of the brain, while the other half forms the spinal cord. In the development of the brain the transverse expansion of the canal is most conspicuous, while in the development of the spinal cord the elongation of the canal predominates. The dilatation of the brain part begins very early, and comprises at first a general dilatation of the whole anlage, and, second, special and greater dilatation of three regions; the three dilatations are known as the three primary cerebral vesicles (*Hirnblasen*), and are designated as *fore-brain* (*Vorderhirn*, prosencephalon), *mid-brain* (*Mittelhirn*, mesencephalon), and *hind-brain* (*Hinterhirn*, metencephalon), respectively. The first vesicle is much the widest, and appears in mammals and probably in all vertebrates very early; in mammals it shows itself plainly in the medullary groove as already noted. When the groove closes the canal

is of course attached to the ectoderm, Fig. 92, but this connection is soon severed, and the medullary, or, as it also called, *neural canal*, becomes an independent structure lying inside the external ectoderm of the embryo, and surrounded by mesodermic cells, which subsequently grow in between the canal and the ectoderm so that the canal comes to lie farther and farther away from the surface, Fig. 103.

The structure of the medullary canal in early stages has been as yet but imperfectly studied. The wall increases steadily in thickness, except in certain parts of the brain. Where it thickens its nuclei multiply and form several irregular layers; the cell bodies around the nuclei are small and connected by numerous processes, so as to produce a protoplasmic network; the protoplasm and nuclei next the lumen early assume the character of epithelial cells, so that the cavity of the medullary canal is lined by a distinct epithelial layer; this layer corresponds to the outside layer of the ectoderm (epidermis); in some parts—as, for instance, the dorsal wall of the fourth ventricle—the single epithelial layers constitute the entire medullary wall. The

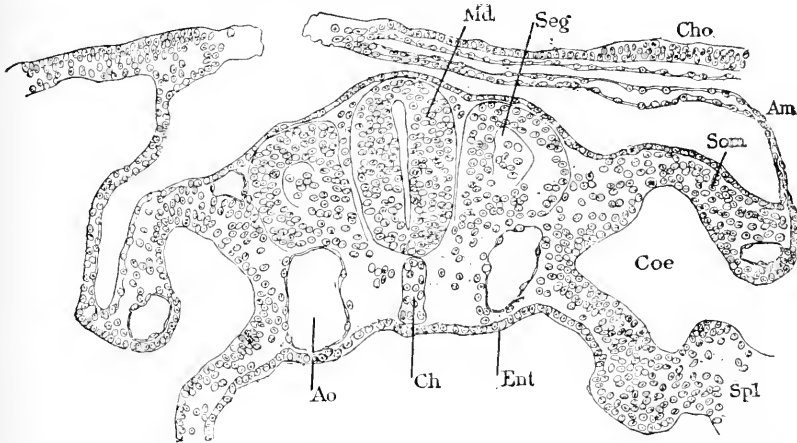


FIG. 103.—Transverse Section of a Rabbit Embryo of Eight Days and Two Hours. *Md*, Medullary canal; *Seg*, primitive segment; *Cho*, chorion; *Am*, amnion; *Som*, somatopleure; *Coe*, coelom; *Spl*, splanchnopleure; *Ent*, entoderm; *Ch*, notochord; *Ao*, aorta.

non-epithelial cells of the canal become, as described in Chapter XXVII., ganglion cells. The nuclei of the medullary canal wall are oval, their long axis being more or less nearly perpendicular to the surface of the canal; each nucleus contains one or several nucleoli. The canal is primarily oval in section, but its lumen is a narrow fissure, Fig. 103, hence the walls are thickest at the sides, and thinner dorsally and ventrally; this peculiarity dominates to a marked degree the subsequent development of the brain and spinal cord.

Evolution of the Medullary Canal.*—Under this head we have to consider, first, what is the primitive vertebrate type of the central nervous system; second, what genetic relation existed between the vertebrate and the invertebrate type.

The opinion generally accepted by embryologists is that the typical vertebrate canal is formed by the closure of the medullary groove.

* Originally published in the *American Naturalist*, Nov., 1889.

This view is advocated by Balfour, and has been so thoroughly accepted by Adam Sedgwick, that he has made it the basis of a speculation, **83.1**, on the original function of the canal; he supposes that it was open behind and excretory; the cilia which are found in the central canal of the spinal cord originally served to produce the excretory current. Van Wijhe, **84.1**, has advanced independently almost the same hypothesis. Both of these speculations overlook the serious difficulty of assuming that the canal is primitive, while in the lowest vertebrates it is clearly a secondary modification. In *Petromyzon*, *Lepidosteus*, and Teleosts, the medullary plate, instead of becoming the floor of an external groove, forms a solid keel-like projection toward the ventral surface. This keel subsequently becomes separated from the superficial layers of the ectoderm, and afterward a central canal is developed in it. In the ganoids, which approach the elasmobranchs in structure, there is, as shown by Salensky, **81.1**, a medullary groove of peculiar form, which suggests a transition from the solid keel to the open groove; again in Amphibia there is evidence that the delamination is still preserved to a slight extent in that group. These considerations lead me to the hypothesis that the nervous system of vertebrates was primitively a solid axial thickening of the ectoderm, and within the class of ganoids became modified into a groove perhaps simply by more precocious development of the central canal; the groove type has been kept in elasmobranchs, amphibians, and anniota. Balfour, "Comp. Embryol.," II., 303, thus defends the opposite view: "It seems almost certain that the formation of the central nervous system from a solid keel-like thickening of the epidermis is a derived and secondary mode, and that the folding of the medullary plate into a canal is primitive. Apart from its greater frequency the latter mode of formation of the central nervous system is shown to be the primitive type by the fact that it offers a simple explanation of the presence of the central canal of the nervous system; while the existence of such a canal cannot easily be explained on the assumption that the central nervous system was originally developed as a keel-like thickening of the epiblast" (epiblast-ectoderm).

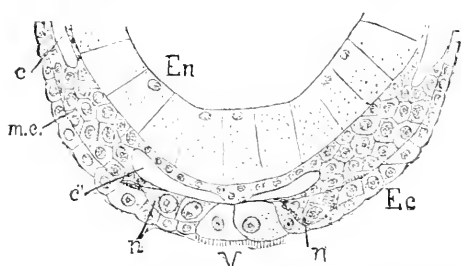


FIG. 104.—Part of a Transverse Section of an Embryo of *Lumbricus Trapezoides*. After Kleinenberg. *En*, Entoderm; *Ec*, ectoderm; *a n.*, anlagen of the nervous system; *V*, cells of the ciliated band separating the two parts of the nervous system; *c, c'*, parts of the coelom; *m.c.*, mesodermal cords.

external ectoderm they extend toward one another inside the ciliated cells of the furrow, and unite in a single nervous band. The origin of the annelidan nerve cord is illustrated by Fig. 104, which repre-

It is not possible at present to decide positively between the two views, but the view which I am inclined to adopt is further justified by the development of the central nervous system in Annelids, which is formed by the coalescence of a pair of linear cords: these cords arise each side of a ciliated longitudinal furrow, first as a single row of ectodermal cells, subsequently as several rows; while still united to the external

sents a transverse section of the embryo of an earthworm, at a stage during which the cells, *n n*, that are to form the nerve cords are still part of the superficial ectoderm, *Ec*, though their future separation is already indicated. In leeches and arthropods the development is very similar. In all these cases the bands split off from the ectoderm. It appears then that in the nearest* invertebrate allies of the vertebrates, the nervous system develops as a thickening along the inner surface of the ectoderm, and delaminates from that layer. It seems to me very natural to suppose, therefore, that the strikingly similar process in the lowest vertebrates is the primitive one, and that the canalization of the medullary plate was evolved within the vertebrate series.

I have assumed that the ventral nerve cords of annelids are homologous with the medullary canal, a view that is now generally accepted by embryologists. Balfour (Works, I., 393, and "Comp. Embryol." II., 311) has suggested a more complicated relation in his hypothesis that the lateral nerve trunks, which are known in many of the lower worms (*e. g.*, nemerteans, have fused on the *ventral* side in annelids, but on the *dorsal* side of the body in the vermician ancestors of vertebrates. In favor of this ingenious surmise no evidence has since been found. Hubrecht denies the homology of the annelidan nerve chain and the vertebrate medulla; he considers, 87.1, 620-624, that the more primitive condition is represented by certain nemertean worms, which, beside two main lateral nerves, have a small longitudinal median nerve; the lateral nerves gave rise to the nerve chain of annelids by their fusion, the median nerve to the medulla of the ancestors of vertebrates. As no intermediate forms, either adult types or embryonic stages, are known to represent any phases of this double metamorphosis, I cannot admit that Hubrecht's bold speculation invalidates what seems to me the well-established homology between annelids and vertebrates.

The remarkable hypothesis of W. H. Gaskell, 90.1, that the medullary canal is homologous with, and derived from, the entodermal canal of crustacea, seems to me unwarrantable.

II. THE NOTOCHORD.

As the notochord is a purely embryonic structure, I present its complete history here.

The notochord (*chorda dorsalis*, *Wirbelsaite*) is a rod of peculiar tissue, constituting the primitive axial skeleton of vertebrates. It begins immediately behind the pituitary body (*hypophysis*) and extends to the caudal extremity. It occurs as a permanent structure in the lower type, and as a temporary one in the embryos of amphibia and amniota, including man. Comparative embryology has shown that it is a greatly modified epithelial band which arises in the median dorsal line of the entoderm, being in position and mode of development analogous to the ectodermal medullary canal, or primitive tubular nervous system.

Numerous embryological articles contain observations on the notochord. The following references may assist students. The best

* With, of course, the possible exception of *Amphioxus*.

general discussion is by Balfour, in his "Comparative Embryology;" the best observations on its origin in mammals is by Heape, **83.1**, for descriptions of the chorda canal see Lieberkühn, **82.1**, **84.1**; Carius, **88.1**, and Van Beneden, **88.3**; for its histology, W. Müller, **71.2**; for its histogenesis, A. Goette, **75.1**, 349-361; for its anterior anatomical relations see Mihalkowics, **74.1**, **75.1**, Froriep, **82.1**, Rabl-Rückhard, **80.1**, and Romiti, **86.1**; for its atrophy in mammals see Leboucq, **80.1**; for its evolution see Ehlers, **85.1**.

Origin from Notochordal Canal.—The notochord appears very early in the course of development; its differentiation from the median dorsal wall of the notochordal canal begins at the time when the medullary groove is not fully marked out posteriorly, and is nowhere closed. The notochordal anlage can be first detected just in front of the primitive streak as an axial band of cells, which at first is not well marked off from the mesoderm; this band forms the median dorsal wall of the blastoporic canal in all vertebrates in which that canal has been identified. The differentiation of the notochordal cells begins usually at the anterior end of the canal and progresses backward, as the blastopore moves backward during concrescence. The differentiation varies as to the time of its beginning; it may begin in the unconcreted embryonic rim, as in *Scyllium*, or much later, as in *Lacerta*.

As the medullary groove (or keel) deepens, it pushes down toward the mid-gut until it comes into actual contact with the notochordal epithelial band, thus dividing the mesoderm into two lateral masses, Fig. 97, one on each side; this also leads to the temporary transverse stretching of the notochord.

Lieberkühn, **82.1**, **84.1**, has directed attention to a special peculiarity in the early development of the notochord in mammals. The notochordal canal is formed throughout its length and then breaks through at various points to fuse with the yolk cavity, so that it may be described as a tube running along the median line, and having an irregular series of openings on its ventral side. The canal is lined by epithelium, which is thickened on the dorsal side to form the anlage of the notochord. In transverse section the chorda appears according to the level of the section to constitute part of a furrow or a canal (compare also Heape, *l. c.*, p. 441, Fig. 40, 41). Lieberkühn calls this canal mesoblastic, and Kölliker follows him in so doing, but this opinion seems to me based upon misconception. Indeed, C. Giacomini's researches, **88.1**, show that the canal terminates in the rabbit in a blastopore, and Van Beneden, **88.3**, has emphasized the fact that the canal helps to form the definitive archenteron. After the notochordal canal has fused with the yolk cavity, the notochordal anlage is, of course, incorporated in the entoderm of the main archenteric cavity, and appears as the median dorsal portion of the entoderm. It early acquires a sharp demarcation and becomes considerably thicker, Fig. 105, than the adjoining entoderm, and forms a distinct though shallow groove.

Separation from the Entoderm.—The notochordal band separates off and the entoderm proper closes across under it, so that the notochordal band lies between the entoderm and the floor of the medullary groove (or later canal) as shown in Figs. 106, 103, and 97

A. This separation does not take place at the anterior extremity of the chorda until somewhat later, so that for a considerable period its front end remains fused with the walls of the archenteron, Fig. 106. Selenka, **87.1**, observed that this front end of the notochord becomes

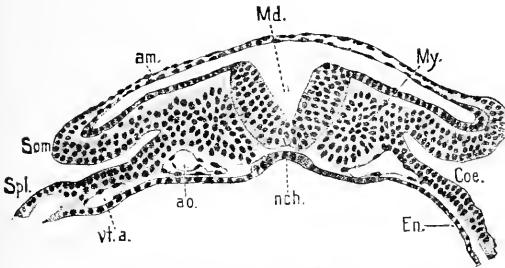


FIG. 105.—Transverse Section of a Mole Embryo, Stage H. After Heape. *am.*, Amnion; *Md.*, medullary groove; *My.*, myotome; *Coe.*, coelom or body cavity; *En.*, entoderm; *nch.*, notochord; *ao.*, aorta; *vt. a.*, vitelline artery; *Som.*, somatic mesoderm; *Spl.*, splanchnic mesoderm.

dilated in the opossum and hollow; the hollow end subsequently forms an irregular sac opening into the anterior end of the intestinal cavity; Selenka names the sac the *Gaumenstasche*; it opens behind the partition which closes the mouth and is entirely distinct from the hypophysal evagination. Further investigations led to the discovery of traces of a similar canalization of the front end of the notochord in other vertebrates (Selenka, **88.1**). The peculiarity shows conclusively that the connection of the notochord with the hypophysis is secondary, and that, therefore, Hubrecht's hypothesis as to the evolution of the notochord is untenable.

The separation from the entoderm is effected, at least in mammals, by the entoderm proper showing itself under the notochord toward the median line, and when the cells from one side meet those of the other they unite with them and form a continuous sheet of entoderm below the notochord cells. It is probable that the separation begins in all vertebrates, as it has been shown to do in several cases, before the whole length of the notochord is formed, and progresses headward; see, for example, McIntosh and Prince's account of the process in teleosts, **90.1**, 743. So, also, in *Triton alpestris*, Bambeke, **80.2**, 90, found

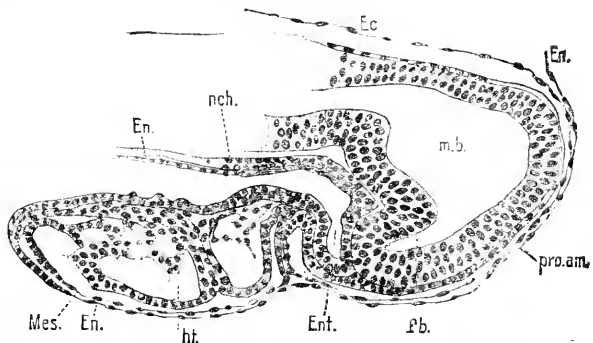


FIG. 106.—Longitudinal Section of the Head End of a Mole Embryo, Stage H. After Heape. *Ec.*, Ectoderm; *En.*, entoderm; *pro.am.*, pro-amnion; *m.b.*, mid-brain; *f.b.*, fore-brain; *Ent.*, entodermic cavity; *ht.*, heart; *mes.*, mesoderm; *nch.*, notochord.

that the separation of the notochord from the entoderm takes place earlier than in the Urodela, and progresses from in back forward. After the separation pigment granules appear in the central portion of the chorda, an important observation, since certain writers have held, I believe erroneously, that the presence of pigment proves that the notochord must be derived from the ectoderm, which is usually pigmented in amphibian ova.

After its separation the chorda is a narrow band of cells starting anteriorly from the wall of the alimentary tract and running backward to the blastopore. So long as the blastoporic canal is open, the chorda terminates in the entodermic epithelium lining the canal. For a certain period the chorda continues growing tailward by accretions of cells from the walls of the blastoporic passage, and after the canal is permanently obliterated the chorda may still continue its lengthening by acquisitions at its caudal end of additional cells from the primitive streak; such cells may, however, properly be regarded as coming from the entodermic lining of the blastopore. We can, then, distinguish two portions of the notochord; the first arising from the epithelium of the notochordal canal, the second presumably from the cellular wall of the obliterated blastopore. Braun and others have sought to attribute essential importance to these differences, but it seems to me improperly. It is more reasonable to say that the chorda arises in the amniota, as in the lower forms, directly from the entoderm, but presents certain secondary modifications in its development.

After it is once formed as a band of cells the notochord passes through various changes of form, but ultimately becomes a cylindrical rod with tapering extremities. It attains considerable size in the embryos of most vertebrates, but in those of placental mammals it is always small, particularly so in the mole (Heape, 83.1). It is probable that in mammals the notochord, when first separated from the entoderm, is a broad flat band, as if compressed between the medullary canal and entoderm (*cf.* Kölliker, "Entwickelungsgesch.," Figs. 194 to 197, and also Heape, 86.2, Pl. XIII., Figs. 36 to 42). The band then draws together, diminishing its transverse and increasing its vertical diameter, until it has acquired a rounded form;* finally its outline becomes circular in cross-section. This series of changes begins near the anterior end of the chorda, and progresses both forward and backward. The nuclei of the notochord tend to gather at first in the central portion of the chorda, but in later stages (shark embryos with fifty and sixty myotomes) the nuclei are found situated peripherally, Rabl, 89.2, 249. The mesoderm early grows in between the entoderm and the notochord, which, however, for a considerable time remains close to the medullary tube. Later the mesoderm penetrates also between the notochord and medulla. The layer of mesodermic cells immediately around the notochord, which are of the well-known mesenchymal type, forms a special sheath, which at first comprises only a single layer of cells, at least in batrachia (Goette, 75.1, 357, Fig. 187). This is the commencement of the so-called outer chorda sheath; it subsequently becomes much thicker. In the lower types it is sometimes an important axial structure; but in most cases it is replaced by cartilage, and in all the amniota the cartilage is replaced by the osseous vertebrae, the intervertebral ligaments, etc. The formation of the vertebral column involves the disappearance of the notochord as described below.

Notochord of Teleosts.—The medullary keel or great neural axial thickening of teleosts extends to the entoderm; the cells at the bottom of this keel next the entoderm give rise to the chorda. There

* A splendid description of the selachian notochord at this stage is given by C. Rabl, 89.2, 213, 214.

being, it is said, no open blastoporic canal in the bony fishes, we can only trace the cells back into the undifferentiated mass of cells with which ectoderm and entoderm also fuse, and which lies at the hind end of the embryo. According to the most generally received opinion, the cells of the notochord arise from the entoderm, and their fusion with the ectoderm of the medullary keel is temporary only. The teleostean chorda separates first from the mesoderm, second from the entoderm, and third from the ectoderm. The development in *Lepidosteus* is similar. The modifications we here encounter will probably be traced back to the general vertebrate type. For discussion of the subject and citations of earlier authorities, see McIntosh and Prince, 90.1, 740-745.

Shape and Relations to Other Parts.—As soon as the head-bend (first cerebral flexure) appears, Fig. 107, the notochord becomes correspondingly bent, and its bend lies close to Rathke's pocket, Fig. 107, *hy*. From Selenka's *Guametasche* there now runs upward and forward a short limb of the notochord, which subsequently atrophies. This limb may remain regular or it may grow and become somewhat irregular before it atrophies; after it is gone *the chorda has a new or secondary anterior extremity*, which Romiti, 86.1, finds in the chick embryo at the end of the fourth and during the fifth day of incubation to be united with an irregular solid cord of cells which grows out from the epithelium of the hypophysis. The cord soon disappears. Its significance is quite unknown. Romiti suggests that it may produce a strain resulting in the pulling out of the hypophysal evagination. This notion seems to me untenable, since the hypophysal invagination begins before there is any union with the notochord. The cranial portion of the notochord has not only the bend shown in Fig. 107, but also follows the other curves of the head; it takes a sinuous course besides within the base of the cranium; finally, in the region corresponding to the middle third of the spheno-occipital cartilage, it makes a great dip ventralward. The sheath of the notochord in the cranial region is converted into the spheno-occipital cartilage; at the dip just mentioned, however, the notochord lies entirely below the cartilage close against the wall of the pharynx (Froriep, 82.1, Romiti, 86.1). Writers before Froriep had represented the chorda as having disappeared at the bottom of the dip.

The anterior termination of the notochord has been carefully studied by Prenant, 91.2, 203, who finds that it has (pig and rabbit) no connection with the hypophysis, but may have a secondary temporary connection with the entoderm just behind Seesel's pocket, and that the part of the notochord nearest the hypophysis very early degenerates, leaving the notochord to terminate above Seesel's pocket;

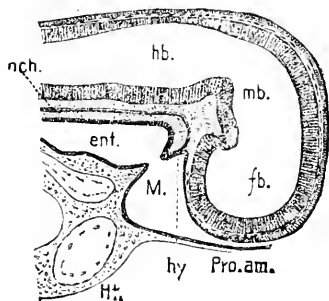


FIG. 107.—Rabbit Embryo of 6 mm.; Median Longitudinal Section of the Head. The connection between the mouth *M.* and pharynx *ent.* is just established; *nch.*, notochord; *hb.*, hind-brain; *mb.*, mid-brain; *fb.*, fore-brain; *pro.am.*, proamnion; *hy*, hypophysis cerebri; *ht*, heart. After Mihalkovics.

according to this view the so-called *præ-chordal* region primitively contains the notochord. The secondary anterior termination of the notochord is close to the infundibulum (and future pituitary body), and it is customary for subsequent stages to divide the head and skull into a *præ-pituitary* and a *post-pituitary region*; the latter region alone contains the notochord, after very early stages.

Histogenesis.—After the notochord has been formed as a rod of cells, its cells undergo a process of histological differentiation, unique in vertebrates. The cells at first become greatly compressed in the line of length of the chorda, and hence appear quite thin in longitudinal sections, Fig. 108, hardly greater in diameter than their own nuclei. The flattened cells are next converted into a highly characteristic reticulum by vacuolization. Thus, in the chick, by the third day some of the central cells become vacuolated, while the peripheral cells are still normal; at first, as in the frog, there seems to be only one large vacuole in each cell, Fig. 108, B. Around the vacuole is

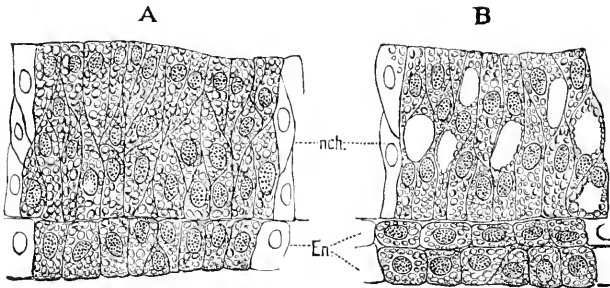


FIG. 108.—Longitudinal Sections of the Notochord of Bombinator. After Goette. A, before the appearance of the vacuoles; B, after the appearance of the vacuoles; *nch.*, notochord; *En.*, entoderm. The cells, as is usual in amphibian embryos, are changed with yolk-granules.

a peripheral layer of granular protoplasm, in which the nucleus lies imbedded, while the vacuoles themselves are filled with a perfectly clear and transparent material, which is supposed to be fluid in its natural condition. During the fourth day (chick) all the cells become vacuolated, with the exception of a single layer of flattened cells at the periphery. (In the anura, it is said, there is no distinct peripheral layer of protoplasmatic cells.) The vacuoles go on enlarging until by the sixth day they have so much increased at the expense of the protoplasm that only a very thin layer of the latter is left at the circumference of the cell, at one part of which, where there is generally more protoplasm than elsewhere, the remains of a nucleus may generally be detected. Thus the notochord becomes transformed into a spongy reticulum, the meshes of which correspond to the vacuoles of the cells and the septa to the remains of their cell walls (Foster and Balfour). As Goette has pointed out, the process is accompanied by an expansion of the cells which is the main factor in the widening and lengthening of the notochord, which goes on *pari passu* with the growth of the surrounding tissue.

The histogenetic process is stated to be essentially similar in mammals (W. Müller, 71.2, 337, 338). There is the central layer of vacuolated cells and the peripheral layer of protoplasmatic cells.

The latter are, however, ultimately converted into vacuolated cells. The cell walls are perforate, having fine pores that correspond probably to intercellular bridges of protoplasm. The *inner chorda sheath* appears early, and is to be regarded as an anhistic basement membrane secreted by the notochordal cells.

Disappearance.—The disappearance of the notochord in man commences with the second month of fetal life. The first step is an alteration of the characteristic histological structure, accompanied by shrinking of the tissues, so that a clear space appears around it. The inner chorda sheath is lost. The cell walls disappear, the tissue

becomes granular, and breaks up into multinucleate, irregularly reticulate masses, Fig. 109, which are gradually resorbed (Leboucq, 80.1). In mammals the resorption progresses more rapidly in the cores of the vertebrae than in the intervertebral spaces, and again more rapidly at the ends than in the centre of each vertebra; hence the chorda persists a little longer in the centre

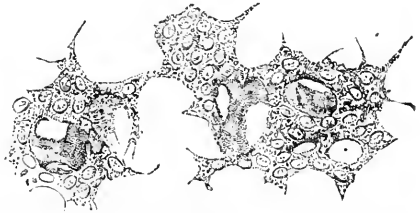


FIG. 109.—Degenerating Notochord Tissue, from the Central Portion of the Intervertebral Disk of a Cow's Embryo. After Leboucq.

of the vertebra, and considerably longer in the intervertebral spaces; in these last the final remnants of the chorda may be detected in man even after birth. The cavity between the vertebral cartilages is a new structure and is not the space left by the notochord, as has been sometimes asserted. It appears, however, that the resorption of the chorda may leave a small space, which becomes included in the intervertebral cavity. A peculiar feature is the frequent persistence of calcified cartilage immediately around the notochord in ossifying vertebræ.

Morphology.—The notochord was for a long time supposed to be exclusively characteristic of vertebrates. It is now known to exist in *Amphioxus*, which is not a true vertebrate, and in the *Tunicata*. Morphologists have long believed that it must have some homologue among the organs of invertebrates. The development of the notochord in the lower vertebrates indicates very plainly what must have been the general character of such an homologous invertebrate organ. In certain fishes and amphibia the notochord has been asserted to arise as a furrow along the median dorsal line of the entoderm; the furrow deepens and then closes over to form a rod separate from the entodermic canal proper. The notochordal rod retains for a time its anterior and posterior connections with the entoderm. It is usually regarded as morphologically a solid canal, a view very open to doubt. Ultimately the ends become detached, and so arises the solid isolated chorda. In the higher vertebrates the course of development is similar, although several of the primitive features in the formation of the chorda are obscured. Ehlers, 85.1, has pointed out that in various invertebrates there is a similar canal, the "Nebendarm" of German writers, which is derived from the entoderm and connected anteriorly and posteriorly with the entodermal cavity. It is a very plausible suggestion, which homolo-

gizes the vertebrate notochord with the invertebrate "Nebendarm." Hubrecht has sought to homologize the notochord with the proboscis of nemertean worms. There is not a single fact which seems to me to justify, even remotely, this attempt at guess-work phylogeny, nor can I find any resemblance of the notochord with the structure in *Balanoglossus* with which Bateson has sought to homologize it.

III. NEURENTERIC CANALS.

The term *neurenteric canal* is used to designate an open communication between the archenteric cavity and the medullary canal. Such communications are found only in early stages; they always pass through the anterior end of the primitive streak and lead, therefore, into the posterior end of the medullary canal or groove; they are present only during a short period. Much confusion has existed in regard to these canals, of which as many as three have been distinguished by M. Braun, 82.3, while several writers recognize two.

The true Neurenteric Canal is probably the blastoporic canal proper, and is to be identified by the notochord terminating in its wall. As stated in Part II. of this chapter, the "chorda-canal" of mammals is the "blastoporic" canal, and therefore also includes the neurenteric canal. As previously described, the blastopore is the opening of the notochordal canal at the anterior end of the primitive streak. The neural ridges or medullary folds extend around and behind or across the blastopore, which, therefore, opens into the posterior extremity of the medullary groove. If now the canal is open at the period of development when the medullary groove is deep or has already closed over, making the medullary canal, then there is a direct communication between the entodermal canal on the one hand and the spinal canal on the other. We owe to Balfour the identification of this canal as the blastopore. It may with propriety be termed the true neurenteric canal, or the canal

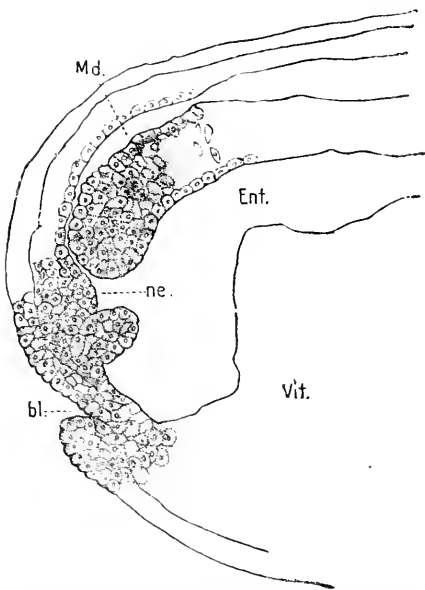


FIG. 110.—Longitudinal Section of a Frog's Ovum shortly after the Closure of the Medullary Groove. The anal canal, *bl.* is only partially cut, but was found open in neighboring sections. *Md.*, medullary canal; *bl.*, anal portions of blastopore; *Vit.*, yolk forming the floor of the entodermic cavity; *Ent.*, neurenteric canal. After Durham.

of Kowalewsky from its discoverer. Kowalewsky first found it in *Amphioxus*, and subsequently demonstrated its occurrence in various fish types.

This canal is well known in Elasmobranchs and Sauropsida under

the name of the blastoporic canal. It has recently been shown to be present in *Petromyzon* by A. Goette, **90.1**. In teleosts it is rudimentary, the passage being only imperfectly indicated (see McIntosh and Prince, **90.1**, 734-736). In the *Amphibia* its relations are more clearly understood than in any other type. According to H. E. Durham, **86.1**, it can be well seen in longitudinal sections of early stages of the frog, Fig. 110, as a short canal, *ne*, opening widely into the entodermic cavity. This canal has also been described in *Bombinator* by A. Goette, **75.1**, and in *Triton* and *Rana* by F. Schanz, **87.1**. Schanz was the first to clearly discriminate between the anal or false blastoporic and the neurenteric or true blastoporic canal. In birds the neurenteric canal was first described by Gasser, **79.1**, in goose embryos, and since then has been found by Braun in several other birds, though as an *open* passage it appears to be usually oblit-

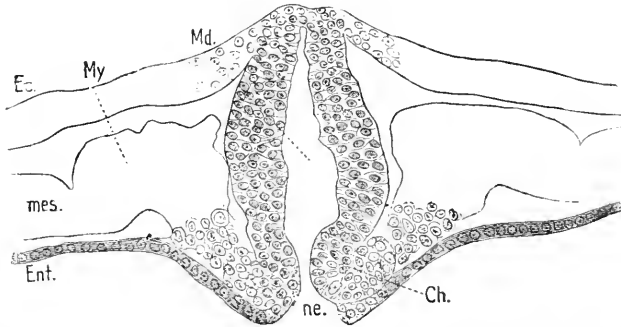


FIG. 111.—Transverse Section of an Embryo Paroquet (*Melopsittacus*) to show the Anterior or true Neurenteric Canal. *Ec.*, Ectoderm; *My.*, myotome; *Md.*, medullary canal; *Ch.*, notochord pierced by the short neurenteric canal, *ne.*; *Ent.*, entoderm; *mes.*, mesoderm. After Max Braun.

erated, as in the chick. Fig. 111 represents a transverse section which passes through the Gasserian or neurenteric canal of the paroquet.

Braun has maintained that in various birds there are two neurenteric canals recognizable, which lie near together. Braun states that in the duck and *Motacilla* the two canals are separated both in the times and position of their occurrence, and that in the Australian paroquet they are present simultaneously. D. Schwarz, **89.1**, criticises Braun's observations and concludes that there is really no second canal. I am inclined to accept this conclusion.

In mammals the open blastoporic canal has been seen by very few observers; it has been carefully studied in the rabbit by C. Giacomini, **88.1**, who shows that the front portion persists for a time as the chorda-canal, while the hind portion, running through the primitive streak, corresponds to the neurenteric canal and is obliterated quite early.

The Anal Canal is also sometimes called the neurenteric canal, and seems to have been especially the subject of misconception. Its full history is given later. Its morphological relations are probably correctly indicated by the observations of Fr. Schanz, **87.1**, which have been confirmed by T. H. Morgan, **90.2**, by Robinson and

Assheton, 91.1, and others. To explain these relations we may start from the stage in amphibian ova, in which the anus of Rusconi is almost closed over; the true blastopore lies at its front edge. As the anus of Rusconi contracts its aperture appears more and more as a mere enlargement of true blastopore, and it is at this stage commonly spoken of as the blastopore; to preserve the distinction we may name this opening the *secondary blastopore*. Alice Johnson, 84.1, had shown that the permanent anus is derived in Triton from this secondary blastopore. H. E. Durham, 86.1, observed that there are two passages in the frog at a little later stage, Fig. 110. Schanz, *l. c.*, found that the medullary ridges meet at their hind ends across the secondary blastopore and divide it into two openings, the anterior, the true blastopore or neurenteric, and the posterior, the anal opening. In many Amphibia the anal canal is often temporarily closed by the tissue growing across it; in later stages the ectoderm forms a slight invagination to develop the anus proper, the partition between it and the archenteron breaking through. The partition is called the anal plate.

The relations of the anal canal in Sauropsida are not yet well ascertained. It is represented by the anal plate, consisting only of ectoderm and entoderm. Although this *anal plate* (*Afterhaut*) has not been actually proved to be homologous with the tissue which temporarily closes the anal canal in amphibians, yet it is hardly possible to question the correctness of the homology, for it separates the anal invagination from the archenteron and subsequently ruptures. The anal membrane recurs in mammals, and if it represents the anal canal in one case it does also in the other. C. Giacomini, 88.1, 287, 288, states that in rabbit embryos with several myotomes the anal plate is grown into a short cord of cells, in which there appears a temporary lumen—this lumen he calls the anal canal. After the canal has disappeared the anal membrane is again found to consist of two epithelial plates, the rupture of which forms the true anal perforation.

Braun's Third Canal.—The third canal, which was first described by Braun, 82.3, is said to occur in older embryos. D. Schwarz, 89.1, 211, denies its existence altogether. The "End-darm" of Gasser and Kölliker becomes the "Schwanzdarm" (post-anal gut, Balfour) of older embryos, which soon becomes divided, at least in birds, into a dilated terminal portion and a narrower neck communicating with the intestine proper. The posterior section then subdivides, and its narrow end-segment lengthens out and unites with the spinal cord. This passage we may designate as Braun's canal. It is not improbable that it is homologous with the amnio-allantoic canal of Gasser, 82.2, which Rauber, 83.2, has nicknamed Cochin-China canal, after a breed of hens in which it seems most constant. In the one case we may suppose the canal to open after, in the other before, the closure of the posterior end of the medullary groove. If the homology is correct it may be further said that the canal is identical with Kupffer's myelo-allantoidean canal; it cannot be brought into relation with the development of the allantois, as believed by Kupffer, 82.2, 83.1, as the allantois and end-darm are both formed before the canal appears.

Significance of the Neurenteric Canal.—As to the morphology and physiology of the canal we know almost nothing. The suggestion of Sedgwick and Van Wijhe, that it is the excretory opening of the tubular nervous system, has already been noticed, p. 179; it will suffice to recall here that no valid evidence in favor of their hypotheses has been found yet. There is no adult form known in which the neurenteric canal persists; were there such an animal we might hope to discover the function of the canal by observation. Morphologically the neurenteric canal, so far as I can judge from present evidence, is part of the persistent blastoporic canal, which is included in the medullary groove, and by the closure of the groove becomes shut off from the exterior. Why the secondary blastopore (prostoma) should be divided into the two openings, the neurenteric and anal, we do not know.

It seems not impossible that a persistent neurenteric canal may occur as an excessively rare anomaly in the adult.

CHAPTER IX.

THE PRIMITIVE DIVISIONS OF THE CŒLOM: ORIGIN OF THE MESENCHYMA.

IN all true vertebrates the cœlom presents the peculiarity of consisting of an upper or dorsal segmented portion and a lower or ventral continuous unsegmented portion. The segmented cœlom consists of a series of discrete separate cavities, each of which communicates with the ventral cœlom.

Now, in annelids (and their arthropodous descendants) the cœlom consists only of separate paired cavities, so that the mesothelium is divided into distinct parts, each inclosing a space; each division is known as a mesomere or mesoblastic somite. Hence we have the morphological question, how has the completely segmented cœlom of annelids become transformed, as we must assume it has, into the partially segmented cœlom of vertebrates? The answer is probably given correctly by Hatschek's investigation of the changes of the mesothelium in *Amphioxus*, 88.1. In *Amphioxus* the entire mesoderm becomes segmented; the ventral cavities of the segments subsequently fuse, while the dorsal parts remain distinct. In the lower vertebrates the segmented cœlom appears first and the unsegmented portion later; whether the latter is temporarily segmented remains for future investigation to determine. In amniota the unsegmented portion of the cœlom appears first, as described in Chapter VI. This must be regarded as a secondary modification, probably connected with the evolution of the amnion; as explained in Chapter XV, the development of the amnion depends upon a precocious and exaggerated development of part of the cœlom.

With these general notions in mind, we can better appreciate the early history of the vertebrate cœlom. We consider—1, the primitive segments; 2, the unsegmented cœlom; 3, division of the primitive segments; 4, the differentiation of the myotome; 5, origin of the mesenchyma; 6, comparison with *Amphioxus*.

The Primitive Segments.*—A segment consists of a pair of cavities symmetrically placed and bounded by mesothelium. The segments are permanent in many invertebrates, but they are greatly modified in all adult vertebrates, and so much modified in the amniota, that they can be said properly to exist only during embryonic stages, although they determine a large part of the adult structure. I have selected the term primitive segments as unlikely to lead to confusion, but numerous other names have been proposed; the one most generally in use is *protovertebra* (*Urwirbel*), which was introduced long ago under the erroneous notion that the segments were the direct precursors of the vertebræ, which they are not, properly speaking. The term *protovertebræ* is, however, more often used in

* On the segments of the head, see p. 200.

a more restricted sense, viz., for that part of the primitive segment which is called the myotome in the following pages. Other terms are *mesoblastic somites*, *mesomeres*, *metameres*, *Ursegmente*.

The *primitive segments* appear very early; the first pair can be recognized in the chick at twenty to twenty-two hours, in the rabbit at the beginning of the eighth day, or even earlier; in both cases the medullary groove is still nowhere closed and the primitive streak is still present. In the anamniota the first segments appear at about the same early stage. In the amniote embryo just before the first segment appears the mesoderm forms a continuous sheet; surface views show that it forms two wings, being divided by the median down-growth of the medullary groove as stated, p. 149. The mesoderm on each side is considerably thicker alongside the axial line than farther away from it; the distinction is well marked and enables us to distinguish two zones, namely, the thicker *segmental zone* near the axis, and the thinner but much wider lateral or *parietal zone*; the segmental zone is the *Stammzone* of German writers, the *Wirbelplatte* of Remak, or *vertebral plate* of Balfour. The first noticeable indication of the formation of the primitive segment is a loos-

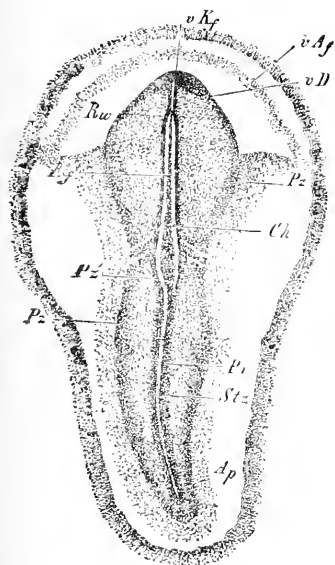


FIG. 112.—Chicken Embryo with one Segment. *Ap*, Area pellucida; *vAf*, anterior crescent; *vKf*, head fold; *Ch*, notochord; *Pz*, parietal zone; *Stz*, Stammzone. From Kölliker. (Compare text.)

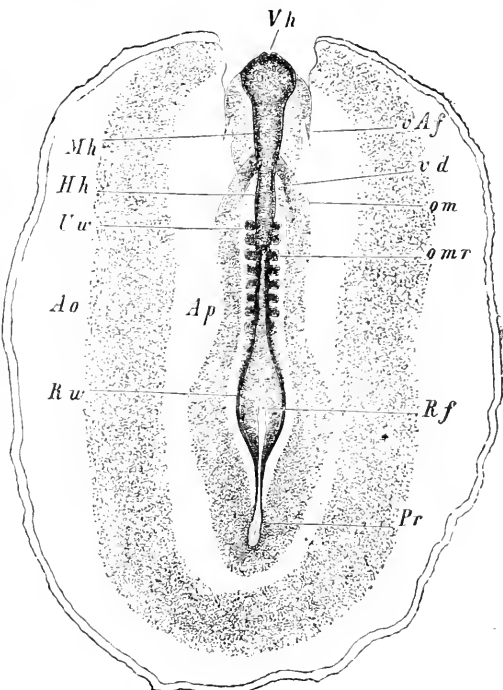


FIG. 113.—Area Vasculosa and Embryo with Eight Segments of a Hen's Egg. *Vh*, Fore-brain; *vAf*, anterior amniotic fold; *Pf*, fovea cardiaca; *omr*, anterior limit of open medullary groove; *Pf*, primitive streak; *Rw*, margin of medullary groove; *Ap*, area pellucida; *Ao*, area opaca; *Uu*, first segment; *Hh*, hind-brain; *Mh*, mid-brain. From Kölliker.

ening of the cells in the segmental zone along a narrow transverse line; in the chick this occurs about 0.14 mm. in front of the

primitive streak, at a time when only a short stretch of the head-end of the medullary groove is formed. Very soon there appears a second transverse loosening of the cells and cleavage of the mesodermic segmental zone takes place. According to A. Goette, **75.1**, 203, the cleavage begins in teleosts and the chick and probably in other vertebrates with a small depression on the ectodermal side, and this depression gradually deepens to a cleft, which divides the segmental plate completely. The disposition of the fissures is such that they include on each side of the axis a cuboidal block of mesoderm, and this block with its fellow on the opposite side constitutes the first primitive segment, Fig. 112. The site of

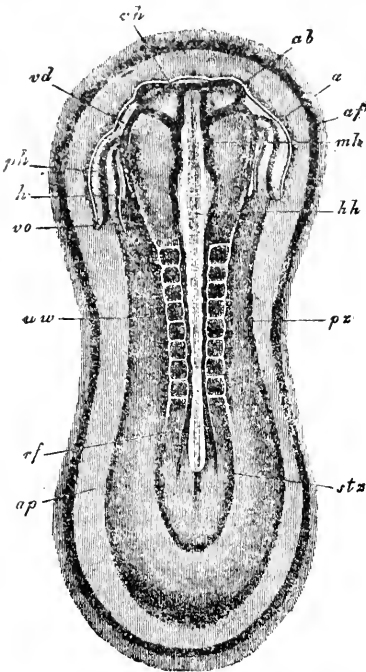


FIG. 114.—Rabbit Embryo with Eight Segments. *vd*, Fore-brain; *ab*, optic vesicles; *a*, heart; *af*, amniotic fold; *mh*, mid-brain; *hh*, hind-brain; *pz*, parietal zone; *stz*, segmental zone; *ap*, area pellucida; *rf*, edge of open medullary groove; *uw*, primitive segment; *vw*, venous end of heart; *h*, heart; *ph*, pericardial cavity; *vd*, fovea cardiaca. From Kölliker.

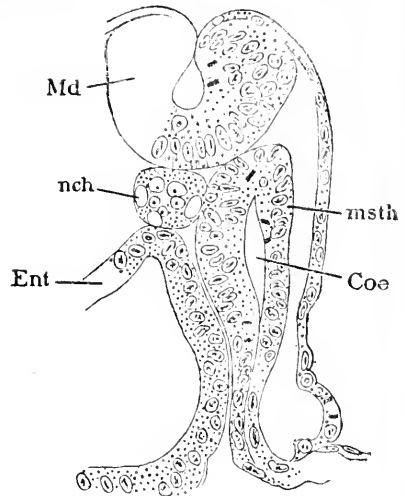


FIG. 115.—Transverse Section of a Pristurus Embryo with Fourteen Segments, through the Centre of the Fourth Segment. *md*, Medullary groove; *Ec*, ectoderm; *msth*, mesothelium; *Coe*, cavity of segment; *Ent*, entoderm; *nch*, notochord. After C. Rabl.

the first segment corresponds to the posterior occipital region; the second segment, at least in the chick, is formed immediately in front of the first; these two segments, according to Chiarugi, **90.1**, 329, are the third and fourth occipital segments, and together with the first and second segments—subsequently found in front of them—abort in all amniota during early embryonic life, as was discovered by Froriep. According to Julia B. Platt, **89.1**, 179, the first division formed in the chick is that between the third and fourth occipital segments, and two segments are subsequently produced in front of this division, while seven are forming behind it. A chick with one segment is shown in Fig. 112. The medullary groove, *Rf*, is short and broad; the anterior end of the embryo, *rKf*, is already rising

above the yolk; the parietal, *Pz*, and segmental zones, *Stz*, are distinct even in the region of the primitive streak, along which the primitive groove, *Pr*, is well marked; the segment is well advanced and another has begun to form in front of it. A chicken embryo with eight segments is shown in Fig. 113, and a rabbit embryo also with eight segments, in Fig. 114; comparison shows many important differences between the two embryos.

The examination of transverse sections shows that the primitive segments in all anamniote vertebrates are hollow and bound by mesothelium on all sides. The relations can be understood readily in elasmobranchs. Fig. 115 is from a *Pristinurus* embryo and shows the cavity of the segment very clearly; the embryo is much more separated from the yolk than is the case with amniote embryos at a corresponding stage, consequently the lateral or parietal zone of mesoderm lies nearly vertical, instead of resting horizontally, as it does upon the yolk of amniota; in the parietal zone there is as yet no cavity (cœlom); the ventral or unsegmented cœlom arises later. It is probable that the segmental cavities spread down into the parietal zone, and that their ventral (*i. e.* lower or so-called parietal) ends fuse together and form one large main body cavity. This probability, as C. Rabl has said, **89.2**, rests upon the analogy with the ascertained process in *Amphioxus*, and upon the fact that the segmental cavities appear first, and expand outward or away from the axis. Whether, however, they do actually give rise to the main cœlom by their partial lateral or ventral fusion or not, there are no observations at present to decide.

Of the development of the *segments in the primitive vertebrates* (marsipobranchs, ganoids, and amphibians), there is not much known, though there are many scattered observations recorded. There appears, however, to be a distinct thickened zone of mesoblast on each side of the axis, and from this zone the segments are developed as pairs of cuboidal blocks of mesothelium; the central cavity of the segment is very small; its mesothelium is thick. The main cœlom is at first a fissure farther away from the axis, and it has not yet been shown that there is from the start a communication between the segmental and the main cœlom, although the mesoblast is continuous. In *Petromyzon*, if I understand Goette aright, the mesoderm is at first solid; Goette states, **90.1**, 48, that in the cervical region the main body cavity appears first, but in the rump the primitive segments acquire their cavities first; that is, while the mesoderm of the parietal zone is still solid. This is important as foreshadowing the precocious development of the cervical cœlom (cavity of the amnio-cardial vesicles) in amniota. In sections the primitive segments in *Petromyzon* and *Amphibia* are triangular, filling out the space between the medullary canal and the adjacent ectoderm and entoderm on each side. In *Bombinator*, A. Goette, **75.1**, 202, and *Petromyzon*, A. Goette, **90.1**, the first segment appears near the middle of the embryo, and new segments are added in front to make the cervical region and a much larger number progressively backward to form the rump of the adult.

In *Sauropsida* transverse sections of the primitive segments, when they are first formed, show no cavity, nor does any appear until con-

siderably later. The development begins with the differentiation of the segmental zone (Remak's *Urwirbelplatte*, Balfour's vertebral plate), which is accomplished by the thickening of the mesoderm near the axis of the embryo. The process is intimately associated with the upward movement of the medullary plate to form the medullary groove, His, 68.1, 81, and Goette, 75.1; the space between the ectoderm and entoderm is enlarged by this movement, and is always nearly filled by the mesoderm; consequently the segmental zone appears triangular in cross-sections, the base of the triangle being against the wall of the medullary groove, its two sides against the ectoderm and entoderm respectively, and its apex merging into the lateral mesoderm, which is very much thinner than the segmental plate. The changes just described show a very exact adjustment of the growth of the mesoderm to changes in the outer germ-layers. Such adjustments occur throughout all embryological developments, and are, I think, due to methods of growth rather than to simple mechanical conditions. His has attributed, 68.1, 81, 93, special influence to the attachments of the mesoderm to the other layers, and the consequent strain upon the segmental plate as the medulla rises; but the enlargement of the plate depends upon the multiplication of the cells, and we cannot assume that the strain causes cell proliferation. At most, one might say that the strain determines the shape of the segmental plate. But is it not more natural to assume that the cells of the mesoderm simply spread out until they fill the available space?

The first sign of the mesomeres is the assumption by the cells, that are to form them, of a more distinctly epithelial arrangement, the

cells radiating in all directions, but there remains in the centre a core or nucleus (*Urwirbelkern*) of cells, Fig. 116, *C*, which have small bodies with anastomosing protoplasmatic processes; it is impossible, at least at present, to state whether this

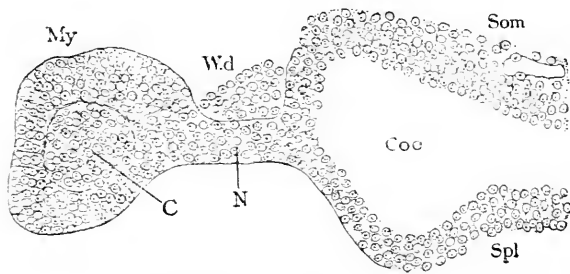


FIG. 116.—Transverse Section through a Recently Formed Primitive Segment of a Chick with Eighteen and Twenty Segments. *My*, Myotome; *W.d.*, Wolffian duct; *Som*, somatic mesoderm; *Co*, coelom (splanchnocoel); *Spl*, splanchnic mesoderm; *N*, nephrotome or intermediate cell mass; *C*, core of myotome. $\times 227$ diams.

an ingrowth from all sides or only from one or two, but I am strongly inclined to think that it is probably part of that side of the primitive segment which is next the medullary canal. The cross-sections further show that the mesomere is more complex than is apparent in surface views, in that it consists of a wider triangular part, Fig. 116, *My*, next the medullary groove, and a narrower lateral portion, *N*, next the parietal zone; it is to the former that the term protovertebra (*Urwirbel*) is restricted by most writers, while the latter is termed the *intermediate cell mass*, as proposed by Balfour; both are parts of the primitive segment. The appear-

ance of an epithelial arrangement of the cells is confined to the "protovertebra" *sensu strictu*. The square blocks seen in surface views correspond to the protovertebræ only and not to the whole segment.

The most exact observations on the primitive segments of *mammals* known to me are those of Heape, 86.2, on the mole, of R. Bonnet, 89.1, on the sheep, and of J. Kollmann, 91.1, on the human embryo. The vertebral plate thickens as the medullary plate rises and becomes triangular in cross-section; the mesodermal cells, which up to this point have been of the anastomosing type, become elongated and radiating, and gradually assume an epithelioid character, which becomes most distinct on the ectodermal side; the cells gradually withdraw from the centre of the segment, leaving a cavity.* The cells of the segment multiply rapidly, most of the divisions taking place in radial, but some in tangential, planes. The segments have the triangular form already noticed in other classes. The cells have branching prolongations, which extend out to the primary germ-layers, and are especially marked on the ectodermal side. In the sheep the cavities of the first four segments, and of them only (Bonnet, *l.c.*, 50), extend through the lateral portions of the segments and communicate with the main cœlom; these four segments Bonnet assigns to the occipital region. A similar series of communications have been recorded for the chick by S. Dexter, 90.1.

The Ventral or Unsegmented Cœlom. †—This portion of the cœlom, which persists in the adult, gives rise to the pericardial, pleural, and abdominal cavities, which are morphologically parts of one continuous cavity, the ventral cœlom. Many terms are in use to designate the ventral cœlom; by English embryologists it is usually called the *pleuro-peritoneal space* or cavity; or often simply *body-cavity* (*Leibeshöhle, cavité somatique*); by German writers it is sometimes termed lateral cœlom, sometimes the *Parietalhöhle*, although the latter term is properly used only for the pleuro-pericardial division of it. Hatschek has proposed *splanchnocœle*, which is adopted in this work.

The splanchnocœle appears in all cases in the parietal zone of the mesoblast as a narrow fissure, the method of origin of which has already been described, p. 151. The fissure rapidly widens and extends toward the axis until it almost reaches the primitive segments and also spreads out laterally and into the so-called extra-embryonic region of the amniota, but there is for a considerable period a circular area inclosing the region of the embryo like a ring, in which the mesoblast contains no cœlom; this mesodermic ring is known as the vascular area (*area vasculosa, Gefässhof*), and has for its special function the production of the first blood-vessels and blood-corpuscles: see Chapter X. In later stages the cœlom extends into the vascular area.

The splanchnocœle is developed earlier, and acquires a greater distention at first in the future cervical region. A. Goette, 90.1, 48-49, states that in *Petromyzon* it precedes in the region of the heart the appearance of the segmental cavity. In the *Amphibia*

* See Bonnet's figure, *l.c.* Arch. Anat. und physiol. 1889, Taf. v. Fig. 5.

† On the splanchnocœle of the head, see also p. 199.

the precocity of the cervical cœlom appears also, and it is perhaps true of other anamniota. The development of the main cœlom is still more hastened in all the amniota, being in them intimately associated with the development of the amnion. In the chick this is very well marked, because as probably in all sauropsida the splanchnocœle enlarges so rapidly in the cervical region that, even while the number of primitive segments is very small, we can recognize a vesicular space in the mesoderm on either side of the head of the embryo; for these spaces, which are the *Parietalhöhlen* of German embryologists, I propose the name of *amnio-cardial vesicles*. They are shown in Fig. 117, *Ves.* Their rapid expansion soon brings

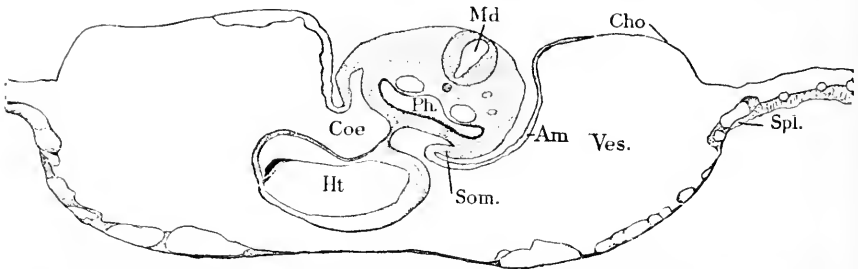


FIG. 117.—Section of a Chick with about Twenty Segments. *Ht.* Heart; *Coe*, cœlom; *Md*, medullary tube; *Ph*, pharynx; *Som*, somatopleure; *Am*, amnion; *Ves*, amnio-cardial vesicles; *Cho*, chorion; *Spl*, splanchnopleure. \times about 40 diams.

them into contact, and then into fusion with one another under the neck of the embryo. The heart is lodged in this cavity, of which the lateral increase produces the so-called head-fold of the amnion. It is on account of this double destiny that the name amnio-cardial vesicles is proposed. The relations, which are traced out through the later stages in Chapter XV., may be more fully understood from Fig. 117, which is a cross-section of a chick through the heart region at an older stage than we are now considering. The posterior limit of the amnio-cardial cœlom is marked by the course of the omphalomesaraic veins, which arise later and establish the communication between the area vasculosa and the venous end of the embryonic heart. The topographical relations are described in Chapter XIII., on the germinal area. In mammals the same peculiarity of the precocious dilatation of the amnio-cardial cœlom probably recurs, but has not yet been properly investigated. In the sheep (Bonnet, 89.1), the amnion appears extraordinarily early, and, as it must be preceded by the formation of the cœlom, we find in the sheep a huge ring of splanchnocœle around the embryo while it is still in the primitive streak stage.

The splanchnocœle of the body proper—that is, of the region behind the neck and heart—appears after the primitive segments, even in the sheep, in which the extra-embryonic cœlom is so very early developed. Moreover, in the body the main cœlom expands more slowly than in the neck. The expansion takes place at first only in the part of the mesoderm next the primitive segments, Fig. 92. Already the thickening of the segmental plate (*Urwirbelplatte*), which accompanied the uprising of the medullary plate, has marked out partially the

region of the embryo from that of the yolk, and now the distention of the splanchnocœle increases and finally completes the demarcation of the embryonic region from the extra-embryonic. The splanchnocœle extends in all amniota only part way through the mesoderm, until quite late in development, so that at a gradually increasing distance from the embryo there is a layer of mesoderm without any cavity, and the cells of which preserve the mesenchymal type. This undivided mesoderm develops the first blood and blood-vessels. After the first vessels of the area have appeared the splanchnocœle spreads out *over* them, so that the first vessels lie then *below* the cœlom—*i. e.*, in the splanchnopleure.

As the splanchnocœle develops, the mesodermal cells assume gradually a more and more distinctly epithelial character, so that the main cœlom becomes bounded by mesothelium, as described in Chapter VI., and the somatic leaf of the mesoderm is differentiated from the splanchnic; toward the axis of the embryo the two leaves pass into one another, and also at the distal edge of the cœlom the two leaves pass without any distinct limit into the unleft mesoderm of the area vasculosa.

In conclusion, I wish to emphasize the fact that the splanchnocœle (pleuroperitoneal cavity) is almost, if not quite, from the start divided into a precociously enlarged cervical portion (amnio-cardial vesicles, Parietalhöhle) and a rump portion (abdominal cavity); the boundary between the two portions is marked by the omphalomesaraic veins, which run from the area vasculosa into the embryo proper at nearly right angles to the embryonic axis. This primitive disposition is of fundamental morphological significance.

Cœlom of the Head.—No thorough investigation of the history of the early stages of the mesoderm in the head has yet been made for any vertebrate. Until this is done we cannot hope to understand the morphology of the head, because the progress of research has demonstrated more and more clearly that the head is made up of series of greatly modified segments, but the number and metamorphoses of the head segments can be determined only by knowing the entire history of the mesoderm. Balfour was the first, **78.3**, to demonstrate the existence of the cœlom in the head, and to partially work out its subdivisions. The subject was further advanced by A. Milnes Marshall, **81.2**, Van Wijhe, **82.1**, A. Dohrn, **90.2**, and others. Marshall and Van Wijhe's results have been subjected by Gegenbaur, **88.1**, 3-8, to criticism, which seems to me by no means fortunate. Gegenbaur's conclusion, that the number of cephalic segments gives no trustworthy indication of the ancestral history I must entirely dissent from, since I believe that the number of mesodermic segments in the head of the embryos of the lower vertebrates is the *only* trustworthy clew to the morphogeny of the head, which we can seek at present.

A. Dohrn, **90.1**, 335, made the discovery of a large number of segments in the head of vertebrate embryo, having observed seventeen or eighteen in the head of *Torpedo marmorata* of 3 mm. Killian, **91.1**, confirms and rectifies (*l. c.*, p. 103) Dohrn's observations, and describes seventeen to eighteen segments, Fig. 118, in the head of Elasmobranchs, as follows: Oral zone with two segments; mandibu-

lar zone with three; spiracular zone with three, corresponding to the first gill cleft; hyoid zone with four, in the region of the second gill cleft; glossopharyngeal zone with two; occipital zone with four.

Killian observed these segments in Balfour's stages F and J, of *Torpedo ocellata*.

In later stages Van Wijhe, **82.1**, whose results have been verified, found only nine segments. The number is presumably reduced chiefly by abortion, but partly also by fusion. Van Wijhe's segments are as follows: The *first* or præ-oral is identical with Balfour's præ-mandibular cavity; and it is identified by Killian with his oral zone; it is possible that the first segment of the oral zone is identical with the "new" head cavity described by Julia B. Platt, **91.2**; Van Wijhe's first segment is small and acquires its cavity late, being solid after the remaining eight myotomes have developed their cavities; it is connected by a short band of cells across the median line with its fellow of the opposite side; this band subsequently (in Balfour's stage L) disappears; the first segment produces four muscles, the rectus

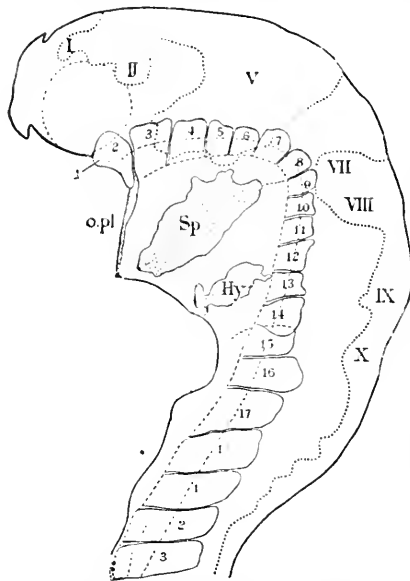


FIG. 118.—Head of an Embryo of *Torpedo Ocellata*, in Balfour's Stage J. I-X. Anlagen of the cephalic ganglia and nerves; 1-3, first three rump segments; *o. pl.* oral plate; *Sp.* "spiracular" cleft, or first gill cleft; *Hy.* hyoid cleft. The dotted circle below I and II indicates the optic vesicle. After Killian.

superior, internus, and inferior, and the obliquus superior. The *second* or mandibular segment (Balfour's mandibular cavity) corresponds with Killian's mandibular zone; its cavity disappears in Balfour's stage O; it produces the muscles of mastication; according to Killian, it is produced by the fusion of three segments. The *third* segment seems also to be the product of the fusion of three primitive segments of Killian's spiracular zone; its cavity has a communication through the hyoid arch with the ventral cœlom (pericardial cavity). The *fourth* segment corresponds in position over the second or hyoid gill cleft with the three segments of Killian's hyoid zone (Dohrn's eleventh to thirteenth segments). The *fifth* segment corresponds to the two segments of Killian's glossopharyngeal zone. Killian's four occipital segments all persist independently of one another to constitute Van Wijhe's sixth to ninth segments, which I think are to be further identified with the four temporarily present hypoglossal or occipital segments which Frioriep has discovered. **86.1**, in amniote embryos. Van Wijhe regarded nine as the total maximum number of segments in the vertebrate head, and sought, **89.2**, to identify nine corresponding segments in *Amphioxus*.

That a series of coelomatic cavities exist in the head of the amphibian embryo was, if I am not mistaken, first observed by Scott and Osborn, 79.1. Houssay, 90.1, has sought to identify the number of cephalic myotomes in the axolotl. He accepts the idea of the exact correspondence between the branchial pouches and the myotomes in segmental order; and as he maintains that there is a gill pouch, which corresponds to the auditory nerve and aborts during embryonic life, and further regards the nose, hypophysis, and mouth each as representing a separate segment, he finds that there must be at least eleven segments in the head of the axolotl, as follows: 1, nose; 2, hypophysis; 3, mouth; 4, "event;" 5, hyo-mandibular; 6, hyoid; 7, ear; 8, first branchial; 9, second; 10, third; 11, fourth branchial; for each of these he assumes a separate myotome. He has actually observed, 90.1, the nine somites corresponding to those described by Van Wijhe (see above), and further claims to have found evidence that the second and third of these are both really double, thus identifying eleven mesomeres, which, he says, 91.1, 58, appear in the following order:

In position	1	2	3	4	5	6	7	8	9	10	11
In time.....	1	2	11	10	6	3	4	5	7	8	9
Or in groups.....	1'	2'	3'	2''	1''	1'''	2'''	3'''	4'''	5'''	6'''

Van Bemmelen, 89.1, 254, in a superb reconstruction of the head of a snake embryo, shows three myotomes belonging to the eyeball, but gives no information concerning them, and represents no other myotomes in the head until the hypoglossal region with its four myotomes is reached. A. Oppel, 90.1, describes the cephalic segments in *Anguis* embryos; he has recorded the presence of Van Wijhe's first to third and sixth to ninth segments.

The splanchnocœle of the head becomes the pericardial cavity of the adult; its mesothelium, where it covers the heart, gives rise to the cardiac muscle, and it is supposed to extend between the gill pouches to produce the muscles of the branchial arches. Along the level of the branchial pouches the splanchnocœle becomes in part divided, as first shown by Balfour, 78.3, into a series of separate cavities by the outgrowth of the gill pouches and the union of the entoderm of each pouch with the ectoderm. Each of these cavities has an elongated form and communicates on the dorsal side with a myotome, and on the ventral side with the pericardial cavity (Van Wijhe, 82.1, Van Bemmelen, 90.1). We may distinguish, therefore, the mandibular cœlom, the hyoid cœlom, and the branchial cœlom (one cavity in each gill arch). The connection of the cavities of the arches with both the myotomes and pericardial cavity is apparently lost, but as to the separation there are no definite observations. The actual cavities in the arches are soon obliterated, but their mesothelial walls persist and produce the branchial muscles; compare Chapter XXI.

Division of the Primitive Segments.—The primitive segments very early divide, each into two parts—the *myotome* (proto-vertebra of authors) next the medullary canal, and the smaller *nephrotome* (*intermediate mass*, Kölliker's *Mittelplatte*); next the lateral plates or mesothelium of the splanchnocœle, Fig. 116. The

division is evidently indicated as soon as the primitive segments are formed, the thicker proximal end being destined for the myotome, the thinner distal end for the nephrotome; the latter originally unites the myotome with the lateral plates, hence its name of "intermediate cell mass"; as its principal function is to develop the nephridia it may be more conveniently named the *nephrotome*, as proposed by Ruckert, **88.1**.

The nephrotome has to separate from the splanchnocœlic mesothelium (lateral plates) on the one side and the myotome upon the other. Unfortunately this double separation has been as yet very inadequately studied, except in the case of elasmobranchs, where the development of the nephridia has been carefully investigated; for details compare Chapter XI. In *Bombinator* a groove appears on the ectodermal side and gradually deepens until it separates the myotome from the rest of the mesoderm; this groove does not pass through in the shortest direction, but extends obliquely upward, A. Goette, **75.1**, 213. The nephrotome loses its connection with the myotome relatively early, but retains, at least in some segments, the connection with the lateral plates for some time longer in most elasmobranchs and amphibians throughout life, but in amniota only during embryonic stages. The exact histological changes by which the nephrotome serves its double connections are still unknown. A. Goette, **90.1**, 49, states that in *Petromyzon* the isolation of the nephrotome takes place in the front end of the body when the mesoderm has a well-developed cœlom, but in the rear part while the mesoderm has no cœlom either in the vertebral or lateral plates.

C. Rabl, **89.2**, has directed especial attention to the fact that in elasmobranchs there is a special outgrowth of the wall of the primitive segments on the side nearest the chorda and from the point where the nephrotome joins the myotome, Fig. 122. This outgrowth* is the beginning of the mesenchyma, and recurs, of course, segmentally, so that the term *sclerotome* may be applied to it, but all trace of segmental division is very soon lost, nor does the segmental origin of the axial mesenchyma, which is developed from these outgrowths, determine the subsequent morphological differentiation, so far as yet known. Rabl likens this outgrowth to an evagination, and points out that the cavity of the nephrotome presents a slight diverticulum at first, where the outgrowth takes place. He compares this evagination with the evagination at a corresponding point in *Amphioxus*, which has been described by Hatschek, **88.1**, and is said to grow up between the myotome and the medulla; in *Amphioxus*, however, the cells retain an epithelial character, while in the vertebrate they are mesenchymal; but as no strict line can be drawn between these two types of tissue, the histological difference cannot be held to invalidate the homology drawn by Rabl.

The *cavity of the primitive segment* varies greatly in the various classes of vertebrates. In the primitive forms, *Petromyzon*, *Amphibians*, etc., the myotomic portion is wedge-shaped, appearing triangular in cross-section, and considerably wider than the cavity of the nephrotome. In elasmobranchs, *cf.* C. Rabl, **89.2**, Taf. X., Figs. 1-6, a similar difference exists at first, but very soon the two

* Compare Rabl, *l.c.* "Morph. Jb." xv., Taf. x., Fig. 4, sk.

walls of the myotome come close together, Fig. 122, obliterating the cavity; the nephrotomic portion, on the contrary, widens meanwhile. In *Lepidosteus* the medullary and entodermal sides of the myotome are represented as several layers of cells thick by Balfour and Parker, **82.1**, Pl. 23, Figs 28, 29, so that the myotome appears partly filled with cells belonging, however, to its inferior wall. We have in this case perhaps a transition to the amniote structure, in which the encroachment of cells is so great that no distinct cavity can be recognized in the myotome, Fig. 116; and since the nephrotomic cavity appears very late, it results that in the amniota there is no distinct cavity whatsoever in the primitive segments, though there is a cavity later in both the myotome and nephrotome.

The primitive aortæ lie close below the myotomes on each side; Figs. 119, 122, 161, 105; a glance at any of these will show the reader that the mesoderm derived from the myotome from the very first comes into contact with and soon envelops the medullary tube, *Md*, the notochord, *Ch*, and the aorta, *Ao*, and also reaches over part of the entodermal wall of the archenteron.

Shape of the Myotome.—As described above, the myotome, when first formed and even before it is separated from the nephrotome, appears more or less nearly square in surface views and triangular in cross-section. Very soon it enlarges in Amphibia and amniota, so as to appear square in section also, Fig. 119. The cavity in Amphibia is very distinct and the epithelial character of the walls well marked; but in all amniota, so far as known, the cavity at this stage is still obliterated by the core of cells (Remak's *Urwirbelkern*). By the assumption of the cuboidal shape the myotome becomes more sharply marked off from the intermediate mass or nephrotome, and as the lateral or main cœlom has been expanding during the same period, there is established a space above the nephrotome and between the myotome and the lateral plates. It is in this space that the primitive longitudinal duct of the urogenital system, Fig. 116, *W.d.*, is situated as soon as developed—a fact which led many writers to attribute the origin of the duct to a differentiation of the intermediate cell mass.

Differentiation of the Myotome.—We can distinguish three steps in the differentiation: 1, production of mesenchyma from the inner wall of the myotome, Fig. 119; 2, production of the true muscle plate, Fig. 120; 3, conversion of the outer wall into mesenchyma to form the dermal layer, Fig. 121.

The production of mesenchyma from the inner wall begins very early, and is marked by a loosening and moving apart of the mesothelial cells until the entire inner wall, at least in amniota, is converted into tissue of the mesenchymal type, Fig. 119, *mes*. Owing to the moving apart of the cells the tissue occupies a large space and fills up the myotomic cavity. While the metamorphosis is going on the cells multiply rapidly. The course of this change of the inner wall has been carefully studied by W. Heape, **86.2**, in the mole, by R. Bonnet, **89.1**, 45–55, in the sheep, and by Erik Müller, **88.1**, in the chick. Müller has further demonstrated that the muscular envelope of the aorta comes from the mesenchyma produced by the inner myotomic wall. In elasmobranchs, according to C. Rabl,

89.2, the greater part of the inner wall of the myotome very early shows the differentiation of muscle fibres, the cells retaining the mesothelial type, Fig. 122, and the mesenchyma is produced only

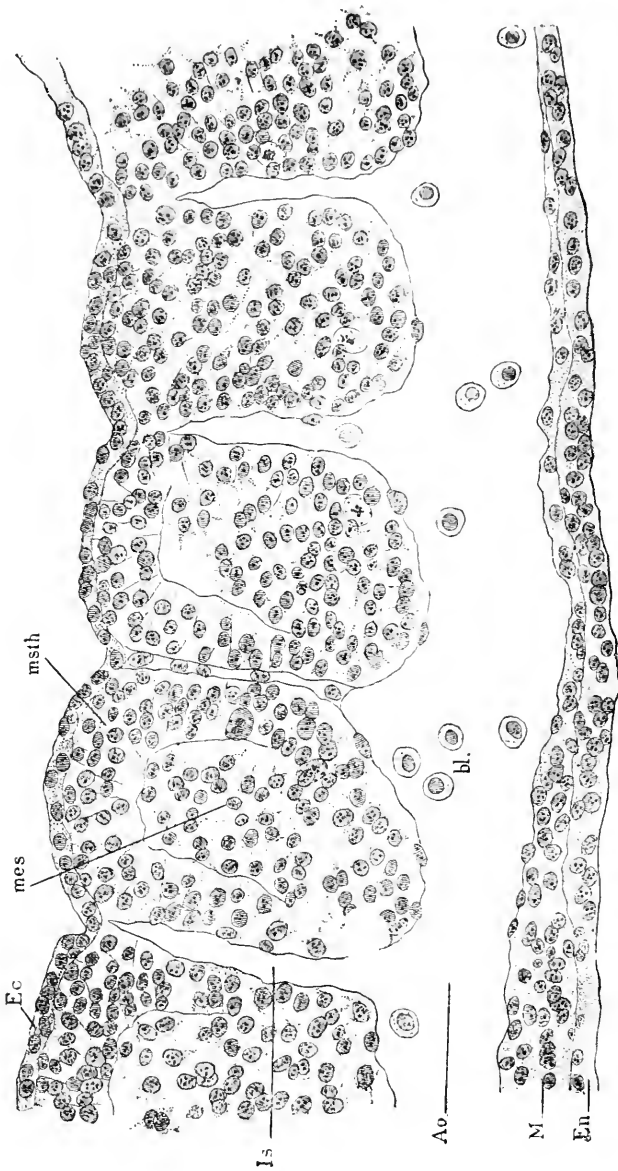


FIG. 119.—Longitudinal Vertical Section through Five Primitive Segments of a Rabbit Embryo of Nine Days and Seventeen Hours. *Ec*, Ectoderm; *mes*, inner wall of segment; *msth*, outer wall of segment. *Is*, intersegmental arteries; *Ao*, aorta; *M*, splanchnic mesoderm; *En*, endoderm. $\times 257$ diams.

from that part of the inner wall, which is nearest the nephrotome (*Mittelpatte* of Remak); in elasmobranchs, therefore, the mesenchyma appears more as an outgrowth from one point—a fact which

leads Rabl to a significant comparison with *Amphioxus*, as stated above. In anniota the persistence of the outgrowth is indicated by the fact that the metamorphosis of the mesothelium of the inner wall begins near the nephrotome; it spreads, however, rapidly, so that nearly the entire wall undergoes the transformation. My own observations are incomplete, but they indicate that in anniota the differentiation of myotomic muscles invariably follows later. Where the inner wall joins the outer the cells retain the mesothelial arrangement for a very considerable period (see Figs. 119 and 121).

The muscle plate proper arises from cells of the inner wall next the myotomic cavity, or we may say—since the cavity is obliterated

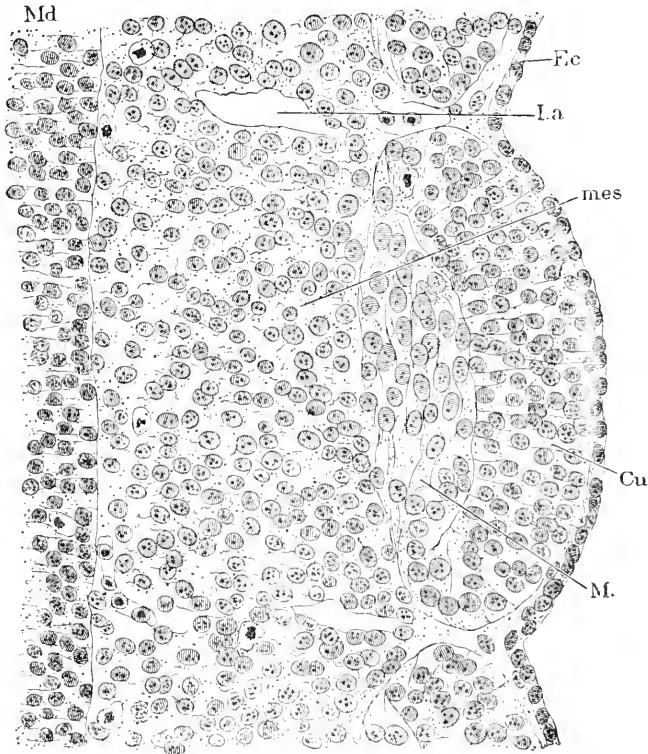


FIG. 120.—Longitudinal Horizontal Section through a Segment of a Rabbit Embryo of Ten and One-half Days. *Md*, Edge of the medullary wall; *Ec*, ectoderm; *I.a.*, intersegmental artery; *mes*, the so-called sclerotome or mesenchyma of the inner wall; *Cu*, outer wall of the myotome (anlage of the cutis); *M*, muscle-plate. / 206 diams.

—from the cells nearest the outer wall. The cells become elongated parallel with the longitudinal axis of the embryo, Fig. 120, *M*; the nuclei also elongate in the same direction, thus becoming oval, and as shown in the figure they are, at least in the chick, larger than the nuclei both of the neighboring mesenchyma, *mes*, and of the outer myotomic wall, *Cu*. The remainder of the inner wall, *mes*, is the *sclerotome* of recent German writers; it consists of mesenchymal cells which are now entirely separated from the parts of the

myotome which are still mesothelial. While the muscle-plate is forming the mesenchyma merges with it, but gradually it becomes sharply marked off from the muscle cells. The muscle-plate is continuous at its edge with the outer wall, *Cu*, and retains the continuity for a very long period. The muscle-plate and outer mesothelium now form a single and highly characteristic structure, familiar to all embryologists; the structure is a double plate, which takes an oblique position in the embryo; as seen in cross-sections the double plate descends from near the dorsal border of the medullary tube downward and outward toward the somatopleure.

The next change is the production of mesenchyma from the outer wall; the cells of the mesothelium move asunder until they come to lie quite far apart, Fig. 121, *Cu*, forming from the start a much

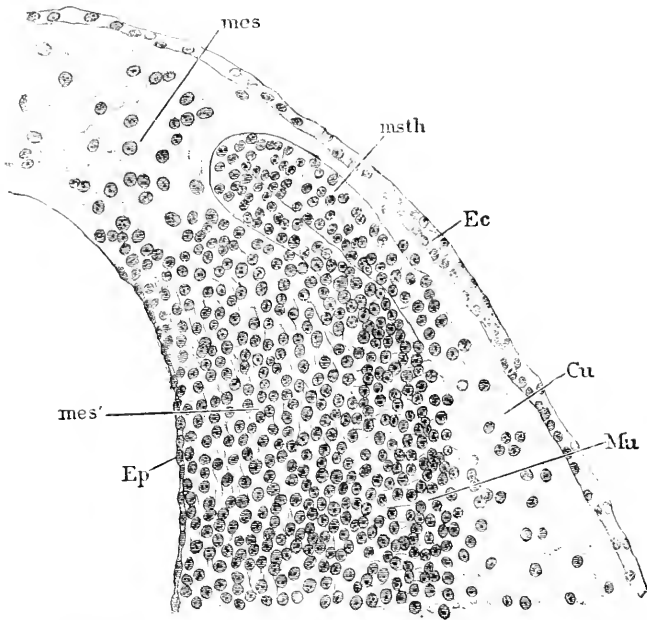


FIG. 121.—Transverse Section through the Upper Part of a Myotome of a Chick of about Seventy Hours. *Mes, mes'*, Mesenchyma of inner wall of myotome; *Ep*, endothelial layer formed against the surface of the medullary tube; *msth*, mesothelial portion of the myotome; *Ec*, ectoderm; *Cu*, mesenchyma (cutis) from outer wall of myotome; *Mu*, muscle-plate, the limits of which are much clearer in the preparation than in the engraving. $\times 296$ diams.

looser tissue than did the mesenchyma from the inner wall; but at this stage, Fig. 121, the inner mesenchyma, *mes*, is spreading around the medullary canal, and as it spreads assumes also a looser texture. The mesothelium, *msth*, still persists around the four margins of the double plate, apparently as an organ to produce cells to be added on the one hand to the muscle plate proper, *Mu*, on the other to the cutis (dermal mesenchyma), *Cu*. In sections the mesothelium usually makes a U-shaped figure, which is highly characteristic of all vertebrate embryos.

In the primitive vertebrates as exemplified by *Petromyzon* (Goette,

90.1, Taf. VI., Figs. 60-63), the flattened myotome consists of two closely appressed epithelial plates with a narrow fissure between them and passing over at their edges into one another; the upper edge of the myotome is nearly on a level with the dorsal margin of the medulla; the myotome inclines obliquely outward and downward and has its lower edge on the level of the archenteric cavity; the outer layer of epithelium is the thinner, while the inner layer is considerably thickened; as the myotome develops farther this difference between the two layers increases.

The amphibian myotomes resemble very closely those of *Petromyzon*, but soon come to differ from them by the multiplication of cells of the inner layer (A. Goette, 75.1, 211, Figs. 138-140), which becomes several cells thick and loses at the same time its distinctly epithelial character in the inner part of the layer, though it retains it in the outer part, there remaining, on the side nearest the entoderm, a single row of cells in epithelial form, so that we have here a condition established secondarily which in the amniota exists almost from the start—namely, a core of looser cells filling the myotomic cavity, but belonging to the entodermal side; it is at this stage that in *Bombinator* the myotome separates from the remaining mesoderm. In later stages the amphibian myotome gives off from probably all parts of its wall cells to form part of the mesenchyma, while the cells which remain form the definite muscle-plate.

Origin of the Mesenchyma.—The first author to trace the origin of the mesenchyma to the primitive mesothelium was Alexander Goette, who fully demonstrated the fact in his great work on the "Unke," 75.1. Goette designates the mesenchyma as *Bildungsgewebe*, and seems to me to have been the first to fully recognize the morphological significance of the tissue. But his work has not hitherto received its deserved attention. Scattered through numerous special papers are isolated observations which might be profitably collated, and which suffice to show that the mesenchyma arises from the mesothelium. In spite of this the brothers Hertwig advanced, 81.1, as stated previously, p. 155, the theory that the two mesodermal tissues are of different origin—a theory which we now know to be false, as, indeed, was proved by Goette six years before the Hertwigs' theory. That all parts of the mesoderm have a common origin was the view of the older embryologists, and, in fact, the differentiation of the middle layer was in the main correctly given by Remak, 50.1. The unity of the mesoderm has always been maintained by Kölliker in his text-books and articles, one of which, 84.4, contains a series of well-founded criticisms of other views and a sufficient defence of his own. Recently the origin of the mesenchyma has been specially investigated by H. Ziegler, C. 88.1, Rabl, 89.2, and Van Wijhe, 89.1, in elasmobranchs, and by R. Bonnet, 89.1, in the sheep.

The mesenchyma rises from cells thrown off from the mesothelium. The entire mesothelium participates in this process, but not to an equal degree, nor at the same time throughout its whole extent. The first part to produce the mesenchymal cells in *elasmobranchs* is the splanchnic leaf at the point where the nephrotome unites with the myotome; at this point, as stated above, there are traces of

an evagination. A little later, Fig. 122, the outer wall of the myotome throws off cells throughout its whole extent, and at the same time a much less active emigration is going on from the nephrotome, while it is not until much later that the walls of the splanchnocoel contribute to the mesenchyma. Whether the mesoderm of the area vasculosa, in which there is at first no coelom, contributes directly to the mesenchyma is uncertain; it certainly produces

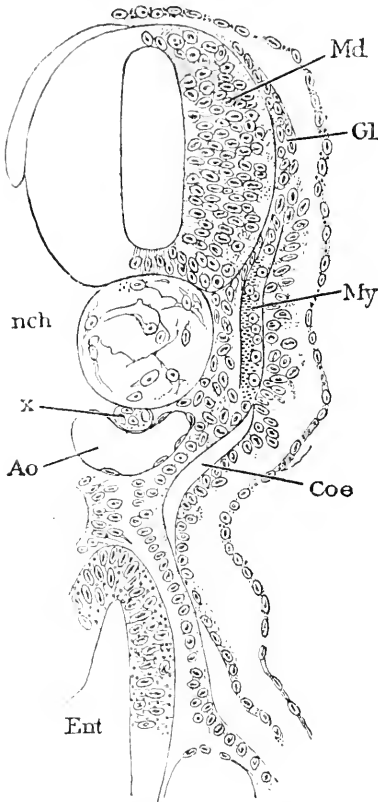


FIG. 122.—*Pristinus* Embryo with Forty-five to Forty-six Segments; Cross-Section of the Anterior Part of the Body. *Md*, Medullary groove; *Gl*, anlage of the ganglion; *My*, myotome; *Coe*, coelom of the nephrotome; *Ent*, entoderm; *Ao*, aorta; *x*, sub-notochordal rod or hypochorda; *nch*, notochord. After C. Rabl.

(see Chapter X.) the blood-vessels, and whether the vessels ought to be considered as mesenchyma or as a distinct tissue is still under debate. An excellent diagram illustrating the mesothelial sources of the mesenchyma is given by H. Ziegler, 88.1, Taf. XIII., Fig. 1. For *amphibians* we have Goette's detailed account; the mesenchyma arises from all parts of the mesothelium, the cells moving off from their epithelial union but remaining connected together by short thick processes, which are never numerous, though variable in number; the cells all contain a great deal of deutoplasm; as development progresses the yolk grains disappear, the cells become entirely protoplasmatic, and the number of intercellular processes increases, the processes at the same time becoming finer and longer. There are regional distinctions in the density of the tissue, which are constant. The tissue increases by additions from the mesothelium during a certain period, and continuously by the proliferation of its own cells. Goette also, 75.1, 497-498, asserts that after the circulation begins leucocytes leave the blood-vessels and are transformed into *Bildungsgewebzellen*; he does not seem to me to offer sufficient proof

to justify this assertion. Goette attributes, *l.c.*, 493, the moving apart of the cells, not, as seems to me most reasonable, to their own growth, but to the accumulation of intercellular fluid, which he assumes to be produced by transfusion from the archenteron. In *mammals and birds* the manner in which the myotome contributes to the mesenchyma is now pretty thoroughly understood, but the share taken by the nephrotome and lateral plates has still to be ascertained. In both classes the metamorphosis of the outer wall occurs much later than that of the inner wall, which very early becomes

considerably thickened by the multiplication of its cells. Heape, 86.2, describes the process in the mole nearly in the following words: The myotomes at Heape's stage H commence first in the anterior region, and gradually assuming the same relations posteriorly, to divide into two portions, an outer arched epithelial portion and a thicker inner portion composed of anastomosing cells of distinctly mesenchymal type, which give rise to the axial mesenchyma, and participate in the formation of the definite muscle-plate. The myotomic cavity is very marked. In the next stage (J) the anterior myotomes exhibit still further changes; the inner layer has grown very considerably, and the row of its cells next the cavity are more closely packed and so have assumed the epithelial form, while the remainder of the layer preserves the anastomosing character of the cells; the inner layer of the myotome is therefore separated into its two parts; the epithelial part becomes continuous with the outer layer, and the two epithelia together constitute the so-called double muscle-plate. Although arising from separate segments the axial mesenchyma loses almost immediately every trace of segmental arrangement, and there is no real proof that its segmental origin has direct influence upon the segmental arrangement of the vertebral and other structures differentiated later from the mesenchyma. Ultimately, as in other vertebrates, the entire outer layer is converted into mesenchyma, which forms the dermal layer, R. Bonnet, 89.1, 54.

Comparison with Amphioxus.—Hatschek's observations, 88.1, on the differentiation of the mesoderm of *Amphioxus* show that there are many striking resemblances with the history of the vertebrate mesoderm as given above. The mesoderm consists at first of a series of paired mesothelial sacs; the ventral portions of the sacs fuse into a continuous splanchnocœle; in a larva several weeks old the inner wall of the dorsal segments is a thick epithelium, which produces the muscles on the inner or entodermal side of the cavity of the segment (*myocœle* of Hatschek); the mesothelium becomes a thin pavement epithelium. After about three months of pelagic-life, the larva changes into *Amphioxus* and takes to the sand. At this time the lower edge of the segment is found to have formed a diverticulum, which stretches upward between the muscles on the one side and the medulla on the other. The segments have also extended into the dorsal and ventral fins and have there formed cavities. These relations are illustrated by the accompanying diagram, Fig. 123, after Hatschek. The points of special interest to us are four: 1, the formation of the splanchnocœle by the fusion of segmental cavities; 2, the development of the muscles exclusively from the inner layer of the second

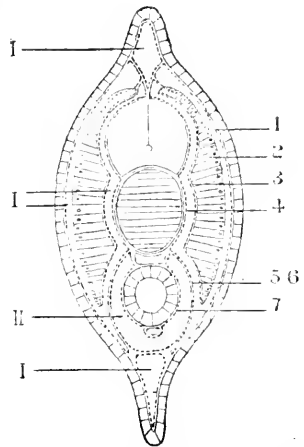


FIG. 123.—Diagram of a Cross Section of a Young *Amphioxus*. I, I, Parts of the coelom of the segment; II, splanchnocœle; 1, outer layer of segment; 2, muscle layer; 3, 4, 5, 6, portions of sclerotomic diverticulum; 7, splanchnic mesoderm around the entoderm. After Hatschek.

dary segments; 3, the absence of differentiation in the outer layer of the segment; 4, the outgrowth of mesothelium passing upward between the muscular layers and the axial structures, medulla, and notochord. It is probable that all these four peculiarities recur in the true vertebrates, though masked principally by the fact that the outer layer of the segment and the epiaxial diverticulum both lose, the former gradually, the latter almost from the start, all trace of epithelial structure, and become converted into mesenchyma. Of course the assumption that the vertebrate splanchnocœle arises in the same way as in *Amphioxus*, is at present entirely hypothetical.

CHAPTER X.

ORIGIN OF THE BLOOD, BLOOD-VESSELS, AND HEART.

THE circulatory system is developed from two anlagen which are at first independent. The *heart* arises in the cervical region of the embryo; the *blood-vessels* and first blood-cells in the extra-embryonic area vasculosa; the blood-vessels subsequently grow into the embryo and unite with the heart. The heart begins to beat before the vessels are connected with it, so that as soon as the connection is established the circulation begins. The heart contains at first only a clear fluid; after the circulation has begun blood-cells come in through the vessels from the area vasculosa. The first blood-cells have a reddish color and a round nucleus. Somewhat later the colorless granular leucocytes appear, but where they arise is uncertain. In all vertebrates except mammals the red cells persist throughout life, but in mammals they are confined to the fœtal period, during which they are gradually replaced by the non-nucleated red-blood globules (plastids). Much confusion exists as to the nature and development of the blood, because the great majority of writers have ignored the important fact that the mammalian adult blood-globules are a new acquisition of that class and are not homologous with the red-blood corpuscles of other vertebrates. Mammals have three kinds of blood corpuscles: red cells, leucocytes, and the adult red globules; all other vertebrates have two kinds only.

An immense deal has been written on the development of the blood in the embryo, and there is perhaps no other question in embryology which has been so much studied and yet left with such a variety of opinions as to its right answer. In the following pages I have endeavored to collate what seem to me the best-established results; but until some one subjects the literature of the subject to a critical revision, based on a thorough comparative investigation of the development of the blood and blood-vessels throughout the vertebrate series, we can hardly expect a satisfactory history of the embryonic blood.

We have to distinguish between the primary and secondary vascular anlagen.

I. BLOOD-VESSELS AND BLOOD.

Primary Vascular Anlagen.—These are cords of cells which appear first in the area vasculosa and rapidly extend into the embryo; the cords form a network; scattered clusters of cells in the cords very early assume the hæmoglobin color and appear as reddish-yellow spots which have long been known, and are described by Pander, Von Baer, 28.2, Remak, 50.1, Prevost et Lebert, 44.1, and others. We owe to His, 68.1, 95–103, the first exact account of the origin

of blood-vessels in the chick; since then the studies of Disse, **79.1**, Götte, **74.1**, Kölliker ("Entwickelungsges."), Balfour, **73.1**, J. Kollmann, **84.3**, Uskow, **87.1**, and others have added a little to the descriptions by His. It is now demonstrated that the blood arises in amniota from the mesoderm and not from the yolk, as was, I believe, first suggested for teleosts by Lereboullet and recently by Ryder. The exact history of the first blood-vessels has yet to be studied in other amniota than the chick.

In the chick the distal portion of the mesoderm has no cœlomatic cavity when the development of the blood begins; the mesoderm lies close against the entoderm or germinal wall (*Keimwall*). The

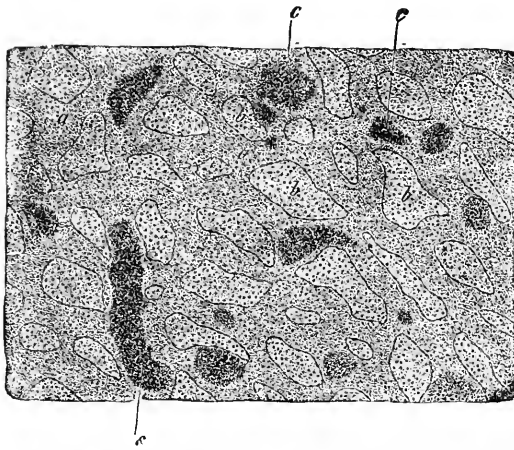


FIG. 124.—Surface View of a small Part of the Vascular Network of an Embryo Chick of two Days. *a a*, Blood-vessels; *b b*, mesoderm between the vessels; *c c*, blood-islands. From Kölliker.

juxtaposition of the two layers has led His and others to consider that the entoderm or yolk gave off the cells which form the mesoderm of the area vasculosa. This portion of the mesoderm was early distinguished by German writers under the name of *Gefäßschicht* or vascular layer (*feuillet angioplastique*), and has been called the *blood-germ* (*Blutkeim*); by His it is identified as a stage of the parablast, see Chapter VI. The first indication of the blood-vessels is a reticulate appearance of the layer, which can be

recognized in surface views at the end of the first day and rapidly increases in extent and distinctness during the second day of incubation. As soon as there are several primitive segments the network shows traces of coloration in irregularly shaped reddish-yellow spots which are largest and most numerous around the caudal end of the embryo; these spots are the so-called blood-islands, Fig. 124. The network appearance is due to thickenings of the mesoderm, as is evident from sections. The two primary layers are separated so that the mesodermic thickenings lie between them. Between the thickenings are irregular lacunæ, Fig. 124, *b b*, which are only partly filled with mesodermic cells; these lacunæ by their subsequent expansion and fusion develop during the latter half of the second day the cœlom of the area vasculosa, and always so that the thickenings (or blood-vessels) are on the entodermal side, Fig. 126. In other words, as soon as the two leaves of the mesoderm are differentiated in the area vasculosa the blood-vessels are found exclusively in the splanchnic leaf. In the sheep they appear also in the somatic leaf, R. Bonnet, **89.1**, 56, or future amnion, but they soon disappear and never contain any blood-corpuscles. The network of blood-vessels of the

vascular area form at first a thick network without distinction of stem or branch, and are all in one layer, none overlying the others (Kölliker, "Grundriss," p. 60), Fig. 125; the edge of the area is marked by a single large vessel which is known as the *vena*, or better, *sinus terminalis*, Fig. 125, *vt*. I have spoken of vessels, but up to this time the vascular anlagen are solid. The *vena terminalis* persists for some time as the distal boundary of the area, while it is spreading farther and farther over the yolk, but by the end of the fourth day it is no longer distinguishable as a distinct structure (Prevost et Lebert, 44.3, 240). The *vena terminalis* ultimately becomes connected with the venous system of the chick, but in rabbits with the arterial system; for this reason the term *sinus* is to be preferred to *vena* as applied to this vessel.




FIG. 125.—Vascular Anlagen of the Area Vasculosa of a Chick of Forty Hours. *ps, ps*, Blood-islands; *vt*, *vena terminalis*. From Kölliker. $\times 36$ diams.

The *blood-islands* are spots where there is a cluster of cells which remain attached to the walls of the vessels in the area vasculosa (see Fig. 126, *bl. is*). The cells develop haemoglobin in their interior, hence the clusters have a reddish color, which renders the islands very conspicuous in surface views of fresh specimens. The blood-islands of the chick appear first in the area opaca, and almost immediately after in the pellucida also. They have at first a rounded or branching form, Fig. 124; in the inner part of the layer they are small and stand alone; toward the periphery they are larger, closer set, and more united with one another; their development is greater around the caudal end of the embryo. They are situated, chiefly, at the nodes of the vascular network. When the solid vascular cords acquire a lumen, the islands, Fig. 126, *bl. is*, remain attached to one side of the vessel, like a thickening of its wall. The cells of the islands ultimately become free blood-corpuscles.

The *growth of the primary anlagen* takes place by the development of buds from the vessels already formed, as first shown accurately by Prevost et Lebert, 44.3, 239; these buds are rounded or pointed and elongated, forming as it were spurs; they often end by meeting one another and uniting; they are usually hollow from the first, and after they meet one another or an adjacent vessel, the cavities become continuous and thus the vascular network is extended. A. Goette, however, maintains, 75.1, 497, that the network arrange-

ment exists from the start in all vertebrates, and that the apparent budding is due to the progress of vascular differentiation into indifferent mesenchymal cells.

In mammals the solid primary anlagen appear in the extra embryonic area vasculosa, and extend later into the embryo. So

far as known to me there has been as yet no exact investigation of their history. They present well-marked blood-islands, which are thickenings of the mesoderm, and make their first appearance in rabbit embryo of the eighth day just before the first primitive segments (Kölliker, "Entwicklungsges.," 266). The growth of the network of solid buds which become hollow in the rabbit by the formation of solid buds which become hollow has been described by Wissowsky, 77.1.

Growth of the Vessels into the Embryo.—The fact that the vessels penetrate the embryo after they have appeared in the area vasculosa was first discovered by His, 68.1, 99, and is now a familiar phenomenon. It is evident that this penetration may take place in two ways: it may be a progressive differentiation of cells already present (*cf.* Goette, 75.1, 539), or it may be an actual in-growth of vaso-formative tissue: the balance of evidence is in favor of the latter alternative, which accordingly, following His in this respect, the majority of embryologists have adopted. In the chick the vascular differentiation extends from the area opaca to the area pellucida, and thence into the body proper of the embryo. But in the lizard (Strahl, Marburg, Sitzber., 1883, 60-71) the vessels appear first in the area

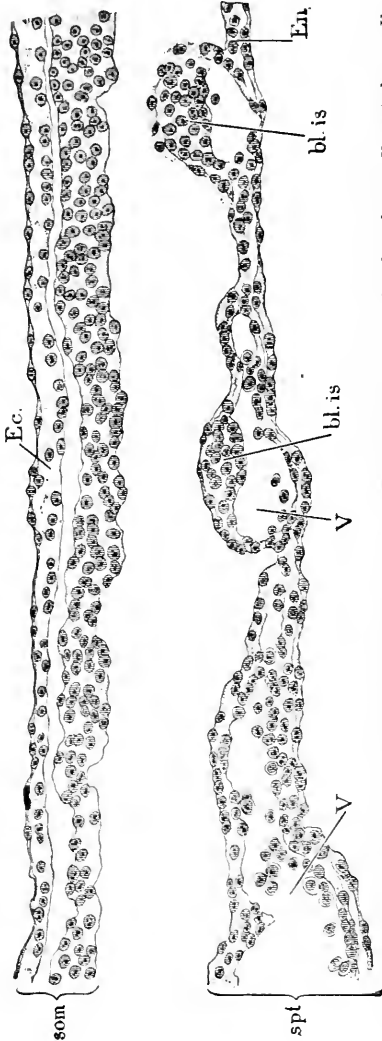


FIG. 194. Section of the Area Vasculosa of a Chick. Som, Somatopleure; Spl, splanchnopleure; Ec, ectoderm; Eu, entoderm; bl. is, blood-island; V, V, blood-vessels. The space between the somatopleure and splanchnopleure is part of the coelom. $\times 227$ diams.

pellucida and thence extend into the area opaca and the embryo. The entrance of the vessels into the embryo chick begins toward the end of the second day. It is effected, according to His, 68.1, 99, by buds, which are at first solid cords, and grow toward the embryo, uniting as they extend into a network; the hollowing

out of the cords likewise progresses centripetally. The penetrating vessels follow certain prescribed paths. A part of the vessels run along the posterior edge of the amnio-cardial vesicles, and enter into connection with the posterior end of the heart which has meanwhile been developed—owing to the early separation of the head end of the embryo from the yolk this is the only part of the heart the vessels can reach directly. While the vessels are approaching the heart their differentiation into various sizes is going on, the smallest ones to remain as capillaries, the larger ones to become arteries or veins; this differentiation, which has yet to be followed step by step, leads to there being only two main vessels, the so-called *omphalo-mesaraic veins*, which actually open into the hind end of the heart. Another set of vessels penetrates along the splanchnopleure of the rump on each side, until they attain the small space between the notochord, myotome, and entoderm, where they fuse (Turstig, 86.1), so as to form a longitudinal vessel, the anlage of the *aorta descendens*, which is primitively double. The aorta appears first at the head end of the rump and hence its development progresses backward; it also grows forward over the heart, bends over ventrally just behind the mouth, and, passing around the blind end of the vorderdarm, approaches the median line and unites with the cephalic end of the tubular heart. An utterly different history of the origin of the aorta, namely, from the median dorsal wall of the archenteron, is asserted by C. K. Hoffmann, 92.1, for the dog-fish. The heart begins to beat before the vessels unite with it; the first blood-cells have already been formed; hence as soon as the union is accomplished the blood-circulation starts up, the blood passing through the aorta to the rump, thence by numerous lateral branches to the area vasculosa, and returning by the two omphalo-mesaraic veins to the heart. The course and modifications of the primitive circulation are described and figured in Chapter XIV., on the germinal area.

Origin of the First Red Blood-Cells.*—I consider it probable that the red blood-cells of all vertebrates arise, as has been maintained by H. Ziegler, 89.1, by proliferation of the endothelial lining of the vessels. This conclusion is based—1, upon the fact that in various vertebrates, notably in bony fishes, elasmobranchs, and all amniota, certain parts of the vascular system are at first solid cords of cells, and of these cords the central portion becomes blood-cells, the peripheral portion the vascular wall; it seems to me that the right interpretation is to regard the central cells as belonging with the outer cells, and therefore equivalent to the product of an endothelial proliferation; 2, upon the origin of red cells from the walls of the venous capillaries of the bony marrow of birds (J. Deuys, 87.1). In all these cases *the blood-cell is a liberated specialized endothelial cell*. A. Goette is the principal opponent of this view, and has maintained that in Petromyzon, 90.1, 66, Amphibia, 75.1, 538, and birds, 74.1, 180–186, the blood-cells of the embryo have an

*It is singular that so close an observer as Balfour should have maintained, as he did, 73.1, that the blood-cells of saurapsida are metamorphosed nuclei, and this view is still adhered to in his "Elements," 2d ed. 1883. Balfour's error was due to the fact that the cells, when first set free, have a minimum quantity of protoplasm around the nucleus, and this he did not observe; the nuclei have too at first a very distinct large nucleolus, which Balfour wrongly assumed to represent the nucleus of the future corpuscle.

origin different from the endothelium, the former arising from the yolk, the latter from the mesoderm. Although Goette is one of the very best of embryological observers, I cannot agree with him on this point, for I feel satisfied that he is in error as regard the chick, while in regard to the lamprey and the land frogs it is possible that Goette's observations are incomplete—certainly his descriptions are less clear than those of the origin of the blood-cells within the vascular anlagen. It must be added that Davidoff has maintained, **84.1**, that in the salamander the blood-cells arise from the surface of the yolk; but his statements need, I think, verification.

The blood-cells of *teleosts* arise, at first at least, in certain large vessels within the embryo (Wenkebach, H. Ziegler, **87.1**, **89.1**, compare also H. Ambert, **56.1**), which are formed as solid cords, the central cells of which are metamorphosed into blood-corpuscles. At the time the circulation begins there are no blood-vessels over the yolk, but definite blood-channels, which are merely grooves on the yolk or passages between the yolk and the ectoderm; these channels subsequently acquire mesenchymal walls when the mesoderm grows out over the yolk. Owing to this peculiarity of the early vitelline circulation blood-cells appear over the yolk before there are blood-vessels, and the observation of this fact seems to have led several observers to the error of attributing the origin of the blood-cells to the yolk or the superficial layer thereof (Kupffer's periblast). For a synopsis of the various opinions see McIntosh and Prince, **90.1**, 782-783. In *elasmobranchs* (J. Kollmann, **85.1**, 297) there are mesodermal blood-islands, which expand and unite, forming a network in the area opaca; the vessels are at first solid, the central cells become blood-cells, the peripheral cells endothelial walls; so far as observations go it is possible, however, that all the cells of the blood-islands become blood-cells, and that the endothelium is simply an overgrowth of mesenchyma, but in view of the development in other vertebrates this possibility has little probability. The development of the blood in reptiles and mammals needs thorough study, but we know that it is closely similar to that in birds. In the *chick*, as stated above, the cells of the blood-islands form the first blood-cells, and this statement probably applies also to all amniota.

For the origin of blood-cells in the embryo see the following section.

Secondary Vascular Anlagen.—These are buds which arise from the vessels already present in the embryo, similar to the buds already described in the area vasculosa. There being no real division between the primary and secondary anlagen the distinction is used merely for convenience of description. The secondary anlagen, like the primary, give rise to the endothelium of the wall only; when a vessel becomes an artery or a vein the media and adventitia are added by differentiation of the surrounding mesenchyma. The secondary anlagen can be found in mammals in various parts of the body during embryonic life, and even after birth, and in Amphibia may be studied during the larval period; the tail of tadpoles being a favorite object for this purpose (Golubew, **69.1**). The secondary anlagen were, so far as I know, first accurately described in batrachians by Prevost et Lebert, **44.1**; they were followed two

years later by Kölliker, 46.2, see also Golubew, 69.1, Arnold, 71.1, and Ranvier's "Traité technique," 618, 623. In mammals they have been well described by Ranvier, 74.2, E. A. Schäfer, 74.1, Kölliker ("Entwickelungsges.," 171, "Grundriss," 63), and others.

The secondary anlagen appear as thorn-shaped points projecting more or less nearly at right angles from the walls of capillaries already formed. A. Goette, 75.1, 544, has maintained that these are not real outgrowths, but differentiations of intercellular processes present *ab initio* in the mesenchyma. These points rapidly elongate into fine threads, which may join the wall of another capillary or the tip of another point; Golubew states that when two points unite in the frog, they overlap and then unite by their sides; while the point is growing the cavity of the parent capillary extends into the base of the point, and penetrates farther and farther, so that the thread-like point becomes gradually enlarged into a capillary blood-vessel. The capillaries formed in this way show a marked tendency to form loops.

Very similar is the account quoted below by E. A. Schaeffer in Quain's "Anatomy," ninth edition, II., 198, 199: "Within the body of the embryo vessels are formed in like manner from cells belonging to the connective tissue. One of the most favorable objects for the study of the development of the blood-vessels and their contained blood-corpuscles is afforded by the subcutaneous tissue of the newborn rat, especially those parts in which fat is being deposited. Here we may observe that many of the connective-tissue corpuscles are much vacuolated, and that the protoplasm of some of them presents a decided reddish tinge. In others the red matter has become condensed in the form of globules within the cells, varying in size from minute specks to spheroids of the diameter of a blood-corpuscle or more. At some parts the tissue is completely studded with these cells, each containing a number of such spheroids, and forming, as it were, 'nests' of blood-corpuscles or minute 'blood-islands.' After a time the cells become elongated and pointed at their ends, sending out processes also to unite with neighboring cells. At the same time the vacuoles in their interior become enlarged, and coalesce to form a cavity with the cell in which the reddish globules, which are now becoming disc-shaped, are found. Finally, the cavity extends through the cell processes into those of neighboring cells and into those sent out from pre-existing capillaries, but a more or less extensive capillary network is often formed long before the connection with the rest of the vascular system is established. Young capillaries do not exhibit the well-known lines when treated with nitrate of silver for the differentiation of the hollowed cells and cell-processes into flattened cellular elements is usually a subsequent process. The mode of extension of the vascular system in growing parts of older animals, as well as in morbid new formations, is quite similar to that here described, except that blood-corpuscles are not developed within the cells which are forming the blood-vessels."

The development of new capillaries in the manner just described also takes place from the vessels formed by vasoformative cells.

The secondary vascular anlagen of the foetal liver have been specially studied by P. Kuborn, 90.1; they correspond to the so-

called foetal hepatic giant cells of early authors, and give rise to vascular walls, red cells, and later (embryos of three or four centimetres) to the red plastids, compare p. 221.

Vasoformative Cells.—In all secondary anlagen of the vessels we have outgrowths of vessels already present; there are also vessels developed from special vasoformative cells, which have no connection with previous vessels; the origin of the vasoformative cells has still to be ascertained, but it may be safely asserted that they are derived from the mesenchyma. These cells were, I believe, discovered by L. Ranvier (74.2, and "Traité technique," 625), who studied them in the omentum of the rabbit before and after birth. He found small spots of milky appearance, which he designates as "taches laiteuses," and which contain ordinary connective-tissue corpuscles, and fibrillæ, numerous leucocytes, and vasoformative cells. The last, in rabbits from two to eight weeks old, are finely granular, branching often anastomosing, elongated cells with elongated nuclei; earlier they are scattered, spindle-shaped cells. Soon a capillary from the neighborhood grows in and unites with the vasoformative network, and thereupon the excavation of the network begins, the lumen of the capillary gradually extending throughout the cluster of vasoformative cells.

Primitive Blood-Vessels.—The first vessels consist merely of a wall of protoplasm with scattered nuclei, and accordingly are all essentially alike in structure; the first differentiation is one of size only, the vessels that are to become arteries and veins rapidly increasing their calibre, while the mesenchyma around them is still undifferentiated. The protoplasmatic wall in cross-sections of a vessel is thick enough to contain a nucleus. The next step in development is the thinning out of the layer, so that the nuclei become protuberant as in the adult endothelium; at the same time the protoplasm becomes divided into distinct cell territories, and intercellular lines are developed and may be impregnated with nitrate of silver, as in the adult.

The vessels grow by the multiplication of the cells of their walls. W. Flemming, 90.1, has shown that in the capillaries the nuclei undergo karyokinetic division, and that the division of the protoplasm takes place later.

The distribution and metamorphoses of the principal vessels are discussed in Chapter XIV.

The red blood-cells are the only elements contained in the blood during the earliest stages of the vertebrate embryo. When the circulation begins the number of corpuscles is small, but rapidly increases thereafter. The cells are at first round (in probably *all* vertebrates); in the chick they measure from 8.3 to 12.5 μ . The nucleus is large, more or less nearly spherical, and surrounded by a layer of protoplasm (Minot, 122), which is so thin as to have been often overlooked. The cells at first are granular and slightly colored (Prevost et Lebert, 44.3, 241; Kölliker, "Grundriss," 63), and then become more colored and homogeneous, scarcely showing the nucleus during life, though it comes out very clearly as soon as the corpuscles are removed from the vessels or acted upon by hardening reagents. The nucleus in hardened corpuscles stains deeply. In

amphibians the young blood-cells, like all the other cells of the embryo, contain numerous yolk granules; as the granules disappear the

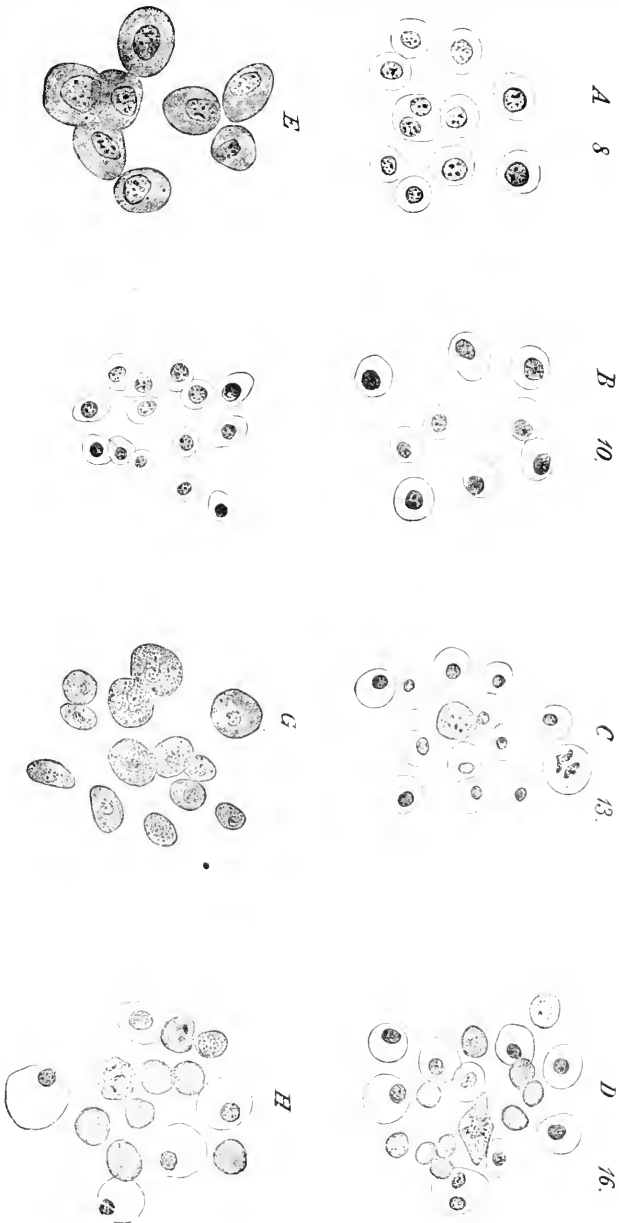


FIG. 127.—The four upper figures (A, B, C, D) represent corpuscles from rabbits, the number giving the ages of the embryos in days; E, from *Acanthias*; F and G, from a chick; H, from a human embryo. [All the figures are magnified 545 diameters.]

nuclei and bodies of the cells both acquire a more homogeneous and opalescent appearance, and at the same time become flattened, elongated, and colored (A. Goette, 75.1, 770).

The primitive form of the vertebrate red-blood cell is probably spherical, or at least spheroidal, and the characteristic mature shape is not assumed until later, as I have learned from my own observations on a considerable variety of embryos. This statement is further supported by A. Goette's observations on *Petromyzon*, **90.1**, 66, and *Bombinator*, **75.1**, 538. In the chick the mature elliptical form begins to predominate during the fourth day; the earlier round form is still encountered for several days, but it gradually becomes rarer (Prevost et Lebert, **44.3**, 242).

Minot, **122**, has outlined the progressive differentiation of the red cells in sharks, salamanders, chicks, and rabbits. The following description refers primarily to the chick: By following the development we find that the protoplasm enlarges for several days, and that during the same time there is a progressive diminution in size of the nucleus, which, however, is completed before the layer of protoplasm reaches its ultimate size. The nucleus is at first granular, and its nucleolus, or nucleoli, stand out clearly; as the nucleolus shrinks it becomes round and is colored darkly and almost uniformly by the usual nuclear stains. This species of blood-corpusele occurs in all vertebrates and represents the *genuine blood-cells*. The blood-cells of mammals pass through the same metamorphoses as those of birds. For example, in rabbit embryos, the cells have reached the ichthyopsidan stage on the eighth day; two days later the nucleus is already smaller, and by the thirteenth day has shrunk to its final dimensions. According to the above description we can distinguish three principal stages: 1, young cells with very little protoplasm; 2, old cells with much protoplasm and granular nucleus; 3, modified cells with shrunken nucleus, which colors darkly and uniformly, Fig. 127. I do not know whether the first form occurs in any living adult vertebrate, although the assumption seems justified that they are the primitive form. On the other hand, the second stage is obviously characteristic of the Ichthyopsida in general, while the third form is typical for the Sauropsida. Therefore, the development of the blood-cells in amniota offers a new confirmation of Louis Agassiz' law (Haeckel's biogenetisches Grundgesetz).

Multiplication of the red cells by division was recorded by Remak, **50.1**, 164, and has since been frequently observed. Special attention was directed to its occurrence by Peremeschko in 1879, **79.1**, **81.1**, and by Bizzozero (*Cbl. med. Wiss.*, 1881, Moleschott's "Unters. zur Naturlehre," XIII.) in 1881, and has since been studied by Bizzozero et Torre, **84.1**, Bizzozero, **84.1**, Funcke, **80.1**, Eberth and Aly, **85.1**, A. Mosso, **88.2**, and others. The division is indirect or karyokinetic, and takes place across the longitudinal axis of the corpusele, with which the nuclear spindle is parallel. The process has been observed in bony fishes, amphibians, adult Sauropsida, and in amniote embryos. The division occurs only in young or partly differentiated corpuseles: the divisions, for example, are abundant in the blood of the chick of from three to five days; the sixth day they are rarer, the tenth seldom, and after hatching are not found in the circulating blood at all (Funcke, *l. c.*). It is, accordingly, safe to assume that the proliferation of the red cells is typical for all vertebrates. Their number is further increased by additions from various

sources in the embryonic and (adult non-mammalian) vertebrates; but, so far as at present known, the mammals have only the red cells, which arise directly from the primary vascular anlagen, therefore the discussion of the maintenance of the supply of red cells falls outside our scope. The problem has been much debated; the investigation which seems to me to have led to the best results is that of J. Denys, **87.1**. For the reader's convenience I cite also the following authorities, but the list is very incomplete: Bayerl, **84.1**, W. H. Howell, **88.1**; Lowit, **87.1**, **91.1**, E. Neumann, **74.1**, Malassez, **82.1**; Obrastzow, **81.1**; G. Pouchet, **80.1**; and Rindfleisch, **80.1**. For additional references see Quain's "Anatomy," ninth edition, II., 40.

Disappearance of the Red Cells.—The red cells form the permanent red-blood globules in all vertebrates except the mammals. In mammals they disappear during embryonic life or soon after birth. Although they persist for a long period, it will be convenient to state here what little is known of their history. How they disappear is not known, although several authors have maintained that they are transformed into red plastids, but this opinion seems to me ill founded. W. H. Howell, **90.1**, reports the interesting discovery that the nucleus of the mature red cells is extruded in mammals leaving the body of the cell; in consequence he maintains the plausible conclusion that the extrusion is the means of developing the non-nucleated red corpuscles, but I am more inclined to regard it as a step in the degeneration and destruction of the red cells. In the human embryo at one month the red cells are the only blood-corpuscles; at two months they are the most numerous, although the plastids have begun to appear; at three months they form only a small minority of the corpuscles.

Origin of Leucocytes.—The origin of the first colorless corpuscles in the embryo is still uncertain. The blood is found to contain for some time only the red cells, the leucocytes appearing in the chick (Prevost et Lebert, **44.3**, 243), about the eighth day of incubation; in the rabbit, it is said, about the ninth day, and in elasmobranchs not until the embryo is well advanced in development, A. Mosso, **88.2**. It is to be noted that after the blood-vessels and red-blood-cells the leucocytes are the first cells to be differentiated from the mesenchyma, the remaining mesenchymal tissues (Chapter XIX.) being differentiated gradually and to a large extent simultaneously. So far as I know, the subject has never been carefully investigated, nor is there even any exact description of the appearance and number of the first leucocytes.

After the lymph-glands appear they probably assume the function of producing leucocytes; but the process in embryonic glands has still to be studied, and accordingly for further information the reader is referred to the standard histologies. That the leucocytes multiply by direct or akinetic division has been recorded by several observers, L. Ranvier, J. Arnold, **84.1**, and others.

Origin of Mammalian Blood-Globules or Red Plastids.—There are many opinions as to the origin of the non-nucleated red blood-globules of mammals. The best-founded conclusion is, it seems to me, that of E. A. Schäfer, who traces them to local differ-

entiations of the protoplasm of the vasifactive cells. This view makes the globules comparable to the plastids of botanists, such, for instance, as the chlorophyll granules. As the terms "globules" and "corpuscles" have been applied indiscriminately to all the formed elements of blood, and as it is desirable to have a simple term which shall also indicate the morphological separation from the other "blood-corpuses," I shall apply the term "*red plastids*" to the non-nucleated mammalian adult red globules. The chief opinion rivalling Schäfer's is that the red plastids are derived from nucleated corpuses, which have lost their nuclei and shrunk, the plastids being always much smaller than the red cells. This view has been specially advocated by Kölliker, "Gewebelehre," 5te Aufl., 1867, p. 638, is found in several subsequent writers, and has been very recently brought forward by Casimiro Mondino, **88.1**, but sufficient observation to justify it has not been furnished in my judgment. The strongest evidence in favor of the conversion of nucleated corpuses into plastids is that which is presented by Howell, **90.1**, and mentioned p. 221. Similar to this view is that which traces the plastids to modifications of leucocytes occurring after birth; F. Sanfelice, **89.1**; the white cells are supposed to shrink, lose their nuclei, and become charged with hæmoglobin. Yet another opinion affirms that the marrow of bones produces from certain of its cells the red plastids, but the defenders of this opinion are by no means agreed among themselves as to how. For a good synopsis of the conflicting theories see Schäfer in Quain's "Anatomy," tenth edition, Vol. I., Pt. II.

The first red plastids certainly arise *in* the vasifactive cells in various parts of the embryo. Schäfer in Quain's "Anatomy," ninth edition, II., 36-37, gives the following description of the process: "A part of the protoplasm of the cell acquires a reddish tinge, and after a time the colored substance becomes condensed in the form of globules within the cells, varying in size from a minute speck to a spheroid of the diameter of a blood-corpusele, or even larger; but gradually the size becomes more uniform. Some parts of the embryonic connective tissue, especially where a vascular tissue such as the fat is about to be developed, are completely studded with cells like these, occupied by a number of colored spheroids and forming nests of blood-corpuses, or minute 'blood-islands.' After a time the cells become elongated and pointed at their ends, and processes grow out to join prolongations of neighboring blood-vessels or of similar cells. At the same time vacuoles form within them, and becoming enlarged coalesce to form a cavity filled with fluid in which the reddish globules, which are now becoming disc-shaped, float. Finally, the cavity extends through the cell processes into those of neighboring cells, and a vascular network is produced, and this becomes eventually united with pre-existing blood-vessels, so that the blood-corpuses which have been formed within the cells in the manner described get into the general circulation. This 'intracellular' mode of development of red blood-corpuses ceases in most animals before birth, although in those which, like the rat, are born very immature it may be continued for a few days after birth. Subsequently, although new vessels are found in the same way, blood-corpuses are not pro-

duced within them, and it becomes necessary to seek for some other source of origin of the red-blood discs, both during the remainder of the period of growth, and also during adult life, for it is certain that the blood-corpuscles are not exempted from the continual expenditure and fresh supply which affect all the other tissues of the body."

Very early in embryonic life the liver, as first pointed out by Kölliker, and more fully demonstrated by Neumann, **74.1**, becomes the principal seat of blood formation. The secondary vascular anlagen are very prominent in the foetal liver and in sheep embryos of four centimetres and more in length. P. Kuborn, **90.1**, has traced the development of red plastids from the protoplasm only, as described by Schäfer. A similar result is reached by R. Nicolaidos, **91.1**, from studying the production of red plastids in the mesentery of young guinea-pigs, see also Wissosky, **77.1**. The process of plastid development is easily followed in the mesentery of the human foetus.

It seems to me probable that research will ultimately establish the origin of red plastids in the adult also, as intracellular protoplasmatic bodies entirely distinct from the nuclei, and in no way to be homologized with cells. Kultschitzki, however (see Hofmann-Schwalbe's *Jahresber.*, 1883, 58-59), asserts that in the lymph-glands of the rabbit the red plastids arise within cells by metamorphosis of the nuclei; to nuclei Balfour traced, he supposed, the red cells of birds, compare p. 215, foot-note.

Origin of the Blood-Plates.—C. Mondino and L. Sala, **88.1**, affirm that the blood-plates multiply by division, and being nucleated in the non-mammalian vertebrates, according to these authors, they divide karyokinetically; while in mammals the plates have no nucleus, but the larger plates have chromatine granules, which, however, divide as do the plates. They state that the plates are present in mammalian blood as soon as it begins to circulate. In the French résumé of their work (*Arch. Ital. Biol.*, XII., 304), they state that Fusari has confirmed their observations in an article in the *Riforma medica*, 13 Agosto, 1889. I question most decidedly the trustworthiness of these statements, for the author's figures suggest at once that they have mistaken distorted blood-globules for blood-plates. No other observations on foetal blood-plates are known to me. It should be added that L. Lilienfeld, **92.1**, has advanced the hypothesis that the plates are derived from leucocyte nuclei, while Howell, **90.1**, suggests that they are the extruded nuclei of red cells.

Morphology of the Blood-Corpuscles.—The following conceptions have been advocated by Minot, **122**. The preceding sections show that the vertebrate blood-corpuscles are of three kinds: 1, Red cells; 2, White cells; 3, Plastids. The red and white cells occur in all (?) vertebrates; the plastids are confined to the mammals. The red cells present three chief modifications; whether the primitive form occurs in any living adult vertebrate I do not know; the second form is persistent in the Ichthyopsida, the third form in the Sauropsida. According to this we must distinguish:

- A. ONE-CELLED BLOOD, *i. e.*, first stage by all vertebrates; the blood contains only red cells with little protoplasm.
- B. TWO-CELLED BLOOD, having red and white cells. The red cells have *either* a large, coarsely granular nucleus (Ichthyopsida)

or a smaller, darkly staining nucleus (Sauropsida, mammalian embryos).

C. PLASTID BLOOD, without red cells, but with white cells and red plastids; occurs only in adult mammals.

Mammalian blood in its development passes through these stages, as well as through the two phases of stage *B*, all in their natural sequence; the ontogenetic order follows the phylogenetic. It seems not improbable that an animal may yet be found with blood intermediate between *B* and *C* in the adult stage.

II. ORIGIN OF THE HEART.

The heart, as has been stated, is developed independently of the blood and blood-vessels; it contains at first a clear fluid, and begins beating *before* the blood-vessels from the area vasculosa have joined it. The primitive form of the heart is a straight median tube on the ventral side of the cervical region; the cephalic end of the tube is connected with the arterial system of the embryo, while the caudal end is primitively connected with the venous system of the yolk. These relations may be traced in all vertebrates, hence the heart arises as the active organ of communication between the yolk or primitive food supply and the embryo.

Primitive Mode of Development of the Heart.—In regard to the development of the heart we have to distinguish the mode still preserved in the primitive vertebrates (marsipobranchs, ganoids, and amphibians), elasmobranchs, and in some but not all teleosts (McIntosh and Prince, 90.1, 775), from the mode in the amniota. In the first mode the heart arises in the median line; in the second mode the heart arises from two lateral anlagen, which subsequently unite in the median line. The difference is not a fundamental one, but is correlated, as first pointed out by Balfour, with the earlier or later separation of the cephalic end of the embryo from the yolk; when that separation is retarded the heart is differentiated before the neck of the embryo is folded off from the yolk, compare Chapter XIII.; this delay occurs in varying degrees in all amniota.

The following account of the origin of the heart in Amphibia is

based on C. Rabl, 86.1, who cites the earlier authorities.

The head of the embryo early becomes free and projects so far that the neck is free from the yolk also. The mesoderm extends forward on each side between ectoderm and ento-

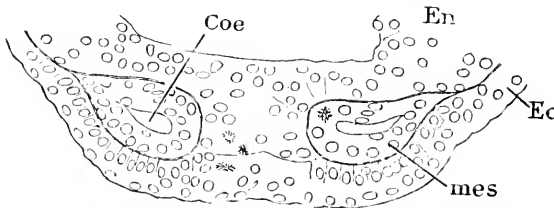


FIG. 128.—*Salamandra Maculosa*; Larva, very Young: Transverse section, to show the Formation of the Coelom in the Heart Region. *Coe*, Coelom; *En*, entoderm; *Ec*, ectoderm; *mes*, mesothelium. After C. Rabl.

derm, and has a coelomatic cavity on each side, Fig. 128, *Coe*. The two wings of mesoderm do not, however, meet on the median ventral line, being separated by a ridge, *En*, of entoderm by which the inner germ-layer comes into immediate contact with the ectoderm, *Ec*.

Whether this ridge is preserved to form the endothelium of the heart or is resorbed into the general entoderm is not positively known. In a later stage, Fig. 129, the two mesodermic wings have met in

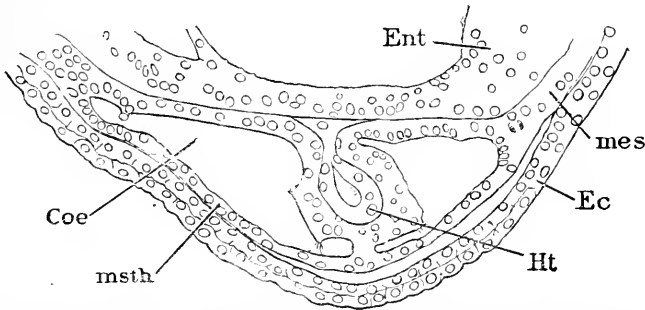


FIG. 129.—*Salamandra Maculosa*; Larva with Branchial Arches. *Coe*, Coelom; *msth*, mesothelium; *Ht*, endothelial heart; *Ec*, ectoderm; *mes*, mesoderm; *Ent*, entoderm. After C. Rabl.

the median line below the intestinal canal; the coelom has expanded; between the mesothelium of each side in the median line is a small mass of cells, *Ht*, which soon shows a central lumen, which becomes the cavity of the heart, while the cells around give rise to the future endothelium; the endothelium is still in contact with the entoderm. Below the heart the mesothelia are in actual contact, forming a double wall, which soon breaks through, so that the coelom on each side opens into the other, or, in other words, there is now a single pericardial cavity. The heart has become a two-layered tube; the inner layer consists of endothelium, the origin of which is discussed in a separate paragraph below; the outer layer consists of mesothelium, which gives rise to the muscular wall of the heart. Later the mesothelium closes over the dorsal side of the endothelium, thus finally separating it from the entoderm. Still later the tubular heart loses its suspension from the dorsal side of the pericardial cavity and is attached only at its anterior or cephalic and posterior or caudal extremities, and hence is free to bend and twist within the pericardial cavity in the manner necessary for the evolution of the heart's adult form.

Amniote Mode of Development of the Heart.—Observations on the heart are to be found in many of the older writers on embryology, notably in Von Baer, Prevost et Lebert, Remak, Bischoff, and Coste, but until the introduction of section cutting the details of the process could not be observed. The foundations of our present knowledge were laid by W. His, 68.1, 83-85, and the subject was further elucidated by Kölliker's invaluable observations on the chick and rabbit, recorded in his "Entwicklungsgeschichte;" Gasser, 77.3, has published an admirable description with figures of the development in the chick; there are besides numerous references to the heart scattered in recent literature; see, for instance, Hensen, 76.1; Heape, 86.2; Selenka, 86.1, *et al.*

In the amniota the cephalic coelom very early dilates to a much greater degree than the coelom elsewhere, thus developing on each side the so-called *Parietalhöhle* of German writers, for which I have

proposed the name of amnio-cardial vesicle. In the chick the early and extreme dilatation of this cavity is well known, and is intimately correlated both with the closure of the archenteron to form the cervical entodermic canal (*Vorderdarm*), and also with the development of the heart and the origin of the amnion. In the chick the dilatation forces the splanchnopleure (splanchnic mesoblast and entoderm) downward on each side; then bends the splanchnopleure in under the embryo until the two membranes meet in the median line and fuse; their fusion shuts off the *Vorderdarm* from the yolk and leaves it as a flattened canal, Fig. 129A, *Ph*; for further details see Chapter XII. The layer of mesothelium bounding the coelom is everywhere distinct; the mesenchyma is well developed all about the medullary canal and notochord, Fig. 129A, but is almost entirely absent from the walls of amnio-cardial vesicles, until we reach the distal vascular area, consequently when the vesicles expand the mesothelium is brought close against that portion of the entoderm which is destined to form the *Vorderdarm*; where the contact takes place there appear between the entoderm and mesothelium a few very irregularly grouped mesenchymal cells, Fig. 129A, *Endo*; these are the anlage of the endothelial lining of the heart, or *Endothelherz* of German embryologists. The mesothelium of each side meets its fellow in the median ventral line, forming a thin partition or ventral mesocardium, Fig. 129A, which subsequently breaks through; from the ventral wall of

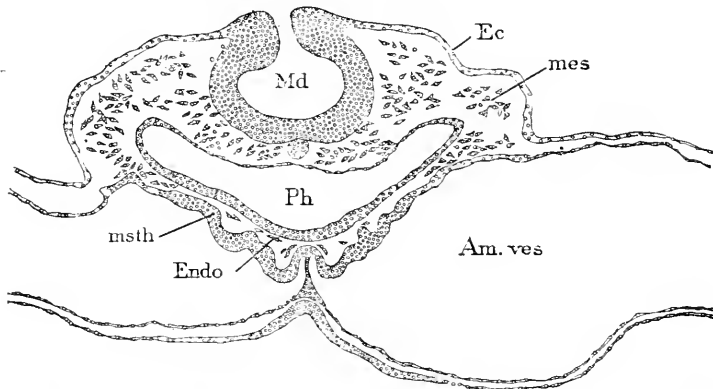


FIG 129A.—Embryo Chick (Minot Coll. No. A.J. Section 384); Section through the Anlage of the Heart. *Md*, Medullary groove; *Ec*, ectoderm; *mes*, mesenchyma; *Am. ves*, amniotic vesicle; *Ph*, pharynx; *msth*, mesothelium; *Endo*, cells to form the endothelium of the heart.

the *Vorderdarm*, *Ph*, the mesothelium bulges out as a much-thickened layer, *msth*, which develops into the muscular wall of the heart, while between this wall and the entoderm of the *Vorderdarm* lie the mesenchymal cells. Development proceeds by the mesothelial fold becoming more protuberant on each side, and the mesenchymal cells assuming the endothelial character, coming to bound several irregular cavities on each side, Fig. 130, *En.ht*; these cavities soon fuse into two main cavities running longitudinally; as the two cavities enlarge they meet in the median line and remain separated at first by a wall of two layers of endothelium; this wall soon breaks through and

there results a single median tube of endothelium connected, by long processes of cells, across quite a wide space with the mesothelium. Excellent figures of all these changes are given by Gasser, 77.3. The heart is now a double tube, connected by the mesothelium with the tissues above and below; but soon the connection on the ventral side is severed, and a little later that on the dorsal, but the attachments are retained as in amphibia at both ends of the tube. A section through the end of the heart is shown in Fig. 130; the ventral

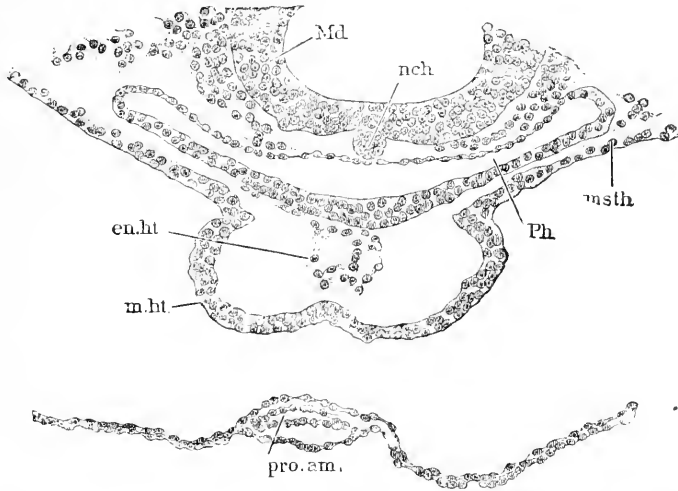


FIG. 130.—Chick Embryo (Minot Coll. No. AL, section 119). *Md*, Wall of medullary tube; *nch*, notochord; *msth*, mesothelium; *Ph*, pharynx; *en.ht*, endothelial heart; *m.ht*, muscular heart.

mesocardium is entirely lost; the dorsal is preserved, as also at the opposite end of the heart, though not in its middle; the thick mesothelial wall or muscular heart is widely removed from the thin inner endothelial heart (*Endothelherz*).

From the preceding account it appears that, owing to the development of the heart beginning before the Vorderdarm closes, the heart is distinctly double in origin, though all trace of the duplex condition is quickly lost. In mammals the double stage lasts longer, the Vorderdarm being closed still later.

Our knowledge of the origin of the heart in *mammals* rests chiefly on the observations of Kölliker upon rabbits; this paragraph is therefore based on the description given in Kölliker's "Grundriss," p. 96, 120. Traces of the heart can be recognized in embryos with five protovertebratæ, and the two anlages are well advanced in embryos with eight to ten segments, and in surface views, Fig. 114, may be seen at either side of the head, bending anteriorly toward the median line, and each connected posteriorly with the developing omphalo-mesaraic vein of the same side; one can also distinguish the parietal cœlomatic cavity about the heart. A transverse section through the region of the heart presents a very uniform picture in all mammals thus far studied; compare Fig. 95 of the opossum with Fig. 114 of the rabbit. The parietal cœlom or amnio-cardial vesicle

is small as compared with that of the chick, Fig. 117, and lies quite distant from the median line; the splanchnic mesothelium forms a large fold, which projects into and nearly fills up the cœlomatic cavity; this fold forms, as in the chick, one-half of the muscular heart; in the interior of this fold lies the endothelial heart, which sends out processes by which it is connected with the surrounding mesothelium. By the bending down of the layers and the expansion of the cœlom the Vorderdarm is shut off and the two lateral heart anlages are brought together in the median line below the Vorderdarm, and there fuse into a single structure; the fusion takes place in such a manner that the two mesothelial folds unite by their edges to form a single thick tubular wall around the double endothelial heart; it is not long, however, before the two endothelial tubes also fuse into one. As in the chick the two mesothelia, when the median heart arises, form a membrane (mesocardium), by which the heart is attached to the tissues above and below; both mesocardial membranes break through, putting the two cœlomatic cavities into communication and leaving the tubular heart suspended by its ends.

In amniota the heart arises from a double anlage, which by the bending down of the splanchnopleure of the Vorderdarm becomes a single median anlage, as in amphibians; C. K. Hoffmann, 84.3, has asserted that in snakes the heart arises from one of the lateral anlages, but Junglôw, 89.1, has rendered it probable that this is merely a blunder of observation. The median heart is at first a nearly straight tube attached by each end to the wall of the pericardial cœlom, and connected in front with the aortæ and behind with the omphalo-mesaraic veins; the tube is double, consisting of a thin inner endothelial wall of mesenchymal origin separated by a considerable space from the outer thicker mesothelial layer, from which the muscular tissue of the heart arises.

Origin of the Endothelium of the Heart.—This is still unsettled. As we have seen, the endothelium has upon its first appearance nothing of an endothelial character, but resembles instead the cells of the mesenchyma at the time; in amphibia they are large and rounded and charged with yolk granules; in amniota they are more like embryonic connective-tissue cells. These cells always appear between the entoderm of the cervical archenteron (Vorderdarm of Von Baer) and the mesoderm bounding the cœlom, and when they first appear there are no other cells near them between the mesothelium and entoderm, compare Figs. 128 and 129. Whence do these cells come? I consider it probable that they are the forward extension of the vascular anlages of the omphalo-mesaraic veins and that just as the endothelial aortæ are formed by the ingrowth of loose strings of cells so are the two veins, and these uniting in the median line form the endothelial heart. This view is hypothetical. A variety of other conflicting views have been advanced, of which the following may be noted. Balfour, "Elements," 85, 89, thinks the cells come from the neighboring mesoblast, as Oellacher had previously considered was probable in teleosts, 73.1, 84. Goette has maintained that in Petromyzon, 90.1, teleosts and amphibians, 75.1, the cells come directly from the entoderm, and C. K. Hoffmann, 92.1, maintains the origin of the heart to be entodermal in elasmobranchs. Rabl,

86.1, expresses himself very cautiously, but inclines to the view that the cells come from the entoderm, and in regard to the sharks he is uncertain, **89.2**, 225. J. Rückert, **88.2**, believes that the cells which become the endothelium are thrown off in elasmobranchs from both the entoderm and mesoderm at the points where the cells first appear. Finally, F. Schwink, **90.1**, asserts that in amphibia the cells are derived neither from the neighboring entoderm nor mesoderm, but that they grow in from the mass of yolk-cells. Schwink's observations seem very careful, and may turn out to confirm the hypothesis of the origin of the endothelial heart from the omphalo-mesaraic veins uniting.

Origin of the Vascular System.—O. Bütschli, **83.3**, has advanced an hypothesis of the phylogenetic origin of the heart and blood-vessels which has much plausibility. He suggests that the heart is a remnant of the primitive or segmentation cavity of the embryo, and is not derived from the secondary or permanent body cavity (schizocoel or enterocoel). He endeavors to reconcile this view with the accounts of the development of the heart in vertebrates, maintaining that it probably arises as a fissure in the mesoderm, remaining as a permanent part from the temporary primitive cavity. More support for the hypothesis is found in arthropods; for it has been observed in several forms that the two edges of the mesoderm approach one another in the median dorsal line, leaving a space between them which belongs to the primitive cavity. This space becomes the heart. Sometimes it is cut off before, sometimes after, the mesoderm is split into segments. These observations were upon the bee (Bütschli), *Geophilus* (Metschnikoff), and *Branchipus* (Claus). An investigation to answer the problem propounded by Bütschli would, it may be safely said, prove fruitful and interesting. For further speculations in this direction see Schimkevitch, **85.1**.

As to the evolution of the vascular system the course of development in the embryo indicates, it seems to me, that the immediate ancestors of vertebrates had no capillary vessels, but only a few large afferent and efferent trunks with a few anastomoses, as is now found in many annelids. With the acquisition of the large yolk the development of accessory blood-channels over the surface of the yolk presumably followed to secure, more efficiently, nutrition for the embryo. These first channels were, if we may rely on the ontogenetic indications, grooves on the surface of the yolk bounded on one side by mesenchymal cells, by the further differentiation of which the grooves become endothelial tubes; in this manner we can account for the blood-vessels appearing first in the extra-embryonic area. Since the blood-cells are developed from the walls of the vessels, it is possible that the walls may have acquired hæmoglobin, and the cells then have been set free by a further evolution, but it is perhaps equally possible that the isolation of the blood-cells from their matrix (the vascular wall) may have preceded the acquisition of hæmoglobin.

CHAPTER XI.

ORIGIN OF THE UROGENITAL SYSTEM.

THE outlines of vertebrate morphology were given, in the main, correctly by the older anatomists, except as regards the urogenital system. In 1875 Carl Semper announced the discovery that the excretory tubules of elasmobranchs have a funnel-shaped opening in the abdominal cavity—a fact discovered by Balfour, 78.3, at about the same time. Both authors recognized that this discovery was profoundly significant, but it is chiefly to Semper that we owe the reform of conceptions in this field. It is unnecessary to attempt a historical review; the reader will find in Max Fürbringer's admirable monograph, 78.1, a thorough, critical, and trustworthy revision of all that had been done up to that time. For notices of the subsequent literature see Rückert, 88.1, Van Wijhe, 89.1, and H. H. Field, 91.1. R. Semon's valuable memoir, 91.1, became accessible to me too late to enable me to remodel this chapter as his results render necessary.

Fundamental Parts of the Urogenital System.—For a general explanatory description we may consider the fundamental parts to be four on each side of the

vertebrate embryo, compare Fig. 131. The four parts are two longitudinal ducts: the pronephric or Wolffian duct, *W. D.*, and the Mullerian duct or oviduct, *M. D.*; and two ridges on the dorsal side of the body-cavity, *Coe*, into which they protrude; each ridge is covered by mesothelium resting on mesenchyma. The smaller ridge, *Gen*, is called the genital, since it is transformed into the genital glands; it lies nearest the median line; its cephalic end is probably identical with the so-called glomus of the pronephros. The larger ridge, *Ex.* is called the Wolffian or nephridial ridge; it contains the transverse excretory tubules (segmental tubules, nephridia) which are developed from the nephrotomes, the expansion of which probably

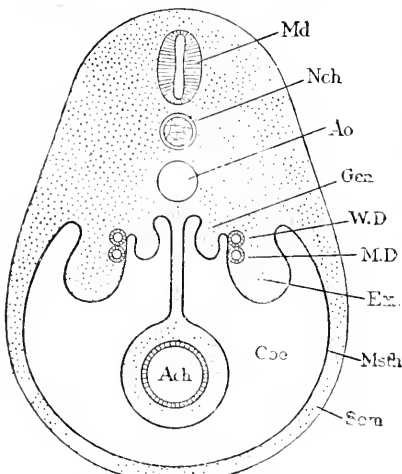


FIG. 131.—Diagrammatic Cross-Section of a Vertebrate to show the Fundamental Relations of the Urogenital System. *Md*, Medullary tube; *Nch*, notochord; *Ao*, aorta; *Gen*, genital ridge; *W. D.*, Wolffian duct; *M. D.*, Müller's duct; *Ex.*, excretory or Wolffian ridge; *Msth*, mesothelium; *Coe*, coelom; *Som*, somatopleure; *Ach*, archenteron.

causes the bulging of the mesothelium, which results in the formation of the Wolffian ridge. The nephridia open into the pronephric

duct. The cephalic end of the nephridial or Wolffian ridge give rise to the pronephros, while the remainder of the ridge is for the chief part at least converted into the Wolffian body (primitive kidney, mesonephros, *Urniere*).

Head-kidney or Pronephros.—The head-kidney being the first part of the urogenital system to be differentiated in the vertebrate embryo, must be regarded as the phylogenetically oldest part. It is found in the embryos of (probably) all vertebrates, but disappears before adult-life in selachians, some teleosts, and all amniota.

The head-kidney is always situated in the segments immediately behind the heart, and is a paired organ with a longitudinal duct, which finally opens into the cloaca or hind end of the alimentary tract; the duct has great morphological importance; its development is described in the next section. The head-kidney consists of from one to five or more transverse tubules which are differentiated from the nephrotomes and have on the one hand an opening into the ventral cœlom or abdominal cavity, and on the other into the longitudinal duct. Each tubule consists of epithelium and when well developed takes a convoluted course. The number of these transverse tubules is said to be greatest in *Myxine*; in *Petromyzon* there are four or five, in *Torpedo* six, *Pristiurus* four, *Cœcilia* four, *Anura* three, *Urodela* two; but in teleosts and cartilaginous ganoids one only. The head-kidney often protrudes somewhat into the body-cavity, and the part of the body-cavity into which it protrudes may become, as in teleosts and the lamprey, shut off from the remaining cœlom. There is also developed a so-called glomus, which is a fold of the mesothelium arising near the base of the mesentery, and con-

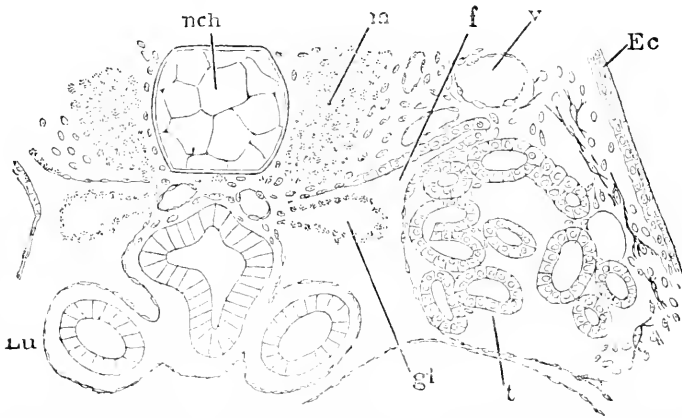


FIG. 132.—*Rana temporaria*. Tadpole of 12 mm. Cross-Section through the pronephros. *nch*, Notochord; *m*, muscles; *f*, funnel-shaped opening of tubule or second nephrotome; *v*, blood-vessels; *Ec*, ectoderm; *t*, tubule of pronephros; *gl*, glomus; *Lu*, lung. After M. Fürbringer. $\times 90$ diams.

taining numerous blood-vessels. The structure of the organ is well illustrated by Fig. 132.

The development of the head-kidney varies considerably in the different classes of vertebrates, so that we are still uncertain as to what are the essential and typical features of its development. The

confusion is probably due to the fact that it is only recently that we have gained the knowledge that between the myotome and the lateral plate comes, in every segment, the nephrotome, to which the origin of the transverse excretory tubule, both of the head-kidney and of the Wolffian body (mesonephros) has been traced in a number of cases. Since we have known that the essential question is, Do the pronephric tubules arise from the nephrotomes? sufficient investigations have not been undertaken. But it has been shown in several cases that the nephrotomes do produce the tubules. The typical mode of development both for the pronephros and mesonephros is, I think, probably as follows: The nephrotomes typically contain a cœlomatic cavity; when they separate from the myotome the myotomic end of the nephrotomic cavity becomes closed, but the other end remains open and becomes the permanent nephrotome opening of the nephric tubules (Segmentalorgane of Semper); the nephrotome now lengthens out and unites secondarily with the pronephric or segmental duct. Until further research of a far more thorough character than anything we yet have shall decide the question, this hypothetical account is the best that can be presented.

In the cylostomes, teleosts, and amphibia the pronephros is said to arise from the mesothelium of the ventral cœlom; but as this takes place so that the mesothelium is close to the myotome, it is more than possible that we have to do really with nephrotomic tissue. If Goette's account of the process in *Petromyzon*, **90.1**, 54, 55, be correct, then it may be that in the lamprey the nephrotomic anlage separates from the myotomes, and while still connected with the lateral plates undergoes segmental division. In the lamprey (Goette, *l. c.*), teleosts (McIntosh and Prince, **90.1**, 783-785), and amphibians (Fürbringer, **78.1**), the mesothelium, which produces the tubules, produces the longitudinal duct also, but in view of what is stated of other vertebrates this has been questioned. Our knowledge of the head-kidney in amphibia has been very much extended by the recent researches of Mollier, **90.1**, Marshall and Bles, **90.1**, R. Semon, **91.1**, and H. H. Field, **91.1**. My lack of personal familiarity with the amphibian pronephros makes me unwilling to attempt a critical summary of their researches.

The pronephros of elasmobranchs begins to develop in (*Pristiurus*) embryos with twenty-seven segments; the three foremost segments are subsequently included in the head, so the fourth is the first segment of the rump (Van Wijhe, **89.1**, 473). In the first four (*Pristiurus*) or six (*Torpedo*) of the rump segments the somatic mesothelium (wrongly termed somatopleure by Van Wijhe) and nephrotome becomes thickened; these thickenings come into contact with one another, and, according to Rückert, **88.1**, with the ectoderm; they subsequently acquire a lumen; thus each nephrotome has an extension of its cavity, and becomes a canal with an opening into the main cœlom, and extending in a curved line outward and backward toward the ectoderm. These four to six canals unite with the longitudinal duct which arises from the ectoderm. Our knowledge is based chiefly on Rückert's very detailed investigations, **88.1**.

In anniota,* the head-kidney was first described by A. Sedgwick,

* For a fuller review and discussion, see H. H. Field, *91.1*, 272-281.

81.1, and has been studied also by Renson, **83.1**, Mihalkovics, **85.1**, Janosik, **85.1**, Wiedersheim, **90.3**, and others. A few scattered observations are inserted by Hoffmann in his "Reptilien," p. 2047-2063 of Broun's "Thierreich." Braun, **77.4**, has shown that in reptiles the nephrotomes become much enlarged and appear as rounded vesicles of epithelium; the anterior three or four of these vesicles retain the open communication of their cavities with the ventral cœlom, and these vesicles correspond to the pronephric anlage. Most of what little we know of their history is due to Mihalkovics, **85.1**, 41-47, 55-66. Each of the pronephric segmental vesicles acquires a communication by means of a fine fissure with the longitudinal duct, which has meanwhile formed between the nephrotomes and the ectoderm. The opening of the vesicle into the ventral cœlom (pleuro-peritoneal cavity) is now closed, and the nephrotome is completely separated from the lateral plates or mesothelium of the body-cavity proper. The next change (Lacerta embryos of 3.5-4.0 mm.) is effected by the lateral wall of the vesicle sinking in, thus converting the round vesicle into a tube bent into an S-shape and having its general course at right angles to the body-axis. It is uncertain whether Mihalkovics has described true pronephric tubules or merely anterior tubules of the Wolffian body. If the structures are pronephric there ought to be some trace of a peritoneal glomerulus near the opening of the tubule, which there is not. On the other hand, if they are Wolffian tubules there should be a glomerulus formed from the tubule itself, and this seems to be the case, (see Mihalkovics, *l. c.*, Taf. I., Fig. 9). R. Wiedersheim, **90.3**, states that the head-kidney is very well developed in crocodile embryos (10-12 mm.) and occupies the anterior end of the urogenital ridge; it merges into the Wolffian body; the right pronephros has sixteen, the left thirteen, funnel-shaped nephrotomes; the glomus is the anterior continuation of the urogenital ridge, and is imperfectly segmentally subdivided; the tailward end of the pronephros is shut off from the main cœlom by a prolongation of the embryonic diaphragm (septum transversum). In *birds* (Mihalkovics, **85.1**, 58) the nephrotomes of the fourth to seventh segments form the pronephric tubules, which open into the body-cavity, and taking a transverse S-like course empty into the lateral duct; on the mesenterial side of the peritoneal opening of the tubule a glomerulus is formed; the relations can be seen in chicks of three to four days, or better in ducks of the same incubation; the pronephric tubules disappear the fourth day, but the glomeruli enlarge somewhat and do not disappear until the seventh day. Balfour and Sedgwick, **78.1**, have advanced a different view; they state that the Müllerian duct, the development of which is described, p. 244, has three anterior openings at first, and these they homologize with the head-kidney; but Sedgwick, **81.1**, has withdrawn his opinion. Renson, **83.1**, Kollmann, **82.2**, and Mihalkovics, **85.1**, moreover, deny the existence of the three openings. In *mammals* the head-kidney has been studied by Renson, **83.1**, 606, who states that in rabbits of ten days the S-shaped tubules with openings into the cœlom are present and empty into the primitive longitudinal duct; they disappear very soon; nothing corresponding to the pronephric glomus has been recorded.

Our knowledge of the pronephros is unsatisfactory. The fullest review of the literature known to me is given by H. H. Field, **91.1**.

The Pronephric Duct.—The primitive longitudinal duct of the urogenital system is known by various names; the most important are pronephric or segmental duct, (*Vornierengang*), and Wolffian duct, but it is doubtful how far the Wolffian duct of the anniota can be homologized with the pronephric duct of anammia, compare below. Both ducts bear the same relation to the pronephros and Wolffian bodies, but differ in their connection with the Müllerian duct, which in selachians seems to arise from the pronephric duct and in anniota arises independently of the Wolffian duct. For the purposes of this paragraph it is assumed that the pronephric and Wolffian ducts are identical, and the term pronephric is used for both.

The pronephric duct is the first longitudinal duct of the urogenital system to appear. When first differentiated it always lies between the nephrotomes and the ectoderm, Fig. 92, W, and always close against the mesodermic tissue. It can be first seen (Kölliker, "Grundriss," 411) in chicks during the second half of the first day, in rabbits about the end of the eighth day in the region of the fourth and fifth segments; it lengthens out very rapidly, so that in the chick the end of the second day it extends nearly or quite to the last segment formed. The intimate association of the duct with the mesoderm led to the general belief that it arose from cells of the intermediate mass (nephrotomes) or from the lateral plates (splanchnocœlic mesothelium). This opinion was shared until recently by many good observers—see the citations of authorities by Fürbringer, **78.1**, and Mihalkovics, **85.1**, 47-52. The first to call it in question seriously was Hensen (Virchow's *Arch.*, XXXVII., 81, foot-note), who in 1866, definitely asserted the origin of the Wolffian duct, as W. His, **65.2**, had previously suggested, from the ectoderm, which overlies the duct when it appears. The matter then was forgotten until attention was recalled to it by the very exact demonstration by Count Spee, **84.1**, that the duct is developed in the guinea-pig in connection with the ectoderm. Spee's discovery has since been confirmed by Flemming, **86.1**, for the rabbit, by Bonnet, **87.1**, for the sheep. But Fleischmann and Martin, **88.1**, were unable to confirm it. No satisfactory evidence of the ectodermal origin in birds has come yet, although G. Brook, **87.1**, has affirmed it; but for reptiles we have good evidence through Perenyi, **87.1**, Ostromoff, **88.1**, and Mitsukuri, **88.1**, while Strahl, **86.1**, failed to find any. The best evidence of all is that furnished for elasmobranchs by J. Beard, **87.1**, Van Wijhe, **86.1**, **89.1**, and J. Rückert, **88.1**; the investigations of the last two authors appear quite conclusive. On the other hand, it must be mentioned that H. V. Wilson, **91.1**, 247, expressly denies the accuracy of Brook's statements, and that H. H. Field, **91.1**, reasserts that in amphibians the duct has no connection with the ectoderm.

The authors who defend the ectodermal origin of the duct essentially agree with one another; they find the tailward end of the duct has a solid cord of cells which ends by fusing with the ectoderm, and where the fusion takes place the cells of the outer layer are often in karyokinesis, as if the cells were proliferating to be added to the

duct. In the amniota the connection exists for a very short distance only, and may be easily overlooked; but the length of the fusion is variable, especially so in *Torpedo*, for Rückert states he found it there extending anywhere from eleven to twenty-five segments, and even differing in extent on the two sides of the same embryo. In a series of transverse sections—for a good figure see J. Rückert, **88.1**, Fig. 35—we see running from back headward—*first*, behind the end of the duct, the thin ectoderm consisting of a single layer of cells; *second*, the thickening of the ectoderm (see Flemming, His' *Archiv*, 1886, Taf. XI., Fig. 7); *third*, the inner layer of cells separated from the outer; this separation may take place in various ways, for the cells to form the duct may make a flat plate or a round cord, or there may even be a groove in the ectoderm, and when the groove closes it is separated as a canal; *fourth*, a cord of cells lying within the ectoderm; the cord is round in section, soon develops a central lumen, and its cells become distinctly epithelial.

In view of the remarkable unanimity of the descriptions by various observers, I think it probable that it will be found ultimately that the pronephric duct is developed from the ectoderm in all vertebrates.

The backward growth of the duct is accomplished by the addition of cells from the ectoderm to its caudal end, and, when it reaches its hindmost extension (*Pristiurus* embryos of about eighty segments, with five open gill-clefts) it passes beyond the limit of the mesoderm; and hence, according to Van Wijhe's observation on elasmobranchs, **89.1**, 486, comes into direct contact with the entoderm or wall of the cloaca (hind end of the archenteron): it then fuses with the entoderm and separates from the ectoderm, after which it develops a lumen; thus the duct comes to open into the cloaca. The cloacal opening is invariably present in all vertebrates during a certain embryonic period at least; it is the permanent condition in anamnia.

The amniote Wolffian duct is round in cross-section when first formed, but soon becomes elliptical. By the changes in position, effected by the further development of the embryo, the duct is brought to run directly below the cardinal vein, and as it enlarges still farther its dorsal epithelium becomes flattened against the vein, and the cross-section of the duct becomes a triangle with the apex down; still later mesenchyma and Wolffian tubules grow between the duct and the vein, which finally becomes widely separated as in Fig. 137. The triangular section of the duct is retained for some time, but the elliptical section is gradually resumed.

The Wolffian Body.—The Wolffian body (*corps de Wolff*, *Urniere*, *mesonephros*, primitive kidney) is the chief occupant of the embryonic Wolffian ridge; in anamnia it is the chief renal organ throughout life; in amniota it disappears during embryonic life, being replaced by the true kidney, except that a small part of the cephalic end is retained, as described in Chapter XXIII., and enters into special relations with the sexual organs.

In its primitive form the Wolffian body appears to have consisted of a series of transverse tubules (Wolffian or segmental tubules) emptying into the Wolffian or pronephric duct. As was shown by Semper's investigations on *Plagiostomes*, **75.2**, there is primitively

one tubule for each segment of the body, and each tubule begins with a funnel-shaped opening into the peritoneal cavity and takes a convoluted transverse course to the laterally situated Wolffian duct. Sedgwick observed that the tubules do not arise as evaginations of

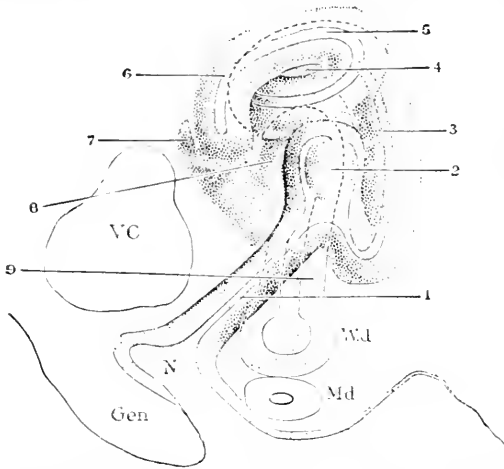


FIG. 133.—Nephridium (or Wolffian Tubule) of an *Acanthias* Embryo of 28.2 mm., seen from the caudal side; reconstructed from the sections. *Gen.*, Genital ridge; *N.*, coelomatic opening of the nephridium; *M.d.*, Müllerian duct; *W.d.*, Wolffian duct; *VC*, vena cardinalis; 1-9, successive portions of the nephridium; at 2 is seen the glomerulus.

the accompanying figure. Fig. 133 gives a caudal view of a Wolffian tubule of an *Acanthias* embryo of 28.2 mm. The tubules begin at *N*, immediately below the cardinal vein, *VC*, and runs obliquely—1, upward and outward to the glomerulus, 2, and then makes several convolutions, 3-9, until it terminates in the longitudinal Wolffian duct, *W. d.* At 2 the tubule is distended to make room for the glomerulus, which projects into it.

The development of the Wolffian body commences in *Salamandra* (Fürbringer, 78.1), with the formation of a series of solid cords derived from the nephrotomes; in the cephalic end of the body, the cords remain connected with the splanchnocœlic mesothelium, but in the remaining segments the cords have no connection with the peritoneal epithelium. A. Sedgwick states that the cords are all without union with the peritoneum in the frog. The connection with the peritoneum, when present, is soon lost. The cords develop a cavity, which acquires a vesicular form; the vesicle becomes flattened and S-shaped; the medial end develops into a Malpighian corpuscle as in the amniota (see below), while the lateral end remains narrower, joins the Wolffian duct, and afterward lengthens out to form the coiled tubule; at the junction of the tubule proper with the corpuscle a canal grows out in a ventral direction which meets the peritoneal epithelium and then develops a funnel-shaped opening (nephrostome) into the body-cavity; the epithelium of the funnel becomes ciliated. The anterior tubules are rudimentary, the first fully developed Wolffian tubules being in the sixth segment behind the pronephros.

the mesothelium of the main coelom or splanchnocœle, which was the view held by Semper and Balfour, but from the intermediate cell mass, and that the cavity of the tubule is the original coelomatic cavity of the nephrotome by which the coelom of the myotome communicates with the splanchnocœle. Subsequently the nephrotome is severed from the myotome, and by elongation becomes a Wolffian tubule; the connection with the splanchnocœle is retained to form the funnel or nephrostome. The disposition of the parts can be understood from the

The tubules are more numerous than the segments—hence the nephrotomes must divide in some way, but just how is unknown. The tubules subsequently become branched, and each branch develops a Malpighian corpuscle and a nephrostome; in the adult the Wolffian body or so-called kidney is studded over with numerous funnels as discovered by Spengel, **73.3**. How the secondary branches develop is still to be ascertained. In amphibians, then, we have two essential differences from the elasmobranchs—namely, the nephrostomes are not the retained openings of the nephrotomes, but new formations, and the number of tubules is greater than one for each segment; this increase in number implies a very precocious subdivision or budding of the nephrotomes, and is a secondary feature; for there is, of course, only one nephrotome on each side in every segment.

In all amniota the nephrotomes all become completely separated from both the myotomes and peritoneum throughout the region of the Wolffian body, except that possibly in a few anterior segments the connection with the peritoneum is retained, as is suggested by Sedgwick's observations (Foster and Balfour's "Embryology," 191) and Kölliker's ("Grundriss," p. 413). Referring to the chick of the third day Balfour thus describes Sedgwick's results: "In front of about the sixteenth segment special parts of the intermediate cell mass remain attached to the peritoneal epithelium on this layer, becoming differentiated, there being several such parts to each segment. The parts of the intermediate cell-mass attached to the peritoneal epithelium becomes converted into S-shaped cords, which soon unite with the Wolffian duct and constitute the primitive Wolffian tubules. Into the commencement of each of these cords the lumen of the body-cavity is for a short distance prolonged, so that this part constitutes a rudimentary peritoneal funnel leading from the body-cavity into the lumen of the Wolffian tubule." (Foster and Balfour's "Elements," second edition, 191).

The following account of the development of the Wolffian body in amniota is based upon Mihalkovics, **85.1**. The tissue of the nephrotome is at first quite loose and not obviously epithelial; it becomes severed in each segment from both myotome and peritoneum; the cells assume a radial arrangement and a cavity appears in the centre; the cavity enlarges and forms a vesicle with epithelial walls; these vesicles were called "Urnierenbläschen" by Remak, "Segmentabläschen" by M. Braum, **77.4**, 133. In the lizards (Braum, *l. c.*) the number of vesicles corresponds with the number of segments, but in birds (Mihalkovics) the vesicles are more numerous than the segments; this may be due to the nephrotomes separating from the myotomes and then expanding less than the muscular plates; Van Wijhe has shown, **89.1**, that the number of Wolffian tubules is *apparently* increased in shark embryos by this process. The lateral wall of the vesicle very soon comes into contact with the Wolffian duct, and the epithelia of the two structures fuse and shortly their cavities open through. The dorsal wall of the vesicle now sinks in, and the connecting piece toward the duct lengthens out; the tubule thus acquires an S-shaped course, Fig. 134; it runs inward from the duct, then downward and outward, and finally downward and inward again, ending in the ladle-shaped blind end, which is the anlage of the

Malpighian corpuscle; the dorsal epithelium of the anlage is considerably thickened, or rather has retained its original thickness, while the ventral epithelial layer thins out rapidly. It is important

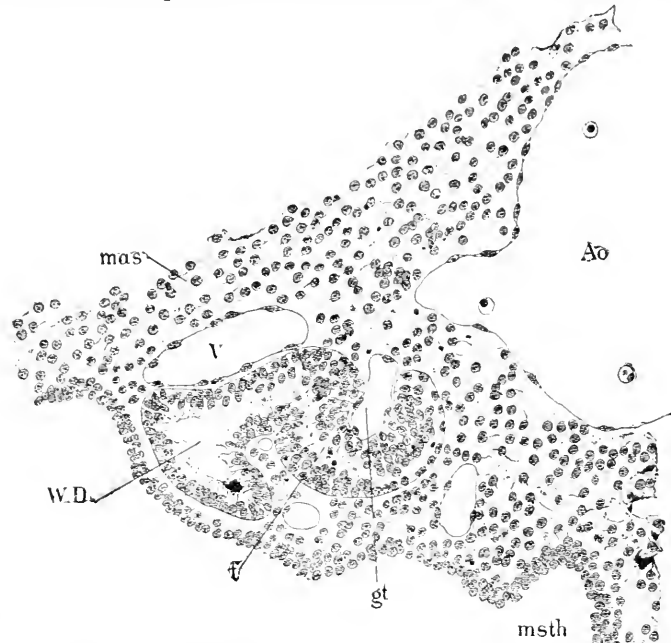


FIG. 134.—Section through a Wolffian Tubule of a Chick with Primitive Segments. *mas*, Meso-derm; *V*, vena cardinalis; *Ao*, aorta; *W.D.*, Wolffian duct; *t*, Wolffian tubule; *gt*, vessel of glomerulus; *msth*, mesothelium.

to note that in amniota the part of the tubule running from the glomerulus to the nephrostome is never developed as in anamnia, all connection with the peritoneum being lost very early indeed. The further development proceeds by the differentiation of the Malpighian corpuscle and the lengthening and coiling of the tubule proper. The

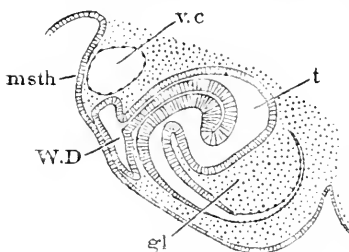


FIG. 135.—Wolffian Tubule of a Sheep Embryo of 9 mm. *msth*, Mesothelium; *v.c*, vena carnalis; *t*, Wolffian tubule; *W.D.*, Wolffian duct; *gl*, glomerulus. After G. Mihalkovics. $\times 70$ diams.

differentiation of the corpuscle takes place by the thinning out of the epithelium of the ladle-shaped blind end of the tubule; the two layers of epithelium, Fig. 135, lie close together, thus reducing the cavity of the corpuscle to a narrow fissure; both layers are convex toward the ventral side; the concavity of the upper layer is filled with mesenchymal tissue, the cells of which are at first loosely together, but soon become densely crowded; into the dense mesenchyma vessels from the neighboring aorta penetrate and form a capillary plexus; the rounded vascular mass covered by epithelium constitutes the glomerulus proper, while the lower layer of epithelium forms the capsule of Bowman, Fig. 138,

The tubule lengthens rapidly and is characterized by a cylinder epithelium somewhat higher than that of the Wolffian duct, *W. d.*; it retains for some time its simple S-shape, although the curves of the S become more and more exaggerated; the Wolffian duct, *W. d.*, at this time appears triangular in cross-section; the base of the triangle is dorsal, being appressed against the overlying cardinal vein. The growth of the tubules and of the mesenchyma around them causes a rapid and increasing protrusion into the body-cavity, resulting in the formation of the Wolffian ridge, see Fig. 136, and Fig. 137.

The transverse course of the tubules, their dilated medial ends and narrower lateral ends opening into the Wolffian duct, can be readily seen in a fresh embryo dissected so as to expose the dorsal wall of the abdomen. The appearances thus obtained were familiar to the older embryologists and have been repeatedly figured.

Mihalkovics thus classifies the various views as to the origin of the Wolffian tubules: *A*, They are evagination of the Wolffian duct, Remak, 50.1, p. xxvii; Waldeyer, 70.1, 119; *B*, They are evaginations either as canals or solid cords of the splanchnocelic mesothelium (lateral plates or peritoneum), Semper, 75.2; Spengel, 76.3; Braun, 77.4; A. Kölliker, "Entwicklungs-ges.:" Fürbringer, 78.1, and others; *C*, They arise from the intermediate cell-mass or nephrotome; this view was approached by many of the older writers, especially in Germany, who designated as *Urnierenblastem* the tissue, which we know now as the nephrotome. The correct view was first brought forward in 1880 by Adam Sedgwick, 80.1, 2, who clearly recognized the significance of the intermediate cell-mass.

Multiplication of the Wolffian Tubules.—After the first set of tubules is developed, secondary additional tubules appear. The origin of these is not certainly known. Mihalkovics, 85.1, 82, follows Bornhaupt and Balfour ("Comp. Embryology") in tracing their formation to a new differentiation of the mesoderm of the Wolffian ridge; but the details of the process are not given by him, so that this view is merely an opinion. Fürbringer, 78.1, thinks the secondary tubules are developed, as he supposes the first to be, as evaginations of the peritoneum, but the evidence is drawn from the Amphibia, and seems to me questionable even for them. Braun, 77.4, 144, follows Spengel, 76.3, in assuming that the Malpighian corpuscles divide and that the division extends along the tubule, thus accounting for the collecting tubules (*Sammelröhrchen*) with branches each ending in a Malpighian corpuscle. Still another method is suggested by Balfour's observation of buds growing out from the segmental vesicles or Malpighian corpuscles, and this explanation has been formally adopted, C. K. Hoffmann, for reptiles (Reptilien of Bronn's "Thierreich," p. 2057); Hoffmann asserts that a bud grows out from a primary corpuscle and forms a blind tube, which lengthens and twists until its blind end joins the Wolffian duct; Malpighian corpuscles with two ducts are, he says, by no means uncommon; later the corpuscles divide and each tubule then has its own corpuscle. I question the accuracy of this account.

However effected it seems certain that there is an increase in all amniota of the number of tubules opening into the Wolffian duct,

and also that some at least of the tubules become branching; it is probable that every tubule ends with a glomerulus. In the chick new corpuscles and tubules appear during the third day in the tenth to twentieth segments and usually on the dorsal side of the primary tubules (Mihalkovics, 85.1, 83); they have at first the form of segmental vesicles (*Urnierbläschen*), and become converted into Wolffian tubules by the same series of changes as the primary vesicles: the more advanced stages are always found headward, the differentiation progressing from in front tailward as with other organs. Tertiary vesicles (and tubules) arise either above, below, or between the primary and secondary tubules, and in sections (chicks five to eight days) one may see at once two or even three tubules opening into the Wolffian duct. Still further tubules are formed in a similar manner: these do not open into the Wolffian duct, but into one of the three sets of tubules already formed. The total number of tubules formed in each segment is at least five or six, probably more, in a chick of seven or eight days (Mihalkovics, 85.1, 88). In mammals it is very rare to see more than one tubule opening into the Wolffian duct in one section.

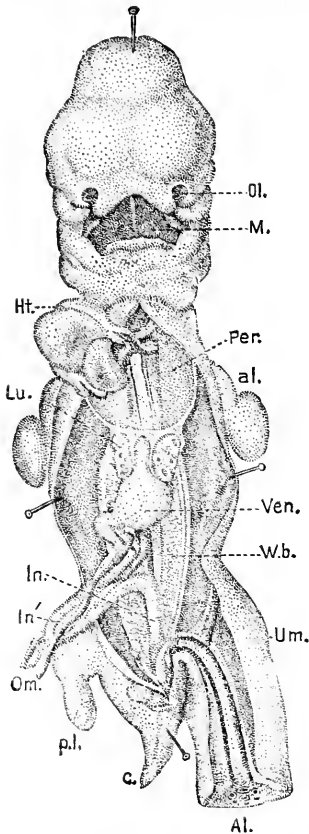


FIG. 136.—Coste's Embryo of Thirty-five Days. *Ol.*, Olfactory pits; *M.*, mouth; *Per.*, pericardium; *al.*, anterior limb; *Ven.*, stomach; *W. b.*, Wolffian body; *Um.*, umbilical cord; *Al.*, allantois-stalk; *c.*, tail; *p. l.*, posterior limb; *Om.*, omphalo-mesaraic veins; *In.*, *In'*, intestine; *Lu.*, lung; *Ht.*, heart. After Coste.

Structure of the Mature Wolffian Body.*

—The Wolffian body reaches its maximum development in the chick of seven to eight days, in rabbits of 18–20 mm., in sheep and cow embryos of 25–30 mm., and in human embryos of the seventh week. The Wolffian bodies occupy nearly the entire length of the Wolffian ridges, but do not extend into the cephalic or caudal ends of the ridges; they appear, therefore, as two longitudinal protuberant masses on either side of the mesentery; they are suspended from the dorsal surface of the body-cavity and stretch from near the rudimentary diaphragm or septum transversum immediately behind the heart into the pelvic region. The Wolffian body tapers toward each end, and on its convex lateral surface can be distinguished the Wolffian duct, and later the Müllerian duct also;

compare Fig. 136. The organ consists of a number of relatively wide, branching, and contorted epithelial tubules, the general course of which is transverse to the axis of the body. One end of the tubule

*The best descriptions of the Wolffian bodies known to me are those by Waldeyer, 70.1, 118, referring to the chick, and Mihalkovics, 85.1, 92, referring to mammals.

opens into the Wolffian duct, the other terminates blindly in a Malpighian corpuscle, which lies toward the medial and ventral surface of the organ, Fig. 137. The tubules are not of uniform structure; the portion which joins the Wolffian duct has a low clear-celled epithelium, Fig. 138, while the rest of the tubule is wider in diameter, Fig. 137, and has a higher cylinder epithelium with more granular cells; it is customary to distinguish the two parts as the collecting and excretory divisions, but we possess no certain knowledge as to the functions of the tubular epithelium.

The secretory portion opens widely into the lateral side of the Malpighian corpuscle; its epithelium changes quite abruptly into the thin epithelium lining the cavity of the corpuscle, and which is

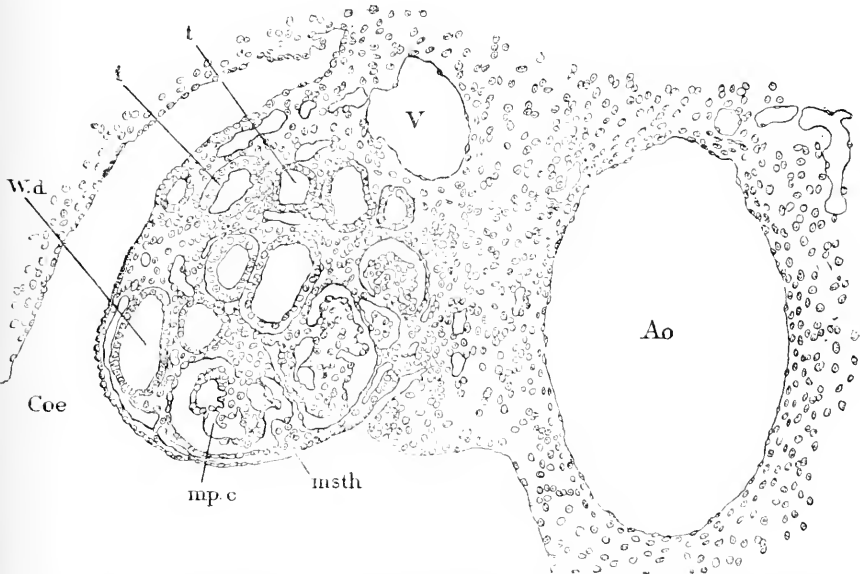


FIG. 137.—Transverse Section of the Wolffian Body or Primitive Kidney of a Rabbit of Thirteen Days. *Coe*, Coelom; *W. d.*, Wolffian duct; *t. t.*, Wolffian tubules; *V*, cardinal vein; *Ao*, aorta; *msth*, mesothelium; *mp. c.*, Malpighian corpuscle. $\times 116$ diams.

known as the capsule of Bowman, Fig. 138; the epithelium is of course reflected over the surface of the glomerulus, which it completely covers; the epithelium of the glomerulus is thicker than that of the capsule, and is characterized by crowded spherical nuclei, very granular in appearance. The glomerulus itself, Fig. 138, is very irregular in shape, being imperfectly divided into lobes and lobules; its interior is occupied chiefly with the wide capillaries of the vascular network, between which is a small amount of embryonic connective tissue. In not quite mature Wolffian bodies the distinction between the dorso-lateral *tubular* and medio-ventral corpuscular zone is very evident, especially in transverse sections, Fig. 137.

The first curve of the S-shaped tubule, or that portion which empties into the Wolffian duct, is probably converted into the collecting tubule, the second curve of the S into the excretory

tubule. In a sheep embryo of 25 mm., according to Mihalkovics, 85.1, 88-89, the collecting tubule ascends from the duct on the lateral side of the body, then bends toward the median line, descends through the midst of the organ, passing just laterally of the Malpighian corpuscles, and turning upward again passes into the much contorted convoluted tubule, which after many turnings opens into the Malpighian corpuscle. The course of the tubules may also be studied by isolating after maceration with hydrochloric acid, as first practised by Dursy.

The accompanying figures 137 and 138, illustrate the structure and relations of the mesonephros in the rabbit of thirteen days, some-

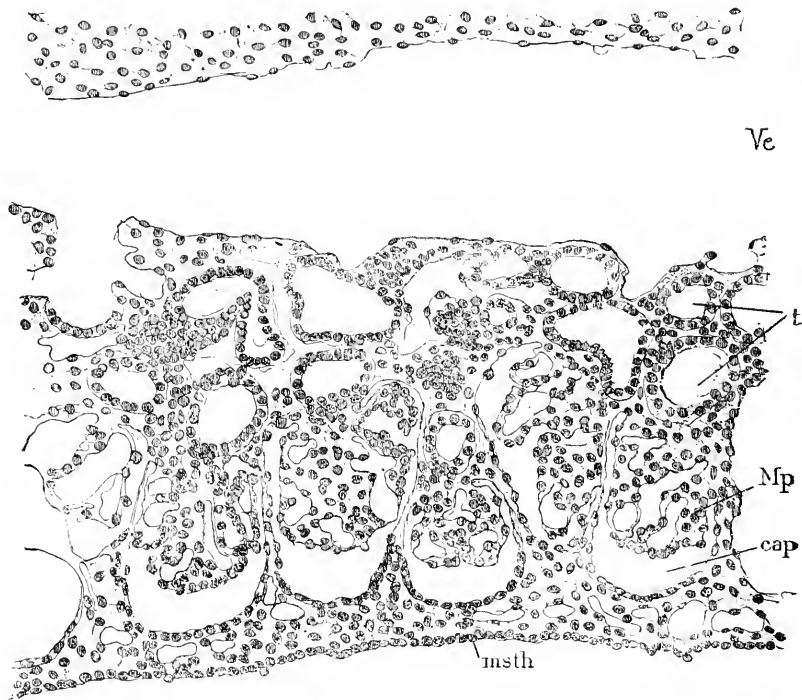


FIG. 138.—Longitudinal Vertical Section of the Wolffian Body of a Rabbit Embryo of Thirteen Days. *Ve*, Cardinal vein, with its endothelium; *t*, Wolffian tubules; *Mp*, Malpighian glomerulus; *cap*, cavity of Bowman's capsule. $\times 116$ diams.

what before the organ has reached its highest development. The transverse section, Fig. 137, shows the Wolffian body hanging obliquely downward into the body-cavity, *Coe*; it is close to the median aorta, *AO*; overlying it is the cardinal vein, *V*, and on its median side is the much smaller genital ridge. The Wolffian duct, *W. d.*, lies about the middle of the lateral side, close to the surface, and causes a slight bulging of the mesothelium, *msth*, at that point. The lateral zone occupied by tubules is very distinct from that occupied by the glomeruli, *mp.c.* The collecting tubules are readily distinguished by their thinner epithelium from the excretory tubules. The longitudinal section, Fig. 138, shows that

the cardinal vein receives numerous branches from the organ, and illustrates more fully the structure of the Malpighian corpuscles; the glomeruli are usually attached to the dorsal side of the capsule, and the epithelium of the capsule is somewhat thicker on the ventral side. Particularly noteworthy is the small amount of connective tissue. The fully developed Wolffian body of amniota has the tubules more closely crowded together, and by its expansion obliterates the genital ridge, Fig. 137, as a distinct protuberance; the Müllerian duct also appears running parallel with the Wolffian duct; finally the shape of the body is changed because the expansion takes place chiefly in the region between the Wolffian duct, *W. d.*, and the cardinal vein, *V.*, thus causing the surface along which the duct runs to face ventrally.

Historical Note.—The following data are taken from Mihalkovics, 85.1, 93. The Wolffian bodies were discovered by Casper Fr. Wolff, "Theoria generat." in 1759. They received their present name from H. Rathke, 20.1, in 1820, but Rathke termed the same organs in mammals *Oken'sche Körper*. In 1824 Jacobson (K. danske Videnskab. Selsk., Kjöbenhavn) introduced the name *Primordialniere*, and discovered that in birds the bodies secrete uric acid. The bodies were recognized in man by J. Fr. Meckel ("Beitr. z. vergl. Anat." I., 71-72) and Johannes Müller, 30.1. The older writers held them to be either beginnings of the kidneys, or sperm ducts, or horns of the uterus, etc. Rathke, *l.c.*, by discovering the origin of the true kidney, led the way to true conceptions. The glomeruli were discovered by Johannes Müller, 30.1. The next important advances were made by Bornhaupt, 67.1. Semper, 75.2, and Balfour, 78.3, founded our present morphological notions of the organs, and Sedgwick, 80.1, 80.2, Van Wijhe, and others have elucidated the genetic relation of the tubules to the nephrotomes. Mihalkovics' fine monograph, 85.1, is the most important recent publication.

Resorption of the Wolffian Bodies.—The cephalic end of the Wolffian body is retained in the adult and enters into special relations with the sexual organs to be described later. The remainder of the organ is resorbed, leaving only a few insignificant remnants. The resorption begins immediately after the bodies have attained their full development, in the chick by the ninth day, in rabbits of 18-20 mm., in human embryos by the eighth week; in man the relations are nearly those of the adult by the sixteenth week. In lizards the bodies are functionally active, at least during the first year of life, so that as we ascend the vertebrate scale we find the functional period of the mesonephros gradually diminishing.

The resorption proceeds as follows: The formation of new tubules and corpuscles ceases, the wide blood-vessels become smaller and their space is taken by interstitial connective tissue. In the secretory tubules the cells lose their characteristics, becoming indifferent cylinder cells, their protoplasm staining deeper than before. The canals remain in this condition until the sixteenth or seventeenth day in the chick and in rabbit embryos until they are 3.5-4.0 cm. long, when the epithelium of the tubules begins to degenerate; the tubules shrink; fine fat granules appear in the cells; the cell boundaries become *first* indistinct and are then lost; the cells break down

to a fatty detritus, which fills the tubules, which thus become solid cords of more or less imperfect cells. Meanwhile the Malpighian corpuscles are also degenerating; their vessels contract and the shrunken glomeruli no longer fill the Bowman's capsules; gradually the corpuscles shrivel up.

The diminution of the mesonephros is accompanied by an enlargement of the sexual ridge, so that the proportion in size of the two structures is reversed, and instead of the sexual anlage forming a small strip on the medial side of the much larger Wolffian body, the body forms a diminishing protuberance along the base of the enlarged sexual anlage (genital ridge, *i. e.* testis or ovary). The base of the genital ridge, by which it is suspended from the dorsal wall of the splanchnocœle, by being narrowed, is converted into the suspensory membrane (mesovarium or mesorchium) of the genital ridge; it is from the lateral side of this membrane (*Gekröse*) that the contracted Wolffian body projects, Fig. 139. As it is converted into connective

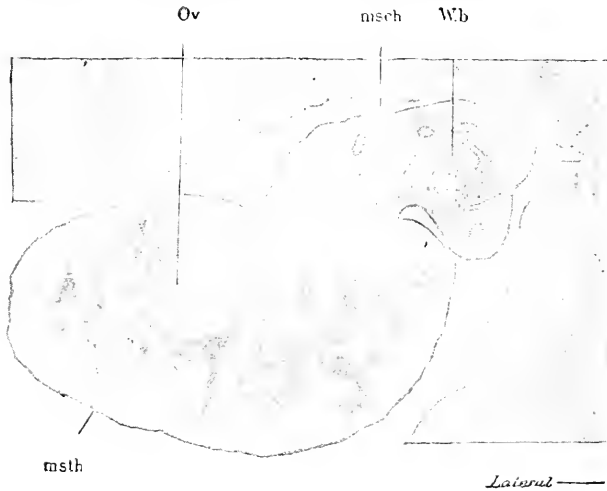


FIG. 139.—Section through the Testis of a Human Embryo of Sixty-three to Sixty-eight Days (Minot Coll. 138). *Or.* Testis with sexual cords; *msch*, mesorchium; *Wb*, Wolffian body. *Msth*, mesothelium, represented by a dark line.

tissue, and as the Wolffian, *W. d.*, and Müllerian ducts, *M. d.*, running in it lengthwise are retained, the mass of the Wolffian body becomes merely the wing connecting the two ducts with the base of the genital ridge; this wing is known in the adult male as the *ligamentum epididymis*, in the female as the *ala resperitilonis*; the detailed history of these changes is given in Chapter XXIII.

The Mullerian Duct.—This duct, which is the primitive female duct, arises in all amniota from the mesothelium of the Wolffian body close to the Wolffian duct, see Fig. 141, *M.D.* It appears relatively late: in chicks about the fifth day, in rabbits about the sixteenth or somewhat before the Wolffian body is mature; it is developed throughout its entire length as soon as the Wolffian body attains its full size. Mihalkovics, 85.1, 285, has described its relations at this stage for pig embryos, 5-6 cm. long; on the

lateral side of the Wolffian body there is a longitudinal whitish band, due to a thickening of the mesothelium; this band is called the *Tubenfalte* by M. Braun, the *Tubenleiste* by Mihalkovics, because it is along this band that the Müllerian duct is differentiated and from a part of that duct the *tuba Fallopii* is developed. The epithelial band stretches on to the rudimentary diaphragm (*septum transversum*); this part of the band has been described by Kölliker ("Entwickelungsges.," 959) as the *Zwerchfellband der Urniere*; the band also stretches caudally along the Wolffian ridge beyond the Wolffian body proper. The "Tubenleiste" quickly becomes more prominent, and its interior is filled with connective tissue (mesenchyma) in the midst of which runs the Müllerian duct close to the Wolffian duct. The Müllerian duct, Fig. 141, *M.D.*, is merely a small tube of epithelium; if we follow it forward it is seen to bend down, join the mesothelium and open into the splanchnocoele close to the anterior end of the genital ridge and to the *septum transversum*; this *ostium abdominale* becomes the fimbriate opening (*Morsus diaboli*), of the Fallopian tube; it is sometimes called the Müllerian funnel.

That the Müllerian duct arises from the mesothelium of the Wolffian body was first maintained in 1865 by Dursy, 65.1, and confirmed by W. Waldeyer, 70.1, 124-126, who conceived that in the chick a band of epithelium is invaginated; Bornhaupt, 67.1, 57, had, however, previously asserted that it is only at the anterior end that the mesothelium is invaginated, and that the duct grows backward, and this view has been generally adopted, see Gasser, 74.1, Sernoff, 74.1, Fürbringer, 78.1, Braun, 77.4, Kölliker, "Entwickelungsges.," 978, Mihalkovics, 85.1, etc. Sedgwick and Balfour (see Foster and Balfour, "Embryology," 215) have modified this view by asserting that there are three successive involutions of the Wolffian mesothelium; but it is probable that these are accidental variations owing to the irregular thickening of the mesothelium.

The development of the "Tubenleiste" precedes the appearance of the Müllerian duct; it is produced by a gradual thickening of the mesothelium along a narrow band running lengthwise of the Wolffian body; in lizards this band is on the ventral side of the body; in birds and mammals on the lateral side; in the latter the "Leiste" becomes more prominent by the increase of connective tissue in it. After the duct is developed the epithelium of the "Tubenleiste" again flattens out. Nothing is known as to the morphological significance of this peculiar mesothelial structure.

The actual development of the Müllerian duct in amniota may be described as follows: The mesothelium on the ventral (reptilia) or lateral (birds and mammals) surface of the Wolffian body is thickened to form the *Tubenfalte*. A triangular area at the cephalic end of the thickened longitudinal band is invaginated; when the invagination is complete we find an oblique funnel widely open to the splanchnocoele, and with its apex lying inside the mesothelium; the connection of the Müllerian funnel with the mesothelium can be readily seen in sections. In birds the invagination is somewhat irregular, so that there may be more or less marked modifications of from one to three or even four invaginations; no special significance attaches to this peculiarity, although Balfour has

sought to homologize the anterior end of the Müllerian duct in amniota with the pronephros; but this homology is untenable in my judgment. The point of the Müllerian funnel is closed and tapering; it grows rapidly backward, elongating as a solid cord, which becomes a canal by the gradual backward extension of the lumen of the funnel into the cord; in its growth the cord follows along underneath the thick mesothelium of the "Tubenleiste," and on the ventral side of the Wolffian duct. It continues (probably solely by the proliferation of its own cells) its growth backward beyond the Wolffian duct through the caudal extremity of the Wolffian ridge to the cloaca, with the entodermal lining of which it ultimately fuses, so that the completed duct opens into the cloaca. While it is developing, the duct continues to enlarge and is therefore for a time wider headward than tailward. In front it appears in cross-sections as an epithelial ring with a considerable lumen; the further back we go the smaller the cross-section becomes. The solid growing point is found in close contact with the epithelium of the Wolffian duct; this fact has led Balfour and Sedgwick, **79.1**, to maintain that the Müllerian duct grows by cells added to its end from the Wolffian duct, but Mihalkovics, **85.1**, 298-299, has shown that this assumption is erroneous. As to the *time* when the duct appears—the Müllerian funnel is developed in lizard embryos of 14-16 mm., or eighteen to nineteen days after the eggs are laid (M. Braun, **77.4**, 182), in snake embryos of 15-18 mm. (Mihalkovics, **85.1**, 290), in ducks the fifth day, in chicks the end of the fourth day.

In elasmobranchs the Müllerian and Wolffian ducts are united in one, as first shown by Semper, **75.2**, and consequently the former appears to be split off from the ventral side of the Wolffian or segmental duct. Semper's observations have since been amply confirmed by several observers, Balfour, Van Wijhe, Rückert, and others. Spengel, **76.3**, 13, has asserted that the duct arises in the same way in certain amphibians. Since this discovery there has been a strong tendency to accept the theory first advanced by Gegenbaur in his "Handbuch der vergleichenden Anatomie," that there was primitively a single urogenital duct, which split into two. This theory is open to obvious objections; the facts upon which it rests are derived chiefly from the embryology of elasmobranchs, a type far removed from the direct line of vertebrate evolution, and presenting many secondary modifications; the origin of the Müllerian duct in elasmobranchs has not been shown to agree with that in any other type, and is known to differ from it essentially in the only type in which the development of the Müllerian duct has been accurately worked out; and finally, even in elasmobranchs the Müllerian funnel arises from the splanchnocœlic mesothelium. Now as we see that in all vertebrates the Müllerian duct lies close to the Wolffian, and as the former is known to arise in part or wholly from the mesothelium, while the latter arises from the ectoderm, we must, I think, assume that the two ducts were primitively distinct and that their temporary union in elasmobranch embryos is a secondary modification, which recurs, perhaps, in no other vertebrate. The view here advocated has been suggested by Jungersen, **89.1**, 196, a pupil of Semper's, and is favored by R. Wiedersheim, **90.3**, 343.

The Genital Fold.—The genital fold is a small longitudinal ridge which appears on the dorsal wall of the splanchnocoel of the embryo, where it is situated between the Wolffian body and the base of the mesentery, Fig. 140, *Gen.* In the elasmobranchs there is an early development of connective tissue in the ridge, which causes it to project considerably; in the primitive vertebrates this is not the case so far as we can judge from the development in *Petromyzon*

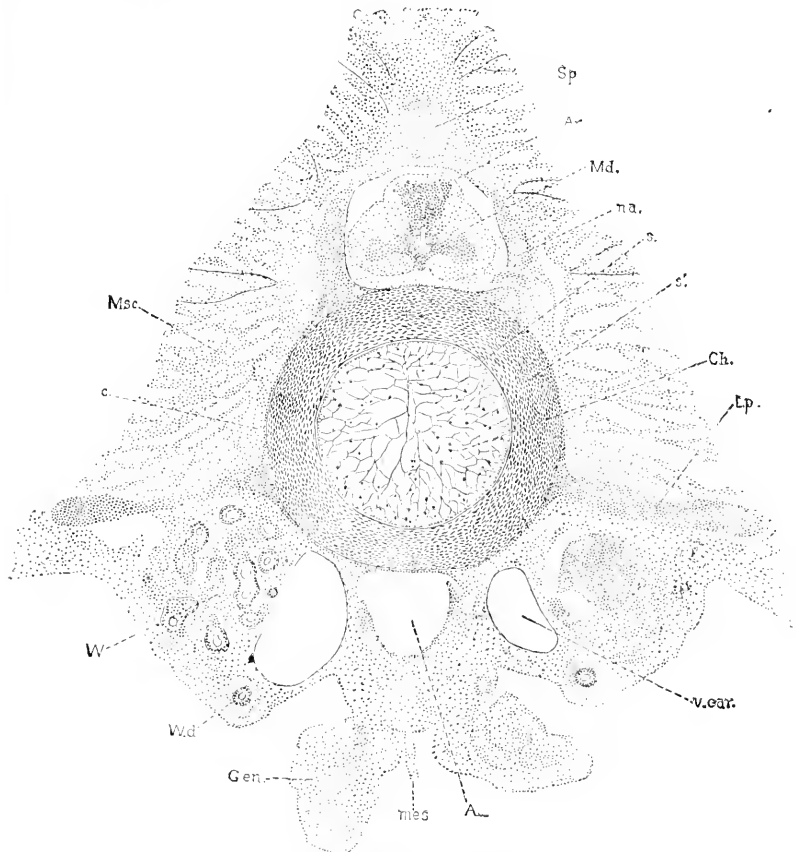


FIG. 140.—Transverse Section through an Advanced Embryo of a Shark, *Scymnus licha*; from the abdominal region (the dots represent nuclei). *Sp.* Spinal process of the vertebra; *Ar.* arachnoid space; *Md.* medulla or spinal cord; *na.* a. neural arches of the vertebra; *s.* inner sheath of the notochord; *s'.* outer sheath of the notochord; *Ch.* notochord; *Ep.* transverse process of the vertebra; *v.ear.* vertebral ear; *v.d.* Wolffian duct; *W.* Wolffian bodies with tubules; *c.* young cartilage; *Msc.* developing muscles.

and amphibians, but the ridge is produced chiefly by a thickening of the peritoneal epithelium; this thickened band of mesothelium was first shown by Waldeyer, 70.1, to give rise to the egg-cells, and has since been shown to share in the development of the spermatozoa, hence it is called the *germinal epithelium* (*Keimepithel*), and must be regarded as the primitive and essential part of the genital glands. In amniota the Wolffian body enlarges so early and

rapidly that it carries the genital fold along with itself, so that the latter becomes merely a band on the medial side of the Wolffian body, Fig. 141. But in all amniota the genital fold is first clearly

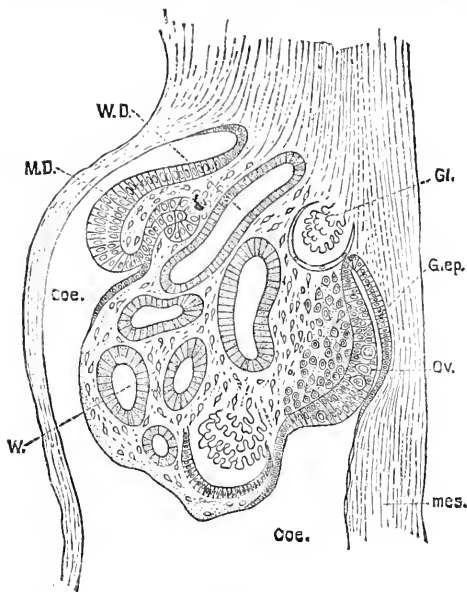


FIG. 141.—Section of the Urogenital Fold of a Chick Embryo of the Fourth Day. W.D., Wolffian duct; M.D., Müller's duct; Coe., coelom; W., Wolffian tubule; Gl., glomerulus; G.ep., genital epithelium; Ov., primitive ova; mes., mesentery. After W. Waldeyer.

marked out by the differentiation of its mesothelium from that of the peritoneum proper. In reptiles this differentiation takes place even before the Wolffian tubules have united with the Wolffian duct, but in mammals it is deferred until the Wolffian body is quite large; hence in the mammals the genital ridge seems to be derived from the Wolffian body; but this must be regarded as a secondary modification.

The genital ridge extends nearly or quite the entire length of the abdominal cavity; its cephalic end is probably the anlage of the glomus of the pronephros; its caudal end remains different, forming the so-called *gubernaculum*; the rest of the ridge, that is, its middle region, which occupies the greater part of its extent, is the

anlage proper of the genital gland.

We can distinguish four stages in the development of the genital ridge: 1, the production of mesenchyma from the mesothelium; 2, the development of the medullary cords; 3, the appearance of the true primitive ova; 4, differentiation of the sexual glands. Let us study these stages in order.

1. Production of the Genital Mesenchyma.—The genital ridge is a product of that portion of the splanchnocœlic mesothelium which lies between the nephrotome or Wolffian tubule, and the base of the future embryo; in very young amniote embryos, Fig. 161, it is that part of the mesothelium nearest the dorsal aorta. This germinal epithelium very early begins throwing off mesenchymal cells from its inner surface; the process has yet to be studied carefully; I find that it is going on both in the germinal epithelium and in the neighboring mesothelium in chicks at the time when the Wolffian tubules have just joined the Wolffian duct, as can be clearly seen in Fig. 134; the mesenchyma, *mes*, extends through the genital region and passes without demarcation into the mesothelium, *msth*. The continued production of mesenchyma has been specially emphasized for all classes of amniota by Mihalkovics, and that the germinal epithelium contributes to the ovarian stroma (in other words, forms

mesenchyma), was discovered as long ago as 1863 by Borsenkow (*Würzburger Naturwiss. Zeitschr.*, IV.), and has been maintained by Egli, 76.1, Balfour, 78.2, K. Schulin, 81.1, and others. The significance of the fact, which was obscure hitherto, is clear enough with our present knowledge of the genesis of the mesenchyma.

The mesenchymal proliferation of the genital mesothelium is accompanied also by the appearance of enlarged clear cells with enlarged clear, distinctly nucleolated nuclei. These cells from their appearance have been termed by most writers primordial ova (*Ureier*) from their assumed identity with the primordial ova of later stages. Mihalkovics, 85.1, has pointed out that they entirely disappear before the development of the ova begins, and that they cannot be identified with a kind of cells which arise much later; he proposes to call them *sexual cells* (*Geschlechtszellen*), but the name is not felicitous; before giving them any special name it will be well to learn more about them. I think they may have to do with the growth of the layer, for such enlargement occurs sometimes when a simple tissue is growing rapidly. The cells in question have been seen in nearly all classes of vertebrates; for sharks see C. Rabl, 89.2, Taf. X., Figs. 7 and 8, Van Wijhe, 89.1, and Rückert, 88.1; for Amphibia see Goette, 75.1; for reptiles see M. Braun, 77.4, 145; for birds and mammals see Mihalkovics, 85.1.

2. Development of the Medullary Cords.—There appears very early in the mesenchyma of the genital fold peculiar cords of closely compacted cells which stretch up above the level of the fold alongside the cardinal vein. The sexual cords are destined to generate the ova or spermatozoa according to the sex of the embryo. Our knowledge of the cords is still unsatisfactory and confused. So far as I know the homologies of these cords have not been thoroughly studied in any of the anamnia, hence the following account is based on the study of amniota. They were first distinctly recognized by Bornhaupt, 67.1; they were carefully studied by M. Braun, 77.4, in reptiles, who terms them *Segmentalstränge* (the name medullary cords (*Markstränge*) was proposed by Kölliker ("Entw.-Ges.," 970); Schmiegelow, 82.1, describes them in birds; in mammals they have been studied by Balfour, 78.2, Ed. Van Beneden, 80.2, M. Nussbaum, 80.1, and especially by Harz, 83.1, whose paper is excellent. Mihalkovics, 85.1, gives a monographic treatment of the cords, calling them *Sexualstränge*. W. Nagel, 89.3, 323, has shown that the true sexual cords are concerned in the production of the ova and spermatozoa, and must be carefully distinguished from the remains of the Wolffian tubules, which can be observed, especially in later stages, in the genital ridge.

The cords appear in *Lacerta* embryos of 12-14 mm., in chicks of the sixth day, in sheep of 10-12 mm., and have been seen in human embryos of 15 mm., or about five weeks. In the lizard they are very large, and appear one in each segment as first shown by M. Braun, who accordingly has named them segmental cords; each cord nearly fills the interior of the genital fold, then stretches upward close to a Malpighian corpuscle of the Wolffian body and rises above to the level of the cardinal vein. Braun held that the cord arises from the epithelium of the Malpighian corpuscle, but Mihal-

kovies maintains that the two structures are always separated. In the chick the cords can be seen the sixth day, but they are smaller and more numerous than in the lizard; at first their borders are vague and they have no definite demarcation from the stroma of the ovary. For a description of these cords in the male chick of seven days see E. Schmiegelow, **82.1**, 161; he terms them "Anlagen der Samenkanälehen." In the sheep (10-11 mm.) the cords first appear without demarcation from the ovarian mesenchyma; in embryos of the sheep and rabbit of 12-14 mm. the cords are more distinct. Of the appearance of the fully formed mammalian medullary cords at the stage preceding the appearance of the primitive ova I know no exact description. They are three or four cells wide, with distinct outlines; are twisted and branching; stain somewhat deeper than the stroma proper of the genital ridge, of which they occupy a large part.

3. Appearance of the Primitive Ova.—Since Semper's researches, **75.2**, it has come to be more and more generally admitted that the development of the genital glands leads in both sexes through an early stage characterized by the appearance of *primitive ova* (*Ureier*, *Primordialeier*, ovoblast). The primitive ova are merely enlarged cells of the germinal epithelium (or of the so-called medullary cords). They are readily recognized by being more transparent than the remaining cells and by having a larger and more transparent nucleus, which a little later has a well-marked nucleolus. These cells have long been known in the ovary, where they can be readily followed along in their development into egg-cells and mature ova, but in the male their history has still to be worked out satisfactorily. Most authors have assumed that in the higher amniota the primitive ova break up in the male and disappear very early, without wandering from their first lair, but Semper, **75.2**, found that they are included in the embryonic seminiferous tubules of the sharks; in amniota no such process has been observed, but Mihalkovics has found in human embryos of 14-16 cm., that the tubules contain cells resembling primitive ova, but in earlier stages there are no such cells. In fact we must admit that the history of the male primitive ova is practically unknown, consequently I give now merely the description of the primitive ova as they appear in the germinal epithelium, deferring the further history of the genital glands to Chapter XXIII.

The primitive ova are modified cells of the germinal epithelium. In urochordates the epithelium is at first a layer of cuboidal cells of uniform character, with small darkly stained nuclei; as soon as the genital ridge begins to protrude (*Acanthias* of 19 mm.), the epithelium becomes thicker and here and there single ones of its cells become much larger, and their nuclei become much larger, spherical, granular, and stain more lightly; the thickening of the epithelium continues as the fold becomes more prominent, but is confined to the medial side of the gland for a certain period; the thickening is accompanied by an increase in the number of clear cells, which tend to lie in groups of three or four, see Semper, **75.2**, 335-345, and Balfour, "Comp. Embryol." I., 55-58. In reptiles, Braun, **77.4**, 145, the history is essentially the same, except that

the genital fold contains little mesenchyma, and therefore the epithelium (*Lacerta* embryos 12-14 mm.) constitutes the greater part of the fold; the primitive ova resembles those of the elasmobranchs and are similarly imbedded in unmodified mesothelial cells. So far as known to me, there are no satisfactory descriptions or figures of the germinal epithelium with primitive ova at the indifferent stage of the genital fold of any bird or mammal whatsoever; it is to be hoped that this omission will soon be made good. There are brief references to the indifferent stage of the higher vertebrates in all the current text-books.

4. Differentiation of the Sexual Glands.—The conversion of the fully developed genital fold into the sexual glands is described in Chapter XXIII.

Evolution of the Urogenital System.—The embryology of vertebrates renders it evident that we have, as stated in the introduction of this chapter, four parts as the primitive constituents of the urogenital system on each side: 1, the genital ridge; 2, the Wolffian ridge; 3, the Wolffian duct; 4, the Müllerian duct. A few words in regard to the probable evolution of each of these is in place.

1. *The genital ridge* is marked out essentially as a specialized area of the splanchnocelic mesothelium, in which the primordial ova are developed. The protuberance of the ridge is increased by the stroma or mesenchyma developed below the mesothelium, but this is presumably a secondary modification. We may, therefore, regard the genital ridge as having been primarily a mesothelial band on the dorsal side of the body-cavity, between the root of the mesentery and the opening (nephrostome) of the nephrotome into the splanchnocœle. This brings us not far from the condition in amphioxus and annelids, for in both types the genital products arise from the mesothelium.

2. *The Wolffian ridge* is the protuberance produced by the increase in size and number of the Wolffian tubules, and its inclusion of the genital ridge is a secondary result of its enlargement in the higher vertebrata. Moreover, it does not at first protrude at all, so that we have to consider not the existence of an actual ridge but the presence of Wolffian tubules as the essential feature. The tubules, as we have seen, are developed from the nephrotomes, and when the nephrotomes have a distinct cavity that cavity is preserved to make the lumen of the tubule. In all true vertebrates, however, the tubule or nephrotome has lost its connection with the myotome, but retains (in the anamniota) the opening (nephrostome) into the splanchnocœle. The connection with the Wolffian duct is secondary, and the manner in which it was acquired cannot be satisfactorily accounted for at present.

Out of the Wolffian ridge there arise three primary organs, the pronephros (head kidney), the Wolffian body (anamniote or primitive kidney), and the true kidney of the amniota (metanephros). Of these the last is not a primitive vertebrate organ, since it is found only in the higher forms; its development as an outgrowth of the Wolffian duct is described in Chapter XXIII.; nothing is known as to its probable evolution. As regards the pronephros and Wolffian

body or mesonephros the first question is whether they are parts of the same series of primitive organs or distinct organs. That they are separate organs has been maintained by several recent writers, notably by Rückert, **88.1**, and Van Wijhe, **89.1**. The former lays stress upon the lateral outgrowths of the nephrotomes of the pronephros, but this is of little importance, especially as the nephrotomes of the mesonephros expand (as in anniota) and their side walls fuse with the pronephric duct; hence I cannot admit that there is any essential difference. Van Wijhe, *l. c.*, 505-506, states: 1, that the pronephros develops earlier than the mesonephros, but in all organs the cephalic portions are more advanced in the embryo than the caudal, and we cannot on this ground any more divide the series of nephrotomes than we can the series of nerves or myotomes: 2, the pronephric and mesonephric tubules differ slightly in origin, but he overlooks that they are both derived from the nephrotomes; 3, the pronephric duct unites with the pronephric tubules as soon as it appears, but the union with the Wolffian tubules is retarded; this point is insignificant, for variations in the time of development of organs are specially characteristic of embryos, and, moreover, Mihalkovics has made it probable that there is a gradual transition: 4, the presence of the glomus is characteristic of the pronephros, but since the glomus is apparently only the anterior end of the genital ridge and as the genital ridge stands in the same relation as the glomus to the nephrostomes this difference can be assigned a secondary value only. It appears then that none of the arguments in favor of an essential distinction have force. On the other hand, the facts—that all the tubules are developed from the nephrotomes, that the nephrotomes in all cases unite by their lateral walls with the pronephric duct, that pronephric and Wolffian tubules never both occur in the same segment, that there is in some and probably in all cases a gradual transition from the pronephric to the Wolffian body—seem to me ample to establish the conclusion that the two organs are parts of a single series. The pronephros is distinguished principally by the glomus or vascularization of the genital fold in its neighborhood, and it becomes separated from the Wolffian body proper by the abortion of several tubules between the pronephros and mesonephros. Why this separation occurred we do not know.

We have, if the view just defended be correct, to consider that the excretory organs were primitively a uniform series of nephrotomic tubules (Semper's segmental organs), each beginning with an opening (nephrostome) into the splanchnocœle without connection with the myotomes, but opening laterally into the Wolffian duct. Semper has sought to homologize these tubules with the segmental organs of annelids; the latter are excretory tubules opening into the cœlum, one on each side for each segment, and emptying externally through the ectoderm. Now if we assume that the line of these external openings became a groove and then a canal, we may pass at once from the annelidan to the vertebrate type, as suggested by Haddon, **85.1**, and "Practical Embryol.," 250, and at the same time account for the ectodermal origin of the Wolffian duct as a survival of a stage intermediate between the annelidan and vertebrate types. The Semper-Haddon hypothesis has much in its favor, and I should

be strongly inclined to adopt it, were it not for the recent investigations of Boveri, 90.1, which suggest that quite a different line of homologies, to be traced through Amphioxus, may be the true one.

3. *The Wolffian duct*, as we have seen, is probably of ectodermal origin. As indicated at the close of the preceding paragraph, there are two hypotheses to account for this assumed origin, namely, Haddon's, 85.1, and Boveri's, 90.1. Haddon, accepting Semper's hypothesis that the tubules are homologous with annelidan segmental organs, assumes that they opened exteriorly and that the line along which they opened became a groove and then a canal. Th. Boveri assumes that the genital chamber of Amphioxus corresponds to part of the nephrotome, and that ducts, which lead in the branchial region of Amphioxus according to Boveri's discovery from the body cavity into the peribranchial chamber, represent the excretory portion proper of the nephrotome; thus he is led to homologize the peribranchial chamber with the Wolffian duct in that both are of ectodermal origin and both receive the nephrotomic tubules; he, however, regards the duct as representing merely a specialized part of the amphioxan peribranchial chamber. Boveri's brilliant comparisons are certainly very seductive, but his observations on Amphioxus do not suffice as yet to carry his conclusion above the hypothetical stage. There is one difficulty which he has overlooked, namely, that by his hypothesis the sexual gland is further from the splanchnocœle and nearer the myotome than is the excretory tubule, whereas in true vertebrates the relations are the reverse of this, so that the sexual glands in the two types would not be homologous, if Boveri's hypothesis were correct.

4. *The Müllerian duct*, as stated in the section on its development, is in my opinion probably not derived from the Wolffian duct as maintained by Gegenbaur, Semper, and their followers, but is a new organ developed from the mesothelium within the vertebrate type. Its evolution, however, is, properly speaking, merely a matter of speculation at present.

CHAPTER XII.

EARLY DEVELOPMENT OF THE ARCHENTERON.

THE archenteron is, strictly speaking, the entire cavity lined by the entoderm, a fact which comes out very clearly in the primitive type of vertebrate development as preserved in Petromyzon, ganoids, and amphibians. In these forms the yolk is the ventral floor of the archenteron and consists of a thick mass of cells, all charged with yolk granules (deutoplasm), see Fig. 70, 17. In all amniota, on the contrary, the first step is the division of the primitive archenteron into the primitive alimentary canal of the embryo and the yolk-sac. Before this occurs the mesoderm has appeared and the cœlom is present in it, so that splanchnic mesoderm is already differentiated and united with the entoderm to form the splanchnopleure; henceforth the two germ-layers develop in close correlation with one another, and the history of the archenteron becomes the history of the splanchnopleure, except that in the cervical region the entodermal canal is developed without the cœlom appearing.

We have to consider the following stages: 1, Separation of the archenteron proper from the yolk-sac; 2, origin of the allantois; 3, origin of the pharynx.

Entodermal Cells.—In the primitive type of vertebrate development (marsipobranchs, ganoids, and amphibia) the archenteric cavity is of small diameter and is bounded, Fig. 102, *Ent*, by cells which differ from those of the surrounding yolks very slightly at first, although they early assume an epithelioid arrangement. In the amniota, on the other hand, the archenteric cavity undergoes great lateral expansion at a very early stage; this has been accompanied by certain modifications in the entoderm, which becomes divided into a cellular part on the dorsal side of the cavity and a multinucleate vitelline part on the under side; moreover the cellular part becomes divided into two regions; one, known as that of the *area pellucida*, includes and surrounds the meroblastic embryo proper, and is characterized by the cells becoming very much flattened and expanded, compare Figs. 144 and 161, and the other, known as that of the *area opaca*, surrounds the first and is characterized by having high cylinder cells, with more or less of remnants of yolk grains in them. The cylinder cells of the opaca entoderm pass toward the embryo into the thin cells of the *area pellucida*, and in the opposite direction when they reach the periphery of the expanded archenteron they pass into the yolk; the transition constitutes the so-called germinal wall. As development progresses we see that the region of the opaca belongs to the yolk-sac and not to the embryo, hence the cylinder cells represent part of the entodermal lining of the yolk-sac, and in the higher mammals the whole yolk-sac is lined by cylinder cells, which represent both the opaca cells and the yolk

mass of Sauropsida, there being no non-cellular yolk in placental mammals. For further details see Chapter XVI., on the yolk-sac.

As soon as the embryonic archenteron begins to separate off in amniote embryos the thin entoderm grows thicker, until in young embryos it resembles a cylinder epithelium, but in the area pellucida around the embryo the entoderm remains thin, the thickening being strictly confined to the embryonic portion.

1. Separation of the Archenteron proper from the Yolk-sac.—The following diagrams, Figs. 142 and 143, may help to render the process clear as it occurs in the Sauropsida; both figures are supposed to represent a hen's ovum with the embryo *in situ* and cut transversely; the embryo is much too large in proportion, and the cœlum is much too wide. In Fig. 142 the archenteron, *Ach*,

is a wide cavity bounded by the cellular entoderm above, and the yolk-mass below; the cellular entoderm in the axial region corresponding to the area pellucida is thin, and thickens at each side corresponding to the area opaca. The mesoderm is divided into its two layers by the cœlomatic space, *Coe*, but it is to be noted that in reality the extension of the cœlom around the yolk is gradual, and at this stage of the embryo is never completed; the splanchnic mesoblast is thus laid against the cellular entoderm on the dorsal side of the archenteric cavity, forming the splanchnopleure, *Spl*; that portion of the splanchnopleure which lies within the area pellucida, and is therefore lined by the thin region of the entoderm, is alone destined to form the intestinal canal or embryonic archenteron. This is effected, as indicated by Fig. 20, p. 35, by a simple folding-down of the splanchnopleure, by which the archenteron is divided into an upper embryonic portion, *In*, the anlage of the intestinal canal, and a lower portion, the walls of which are constituted chiefly by the enormous mass of yolk. In the next stage, Fig. 19, the separation of the yolk-sac, *Yolk*, from the embryonic archenteron is still more marked than before; there remains, however, a narrow connection between the intestinal canal, *In*, and the yolk-sac, *Yolk*, making, as it were, a hollow pedicle; the pedicle is known as the yolk-stalk or vitelline stalk.

If we view the embryo in longitudinal section we find the relations are similar and that the head and the tail end of the embryo become free from the yolk, and as the embryo grows its head and tail project more and more. This is often described as a separation of the embryo by the folding-in of the germ-layers, but this traditional description is incorrect, for the separation of the embryo is really

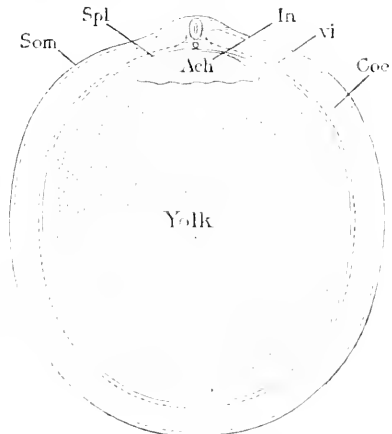


FIG. 142. — Diagrammatic Section of the Yolk of a Hen's Egg at an Early Stage to show the Relations of the Archenteron, *Ach*, to the Yolk-sac. *Som*, Somatopleure; *Spl*, splanchnopleure; *In*, intestinal portion of archenteron; *vi*, vitelline portion of archenteron; *Coe*, cœlom; *Yolk*, yolk mass.

due to the expansion of the embryo, not to the constriction of its connection with the yolk, compare Chapter XIII. The accompanying diagrams, Fig. 143, A, B, and C, show at a glance how the

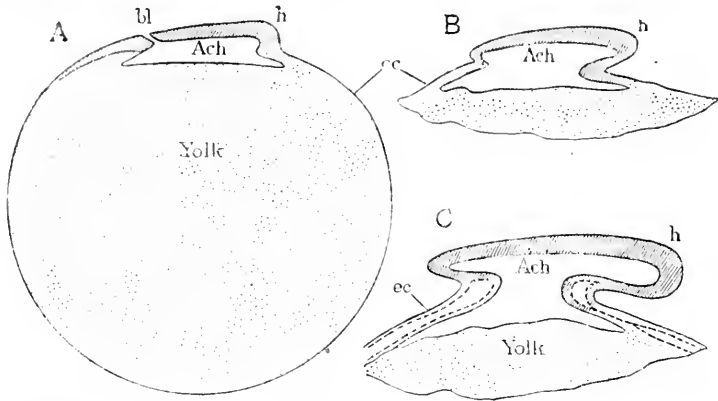


FIG. 143.—Diagrams to Illustrate the Separation of the Embryo from the Yolk. *bl*, Blastopore; *h*, head; *Ach*, archenteron; *ec*, ectoderm; *Yolk*, yolk-mass.

original width of the communication is retained, while the intestinal canal, or embryonic archenteron, extends forward and backward. In A, the archenteron is open to the yolk throughout its entire extent; in B, the head has begun to be free, and with it the archenteric cavity has begun to extend forward and forms a distinct cephalic portion, which is entirely within the embryo and is not open directly to the yolk; in C, the tail has also grown forth from the yolk and the archenteron with it, so that now we have a caudal embryonic archenteron. By further development the embryo enlarges more and more, but the opening into the yolk-sac remains nearly the same *absolute* size. I know of no exact data as to the dimensions. The proportion between the yolk-stalk and the embryo steadily changes, the stalk becoming *relatively* smaller.

I believe that the entire separation of the archenteron from the yolk-sac is due to the primitive connection being retained with little or no change of size while the embryo is growing, and that the bending of the layers, instead of being the cause of the closure of the archenteron, is the result of the arrested growth of the splanchnopleure where it passes from the embryo proper to the yolk-sac.

The development in *mammals* proceeds in the same manner as here described for the *Sauropsida*, but the appearances are modified principally in two ways: *first*, by the loss of the yolk material, and *second*, by the retarded development of the mesoderm. The loss of yolk leaves the yolk-sac a hollow body lined by well-developed epithelium (entoderm), a condition reached by the *Sauropsida* only after most of the yolk matter (deutoplasm) has been resorbed, see Chapter XVI. The delayed expansion of the mesoderm is very marked in the rabbit, and probably in other mammals; in the rabbit the embryo becomes separated from the yolk-sac and far advanced in development, while the mesoderm extends only over the embryonic hemisphere of the ovum; hence in the rabbit the yolk-sac is complete

only over half its surface; the complete sac of the entoderm is present, but only the embryonic half of the entodermal sac is covered by mesoderm and separated from the ectoderm by a cœlom; the inferior half of the sac has its entoderm lying directly against the ectoderm, and this half, moreover, degenerates and entirely disappears, as discovered by Duval, 90.1.

In *man* the mesoderm extends completely around the embryo at a very early stage, and so also does the cœlom; in the earliest known human embryos both of these processes had been finished and the yolk-sac lay entirely free, the fundamental morphological relations agreeing with the diagram, Fig. 166. For details see the descriptions of young human embryos in Chapter XIII.

The actual appearance of a rabbit embryo as seen in cross sections is indicated by Fig. 144, while a similar stage in the chick is shown

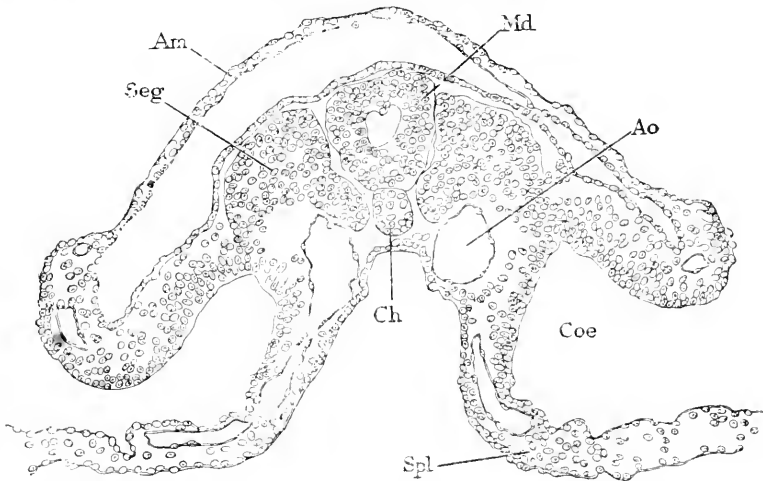


FIG. 144.—Cross-Section of a Rabbit Embryo of Eight Days and Two Hours. *Seg*, Primitive segment; *Am*, amnion; *Md*, medullary tube; *Ao*, aorta; *Coe*, splanchnocœle; *Spl*, splanchnopleure; *Ch*, notochord. $\times 144$ diams.

by Fig. 161; in both the embryo only is represented, and the space below the splanchnopleure, *Spl*, is the part of the archenteric cavity underlaid by yolk in the natural condition.

The portion of the embryonic archenteron, Fig. 143, C, in front of the yolk-sac, gives rise to the pharynx, œsophagus, stomach, anterior part of the intestine proper, and all their appendages. The portion behind the yolk-stalk produces most of the small, and the whole of the large intestine and its appendages. The first development of the anterior division is the differentiation of the pharynx, of the posterior the formation of the allantois; as the latter organ always appears earlier than the former we must consider it first.

Origin of the Allantois.—The first indication of the allantois in all amniota is a considerable accumulation of mesenchyma around and below the posterior extremity of the embryonic archenteron. This accumulation is probably a remnant of the primitive streak. A longitudinal section, Fig. 145, shows the relations clearly, as

found in the sheep at about sixteen days; the corresponding stage occurs in the chick at the end of the second day; the three germ-layers are all fused in the primitive streak, *pr. s.*; the anal membrane, *a. m.*, is well marked by the absence of mesoderm; the amnion,

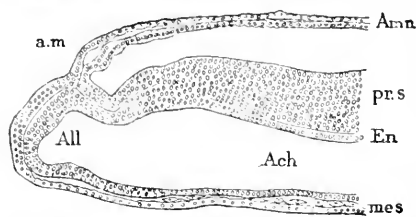


FIG. 145.—Longitudinal Section of the Posterior End of a Sheep Embryo of Sixteen Days. After R. Bonnet. *Amn*, Amnion; *a. m.*, anal membrane; *pr. s.*, primitive streak; *En*, entoderm; *Ach*, archenteric cavity, or archenteron; *All*, allantoic diverticulum; *Mes*, mesoderm.

Am, arises close behind; the archenteric cavity forms a wide diverticulum behind the anal membrane, and this diverticulum, *All*, is the commencement of the allantois; it is lined by the entoderm, *En*, and has an external layer of thickened mesoderm, *mes*. The development of the allantois in the chick has been studied in detail by E. Gasser, 74.1, and by P. von Dobrynin, 71.1. It begins before the anal

membrane is formed as a small pouch extending upward into the hind end of the primitive streak; the tip of this pouch lies just behind the bottom of the furrow, which marks off the caudal extremity of the embryo; the bottom of this furrow is the site of the anal plate; the pouch gradually enlarges and assumes the dipper shape, very much as in the sheep, Fig. 145, *All*; in the chick, however, this stage is reached relatively later than in mammals, for in the chick we find the tail already far advanced, so that it not only projects freely but has begun to curl over downward so as to bring the allantois and anus on to the ventral side of the body as well as to cause the formation of the enddarm, which is a short extension of the archenteron into the caudal extremity. The whole series of metamorphoses is admirably illustrated by Gasser, *l. c.*, Taf. I. In mammals the formation of the tail is somewhat retarded, but in them also it results in curling over and so bringing both the allantois and the anal plate on to the ventral side, with the further result that the allantois now comes to lie headward of the anal plate, although before the curling over it lay behind it.

It is important to note that the amnion arises between the anal plate and the allantois, and, as shown in Fig. 145, fuses with the wall of the allantois.

The allantois is characterized by the rapid development of its mesoderm, which seems to be derived from the middle cells of the hind end of the primitive streak. The amount of the allantoic mesoderm is subject to much variation during the early stages of the organ, being much greater in mammals than in birds, so far as observed. The mesoderm is particularly conspicuous in rodents; in the rabbit it makes a distinct mound, compare Fig. 196; in the guinea-pig (E. Selenka, 84.1, Taf. XI.) it acquires an excessive size, becoming larger than all the rest of the embryo; in *Mus* the precocious development is almost equally marked; it is into this mass of mesoderm that the allantoic diverticulum of the archenteron grows. In the opossum (Selenka, 87.1, 139) the amount of mesoderm is more nearly as in the rabbit. The mesoderm is also characterized in rodents, and perhaps in other mammals, by its precocious

vascularization, which has been expressly emphasized for the rabbit by C. Rabl, **89.2**, 152, Taf. IX., Fig. 14; the vessels give the tissue a spongy character. The protuberance caused by the allantoic mesoderm is termed *Allantoishöcker* by recent German writers, the *Allantoiswulst* by Kölliker.

The earliest stages of the human allantois are not known. There has been some discussion as to whether there is a free allantois, but no proof that such a stage occurs has been brought. The matter is discussed in the chapter on the youngest known human embryos, and in that on the umbilical cord, compare also Fr. Keibel, **91.4**.

Primitive Anus.—The terminal portion of the intestinal canal receives in early stages the urogenital ducts, a condition which is permanent in the Sauropsida; the portion of the archenteron common to these ducts is known as the *cloaca*. The ectoderm in amniota forms very early a small *anal invagination* (proctodæum) which grows in toward the cloaca until the ectoderm and entoderm come into contact; the membrane formed by the two epithelia breaks through and the cloaca thereby acquires an opening to the exterior; this opening subsequently divides into two: 1, the urogenital opening; 2, the permanent anus; in distinction from the latter the cloacal opening may be called the *primitive anus*.

In amniota the anal membrane arises in the anterior region of the primitive streak some distance behind the neurenteric or chorda canal. It has been studied in birds by Bornhaupt, **67.1**, and more fully by Gasser, **80.1**. It has been noticed in *Lacerta* by H. Strahl, **86.2**, 166, who states that it appears in that type at a much later stage than in birds or mammals. In mammals it was mentioned first, I think, by Kölliker, **83.1**, and has been since then studied by H. Strahl, **86.2**, F. Keibel, **88.2**, 410, R. Bonnet, **89.1**, 90, Ketterer, **90.2**, Tourneux, **90.3**, and especially by C. Giacomini, **88.1**, most of all these observations having been made on the rabbit. In rabbit embryos with five pairs of myotomes, the anal membrane can be distinctly recognized near the rear of the primitive streak, compare Strahl, *l. c.*, Taf. IV., Fig. 6; it begins as a slight depression of the ectoderm; behind it are situated the amniotic fold and the allantois; the depression rapidly deepens, pushing away the mesodermic cells until the ectoderm comes into contact with the entoderm, which at this spot becomes, meanwhile, thickened into a cylinder epithelium; when the contact takes place a slight entodermic depression appears. The two layers soon become indistinguishable, and by the proliferation of their cells produce a cord of cells; a similar cord has been found in the sheep by R. Bonnet, **88.1**, and in the guinea-pig by F. Keibel, **88.2**; the latter states that the cord is connected only with the ectoderm; the cord is completely surrounded by typical primitive-streak tissue; according to Giacomini, **88.1**, 287, the cord develops very soon a transient lumen, which he calls the "anal canal." While during the further development of the embryo the caudal extremity is rolled over ventralward, the cord changes in character, becoming a membrane, and at the same time it is brought on to the ventral side of the body and comes to lie behind, instead of in front, of the amnion as it did before the rolling up of the embryo. The change just referred to consists in rendering

the two epithelia distinct again and converting each into a single cell-layer, making a double epithelial membrane from which the mesoderm is entirely excluded, and which has been appropriately named the *anal membrane* by Strahl. The membrane lies at the bottom of a shallow pit, which is commonly viewed as an ectodermal invagination, and has been called the *Afterdarm* by German, proctodæum by some English writers. It is to be regarded as the rudimentary homologue of the well-developed invagination of annelids and other invertebrates, which forms in them a considerable portion of the digestive canal; the anal invagination results in invertebrates in the formation of the so-called *Hinterdarm* (hind-gut of Foster and Balfour), which must not be confused with the vertebrate *Hinterdarm*, which is derived from the archenteron.

The rupture of the anal membrane is said to occur in the rabbit about the twelfth (Kölliker, "Grundriss," 359) or thirteenth day (Strahl, 86.2, 165). I know of no exact description of the process in mammals. In the chick the epithelial cord arises and becomes perforated, according to Gasser, without passing into the stage of *anal membrane* observed in mammals; irregular cavities appear in the cord (Gasser, *l. c.*, Taf. XIII., Figs. 6a, 7a); these cavities enlarge and fuse, the cells of the cord or plate meanwhile undergoing degenerative changes; the rupture is completed about the fifteenth day of incubation. The anal ectodermal invagination is somewhat more marked than in mammals and gives rise on its dorsal side to a considerable diverticulum, the *bursa Fabricii*, which is found in birds but not in mammals or reptiles.

The *anus of the lower vertebrates* arises, as has already been shown, in intimate relation with the blastopore. This fact was first discovered by Max Schultze, 56.1, in *Petromyzon*, ascertained in alytes by Gasser, 82.3, in the newt by Alice Johnson, 84.1, in *Rana* by Durham, 86.1. The nature of this relation was first elucidated by Schanz, 87.1, and has since been worked out for various amphibia, as described, p. 189.

The Enddarm.—The prolongation of the archenteron into the tail of amniote embryos is generally known as the *Enddarm*, the German name most in use; it is also called *Schwanzdarm*, *tail-gut*, and *post-anal gut*. It results from the differentiation and rolling over of the tail. The tail is produced by the growth of the tissue of the primitive streak between the anal membrane and the blastopore or neurenteric canal, compare Chapter XIII.; the growth occurs in such a way that the tissue curls downward, and folds off the region of the archenteron underlying the primitive streak, and the disposition becomes as shown in Fig. 102 of Kölliker's "Grundriss," 2te Aufl., the enddarm extending into the tail behind the ventrally situated anal membrane.

I consider the enddarm to be distinct from the neurenteric canal, with which Balfour ("Comp. Embryol.," II., 193, Fig. 124) brings it into relation. O. Hertwig apparently agrees with Balfour, since he copies the latter's diagram ("Entwickelungsges.," 3te Aufl., Fig. 126). It seems to be confined to early embryonic life, but there are a few data as to its ultimate fate. Prenant, 91.2, 231, studying the rabbit found the post-anal gut to be a short wide pouch before the tail

develops; as the tail develops, the gut extends into it and becomes long and narrow, and its posterior extremity merges with the fused anlagen of the medullary tube and notochord. In still older embryos it degenerates.

Origin of the Vorderdarm.—As is well known the first part of the embryo in vertebrates to project from the yolk is the head end. In the same measure as the head and neck become free the portion of the archenteron which pertains to them becomes closed below and shut off from the yolk. A longitudinal section of a chick in which the head has just become free is shown in Fig. 146. In consequence of the head end, H, having grown forward above the proamnion, *pro. a*, which overlies the extra embryonic archenteric cavity, it has become free on all sides, and at the same time the archenteron has been carried forward with the head, making the so-called Vorderdarm, *Vd*, of German authors. The term *fore-gut* has been proposed by Foster and Balfour as an equivalent English term, but has not come into general use, so I have preferred to use the German term. Vorderdarm is also used in invertebrate embryology, but in a different sense, for it designates the oral invagination of the ectoderm,




FIG. 146.—Longitudinal Median Section of Young Chick Embryo. H, Head; *Vd*, vorderdarm; *mes*, mesoderm; *fo*, fovea cardiaca; *p*, pericardial cavity; *pro. a*, proamnion; *Ach*, archenteric cavity; *Pr. s*, primitive streak.

whereas the vertebrate vorderdarm is the cephalic portion of the archenteron.

Even at the stage of Fig. 146, the vorderdarm has begun to be differentiated into an anterior division and a posterior, which at this time are distinguished chiefly by the cœlom, *p*, being present only in the mesoderm below the posterior division. The anterior division forms the pharynx proper. The distinction between the two parts of the vorderdarm has long been recognized (see, for example, Goette's observations on *Bombinator*, 75.1, 221), but its morphological significance has been overlooked. The vorderdarm is a short canal under the anterior end of the medullary groove; it ends blindly in front, but opens widely behind into the general archenteric cavity; this opening is termed the *fovea cardiaca* (*vordere Darmöffnung* of Kölliker), having been so named by C. F. Wolff. The fovea is easily seen, when the chick embryo is removed from the yolk in the usual manner, and viewed from the under side; its curving edge marks the end of the closed archenteron behind which the archenteric cavity of the embryo opens directly into the yolk-sac. In transverse sections, Fig. 147, the vorderdarm appears widely expanded sideways, but compressed dorso-ventrally, and also bent, the concavity being upward; it is, of course, completely lined by entoderm, the cells of which form a very thin layer on the dorsal side and a much thicker layer on the ventral side; moreover, on the ventral side the entoderm is thickened toward the median line. These features are highly characteristic, but their significance is quite unknown. Are they ancestral in origin?

In the explanations usually given, the development of the vorderdarm is not attributed to the forward growth of the head, but to the down-folding of the splanchnopleures. Indeed if sections of successive stages be compared the idea appears justified, for at first the cephalic archenteron opens widely into the yolk-sac, then as the head of the embryo begins to rise up and project forward from the yolk it seems as if the sides of the head were being tucked under; but if it

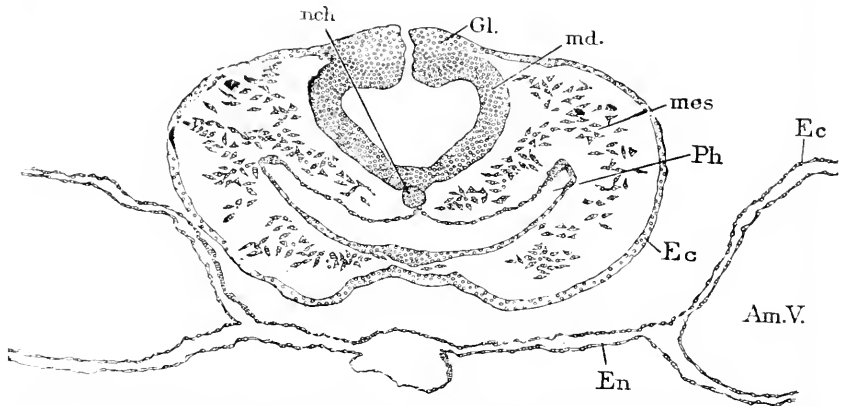


FIG. 147.—Transverse Section of the Head of a Chick Embryo with seven Segments. *nch*, Notochord; *Gl.*, ganglion; *md.*, medullary wall; *mes*, mesoderm; *Ph*, pharynx; *Ec*, ectoderm; *En*, entoderm; *Am.V.*, amniotic vesicle.

be remembered that the head is growing and that the opening between the archenteron proper and the yolk enlarges very little, it will be clear that the growth of the head is the real cause of the formation of the vorderdarm.

In mammals the process is the same as in birds, but the vorderdarm is less expanded laterally and less compressed dorso-ventrally than in the chick, hence the appearance in cross-section is somewhat different. In the opossum, however, there is a marked resemblance to the avian type in the shape of the vorderdarm, see Selenka, 86.1, Taf. XXII., Figs. 9-10, and it is probable that more careful study will show that the mammalian vorderdarm passes through the flattened form before assuming its more familiar shape.

The Oral Plate.—The fact that the anterior end of the vorderdarm lies against the ectoderm has long been known for advanced embryos. The two germ-layers, entoderm and ectoderm are soldered together with no mesoderm between them, thus forming a double epithelial plate (as shown in Figs. 106 and 170, *o.pl.*), which separates the buccal from the archenteric cavity. The plate, which may be called the oral plate (*membrana fauces*, *Rachenhaut*, *Mundrachenhaut*), by its subsequent rupture brings the mouth into communication with the pharynx.

Fr. Carius, 88.1, 22, has shown that the oral plate is present in the rabbit at a very early stage, the spot where the entoderm and ectoderm come into contact being distinguishable before the head is separated from the yolk. This spot lies just in front of the interior end of the medullary groove and of the chorda, the end of which

fuses with the entoderm of the membrane. As the head of the embryo grows forward and bends downward toward the yolk the oral plate is rolled over so as to lie on the ventral side of the embryo, and to constitute part of the ventral floor of the vorderdarm as shown in Fig. 106.

Origin of the Pharynx.—From what has been said in the preceding section it appears that the vorderdarm very early divides into an anterior part without any splanchnocœle in the surrounding mesoderm and a posterior part, underneath which lies the pericardial division of the cœlom. The anterior division becomes the pharynx proper and is remarkable for its rapid enlargement during the earliest embryonic periods of amniota; the large size of the pharynx is characteristic of the lower vertebrates, hence we have in the pharynx another illustration of the appearance in the embryo of a higher form of features characteristic of the adult lower forms. The posterior or epicardial division of the vorderdarm undergoes differentiation later than the pharynx, but ultimately gives rise to the œsophagus and stomach; as the lungs arise near the junction of the two divisions, it is not quite certain, at present, whether they make part of the anterior or posterior division.

The pharynx then is the anterior portion of the vorderdarm, and is further characterized by never having a continuous cœlomatic cavity developed in the mesoderm surrounding it.

The relations of the pharyngeal entoderm to the ectoderm are extremely important to the morphologist, since they result in the formation, 1, of the oral plate and consequently of the mouth cavity; 2, of the gill-clefts, which in their turn determine to a large extent the complex morphology of the head.

The Branchial Clefts, or gill-clefts, are permanent structures in the fishes and tailed amphibia, larval structures in anoura, and embryonic structures in amniota. They arise as a series of paired pouches from the sides of the pharynx. They are called *Schlund-, Kiemen- or Visceral-spalten* in German; *fentes branchiales* in French.

The number of gill-clefts varies in the different classes of vertebrates. In mammals and birds there are four; in reptiles, tailed amphibians, and most fishes, five; among the selachians, however, the number is variable, there being often six and in the Notidanidæ eight, it is said. In the lamprey there are eight during larval life, but the first aborts when the larva (*Ammocetes*) changes into the adult (*Petromyzon*). In *Amphioxus* the pharynx has eighty to one hundred openings and even more. These facts have led to the general conclusion that within the vertebrate series the number of gill-clefts has been gradually reduced—a hypothesis of great importance, from its bearing upon the solution of the morphology of the head.

In all *birds and mammals* there are four pairs of gill pouches developed, all in essentially the same manner. The anterior pair appears first, the others in succession behind it. The entoderm of the pharynx forms a small outgrowth on each side, making a pouch, which expands until it reaches the ectoderm. Soon a second pair of outgrowths appear behind the first, and a third and a fourth. For a long time it was believed that the membrane formed by the ento-

derm and ectoderm at the end of each pouch ruptured and converted each pouch into an actual cleft or opening by which a free passage was established through the side of the neck into the pharynx, as occurs in all Ichthyopsida. W. His pointed out, **81.1**, 319, that this was open to question, and later showed that the membrane is not ruptured in birds and mammals—a conclusion which has since been confirmed by Born, **83.1**, 275, Kölliker, "Grundriss," p. 77, and Piersol, and which is, I think, probably correct, for those who have called it in question (De Meuron, Kastschenko, and Liessner) seem to me to have offered insufficient evidence. Piersol, **88.1**, 162, studied the question with great care in the rabbit, and finds no satisfactory evidence of the closing membrane being ruptured in any of the branchial clefts at any time.

The shape of the pharynx and its four pairs of branchial pouches has been carefully studied in the rabbit by G. A. Piersol, **88.1**, by means of models of the cavity at various ages, constructed in wax by Born's method. Two views of the model or cast of the pharyngeal cavity at eleven days are given in Fig. 148. As the oral plate is already ruptured at this age, the buccal and pharyngeal cavities

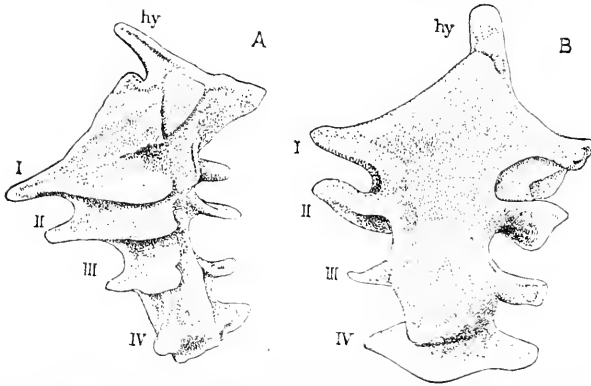


FIG. 148.—Two Views of a Wax Model of the Cavity of the Pharynx of a Rabbit Embryo of Eleven Days. A, Showing the lateral and ventral surface; B, showing dorsal and lateral surface. After Piersol.

have fused, and the models show also the oral evagination of the hypophysis, *hy*. The figures sufficiently indicate the complex configuration of the pouches with their wing-like expansions and ascending dorsal points, as well as the progressive diminution in size from the first to the fourth pouch.

It must be borne in mind that while the gill-slits are developing the head is growing, and therefore lengthening, so that the pharyngeal portion of the vorderdarm elongates. At the time the first gill-cleft is formed there is not room for the remaining clefts, but the growth of the pharynx provides the needed room soon. Thus in the chick there is at first only a very small distance between the region of the pericardium (and heart) and the anterior extremity of the embryo (see Fig. 146), but by the end of the third day there is a considerable interval between the anterior end of the heart and the actual head. This interval constitutes the embryonic neck, and cor-

responds to the pharyngeal region, and is characterized by two principal features: 1, the absence of a splanchnocœle; 2, the presence of the gill pouches.

As soon as the pharyngeal evaginations reach the ectoderm they become attached to it, first on the dorsal side and then downward until the attachment is completed throughout the whole area of contact (A. Goette, 75.1, 222). It seems now as if the ectoderm were actually held down where resting upon the entoderm, for we see as the next phase that the germ-layers grow freely in front and behind each gill pouch, thus producing columns, which are placed at the side of the pharynx and are separated from one another by the gill-clefts. As there are four gill-clefts it follows that there are five columns. These columns are known as the branchial arches, also as the gill or visceral arches (*Kiemenbögen*, *Visceralbögen*, *arcs branchiaux*). Each arch is marked out by projecting into the pharynx and upon the outside, and consequently soon after the gill pouches are developed the arches become easily distinguishable upon the exterior, and the depressions between them show the positions of the pouches. The depressions become part of the gill-clefts when the membrane (ectoderm and entoderm) breaks through; hence, when the clefts become, as in the lower vertebrates, open passages, their lining is partly of entodermic, partly of ectodermic origin, but as the epithelia fuse perfectly, the line of demarcation cannot be distinguished in the open clefts.

As to the time at which the gill-clefts appear, we need more exact information. C. Rabl, 89.2, 216, gives the following data for selachian embryos (*Pristiurus*):

Embryos with 18 myotomes		show the first gill pouch.
"	23-24	" the second pouch beginning.
"	26-27	" the second pouch well formed.
"	31-32	" the third pouch well advanced.
"	38-40	" the fourth pouch beginning.
"	45-46	" the fourth pouch completed, and the second breaking through.
"	54-59	" the fifth pouch begun, and the first and third breaking through.
"	66-68	" the first, second, and third pouches are clefts, the fourth is breaking through.
"	74	" the sixth pouch is forming, the first four are open, the fifth opening.

In the chick the gill-clefts begin to appear with third day, the fourth being present at the end of that day. In the rabbit the first pouch is seen the ninth day, and the fourth the tenth day. In man the pouches are developed during the beginning of the third week.

The pharynx expands rapidly in all directions during the development of the branchial clefts, and there is a corresponding enlargement of the cervical region, whereby the form of the embryo is affected. The external features resulting from the development of the pharynx are described in Chapter XIII., to which the reader is referred. It may, however, help to make the fundamental relations of the pharynx clear, to insert here the figure of a longitudinal horizontal sec-

tion of a dog-fish embryo. The pharynx is a very wide cavity, *Ph*, the sides of which are bounded by the five gill-arches; the gill-clefts behind each of the arches are already open through; the space in front of the first arch, *I*, is part of the opening of the mouth, which came into communication with the pharynx at a much earlier stage than that represented in the figure. The size of the pharynx forms a striking contrast with that of the intestinal canal, *In*; each branchial arch consists of a mass of connective tissue bounded by a layer of epithelium derived partly from the entoderm of the pharynx, partly from the ectoderm.

The *shapes and positions* of the gill-slits are remarkably uniform in all verte-

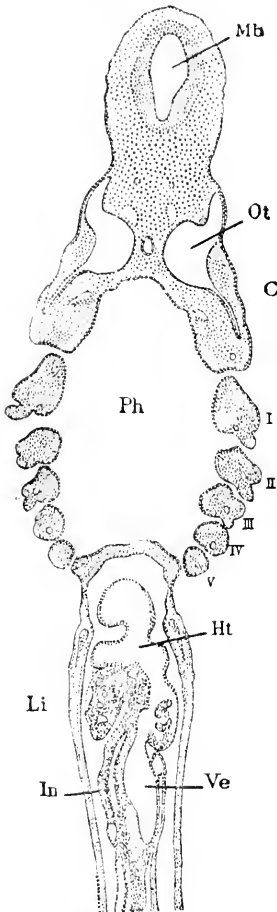


FIG. 149.—*Acanthias* Embryo of 17 mm. Horizontal section of the anterior half. *Mb*, Mid-brain; *Ot*, otocyst; *C*, cochlea or lagena; *Ph*, pharynx; *I*, *II*, *III*, *IV*, *V*, gill-arches; *Ht*, heart; *Ve*, vein; *In*, intestine. *Li*, liver.

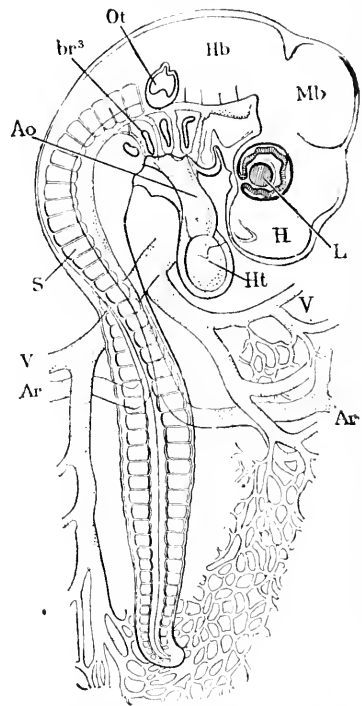


FIG. 150.—Chicken Embryo of Sixty-eight hours. *Ar*, Vitelline artery; *V*, vitelline vein; *S*, segment; *Ao*, aorta; *br*³, third branchial cleft; *Ot*, otocyst; *Hb*, hind brain; *Mb*, mid-brain; *L*, lens; *H*, hemisphere; *Ht*, heart.

brates. They are elongated dorso-ventrally and narrow in the direction of the longitudinal axis of the embryo, Fig. 150. The first is the largest and the remaining ones gradually diminish from in front backward. Viewed from the outside they are seen not to be strictly parallel, but to converge somewhat toward the ventral side, the angle between the first and second clefts being the largest. It

is also noteworthy that the lower edges of the clefts recede further and further from the median ventral line from the first to the last cleft, Fig. 151; the first clefts nearly meet on the ventral side, while the fourth and fifth clefts are far apart. The observation of this peculiarity has led to the supposition that the mouth may have been evolved by the meeting of two gill-clefts which have fused into one opening on the median line; this hypothesis is discussed in the section on the evolution of the mouth.

The Branchial Arches.—These are structures of great morphological importance, which undergo modifications of increasing complexity as we ascend the vertebrate series. They are also termed gill-arches and visceral arches (*Kiemenbögen*, *Visceralbögen*). In their earliest form they are merely the columns of tissue bordering the gill-clefts; in a horizontal section of the pharynx of an embryo they are cut transversely and are then seen to consist merely of a core of mesenchyma, surrounded by a layer of cylinder epithelium, derived in part from the ectoderm, in part from the entoderm, as explained above. In those cases where, as in the amniota, the gill-clefts do not become open, of course the ectoderm from one arch passes across to the next, and the entoderm likewise, but not the mesoderm, compare Fig. 258. As previously stated the inner and outer layers together form a membrane (*Verschlussplatte*), which closes the gill-cleft.

In more advanced stages additional parts are gradually differentiated in each gill-arch. Typically there are four principal structures developed, an aortic vessel, a downgrowth of the myotome overlying the dorsal end of the arch, two branches of nerves, and a rod of cartilage—and they appear in the order named. The aortic vessels arise very early and establish a direct communication between the ventral and dorsal aortæ, and are called the aortic arches. Their arrangement and metamorphoses are discussed in Chapter XXIV. Fig. 152 shows the aortic arch, *A*, in a cross section of a gill-arch. The parts have a typical primitive arrangement from which all modifications are derived. The details are discussed in subsequent chapters.

Viewed externally the gill-arches present the following peculiarities in amniote embryos at the stage when the gill-arches have their maximum typical development. The first arch divides the mouth from the first branchial cleft, and has its lower end enlarged and somewhat knob-like; the second arch has a similar knob, but a little smaller; at first the four knobs are quite distinct, but they soon fuse and

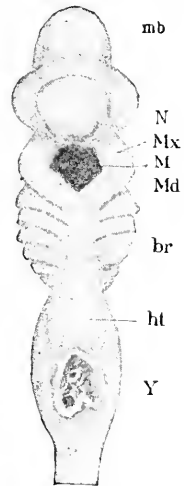


FIG. 151.—Acanthias of 17 mm. *mb*, Mid-brain; *N*, nasal pit; *Mx*, maxilla; *M*, mouth; *Md*, mandible; *br*, gill-arches; *ht*, heart; *Y*, yolk stalk.

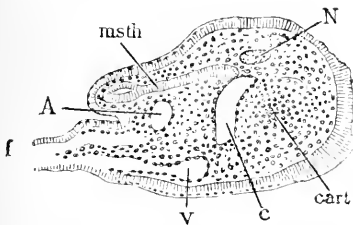


FIG. 152.—Cross Section of a Branchial Arch of an Advanced Shark Embryo, *Pristiurus*. *f*, Branchial filament; *A*, aortic arch; *msth*, mesothelium; *N*, nerve; *cart*, cartilage; *v*, communicating vein; *v*, vein. After A. Dohrn.

become more or less indistinct; the third and fourth arches, on the contrary, simply thin out and melt into the general ventral surface. The anterior (cranial) border of the mouth, after the buccal cavity has formed, is also thickened and its upper end joins the dorsal end of the first branchial arch and hence is sometimes called the maxillary process (*Oberkieferfortsatz*) of the first arch. Additional data and figures of the external appearances are given in Chapter XXVI.

Seessel's Pocket.—This term is applied to a small diverticulum which appears in birds and mammals on the dorsal side of the pharynx. It was first described by Seessel, 78.1, and has been noted since by various observers, Piersol, 88.1, *et al.*

Origin of the Liver.—The liver in the primitive type of development, as preserved in *Petromyzon* and amphibia, appears exceedingly early, Fig. 153 (compare also A. Goette's figures 75.1, Taf. II., Figs. 34-38). It is a diverticulum of the archenteron, Fig. 153, *Li*, near its anterior extremity, and projecting on the ventral side downward into the mass of yolk-cells. The short stretch of the archenteron in front of the hepatic evagination is the homologue of the *vorderdarm*, which shows, however,

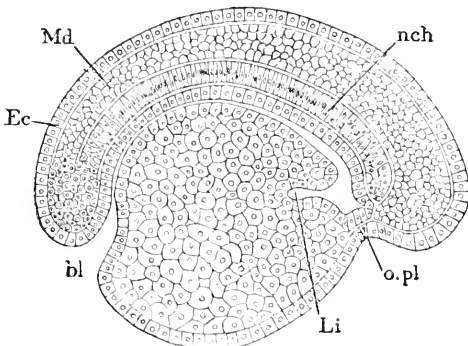


FIG. 153.—Longitudinal Section of an Embryo of *Petromyzon planeri*, Four Days Old, Reared at Naples. *Md*, Medullary tube; *Ec*, ectoderm; *bl*, blastopore; *nch*, notochord; *o.pl*, oral plate; *Li*, liver. After Kupffer.

no trace, as yet, of its subsequent division into pharyngeal and epicardial regions. When, however, the heart appears the two regions of the *vorderdarm* become distinguishable, and the liver diverticulum is seen to lie immediately behind the posterior or venous extremity of the heart. It is probable from these facts that the liver is an older organ in the ancestral history of vertebrates than the pharynx or even the heart.

The situation of the liver causes it to lie close to the veins, which are subsequently developed to pass from the yolk to the heart; these veins are especially developed in amniota and are known as the omphalo-mesaraic veins. The further development, to be described later, brings the liver into peculiar intimate relations with the venous circulation.

In elasmobranchs (Balfour, "Works," I., 455) the liver arises during stage I (*i. e.*, three gill-pouches begun, but the first not open yet) as a ventral outgrowth at the hind end of the *vorderdarm* and immediately in front of the union of the yolk-sac with the archenteron, or in other words just in front of the yolk-duct or umbilical canal, thus bringing the liver into proximity with the vitelline veins entering the heart. As the gill-pouches are present the pharynx is already differentiated, and, therefore, the liver arises relatively later than in *Petromyzon* and the amphibians. "Almost as soon as it is formed this outgrowth develops two lateral diverticula, opening into a median canal. The two diverticula are the rudimentary lobes of the

liver, and the median duct is the rudiment of the common bile duct (*ductus choledochus*) and gall bladder. By stage K the hepatic diverticula have begun to bud out a number of small hollow knobs."

In teleosts the liver arises quite late, *e. g.*, in trout the twenty-fifth day—as a solid outgrowth from the archenteron close behind the heart—thus offering one of the many instances of a solid growth in the embryo replacing a hollow growth. (McIntosh and Prince, 90.1, 774, give their own and cite some previous observations.)

In amniota the anlage of the liver arises in the same position as in the anamnia, but has the peculiarity of showing its bifurcation almost, if not quite, from the start, at least in birds and mammals. The two forks embrace between them the omphalo-mesaraic or vitelline veins just before they empty into the sinus venosus. In the chick the anlage appears between the fifty-fifth and sixtieth hour (Foster and Balfour, "Elements," 178, 179), the right fork being in all cases of greater length but less diameter than the left. In the rabbit (Uskow, 83.2, 220) the anlage appears during the tenth day, and on the eleventh sends out branches; according to Kölliker ("Grundriss," 372) only the left branch appears on the tenth day, the right on the day following. In man the anlage is well marked in embryos of three millimetres (His, 81.1, Taf. XI., fig. 7-8, also "Anat. Mensch. Embry.," Heft III., 16-17). His has shown, 81.1, 322-323, that the liver anlage is a long strip on the ventral side of the vorderdarm, and that when the vorderdarm is separated off from the yolk-sac the most ventral part of the entoderm of the vorderdarm already shows traces of the hepatic differentiation. In front of and above the heart the vorderdarm is completely shut off from the rest of the archenteron (cavity of the future yolk-sac), but immediately behind the heart the entoderm, as it passes from the vorderdarm around the edge of the fovea cardiaca, and so out on to the extra-embryonic region, is caught, so to speak, and forms the anlage of the liver, so that the liver is initiated not so much by a local growth of the entoderm as by retention of the downward extension of the layer, which results from the manner by which the embryo is separated from the yolk. The point is important as an illustration of the comparatively simple mechanical factors of development.

Relation of the Liver to the Septum Transversum.—The tissue through which the vitelline veins pass to enter the heart forms a transverse partition, which divides the pericardial cœlom from the abdominal cœlom. This partition is the rudiment of the diaphragm, and has been named the septum transversum by W. His. It lies just behind the heart, and forms the ventral edge of the fovea cardiaca, or opening of the vorderdarm into the general archenteron; it is overlaid in the median line by the hind end of the vorderdarm, and consequently the anlage of the liver is situated in the dorsal median portion of the septum. As the great veins also pass through the septum to reach the heart, the hepatic anlage comes into immediate contact with the veins; in their further development the veins and entodermal liver are closely connected, with the result of complex modifications in both parts.

Comparison of Mammalian and Amphibian Archenteron.

—For the convenience of students I have inserted the accompanying

diagrams, Fig. 154, A and B. They are extremely conventionalized and may be considered especially inaccurate in that they fail to show the way in which the head (and with it the vorderdarm) projects forward, and in that the heart and liver are omitted. *Emb* is the axis of the embryo represented in nature by the medullary tube and notochord; *bl* is the blastopore or neurenteric canal, behind which

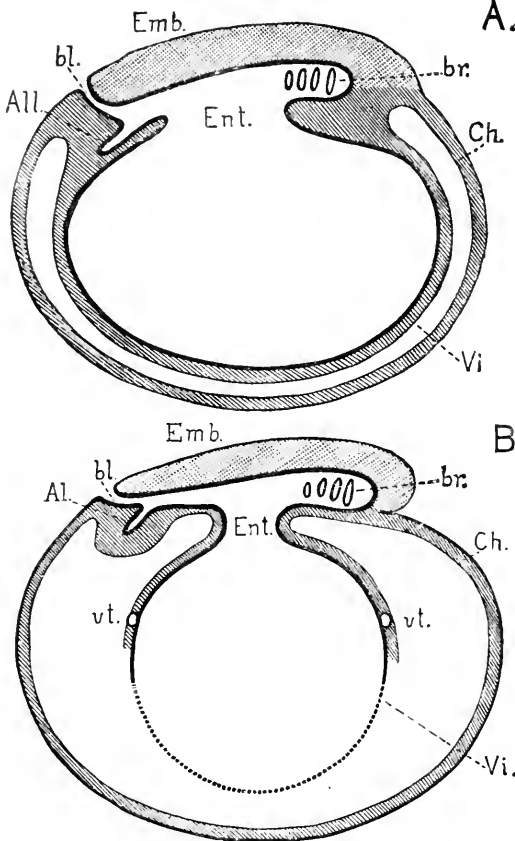


FIG. 154.—Diagrams to Indicate the Fundamental Relations of the Archenteron. A, in amphibia; B, in mammals. For explanation of the letters see the text.

the anal opening or anal plate should be added were the diagram to be completed. *All* is the infra-blastoporic diverticulum or allantois; *Ent* is the cavity of the archenteron—the letters being placed where the archenteron of the embryo proper passes into that of the yolk-sac; *br* indicates the four gill-slits. The yolk-sac, *Vi*, is represented as enveloped in mesoderm, indicated by a shaded layer and lined by entoderm which is indicated by a broad black line; it must be remembered that in amphibians, A, the cavity is really filled with yolk-cells, which are represented in mammals, B, only by a layer of epithelial cells. *Ch* is the chorion, consisting of a layer of ectoderm indicated by the outside black line, and a layer of mesoderm, indicated by shading. Between the chorion and the yolk-sac lies a space which is the extra-embryonic coelom. In amphibia this part of the coelom develops gradually; in man it is developed very early completely around the yolk-sac; in rabbits it never extends more than half-way round, and other variations occur in other mammals; to suggest these differences in mammals the lower half of the yolk-sac in B is drawn with a dotted line only; *vt*. is the vena terminalis.

These diagrams suffice to show that the closest homologies exist between the two types, however much the actual proportions may differ. The primitive homologies of the archenteron hold true of all vertebrates.

A.
B.

CHAPTER XIII.

THE GERMINAL AREA, THE EMBRYO AND ITS APPENDAGES.

I. THE GERMINAL AREA.

Definition.—The germinal area (*area germinativa*, *area embryonalis*, *Keimhof*, *aire germinative*) is that portion of the meroblastic vertebrate ovum in the centre of which the embryo is differentiated. It therefore comprises both the embryo proper and the region immediately surrounding it. It exists in all amniota, but of course in the higher mammals, owing to the loss of yolk in the ovum, the primitive relations are less clear than in Sauropsida. The area is further characterized by various gradually developed peculiarities, three of which deserve special mention. To take them in the order of their appearance, the three peculiarities are, *first*, the extension of the archenteric cavity under nearly the whole of the area; *second*, the extension of the coelom over nearly the whole of the area; *third*, the development of blood-vessels and blood beginning peripherally in the splanchnic leaf of the mesoderm and extending gradually into the embryo.

1. *Extension of the Archenteric Cavity.*—As shown in the previous chapter, only a small part of the archenteron of amniota is taken up into the embryo, and the rest of the cavity remains as the cavity of the yolk-sac, and therefore the entoderm of the area belongs, for the most part, to the future yolk-sac. As pointed out in the section on the entodermal cells in the preceding chapter, it is only on the upper side of the expanded archenteron that the entoderm becomes distinctly cellular; on the lower side the yolk is multinucleate, but not divided into discrete cells; at the edge of the expanded cavity the upper cellular layer passes gradually into the yolk and the region of the transition is known as the *germinal wall*, the structure of which is discussed in the chapter on the yolk-sac. As previously pointed out, the cells very early assume two forms, becoming thin and flattened in the central region of the area, and remaining as long cylinder cells in the peripheral zone; this difference results in a greater transparency in the central zone, which has accordingly received the name of *area pellucida*, while the peripheral zone, owing to its relatively great opacity, has been named the *area opaca*. Another result of the extension of the archenteron is that all the layers above it can be easily removed from the rest of the ovum, keeping their natural connections otherwise intact; they form when thus removed a thin membrane, which, following the terminology of the older embryologists, we commonly speak of as the blastoderm; compare the section on the meroblastic embryo, p. 128.

2. *The extension of the coelom* of course divides the mesoderm into an upper (somatic) and lower (splanchnic) layer. But the division does not take place in certain definite regions, which are, 1, the

primitive streak; 2, the axis of the embryo; 3, the proamniotic area, in which for a long period there is no mesoderm in amniota. It might also be added that as the mesoderm is excluded from the oral and anal membranes there is no coelom in them. Throughout the rest of the germinal area the coelom gradually extends, but for a long time it fails to reach, and in certain animals never reaches, the periphery of the constantly expanding mesoderm. The history of the embryonic coelom is given in special chapters, the history of the extra-embryonic coelom is indicated in the section of this chapter upon the origin of the amnion.

3. *The appearance of the blood-vessels and blood* has been considered in Chapter X.; it leads to the differentiation of the *area vasculosa* (*Gefäßhof*, *aire vasculaire*), which is the region of the extra-embryonic circulation. As soon as the embryonic area contains a distinct vascular network, there appears a peripheral vessel which marks the boundary of the area vasculosa, and is called the *sinus terminalis*. The vasculosa does not reach to the outer boundary of the germinal area, so that the region of the blood-vessels is inclosed in a ring which is known as the *area vitellina*.

Topography.—The first differentiation in the germinal area, which can be clearly recognized by the naked eye, is the appearance

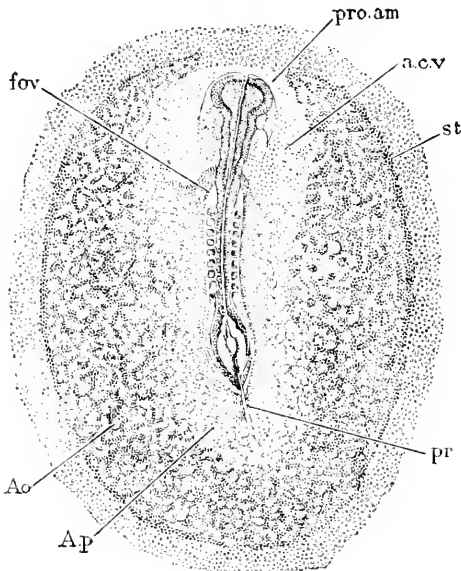


FIG. 155.—Chicken Embryo and Germ Area, after Twenty-seven Hours' Incubation. *fov*, Fovea cardiaca; *pro. am*, proamniotic area; *a. c. v*, amnio-cardial vesicle; *st*, sinus terminalis; *pr*, primitive groove; *Ao*, area opaca; *Ap*, area pellucida. After Duval.

of the area pellucida, which is shortly followed by that of the primitive streak, Fig. 78, p. 131. Further progress results in the gradual differentiation of the embryo, the steady expansion of the germinal area over the yolk, in the sharper demarcation of the area pellucida, which becomes pear-shaped, and in the appearance of the blood-vessels. Fig. 155 represents the embryonic area of a hen's ovum after about thirty hours' incubation. The embryo is well advanced in development, for although the primitive streak, *pr*, still remains in part and the medullary groove, *Md*, is still open behind, the brain is already marked out and the head has become partly free; alongside the medulla lie nine pairs of segments (proto-vertebræ, *auct.*); around the embryo one easily recognizes the pear-shaped area pellucida, *A. p.*, and the darker area opaca, *Ao*, by which it is inclosed; the area vasculosa stands out conspicuously and is bounded by the already distinguishable sinus terminalis, *st*; around and underneath the head is the translucent proamniotic area, *pro. am*, from

of the area pellucida, which is shortly followed by that of the primitive streak, Fig. 78, p. 131. Further progress results in the gradual differentiation of the embryo, the steady expansion of the germinal area over the yolk, in the sharper demarcation of the area pellucida, which becomes pear-shaped, and in the appearance of the blood-vessels. Fig. 155 represents the embryonic area of a hen's ovum after about thirty hours' incubation. The embryo is well advanced in development, for although the primitive streak, *pr*, still remains in part and the medullary groove, *Md*, is still open behind, the brain is already marked out and the head has become partly free; alongside the medulla lie nine pairs of segments (proto-vertebræ, *auct.*); around the embryo one easily recognizes the pear-shaped area pellucida, *A. p.*, and the darker area opaca, *Ao*, by which it is inclosed; the area vasculosa stands out conspicuously and is bounded by the already distinguishable sinus terminalis, *st*; around and underneath the head is the translucent proamniotic area, *pro. am*, from

which the mesoderm is altogether absent, and which therefore cannot contain any blood-vessels, nor are there at this stage any vessels in front of the proamnion.

In the ovum of the mammalia there occurs a modification of the ectoderm, where that layer is attached to the walls of the maternal uterus. The region over which the attachment takes place gives rise in the higher mammals to the placenta. Hence the area of modified ectoderm may be called the placental area. It has been, as yet, very little studied. As it is not possible at present to speak in general terms of the embryonic area of mammals, I confine myself to a description of the area in the much-studied rabbit, following

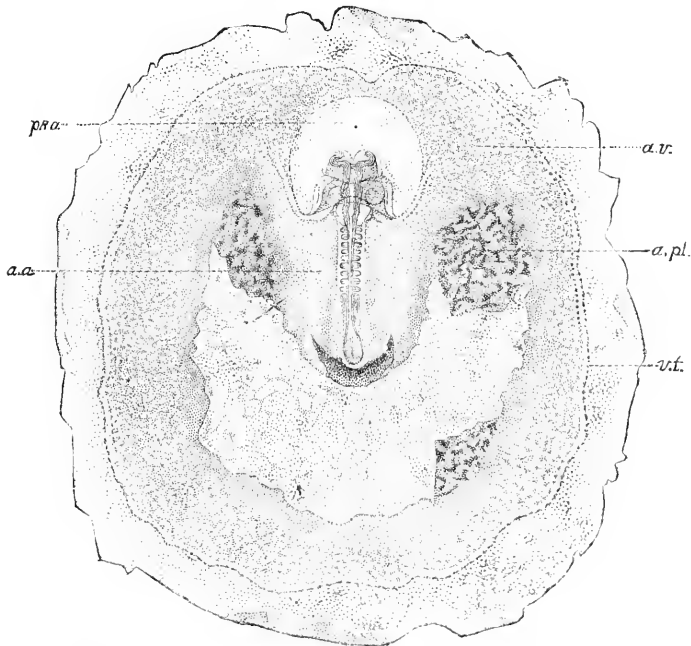


FIG. 156.—Embryonic Area of a Rabbit of Eleven Days, with the Placental Area Partly Torn Off. After Van Beneden and Julin. *pr. a.*, Proamnion; *a. a.*, amniotic area, approximately identical with the area pellucida; *a. v.*, area vasculosa; *a. pl.*, area placentalis; *v. t.*, sinus terminalis.

Van Beneden and Julin, 84.1. The germinative area, Fig. 156, is nearly circular, and at the stage figured shows the following peculiarities. The nearly straight embryo lies in the centre and exhibits plainly the central nervous system and the proto-vertebræ; around the head of the embryo is a clear space, *pr. a.*, the pro-amniotic area, over which no mesoderm is developed; around the sides and hind end of the embryo is another light place which contains mesoderm, but is distinguished by the retarded vascularization; this is the amniotic area, *a. a.*, and is converted by a process of up-folding into the annion, which covers the posterior portion of the rabbit embryo. The remainder of the germinal disc constitutes the area vasculosa, *a. v.*, with the terminal sinus, blood-islands, etc. The area consists of two membranes, the upper, the somatopleure,

the lower, the splanchnopleure; a large portion of the former behind the embryo has been torn off, *a. pl.*; this defect is due to the fact that over this region villousities have appeared, and a close connection established between this region and the uterine wall; it is by this means that the ovum is attached; hence, when the embryo is removed from the uterus, this area of the splanchnopleure (chorion) remains adherent to the uterus. As development proceeds, the allantois grows up against this area, over which the differentiation of the placenta takes place; hence the name, area placentalis.

Area Vasculosa.—Soon after the capillary network of the area opaca and pellucida has penetrated the embryo, certain lines of the network begin to widen, and soon distinctly assume the size and functions of main trunks; some of these unite with the posterior

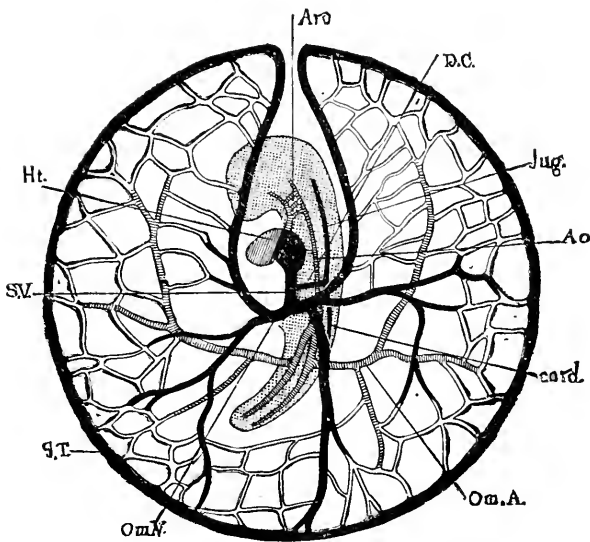


FIG. 157.—Diagram of the Circulation in a Chick at the End of the Third Day, as seen from the Under or Ventral Side. The embryo, with the exception of the heart, *Ht.*, is dotted; *Arc.*, aortic arches; *D.C.*, ductus Cuvieri; *Jug.*, jugular vein; *card.*, cardinal vein. The remaining letters are explained in the text. The veins are black; the arteries cross-lined.

venous end of the heart, which has meanwhile been formed in the embryo, and others become connected with the anterior or aortic end; even before this the heart has begun to beat, so that, as soon as all connections are made, the primitive circulation starts up. The arrangement of the vessels is not the same in birds and mammals, although commonly so stated. The disposition in birds is indicated by the diagram shown in Fig. 157, in which, it should be remembered, the embryo and the capillary network are drawn many times too large in proportion to the area vasculosa. The area is bounded by a broad circular vessel, the sinus terminalis, *S.T.*, which constitutes a portion of the venous system in birds, for in front of the head of the embryo the sinus leaves a gap, and is reflected back along the sides of the body of the embryo to make two large veins, which, after uniting with other venous channels coming from various parts of

the area vasculosa on each side, enter the embryo as two large trunks, *Om. V.*, known as the *omphalo-mesaraic veins*; these two veins unite in a median vessel, the *sinus venosus, S. V.*, which runs straight forward and enters the posterior end of the heart. The sinus venosus also receives the veins from the body of the embryo, namely, the jugulars, *Jug.*, and cardinals, *card.*; the former from in front unite each with the cardinal of the same side, making a short transverse trunk, known as the *ductus Cuvieri, D. C.*; the two ducts empty into the sinus venosus. The entire venous current is thus brought to the heart in a united stream; it passes out through the aorta; the greater part ascends the aortic arches and passes back as shown in the figure, *Ao.*, and divides at the posterior fork of the aorta, the bulk of the two currents passing out through omphalic arteries, *Om. A.*, and thence to the capillaries of the area vasculosa and so on to the venous trunks again. As shown in the figure, which presents the under side of the area, the left omphalo-mesaraic vein preponderates, and in the latter stages this difference becomes more marked until finally the right stem is very inconsiderable in comparison with the great left vein. The time at which the disparity commences is extremely variable, as is also the degree of inequality between the two veins.

The following description probably represents what was the primitive condition of vessels in the mammalian area vasculosa. It

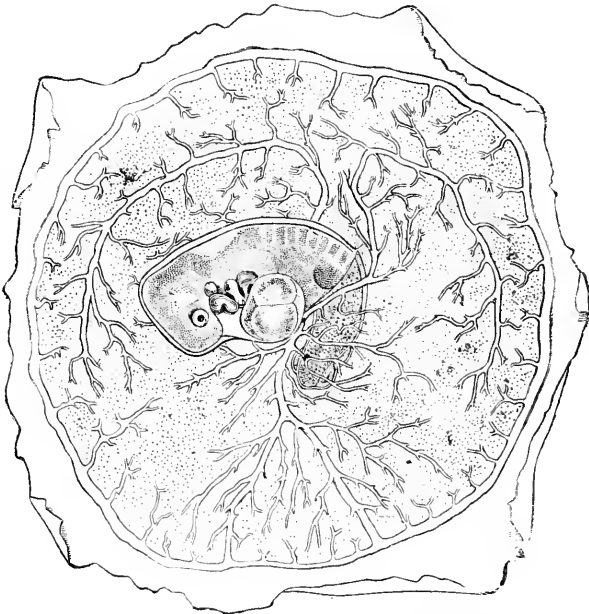


FIG. 158.—Area Vasculosa and Embryo of a Rabbit. After Van Beneden and Julin.

applies to an early stage in the rabbit, which has been figured by Bischoff, 42.1, Tab. XIV., Fig. 60, whose figure is copied in Kölliker's "Grundriss," Fig. 90, p. 109. An essentially similar arrange-

ment of the vessels exists also at a corresponding stage in the dog, Bischoff, 45.1, Taf. VII., Fig. 37, C. The veins are much more symmetrical than in the chick, and have the same general plan; the sinus terminalis belongs to the venous system, so that the connection with the arterial circulation, found later, is secondary; the aorta of the embryo is double, and gives off on each side (segmentally arranged?) transverse branches, one of which develops into the large trunk shown in Fig. 158; the network of small vessels forms *two* layers, of which the upper is connected with the arteries, the lower with the veins. The change from the earlier condition to the later has still to be followed.

Selenka has figured the vascular area of an opossum, 86.1, Taf. XXIII., Fig. 3, in a condition which suggests at once a transition from between that just described and that described in the next paragraph; the figure shows the veins without direct connection with the sinus, while the aorta, though it gives off numerous small branches, has extended tailward of the embryo and joined the sinus.

According to Van Beneden's recent researches on the rabbit the arrangement of the main vessels in the area vasculosa at a later stage is quite different. The sinus terminalis forms a *complete* ring, Fig. 158, and is connected with the *arterial* system by a single trunk, which corresponds to the left omphalic artery of the bird. For some time the connection between the embryonic arteries and the area vasculosa is entirely through capillaries, and the arterial trunk on the vascular area does not appear in the rabbit for several days. There are two veins, one arising from each side of the body and passing out on to the area vasculosa over the back of the embryo; they are the two large upper vessels in the figure.

Growth of the Vascular Area.—As the blood-vessels appear at first only in the splanchnic mesoderm, the vascular area belongs to the splanchnopleure, or, in other words, is part of the wall of the yolk-sac; hence the circulation of the area is often spoken of as the vitelline circulation. The growth of the vascular area is therefore part of the history of the yolk-sac, and is considered now from convenience merely. The expansion of the vascular area is due to the growth and differentiation of the mesoderm, and in those mammals in which, as in the rabbit, the mesoderm extends only part way over the yolk, the vascular area cannot spread over the whole blastodermic vesicle; but in those mammals in which, as in man, the mesoderm grows completely around the yolk, the vascular area may also extend completely around the yolk, with the consequence of the disappearance of the sinus terminalis. In the earliest known stages of man, the yolk-sac was found completely vascularized.

The gradual spread of the area vasculosa over the yolk may be readily followed in the hen's egg. It is due, as just stated, to the growth and differentiation of the mesoderm. The size of the vascular area is very variable, but the following table represents the approximate sizes, for several ages, as measured on blastoderms removed from the yolk, flattened and hardened; the total circumference of the hen's yolk is about 90 mm. The area vasculosa of the chick measures—

At 2 days about 9 mm. in transverse diameter.

" 2.5 "	" 15 "	" "	" "	" "
" 3 "	" 19 "	" "	" "	" "
" 3.5 "	" 22 "	" "	" "	" "
" 4 "	" 26 "	" "	" "	" "
" 4.5 "	" 30 "	" "	" "	" "
" 6 "	" 40 "	" "	" "	" "

It is not until the seventeenth day of incubation that the yolk is completely overgrown by the vascular area, Duval "Atlas," Fig. 651.

II. THE FORM OF THE EMBRYO.

It has been pointed out already that among vertebrates there are two principal types of embryonic form: one, which is the more primitive, characterized by the yolk-mass being included in the body of the embryo; the other is secondary and characterized by the separation of the embryo and the yolk.

The primitive type of vertebrate embryo is found in the lampreys, ganoids, and amphibians; the ventral side of the embryo is very much distended to allow room for the yolk, which consists, after the segmentation is completed, of a mass of cells, which lie for the most part below the archenteric cavity, as cross-sections show at once. As the development progresses, the embryo lengthens out, but the swelling caused by the yolk persists for a long period, the yolk material being only gradually resorbed by the embryo; the swelling is readily recognized, even up to larval stages.

The secondary type of vertebrate embryo is found in elasmobranchs and amniota. In *elasmobranchs*, when the embryo appears it occupies only a small part of the ovum, which is very large and contains much yolk. Soon after the appearance of the medullary groove, the head of the embryo begins to grow forward entirely free from and above the yolk; and by the time the medullary groove is converted into the medullary canal the tail begins to grow backward in a similar manner independently of the yolk; hence, only the central region of the embryo remains connected with the yolk. As the growth of the embryo continues, while the area of its body attached to the yolk increases very little in size, it follows that the connection becomes relatively smaller, until it becomes merely a narrow stalk as compared either with the embryo or the mass of yolk. The traditional and often-repeated description of the separation of the embryo from the yolk attributes the separation to a folding off of the embryo by the germ-layers being tucked in under the embryonic anlage, but it seems to me that the process is only apparent, and that it is by its own growth, as above described, that the embryo becomes partly separated from the yolk; and I hold the same view as regards the amniota.

The yolk is covered by the extra-embryonic extensions of the mesoderm and ectoderm, the yolk proper being, of course, entoderm. If the mesoderm develops a cœlomatic fissure around the yolk, we have the non-embryonic parts of the ovum converted into a double sac; an outer sac formed by the united ectoderm and mesoderm (somatopleure), and an inner sac of mesoderm filled with the yolk-

mass (vitelline entoderm), the two representing the splanchnopleure. The outer sac in all vertebrates may be called the *chorion*, the name by which it is known in mammalia; the inner sac is the *yolk-sac* or *umbilical vesicle*.

In *amniota*, the separation of the embryo from the yolk takes place in the same general manner as just described for elasmobranchs, but there are additional complications due to the development of the amnion and allantois taking place very early—see the following division of this chapter.

Form of the Amniote Embryo.—It is not proposed to give here a comparative account of the forms of amniote embryos at successive stages, but merely to briefly indicate the characteristics of the stage in which all the principal anlages of the primary organs are present, but not specialized. The stage may be taken to be that of the hen's ovum at fifty to sixty hours of incubation, Fig. 150. The blastoderm reaches at this time over nearly half of the yolk, the extreme margin of the opaque area being near the equator, but the vascular area is much smaller, being only about 20 mm. in diameter; still smaller is the pear-shaped area pellucida, in the centre of which lies the rapidly growing embryo. At this period the vascular area may be said to be in the stage of its most complete development; for though it will afterward become larger, it will at the same time become less definite and relatively less important. The arterial system already has its main trunks, Fig. 157. *A.v.*, and the main stems of the omphalo-mesaraic veins, *om. V*, are differentiated. As regards the embryo the most striking features are the advanced development of the head and the slight differentiation of the tail. The head has grown forward so as to be entirely free from the yolk, and is turned so that its left side rests upon the yolk, and as the tail end of the embryo still rests symmetrically upon the yolk, it follows that the intermediate portion of the body is twisted. This warping or torsion of the embryo, in order that the side of the flattened head may rest upon the yolk, occurs in Sauropsida and to a slight extent in placental mammals, but not among any of the Ichthyopsida. We must, therefore, regard it as a special feature of the amniote embryo, which has been lost in the placental mammals, probably as a result of the loss of food yolk in the ovum. The head is remarkable for the advanced differentiation of its parts; the anlages of the eye, Fig. 150, *L*, and ear, *Ot*, are present; four branchial pouches are developed, *br*³; the heart is large and already bent, *Ht*; the medullary tube is very much dilated and distinctly divided into its three primary vesicles, *H*, *Mb*, *Hb*. The head is also bent at the region of the mid-brain, *Mb*, so as to form almost a right angle with the axis of the hind-brain, *Hb*, and neck. This *head-bend* or cervical flexure is highly characteristic of all vertebrates; it is beautifully shown in elasmobranch embryos, and can be easily recognized in all classes. It is a bend in the median plane of the embryo by which the end of the head is brought over toward the heart, *Ht*. Following along backward we encounter the first distinct segments just behind the otocyst, *Ot*, and can follow them some distance behind the vitelline arteries, until they merge into the undivided segmental zone, *Ar*; the limit of the body of the embryo is already indicated by the

parietal zone, but the zone will be encroached upon by the vascular area, and the whole zone of this stage is not destined to be included in the body of the embryo.

In a sheep embryo,* although the fundamental characteristics are the same, there are many minor differences both from the chicken and the rabbit. The most striking peculiarities of the embryo are due to the foetal appendages, the development of which presents special modifications in ruminants, as more fully described in the next division of this chapter; the yolk-sac is long and narrow, and is connected by a broad twisted yolk-stalk with the embryo; the allantois has already become a very large transversely expanded vesicle; the amnion invests the embryo closely and gives off a long cord (*Amnionstrang*), by which it is still attached to the chorion. The embryo, 5 mm. in length, is curving throughout its length; the head-bend is developed, and consequently the end of the head lies near the heart; the torsion of the whole embryo is very marked, the dorsal side of the fore-brain facing us, of the neck being turned away from us, of the tail facing us again; the embryo makes nearly one complete spiral turn. The head is small, laterally compressed, and less advanced than in the chick described above, for the anlage of the eye is only just begun; that of the ear is not differentiated, and the first two visceral arches are present, while the third is only just beginning. The medullary groove is still open in the region of the forebrain, and widely open at its tail end, but closed throughout the rest of its length; there are fourteen segments; none of the vessels yet contain any red blood.

Typical Embryo in Cross-Section.—For this purpose I select a dog-fish embryo. The following description is intended especially for the convenience of students. The body is bounded by a single layer of ectodermal cells, *Ec*, the anlage of the future epidermis; the central nervous system, *Md*, appears as a tube, with very much thickened cellular walls; it lies on the dorsal side of the embryo, and although developed from the outer germ-layer, has no connection with the ectoderm; below the nervous system lies the very large notochord, *nch*, which contains a loose network in its centre, and a denser peripheral layer of cells; it is invested by a thin hyaline structureless sheath; the notochord as we ascend the vertebrate series diminishes in size; at corresponding stages in amphibians it is decidedly smaller in proportion to the medullary tube than in sharks—in birds its diameter is not more than a fifth—in mammals not more than a twelfth of the diameter of the medullary tube. Below the notochord comes the dorsal aorta, *Ao*, on either side of which, a little lower in position, may be seen a cardinal vein, *c.V*, while between the notochord and aorta is a small string of cells known as the subnotochordal rod or hypochorda, a structure which has not yet been observed in any of the amniota. The body-cavity proper, or splanchnocœle, *Coe*, is a wide space, bounded externally by the body walls, *Som*, and containing the intestinal canal, *In*, which has been developed from the splanchnopleures, and which is suspended from the dorsal wall by the membranous mesentery; the cavity of the intestine is lined by entoderm, *Eu*, and takes a spiral course which is

* See Bonnet, 89. 1, Fig. 13.

characteristic of the elasmobranchs, but is not encountered in other classes; the abdominal cavity is lined by the epithelial mesoderm or mesothelium. The primitive longitudinal urogenital duct appears in cross section just above the splanchnocœle, *Coe*, while near it on one side can be seen the opening of one of the transverse Wolffian or segmental tubules, *st*,

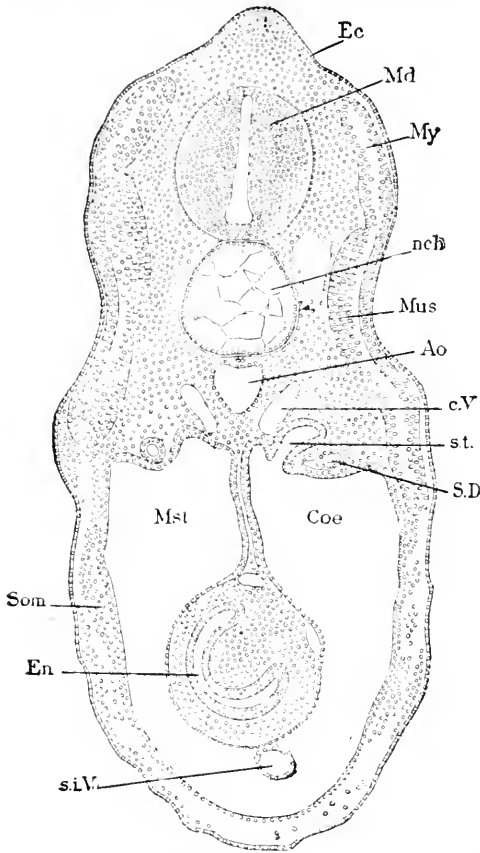


FIG. 159.—Transverse Section of the Rump of a Dog-Fish Embryo, 14 mm. long. *Ec*, Ectoderm; *Md*, medullary tube; *My*, myotome; *nch*, notochord; *Mus*, muscle; *Ao*, aorta; *cV*, cardinal vein; *st*, segmental tubule; *S. D.*, segmental or Wolffian duct; *Coe*, coelom; *Mst*, mesentery (the reference line has been omitted); *Som*, somatopleure; *En*, entoderm; *siV*, sub-intestinal vein.

if the tubule is followed out its other end is found to open into the Wolffian duct; in amniota the opening into the body-cavity is lost at a much earlier stage. The myotome, *My*, which also is developed from the primitive segment, is a double plate, its two walls being so closely appressed that the cavity between them is completely obliterated; the inner wall is partly converted into muscular tissue. The mesenchyma, *mes*, has grown more than any other tissue, and constitutes in bulk the greater part of the embryo; it is destined before adult life is attained, to be differentiated into a large variety of tissues.

III. ORIGIN OF THE FŒTAL APPENDAGES.

Under this head we have to consider the origins of the chorion, yolk-sac, allantois, proamion and amnion, but as we have already considered the development of the yolk-sac, p. 255, the allantois, p. 257, and the proamion, p. 150, we shall recur to them now incidentally only, and concern ourselves principally with chorion and amnion.

Extension of the Extra-Embryonic Cœlom.—The distance to which the cœlom can extend around the ovum depends upon the extension of the mesoderm, for of course the cavity cannot go farther than the layer within which it is developed. Now, as we have seen, the mesoderm expands gradually and a little more slowly than the

germinal area. This gradual expansion occurs in all vertebrates. In the primitive type (Petromyzon and amphibians) the mesoderm and the cœlom both grow completely around the yolk; and this was undoubtedly the primitive condition, but in the lower anniota the growth of the mesoderm has to be much greater in order to cover the enormous yolk mass; hence in anniota the spread of the mesoderm is slow and long continued, and the embryo advances far in its development before the yolk is inclosed. In mammals the expansion of the mesoderm over the yolk-sac is also slow, and in rabbits (and probably in their allies) the mesoderm never extends over the whole yolk-sac, but in man, on the contrary, the cœlom as well as the mesoderm are developed completely around the yolk-sac very early. No explanation of these differences among mammalia can be offered at present.

In the lampreys and amphibians the appearance of the cœlom around the yolk merely completes the separation of the body-wall or somatopleure of the embryo. In the anniota it also separates the somatopleure from the splanchnic mesoderm around the yolk, but owing to the division of the developing ovum into embryo proper and yolk-sac, only a small part of the somatopleure shares in the formation of the embryo, while the rest acts as a covering membrane of the yolk. This membrane in the mammalia is universally known as the chorion, and I shall apply this name to it hereafter for all vertebrates.

Primitive Chorion.—The chorion has been defined by Minot (Buck's "Handb.," II., 143) to be the *whole of that portion of the extra-embryonic somatopleure which is not concerned in the formation of the amnion*. The term primitive chorion may be employed for the whole extra-embryonic somatopleure before the differentiation of the amnion from it, and the term chorion or true chorion be still used, as defined, for what remains of the membrane after the separation of the amnion.

The somatopleure consists of two layers—the ectoderm and somatic mesoderm. The ectoderm consists of a single layer of epithelial cells. The mesoderm consists of a layer of mesothelium next the cœlom, and a thicker layer of mesenchyma between the mesothelium and ectoderm. The exact appearances of these layers are described with the aid of figures in the special chapters on the amnion and chorion.

Origin of the Amnion.—The amnion is developed out of that part of the extra-embryonic somatopleure which immediately surrounds the embryo and the proamniotic area, or in other words, the anniotic region of the germinal area is part of the area pellucida, and perhaps includes the whole of the pellucida. The amnion owes its development to the expansion of the cœlom. In the Sauropsida the process is about the same in all forms, but in mammals there are several modifications of the development known; hence we consider first the sauropsidan, then the mammalian types.

In the *Sauropsida* the formation of the amnion begins with the appearance of the amnio-cardial vesicles, p. 198, which form conspicuous dilatations on either side of the neck. Fig. 117; the vesicles steadily enlarge and spread laterally and forward so as to inclose the

proamniotic area, and finally fuse in front of it. The dilatation takes place in such a manner that the splanchnopleure is bent down slightly, while the somatopleure is bent upward to an extreme degree, forming a sort of dome. Transverse sections of a chick at this stage, at the level of the heart, show, Fig. 117, the amnio-cardial vesicle of each side fused with its fellow in the median line below the heart, *Ht*: the somatopleure, *Som*, of the embryo makes a sharp turn outward and upward, *Am*, and then bends away again, *Cho*, from the embryo and finally joins the splanchnopleure of the yolk, *Spl*. As the upbending of the somatopleure goes on around the entire head of the embryo, it follows that the cephalic end of the embryo lies in a depression, the sides of which are formed by a part, *Am*, of the extra-embryonic somatopleure. While this is going on, the head of the embryo bends over, and the whole head gradually rolls over ventralward and thus is forced into the yolk, but since the proamni-

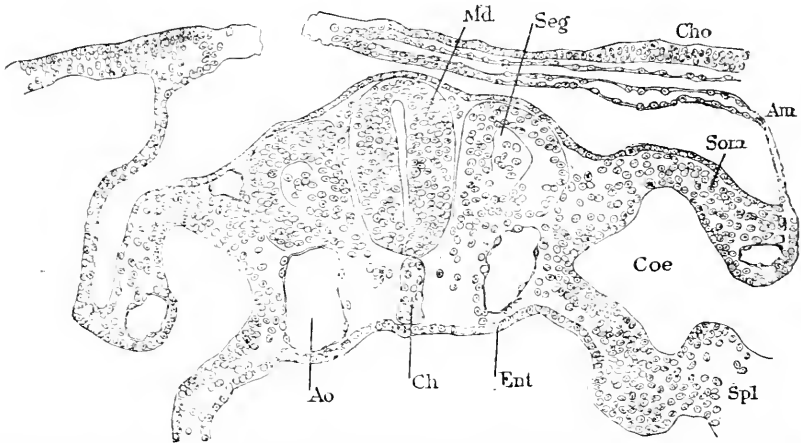


FIG. 100.—Section through the Rump of a Rabbit Embryo of Eight Days and Three Hours. *Md*, Medullary tube; *Seg*, primitive segment; *Cho*, chorion; *Am*, amnion; *Som*, somatopleure of embryo; *Coe*, coelom; *Spl*, splanchnopleure; *Ent*, entoderm; *Ch*, notochord; *Ao*, aorta.

otic area lies just here, it is invaginated along with the head, and consequently the head seems covered by a proamniotic membrane, which is known as the cephalic cap (*Kopfkappe*, *capuchon céphalique*). This cap is very noticeable in young chicks, for the head is hidden in it, while the rest of the embryo is uncovered. The actual relations are still further complicated by the singular fact that the edge of the cap is extended backward by the growth of the ectoderm alone, as shown by Duval; the backward growth of the ectoderm occurs also in turtle embryos, and to a much greater distance than in birds before the mesoderm follows it (K. Mitsukuri, 90.1). Sooner or later the mesoderm penetrates the ectodermal fold, and the coelom appears in it as a forward extension of the cavities of the amnio-cardial vesicles.

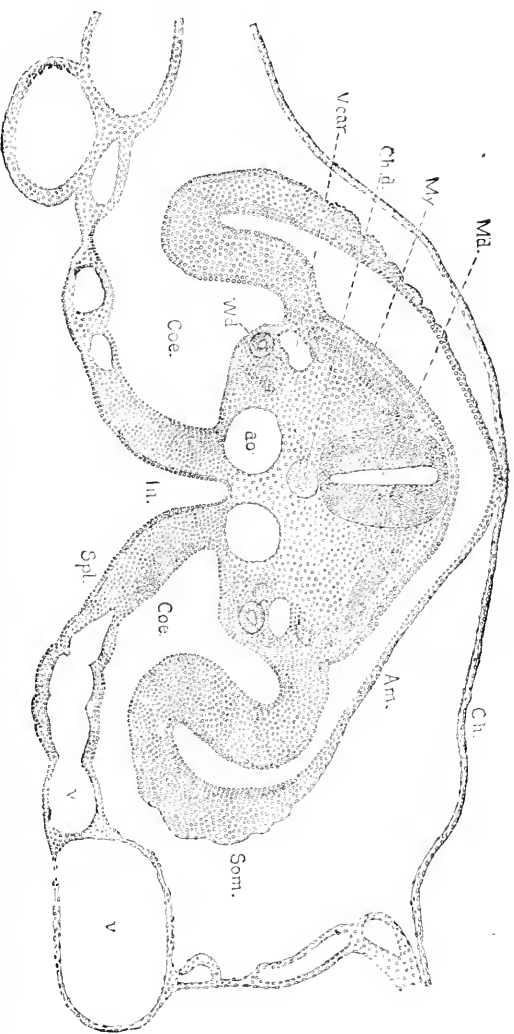
The cephalic end of the embryo now soon becomes completely covered over by the extra-embryonic somatopleure; this is due to the expansion of the coelom on all sides.

The changes in the extra-embryonic somatopleure around the pos-

terior half of the embryo, are similar in a general way to those around the anterior half, but the dilatation of the cœlom is confined to the extra-embryonic region, hence the pictures obtained from cross sections of the two parts of the embryo present certain essential differences. Fig. 161 is a section through the rump; here we see

that the dilatation of the cœlom causes the somatopleure to form a longitudinal fold along each side of the embryo; each fold, passing backward, joins its fellow behind the embryo, so that they may be described conjointly as the tail-fold (*Schwanzkappe, capuchon caudale*). The tail-fold is developed considerably later than the head-fold, but as one grows forward and the other grows back, they finally meet and constitute the complete amniotic fold around the entire embryo. The tail-fold gradually closes over the embryo; the process may be understood from the accompanying figures. Fig. 160 represents a cross-section of a rabbit embryo. The somatopleure, *Som*, of the embryo bends over as the amnion, *Am*, so as to cover the embryo, above which it again bends outward as the chorion, *Cho*; we can already distinguish the embryonic, amniotic, and chorionic portions of the somatopleure from one another; where the amniotic portion joins the chorionic, the edge is prolonged by a thickening of the ectoderm, which reminds us of the similar thickening at the edge of the cephalic cap; the two edges have almost met over the back of the embryo; the

FIG. 161. — Transverse section of the Rump of an Embryo Chick of the Third Day. *V. cot.*, Yolk cavity; *Ch. d.*, *Md.*, notochord; *Am.*, amnion; *Md.*, notochord; *Ch. d.*, chorion; *Am.*, amnion; *Som.*, somatopleure; *v. e.*, blood vessels; *Coe.*, cœlom; *Spl.*, splanchnopleure; *In.*, cavity of the future intestine; *W.D.*, Wolffian duct.



embryonic, amniotic, and chorionic portions of the somatopleure from one another; where the amniotic portion joins the chorionic, the edge is prolonged by a thickening of the ectoderm, which reminds us of the similar thickening at the edge of the cephalic cap; the two edges have almost met over the back of the embryo; the

asymmetry of the folds exists in all amniota and, as shown in the figure, is very marked in the rabbit, but is much less marked in the Sauropsida. In the next stage, Fig. 161, the folds have actually met; their edges grow together by their ectodermal thickening; for some time the thickened ectoderm persists and offers in sections a characteristic feature; after a time the mesoderm grows across, and the ectoderm of the amnion is entirely separated from that of the chorion; still later the cavity of the chorion also penetrates and completes the final separation of the amnion from the chorion, Fig. 19. The process of separation is essentially the same in the case of the cephalic amnion. The separation of the amnion from the chorion progresses most rapidly at the head end; at the tail end it begins later and progresses forward; hence the portion of the amnion over the middle of the rump is the last to be formed, as can at once be seen if the fresh ovum be examined.

In surface views the gradual closure of the amniotic folds over the embryo can be beautifully followed; for example, in the hen's ovum incubated about sixty hours, we find the anterior half of the embryo entirely hidden by the cephalic cap, while the posterior third of the rump is also covered by the tail-fold, and at the sides of the rump the amniotic folds have partially arched over the embryo. These arrangements leave a small longitudinal oval opening through which we can look down upon the embryo. The opening gradually diminishes as the edges of the folds advance, and is finally closed by the meeting of the edges from all sides. As the edges have their ectoderm thickened, their final meeting is marked by a local thickening of the ectoderm, which persists for some time after the actual closure. In ruminants the connection between the amnion and chorion at the point of final closure is retained for a long time by means of tissue, which grows out into a long thread, the so-called *amniotic cord* (*Amnionsstrang*). A somewhat similar structure occurs in the opossum, Selenka, 87.1, Taf. XXV., Fig. 2.

After the amniotic folds have closed, the embryo is surrounded by two membranes, both derived from the extra-embryonic somatopleure. Of these the outer is the true chorion, Fig. 19, *Cho*, the inner the amnion; from the manner of their formation the former has its ectodermal layer external, the latter its ectoderm internal or facing the embryo. The amnion, Fig. 19, *Am*, is the direct prolongation of the somatopleure of the embryo; the space between the amnion and the embryo is called the *amniotic cavity*; it is lined throughout by ectoderm.

In *mammals* the development of the amnion was presumably at first like that in the Sauropsida, for not only do we find many traces of it still preserved, but also Selenka, 86.1, 130, has shown that in the opossum the sauropsidan stage is passed through, although somewhat modified by the excessive development of the proamnion. The increased importance of the proamnion can be seen also in the rabbit (Van Beneden and Julin), and is possibly characteristic of mammals as a class. In the two animals mentioned, more than half of the embryo is covered by the proamnion at the time the amnion closes, and hence the amnio-cardial vesicles cannot attain the size or importance they have in birds, and they are unable, in the opossum, to extend around

the proamniotic area; hence in front of that area there is no cœlom developed, the three germ-layers remaining in close contact and forming, as it were, a single membrane; in the rabbit the cœlom does appear in front, as in birds.

In *ruminants* the amnion appears very early, the folds being well advanced before the medullary groove appears. The formation of the amnion is induced by the precocious development of the extra-embryonic cœlom, which, as Bonnet's researches on the sheep, 89.1, have proven, extend very early around the embryo in a wide oval ring, which, by raising the somatopleure, forms an annular amniotic fold, before the embryo can be said to be differentiated; these folds close over the anlage of the embryo, and by their union produce the two foetal membranes, amnion and chorion, in the same manner as in birds; as already mentioned, there is formed at the point of closure a long cord of tissue (*funiculus amnii*), by which the two membranes remain united for a considerable period.

In the *rodents* with so-called inversion of the germ-layers (*e. g.*, guinea-pigs, rats, mice, etc.), the development of the amnion is extremely modified from the original type. The cavity of the Träger, Fig. 87, *a*, becomes in part the cavity of the amnion. The manner in which this takes place and the way in which the process may be deduced from the primitive mode of development are both well illustrated by Selenka's diagrams, 84.1, Taf. XVI.

The *human amnion* in the earliest stages yet known has been found completely closed over the embryo, so that nothing is known as to its development by direct observation. The earliest known disposition was first described by W. His, whose account has been confirmed by subsequent observers. The embryo is from 2.5 to 3.0 mm. long; its relations to the rest of the ovum are indicated by the diagram, Fig. 162, B; it rests upon the large yolk-sac, *V*, and is connected by a short stalk, *Al*, with the chorion, *Ch*. The amnion arises under the head at the junction of the embryo and yolk-sac, and from the sides of the embryo and from the sides of the allantoic-stalk, and arching over the dorsal side of the embryo completely incloses it. To explain this disposition His has advanced the following hypothesis as to the

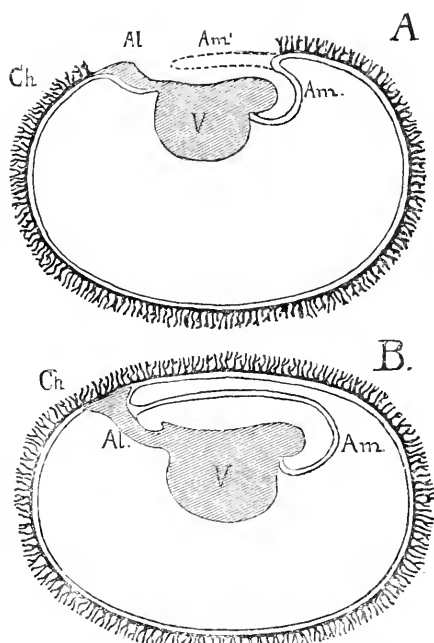


FIG. 162.—Diagrams to illustrate His' theory of the Origin of the Human Amnion: A, First stage; B, second stage. *Am*, Amnion; *Al*, allantoic-stalk or Bauchstiel; *Ch*, chorion, the villi of which are drawn smaller and more numerous than in nature; *V*, yolk-sac.

course of development. The embryo arises upon the surface of the blastodermic vesicle in the usual manner; its somatopleure passes over into the primitive chorion, which is, at an extremely early age, completely separated from the yolk-sac; the chorion now forms a fold, as shown in Fig. 162, A, which arches backward over the head of the embryo; while the tail end of the embryo, retaining its direct connection with the chorion, becomes the allantoidean stalk, *Al*. The head-fold, of which the inner leaf is the amnion, *Am*, the outer leaf a part of the true chorion, grows backward over the embryo as indicated by the dotted line, *Am'*, until it finally reaches the allantois-stalk, *Al*, and thus completely covers in the embryo. This hypothesis is probably correct, but it is possible that the amnion is preceded by a true proamnion, which becomes obliterated very early by the precocious development of the mesoderm and the cœlom in the human ovum. If Graf Spec's plausible suggestion, 89.1. 170, that there is a so-called inversion of the germ-layers in the human embryo be verified, then we shall probably find that the human amnion is developed according to the rodent type mentioned above.

The True Chorion is that portion of the extra-embryonic somatopleure which remains around the ovum after the separation of the amnion; it consists of an outer layer of ectoderm and an inner layer of mesoderm; the cavity within it is part of the cœlom. By the closure of the amniotic folds the chorion becomes a membrane surrounding all the other parts of the ovum, and makes a complete bag, which is termed the chorionic vesicle. The chorion is the outermost of the fœtal envelopes. It is sometimes termed the serous membrane or envelope (*membrana serosa*, *seröse Hülle*), especially in writings on sauropsidan embryology. Its relations may be rendered clear by the help of diagrams, Figs. 20 and 19.

IV. KNOWN HUMAN OVA OF THE SECOND AND THIRD WEEKS.

As no synopsis has ever been made of our knowledge of the early stages of man, I have attempted to collate all the descriptions of embryos not over three weeks. A summary of the descriptions is given, p. 308.

Classification by Stages.—Any attempt to divide embryos into stages must necessarily establish artificial groups, for in nature there is no demarcation. Division into stages is for convenience, and ought, therefore, to be made by natural and obvious characteristics. After much deliberation I have chosen eight stages, which seem to me natural and convenient, and I have classified the thirty-eight embryos reviewed in the preceding pages, placing them according to my best judgment in their respective stages; when the assignment is doubtful I have indicated it by an interrogation mark.

First Stage: Appearance of the primitive streak.

1. Reichert's.
2. Breus'.
3. Wharton Jones'.
4. Ahlfeld's.
5. Beigel and Löwe's.

- 7. Kollmann's *a*.
- 8. " *b*.
- 9. Schwabe's.
- Second Stage:* Appearance of the medullary plate.
 - 10. W. His' XLIV. (Bff).
 - 11. Keibel's.
 - 12. Spee's.
- Third Stage:* Appearance of the medullary groove.
 - 13. W. His' E.
 - 14. Allen Thomson's No. I.
 - 15. W. His' SR.
 - 16. Allen Thomson's No. II.
- Fourth Stage:* Formation of the heart and medullary canal.
 - 17. Spee's second embryo.
 - 18. Kollmann's embryo of 2.2 mm.
 - 19. Von Baer's youngest ovum.
- Fifth Stage:* First external gill-cleft.
 - None.
- Sixth Stage:* Two external gill-clefts.
 - 20. Minot's No. 195.
 - 21. " No. 143.
 - 22. W. His' LXVIII. (Lg).
 - 23. " " LXVI. (Sch. I.).
 - 24. " " L.
 - 24A. Janosik's.
 - 25. Coste's.
 - 26. Schroeder van der Kolk's.
 - ? 27. Hennig's.
 - ?? (9. Schwabe's.)
 - ? 28. Remy's.
- Seventh Stage:* Three external gill-clefts.
 - 28A. Chiarugi's.
 - 29. W. His', Rf.
 - 30. " M.
 - 31. " BB.
 - 32. " Lr.
 - 33. Allen Thompson's No. III.
 - ? 35. Ecker's.
 - ? 36. Hecker's.
 - ? 5. Beigel's (abnormal).
- Eighth Stage:* Four external gill-clefts.
 - ? 34. Von Baer's.
 - ? 37. Johannes Müller's.
 - 38. R. Wagner's.

Descriptions of the Known Ova. 1.—Reichert's ovum, 73.1, was thought by him to be twelve or thirteen days old, and probably correctly so, as it was obtained at a post-mortem examination of a young German girl under circumstances which render the estimate of the age quite trustworthy. The ovum itself was very imperfectly examined by Reichert, whose very lengthy memoir deals largely with cognate subjects and contains much speculative matter. The actual

description of the ovum is brief (pp. 25-28); but as far as he went Reichert worked with exemplary accuracy, which gives value to his research. The ovum in question was a flattened sphere with a short diameter of 3.3 mm., and an equatorial diameter of 5.5 mm.; smooth around both poles, and with a marginal or equatorial zone of villi separating the two smooth areas. The smaller and flatter of these two areas faced the uterine wall and bore on its inner surface (*i.e.*, within the ovum) a small accumulation of rounded cells. The opposite area was more convex. The villi were short (0.2 mm.) thick cylinders with rounded ends and no branches. The walls of the vesicle consisted only of epithelium, which also formed the simple hollow villi. The contents of the vesicle were: 1, The inner cell-mass lying, as before mentioned, at one pole; 2, A network of threads, apparently the result of coagulation of the contained fluid, for no nuclei were found in it. Kollmann, **79.1**, 294, thinks that Reichert's ovum must have had really two layers forming the vesicular walls—an inner one mesoderm (young connective tissue) and an outer one of true epithelium; further, that the true epithelium had been lost, and that

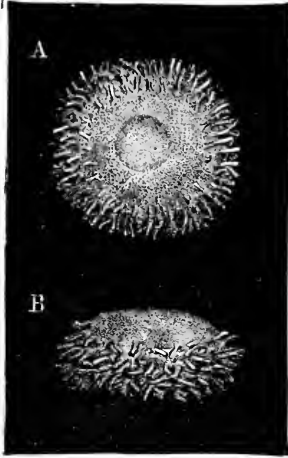


FIG. 163. — Reichert's Ovum. Two views engraved from the original plate

only the connective tissue remained, which Reichert mistook for epithelium. This supposition is, I think, not probable. Reichert's ovum is presumably younger than any other hitherto described, and may have been in the stage before the mesoderm had grown over the chorion. The villi are described as hollow by Reichert—a statement not compatible with the supposition that he mistook a solid core of mesoderm for the hollow shell of the ectoderm; we know now that young villi usually contain no mesoderm at first.

2. Breus' ovum, **77.1**, must be considered further advanced than Reichert's, although the author fixes its age as presumably ten days. The total diameter of the ovum including the villi was only 5 mm., and as the villi were about 1 mm. long, the diameter of the chorionic vesicle must have been about 3 mm. The villi, some branched, but mostly without branches, were thick set, but left one spot bald, agreeing in this with Jones' ovum (see below). The chorion was smooth on its inner surface, and consisted of (1) an outer epithelial layer, and (2) an inner connective-tissue layer which sent out extensions partly filling the villi. The ovum contained a thready mass which Breus thinks was probably a product of coagulation, and an inner cell-mass about 1 mm. long and 0.5 mm. wide. The presence of villi and the existence of the mesodermic layer of the chorion, contrasted with the absence of any embryonic structure, led Breus to consider his ovum abnormal. But it is rather the contrary conclusion we must draw, since all our knowledge points to the deduction that, as compared with the embryo, the development of the chorion is very precocious in mammalia. I deem it, therefore, probable that Breus'

ovum was normal, and that the inner cell-mass he describes was in reality the embryo, compare Keibel's ovum.

3. Wharton Jones, **37.1**, long ago described briefly a human ovum, the chorion of which measures in his figure (said to be natural size) 6 by 4 mm. The following is all that can be gathered from Jones' description: The ovum was already covered by the decidua, and bore shaggy villi on the side toward the uterus, while the other side was bald. "The whole cavity of the chorion was filled with a fine gelatinous cellular tissue, imbedded in which, toward one extremity of the ovum, was a small round body; it was evidently the vesicular blastoderma. On being taken and examined under the microscope, it presented the same friable, globular structure found in the vesicular blastoderma of the rabbit in the preceding observation. There was no vitellary membrane to be seen." To judge from the minute figure given, the villi were already branched; in Reichert's ovum they were still simple.

4. Ahlfeld's ovum, **78.1**, represents perhaps the same age as Jones', but he does not give its diameter, which appears from incidental references to have been about 5 mm. The author's description is not exhaustive by any means, but he mentions two points of great interest: first, the presence of a layer of connective tissue (mesoderm) underneath the chorionic epithelium, and extending into but only partially filling the villi of the chorion; second, the character of the villi, which are slightly branched and are constricted at the base, only their tips touched the surface of the decidua (reflexa and serotina). He also states that the epithelium of the villi precedes in its growth the connective tissue. This ovum was supposed to be fourteen to sixteen days old (?). Owing to an accident, no observations of its internal contents were made.

5, 6. Beigel's ovum, **78.1**, of which he maintains that it is the third smallest known, is, if we may judge from his plate, certainly abnormal to an extreme degree. I hold it to be a malformed ovum of the fifth or sixth week. The ovum described by Beigel and Löwe, **77.1**, is of an even more questionable character. Moreover, their account is considered by Breus and Ahlfeld to be very inaccurate. It is noteworthy that Beigel and Löwe have also noticed the early presence of the mesoderm under the chorionic epithelium. Löwe, **79.1**, defends himself against Ahlfeld's attack, and insists with justice upon the presence of connective tissue on the inside of the chorion in ova of the second and third week.

7, 8. Kollmann's memoir, **79.1**, is by far the most valuable which had appeared up to the time of its publication upon the structure of very young human ova. He describes two ova, *a* and *b*, both preserved in the anatomical collection at Basle. Ovum *a* had been placed in glycerin and water, which preserved the form of the specimen but ruined it histologically; nothing was made out as to the contents of the chorionic vesicle. The vesicle itself measured 5.5 by 4.5 mm., and therefore was slightly flattened. This measure does not include the villi, which were from 1 to 1.2 mm. long, and repeatedly branched. Ovum *b*, 5.5 mm. in diameter, was well preserved in alcohol; the villi were somewhat branched: the contents of the ovum were lost. On the other hand, the uterus belonging to this

ovum was also preserved, and forms the basis of a very valuable description of the uterus in early pregnancy, to which I hope to recur on another occasion. Kollmann's two ova are both much more advanced than those of Reichert, Breus, and Jones, as is shown by their greater size and the branching of the villi. It is a matter of profound regret that only the chorion was left, but, fortunately, Kollmann has taken good advantage of his opportunity. His paper also gives an excellent critical analysis of nearly all the previous literature. He points out that the two primitive layers of the chorion are probably normally present at this stage. The chorion of his ova, he says, consists of "einer Lage jugendlichen, embryonalen Bindegewebes, das zahlreiche Rund- und Spindelzellen enthält, und das bedeckt wird von einer einfachen Lage platter Zellen" (p. 293). He then passes the literature in review, and insists strongly upon the fact that the two layers have been distinguished in nearly all the very young human ova known except Reichert's. Kollmann, therefore, as was mentioned above, questions, I think without sufficient foundation, the accuracy of Reichert's account. Concerning the connective-tissue layer Kollmann says but little. As regards the epithelium, he points out that the nuclei occupy a basal position so that the outer parts of the cells form a granular stratum, which some authors have considered a distinct membrane. The author supposes this granular stratum to become the cuticula described in later stages. Jassinsky, 67.1, is the chief defender of the existence of a cuticula, which, however, he designates under the extraordinary name of tunica propria, extraordinary because the term is properly applied to the layer of connective tissue immediately upon which an epithelium rests. It is probable in the light of our present knowledge that Kollmann saw the outer darker layer found in Spee's ovum, see below, and in many others a little older. This outer layer is nucleated, but the nuclei might be overlooked. Finally Kollmann adds (p. 297 ff.) observations on the growth of the villi in ova of the fourth week. The outgrowth of branches is very rapid, and occurs with every degree of participation of the connective tissue. There are two extremes: 1. A bud consisting wholly of epithelium, which may stretch out into a process with a long thin pellicle and a thickened end, the whole remaining until it has become quite large without any connective tissue. 2. A thick bud with a well-developed core of connective tissue; such a bud probably grows out as a nearly cylindrical branch. Between these two extremes every intermediate state can be found. The various forms of growing branches may lie close together. Probably this complex mode of growth persists in older villi, which would explain the multiplicity of forms in the villous branches.

9. Schwabe, 79.1, has described an ovum which he considers thirteen to fifteen days old, but he is certainly mistaken, since both the data he gives as to the age and his account of the embryo shows that it is more advanced and belongs distinctly in the third week. In connection with Kollmann's observations we must notice those of Orti, 77.1, who has shown that at all ages, even at full term, the villi of the chorion in the placenta have epithelial buds, which are at first hollow and are afterward filled up with a vascular-

ized ingrowth of connective tissue. Apropos of this observation Orth discusses Boll's theory of growth, making the point that in this case the shaping of the parts depends primarily upon the growth of epithelium. Boll had maintained, as a general principle, that in the development of organs the shaping is dependent on the co-operation of the epithelial and connective tissues.

10. His' embryo, XLIV. (Bff), described in his "Anat. menschlicher Embryonen," Heft II., pp. 32 and 87, belonged to a chorionic vesicle measuring 7 by 8 mm.; the vesicle was somewhat flattened, and on one part had fewer villi than elsewhere; the villi were branched. Closely attached to the inner surface was a small body 1.4 mm. long in its greatest diameter; the body consisted apparently of a yolk-sac and closed amnion; of the embryo no further description has yet been published.

11. The ovum described by Keibel, 90.1, consisted of a somewhat flattened chorionic vesicle more than half covered with little villi and containing a somewhat distorted embryo. The vesicle measured 8.5 by 7.75 by 6.0 mm. The villi were arranged in a band or zone leaving the two flattened poles of the ovum smooth as in Reichert's ovum; the smooth areas were of very unequal size, at the edge of the smaller one the embryo was attached by means of its allantois-stalk to the inner surface of the chorion. The embryo, about 1 mm. long, was found twisted at its hind end, which was continued as an allantois-stalk attached to the chorion; the stalk was nearly or quite as large as the embryo proper; the yolk was broadly attached along nearly the whole length of the embryo, and opposite the embryo the yolk-sac was attached to the chorion as if the coelom had not completely developed. Sections showed that there was no medullary groove yet formed, but the amnion was already closed over the embryo. Keibel places his embryo as intermediate between His' embryo, XLIV., and Spee's embryo. Keibel's ovum resembled externally those of Reichert and Wharton Jones, and as it contained an embryo, he suggests that it is probable that the ova of Reichert and Jones also contained an embryo without medullary groove, but with an allantoic-stalk nearly as large as the embryo. But it seems to me that since Keibel's ovum is nearly twice as large, it cannot be of the same stage; the presence of the equatorial zone of villi is explainable as an instance of retarded development. The excessive variability of embryos is well known.

12. Spee's embryo, 89.1, was contained in a chorionic vesicle measuring, including the villi, 8.5 by 10 by 6.5 mm. The tips of the villi were attached to the surface of the decidual capsule. The embryo was attached by a very short allantoic-stalk to the chorion, and was closely invested by the amnion; the attachment of the yolk-sac occupied nearly the entire length of the embryo, for the head-end had scarcely begun to project; the embryo was 1.54 mm. long; its dorsal surface was occupied by the very broad medullary plate of thickened ectoderm; as seen from above the plate seemed somewhat constricted in the middle of the embryo, owing to the arching of the body at that region; the centre of the plate showed a narrow longitudinal furrow, Fig. 164, *f*; at the caudal end this furrow widened out and disappeared; just behind it was the open and relatively

large neurenteric canal behind which was the short remnant of the primitive streak. The embryo was cut into transverse sections, of which there were about 180, counting the allantois-stalk (*Bauchstiel*); section 81, counted from the head, is represented in Fig. 164; the

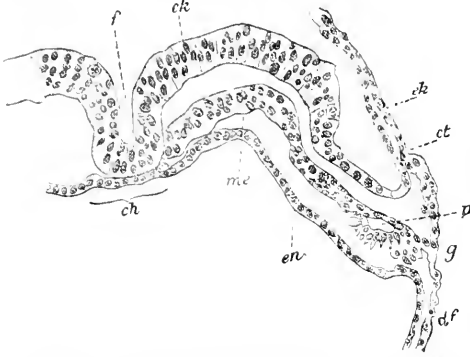


FIG. 164.—Cross-Section of Spee's Embryo. Explanation in text.

ectoderm, *ek*, is very much thickened to constitute the medullary plate, *Md*; the narrow central longitudinal furrow, *f*, mentioned above is very noticeable; outside of the embryo the ectoderm is reflected on to the amnion, *ct*, over the back of the embryo. The entoderm, *en*, is a thin layer of cells in the centre of which the notochordal band can be distinguished; in sections nearer the neurenteric canal the band is better marked, being

there much thicker than the remaining entoderm. The mesoderm, *me*, is a distinct layer, although, as other sections show, it is fused in the median line of the primitive streak behind the neurenteric canal with both ectoderm and entoderm. The embryonic cœlum has only just begun to appear as a small fissure, *p*, but the extra embryonic cœlum is completed, so that outside the embryo the mesoderm is completely divided into a somatic leaf, *ct*, which helps form the amnion and chorion, and a splanchnic leaf, *df*, which forms one layer of the wall of the yolk-sac. The sections through the head-end show that the head had grown forward far enough to lead the separation of the very short vorderdarm; sections through the allantois-stalk showed that the allantoic diverticulum extended as a small canal through the great accumulation of mesoderm; throughout the rest of its extent the archenteron is nowhere differentiated from the yolk-sac. Fig. 165 is a section passing through the neurenteric canal, which leads through the centre of the medullary plate into the wide yolk-sac; the part of the sac farthest from the embryo has its mesoderm thickened and vascularized, the vessels containing young blood-cells often in some stage of division. The chorion of Spee's embryo had a layer of mesoderm, with cells of a well-marked mesenchymal type, and an outer layer of ectoderm consisting of a thinner outer layer darkly stained, without distinct cell boundaries, but with

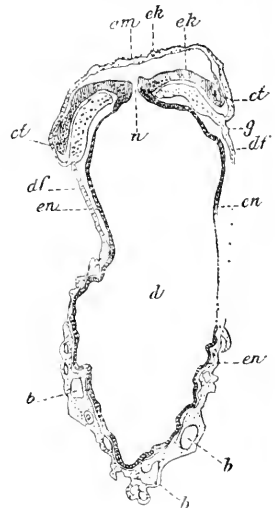


FIG. 165.—Section Passing through the Blastopore of Spee's Embryo. *am*, Amnion; *ek*, ectoderm; *ct*, amniotic mesoderm; *g*, meeting point of somatopleure and splanchnopleure; *df*, mesoderm of yolk-sac; *b b b*, blood vessels; *en*, entoderm; *u*, blastopore; *d*, cavity of yolk-sac. After Graf Spee.

small nuclei and an inner lighter layer of distinct cells with larger nuclei; the ectoderm appeared somewhat as if ciliated. Unfortunately Spee gives no account of the villi beyond a few words to say that they resembled those of later stages.

13. We come now to the embryos with a well-developed medullary groove; the number of these is four. Their probable age is about fourteen days. The least advanced is His' embryo E ("Anat. mensch. Embryonen," I., Heft I., p.145), of which only His' sketches are available, the attempt to microtome the specimen not having been fortunate. The ovum was presumably normal; it measured 8.5 by 5.5 mm., and was entirely covered by short branching villi. For the convenience of the reader I have constructed from the author's sketches and descriptions the accompanying diagram. His states that the chorionic vesicle bore at one point a thick stalk, *Al*, which ran to the posterior end of the embryo; the length of the embryo from the anterior extremity to the base of the stalk was 2.6 mm. The head-end of the embryo was somewhat thickened, and apparently showed the medullary groove still open. The small, round yolk-sac had a broad connection with the ventral surface of the embryo. The amnion sprang from the allantois and passed over the head of the embryo. The disposition of the caudal extremity was not made out. There were no limbs, gill-clefts, nor organs of any kind discernible—not even a protuberance between the head and yolk-sac, such as marks the position of the heart in older embryos.

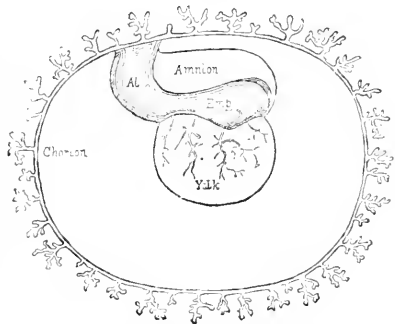


FIG. 166.—Diagram of His' Embryo E: Age fourteen (?) days; length about 2.3 mm. The embryo is not represented in quite its natural attitude; the proportion of the parts is not accurate; the villi of the chorion and the vessels on the yolk are purely diagrammatic as to their number and shape. *Emb*, Embryo; *Al*, supposed stalk of the allantois.

14. Allen Thomson, 39.1, published an excellent article on young human ova in 1839. He gives a very good critical review of what previous authors had written, and describes himself three embryos, which have become classical, for the figures and descriptions given of them by Thomson have been copied again and again. They are especially known by the reproductions in Kölliker's "Embryologies," and in Quain's "Anatomy." Two of these embryos (numbered I. and II. by Thomson) belong in the group we are now considering. I cannot, however, admit at present that either of them is certainly fully normal, though perhaps they are only slightly malformed. In number I., (see Kölliker's "Grundriss," 1884, Fig. 112, and "Entwickelungsgeschichte," 1879, Fig. 225) the yolk-sac was abnormally dilated and the characteristics of the embryo were not ascertained. His ("Anat. Emb." Heft II., pp. 35-36) has shown that the embryo proper was not observed, and that what Thomson called the embryo was really only the amnion, springing from the allantois-stalk and passing over the embryo. Kölliker questions the accuracy of this interpretation, but upon what ground is not evident, for, so far as I can

see, it accords perfectly with our present knowledge. The embryo in question was presumably little advanced beyond His' embryo E, Fig. 165, but had an abnormally hypertrophied yolk-sac. As no sufficient description of the embryo exists, and as it is quite certain that the specimen was more or less abnormal, it cannot be longer regarded as a fair representative of a young ovum.

15. The third embryo of this group, His' SR (L., Heft I., 140-144) measured 2.2 mm. in length, and was probably fourteen days old. The chorion was 9 by 8 mm. in diameter. It shows considerable advance of development beyond the three embryos above considered. The neck of the yolk-sac is already somewhat contracted, or, in other words, the connection between the embryo and the yolk-sac is no longer so broad and long as it was. The head is considerably enlarged; between it and the anterior wall of the yolk-sac is a large thickening corresponding to the heart. From the under side of the caudal extremity runs off the stalk of the allantois, which is still short and thick; the amnion lies quite close to the embryo; the medullary ridges are still separated by an open, though deep, and relatively narrow groove; myotomes (protovertebræ, *auct.*²) are present, but their number was not ascertained. When the embryo is viewed in profile, the middle of the back shows a marked concavity which has been noticed in other older embryos, and is probably an artificial distortion. We shall have to return to this matter. Small openings were visible on the inner surface of the chorion. These I take to be the openings to the still hollow villi, such as have been seen in both younger and older ova. His attempted to obtain sections of his specimen, but when cut the sections fell into fragments.

16. Much more valuable is the account of Thomson's second ovum, which he had better opportunities of studying. The original description has been supplemented by His, "Anat. Embry.," II., p. 34, who examined Thomson's original drawings, and called attention to an important error in the engraving in Thomson's plate. Kölliker, however, still reproduces the incorrect figure in the second edition of his "Grundriss," Fig. 114. An erroneous figure is also reproduced in Ecker's "Icones," Taf. XXV., Fig. 3. The chorionic vesicle measured 0.60 by 0.45 of an inch, and was covered with branching villi. The contained embryo was very small; according to Kölliker, only 2.5 mm. The embryo rested upon the round yolk-sac of 2.2 mm. The embryo consisted of two thick longitudinal ridges, Fig. 167, A, which curved round in front so as to become continuous with one another, and were broken off posteriorly—an important fact noted by His (*cf. sup.*). These ridges are presumably the medullary folds. At the hind-end of the embryo was a tear, making a hole into the hollow yolk-sac. As His suggests, this is probably where the allantois was inserted and broken off. No amnion was observed,

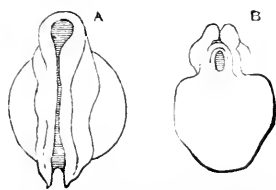


FIG. 167.—Thomson's Second Ovum. A, Embryo from above; B, embryo from behind.

* It must be remembered that the term protovertebræ is an entire misnomer, and is inherited from the time when the primitive muscular segments (myotomes) were mistaken for the commencements of the vertebræ.

and the nature of the connection of the embryo with the chorion was not ascertained. What we learn from this embryo is something more definite than is afforded by His' observations as to the size and disposition of the medullary ridges and the hollowness of the yolk-sac. The apparent hypertrophy of the chorion enforces caution as to accepting the embryo as normal; but it is not rare to find in abortions a small typical embryo with an enormously dilated chorion, so that it is not impossible that the embryo in the present case was quite normal.

17. Spee has briefly described a second ovum, but his account is not now accessible to me. According to the notes given by Fr. Keibel, 90.1, 261, the chorionic vesicle measured 15x14x10 mm., the yolk-sac 3.5 mm. The embryo had seven myotomes, and its age in maximo was thirteen days.

18. J. Kollmann, 89.1, 108-121, describes an embryo of about 2.2 mm.; the yolk-sac was attached to the embryo, Fig. 168, for a dis-

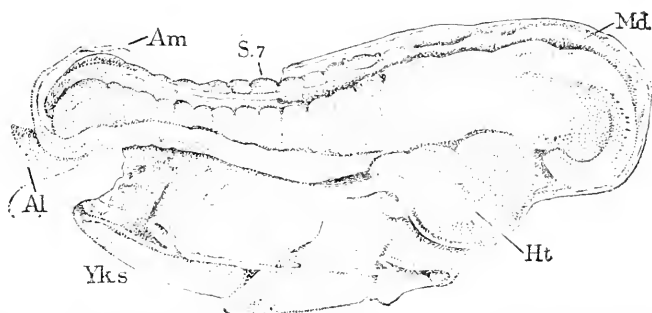


FIG. 168.—Human Embryo of Thirteen to Fourteen Days. *Am*, Amnion; *S. 7*, seventh segment; *Md*, medullary groove, still open; *Ht*, heart; *Yks*, yolk-sac; *Al*, allantois-stalk. After J. Kollmann.

tance of 1.5 mm., leaving the head to project 0.58 mm., the tail to project 0.3 mm. The head is already somewhat enlarged and slightly bent over ventralward; it forms at least a third of the whole embryo; there were thirteen * primitive segments which marked themselves externally; the segmented region of the body is bent so that its dorsal outline is concave; the medullary groove is open throughout the anterior two-thirds of its length, but the caudal third is closed; the tail is slightly curled over, and is connected on its under side with a thick, short allantois-stalk, or *Bauchstiel*, by which the embryo is attached to the chorion; there are no visceral or branchial arches, although the gill pouches may have begun forming in the pharynx; no anlage of the eye or ear could be distinguished; the oral invagination has formed, but the oral plate (*Rachenhaut*) is still intact; the heart is not straight but an already much bent tube, which receives at its hind end the two veins from the yolk-sac, which consists of vascularized mesoderm and an entodermal lining. The amnion was a thin, transparent membrane springing from the body of the embryo close around the yolk-sac, and enveloping the embryo very closely. The chorion formed a vesicle covered

* The figure shows fifteen segments.

externally by branching villi; its diameter including the villi was 18. cm. Although the data were not very satisfactory, Kollmann estimated the age of this specimen to be thirteen to fourteen days.

19. The description of the ovum of thirteen to fourteen days by Von Baer, 88.1, was drawn up over sixty years ago. The ovum measured a little over three lines, and was covered with villi; the embryo was about two-thirds of a line long; Von Baer appears to have recognized the amnion and yolk-sac and to have seen the allantoic-stalk (his *Harnsack*), though he did not observe its connection with the chorion; as he states that the back was already formed, it is probable that the medullary groove was closed. It is with much hesitation that I place the embryo here in the series.

There has been, so far as I am aware, no human embryo with one gill-cleft described, unless, indeed, Coste's embryo described below was such. But several with two clefts marked externally have been described, most of them by His. Those of them which can be assumed to be normal present a remarkable bend in the back or *dorsal flexure*, by

which their shape is so much altered from that of the slightly younger stage, and so unlike that of the next older stage, that the embryos with the dorsal flexure might be considered abnormal had we not positive reasons to the contrary. Indeed it seems probable that embryos in this stage may have been, because assumed to be abnormal, discarded. His' embryo L, described below, and perhaps Coste's, p. 300, both probably belong in this stage and were artificially straightened out. Nothing similar to the dorsal flexure of the human embryo has been observed in any other vertebrate, though it may occur in apes and monkeys.

20, 21. Two specimens in my collection are in this stage. The younger of these is represented in Fig. 169, and is very near the embryo designated as *Lg* by His; just behind the heart the whole body bends downward and then bends abruptly upward, so that the caudal end of the embryo runs nearly at right angles to the pharyngeal region; from the under side of the tail end runs off the thick allantoic-stalk by which the embryo was attached to the chorion. The other features observed are shown in the figures. Sections

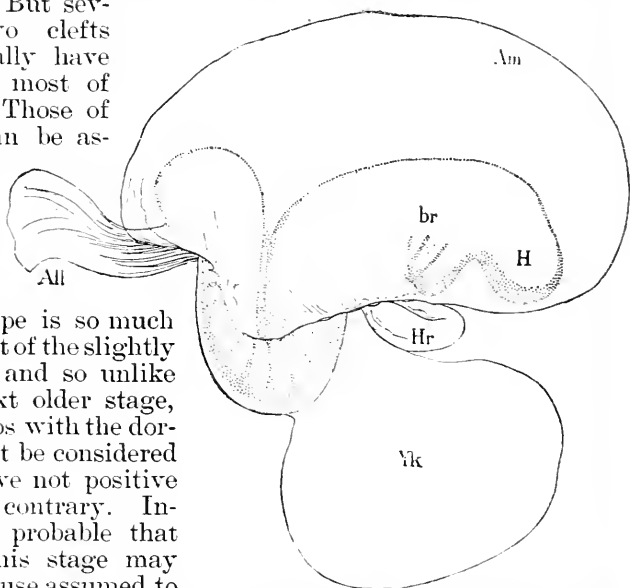


FIG. 169.—Embryo of the Beginning of Third Week (Minot Coll., No. 195). *All*, Allantois; *Am*, amnion; *br*, branchial region; *H*, fore-brain; *Hr*, heart; *Yk*, yolk.

showed that the specimen was imperfectly preserved, and I cannot be sure that it was entirely normal in shape, though it differs but little from the certainly normal embryos of His. My second specimen (Coll. No. 143) is a little older, I think, but as it is somewhat distorted, it is hardly worth figuring and describing separately.

22, 23. Far better preserved are the two embryos of His, which he has studied with such splendid thoroughness. He designates them as Lg (or LXVIII.) and Sch. 1, (or LXVI.), Fig. 17, p. 39. They resemble one another very closely, the most marked differences being that in Sch the heart is more exposed and the neck of the yolk-sac more constricted than in Lg. Lg measured 2.15 mm.; Sch, 2.20 mm. The differences noted indicate that the latter is slightly more advanced. The following description applies especially to Lg. In external form the embryo is very similar to Minot's Fig. 169, but no trace of a third gill-cleft was visible externally, and the amnion was attached along nearly the entire length of the allantois-stalk (His' *Bauchstiel*). The anatomy can be understood from the accompanying Fig. 170. The head bend being well marked, the central nervous system makes at the mid-brain, a bend at nearly a right angle, so that the fore-brain is brought very near the heart, which lies in the large pericardial sac, which protrudes conspicuously between the head of the embryo and the yolk-sac. Between the head and the pericardial sac is situated the oral invagination or future mouth cavity, separated from the vorderdarm by an intact oral Plate (*Rachenhaut*) *o.pl.* As regards the archenteron we find the vorderdarm above the heart, *Ht*, with two gill pouches formed at its head-end and its lower end widened; out of this wider part the lungs and the stomach are to be differentiated in later stages; the vorderdarm is compressed dorso-ventrally but widely expanded transversely; the middle portion of the archenteron opens widely into the yolk-sac; where the vorderdarm joins this middle division is found the outgrowth of the liver, *Li*, extending toward the heart; in the posterior region of the embryo the archenteron has also become distinct from the yolk-sac and ends with a dilatation (His' *bursa*) in the tail of the embryo; from the under side of the bursa runs out the allantoic diverticulum, *All*, which extends as a narrow tube of entoderm through the allantoic stalk to the level of the chorion where it ends blindly. The central nervous system forms in bulk a very large part of the embryo; from the fore-brain the optic vesicles, *Op*, have grown out; the mid-brain is only slightly dilated; the hind-brain is as long as the mid- and fore-brain together, and is nearly as

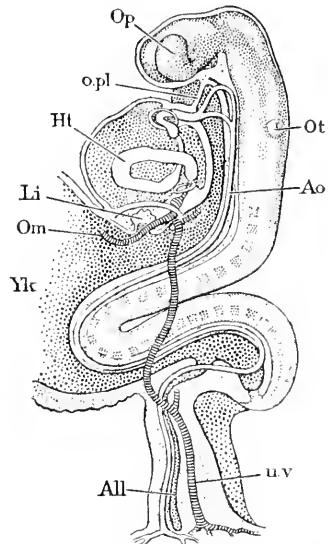


FIG. 170.—Human Embryo of 2.15 mm; Anatomy Reconstructed from the Sections. *Op*, Optic vesicle; *o.pl*, oral plate; *Ht*, endothelial heart; *Li*, liver; *Om*, omphalo-mesaraic vein; *Yk*, yolk-sac; *All*, allantoic diverticulum of archenteron; *Ot*, otoecyst; *Ao*, aorta; *u.v*, umbilical vein. After W. His.

long as the vorderdarm, which it overlies; near the centre of the hind-brain lies the open ectodermal invagination, *Ot*, destined to form the auditory vesicle or otocyst; the remainder of the medullary canal corresponds to the future spinal cord and gradually tapers tailward; alongside it His was able to distinguish in Lg twenty-nine myotomes. The heart, *Hh*, is very largely and asymmetrically bent; the heart at this stage and for some time later may be described as consisting of two tubes, a small inner one, *Hh*, formed of endothelial cells, and a larger outer one formed chiefly of contractile elements, which are gradually differentiated into the striated muscles of the adult heart. The way in which the heart is bent can be best seen in front views; the great veins enter the heart in the median line just above the liver; the heart tube runs toward the head and the left side, making the auricular limbs; then the tube bends to the ventral side and runs obliquely backward to the right side, making the ventricular limb, and finally takes a curving course as indicated in the figures to the median line, and ends close behind the mouth; this third part is the aortic limb. The endothelial heart tube is continued beyond the pericardial cavity as the aorta, which soon divides into two branches on each side, which pass up around the pharynx, one branch in front of each gill-cleft; the front branch curves over, and, passing tailward, joins the second branch; the branches which pass around the pharynx are known as the aortic arches; the united vessels run toward the tail on the dorsal side of the pharynx; they are called the dorsal aortæ, and by uniting in the median line form the single dorsal aorta, which runs away back nearly to the tail of the embryo, where it forks, and its branches, passing one on each side of the intestinal canal, enter the allantois-stalk and run to the chorion, where they branch out. The veins of the embryo are the jugular, which comes from the head and meets cardinal vein from the rump about at the level of the liver; these two veins unite as a short stem, which runs transversely toward the venous end of the heart and is termed the ductus Cuvieri; the ductus is joined, as in adult fishes, by the omphalomesaraic vein, *Om* coming on the same side from the yolk-sac, and the umbilical vein, *u.v.*, coming from the allantois; the four united veins meet their fellows from the opposite side and form with them the median *sinus reuniens*, which communicates directly with the heart: the course of the umbilical vein is curious, as it takes a short cut from the allantois through the somatopleure along the base of the amnion to the heart; how this course is possible can be understood by comparing figures 17 and 166.

24. We pass now to His' embryo L, and Coste's youngest embryo. It must be seriously doubted whether either of these embryos represent the normal shape. The former had two gill-slits and parts of it were torn away, so that we may surmise that it had had the dorsal flexure but was artificially straightened. Concerning Coste's embryo see the next paragraph. His' embryo L is described in his "Anat. menschl. Embryonen." Heft I., pp. 135-139. It measured 2.4 mm. in length, and was obtained from a chorionic vesicle of 8 to 9 mm. diameter. The specimen had been considerably injured, and no exact knowledge could be obtained in regard to the heart or the disposition of the allantois or the amnion. Precisely these three points are

elucidated by Coste, while His has worked out the internal anatomy of his specimen; in short, the two descriptions complement one another in a remarkable manner. Nearly all that His ascertained is represented in the accompanying illustrations, Fig. 171. A gives a side view showing the thickening of the head-end and the upward

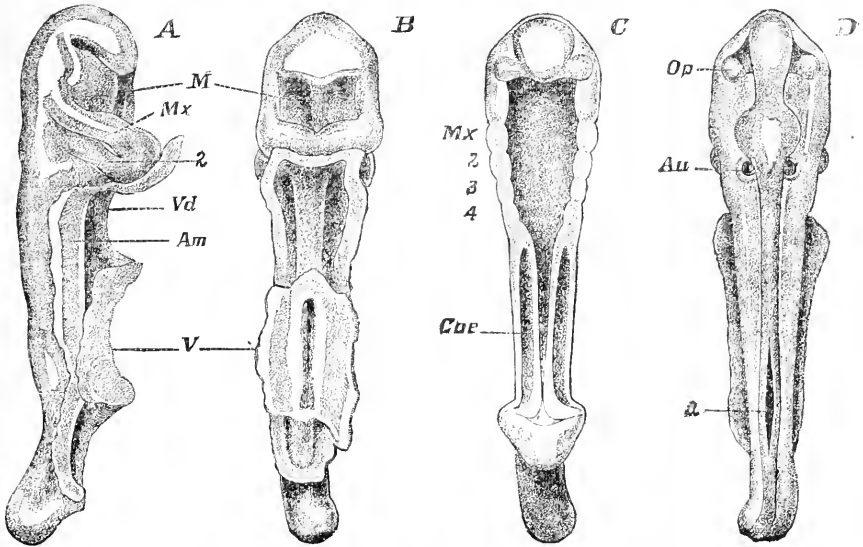


FIG. 171.—His' Embryo L. 2.4 mm. long. A, Side view; B, ventral view; C, ventral view, showing the central nervous system. M, Mouth; Mx, inferior maxilla or mandible; 2, hyoid arch; Vd, vorderdarm; V, splanchnopleura of the yolk-sac; 2, 3, and 4, gill arches; Coe, coelom or primitive body-cavity; Op, optic vesicle; Au, auditory vesicle (otocyst); a, point where the medullary groove has not yet closed.

curving of the tail, and the two gill-slits in the cervical region; the mouth, *M*, is very large; between it and the first gill-slit intervenes the thick ridge, *Mx*, of the first gill arch (branchial or visceral arch, *auct.*), which becomes the mandible; between the two slits is the second or hyoidean arch, in connection with which the hyoid bone afterward arises. A large body cavity is present, *C*, *Coe*; the walls of the body (somatopleures) pass over along an extended line into the amnion; the connection between the embryo and the yolk-sac is already much restricted compared with Coste's embryo, Fig. 172; at the side of the head a line and shadow mark the position of the optic vesicle. B is a ventral view; it shows the large wide mouth, *M*, which, according to His, was apparently in communication with the intestinal canal, which is nothing but a straight tube with a great pharyngeal dilatation, and a wide open union with the yolk-sac; the median light band shown at the back of the mouth is the central nervous system shining through the covering tissue. C is intended to show the digestive tract, and is partly a horizontal section. Especially to be noticed is the enormous size of the pharynx (the region of the branchial arches), the straight, short intestine, and on each side of the latter the distinct body-cavity, *Coe*; there are indications of four visceral arches, *Mx*, 2, 3, and 4; in front of the pharynx is

shown the ventral surface of the fore-brain or first cerebral vesicle, with its lateral diverticula, the optic vesicles. D is a dorsal view of the brain and medullary canal which is still open at *a*. The brain and spinal cord are already differentiated by the dilatation of the former. The brain subdivides very early in all vertebrate embryos into three dilatations or primary vesicles; but in this embryo the two anterior dilatations are not yet clearly separated from one another, hence there is only one widening of the brain in front; the front end is seen to bend downward and give off the conspicuous optic vesicles, *Op*, which, therefore, arise before there is any trace of the cerebral hemisphere—an important fact; the posterior and larger dilatation is the primitive medulla oblongata; no trace of the cerebellum has appeared. The whole nervous system is a tube the walls of which are of nearly uniform thickness, except that the dorsal wall of the third vesicle (the cavity of which becomes the fourth ventricle of the adult) is very thin. This thin wall is persistent in the adult and never develops into nervous substance. On each side of the medulla lies a round cyst, the auditory sac, *Au*, the beginning of the adult membranous labyrinth. Three other points not shown in the figures remain to be noticed. 1. In the tissue at the back of each body-cavity, *Coe*, was found a single longitudinal epithelial canal, the Wolffian duct, the first part of the urogenital apparatus to be developed. 2. Close below the nervous system lay a median rod of cells with a small central cavity; this rod is the *notochord* or *chorda dorsalis*, the primitive embryonic axis around which the vertebræ are formed later. 3. All the tissues are still embryonic—that is, the cells are not yet differentiated into tissues. Unfortunately, the number and disposition of the myotomes were not ascertained.

24A. Janosik, **87.1**, describes an embryo with two gill pouches and three aortic arches, giving a few anatomical details.

25. Coste's embryo has been beautifully figured in his great work, **47.1**. It is possible that it really belongs to an older stage with the dorsal bend, compare Fig. 169, and that it was stretched out by Coste; the difficulty of assigning it its place is due to the entire uncertainty as to its actual dimensions. Coste's private collection is, I believe, now in the College of France, but upon search this particular specimen could not be found, so that His' inquiries to ascertain its actual length were resultless. Kölliker states that it was 4.4 mm. long, but his authority for the statement is not given; the measure was probably taken from Coste's figure, "*grandeur naturelle*." Since embryos of this length are far more developed than Coste's, it is probable that Coste's data as to the magnification of his figures are inaccurate. If we assume the embryo to have been really about 2.5 mm., it will then agree, except as to the great length of the rump, very closely with what we know otherwise of such young embryos. I give the accompanying figures, which are careful copies from the original plates published by Coste (4 "*Espèce humaine*," Pl. II.), whose illustrations, made by his assistant, Gerbe, have never been surpassed for beauty and life-like accuracy. The embryo in question was inclosed in a villous chorion, Fig. 172, and was provided with a large vitelline sac, *V*, having a very broad connection with the embryo and covered with a network of vessels, in which was a

fluid not yet red. A thick allantois-stalk, *Al*, can be seen running from the under side of the embryo's tail to the chorion; from the anterior side of the stalk springs the amnion, *Am*, completely inclos-

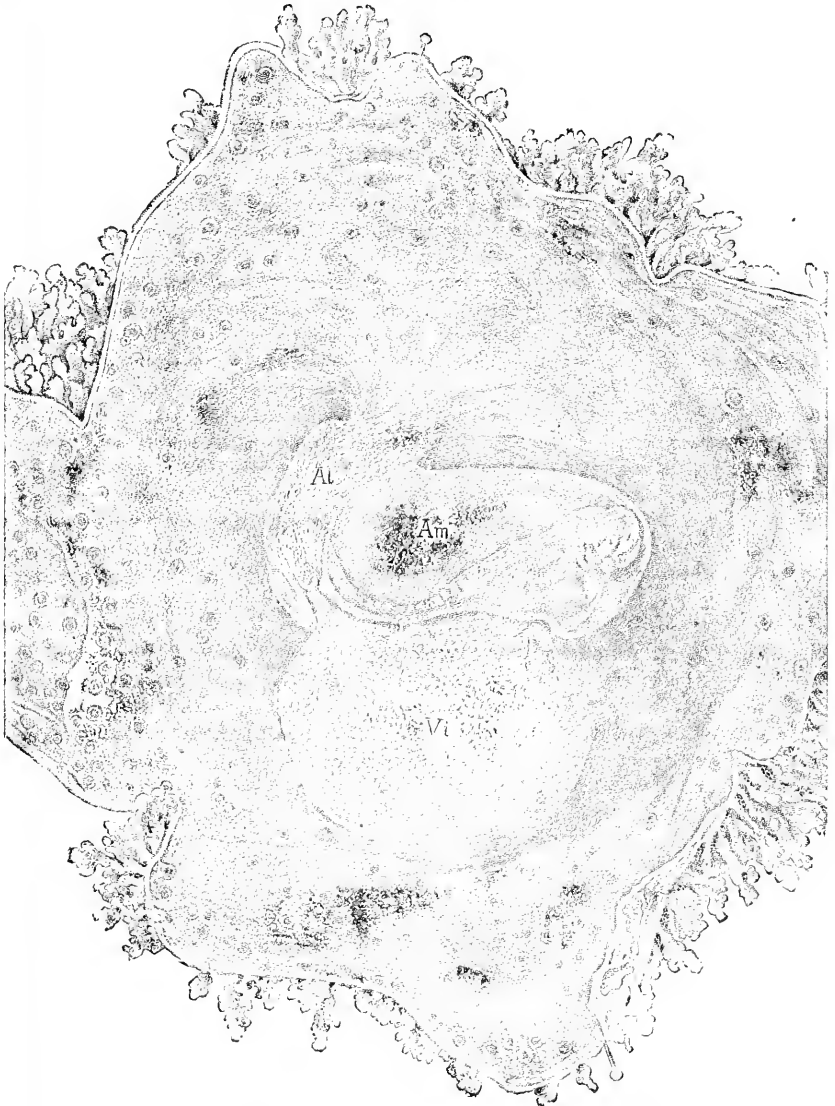


FIG. 172.—Ovum Supposed to be from Fifteen to Eighteen Days Old; after Coste. The chorion has been opened and spread out to show the embryo and its annexa. *Al*, Allantois; *Am*, amnion surrounding the embryo.

ing the embryo. It is important to notice that in this, as in still older embryos, the disposition of the amnion is essentially the same as in the earliest stages (*c. sup.*); the line of attachment of the amnion is down the sides of the allantois and around the embryo about

on a line with the top of the yolk. As regards the embryo, it is drawn slightly canted on to its left side; its back is concave; the head-end is thickest and shows three gill-arches, hence there were

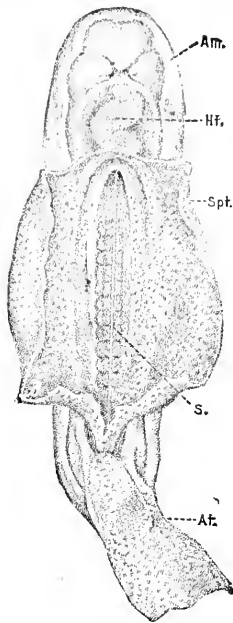


FIG. 173.—Embryo Supposed to be from Fifteen to Eighteen Days Old; after Coste. Ventral view; the vitelline sac has been removed. *Am.*, Amnion; *Ht.*, heart; *Spt.*, splanchnopleure, extending beyond the embryo to form the yolk-sac; *S.*, chorda dorsalis with a row of myotomes on each side. *Al.*, stalk of the allantois.

probably two branchial clefts; behind and below the gill-clefts can be seen the heart, already a bent tube, shining through; behind the arches again, but on the dorsal side, the light-looking œsophagus is distinguishable; in the figure a wedge-shaped shadow intervenes between the straight œsophagus and the bent heart; the heart causes a conspicuous bulging of the body between the head and the yolk-sac; the caudal extremity is thick and rounded, and curves upward. Fig. 173 is a ventral view of the same embryo after most of the yolk-sac has been cut off; its walls, *Spt.* (splanchnopleure), are seen to pass over without any break into those of the intestinal cavity. In the central line the chorda dorsalis, *s.*, can be perceived through the translucent dorsal wall of the intestinal cavity; it is flanked on each side by the row of square muscular segments (myotomes). We see the large allantois, *Al.*, behind, and in front the tubular heart, *Ht.*, with a decided flexure to the right of the embryo; the anterior end of the heart makes an opposite bend, separating off a limb, which becomes the *bulbus aortæ*. The chorion consisted of two membranes, one of which passes continuously over the inner surface of the chorion, while the other outer membrane alone forms the hollow villi, Figs. 172 and 176; hence, in looking at

the inside of the chorion, we see numerous round openings which do not penetrate the inner membrane. Fortunately we learn from Kölliker ("Entwicklungsgeschichte," 1879, p. 309) who had an opportunity in 1861 to examine the chorion, that the outer membrane was epithelial with cells of the same character as in the epithelium of older vascularized villi,* and that the inner layer consisted of developing connective tissue, and carried fine blood-vessels. It thus appears that Coste was the first to observe the rôle of the epithelium in the growth of the villi.

26, 27, 28. It will be as well to mention here, rather than later,

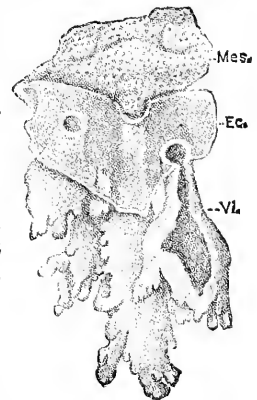


FIG. 174.—Fragment of the Chorion of Fig. 4, highly magnified. *Ec.*, Epithelial layer; *Mes.*, connective-tissue layer; *Vl.*, chorionic villi, formed wholly of epithelium.

* "Hierbei zeigte sich, dass die Zotten und die sie tragende Haut ganz und gar aus epithelartigen Zellen, von derselben Beschaffenheit wie des Epithels der späteren gefäßhaltigen Chorionzotten bestehen."—Kölliker, *l.c.*

three descriptions of young embryos, which either belong in this stage or are a little older. Of these descriptions Remy's alone brings much of any positive information, but the size and age of his embryo can only be guessed at. The first of the embryos is Schröder van der Kolk's (51.1, p. 106 *ff.*, with figures on Pl. II.). Kolk's figures are not very clear. He states that his specimen had two gill-clefts and measured 1.8 mm. in length; one can but ask, Was it not really larger? Kolk's figure suggests that the specimen was doubled up; if this was the case, the embryo, when straightened out, would agree fairly well with His' embryo L, above described. Professor His, for reasons not clear to me, considers Kolk's specimen as somewhat older, but to this opinion I am unwilling to accede. The second embryo is that of Hennig, whose description, 73.1, leaves very much, and whose figures leave everything to be desired. From this paper we can gather very little, except confirmation of Coste's statements in regard to, (1) the disposition of the amnion and its connection with the stalk of the allantois; (2) the absence of a yolk-stalk. Schwabe's, 79.1, embryo, to which reference has already been made, and which he assumes to be thirteen to fifteen days old, was probably sixteen to twenty days old, as shown both by his own data and by the description of the ovum. Very likely it was a little younger than Coste's embryo, *v. sup.* There were a well-developed yolk-sac and an amnion closely investing the embryo, which was connected with the chorion by a short allantoic stem. The chorionic villi were considerably branched and entirely filled with mesoderm; their tips had little thickenings of the epithelium by which they were attached to the decidua; this was the only connection between the foetal and maternal tissues. This last fact is an interesting confirmation of the observations of Ahlfeld and Langhans. Remy's embryo, 80.1, was also a young one, but its exact age is not stated, nor are the measures of its length given except in the title, where it is called "long d'un centimètre." From the stage of development, and from the statement in the text that the chorionic cavity measured 20x10 mm., it seems impossible that the embryo was so large; we should rather expect an embryo of 3 mm. Remy's figure is too inexact for one to make out the form of the embryo. If he gives the length correctly, the specimen must have been a month old. As to its structure, Remy gives the following details: The medullary canal was still united with the ectoderm at its lower end, and extensively so over the fourth ventricle, which was entirely closed. The heart already had muscular striæ. The epidermis had two layers of cells, the outer somewhat flattened, the inner cuboidal. The cutis was not differentiated. The epithelium of the chorion he describes as maternal—a common error. He also distinguished the inner membrane of the chorion, the allantoic. He has also seen, apparently, what is known as Langhans' cellular layer, but has taken it for a deep portion of the epithelium, which he accordingly calls many-layered.

The stage with three gill-clefts is known through five embryos, four of which have been studied by His, and belong to the end of this stage, since in all, except one (Rf), of which we have no detailed description, the fourth gill-pouch of the pharynx was partly formed, and in all there were five aortic arches. The fifth embryo is de-

scribed by Chiarugi, and had three gill-clefts and three aortic arches; it therefore belongs to the beginning of this stage.

28 A. Chiarugi's embryo, **88.1**, had a very marked dorsal flexure (*insenatura dorsale*); its greatest length was 2.6 mm.; its chorionic vesicle measured 15x12x8 mm.; the villi were much longer (1.5 mm.) than upon the other. The embryo had three gill-clefts showing externally, and unlike the two embryos of His, BB, Lr, only three internal gill-pouches and three aortic arches; the otocyst was closed but still connected with the ectoderm; the yolk-sac had a broad connection with embryo, and measured in vertical diameter 1.9 mm.; in transverse, 1.8 mm.; in antero-posterior, 1.6 mm. These points show that the embryo was intermediate between His' L and M. In Chiarugi's specimen the Wolffian bodies had become protuberant; the cephalic and spinal ganglia were present, but the spinal motor roots were not developed; the notochord measured 30 μ in transverse, 24 μ in dorso-ventral diameter, and its caudal termination was indistinct. Chiarugi gives a full and admirable description of all the parts, but as in the respects not specially mentioned above, the structure is very similar to that of other embryos with three gill-clefts, further details may be omitted.

29--32. The four embryos with three gill-clefts described by His have been designated by him as Rf; M, Fig. 175—BB, and Lr, Fig. 16—they being named in the presumable order of development. M

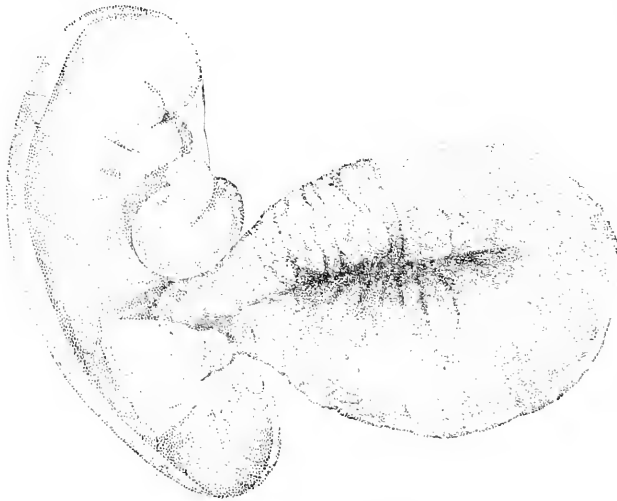


FIG. 175.—His' embryo M.

and Lr are probably the most perfect; Rf is somewhat rolled up; BB has a distinct dorsal flexure, but, as His himself remarks, this was probably due to a mechanical strain and is artificial: hence we may assume that in all embryos of this stage the dorsal flexure has disappeared and the back has become convex.

The four embryos are described and figured in His' "Anatomie menschlicher Embryonen," Heft I.—III." Of M a systematic anatomical description is given (Heft I., 166-134), and additional details concerning BB and Lr are scattered through Heft III. The lengths are: M, 2.6 mm.; BB, 3.2 mm.; Lr, 4.2 mm.; Rf being rolled up could not be measured satisfactorily. The chorionic vesicle of M measured 7.5x8.0 mm.; of BB, 11x14 mm. From the data given by His, the age of BB may be estimated at probably twenty to twenty-one days.

The head is bent down, the back very convex, and the caudal extremity is rolled up and turned toward the right—in Lr, however, to the left—while the head is twisted slightly toward the left; the long axis of the body, therefore, describes a large segment of a spiral revolution; the spiral form is more marked in embryos a little older; it is, of course, produced by the more rapid growth of one side; in view of the differences between right and left in the adult, it is very interesting to find differences between symmetrical parts showing so very early in the heart of the embryo and the twisting of the body. The caudal end of the body has grown very much; the allantois-stalk has presumably lengthened; the neck of the yolk-sac is much constricted; the gill-clefts can be distinguished externally; the otocyst, Fig. 178, *ot*, has become somewhat pear-shaped. The neural canal is completely closed; the mid-brain and fore-brain have become perfectly distinct, and the latter has begun to form the hemispheres in front. The mouth is large, and at its upper corner the protuberance of the maxillary process is marked; the mandibular process is very prominent. Fig. 176, a geometrical reconstruction from the sections, shows the anatomy of the entodermic canal.

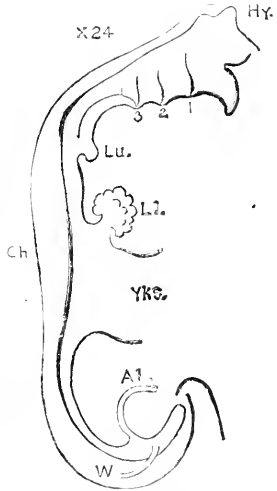


FIG. 176.—Digestive Canal of His' Embryo Lr, 4.2 mm. long. (Compare Fig. 16, p. 38, and Fig. 444.)

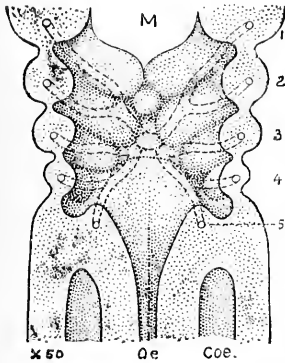


FIG. 177.—Anterior Wall of the Pharynx of His' Embryo BB, 3.2 mm. long. 1-4, The gill-arches, each containing an aortic arch shown by dotted lines; 5, fifth aortic arch; *M*, mouth; *Oe.*, oesophagus or vorderdarm; *Coe.*, celom. After W. His.

to the left and opens into the broad canal, *Yks.* of the yolk-sac; just in front of the yolk-sac there is a small ventral diverticulum, *Li.*, the commencement of the liver; behind the yolk-sac the cylindrical intestine runs over into the tail, where it expands into the bursa of His, and gives off a cylindrical canal, which has very thick connective-tissue walls, and is the allantoic-stalk, *A1.*, which carries the two allantoic veins and the two large allantoic arteries, Fig. 178. Fig. 177 gives a view of the anterior wall of the pharynx of BB; in front is the large opening of the mouth, *M*, the oral plate between the mouth cavity and the vorderdarm having disappeared; the wide pharynx shows four gill-pouches, and at its lower end gradually contracts and passes into the narrow oesophagus. The aortic vessels are indicated by dotted lines; the cardiac aorta reaches the pharynx between the bases of the second and third gill-arches, and divides into two branches on each side; the anterior branch forks and runs through the first and second arches; the

posterior branch forks, one fork going to the third, and the other after again forking supplies the fourth and fifth arches; this arrangement of the aorta is typical. Between the bases of the first and second arches is a small protuberance which is the anlage of the tongue, and is named by His the *tuberculum impar*. The body-cavity of the abdomen has on each side of its dorsal surface a longitudinal ridge, the commencement of the Wolffian body; the ridge already contains traces of the canals of the Wolffian body. Of special interest is the arrangement of the circulatory apparatus, Fig.

178. In the figure the arteries are shaded dark. The heart is an S-shaped tube, the venous end is con-

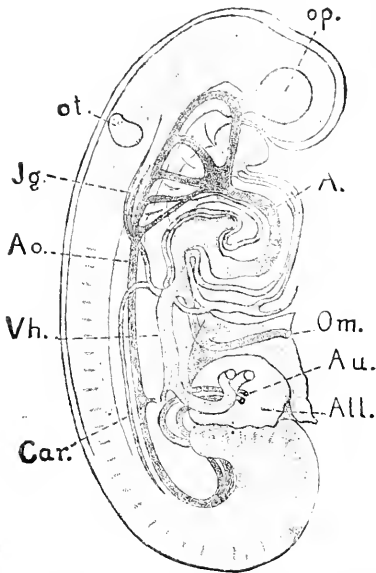


FIG. 178.—W. His' Embryo M. *op.*, Optic vesicle; *A.*, aorta; *Om.*, omphalo-mesaraic vein; *Au.*, arteria umbilicales; *All.*, allantois; *Car.*, cardinal veins; *Vh.*, right umbilical vein; *Ao.*, dorsal aorta; *Jg.*, jugular vein; *ot.*, otoecyst. After W. His.

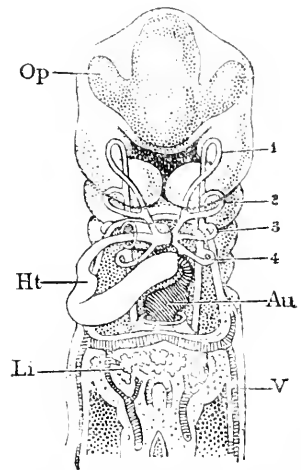


FIG. 179.—Reconstruction of His' Embryo BB. 3. 2 mm. long, to show the Course of the Endothelial Heart, *Ht.*, and aortic arches. *Op.*, Optic vesicle; *Ht.*, heart; *Li.*, liver; 1-4, aortic arches; *V.*, allantoic vein; *Au.*, auricle. After W. His.

vox toward the head, the arterial end convex toward the tail; when viewed from in front the venous portion is seen on the left, Fig. 179, the arterial portion on the right of the embryo. The heart is continued forward by the large aorta, *Ao.*, which gives off five branches on each side of the neck; these branches unite again on the dorsal side and run backward to unite with the fellow-stem, and so form the single median dorsal aorta, *Ao.*, which runs way back and terminates in two large branches, Fig. 178, *Au.*, which curving round pass out through the allantois-stalk. The five branches in the neck are known as the aortic arches, and the column of tissue around each branch constitutes a so-called branchial or visceral arch; between the five arches are four spaces, in each of which a gill-cleft is ultimately formed. The reconstruction of *Lr* in a side view, Fig. 180, affords further information concerning the disposition of the heart and large blood-vessels. The veins, as is there shown, are, 1, the jugular, *J.*, and cardinal, *car.*; which unite and form a single

transverse stem, the ductus Cuvieri, *D.C.*; the cardinal veins receive chiefly the blood from the Wolffian bodies and atrophy later with those bodies; 2, the large umbilical veins which pass up, *Al.v.* from the allantois and also open into the ducti Cuvieri, but nearer the heart than the jugulars and cardinals; 3, the omphalo-mesaraic veins, *Om*, which come up from the yolk-sac. More precise details of the course of the veins through the region of the liver will be found in Chapter XXIX. The conformation of the body-cavity (splanchnocœle) can be better considered in connection with the history of the septum transversum, Chapter XXII.

33--36. Of other embryos about the stage of those described in the preceding pages several are known. His has referred the following to this stage:

1. Allen Thomson's ovum III. (2), **39.1.**
2. C. E. von Baer's described in his "Entwicklungsgeschichte," Bd. II., 361-363, Taf. VI., Figs. 15-19; also in Von Siebold's *Journal für Geburtshülfe* (1834), XIV., 409.
3. Schroeder van der Kolk's (5), **51.1.**
4. Alexander Ecker's (9) **73.1.**
5. Prof. Hecker's (*vide infra*).
6. Beigel's (*vide infra*).
7. Bruch's (10).

Of these Thomson's embryo, the figure of which reduced in scale may be found in His ("Anat. menschl. Embryonen," Heft II., Fig. 18, p. 32, marked A. T.3), is the only one deserving much attention.

Thomson's embryo resembles His's M (see below) quite closely, not only in general form but also in the possession of distinct gill-clefts and the great prominence of the heart. Its length is given by Thomson at one-eighth of an inch, about 3 mm. Von Baer's embryo, on the contrary, was only 2 mm. long; it was surrounded by an amnion of about 4.5 mm. diameter, which is abnormally large; Von Baer observed four open gill-slits; the hind end of the body was partially atrophied, which accounts for the short length. Van der Kolk's embryo, as I have already stated, I refer not to this but to the previous stage, perhaps mistakenly, but I think not. In Ecker's ovum the chorion measured 12 by 9 mm., and the embryo only 2 mm.; the author's description is very meagre and his figures not distinct; Ecker expressly compares it with an ovum of Wagner's, figured in

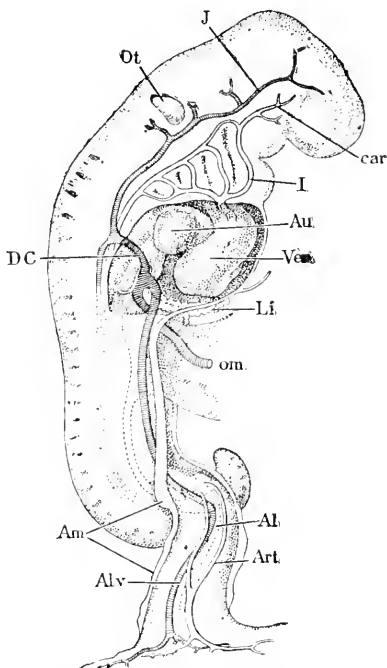


FIG. 180.—Reconstruction of His' Embryo, *Lr.* (Fig. 16). *Ot*, Otocyst; *J*, jugular; *car*, carotid; *I*, first aortic arch; *Au*, auricle; *Ven*, ventricle; *Li*, liver; *om*, omphalo-mesaraic vein; *Al*, allantoic diverticulum; *Art*, allantoic artery; *Alv*, allantoic vein; *Am*, origin of the amnion; *D. C.*, ductus Cuvieri. After W. His.

Wagner's "Icones Physiologicae," and again in Ecker's "Icones Physiologicae," Taf. XXV., Fig. V.; but the comparison apparently refers only to the chorion, for Wagner's embryo was evidently older, being 4.5 mm. long and having external traces of limbs. Hecker's ovum (5) I know only through Prof. His' reference, which leaves the impression that Hecker's description is so unsatisfactory as to render it a matter of surmise exactly what stage of development the specimen had reached. In regard to Beigel's ovum I have already expressed, p. 289, my opinion that it is a much older and abnormal embryo; I do not differ from Prof. His as to the slight value attaching to Beigel's description. Bruch's embryo (Abh. Senck. Ges. VI., Taf. X. [40]) appears to me from his description and plate to have been very abnormal. Of these seven embryos Kolk's and Beigel's do not belong to this stage; Von Baer's and Bruch's were abnormal; Hecker's is questionable, Ecker's somewhat uncertain, and Thomson's the only satisfactory one. Of Thomson's only the general appearance is described, but that confirms what we learn from His' observations on this stage.

37, 38. Of embryos with four gill-clefts we possess no satisfactory descriptions, unless, indeed, we regard His' embryo Lr, described above, as belonging to this stage, since the fourth pharyngeal gill-pouch is found in it. To this stage may perhaps be assigned the embryo described by Johannes Müller ("Physiologie." 4te Aufl., Bd. II., §13, Taf., and in Müller's *Archiv*, 1834, p. 8, and 1836, p. clxvii), and also Wagner's embryo (Wagner's "Icones Physiol.," Taf. VIII., Figs. 2 and 3, also in Ecker's "Icones Physiol.," Taf. XXV., Fig. 5); important critical remarks on these two embryos may be found in His' "Anat. menschlicher Embryonen," Heft 1, 162-163, and Heft II., 41-43). Müller's embryo was about 5.5 mm. alone, Wagner's 4.5 mm. They both had a marked dorsal flexure resembling that normally present in embryos with two gill-clefts; but this flexure was probably produced artificially by a strain upon the yolk-sac pulling the back down; the flexure is to be regarded as artificial, because in embryos which were certainly normal it was not found in the next younger or the next older stage. How easily the flexure may be produced is shown by His' observation of its occurring in his embryo W, while he was manipulating it. Neither of the two embryos under consideration are described or figured with sufficient accuracy of detail to justify a fuller description of them. As Von Baer states of his embryo, 34, that it had four clefts, it must be held to belong in this stage probably.

Summary. Known Young Human Ova.—The detailed descriptions of the preceding pages, 287 to 308, are summarized in the following paragraphs.

FIRST STAGE: * PRIMITIVE STREAK.—No human ovum has been observed to have a primitive streak, but there are several which are younger than the embryos with open medullary groove, and therefore presumably are in this stage; unfortunately there is a satisfactory description of the embryonic structures in no one of them. To this group have been assigned the embryos 1 to 9, but of these Beigel's (5) is certainly abnormal, and Schwabe's (9) is probably

* For definitions of the stages, see p. 286, *ante*.

both abnormal and much older. From the preceding review of the remaining seven ova the following conclusions may be drawn: The human ovum by the twelfth or thirteenth day is a rounded, somewhat flattened sac of three to four millimetres in diameter, bearing an equatorial zone of short unbranched villi; the villi are probably formed by the ectoderm only; the wall of the sac is ectoderm, whether underlaid by somatic mesoderm or not is uncertain; to the inner wall of the sac over one of the bare poles of the ovum is attached a mass of cells, constituting the anlage of the embryo; as to the arrangement of these cells we possess no knowledge.

In the next stage the villi have spread over the germinal area and have become slightly branched; the villi next appear over the opposite pole of the ovum and rapidly increase their length and ramifications. The germinal area faces the uterine wall (Jones' ovum, 3). By the time villi are present over the whole vesicle there is probably always a layer of connective tissue underlying the epithelium (Breus 2, Ahfeld 4, Löwe 5, etc.), but no embryonic structures have been recognized. The ova of twelve to fourteen days are already completely inclosed by the decidua (reflexa and serotina); only the tips of the villi adhere to, or are even in contact with, the decidua; this is the only connection between the maternal and foetal tissue, for neither does the uterine mucosa grow in between the villi, nor do the villi penetrate the cavities of the uterine glands. The epithelium of the chorion and villi is only imperfectly marked with boundaries for the single cells; its nuclei all occupy a basal position, leaving a distinct outer layer, often mistaken for a separate structure. The epithelium forms buds which become branches of the villi. These buds may grow out to a considerable size without connective tissue (hollow villi), or the connective tissue may penetrate into them from the start (solid villi). The human ovum, then, is remarkable for its precocious development of the chorion, both as regards the villi and the connective tissue or mesodermic layer, and for its early complete encapsulation by the decidua. All these events (according to the scanty observations yet made) precede the appearance of the embryo. It is also noteworthy that the villi are first developed around the equator, next over the germinal area pole, and last over the area of the opposite pole.

SECOND STAGE: MEDULLARY PLATE.—To this stage I assign the embryos, His' XLIV. or Bff (10), Keibel's, 11, and Spee's, 12, and I think they belong in the order named. The chorionic vesicle is rounded and somewhat flattened; in its greatest diameter it measures 8-10 mm.: it is beset with short branching villi, which are present over the entire surface except in one case, where they formed an equatorial band as in Reichert's ovum 1. The chorion had a distinct ectodermal and a distinct mesodermal layer; the former, at least in Spee's embryo, had two strata of cells, as is characteristic of the chorion. To the inner surface of the chorion was attached a thick allantois-stalk (*Bauchstiel*), which, curving slightly, passed over without any demarcation into the embryo, which in Keibel's ovum measured about 1 mm, in Spee's about 1.5 mm. From the sides of the allantois-stalk and of the embryo sprang the thin amnion, which was completely closed. Along nearly the entire length

of the ventral surface of the embryo was attached the yolk-sac, which was of rounded form and about equal in diameter to the length of the embryo; in Keibel's ovum the yolk-sac had blood-vessels containing nucleated blood-corpuscles, and was a hollow vesicle whose thin walls were composed of a fine lining of entoderm, and a thicker sheet of mesoderm. Spee was able to study his embryo in detail; it had a well-marked medullary plate with a median furrow, Fig. 164; at the posterior end of the plate was the primitive streak, and at the anterior end of the primitive streak was an opening (named by Spee the neurenteric canal) leading into the entodermal cavity; the head had grown forward sufficiently to indicate the development of the vorderdarm; the notochord was present, as a median band of entodermal cells, running forward from the neurenteric canal; the allantoic diverticulum extended as a narrow tube of entoderm through the allantois-stalk to the chorion; the cœlom had not appeared in the embryo proper; the anlage of the heart was not present.

This stage is, therefore, characterized by the size of the chorionic vesicle, 8-10 mm., the completed development of the extra-embryonic cœlom, and the absence of the embryonic cœlom and heart anlage; by the presence of the medullary plate, neurenteric (or blastoporic) canal, notochordal band in the entoderm, the vascularized yolk-sac, the thick allantois-stalk with the tubular allantoic diverticulum. The general arrangement can be understood from the diagram, Fig. 166.

THIRD STAGE: MEDULLARY GROOVE.—The development of both the embryo and its appendages has advanced. Particularly noteworthy are the large size of the medullary ridges and the precocious differentiation of the chorion and amnion. The youngest embryos of this group are in the neighborhood of 2.2 mm. in length (Thomson gives the length of his embryo I. as 2.5 mm., but the criticisms made above render it plain that this measure probably refers to the length of the amnion plus the allantois-stalk); the embryo not seen by Thomson was presumably shorter. The embryo has a broad attachment to the yolk-sac, which in diameter nearly equals the length of the embryo and is already furnished with blood-vessels. The most conspicuous character of the embryo is the presence of two very thick dorsal ridges—medullary folds, running the whole length of the embryo and inclosing the medullary groove, central nervous system to be, between them; the cephalic extremity is somewhat thickened; from the ventral side of the caudal extremity springs the short and thick allantois-stalk, the opposite end of which is inserted into the chorion. The amnion completely incloses the embryo, and is attached on the one hand to the allantois-stalk, on the other to the embryo nearly parallel to the junction of the embryo and the yolk-sac. The next change involves not merely the growth of the embryo, but also the thickening of its cephalic end, the development of the great heart protuberance between the yolk-sac and the head, the concave flexion of the back, and the deepening of the medullary groove, which, however, still remains open. The chorion forms a relatively large vesicle, its average diameter being about 8 mm., but the four specimens vary from 5.7 to 15 mm. The chorion bears villi over its whole surface; the villi are considerably branched.

Probably the villi are formed chiefly if not solely by epithelium, and probably, also, there is a layer of connective tissue, very likely already vascular, which lines the chorion, but does not extend into the villi. There are many still unsolved problems as to the development of man. It will be observed that not a single one of the ova hitherto noticed has been adequately investigated, and that no specimens have yet been studied at all, showing the first appearance of the embryo, the origin of the amnion or of the allantois, or of the yolk-sac; and finally, that of all the earliest stages our knowledge is extremely imperfect. It is, therefore, much to be hoped that all who obtain available specimens will carefully preserve them and intrust them to a competent investigator. From the above considerations it is also evident that the summary just given can be only tentative.

FOURTH STAGE: THE HEART.—In this stage the embryo is probably 2.2 to 2.5 mm. long; the head projects in front of the yolk, and on the under side of the cervical region the heart has appeared; the deep neural groove is partly closed to form the medullary canal, but is open along the cephalic region; the dorsal outline is slightly concave; the myotomes have appeared, the number varying; Spee found seven, Kollmann thirteen; the caudal end of the embryo also projects beyond the yolk, but less than does the head; the auditory invagination is probably not yet formed; there are no gill-clefts showing externally.

Concerning the chorionic vesicle at this stage, satisfactory data are lacking.

FIFTH STAGE: ONE GILL-CLEFT.—No human embryo with only one gill-cleft showing externally is known.

SIXTH STAGE: TWO GILL-CLEFTS AND DORSAL FLEXURE.—To this stage we must assign not only my two specimens referred to above, 20 and 21, and His' Lg, 22, and Sch 1, 23, but also His' L, 24, and probably Coste's, although in neither of the latter does the dorsal flexure appear. It is possible that Schroeder van der Kolk's ovum, 26, Hennig's, 27, Schwabe's, 9, and Remy's, 28, also belong in this stage, but for reasons given above in detail the position of these four is very doubtful, that of Schwabe's especially so. In His' embryo L, and in Coste's, the dorsal flexure was probably obliterated artificially, leaving only the four embryos, 20-23, upon which the following synopsis is based, with the addition of some anatomical facts derived from Nos. 24 and 25.

The general shape of the embryo and its remarkable dorsal flexure can be best understood from Fig. 17. The head bend is very marked and the tail end of the embryo is also bent over ventralward; the yolk-sac extends from the heart backward to where the body of the embryo turns to make the dorsal flexure; the heart is large and very protuberant; it is bent so that we can clearly distinguish the auricular, ventricular, and aortic limbs, and it consists of a smaller inner tube, the endothelial heart, or endocardium (which is continuous at one end with the walls of the veins, at the other with the walls of the aorta), and of an outer larger tube, the muscular heart or myocardium; between the two heart tubes is a considerable space; there are two gill-clefts and, at least in the youngest specimens, only two aortic arches, one in front of each cleft; between the head


and the heart the oral invagination has been formed but is still separated by the oral plate (*Rachenhaut*) from the vorderdarm; above the gill-clefts is the open ectodermal invagination of the otocyst, which in His' embryo L, 24, had become a closed vesicle. The central nervous system is very large compared with the whole embryo; the brain comprises in length about one-half of the medullary canal; the optic vesicles are large, and the optic stalks are well differentiated; the head bend takes place in the region of the mid-brain, which is imperfectly separated from the fore-brain; the hind-brain is about equal to the fore and mid brains together in length; there were twenty-nine myotomes in His' embryo Lg, 22. The vorderdarm is flattened dorso-ventrally; the liver is developing in the septum transversum; the middle portion of the intestine opens into the yolk-sac, the posterior portion is closed and at its caudal termination is dilated to form the bursa of His, and curves over to pass as the narrow tubular allantoic diverticulum through the allantois-stalk to the level of the chorion. The veins show the typical arrangement, the jugulars joined by the cardinals form the ducti Cuvieri, and these after receiving the omphalo-mesaraic (or vitelline) and the umbilical (or allantoic) veins unite in the median line as the sinus reuniens; the course of the allantoic veins is peculiar and may be described as a short cut through the somatopleure along the line where the body wall of the embryo is deflected back to form the annion.

SEVENTH STAGE: THREE GILL-CLEFTS.—All the accurately known embryos, except one, 28A, belonging to this stage, belong to the end of it, and one of them, His' Lr, 32, is so far advanced that it might almost be classed in the next stage. Five good embryos, 29-33, are to be placed here, and four others, 34, 35, 36, and 5 have been associated with them, but the latter are all doubtful cases; the best of them being Von Baer's, 34, which probably should be put in the eighth stage. For reasons stated in the section on the dorsal flexure, p. 313, the flexure is probably normally absent in embryos at the close of the seventh stage. The described embryos vary from 2.6 to 4.2 mm. in length; His' M, 30, was 2.6 mm. long, and its chorionic vesicle measured 11 by 14 mm. His' BB, 31, was 3.2 mm. long, and its chorionic vesicle measured 11 by 14 mm: the age of BB was probably twenty to twenty-one days. The back of the embryo is normally (or at least usually) convex; the head is bent to one side (usually to the right) and the tail to the other, the whole embryo having a spiral twist; there are three gill-clefts showing externally; the tail end has grown considerably and the allantois-stalk has lengthened; the yolk-stalk (neck of the yolk-sac) is both relatively and absolutely smaller than in the previous stage, but the embryo is larger. The heart has grown very much; in the older specimens the development of the auricular pouches has begun. The otocyst is a closed pear-shaped vesicle, its apex pointing toward the dorsal side. The mouth cavity has deepened, the oral plate is ruptured; above the mouth the maxillary process can be distinguished. The pharynx is wide, compressed dorso-ventrally, and has in the known specimens four gill-pouches, and on its median ventral floor a small prominence, His' tuberculum impar, the anlage of the tongue; the diverticulum of the liver is well marked in the youngest,

and enlarged and branching in the oldest specimens; the Wolffian ridge is distinguishable and contains Wolffian tubules, but as to the number and form of these we possess no exact information. The medullary canal is closed throughout its length; the mid and fore brains have become clearly separated since the sixth stage. As regards the circulatory system, besides the appearance of the auricles and the general advance of the heart, we have to note that the great veins passing through the septum transversum have begun their transformations into the hepatic system, and that the aorta has five aortic arches, the two first coming from one branch, the remaining three from another branch on each side; no embryos are known with only four aortic arches.


EIGHTH STAGE: FOUR GILL-CLEFTS.—The three embryos, 34, 37, 38, which were apparently in this stage, are so imperfectly known that there is practically nothing definite to say in regard to their anatomy. Wagner's specimen, 38, measured 4.5 mm.; Müller's, 37, 5.5 mm.

The Dorsal Flexure.—In a number of embryos with from two to four gill-clefts there has been observed a deep bend in the rump, which suggests at once the effect of a pull upon the yolk having produced a sharp concavity in the back, compare Fig. 169. In embryos with two gill-clefts this bend, for which I propose the term dorsal flexure (*Rückenkrümmung*), has been shown by His to be normal. In older embryos it seems to be abnormal, for in one with three clefts and the dorsal flexure, 31, the tissues in the region of the bend were lacerated, and in a still older specimen (W of His) the bend was artificially produced while the embryo was being manipulated. The facts indicate that the back is too long for the somatopleure at the side of the body, and that it finds room at the stage with two gill-clefts by becoming concave; later it springs into a new position of equilibrium by becoming convex: it is possible that the change from the concave to the convex position is very abrupt, and it is probable that the time of its occurrence is very variable, so that we may find hereafter embryos in the seventh and eighth stages, which are perfectly normal though still having the dorsal flexure.



PART IV.

THE FETAL APPENDAGES.



CHAPTER XIV.

THE HUMAN CHORION.

THE human chorion has been the object of greater misconception than perhaps any other organ of the body. Even at the present time there prevail numerous false notions concerning it, and many of these errors are repeated in some of the best accredited text-books. The literature of the subject includes a majority of papers of little value, and often remarkable for the gross crudity of the observations they record and for the ignorance displayed by their authors of other and better observations. The literature also includes numerous papers by investigators of exceptional accuracy and intelligence, such as Coste, Farre, Turner, Langhans, Waldeyer, etc., by which we are enabled to give a fairly complete history of the chorion. This chapter is based chiefly on the account given in my paper on "The Uterus and Embryo," 98.

General Description.—The chorion has already been defined as the whole of that portion of the extra-embryonic somatopleure, which is not concerned in the formation of the amnion. The human chorion, as stated above, p. 281, is remarkable for its very early complete separation from the yolk-sac and for the precocious appearance of its villi. As shown in the previous chapter, both of these developments have taken place in all the very young human ova hitherto obtained, even in Reichert's ovum, which is supposed to be the youngest known, see p. 287. At about twelve days the chorionic vesicle is a closed sac, somewhat flattened and 3-4 mm. in greatest diameter; around its equator there is a broad zone of simple villi. About a day later the vesicle is 1 mm. larger, and the villi, which are beginning to branch, have developed over one of the polar areas, and soon after develop over the second pole also, though less thickly than elsewhere. The fourteenth day the vesicle measures about 6 mm.

In all these cases the vesicle is found completely encapsuled in the decidua, and the decidua reflexa is closed over it. The tips of the villi alone touch the decidual surface, to which they are lightly attached, for they can be pulled off from it without their breaking, Spee, 89.1, 160. This arrangement leaves a space which is bounded on the one side by the maternal decidua, on the other by the foetal chorion, and which is crossed by the foetal villi; it is commonly designated as the *intervillous space*.

As to the growth of the chorionic vesicle I have failed to find any extended observations, and can only express the hope that the omission may be soon supplied. The growth at first is very rapid, so that during the second month there is always a considerable space around the embryo and amnion, but after the second month the space is

relatively diminished by the growth of the foetus. W. His gives the following table ("Anat. Mensch. Embryonen," Heft II., 21).

Diameter of Chorion,	< 1.5 cm.;	Embryo,	2-4 mm.
" " "	1.5-3.0 "	" "	4-10 "
" " "	2.5-4.0 "	" "	10-15 "
" " "	3.5-5.0 "	" "	15-20 "
" " "	4.0-6.0 "	" "	20-25 "

The contents of the vesicle are, *first*, the embryo with its allantois-stalk and yolk-sac, and, *second*, the *chorionic fluid*; concerning the latter I know of no exact observations, but it probably resembles, if indeed it be not identical with, the amniotic fluid, compare p. 337.

The history of the villi is given below in detail; in this paragraph we need refer only to the changes in the villi, by which the membrane is differentiated into the *chorion laeve* and the *chorion frondosum*. I consider it doubtful whether the number of villi increases at all after a comparatively early stage, but over all that part of the chorion which overlies the decidua serotina (*cf.* Chapter I.) the villi continue to grow both in size and in the number of their branches for a long time—perhaps through the entire period of pregnancy; this area of enlarged villi presents a shaggy appearance and hence is called the chorion frondosum; it participates in the formation of the placenta; the allantois-stalk (or later the umbilical cord) is always inserted into the chorion frondosum. Over all the remainder of the chorion, which lies against the decidua reflexa, the villi gradually atrophy during the second month, so that this region becomes smooth, and hence is termed the chorion laeve.

The chorion consists histologically of an external layer of epithelial ectoderm and an inner thicker layer of mesoderm; whether the mesoderm is divisible into a mesenchyma and mesothelium, as the development of the chorion out of the somatopleure leads us to expect, is uncertain, but if there is an interior layer of epithelium on the mesodermal surface it must be extremely thin, for I cannot detect it in my sections; the bulk of the mesoderm is undoubtedly mesenchymal. The ectoderm in the earliest stages known consists of two clearly differentiated layers, a thinner outer one with small nuclei and without recognizable cell boundaries, and an inner one consisting of distinct cells with large nuclei. The outer layer has been regarded by some authors as maternal tissue—an opinion discussed in the section on the histology, p. 322.

The chorion is at first vascular throughout its entire extent, receiving its blood from the embryo via the allantois-stalk through two arteries, and returning it by the same route through two veins, see Chapter XVII. The vessels early penetrate the villi, but as the villi disappear from the chorion laeve the blood-vessels also abort there and remain only over the chorion frondosum (compare Chapter XVII.), to maintain the circulation of the fetal placenta.

Chorionic Villi. *Development.*—As has been stated both in the review of the youngest known human ova, and in the general description of the chorion, the villi arise in a broad zone around the equator of the somewhat flattened chorionic vesicle, and soon after appear over both polar areas; they are at first clumsy cylinders which may grow to a millimetre in length before they begin branch-

ing. They arise, as shown long ago by the observations of Coste, as outgrowths of the ectoderm only, Fig. 174; the hollowness of the villi and their clumsy shape are to be especially noted. The mesoderm grows into them subsequently. The openings into the villi can also be seen in Fig. 172, scattered over the surface of the chorion.

Branching.—The branches of the villi grow out in a similar manner, the process being led, as it were, by the ectoderm. Orth in a special paper, 78.1, has used these facts to argue against Boll's "Princip des Wachsthums." Kollmann's observations, 79.1, 297, on the growth of villi during the fourth week are particularly instructive. The outgrowth of the branches is very rapid and occurs with every degree of participation of the connective tissue. The two extremes are: 1, a bud consisting wholly of epithelium, which may become a process with a long thin pedicle, and a thickened free end remaining entirely without mesoderm; 2, a thick bud with a well-developed core of connective tissue, and having a nearly cylindrical form. Between these extremes every intermediate state can be found. Other observers have noted this peculiar manner of growth, which I have found still going on in the placental chorion during the fourth month. Robin, 54.1, appears also to have crudely observed both the young hollow villi and the solid epithelial buds. The blood-vessels he traces to the division of the cavity of the villi into an artery and a vein; from the nature of things he offers no observations in support of this assertion.

Only the tips of the villi touch the surface of the decidua either at first or subsequently, except, of course, over the chorion læve during the abortion of the villi. The tips of the villi are attached to the uterine surface; they penetrate the decidua for a short distance, but even in the placental area at the close of gestation the penetration is slight and the villi make their way only into the surface stratum of the decidua serotina. There is no evidence of any sort that the villi penetrate the glands at any period. The relation of the villi to the decidua has now been so accurately ascertained that there can be, I think, no longer any question whatsoever on this point. The best discussion is by Langhans, 77.1, p. 231 ff.

The shape of the villi varies according to the part of the chorion and the age of the embryo. They gradually abort over the chorion læve, and gradually grow over the chorion frondosum. Let us begin with the placental villi: At first they are short, thick-set bodies of irregular shape, as shown in Fig. 174; at twelve weeks their form is extremely characteristic, Fig. 181; the main stem gives off numerous branches at more or less acute angles, and these again other branches, until at last the terminal twigs are reached; the whole of the space between the chorion and decidua is occupied by these ramifications; the branches and twigs, as the illustration shows, are extremely irregular and variable, although in general they may be described as club-shaped, being more or less constricted at their bases. The branches may be bigger than the trunk which bears them, or of any less size; some of the smallest are merely slender outgrowths of the epithelial covering of the villus, such as have already been alluded to. Gradually there is a change. During the fifth month we find the irregularity, though still very marked, decidedly less

exaggerated, Fig. 182; the branches tend to go off at more nearly right angles; one finds very numerous free ends, as of course only a small proportion of the branches touch the decidual surface; the

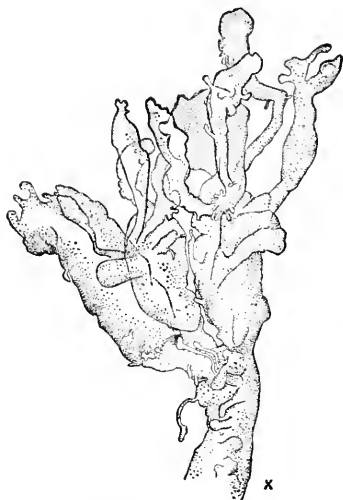


FIG. 181.—Isolated Terminal Branch of a Villus from the Chorion of an Embryo of Twelve Weeks.

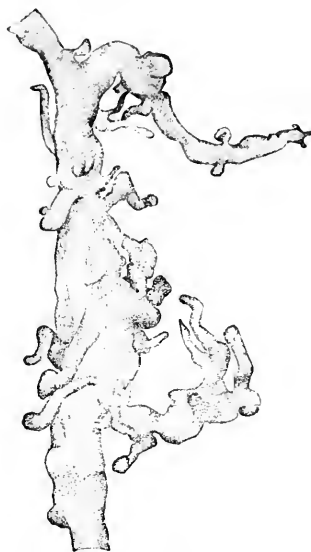

FIG. 182.—Villous Stem from a Placenta of the Fifth Month. $\times 9$ diams.

branches, too, are less out of proportion to the stems, less constricted at their bases, or, in other words, less remote from the cylindrical form; the awkward cucumber-shapes of the twelfth week are no longer found except here and there. The change continues in the same direction; that is, is toward greater regularity of configuration. It is hardly necessary to describe the intermediate phases

that have been examined, but it will suffice to describe the form at full term, Fig. 183, when the branches are long, slender, and less closely set, as well as less subdivided, than at earlier stages; they have nodular projections like branches arrested at the beginning of their development; there are numerous spots upon the

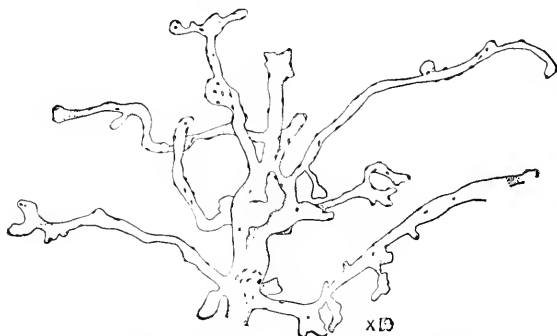

FIG. 183.—Terminal Villi of a Placenta at Full Term. The little spots represent the proliferation islands of the covering epithelium.

surfaces of the villi; microscopical examination shows that these spots are *proliferation islands*, as we may call them, or little thickenings of the ectoderm with crowded nuclei. It appears that not all

the villi change to the slender form; for some villi, having still the earlier, thicker form, are found even in the mature placenta, a fact already noticed by Jassinsky, 67.1, 346. These thick villi usually show also a distinct "cellular layer" in their ectoderm, a peculiarity to be considered below again. Seiler, 32.1, has given figures of the villi at various ages, but fails to show the characteristic forms.

Langhans has observed the alteration in the villi, 77.1, 199, and even justly remarks that many of the villi in so-called "moulds" are not pathological, as they have been frequently considered, but normal young villi. The differences in the villi according to age are very conspicuous in sections. The sections should, of course, be made so that the fragments of the villi will remain *in situ*; imbedding in cello-dine is convenient for this purpose; if this end

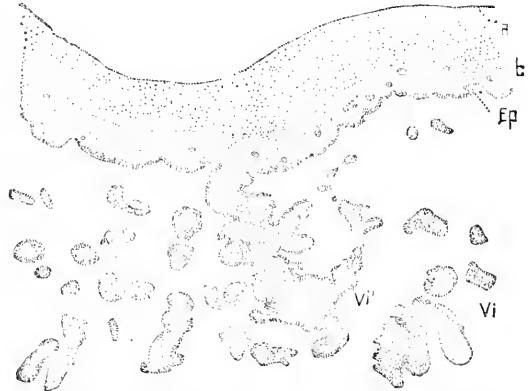

FIG. 184.—Section of the Chorion at Three Weeks. *a*, layer of coagulum; *b*, mesoderm of chorion; *Ep*, epithelium, also extending over the villi, *Vi* and *Vi'*; the mesoderm, *b*, contains a number of blood-vessels, nearly all in transverse section. $\times 65$ diams.

be attained, one finds below the chorionic membrane numerous sections of villi; if the specimen be a young chorion—first to third month—the villi are large, with a good deal of room between them; their outlines are very irregular and there are relatively few small branches, Fig. 184. The older the specimen, the larger the proportion of small branches. In an old chorion—seventh to ninth month—the number of small villi of nearly uniform size is very striking

(see the figure of a section through a placenta *in situ*, given in Fig. 213).

The abortion of the villi of the chorion here takes place by an arrest of development and a subsequent slow degeneration of the tissues, which lose all recognizable organization in the protoplasm, and to a large extent of the nuclei; at the same time they alter their shape, Fig. 185, becoming more and more filamentous; by the fourth month only a few tapering threads, with very few branches, remain

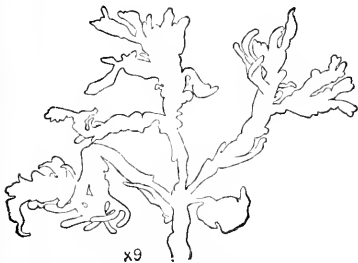


FIG. 185.—Abortng Villus from a Chorion of the Second Month.

The villi disappear almost completely from the laeve, except near the edge of the placenta, where they are to be found, even in the after-birth, imbedded in the degenerated epithelium of the chorion and the upper layers of the decidua, as shown by Minot, 98, the epithelium and decidua being so fused at this point that it is impossible to determine any line of demarcation between them.

Histology of the Chorion.—The chorion being a portion of the somatopleure consists, of course, of two primary layers, the mesoderm and ectoderm. During the second half of the first month, the earliest period concerning which we have any accurate knowledge, the mesoderm is already a vascular layer of considerable thickness (Figs. 184 and 188, *mes*), and the epithelium (ectoderm) has two layers of cells Fig. 188, *a* and *b*; of which the outer is the darker in specimens stained with osmic acid, carmine, cochineal, or hæmatoxylin, and has also smaller and more granular nuclei. The same distinction exists in the two-layered stage of the ectoderm of the umbilical cord, Fig. 208, and of the foetal skin. Hitherto most authors have entirely overlooked the inner layer at early stages. It was first clearly recognized by Langhans, who directed attention to it in a special memoir, **82.1**, he having already described its later history, **77.1**. In some earlier writers are allusions to the layer. Kast-schenko, in his paper on the chorionic epithelium, has also described it, although he has not followed its history very far. The interpretation to be offered seems to me clearly to be that the chorionic epithelium advances in its differentiation to a stage equivalent to the two-layered stage of the epidermis and there stops; whatever further change occurs is degenerative.

The two primitive layers of the chorionic epithelium have been more or less clearly observed at later stages by several anatomists, and have been variously interpreted. Ercolani and Turner regard them as absolutely distinct, assigning the deep layer to the chorion as its true and only epithelium, and the outer layer to the uterus, thus enabling themselves to conceive the villi as covered by maternal as well as a foetal epithelium, so that maternal blood found between the villi is still within the maternal tissue. After accepting the outer layer as maternal, the question as to its origin still remained. Some authors affirmed it to be the uterine epithelium, others to be the lining of expanded uterine blood sinuses. So far as I am aware, no one has made observations to show by the developmental history of the layer that one or the other of the last-mentioned hypotheses is correct. When we consider the precision and exactitude of Kast-schenko's observations, which actual specimens enable one to verify, there is in my judgment no reason left for differing from the conclusion that both layers are parts of the foetal ectoderm.

Governed by the difficulty of accounting for the presence of maternal blood in the intravillous spaces, and therefore apparently outside the maternal tissues, several investigators have been led to seek for at least an endothelium outside the chorionic epithelium. Some authors, as, for instance, Winkler, have asserted the existence of such an endothelium, but after a prolonged and careful search I fail to find anything of the kind, and in this result it seems to me the best observers are agreed. Waldeyer, **90.1**, 33, has recently again advocated the existence of an endothelium, but from his description it appears to me that his supposed endothelium is only the outer layer of the ectoderm. Keibel, **89.2**, reports a very different observation; in a young ovum (twenty-five days?) he found a very thin endothelial layer outside of the two layers of ectoderm, and enclosing the maternal blood. Now in the rabbit the placental villi grow down

into the uterine mucosa; the intervillous maternal tissue disappears, leaving only the maternal capillaries, which become enormously hypertrophied and take up the entire intervillous room; in consequence the capillary endothelium immediately covers the villi; later this endothelium also aborts, leaving the blood of the uterus to circulate in channels bounded by the chorionic epithelium. If we assume that the process of development is similar in man, but is completed very precociously, we can understand both Keibel's observation and the failure to detect any true endothelium in later stages. For a full review of the many conflicting opinions concerning the covering of the villi, see W. Waldeyer, **90.1**, 33-47.

Differentiation of the Ectoderm.—The epithelium of the chorion becomes differentiated in three different ways: 1, upon the chorion frondosum; 2, upon the chorion læve; 3, upon the villi. For a correct knowledge of the remarkable changes which the epithelium undergoes, particularly in the placenta, we are indebted to the unusually exact investigations of Langhans, **77.1**, and **82.1**. This author left two points of importance unsettled; namely, the origin of his "*Zellschicht*," and of the "*canalisirtes Fibrin*." Kastschenko has traced the cellular layer (*Zellschicht*) to the epithelium, as already stated; compare pp. 463-469 of his memoir, **85.1**. My own observations show, I think, conclusively that the canalized fibrin arises through a degenerative metamorphosis of the epithelium, which begins in the outer layer and may invade the inner layer (Langhans' *Zellschicht*). Let us consider separately the three series of modifications of the chorionic ectoderm.

In the region of the chorion frondosum the inner layer of the ectoderm (the cellular layer of Langhans) becomes irregularly thickened in patches, which present every possible degree of variation as to number and as to their breadth and thickness. Although at first the cellular layer is more or less continuous and composed of uniform cells, this is not the case in later stages. We must assume that with the growth of the membrane the epithelium increases in area, but remains in many places single-layered, developing no *Zellschicht*. The patches of cells have been well described by Langhans, **77.1**, and Kastschenko, **85.1**, 466, and are represented with lower power in Fig. 189, *c*, and with a higher power in Fig. 186, *c*. They vary much in appearance; the cells are more distinct in the small patches, but are less individual in the large patches, owing to the spread of the process of degeneration into the layer, Fig. 186, *c*. The cell bodies are lightly stained, and the granular nuclei are not very sharply defined and vary in size and shape. The cellular layer is always sharply defined against the stroma, although there is no true basement membrane, but toward the outer layer of the ectoderm its boundary is sometimes distinct, sometimes lost in a gradual transition.

The outer layer of the ectoderm of the frondosum is even more variable. As stated by Kastschenko, it is primitively a dense protoplasmic reticulum, with nuclei in a single layer and without any cell boundaries. In the chorion frondosum at four months and after I find spots where this structure still prevails either with or without an underlying cellular layer; in other spots the layer is thickened and

contains an increased number of nuclei, which are sometimes crowded in a bunch; elsewhere the layer is thinned out and has no nuclei; in still other spots the thickening has gone on much further, and usually but not always, where the outer layer is much thickened the cellular layer under it is also thickened; wherever it is thickened, and occasionally where it is thin, the outer layer of the ectoderm shows a marked tendency to degenerate into canalized fibrin, Fig. 189, *Fbr*, and Fig. 186, *fb*. It is not difficult to assure one's-self that the fibrin arises by direct metamorphosis of the ectoderm. I now think that its formation begins in the outer layer and thence

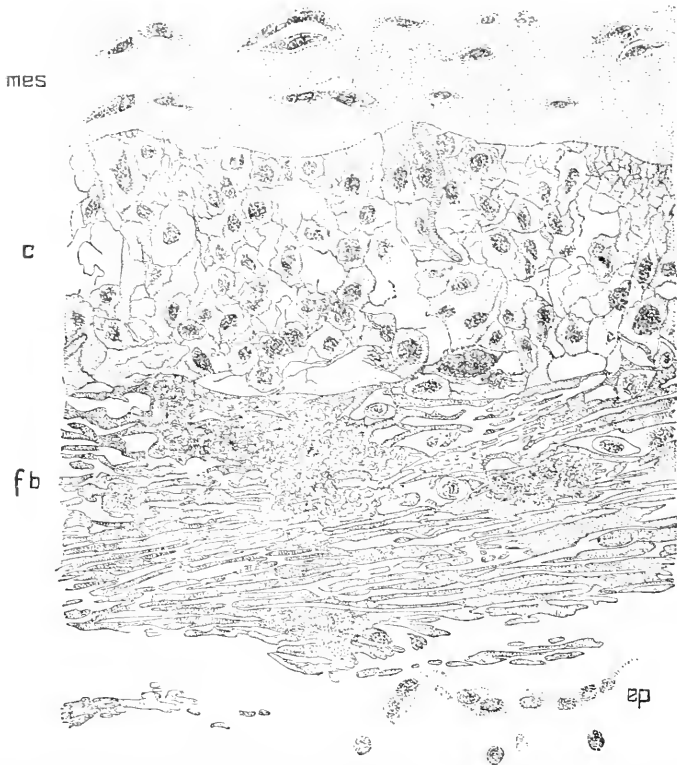


FIG. 186.—Placental Chorion of an Embryo of Seven Months; Vertical Section through the Ectoderm and Portion of the Adjacent Stroma. *mes*, Mesodermic stroma; *c*, cell layer; *fb*, fibrin layer; *ep*, remnant of epithelium. \times 445 diams.

spreads into the cellular layer; for, in fact, when both layers are distinguishable, as in Fig. 186, the fibrin layer, *fb*, is always external, and the external layer of nucleated protoplasm has either totally disappeared or is represented by mere remnants as in Fig. 186, *ep*. The fibrin layer consists of a hyaline very refringent substance permeated by numerous channels, Fig. 186, *fb*; the substance has a violent affinity for carmine and hæmatoxylin, and is always the most deeply colored part of a stained section; the channels tend to run more or less parallel to the surface of the chorion, and are connected by

numerous cross-channels; some of the channels contain cells or nuclei. This complex system of canals is by no means of uniform appearance in all parts of the placenta, both the spaces and dissepiments varying in size and shape. The fibrin often sends, as shown in Fig. 186, long outshoots into the cellular layers upon which it seems to encroach. The frequency of these images in my preparations led me to the opinion* that the fibrin arises from the cellular layer only, and I concluded that the ectoderm was first transformed into the so-called cellular layer, which was then transformed into fibrin. It still appears to me that much of the degeneration goes by these stages; but, on the other hand, it seems clear that the degeneration begins, as above stated, in the outer layer. Another appearance is presented by the ectoderm where it is thickened and wholly transformed into the cellular layer. In brief: the ectoderm of the placental chorionic mesoderm undergoes patchwise manifold changes; it exists in three chief forms: 1, the nucleated protoplasm: 2, the cellular layer; 3, canalized fibrin. A patch of the ectoderm may consist of any one of these modifications, of any two, or of all three, but they have fixed relative positions, for when the nucleated protoplasm is present it always covers the free surface of the chorion; when the cellular layer is present it always lies next the mesoderm; and when all three forms are present over the same part, the fibrin is always the middle stratum. In general terms it may be said that the amount of canalized fibrin increases with the age of the placenta, but it is very variable in its degree of development. The peculiar layer into which the ectoderm is transformed has long puzzled anatomists. E. H. Weber recognized the fibrin layer and described its appearance correctly; it has probably been often seen, but generally regarded as either pathological or a blood coagulum. Robin, for instance, may be cited, 54.1, 70-71, as one who saw without observing correctly and understandingly the tissue in question. An important gain was made when Winkler recognized the modified ectoderm as a constant layer, and in 1872 directed especial attention to it under the name of "*Schlussplatte*," 72.1. Kölliker ("Entwickelungsgeschichte," 2te Aufl. 337) added essentially to our knowledge of its structure, but it is to Langhans that we owe the first clear light. Meanwhile other writers, following the lead of Ercolani and Turner, 79.1, 551-553, have been influenced chiefly by the presence of the cellular layer, in the large size of the elements of which they found a resemblance to the decidual cells which has guided them to the conclusion that the cellular layer is derived from the wall of the uterus. This error has been definitely corrected by Kastschenko, as already stated. In further support of the conclusion that the chorionic cellular layer is not decidual, may be brought forward the fact that there is a certain immigration of decidual cells into the placenta at its margin; but they remain entirely distinct from the cells of the cellular layer. This is readily seen in radial sections through the margin of a placenta from a normal afterbirth; compare, below, the account of the ectoderm of the chorion laeve. The origin of the canalized fibrin from blood, which Langhans left in his first paper as an open possibility, and which even so recent a

* Anatom. Anzeiger, ii., 23.

writer as Ruge, 86.1, 123 and 130, has advocated, cannot be maintained. Of course there may be a deposit of blood fibrin (coagulum), but it would be pathological, and, therefore, to be distinguished from the normal fibrin of ectodermal origin. Moreover, the microscopic appearance of a blood clot or thrombus is so extremely characteristic that one can readily distinguish it from the placental canalized fibrin.

The ectoderm of the villi of the placenta differs from that of the chorionic membrane in several respects: 1. The cellular layer after the first month becomes less and less conspicuous, and after the fourth month is present only in a few isolated patches, known as the *Zellknoten*, and carefully described by Langhans and Kastschenko; both of these authors were impressed by the resemblance of the cells to those of the decidua serotina; Langhans concludes that the *Zellknoten* arise from the serotina, but Kastschenko, having traced their development from the chorionic epithelium, denies his predecessor's conclusion, but, still clinging to the idea of a genetic connection between the *Zellknoten* and the decidua, reverses the reasoning and concludes that the decidual cells arise in part, at least, from the *Knoten*. Neither of these authors have found the intermediate forms between the two types of cells, and when we examine their descriptions critically we find that they have really no evidence except the likeness of the cells to offer in favor of their genetic relationship, and accordingly Langhans expresses himself with characteristic caution. To me the resemblance appears altogether superficial; hence my conclusion that the *Zellknoten* are remnants of the cellular layer. 2. For the most part the villi remain covered by the nucleated protoplasm, which in many places is thickened. In the later stages these thickenings are small and numerous, constituting the so-called "*Proliferations-inseln*;" compare Fig. 183. Many of the little thickenings appear in sections of the villi, and here and there are converted into fibrin. I have interpreted them (Wood's "Reference Handbook of the Medical Sciences," V., 695) as commencing buds, and consider that in earlier stages they grow into branches, but in later stages are in part, at least, arrested in their development. 3. The proliferation islands are converted into canalized fibrin, and at the same time grow and fuse, forming larger patches, particularly on the larger stems; in this manner are produced the large areas and columns of fibrin found in the placenta at four months and after; they have been well described by Langhans, and form a striking feature in sections of placenta. Some of the columns, as stated by Langhans, stretch along the villi from the chorionic membrane to the surface of the serotina as if to act as supports. Ercolani appears, if I understand his account, to have seen the fibrin columns without, however, ascertaining either their structure or their origin. 4. Over the tips of the villi, which are bent considerably where they are imbedded in the decidua serotina, the relations are not clear; the epithelium is certainly not present in its original form over the imbedded ends of the villi, which are, however, surrounded by a hyaline tissue of the character of the canalized fibrin, except that the canals are often indistinct or even wanting; the hyaline tissue forms an almost continuous coat over the decidual surface;

in earlier stages the ectoderm of the terminal villi is often considerably expanded. The natural interpretation of these facts is that the ectoderm of the villi expands over the decidua serotina and degenerates. In this manner we account for both the absence of any cellular ectoderm over the ends of the villi and the presence of canalized fibrin upon the serotinal surface; but the hypothesis must await the final test by observation.

The ectoderm of the chorion læve loses by the seventh month all traces of the protoplasmic layer, and is without any canalized fibrin, except near the placenta; *cf. infra*. It is transformed into a *Zellschicht*. In a section of the læve, *in situ*, at seven months, Fig. 15, the chorionic epithelium, *c*, rests directly upon the decidua, which has none of its own. The ectodermal cells lie two or three deep; they are described by Kölliker and Langhans, the former designating them as the chorionic epithelium, while the latter doubtfully traces their origin to the uterus. That Kölliker ("Entwickelungsgeschichte"), 2te Aufl., p. 322) is right, I am confident. It is easy to follow the layer of cells in question at the edge of the placenta, and see that it is directly continuous with the cellular layer of the frondosum, which it resembles in character. On the other hand the ectodermal cells of the læve are distinct in character from the decidual cells next to them, Fig. 15, having smaller and more darkly stained nuclei, and much more coarsely granular protoplasm; the ectodermal cells are much smaller than the decidual. The ectoderm is sharply marked off from the decidua, but its surface is often corrugated, and then the line of separation between the tissues is irregular, and in sections it may even appear that there is a true interpenetration and mingling of the decidual and ectodermal cells; but it is only apparent, and the demarcation is always preserved.

Differentiation of the Mesoderm.—The further history of the chorionic mesoderm is so fully given by Langhans in his invaluable memoir, 77.1, and Kastschenko, 85.1, that my own observations have afforded little to be added. In the earliest stage I have been able to examine, an ovum of the third week, the matrix of the chorionic connective tissue in a preparation stained with cochineal or hæmatoxylin, and imbedded in paraffin for cutting, appears hyaline and glistening, owing to its refrangibility, Fig. 187; it has lacunæ in which the cells lie; the cell bodies are either shrunken or colorless, so that the lacunæ, except for the staining of their contained nuclei, are clear and light. This appearance I find again in specimens a little older. The image is entirely distinct from that of the same layer later, for then the cells are stained darker than the matrix, which at the same time has lost its homogeneous character, and acquired a fibrillated look. Very different from my own sections are several which I owe to the kindness of Professor Langhans of Bern, and which that distinguished investigator informs me are from a three weeks' ovum, which had been preserved in osmic acid, Fig. 188. In Professor Langhans' preparations the cells are all stained much deeper than the matrix; they have an elongated form, and run in various directions more or less parallel to the epithelium, *ect*; hence many of them are cut transversely or obliquely. Whether the differences noted are due to the methods of preparation

must be decided by preserving the same chorion in part with osmic acid, in part with Müller's fluid or picrosulphuric acid, the latter being the reagents I have used. In specimens of the tenth week the matrix of the chorionic mesoderm has quite altered in character, being no longer homogeneous, and at the same time it has increased in thickness. For the most part the matrix stains lightly, and where it is lighter it contains fibrils of extreme fineness and running curly courses; there are also streaks of lightly stained matrix, giving the impression of fibres resulting from portions of the primitive colorable matrix being left. In other parts of the layer the primitive matrix is still present, and we find a homogeneous well-colored basal substance, the cell lacunæ of which appear light by contrast, as in Fig. 187. One can distinguish also the commencement of the perivascular

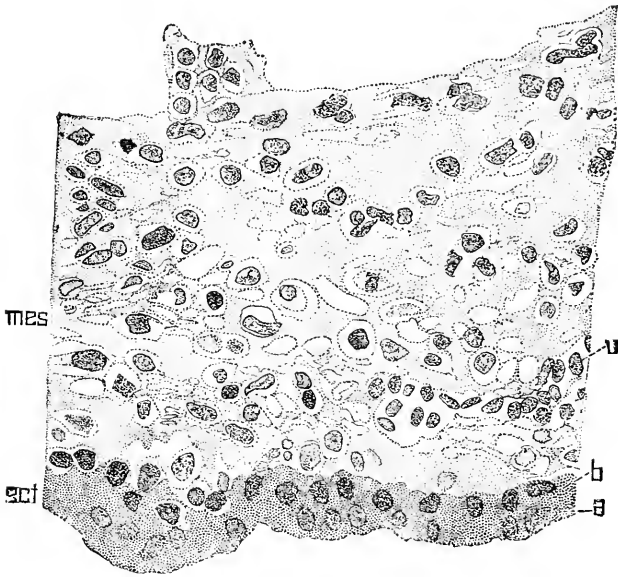


FIG. 187.—Section of the Chorionic Membrane of an Ovum Supposed to Belong to the Third Week. *ect*, Ectoderm; *mes*, mesoderm; *a*, outer, *b*, inner layer of ectoderm; stained with aluminocochineal. $\times 445$ diams.

coats, at least of the larger vessels, the matrix being quite dense around them and the cells elongated almost into fibres, and possessing a slightly increased affinity for coloring-matters. The larger blood-vessels and unmetamorphosed part of the layer occupy a middle portion between the two surfaces, but the smaller blood-vessels lie near the ectoderm (compare Fig. 187, *v*), thus presaging the formation of Langhans' vascular layer (*Gefässschicht*). The development of the mesoderm of the chorion læve stops at about this stage, or at the stage when the matrix has completely changed from its first stage; in the region of the frondosum, however, development proceeds much further by the production of fibres throughout the whole of the layer; usually, but not invariably, the fibres become much more numerous near the ectoderm than in the inner parts of the mesoderm,

thus differentiating a well-marked sub-epithelial fibrillar layer, Fig. 189, *fib*, from the deeper and wider stroma, *Str*. The fibrillar layer is that commonly spoken of as the connective tissue layer of the

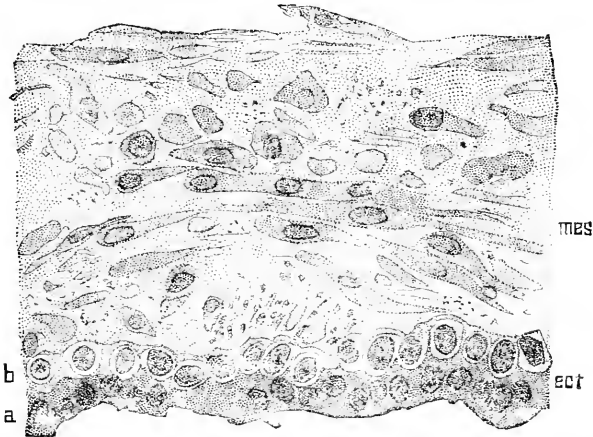


FIG. 188.—Section of the Chorionic Membrane of an Embryo of Three Weeks; stained with osmic acid. *mes*, Mesoderm; *ect*, ectoderm; *a* outer, *b*, inner layer of ectoderm. From a section prepared by Prof. Theodor Langhans. $\times 445$ diams.

chorion; for details of its structure, including the “*Gefässschicht*,” see Langhans and Kastschenko. The inner layer, *Str*, is called the *Gallertschicht* by many German writers, and seems to be what Kölliker (“*Entwicklungsgeschichte*,” 2te Aufl., p. 322) designates as




FIG. 189.—Section of the Amnion and Placental Chorion of the Fifth Month. *Ep*, Amniotic epithelium; *Am*, amnion; *Str*, stroma; *Fib*, fibrillar layer; *fbr*, fibrin layer; *c*, cellular layer; *V*, *Vi*, villi. (From a section cut in celloidin, and stained with Weigert's hematoxylin. The drawing is only approximately correct as to details.) $\times 71$ diams.

“*Gallertgewebe zwischen Chorion und Amnion*,” it usually contains a considerable number of large granular wandering cells.

Jungbluth, 69.1, describes a network of capillaries which exist during the first half of pregnancy, apparently in the upper part of the stroma—*i. e.*, next the amnion—but I fail to find any. Where the amnion comes into contact with the chorion the adjacent parts of the two membranes are more or less loosened, forming a network of strands by which the membranes are united; most of the uniting strands appear to belong rather to the chorion than to the amnion. This loose tissue is perhaps that which Kölliker designates as a *Gallertgewebe* distinct from the chorion.

Although the chorion bounds the cœlom, I have observed no mesothelium upon its mesodermic surface; but I have not made search for it by any special methods. In the rabbit, it will be remembered, the mesothelium is very evident over the placenta, but the rabbit differs from man by the absence of union between the amnion and chorion. Nor have I been able to find any basement membrane, properly so-called, under the chorionic ectoderm. As to the appearance which suggests it, I accept Kastschenko's explanation, 85.1, 455.

The mesoderm in the villi is differentiated otherwise than that of the membrane of the chorion. In the youngest stage I have exam-

ined there is some of the primitive matrix present in the villi; and I presume that earlier the whole mesoderm has the same character. In my specimen (three weeks) the change is progressing. I have not succeeded in satisfying myself as to the process of change which takes place, but I think it probably essentially as follows: The cells gradually develop large bodies and acquire a more decided affinity for color-

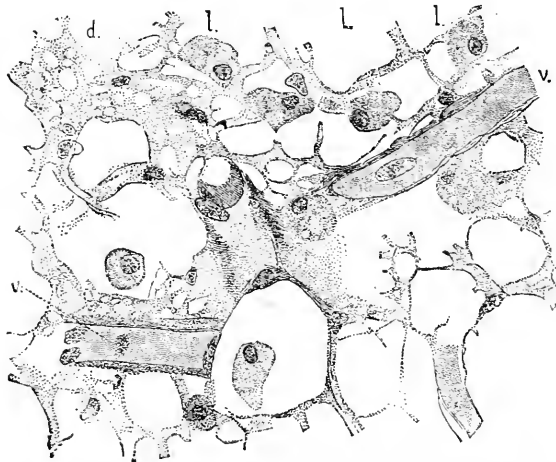


FIG. 190.—Adenoid Tissue of a Villus from a Placenta of Four Months. *ll*, Wandering cells; *v*, *v*, capillary blood-vessels; *d*, finer meshwork from near a capillary. $\times 352$ diamis.

ing-matters; meanwhile vacuoles appear in the matrix, presumably by its modification into a new substance; the vacuoles increase in size and number, transforming the matrix into a network and ultimately causing its total disappearance, leaving the intercellular spaces filled entirely with the new substance, which has come from a metamorphosis of the original matrix; probably this new substance is more or less fluid, since wandering cells are scattered freely through it. Leaving this half-hypothetical history, let us pass on to direct observations. In the placental villi of embryos of four months and older, the mesoderm exists in two principal forms—adenoid tissue and fibre-cell tissue around the blood-vessels. The adenoid tissue, Fig. 190, is that of which the supposed development

has just been sketched; it may be considered as the proper tissue of the villus. It consists of a network of protoplasmic threads, which start from nucleated masses (cells). There are many large meshes which are partly occupied by the coarsely granular wandering cells, *l.l.*, which are scattered about, and are usually present in large numbers. About the capillaries the network is much more finely spun. Kastschenko, 85.1, 454, found the wandering cells most abundant near the epithelium, but I have noticed no such peculiarity except that they do not often enter the dense perivascular tissue; and as the blood-vessels are centrally situated, the adenoid tissue and the wandering cells in it are of course more peripheral. It seems to me that the leucocytes are distributed more or less evenly throughout the adenoid tissue. I fail to recognize any intercellular substance. The abundance of nuclei deserves special mention. Around all the non-capillary vessels the mesoderm is very different, for it exhibits distinct intercellular substance, with a tendency to fibrillar differentiation in quite a wide zone around the blood-vessels; in this zone the cells become elongated and irregularly fusiform; around the larger vessels the cells are grouped in lamina, making the structure similar to that already described in the walls of the vessels of the umbilical cord; after the perivascular coats acquire a certain thickness the cells of the inner layers are more elongated, more regularly fusiform, and more closely packed than those of the outer layer; the transition from the denser to the looser tissue is gradual. We are perhaps entitled to recognize in the denser inner layer the *media*, in the outer looser layer the *adventitia*, although neither of the layers has by any means the full histological differentiation characteristic of the like-named layers of the blood-vessels of the adult.

Blood-Vessels of the Chorion.—As already stated the entire chorion is vascular at an early stage, but the vessels abort very soon over the chorion keve, while over the frondosum they acquire a great development in connection with the formation of the placenta; it seems to me more convenient to deal with them in connection with that organ, and accordingly the reader is referred to Chapter XVII.

Fluid Contents of the Chorionic Vesicle.—In early stages, as we have seen, there is a large chorionic cavity, which in later stages is obliterated by the expansion of the amnion. The space between the chorion on the one hand and the amnion and the yolk-sac on the other is filled with a fluid, which is coagulated by the action of the hardening agents, making a network of threads. This observation, which has been often verified, is all that we know concerning the nature of the chorionic fluid; it is probably of a serous character and may very likely be found to contain free connective-tissue cells (wandering cells or leucocytes).

Evolution of the Chorion.—There can be little doubt, if any, that the chorion arose by the growth and expansion of the abdominal somatopleure, in result of the increase of the yolk-material in the earliest amniota. It can, therefore, not be regarded as originally a new organ. When the amniote type of development was evolved a portion of the original chorion was differentiated and separated as the amnion from the primitive membrane, leaving the rest as the true chorion (false amnion or membrana serosa), enclosing all the other

parts of the embryo and making the chorionic vesicle. This vesicle, therefore, results from the development of the amnion, or perhaps the formation of the amnion is a result of the development of the vesicle. It is customary to refer to the amnion as playing the leading rôle, but of this there is no certain proof, though the conception is natural and plausible. The possession of a true chorion is as characteristic as the possession of an amnion or allantois in the higher vertebrates, so that from a morphological standpoint the term *Chorionida* would be as appropriate and justifiable as the terms *Allantoidea* or the more generally used *Amniota*.

In the mammalia the chorion, being the outermost member of the ovum, is brought into immediate contact with the uterine wall, and has consequently undergone many and complex modifications in connection with the evolution of the placenta. But while the chorion in the placental mammals is the organ of communication between the mother (uterus) and embryo, its vascular connection with the latter is maintained through the intervention of the allantois, which thus co-operates in an essential manner in developing the placenta, though, strictly speaking, it does not participate in forming the actual placenta, meaning by placenta the organ produced through the intimate union of foetal and maternal tissues. It is evident that, as Minot has maintained, the placenta is necessarily chorionic. Further remarks on this subject will be found in Chapter XVII., "The Placenta."

CHAPTER XV.

THE AMNION AND PROAMNION.

Definition of the Amnion.—The amnion is a thin, pellucid, non-vascular membrane, and is the innermost of the envelopes enclosing the embryo or fœtus. Its origin and formation have been described already, p. 281. Morphologically it is a part of the body-wall (somatopleure) of the fœtus, and therefore consists, as we have seen, of two layers, one epithelial continuous with the ectoderm (sen epidermis) of the embryo, the second of loose connective tissue continuous with the somatic mesoderm (outer leaf of mesoderm after the appearance of the body-cavity). The epithelial layer is turned toward the embryo, and the connective-tissue layer consequently lies upon the outside of the amnion away from the embryo, and toward the chorion and the uterine wall.

Growth of the Amnion.—Concerning the growth of the amnion I know of no exact measurements. During the first three weeks it stands off a little from the embryo, but during the fourth week the latter grows so rapidly that it takes up nearly the whole of the amniotic cavity; during the second month the amnion enlarges rapidly so as to leave considerable space for the amniotic fluid; the amnion continues, of course, to expand during all the following months, but after the fourth month it fits pretty closely around the embryo, but is kept distended by the amniotic fluid.

The amnion does not grow around the allantois-stalk or umbilical cord of man as it is commonly stated to do, but, on the contrary, springs from the stalk in the same manner as from the body of the embryo, and is separated from the stalk in the course of development, as is described more fully below, in connection with the histology of the allantois-stalk.

Histology of the Amnion.—For a certain period after it is first formed the amnion, in all embryos I have been able to examine, consists of two layers of cells, both very thin and with the nuclei considerable distances apart, but sometimes in little groups; between the two layers is a distinct space. The ectodermal layer is the most regular and the best defined as to its inner boundary. The mesodermal layer is more or less irregular and sends at intervals a process across the space between the two layers to be attached to the ectoderm.

In a human amnion of a normal two months' embryo, Fig. 191, the mesoderm has become very much thicker, and is readily seen to be separated into two parts, the thin mesothelial layer, *msth*, covering the surface of the amnion toward the chorion, and a mesenchymal layer, *mes*, which makes up the greater part of the membrane; the mesenchyma is probably derived from the mesothelium by proliferation and migration; I have noticed many indications of the process, but have never studied it carefully. The ectoderm, *Ec*, is very

much in the condition just described for the earlier stage, but in specimens of three months' amnia it has become thicker, and its cells are beginning to change into the cuboidal form of later stages.

No blood-vessels or nerves are known to exist in the amnion of

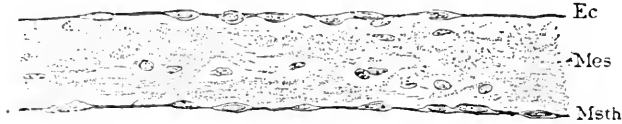

FIG. 191.—Section of the Amnion Covering the Placenta of a Two Months' Embryo. *Ec*, Ectoderm; *mes*, mesoderm (mesenchymal); *msth*, mesothelium. $\times 250$ diams.

the human embryo, although in sheep embryos in very early stages the vessels have been noticed by Bonnet to extend a short distance into the amnion from the body-wall.

Histological Differentiation.—The tissues of the amnion do not progress beyond an early embryonic stage; the ectoderm remain-

ing at the one-layered stage, the mesoderm preserving much of the primitive matrix. Emery ("Arch. Ital. Biol.," III., 37) has directed attention to the primitive homogeneous matrix of the vertebrate mesoderm, and especially to the separate sub-epidermal layer of the embryo, which contains no cells at first. In the human amnion there is a non-cellular layer under the epithelium, as is well shown in Fig. 192, A and B. Sometimes this layer is invaded to a certain extent by connective tissue-cells, B; in other cases the portion of the matrix toward the chorion acquires a fibrillar character, A, as if partially resorbed, but in no case have I seen the matrix entirely altered from its primitive character.

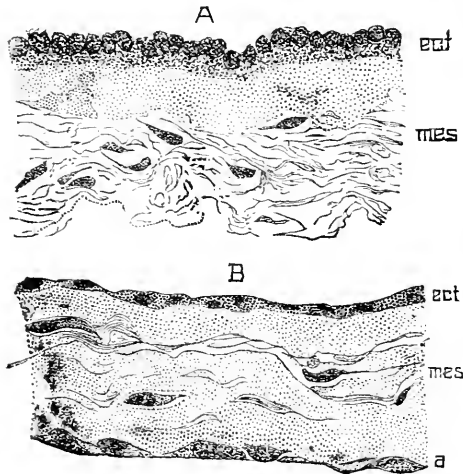


FIG. 192.—Two Sections of the Placental Amnion; A, from an embryo of the eighth month; B, at term. *ect*, Ectoderm; *mes*, mesoderm; *a*, layer of mesodermic cells. $\times 340$ diams.

The cells of the mesoderm lie in lacunæ; they are flattened in the plane parallel to the surface, and hence in vertical sections, Fig. 192, appear more or less fusiform. They present no special features, so far as I have observed, to distinguish them from other embryonic connective-tissue cells. Their bodies have little affinity for coloring-matters, hence it is difficult to follow the processes by which the cells are united. Their nuclei are at first round or oval. After the third month they often show a great variety of alterations in shape and size, Figs. 193, 194; some of the nuclei are then very large, with a distinct network, *d*; others are smaller and differ but slightly from the normal; some are very irregular, *b*, and others again strangely elongated, *a*; many other forms

beside those represented in Fig. 193, are to be found. The changes indicated I consider of a degenerative character, and in fact many of the nuclei are breaking down, for one finds in some specimens every stage between a nucleus and scattered granules—nuclei, nuclei with indistinct membranes, nuclei without membranes, masses of granular matter, clusters of granules crowded together, and finally other clusters more or less scattered. This degenerative process may be compared with that described by Phisalix (*Arch. Zool. Éxpt.*, Sér. II., T. III., 382) as occurring in the blood-cells of the spleen of teleosts. Compare also the chromatine degeneration observed by Flemming to occur in ova of the vertebrate ovary (His and Braune's *Archiv*, 1885, 221-244). In the human amnion the nuclear degeneration described is not always to be recognized so clearly, although the nuclei in all amnia older than three months, which I have observed, are more or less irregular and distorted. Finally it is to be added that not infrequently the cells form a distinct epithelioid layer upon the surface of the amnion next the chorion as represented in Fig. 192, B, *a*. The epithelium of the amnion varies in appearance, as seen in transverse sections. Usually the cells are cuboidal or low cylinders, Fig. 192, A, each with a rounded top, in which is situated the more or less nearly spherical nucleus; sometimes, however, the nuclei lie deeper down. Less frequently the epithelium is thin, Fig. 192, B, and its nuclei, which are transversely elongated, lie further apart. It is probable that those differences are not structural, but conditional upon the greater or less degree to which the amnion is stretched. I have observed no constant differences between the placental and the remaining amnion.

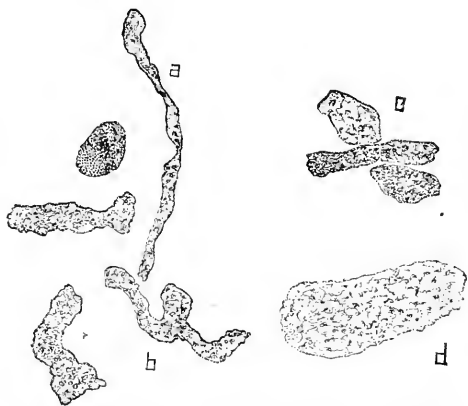


FIG. 193.—A Natural Group of Nuclei from the Mesoderm of the Amnion of a Fœtus of the Fifth month. $\times 1225$ diams.

usually the cells are cuboidal or low cylinders, Fig. 192, A, each with a rounded top, in which is situated the more or less nearly spherical nucleus; sometimes, however, the nuclei lie deeper down. Less frequently the epithelium is thin, Fig. 192, B, and its nuclei, which are transversely elongated, lie further apart. It is probable that those differences are not structural, but conditional upon the greater or less degree to which the amnion is stretched. I have observed no constant differences between the placental and the remaining amnion.

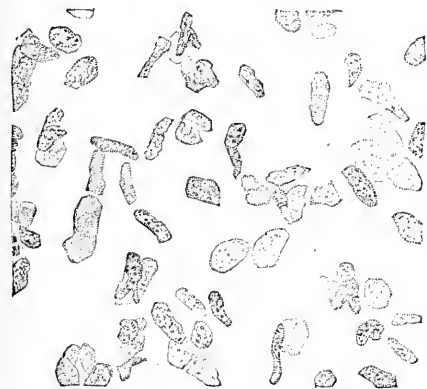


FIG. 194.—Mesodermic Nuclei of the Amnion of an Embryo of about Four Months. $\times 713$ diams.

The most interesting peculiarity of the epithelium is best seen in surface views; namely, the intercellular bridges. They display themselves with a clearness which I have never seen in other epithelia; see Fig. 195.

The nuclei, *nu*, are relatively large, rounded, with distinct outlines; they have a more or less well marked intra-nuclear network, with thickened nodes, and a small number of deeply stained granules, which are probably chromatin. Each nucleus is surrounded by a cell-body, *pl*, and the adjacent cell-bodies are separated from one another by clear spaces. With high powers, as represented in the

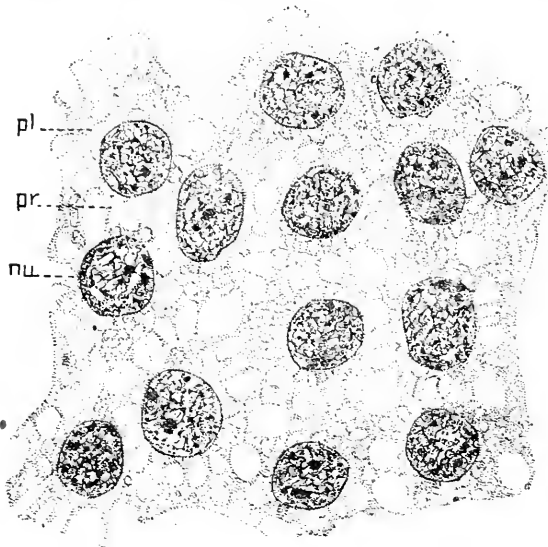


FIG. 195.—Surface View of the Amniotic Epithelium of an Embryo of 144 Days; stained with alum-haematoxylin and eosine. *Pl*, Protoplasm; *pr*, intercellular processes; *nu*, nucleus, $\times 1255$ diams.

figure, one sees that these spaces are separated from one another by threads of material, *pr*, stretching across as bridges, connecting neighboring cells. Examined attentively, the protoplasm of the cells exhibits a vacuolated appearance. One is thus led to view the epithelium as a sponge-work of protoplasm somewhat condensed around each nucleus: according to this interpretation the intercellular spaces are large meshes of the sponge-work, and the intercellular bridges are protoplasmic. A recent paper* by Monsieur Manille Ide, which I owe to the kindness

of the author, brings a series of interesting observations to show that the intercellular bridge of the rete Malpighi of the mammalian epidermis are not protoplasmic, but processes of the cell membranes. This paper has led me to examine my preparations of the amniotic epithelium, but I have been unable to find in them any indications of membranes around the cells or reasons for considering the intercellular bridges as other than protoplasmic in constitution. Whether this result is due to the imperfection of my preparation, or is in accordance with the truth, must be decided by further investigation. Winogradow has called attention. 72.1, to clear spaces among the epithelial cells; these spaces resemble vesicles, and in hardened specimens have granular contents; they are a little larger than the neighboring cells, and seem to have no nucleus. As to the nature of these spaces I can express no definite opinion; they are probably what some authors have described as stomata. The ectodermal cells seem to partially degenerate during the latter half of pregnancy, for the cell boundaries become less distinct and

* Manille Ide. "La Membrane des Cellules du Corps Muqueux de Malpighi, La Cellule." IV., 2me fasc., 1888.

the nuclei become more and more difficult to stain, but the constancy and extent of these changes have never been investigated.

Meola, **84.1**, ascribes a much more complex structure to the amnion than his predecessors, in which he is followed by Viti, **86.1**. Both of these authors subdivide the mesodermic stratum into three layers: a *lamina connetivale*, next the ectoderm, a *sostanza intermedia*, and a *membrana limitante*. As to the histological details, Viti differs somewhat from Meola, but agrees with him in finding a histological distinction between the three layers enumerated. The extent to which I can distinguish three layers is indicated by the description of the mesoderm given above; I have been unable to find the marked structural differences affirmed by Viti. Viti's paper is to be commended for its excellent historical reviews, particularly for his summary of the various theories as to the origin of the amniotic fluid. Winogradow, **72.1**, has described in chloride of gold preparations a fine network of clear spaces, which suggest the existence of lymph channels in the mesodermic layers.

Union of the Amnion and Chorion.—At first there is a considerable distance between the amnion and chorion, which condition is maintained in man during the first two months, but during the third month the amnion gradually comes to lie against the chorion, and after that a loose connection is established between the two membranes, their mesodermic layers becoming gently agglutinated. The connection remains always very slight, so that the amnion can always be readily peeled off. As to the nature of the connection nothing definite is known; sections show that there is a space between the amnion and chorion filled with a transparent matrix, which, at least in hardened specimens, sometimes presents a somewhat fibrillar appearance; in this matrix are scattered a few cells, but whether they are connective tissue (mesenchyma) or wandering cells, and whether they are derived from the amnion or the chorion, I do not know. The layer in question is designated by Kölliker ("Entwickelungsgeschichte," 322) as *Gallertgewebe*, and his opinion, with which I agree, is that the layer probably belongs to the chorion.

Amniotic Fluid.—The amniotic fluid, known as the *liquor amnii*, the *Fruchtwasser* of German writers, is a serous liquid, which entirely fills the cavity of the amnion, and bathes the embryo on all sides. We consider in this article—1, its functions; 2, its quantity; 3, its composition; 4, its origin.

FUNCTIONS.—The amniotic fluid obviously serves for the mechanical protection of the fœtus against sudden shocks, blows, or pressure; assists in the maintenance of a constant temperature, and affords the fœtus scope for its movements *in utero*. When deficient in quantity it may no longer prevent the pressure of the uterine walls from acting on the child, in which case deformities may result. It keeps the skin of the fœtus moist and does the same for the genital passages of the mother during delivery; it is, however, not essential to the act of birth, as is shown by, 1, the delivery in some cases several hours after the outflow of the fluid, and, 2, the delivery of the child with the membranes intact.

The chief function of the fluid, however, appears to be to serve as a water-supply to the embryo. It is probable that during the early

stages of foetal life, possibly during the greater part or even the whole period of intra-uterine existence, the embryo absorbs considerable quantities of fluid directly through the skin, but of this absorption we have no direct certain proof. On the other hand, the swallowing of the *liquor amnii* by the foetus *per os* is well established, *first*, by direct observations of the bird's ovum; *second*, by the finding in the mammalian digestive tract of remnants of foetal epidermis, hairs, and of the *vernix caseosa*, which can have reached their site only by being swallowed while floating in the amniotic fluids. That the embryo chick swallows the amniotic liquid was known to Harvey (1651), and is said to have been observed by Haller; renewal and extension of these observations is much needed. As regards the swallowing by the mammalian foetus there are many observations. Needham, Haller, Moriggia, and many others have found meconium in the stomach of the foetus; the presence of epidermal scales in the foetal digestive tract appears to be constant; the presence of hairs and fat (*vernix caseosa*), or of fatty acids derived from the fatty *vernix*, is very common in the meconium. The fact that the foetus does swallow is established, and analogy with the bird suggests that it swallows constantly the liquor amnii, together with such detritus as may be suspended in it. As the fluid contains only one to two per cent solids, it can hardly serve as nourishment to the embryo. The above considerations, taken collectively, render the supposition plausible that the foetus obtains much of its water from the amniotic fluid.

QUANTITY.—The amount of amniotic fluid at full term has been estimated by Fehling, 79.1, and Levison, 76.1. The former burst the envelope with the finger or with a trocar, collected and measured the outflowing liquid; the after-flow was collected upon a tared linen lying on a waterproof sheet. The minimum obtained in any case was 265 c.c., the maximum 2300 c.c. (certainly abnormal). The average amount at full term was 680 c.c.; for foetus from the middle of the ninth to the middle of the tenth lunar month, 423 c.c. Fehling observed thirty-four cases. Levison found the average of twenty-two cases, 821 gms.; Gassner the average of thirty-five cases, 1730 gms.; but as Gassner's results seem to deserve less confidence, we may safely conclude that at full term there is usually under one litre of amniotic fluid, while it must be remembered that the amount is extremely variable. Richard Haidlen, 85.1, gives a table of forty-three observations of the amount of the amniotic fluid determined according to Fehling's method, *vide supra*, and has recorded also for each case the sex, length, and weight of the child, the weight of the after-birth, the length of the umbilical cord, etc. Combining his observations with those of Fehling (thirty-four cases), he is still unable to detect any constant relation between the amount of the fluid and the weight of the child, the weight of the after-birth, or the length of the umbilical cord. Haidlen's method of tabulation, however, hardly corresponds to the requirements of rigid statistics, and it is possible that a reworking of his figures will give different results. I find the average of his observations to be 714 c.c. of fluid; taking out two isolated extreme observations, one of 50 c.c., and one of 7000 c.c. (hydramnios), the average of forty-one observations is only

577 c.c. Haidlen failed to find any proportion between the percentage of solids and the amount of the fluid.

The amount during development gradually increases, but no exact proportion exists between the stage of development of the foetus and the amount of fluid. Fehling attempted to show a relation between the length of the umbilical cord and the quantity, but Krukenberg, **84.1**, demonstrated from Fehling's own figures, **79.1**, that this conclusion was untenable.

Döderlein, **90.1**, has shown that in the cow the quantity of the fluid increases during the early part of pregnancy and diminishes during the latter part; the exact figures are given in the table below. It is probably that a similar variation occurs in man.

COMPOSITION.—The liquor amnii has the character of a serous fluid. Levison found its specific gravity to vary from 1.0005 to 1.0070, while, according to Prochownick, **77.1**, it varies from 1.0069 to 1.0082. The latter found it to contain between 1.07 and 1.60 per cent dry solids, giving 0.51 to 0.88 per cent ash. With the increase of quantity there is no constant diminution of the percentage of solids. The following table compiled from Vogt and Scherer, **49.1**, indicates the little that is known concerning the changes in composition during gestation:

	3 months	4 months	5 months	6 months	10 months
Water.....	983.47	979.45	975.84	990.39	991.74
Albumen and Mucin.....		10.77	7.67	6.67	0.82
Extracts.....	7.28	3.69	7.24	0.34	0.60
Salts.....	9.25	6.09	9.25	2.70	7.06

Döderlein, **90.1**, has investigated the amniotic fluid of the cow; his work appears painstaking and reliable. His chief results are embodied in the following tables:

	AMNIOTIC FLUID.				
	NaCl.	NaO.	KO.	Ca.	Mg.
Average per cent.....	0.586	0.367	0.060	0.014	0.0038
No. of obs.....	10	7	7	10	9

Embryos.			Fluid.				Stomach.
1.	2.	3.	4.	5.	6.	7.	8.
No.	Wt. grms.	c.c.	Per cent of Wt. of emb.	Total N.	Proteid N.	N—Prot. N.	cc. contents.
1	33	110	333
2	87	160	183
3	276	750	272	0.039	0.011	0.028	100
4	360	1,200	333	8
5	480	1,300	270
6	600	2,000	333	20
7	1,380	2,900	210	0.028	0.008	0.020	30
8	1,700	3,400	200	30
9	1,800	4,320	240	0.020	0.009	0.020	100
10	5,123	3,200	62	0.043	0.013	0.030	160
11	6,630	1,550	23	0.048	0.019	0.020	250
12	6,700	2,500	37	0.048	0.026	0.022	130
13	8,350	1,200	14	0.047	0.025	0.022	400
14	11,300	1,800	15	0.060	0.040	0.030	10
15	14,900	1,300	8	0.105	0.072	0.033	300

In the cow at term the per cent. of albuminoids in eight observations was 0.154, 0.464, 0.280, 0.440, 0.268, 0.610, 0.247, making an average of 0.348 per cent. These figures show that the fluid can have practically no nutritive value.

It is clear that there is a great diminution in the amount of albumen, especially toward the last month, and there is apparently a small diminution in the percentage of salts. The salts are such as are usually contained in serous fluids. In connection with the albumen it may be remarked that the fluid contains no fibrin-forming material, as has been shown by Gusserow, 78.1. There is a small quantity of urea, but not more than is found in other serous fluids; hence, the presence of urea is no argument in favor of the view that the amniotic fluid is an excretion of the foetal kidney. Early in gestation the amount is small, but it gradually increases until the ninth month, 0.030 per cent, and tenth, 0.045 per cent (Fehling). The figures of various authors differ greatly—sometimes no urea being found (*cf.* Preyer, "Specielle Physiologie des Embryos," p. 289). Finally we have to note the presence of lymph-corpuscles, but whether they are always present, and, if so, in what numbers, is unknown; in a few cases they have been found in large numbers.

ORIGIN.—It is a hypothesis of long standing that the liquor amnii is an excretion of the foetus, and opinion has inclined to regard it as the product of the foetal urinary apparatus. There is, however, no satisfactory argument of any kind in favor of this view, but, on the contrary, there are many forcible objections to it, and, moreover, there is strong evidence to show that it is derived from the mother by direct transudation. It is to be considered, *firstly*, that the liquor has the composition of a serous fluid, transuded from the blood-vessels, and does not resemble urine; like other serous fluids it contains a small amount of urea, but this is no indication whatsoever of the urinary origin of the fluid; *secondly*, that the foetal penis is completely closed during the greater part of embryonic life, because after the closure of the raphe on the stalk the glans remains long imperforate, so that in the male, at least, the direct discharge of the urine into the amniotic cavity is impossible; unless, therefore, we are ready to attribute the formation of the fluid to different sources in the two sexes, we cannot assume the kidney to be the source of the fluid in either sex; *thirdly*, that the fluid is not excreted by the epidermal glands is proved by the very late development thereof, and the early and abundant formation of the fluid; *fourthly*, that the amniotic fluid appears very early, being certainly present in the third week, at which time the embryo is entirely without excretory or glandular organs of any kind, and all its tissues are still undifferentiated; *lastly*, that it seems improbable that the foetus, which constantly requires water for its own use, should excrete a large quantity only to swallow it again.

That the *liquor* transudes directly from the uterine wall or from the chorion through the amnion into the amniotic cavity is indicated, *first*, by the composition of the fluid; *second*, by experimental evidence that certain salts can pass directly from the mother into the fluid without passing through the foetus, at least during the latter part of pregnancy. Zuntz, Pflüger's *Archiv*, XVI., 548, was the first

to make such an experiment; he injected an aqueous solution of sulph-indigotate of sodium into the jugular vein of a pregnant rabbit; the liquor amnii showed a distinct blue color, while no trace of blue was found in any part of the fœtus. Wiener, 81.1, repeated and extended this observation, and G. Krukenberg made similar experiments with like results, with iodide of potassium. R. Haidlen, 85.1, also repeated Krukenberg's experiment of giving women iodide of potassium in the early stages of labor, and also small repeated doses for several days before labor; in each case he found the salt in the amniotic fluid, and also in the first urine of the child. This experiment, therefore, does not show whether the diffusion takes place from the uterine wall or the fœtus into the amniotic cavity:

All the facts taken collectively led Minot (Buck's "Handbook," I., 141) to the theory that the liquor amnii is a product of the osmotic function of the amnion; that, during the earliest period, the osmosis takes place from the fluid in the space between the amnion and chorion; that during a certain interval, namely, while the superficial capillaries of the chorion maintain an active circulation in that membrane (*cf.* Chorion), the fluid may come from the chorion, and, therefore, indirectly from the fœtus; and finally that during at least the latter half of pregnancy the transfusion occurs from the decidua through the chorion and amnion both. That the amnion itself produces the liquid it encloses is highly probable, but the exact source of supply upon which the amnion draws is much more uncertain.

Proamnion.—This convenient term was introduced by Ed. van Beneden to designate that part of the *area embryonalis* at the sides and in front of the head of the developing embryo, which remains without mesoderm for a considerable period, so that the ectoderm and entoderm are brought in the region of the proamnion into immediate contact. As found in one stage of the rabbit, it has already been figured in this work, p. 183, Fig. 106. A later stage in the rabbit, as seen in longitudinal section, is figured by Kölliker in his "Grundriss," 2te Aufl., 107. We find that it had been observed in the chick by Remak, His, 68.1, 9, Gasser, 77.3, 463, and Kölliker. Strahl was the first to direct special attention to it. But the earliest description of the proamnion known to me is that of C. Dareste, 66.1, who gives a very exact account of the expansion of the mesoderm (*feuillet vasculaire*) in such a manner as to leave an area in front of the head without mesoderm. Dareste is, therefore, to be considered the discoverer of the proamnion. It has since been observed by various writers: Van Beneden and Julin have described it in the rabbit, Heape in the mole, and recently its exact history has been admirably worked out in the chick by Ravn. The proamnion, then, has been observed in representatives of the classes Reptilia, Aves, and Mammalia; hence we may conclude that it is common to all amniota. It will be remembered that the mesoderm grows out in all directions from the blastopore, or hinder end of the primitive streak. In a chick of twenty-seven hours the front edge of the mesoderm is a somewhat irregular transverse line, which crosses the germinal area about at the front border of the head. This line is well shown in His' drawings, *loc. cit.*, Pl. XII., Fig. 14. As the mesoderm expands it does not grow forward in the median line, but

does grow forward at the sides of the area pellucida in front of the head of the embryo, p. 150. A space is thus enclosed between the mesoderm on each side; this space later becomes the proamnion; it contains no mesoderm. Later on the lateral portions of the mesoderm approach the median line again, some distance in front of the head, so that now the proamnionic area is completely surrounded by mesoderm, Fig. 156, *Pr.a.* We see, as the next phase of development, the head amniotic fold arising in such a position that the proamnion is embraced between the arc of this fold and the head of the embryo; the proamnion, therefore, constitutes the floor of the pit formed by the upgrowth of the head amnion. The appearances at this stage, as seen in longitudinal sections, Fig. 106, are extremely characteristic; the proamnion, *Pro-am*, springs from the wall of the pericardial chamber and passes round the head of the embryo; the proamnionic ectoderm passes upward on the embryo, and its entoderm passes backward under the heart, as a thin layer of cells, *En*, which joins the lining of the archenteron. In the chick the proamnion never acquires any considerable development, but gradually disappears by encroachments of the mesoderm upon all sides, as has been well described by Ravn, whose Fig. 3, *loc. cit.*, Pl. XXI., will serve to give a clear general notion of the relation of the proamnion to the head and to the true amnion in the chick. The disappearance of the proamnion in the chick involves some curious appearances in sections of embryos, which have not been understood hitherto, but which Ravn had correctly and fully elucidated, so far as I can judge; see also the less thorough observations of Shore and Pickering, 89.1.

In the rabbit, according to Van Beneden and Julin, whose observations have been confirmed to a certain extent by Kölliker and Heape, the rôle of the proamnion is more considerable. The history of the proamnion, as given by Van Beneden, may be followed easily by the aid of the accompanying diagrams, Fig. 196, copied from Van Beneden. In A, the proamnion, *pro. A*, is very small, and the allantois, *Al*, is just growing out. In B, the embryo, which for greater clearness has been shaded with stippling, has grown very much, and the anterior half of its body is bent down at a sharp angle into the yolk-sac. The embryo, however, remains separated from the cavity, *Y*, of the yolk-sac by the proamnion, which forms, as it were, a hood, *pro. A*, over the anterior extremity of the embryo. The amnion proper is as yet developed only over the posterior end of the embryo. For the further history of the amnion see above. The proamnion, as can be seen in C and D, retains its importance as a foetal covering for a considerable period, during which the amnion, *am*, and allantois, *Al*, are rapidly pursuing their development. After the stage shown in Fig. 196, D, by the expansion of the cavity marked *Coe'*, the amnion proper, *am*, encroaches more and more upon the proamnion, *pro. A*, until at last the embryo is entirely covered by the true amnion, and the proamnion is altogether lost. It is to be noted especially that the amnion develops principally over the posterior end of the embryo, and grows forward. To this fact reference will be made again directly.

So far as at present known the greatest development of the proamnion is in the opossum, Fig. 202, where it covers ultimately the

entire embryo; at first there is a true amnion over the caudal half of the rump of the embryo, but this gradually disappears and the proamnion replaces it. As in the rabbit the proamnion projects into the hollow yolk-sac, hence in the opossum the embryo may be said to lie in the proamniotic pocket, inside the yolk-sac, as it were. It must not be forgotten, however, that the cavity of the proamnion is

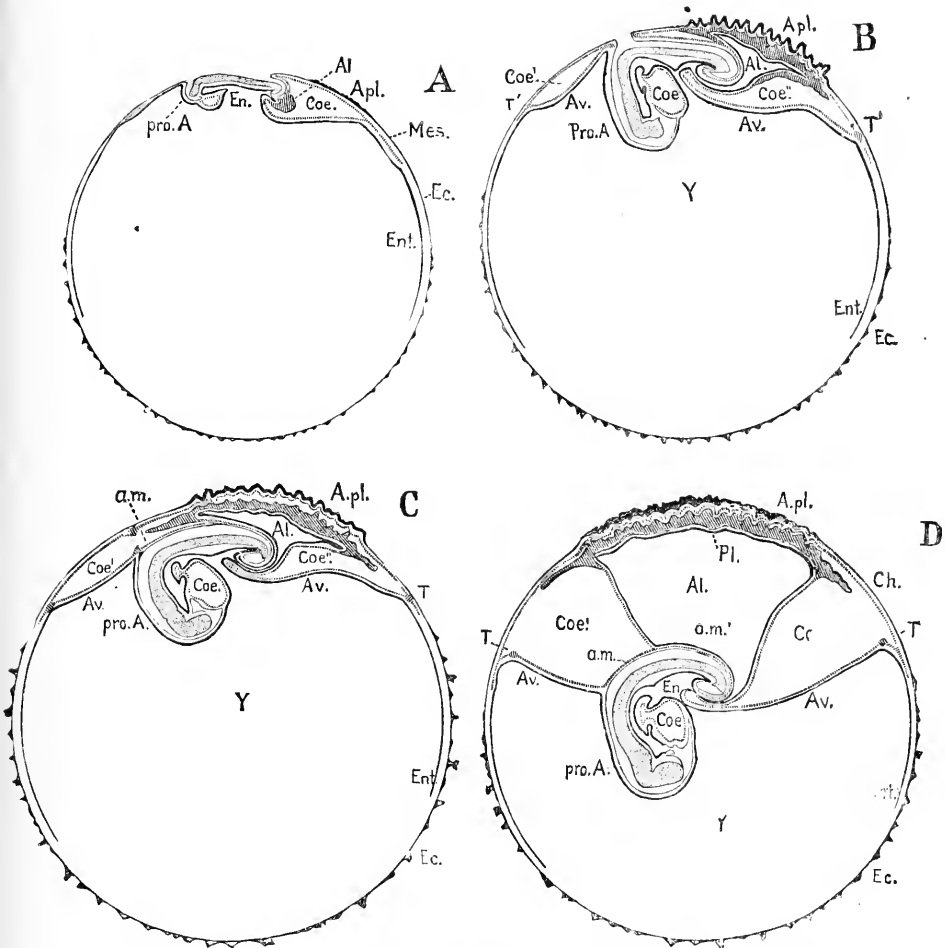


FIG. 196.—Diagram of the Development of the Foetal Adnexa in the Rabbit. (After Van Beneden and Julin.) A, B, C, D, Successive stages; *pro. A*, pro-amnion; *Av.*, area vasculosa; *Coe.*, coelom; *Coe'*, *Coe''*, extra embryonic portion of the coelom; *En.*, entodermic cavity of the embryo; *Ent.*, extra-embryonic entoderm; *Ec.*, ectoderm; *Mes.*, mesoderm; *Apl.*, area placentalis; *Al.*, allantois; *T*, terminal sinus of the area vasculosa; *Y*, yolk-sac; *Am.*, amnion; *Am'*, portion of the amnion united with the wall of the allantois; *Ch.*, chorion.

morphologically outside the yolk-sac, as is clearly shown in the diagrams of Fig. 169.

In certain mammalia there is no proamnion, owing probably to modifications in the early development of the mesoderm, leading to

a precocious invasion of the proamniotic area by the middle germ-layer. This seems to be the case in all rodents with inverted germ-layers (guinea-pigs, rats, etc., *cf.* p. 141), also in the sheep, Bonnet, **89.1**, 19, and probably other ruminants, and finally in man. The earliest stages of human development which we have yet obtained show us the mesoderm completely developed around the entire ovum and separated over the whole of the extra-embryonic region into a somatic (or chorionic) and splanchnic (or yolk-sac) layer, the amnion fully formed, and no proamnion. It is quite possible that at an early stage in the formation of the mesoderm there is an area corresponding to the proamnion, but it must be obliterated almost immediately.

Evolution of the Amnion.—That the amnion is a modification of part of the extra-embryonic somatopleure (primitive chorion) is certain from its development, but beyond this nothing definite is known as to its evolution or phylogenetic origin. Nor do the speculations of Balfour, "Comp. Embryol.," II., 309, nor of Van Beneden and Julin, **84.1**, 425, nor of J. A. Ryder, **86.3**, seem satisfactory. Balfour says: "The origin of the amnion is more difficult to explain than that of the allantois; and it does not seem possible to derive it from any pre-existing organ. It appears to me, however, very probable that it was evolved, *pari passu*, with the allantois, as a simple fold of the somatopleure round the embryo, into which the allantois extended itself as it increased in size and became a respiratory organ. It would be obviously advantageous for such a fold, having once started, to become larger and larger, in order to give more and more room for the allantois to spread into."

Van Beneden and Julin say: "Dans notre opinion la cause déterminante de la formation de l'enveloppe amniotique réside dans la descente de l'embryon déterminée elle même par le poids du corps. C'est par une accélération du développement que la cavité amniotique en est venu a se former quand l'embryon ne possède encore qu'un poids insignifiant." Essentially the same view has been advocated by Shore and Pickering, **89.1**, 16. The chief objection to this theory is that it really gives no cause for the expansion of the somatopleure and chorion; there is no proof that a mere strain of weight can cause the cells of a membrane to proliferate, and since such proliferation is the immediate cause of the growth of the amnion, Van Beneden and Julin must assume for their theory that the strain of weight does cause proliferation; but this assumption lacks support. Moreover they give no evidence to show that the embryo, *in utero*, is situated in the primitive amniota upon the upper side of the ovum, although it is probable such was the case.

Ryder's theory, **86.3**, of the origin of the amnion, like that of Van Beneden and Julin, to which he does not refer, is purely mechanical; but Ryder seeks the cause in a rigid *zona radiata* forcing the embryo down into the yolk. See his summary, *loc. cit.*, p. 184. So far as we know, however, the embryo of the Sauropsida cannot be said to sink into the yolk, and so lead to the development of an amnion; but, on the contrary, the amniotic folds rise up clear above the yolk. Moreover, the formation of the amnion is really a very complex process, part arising from the proamnion, part by a dilation of the pericardial cavity (*Parietal-Höhle*), and part as the extra-embryonic tail

folds. These facts speak in my judgment unequivocally against the amnion having arisen by the sinking of the embryo into the yolk-sac. Nor is there any justification, I think, for seeking these simple mechanical explanations, which are worthy of Herbert Spencer, since the formation of the amnion depends upon inequalities in the growth power of the germ-layers, and only such explanation can be valid, as explains that inequality—which Ryder's hypothesis fails to do, so far as I can see.

CHAPTER XVI.

THE YOLK-SAC, ALLANTOIS, AND UMBILICAL CORD.

THE three structures mentioned in the heading of this chapter have such intimate relations with one another in the human embryo that it is convenient to study them together; but it should not be forgotten that morphologically the yolk-sac and allantois are absolutely distinct organs, as their development in the embryo clearly demonstrates.

I. THE YOLK-SAC.

General Morphology.—As the yolk-sac is the container of the nutritive yolk, destined to be assimilated by the embryo, the evolution of the yolk-sac must have depended primarily upon the accumulation of yolk in the egg-cell. In the primitive form of vertebrate

development (Petromyzon, Ganoids, Amphibia), we find this material comes to lie in the walls of the digestive tract between the heart and the allantois, and chiefly on the ventral side of the canal; the yolk of the embryo is situated, in other words, in the region of the abdominal cavity. When the liver appears it separates the heart from the mass of yolk in the entoderm. As soon as the mesoderm is developed completely around the ovum it of

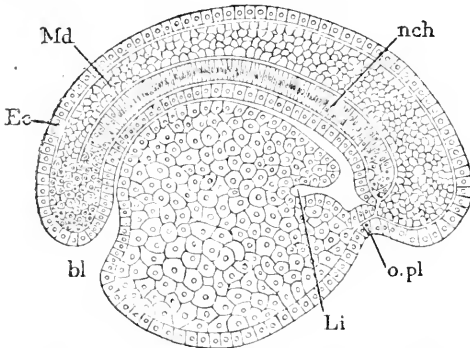


FIG. 197.—Longitudinal Median Section of a Petromyzon Larva. *Ec*, Ectoderm; *Md*, medulla; *nch*, notochord; *o.pl*, oral plate; *Li*, liver pouch, extending into the mass of the yolk cells; *bl*, blastopore. After C. Kupffer.

course separates the yolk and the ectoderm, and as soon as the coelom is developed in the abdominal region there is a layer of mesoderm enclosing the yolk; now as the yolk is entodermal it follows that the yolk, together with the mesoderm layer around, are morphologically part of the splanchnopleure. This splanchnopleuric bag is the homologue of the yolk-sac. In the meroblastic anamniota* (elasmobranchs) there is a separation of the yolk-sac from the embryo, and it hangs down from the intestinal canal of the embryo by a small stalk; but it is covered by the somatopleure just as in the more primitive types, so that the true yolk-sac is inclosed in a second membrane. The same arrangement exists in the amniota; there is an inner or true yolk-sac formed by the vitelline entoderm and splanchnic mesoderm, and an

* For some further details see P. Mayer, 87.1, 346.

outer somatopleuric sac, homologous with the external membrane of the elasmobranch, but commonly known as the *membrana serosa* in Sauropsida, and as the *primitive chorion* in mammals. The term yolk-sac, as applied to the elasmobranchs, includes both the inner or true yolk-sac and the outer somatopleuric covering, homologous with the chorion; but as applied to amniota, it commonly refers only to the inner sac, to the exclusion of the chorion.

Yolk-Sac of Sauropsida.—The manner in which the embryonic archenteron is separated from the yolk-sac has already been described, p. 255, and we saw that the peripheral part of the area pellucida, the whole of the area opaca, of the so-called germinal wall and of the yolk-mass are included in the yolk-sac; all the parts mentioned constituting collectively the entodermal lining of the yolk-sac. The whole of the vitelline entoderm tends to assume a distinctly epithelial structure; the change begins in the region of the embryo and thence spreads gradually in all directions; in the region of the area pellucida the vitelline epithelium (*Dottersackepithel*) has thin wide cells; in the region of the area opaca the cells are high cylinder cells, Fig. 198, *c*, of somewhat irregular shape, containing a loose

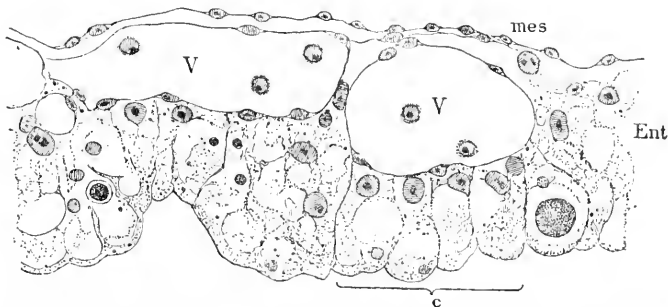


FIG. 198.—Wall of the Yolk-Sac in the Area Opaca of a Chick of the Second Day. *Mes*, Mesoderm; *V*, *V*, blood-vessels containing a few young blood-cells; *Ent*, entoderm; *c*, four entodermal cells showing distinctly. (Compare with Fig. 201.)

network of granular protoplasm; the lower ends of the cells are rounded and projecting and have a well-marked border of dense protoplasm; the nuclei are variable in size, but for the most part large, often three or four times greater in diameter than the neighboring mesodermic nuclei; they have usually one, sometimes two, conspicuous nucleoli; the nuclei always lie on the upper or basal ends of the cells, generally near one side—a point best made out in surface views; the cells further contain yolk grains, which appear to be undergoing resorption; near the area pellucida the cells are smaller, the network of protoplasm closer, and the yolk grains either absent altogether, or, if present, small in size and few in number; the transition to the thin entoderm of the area pellucida is quite abrupt, according to H. Virchow, 75.1, but I have found in some cases a gradual change. Toward the periphery of the area opaca the entodermal cells become larger and richer in yolk-grains and pass gradually into the germinal wall. The cylinder cells of the opaca entoderm stand at various inclinations, so that they are cut obliquely for the most part; consequently only here and there can we recognize them clearly,

as in Fig. 198, c. The germinal wall is the connecting link between the epithelium on the dorsal side of the cavity of the yolk-sac and the yolk forming the floor on the ventral side of the cavity. The structure and metamorphoses of the germinal wall have been the subjects of much discussion, leading to very little result, for many authors have sought in the germinal wall the origin of mesodermal and even of ectodermal cells; that all such views are erroneous was demonstrated by H. Virchow, 75.1; it would have saved a great deal of confusion if his admirable little paper had received the attention it deserves. H. Virchow has since confirmed and amplified his results in two valuable memoirs, 91.1, 92.1.* The germinal wall is the transition from the cellular opaca entoderm to the non-cellular yolk, hence it consists of protoplasm charged with yolk grains and having numerous nuclei, which toward the embryo become situated in discrete cells, which, as we pass to the opaca, gradually take on a more and more epithelial character; the non-cellular yolk has nuclei also, but they are further apart than those of the germ wall; these nuclei are the so-called parablasic nuclei (see p. 352). As development proceeds we see the area pellucida encroach upon the opaca, the area opaca upon the germinal wall, and the germinal wall upon the yolk proper; the whole series of changes may be described as a centrifugal metamorphosis.

The mesoderm of the yolk-sac is a thin layer which gradually spreads over the yolk, and so slowly that, according to M. Duval ("Atlas," Fig. 652), it does not completely enclose the yolk until the seventeenth day in the chick. The early appearance of blood-vessels in it marks out the area vasculosa, which is a part of the yolk-sac; the expansion of the vascular area has already been described, p. 276. A further peculiarity of the mesoderm is that it sends down partitions into the mass of yolk, carrying along the blood-vessels, and thus increasing the absorbent surface; the partitions in the chick begin to appear during the sixth day, and continue multiplying and growing for at least ten days.

As the yolk-sac contains the nutritive material for the embryo, it diminishes in size as the latter grows; the shrinkage causes the sac to become, the sixth or seventh day in the chick, flaccid and somewhat irregular in shape, two peculiarities which become more and more marked as development progresses. By the eighteenth day the sac is very much smaller; by the nineteenth the reduction is still more striking and the sac begins to be withdrawn within the body of the chick, and before hatching the embryo takes in the yolk-sac completely through the umbilical opening; during its retraction the sac has a characteristic hour-glass shape, owing to the narrowness of the umbilicus.

Concerning the structure of the yolk-mass during the resorption of the yolk material we know very little, and of the physiology of the assimilation of the yolk, almost nothing. Von Baer pointed out, 28.3, that the yolk becomes more fluid in the chick, and H. Rathke, 39.1, 113, that in the snake the separate yolk-granules disappear, and the yolk becomes a greenish-yellow homogeneous translucent

* I regret that these memoirs came to my hands too late to enable me to incorporate Virchow's results in the text.

fluid. H. Strahl, **87.1**, gives an important account of the yolk-sac in the lizard, showing that the dissepiments of mesoderm are covered with large yolk-cells—the whole yolk apparently becoming cellular in later stages; the cavity of the sac is very distinct; the sac itself becomes flattened; and it is only on the inferior side that the dissepiments acquire a considerable development, and on this lower side the cellular structure is perhaps never fully attained. The regular form of the yolk-sac persists in the lizard, but in the snake, H. Rathke, **39.1**, 183–184, it becomes flaccid and irregular.

Yolk-Sac of Mammals.—In order to understand clearly the development of the mammalian yolk-sac, it is best to start with the two-layered blastodermic vesicle, with a small embryonic area in which there is mesoderm; the inner layer of the vesicle is the homologue of the yolk-mass of Sauropsida, and is able to assume the cellular structure owing to the loss of yolk, which is undoubtedly also the cause of the large size of the cavity of the vesicle—this cavity being, as we have seen, the vitelline cavity; the inner vesicle then is the homologue of the entodermal part of the yolk-sac. The extra-embryonic mesoderm and coelom are extremely variable in extent in the mammalian ovum; in man, as we have seen, the mesoderm is very early developed completely around the yolk-vesicle, and so is the coelom, so that in the earliest accurately known of human stages the yolk-sac and chorion are completely differentiated. In the sheep, and probably in all ruminants, there is a similar early separation of the yolk-sac and chorion. In the rabbit the mesoderm never extends over more than about half of the blastodermic vesicle, but the coelom extends nearly to the periphery of the sheet of mesoderm; hence we have a half-way separation of the yolk-sac and chorion. In the opossum the mesoderm extends about half-way over the blastodermic vesicle, but the coelom is developed only around the allantois, so that there is only a very partial separation of the yolk-sac and the chorion. In both rabbit and opossum the lower half of the yolk-vesicle is in direct contact with the ectoderm, preserving to this extent the condition of the stage of the two-layered blastodermic vesicles.

That the partial extension of the mesoderm represents a modified condition is evident, since in all non-mammalian vertebrates both mesoderm and coelom extend completely around the yolk. Hence, the complete separation of the yolk-sac in man and the sheep is nearer the ancestral type than the relations of the extra-embryonic germ-layers to one another in the rabbit and the opossum. The question as to what was the primitive mammalian arrangement must be left open; we cannot say whether the opossum or man most nearly represents the ancestral type.

MAN.—The human yolk-sac is an appendage of the digestive canal formed by the extra-embryonic somatopleure. At the beginning of the third week the diameter of the yolk-sac is about equal to the length of the embryo. By the middle of the third week the sac has become distinctly pear-shaped and is attached by its pointed end to the intestinal canal of the embryo, Fig. 17. The sac continues growing up to the end of the fourth week, after which it enlarges very slightly, if at all; its diameter is from 7–11 mm. It is then a pear-shaped vesicle attached by a long stalk to the intestine, the

stalk having been formed by the lengthening of the neck of the yolk-sac, Fig. 169. Sections show that the sac is hollow, with a lining of entodermal cells, and a thicker layer of mesoderm, containing blood-vessels; the network of vessels imparts a characteristic appearance to the external or mesodermic surface of the yolk-sac, compare Fig. 175. The accompanying Fig. 199 represents a section of the yolk-sac of an embryo of about 1 mm., after Keibel. The cavity of the yolk-sac extends at first through the stalk to the intestine, but it early becomes obliterated in the stalk. The entoderm disappears altogether and quite early in the yolk-stalk; thus in an embryo of 12.5 mm., His ("Anat. menschl. Embryonen," III., 20) found only remnants of it in the stalk. In the vesicle itself the entoderm consisted in a very young ovum of a single layer of cuboidal cells (Graf Spee, 90.1, 163), but is

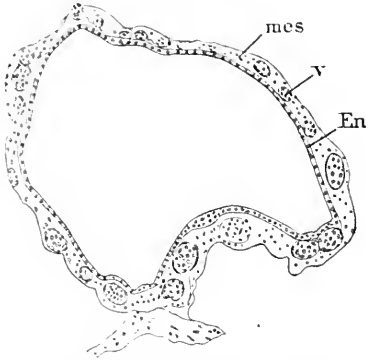


FIG. 199.—Section of the Yolk-Sac of a Human Embryo (No. 11, p. 291). Ent., Entoderm; mes., mesoderm; V., blood-vessels. After Fr. Keibel.

said to become fatty and to change into a pavement epithelium, which is also thrown up into vascular villi (Kölliker). In regard to the further contents of the yolk-sac, Von Baer states, 37.1, 272, that in young ova (at six to seven weeks) the contents are sometimes as thick and yellow as the yolk of a bird's egg; in ova of this period the thinner the contents the more rounded and fully distended is the yolk-sac. A little later the contents are always fluid, but at the end of pregnancy, according to B. S. Schultze, 61.1, when the sac has shrunk to 4-7 mm. in diameter, it contains variable quantities of fatty substances and carbonates. It thus appears that during the first month, at least, the yolk-sac does contain more or less true yolk—an idea which is confirmed by Rauber's observations on the rabbit's ovum. It seems indeed probable that the rudimentary yolk-sac of man still performs for a short period the function of a food reservoir for the embryo, amnion, and the chorion. (B. S. Schultze, 61.1).

SHEEP.—The two-layered blastodermic vesicle, with an embryonic shield, has an elongated form; the mesoderm spreads out gradually between the ectoderm and entoderm (yolk-vesicle) starting from the shield; the cœlom is developed in it as it spreads, so that by the thirteenth day (R. Bonnet, 89.1, Taf. VI., Fig. 3) about a third of the ovum is furnished with mesoderm, and in this third the splanchnopleure of the yolk-sac is completely separated from the chorionic somatopleure, while elsewhere the yolk entoderm is still directly in contact with the ectoderm; this stage, see Fig. 200, is as far as development progresses in the rabbit. In the sheep the development of the mesoderm and the cœlom proceeds, until about the seventeenth day the yolk-sac is completely separated from the chorion; the yolk-stalk remains short, but the yolk-sac proper becomes drawn out and twisted, following in its growth the characteristic elongation of the ruminant chorionic vesicle.

RABBIT.—The development of the extra-embryonic mesoderm and cœlum is entirely arrested at about the stage reached by the sheep on the thirteenth day, so that the yolk-sac and chorion are never differentiated over more than half the ovum, the inferior hemisphere of which remains in the stage of a two-layered blastodermic vesicle, and is said by Duval to degenerate and be resorbed. The accompanying diagram will suffice to render the disposition clear; it will be seen at once that the chorion, *Cho*, exists only part-way round the ovum. I introduce here Fig. 201 of a section through the wall of the yolk-sac of a rabbit embryo of thirteen days; the structure closely resembles that of the area

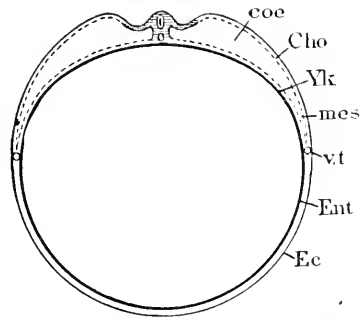


FIG. 200.—Diagram of the Embryo and Yolk-Sac of a Rabbit. *coe*, Cœlum; *Cho*, chorion; *Ylk*, yolk-sac; *mes*, mesoderm; *v.t.*, vena terminalis; *Ent*, entoderm; *Ec*, ectoderm.

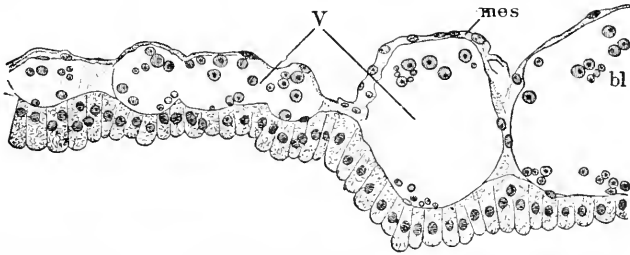


FIG. 201.—Vertical Section of the Wall of the Yolk-Sac of a Rabbit Embryo of Thirteen Days. *VV*, Blood-vessels; *bl*, blood-cells; *mes*, mesoderm.

opaca of the bird's yolk-sac, Fig. 198, except that the entodermal cylinder epithelium is composed of much smaller cells in the rabbit, owing to the absence of yolk.

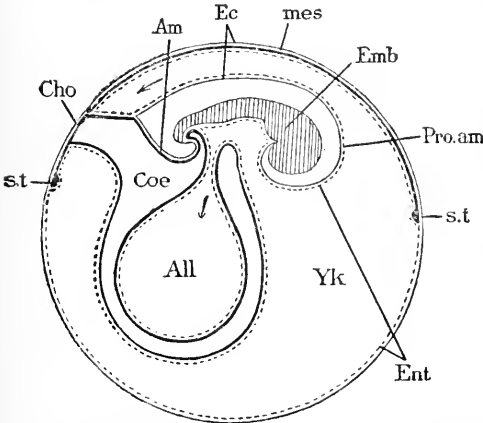


FIG. 202.—Diagram of an Opossum Embryo and its Appendages. *st*, Sinus terminalis; *Cho*, chorion; *Am*, amnion; *Ec*, ectoderm; *mes*, mesoderm; *Emb*, embryo; *Pro. am*, pro-amnion; *Ent*, entoderm; *Yk*, cavity of yolk-sac; *All*, allantois; *Coe*, cœlum. After E. Selenka.

OPOSSUM.—Our knowledge rests mainly upon the observations of Selenka, 87.1, whose diagram I have copied, Fig. 202; the embryo, *Emb*, is almost entirely covered by the pro-amnion, *Pro. am*, the amnion, *Am*, being very much reduced; the allantois, *All*, projects also into the yolk-sac cavity, *Yk*; owing to the development of the pro-amnion and allantois the cavity, *Yk*, of the yolk-sac acquires a very complicated form; the extra-embryonic cœlum, *Coe*, is hardly more

than a space around the allantois, and consequently the true chorion is reduced to an insignificant area, *Cho*; the extra-embryonic mesoderm, *mes*, extends over nearly half the ovum, from *st* to *st*, but contains—except around the allantois—no cœlom; in this sheet of mesoderm the blood-vessels of the area vasculosa are developed; and as there is no cœlom over the area, the vessels are almost as closely related to the ectoderm, *Ec*, as to the entoderm, *Ent*. Here, then, we have the mesoderm spreading out as in the rabbit, but the development of the cœlom is arrested. Although the opossum stands low in the mammalian scale, its fetal membranes show many changes from the sauropsidan type and are probably modified in an aberrant manner, differently from mammals of other classes. For the peculiar relations of the yolk-sac to the allantois, see the description of the latter organ.

The So-called Parablasic Nuclei of the Yolk.—In meroblastic vertebrate ova, after the embryo is formed, there appear in the yolk near its surface underneath the extra-embryonic blastoderm peculiar large nuclei, which are commonly designated as the parablasic nuclei. The following description applies to *Pristiurus*.* The extra-embryonic ectoderm is a thin, much-flattened epithelium lying close to the yolk; below the ectoderm is the superficial layer of the yolk, a broad stratum of protoplasm with scattered small yolk granules; a little deeper down a row of irregular vascular spaces, and again a little deeper a layer of very big nuclei, each with a distinct intranuclear network and several deeply-stained nucleoli; the nuclei vary in size, being from two to five times the diameter of the nuclei in the embryo. The upper part of the protoplasmic stratum contains numerous small and a few larger yolk-grains, and contains near and under the embryo small nuclei; the middle part of the stratum contains the vacuoles, the big nuclei, and but few yolk grains; the deepest part contains larger granules and merges gradually into the yolk proper. (See also His, 82.1, 75, and Rückert, 85.1.) Rückert designates these nuclei as "*Merocytenkerne*," and the cells which they represent as "*Merocyten*." H. E. Ziegler, 87.1, states that the parablasic nuclei of teleosts multiply up to a certain stage by indirect division, but later they assume a peculiar habitus and multiply by indirect division, and assume various shapes. These changes are perhaps connected with the death of the nuclei, their active functions being completed. The special function of the protoplasmic layer appears to be the assimilation of the nutritive yolk. Rückert also maintains, but without proper evidence, it seems to me, that merocytes become cells, some of which join the ectoderm, some the entoderm, and yet others the mesenchyma. In the Sauropsida we find similar nuclei and similar relations of the nucleated layer, but in them the protoplasmic layer becomes the epithelium of the yolk—see especially H. Strahl, 87.1—and I consider it probable that these parablasic nuclei in all meroblastic ova belong to the vitelline entoderm. J. Rückert, 92.3, claims that some of the "parablasic nuclei" are derived from spermatozoa, which enter the yolk but do not unite with the female pronucleus; it is doubtful whether

* From sections in the collection of Professor His, which he generously permitted me to study.

or not any of these spermatozoa nuclei share in the production of embryonic tissue.

In holoblastic mammalian ova the vitelline entoderm is cellular, and no nuclei are known similar to large "parablastic" nuclei of meroblastic ova.

II. THE ALLANTOIS.

The origin of the allantois we have already described, p. 257. It arises as an entodermal evagination behind or below the blastopore and anus, and extending into the anterior end of the primitive streak.

Allantois of Sauropsida.—The allantois becomes rapidly distended by the enlargement of its entodermal cavity, and hence comes to project freely into the coelom as a vesicle, attached by a pedicle to the anal end of the intestinal canal. This vesicle is of course formed by the splanchnopleure, and therefore lined by entoderm, with an outer layer of mesoderm. In the chick the vesicle is about as large as the eye by the middle of the fourth day, and after that grows very rapidly, becoming bent so as to project on the right side of the embryo; by the end of the fourth day it is already about as large as the mid-brain at that stage (*cf.* Duval, "Atlas," Fig. 122). During this expansion its mesoblastic walls, which are at first very thick, become thinner, and at the same time the allantoic blood circulation becomes important. The blood is supplied directly from the dorsal aorta, which terminates in a fork, of which each branch is an allantoic artery, and the blood is returned by two allantoic veins, which run along in the body walls. By the third day in the chick they are found, after having united into a single trunk, to open into the vitelline vein, close behind the liver. The allantois continues enlarging, and pushes its way very rapidly into the extra-embryonic coelom, between the amnion and chorion (serosa or false amnion). Curving up around the right side of the embryo the vesicle comes to lie on the dorsal side, above the amnion, and separated from the shell by nothing more than the thin chorion. In this position its rapid growth continues; it forms a flattened bag, covering the right side of the embryo, and rapidly spreading out in all directions. It is filled with fluid, so that in spite of its flattened form its opposite walls are distinctly separated from one another. The expansion steadily continues, so that by the ninth day the allantoic vesicle nearly surrounds the yolk; during the eleventh day the outer wall of the allantois begins to grow, together with the chorion; hence in opening an egg during the later stages of incubation, there is much danger of tearing the allantois when the shell membrane is removed. The embryo may now be said to be surrounded by two new membranes—the outer and inner walls of the allantois. About the sixteenth day the allantoic sac completely envelops the ovum, and by the seventeenth its edges fuse. The closure, according to Duval, **84.2**, takes place in such a manner that there is formed a sac of ectoderm, inclosing the remnant of white at the pointed end of the ovum; this sac, as well as the yolk, is inclosed by the allantois.

Histology.—Concerning the tissues of the allantois we possess

very little information; the entodermal lining appears, at least in advanced stages, as a low cuboidal epithelium, while the mesoderm is thicker and consists of more or less widely separated mesenchymal cells, covered by a thin mesothelium; the mesoderm contains blood-vessels; and since contractile pulsations have been observed in the allantois of the chick toward the close of incubation, it is probable that some of the mesenchymal cells assume the form of smooth muscle fibres. Where the allantois fuses with the chorion (*membrana serosa*) the mesothelium of both layers disappears, and there is no demarcation or difference between the allantoic and chorionic mesenchyma—compare Duval, **84.2**, Pl. IX., Fig. 8.

Allantois in Mammals.—The allantois is very variously developed in the mammalia, being a distinct vesicle in most forms, but never growing around the embryo and yolk, as in birds. In the *opossum*, Selenka, **87.1**, 141, the allantois does not even come in contact with the chorion, but invaginates the wall of the yolk-sac, as shown by the diagram, Fig. 202; the wall of the yolk-sac forms a pocket in which the allantoic vesicle is lodged; the walls of the two organs do not unite; the pocket in the yolk-sac has curious relations to the main blood-vessels running from the embryo to the *area vasculosa*, for the two *omphalo-mesaraic* veins run straight back from the embryo along the edges of the mouth of the pocket, while the single *omphalo-mesaraic* artery runs in a great arch in the median plane round the bottom of the pocket. These features are beautifully illustrated by Selenka, **87.1**, Taf. XXVII., Figs. 1-4. The allantoic wall is figured by him, Fig. 4, Taf. XXV., as consisting, in an embryo six days old, of an inner layer of entodermal cuboidal epithelium, a thin outer layer of mesothelium, and a thicker layer of vascular mesenchyma. In the *rabbit* (and probably all rodents) the allantois becomes a moderate-sized vesicle, Fig. 196, *All*, which grows out until it reaches the placenta chorion, with which it unites to co-operate in the development of the placenta. In *insectivora* the allantois seems to resemble that of the rodents, though it acquires greater size; exact investigations are much needed. In *ruminants* the allantois expands very early, growing out transversely and continuing to enlarge with extraordinary rapidity until it takes up most of the chorionic vesicle, thus becoming, relatively to the embryo, of enormous size. For further details see R. Bonnet, **89.1**, 26-36, and Bischoff, **54.1**. A few histological facts may be gleaned from the very verbose article on the allantois by A. Dastre, **76.1**, 17-44.

MAN.—The allantois in man and other primates is essentially different from that of any other known amniote. It never becomes a free vesicle, but always remains a narrow tubular diverticulum. In man the embryo, when the amnion is formed, becomes everywhere separated from the chorion, except at the hind end, where the accumulation of mesodermal cells into which the allantoic diverticulum extends, see Figs. 170, 180, and 222, constitutes a thick stalk. This stalk has been named the *Bauchstiel* by W. His; it may be regarded as a direct prolongation of the body of the embryo; it permanently connects the embryo proper with the chorion. The amnion springs from the sides of the *Bauchstiel* in the same manner as from

the body of the embryo. "In man, therefore, there is no free allantois, and the history of the organ may be said to be reduced to that of the entodermal allantoic diverticulum. The entodermal allantois is a small, long, epithelial tube extending, as we have seen, to the chorion, p. 297, Fig. 110. The tube increases very little in diameter, after the second month; compare A and B, Fig. 444. It is very persistent, appearing usually even in the cord at full term, at least in the proximal end, according to Kölliker ("Entwickelungsgesch.," 2te Aufl., p. 34). After the second month it is a small group of epithelioid cells, with distinct walls, irregularly granular contents, and round nuclei; around the cells, Fig. 203, *ent*, which may or may not show a remnant of the central cavity, there is a slight condensation, *mes*, of the connective tissue to form, as it were, an envelope. This structure has been regarded by Ahlfeld and others as the persistent yolk-sac. I think the correct interpretation was first suggested by Kölliker.

It has been supposed by some writers that the human allantois grew out as a free vesicle. Haeckel even went so far as to prophesy that when a human embryo of the right stage should be obtained, this condition would be found. Shortly after this W. Krause published a description, 76.1, of an embryo, which he said was human and had a free allantois. Both Haeckel and Krause were mistaken, the former through hasty and unfounded speculation, the latter through an error as to the identity of his embryo. W. His has shown that it was certainly not human, probably not even mammalian, but avian, 80.1, ??. Krause still maintained that it was human. The discussion as to this specimen was a long and animated one, but has now little interest except historically. See Krause, 80.1, 81.1, 2, Kölliker, "Entwickelungsgesch.," 1879, 306, 1013, Ahlfeld (*Cbl. für Gynäk.*, 1880, No. 25), Krause, *ibid.*, 81.1, and Ecker in His' *Arch. f. Anat.*, 1880, 405.

Allantoic Fluid.—The fluid contents of the allantois cannot be well studied in man, owing to the minute size of the cavity of the organ; but when the allantois becomes a large sac, as in the cow and pig, the fluid is readily collected. There are many observations recorded concerning the chemical composition of the fluid, but the best work known to me is that of Döderlein, 90.1, on the fluid in cow embryos. His results may be summarized as follows:

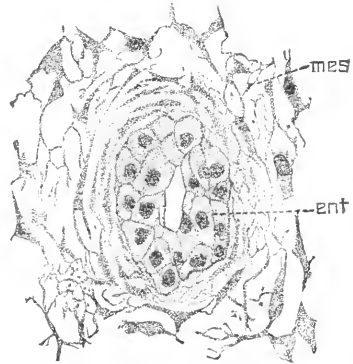


FIG. 203.—Section of the Allantois from the Umbilical Cord of an Embryo of Three Months. *ent*, Entoderm; *mes*, mesoderm. $\times 340$ diams.

ALLANTOIC FLUID (COW).

	NaCl.	NaO.	KO	Ca.	Mg.
Average per cent.....	0.244	0.163	0.093	0.015	0.049
No. of obs.....	8	8	8	10	8

Embryo.			Fluid.			
1.	2.	3.	4.	5.	6.	7.
No.	Wt. grms.	c.c.	Per cent of Wt. of emb.	Total N.	Proteid N.	N—Prot. N.
1	33	75	27			
2	87	90	103			
3	276	200	72	0.135	0.049	0.086
4	300	400	111			
5	480	850	177			
6	600	850	141			
7	1,380	2,400	173	0.124	0.092	0.032
8	1,700	1,300	76			
9	1,800	1,400	77	0.164	0.141	0.023
10	5,123	2,000	38	0.271	0.124	0.147
11	6,690	2,450	36	0.248	0.141	0.107
12	6,700	3,500	52	0.196	0.122	0.074
13	8,350	6,500	77	0.202	0.141	0.061
14	11,300	5,000	44	0.329	0.187	0.142
15	14,300	6,690	44	0.429	0.229	0.209

The allantoic fluid differs markedly from the amniotic—compare the tables above with those on p. 339—and shows in its composition that it is an excretory product of the fœtus, coming from the Wolffian bodies and the kidneys. In the chick, by the sixteenth day, deposits of water become abundant in the fluid (Foster and Balfour's "Elements," second edition, 280).

Notices of several of the earlier investigations on the allantoic fluid may be found in A. Dastre, **76.1**, 45-61, together with some results of his own.

III. THE UMBILICAL CORD.

Bauchstiel.—As the Bauchstiel is the anlage of the human umbilical cord, we must consider its structure and relations. As we have already seen, it is the prolongation of the tail of the embryo, Fig. 166, *Al*, running to the chorion and containing the tubular allantoic diverticulum, Fig. 170, *Al*; it consists mainly of mesoderm, and from its side springs the amnion. Prof. His ("Anat. menschl. Embryonen," Heft III., 222-226) has made a special comparison which shows that the fundamental morphological relations are the same in the human Bauchstiel as in the embryo proper, and that there are even traces of a rudimentary medullary groove. The resemblance is illustrated by the accompanying Fig. 204. The amnion, *Am*, arches over the dorsal side, which is covered over by thickened ectoderm, *md*, which His regards as the rudiment of the medullary groove; the archenteron is represented by the allantoic diverticulum, *All*, lined by the entodermal epithelium; in the meso-

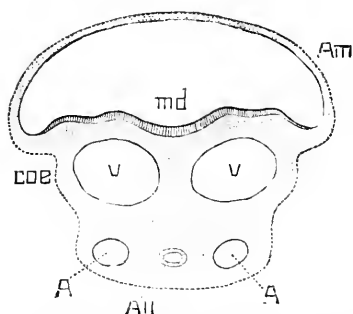


FIG. 204.—Diagrammatic Section of the Bauchstiel of a Human Embryo, modified from W. His. *Am*, Amnion; *md*, medullary groove; *V, V*, umbilical veins; *A, A*, umbilical arteries; *All*, allantois; *coe*, cœlum.

coelom, *coe*, arches over the dorsal side, which is covered over by thickened ectoderm, *md*, which His regards as the rudiment of the medullary groove; the archenteron is represented by the allantoic diverticulum, *All*, lined by the entodermal epithelium; in the meso-

derm run the two large allantoic veins, *V*, *V*, and the two smaller arteries, *A*, *A*; the space around the cord is of course part of the embryonic cœlom, *coe*; the amnion represents the somatopleure, the walls of the allantois the closed splanchnopleure.

To convert the "Bauchstiel" into the umbilical cord, the somatopleure bends down on each side, and finally closing on the ventral side below the allantois, shutting in a portion of the cœlom, and becomes separated from the amnion. The amnion separates from the embryo first, then from the embryonic end of the Bauchstiel, and last of all from the distal end of the Bauchstiel; hence, when the closure of the somatopleure is completed the amnion arises no longer from the embryo, but only from the end of the cord, where it joins the chorion. The closure of the Bauchstiel forms a long tube running from the embryo to the chorion; the cavity of this tube is part of the cœlom; the whole tube is known as the umbilical cord.

When the cœlom of the cord is shut off, it is shut off in such a way that the long, narrow stalk of the yolk-sac, or the so-called vitelline duct is included, compare Fig. 222, *v.s.* This is possible owing to the rolling up of the embryo, which, as shown in Figs. 169, 172, 175, and 222, brings the Bauchstiel into close proximity with the neck of the yolk-sac.

The development of the cord shows that it is never covered by the amnion, which, on the contrary, is always separate from the cord proper. This point is important to note, because in most text-books the cord is erroneously described as covered by the amnion—compare Minot, 98, 380.

Development of the Cord.—The origin of the cord from the Bauchstiel has been described in the preceding section. The

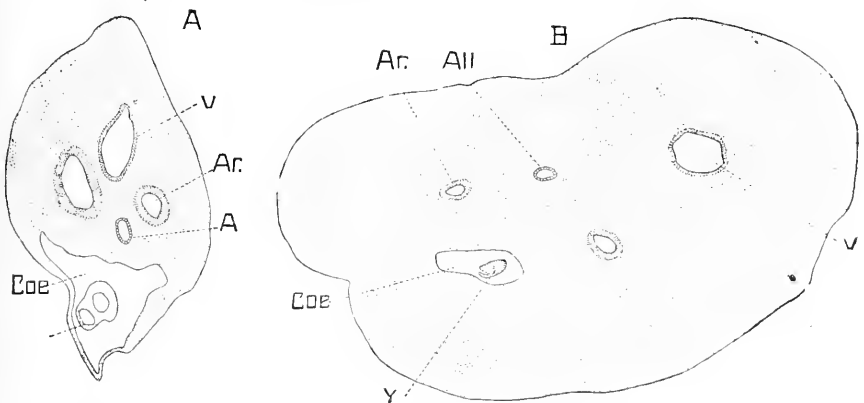


FIG. 205.—Sections of Human Umbilical Cords. A. Embryo of 21 mm; B. embryo of sixty-four and sixty-nine days; *v*, left umbilical vein; *Ar*, arteries; *All*, allantois; *Coe*, cœlom; *Y*, yolk-stalk or vitelline duct.

structure and growth of the cord may be best studied in cross-sections, Fig. 205. The cœlom, *Coe*, is a large cavity and contains the yolk-stalk, *Y*, with its two vessels, and its entodermic cavity entirely obliterated; near the embryo the cœlom may become much enlarged, and is often found during the second month, and even later,

to contain a few coils of the intestine; above the body-cavity is the duct of the allantois, *All*, lined by entodermal epithelium; and in this region are situated the two arteries and single vein; the section is bounded by ectoderm.* The further development of the cord depends upon three factors: 1, the growth of the connective tissue and blood-vessels; 2, the abortion of the coelom yolk-stalk and allantois duct, in the order named; 3, differentiation of the connective tissue and of the ectoderm.

The growth and differentiation of the mesoderm proceed rapidly, encroaching upon the coelom, which is obliterated (early in the fourth month). At first the connective tissue, Fig. 206, is composed merely

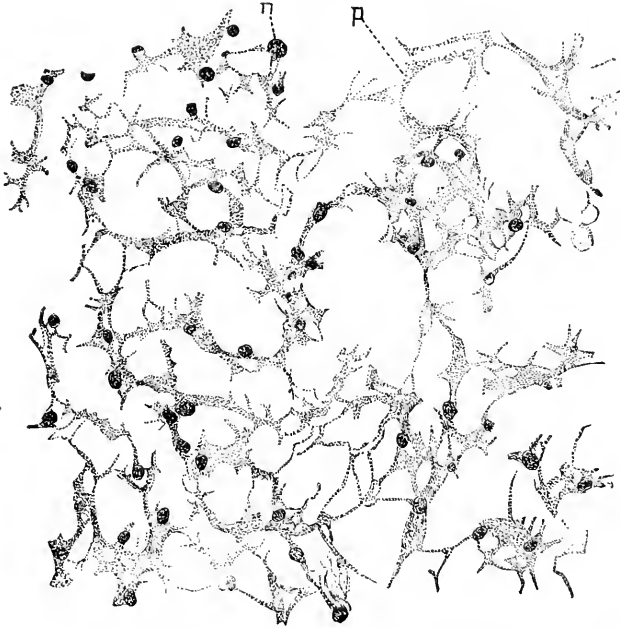


FIG. 206.—Connective Tissue of the Umbilical Cord of an Embryo of 21 mm. $\times 540$ diameters. Stained with alum, cochineal, and eosin.

of numerous cells embedded in a clear substance; the cells form a complex network, of which the filaments and meshes are extremely variable in size; the nuclei are oval, granular, and do not have always accumulations of protoplasm about them, forming main cell-bodies.†

I notice also a few cells, which I suppose to be leucocytes, but see no other structures. By the end of the third month the cells have assumed nearly their definite form; the protoplasm has increased in amount and forms a large cell-body around each nucleus, Fig. 207. The network has become simpler and coarser, the meshes bigger, and the filaments fewer and thicker; in the matrix are numerous connec-

* The ectoderm is often wanting, owing to its frequent destruction post mortem.

† It is possible that the reticulum here described as cellular is, in part at least, composed of remnants of an early matrix, which shrinks up and is replaced by the clear matrix here described; my observations do not settle this question of the nature of the reticulum.

tive-tissue fibrils, not yet disposed in bundles except here and there; as they curl in all directions many of them are cut transversely, and therefore appear as dots. In older cords there is an obvious increase in the number of fibrils, and they form wavy bundles. In the cord at term the matrix contains mucin, and may be stained by alum haematoxylin; at what period the reaction is first developed I have not ascertained. I have observed nothing to indicate the presence of special lymph-channels in the cord at any period, but I have not investigated the point. Tait's lymph-channels are merely the intercellular spaces.

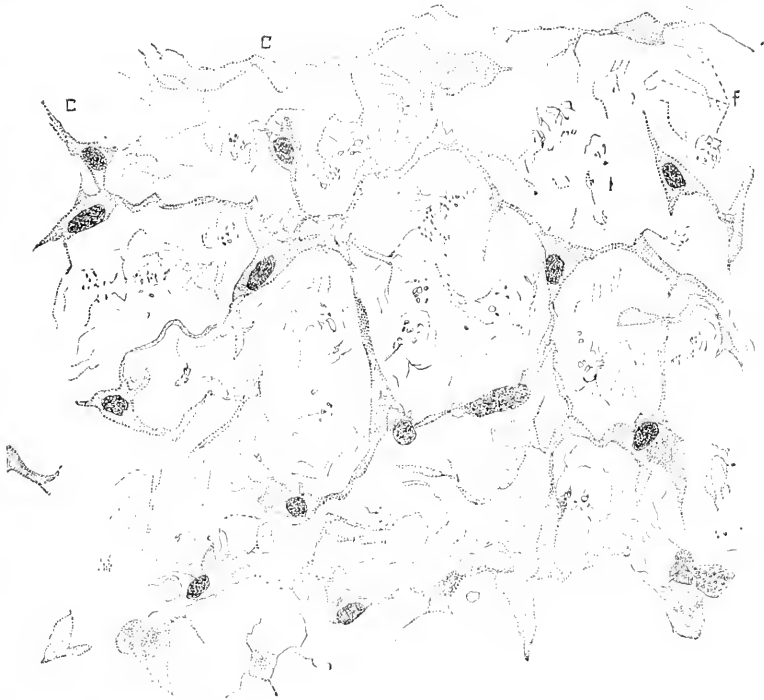


FIG. 207.—Connective Tissue of the Umbilical Cord of a Human Embryo of about three Months. $\times 511$ diameters. Stained with alum, cochineal, and eosin.

The ectoderm is at first a single layer of cells, a condition which is permanent over the amnion; in an embryo of three months I find the two-layered stage, Fig. 208. The outer layer is granular, and in some parts each cell protrudes like a dome;* the inner layer consists of larger, clearer cells. By the fifth month the stratification of the epithelium becomes more evident and cornification begins. The ectoderm (*Ec*), therefore, develops like the epidermi proper, although much more slowly, so that it never gets beyond the stage which the true epidermis reaches by perhaps the fourth month; on the other hand it differs entirely from the amniotic epithelium.

* From the investigations of Dr. J. T. Bowen on the development of the epidermis, which he has been carrying on in the histological laboratory of the Harvard Medical School, it seems to me probable that this external layer is homologous with epithelium.

The blood-vessels steadily enlarge and acquire thick muscular walls. In the cord of an embryo of 21 mm., Fig. 205, the arterial *muscularis* is well marked, the venous *muscularis* just beginning to show. At sixty-three days I find the coat thickened on all the vessels; there is a gradual passage from the muscle cells to the surrounding connective tissue, so that one wins the impression that the

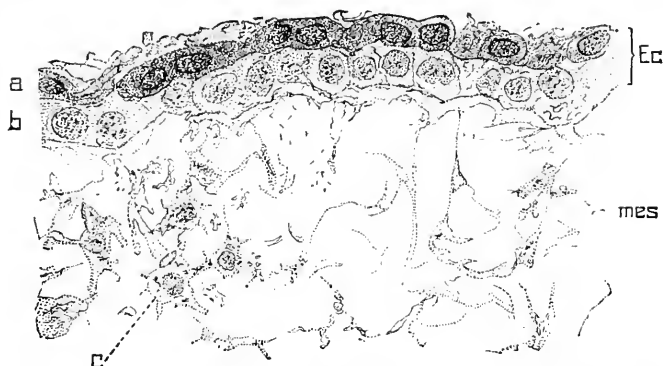

FIG. 208.—Epithelial Covering of the Umbilical Cord of an Embryo of three Months. $\times 545$ diameters.

connective-tissue cells are being directly metamorphosed into muscular cells. By the fifth month the demarcation of the muscular coats is quite sharp, and it is probable that the further growth of the layer depends upon the growth of the elements it already contains and not upon the accretion of new ones; that the muscle-cells do actually become bigger is easily ascertained by direct observation.*

The obliteration of the cœlom goes on rapidly during the second and third months, and by the beginning of the fourth is nearly or quite completed. The vitelline duct persists longer, but seems to disappear by the sixth month; for a time it is distinguishable as a shrunken remnant in the midst of the connective-tissue cells of the cord. The allantoic duct occupies usually a position between the two arteries; it attains its maximum diameter about the fifth week, when it is a small epithelial tube, Fig. 203, of irregular width, as which it remains for some time without noticeable alteration; during the third month it loses this character and becomes solid, by the enlargement of its epithelial cells; the duct persists up to birth in this form, though losing, according to Kölliker, its complete continuity; after it becomes solid there is a slight condensation of tissue around it.

The Human Umbilical Cord at Birth.—The human cord is a long twisted rope of tissue, whitish in color, and attached by one end to the navel of the embryo, by the other to the surface of the placenta. Its dimensions are extremely variable at all periods; at birth it is usually about fifty-five centimetres long and twelve millimetres thick; it is said that cords only fifteen centimetres long as one extreme, and over one hundred and sixty centimetres long as the

* This offers another example of the rule that growth and cell multiplication may be distinct processes. Compare Merz's remarks, "Denkschr. Wien. Akad.," liii., pp. 34-41, 1887.

other extreme, have been observed. Its surface is smooth and glistening, except at the constricted foetal end, where the epidermis stretches about one centimetre on to the cord. The placental end expands to fuse with the chorionic membrane. The placental insertion is generally eccentric, that is, the cord joins the placenta at a point between the centre and margin of the latter organ; usually the eccentricity is well marked, and not infrequently is so great that insertion becomes marginal; in still rarer cases the cord joins the chorion outside the region of the placenta (*insertio relamentosa*). Occasionally the cord forks before joining the chorion (*insertio furcata*).

The twisting of the cord is always well marked externally at the time of birth by the spiral ridges within each of which a large blood-vessel runs. I have observed the number of spirals to vary from three to thirty-two; the turns, beginning at the embryo, go usually from left to right, but sometimes from right to left. The cause of the twisting, which begins about the middle of the second month, has been much and very unprofitably discussed. Of the many theories on the subject which have been advanced, there is not one, so far as I know, having the slightest claim to acceptance. These vagaries have been collated by Hyrtl, 70.1, and also less fully by Lawson Tait, 76.1, who adds to them. All we can say is that the vessels grow faster in length than the cord as a whole, and therefore assume the spiral disposition; the cause of this inequality is as completely unknown to us as the causes of all the other inequalities of growth which occur in the embryo. One point must be specially mentioned, namely, that there is no reason to suppose that the cord as a whole actually twists any more than the spiral intestine of a shark is formed by twisting; many writers have falsely assumed the occurrence of this twisting motion, and have dissertated at no little length on the revolutions of the embryo *in utero*. There is no evidence that such revolutions occur, nor have we any ground for assuming that the twisted *appearance* of the cord is due to an actual twisting like that of a rope; if a long rubber tube forms a coil within a short glass cylinder, it does not indicate that the cylinder has been twisted.

The cord is covered by a layer of epithelium which is continuous at the distal end with the epithelium of the amnion. Its interior consists of a peculiar embryonic connective tissue known as Wharton's jelly, which is described below; in this jelly are found at birth three large blood-vessels, and usually a few degenerated remnants of the epithelium of the allantoidis. There are no capillaries except close to the navel, and, in spite of the opinion of some writers, it appears safe to say that there are no lymph-vessels,* and no nerves in the distal part of the cord. Schott, 36.1, claims to have followed branches of the hepatic plexus along the vein three or four centimetres into the cord, and branches of the plexus of the colon and uterus an equal distance along the arteries. Valentin has found nerves even further, 8-11 ctm. from the navel. As Kölliker remarks

* Wandering cells occur in the intercellular spaces of Wharton's jelly, and it is possible that there are lymph *channels* in the matrix, though no vessels. Compare particularly Köster's paper.

in his larger text-book, 79.2, p. 341, the absence of nerves in the distal portion of the cord and in the chorion is of no little physiological interest, since the blood-vessels are so contractile. In a cross section, Fig. 209, as usually obtained, the vessels are found contracted,

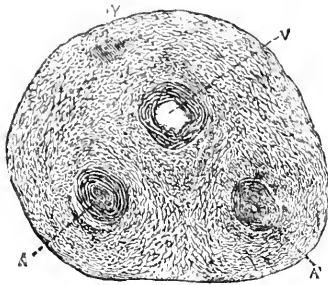


FIG. 209.—Cross-Section of an Umbilical Cord at Term. \times about 12 diameters. Y, Remnant of the allantois; V, omphalo-mesaraic vein; A, A, umbilical arteries.

the arteries, AA, with their cavities almost obliterated. The vessels have thick walls composed of a muscular coat and rudimentary intima, but without any special external connective-tissue layer. The vessels differ from adult vessels of similar calibre in many respects; there is no elastic tissue so far as I have observed in any part; the muscle-cells are short, fusiform, loosely arranged, and run in various directions; next the intima the fibres are longitudinal in trend; in the rest of the coat they are grouped in laminae, which have the fibres obliquely in one direction or another, thus giving rise to the appearance of alternating spiral coats, noticed by Lawson Tait, 76.1

(p. 434 and Plate XIII., Figs. 17 and 18). The muscular coat passes over without any sharp demarcation into the surrounding tissue, known as Wharton's jelly, which consists of scattered anastomosing cells, compare Fig. 207, and a muciparous matrix with very numerous connective-tissue fibres. The cells and fibres tend to arrange themselves in concentric lines around the blood-vessels and parallel to the surface of the cord, Fig. 209, so that we may speak of four systems; within each system the cells tend to an elongated form, but where the systems approach one another the cells become more triangular, as seen in section, Fig. 209, and show three or four main processes. These triangular cells form, of course, long columns which are more or less distinct from the tissue encompassing the vessels; to these columns the name of *chordae funiculæ* has been applied by Hyrtl; they are said to have been noticed by Woortwyck over a century ago. The external covering of the cord is a stratified epithelium, of which the outer layer is distinctly corneous; sometimes there are spaces without cells, which have been regarded as true lymph stomata (Köster and also Tait); the middle layer is composed of clear cells, and the basal layer of granular cuboidal cells; in section the appearances are closely comparable to those of the embryonic epidermis from parts where there are no hairs, and at the time when the horny layer begins to appear. As there is no differentiated connective-tissue layer beneath the epithelium, the covering of the cord is best described as embryonic skin. According to current descriptions the cord is said to be covered by the amnion, but this is obviously an error, as shown by His' observations upon the development, and my own upon the histology of the cord.

There is usually to be seen in sections of the cord at term, according to Kölliker, 79.2, p. 344, especially in sections from the proximal end and middle region, a small group of epithelioid cells, with dis-

tinct walls, irregular granular contents, and rounded nuclei; around the cells, Fig. 203, there is a slight condensation of the connective tissue to form, as it were, an envelope. This structure has been regarded by some writers as the persistent yolk-stalk, as, for example, by Ahlfeld (*Arch. für Gynäk.*, VIII., 363). Kölliker, 79.2, p. 344, considered it to be the remnant of the allantoic cavity—a supposition which my own observations confirm.

CHAPTER XVII.

THE PLACENTA.

FOR convenience the placenta may be considered as an organ by itself rather than as a derivative of the chorion and of the decidua, which it must be considered from a strictly morphological standpoint. I give as full an account of the human placenta as possible.

I. THE HUMAN PLACENTA.

Placenta at Full Term.—The human placenta (*Mutterkuchen*) is a disc of tissue to which the umbilical cord of the child is attached by its distal end. As a result of normal labor the amnion and chorion, by which the foetus in utero is surrounded, are ruptured; the child is then expelled, but by means of the long umbilical cord remains attached to the uterus; after an interval the placenta with which the cord retains its connection is loosened from the uterine wall and expelled, together with the foetal envelopes and portions of the decidual membrane (uterine mucosa) of the mother; the parts thus thrown off secondarily constitute the so-called *afterbirth* of obstetricians.

The placenta at full term, as thus obtained by natural expulsion, is a moist mass, containing a great deal of blood, spongy in texture, about seven inches in diameter, but very variable in size, being roughly proportionate to the bulk of the child; usually oval, sometimes round, but not infrequently irregular in shape. One surface is smooth and covered by a pellucid membrane (the amnion), and reddish-gray in color; to this surface the umbilical cord is attached, and it shows the arteries and veins branching out irregularly from the cord over the surface of the placenta, Fig. 210. The opposite surface is rough, lacerated, and is usually covered irregularly with more or less blood, which is often dark and clotted. When the blood is removed the surface is seen to be crossed by a system of grooves which divide the placental tissue into irregular areas, each perhaps an inch or so in diameter; these areas are called cotyledons. The placenta is about twenty-five or thirty millimetres thick, but thins out rapidly at the edges, and its tissue passes over without a break into thin foetal membranes, which accordingly spring, as it were, from the margin of the placenta.

When *in situ* the placenta is fastened to the walls of the uterus by its rough or cotyledonary surface; its smooth, amniotic surface faces the cavity in which the foetus lies.

A more detailed examination of the gross appearances of a placenta discharged at term leads to the following additional observations: The color is a reddish or purplish gray, varying in tint according to the condition of the blood, and mottled between the divaricating

blood-vessels by patches and networks of pale yellowish or flesh color. The light pattern is produced by the tissue of the villi shining through the membrane of the chorion. These appearances are less distinct when the placenta, as is usually the case, is covered by the thin amnion. The amnion, however, is very easily detached as far as the insertion of the umbilical cord, but from the latter it cannot be pulled off. The blood-vessels run out in all directions from the end of the cord; each vessel produces a ridge upon the placental surface

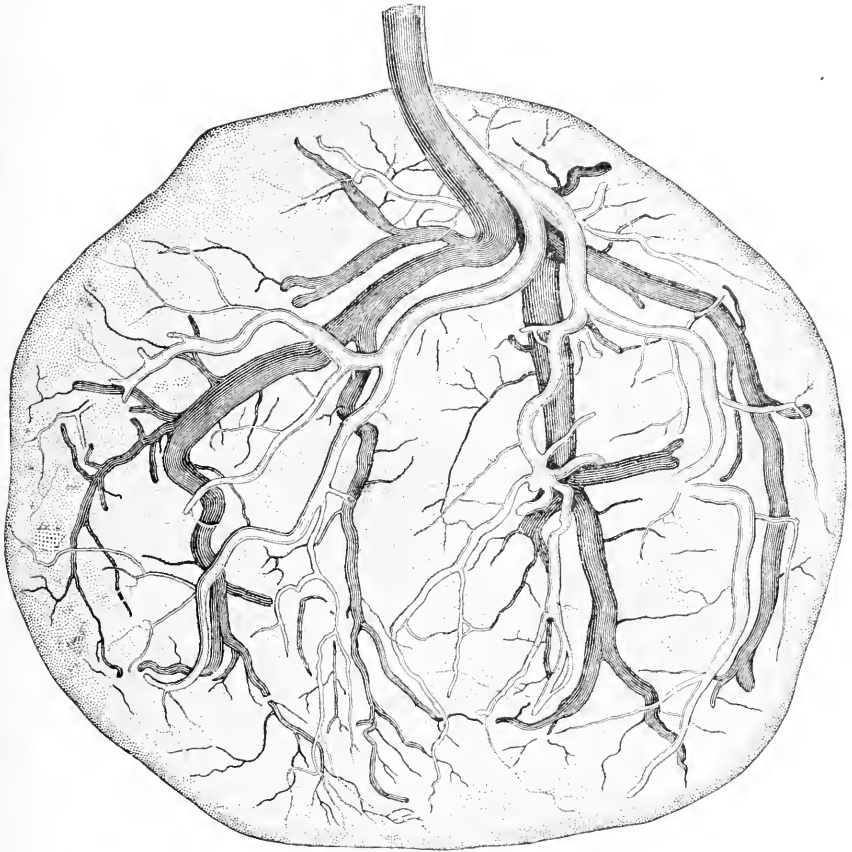


FIG. 210.—Placenta at full Term, doubly Injected by Dr. H. P. Quincy to show the Distribution of the Vessels upon the Surface.

so that its course is readily followed. The arteries and veins are more easily distinguished after double injection, as is shown in Fig. 210.

The two kinds of vessels do not run together; the arteries lie nearer the surface, the veins deeper; the arteries fork repeatedly, until they are represented only by small branches and fine vessels; some of the small branches disappear quite suddenly by dipping down into the deeper-lying tissue in order to pass into the villi. The veins, Fig. 210, are considerably larger than the arteries; they branch in a sim-

ilar manner, but some of the trunks disappear from the surface more abruptly than is the case with the arteries. There is the greatest possible variability in the vessels of the placenta; I have never seen two placenta with vessels alike. So far as I have observed, the insertion of the cord is always obviously eccentric; the degree of eccentricity is variable and is easily seen to be related to the distribution of the vessels.

The insertion of the cord may even be entirely outside the placenta, which yet, as B. S. Schultze has shown, may otherwise be normally developed. Such insertions are called velamentous. The usual type is shown in Fig. 210. The arteries come down together from the cord; they usually, but not always, anastomose by a short transverse vessel, which lies about half an inch above the surface of the placenta; it could not be shown in Fig. 210.

I have never noticed any arterial or venous anastomoses on the surface of the placenta. The arteries there spread out in a manner which may be described as roughly symmetrical. The veins partially follows the course of the arteries. When the cord is inserted near the margin the symmetry of the placental vessels is greater; when the insertion is nearer the centre the symmetry is less than in Fig. 210.

The reverse or uterine surface of the placenta is rough and divided into numerous rounded oval or angular portions termed lobes or cotyledons,* as stated above. These vary from half an inch to an inch and a half in diameter. The whole of this surface consists of a thin, soft, somewhat leathery investment of decidua membrane, which dips down in various parts to form the grooves that separate the cotyledons from each other. This layer is a portion of the decidua serotina, which, as long as the parts are *in situ*, constitutes the boundary between the placenta and the muscular substance of the uterus, but which at the time of labor becomes split asunder, so that while a portion is carried off along with the placenta and constitutes its external membrane, the rest remains attached to the inner surface of the uterus. If a placenta is cut through it is found to consist of a spongy mass containing a large quantity of blood and bounded by two membranes, each less than a millimetre thick; the upper one is the chorion covered by the still thinner amnion, and greatly thickened where the vessels lie in it; the lower one is the decidua tissue together with the ends of the villi imbedded in it (*cf.* especially p. 17 and Fig. 211); it represents only a portion of the decidua, the other portion has remained upon the uterine wall. The spongy mass is found upon examination to consist of an immense number of tufts of fine rods of tissue, which are irregularly cylindrical in shape. Further examination shows that they are twigs, Fig. 183, with rounded ends and springing from little branchlets, which in their turn arise from branches, and so on, until a large main stem is found, which starts from the chorion. This branching system is richly supplied with blood from the foetal vessels on the surface of the placenta. The villi are interwoven so that the twigs of one branch are interlaced with those of another, and apparently separate

* The division of the placenta into cotyledons is not primary, but, on the contrary, is not developed until the fourth or fifth month.

twigs may grow together and their vessels anastomose; but on this point I am unable to speak positively.

The villous twigs next the surface of the decidua penetrate that tissue a slight distance.

The intervillous spaces are filled, or nearly so, with blood; they form a complex system of channels. The intervillous blood, as we know from the researches of Farre, Turner, and Waldeyer, is maternal. Farre says, in his article in Todd's "Cyclopædia," V. Suppl., p. 716, in reference to the placental decidua: "Numerous valve-like apertures are observed upon all parts of the surface; they are the

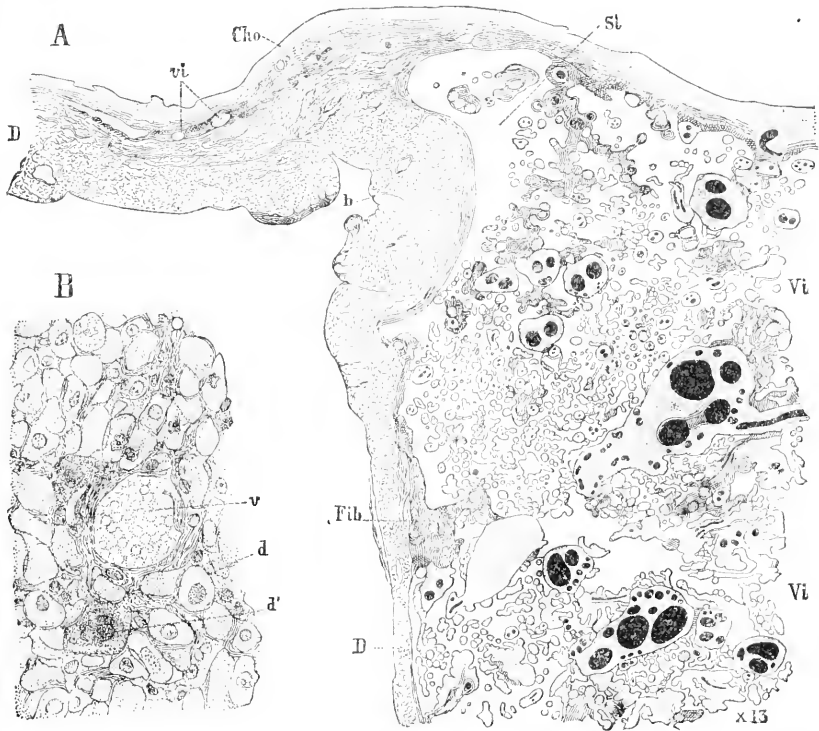


FIG. 211.—Placenta at Full Term. A, Vertical section through the margin; D, decidua; *vi.*, aborted villi outside the placenta; *Cho.*, chorion; *St.*, sinus; *Vi.*, placental villi; *Fib.*, fibrin; B, portion of A, more magnified to show the decidual tissue near *b*; *v.*, blood-vessel; *d.*, *d'*, decidual cells; *d.*, with one nucleus; *d'*, with several nuclei.

orifices of the veins, which have been torn off from the uterus. A probe passed into any one of these, after taking an oblique direction, enters at once into the placental substance. Small arteries about half an inch in length are also everywhere observed imbedded in this layer. After making several sharp spiral turns they likewise suddenly open into the placenta;" and on p. 719 he adds: "These venous orifices occupy three situations. The first and most numerous are scattered over the inner side of the general layer of decidua, which constitutes the upper boundary of the placenta; the second form openings upon the sides of the decidual prolongations or

dissepiments which separate the lobes (cotyledons) from each other; while the third lead directly into the interrupted channel in the margin, termed the circular sinus." The circular sinus (Fig. 211) is merely a space at the edge of the placenta which is left comparatively free from the villi. It is not a continuous channel, but is interrupted here and there. Subsequent writers have gone but little beyond Farre's account, which has been entirely overlooked by most recent German investigators, who accordingly announce facts known to Farre as new discoveries. Under these circumstances it seems no more than just to direct renewed attention to Farre's masterly article. To study the histology of the placenta sections are best made after imbedding the organ in celloidin. Fig. 211 represents parts of a section of a placenta at term from which the amnion was removed. Fig. 211, A, represents the placental margin magnified thirteen diameters; B, a portion of the decidua near *b* in A, but more highly magnified. The chorion, *Cho*, and decidua, *D*, are in immediate contact at the left of the figure, that is, outside the placenta, though remnants of a few aborted villi, *vi*, are still plainly recognizable; but they are found only close about the placenta. At the margin of the placenta and in its neighborhood the chorion and decidua are not clearly delimited, but, on the contrary, the decidual cells find here an opportunity to penetrate the chorionic membrane. The placental chorion exhibits its characteristic stratification a short distance within the margin. I have found, however, that the distinctness of that stratification varies considerably, not only in different placenta, but also in different parts of the same placenta. The decidua, *D*,

outside the placenta is very thick, but at the edge it begins to thin out, and, as it passes over the under side of the placenta, rapidly becomes so much reduced as to be even less in thickness than the chorion, *Cho*. The decidua is characterized by an immense number of large decidual cells, not scattered about as in Fig. 10, but densely packed. Fig. 211, B, the cells are irregularly oval in outline, clear, or somewhat granular,

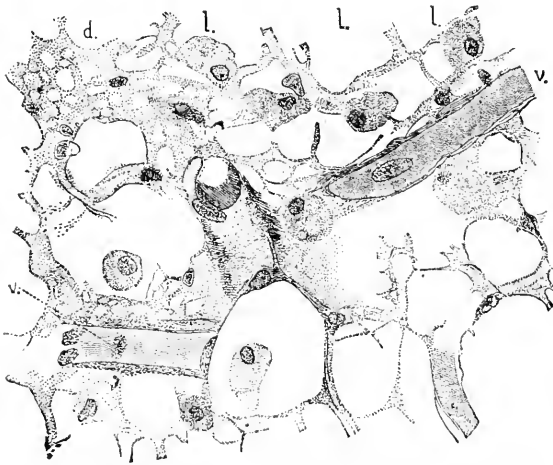


FIG. 212.—Mesenchymal Tissue of a Villus, from a Placenta of four Months. *l l*, Leucocytes; *c v*, capillary blood-vessels; *d*, finer mesh-work from near a capillary.

and have usually a single nucleus; a few are larger, more granular and multinucleate.

At the edge of the placenta the chorion and decidua separate; where they first part there are very few villi, Fig. 211, *Si*, but elsewhere the room between them is occupied by innumerable branches of

villi, *V_i*, *V_i*, with narrow spaces between for the blood; the sections of the villi are of all sizes and shapes; they all contain blood-vessels, but only the larger ones can be distinguished with the magnification of Fig. 211, A, where they have been made as distinct as possible by being drawn black. The spaces between the villi have been left white, the blood which partially filled them not being represented.

Placenta in Situ.—The placenta in its natural position in the uterus follows the curvature of the uterine walls, hence its free or amniotic surface is slightly concave, its decidual surface is strongly convex; it is thickest in its centre and thins out gradually toward its edge. There is no definite boundary between the portion of the decidua serotina which is to be torn off with the placenta, and the part which is to remain in the uterus after delivery.

Vertical sections through the uterus with the placenta in place are very instructive. Fig. 213 represents such a section through a placenta of about seven months. The thin amnion, *Am*, clothes the inner surface of the chorionic membrane, *Cho*; this membrane is separated from the decidua, *D*, by a dense forest of villi; in the younger specimens the distance between the chorion is considerably less than the thickness of the uterine wall, *D, Mc*, but in the present specimen, Fig. 213, it is much greater; in younger stages the villi are much less numerous, and much smaller than in the older one; these differences correspond to the growth of the placenta and to the changes in shape of the chorionic villi already described, p. 319. The ends of some of the villi touch and are imbedded in the decidual tissue; these imbedded ends are without covering epithelium, but their connective tissue is immediately surrounded by hyaline substance, which is probably the degenerated epithelium. The decidua is plainly divided into an upper compact, and a lower cavernous layer, see p. 8. The section passes through a wide arterial vessel, *Ve*.

Fœtal Circulation of the Placenta.—The following paragraph refers to the placenta during the later months of pregnancy; it is copied almost without change from my article on the placenta in Buck's "Ref. Handb. Med. Sci.," V., 696-697.

To follow the course of the fœtal blood-vessels within the placenta, the best method is by corrosion injections. These may be made either with fusible metal, wax, or celloidin. The first is specially suited for the study of the large trunks; the latter for that of the smaller vessels also. I have a very beautiful celloidin injection by Dr. S. J. Mixer, which, with others of wax and metals, has served as the basis of the following description: The veins leave the surface somewhat more abruptly than do the arteries, which gives off more small branches to the surface than do the veins, Fig. 210. Both kinds of vessels leave the surface by curving downward for a short distance into the trunk of a villus; the vessels then divide, and their branches again take a more horizontal course; the branches then curl over downward, and after a second short descent toward the decidua, again send out horizontal branches. The result of this arrangement is a terrace-like appearance in the course of the vessels; they approach the uterine side of the placenta in this very characteristic manner. The number of terraces is variable; usually there are

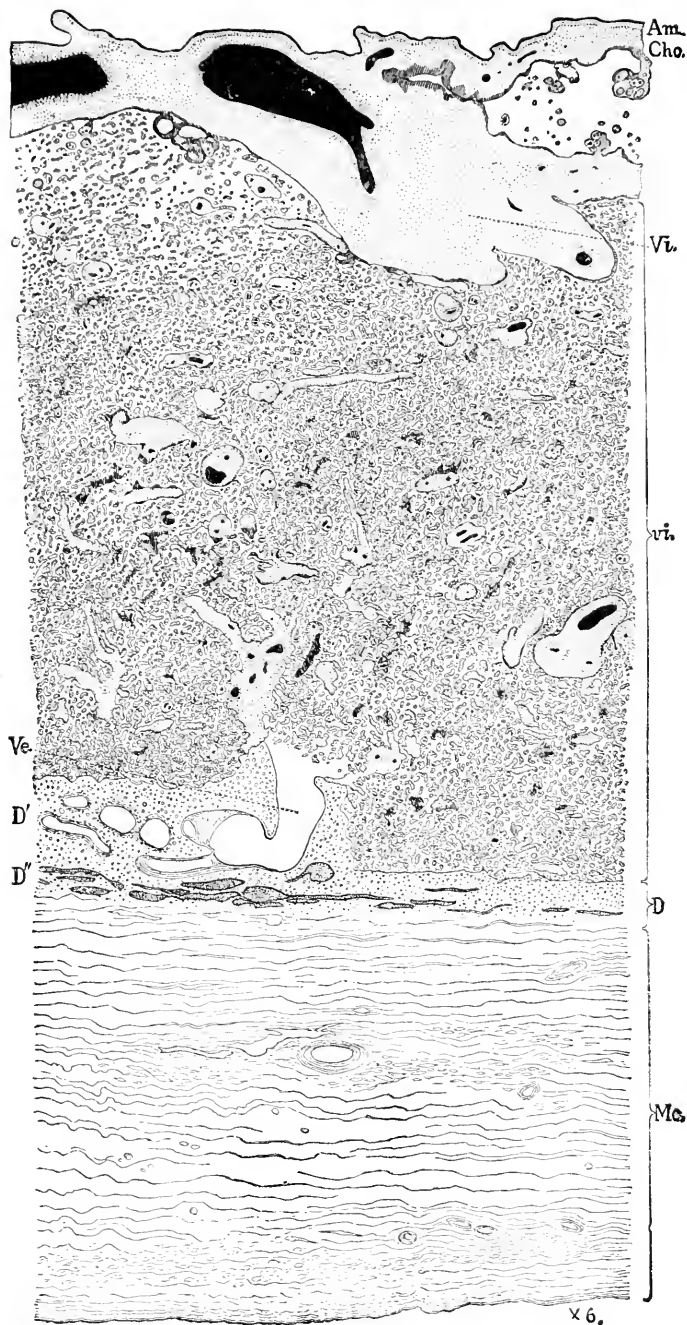


FIG. 213.—Section through a normal Placenta of about seven Months, *in situ*. *Am.*, Amnion; *Cho.*, chorion; *Vi.*, villus trunk; *vi.*, sections of villi in the substance of the placenta; *D.*, decidua; *Mc.*, muscularis; *D'*, compact layer of decidua; *Ve.*, uterine blood-vessels (or gland?) opening into the placenta. The fetal blood-vessels are drawn black; the maternal blood spaces are left white; the chorionic tissue is stippled except the canalized fibrin, which is shaded by lines; the remnants of the gland cavities in *D''* are stippled dark. (Drawn from nature by J. H. Emerton.)

two or three, but sometimes there is only one, or they may number four or even five. Arrived at the end of its terraces the main vessel takes a more nearly perpendicular course, and rapidly subdivides. Immediately after entering the villi, the arteries and veins give off but few capillaries, but after a short course in the main stalk of the villus the vessels give rise to many branchlets, and gradually the character of the circulation changes until in the smallest villous twigs there are capillaries only, Fig. 214. The vascular trunks have a marked tendency to dichotomous division which is maintained within the villi to a certain extent; the arterioles and veinlets in the mature placenta go from their trunks at wide angles for the most part, and subdivide in the same manner, so that they spread out through the whole substance of the placenta. The vessels next

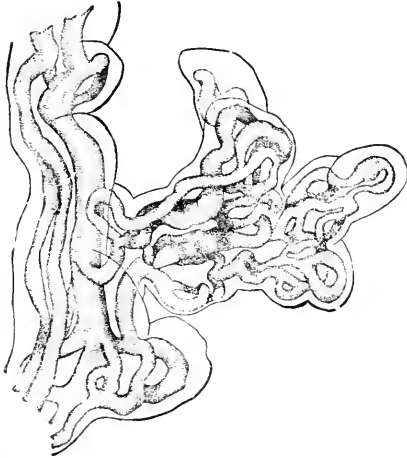

FIG. 214.—Portion of an injected Villus from a Placenta of about five Months; magnified 210 diams.

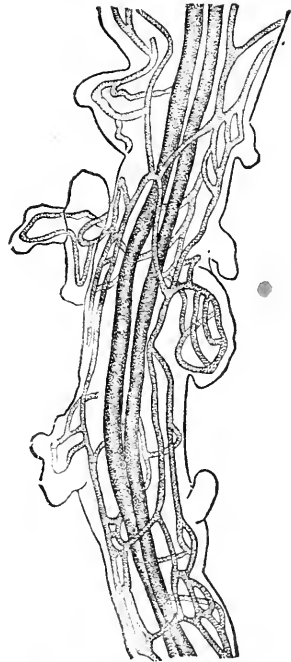


FIG. 215.—Placenta of about five Months; Portion of a small Villus to show the Central Vessels and Superficial Capillaries. $\times 105$ diams.

the decidua take a more horizontal trend, like the top branches of a wind-swept tree. As the vessels run in the villi, of course the way in which the latter branch out determine the paths of the former; hence, by following the distribution of the vessels we inform ourselves as to the ramifications of the villi. Thus the horizontal course of the vessels on the uterine side of the placenta corresponds to the well-known fact that the ends of the villi attached to the uterus become bent and adhere by their sides to the decidual surface.

The capillaries of the villi are remarkable for their large size, and on this account have been described as arteries or veins by E. H. Weber, Goodsir, and other writers. Their calibre is often sufficient for from four to six blood-discs abreast. They are very variable in diameter, and also peculiar in exhibiting sudden constrictions and dilatations, Fig. 214. In the short bud-like branches there is often only a single capillary loop, but as the branch becomes larger the

number of loops increases, and they form anastomoses. In branches large enough to serve as a stem, some one or two of the vessels may be enlarged, as may be seen in Fig. 214; in the branches large enough to admit of it, there are two (or sometimes only one) longitudinal central vessels, an artery and vein, and a superficial network of capillaries, Fig. 215. Goodsir and other early writers laid great stress on the formation of the capillary loops, but this feature is a common one in the development of the foetal vascular system, as is also the width of the capillaries. In my opinion these peculiarities are characteristic rather of the foetus than specifically of the placenta. In some of the older writers (Goodsir, Farre, *et al.*) it is asserted that the true capillary systems disappear toward the end of gestation. I am unable to confirm this, but find instead that in the slender terminal villi of the placenta at term there is often only a single, sometimes long, capillary loop; the capillary is very wide, and its width is probably the reason of its having been held formerly to be a vein or an artery.

Maternal Circulation of the Placenta.—The course of the maternal blood in the placenta has been the subject of nearly constant debate for a century past, and the problem has received its final answer only within the last few years. The discovery of the facts belongs to so many authors that it seems not worth while to attempt to cite the authorities for each detail, accordingly I give a summary of what is known, and in an historical note refer to the principal investigations.

The arteries and veins both open upon the surface of the decidua, at least during the later half of pregnancy; concerning the circulation during the first half of pregnancy we possess no positive information, although the fundamental arrangements are presumably the same. The blood, which is poured out from the arteries, circulates in the intervillous spaces, which act as maternal blood channels.

Both arteries and veins change the character of their walls as they approach the surface of the decidua; when they enter the decidua they are nearly or quite without muscular walls, and can, therefore, be recognized as arteries or veins, not by their histological structure, but only by their size and their continuity with undoubted arteries and veins in the muscularis; during their passage through the decidua their walls gradually become reduced to the endothelial layer; but the arteries have, what the veins do not have, a thin clear layer just outside the endothelium; this layer colors readily with carmine, contains a few scattered nuclei, and is probably the result of degeneration; it ceases before the artery actually reaches the surface. The endothelial nuclei of the veins project distinctly into the lumen of the vessel. Waldeyer, 90.1, 33, summarizes the differences between the arteries and veins as follows: The *arteries* are smaller; they take a spiral course and run within special columns of fibrous connective tissue; they make numerous turns within the decidua, and lie in the broad ridges of the membrane; they usually do not branch but terminate with a single opening, which generally lies in the upper or lateral part of a decidua ridge; the opening is narrow and the villi do not project into it at all or but slightly; the terminal

piece of the artery is round in cross-section; the artery in the decidua has a special layer outside the endothelium, to within a short distance of the opening. The *veins* are, generally speaking, wider; they have no special sheaths, and do not run in spiral, but in direct courses, more or less parallel to the surface; their openings lie, for the most part, between the ridges (septa) and never at the summits of the ridges; from the border vein (*Grenzvene*, Waldeyer) run out terminal branches which open on the surface and are usually numerous; the chorionic villi project into the mouths of the veins and reach down even into the "Grenzvenen;" the mouths of the veins are irregularly shaped, and the veins themselves are irregular, in cross-section, never circular. The position of the vascular openings is such that the arterial blood flows out from the septa, while the venous blood flows off through the surface between the septa; hence, as pointed out by Bumm, 90.1, each cotyledon represents a more or less distinct circulatory region, the blood entering at the sides and leaving at the bottom.

Historical Note.—The long prevalent erroneous view that there is a direct communication between the maternal and foetal circulations originated I believe with Haller ("Elementa Physiologiae," VIII.). It was revived again by Flourens, 36.1, and though long since entirely disproved is still encountered from time to time. The first important evidence of the circulation of the blood in the intervillous spaces was brought by E. H. Weber, whose investigations were published in Hildebrandt's "Handbuch der Anatomie des Menschen," 4te Auflage, IV., 490. Weber's doctrine was adopted by most subsequent investigators. The most important additions to his observations were made by Farre, 58.1, and Turner, 73.1, 76.1, 76.3, 77.1, 77.2, 88.1, until we come to the recent researches of Langhans, 77.1, 82.1, and his pupils, Nitabuch, 87.1, Rohr, 89.1, etc.; of Waldeyer, 87.1, 90.1, of Bumm, 90.1, Minot, 98, Bloch, 89.1, and others, which have finally settled the problem. That the intervillous spaces normally contain blood was seriously questioned by Braxton Hicks, 72.1, whose doubts were again brought prominently forward by C. Ruge, 86.1. Ruge's position I was inclined at first to adopt (see Minot, *Anat. Anzeiger*, II., 19), but I have since become entirely convinced of the correctness of Weber's doctrine as established by Langhans, Waldeyer, etc. A thorough and very valuable critical review of the whole subject is given by Waldeyer, 90.1, upon whose citations this note is based, but I have referred only to a few of the numerous authorities quoted by Waldeyer.

Nutrition of the Foetus.—The mechanism of the transfer of nourishment from the uterus to the child is not well understood. It is evident that the supply must come from the maternal blood and reach the foetus through the veins of the umbilical cord; although the amniotic fluid may be a source of supply, as some have maintained, yet at most its rôle can be only secondary and the main transfer of material must take place through the placenta. Our present knowledge of the structure of the organ renders it unnecessary to discuss the old theory recently revived by Currie, of a direct communication between the maternal and foetal vessels, for we know

positively that no such communication exists. This theory has been put forward again with the modification that the vascular walls will let small solid particles through. Thus Koubassoff, on the basis of some inconclusive experiments, sought to maintain that microbes, and *ergo* other solid particles, could pass from mother to embryo (see *Comptes Rendus Acad. Paris*, t. CL., 508-510). More careful tests by Marie Miropolsky failed to confirm this (*Arch. de Physiol., n. et p.*, 1885, 101-108). A *second* theory, at present the best accredited, is that of diffusion, which finds its chief basis in the elaborate arrangements found in all placental types for bringing the foetal and maternal blood into immediate proximity. A *third* theory is that Rauber, 79, who attributes the chief rôle in the nutrition of the embryo to the immigration, by way of the placenta, of maternal leucocytes. A *fourth* theory attributes an active part to the utricular glands, which are supposed to pour out a nutrient secretion into the intervillous spaces, where it is taken up by the chorionic villi. It is impossible at present to form a final judgment upon these theories. As we have seen, the intervillous spaces are probably maternal blood-channels at all periods, so that, from a very early stage on, the conditions for the transfer of material, either by a migration of leucocytes or by simple transfusion, are established. Rauber's leucocyte theory has not commended itself to me, and I incline to accept the transfusion theory. That the uterine milk exists in man has not been proven, and the occurrence of such a secretion is not compatible with the degeneration of the glandular epithelium observed by Minot, see p. 10.

II. THEORY OF THE PLACENTA.*

Attachment of the Embryo.—That the rabbit embryo is attached to the surface of the uterus by a thickened region (*area placentalis*) of the ectoderm of the germinative area was first shown by Van Beneden and Julin, 84.1; this discovery has since been confirmed by Minot, 98, Masius, 89.1, Duval, 89.1, and others. That a similar method of attachment exists in other mammals has been shown by Strahl, 89.1, 4, 90.1; in the dog it has been recorded by G. Heinrichus, 89.1. In all these cases the thickened ectoderm is found to be closely adherent to the uterine surface, upon which it is apt to remain when the ovum is forcibly removed; it fits exactly to the surface of the maternal epithelium; there is no visible layer of cement, and we do not know how the adherence is made so close.

It is probable that we have here the primitive form of attachment, and that therefore the evolution of the placenta began with the differentiation of the ectoderm of the *area placentalis*.

There is another type of attachment found in the hedgehog and in rodent ova with inversion of the germ-layers, characterized by the ovum being so closely invested by the uterine mucosa that the whole surface of the ovum comes in contact with the maternal tissues (see E. Selenka, 84.1, and Hubrecht's superb monograph on the placenta of the hedgehog, 89.1).

* Reference is made especially to the true chorionic placenta.

Degeneration of Uterine Tissues.—Over the region of the placental attachment, which varies in different animals as to position, there occurs an extensive degeneration of the tissues of the uterine mucosa, affecting both the covering epithelium, the glands, and the connective tissue. The degeneration takes place most rapidly in the epithelium and glands, while the connective tissue undergoes an extensive hypertrophic metamorphosis, usually in the form of the development of decidual cells, before the degenerative change acquires the upper hand. The nature and extent of the degenerative changes have become known for various types by investigations published since 1888, several of which appeared during 1889 (Minot, 89, 98, Masius, 89.1, Heinricius, 89.1, Duval, 89.1, Hubrecht, 89.1, Strahl, 89.1, 4, etc.), and represent simultaneous and independent researches. In view of what we now know it must be considered probable that in all placental mammals, or at least in the orders of the unguiculate series, the uterine degeneration is an invariable factor in the development of the placenta.

The form of degeneration is not fixed, but varies greatly. This is illustrated by the history of the decidua in man and in the rabbit. Other modifications occur in the dog, the hedgehog, the mole, and doubtless in other animals.

The result of the degeneration is: *first*, to bring the chorionic ectoderm of the embryo into direct contact with the connective tissue of the mucosa uteri in consequence of the degeneration and resorption of the epithelium, including the glands; *second*, to allow the maternal vessels by simple expansion to come into contact with the foetal chorion. In the rodents the degeneration goes so far in the neighborhood of the chorion that all (or nearly all) the maternal tissue disappears, leaving the maternal blood to bathe the surface of the chorion, or, to speak more exactly, of the chorionic villi. It is probable that similar changes take place in man, but in the earliest stages yet studied they appear to have been already completed, so that in the region of the villi the maternal tissues have completely disappeared, unless the endothelial layer described by Keibel be maternal, *v. s.*, p. 322. Heinricius has maintained that in the dog part of the glandular epithelium remains.

Outgrowth of Chorionic Villi.—These are restricted at first to the small placental area, but as that area may itself grow and take up more and more of the chorion, we get various modifications of the villous area. The more primitive types preserve the discoidal plan, illustrated by the rabbit; in other cases the placental or villous area expands until it forms a belt or zone around the ovum (carnivora); but the development in the dog shows that the discoidal form is the earlier, and changes into the zonary; in man the placental area spreads over the whole chorion.

The villi appear to arise as outgrowths of the ectoderm only; after the outgrowths have attained a certain size the mesoderm of the chorion grows into them. The villi grow into the maternal tissues, and acquire great length and numerous branches, by which their form becomes extremely complicated. Their form is highly characteristic of the various orders; it is known exactly only in man, but is certainly very different in various animals.

The villi occupy only a part of the mucosa, there being always a considerable layer of decidual membrane left between the end of the villi and the muscularis.

The villi, as here described, consist of a core of mesoderm covered by fetal ectoderm, and are essentially different from the ectodermal outgrowths assumed by Duval* to exist in the rabbit.

Union of the Allantois with the Chorion.—We know two principal modifications of the union of the allantois with the chorion: 1. The allantois joins the chorion early, and serves as the stalk, connecting the embryo with chorion; in this type the allantois brings the blood-vessels to the chorion and the vessels then ramify over the chorion itself, which has therefore its own circulation, though dependent upon the allantois; this modification is characteristic of the unguiculate series of mammals. 2. The allantois grows out into a large vesicle, which has for some time no connection with the chorion but maintains a well-developed circulation of its own; its expansion brings it ultimately into contact with the chorion, and its outer or mesodermic layer grows together with the inner or mesodermic layer of the chorion (Bonnet, 89.1) which thus becomes indirectly vascularized; this modification is characteristic of the unguiculate series of mammals. How far other modifications, distinct from these, may exist, we cannot say at present.

We have then two types: 1, the chorion has its own vessels (unguiculates); 2, the chorion acquires vessels by growing together with the vascular walls of the allantoic vesicle (ungulates).

In both cases the chorion is the part of the fœtus and the only part in direct contact with the uterine wall, and therefore in both cases it is the essential part of the fœtal placenta. In unguiculates the chorion, after it receives its blood-vessels, has its own blood supply and circulation, and therefore suffices to develop the placenta. In unguicates the circulation is entirely allantoic, and the walls of the allantois are essential to maintain the fœtal circulation of the placenta; the chorion, therefore, does not suffice to develop the fœtal placenta. While we recognize that the chorion is always the means of union between the mother and the offspring, we may conveniently distinguish the unguiculate type as having a true *chorionic placenta*, and the unguiculate type as having an *allantoic placenta*.

Evolution of the Placenta.—As regards the evolution of the placenta, our conceptions are still very obscure. The opinion was long, and perhaps still is, generally prevalent that the placenta is primarily an organ of the allantois. This notion was one of those theories which sometimes become current without ever having been supported by adequate proof, and are repeated until tradition has rendered them venerable and age gives them a dignity their worth does not entitle them to. The principal support of this theory was derived from the fact that the allantois is connected with the placental circulation. Balfour in 1881 ("Works," I., 743) sought to modify this view by attributing importance to the relations of the yolk-sac, which he believed to be the means of maintaining the circulation.

* Erroneously, as I believe.

In his "Comparative Embryology," II., 249, Balfour reprints most of the article cited. Minot, 98, 433, laid stress upon the rôle of the chorion and upon the fact that the placenta is necessarily always a product of the chorion, and further upon the fact that the allantois in man is permanently (and in the rabbit primarily) merely a stalk of connection between the embryo and the chorion. The investigations mentioned in this chapter which have been recently published seem to me to greatly strengthen my view. It is by the chorion that the ovum is attached, except in certain rodents in which the development has obviously been modified. It is from the chorion that the foetal villi grow out. On the other hand, it is evident that the yolk-sac is primitively a product of the splanchnopleure and distinct from the somatopleuric chorion; the failure of the mesoderm and cœlom to spread completely over the yolk (entoderm of the blastodermic vesicle) in certain mammals does not alter the fundamental relations. It is true that in certain marsupials the chorion is very imperfectly separated from the yolk-sac, but it does not appear that this represents an ancestral stage of the mammalia; on the contrary, it is probably a purely marsupial modification. I am therefore unable to recognize any reason for connecting the evolution of the placenta with the yolk-sac or vitelline circulation. The rôle of the allantois is secondary; it serves as a medium of blood supply, either, as we have seen, as a carrier of vascular trunks to supply the circulation of the chorion (unguiculates) or bringing its own circulation into play by growing together with a non-vascular chorion.

The question remains whether the unguiculate or the unguulate type of placenta is to be regarded as the more primitive. At first thought the resemblance of the foetal envelopes of unguulates to those of Sauropsida leads us to conclude that the allantoic placenta must be the more primitive; the resemblance referred to consists in the early complete separation of the chorion (serosa) from the other parts and in the development of the allantois as a large free vesicle. But the unguulates are highly modified mammals not related closely to the lower placentalia, while the unguiculates do merge into a generalized mammalian type. When we consider further that the lower unguiculates show the typical chorionic placenta in its full perfection, the conclusion is unavoidable that this is the nearer type to the ancestral. In fact, the placenta appears in animals with the chorionic type of the organ before the allantois becomes free, and the great size of the allantoic blood-vessels is connected primitively, not with the allantois, but with the already important chorionic circulation; the placenta is here interpolated in the ontogeny before the specialization of the allantois, which functions as the vascular pathway between the chorion and embryo, both primitively and permanently. The enlargement of the allantois in unguulate mammals is a supervening change, effected perhaps by an atavistic recurrence to reptilian ontogeny.

Ryder, 87.6, has advanced the theory that the zonary placenta is older than the discoidal, but Minot, 98, 434, has shown that this view is untenable.


The degenerative changes in the uterus occur, so far at present known, only in connection with the chorionic placenta; in the un-

gulates the uterine mucosa is modified in structure in connection with the development of the placenta, but the modifications are not known to be degenerative; hence in the allantoic placenta the maternal blood flows in maternal blood-vessels, and it is always separated by maternal connective tissue and epithelium from the chorion.

Theory of the Placenta.—According to the views explained in the preceding pages, I hold the placenta to be an organ of the chorion; that primitively the chorion had its own circulation, and formed the discoidal placenta by developing villi which grew down into the degenerating uterine mucosa; by the degeneration of the maternal tissues the maternal blood is brought closer to the villi, and the degeneration may go so far that all the tissue of the uterus between the villi disappears: a layer of the mucosa is preserved between the ends of the villi and the muscularis uteri to form the so-called decidua; the placenta receives its foetal blood by the means of large vessels running in the mesoderm of the allantois. From this discoidal chorionic placenta the zonary placenta of carnivora, the diffuse placenta of the lower primates, and the metadiscoidal placenta of man have been evolved.

A second type of placenta, perhaps evolved from the first, is found in ungulates, and is characterized by a vascular allantoic vesicle uniting with a non-vascular chorion to form the foetal placenta, and by the absence of degeneration in the maternal tissue. This type is the allantoic placenta, which offers many interesting modifications.

PART V.
THE FETUS.



CHAPTER XVIII.

GROWTH AND EXTERNAL DEVELOPMENT OF THE HUMAN EMBRYO AND FŒTUS.

THE two sections following on the growth of the fœtus and the weight at birth are taken from my article on "Growth" in Buck's "Reference Handb. Med. Sci.," III., 394. A more accurate conception of the growth of the embryo can, however, be gathered from the figures in the latter part of this chapter.

Growth of the Fœtus.—The difficulty of determining the age of the human fœtus and of obtaining specimens certainly fresh and normal has prevented our having any definite information on this subject. Preyer has compiled the following table of the length of the human embryo in centimetres:

Lunar Month.	Toldt. (200 obs.)	Hennig. (100 obs.)	Hecker.
First,	1.5 (1.3)	0.75	
Second,	3.5	4.0	
Third,	7.0	8.4	4 to 9
Fourth,	12.0	16.2	10 to 17
Fifth,	20.0	27.5	18 to 27
Sixth,	30.0	35.25	28 to 34
Seventh,	35.0	40.25	35 to 38
Eighth,	40.0	44.3	39 to 41
Ninth,	45.0	47.2	42 to 44
Tenth,	50.0	(49.0)	45 to 47

If the absolute length at the end of each month is divided by the increase during that month we obtain what Preyer calls the relative growth. Hennig's figures give the following relative growth for each month: First, 1,000; second, 0.812; third, 0.523; fourth, 0.419; fifth, 0.410; sixth, 0.219; seventh, 0.124; eighth, 0.093; ninth, 0.069; tenth, 0.037. All the above data are obviously inexact. Toldt's are evidently cooked up and not derived from observation, nor do the lengths mean the same thing, for of the early stages the head and trunk only were measured; of the later stages the head, trunk, and legs. A falser and more misleading device for studying growth has never been put in practice. The fœtus, too, being spirally coiled in early stages cannot have its length determined accurately. Far better would it be to always determine the weight. The growth of the fœtus in weight has been most inadequately studied, although the weight is the *only* available measure of the growth of the fœtus as a whole. Hecker's data are perhaps the best. The weights are in grammes:

Month.	Maximum.	Minimum.	Average.
Third,	20	5	11
Fourth,	120	10	57
Fifth,	500	75	284
Sixth,	1,280	375	634
Seventh,	2,250	780	1,218
Eighth,	2,438	1,093	1,569
Ninth,	2,906	1,500	1,971
Tenth,	1,562

The range of the maxima and the minima suggests that errors in the determination of the ages may have occurred—such errors of a month are not rare with obstetricians.

Appended here are Hecker's data as to the weight of the placenta in grammes, and the length of the umbilical cord in centimetres:

Month.	No. of obs.	Placenta.	Cord.
Third,	3	36	7
Fourth,	17	80	19
Fifth,	24	178	31
Sixth,	14	273	37
Seventh,	19	374	42
Eighth,	32	451	46
Ninth,	45	461	47
Tenth,	62	481	51

2. *Weight of the New-Born Child.*—It is subject to very considerable variations. For middle Europe the average may be held to be about 3,340 grammes for boys, 3,190 for girls, the latter being somewhat lighter. The variations are very great, ranging from 1,000 to 5,000 grammes. For instance, the following table is given by Pfannkuch, who unfortunately jumbles the two sexes together:

Kilos.	Obs.	Kilos.	Obs.
1.50 to 2.00	23	3.00 to 3.25	150
2.00 to 2.25	36	3.25 to 3.50	115
2.25 to 2.50	52	3.50 to 3.75	79
2.50 to 2.75	90	3.75 to 4.00	46
2.75 to 3.00	110	4.00 to 4.50	13

It will be noticed that the maximum number of cases (150) falls between 3.00 and 3.25 kilos., and that the further the weight is removed on either side, above or below from this mean, the fewer are the cases. The tables by other authors show the same general results, with usually slight differences in the quantitative values. For the most part these tables cannot be combined with one another, for they nearly all fail to fulfil some obvious requirement of good statistics; indeed, amateur statistics are generally provoking to the expert. It is, therefore, not desirable to attempt an analysis of the recorded data. As an example of statistics at once valuable and grossly defective, the following table is given after Siebold. The author gives the weights in pounds, but has neglected to say, as is necessary in Germany, what kind of pounds, hence the metric equivalents cannot be calculated. Moreover the number of cases weighing even pounds and half-pounds is far in excess of those weighing pounds and one-fourth or three-fourths, which shows inaccurate weighing, of course. To correct this the quarter-pound groups of original table are condensed into half-pound groups:

Weight in lbs.	Boys.	Girls.	Weight in lbs.	Boys.	Girls.
4.0 to 4.5	4	10	7.5 to 8.0	286	200
4.5 to 5.0	19	24	8.0 to 8.5	101	44
5.0 to 5.5	44	53	8.5 to 9.0	79	42
5.5 to 6.0	172	195	9.0 to 9.5	15	14
6.0 to 6.5	220	235	9.5 to 10.0	7	2
6.5 to 7.0	353	353	10.0 to 10.5	—	1
7.0 to 7.5	286	240	10.5 to 11.0	—	1

The extremes recorded in medical literature are very far apart, and statements of excessively large size are by no means rare, but can be received with incredulity only, as, for instance, the case reported of a still-born child weighing 8,250 gms. (*Berlin. klin. Wochenschr.*, 1878, No. 14)! Vierordt gives as the accredited extremes 717 gms. (Riter), and 6,123 gms. (Wright.)

The factors which determine the weight at birth are very obscure. It is, of course, safe to say vaguely that it depends on the nutrition of the fetus; it is probable that individual differences in the rate of growth exist before as well as after birth, and it is probable that the length of gestation is the most influential single factor, to judge from my own experiments on the growth of mammals.

It has been demonstrated that the variations in the weight of the child depend upon various maternal circumstances.

First. It is correlated with the age of the mother, as is shown in the following table, giving the weight of the children in grammes according to three observers:

Age of mother.	Ingersley.	Fassbender.	Petersson.
15 to 19 years	3,241	3,271	3,451
20 to 24 "	3,299	3,240	3,485
25 to 29 "	3,342	3,333	3,591
30 to 34 "	3,375	3,367	4,062
35 to 39 "	3,428	} 3,292 }	3,591
40 to 44 "	3,326		3,676

From such tables we learn that very young mothers have the smallest children, and those of about thirty-five years the heaviest. It is much to be regretted that the tables do not show the correlation by single years and also the number of observations.

Second. The weight of the child increases with the weight (Gassner) and length (Frankenhäuser) of the mother. Gassner states that the weight of the child is to that of the mother as 1 to 19.13, or 5.23 per cent of the maternal weight. Frankenhäuser states that if the height of the mother is less than 4 feet 6 inches the child weighs 6 lb. 15 oz.; if it is 4 feet 6 inches to 4 feet 11 inches, the child weighs 6 lbs. 25 oz.; if it is more than 4 feet 11 inches, the child weighs 7 lb. 3 oz.

Third. The weight of the child increases according to the number of previous pregnancies, as indicated by the following table:

Number of pregnancies.	Hecker. (Grms.)	Ingersley. (Grms.)
One.	3,201	3,254
Two.	3,330	3,391
Three.	3,353	3,400
Four.	3,360	3,424
Five.	3,412	3,500
Six.	3,353	—

Here again we encounter faulty statistics, for it is not shown that we have any other effect than that of age, for the conclusion claimed cannot be established until it is proved that primiparæ have smaller children than multiparæ of the same age.

Fourth. Negri has maintained (*Annali di Ostetrica*, 1885) that the compilation of three hundred and thirty-three observations show that the children of women whose first menstruation is early are larger than the children of those whose first menstruation is late.

Fifth and Sixth. The influence of race and climate, which have not yet been subjected to any proper exact study.

In conclusion I may add that it seems to me probable that all these influences produce their effect principally by prolonging or abbreviating the period of gestation. In other words, the variations in the weight of children at birth are to be referred immediately to two principal causes: 1, Differences in the age at birth; 2, individual differences of the rate of growth in utero.

Measuring the Length of Embryos.—Owing to many changes in the curvatures of the longitudinal axis of the human embryo it is impracticable to employ any one system of measurement, to obtain comparable results for all ages. On this account I have adopted the system of giving in all cases the greatest length along a straight line, the embryo being measured in its natural attitude—excluding, however, the limbs from the measurement.

His adopts for embryos of four to ten weeks what he calls the *Nackentlänge* ("Anat. menschl. Embryonen," Heft II., 5) or the distance in a straight line from the neck bend to the caudal bend, but as this cannot be measured accurately in later stages I have thought it best to give up this measure. Hence it results that the length of an embryo as given by His is often different from that given in this work.

Embryos of Known Ages.—As already pointed out, we have to reckon from the last day of the menstrual period as the date of conception, but this date is never quite certain, hence there is always some doubt as to the age of every embryo. We owe to Professor His most of our information in regard to the form and size of the embryo at successive ages during the first two months, see his "Anatomie menschl. Embryonen," Heft II., 1882, especially pp. 25 and 72, also Heft I., 166, Heft III., 236-254, and Taf. X., which gives figures at a uniform scale of twenty-five embryos of the first two months.

The development of the embryo during the first three weeks has already been described and illustrated. Up to the end of the ninth week the form and size of the embryo undergo a correlated development, so that generally an embryo, at a given stage of development in *form*, will agree with its fellows in *size*; but to this rule there are not infrequent exceptions, and sometimes an embryo is found much larger than others at the same stage (His, *l.c.*, Heft III., 240). Moreover the variability of embryos is very great, for in specimens otherwise alike we find this or that organ retarded or advanced in development, as compared with the embryo as a whole. Nevertheless it is possible with the information at present at command to determine the age of an embryo within two days plus or minus up

to the end of the ninth week. For the development during the third month we possess as yet no satisfactory information, but embryos three months old are quite frequently obtained, and my own collection gives a good series of specimens up to the end of the fifth month.

Twenty-three Days.—The first figure I give is that of His' embryo *a*, Fig. 216, described by him in his "Anat. menschl. Embryonen," Heft I., 100–115. The specimen was from a chorionic vesicle measuring 2.5 by 3.0 cm.; the greatest length of the embryo was 4 mm., measured from the end of the hind-brain, *iv*, to the fourteenth segment of the rump. It lay with its *left* side against the chorion, with which it was connected by a short allantoic stalk; the yolk-sac measured 2.7 by 3.0 mm., and had a short pedicle. His states that the probable age of the specimen was twenty-three days, and apparently bases the determination upon comparison with slightly younger and older specimens of known age. The shape of the embryo is very different from that of Fig. 180, p. 307, owing to the whole body having become rolled up, so that the dorsal outline describes more than a complete circle; the body has a marked spiral twist, the head being bent to the right, the tail to the left; the bending of the body is specially marked at the region of the mid-brain (head-bend) and at the posterior limit of the hind-brain (neck-bend, *Nackenkrümmung*).

The primitive segments show externally; the anlagen of both pairs of limbs have appeared as outgrowths of the so-called Wolffian ridge, but the leg is less developed than the arm. In the region of the head the divisions of the cerebral vesicles can be recognized. The optic vesicles are indicated by small protuberances. The oval otocyst lies about at the level of the second gill-cleft. The cephalic border of the mouth has become ridge-like; the dorsal end of the ridge joins the dorsal end of first visceral arch, which is known as the mandibular arch: the ridge on the cephalic side is known as the maxillary arch. The second, third, and fourth gill-arches are distinct and behind each the imperforate gill-cleft can be distinguished, but the fifth arch is indistinct. The heart forms a marked protuberance, the bulbus aortæ showing most on the left side, Fig. 216, and the ventricles on the right.

An embryo of C. Rabl's, very similar to His' *a*, just described, is figured by O. Hertwig, "Entwickelungsges.," 3te Aufl., Fig. 137. His points out that the embryos numbered by him XXVI., (D 2), LVI., (W), and LVII., (R), are very near the one just described, though a little older. In the same group belongs the embryo of Coste, 47.1, Pl. II., Fig. 5, of which the age was determined at twenty to twenty-five days; also Thompson's fourth embryo, figured

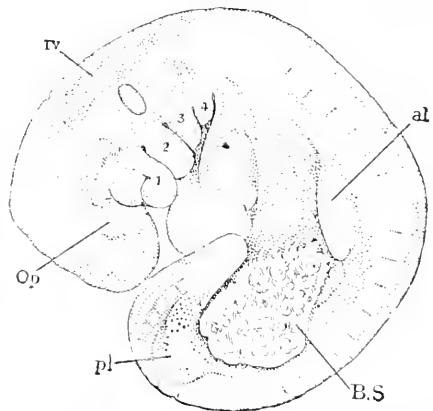


FIG. 216.—His' Embryo *a*. Age probably twenty-three Days. \times about 10 diameters.

and described by Kölliker, "Entwickelungsges.," p. 311, Fig. 231; also that described by Hensen, 77.1, and finally Ecker's specimen, 80.1. Of all these Coste's most deserves attention on account of the superb manner in which it has been figured. Concerning His' embryo R, some data about the cœlom have been given by His, 81.1, 311.

Twenty-five Days.—Embryos of this age are extremely rare. Fol has given a full but not wholly satisfactory description, 84.2,

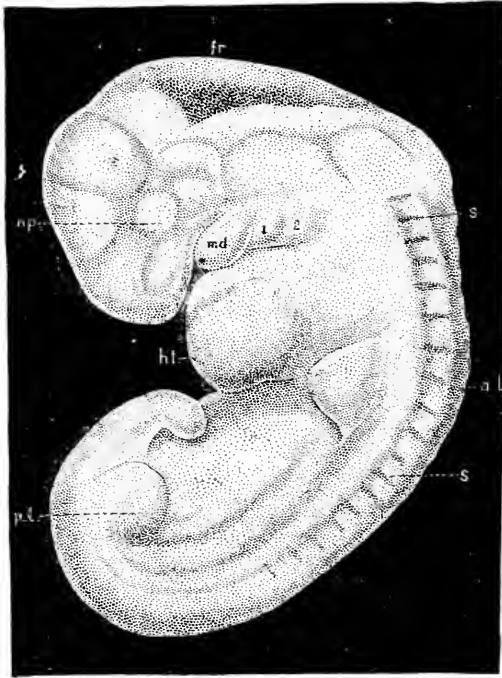


FIG. 217.—Fol's Embryo of 5.6 mm., probably twenty-five Days old. *op*, Position of the optic vesicle; *fr*, fossa rhomboidalis; *s.s.*, segments; *a.l.*, anterior limb; *p.l.*, posterior limb; *md*, mandibular, 1, hyoid; 2, bronchial arch.

of an embryo presumably of this age, though no data were obtained in regard to it. The embryo, Fig. 217, as compared with that at twenty-three days, has grown rapidly; its greatest length is 5.6 mm.; its form has changed by the body having partially unrolled, but the head-bend and neck-bend remain and are more prominent than before, owing to the embryo as a whole being less curved. The region of the fore-brain is brought close to the heart, the head being still bent to the right: the limbs are a little larger and there is a well developed, distinct tail. The other principal change is that only three gill-arches show externally, *md*, 1, 2, the third and fourth being already invaginated in

connection with the formation of the cervical sinns. It must be added that this embryo was not quite normal, as is shown especially by the condition of its veins. The representation of the external form of the head in the figure is probably not entirely correct.

Twenty-six Days.—Mall, 91.3, gives a superb figure and complete anatomical description of an embryo, the probable age of which he fixes at twenty-six days.

Twenty-seven to Twenty-eight Days.—Embryos of this age are characterized by the extreme development of the neck-bend, Fig. 218, the apex of which forms, as it were, the summit of the embryo; the greatest length from this apex is 7-8 mm. To the age of about twenty-eight days are to be assigned the embryo described by Johannes Müller, 30.2, one figured by Coste, 47.1, Pl. III., one described by Waldeyer, 62.1, and four embryos in His' collection,

numbered by him ("Anat. menschl. Embryonen," Heft II., 8), I. (B), LXI. (Eck. I.), II., (A), and XL. (3tt.); concerning XL. see His, *l.c.*, pp. 24, 92. Of A and B His has published a detailed anatomical account ("Anat. menschl. Embryonen," Heft I., 14-99).

I choose for my illustration Fig. 218, His' embryo A, because it shows the neck-bend most perfectly; how entirely the prominence of the neck-bend alters the shape of the embryo will appear immediately if Fig. 218 be compared with Fig. 175. As changes since the twenty-fifth day we note especially the distinctness of the olfactory pit (*Riechgrube*) and of the still open invagination to form the lens of the eye, the deepening of the cervical sinus (*sinus præcervicalis* of His), and the partial closure of the allantois-stalk (*Bauchstiel*) around the proximal

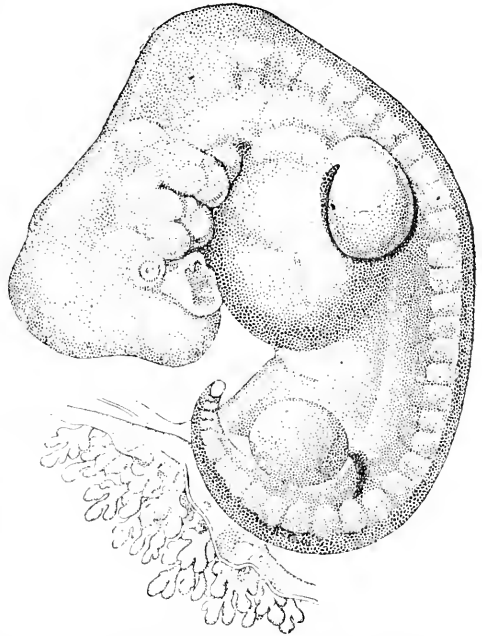


FIG. 218.—His' Embryo A, 7.5 mm. long. Probable age twenty-eight days. $\times 10$ diams.

part of the now narrow pedicle of the yolk-sac; the closure of the *Bauchstiel* forms the umbilical cord, but the cord itself is very short and in proportion to the embryo very thick. In all parts there has been an obvious development since the twenty-fifth day, Fig. 217, but further details may be omitted. Comparison of this embryo with others of the same stage show that there is a considerable variation as to the nature and degree of curvature of the back, in consequence of which the specimens differ somewhat in general form, though agreeing closely in structure.

Twenty-nine to Thirty Days.—Embryos 8-10 mm. A number of specimens, which probably belong to the middle of the fifth week are known. For my illustration I give a drawing, Fig. 219, of an embryo sent to me by Dr. H. J. Garigues of New York; the data suffice only to determine the age as the fifth week; the specimen appeared normal and well-preserved, but upon microtoming it, it was found to be in poor condition histologically; it has interest because it shows with especial clearness the relations of the fetal appendages. The embryo proper has begun to straighten its body, and as the outline over the region of the medulla oblongata, compare Fig. 217, *Fr*, has become less curved, the head begins to appear to form a right angle with the body; the olfactory pit, *ol*, has deepened; the lens of the eye, *op*, is well marked, as is also the lachrymal groove descending from the eye; the cervical sinus, *c.s.*, has deepened but is still open;

the limbs have lengthened and in other specimens begin to show the differentiation of the hand and foot. About two-thirds of the allantois-stalk has closed to form the umbilical cord, *Um*, from the end of which extends the amnion, *Am*. The long yolk-stalk, *Vi.s*, ends in the pear-shaped yolk-sac, *Vi*; the allantois-stalk or Bauchstiel, *Bs*, which runs to the chorion, *Cho*.

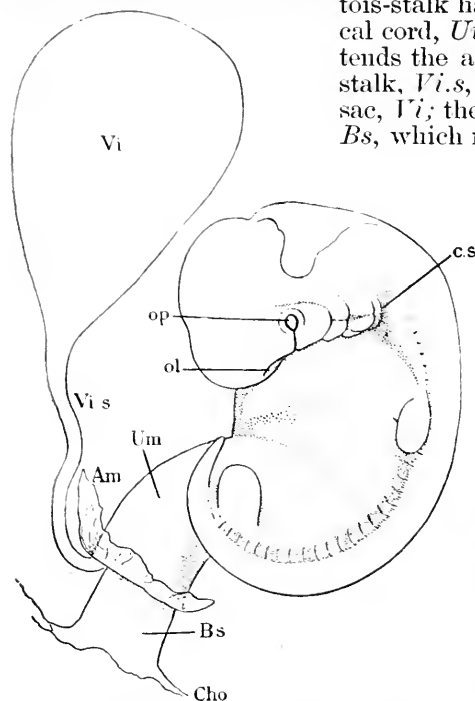


Fig. 219.—Embryo of 9.8 mm. Minot Collection No. 145. Probable age thirty days. $\times 5$ diams.

In this group belong the embryo of Rabl (O. Hertwig, "Entwickelungsges.," 3te Aufl., Fig. 158), the embryo of 10 mm. of which Phisalix gives a detailed anatomical description, 88.1,—also seven embryos, enumerated by His, "Anat. menschl. Embryonen," Heft II., 8, and described there p. 45-7, and His' embryo Pr., *l. c.*, p. 10, 238, Taf. X., Fig. 8, Taf. XIII., Fig. 47—this last by far the most perfect drawing of this stage which we possess.

Thirty-one to Thirty-two Days.—Embryos of 10-12 mm. (see His, *l. c.*, Heft II., 47-51 and, for a list of ten specimens, p. 8-9, Taf. X., Figs. 13, 14, and 15, Taf.

XIII., Fig. 6). The age of the embryo at this stage can as yet only be estimated, as in no case have we data sufficient for a reliable determination. For a typical illustration of this stage we may take His' Br. 1, *l. c.*, Taf. XIII., Fig. 6, which measured 11 mm. The back has straightened out, though the lower end of the body is still rolled over; the head has risen somewhat and enlarged both absolutely and in proportion to the rest of the body. Between the end of the region of the hind-brain and the level of the arm the outline has become slightly concave; this concavity His designates as the *Nackengrube*. The cervical sinus is so deep that the second, third, and fourth gill-clefts have disappeared from the external surface; the first gill-cleft remains and can already be recognized as the anlage of the external auditory meatus; it is separated from the mouth by the prominent mandibular arch. On the cephalic side of the mouth the maxillary process has become more prominent, but the two processes do not yet meet in the median line. The primitive segments are still marked externally. The limbs show the tripartite division; the fore limb is more advanced than the hind limb; the division of the digits of the hand is just indicated. The abdomen bulges out owing to the growth of the liver. There is a true tail, which is now near its maximum develop-

ment. The umbilical cord has lengthened and shows the commencing spiral twisting; the amnion springs from the end of the cord, leaving only a short stretch of the allantois-stalk between the cord proper and the chorion; the amnion lies close to the embryo. In the fresh specimen something can be seen of the shape of the brain; especially noteworthy, among the points thus to be recognized, is the sharp bend (*Brückenkrümmung*) at the deep-lying anterior end of the hind-brain or region of the sinus rhomboidalis.

In embryos a little older than these the changes in form above mentioned have progressed further. The specimens measure 12-13 mm. The body is straighter; the head is larger and has risen so as to be at about right angles to the body; the concavity below the hind-brain in the outline of the neck (*Nackenkrümmung*) is more marked; the limbs are longer, the fingers more distinctly marked; the tail is at its maximum development as a free appendage; where the mandibles meet in the median line the separation of lip and chin has begun; the second gill-cleft is invaginated into the cervical sinus and can no longer be seen on the outside.

Thirty-five Days.—Embryos of 14 mm. The correlation of age and size of this stage cannot be regarded as absolute, though we can

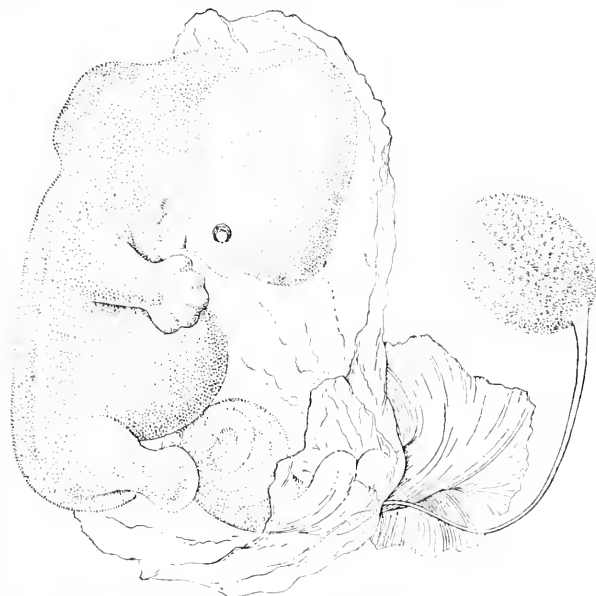

FIG. 220.—Embryo of about 14 mm. Minot Collection No. 120. Assumed age, thirty-five days. $\times 5$ diams.



FIG. 221.—Dorsal View of an Embryo of about 14 mm. Minot Collection, No. 120. Assumed age, thirty-five days. $\times 5$ diams. (Compare Fig. 220).

say (His, *l.c.*, Heft III., 239) that embryos of this length are about five weeks old. The body is now nearly straight; the limbs project beyond the outline of the body in profile views; the abdomen, owing to the large size of the heart and liver, bulges far out; in side views the area of the head is about equal to that of the rest of the body; the outline of the head shows the head-bend and neck-bend most clearly marked; the neck-bend is characterized by the prominence at that

point; the prominence is often less than in Fig. 220. The umbilical cord frequently contains one or several coils of the intestine and makes one or two spiral turns. The stalk of the yolk-sac is long, and projects quite far from the end of the cord between the amnion and chorion. In a dorsal view we can see that the limbs are some-

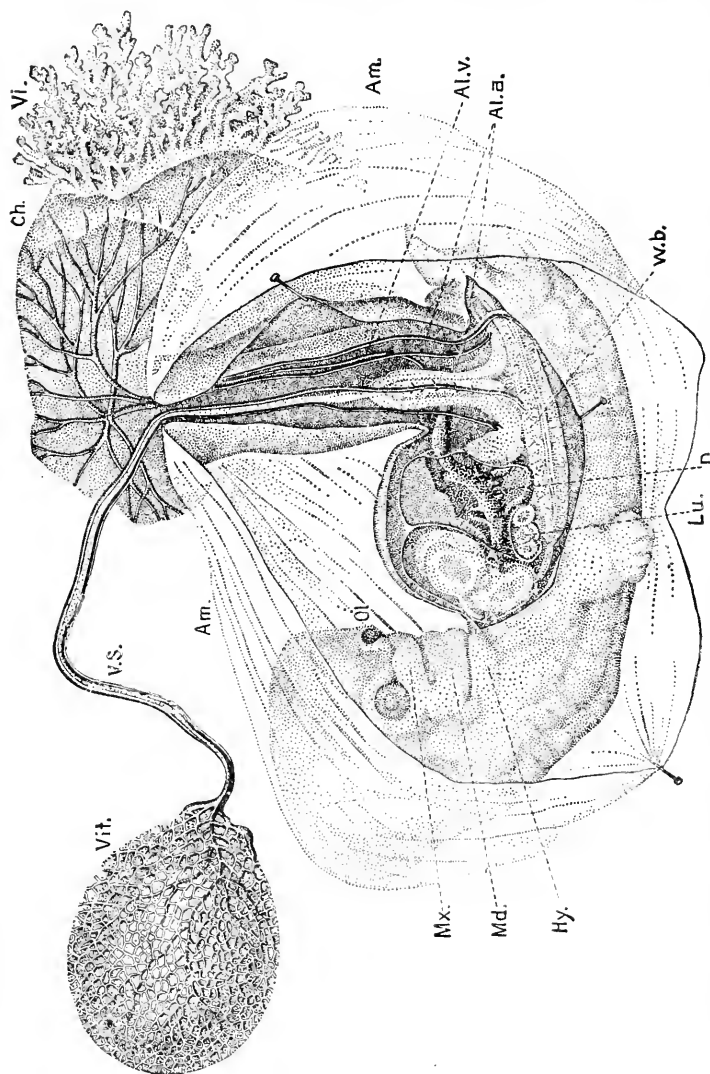


FIG. 222.—Embryo of about thirty five Days. *V.S.*, Vitelline stalk; *V.S.*, Yolk-sac; *Am.*, amnion; *Ch.*, chorion; *Vl.*, villi; *Al.v.*, allantoic vein; *Al.a.*, allantoic artery; *L.v.*, main vein of the liver; *L.a.*, main artery of the liver; *Hy.*, hyoid arch; *Mx.*, maxillary process; *Md.*, mandibular arch; *Ol.*, olfactory process. After Coste.

what flattened and in a plane nearly parallel with the longitudinal axis of the embryo, but the planes of the arms are inclined so as to meet above the head, and the planes of the legs are inclined so as to meet below the tail. Owing to the flattening of the limbs we can already distinguish the inner or palmar surfaces from the outer.

Noteworthy is the irregularly crenulated appearance of the walls of the medullary tube or spinal cord.

Fig. 222 is copied from Coste, and is valuable on account of the very large number of anatomical facts which it records. Coste gives no data but states that the specimen was "about thirty-five days old."

Thirty-eight Days.—Embryo of 15 mm., in a chorionic vesicle of 45 by 40 mm. The age of this specimen, Fig. 223, is known by estimate only. It has been su-

perbly figured by His ("Anat. menschl. Embryonen," Taf. XIV., Fig. 5). This stage represents the transition from the embryo to the foetus, because after the fortieth day the form is distinctly human. The head has risen considerably, and the back has straightened still more, the rectangular neck-bend thus becoming emphasized. The body has become still more protuberant on the ventral side, and in side views the arms no longer reach to the outline of the body.

Forty Days.—Embryos of 19 mm. The head has risen far toward its definite position, with the result of a very rapid apparent increase in the length of the embryo. The change of position of the head results in bringing the mid-brain finally directly above the hind-brain,

the embryo being conceived as having the body vertical. During the elevation of the head the concavity (*Nackengrube*) at the base of the neck is gradually obliterated. In both head and rump the external modelling, which in earlier stages indicated more or less the position of the internal organs, has become blurred and in the next stage is found to have nearly or quite disappeared. The maxillary processes have met and united in the median line. The anlagen of the eyelids have developed. The concha of the ear is indicated. The arm reaches beyond the heart; the fingers appear as separate outgrowths.

Fifty Days.—Embryo of 21 mm. I have a fair specimen which came into my possession with no history whatever, but it agrees very closely with Fig. 23, Taf. X., in His' "Anat. menschl. Embryonen," of His' embryo Ltz, of which he fixes the probable age as just over seven weeks. The head is nearer its final position than in Fig. 223, and relatively larger in proportion to the body. In the eye, cornea and conjunctiva are clearly separated; the face has the fetal form, the nose, mouth, and chin being fully marked off. The arms are clearly divided into upper and lower segments; the five digits are

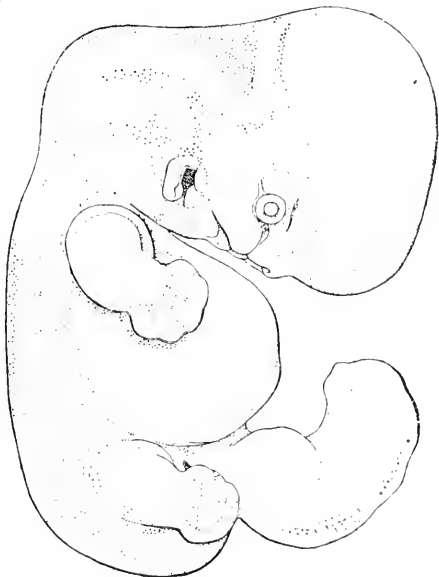

FIG. 223.—His' Embryo XXXIV. (Dr.), 15 mm. long from the Neck-bend to the Coccygeal Bend. Age estimated at thirty-seven to thirty-eight days. $\times 5$ diams.

well developed; the hands rest over the heart and nearly touch one another. In the specimen figured the outline of the abdomen is abnormal. The leg shows the tripartite division; the toes are just beginning to be free, but the hind limb is much less advanced than the fore limb. The tail is still a freely projecting appendage.

Fifty-three Days.—Embryo of 22 mm. The specimen, Fig. 224, is probably not quite normal, but except for the extreme and unusual curvature of the back it agrees closely with His' embryo Zw, which is figured by him, *l.c.*, Fig. 24, Taf. X., as a normal embryo of presumably about seven and one-half weeks. My specimen I received in 1884 with the following history: "Menstruation began January 26th. February and March slight show every few days. Abortion March 30th," which is insufficient to de-

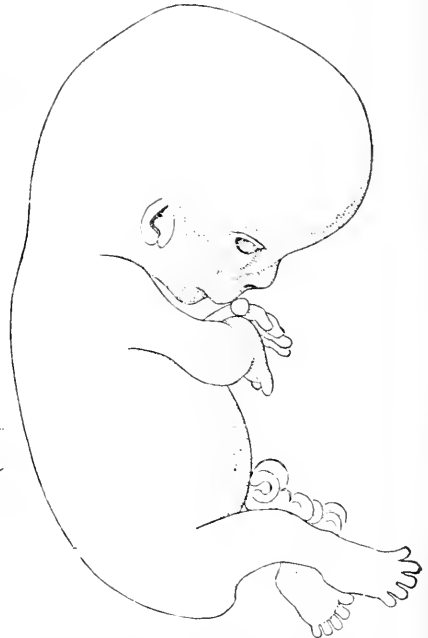
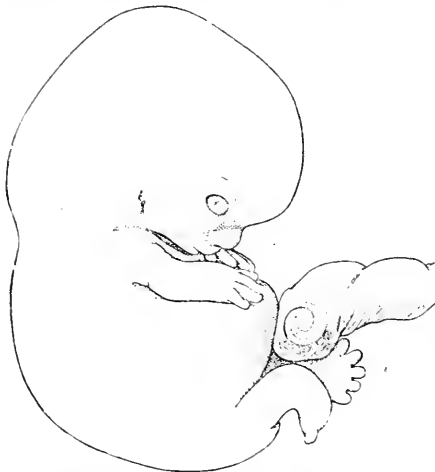
FIG. 224.—Embryo of 22 mm. Minot Collection, No. 54. Probable age, fifty-three days. $\times 3$ diams.

FIG. 225.—Embryo of 28 mm. No. 144 of Minot Collection. Assumed age, sixty days. $\times 3$ diams.

termine the age. As compared with the last stage there are comparatively few changes of external form; the most noteworthy are perhaps the increased development of the legs and feet and the commencing disappearance of the free tail. At this time the protrusion of the coils of the intestine into the coelom of the umbilical cord is about at its maximum.

Sixty Days.—Embryo of 28 mm. The specimen figured resembles closely in form, though larger than, His' embryo Wt (Fig. 25, Taf. X., *l.c.*), which he has determined as a normal embryo of about eight and one-half weeks. My specimen, Fig. 225, came to me with no data. The head is still larger in proportion to the body than in Fig. 223. The face shows the two lines, which, as seen in profile, mark the two ridges which run over the cheek, one alongside the nose to the corner of the mouth, the other from the eye; these ridges are highly characteristic of the ninth week, and traces of them

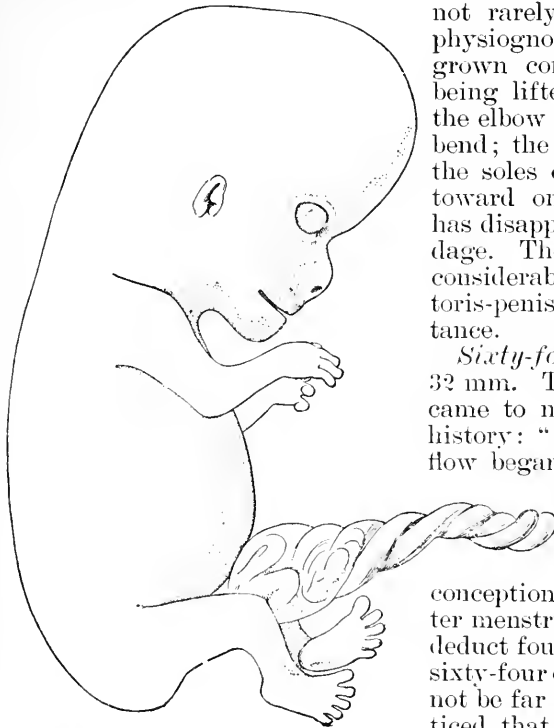


FIG. 226.—Embryo of 32 mm. No. 138 Minot Collection. Probable age sixty-four days. $\times 3$ diams.

not rarely persist in the adult physiognomy. The limbs have grown considerably, the hands being lifted toward the face; at the elbow there is a considerable bend; the toes are all free and the soles of the feet are turned toward one another. The tail has disappeared as a free appendage. The external genitalia are considerably developed; the clitoris-penis projects some distance.

Sixty-four Days.—Embryo of 32 mm. The specimen, Fig. 226, came to me with the following history: "January 4th, 1886, last flow began; March 13th, 1886, abortion;" between these two dates are sixty-eight days; but as the flow took place conception probably occurred after menstruation, therefore if we deduct four days, making the age sixty-four days, we shall probably not be far wrong. It will be noticed that the head has not yet assumed its final angle with the body. On the other hand the protuberance of the abdomen is

much reduced, so that the body as a whole has begun to have a more slender form than in earlier stages. In

this specimen the eyelids have not even begun to meet: in another I have they have met, Fig. 227, except just in the centre where is still a loophole. This specimen was brought to me with the statement that it was just sixty days. I endeavored, unsuccessfully, to get the exact

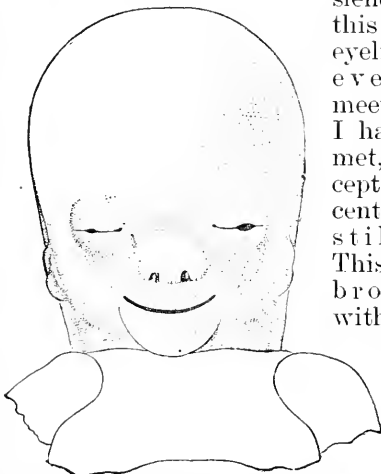


FIG. 227.—Embryo of 34 mm. No. 39 Minot Collection. Front View of Face. $\times 3$ diams.

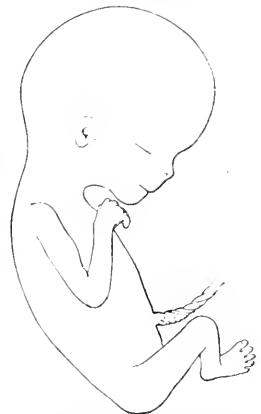

FIG. 228.—Embryo of 55 mm. No. 97 Minot Collection. Assumed age, seventy-five days. Natural size.

data. The large size, 43 mm., and advanced development of the embryo led me to consider the age given as erroneous, and to believe the true age

to be perhaps sixty-seven days.

Seventy-five Days.—Embryo of 55 mm. I figure next, Fig. 228, a fœtus concerning which I possess no data. Comparison with embryos of two and three months leads me to place it a little under half-way between them. The specimen has essentially the configuration of the young child; but

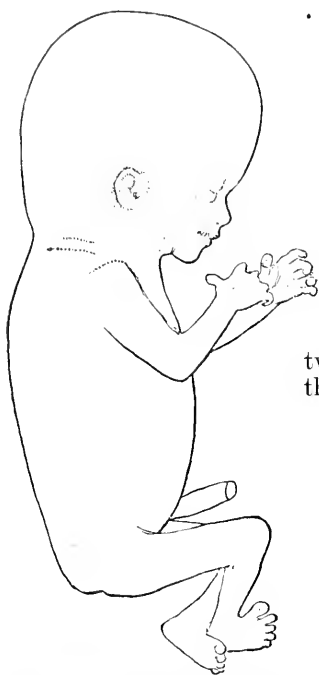

FIG. 229.—Embryo of 78 mm. No. 74 Minot Collection. Age three months.

the head is very large, and the body slender; the position of the limbs is typical; the upper arm is bent down, the forearm extends toward the chin; the knee is bent so as to throw the foot toward the median line; the soles of the feet are placed obliquely facing one another; the anlagen of the nails can be recognized on both the fingers and toes.

Embryos of the eleventh and twelfth weeks are very rarely obtained. I have never had a normal one of this period with data to determine the age.

Three Months.—Embryos of 78-80 mm. In my experience there

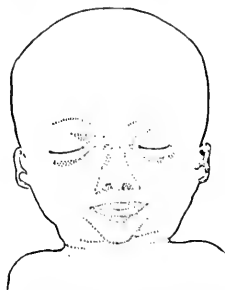

FIG. 230.—Front View of the Head and Face of the Embryo, Fig. 229.

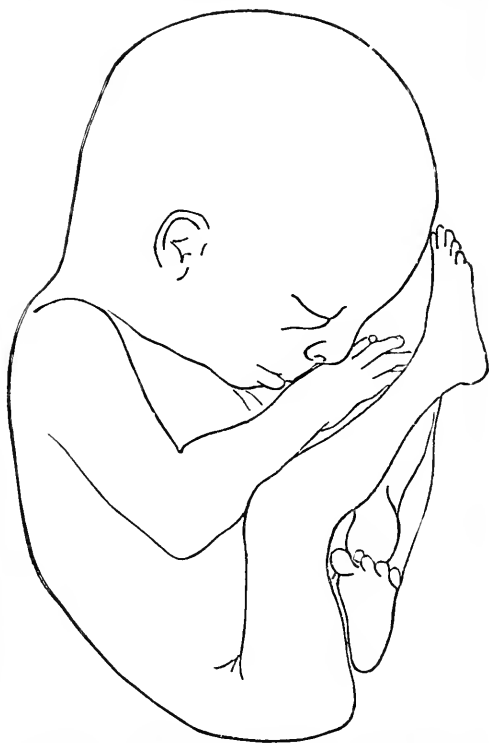


FIG. 231.—Embryo of about 120 mm. No. 61 Minot Collection. Assumed age, one hundred and ten days. Natural size.

is no other age at which abortion of normal embryos occurs so frequently as at three months, and I possess a number of specimens of this age, which agree very closely with another in size and form. The foetus drawn in Fig. 229 may be taken to represent very accurately the form and size of the human embryo at three months. The position of the limbs is typical for this age, but there are slight variations in that the hands, one or both, may project more or be higher or lower; usually the right foot lies in front of the left, but not always. Fig. 230 gives the front view of face of the same embryo to show the closed eyelids, the broad triangular nose, the thick lips and pointed chin.

Three and One-half Months.—Embryos of 108–110 mm. I have several specimens which represent this age. I figure two of them, one to show the natural attitude, Fig. 231, in utero, the other to show the natural attitude assumed by the embryo when released from its membranes. The first specimen came to me with no history, but as it is certainly a little larger than several other foetus of about one hundred and six days it is probably a little older. The head is bent forward, Fig. 231; the back is curved; the arms and legs are both raised toward the face; the right leg is nearly straight so that the toes are brought against the forehead, while the left leg is bent at the knee, bringing the left foot against the right thigh. In this attitude the embryo fills out as perfectly as possible an oval space, and fits therefore the cavity of the uterus. The second specimen, Fig. 232, shows the attitude assumed by the embryo when free, and proves that the position in utero, Fig. 231, is a constrained one. This foetus was received November 30th, 1883. The delivery took place on the morning of that day, and the

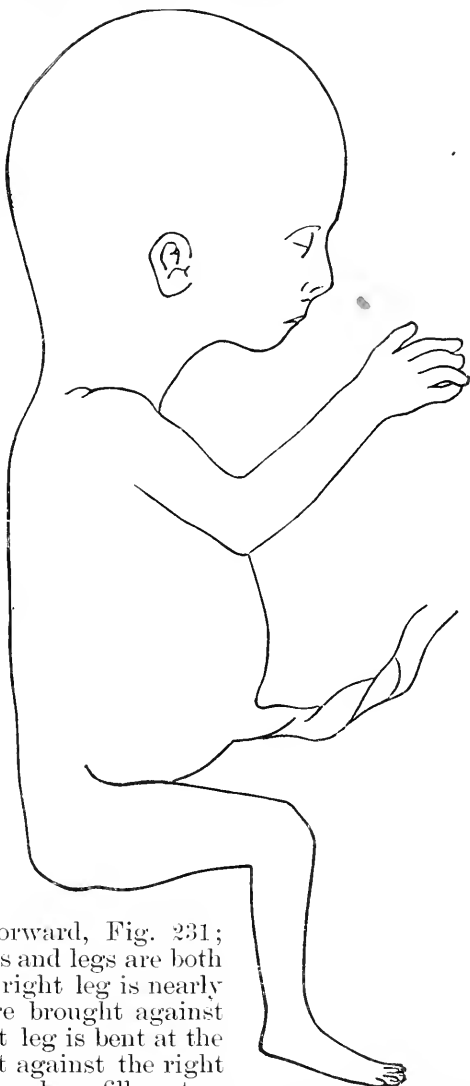


FIG. 232.—Embryo of 118 mm. No. 15 Minot Collection. Age, one hundred and six days. Natural size.

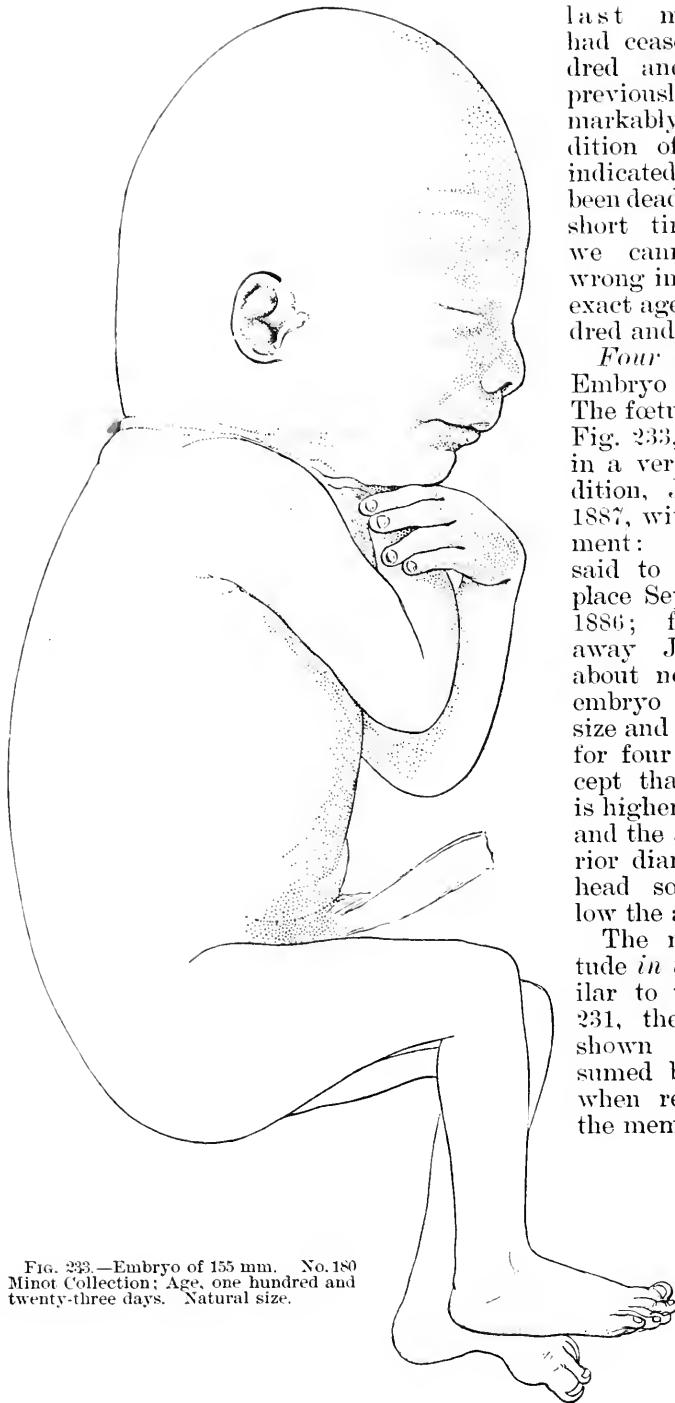

FIG. 233.—Embryo of 155 mm. No. 180 Minot Collection; Age, one hundred and twenty-three days. Natural size.

last menstruation had ceased one hundred and six days previously; the remarkably fresh condition of the fœtus indicated that it had been dead only a very short time, so that we cannot be far wrong in putting its exact age at one hundred and six days.

Four Months.—Embryo 155 mm. The fœtus, shown in Fig. 233, came to me in a very fresh condition, January 2d, 1887, with the statement: "Conception said to have taken place September 1st, 1886; fœtus came away January 2d, about noon." The embryo is typical in size and development for four months, except that the crown is higher than usual, and the antero-posterior diameter of the head somewhat below the average.

The natural attitude *in utero* is similar to that of Fig. 231, the attitude shown is that assumed by the fœtus, when released from the membranes.

CHAPTER XIX.

THE MESENCHYMAL TISSUES.

As the numerous tissues which result from the differentiation of the mesenchyma enter to a greater or less extent into the formation of the organs of which the main parts are derived from the ectoderm, entoderm, or mesothelium, it is desirable to begin the study of the organs with a general review of the mesenchyma. The development of the skeleton is treated in the next chapter, p. 422.

Classification of Mesenchymal Tissues.—The fundamental and essential characteristic of the mesenchyma is, that the cells are some distance apart, but connected together by their own protoplasmatic processes. The tissue is made up of anastomosing cells. The spaces left between the cells are filled with *intercellular substance*, which, owing to the size of the spaces, constitutes a large part of the tissue. In this respect the mesenchyma offers a marked contrast to all epithelia, for the latter have the intercellular substance reduced to a minimum. The intercellular substance is an extremely important factor in the differentiation of the mesenchymal tissues; in fact so important that it affords a better basis for the classification of the tissues than the cells themselves. To these fundamental conceptions I attribute a great value.

In the primitive stage we have cells with small protoplasmatic bodies, connected by few processes and imbedded in a homogeneous matrix (intercellular substance). We can distinguish in subsequent changes three main sets of modifications: 1, those which are specially characterized by changes in the basal substance; 2, those characterized chiefly by changes in the cells; 3, those characterized by the special arrangement of the tissues produced by the differentiations of the mesenchyma.

In the first series I put the development of connective-tissue fibrils and fibres, of the intercellular network both elastic and non-elastic, of mucin, as in Wharton's jelly, of cartilage (chondrification), of bone (ossification), and also the disappearance (or liquefaction?) of the basal substance, and finally its hypertrophy.

In the second series I put the development of the blood-vessels, of the lymphatic vessels, muscle-cells, fat-cells, pigment-cells, and of the marrow of bones.

In the third series I put the development of the connective-tissue cavities such as the synovial, bursal, and subarachnoid, and the formation of special layers such as the subepithelial basement membranes, the submucosa, the cutis, and so forth. What little there is to be said in regard to the special layers will be found in connection with the history of the special organs of which they form parts.

The following table gives the classification adopted. It must be

borne in mind that the classification is somewhat arbitrary, since in all the tissues modifications occur in both the cells and the inter-cellular substance; moreover, several differentiations may occur simultaneously or successively in the same part; for instance, the fibrillæ and network are usually found together; cartilage may or may not have fibrillæ and elastic tissue.

MESENCHYMAL TISSUES.

First Series. (Changes in matrix).	Second Series. (Changes in Cells.)	Third Series. (Special arrangements).
1. Fibrils.	1. Blood-vessels.	1. Cavities.
2. Network.	2. Lymphatics.	<i>a.</i> synovial.
<i>a.</i> yellow elastic.	3. Muscle-cells.	<i>b.</i> bursal.
<i>b.</i> white non-elastic.	4. Fat-cells.	<i>c.</i> subarachnoid.
3. Mucin.	5. Pigment-cells.	2. Membranes.
4. Chondrification.	6. Marrow.	<i>a.</i> basement.
5. Ossification.		<i>b.</i> submucous.
6. Disappearance.		<i>c.</i> dermal.
? by liquefaction.		<i>etc.</i>
7. Hypertrophy.		3. Ligaments.
		4. Tendons.

Embryonic Mesenchyma.—Concerning the very early history of the mesenchyma we have little satisfactory knowledge beyond the fact that the cells of the mesoderm are at first closely crowded and as they move apart are seen to remain connected together by protoplasmatic processes.

As regards the shape of the cells I distinguish two stages, of which the earlier has not hitherto been definitely recognized. In the *first* stage, which I have observed to occur to elasmobranchs, birds, and mammals, the protoplasm forms a complex network in which the nuclei are scattered at irregular intervals; around the nuclei there is often little or no condensation of protoplasm, so that there are, properly speaking, no perinuclear cell bodies. The tissue corresponds, therefore, very poorly to our conventional conceptions. This stage is well represented by the mesoderm of the umbilical cord in a human embryo of about seven weeks, Fig. 206, p. 358. The form of the cells—or, if the expression be preferred, of the nodes of the reticulum—varies greatly, but in a definite manner in the various regions of the embryo; the variations depend chiefly upon the density of the tissue and its trend; for instance, in amniote embryos with two to four gill-clefts there is always a distinct contrast between the dermal mesenchyma, which is of loose texture and with no decided trend, and the mesenchyma between the muscle-plate and the medullary tube, which is dense and has elongated cells. The differences have never been comprehensively studied, and we can only say that they are the expression of unlike conditions of origin and growth of the various parts of the mesenchyma. In the *second* stage, which seems to be reached by all the cells of the mesenchyma sooner or later in all vertebrates, the protoplasm has formed distinct cell-bodies around the nuclei, and there are no considerable accumulations of protoplasm except around the nuclei. This stage is illustrated by the human umbilical cord at three months, Fig. 207, p. 359, and is still more typically and characteristically shown by the mesoderm of a chick of the third or fourth day, or in a rabbit embryo

of ten or eleven days; in the dog-fish this stage is not reached until considerably later in the development than in the amniote embryo. In the chick, Fig. 234, the cells have a large nucleus of rounded form, with a distinct intranuclear reticulum of protoplasm and one or several granules of chromatin; the nucleus is surrounded by granular protoplasm, constituting a small cell-body, which sends off tapering processes to unite with similar processes of other cells; the processes are sometimes very short, but vary in length up to two or three times the diameter of the cell-bodies. The length of the processes also varies in different regions, so that the cells in one region are more or

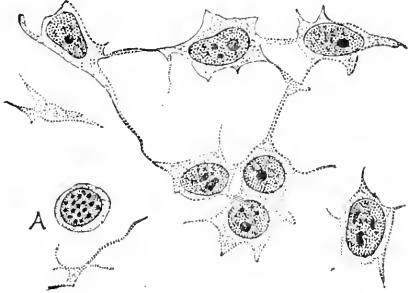


FIG. 234.—Mesenchyma of a Chick Embryo of the Third Day from Close to the Oocyte. A, a nucleus in karyokinesis; the chromatin loops are seen in cross-section.

less crowded than in others; the cells also vary in shape, being elongated in certain districts; these differences are all significant as the results of previous development and as establishing conditions for the subsequent development. In young mammalian embryos the cell-bodies are less well marked than in the chick, and the processes form a network of fine threads between the cells, as can be seen in places in rabbit embryos, as late at least as the seventeenth day.

The matrix is perfectly clear, homogeneous, colorless, and structureless; it is of slight consistency, and scarcely stains with any of the most used histological dyes.

Intercellular Differentiation.—The means by which differentiation of the mesenchymal matrix is effected are little understood. If we accept the view, which is, however, as yet by no means beyond doubt, that the fibrils and network arise from the cells, we can account for a part, but only for a part, of the intercellular structures. If, on the other hand, we hold that all intercellular structures are of intercellular origin, then we can assume that there is some general principle in accordance with which they are all produced. Even in this case the cells must have some influence, since their presence and vitality are essential conditions.

Experiments published by Harting are suggestive in this connection.

Connective-Tissue Fibrils.—The fine fibrils of the adult connective tissue appear quite early in the embryo in the intercellular substance. There are two theories of the origin of the fibrils: 1, they arise from cells; 2, they arise from the matrix. Their origin from cells was the view of the founder of the modern cell theory, Theodore Schwann, 39.1, who thought that the cells grew in length and split into bundles of fibrils. Various modifications of this theory have since appeared; thus Obersteiner (Sitzungsber. Wien. Akad., LVI., 251) traces the fibrillæ to outgrowth of spindle-shaped mesenchymal cells. Max Schultze (Reichert's *Archiv*, 1861, 13) thought that the cells fused together and their fused parts formed the fibrillæ as well as the intercellular substance, thus tracing the fibrillæ

to a differentiation of the peripheral parts of the cells—a view which, somewhat modified, has been revived by B. Lwoff, 89.1, who maintains that the fibrillæ arise from the surface of the cells, nearly the whole body of each cell being converted into fibrillæ, which extend along whole rows of cells and along their processes, enveloping the protoplasm. The origin of the fibrils by deposition in the matrix was first maintained by Henle ("Allgemeine Anatomie," Erste Aufl., 379) and was, in my judgment, demonstrated by Rollet's investigations, recorded in Stricker's "Gewebelehre," 1871, 62-67, upon the omentum, and by Ranvier's later observations ("Traité technique d'Histologie," 405-411). Kölliker, whose judgments upon histological problems are rarely mistaken, has accepted in his "Gewebelehre," 6te Aufl., 123, the intercellular origin of the fibrils.

If we examine a tissue in which the fibrils are just beginning to appear, as, for instance, the human umbilical cord toward the end of the third month, Fig. 207, p. 359, or the omentum of a sheep embryo

of 17 cm., we find the fibrils running singly and in every direction, both parallel with the cells and their processes and at all angles with them. The omentum, as pointed out by Rollet, is a particularly favorable object, for we are sure of having the entire length of the fibres. The cells of the omentum gradually assume (sheep embryos 4-7 cm.) an elongated spindle form, remaining connected together only by very few processes, which arise chiefly from the end of the cells; the nuclei become oval, and when stained with hæmatoxylin have a distinct membrane, and consist of a clear outer layer and a dark granular central part. Between the cells, and for the most part remote from them, appear the fibrils, which grow in length and number. In later stages, Fig. 235, the cells of the omentum are more attenuated, and their ends are united so as to form a network,

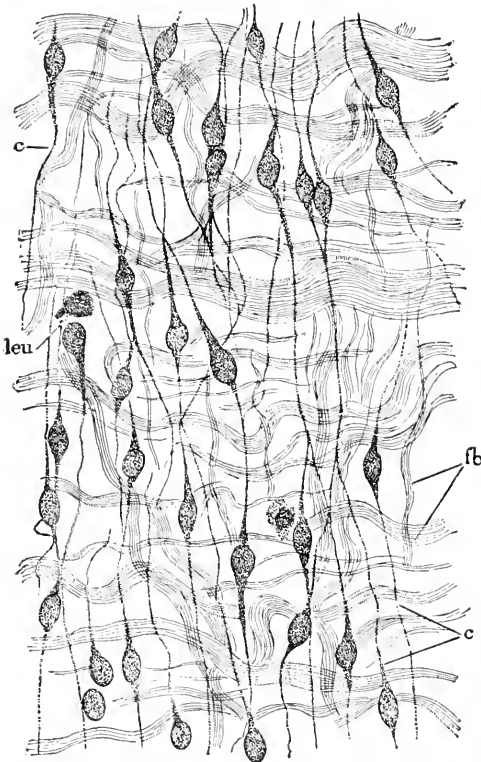


FIG. 235.—Omentum of a Human Embryo of five Months. *c c*, Connective cells forming a network; *leu*, leucocyte; *fb*, fibrillæ $\times 363$ diams.

though some of the cells appear to terminate without any connection with their fellows; the nuclei are more finely granular and have lost the clear outer zone, characteristic of earlier stages. The fibrillæ have grown in length and increased enormously in number;

they form bundles which take a wavy course; these bundles frequently subdivide and unite, so that they form a network; their course and arrangement are independent of the trend of the cells, and there is nothing to suggest any genetic connection between the cells and the bundles of fibrils. Scattered about there are also usually a few leucocytes, Fig. 235, *leu*, which are readily distinguishable from the true mesenchymal cells or so-called connective-tissue corpuscles, *c. c.* The bundles of fibrils correspond to the *connective-tissue "fibres"* of the adult; each fibre consists of a large number of fibrils. The embryonic fibrils differ from those of the adult in staining much more readily. The growth of the fibres depends upon multiplication of the fibrils for Harting ("Récherches micrométriques sur le développement des Tissus," etc., 1845, p. 53) found that the fibrils measured 0.0010–0.0014 mm. in the foetus and from 0.0007–0.0017 mm. in the adult; as, therefore, the fibrils do not thicken they must increase in number as the bundles or fibres enlarge.

Ranvier, *l.c.*, finds that the fibrillæ have no connection with the cells in three tissues, which he has studied in regard to this point, namely, the embryonic dermis, the developing tendon, and the sclerotic cartilage of rays. E. A. Schäfer (Quain's "Anatomy," ninth edition, II., 72) writes as follows: "The view which supposes that a direct conversion of the protoplasm of the connective-tissue cells takes place into fibres, both white and elastic, has of late years been widely adopted, but it seems to rest less upon observation than upon a desire to interpret the facts in accordance with the conceptions of Beale and M. Schultze, according to which every part of an organized body consists either of protoplasm (formative matter), or of material which has been protoplasm (formed material), and the idea of deposition or change occurring outside the cells in the intercellular substance is excluded. But it is not difficult to show that a formation of fibres may occur in soft substances in the animal organism, independently of the direct agency of cells, although the materials for such formation may be furnished by cells. Thus in those cœlenterate animals in which a low form of connective tissue first makes its appearance, this is distinguished by a total absence of cellular elements, the ground-substance being first developed and fibres becoming formed in it. Again, the fibres of the shell-membrane of the bird's egg are certainly not formed by the direct conversion of the protoplasm of the cells which line the oviduct, although it is probably in matter secreted by those cells, and through their agency, that the deposit occurs in a fibrous form."

Intercellular Network or Elastic Tissue.—The intercellular substance of the adult contains in most parts of the mesenchyma a network which varies greatly in appearance. This network has hitherto been described usually as being formed of elastic fibres; now since the material which forms the network does not always resemble fibres, but often rather lamellæ, and since, as shown by F. Mall, 88.3, 91.1, some parts of the network do not contain elastin, it seems very undesirable to continue the use of the term elastic fibres, which is entirely misleading. I shall therefore speak of the two forms of tissue as *yellow elastic network* and *white non-elastic network* respectively. Mall states that there is a non-elastic mate-

rial which alone forms the white network, but which in the yellow network forms a sheath around the elastic core.

Concerning the development of the network we possess little accurate knowledge. Just as with regard to the intercellular fibrils, p. 399, there are two theories: according to one, the network arises by metamorphosis of the cells; according to the other, by differentiation of the matrix. The origin from ramifying cells was the old theory and seems at first thought plausible—see Donders' remarks in *Zeit. wissensch. Zool.*, III., 358—for if we assume the cell processes to be converted into elastin a network would result. The attempt, however, to demonstrate the actual metamorphosis has hitherto been unsuccessful. Kuskow, **87.1**, found that in the ligamentum nuchæ of the embryo, after digestion in cold pepsin solution, the elastic fibres could be seen uniting with the elongated mesenchymal nuclei, usually with the ends, sometimes with the sides of the nuclei. Heller, whose paper I know only from the abstract in Hofmann-Schwalbe's *Jahresbericht* for 1887, 126-127, is said to have seen the connection with nuclei both in the ligamentum nuchæ and in the very young arytenoid cartilage of the embryo; in the cartilage of the ear, on the other hand, Heller states that there is no connection of the elastic fibres with either the nuclei or the cells. These observations show that the elastic tissue may enter into special relation to the nuclei, but throw no light on the significance of the connection; we do not yet know whether the fibres develop independently and afterward unite with the nuclei, or are united with them from the start. Kuskow's suggestion that the elastic network is formed by the nuclei is not likely to be verified, because nuclei never form outgrowths or unite with one another to make reticula, so far as heretofore known.

If the connection with the nuclei is secondary, then the network may be intercellular in origin.

Ranvier, "Traité technique," 401, 411, has shown that the elastic tissue first appears in the form of rows of granules or minute globules, probably of elastin, which subsequently fuse together into a network the lines of which are marked out by the original deposition of the globules. To form an elastic membrane the globules, instead of being arranged in lines, are deposited in small patches, and by their fusion form a plate. In elastic cartilage the granules first make their appearance, it is true, in the immediate neighborhood of the cartilage cells. This renders it not improbable that the deposition of the granules is influenced by the cells, but does not prove that they are formed by a direct conversion of the cell-protoplasm. Indeed the subsequent extension of the fibres into those parts of the matrix that were previously clear of them and in which no such direct conversion of the protoplasm seems possible is a strong argument in favor of the deposition hypothesis. For an admirable discussion of the two views see H. Rabl-Rückhard, **63.1**.

As to the time when the elastic fibres appear we may say in general that it is quite late. They appear in the ligamentum nuchæ of cow embryos of 15 cm.; in the cartilage of the ear in embryos of 30 to 32 cm., and human embryos of five months, Rabl-Rückhard, **63.1**, 43; in the arytenoid cartilage in cow embryos of 55 cm.; in adult fibro-elastic cartilage the elastic network is still de-

veloping, and is not formed at all in the sheaths of nerves until adult life.

The elastic network grows by thickening the fibres and plates, which are found much larger in diameter in the adult than in the foetus. In this respect it forms a striking contrast with the intercellular fibrillæ, which grow principally by multiplication.

Concerning the development of the white non-elastic network we know almost nothing.

Mucous Tissue or Wharton's Jelly.—In man this tissue occurs only in the umbilical cord. It is characterized by the development of mucin in the intercellular substance. The tissue has already been described, p. 358, and I have only to add that the mucin is present in a diffuse form, and has, so far as yet known, no special structural arrangement. Mucous tissue is said to occur in various parts of the body in fishes, but unless it contains *intercellular* mucin it cannot be regarded as true mucous tissue, in the sense here considered.

Cartilage.—Cartilage begins to be differentiated earlier than any other of the mesenchymal tissues, except the blood-vessels, which are developed much earlier, and perhaps the smooth muscle-cells. It is probably older phylogenetically than any of the other tissues of the group except the two mentioned, for not only does it appear very early in the embryo, but is found in invertebrates. It is for convenience only that I consider cartilage after the fibrillæ and elastic network, for both of these intercellular structures appear in certain forms of cartilage. In this section the history of cartilage is considered under the following heads: 1, condensation of the mesenchymal tissue to form the anlage of the cartilage; 2, appearance of the matrix; 3, young cartilage; 4, growth of cartilage; 5, mature cartilage; 6, fibrillar cartilage; 7, elastic network cartilage.

1. *Condensation of the Tissue.*—This takes place simply by the cells becoming very much more closely crowded together than in the surrounding mesoderm; at first merely the central portion of the anlage is thus marked out and there is a very gradual transition to the looser mesenchyma about; for every piece of cartilage there is a separate anlage, which is distinct from the start; one exception to this rule occurs in the case of the vertebræ, as has been stated by Gegenbaur, and has been shown with great precision for birds and mammals by A. Froriep, **83.1**, **86.1**. Another exception is offered by cartilages of the limbs of amphibia, which Goette and H. Strasser, **79.1**, have shown to be coalesced, when they first appear.

As development progresses, the anlage becomes more and more sharply defined until at last its limit can be determined within a cell or two. The cartilage cells are now so crowded that the nuclei, as has been observed in all classes of vertebrates, seem almost to actually touch one another—see H. Strasser, **79.1**, 245, and A. Froriep, **86.1**, 73.

When the anlage is completed its peripheral cells become elongated and form the anlage of the perichondrium; while the central cells, by taking on the rounded form, begin their metamorphosis into cartilage cells; the perichondrium is a thin layer. C. Hasse, **79.1**, **2**, thinks that the cells assume a spindle shape first, and afterward

take on the rounded form, at least in elasmobranchs. It is uncertain whether the two stages can be distinguished in the higher vertebrates.

The first cartilaginous anlagen appear in the chick during the fifth day, and in the rabbit, I think, about the thirteenth day. The vertebral are probably always the first cartilages to be indicated by completed anlagen. The other cartilages become recognizable later; the exact times need to be determined by closer study than has yet been attempted.

2. *Appearance of the Matrix.*—*Præ-cartilage* (prochondrium, *Vorknorpel*).—The intercellular substance, as the cells begin to move apart and lose their connections with one another, gradually assumes a greater density and finally becomes highly refractile and quite resistant mechanically and chemically, and at the same time acquires, at least in many cases, a great affinity for carmine and hæmatoxylin. Hasse, **79.2**, states that this color-reaction always appears in the young cartilage of elasmobranchs, and therefore he proposes to distinguish the stage as a distinct one, since the matrix of the fully differentiated hyaline cartilage does not stain; for the young cartilage with colorable matrix he proposes the term *Vorknorpel*, which I have rendered *præ-cartilage*. Hasse states that in the *præ-cartilage* of elasmobranchs the matrix consists of numerous fibrillæ held together by a cementing substance. This is now generally held to be the structure of the matrix in adult hyaline cartilage—see, for instance, Spronck, **87.1**, and Kolster, **87.1**, who both give references to the preceding literature. Hasse further states that in *præ-cartilage* the matrix is of uniform structure throughout, and that there are no capsules around the cells. The cells of young cartilage are said to contain glycogen; Rouget claims to have found it in the sheep embryo at two months. Many authors have held that the matrix was formed as a series of capsules, one around each cell; the capsules grow and fuse. In support of this view there are no satisfactory observations known to me. As it is adopted in Quain's "Anatomy" by Schaefer (ninth edition, II., 84), I presume it rests upon some good authority, which I have overlooked.

When the condensed mesenchyma is beginning to change, dark irregular masses appear among the cells; these are the "prochondral elements" of H. Strasser, **79.1**. Alice Johnson, **83.1**, 400, states that they may be seen in the hind limb of the chick about the sixth day, and she interprets them as degenerated cells which have lost their nuclei.

3. *Young hyaline cartilage* differs but little from that just described, except that the matrix has increased and the cells are slightly larger. It is to be considered as the primitive form of tissue, from which all the modifications of adult cartilage are derived. In the thyroid cartilage of a three-months human embryo I find the cells farther apart and a little larger than in younger stages; the cells are still small and are here and there in groups of two; they are not round but more or less compressed in shape, and some of them appear to contain fat granules. In the same cartilage at four months the general appearance is the same as before, but the matrix stains unevenly; around the cells it is light, but between the cells intervenes a darker-colored portion which forms a network through the tissue.

In the neighborhood of the prochondrium the matrix is altogether light and the cells are in part larger, rounder, and with distinct spherical nuclei. In the tracheal cartilage of embryos of about seven months the cells are decidedly larger than those of the thyroid just described; the rounded nuclei are very distinct; the protoplasm is granular and entirely fills the cell space (lacuna) of the matrix; the cells exhibit only a very slight tendency to form cell groups as in mature cartilage, nor are there any signs I can recognize as such, of the degenerative changes which can be seen in the adult.

4. *Growth of Cartilage*.—The matrix presumably grows by intussusception, and not, as some authors have maintained, by the continual conversion of the superficial protoplasm of the cells into matrix. If such a conversion took place we should expect to see the cells diminish in size, whereas they increase. The cells increase in number by division, and by additions from the perichondrium; of the two factors the latter is probably the more important.

The division of cartilage cells has been especially studied by W. Schleicher, 79.1. The division is indirect. The nuclear membrane first of all disappears or is converted into filaments which soon become lost among the other filaments developed within the nucleus. The filaments are at first short and irregular, but soon take on a stellate arrangement, and the chromatin becomes grouped into an equatorial plate, which divides, one group of chromatin elements moving toward one pole, the other toward the opposite pole. The division of the protoplasm is not effected as usual in animal cells, but by means of a cell-plate, as in many vegetable tissues; the cell-plate forms a partition in the middle of the elongated binucleate cell; the plate grows and becomes the matrix between the two daughter cells. As the plate thickens slowly the cells remain near together for some time, and one or both them may again divide with the result that there is a group of three or four cells. This grouping is highly characteristic of adult cartilage, but exactly when it first appears I do not know. It does not appear in embryonic cartilage, so that we must assume either that in the embryo the cartilage cells do not divide, or else that they divide and move apart very rapidly. In either case the grouping of the cells remains a sign of age, and ought perhaps to be regarded as the expression of a diminished vitality.

Concerning the exact history of the perichondrial cells as they change into cartilage cells special investigation is needed. At present we can say hardly more than that the change takes place.

5. *Mature Hyaline Cartilage*.—The hyaline cartilage of the adult exists in two principal modifications, both characterized by the great development of the matrix and by having the cells for the most part in groups of two, three, or four, but distinguished by having in the one case large cells with round nuclei and well-developed protoplasmic bodies, and in the other cells which have shrunk somewhat and are often compressed, with nuclei which are often indistinct and irregular, and protoplasm which frequently contains fat globules. I believe that we have to do with two stages in the life-history of cartilage, and that the first modification, in which the cells are large, is the earlier stage, and represents the maximum of development, while the second, in which the cells are shrunk and fatty, represents a later

stage, with more or less degeneration. Dekhuyzen, whose papers I know only through the abstract prepared by himself for Hofmann-Schwalbe, *Jahresbericht f.* 1889, 82-83, was the first to interpret the mature cartilage as a degenerating tissue. In deciding upon the order of the two stages I have been guided chiefly by my observations upon the growing cartilages of the lung in rodents, for in them the large, round, protoplasmatic cells lie between the connective-tissue cells on the one hand, and the fatty, compressed cartilage cells on the other, and clearly present a transitional stage of the transformation of the perichondrial cell into the old cartilage cell, and by the further observation that in the child at birth the bronchial cartilage consists entirely of large, rounded cells with spherical nuclei. The changes which are here noted as degenerative begin very early; thus Dekhuyzen states that they are well advanced in the epiglottis of the dog at birth.

Little has been done upon the development of the matrix, but numerous researches have been made upon the structure and chemical composition of the adult matrix. A little upon the chemical development after birth may be found in Möner (Schwalbe's *Jahresber. f.* 1889, 81-82).

6. *Fibro-cartilage* appears first in the form of hyaline cartilage, and the fibrillæ, which appear in the matrix and seem to be homologous with the ordinary intercellular connective-tissue fibrillæ, are developed earlier or later.

7. *Elastic cartilage* also appears as hyaline cartilage, in which an elastic network is subsequently developed.

Degeneration of Ossifying Cartilage.—Besides the changes of a degenerative character, above referred to, the skeletal cartilages undergo a complete resorption, whenever in the course of development they are to be replaced by bone, except that in a few parts the cartilage is changed directly into bone. There are two forms of the resorption of cartilage, the direct and the indirect. The direct resorption occurs in only a few cases, as for instance in the greater part of Meckel's cartilage, and is characterized by the gradual disappearance of the cartilage without any preceding striking change in it. The indirect resorption occurs whenever the development of bone begins in the interior of a cartilage, and is accompanied by very remarkable structural alterations in the cartilage. So far as I know no exact study of the direct resorption of cartilage has yet been made, while the indirect resorption has been investigated again and again.

The *indirect resorption* begins in the centre of the cartilage; the first step in the process is an enlargement of the single cartilage cells, without much or any change in the amount of the matrix between them, but the matrix assumes a granular appearance and acquires a gritty feel to the knife owing to the formation of calcareous deposits. Meanwhile the cartilage above and below the centre of degeneration becomes enlarged and piled up in elongated groups or columns which radiate from the centre for a certain distance toward either end. The radiating columns of cells taper toward their ends away from the centre, the end cells being smaller. In the matrix between the columns calcification takes place, so that calcified partitions separate

the columns from one another. Turning now to the cells we find that they are undergoing a hypertrophic degeneration, for their enlargement precedes their breaking down. There has been no sufficient study of the changes in the cells, but so far as my own observations enable me to judge the changes are probably as follows, Fig. 238. The cell enlarges and its protoplasm becomes granular; the enlargement continues and the cell appears to encroach upon the matrix more and more until ultimately adjacent cell-cavities coalesce; while this corrosion of the matrix is progressing the protoplasm of the cell becomes vacuolated; its nucleus becomes irregular and indistinct, and sooner or later disintegrates; the cell then contracts and forms a flattened body, which stains more or less, but exhibits no distinct structure, unless now and then some trace of the original nucleus; after the cells have shrunk their cavities fuse together, and sooner or later the cells break down into mere granular detritus. The coalescence of the cell-cavities does not take place equally in all directions, but principally as shown in Fig. 238, along radiating lines; hence there arise a series of radiating cavities separated by partitions formed by the calcified matrix. While these changes are going on in the interior of the cartilage, columns of the surrounding connective tissue go into the cartilage at various points, but always toward the degenerating tissue; each column contains blood-vessels also. As to why or how these columns penetrate the firm cartilage with their own soft tissues, we know nothing. The columns reach the centre of degeneration just as the cells of the cartilage break down and the ingrowing new connective tissue at once fills the spaces formed in the cartilage and proceeds in its new site to produce bone. The degenerative process now extends toward both ends of the cartilage and is followed by the formation of bone. The whole series of changes is commonly termed the ossification of cartilage, but this is incorrect, for the cartilage is destroyed, not ossified. The conjunction of the two sets of processes, Fig. 238, creates very singular microscopical pictures, which for a long time puzzled investigators. For further details see the following section on ossification.

Ossification.—Bone is a mesenchymatous tissue, in which the cells have a characteristic shape and the matrix or intercellular substance is large in amount and calcified. It is derived always by a direct metamorphosis of embryonic connective tissue or of embryonic cartilage, and of periosteum. The ossification of cartilage plays a small part—for instance, at the angle of the jaw it has been observed to occur by J. Brock, 76.1, who found the cartilage cells changing into bone cells there, though nowhere else in the mandible. Most bones are formed by the ossification of the connective-tissue cells or undifferentiated mesenchyma, and by layers of bone added by the ossification of the periosteum. Bony tissue after it is once formed does not grow except by additions to its surface. In the simplest form of ossification we have a layer or membrane of connective tissue, in which the tissue changes into bone; this is called intramembranous, direct, or *metaplastic* ossification. The direct ossification of cartilage should also be placed under this head. As a modification of the simple ossification we must regard the ossification to replace cartilage, which is termed the intra-cartilaginous, indirect,

or *neoplastic* ossification. In both types the actual processes of ossification are essentially the same, and the bone is completed by the co-operation of the periost.

Metaplastic Ossification.—This may be conveniently studied in the parietal bone of the human embryo. About the end of the third

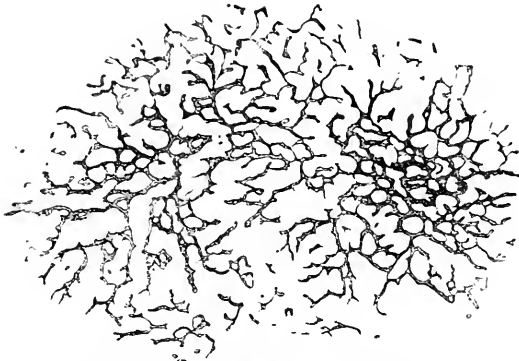


FIG. 236.—Parietal Bone of a Human Embryo of fourteen Weeks. After Kölliker. $\times 18$ diams.

month, in the parietal region of the membranous skull there appear minute calcified spicules, which rapidly increase in number and grow both in diameter and length so that they soon fuse together and form an irregular network, Fig. 236. The meshes of the network are filled with mesenchymal cells, which are continually forming bone upon the surface of the spicules. Some-

upon the surface of the young bone, and adds osseous tissue to it.

The transformation of the mesenchyma into bone is illustrated by

Fig. 237, which represents a transverse section of the foetal mandible. The mandible is closely invested by the fibrous periosteum, *per*, which is in part artificially separated from the bone, *Os*, the irregular bars of which have already acquired considerable thickness; the spaces in the interior of the bony mandible are filled with a loose mesenchyma, the cells of which have large rounded, finely granular nuclei, with but little protoplasm forming cell-bodies; the cells are connected by a rich network of fine granular threads with one another. Some of the cells lie directly against the bone, either just touching it, or half or wholly imbedded in it; those which are in the bone are true bone cells, and are easily recognized as modified embryonic connective-tissue cells, which have gradually accumulated more

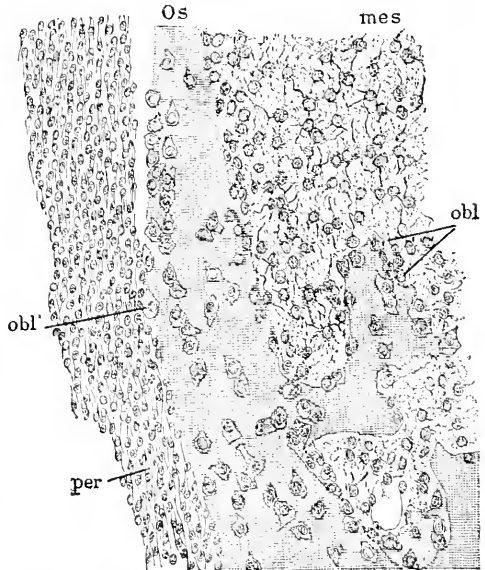


FIG. 237.—Transverse Section of the Mandible of a Human Embryo of the tenth Week. Minot Collection, No. 138. *Os*, Bone; *mes*, mesenchyma; *obl*, *obl'*, osteoblasts; *per*, periosteum. $\times 237$ diams.

and more protoplasm so that, since the cells begin to enlarge as soon as they touch the bone, they are found to have grown considerably by the time they are completely imbedded. The connective-tissue cells, which lie against the bone, are known as *osteoblasts*, a name proposed by Gegenbaur in 1864; though often close together they always are separated by distinct spaces from one another; they are rounded, polyhedral, or triangular in form, and frequently are so crowded over the surface of the bone that they present a distinctly epithelioid arrangement; the nucleus usually lies toward one side or end of the cell. The osteoblasts become imbedded in the bony matrix and thereby converted into bone cells, not by migration, but by the growth of the calcified matrix, the formation of which goes on first on the side of the osteoblast toward the bone, and gradually advancing overgrows the osteoblast and continues beyond it. The history of the intercellular threads of protoplasm during the transformation of the connective-tissue cell into an osteoblast, and then into a bone-cell, has, so far as I am aware, never been followed out. It seems to me probable that the threads are preserved and lead to the development of the canaliculi, just as the cell-bodies produce the so-called lacunæ. Whether threads of protoplasm run through the canaliculi in the mature bone or not is still under dispute. Beside the osteoblasts in the interior of mandible there are others, Fig. 237, *obl'*, which are derived from the cells of the periost, *per*, and although the periosteal cells are of a very different character from those of the mesenchyma, *mes*, in the interior of the mandible, yet all the osteoblasts are alike. E. A. Schäfer has directed attention to what he calls the *osteogenetic fibres*.^{*} Upon close observation of the growing spicules of the parietal bone the calcified parts appear granular, and from them Schäfer finds that there run out for a little way soft and pliant bundles of transparent fibres. They exhibit a faint fibrillation and have been compared to bundles of white connective-tissue fibrils, with which in some situations they appear to be continuous. But although similar in chemical composition, they are somewhat different from these in appearance, having a stiffer aspect and straighter course, besides being less distinctly fibrillated. The fibres become calcified by the deposition within them of earthy salts in the form of minute globules, which produce a darkish granular opacity, until the interstices between the globules also become calcified, and the minute globules, becoming thus fused together, the bone again looks comparatively clear. It is stated that the fibrils themselves are not calcified, but the calcification affects the portion of matrix which unites them into the osteogenic fibres, so that these may be described as being calcified. The bundles of osteogenic fibres which prolong the bony spicules generally spread out from the end of each spicule so as to come in contact with those from adjacent spicules. When this happens, the innermost or proximal fibres frequently grow together, while the other fibres partially intercross as they grow further into the membrane. The ossific process extends into the osteogenic fibres *pari passu* with their growth, and thus new bony spicules become continually formed by calcification of the groups or bundles

^{*} This account of the osteogenetic fibres is taken with some slight changes from Quain's "Anatomy," ninth edition.

of osteogenic fibres. The earthy deposit not only involves the osteogenic fibres, but also the ground-substance of the tissue in which they lie. It occasionally appears in an isolated patch here and there on some of the osteogenic fibres in advance of the main area of ossification. The osteogenic fibres become comparatively indistinct as they and the substance between them calcifies; they appear, however, to persist in the form of decussating fibres, such as are seen in the adult bone, although in the embryonic bone their disposition is less lamellated, the bony matter having a somewhat coarsely reticular structure.

Neoplastic Ossification.—When bone replaces degenerated cartilage, the method of bone formation is essentially the same as when of ossification takes place in connective tissue, except for one feature, namely, that the bone is first deposited against the calcified remnants of the cartilaginous matrix as soon as the cartilage cells have disappeared. A section through an ossifying long bone or vertebra, Fig. 238, presents a highly characteristic picture, and if the section be made as in the figure, parallel to the columns of cartilage cells, all the phases can be seen in a single successful preparation. The section figured was stained with Beale's carmine and alum hæmatoxylin, by which method not only are the cells and nuclei brought out clearly, but also the calcified cartilage is made deep blue, while the bone is deep red. In the upper part of the figure, C, the cartilage cells are just forming groups or columns, which a little lower down, C', are very distinct; lower down again, C'', the cavities, in which the columns of cartilage cells lie, have fused together into large spaces; in these spaces the cartilage cells, c, are scattered in various stages of disintegration; the adjacent spaces are separated from one another by partitions formed of ossified cartilaginous matrix, Ma, which appears a deep blue in marked contrast to the uncalcified matrix of the upper part of the figure, where the matrix is almost uncolored. The remnants of calcified matrix extend far below the cartilage. At the level indicated by the bracket, L, the new mesenchyma, mes, is found penetrating the spaces between the blue partitions, Ma; the mesenchyma is accompanied by blood-vessels, which are easily recognized, V, by their endothelial walls. Some of the invading mesenchymal cells lay themselves against the surfaces of the calcified partitions, become osteoblasts and produce bone, which thickens by additions to its surface. Thus the calcified remains of the cartilage become coated with bone, which in the preparation described has a rich red stain. As in the lower part of the figure the development is more advanced, we find there the layer of bone, B, much thicker than nearer the cartilage. Fig. 239 is a very accurate drawing of part of a section of a vertebra of a four-months' embryo so made that the columns of cartilage cells are cut at right angles; the level of the section corresponds to the lower part of bracket L, Fig. 238. The cartilage cells have disappeared and have been replaced by the invading mesenchyma; the network of partitions formed by the remnants of the calcified matrix, Ma, of the cartilage is at once recognized, as can also be recognized the transformation of the cells into osteoblasts, obl, and the deposit of bone, B, upon the partition; noteworthy are also the osteoclasts, Osc, to which

fuller reference is made in the following paragraph on the growth of bone.

In the long bones the periosteal ossification has great importance,

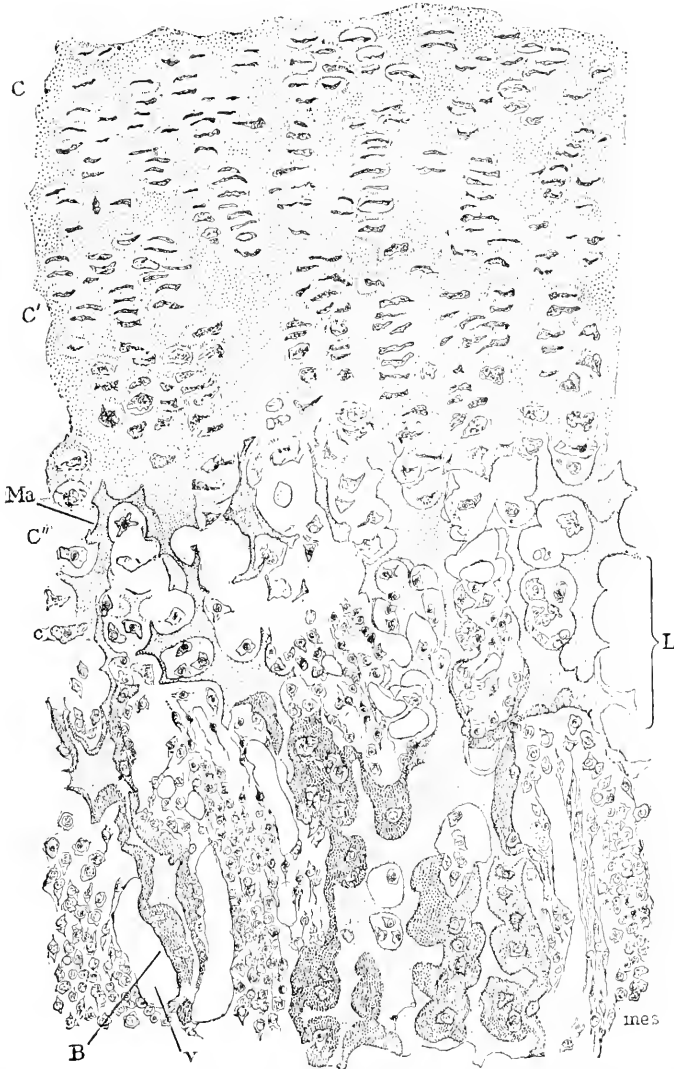

FIG. 238.—From a Section of an Ossifying Vertebra of a Human Embryo of four Months. Minot Collection, No. 35. *C*, *C'*, *C''*, Cartilage; *C*, region where the cells are beginning to form rows; *C'*, region of the cells in columns; *C''*, region where the cells are breaking down, and where the cell spaces are separated by calcified cartilaginous matrix, *Ma*, *c*, degenerated cartilage cell; *B*, layer of bone; *V*, blood-vessels; *mes*, ingrowing mesenchyma; *L*, level of ossification. $\times 172$ diams.

and as it proceeds very rapidly at first in the central part of the bone, most of the shaft is formed from the periost—compare Quain's "Anat.," ninth edition, II., Fig. 109.

We have learned that the development of bone may take place from embryonic connective fibrillar tissue (periost), or from cartilage, but whatever its origin, it has always nearly, if not quite, the same structure. This is true both of the cells and the matrix.

Historical Note.—I have purposely abstained from attempting a full history of ossification. For full and comprehensive accounts I refer to Quain's "Anatomy," Ranvier's "Traité technique d'Histologie," Kölliker's "Gewebelehre," Krause's "Anatomie," etc. For a good review of the literature up to 1858, see H. Müller, 58.2, and for

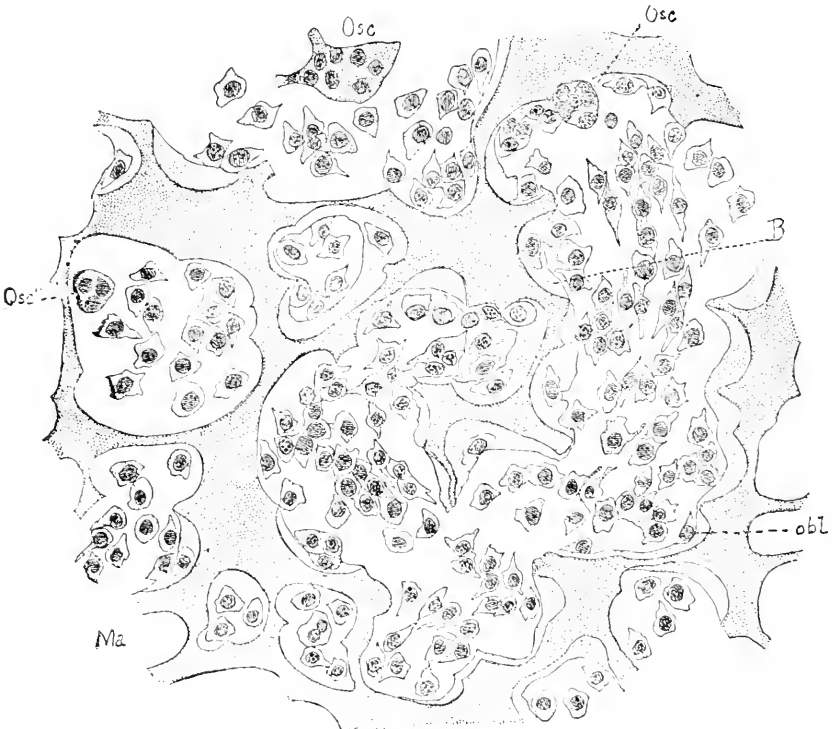


FIG. 239.—Section of a Vertebra of the same Embryo at right Angles to the Plane of Fig. 238, and corresponding in level to the lower part of the bracket *L*, Fig. 238. *Osc*, *Osc'*, *Osc''*, osteoclasts; *B*, bone; *obl*, osteoblasts; *Ma*, calcified matrix of cartilage. Stained with hæmatoxylin and eosine. $\times 356$ diams.

references to the more important later authorities see Ranvier's "Traité," Rollett's chapter in Stricker's "Gewebelehre," and Masquelin's "Memoir."

Growth of Bone.—It is a well-known fact that the bones do not grow in the ordinary sense; the bone cells cannot multiply; the apparent growth of bone is accomplished by the destruction of the bone already formed and the production of new bone. The destruction of the bone is effected by means of large multinucleate cells, Fig. 239, *Osc*, which are derived from the mesenchymal cells, but just how is not clear. The cells in question have been named *myeloplaxes* (or *myeloplacques*), by Robin and French histologists, and *osteoclasts*

(bone-destroyers) by Kölliker. They are frequently found against the surface of the bone, on cartilage, Fig. 239, *Osc'*, and in that case lie in a little concavity formed by the eating away of the bone. As the development of these cells is not known and as their functions have been but little studied in the embryo, the detailed examination of their structure and history may be omitted here. Full accounts of the growth of bone may be found in all the standard histologies.

Disappearance of Intercellular Substance.—In the adult there are various spaces in the mesenchymal tissues, which are in the natural condition filled with fluid, such as the so-called lymph spaces and lymph channels; these spaces have no cellular walls. In the lymph glands also there is much fluid between the cells and reticulum of the gland. We must, therefore, assume that the intercellular substance has in some way been replaced, but whether it has been liquefied, or resorbed and fluid supplied in its stead, or simply cavities developed in it, we do not know. We can, therefore, do nothing more than note the gap in our knowledge.

Hypertrophy of Intercellular Substance.—By this I do not mean the increase which occurs in connection with the development of fibrillæ, elastic network, or cartilage, but the hypertrophy of the clear homogeneous matrix of the young mesenchyma or embryonic connective tissue. Such an hypertrophy occurs in the amnion, in the young cutis, and elsewhere, and it is probably the most important factor in the histogenesis of the vitreous and aqueous humors; as to how this hypertrophy is effected nothing is known. For the history of the vitreous humor see Chapter XXVIII.

Blood-Vessels are the earliest of the mesenchymal tissues to be differentiated. Their history has already been given in full. See Chapter X.

Lymphatic System consists of lymph spaces, lymphatic vessels, and lymph glands. The lymph spaces are merely channels in the intercellular substance, concerning the development of which nothing has been ascertained, and not much is known concerning the development of the vessels or glands.

Lymphatic Vessels.—Kölliker ("Gewebelehre," 5te Aufl., 599-600) states that in tails of tadpoles the lymph vessels can be seen developing, in similar manner to the blood-vessels, by the hollowing out of mesenchymal cells. Klein has come to the same conclusion from the study of the development of lymphatics in serous membranes. According to Klein a vacuole is formed within one of the cells of the connective tissue, and becomes gradually larger, so as ultimately to produce a cavity filled with fluid, while the protoplasm of the cell thins out to form the wall around the cavity. He also adds that from this wall portions bud inward into the cavity, and detaching themselves become lymph corpuscles—but this history cannot be accepted without better foundation. To form vessels the vesicular cells become connected together. The protoplasmatic walls become multinucleate and are differentiated into the lining endothelium. A. Budge's incompleated investigation of the development of the lymphatics in the chick, **87.1**, was published posthumously by Professor W. His, and is an admirable piece of thorough work. The main part of the published memoir is devoted to the history of the

formation of the cœlom by the fusion of a network of channels in the mesoderm, see p. 151. Budge states that after the cœlom is developed some of the channels are still found in the somatopleure, and represent the primitive lymphatics; the somatopleure at this stage has no blood-vessels and the splanchnopleure no lymph-vessels. The primitive lymph-vessels communicate directly with the cœlom. Later on the ductus thoracicus appears and establishes the communication between the lymphatics and the blood-vessels. Unfortunately

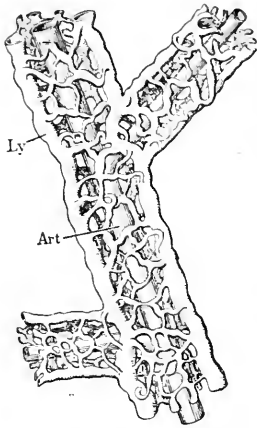


FIG. 240.—Artery from the Allantois of a Chick, surrounded by a Network of Lymphatics. After Albrecht Budge.

the published paper contains no details about the development of the ductus. In a short note (*Centralbl. Med. Wiss.*, 1881, No. 34) Budge has reported that in the allantois of a chick of eighteen to twenty days there are abundant lymphatics which can be injected with a subcutaneous syringe. The vessels accompanying the arteries, forming networks around them, Fig. 240, extend along the arteriæ umbilicales to enter the body and run along the aorta (see Budge, **87.1**, 60, and Taf. VI., Fig. 2) as paired ducti, which are connected with one another by smaller cross stems, and unite in the upper part of the thorax into a single duct, which, however, again forks and has a double opening into the veins. The right umbilical lymph stem appears to atrophy later. In connection with the allantoic lymphatics Budge has found (see His and Braune's *Arch. f. Anat.*, 1882, 350) in chick embryos of ten to twenty days, lymph hearts, which lie in the angle between the pelvis and coccyx.

Lymph-Glands.—Concerning the development of the glands I know of three papers, Sertoli, **66.1**, Chievitz, **81.1**, and a dissertation by Orth (Bonn, 1870), which last I have not seen. Kölliker quotes also Breschet ("Le Système lymphatique," Paris, 1836, 185) and Engel (*Prag. Viertelj.*, II., 111, 1850) as maintaining that the glands arise each as a plexus of lymph vessels—a view which the observations of Sertoli have set aside. To study the early stages, glands must be chosen, the exact position of which in relation to other parts can be determined, in order that the condition of the tissue before the differentiation of the gland can be ascertained. With this in view Sertoli selected the mesenterial glands in cow embryos and Chievitz the same in the pig and the inguinal gland in man. Sertoli found in four-inch embryos fissures in the connective tissue of the mesentery where the glands were to appear; in four-inch embryos these spots were further marked out by the crowding of nuclei around them. In six-and-a-half-inch embryos the anlages were pear-shaped, the pointed end being toward the radix mesenterii; the pointed end alone contains lymph spaces, while the blunt end in which the nuclei are crowded is the anlage of the future cortex of the gland. Somewhat later the fibrous envelopes of the glands are differentiated, and as soon as their formation begins, the growth of the glands by accession from the surrounding mesenchyma ceases. Chievitz studied the

human inguinal gland; its anlage is clearly recognizable at about three months, and at three and one-half months the cortical portion with crowded nuclei can be distinguished from the medullary, in which there are spaces; the gland is separated from the surrounding tissue by a fissure which is crossed by a few threads; the fissure does not extend across the part of the gland corresponding to the future hilus; the cells of the glands have large granular nuclei, and are easily distinguished from the lymphoid cells, which are much smaller with spherical refringent nuclei; at first there are very few lymphoid cells, but they increase in number. Concerning the development of the reticulum, which Ranvier ("Traité technique," 678) has shown to be distinct in the mature glands from the branching cells, we have no information.

Spleen.—Although the development of the spleen must offer many points of great interest, it has received very little attention. In O. Hertwig's text-book no mention of the spleen is made; Kölliker, in both his text-books, dismisses the organ with a single brief paragraph. A little fuller is the notice by W. Müller, in Stricker's "Handbuch der Gewebelehre," 260. Of special investigations there are three short ones, Peremeschko, 67.1, 2, and F. Maurer, 90.1, and the longer article on the spleen in fishes by E. Lagnesse, 90.1.

The spleen is developed out of a mesenchymal anlage, which becomes recognizable in the human embryo toward the end of the second month. In all amniota it is situated in the mesogastrium near the pancreas, and close to large arterial vessels. Its first differentiation appears to be due to an accumulation of rather large lymphoid cells with large granular nuclei, and to the moving apart of the mesenchymal cells, which are much smaller than the lymphoid. Concerning the origin of the lymphoid cells we have only the observations of F. Maurer, 90, who found in tadpoles, measuring from 6-8 mm. from mouth to anus, of the frog, *Rana temporaria*, that the entoderm gives off cells which pass into the mesenchyma and give rise to the first lymphoid cells. Maurer also obtained evidence that the same process occurs in the tailed amphibians. During the third month, in man (Kölliker), the blood-vessels penetrate the organ, which soon becomes rich in blood. W. Müller states that the further development proceeds rapidly, so that in the human foetus of eight centimetres in length the various constituents are already differentiated. The cells lying beneath the peritoneal epithelium become elongated, and form fusiform nucleated bodies, and similar ones at an early period invest the larger vessels. From both small processes are given off which grow toward one another and represent the commencement of the trabecular system. Along the arterial branches denser accumulations of small nucleated cells may already be discerned, which are conspicuous in tinted preparations by their deep color, and these form by far the chief constituent of the pulp. This consists of cells with from one to three nuclei and a delicate intercellular substance, forming plexuses, the interstices of which are constantly filled with blood-corpuscles. According to Peremeschko, there are now developed larger protoplasmic corpuscles in the tissue of the pulp containing from two to six nuclei, that are capable of performing amœboid movements, and which, toward the end of

embryonic life, atrophy. In the further course of development the several constituents increase in volume, and a part of the fusiform cells of the capsule and the vascular sheaths develop into smooth muscular tissue. The arterial sheaths, containing numerous cells, are clearly distinguishable from the pulp, and from the middle of embryonic life the Malpighian corpuscles are recognizable. Concerning the size of the foetal spleen I know only of the statement by Kölliker, "Grundriss," 380, that in man by the eighth week the anlage measures 0.62×0.31 mm., and in the third month 1.7×1.13 mm.

In the embryo at six months the spleen already has its triangular form in outline; the fibrous sheath or capsule, *C*, is differentiated;

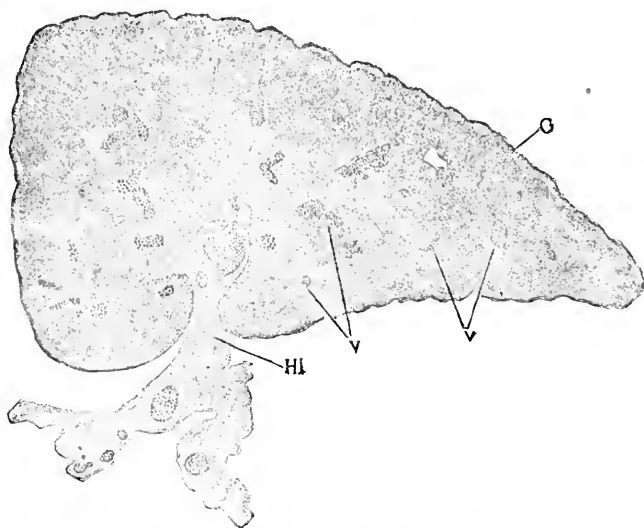


FIG. 241.—Section of the Spleen of a Human Embryo of six Months. *C*, Capsule; *Hi*, hilus; *V V*, blood-vessels. (The Embryo is Minot Collection, No. 8.)

the hilus, *Hi*, is wide; the main blood-vessels are remarkable for their size, and are encased in the sheaths of muscle fibres as in the adult; the differentiation of the Malpighian corpuscles is indicated by the scattered areas, in which the cells are more crowded, which therefore appear darker in the stained specimen. In a thin section (0.01 mm.) of a somewhat younger spleen the reticulum of the spleen, the abundant blood capillaries, and the immense number of pulp-cells I find all well shown; the pulp cells have round, finely granular nuclei with a very small amount of protoplasm; I see also a much less number of smaller oval nuclei, which seem to belong to the reticulum.

Laguesse's monograph, 90.1, on the spleen of fishes is a conscientious and valuable work. The spleen appears late, some time after the pancreas, in the mesenchymal wall of the duodenum close to and on the left side of the insertion of the mesentery, and in close relation with the subintestinal vein. The anlage is first recognizable by the condensation of the tissue and the accumulation of free cells in its meshes. The developing spleen gradually comes into closer relations with the stomach and separated from the duodenum, and

is ultimately situated in the mesogastrium. The origin of the free cells was not ascertained, but the author is inclined to trace them to the mesenchyma rather than to accept F. Maurer's view. They are small, have rounded granular nuclei (Laguesse's *noyau d'origine*) and very little protoplasm; according to Laguesse they give rise some to leucocytes, others to red cells; but in regard to this I think there is need of further evidence, for in other cases we know that leucocytes and red blood-cells (*hématies*) have different origins. The network is produced *in situ* by the mesenchymal cells, the processes of which gradually become more resistant, refringent, and homogeneous, while the nuclei gradually disappear more or less completely. This confirms the view so long defended by Kölliker, as to the nature of the reticulum of the spleen. The cavities of the spleen form a rich network, which very soon enters into direct communication with branches which develop from the subintestinal (portal) vein, but the similar connection with the arteries is not established until later; after the arteries have penetrated there is a circulation through the spleen and many of its free cells are carried off, but in places aside from the currents there remain accumulations of multiplying free cells; such accumulations are found especially around the large arteries. The veins in the spleen consist only of an endothelium, but in the adult are in part encased in a sort of basement membrane formed by condensation of the spleen reticulum around the larger vessels.

Smooth-Muscle Fibres.—That these are simply modified mesenchymal cells seem to me no longer open to doubt, as explained in Chapter VI. on the mesoderm. This implies that the hypothesis so long upheld by His, that the muscles are genetically distinct from the connective-tissue elements, must be definitely laid aside. His classed the muscles as archiblastic elements. His pupil, Erik Müller, has sought in a special article, 88.1, to justify His' view, but the history he gives is, that the inner mesothelium of the primitive segment breaks up into mesenchyma, and that some of these mesenchymal cells form the peri-endothelial walls of the aorta—a fact I can verify from my own observations on birds and mammals—but others of the cells, coming from the inner wall of the segment, form connective tissue, so that in this instance we have a proof of the identical mesenchymal origin of the two tissues. So also in the umbilical cord, it can be seen after the third month that the vessels are surrounded by smooth muscle cells, which gradually pass into mesenchymal cells proper; as the muscular walls thicken with age it seems evident that the transition represents an actual transformation of the connective-tissue cells into muscle cells, but the details of the process have still to be worked out. The earliest definite proof, known to me, that no line can be drawn between smooth muscle and connective tissue is that afforded by Flemming's observations, 78.2, on the bladder of salamanders, in which both tissues with all intermediate forms occur.

Concerning the histogenetic transformation of mesenchyma into smooth muscle we possess no detailed or accurate information.

Fat-cells first appear in the human embryo, it is said, about the fourteenth week, and after their first appearance gradually increase in size and number up to the time of birth, when, however, the fat

cells are still much smaller than in the adult. The fat cells are derived from the embryonic connective-tissue cells or mesenchyma, as has been demonstrated by Flemming, **71.1**, **71.2**, whose view was questioned by L. Ranvier ("Traité"), and the Hoggans, **79.1**. Ranvier's observations were incomplete, in that he did not ascertain the origin of the cell which forms the fat-cells, as Flemming has pointed out in his reply, **79.1**, to the criticisms upon his work. The investigations of the Hoggans appear to me untrustworthy.

The fat cells are always developed in groups or clusters, and each cluster is supplied with an abundant network of blood capillaries.

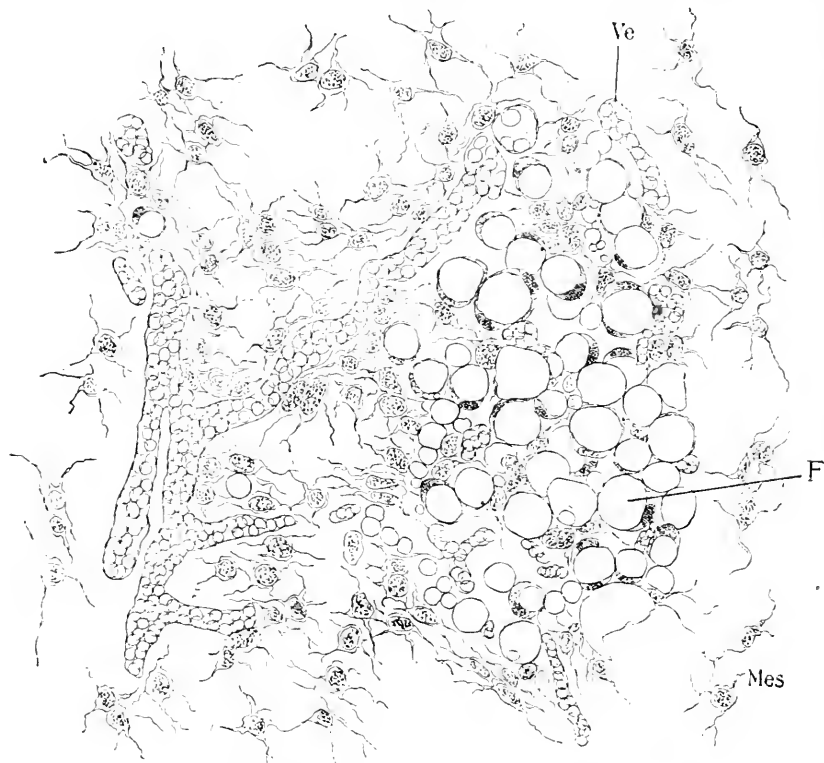

FIG. 242. — Fat Island from the Skin of a Human Embryo of five Months. Minot Collection, No. 95. *Ve*, Blood-vessel; *Mes*, mesenchyma or embryonic connective tissue; *F*, fat cells. $\times 310$ diams.

The fat cells always occur in the neighborhood of blood-vessels, so that one is almost compelled to conclude that superabundant food supply is an essential condition of their development. Some interesting studies on the circulation in fat tissue have been published by J. Schöbl, **85.1**. The clusters of fat cells may be called fat islands, a term less likely to mislead students than that of fat globule, which has been used. Fig. 242 represents a section of a fat island in the embryonic cutis, drawn very exactly from the preparation, which had been stained with alum cochineal and eosine; the mesenchymal cells, *Mes*, are scattered around and completely isolate the fat islands

from one another; the fat cells, *F*, form a group by themselves; each cell has a large globule of fat surrounded by a thin layer of protoplasm, which is thickened on one side, where the nucleus is situated; the smaller the cell the more distinctly does the layer of protoplasm stand out; the nuclei are compressed, smaller than those of the surrounding mesenchyma, and more darkly stained; the difference between the staining of the fat-cell and the other nuclei is exaggerated in the drawing. By their subsequent growth and expansion the fat islands may fuse together, thus forming a more or less continuous fatty layer.

As regards the history of the single cells our knowledge rests chiefly on the admirable researches of Flemming, *l.c.* The cells lose their connections with one another and assume a somewhat rounded form, and the amount of protoplasm increases; the nucleus comes to lie on one side of the cell either before the fat granules are developed or just as they are beginning to appear; according as the nucleus is peripheral or central the fat is at first on one side or around the periphery of the cell. In either case the fat soon collects in one main globule, with other small ones about it in the protoplasm, and thus the condition of the young fat cells, as in Fig. 242, is attained. Soon after the nucleus has been forced to one side by the fat the membrane of the cell appears. It is probable that the fat is accumulated within the cells before it becomes microscopically visible as granules, for Stolnikow (*Arch. Anat. u. Physiol., Suppl.*, 1887, p. 1), has observed that the fat in the liver cells of frogs after phosphorus poisoning may be present in considerable quantities without appearing in granules. Upon this stress has been laid by Gaule, 90.1, as indicating that the fat is bound to some other compound, perhaps lecithin. This lends support to the suggestion of Poljakoff, 88.1, that the dull ("matten") granules, which appear in the protoplasm before or along with the first minute fat granules and disappear as the fat increases, are made up of fat combined with some albuminoid.

The degeneration or regression of fat cells has been studied by Flemming and Poljakoff, but as the change does not occur before birth it does not fall within our scope, beyond noticing the suggestion that Ehrlich's Mastzellen (*plasma cells*) are regressive stages of fat cells.

Pigment Cells.—Concerning their development in the embryo I know of no exact investigation. What Goette gives, 75. 1, 521-522, is largely speculative. Flemming, 90.1, has shown that the pigment cells multiply by indirect division in salamander larvæ, and that the scission of the protoplasm may be delayed. K. W. Zimmermann, 90.1, has given some further details. The divisional process offers several interesting features.

The pigment granules which give color to the epidermis are not of epidermal origin, but arise in mesenchymal cells, which wander in from the underlying cutis. The source of the pigment was discovered by Aeby, 85.1, whose observations have been extended and confirmed by Kölliker, 87.2, 3, "Gewebelehre," 6te Aufl., 202, List, 89.1, and Piersol, 90.2. Kodis, 89.1, on the other hand, has maintained that the pigment cells are formed in the epidermis and wander thence into the cutis, but Kodis fails, I think, to prove his point. In anniota the first pigment appears in small granular cells

in the basal layer of the epidermis (lizard, 40 mm.; chick of ten days; cat, 47 mm.). These cells resemble leucocytes so much that Ködiz has designated them as "*leucocytoide Zellen*;" they lie between the true epidermal cells; the protoplasm is small in amount when the pigment begins to appear, but as the pigment increases the cell enlarges and passes from an apparently round to a distinctly stellate form. In *mammals* the bodies of the cells are composed at first of clear, homogeneous, faintly granular protoplasm, in the midst of which sharply defined oval nuclei are seen; in short, they resemble the cells of the underlying cutis and are probably immigrant mesenchymal cells. The earliest pigment particles are sparingly and irregularly distributed, but soon evince a tendency to aggregate about the nucleus, around which a brown wreath is soon formed. Subsequently pigment cells appear also in the cutis and exhibit a strong tendency to collect beneath the epidermis and to form there rich networks. These cells send processes into the epithelium, to be followed often by the greater part of the cell; it is thus that the pictures of immigrating pigment cells arise.

As to the source of the pigment granules, they seem to be formed within the pigment cells and not to be taken up, as some writers have suggested, as preformed particles from outside. It is possible that the pigment is connected genetically with the hæmoglobin, but of this there is no definite proof. For a discussion of the source of pigment granules see Maass (*Arch. f. mikrosk. Anat.*, XXXIV., 452) and Piersol, *l.c.*

Marrow.—The marrow of bone is derived from the mesenchyma, which, as above described, p. 410, enters the space left by the degenerating cartilage; some of these mesenchymal cells become osteoblasts, while the remainder produce the marrow of the future bone. The marrow has a very complex structure in the adult, and numerous investigations upon its adult structure have been published. In these publications are scattered a good many observations on the fœtal marrow, but as they have never been properly collated, and as there is no comprehensive research upon the development of the fœtal marrow, I reluctantly forego the attempt to describe the histogenesis of the tissue—a subject which would certainly well repay competent thorough study. I will only add that the suggestion made by Ranvier ("Traité technique," 439), that the cells of the degenerating cartilage produce marrow cells, cannot in my opinion be upheld, for it appears to me unquestionable that the cells of the cartilage are disintegrated.

Mesenchymal Cavities.—Under this head I do not include the blood-vessels, nor lymph-vessels, nor the lymph channels of the intercellular substance and lymph spaces of the lymphatic glands, but only those spaces which have, so to speak, passive functions, are filled with serous fluid, and are entirely bounded by mesenchyma. For example: the channels around the membranous labyrinth of the ear (compare the second division on the ear in Chapter XXVII.), the subarachnoid space, the synovial and bursal cavities. These are probably all formed by the cells breaking apart, and are further characterized by the tendency of the layer of mesenchymal cells immediately round the cavity to become crowded until they form a dis-

tinct lining endothelium. The degree to which this tendency is evinced varies extremely, and we may have the cells either simply somewhat crowded, or converted into an endothelium in patches, or wholly endothelium. The transition from one form of tissue to the other can be seen in the adult synovial cavities, and is important as additional evidence of the slight real difference between mesenchyma and epithelium.

I know no observations on the development of the arachnoid spaces. *Synovial and Bursal Cavities.*—The development of the synovial cavities has been studied by Hagen-Torn, **82.1**. Between the cartilages of the limbs there is left undifferentiated mesenchyma, which very early acquires blood-vessels and shows later an increased vascularity. The formation of the cavity begins in the centre between the cartilages, and is first indicated by the tissue becoming less dense there (rabbit embryos 19–20 mm.); some of the central cells undergo a mucoid degeneration and disappear, others become spindle-shaped and change into cartilage cells, with the result that the ends of the skeletal cartilages are now separated from one another only by a slight space. At the sides of the cavity the mesenchyma forms the synovial membrane, which is merely very vascular, fibrillar connective tissue; upon the synovial surface patches of endothelium are developed. Villi, if formed at all, appear in later stages and always at the sides of the cavity by the synovial membrane proper.

Membranes.—The development of the various membranes and special mesenchymal layers, such as the submucosa, dermis, etc., is considered in connection with the various organs, to which they belong. There is one general feature which may be mentioned here, namely, the so-called *basement membranes*. By this term is now generally understood the layers of endothelioid cells found immediately underneath various epithelia; for instance, under the endoderm (epithelium) of the intestine, around the Graafian follicles of the ovary, around the seminiferous tubules, and the urinary tubules. These membranes, often designated as *tunicæ propriae*, are undoubtedly the product of the mesenchyma, though nothing is known of their development. They have the general morphological interest of demonstrating the tendency of the mesenchyma to revert to the epithelioid type.

Ligaments and Tendons.—Both structures are modifications of fibrillæ and elastic connective tissue. The tendons consist almost wholly of fibrillæ running all in the same direction. The ligaments vary more, and may consist either of fibrillar or elastic tissue or both. The development of the ligaments has scarcely been studied; that of tendons has been investigated by L. Ranvier, **74.1**, also his "Traité technique," 407; the regeneration and growth of the tendon tissue in the adult has been studied by several authorities—see A. Beltzow, **83.1**. We learn, however, little beyond the fact that where tendon is to be formed the cells arrange themselves in rows, parallel with the length of the future tendon; the fibrillæ are developed between the rows and parallel to them, and gradually increase until they occupy the entire space between the cells. By what stages the cells pass from the condition of simple mesenchyma to the singular shapes of the adult tendon cells is unknown.

CHAPTER XX.

THE SKELETON.

THE literature of the skeleton is very extensive as regards both its development and comparative anatomy. The ease with which skeletons can be prepared and the importance of the hard parts to the palaeontologist has long given the skeleton a prominence in morphological research far in excess of its importance as compared with the other systems. Although the skeleton is in the *mechanical* sense the framework of the body, it is not so in the *morphological* sense, because so far is it from being the framework upon which the body is built up, that its development is entirely subsidiary to the development of other systems, and is dominated by the arrangement of other tissues and organs, which have been formed and arranged before the skeleton even begins to appear.

In this chapter there is no attempt to give an exhaustive treatise upon the development, but by following the summaries given by Kölliker ("Entwicklungsgeschichte," 2te Aufl., 401-502), Hertwig ("Lehrbuch," 3te Aufl., 492-543), and W. K. Parker ("Morphology of the Skull"), and consultation of the more important original authorities, I have endeavored to write a comprehensive account of the subject.

Stages of the Skeleton.—We must distinguish between the stages of the skeleton as a whole, and the stages in the histogenesis of the bones. It must also be constantly borne in mind that the vertebrates have two morphologically distinct skeletons, the primary cartilaginous skeleton, which in the higher forms becomes partly ossified, and the secondary skeleton composed of dermal bones.

1. *Notochordal Stage.*—Permanent in amphioxus. In this stage the only skeleton is the axial rod of the notochord, and it is found to be the first stage in all vertebrate embryos.

2. *The Membranous Stage.*—The second stage in all true vertebrates and the permanent one in marsipobranchs. The mesenchyma is condensed around the notochord and strengthens thus the axis.

3. *The Primary Cartilaginous Stage.*—The principal parts of the primary skeleton are represented by separate cartilages.

4. *The Completed Cartilaginous Stage.*—In which all the parts of the primary skeleton are present in the form of cartilages. No definite line can be drawn between this stage and the preceding, nor between it and the following.

5. *Stage of the dermal skeleton,* characterized by the development of sundry bones in the dermis. Dermal bones begin to develop before the cartilages ossify, and are present in cartilaginous fishes, hence they must be considered as older, and therefore belonging to an earlier stage, than the bones replacing cartilages.

6. *Stage with osseous primary skeleton*, characterized by the primary cartilages being replaced by bone. The replacement is very gradual and never becomes complete; it begins in some of the cartilages before others are developed; it is, accordingly, impossible to establish any definite limit in time for this stage.

The most logical treatment would be to deal with these six stages in their natural sequence, but it has appeared to me more convenient to give the complete history of the notochord by itself (see p. 181), to add a section upon the membranous stage, and then to present the entire history of the primary skeleton under two main heads, the axial skeleton, p. 424, and the appendicular, p. 448; leaving the dermal skeleton till the last, p. 461, although it is ontogenetically and phylogenetically older than the osseous primary skeleton. The chapter closes, p. 465, with some general remarks on the morphology of the skull.

Membranous Stage.—As we have already seen, the mesothelium of the inner side of the primitive segments produces the mesenchymal cells, which invest the notochord and medullary canal. Recent writers have tended to regard this periaxial mesenchyma as segmented, and Van Wijhe even proposes to bestow the special name of *sklerotome* upon each of the mesenchymal segments. It is true that owing to its segmented origin the tissue does show for a time traces of metameric division, but the division becomes unrecognizable long before there is any mesenchymal skeleton indicated. The primary segmentation plays no immediate part in the development of the separate vertebrae. These considerations render it unjustifiable to regard the periaxial mesenchyma as segmented. We ought not to speak of sklerotomes unless we are prepared to speak of dermatomes, because the anlage of the dermal mesenchyma is as much segmented as the anlage of the periaxial mesenchyma. The question under consideration arose from a mistake of the older embryologists, who believed that the primitive segments were the direct anlages of the vertebrae, and accordingly named them protovertebrae (*Urwirbel*); unfortunately this misleading term is still in use. Then came the discovery that the true vertebrae are developed apparently between the primitive segments or in alternation with them. Remak formulated the hypothesis of resegmentation of the skeleton (*Neugliederung des Axenskelets*), which is wrong in assuming that the segmentation of the skeleton is not parallel with the primary segments, but is right in assuming that there is a primary segmentation of the skeleton, corresponding to the original mesothelial segments. Remak's conception has perpetuated itself to this day, and is carefully repeated in current text-books; were it correct in its entirety then the *membranous stage* we are now considering would not occur.

The first step toward the development of the perichordal skeleton is the fusion of the loose mesenchyma, derived from the segmented mesothelium, into a continuous mass of cells, which grow around the notochord and separate it first from the entoderm and later from the medullary canal, and grow around the medullary canal and close over it slowly, and also grow around the primitive aorta, see Figs. 161 and 103. This mesenchyma is of a loose but not quite uniform

character, and the cells early begin to condense in the immediate neighborhood of the notochord and nervous system. Around the notochord the cells gradually become very closely crowded and form what is known in the lower vertebrates as the chorda sheath, in the amniote embryo as the investing mass, but in the amniota the uniform *continuous* sheath exists only around the anterior end of the notochord where the investing mass participates in the formation of the cranium, while throughout the remainder of the embryo, as has been shown by A. Froriep, the condensed mesenchymal anlage is divided from the start more or less distinctly into separate vertebral masses, which in stained sections stand out conspicuously. Froriep has studied the development of the vertebræ in the chick, **83.1**, and mammals (cow embryos), **86.1**.

I. AXIAL SKELETON.

Vertebral Column.—As to how far forward the vertebral column extends in the head we have no means of deciding positively, but as the occipital region of the skull is developed by the fusion of vertebræ, and as these vertebræ appear less and less distinctly as we pass forward from the neck, and as the number of occipital vertebræ is greater in birds than in mammals, we cannot avoid the supposition that the number of vertebræ fused in the head was once greater than now appears in the mammalian embryo. There is accordingly much uncertainty as to the number of cephalic vertebræ. But though the number of vertebræ is not exactly known, we can fix the *position* of the cephalic end of the vertebral column, as coincident with the cephalic end of the notochord, which is close to the hypophysis or pituitary body. The notochord becomes invested almost up to its cephalic extremity by the condensed mesenchymal sheath, which is found in the occipital region, as in the body, to be the blastema out of which are differentiated the anlages of the vertebræ; it appears, therefore, no mere imagination to regard this as homologous with the vertebral column throughout, but with the development of the vertebræ inhibited entirely in the anterior, partially in the posterior occipital region. In front of the pituitary body the notochord and consequently the investing mass do not extend. We must in fact divide the head into a præ-pituitary unvertebrated and a post-pituitary vertebrated region. The remaining vertebræ to the end of the tail develop all much alike. They assume, however, modified forms in the various regions, but the origin in the embryo of the differences between the cervical, dorsal, and lumbar vertebræ has never been worked out. Special modifications of the first and second cervical vertebræ take place in mammals to form the atlas and epistropheus or axis, in the five sacral vertebræ to form the sacrum, and in the caudal vertebræ to form the coccyx.

Typical Development of a Vertebra.—Our exact knowledge rests mainly upon the investigations of August Froriep, **83.1**, **86.1**, on chick and cow embryos. The investing mass or condensed perichordal mesenchyma forms a continuous sheath around the notochord. At a point corresponding to the centre of each mesodermic segment, or a little on the cephalic side of each segment, the investing

mass becomes thicker in diameter and its tissue more condensed; the condensation is very noticeable in stained sections and is the first sign of the vertebral formation; the condensation spreads rapidly, extending sideways, upward, and backward with the result of forming a bow of dense mesenchyma, the primitive vertebral bow (*Wirbelbogen*) of Froriep. These bows are distinct from the bodies of the vertebræ, which arise later from separate anlagen. The bows pass on the ventral side of the notochord, and thence arch on each side, Fig. 243, tailward and dorsward, so as to end at the caudal edge of the muscle plate of the segment to which they belong, and ending, therefore, just in front of the intersegmental artery, *v*, and of the spinal nerve, *N*, from the sensory ganglion of the next following segment. We see here that the vertebræ are strictly segmental structures and not intersegmental as has been commonly assumed since

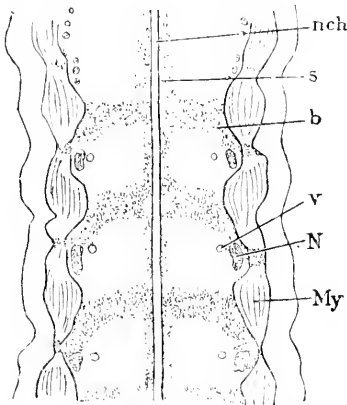


FIG. 243.—Reconstruction of the Last Occipital, and First Two Cervical Vertebrae of a Cow Embryo of 8.8 mm., the notochord and axis being assumed to be straight. *nch*, Notochord; *s*, sheath of notochord; *b*, bow of occipital vertebra; *v*, segmental artery; *N*, nerve; *My*, myotome. After A. Froriep. $\times 32$ diams.

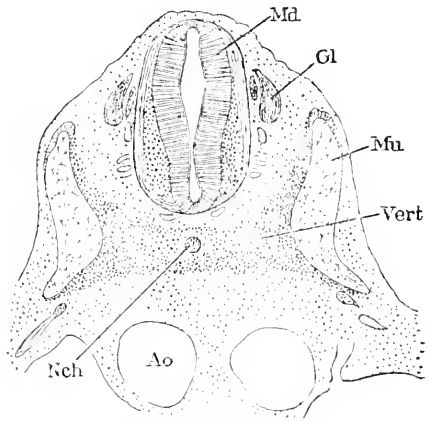


FIG. 244.—Cross-Section of the Anlage of Second Cervical Vertebra of a Cow Embryo of 8.8 mm. *Md*, Medullary canal; *Gl*, ganglion of the second cervical nerve; *Mu*, muscle plate of the second cervical segment (Froriep's first cervical muscle plate); *Nch*, notochord; *Vert*, anlage of the vertebra; *Ao*, aorta. After Froriep.

Remak. The course of the bow, as compared with the transverse plane of the body of the embryo, is oblique, so that while the centre of the bow next the notochord is near the centre of the segment, the tips of the bow lie at the caudal limit of the segment and ultimately separate the muscle plate of its own segment from that of the next following. The obliquity of the bow appears to me to be determined primarily by the arrangement of the spinal ganglia, the dorsal ends of which fill out the width of the segment, while the lower pointed end is carried forward to the anterior border of the segment; this disposition leaves the caudal side of the segment free for the mesenchyma and the differentiation of the vertebral bow; the obliquity is further assisted by the form of the muscle plate, as can be seen in Fig. 243. The portion of the bow underneath the chorda in the median line is termed the hypochordal brace (*Spange*) and in its ultimate development differs considerably from the rest of the bow. The investing mass around the notochord on the caudal side of the

bow and above it becomes later the anlage of the body of the vertebra. The vertebral bow may be regarded as the *primitive stage*; it is found in the chick from the middle of the fourth to the middle of the fifth day; in cow embryos of 7-11 mm.

The vertebral bow is destined to form the processes of the vertebra, and the manner in which its ends spread out against the muscle plate can be well seen in a cross-section, Fig. 244. At the time the bow is differentiated the muscle plate has become protuberant toward the notochord, and when the dense mesenchyma forming the bow spreads out it is forced by the muscle plate to grow dorsalward, and ventralward, and thereby to become, as it were, branched; the dorsal branch is the anlage of the neural arch; the ventral branch the anlage of the transverse or costal process, because it grows out still farther to form the anlage of the rib.

There follows a transitional state which is characterized by the gradual development of the cartilaginous vertebra. This stage extends in the chick from the middle of the fifth to the middle of the sixth day, and is found in cow embryos of 12-17 mm. The notochord exhibits signs of retrogressive change, and is contracted at the level of the vertebral bow. The part of the investing mass (perichordal mesenchyma) immediately over the centre of the bow or hypochordal brace becomes the anlage of the *intervertebral ligament*, its cells becoming first less crowded and then acquiring an elongated form; out of this anlage the adult ligament is slowly differentiated, chiefly by the development of connective-tissue fibrillæ. The investing mass behind the hypochordal brace develops into the cartilaginous body of the vertebra, in the mammal before, in the bird after, cartilage begins to appear in the vertebral bow. In the mammals there are two centres of chondrification, which may be recognized in the bird also, although they are in the latter connected with one another under the chorda. The process of chondrification continues until out of the investing mass the separate vertebral body is differentiated. Meanwhile the chondrification goes on in the vertebral bow, and in birds the whole bow is converted into cartilage and unites with the body to form the completed vertebra. In mammals except in the occipital and anterior cervical vertebræ the central part does not form cartilage but remains as a dense mesenchymal band, which can be recognized as a more or less distinct structure for some time, but is ultimately lost in the substance of the intervertebral ligament. A median longitudinal section of a cow embryo a little more advanced, Fig. 245, shows the persistence of the hypochordal brace.

The permanent stage is reached by the fusion of the cartilage of the bow with that of the body, which may be said to be completed in the chick by the middle of the seventh day, and in cow embryos of 22 mm. In the chick the whole bow is differentiated into cartilage, and its central part fuses with the vertebral body. In mammals this fusion does not take place except in the occiput, but the two ends of each bow become cartilaginous and fuse with the corresponding vertebral body, except in the case of the first cervical vertebra, see p. 430. The central portion of the bow in all vertebræ below the first cervical disappears and is lost in the intervertebral

ligament. In a longitudinal section, Fig. 245, it can be seen that the first bow is a well-developed cartilaginous piece, *Sc*, while the second, is only partially chondrified, while the third and fourth are almost lost in the intervertebral ligament. The first bow, as just stated, forms the atlas. During the development of the cartilage the vertebra continues growing and the arches extend farther from the body; the neural arches gradually close over the medullary canal, the closure taking place much earlier in the chick

than in the mammal. In the human embryo the neural arches extend at eight weeks only a short distance up the side of the spinal cord; at three months they have come in contact on the dorsal side in the dorsal region, but are still quite far apart in the lumbar and sacral regions (Kölliker, "Grundriss," 191) and by the fourth month all the arches have closed. The development of the spinous process needs to be further investigated. The ventral processes, Fig. 244, spread downward and are brought, owing to the primitive inclination of the vertebral bow, to the caudal boundary of the segment to which they belong, and as they lie at the caudal edge of the muscle plate of their respective segments, they contribute to separate that plate from the next following. These processes lose their continuity with the vertebra proper, but remain connected with it by ligaments; they thus become the independent anlagen of the ribs, where true ribs are developed.

Another point deserving attention is the relation of the vertebrae to the vertebral artery which arises, as described in Chapter XXIV., as a series of longitudinal anastomoses between the intersegmental arteries; the vertebral artery begins to appear in cow embryos of 12 mm., and is a continuous stem in those of 15 mm. The vessel forming the anastomosis grows through the mass of the vertebral bow during the transitional stage, while the mesenchyma is not very dense at the point penetrated by the artery. This discovery, which we owe to Froriep, sets aside the statement, which has become traditional, that the developing vertebra grows around the artery, and shows instead that the artery grows through the developing anlage of the

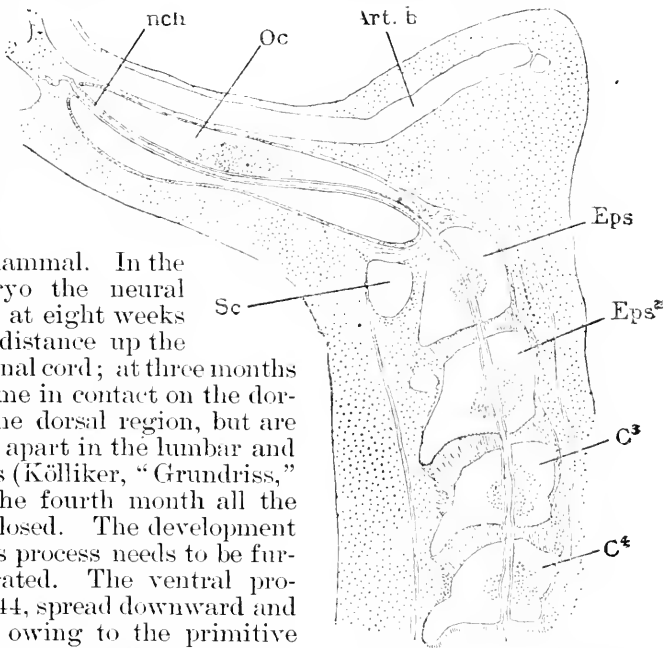


FIG. 245.—Longitudinal Median Section of the Upper Portion of the Vertebral Column of a Cow Embryo of 22.5 mm. *Nch*, notochord; *Oc*, occipital cartilage; *Art. b*, arteria basilaris; *Eps*, *Eps*², *C*³, *C*⁴, bodies of first and second cervical vertebrae; *C*³, *C*⁴, bodies of third and fourth vertebrae; *sc*, anlage of Atlas. After Froriep.

vertebra. The artery, by its position, may be said to mark approximately the boundary between the neural and costal processes of the vertebra.

The ossification of the vertebrae does not alter the morphology of the cartilaginous stage, and it is doubtful whether it is accompanied by any noteworthy change in the form of the single skeletal pieces. The ossification begins with two centres, one in each neural arch, and is continued by a third centre in the body of the vertebra. The centres in the neural arches lie near the body proper; that of the body appears in man about the seventh week. The centres of ossification of the body become recognizable first in the dorsal region, and from there their differentiation progresses successively from vertebra to vertebra, both headward and tailward. The centre is situated at first on the dorsal side of the chorda (Robin), but as the centre extends it incloses the notochord, which is gradually obliterated so that it can no longer be distinguished after the actual formation of bone has commenced. The progress of ossification is very slow; thus the preliminary degeneration covers the period, in cow embryos, in which their length increases from 2.2 to 6.0 cm., and it is not until the latter length has been attained that the actual deposit of bone begins (Froriep, 86.1, 130). In man the centres do not attain the surface of the cartilage until the fourth or fifth month. Ultimately* the three deposits of bone fuse into a single osseous vertebra, but for a long period before this cartilage remains between the bony arches and the bony body, and on the dorsal side between the arches; these cartilaginous areas act as growing zones. The epiphyses are separate centres of ossification, which appear one on the cranial side, one on the caudal side of the body of each vertebra, but not until after birth. The development of the epiphyses and their fusion with the main body have been investigated by Schwegel, 58.1. To complete the adult bony vertebra there are five centres of ossification requisite.

Summary.—Every vertebra is developed within the limits of a single segment, that is, out of the mesenchyma produced from the inner wall of a single segment. This point is especially important because it is commonly stated that each vertebra is derived from adjacent parts of two segments. Each vertebra has two distinct parts, the vertebral bow (*Wirbelbogen*) and the vertebral body (*Wirbelkörper*); both parts in their first stage consist of condensed mesenchymal tissue. The bow appears first and is an arched band of tissue passing under the notochord, thence running obliquely backward and terminating on the caudal side of the muscle plate of the segment. The body appears later in each segment just behind the median part of the bow. The bow and the body both chondrify and fuse with one another, except in the first cervical segment; in birds the whole bow becomes cartilaginous, but in mammals the middle part of the bow atrophies, except in the first cervical segment. The lateral portions of the bow form both the neural and costal arches; the distal parts of the latter separate from the vertebra proper to form the anlagen of the ribs. The morphology of the vertebral column is com-

* During the first year after birth the arches unite dorsally, between the third and eighth year the arches unite with the body.

pletely determined while it is in the cartilaginous stage; ossification is merely a supplementary process and produces no important change in the form or anatomical relations of the vertebræ.

Froriep's discovery that the vertebral bow and body are distinct pieces must be considered very important, and at once suggests comparison with those palæozoic reptiles in which centra and intercentra have been distinguished in the vertebral columns, but this comparison has yet to be worked out. For a general paper on the intercentrum see Cope, 86.4, also G. Baur, 86.1, for a discussion of the morphology of vertebræ from the palæontological point of view.

Evolution of Vertebræ.—We have no positive knowledge, nor even valuable theories, as to the causes which first led to the evolution of vertebræ, though unscientific hypotheses have been abundant. There is one important consideration which has been rather neglected, though almost self-evident, namely, that vertebræ have arisen within the vertebrate series, the perichordal mesenchyma in the lowest vertebrates not being divided into vertebræ, there being, in short, so-called vertebrates without vertebræ. As the higher fishes have vertebræ, it is evident that the vertebral column was evolved within the class of fishes.

The embryological development of the vertebræ indicates that they are compound bodies, as above shown. We are thus led to distinguish four stages in the differentiation of the axial skeleton:

1. Notochordal stage.
2. Perichordal stage.
3. Froriep's stage (vertebral bow and centre not united).
4. Vertebral stage (vertebral bow and centre united).

The first stage is permanent in *Amphioxus*; the second is permanent in *Petromyzon*; the third will perhaps be found permanent in *Chimæra*; the fourth is permanent in *Amphibia* and *Amniota*. The skull may be looked upon as in part a modification of the second stage in the head region.

Occipital Vertebræ.—The occipital bone of the adult is the final outcome of the fusion and ossification of an uncertain number of vertebræ. The investing mass of the cephalic portion of the notochord forms the anlage of the occipital skeleton. This anlage terminates a short distance behind the hypophysis. In birds and mammalia it may be divided into two regions, comprising each about half the length of the anlage; the anterior or pituitary half does not ossify, even in the earliest embryonic stages, so far as known, any trace of division into separate vertebral masses; the posterior or cervical half does show clear division at an early stage into four vertebræ (in the chick into five vertebræ), but of these only the last appears as a perfectly distinct, well-differentiated vertebræ, but even this vertebræ, when its chondrification begins, merges into the general occipital mass (A. Froriep, 83.1, 86.1). The vertebræ of the mammalian occiput correspond to four segments, of which the hypoglossus represents the nerves. Fig. 246 is a frontal projection of the cephalic end of the mesenchymal vertebral column of an embryo, 15.5 mm. long, from a cow. The nerves, N, mark the divisions between the vertebræ, as do also the intersegmental arteries, *v*; the anterior vertebræ are already fused, *Oc*, but the fourth is

perfectly differentiated and closely similar to the succeeding vertebrae. Three hypoglossal nerves traverse the occipital anlage. In embryos of 18.5 mm. the occipital vertebra is found to have fused with the occipital mass, though the ends of its vertebral bow project enough to still indicate the original division of which all trace is lost in slightly older embryos.

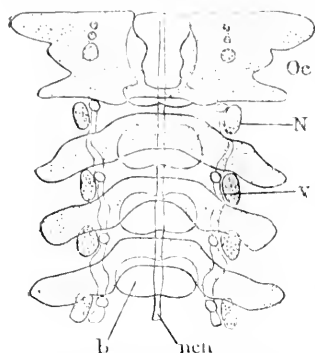


FIG. 246.—Frontal Projection of the Cephalic Part of a Vertebral Column of a Cow Embryo, 15.5 mm. long

In the occipital mass chondrification begins on each side of the notochord, *nch*, just as it does in the bodies of the individual vertebrae, and it begins before the fourth vertebra (Froriep's occipital vertebra) unites with those in front. The result of the chondrification is to produce two bars of cartilage which extend alongside the occipital notochord, but of course, as the histogenetic change spreads, the cartilage unites and finally extends through the entire anlage. The bars of cartilage are known as the *parachordals*, and are commonly, but erroneously, described as the primitive anlage of the occipital cranium, whereas in reality they indicate only the growth of the centres of chondrification in the anlage. I can recognize no grounds at present for assigning any special morphological meaning to the *parachordals*.

Atlas and Epistropheus.—The first and second cervical vertebrae undergo remarkable modifications, which are established during the transitional stage of the vertebrae—in other words, while the vertebral anlages are chondrifying. In mammals the first cervical vertebra develops two cartilages, one of which is formed out of the whole vertebral bow and gives rise to the atlas, and the other is formed out of the vertebral body. The later cartilage fuses with the second vertebra and with it forms the epistropheus or axis. Our precise knowledge of the development of these two vertebrae rests principally upon the admirable researches of A. Froriep, **83.1**, **86.1**, though previous investigators had established that the first vertebra forms the so-called odontoid process of the epistropheus, see Ch. Robin, **64.1**, and C. Hasse, **73.1**. In birds, but not in mammals, the central portion of the vertebral bow of the second cervical segment also contributes to the formation of the epistropheus; in mammals it disappears or is merged in the intervertebral ligament. Owing to this difference the atlanto-epistrophic articulation is not strictly homologous in the two classes, being formed in birds by the vertebral bow of the second segment; in mammals by the expanded caudal part of the vertebral body of the first segment of the neck. The specialization of the two vertebrae begins when their chondrification is well advanced (cow embryos, 17–18 mm.), for we see then that the whole of the first vertebral bow is changing into cartilage to form the atlas, and that it does not grow together with the body. Meanwhile in mammals the body of the first vertebra is changing form, its cephalic end becoming conical to make the anlage of the

odontoid process, and the caudal part broadening out, and making a shoulder laterally and ventrally around the base of the odontoid process; this shoulder forms the articulation with the atlas. The expansion of the first vertebral body forces the vertebral artery and the second cervical nerve out laterally; the bend of the artery thus produced is permanent; the expansion also brings the first body into contact with the bases of the transverse processes of the second vertebra; the intervertebral tissue (ligament) between them disappearing; the two vertebræ unite by their two points of contact, and thereafter their fusion progresses toward the median line, until all the tissue of the intervertebral ligament is obliterated and the two cartilages have fused into one, the epistrophæus.

The atlas ossifies from three centres, two of which correspond to and appear about the same time as those of the neighboring vertebral bows (neural arches), while the third does not appear until after birth, and is situated in the middle of the ventral arch of the atlas (corresponding to the primitive hypochordal brace, Froriep's *Spange*). Often there is also a separate centre for the spinous process. The two primitive centres unite on the dorsal side during the third year, and with the ventral centre in the fifth to sixth year.

The epistrophæus, in accordance with its development, has four centres, one for the body of its first vertebra or the odontoid process, one for its own body, and two for its neural arches. The two first-named centres appear during the fourth or fifth month. The fusion of the centres may not be completed until the sixth or seventh year, and up to that age the tip of the odontoid process remains unossified.

Sacral Vertebræ.—In man there are five vertebræ, characterized by their peculiar form and by their articulation with the pelvis, and which begin at eighteen years to slowly unite into a single bone known in anatomy as the *os sacrum*. In other animals, however, the sacrum is not formed out of the same vertebræ, if we count from the last cervical vertebra, nor out of the same number of vertebræ. Various attempts have been made to explain these divergences—see especially Rosenberg, 76.1—but no certain result has yet been reached. Of the history of these vertebræ we have no such exact knowledge as Froriep's researches have given us concerning the cervical vertebræ.

The processes form neural arches and lateral processes (*Seitenfortsätze*) which were commonly homologized with the costal processes of other vertebræ, principally upon comparative-anatomical grounds. The chief embryological evidence in favor of this homology was the fact that the lateral processes have a separate centre of ossification, making, together with the three usual centres, five primary centres for each sacral vertebra. In 1875 Rosenberg, 75.1, showed that the anlagen of the sacral ribs can be seen in human embryos, and that the proximal ends of these change into cartilage and fuse with the true transverse processes of the vertebræ—very much as happens with the thirteenth rib in man.

Coccygeal and Caudal Vertebræ.—Behind the sacrum there are nine segments to be found in the human embryo of 8-9 mm., as discovered by H. Fol, 85.1. From the sacrum tailward they are

found progressively more and more rudimentary, and only from three to five of the segments immediately following the sacrum developed ossified vertebrae. These are the so-called coccygeal vertebrae, concerning the embryology of which we know nothing. It is probable that some of the segments behind the coccyx form at least mesenchymal, if not cartilaginous, vertebrae, and Fol's observations suggest that the last coccygeal vertebra is really the product of the fusion of several caudal vertebrae.

Only the first coccygeal vertebra begins to ossify before birth. This, the thirtieth vertebra, has been shown by E. Rosenberg, **76.1**, to be in the embryo really a sacral vertebra, but it separates in the course of development from the sacrum, and becomes the first of the coccygeal series.

Ribs and Sternum.—The ribs and sternum are vertebral structures, and therefore strictly segmental. This statement seems to me an unavoidable deduction from Froriep's observations on the development of the costal processes of the vertebrae, but it is directly opposed to the conception current among morphologists, according to which the ribs are intersegmental. That the sternum is a morphological product of the ribs is, I believe, the accepted opinion of both comparative anatomists and embryologists. That it is so in man has been put beyond doubt by G. Ruge's investigations, **80.1**, see also C. K. Hofmann, **80.1**.

1. **RIBS.**—Comparative anatomy renders it probable that every vertebra had ribs primitively, and most of them have still in the human embryo the anlagen of ribs. In man there are only twelve vertebrae (eighth to nineteenth) of which the costal anlagen are represented in the adult by true ribs; traces of a thirteenth pair of ribs belonging to the twentieth vertebra appear in the human embryo, and as a rare anomaly the thirteenth pair occurs in the adult. In the cervical region there are found costal processes of the vertebrae, also in the lumbar and sacral region; in the last-named region the processes acquire a certain independence, but soon lose it and fuse with the vertebrae proper. These variations should be borne in mind while reading the following paragraph, which attempts to give the general history of a typical rib.

The ends of the vertebral bows grow out as shown by Froriep, **86.1**, until they come in contact with the muscle plates of their own segments. By the bulging of the plate the end of the bow is forced to expand dorso-ventrally, and there is thus given the primary division into dorsal or neural, and ventral or costal process. The spinal ganglion forces the end of the bow, compare Fig. 243, p. 425, to grow toward the posterior limit of the segment, and this permits the costal process to grow out past the caudal edge of the muscle plate and to there become the anlage of the rib, which is not therefore an intersegmental structure, as current tradition has it, but truly segmental; the rib and the myotome headward of it belong to the same somite, and the rib owes its apparently intersegmental position to its situation at the caudal limit of the segment, behind the muscular anlage. Whether the costal anlage is produced as an actual outgrowth of the condensed mesenchyma of the vertebral blastema or by differentiation of the mesenchyma *in loco*, we do not know; nor do we

know what limits the rib in the transverse plane so that it is merely a rod and not a wide and high partition wall. In this stage the rib is directly continuous with the vertebra, but when by changing into cartilage it passes into the next stage, it separates from the vertebra by the development of a fibrous ligament, forming the primary articulation between the rib and spinal column. The division takes place obliquely, thus allowing the head of the rib to come in contact with the body of the vertebra, and to articulate, by its dorsal surface, with the ventral surface of the future transverse process. In the course of its further development the single primitive articulation becomes divided and the secondary, or adult condition, is established with one articulation with the transverse process, and a second with the body of the vertebra. In the case of the ribs, which become rudimentary, the development ceases at this stage, and only the proximal end of the rib chondrifies; the small remnant of cartilage unites with the transverse process of the vertebra, re-establishing by a secondary union the primary connection.

The true ribs, as those belonging to the dorsal vertebræ of mammals are called, extend a considerable distance through the somatopleure toward the median ventral line, but, as discovered by H. Rathke, **38.2**, 365, before they reach the middle ventral line the ribs produce the anlagen of the sternum, and of the intercostal ligament, at first as condensed mesenchyma, which afterward becomes histologically differentiated—see the next section on the sternum. The ribs extend to unequal distances, the first coming nearest the ventral line, the last terminating farthest from it. In the human embryo of from 2 to 3 cm. there is present a thirteenth true rib (Rosenberg, **75.1**, 89-91); the proximal end chondrifies and fuses with the vertebra. This valuable observation shows that the so-called first lumbar vertebra of man is really the last dorsal vertebra, and in its embryonic stage is strictly comparable with the thirteenth dorsal vertebra of *Troglodytes*. As in *Hylobates* the twenty-first vertebra sometimes has ribs, the evidence within the primates suffices to prove that the lumbar region was evolved at the expense of the dorsal.

The ribs are only partly ossified, hence the osseous rib of the adult represents only a portion of the whole primitive rib, the most distal part of which has been reserved to contribute to the sternum (or intercostal ligament), and another part of which remains in the cartilaginous stage to unite the costal bone with the sternum or intercostal ligament. Each primitive rib is therefore divided into three parts: 1, the proximal bony division, *the* rib of human anatomists; 2, the middle cartilaginous division, the costal cartilage; 3, the distal sternal or ligamentous division. By the differentiation of fibrillar tissue out of the original costal anlage articulations are developed for the costal cartilages at their proximal ends with the bony ribs, and at their distal ends with the sternum. The exact history of these differentiations has still to be worked out.

The ossification of the ribs begins during the second month, according to Kölliker, and there is but a single centre. Schwegel, **58.1**, states that epiphyseal centres appear eight to fourteen years after birth in the head and tubercle, that is, for both vertebral artic-

ulations; the epiphyses do not unite with the main bone until later; often not until the twenty-fifth year.

2. STERNUM.—The breast bone is developed from the ends of the ribs, but the early stages have still to be ascertained by following out the relations while the anlagen are in the mesenchymal stages. Hitherto investigations have begun only with the cartilaginous stage. It seems probable that the costal anlagen grow beyond the ventral limits of the muscle plates and then bend headward, and by uniting, form a longitudinal sternal anlage on each side at some little distance from the median line. The cartilaginous half-sternum appears in rabbits the seventeenth day; they are still separate in chicks of the eighth day, in pig embryos of about 27 mm. in human embryos of 24 mm. In the chick the halves are uniting during the seventh day, and in pig embryos of about 50 mm., the halves are fully united. The sternal anlagen (Ruge's *Sternalleisten*) arise from the ends of the first to seventh ribs, and accordingly are nearest together toward the head and diverge tailward. My own observations lead me to think it probable that the connection really extends to all the ribs, but between the seventh and twelfth ribs it becomes fibrillar, and gives rise to the intercostal ligament, which, therefore, is morphologically the prolongation of the sternum. The sternal halves gradually coalesce, beginning at their upper ends. In many mammals the sternum shows plainly its metameric origin and consists of separate pieces metamericly arranged, and there is a separate centre of ossification for each piece. In man, on the contrary, the originally continuous cartilage forms three pieces, the uppermost of which belongs only to the first sternal segment or first pair of ribs according to G. Ruge, **80.1**, but, according to W. K. Parker, also is formed partly at the expense of the aborted last cervical rib; the middle piece corresponding to the second to seventh segment; and the third piece, which remains chiefly or wholly cartilaginous. The first piece is the *manubrium*, the second piece is the *body* of the sternum, and the third piece is the *ensiform* or *xiphoid cartilage*. G. Ruge, **80.1**, found in human embryos two small suprasternal cartilages which fuse with one another and then with the manubrium; the significance of these cartilages is uncertain.

The sternum ossifies with one centre in the manubrium, and in man with an irregular number of centres in the body. Its ossification does not begin until the sixth month.

The double origin of the sternum and its dependence upon the ribs was discovered by H. Rathke, **38.2**, 363. This discovery was confirmed and extended twenty years later by W. K. Parker, **58.2**, and more recently by A. Goette, Hofmann, **80.1**, and G. Ruge, **80.1**; the last is an admirable investigation of the development of the sternum in man.

Trabeculæ Cranii.—H. Rathke discovered that at the same time that the cartilaginous tissue develops in the occipital skeleton there appear two curved bars of cartilage in front of the notochord. These cartilages by their fusion and expansion form the whole of the prechordal chondrocranium, and were named by Rathke the trabeculæ cranii. All subsequent writers have made Rathke's discovery the starting-point of their accounts of the development of the anterior

part of the skull. But the morphological differentiation of the skeleton, as we have already seen in the case of the vertebræ, etc., is given by condensed mesenchyma, and the cartilage, when it first appears and for a considerable period afterward, does not by any means correspond to the real shape of the skeletal piece. Now nearly all the information we possess as to the early stages of the skull is concerning the progress of the so-called chondrocranium, and since this is really for a considerable period merely the history of the progress of chondrification in the already formed mesenchymal skeleton of the cranium, it results that concerning the early stages of the skull we have almost no available information, nor can we hope to understand the morphology of the skull until its developmental history through the mesenchymal stages shall have been followed, as has been that of the cervical vertebræ by Froriep. Concerning the history of the cartilage of the skull we possess an immense fund of information, owing chiefly to the long series of splendid monographs by W. Kitchen Parker (1866-1886), the chief results of which have been summed up by himself and Mr. Bettany in a single comprehensive volume, 77.1.

From what has been said it is clear that the shape of the præ-chordal cartilaginous skull has very little morphological significance until the mesenchymal skull is completely chondrified; until then the growth of the cartilage represents merely the advance of a histological modification within the skeletal piece. Unfortunately it is impossible at present to say when the cartilage does begin to represent the shape of the cranium. As the history of the early stages of the præ-chordal cartilage has very little morphological value it may be very briefly given.

The trabeculæ cranii of the pig* may be taken as typical representatives of the mammalian trabeculæ, and show essentially the same arrangement as are found in all other vertebrates, although the form and proportions vary from class to class. In pig embryos of about 16 mm., the trabeculæ cranii appear as two curving rods of cartilage, united in front, but separated behind; in general shape they resemble calipers; they lie anteriorly between the olfactory pits and the brain, and form from the start a skeletal partition between these two structures. As shown in Fig. 247, *Tr*, the trabeculæ separate posteriorly some distance in front of the hypophysis, *H*, then curving toward the median line, taper and end in points immediately behind the hypophysis. The anterior end of each trabecula is bent over outward and downward, forming the *cornu trabeculæ*, and causing a projection on

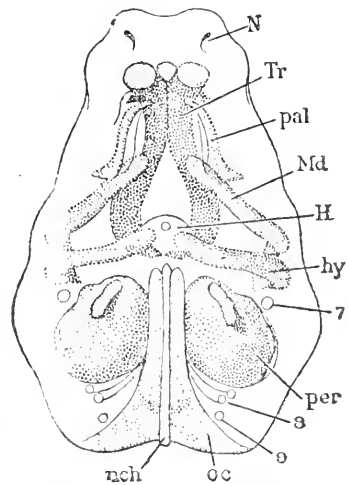


FIG. 247.—Embryo Pig of about 16 mm. Cranial elements seen from below. *N*, Olfactory pit; *Tr*, trabecula; *pal*, palatopterygoid plate; *Md*, Meckel's cartilage; *H*, hypophysis; *hy*, hyoid cartilage; *per*, periotic capsules; *oc*, occipital cartilage; *och*, notochord; 7, facial nerve; 9, glossopharyngeal; 10, vagus. After W. K. Parker.

* I follow the account given in Parker and Bettany's "Morphology of the Skull," chapter viii.

either side of the palate in the mouth cavity behind the olfactory pits. These pits are situated entirely in front of the trabeculae at this stage, but between them there is an internasal septum of mesenchyma, and into this septum there already extend two cartilaginous laminae which are the prolongations of the trabeculae. In the course of their further development the trabeculae fuse throughout

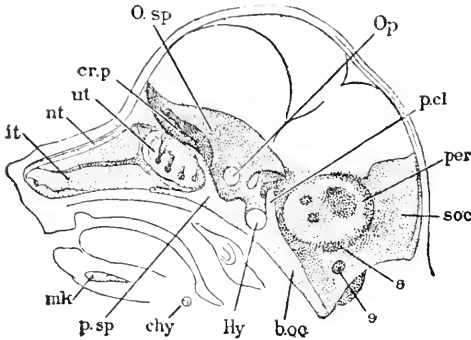


FIG. 248.—Embryo Fig. One and one-third Inch long; Median Longitudinal Section of the Head: the nasal septum and brain have been removed. After W. K. Parker. (For explanation of lettering see text.)

their entire extent. In pigs one inch long the internasal cartilages have nearly or quite fused into a single median piece, and the trabeculae proper are united also except around the hypophysis, which they closely embrace. At this stage we see further that the trabecular cartilage is extending sideways, outward and upward around the brain, outward and downward around the olfactory pits. In embryos an inch and a third long the posterior ends of the trabeculae have united with the anterior end of the occipital cartilage, thus forming a continuous floor of cartilage, which underlies the brain, and in front overlies the olfactory pits, and has also developed under the hypophysis, which thus becomes definitely separated from the mouth cavity and inclosed within the brain case. We find at this stage also that the cartilaginous periotic capsules have begun to fuse with the lateral portions of the occipital cartilage, thus making one continuous skeletal piece, which is known as the primitive chondrocranium, but it does not correspond to the real cranium at this stage, for beyond the limits of the cartilage the skeleton around the brain and olfactory pits is already formed as condensed mesenchyma. The general arrangement and the outgrowths from the trabecular mass are shown in Fig. 248. The hypophysis, *Hy*, lies in a deep fossa, which remains in the adult and is known as the *sella turcica*: on the caudal side of the hypophysis the fused ends of the trabeculae have risen as a transverse plate, the posterior clinoid ridge, *p.cl.*, and in front of the hypophysis is the much smaller anterior clinoid ridge; *p.sp* indicates the region of the future præ-sphenoid bone, the cartilage of which is continued directly forward in the nasal septum as the ethmoidal plate; from the sides of cartilage there spring two lateral plates, which curve upward and outward around the brain; the anterior and larger of these plates is the orbito-sphenoid, *O.sp.*, which spreads out between the brain and the eyeball, and extends far back toward the periotic capsule, *per*: during its development the orbito-sphenoid cartilage grows around the optic nerve, thus forming the optic foramen, *Op.*, which is near the base of the plate; the smaller of the plates is the ali-sphenoid, and springs from the region of the two clinoid ridges; it is short and thick and has a downward process, which extends to the palato-

pterygoid bar and represents the external pterygoid cartilage; this process being external does not show in the figure. Between the ali-sphenoid and the periotic capsule is a shallow fossa for the Gasserian ganglion, and from the ganglion the main stem of the fifth or trigeminal nerve passes out through a foramen. The superior maxillary division of the trigeminal passes out between the orbito- and ali-sphenoids. The nasal cavities are large and complex; they already occupy more than half the length of the head, and in part underlie the brain; the partition which separates the nasal cavity from the overlying olfactory lobes is composed of undifferentiated mesenchyma, which is traversed by the olfactory nerve fibres, but at the present stage, or a little later, the partition chondrifies by an extension of the cartilage of the ethmoidal plate, with the result of producing the cribriform plate, *cr. p.* The shape of the nasal chambers is rendered complex by the turbinal prominences on the lateral wall of each chamber as described in Chapter XXVIII. Already in the previous stage the median ethmoidal plate had sent outgrowing laminae of cartilage one on each side over the top and down on the outside of each nasal cavity, and from the lateral cartilage there appear ingrowths into each turbinal prominence. The relations of the cartilage to the nasal chambers can be more readily

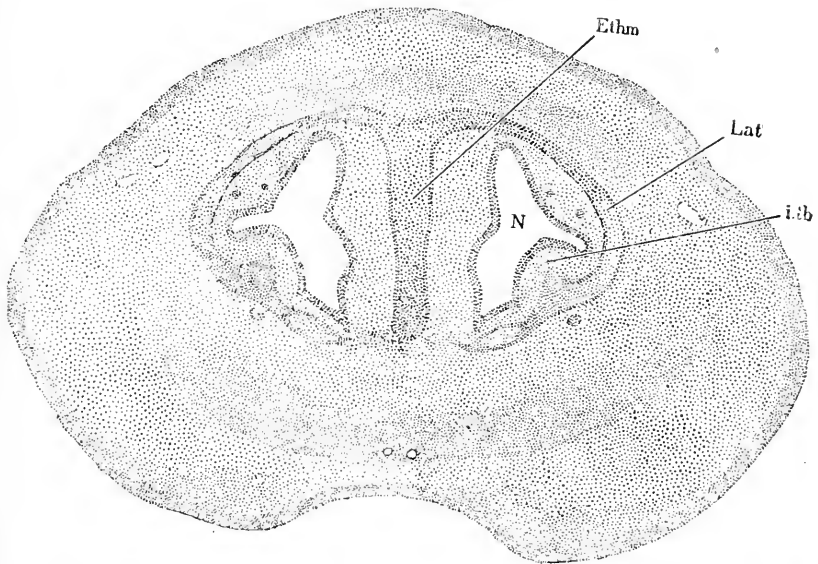


FIG. 249.—Section of the Anterior Portion of the Snout of an Embryo Fig. *Ethm*, Median ethmoidal plate; *lat*, lateral nasal cartilage; *i.tb*, inferior turbinal prominence into which the cartilage has begun to penetrate; *N*, nasal cavity.

understood in a cross-section, Fig 249, which calls for no further description than is afforded above and in the explanation of the figure. As partly indicated by Fig. 248, there are five turbinal prominences, the ali-nasal, the inferior, *it*, the middle, *nt*, and the upper *u.tb*—the last two mentioned being, however, hardly distinct from one another at this stage. It now remains only to add that at the

ventral side of the anterior edge of the ethmoidal plate the *cornua trabecularum* are still present; the cornua are the anlagen of the ali-nasal cartilages.

In man the history of the chondrocranium is very similar to that just given for the pig, as we know through the investigations of Spöndli, 46.1, Vrolik, 73.1, Virchow, 57.1, and Van Noorden, 87.1, and others.

The general significance of the chondrocranium is discussed in the section on the morphology of the skull, p. 465.

Periotic Capsules.—This name has been employed by Huxley, and may be conveniently retained, to designate the independent cartilages, which appear very early around the otocysts, and later become integral parts of the primitive chondrocranium by coalescing with the occipital cartilage. In pig embryos of about 16 mm. they appear as two rounded masses, Fig. 247, *per*, close alongside the anterior half of the occipital cartilage, against which they lie with a nearly straight margin, while the rest of their outline is rounded. The aqueductus vestibuli is left as an opening in the cartilage on the upper and inner edge; the facial nerve, 7, enters the capsule a little behind this, its passage being the *aqueductus Fallopii*. As regards the inclosed otocyst we find that the semicircular canals and cochlea are just budding forth. At this stage there is sort of plug of non-cartilaginous mesenchyma still left in the external wall of the capsule. The neighboring cranial nerves show a characteristic relation to the capsules. The trigeminus passes out between the capsule and caudal extremities of the trabeculae. In the angle between the capsule and the occipital cartilage there pass out three nerves, the glosso-pharyngeal, 9, the vagus, 10, and the hypoglossus, 11. In embryo pigs of one inch the capsules have begun to coalesce posteriorly with the occipital cartilage, and in those an inch and a third long they are found coalesced along nearly the whole line of contact between the capsules and the basilar plate.

Concerning the origin of the periotic capsules we possess no accurate knowledge, and cannot even say whether they represent primarily distinct skeletal pieces or merely separate centres of chondrification in a larger mesenchymal skeletal piece. The latter appears to me the more probable alternative, and it may be further suggested that the capsules are differentiations of the lateral outgrowths of the investing mass of the cephalic notochord. The questions raised can be answered only by a careful investigation of the mesenchymal cranium.

Ultimate History of the Chondrocranium.—The primitive cartilaginous skull is formed by the fusion and expansion of the occipital cartilage, the trabeculae cranii, and the periotic capsules. It occupies the floor of the cranial cavity and the roof of the olfactory cavities, and has certain lateral expansions. The arrangement of these can be understood from the accompanying Fig. 250, although the figure represents a stage in which ossification has begun. Between the nasal cavities lies the mesethmoid septum from the dorsal side of which spring the ali-nasals, *oln*, covering the dorsal and lateral parts of the nasal cavities; from the mesethmoid extend also the plates forming the ali-ethmoids and middle turbinal, *mtb*;

also the cribriform plate, *cr*, through which the olfactory nerve passes. The orbito-sphenoidal wings, *obs*, are large and rise from the præ-sphenoid; the ali-sphenoidal wings are smaller, *al*; between the two sphenoid wings is the foramen lacerum; the periotic capsules are large and fill out nearly the whole space between the ali-sphenoids and the wings of the occipital. The occipital has expanded completely around the foramen magnum, *f.m*, through which the spinal cord enters the brain-case, so as to form on the dorsal side the supra-occipital, *s.oc*.

In the fishes the chondrocranium passes through a stage corresponding closely to that just described, except that in them there is no bone formed; but whereas in the mammal the chondrocranium does not pass beyond this stage, in the fishes it continues growing until the brain is completely inclosed and there is a perfect cartilaginous skull, at least in the lower forms, marsipobranchs, ganoids, and selachians. We must, then, distinguish two types of chondrocranium, according as it does or does not completely encase the brain. The latter is the type exclusively found in mammalia.

The mammalian chondrocranium is represented in the adult by a number of distinct bones, which represent also a still larger number of bones of lower types. As to how the originally continuous cartilage becomes divided into separate bones, our notions are somewhat vague. In the division the centres of ossification play a leading rôle, of course, but not in the sense that every centre invariably results in the formation of a separate bone. The second important factor is the development of the sutures, which form the boundaries of the bones. The sutures are of two kinds, those marked out by the edges of the chondrocranium itself, and those produced in the cartilage. Although a knowledge of the history of the sutures must be considered of the utmost importance for the elucidation of the morphology of the skull, such knowledge appears never to have been sought. Besides those parts of the cartilaginous skull which make bones there are certain others, few in number and small in size, which atrophy. We have then to present the history of the ossification and partial atrophy of the chondrocranium.

OSSIFICATION.—The *occipital region* begins to ossify during the early part of the third month in human embryos; comparative anatomy teaches that the occipital bone of man is homologous with five bones—the median ventral basi-occipital bordering the front or ventral side of the foramen magnum, the paired lateral ex-occipitals bordering the sides of the foramen and including the condyles by which the occiput articulates with the axis, and the paired supra-occipitals, which, however, are often united into a dorsal median bone; in

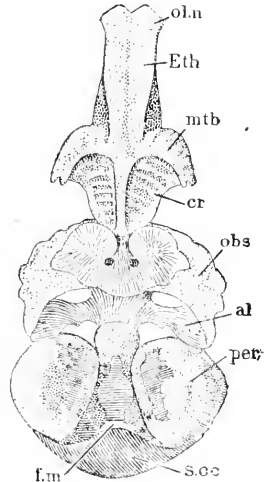


FIG. 250. — Embryo Pig, six Inches Long, Partly Ossified Chondrocranium seen from above. *ol.n*, Ali-nasal; *eth*, ethmoid; *mtb*, middle turbinate; *cr*, cribriform plate; *obs*, orbito-sphenoid; *al*, ali-sphenoid; *per*, periotic capsule; *b.oc*, basi-occipital; *f.m*, foramen magnum, *s.oc*, supra-occipital. Natural size. After W. K. Parker.

agreement with this homology there are five centres in the occipital cranium, namely, the basi-occipital, the two ex-occipital or condylar, and two supra-occipital, which, however, very soon unite; according to Kölliker there is also later a small deposit of dermal bone added to the supra-occipital. The ex-occipitals do not unite with the supra-occipitals until one or two years after birth, nor with the basi-occipitals until the fifth or sixth year. In the *sphenoid region* ossification begins during the second half of the third month in the human embryo, and takes place from six principal centres corresponding to the six bones with which the human sphenoid bone is homologized by comparative anatomists. The six centres are: 1, the basi-sphenoid in the neighborhood of the hypophysis, and said by Kölliker to be due to the fusion of two minor centres; 2, the pre-sphenoid, which appears in the median line near the optic foramina, and is likewise said to consist of two minor fused centres; the pre-sphenoid, at least in the pig, is the last of the six centres to appear; 3, 4, the ali-sphenoid centres, one in each wing, Fig. 250, *al*; they appear a little later than the basi-sphenoid centre; 5, 6, the orbito-sphenoid centres, which unite with the præ-sphenoid after the fifth month; the præ-sphenoid and basi-sphenoid do not unite until several years after birth, and even at thirteen years Virchow has found remnants of cartilage between the two bones. In the *periotic region* there are three main centres, which are taken to represent as many distinct bones, although they unite in mammals into a single bone, the *os petrosum*; in man the petrous bone is found to have fused with the dermal bone, known as the *squamosum*, and also with the ring of bone formed around the tympanum of the ear, and known as the annulus tympanicus; from the union of these five bones arises the temporal bone of human anatomy. The three centres which appear in the periotic capsules are termed the pro-otic, opisthotic, and epiotic, and are considered to represent the separate bones bearing the same names in lower vertebrates; the pro-otic centre is by its position in close relation with the anterior vertical semicircular canal, between which and the exit of the third division of the fifth nerve it lies; in pig embryos of six inches it forms a patch of bone lying under the fore part of the cochlea above and in front of the fenestra ovalis, and extending to the junction of the anterior and posterior semicircular canals; the opisthotic centre is on the lower and posterior surface of the capsule, placed so that most of the bulbous portion of the cochlea lies dorsal to it; one of its processes lies between the fenestra ovalis and the fenestra rotunda, close in front of the head of the stylo-hyal cartilage; the epiotic centre develops somewhat more tardily; it is in especial relation with the posterior vertical semicircular canal, and when it first appears (pig embryos of six inches) is a small piece just above the stylo-hyal process and foramen rotundum, and behind both the foramen ovale and the above-mentioned opisthotic process. According to A. J. Vrolik, 73.1, the ossification of the periotic capsules proceeds somewhat differently in man, there being four centres which coalesce by the sixth month of foetal life. In the *ethmoidal region*, including the cribriform plate, the lateral nasal and turbinal cartilages, ossification takes place very late, and the morphological significance or homologies of the various centres is little understood.

In the pig at birth the median cartilage is unossified, the cribriform plate is about to begin ossification, being invaded by vascular mesenchyma, the upper and middle turbinals are partially ossified, the inferior turbinals almost completely ossified. In man a similar condition is reached about the seventh month of foetal life. The human ethmoid proper does not ossify until the first year after birth.

ATROPHY.—There are certain parts of the chondrocranium which do not ossify, but are lost in the adult. The exact process by which they are resorbed is not known. The following parts are said to disappear: the cornua trabeculae; 2, the cartilage under the nasals; 3, Spöndli's so-called frontal plate, or that portion of the orbito-sphenoid outside of which the frontal bone is developed; 4, the parietal plate or a small portion of the ex-occipital outside of which the parietal bone is developed; 5, a small portion of the ali-sphenoid (ala magna) outside of which the parietal bone is developed; 6, the cartilaginous capsules of the sphenoidal, maxillary, and frontal sinuses; 7, parts of the turbinal cartilages.

Dursy, 69.1, 203, has maintained that some of these cartilages do not really disappear by atrophy, but by becoming ossified and united with the dermal bones overlying them. Kölliker ("Entwickelungsgeschichte," 456), without absolutely denying the correctness of Dursy's view, states that he has been unable to confirm it by his own observations.

The following description of the primordial skull of *Tatusia* (one of the Insectivora) in W. K. Parker's own words, 86.1, 7-10, brings out many points of morphological importance:* "So great is the uniformity of the early chondrocranium in the eutheria or placental mammals, that the drawing, Fig. 251, made from the skull of an outlying and low type, might serve as a diagram wherewith to illustrate the skull at this stage of the types of this order, and of all the orders above it. The figure of a chondrocranium like this, but a little less advanced, before the osseous centres have commenced in it—that of the mole—will be given in my next paper; and such a skull is very near to that of a shark, or, still better, of a skate. The parts, or rather, *regions*, of which it is composed, correspond very exactly with what is seen in those generalized, but not *low*, fishes; and in this specimen with long centres appearing, the level is obtained which is permanent in the skull of the dipnoi, and of such a low ganoid as the paddle-fish (*Polyodon*).† As in cartilaginous fishes and amphibians, the chondrocranium may be compared to a basin or a boat, the upper part being unfinished, leaving a membranous fontanelle of greater or less extent; this is only partially filled in, at present, by the investing bones, the frontals and parietals (*f.*, *p.*). The outline of this sectional view is very elegant, and quite similar to that of a vertical section of a bird's skull at a like stage, except that the nasal roof-cartilages run on along the whole extent of the median keeled bar—the intertrabecula; in the bird they stop short, leaving a free cartilaginous rostrum, like that of a shark or skate, which, however, only lasts until it has served as a model

* Compare also Parker, 86.2. "On the Skull of Insectivora."

† See Bridge, "On the Skull of the *Polyodon Felium*," Phil. Trans., 1872. Plates 55-57, pp. 683-863.

on which the huge premaxillaries of the bird are formed. In the sides of this hollow cartilaginous structure near the hind part the large oval auditory capsules (*a.sc*, *chl*) are seen to have great distinctness; they are, however, confluent with the chondrocranium proper at various points—above, behind, and below, as the section will show. These are the only sense capsules displayed in a preparation of this kind, for the eyeballs are quite free from the solid cranial structure (and are, indeed, outside in such a view as this) and the left nasal labyrinth has been removed. Before describing this figure in detail there is one remark to be made, namely, that here we have clearly shown the true *diagnostic mark* of a mammalian skull. This mark is the *rupture* of the side walls, due to the pressure of the large lateral masses of the cerebrum. In front of the auditory capsules there is a large, elegantly semicircular opening, the crown

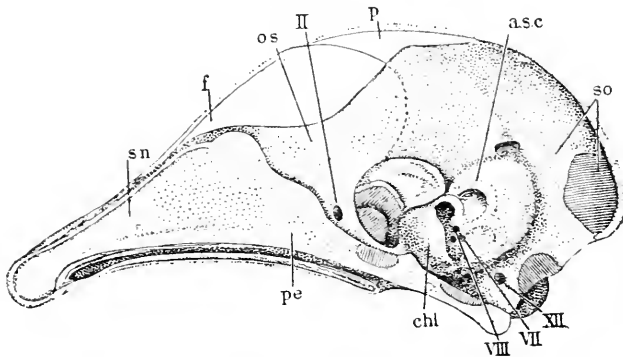


FIG. 251.—Chondrocranium of an Insectivorous Mammal (*Tatusia*). After W. K. Parker. Explanation in text.

of the arch looking upward and forward. Only the lower half of the wall has thus broken outward; this 'fault' forms the ali-sphenoid, while the orbito-sphenoid (*o.s*), the so-called 'lesser wing,' is many times its size and is continuous, over the archways, with the cartilage that runs on backward, into the supra-occipital region (*so*). There is nothing similar to this in that sauropsidan skull which comes nearest to that of the mammal, the skull of the crocodile (see *Trans. Zool. Soc.*, Vol. XI., Plate 65), while in birds the orbito-sphenoids are very small, even when they are most developed, as in *Struthio* (see *Phil. Trans.*, 1866, Plate 7), and in that class the ali-sphenoids almost finish the cranial cavity, being turned inward toward each other, on each side of the back part of the orbital septum. I lay special stress upon this rupture outward of the ali-sphenoid, and on the fact that the nasal roofs utilize the whole of the huge high-crested intertrabecula, because these are the most distinctive marks of the mammalian skull, and they arise out of two things in which the mammal shows its great superiority to even the highest Sauropsida, namely, the huge volume of the cerebrum, and the tenfold complexity of the nasal labyrinth. A third clear diagnostic is seen in this very figure; this is the peculiar development of the antero-inferior part of the oblique auditory capsule,

due to the development of the coils of the cochlea. So that, at once correlated with the sudden expansion, so to speak, of the cerebrum, we have these *new* and most important improvements in the organs of smell and of hearing. At first sight, seeing how large the median bar (intertrabecula) is, with its internasal crest (perpendicular ethmoid and septum nasi—*pe, s.u.*), it might be supposed that the mammalian skull was of the *high* kind, like that seen in many teleostean fishes, in lizards, and in birds. It is not so, however, but belongs to the *low* kind, seen in selachians and amphibians; and, like theirs, is hinged on the spine by a pair of occipital condyles. Hence the eyeballs are kept far apart, instead of coming very near each other as in most birds, where often nothing but a membranous fenestra is found between the right and left capsules and their special muscular apparatus. But the *face* as well as the *skull* of the mammal shows marks of excellence, such as are not seen in the Sauropsida, even in the higher kinds as crocodiles and birds. The great development of the nasal organs is correlated with a most remarkable growth of the bones of the upper jaw and the palate to form the 'hard palate.' This is found in rudiment even in the chelonia and in birds; but especially in the crocodilia, where, however, its excessive development—as in certain Edentata, *e. g. Myrmecophaga*—is not dependent upon or correlated with any great improvement in the organs of smell, but has to do with the peculiar manner in which these monsters take their prey."

Branchial Skeleton.—Every branchial arch contains a skeletal element, which in its primitive form in all vertebrate embryos* is a bar or rod of condensed mesenchyma, which very early changes into cartilage. The number of these bars of course depends upon the number of gill-arches, compare p. 263, and hence in the mammalia there are five branchial cartilages on each side, which begin dorsally near the cranium, and curving around the sides of the pharynx end near the median ventral line, Fig. 177. The position of the cartilage can be seen in a section of a branchial arch, Fig. 152, to be alongside of the artery or aortic arch, and on the pharyngeal side of the cœlom of the branchial arch. The constant recurrence of the simple stage just described in all vertebrates (except, perhaps, in marsipobranchs), renders it highly probable that forms existed at one time with such a branchial skeleton; but no such forms are known to exist at the present day.

It will be convenient to state the divisions which comparative anatomy teaches us may be considered typical for each branchial cartilage. The divisions are usually given as four: 1, pharyngo-branchial, or dorsal segments, which has usually a horizontal course; 2, the epi-branchial, and, 3, cerato-branchial, both at the sides of the pharynx; 4, the hypo-branchial or ventral segment, which typically articulates with a median unpaired cartilage known as the basi-branchial, or copula. In the aquatic vertebrates the bars usually send out supporting cartilages into the branchial lamellæ, but in mammals there is no trace of any similar outgrowths even during embryonic periods.

* Except, perhaps, in the marsipobranchs, the branchial skeleton of which is possibly not homologous with that of the higher vertebrates. See, however, Anton Dohrn, 84, 1.

In mammals the earliest stage of the branchial skeleton has never been accurately described; this is because investigators have hitherto been content to begin with the cartilaginous stage, instead of the mesenchymal stage, and, consequently we are left with no definite information as to the bars of the fourth and fifth arches, and with insufficient information as to the origin of the bars of the first to third arches. In selachians, according to Anton Dohrn, **84.1**, 110-111, the differentiation of the cartilage of the branchial arches begins shortly after the branchial filaments have appeared as a condensation of the mesenchyma, Fig. 152, *C*, situated on the pharyngeal side of the arch and tailward of the mesothelial anlage, *In.m.*, of the inner muscles. For the further history see Dohrn, *l. c.*, 114. In regard to the history of the branchial skeleton from the cartilaginous stage on, we have very full information, chiefly owing to the extensive investigations of W. K. Parker, also in part through Kölliker, Dollo, Salensky, **80.1**, Fraser, **82.1**, and others. Each pair of bars passes through a distinct series of modifications, therefore it will be convenient to present the history of each pair separately. We shall call the skeleton of the first arch the mandibular bars, that of the second the hyoid bars, of the third the thyro-hyal bars.

MANDIBULAR BARS.—The adaptations of both the mandibular and hyoid bars to functions entirely different from those which they primitively served, are most remarkable. In mammals the mandibular bar becomes primarily divided into two parts, a dorsal piece corresponding to the palatoquadrate of comparative anatomy, and a ventral piece known as Meckel's cartilage. The commencement of the corresponding division of the mandibular bar may be seen in a dog-fish embryo of about 23 mm., the upper end of the bar being enlarged and sending out a process which runs forward on the cranial side of the mouth and later joins the trabecula; this process is the palato-ptyergoid; another process, the meta-ptyergoid, runs upward; the wider part uniting the two processes is homologous with the quadrate; in elasmobranchs the meta-ptyergoid process becomes ligamentous. In mammals the early stages have not been worked out. Parker states that in embryo pigs of about 16 mm. the cartilaginous palato-ptyergoid bars, Fig. 247, are less definitely developed than the other skeletal elements present at this stage, but are more or less distinct from the rest of the mandibular bar; the palato-ptyergoids are situated in the maxillary process, so that, starting from the dorsal end of the mandibular arches, they run obliquely downward and forward toward the anterior end of the trabeculæ; anteriorly, they converge toward the median line, but do not meet. In the mandibular arch itself is the rod-like Meckel's cartilage, Fig. 247, *Md.* Between the ptyergoid plate and the cartilage of Meckel is a space in which Parker figures no skeletal element, but which is occupied by the quadrate element, which in mammals is the anlage of incus. At the same stage (embryo pig, 16 mm.) the lower divisions of mandibular bar or the Meckel's cartilages are much stouter and are better differentiated from the mesenchyma than the palato-ptyergoids; they are situated in the mandibular processes, and do not meet in the median line. Each Meckel's cartilage is a rounded rod, but its dorsal extremity forms a hook, is somewhat enlarged, and is

situated close to the upper border of the first branchial cleft. In pigs a little older (25 mm.) the hook is longer and the end of the cartilage is thicker, making it easy to recognize in it the anlage of the malleus, the hook being the future manubrium or handle of the malleus. In pigs two and one-half inches long the malleus is separately ossified, but is not separated from the cartilage of the jaw. When the final separation takes place I do not know.

Meckel's cartilage proper may be defined as the ventral segment of the first branchial bar. In mammals the two cartilages always unite in the median line, although in man the actual union is said not to have been observed. The lower portions of the cartilage ossify metaplastically but not to the median line, and this ossification begins in man during the third month. The bony part is incorporated in the permanent mandible, but the rest of the cartilage atrophies and entirely disappears except a small portion of the end next the malleus, which becomes changed into fibrillar tissue and remains, according to Kölliker, "Grundriss," 320, as the *ligamentum laterale internum maxillæ inferioris*. Meckel's cartilage is the homologue of the cartilaginous mandible of the lower fishes, but is not homologous with the bony mandible of the amniota, which is developed later and belongs to the class of the dermal bones.

Summary.—The primitive cartilaginous rod of the first branchial arch gives rise first to a palato-quadrate dorsal segment and a ventral or Meckelian segment. The palato-quadrate segment subdivides into the palato-pterygoid plate and the quadrate or incus. In the earliest accurately known mammalian stage the palato-pterygoid and incus are already separate, but it may be safely assumed that in a still earlier stage they constitute one piece. The Meckelian segment subdivides into the malleus and the Meckelian cartilage proper; the latter unites in the median ventral line with its fellow. One inevitably inclines to homologize the parts with a typical branchial arch as follows: The palato-pterygoid is the pharyngo-branchial; the incus is the epi-branchial; the malleus is the cerato-branchial; the Meckel's cartilage is the hypo-branchial; the united ends of the cartilages are the copula. These homologies are, however, somewhat hypothetical, principally because the homologies of the malleus are not clearly ascertained, and we cannot say what element of the lower vertebrates it represents.

The course of the palato-pterygoid at such a marked angle to the Meckel's cartilage is probably due to the head-bend. Very likely the head-bend is causally connected also with the peculiar forms assumed by the incus and malleus.

HYOID BARS, or *Reichert's cartilages*, as they have been named by Kölliker, are the skeletal elements of the second or hyoid branchial arch, and they are typically divided, like the other bars in the lower vertebrates, into four parts, the dorsal one of which (pharyngo-branchial) fuses quite early with the cartilaginous periotic capsules, and becoming ossified appears in the human adult as the *styloid process*; the second part (epi-branchial) becomes partly ligamentous in all placental mammals, and perhaps wholly ligamentous in man; the third part (cerato-branchial) and fourth part (hypo-branchial) both become cartilaginous and ossify early, so as to form a single

piece of bone, which perhaps includes also some bone derived from the second part also. This single piece of bone is known in the adult as the lesser horn of the hyoid. The adult hyoid bar then comprises the styloid process, the stylo-hyal ligament, and the lesser hyoid cornua. The main body of the hyoid probably belongs to the next branchial arch, but the hyoid bars unite with it very early.

It was long maintained by Huxley, 69.1, and W. K. Parker (Parker and Bettany, "Skull") that the incus was derived from the hyoid bar, but since Salensky, 80.1, showed that the incus is developed from the mandibular bar, Parker, 86.1, 10, has retracted his former opinion. Reickert, 37.1, thought that the stapes was derived from the hyoid bar, but recent investigations show that this is not the case, although Rabl, 87.1, has shown that the stapes is developed within the territory of the second branchial arch. O. Hertwig ("Lehrbuch," 3te Aufl., 509) suggested that the stapes was a double bone, one part of which is derived from the branchial skeleton, but Staderini, 91.1, has proved that this suggestion cannot be adopted—see Chapter XXVIII.

The following quotation from W. K. Parker, 86.1, 10, 11, gives some insight into the discussion about the incus, which may be said to have ended with the admissions made in the course of the quoted sentences. "But that great improvement just spoken of as appearing in the organ of hearing in the mammal has wrought a change in the hinder face that has *two* most important bearings. From the first promise of an ear-drum in the tailed Amphibia, to its highest fulfilment in the noblest of the oviparous tribes—the birds that nestle on high ('aves altrices')—the only element from the visceral arches that is used for carrying the vibrations of the air inward to the organ of hearing is the uppermost part of the hyoid arch—the 'pharyngo-branchial' element of the second postoral arch, to speak morphologically. From the salamandroids to the singing birds, all through the Amphibia and Sauropsida, the first postoral arch which forms both the upper and lower jaw is only segmented *once*, that is, into an epi-branchial and a cerato-branchial element or joint. The upper piece is specially termed the 'quadrate' and the lower the 'articulo Meckelian;' the one forms the swinging piece, hinge, or pier, to the 'compound lower jaw,' and the other its axis or pith, the part which becomes covered with more or fewer 'investing bones.' In these low 'Eutheria' and also in both the 'Metatheria' and the 'Prototheria' (Marsupials and Monotremes), the modified visceral rod that runs through the drum cavity has two new elements added to the *one* (single or variously segmented) element derived from the hyoid arch. This is an apparently *sudden* change, for we have it in the lowest or teatless mammals; their *ancestry* that should show us the earlier steps of the change are unfortunately all extinct. In this dilemma not only zoölogy, but palæontology also, fails us utterly, but embryology comes in with every stage and every link. I have worked out the early conditions of these parts in several kinds of Marsupials, and in the young of Ornithorhynchus; but even in the lower Euthreia, the Edentata, now to be described, and in the large and varied group of the Insectivora, I have been able to trace every step in the transformation of these parts. I am now satisfied that

the *incus* is the upper element of the first or mandibular arch; both Professor Salensky's and Professor Fraser's researches put this, I think, beyond doubt; and my own attempts for a long time to make the hyoid theory of this part agree with facts, only kept the subject in hopeless confusion. The new elements of the ear-chain are then the arrested quadrate or incus, and the arrested and *amputated* articular region of the articulo-Meckelian rod or primary lower jaw. The bony part of the 'ramus' is the well-known dentary with the coronoid and splenial bones in a sub-distinct state; the cartilage for the *new articulation* of the lower jaw is derived from a large superficial slab—a 'lower labial'—the like of which is not found again until we get as low down as the Chimæroids. From this is derived the hinder half of the ramus by transformation of its substance into bone; and from this we get the cartilage, both of the condyle and the glenoid cavity, and also of the intervening 'meniscus.' Of course the drum cavity is the 'first cleft,' and the concha auris with its segmented *meatus-tube*—the tympanic bone, the tympanic bulla, and the cartilaginous lining of the Eustachian tube—all these are parts of a curiously specialized opercular growth belonging to the hinder edge of the first visceral fold and arch. This last assertion has not been made as a stride across the types from the mammal to the elasmobranch, but is the result of a very slow step-by-step process, made during many years 'along all the lines' of vertebrate morphology."

THYRO-HYOID BARS.—Whether these bars extend in the mesenchymal stage through the entire length of the third branchial arches or not is not known, but their lower ends are chondrified and later ossified to form the principal part of the hyoid bone. There appears very early a median azygous element or copula, which in pigs of 16 mm. is already cartilaginous and united with not only the thyro-hyoid bars but also with the recurved ends of the hyoid bars. This copula is called the basi-hyal, and is the anlage of the main body of the hyoid bone; it is said to belong to the third branchial arch, although the hyoid bars unite with it. It is at first small in size, but as development progresses it enlarges considerably, while the ventral ends of the hyoid bars grow but little; it results that the relative size of the parts is changed, and the rudiments of the hyoid bars, which start nearly equal in diameter to the basi-hyal, appear in the adult as the lesser horns. The thyro-hyoid cartilages, on the other hand, grow at about the same rate as the basi-hyal and become the greater horns of the adult hyoid bone.

The hyoid bone of mammals is formed by the ventral portions of the hyoid bars (lesser cornua), the ventral portions of the thyro-hyoid bars and the copula of the third pair of branchial arches. In accordance with its development the hyoid bone has five centres of ossification, one for the body and one for each of its four horns. Ossification begins in man in the great cornua and body during the last month of foetal life, and in the small cornua during the first year after birth. The great cornua and body do not unite until middle life, and the lesser cornua usually remain distinct, though sometimes found united with the body at advanced ages.

II. THE LIMBS AND APPENDICULAR SKELETON.

Origin of Vertebrate Limbs.—The morphological value of the limbs of vertebrates has long been the subject of discussion and speculation, and at the present time the solution of the problem is theoretical rather than positive. It is unnecessary to give a résumé of the older hypotheses as to the archetype of the limbs, though I may refer those interested to Owen's article "On the Nature of Limbs," and Goodsir's essay "On the Morphological Constitution of Limbs," Edinburgh, *New Philos. Journ.*, 1857. Gegenbaur has advanced an hypothesis of the origin of limbs in support of which his memoir, **76.1**, brought very scanty evidence. According to this hypothesis the limbs are modified branchial skeletons, the shoulder and pelvic girdles representing the branchial bar, and the skeletal pieces of the limbs proper representing branchial rays; the central ray formed the axis of the limb, and the remaining rays gradually became articulated with the axial ray, and thus produced the type of limb found in *Ceratodus*, and which Gegenbaur regards as the primitive type from which all vertebrate limbs are derived. This theory, which was adopted by Huxley (on *Ceratodus*, *Proc. Zool. Soc.*, London, 1876), has attracted great attention, although it has been definitely set aside by the observations of Balfour, **81.1**, on the development of the limbs of *Scyllium*, which demonstrated that the limbs arise as parts of a longitudinal fold, which runs along the side of body, both fore and hind limb being part of the same fold. Were Gegenbaur's hypothesis correct, the limbs should arise as transverse or vertical folds. Under these circumstances it seems to me that Gegenbaur's theory has merely historical interest.

The only theory having any standing at present is the one adopted by Balfour ("Comp. Embryology," II.) according to which the limbs are specialized portions of a lateral fin-fold, similar to the dorsal and ventral median fin-folds of fishes. The resemblance of the lateral fins or true limbs to the median fins in general structure is obvious in many fishes, and especially in teleosts, and renders direct comparison very natural. Such comparison is suggested by several writers, but was first definitely worked out by J. K. Thacker, **77.1**, and at about the same time advocated by St. George Mivart, **79.1**, both these authors basing their conclusions upon comparative anatomical studies. Their general result was that the structure of limbs could be explained by assuming that they are specialized portions of lateral fin-folds, having a structure similar to that of the median fin-folds. At about the same time appeared the chapter of Balfour's monograph on the development of elasmobranch fishes, in which he advocated a similar theory upon embryological grounds, and by his observations put the theory upon a firm basis. It is a remarkable coincidence that the same hypothesis was formulated independently and published at about the same time by three investigators. These views were attacked by Von Davidoff, **79.1**, then a pupil of Gegenbaur's, and to Davidoff's paper Gegenbaur added a note upholding his theory; these criticisms were adequately answered by Balfour, **81.1** ("Reprinted Works," I., 714).

From the manner of their development it is obvious that the limbs

have a flattened form and a dorsal (or extensor) surface, and a ventral (or flexor) surface, and as soon as they project from the body, as they do at right angles, there is an anterior or cranial border and a posterior or caudal border. The development of the limbs in Scyllium, as described by Balfour, throws important light on the primitive position of these borders. Balfour ("Comp. Embryol.," II., 612) says: "The direction of the original ridge which connects the two fins of each side is nearly, though not quite, longitudinal, sloping somewhat obliquely downward. It thus comes about that the attachment of each pair of limbs is somewhat on a slant, and that the pelvic pair nearly meet each other in the median ventral line a little way behind the anus. The elongated ridge, forming the rudiment of each fin, gradually projects more and more, and so becomes broader in proportion to its length, but at the same time its actual attachment to the side of the body becomes shortened from behind forward, so that what was originally the *attached border* becomes in part converted into the *posterior border*. This process is much more completely carried out in the case of the pectoral fins than in that of the pelvic, and the changes of form undergone by the pectoral fin in its development may be gathered from my figures. In Scyllium the development of both the pectoral and pelvic fins is very similar. In both fins

the skeleton in its earliest stage consists of a bar springing from the posterior side of the pectoral or pelvic girder, and running backward parallel to the long axis of the body. The outer side of this bar is continued into a plate which extends into the fin, and which becomes very early segmented into a series of parallel rays at right angles to the longitudinal bar.

In other words, the primitive skeleton of both the fins consists of a longitudinal bar

running along the base of the fin and giving off at right angles a series of rays which pass into the fin. The longitudinal bar, which may be called the basi-ptyerygium, is, moreover, continuous in front with the pectoral or pelvic girdle as the case may be. My observations show that the embryonic skeleton of the paired fin consists of a series of parallel rays similar to those of the unpaired fins. These rays support the soft part of the fin, which has the form of a longitudinal ridge, and are continuous at their base with a longitudinal bar, which may very probably be due to secondary development. As pointed out by Mivart, a longitudinal bar is also occasionally formed to support the cartilaginous rays of unpaired fins."

Balfour's observations show that there was a primitive longitudinal skeletal piece at the base of the limb-fold, and that from this rays are developed which run out into the fold; Mivart assumed

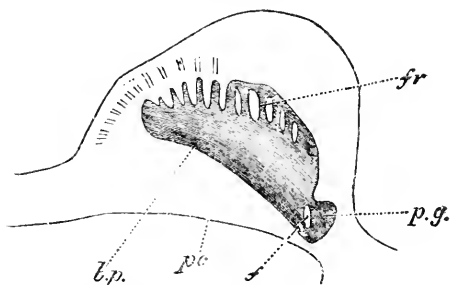


FIG. 252.—Pectoral Fin of a Young Embryo of Scyllium in Longitudinal and Horizontal Section. The skeleton of the fin was still in the condition of embryonic cartilage; *b. p.*, basi-ptyerygium (eventual meta-ptyerygium); *fr.*, fin rays; *p. g.*, pectoral girdle in transverse section; *f.*, foramen in pectoral girdle; *p. c.*, wall of peritoneal cavity.

that the rays were primitive and the longitudinal piece the product of the fusion of the bases of the rays. As the limb grows out its base becomes free and constitutes the posterior border, and the basal skeletal piece appears as the axis of the limb, while the fin-rays run off from one side toward the primitive outer or ultimate cephalic border of the fin; on the caudal side of the axis there are necessarily no fin-rays. If we assume, as we must, that Scyllium illustrates the general type of fin development, then a condition in which, as in the fins of the adult *Ceratodus*, there are rays on both sides of the axis must be considered a secondary condition. The *Ceratodus* type is known as the archipterygium, and, as already stated, has been held by Gegenbaur to be the ancestral form of vertebrate limbs. But our knowledge of the development and morphology of fins renders it impossible to accept this view, at least at present.

The *archipterygium* may be defined as a skeletal limb axis with rays coming off on both sides; no such fins are known among the lower fishes, but only among the higher (Dipnoi); this fact offers another serious obstacle to regarding the archipterygium as the primitive ancestral form, but suggests that it may represent the ancestral form of the pentadactyle limbs of amphibia and mammals. I think much may be said in favor of this suggestion, and indeed it is largely on account of the possibility of deducing the pentadactyle limbs from it that the archipterygium has been regarded as an archtype by Gegenbaur and his followers.

The *cheiropterygium* is the archtype or ancestral form of the pentadactyle limb. Its essential characteristic is the division into four segments:

- | | | | |
|-----------------|---------------|--------------|------------|
| 1. { Upper arm. | 2. { Forearm. | 3. { Carpus. | 4. { Hand. |
| { Upper leg. | { Lower leg. | { Tarsus. | { Foot. |

The upper segment contains one long bone (humerus or femur); the second segment contains two long bones (radius or tibia, and ulna or fibula); the third segment contains nine small bones (carpals or tarsals); the fourth segment consists of separate digits, five in number, hence the term pentadactyle applied to this type of limb; each digit has a proximal or basal bone (metacarpal or metatarsal) upon which follows a linear series of phalanges, separate bones variable in number. It is convenient always to count the digits in the same way, commencing from the radial or tibial side; thus the thumb is the first digit of the hand, the great toe the first digit of the foot.

The arrangement of the carpal and tarsal bones is greatly modified not only in the amniota but also in many of the amphibia, both by the suppression of some of the nine bones and by fusions among them. The nine bones are the intermedium between the distal ends of the radius and ulna, the radiale and ulnare at the distal ends of the radius and ulna respectively; the two centralia, on the distal side of the intermedium; between these four and the metacarpals (or metatarsals) follow the five *carpalia* or *tarsalia*. In most pentadactyle limbs the two centralia are fused into one bone, the *centrale*. In many cases some of the bones are suppressed. The following table shows the homologies in man:

Ulnare (fibulare).	Cuneiforme.	Calcaneum.
Intermedium.	Lunare.	} Astragalus.
Radiale (tibiale).	Scaphoid.	
Centralia.		(?) Naviculare.
1.	1. Carpale.	1. Tarsale.
2. (Carpalia).	2.	2.
3. (Tarsalia).	3.	3.
4.	} Unciforme.	} Cuboides.
5.		

The pisiforme is a sesamoid bone developed in the tendon of the flexor carpi ulnaris, and has nothing to do with the primitive carpus.

It is generally taught that there is one series of bones which represents the true axis of the limb, and that the other bones represent a series of rays coming off from it. This supposed axis begins with the humerus (femur), is continued through the ulna (fibula), and terminates with one of the digits, but which digit authorities are not agreed; thus Gegenbaur carries the axis through the ulnare fifth metacarpal and fifth digit, which makes the first ray pass off from the humerus and include the radius, radiale, first carpal, and first digit; the second ray arises from the ulna and includes the intermedium, one centrale, and the second digit; the third ray springs from the ulnare and includes one centrale and the third digit; the fourth ray springs from the fifth carpale and includes the fourth carpale and the fourth digit; similarly, changing the names, in the hind limb, see Gegenbaur, "Grundriss d. vergl. Anatomie," 1878, 512, Fig. 273. Wiedersheim, on the contrary, carries the axis (see his "Grundriss der vergl. Anatomie," 2te Aufl., Fig. 110) through the ulna (fibula), intermedium, both centralia, second carpale (tarsale), and second digit. Such divergences of opinion raise doubts as to the existence of any true axis at all.

A full discussion of the morphology of the limbs does not fall within the scope of this work, because our conceptions are not based upon embryological observations. I shall, therefore, merely refer to the recent papers of G. B. Howes, **87.1**, J. A. Ryder, **87.1**, D'Arcy Thompson, **86.1**, Hatschek, **89.1**, and E. E. Prince, **90.1**.

Relation to the Somites.—Each limb arises along the territory of several somites, and receives outgrowths from the muscle plates of several successive segments, and with these outgrowths, which produce the muscles of the limbs, come the nerves of several segments, so that the fact that the limb arises along a considerable length of the body explains several important features in the development of limbs—features which remain inexplicable if we accept Gegenbaur's theory of the evolution of the limb from a branchial arch, because this theory confines the primitive limb to a single segment, whereas at its very earliest stage it is already related to several segments. As to the exact number of limb somites we are in doubt. Balfour's observations indicate that each limb was originally attached along a considerable number of segments, but that on the caudal side the attachment becomes shortened. As it is not until this restriction of the base has taken place, that the muscle plates penetrate the limb, it follows that the muscles of the limb are derived from a less number of segments than corresponded to the primitive attachment.

This reduced number is probably five in the amniota, but certainty on this point is yet to be reached.

Concerning the position of the limbs, as regards their distance from the head and the segments to which they belong, we have little exact knowledge. A. M. Paterson, 91.2, holds that the position in this sense is not uniform among the mammalia; he bases this opinion upon the innervation which is variable. The variation is much less for the fore than the hind limb; the former is, as a rule, innervated from the lower cervical and upper thoracic segments; the twenty-fifth spinal nerve is the only one invariably present in the hind limb of mammals, while the nerve plexus may begin, according to the species, with any of the nerves from the twenty-first to the twenty-fifth, and, as it usually comprises five or six spinal nerves, it ends with the twenty-fifth to twenty-ninth nerve. It is thus probable that the hind limb readily shifts its position. As the sacrum is always developed in connection with the limb it follows that the number of præ-sacral vertebræ must vary, although there is no intercalation or obliteration of vertebræ.

Position of the Limbs.—The primitive position of the limbs is at right angles to the body in a plane nearly parallel with the longitudinal body-axis. The first change is the appearance of two bends which give the limb the position which is permanent in amphibia; the bends are similar in the fore and hind limbs. The first bend (elbow or knee) is at the end of the upper limb (humerus or femur), and is such that the lower limb is flexed downward (ventralward) and toward the median line; the second bend is at the carpus (tarsus) and is in the opposite direction or outward. Thus the ventral aspects of the forearms and lower legs come to look inwardly and their dorsal aspects outwardly; while the ventral aspects of the hands and feet look downward and their dorsal aspects upward. This change is obviously correlated with the change from aquatic to terrestrial life and the consequent substitution of legs for fins. When the position of the limbs has been no further altered than this, the radius and tibia are found on the cranial side, the ulna and fibula on the caudal side of their respective limbs. The second step is the torsion of the limbs, which is similar in both pairs and occurs in all mammalia, the result of which is that the digits point headward, the first digit being in both hind and fore limbs toward the median line. This is the arrangement which is permanent in the *reptilia* and in the *lower mammalia*. The torsion, by which the change is effected, does not take place in the arm or leg itself, but at the shoulder or hip. The third change is the torsion of the upper arm (not known to occur in the leg) by which the distal end of the humerus is twisted over through an angle in man of nearly or quite one hundred and eighty degrees; by this torsion the head of the radius, which before the change was on the inner side of the arm, is brought across in front of the ulna to the outer side, with the result that if the hand is kept in its primitive position, palm down, the forearm is twisted in the reverse direction to the upper arm; this third change is accompanied by accessory modifications in the joints and muscles by which the radius becomes so movable that it can be employed to turn the hand with the palm either up (supination) or down (pronation).

Anatomists are not entirely agreed as to the alterations in the positions of the limbs. The above formularization of the changes is based partly upon that given by Huxley in his "Anatomy of Vertebrated Animals," 32-33, and on Hatschek, 89.1, partly on a few observations I have made on skeletons.

It is to be expected that the limbs of the higher mammalia pass through the three stages of limb position which may be conveniently designated as amphibian, reptilian, and mammalian. Unfortunately there are no observations as yet to show whether this is the case or not. This gap in our knowledge offers a favorable opportunity for a research.

Shoulder Girdle.—The anlage of the shoulder girdle is probably continuous in all vertebrates, as it has been shown to be in the fishes, with the anlage of the base of the limb, but in the amniota it early becomes a separate cartilage, lying in one plane and extending dorso-ventrally. In mammals there is a large dorsal segment of this cartilage above the articulation with the humerus (glenoid fossa) and a much smaller segment below the articulation. The dorsal segment develops into the large shoulder blade, while the ventral segment forms merely the small coracoid process, although it is the homologue of the large and independent coracoid bone of sauropsida and amphibia. It is to be noted that Sabatier, 80.1, has homologized the "coracoid" process with the præ-coracoid, and holds that the upper third of the mammalian glenoid fossa, which ossifies from a separate centre, represents the true coracoid, but this view has not been accepted.

Little is known concerning the development of the scapula in mammalia beyond what is given in W. K. Parker's monograph, 68.1, a work which has by no means received the attention it deserves. Owing to the reduction of the coracoid in mammalia the history of the scapula is practically that of the entire shoulder girdle. Parker, *l. c.*, p. 223-224, records some observations on the scapula of human embryos. In an embryo $5\frac{1}{2}$ inches long, the scapula, Fig. 253, already has much of its persistent form and is ossified through about half its extent, *b*; the small size of the præ-scapular region, *p.sc.*, and the great size of the acromion, *Acr.*, are features in which the embryonic shoulder blade differs strikingly from that of the adult; in an earlier stage, embryo of $2\frac{1}{4}$ inches the præ-scapula is proportionately still smaller, and the acromion thicker and more curved toward the clavicle. The meso-scapular ridge, *msc.*, is the thick prolongation of the acromion. The coracoid process,

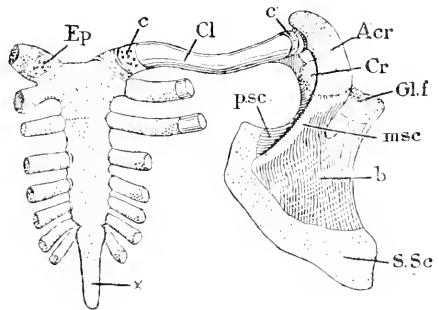


FIG. 253.—Scapula of a Human Embryo of five and one-half inches, Dorsal View. Natural size. *Ep.*, Goette's episternal element (Parker's omosternum); *c.*, cartilage at end of clavicle; *Cl.*, termed by Parker præ-coracoid; *c'*, cartilage at scapular end of clavicle, termed by Parker meso-scapular segment; *Acr.*, acromion; *Cr.*, coracoid process; *gl.f.*, glenoid fossa; *b.*, bony portion; *msc.*, meso-scapula; *S.Sc.*, supra-scapula; *p.sc.*, præ-scapula. After W. K. Parker.

is the thick prolongation of the acromion. The coracoid process,

C7. is small and slightly curved; it is connected by a fibrous band with the end of the clavicle, but the cartilaginous end of the clavicle (Parker's so-called meso-scapular segment) is articulated by a synovial joint at this stage with the end of the acromion. The coracoid has its own centre of ossification, to which are added at the time of puberty two epiphysal centres (Rambaud and Renault)—its ossification thus indicating its morphological individuality. The acromion has two, sometimes three, centres, which appear between the fourteenth and sixteenth years and soon coalesce, but the ossified acromion does not unite with the scapula until eight to ten years later. There is a separate centre for the inferior angle (supra-scapular) and for the upper part of the glenoid cavity.

Clavicle.—Opinions differ as to whether the clavicle is a dermal bone or an integral portion of the scapular arch. It is, as discovered by C. Bruch, 53.1, 371-372, the first bone formed in the human embryo its ossification going on during the seventh week. Gegenbaur, has shown that the bone commences by ossification of mesenchyma; then cartilaginous masses appear at each end, which are, however, softer and have less basal substance than most embryonic cartilage; these cartilages serve to maintain the growth in length of the clavicle. Kölliker states ("Entwicklungsgeschichte," 1879, p. 495) that he has verified on rabbit embryos Gegenbaur's observations, though he regards the tissue of the anlage as intermediate between mesenchyma and true cartilage. Kölliker adds that there is a separate centre of ossification, which may be compared to an epiphysis at the sternal end. This epiphysal piece was first described by W. K. Parker, 68.1, 223-224, and was shown by him to become distinct while still cartilage: Parker terms it the præcoracoid, although this name is properly applied to an entirely different bone. These peculiarities in the development of the clavicle, together with Rathke's statement that the clavicular anlage is at first continuous with that of the coraco-scapular arch, and certain observations of his own, have led Alex. Goette, 77.1, to maintain that the clavicle is an element of the shoulder. Goette's observations have been in part confirmed by C. K. Hofmann, 79.1. Gegenbaur regards the mammalian clavicle as a compound bone homologous with both the true dermal clavicle (Decknochen des Procoracoids) and the cartilaginous præcoracoid of fishes, the two originally separate skeletal elements having united with one another; by this double homology Gegenbaur explains the peculiar development of the bone; compare his "Grundriss d. vergl. Anatomie," 2te Aufl., 501. It is possible, however, that we attribute too great morphological meaning to the appearance of cartilage, and that partial chondrification of the clavicular anlage does not mean, as Gegenbaur thinks, a separate element of the skeleton, or, as Goette thinks, connection with the shoulder girdle, but is merely a modification of the histogenetic development—compare the paragraph on the mandible, p. 444. We cannot hope to understand the homologies of the clavicle until its development shall have been completely traced, beginning with the earliest mesenchymal stage.

Episternum.—Whether there is any episternum in the human embryo is uncertain. Perhaps the suprasternal cartilages just men-

tioned as having been described by G. Ruge, 80.1, are its representatives. K. Bardeleben, 79.1, has sought to homologize the deep portion of the interclavicular ligament as the rudiment of the human episternum. A. Goette, who has worked out, 77.1, the development of the parts more fully than any other anatomist, finds that "paired interclavicular elements grow out backward from the ventral ends of the clavicles, and uniting together form a somewhat T-shaped interclavicle overlying the front end of the sternum. This condition is permanent in the *Ornithodelphia* except that the anterior part of the sternum undergoes atrophy. But in the higher forms the interclavicle becomes almost at once divided into three parts, of which the two lateral remain distinct, while the median element fuses with the subjacent part of the sternum and constitutes with it the presternum (*manubrium sterni*). If Goette's facts are to be trusted, and they have been to a large extent confirmed by Hofmann, his homologies appear to be satisfactorily established." (Balfour.)

Pelvic Girdle.—The pelvic girdle resembles the pectoral; it consists of a bar of cartilage which articulates with the femur; the articular cavity is known as the acetabulum and divides the girdle into a dorsal and ventral segment, as the glenoid fossa divides the scapular arch. The dorsal pelvic division is called the iliac section, the ventral division the pubic section. The iliac section has no connection with the vertebral column in fishes, but is articulated with the sacral vertebrae in amphibia and amniota. The pubic section meets its fellow in the median ventral line; in amphibia it becomes more expanded and plate-like, and there appears an interruption of the cartilage by which the obturator foramen is formed; this foramen divides the pubic section into a cephalic portion or pubis, and a caudal portion or ischium. In mammals the foramen is enlarged so that ischium and pubis are more distinct than in amphibia.

Balfour ("Comp. Embryology," II., 606) found that the mode of development of the pelvic girdle in *Scyllium* is very similar to that of the pectoral girdle. There is a bar on each side continuous on its posterior border with the basal element of the fin (Figs. 345 and 347). This bar meets and unites with its fellow.

Concerning the early development of the girdle in amniota I know of only the observations of A. Bunge, whose dissertation I have not seen, and those of Alice Johnson, 83.1, on the chick. The latter shows that the girdle is continuous with the femur at first; the ischium and pubis grow out separately from the acetabular region, both growing ventralward, the former on the caudal, the latter on the cephalic, side of the crural nerve; if the ischium and pubis were to unite distally, which, however, they do not do in the chick, they would inclose a space homologous with the obturator foramen. This observation renders it improbable that the ischium and pubis are together homologous with the pubic section of the girdle in fishes, and indicates that one of them is a new element—added in the amphibia perhaps. The pubis sends out a process headward from just below the acetabulum; this process is the pre-pubis; it is well

* "Entwick. Beckengürtels." Inaug. Diss., Dorpat, 1880.

developed in the Ornithorhynchus, but is rudimentary in the higher mammalia.

Skeleton of the Arm.—Our knowledge of the development of the skeleton of the fore limb in mammalia is very imperfect. It rests chiefly on the data furnished by Henke and Reyher, **74.1**, supplemented by E. Rosenberg's valuable investigations of the centrale carpi in man, **75.1**, and a few observations recorded by Kölliker in his "Entwicklungsgeschichte," 2te Aufl., and by C. Emery, **90.1**. To these references ought to be added one to the paper on the development of ungulate limbs by Alexander Rosenberg, **73.1**, which, however, has less direct interest for us.

The skeleton of the arm in mammals (as in amphibia also, H. Strasser, **79.1**) in its earliest mesenchymal stage forms an uninterrupted anlage (Kölliker, *l.c.*, 491), with no indication of its future subdivision, and is, moreover, probably continuous with the anlage of the pectoral girdle. As soon as chondrifications begin the individual skeletal pieces are indicated by corresponding separate centres of chondrification, which begin near the centre of each piece and spread toward its periphery. The separation of each digital series is given in the primitive mesenchymal anlage, which also shows, according to C. Emery, **90.1**, 296, traces of a sixth digit (*præ-pollux*) in front of the thumb; the sixth digit persists as a rudiment and only for a short time. The condensed mesenchyma between two adjacent cartilages becomes fibrillar and produces the articulations. On the development of the joints, see p. 460. When, however, two cartilages fuse into one, as occurs in man with several of the carpals, the fusion takes place very early and no articulation is formed. It may be noted here that the joints are not differentiated until six or eight weeks after chondrification begins.

In the human embryo at six weeks nearly all the skeletal pieces are present; the ends of the humerus are somewhat enlarged; the ulna has a *processus anconæus* already; the radius shows both head and neck; the metacarpals are beginning to chondrify. By the eighth week the phalanges are cartilaginous, having begun to chondrify (Kölliker, "Entwicklungsgeschichte," 2te Aufl., 491) when the five digits became distinctly indicated by marginal notches in the hand, and in the humerus the calcification of the cartilage, preliminary to its degeneration and replacement by bone, has begun; the articular surfaces of the cartilages are becoming more sharply defined (Henke u. Reyher, **74.1**, 224-230). These authors discovered, *l.c.*, p. 268, that the centrale exists as a separate structure in embryos of the second month. E. Rosenberg, **75.1**, 172-191, has traced out the history of the centrale very carefully; it is characterized by having less intercellular substance than the other carpal cartilages, and by never changing into bone, except as a rare anomaly; normally it is gradually absorbed in older embryos and disappears, the space it occupied being taken up by the enlargement of the radiale (scaphoid). Henke and Reyher have observed a tenth carpal also which was perhaps merely a transitory (Gegenbaur's "radial sesamoid") bone—at least this suggestion of E. Rosenberg's is a plausible explanation.

OSSIFICATION.—"In the *humerus* a nucleus appears near the mid-

dle of the shaft in the eighth week. It gradually extends, until at birth only the ends of the bone are cartilaginous. In the first year the nucleus of the head appears, and during the third year that for the great tuberosity. The lesser tuberosity is either ossified from a distinct nucleus, which appears in the fifth year, or by extension of ossification from the great tuberosity. These nuclei join together about the sixth year to form an epiphysis which is not united to the shaft till the twentieth year. In the cartilage of the lower end of the bone four separate nuclei are seen, the first appearing in the capitellum in the third year. The nucleus of the internal condyle appears in the fifth year, that of the trochlear in the eleventh or twelfth year, and that of the external condyle in the thirteenth or fourteenth year. The nucleus of the internal condyle forms a distinct epiphysis, which unites with the shaft in the eighteenth year; the other three nuclei coalesce to form an epiphysis, which is united to the shaft in the sixteenth or seventeenth year.

"The *radius* is developed from a nucleus which appears in the middle of the shaft in the eighth week, and from an epiphysal nucleus in each extremity which only appears some time after birth. The nucleus in the carpal extremity appears at the end of the second year, while that of the head is not seen till the fifth or sixth year. The superior epiphysis and shaft unite about the seventeenth or eighteenth year; the inferior epiphysis and shaft unite about the twentieth year.

"The *ulna* is ossified similarly to the radius but begins a little later. The nucleus of the shaft appears about the eighth week, that of the carpal extremity in the fourth or fifth year. The upper extremity grows mainly from the shaft, but at the end of the olecranon a small epiphysis is formed from a nucleus which appears in the tenth year. This epiphysis is united to the shaft about the seventeenth year; the inferior epiphysis about the twentieth year.

"From what is stated above it appears that in the bones of the arm and forearm the epiphyses which meet at the elbow-joint begin to ossify later, and unite with their shafts earlier, than those at the opposite ends of the bones; whereas in the bones of the thigh and leg the epiphyses at the knee-joint are the soonest to ossify (except in the fibula) and the latest to unite with their shafts. In the bones of the arm and forearm the arterial foramina are directed toward the elbow; in those of the thigh and leg they are directed away from the knee. Thus, in each bone the epiphysis of the extremity toward which the canal of the medullary artery is directed is the first to be united to the shaft. It is found also that while the elongation of the long bones is chiefly the result of addition to the shaft at the epiphysal synchondroses, the growth takes place more rapidly, and is continued longer, at the end where the epiphysis is last united; and the oblique direction of the vascular canals is due to this inequality of growth, which causes a shifting of the investing periosteum, and so draws the proximal portion of the medullary artery toward the more rapidly growing end.

"The *carpus* is entirely cartilaginous at birth. Each carpal bone is ossified from a single nucleus. The nucleus of the *os magnum* appears in the first year; that of the *unciform* in the first or second

year; that of the pyramidal in the third year; those of the trapezium and the lunar bone in the fifth year; that of the scaphoid in the sixth or seventh year; that of the trapezoid in the seventh or eighth year; and that of the pisiform in the twelfth year.

"The *metacarpal bones* and *phalanges* are usually formed each from a principal centre for the shaft and one epiphysis. The ossification of the shaft begins about the eighth or ninth week. In the inner four metacarpal bones the epiphysis is at the distal extremity, while in the metacarpal bone of the thumb and in the phalanges it is placed at the proximal extremity. In many instances, however, there is also a distal epiphysis visible in the first metacarpal bone at the age of seven or eight years, and there are even traces of a proximal epiphysis in the second metacarpal. In the seal and some other animals there are always two epiphyses in these bones. The epiphyses begin to be ossified from the third to the fifth year, and are united to their respective shafts about the twentieth year. The terminal phalanges of the digits present the remarkable peculiarity that the ossification of their shafts commences at the distal extremity, instead of in the middle of their length, as is the case with the other phalanges and with the long bones generally (F. A. Dixey)." (G. D. Thane in Quain's "Anat.," tenth edition.)

Skeleton of the Leg.—The primitive mesenchymal anlagen of the skeleton of the leg, like that of the arm, is continuous throughout in amphibia, H. Strasser, 79.1, and birds, Alice Johnson, 85.1, and therefore probably in mammals also, and in birds it is continuous also with the pelvic girdle, which appears as an outgrowth of the skeletal anlage of the limb proper. As in the arm chondrification blocks out the separate skeletal pieces. The formation of cartilage begins in the chick the sixth day and becomes well marked by the seventh day, when Strasser's "prochondral elements," p. 404, have already disappeared (Johnson, *l. c.*).

In the human embryo at six weeks all the skeletal parts are mapped out in cartilage, except the terminal phalanges, which are still entirely mesenchymal. The plan of structure is essentially the same as in the arm at the same age, but the differentiation is less advanced; the femur has already neck and trochanter, is slightly curved, and its lower end is enlarged, with two condyles and the incisura intercondyloidea recognizable; the tibia has broad condyles at its upper end and is suddenly restricted immediately below, and slowly increases in diameter toward the tarsus, to end with a surface so oblique as to be nearly parallel with the length of the limb; the astragalus (talus) consists of a lower main portion, the homologue of the tibials, and an upper process lying between the tibia and fibula, and homologous with the intermedium; the fibulare (calcaneum) is not so long as the astragalus, and is separated by articular mesenchyma from both the fibula and astragalus, alongside of which last it is situated, but this situation is found to alter gradually, beginning to alter in embryos but little over six weeks. In the digital rays the metatarsi and first phalanges only are differentiated (Henke and Reyher, 74.1, 230-234).

In an embryo of nearly six months the ankle has, I have found, essentially the adult form. As shown in a vertical section, Fig. 254,

the lower ends of the tibia, *Tb*, and fibula, *Fb*, are still cartilaginous; the astragalus, *Astr*, and calcaneum or os calcis, *Cal*, are wholly cartilaginous, although penetrated by vessels preparatory to their later ossification. The astragalus, *Astr*, is in quite different relations from those found at six weeks; it underlies the tibia, and shows clearly the subdivision of its tibial articulation into the joint with the main shaft, *Tb*, and with the internal malleolus, *m*; by its external surface it articulates with the fibula, *Fib*; by its lower surface with the os calcis, *Cal*. All of these articulations are well differentiated. At its lower internal angle the cartilage of the astragalus is interrupted to allow the irruption of the vascular mesenchyma.

OSSIFICATION. — “The *femur* is developed from one principal ossific centre for the shaft which appears in the seventh week, and from four epiphyses, the centres for which appear in the following order: A single nucleus for the lower extremity appears shortly before birth, one for the head appears in the first year, one for the great trochanter in the fourth year, and one for the small trochanter in the thirteenth or fourteenth year. These epiphyses become united to the shaft in an order the reverse of that of their appearance. The small trochanter is united about the seventeenth year, the great trochanter about the eighteenth year, the head from the eighteenth to the nineteenth year, and the lower extremity soon after the twentieth year. The neck of the femur is formed by extension of ossification from the shaft.

“The *tibia* and *fibula* each present, besides the principal centre for the shaft, a superior and an inferior epiphysis. In the tibia the centre for the shaft appears in the seventh week; that for the upper extremity including both tuberosities and the tubercle, appears most frequently before, but sometimes after birth; and that for the inferior extremity and internal malleolus appears in the second year. The tubercle is occasionally formed from a separate centre. The lower epiphysis and shaft unite in the eighteenth or nineteenth year, the upper epiphysis and shaft in the twenty-first or twenty-second year. In the fibula the centre for the shaft appears rather later than in the tibia; that for the lower extremity appears in the second year, and that for the upper, unlike that of the tibia, not till the third or fourth year. The lower epiphysis and shaft unite about the twenty-first year, the upper epiphysis and shaft about the twenty-fourth year.

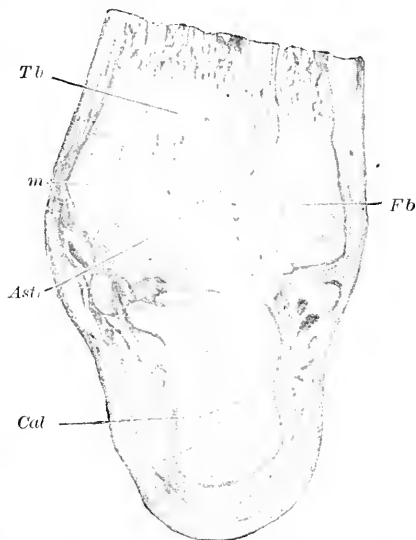


FIG. 254.—Vertical Section of the Ankle of a Human Embryo of nearly six Months. Minot Collection, No. 109. *Tb*, Tibia. *Fb*, fibula; *m*, internal malleolus of the tibia; *Astr*, astragalus; *Cal*, calcaneum (os calcis). $\times 3$ diams.

"The *tarsal bones* are ossified in cartilage, each from a single nucleus with the exception of the os calcis, which in addition to its proper osseous centre has an epiphysis upon its posterior extremity. The principal nucleus of the os calcis appears in the sixth month of foetal life; its epiphysis begins to be ossified in the tenth year, and is united to the tuberosity in the fifteenth or sixteenth year. The nucleus of the astragalus appears in the seventh month; that of the cuboid about the time of birth; that of the external cuneiform in the first year; that of the internal cuneiform in the third year; that of the middle cuneiform in the fourth year, and that of the navicular in the fourth or fifth year.

"The *metatarsal bones* and *phalanges* agree respectively with the corresponding bones of the hand, in the mode of their ossification. Each bone is formed from a principal piece and one epiphysis; and while in the four outer metatarsal bones the epiphysis is at the distal extremity, in the metatarsal bone of the great toe and in the phalanges it is placed at the proximal extremity. In the first metatarsal bone there is also to be observed, as in the first metacarpal, a tendency to the formation of a second or distal epiphysis (A. Thomson). In the metatarsal bones the nuclei of the shafts appear in the eighth or ninth week. The epiphyses appear from the third to the eighth year, and unite with the shafts from the eighteenth to the twentieth year. The nuclei of the shafts of the phalanges appear in the ninth or tenth week. The epiphyses appear from the fourth to the eighth year, and unite with the shafts from the nineteenth to the twenty-first year." (G. D. Thane in Quain's "Anatomy," ninth edition.)

Joints of the Limbs.—Our knowledge of the development of the joints is based chiefly upon the researches of Henke and Reyher, 74.1, Bernays, 78.1, and Hepburn, 89.1; Hagen-Torn's article, 82.1, is chiefly on the histogenesis of the synovial membrane, see p. 421. Where a joint is to be formed the cells become elongated at right angles to the axis of the anlage (*synarthrodial stage*), the tissue becomes fibrillar and in its midst the cavity appears (*diarthrodial stage*); chondrification soon extends to the cavity, the articulating surfaces thus becoming cartilaginous. The development of the joints is very gradual, but by the end of the third month there are true articulating surfaces, which gradually become better developed; the development of the joints progresses distally, thus the elbow-joint is developed much earlier than the finger-joints; the articulations of the arm appear sooner than the corresponding ones in the leg, thus the knee-joint appears later than the elbow-joint. Bernays, 78.1, states that the synarthrodial stage of the knee begins in a human embryo of 2 cm., and still persists in one of 3 cm.; in the latter, although there is still no articular cavity, yet the articular ends of the femur and tibia are shaped nearly as at birth—an important observation because it shows that the articulating surfaces are shaped before any free motions can begin. In the three-centimetre embryo the growth of the lateral tibial condyle has already forced the fibula out of its intimate connection with the femur, which is characteristic both for the earlier stage in man and for ancestral types. By comparative anatomy Bernays has sought to prove that

synarthrodial joints are characteristic of the fishes, imperfect diarthrodial joints of the amphibia, perfect ones of the amniota. Hepburn, 89.1, adds but little to our knowledge, but his paper is valuable for an admirable synopsis of the stages of joint differentiation and of the classification of joints from the embryological standpoint. Hepburn's classification is essentially as follows: Syndesmosis, synchondrosis, primitive articular cavity, amphiarthrosis, diarthrosis (simple, double with meniscus); the diarthroses show the following stages: 1, surfaces become cartilaginous; 2, capsular ligament formed; 3, other ligaments formed; 4, synovial membrane developed.

III. DERMAL BONES.

It has been long known that not all the bones are præformed in cartilage, and that some of them, especially of the head, are developed from soft tissue. The latter were known to the older anatomists as *membrane bones*. In the years 1845-50 the origin of the membrane bones was actively debated, and at that time the term *secondary bones* was substituted for the earlier designation, and the terms *Belegknochen* and *Deckknochen* were introduced by Kölliker, whose investigations played the principal part in demonstrating that the membrane bones are developed by the direct ossification of young connective tissue, or—as we should now say—of mesenchyma. Those who wish to follow this discussion are referred to Kölliker, 50.2, where references are given to various authorities of the time, and also to Kölliker's "Bericht der Zootom. Anstalt in Würzburg," and his "Entwicklungsgeschichte," 2te Aufl., 463. The dermal bones of the head may lie close against the cartilage (or bone) of the primordial skull, and in that case are often called *splint bones* or *splenia bones*.

In the lower vertebrates the membrane bones acquire a greater development than in higher forms, and in certain ganoids and teleosts are developed over nearly the entire body, whereas in the amniota they are confined to the head.

O. Hertwig's brilliant researches, 74.1, 2, 76.1, 79.1, have demonstrated that the dermal bones are homologous with the plates formed by the fusion of epidermal teeth or so-called placoid scales. The placoid scales are true teeth developed in the skin and supported by a base of bone; by the fusion of adjacent bony bases we may have an osseous plate developed in the cutis. In tailed amphibia several of the membrane bones arise as dentiferous plates, but later in the development the teeth are resorbed leaving merely the bony plate, but in anoura the homologous bones are developed without teeth being formed at all. The inevitable conclusion from these facts is that the dermal skeleton has been evolved through three principal stages: 1, scattered independent dermal teeth (placoid scales); 2, teeth-bearing plates formed by the fusion of the expanded bases of adjacent teeth (exo-skeleton); 3, membrane bones developing without teeth appearing (dermal bones of tailless amphibia and amniota).

The plates or bones of the dermal skeleton are not the same throughout the vertebrate series; among the fishes there are numer-

ous modifications, the homologies of which have not yet been thoroughly elucidated; in the amphibia we encounter all the elements of the dermal skeleton of the amniote head, and comparative anatomists have succeeded in homologizing some of these elements with plates in fishes, but as much remains to be done, and as the conclusions have not hitherto been based upon much embryological evidence, I shall not attempt to enter into these difficult discussions.

Typical Dermal Bones of Amniota.—In amniota the dermal bones are confined to the skull and face. There are, 1, four pairs of bones on the dorsal side, namely, the *nasals* overlying the olfactory chambers; the *frontals* overlying the anterior part of the brain cavity; the *parietals* overlying the middle part of the brain cavity, and the *interparietals* overlying the anterior part of the occipital region; the frontals, parietals, and interparietals, together with the supra-occipital, constitute the roof of the skull; when the cartilaginous skull spreads upward it goes under the territory of the frontals, parietals, and interparietals, and when it ossifies it may contribute to a greater or less extent to the bones in question, so that they are not exclusively membranous in origin (Dursy). Between the parietals and supra-occipital is the *interparietal*; 2. The small *lachrymals* situated between the nasals, frontals, and the eye on each side (in certain reptiles there are additional periorbital bones), and the *squamosal*, occupying the space between the parietals, ali-sphenoids, and occipitals, and overlying that portion of the mandibular bar which forms the quadrate of reptilia (incus of mammalia); the squamosal is perhaps the homologue of the præ-opercular of fishes, as maintained by Huxley, or perhaps of the ganoid supratemporal as suggested by Balfour, "Comp. Embryol.," II., 593. 3. The bones associated with the mandibular branchial bar; these are, *first*, those associated with the palato-quadrate bars and appearing in the roof of the mouth, the *vomere*, *palatines*, and *pterygoids*; second, a series associated with Meckel's cartilage, and consisting primarily, according to comparative anatomists, of three dermal bones, the distal *dentale*, the smaller *articulare*, and in the angle between these two the small *angulare*; but in mammals there is only a single bone developed from the mesenchyma around Meckel's cartilage, which evidently represents the dentale, but whether or not it also represents the articulare and angulare has not been definitely settled. 4. The series associated with the maxillary processes, four on each side forming a row; beginning at the ventral end of the process these four bones are the *præ-maxilla*, *maxilla*, *jugal*, and *quadrato-jugal*. 5. The median *para-sphenoid*, which is developed in the roof of the mouth in many fishes (but not in elasmobranchs or marsipobranchs), in amphibia, and in sauropsida, in which last it is less important and becomes indistinguishably fused with the sphenoid in the adult; in mammalia it has not been found, though probably morphologically present in the sphenoid—a probability which it would be worth testing by a special investigation. 6. The *tympantal* bone formed around the drum of the ear.

The Dermal Bones in Man.—The numerous dermal bones, mentioned as characteristic for the amniota at large, have all been identified in the adult human skull, except the articulare, angulare,

quadrato-jugular, and para-sphenoid. The four bones mentioned are, however, all probably represented by definite parts as follows: the interparietal by the upper median portion of the supra-occipital; the articulare and angulare by parts of the adult mandible; the quadrato-jugular by one of the ossificatory centres of the jugal, and the para-sphenoid by part of the sphenoid. The nasals, parietals, lachrymals, vomer, and jugal remain independent bones, while the frontals and palatines are also independent except that each pair forms but a single bone. On the other hand the squamosals, pterygoids, dentals, are united with certain parts of the primordial skull. Finally the præ-maxillaries and maxillaries fuse into a single bone, of which the part bearing the four upper incisors corresponds to the præ-maxillaries.

A tabular view of the homologies of the human skull is given on p. 465.

The following data afford additional information concerning the development of the single dermal bones.

1. *Nasals* are each ossified from a single centre which appears about the eighth week.

2. *Frontal* is ossified from two centres, one for each frontal appearing about the seventh week. At birth the frontals are still entirely distinct, but they become united during the first year after birth by the median "frontal" suture, which usually becomes obliterated by osseous union taking place from below upward during the second year, but not infrequently the suture persists throughout life.

3. *Parietals* are each ossified from a single centre which appears in the site of the parietal eminence about the seventh week. The eminence is very conspicuous in the young bone and gives a marked character to the form of the skull for a number of years in early life.

4. *Interparietals* are represented by the upper pair of centres of the supra-occipital region; these centres appear during the seventh week in the mesenchyma overlying the supra-occipital cartilage. The interparietals usually unite with the true occipitals, but occasionally they remain distinct and are then separated from the supra-occipital by a suture running transversely from one lateral angle of the occipital bone to the other.

5. *Lachrymals* are each ossified from a single centre, which appears about the eighth week.

6. *Squamosals* are each ossified from a single centre, which appears in its lower part about the seventh or eighth week; ossification spreads upward in the squamosum proper, and outward into the zygomatic process. At birth the squamosal is still separated from the petriotic capsules, but during the first year bony union is effected and the squamosal becomes a part of the temporal bone of the adult.

7. *Vomer* is ossified from a single nucleus appearing at the hinder part about the eighth week. From this nucleus two laminae are developed, which pass up on either side of the median line and embrace the lower part of the cartilaginous internasal septum. These laminae gradually coalesce from behind forward till the age of puberty, thus forming a mesial plate, with only a groove remaining on its superior and anterior margins.

8. *Palatine* is ossified from a single centre which appears in the

seventh or eighth week at the angle between its horizontal and ascending parts.

9. *Pterygoids* are each ossified from a single centre which appears during the fourth month; during the fifth or sixth month the pterygoids unite with the ossified pterygoid processes (future external pterygoid plates) of the ali-sphenoids and thus become the internal pterygoid plates of the adult basi-sphenoid.

10. *Præ-maxillaries* have been studied by Th. Kölliker, **82.1**; they ossify later than the maxillaries and appear just before the palate fissure closes, and after the fissure has closed they are found united with the maxillaries so that the period of their independent existence is very short; but in the ninth week traces of the primitive division are still present, and even these traces disappear by end of the tenth week. The præ-maxillaries carry the four upper incisors. A special interest attaches to these bones because their homologies in man were ascertained by Goette.

11. *Maxillaries* begin to ossify toward the end of the second month and offer the peculiarity of starting from several spots, which, however, speedily fuse and cannot be regarded as separate centres. This peculiarity was first recorded by Beclard, **20.1**, and his observation has been confirmed by Rambaud et Renault, and more recently by Callender, **70.1**, 163. As stated above, the maxillaries and præ-maxillaries are united before the tenth week.

12. *Jugals*, or malars, begin to ossify about the eighth week. According to Rambaud et Renault, ossification begins from three points, which are found united by the fourth month.

13. *Mandible*. The mandible of the adult is a compound bone, for it includes both the dermal bone and the ossified lower ends of Meckel's cartilage, most of which, however, is resorbed, and it is further peculiar in having cartilage developed at the ends of both the coronoid and condylar processes. The two mandibles are distinct at birth, but during the first year their lower or ventral ends unite, but in a pig embryo of two and a half inches Parker ("Morphology of the Skull," 290) describes the ends of Meckel's cartilages as united, and it is probable that the cartilaginous jaws of the human embryo are similarly united. The development of the human mandible has been studied by Masquelin, **78.1**; in an embryo of 5 cm. the cartilage of Meckel is entirely surrounded by mesenchymal bone, and in embryos of 17 cm. there are only slight calcified remains of the cartilage, except in the lower ends near the symphysis, where, as shown by Kölliker, the cartilage participates in the ossification of the mandible; the cartilage of the coronoid process was found in embryos of 7.5 and 9.5 cm., and in the later cartilage along the alveolar border; the cartilage of the condyle is developed still earlier; the three cartilages upon each mandible undergo direct ossification. Strelzoff, **73.1**, was led by the observation of these cartilages to maintain that the entire jaw is preformed in cartilage, but that this view is erroneous was demonstrated in an admirable paper by J. Brock, **76.1**. It is evident that the accessory cartilage of the mandible is morphologically distinct from that of the primordial skeleton.

14. *Tympanals* develop during the third month each from a centre which appears in the lower part of the external membranous

wall of the tympanum and extends upward until a nearly complete bony ring is formed, inclosing the tympanic membrane; before birth the ends of the open ring become united with the squamosal, and thus incorporated in the great temporal bone of the adult.

The Fontanelles.—These are membranous intervals between the incomplete angles of the parietal and neighboring bones, in some of which movements of the soft wall of the cranium may be observed in connection with variations in the state of the circulation and respiration. They are at the time of birth six in number, two median, anterior and posterior, and four lateral. The *anterior* fontanelle, situated between the antero-superior angles of the parietal bones and the superior angles of the ununited halves of the frontal bone, is quadrangular in form and remains open for some time after birth. The *posterior* fontanelle, situated between the postero-superior angles of the parietal bones and the superior angle of the occipital bone, is triangular in shape. It is filled up before birth, but the edges of the bones being united by membrane only are still freely movable upon each other. The *lateral* fontanelles, small and of irregular form, are situated at the inferior angles of the parietal bones. The fontanelles are gradually filled up by the extension of ossification into the membrane which occupies them, thus completing the angles of the bones and forming the sutures. The closure, especially of the posterior and lateral, is often assisted by the development of Wormian bones in these situations. All traces of these unossified spaces disappear before the age of four years.

IV. MORPHOLOGY OF THE SKULL.

We are now in a position to consider several questions concerning the skull as a whole. What is presented on these questions I have divided under the following headings into sections: 1. Homologies of the bones of the human skull. 2. Relations of the primary and secondary skull. 3. Position of the facial apparatus. 4. Significance of the trabeculæ cranii. 5. Theories of the skull. The detailed history of each element of the skull is given, as fully as practicable, in the preceding pages.

Homologies of the Bones of the Human Skull.—These have been discussed in the preceding pages of this chapter, but it will be convenient to present the conclusions arrived at in a tabular form:

HUMAN.	TYPICAL AMNIOTE.
A. CRANIAL.—Ethmoid and turbinals.	Ethmoid and turbinals.
Præ-sphenoid.	Præ-sphenoid, orbito-sphenoids (alæ minores), and pterygoids.
Basi-sphenoid.	Basi-sphenoid, ali-sphenoids (alæ majores) (? and para-sphenoid).
Occipital.	Basi-occipital, ex-occipitals, supraoccipitals, and interparietal.
Temporal.	Periotic capsule (pro-otic, opisthotic, epiotic) squamosal, annulus tympanicus, and styloid process (upper end of hyoid bar).

HUMAN.	TYPICAL AMNIOTE.
B. FACIAL.—Nasals.	Nasals.
Lachrymals.	Lachrymals.
Jugal.	Jugal.
Superior maxillary.	Præmaxillæ and maxillæ.
Vomer.	Vomer.
Palatine.	Palatines.
Mandible.	Dentale (? Articulare and angulare) and lower part of Meckel's cartilage.

Relations of the Primary and Secondary Skull.—Comparative anatomy and embryology alike teach us that we must attribute to the skull a double origin, or rather that there are two skulls, one outside the other, which were primitively distinct from one another, but in the progress of evolution from the earliest fish type to the higher mammalia the union between the two skulls becomes more and more intimate. The inner skull is what is known as the primordial skull, with which I include the branchial skeleton; the outer skull comprises the series of dermal bones of the cranial and facial regions.

The primary skull appears first as the continuation into the region of the head of the axial mesenchymal skeleton, which in the neck and rump is the anlage of the vertebræ. That the mesenchymal skull represents in part, at least, a series of vertebræ is certain, and we find it sending dorsal outgrowths to inclose the brain just as the true vertebræ cover in the spinal cord. The mesenchymal skull also extends in front of the hypophysis, where it produces the trabeculæ cranii. What little can be surmised concerning the original homologues of this part of the skull is given in the section on the trabeculæ, p. 434. The mesenchymal skull grows so as to completely incase the brain and partially incase the olfactory chambers. While it is growing six centres of chondrification appear in it: namely, two trabecular, two parachordal, and two periotic; each centre forms a cartilage, which is extraordinarily uniform in shape and relations throughout the entire vertebrate series; the six cartilages remain distinct for a very short time only; the two trabeculæ unite first, the two parachordals next, third the united parachordals (or occipital) coalesce with the periotic capsules and later with the caudal ends of the trabeculæ, thus forming a large floor of cartilage under the brain. In the lower forms chondrification spreads until the entire primary skull becomes cartilaginous, and it is in this condition we find the skull in many of the fishes.

In the amphibia and amniota there is a progressive reduction of the cartilaginous skull by which its development as a roof over the brain is more and more diminished. This reduction leaves an opening as it were on the dorsal side, and at once increases the importance of the covering dermal bones—frontals, parietals, and interparietals. In Sauropsida the opening is larger than in amphibia, and in the mammalia there is further progressive increase in size, as shown by Parker's observations, the opening being larger in pigs than in insectivora and edentates. In mammals there is a further loss, which is not found in other classes, namely, an absence of chondrification in the region between the ali-sphenoids and periotic capsules, by which the importance of the squamosal—the dermal

bone of the region—is increased; see W. K. Parker, 86.1, 8, who speaks of the disappearance of the cartilage under the squamosal as “the true diagnostic mark” of the mammalian chondrocranium. Reduction of the cartilages of the branchial skeleton also progresses from the lower to the higher vertebrates. This shows itself in mammals not only in the total disappearance of the cartilages of the fourth and fifth arches, but also in the partial disappearance of the thyro-hyoid bars and the imperfect development of the hyoid bars. It shows itself further in the reduction of the mandibulars, for not only is the greater part of Meekel’s cartilage resorbed as in all amniota, but also the palato-quadrates is very much reduced. As the palato-quadrates is an important part of the skull in the amphibia, the palatines and pterygoids appear as true splint bones, whereas in mammalia they have greater independence. It is clear from the above that the evolution of the mammalian skull has depended to a large extent upon the reduction or partial degeneration of the inner skull, or primordial chondrocranium.

The secondary or outer skull is not so old as the inner skull, and originated in the higher fishes as a series of dermal bony plates, which overlaid the primary skull, and probably formed a nearly complete case for the head, including the face. The definite arrangement of the plates, as perpetuated and modified in mammalia, appears in the amphibia, and was perhaps evolved during the transition from the fish to the amphibian type. The dermal plates (membrane bones) may either remain as splint-bones, as for instance is the case with the vomer, or they may coalesce with the underlying portions of the chondrocranium, as for instance occurs with the interparietals in primates, or they may remain where the cartilage disappears beneath them, as for instance the frontals. Already in the amphibians the co-ordination and fusion of the inner and outer skulls into one complex skull is established, and in the amniota the welding together is carried still further, and the elements of the outer skull, *i.e.* the dermal bones, acquire increased importance as the inner skull, *i.e.* chondrocranium, is reduced. In brief, the evolution of the mammalian skull has depended largely upon increased morphological prominence of the dermal bones.

If we designate the formation of the chondrocranium as the *first* stage, and the formation of the dermal bones as the *second* stage in the evolution of the skull, we may designate the ossification of the primordial chondrocranium as the *third* stage. As to what caused that ossification, we have not even an hypothesis, and we are equally in the dark as to how the number of separate bones, or centres of ossification, was determined. It is noteworthy that the number of the primordial bones is extraordinarily constant.

Finally, let me emphasize the fact that, given the full number of bones, there is a sustained tendency to reduce them by fusion. The number of skull bones is less in the amphibia than in the teleosts, in edentates than in amphibians, in man than in edentates. A thorough comparative study of the number of the skull bones is much to be desired.

Position of the Facial Apparatus.—Owing to the head-bend of the embryo, the oral invagination, or mouth cavity, is brought

between the fore-brain and the heart, and upon the ventral surface, and this is the permanent position in the sharks. If we follow through the vertebrate series, or the development of an amniote, we find in either case a steady increase in the region of the olfactory and oral invaginations, in consequence of which it projects more and more, and further by a throwing of the whole head upward the face is brought forward and projects in front of the brain. In man this condition is again modified: *first*, because the upright position renders it unnecessary to bend the head as in quadrupeds, and, therefore the head is left facing ventralward; *second*, because the enormous development of cerebral hemispheres has rendered an enlargement of the brain cavity necessary, and this enlargement has taken place by extending the cavity over the olfactory regions as well as by enlarging the whole cranium; *third*, because the development of the facial apparatus is arrested at an embryonic stage, the production of a long snout being really an advance of development (Minot, 35), which does not take place in man.

Significance of the Trabeculæ Cranii.—Concerning the nature of the trabeculæ we have no satisfactory conceptions. They are a temporary stage of the chondrification of the mesenchymal skeleton in front of the notochord, and it seems to me as improbable that they have any important morphological significance, as it is improbable that the rounded form of the bony centre of a half-ossified vertebra has any important meaning. It cannot be too strongly insisted upon that the morphological condition is determined by the shape of the mesenchymal anlage, of which the trabeculæ are merely a part. So far as I am aware, not a single investigator has described this anlage accurately and fully.

I consider it not improbable that the axial perichordal mesenchymal skeleton sends an outgrowth past the hypophysis to inclose the fore-brain, and that, assuming that the infundibulum marks the true anterior limit of the medullary canal, the trabecular anlage is not a prolongation of the floor of the cranium, but an upgrowth, which owing to the head-bend has come to lie in the line of the cranial axis.

Theories of the Skull.—It was noticed a long time ago that the skull has resemblance to vertebræ; the skull has the greatest thickness on the ventral side of the brain and arches over the central nervous system, and thus possesses two of the chief characteristics of the vertebræ. It was, therefore, natural to seek to compare the skull homologically with vertebræ. It is said that during the eighteenth century this comparison acquired greater prominence and was definitely formulated by Vicq d'Azyr.* These comparisons of Vicq d'Azyr and others proceeded upon a false basis, and it was not until 1872, when Gegenbaur, 72.1, opened an entirely new method of solving the morphology of the head, that correct views began to be formed. Another great stride was made by Froriep's observations on the development of the occiput, p. 429. I have placed what I have to say under the three headings of Vicq d'Azyr's theory, Gegenbaur's theory, and Froriep's law.

1. VICQ D'AZYR'S THEORY.—According to this theory the skull consists of several vertebræ. Whether d'Azyr really originated it,

*I have not succeeded in finding anything in Vicq d'Azyr's "Œuvres" to justify this statement.

I cannot say. It was taken up by Oken, who is often quoted as the founder of it, and later also by Goette, who by some authors has been cited as the father of the theory. The history of the theory and of the modification it underwent is given by R. Virchow ("Goette als Naturforscher").

One of the earliest suggestions of the vertebral theory is that of Burdin, independently made about the same time by Heilmeyer. These authors compared the skull to a single complex vertebra. Oken conceived that there were four cranial vertebræ, and this was the notion most in favor until 1858. Goette counted six vertebræ, of which three belonged to the facial apparatus. As to the number of these supposed vertebræ there is a very extensive literature, which possesses an interest purely historical. Let it suffice, therefore, to state aphoristically that three vertebræ were advocated by Spix, Meckel, Burdach and Carus; four by Oken, Bojanus, and Owen; six by McClise; seven by Geoffrey.

The death-blow to this long-lived error was dealt by Huxley in his Croonian lecture delivered in 1858, **58.1**—a great achievement, for it at once terminated the history of the old vertebral theory of the skull, and paved the way for Gegenbaur.

GEGENBAUR'S THEORY.—In 1872 Gegenbaur published his great work, **72.1**, on the cephalic skeleton of Selachians, in which he took the ground that the skull does not represent a series of vertebræ, but that it arose out of the axial or perichordal skeleton before distinct vertebræ were formed in the axial region; he further maintained that the head includes a number of segments, which he sought to ascertain by determining the segmental arrangement of the cranial nerves. This was a great step and in the right direction. F. M. Balfour, **78.3**, was, I believe, the first to endeavor to trace out the actual number of segments (mesoblastic somites) in the head of embryos. A vast amount of labor has been expended by subsequent writers in investigating the development of the cephalic myotomes and cranial nerves, but much remains to be done before the morphological constitution of the head shall be understood, but we are already in a position to say that Gegenbaur's thesis—that the primary or inner skull is developed from the axial skeleton but not from vertebræ—is correct except as regards the hypoglossal region. For further observations on the segmentation of the head see Chapter XXVI.

FRORIEP'S LAW.—Froriep's investigations, p. 429, have demonstrated that the skull has extended itself, in the amniota at least, by the annexation of true vertebræ, corresponding to segments of which the hypoglossus represents the nerve. The head has grown at the expense of the neck.

PRESENT THEORY OF THE SKULL.—The primary skull was developed out of the axial (perichordal) skeleton, in the region of the brain, where the dorsal and ventral nerve roots are not united into a single nerve for each segment; the primary skull has grown at least in the amniota by the annexation of several cervical vertebræ; a secondary skull was developed outside the primary cartilaginous skull by the formation of dermal bones. In the higher forms the primary skull partly disappears; what remains, together with the secondary or dermal skull, constitutes the actual skull of the adult.

CHAPTER XXI.

THE MESOTHELIAL MUSCLES.

THE muscle fibres fall into two main classes, the smooth or mesenchymal fibres, which have been already considered, p. 417, and striated or mesothelial muscles. The latter fall into three groups; 1, the skeletal muscles; 2, the branchial muscles; 3, the cardiac muscles. The first are developed from the epithelial muscle plates, the origin of which from the mesothelial primitive segments has been already described, p. 205; the second are developed from the mesothelium of the branchial cœlomatic cavities (head cavities of Balfour) see p. 478; the latter are developed from the mesothelial wall of the heart of the embryo and constitute the so-called "muscular heart" (*Muskelherz*), see p. 227.

The Segmental or Skeletal Muscle Fibre.—Remak, 50.1, was the first, if I am not mistaken, to show that the primitive segment, or as he termed it the "protovertebra," forms both the anlage of the axial mesenchyma and of the muscles; he also thought that the "protovertebra" formed the spinal ganglion, an error which was corrected by His, 68.1. To the myotome, or the two layers of the mesothelium remaining after the differentiation of the periaxial mesenchyma (Van Wijhe's sclerotome), Remak applied the term *Rückenplatte*. After Remak (1850) followed a series of investigations and discussions as to the histogenesis of the striated muscle fibre. The chief differences of opinion were as to whether, as originally maintained by Remak, each fibre is developed from a single cell, or, as suggested by Theodore Schwann, out of the fusion of several cells. The latter view was advocated by Margo, 59.1, in 1859; Margo studied the muscle corpuscles, terming them sarcoplasts, and regarding them as so many separate cells which had united to form the muscle fibre. That Remak was right was maintained by Kölliker in 1857, 57.1, on the basis of his own observations, and also by Max Schultze in a masterly essay, 61.1, which at the same time laid the foundation of the modern doctrine of cells, and anticipated Heitzmann's observations on the union of the cells by over twenty years. In the same year, 1861, appeared Deiters' paper, 61.1, and the year after, F. E. Schulze's, 62.1, who together with Max Schultze conclusively established Remak's opinion as correct. Nevertheless we find the Schwann-Margo hypothesis reappearing from time to time, although it has never had any sound observational basis to rest upon. A synopsis of various papers upon the development of striated muscle fibres is given by Calberla, 76.1, and more fully by G. Born in his dissertation, 73.1. That the striated muscles have an epithelial origin was first emphasized by the two Hertwigs, 81.1, 61-66, who demonstrated at the same time that only the

inner layer of the myotome forms muscle, not both plates as had been wrongly stated by Balfour, "Comp. Embryology," II., to be the case in elasmobranchs. Since then it has been ascertained beyond question that the outer layer gives rise to the dermis (compare p. 206), Kaestner's contrary conclusions, **90.1**, being attributable, in my judgment, to his imperfect observation.

The single muscle fibre arises from a single epithelial (mesothelial) cell of the muscle plate or inner wall of the myotome. In the amphibia each cell elongates in a direction parallel with the axis of the body until, as shown by F. E. Schultze, **62.1**, it stretches the entire length of the segment; it seems to me that each cell extends the entire length (cephalo-caudal) of the segment in sharks and chick embryos also, but I have not studied the point sufficiently. Paterson, **87.1**, asserts that in chicks the cells lengthen but remain shorter than the segment. In amphibia the cells are crowded with yolk granules, which, however, are gradually resorbed; thus in the frog they at first hide the nuclei, but by the fourth day are sufficiently reduced to allow the nuclei to be seen easily in the fresh unstained specimen (Calberla, **76.1**); in amniota, on the other hand, there are exceedingly few yolk grains left in the muscle plate. The first evidence of striation appears in the frog toward the end of the fifth day, on *one* side of the cell, Fig. 225, as first recorded by F. E. Schultze, **62.1**, and since frequently confirmed (*e.g.*, by Calberla and Ranvier, "Traité technique d'Histologie," 516). The side upon which the striation first appears has been observed in elasmobranchs by C. Rabl, **89.2**, 239, to be the side toward the notochord, or farthest from the cavity of the myotome. In *Petromyzon*, A. Goette, **90.1**, 50, the fibrillæ are found to form a peripheral layer so very early that it is doubtful whether they first appear on one side of the cell only or not. The striation continues to develop until it passes completely around the cell, forming a peripheral layer (Deiters, **61.1**, Kölliker, "Gebewelehre," 6te Aufl., p. 401) as illustrated in Fig. 256. At about this time, perhaps sooner in some forms and later in others, the nucleus divides, and by repetitions of the divisional process the cell soon becomes multinucleate. C. Rabl, **89.2**, 242, directs attention to the fact that the nuclei of the muscle-plate in sharks stain more lightly than the mesenchymal nuclei and contain an elongated chromatine granule; in the chick I have observed the same nuclear peculiarity. Later the nuclei lose this main granule and have instead a number of smaller ones, Fig. 256, *mn*. The muscle fibre acquires its membranous sheath, *sarcolemma*, some time later. As to the exact time I have found no positive data;

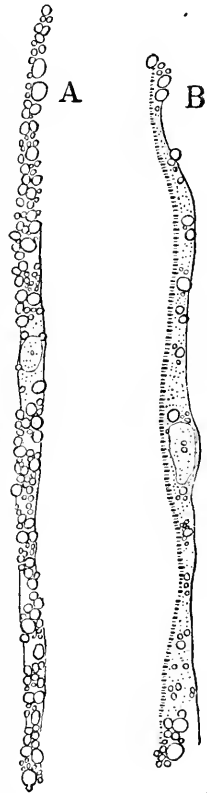


FIG. 255. — Isolated Muscle Fibres of a Frog Embryo. A, Showing yolk grains (partly resorbed) and nucleus; B, with the muscular striation just appearing on one side.

but authorities are agreed that the fibre remains naked for a considerable period. During the early stages of their differentiation, the muscle fibres retain the epithelial arrangement, that is, remain closely packed; not long after the appearance of the fibrillæ and striation, the fibres begin to separate and connective tissue grows in between them. During their separation the fibres become massed in bundles instead of in epithelial layers. The central portion of the young muscle fibre is granular, and contains not only the nuclei and the remains of the yolk material, but also a considerable quantity of glycogen (Ranvier, "Traité technique d'Histologie," 515). As this substance is very readily dissolved out, it is probable that the clear empty appearance of the central

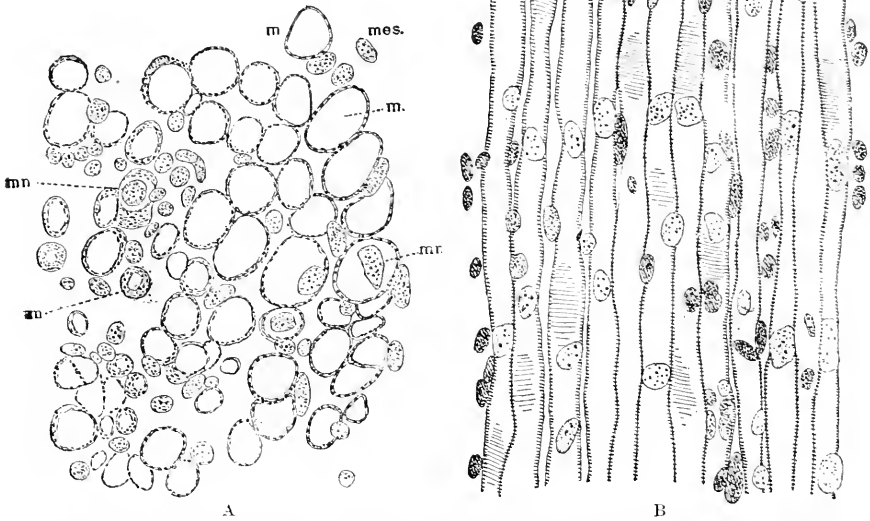


FIG. 256.—A, Transverse; B, Longitudinal Section of Muscle Fibres in the Neck of a Human Embryo of sixty-three to sixty-eight Days. Minot Collection, No. 138. *m.m.m.* Muscle fibres; *mn*, muscle fibres showing the central nuclei; *mes.*, mesenchymal nuclei. A \times about 750 diams.

portion of the fibres, which is so striking in sections of hardened embryos, see Fig. 256, A, is due to the loss of the glycogen. The mantle of striated muscle-substance gradually increases until the whole fibre is fibrillated and the muscle no longer appears hollow. The time at which the muscle fibres become "solid" varies from embryo to embryo and from muscle to muscle. In the human embryo at the end of the fifth or beginning of the sixth month most of the fibres of the upper extremity are solid, but it is not until the seventh month that those of the lower extremity become solid, W. Felix, 89.1, 232. The nuclei have at first an axial position, but toward the end of the third month some of them lie in the mantle, compare also p. 474.

The size of the fibres is smaller in the embryo than in the adult, but Felix, 89.1, 233, points out that up to latter part of the third

month in man the fibres increase in size, many having at two and one-half months a diameter of from 13–19 μ , but later they are smaller owing probably to the division of the fibres, and it is not until birth that the same diameter is again reached by the single fibres.

Fibrillæ.—Before discussing the origin of the fibrillæ it is necessary to remove an unfortunate confusion which has prevailed in the use of the term. By fibrillæ is sometimes meant the longitudinal threads of protoplasm, but more often is meant the material between adjacent longitudinal threads. Corresponding to the two usages of the word “fibrilla,” there are two essentially different conceptions of the structure of the adult muscle fibre. According to the older view, which is currently repeated in text-books of anatomy and histology, the “primitive fibrillæ” into which a muscle fibre may be mechanically divided under certain conditions are the contractile portions of the fibre; the ends of the “primitive fibrillæ” are the so-called Cohnheim’s areas, and the “sarcolemmal elements” are the divisions of the “primitive fibrillæ.” Henle (“Allgemeine Anatomie,” 1841, p. 580) recognized that there was substance left between the fibrillæ; later Leydig (Müller’s *Arch.*, 1856, 156) and Kölliker (*Zeit. Wiss. Zool.*, VIII., 316) pointed out its general occurrence. Max Schultze, **61.1**, 3, shows that this material was the derivative of the protoplasm of the muscle cells. L. Gerlach* was the first, so far as I know, to demonstrate that this interfibrillar material formed a reticulum, but he regarded it as the prolongation of the nerve. The reticulate structure appears to have been recognized also by G. Thin (*Quart. Journ. Microsc. Sci.*, 1876, XVI. 251). No special significance seems to have been attributed to all these observations until 1881, when Retzius, **81.2**, proposed the new conception of the structure of muscle fibres, according to which the material between the so-called “primitive fibrillæ” is the essential part of the fibre; this material is part of the protoplasmatic network of the cell which makes the muscle. According to Retzius, the essential feature of the muscle fibre is the peculiar and characteristic arrangement of this network, by which the striation is caused. The fibrillæ of embryologists are threads of protoplasm and are not the same as the “primitive fibrillæ” of histologists, but are characterized by staining readily. That the fibrillation was developed by a metamorphosis of the protoplasm of the young muscle cell has long been the conception of embryologists, see for example Max Schultze’s article, **61.1**, published in 1861. L. Bremer, **83.1**, was the first to place this conception upon a firm basis of observation, by tracing out further than had been done before the transformation of the protoplasmatic network of the developing fibre. Retzius’ results were extended and made the basis of a theory of the structure and contraction of the muscle fibre by B. Melland, **85.1**, and C. F. Marshall, **87.1**, **90.1**, both working in A. Milnes Marshall’s laboratory at the Owens College; compare also Bütschli und Schewiakoff, **91.1**. This series of investigations render it necessary to accept Retzius’ view—although Kölliker in the sixth edition of his “Gewebelehre” throws the weight of his great authority against it. As it now stands Retzius’ view

* Gerlach, “Das Verhältniss der Nerven zu den Muskeln der Wirbelthiere,” Leipzig, 1874. See also *Arch. f. Microsc. Anat.*, xiii., 1877, 397.

may be summarized thus: fibrillæ and sarcois elements are post-mortem effects due to the cleavage of the matrix; the muscle fibre really consists of a homogeneous matrix which is traversed by a very regular reticulum, made of longitudinal threads connected at regular intervals by transverse threads, corresponding in position to Krause's membrane; at the nodes, where the cross and long threads unite, there are little thickenings. The thickenings correspond to the balls of Schäfer's dumb-bells, the handles of which are the long threads, compare Schäfer, *Philosophical Transactions*, 1873. Between every two Krause's membranes are numerous fine cross threads, which cause the appearance of the dark bands and therefore of the transverse striation.

The transformation of the reticulum of the multinucleate cell of the myotome into the network of the adult muscle fibre has been most carefully described by L. Bremer, **83.1**, whose results may be summarized as follows: The nucleus of the muscle fibre, together with the protoplasm surrounding it, constitutes the so-called muscle corpuscle; the corpuscle is much more prominent in young than in old muscle, for its protoplasm is gradually differentiated into muscular substance; a small number of corpuscles enter into the formation of each fibre; the substance of the muscle forms a network, which was first partially recognized by Heitzmann (*Wien. Sitzungsber.*, XVII., Abth. 3, 1873); the meshes of this network appear polygonal in transverse—rectangular in longitudinal, sections; the network is a modification of the protoplasmatic network of the corpuscles, and is so arranged that there are alternating rows, both transverse and longitudinal, of fine knots and large knots (corresponding to the fine and broad striæ); the fine knots are connected by fine threads, and the large knots by coarse threads; hence there is a fine and a coarse net.

MULTIPLICATION OF MUSCLE FIBRES.—That the muscle fibres multiply during embryonic life can hardly be questioned at present. Two methods of accounting for the multiplication have been advocated, the first that it is effected by the intervention of sarcoplasts (Margo), the second that it is by a direct longitudinal fusion of the fibre (Weismann, **61.1**). I consider the latter view the correct one.

1. *Margo's Theory.*—Bremer's results, **83.1**, on this question are as follows: The post-embryonic multiplication of fibres takes place by means of the structures described by Margo (**59.1**, 229) under the name of *sarcoplasten*; these are lines or chains of muscle corpuscles, united by the protoplasm net, and derived by proliferation from the corpuscles of the original fibres; the sarcoplast gradually separates from the parent fibre, undergoing muscular differentiation meanwhile, and also becoming connected with the nerve. The growth of the fibre is initiated by a multiplication of the corpuscles; the sarcolemma is not present at first, but appears later, being probably formed by the fused cell membranes of the corpuscles, to which appears to be added a coat of connective tissue, and also around the motor plate between the two sarcolemmic coats appears an extension of Henle's sheath of the nerve. Paneth has recently renewed, **85.1**, Margo's observations, **59.1**, giving a careful description of the sarcoplasts and maintaining that they are the agents of fibre multipli-

cation. Sigmund Mayer, **86.1**, attacked Paneth, because he found muscle corpuscles abundant in the fibres of the tail in tadpoles during the process of resorption, and hence concluded that he corpuscles are muscle destroyers (*sarcolytes*). This opinion has been accepted by Barfurth, **87.1**, but the mere presence of the corpuscles, while the muscle fibres are becoming destroyed, is, as Paneth justly replied, **87.1**, no evidence whatever that they have a sarcolytic function. There remains, however, another hypothesis which has been advanced by Felix, **89.1**, 253, namely, that the so-called sarcoplasts represent muscle fibres partly degenerated. Felix's interpretation is the one which has most commended itself to me.

2. *Weismann's Theory*.—Felix's conclusions are, that from the middle of the third month until the end of foetal life there are, in the muscles, fibres with multiplied nuclei, which are arranged in rows. These fibres with multiple nuclei are of two kinds, those with a single and those with several rows of nuclei. In the first kind the nuclei are central, color deeply, lie transversely, and differ but little from one another; fibres of this kind do not divide though they may grow; some of them degenerate and form Margo's sarcoplasts. The second kind of fibres have several rows of nuclei in the mantle or fibrillar layer; in the middle part of the rows the nuclei are closely crowded and compressed into all possible forms; this crowding probably marks the centre of proliferation. The fibre divides into daughter fibres, one for each row of nuclei. The fibre becomes enveloped in a sheath, rich in nuclei and vessels, and this sheath persists while the fibre is dividing; afterwards it disappears. The daughter fibres may also divide, but apparently usually into two only.

The areas, in which the nuclei are crowded together, have long been known, though imperfectly described. They are usually termed *Muskelknospen* or *Muskelspindel* by German writers, and they mark the point where the union with the nerve is established. They were known to Weismann in 1861, **61.1**, and were shortly after described by Kölliker, **62.1**, in amphibia. Von Franqué, **90.1**, records some observations upon them and gives references to the scattered observations upon them made by a number of writers.

The Muscle Plates.—The development of the muscle plates has already been described. There is unfortunately little to be added at present concerning their later history. When the outer leaf of the myotome is changed into the mesenchyma of the dermis, the cells nearest the muscle plate on all sides retain for a considerable period their epithelial arrangement, and appear to act as a growing layer, and presumably contribute both to the mesenchyma on one side (compare Fig. 257) and the muscle plate on the other. Certainly the muscle plate continues to grow in all directions, but most rapidly dorsalward over the medullary canal and ventralward into the somatopleure. At the same time the muscle plates not only lengthen out as the whole trunk lengthens, but each one grows forward under the one in front, and thus is produced the stage so characteristic of fishes, with the muscular segments oblique and the hind border of each overlapping the

segment next behind. That the imbrication is produced as stated seems to me clear from the study of shark embryos, in which the original position of the segment is indicated by the nerves, ganglia, and inter-segmental arteries; the hind edge of the muscle plate coin-

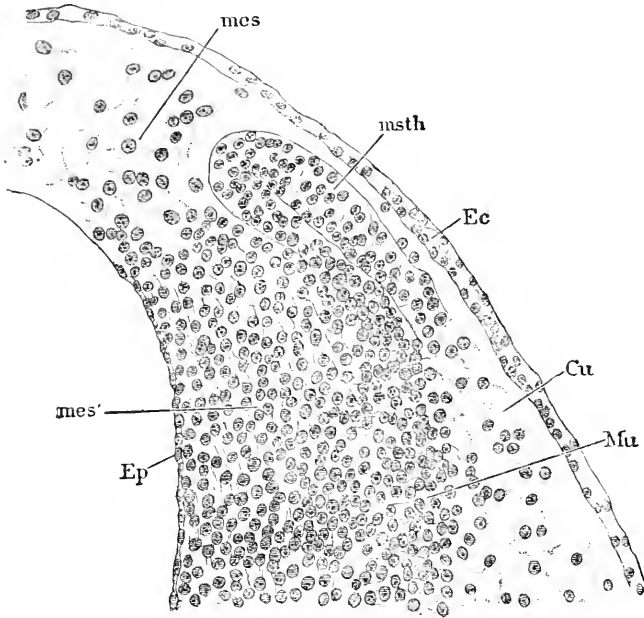


FIG. 257.—Chick Embryo. Transverse Section of the Upper Part of a Myotome. *mes, mes'*, Mesenchyma; *msth*, mesothelium; *Ec*, ectoderm; *Cu*, cutis; *Mu*, muscle-plate; *Ep*, epithelioid layer. $\times 296$ diams.

cides with posterior limit of its segment thus determined, while the anterior edge is clearly within the territory of the next segment in front.

In the region of the limbs the muscle plates send in elasmobranchs buds into the limbs to produce their muscles, as discovered by Balfour, "Comp. Embryology," II., 673. According to Dohrn, **84.1**, 163, this budding takes place after all the gill-clefts have become open, and the cartilage is just beginning to appear in the branchial arches; each myotome produces an anterior and posterior bud, which both point outward and downward; the buds have at first a spherical form, but soon separate from the parent muscle plate, and elongate, and later divide each into two, a dorsal and ventral secondary bud, so that from each myotome there are produced four buds. The main muscle plate continues its growth into the abdominal somatopleure. The number of myotomes which contribute to the limbs is uncertain, but there are several. It is probable that in all amniota the myotomes also send buds to form the muscles of the limbs. Van Bemelen, **89.1**, 242, has shown that in snake embryos with the fifth gill-cleft just formed, the myotome of the second to tenth post-occipital segments send downgrowths into the limbs, and continue on in

the somatopleure ventralward. Of the eight segments the first three have their outgrowths oblique to enter the limbs. Paterson, **87.1**, has expressly denied this origin for the chick, but as he was able to distinguish only a confused mass of mesoderm in the young limbs, his opinion cannot carry weight, but must be considered based upon imperfect observation.

ABORTION.—A certain number of muscle plates disappear during early embryonic life. Thus Froriep has shown, **86.1**, that in the cow embryo there are four rudimentary muscle plates in the region of the occiput or hypoglossus, which, however, all disappear very early. It is probable that there were once other muscle plates in the head which have now disappeared, compare p. 200. Further, it is probable that in man there are rudimentary muscle plates in the embryonic tail, which has been shown by Fol to contain at least nine rudimentary segments, some of which may advance into the muscle-plate stage.

Myotomic Muscles.—There is no part of embryology so obscure at present as the development of the muscular system. Scarcely the most elementary questions have been answered. Not only has the development of the single muscles from the mesothelial plates scarcely been studied, but also the very significance and the arrangement of these plates in the head is wrapped in uncertainty, see p. 200.

The following points in regard to the cephalic myotomes have been ascertained. Of Van Wijhe's nine myotomes, seen in elasmobranchs, the *first* comes to lie against the optic vesicle and gives rise to the rectus superior, rectus inferior, and obliquus inferior of the eye; the *second* produces the obliquus superior, and the *third* the rectus externus; a good figure of the three myotomes which form the eye muscles, as observed in an elasmobranch embryo, is given by A. Froriep, *Anat. Anzeiger*, N. 56, see also Miss Platt's figures **91.2**; the *fourth*, *fifth*, and *sixth* disappear; the *eighth*, *ninth*, and *tenth* produce muscles running from the skull to the shoulder girdle. Froriep, **86.1**, has shown that there are four myotomes in the occipital hypoglossal region of mammals, which early become rudimentary, but Van Bemmelen has observed, **89.1**, 241, that these four myotomes together with that of the first cervical (atlas) segment grow obliquely ventralward, so as to meet and unite into a single cord which descends behind the last (in reptiles the fifth) gill-cleft, accompanied by the hypoglossal nerves, and then curving forward grows into the tongue and there produces the lingual musculature. This explanation of the origin of the muscles of the tongue is probably correct, but it differs from that offered by Froriep, **85.1**, and still more from that of His ("Anat. menschl. Embryonen," III., 92). According to Van Wijhe, **82.1**, the coracohyoid muscle of sharks arises, like the mammalian lingual muscles, from the downgrowth of the posterior cephalic and anterior cervical myotomes.

As regards the development of the muscles of the rump and limbs we possess, so far as I am aware, practically no information beyond the little which has been noticed in connection with the history of the muscle plates, p. 200.

Muscles of the Branchial Arches.—That these muscles all arise from the mesothelium of the arches is now generally believed

although by no means rigidly demonstrated, except for elasmobranchs; Van Wijhe, **82.1**, states that the coracobranchialis and coracomandibularis muscles of sharks are developed from the pericardial mesothelium. Anton Dohrn, **84.1**, 109-114, finds in selachians that the mesothelial tube lengthens with the whole arch and by expanding in the transverse plane becomes a plate, Fig. 258, *msth*, which stretches across the arch between the nerve in front and the anlage of the cartilage behind; the cœlomatic cavity is obliterated except on the outer side of the arch; the plate then divides close to the nerve. The

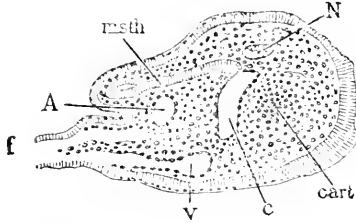


FIG. 258.—Transverse Section of a Branchial Arch of a Selachian Embryo. *f*, Branchial filament; *msth*, mesothelium; *A*, artery; *V*, anterior vein; *C*, connecting vein; *cart*, cartilage; *N*, nerve.

further history is complicated and need not be presented here, as nothing definite is known as to the homologies of the branchial muscles of sharks with those of anniota.

His ("Anat. menschlicher Embryonen," Heft III., 92) has endeavored to indicate to which arches certain muscles belong, but has not worked out the actual development. He assigns the palatoglossus, styloglossus and levator palati molliis to the second arch (counting the mandibular as the first); the stylopharyngeus and perhaps both the palato-pharyngeus and hypoglossus to the third arch. Of the constrictors of the pharynx the upper probably belongs to the third arch, but the middle and lower to the fourth arch.

C. Rabl, **87.1**, maintains that the myothelium of the hyoid arch forms the embryonic platysma, which spreads out in front of and behind the external ear (hyoid cleft) and breaks up into the individual superficial muscles of the face and epicranium. The stapedius muscle also belongs to the hyoid, according to Rabl.

Mandibular Muscles.—Their development in the chick has been studied by Kaczander, **85.1**. The muscles form at first a continuous mass, which grows by multiplication of the fibres. The mass is divided into separate muscles by the ingrowth of fibrillar connective-tissue partitions, and by the development of the osseous mandible, which separates the muscles attached to the connective tissue from those having an insertion on the Meckel's cartilage. The change in the direction of the course of the fibres results from the muscles adapting themselves to changes in the form of the jaw. The insertion into the mesenchymal anlage of the mandible remains unaltered when the anlage ossifies. There is no migration of the insertions.

Dohrn, **84.1**, 113, states that in sharks the developmental history of the mandibular muscles is quite different from that of the muscles of the succeeding arches.

Muscles of the Heart.—The exact history of the genesis of the cardiac muscle fibre has still to be worked out. In the rabbit (Kölliker, "Grundriss," 2te Aufl., 383) the musculature of the heart appears the ninth day, and by the tenth or eleventh day is developed over the entire organ, including the bulbus aortæ. The muscles soon arrange themselves into a spongy structure, each web of the sponge-work being covered by endothelium, Fig. 290, but during the third

and fourth month the musculature gradually becomes more compact, so that at the beginning of the fifth month the spongy structure is confined to the innermost layers of the muscular wall. The striations appear, according to A.C. Bernays, 76.1, 487, upon one side of the branching, protoplasmatic muscle cells (embryo calf of 12-16 mm.) and later around the periphery of the cells somewhat as in the myotomic muscle cell.

CHAPTER XXII.

THE SPLANCHNOCÆLE AND SEPTUM TRANSVERSUM. THE SUPRA-RENAL CAPSULES.

THE history of the splanchnocœle of the head has already been given as fully as our present knowledge permits, see p. 201, and except of that part which forms the pericardium. In this chapter the subdivision of the main ventral cœlom or splanchnocœle into the pericardial, pleural, and abdominal cavities, and in connection therewith the development of the diaphragm, is described. It is to be remembered that the cœlomatic cavities of the gill arches are possibly part of the splanchnocœle.

Development of the Septum Transversum.—The term septum transversum was first introduced by Wilhelm His in his description of his embryo M ("Anatomie menschlicher Embryonen," Heft I.). Our present knowledge of its formation and metamorphoses rests chiefly upon the investigations of His, *l.c.*, Heft III., also 81.1, and of Ed. Ravn, 89.2.

The *septum transversum* is the primary partition across the body, the heart being on the cranial side, the abdomen on the caudal side of the partition; while above it the cœlom forms a passage on each side of the median plane; these passages become the pleural cavities. The septum is quite thick; it includes the anlage of liver; by it all the veins make their entrance into the heart; later on the anlages of the supra-renal capsules also appear in it; it is itself the anlage of both the diaphragm and of the membrane separating the pericardial and pleural cavities of the adult. The character and general relations of the septum can be understood from Fig. 259. The septum divides the pericardial cavity, *p.c.*, from the main abdominal cavity, *Ab.c.*; the heart is supposed to be in great part removed.

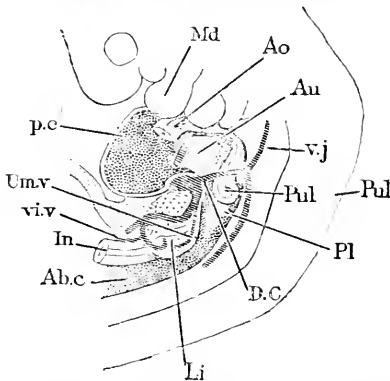


FIG. 259.—His' Embryo R, 5 mm. Reconstruction to show the Septum Transversum. *p.c.* Pericardial cavity; *Md.* mandible; *Ao.* aorta; *Au.* auricular end of heart; *v.v.* vena jugularis; *D.C.* ductus Cuvieri; *Pul.* lung; *Pl.* pleural cavity; *Li.* liver; *Ab.c.* abdominal cavity; *In.* intestine; *Um.v.* umbilical vein; *v.v.* vitelline vein.

The septum appears to be much enlarged by the growth of the liver, which at the stage represented has become, as it were, an appendage, *Li.*, of the septum proper, which may be conveniently defined as the layer of connective tissue next the pericardial sac. Above the septum is the small passage, *Pl.*, into which the lung, *Pul.*, is beginning to project, and which becomes the pleural cavity of the adult; at this

stage it is termed the *recessus parietalis dorsalis* by His. It will be recalled, that the cœlom forms originally two splanchnocœlic cavities; in the region of the heart the partition disappears, leaving a single pericardial cavity; in the abdomen the partition (ventral mesentery) below the intestine disappears, so that the two cavities are brought into communication, while on the dorsal side of the septum the partition remains; but the two pleural splanchnocœles always are distinct and never communicate directly with one another. The arrangement of the veins is important. The jugular, *v.j.*, coming from the head, and the cardinal, coming from the rump (Wolfian body), unite on the dorsal side of the cephalic end of the pleural cavity into a single stem, the ductus Cuvieri (future *vena cava superior*), which passes in the somatopleure around the outside of the pleural cavity to join the other veins in the dorsal part of the septum. The ductus Cuvieri, *D.C.*, is just at the boundary of the pericardial and pleural cavities, and its growth is the essential factor in shutting the opening. The umbilical vein, *Um. v.*, joins the ductus just as it enters the septum. The vitelline or omphalo-mesaraic veins enter the septum nearer the median line; the four veins which are thus united form the large sinus reuniens (see Chapter XXIV.) from which the blood is poured into the heart.

The origin of the septum in mammals * has been studied as yet only in the rabbit by Uskow, 83.1, His, and Ravn. The following description is based on Ravn's 89.2,

124-139. The head, *H*, of the embryo early grows forward, Fig. 260, so as to intrude upon the region of the proamnion, *Pro. A*, and hence, as will be evident by an inspection of the figure, the head is bounded in front and at the sides by the proamnion, and therefore the cœlom of the head cannot communicate with the extra-embryonic cœlom directly. Around the edge of the proamnion runs the omphalo-mesaraic vein, *om.v.*, the continuation of which is the anlage of the heart, *Ht*; on the double origin of the rabbit's heart, see p. 227. The vein projects considerably above the level of the splanchnopleure in which it runs, and this projection gradually increases until the wall of the vein reaches to and unites with the overlying somatopleure, and thus divides the cœlom into two parts, the recessus parietalis dorsalis, *r.p.d.*, and the recessus parietalis ventralis, *r.p.v.* This division is confined to the region of communication between the pericardial cavity, *P*, and the remaining cœlom, as indicated by the position of the reference letters *r.p.d.*, and *r.p.v.* A cross-section

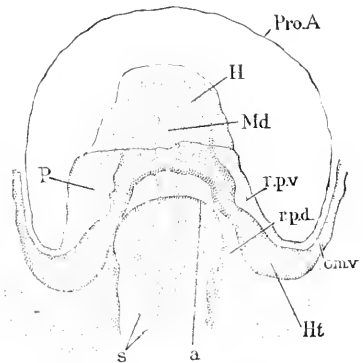


FIG. 260.—Head of a Rabbit Embryo, with Segments, seen from the under Side. *Pro.A*, Outline of proamnion; *H*, head; *om.v.*, omphalo-mesaraic vein; *Ht*, anlage of heart; *a*, margin of the opening of the Vorderdarm; *s*, primitive segments; *Md*, medullary canal; *r.p.v.*, recessus parietalis ventralis; *r.p.d.*, recessus parietalis dorsalis; *P*, pericardial cavity. $\times 25$ diams. After Ed. Ravn.

* On the development of the diaphragm in the chick see Lockwood, 88.1; in lizards see Ravn, 89.3.

of a little older stage with the vorderdarm just closing is represented in Fig. 261, and will help to

elucidate the disposition of the parts. The ventral recessus early becomes closed at its hinder extremity and is thereby converted into a third pocket of the pericardial cœlom, which His has described under the name of the *bursa parietalis*. The bursæ subsequently become merged with the pericardial cavity. The dorsal recessus, Fig. 261, *r.p.d.*, is the anlage of the pleural cavity and persists for some time open at both ends. The partition dividing the two recessi from one another, and containing the omphalo-mesaraic veins, is the anlage of the lateral portions of septum transversum (Cadiat's *cloison mésodermique*, Kölliker's *mesocardium laterale*, Uskow's *Verwachsungsbrücke*).

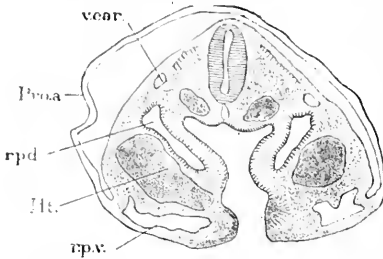


FIG. 261.—Rabbit Embryo, Eight and a Half Days, with Eleven or Twelve Somites: Cross Section. *Pro.a.*, Pro-amnion; *v. car.*, cardinal vein; *r.p.d.*, recessus parietalis dorsalis (pleural cavity); *Ht.*, anlage of the heart; *r.p.v.*, recessus parietalis ventralis; *Ph.*, pharynx. $\times 40$ diams. After Ravn.

By the further growth of the embryo the head lengthens and with it the median heart formed by the union of the two heart anlages. The splanchnopleuric wall at *fo*, Fig. 146, bounds not only the opening of the vorderdarm into the yolk-sac, but also the posterior wall of the pericardial cavity, and is the anlage of the median portion of the septum transversum. As the liver is developed at the hind end of the vorderdarm it has to grow out into this wall, *fo*, and consequently contributes to the thickening of the septum transversum. The septum is further expanded by the development of the remaining veins, (jugulars, cardinals, and umbilicals), which are all ultimately united with the omphalo-mesaraics to constitute the great sinus reuniens.

In brief: the septum transversum includes the median part of the splanchnopleuric wall separating the pericardial cavity from the neck of the yolk-sac, and the two lateral parts resulting from the two up-growths of the splanchnopleure to carry the omphalo-mesaraic or vitelline veins to the heart. It is, therefore, entirely a product of the splanchnopleure.

Separation of the Pleural and Pericardial Cavities.—The septum transversum separates the two cavities as soon as it is formed, and in the adult the primitive arrangement is easily traced in part, despite the great expansion of the pulmonary cœlom. The septum leaves, however, a direct communication open as shown in Fig. 259, where the ducts of Cuvier, *D.C.*, descend from the dorsal to the ventral side. The figure further shows that the septum is oblique, so that the pericardial cavity in part underlies the pleural cavity. As development progresses, the three cavities all expand, and more and more of the pericardial cavity comes to lie on the ventral side of the pleural cavities, leaving a part of the septum transversum as a partition, which, of course, runs as far headward as the ductus Cuvieri, *D.C.* This partition early becomes thin, and is the *membrana pleuro-pericardiaca* which was partly described by F.

T. Schmidt, **70.1**, and Uskow, **83.1**, and more fully by His, **81.1**, 313, and Ravn, **89.2**, 136. The anterior passage is closed by the growth of the ductus Cuvieri, which, like all the chief veins of the embryo, has an enormous size; it causes, therefore, a projection which ultimately shuts the passage to the pericardium completely. Exactly at what time the shutting off occurs is not stated, but probably during the fifth week in the human embryo, and in the rabbit by the fifteenth day. The separation of the pleural from the abdominal cavity takes place much later.

Expansion of the Pleural Cavities.—Concerning the gradual enlargement of the pleural cavities very little is known beyond the fact that they enlarge at the same rate as the lungs. In the rabbit at fifteen days they are together about half as large as the pericardial cavity.

As stated above, the primitive pleural cavity is on the dorsal side of the septum, and the cephalic limit of the septum is marked by the ductus Cuvieri, or future vena cava superior. Part of the septum is used to develop the pleuro-pericardial membrane, while the remainder, which includes the hepatic attachment, develops into the diaphragm; beyond the caudal boundary of the septum the lungs never project. These considerations show that the pleural cavities lie entirely within the territory of the septum, and that their expansion takes place within the septum. This conception renders it necessary to regard the thorax of the adult as chiefly occupied by the distended septum transversum, and involves important changes in our morphological notions concerning the adult condition.

Mesocardium, Mediastinum, and Mesentery.—These membranes are the remains of the tissue which originally divides the cœlom of one side from that of the other. The tissue disappears for the most part around the heart, so that the pericardial cavity is continuous on both the dorsal and ventral sides of the heart. In the abdomen this continuity is established only on the ventral, not on the dorsal, side of the intestinal canal, and the tissue between the two lateral cœloms remains to form a very thin membrane, the mesentery, by which the intestine is attached to the median dorsal wall of the abdomen. Between the two pleural cavities the tissue remains, forming a thick partition, the mediastinum. Concerning the genesis of these membranes little is known.

Sac of the Omentum and Foramen of Winslow.*—In the chick soon after the lungs have grown out from the œsophagus, and just when the first forking has begun, the abdominal cœlom is found to form two blind diverticula lined by well-marked mesothelium and extending until they come into direct contact with the pulmonary endoderm. Of these diverticula I have found no mention. Similar ones have been observed in the rabbit by Ravn, **89.2**, 139; their formation is connected with the prolongation of the ridge of mesoderm on the side of the œsophagus. The ridge on the left side, and with it the diverticulum, disappears very early, but that on the right side persists and enlarges, the vena cava inferior being developed within it, on which account Ravn terms it the "*vena cava Falte*." This fold extends down into the abdomen; the cœlomatic diverticu-

* Compare also chapter xxix

lum between it and the intestinal canal, Fig. 262, is the "recessus superior sacci omenti" of W. His ("Anat. menschl. Embryonen," Heft I., p. 65). While this growth of the "vena cava Falte" is taking place the stomach has been developing its great bend to

the left as indicated by the dotted lines in Fig. 262, carrying with it, of course, the mesogastrium and mesentery of the duodenum, and thus forming a sac, the entrance to which is partially closed by the vena cava Falte. The sac is the *saccus omenti*, the entrance to it is the *foramen of Winslow*, *F.W.* The saccus is bounded on the dorsal side and on the left by the mesogastrium; on the ventral side by the stomach, the position of which at a level nearer the observer may be easily imagined from the figure; and on the right by the vena cava Falte, *v.c.i.*

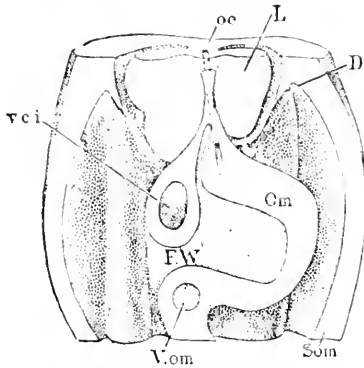


FIG. 262.—Model of Part of the Pleural and Abdominal Cavities of a Rat Embryo at a Stage Corresponding to a Rabbit at fifteen Days. *oc*, Oesophagus; *L*, lung; *D*, anlage of fold to form the diaphragm; *Om*, omentum; *Som*, somatopleure; *V.om*, omphalomesaraic vein; *F.W.*, foramen of Winslow; *v.c.i.*, vein in the plica venæ cavæ of Ravn. After Ravn.

called *lobus inferior medialis* of the right lung, and persists in the adult. A similar cavity (*Schleimscheide*) is found also in rats and mice, and is presumably developed in the same way. Ravn thinks it probable that an homologous cavity is present in the human embryo, but aborts.

Separation of the Pleural and Abdominal Cavities.—

This takes place much later than the separation of the pleural and pericardial cavities, for it is not effected in the rabbit until the seventeenth day, and Kölliker records that it had not taken place in a two-months' human embryo. This agrees with the fact that the separation takes place only in the mammals, not in other vertebrates. Ravn, 89.2, 147, is the only investigator who has attempted to follow out the process accurately. A fold is formed, Fig. 262, which lies obliquely between the lungs and the Wolffian body on each side, and which in the rabbit at fifteen days is found to somewhat contract the opening between the pleural and abdominal cavities; the fold extends almost if not completely around the opening, making as it were a circular shelf. Another factor, as pointed out by His, is the expansion of the liver. I have observed also, in studying Professor His' embryo Zw.* that the anlage of the supra-renal capsule had appeared in the septum transversum on the ventral side of, and close to, the peritoneal opening of the pleural cavity, so that the con-

My grateful acknowledgments are due to Professor His for the very generous manner in which he placed his material at my disposal, during a few weeks I had the pleasure to spend in Leipzig in 1887.

clusion was inevitable that the final factor in completing the closure of the opening was the growth of the supra-renal capsule.

Diaphragm.—The diaphragm (*Zwerchfell*) is developed from that portion of the septum transversum which intervenes between the pericardial and abdominal cavities, and from the fold which shuts off the connection of the pleural cavities with the abdominal. The veins pass through the diaphragm to the heart, and to the area around the veins the liver is permanently attached; it is out of the remainder of the diaphragm that the muscular part and the centrum tendineum are developed, but concerning their development no observations whatever are known to me.

Lining Membranes of the Splanchnocœle.—These membranes are the pericardial, pleural, and peritoneal. They each consist of a layer of specialized connective tissue and the mesothelium, which is found in the adult to have lost its primitive character of a cuboidal epithelium and to have become a thin layer or endothelium. Concerning the manner in which the transformation is effected, there are few reliable observations—compare Chapter XXIX.

THE SUPRA-RENAL CAPSULES.

It is only with considerable hesitation that I have decided to treat the supra-renal capsules as organs developed in the septum transversum on the ventral side of the pleuro-peritoneal opening. I have made observations which lead me to think this view necessary from the facts of development, but I have not been able hitherto to continue the research to a satisfactory conclusion. As the kidney grows forward until it reaches the dorsal pillars of the diaphragm, the supra-renals would come in juxtaposition with the upper end of the kidneys, whether the capsules began their development on the dorsal side of the pleuro-peritoneal opening or on the ventral side, for in the latter case the closure of the opening would bring the capsules near the kidneys. At present I am inclined to the belief that the mesenchymal portion of the supra-renals arises on the ventral side of the opening and the sympathetic portion on the dorsal side. That this view is right is confirmed by the observation that the capsule lies entirely on the ventral side of the kidney in the human embryo at two months and at three.

Mesenchymal Anlage.—The mesothelium in the region of the vena cava inferior and septum transversum throws off cells to contribute to the mesenchyma. Janosik, 83.1, who observed this process at the point where the supra-renals develop in mammals, concluded that it was a special process and that the supra-renal capsules must, therefore, be considered as derivatives of the peritoneum. The recognition since then of the genetic relation of the whole mesenchyma to mesothelium renders it unnecessary to assume a special relation for a single mesenchymal organ. The same criticism applies also to Weldon, 85.1, who, having observed the production of mesenchyma from the mesothelium of the nephrotomes, or segmental vesicles, in lizards and sharks, concludes that there is a special genetic relation between the supra-renals and the segmental organs. In reptiles, soon after the vena cava is formed, there appears on each side of that vein a small cluster of crowded mesenchymal

cells (Max Braun, **82.1**), which increases quite rapidly; the cells of the cluster gradually arrange themselves in cords which become more and more twisted and united; numerous blood-vessels are early developed between the cells, probably by ingrowth from the adjacent Wolffian bodies. The nearness of the first trace of the supra-renals to the vena cava has also been noted by Gottschau, **83.1**, by Mitsukuri, **82.1**, and Weldon, **85.1**. In the rabbit the first distinct trace of crowding of the cells and of their enlargement to form the anlage of the supra-renals may be seen on the twelfth day; on the fourteenth day the anlages are well marked (Mitsukuri, **82.1**); by the sixteenth day the sympathetic anlage is surrounded by the mesenchymal. In the sheep (Gottschau, **83.1**, 449) the anlage can be recognized in embryos 9 mm. long; it is in contact with the sympathetic ganglion tissue in embryos of 11 mm. and in those of 13 mm. has become quite sharply defined against the surrounding mesenchyma. In the pig the first trace is seen in 9 mm. embryos according to Gottschau, **83.1**, 452.

Balfour, **81.3**, homologizes the mesenchymal anlage with the so-called inter-renal bodies of elasmobranchs.

Sympathetic Anlage.—On the dorsal side and somewhat toward the median line of each mesenchymal anlage appear a cluster of small cells, which are stained brown by bichromate of potassium, as first observed by M. Braun, **82.1**, 25, in reptile embryos. These cells are derived from the chain of sympathetic ganglia, and are characterized by being smaller and more granular and by having smaller nuclei than the cells of the mesenchymal anlage. I have noticed that in specimens colored with alum-cochineal they stand out conspicuously owing to their deeper staining. In rabbits of fourteen days, the sympathetic anlage has become very distinct and has increased in size, and in those of sixteen days it is found surrounding the mesenchymal supra-renal and more or less separated from the ganglion proper. At this time traces of young ganglion cells and of nerve-fibres are said to be clearly recognized. F. M. Balfour, **81.3**, and in his "Comparative Embryology," II., 664, homologizes the sympathetic anlage with the so-called "true supra-renals" of elasmobranchs, bodies which develop from the sympathetic ganglia. According to Balfour (monograph of Elasmobranchs, "Works," I., 472), who greatly extended Semper's observations, **75.2**, in shark embryos in Balfour's stage L the ganglia of the sympathetic chain are partially divided into two parts: one the future ganglion proper, the other the anlage of the supra-renal, which receives a direct artery from the aorta. By stage O these supra-renal anlages have acquired a distinct mesenchymal investment, which penetrates into their interior and divides it, especially in the case of the anterior anlages, into a number of distinct alveoli. By stage Q, the cells are differentiated into larger (ganglionic?) cells and smaller ones, which Balfour holds to form the true supra-renal tissue.

The observations thus far made indicate that the sympathetic anlage is derived from a series of spinal ganglia, which give off a series of supra-renal parts; these parts remain distinct in elasmobranchs, but fuse into one mass on each side in amniota. Rudimentary ganglion cells arise, but soon abort.

Union and Ultimate Fate of the Two Anlages.—The mesenchymal and sympathetic portions very soon come into contact (sheep of 11 mm., rabbits of the fourteenth day). At first, in anniota at least, the sympathetic anlage grows most rapidly and partially surrounds the mesenchymal portion, but soon the relations are reversed and gradually the mesenchymal portion completely invests the sympathetic part, but for some time there remains a hilus on the inner side toward the posterior end of the organ. Fig. 263 shows a

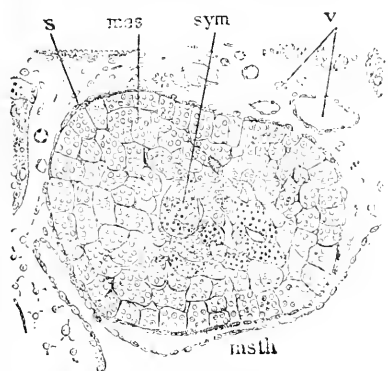


FIG. 263.—Section of the Supra-renal Body of a Rabbit Embryo of twenty-six Days. *mes*, Mesenchymal portion; *sym*, sympathetic portion; *v*, blood-vessels; *s*, mesenchymal sheath; *msth*, mesothelium lining the body-cavity. After Mitsukuri.

transverse section of the left supra-renal taken about the middle of the body from a rabbit embryo of twenty-six days. The cortex is already made up of distinct cell-groups, which, however, are not yet differentiated into the adult cortical and medullary zones. Capillaries are well formed between the adjacent cell-groups. The sympathetic portion, *sym*, is divided into irregular groups of cells, which stain readily and are situated exclusively in the central region; between these groups are relatively large blood-vessels, *v*. The connective tissue has formed a sheath, *s*, around the organ. Mitsukuri states that the masses

of nervous origin are now full of "distinct ganglion cells, supported in a connective-tissue framework; scattered among the larger cells are smaller cells." This may be regarded as perhaps the Sauropsidan condition, since according to Hans Rabl, 91.1, the two supra-renal tissues persist in birds throughout life, interlaced with one another.

Mitsukuri believed that the medulla of the adult capsules arises from the sympathetic anlage, but Gottschau, 83.1, showed that this was not the case, though he failed to ascertain what became of the sympathetic masses. By a considerable series of observations on the supra-renal capsules of human embryos, I have ascertained that there are groups of cells which gradually disappear and take no part in the production of the adult organ. The cells are in clusters in the central portion of the organ and stain very readily, so that they stand out conspicuously in the sections. In appearance they resemble the cells assigned to a sympathetic origin in the rabbit, and I should feel no doubt that they are the same were it not that I fail to find them in embryos of the second month, so that if they are really of sympathetic origin then the union of the two anlages must take place at a considerably later stage in man than in other animals. These groups of cells are readily seen in the three-months' embryo, but in the four-months' embryo they are disappearing and many of the clusters are hollow, their cavities being filled with what is apparently a coagulum; by the seventh month the clusters have, so far as I have hitherto observed, entirely disappeared. That both the cortex and

medulla of the adult organ are formed in man from the mesenchymal cells, as Gottschau, 83.1, showed was the case in several mammals, is, I think, beyond question. The cords of cells are at first uniform throughout, but I find that toward the end of the second month the cells of the cords multiply and become smaller, while at the same time the cords assume a more radial position and regular arrangement around the periphery; there is thus developed a *cortex*, characterized by radiating, small-celled cords and a *medulla*, characterized by irregular, large-celled cords. In the cortex the cords are wide and contain numerous cells; toward the interior the cords break up into small ones, which pursue the same radial course and consist of cells which gradually increase in size toward the centre of the organ. The cords are marked off by wide capillaries, with distinct endothelial walls, between which and the supra-renal cords there appears to be no connective tissue, although in the medulla there is more or

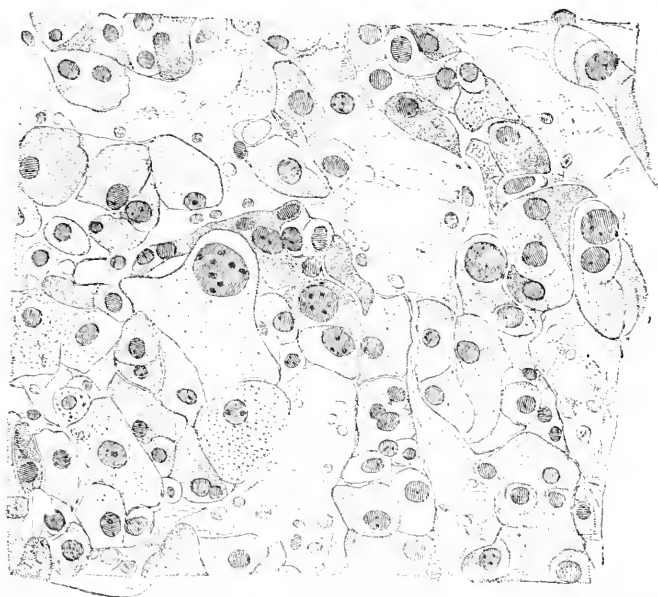


FIG. 264.—Supra-renal Capsule of a four-months' Human Embryo. Minot Collection, No. 35. Cross section of the medulla. \times about 500 diams.

less connective tissue developed early around the vessels, Fig. 264. It seems to me that the cortex grows at the expense of the medulla, the deep-lying large cells dividing into smaller ones. The medulla of a four-months' embryo is represented in Fig. 264.

The cords of supra-renal cells are very irregular and often connected together, but are readily seen to be directly continuous with the cortical cords. The medullary cords are much more widely separated than those of the cortex from one another, the spaces between them being filled with connective tissue and blood-vessels, none of which have any adventitial or muscular walls. The great variety of appearances presented by the cells of the cords is indi-

cated in the figure; large and small, regularly and irregularly shaped, uninucleate and multinucleate, light-stained and darkly-stained cells lie jumbled together without obvious law of arrangement. The significance of this strange picture is unknown. It should be noted that the nuclei of the cord-cells are all, or nearly all, decidedly larger than those of the adjacent connective tissue. As development proceeds the cells become gradually more uniform in appearance, and offer by the seventh month little variety; also the continuity of the cords is lessened in the medulla and the blood-vessels become larger. It is evident that there is no fundamental difference between cortex and medulla—in the former the cords have a radial trend, in the latter they run irregularly; the medulla is also characterized by having larger supra-renal cells and a richer blood supply.

Form and Size of the Supra-renals.—The supra-renal capsules have at first a rounded form and lie on the ventral side of the cephalic end of the kidney. Probably about the third month they begin to spread on to the dorsal side of the kidney, the head end of which they invest like a cap. The capsules grow at first very rapidly, afterward more slowly, and as the kidneys grow more steadily the relative size of the capsules compared with the kidneys passes through striking changes.

CHAPTER XXIII.

THE UROGENITAL SYSTEM.

THE early history of the urogenital system has already been given, Chapter XI., p. 230. We have now to consider the differentiation of the male and female type from the indifferent condition. In order to render the complex changes clear, it has seemed to me advisable to give first a general history of the metamorphoses, so as to bring out first the homologies in the two sexes, next to present the special histories of the single parts, and finally to append an account of the external genitalia.

I. GENERAL HISTORY.

The Indifferent Stage. I.—The early history of the urogenital system has been given in Chapter XI.; nevertheless it will be convenient to present here a generalized diagram of the indifferent stage, for comparison with diagrams of the differentiated system male and female. The indifferent stage is characterized by all the organs being contained in two longitudinal urogenital ridges Fig. 265, one on each side of the body and projecting from the dorsal wall into the peritoneal cavity. At the caudal end of the abdomen the two ridges draw closer together and finally come into contact with the anal region of the intestinal canal. The ridge is constituted chiefly by the Wolffian body, *w.b.*, and it therefore contains the Wolffian tubules and the Wolffian duct, *W.D.*, which is situated on the side of the ridge farthest from the mesentery, *mes.* Close alongside the Wolffian duct lies the Müllerian duct, *M.D.* Both ducts open into the cloaca, *Cl.*, or terminal division of the intestine.

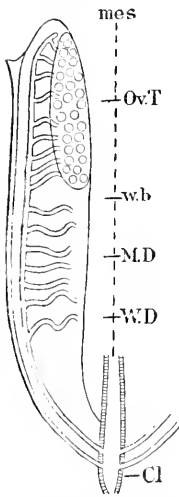


FIG. 265.—Diagram of the Indifferent Stage of the Urogenital System of Amniota. Explanation in text

Changes in Both Sexes.—The essential or fundamental difference between the two sexes is the change of the genital ridge into an ovary or testis according to the sex. The secondary differences are chiefly in the modifications of the ducts, and as regards these the most important changes are that in the male the Wolffian duct becomes the genital duct (duct of the epididymis, vas deferens, and ductus ejaculatorius), while in the female the Müllerian duct becomes the genital duct (Fallopian tube or oviduct, uterus, and vagina). Before considering the changes more in detail it will be convenient to divide them into two groups; 1, common to both sexes; 2, characteristic of one sex.

1. CHANGES COMMON TO BOTH SEXES.—There are three important changes from the indifferent stage to be noted under this head: A, the union of the caudal ends of the urogenital ridges to form a single median *genital cord*; B, the anterior end of the Wolffian body persists and undergoes modification in connection with the genital glands, by which two separate organs are produced in each sex; C, in the course of development the genital organs become restricted to the lower (or caudal) end of the abdomen, and do not continue to stretch the whole length of the abdomen as at first. Another important series of changes is that by which the cephalic portion of the urogenital ridge acquires in the female a transverse position, in consequence of which the upper or cephalic end of the Müllerian duct, or in other words the future Fallopian tube, runs transversely. This change occurs in the male also, but is less noticeable and is, to a certain extent, masked by the migration of the testis from the abdomen through the inguinal ring into the scrotum.

2. CHANGES CHARACTERISTIC OF ONE SEX ONLY.—A. MALE.—The general plan of the urogenital ridge in the male is indicated in the diagram Fig. 266. In the male, as stated above, the sexual gland becomes a testis by the development of seminiferous tubules, and the Wolffian duct becomes the genital duct. The connection between the Wolffian duct and the seminiferous tubules is established by means of the anterior tubules of the Wolffian body. There are special

extensions of these tubules into the testis, which anite with the seminiferous tubules and form a series of anastomoses with one another within the testis (compare Fig. 266), constituting the rete testis, while the tubules proper of the anterior part of the Wolffian body remain to serve as the channels of connection (vasa efferentia) between the rete testis and the Wolffian duct, which is thus enabled to serve as the spermiduct. A portion of the anterior Wolffian tubules persist as a separate group, which is known as the organ of Giraldès, or paradidymis of Waldeyer. The spermiduct becomes differentiated into three principal divisions: 1, the coiled portion nearest the testis constituting the duct of the epididymis; 2, the long vas deferens running through the urogenital fold, to where the two folds unite to constitute the genital cord; 3, the ductus ejaculatorius,

developed below the point where the seminal vesicles are formed and within the genital cord. The Müllerian ducts remain rudimentary and their middle portions usually abort, leaving the upper fimbriate

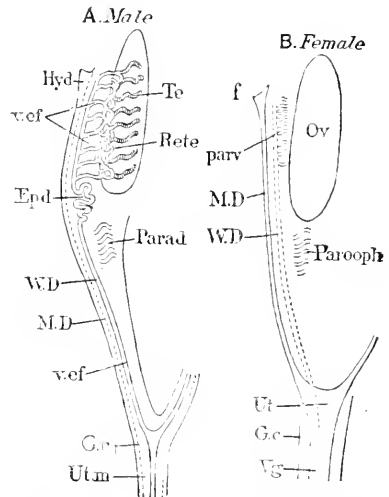


FIG. 266.—Diagram to Illustrate the Homologies of the Sexual Apparatus. *Hyd.* Hydatid; *v. ef.* vasa efferentia; *Epd.* duct of epididymis; *W.D.* Wolffian duct; *M.D.* Müller's duct; *G.c.* genital cord; *Ut.m.* uterus masculinus; *Te.* testis; *Rete.* rete Halleri; *Parad.* paradidymis; *f.* fimbria; *parv.* parovarium or epophoron; *Ut.* uterus; *G.c.* genital cord; *Vg.* vagina; *Ov.* ovary; *parooph.* paroo-phoron.

ends to develop into the so-called hydatids of Morgagni, and the lower or caudal ends to unite within the genital cord to form the so-called uterus masculinus (prostatic vesicle), a rudimentary representative of the female uterus and vagina.

B. FEMALE.—The general plan of the urogenital ridge in the female is indicated by the diagram, Fig. 266. In the female, as stated above, the sexual gland becomes an ovary, by the development of ovic follicles, and the Müllerian duct becomes the genital duct. The Wolffian duct remains rudimentary and in part disappears: it persists in the genital cord as the duct of Gärtner, but does not, so far as known, unite with its fellow; it persists also at its upper or cephalic end as the duct of the parovarium (epoöphoron, organ of Rosenmüller), which comprises the group of Wolffian tubules in the female homologous with the vasa efferentia of the male. There also persists a group of Wolffian tubules, which has been named the paroöphoron by Waldeyer and is homologous with the male organ of Giraldès. The Müllerian ducts unite within the genital cord to a single median duct, which enlarges greatly and is differentiated into the uterus and vagina; the upper or cephalic portions remain separate and form the Fallopian tubes or oviducts proper; the Müllerian funnel becomes the fimbriate opening of the Fallopian tube.

Homologies between the Sexes.—These may be readily followed by means of the accompanying diagrams, Fig. 266. A and B, and the table given below. The diagrams call for no further explanation than is given on the figures.

TABULAR VIEW OF THE HOMOLOGIES OF THE HUMAN UROGENITAL APPARATUS IN THE TWO SEXES.

INDIFFERENT STAGE.	MALE.	FEMALE.
Genital ridge.	Testis.	Ovary.
Wolffian tubules.	1. Epididymis.	1. Epoöphoron.
	2. Paraididymis.	2. Parovarium.
Wolffian ducts.	3. Vas deferens.	3. Duct of Gärtner.
	(Vesicula seminalis.)	
	4. Ductus ejaculatorius.	4. (Usually aborts.)
	5. Hydatid of Morgagni.	5. Fimbriate opening.
Müllerian duct.	6. (Usually aborts.)	6. Fallopian tube.
	7. Uterus masculinus.	7. Uterus.
	8. (Usually undeveloped.)	8. Vagina.
	9. Vermum montanum.	9. Hymen.
Urogenital sinus.	10. Urethra.	10. Urethra and vestibule.
	11. Cowper's glands.	11. Bartholini's glands.
Genital eminence.	12. Penis.	12. Clitoris and nymphæ.
External labia.	13. Scrotum.	13. Labia majora.

II. SPECIAL HISTORIES OF THE UROGENITAL ORGANS.

Sexual Glands.—A. MALE.—The *testis* becomes recognizable by its histological character in the human embryo according to W. Nagel, 89.3, 309, at five weeks; according to Benda, 89.1, at six weeks. It can be distinguished from the ovaries by its external form in the three months' embryo. By the abortion of the Wolffian body and by the growth of the testis the latter becomes the principal organ of the urogenital fold in the male. The Wolffian part of the fold remains to form the mesorchium, the lower or caudal portion of the

fold remaining as the gubernaculum. By the fourth month the testis has assumed its permanent form, but its growth continues.

The rôle of the Wolffian tubules in the genesis of the testis is described below, p. 500.

Histogenesis.—The subsequent account of the development of the testis follows Nagel, 89.3, closely, whose results I accept, both as regards his observations and his criticism of previous investigations, although they require modification owing to what has become known concerning the genetic relation of the mesenchyma to the mesothelium of the genital ridge, see p. 248. As described in Chapter XII. the genital mesothelium throws off cells, which at first assume entirely the character of loose mesenchyma, and later remain crowded together with scarcely a trace of division from the parent epithelium; in this denser tissue appear large cells, the so-called "Ureier." Out of this anlage are developed epithelioid cords, the sexual cords, which include some of the ureier, and become more and more separated from one another by the development of loose mesenchyma or embryonic connective tissue between them. Nagel finds that the male sexual gland, Fig. 267, may be recognized even in

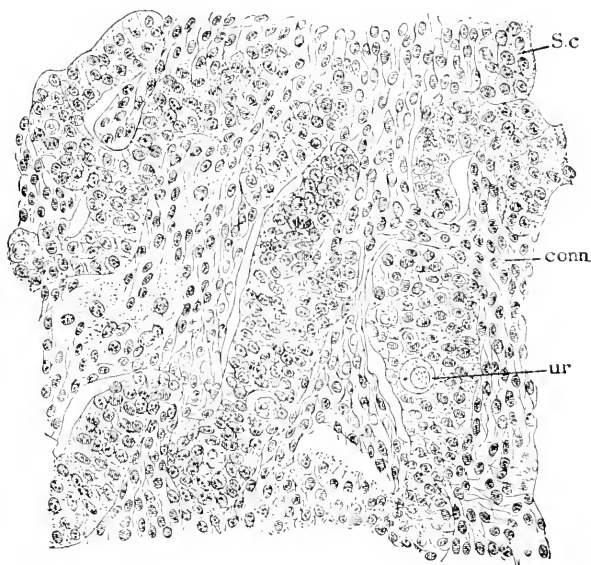


Fig. 267.—Section of the Testis of a Human Embryo of sixty-three to sixty-eight Days. S.c, Sexual cords; ur, ureier; conn, mesenchyma.

an embryo of 13 mm. by the small number of the ureier as compared with the ovary of corresponding age. In the testis at this stage (human embryo of 13 mm.), the sexual cords are not yet very distinct and are connected with the superficial epithelium. In an embryo of nine weeks, Fig. 267, the sexual gland* is covered by a regular cuboidal epithelium, distinctly bounded against the under-

* In accordance with Kölliker's description and figure ("Grundriss," Fig. 288), this gland would be an ovary, but Von Ackeren states that Kölliker has become doubtful in regard to his Fig. 288, and I think it must be regarded as the section of a testis.

lying tissue, which is composed of mesenchyma with sexual cords, *S.c.* which are not connected with the mesothelium; the submesothelial layer is the anlage of the *tunica albuginea*; as no corresponding layer exists in the ovary, its presence in the male gland at this stage establishes one of the most characteristic features of the testis: in the albuginea, connective-tissue fibrillæ are just beginning to appear. The central portion of the testis is occupied by sharply defined sexual cords, which frequently anastomose with one another and contain here and there an "Ureï," or sexual cell of Mihalkovics; the sexual cells are clearer and larger than the other cells of the cords, measuring 11μ with nuclei of 8μ diameter. In an embryo of 35 mm. the general structure is much the same, but the albuginea is thicker and more fibrillar, and the cords are more regular in their arrangement; the cords are about 32μ thick and their cells show a somewhat epithelioid arrangement; the few sexual cells they contain now measure 14–16 μ . In an embryo of ten centimetres a new feature is found in the presence of the interstitial cells. These are large cells which lie between the sexual cords, and are probably developed by the enlargement of the connective-tissue cells between the cords: they are spindle-shaped or polyhedral, with several processes each; their protoplasm offers a peculiar mat appearance; their nuclei are large, with one or two nucleoli and a distinct intranuclear network.

The cords are the solid anlages of the seminiferous tubules. The question has been debated at great length whether they are differentiated from the stroma or the epithelium of the genital ridge—compare the synopsis of opinions given by Nagel—but as the epithelium (mesothelium) produces the mesenchyma or stroma, the question appears to me insignificant. The further history of the sexual cords (future seminiferous tubules) has been most fully studied by C. Benda, **89.1**, compare also Prenant, **89.1**, **90.1**. The cords remain solid throughout foetal life, the smaller cells having a radial position and epithelioid arrangement, but the nuclei are irregularly placed, so that it is difficult to decide whether the cells are in a single row or not around the centre of the cord. The large ureier are irregularly distributed—less irregularly in man than in other animals—but they are always completely imbedded in the other cells and show a tendency to lie near the periphery of the cord in man, rodents, dogs, and cats, near the centre in ruminants (ox). As to their number, few ureier are found in the cords of man, while in rodents they are very numerous; dogs and cats occupying an intermediate position as to number. The condition described is attained in man about the sixth week, in the rabbit the seventeenth day, and persists with little change not only throughout the foetal period, but until the time of puberty, when the cords change to seminiferous tubules.

The conversion of the male sexual cords into the seminiferous tubules, being post-foetal, does not fall within the scope of this work. The reader is referred to the investigations of Prenant, **89.1**, Benda, **89.1**, and F. Hermann, **89.2**. According to Benda the epithelioid cells give rise to the columns of Sertoli (Benda's *Fusszellen*) and the ureier to the spermatoocytes (Benda's *Samenstammzellen*). This

is in accordance with Benda's hypothesis that the spermatocytes have no genetic relation with Sertoli's columns, an hypothesis which is not yet established firmly—compare Chapter III.

B. FEMALE.—The *ovary* becomes histologically recognizable about the same time as the testis, *i.e.* six weeks; it can be readily distinguished from the testis in the three months' human embryo by its external form. In consequence of the abortion of the Wolffian body and of its own growth the ovary is already the principal organ of the urogenital fold at three months. As the greater part of the fold has thinned out to constitute the broad ligament, the relations found in the adult are established at the age under consideration.

Histogenesis of the Ovary.—According to Nagel the ovary may be distinguished from the testis in human embryos of only 12–13 mm. by the greater abundance of the developed and developing

ureier. In an embryo of 12 mm. Nagel, 89.3, 305, describes the ovary as consisting of the proliferated germinal epithelium; the proliferated cells are of two kinds, the more numerous are smaller, and have more darkly stained nuclei; the less numerous are the young ureier with lighter stained granular nuclei. In an embryo of 20 mm. the ovary projects a little from the surface of the urogenital ridge, and is filled with the cells from the epithelium, the two kinds being present, and, as before, with numerous transitional stages be-

tween them; the ureier measure 10–16 μ with a nucleus of 8 μ diameter—the smaller cells 8 μ with a nucleus of 5 μ ; in the centre, spindle-shaped connective-tissue cells are appearing. In an embryo of 30 mm. the ovary projects still more from the Wolffian body; the ureier are larger, 16 μ , and the connective tissue or stroma is more developed and has capillaries. Nagel has studied also embryos between 3 and 7 cm. in length, but we may pass at once to the latter. In embryos of 7 cm. the ovary is triangular in section, the apex of the triangle corresponding to the attachment to the Wolffian body or future broad ligament. The connective tissue now forms partitions, which divide the remaining cells into groups, Fig. 268, but the partitions fade out toward the surface, which is covered by a single layer of cells, which has begun to assume the character of an epithelium entirely distinct from the underlying cells. In an embryo of 11 cm. the covering epithelium of the ovary has become more sharply bounded and the development of the stroma has extended

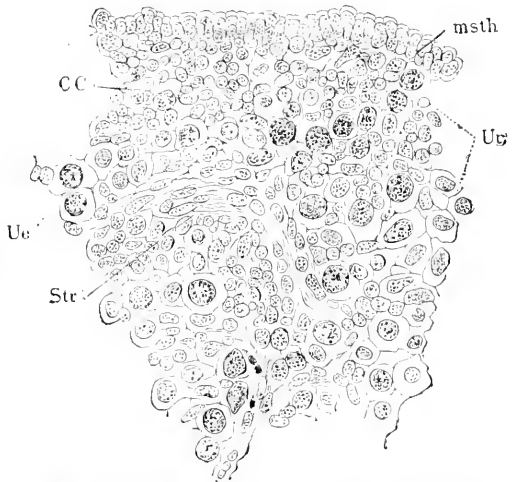


FIG. 268.—Section of the Ovary of a Human Embryo of 7 cm. *Msth*, Mesothelium; *Ue*, ureier; *cc*, proliferated small cells; *Str*, stroma or connective tissue. After W. Nagel.

quite to the surface, dividing the proliferated cells into rounded groups of small cells and ureier, which are at this stage very numerous, and indeed outnumber the small cells in the balls. These balls are a highly characteristic feature of the young mammalian ovary, but their arrangement and connections with one another have been as yet only very imperfectly studied; nevertheless it seems safe to say that they are not separate masses, but, as seen under the microscope, sections of contorted and anastomosing cords. If this view is correct then there is an evident resemblance between the testis and ovary, there being in both cords derived from the germinal epithelium, containing ureier and separated from one another by vascular connective tissue. The ovary differs from the testis in having larger cords and a much larger absolute and proportionate number of ureier. That we have to do with sexual cords is evident in later stages, where the cords are very distinct and are found still connected with the covering mesothelium (Waldeyer's *Keimepithel*); in their later stage, the ovarian sexual cords are known as Pflüger's cords (Pflüger'schen Schläuche), being named after their discoverer, and they differ considerably from their earlier stage in that they include a large number of small or follicular cells, which completely surround the ureier and separate them from one another, by constituting an epithelioid layer or follicle around each urei. The transition from the stage of the balls, as we may call it, to the stage of Pflüger's cords has not been clearly ascertained, because the origin of the small or follicular cells is still uncertain but I agree with O. Hertwig ("Lehrbuch d. Entwicklungsgesch.," 3te Aufl., 321) that they are cells of the original cords derived from the mesothelium of the ovary, although Rouget and so eminent an authority as Kölliker ("Grundriss," 423) have maintained that the medullary cords grow around the ureier and produce the follicles; Kölliker seems to me not to have offered sufficient evidence to render his view probable. Another view is that advocated by Foulis, 76.1, who believes that the ureier becomes entirely free and that the follicles are developed from the stroma cells—a conception which cannot be maintained. If we assume, as we apparently must, that the follicular cells arise from the sexual cords, the question would still remain, whether they are derived from some of the original small cells or from the ureier; that the latter derivation is the actual one is to my mind probable, because there appears to be a stage in the development of the sexual cords of the mammalian ovary in which all the cells are converted into ureier; but until further investigations shall have decided it, the question of the origin of the follicular cells must be considered an open one. Mihalkovics, 85.1, 449, discusses carefully the origin of these cells, but owing to the distinction he draws between the sexual cords and the proliferation of the germinal epithelium to form the ureier, it is impossible to follow his own account: Mihalkovics also gives an admirable review, pp. 423-428, of the literature upon the development of the ovary.

Gubernaculum, Processus Vaginalis, and Descent of the Testis.—The descent of the testis begins very early, the change in position being evident by the tenth week, but the passage into the scrotum does not begin until the seventh month. The testis

makes three movements: 1, backward to near the inguinal ring; 2, forward a short distance, during the period of the formation of the muscular gubernaculum; 3, downward into the processus vaginalis. The processus does not extend completely into the scrotum during foetal life, hence the foetal scrotum has no cavity and never contains the testis, but on the contrary is filled by a very vascular connective tissue like the *labia* of the female. At birth the processus lies partially in the scrotum.

The cause of the descent of the testis has been much discussed and many fanciful explanations have been propounded. There is no reason for supposing that these movements are in any wise different from the numerous other movements of organs and changes of form occurring during the course of development. These changes are all due to inequalities of growth in the tissues, but the causes of these inequalities are not yet ascertained. A long-prevalent tendency has tainted the study of the generative organs with mysticism, and it must be attributed to this tendency that so many far-fetched explanations of the descensus testiculorum have been published. The changes in the gubernaculum are probably the immediate causes of a part of the changes in the position of the testis; the growth of the gubernaculum accounts for the forward movement, and its atrophy for the passage along the wall of the processus vaginalis; it must be added here that the testis also accompanies the downgrowth of the processus, and is *not* dragged down merely by the shortening of the gubernaculum. Some writers have supposed that the muscles of the gubernaculum effect the descent by their contraction, but this view lacks foundation.

The descensus has been carefully studied in the human embryo by Bramann, 84.1. The details of the process are as follows: The urogenital fold is a long structure reaching to the posterior or caudal end of the abdomen. The greater part forms the Wolffian body, and when this atrophies the fold is much reduced; toward the head end it contains the testis and the remnant of the Wolffian body (epididymis), the portion of the fold dorsal of these acting as a suspensory membrane to which the name of *mesorchium* has been given, and which is comparable to the mesentery; it is quite thick, but finally disappears. The part of the urogenital fold tailward of the testis contains the Wolffian duct (vas deferens) and runs to the point of the abdomen, where the inguinal ring is developed. A portion of this region of the fold is converted into the gubernaculum Hunteri, by an ingrowth of muscular fibres from the obliquus internus and obl. transversus. The mesorchium, together with the posterior part of the fold, including the gubernaculum, is the homologue in the male of the broad ligament of the female. To complete the statement of the homologies, it may be added that the gubernaculum becomes the cremaster, and is said to be the equivalent of the round ligament of the uterus in the other sex; the latter identification needs confirmation.

The *first* change which occurs is the nearly complete disappearance of the long piece of the urogenital fold, which lies tailward of the testis. Accordingly we find the male gland at the end of the second month has moved into the immediate neighborhood of the

inguinal ring, with which it is connected by the short remnant of the fold, Fig. 269, A. The *vas deferens* has a nearly horizontal transverse course. The *second* change is the conversion of this hind remnant of the urogenital fold into the gubernaculum, a process which begins with the fourth and ends with the sixth month, it requiring about two months for the gubernaculum to attain its maximum size. To form the structure in question, the fold behind the testis enlarges both longitudinally and transversely until it measures 8-9 mm. by 3-4 mm.; the testis moves forward meanwhile a corresponding distance. At first the gubernaculum consists only of the

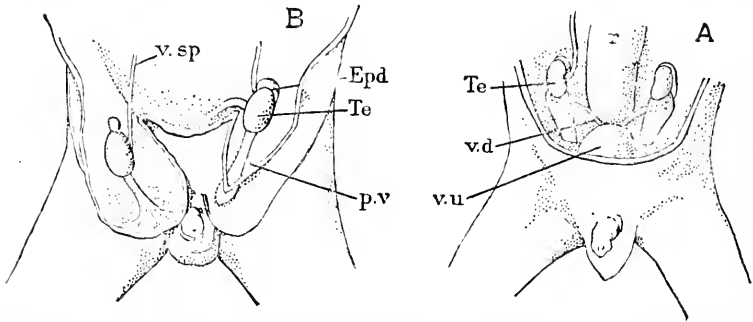


FIG. 269 (To Illustrate the Descensus Testicularum).—A, Fœtus of Fourteen to Fifteen Weeks. $\times 2$ diams. B, Fœtus of the first half of the seventh month with the processus vaginalis opened. *Te*, Testis; *epd*, epididymis; *v.d*, vas deferens; *p.v*, processus vaginalis; *r*, rectum; *v.u*, bladder; *v.sp*, vasa spermatica. After Bramann.

peritoneum and the inclosed connective tissue, but soon muscular fibres appear in its caudal portion; these fibres can be traced to a connection with the obliquus internus and obliquus transversus; they form a sheath or mantle underneath the peritoneum and around a central core of connective tissue; at first they do not reach to the testis, but stop at that point where the gubernaculum is crossed by the vas deferens. They appear to extend farther forward later. The fibres are not parallel, but quite irregular in their courses. At the lower end of the muscle a bundle of connective fibres extends beyond the gubernaculum into the side of the processus (see below). The gubernaculum is now completely differentiated. This stage of the organ is permanent in some rodents and other mammals, low in the series, and must be considered of great phylogenetic significance. Attention is directed to the fact that its muscular fibres are striped, and to its shape shown in the figure, because both points accentuate the resemblance to the rodent cremaster. While the gubernaculum is being formed there appears at its caudal end a little pouch made by an evagination of the peritoneum at the inguinal ring. This is the anlage of the *processus vaginalis*; it lies laterally and ventrally of the end of the gubernaculum; it enlarges very slowly up to the end of the sixth month, but after that more rapidly. The *third* change is the true descent of the testis; the evagination of the processus includes not only a considerable peritoneal surface, but also the gubernaculum, and later the testis; in other words the urogenital fold extends down the processus and forms, indeed, the dorso-medial wall of the sac; as the sac grows down, the fold (gubernacu-

lum and testis) grows with it, Fig. 269, B. In a transverse section the lumen of the processus vaginalis appears somewhat crescent-like, the concave wall corresponding to the protuberance of the urogenital fold, the convex wall to the peritoneal covering. The mesorchium disappears during the descent into the processus. Early in the seventh month, the testis is drawn into the mouth of the sac, Fig. 269, B, and shortly after lies wholly in the interior thereof. But the testis descends to the bottom of the processus; this translation is accomplished during the seventh and eighth months, first by a shortening of the gubernaculum, second by a slipping down of the testis over the muscles; the portion of the gubernaculum between the testis and the base of the processus is reduced to an inconspicuous band of connective tissue. The muscle now lies between the testis and the base of the penis and is developed in that position into the cremaster. At last the processus enters the scrotum, and an entirely new relation of parts is established; the transportation of the testis into the scrotum represents a very advanced stage, since it takes place only in the higher mammals, and accordingly we find it to occur very late in the development of man.

The Broad Ligament.—The broad ligament of human anatomy is the persistent urogenital fold, reduced to a relatively thin suspensory membrane for the ovary and uterus by the abortion of the Wolffian tubules. The fundamental relations here involved may be readily understood from Fig. 270, which represents a section through the urogenital fold of a human embryo of the third month; the fold is suspended from the dorsal wall of the abdomen; the Wolffian body is considerably aborted and divided into two parts, one of which, near the base of the fold, is the anlage of the parovarium, *Par*, the other, near Müller's duct, *Md*, is the anlage of the epoöphoron, *Epo*.

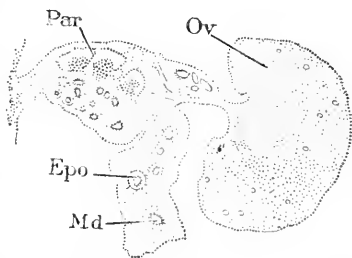


FIG. 270.—Cross-section of the Ovary and Wolffian Body of a Human Embryo of the Third Month. *Par*, Parovarium; *Epo*, epoöphoron; *M. D.*, Müller's duct or Fallopian tube; *Ov*, ovary. After W. Nagel.

The ovary, *Ov*, projects from what was originally the medial side of the Wolffian body, with which it is connected by a thin mesovarium. As in the adult the broad ligament contains the parovarium and epoöphoron, it is evident that it is really the Wolffian body, converted into a suspensory membrane, most of the Wolffian tubules being aborted.

The development of the broad ligament is accompanied by a change of position, first of the whole genital fold, second of that part of the fold which forms the ligament. It will be remembered that the two folds unite in part to form the genital cord, out of which the uterus and vagina are developed; the remainder of each urogenital ridge is transformed in the female into the broad ligament and ovary. As the fetus grows, the urogenital ridge fails to grow proportionately, and after the second month becomes more and more restricted to the caudal or pelvic end of the abdomen. Its relative position is so rapidly shifted that by the end of the third month it already occu-

pies its permanent situation. While this modification is being established the Wolffian body in large part aborts, and the portion of the fold in front of the genital cords comes to occupy an oblique and finally a nearly transverse position, which is permanently retained, so that the broad ligament is always obliquely transverse. At three months the ovary is as long (3 mm.) as the Fallopian tube, and stretches in an obliquely transverse direction from the upper or cephalic end of the genital cord (future uterus) to the Müllerian funnel or fimbriate opening of the Fallopian tube. By the fourth month the transverse position is more marked, and since the ovary is originally on the medial side of the urogenital ridge, it remains on that side, and accordingly is situated on what is known in human anatomy as the dorsal side of the ligament.

The development of the round ligament and of the ligament of the ovary have been but little studied by modern methods; Mihalkovics, **85.1**, 418, and G. Wieger, **85.1**, have shown that they are parts of the same cord of tissues, and that by the assumption by the ovary of its transverse position this cord of tissue is subdivided into the two ligaments by becoming bent at the summit of the uterus. The primitive ligament is usually regarded as the homologue of the gubernaculum of the male.

Epididymis and Epoophoron.—It is desirable to treat this organ, which is known under different names in the two sexes, as a single organ, not, as is often done, as a distinct organ in each sex. In both sexes there is a small number of permanently preserved and considerably modified Wolffian tubules from the anterior part of the urogenital ridge, which remain permanently connected with the cephalic or upper end of Wolffian duct. The organ thus formed becomes in both sexes very closely associated with, indeed we might better say incorporated in, the sexual gland. In the female the organ is rudimentary and has been variously named; as it was first accurately described by Rosenmüller, **02.1**, it has been widely known as the "organ of Rosenmüller;" Kobelt, who demonstrated, **47.1**, that it was a remnant of the primitive kidney, introduced the term "parovarium." Waldeyer has proposed, **70.1**, 142, "epoöphoron" to be comparable with the epididymis, with which he recognized the parovarium to be homologous. In the male the organ has great functional importance, for its tubules serve to convey the spermatozoa from the seminiferous tubules to the Wolffian duct, and accordingly it is in the male that the full development of the organ is attained.

A. EPIDIDYMIS.—In the male human embryo of the third month there are found from ten to twenty tubules in the anterior part of the Wolffian body, which have become connected with sexual cords or future seminiferous tubules of the testis, and have retained also their connection with the Wolffian duct. These tubules constitute the epididymis, and the portion of the Wolffian duct which follows immediately below them, by becoming very much convoluted gives rise to the so-called head of the epididymis. At three months (Kölliker, "Grundriss," 2te Aufl., 426) traces of glomeruli can be still found in the primitive kidney, and the epithelial tubules anastomose with one another in the region between the Wolffian body proper

and the testis proper. These anastomoses constitute the *rete Halleri*, while the Wolffian tubules become the *vasa efferentia* of the adult. According to Kölliker, *l.c.*, the vasa become convoluted during the fourth and fifth month, and thereby develop the so-called *coni vasculosi*.

The early development of the epididymis is known chiefly through Braun's observations, 77.4, 149, on reptile embryos. Solid outgrowths appear early from the walls of the Malpighian corpuscles of the Wolffian body, and these penetrate toward the testis as cords, which subsequently acquire a lumen. The primitive connection is between the tubules of the testis and the mesonephric glomeruli—a disposition which is permanent in some of the amphibia (see J. W. Spengel), but in all amniota the glomeruli disappear. C. K. Hofmann (Bronn's "Thierreich," VI., III. Abth., p. 2062) asserts, in opposition to Braun, that the glomeruli persist in *Lacerta agilis* at least one year after hatching. In mammals, Mihalkovics, 85.1, 472, found the outgrowths from the glomeruli in cat, dog, and rabbit embryos of 5-6 cm., but the Malpighian corpuscles disappear early during embryonic life.

B. EPOÖPHORON (or organ of Rosenmüller).—Beyond tracing out the general history far enough to establish the homology with the epididymis (Waldeyer, 70.1, 142), little has been done to elucidate the development of the organ in the embryo. It has been already pointed out that the medullary cords of the ovary are presumably parts of the epoöphoron. The epoöphoron is formed from perhaps ten to fifteen Wolffian tubules, and the outgrowths from the Malpighian corpuscles remain, in part at least, solid cellular cords; the Malpighian corpuscles of the organ disappear very early in the human embryo (? third month). F. Tournoux, 88.3, has described the epoöphoron in various mammals and in the human species at birth and in the adult, and has shown that its structure entirely confirms its homology with the epididymis.

Paradidymis and Paroöphoron.—By these names is designated, in males and females respectively, the organ constituted by the persistent tubules of the posterior part of the Wolffian body. The organ was first described in the male by Giraldès, 61.1, under the name of the "corps innominé," and was first described in the female by Waldeyer, 70.1, 142. The persistent rudimentary mesonephros of the human embryo has a yellowish color; the tubules are wide, their cells pale with indistinct nuclei, and have not only no connection with the sexual gland, but have lost their original connection with the Wolffian duct. The position of the organ in the male and female human embryo of about three months has been figured by Waldeyer. The interesting post-fœtal changes have been made the subject of an excellent paper by Czerny, 89.1.

Genital Cord.—That the posterior (lower or caudal) ends of the two urogenital ridges unite into a single median mass, the genital cord, has been pointed out above, p. 491. The genital cord is a structure peculiarly characteristic of the placental mammalia, being found only in them and in certain marsupials. It does not occur in monotremes or Sauropsida. The genital cord and its significance were first recognized by Thiersch, 52.1. The fullest history of the

cord yet published is that given by Mihalkovics, **85.1**, 324-347, upon which this section is based.

The pelvic portions of the two urogenital ridges unite so as to form a transverse partition (rabbit embryo of about 14 mm., pig embryo of about 30 mm.). This partition is the genital cord (*Genitalstrang*) of Thiersch. It stretches across between the rectum, which is on the dorsal side, and the allantois on the ventral side, compare Fig. 271; it is thick and the mesenchyma of which it is chiefly composed is a dense tissue. At the time the two ridges unite, their pelvic ends contain only the Wolffian ducts, hence the Müllerian ducts, as they develop, grow into the already formed genital cord, and in the female (human embryo of 3 cm.) begin to unite almost immediately after they appear in the cord. The formation and position of the partition is well illustrated by Mihalkovics, **85.1**, Figs. 114 and 115. After the genital cord is once formed, it is drawn more and more into the pelvis, and as the coelom extends farther into the pelvis on the dorsal than on the ventral side of the

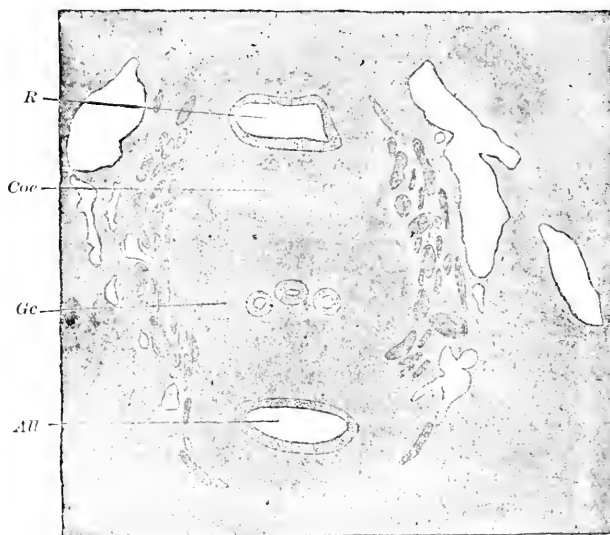


FIG. 271.—Cross Section of the Rectum, Genital Cord, and Allantois of a Male Human Embryo of about two Months. *R*, Rectum; *Coe*, coelom; *Ge*, genital cord, with the two Wolffian ducts, and the median united Müllerian ducts between them; *All*, allantois.

cord, we obtain in sections the picture reproduced in Fig. 271, which shows the typical relations of the genital cord in the indifferent stage; the cord consists chiefly of a very dense mesenchyma, and is quite sharply bounded, except against the allantois, and it contains three longitudinal epithelial tubes, of which the median represents the united Müllerian ducts, the two lateral the Wolffian ducts, *W.d.*

Wolffian Duct.—The cephalic end of the duct remains, as we have seen, in connection with the anterior Wolffian tubules as the duct of the epididymis of the male, of the epoöphoron of the female. In the male it also forms the adult spermiduct and the vesiculæ seminales,

in the female the rudimentary duct of Gärtner. It is important to note that in both sexes the Wolffian duct contributes to the formation of the utero-vaginal canal (fused Müllerian ducts) according to the observations of Mihalkovics, **85.1**, and Tourneux, **87.2**, upon the male, and of Van Ackeren, **89.1**, upon the female.

A. SPERMIDUCT OF THE MALE.—Since the demonstration, by Johannes Müller, that the Wolffian duct becomes the spermiduct, little has been done upon the history of the male canal. Thiersch in 1853 drew attention to the union of the caudal parts of the urogenital fold as the genital cord, see above. This cord exists temporarily in the embryo of man, and while it lasts the two spermiducts run through it, together with the two Müllerian ducts, which partially abort later. This stage is described and figured by Kölliker ("Entwicklungsgeschichte," 1879, p. 985 and Fig. 598). Later the genital cord divides, and its dense tissue forms a thick wall around each epithelial Wolffian duct.

The *vesicula seminalis* arises as a lateral evagination of the Wolffian duct. At five months the evagination is a simple sac about 1 mm. long, and is situated entirely within the genital cord. The evagination passes at first out horizontally, and then bends upward (Mihalkovics, **85.1**, 379).

B. GÄRTNER'S CANALS OF THE FEMALE, so named after their discoverer, are epithelial tubes which are sometimes found in the walls of the uterus, and even of the vagina, one on each side. Their significance is said to have been first recognized by Jacobson in 1830 and to have been clearly demonstrated by Kobelt in 1847. It is known that the Wolffian ducts always run through the genital cord, Fig. 271, and can be usually seen in cross sections of the uterine portion of the genital cord of the female human embryo of four to five months, and occasionally in older specimens, and even in the adult. On the disappearance of the Wolffian duct see Van Ackeren, **89.1**, 34. In the foetus the Wolffian ducts open into the vagina during the fourth month; their ends dilate and the dilated cavities fuse with the lumen of the vagina.

Müllerian Duct.—The history of this duct is the reverse of that of the Wolffian duct, since it becomes rudimentary in the male, and the functional sexual duct in the female.

A. MALE.—**HYDATID OF MORGAGNI AND UTERUS MASCULINUS.**—In the male the middle part of the Müllerian duct usually aborts, leaving the upper part with its open funnel close to the testis and the lower part within the genital cord. The upper part gives rise to the *hydatid of Morgagni* as maintained by Kobelt, **47.1**, and later by Waldeyer, **70.1**, 127. This explanation of the origin of the hydatid has by no means been put beyond question by strict observations—but we need no additional evidence to set aside the notion of Fleischl and Krause that the hydatid is the homologue of the ovary (!). The lower part of the Müllerian duct is contained within the genital cord, where it unites with its fellow to form a single median canal between the two Wolffian ducts—compare Kölliker, "Entwicklungsgeschichte," 1879, Fig. 598, *m*. This canal corresponds to the cavity of the uterus and vagina in the female. It varies greatly in its degree of development in individuals, but

usually persists in the adult as a small sac, known as the *uterus masculinus* or *vesicula prostatica*. According to E. H. Weber, the vesicula, which is rudimentary in man, is well developed in various mammals. For references to the literature of the subject, and an account of the organ in the rabbit, see V. von Mihalkovics, **85.1**, 364-378: The Wolffian duct contributes to the formation of the uterus masculinus, as it does to the formation of the vagina in the female, see p. 506.

B. FEMALE.—FALLOPIAN TUBE, UTERUS, AND VAGINA.—These are developed from the Müllerian ducts, but it is to be remembered that, strictly speaking, the epithelial Müllerian ducts produce only the epithelial lining of the adult tuba, uterus, and vagina, and that the connective tissue, which forms the thickest part of the walls in the adult, is developed from the mesenchyma of the urogenital fold.

Fallopian Tube.—The fullest account is that given by Mihalkovics, **85.1**, 304-306. The tube is developed from that part of the Müllerian duct which runs along the Wolffian body and is not included in the genital cord. The epithelium becomes much thinner except in the funnel, where it retains its cylindrical character. Later—in chicks about the eighth to tenth day—the mesenchyma begins to condense around the duct, thus initiating the development of the connective-tissue

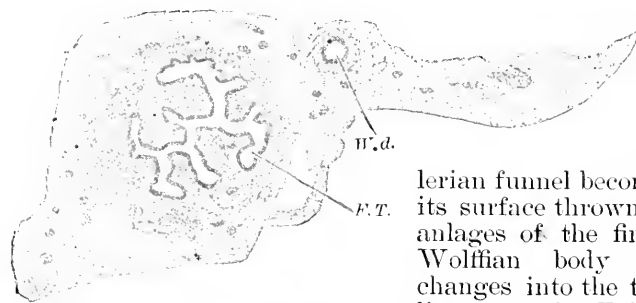


FIG. 272.—Section of Broad Ligament of a Female Human Embryo of four Months. Mimot Collection, No. 35. To show the Fallopian tube, *F.T.*, and Wolffian duct, *W.d.*

coats of the tube; shortly after the mesenchyma wall begins to develop the Müllerian funnel becomes larger, and its surface thrown into folds—the anlagen of the fimbriae. As the Wolffian body atrophies and changes into the transverse broad ligament, the Fallopian tube appears more and more at the edge of the urogenital fold, and changes its primitive longitudinal course to a transverse one—the primitive course being retained until the end of the third month. After the third month the tube elongates faster than the broad ligament and consequently assumes a sinuous course. By the sixth or seventh month, the definite transverse position is attained. By the fourth month, Fig. 272, the folds at the ovarian end of the tube, *F.T.*, are well developed, but the thick dense mesenchymal coat is not yet divided into muscular and adventitial layers; at this time the small Wolffian duct, *W.d.*, still persists, though later it usually disappears.

Uterus and Vagina.—As stated above, p. 502, the genital cord contains four ducts, compare Fig. 271: the two laterally placed Wolffian ducts, and the two Müllerian ducts, which lie nearer the median line and more dorsally. In man the genital cord is the anlage of both the uterus and the vagina; within the cord the two Müllerian ducts unite in the median line, forming a single canal;

the cephalad portion of this canal becomes dilated into the uterine cavity, and its epithelium becomes the lining of the uterus; the caudad portion develops into the vagina; the mesodermic tissue of the cord is converted into the muscular and connective tissue layers of the adult passages; finally the Wolffian ducts atrophy, ususally completely, but they sometimes persist to a greater or less extent as rudiments, known as Gärtner's canals, which lie on one or both sides in the walls of the uterus.

Our knowledge of the development of the uterus and vagina is based upon numerous investigations. The fusion of the Müllerian ducts was known to Johannes Müller, **30.1**, in 1830, but he failed to ascertain that the fusion produced not only the uterus, but also the vagina; the latter was regarded for some time as a derivative of the urogenital sinus. This error was corrected by Bischoff in his manual of "Embryology." Important advances were made by Thiersch, **52.1**, and by Leuckart in his important article "Zeugung," in Wagner's "Handwörterbuch," 1853. We pass to the modern period of investigations based chiefly on the microscopic study of sections. L. Fürst described in 1867 the fusion of the Müllerian ducts very accurately. H. Dohrn's researches ("Schriften Ges. Nat.-wiss.," Marburg, 1869, No. 3, also Bd. IX., 1871, p. 255) confirmed Fürst's observations and did much to elucidate the history of the uterus. Finally may be mentioned the very admirable monographs of Tourneux and Legay, **84.1**, of Mihalkovics, **85.1**, 332 and 347, and W. Nagel, **91.2**, which have been my chief guides in the preparation of the following account, and to which I refer the reader for a fuller index of the literature. Interesting additional details have been recorded by Van Ackeren, **89.1**.

The genital cord extends by the fourth month from the insertion of the Hunterian or round ligaments to the urogenital sinus. The Müller's ducts fuse in the median line between these two points, except at the upper end; that is to say, the ducts diverge, after the complete fusion, a little below the round ligaments and these divergent portions become the horns of the uterus. The fusion commences at the end of the eighth week about two-thirds of the way down from the cephalad end of the cord to the urogenital sinus, and progresses from that point both upward and downward, but the upper two-thirds are united before the lower extremities. The process is completed according to Fürst by the end of the third month. In the pig, mouse, and rabbit, the fusion commences at the same relative point, but in the sheep it begins higher up. The single canal thus produced is known as the *genital canal*, or better as the *utero-vaginal canal*. A failure of the lower ends to fuse leaves two openings (double or biperforate hymen).

W. Nagel, **91.1**, has pointed out that the genital cord becomes bent very early in the human embryo, so as to divide the cord into an upper or uterine limb, which is inclined ventralward over the bladder, and lower or vaginal limb, which runs longitudinally between the bladder and rectum. At the end of the third month, the simple epithelium lining the cavity of the canal changes its character in its lower third, becoming there a stratified pavement epithelium, which passes over very gradually into the cylindrical epithelium

of the upper portion. The change progresses upward, and as it advances, the demarcation between the two kinds of epithelium becomes sharper. By the eighth month the passage is abrupt and occurs at the middle of the canal. The stratified epithelium lines the vaginal limb, which occupies half the genital cord at birth. After birth the uterine limb enlarges more rapidly than the vaginal.

VAGINA.—During the fourth month the vaginal limb expands laterally and becomes flattened dorso-ventrally. Its two epithelial surfaces meet and grow together, closing the lumen of the vagina and forming an epithelial lamina, the cells of which now commence a rapid proliferation which thickens the vagina and forces down its lower end, thus forming the hymen because the actual diameter of the vagina, where it is connected with the sinus, does not share in the general dilatation. The epithelial plate of the vagina has two features requiring special mention: 1. A short distance above the sinus it is T-shaped in transverse section; the two side portions are probably remnants of the Wolffian ducts which unite with the vagina at this point. In this connection it is significant to observe that in the cow the persistent ducts of Gärtner (Wolff) open into the vagina; the question arises whether this connection is not general in the Placentalia. 2. At its upper end the lamina forms a cup-shaped outgrowth, which embraces the lower end of the uterus. Everywhere between the two points thus specialized the lamina is crescentic in section, the concavity facing the back. The anlagen of the rugæ of the vagina appear during the end of the fourth month as budding ridges on the outside of the lamina. Finally the permanent lumen of the vagina begins to appear during the sixth month and is formed by the breaking down of the central cells of the lamina. This process penetrates the cup-shaped outgrowth just described, so that the lower end of the uterus protrudes into the vagina, in consequence, be it remarked, of the vagina growing up around the extremity of the uterus. The stratified epithelium often extends a short distance inside the os uteri.

UTERUS.—The cavity of the uterine limb is always open, and its epithelium composed of a single layer of cells, which diminish in height from 50 μ (third month) to 25 μ (eighth month). A short time before birth the epithelium of the cervix develops into beaker cells. This transformation has been well described by Möricke, 82.1. The cells increase in length and the nuclei move toward the base of the layer; the upper portion becomes clear and no longer stains with picrocarmine owing to the formation of mucus. These cells secrete the mucous plug which fills the cervix at birth. As far as ascertained there are no cilia in the foetal uterus. The development of the arbor vitæ of the uterus commences at the end of the fourth month with the appearance of the main stems (rachis), which extend from a little above the future os nearly to the fundus. Their disposition is asymmetrical, the two stems of the posterior wall lying to the left, of the anterior wall to the right; hence the cavity of the uterus is somewhat S-shaped in section. The arbor vitæ is merely a set of folds of the uterine mucosa.

The mesoderm of the genital cord differentiates very slowly. The first noticeable change is the increased vascularity of the part next

the epithelium; this vascular layer becomes the mucosa, and the tissue outside it the muscularis. The latter does not become distinct histologically until the close of the fifth month. The muscular fibres are very irregularly disposed; however, the trend of the inner ones is circular, of the outer longitudinal.

The glands of the uterus and vagina do not appear until after birth, except in the cervix uteri, the glands of which arise the middle of the fifth month (Van Ackeren, 89.1). Cadiat, 84.1, maintains that those of the corpus uterus arise during fetal life. This opinion I consider erroneous; has not Cadiat mistaken folds of the arbor vitæ for the anlagen of glands?

The following table indicates the growth of the uterus and vagina:

Fœtus from vertex to coccyx.	Supposed Age.	Canal, Length.	Vagina, Length.	Uterus.
7.5 cm.		5. mm.	2.2 mm.	2.8 mm.
9.0.		6.5	3.5	3.0
12.5.		13.0	6.5	6.5
16.0.		21.	10.	11.
20.		29.	16.	13.
Child.	Eight days.	35.	10.	25.
Child.	Four months.	50.	30.	20.
Child.	Three years.	65.	40.	25.

A few words must be added concerning the comparative morphology of the uterus. The round or Hunter's ligaments mark in all mammals the division between the Fallopian and the uterine portion of Müller's ducts. In man the whole of the uterine division is included in the genital cord and participates in the formation of the single median uterus.

HYMEN.—The hymen is said to be the homologue of the verum montanum of the male urethra. It appears about the beginning of the fifth month as a transverse ridge situated on the ventral side of the vestibular end of the vagina, and projecting into the urogenital sinus (vestibulum). At this time the vagina begins its dilatation, and as it widens it appears to force down the hymen, which is thereby rendered more protuberant. The hymen is a thin non-muscular fold covered on one surface by the epithelium of the sinus, and on the other by the epithelium of the vagina, the latter being much thicker than the former. The hymen grows rapidly after its first appearance. When, as may happen by an arrest of development, the lower ends of the Müllerian ducts do not fuse, the hymen presents two orifices leading into a single vagina (H. Dohrn, 75.1; Tourneux and Legay, 84.1, 345). The development of the hymen has been studied by H. Dohrn, 75.1, 78.1, Tourneux et Legay, 84.1, Mihalkovics, 85.1, 349, and Van Ackeren, 89.1, 30.

Development of the Kidney.*—The true or permanent mammote kidney has no homologue, so far as known, in the amniota, the so-called kidneys of the latter being Wolffian bodies (mesonephri). We are entirely unable at present to trace the probable evolution of the kidney, for the view advanced by Semper, 75.2, that it is a modification of the hind end of the Wolffian body is negated by the

* For further details see Ove Hamburger, 50.1.

embryonic development of the kidney. Nor do we possess any light as to the factors by which the development of the kidneys is initiated in embryos. In short, we are compelled to confine ourselves to a bare narration of the actual development, as known at present.

THE RENAL ANLAGE.—The renal anlage consists of three parts, the epithelial evagination of the Wolffian duct, the condensed mesenchyma, and Braun's cords, which appear in the order named.

The epithelial evagination appears on the dorsal side of the Wolffian duct near the opening of the duct into the intestinal canal (cloaca). The evagination appears in the chick at the end of the fourth day, in crocodiles of 12 mm., in *Lacerta agilis* about eight days after the eggs are laid, in the rabbit the eleventh day, in sheep embryos of 8 mm., in human embryos of 5 mm. The evagination rapidly changes in character: *first*, by elongating forward and by the enlargement of its cephalic end, Fig. 444, *N*; *second*, by acquiring (in the chick by the sixth day) a direct opening into the urogenital sinus or hind end of the intestinal canal. The enlarged blind end is the anlage of the epithelial portions of the kidney, that is to say, of the lining of the pelvis and of the renal tubules; the remainder of the evagination becomes a long narrow tube, which may be at once designated as the ureter, although it corresponds, of course, only to the epithelial lining of the adult ureter. The way in which the evagination grows is well illustrated in Fig. 444, *B, D, C*.

The blind end of the renal evagination grows forward on the dorsal side of the Wolffian body and continues this growth while it is developing into the kidney, so that the more advanced the kidney in its differentiation, the more of the Wolffian body is covered dorsally by it. The mesenchyma around the blind end very soon becomes condensed, but the condensation, at least in crocodiles, occurs chiefly on the medial side of the renal tube. The relations just described are well illustrated in Fig. 273. The condensed mesenchyma can be followed some distance along the ureter and there gradually becomes looser, and its concentric arrangement disappears (Wiedersheim, 90.3, 446). The primitive anlage of the kidney, therefore, comprises the dilated end of an

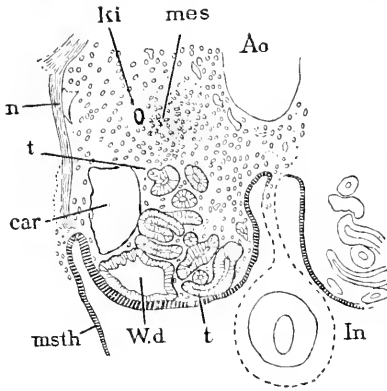


FIG. 273.—Cross Section through the Hind End of the Left Wolffian Body of a Crocodile Embryo of 12 mm. *N*, Nerve; *Ao*, aorta; *M*, mesentery; *In*, intestinal canal; *t, t*, Wolffian tubules; *W. d.*, Wolffian duct; *msth*, mesothelium; *car*, cardinal vein; *ki*, evagination to form the kidney; *mes*, condensed mesenchyma. After Wiedersheim.

epithelial tube and condensed mesenchyma. It is convenient to consider the history of the two separately.

MESENCHYMA.—The histogenesis of the mesenchymal portions of the kidney is almost unknown. It seems to me particularly desirable that the history of the blood-vessels should be ascertained. Golgi, 89.1, 341, observed that in the foetal kidney the arteries subdivide and form an irregular network of capillaries in the peripheral portion

of the organ, and when the glomerulus begins to form it contains a single loop of this network, and later from this primary loop secondary loops bud forth until the circulation of the glomerulus is completed.

It is important to note that the fibrous capsule is developed very early, before there are any glomeruli—for instance, it is present in the kidney of an embryo rabbit of fifteen days, and at sixteen days is figured as quite thick by Kölliker ("Entwickelungsgesch.," 1879, Fig. 581). The capsule is definitely present in human embryos of 20–25 mm. length and is formed of spindle-shaped anastomosing cells (W. Nagel, **89.3**, 367). My observations have led me to believe that the capsule is the essential mechanical condition for the development of the glomeruli, compare below.

TUBULES AND MALPIGHIAN CORPUSCLES.—The tubules arise as branches of the blind end of the renal evagination and the blind ends of the branches form the so-called Malpighian corpuscles. The branching begins very early, compare Fig. 444, *D, C*, and gradually a distinction becomes recognizable between the enlarged end of the ureter, destined to form the pelvis and the tubules proper—a distinction which becomes more and more marked as development progresses. The branches are at first short but wide, and form wide angles with one another; their walls are a rather high cylinder epithelium. At an early period—in the rabbit by the fourteenth day—the branches reach the capsule, which has meanwhile been differentiated from the surrounding mesenchyma. The capsule seems to prevent the further elongation of the branch in its line of growth, and to force the end of the branch to curl over, thus by a simple mechanical condition causing the formation of the anlage of the Malpighian corpuscle. This rôle of the capsule has not been noticed hitherto, so far as I am aware. My attention was called to it by observing that in older kidneys (human embryos of three, four, and five months) the formation of the Malpighian corpuscles always goes on close against the capsule, Fig. 274: one sees a straight collecting tubule, which runs to the capsule and there bends over into the anlage of the convoluted tubule and Malpighian corpuscle; the younger the corpuscle the nearer is it to the capsule. To explain the difference in position, we must assume that the corpuscles remain approximately where they arise and that the capsule enlarges, and thereby gives opportunity for new Malpighian corpuscles to be developed outside of the older ones—examination of the carefully drawn Fig. 276 will make the distribution of the corpuscles clear. The *collect-*

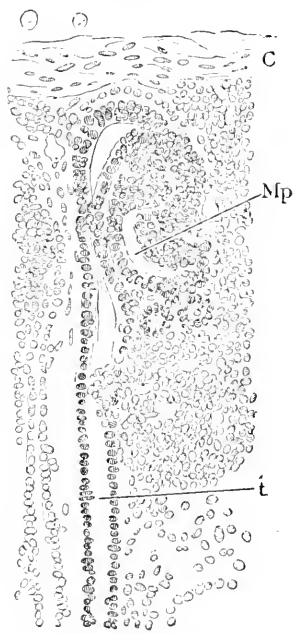


FIG. 274.—Section of a Kidney, Human Embryo of about five Months. Minot Collection, No. 34. *C*, Fibrous capsule; *Mp*, Malpighian corpuscle; *t*, collecting tubule.

ing tubules appear to all arise as branches, at first from the end of the ureter, after that from the collecting tubules already formed—the details of their development have still to be ascertained; at first the branches devaricate at wide angles, but later they show the characteristic U-shaped fork of the adult, compare Fig. 276, *col.* The *convoluted tubules and Malpighian corpuscles* develop according to Golgi, 89.1, as follows: The end of the tubules bend over, Fig. 275, into an S-shape; in Golgi's diagrams each main tubule is represented as forming two convoluted tubules at once; whether this is the case is not quite clear from his text, but it is probably true. I think, of the first-formed Malpighian corpuscles, but later each straight tubule forms, so far as I can observe, only one corpuscle and convoluted tubule. The different parts of the S-shaped tubule have each their fixed destiny. The end of the S (in the diagrams the lower part) receives the vascular loop, which gives rise to the blood-vessels of the future glomerulus, *gl*; the lower limb of the S, *a*, elongates enormously and forms the first division of the convoluted tubule including the loop of Henle, *H*; the upper limb, *b*, of the S also elongates very much—though less than the lower limb—and is

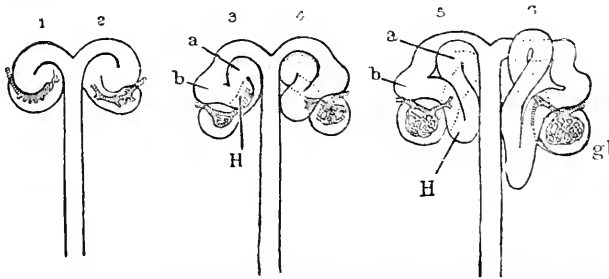


FIG. 275.—Semidiagrammatic Figures of Developing Renal Tubules of a Mammal. 1, 2, 3, 4, 5, 6, Successive stages; *gl*, blood-vessels of glomerulus; *a*, first, *b*, second portion of convoluted tubule; *H*, Henle's loop. After Golgi.

the anlage of the second division of the convoluted tubule; where the two limbs join the tubule passes close to the Malpighian corpuscle and seems to be intimately attached to it. This attachment is preserved, according to Golgi, in the adult kidney. During development it acts as a fixed point, which parts the convoluted tubule into two primary divisions, which, as is well known, are persistent. Henle's loop rapidly elongates in the direction parallel to the straight or collecting tubule and toward the medulla, its elongation perhaps explaining why it increases in diameter less rapidly than the remaining parts of the tubules. The development of the corpuscles has been described quite fully by Toldt, 74.1, and also by Kölliker in his "Entwicklungsgeschichte, 1879," 949, but it is to be noted that the S-shaped tubule is not merely the anlage of the Malpighian corpuscles, as supposed by these authors, but also of the convoluted tubule. The blind end alone forms the corpuscle; the wall of this end is pushed in by the very formation of the S, and the end assumes somewhat the shape of a rubber ball with one side pushed in (Toldt), in the concavity of which a network of capillaries appears, Fig. 275, *gl*. In older kidneys of the human embryo, the concave side is always

turned away from the straight collecting tubule with which the corpuscle is connected, Fig. 276. The epithelium upon the convex side is much thinner than that of the concave side, and as development progresses this difference becomes more marked; the space of the

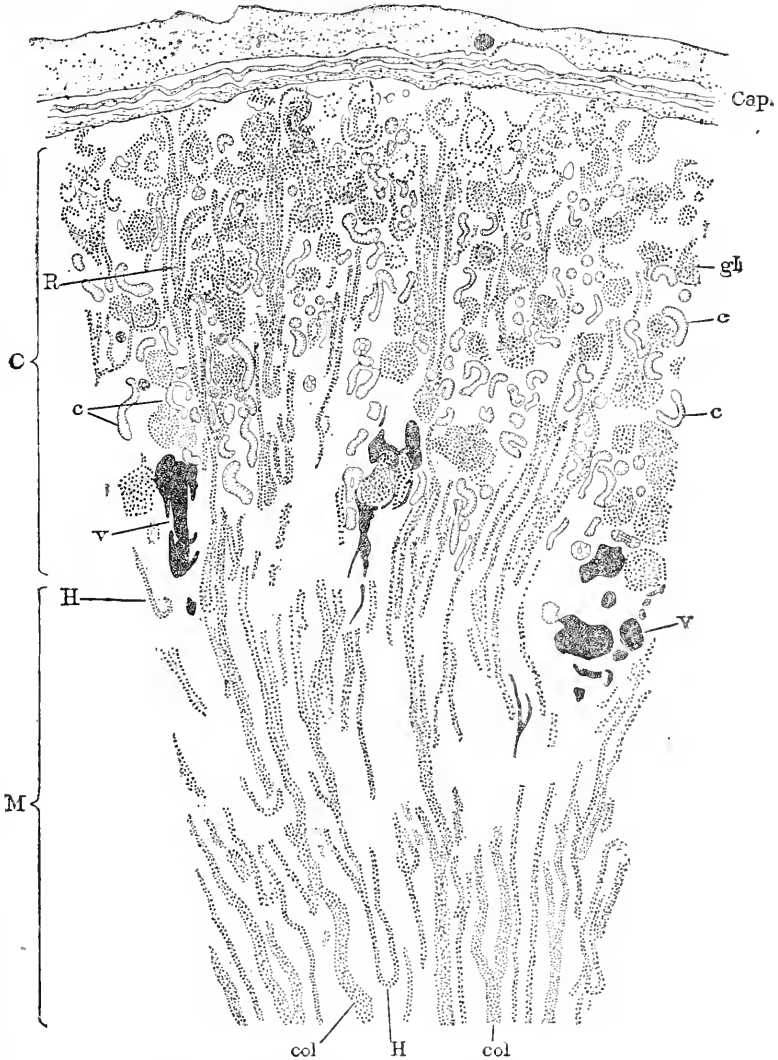


FIG. 276.—Section Parallel to the Medullary Rays of the Kidney of a Human Fœtus of about five Months. Minot Collection, No. 34. Explanation in text.

tubule is the cavity of the corpuscle; the thin epithelium is the lining of Bowman's capsule; the thicker epithelium covers the glomerulus. The further differentiation depends chiefly upon the assumption of the spherical form and upon the growth of the glomerulus and its vessels. The original area, by which the vessels enter the glomer-

ulus, remains about the same, or perhaps even diminishes in size, but the Malpighian corpuscle grows, and hence the neck by which the vessels enter becomes relatively much smaller. The corpuscles continue their growth for a long period, and are smaller in the fœtus than in the adult, therefore they must continue to grow after birth.

Some authors have maintained that there is an atrophy of some of the tubules of the fœtal kidney, but I agree with Golgi, 89.1, in believing that of this there is no valid evidence.

I present figures of two typical sections of human fœtal kidneys, Figs. 276, 277. The first, Fig. 276, represents a radial section of a




FIG. 277.—Cross Sections of the Medullary Tubules of the Kidney of a Human Embryo of about Five Months. Minot Collection, No. 34. Explanation in text.

kidney at about five months. The capsule, *Cap*, is fibrous and thick. The separation of the cortical, *C*, and medullary zones, *M*, is given by the distribution of the Malpighian corpuscles, of which the youngest stages are found near, the oldest farthest from, the capsule; between the two zones are situated the main blood-vessels, *rv*, drawn dark in the figure; the medullary rays, *R*, are distinct, but consist each of only a few tubules: the convoluted tubules, *cc*, are very pale and not all of them are represented; to render the figure clearer they are drawn without nuclei; Henle's loops, *H*, are found at all levels, and show, as yet, no very distinctive histological features;

the collecting tubules, *coll*, are large and show the typical branching with great perfection. Especially characteristic of the foetal kidney is the large proportion of connective tissue, and the consequent wide separation of the tubules. The second section is through the medulla at right angles to the direction of the tubules, Fig. 277. Here the wide separation of the tubules by connective tissue is more apparent than in the previous figure. The collecting tubules are large and have a cylinder epithelium with evenly placed nuclei; the Henle's tubules, *H*, are much smaller, but vary greatly in size; as Golgi has pointed out, it is sometimes the ascending, sometimes the descending, limb which is small. Every collecting tubule is surrounded by a space, which at first I thought artificial, but as I find it in all specimens, including the freshest and best preserved, I conclude that it exists during life, and regard it as probably a lymph space.

BRAUN'S CORDS.—Max Braun, 77.4, 199-201, described cords of cells, which extend in very early stages of the embryos of lizards through the renal anlage. These cords differ but little from the rest of the mesenchyma, except in having their cells more closely crowded together, and that they can be traced to a direct connection with the mesothelium. This observation has since been confirmed—on chicks by A. Sedgwick, 80.1, on crocodile and turtle embryos by R. Wiedersheim, 90.3. The cords I must regard from Braun's own descriptions as merely the beginning of the condensed mesenchyma of the renal anlage. The three authors who have observed the cords regard them as the anlages of the convoluted tubules, though they bring no direct proof in support of this view, and since it has been positively demonstrated that the convoluted tubules arise from the collecting tubules, the view in question must be abandoned.

SHAPE.—The kidney is early marked out definitely by the development of its capsule, and in its first form is already "kidney-shaped," and has a smooth surface. When the development of the Malpighian corpuscles begins, the surface of the kidney changes, and at ten weeks (Burdach) is already divided into lobes, separated from one another by shallow but sharply defined depressions. The number of lobes is usually about eighteen in the human embryo, but Burdach ("Physiologie," Bd. II., 1828) describes eight lobes at ten weeks. The lobate stage is found in all amniota and is permanent in Sauropsida and cetaceans, but in most mammalia is confined to the foetal period. In man the lobes disappear soon after birth and the surface of the kidney again becomes smooth. Each lobe corresponds to the base of a Malpighian pyramid.

The appearance of the foetal kidney is also affected by its upper end being covered by the relatively large hood formed by the supra-renal capsule.

HUMAN KIDNEY.—The following dates as to the development in man are taken chiefly from Kölliker's "Entwicklungsgeschichte," 1879, p. 952. In an embryo six or seven weeks old the kidney measured $1\frac{2}{3}$ mm., was flattened, bean-shaped, and overlaid the Wolffian body. In the eighth week, it measured 2.5 mm. long, and lay far behind the large supra-renal capsule, with which it comes in contact during the third month. The lobules, as first fully described by

Toldt, **74.1**, appear during the second month and remain marked upon the external renal surface throughout foetal life. The Malpighian corpuscles begin to form toward the end of the second month, and continue forming until a few weeks after birth. The Henle's loops, as shown by Golgi, **89.1**, begin their development immediately after the corpuscles appear, and may be recognized in three-months' embryos, as I have observed, but are not well developed until the fourth month.

URETER.—Concerning the embryonic history of the ureter little is known. Kupffer, **65.1**, **66.1**, has shown that the stretch of the Wolffian duct between the original evagination and the urogenital sinus elongates somewhat, but as development proceeds this part becomes included more and more in the sinus, with the result that the two canals open separately. During these changes, the ureter becomes twisted so that its opening is situated in front of that of the Wolffian duct.

As to the histogenesis of the ureter I know of no observations.

HISTORICAL NOTE.—Remak, **50.1**, was the first to describe correctly the development of the kidney; he observed the forward growth of the ureter from the cloaca, the enlargement of the end of the ureter, and the outgrowth from it to produce the collecting and convoluted tubules. Kupffer, **65.1**, **66.1**, showed that the ureter was an evagination of the Wolffian duct near the cloaca, and this has since been confirmed by numerous observations on all classes of amniota; Kupffer added also the erroneous notion that the uriniferous tubules do not all arise as products of the ureter. Unfortunately Kupffer's error was upheld by Bornhaupt, **67.1**, Colberg (*Cbl. Med. Wiss.*, 1863). Goette, Thaysen, **73.1**, Braun, **77.4**, Sedgwick, **80.1**, Balfour, Riedel, **74.1**, and Emery, **83.1**, and even Wiedersheim, **90.3**. The authors since Braun have been largely influenced by theoretical considerations, especially by the wish to demonstrate that the true kidney is developed similarly to the Wolffian body (mesonephros), in other words that its secretory tubules are different in origin from its ducts. Remak's original view found few upholders, of whom Waldeyer, **70.1**, 132, Toldt, **74.1**, Kölliker ("Entwickelungsgeschichte," 1879), and Golgi, **89.1**, and W. Nagel, **89.3**, 365, are certainly the most important. Golgi may be said to have put the matter beyond debate so far as mammals are concerned. My own observations enable me to affirm with confidence that the tubules arise as evaginations of the ureter, and that in man the convoluted tubules and Malpighian corpuscles arise as branches of the collecting tubules. The facts are so clear that it is difficult now to understand how the opinion could have been entertained that the convoluted tubules arose from the blastema, and not as outgrowths of the collecting tubules.

Allantois and Bladder.—That portion of the allantois which lies within the body of the embryo, and extends from the anus to the umbilicus, becomes the bladder. It has been mentioned already that the ureters very early separate entirely in mammals from the Wolffian ducts and come to open into the neck of the allantois. The dilatation of the embryonic portion of the allantois to a fusiform vesicle begins in man during the second month; one end of the vesicle is connected

with the anal end of the intestinal canal, while the other end tapers out and is prolonged as the so-called urachus, into which the cavity of the vesicle is prolonged, but at some time not yet definitely ascertained the cavity of the urachus disappears, though seldom completely, for Luschka (Virchow's *Arch.*, XXIII.) found remnants of it even in the adult. The urachus is transformed into the ligamentum vesicæ medium (Kölliker, "Entwickelungsgesch.," 1879, p. 953).

The main vesicle becomes the bladder. The entoderm of the allantois becomes the epithelium, and the mesenchyma becomes the connective tissue and muscular walls of the bladder. The histogenesis and changes in shape of the embryonic bladder have still to be investigated.

Recently Retterer, 90.1, and Keibel, 91.1, have revived Rathke's conception, 32.1, I., 57, that the bladder is an outgrowth of the cloaca, which becomes early divided into a dorsal or intestinal and ventral or allantoic division. The distinction seems to me arbitrary between this notion and the view adopted above, since the allantois is in any case a prolongation of the entodermal canal, and neither Retterer nor Keibel show that there is a true division of the cloaca.

Urogenital Sinus.—I base this section upon Mihalkovics' monograph, 85.1, 307-324. As shown in Fig. 444, the allantois is the direct continuation of the intestinal canal, and the urogenital ducts open into the allantoic portion or the part of the canal on the ventral side of the future anus. After the anus is formed, there is a terminal portion, the so-called *cloaca*, into which both the intestinal canal proper and the allantoic canal open. The greater part of the allantois dilates into the bladder, but between the bladder and the cloaca the allantoic canal remains narrower; it is into this narrower portion that the Müllerian ducts open; the stretch between the bladder proper and the opening of Müller's duct is the urethra in the strict sense, while the part below received from Johannes Müller the name of *sinus urogenitalis*. The female adult urethra corresponds to the urethra as here defined,* but the male urethra includes both the urethra and the sinus. This may be called the monotreme stage, and is characterized by there being merely a single or cloacal opening, through which the excrement, urine, and genital products are discharged; the stage is the permanent one in non-mammalian vertebrates and in monotremata. An important advance is made in placental mammals by the subdivision of the cloacal opening into the ventral urogenital opening and the dorsal anal opening, which takes place in the human embryo about the fourteenth week, and involves the complete separation of the urogenital sinus from the intestinal canal. In the male the closure of the raphe penis converts the sinus into the prolongation of the urethra proper, as we may term the neck of the allantois or bladder above the opening of the fused Müllerian ducts (*uterus masculinus*). In the female the sinus persists as the vestibulum into which the urethra and vagina both open. The separated urogenital and anal openings lie at first in a shallow fossa or recess, the raised edges of which represent the anlagen of the external genitalia; see the following section.

PROSTATIC GLAND.—This gland is present during the fourth

* The relations are well shown by Kölliker, "Grundriss," Fig. 295.

(Kölliker) or fifth month (Mihalkovics) as a series of branching evaginations of the epithelium of the upper end of the urogenital sinus, which expand into wide irregular cavities. The muscular tissue is developed much later from the mesenchyma of the walls of the sinus (Kölliker, "Entwickelungs-ges.," 1879, p. 1000, and Mihalkovics, **85.1**, 378). The evaginations make their first appearance, according to Tourneux, **89.1**, 257, about the twelfth or thirteenth week, and persist in the female, though more or less in a rudimentary condition (Tourneux, Soc. Biol., Paris, Jan., 1888).

COWPER'S AND BARTHOLINI'S GLANDS.*—These names are applied to the same glands in the male and female respectively; they arise as paired evaginations of the lower part of the urogenital sinus. According to Van Ackeren, **89.1**, 44, the glands of Bartholini begin their development in man toward the end of the fourth month; during the fifth month the branches (*acini*) increase in number and are found separated from one another by considerable mesenchymal tissues: by the sixth month, as already described by R. Geigel, **83.1**, they form considerable organs 1×1.8 mm., of rounded form, but the left gland is a little smaller than the right; the acini now lie close together.

III. EXTERNAL GENITALIA.

The main facts in the development of the external genitalia, and the homologies between the two sexes, were worked out by Tiedemann—see his "Anatomie der kopflosen Misgeburten," Landshut, 1813, p. 84. A very good description of the foetal penis and clitoris is given by Joh. Fr. Meckel in his "Handbuch der menschlichen Anatomie," 1815-1820, so that Johannes Müller in 1830, **30.1**, could add but little. Some further details have been given by H. Rathke, **32.2**, and by Kölliker. Ecker in his "Icones Physiologicae" has given a series of figures, which have been extensively copied in text-books, and have been reproduced in the well-known and somewhat inaccurate wax models of Ziegler. In 1888-89 appeared Tourneux's admirable monographs, **88.1**, **89.1**, upon which the following account is based. We have to consider the history, 1, of the genital tubercle (penis-clitoris), 2, of the genital labia (scrotum-labia majora). The external genitals are homologous in the two sexes, but in the male they are more specialized than in the female; the condition in the adult female corresponds to that of the foetal male.

Genital Tubercle.—The anal plate becomes very much thickened until it constitutes—sheep embryos 13-25 mm., pig embryos 14-20 mm.—a thick plug of epithelium, on the dorsal side of which appears an external invagination, Fig. 278, the *vestibule anale* of Tourneux, which gradually penetrates until it leaves only a thin epithelial membrane to close the rectum, while the main plug (*bouchon cloacal*) closes the urogenital sinus or pedicle of the allantois, *S. ug.* The accumulation of mesenchyma on the ventral side of the epithelial plug, *pl.* of the cloaca is indicated by an external prominence, which may be already designated as the genital tubercle, *t. g.* As development progresses the genital tubercle rapidly

*The paper by Swiecicki in Gerlach's "Beiträge," 1883, I have not seen.

lengthens and the epithelium upon its dorsal side is reduced from a great plug to a thin layer, and by the disappearance of the plug both rectum and urogenital sinus become open to the exterior; the mass of tissue between the two openings is termed by Tourneux the *repli* or *éperon périnéal*. The genital tubercle owes its origin to the thickening of the anal plate, it gives rise to the penis in the male, to the clitoris and nymphæ in the female. The tubercle is quite prominent—measuring 1.5 mm. in length—in the human embryo by the tenth week and is then found to have its end knob-like, indicating the future glans, and its dorsal or anal side with a shallow groove, which directly prolongs the channel of the urogenital sinus, but only as far as the knob of the glans. About the tenth week there appear two eminences alongside the genital tubercle and the urogenital opening, which we may call the genital labia—compare Fig. 280, *lab*. The labia are solid hillocks of mesenchyma with a covering of epithelium, see Fig. 281.

In the female they persist as the labia majora and in the male as the scrotum.

PENIS.—In the male the genital tubercle continues elongating as follows:

Fœtus...	40.	50.	60.	105.	mm.
Penis....	2.	2.5	3.	3.5	mm.

and its dorsal groove not only deepens while it remains very narrow, but also closes, beginning at the base; the line of closure remains permanently marked by the raphe of the penis; the effect of the closure is to form an epithelial canal which prolongs the urogenital sinus (or urethra) into the penis; the epithelial canal separates from the epithelium covering the penis, except just below the glans, where the permanent opening is established. During the third month there appears first an epithelial ridge upon the glans, as in Fig. 280; this ridge lies in the prolongation of the groove; it soon disappears and the groove extends gradually on to the glans. It is at this stage (end of the third month) that the thick prepuce of the glans begins to develop, but the groove on the anal side prevents its forming a complete ring around the organ. The prepuce appears as a slight ridge which overgrows the glans, the epithelium of the inner surface uniting, as the fold extends, with the epithelium of the glans—the two epithelia fusing into one solid plate, Fig. 297, *ep*. Later the groove becomes closed to a canal, and the terminal opening of the canal is shut by the growth of the epithelium, Fig. 279, *a*, which plugs up the orifice. This fact is important from its bearing on the question of the origin of the amniotic fluid, p. 340. The two epithelial layers of the prepuce are separated by mesoderm. The relations which now exist can be better explained by reference to Fig. 279, which shows the glans in longitudinal section; observe the thickened epithelium, *a*, closing the orifice of the urethra; also

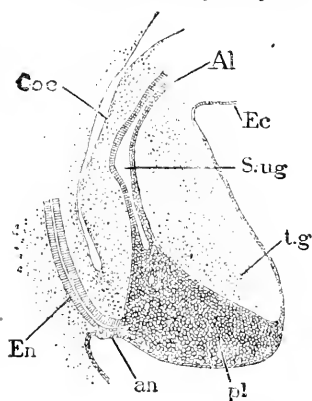


FIG. 278.—Longitudinal Median Section of the Cloaca of a Sheep Embryo of 18 mm. *Coe*, Cœlom; *Al*, allantois; *Ec*, ectoderm; *S. ug*, sinus urogenitalis; *t.g*, genital tubercle; *pl*, epithelium; *an*, anal plate; *En*, entoderm. $\times 22$ diams. After Tourneux.

that the epithelial plate—and consequently the prepuce also—extends further on the ventral side, *ep*, than on the dorsal, and that though

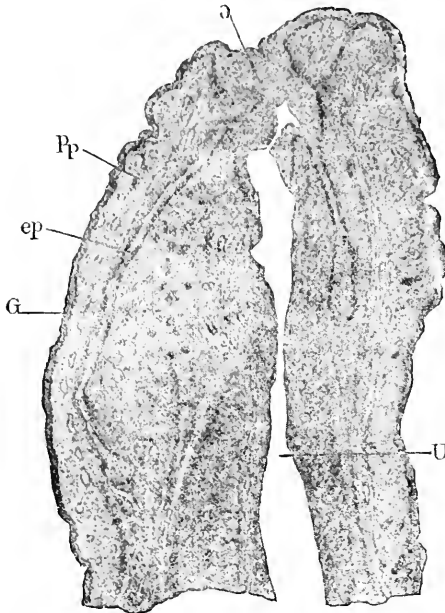


FIG. 279.—Longitudinal Section of the Penis of a Human Embryo of about five Months. Minot Coll. No. 34. *a*, Epithelial plug; *Pp*, prepuce; *ep*, epithelial lamina between prepuce and glans; *G*, glans; *U*, urethra.

the glans, *G*, is very vascular, the corpus cavernosum is remarkable for the absence of blood-vessels. Finally there may be noticed in the epithelial plate, *ep*, several places where the cells are arranged more or less concentrically; the appearances have been thought by Schweigger-Seidel, 66.1, to be connected with the cleavage of the epithelial plate to form the epithelium of the prepuce and of the glans. This cleavage does not take place until after birth, but just when is not known.

The *corpus cavernosum* develops slowly; it is first marked out as a dense mesenchyma, in which the blood capillaries develop more and more, beginning in the third month; but it is not until the sixth month that the capillaries begin to show any marked dilatation. The *cor-*

pus spongiosum develops also chiefly by the expansion of capillaries, but considerably later than the cavernosum. Retterer (Soc. Biol., Paris, 1889, p. 399) states that in various mammals the corpus cavernosum is very dense and fibrous before any blood-vessels appear in it.

CLITORIS AND NYMPHÆ.—The development of the genital tubercle in the female is in all respects similar to that of the male, but it does not pass beyond the stage in which there is an open urethral groove. The glans and prepuce are formed, as in the male, to constitute the clitoris, but the borders of the urethral groove do not unite, as they do in the male to form the stalk of the penis, but remain as elevated ridges known as the labia minora or nymphæ in the adult. During the third month the difference between the male and female tubercle becomes more and more clearly marked, and the distance between the urogenital and anal openings increases. By the end of the third month, Fig. 280, the glans measures about 1 mm., while the lips (anlages of the nymphæ) of the urethral groove measure about 3 mm. in length; around the base of the glans can be seen the commencing fold of the preputium,

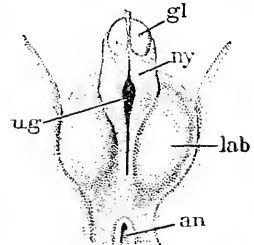


FIG. 280.—External Genitalia. Female Embryo of 105 mm. *gl*, Glans; *ny*, nymphæ; *lab*, labia majora; *an*, anus; *ug*, urogenital opening. After Tournoux. \times about 5 diams.

and upon the glans can be seen the median epithelial crest, which subsequently disappears, the urethral groove extending on to the glans during the fourth month.

The groove persists, so that in the adult the prepuce does not extend, as in the male, completely around the glans, but is cleft on the

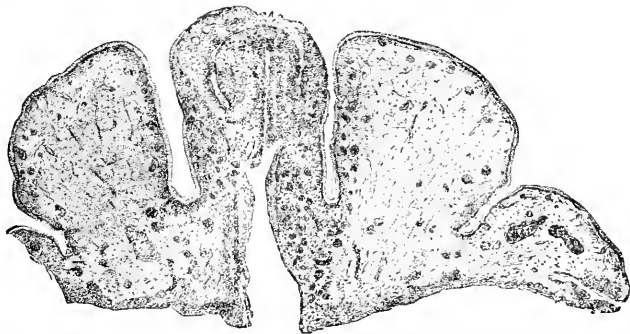


FIG. 281.—Section of the Clitoris and Labia Majora of a Human Embryo of about four and one-half Months. (Minot Collection No. 49.)

analside. Tourneux, 89.1, 254, observed in two cases epithelial ingrowths from the epithelium of the groove of the glans; these ingrowths he regards as the anlagen of the “glande clitoridienne” of Werthheimer (*Journ. de l'Anat. et Physiol.*, 1883), the homologue of the mucous glands of the sinus of Guerin in the male. The mes-

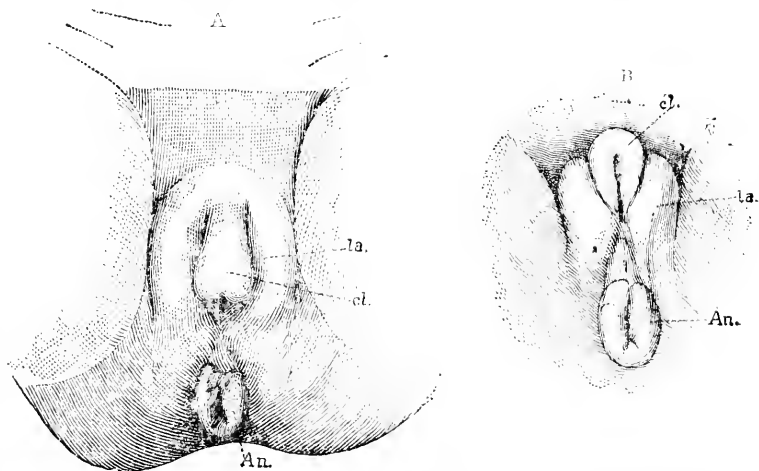


FIG. 282.—External Genitalia of the Female Human Fœtus at about four Months. Minot Collection No. 57. A, Ventral, B, perineal view. *cl.*, Clitoris; *la.*, labia majora; *An.*, anus.

enchyma of the glans persists at a stage corresponding approximately to that of the homologous tissue in the male at eight months, but the corpora cavernosa develop as in the male into true erectile tissue. The accompanying Fig. 281 represents a section of the clitoris and labia majores of a fœtus of the fifth month, the urethra

extends into the glans, which is covered by the prepuce; the glans is almost buried between the large labia majora.

Scrotum and Labia Majora.—There appear two prominences during the tenth week, one on each side of the genital tubercle. These prominences, which are merely hillocks, so to speak, of mesoderm covered by foetal epidermis, are the anlagen of the male scrotum and the female labia majora. Their relations are well shown in Fig. 280. In both sexes the genital labia attain considerable size; in the female the foetal type, Fig. 282, is but slightly modified, but in the male the two labia meet and unite during the fourth month between the base of the penis and the anus to form the scrotum; the raphe marks in the adult the line of junction; as stated above, p. 498, the vaginal processes grow into the scrotum and later the testis descends into it, p. 499.

CHAPTER XXIV.

TRANSFORMATIONS OF THE HEART AND BLOOD-VESSELS.

WE have already considered, Chapter X., the origin and early history of the heart and blood-vessels, and have now to consider the metamorphoses of the foetal organs of circulation to the time of birth. We shall take up, 1, the heart; 2, the arteries; 3, the veins.

I. TRANSFORMATION OF THE HEART.

We left the heart, p. 288, as a median longitudinal tube, with double walls, the inner endothelium, and the outer mesothelial or muscular; the double tube was free except at its ends, which were attached to the walls of the pericardium; the anterior end communicated with the aortic vessels, the posterior (caudal) end with the veins united in the septum transversum. To develop the adult heart out of this simple tube, five principal sets of changes occur: 1, the bending of the tubular heart; 2, the outgrowth of the auricles; 3, changes in the thickness and histological constitution of the walls; 4, the development of valves; 5, the appearance of secondary partitions dividing the right heart from the left.

The literature upon the heart is very extensive, but the history given by His, "Anat. menschl. Embryonen," Heft III., 129-184, of the human heart, and that given by Born of the rabbit's heart, **89.1**, are so thorough that I have relied chiefly on these two authors. Special mention ought also to be made of Carl Röse's dissertation, **88.1**. Besides the special papers on the heart, there are numerous observations scattered in general works. The general development of the chick's heart is described in the text-books of Kölliker and of Foster and Balfour, and in J. Masius' excellent article, **89.2**, based upon models constructed by Born's method. Of earlier papers that of Lindes, **65.1**, is specially noteworthy, and, as pointed out by His and Born, far in advance of his time.

Bending of the Heart and Formation of the Auricles.— After the disappearance of the mesocardium on both the dorsal and ventral side of the primitive heart, the heart is attached only by its aortic and venous ends. The early enlargement of the pericardial cavity has been already described; its size is important as affording the heart room to elongate, bend, and enlarge. The straight median heart grows rapidly, and to find room bends to the right; in the chick the bending begins at the close of the first day and increases very rapidly during the second day, Fig. 283, and becoming at the same time more complicated by the assumption of an irregular S-shape. In mammals the same form is assumed, and is found in the rabbit at nine days, in human embryos of 2.15 mm., Fig. 284.

The venous end of the heart Fig. 284, *V.I*, lies somewhat to the left and extends for a short distance toward the head and then passes into the ventricular portion of the tube, which curves, as shown in the cut, *V. l*, on to the ventral side, where it crosses obliquely to the right side, and then bending dorsalward finally runs toward the head and becoming narrower passes into the bulbous aortæ, *A. b*, or division of the heart tube, which passes in the median line into the trunk of the aorta. At this stage there is a very short venous or auricular division of the heart, a very long, thick, and much bent ventricular division, and a bulbous division of intermediate dimensions. The differentiation of these divisions comes out more clearly from the study of the endothelial heart (or heart cavities) at this stage, Fig. 285. The general course of the heart may be best understood by combining this figure with the preceding, remembering that Fig. 284 shows the muscular heart, which at this stage is still separated by a considerable space from the endothelial heart, and is much larger than the inner tube. In Fig. 285 the divisions of the heart are clearly marked; the auricular division, *V. h*, is very short and receives the omphalo-mesaraic, *v. o. m*, and umbilical, *v. u*, veins and the ducti Cuvieri on each side; it is continued

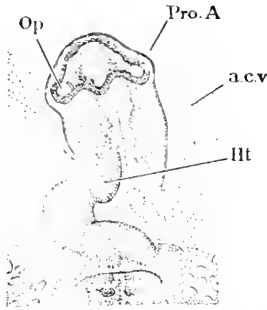


FIG. 283.—Head of Chick of Thirty-eight Hours seen from the Under Side. *Op*, Optic vesicles; *Pro. A*, proamion; *a. c. v.*, amnio-cardial vesicle; *Ht*, heart. $\times 26$ diams. After Duval.

stage is still separated by a considerable space from the endothelial heart, and is much larger than the inner tube. In Fig. 285 the divisions of the heart are clearly marked; the auricular division, *V. h*, is very short and receives the omphalo-mesaraic, *v. o. m*, and umbilical, *v. u*, veins and the ducti Cuvieri on each side; it is continued

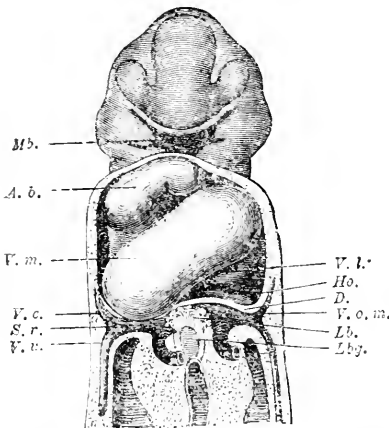


FIG. 284.—Reconstruction of the Heart and Veins of a Human Embryo of 2.15 mm. (His' embryo Lg.). *Mb*, Mouth; *A. b.*, bulbus aortæ; *V. m.*, left ventricle; *V. c.*, vena cava superior; *S. r.*, sinus rennibus; *v. u.*, vena umbilicalis; *V. l.*, venous limb of heart; *Ho.*, anlage of auricle; *D.*, septum transversum; *Lb.*, liver; *Lbg.*, hepatic duct. $\times 40$ diams. After W. His.

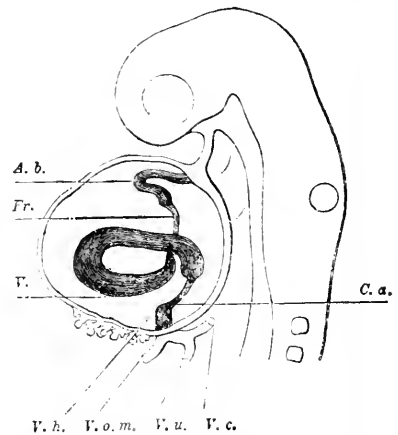


FIG. 285.—Endothelial Heart of a Human Embryo of 2.15 mm., seen from the Left Side (His' Embryo Lg.). *A. b.*, Bulbus aortæ; *Fr.*, fretum Halleri; *V.*, ventricle; *V. h.*, auricle; *V. o. m.*, vena omphalo-mesaraica; *V. u.*, vena umbilicalis; *V. c.*, vena cava; *C. a.*, auricular canal. $\times 40$ diams. After W. His.

headward by a portion, *C. a*, the auricular canal, which connects the auricle with the ventricle, *V*. The ventricle, *V*, is the widest and longest division of the heart; it describes a somewhat complex curve

from left to right, and is then continued headward on the right side of the embryo by a very narrow division, the fretum Halleri, *Fr*, which leads into the somewhat wider and curving bulbus aortæ. In a slightly older stage, Fig. 286, the lateral outgrowths of the auricular division have appeared, *Vh*, and are the anlagen of the true auricular cavities; the two limbs of the ventricle are now nearer together and where they join have a distinct apex, which, owing to the increased bending of the heart, lies a little below (in the figure) the level of the auricles, *Vh*. The irregularly S-like course of the heart is very evident in this figure; one loop of the S is constituted by the auricular division, *Vh*, the auricular canal, *C.a*, and part of the ventricle *V*; the second loop of the S is constituted by the whole of the ventricle, by the fretum Halleri, *Fr*, and the bulbus, *A.b*. As the auricular division comprises only about a sixth of the length of the heart tube and consequently only about a third of one loop of the S, we cannot say that the heart consists of a venous and an arterial

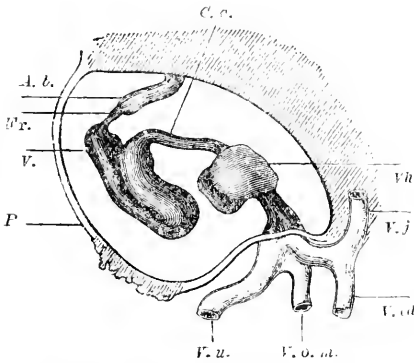


FIG. 286.—Reconstructed Side View of the Endothelial Heart of a Human Embryo of 4.2 mm. (His' Embryo L.). *C.a.* Auricular canal; *A.b.* bulbus aortæ; *Fr.* fretum Halleri; *V.* ventricle; *P.* wall of pericardium; *v.u.* vena umbilicalis; *v.o.m.* vena omphalo-mesaraica; *V.cd.* cardinal vein; *V.j.* jugular vein; *Vh.* auricle. $\times 40$ diams. After W. His.

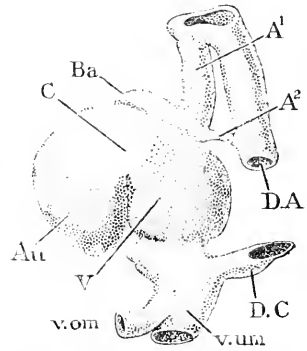


FIG. 287.—Model of the Muscular Heart of a Rabbit Embryo of nine to nine and one-half Days, seen from the left side. *C.* Auricular canal; *Ba.* bulbus aortæ; *A¹*, first, *A²*, second aortic arch; *D.A.* dorsal aorta; *D.C.* ductus Cuvieri; *v.um.* vena umbilicalis; *v.om.* vena omphalo-mesaraica; *Au.* auricle; *V.* ventricle. $\times 60$ diams. After G. Born.

loop. This mode of description has unfortunately been often used, and has led to much unnecessary confusion.

The heart of the rabbit agrees closely with that of man. Fig. 287 is a side view of the rabbit's heart at nine to nine and one-half days, with the first aortic arch, *A¹*, fully developed, and the second, *A²*, just forming. The model shows especially well the union of the three venous trunks of each side in the large median sinus reuniens, which opens into the auricle; later the sinus merges with the right auricle and so disappears as a separate division. It will be noticed upon comparison of Figs. 288 and 287 that the muscular heart shows the division of the cardiac tube far less distinctly than does the endothelial heart, nevertheless the auricles, *Au*, auricular canal, *C*, and ventricle, *V*, are perfectly distinguishable in the model of the muscular heart, Fig. 287. The most conspicuous of the changes which now follow are, first, the descent of the ventricle and second

the enlargement of the two diverticula of the auricles. Both changes are well illustrated by the heart of a rabbit at twelve and one-half days—see Born, *l. c.*, Fig. 19. Comparison of this figure with the preceding renders evident that the ventricle has descended so as to lie below, *i. e.*, farther tailward, nevertheless the arterial exit of the heart tube (or the transit to the aorta) lies, as before, above or headward of the auricles, so that the descent of the ventricle has depended upon or been accompanied by—we may express it either way—the lengthening of the bulbus aortæ, *B. a.* Fig. 288 represents the endothelial heart of a human embryo at about the stage we are now considering, and illustrates how the auricles, *Ho*, enlarge on each side and embrace the bulbus aortæ between them, and also how between the two sides of the ventricle the heart tube is somewhat constricted, forming, as it were, a narrow passage. Into the space left by this

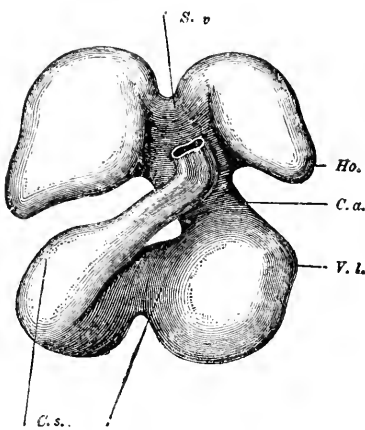


FIG. 288.—Endothelial Heart of a Human Embryo of 5 mm. (His' Embryo R). *S. v.*, Sinus venosus; *Ho.*, auricle; *C. a.*, auricular canal; *V. L.*, ventricle; *p.*, passage between the two sides of the ventricle; *C. s.*, conus arteriosus. $\times 40$ diams. After W. His.

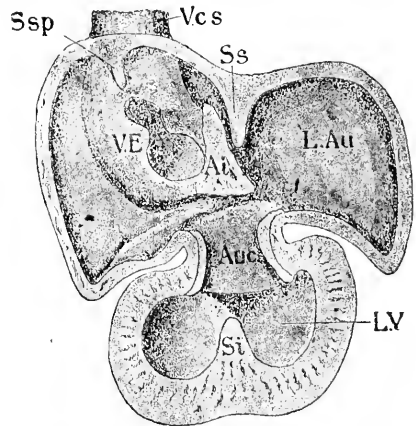


FIG. 289.—Inner Surface of the Heart of a Human Embryo of 10 mm. (His' Embryo Pt.). *V. cs.*, Vena cava superior; *S. sp.*, septum spurium of His; *S. s.*, septum superius; *L. Au.*, auricle of left side; *Auc.*, auricular canal; *V. E.*, ventricle; *S. i.*, septum inferius; *V. E.*, Eustachian valve; *A. i.*, area interposita. $\times 24$ diams. After W. His.

constriction grows tissue from the wall of the muscular heart, which tissue gives rise to the septum inferius, that plays the chief part in the ultimate division of the right from the left ventricle.

We turn now to the consideration of the interior of the heart at a slightly more advanced stage, in which the muscular and endothelial hearts are closely conjoined, owing chiefly to the growth of the muscular heart having obliterated the space between it and the endothelium. Fig. 289 exhibits a view of the inside of the heart of a human embryo of ten millimetres. The two auricles have expanded so as to meet above, leaving, however, a partition, which is known as the *septum superius*, *S. s.*; between the two sides of the ventricle is another partly developed partition, produced as just described and known as the *septum inferius*; in the auricular canal there is also a projecting cushion, which in conjunction with its fellow tends to divide the right from the left side of the auricular canal. We

thus encounter at three points the commencements of the ultimate division of the heart into right and left sides. The opening of the venous sinus reuniens is no longer in the median line, but upon the right side of the heart, or in other words, into the right auricle. The opening itself is bordered by two thin folds or rudimentary valves, of which the lateral one, *V.E.*, is the anlage of both the valvula Eustachii and the valvula Thebesii, while the medial fold ultimately disappears; as it exists in the embryo it has been named by His the *valvula vestibuli sinistra*. Above the venous orifice is a small septum, *S.sp.*, which disappears early in foetal life and is therefore known as the septum spurium. The septum spurium may be regarded as the prolongation upward of the united right and left venous valves. The space between the spurious and the superior septa is named by Born the *spatium interseptale*; it is indicated for a time by a bulge upon the exterior; it merges with the general cavity of the right auricle, when the spurious septum disappears. Below the valvula sinistra, and between it and the septum superius, is the *spina vestibuli*, *Ai.*, of His; it is identical with the so-called area interposita of earlier stages. The *area interposita* is composed of connective tissue and contains no muscle fibres; it is wedge-shaped, and as seen in the interior of the heart, Fig. 289, presents a triangular outline. It belongs, strictly speaking, to the septum transversum, and corresponds to part of the area by which the venous end of the heart is permanently attached to the septum transversum or diaphragm. The septum superius or interauricular partition extends on to the area interposita, and there fades out.

The Primitive Ventricle.—The ventricle is at first simply a bent tube; it may therefore be described as consisting of two limbs, which pass into one another at the apex of the ventricle, Figs. 286 and 288. The connection between the two limbs is originally very narrow, but it early widens out so much that the two limbs may be said to fuse into one general cavity. This may be called the stage of the primitive ventricle, since it is characteristic of the ichthyopsida. While the two limbs are fusing, the junction with the ventricle of the aorta (fretum Halleri, as the narrow part of the aorta is called) moves toward the median line and takes up its permanent position just in front of the auricular canal. The change in position of the beginning or ventricular end of the aorta allows the aorta, Fig. 288, *C.s.*, to take a nearly straight course between the auricles. The apex of the primitive ventricle is rounded, and it is not until some time after the heart is completely divided that the ventricle assumes the adult pointed shape.

Changes in the Walls of the Heart.—We consider here, 1, the histogenesis of the heart; 2, thickness of the walls; 3, the special connective tissue or non-muscular areas.

1. **HISTOGENESIS.**—For what little is known concerning the development of muscle fibres see p. 478. The heart consists originally of the endothelial tube and the outer muscular tube. The *endothelium*, Fig. 290, *endo.*, retains its primitive character as a thin layer lining the cavity of the heart, but the exact appearance of the cells at successive stages has still to be observed: so far as known the endothelium does not give off any cells to fill up the space between it and

the muscular heart. As soon as the inner surface of the ventricle becomes irregular, Fig. 290, *Ven*, we find the endothelium close against the muscular wall and following it exactly.

The *muscular heart* or outer heart tube produces the pericardial covering (mesothelium) of the heart, the muscle fibres, and the connective tissue; Fig. 290 illustrates the general course of these modifications. The muscular heart tube begins to thicken, and throws off a certain number of cells which assume a mesenchymal character, and stretch across the space between the outer and inner heart,

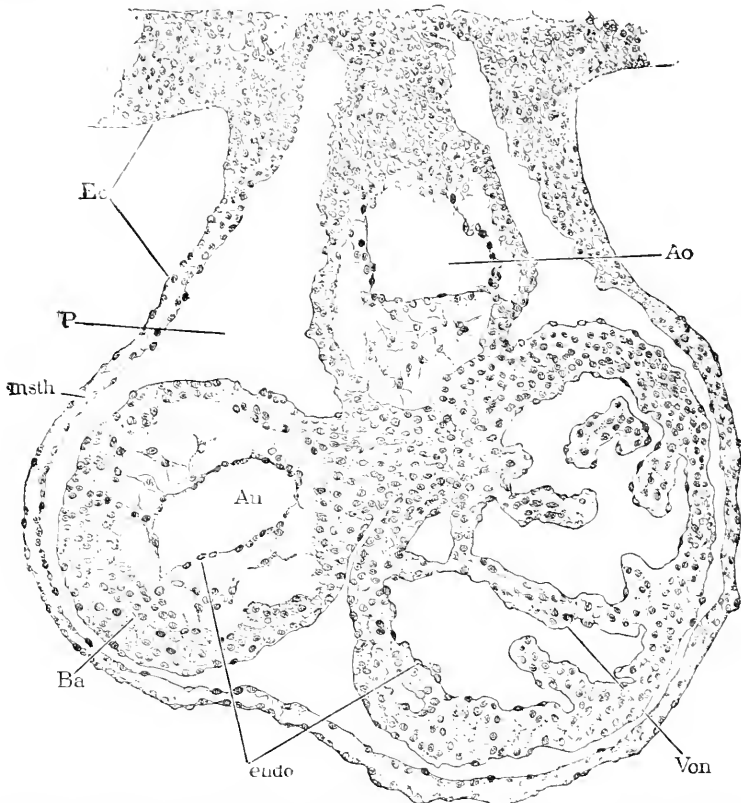


FIG. 290.—Section of the Heart and Pericardial Cavity of a Rabbit Embryo of ten and one-half Days. *Ec*, Ectoderm; *P*, pericardial cavity; *Msth*, mesothelium; *Ba*, bulbus aortæ; *endo*, endothelium; *Ven*, ventricle; *Ao*, aorta.

as is shown in the bulbus aortæ, *Ba*, of Fig. 290. Gradually the number of these cells increases until the entire space is occupied and the muscular heart is a compact wall reaching to the endothelium. During its growth we see the muscular heart acquire a more and more clearly differentiated external layer of endothelioid cells: as indicated in the figure the layer is particularly distinct in the ten and a half days' rabbit over the ventricle. The remaining cells become for the most part muscle fibres, but others retain the mesenchymal character and give rise to the connective tissue, and perhaps

also to the blood-vessels of the heart—when the blood-vessels first appear in the cardiac walls I do not know.

2. THICKNESS OF THE WALLS.—From what has been said it is evident that the thickness of the walls depends upon the growth of the muscular heart, which takes place so that each division of the bent heart has its characteristic thickness of wall. In the auricles the walls never become very thick, and are always of about the same diameter throughout, excepting where the veins enter and the heart is attached to the septum transversum. In the auricular canal the walls become considerably thicker than in the auricles, and much less thick than in the ventricles, where the walls are most developed, and form many irregular projections into the interior of the heart so that the tissue assumes a spongy appearance, Fig. 290, *Ven*, which early becomes one of the most marked characteristics of the ventricles. G. A. Gibson, 91.1, found that during foetal life the walls of both ventricles are approximately equal in thickness, therefore the thickness of the adult left ventricle is acquired after birth. In the bulbus aortæ the walls become a little thicker than in the auricles.

3. NON-MUSCULAR AREAS OF THE HEART.—There are several spots where connective tissue is developed to the complete or partial exclusion of the muscle-fibres of the outer heart. These spots have great importance in the differentiation of the heart. They are: the area interposita; the thickened edge of the septum superius; the bolsters of the auricular canal; and the ridges in the bulbus aortæ.

Sinus Venosus.—A venous sinus, more or less distinct from the auricles and formed by the union of the large veins entering the heart, is found temporarily in mammalian embryos, and represents the adult condition of reptiles. At first the sinus, for which His uses the name *sinus reuniens*, is symmetrically placed in the septum transversum at the venous end of the heart. As soon as the heart has become bent and the descent of the ventricles has occurred, the sinus necessarily lies on the dorsal side of the auricular division of the heart and appears partly free from the septum transversum as a short piece, Fig. 287, between the septum and the auricle. The sinus is long in the transverse direction, narrow in the longitudinal and dorso-ventral direction of the embryo. But as the lateral outgrowths forming the auricles are developed, the lateral ends of the sinus are bent headward, so that it becomes somewhat horse-shoe-shaped—the convexity being toward the apex of the heart. At the same time the sinus grows much less rapidly than the auricles; thus it becomes proportionately smaller in later stages—in a rabbit of fourteen days its length is equal to only half the width of the auricles. Into the ends of the sinus open the ducts of Cuvier, Fig. 287, *D. C.*, and on each side but nearer the median line the omphalomesaraic and umbilical veins (rabbits of eleven days). The two mesaraic and umbilical openings are, however, soon replaced by a single vein, the vena cava inferior, which opens on the *right* side of the sinus, Fig. 287. The cava inferior is present in rabbits of twelve and one-half days, and its development is described later in this chapter. By the time the cava inferior is developed, the sinus is no longer found opening into the heart in the median line, but upon the right side, Fig. 287; this change Born attributes to the manner

in which the partial separation of the sinus from the septum transversum is effected; the furrow or groove, which produces the separation, cutting in deeper on the left than on the right side, thus forcing the veins from the left side over to the right. The actual opening of the sinus into the right auricle is elongated and oblique, as shown in Fig. 289, and is bordered by two valves, which unite at the upper end of the heart and are continued as the septum spurium. The history of the valves is given below, p. 532. The sinus as a whole bulges somewhat into the interior of the auricle. The stage to which we have now traced the sinus venosus is found in the human embryo of 10 mm.

In the course of its further development the mammalian sinus merges into the right auricle and entirely disappears as a distinct division. The modification is accomplished very gradually, by the expansion of the right auricle backward and downward;* it thus embraces the whole of the right horn of the sinus, converting the right horn into a part of the auricular cavity, and the dorsal or posterior wall of the horn into an integral part of the auricular wall, consequently the valves of the venous opening appear to spring from the posterior wall of the heart. The three permanent body veins open as before with a common oblique mouth: compare Fig. 289. The upper end of this orifice corresponds to the opening of the vena cava superior dextra, the lower end to the opening of the vena cava inferior, the middle to the opening of vena cava superior sinistra. The sinus is found almost completely merged in the auricle in rabbit embryos of about twenty days, and its limits can be traced in considerably older stages, and according to His even in the adult human heart.

The left horn of the sinus remains outside the auricle and becomes the coronary sinus of the adult.

Division into Right and Left Hearts.—The developmental conditions which result in the complete division of the heart are established by the primitive bending of the heart and the outgrowth of the auricles; the former initiates the division of the ventricle, the latter the final separation of the two auricles. The division is supplemented by that of the auricular canal and aorta. Accordingly we may consider the division of the heart under four heads: division of, 1, the auricles; 2, the auricular canals; 3, the ventricle; 4, the aorta.

1. DIVISION OF THE AURICLES.—The histories of the process: given by His and Born, differ in several essential points. I follow the latter authority, *l. c.*, pp. 308–312, as giving the presumably correct account. When the two auricles grow forth, they expand upward, but there remains between them a partition, Fig. 291, to which His applies the name of *septum superius*, Born the name *septum primum*. As the auricles continue to expand, the septum of course increases by the continued meeting of the auricles, and it also increases, without doubt, by its own growth. The septum early acquires a very characteristic appearance by the thickening of its lower edge, Fig. 292, just above the auricular canal; the thin part of the partition contains muscle fibres, but the thickened edge

* I follow Born, 89, 1, 326, but not intelligently, for I have been unable to understand fully his account of the merging of the sinus in the auricles.

consists of embryonic connective tissue; the septum is, of course, covered with endothelium. Seen from the side, the edge of the septum presents a curved outline, being concave toward the ventricle.

The only connection between the auricle is now under the edge of the septum. This communication has been homologized with the foramen ovale of the foetal heart in later stages. Born has shown that this homology, which was maintained by his predecessors, is incorrect, and that the septum grows down to the auricular canal, *C*, and by uniting with the partition developed in the canal closes permanently the primary communication (*ostium primum* of Born).

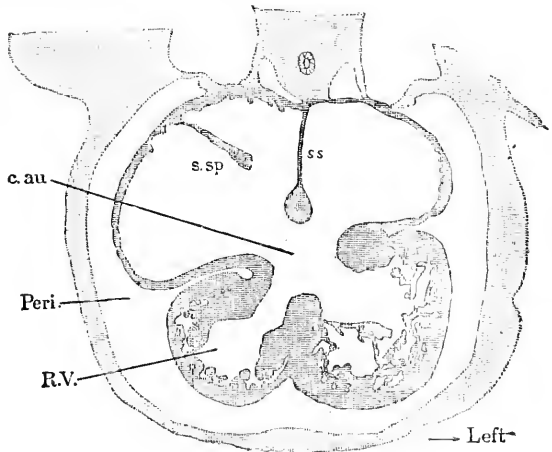


FIG. 291.—Section in the Frontal Plane through the Heart of a Rabbit Embryo of thirteen Days. *c.au*, Canalis auricularis; *s.sp*, septum spurium; *ss*, septum superius; *R.V.*, right ventricle; *Peri.*, pericardial cavity. $\times 117$ diams.

The true *foramen ovale* is developed as a perforation of the upper part of the septum superius. This perforation is termed by Born the *ostium secundum*, *l. c.*, p. 311. It appears in rabbit embryos of 14 mm. (about fifteen days); it is small at first and situated close to the wall of the auricle; as to how it is developed, Born gives no information. It soon enlarges, and in rabbits of 7.3 mm. or nearly thirteen days is about the same size as the earlier communication (*ostium primum*), which; from this stage on, gradually contracts until in rabbits of 10–12 mm. it has closed. In rabbits of ten millimetres (thirteen and one-fourth days) a new septum appears above the foramen ovale; it is crescentic in shape, and belongs to the right auricle, since it springs a little to the right of the insertion of the septum superius. This new partition (*septum secundum*) was first recognized by Born, and can be followed a little way alongside the septum superius: it is also distinguished by being thicker than the septum superius; its edge forms part (*limbus Vieussenii*) of the boundary of the foramen ovale. The foramen ovale remains open during foetal life, and in man is not completely closed until some time after birth.

On the posterior wall of the auricle the septum superius runs on to the area interposita of His, see p. 525, and can for part of its extent be regarded as an upgrowth of that area. Born, in opposition to His, attributes little special importance to this relation. The closure of the primary communication between the auricles is better described in connection with the division of the auricular canal.

2. DIVISION OF THE AURICULAR CANAL.—The auricular canal

in human embryos of 8 mm. is found, as it were, invaginated into the ventricle, Fig. 292, *c, c'*. There appear also two prominences of connective tissue, one on the posterior, one on the anterior wall of the canal. These prominences are the *Endothelkissen* of F. F. Schmidt, 70.1, the *Endocardkissen* of Born, *l.c.*, 320. They increase in height until they meet and unite (rabbit embryos of about thirteen

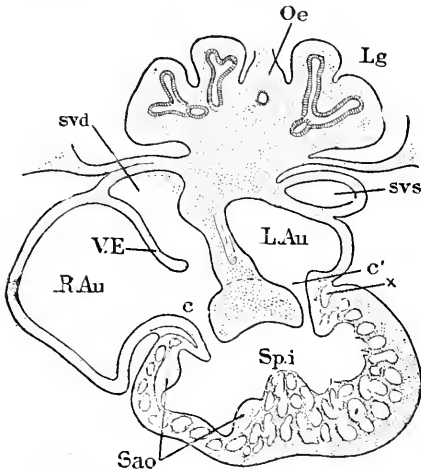


FIG. 292.—Oblique Section of the Heart of a Human Embryo of 8.5 mm. (His' Embryo I.). Oe, Esophagus; Lg, lung; svs, sinus venosus sinister; L.Au, left auricle; R.Au, right auricle; *c, c'*, channels of auricular canal; *x*, connective tissue; Spi, septum inferius; Sao, anlagen of aortic septum; E, Eustachian valve; svd, sinus venosus dexter. $\times 24$ diams. After W. His.

days) so as to divide the passage of the auricular canal into two channels, *c* and *c'*. The prominences are wide; hence, when they meet, the greater part of the canal is closed and the channels are relatively small. Each channel maintains the direct connection between the auricle and ventricle of its own side, and is triangular in section. The triangular section is a necessary consequence of the mode of formation; each prominence forms a side, and the original wall of the canal makes the third side. While the prominences are joining one another, the edge of the septum superius also unites with them, so that, except for the open foramen ovale, both auricles and the auricular canal are divided before the ventricles. His has

proposed so designate the septum thus formed by the term *septum intermedium*, but a special new term seems to me superfluous. As shown in Fig. 292, the septum consists of a thinner part between the auricles and a thicker part in the auricular canal. His attributes considerable importance to the area interposita, as contributing to unite the septum superius with the prominences of the auricular canal; compare p. 525.

The auricular canal soon ceases to be a recognizably distinct part of the heart, and is represented only by the openings between the auricles and ventricles (*ostia atrio-ventriculares*), and by the atrio-ventricular valves.

3. DIVISION OF THE VENTRICLES.—The two limbs of the ventricle are, it will be remembered, at first entirely distinct, Fig. 286, and even after the ventricle has grown considerably and the connection between the two limbs has widened so much that they form essentially one continuous cavity, the original division between the left limb and the right limb is marked by a groove on the external surface. This groove corresponds to a fold of the cardiac wall, and hence is represented in the interior of the heart by a projection which grows, as development proceeds, although the external groove is gradually obliterated. The growth of the projection establishes the partition between the ventricles, which is known as the *septum*

inferius, Fig. 292, *Sp.i.* This septum is thick, and consists chiefly of muscle fibres; it has a partially trabecular structure, and certain of its trabeculæ are ultimately transformed into chordæ of the atrio-ventricular valves. In a side view the upper edge of the septum is seen to be curving, the septum as a whole being crescent-shaped; it is situated somewhat to the right side of the median line, Fig. 291. After it is fully developed (rabbit embryos of 10 mm.) the septum reaches nearly to the auricular canal and if it were prolonged it would join the right-hand side of the partition in the auricular canal; on the posterior side of the heart the septum does actually join the auricular canal, but on the anterior side it fades out toward the aorta. In brief, the broad communication between the two ventricles becomes an interventricular foramen bounded by the partition of the auricular canal and by the edge of the septum *inferius*; it repeats for the ventricles the rôle of the foramen ovale for the auricles, p. 529, but were it to close over, as does the foramen ovale, the left ventricle would have no exit, because, as already described (compare Fig. 288), the aorta is the prolongation of the right limb of the ventricle. In order to furnish the necessary outlet the aorta is divided into two vessels, and one of these (*aorta vera*) becomes connected through the interventricular foramen exclusively with the left ventricle, thereby rendering the separation of the ventricles complete. Accordingly, to fully understand this separation we must follow the history of the division of the aorta.

4. DIVISION OF THE AORTA.—The cardiac aorta comprises the *fretum Halleri* and *bulbus aortæ*, which at an early stage differ in the width of their cavities, Fig. 286. This difference is soon lost, and the cavity (endothelial aorta) becomes flattened except in the *truncus aortæ* or upper part of the *bulbus*, where the cylindrical form is retained. The plane of the flattened cavity changes; it is sagittal where the aorta arises from the *conus arteriosus* of the right ventricle, and as we ascend along the aorta we find the anterior edge of the cavity moving toward the left until the plane of the flattened cavity becomes transverse. Meanwhile the muscular wall of the aortic heart has developed, partly into muscle, partly into connective tissue, and this connective tissue develops into a ridge on each side of the flattened cavity. The ridges increase and unite, thus dividing the aorta into two channels, the anterior or left channel becoming

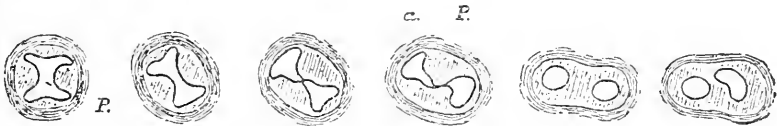


FIG. 293.—Sections at Different Levels through the Cardiac Aorta of a Human Embryo of 11.5 mm. (His' Embryo Rg). The lowest section is on the left, the highest on the right. *a.*, Aorta; *P*, pulmonary division. $\times 15$ diams. After W. His.

that of the pulmonary artery, the posterior or right channel becoming the permanent true aortic cavity. The union of the ridges begins just where the aorta divides to form the aortic arches, and the partition at this point is sagittal, *cf.* Fig. 293. The formation of the partition progresses downward toward the ventricle, the plane of

the partition gradually changing to transverse. The two ridges are found to extend into the ventricle, and participate in the closure of the interventricular foramen, by developing an oblique partition which grows down to the edge of the septum inferius, and thus converts the interventricular foramen into the orifice of the true aorta. The blood in leaving the left ventricle must now pass through the foramen, then across a space which originally belonged to the right ventricle, but which has been shut off by the down-growth of the septum aorticum. The ventricular extension of the aortic partition is effected chiefly by the left or anterior ridge, the right or posterior ridge passing out more on to the lateral wall of the ventricle where it fades out; the left ridge (rabbit embryos of 14 mm.) runs on to the edge of the septum inferius. The division of the aorta and ventricle is completed in rabbit embryos of about sixteen days.

At the upper end of the aorta the partition extends so that the fifth aortic arches are connected only with the pulmonary aorta, while the remaining arches are connected with the true aorta only. Soon after the internal partition is formed, the external division commences as two grooves on the outside of the aorta, beginning just between the fourth and fifth aortic arches. The two grooves extend to the ventricle and gradually deepen, until the aorta is completely divided into two vessels (Born, *l.c.*, 337), which have, as soon as they are separated, both their connections with the heart and their relative positions to one another essentially as in the adult.

The heart is now completely divided.

Valves of the Heart.—The entrances of the pulmonary veins have no valves; the entrances of the body veins have two valves in the embryo, of which the left disappears and the right persists as the Eustachian valve and Thebesian valve; the right atrioventricular passage has the tricuspid, the left the bicuspid or mitral valve. The entrances of the pulmonary or right, and true or left aorta are each guarded by three semilunar valves. As is well known, all these valves are set so as to favor the flow of blood toward the arteries and prevent its flow toward the veins. We shall consider, 1, the venous valves: 2, the atrioventricular valves: 3, the aortic valves.

1. **THE VENOUS VALVES.**—In a human embryo of 10 mm., the opening of the body veins or sinus venosus into the right auricle is guarded, as shown in Fig. 289, by two valves or thin flaps of the heart walls; at the upper side of the oblique opening the two valves unite and are continued as the septum spurium, *S.sp.*; the left valve lies near the septum superius and merges into the area interposita; the right valve is from the start much larger than the left, and develops into the valvula Eustachii and valvula Thebesii. The venous valves owe their origin to the sinus venosus being pushed into the right auricle and in consequence forming a fold which projects around the venous orifice into the cavity of the heart. The edge of this fold grows considerably and becomes the anlage of the venous valves.

The *left valve* gradually disappears—probably completely or nearly so. But His thought it contributed to form part of the edge of the foramen ovale. Born's later observations, *l.c.*, 331, suggest rather that it never unites with the septum superius (inter-auricular partition) but simply aborts, and for a time (embryos of the fourth month)

can be recognized as a slight ridge on the posterior wall of the auricle.

The *right valve*, which is always larger than the left, persists in greater part. Early in its development it begins to grow unequally, so that there is a larger upper flap bounding the main venous openings, and a smaller lower flap bounding the mouth of the coronary vein; the two flaps are, of course, continuous with one another though separated by a notch; the upper flap is the anlage of the Eustachian, the lower of the Thebesian valve. The Eustachian valve does not include the whole upper division of the primitive valve, for the uppermost part aborts, though it can still be traced in the human embryo of four months and even at seven months (Born, p. 332).

The *septum spurium* is to be regarded as the prolongation of the united right and left venous valves. As it contains muscular fibres, its probable function is, as suggested by Born, to draw the two valves together and prevent the back flow of the blood, a function of great importance in the embryonic heart before the atrioventricular valves are developed. In a human embryo of 34 mm. (beginning of the third month), the septum is so much reduced that it would not be recognized without knowledge of the preceding stages, and at this time we find the tricuspid and mitral valves in action.

2. THE ATRIOVENTRICULAR VALVES.—Their development has been studied by Bernays, 76.1, whose results have been confirmed by Born, 89.1, 340. W. His' observations ("Anat. menschl. Embryonen," Heft III., 152-160) also are important. The valves proper—in distinction to the muscles and tendons, which belong to the ventricle—are to be regarded as morphologically modifications of the walls of the auricular canal, the canal being to a certain extent invaginated into the ventricles (W. His, *l.c.*, Fig. 105). The invaginated portions of the canal become the anlages of the atrioventricular valves, on the left side the mitral, and on the right the tricuspid. When the auricular canal divides into the two atrioventricular channels, each channel or ostium is triangular in section, and as this form is preserved on the right side of the heart, there are three valves developed, one as the prolongation of each of the three walls of the ostium, but on the left side, in consequence of as yet undetermined conditions, there are developed only two, the mitral valves. In each case the lateral valves are developed from a fold of the heart wall, which, as indicated at *x* in Fig. 292, is formed partly by the wall of the auricular canal, partly by the wall of the ventricle, and partly by connective tissue in the interior of the fold. The medial valves—one on the left side, two on the right—may be described as prolongations of the septum intermedium, Fig. 292. The muscular trabeculæ of the ventricle are, almost from the start, connected with the ventricular surfaces of the atrioventricular valves; out of these trabeculæ are developed the chords of the valves, known in the adult as the papillary muscles and chordæ tendineæ. The trabeculæ are originally very irregular in their arrangement, but as development progresses those which are connected with the valves become longer and slenderer, and descend in main lines directly from

the valves to the ventricular walls, but preserve the network character. A little later (pig and calf embryos of 45–60 mm.) the valvular trabeculæ become very slender though still muscular, in the neighborhood of the valves, but toward the apex of the heart the fine trabeculæ unite into plump bundles, the papillary muscles (Bernays, **76.1**, 495. At this stage each papillary muscle breaks up into some six or eight muscular cords, which are inserted into the valves. In older embryos (in man during the fifth month) the muscular cords change into tendinous chords; the muscular tissue in them disappears and is replaced by mesenchyma, which becomes fibrillar; hence each papillary muscle is connected by several filamentous tendons with its valve. The slender tendons are the chordæ tendineæ of the human anatomy.

3. THE AORTIC OR SEMILUNAR VALVES.—Before the bulbus aortæ completely divides into the true and the pulmonary aortæ, there appear four small protuberances at its ventricular orifice. Each protuberance is a mass of connective tissue covered by endothelium; two of them are merely the ends of the ridges, described p. 531, by which the aorta is divided. When the division is completed, the ends of the two ridges are also divided, making four protuberances, or in all six—three for each aortic trunk. These protuberances are the anlagen of the semilunar valves, and may be seen in a human embryo of seven weeks. They grow until they meet so as to close the aortic entrances, and assume the adult form by becoming concave. Their exact history has still to be worked out; compare Tonge, **70.1**, 387, on the semilunar valves of the embryo chick.

II. THE ARTERIAL SYSTEM.

We left the arterial system consisting of the cardiac aorta, the five aortic arches, and four carotids, the dorsal aorta, vitelline or omphalo-mesaraic arteries, and allantoic arteries (see p. 274–276) and have now to trace the changes which result in the adult system of arteries—changes which are very numerous.

Aortic Arches.—The general scheme of the metamorphosis of the great arteries of the five gill-arches is indicated by the diagrams, Fig. 294. A is the primitive condition: The wide pharynx, *Ph*, is shaded to suggest its rounded form; the four gill-clefts of the left side, are also indicated, 1, 2, 3, 4. From the heart, *Ht*, runs out the aorta, which soon forks; each fork gives off five branches, I, II, III, IV, V, one in front of each cleft and a fifth behind the fourth cleft. On the dorsal side the five arches unite into a common trunk, which joins the corresponding trunk from the opposite side to form the median dorsal aorta, *Ao*. Now, as the clefts develop from in front backward, so the first branchial arch arises first, the second next, and so on, until the series is completed; shortly after each arch is formed the aortic vessel appears in it.

The disposition in the human embryo corresponds entirely to the diagram, for the relations are all the same, although, owing to the rolling up of the embryo, the primitive topography is disturbed: thus in Fig. 300, we at once recognize the four clefts and the five arches.

The homologies of this complicated aortic system with that of the

adult mammal are shown in the diagram Fig. 294, B. The shaded parts are preserved in the adult; the others disappear. The parts lost are the first and second arches; the dorsal connection between the third and fourth left arches; the upper part of the left fifth arch; there disappear on the right side the upper part of the fourth and the whole of the fifth arch, and also the dorsal connection of the arches with the median dorsal aorta, *Ao*. There remain parts as follows: 1. The heart aorta, which by an internal septum is divided into two aortæ (p. 531), one of which maintains a communication with the right ventricle and is continuous headward with the fifth arch of the left side; from the middle of this arch springs a vessel which soon forks to make the two pulmonary arteries, *P*; during

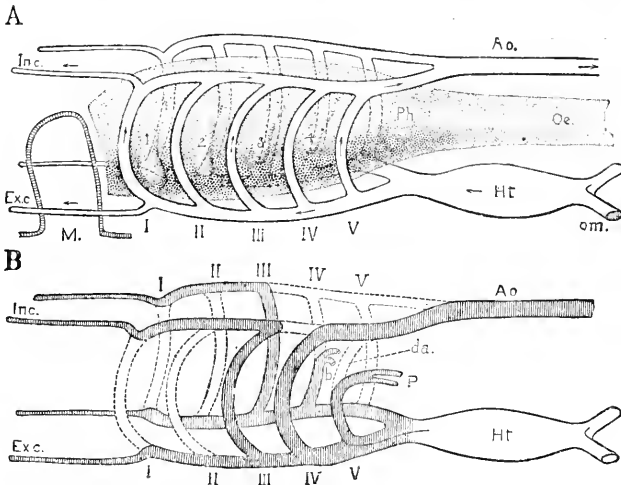


FIG. 294.—A, Diagram of Pharynx of an Amniote Vertebrate. 1, 2, 3, 4. Gill pouches (clefts) of the pharynx, *Ph*; *Oe*, oesophagus; I, II, III, IV, V, aortic arches springing from the fork of the aorta of the heart, *HT*; on the dorsal side the five arches again unite into a single trunk, which joins its opposite fellow to form the median dorsal aorta, *Ao*; *M*, invagination of the ectoderm to form the mouth; *Exc.*, external carotid springing from the ventral side of the first aortic arch; *In.c.*, internal carotid, springing from the dorsal side of the first aortic arch; *om*, omphalo-mesaraic veins emptying into the heart. The arrows indicate the direction of the blood-currents. B, diagram of gill-arches as preserved in mammalia; the shaded portions are those retained, the unshaded vessels are lost; *da*, ductus arteriosus; *P*, pulmonary artery. The other letters are the same as above.

foetal life the upper part of this arch, *da*, persists as the well-known ductus arteriosus, so that there is a direct communication between the pulmonary and the body aorta. Soon after birth the lumen of the ductus is obliterated. 2. The left fourth arch, which is very much enlarged, to constitute the permanent aortic arch; as shown in the diagram, the obliteration of parts is such that the left fourth arch is the only permanent channel of communication between the heart and the dorsal aorta, *Ao*; hence the aorta of the adult springs from the heart, and gives off to the right a branch, then makes itself a great arch on the left side up to the back, where it is continued down, *i.e.* tailward. 3. The third arches on both sides, appearing, as the figure clearly shows they must, as portions of the internal carotid, *In.c.*; the ventral stem between the third and fourth arches is the common carotid of the adult on each side, while the continua-

tion of that stem headward becomes part of the external carotid. 4. The right fork of the aorta becomes the arteria innominata, *a*; part of the right fourth arch remains as the right subclavian artery, *b*; the corresponding left subclavian being given off from the corresponding left arch, that is to say, by the great arch of the aorta. The ventral stem between the right third and fourth arches becomes the common carotid of the right side.

But, though the connections and metamorphoses of the aortic arches are sufficiently illustrated by Fig. 294 to elucidate the homologies, yet the actual course of the arches is somewhat different, Fig. 295, the branching taking place as described p. 306. The cardiac aorta at first opens under the pharynx between the bases of the mandibular and hyoid arches, but by the time the five aortic arches are developed it has moved tailward; finally when during the second

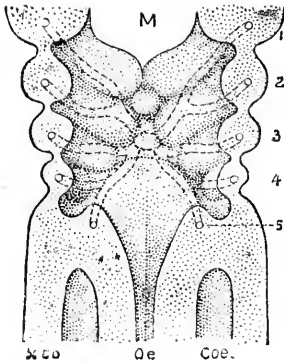


FIG. 295.—Anterior Wall of the Pharynx of a Human Embryo of 3.2 mm. length. 1 to 4, Gill-pouches; the ectodermal pouches are separated by thin walls from the endodermal; the gill-arches show the aortic arches drawn in dotted lines and arising from the heart aorta, *Co.*; *M*, mouth; *Oe.*, oesophagus; *Coe.*, body cavity. $\times 50$ diams. After His.

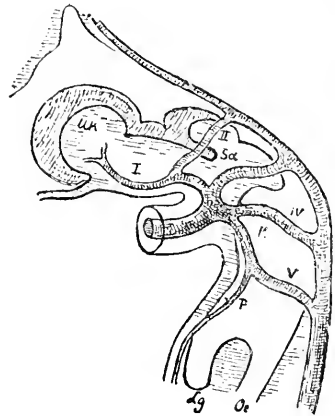


FIG. 296.—Aortic System of His' Embryo B1, 4.25 mm. I-V, Aortic arches; *Uk*, mandible; *Sd*, thyroid gland; *K*, main aorta; *P*, pulmonary artery; *Lg*, lung; *Oe*, oesophagus; $\times 36$ diams. After W. His.

month the head is bent back or raised, compare Chapter XVIII., Figs. 223, 226, and the front of the neck elongates, the heart remains on the level with the thorax, and the position of the aorta is relatively lowered. The five aortic arches are found in human embryos of 2.6-3.2 mm., and all persist for a short time, but as soon as the neck bend begins to develop (embryos of 4 mm.) the disappearance of the first aortic arch occurs, Fig. 296, to be very soon followed by the disappearance of the third arch, but the dorsal part of these arches persists, as already explained, as the internal carotid, while the ventral part persists as the stem of the external carotid, which gives off in the region of the hyoid arch a branch, and in the region of the mandibular arch a second branch. The branches are designated by His ("Anat. menschl. Embryonen," Heft III., 187) as the *arteria lingualis* and *arteria maxillaris communis* respectively. The arrangement with three arches open, the first and second closed, is shown in Fig. 298. As both the third arches and the left fourth per-

sist, we have next to consider the modification of the right fourth arch (*Aorta descendens dextra*), which in embryos of 3 mm., and even less, is smaller in diameter than the corresponding left arch, a difference which His is inclined to attribute to the oblique insertion of the cardiac aorta rendering the left arch the more direct continuation of the cardiac aorta. Curiously enough the difference is lost temporarily (embryos of 7–10 mm.), but becomes very marked again in those of 11–12 mm., Fig. 297, so that it now is hardly more than a branch of the aorta, supplying the carotid and vertebral arteries, *v*, of the right side. In an embryo of 13.8 mm. the right fifth arch has disappeared, and with it the piece connecting it with aorta descendens dextra. The disposition of the main stems persists at this stage, with little change except in their diameters until after birth. The cardiac aorta (*aorta ascendens*) divides into, 1, the smaller left arch (*arteria anonyma*) which is continued as the *arteria subclavia* and gives off as a branch the stem leading to the first, second, and third arches of the right side; this stem is the right *carotis communis*; and into, 2, the larger left arch, *arcus aortæ*, which is homologous with the *arteria anonyma* and like it gives off the carotis communis and subclavia of its side, and is then continued on to the permanent dorsal aorta. The connection of the *arteria anonyma* (right fourth arch) with the dorsal aorta is preserved for some time.

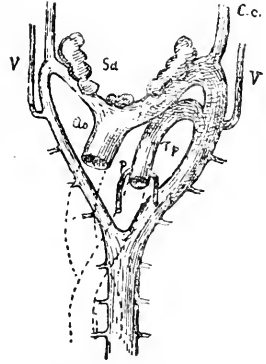


FIG. 297.—Aortic System of His' Embryo St. 12.5 mm., seen from the front. *V*, Vertebral artery; *Ao*, aorta; *Sa*, thyroid gland; *C.c.*, carotis communis; *T.p.*, truncus pulmonalis; *R*, pulmonary artery. $\times 24$ diam. after W. His.

The history of the fifth arches is given in the section on the pulmonary arteries, p. 538.

DEVELOPMENT OF THE AORTIC WALL.—The aortæ, like all other blood-vessels, consist at first of a simple endothelium, to which are added the muscular and adventitial walls by differentiation of the surrounding mesenchyma, which begins to condense around the aortæ by the end of the second month, and during the second month the separation of the mesenchymal coat into tunica media and tunica adventitia becomes apparent (see His, "Anat. menschl. Embryonen," Heft III., 198, also Morpurgo, 85.1). Erik Müller's paper, 88.1, describes, strictly speaking, not the origin of the muscular tissue of the aorta, but of the primitive mesenchyma from the inner wall of the primitive segments.

AORTIC ARCHES IN BRANCHIATE VERTEBRATES.—In aquatic vertebrates the aortic arches do not remain as large vessels, but they break up into smaller vessels and capillaries, which are distributed through the branchial filaments, or respiratory outgrowths of the gill-arches. When this modification occurs the ventral end of each aortic arch acts as the afferent stem (branchial artery) and the dorsal end as the efferent stem (branchial vein) of the gill. It is evident that the branchial veins are morphologically distinct from the true veins, and belong not to the venous, but to the arterial, system.

EVOLUTION OF THE AORTIC ARCHES.—That there were in the early vertebrates more gill-arches than are preserved in the amniota, has been stated already. But the exact number is uncertain, and as there must have been one aortic trunk in each gill-arch the number of the aortic arches is uncertain. It seems, however, probable that there were at least nine as indicated by the structure of marsipobranchs (Julin, **87.3**) and *Chlamydoselachus* (Howard Ayers, **89.1**). Indeed, von Boas, **87.1**, has adduced weighty evidence to support his belief that even in amniota the number of aortic arches is six, a belief which Zimmerman, **89.1**, has supported. To settle this question must be left to research based upon very extended comparative anatomical and embryological observations.

It is improbable, as Ayers, **89.1**, has demonstrated, that the united dorsal ends of the aortic arches, which form two stems, represent the forward continuation of the median aorta, but that rather there was primitively a median dorsal aorta extending over the pharynx to the hypophysis, and that there were lateral anastomoses which have been preserved while the cephalic median aorta has disappeared. Ayer's hypothesis, which seems to me well justified, is incompatible with the current notion that the dorsal aorta represents two stems fused in the median line—a notion which has been specially advocated by Macalister (*Jour. Anat. and Physiol.*, XX., 193, 1886). The special importance of the question at present is its bearing on the comparison of the arterial systems of vertebrates and annelids.

The abortion of the aortic arches is attributed by general consent to the head-bend, and consequent cramping of the branchial region, but the factors which have caused the modification of the five partially preserved arches of mammals have still to be ascertained. Hochstetter, **90.1**, 577, suggests that the development of a new trunk of supply—the internal mammary—for the anterior intercostal arteries may have been concerned in the abortion of the right aortic root and the changed position of the left aortic root, but leaves his thought unexplained.

Internal Carotids.—As indicated in the diagram, Fig. 294, the internal carotids are developed out of the first, second, and third aortic arches; the third arch loses its connection on the dorsal side with the fourth arch, but keeps its connection with the second and first; there is thus a direct blood-channel from the cardiac aorta to the vessel, which runs from the dorsal end of the first arch to the head and brain, Fig. 294, *In. c.* The internal carotid of the adult comprises the third aortic arch, the dorsal part of the second arch, the dorsal part of the first arch, and the whole of the true internal carotid of the embryo. His ("Anat. mensch. Embryonen," Heft III., 192) states that in *man* the dorsal connection between the fourth and fifth arches is lost during the fifth week; and points out that, as the heart and cardiac aorta descend, the position of the third arch becomes more and more oblique, compare Fig. 298.

Pulmonary Aorta and Arteries.—In *Sauropsida* the fifth aortic arches are preserved on both sides, in reptiles completely, in birds partially, but in mammals the fifth arch entirely disappears on the right side and partially on the left, as established by the classic investigations of Heinrich Rathke, **57.1**. In all amniota the lungs

are supplied by arterial branches springing from the middle of the fifth aortic arch, in Sauropsida on both sides, in mammals on the left side only, Fig. 298, *P*. The right fifth arch disappears in man very early, but the left persists throughout fetal life. Concerning the development of the pulmonary artery proper, *i.e.* the branch from the arch to the lungs, Fig. 298, *P*, little is known. His ("Anat. mensch. Embryonen," Heft II., 186) finds the reptilian condition—the right and left fifth arches, each producing a branch to the lungs—in an embryo of 4.2 mm. and more distinctly developed in embryos of 5–6 mm. but later both pulmonary arteries are found to spring by a common stem from the left fifth arch. How the change comes about I do not know, and I have found no explanation of it.

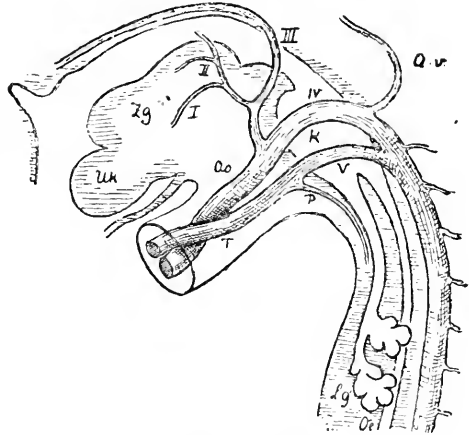


FIG. 298.—Aortic System of W. His' Embryo Fig. 11.5 mm. *Uk*, Mandible; *Zg*, tongue; I-V, aortic arches; *Ar*, vertebral artery; *P*, pulmonary artery; *Lg*, lung; *Oe*, oesophagus; *T*, truncus pulmonalis; *Ao*, aorta. \times 18 diams. After W. His.

The arteries have a special relation to the bronchi, as is explained in the section on the lungs in Chapter XXIX. Returning now to Fig. 298, it will be observed that the pulmonary artery, *P*, divides the fifth aortic arch into a lower part, *T*, connected with the heart, and an upper part, *V*, connected with the dorsal aorta. The lower part is the future trunk of the pulmonary artery, and as the lungs develop the pulmonary artery increases in calibre until it equals the trunk, *T*, in diameter. The upper part, *V*, is known as the *ductus arteriosus* or *ductus Botalli* (*Botallischer Gang*) and it remains throughout the fetal period as an open channel, so that blood from the right ventricle flows in part to the lungs, in part into the dorsal aorta. As stated above, the lumen of the ductus arteriosus disappears soon after birth.

Dorsal Aorta and Its Branches.—There are many valuable observations on the foetal arteries scattered in the works of the older embryologists, in the descriptions of human embryos (Chapter XVIII.) and in articles dealing with the development of special organs, but these observations have never been collated, nor has any attempt been made, so far as I am aware, to study comprehensively the morphology of the dorsal aorta and its branches. This is the more singular as much labor as been expended upon the aortic arches and veins. An exception has been made in the case of the intersegmental and vertebral arteries, see below.

That the dorsal aorta is formed very early by the ingrowth of the omphalo-mesaraic arteries and that these arteries are the primitive branches of the aorta has been already explained. The next branches to be formed are the umbilical or allantoic, which very early acquire

a large size and appear as the main branches of the aorta, but the dorsal aorta is prolonged to the tail, and in tailed vertebrates persists as a permanent and considerable vessel (*arteria caudalis*) but in man it remains only as a small vessel, the *sacra media*. From the umbilical arteries, as soon as the anlagen of the legs appear, arise branches, the *iliac arteries*, one on each side to supply the corresponding limbs. With the progress of development the iliacs become the main branches, and the allantoic vessels are very much reduced, becoming the relatively small *hypogastric arteries* of the adult. Of the omphalo-mesaraic or vitelline arteries the left aborts very early, while the right persists, and soon develops the *arteria mesenterica superior* as a small branch, which ultimately becomes the principal continuation of the main stem.

INTERSEGMENTAL ARTERIES.—The first branches of the aorta to appear in the embryo are a series of small vessels, which pass upward and outward on each side of the embryo. One of these vessels is to be found between every adjacent pair of myotomes, and hence they have been called the interprotovertebral arteries. In the region of the pharynx where the aorta is double, each aorta gives rise to the intersegmental arteries of its own side. Farther from the head the

vessels arise in pairs from the dorsal aorta. In longitudinal horizontal (*i.e.* frontal) sections of the primitive segments the intersegmental arteries show very well, compare Fig. 119, *Is*. The metamorphoses of the vessels under consideration have been worked out for the region of the head and neck by Froiep, 36.1 (pp 89, 96, 103, 108, 139), and Fr. Hochstetter, 90.1, 90.3. There are six intersegmental arteries between the seven cervical segments; of these the sixth gives rise to the arteria subclavia as a branch. There are also two segmental arteries headward of the cervical ones; these two lie respectively between the first cervical and the last occipital segments, and between the last and the penultimate occipital segments. Of these eight arteries the first very early aborts, the second gives rise to a vessel which runs forward in the head to the mid-brain and there joins the internal carotid, Fig. 299. A series of anastomoses are now developed between the intersegmental arteries of the neck and united and enlarged anastomosing vessels, Fig. 299, *Av*, appear as a prolongation through the

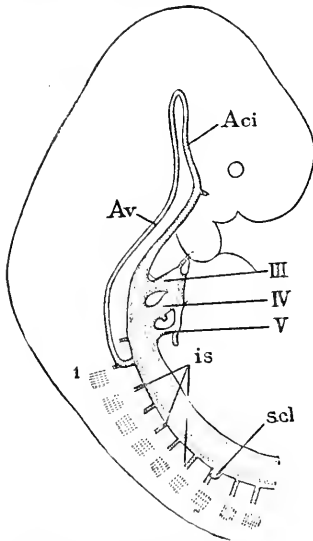


FIG. 299.—Reconstruction of the Arteries of the Head and Neck of a Rabbit Embryo at the end of the eleventh Day. 1-7, Cervical spinal ganglia; *Av*, arteria vertebralis; *Aci*, arteria carotis interna; *is*, intersegmental artery; *scl*, sub-clavian artery; III, IV, V, aortic arches, IV showing the rudiment of Zimmerman's arch. After Fr. Hochstetter.

neck of the vertebral artery. The intersegmental branches rapidly abort, except the sixth in the neck which persists as the stem, Fig. 299, *scl*, of the vertebral artery, and as soon as the fore limb buds out (rabbits of eleven days) sends a branch to it, which becomes the subclavian

artery. The artery between the sixth and seventh cervical vertebræ is thus seen to acquire a special importance, as it becomes the stem of the sub-clavian and vertebral arteries of the adult. We also learn that the vertebral artery is the earlier developed, and that, therefore, the sub-clavian is morphologically a branch of the vertebral artery, instead of the vertebral being a branch of the subclavian, as usually described in human anatomy. The small original intersegmental arteries persist on the dorsal side of the vertebral artery in the neck, and supply in the adult the circulation of the vertebral column. The next following intersegmental arteries, *i. e.* those between the seventh cervical and first thoracic, and between the first four or five thoracic segments, undergo a similar change, a secondary longitudinal vessel being developed between them also (rabbits of thirteen days), and as they disappear, this vessel becomes a branch—*intercostalis superior* of human anatomy—of the common stem of the vertebral and sub-clavian arteries. Hochstetter states, 90.1, 577, that the internal mammary arises as a branch of the subclavian at about the same time as the superior intercostal.

The subclavian does not long retain its original position, but enlarges and migrates from the dorsal to the ventral side of the sympathetic ganglion chain (Hochstetter, 90.1, 578-580).

The remaining intersegmental arteries of the thorax are said to give rise to the intercostal arteries.

The vertebral arteries unite in the occipital region (human embryo of 10 mm. according to W. His, *l.c.*, 193) to form the *arteria basilaris*, Fig. 245, while further forward they remain distinct, resulting in the development of the *circulus Willisii*.

UMBILICAL ARTERIES.—These acquire a large size in the human embryo and owing to the reduction of the caudal artery (*sacra media*) appear as the terminal forks of the dorsal aorta. They curve around past the cloaca, run in the walls of the allantois or anlage of the bladder, to the umbilicus, and thence through the umbilical cord to the placenta. They develop each a branch, which runs to the hind limb as soon as it buds forth. Until birth the umbilical artery persists as the main stem, but after birth, having lost its main function, it ceases to develop and becomes the hypogastric artery of the adult. The branch to the leg (the common iliac) continues to enlarge and after birth becomes more and more the chief vessel, so that the root of the umbilical artery is converted into the beginning of the iliac artery and the hypogastric into a branch of the iliac. The precise history of these vessels has still to be worked out thoroughly.

III. THE VENOUS SYSTEM.

The Primitive Veins.—By this heading I mean the jugular, cardinal, vitelline, and umbilical veins, or main venous stems of the first completed embryonic circulation. The initial arrangement of the four pairs of trunk veins can be studied in a human embryo of 4.2 mm., Fig. 300. From the head, where it extends to the fore-brain and has several branches, comes the jugular vein, *Jg*, descending nearly to the level of the septum transversum. From the tail comes the cardinal vein—the posterior cardinal of comparative

anatomy—to meet the jugular vein. Only part of the cardinal vein is drawn in the figure; in reality it extends the whole length of the rump and ends in the tail. In a

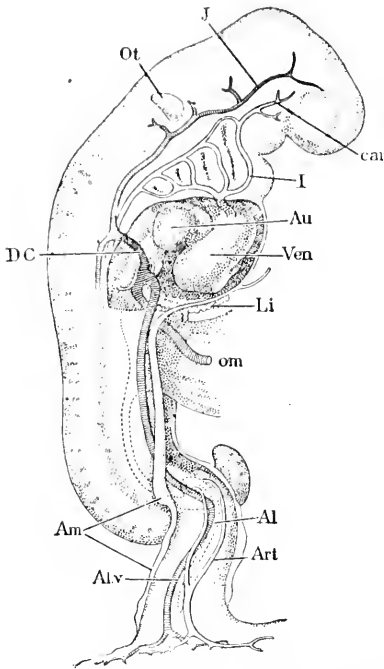


FIG. 300.—His' Embryo Lr (4.2 mm.). Reconstruction to show the Course of the Blood-Vessels. *J*, Jugular vein; *Ot*, otocyst; *D.C.*, ductus Cuvieri; *Am*, edge of amnion; *Al.v.*, allantoic vein; *car*, internal carotid; *I*, first aortic arch; *Au*, auricle; *Ven*, ventricle; *Li*, liver; *om*, vitelline vein; *Al*, allantoic diverticulum; *Art*, allantoic artery. After W. His.

From the yolk-sac come up the two *vitelline* (omphalo-mesaraic) veins, one on each side, *om*, and from the allantois stalk pass up through the somatopleure the two allantoic veins, also one on each side, Fig. 300, *Al.v.* A cross section through the rump shows the difference in situation of the cardinal vein, Fig. 301, *C*, in the splanchnopleure above the Wolffian body, and the umbilical vein, *Uv*, in the somatopleure. The umbilical vein empties into the ductus Cuvieri; the vitelline vein into the sinus venosus. For good figures of the relation of the primitive veins to the rabbit's heart, see Born, 89.1, Taf. XX., Fig. 15. The veins, as they approach the heart, pass by the anlage of the liver, and as this organ develops it enters into intimate relations with the vessels, which undergo numerous modifications. It will be convenient to consider the changes in the hepatic veins collectively, and therefore we take up first those

cross section the cardinal vein is seen to be situated originally in the splanchnopleure of the embryo, just at the level of the nephrotomes (or intermediate cell masses). This position being kept brings the vein, as soon as the Wolffian tubules are developed, to lie just above the Wolffian body, and lateral of the aorta, compare Figs. 301, 135, and 137. The jugular vein occupies the corresponding situation in the neck, but at the level of the segments, which in the chick shows an open connection with the splanchnocoel (S. Dexter, 91.1), crosses from the splanchnopleure between the myotomes and splanchnocoel to the somatopleure and runs forward to the head.

The jugular and cardinal veins unite forming a common trunk, Fig. 300, *D.C.*—the *ductus Cuvieri*—which passes in an oblique, transverse direction in the somatopleure to the anterior edge of the septum transversum, and there bends toward the median ventral line to empty into the venous end of the heart by way of the sinus venosus.

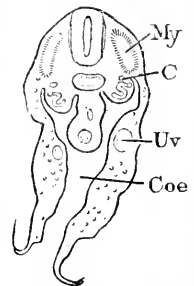


FIG. 301.—Cross Section through the Hinder Part of His' Embryo R (5 mm.). *My*, Myotome; *C*, cardinal vein; *Uv*, umbilical vein; *Coe*, coelom. $\times 20$ diams. After W. His.

changes in the primary veins which are not associated with the development of the liver. But to do this we must present the early history of the *vena cava inferior*.

Vena Cava Inferior.—This is a large unpaired vessel, which is developed somewhat later—in rabbits not until the twelfth day—than the four pairs of primary veins. Our present knowledge of its development rests chiefly upon F. Hochstetter's admirable investigations, 87.2, 88.1, 88.3. It arises as a small vessel from the ductus venosus of the liver and running through the hepatic substance is continued on the right side ventrad of the aorta in the tissue between the two primitive kidneys, Fig. 302, A, *ci*, to a point a little beyond the aortic origin of the superior mesenteric artery. It gradually enlarges and forms two fine branches, which pass around the aorta and anastomose with the cardinal veins, the communication

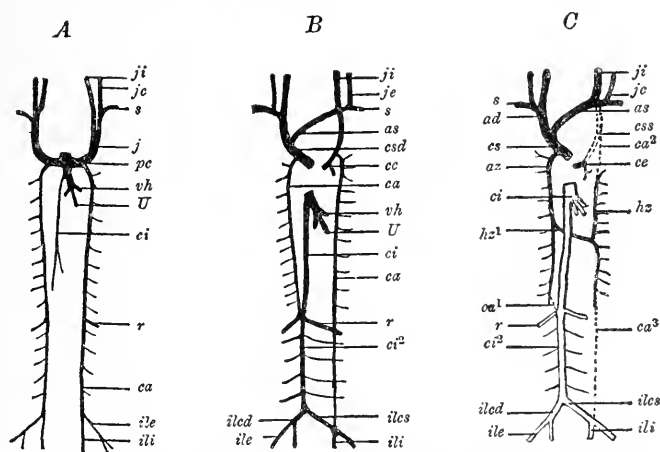


FIG. 302.—Three Diagrams to illustrate the Transformation of the Venous System. After O. Hertwig. (Explanations in the text.)

being established about at the origin of the renal vein, Fig. 302, A, *r*. By the thirteenth day the anterior portion of the cardinal vein is nearly aborted. The lower part of the right cardinal appears now as the direct continuation of the enlarged vena cava, and in fact is the anlage of the lower part of the adult cava inferior, Fig. 302, C. By the fourteenth day the *renal veins* appear as branches of the cava, and the caudal ends of the two cardinals are united, thus converting the lower branches of both these veins into branches of the cava inferior. But in man this fusion of the cardinal veins does not take place, but instead there is developed a cross anastomosis by which the lower ramifications of the left cardinal become branches of the cava, Fig. 302. C in Fig. 302 represents diagrammatically the permanent condition. The true vena cava inferior extends only to the renal veins, *r*, which are persistent segmental branches of the cardinal veins; beyond this point the cava is really the persistent right cardinal vein; a cross anastomosis, *iles*, becomes the left common iliac, while the terminal branches of the cardinals are converted into the external and internal iliaes on each side, and empty their

blood into the right cardinal, or lower segment of the adult cava inferior.

Metamorphoses of the Primitive Veins.—By a series of changes beginning very early indeed in the embryo the four pairs of symmetrically placed veins take on an asymmetrical arrangement. The chief factors of the change are, 1, the development of new cross trunks, which become main stems; 2, the abortion of parts of the primitive veins; 3, migration of the vessels.

The changes which occur in the venous sinus have been already indicated; those which occur in the liver are described in a separate section below.

Changes of the Ductus Cuvieri and their Connections.—We have already noticed the relations of the ductus to the horns of the sinus venosus, p. 527, and the rôle of the ductus in shutting off the pleural from the pericardial cavity, p. 482. The transformation of the ductus begins with a change in their position, their course becoming steeper, in consequence of the descent of the heart, and at the same time they project across the opening of the pleural cavity into the pericardial cavity, and by finally closing across this opening the ductus are enabled to unite with the mediastinum, thus bringing the two veins nearer together. Of the veins supplying the ductus the jugulars continue to develop and with the growth of the head to acquire an increasing importance, while the cardinal veins have their circulation impeded owing to the competition of the vena cava inferior; the preponderance of the jugular is further increased by the vein of the fore limb, the *subclavian*, Fig. 302, A. s., emptying into it. The two sides of the sinus venosus early become asymmetrical, and, owing to the migration of the sinus toward the right side of the heart, p. 527, the right ductus (the future *vena cava superior dextra*) has a shorter and more direct course to the heart than the left ductus, which has to bend around the left auricle toward the right. The left ductus runs along the coronary groove of the heart, and there receives the coronary vein, concerning the development of which we have no definite information. This may be called the Sauropsidan stage, since it is permanent in all reptiles and birds; but it is said to be retained in certain mammals. In man, however, a further stage is reached by the partial abortion of the left ductus (*vena cava superior sinistra*). The reduction begins with the development of a cross anastomosis, Fig. 302, B, *as*, between the two jugulars. The anastomosing vessel, which is the future *vena anonyma sinistra*, runs obliquely from the left to the right jugular, where the conditions for the return of blood to the heart are more favorable; the cross vessel enlarges and in the same measure the right ductus enlarges also, with the further consequence that the right cava usurps more and more of the blood from the left jugular. This leads to the gradual closure of the left ductus Cuvieri (*cava sinistra*) except of the end next the heart, which persists as the vein delivering the vena coronaria into the right auricle. We thus learn that the cardiac orifice of the coronary vein is really the mouth of the vena cava superior sinistra. The development of the valve (*valvula Thebesii*) of this orifice is described p. 532.

The cardinal veins undergo a similar change to the jugulars, see

Fig. 302, C, in that a cross vein appears which takes the blood of the left cardinal into the right, so that the stream of both cardinals is poured into the right ductus Cuvieri (cava sup. dextra). In the account of the vena cava inferior it has been explained how the lower parts of the two cardinals are changed, and only the upper parts left. As the main function of the cardinals appears to be to maintain the circulation of the Wolffian bodies, the cardinals lose their importance as the bodies abort. They persist, however, in part to give rise to the *azygos* and *hemiazzygos veins* of the adult, as sufficiently indicated by Fig. 302, C, *az*, *hz*¹, *hz*.

Veins of the Hand and Foot.—Fr. Hochstetter, 91.1, has shown that in all amniota there is a vein (*Randvene*) which runs around the edge of the hand (or foot) but when the digits appear this "randvene" is divided and gradually disappears. The veins are developed as a network of capillaries, connected with the randvene and the venous trunk of the limb. As the digits grow out, the randvene persists on each side of each digit, but is interrupted at the apex. The randvene thus gives rise to the digital veins and probably also is continued on the ulnar side as the permanent vein of the arm, and correspondingly on the leg.

Hepatic Veins.—The following account is an abstract of His' researches ("Anat. menschl. Embryonen," Heft III., 200-210). The liver grows out into the septum transversum and by its enlargement comes very soon into contact with the vitelline and umbilical veins on their way to the sinus venosus. The hepatic cylinders grow into the veins, pushing, however, the vascular endothelium before them, and dividing the veins into numerous channels, which constitute a network of fine branches. The four vessels are thus broken up into smaller vessels, but for a while they persist in part as larger stems leading from the liver to the sinus venosus. The liver is now supplied with all the blood from the chorion (placenta) and the yolk-sac. This stage is found in a human embryo of 4.25 mm., Fig. 303. The united umbilical veins of the allantoic-stalk, *All*, pass up to the liver in the somatopleure of each side of the body; the left umbilical, *v.u".s.*, is already decidedly larger than the right; both

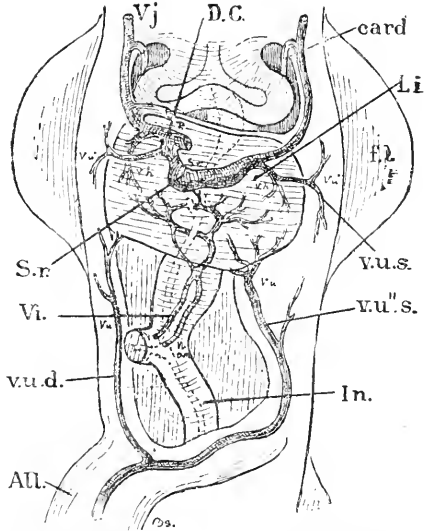


FIG. 303.—Reconstruction of a Human Embryo (His' Bl.) of 4.25 mm. Front view. *Vj*, Jugular vein; *card*, cardinal vein; *D.C.*, ductus Cuvieri; *Li*, liver; *S.v.*, sinus venosus; *fl*, fore limb; *v.u.s.*, upper part of left umbilical vein; *v.u".s.*, lower part of same; *All*, allantoic stalk; *In.*, intestine; *v.u.d.*, right umbilical vein; *V*, vitelline vein. $\times 18$ diams. After W. His.

veins break up within or near the liver into small vessels. The two vitelline veins, *Vi*, run in the splanchnopleure or wall of the intestine and unite just before they attain the liver, then separate and pass

around the entodermal intestinal canal to unite again on its dorsal side, making a complete venous ring; they then again separate and pass back again around the intestine, forming a second complete ring before they break up into small hepatic vessels. On the right side the umbilical and vitelline trunks remain separate as they leave the liver, and open separately into the sinus venosus, but on the left side the two trunks unite, as shown in the figure, and empty by a common stem into the venous sinus, *S.v.*

In the next stage the lower part of the right umbilical has no longer any connection with the upper part of the same vessel, and, therefore,

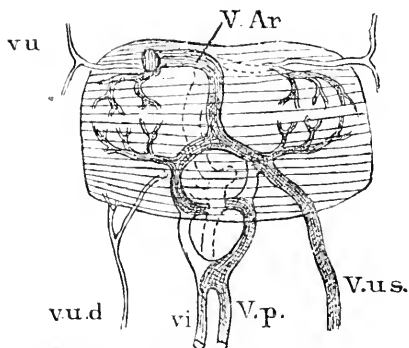


FIG. 304. — Reconstruction of the Venous Trunks and Liver of His' Embryo R. 5 mm. *V.p.*, Portal vein; *v.u.*, right umbilical vein; *V.Ar.*, Vena Arantii; *V.u.s.*, Vena umbilicalis sinistra; *vi*, vitelline veins; *V.u.d.*, Vena umbilicalis dextra. The vessels left white are aborted. $\times 40$ diam. After W. His.

still persists. It will be seen that this stage and the preceding is, that whereas previously all the blood passed the liver through small vessels, now only part of it flows through small vessels, the rest through large trunks directly to the heart.

The third stage is established by developing the single portal vein out of the two vitelline veins. This is accomplished as indicated by the diagram, Fig. 304, which is to be compared with the previous figure. The left side of the upper ring formed by the vitelline veins, Fig. 303, *vi*, and the right side of the lower ring persist, leaving parts of each ring to form a single continuous vessel, the *vena portæ*, which from its mode of origin necessarily makes one complete spiral turn around the intestine. Herewith the condition is reached which persists throughout foetal life, Fig. 305. The portal vein and left umbilical vein supply the liver with venous blood, and also form within the liver near its lower surface two large stems which unite and are continued forward by the single *vena Arantii*. These three great veins after the third month are found to lie near the median plane, and to follow straighter courses than in Fig. 305.

The final stage is not reached until after birth, when the umbilical vein rapidly aborts. A little later the large channel formed within the liver by the *venæ portæ* and *Arantii* also disappears, except that the part between the union of the *vena cava inferior* with the *vena*

since it continues to act as a venous path, its stream is directed downward. The left umbilical vein, on the contrary, has increased in size, Fig. 304, *V.u.s.*, and is prolonged within the liver by a large stem, which joins the left side of the upper venous ring formed by the vitelline veins, *vi*. The upper ring is connected by a newly developed large trunk, *V.ar.*, the *vena ascendens*, or *vena Arantii*—as to the origin of which we possess as yet no satisfactory data. Remnants of the portions of the umbilical and vitelline veins, which in the previous stage took the blood from the liver to the sinus venosus, the essential difference between this stage and the preceding is, that whereas previously all the blood passed the liver through small vessels, now only part of it flows through small vessels, the rest through large trunks directly to the heart.

Arantii (ductus venosus) and the heart is retained and functions as the cardiac end of the adult cava inferior. In the fourth or adult stage, the liver is supplied by the portal vein, the representative of the vitelline or omphalo-mesaraic veins of the embryo, and all the portal blood passes through the liver in small vessels (capillaries), though, of course, larger venous branches persist to distribute the blood to, and collect it from, the capillaries of the hepatic lobules.

Pulmonary Veins.—It was first shown by Fr. Schmidt, 70.1, that the pulmonary veins are four vessels, which unite into a short common stem emptying into the left auricle. Their history has been further elucidated by His, 87.3, 103, and G. Born, 89.1, 313, 334. The common stem appears first as a capillary vessel arising from the left auricle near the interauricular septum (twelve days' rabbits); the small vessel runs through the mesocardium posterius directly toward the anlage of the lungs; by enlarging and branching this vessel forms the system of the pulmonary veins, but for some time after its appearance it remains small. The development is not the same in the rabbit and in man; in the latter the common stem enlarges and merges into the auricular cavity, at first as a recess, later without demarcation; hence the four pulmonary

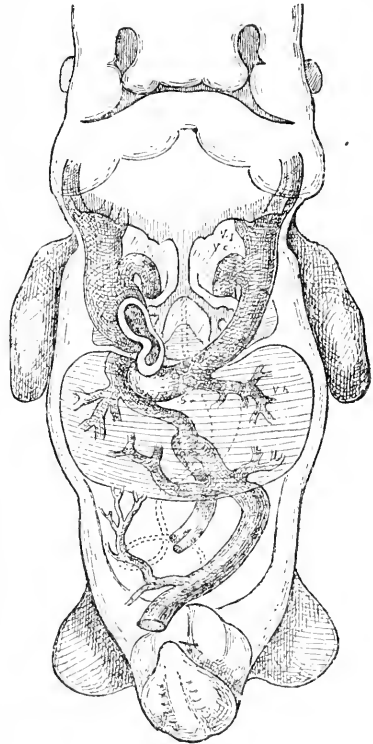


FIG. 305.—Reconstruction of the Venous System of His' Embryo Rg, 11.5 mm.

veins open into the heart by two orifices, the two veins on each side uniting before they empty. Still later (two months' embryo) the four veins each open separately, more of the vein being annexed by the heart. In the rabbit the primitive condition is permanent, and the four pulmonary veins unite before joining the heart.

The course of the four veins in the lungs has been described by His, 87.3, 103. They run from the central stem one to each lobe of the lung; in other words, from the start there is an upper and a lower vein in each lung; the pulmonary veins are situated below the forking of the trachea, and this relative position the main stems retain throughout life,—compare Fig. 459.

CHAPTER XXV.

THE EPIDERMAL SYSTEM.

THAT portion of the ectoderm which remains upon the surface of the embryo is called the epidermis; it constitutes the outer skin; for convenience the inner skin (cutis or dermis) is treated in connection with the history of the true skin in this chapter. We have also to consider the development of the following epidermal appendages: nails, hairs, and glands.

I. THE SKIN.

Epidermis.—The ectoderm of all amniote vertebrates is at first a single layer of cells, which presents considerable variations in appearance not only in different classes, but also at different stages of the same species, and even in different parts of the same embryo. Since in all invertebrates the ectoderm consists of a single epithelial layer, we may call the first stage of the vertebrate epidermis the *invertebrate stage*. The appearance of the ectoderm while in this stage has been indicated by the figures and descriptions scattered through Chapters V.—XV., and until a comprehensive study of the ectoderm of amniota in the one-layered condition shall have been made, it is impossible to give a minute description of it possessing much value or any interest. The epidermis of *Amphioxus* and the ectoderm of the amnion never pass beyond the one-layered stage, p. 335.

In its *second stage* the epidermis becomes two-layered. The cells of the single layer become irregularly placed; some have their nuclei

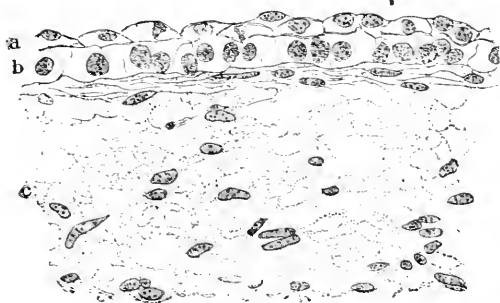


FIG. 306.—Section of the Skin of a Human Embryo of sixty-three to sixty-eight Days. Minot Collection, No. 138. a, Outer layer of epidermis; b, inner layer of epidermis; c, cutis.

nearer the outer, others nearer the inner, surface of the ectoderm. The difference rapidly increases, and though for a time the cells stretch through the whole thickness of the layer, yet they gradually draw away, some from the upper, others from the lower, surface, until they have definitely arranged themselves in two distinct layers, Fig. 306. This stage is established in the

human embryo by the end of the first month, and persists over part certainly of the embryo, at least until the close of the second month.

In stained sections the outer layer, Fig. 306, *a*, is composed of somewhat flattened cells, with irregularly shaped, slightly granular nuclei, and are darker and thicker walls than the cells of the inner layer. These latter, Fig. 306, *b*, are larger and clearer, and have larger, more granular nuclei of round shapes. The appearance of the outer cells suggests a necrotic change. Bowen's careful researches, **88.1**, render it probable that the outer layer is the epitrichium, compare below.

It is a remarkable fact that the primitive blastoderm in amphibia, teleosts, and ganoids never passes from the several-layered to the one-layered condition, but only to the two-layered condition. For description of this stage in *Bombinator*, see A. Goette, **75.1**, and in teleosts see M'Intosh and Prince, **90.1**, 739, in *Lepidosteus*, Balfour and Parker, **82.1**. The development, therefore, in this group of forms, offers a marked difference from that found in marsipobranchs and amniota, but since in *Petromyzon* we encounter the one-layered stage, we must consider the succession of stages adopted in this chapter as the primitive one, and conclude that the precocious appearance of the two-layered stage in amphibians, etc., is a secondary modification, the cause of which is unknown. That the two layers of the epidermis are homologous throughout the vertebrate series, we have no reason to doubt (Balfour, "Comp. Embryol.," II., 300). Where the epidermis has an initial division into two layers, the inner is commonly termed the nervous layer, and it has the main share in forming all the organs derived from the epidermis; the outer layer, according to homologies I hold to be probable, must be identified with amniota epitrichium, although unlike the true epitrichium it disappears as a distinct layer, its cells showing themselves between those of the inner layer (Goette, **75.1**, 158).

The ectoderm of the chorion and umbilical cord never advances beyond this stage, unless we regard the formation of the chorionic cellular layer as such an advance.

The *third stage* is very gradually reached by the increase in the number of layers until there are several. I consider it probable that this stage is established in two ways—one, the more primitive, involves the disappearance of a distinct outer layer, as in amphibia; the other depends upon the preservation of the outer layer, as the epitrichium. This view can be advanced, at present, only as an hypothesis.

1. *The primitive method* is maintained in amniota only over very limited special regions; as such I venture to designate the cornea, the nasal pits, the mouth cavity and lips, and the anal ectoderm. Over these parts the distinct outer layer disappears as such, and we have developed a stratified epithelium, which never produces a true horny layer, but consists of a basal row of protoplasmatic cells, and several layers of cells above, which are clear in appearance and have thickened walls. The details of the process of differentiation have not yet been worked out.

2. *The secondary method* of forming the several-layered epidermis is established over the skin proper. It can be well seen in the human embryo of the third month. In an embryo of two and one-half months, Fig. 307, there are four to five layers of cells. The

basal layer, *b*, is composed of a single row of cuboidal cells, which are rich in protoplasm, though small in size, and which have round nuclei. This basal layer persists throughout life in all amniota, and is one of the most characteristic features of the amniote epidermis.

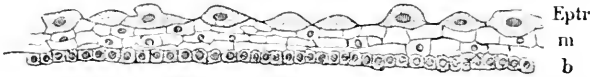

FIG. 307.—Epidermis from the Occiput of the Human Embryo of two and one-half Months. *Eptr*, Epitrichial layer; *m*, Malpighian layer; *b*, basal layer. After Bowen.

Above the basal comes the middle layer, which varies from two to three cells in thickness; its cells are irregular in shape and size, and are so large that the nuclei of many of them do not appear in the section. The outermost layer, *Eptr*, is the epitrichium, and consists of a single layer of large dark cells, which from their arching up may be termed *dome cells*. It is probable that the epitrichium is the outer layer of the second stage preserved and modified, and that all the middle cells come from the inner layer of the previous stage, but conclusive proof of this identification is still required. The history of the epitrichium is treated in the next section.

The *fourth stage* is characterized by the presence of a horny layer (*stratum corneum*). The stratum corneum presents marked variations in structure, and it is probable that, as explained in the following paragraph, at least two morphologically distinct layers have been confused under a common name. Unfortunately almost nothing is known concerning the genesis of the horny layer. Bowen's observations, 89.1, render it probable that it arises from the epitrichium, but if this view be adopted we encounter certain difficulties which our present knowledge cannot remove. If Bowen's hypothesis is correct, we must define the fourth stage as characterized by the cornification of the thickened epitrichium. Concerning the process of cornification we possess some information, which is referred to more fully under the head of nails, p. 555. When the horny layer is produced the skin is considerably thickened and the number of layers of cells which it comprises is much increased. The line of division between the horny layer and the underlying mucous or Malpighian layer becomes quite sharp. It must be assumed that cells of the deep layer are added to the horny layer.

The *fifth stage* is established by the development of the *stratum lucidum*. Bowen has made the important discovery that the stratum lucidum of the human embryo lies immediately underneath the epitrichium, and is directly continuous with the nail, and the epitrichium is continuous with the horny layer outside the stratum lucidum. Bowen suggests, 89.1, 449, that, where there is no epitrichial layer nor characteristic stratum lucidum (Zander's Typus B, 88.1), the stratum really extends over the Malpighian layer, being modified and constituting the horny layer of those parts. The essential characteristic of the stratum lucidum is that its cells are solidly cornified, their nuclei being obliterated. When the epitrichial cells cornify they acquire thickened walls, but remain hollow (Zander's Typus A, 86.1, 88.1). The histogenesis of the stratum lucidum is de-

scribed in the section on the nails, p. 555, the process having scarcely been studied except in connection with the investigation of the nails.

The ridges (*rêtes d'Henle*) on the under or dermal side of the epidermis begin to appear on the hairless parts, according to Blaschko, **87.1**, about the fourth month, but on the hairy parts, where they are always rudimentary, they do not appear until toward the end of foetal life. There are primary and secondary ridges. The former are the first developed, and from them the solid out-growths to form the sweat glands originate. Fig. 308 represents

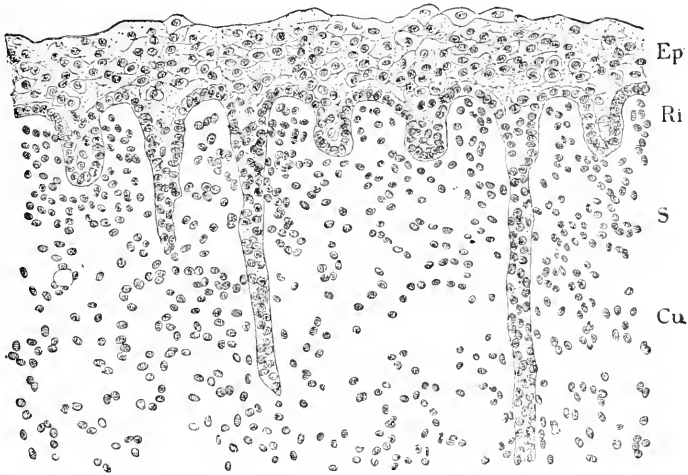


FIG. 308.—Section of the Skin of the under Side of the Right Second Toe of four months' Embryo, Minot Collection, No. 123. *Ep*, Epidermis; *Ri*, primary ridge of epidermis; *S*, sweat gland; *Cu*, cutis.

a section across the primary ridges: the epidermis is some seven or eight cells thick, its outer surface irregular, but not thrown into folds or ridges; the structure of the superficial layer is indistinct but the epitrichium seems to have disappeared; the dermal surface is thrown up into regular rounded equidistant ridges, *Ri*, from which grow out here and there the solid anlagen of sweat-glands, *S*. These ridges do not arise all at the same time, but their formation spreads from sundry centres, nor do the ridges run in straight lines altogether, but on the contrary in parallel curves. The ridges under the nails appear first (three and one-half months) under their distal and lateral borders, later under their central and proximal portions; additional ridges appear between those first formed (F. Curtis, **89.2**, 179). In the next stage, which is assumed by the epidermis only upon the palms and soles, the outer surface forms a low ridge over each of the inner ridges. The external ridges with the openings of the sweat glands upon them are easily seen upon the adult hand. When the external ridges are developed there appear also secondary ridges on the dermal side, between the primary ridges. The secondary are much smaller than the primary ridges and underlie the grooves separating the external ridges.

The origin of epidermal pigment has been already discussed, p. 419.

Epitrichium.—The external layer of the skin is known to be stratified in all amniota, but the homologies of the strata have never been satisfactorily determined. That the mucous or Malpighian layer is the same in all classes is evident, but that the horny layer comprises two distinct strata is, I think, extremely probable, as stated above. One stratum may be homologized with the stratum lucidum, the other with the epitrichium. Where the epitrichium is lost (nails and hairy skin) the stratum lucidum forms the superficial layer of the epidermis, but when the epitrichium is preserved, it forms the outer layer and the stratum lucidum underlies it. The history of the epitrichium is the key to the morphology of the amniote epidermis.

The epitrichium was discovered by Welcker, 64.1, in the embryos of a sloth (*Bradypus*), where it forms a continuous membrane overlying the hairs. Welcker found the layer in several mammals, including man, and demonstrated that it belongs to the epidermis, becoming separated from the rest of the outer skin, when the hairs grow forth. In the sloth it forms, so to speak, an extra fœtal envelope, which we find mentioned by Eschricht and Ebsen (*Müller's Arch.*, 1837, 41) and and by Simon (*Müller's Arch.*, 1841, 370-372), but these authors did not ascertain its origin. Kerbert, 77.1, demonstrated the epitrichium in reptiles; Jeffries, 83.1, and Gardiner, 84.1, in birds—the latter author adding also considerably to our knowledge of the layer in mammals. Kölliker failed to recognize the layer in man (see his "*Entwickelungsges.*," 1879, and "*Gewebelehre*," 6te Aufl., 204). Minot, 86, showed that the layer is present in the human embryo at certain stages and is absolutely distinct from the underlying horny layer. The history of the human epitrichium has been quite fully

worked out by J. T. Bowen, 89.1.

The epitrichium becomes well marked during the third month, as a single layer of cells of large size, and each arching up from the surface, Fig. 307, *Eptr.* Over the hairy parts of the skin the development does not seem to progress beyond this stage. The cells of the epitrichium enlarge and gradually flatten down, but before they are completely flattened there intervenes a condition in which the expanded cells are flattened except in their central part, which forms a dome-like projection on each cell; into this dome the nucleus and protoplasm of the cell are found withdrawn and degenerating. Later the cells are very large, Fig. 309,

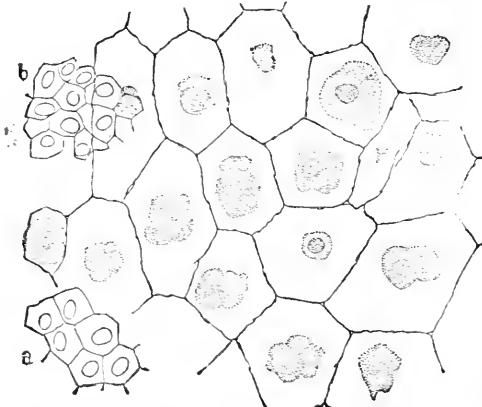


FIG. 309.—Epitrichium of a Human Embryo of the Fifth Month. *a, b*, Cells of two layers of the underlying horny layer drawn on the same scale.

Later the cells are very large, Fig. 309,

three to six times the diameter of the underlying epidermal cells; there are no transitional forms, as Kölliker has erroneously maintained, between the epitrichial and the underlying cells. The outlines of the cells are polygonal and very distinct; in the middle of each cell is an irregular lump of degenerated protoplasm, in which the nucleus can sometimes be distinguished. The epitrichium overlies the hairs; those hairs which project from their follicles lie between the epitrichium and the rest of the epidermis.

Over the hairless parts of the skin the epitrichium probably persists and becomes several-layered, except that it disappears in great part over the nails, see p. 555. Thus, in an embryo of three months, there appear on the palms several layers of cells, all of which have the vesicular character and dark look of the cells of the single-layered stage. It is unknown how this growth of the epitrichium is effected; the primitive epitrichial cells have so much the appearance of degenerating tissue, that it is improbable that they proliferate, hence we must assume that the growth is effected by the addition of cells from the deeper layers. It was indicated above that in other parts the many-layered epitrichium probably undergoes cornification according to Zander's Typus A, and forms the stratum corneum of authors, which is found overlying the stratum lucidum. This probability rests chiefly upon Bowen's observation that the epitrichium over the developing nail is continuous with the horny layer. If we accept this interpretation, we must say that the epitrichial cell cornifies so as to form a thick-walled vesicle, while the underlying cells cornify so as to form solid scales (Zander's Typus B, 88.1). That the epitrichium in birds and mammals may become horny was demonstrated by Gardiner's careful researches, 84.1.

Dermis.—Although the dermis or cutis is of exclusively mesenchymal origin, it is convenient to consider its development in connection with that of the external skin. In very early stages the mesenchyma extends to the ectoderm, but shows no trace of a special layer under the epidermis. This layer is, however, well marked in embryos of two months by the condensation of the dermal mesenchyma, the cells becoming flattened in a plane parallel with the surface, and hence they appear somewhat elongated in vertical sections of the skin, Fig. 306, *c*: the nuclei are granular, the protoplasm forms a rich network of great delicacy. Later the protoplasm is, I find, more condensed around the nuclei, and the cells have more individuality; at the same time the protoplasmatic network becomes coarser and simpler in character. During the third month (Kölliker, "Entwickelungsges.," 1879, p. 774) the primitive dermis becomes differentiated into two layers, the true dermal (*corium*, *Lederhaut*) and the subdermal (*Unterhautzellgewebe*), the tissue being more condensed in the former and more fibrillar in the latter. During the latter half of the fourth month fat cells arise in the subdermal layer and steadily increase thereafter in both number and size, and by the end of the fifth month the whitish fat islands are conspicuous to the naked eye. The skin now comprises, Fig. 310, the epidermis, *Ep*, the dermis or cutis, *Cn*, and the fat-layer *F'*; below is loose connective tissue, *c*. The hairs grow to the bottom of the fatty layer. The origin of the columnæ adiposæ (J. C. Warren, 77.1), calls for

investigation. The papillæ of the dermis can be first seen during the sixth month (Kölliker, *l.c.*) on the hand and feet, forming a double

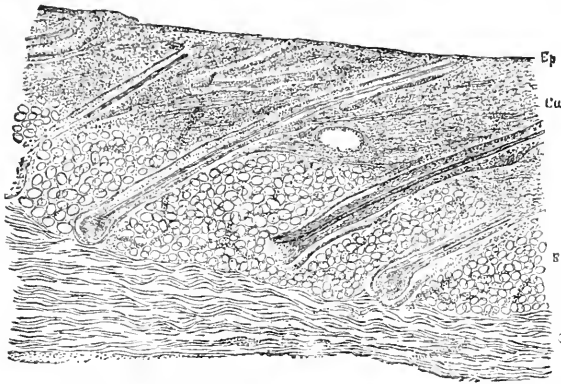


FIG. 310.—Vertical Section of the Skin of a Human Embryo of the fifth Month. *Ep*, Epidermis; *Cu*, cutis; *F*, fat layer; *c*, loose connective tissue.

row between every pair of primary ridges, Fig. 308, *Ri*. The elastic fibres appear during the seventh month (Kölliker, "Entwickelungs-ges.," 2te Aufl., 776).

II. NAILS AND HAIRS.

Nails.—A nail is a modified area of the stratum lucidum, situated upon the upper side of the terminal joint of a digit and laid bare by the loss of the overlying epitrichium. This definition is essentially different from that hitherto current, and is based on Bowen's discoveries, 89.1.

The first indication of the nails may be seen in the human embryo at the beginning of the third month as a thickening of the epitrichium over the end of the digit. In most mammals this position is permanent and there is developed a terminal claw, but in man, as discovered by Zander, 84.1, the terminal position is transitory, and the unguis migrates on to the dorsal side of the digit. The change of position is attributed by Kölliker, 88.2, 25, to the growth and expansion of the palmar side of the finger-tip. A secondary result of the migration of the nail is the transfer of the terminal branches of the two digital nerves of the palmar surface to the back of the finger (toe) tips, Zander, 84.1. The nail area is marked out quite definitely by a limiting groove or depression which persists more or less distinctly throughout life.

As soon as the nail area has reached its dorsal permanent position, there appears at its proximal edge an oblique ingrowth of the Malpighian layer of the epidermis, to form the so-called root of the nail. The epitrichium over the nail is much thickened—see Bowen, *l.c.*, Fig. 3—but is thickest near and beyond the distal edge of the nail. The primary ridges of the Malpighian layer now appear, but only over the palmar surface of the finger or toe tip, and as they do not appear until much later under the nail, they establish a marked difference between the epidermis surrounding and that covering the

nail area. The epitrichial layer over the area has received the special name of *eponychium* from Unna, 76.1. Until the fourth month there is little change except that the anlage of the root of the nail grows considerably, and at the same time becomes more and more inclined toward a horizontal position, a change which progresses until by the eighth month the nail-root is horizontal, *i.e.*, in the same plane with the nail-bed proper—compare Fig. 311.

About the beginning of the fourth month there appear, Kölliker, 88.2, 4, granules in the uppermost cells of the Malpighian layer. The granules are rounded in form, variable in size and have a decided affinity for coloring matters, especially for acid fuchsin, Zander, 86.1, 285. Very soon the cells form a stratum lucidum, which appears first in the distal part of the unguis area and is very thin, thence spreads proximalward, and, last of all, appears in the nail-root, being there also preceded by the granular cells. By the middle of the fourth month the stratum lucidum is present over the whole nail and also extends on to the palmar surface, Fig. 311, *s.l.* The granules have been supposed to be identical with eleidin, but on this point there has been some discussion, which is summarized by Kölliker ("Gewebelehre," 6te Aufl., 216); Ranvier ("Traité technique d'Histologie," 886) was the first to observe that the granules differ somewhat from true eleidin. There can be little question, if any, that the granules are directly connected with the cornification of the cells to form the nail proper. The granules were described by Brook in 1883, in a paper (Schenk's "Mitth.," II., 159), which I have not seen, and their relation to keratosis was more fully studied by Zander, 86.1, whose results have been in the main confirmed by Kölliker, 88.2, and F. Curtis, 89.2. The walls of the granular cells gradually become thickened (marginal keratinization of Curtis), the cell becomes flattened, its nucleus disappears, the walls unite, and there is thus produced a horny scale in the place of the cell. By the transformation of additional cells, the horny stratum lucidum is constantly thickened on its under side—compare Fig. 163, in Kölliker's "Gewebelehre," 6te Aufl. During the fifth month the development of the stratum gradually extends beyond the nail area over the rest of the finger-tips, and more slowly into the nail-root.

The epitrichium disappears over the nail at about five months, first in the centre, then toward the base, sides, and distal end, but a small band persists as the *perionix* across the root of the nail, Fig. 311, *Ep'*, and a large mass, *Ep''*, forms a conspicuous ridge after the fifth month, across the distal end of the nail, and is continued over the palmar surface of the digit, as a considerable horny layer covering the stratum lucidum, *s.l.* The nail, *N*, although the direct continuation of the stratum lucidum, has, of course, its surface exposed. The epitrichium varies greatly in appearance, for it may either preserve more or less the vesicular form of its cells, or its cells may be more or less cornified and flattened. It is probably owing to the frequency of the latter modification that the nature of the layer has been overlooked. The cornification of the epitrichium is preceded by the appearance of eleidin granules in its cells, Curtis, 89.2, 17.

The final step in the development of the nail is the change by

which its distal edge becomes free, according to Kölliker, **88.2**, 7, by desquamation of the stratum lucidum at the point where the nail passes distally into the stratum of the palmar surface.

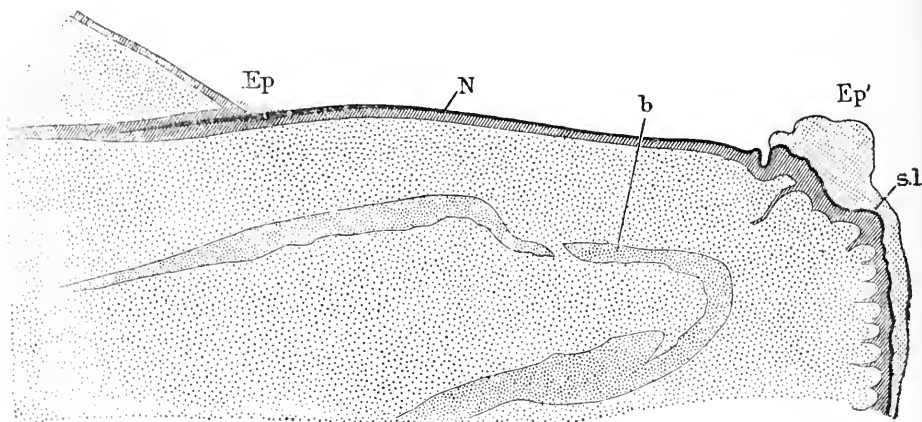


FIG. 311.—Longitudinal Section of the Nail of the Great Toe of a Human Embryo of five Months. Minot Coll. No. 95. *Ep*, Remnant of epitrichium; *Ep'*, distal ridge of epitrichium; *N*, nail; *sl*, stratum lucidum; *b*, bone. From a section by Dr. Bowen, stained with acid fuchsin.

Morphology.—The discovery that the nails are modified portions of the stratum lucidum gives the question of their evolution an entirely new aspect. It renders it probable that the claws and hoofs are also derived from the stratum lucidum, and that the development and changes of this layer of the epidermis will have to be carefully investigated in the lowest amniota before we can hope to understand the origin of claws.

It may be safely assumed that the nail is a modified claw. Zander, **84.1**, having observed the primitive terminal position of the nail area (*Nagelfeld*) in the human embryo, and its subsequent migration to the dorsal side of the digit, concluded that the human nail represented a terminal claw flattened out, and that the centre of the nail must correspond to the point of the claw. Boas, **84.1**, from comparative anatomical studies on claws, hoofs, and nails, established a distinction between the volar side and the palmar side of claws and hoofs, and homologized the nail with the volar side of a claw, which may therefore be termed the *nail-plate* (*Nagelplatte*); Boas further maintained that the palmar side (sole-plate, *Sohlenhorn*) of the claw becomes rudimentary in man, and believed that its representative is the small area of epidermis under the edge of the nail in the adult; this area probably corresponds to that which in the embryo is covered by the epitrichial ridge, Fig. 311, *Ep'*, at the distal edge of the nail. This interpretation has been adopted by Gegenbaur, **85.1**, in whose laboratory Boas' researches were carried out. In view of our present knowledge it seems to me that Boas' conception must be accepted, with the modification, however, that the stratum lucidum covered by epitrichium over the end of the digit must be considered the homologue of the sole-plate (*Sohlenhorn*), and that not merely the epitrichial ridge at the edge represents the

sole-plate. To decide the question, we must acquire exact knowledge of the relation of the sole-plate to the stratum lucidum in clawed and hoofed mammals.

Hairs.—A hair is a long downgrowth of the mucous layer of the epidermis into the cutis, Fig. 312, A; into the enlarged end of the downgrowth extends a papilla, *p*, of mesenchymal tissue; the downgrowth separates into two parts, the axial or hair proper, *H*, which grows upward and projects above the surface, and a peripheral part or follicle, *f*. At the base of the hair, the hair itself and the follicle unite.

The hairs arise in man as solid processes of the epidermis, the ends of which very soon expand, Fig. 313, 5, 6, and acquire the dermal papilla, 7. In other cases, as has been observed by Alexander Goette 68.1, and also, it is said, by Reissner and Feiertag, the papilla is formed first, as a slight projection of the dermis into the Malpighian layer of the ectoderm; the overlying epidermis then forms a downgrowth, which carries the papilla with it; in other respects the hair develops as in man. O. Hertwig ("Entwicklungsgeschichte," 3te Aufl., 436) regards the type of development in which the papilla appears first, as the more primitive; this view is plausible, and enables us to assume that the hairs were evolved by modifications of the epidermis, overlying special dermal papillæ. Hertwig fortifies his hypothesis by comparison with the teeth, which in the lower vertebrates are developed from dermal papillæ, while in the higher forms there is a deep ingrowth of the epidermis before the mesenchymal papilla of the dental germ appears.

The hair anlagen appear in the human embryo at about three months, and can be first seen over the forehead and eyebrows, but very soon (sixteenth to seventeenth week) are developed over the entire head, and a little later the rest of the body, so far as it is ever hairy—on the limbs the hairs appear about the twentieth week. By the end of the fifth month, all the hairy areas are marked out. From the third to the seventh month at least—my observations do not go further—new hair anlagen continue to arise, so that one finds various stages at once. It is thus possible to study in one preparation the gradual differentiation of the hair. In embryos of five to seven months, which have died and been retained in utero, the epidermis is usually loosened and may be isolated.* Such a piece of epidermis stained with alum hæmatoxylin and viewed from the under side is represented in Fig. 313. I distinguish two kinds of nuclei, those which are more darkly stained and those which are lighter. Some of the light nuclei appear dark because of the epitrichial cells underlying them. The darkly stained nuclei all belong to cells which participate in the formation of hairs. At first the dark nuclei make a little cluster, as at 1 and 2; the clusters grow in size—one a little larger is seen just to the left of that numbered 2, one a good deal larger is shown at 3. Sections show that such clusters are on the under-side of the epidermis and form slight protuberances or rudimentary papillæ; the papillæ lengthen out and acquire rounded ends, 4; they grow rapidly down into the cutis, and by the contrac-

* The process may be imitated by soaking the skin of a fœtus for several days in a 0.75 per cent salt solution to which a little thymol has been added to render it aseptic.

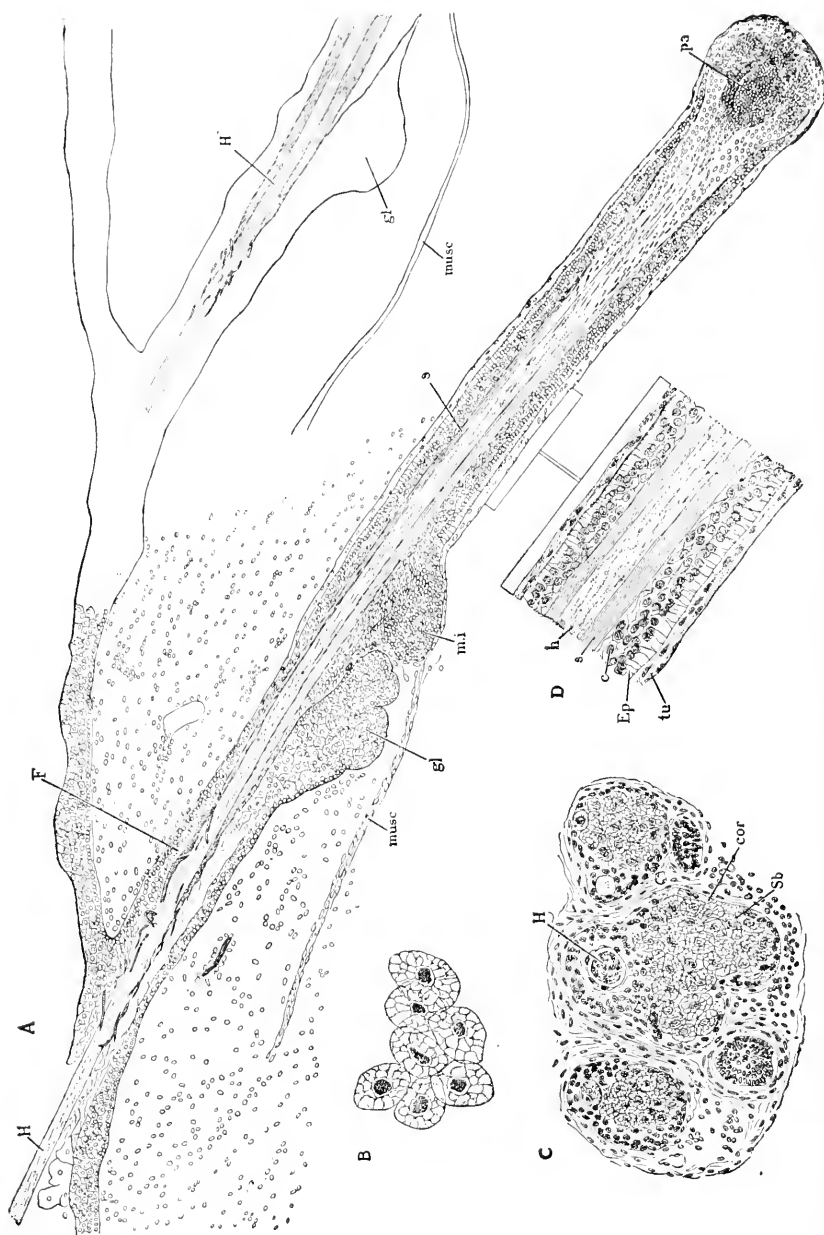


FIG. 312.—Development of Hairs in a Human Embryo of about seven Months. A, Longitudinal section of hairs; B, central cells of sebaceous glands, highly magnified; C, transverse section of a group of hairs; D, part of A highly magnified. *H*, hair; *F*, follicle; *musc.*, muscle; *gl.*, gland; *m.l.*, inner follicular sheath; *pa*, papilla; *v.*, blood vessel; *h*, hair; *c.*, cellular layer; *Ep*, epithelial layer; *tu*, connective-tissue tunie; *cor*, cortical cells of gland; *sc.*, sebaceous cells.

tion of their upper part become club-shaped, 5 and 6. The next step is the formation of the dermal papillæ of the hair, 7; a little notch arises at the thick end of the epidermal ingrowth, and the tissue filling this notch is the so-called dermal papilla. The figure presents also a well-developed hair; here the axial portion of the papilla has

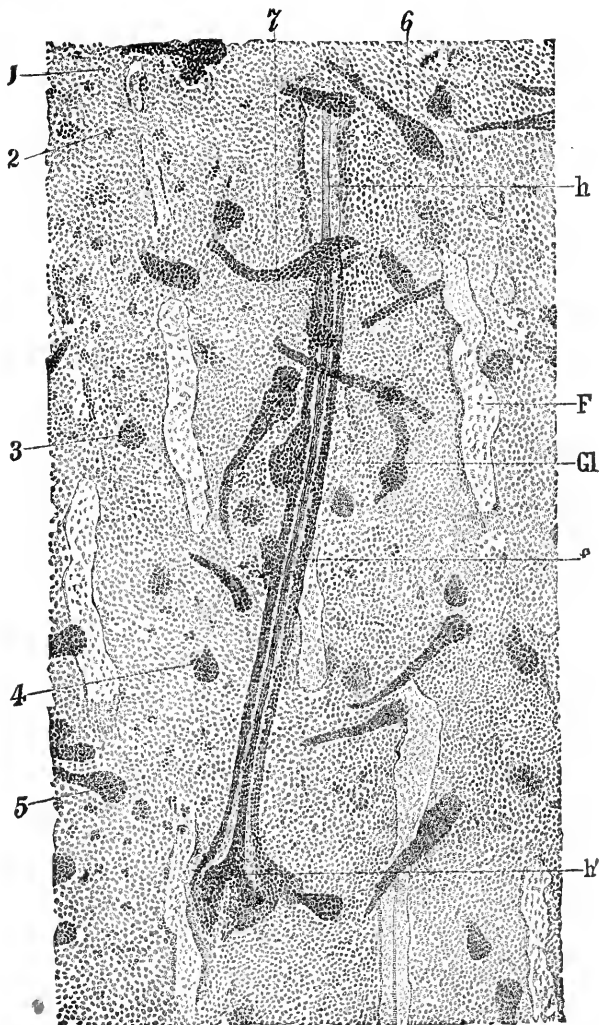


FIG. 313.—Isolated Epidermis of a Human Embryo of five to six Months. 1-7, Hair anlagen in successive stages; *h*, hair; *F*, follicle from which the hair has been pulled out; *Gl*, anlage of sebaceous gland; *f*, wall of follicle; *h'*, bulb of hair.

formed the hair, *h*, while the cortical portion has formed the follicle, *f*; the end of the hair is thickened, *h'*, as the so-called hair-bulb; the sebaceous gland, *Gl*, has begun to grow out from the follicular walls. In the upper part of the follicle the hair lies quite free, hence in several places where the hairs have been forcibly torn off the upper part

of the follicle, *F*, still remains, while the lower part attached to the hair is gone.

The differentiation of the hair in the axis of the downgrowth begins about three to five weeks after the anlage appears, when the anlages are from 0.25-0.40 mm. long, and before the dermal papilla is recognizable. Two changes mark the commencing differentiation of the hair and the follicle: 1, the axial cells elongate in the direction of the future hair: 2, the outermost layer of cells assumes the character of a cuboidal epithelium. The next step is the formation of the papilla, Fig. 313, 7, which is followed by the separation, in anlages of 0.6-0.7 mm., of the axial mass of elongated cells into a smaller darker central portion, the hair proper, Fig. 312, *H*, and a lighter portion, which constitutes the inner follicular sheath, *s*. It is at this stage that the sebaceous glands, Fig. 313, *Gl*, and Fig. 312, *A*, *gl*, buds from the follicular tissue. At the enlarged base of the hair the layers all merge into one another. The hair proper grows in length very much, in diameter very little, and by its elongation penetrates the epidermal layers, being accompanied by the inner follicular sheath. As all the hair anlages descend obliquely, the hair penetrates the epidermis obliquely and within the epidermis is bent down. By its continued elongation it finally reaches the surface of the skin, and its tip remains covered only by the epitrichium (Minot, 83), and when that disappears the hair is free. The detailed history of the hair follicles calls for much further study. I have observed the following details: In a longitudinal section of a fully developed hair, Fig. 312, *A*, the upper part of the follicle, *F*, is seen to have a central cavity, which is partly filled by the fragments of the broken-down inner follicular sheath; on the lower side of the hair, and at the end of the hollow division of the follicle, is the anlage of the sebaceous gland, *gl*: from this point down there is no space between the wall of the follicle and the hair; immediately below the gland is an eminence, *m.i*, which is formed by a thickening of the follicle, and serves for the insertion of the slender muscle, *musc*, the *erector pili*. How this muscle arises is unknown. The thickening of the follicle where the muscle is attached is not mentioned in the text-books I have consulted. From repeated observations I conclude that it is a typical feature of the human hair. It has been described and figured by Unna, 76.1. Below the muscular insertion the follicle is differentiated into three layers, which are better shown under a higher power, Fig. 312, *D*; there is an innermost sharply limited horny layer, *S*, with no trace of cellular structure, a middle layer of granular cells, *c*, and an outermost layer of clear epithelioid cells, *Ep*, having their nuclei in their bases toward the hair, *h*. The follicle is incased in a fibrous mesenchymal tunica propria, *tu*. Returning to Fig. 312, *A*, the two outer layers of the follicle are seen to merge into one another toward the base of the hair, and to thin out and disappear; the inner sheath, *s*, on the contrary, thickens, becomes more and more distinctly cellular, and finally expands as the hair bulb around the papilla. The hair proper, *H*, is of nearly uniform diameter until it reaches the bulb, where it expands to embrace the papilla, *pa*, and fuses with the inner follicular sheath. A network of blood-vessels, *v*, in the tunica propria

is spun around the bulb, but vessels have not, in the stage figured, penetrated the papilla itself, *pa*.

Lanugo is the term applied to the first coat of hairs in the embryo. This coat is a conspicuous feature at seven months. It is to be regarded as the embryonic reproduction in man of an ancestral simian characteristic (Darwin, "Descent of Man," Chap. I.). The hairs are fine, compared with those of the adult, and are therefore usually described as woolly hairs; they are lost from most parts of the body, and replaced by larger and coarser hairs. Over the face the lanugo persists throughout life, but owing to its fineness and loss of color is not usually noticed.

Loss and Renewal of Hairs.—The length of life of a single hair is not long, for, as is well known, the hairs are continually shed. In many mammals the shedding is an annual process, but in man it takes place constantly. As the number of hairs, except in cases of baldness, does not diminish sensibly, it follows that new hairs must be continually formed.

The loss of hairs begins during foetal life. The hairs shed by the foetus fall into the amniotic fluid and are sometimes swallowed by the embryo and found in the meconium, see Chap. XXIX. Immediately after birth the shedding of the lanugo occurs, its place being taken in certain parts by coarser hairs. The shedding of the hair is initiated by changes in the hair bulb, or expanded end of the hair fitted over the papilla; the multiplication of cells in the bulb, by means of which the growth of the hair is maintained, ceases, and the bulb atrophies, separates from the papilla, and breaks up into a bundle of fibres; the hairs in which the bulbs have become fibrous are the *Kolbenhaare* of J. Henle, the *Beethaare* of P. Unna, 76.1. That these hairs which have no papillæ cannot grow has been demonstrated experimentally by L. Ranvier. For a time the hair is still retained in place by the sheath of the follicle pressing against it. It is finally either pulled out by some outside force, or pressed out by the secondary hair (*Ersatzhaare*); there is also an actual shortening of the follicle of the atrophying hair, a fact observed by von Ebner, 76.1, and confirmed by Kölliker ("Gewebelehre," 6te Aufl., 241.

As to the development of the secondary or replacement hairs (*Ersatzhaare*), authors are not agreed. That there is a long continued production of new hair-germs during foetal life is well known, and that the process is continued after birth has been maintained by several writers, but such hairs cannot be regarded as secondary but only as primary hairs. The true secondary hairs are those which arise from the follicles of previous hairs. According to some authors, the old papilla is preserved and the new hair is formed over it, but this opinion does not appear to me to rest upon satisfactory observations. Far better founded is the view of Kölliker ("Gewebelehre," 5te Aufl., 1867, p. 137), that the new hairs are developed from buds, which spring from the base of the old follicles soon after the old hair bulb has atrophied; the buds are small in diameter, and lengthen out the old follicle; the cells show, at first, no differentiation, the bud resembling closely a young hair germ; in it a new hair is developed in the same way as in the primary hair germs. The

figure showing the development of the secondary hairs given by Kölliker in his "Gewebelehre," 5te Aufl., have been reproduced by him in the sixth edition, Figs. 186 and 187, also in his "Entwicklungsgeschichte," 1879, Figs. 476, 477.

Sebaceous Glands.—As the sebaceous glands are outgrowths of the hair follicles, they are appropriately treated here. They appear as thickenings of the follicles of the hair germs, about the time the hair proper reaches the level of the epidermis. The thickenings are solid, and as they enlarge become somewhat lobulated, Fig. 312, A, *gl*; they usually are situated on the under side of the hair, Fig. 312, A, *C*, but sometimes spring laterally. Even before the lobulation begins, the anlage is seen to be differentiated into an outer layer, Fig. 312, C, *cor*, in which the cells retain their original character, and are small and granular: and a central mass of larger modified cells, *Sb*. The latter increase in number until they find an exit into the cavity of the follicle, Fig. 312, A, *gl*. According to Kölliker ("Entwicklungsgesch.," 1879, p. 797) the central cells contain fat globules and are discharged into the follicle, thereby becoming the secretion of the gland; the cortical layer persists as the germinating bed of new fatty central cells. In specimens hardened in alcohol, stained in alum cochineal, and cut in paraffine, the central cells of the sebaceous glands of the fœtus present a highly characteristic appearance; they are rounded or oval, and much larger than the cortical cells, Fig. 312, C. Under a high power, Fig. 312, B, each cell is seen to be separated from its fellows, to have a distinct outline, a coarse intracellular network and a finely granular rounded nucleus, lying in a perinuclear space, which is darker than the rest of the cells. The further development of the gland consists principally in the addition of lobules, which arise as buds of the cortical layer, the fatty central cells developing later in each bud (alveolus); the neck connecting the lobules with the hair follicle becomes the duct of the gland. The growing gland spreads around its hair follicle, but the position of its duct permanently indicates its origin from the under side of the hair.

As the development of the sebaceous glands begins at a definite stage of the hairs, and as the hair germs continue arising throughout fœtal life, so we encounter, at any time after the fifth month, glands in various stages. The first glands, according to Kölliker, appear on the head at about four and one-half months, on the body at about five months.

Vernix Caseosa.—As we have learned from their development the sebaceous glands begin their secretory activity by the end of the fifth month. Their fatty secretion is discharged on the surface, and, together with the shed portions of the epidermis, usually forms a more or less extensive coating of the embryo. Minot, 83, has suggested that the persistence of the epitrichium may be a factor in the formation of the coating, which is known as the vernix caseosa (*smegma embryonum*, *Käseförmig*, *Fruchtschmiere*). Simon ("Med.Chemie." II., 486) is said to have been the first to show that the vernix consists entirely of sebaceous cells, fat globules and epidermal cells, and therefore could not be a product, as some of the older writers imagined, of the amniotic fluid. Quantitatively the epidermal cells

are the chief components. The vernix becomes conspicuous during the sixth month and increases until birth. It is extremely variable in amount. Kölliker states that Buck ("De vernice caseosa," Halis, 1844) found it might increase to 3.5 drachms in weight. In other cases it is almost entirely absent. Elsässer (Schmidt's *Jahrbücher*, Bd. VII., 1833) found that about half the children of both sexes are born without vernix caseosa, the other half with a varying amount.

On the chemical composition of the vernix see Davy (London *Med. Gazette*, 1844) and Buck ("De vernice caseosa," Halis, 1844). The vernix contains nine to ten per cent fats and seventy-eight to eighty-four per cent water.

III. GLANDS OF THE SKIN.

The development of the sebaceous glands of the hair has been described, p. 562; concerning the development of the other sebaceous glands, such as those of the external ear and of the prepuce, little is known: the glands of the eyeballs and eyelids are treated in Chapter XXVIII.; there remain to be considered here the sweat glands and the mammary glands.

Sweat Glands.—They arise as solid ingrowths of the Malpighian layer of the epidermis, somewhat similar at first to young hair-germs. They may be distinguished from hair-germs by their descending perpendicularly instead of obliquely, and by appearing in the fresh state—not whitish, like hair-germs, but yellowish. They appear on the hairless parts (soles and palms) early during the fifth month, but not until much later on the hairy parts. Kölliker, 88.2, 15, has observed that the sweat glands are developed earlier on the under than on the upper side of the digits, and earlier on the third digit than on the others. The ingrowths arise on the soles and palms from the primary ridges, Fig. 308, S. The lower end is somewhat thicker than the upper part of the ingrowth, which rapidly elongates, passes through the dermis proper, and when it reaches the fatty layer or subdermal tissue, the anlage of the gland begins to assume a contorted course, the end of the gland rolling over toward the epidermis, Fig. 314.

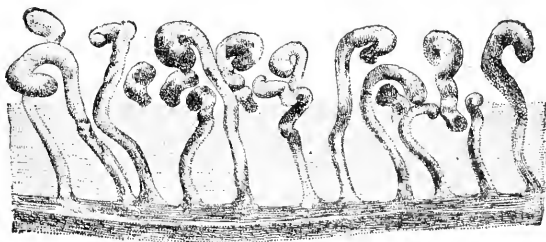


FIG. 314.—Section of the Sole of the Foot of a Fœtus of the fifth Month, to show the Sweat Glands, which arise from the inner or Malpighian layer of the epidermis.

The lumen of the gland can be readily distinguished at this time, but does not extend through the epidermis until later—on the foot, not until the seventh month (Kölliker). This fact is important, because it sets aside the notion, formerly advanced, that the sweat glands produce the liquor amnii. At the time of birth, the glands are longer, more coiled, and their ducts take a spiral course, but the spiral turns are by no means so close together or so numerous as in the adult.

Mammary Glands.—The milk glands vary in position. It is probable that there were typically two rows of glands, and that different portions of these rows are preserved in different mammals, *e. g.*, the headward portions in primates, the tailward portions in ruminants.

According to O. Schultze, 92.1, the first trace of the mammae may be observed, in pig embryos of 15 mm. and rabbit embryos of thirteen to fourteen days, as a continuous ridge-like thickening (*Milchlinie*) running from the fore-limb to the inguinal fold. In the next stage (20 mm.) the ridge is specially thickened—in the pig at 5-7 points, at each of which a mamma is developed; each local thickening becomes separate and assumes a rounded form. The local thickening of the epidermis is the anlage of a milk gland, and this anlage has been long known and marks the site of the future nipple.

In man the thickening may be observed toward the end of the second month. It is at first very slight, though it causes a discernible external protuberance. Later it projects from the epidermis into the dermis. The thickening commences when the epidermis is two-layered and solely at the expense of the inner layer, the outer layer persisting for a time as a distinct epitrichium, Fig. 315, A, *Eptr*. The epithelial ingrowth, Fig. 315, B, *Ep.in*, enlarges, and the cells in its central portion gradually cornify and fall out, so that the ingrowth becomes hollow; but the excavation progresses very slowly and sometimes is not completed until after birth. Soon after the hollowing has begun the ingrowth sends out buds, which resemble, in their appearance and early development, true sweat glands. The organ may be said to be now in the monotreme stage. C. Gegenbaur showed in 1886 that in *Echidna* the mamma is a depressed area of the skin, from which spring a number of lacteal glands resembling the sweat glands in appearance. The depressed area Gegenbaur terms the *Drüsenfeld* (gland area). It seems to me be-

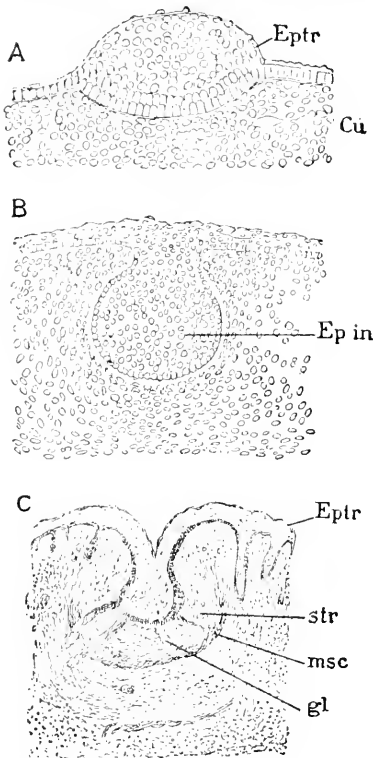


FIG. 315.—Development of the Mammary Gland in the Rabbit. A, Embryo of 17 mm. B, embryo of 20 mm. C, embryo of 55-80 mm. *Eptr*, epitrichium; *Ep*, epidermis; *Ep.in*, epidermal ingrowth; *Cu*, dermis; *gl*, milk glands proper; *Msc*, anlage of muscle; *str*, stroma of gland. (A and B are much more highly magnified than C.) After Rein.

yond possible question that the thickening of the outer skin to form the depressed area by a subsequent loss of cells in no wise militates against the homology here maintained, and which was first advanced by Gegenbaur.

In the stage of Fig. 315, C, all the parts of the adult gland may be recognized. The tissue around the epithelial ingrowth, *Ep. in*, is destined to form the protuberant nipple, of which the dermal tissue is clearly differentiated during foetal life, although the nipple does not usually become protuberant, according to Rein, 82.1, until after birth. The boundary of the dermal tissue of the nipple is marked by a distinct layer of smooth muscle fibres, *msc.* Outside or below the muscular layer is the fibrillar connective-tissue stroma, *str*, into which the glands grow, and within which they are differentiated.

The next stage of development is reached by a series of changes, of which the most important are: 1, the obliteration of the depression, which arose by the hollowing out of the epithelial ingrowth; 2, the development of branches from, and cavities in, the milk glands proper; 3, the development of the fat layer under the gland; and, 4, the growth of the nipple. The branching of the glands begins with the seventh month, and even at the time of birth is very slightly advanced. The lumen of the glands appears first in their enlarged lower ends, not long before birth, and then extends toward the mouth of the glands. In each gland we can distinguish: 1, the terminal branched glandular portion, and, 2, the duct. The duct consists of a wide part, *sinus lacteus* of authors, next the secretory portion, and a narrow part, which extends into the nipple and opens there on the apex; the orifice of the duct is funnel-shaped, and hence is termed the *pars infundibularis*. The fat layer is a continuation of that of the skin, locally thickened; about five or eight years after birth fat develops also in the stroma of the mamma between the gland tubules.

The course of development has been shown by Rein to be essentially the same in several classes of mammals as in man. There are, however, noteworthy secondary differences, particularly in ruminants; in them the nipple is precociously developed and the epithelial ingrowth carried up on to its apex before the gland buds appear; the central cells of the ingrowth disappear as in man, but the depression left by their loss is not obliterated, but is permanent. Moreover, there is only a single gland bud developed, which grows out to a considerable length to attain the base of the long nipple or teat, where it branches. Consequently in ruminants there is but a single duct through the nipple, instead of several as in man and most mammals. In the horse (Rein, 82.2, 685) the epithelial ingrowth forms two buds, hence there are two ducts in the adult.

Milk at Birth.—Although the mammary gland is immaturely developed at birth, yet, as is well known, there is frequently a secretion discharged from it for a few days after birth. Scanzoni, de Sinéty, and Rein, 82.1, 464, have shown that this secretion is true milk. It is known in German as *Hexenmilch*.

Montgomery's glands have been shown by Rein, 82.1, 470, to be accessory rudimentary milk glands.

EVOLUTION OF THE MAMMARY GLAND.—That the mammary gland arose through specialization of a group of epidermal glands, is a necessary deduction from the facts of comparative anatomy and embryology. Several authors have thought that the milk gland was evolved from the sebaceous glands, others from the sweat glands.

The latter opinion rests upon strong evidence, the former principally upon the analogy of there being considerable fat in both the sebaceous and lacteal secretions. Haidenhain (Hermann's "Physiologie," Bd. V., 380) has shown that in the milk glands there is no fatty metamorphosis of the central cells, as in sebaceous glands, but a secretion from the gland walls, as in the sweat glands, so that there is nothing in the structure or function of the adult gland to justify a comparison with the sebaceous type. As regards the embryological development, the primary epithelial ingrowth, Fig. 315, A, *Ep. in.*, is, I think, to be regarded merely as the result of a modified method of developing the depressed glandular area (*Drüsenfeld*); the glands, *sensu strictu*, arise as solid, long, slender ingrowths of the Malpighian layer, and resemble closely the true sweat-gland anlagen and not the sebaceous glands. Another point of importance is the resemblance, which has been observed by Gegenbaur, 86.1, between the milk glands of the lowest mammalia and the sweat glands. The derivation of the milk glands from the sweat glands is indicated by the structure and mode of secretion of the adult mamma, by the development of the gland, and by the structure of the gland in the Echidna.

Gegenbaur, 75.1, 86.1, has maintained that there are two types of milk glands, one type modified sweat glands, the other type modified sebaceous glands; he has maintained, also, that there are two types of nipple. The embryology of the organ shows that both the nipple and the gland are of one type, certainly in most, probably in all, mammalia. Gegenbaur's conception that there are two morphologically distinct forms of nipple was based upon Huss' observations, which are inaccurate in several important respects.

LITERATURE.—Our knowledge of the development of the mammae was derived chiefly from the observations of Langer, 52.1, and of Kölliker ("Gewebelehre," 1867), until Huss in 1873, 73.1, greatly widened our acquaintance with the early stages in man and ruminants. Huss' memoir contained important errors, especially as to the origin of the ruminant teat, and these errors led Gegenbaur, 73.1, 75.1, to his notion of two types of teats—a notion which has passed into the text-books, although shown by Rein to be untenable. H. Klaatsch, 84.1, argues against Rein in favor of Gegenbaur, but does not, it seems to me, invalidate either Rein's observations or conclusions. Rein's investigations, 82.1, 82.2, easily take the first place. Creighton's paper, 77.1, added but little, how little may be judged from his conclusion that the glands are developed from the mesoderm.

CHAPTER XXVI.

THE MOUTH CAVITY AND FACE.

THE face may be said to be a characteristic of the higher vertebrates, and to acquire increased importance as we ascend the series. In the marsipobranchs, ganoids, and selachians, the face does not form a projecting apparatus, there being merely an area on the ventral side of the head, which is distinguished by including the mouth and the nasal pits. The primitive arrangement is somewhat masked in the marsipobranchs by the modification of the mouth into a large sucking apparatus, but in ganoids and elasmobranchs it is preserved throughout life with little alteration. That the vertebrate mouth belongs primitively on the under side of the head, and is at first a simple transversely expanded orifice, is clearly established by the embryology of every vertebrate class. Balfour ("Comparative Embryology," II., 317) seems to have been the first to definitely formulate this generalization. The evolution of the face, so far as we could judge at present, depended, *first*, upon the enlargement and fusion of the oral and nasal cavities, which involved a change of site for the hypophysis; *second*, upon the partial separation of the nasal and oral cavities, leaving the posterior nares open; *third*, upon the growth and specialization of the facial region, of which the elongation of the jaws is the most conspicuous indication; *fourth*, upon the development of a prominent external nose. At the same time there occur modifications of position in the face in relation to the brain and its case or cranium, which it will be well to mention briefly in order to render the following sections of this chapter clearer.

The position of the face, or oral region, is originally determined by the head-bend, as is more fully explained in the following section, see also Fig. 319. If we imagine a median longitudinal section of the head to occupy a rectangular area divided into quarters, then we may say the lower posterior quarter corresponds to the mouth region, the other three quarters to the brain. As development progresses, the oral quarter enlarges out of proportion to the rest of the head so as to project forward in front of the fore-brain; in this stage, which is represented by the adult amphibians, the bulk of the facial apparatus is very great proportionately to the cranium. In the reptiles, the oral region is elongated still further in front of the brain case, resulting in the long snout. In mammals a third stage is established by the great increase in size of the brain, especially of the cerebral hemispheres, in consequence of which the brain comes to extend over the snout, as it were; in man, whose brain has the maximum enlargement, the facial apparatus is almost entirely covered by the brain. The modifications involved in the increase of the brain in

mammalia, so far as the skull is concerned, have been considered p. 467; they are well indicated by Wiedersheim in his "Grundriss der vergleichenden Anatomie," 2te Aufl., Fig. 84. In brief, the facial apparatus, 1, underlies the hind brain, as in elasmobranchs; 2, projects in front of the brain (amphibia, reptiles); 3, is covered by the cerebrum (mammals).

Formation of the Oral Cavity.—When the medullary tube enlarges to form the brain—see Chapter XXVII.—the end of the head bends over to make room for that enlargement. The bending of the head carries the oral plate over on to the ventral side of the freely projecting head, compare p. 262. In Fig. 106, the head-bend is just developing; *Ent*, indicates the anterior extremity of the entodermal canal, and the reference line crosses the oral plate, or membrane formed by the union of the entoderm and ectoderm; the oral plate occupies the entire space between the fore-brain, *fb*, and heart, *ht*, and there is as yet, properly speaking, no oral cavity, but it arises by the next changes which occur. The changes which develop the mouth cavity are the growth of the brain and of the pericardial cavity, both of which expand ventrally, leaving a space—the mouth cavity—between them, Fig. 170. Laterally the cavity is bounded by a wall or sheet of tissue, which stretches from the pericardial somatopleure to the head and is the Anlage of the cheek; it may be called the *cheek plate* (*Wangenplatte*). The mouth cavity is now a shallow fossa between the head and the heart, and still without connection with the entodermal canal (human embryo of 2.15 mm. with two aortic arches). The fossa cannot, strictly speaking, be regarded as an invagination, such as is the invertebrate vorderdarm, p. 261, but is rather the result of the growth of the parts surrounding the oral plate. The oral pit is lined by ectoderm.

While the oral fossa is developing, the formation of the gill pouches begins. About the time the third branchial arch is formed, the oral plate ruptures in the human embryo, and the oral fossa communicates widely with the pharynx, Fig. 320. Upon the lateral and ventral sides no boundary can be found later, but upon the dorsal or cranial side a projection persists, Fig. 319, in front of which appears an evagination of the oral fossa, to constitute the Anlage of the hypophysis cerebri or pituitary body (see below, p. 571), and behind which appears a second evagination from the pharynx to constitute the so-called Seessel's pocket, p. 268. The oral cavity proper and the pharynx are now merged into a single wide cavity, Fig. 320, for which we have in English no special term—in German it is sometimes called the *Mundrachenraum* (His, "Anat. menschl. Embryonen," Heft III., 26). The ectodermal mouth cavity, or oral fossa, does not correspond to the mouth cavity of the adult, for the adult cavity must include part of the pharynx, since it includes the tongue, which is developed from the floor of the pharynx, and in fact His has shown ("Anat. menschl. Embryonen," Heft III., 31) that the arcus palato-glossi, which are taken as the boundary between mouth and pharynx in the adult, are derived from the second or hyoid arches of the pharynx. Hence the adult mouth cavity includes the ectodermal oral fossa plus the region of the first gill-arches of the pharynx

In human embryos of the third week the mouth is a five-sided orifice, and I observe that the same shape appears in other mammalian embryos, and also in both amphibian and elasmobranch embryos, Fig. 316, hence it is probably characteristic of all vertebrates in the stage with five unmodified aortic arches. The mouth is bounded (His, "Anat. menschl. Embryonen," Heft III., 30) anteriorly by the wall (*Stirnvlust*) of the head covering the fore-brain between the nasal pits, Fig. 316, *N*, laterally by the maxillary processes, *Mx*, and latero-posteriorly by the mandibular processes, *Md*; the latter are the first branchial arches, and unlike the following arches, *br*, they meet in the median ventral line.

Another important factor in the development of the oral region is the descent or migration of the heart. It will be remembered that the aortic end of the heart moves from the anterior or buccal end of the pharynx, tailward. The change in the heart's position leaves the greater part of the pharynx free to be differentiated in intimate association with the oral region, and the change also separates the mouth and the heart, so that very early we find the caudal or lower boundary of the mouth to be no longer the pericardial somatopleure, but the mandibular processes or arches, the ventral ends of which are developed between the mouth and heart.

In certain *teleosts*, some time after the first pair of gill-pouches develop, the mouth breaks through in the ventral region of these pockets as a bi-lateral involution of the ectoderm, fusing with the entoderm and opening on each side of a central partition; neither involution crosses the median line. The double oral invagination was discovered by A. Dohrn, 82.1, and the discovery has been confirmed by J. B. Platt, 91.1, 263. In other *teleosts* (McIntosh and Prince, 90.1, 773) the mouth is single and median in origin, as in the remaining vertebrates. The significance of the aberrant double origin is unknown, though Dohrn interprets it as evidence of the evolution of the mouth by the fusion of two gill-clefts.

The Evolution of the Vertebrate Mouth is still one of the most puzzling of the unsettled problems of morphology. The increase of extent of the mouth cavity in the higher as compared with the lower vertebrates is discussed in the next section on the hypophysis. The present section treats only of the *origin* of the vertebrate mouth. The first question is, necessarily, whether the mouth of vertebrates is homologous with the mouth of invertebrates or is a new structure. The formation of the embryo by conrescence enables us, I think, to decide between these alternatives. In *Peripatus*, the leeches, and the annelids with well-marked conrescence, the union of the ectental lines is incomplete, the anterior and posterior ends not meeting, but leaving the two ends of the elongated gastrula mouth

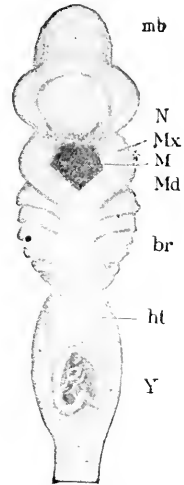


FIG. 316.—*Acanthias* Embryo of 17 mm., under side. *mb*, Mid-brain; *N*, nasal pit; *Mx*, maxillary process; *Md*, mandibular process; *br*, branchial arches; *ht*, position of heart; *Y*, yolk stalk cut across.

open, to form the mouth and anus respectively; the mouth is carried inward by the invagination of the vorderdarm, and the primitive mouth is thereafter merely the opening of the vorderdarm or œsophagus into the archenteric canal.* In those invertebrates in which the process of concrecence is plainly marked, the mouth is seen to be the anterior extremity of the gastrula mouth, and to be bounded by the ectental line; the site of the invertebrate mouth is where concrecence begins, and it is, therefore surrounded by the ectodermal neural plate,† forming the brain (*Scheitelplatte*), œsoph-

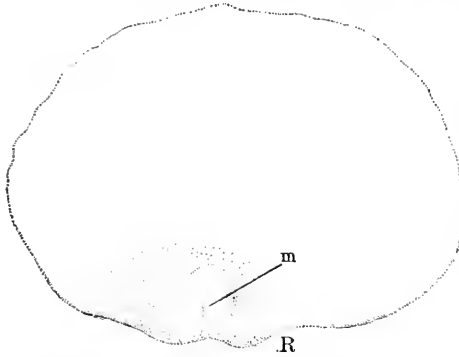


FIG. 317.—Blastoderm of a Dog-Fish, *Acanthias*, with commencing Concrecence. *M*, Point corresponding to invertebrate mouth; *R*, blastodermic rim.

ageal commissures, and ventral nerve chain (*Bauchganglien-kette*). The corresponding point in the vertebrate embryo is easily found, being between the optic evaginations at the place marked *m*, in Fig. 317, and which probably corresponds to the future infundibulum in position. So far as I am aware, the relations at this point during early stages in vertebrates have never been thoroughly studied with the intention of ascertaining whether any traces of a communication with the archenteron could be found.

Until this is done, there can be, in my judgment, little hope of our knowing what has become of the invertebrate mouth.

The above determination of the site where we have to search for the original mouth may be accepted with considerable confidence. If it is correct, it sets aside two hypotheses which have attracted attention: *first*, the hypothesis that the vertebrate mouth is identical with that of the invertebrate, and, *second*, the hypothesis that the old mouth is represented by the hypophysis,‡ for neither of these structures are derived from any part of the gastrula mouth. That both these hypotheses are untenable is evidenced by the deductions involved in their adoption. The annelid brain lies in front of the mouth; if, therefore, either the hypophysis or the mouth of vertebrates is identical with the annelid mouth, then the brain and spinal cord must correspond to the ventral nerve chain only, and the annelid brain must have entirely disappeared. The vertebrate brain and eyes thus become new structures—a conception which seems to me

* The meaning of the double origin of the mouth described by C. Semper in budding annelids and by Kleinenberg in *Lopadorhynchus* has not been explained. That it has the significance attributed to it by Kleinenberg can hardly be admitted, for there is no evidence that it represents a primitive mode of development.

† It seems to me justifiable to speak of this as a continuous neural plate, although there is a certain independence of development between the "Scheitelplatte" and ventral chain, and although the commissures develop later.

‡ That the hypophysis represents the annelid œsophagus was first suggested by A. Dohrn, 72.2, but he has since withdrawn his opinion. Similar was Richard Owen's felicitous homology of the hypophysis, infundibulum, and pineal gland with the old œsophagus (*Proc. Linn. Soc.*, London, xvii). Beard has revived Dohrn's theory, but has not succeeded in rendering it more plausible, to my judgment. Compare A. Dohrn, 83.1.

indefensible. Another deduction involved in the views under discussion is that a line of concrescence runs from the hypophysis or mouth to the fore-brain, representing the closure of the gastrula along that distance—yet of such a line not a trace can be detected.

As the infundibulum is an invagination of the ectoderm toward the archenteron developed at or near the point where the invertebrate mouth lay, it is quite possible that it corresponds to the oral invagination (vorderdarm) of annelids. This identification has been more or less in the minds of morphologists for twenty years past, but no one has yet brought decisive evidence to justify it; nevertheless, its plausibility must be admitted.

Since the vertebrate mouth is regarded as a new structure, the *second* question comes: How did it arise? As we have seen, the first trace of the mouth is the oral plate, p. 262, formed by the union of the ectoderm and entoderm over a small area without mesoderm in front of the brain; by the development of the head-bend the plate is carried over on to the ventral side and the oral cavity is developed. There is nothing in this history which we can recognize as a clew to the origin of the mouth, but, on the other hand, there is nothing in it strictly incompatible with Anton Dohrn's hypothesis that the mouth of vertebrates represents two gill-slits united in the median ventral line. The chief facts in favor of Dohrn's suggestion seem to me to be: *first*, that the trigeminal nerve shows the same relation to the mouth as other cranial nerves (facial, glosso-pharyngeal, and vagus) to the gill-clefts: *second*, that the gill-clefts approach the median line anteriorly, the first pair being nearest, the last pair furthest from the middle plane; *third*, that the oral plate is formed like the membrane across a gill-cleft (*Verschlussplatte*), p. 264, of ectoderm and entoderm united without mesoderm. Dohrn has recurred repeatedly to this hypothesis in his "Studien."

Two other theories have to be mentioned, namely, Semper's and Balfour's. The former, 76.3, 336, observed a small ectodermal pit on the dorsal side of the head of a leech, which suggested the possibility of such a pit deepening and becoming connected with the archenteron, and so creating a new mouth. Balfour ("Works," I., 392-394) has suggested that vertebrates and annelids arose from an ancestor with lateral nerve cords, and that in annelids the cords united to form a median *ventral* chain, in vertebrates to form a median *dorsal* chain, so that in the former there is, in the latter there is not, an œsophageal ring. The development of both types by concrescence proves that the neural sides are identical in annelids and vertebrates. Therefore Balfour's hypothesis falls—and with it of course, Gegenbaur's—that the brain is the same in both types, but that the vertebrate spinal cord is an outgrowth of the annelidan supra-œsophageal ganglion, the annelidan ventral chain being lost in vertebrates.

Hypophysis.—The hypophysis cerebri, Rathke's pocket or pituitary body (*Hirnanhang*), is a structure of very problematical significance, which has been much studied and speculated upon by embryologists. It arises in all vertebrates as an evagination of the ectoderm near the dorsal border of the oral plate, but is separated from the plate by a fold of the ectoderm. In *Petromyzon*, Fig. 318,

the fold, *F*, acquires great size, and develop into the roof of the mouth the hypophysal invagination, *hy*, is

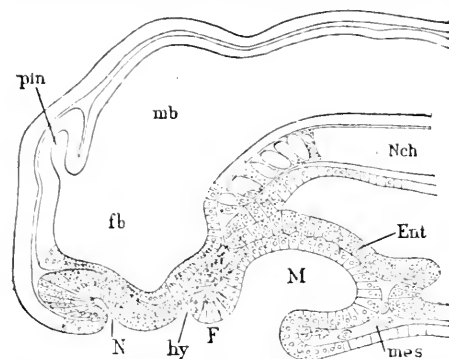


FIG. 318.—Longitudinal Median Section of a recently hatched Larva of *Petromyzon*. *fb*, Fore-brain; *pin*, pineal gland; *mb*, mid-brain; *Nch*, notochord; *Ent*, entoderm; *mes*, mesoderm; *M*, mouth cavity; *F*, fold between hypophysis and mouth; *hy*, hypophysis; *N*, nasal pit. After C. Kupffer.

as to be almost wholly included in the oral cavity, and accordingly the fold, Fig. 319, *F*, and hypophysis, *hy*, now appear as appendages of the oral cavity, for I homologize the transverse fold, Fig. 319, *F*, which borders the hypophysis in shark embryos, with the fold, Fig. 318, *F*, which forms the upper lip in the lamprey. In amphibians, according to A. Goette's observations, 75.1, 288, 317, upon *Bombinator*, the hypophysis arises as a solid ingrowth from the nervous layer (*cf.* p. 549) of the ectoderm, in front of the mouth, and, as development proceeds, there follows the inclusion of the hypophysal

is shown by Dohrn, 83.1, to and the upper lip; accordingly outside the oral cavity proper, and more intimately associated with the olfactory area and nasal pit, *N*. The hypophysis runs toward the end of the notochord, *nch*, and is nearly met by a small blind diverticulum of the archenteron, which is presumably homologous with Seesel's pocket, p. 268, of amniota; in the lamprey the hypophysis early gives rise to glandular diverticula, and itself becomes the adult nasal duct of authors. In elasmobranchs, owing, probably, to the increased head-bend and size of the fore-brain, the region between the nose and oral plate is turned in so

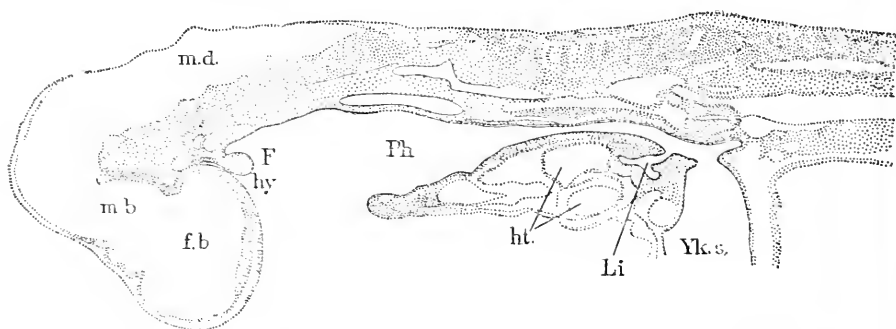


FIG. 319.—Longitudinal Section of an *Acanthias* Embryo of 13.2 mm. *fb*, Fore-brain; *m.b.*, mid-brain; *m.d.*, medulla oblongata; *hy*, hypophysis evagination; *F*, fold separating hypophysis and archenteron; *Ph*, pharynx; *ht*, heart; *Li*, anlage of liver; *Yk.s.*, yolk-stalk.

area in the general mouth cavity; there is no distinct fold between the hypophysis and the oral plate. In amniota nearly the whole ectodermal area between the oral plate and the nasal pits is turned in and incorporated with the mouth cavity before the evagination to form the hypophysis appears; hence, the organ develops as an out-

growth of the oral chamber. The comparative embryology of the pituitary body teaches us that the mouth cavity increases, as we ascend the vertebrate series, by the annexation of neighboring territory, and that the primitive upper lip of vertebrates disappears, with the further consequence that in cyclostomes the homologue of the maxillary process is to be sought, not in the lip, but between the hypophysis and nasal pits.

In mammals the hypophysis is first indicated (Kölliker, "Entwickelungsgesch.," 1879, p. 302) by a slight groove a little in front of the oral plate, but it does not have the form of a distinct evagination until after the oral plate (*Rachenhaut*) is ruptured. The ectoderm of the mouth over the hypophysal area lies against, and is apparently intimately soldered to, the ectoderm of the brain, a point

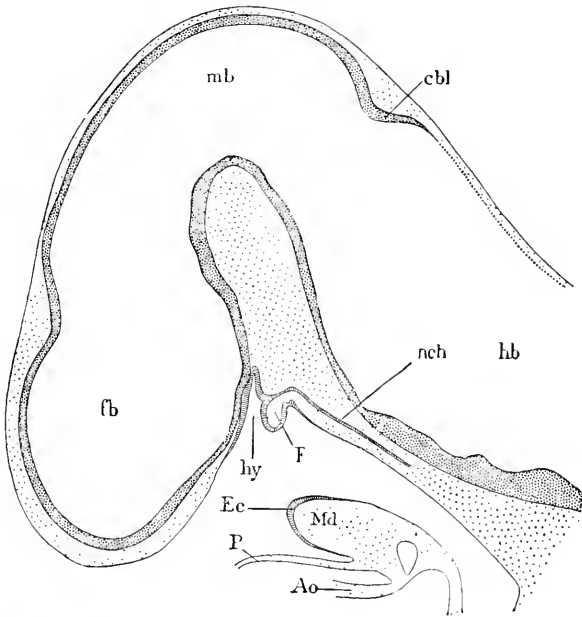


FIG. 320.—Median Section of the Head of a Rabbit Embryo of thirteen and one-half Days. *fb*, Fore-brain; *mb*, mid-brain; *cbl*, cerebellum; *hb*, hind-brain; *nch*, notochord; *hy*, hypophysis; *F*, fold corresponding to the lip of Petromyzon; *Ec*, ectoderm; *P*, somatopleuric wall of pericardium; *Md*, mandible; *Ao*, wall of the aorta.

which has been generally overlooked, but which seems to me of great importance. It is commonly stated, *e. g.*, by Kraushaar, 85.1, 87, that, when the oral plate ruptures, a portion of it persists upon the dorsal side, and is the beginning of the fold which separates the hypophysis from the pharynx. I think that this is probably not the case, but that all trace of the oral plate disappears and that a new fold arises as a duplicature of the ectoderm filled with mesoderm, Fig. 320, *F*. This new fold I homologize with the lip of Petromyzon, Fig. 318, *F*. The hypophysis is now, Fig. 320, *hy*, a diverticulum of the oral cavity, with one wall attached to the brain, and the other formed by a fold dividing the hypophysis from the mouth. The

epithelium of the mouth is one-layered, and not thickened, as is that of the hypophysis; the cells are multiplying rapidly in the stage figured, there being numerous karyokinetic figures, which, so far as I have seen, are always near the free surface of the epithelium. The relations of the notochord to the hypophysal wall have been discussed, p. 183; in the specimen figured above, there is a connection between the chorda and the lower posterior part of the hypophysis. The organ in the stage of open invagination was described by Rathke, hence the invagination is often called "Rathke's pocket;" Rathke supposed, erroneously, that it was developed from the archenteron (pharynx).

The hypophysal diverticulum now elongates and its upper end expands to a considerable vesicle, the lower end remaining narrow as the *pedicle*. At the same time the floor of the brain forms an outgrowth behind the hypophysis, which is the anlage of the infundibulum—compare Chapter XXVII. The two diverticula have their walls united. It is probable that the cementing together over the hypophysal area of the buccal and cerebral ectoderm is the mechanical condition causing the formation of the two diverticula. The hypophysis now grows rapidly; the pedicle elongates and its lumen is obliterated; the mesenchyma meanwhile condenses to form the base of the skull (sphenoid); the pedicle aborts entirely (in the rabbit by the sixteenth day) but the position for its passage through the sphenoid is marked a little longer, but is ultimately obliterated by the growth of the sphenoidal cartilage. According to Miklucho-Maclay (70.1, 40, Anm.) the passage persists in sharks. Lanzert (see Henle's *Jahresbericht*, 1868, p. 88) found traces of the passage, named by him *canalis cranio-pharyngeus*, in children at birth in ten cases out of one hundred. There is then left merely the upper end of the hypophysis as a closed epithelial vesicle lying in the future sella turcica close to the infundibulum. The vesicle becomes flattened in the longitudinal direction, and the flattened vesicle soon acquires, at least in the pig, a yoke shape in section by becoming first convex toward the fore-brain, then concave in its centre, toward the infundibulum, as may be observed in a pig embryo of 18 mm. (Kölliker, "Entwickelungsges.," 2te Aufl., Fig. 329.) The vesicle completes its development by sending out hollow buds from its anterior wall (rabbits, 20–30 mm.); in birds, according to W. Müller, 71.4, and Mihalkovics, 77.1, buds arise from both walls. The buds elongate and branch; numerous blood-vessels are developed between them; the buds separate from the parent vesicle (rabbits of 40 mm.), but continue to grow; their lumen disappears, and they produce a highly vascularized complex of hypophysal cords. Kölliker thinks ("Entwickelungsgeschichte," 1879, 531) that the main vesicle persists recognizably in man into adult life.

The infundibulum also contributes to the production of the adult hypophysis of mammals, although in lower vertebrates it persists as an integral portion of the brain, and is differentiated into ganglionic tissue. As first shown by W. Müller, 71.4, the pointed end of the infundibulum undergoes in amniota an enlargement, beginning in sheep embryos of 35 mm., in pig embryos of 32 mm. (Kölliker, "Entwickelungsges.," 1879, 531). The knob-like enlargement loses

its cavity, and although the differentiation of nervous tissue begins in it, its cells early acquire an indifferent character, and it is penetrated by blood-vessels and connective tissue; the connection with the brain is permanently retained. The knob is designated in the adult as the posterior lobe of the hypophysis, although it can in no sense be regarded as part of the true hypophysis.

Historical Note.—The following memoranda are taken from Mihalkovics, **77.1**, and Kraushaar, **85.1**. The older authors regarded the hypophysis as part of the brain; this conception was held by Von Baer "Entw.-Ges.," I., 104, 103, and II., 293, and found as late as 1862 a defender in F. Schmidt, **62.1**, 51, although Rathke had discovered the hypophysal evagination in 1838, **38.1**, and Rathke's discovery had been confirmed by Kölliker ("Entwickelungsges.," 1861, p. 242). Rathke subsequently, **61.1**, 100, withdrew his opinion that the evagination formed the hypophysis, but W. Müller, **71.1**, demonstrated that it was unquestionably correct, but retained the erroneous opinion that the evagination was developed from the archenteron. That the evagination belongs to the oral cavity was finally proven for amphibia by A. Goette, **75.1**, and for mammals by Mihalkovics, whose researches, **77.1**, 83-94, are the most important yet made on the organ. Mihalkovics' results on mammalia have been confirmed by Kölliker, **79.2**, Kraushaar, **85.1** (His, "Anat. menschl. Embryonen"), and others. The development of the hypophysis in the lamprey has been especially studied by Dohrn, **83.1**, whose results have been confirmed by subsequent investigators (Scott, **83.2**, Shipley, **88.1**, Kupffer, **90.1**).

That the notochord had some connection with the hypophysis has been held by several authors. C. B. Reichert, **40.1**, 179, regarded the pituitary body as the end of the notochord, but twice later, 1861 and 1878, changed his opinion. Dursy, **69.1**, maintained that the notochord was united with the pocket of Rathke, and formed part of the hypophysis; see also J. B. Platt, **91.1**.

Nasal Pits.—In this section the development of the cavity of the nose is taken up—for the history of the olfactory organ proper, see Chapter XXVIII. The formation of the nasal pits begins with the differentiation of the *olfactory plates*, which are two areas of thickened epidermis situated just in front of the mouth and in actual contact with the wall of the fore-brain. The plates give rise to the olfactory epithelium of the adult. In *Petromyzon* instead of two plates there is a single median one, which extends to the anlage of the hypophysis, Fig. 318. This fact renders it probable that primitively there was a single median plate in vertebrates, which has become divided; in the lamprey such division is established later. H. Ayers, **90.1**, 240, however, states that the nasal area or olfactory plate of the larval lamprey is divided by a median non-olfactive raphe into two lateral pockets, right and left, to which the right and left olfactory nerves are respectively distributed. It is possible that more exact observation will show that in all vertebrates there is at first a single plate, which is early divided. Balfour, "Comp. Embryol.," II., 533, regards the condition in *Petromyzon* as secondary, but gives no evidence to support his opinion, which was, perhaps, really due to the tradition which says the vertebrate olfactory organ is paired.

The nasal pits proper are developed, as pointed out by A. Goette, 75.1, not by the invagination of the olfactory plate, which is apposed to the brain *ab initio*, but by the upgrowth of the ectoderm and mesoderm around the plate.

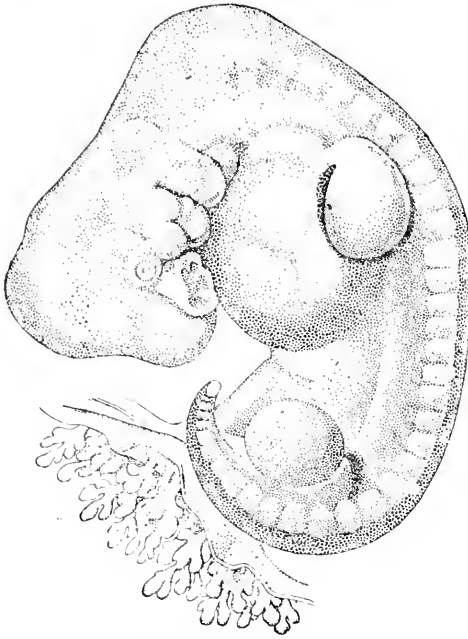


FIG. 321.—His' Embryo A, 7.5 mm.

The growth of the nasal pits in man has been described by His ("Anat. menschl. Embryonen," Heft III., 45-55). There are two principal changes, 1, the growth of the tissues around the olfactory plate; 2, the migration of the pits away from the brain. Fig. 322 gives a view of an early stage in which the pits are small and shallow and the tissue is forming a ridge around them, which, however, does not extend on to the oral side, so that the pits open freely into the mouth cavity. The nasal pits are widely separated by a projecting mass of tissue, which I propose to call the *nasal process*, and which is the *Stirnfortsatz* of German embryologists. Between the nasal pit on each side and the mouth the anlage of the nasal process is thickened and rounded, making a protuberance—the *processus globularis* of His. The nasal process includes the partition between the two nasal chambers, the anlage of the future nose and of the future intermaxillary region of the upper lip. The maxillary process extends between the mouth and eye, toward the nasal pit, and later by joining the *processus globularis* begins the separation of the nasal and buccal

mesoderm around the plate. The upgrowth takes place on the medial, upper, and lateral side of each plate, and hence forms two pits with a partition, the future *septum narium*, between them. They are the nasal pits and communicate along their whole lower side directly with the mouth cavity, Fig. 322. The mode of development of the nasal pits or sacs renders it highly probable, it seems to me, that the essential mechanical condition is, as with the hypophysis, the union of the epidermal plate with the brain wall. The nasal pit is at first very shallow, Fig. 321, and the olfactory plate is exposed laterally; and there can be seen at its lower part a small depression, the anlage of the organ of Jacobson.

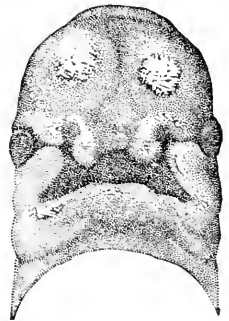


FIG. 322.—Facial Region of a Human Embryo of 8 mm.; front view. After W. His. $\times 10$ diams.

chambers and completes the permanent upper border of the mouth—compare Fig. 324, *L, Mx.* As development proceeds, the lateral ridge, see Fig. 321, grows forward and covers in the nasal pit from the side, and may therefore be regarded as the anlage of the wing of the adult nose. We now have the two external nares. Turning to the growth of the nasal chambers, we find that they enlarge as the whole face enlarges, and that they occupy an increasing space, Fig. 323, *Nh*, opening widely into the mouth cavity above the palate shelf. The figure shows that the

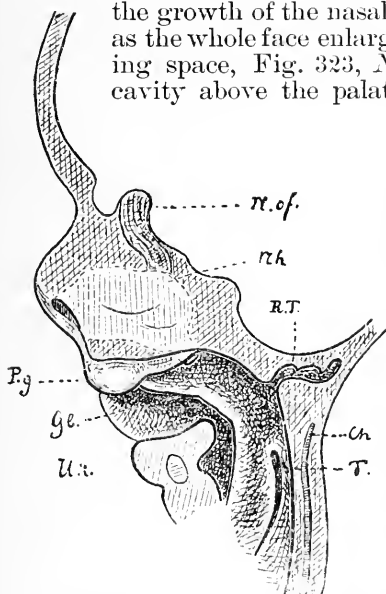


FIG. 323.—Reconstruction of the Face of His' Embryo Sch. *N.of.*, Olfactory nerve; *Nh*, nasal cavity; *R.T.*, Rathke's pocket; *Ch*, notochord; *T.*, tonsil; *P.g.*, processus globularis; *Gl.*, palate anlage; *U.x.*, mandible. After W. His.

palate develops from the walls of the mouth cavity, and the space above it is, therefore, oral, not nasal; hence the nasal cavity of the adult includes more than the nasal pit of the embryo. It is from the nasal pits proper that the so-called labyrinth of the nose is formed. The development of the labyrinth begins with the appearance—in man during the third month—of three projecting folds on the lateral wall of each nasal chamber, Fig. 326, the folds are the upper, middle, and lower turbinal folds (*Nasenscheln*) and consist at first each of a duplication of the ectoderm filled with indifferent mesenchyma, which, however, very early changes into cartilage; the turbinal cartilage is a consequence, not a cause, as often stated, of the development of the turbinal fold. The formation of the labyrinth advances by the formation of outgrowths, which become the ethmoidal sinuses, by the appearance—in man during the sixth month—of the antrum Highmorii, or expansion of the nasal cavity, into the region of the superior maxilla, and finally by the evaginations to form the sphenoidal and frontal sinus, which, however, do not arise in man until after birth. Finally we consider the separation of the olfactory plate from the brain. This does not take place until the olfactory ganglion develops from the epithelium (ectoderm) of the plate. The olfactory nerve fibres are developed very early, in the chick during the third day—compare Chapter XXVII. The fibres lengthen, the olfactory and neural epithelia separate, and ultimately the osseous cribriform plate is developed between them.

For observations on the development of the posterior nares, see Fr. Hochstetter, 91.2.

JACOBSON'S ORGAN.—The organ of Jacobson arises very early as a small distinct invagination, on the medial wall of the nasal pit, as first stated by Dursy, 69.1. Our knowledge of its development is due chiefly to Kölliker, 77.2, 79.2, 766, and Fleischer, 78.1. At four months it is a cylindrical blind canal, running from its

original orifice backward in the septum narii. It is surrounded by a small cartilage (Jacobson's cartilage) near its orifice; this separate cartilage is derived from a growth of the main cartilage of the septum. The canal is innervated by the olfactory nerves, and in certain mammals it is much more developed than in man.

THE EXTERNAL NOSE is developed toward the end of the second month by a growth of the nasal process (His, "Anat. menschl. Embryonen," III., 35). It is at first short and broad, having at three months very nearly the shape which is permanent in certain negro races. The external nares and wings of the nose are carried forward with the general nasal upgrowth. At three months the external nares are usually completely closed by the growth of their epithelium, which forms a plug of gelatinous consistency. The plug disappears after the fifth month (Kölliker, "Entwicklungsges.," 1879, 767).

Maxillary Process.—Reference has already been made to that thickening of the upper edge of the mouth, which appears almost as a continuation of the mandibular arch, and which is known as the maxillary process, or sometimes as the superior maxillary process (*Oberkieferfortsatz*). It is termed a process, because from its small size and position it appears at first like a bud from the mandibular arch. Later it stretches farther forward, and when the mouth has changed from its original pentagonal shape to a transverse slit, Fig. 322, the maxillary process no longer appears specially connected with the mandibular arch, but is united with the edge of the nasal process as above described, p. 576. A thorough study of the primitive relations and growth of the maxillary process is much needed. It is possible that, as several authorities have maintained, it is morphologically the upper part of the mandibular arch, which, in consequence of the head-bend, makes an angle with the mandible proper. Although this hypothesis commends itself to the embryologist, it needs a firmer basis than it yet has to stand upon.

Mandibular Arch.—The first branchial arch forms the lower boundary of the mouth, and by its long-continued growth develops into the projecting lower jaw. The history of the skeleton and muscles of the lower jaw are treated, p. 444 and 478, respectively. The chin is at first retreating and does not become distinctly prominent until the fifth month. The growth of the jaws increases the separation of the mouth from the heart.

Lips and Gums.—Very soon after the upper jaw has been formed by the union of the maxillary and nasal processes, its oral surface develops two parallel ridges, Fig. 324, of which the outer and more bulky, *L*, *Mx*, is the anlage of the upper lip, and the inner and smaller, *D*, the anlage of the gums (*gingivæ*, dental ridge). At about the same time, or a little later, similar ridges develop on the lower jaws.

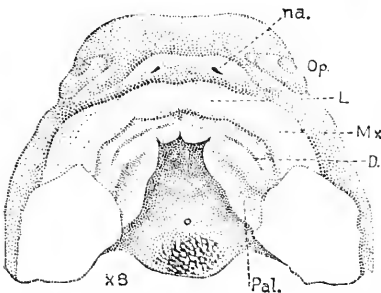


FIG. 324.—View of the Roof of the Mouth of a Human Embryo. *na.*, Nares; *Op.*, eye; *L*, portion of lip developed from the nasal process; *Mx.*, portion of the upper lips developed from the maxillary process; *D.*, dental groove on the gums; *Pal.*, palate. $\times 8$ diams. After W. His.

The histogenesis of the lips and gums has not been investigated. From the study of sections of the lower lip of a foetus of six months, which I have prepared, I consider it probable that the peculiar epithelium of the lips arises, 1, by the disappearance of both the epitrichium and stratum lucidum, and, 2, the distention of the remaining cells—a basal growing layer being retained. In a rabbit of thirteen days, the epitrichium runs over the region of the future lip. In a pig embryo of about 3.5 cm., the epitrichium is still present, and the cells below are enlarging and beginning to cornify.

The glands of the lips, according to Kölliker, "Entwickelungsges.," 1876, 828, arise during the fourth month as solid ingrowths of the epithelium, and later send out each eight to ten branches, which, while still solid, form a pretty rosette.

Formation of the Palate.—As soon as the external nares are separated from the mouth, there is a partition between the nasal pits

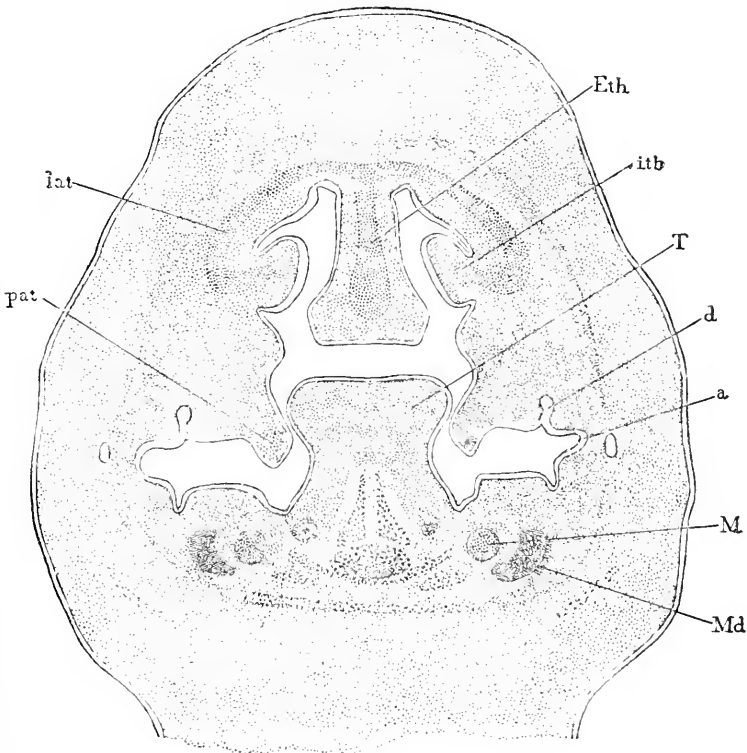


FIG. 325.—Frontal Section of the Oral and Nasal Chambers of a young Cow Embryo. *pat.* Palate; *lat.* lateral cartilage; *Eth.* ethmoid plate; *itb.* inferior turbinal; *T.* tongue; *d.* dental germ; *a.* oral angle; *M.* Meckel's cartilage; *Md.* mandible.

and the mouth. This partition, in which the intermaxillary bone is differentiated later, is supplemented by another partition, the true palate, Fig. 324, *Pal*, which shuts off the upper part of the oral cavity from the lower, thus adding the upper part to the nasal chambers. The palate is a secondary structure, which divides the mouth into an

upper respiratory passage and a lower lingual or digestive passage. The palate arises as two shelf-like growths of the inner side of each maxillary process, Fig. 324, *Pal*, and is completed by the union of the two shelves in the median line. As seen in a side view the shelves are represented in Fig. 323, *Gl*, they arch so as to descend

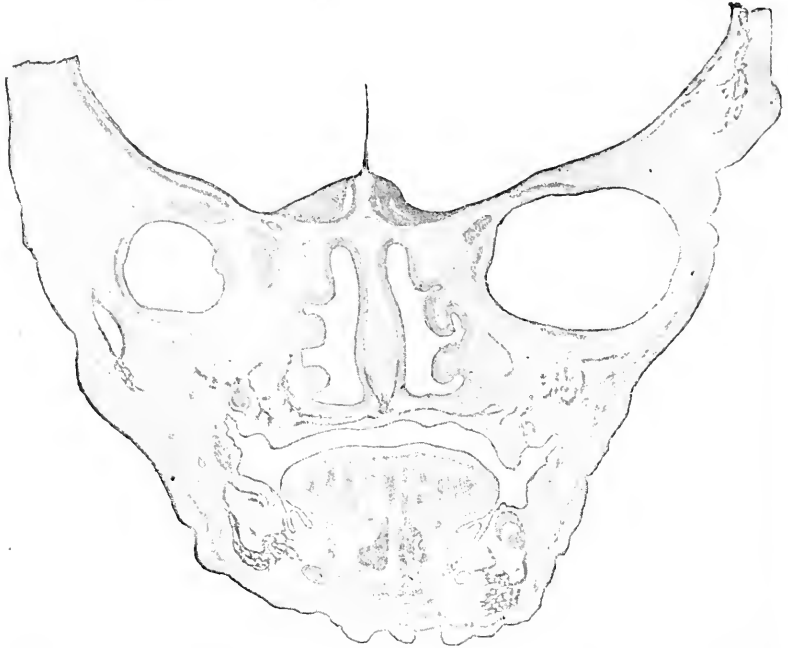

FIG. 326.—Frontal Section of the Nasal and Oral Cavities of a Human Embryo of three Months (Minot Coll. No. 41).

a certain distance into the pharynx, but in the pharynx their growth is arrested, though they may be still recognized in the adult. In the region of the tongue, which includes more than the primitive oral cavity, the palate shelves continue growing. At first they project obliquely downward toward the floor of the mouth, Fig. 325, *pat*, and the tongue, *T*, rises high between them, and appears in sections which, like the one represented in Fig. 325, pass through the internal nares, to be about to join the internasal septum. As the lower jaw grows, the floor of the mouth is lowered and the tongue is thereby brought further away from the internasal septum. At the same time the palate shelves take a more horizontal position and pass toward one another above the tongue and below the nasal septum, and meet in the middle line where they unite. From their original position, see Fig. 325, *pat*, the shelves necessarily meet in front (toward the lips) first, and unite behind (toward the pharynx) later. In the human embryo the union begins at eight weeks, and at nine weeks is completed for the region of the future hard palate, and by eleven weeks is usually completed for the soft palate also. The palate shelves extend back across the second and third branchial arches; by the migration of the first gill pouch, or, in other words,

of the Eustachian tube, the Eustachian opening comes to lie above the palate (uvula) while the second cleft remains lower down and lies below the palate, as the anlage of the tonsil, His, "Anat. menschl. Embryonen," Heft III., 82. The *uvula* appears during the latter half of the third month as a projection of the border of the soft palate. Soon after the two palatal shelves have united with one another the nasal septum unites with the palate also, Fig. 326, and thereby the permanent or adult relations of the cavities are established.

Lachrymal Duct.—The canal which leads from the corner of the eye to the nose (*Thrännenasengang* of G. Born) is not found in fishes, but only in amphibia and amniota. The site of this duct is very early marked out by the lachrymal groove, Fig. 322, running down from the eye to the invagination, or to the nasal pit as soon as the latter appears. This groove is bordered above by what is known as the lateral nasal process or prominent surface between the nasal pit and the eye—compare Fig. 322—and is bordered below by the maxillary process. This groove soon disappears and leaves, so far as known, no trace. It was supposed by Kölliker ("Entwickelungsgesch.," 1879, 469) to be the anlage of the duct—an opinion which Born's observations on amphibians, 76.1, and on Sauropsida, 78.1, 83.3, followed by those of Legal, 81.1, 83.1, on mammals, showed to be erroneous.

The duct arises along the line of the lachrymal groove as a thickening of the under side of the epidermis, which appears about the time that the cartilage develops around the nasal cavities—in man, according to Ewetzky, 88.1, at the end of the fifth or beginning of the sixth week. The thickening increases until it forms a ridge, which finally separates as a solid cord from the epidermis, except at each end; the cord then acquires a lumen, thereby becoming an epithelial canal. In man the upper end of the solid cord broadens out at the inner canthus and then divides into two forks, each of which acquires a lumen, with the result of producing a bifurcation of the duct (Ewetzky). In the pig, the bifurcation is developed, but one fork aborts, according to Legal, 83.1.

Teeth.—The development of the teeth in man and other mammals has been much studied, and has been repeatedly described by competent authorities in comprehensive summaries. I have, therefore, deemed it unnecessary to go over many of the original articles carefully, and instead base the following synopsis chiefly upon Waldeyer, 72.1, Kölliker, 79.2, 815, Tomes ("Dental Anatomy"), Von Ebner, 90.1, and O. Hertwig. The list of authorities is given in my "Bibliography" under "*Teeth*," but it is far from complete; for further lists see Waldeyer and Von Ebner. For a very admirable critical synopsis of the various notions that have been advanced concerning the histogenesis of the teeth, see Von Ebner, 90.1, 249–252. It must be remembered that most of the articles upon the human teeth are by more or less incompetent writers.

DERMAL TEETH OF SHARKS.—The teeth were primitively organs of the skin and widely developed over the surface of the body, and as stated before, p. 461, they have played an important rôle in the genesis of the skeleton. It is, therefore, to the fishes that we must

turn to ascertain the primitive mode of tooth formation, choosing the sharks, since they have been the most thoroughly studied in this regard, thanks chiefly to O. Hertwig, 74.1,2. The teeth of sharks are generally known as placoid scales. The tooth begins as

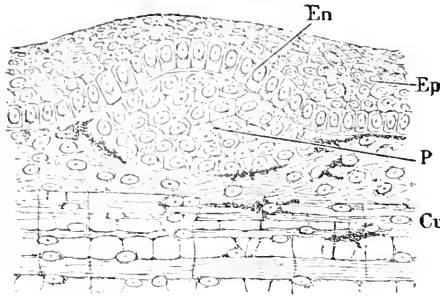


FIG. 327. —Dental Papilla of a Dermal Tooth of an Acanthias Embryo of 10 cm. *En.* Enamel organ; *p.* papilla; *Ep.* epidermis; *Cu.* dermis. After O. Hertwig.

a mesenchymal papilla, Fig. 327, composed of crowded cells and projecting into the epidermis. The layer of epidermal cells overlying the papilla changes in character, its cells gradually lengthening into very long cylinders, and becomes the enamel organ. By further development the epidermis thickens, the papilla projects into it, and becoming narrow and longer, and taking an oblique position, gradually assumes the shape of the tooth.

Ossification now begins over the surface of the papilla; there arises a layer of epithelioid osteoblasts, and between these and the enamel organ the development of bone, or, as it is called in teeth, of ivory, begins; the osteoblasts persist, and the bony structure is developed only between them and the epidermis, forming a stratum which grows in thickness. At the same time the enamel organ begins to deposit the calcified layer, known as enamel, over the papilla. Later the tooth acquires a support by the direct ossification of the connective tissue at its base, and is then a completed "placoid scale."

The teeth of the mouth depart from this primitive mode of development, for they do not arise on the surface, but deep down, Fig.

328, because the dentiferous epithelium grows down into the dermis, forming an oblique shelf, which may be regarded as a special tooth-forming organ. On the under side of the shelf the teeth are developed in the same way as over the skin, although they are much larger.

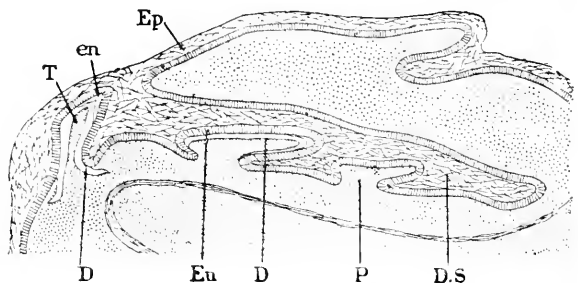


FIG. 328. —Section of the Lower Jaw of an Acanthias Embryo of 10 cm. *T.* Tooth; *en.* enamel cap; *Ep.* epidermis; *D.* dentine; *Eu.* enamel cells; *P.* dental papilla; *D.S.* dental shelf. After O. Hertwig.

The teeth are, however, in various stages of development, and only one is fully exposed; when, as happens in time, it is lost, the next tooth behind replaces it, and since the production of new tooth germs goes on in adult life, the replacement of teeth in the shark's jaw continues indefinitely; hence sharks are termed *polyphyodont*. Mammals have two sets of teeth, and hence are called *diphyodont*.

We learn from the sharks that a tooth is a papilla which projects into the epidermis, and, ossifying in a peculiar way, changes into ivory around the soft core or pulp; to the papilla the epidermis adds a layer of enamel. The tooth proper unites with a small plate of dermal bone at its base. By a modification in the jaws, the epidermis first grows into the dermis, and then the dermal tooth papilla is developed. In the higher vertebrates the teeth of the jaws only are developed, and they arise in the modified way we have noted in the selachian jaw.

AMNIOTE TOOTH-GERMS.—The first indication of the development of tooth-germs in mammals is the appearance of a thickening of the epithelium covering the jaw; the thickening forms a curving ridge on the under side of the epithelium.

According to C. Röse, 91.2, 451, the ridge appears in the human embryo during the sixth week. The ridge expands, Fig. 329, and subdivides into an outer portion, *L.gr.*, the anlage of the groove between the lip and gum, and an inner portion, *d.sh.*, the dental shelf, which grows obliquely inward; on the under side (in the upper jaw on the corresponding upper side) of the shelf arise the dental papillæ, *Pp.*

The dental shelf (*Zahnteiste*) is homologous with the similar structure in the shark. Its history in the human embryo has been investigated by C. Röse, 91.2. The papillæ for the milk-teeth are formed on the under side of the shelf, Fig. 329, and it is thus possible for the shelf to continue growing toward the lingual side, so that a second set of germs is developed for the permanent teeth. The end of the shelf toward the articulation of the jaws is prolonged without retaining the direct connection with the epithelium, and from this prolongation arise the enamel organs for the three permanent molars. Wherever a tooth-germ arises, the dental shelf is locally enlarged, and the local enlargement constitutes an enamel organ which projects from the under side of the shelf. The portions of the shelf between the enamel organs gradually break up, forming first an irregular network, and later separate fragments, which may persist throughout life and lead to various pathological structures: while the permanent germs are forming the shelf is solid between them, although it has assumed the reticulate structure between the germs of the milk-teeth. In consequence of the reticular formation, the fully developed enamel organs have several bands or threads, by which they are connected with the dental shelf proper.

Fig. 330 represents the under side of a model of the epithelium of the gum of the upper jaw of a human embryo of 40 mm. reconstructed by C. Röse from the sections, Fig. 329. *L.gr.* is the ridge corresponding to the groove between the lip and gum; *pal* is the surface of the palate; *d.sh.* is the dental shelf, the ten cups or depressions on which correspond to the papillæ for the ten milk-teeth.

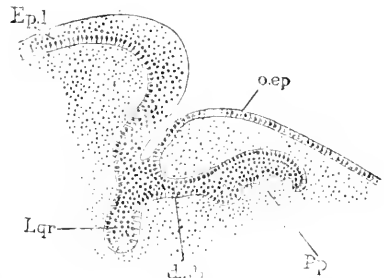

FIG. 329.—Section of Part of the Lower Jaw of a Human Embryo of 40 mm. *Ep.l.* Epithelium of lip; *o.ep.* oral epithelium; *L.gr.* anlage of lip groove; *d.sh.* dental shelf; *Pp.* papilla. After C. Röse.

After the shelf has developed somewhat, its line of connection with the epithelium of the gum becomes marked by a superficial groove, as may be seen in the human embryo of eight to ten weeks, Fig. 324, *D*. This groove was formerly supposed to be the first trace of the dental shelf, but Röse's observations correct the supposition.

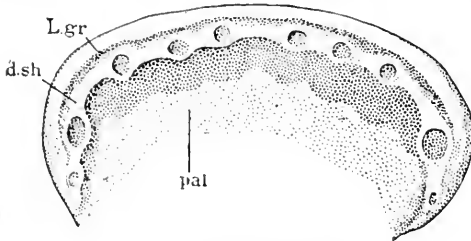


FIG. 330.—Explanation in text.

The second step in mammals is the formation of outgrowths (in man ten in each jaw) from the under side of the dental shelf; each outgrowth is the anlage of an enamel organ for a milk-tooth. The derivation of the enamel organ from the epidermis was discovered by Kölliker. The outgrowth is covered toward the mesoderm by a layer of cylindrical epithelial cells, the continuation of the basal layer of the epidermis, while the core is filled with polygonal cells, which resemble those of the middle part of the Malpighian layer of the skin. The outgrowths, after penetrating a short distance, expand at their lower ends, but remain each connected by a narrow neck with the overlying epidermis. The expanded end is the enamel germ proper; it very soon assumes a triangular outline as seen in sections, owing to the flattening of its under side, and at the same time it moves somewhat toward the lips. Meanwhile the shelf continues growing on the lingual side of each ingrowth, to produce the enamel organs destined for the second or permanent teeth. At this stage we notice that the mesenchyma under the flattened end of the enamel organ has become more dense, to form the anlage of the dental papilla, and is beginning to develop fibrillæ around both the enamel germ and the papillary anlage. The fibrillar envelope is the future dental follicle (*Zahnsack*).

The third step is the final differentiation of the enamel organ and the accompanying shaping of the papilla. The enamel organ, Fig. 331, continues growing and becomes concave on its under side, so that the mesoderm underneath acquires the shape of a papilla. It is now that the form of the tooth is determined by the form assumed by the papilla, which in its turn is probably determined by the growth of the enamel organ. Von Brunn, 87.1, has shown that the enamel organ extends over the papilla of various mammals not only as far as the enamel is formed, but also as a thin layer to the base of the papilla, or over the future root. Over the root, *after* the tooth is shaped, the enamel organ aborts. The apex of the root is never covered. C. Röse, 91.2, has shown that in man also the enamel organ extends at first over the root, but subsequently aborts.

A fully developed tooth germ consists of, 1, the follicle, 2, the enamel germ with its neck running to the dental shelf, the edge of which grows on, Fig. 331, *B*, to form the secondary teeth, and, 3, the papilla.

THE FOLLICLE is merely an envelope of connective tissue, Fig. 331, in which we can distinguish, according to Kölliker, an outer

denser and inner looser layer; in the latter the cells are more distinct and the fibrillæ are less numerous than in the former. A rich network of capillary vessels is developed in the follicle, Fig. 331, *v*, and appears in part as a series of villous-like growths into the enamel organ. The follicle develops first over the lower part of the

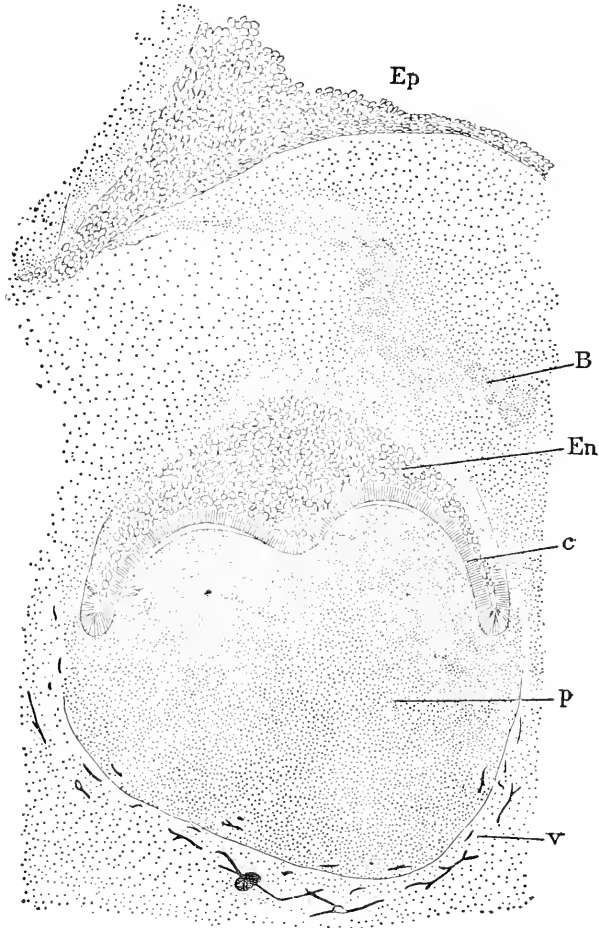


FIG. 331.—Vertical Section of a Molar Tooth Germ of a Human Embryo of 160 mm. *Ep*, Epithelium of the dental furrow; *B*, bud for secondary germ; *En*, central cells of the enamel organ; *c*, enamel cells; *p*, mesenchymal papilla; *v*, follicular envelope with blood-vessels.

papilla, then over the enamel organ, the neck of which aborts and the follicle closes over, completely separating the enamel organ from its parent epidermis.

THE ENAMEL ORGAN changes greatly in appearance. The layer of cylinder cells is well preserved only over the concave side, Fig. 331, *c*, where the epithelium is in contact with the dental papilla. In the neck the cells become appressed and irregular in form. Over the convex surface of the enamel organ the cells become lower and

cuboidal, and ultimately atrophy and flatten out, but, so far as I know, no exact study has yet been made of the changes they pass through. The convex surface becomes very irregular by upgrowths of cells, crowded together; it is between these upgrowths that the vascular villi of the follicle are formed. The layer of cylinder cells over the papilla become much elongated and as their nuclei, after the enamel has begun to form, are nearly all placed at about the same level, they constitute one of the most beautifully regular epithelial layers known. These cells covering the papilla are known as the enamel cells (*Schmelzzellen*, *ameloblasts*, *membrana adamantina* of Raschkow) because they produce the enamel, as described below. The enamel cells average about 40 μ in length, and at birth about 6-7 μ in width; their outer ends, *i. e.* away from the papilla, are furnished with prickles or thread-bridges by which the cells are

connected, Fig. 332, with one another and the neighboring cells of the enamel organ; the bodies of the cells are finely granular, and not infrequently have larger glistening granules at their lower or papillary ends; their nuclei are elliptical and 10-12 μ long; before the enamel appears they lie at various levels; after it appears they are found, with rare exceptions, Fig. 332, *b*, near the upper ends of the cells, all at one level. The lower or papillary ends have the processes of Tomes, so named from their discoverer; these appear when the enamel begins to form; they are short, thick, and tapering, one on each cell; they often seem fibrillated, and are always separated from the cell proper by a small cuticular border; while *in situ* Tomes' processes are fitted into sockets on the surface of the enamel. The enamel cells have, probably, no membrane on their sides. After the formation of the enamel is completed the enamel cells degenerate and are lost, except, 1, that their border persists as a horny membrane, cuticula eboris, covering the enamel, and, 2, that a few groups of cells may remain for a long time as isolated epithelial bodies in the dental follicle (Malassez). The cells in the

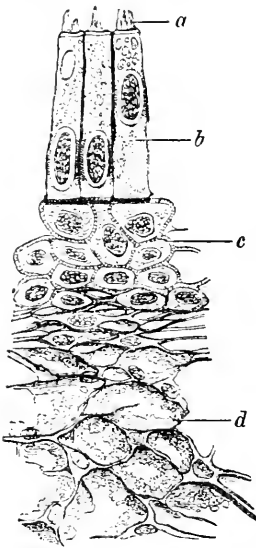


FIG. 332.—Part of the Enamel Organ of a New-Born Child; Ineisor Germ. *a*, Tomes' processes; *b*, enamel cells; *c*, middle layer of prickle cells; *d*, central or pulp-cells. After V. von Ebner. X about 550 diams.

centre of the enamel organ undergo a very peculiar metamorphosis. They remain united together by a few thread-like processes, and, therefore, have a certain degree of resemblance to the embryonic connective tissue cells, but the intercellular spaces do not contain in the enamel organ any homogeneous matrix, but merely fluid. The steps by which this metamorphosis of the central cells is accomplished are still imperfectly known. A few layers of the central cells of the enamel organ retain more of their primitive character, Fig. 332, *c*. These cells constitute the intermediate layer of Kölliker; they are polygonal, granular, and connected with one another by intercellular threads (prickles).

THE DENTAL PAPILLA consists at first, as stated above, of crowded mesenchymal cells. Blood-vessels appear in it very soon after the enamel organ has become concave on the lower side. The papilla acquires very nearly its permanent shape before any further differentiation of its tissue begins. The shape of the papilla is probably determined entirely by the enamel organ, by which it is completely embraced, see above. During the fourth month the cells nearest the surface enlarge—principally by the growth of their protoplasm. They appear as a continuous layer next the enamel organ; their function is to produce the dentine between themselves and the enamel organ, hence they are called odontoblasts (*membrana eboris*, Kölliker); they are to be regarded as modified osteoblasts. The deposit of dentine begins in the milk-teeth toward the end of the fourth month. In a vertical section of a developing papilla, one can see several stages, because the development advances more rapidly toward the apex and more slowly toward the base of the papilla. The tissues underneath the odontoblast layer constitute the so-called pulp of the tooth. The connective-tissue cells of the embryonic pulp are small and have numerous very fine and branching processes which impart a fibrillated appearance to the tissue, but so far as known there are no true intercellular fibrillæ in the pulp. The cells are somewhat more crowded directly under the odontoblasts than in the interior of the papilla.

ENAMEL.—The deposit of enamel begins on the milk-teeth toward the end of the fourth month. According to our present knowledge, the formation of enamel must be conceived about as follows: Each enamel cell forms an enamel prism by the metamorphosis of the lower end of the cell into a calcified column; a cement, which is also calcified, holds the prisms together; the cement is presumably a derivative of the inter-cellular substance between the enamel cells. Enamel is, therefore, essentially different from bone and dentine, in neither of which do the cells calcify, yet the enamel cells resemble odontoblasts in many respects. The first step toward the production of an enamel prism is the change of the protoplasm at the lower or papillary end of the enamel cell into a homogeneous mass, resembling a cuticular cell border; by the union of the borders of adjacent cells, a continuous membrane or cuticula is generated. We must assume that this membrane grows upon its upper side by apposition from the enamel cells, and becomes modified on its lower or papillary side at nearly the same rate. The modification consists in the production of the fibrous tuft, Fig. 332, *a*, described above, at the end of each enamel cell. The lower end of this tuft (Tomes' process) calcifies and becomes the beginning of the enamel prism. The enamel prisms begin small in diameter with considerable cementing substance between, but, as they lengthen, their diameter increases so much that there is little or no space for cementing substance between them. The enamel prisms lengthen by apposition on their ends adjoining the enamel cells, yet for a long time the cells maintain their size, perhaps nourishing themselves at the expense of the central cells of the enamel organ, which gradually atrophies as the enamel thickens. From their mode of growth, it follows that the prisms stretch through the whole thickness of the layer of enamel.

Since the enamel prisms widen out toward the surface of the tooth, it is probable that the enamel cells increase in diameter as the enamel begins to form. The cells cease multiplying by the time the enamel begins to form. The enamel prisms undergo further changes after birth. They become harder and thicker at the expense of the cementing substance between them. At birth it is still relatively easy to break up the enamel into its prisms, and to a certain extent to break the prisms so as to obtain indications of fibrillated structure.

DENTINE.—The odontoblasts, as stated above, are modified mesenchymal cells, which form an epithelioid layer over the surface of the papilla. The odontoblasts are, at first, short cylinder cells, each with an oval nucleus toward the end of the cell farthest from the enamel organ. They keep their mesenchymal character in that they are connected by processes with one another and with the underlying cells of the papilla. The first change in the odontoblasts preparatory to the deposit of dentine is the appearance of the so-called *membrana præformativa*, a clear homogeneous membrane consisting apparently of anisotropic intercellular substance. The membrana always lies next the odontoblasts and is best interpreted as the layer of uncalcified dentine, see C. Röse, 91.2, 470. There now

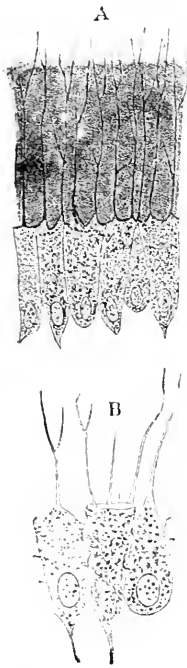


FIG. 333. — Odontoblasts from Cow Embryos. A, of 30 cm.; B, of 24 cm. After Franz Boll.

arise the *dental processes*, which are prolongations of the odontoblasts toward the enamel organ as far as the *membrana præformativa*. The processes vary much in size, but are generally about one-sixth to one-fourth the diameter of the cells; each cell usually has one dentinal process only, but sometimes there are two, and even as many as six have been seen by Boll. Between the dentinal processes a clear anisotropic substance is formed, which gradually increases in thickness, the processes lengthening correspondingly, until a considerable layer, which may be described as uncalcified dentine, intervenes between the odontoblasts and the enamel organ. Calcification sets in next the enamel and progresses toward the papilla; at the same time the deposit of uncalcified dentine is continued by the odontoblasts. The calcification is incomplete; the uncalcified spots are known in the adult tooth as the *interglobular spaces*. The *membrana præformativa* cannot, as suggested by Von Ebner, 90.1, 244, be resorbed by the enamel organ, since it is not in contact with it, but it is to be observed in well-developed teeth, and is perhaps present throughout life. It has given rise to many misconceptions. The matrix of the dentine was supposed by Waldeyer to be produced by a metamorphosis of the protoplasm of the odontoblasts, but this point is open to discussion. The question is part of the more general one—What is the origin of intercellular

substance? Compare p. 399. As the dentine increases in thickness the odontoblasts become longer and narrower, Fig. 333, B, and the

dentinal processes finer, more numerous and branching, the branches anastomosing with one another. The processes persist and never calcify, the spaces they occupy being the *dental canaliculi* of the adult. The ends of the odontoblasts toward the dentine become, for the most part, as it were, squared off, while the lower ends become more or less pointed, Fig. 333. The odontoblasts lose much of their regularity of arrangement, as the dentine nears completion, but they are still found in the adult. In old age they become comparatively inconspicuous and assume a rounded or ovoid shape (Tomes' "Dental Anat.," 1876, p. 97).

THE CEMENT is merely a layer of bone developed by ossification of the dental follicle over the root of the tooth. It differs from ordinary bone by the greater abundance of Sharpey's fibres in it. Its development begins on the milk-teeth during the fifth month, and takes place after the type of periosteal ossification.

AGE OF DEVELOPMENT.—The following table indicates approximately the ages at which the various stages of development are passed by the different teeth. To complete the table it must be added, 1, that the first permanent molar arises the fifteenth or sixteenth week like a milk-tooth as a bud from the epithelium of the dental groove; 2, that the second molar begins as a bud from the neck of the first about the third month after birth, and, 3, that, according to Magitot, the germ of the third molar, or wisdom-tooth, begins as an enamel bud from the neck of the second molar, about the third year (C. S. Tomes, "Dental Anat.," 1876, p. 128.)

Age, Weeks.	Milk teeth.	Permanent teeth (except molars).	First molars.
7th.....	Dental groove and ridge.		
8th.....	Enamel organs bud.		
9th.....	Enamel organ concaves.		
10th.....	Follicular wall.		
15th.....	Enamel organ fully differentiated.		Enamel bud appears.
16th.....	Follicle closes above germ. Neck of enamel organ resorbed.	Enamel buds appear.....	
17th.....	Dentine appears on incisors and canines.....		Papilla.
18th.....	Dentine appears on first and second molars.		Follicle.
20th.....	Dentine caps, 0.04-0.06 in. high.	Papilla formed.....	Follicle closes.
25th.....	" 0.05-0.07 "		Dentine appears
28th.....	" 0.08-0.09 "	Enamel organ fully differentiated; follicle well formed.	
32d.....	" 0.09-0.11 "		Cusps coalesce.
35th.....	" 0.11-0.12 "		
39th.....	" 0.12-0.14 "	Follicle closes above germ.	
After birth		Enamel and dentine appear.	

Double Dentition of Mammals.—The manner in which the teeth are renewed in the shark's jaw has been described, p. 582, Fig. 328; the new tooth-germs arise as outgrowths on the lingual side of the old. In mammals there is the same relation between the earlier milk-teeth and the later permanent teeth. It is, therefore, justifiable to assume that the diphyodont mammal preserves in a reduced degree the piscian power of renewing the teeth, and that the milk-teeth represent the primary dentition. Such, however, is not the view of Flower, 67.1, who considers that the present mammals are derived

from monophyodont ancestors, and have acquired the milk-teeth secondarily by interpolation. This conception has been more recently adopted and defended by Oldfield Thomas (Phil. Trans., 1887, 451). For criticisms of these authors see Lataste, 89.1, who also advances a more complicated hypothesis. Flower's hypothesis was based on the belief that marsupials, which have only one set of teeth, possess the permanent set, but W. Kükenthal, 91.1, has found that the teeth of *Didelphys* (opossum) correspond to the milk-teeth, and that the germs of the permanent teeth are present in the embryo and abort without forming any tooth except the third præmolar (so-called first molar) of the upper jaw, which belongs to the second dentition.

As to the evolution of the complicated forms assumed by the teeth of mammalia, see E. D. Cope, 74.1, and H. F. Osborn, 88.2.

Salivary Glands.—The mouth cavity of amniotes is furnished with numerous glands, which in Sauropsida are found in part variously gathered into groups, in part scattered singly. In mammals scattered single glands are found, but instead of groups of glands there are three pairs of large glands, each with a long single duct. The three pairs are the salivary glands and are known only in mammals. It has been suggested that each salivary gland corresponds to a group of oral glands in reptiles, but the attempts to determine the homologies involved in this assumption have failed, compare Reichel, 83.1, and Ercole Giacomini, 90.1. On the other hand the development, I believe, indicates clearly that each salivary gland is a single oral gland greatly enlarged, for it arises from a single invagination and in an early stage has a marked resemblance to an ordinary branching gland of the mouth.

Concerning the development of the small oral glands in man, a few observations are recorded by Kölliker ("Mikrosk. Anat." II., 2, and "Entwickelungsges.," 1879, 828) who also gives a few data concerning the salivaries. The development of the latter glands is known to us chiefly through the researches of J. H. Chiewitz, 85.1. The glands appear in the following order: submaxillary, sublingual, parotid. The submaxillary anlage can be seen in a pig embryo of 21 mm. and in a human embryo of about six weeks; the parotid appears in man by the end of the eighth week. As to the position of the anlages: the mouth at the time they appear has a characteristic shape in section, Fig. 325, being—if we imagine the tongue removed—like an inverted \perp , and there is at each side an angle, α ; it is from the epithelium along this angle that the solid outgrowth to form the parotis takes place. The base of the tongue forms an angle on each side with the floor of the mouth, Fig. 325; it is from this angle that the solid outgrowths of the buccal epithelium take place to form the sublingual and submaxillary glands, the former near the front, the latter near the back of the tongue. The anlages of the parotid and submaxillary are at first at about the same distance back from the frenulum of the tongue, but as development proceeds the submaxillary orifice migrates forward, the parotid backward. The following measurements are from Chiewitz, 85.1, 422.

Age of embryo in weeks.....	6	8	10	12
Submaxillary gland, distance from frenulum..	0.52	0.32	0.36	0.12 mm.
Parotid gland ..		0.34	1.08	1.10 mm.

The outgrowth of the salivary anlage is at first a cylinder, which, however, soon begins to lengthen and branch; the ends of the branches enlarge, and ultimately develop into the alveoli. The gland is now further characterized by the condensation of the connective tissue about its branches into a globular mass, which is sharply defined, Fig. 334, *a*, against the neighboring looser con-

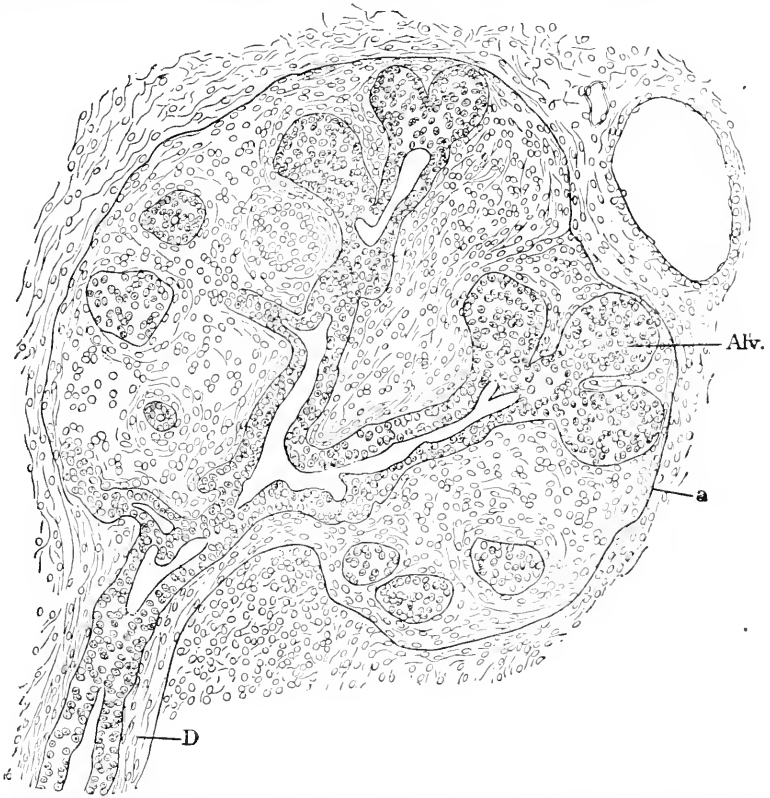


FIG. 334.—Section of the Submaxillary Gland of a Human Embryo of sixty-three to sixty-eight Days. Minot Coll. No. 138. *Alv.*, Alveolus; *a*, connective-tissue sheath of gland; *D*, duct.

nective tissue. The lumen of the gland appears first in the main duct, then in its branches, and, last of all, in the alveoli; it develops, not by the abortion of the cells in the centre, but by the cells moving asunder so as to leave a central cavity, while they themselves assume an epithelial arrangement. The alveoli are still solid at the beginning of the fifth month, but in an embryo of twenty-two weeks were found by Chiewitz, *l.c.*, 427, to be all hollow. At this time the epithelium consists of a single layer of cylinder cells; in the ducts the nuclei are so placed that they form, as in earlier stages also, Fig. 334, *D*, two rows; the nuclei of the outer row are somewhat smaller and stain more readily than those of the inner row; in the alveoli the cells are at first all alike, but after the alveoli become hollow some of the cells become enlarged to form muciparous beaker-cells,

while others remain smaller and protoplasmatic; these smaller cells become partly covered in by the neighboring beaker-cells, and thus develop into the semilunar cells of the adult.

Between the anlagen of the sublingual and submaxillary glands, there appear later—twelfth-week in man—some eleven to thirteen gland anlagen, which in their mode of development resemble small salivary glands, Chiewitz, 85.1, 423. These are termed by Chiewitz alveolingual glands, and have been often confounded with the true sublingual gland.

Tongue.—Although the tongue is developed from the floor of the pharynx, yet it becomes so entirely an appendage of the mouth that it may be appropriately treated here. Our knowledge of the development of the tongue is derived chiefly from Dursy, 69.1, and His, ("Anat. menschl. Embryonen," III., 64-81).

The first distinct trace of the tongue is a small tubercle which appears in the middle line on the floor of the pharynx between the

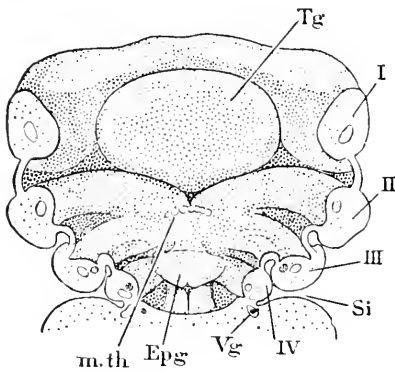


FIG. 335.—Reconstruction of the Pharynx of a Human Embryo (His' Pr. 10 mm.). *Tg*, Tongue; I, II, III, IV, branchial arches; *Si*, sinus cervicalis; *Vg*, vagus nerve; *Epg*, epiglottis; *m.th.*, median thyroid anlage. After W. His. $\times 24$ diams.

ends of the first and second (*i.e.*, mandibular and hyoid) arches. It was supposed by Dursy to be formed by the fusion of the lower ends of the mandibular arches, but His has shown that it is single and median, and accordingly has termed it *tuberculum impar*, Fig. 177. Immediately behind the tubercle appears the evagination to form the thyroid gland, see Chapter XXIX. Very soon after the tubercle has appeared the lower ends of the second and third arches fuse—human embryos of 7 mm.—and their fused ends constitute the anlagen of the back of the tongue. The tubercle now rapidly enlarges, Fig. 335, *Tg*, and becomes easily

recognizable as the front part of the tongue. The site of the thyroid evagination remains as a fixed point, which is often marked by a small depression, the *foramen cæcum* of Morgagni; the duct of the thyroid sometimes persists and is then found starting from the foramen cæcum. The front and back of the tongue are marked off, Fig. 335, by two oblique lines, which start from the foramen, and together form a widely open V. This V can be traced—as pointed out by His, *l.c.*, 79—in the adult tongue; the part behind the V has its surface thrown into ridges, and over it there are glands, which appear during the third month; the part in front has papillæ developed under its epithelium, and the papillæ circumvallatæ are situated a little (5-8 mm.) in front of the V, but in lines parallel with it; the circumvallate papillæ do not, therefore, represent the division line between the front and back of the tongue. The largest part of the tongue is developed from the tuberculum impar, the less part from the region of the second and third branchial arches—hence the tongue is a derivative of the pharynx and not of the oral cavity.

CHAPTER XXVII.

THE NERVOUS SYSTEM.

THE formation of the vertebrate cerebrospinal axis has already been treated at length, pp. 173-181. In its first stage it appears as the medullary tube with ectodermal walls. The second stage is the differentiation of the brain from the spinal cord by the enlargement of the anterior end of the tube. The sharp distinction which we have just drawn between the stages does not maintain itself in the amniota. In fact the medullary groove widens at its cephalic end before it closes to form a tube, so that the brain is indicated in the embryo before the medullary tube is formed. Moreover the development of the brain progresses while the groove is closing, so that the brain is already quite advanced before the medullary tube is closed at its caudal end. These irregularities in the development of the central nervous system render it impossible to decide at present whether the simple medullary tube without a brain enlargement, or a (perhaps solid) central nervous system with a brain enlargement, represents the phylogenetically primitive condition. The difficulty of reaching a decision is still further increased by the fact that the tubular condition of the nervous system was probably acquired within the vertebrate series, see p. 180.

Definition of the Brain.—The vertebrate brain is the anterior portion of the medullary tube, and is characterized by two primary features: 1, the enlargement of the tube; 2, its special associations with higher sense organs (olfactory, visual, and auditory). The brain is further characterized in all true vertebrates: 1, by having three principal enlargements separated from one another by two constrictions (H. Ayers, 90.1, claims that the three enlargements can be traced in *Amphioxus* also); 2, by being bent at the region of the second enlargement (mid-brain) owing to the development of the head-bend of the embryo; 3, by containing the principal centres for the co-ordination of sensations and movements. All modifications of the brain can be traced back to this primitive type, and it seems probable that the evolution of the brain has been dominated by the advantages of more perfect co-ordinating apparatus, as the special senses on the one hand and the locomotive organization on the other acquired a higher development.

Cerebral Vesicles.—The enlargement which produces the brain extends about half the length of the embryo, compare Figs. 114 and 155, and takes place unevenly, so that there are produced three successive lobes, which are known as the primary cerebral vesicles, Fig. 113 and 114; the second and third vesicles (mid-brain and hind-brain) are often imperfectly divided from one another. The three vesicles subsequently subdivide, so as to form—to follow the tradi-

tional description—five secondary vesicles. It has long been customary to describe the medulla as dilating to form the three and later five vesicles, but unfortunately the descriptions have been so much conventionalized in subservience to tradition that they are misleading in several important respects. The attempt is here made to give an untrammelled objective account.

OPTIC EVAGINATIONS.—The first indication of brain formation seems to me to be the widening of the extreme anterior end of the medullary plate or groove, which can be recognized in all vertebrate embryos at a very early stage. In elasmobranchs it appears to me evident that the widening is due to the very process of concrescence itself, and is initiated while the ectental lines are approaching one another, and is fully marked before the longitudinal axis of the embryo is completed by concrescence. Fig. 317 represents a dog-fish embryo; *m* is the point at which concrescence has begun; it will be observed that the embryonic rim curves around this point and in consequence

is spread out laterally; in later stages the lateral protrusion, which we see initiated in Fig. 317, at *m*, becomes still more marked and can be followed until it is evidently the optic diverticulum. In mammals we find the medullary groove specially widened at its anterior end—noticeably so in the mole, Fig. 99, *op*. A cross section through the optic vesicle at this stage offers a very singular appearance, Fig. 100; the entoderm, *En*, has not closed over, although the notochord, *nch*, is already distinguishable under the medullary groove; the ectoderm, *Ec*, is greatly thickened on the dorsal side to form the very wide medullary plate, which has a median depression, *Mp*, corresponding to the medullary groove proper, and two lateral depressions corresponding each to an optic vesicle. If we imagine the medullary plate to bend upward and to close over itself, then the two edges of the optic depressions, *op*, which are outermost in Fig. 100, will meet in the median line, and as soon as the groove, by closing, becomes a tube, there will be at this point two lateral diverticula, having the same characteristically thickened ectodermal lining as the rest of the medullary tube. These diverticula are the so-called optic vesicles, which are ultimately transformed into the optic nerve, retina, and choroid of the eye.

In the chick the optic vesicles become clearly indicated by the twenty-fourth hour, when there are from five to seven distinct pairs of primitive segments, and the head projects slightly over the proamniotic area. Before the medullary groove has closed anywhere the optic diverticula are quite distinct. In a

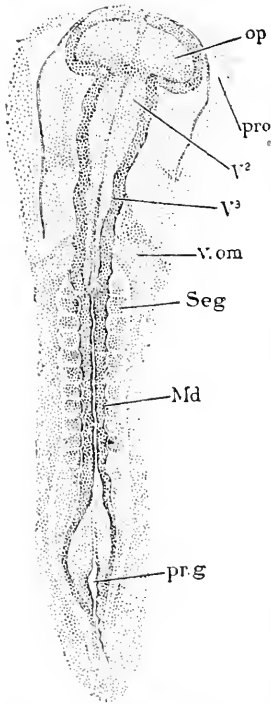


FIG. 336.—Chick Embryo of twenty-nine Hours. *op*, Optic vesicle; *pro*, proamniotic; *V*², second cerebral vesicle or mid-brain; *V*³, hind-brain; *v.om*, omphalo-mesaraic vein; *seg*, primitive segment; *Md*, medullary tube; *pr.g*, primitive groove. After M. Duval.

chick of twenty-nine hours, Fig. 336, the vesicles, *op*, are very large, their growth being an important factor in the precocious distention of the head.

WIDENING OF THE MEDULLARY TUBE.—While the optic vesicles are developing the medullary tube expands in diameter throughout its cranial or anterior half, without there being at first much change in the structure of its walls or much evidence of subdivision, but very soon the expansion becomes unequal, so that the tube is slightly constricted immediately behind the optic vesicles, Fig. 336, *op*; then follows a slight dilatation, V^2 , the mid-brain (*Mittelhirn*), which is separated by a second constriction from the long and large hind-brain, V^3 (*Hinterhirn*), which is widest in front and gradually diminishes in diameter, and merges without distinct boundary into the posterior unexpanded portion of the medullary tube or future spinal cord. Transverse sections show that the widening, by which the brain is differentiated from the cord, is due chiefly to the enlargement of the medullary cavity, and that the walls change but little in thickness until the three vesicles are differentiated, when the walls begin a series of characteristic modifications.

THE THREE PRIMARY VESICLES (*Gehirnbläschen, vesiculæ cerebrales*) were known to Malpighi and Haller according to Tiedemann, 61.1, 9. Bischoff, 45.1, 170, appears to have been the first to observe that they are formed before the medullary groove is entirely closed in the cephalic region. Owing to the fact that the optic vesicles grow out so early and that the remainder of the brain as a whole widens out, we ought, perhaps, to accept A. Goette's view, 75.1, 280, that a double division precedes the triple. In this case we should have to describe the mid-brain and hind-brain as arising by the subdivision of the second primary enlargement.

1. *The Fore-Brain.*—As we have seen above, the fore-brain originally includes the optic vesicles, which primitively show no trace of any demarcation from the central portion of the fore-brain. This condition, however, does not last long, for the central portion of the fore-brain soon begins to expand upward and forward, making a separate central enlargement, which may be designated as the *permanent fore-brain*. Meanwhile the distal ends of the optic diverticula also dilate rapidly, while the part of each diverticulum nearest the fore-brain proper grows slowly. It is often erroneously stated that part of the optic vesicle is constricted: in reality it enlarges, though relatively slowly. From these modifications there are developed a wide median fore-brain and two lateral optic vesicles connected by tubular stalks with the ventral side of the brain proper, Fig. 337.* In short, the primitive vesicle is divided into three

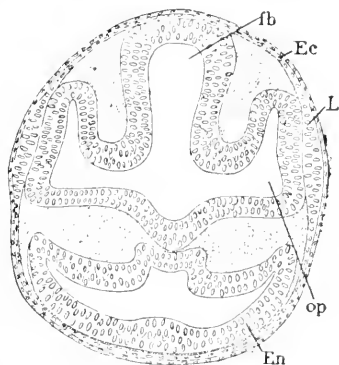


FIG. 337.—Cross Section through the Fore-Brain and Optic Vesicles of a *Lepidosteus* Embryo of eight Days. *fb*, Fore-brain; *Ec*, ectoderm; *L*, anlage of lens; *op*, optic vesicle; *En*, entoderm. After Balfour and Parker.

* Compare also Figs. 170, 171, and 179.

parts, one median and two lateral, and it is only the median part that enters into the formation of the brain. The history of the median division is, therefore, treated in this chapter, while that of the two lateral divisions is dealt with in Chapter XXVIII., on the organs of sense. It may, however, be stated now, in order to facilitate the comprehension of the figures, that the optic vesicles expand dorsward, Fig. 337, *op*. It should be noted that the walls of the fore-brain and optic vesicle are still nearly uniform in thickness, and, so far as yet observed, in structure. The changes described in this paragraph occur in the chick at about thirty-two to forty hours, in the rabbit the ninth day, in man about the eighteenth day.

The next series of changes in the fore-brain lead to the differentiation of the cerebral hemispheres. By a long-continued tradition it has become customary to describe the process as the subdivision of the primary vesicle into two secondary vesicles, designated as the fore-brain proper (*Vorderhirn, prosencephalon*) and 'tween-brain (*Zwischenhirn, thalamencephalon*). Such a description, however, seems to me hardly justified either by embryology or comparative anatomy, and to be especially apt to mislead and confuse. In fact

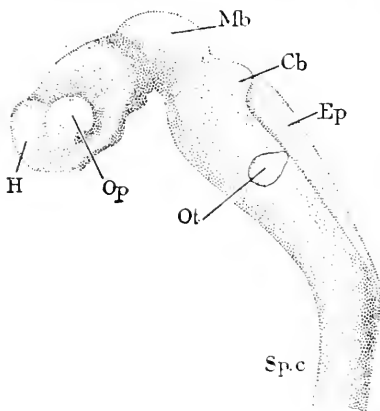


FIG. 338.—Brain of Embryo No. 22, p. 297 (His' Lg). *H*, Anlage of hemispheres; *Mb*, mid-brain; *Cb*, future cerebellum; *Ep*, ependyma; *Ot*, auditory vesicle; *Sp.c*, spinal cord; *Op*, optic vesicle. After W. His. X 23 diams. Compare Fig. 342.

every embryologist must admit that it is scarcely correct to say that the fore-brain divides into two vesicles, from the anterior of which the cerebral hemispheres grow out. It is more in accord with the actual facts to describe the hemispheres as appendages of the fore-brain, that is to say, of the so-called *Zwischenhirn* or thalamencephalon. Accordingly I present the history of the origin of the cerebral hemispheres somewhat differently from usual, though, of course, without changing the facts. For convenience I defer mention of the head-bend (see p. 600), which develops while the hemispheres are arising. Soon after the optic vesicles have become stalked the extreme anterior end of the first vesicle enlarges and pushes itself, so to speak, forward and, owing to the head-bend, downward. The flexure is at first slight, but increases as development proceeds, compare p. 600. The enlarged end of the medullary tube is in no way divided off from the first cerebral vesicle until the end begins to dilate toward each side to produce the hemispheres. The manner in which the hemispheres grow out can be better understood from the Figs. 338, 339, and 340, than from any mere description. At first, as just indicated, they form an undivided common anterior enlargement, but the lateral expansion begins very early, and with it the anlages of the two hemispheres are given. If the position of the hemispheres is observed carefully, Fig. 338, *H*, it will be seen at once that it is the product of the dorsal side, and that the ventral half of the primi-

every embryologist must admit that it is scarcely correct to say that the fore-brain divides into two vesicles, from the anterior of which the cerebral hemispheres grow out. It is more in accord with the actual facts to describe the hemispheres as appendages of the fore-brain, that is to say, of the so-called *Zwischenhirn* or thalamencephalon. Accordingly I present the history of the origin of the cerebral hemispheres somewhat differently from usual, though, of course, without changing the facts. For convenience I defer mention of the head-bend (see p. 600), which develops while the hemispheres are arising. Soon after the optic vesicles have become stalked the extreme anterior end of the first vesicle enlarges and pushes itself, so to speak,

tive fore-brain, as shown by W. His, 89.4, does not participate in the outgrowth. The consideration of this important fact demonstrates that the hemispheres cannot be strictly compared with one of the primary vesicles, each of which includes a ventral as well as a dorsal portion of the medullary tube. The origin of the hemispheres from the dorsal side has so great importance morphologically that special emphasis must be laid upon the fact. The ventral boundary of the hemispheres must be placed near the optic stalks, so that the hemispheres include that portion of the brain wall which unites with the ectoderm to form the olfactory plate, already described, p. 575.

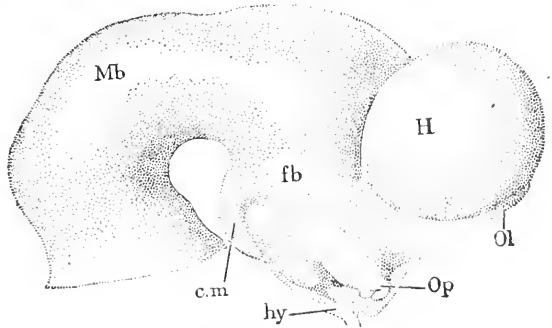


FIG. 339.—Reconstruction of the Brain of His' Embryo Ko (*Nackentlänge*, 10.2 mm.). Mb, Mid-brain; fb, fore-brain; H, hemisphere; Ol, olfactory lobe; Op, optic nerve; hy, hypophysis; cm, corpus mamillare. After W. His.

The cerebral hemispheres grow more rapidly than any other part of the brain, see Fig. 339, H, but their growth is principally in their distal parts, so that, like the optic vesicles, they become large pouches connected by relatively small hollow stalks with the fore-brain. The stalk is short. The passage through the stalk is called the *foramen of Munroe*, Fig. 340, *f.m.* As this foramen enlarges but little, while the brain increases enormously, it appears in the adult as a small opening in proportion to the size of the whole brain. Although the foramen enlarges absolutely, it is sometimes described erroneously as becoming smaller during development. While the hemispheres are expanding

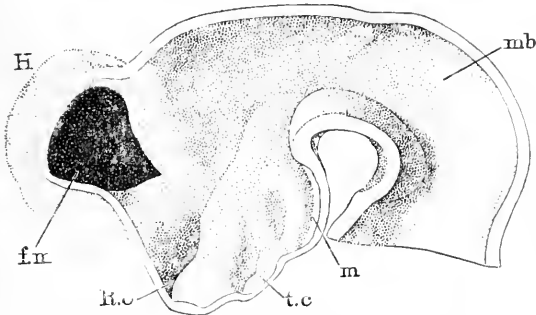


FIG. 340.—Reconstructed Median View of the Fore-Brain of His' Embryo Ko (*Nackentlänge*, 10.2 mm.). H, Hemisphere; f.m., foramen of Munroe; R.o., recessus opticus; t.c., tuber cinereum; m, corpus mamillare; mb, mid-brain. After W. His.

the olfactory plate, Fig. 339, Ol, acquires a more marked differentiation beneath them and shows traces of division into a dorsal or anterior, and ventral or posterior, lobe. Even at the stage of Fig. 339, it can still be recognized that the olfactory region corresponds to what was, before the brain was bent, part of the extreme anterior wall of the fore-brain. But the olfactory region is already paired, and is associated in its development with the hemispheres. This leaves a part of the wall of the fore-brain in the median line, Fig. 340 (between the reference lines *f.m.* and *R.o.*), which is known as the *lamina terminalis* and represents throughout

the extreme anterior wall of the fore-brain. But the olfactory region is already paired, and is associated in its development with the hemispheres. This leaves a part of the wall of the fore-brain in the median line, Fig. 340 (between the reference lines *f.m.* and *R.o.*), which is known as the *lamina terminalis* and represents throughout

life the extreme anterior wall of the fore-brain. As seen in Fig. 340, it extends from the level of the foramen of Munroe to the level of the optic stalks. In the same figure it can also be seen that the hemispheres and olfactory lobe project further forward than the lamina. The hemispheres expand, not only upward and forward in regard to the longitudinal axis of the fore-brain, but also backward, as can be well seen in Figs. 339 and 341. The history of the hemispheres is given more fully and for later stages below, p. 690.

The primary differentiations of the floor or ventral wall of the fore-brain are also clearly indicated in a human embryo of 10–12 mm. (*Nackentlänge*), Figs. 339 and 341. The lower part of the fore-brain has expanded, forming, as it were, a hanging pouch, Fig. 339, from which pass off the optic stalks, *Op*. Following the median wall of the pouch around from the mid-brain to the level of the foramen of Monroe, Fig. 340, *f.m*, we find, *first*, a protuberance, *m*, which extends nearly half-way to the optic stalk, and indicates the future mammillary bodies; *second*, a slight swelling, *t.c*, which marks the future tuber cinereum; *third*, the future apex of the infundibulum; *fourth*, the area of the brain wall united with the hypophysis; and *fifth*, the lamina terminalis, just beyond the recessus opticus, *R.o*.

2. *The Mid-Brain.*—The second cerebral vesicle undergoes less modification than the first and third. Its walls are at first of nearly uniform thickness, see Duval, "Atlas," Fig. 255. It is oval or round in transverse section. It is situated at the point where the head-bend takes place (compare p. 600), and by the head-bend its shape is profoundly altered, its dorsal surface becoming more arched and expanded, Fig. 338, *Mb*, while its ventral wall as seen in profile becomes concave; further, the dorsal wall becomes relatively much thinner than the ventral wall. The cavity of the mid-brain remains very large, and during the early expansion of the brain the communication between the fore-brain and mid-brain enlarges more than does the passage between the mid- and hind-brain. This is commonly expressed by saying that the constriction between the first and second cerebral vesicles is much less marked than between the second and third.

In the lower vertebrates the fore-brain and hind-brain do not advance either in growth or complication as in the amniota. In birds and reptiles the mid-brain develops to a greater extent than in mammals, and in the embryo early acquires great size, see Fig. 396, II. In mammals, on the other hand, the mid-brain grows more slowly. Roughly speaking, then, we may say that the importance of the mid-brain diminishes as we ascend the vertebrate series, and that it does not participate in the advance of organization which characterizes the first and third cerebral vesicles.

3. *Hind-Brain.*—The third cerebral vesicle is especially characterized by the great expansion of its very thin dorsal wall, by the thickening of the dorsal wall immediately behind the constriction separating the second from the third vesicle, and by the great and prominent bend formed by the ventral wall of the hind-brain, Fig. 341, *Hb*. The thin dorsal wall corresponds to the epithelial ependyma of the adult; its morphological significance is explained in the

section on the zones of His, p. 606. The dorsal thickening is the anlage of the cerebellum and corresponds to a commissure found in the lower vertebrates. The apex of the ventral flexure is the anlage of the pons Varolii of the adult. The thickened floor of the hind-brain, between the pons and the spinal cord, *sp.c.*, gives rise to the medulla oblongata. We thus have the four chief structures, which develop from the hind-brain, definitely mapped out by the earliest changes. The modifications which result in this four-fold differentiation all take place simultaneously and are interdependent. They are the result of two factors: 1, the unequal development of different regions of the medullary walls; 2, the appearance of the Varolian bend (*Brückenkrümmung*). These factors are considered later.

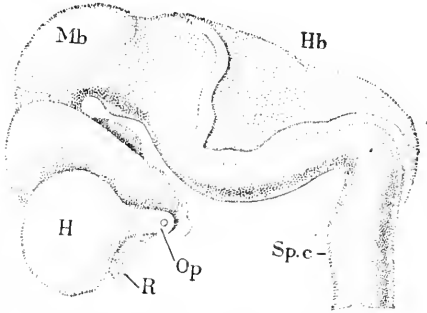


FIG. 341.—Brain of a Human Embryo of five Weeks (His' Embryo Sch.). *H*, Hemisphere; *R*, olfactory lobe; *Op*, optic nerve; *Mb*, mid-brain; *Hb*, hind-brain; *Sp.c.*, spinal cord. After W. His.

It is usually stated that the hind-brain subdivides into two vesicles, for which the names secondary hind-brain and after-brain (*Nachhirn*) have been employed; the *Nachhirn* is the part nearest the spinal cord. In fact, it is convenient to designate the anterior part of the hind-brain, out of which the cerebellum and pons Varolii arise, as the hind-brain proper (*metencephalon*) and the posterior part as the *Nachhirn* (*epeucephalon* or *myelencephalon*) or, better, as the medulla oblongata. On the other hand, it is incorrect to speak of the primitive hind-brain as forming two secondary vesicles. This error goes back to the time of Von Baer, II., 106, who observed such division in the chicken embryo. It has also been described and figured by Mihalkovics, 77.1, 25, Taf. IV., Fig. 33, in a chick of fifty-eight hours. These authors, and most others who have written on the subject, assumed that their observations were upon a constant and typical condition. In reality there is great irregularity in the growth of the walls of the hind-brain, and sometimes in birds and perhaps in reptiles the third cerebral vesicle is temporarily more dilated at its anterior end than elsewhere. The dilatation soon disappears, and no proof has been brought yet, to my knowledge, to establish an identity between it and the region corresponding to the cerebellum and pons—it seems to take in more than the cerebellum, less than the pons. In chicken embryos the separate dilatation is usually wanting, and it has, so far as I know, never been observed in any mammalian or ichthyopsidan embryo. It is interesting to note that Balfour, "Comp. Embryol." II., 424, though he does not expressly mention the error of the traditional description, yet skilfully avoids adopting it in his account of the hind-brain.

The shape of the hind-brain requires more detailed description. As seen in Fig. 338, the hind-brain at the time of the development of the head-bend is more than equal to all the rest of the brain in length. It begins with the constriction or isthmus behind the mid-

brain and at first widens rapidly, then gradually tapers to the neck-bend, where it passes into the spinal cord. Viewed from the dorsal side, Fig. 342, the anterior constriction or isthmus is still more noticeable, and we can also see the kite-shaped outline of the thin roof.

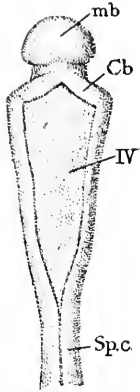


FIG. 342.—Hind-Brain of a Human Embryo (No. 22, p. 297, His' Lg.), seen from the dorsal side. *mb*, Mid-brain; *Cb*, cerebellum; *IV*, fourth ventricle; *Sp.c.*, spinal cord. After W. His. Compare Fig. 338.

Comparison of the figure with the following, Fig. 343, representing a slightly older stage, affords an idea of the widening of the medulla, while comparison of Figs. 338 and 341 will indicate its modifications as seen in profile. It is important to observe that there is, as yet, no cerebellum, but only a thickening of the dorsal wall close to the isthmus. This thickening is the anlage of the cerebellum, and is to be homologized with the commissure found in the corresponding position in Ichthyopsida.

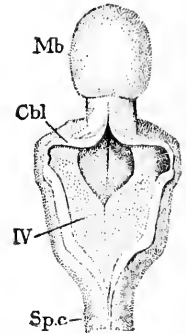


FIG. 343.—Dorsal View of the Hind-Brain of a Human Embryo of one Month (His' Ru). *Mb*, Mid-brain; *Cbl*, cerebellum; *IV*, fourth ventricle; *Sp.c.*, spinal cord. After W. His.

Cerebral Flexures.—The axis of the neuron may be described as straight, for it is actually very nearly so, up to the stage when the optic vesicles begin to be constricted off—see Figs. 99 and 336.

While the dilatation to form the second cerebral vesicle or mid-brain is taking place, the primary head-bend of the embryo is established, involving the brain. The bend of the brain takes place at the level of the mid-brain; the fore-brain is bent over ventralward until it forms a right angle with the hind-brain, Fig. 338, the actual flexure being almost confined to the mid-brain, in which, as can be seen in the figure, the cerebral axis curves very much, while in the hind-brain it remains nearly straight, and in the fore-brain is slightly bowed only. This bend may be called the mid-brain or *primary flexure*.^{*} During the early stages of the hemispherical outgrowths the flexure increases until the axis of the fore-brain forms an acute angle with that of the hind-brain, Fig. 320. Mihalkovics, 77.1, 39, proposes to distinguish the right-angled stage as the *Hakenkrümmung*, and the later acute-angled stage as the *Kopfbeuge*. Such a distinction is entirely arbitrary, and the suggestion has not been adopted. The angle becomes ultimately so sharp that the floor of the fore-brain becomes nearly parallel with that of the hind-brain.

The second bend to appear is at the junction of the hind-brain (medulla oblongata) and spinal cord, Fig. 338, and is termed the neck-bend (*Nacktenkrümmung*). Like the primary bend it affects the whole head; the summit of its angle appears in the embryo when seen in profile, compare Figs. 220 and 223, during several early stages as a projection (His' *Nackenhöcker*), which is, however, soon obliterated. The neck-bend develops later than the head-bend, not appearing in mammals until the hemisphere anlagen have begun

^{*} It is called by Reichert *Gesichtskopfbeuge*; by Dursy, *Kopfbeuge*; by Kölliker, *vordere Kopfkrümmung*; by His, *Scheitelkrümmung*.

to grow out separately. It is very slight in the Ichthyopsida; in the reptiles and birds it is more developed, but it attains its maximum only in the mammalia, and notably in man. In human embryos the neck-bend increases from the third to the end of the fifth week, when it reaches its maximum, the hind-brain then forming nearly a right angle with the spinal cord, Fig. 341. Later the bend becomes less again, owing to the gradual erection of the head as already described and illustrated in Chapter XVIII. for the human embryo.

The third cerebral flexure is known as the *Varolian bend* (Kölliker's *Brückenkrümmung*) and is essentially different from the two flexures just described, for it is not a bend of the whole medullary tube, as are they, but a bend of the ventral side of the hind-brain, Fig. 341, the dorsal side remaining as seen in profile, nearly straight. As already mentioned, the greater part of the dorsal wall of the hind-brain is a thin membrane, and this membrane takes no part in the formation of the Varolian bend, which depends on the growth of the thick walls of the floor of the hind-brain, and with this growth the bend increases, its formation being accompanied by the lateral expansion of the hind-brain at its anterior or cerebellar end, Fig. 343.

The cause of all the cerebral flexures is, of course, the unequal growth of the various parts. Herein the growth of the brain is certainly the principal factor in determining the result. The general conception of the influence of the unequal growth of the brain dates back to Von Baer, and was revived by Rathke. W. His was the first to attempt an analysis of the mechanical conditions, and to demonstrate that the shaping of the brain depends to a large degree upon these conditions, which are many of them relatively obvious and simple. His has given in his semi-popular work, "Unsere Körperform," 74.1, pp. 93-118, an admirable presentation of his results, which have not yet received from embryologists the attention which their exceptional importance demands.

Origin of the Sensory Ganglia.—To fully understand the history of the ganglia the reader should consult the section on the ganglionic sense-organs in the following chapter. The origin of the ganglia has been carefully traced in a human embryo* with thirteen segments, by M. von Lenhossék, 91.1, three of whose figures I reproduce, Fig. 344. As seen in A, the ectodermal cells, *Gl*, which immediately adjoin the medullary plate, differ in size and by their rounded form from the cells of the neighboring ectoderm and of the medulla. These cells constitute two bands, which unite in a single median band when the medullary groove closes. The median band has been termed the *Zwischenstrang* in the chick embryo by His, but is more usually termed the *neural crest* or ridge (*Neuralleiste*), as proposed by Balfour. In B, the cells are about to unite in the median line. In C they have united, and though incorporated in the medulla and separated entirely from the external ectoderm are readily distinguished from the cells of the medullary plate proper. The cells are also growing out on each side, *Gl*, toward the myotome. The emigration continues until all the cells are transferred from the median line to the lateral masses, *Gl*, which are the anlagen of the

* This embryo is the one designated as No. 18, and described p. 395.

sensory ganglia. As the cells depart from the neural crest the medullary plate proper closes over in the median dorsal line. The ganglionic lateral masses exhibit a segmental arrangement very

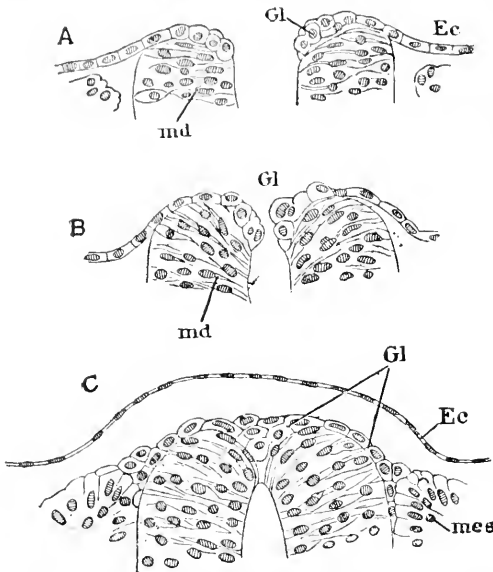


FIG. 34.—Sections through the Cervical Part of the Medulla of a Human Embryo with thirteen Segments. A, In front of the segments where the medullary groove is widely open; B, a little further back, where the medullary groove is just closing; C, at the level of the third segment. *Ec*, Ectoderm; *Gl*, ganglionic anlage; *md*, medulla; *mes*, mesoderm. After Lenhossék.

early, so that the cells appear in clusters, each cluster on the inner side of a myotome. According to Chiarugi, 90.1, these clusters, at least in the post-auditory region of the head, are bud-like growths from the neural crest; between the clusters the crest persists for a short time like a commissure. These clusters are found in older stages to enlarge rapidly and to move farther down toward the notochord. They are the rudimentary ganglia. The ganglia are always strictly segmental in position, both when first formed and later. This is especially noticeable when they attain their maximum relative size, for they then occupy the whole width of a segment.

W. His, 90.1, has rendered it highly probable that the cells which form the anlagen of the spinal ganglia emigrate singly from the ectoderm; these cells bear an obvious resemblance to the germinating cells, which become the neuroblasts of the medullary tube; see also the account of the olfactory ganglion, Chapter XXVIII.

In all vertebrates the ganglia are developed essentially as in man, but the process varies considerably in detail. Thus in *Petromyzon* according to Kupffer, 90.1, 486, Taf. XXVIII, Figs. 22, 23, 24, and 36, the medullary cord is completely formed, and afterward the cells are differentiated to form the dorsal median neural crest (*Ganglienleiste*, *Nervenleiste*). The account given by Kupffer differs from that given by Sagemehl, 82.1, which has been accepted by Shipley, 88.1, and Scott, 87.1. If Kupffer is right, then the lamprey is characterized by a very late differentiation of the neural crest. This is true also of elasmobranchs, see Balfour, "Comp. Embryol.," II., 449, Rabl, 89.2, 223, Taf. X., Figs. 34 and 35, also Kastschenko, 88.1, 463; in this class the medullary canal is completely formed, and the neural crest appears afterward, and moreover without any marked differentiation of its cells from those of the medullary tissue proper. In the axolotl, Lenhossék, 91.1, 19-21, finds the neural crest early separated from the medullary canal, which closes dorsally by a single row of cells, each of which stretches completely across, see

his Fig. 10. In birds, as first observed by W. His, 68.1, 78, the neural crest is a separate distinct thickening of the ectoderm, which can be seen, at least in the cephalic region, while the medullary groove is still open, Fig. 147, *Gl*; it is readily distinguished by the larger size of its cells from the tissue of the medullary plate. This band was termed by His the intermediate cord (*Zwischenstrang*) and he was the first not only to demonstrate the existence of a neural crest, but also its genetic relations to the ganglia.

In certain cases there appears, while the medullary groove is still open, a slight groove in the ectoderm close to, and parallel with; the edge of the medullary plate. This groove has been named by His, 68.1, the *Zwischenrinne*. It apparently results, as suggested by Chiarugi, 91.1, from the effort of the ectoderm to fit in between the edge of the medulla and the myotomes. The ectoderm, even when there is no groove, is thickened along this line, and this thickening was formerly thought to be connected with the development of the neural crest. This appears, as Beard, 88.3, 160, has correctly maintained, not to be the case. Beard has adopted with this correction His' view of the origin of ganglia, but, without giving his reasons for so doing, advances it as a new conception.

In regard to the early history of the ganglia the following points deserve special mention: 1, the ridge appears first in the region of the hind-brain, and thence its development progresses forward and tailward; the same law governs the appearance of the separate ganglionic anlagen; 2, the ganglia arise near the dorsal summit of the neuron, as seen in cross sections, but rapidly migrate toward the notochord until they reach their permanent level alongside the medullary tube; 3, as they descend the ganglion anlagen lose all connection, so far as can be observed, with the medullary tube. Kölliker, however, expressly states ("Grundriss," 2te Aufl., 267) that the ganglia always remain connected dorsally with the medullary tube; 4, the continuity of the neural crest is preserved, it remaining as a slender band connecting on each side of the body the dorsal parts of the ganglia with one another longitudinally. The connecting band may be called the *ganglionic commissure*. It has been observed by Kölliker ("Grundriss," 2te Aufl., 268) in a human embryo of the fourth week.

The ganglionic commissure is undoubtedly a very important morphological structure, as insisted upon by Balfour, "Comp. Embryol.," II. 450-451. There are a number of valuable observations upon it scattered in various articles, but until these shall have been collated or considerably extended, it will remain impossible to give a satisfactory account of the commissure, its significance or its fate. A special investigation of this problem is much to be desired.

CEPHALIC GANGLIA.—As the ganglia of the head differ somewhat in their primitive arrangement from those of the rump, I add a brief description of them.

As long ago as 1847 Remak described in chick embryos of sixty hours the four ganglia of the head to which the neural crest primarily gives rise, at least in amniota. W. His, 68.1, 106, 168, gave a fuller description and studied also earlier stages. No study of the ganglia corresponding to the present requirements and resources of

embryology has yet been attempted. The four ganglia to be seen in the chick before the head-bend appears are thus described by His, **88.2**, 417: There are two ganglionic masses in front of and two behind the auditory vesicle; the foremost of these is the trigeminal ganglion, which is very long, occupying nearly half the length of the head; it begins in front of the optic vesicle, perhaps even at the olfactory pit, passes along the dorsal side of the optic vesicle, alongside the mid-brain, and ends a short distance after the beginning of the hind-brain. Later this large ganglion separates into the ciliary ganglion and the trigeminal ganglion proper, the former arising from that part of the original anlage which is near the optic vesicle. A. Frosiep, **91.2**, has observed that in torpedo embryos of 6 mm. the trigeminal ganglion also sends a large branch, which runs straight to the dorsal side of the isthmus to the point where the trochlear nerve arises later; this branch may be called the trochlear arm; in embryos of 9 mm. the arm is represented only by a few groups of cells; and in embryos of 16 mm. one of these groups still persists as a small ganglion appended to the trochlear nerve. In embryos of 20 mm. even this remnant of the trochlear arm had disappeared. The second ganglion lies between the trigeminal and the auditory vesicle, and is known from the nerves with which it becomes connected as the acustico-facialis. The third and fourth ganglia lie behind the otocyst, and are concerned in the development of the glosso-pharyngeal and vagus nerves respectively. The second, third, and fourth ganglia are much smaller than the trigeminal, and in a chick at sixty hours are of about the same size as the otocyst and primitive segments at the same stage.

The form of the four cephalic ganglia as seen in cross sections (of the human embryo at least) is very characteristic, His, **82.3**, 371. The trigeminal appears oval; the acustico-facial subdivided by diverging bundles of fibres; the glosso-pharyngeal is almost circular; the vagus is like a long spindle.

Neuromeres.—The entire medullary tube undergoes a segmentation by a series of alternating slight enlargements and constrictions. Each enlargement is supposed to give rise typically to a pair of ventral nerve-roots and is joined by the corresponding dorsal (or ganglionic) roots. In certain neuromeres of the brain this relation to the nerve-roots is modified and even obliterated. The neuromeres are most distinct in amniota at the stage when the hemispheres are just beginning to grow out from the fore-brain, and, after persisting for a short time distinctly marked, are gradually, but rapidly, obliterated. They appear first in the hind-brain and cervical region, and from thence they appear progressively toward the fore-brain and the tail. Their appearance seems to depend upon the development of the primitive segments of the mesothelium (compare p. 192). When the segments are fully formed, and before their inner wall has changed into mesenchymal tissue, they press against the medullary tube, and oppose its enlargement; at least one sees that the tube becomes slightly constricted between each pair of segments and slightly enlarged opposite each intersegmental space. Each intersegmental dilation is a neuromere, and later produces the nerve for the segment (? behind it).

A caution is here necessary. Each neuromere produces a pair of nerves, but when the first trace of roots appears, they are seen to spring from the constriction between the neuromere, but later from the neuromere. The origin from the neuromere is therefore secondary, as pointed out by Julia B. Platt, 89.1, who, however, has ignored the difference between the ganglionic and medullary nerve fibres. I deem it probable that the neuromeres, as here described, really comprise each a half of two adjacent *true* neuromeres.

Each neuromere is separated from its fellows by an external dorsal-ventral constriction and opposite this an internal sharp dorsal-ventral ridge, Fig. 345, *aa*, so that in a longitudinal horizontal section, Fig. 345, each half of a neuromere forms a small arc of a circle. So far as at present known, the constrictions are confined to the sides of the medullary tube and do not cross either the dorsal or the ventral plate of the neuron. Fig. 345 shows the arrangement of the cells in the neuromeres at a very early stage. The elongated cells are placed radially to the inner curved surface of the neuromere. The nuclei are generally nearer the outer surface, and approach the inner surface only toward the apex of the dividing ridge. On the line between the apex of the internal ridge and the pit of the external depression the nuclei are crowded together, but the cells of one neuromere do not extend into another neuromere. Often a light space marks the boundary between the adjacent neural segments.

As to the number of neuromeres our knowledge is still defective. It is not impossible that the number in the head, especially in the fore-brain and vagus region of the hind-brain, is less in the amniota than in primitive vertebrates, for there is evidence that the number of mesodermic segments has been reduced in the head, and it is probable that the formation of the neuromeres is conditional upon the presence of the mesodermic segments. In the spinal cord there is evidently a neuromere for each pair of nerves; for example, in chicken embryos of the second day the neuromeres are readily seen to correspond exactly, as do later the nerves, with the number of segments; compare Duval's Atlas, Figs. 84, 89, 93, 98, 100, 102. In the hind-brain of a lizard (*Anolis*) and of the chick, McClure, 90.1, finds six neuromeres (but in *amblystoma* five only): these six he assigns to the following nerves,* beginning in front, trigeminal, abducens, facial, auditory, glosso-pharyngeal, and vagus; he believes that the abducens neuromere is wanting in the newt. In the mid-brain we find as yet no evidence of neuromeres among the amniota, but Kupffer, 86.1, states that in teleosts two can be distinguished, and W.

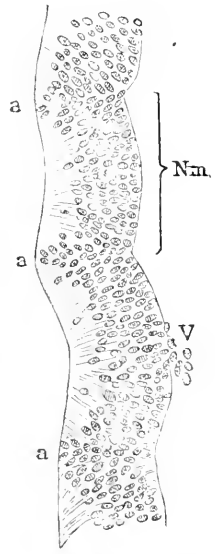


FIG. 345.—Longitudinal Horizontal Section of the Wall of the Hind-Brain of a Young Embryo of a Lizard, *Anolis Sagrei*. *Nm*, Neuromere; *a, a, a*, internal ridge between the neuromeres; *V*, anlage of the fifth nerve. After H. Orr.

* It is to be mentioned that McClure overlooks the fact that the neuromeres can have no genetic relation to the ganglionic nerves, *cf.* p. 619.

B. Scott, **87.1**, Pl. IX., Fig. 15, has given a figure which suggests the existence of two or possibly three neuromeres in the mid-brain of Petromyzon. The fact that two nerves—the oculo-motor and trochlear—arise from the mid-brain, renders it probable that there are corresponding neural segments. In the fore-brain McClure has observed two neuromeres in *Amblystoma*, *Anolis*, and the chick; in *Anolis* these are seen in the region of the *Zwischenhirn* (*thalamencephalon*) after the optic vesicles have become stalked and the hemisphere anlagen have appeared. McClure calls the anterior of these the olfactory neuromere, and says it is connected with the olfactory nerves. I question the existence of such a connection, of which no evidence is given, because the olfactory nerves do not arise from the *Zwischenhirn*. The second neuromere is called the optic by McClure, and is stated by him to produce no nerve.

The total number of neuromeres in the head, exclusive of those belonging to the hypoglossus, is fixed at ten by McClure, **90.1**, 51.

Historical Note.—The neuromeres were observed by C. E. von Baer, **28.2**, 64, 74, in chicken embryos of the third and fourth day, and were figured in a dog embryo by Bischoff, and were noticed by Remak, **50.1**, § 28, 67, Dürsy, **69.1**, A. Goette, **75.1**, Taf. VIII., Fig. 151, Mihalkovics, **77.1**, 49, Béranek, **84.1**, W. B. Scott, **87.1**, 273, Michael v. Lenhossék (in man), **91.1**, 5. Foster and Balfour ("Embryology," 1st ed., 137) were the first to suggest their segmental value, and this suggestion was adopted by Anton Dohrn, **75.2**. C. Kupffer, **86.1**, definitely asserted that they indicate a "primary metamerism" (segmentation) of the medullary tube. Orr, **87.1**, 335, was the first to clearly demonstrate their relations to the nerves, and these relations were specially studied by McClure, **90.1**. The term "neuromere" was introduced by Orr.

The Zones of His.—By this name I propose to designate the four thickenings which run the entire length of the medullary cord, and the morphological significance of which was first fully recognized and elucidated by W. His, **88.3**, 350. In this connection we have also to consider the thin portions of the medullary walls on the dorsal and ventral sides of the neuron. These portions are termed by His, **86.1**, 483, respectively "*Deckplatte*" and "*Bodenplatte*." L. Löwe, **80.2**, had insisted upon the importance of the thickenings running lengthwise of the neuron, but failed to discover their relations to the nerves. These relations have been made clear by His.

The wall of the medullary tube is of uneven thickness even in the earliest stages. As seen in cross section, Figs. 161 and 103, the external outline is oval in amniota (more nearly round, however, in ichthyopsida) while the outline of the cavity of the tube is compressed from side to side. In other words, the walls are thin on the median line dorsally and ventrally, and much thicker on each side. We have then from the start two thickened bands, which can be traced back, as described in Chapter VIII., to the double thickening of the medullary plate. In the brain the thickenings can also be traced without difficulty, although in early stages they are less sharply marked than in the spinal cord, Fig. 161.

The next stage is reached by the subdivision of each lateral thick-

ening into a dorsal and a ventral thickening. The change is most readily studied in the spinal cord, to which, therefore, the following description primarily refers.* The central canal widens out in its dorsal part, Fig. 346, but so that it remains in its extreme uppermost part a slit, as it does also through most of its ventral part. The widening of the canal cuts into the lateral wall of the medulla, leaving a smaller upper thickening, which I propose to call the *dorsal zone of His, D*, and a larger ventral thickening, which I shall name the *ventral zone of His, V*. The dorsal zone forms in cross sections a high rounded prominence into the central canal, and carries in its outermost layer the longitudinal bundles of nerve fibres, which enter the cord from the ganglia through the dorsal roots, *D.R.*, and constitute the anlage of the posterior horn; the zone is connected by means of the thin deck-plate, *d.pl.*, with its fellow of the opposite side. The ventral zone, *V*, exceeds the dorsal in both height and width; its boundary toward the central canal is convex; externally it gives off the fibres which constitute the ventral or motor nerve-root. Between it and the dorsal column there is, at least in the human embryo, a temporary external groove, but the connection between the dorsal and ventral zone on the same side remains broad. The ventral zone is connected with its fellow by the thin Bodenplatte, *b*.

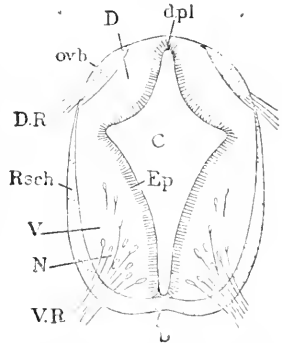


FIG. 346.—Diagrammatic Section of the Embryonic Spinal Cord. *d.pl.*, Deck-plate; *D*, dorsal zone; *ovb.*, oval bundle; *D.R.*, dorsal root; *Rsch.*, Randschleier; *V*, ventral zone; *N.*, neuroblasts; *V.R.*, ventral root; *b.*, Bodenplatte; *C*, central canal; *ep.*, ependymal layer.

His at first, **86.1**, 497, termed the dorsal and ventral zones respectively *hinteres Markprisma* and *vorderen Markcylinder*, but later, **88.3**, 350, named them respectively *Flügelplatte* and *Grundplatte*. The external groove, which in man separates the two zones, has an upper angle near the dorsal root; this angle corresponds to His' *Randfurche*; and it has also an angle next the ventral column; this lower angle corresponds to His' *Cylinderfurche*. As the groove and its angles are temporary, it seems to me unnecessary to give them special names.

We distinguish, then, six longitudinal zones in the embryonic cord. These are:

1. Deck-plate.
- 2,3. Dorsal zones of His.
- 4,5. Ventral zones of His.
6. Bodenplatte.

The six zones appear in each division of the brain with characteristic modifications, which have been thoroughly studied by His, **88.3**, **89.4**, **90.2**, and must now be passed in review.

1. MEDULLA OBLONGATA.—The course of development differs from that of the spinal cord somewhat, owing chiefly to the precocious widening of the region and the accompanying expansion of the deck-plate to form a large rhomboid epithelial membrane, as already

* Further details are given in the section on the spinal cord, p. 658.

described and figured, p. 600, Fig. 343. Owing to the expansion of the deck-plate the lateral walls flare outward, and consequently the zones of His, which are developed from those walls, are changed in position. We may distinguish five regions in the medulla oblongata (His, 90.2, 5), as follows:

1. The transitional region, next the neck-bend and adjoining the spinal cord.
2. The region of the calamus scriptorius, which is imperfectly separated from the transitional region in the embryo, although perfectly distinct from it in the adult.
3. The region of greatest width, which includes the part nearest the auditory vesicle and about the origin of the trigeminal nerve.
4. The region of the cerebellum and pons Varolii.
5. The isthmus or narrow connection with the mid-brain.

The widening begins (in human embryos during the third week), as indicated in Fig. 347, in the headward part of the medulla, the ventral part of the central canal remaining very narrow; the change suggests the differentiation of the dorsal and ventral zones. As the widening continues (human embryos of the fourth week), the lumen becomes more triangular, and later five-sided in section, Fig. 348. The largest side is dorsal and is constituted by the widened deck-plate; the other four correspond to the zones of His; the dorsal zones form a decided angle with the ventral ones; each zone as seen in section projects toward the interior, appearing concave on the outer, convex on the inner side. The assumption of the five-sided form is not simultaneous throughout the medulla oblongata. The widening of the medullary tube continues, and becomes so extreme in the third region that the zones of His are brought by the enormous expansion of the deck-plate into one plane, Fig. 350. While this is being accomplished there appears, along the morphologically dorsal edge of the dorsal zone of His, a fold by which that edge is bent over outward and downward, Fig. 349. This everted edge has been named by His, 88.3, 356, the *Rautenlippe*; it extends through the regions I.-IV., and in fresh human embryos of five weeks may be

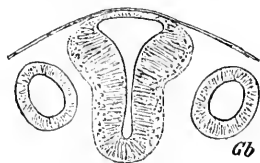


FIG. 347.—Section of the Medulla and Otocysts, *Gb*, of a human Embryo (His' BB) of 3.2 mm. After W. His. $\times 70$ diams.

be seen as a bright border around the edge of the rhomboid sinus formed by the deck-plate. The *Rautenlippe* is simply a fold, and is accordingly separated by an external groove from the rest of the dorsal column, while internally there is another groove, Figs. 349 and 350, C, which is bounded on one side by the bent-over edge of the dorsal zone, on the other by the lateral margin of the deck-plate. The

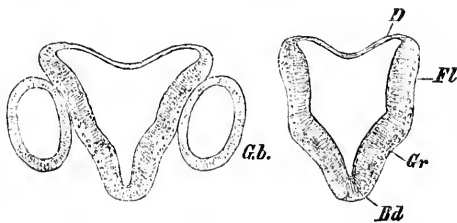


FIG. 348.—Sections through the Regions 3 and 5 of the Hind-brain of His' Embryo a. *Gb*, Otocyst; *D*, deck-plate; *FL*, dorsal zone; *Gr*, ventral zone; *Bd*, Bodenplatte. After W. His. $\times 30$ diams.

grooves are designated by His respectively outer and inner *lip-groove* (*Lippenfurche*). The junction of the Rautenlippe and the deck-plate is distinguished by His as the *Tœnia*. The Rautenlippe plays an important rôle in the differentiation of both the medulla oblongata and of the cerebellum. By the end of the fifth week in the human embryo the expansion is carried so far in the region of greatest width that the dorsal zones are forced over so as to be in a lower plane ventral of the plane of the dorsal zones. Later the process of bending down the dorsal zones occurs also in the region of the calamus, though it is not carried so far as in the region of greatest width. In the region of the cerebellum, on the contrary, the medullary wall constituting the dorsal zone does not bend over, but remains nearly in a vertical plane.

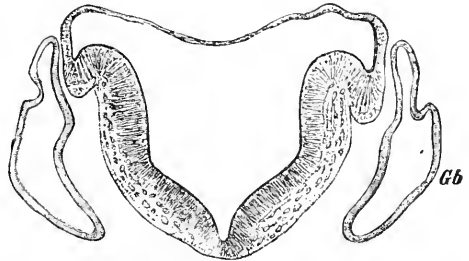


FIG. 349.—Section through the Region 3 of the Hind-brain of His' Embryo A (compare Fig. 218). Gb, Otocyst. After W. His.

In human embryos of the latter part of the second month, His found, 90.2, 20, the following relations: The Rautenlippe begins as a small band in the transitional region and runs forward, increasing in width until it reaches the lower half of the region of the calamus scriptorius, then diminishes in width throughout the region of greatest width, and finally attains its maximum size in the cerebellar region; at its anterior extremity the lippe tapers off to end in a point. The external groove between the Rautenlippe and rest of the dorsal column of His becomes obliterated by the walls of the groove growing together. The union of the walls does not take place simul-

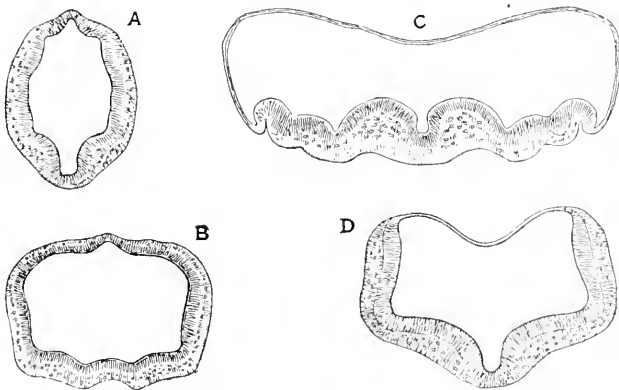


FIG. 350.—Four Sections of the Brain of a Human Embryo of about five Weeks. A, Mid-brain. B, Isthmus. C, fourth region of hind-brain; D, fifth region of hind-brain. After W. His.

tanously throughout; it occurs very early in the region of the calamus, much later in the cerebellar region, where the groove becomes especially deep. In the region of the medulla oblongata

proper the union is in part temporary, while in that of the cerebellum it is permanent.

The isthmus, Fig. 350, B, or part connecting with the mid-brain, is characterized by remaining smaller than the rest of the third cerebral vesicle and by the absence of the expansion of its deck-plate. As seen in cross section, Fig. 350, B, in a human embryo of five weeks, it appears somewhat compressed from side to side, and the deck-plate and Bodenplatte project somewhat, producing each a slight external median ridge (His, 88.3, 357).

The expanded deck-plate in man, up to the middle of the second month, arches over the wide cavity of the medulla oblongata; in older human embryos, owing to the growth of the cerebellum, it becomes bent, so as to form a transverse fold, the *plica chorioidea*, which is situated close behind the cerebellum and projects inward toward the floor of the fourth ventricle. The fold is anlage of the choroid plexus (His, 90.2, 20).

2. MID-BRAIN.—In the embryonic mid-brain, Fig. 350, A, the transverse diameter exceeds the vertical. The deck-plate projects as in the isthmus, but the Bodenplatte is broadened and thickened, and having become convex toward the interior, concave toward the exterior, constitutes an internal ridge and external longitudinal

groove. The ventral zones of His are well defined and are much narrower in extent than the dorsal zones, which constitute the largest part of the wall of the mid-brain, and which merge without any distinct boundary into the deck-plate (His, 88.3, 357). Later, that is to say, by the time the oculo-motorius has grown forth from the mid-brain, the boundaries of the six primary longitudinal zones are almost obliterated, compare Fig. 367, and still later they entirely disappear.*

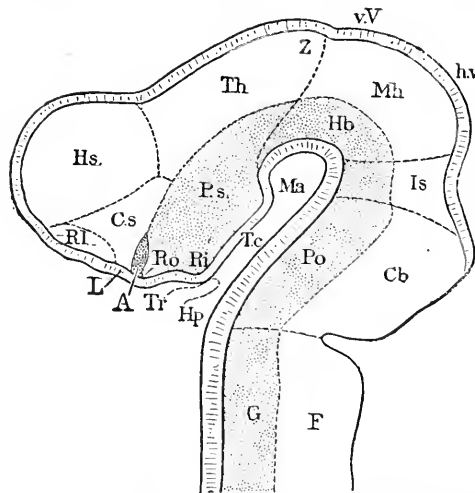


FIG. 351.—Brain of His' Embryo Br. 3 (Nackenzlänge, 6.9 mm.). *Hs.*, Hemisphere; *Cs.*, corpus striatum; *Rl.*, olfactory lobe; *Ro.*, recessus opticus; *A.*, entrance to optic nerve; *L.*, lamina terminalis; *Tr.*, infundibulum; *Hp.*, hypophysis; *Ri.*, recessus infundibuli; *Ps.*, pars subthalamica; *Th.*, thalamus; *Z.*, anlage of pineal gland; *v.V.*, anterior, *h.v.*, posterior region of the future corpora quadrigemina; *Mh.*, mid-brain; *Hb.*, tegmentum; *Is.*, isthmus; *Po.*, pons Varolii; *Cb.*, cerebellum; *G.*, ventral zone of His; *F.*, dorsal zone of His. After W. His.

The ventral zone tends to arch inward, while the larger dorsal zone tends to arch outward. His, 89.4, 679–685, has endeavored to trace out the exact course of the zones in the fore-brain, a most difficult

* Since writing this I have been led to think that the division of dorsal and ventral zones can be traced in the aqueductus in the adult; further observations are needed.

task, owing to the flexures and to the outgrowth of the optic vesicles and of the hemispheres. He concludes that the two ventral zones extend primitively to the optic chiasma and include at least a part (the retinal) or the whole of the optic evaginations. As shown in the diagram, Fig. 351, this makes the regio sub-thalamica, *P.s.*, the mammillary process, *Ma*, tuber cinereum, *Tc*, and recessus infundibuli, *Ri*, derivatives of the ventral zone (*Grundplatte*); while on the other hand, the optic thalami, *Th*, hemispheres, *Hs*, corpus striatum, *Cs*, and olfactory lobe, *Rl*, are derivatives of the dorsal column (*Flügelplatte*).

The Bodenplatte loses its individuality in the fore-brain, but the deck-plate becomes much specialized, as described in connection with the history of the fore-brain, given later.

The division between the ventral and dorsal zones is readily traced in the wall of the third ventricle of the adult; it is the sulcus Munroi of Reichert, and extends from the lower edge of the foramen of Munroe to the aqueductus Sylvii; this groove is figured in Obersteiner's "Handbook" and elsewhere, but is often omitted in anatomical figures in which it should be represented. As a morphological division it is, of course, of fundamental importance.

Origin of Nerve-Cells.—The first step in the histological differentiation of the medullary walls is the separation of the cells into two classes: 1, the *spongioblasts*, or young neuroglia cells; 2, the *germinating cells*, which are the parents of the young nerve cells or *neuroblasts*. This section deals with the germinating cells and their transformation into neuroblasts. The history of the spongioblasts is sketched in the two following sections.

The medullary tube is at first composed of a single layer of simple epithelial cells of a nearly uniform character—a fact which was discovered by Victor Hensen, **76.1**, 383; the discovery has since been verified for all classes of vertebrates. There soon appear special cells of a rounded form in the medullary epithelium on the side of the epithelium toward the central cavity. These cells divide actively and have been named the germinating cells. The germinating cells (*Keimzellen des Markes*, His, **89.1**, 314) are the only ones which undergo division, and as their nuclei divide indirectly, we can readily determine the distribution of these cells by that of the karyokinetic figures in the embryonic neuron. Altmann, in 1881, first pointed out that the figures of nuclear division in parts of the central nervous system of the embryo are found next the central canal, and that, therefore, the pericentral stratum is the growing layer. These observations have since been confirmed and extended by Uskoff, **82.1**, Rauber, **86.1**, Merk, **85.1**, and W. Vignal, **84.1**, 208–210, who appears to have been unacquainted with the earlier German observations. In his last paper, **87.1**, Merk points out that there is much greater variety in the distribution of karyokinetic figures in the medullary canal than appeared from previous researches, and that each region has its characteristics. Thus in the retina the growing layer is external* or next the mesoderm; in the corpus striatum and thalamus opticus the proliferation takes place through the whole thickness of the wall, etc. Special stress is laid by Merk

*I feel much doubt as to Merk's accuracy in regard to this point.

upon the difference between cell multiplication, which does not necessarily mean synchronous increase of substance, and cell growth, which does mean increase of substance. The growth of the nervous system depends chiefly on the enlargement of the cells, as Boll, **73.1**, and Eichhorst, **75.1**, maintained long ago, and it is incorrect to follow the custom of using the terms proliferation and growth as synonymous.

The typical germinating cells (His, **89.1**, 315) are round or slightly oval, and measure from 10 to 14 μ in diameter. The nuclei measure from 4 to 8 μ ; in the resting stage they are oval, with a distinct outline, and scattered chromatine granules; but most of the nuclei in young embryos are in some stage of indirect division and therefore have no distinct outline, while their chromatine granules are large, conspicuous, and variously grouped according to the stage of karyokinesis, Fig. 352. The protoplasm forms a clear, broad cell-body, and with higher powers can be seen to form a granular endoplasm and a non-granular ectoplasm. The cells lie between the processes of the neuroglia cells, and lie typically as in Fig. 352, in the rounded spaces between those processes, close to the thin *membrana limitans interna*, which is described in the next section on the neuroglia. The number of the germinating cells is very large in the human embryo at four weeks, so that in places they seem to form an almost continuous layer. Later they gradually diminish in number, and the spaces occupied by them persist empty for a time. As to the disappearance of the cells our information is incomplete, but it is probable that they are all changed into neuroblasts. That most of them do so change has been proved by His, **89.1**, 318; see the sections on the origin of the neuroglia, below, and of the nerve fibres, p. 616.

Origin of the Neuroglia.—The following account refers especially to the human embryo, and is based on His' observations. The cells of the medullary tube have at first a distinctly epithelial character, and in very thin sections ($\frac{1}{200}$ - $\frac{1}{300}$ mm.) of well-preserved specimens each cell can be seen to extend radially through the entire thickness of the wall. So long as the epithelial character is preserved, there is an outer and an inner zone without nuclei with a middle layer containing all the nuclei, which increase in number as the development progresses. There next appear cells in the inner non-nucleate layer; these are the germinating-cells; they differ from the other cells of the cord, and according to His, **89.1**, 321, give rise to the young nerve-cells. All the remaining cells, the nuclei of which remain in the middle zone, give rise to the neuroglia, and are accordingly named *spongioblasts* by His. The change of the epithelial cells into spongioblasts can be particularly well studied in elasmobranch embryos (*e. g.*, *Pristiurus* of $4\frac{1}{2}$ mm.). The elongated cells acquire a vacuolated appearance; the cell boundaries become indistinct; the substance of the cell-body takes on more and more of a trabecular character, and there results a network of metamorphosed cell material instead of a layer of discrete epithelial cells (His, **89.1**, 350). While the spongioblast network (myelo-spongium, neurospongium, neuroglia) is developing, the protoplasm alters into a substance which is more homogeneous, more highly refractile, and

more readily stained than protoplasm. In other vertebrates the conversion of the epithelial cell into a spongioblast takes place in a similar manner, as has been demonstrated by His' observations on mammals, birds, amphibians, and fishes. Each spongioblast has (His, 89.1, 327) two main processes, an outer and an inner, and several smaller lateral processes. The inner processes run to the inner boundary, where their ends unite to form the *membrana limitans interna*: the character of these processes calls for further study, because, though they usually run without dividing, yet in certain cases they have been found giving off branches; the ends of the fibres break up into fine branches which unite to make a close network, and this network is the *membrana limitans*. The outer processes always branch, their branches being most developed in the outer non-nucleated layer, Fig.

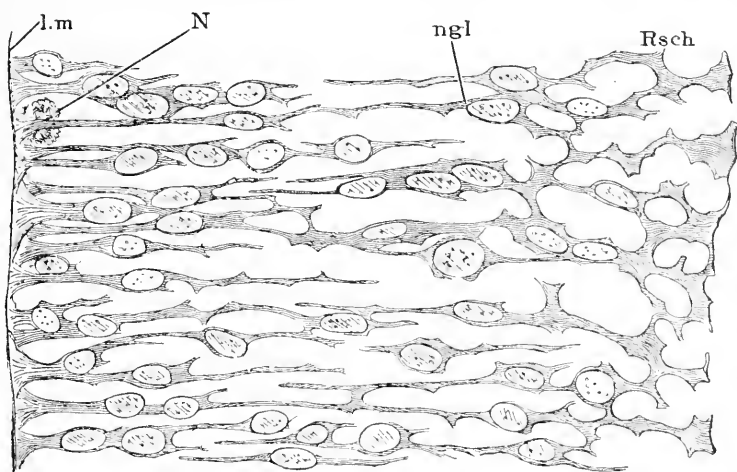


FIG. 352.—Neuroglia of the Dorsal Zone of the Spinal Cord of a Human Embryo of about three and one-half Weeks. *N*, Young neuroblast; *l.m.*, limitans interna; *Rsch*, Randschleier. After W. His. $\times 880$ diams.

352, *Rsch* (His' *Randschleier*); the branches form a network, which appears most distinctly in the outer layer. The nuclei are oval, and, as just remarked, lie at various levels; around each nucleus is an accumulation of protoplasm, which may for convenience be distinguished as the cell-body; the cell-bodies also give off processes, which anastomose with one another. The cells become still more elongated as the embryo advances, and tend to gather more or less in little groups, as may be seen in human embryos of the sixth and seventh week.

It is to be noted that neither the ventral plate (His' *Bodenplatte*) nor the dorsal plate (His' *Deckplatte*) undergo the same histological differentiation as the lateral zones of His. Neither plate develops any young nerve-cells (neuroblasts); the ventral plate changes entirely into neuroglia, into which the nerve fibres penetrate secondarily to make the anterior commissure. The dorsal plate retains its primitive, simple, epithelial character wherever there is an ependyma, but elsewhere its cells also become spongioblasts.

The history of the neuroglia shows that it is in no wise related to

the mesenchyma or true connective tissue. This relationship was for a long time and generally assumed. Golgi was the first to discover the ectodermal character of the neuroglia ("Studi s. f. anat. d. organi centr. syst. Nerv.," p. 178). Without reference to Golgi's discovery, Gierke, 85.1, 498, upon a somewhat imperfect basis of observation positively asserted the exclusively ectodermal origin, and the question was definitely settled by W. His. Since then the neuroglia in the embryo has been asserted by Lachi, 90.1, to be partly at least, immigrant connective tissue, but that Lachi's view is erroneous has been more than sufficiently demonstrated by Cajal, 90.1, and M. von Lenhossék, 91.2.

Specialization of the Neuroglia.—We know, chiefly through Gierke's researches, 85.1, that the neuroglia assumes various characteristic modifications in the different regions of the adult central nervous system. Gierke, *l.c.*, 496-505, gives some observations on the differentiation of the neuroglia in the embryo, but I have been able to find little in these pages sufficiently definite for use. Gierke held that the matrix of the neuroglia was a modification of the peripheral parts of the embryonic cells, an opinion which I deem erroneous.

All the spongioblasts in the embryo stretch through the entire thickness of the medullary wall and have a correspondingly elongated

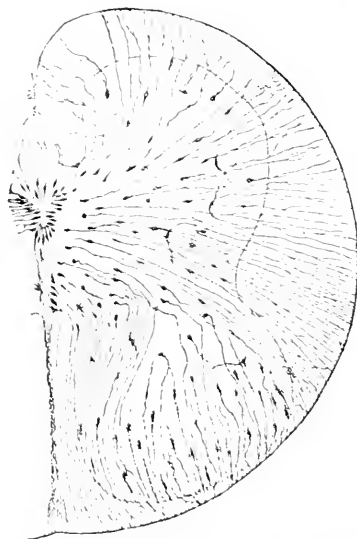


FIG. 353.—Cross Section of the Spinal Cord of a Human Embryo of 14 mm. treated by Golgi's Chromium-Osmic method, to show the Neuroglia Cells. The gray matter is indicated by an outline. After von Lenhossék.

form. When treated by Golgi's chromic-osmium method a portion of the spongioblasts are found in two to four days to be colored, and may be easily followed, as in the same length of time the nerve-cells are not colored, though the blood-vessels are. The method has been applied by Golgi himself, 90.3, and by Ramon y Cajal, 90.1, to the chick embryo, by M. von Lenhossék, 91.2, to the human embryo, and by Nansen* to Myxine. From these investigations we have learned that the spongioblasts become very much elongated and remain very slender; where the nucleus is situated, the cell is thickened. At first the nuclei are confined to the gray matter, but as development progresses the nuclei appear to migrate, so that gradually their number through the gray matter diminishes, while they accumulate in a closer layer, Fig. 354, around the central canal and in the outer neuroglia layer (*Randschleier*). Many of

the cells now appear to lose their central ends, Fig. 353, so that only the prolongation of the nucleated body toward the outer surface of the medulla is preserved. Later the distal prolongation is also lost, and the secondary branches, which have been meanwhile developed, con-

* Nansen's paper was published by the Museum at Bergen in 1886. I have not seen it.

vert the elongated cell into the so-called Deiters' or spider cell, Fig. 354. Lenhossék, **91.2**, has traced the changes both in the gray and white matter, and found typical modifications in each part of each layer. W. Vignal, **88.1**, 320, though he failed to recognize the neuroglia until advanced stages, reports some observations on the later differentiation of the neuroglia in the cerebrum of the human foetus; at seven months the cells have transparent bodies with numerous granules which can be seen when the cells are examined in water, but not when they are mounted in glycerin; they have numerous processes and a round or oval nucleolated nucleus. At eight months the cerebral neuroglia cells vary in size, but some are much enlarged and their processes show traces of the change into a homogeneous refringent substance, see Vignal, *l.c.*, Pl. XI., Fig 2, *a*.

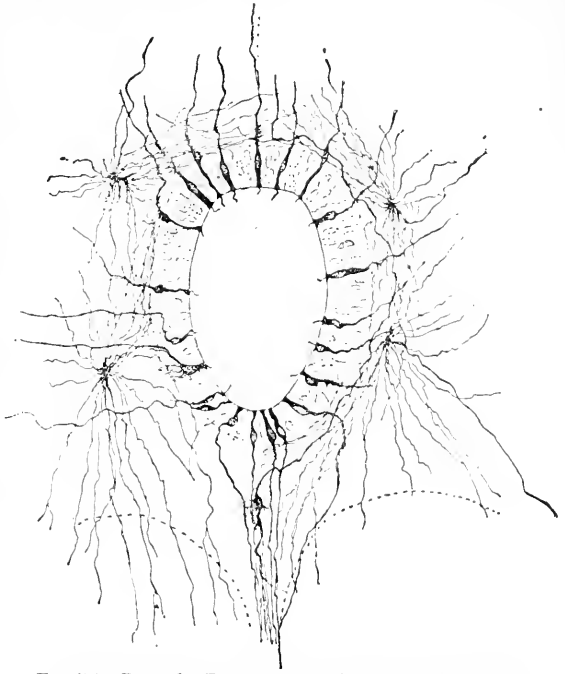


FIG. 354.—Part of a Transverse Section of the Spinal Cord of a Human Embryo of 23 cm. The specimen was treated by Golgi's method (chromium-osmic), and shows the differentiation of the ependyma and the Deiters' cells.

While some of the spongioblasts have their main nucleated bodies retained in the gray or white matter, others have their bodies placed close around the central canal, Fig. 354, where they form the so-called epithelium of the central canal, or *ependyma*, as it may be better called. These ependymal cells stretch out through the entire diameter of the medullary wall, there being a fine radial process, Fig. 353, which passes outward through the gray and white matter, as was first recorded by Golgi, and later by Gierke, **85.1**, 499, and has since been more fully described by Cajal and Lenhossék. The cilia on the inner ends of the ependyma cells appear in the human embryo about the end of the fifth week (His, **89.1**, 330). Eichhorst, **75.1**, records that in a three months' embryo the cilia are present on some of the cells around the canal but not on others. Löwe, **83.1**, observed that the ependyma cells resemble spongioblasts, but failed to recognize their identity.

One sees readily in embryos of mammals, when about 10 mm. long, a broad layer of nuclei close to the cavity of the medullary tube; later, where the canal obliterates no trace of this layer is preserved, but where the lumen of the canal is permanent there persists a narrow layer of crowded ependymal nuclei. This is because many

of the cells have changed into true neuroglia cells, and the broad layer has been in part annexed to the gray matter or neuroblast layer.

Layers of the Medullary Wall.—By the time the neuroblasts are differentiated we can distinguish three primary layers which persist throughout life with sundry secondary modifications. There is an outer layer of neuroglia network, Fig. 352, which is the anlage (or homologous with the anlage) of the white matter of the spinal cord; it has been named the *Randschleier* by His, and this name I have adopted, although it might be better named the outer neuroglia layer. There is a middle layer, in which all the neuroblasts are situated, and which is the anlage of the gray matter of the central nervous system throughout; it has been named the *mantle layer*. Finally there is an innermost layer, in which at first germinating cells are situated, but which, after their emigration, consists merely of spongioblasts; this is the *Innenschicht* of His, and may be defined as the ependymal layer; during development it is reduced by the encroachment of the mantle or neuroblastic layer.

We distinguish then:

1. *Randschleier*, or outer neuroglia layer (white matter).
2. *Mantle layer*, or middle layer in which all the neuroblasts are situated (gray matter).
3. *Inner layer*, or inner neuroglia layer (ependyma).

Origin of Nerve Fibres.—We know through the researches of Wm. His, 86.2, 88.1, 88.3, that there are two sets of nerve-fibres developed in the vertebrate embryo—one set from the medulla, and another from the ganglia. Each medullary fibre arises as an outgrowth from one pole of a nerve-cell, situated in the wall of the medullary tube; each ganglionic fibre arises, on the contrary, by the outgrowth of two opposed poles of a nerve-cell. The cell of the medullary fibre is terminal, while that of the ganglionic fibre is interpolated in the course of the fibre. There is, in fact, a profound morphological difference between the two classes of nerve-fibres, and it is necessary to consider their development separately.

MEDULLARY FIBRES.—In the section upon the neuroglia, it was pointed out that, when the medullary tube closes, the cells which form its walls are all similar to one another. About the end of the third week in human embryos the cells lose their uniform character and become differentiated into the neuroglia cells, which form a network, and the nerve-cells, which lie scattered about and produce nerve-fibres, while the neuroglia is developing. While these changes are going on, the medullary tube grows rapidly and in the nucleated layer of its walls two primary layers become distinguishable: these are the so-called inner layer and the outer or *mantle layer*, Fig. 377. In the latter are situated all the cells which give rise to nerve-fibres, but later, that is, after the blood-vessels have penetrated the medulla, nerve-cells encroach more and more upon the inner layer also (His, 86.2, 509). It is to be noted that the more superficial position of the nerve-cells, which is permanently maintained in the cerebellum and in the cerebral hemispheres, is originally characteristic of the entire neuron. The deep position which the cells have in certain parts in the adult—as, for example, in the spinal cord—is produced secondarily by the growth of nerve-fibres in the *Randschleier*. This

change is very early indicated in the spinal cord by the growth of the Randschleier. In the inner layer, the cells and their oval nuclei are crowded, and it is here only that all division goes on; the peculiar position of the karyokinetic figures has been described, p. 611.

The nerve-cells, according to W. His, **89.1**, 318-326, are all descended from the germinating cells described above, p. 612, and migrate from the inner layer into the mantle layer. That the nerve-cells arise near the central canal and migrate into the mantle layer, was discovered in 1884 by Herms, **84.1**, in his studies upon the facialis neuroblasts of the lamprey.

The metamorphosis begins by the protoplasm of the germinal cell accumulating on the side of the nucleus away from the cavity of the medulla and there elongating itself into a point, which in its turn soon elongates into the beginning of the nerve-fibre; the fibre, therefore, always points away from the cavity, Fig. 355, *N*. The elongation of the fibre continues apparently at the expense of the protoplasm already accumulated in the cell; the fibre accordingly grows very rapidly at first, and soon passes beyond the medulla, but later the elongation is much slower, for it then depends upon the actual growth of the fibre itself. When the fibre begins to develop, the cells begin to migrate toward the outer part of the medulla to form the mantle layer and are found a short distance from the membrana limitans interna. The reason that the young nerve-cells migrate only to a certain point is found apparently in the structure of the outer non-nucleated zone, as pointed out by His, **89.1**, 336. The neuroglia network, as can be seen in Fig. 352, is so dense in this zone that it blocks the way for all, or nearly all, the neuroblasts. In later stages the meshes become larger again, and the blood-vessels are able to penetrate it to enter the neuron. The nuclei of the migrating cells are oval and, for the most part, have a single nucleolus; the protoplasm is principally accumulated in a pyramidal mass at the distal end of the nucleus, the apex of the pyramid being prolonged as the axis-cylinder process; the protoplasm forms only an exceedingly thin layer around the sides and proximal end of the nucleus. At this stage of the cells, the protoplasm stains deeply, and in stained sections the distal ends of the nuclei are often obscured or even hidden; when this is not the case, the distal ends of the nuclei are pointed—a peculiarity which becomes more marked in a slightly more advanced stage. The cells continue their migration and development until they reach the mantle layer as fully differentiated young nerve-cells, which are characterized by having an oval non-nucleolated nucleus, with only a very thin envelope of protoplasm, the rest of the protoplasm having been converted into the nerve-fibre.

According to W. His, **88.1**, 370, **89.1**, 316, the mantle layer consists in the human embryo at four weeks almost entirely of young nerve-cells, and contains only very few neuroglia cells. The nerve-

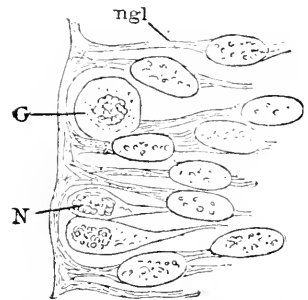


FIG. 355.—From a Section of the Medulla Oblongata of His' Embryo Br³. *ngl*, Neuroglia cells; *G*, germinating cell; *N*, neuroblast. After W. His. $\times 880$ diams.

cells he names *neuroblasts*; they present the following characteristics: they have an oval nucleus (9–11 μ long and 4.5–5.5 μ wide) at the distal end of which is a small cone of protoplasm, which is continued as the nerve-fibre; the nucleus contains considerable chromatin in the form of scattered granules connected by delicate threads; the envelope of protoplasm is exceedingly thin, so that when the nuclei are cut transversely or obliquely they seem almost without protoplasm, and represent the so-called naked nuclei of the mantle layer; the nerve-fibre is of nearly uniform diameter, and presents, as does also the protoplasmic cone from which it springs, a longitudinal fibrillated appearance. The neuroblasts often lie in groups; in such cases the fibres from one group unite in a long cone or bundle, and continue their growth in association, Fig. 356. The young cells have no other outgrowths, the branching processes, which are so characteristic of the adult nerve-cell, not developing until much later.

The paths taken by the rapidly lengthening medullary nerve-fibres have next to be considered. The fibres may be divided into two classes, according as they make an immediate exit from the neuron or first grow within it. The latter class include, *first*, fibres which cross

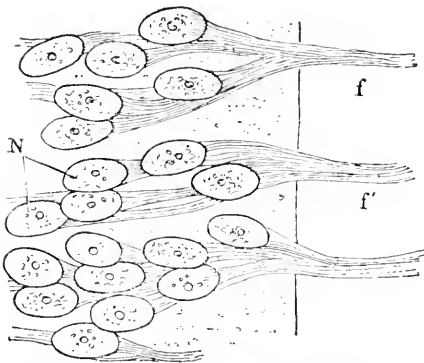


FIG. 356.—Group of Motor Neuroblasts and Nerve-Fibres from a Transverse Section of the Spinal Cord of a Cat Embryo of 6 mm. (N L). After W. His.

through the Bodenplatte to the opposite side; they constitute the *formatio arcuata*, Fig. 377; *second*, fibres which take a longitudinal course in the *Randschleier*; it may be noted that, according to M. von Lenhossék, 91.3, 123, the nerve-cells, which give off fibres to run longitudinally, can be first seen in the chick the sixth day, which is later than the other cells; their fibres are, moreover, characterized by their branching (*Collateralen* of Kölliker); *third*, fibres which join the ganglionic or dorsal root. M. von Lenhossék, 91.3, has observed in a four-days' chick medullary fibres which joined the ganglionic root.

The neuroblasts of His have now been found, described, and figured in every class of vertebrates except the dipnoans. They have everywhere the same essential character, though presenting minor variations. They are unusually small in Petromyzon; in amphibians unusually large; in the frog they are pigmented; in the trout they are particularly numerous and distinct; the trout is further remarkable for having a few unusually large neuroblasts on the dorsal side of the embryonic spinal cord. For further details see His, 89.1, 331–356.

Elasmobranchs offer the peculiarity that the motor nerve-roots become invaded by mesenchymal cells very soon after the fibres grow out of the medulla, hence the roots contain nuclei at a very early stage. The nuclei were first observed by Balfour, 78.3, 76, who

drew the erroneous conclusion that the roots arose as cords of cells, and that the nerve-fibres were developed later. This error has been kept up by Van Wijhe and J. Beard, **88.3**, 192, but discussion of it is passed, compare His, **89.1** 344, Kastschenko, **88.1**, 465, and Dohrn, **91.2**, who have proven that in the cartilaginous fishes the motor nerve-fibres grow out from the medulla as in all other vertebrates. Dohrn has further maintained, **88.1**, that in elasmobranchs medullary cells migrate from the medulla with the nerve-fibres. His, **89.1**, questioned the correctness of this opinion, but Dohrn, **91.1**, has renewed his assertion and offers additional evidence. He ascertained nothing as to the ultimate fate of the emigrant cells.

GANGLIONIC FIBRES.—The exact history of the earliest changes in the cells of the ganglia, p. 601, has still to be worked out. His,

however, has shown that in the human embryo they all become bipolar, that is to say, much elongated; one end pointing toward the dorsal side of the ganglion and lengthening out as a nerve-fibre, which penetrates the myelon, the other end pointing toward the ventral side of the ganglion and lengthening out as a peripheral nerve-fibre. Fig. 357 represents a group of bipolar cells from a spinal ganglion of a young human embryo. The cells are gathered in groups and the fibres from one group unite in primary bundles. When the cell is turned so as to be viewed in profile, it is seen that the oval nucleus occupies an eccentric position and is surrounded by a mass of protoplasm, which gives off the nerve-fibre in two opposed directions, so that one might almost say that there is a nerve-fibre with a cell appended to its side.

In an embryo of six weeks, the cells are still of this type, and resemble the bipolar cells described by Freud in the ganglia of *Petromyzon*. In an embryo of seven weeks the mesenchymal cells had begun to grow into the ganglion between the ectodermal cells, which thereafter begin to change into pear-shaped appendages of the fibres, with the result of developing the T-joints of Ranvier. On the development of the cells proper see p. 626.

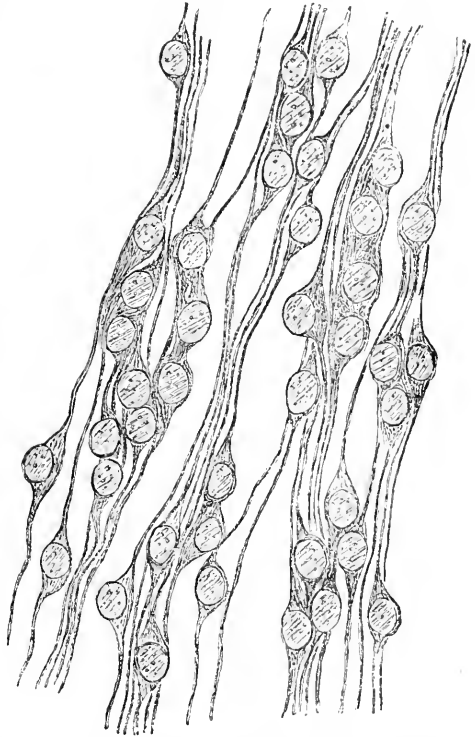


FIG. 357.—Bipolar Cells from a Spinal Ganglion of an Embryo (His' embryo N). After W. His. \times about 500 diams.

The dorsal processes of the cells enter the myelon as sensory roots. The number of entering fibres is at first small, but gradually increases. Within the myelon the fibres at first all take a longitudinal course in the outer layer (*Randschleier* of His), some of the fibres passing headward, others tailward, but later fibres course within the myelon directly toward the nerve-cells of the mantle layer. According to Ramon y Cajal, 90.1, 92, the ganglionic fibres penetrate the medulla and there fork; each branch curves around and becomes a longitudinal fibre, but the two branches run in opposite directions as fibres in the *Randschleier*; these fibres give off fine branches nearly at right angles, which penetrate the gray matter and there ramify, but without forming a true network, compare Fig. 358; the branches running to the gray matter our author names "collaterals;" their ramifications, at least at first, are confined to the gray matter of the dorsal zone of His. Ramon y Cajal's important discovery has been confirmed by Kölliker, who has also made important additions to

our knowledge of the distribution of the sensory fibres within the cord.

The distal or ventral processes extend in one group from each ganglion as the sensory root.

The formation of the nerve roots may be superbly demonstrated, as discovered by Ramon y Cajal, 90.1, by the application of Golgi's bichromate-silver method to embryos (chicks of four to sixteen days, and mammals of corresponding stages), see Fig. 358. Such preparations demonstrate further the early development of the

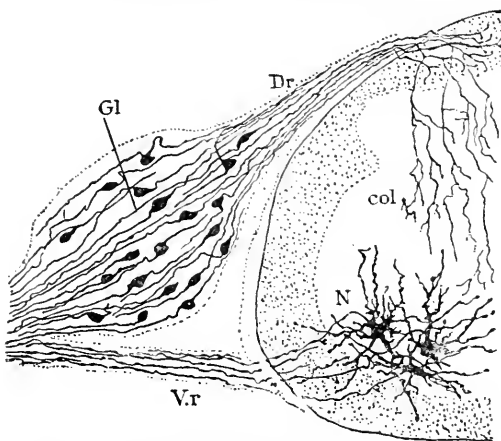


FIG. 358.—Transverse Section of the Dorsal Cord and Ganglion of a Chick of nine Days. Vr., Anterior; Dr., posterior root; G1, ganglion of dorsal root; col., collateral, with its branches; N., medullary neuroblasts with dendrites and axis-cylinder. After Cajal.

dendrites of the medullary nerve-cells, and the abundant intra-myelic ramifications of the "collaterals" of the ganglionic fibres.

Historical Note.—The first suggestion that all sensory nerve-fibres arise from the ganglia and grow centrifugally and centripetally, was made by W. His (His' *Archiv*, 1881, p. 477) who brought positive proof of the correctness of his view in 1886, 86.2, 490, and later showed that it was true not only of the spinal, but also of the cephalic, ganglia, 88.1, 374, 88.3, 368.

MEDULLARY SHEATHS.—All the nerve-fibres are at first simple processes of the nerve or ganglion cells, and they persist in that condition for a long time, but finally there is developed around those fibres, which are destined to form medullated fibres in the adult, a covering of mesenchymal cells. No trace of this covering can be seen in mammals until after the nerves have grown out and ramified through the entire embryo. We have at this stage, as well as later,

to distinguish between the bundles of fibres or nerves proper, and the fibres running singly or terminal branches of the nerves.

When a nerve consists of several or more fibres, the mesenchyma forms an envelope around it (Vignal, **83.1**, 518), which in certain cases at least, and perhaps always, is very distinct and sharply defined (Kölliker, "Gewebelehre," 6te Aufl., p. 152, Fig. 113). * There next follows the penetration of the nerve by the mesenchymal cells, which make their way in between the fibres. In the case of very small nerves and of single fibres, the cells of the connective tissue have direct access to the single fibres.

Whether the cells reach the fibres directly or not, has no influence on their further differentiation. They lay themselves against the nerve-fibre, from place to place, and grow around it so intimately that it becomes difficult to distinguish the boundary between the original fibre and its accessory envelope, and one is inclined, at first sight, to conclude that the fibre has merely become thicker and nucleated.* In reality, the mesenchymal cells close around the fibre, which they cover like a chain of elongated beads. Each cell is the anlage of a medullary segment; the junction of two adjacent cells is the anlage of a node of Ranvier; the nucleus becomes the internodal nucleus of Schwann's sheath. Each cell is at first short and protoplasmatic. The cells multiply; Kölliker, **85.2**, has observed them dividing in amphibians; W. Vignal maintains that new cells are interpolated in mammalian embryos between those already enveloping a fibre. It seems possible that the cells may increase in number by both means. They also grow quite rapidly in both length and diameter.

The differentiation of the cells into the three sheaths of an adult fibre depends upon their forming each a membrane and an internal deposit of myeline. The nucleus takes and keeps its position near the centre of the cell and retains a small quantity of granular protoplasm permanently about itself. In regard to the formation of the membrane, I know of no satisfactory observations, but I think it probable that a membrane is formed over the entire surface of the cell, and that it is this membrane on the outside of the cell which is known as the sheath of Schwann, and on the inside of the cell next the axis-cylinder may be termed the periaxial sheath. This supposition needs to be verified by observation. The medulla or myeline appears quite late—in the cow toward the fourth month, in the sheep at seventy days, according to W. Vignal's observations,

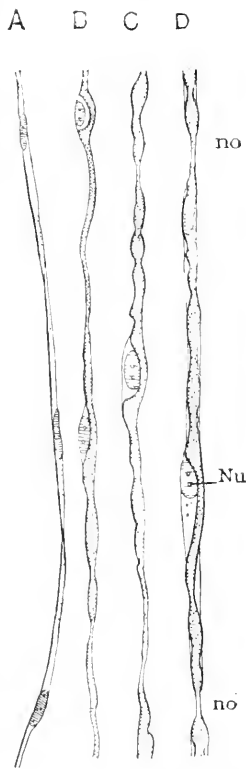


FIG. 359.—Isolated Nerve Fibres from the Sciatic Nerve of a Sheep Embryo of 150 mm. A, B, C, D, successive stages in the growth of the medullary sheath. no, Node of Ranvier; Nu, nucleus. After W. Vignal. \times nearly 400 diams.

* See Kölliker, Zeit. wiss. Zool., XLIII., Taf. I.

83.1, 523, on the sciatic nerve. The myeline begins to appear at the same time in many, but not in all the fibres of a nerve, and it develops later in the peripheral than in the proximal portion of a nerve, and can be earliest observed in the spinal cord. It appears at first as a very thin layer in the mesenchymal cell and next to the axis-cylinder; it is usually deposited simultaneously throughout the entire length of the cell, but sometimes the deposit begins at the centre of the cell; the myeline layer is usually continuous from the start, but sometimes it constitutes a series of separate masses, which grow and unite into a continuous layer; at this stage one observes that the axis-cylinder is pressed aside by the nucleus of the myeline cell. The deposit of myeline gradually increases, and forms a more regular layer; at the same time the boundary (Ranvier's node) between adjacent cells becomes more distinct and the cells (internodal segments) elongate.

Historical Note.—Our knowledge of the history of the peripheral nerve-fibres is largely based on the study of the tail of tadpoles, see Rouget, **75.1**, W. Vignal, **83.1, 83.2**, and Kölliker both for observations and references to the literature. The development of the fibres in mammals has been studied by Vignal, *l.c.*, and by Axel Key and Retzius (*Arch. mikrosk Anat.*, IX., 308).

Origin and Growth of Nerves.—There are two sets of nerves, corresponding to the two classes of nerve-fibres. Every nerve consists of a bundle of nerve-fibres. Each ganglion and each lateral half of a neuromere sends out a bundle of nerve-fibres, or a nerve, as we may better say. There are, therefore, typically for every segment four primary nerves, two on each side, a dorsal ganglionic and a ventral medullary nerve; usually the two nerves on the same side of a segment unite at a short distance from the myelon into a single trunk; in this case the ganglionic nerve becomes the dorsal or posterior root of anatomy, and the medullary nerve the ventral or anterior root of the nerve trunk. Nearly all the spinal and several of the cranial nerves conform to this type. In certain cranial nerves, however, we have only ganglionic, in others only medullary fibres. The development of the various nerves is considered later; that of the nerve-fibres is described in the preceding section; we shall, therefore, treat here only the general principles of embryonic nerve growth.

As to the mechanical means by which the fibres are first gathered into bundles, we have little positive information. In the case of the medullary fibres the paths are probably prescribed, as suggested by His, by the structure of the previously developed neuroglia. In the case of the ganglionic fibres they seem to be brought together by the pointed shape assumed by the ganglion as a whole.

The nerve-fibres, as they grow peripherally, are gathered into short stems (nerve-trunks). Each stem, whether motor or sensory, consists (His, **88.1**, 375) of a number of fine fibres without nuclei; within the stem the fibres run all in the same general direction, but some of them take partly crooked courses. Paterson, **91.1**, 168, has observed that the nerve-fibres increase in thickness in the spinal nerves of mammals, while they are growing to their destinations; the fibres in these nerves take characteristic wavy courses. Meso-

blastic cells penetrate the stem, which then becomes nucleated: in the human embryo the number of mesoblastic nuclei in the nerves remains small for a long period, during which the nerves appear light and conspicuous in stained sections, owing to their poverty in cells. The ends of the nerves are at first broad and blunt, and it is only by repeated branching that the nerves acquire finer endings. The ends are at first so blunt that the nerves appear as if chopped off, Figs. 86 and 360, a peculiarity which formerly misled many observers to conclude that they had not found the end of the nerve at all. All the nerves take a straight course at first and always tend to grow in a straight line representing the prolongation of the nerve-fibres. This law, which was discovered by His, applies to all nerves, even to those which take a complicated course in the adult. This is well illustrated by the early stages of the nerves to the eyes, or of the vagus, or of the cervical nerves, etc.

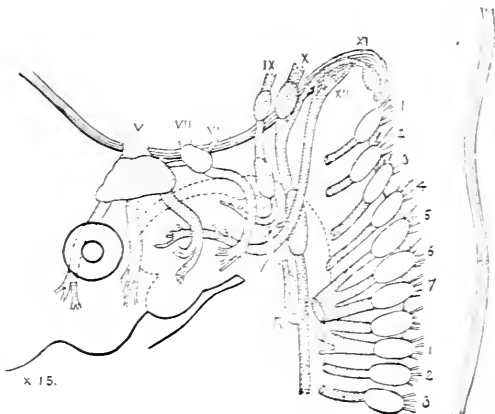


FIG. 360.—Part of the Nerves of a Human Embryo of 13.8 mm. V-XII, cephalic nerves according to the usual enumeration; 1-7, cervical nerves; R, recurrent laryngeal. After W. His.

The straight course of a nerve is modified in two ways: by encountering an obstacle, or by a change in the relative positions of parts with which the nerve has become connected. When a nerve encounters an obstacle it is either deflected from its course or forced to divide. The most important obstacles are cartilages, blood-vessels, and cavities lined by epithelium, and it is, therefore, necessary that these tissues be differentiated at the proper points in the embryo, before the nerve arrives, or else the necessary mechanical conditions for effecting the normal distribution of the nerve are not established. For example, the third branch of the trigeminus when it strikes Meckel's cartilage divides into the ramus lingualis and the ramus mandibularis, and the hypoglossal nerve when it strikes the wall of the jugular vein divides into its descending and lingual branches (His, 88.1, 376). After a nerve is deflected it grows forward in the direction of the fibres at the growing blunt end of the nerve. Similarly when a nerve is divided each branch tends to grow straight forward in the direction of the fibres at the end of the branch. After a nerve has entered a given part of an embryo it retains a permanent connection with that part, and it is largely owing to the secondary migration of organs that the distribution of the nerves becomes so complicated in the adult. It is evident that the migration of the organs must take place after the nerves have reached them. Perhaps the most striking illustration of the translation of an organ with its nerve is afforded by the descent of the testis—compare also the recurrent laryngeal, Fig. 360, R.

As the nerves all grow forth in planes at nearly right angles to the axis of the neuron, it follows that the direction taken by each nerve depends largely upon the cerebral flexures and the curvature of the spinal cord. This is admirably illustrated in the human embryo, Fig. 360. The figure also shows that certain of the nerves, as is more fully explained in the section on the spinal nerves, are brought into contact with one another and unite, forming the plexuses.

What has been said suffices to indicate some of the simple and almost self-evident mechanical conditions of nerve development.

Hensen has suggested, 76.1, that the nerve fibres have from the start their permanent connections, and that as the cells divide and move apart, the nerve-fibres divide and lengthen out, and he has referred to the filaments seen in the mesoderm of young embryos as being such nerve-fibres. This suggestion cannot be adopted, since the outgrowth of the nerve-fibres has been observed; moreover Altmann, 85.1, has pointed out that the fibres seen in the embryonic mesoderm are really processes of the mesodermic cells, and, as shown in the excellent Fig. 2 of his plate, are quite distinct both from the ectoderm and entoderm; Kölliker also, 85.2, remarks that in the tail of the tadpole the number of nerve-fibres, and of the branches and anastomoses thereof, increases with the age of the animal, they being at first very few in number, so few that it is evident that the innervation of most parts must be developed later, there not being at first branches enough to supply all the terminal organs, which are ultimately furnished with nerves.

Union of Nerves and Muscles.—Trinchese, 86.1, gives a few details as to the changes in the muscle-fibres which precede and coincide with the union of the nerve-fibre with the muscle-fibre, but as he gives no figures, I am unable to follow his description.

Further Development of Nerve-Cells.—The early history of the nerve-cells has already been given, and the final differentiation of the nerve-fibres traced. We have now to consider the histogenetic changes in the main cell bodies, and their nuclei, *first* in the medullary, *second* in the ganglionic nerve-cells.

1. MEDULLARY NERVE-CELLS.—

We possess little satisfactory information concerning the phases of the young nerve-cells. The protoplasm of the neuroblast of His is apparently utilized to make the nerve-fibre, so that very little is left around the nucleus; hence, in sections and in cells isolated by maceration the nucleus appears almost naked. The nerve-cell nucleus early becomes recognizable by its distinct nucleolus, Fig. 361, *nu*. The next change consists in a growth of the nucleus and of the

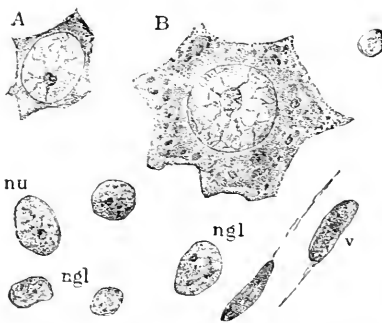


FIG. 361.—Cells and Nuclei from the Cervical Region of the Spinal Cord of a Human Embryo (Minot Coll. 66) of 100 Days. *A*, Young ganglion cell; *B*, older ganglion cell; *ngl*, neuroglia nuclei; *nu*, ganglion cell nucleus before the court of protoplasm has formed around it; *v*, nuclei of blood-vessels. \times about 1,000 diams.

court of protoplasm around it. The outline of the cell now becomes irregular and the production of the protoplasmatic process begins,

Fig. 361, *A*. The first of these processes (dendrites) probably arises during the second month, not, as formerly supposed, during the fourth month. W. His, **90.2**, 50, observed that the neuroblasts had one or two short, blunt processes running off from the pole opposite the nerve-fibres; in the medulla oblongata of the human embryo these processes were probably the beginning dendritic branches. In later periods (*e.g.*, sixth month) I find various stages at once. In more advanced ganglion cells the nucleus is very much enlarged, Fig. 361, *B*, as is also its nucleolus, and the nucleoplasma is vacuolated. The protoplasm has grown very much, and I find it, at least in the motor cells of the spinal cord of the human foetus, divided into an inner finely granular layer, and an outer layer with coarser granules, which I have not observed after birth. The further development consists, so far as known, simply in growth of all the parts. As to the progress of the dendrites, or protoplasmatic processes, the observations are unsatisfactory, owing chiefly to the failure of investigators to recognize the difference between the neuroglia and nerve-cells.* In the chick the dendrites arise very early, as shown by Cajal and Lenhossék, **91.3**, 118, beginning, namely, during the third and fourth days of incubation; the first motor-cells of the spinal cord have branching dendrites the fifth day. The branches of the nerve-cells become very numerous and extend into the Randschleier of the embryo, and their interlacing causes a large part of the network appearance which is so characteristic of the embryonic cord. There is no evidence sufficient, I think, to prove that the processes of neighboring nerve-cells unite; compare W. Vignal, **88.1**, 226, and Kölliker, "Verh. Anat. Ges.," V., 7, His, **90.1**, M. von Lenhossék, **91.3**.

The cord and each part of the brain has, as is well known, in the adult its special and characteristically shaped nerve-cells. Concerning the evolution in the foetus of these modifications, we know very little. An isolated motor-cell from the *cord* of a sheep embryo of 10 cm. is figured and described by W. Vignal, **84.1**, 231-233. In older stages the cells become larger, their processes larger and more branched, and fibrillated—Vignal, *l.c.*, 369-375, describes the forms in human embryos of six, seven, eight, and nine months. In the *cerebellum*, Vignal, **88.1**, 329, observed the first trace of the enlargement of the cells of Purkinje in a foetus of five months; a month later the cells are larger and conspicuous, and they offer the peculiarity that their protoplasm is gathered almost wholly on the side of the nucleus toward the surface of the brain. At six months Vignal could distinguish also the bodies of the small nerve-cells of the granular layer. In the *cerebral hemispheres* the enlargement of the nuclei and protoplasm of the large pyramidal cells (Meynert's third layer) begins, according to W. Vignal, **88.1**, 250, at five and a-half months in the human embryo; the protoplasm presents an irregular outline; the nuclei stain more deeply than the neighboring ones. During the sixth month the cells elongate toward the exterior and so assume their characteristic "pyramidal" form; their protoplasm is finely granular without very distinct outlines, and their processes or dendrites are neither long nor much branched. At birth the cells

* This is notably the case with Vignal, who failed to recognize the neuroglia cells before the fourth month, **88.1**, 319.

are found in various stages, both in the second and third layer of Meynert, but the most advanced of the large cells differ but little except in size (see Vignal, *l.c.*, Pl. IX., Fig. 2, *a*) from those at seven months. The enlargement of the nerve-cells of the second layer occurs during the eighth month. Magini, **88.1**, affirms that the cells do not have the pyramidal shape in the foetal hemispheres, but resemble rather the cerebellar Purkinje's cells, and states that when the cells are colored with Golgi's osmio-bichromate silver mixture, their processes appear varicose, having scattered nodular thickenings.

As regards the time of development of the nerve-cells, Below, **88.1**, reports that the cells appear first in the spinal cord and then in the brain in the following order: In the medulla oblongata, cerebellum, mid-brain, cerebrum. He further states that in animals born helpless (man, dog, cat, rat, mouse, rabbit) the cells are much less developed in the brain than in those animals which are immediately active (horse, cow, pig, sheep, Guinea-pig). Vignal states, **88.1**, that the Purkinje's cells (nerve-cells of the cerebellum) acquire their cell-bodies in man about the sixth month, while the pyramidal cells of the cerebral cortex do not become equally distinct until the eighth month.

2. GANGLIONIC NERVE-CELLS.—These are all spindle-shaped bipolar cells in early stages, as above described; the cell-body and

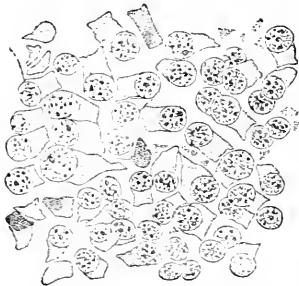

FIG. 362.—Spinal Ganglion Cells from a Longitudinal Horizontal Section of a Human Embryo of the tenth Week.

nucleus draw early to one side so as to appear as a lateral appendage to the nerve-fibres, Fig. 362. There can be little doubt that the cell-body draws more and more to one side, and becomes pear-shaped; and that then the pointed end elongates until it becomes a nerve-fibre, which joins at an angle the earlier fibre developed from the two poles of the cell. That the cells thus develop appears probable from the scanty observations we possess, and also because the development would agree with the series of forms which have been traced by G. Retzius, **80.1**, through the vertebrate series. For example, in the lowest true vertebrate (*Petromyzon*) Freud, **78.1**, finds that the bi-polar form of the cells is permanent in the adult. The unipolar form is found in all amphibians and amniota. In a human embryo of the tenth week, I find the cells in various stages of progress, Fig. 362; the nuclei are round, as seen in horizontal sections of the ganglia, granular with distinct intra-nuclear network; they vary in size: the smaller have so little protoplasm about them that they appear almost naked; the amount of protoplasm increases with the size of the nucleus; the protoplasm lies on one side of the nucleus, and assumes a triangular or quadrilateral outline in the sections: between the cells lie the triangular sections of the nerve-fibres, the fibrillæ of which appear as dots.

In the sympathetic ganglia, the nerve-cells, the origin of which is discussed p. 630, retain the bi-polar form, but the two poles are

brought near together, and one pole gives rise to the spiral, the other to the straight fibre of Beale and Arnold. Concerning the development of these cells, I know of no detailed observations.

Spinal Nerves.—It is singular that, although the early history of the spinal nerves up to the period of the union of the nerve-roots has been the object of much investigation, yet their later history has been very little studied. Almost the only observations of importance are those of W. His, **88.3**, 380–385. More has been done to elucidate the history of the hypoglossus and spinal accessory nerves, which, though morphologically derived from the spinal cord, have been annexed by the head, and may be conveniently regarded as cephalic nerves.

The results obtained by His, *l.c.*, are as follows: The nerves toward the head develop more rapidly than those toward the tail. The nerve trunk formed by the union of the two roots, p. 622, grows at first in a plane approximately at right angles to the axis of the spinal cord, but owing to changes in the curvature of the cord the cervical and lumbar nerves very early appear oblique, Fig. 363. The obliquity increases especially in the neck, where the neck-bend is gradually lessened as the head of the embryo rises (compare Chap. XVIII.). After the trunk has grown a short distance the fibres at the distal end are seen to tend to spread apart, and this spreading seems to initiate the branching of the nerve without any special obstacle causing it to divide in the way described on p. 623, for by their spreading the ends of adjacent nerves are brought into contact in the cervical and lumbar regions, and by uniting begin the formation of the brachial and lumbar plexus. A portion of the fibres from one nerve join those of another, and the united portions constitute a new nerve trunk. In an embryo of 7 mm. (His, *l.c.*, Tab. II., Fig. 4) the anlagen of the cervical and brachial plexus are present, that of the lumbar flexure about to develop. In an embryo of 10 mm., Fig. 363, one can recognize, 1, the *N. occipitalis minor* arising from the first and second nerve; 2, 3, the *N. auricularis magnus* and *N. cervicalis superficialis* coming from the second and third nerves; 4, *Nu. supraclaviculares*, and 5, the *N. phrenicus*. The phrenic nerve, *P*, descends steeply past the brachial plexus and the wall of the thorax where it is lodged in a small ridge immediately behind the vena cava superior. The brachial plexus is formed by the fifth to eighth cervical and first dorsal nerves. In Fig. 363, the position of the arm anlage is indicated by a dotted line; it will be seen that it is such that one branch from the fifth nerve does not enter the arm; the fibres which enter the arm become grouped in three main stems, but the steps by which they become so grouped have not been clearly worked out. The second and third dorsal nerves have each an intercosto-humeral branch running toward the brachial plexus. The remaining dorsal nerves at this stage require no special description. Turning to the sacral nerves we find the first gives off two independent branches, the *ileo-hypogastric*, *ih*, and *ileo-inguinalis*, *ii*, and a third branch, which unites with fibres from the second nerve to form the *genito-cruralis*, *gc*. The second to fifth sacral nerves together with the first to third coccygeal nerves unite to form four nerve trunks, which enter the leg, and one which does not. The

attachment of the leg is indicated by a dotted line; the four nerves of the extremity are the *cutaneus externus*, *c.e.*; the *cruralis*, *c.r.*;

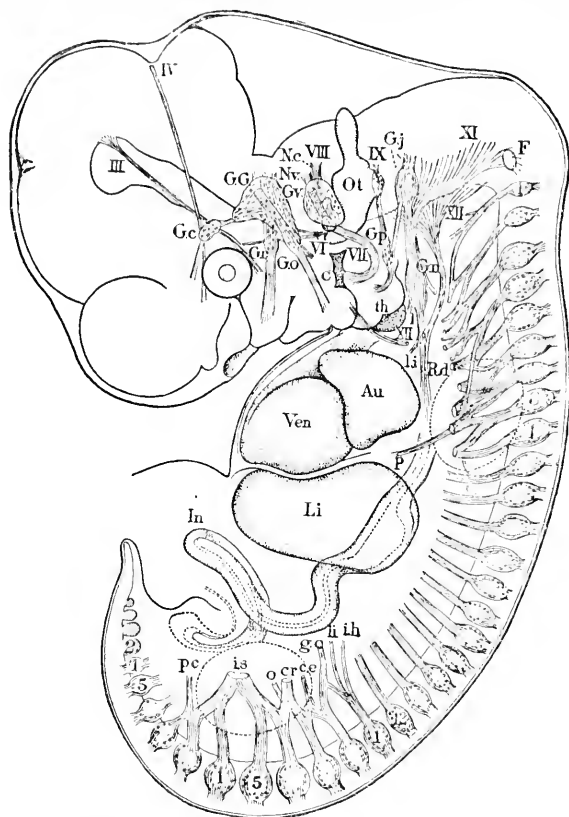
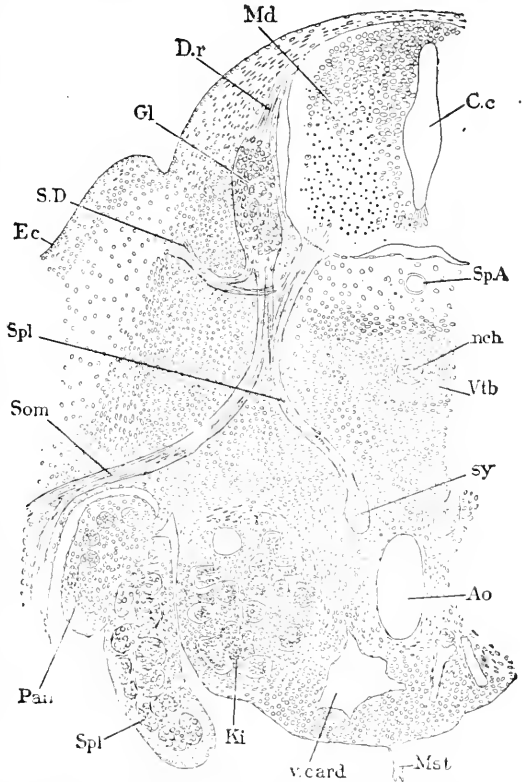


FIG. 363.—Peripheral Nervous System of a Human Embryo of about 10 mm. (His' Ko), reconstructed from the sections III-XII, cephalic nerves. *F.*, Froriep's ganglion; 1-8, cervical ganglia; 1-12, dorsal ganglia; 1-5, lumbar ganglia; 1-5, sacral ganglia; *Ot.*, otocyst; *Ven.*, ventricle; *Au.*, auricle; *Li.*, liver; *P.*, phrenic nerve; *th.*, anlage of thyroid; *In.*, intestine. (For the remaining letters see text; the positions of the limbs are indicated by dotted lines.) After W. His.

obturatorius, *o.*; and the *ischiadicus*, *i.s.* The nerve stem below the leg is the *pudendus communis*, *pic.*

We know very little concerning the development of branches of the spinal nerves, other than those resulting from the contact of nerves with one another, and which are concerned in the production of the plexus. We know from comparative anatomy that a spinal nerve has typically a dorsal branch, which carries, 1, motor fibres to the myotome (or its product the muscles) and, 2, sensory fibres to the skin of the back, and a ventral branch, which itself divides into two branches, one running to the somatopleuric wall of the splanchnocœle and the other running to the splanchnopleure or viscera. This type, as we know from Paterson's observations, 87.1, 91.1, reappears in the development of mammals. The trunk formed by the union of the sensory and motor roots grows only a very short

distance before it undergoes its first or primary division, one branch running to the primitive segment, the other continuing obliquely downward and outward. The cause of this division I do not know, but I think it possible that it may be due to the nerve encountering the edge of the muscle plate. We now have the dorsal and ventral branches; the latter grows on until, as shown by Paterson's observations, 91.1, it encounters the mesothelium of the dorsalmost angle of splanchnocœle, whereupon the branch is forced to divide (rat embryo eight to nine days) into a somatic and a splanchnic branch, Fig. 364, *N.som*, and *N.spl*. In this case the mechanical cause of the division seems unmistakable. The splanchnic branch, at least in the case of the dorsal and lumbar nerves of mammalia, is still further deflected to a horizontal course by the cardinal vein, and is thus directed toward the aorta and enabled to join Paterson's sympathetic cord. The somatic branch grows into the somatopleure, but very soon divides—cause unknown—into two branches. The further history of the somatic nerve branches has still to be ascertained. About



the time these changes are going on, there is developed an increased separation of the roots of the primary dorsal and ventral rami, so that each has its discrete bundle of ganglionic and medullary nerve-fibres, Fig. 364.

CERVICAL NERVES.—W. His, 88.3, 360, points out that, while the medullary neuroblasts send their fibres all into the ventral roots throughout the greater part of the spinal cord, yet in the upper cervical region the neuroblasts in the zone of the future lateral horn send their fibres out in nerve bundles near the entrance of the ganglionic fibres. We have in this peculiarity a transition to the cerebral type, in which the dorsal root is formed partly by medullary fibres.

FIG. 364.—Transverse Section of a Mouse Embryo of about seventeen to eighteen Days, through the Lumbar Region. *Md*, Medulla spinalis; *Dr*, dorsal root; *Gl*, ganglion; *S.D.*, superior division of nerve; *Ec*, ectoderm; *Spl*, splanchnic branch; *Som*, somatic branch of nerve; *Pan*, pancreas; *Spl*, spleen; *Ki*, kidney; *v.card*, cardinal vein; *mst*, mesentery; *Ao*, aorta; *Sy*, sympathetic anlage; *Vtb*, vertebral anlage; *nch*, notochord; *Sp.A*, spinal artery; *C.c*, central canal. After A. M. Paterson. (The figure is compiled from several successive sections.)

In birds and reptiles the first and second cervical ganglia are present only during a very short early embryonic period (Chiarugi, 89.2, 334) and then disappear entirely, as was discovered by Froriep, 82.1, 83.1. Froriep also observed that in mammals the ganglia continue their development, being present in the adult.

Sympathetic System.—Two views have been advanced in regard to the origin of the sympathetic system. The older view, that of Remak, was that it arose *in situ* from the mesoblast; the later view, that of Balfour, was that it arose as a series of buds from the spinal nerves, the buds afterward becoming connected to form two main chains of sympathetic ganglia. Remak's view has been re-established by A. M. Paterson, upon whose memoir, 91.1, I base the following account. It is possible that His' suggestion, 90.1, is correct, and that the cells of the sympathetic are not mesenchymal, but cells which have emigrated singly from the ganglia. Good summaries of the literature on the subject are given by Onodi, 86.1, and Paterson.

The first trace of the sympathetic may be seen in a mouse embryo of eight days (rat of 7 mm.) at a stage when the spinal nerve has nearly reached the mesothelium of the splanchnocœle, and the Wolffian tubules have just appeared. In the interval between the aorta and the cardinal vein the uniformity of the mesenchyma is now broken by a group of cells, which differ strikingly from their neighbors; the cells stain deeply; their nuclei are large and often possess a considerable number of nucleoli. This mass of specialized cells is bilaterally symmetrical and extends from the level of the cephalic border of the fore-limb to the level of the stomach. It constitutes a cord on each side, and is the anlage of the sympathetic system. The cord is comparatively large anteriorly, and gradually tapers off and becomes indistinct posteriorly. It has no connection with the spinal nerves or ganglia. Longitudinal sections show that the cells are fusiform and elongated lengthwise of the cord, and that the cord offers no trace of segmentation.

The next step in the development is the union of the spinal nerves with the sympathetic cord; the union takes place only in the dorsal and lumbar region, not in the neck or in any segment of the body posterior to the bifurcation of the aorta. It is the splanchnic branch only which joins the sympathetic cord, Fig. 364, *Spl.* In rat embryos of 8.5 mm. (eight to nine days) the cord is slightly larger than before, but is still in close proximity to the aorta and presents no sign of constriction or segmentation; the ventral branch of the nerve has just reached the angle of the splanchnocœle and is dividing. In mice embryos of nine days the branch has grown about half-way to the cord; in those of ten days it has almost reached—in those of eleven days it has actually joined—the cord. The cord itself now has ventral branches and its cells mingle with the nerve-fibres, and later the cells migrate along the nerves. In the anterior thoracic region the whole of the splanchnic branch joins the cord, but in the lower thoracic and in the abdominal regions some of the fibres pass beyond. In the neck above the point of origin of the vertebral artery the splanchnic branches, as already stated, have no connection with the sympathetic cord. After union with the nerve, the cord loses its boundaries, and

its cells acquire, Fig. 365, *Sy*, greater size and branching processes. Though the splanchnic nerve branch elongates considerably it continues to end in the cord. It was the observation of this condition coupled with the assumed necessity of tracing all supposed nerve-cells to an ectodermal origin, which led Balfour to his theory of the origin of the sympathetic cord. The splanchnic nerve-fibres distribute themselves through the cord and its branches, also penetrating the cervical portion of the cord which does not receive any of the cervical nerves.

"In transverse sections," says Paterson, *l.c.*, p. 171, "of a human embryo about the end of the first month, hardened in spirit and stained with aniline blue-black, the sympathetic cord has very much the character just described. The cord itself

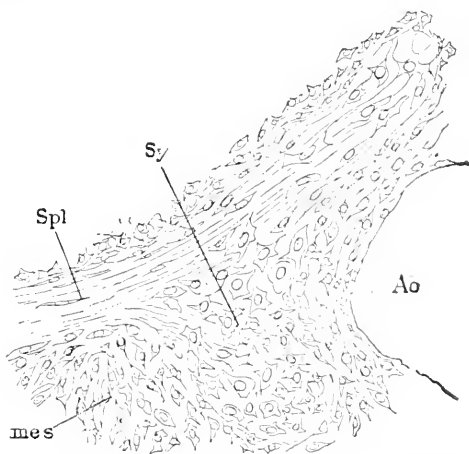


FIG. 365.—Transverse Section of the Sympathetic Cord from the Lower Dorsal Region of a Rat Embryo of about thirteen Days. *Spl*, Splanchnic nerve branch; *Sy*, sympathetic cord; *Ao*, aorta; *mes*, mesenchyma. After Paterson.

is large and uniform in width, widening out anteriorly to form the inferior cervical ganglion; beyond this it narrows, encloses the subclavian artery, and forms a fibrous cord; this again becomes cellular, and widens out into the "superior" cervical ganglion. No splanchnic branches join the cord in front of the level of the inferior cervical ganglion. In the thorax (Plate 28, Fig. 16) the splanchnic branches are seen (*spl*) arising from both roots of the spinal nerve (*I, D*), and, as in the figure, terminating wholly in the sympathetic cords (*sy*). Sometimes a small portion of a splanchnic branch can be traced round the ventral side of the cord, accompanied by a cellular branch from it. In the hinder thoracic region, a small part only of the splanchnic branch joins the cord, the greater part, along with cellular outgrowths from the sympathetic, passing onward to form the solar plexus and semilunar ganglia, which are seen in process of formation on the ventral aspect of the aorta. A similar fibro-cellular bundle passes to join the supra-renal body. In the lumbar region the splanchnic branch can be seen for a considerable distance almost entirely unconnected with the sympathetic cord, and separated by an interval from it. The cord gradually narrows as it is followed backward, and becoming attenuated disappears at the point of bifurcation of the aorta."

The third step is the gangliation of the cord, that is to say, the formation of the series of enlargements, which constitute the adult ganglia, the thinner portions of the cord persisting as the inter-ganglionic commissures. The commissures come gradually to consist chiefly of nerve-fibres. The ganglionic thickenings first appear (human embryo of 18–19 mm., mouse embryo nineteen days) where

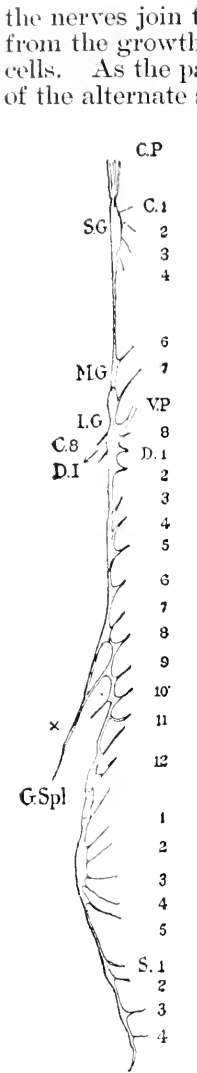


FIG. 366.—Sympathetic Ganglia of One Side of a Human Embryo of the fifth Month. The numbers refer to the nerves connected with the ganglionic chain. C.P., Carotid plexus; S.G., superior ganglion; M.G., middle ganglion; I.G., inferior ganglion; G.Spl., great splanchnic nerve. After A. M. Paterson.

the nerves join the mesenchymal sympathetic, and presumably result from the growth locally of both the nerve-fibres and the sympathetic cells. As the parts gradually attain their adult form, the regularity of the alternate swelling and constriction does not persist, but as the ganglia become defined in form their position tends to become irregular; while one may lie in the interval between two vertebræ, the next may be seen opposite the vertebra itself. The parts derived from the sympathetic cord in the neck above the inferior cervical ganglion may be regarded as belonging to the peripheral or collateral distribution of the sympathetic nerve, because they have no direct connection with the cervical nerves. A fibro-cellular bundle springs from the cord and accompanies the vertebral artery; beyond this the original cord, which is at first terminated at the level of the mouth, becomes constricted by the formation of a fibro-cellular commissure separating off the superior cervical ganglion. This ganglion ends headward in a fibrous bundle, which accompanies and is lost upon the internal carotid artery beneath the auditory capsule. The middle cervical ganglion, when present, is to be regarded as formed of a group of cells, which have been included in the commissure, Fig. 366, *MG*. The connections of the sympathetic cord with the cranial nerves have yet to be investigated. As regards the caudal termination, the sympathetic cord is at first ill-defined behind the region of the kidneys; it gradually extends further back, alongside the aorta and middle sacral artery, where the two cords become closely approximated. They become gradually more and more attenuated, and finally disappear. Near their termination they are joined together on the dorsal aspect of the middle sacral artery by cellular commissures, from which the connecting loop and *ganglion impar* are developed. No fusion of the two cords can be seen until they have reached their permanent posterior limit. The sympathetic cord behind the lumbar region may be regarded as belonging to the peripheral distribution of the cord for the same reasons as the cervical portion.

The peripheral branches from the sympathetic cord, including the collateral ganglia, as well as the medullary portions of the supra-renal bodies, the superior cervical ganglia, etc., are formed by outgrowths from the cord, which are at first cellular. These give rise to ganglia, nerves, and plexuses, and are accompanied by the parts of the splanchnic branches of the spinal nerves, which do not join the ganglia. In this category are placed doubtfully the gray *rami communicantes*.

General Morphology of the Cephalic Nerves.*—It is now generally believed by embryologists that the nerves which spring from the brain form a part of the same morphological series as the spinal nerves. Unlike the spinal nerves they vary greatly among themselves both in their development and in their permanent character, and at least one of them, the optic nerve, appears to have a different morphological value from a true nerve. It is, therefore, impossible to give, as was attempted for the spinal nerves, a comprehensive history of the nerves of the head, but instead we must study each nerve separately.

The following table gives a list of the cerebral nerves and shows with which division of the brain each is connected:

TABLE OF THE CRANIAL NERVES.

Vesicle.	Nerve.
First.....	I. Olfactory. II. Optic.
Second.....	III. Oculo-motor. IV. Trochlearis.
Third.....	V. Trigeminus. VI. Abducens. VII. Facial. VIII. Auditory. IX. Glosso-pharyngeal. X. Vagus.
Spinal cord.....	XI. Spinal accessory. XII. Hypoglossus.

I give below the separate history of each nerve, and in the following paragraphs of this section I have discussed certain general questions of the morphology of the cerebral nerves.

The first point to be emphasized in regard to the cephalic nerves is that, as discovered by W. His, **88.3**, there are three sets of roots, one ganglionic, the other two medullary. The ganglionic roots are part of the same series as the sensory roots of the spinal cord. The two sets of medullary roots are parts of the same series as the single set of spinal motor roots. It is, therefore, a peculiarity of the brain, that its medullary fibres have their points of exit along two longitudinal lines on each side. Both lines are situated in the ventral zone of His: one is toward the Bodenplatte and may be regarded as the prolongation of the line of the ventral roots of the spinal cord; the other is close to the edge of the dorsal zone of His, and, therefore, immediately below the ganglionic root. It appears a justifiable hypothesis to assume that every segment in the head had originally its segmental nerve, and that every nerve had three roots, one sensory and two motor, *i. e.*, one *lateral* and one *ventral* motor root. The lateral root is the distinguishing characteristic of a typical cephalic nerve, † but its existence has been long overlooked because

* For an admirable résumé of the progress up to 1888 of our knowledge of the development of cephalic nerves see W. His, 88.2, 379-409.

† I cannot but think that the spinal nerves also will be found to have lateral roots.

it is so closely joined to the ganglionic or dorsal root that it has been generally mistaken for a part of a dorsal root. It is this mistake which has been the principal obstacle in the way of investigations upon the morphology of the cephalic nerves, and the correction of this mistake by His is, to my mind, the most important contribution to the morphology of the brain which has been made for a long time past. The relation of the three roots is well illustrated in Fig. 370.

As stated in Chapter IX. there are probably seventeen or eighteen segments in the vertebrate head, and perhaps seventeen or eighteen neuromeres in the brain (see above). As yet, however, only twelve nerves have been observed in any adult vertebrate. Of these nerves some are purely ganglionic, others are purely medullary, and still others are mixed, and one of them (*hypoglossus*) arises by the fusion of parts of four nerves; of the medullary nerves, some represent lateral roots, like the accessorius, others ventral roots like the abducens. If, therefore, the cephalic nerves were derived from seventeen or eighteen segmental nerves, they must have undergone very extensive modifications. Morphologists are endeavoring to trace out these modifications, and to establish thereby the hypothesis that the cranial nerves represent a series of segmental nerves. That these endeavors will be successful can hardly be doubted by competent embryologists.

The second point to be emphasized is that the gill-clefts are not segmentally arranged, and that all attempts to ascertain the segmental value of cranial nerves by determining their relations to the gill-clefts are based upon an erroneous assumption. As explained in Chapter IX., each of the three anterior gill-clefts, counting the mouth as one, corresponds to several segments. It is possible that the posterior clefts are segmentally arranged, but these clefts are without branchial nerves of their own, being innervated from the vagus. As regards the nerves connected with the clefts, to wit, the trigeminal, facial, glosso-pharyngeal, and vagus, we can conceive them as representing each several segmental nerves, either by being the product of the fusion of several primitive nerves, or by being one each of a group of nerves, the rest of which are aborted. The branchial nerves are recurred to in a paragraph below.

A third important point is the subdivision of each primary cephalic ganglion into an upper (lateral or main) ganglion, and a lower (or epibranchial) ganglion. The development of the lamprey, as worked out by C. Kupffer, suggests that every cephalic ganglion had primitively two direct connections with the epidermis to make the lateral and epibranchial organs, and the development in the amniota suggests that two ganglia are differentiated from the primitive one, and that in some cases a cephalic ganglion represents the primitive, in others one of the secondary, ganglia. Thus we may hypothetically regard the ciliary and trigeminal ganglia as primary; the acoustic as a secondary lateral line ganglion; the facial as a secondary epibranchial ganglion; while in the case of the glosso-pharyngeal and vagus nerves, both secondary ganglia are preserved, Ehrenritter's and the jugular ganglia being assigned to the lateral, the petrosum and nodosum to the epibranchial series. I can, of course, only suggest this hypothesis as an obvious corollary of Kupffer's discov-

ery, and though its justification must be left to the future, yet it seems to me now very plausible.

The nerves of the head have very different values, and are by no means morphologically equivalent one to another. It seems certain, however, that not one can be homologized with a single complete segmental nerve, that is to say, a nerve in which, aside from its commissures, there are to be found all the nerve-fibres, both ganglionic and medullary, of one segment united in one main trunk. On the contrary, no cephalic nerve is the equivalent of more than a part of a complete segmental nerve. Even those cerebral nerves which are derived from the fusion of several nerves do not include the whole of each nerve component.

We may conveniently distinguish between those nerves of the head which are derived from part of a single segmental nerve, and those derived from the fusion of parts of several segmental nerves. Unfortunately this distinction rests at present chiefly on hypothetical identifications. We have to class provisionally, as single nerves, olfactory, oculo-motor, trochlear, and abducens—and perhaps acoustic, as compound nerves, trigeminal, facial, glosso-pharyngeal (?), vagus (?), accessorius, and hypoglossal.

Concerning the roots, a few general remarks may be made. We have already insisted upon the triple division into dorsal sensory roots, lateral motor roots, and ventral motor roots. The dorsal and lateral roots are situated so closely together, the former at the ventral edge of the dorsal zone of His, the latter at the dorsal edge of the ventral zone, that they appear as one root so long as the origin of the fibres is not considered. We have, in fact, several nerves, which arise *apparently* from one root, but which *in reality* arise from two roots closely united; such are the trigeminal, facial, glosso-pharyngeal, and vagus nerves. If the lateral root aborts, the sensory root may remain; such nerves are the olfactory and acoustic. In the reverse case the lateral root persists, as occurs with the oculo-motor (?), trochlear, and spinal accessory nerves. The ventral motor roots, like those of the spinal cord, to which they are partially equivalent, have an independent exit: they persist only in the abducens and hypoglossus.

A constant feature of the persistent ganglia is probably that the ganglionic fibres as soon as they enter the medulla form a longitudinal bundle, which grows tailward close to the outer surface and in the lower part of the dorsal zone of His. This bundle is homologous with the similar bundle in the spinal cord. The bundle is known as the ascending tract in the anatomy of the brain and behind the vagus as the tractus solitarius. It has been shown to receive fibres in the embryo from the trigeminal, facial, glosso-pharyngeal, and vagus ganglia.

I will now give a synopsis of the interpretations of the twelve cerebral nerves, which appear to me indicated by our present knowledge of the development of the nerves, as reviewed in the following twelve sections, and by our knowledge of the position of the cephalic segments as described in Chapter IX.

I append a table, modified from Zimmermann, 91.1, 109, which indicates the relations of the nerves to the neuromeres so far as at

present rendered probable. The assignments made in the table are in my judgment all more or less problematical.

1. *Olfactory*. Probably ganglionic, though the development of its ganglion differs from that of the other ganglia; belongs to the first (and second?) segment.
2. *Optic*. Probably not a true nerve.
3. *Oculomotor*. Lateral root with sensory ganglion, which aborts very early; belongs to the first or second segment of the mid-brain.
4. *Trochlear*. Lateral root with sensory ganglion, which aborts very early; belongs to third segment of mid-brain.
5. *Trigemimus*. Sensory and lateral roots of several segments.
6. *Abduzens*. Ventral root, perhaps of a single segment, and of the same segment to which the facial nerve belongs.
- 7, 8. *Facialis-acusticus*. Sensory and lateral roots of several nerves. The acustic may include two distinct ganglia and would then represent two sensory roots. The facial intervenes between the two parts of the acustic, and may prove to be the sensory and lateral roots of one segment.
9. *Glosso-pharyngeus*. Sensory and lateral roots of one, possibly two segments.
10. *Vagus*. Sensory and lateral roots of a single segment, but secondarily connected by means of a persistent epibranchial commissure with the innervation of several gill-clefts of the hypoglossal region.
11. *Accessorius*. Lateral roots of four hypoglossal nerves, of which the ganglia are temporarily developed, with accessions of fibres from cervical nerves.
12. *Hypoglossus*. Ventral roots of four occipital nerves of which the ganglia are temporarily present and of which the lateral roots form the accessorius.

	Neuromere.	Dorsal root.	Lateral root.	Ventral root.			
FORE-BRAIN.	1	Olfactory.					
	2						
MID-BRAIN.	3		Motor-oculi. (? Motor-oculi.) Trochlear.				
	4						
	5						
HIND-BRAIN.	6)	Trigemimus.	Trigemimus.				
	7)						
	8)						
	9				? Acusticus.		
	10				Facialis.	Abduzens.	
	11				Acusticus.		
	12				Glosso-pharyngeus.	Glosso-pharyngeus.	
	13				Vagus.	Vagus.	
	14					Accessorius.	Hypoglossus.
	15					Accessorius.	Hypoglossus.
16		Accessorius.	Hypoglossus.				
17		Accessorius.	Hypoglossus.				

BRANCHIAL NERVES.—The relations of the nerves to the segments (myotomes and neuromeres) are primitive, the relations to the branchial arches and gill-clefts are secondary. Indeed we must assume that the vertebrates had segmented ancestors, who acquired

gill-clefts, segments being phylogenetically much older than gill-clefts. The ancestral nerves were adapted to the gill-clefts, and we may some day know the history of that adaptation and the modifications consequent upon it. At present we can only say that, contrary to the assumption which has prevailed for twenty years, the gill-clefts are not segmental and therefore the branchial nerves are not in segmental order.

The unquestionable branchial nerves are the facial, glosso-pharyngeus, and vagus. To the same series we must probably assign the trigeminus after subtraction of its ophthalmic branch, for it enters into the same relations to the mouth as the other nerves mentioned to the gill-clefts; as we have seen, the mouth is probably a modified pair of gill-clefts. Counting the mouth as a gill-cleft, we may say that each of the four nerves arises by the union of a lateral root with a ganglion to form a common nerve-trunk, which springs from or passes by the epibranchial organ of the ganglion and descends behind the cleft with which the nerve is associated, in the visceral arch between that cleft and the next following. Later there arises a branch which passes in front of the cleft; the main stem is then known as the post-trematic branch, the secondary branch as the præ-trematic branch. In the lamprey the whole series of epibranchial organs are connected by a continuous longitudinal commissure. In mammalia all trace of the commissure is lost except behind the vagus, which thus is permanently associated with the fourth and fifth clefts of amniota, to which it does not morphologically belong. Gegenbaur's hypothesis that the vagus represents several branchial nerves is not tenable, for reasons explained below. I regard it as probable that the hypoglossus, with which I include the accessorius, will be ultimately recognized as including the branchial nerves of the fourth and fifth clefts, if indeed these clefts ever possessed true branchial nerves.

I. Olfactory Nerve.—Van Wijhe, 82.1, 18, has sought to prove that the olfactory nerve is not really the first but the second of the cerebral nerves, and that it arises further back morphologically than the optic nerve. The development of the fore-brain, as worked out by His in the human embryo, p. 595, renders it very difficult to accept this notion, and the arguments presented by Chiarugi, 91.1, seem to me conclusive that the olfactory nerve is really in front of the optic.

His, 89.4, 717-723, finds in the human embryo that the nerve develops as follows: The first step is the separation of the olfactory plate, p. 575, from the wall of the brain by an ingrowth of mesenchyma. This separation has been observed by Kölliker, 90.5, in chicken embryos of the fourth day and in a cow embryo of 10 mm. The second step is the production of the olfactory ganglion; the ectodermal cells of the olfactory plate multiply, the karyokinetic figures being found next the outer or free surface of the layer; the cells thus produced assume the appearance of medullary neuroblasts, and at four weeks are found migrating toward the mesenchymal surface, so that the base of the layer of the olfactory ectoderm becomes crowded with nuclei; the protoplasm of these neuroblasts is collected on one side of the nucleus in a pointed mass; the cells now

grow forth from the ectoderm and constitute the anlage of the ganglion between the ectoderm and the brain. The third step consists in the assumption of the bi-polar form* by the cells of the ganglion, and the elongation of the poles on the one side as centripetal nerve-fibres which join the brain, on the other as centrifugal fibres which join the olfactory epithelium (embryos of five weeks). It thus appears that the development of the nerve is accomplished during the fifth week in the human embryo. Kölliker has observed that in the rabbit of thirteen days the ganglion has reached the olfactory lobe, but its centripetal fibres have not penetrated the wall of the lobe; he also observed in the same rabbit that the nuclei of the ganglion were dividing karyokinetically, and he considers it probable that these divisions result in forming chains of cells, each chain developing into one nerve-fibre, and he thinks that in the adult the fibres are multinucleate. Chiarugi states, **91.1**, that the olfactory nerve is present in the guinea-pig embryo of 4.7 mm., before there is any olfactory lobe, and that it extends from the brain wall to the olfactory plate. Miss Platt, **91.1**, 260, affirms that the olfactory ganglion is derived from the neural crest, but has published no proof of this affirmation.

Concerning the morphological interpretation of the olfactory nerve no satisfactory conclusions are yet possible. Marshall, **78.1**, **82.1**, advanced the theory that it is a true segmental nerve, or at least the dorsal root of one, but its development differs so much from that of the ordinary ganglionic nerve that I hesitate to accept this theory. Marshall has sought to strengthen his theory by homologizing the nasal pits with a pair of gill-clefts, but the observations he has reported, **79.1**, do not seem to me to justify the homology, and he has failed to attribute weight to the fact that gill-clefts are primarily evaginations of the entoderm, while the nasal pits are invaginations of the ectoderm and have no connection with the pharynx in any vertebrate. J. Beard, **85.1**, modified Marshall's theory, and homologizes the olfactory plate and its ganglion with an epibranchial or lateral sense organ. We know (Chap. XXVIII.) that the ganglionic sense organs arise by a union of the ganglion with the ectoderm, but the olfactory sense organs arise by a differentiation of both the sensory ectoderm and the ganglion from a common ectodermal plate. Nevertheless, it remains a tempting hypothesis, which places the nose in the series of segmental sense organs, but at present it is still merely an hypothesis with no secure basis. If it is verified hereafter, we may recognize in the olfactory nerve a true ganglionic nerve or dorsal root, or perhaps the representative of a series of roots, since it is possible that a number of segments have disappeared from the præ-oral region, and each segment may be supposed to have had its nerve.

That the olfactory nerve corresponds to a spinal dorsal root is rendered probable by, 1, the formation of its fibres from bi-polar cells; 2, the ingrowth of the fibres from the ganglion into the wall of the neuron.

II. The Optic Nerve.—The development of the optic nerve is treated together with that of the eye, Chapter XXVIII. Concerning

* Chiarugi, 91.1, suggests that some of the cells may be more than bipolar.

the morphological value of the optic nerve nothing is known, nor can we hope to form any satisfactory hypothesis as to its value until the development of the optic nerve-fibres is thoroughly understood. At present we are unable to say whether it is to be regarded as a modification of a true nerve or of a cerebral commissure.

III. The Oculo-motor Nerve.—The oculo-motor nerve, according to W. His, **88.3**, 366, arises from neuroblasts of the ventral column of His in the mid-brain, Fig. 367; transverse sections of the brain of this embryo are represented in Figs. 368, 369, 370. W. His, **88.3**, Fig. 26, has figured the nucleus of the third nerve as a broad group of pear-shaped neuroblasts, which give off the centrifugal fibres of the nerve; some of the oculo-motor neuroblasts point centralward (His, *l.c.*, P. Martin, **90.1**), and Martin states that he has observed bi-polar forms in the cat; as to the further history of these two peculiar kinds of cells we have no information. As shown in Fig. 363, the nerve grows in a perfectly straight line to the caudal edge of the eyeball, where it joins the anlage of the eye-muscles. Here the nerve must branch, since it is distributed in the adult to five muscles, viz.: the levator palpebræ, rectus superior, rectus internus, rectus inferior, and obliquus inferior. No observations on the development of these branches in the mammalian embryo are known to me.

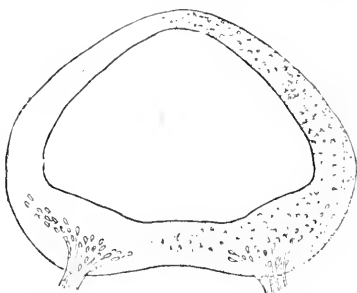


FIG. 367.—Transverse Section through the Posterior Part of the Mid-brain of a Human Embryo of five weeks (His' embryo Ko).

The development of the motor oculi in elasmobranchs has been much studied, with conflicting results. In *Scyllium* and *Pristiurus* it appears, according to Van Wijhe, **82.1**, 22, while the third gill-cleft is developing, which is about the stage when the anterior roots of the spinal nerves develop according to Balfour. In Balfour's stage L, the nerve after crossing the *opthalmicus profundus* runs to the posterior edge of the "first myotome" of Van Wijhe; compare A. M. Marshall, **81.2**. The path of the nerve passes the ciliary ganglion (ganglion mesocephalicum of Beard and Dohrn), but has no connection with that ganglion (Dohrn, **91.1**, 6), as has been erroneously assumed by some writers. Miss Platt, on the contrary, says, **91.2**, 99, that the nerve begins as a single cell thrown off from the ciliary ganglion. This view rests probably on erroneous interpretation of observations, for it cannot be admitted that a motor nerve is formed by ganglionic fibres. Dohrn, *l.c.*, affirms positively that medullary cells leave the wall of the brain and enter the nerve, and he traces to these cells the development of those which constitute the ganglion of the nerve; but his observations are very far from convincing to me, and I still regard it as possible that the cells observed in the nerves are mesenchymal, and if this is the case then it is also possible that the ganglion of the nerve is of mesenchymal origin and homologous with a sympathetic ganglion.

The ganglion of the oculo-motor nerve in selachians was discovered

by G. Schwalbe (*Jenaische Zeitschr.*, 1879), and was identified by him with the ciliary ganglion of human anatomy. Van Wijhe found the oculo-motor ganglion in his embryos in Balfour's stage O, and pointed out that it was distinct from the true ciliary ganglion, which belongs to the ophthalmicus profundus nerve. C. K. Hoffmann, **85.1**, 302, recognized the two ganglia in reptiles, but applied the term ciliary to the ganglion of the oculo-motor, and the term ophthalmic to that of the ophthalmicus profundus. J. Beard, **87.2**, put an end to confusing the two ganglia, but unfortunately proposed to restrict the term ciliary to the oculo-motor ganglion, and to introduce the name of *mesocephalic* for the ophthalmic or *true* ciliary ganglion. Beard's nomenclature is erroneous, for, as shown by His, **88.2**, 421, the ciliary ganglion of the embryo is identical with the ciliary ganglion of the adult, and the oculo-motor ganglion is always morphologically distinct from the ciliary. Beard's proposal added to the existing confusion by misapplying the term ciliary. Antonelli, so far as one can judge from the abstract of his researches, **90.1**, has again confounded the oculo-motor and ciliary ganglion. The true oculo-motor ganglion has yet to be discovered in mammalia. For notices of the conflicting descriptions of the structure of the adult oculo-motor ganglion, see A. Dohrn, **91.1**, 16-28.

If the known oculo-motor ganglion is sympathetic, then it is possible that the thalamic nerve discovered by Miss Platt and described in the following section, is really the true ganglion of the third nerve.

III.a. The Thalamic Nerve.—Julia B. Platt, **91.2**, 97, discovered a rudimentary ganglion in *Acanthias* embryos appended to the dorsal part of the mid-brain close to the fore-brain. In a subsequent paper, **91.1**, she has added further details. The ganglion is developed from the neural crest and retains a connection with the ciliary ganglion along what must be regarded as the epibranchial line commissure. The commissure is stated to give rise to the ramus ophthalmicus profundus of the adult. The ganglion proper has a transitory existence. It seems to me probable that the ganglion

may prove to be, as suggested in the last section, the true primitive ganglion of the oculo-motor.

IV. The Nervus Trochlearis, or Patheticus.—The origin of this nerve in the embryo long eluded investigation; thus Marshall and Spencer, **81.1**, and Van Wijhe, **82.1**, 25, failed to ascertain its early history. His, in 1888, **88.3**, 365, reported that in a human embryo of the fifth week the fourth nerve can be traced, Fig. 368, from its point of exit from near the median dorsal line of the isthmus (compare Fig. 363, IV) as a bundle of fibres running down through the mantle layer of the medullary wall to a group of neuroblasts, from which the nerve arises, and which are situated in the part

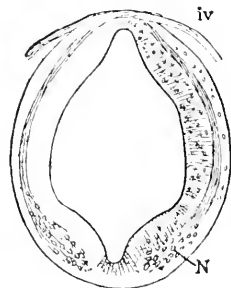


FIG. 368.—Section of the Brain of a five Weeks Embryo (His' Ko). IV, Fourth nerve; N, neuroblasts of the nerve in the ventral zone of His. After W. His.

of the medullary tube corresponding to the ventral zone of His. It must be assumed that the neuroblasts send out the fibres in a different direction from what we find in the case of all other medullary

nerve-roots, but Martin's observations, noted below, indicate that the peculiar course of the fibres results from migration of the neuroblasts. It may be added that the position of the nucleus of the nerve in the adult agrees with that of the neuroblasts, as observed in the embryo by His. P. Martin, 90.1, reports that in the cat the fibres do not cross in the earliest stage, but make their exit on the same side on which their neuroblasts are situated, and that the neuroblasts themselves lie at first higher up, and later migrate to the ventral position, in which they were seen by His, as just stated. Froriep, 90.1, 57, has observed in young torpedo embryos that the nerve of either side receives fibres from both sides, and both he and Dohrn, 91.1, have observed in elasmobranch embryos that the nerve forms a plexus of its own fibres on its way from the brain to the muscles it innervates.

Dohrn, 91.1, 9-11, has observed cells in the course of the nerve, especially at certain points where they are accumulated so as to produce a thickening of the nerve. Dohrn designates these cells as nerve cells derived from the medullary canal, but neither his description nor figures justify this conclusion. It is more probable that these cells are surviving remnants of the trochlear ganglion or possibly merely immigrated mesenchymal cells.

The ganglion of the trochlearis was discovered independently by A. Froriep, 91.2, and Julia B. Platt, 91.2, in elasmobranchs. It is a part of the neural crest, and is continuous for a time with the anlage of the trigeminal ganglion; the connected band of cells breaks down irregularly, but its scattered remnants persist for a time along the original line. At this stage the motor-fibres grow out from the medulla near the dorsal summit of the ganglion, and the permanent trochlearis is developed. Miss Platt* speaks of the ganglion as the "primitive trochlearis," and she interprets, p. 97, the ramus ophthalmicus superficialis trigemini as a survival of the original connection between the trigeminal and trochlear ganglia. As the connection here mentioned is on the level of the dorsal line of the neuron, it may be regarded as a part of a lateral line commissure. The discovery of the ganglion of the fourth nerve further demonstrates that the motor fibres represent a lateral root. In torpedo embryos of 16 mm. Froriep, *l.c.*, 56, has found a small group of ganglion cells, which soon disappear, but at this stage are appended to the caudal side of the nerve a short distance below the ventral limit of the mid-brain. These cells are probably a remnant of the original ganglion. Miss Platt thinks that the trochlear ganglion also contributes to the ciliary ganglion, but her proof of this appears unsatisfactory to me.

V. The Trigeminal Nerve.—This is one of the most complicated nerves of the head. It is developed from both the ganglia and the medullary tube, and has permanently both sensory and motor roots. Its ganglionic portion is double, comprising the ciliary or ophthalmic ganglion and the Gasserian, and it will be advantageous to consider these two parts as morphologically distinct. The motor root forms a single bundle; the nerve enters into special relations

* Miss Platt's description is somewhat obscured by her overlooking the fundamental difference between medullary and ganglionic nerves.

with the epidermis, and finally it develops a typical system of branches. Each of these fundamental characteristics forms the subject of a separate paragraph following.

GANGLION CILIARE AND NERVUS OPHTHALMICUS PROFUNDUS.—This is the ganglion which has been long and generally known as the ciliary, and becomes the ciliary of the adult; for mention of other names applied to it see p. 640. The centrifugal nerve arising from the ganglion is known as the ramus ophthalmicus profundus, the centripetal nerve as the radix longa, which joins the trigeminal ganglion before the radix enters the brain. How the ciliary ganglion becomes separated from the trigeminal is unknown, so far as anniota are concerned, but in elasmobranchs Van Wijhe thinks, **82.1**, 20, that a considerable middle portion of the originally continuous ganglionic mass disappears. In the human embryo at one month the ciliary ganglion is connected with the trigeminal by a bundle of fibres without cells, His, **88.3**, 372. Beard, **85.1**, 30, was the first to observe that the ganglion unites with an epidermal thickening of the lateral line. He says: "Cells are then proliferated off from the skin to form the ganglion, and the outer portion of the thickening begins to form the primitive branchial * sense organ. From the thickening cells are given off for some time until a large ganglionic mass is formed, which still for some time remains fused with the skin." C. Kupffer, **91.1**, has found in *Petromyzon* embryos a large ganglion, Fig. 407, which lies in front of the trigeminal ganglion; this ganglion is probably the ciliary and it has connection in the larva (*Ammocetes*) of 4 mm. with an epibranchial organ: this suggests that there may be an epibranchial organ of the ciliary ganglion in the higher vertebrate embryos.

It is probable that the cells of the ciliary ganglion become bi-polar and produce ganglionic fibres, but, so far as I am aware, no observations on the origin of the nerve have been published. If the nerve arises as suggested, then the centrifugal fibres must constitute the ophthalmic nerve, the centripetal the radix longa, or as it is called in human anatomy the ophthalmic branch of the trigeminal, compare Fig. 363. In this figure the ciliary ganglion overlies the eye and is united with the trigeminal ganglion, *G.G.*, and sends its nerve forward toward the fore-brain. Why the fibres pass to the brain by way of the trigeminal, instead of making an independent entrance, is unknown. A. M. Marshall found the nerve to run forward from the ganglion in elasmobranch embryos in Balfour's stage K, past the upper border of Van Wijhe's first segment and the inner side of the eye, to end at a point just dorsal of the nasal pit. Some further details are given by Van Wijhe, **82.1**, 20-22.

2. **GANGLION GASSERI, OR TRIGEMINAL PROPER.**—After the separation of the ciliary ganglion the Gasserian (His, **88.3**, 372) has in side view, Fig. 363, *G.G.*, a somewhat triangular form in the human embryo; its apex points dorsalward and sends the centripetal nerve-fibres into the brain. The peripheral nerves it gives off are accompanied by some of the ganglion cells, which are thought by His to be destined to form the anlagen of the *ganglion rhinicum* and *g. oticum*. The fibres which enter the brain do so near the

* In consequence of later researches we should substitute "lateral" for "branchial."

angle formed by the junction of the dorsal and ventral zones of His, and there take a longitudinal course as a bundle of fibres homologous with the longitudinal bundle formed by the spinal nerves. This bundle is the *tractus trigeminus* or ascending trigeminal root of authors; it lies close to the surface of the brain and is oval in section, being flattened laterally, His, *l.c.*, Fig. 27. The bundle grows slowly down toward the spinal cord. In the adult it is said to extend into the cervical cord.

Kupffer, 91.1, 41, has observed that in *Petromyzon* larvæ of 4 mm. the trigeminal ganglion overlies the mouth cavity, Fig. 407; it has a strong root and the root contains fibrillæ, and its main peripheral stem branches near the ganglion to form the maxillary and mandibular branches, both of which are compact cords of fibres with nuclei among them and partially covered by a cellular sheath. The main trunk is also connected with the thickening of the epidermis, which constitutes the third of the four epibranchial organs overlying the mouth at this stage. Frorip, 85.1, 43, searched carefully but unsuccessfully for an epibranchial organ connected with the Gasserian ganglion in mammalian embryos.

3. MOTOR ROOT OR PORTIO MINOR.—The motor root of the trigeminus is developed from neuroblasts of the ventral zone of His in the hind-brain at the level of the Varolian bend, Fig. 363. These neuroblasts are gathered together, forming the trigeminal nucleus, which early becomes recognizable. The nucleus lies, Fig. 369, near the junction of the ventral and dorsal columns and therefore close to the ascending sensory root, *ov*, of the trigeminus. The fibres from the neuroblasts are gathered into a single stem and make their exit, as shown in Fig. 369, near the dorso-lateral edge of the ventral zone (His, 88.3, 365).

4. PERIPHERAL BRANCHES.—The trigeminus is so named because in man it was observed to have three

branches. One branch, as we have seen, runs to the ciliary ganglion, and must be considered as belonging morphologically rather to that ganglion, than to the Casserian. The other two branches run respectively to the maxillary and mandibular regions. In the lamprey, Kupffer, 91.1, 41, the two branches arise from a common stem, but

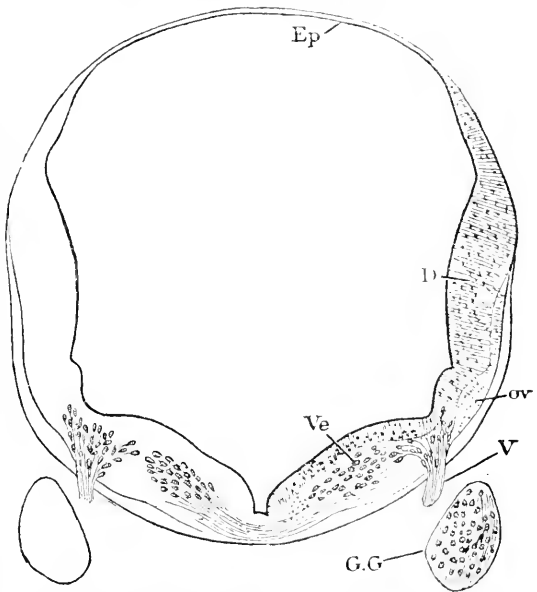


FIG. 369.—Section of the Brain of a five Weeks Embryo (His' Ko). *Ep*, Ependyma; *D*, dorsal zone; *Ve*, ventral zone; *ov*, oval bundle or ascending tract; *V*, fifth or trigeminal nerve; *G.G.*, ganglion Gasseri. After W. His.

in the human embryo they arise separately from the ganglion. Whether the maxillary and mandibular nerves are to be regarded as branches of one nerve or not, must be decided by further investigations. It is possible that they are distinct and their union secondary, but the usual view is that they are primitive branches. This view has found favor chiefly from theoretical considerations: if the mouth be interpreted as representing a pair of gill-clefts, then the trigeminus may be interpreted as the nerve of that cleft, and its two branches, one in front of, the other behind, the mouth, may be compared with the branches of the branchial nerves.

No satisfactory observations on the growth of the branches are known to me. The subject would well repay a careful investigation.

VI. Abducens Nerve.—This nerve is formed exclusively of medullary nerve-fibres. The neuroblasts which produce these fibres have been found by His, **88.3**, 365, in a human embryo of five weeks, to be situated in the ventral zone of His toward the median ventral line, Fig. 370, and the fibres pass out directly from the wall of the brain, hence the exit of the root lies in a line with that of the hypoglossal nerve and much nearer the ventral line than the exits of the main branchial nerves (trigeminus, facialis, glosso-pharyngeus, and vagus)—compare Fig. 363. Fig. 370 also shows the peculiar manner in which the abducens is embraced by the inner root of the facial. The fibres do not pass out in one bundle, but as first observed by A. M. Marshall, **78.1**, in several (four to seven) small bundles.

The facts that the abducens has no ganglion and arises from the ventral side of the brain, were discovered by A. M. Marshall, **78.1**, and verified by Van Wijhe, **82.1**, 28. Both authors interpreted it as a ventral root, homologous with a spinal ventral root, and correlated with a dorsal root represented by the facialis. His, **88.3**, has shown that the relations are more complicated, and has rendered Marshall's simple hypothesis untenable.

As regards the growth of the nerve, little is known. In torpedo embryos of 16 mm. (Froiep **91.2**, Fig. 1) it runs straight forward to the caudal end of Van Wijhe's third segment, which is the anlage of the external rectus muscle of the eye. A. Dohrn, **91.1**, 11-16, states that in elasmobranchs the nerve appears in Balfour's stage L; at first only two, later more fibres could be observed. The nerve at the time it reaches the rectus anlage is very thin, later it is much thicker. Dohrn also asserts that medullary cells continue to enter the nerve and migrate along it during a prolonged period.

VII.-VIII. The facial and acoustic nerves are developed in all vertebrates in such intimate connection with one another, that they are necessarily treated together. We shall take up: 1, the development of the ganglion; 2, the motor roots; 3, separation of the acoustic ganglion; 4, the peripheral branches.

1. **GANGLION ACOUSTIC-FACIALE.**—As already stated, p. 604, this is the smaller and posterior of the two primary ganglionic masses, which may be seen in front of the otocyst in a chick of thirty to forty hours and in corresponding stages of other amniote embryos. His, **88.3**, 372, gives the following description of the ganglion in a five weeks' human embryo: It lies close in front of the auditory vesicle, Fig. 363, *Gv*; it is somewhat triangular in form, with its apex to-

ward the dorsal side; in sections its elements present a characteristic fan-like grouping, which recurs in no other ganglion, and which is due to the twisted course of the fibres of the vestibular and cochlear branches of the acoustic nerve. The ganglion includes three masses of neuroblasts: the innermost or medial mass, Fig. 370, *c.VIII.*, is the anlage of the *ganglion cochlere*, and sends its centripetal fibres as shown in the illustration dorso-laterally; the outermost or lateral mass is the anlage, *v.VIII.*, of the *ganglion vestibulare*, and its fibres enter the brain with a dorso-medial inclination; the middle mass is the anlage of the facialis or *ganglion geniculi*; it lies somewhat lower down than the other two, and its centripetal fibres form a strikingly compact cord within the substance of the brain.* Paul Martin, 90.3, 229, has observed in cat embryos of 0.8-0.9 mm. that certain fibres of the facialis bend over so as to form a longitudinal cord which later joins the ascending glosso-pharyngeal tract, which is, therefore not merely by glosso-pharyngeal fibres.

The whole of the triple ganglion becomes later included in the cartilaginous mass of the *os petrosum*, but a few cells are retained on the cerebral side and form a ganglion, which is known by various names, and which His proposes to call the *intracranial*. According to C. Kupffer, 91.1, the acustico-facialis ganglion of the lamprey unites in the embryo with four spots of the epidermis, two along the lateral and two along the epibranchial line. Of the former one is a union with the epithelial wall of the auditory invagination, the other lies further headward, being situated between the otocyst and the trigeminal ganglion; where the anterior union takes place the epidermal cells contribute to the development of the facial ganglion. The two lower unions take place by means of ventral prolongations of the ganglion, which unite with epidermal thickenings above the first and second gill-clefts respectively. Kupffer's statements suggest that the ganglion is really double, otherwise it is difficult to understand why it should have two lateral line organs and two epibranchial organs. Van Wijhe observed in elasmobranchs, 82.3, 26, that the facial gan-

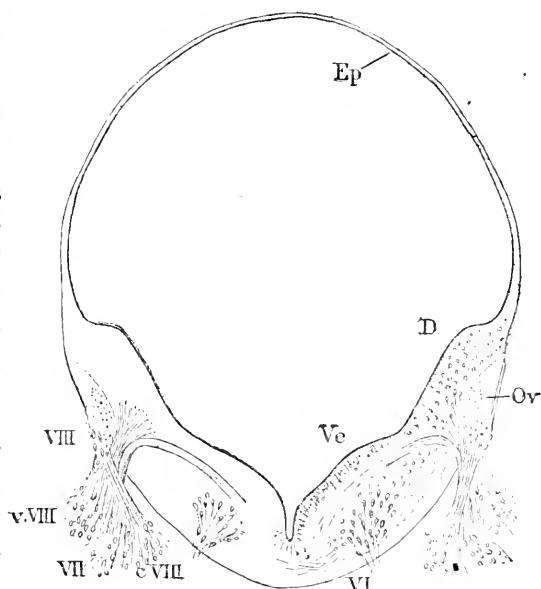


Fig. 370.—Section of the Brain of a Human Embryo of five Weeks (His' Ko). *Ep*, Ependyma; *D*, dorsal zone; *Ve*, ventral zone; *or*, oval bundle or ascending tract; *VI*, sixth nerve; *VIII*, eighth nerve (intra-cranial ganglion); *v.VIII*, vestibular branch; *VII*, seventh nerve; *c.VIII*, cochlear branch. After W. His.

* His, *l.c.*, foot-note, points out that the figure of this ganglion in his "Anat.menschl. Embryonen," Heft 1, p. 44, is not correct.

gion unites along what we now regard as the lateral line and again above the first gill-cleft with the epidermis; the latter connection can be seen in Balfour's stage K. Beard, **85.1**, also observed the epibranchial connection. In amniota the lateral line connection has not yet been described, but Kupffer, **91.1**, 52, states that it has been found in birds. The epibranchial connection of the facial ganglion has been very carefully studied in mammals by A. Froriep, **85.1**; it is present in cow embryos of 6-12 mm., and is most distinct in those of from 7-9 mm., that is to say, with three gill-clefts, well developed externally; the lower end of the ganglion is somewhat pointed and joins a small thickened area of the epidermis exactly at the dorsal margin of the first or hyomandibular cleft (Froriep, *l.c.*, Taf. I., Fig. I.); there is no distinct boundary between epidermis and the ganglion, and it is possible that the former contributes cells to the latter; the thickened area is slightly invaginated below the level of the surrounding epidermis; a little later the ganglion is found to have made a clean-cut separation from the skin.

The fate of the facial ganglion proper has yet to be traced. The embryonic facial nerve has in its ganglion, of course, ganglionic neuroblasts, and must be regarded as originally a mixed nerve.

2. MOTOR ROOTS.—Our knowledge of these is derived almost exclusively from the observations of His, **88.3**, 362, for His is almost the only embryologist who has studied the histological development of nerves, and it is only by such study that the history of the motor roots can be followed. In a human embryo of five weeks, the facial nerve-fibres leave the brain as a compact bundle, a little distance headward of the auditory vesicle and at a point just ventral of the root of the acusticus; this bundle may be followed, Fig. 370, for some distance within the brain, ascending at first, then arching over and descending near the border between the mantle layer and the inner layer toward the median ventral line, where its fibres spread out and apparently take a longitudinal course; the facialis neuroblasts are situated in the lateral part of the ventral zone of His and lie in the region of the otocyst; the course of the fibres from the neuroblasts to the actual root has not been fully traced, but His thinks they join the *formatio arcuata*, then enter the longitudinal bundle near the median line and form there the arching bundle of fibres just described. The circuitous course of the motor fibres is very early developed, but no reason for that course is yet known.

3. HISTORY OF THE ACOUSTIC GANGLION AND ITS NERVE BRANCHES.—The following account is based on a paper by Willh. His, jun., **89.1**, in which the development in the human embryo is described, and the previous researches of others are reviewed. As stated in the previous paragraph, traces of the triple division of the ganglion are evident toward the end of the fourth week. By the middle of the fourth week the auditory vesicle, Fig. 371, shows the anlagen of the cochlea and the semicircular canals, and the ganglion shows clearly its triple division; the facial nerve has its characteristic bend, for it descends from the brain very steeply, passes through the horizontal ganglion geniculi, *G.g.*, and then descends again. The acoustic ganglion lies closer to the brain-wall than the facial and is divided by the latter into the upper and outer ganglion vestibuli, *G.v.*, and the

lower and inner ganglion cochleæ, *Gco*. The facial ganglion descends to a lower level than the acoustic, and therewith the two have finally separated. A few days later the division of the acoustic ganglion into an upper and lower part becomes still more marked, because the root of the facialis takes a more nearly horizontal course to the facial ganglion and then descends. Both parts of the acoustic ganglion lie in front of the otocyst and come in contact only with its front wall, and it is only on this wall that the maculæ acusticæ are developed. At five weeks the semicircular canals having formed and the twisting of the cochlea having begun, the fibres of the acoustic ganglion are found united with the auditory vesicle. The fibres from the cochlear ganglion form a stem, the *nervus cochlearis*, and two smaller branches, corresponding to the middle branch of otologists, which run respectively to the anlage of the *macula sacculi* and the anlage of the *macula ampullæ posterioris*. The fibres from the vestibular ganglion form a single stem running to a spot which includes the anlages of three maculæ, namely, of the vestibule and of the

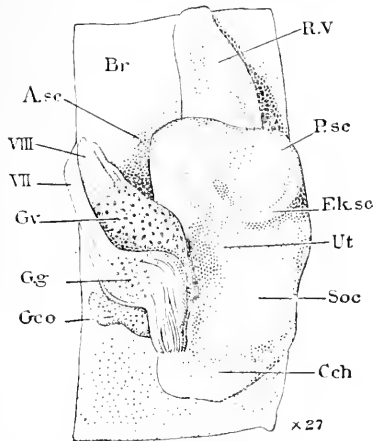


FIG. 371.—Otocysts and Nerves of a Human Embryo of four and a half Weeks ("Nackenslänge," 10.2 mm.) Reconstruction. *Br*, Wall of brain; *A.sc*, anterior; *P.sc*, posterior; *Ek.sc*, external semicircular canal anlage; *VIII*, auditory nerve; *VII*, facial nerve; *Gr*, ganglion vestibuli; *Gg*, ganglion geniculi; *Gco*, ganglion cochleæ; *R.V.*, recessus vestibuli; *Ut*, utriculus; *Soc*, sacculus; *Cch*, cochlea. After W. His, junior.

vestibular ganglion form a single stem running to a spot which includes the anlages of three maculæ, namely, of the vestibule and of the

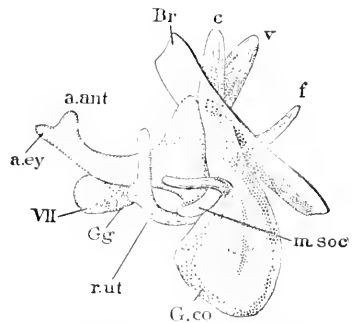


FIG. 372.—Acoustic Ganglia of a Human Embryo of two Months. The figure represents a model of the ganglia of the left side seen from behind. *Br*, Surface of brain; *c*, cochlear root; *r*, vestibular root; *f*, facial root; *m.soc*, branch to macula sacculi; *G.co*, ganglion cochleæ; *r.ut*, branch to recessus utriculi; *Gg*, ganglion geniculi; *VII*, facial nerve; *a.cy*, branch to anterior ampulla; *a.ant*, branch to anterior ampulla. After W. His, junior.

anterior and external ampullæ; in more advanced stages the maculæ separate and each receives a separate branch of the vestibular nerve; this is an excellent illustration of the dependence of nerve branches upon secondary changes in their peripheral connections. While the nerve branches are developing the ganglia elongate ventralward, and at the same time changes occur in the distribution of the ganglion cells. In the cochlear ganglion most of the cells remain near the cochlea, where they are ultimately converted into the *spiral ganglion*; others ascend with the fibres to the brain, at the edge of which they accumulate, being stopped by the dense neuroglia (*Randschleier*), and give rise to His' inter-cranial ganglion, mentioned above; still others remain strung out along the line where the cochlear ganglion is in contact with the vestibular; this line of ganglion cells is called

the *Zwischen-ganglion* by W. His, jun.; the fibres from these cells constitute the branches running to the sacculus and the posterior ampulla. In the vestibular ganglion the cells are more evenly scattered and persist in the adult distributed along the nerve. The further development consists in little more than a series of adaptations to the advancing differentiation of the membranous labyrinth. Fig. 372 represents the parts just described, but in a somewhat more advanced stage. As to the course of the fibres within the brain, we possess no satisfactory information; see W. His, jun., *l.c.*, p. 17-19.

4. PERIPHERAL BRANCHES OF THE FACIALIS.—In mammalian embryos, soon after the facial ganglion has united with the epidermis to form the epibranchial organ over the hyo-mandibular cleft, the nerve proper grows down into the hyoid arch, and thus develops the homologue of Van Wijhe's post-trematic branch. Somewhat later, Froriep, **85.1**, 44, another branch is formed from the oral side of the ganglion, and this branch, which is probably homologous with the rami præ-trematicus and pharyngeus of selachians, extends into the mandibular arch. Froriep has observed, **87.1**, in torpedo embryos in Balfour's stage L, a branch of the post-trematic facial running forward below the gill-cleft into the mandibular region to there innervate a mucous canal; this branch Froriep considers the homologue of the chorda tympani of amniota; the union of the chorda with the trigeminus is secondary. The branches in elasmobranch embryos have been carefully described by Van Wijhe, **82.1**, 25-29, who refers also to the earlier observations of Balfour and of Marshall and Spencer.

Rabl, **87.1**, ascribes the peculiar distribution of the facialis in the adult mammal to the fact that it innervates the myothelium of the hyoid arch; this myothelium develops into the embryonic platysma, and the platysma spreads out and is ultimately differentiated into the superficial facial muscles. The nerve follows the muscle, and as the latter subdivides the former branches correspondingly.

IX. **The glosso-pharyngeal nerve** has been taken by many embryologists as the most typical nerve of the head, because it has two distinct roots and its relations to the second gill-cleft are very clear, and it has been assumed that the cranial nerves typically all have two roots and are similarly related to gill-clefts; compare His, **88.2**, 423. It is to be remembered that the assumption that the glosso-pharyngeus is *par excellence* the typical cerebral nerve is the outcome of the necessities of a certain school of speculative morphologists. The assumption is by hypothesis, and is by no means sufficiently upheld by observation. We will consider: 1, the ganglion and its sense organs; 2, the motor roots; 3, the peripheral branches.

1. **THE GANGLION AND ITS SENSE ORGANS.**—The ganglion is the third of the four primary ganglionic masses of the head, and is situated immediately behind the otocyst. It forms at first a continuous anlage with the vagus ganglion. In a chick of thirty to forty hours, seen from above, it appears as a rounded mass about equal to the auditory vesicle in size (His, **88.1**, 417). It has been commonly stated since Marshall's paper, **78.1**, in 1878, that there is first formed a common ganglionic mass behind the ear, and that this mass divides

into two ganglia, the glosso-pharyngeal and vagus. Chiarugi, however, **90.1**, 336, believes that the ganglion of the eighth nerve arises in Sauropsida as an independent outgrowth of the ganglionic cord (neural crest), and appears before the vagus. He finds, p. 426, that in the rabbit the two ganglia are distinct though they appear at nearly the same time (embryos of 4.5 mm.). In the human embryo the cells become bi-polar and produce nerve-fibres during the fifth week. The primitive mass, according to His, **88.3**, 374, early divides into an upper or dorsal smaller spindle-shaped part, *Ehrenritter's ganglion*, and a lower or ventral larger oval part, the *ganglion petrosus proprium*, Fig. 363, *Gp.* The former lies close behind the auditory vesicle and later is covered by the cochlea; the latter moves away from the otocyst to take a place on a level with the pharynx. The centripetal fibres form a single bundle, which enters the brain near the lower edge of the dorsal zones of His, and there taking a longitudinal course descends toward the spinal cord;* within the medullary wall the fibres constitute the ascending glosso-pharyngeal tract. In an embryo of 6.9 mm. NL (His' Br³) His, *l.c.*, found the tract not to have reached the vagus region, but later it is longer and the fibres mingling with those of the vagus form a very characteristic cord, the *tractus solitarius*, which can be followed into the spinal cord. It is probable that both the trigeminal and facial ganglia send fibres to this tractus.

The nerve was erroneously supposed by Balfour ("Works," I., 425), Marshall and Van Wijhe, **82.1**, 9, to arise exclusively from the ganglion, as owing to their neglect to consider the origin of the nerve-fibres they failed to see the true motor roots. Proceeding upon this false assumption they have endeavored to interpret the nerve as the morphological equivalent of a dorsal spinal root. His' observations oblige us to discard this interpretation.

C. Kupffer, **91.1**, 44, found in the lamprey that the glosso-pharyngeal ganglion is differentiated later than the other cephalic ganglia, and is at first intimately associated with the anlagen of the auditory vesicle and facial ganglion. Like the other ganglia it is soldered in the embryo to the epidermis of the lateral line, and after widening out at its ventral end it unites (ammocetes of 4 mm.) broadly with the epidermis a second time to form the epibranchial organ above and in front of the third gill-cleft, Fig. 407.

In Petromyzon, as just stated, the ganglion has the lateral and epibranchial organs, and it is probable that both exist in other vertebrates; but as yet only the mammalian epibranchial organs have been accurately studied by Froriep, **85.1**, although the lateral line organ was seen by Van Wijhe, **82.1**, 29, in shark embryos in Balfour's stage K. Froriep, *l.c.*, p. 12, observed in cow embryos of 8.5 mm. that at the dorsal border of the second gill-cleft there is a slightly depressed area of thickened epidermis, which is united with the lower part of the ganglion; in embryos of 16 mm. the organ has disappeared, but its final history is somewhat uncertain (p. 46).

2. MOTOR ROOT.—The origin of the motor-roots in the embryo has, so far as I am aware, been studied only by W. His, **88.3**, 361.

* The arrangement is figured by W. His, 88.3, Fig. 22; it is similar to that of the vagus. See Fig.

The neuroblasts are gathered in the upper part of the ventral zone of His, as a group which is quite clearly separated from the neuroblasts of the facial and vagus nerves. The fibres from these neuroblasts are gathered into a single bundle, which leaves the medullary wall near the dorsal end of the ganglion, so that it seems to form, if we disregard the origin of the fibres, a part of the true dorsal or ganglionic root; compare p. 648.

3. PERIPHERAL BRANCHES.—The glosso-pharyngeus enters into close relations with the second gill-cleft. As long known through comparative anatomy, the nerve typically forms two branches when it reaches the gill-cleft, and the general history of these branches has been followed in elasmobranch embryos by Balfour, Van Wijhe, and Beard. One branch runs in front of the gill-cleft—in other words, in the posterior part of the hyoid arch; this branch is the *præ-trematic* of Van Wijhe, **82.1** (*præ-branchial* of Beard). The other branch runs behind the gill-cleft—in other words, in the anterior part of the first branchial arch; this branch is the *post-trematic* of Van Wijhe (*post-branchial* of J. Beard). These branches are both developed after the epibranchial organ, and in fishes are nearly equal in size.

In mammals, according to Froriep, **85.1**, 13, 20, 44, the post-trematic becomes the main stem, which is found in cow embryos of 8.8 mm. running through the first branchial arch and curving forward below the gill-cleft, while the præ-trematic branch is a very small bundle of fibres at this stage, and apparently persists as the *nervus tympanicus* of the adult. The post-trematic is the *ramus lingualis* of the adult, the ramus pharyngeus being added in later developmental stages. It may be noted that the so-called pharyngeus of elasmobranchs belongs to the præ-trematic.

In the human embryo the nerve grows straight down from the medulla at first (His' Br³), but in an embryo of four and one-half weeks (His' Ko) it is already bent at its end owing to the dislocation of the parts of the pharynx, His, **88.3**, 379. Noteworthy is the early union of the ganglion petrosum with the ganglion nodosum by an oblique anastomosing branch, Fig. 363, the development of which has not yet been followed.

X. **The Vagus Nerve.**—A few words on the general morphology of this nerve may be prefixed to the history of its development. Gegenbaur, **71.1**, **72.1**, directed especial attention to the fact that, unlike any other nerve of the head, the vagus supplies several gill-clefts; all the clefts, whatever their number, behind the glosso-pharyngeal cleft being innervated by the tenth nerve, which in fishes shows its relations clearly, since it sends off a præ-trematic and post-trematic branch for each gill-cleft of the vagus series. The number of the branches in any form, of course, depends upon the number of clefts preserved in that form. As Gegenbaur had formed the theory that the cephalic nerves correspond with the gill-clefts, there being a nerve for each cleft, he necessarily concluded that the vagus was the morphological equivalent of several branchial nerves. This conception of the vagus has been generally adopted, and has been so generally taught, that many of the younger morphologists seem to have forgotten that it has remained a bold hypothesis, and

that there is no evidence whatever of an actual fusion of several nerves into one vagus nerve to be obtained from vertebrate embryology. Nevertheless, Gegenbaur's theory has dominated all investigations of the last twenty years.

We now know—compare p. 200—that the gill-pouches only imitate the segmental arrangement, and are in reality much less numerous than the true segments of the branchial region, and that the nerves do not correspond to the number of segments. In view of the great irregularities of the nerves as compared with the myotomes of the head, we are no longer justified in interpreting the vagus so as to make it conform to a theoretical order, which is definitely ascertained not to agree with the real order—in other words, it is not necessary to suppose that each gill-cleft had a separate nerve and just one nerve. Further we must conceive that there was primitively a chain of epibranchial organs, which were connected longitudinally with one another, and transversely with several hypoglossal nerves, but we have at present no reason for assuming that the series of cephalic nerves extended as far as the epibranchial organs. On the contrary the series of epibranchial organs (like those of the lateral line) may have extended tailward, by the growth of a branch consisting of nerve fibres derived from probably several hypoglossal nerves; both the lateral and epibranchial branches while they grow are united with the epidermis.

I conceive the primitive condition to have been one in which there were, presumably, four cephalic nerves behind the vagus, and that these nerves had each its epibranchial organ; the four nerves are now represented by the hypoglossus and accessorius. The epibranchial organs were connected with one another by a longitudinal commissure, which persisted while the four hypoglossal ganglia disappeared, and thus the epibranchial organs and the nerve branches running from them to the gill-clefts became, apparently, branches of the vagus. While one thus recognizes the relation of the vagus to several gill-clefts, that relation is not primary, but secondary and acquired, and does not in my judgment lend support to Gegenbaur's hypothesis. Another consequence of the abortion of the hypoglossal ganglia has been to leave their lateral medullary roots to be modified into a separate nerve-stem, the accessorius, and to join the ganglion of the vagus.

The considerations advanced above lead me to the conviction that Gegenbaur's conception of the vagus as morphologically equivalent to several nerves can no longer be maintained, and instead we must return to the older view and again look upon the relation of the vagus to the posterior gill-clefts as the result of the distribution of a branch, which may be named the *nervus epibranchialis*, and which, so far as its connections with the epidermis are concerned, may be compared with the lateral nerve. That Gegenbaur's theory is untenable is shown by the development of the hypoglossal nerve, which includes the nerves of the segments immediately behind the vagus nerve and above the posterior branchial clefts, so that, as a matter of fact, the segmental nerves of the posterior branchial region are incorporated not in the tenth, but in the twelfth nerve.

1. GANGLION AND GANGLIONIC ORGANS.—The ganglionic crest

behind the otocyst develops its two large ganglia somewhat later than does the mass in front of the otocyst; thus in a torpedo embryo of 6 mm. Froriep, **98.2**, 60, found the two anterior ganglia divided, but the two posterior were undivided. The ganglion is in amniota at first a rounded mass, which may be seen in a chick of thirty to forty hours lying immediately behind the glosso-pharyngeal ganglion, which it about equals in size (W. His, **88.2**, 417, Fig. 2). The exact history of the ganglion has never been followed. Chiarugi, **90.1**, observed that the ganglion arises in reptiles as a conical bud, which grows down from the neural crest; later (*Lacerta* embryos of 5.5 mm.) it arises by three bundles of fibres, of which the first and last represent the persistent neural crest and unite the ganglion respectively to the glosso-pharyngeus and first cervical ganglia, while the middle bundle is the root proper, connecting the vagus ganglion with the neuron. This stage has been described by Béraneck and was the earliest seen by him. In mammals (Chiarugi, **90.1**, 42-46) the ganglion also arises independently, and as it grows ventralward, passes outside of the jugular vein and aorta, unlike the glosso-pharyngeal ganglion, which passes inside these vessels. In rabbit embryos of 6.5 mm. Chiarugi found the ganglion attached by slender commissures to the glosso-pharyngeal ganglion in front and the first cervical behind. The medullary root next lengthens considerably, and in embryos of 11 mm. the ganglion is subdivided into the dorsal *ganglion jugulare* and the ventral *ganglion nodosum*. In a cow embryo of 8-9 mm. the ganglion is much larger than the glosso-pharyngeal or facial, and extends over the third, fourth, and fifth clefts (Froriep, **85.1**). It elongates in an oblique dorso-ventral direction. In a human embryo of four and one-half weeks (W. His, **88.3**, 375) it is very long and divided, as just mentioned for rabbits, into an upper ganglion *jugulare* and a lower ganglion *nodosum*, Fig. 363, *Gj* and *Gn*, connected by a narrower fibrous tract, along which are scattered a few ganglion cells. The jugular ganglion is spindle-shaped, and has on its inner side a bundle of fibres which enters the lower edge of the dorsal zone of His, Fig. 379, there takes a longitudinal course toward the spinal cord as a well-marked *ascending vagus tract*: the tract is at first very short; it is soon joined by the fibres of the trigeminal tract, and the two sets of fibres uniting constitute the so-called *tractus solitarius*, as mentioned above in describing the trigeminal ganglion, p. 642. The *tractus solitarius*, as shown in Fig. 379, has at first a superficial position, but later it loses this place in appearance, being covered over by the *Randlippe* of His, compare p. 666 and Fig. 381.

The vagus ganglion probably has both lateral and epibranchial organs in the embryos of all vertebrates. In elasmobranchs both were seen by Van Wijhe, **82.1**, and have been more accurately described by Froriep, **91.2**. In Petromyzon they have been described by Kupffer, **91.1**. In teleosts the lateral line organs are greatly developed, and there are a good many observations on the organs themselves, but I recall none on the dependence of the organs upon the ganglion proper. Kupffer, *l.c.*, states that in birds both the lateral and epibranchial fusion of the ganglion with the epidermis can be seen. The epibranchial organ in mammalian embryos has been

carefully studied by Froriep, **85.1**. Fig. 373 represents a transverse section of a torpedo embryo of 12 mm. in which the vagus ganglion shows its two connections with the epidermis, first at the lateral line, secondly over the fourth gill-cleft, where the thickening of ectoderm is very considerable. In this embryo (Froriep, **91.2**, 61) the vagus ganglion is connected with the epibranchial organs over the second to sixth cleft, and with six smaller lateral organs, which all lie in the region of the fourth and fifth clefts, and in the headward prolongation of the lateral line proper. The section figured passes through the fourth epibranchial organ. In a lamprey larva of 4 mm. the vagus ganglion, Fig. 407, as seen from the side, is triangular, the apex pointing tailward and being prolonged as the lateral line; the upper angle forms the dorsal root; the lower angle is prolonged and joins the epibranchial organ in front of and above the fourth gill-cleft; this organ is the seventh at this stage, and is connected with the epibranchial organ in front and the chain of five organs over the fourth to eighth gill-cleft. As regards mammals, Froriep, **85.1**, states that the vagus ganglion is found in cow's embryos of 8.7 mm. to be the largest of the cephalic ganglia, and to overlie the third cleft and the region of the still undeveloped fourth and fifth clefts; above the third cleft and from these down beyond the level of the fifth aortic arch, it is found united with the epidermis over an area about 0.75 mm. long and from 0.19 to 0.23 mm. wide. In an embryo of 12 mm. the epidermis of the area of epibranchial contact has become invaginated and lies at the bottom of a narrow fissure, but is much reduced in size. The fissure and contact can be still found in embryos of 15 mm.

2. MOTOR ROOTS.—The neuroblasts, which form the motor roots of the vagus, are situated according to His, **88.3**, 360–362, in the ventral zone of His, but toward its dorsal side, and the fibres make their exit from near the dorsal limit of the ventral zone and close to the entrance of the ganglionic root. The vagus neuroblasts are situated along the same line as those of the spinal accessory nerve and are not marked off from them in any way; compare Fig. 379.

3. PERIPHERAL BRANCHES.—The vagus ganglion in young elasmobranchs sends off four branches to the gill-clefts; each branch runs behind the gill-cleft to which it belongs, and is associated with the corresponding epibranchial organ; the first to third branches are nearly alike in size, but are smaller than the large fourth branch, which is further distinguished by continuing on beyond the pharyngeal region and by becoming the *ramus intestinalis* of the adult (Van Wijhe, **82.1**, 32, Froriep, **91.2**, 61). Later this fourth branch is also connected with the epibranchial organ of the sixth cleft. The four

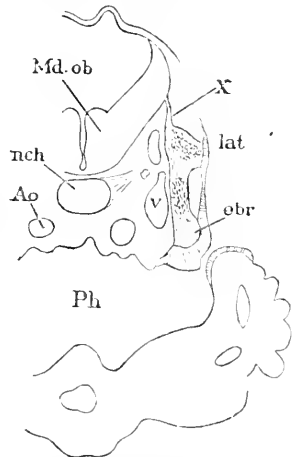


FIG. 373.—Torpedo Embryo of 12 mm. Cross section. *Md.ob.*, Medulla oblongata; *nch.*, notochord; *Ao.*, aorta; *Ph.*, pharynx; *X.*, tenth nerve or vagus; *lat.*, lateral organ; *obr.*, epibranchial organ; *v.*, vein. After Froriep.

branches behind the gill-clefts are to be regarded as post-trematic nerves and the fourth is presumably equivalent to two post-trematic nerves. The præ-trematic branches arise later as outgrowths of the ganglion from the region of the epibranchial organs, and also the pharyngeal branches arise similarly. Van Wijhe, *l.c.*, p. 31, found that in Balfour's stage K the ganglion has one dorsal branch, and gives off the so-called lateral nerve; the dorsal branch Van Wijhe identifies as the ramus supra-temporalis; it is connected with the epidermis of the lateral line. It is probable that both the dorsal and the lateral nerves are derivatives of the connection of the ganglion with the lateral line. As Van Wijhe neglected the difference between the ganglion and the nerve his investigations must be extended before we can decide whether the four branches to the gill-cleft arise from the ganglion proper or from a nerve-trunk which was mistaken for a prolongation of the ganglion. The question raised is important, since upon the answer must depend, to a large extent, our notion of the origin of the nerve, whether it represents one nerve much branched or several nerves which have been fused. Balfour's account of the development of the vagus in sharks differs somewhat from Van Wijhe's—see Balfour's "Comp. Embryology," II., 457.

In mammals the early condition of the vagus branches has been partially described by A. Froriep, **85.1**. In cow embryos of 8.7–8.8 mm. the vagus surpasses all other nerves in size; in those of 12 mm. the ganglion jugulare is well differentiated from the ganglion nodosum, and from the former the main trunk extends for about 0.4 mm. as the anlage of the ramus intestinalis; the trunk at this stage consists entirely of nerve-fibres and contains no cells; the fibres pass through the medial half of the ganglion. As to the branches to the gill-arches and the lateral line no published observations are known to me.

Lateral Nerve.—This branch of the vagus is one of the best known nerves of the Ichthyopsida, and is connected with the sensory organs of the lateral line. The homologues in amniota of the lateral nerve have never been satisfactorily determined. The nerve itself is perhaps a partial survival of a connection of the epidermis with the ganglia, which originally extended along the head as well as along the body, and which was associated with the series of lateral sense organs; compare C. Julin, **87.3**. In amphibia (A. Goette, **75.1**, 672) and in elasmobranchs (C. Semper, **76.3**, 398, Van Wijhe, **82.1**, 33) the growing end of the lateral nerve has been seen to merge in the epidermis, and these observers suggest that the nerve may grow at the expense of the epidermis; but this notion is scarcely compatible with our present knowledge of the genesis of nerve-fibres.

XI. **The spinal accessory nerve** (*accessorius Willissi*) is characteristic of the amniota and is not found in the anamniota. It must, therefore, be regarded as a nerve which has been evolved within the vertebrate series, and its development indicates that it arose by a collective modification of the motor fibres of the dorsal roots of the hypoglossus. It comprises no ganglionic fibres. Chiari, **90.1**, found in reptiles, birds, and mammals that the neural crest persists, as it does in elasmobranchs according to Van Wijhe, **82.1**, 32, between the vagus and first cervical ganglion, and con-

tinues as a cellular cord, both while the hypoglossal ganglia grow out from it and after these ganglia abort. He regards it as the anlage of the accessorius, and this is probably correct, but not in the sense that its cells produce the nerve, for the nerve contains no ganglionic fibres, but in the sense that it prescribes the path for the motor-fibres and conducts them to the vagus ganglion. I venture the hypothesis, that if the hypoglossal ganglia were preserved the fibres of the accessorius would not run to the vagus, but chiefly if not wholly to the twelfth nerve. His, **88.3**, 360-362, found the neuroblasts which give rise to the accessorius fibres to be distributed, as shown in Fig. 374, along the dorsal part of the ventral zone, throughout the vagus and hypoglossal regions, *i.e.*, roughly the lower third of the medulla oblongata; the fibres, unlike those of the hypoglossus, make their exit near the dorsal zone; the fibres leave the medullary wall as a series of little bundles, which unite into a nerve which runs forward nearly parallel with the medulla, being probably guided by the ganglionic cord, and joins first the vagus ganglion, then the main vagus-trunk, Fig. 363, XI. The longitudinal trunk of the accessorius is regarded by Chiarugi, **90.1**, 317, as a modification of the original neural crest transformed in the occipital region into a commissural cord. Some further details are given by Froriep, **85.1**, as to this nerve in ruminant embryos. As regards the branches of the nerve, His, **88.3**, 380, finds that in the human embryo of four and one-half weeks the adult relations are already established, Fig. 363, in that the fibres all join the vagus and run for the greater part with its descending stem, but a part of them pass off as the independent *ramus externus N. accessorii*; compare also Froriep, **85.1**, 13-14.

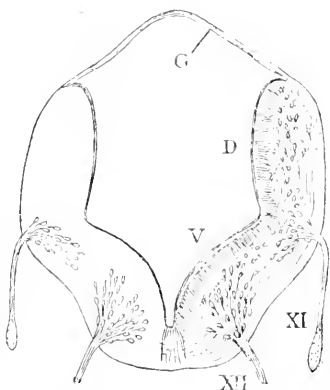


FIG. 374.—Section of the Medulla Oblongata of a five-weeks' Human Embryo (His' Ko). Ep, Ependyma; D, dorsal zone of His; V, ventral zone; XI, accessorius; XII, hypoglossus. After W. His.

XII. The hypoglossal nerve of mammals has been shown by Froriep, **85.1**, to be the result of the fusion of several nerves, probably four, closely similar to the true spinal nerves in character. Froriep's results have had confirmation by P. Martin's observations; **90.3** on the cat, Chiarugi's, **89.2**, on several mammals, and Van Bemmelen's, **89.1**, on reptiles. As the homologies of the hypoglossus among Ichthyopsida are not clearly understood, I shall confine myself to the development of the nerve in the higher forms. We shall consider in order, 1, the ganglia; 2, the motor roots; 3, the branches.

The development of the hypoglossus suggests that it arose by modification and fusion of at least four segmental nerves situated between the vagus and the first cervical nerve. The modifications consist in the disappearance of the ganglia and the conversion of the motor-fibres of the dorsal roots into the accessorius nerve, and in the disappearance of at least the anterior of the ventral roots. The nerve

retains its primitive relations, since the lingual muscles it innervates are developed from the occipital myotomes.

1. THE GANGLIA.—There are found in the occipital region of young mammalian embryos three ganglia, which abort before they are fully differentiated. These ganglia have a marked resemblance to the true spinal ganglia. They are connected with a part of the neuron which belongs presumably not to the medulla oblongata, but to the spinal cord. If this is really the case the ganglia are true spinal ganglia, not cephalic. Chiarugi, **89.2**, found that the ganglia are preceded by a continuous stretch of the neural crest, which appears as if a commissural link between the vagus and first cervical ganglia, *e.g.*, in *Lacerta* embryos of 2.7 mm. From this pseudo-commissure there grow out in *Lacerta* at first two ganglia, which overlie and extend in front of respectively the third and fourth occipital myotomes, and there is perhaps a third ganglion, that is to say, one for the second occipital myotome; the three ganglia have only a fugitive existence, and are no longer present in embryos of 5.5 mm. It may be well to recall that the first cervical ganglion also aborts in Sauropsida during early embryonic life, compare p. 630. Chiarugi, *l.c.*, 339, found the three rudimentary occipital ganglia in the chick embryo of the third day, corresponding to the second, third, and fourth occipital myotomes. In the rabbit only two ganglia are known in the occipital region; these have been observed by Chiarugi, *l.c.*, 430, in embryos of 6.5 mm. associated with the third and fourth occipital myotomes; the posterior of the ganglia is the larger. In cow embryos of 8.7 mm., Froriep, **82.1**, **85.1**, 16, found one occipital ganglion in association with the last occipital myotome, there being three myotomes. We may assume that there are earlier two ganglia and four segments in the cow embryo as in the rabbit, and that by the stage studied by Froriep the foremost segment and foremost ganglion have disappeared. In cow embryos of 12 mm., Froriep, **85.1**, 24, found the ganglion of the fourth segment still present and its ventral end united with the hypoglossal motor roots of the same segment, but in embryos of 15 mm. the ganglion shows indications of abortion, *l.c.*, p. 33. In the human embryo, Fig. 360, the ganglion of the fourth occipital segment has been observed by His ("Anat. menschl. Embryonen," Heft III., 89, also **88.1**, 401) in embryos of 13–14 mm.; later it is found to have disappeared. His proposes to name the ganglion after its discoverer, *Froriep's ganglion*. Kazzander, **91.1**, has directed attention to various cases in which a hypoglossal (Froriep's?) ganglion has been observed in man and other mammals in the adult stage, and reports a new case of its presence in a human adult.

The facts presented in the preceding paragraph render it probable that in all amniota there are at least three * ganglia present during very early stages in the occipital region; that these ganglia belong to the second, third, and fourth segments of the region, and to the hypoglossal nerve, and that they successively disappear, the last persisting for some time longer in mammalian than in sauropsidan embryos. I think that we may expect to obtain evidence that there is still another hypoglossal ganglion, namely, for the first segment.

* P. Martin, 90.3, 230, affirms that he finds in the cat five rudimentary hypoglossal ganglia.

Although the occipital ganglia entirely disappear, the ganglionic cord, from which they arise, persists and serves as the anlage of the accessorius as stated in the preceding section.

No ganglionic sense organs connected with the hypoglossus have yet been recognized, but it is to me probable that the part of the lateral line near the vagus represents hypoglossal lateral organs. Suitable investigations on Ichthyopsida might result in confirming this suggestion.

Historical Note.—The last hypoglossal ganglion was discovered by Froriep in 1882, in ruminant embryos, and its history has since been further studied by him. His, in 1888, recognized its presence in the human embryo. Chiarugi, **89.2**, **90.1**, has studied the ganglia in reptiles, birds, and mammals, and our present knowledge rests to a large extent solely upon his observations. P. Martin, **90.3**, has observed the ganglia in cat embryos.

2. MOTOR ROOTS.—The neuroblasts which give rise to the hypoglossus lie, in the human embryo, in the ventral part of the ventral zone of His, Fig. 374, and their fibres make their exit from the medulla not far from the *Bodenplatte* (His, **88.3**, 361). The fibres are gathered into bundles. According to His, these bundles are quite numerous and are found even below the vagus ganglion. I consider it probable that His is mistaken in regard to this, and that the fibres leave the medulla in man only in the region behind the vagus—in other words, in the region of the four occipital segments, and in four segmentally arranged bundles. That there are three, and probably four, segmental motor roots in cow embryos has been shown by Froriep, **85.1**, 16, but P. Martin records, **90.3**, 230, that in cat embryos, representing younger stages than Froriep studied, there are five distinct roots (? of which one cervical). Chiarugi, **89.2**, **90.1**, has observed five segmentally arranged roots in Lacerta, the first root lying in front of, the remaining four corresponding to, the four occipital segments; four roots in *Tropidonotus*; three roots in chicks toward the end of the third day, the first occipital segment having no root; and finally two roots in rabbit embryos. Van Bemmelen, **89.1**, 243, describes in Lacerta five well-developed hypoglossal ventral roots, and has noticed fibres further forward toward the vagus, which suggest to him the possibility of yet more roots; he further records that motor fibres are added from the first and a little later also from the second cervical nerve.

3. BRANCHES.—It will be remembered that the posterior branchial arches are invaginated, the invagination constituting the *sinus cervicalis*. The hypoglossal nerve in a human embryo of the fifth week, Fig. 363, was observed by W. His, **88.3**, 380, to pass around this sinus, going behind and below it and there curving forward into the tongue; as shown in the figure, the nerve crosses the vagus below the ganglion nodosum, and after crossing gives off a branch, *ramus descendens*, which runs along the lateral side of the jugular vein parallel to the vagus trunk. The mechanical cause of the formation of this branch, I do not know. Chiarugi, **90.1**, 432, has observed that the distribution of the nerve is essentially the same in rabbit embryos as in human.

In Lacerta, Van Bemmelen, **89.1**, finds that the course of the

nerve, as it curves around to enter the tongue, is closely parallel to the united prolongation of the five myotomes (four occipital and one cervical) which grow like a single cord (Froriep's *Schulterzuugenstrang*) into the tongue to produce the lingual muscles. Chiarugi, 90.1, 321, states that in lizard embryos the nerve-trunk runs outside the jugular vein, from which it is separated by the intervention of the vagus and of the carotid artery, and accompanies a branch of the jugular, which runs to the mandible and is probably the sub-maxillary vein.

Spinal Cord.—The differentiation of the cord and brain is effected by the development of the cerebral vesicles. The histogenesis of the

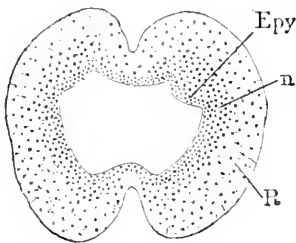


FIG. 375.—Lower end of the Spinal Cord of a Human Embryo of three Months. *Epy*, Ependymal layer; *n*, neuroblast layer; *R*, outer neuroglia layer or Randschleier.

cord has been described in the sections on the neuroglia and the nerve-fibres. The following paragraphs refer chiefly to the cord without regard to the peculiarities offered by the lower end of cord, Fig. 375, in which we find the typical developmental features very imperfectly followed. This is due, presumably, to the partially abortive history of the caudal end of the neuron in mammalia. The following descriptions are based in large part on His' memoir, 86.2.

1. GENERAL GROWTH.—The following account is based upon that of Kölliker ("Grundriss," 2te Aufl., 260). The medullary groove is found completely closed in the region of the spinal cord in a chick embryo with thirteen primitive segments, and in slightly more advanced human embryos. But the posterior end remains for a while as a solid mass, which terminates by fusion with the ectoderm. When the primitive segments are all formed, the end of the cord separates from the ectoderm. At this stage the cord extends as far as the segments. In human embryos the cord equals the vertebral column in length up to the end of the third month. After the fourth month the vertebral column outgrows the spinal cord, which, although it absolutely lengthens, becomes relatively shorter, so that the distance from its end to the end of the spinal canal increases. This apparent ascent of the cord (*ascensus medullæ spinalis*) might be more properly described as a descent of the vertebræ. A secondary result of the changed position is that the nerves running out from the lower end of the cord, since their exits between the vertebræ are below the end of the cord, are forced to take a more and more longitudinal course within the spinal canal. There results a series of nerve-roots, which after the fourth month elongate as the vertebræ descend, and thus gradually produce the so-called *cauda equina*. The filum terminalis is developed, according to Kölliker, from the pia mater, and is therefore, properly speaking, not a nervous structure. The upper part of the filum, however, even in the adult contains a prolongation of the spinal cord with its central canal; compare Tourneux et Hermann, 87.3.

The cervical and lumbar enlargement of the spinal cord are indicated in the human embryo at two months and are well developed at three months.

2. CENTRAL CANAL.—The central canal has at first the form in sections which is shown in Figs. 159, 160, and 161, being flattened from side and elongated dorsal-ventrally, but is often more or less irregular in shape. I have observed that in birds and mammals there is a tendency for the walls of the canal to come temporarily into close contact along two longitudinal lines, so that the canal appears at the first glance to be divided into three channels. This condition may be well seen in the rabbit, and it is probably of wide, possibly of constant, occurrence. As to its significance, I have no clew. The contact is soon lost, and the canal becomes freely open again throughout its extent.

There now occurs a change of shape, *cf.* p. 607, by which the canal cuts into the thick medullary wall on each side, dividing it into the upper and small dorsal zone of His, and the lower and larger ventral zone of His, see W. His, 86.2, p. 497, Fig. 6. This change occurs in the human embryo toward the end of the fourth week and attains its maximum about the beginning of the sixth week. It is precisely during this period that the medullary nerves grow out from, and the ganglionic nerves grow into, the spinal cord; the former arising from the ventral zone, the latter entering the dorsal zone. The dorsal plate is curved inward, making a median ridge internally and a median groove externally; on either side of the latter there is a projecting fold, where the deck-plate curves over (the fold is the anlage of Goll's cord).

About the eighth week the canal begins to contract (compare His, 86.2, Figs. 6-9) between the dorsal zones until the walls first meet and then unite. Thus in a foetus of the tenth week, Fig. 376, the union has already taken place except at the very dorsalmost part of the canal, where a small remnant of the original cavity persists; whether this is always the case, I do not know. In older stages all traces of the canal (both its cavity and its epithelium) have disappeared, not only between the dorsal zones of His, but also between the upper part of the ventral zones. In Fig. 376, the boundary between the dorsal and ventral zones is marked by the insertion of the dorsal nerve-root. The lower part of the central canal remains open, and presents in section certain definite curves of outline, which deserve closer study. The open part of the canal is elongated dorsal-ventrally, but toward the close of foetal life it becomes more rounded in form, and in the adult is elongated transversely. In the caudal end of the human cord the cavity is large, Fig. 375, and does not go through the same changes of shape as in the rest of the cord.

It seems to me that the dorsal part of the central canal is obliterated by the union of its walls and the subsequent atrophy of its so-called epithelium, although the exact steps of the atrophy are unknown. In the adult the line of the central canal on the dorsal side is represented by the *posterior fissure*, which is merely a thin partition of vascularized tissue and not a true fissure. It seems probable that the tissue as claimed by Barnes, 84.1, is really derived from the cells lining the central canal, and is, therefore, to be classed morphologically with neuroglia. Waldeyer, 76.1, and others speak of a contraction of the canal, and of its being pushed in by the ingrowth of the posterior columns. This view is incorrect, for, as shown in

Fig. 376, the central canal exists between the posterior columns, even after the columns of Goll and Burdach can be recognized, in what are essentially their permanent positions. A. Robinson, 91.1, 90, calls attention to the fact that the cord widens at an early stage in rodents, so that in section it appears nearly round instead of oval; this change causes a slight diminution in the dorsal-ventral diameter

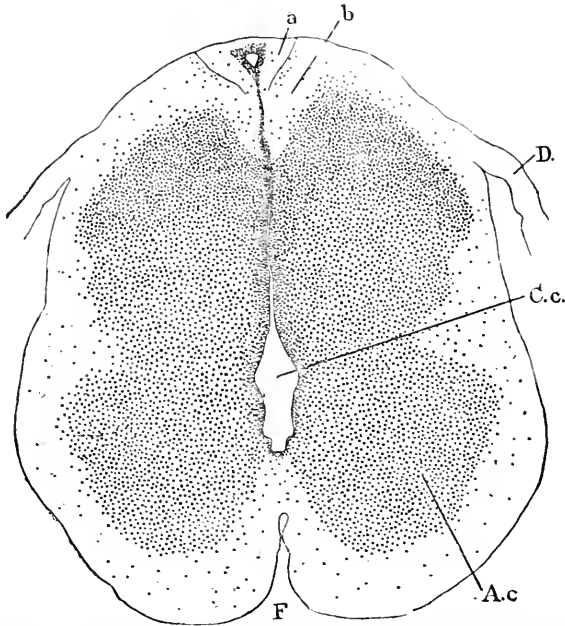


FIG. 376.—Section of the Spinal Cord of a Human Embryo of sixty-three to sixty-eight Days. Minot Coll., No. 138. (Dorsal region), *a*, Goll's cord; *b*, Burdach's cord (*Keilstrang*); *D.*, dorsal root; *C.c.*, central canal; *A.c.*, anterior cornu; *F.*, anterior fissure.

of the central canal. I cannot regard this diminution as a step toward the obliteration of the canal.

The *anterior fissure* begins to develop during the early part of the eighth week, and arises by the growth of the cord, which takes place, as indicated in Fig. 377, so as to produce two bulging ridges on the ventral side of the cord. The median space between the ridges is the future anterior fissure; it is occupied by fibrous connective tissue enveloping the cord; it is, therefore, a true fissure, for across it there is no connection between the nervous tissue of the two sides. Indeed, part of the original surface of the cord bounds the fissure on either side, and therefore we may correctly describe the tissue in the fissure as part of the envelope (*pia mater*) of the cord. As the embryo advances the ridges grow and the fissure deepens; the growth of the ridges is largely due to the expansion of the gray matter to form the anterior horns.

There is no atrophy of the ventral portion of the canal as Löwe, 80.1, 114, asserted, but the central canal of the adult represents the ventral portion of the primitive canal.

3. GROWTH OF THE MANTLE LAYER.—The mantle layer in man (His) and rodents (A. Robinson, 91.1) first appears in the region of the ventral zones of His, forming in sections a triangular mass on each side between the inner layer and the Randschleier; it gradually thickens, and at the same time its development progresses dorsalward and encroaches also upon the inner layer. There is thus a stage (in rats when the cartilaginous bodies of the vertebræ arise) in which the inner layer is very much reduced in the ventral columns, and gradually increases in thickness dorsalward, becoming in the dorsal zone thicker than the mantle layer, which, however, soon grows at the expense of the inner layer, which is ultimately reduced to the lining or so-called epithelium of the central canal. The mantle layer is easily recognized by the large size of its elongated nuclei, and by the fact that some of the nuclei are elongated dorsal-ventrally and others radially; in the inner layer the nuclei are smaller and all point radially.

4. DORSAL ZONE OF HIS.—The origin of this division of the cord has already been described, p. 607. In a human embryo of 12.5 mm., W. His, 86.2, 497, found the dorsal zone to begin with a broad arch from the deck-plate, to form a marked projection into the central canal, and to have upon its outer surface a rounded projection, *ov.b*, which His calls the *oval bundle (ovules Bündel)*; the projection is a product of the Randschleier and contains the ganglionic fibres, which have entered the medullary wall and run lengthwise within it; the oval bundle at this stage extends about half the distance from the sensory root, which enters the ventral border of the bundle, to the median dorsal line; the oval bundle is the anlage of the greater part of the posterior column of the adult. The oval bundle now steadily enlarges and creeps dorsalward until it reaches the arch formed by the passage of the dorsal zone into the deck-plate, *d.pl*. The arch gives rise to Goll's cords. The two cords of Goll become closely united with one another by the obliteration of the central canal between them, Fig. 378. The oval bundle meanwhile creeps still further and makes its way between the cords of Goll and the gray matter until it meets its fellow from the opposite side below the cords of Goll; thus arise the *cords of Burdach (Burdachsche Keilstränge)*, Fig. 378, *b*. At this stage—embryo of the tenth week—the dorsal zone of His is no longer distinctly marked off from the ventral zone except by the position of the sensory root. The inner and mantle layers have become the gray matter and they are completely covered by the expansion of the oval bundle, that is to say, by a layer produced from the primitive Randschleier of His, p. 616, and containing chiefly longitudinal ganglionic fibres. The layer developed from the oval bundle may be subdivided

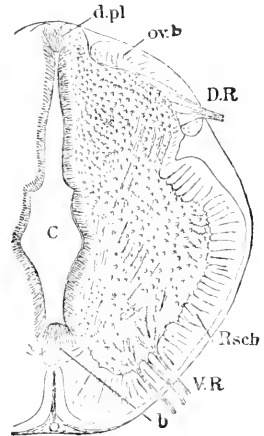


FIG. 377.—Transverse Section of the Spinal Cord from the Upper Dorsal Region of a Human Embryo of six Weeks (His' Zw). *d.pl*, Deck-plate; *ov.b*, oval bundle of dorsal zone; *D.R.*, dorsal root; *Rsch.*, Randschleier of ventral zone; *b*, floor-plate; *V.R.*, ventral root. After W. His. X 44 diams.

into two parts: the medial Burdach's cords and the lateral portion of the posterior columns. Outside of and above Burdach's cords are Goll's cords, which are developed from the arch by which the deck-plate originally passed into the dorsal zone of His in the embryo. The fibres in Goll's cords are developed rather late.

The neuroblasts of the mantle layer of the dorsal zone send their nerve-fibres ventralward; the fibres constitute the *formatio arcuata*. As indicated in Fig. 378, only part of the posterior horn of the adult probably is developed from the dorsal zone. The inner and mantle layer give rise to the gray matter, which increases rapidly after the middle of the second month, owing partly to the multiplication of its cells, partly to the penetration of blood-vessels, and the accompanying loosening of the tissue; this loosening (*Auflockerung*) progresses from the head backward. At three months the posterior horn is still broad and short in section, but it gradually becomes long and narrow.

Substantia Gelatinosa Rolandi.—This tissue is probably the neuroglia plus numerous nerve-cells of the tip of the anterior horn, developed in the mantle layer. As the cells of the embryonic mantle layer are apparently *all* neuroblasts, His, 86.2, 508, assumed that there are cells, which migrate into the layer to form the gelatinous substance. The origin of these cells he did not observe. Gierke, 86.1, 144, pointed out that most of the elements are very small nerve-cells. H. K. Corning, 88.1, found that in the dorsal part of the inner layer of the dorsal zone of His, the development is greatly retarded, and he interprets the substance of Roland as a tissue persisting in a somewhat embryonic condition, and not having the same differentiation of its cellular elements that we find in other parts of the cord.

5. VENTRAL ZONES OF HIS.—The ventral zones are larger and more complex than the dorsal zones. At six weeks, Fig. 377, they comprise at least three-fourths of the cord; each zone consists of an upper connecting piece, His' *Schaltstück*, and a wider lower segment; the width of the latter is due to the great thickening of the inner and mantle layers; the *Randschleier* or *anlage* of the white substance extends completely over the outer surface of the zone as a layer or envelope, which varies but little in thickness. Owing to the projection of the oval bundle and of the lower segment, the *Schaltstück* is marked externally as a wide groove; His designates the angle of this groove next the oval bundle as the *Randfurche*, the angle next the lower segment as the *Cylinderfurche* (His, 86.2, 498). As development progresses, the *Schaltstück* relatively diminishes, while the lower segment increases, so that the groove just described is gradually obliterated; nevertheless it can long be recognized. The gray matter of the *Schaltstück* is to be considered as the *anlage* of the *cervix cornu*. For a considerable period the *Randschleier* or *anlage* of the white substance of the connecting piece remains thin, compare Fig. 377, but toward the end of the second month it begins to thicken until the groove is obliterated, but the thickened portion still retains, according to His, a certain individuality, and may be identified as the *anlage* of the lateral pyramidal cord (*Hinterseitenstrang*).

The lower segment of the ventral zone is the anlage of the anterior horn, the anterior column, and a large part of the lateral column. It is characterized by its early and rapid growth, at first chiefly of the gray matter, later of the white matter (Randschleier) also, compare Figs. 377 and 376. The exit of the ventral root divides the white substance into the anlage of the lateral column and the anlage of the anterior column or cord.

The growth of the gray matter depends chiefly on the multiplication of the germinating cells and the growth of the neuroblasts in the mantle layer. As the neuroblasts are most numerous in the ventral part, there results the precocious enlargement of the lower segment as compared with that of the rest of the cord. The neuroblasts of the lower segment send out their nerve-fibres mostly in small bundles. The nerve-fibres of the formatio arcuata coming from the neuroblasts of the dorsal zone also enter the lower segment, and as some of these fibres are developed later their paths cross those of earlier fibres, owing to the changed relative positions. Not all the neuroblasts send their fibres directly into the ventral roots; on the contrary, some of them are found placed longitudinally in the lower segment. Thus the gray matter of the anterior horn becomes very complicated at an early stage. The growth of the nerve-cells of the ventral column has already been described, p. 624.

5. GRAY AND WHITE MATTER OF THE FŒTUS.—Concerning the development of the cord during the fetal period (middle of the third month until birth) we know very little.

As regards the outline of the gray matter we find that the anterior and posterior horns at three months are of about the same size and shape, and have a very broad connection with one another, compare W. His, 86.2, 505. At five months the cord has grown very much, Fig. 378, and the central canal having remained stationary is relatively much smaller. In sections from an embryo of this age, I observe a peripheral denser layer surrounding a central looser area, which is divided, Fig. 378, into two parts by the anterior fissure and Burdach's cords; if this lighter area corresponds to the gray matter, then at this stage the anterior and posterior horns are fused, and the horns are not finally shaped out until later.

As regards the white matter: some scattered observations are recorded by Kölliker in the second edition of his "Entwicklungsgeschichte," and there

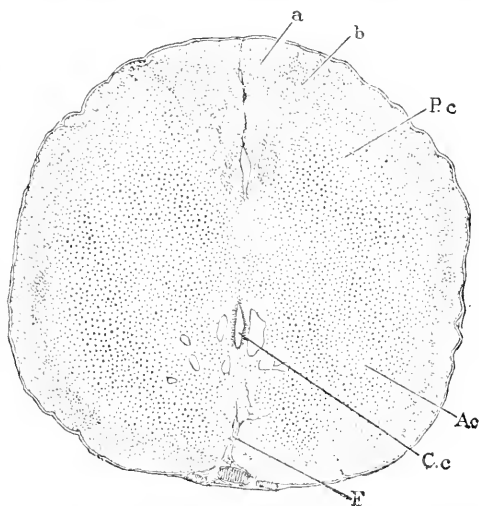


FIG. 378.—Lower Cervical Cord of a Human Embryo of about five Months. *a*, Goll's cord; *b*, Burdach's cord; *P.c.*, posterior horn; *A.c.*, anterior horn; *C.c.*, central canal; *F*, anterior fissure.

are a good many observations by various authors on the appearance of the medullary sheaths of the nerve-fibres, which are at first naked. Flechsig, **76.1**, drew attention to the fact that the sheaths appeared at different periods for different tracts, and he sought by extended observations to trace the course of the fibres within the cord of the embryo by following the course of the tracts with sheaths as distinguished from those without. Flechsig's observations have been extended by Bechterew, M. von Lenhossék, **89.1**, and several others. References to the various authorities are given by von Lenhossék. A proper collation of the results obtained has yet to be made. Lenhossék finds that the medullary sheaths appear on the fibres of the posterior roots and on the fibres of Burdach's column about the same time, but that the fibres of Goll's column are not medullated until a few days later. He has discovered, further, that at a certain period the fibres of the lower part of Goll's column are medullated, while in the lower cervical region only those fibres which form the ventral part of the column have received white sheaths, and that in the upper cervical region none of the fibres of this column are medullated. He concludes, therefore, that the medullation of Goll's column is centripetal in direction, and that the fibres which form it have a long course, but he thinks that there is no anatomical proof that any of the fibres of the posterior roots pass directly into the postero-internal columns. It is now generally allowed that the deposition of white matter upon the axis cylinders takes place first in the neighborhood of the cells from which they spring, and proceeds thence toward the termination of the axial process. This being the case, it follows that as the columns of Burdach consist principally of posterior root fibres which have just entered the cord, they will become medullated very shortly after the fibres of the posterior roots themselves, while the column of Goll, which is formed of fibres of the posterior roots which have entered the cord at a considerably lower level, will become medullated at a later period.

Cajal, **90.1**, discovered that the fibres of the white substance of the spinal cord give off fine branches nearly at right angles, which penetrate the gray matter; these branches he names the collaterals, *l.c.*, p. 88, and they have since been found in the adult by Kölliker, **90.2**. They appear very early in the embryo, and after the medullary sheaths appear they are seen to go off from the main fibre at the nodes of Ranvier.

6. BLOOD-VESSELS.—The first appearance of the blood-vessels in the cord has been studied by W. His, **65.1**, 15, **86.2**, 493. The spinal cord lies in a canal, the walls of which are formed by embryonic connective tissue and represent the anlage of the pia mater. During the embryonic period of the human embryo the cord is in contact with the wall of the spinal canal only along the median dorsal line. The walls of the canal contain capillaries which are developed during the third week in the region of the head from the aorta, in the rump from the intervertebral arteries.

These capillaries form anastomoses which produce four longitudinal vessels, two near the ventral median line, one close below each sensory root. From these four vessels vascular buds penetrate the

spinal cord, the branches from the ventral arteries preceding the others in their development; *cf.* His, 86.2, Taf. I., Fig. 2. The two ventral arteries become included in the anterior fissure; during the sixth or seventh week they unite into a single median vessel at the bottom of the fissure, *i. e.*, near the central canal; this vessel is the *arteria sulci*, and is the principal source of supply for the gray matter. From the two vessels next the sensory roots branches enter to the region of the future posterior horn.

The vascular buds consist of elongated vasoformative cells, which force their way through the neuroglia network; by the time the buds have become vessels, there are considerable perivascular spaces, as if the neuroglia had contracted away from the blood-vessel.

After the vessels have penetrated it, the cord develops more rapidly, as if better nourished (His, 86.2, 496).

Medulla Oblongata.—The term is now restricted to the portion of the brain extending from the spinal cord to the Varolian bend. Our knowledge of its development is derived mainly from the superb researches of His, whose predecessors had given us little more than generalized descriptions of the external form. This section is, therefore, based on His' paper, 90.2, which, however, deals with the development of the region of the calamus scriptorius only, to which region accordingly the following account mainly refers. The presence of the zones of His and the appearance of the Rautenlippe have already been described, p. 608. The division of the medullary walls into four zones (p. 606) dominates the structure of the medulla oblongata throughout life, and the division of the ventral and dorsal zones of His can be traced in the floor of the fourth ventricle of the adult. The secondary complications of the medulla are largely owing to the modifications due to the transformation of the Rautenlippe, and in lesser degree to the fact that the anterior fissure of the spinal cord is replaced by a thickening of the Bodenplatte, which allows the nerve-fibres to cross from one side to the other directly. The following more detailed history may be more easily understood if these general characteristics of the medulla are born in mind, than would be otherwise possible.

As His points out, 90.2, 66, the adult medulla contains in every transverse section parts which have been present from the start and others which have been added later; the former as a rule lie nearer the ventricle; the added parts lie nearer the outside, but a portion of them mingle with the older parts, it being especially the fibres which traverse the medulla as they develop in manifold directions. Nevertheless, in a general way, we may affirm that the further from the ventricle in the adult, the later was the development in the embryo. The first cells to be differentiated are the spongioblasts, which constitute the ependyma in the adult. Next arise the neuroblasts which migrate into the mantle layer; the earliest nerve-fibres alone give rise directly to nerve-roots; the later ones take their paths within the medulla. Third arise the fibres of the *formatio arcuata*, which lies in the outer part of the mantle layer and sends its fibres from side to side, and the homologue (*tractus solitarius*) of the oval bundle of spinal cord sensory fibres. Fourth, the parts already formed are covered in by the Rautenlippe and the stream of neuroblasts which

it sends toward the median line. Outside of all these finally ensues a development of transverse and longitudinal fibres, the latter including the funiculus restiformis and the tractus intermedius of His.

ZONES OF HIS IN THE ADULT.—As will be shown below, the tractus solitarius is a bundle of fibres running longitudinally and homologous with the "oval bundle" of sensory fibres in the spinal cord, and it indicates permanently the lower boundary of the dorsal zone of His. In the embryo the two columns primitively meet at a decided angle, and this angle is marked by a groove in the wall of the central canal, or, as we should say in referring to the adult, in the floor of the fourth ventricle. There is always a median groove, which extends from the opening of the central canal to the aqueductus Sylviae, and marks the limit between the two ventral zones of His, although they partially conalesce during embryonic life; on each side of the groove is the ventral zone, the surface of which projects slightly and is known in descriptive anatomy as the eminentia teres. The groove between the dorsal and ventral zone is very shallow and partially obliterated in the adult; it persists, however, in three depressions, namely, the fovea posterior of the ala cinerea, the fovea anterior, and the sharp depression between the eminentia teres and the peduncles of the cerebellum; opposite Schwalbe's tuberculum acusticum the groove is almost obliterated. By this division we see that the ala cinerea and corpora restiformia are parts of the dorsal zone of His.

DORSAL ZONE OF HIS.—This part of the medulla (*Flügeliste* of W. His) undergoes fundamental modifications owing to the development of the Rautenlippe, p. 608. It also changes its position with relation to the ventral zone in consequence of the long continued expansion of the deck-plate, or, in other words, in consequence of the so-called opening of the medulla. When first fully differentiated the ventral zones, as seen in cross sections, Figs. 348 and 349, ascend obliquely from the median line, but the dorsal zones

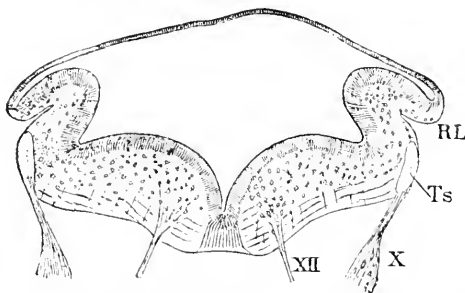


FIG. 379.—Transverse Section of the Medulla Oblongata of His' Embryo Ru (Nackenzlänge, 9.1 mm). After W. His. *RL*, Rautenlippe; *Ts*, tractus solitarius; *X*, vagus nerve; *XII*, hypoglossal nerve. $\times 40$ diams.

appear nearly parallel with the median plane. In the next stage, Fig. 379, the ventral zones diverge so much from one another that they both lie nearly in the same horizontal plane; at the same time (beginning of the fifth week) the dorsal zone bends over throughout its length to form the Rautenlippe, *RL*: the lower limit of the dorsal zone is marked by the position of the tractus solitarius, *Ts*. Within a

few days the Rautenlippe unites with the main fold of the zone and continues to grow toward the median ventral line passing outside of the tractus solitarius, which thus becomes buried, and, instead of lying superficially, is thereafter deep below the outer surface. The modified dorsal zone formed by the union of the

two folds is termed by His, 90.2, 33, *Flügelwulst*. With the beginning of the sixth week the *Flügelwulst* bends over outward so that its inner surface faces dorsalward and its outer surface ventralward. The dorsal and ventral zones are now nearly in the same plane, and the groove on the inner surface between the zones is nearly obliterated, Fig. 380. There next arises the secondary Rau-

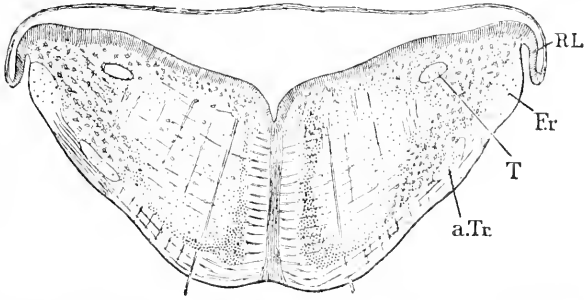


FIG. 380.—Transverse Section of the Medulla Oblongata of His' Embryo Mr. *T*, Tractus solitarius; *Er*, secondary Rautenlippe; *Er*, funiculus restiformis; *a.Tr.*, ascending trigeminal tract. After W. His. $\times 10$ diams.

tenlippe of His, Fig. 380, *RL*, which is apparently not a nervous structure, but merely a transition from the dorsal zone to the ependyma or expanded deck-plate; it must not be confounded with the true or primary Rautenlippe. If the size of the parts developed from the dorsal zone be compared with that of the ventral column in Fig. 380—the tractus solitarius, *T*, marks the boundary—it will be evident that scarcely a fifth of the adult medulla is developed from the dorsal zone.

The dorsal zone becomes the *corpus restiforme* of the adult, including the tracts of longitudinal fibres associated with it; these are the *tractus solitarius*, Fig. 380, *T*, the *funiculus restiformis*, *Er*, and probably the *ascending trigeminal tract*, *a.Tr.* This last probably only, because at the time and place it appears the exact boundary between the two zones cannot be determined. Further toward the spinal cord the restiform body merges into the clava, which passes into the fasciculus gracilis, which in its turn is prolonged into the columns of Goll in the spinal cord. During the fifth month the clava occupies nearly a transverse direction (Kölliker, "Entwickelungsges.," 2te Aufl., 549). The detailed history of the restiform body has still to be traced. The tractus solitarius arises very early, owing to the penetration of fibres from the cerebral ganglia into the medulla; these fibres, like those of the spinal nerves, take a longitudinal course and appear in sections as a compact bundle situated in the Randschleier of the dorsal zone of His, as has been already described in detail in the account of the cephalic nerves. As stated above, the Rautenlippe during the fifth week buries the solitary tract. Its development shows that it is homologous with the columns of Burdach of the spinal cord, although in the medulla it loses its original superficial position, which it retains in the cord. After the Rautenlippe has united with the inner fold of the dorsal zone a layer of neuroglia is developed over the new external sur-

face of the zone; this layer is continuous with the Randschleier of the ventral zone, compare Fig. 360; in it appear two bundles of longitudinal fibres, *Fr* and *a.Tr*, also transverse or so-called arcuate fibres. The most lateral of these bundles, *Fr*, is the funiculus restiformis; it is scarcely noticeable until the secondary Rautenlippe is formed; the fibres are coarse; the ventro-medial portion is penetrated by arcuate fibres; the fibres of the bundle first appear near the cord, later higher up; most of its fibres are arcuate ones, which bend and take a longitudinal course; these arcuate fibres of the funiculus probably arise from the cells of the olivary body of the ventral zone of the opposite side (His, 90.2, 57). The ventro-medial bundle, Fig. 380, *a.Tr*, in the outer neuroglia layer, is the *tractus intermedius* of His, a term which he employs because the bundle includes not only ascending sensory fibres, but probably also fibres running from the cerebellum to the spinal cord; in descriptive anatomy the bundle is usually known as the ascending trigeminal tract or root; the bundle is oval in section and consists of coarse longitudinal fibres, and is crossed by arcuate or transverse fibres; its development begins anteriorly and progresses tailward (His, 90.2, 56).

The *neuroblasts* of the dorsal zone have a remarkable history, according to W. His, 88.3, 90.2, 35-44. They arise early and rapidly become abundant (see p. 611), and their production continues until the end of the second month, when it ceases altogether, His, 90.2, 47. The neuroblasts develop during the fourth week, that is to say, before the formation of the Rautenlippe begins, and produce the arcuate fibres and the primitive cerebral motor roots, as above described for the single nerves. These neuroblasts, therefore, resemble in their development those of the spinal cord. The neuroblasts which arise later have in large part a different history, accomplishing a peculiar migration, which has no parallel in the spinal cord. In the medulla, as in the cord, the production of neuroblasts begins on the ventral side and progresses for a week or more dorsalward, and consequently, when the germinating cells or parent cells of the neuroblasts have disappeared in the ventral zone, they are still present in the dorsal zone and continue to change into young nerve-cells while the Rautenlippe is bending over. The confluence of the Lippe with the main fold of the dorsal zone opens the way for the neuroblasts of the Rautenlippe to migrate from their site of origin past the outside of the tractus solitarius toward the ventral zone of His, which they enter, and accumulating in its lower part, Fig. 381, there contribute, together with other neuroblasts which come from the dorsal zone by migrating in paths inside the tractus solitarius, to the development of the olivary bodies. The cause of the migration of the neuroblasts is entirely unknown, but their wandering from the Rautenlippe is one of the most distinctive characteristics of the medulla oblongata.

VENTRAL ZONE OF HIS.—This zone is at first about the same as the dorsal in size, Fig. 379, but it rapidly outgrows the dorsal zone and constitutes more than three-fourths of the adult medulla. Its development has an obvious resemblance to that of the ventral zone in the spinal cord, for there is a similar rapid expansion and consequent bulging inward and outward, and the expansion

is due chiefly to the mantle layer, the Randschleier remaining thin. There are three chief factors which cause the development to differ from that in the spinal cord. These are, 1, the bending of the zones outward and downward until they come to lie in nearly the same horizontal plane, compare Fig. 379 with Fig. 380; 2, the absence of the anterior fissure, which is obliterated by the growth of the Bodenplatte to constitute the raphe; 3, the peculiar arrangement which is gradually assumed by the gray matter, developed out of the mantle layer; 4, the nerve-fibres in the Randschleier also take different courses from that which they take in the white matter of the spinal cord. These four sets of features are considered in the four following paragraphs.

1. *The bending of the ventral zones*, like that of the dorsal, is part of the process of the so-called opening of the medulla correlated with the expansion of the deck-plate. The general character of the movement has been already described, p. 609. We have merely to add that, while it is going on, the inner surface of the zone, which constitutes the larger part of the floor of the fourth ventricle, becomes protuberant and bulges inward, forming a wide, rounded, longitudinal ridge, Fig. 381; the two ridges are separated from one another

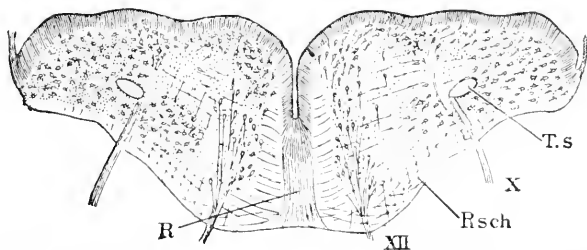


Fig. 381.—Section through the Medulla Oblongata of His' Embryo CR. *T.s.* Tractus solitarius; *X*, vagus nerve; *Rsch*, Randschleier; *XII*, hypoglossal nerve; *R*, raphe. After W. His.

by a narrow, deep median fissure or groove, which in later stages opens somewhat, so as to appear V-shaped in cross section, and persists throughout life in that form. As the groove deepens but little, if at all, after the second month, while the medulla continues to enlarge, it follows that the groove becomes not absolutely, as sometimes stated, but relatively smaller. His speaks of its opposite walls uniting and the groove thus diminishing, but he gives no direct evidence of such conrescence, and his figures show no diminution of size in the groove during later stages. In Fig. 381, another effect of the interior bulging is shown, namely, that that part of the surface of the ventral zone is brought into nearly the same plane as the inner surface of the dorsal zone, and as the groove between the two zones is nearly obliterated, the floor of the medullary cavity (fourth ventricle) is rendered comparatively even.

2. *The raphe* arises by a thickening of the Bodenplatte and is primitively a partition of neuroglia, which is subsequently penetrated by fibres crossing from side to side. In the spinal cord the Bodenplatte remains thin though it gives rise to neuroglia, and by the passage through it of nerve-fibres forms the anterior white commissure. We must, therefore, homologize the raphe with this commissure.

As the ventral zones thicken during the second month and project more and more ventralward, the growth of the Bodenplatte in the medulla oblongata obliterates the fissure almost, but not quite, completely, which would otherwise be formed between them, as in the cord. The growth of the Platte depends on the elongation of its cells (spongioblasts, for it contains few or no neuroblasts), which is accompanied by a movement outward of some of its nucleated cell-fibres, which are at first all situated close to the central canal. By the end of the first month fibres cross the septum, and thereafter the number of fibres crossing it steadily increases. It allows no neuroblasts to pass (His, 90.2, 27, 55).

3. *The gray matter* or mantle layer increases very rapidly and is the principal factor in the enlargement of the ventral zone. Its development involves, as elsewhere in the neuron, the gradual reduction of the inner layer until only the ependyma remains. The gray matter is, of course, homologous with the anterior horn of the spinal cord; but whereas in the spinal cord the nerve-cells and nerve-fibres are irregularly arranged, in the medulla they produce a highly characteristic pattern by their distribution. The greater part of the gray matter in the ventral zone of the medulla is converted into the *formatio reticularis*, His, 90.2, 51. The *formatio reticularis* has from the very start a more or less distinctly four-sided outline, as seen in cross sections; it is marked out by the bundles of nerve-fibres crossing one another at right angles. One side faces the fourth ventricle, Fig. 381; one faces the raphe; the third faces the outer wall of the medulla, and the fourth, which is irregular and somewhat undefined, faces the dorsal zone. The reticulate appearance of this area is due to the crossing of the fibres at right angles to one another. The fibres are first radial, second arcuate or transverse running toward or from the raphe, and third longitudinal; the last set of fibres are developed later than the first two. The fibres are united in bundles, which grow in size by the addition of fibres which join them as development progresses; the fibres are accompanied by a limited number of neuroblasts migrating along the bundles. The *formatio reticularis* is clearly mapped out by the end of the fourth week, and its development commences as soon as the nerve-fibres begin to grow out from the neuroblasts, for the fibres at once follow their definite courses, one set taking radial paths, another set taking transverse courses. A similar arrangement is found in the mantle layer of the spinal cord, but is obscured by the further development, instead of being preserved and emphasized as in the medulla.

In embryos of six weeks and older the *formatio reticularis* is entirely surrounded by a crowd of neuroblasts. Of these the accumulation on the inner side, or toward the fourth ventricle, is the oldest and consists of neuroblasts developed *in loco*; it is very distinct at the beginning of the fifth week. The neuroblasts on the lateral side are, of course, those which belong to the dorsal zones of His. Those on the medial and outer side, on the contrary, are immigrant cells, which have travelled to their location after the union of the Rautenlippe with the main wall. The stream of cells passes, as we have seen, on both sides of the tractus solitarius, Fig. 381; that

outside the tractus comes from the Rautenlippe, and is at first (fifth week) small, but later increases very much. The stream progresses around the edge, or, better expressed, over the surface of the formatio until its outer and medial surfaces are covered by scattered neuroblasts, forming a continuous sheet (*Grünzplatte* of His, 90.2, 42), which the subsequent development transforms into the cellular layer of the *olivary body*, compare Fig. 381. The olivary cell band has at first no very definite boundary; the cells are here and there more crowded than elsewhere (His, 90.2, 52); the fibres which spring from them gather into bundles and run toward the raphe; by the end of the third month the olivary band has become folded and appears to contain all the cells it is to receive. The band gives rise ultimately to both the upper and lower olivary bodies—in the region of the hypoglossus to the accessory olivary body (*Neubeuolire*) and in the region of the pons to the *zackiger Brückenkeru* of His. The layer of neuroblasts between the formatio reticularis and the ependyma is the anlage of the sub-ependymal motor nuclei, His, *l.c.*, p. 50. It may prove an assistance in following the description of the medullary structure to point out that in a rough way there are four layers distinguishable: 1, externally is the layer of white matter developed from the Randschleier, and which may be followed into the dorsal zone, see Fig. 381; 2, internally is the sub-ependymal layer of neuroblasts, which is continued laterally into the gray matter of the dorsal zone (*corpus restiforme*); 3, inside the external fibrous layer is the sheet of olivary neuroblasts, which merge into the lateral gray matter of the dorsal zone; 4, the layer of the formatio reticularis between the sub-ependymal layer and the olivary body; this layer may be considered as continued laterally by the tractus solitarius, but topographically only, for the formatio reticularis arises from the gray matter, the tractus, as we have seen, from the primitive Randschleier, so that one cannot be the morphological continuation of the other.

4. *The Randschleier* includes the homologues of the anterior and lateral cords of white substance in the spinal cord, being divided by the exit of the ventral roots (hypoglossus and abducens) into two regions, Fig. 381, one medial region adjoining the raphe, the other ventral, situated at the exposed outer ventral surface; the former corresponds to the anterior, the latter to the lateral columns, and the latter spreads, as we have seen, over the dorsal zone after the concrescence of the Rautenlippe. The two regions meet, of course, along the line of the ventral roots, forming a rounded angle with one another (His, 90.2, 54). The medial region, as soon as the nerve-fibres begin to develop, acquires both longitudinal fibres and transverse fibres, the latter running to the raphe or thickened Bodenplatte; as development progresses the number of fibres increases and they group themselves into bundles; the primitive longitudinal fibres, like those of the spinal cord, are derived from the gray matter of the opposite side; this primitive longitudinal bundle persists throughout life; it is the *hinterer Laugsbündel* of Flechsig. During the second month the medial region grows rapidly, expanding at the same rate as the raphe, but the primitive longitudinal bundle is kept confined near the ventricle so that below it is a layer of neuroglia

between the *formatio reticularis* and the raphe; this layer is crossed by bundles of arcuate fibres, which enter through the raphe from the opposite side and most of which join the *formatio reticularis*; during the fourth month longitudinal fibres constituting the so-called pyramids are developed in this ventral part of the medial region. The very late development of the pyramids was discovered by Flechsig, **76.1**, 132, 142.

The ventral region of the *Randschleier*, extending from the exit of the ventral roots, Fig. 381, XII, to the dorsal zone, is, of course, homologous with the region of the lateral columns of the spinal cord; it is identical with the medial part of the *weisse Randzone* of Flechsig, **76.1**. When the olivary band of neuroblasts becomes folded, some of the folds cut so deep into the white layer that it is almost obliterated at those points. About the middle of the second month fibres from the raphe enter the layer and ultimately pass on to form the *funiculus restiformis*; the number of these fibres, though small at first, is large by the end of the second month. There appear during the second month fine longitudinal fibres in the layer.

Pons Varolii.—The pons is developed out of the floor of the third primitive vesicle of the brain, in front of the Varolian bend. Concerning its history we possess no detailed information. Kölliker (*Grundriss*, 2te Aufl., 250) states that the characteristic transverse fibres appear during the third month as a narrow, thin band, and that the pons grows as the lobes of the cerebellum become larger and more distinct. He notes further as characteristic of the foetal brain that the *corpus restiforme* seems to merge in part with the lateral part of the pons, and apparently some of the fibres of the corpus bend toward the median ventral line and enter the pons. The growth of the pons is rapid. In embryos of the fourth month and older, the pons can be at once recognized as a commissure between the two sides of the cerebellum.

As to the fate of neuroblasts present in the pons, and as to the origin of the nerve-fibres of the pons, nothing is, as yet, known. It will probably be found that the development of the pons is similar to that of the ventral zones of His in the medulla oblongata.

Cerebellum.—The morphologically primitive relations and position of the cerebellum are well shown in the frog's brain, Fig. 393. It is a thickening of the brain walls extending across the median dorsal line; its formation, therefore, involves the thickening of the deck-plate; the cerebellum is situated between the medulla oblongata and the isthmus or constricted portion of the medullary tube connecting the hind- and mid-brains. His, **90.2**, 24, states incidentally that it is developed in man at least from the dorsal zone of His (*Flügelplatte*); unfortunately his investigations on the cerebellum are still unpublished.

The following account of the development of the external form of the cerebellum is based on Mihalkovics, **77.1**, 53-57. In its first stage the cerebellum is merely a lamella across the dorsal side of the hind-brain; its posterior limit is marked by the point where the expansion of the deck-plate begins; toward the mid-brain the lamella merges into the isthmus without any demarcation (human embryo

of the fourth week), compare Fig. 342. At this stage the cerebellum rises as a transverse plate inclined at a wide angle to the axis of the medulla oblongata, and bears an obvious resemblance to the amphibian cerebellum, compare Figs. 382 and 393. While the Varolian bend (*Brückenbenge*) is developing the lamella thickens and widens; its posterior border passes gradually into the thin and expanded deck-plate of the medulla; the transitional part is the secondary Rautenlippe, and does not participate in the formation of the cerebellum, but is the anlage of the *velum medullare posticum* (*hinteres Marksegel*) p. 677. The further development of the lamella in the chick has been investigated by Lahousse, 88.1; it continues growing in all dimensions; by the third day it begins to arch forward and upward until it encloses a space, which is a diverticulum of the fourth ventricle, Fig. 383; the convolutions are distinctly marked on the ninth day and are merely superficial transverse ridges, not folds of the wall.

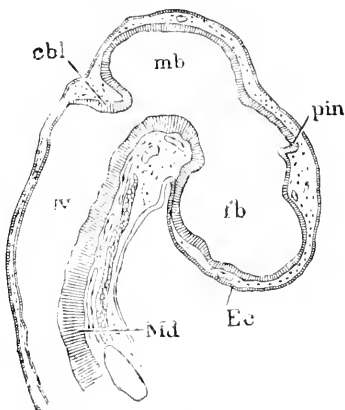


FIG. 382.—Median Section of the Brain of a Chick Embryo of about four Days. *cbl*, Cerebellum; *mb*, mid-brain; *pin*, pineal anlage; *fb*, fore-brain; *Ec*, ectoderm; *IV*, fourth ventricle; *Md*, floor of medulla oblongata. After Lahousse.

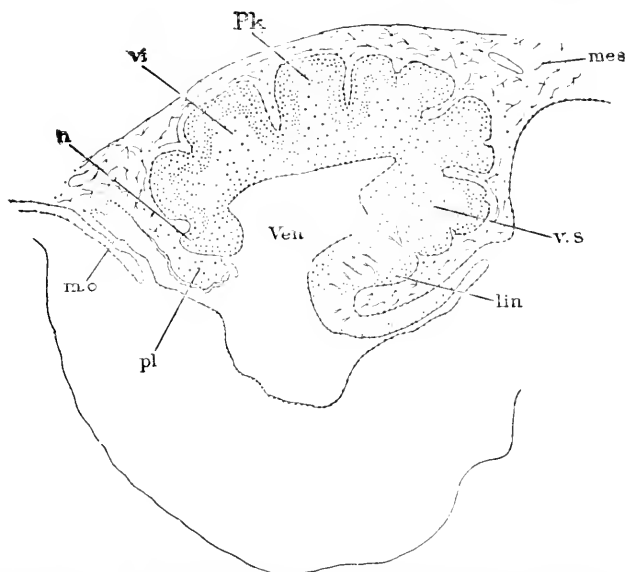


FIG. 383.—Longitudinal Median Section of the Cerebellum of a Chick of about twelve Days. *n*, Nodus; *v.i*, vermis inferior; *Pk*, layer of Purkinje's cells; *mea*, mesoderm; *v.s*, vermis superior; *lin*, lingula; *pl*, plexus; *m.o*, membrana obturator. After E. Lahousse.

It is probable that in the mammalian embryo a similar bending of the lamella takes place, but that the diverticulum is obliterated

by the growth of the cerebellar walls, but observations are wanting to verify this supposition. There is never present any large open diverticulum in the mammalian embryo (Kölliker, "Entwickelungsges." 2te Aufl., 537). The lamellar anlage of the mammalian cerebellum grows rapidly into a rounded protuberance, the transverse diameter of which exceeds the longitudinal. As seen from above, the cerebellum now appears somewhat pointed laterally. The lateral ends of the lamella expand and form the anlage of the cerebellar hemispheres, leaving the median portion as the anlage of the vermis. There now soon appear (beginning of the fourth month in man, cow embryo of 80 mm.) a series of four transverse grooves, by which the surface of the vermis is divided into five primary ridges (gyri), which persist as five primary lobes throughout life; two of the transverse lobes belong to the upper surface;

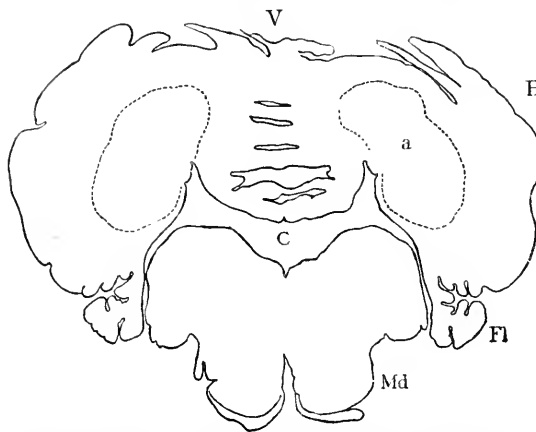


FIG. 384.—Section through the Cerebellum and Medulla Oblongata of a Human Embryo of one hundred and sixty Days. Minot Coll. No. 66. *V*, Vermis; *H*, hemispheres; *Fl*, flocculus; *Md*, medulla oblongata; *C*, Central canal. $\times 4$ diams.

the lower surface; they are respectively the quadrate or antero-superior, the postero-superior, the postero-inferior, pyramidal, and the uvula. During the fourth month the hemispheres grow rapidly, so that at five months they equal and thereafter surpass the central vermis more and more in size. The primary transverse lobes spread onto the hemispheres during the fourth month, and they persist there as in the vermis throughout

life. In descriptive anatomy an astounding variety of names are applied to the various parts of each lobe; it would be an essential gain if at least three-fourths of these names could be discarded. Each of the five primary lobes becomes subdivided by additional grooves, most of which are approximately parallel to the primary grooves; the subdivision continues until the full number of folia are produced, which is probably accomplished before birth. The fifth or most posterior lobe forms an independent expansion on each side, beginning in the fourth month to form the flocculus, Fig. 384, *Fl*. A number of additional details as to the human cerebellum at various stages are given by Kölliker ("Entwickelungsges." 2te Aufl., 542-548).

The *histogenesis* of the cerebellum has been studied in the chick by Lahousse, 88.1, and in man by Bellonci et Stefani, 89.1, and Vignal, 88.1. In the chick at six days (Lahousse, Fig. 28) both the mantle and inner layers are crowded with nuclei and form about three-fourths of the wall in section, the remaining fourth being constituted by the Randschleier in which there are a few nuclei; between

the spongioblasts are seen the dividing germinating cells (p. 613) close to the central canal. The Randschleier of the cerebellum is the *graue moleculäre Decklamelle* of Löwe, 80.2, or *enveloppe moléculaire grise* of Lahousse, *l.c.*, p. 63. At the sixth day there begins to appear in the Randschleier a stream of cells, which probably come from the Rautenlippe of the cerebellum, but as the Lippe was not known to Lahousse he gives no information on this point.* These cells are elongated parallel to the surface of the cerebellum, close to which they appear. Their immigration results finally in the conversion of the Randschleier into the outer layer of the adult. During the eighth day the nerve-fibres appear, the differentiation of the mantle and inner layers is easily recognized, and the Randschleier now comprises three layers, a thin outer or superficial neuroglia layer, a middle gray richly nucleated layer, in which the immigrant cells are situated, and a third layer next the mantle layer, having scattered nuclei. The ninth day we can make out the following layers beginning within: 1, the ependyma; 2, the inner layer; 3, the mantle or gray molecular layer, some of the cells along the outer edge of which are changing into Purkinje's cells, making another layer, 4; 5, the neuroglia layer or inner part of the Randschleier; and, 6, the outermost layer containing immigrant cells (Löwe's *Zellstrief*), cells which are probably neuroblasts.

The six layers just enumerated can be recognized in the mammalian embryo, and have been described by W. Vignal, 88.1, 327-334, Pl. XII., who, however, failed entirely to recognize the early differentiation of the neuroblasts and neuroglia. There is a thin outermost layer without nuclei, next follows a broader layer crowded with nuclei; these belong to the cells which have migrated into the embryonic Randschleier, and they form a well-marked layer throughout fetal life; this layer, so far as I know, was first observed by Obersteiner (Sitzber. Wiener Akad. Wiss., 1870), in the cerebellum of new-born children; and it may be conveniently designated as the *outer nuclear layer*; it disappears as a distinct layer during childhood. Bellonci et Stefani, 89.1, 23, state that two zones may be distinguished in Obersteiner's layer, an outer zone with numerous karyokinetic figures and crowded round nucleolated nuclei, and an inner zone with the nuclei elongated and less crowded. In pigeons of twelve days' incubation, some of

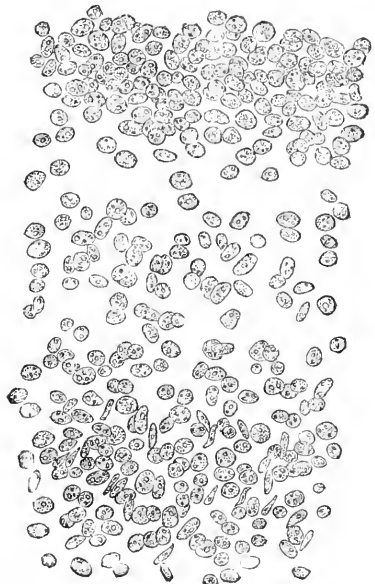


FIG. 385.—Section of the Cerebellum of a Human Embryo of one hundred and sixty Days. Minot Coll., No. 66. Under the surface is seen the crowded outer nuclear layer, and deeper down the outer portion of the mantle layer, with crowded nuclei, some of which are elongated.

*Löwe came very near discovering the Rautenlippe, for he observed that the ependyma was reflected on to the outside of the cerebellum.

the cells of the outer nuclei have developed dendritic processes, which extend even into the inner nuclear layer. Immediately below the outer nuclear layer is one with few nuclei, and then we come to the broad band of crowded nuclei belonging to the mantle layer proper; everything outside the mantle layer is derived from the primitive Randschleier. The cells of Purkinje are recognizable in the human fœtus of five months and their external branches at six months; at seven months their inner ends are rounded, but at birth pointed and apparently prolonged as a process running into the mantle layer (axis-cylinder process?).

The Fourth Ventricle and its Roof.—The fourth ventricle has long been known to embryologists as the expanded central canal of the hind-brain, and as enclosed completely by the medullary wall. The expansion of the deck-plate and consequent thinness of the dorsal wall of the ventricle was known to Von Baer, but he supposed that this wall was lost in the adult, 28.2, 74, 37.1, 108. Remak, 50.1, 33, maintained this opinion for the chick; Rathke, 39.1, 37, 38, 20.1, Th. IV, 14, for reptiles and anamniota. We owe to Kölliker ("Entwickelungsges.," 1ste Aufl., 243) the discovery of its persistence; to Hensen (*Arch. f. Mikrosk. Anat.*, II. 424) the demonstration that it forms the epithelial covering of the choroid plexus.* Several writers have thought that the membrane was broken through at certain points, but it probably is really continuous throughout life. The fourth ventricle is to be regarded, then, as an expansion of the central canal permanently bounded by the original medullary walls.

The fourth ventricle has, as seen from above, a rhomboid shape, Figs. 342, 343; it tapers down anteriorly to the central canal (aqueductus Sylvie) of the mid-brain, posteriorly to the central canal of the spinal cord. It is widest at the level of the Varolian bend and in the adult the lateral angles of the embryo persist as the *recessus laterales*. The so-called floor of the ventricle is constituted by the inner surface of the dorsal and ventral zones of His, already described.

The roof of the ventricle behind the cerebellum is derived from the deck-plate, compare p. 608; it becomes subdivided into three parts, the dorsal ependyma, the secondary Rautenlippe, and the epithelial covering of the choroid plexus of the fourth ventricle. The deck-plate is a layer of epithelium and preserves its simple epithelial character through most of its extent and throughout life. In the human embryo at four weeks (His, 90.2, 29) it is a single layer of cells, 8 μ high by 10 μ wide, but toward the edges of the plate the cells become a little higher and narrower; the number of cells increases (whether by their own division or not, is uncertain) so that the cells become higher (11–13 μ) during the second month, although the area of the membrane greatly enlarges.

Where the deck-plate joins the lateral wall of the medulla it becomes thickened, forming the secondary Rautenlippe, p. 667. When the main deck-plate and the choroid plexus are removed from an embryo of two months or older, the Rautenlippe appears as a

*These references are taken without verification from Mihalkovics, 77.1, 60. The reference to Hensen has been verified, being to an incidental observation in a paper on the eyes of snails.

narrow whitish band along the edges of the *fovea rhomboidalis*, or, in other words, of the medulla oblongata and cerebellum. The band persists throughout life and is known in descriptive anatomy by three different names; the part attached to the cerebellum is termed the *velum medullare posticum* (*hinteres Markseigel*); the part along the edge of the medulla oblongata is termed the *Tænia fosse rhomboidalis* or *ligula* (*Riemchen*); the part at the posterior apex of the rhomboid opening is termed the *obex* (*Riegel*).

The choroid plexus is an ingrowth of the deck-plate accompanied by vascular mesenchyma and projecting into the cavity of the fourth ventricle. In the amphibia, Fig. 393, the half of the deck-plate nearest the cerebellum forms a series of irregular rounded projections into the cavity of the fourth ventricle, and each of these projections contains mesenchyma (*i. e.* connective tissue and blood-vessels). In mammals we find the same choroid area, but it is pushed in, as a whole, into the cavity. In the placentalia at least, the invagination of the whole area precedes in the embryo the formation of the irregularities of the surface. The invagination, *cf.* Fig. 386, may be seen in the human embryo of five or six weeks as a transverse fold of the deck-plate extending quite deep down, and resulting, apparently, from the excessive development of the Varolian bend. The fold is the anlage of the choroid plexus. By its further development the anlage assumes a more and more complex and irregular form, but it remains always a fold of mesenchyma richly vascular and covered by the epithelial deck-plate. In the human embryo at four months (Kölliker, "Entwickelungsges.," 2te Aufl., 540) the position of the fold can be seen, when the medulla oblongata is viewed from above, as a narrow transverse line, along which the mesenchyma (connective tissue of the pia mater) enters the fold, and which is situated close behind the cerebellum; in front of and behind this line the deck-plate forms a transverse ridge (*gyrus choroideus anterior* and *posterior*); the two ridges might, at first sight, be mistaken for portions of the cerebellum.

The Mid-brain.—Concerning the second cerebral vesicle our information is very imperfect, and amounts to little more than a knowledge of its general form at successive stages; it is derived chiefly from Mihalkovics, 77.1, 63-68, and Kölliker, "Entwickelungsges." 2te Aufl., 535. The mid-brain is remarkable for its precocious expansion, Fig. 341, and for the fact that in young embryos it occupies—owing to the cephalic flexures—the highest part or summit of the head, Fig. 338. In both the figures just referred to, the mid-brain appears as a vesicle with a large cavity and thin walls constricted in front as it joins the fore-brain—behind, as it joins the hind-brain. We have no knowledge of the separate histories of the six longitudinal zones (deck-plate, the four zones of His, and the Bodenplatte). The floor of the mid-brain very early begins to thicken, and the thickening includes the Bodenplatte, for it extends across the median line. On the dorsal side the median line has, in young human embryos at least, an external ridge with a corresponding internal groove, both resulting from a median fold of the medullary wall. The whole dorsal side of the mid-brain expands considerably (human embryos of four weeks); especially is this the case in Sauropsida,

as may be well seen in a chick embryo of the fourth day, Fig. 382. The mid-brain now grows steadily, though much less than the fore- and hind-brains, so that the cerebrum and cerebellum outstrip it. Its growth is principally a thickening of its walls and an increase of its length, but with little enlargement of its cavity; hence the cavity becomes relatively smaller, though it persists throughout life as the part of the central canal known as the *aqueductus Sylvii*, and intervening between fore-brain (third ventricle) and hind-brain (fourth ventricle).

The ventral part (? ventral zones of His) of the mid-brain develops into the *peduncles of the cerebrum*; the projecting of the peduncles as rounded longitudinal ridges on either side of the median

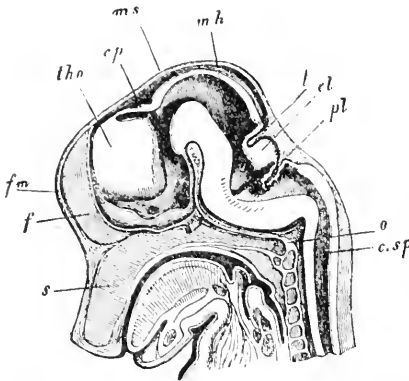


FIG. 386.—Median Section of the Head of a Sheep Embryo of 36 mm. *s*, Septum narium; *f*, falx cerebri; *f.m.*, foramen of Munro; *thm*, thalamus; *cp*, commissura posterior; *ms*, tegumentum; *mh*, midbrain; *l*, tentorium; *cl*, cerebellum; *pl*, choroid plexus. After Kölliker. $\times 3$ diams.

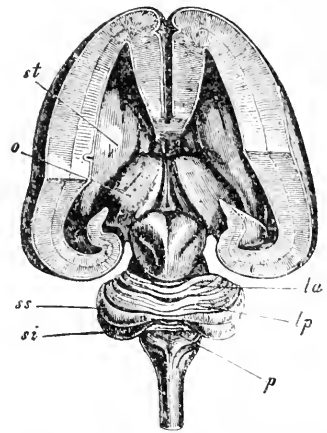


FIG. 387.—Brain, Human Fœtus, five Months. *st*, Corpus striatum; *o*, thalamus opticus; *la*, lobus lunatus anterior; *lp*, lobus lunatus posterior; *ss*, semilunaris superior; *si*, semilunaris inferior; *p*, pyramis. After Kölliker. Natural size.

ventral line becomes noticeable during the third month; they remain small until the fifth month, when the fibres from the pyramids of the medulla oblongata begin to penetrate them, and thereupon they enlarge and at the same time the longitudinal concavity of the ventral side is obliterated. It is probable that the Bodenplatte thickens, somewhat as in the medulla, and persists as a median raphe.

The *corpora quadrigemina* arise from the dorsal side of the mid-brain, and will, perhaps, be found to represent the dorsal zones of His. The dorsal wall of the mid-brain is at first evenly arched and smooth; at five weeks there is a median ridge, as already noted; during the third month the ridge is replaced by a groove; during the fifth month there appear two oblique grooves which run inward and backward, one on each side, Fig. 387, and complete the subdivision of the surface into the four corpora quadrigemina. Concerning the development of the posterior commissure, which is a bundle of fibres crossing the dorsal wall of the brain just in front of the corpora, see p. 686.

Owing to the fact that the mid-brain grows much less than the fore- and hind-brains, it is gradually covered over, principally by the expansion of the hemispheres. At the beginning of the third month the hemispheres have expanded to the edge of the mid-brain; at three months they half cover it; at four months they cover all but a small piece; at five months the whole of the mid-brain.

Median Portion of the Fore-Brain.—The manner in which the primitive fore-brain is divided into two lateral parts or hemispheres and one median part (*Thalamencephalon*, *Zwischenhirn*), after the outgrowth of the optic vesicles, has been described. The cavity (enlarged central canal) of the median part is the third ventricle of descriptive anatomy; therefore, the median part is sometimes called the *region of the third ventricle*. For convenience the hemispheres are treated in a separate section. It has already been pointed out that it is misleading to describe the primitive fore-brain (first vesicle) as dividing into two secondary vesicles. To divide the median portion of the fore-brain into two parts, as is traditionally done, is arbitrary. We shall, therefore, in this section consider not only the thalamencephalon as usually defined, but also the lamina terminalis and the commissures, etc.

1. GENERAL SHAPE.—By the fifth week the median portion of the fore-brain has assumed nearly its definite form. Across the anterior median line extends that portion of the medullary wall connecting the two hemispheres known as the *lamina terminalis*, Fig. 340, between *f.m* and *R.o*. Above and around the dorsal side of the foramen of Monro the medullary wall is continued in the median line, Fig. 340, but is modified first to form the corpus callosum, second the choroid plexus, two structures of which the history is presented below. The corpus callosum is a thickening produced by fibres, forming a transverse commissure between the two hemispheres. The choroid plexus is a fold of the medullary wall which projects into the cavity of the brain, Fig. 388, *Plx*. The cerebral hemispheres are outgrowths from the anterior part of the forebrain, Fig. 339; the passage from the cavity of the hemispheres to the median cavity is the foramen of Monro, Fig. 390, *m*; the part of the fore-brain between the foramen of Monro and the mid-brain corresponds to the thalamencephalon, or *Zwischenhirn* as ordinarily defined. The thalamencephalon as viewed in dorsal aspect in a human embryo of five weeks, Fig. 388, *Z*, has somewhat of a cask-shape. The anterior

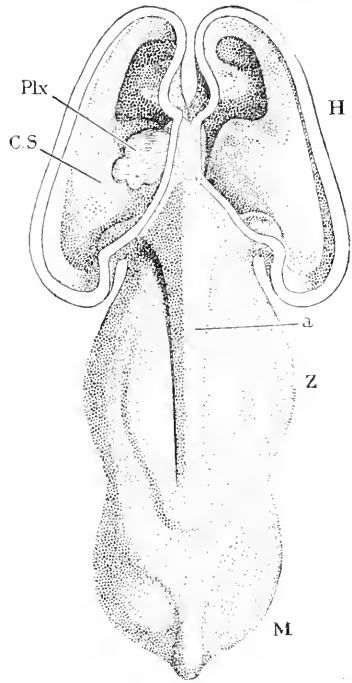


FIG. 388.—Part of Brain of His' Embryo CR. (Nacktenlänge, 13.6 mm.) *Plx*, Plexus; *C.S.*, corpus striatum; *H*, hemisphere; *a*, deck plate of fore-brain; *Z*, thalamencephalon (*Zwischenhirn*); *M*, mid-brain. After W. His.

end adjoining the hemispheres is narrower than the posterior end adjoining the mid-brain; the anterior half of the thalamencephalon slopes inward. Along the median dorsal line is a ridge, *a*, which is developed as a fold of the deck-plate during the fifth week; toward the hemispheres the ridge widens out and disappears; the continuation of the deck-plate between the hemispheres corresponds to the tela choroidea; toward the mid-brain the ridge merges into a median evagination of the brain-wall; this evagination is the anlage of the pineal gland, p. 688; there are soon developed the two ridges which diverge V-like from the pineal anlage to run forward along the median ridge, and which are destined to form the *pars habenularis* (ganglia habenulæ, laminae medullares, and pineal stalk) of the pineal lobe.

Viewed in median section, Fig. 340, the median fore-brain is seen to have a great downward prolongation which begins to form during the fourth week, develops rapidly during the fifth week, and persists throughout life. The enlargement may be designated as the sub-thalamic or infundibular; subthalamie because it lies below the region in which the optic thalami arise, infundibular because its apex is the recessus infundibuli. As seen in section the enlargement has, 1, a posterior wall, *M*, which descends at nearly a right angle to the axis of the mid-brain; the posterior wall is convex, and it is the anlage of the mammillary tubercles; 2, a lower wall which includes the anlage of the tuber cinereum, *t.c.* of the infundibulum, and of the optic chiasma; 3, an anterior wall constituted by the lamina terminalis. At the angle where the anterior and lower walls meet, the *recessus opticus*, *R.o.*, leads off laterally into the hollow stalk (anlage of the optic nerve) of the optic vesicle. Higher up lies the foramen of Monro, *fm*, leading into the cavity of the hemispheres, *H*. In the figure there is seen a groove which runs from the recessus opticus, *R.o.*, to the mid-brain; this groove marks the division line between the dorsal and ventral zones of His; it persists in part throughout life. The persistent part was named the *sulcus Monroi* by Reichert because it runs later from the lower edge of the foramen of Monro, the foramen extending as it develops much closer to the recessus opticus than it does in the early stage of Fig. 340.

In older stages the median fore-brain shows many minor modifications, but its fundamental shape and division, as found at five weeks, are permanently retained. The most important alterations are due, *first*, to thickening of the walls, which is especially great in the region of the optic thalami; *second*, to the fact that the foramen of Monro does not enlarge with the growth of the brain, and therefore becomes *relatively* small, compare Figs. 340 and 386.

APPEARANCE IN CROSS SECTIONS.—Fig. 389 is a section of the thalamencephalon of a five weeks' embryo nearly at right angles to its axis. In the median line is the deck-plate, *d.pl.*, with its three folds already described; the division between the dorsal, *Th*, and ventral, *s.Th*, zones of His is well marked by the sulcus Monroi. The Bodenplatte forms the mammillary groove, *Ma*, which is bordered by two eminences internally; the eminences are the cross sections of two ridges, which border the groove and unite with one another in the median line between the tuber cinereum and the

mammillary region proper; the ridges are the anlagen of the mammillary tubercles.

Fig. 390 represents a much older stage and serves to show the thickening of the walls and the origin of the choroid plexus; the section passes through the foramen of Monro, *m*, and the optic chiasma, *ch*; and the plane of the section may be approximately recognized from Fig. 388. Very striking is the great thickening of the brain-walls to form the anlage of the corpus striatum, *st*, in the hemispheres, and

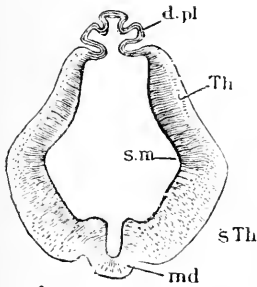


FIG. 389.—Section of the Thalamencephalon of an Embryo of five Weeks (His' Sch). *d.pl.* Deck-plate; *Th*, anlage of thalamus (dorsal zone of His); *s.Th.* sulcus Monroi; *s.Th.* pars subthalamica (ventral zone of His); *md*, mammillary groove (Bodenplatte, on either side of which appear the mammillary tubercles). After W. His. $\times 23$ diams.

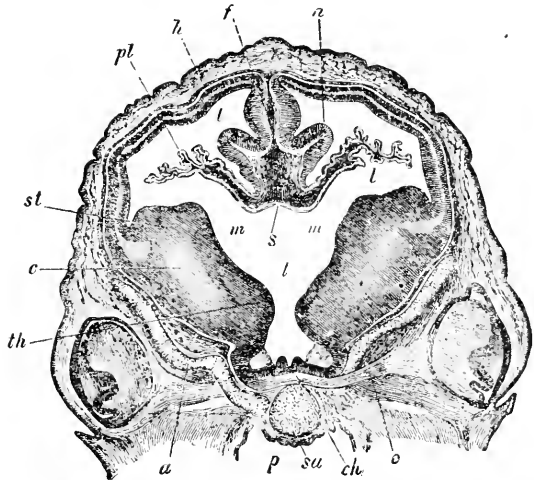


FIG. 390.—Section of the Fore-Brain of a Sheep Embryo of 17 mm. *n*, Hippocampal fold; *f*, falx; *l*, lateral ventricle; *h*, wall of hemisphere; *pl*, choroid plexus; *st*, corpus striatum; *c*, pedunculus cerebri; *th*, thalamus; *m*, foramen of Monro; *s*, deck-plate; *t*, third ventricle; *a*, orbito-sphenoid cartilage; *p*, pharynx; *su*, præ-sphenoid cartilage; *ch*, optic chiasma; *o*, optic nerve. After Kölliker. $\times 10$ diams.

of the optic thalamus, *th*, and the pars subthalamica in the middle part. The deck-plate, *s*, closes the third ventricle *t*, above. The medial wall of each hemisphere is bent in, *n*, owing to the *Bogenfurche*, p. 696. The wall of the hemisphere does not join the deck-plate, *s*, directly below the *Bogenfurche*, but changes into an epithelial membrane, which forms an irregular fold, *pl*, projecting far into the cavity, *l*, of the hemisphere, or lateral ventricle; this fold is the choroid plexus, see below.

THE DECK-PLATE.—The entire deck-plate except the pineal (and paraphysal) parts assumes an epithelial character. It produces the pineal gland, see p. 688, the paraphysis, see p. 690, and the choroid plexus, and persists in part as the *tela choroidea*. The pineal gland and paraphysis are so far independent organs that they are treated in separate sections. We are, therefore, here chiefly concerned with the choroid plexus.

The Choroid Plexus.—When the hemispheres begin to grow out, the deck-plate between them and above the foramen of Monro is convex, but it soon becomes concave and during the fifth week the deck-plate forms a fold on each side projecting into the lateral ventricle. The space between the two hemispheres is occupied by mesenchyma, which grows into the lateral fold carrying blood-vessels

with it; the fold is the anlage of the choroid plexus; its relations are well shown in Fig. 391. At first the choroid fold contains no connective tissue, the ingrowth of mesenchyma following after the fold is formed; the fold, therefore, owes its origin to the growth of the deck-plate. Examined in a side view the fold is seen to be thin, but long; it ends abruptly in front, but disappears posteriorly more gradually (His, 89.4, 695). The deck-plate becomes a layer of cuboidal epithelium covering the choroidal fold, and merging on the one hand into the wall of the hemisphere and on the other, Fig. 391, into the median part, *tela choroidea*, of the deck-plate. The tela is itself an epithelial layer, which is continuous in front with the lamina terminalis, behind with the pineal anlage. During its further development (*cf.* Mihalkovics, 77.1, 114-117), the fold increases in length and diameter, and its surface is thrown up into rounded protuberances, which grow into irregular processes. The fold takes its place in the lower part of the lateral ventricle, lying close against the basal surface (ganglia) of the hemispheres (Mihalkovics, 77.1, Taf. 1, Fig. 10). The size and complexity of the choroid plexus are correlated with the degree of development of the hemispheres, and the plexus is, therefore, largest and most specialized in the mammalia. The plexus in the human embryo enlarges more rapidly than the lateral ventricle so that by the fourth or fifth month it quite fills the lateral ventricle, but after that period the plexus lags somewhat, and there is gradually produced the space around it as found in the adult.

The connection of the choroid fold with the medullary walls of the hemispheres extends during embryonic life for some distance backward from the foramen of Monro. The exact history of this modification has never been traced.

LAMINA TERMINALIS.—The embryonic history of the lamina terminalis was long imperfectly understood, but it has been cleared up by F. Marchand's investigations, 91.1, on human embryos. It may be regarded either as a prolongation of the deck-plate, or, as suggested by His, 88.3, as the result of the union of the dorsal zones of His (*Flügelplatten*) in front. It is the median portion of the medullary wall, Figs. 340, 341, in front of the recessus opticus and foramen of Monro; it unites the two hemispheres, being, of course, continuous with their walls, and it closes the third ventricle anteriorly; it is continuous above with the tela choroidea, Fig. 395, below with the optic chiasma (or anlage thereof). At five weeks it is a thin plate, Fig. 340, of about the same thickness as the deck-plate, and with cells but little if at all differentiated.

The upper part of the lamina terminalis becomes very much thickened, and forms (Mihalkovics, 77.1, 122) a broad band of triangular section after the fourth week, uniting the two hemispheres. This band is the anlage of the septum lucidum, the corpus callosum, the fornix, and the anterior commissure, Fig. 391; the lower apex of the triangle is the anlage of the anterior commissure, *ca.*; the posterior vertical border of the fornix; the upper horizontal border of the corpus callosum, *c.c.*, and the remainder of the area is the anlage of the septum pellucidum. It is usually described as resulting from the concrescence of the two hemispheres, but I consider it simpler

and more natural to regard it as a thickening of the lamina terminalis, which it is morphologically. The anlage may be well seen in a median longitudinal section of the brain of a cow embryo of 8 cm. (Mihalkovics, *l.c.*, Fig. 17) or of a human embryo of the third to fifth month, Fig. 391. The anterior commissure acquires its fibres before they appear in any other part of the lamina terminalis, and early become separated from the fornix and septum lucidum a short distance. The thickening lies below the Bogenfurche, *bf*, and in front of the foramen of Monro. In it the fibres to form the anterior commissure and the fornix have been observed to appear in rabbit embryos of 25–30 mm., and those to form the corpus callosum in rabbit embryos of 35–40 mm. (Mihalkovics, *l.c.*, 123, 124) in pig embryos of 8 mm. (Blumenau, 91.1, 6).

The fornix, corpus callosum, and septum lucidum together form a triangle, which after its formation expands throughout foetal life. The anterior apex, where the fornix and callosum meet, grows forward, and the posterior apex, corresponding to the end or splenium of the callosum, grows backward; the corpus callosum is thus not only lengthened but carried backward, Fig. 392, *cc*, above the foramen of Monro and the optic thalamus, *Th*.

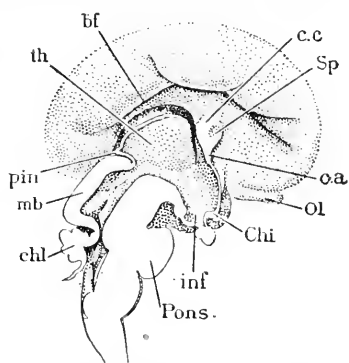


FIG. 391.—Brain of a Human Embryo of about three Months (according to Marchand, four months). *th*, Optic thalamus; *bf*, Bogenfurche; *cc*, corpus callosum; *Sp*, septum lucidum; *c a*, anterior commissure; *Ol*, olfactory lobe; *Chi*, optic chiasma; *inf*, infundibulum; *Pons.*, pons Varolii; *chl*, cerebellum; *mb*, midbrain; *pin*, pineal gland. After F. Marchand. $\times 1\frac{1}{2}$ diams.

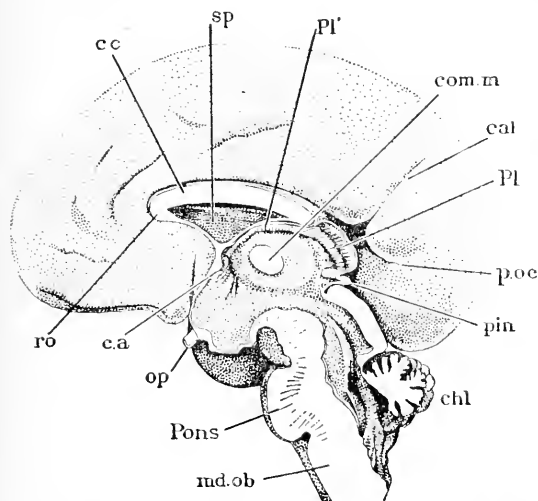


FIG. 392.—Brain of a Human Embryo of the fourth Month. *cc*, Corpus callosum; *sp*, septum lucidum; *Pl*, *Pl'*, choroid plexus; *com m*, commissura mollis; *cal*, calcarine fissure; *p. oc*, parieto-occipital fissure; *pin*, pineal gland; *chl*, cerebellum; *md. ob*, medulla oblongata; *Pons*, pons Varolii; *op*, optic nerve; *c. a*, commissura anterior; *ro*, rostrum. After F. Marchand $\times 1\frac{1}{2}$ diams.

Med. Torino, Nov.–Dec., 1883), that the corpus callosum is covered by a thin but constant layer of gray matter, is very significant. The statement has been verified by Blumenau, 91.1.

The *septum pellucidum* (or *lucidum*) is developed from of the thickened lamina terminalis between the corpus callosum and the fornix. The area is at first very small, but rapidly enlarges. At four months a small cavity appears in it, Fig. 391, *Sp*, which enlarges as the septum grows and becomes the ventricle of the septum (*ventriculus quintus, pseudocæle*), see F. Marchand, 91.1, 21. The origin of the cavity is uncertain; it has no connection with any of the brain cavities proper; Prof. B. G. Wilder writes me that in man and anthropoids it is wholly circumscribed by brain tissue; it is much narrower in other mammals, but the pia does not extend into it. Marchand thinks it probably arises as a cleft in the tissue.

COMMISSURES AND FORNIX.—A commissure is a tract of transverse fibres connecting the two sides of the nervous system. In the mammalian brain three such tracts are known to arise in the territory of the first vesicle; they are: 1, the *anterior commissure*; 2, the *corpus callosum*; 3, the *posterior commissure*. The anterior commissure and corpus callosum are developed, one might also say, as parts of the septum pellucidum and belong morphologically to the lamina terminalis. The *fornix* may be defined as a longitudinal commissure. For the general relations of the commissures and septum to the lamina, see above. Osborn, with great ability, has traced the homologies of the three commissures throughout nearly the entire vertebrate series, and has shown, 86.1, 87.1, that, contrary to previous belief, the corpus callosum is not confined to the mammalia, but is present in birds, reptiles, and amphibia, and probably in fishes, and further that in amniota and amphibia the anterior commissure comprises always two divisions—an olfactory and a temporal. Mammals, therefore, are distinguished from other vertebrates, not by the possession of the corpus callosum, but by its great size, which we may safely correlate with the great size of the mammalian hemispheres. The typical position of the commissures is shown in Fig. 393; the posterior commissure, *P*, lies behind the

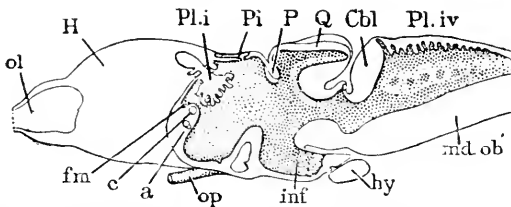


FIG. 393.—Median View of a Frog's Brain. *ol*, Olfactory nerve; *H*, hemisphere; *Pl. i*, choroid plexus of fore-brain; *Pi*, pineal gland; *p*, posterior commissure; *Q*, mid-brain; *Cbl*, cerebellum; *Pl. iv*, choroid plexus of hind-brain; *fn*, foramen of Monro; *c*, corpus callosum; *a*, anterior commissure; *op*, optic nerve; *inf*, infundibulum; *hy*, hypophysis; *md. ob*, medulla oblongata. After H. F. Osborn.

pineal gland, *pi*, close to the corpora bigemina (mid-brain); the corpus callosum, *c*, lies close to the foramen of Monro, *fn*, and the anterior commissure is situated lower down, *a*, in the lamina terminalis, and it consists of two bundles of fibres, an upper larger *pars olfactoria* and a lower smaller *pars temporalis*; the fibres of the temporal bundle are distributed to the temporal portion of the so-called mantle, Fig. 394; the fibres of the olfactory portion run in

part to the olfactory lobes, but also give off a frontal branch bundle to the frontal region of the mantle. The mammalian corpus callosum consists of an anterior or frontal division supplying the dorso-medial portions of the mantle, and a posterior division, the commissura cornu Ammonis, supplying the mantle area above the Ammon's horn (H. F. Osborn, **87.1**, 540).

The development of the commissures in marsupials (Osborn, **87.1**, 536) shows that the homologies established by Osborn are correct. But in sheep the development is so far modified that these homologies are less clearly brought out. The development in sheep is thus described by Osborn, **87.1**, 535: "In the 30 mm. stage the hemispheres have already partially united in front of the primitive lamina terminalis forming the terminal plate. The anterior commissure now appears as a delicate thread of fibres in the lateral region of the brain stem. The hippocampal sulcus is well marked. At 35 mm. the anterior commissure extends slightly nearer the median line. In an embryo of 37 mm. the terminal plate

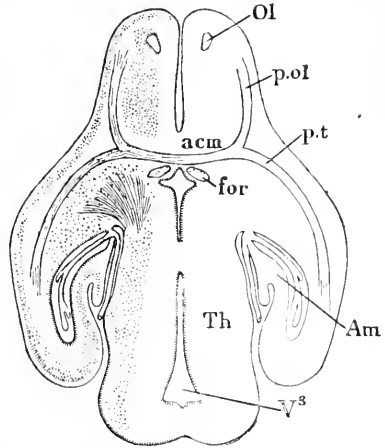


FIG. 394.—Section through the Fore-Brain of a Foetal Guinea Pig. *Ol*, Olfactory lobe; *acm*, anterior commissure, dividing into the pars olfactoria, *p.ol*, and the pars temporalis, *p.t*; *for*, fornix; *Am*, Ammon's horn; *Th*, optic thalamus; *V*³, third ventricle. After H. F. Osborn.

has extended considerably forward. The anterior commissure shows a division into the pars olfactoria and temporalis, while in the median line its fibres begin to unite with those of the opposite hemisphere. This union does not take place in the terminal plate, as stated by Mihalkovics, but in front of it, *i.e.*, the plate does not form the ground substance to be traversed by these fibres. On the other hand the fibres bridge the fissure which is gradually closing in front of the terminal plate. Immediately above the anterior commissure, on either side, are descending fibres which represent the first stage of the *fornix*. These appear before the anterior commissure crosses the median line. This stage corresponds closely to that figured by Mihalkovics, **77.1**, Taf. VII. Fig. 60. In the next stage the terminal plate has extended in front of the anterior commissure, the fornix fibres are more numerous, and at their upper limit a few fibres are observed extending toward the median line; these are the earliest callosal elements. At 49 mm., which follows a considerable interval of development, the hippocampal sulcus is very deep and the terminal plate is much more extensive. In its lower portion the anterior commissure, now a compact bundle, extends laterally above the cerebral peduncles. The columns of the fornix are well defined, and between them in the upper portion of the plate pass the fibres of the corpus callosum. A careful study of these fibres shows that, like those of the anterior commissure, they unite with each other in front of the terminal plate. The callosal fibres disappear as they pass around the hippocampal

sulcus. Above this sulcus is an interval in the inner wall of the ventricle in which no fibres can be observed, but in the roof of the ventricle are the fibres of the corona radiata. This leads me to doubt whether the fibres extend at an early stage from the corona radiata into the corpus callosum, as stated by Mihalkovics. It seems rather that this is a subsequent union. This stage differs considerably from that figured by Mihalkovics as the initial stage of the corpus callosum."

The *posterior commissure* has been but little studied embryologically. Its position may be recognized (Kölliker, "Entwickelungsges.," 2te Aufl., 525) in a sheep embryo of 29 mm. as a slight thickening of the dorsal wall of the fore-brain close to the mid-brain. The fibres of this commissure appear in the chick the latter part of the fourth day, according to Mihalkovics, 77.1, 73.

DORSAL ZONE OF HIS (*Optic Thalami*).—The dorsal zone of His in the fore-brain forms the hemispheres and in the median portion produces the optic thalami. The thalami may be defined as thickenings of the dorsal zones continuous with the thickenings which produce the corpora striata of the hemispheres. It will be remembered that the lower limit of the dorsal zone is marked by the sulcus Monroi. The development of the thalamus has been outlined by Kölliker in both his text-books; the early stages in man (fourth to twelfth week) have been investigated by W. His, 89.4, 701, 731. The sulcus Monroi becomes evident during the fourth week and very distinct during the fifth; later it becomes shallower, but persists.

At the beginning of the fourth week the thalamic region is concave toward the ventricle. During that week the thickening of the

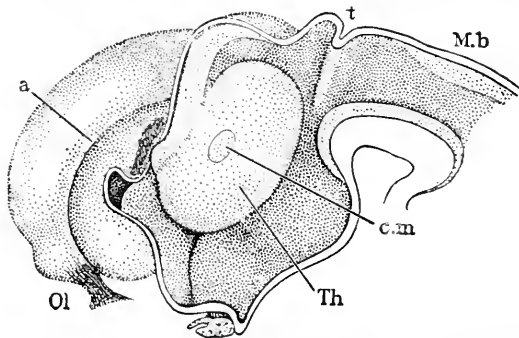


FIG. 395.—Reconstruction of the Brain of an Embryo of about seven and one-half Weeks (His' Zr). *Ol*, Olfactory nerve; *a*, Ammon's groove; *t*, epiphysis; *Mb*, mid-brain; *c.m.*, commissura mollis; *Th*, optic thalamus. After W. His. $\times 10$ diams.

walls in both the thalamic and sub-thalamic regions begins, and by the end of the fifth week the wall projects in both regions convexly into the cavity of the third ventricle. The thalamic thickening does not extend throughout the dorsal zone of the thalamencephalon, but only in a circumscribed region. It accordingly produces a large tuber, Fig. 395, *Th*, the long-

continued growth of which converts the third ventricle into a narrow fissure. The tubers meet toward the end of the second month and actually unite over a small area across the median line, their union constituting the *commissura mollis*, *cm*. Mihalkovics, 77.1, 71, assigned the formation of the commissura mollis to the fifth month, and this date is confirmed by F. Marchand, 91.1, 310. His thinks that the commissure is formed earlier. Above the tuber thalamicum is a groove named the

sulcus habenulæ by His. It corresponds to the external ridge described, p. 680, as running obliquely along the upper surface of the thalamencephalon to the pineal anlage. Below the tuber is, of course, the sulcus Monroi; the two grooves are united behind the tuber, where they are also joined by a transverse groove, the *sulcus pineale*; where all these grooves meet there is a slight lateral enlargement or recess, *recessus geniculi*, of the ventricle. As the tuber enlarges the recessus deepens and is narrowed so that at two months and a half there is only a small fissure visible. Later even this fissure disappears; its walls probably give origin to the "centre median" of Luys (*mediane Sehügelcentrum*).

The part of the dorsal zone between the thalamic tuber and the mid-brain is known as the *pars retrothalamica*; it includes the pulvinar, the brachia of the corpora quadrigemina, and the corpus geniculatum.

VENTRAL ZONE OF HIS.—This comprises, as already stated, the region of the thalamencephalon below the sulcus Monroi; for this part Forel ("Untersuch. üb. d. Haubenregion," *Arch. f. Psychiatrie*, Bd. VII.) has proposed the convenient name of *pars subthalamica*. Concerning its embryonic history almost nothing is known. It becomes very thick and is usually described as part of the optic thalamus.

FLOOR OF THE THIRD VENTRICLE.—Along the floor of the ventricle on or near the median line are developed the following structures: *a*, substantia perforata posterior; *b*, mammillary tubercles; *c*, tuber cinereum; *d*, infundibulum; *e*, optic chiasma; *f*, lamina terminalis, but this last does not properly belong to the floor. What relation the Bodenplatte bears to the production of the first five structures is still uncertain. In regard to this development little is known.

a. Substantia perforata posterior perhaps really all belongs to the mid-brain. It becomes distinct during the fourth month.

b. Mammillary tubercles (corpora albicantia, candicantia, *Markkügelchen*) begins, Fig. 340, *m*, as a single relatively large convex projection of the medullary wall. As the brain enlarges the mammillary region grows very slowly and hence becomes relatively small (W. His, 89.4). According to Mihalkovics, 77.1, 72, a median groove arises early in the fourth month dividing the region into two tubercles, which later become white (owing to the development of medullated nerve-fibres?).

c. Tuber Cinereum.—This is part of the floor between the mammillary tubercles and the infundibulum proper, see Fig. 340, *t, c*. Concerning its development no details are known.

d. Infundibulum.—In rabbit embryos of 12–16 mm. and in human embryos of five weeks there is found developing a small cylindrical outgrowth of the brain, which is known as the *processus infundibuli*. The outgrowth takes place in the median line immediately in front of the tuber cinereum and behind the optic chiasma, Figs. 391 and 401, *Inf*. It very soon comes in contact with the hypophysal outgrowth of the mouth, and is ultimately transformed into the posterior lobe of the pituitary body as already described, p. 574. His' observations, 89.4, 706, on the human embryo confirm

in most respects Mihalkovics' account of the development in the rabbit.

e. Optic Chiasma and Recessus.—The optic chiasma and tracts together constitute a transverse ridge-like thickening of the wall of the brain to allow the passage of the nerve-fibres of the optic nerves. Laterally the ridges merge into the optic nerve; the recessus opticus is bounded behind by the ridges, in front by the lamina terminalis. The optic ridges (*Schstreif* of Mihalkovics, 77.1, 78) accordingly are first indicated when the groove of the recessus opticus develops, and they become strongly marked as the optic nerve-fibres appear. In the chick the fibres have been observed in the latter part of the fourth day passing from one side of the brain through the optic ridge to the optic nerve of the opposite side, Mihalkovics, *l.c.* The growth of the fibres is centrifugal.

The *recessus opticus*, which was first described by J. Michel in 1872, leads to the optic nerve, being a transverse groove, Fig. 399, *R.op.* It is more marked at birth than in the adult, but may be traced throughout life. For notices of the scanty literature previous to 1877, upon the chiasma and recessus, see Mihalkovics, 77.1, 80–82.

Pineal Gland (*Epiphysis, couarium, pineal or parietal eye, Zirbel, Zirbeldrüse*).—The pineal gland or epiphysis is developed as a median dorsal evagination of the medullary wall of the fore-brain a short distance in front of the mid-brain; between it and the mid-brain is situated the posterior commissure, p. 684. Its site is said by A. Goette, 75.1, to be identical in Bombinator with that of the anterior neuroporus, or point where the medullary groove closes last

in the head; if this coincidence is true of vertebrates generally, it must have some, perhaps important, significance. The development of the epiphysis in reptiles and lower invertebrates indicates that it was primitively a median eye, which survives as a rudiment, compare below.

The pineal evagination appears after the development of the brain is quite advanced (chick, end of fourth day, in the rabbit the fourteenth day, in white mice of 9.5 mm., in sheep embryos of 3.5 mm., in man at about the sixth week); it therefore cannot—as Mihalkovics, 77.1, 95, justly observes against A. Goette, 75.1, 315–316—

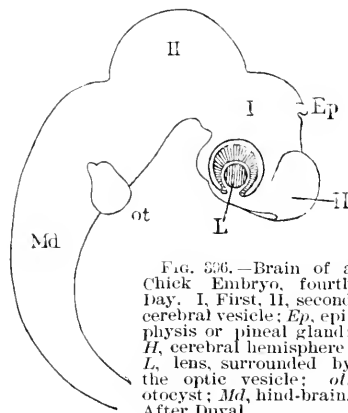


FIG. 336.—Brain of a Chick Embryo, fourth Day. I, First, II, second cerebral vesicle; Ep, epiphysis or pineal gland; H, cerebral hemisphere; L, lens, surrounded by the optic vesicle; ot, otocyst; Md, hind-brain. After Duval.

be interpreted as resulting from the connection at the neuropore of the medullary wall with the epidermis, for the two layers are separated by intervening mesenchyma in amniote embryos long before the evagination appears. In birds the evagination points forward, in mammals backward; this difference is probably due to the greater development of the corpus callosum forcing the pineal gland back in mammalia. Our knowledge of its development in mammals and birds we owe chiefly to Mihalkovics, 77.1, 94, whose results have

been confirmed by Kraushaar's observations on white mice, **85.1**. The evagination lengthens out until it nearly reaches the epidermis; it is a tube or sac communicating with the fourth ventricle, ending blindly, and having walls composed of cylinder cells. The sac next enlarges at its upper end, and the wall of the enlargement after thickening forms buds (chick fifth day, rabbit embryos of 20-25 mm.), which are hollow and retain in the chick their primitive form but in mammals the hollow buds become filled with proliferated epithelial cells, which take on rounded and polygonal forms and are presumably degenerated elements; the cells have processes and lie more or less separated from one another.

In reptiles the epiphysis assumes a more complicated structure, but in many forms its differentiation is more or less imperfect. When carried to its highest known development the pineal sac is differentiated into three parts, a distal eye-like enlargement close to the epidermis, a middle, narrow part like an optic nerve, and a proximal larger part, as shown by W. B. Spencer, **86.1**, whose results have since been verified and extended by Béranec, **87.1**, Beard, **88.2**, Francotte, **87.1**, **88.1**, McKay, **89.1**, Owsjannikow, **88.1**, Ritter, **91.1**, Strahl and Martin, **88.1**, and Wiedersheim, **86.1**. A synopsis of the development of the reptilian epiphysis is given by C. K. Hoffmann in Bronn's "Thierreich," VI., Abth. III., 1981-1993. The distal end of the evagination lies near the epidermis; it early enlarges into a hollow globe, which soon flattens out somewhat; the wall on the side next the epidermis thickens and assumes a lens-like character; the wall on the opposite side is, of course, united with the stalk and assumes a retinal character. Strahl and Martin, *l.c.*, observed in the retinal region the differentiation of the Randschleier and of the nuclear layer, and the presence of karyokinetic figures next the cavity, so that the primary stratification is the same as in the wall of the brain proper; later pigment granules are deposited in the part of the retinal layer toward the lens, and nerve-fibres can be observed in the stalk. There can be little question that the structure in question is a true, though rudimentary eye. It has also been observed in lampreys and amphibians.

The morphological significance of the pineal body is still under debate. The fact that it forms an eye in *Petromyzon* indicates that the optic character was primitive, but it appears to have lost that character along the lines of descent leading to the teleosts and elasmobranchs, while it has retained it along the lines leading to the amphibians and reptiles, becoming in them more or less rudimentary and disappearing altogether in the birds. As the pineal eye is the distal part of the epiphysis only, and is wanting in mammals (compare, however, H. F. Osborn, *Science*, Jan., 1886), the suggestion is inevitable that the pineal gland of mammalian anatomy is homologous with the proximal part only of the reptilian epiphysis.

Historical Note.—The first suggestion that the epiphysis might represent a visual organ was, so far as known to me, made by Rabl-Rückhard, **82.1**; it was renewed by Ahlborn, **84.1**, but was first definitely verified by De Graaf, **86.1**, whose article, together with Baldwin Spencer's admirable memoir, **86.1**, forms the basis of our present knowledge of the pineal eye. Leydig, **88.4**, **90.1**, attempted,

but unsuccessfully, to prove that the pineal eye could not be a sense organ. As regards the development, the principal authorities are Mihalkovics, 77.1, for mammals, Béraneck, 87.1, and Strahl and Martin, 88.1, for reptiles.

Paraphysis.—Under the name of paraphysis, or "*Stirnorgan*," Selenka, 90.1, has described a second evagination from the median dorsal wall of the fore-brain, which is similar to the epiphysis. It is further forward, being between the origin of the hemispheres. Selenka very doubtfully compares it with the median auditory organ of ascidians, as the epiphysis has been compared to the median eye of ascidians. Selenka has observed the organ in sharks, reptiles, and marsupials. In reptiles, just after the pineal evagination has begun in the embryo, there appears another evagination some distance in front of it and also in the median dorsal line, to develop the paraphysis. The evagination grows backward until it reaches the epiphysis; after the pineal eye is cut off, it shoves itself under the pineal eye, but without uniting with it; the end of the paraphysis is enlarged and forms a number of fine hollow buds; its proximal part or stalk is round or oval in cross sections; throughout the embryonic period the cavity remains in communication with the third ventricle; the fate of the organ after birth is unknown. Unfortunately Selenka gives no figures.

The paraphysis has been observed by Charles Hill, 91.1, in the embryo of 7 mm. of *Corregonus* (a teleost) to grow out asymmetrically from the wall of the brain just in front of the epiphysis; it is about half the size of the epiphysis.

Cerebral Hemispheres.—A previous section is devoted to the development of the median portion of the fore-brain, and accordingly in this section we confine ourselves to the lateral outgrowths or hemispheres of the fore-brain. The hemispheres arise, as has been described, as diverticula of the dorsal zone of His in the anterior half of the fore-brain, and therefore they can never develop any structures homologous with parts arising from the deck-plate, the ventral zones of His, or the *Bodenplatte*. The choroid plexus might be taken as an exception to this law, but, as its development teaches us, it is not morphologically part of the hemispheres. For convenience the cerebral convolutions are considered in a separate section, p. 695.

GENERAL GROWTH.—The hemispheres of the human embryo of four weeks have been described, p. 596. They continue to enlarge throughout the entire foetal period, but their connection with the middle portion of the fore-brain does not enlarge correspondingly. There is but little (? if any) enlargement of the foramen of Monro after the fifth week, but there is a considerable growth of the walls of the foramen, so that the actual size of the structures connecting the hemispheres with the median fore-brain increases very considerably, but the enlargement of the hemispheres is still more rapid, so that they become and remain large, pedunculate, vesicular lateral appendages, and project beyond the median fore-brain forward, upward, and in later stages backward so as to cover the mid-brain also. The enormous expansion of the hemispheres is one of the most characteristic features of the amniote embryo, but the expan-

sion is greater in mammals than in reptiles, in man than in any other mammal. The size of the hemispheres in the adult is closely correlated with the degree of mental development of the species. The fundamental relations of the hemispheres to the fore-brain are clear from Fig. 388; while retaining their strictly limited connection with the anterior part of the median fore-brain by means of the medullary walls bounding the foramen of Monro, *f.M*, the hemispheres are expanding in every direction. In front and above the two hemispheres have walls which face one another and are separated by a narrow constantly deepening fissure, Fig. 390, *f*, which is filled with mesenchymal tissue constituting the anlage of the *falx cerebri* (*Hirnsichel*). Posteriorly a groove separates the hemisphere from the Zwischenhirn. In a lateral view the hemisphere shows a wide, shallow depression at five weeks,

which gradually becomes more marked, Fig. 397, and is ultimately transformed into the fissure of Sylvius. Corresponding to the external depression there is an internal projection of the wall of the hemisphere into the cavity of the lateral ventricle; this projection is the first indication of the *corpus striatum*, which arises as a thickening of the wall extending not only over the region of the fossa of Sylvius, but also past the foramen of Monro, to be continued as the thickening of the thalamencephalic wall, which produces the thalamus opticus, p. 686. We thus have a hemisphere the floor wall of which is thickened to form the

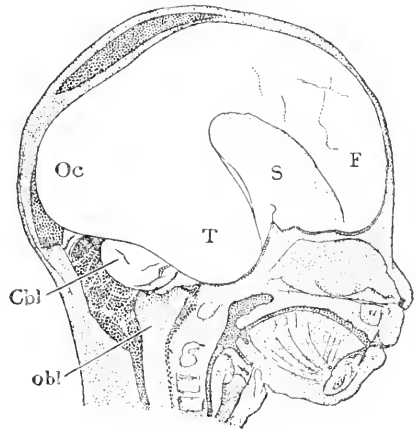


FIG. 397. — Human Embryo of about four Months; brain *in situ*. *Oc*, Occipital lobe; *T*, temporal lobe; *S*, fissure of Sylvius; *F*, frontal lobe; *Cbl*, cerebellum; *obl*, medulla oblongata. Natural size.

anlage of the so-called basal ganglia, while the rest of the wall is thin and is designated as the mantle (*pallium*). While the Sylvian fossa is appearing the anlage of the olfactory lobe is differentiated, Fig. 341, *R*, by the bulging forth of the lower anterior wall of the hemisphere,* and is soon marked off from the hemisphere proper by a distinct groove, the rhinal fissure of comparative anatomy. We find that the hemispherical vesicle is now divisible into three primary regions, which all persist throughout life; these are:

1. *The mantle* (for detailed history, see p. 694).
2. *The basal ganglia* (for detailed history, see p. 694-5).
3. *Olfactory lobe* (for detailed history, see p. 703).

The mantle outgrows the other parts and forms nearly the whole of the convoluted surface of the adult brain. During the fifth week the choroid plexus grows into the lateral ventricle, compare p. 681, and thereafter forms a conspicuous structure, but it is not part of the hemisphere in a strictly morphological sense.

* Wm. Turner, 91.2, from his observations on the comparative anatomy of the brain, concludes that the olfactory lobe or rhinencephalon stretches further back and includes the lobus hippocampi.

As stated above, the upward expansion of the hemispheres causes them each to have a medial wall, bounding the fissure in which the falx cerebri is developed. Along this wall is developed a fold, which is marked by an external groove and an internal ridge; the groove is the *Bogenfurche* of German embryologists, Fig. 395, *a*, 401, *a*, Fig. 391, *bf*; and is in part equivalent to the callosal fissure or groove of the adult, while the internal ridge is the anlage of the cornu Ammonis. The *Bogenfurche* begins at the olfactory lobe, which it crosses, and divides it into an anterior and posterior part (see p. 703); the *Bogenfurche* then curves around, Fig. 401, *a*, parallel with the edge of the foramen of Monro. It begins to develop anteriorly and gradually extends further and further backward, until it is a long arching groove, terminating in the temporal lobe (*lobus hippocampi*). It must be remembered that the posterior end of the groove arises in reality by itself as the hippocampal groove (*Ammons-furche*) but the two ends soon join, making one long fissure as described (W. His, 89.4, 697). At its posterior end the groove forms two branches, each corresponding to a fold of the brain wall; one branch is the anlage of the parieto-occipital, the other of the calcarine fissure. These three fissures (*Bogenfurche* and its two branches) and the Sylvian fissure are the only fissures which arise as folds of the brain. Mihalkovics, 77.1, has proposed for them the distinctive name of *Totalfurchen* (total grooves). All other fissures (*sulci*) are merely depressions of the cortical surface, not folds of the brain-wall. When the corpus callosum is developed, p. 683, it gradually occupies by its enormous expansion most of the space under the *Bogenfurche*, so that the fissure (*sulcus corp. callosi*), is almost hidden above the corpus callosum in the adult. The internal ridge corresponding to the *Bogenfurche*, has, of course, the same arched course; it begins at the olfactory lobe, curves upward and backward around the foramen of Monro, and bending downward terminates behind the corpus striatum in the temporal region. Its course may be understood from Fig. 388 and Fig. 395. As to the fate of the frontal end of the ridge, we have no satisfactory knowledge; the posterior end is the anlage of the hippocampus, the ridge corresponding to the main groove developing into the *hippocampus major* (cornu Ammonis), and the ridge corresponding to the branch (*sulcus calcarinus*) developing into the *hippocampus minor* (*calcar avis*).

The three lobes (frontal, temporal, and occipital) of the adult are very gradually evolved. The first step in their differentiation is the development of the fossa Sylvie. The fossa may be recognized in a human embryo of five weeks. It seems to owe its origin to the fact that the brain-wall forming the fossa grows principally in thickness to produce the corpus striatum, while the mantle grows very rapidly in superficies; it follows that the mantle region expands and projects beyond the thick-walled fossa, Fig. 397; the mantle at this stage forms a vesicular *frontal lobe*, *F*, and a vesicular post-Sylvian lobe, each with thin walls and each including a portion of the wide lateral ventricle. The post-Sylvian lobe becomes in part the *temporal lobe*, *T*, but it also expands toward the cerebellum, and its expansion forms the *occipital lobe*, Fig. 397, *Oc*. The frontal and temporal

lobes may therefore be regarded as primary, the occipital lobe as a secondary or later acquisition.

Each lobe includes a portion of the lateral ventricle; the portion in the frontal lobe becomes the anterior cornu; the portion in the temporal lobe the descending cornu; the portion (*recessus occipitalis*) in the occipital lobe the posterior cornu. Now the Bogenfurcher extends down behind the fossa of Sylvius, therefore along the medial wall of the temporal lobe; hence the inner ridge corresponding to the Bogenfurcher projects into the ventricular cavity of that lobe; now the ridge is the anlage of the hippocampus major (cornu Ammonis), which remains throughout life a ridge projecting into the descending cornu. It will be recalled further that the Bogenfurcher has a branch, the calcarine sulcus, Fig. 392, *cal*, which runs on to the medial wall of the occipital lobe, and has corresponding to it a ridge projecting into the ventricular cavity of that lobe; this ridge likewise persists throughout life and is the *hippocampus minor* (*calcar avis*) of descriptive anatomy. The exact history of the modifications in the shape of the lateral ventricle during the foetal period has still to be worked out.

The fossa of Sylvius undergoes important modifications (compare Mihalkovics, 77.1, 149). At the end of the second month the hemisphere in side view has a bean-like shape, the hilus facing downward; the fossa is situated at the hilus. At three months the fossa is about as high as broad; during the fourth and fifth months it becomes more sharply defined and has a marked inclination toward the occiput. The floor of the fossa corresponds to the corpus striatum and island of Reil; the brain-wall constituting the floor is very much thickened; the external surface of the floor, which is seen when the brain is viewed from the side, is the so-called island of Reil. Morphologically the island and the corpus striatum are parts of the same structure. During the sixth month the edges of the fossa begin to spread over the island and cover it in, so that by the ninth month it is entirely buried, and can be seen only by opening the Sylvian fissure.

The thickness of the walls of the hemisphere apparently increases throughout the second to ninth month. In the region of the basal ganglia the thickening takes place very early and becomes very great. The mantle thickens more slowly and never equals the basal ganglia in thickness.

The size of the hemispheres, as a whole, increases very rapidly for a long period, so that at birth they more than equal all the rest of the brain in volume. They cover first the thalamencephalon, later the mid-brain also, still later the cerebellum also. Owing to the growth of the cerebellum after the fifth month it is less completely covered by the hemispheres at the end than during the middle period of foetal life.

FORAMEN OF MONRO.—The foramen of Monro is at first, Fig. 337, a rounded opening, which soon becomes pointed at its lower side. As to its actual size in successive stages we have no measurements; it is converted into a fissure-like opening, and is commonly said to diminish in size, but I think it probable that the diminution

is relative only, not absolute. A knowledge of the fœtal history of the foramen would be a desirable addition to Embryology.

MANTLE OR PALLIUM.—The mantle comprises all that part of the hemispheres which enters into the formation of neither the olfactory lobes (*rhinencephalon*) nor basal ganglia (*Bodentheil, Stammtheil*). Its general history we have already reviewed; the development of its convolutions is treated in the next section; we have, therefore, to present only what little is known of the histogenesis of the cortex cerebri, the cortex being the superficial stratum of the mantle.

Histogenesis.—For the development of the nerve-cells, see p. 624. We have to add here what little is known concerning the development of the layers of the cortex, following Vignal, **88.1**, 242, who also gives, p. 232, a summary of previous work. In a rabbit embryo of fourteen days the Randschleier is still thin, while the mantle layer

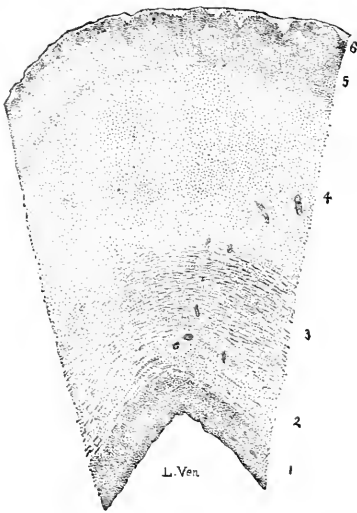


FIG. 398.—Section through the Lateral Wall of the Cerebral Hemisphere of a Human Embryo of four Months. Minot Coll. 31. Each dot represents a nucleus. 1-6, successive layers, each characterized by the distribution of its nuclei.

with rounded nuclei and the inner layer with elongated nuclei have both grown very much. In later stages, Fig. 398, I find six main layers, the homologies of which with the layers, both of earlier and of adult stages, have still to be determined. The outermost layer is thin, 6, and contains very few nuclei; below is a broader layer with the nuclei grouped chiefly in radial lines, 5; this layer is the anlage of the cortex cerebri, *sensu stricto*, and is seen to consist of three strata; it is along the inner edge of this layer that the great pyramidal cells arise to form the third layer of Meynert, while the rest of the layer produces the second layer of Meynert. Now if, as I hold to be probable, the large pyramidal cells are homologous with the Purkinje cells of the cerebellum, then layers 5 and 6 of Fig. 398 are derived from the original Randschleier. But in the present state of our knowledge another interpretation is equally possible—namely, that layers 1-4 are derived from the inner layer of the embryo, layer 5 from the mantle layer, layer 6 from the Randschleier.

For a comparison of the layers of the cortex in various air-breathing vertebrates see Nakagawa, **90.1**.

The medullated nerve-fibres of the mantle do not appear until after birth, S. Fuchs, **84.1**, 181.

BASAL GANGLIA.—The corpus striatum and the various parts associated with it arise from the thickened wall of the fossa of Sylvius. This thickening is continuous past the posterior side of the foramen of Monro with that thickening of the dorsal zone of His, which produces the thalamus opticus of the median fore-brain, p. 686. The part of the thickening, which connects the corpus stri-

atum proper with the median fore-brain, develops into part of the so-called peduncles of the hemispheres of the adult; constituting what is termed by W. His, 89.4, 700, the *Streifenhügelstiel*. The commencement of the thickening may be observed in rabbit embryos of 12-13 mm. (Mihalkovics, 77.1, 110), in the human embryo at four weeks; it necessarily coincides with the first formation of the fissure of Sylvius. The thickening soon becomes (His, 89.4, 699) a considerable prominence; it is broad, forming what may be called the floor of the hemisphere; it stretches from the lamina terminalis and the anlage of the olfactory lobe across the fossa of Sylvius and behind the foramen of Monro, where it joins the anlage of the optic thalamus. Even at the beginning of the fifth week traces of the division of the corpus into three limbs can be detected; a lower limb (*hinterer Schenkel* of His) runs to the lamina terminalis; on the upper limb (*vorderer Schenkel* of His) to the anterior olfactory lobe, and a middle limb to the posterior olfactory lobe. The middle and lower limbs together form the *crus mediale*, the upper limb the *crus laterale* of descriptive anatomy—compare Fig. 399, which well illustrates the primitive form and subdivision of the arching corpus striatum. Later, in the same measure as the hemisphere expands toward the cerebellum, the posterior part of the corpus striatum grows. A groove, which persists into late foetal periods, marks the division between the corpus and the optic thalamus; the groove ultimately becomes obliterated, and the tissue which fills it up is the anlage of the *stria cornea* or *terminalis* (*lamina semicircularis*); His proposes, therefore, to designate the groove as the *sulcus stria corneae*. The origin of the stria cornea (*Hornstreif*) was discovered by Mihalkovics 77.1, 133.

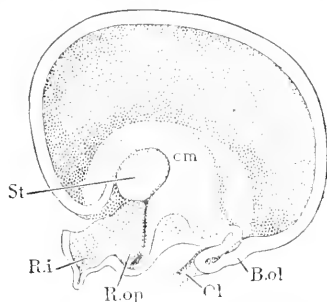


FIG. 399.—View of the Hemisphere of a Human Embryo from the early part of the third Month. *St.* Stalk of the corpus striatum, or thickening by which it is joined to the pars subthalamica; *cm*, crus mediale of the corpus striatum; *B. ol.*, olfactory lobe; *Ol.*, nervus olfactorius; *R. op.*, recessus opticus; *R. i.*, recessus infundibuli. After W. His. \times about 5 diams.

Cerebral Convulsions.—We must divide the so-called fissures which produce the convulsions (gyri) of the brain into two classes, the primary folds and the secondary fissures. The former are literally folds of the entire brain-wall, and were, therefore, appropriately termed "*Totalfurchen*" by Mihalkovics, 77.1, 146, who first clearly recognized them as a distinct class of fissures. The latter are merely narrow groove-like depressions of the surface of the hemispheres.

1. PRIMARY FOLDS.—These are the fossa Sylvii and the Bogenfurche; the latter has at its posterior end two branches, known as the calcarine and parieto-occipital fissures respectively. To these we ought possibly to add the *fissura collateralis*, p. 701, which is situated on the lower surface of the temporal lobe.

The *fossa of Sylvius*, as already stated, p. 692, is at first a wide, shallow depression, which gradually deepens. The wall of the depression is very much thickened to make the corpus striatum; the outer part of the wall makes, of course, the floor of the fossa, and

this floor becomes the island of Reil in the adult. The growth and expansion of the mantle causes it to project farther and farther, thereby deepening the fossa. At four months, Fig. 397, *S*, it is very wide and ascends backward between the frontal, *F*, and temporal, *T*, lobes. At the beginning




FIG. 400.—Outlines of the Fissure of Sylvius of Human Embryos at Successive Lunar Months. After G. Mihalkovics.

of the fifth month (Mihalkovics, 77.1, 150) the fossa has become deeper, longer, and more oblique, and its anterior margin is broken

by an angle, Fig. 400, 5. The two margins gradually approach one another, concealing the floor of the fossa or island of Reil, and meanwhile the angular notch of the anterior margin becomes more marked. The changes continue until, as shown in the figure, the opening of the fossa is a narrow Y-shaped cleft, 9, leading down into the fossa proper and the island of Reil. The walls of the fossa of Sylvius, including the island, acquire secondary furrows during the ninth month. The part of the margin of the fissure between the two forks of the Y is sometimes termed the *operculum*. The *Bogenfurche*, or *fissura prima*, arises very early. Its anterior part appears first, beginning as stated above, p. 692, at the olfactory lobe, thence passing along the medial wall of the hemisphere in a curved line, which may be roughly described as parallel with the lamina terminalis and tela choroidea, Fig. 401, *a*. The posterior part of the *Bogenfurche* appears later; it corresponds to the *Ammonsfurche* of Mihalkovics, 77.1, 145 (*sulcus hippocampi* of Huxley); it begins on the medial wall of the temporal lobe, and gradually extends upward and forward until toward the latter part of the second month it joins the anterior part, and the union of the two produces the great *Bogenfurche*, which begins at the olfactory lobe, runs widely arching along the medial wall, and terminates at the lobus hippocampi, p. 691. Corresponding to the external groove is an internal ridge, the ridge persists in the posterior part as the hippocampus, but its fate in the region of the frontal lobe is obscure. Below the ridge is a strip of the hemispherical wall, the *Randbogen* (*gyrus arcuatus*) of F. Schmidt, 62.1. In the adult a large part of the *Randbogen* is occupied by the very large corpus callosum, above which persists the *Bogenfurche* as the callosal groove. The portion of the *Randbogen* immediately behind the callosum develops during the first half of the fifth month little transverse ridges upon its surface, and thereby becomes the recognizable anlage of the *gyrus dentatus* (Mihalkovics, 77.1, 147). The extreme posterior end of the *Randbogen* is bent upon itself, hook-like, and is easily identified as the anlage of the *gyrus uncinatus*.

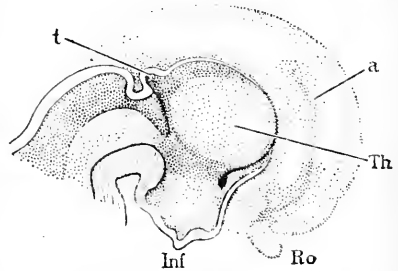


FIG. 401.—Median View of the Fore-Brain of a Human Embryo from the beginning of the third Month. *t*, Pineal anlage; *a*, *Bogenfurche*; *Th*, optic thalamus; *Ro*, bulbus olfactorius; *Inf*, infundibulum. After W. His. \times about 3 diams.

From the posterior part of the Bogenfurcher run out, both from nearly the same point, its two branches, the *fissura calcarina* and the *fissura parieto-occipitalis*, Fig. 402, *a, b*, which both appear while the occipital lobe is growing out, the calcarine fissure, *a*, usually, but not always (His, 74.1, 114), arising before the parieto-occipital, *b*, which last first develops at the beginning of the fourth month (Mihalkovics, 77.1, 146). Both fissures run upward and backward on the medial wall of the hemisphere, and as they diverge they enclose a space between them, which corresponds to the so-called cuneate lobe of the adult. To these two branches of the Bogenfurcher correspond internal ridges (*cf.* His, 74.1, Fig. 113), but the ridge corresponding to the parieto-occipital fissure is subsequently obliterated as the brain wall thickens, while that corresponding to the calcarine fissure persists, and, as indicated by its name, becomes the *calcar avis*, or *hippocampus minor*, p. 693.

During the seventh month the parieto-occipital fissure extends beyond the medial wall on to the external wall of the hemispheres, and by its extension establishes the life-long boundary between the parietal and occipital lobes. The anterior boundary of the parietal lobe is the fissure of Rolando, see below.

2. SECONDARY FURROWS.—These, as defined above, are merely grooves upon the surface, not folds of the walls, and they have, therefore, no corresponding internal ridges on the ventricular side of the brain-wall. We may conveniently divide them into main or essential fissures and accessory or unessential fissures.

The MAIN FISSURES may be enumerated as follows:

- | | |
|-----------------------------------|---|
| 1. Calloso-marginal or splenial. | 5. Fissures of the temporal lobe. |
| 2. Fissure of Rolando. | <i>a.</i> superior temporal. |
| 3. Fissures of the frontal lobe. | <i>b.</i> inferior temporal. |
| <i>a.</i> præcentral. | <i>c.</i> occipito-temporal or col- |
| <i>b.</i> superior frontal. | lateral (compare 6, <i>d</i>). |
| <i>c.</i> inferior frontal. | 6. Fissures of the occipital lobe. |
| <i>d.</i> olfactory or rectus. | <i>a.</i> ascending perpendicular. |
| <i>e.</i> tri-radiate. | <i>b.</i> superior occipital. |
| <i>f.</i> internal frontal. | <i>c.</i> inferior occipital (sagittal). |
| 4. Fissures of the parietal lobe. | <i>d.</i> occipito-temporal (compare 5, <i>c</i>). |
| <i>a.</i> Intraparietal. | 7. Fissures of the island of Reil. |
| <i>b.</i> retrocentral. | <i>a.</i> central. |
| | <i>b.</i> præcentral. |
| | <i>c.</i> postcentral. |

The primitive type of the fissures and of the convolutions between them is marked in the adult by the accessory fissures, which join the primary fissures or arise from them, and also by secondary bridges by which two adjacent convolutions are connected with one another across a fissure.

The *calloso-marginal* or *splenial fissure*, Fig. 402, *e*, arises about the middle of the fifth month, in front of and above the corpus callosum, *cc*, by the fusion of two or three shorter fissures; the area of the hemispherical mantle between the calloso-marginal fissure and the

corpus callosum is the *gyrus fornicatus*. Behind the main fissure, *e*, are several subsidiary fissures which vary considerably in different brains in both number and arrangement; they appear usually to unite with the calloso-marginal fissure, which is thus prolonged further back above the corpus callosum, *cc*, and usually the added

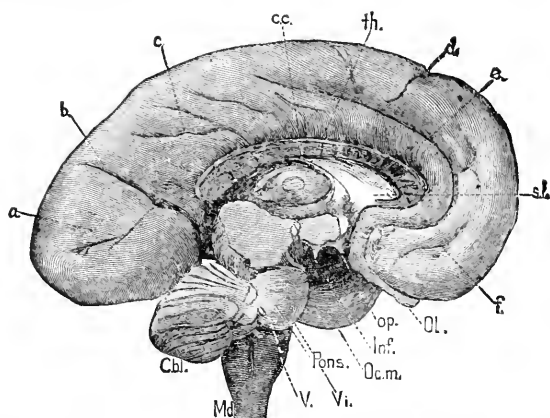


FIG. 402.—Brain of Human Embryo of the fifth Month after Removal of the Right Hemisphere. *a*, Calcarine fissure; *b*, parieto-occipital; *c*, accessory fissure of calloso-marginal; *cc*, corpus callosum; *th*, optic thalamus; *d*, precentral superior; *e*, calloso-marginal; *sl*, septum lucidum; *f*, internal frontal; *Ol.*, olfactory lobe; *op.*, optic nerve; *Inf.*, infundibulum; *Oc.m.*, oculomotor nerve; *Pons.*, pons Varolii; *Vi.*, sixth nerve; *V.*, trigeminus; *Md.*, medulla oblongata; *Cbl.*, cerebellum. Natural size. (Compare Fig. 404.)

secondary fissures cause the calloso-marginal to terminate posteriorly with an upward turn, a short distance behind the upper end of the fissure of Rolando.

The development of the *fissure of Rolando* has been carefully studied by D. J. Cunningham, 90.1, whose account is as follows: There is some variability in the time at which the fissure makes its appearance. The more usual time is the last week or ten days of the fifth month, but it is not uncommon to meet with hemispheres well on in the sixth month of development with no sign of the fissure. As a general rule, the fissure of Rolando is developed in two separate and distinct pieces, Fig. 403, *Ro'*, *Ro''*. The lower portion appears in the form of a shallow oblique groove, which represents the lower two-thirds of the fully-formed sulcus. It always makes its appearance before the upper piece. Its lower end is placed close to the coronal suture—perhaps, indeed, it may lie immediately subjacent to the suture—while the upper end lies further back, and reaches a point midway between the upper margin of the hemisphere and the Sylvian fossa. The upper piece of the fissure makes its appearance in the form of a deep pit or depression between the upper end of the lower portion and the margin of the hemisphere. An eminence separates the two portions of the fissure from each other. Soon, however, a faint furrow runs over the summit of this elevated intervening piece of the cortex, and the two primitive portions of the sulcus are partially united to each other. As development goes on the more complete does the union become, and the more fully is the intervening eminence borne down into the bottom of

the fissure. As a rule, the confluence takes place rapidly, but in many cases the process appears to be retarded. Among my specimens I have several hemispheres which, although close upon the seventh month, show still a complete severance of the two constituent elements of the furrow. But the portion of cerebral cortex which intervenes between the two parts of the fissure is not entirely obliterated. It disappears from the surface, it is true, but it is still to be discerned, even in the adult brain, in the bottom of the fissure, in that shallowing or deep annectant gyrus which we have described at the junction of the upper and middle thirds of the sulcus. In some rare cases, as stated by Cunningham, the two original portions of the fissure of Rolando remain quite distinct throughout life. In these the intervening bridge of cortex remains on the surface, and is not pressed down by the fusion of the upper and lower divisions of the fissure. We have noted that the same deep annectant gyrus may be observed in the fissure of Rolando of the chimpanzee and

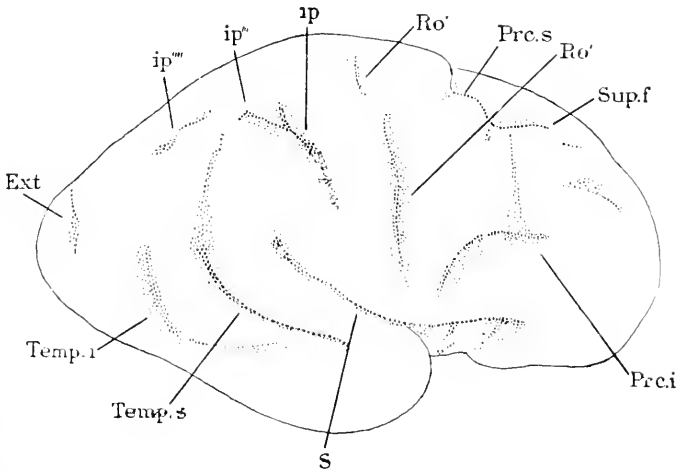


FIG. 403.—Right Hemisphere, Natural Size, of a Fœtus of nearly seven Months. *ip*, Interparietal fissure partly formed; *Ro'*, upper, *Ro'*, lower piece of fissure of Rolando; *Prc.s*, superior præcentral fissure; *sup.f*, superior frontal; *Prc.i*, inferior præcentral; *S*, Sylvian fissure; *Temp.s*, temporalis superior; *Temp.i*, temporalis inferior; *Ext*, external perpendicular fissure of Bischoff. After D. J. Cunningham.

orang. We may assume, therefore, that the interrupted form of development of this sulcus holds good among the anthropoid apes as well as in man. With regard to the lower apes, we have no evidence one way or the other. The development of the fissures in the brain of the ape is still virtually unknown; and if we examine the bottom of the fissure of Rolando and the other primary furrows in a low ape, we find a uniform depth throughout, and an absolute absence of deep annectant gyri. It is dangerous to argue from the adult condition alone, but still the appearances are such as would lead us to infer that the continuous and not the disrupted form of development of the primary fissures holds good among the lower apes. The lower end of the fissure of Rolando is sometimes lengthened out by union with a small accessory fissure (fissure of Ober-

staller, "Das Stirnhirn," 1890) so as to be prolonged to the fissure of Sylvius. The inferior genu of the fissure of Rolando appears usually about the seventh month and always before the superior genu, in the lower piece of the fissure; the superior genu is developed at the junction of the upper and lower piece. From the seventh month onward the convolution (posterior central), behind the fissure grows more rapidly than the convolution (ascending frontal) in front of it.

The fissure of Rolando was first so named by Leuret in 1839 ("Anat. comp. du Système nerveux"); in Germany it is usually termed the central fissure. It is the now accepted division between the frontal and parietal lobes. Next to the central or interhemispherical fissure and the Sylvian fissure it is the most important landmark in the topography of the human cerebrum. It is, however, *not* a primary or essential fissure throughout those mammalia having convolutions.

The Fissures of the Frontal Lobe.—The *pre-central* arises generally toward the end of the sixth month, and, therefore, some time

after the fissure of Rolando, but not invariably, for it has been observed to precede the fissure of Rolando, see D. J. Cunningham, 90.1, Pl. I., Fig. 1; it can be identified by its position, it lying in front of the parietal bone, which covers the fissure of Rolando.

It runs nearly parallel with the fissure of Rolando, and arises from two pieces (Cunningham, *l.c.*, p. 7, compare Fig. 403, *Pre.i*, and *Pre.s*), which usually remain distinct but are sometimes united. The development of the *superior* and *inferior frontal fissures* is obscure. If the brain be viewed from below, Fig. 404, the lower surface of the frontal lobe offers at five to six months three depressions, which I have found to be remarkably constant. One of these is the *sulcus rectus* or *olfactorius*, in which the olfactory bulbus, *Ol*, is lodged. The other two are small;

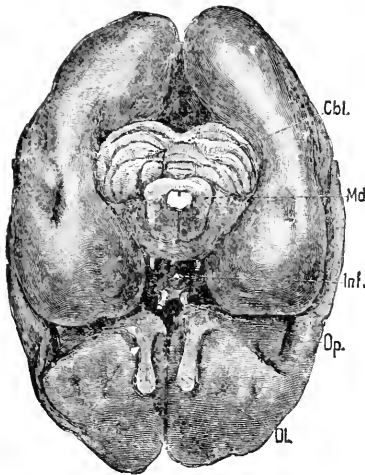


FIG. 404.—Under Side of the Brain of a Human Embryo of the fifth Month. *Cbl*, Cerebellum; *Md*, medulla oblongata; *inf*, infundibulum; *Op*, optic nerve; *Ol*, olfactory lobe. Natural size. (Compare Fig. 402.)

they unite later with one another, and forming branches give origin to the inappropriately named *tri-radiate fissure*. I have to add here what may be called a new fissure, which appears not to have been hitherto generally recognized, although so far as my uncompleted observations go, it seems very constant both in embryos and adults;* I name it the *internal frontal fissure*; it is situated on the medial wall of the frontal lobe, Fig. 402, *f*, and runs approximately parallel with the callosomarginal fissure; it divides the marginal or so-called first frontal convolution into two parts; if the conclusion that the internal frontal fissure is primary and constant be verified, it will be necessary to subdivide the marginal convolution as now defined.

* The fissure is perfectly shown in Dalton's "Topographical Anatomy of the Brain," vol. I., pls. vi. and vii., and in several well-known text-books it is clearly figured.

The Fissures of the Parietal Lobe.—The *intra-parietal fissure* arises (Mihalkovics, 77.1, 154) as two limbs during the sixth month; one limb is parallel with the fissure of Rolando, and not far behind it; the other limb has a more longitudinal course and lies not far from the median plane; during the eighth month the two limbs unite. During the seventh month, according to Mihalkovics, *l.c.*, a *retro-central fissure* appears between the ascending limbs of the intraparietal and the fissure of Rolando. Along the median wall of the parietal lobe extends only the callosomarginal fissure, Fig. 402, *e*, and its branches, *c*.

The Fissures of the Temporal Lobe.—During the sixth month there appears the *superior temporal fissure* on the external surface of the lobe and parallel with the adjacent margin of the great Sylvian fissure, compare Fig. 403, *Temp. s*. Usually somewhat later appears another fissure, the *inferior temporal*, immediately below and parallel with the last mentioned; the second fissure, Fig. 403, *Temp. i.*, is often discontinuous. On the lower surface of the lobe is developed during the sixth month also the great *occipito-temporal fissure*, the *fissura collateralis* of Huxley; this fissure varies greatly in length; it normally extends far into the occipital lobe, hence its name, and sometimes runs so far forward as to border the gyrus hippocampi. The collateral fissure is very deep, and there is a projection on the inner side of the brain corresponding to it, and which is known as the *eminentia collateralis* of Meckel; this fissure ought, perhaps, to be classed with the primary folds, p. 695. The collateral fissure, according to D. J. Cunningham, 91.2, 344, is continued forward in the middle foetal life by the incisura temporalis and the limiting fissure of the insula Reilii; these three grooves may be taken as making the limits of the temporal lobe, but in later stages the originally evident relations of the three grooves to one another become obscured. During the ninth month of foetal life an accessory transverse fissure on the under side of the temporal lobe unites with the limiting fissure of the insula, and therefore in the adult the fissure appears to have changed its primitive course.

The Fissures of the Occipital Lobe.—This lobe has three surfaces, an inner or medial, an external, and a lower or cerebellar. On the medial surface the lobe is bounded anteriorly by the parieto-occipital fissure, Fig. 402, *b*, and shows the calcarine fissure, *a*, the origin of both which is described p. 697. The area between these two fissures is the *cuneate lobule* (*Zwickel*). On the external surface the first fissure to appear is a small, short one, Fig. 403, *Ext*, the *ascending perpendicular* of Bischoff, 68.1, 447; the horizontal limb of the intraparietal fissure extends on to the occipital lobe, and probably joins the fissure of Bischoff; the prolonged intraparietal is known as the *superior occipital* fissure. Later (eighth month) arises lower the longitudinal *inferior occipital* (*sulcus sagittalis*). On the lower surface during the sixth month appears the great occipital temporal fissure, which, as stated above, also belongs to the temporal lobe. The data of this paragraph are chiefly from Mihalkovics, 77.1, 155.

The Fissures of the Island of Reil.—The best account of the adult fissures of the insula is probably that of Oberstaller (*Anat. Anzeiger*, 1887, p. 739). He finds four vertical fissures: the first

and second præcentral, the central, and the post-central, as they may be called; as the second præ-central is small and insignificant, it may be regarded as accessory. Their development has been studied by D. J. Cunningham, 91.2. In the latter half of the fifth month the *central fissure* (*sulcus centralis insulae*) becomes evident as a faint linear furrow which runs upward and backward from the lower part of the Sylvian fossa; from the very first it lies accurately in the line of the fissure of Rolando, and it appears at the same date; it is situated much nearer the hinder end of the insula than at later stages, owing to the growth of the posterior part of the insula. The *first præ-central fissure* is developed a little later, but as a general rule before the end of the fifth month, and lies accurately in line with the sulcus præ-centralis inferior of the frontal lobe; during the last month of foetal life its upper end generally moves forward to a slight extent so that its relation to the frontal præ-central is marked; it is remarkable that for a certain period the præ-central fissure is better marked than the central, but during the eighth month it loses this pre-eminence. Guldberg (*Anat. Anzeiger*, Oct., 1887) mistook the præ-central for the central fissure. The *post-central fissure* is much later in making its appearance. As a rule, it does not show until the middle of the sixth month or even later; its development coincides with that of the intraparietal fissure, the line of which it prolongs.

The remarkable coincidence of three main fissures of the island of Reil with the lines prolonging respectively the præ-central inferior, the fissure of Rolando, and the intraparietal necessarily suggests that the insular fissures are parts of the same fissures as those of the mantle enumerated.

THE ACCESSORY FISSURES.—Beside the main fissures the human brain has a large number of short fissures of an irregular and variable character, and which modify and mask the primary fissures to a variable extent. These accessory fissures appear during the last month of foetal life, for the most part as branches of earlier fissures, but in small part as independent grooves. Whether or not other fissures are developed after birth I do not know. The laws governing the appearance of the accessory sulci have not yet been ascertained.

3. TRANSITORY FISSURES.—The question is still under debate as to whether there are in early stages of the fœtus temporary folds or not. Bischoff, His, and others, with whom I am strongly inclined to agree, consider the irregular folds, which are often to be observed on the surface of the cerebrum from the first to the fourth month, as artificial and accidental. On the other hand, Kölliker, Ecker, Mihalkovics, 77.1, 144, and others, consider that the folds are normally present.

4. EVOLUTION OF THE FISSURES.—It is well known that there are several types of convolutions, and that different fissures are typical of different orders of mammalia. It is probable that all the fissures (*i. e.*, secondary furrows) of the human brain were evolved within the series of primates, and it is doubtful whether they are any of them homologous with the fissures in other mammalian orders; compare Sir Wm. Turner, 90.2.

5. HISTORICAL NOTE.—Our knowledge of the foetal fissures and convolutions was very slight until Reichert ("Der Bau des menschlichen Gehirns," 1859, 76-90). More thorough were the valuable memoirs of Bischoff, 68.1, and Ecker, 83.1. The mechanical factors concerned in the production of the convolutions have been discussed by His, 74.1, 110-117. D. J. Cunningham has made, 90.1, 91.2, important additions to our knowledge of the development. Of the anatomical papers on the convolutions many are of morphological value; among them Sir Wm. Turner's address, 90.2, is of the first value to the embryologist. Of the knowledge of the subject up to 1877, Mihalkovics gives an admirable summary, 77.1, upon which I have drawn freely.

Olfactory Lobes (*Riechlappen*).—The following account is based upon the researches of His, 89.4. The olfactory lobe arises by differentiation of an area of the wall of the primitive hemisphere. The differentiation begins in the human embryo during the fourth week as the hemispheres begin to enlarge, and affects the area adjoining the median lamina terminalis, compare Fig. 339, *Ol*. The olfactory area, as it may be called, expands with the hemispheres, and thus soon extends well forward in front of the lamina terminalis; it then constitutes a slight longitudinal ridge with a corresponding internal groove, along the under side of the cerebral hemisphere, Fig. 341. The area now appears as a fold of the hemispherical wall. There now develops the primary groove (*primäre Bogenfurche*) p. 692, and this extends not only in an arch along the medial surface of the hemispherical wall but also curves on to the olfactory ridge, and by crossing it transversely divides the ridge into an anterior and a posterior segment, Fig. 399. The ridge next separates from the hemisphere, so as to be converted into a blind tubular diverticulum, which remains connected at its posterior end with the hemisphere, and we now have an olfactory lobe, which has a central cavity in direct communication with the lateral ventricle; the lobe has two segments, one posterior connected with the brain, the other anterior and comprising a narrower part or stalk, and an enlarged end; the stalk is the anlage of the *tractus olfactorius* and *trigonum*; the enlarged end is the anlage of the *bulbus olfactorius*. The posterior segment becomes the posterior olfactory lobe, a part of the brain which has been long imperfectly recognized; it comprises the *pedunculus corporis callosi* (or *gyrus subcallosus* of Zuckerkandl); the outer and inner roots of the olfactory nerve, and the *substantia perforata anterior*.

The olfactory ganglion of the embryo unites with the bulbus olfactorius. The union takes place during the latter part of the fifth week, Fig. 405. The origin of the olfactory ganglion is described p. 637. It grows upward, and as during the fifth week the end or bulbus of the olfactory lobe bends toward the median line, Fig. 405, the ganglion lies close behind the bulbus, in the groove which may be regarded as the prolongation above described of the Bogenfurche or primary fissure across the lobe. The ganglion now spreads around the bulbus, and unites with it, as may be seen on the right side in Fig. 405, and forms a superficial layer over the surface of the bulbus, which thus has three layers—the outer ganglionic layer, the neuro-

glia layer corresponding to the Randschleier, and the inner nucleated layer corresponding to the inner layer and mantle layer of the spinal cord. The transformation of these into the adult layers has still to be worked out. Owing to the fusion of the ganglion with the bulbus there can be no nerve-trunk running from the ganglion to the brain;

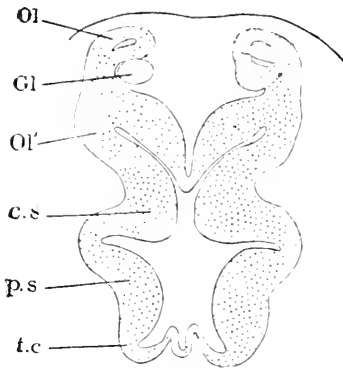


FIG. 405.—Section of the Fore-brain of a Human Embryo of nearly five Weeks (His' Sch.). *Ol*, anterior; *Ol'*, posterior division of olfactory lobe; *Gl*, olfactory ganglion; *c.s.*, corpus striatum; *p.s.*, pars sub-thalamica; *t.c.*, tuber cinereum. After W. His.

the centrifugal fibres from the ganglionic layer run off in bundles, which form a plexus-like network on their way to be distributed to the olfactory epithelium covering the upper turbinal fold (*obere Muschel*). The fusion of the ganglion with the bulbus explains why the olfactory fibres appear in the adult to arise from the wall of the lobe, although not medullary nerve-fibres.

During the second month the hemispheres expand so rapidly that they carry the base or posterior part of the olfactory lobe forward, while the bulbus remains attached to the ganglion so that the bulbus at the end of the second month is bent back and lies under the posterior segment, but during the third month the bulbus bends forward again and assumes its permanent position.

During the third month also, the anterior half of the lobe lengthens out and becomes clearly differentiated into bulbus, tractus, and trigonum. The cavity of the olfactory lobe becomes obliterated in great part before adult life, but exactly how or when is not known.

Evolution of the Head.—We are now in a position to review briefly the factors which have determined the differentiation of the head. The conception that the head is composed of a number of segments has now been current for nearly a century. For a long time the attempts to determine the number of cephalic segments were confined to the study of the skull, following Oken's idea that the skull is composed of a number of vertebræ. We have already seen, p. 469, that all such attempts were necessarily fruitless. A great advance was made when Gegenbaur, in 1872, sought to determine the segmental value of the cranial nerves, compare p. 469, but the correct and only way was pointed out by Balfour, who sought to determine the number of actual segments in the embryonic head, compare p. 199. Van Wijhe found of the true myotomes at least nine in shark embryos, and Dohrn has found in a very young stage of the torpedo about twice that number, compare p. 200 and Fig. 118. It has thus been proved that the head is a segmented region in which the majority of the segments abort very early in the embryo.

The next step must be to ascertain what causes have resulted in, and what effects have resulted from, the disappearance of myotomes in the head. The first thing to indicate the formation of the head is, in the embryo of all classes of vertebrates, the dilatation of the medullary tube to form this brain, a dilatation which crowds the mesoderm down on the ventral side of the neural tube. I think also

that the enlargement of the brain is the direct cause of the formation of the head-bend, and that probably the proamniotic area has the rôle to play of preventing the directly forward growth of brain, because there being no mesoderm in the proamnion the entoderm and ectoderm are united and the head cannot develop across the area, and consequently bends to allow the elongation of the cerebral vesicles. The head-bend still further crowds the myotomes, compare Fig. 118, and it is to this crowding that the abortion of the myotomes is to be attributed, according to my hypothesis.

The effects of the abortion of the cephalic segments have been to prevent the development of the primordial skeleton into separate vertebral masses, and to prevent the development of the cranial nerves on the type of those of the spinal cord. It must, however, be admitted that the correlation between the arrangement of the nerves and the development or abortion of segments is very obscure.

Another factor in the evolution of the head, which enters into action much later, is the development of gill pouches with their resultant modifications of the gill-arches, formation of the branchial skeleton, etc. Noteworthy is the fact that the coelom of each arch connects a myotome with the splanchnocœle (pericardial cavity) and is apparently homologous with the nephrotome of a rump segment. If this homology is correct we must describe it as a further peculiarity of the head that its nephrotomes give rise, not to excretory tubules, but to branchial striated muscles, see p. 478.

A third factor which comes into play still later is the annexation to the occipital region of at least four true cervical (hypoglossal) segments with their vertebræ and nerves, compare p. 429 and 665.

The skull plays a subsidiary part and is an accessory structure added after all the essential morphological characteristics of the head are present. The erroneous notion that the skeleton is the framework upon which the body is built has been discarded by embryology. That the organs of special sense have had a profound influence on the head during its evolution cannot be doubted, but, while we put down the possession of the olfactory, visual, and auditory organs as essential characteristics of the head, we cannot say, so far as we can recognize at present, that they have influenced the constitution of the head nearly as much as the other factors.

We must for the present define the head as the anterior region of the body, in which the medullary tube is enlarged, the segments consequently aborted, and the skeleton therefore not divided into vertebræ, nor the nerves with dorsal and ventral roots united; which possesses the three organs of special sense; in which the gill-clefts are developed; and which has increased its original territory by the annexation (at least in amniota) of several cervical segments.

CHAPTER XXVIII.

THE SENSE-ORGANS.

IN this chapter we have to consider a large number of structures. Concerning the lower sense-organs, touch, taste, etc., we know almost nothing; concerning the olfactory organ a little, concerning the eye and ear a good deal—on the embryological side, of course. We have further to emphasize those traces which have been discovered of long series of sense-organs, of which the nose, eye, and ear are probably derivatives, in the ancestors of vertebrates, although in all known vertebrates most of these series have become rudimentary or lost. The serial sense-organs I designate under the comprehensive name of ganglionic sense-organs. There are probably two, and only two, series along each side of the body: one series, the upper, corresponds to the lateral line of comparative anatomy, the other to the epibranchial line. The olfactory, visual, and auditory organs are probably specialized ganglionic sense-organs. The organs of touch, taste, etc., have not yet been shown to have any genetic relationship to the ganglionic sense-organs.

Ganglionic Sense-Organs.*—By this term I propose to designate the series of organs formed by the temporary or permanent union of the sensory ganglia, described in the previous chapter, with the epidermis. The discovery that such a class of organs exists, and that the ear probably, the eye and nose possibly, belong to the class, was due to Froriep, **85.1**, whose article marks an important step in vertebrate morphology. The temporary connection of certain ganglia with the epidermis was, so far as I know, first discovered by J. W. Van Wijhe, **82.1**, in elasmobranch embryos, and has been especially studied by Beard, **85.1**, whose researches have proved valuable and suggestive, though his publications are marred by premature and too diagrammatic generalizations. Beard proposes the name of *branchial sense-organs*, but the term most generally used is *segmental sense-organs*, because the organs are believed to be repeated in each segment. The term adopted here, "ganglionic," is purely descriptive, and involves no theory as do the two others just mentioned, and moreover serves to indicate also the distinction between the two main classes of sense-organs.

As an example of a typical ganglionic sense-organ of an embryo we may take the front ganglion of a young elasmobranch. This ganglion belongs to the third cranial or oculo-motor nerve. According to Beard it grows out from the neural crest of the mid-brain shortly before the closure of the medullary groove at that point. It soon comes in contact with the epidermis, which thickens where the

* Additional details are given in connection with the history of the cephalic nerves in the preceding chapter, p. 633.

ganglion touches it. The thickened epidermis and the ganglion then fuse, Fig. 406, the former becoming depressed so as to make a shallow pit. The boundary between the two tissues becomes indistinct. According to Beard some of the cells are specialized later to form what he terms the supra-branchial nerve, and of this his figure, Fig. 406, indicates the commencement, *Sp.n.* Similar fusions have been demonstrated in the amniota by Froriep in the case of the ganglia of the facial, glosso-pharyngeal, and vagus nerves; the site of the fusion is for each of these ganglia directly above the gill-cleft to which the nerve of the ganglion belongs. The term branchial sense-organ has reference to this position, which is assumed by Beard to be typical for all the organs of the class.

C. Kupffer, 91.1, has shown that in *Petromyzon* the ganglia form two series of unions with the epidermis, and maintains that at each point of union cells are budded off from the epidermis and incorporated in the ganglion which is so enlarged. Fig. 407 illustrates the arrangement of the ganglia as found by him in a young *Petromyzon* (*Ammocetes* of 4 mm.). The five great ganglia of the head (the ciliary, I.; trigeminal, II.; acoustico-facial, III.; glosso-pharyngeal, IV.; and vagus, V.) are each connected with the epidermis and receive cells from it; the line of the ganglia is prolonged backward by the lateral line; if the line of the ganglia were continued forward it would, allowing for the bend of the head, terminate in the nasal pit, *N*, or anlage of the olfactory organ; the ear (otocyst) lies directly along the line of the ganglia, and represents,

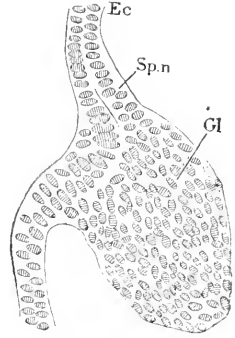


FIG. 406.—Horizontal Section of Oculomotor Ganglion of a Young *Torpedo* Embryo. *Ep.* Epidermis; *Sp.n.* supra-branchial nerve anlage, according to Beard; *Gl.* ganglion. Highly magnified. After John Beard.

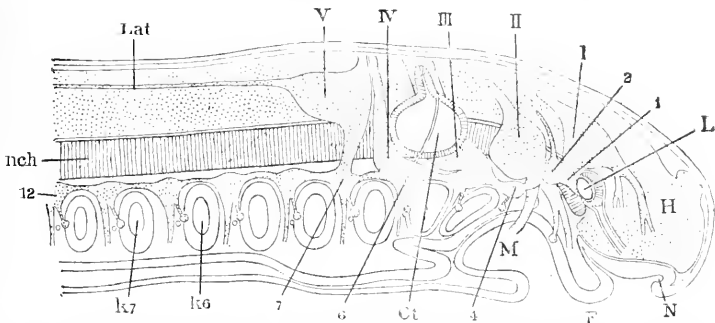


FIG. 407.—Reconstruction to show the Cephalic Ganglia of a *Petromyzon* Larva, 4 mm. long. *Lat.* Lateral nerve; I-V. cephalic ganglia; *L.* lens of eye; *H.* fore-brain; *N.* nasal pit; *F.* fold between the hypophysis and mouth; *M.* mouth cavity; 1, 4, 6, 7, 12. epibranchial ganglia, serially numbered; *Ot.* otocyst; *K6, K7.* gill pouches, serially numbered; *nch.* notochord. After C. Kupffer.

as has been long known, an epidermal area in contact with the acoustic ganglion; the olfactory area, as we have seen, p. 637, also throws off cells and produces a ganglion, which we may, hypothetically at least, add to the chain of ganglia I.-V. We have then the

lateral line prolonged forward by the five primary cephalic ganglia, and by the olfactory ganglion the entire length of the head. It is, I think, not carrying speculation too far to suggest that the retina of the eye represents another ganglionic area, which has been displaced by being involved in the invagination to form the fore-brain; it is perhaps not superfluous to add that the acceptance of this speculation encounters difficulties which cannot, at present, be removed. Each of the primary ganglia, Fig. 407, I.-V., is prolonged downward and joins a chain of epibranchial ganglia, which are connected together longitudinally with one another and are much smaller than the main or lateral ganglia; every epibranchial ganglion, also, is connected with the epidermis and receives cells from it; the epibranchial chain begins immediately behind the lens of the eye and is continued far backward above the mouth and then above the gill-clefts. Kupffer figures twelve epibranchial ganglion; the first is immediately behind the lens of the eye and is united with the ciliary ganglion, I.; the second, third, and fourth overlie the mouth, the third being connected with the trigeminal ganglion, II.; the fifth to twelfth ganglia lie each above a gill-cleft, there being eight gill-clefts present at this stage; the fourth and fifth appear to be connected with the acoustico-facial lateral ganglion, III., the sixth with the glosso-pharyngeal, IV., the seventh with the vagus ganglion, V.

As Kupffer points out, *l.c.*, 49, we have to do in *Petromyzon* with very primitive conditions, which must contribute much toward the comprehension of the morphology of the ganglia and sense-organs of the higher vertebrates. There can be little doubt that the lateral ganglia and sense-organs as one series, and the epibranchial ganglia and sense-organs as another series, are common to all vertebrates. As already stated, it seems certain that the ear, probable that the olfactory organ, and possible that the eye all belong to the lateral series, and there can be little doubt that the organs discovered by Froriep, and now generally known as branchial sense-organs, are members of the epibranchial series. I deem it extremely probable that further investigation will demonstrate the existence of both series in the embryos of all vertebrates.

There is little in the embryonic organs described, beyond the union of nervous and epidermal tissue, to suggest comparison with a histologically specialized sensory apparatus; nevertheless we may safely interpret both the lateral and epibranchial structures as rudimentary sense-organs, because in the case of the ear and nose, as described below, such a union constitutes an essential stage in the development, and because the fact that the organs of other ganglia abort during embryonic life accounts for the lack of the histological differentiation. The number and fate of the rudimentary ganglionic sense-organs has been discussed in connection with the history of the separate cranial nerves. The problem of the homologies of the organs with sense-organs of invertebrates is still too obscure to be profitably discussed here.

Very suggestive in this connection are the observations of H. V. Wilson, 91.1, 244-253, of a thickening of the nervous layer of the epidermis on either side of the head in the bass embryo (*Serranus atrarius*). This thickening forms a long, shallow furrow, which

subsequently divides into three parts, of which the first becomes a sense-organ over the gill-cleft, the second the auditory invagination, and the third, the anlage of the sense-organs of the lateral line. This peculiar development confirms the notion that all these organs belong in one series, but the appearance of a continuous thickening as the anlage of them all has, as yet, been observed only in this fish, and may not indicate a corresponding ancestral condition. Unfortunately Wilson was unable to make out anything as to the connection of the sensory plate with the ganglia. The sense-organ above the gill-cleft, though differentiated, is a larval structure only, and disappears in the adult.

EVOLUTION OF THE GANGLIONIC SENSE-ORGANS.—Lenhossék, 92.1, has shown that in the earth-worm there are cells scattered through the epidermis which give off fibres which run to the central nervous system, and there like vertebrate sensory fibres fork; one fork runs headward, the other tailward within the central ganglionic chain. This important discovery renders it probable that sensory ganglion cells and sensory cells were originally one, and that the ganglion cells of vertebrates are nerve-sense cells, which have migrated from the epidermis. The ganglionic sense-organs in this way are traced to a genetic condition arrested, for we may assume that they correspond to areas in which the nerve-sense cells are congregated, and that part of the cells remain in the epidermis, while others migrate from it to constitute the ganglion. Lenhossék's discovery leads him to the further hypothesis that the special sense-cells connected with a nerve-fibre, such as occur in taste-bulbs, the olfactory membrane, and the organ of Corti, are really comparable to the nerve-sense cells of *Lumbricus*, and are true neuroblasts in that they produce the nerve-fibres connected with them; hitherto we have assumed that the nerve-fibre grew to the cell. It seems to me that Lenhossék's hypothesis is likely to be verified with revolutionary results for our conceptions of the morphology of the nervous system and sense-organs.

The Special Sense-Cells.—I wish to point out that there is a remarkable uniformity in the specialization of the sense-cells in the organs of taste, smell, sight, and hearing, which at once suggests that they are all derived from a common form. The cells are elongated and have, 1, a lower tapering infra-nuclear member, which is a portion of the protoplasmic body of the cell, and is, probably, always connected with a nerve-fibril; 2, an upper supra-nuclear member, which is also part of the protoplasmic cell body and stretches to the surface of the epithelial layer in which the special sense-cells are situated; 3, a projection above the surface of the epithelium; the projection is different in character from the protoplasm; it differs also according to the organ; the projection is called a hair or cilium in the case of the organs of taste, smell, and hearing, a rod or cone in the case of the eye.

The obvious similarity of the special sense-cells confirms, I believe, the theory that the special sense-organs are modifications of ganglionic sense-organs, which in the ancestors of vertebrates were all similar and perhaps served a generalized sensory function. Perhaps the sense-cells are also nerve-sense cells, as suggested by Lenhossék (above).

Organs of Touch and Taste.—I have been unable to find a single word as to the development of any tactile organs by any writer.

ORGANS OF TASTE.—The development of the organs of taste has been studied by A. Lustig, **84.1**, Fr. Herrmann, **85.1**, and Fr. Tuckermann, **89.1**, **89.2**. The development takes place quite late; the papillæ (or folds) are produced first, the taste-bulbs upon them arising later. In the rabbit the formation of the papillæ begins with the third week; in man Tuckermann found on the fœtal tongue five circumvallate papillæ at four months, six at five and a half, eight at six and seven months; at four months the development of taste-bulbs had hardly begun; at six months the bulbs are numerous and the papillæ have become lobate.

Olfactory Membrane.—The development of the nasal pits and their enlargement to form the nasal cavity is described, p. 575; the development of the olfactory ganglion and nerve from olfactory epithelium is described, p. 637. Concerning the further history of the olfactory membrane and the genesis of its sense-cells nothing is known.

It may be recalled that Blauc, **84.1**, has recorded that in various fishes the olfactory cells are collected in groups, having a very striking similarity to both the taste-bulbs and the sense-organs of the lateral line of anamniota. In mammals the olfactory cells are not so grouped, but it is possible they may be so in the embryo. As the organs of the lateral line are ganglionic sense-organs, Blauc's observations offer additional evidence for interpreting the organ of smell as likewise a ganglionic sense-organ.

DEVELOPMENT OF THE EYE.

The Optic Vesicles.—The first stages of the optic vesicles as diverticula of the fore-brain have been traced above, p. 594. The vesicles form the retina, the choroid coat, and the optic nerve of the adult eye; the differentiation of the anlagen of these three parts forms the subject of this section.

The following account of the early changes in the shape of the optic vesicles in the human embryo is based on His, **89.4**, 685, who has also traced, **68.1**, 104, 132, and **74.1**, 100, the corresponding changes in the chick. The vesicles become stalked by the fourth week; the stalk, Fig. 337, springs from the lower edge of the fore-brain (thalamencephalon) just in front of the infundibular region; the base is broad, but very rapidly tapers down to the narrow stalk proper; the end of the vesicle is enlarged and the enlargement expands upward and backward, as in all vertebrates. The outer and lower posterior wall of the vesicle and part of the posterior wall of the stalk become pushed in, and thereby the vesicle is changed into the so-called "optic cup." The invagination is probably due in man, as in the chick (Foster and Balfour, "Elements," 2d ed., p. 134) and in the rabbit (as I have observed), to the contact of the distal wall of the optic vesicle with the overlying epidermis; where the contact occurs the wall of the vesicle and the epidermis becomes apparently closely united, as if glued together; the union takes place in the chick the end of the second day, in the rabbit the end of the

ninth; over the area of the union both layers become thickened, Fig. 408; the thickened vesicular area is the anlage of the retina, while the epidermal thickening is the anlage of the lens of the eye, compare Fig. 409, *R*, *L*. The lens area very soon begins to be pushed in, and thereby the retinal anlage is carried back, Figs. 409 and 412, toward the posterior wall of the optic vesicle, and at the same time the cavity of the vesicle is correspondingly reduced. The optic vesicle now has two parts differentiated, the thickened invaginated retinal area, Figs. 409 and 412, *R*, and the thinner posterior pigment layer. The optic cup and lens both grow very rapidly, and the differentiation of the retinal and pigment layers progresses equally. In the rabbit at thirteen days, Fig. 409, I find the hollow optic nerve, *N*, running from the brain to the eye; its walls are continuous, as explained below, with both the pigment, *P*, and retinal anlages; the pigment layer, *P*, is thin, and pigment granules have begun to appear in it; it extends in the form of a wide beaker almost to the epidermis, *Ec*, where it is reflected toward the lens and passes over into the retinal anlage, *R*, which

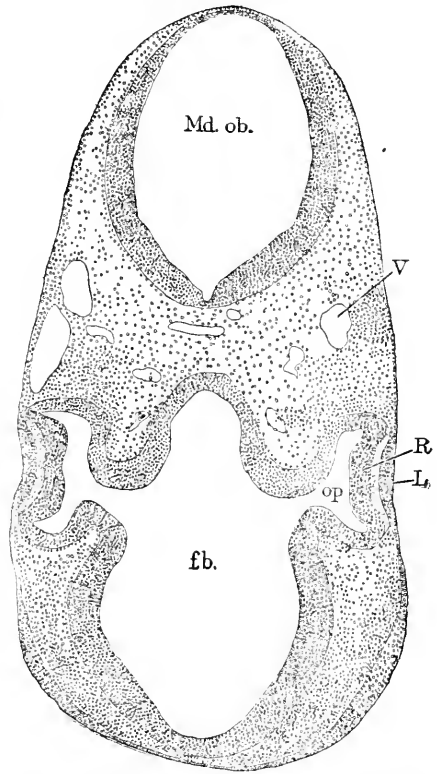


FIG. 408.—Rabbit Embryo of ten and one-half Days; Section of Head. *Md. ob.*, Region of the medulla oblongata; *V*, blood-vessel; *R*, anlage of retina; *L*, anlage of lens; *op*, optic vesicle; *fb*, fore-brain.

represents the outer wall of the optic vesicle. The retina, *R*, has become a thick wall, in which we can distinguish, as in the wall of the medullary tube proper, an inner wide zone with numerous nuclei and an outer narrow zone with nuclei; the outer zone lies toward the lens; it must be homologized with the Randschleier. The retina as a whole forms a wide cup, which is almost completely filled by the large lens, *L*, lodged in it. Between the lens and retina is the anlage of the future aqueous humor; at this stage the anlage is merely a small ingrowth of vascular mesenchymal tissue, *tu.v.*

The invagination of the wall of the optic vesicle is not confined to the retinal area, but also extends along the stalk (anlage of the optic nerve). Fig. 414 represents a section of the invaginated stalk. W. His' Fig. 11, 89.4, makes clear the arrangement in a human embryo at about four weeks; the invagination appears as a fissure running from the under side of the retinal cup and then curving so as to extend along the posterior side of the optic stalk; the upper

border of the fissure is the *Seilenteiste* of His, the lower border the *Basilarleiste* of His; the fissure is known as the *choroid fissure*; it is occupied by mesenchyma; and there is developed, probably, early in the fifth week in man, a blood-vessel, which runs along the furrow to branch out in the retinal cup between the retina and the lens; this vessel is the *arteria centralis retinae* or *arteria hyaloidea*. During the fifth week the choroid fissure begins to close; the closure

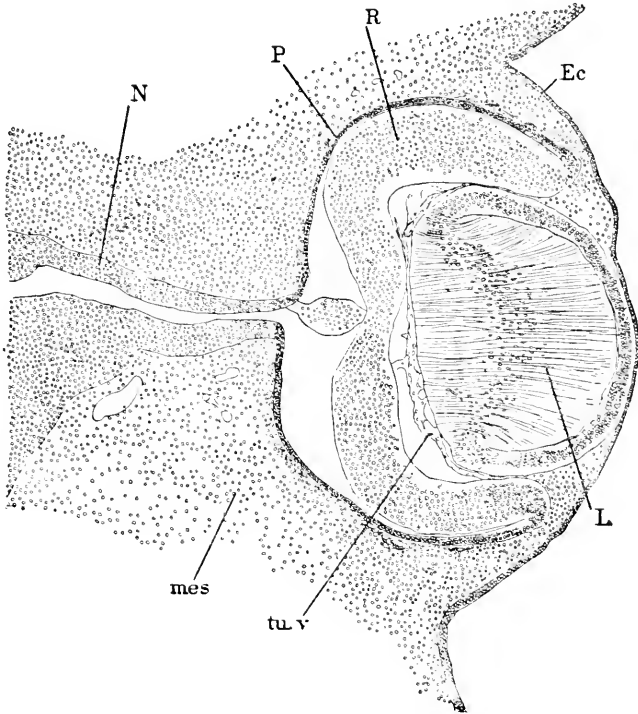


FIG. 409.—Rabbit Embryo of thirteen Days; Section of the Eye. N, Optic nerve; P, Pigment layer; R, retina; Ec, epidermis; L, lens; tu.v, tunica vasculosa; mes, mesenchyma.

commences at the proximal end and progresses toward the retinal end of the stalk; a little later the fissure closes at the lower edge of the retina; there is thus left, Fig. 410, *Ch.f*, a short stretch of the fissure open. It is through this opening that the *arteria centralis*, *Art*, enters and passes on to the hollow of the retinal cup; it is prolonged through the vitreous humor, and there breaks up into numerous branches, which run toward the posterior surface of the lens, where the terminal branches spread out to produce the tunica vasculosa enveloping the lens. In the human embryo at three months the central artery gives off a cone of branches with no main stem (or *arteria hyaloidea* proper) which run through the vitreous humor to the lens; and at this age the atrophy of the vessels has begun (O. Schultze, 1892, in "Festschrift zum 50jähr. Doktorjub. von Kölliker"). At five to six months most of the branches have aborted, and the main

hyaloid trunk is developed as a continuation of the arteria centralis through the vitreous humor. During the last month of foetal life the vessels of the vitreous humor abort completely, and the only trace of their existence to be preserved is the *canalis hyaloideus*, which corresponds to the space originally occupied by the main stem of the artery. With the disappearance of the artery the last remnant of the choroid fissure closes.

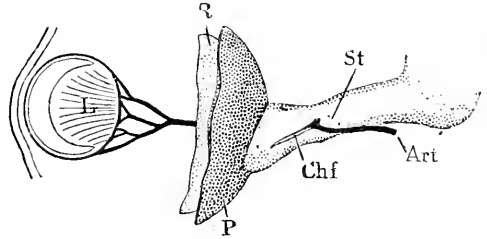


FIG. 410.—Reconstruction from His' Embryo Sch. 13.8 mm. (Nackenlänge). L, Lens; R, retina; P, pigment layer; Ch.f, choroid fissure; St, optic stalk; Art, arteria centralis. After W. His. \times about 50 diams.

The *secondary optic cup* is the term employed to designate the double-walled cup formed by the invaginated retina and the pigment membrane covering it. The opening of this cup is closed by the lens, and so remains throughout life. As seen in Fig. 409, the lens at first nearly fills the cup, but as the retina and pigment layer grow rapidly, the optic cup enlarges and becomes the anlage of the ball of the eye, and the space between the lens and the retina is increased until it assumes the adult dimensions; the space is occupied by loose immigrant mesenchyma, which forms the anlage of the vitreous humor. As the eye expands the tissue around it is condensed and forms an envelope of connective tissue inclosing the optic cup or eyeball; the envelope is the anlage of the *sclera* and *choroid*. I regard it as probable that the condensation is a mechanical result of the expansion of the optic cup.

The *position* of the eye is at first lateral, with the axis turned slightly forward; in the course of its further development (His, 89.4, 689) it moves more and more from its original site downward and forward. Until the end of the first month it lies near the side of the thalamencephalon and higher up than the infundibular process. During the fifth week it gradually descends from this level, and later swings around more and more toward the front, and by the end of the second month it lies below the olfactory lobe. During the latter half of the second month the two eyes have their axes at an angle to one another of about 90 degrees; during the second month the angle further diminishes, and ultimately—the exact time is not known—the axes become parallel with one another. The insertion of the optic stalk is from the start eccentric; at first it is on the lower side of the optic cup, but as the eye migrates it comes to lie on the inner side of the eyeball; it remains eccentric throughout life. At no time does the insertion of the stalk (optic nerve) coincide with the position of the macula lutea, as has been erroneously assumed.

By referring to Fig. 409, it will be seen that the edge of the optic cup lies on the outer surface of the lens; this is always the case. The orifice of the cup is the future *pupil* of the eye; it is a circular opening through which the surface of the lens is exposed. As the eye grows the lens enlarges, but the orifice of the cup (or pupil) does not

become larger;* hence there comes to be a portion of the optic cup which rests on the anterior surface of the lens, Fig. 411, *Uv*. In the region of the optic cup around the edge of the lens and on the front surface of the lens, both layers (retinal, *R*, and pigment, *p*) of the cup become thin and very closely united, so that from an early stage their development progresses as if they were one layer; a short distance from the lens the retinal layer thickens and extends over the rest of the optic cup as the anlage of the true retina. The thin-walled portion of the optic cup may be called the *lenticular zone*; the portion of the zone around the pupil and resting on the lens forms the double epithelial pigment layer of the adult iris and might be appropriately designated as the *primitive iris*; the portion of the zone around the lens, or, in other words, between the edge of the lens and retina proper, early becomes thrown into folds, which give rise to the

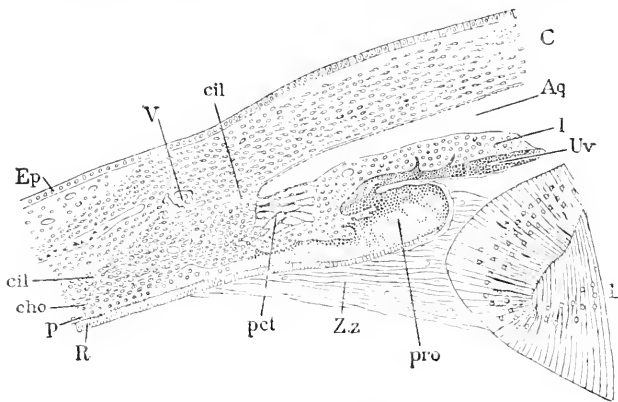


FIG. 411.—Section through the Iris Region of the Eye of a Chick of thirteen Days. *Ep*, Epidermis; *cil*, ciliary muscle; *cil'*, ciliary ligament; *c*, blood-vessel (canal of Schlemm); *c*, cornea; *Aq*, aqueous chamber; *I*, iris; *Uv*, uvea; *L*, lens; *pro*, ciliary process; *Zz*, zonula Zinnii; *pct*, pectinate ligament; *R*, retinal layer; *p*, pigment layer; *cho*, choroid layer. After Angelucci.

ciliary processes, and in the adult it persists as the epithelial pigment covering of the ciliary processes.

It must be expressly stated that the usual description of the development of the iris by a growth of the optic cup over the lens is erroneous; the walls of the cup expand away from the pupil; were the usual description correct the pupil of the embryonic eye would have to be larger than the iris in the adult; in other words, larger than is the whole embryo, when the pupil is first developed.

Lens.—The lens is developed from the ectoderm, which comes in contact with the outgrowing optic vesicles; the distal wall of each vesicle becoming closely united with a nearly circular area of the epidermis at the side of the head. The attached epidermal area thickens and forms the anlage of the lens, Fig. 412, *L*, while the attached wall of the optic vesicle also thickens and forms the anlage of the retina, *R*. It is interesting to note that the karyokinetic figures in the lens anlage are toward the outer surface, and those of the retinal anlage toward the cavity of the optic vesicle, and are there-

*There are no exact measurements, and it is quite possible that the pupillar orifice enlarges slightly, but not at all in proportion to the lens.

fore in homologous situations in both ectodermal layers. The lens area now becomes invaginated, Fig. 412, and may easily be seen in rabbit embryos of the eleventh day, a chick of two days, or the human embryo of the fourth week, as a small pit at the side of the head. To such an extent does the involution of superficial ectoderm take place, that the front or retinal wall of the optic vesicle, as stated in the preceding section, is pushed close up to the hind or pigment wall, and the cavity of the vesicle is almost obliterated, Fig. 409. Meanwhile, as the pit deepens, its mouth closes over, and the pit becomes a completely closed sac, which at once breaks away from the overlying epidermis, which forms a continuous layer in front of it, all traces of the original opening being lost. The closed sac is the lens; it occupies the secondary optic cup, Fig. 409, and later when the cup expands the lens closes the mouth of the cup, Fig. 413. At this stage the lens, *L*, is a rounded, somewhat flattened vesicle with thick walls, and is a strictly ectodermal organ. The

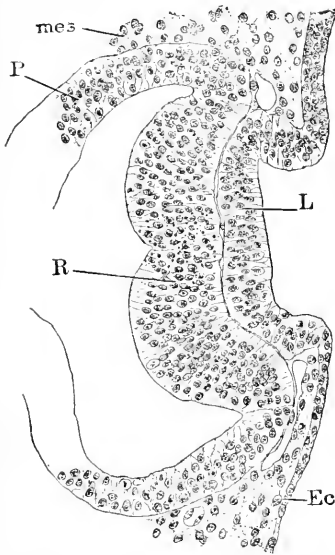


FIG. 412.—Rabbit Embryo of ten and one-half Days; Section of the Lens Anlage. *mes*, Mesoderm; *P*, pigment layer; *R*, retina; *L*, lens; *Ec*, ectoderm.

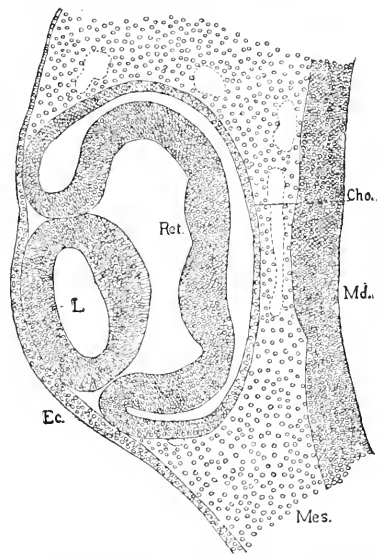


FIG. 413.—Vertical Section of the Eye of a Chick Embryo of the third Day. *Ec*, Ectoderm; *L*, lens; *Ret.*, retina; *Cho.*, choroid layer; *Md.*, wall of brain; *Mes.*, mesenchyma. $\times 108$ diams.

space between the retina, *R*, and the lens, *L*, gradually increases to form the posterior chamber of the eye, which is occupied by the vitreous humor, p. 723. In the chick the separation of lens and retina takes place before, in mammals after, the differentiation of the walls of the vesicular lens has begun, compare Fig. 409 with Fig. 413.

The next step is the thinning of the outer or anterior wall of the lens, and the great thickening of its posterior or inner wall. The thickening of the inner wall is rapid, and soon obliterates the original cavity of the lens. This cavity is filled in birds with fluid, but in mammals contains scattered cells, which break down and disappear as the cavity closes; these cells, I think, are probably part of the

epitrichial layer of the epidermis. The minute structure of the walls of the lens in its vesicular stage is not known, but it is probably an epithelium of cylinder cells, every cell stretching through the entire thickness of the wall, but the nuclei are scattered at various levels. The anterior wall gradually thins out and is converted into a simple thin layer of cuboidal cells with round nuclei, and is known in descriptive anatomy as the epithelium of the lens. The posterior wall, Fig. 409, thickens rapidly by the growth of its cells, which elongate enormously, without, however, increasing much in thickness, thus being metamorphosed into the so-called fibres of the lens. The nuclei of the fibres tend to occupy a middle position, hence there is a band of nuclei across the middle of the thickened wall, as shown in Fig. 409. The lens fibre is merely an elongated epithelial cell, and as such it may be readily recognized in the adult. The fibres change their composition so as to be better fitted for the optical functions of the lens than protoplasmatic cells would be, but how the protoplasm of the cells is metamorphosed is unknown. The fibres all stretch through the whole thickness of the wall, but become bent so as to form three well-defined systems of curves, so arranged at birth that the systems on the front of the lens alternate in the direction of the fibres with those on the back of the lens, see O. Hertwig's diagram ("Entwickelungsges.," 3te Aufl., Fig. 268). At the edge of the lens the anterior epithelium is continuous, Fig. 411, with the thickened posterior wall or layer of lens fibres, and there is a gradual transition between the two.

The growth of the lens is, of course, largely due to the growth of the fibres, but it is supposed that cells are added at the edges of the lens from the anterior to the posterior wall, and converted into fibres, thus adding new fibres. So far as known, there is no proliferation of the fibres themselves. About two-thirds of the total growth of the lens is accomplished before birth. Huschke is stated to have found the average weight of the lens to be, at birth, 123 milligrammes, in the adult 190.

CAPSULE OF THE LENS.—Around the lens of the adult is found an anhistic membrane, known as the capsule of the lens. The membrane is presumably homologous with the anhistic layer found under the ectoderm elsewhere and which is permanent in the amnion, p. 334. We have little knowledge of the history of the capsule of the lens in the embryo, except that it grows in thickness and contains no cells. Kölliker ("Entwickelungsges.," 2te Aufl., 636) regards the capsule as the product of the lens, but it more usually is regarded as a specialized part of the matrix of the surrounding mesenchyma.

TUNICA VASCULOSA LENTIS.*—The lens early becomes surrounded by a special mesenchymal membrane richly vascularized by branches of the arteria centralis, p. 712, Fig. 410, which reaches the lens from behind, and by branches of the arterial circulus iridis, which reach the lens about its equator. As the lens, being an epithelial structure, contains no vessels itself, its rapid growth on the embryo is probably dependent on supply from the tunica vasculosa. The vessels radiate out from the central artery over the inner wall of the lens,

* The principal authority is O. Schultze, "Festschrift zum 50jährigen Doktorjubiläum von Kölliker," 1892.

and, branching as they go, pass around the edge of the lens and branch in loops on the anterior surface (see Kölliker, "Entwickelungsgesch.," 2te Aufl., p. 650). The network is particularly fine and close about the equator of the lens (O. Schultze); it will be remembered that it is principally at the equator that the growth of the lens is supposed to take place. The veins are small vessels which pass off in more or less radial directions from the edge of the lens and join the venæ vorticosæ of the choroid coat. Until O. Schultze's investigations the veins were practically unknown. The tunica vasculosa also extends across the pupil, but toward the close of fetal life the vessels abort under the pupil, which thereafter is bordered by characteristic vascular loops (see Kölliker, "Entwickelungsgesch.," 2te Aufl., Fig. 409).

In descriptive anatomy three names are employed, each for a part of the tunica vasculosa; at the back of the lens it is the *membrana capsularis*; at the front of the lens in the centre the *membrana pupillaris*, and around the centre (*i. e.*, beneath the iris) the *membrana capsulo-pupillaris* (*cf.* Kölliker, *l.c.*, p. 649). All these names ought to be discarded. If the *membrana pupillaris* persists there results atresia pupillæ congenita. The pupillary membrane is wanting in birds (Angelucci, **81.1**, 159).

The tunica attains its greatest development in man during the seventh month and usually disappears before birth, but the time of its disappearance seems to be variable.

Optic Nerve.—The hollow optic stalk develops into the optic nerve, first by becoming solid, second by acquiring nerve-fibres. It becomes solid by the growth of its own walls and the gradual obliteration of its cavity thereby. It acquires nerve-fibres from the thalamencephalon and from the retina, the former set of fibres growing centrifugally, the latter centripetally. Formerly it was assumed that the optic nerve-fibres arose *in loco* from the cells of the nerves (see for example Hiltner, **85.1**), but there have been no actual observations to support the assumption. It is possible that the nerve, being part of the medullary tube, develops neuroblasts, but it is certain that most of the fibres, if not all, come from the brain and retina, the largest contingent from the brain. Falchi, **87.2**, searched for neuroblasts in the optic nerve of cow embryos, but found none.

The choroid fissure permits the wall of the optic stalk to remain directly continuous with the retina, as already explained. The optic stalk consists of a basal or inner part, and an outer or distal part, along which latter alone the choroid fissure extends. Fig. 414 represents a transverse section of the optic nerve as obtained from a sagittal section of a rabbit embryo of thirteen days. In the fissure, as described, p. 712, the arteria centralis retinae is developed. The length of the choroid fissure varies, it being longer in mammals than in birds, and longer in man than in certain other mammals. Throughout the length of the optic stalk the central cavity is obliterated; the obliteration begins next the brain and progresses toward the retina; it is completed in the chick by the seventh day (Mihal-kovics, **77.1**, 79), in man probably by the third month; in man the closure begins during the seventh week (W. His, **89.4**, 690). In

the distal part of the stalk the choroid fissure also becomes closed, but much later than the central cavity. By these changes the hollow stalk is converted into a solid cylindrical cord continuous with the retina.

The tissue of the stalk, while its cavity is disappearing, changes into neuroglia; in the chick during the fifth day (Mihalkovics, 77.1, 79) appears a clearer layer round the outside, with nerve-fibres in it;

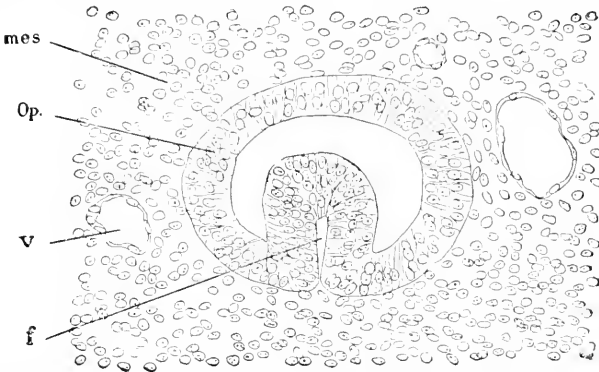


FIG. 414.—Section of the Distal Portion of the Optic Nerve of a Rabbit Embryo of thirteen Days. *mes*, Mesoderm; *Op.*, outer wall of optic nerve; *v*, blood-vessel; *f*, choroid fissure. $\times 113$ diams.

this layer is, perhaps, homologous with the Randschleier, p. 613, of the central nervous system. After the nerve has become solid Kölliker ("Grundriss," 3te Aufl., 299) finds the following structure: The cells are placed radially and form a delicate network, the meshes of which are extended longitudinally, and contain numerous bundles of fine nerve-fibres; and there are also cells arranged in longitudinal rows, which share with the radial cells in forming the network. The nuclei of the radial cells in cow embryos are oval and nucleolated (Falchi, 87.2).

The nerve-fibres of the opticus begin to appear in the chick the fifth day. Mihalkovics and Kölliker have shown that fibres arise in the wall of the thalamencephalon and grow in a bundle toward the median ventral line following the tractus opticus, p. 688. As each bundle continues to grow in its original direction they cross one another, and each enters the nerve of the opposite side and grows along it toward the retina; the crossing of the fibres constitutes the *optic chiasma*; from the mode of development it is evident that all the fibres from one side must cross to the nerve of the opposite side. The progress of the centrifugal fibres has yet to be accurately followed. The retina (p. 719) contains in the embryo true neuroblasts, which send off centripetal fibres through the optic nerve to the brain. Froriep, 91.1, has observed in an embryo of *Torpedo ocellata*, in Balfour's stage M, retinal neuroblasts, sending fibres into the optic nerve about one-sixth of the length of the nerve toward the brain and before any other nerve-fibres are present. This observation raises the question whether or not the centripetal fibres are developed in other vertebrates also, before the centrifugal. The origin of optic

nerve-fibres from the retina was, I believe, first suggested by W. Müller, 74.1, 37; the suggestion has been confirmed by the observations of His, 90.1, on mammals, and by those of Keibel, 89.1, on reptiles.

Bernheimer, 89.1, has studied the progressive development of the sheaths of the optic nerve-fibres, and reached interesting conclusions by this means as to the course of the fibres.

The optic nerve enlarges both in length and diameter, its enlargement being due to the multiplication of its cells and the growth of its nerve-fibres. It is probably owing to its enlargement that the neighboring mesenchyma around becomes condensed and forms a connective-tissue envelope around the nerve. Concerning the histogenesis of this envelope we know only that it becomes differentiated into two layers—an inner highly vascular layer continuous on the one hand with the pia mater of the brain, on the other with the choroid of the eye, and an outer fibrillar layer continuous with the dura mater of the brain and the sclera of the eye.

Retina.—If we consider the structure of the retina, compared with that of the embryonic brain, I think the same three primary layers can be recognized as in the dorsal and ventral zones of the central nervous system, see p. 616. Next to the pigment layer is the membrana limitans externa, which is the boundary of the retinal layer proper toward the brain cavity, which in the eye is represented by the fissure between the pigment layer and the retina proper, Fig. 409, *R*. The projection of the rods and cones across this fissure and into the pigment layer is secondary, as explained below. The limitans externa is, therefore, the homologue of the limitans interna of the brain and spinal cord. The cells with their nuclei next this membrane correspond to the inner neuroglia layer, which in the spinal cord becomes the lining epithelium, in the brain the inner white matter plus the ependyma, and in the retina the outer nuclear (or granular) layer and perhaps, also, the inner reticular layer and the inner nuclear layer. These layers of the retina might, therefore, collectively be called the ependymal layer. The nerve-fibre layer is to be homologized with the Randschleier (p. 613). The middle part of the retina between the inner nuclear layer and the internal nerve-fibre layer is comparable to the mantle layer or gray-matter layer of the medullary wall; it includes the inner reticular (or molecular) layer and the ganglion-cell layer of descriptive anatomy. The homologies drawn are probably correct, but they can be definitely accepted only if verified by a fuller knowledge of the development of the retina than we possess at present.

The first step in the histogenesis of the retina proper is the differentiation of the narrow inner zone (*i.e.*, toward the lens), which contains no nuclei, and a wide outer zone (*i.e.*, toward the pigment layer) with numerous nuclei in many layers; this stage may be seen in rabbit embryos of 4-5 mm. (Löwe, 78.1, 602). The narrow zone I identify with the Randschleier (p. 613) of the spinal cord, and the wider nucleated zone with the mantle and inner neuroglia layer of the axial medullary tube.

The second step is the subdivision of the wide nucleated zone into two layers of about equal thickness and distinguished by the

character of their nuclei; the nuclei of the outer are smaller, more oval, and stain more deeply than those of the inner layer. This stage may be observed in a rabbit embryo of 20 mm. or human of 38 mm; it has been described and figured crudely by Löwe, **78.1**, 604, and accurately by Falchi, **87.2**. I interpret the two layers as representing respectively the inner neuroglia layer (ependymal layer) and the mantle layer (gray matter) of the brain. The outer layer with smaller nuclei is to be regarded as the anlage of the outer nuclear layer, and later produces the rods and cones. The inner layer undergoes further modification.

The third step is the differentiation, 1, of the inner layer (just described and homologized with the mantle layer) into two distinct layers: the inner reticular layer and the ganglion-cell layer; 2, of the outer layer (just described and homologized with the inner neuroglia layer of the brain) into three distinct layers: the outer nuclear layer, the outer reticular layer, and the inner nuclear layer. The five layers are partially distinct in the rabbit at birth, although their differentiation is then still far from completed, but are clearly marked out in a human embryo of 215 mm. (Falchi, **87.2**, Fig. 3, p. 387-389).

The fourth step is the development of the rods and cones, which was superbly investigated by Max Schultze in 1866, **66.1**, 236-247. Until quite an advanced period the membrana limitans externa of the retinal layer proper remains smooth. There then appear numerous small projections over the surface of the membrana limitans; the projections are rounded in form, and are of two sizes, Fig. 415; the

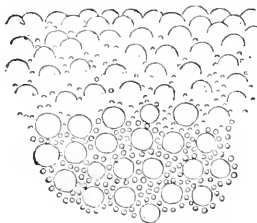


FIG. 415.—Surface View of the Membrana Limitans Externa with the Developing Rods and Cones of a Chick of fifteen to sixteen Days, Examined Fresh in Vitreous Humor. After Max Schultze. $\times 400$ -500 diams.

larger ones are the anlages of the rods, the smaller ones of the cones, the latter being much the most numerous in the chick. The young rods and cones are at first hemispherical in shape, and each is an outgrowth of an elongated sense-cell, the nucleus of which is situated in the outer nuclear layer; according to Falchi, **87.2**, the nucleus of the cell is lodged in the rods, at least when they begin to form. The rods and cones both elongate and penetrate the pigment layer, *cf. infra*, in which they are completely imbedded. The rods and cones develop first their inner members, and as they

grow longer their tips assume the character of outer members. In the chick about the eighteenth day there appear in the cones first very small red oil globules, then yellow ones. It is probable that in the chick after hatching the rods and cones grow only in size, not in number. It should be noted that Babuchin, **65.1**, states that in the frog the rods and cones at first differ from one another but little. The development of the rods and cones begins in the chick the seventh to tenth day; they are present in man and ruminants at birth, though smaller in size than in the adult; in rabbits and cats, and probably in other mammals born blind, they are not present until after birth. Falchi, **87.2**, 387, has observed the rods just commencing in a human embryo of 215 mm.

The cells in the retina become differentiated into two main classes,

nerve-cells and supporting or neuroglia cells. With the former I include the cells which abut permanently against the *membrana limitans externa*, and which by producing the rods and cones become the sensory cells of the adult. As to the exact series of changes through which the cells pass, our information is scanty. The series of histogenetic changes do not progress uniformly throughout the retina, but are more rapid toward the optic nerve, less rapid toward the lens, or, better said, toward the ciliary body.

The retina proper grows more rapidly than the remaining parts of the eye, and therefore is thrown into folds. The folds begin to appear in the human embryo during the third month. According to Kölliker ("Grundriss," 2te Aufl., 296) the first fold arises below the entrance of the optic nerve and numerous other folds are added later. Toward the end of foetal life all the folds gradually disappear, and at birth the retina is again smooth.

The macula lutea is developed after birth.

PIGMENT LAYER.—The outer lamina of the secondary optic cup, Fig. 412, *P*, very early becomes a simple cuboidal epithelium; pigment granules develop in this layer in the rabbit about the thirteenth day, Fig. 409. The pigmented epithelium comes to lie close against the *limitans externa* of the retinal layer proper. When the rods and cones develop they grow into the layer and become, as it were, buried in pigment; the pigmented epithelium becomes thicker as the rods and cones become longer, and remains throughout life a distinctly epithelial membrane. Its function is supposed to be to optically isolate the rods and cones from one another.

BLOOD-VESSELS OF THE RETINA.—The following paragraph is based on O. Schultze's admirable memoir on the blood-vessels of the foetal eye ("Festschrift zum 50jähr. Doktorjubiläum von Kölliker," 1892), where references to the previous observations may be found. A layer of mesenchymal cells is developed quite late (pig embryo of 90 mm., in man *after* the third month) over the surface of the retina toward the vitreous humor; the cells arrange themselves in a very distinct network and are then hollowed out to form blood-vessels. The vascularization begins next the optic nerve and spreads toward the lens, with the result of forming a layer of vessels (*membrana vasculosa retinae*) which may be injected, and then presents a highly characteristic appearance, Fig. 416. Red blood plastids develop in the network; the

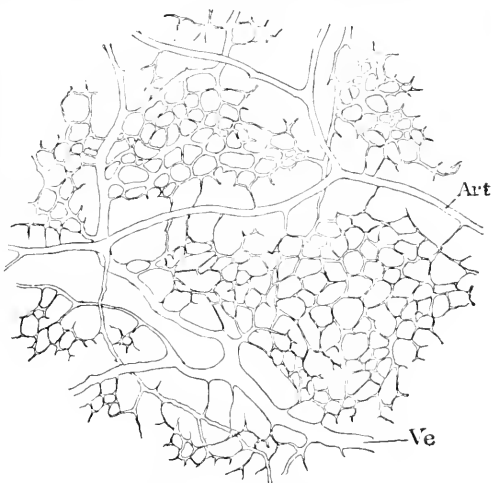


FIG. 416.—Injected Vascular Membrane of the Retina of the Eye of a Pig Embryo, 16 cm. long. *Art*, Artery; *Ve*, vein. After O. Schultze.

vessels were observed in a pig embryo of 175 mm. to have grown from the membrane into the retina. The network is not connected with the arteria centralis retinae, but with vessels which enter around the periphery of the optic nerve.

Lenticular Zone.—The term is defined p. 714. The lenticular zone of the secondary optic cup forms the parts beyond the ora serrata, viz., the ciliary processes and the uvea. The opening of the optic cup is the pupil, Fig. 413, and in early stages is just filled by the lens; at the stage of Fig. 412, the two layers of the optic cup are essentially uniform in character throughout their extent; later, while the optic cup and lens are enlarging, the character of the walls of the optic cup changes, and in a circular zone around the pupil both the pigment layer and the retinal layer of the cup become simple cuboidal epithelium; the thin-walled portion of the optic cup is what I have named the lenticular zone, *cf.* Fig. 411. The pigment layer of the zone very early acquires pigment granules (in the rabbit by the thirteenth day) and thereafter changes but little histologically. The retinal layer begins to thin out in cow embryos of about 30 mm., in rabbit embryos about the sixteenth day, and it quite slowly assumes the form of a cuboidal epithelium. The lenticular zone increases in width, but of its rate of growth I find no record published; as it becomes wider, we see that one portion of it overlies the lens, though separated from the lens by the tunica vasculosa lentis; and another portion, which adjoins the true retina, does not rest on the lens. The portion overlying the lens is the anlage of the uvea of the iris, Fig. 417, *Ur*; the other portion is the anlage of the ciliary processes. The two epithelia of the lenticular zone become closely adherent to one another, and in their further development act as if constituting one layer.

THE UVEA is the name usually applied to the lenticular zone in the adult, and may be defined as the double epithelial layer covering the choroid processes and the inner surface of the iris, Fig. 417, *Ur*.

THE CHOROID PROCESSES, Fig. 417, arise toward the end of the second month, or early in the third, as folds of the uvea around the edge of the lens; the folds are filled with vascular mesenchyma and gradually increase in height; they are well developed by the fourth month; in the fifth month Kölliker ("Entwickelungsges.," 2te Aufl., 680) found the processes 0.12–0.18 mm. high and 0.10–0.12 mm. wide. The pigment of the uvea is much darker in the embryo over the choroid processes than elsewhere.

Sclera and Choroid.—The primitive eyeball consists of the optic cup and lens, and, as it expands, the connective tissue around it becomes condensed, forming a mesenchymal envelope, out of which the sclera and choroid coats are gradually evolved. The sclera (sclerotic coat) may be homologized with the dura mater, the choroid with the pia mater.

The sclera is developed from the outer part of the mesenchymal envelope, and is thickened by accretions from the surrounding mesoderm as the eye enlarges; during foetal life the sclera has no definite external boundary and is comparatively thin; at what period the connective-tissue fibrillae in it begin to develop I do not know.

The choroid or vascular layer is developed from the inner part of the mesenchymal envelope, and, indeed, may be said to begin before

condensation of the connective tissue has begun around the eye, because a capillary network appears very early, making a special vascular layer over the pigment layer of the optic cup—this stage may be seen in a cow embryo of 23 mm. (Kölliker, "Entwickelungsges.," 2te Aufl., Fig. 422). This primitive vascular tunic is continuous with the tunica vasculosa lentis, p. 716. Concerning the histogenesis of the choroid, I have found no satisfactory observations.

Vitreous Humor.—By this name is designated the mesenchymal tissue which fills the cavity of the optic cup between the retina and the lens. The tissue appears very early, growing into the optic cup through the choroid fissure, and accompanying the blood-vessels, which form the vascular tunic of the retina and lens; the tissue at first contains typical anastomosing mesenchymal cells with a large amount of basal substance between them (rabbit of thirteen days). Keibel affirms, 86.1, that no mesenchyma except the blood-vessels grows in, but my sections show conclusively that, as concerns rabbit embryos, he is in error. In the chick, on the other hand, the cells and blood-vessels are both absent (Angelucci, 81.1).

As to the histogenesis of the vitreous humor our knowledge is very unsatisfactory. It probably consists principally in an enormous development of the basal substance, with, perhaps, ultimate abortion of the mesenchymal cells. The space originally occupied by the stem of the central artery persists and is called the *hyaloid canal*. Over the surface of the vitreous humor is developed a homogeneous layer without cells, known as the hyaloid membrane, which, therefore, covers the retina, the ciliary processes, and the lens. In the ciliary region it becomes so much thickened that the processes are, so to speak, entirely imbedded in it. The thickened hyaloid membrane of the ciliary region constitutes the *suspensory ligament* (*zonula Zinnii*) of the lens; it differs from other parts of the membrane in that it develops radiating connective-tissue fibrils. The fibrils (Angelucci, 81.1, 157) appear in the chick about the ninth day and in cow embryos of about 90 mm.; the number of fibrils is at first small, but increases afterward very much. A hyaloid membrane is also developed over the outer or anterior surface of the lens and is continuous with the suspensory ligament. The lens is thus completely covered by a hyaloid layer, which is known in the adult as the *capsule of the lens*.

The wandering cells, which are found in the adult vitreous humor, are at first not present, but immigrate later—when, I do not know—although they can be distinguished in quite early stages. They take, of course, no share in the production of the blood-vessels.

Anterior Mesenchyma of the Eye.—The lens at first lies close against the epidermis. Later the mesenchyma grows in between and forms a layer of some thickness; a cavity (anterior chamber of the eye) which is at first fissure-like appears in the mesenchymal layer, and divides it into an inner, thinner sheet next the lens, and an outer, thicker sheet next the epidermis; the inner sheet includes part of the tunica vasculosa of the lens and the connective tissue of the iris; the outer sheet the connective tissue of the cornea. The cells around the cavity assume an epithelial char-

acter, epithelium of the anterior chamber, which covers the outer surface of the iris and the inner surface of the cornea.

The ingrowth of the anterior mesenchyma begins in the chick during the fourth day, in the rabbit the fourteenth day; that is to say, not until the thickening of the posterior wall of the lens is well advanced. According to Kessler, **77.1**, a homogeneous layer is formed between the lens and epidermis before the cells penetrate there; he names the homogeneous layer *cornea propria*, and considers it a product of the epithelium, but Kölliker ("Entwickelungs-ges.," 2te Aufl., 669) points out that it is more naturally to be regarded as mesodermal basal substance. The cells of the neighboring mesenchyma gradually make their way into the homogeneous layer and form at first (chick, sixth day) a single layer between the lens and ectoderm; thereafter the number of layers of cells gradually increases. Meanwhile the branches of the arteria centralis retinae spread out and pass on to the anterior surface of the lens, thus converting the innermost part of the mesoderm in front of the lens into the anterior portion of the tunica vasculosa of the lens. The remaining and thicker portion of the mesodermic layer between the lens and epidermis is the anlage of the connective tissue of the cornea.

The next step is the production of the anterior chamber of the eye, which arises as a narrow fissure between the tunica vasculosa and the corneal anlage (Kölliker, "Entwicklungsgeschichte," 2te Aufl., 671). In mammals there appear first (cow embryos 90 mm.) a series of small spaces between the papillary membrane and the cornea proper, and these spaces subsequently fuse into a continuous fissure (Angelucci, **81.1**, 161). I have observed the continuous fissure in a rabbit embryo of sixteen days. It extends at first only to the edge of the pupil, but it soon develops beyond the edge (rabbit eighteen days) until it overlies the whole of the uvea; by this means the iris is formed; the iris is, so to speak, a circular shelf of mesenchymal tissue bounding the pupil, and itself bounded externally by the cavity of the anterior chamber and covered internally by the uvea, p. 722. Concerning the growth of the anterior chamber we lack precise observations. It is to be regarded as a serous cavity, and the *aqueous humor* as a serous fluid filling the cavity.

In the chick the tunica vasculosa of the lens does not extend across the pupilla; the first layer of mesenchymal cells which grows in between the lens and epidermis at once forms a thin epithelium (or so-called endothelium), and the space between this layer and the lens becomes the anterior chamber; the layer itself becomes the inner layer of the cornea, Angelucci, **81.1**.

CANAL OF SCHLEMM.—This term is applied to small persistent vessels, Fig. 417, *v*, on the inner side of the cornea where it joins the iris. Angelucci, **81.1**, 163, has observed that these vessels appear early (pig 23 mm.) and persist in birds and mammals throughout life.

Cornea.—The cornea consists of two layers: 1, the layer of mesoderm bounding externally the anterior chamber of the eye; 2, the epidermis overlying this area.

The mesoderm is a layer of mesenchyma which increases in thickness and in the number of its cells. The cells next the anterior cham-

ber assume an epithelioid character and finally become a true cuboidal epithelium. The remaining cells, which are widely separated by basal substance, become flattened out; they are commonly termed *corneal corpuscles* in the adult; bundles of connective-tissue fibrils are developed in the basal substance—just when is uncertain. Against the epithelial lining of the anterior chamber and against the corneal epidermis is developed a hyaloid membrane similar to that formed by the vitreous humor; these membranes have been named respectively *elastica interna* (or *membrane of Descemet*) and *elastica externa*. As neither membrane contains any elastic tissue, both names are to be regretted. Kölliker failed to find either hyaloid membrane of the cornea in rabbits of twenty days (see His, "Entwickelungsges.," 2te Aufl., 673) and it is probable that they are both developed late, contrary to Kessler's opinion. The corneal mesoderm contains blood-vessels during foetal life and in man, at least, at birth (Kölliker, *l.c.*).

The corneal epithelium (epidermis) develops, so far as known, like the epidermis, but its development is arrested at what I have called the amphibian stage, that is to say, there are several layers of cells, but the superficial cells are not flattened out and there is no stratum corneum. Kölliker ("Entwickelungsgesch.," 2te Aufl., 698) has observed in rabbit embryos that just before the eyelids meet (eighteenth day) the uncovered part of the corneal epithelium is thickened, and that this thickening disappears when the eyelids unite.

Iris and Ciliary Muscle.—The iris results from the extension of the anterior chamber of the eye; it may be described as a circular

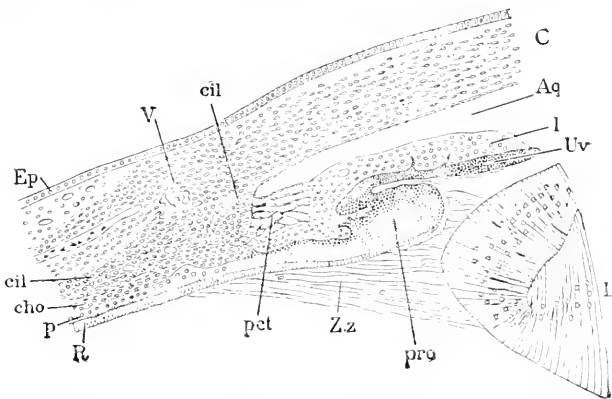


FIG. 417.—Section through the Iris Region of the Eye of a Chick of thirteen Days. *Ep*, Epidermis; *cil*, ciliary muscle; *cil'*, ciliary ligament; *V*, blood-vessel (canal of Schlemm); *C*, cornea; *Aq*, aqueous chamber; *I*, iris; *Uv*, uvea; *L*, lens; *pro*, ciliary process; *Zz*, zonula Zinnii; *pct*, pectinate ligament; *R*, retinal layer; *p*, pigment layer; *cho*, choroid layer. After Angelucci.

shelf of mesoderm covered on its outer side by the mesodermic epithelium lining the anterior chamber of the eye, and covered on its inner side by the uvea, Fig. 417, *Uv*. The mesoderm of the iris, *I*, is directly continuous with the choroid envelope, *cho*, of the eye, and differs in character from the mesenchyma of the cornea and sclera, and it is to be regarded as a prolongation of the choroid layer, *cho*.

The choroid layer, Fig. 417, *cho*, thickens considerably as we

approach the ciliary processes, *pro*, from the retinal side. The thickening subdivides into two layers, the choroid proper, *cho*, and the ciliary layer, *cil'*, *cil*, *pct*: the ciliary layer is at first alike in structure throughout its extent, but very soon the part of this layer nearest the ciliary processes and the iris changes in character, the tissue becomes looser, the cells move apart, and spaces appear between them: the cells lengthen out, assume a more fibrous character, and constitute the *ligamentum pectinatum* of anatomy; the spaces correspond to *Fontana's canals*.

The remainder of the ciliary layer is converted into the ciliary muscle; the part of the anlage next the pectinate ligament becomes the ligament, *cil'*: the part farther from the lens becomes the muscle proper, *cil*; the boundary between the two parts last mentioned is approximately indicated by the position of the canal of Schlemm, Fig. 417, *V* (compare p. 724). Angelucci, 81.1, 162, observed the fibres of the ciliary muscle to be transversely striated in the chick the last day of incubation.

The Eyelids arise quite early (cow embryo of 23 mm., rabbit of sixteen days) as two folds of the integument, a little above and below the cornea,* and they grow toward one another until they actually meet and unite, Fig. 418. Each fold consists of undifferentiated mesenchyma and is covered on both sides by the epidermis. The folds cover not only the cornea proper, but also a certain space around it; this space is the future *conjunctiva*. As the lids approach one another the epidermis along the edge of each fold thickens (cow embryo of 35 mm.; rabbit embryo of nineteen days). When the edges of the folds meet, their epidermal thickenings unite and all trace of any boundary disappears, as shown by Donders (*Graefe's Archiv*, IV., 291) and Schweigger-Seidl, 66.1, 228; it is said that the lids were formerly supposed to be simply adherent, but in reality they actually grow together. The union of the lids takes place in man early during the third month, in the rabbit the twentieth day, according to Kölliker (*"Entwicklungsgesch."*, 2te Aufl., 698). The union of the lids is probably inherited from reptilian ancestors, since in certain reptiles the union is permanent. The union persists in man until a short time before birth, when the eyelids permanently separate; the separation is, I think, probably effected by the breaking down of the cells in the centre of the epithelial layer

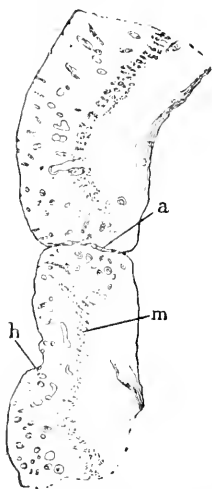


FIG. 418.—United Eyelids of a Human Embryo of about four Months, seen in Vertical Section. *a*, United surfaces; *m*, muscle; *h*, hair.

uniting the eyelids. The eyelids do not open in dogs and rabbits until after birth.

The histological differentiation of the eyelids begins after they are soldered together. The epidermis on the outside produces hairs. The congested epithelium of the edges produces large hairs (*eyelashes*) and sebaceous glands. The latter develop in a similar

* Well shown in Fig. 429 of Kölliker's *"Entwicklungsgesch."*, 2te Aufl., 1879.

manner to the sebaceous glands of the skin, p. 562, but subsequently acquire a large size and are known in the adult as the *Meibomian glands*. The free ends of the eyelashes are imbedded in the epithelium between the lids until the eyes open. The mesoderm develops three layers: an outer, continuous with the dermis of the neighboring skin; an inner, continuous with the connective tissue of the conjunctiva; and a middle, in which muscle fibres are developed, Fig. 418. As I observe the muscles of the eyelids to be continuous with the platysma of the head, it is probable that they are modifications of a part of the platysma.

Membrana Nictitans (Third eyelid, plica semilunaris, Nickhaut).—The third eyelid is well developed in birds, etc., but is rudimentary in man. Concerning its development, nothing accurate is known.

Tear Gland (Lachrymal gland, Thränen-drüse).—The tear gland arises in man during the third month as a solid downgrowth of the epithelium of the conjunctiva on the nasal side of the eyeball and close to the upper lid, and almost at once forms solid branches; the solid anlage afterward becomes hollow (Kölliker, "Entwickelungs-ges.," 2te Aufl., 699). The formation of the tear gland begins in the chick the eighth day (Remak, 50.1, 92).

The formation of the lachrymal duct is described p. 580.

Evolution of the Vertebrate Eye.—This subject is, as yet, by no means ripe for discussion, for we have not only no definite clew to the homologies of the vertebrate eye with any invertebrate eye, but also no collation of our knowledge of the eye sufficient to trace the comparative anatomy of the eye within the vertebrate series. In regard to the evolution of the eye within the vertebrate series see W. Müller, 74.1.

There are two hypotheses as to the origin of the vertebrate eyes: *one*, that they are derived from a single median eye; this is the hypothesis of those who put foremost the affinities of vertebrates through Amphioxus with the tunicates, which are animals with a single median eye; the *other*, that they are derived from the paired eyes of annelids. The first hypothesis has recently found an advocate in Howard Ayers, 90.1, 228, but he offers little in support of his opinion beyond his longing to establish a complete homology between Amphioxus and true vertebrates. The second hypothesis is a corollary of Semper's theory that vertebrates were evolved from annelids, and because that theory has become more probable as our knowledge has increased, it follows that the second hypothesis has also gained in probability. For an able, though speculative, discussion of the way in which the hypothesis can be worked out, see J. von Kennell, 91.1.

Anton Dohrn's hypothetical speculations, 86.2, as to the phylogenesis of the eye, are not likely, it seems to me, to prove of permanent value.

DEVELOPMENT OF THE EAR.

Morphologically the vertebrate ear consists of two entirely distinct parts: 1, the auditory organ proper, the otocyst, or so-called membranous labyrinth; 2, the accessory parts, the meatus auditorius

externus, the tympanum and ear bones, and the Eustachian tube, to which we may add the external ear, or so-called concha. The development of these two parts is very distinct; the membranous labyrinth arises as an invagination of the ectoderm; the ear passages and ossicles arise by modifications of certain of the branchial arches and clefts of the embryo; the concha again has an independent development. Accordingly we take up in order the history of the otocyst, of the auditory passages and ear bones, and of the external ear.

The membranous labyrinth is developed from a simple otocyst, which is at first a spheroidal sac of epithelium, and arises as an invagination of the ectoderm (epidermis) just over the first visceral or branchial arch. In the history of the labyrinth it is convenient to distinguish the following stages: 1, origin of the otocyst; 2, first appearance of the recessus labyrinthis vestibuli; 3, commencement of the semicircular canals; 4, outgrowth of the cochlea; 5, separation of the sacculus from the vestibule. During all these changes the otocyst or labyrinth is a closed sac or cavity, with a continuous epithelial lining. The process of differentiation may be considered twofold: 1, the gradual conversion of the simple otocyst into a very complex one; 2, the specialization of certain areas of the epithelium (maculæ acusticæ), connected with the acoustic nerve.

1. Origin of the Otocyst.—The ear arises as a lateral pit, lying somewhat dorsally and opposite about the middle of the medulla

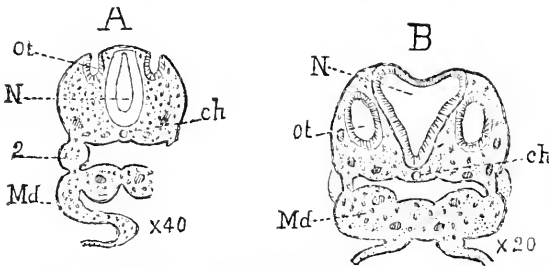


FIG. 419.—Sections of Human Embryos showing the Otocyst; A, embryo of 2.4 mm.; B, embryo of 4 mm. *ot*, Otocyst; *N*, nervous system, *Md*, mandibular arch; *2*, hyoid arch; *ch*, chorda dorsalis. After W His.

oblongata, and just above the first gill-cleft. The pit is an invagination of the outer germ layer (ectoderm) and is at first wide open. This stage has been observed by His in a human embryo of 2.4 mm., Fig. 419, A. In the chick the first sign of the future auditory organ is a

local thickening of the ectoderm, usually after thirty hours' incubation; this thickened area is afterward invaginated and forms the lining of the otocyst. In fact, the difference between the newly arisen auditory vesicle and the ectoderm, in respect of the thickness of the two epithelia, is very striking, and the character of the otocyst epithelium is very important, because it exhibits an analogy between it and the rudimentary ganglionic sense-organs. As suggested by Froriep, there is probably a true serial homology in this case; and the ear is one of a series of organs extending along the lateral line, none of which, except the ear and nose, persist in mammals save during early embryonic stages, *cf.* p. 708. In short, the derivation of the complex membranous labyrinth of man from the specialization of one of a long series of general sense-organs in lower ancestral forms is extremely probable.

The mouth of the pit very soon closes over, and the invagination becomes a closed sac, which quickly loses its connection with the ectoderm, making a separate spheroidal vesicle, the otocyst, Fig. 419, B, *ot.* The sac is lined by a quite thick epithelium, which contains the nuclei scattered at various levels, Fig. 420, and is built up apparently of slender columnar cells, bellied out where each cell contains its nucleus. As yet the embryonic connective tissue (mesoderm) has formed no envelope around the epithelium, but later the cells about the vesicle condense around it and constitute a sub-epithelial membrane. The epithelium retains its cylindrical form over and immediately on the borders of all the areas, where the sensory hair-cells or so-called auditory cells are developed; over all the remaining portions it ultimately thins out, becoming either a cuboidal or a pavement epithelium. In fishes there are seven; in amphibians, reptiles, and birds eight, in man only six, of these areas of sensory cells. It is desirable to call attention to this thinning out, because it is usual to find it stated that a thickening arises, when, in reality,

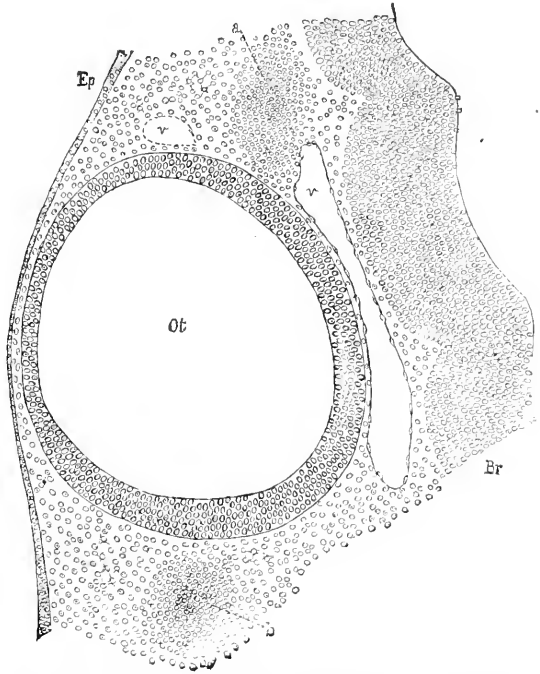


FIG. 420.—Horizontal Section of the Otocyst of a Chick of the third Day. *Ot.*, Otocyst; *Ep.*, epidermis; *Br.*, walls of the brain (medulla); *v*, blood-vessels.

it is the thinning of adjacent parts which effects the differentiation, and though there may be an absolute thickening also, yet the thinning round about is the principal factor.

2. Recessus Vestibuli.—The otocyst next loses its spherical form by the development of a prolongation on the dorsal side, in consequence of which it acquires somewhat of a pear shape. The upper tapering end is the commencement of the *recessus vestibuli* or *aqueductus endolymphaticus*, Fig. 421, *Rec.* The acoustico-facial ganglion is in actual contact, as stated p. 646, with the anterior wall of the otocyst, and it is probable by analogy that

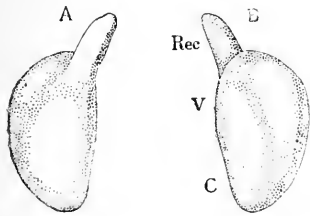


FIG. 421.—Left Otocyst of a Human Embryo of about four Weeks: A, from the inner, B, from outer side. *Rec.*, Recessus vestibuli, *V.*, vestibular region; *C.*, cochlear region. After W. His, juv. $\times 30$ diams.

which join the ganglion; compare the history of the olfactory ganglion, p. 637. The lower portion soon changes its configuration, and in a human embryo of about four weeks was found by Kölliker ("Entwickelungsges." 2te Aufl.), to have a new rounded protuberance behind and a little outside the base of the recessus, which marks the situation of the future vestibule; some traces of the semicircular canals were already indicated; the lower end of the pear was somewhat elongated preparatory to the outgrowth of the cochlea. The otocysts at this time lie near the middle of the hind-brain,

Figs. 171, *D*, and 338, *ot*; as seen in cross sections, Fig. 422, of the head the otocysts are pear-shaped and

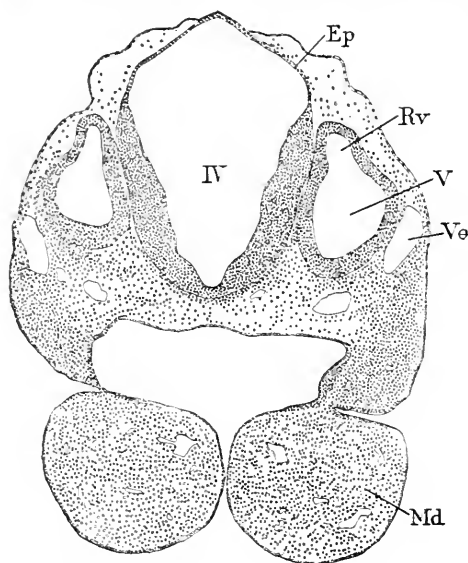


FIG. 422.—Transverse Section of the Head of a Rabbit Embryo of ten and one-half Days. *IV*, Fourth ventricle; *Ep*, ependyma; *Rv*, recessus vestibuli; *V*, vestibule of otocyst; *Ve*, vein; *Md*, mandible.

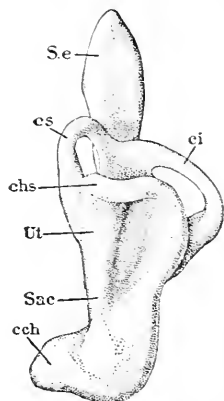


FIG. 423.—Left Otocyst of a Human Embryo of about five Weeks, seen from outside and below. *S.e*, Saccus endolymphaticus; *cs*, upper; *ci*, lower; *chs*, horizontal semicircular canal; *Ut*, utricle; *Sac*, sacculus; *cch*, cochlea. After W. His, Jr. $\times 30$ diams.

closely appressed to the dorsal zones of His of the medulla oblongata. The recessus vestibuli rapidly enlarges, and its upper end becomes dilated, Fig. 423, to form the saccus endolymphaticus, *S.e*, the narrower portion develops into the ductus endolymphaticus of authors. The ductus subsequently becomes greatly elongated, and reaches through the whole pars petrosa, so that the saccus lies within the skull in the dura mater. Kölliker (in his "Entwickelungsgeschichte," pp. 744, 745) gives a fragmentary series of measurements of the recessus in mammalian embryos of various ages.

3. The semicircular canals arise next from the walls of the primitive vestibule, and rapidly acquire great prominence, while the cochlea grows out slowly. Each canal first appears as a narrow fold, Fig. 371, *A.sc*, *P.sc*, *Ek.sc*, a wide but thin evagination. In the middle of each evagination the opposite walls meet and coalesce, leaving only the rim of the original flat pouch; this rim is the permanent semicircular canal. N. Rüdinger, 88.2, asserts that each semicircular canal arises from two buds, which elongate as blind tubes, and

the tubes uniting form a complete canal. The later investigations of R. Krause, 90.1, and W. His, Jr., 89.1, confirm the older, not Rüdinger's view. The canals do not all develop synchronously; the upper vertical canal is first differentiated (R. Krause, 90.1, 300), next the lower vertical canal, and last the outer or horizontal canal. W. His found in a human embryo of five weeks that the three evaginations were present, but only the two vertical canals had become rings, Fig. 423. The further development of the canal consists in the gradual assumption of the adult form and size, the ampullæ appearing quite early, Fig. 425. The embryonic connective tissue about the organ, as a whole, is gradually converted into cartilage and ultimately ossifies. The connective tissue (mesoderm) immediately about the otocyst has a different history, which may be readily followed in connection with the study of the semicircular canals, and hence may be mentioned now. In Fig. 425, the epithelial semicircular canal, *m*, *l*, is seen surrounded by a cartilage, *c*, but separated from it by a thick layer of gelatinous tissue, *g*, and the fibrous perichondrium (future periosteum), *f*. Later, the layer, *g*, is separated into a thin subepithelial layer, which persists, and a main or gelatinous layer proper, which atrophies, thus leaving the peri-lymphatic space about the canal. The gelatinous layer consists of anastomosing connective-tissue cells, with, according to Kölliker, a liquid matrix. The meshes of the network gradually increase in size, until finally only a few threads are left, thereby establishing the condition in the adult. As far as known, the whole of the peri-lymphatic spaces are formed in this manner, including, of course, the scala tympani and the scala vestibuli of the cochlea.

The ampullæ of the semicircular canals appear quite early as enlargements of the canals and develop each a macula acustica, which is stated by Kölliker to be found in older embryos covered with a delicate cuticula of considerable thickness, the membrana tectoria of Hasse, the cupula terminalis of Lang.

4. The cochlea is the third part to grow out from the primordial otocyst, Fig. 423, *coh*: the commencing outgrowth may be observed in a human embryo of five weeks, a sheep embryo of 16 mm., pig of 18 mm., rabbit of 10 mm. It arises from the lower end of the vesicle and grows downward, inward, and forward, Fig. 423, as a canal somewhat flattened in one diameter and therefore oval in transverse section. The epithelial cochlear canal lengthens very much, and, as it lengthens, curves more and more, Fig. 425: on its concave upper side appears the commencement of the future ganglion spirale, compare p. 646. The cochlear canal is the anlage of the *scala media* of the adult. In the stage of Fig. 423 it closely resembles the condition found in adult monotremes, and also the lagena

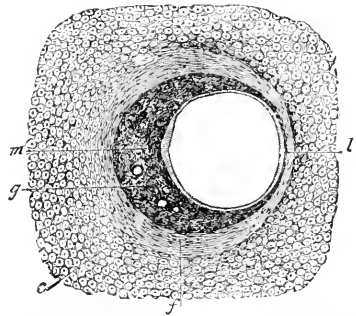


Fig. 424. — Transverse Section of the Semicircular Canal of an Embryo Rabbit of twenty-four Days. *m*, *l*, Epithelium of the canal; *g*, gelatinous tissue; *c*, cartilage; *f*, fibrous perichondrium. After Kölliker. $\times 41.5$ diams.

(cochlea) of birds. By further elongation and coiling the canal gradually assumes the final shape of the scala media. In man there is one complete coil by the eighth week, Fig. 425, and by the twelfth

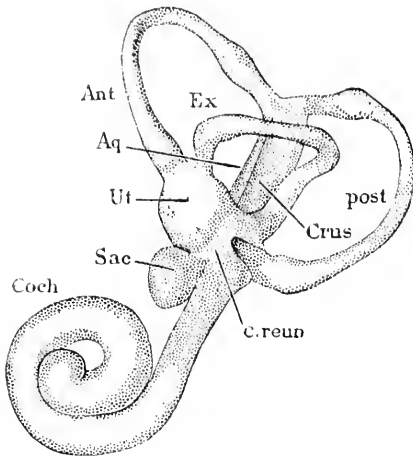


FIG. 425.—Left Otocyst of a Human Embryo of about two Months. *Ant*, Anterior, *Ex*, external, *post*, posterior semicircular canal; *Crus*, crus commune; *c.reun*, canalis reuniens; *Aq*, aqueductus vestibuli; *Ut*, utricle; *Sac*, saccule; *Coch*, cochlea. After W. His, Jr. $\times 20$ diams.

week all the coils are formed. Baginsky, 86.1, has observed that in very young rabbit embryos there are numerous karyokinetic figures in the walls of the cochlear canal; later (embryos of 50–60 mm.) they can no longer be found; they continue longest at the apex; these observations show that the canal grows throughout its extent and not merely at its apex.

Histogenesis of the Cochlea.

—Our knowledge of this subject rests principally upon the elaborate researches of Böttcher, 89.1, which have been confirmed and supplemented by Gottstein, Kölliker (“*Entwicklungsgeschichte*,” 2te Aufl.), Pritchard, 79.1, Baginsky, 86.1, and others. The histological development of the cochlea

is the same throughout its entire length, but progresses most rapidly at the base, or the stretch nearest the vestibule. I append here the complete history of the cochlea. The first change in the epithelium is in the height of the cells, those upon the upper side thin out; in other words, that portion of the epithelium decreases in thickness; it remains a perfectly simple columnar epithelium, Fig. 426, *Ep*, and forms the lining of one side of Reissner's membrane, and the outer wall of the scale. The lower portion of the epithelium which remains thicker forms the crista, the sulcus, and Corti's organ. The two divisions of the epithelium are not sharply separated, but pass gradually into each other.

The second change is that the loss in thickness of the epithelium is continued on the under side, or the wall next the scala tympani, so as to leave two thick epithelial ridges, which are of very unequal dimensions. The larger ridge lies nearest the columella and becomes the thick lining of the *sulcus spiralis*. It very early acquires a thick cuticula, the beginning of the *membrana tectoria*. A very different view is announced by Howard Ayers, 91.2, who states that he has ascertained that the *membrana tectoria* is really composed of very long hairs, which spring from the cells of the organ of Corti, and that it is, therefore, in no sense a cuticular structure. The smaller ridge lies nearer the *ligamentum spirale*, and is metamorphosed into the organ of Corti, including the supporting cells, the inner and outer hair cells, and Corti's rods. Very soon after the two ridges are distinctly formed, the *lamina spiralis* begins to grow up between the sulcus or broad inner ridge, and

the axis of the cochlea to develop into the *crista*. The epithelium on the *crista* is thus maintained with its upper surface even with that of the sulcus. Over both parts stretches the cuticula, Fig. 426, *mt*, which gradually thickens into the fully developed tectorial membrane, which has been hitherto supposed to have, at no time, any histogenetic connection with the organ of Corti—compare the reference to Ayers' view above—although it grows out so far as to overhang it. The membrane always remains firmly attached to the *crista*, but is loosely united to the epithelium of the sulcus internus, and in the adult it is probably entirely separated from the sulcus and attached only to the *crista*. From some unknown cause the lower boundary of the epithelium of the *crista* becomes indistinguishable. The cells in the sulcus apparently assume an oblique position, so that in sections there seem to be several layers of cells. Middendorf and others have been misled to describe a stratified (*mehrschichtiges*) epithelium in the sulcus.

The small ridge or anlage of the organ of Corti, Fig. 426, 1-7, is made up of four sets of cells; each set is disposed in a longitudinal row following the spiral curve of the cochlea. The first row, or that nearest the sulcus, *sul*, is composed of a single line of cells, the future inner hair cells. The second row is composed of two lines of cells, 1, 2, the future rods of Corti; in early stages, as shown in

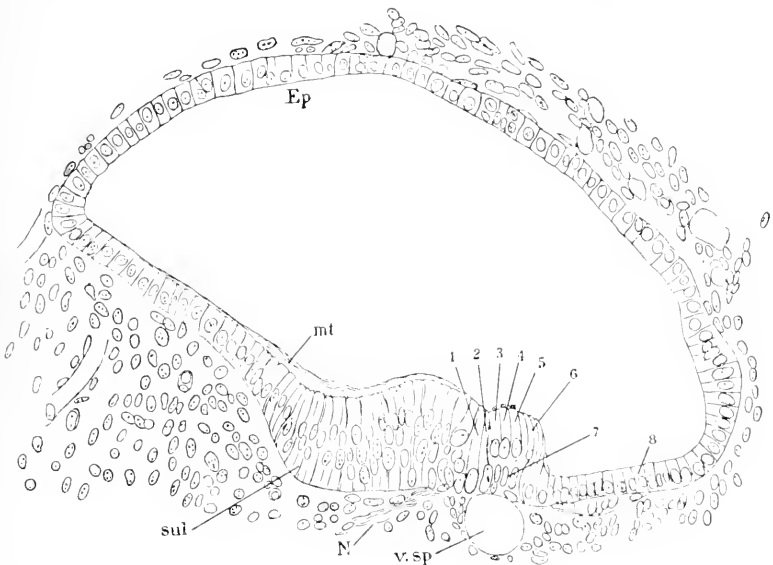


FIG. 426.—Transverse Section of Scala Media Cochlearis of a Rabbit Embryo of 55 mm. *Ep*, epithelium of Reissner's membrane; *mt*, membrane tectoria; *sul*, sulcus; *N*, nerve; *v. sp.*, vas spirale; 1-6, cell rows of Corti's organ; 7, Deiter's cells; 8, outer cells. After Baginsky.

the figure, the cell next the inner hair-cell is considerably larger than its fellow, but later their relative sizes are reversed (Baginsky, 86.1); the third row includes three main lines of cells, 3, 4, 5, the outer hair cells; and the fourth row, 6, has several lines of cells, which become the supporting cells. The further differentiation of

the four rows is followed best in transverse sections of the ridge, and in the following description reference is made to the appearance seen in such sections.

The inner cell slopes toward the centre of the ridge, has a broad base, a narrower top, and a single clear, oval nucleus toward its basis,

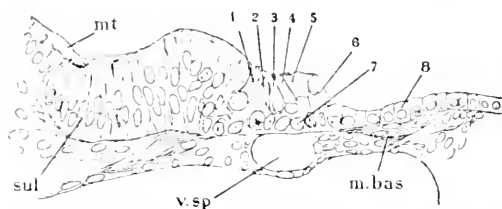


FIG. 427.—Section through Corti's Organ of the Lower Coil of the Cochlea of a Rabbit Embryo of 75 mm. *m. bas.* Membrana basilaris; 1, inner hair cell; 2, Corti's cells. Other letters as in Fig. 426. After B. Baginsky.

are viewed from the surface, the hairs are seen to mark out a horseshoe on the top of each cell. The open end of the horseshoe always faces inward, *i.e.*, toward the columella. The base of the cell also acquires one, or, according to Böttcher, two nuclei; the cell becomes finely granular, and is finally incorporated in Waldeyer's "Körnerschicht." Baginsky, **86.1**, 29, maintains, probably rightly, that the two nuclei below the inner hair-cell belong to distinct cells, and are not derived from the inner hair-cell; he compares them to the so-called Deiter's cells between the bases of the outer hair-cells.

The second and third cells broaden at their bases, where lie their spherical nuclei. The bases widen out rapidly (immediately after birth in dogs) until the two cells form a triangle in section; the width of the base of the triangle exceeds its height. Böttcher, **69.1**, supposed that this triangle was a single cell with two nuclei; that Böttcher was in error was shown by B. Baginsky, **86.1**, 26. Meanwhile the two nuclei place themselves near the two lower angles of the cells. Next, the cells lose their finely granular appearance and become striated (rabbit embryo of 75 mm.), first along the inner side of the inner rod-cell, or next the inner hair-cell; second, along the outer side of the outer rod-cell, or next the outer hair-cells. The striated lateral portions of the two cells form the two Corti's rods, *sensu strictu*. A triangular space between the rods and the basement membrane is soon hollowed out, thus forming the tunnel under the arching rods. The protoplasm of the cells is next reduced to small nucleated masses, one at the base of each rod. The further development takes place principally by the growth of the rods, until they assume their ultimate shape and size. Recent investigations have added little to the account of the structure of Corti's rods, given by Waldeyer in Stricker's "Handbuch," 1873, pp. 931-934.

The third band, which is three cells wide, Fig. 427, 3, 4, 5, forms the outer hair-cells. Like the other cells, they acquire two nuclei, a larger oval one above, and a smaller one below. This was first observed by Pritchard. The two parts around the two nuclei early become separated into an upper cell (Corti's cells or absteigende Hörzellen) and a lower cell (Deiter's cells or aufsteigende Hörzellen), 7. The base

Fig. 427, 1. It becomes the inner hair-cell, with a distinct nucleus of its own, a somewhat coarsely granular protoplasm, and a horseshoe of hairs upon its free upper surface, and a tapering base, which last is probably connected with a nerve-fibre. When the auditory cells of Corti's organ

of the upper cells is at first rounded off, but subsequently a fine process extends down to the *membrana basilaris*, and the base tapers gradually into the process. The cells become slenderer, and acquire an oblique position about the time of birth. The rod (*Stäbchen* or *Haupthaar*) and the horseshoes of hairs (*cf. supra*) are developed upon the free ends of the cells during the later stages of foetal life. The lower cells taper at their upper ends, which are continued each by a fine process. They were supposed by Waldeyer and others to be united in the adult with the upper cells, thus forming twin cells; which have been most fully described by Lavdowsky and Nuel. The development of these twin cells is by no means clearly understood yet. The upper and lower cells appear distinctly separate in new-born and young animals. The upper cells enlarge at the expense of the lower. The nucleus becomes smaller and is placed near the top of the cell. The rod (*Haupthaar*) disappears. The horseshoe of hairs opens toward the Corti's rods, as can be best seen in silver preparations. The hairs are more like short rods, vitreous, with rounded ends, and are parts of the cell, not of the *membrana reticularis*. The basal process of the upper cell is inclosed by (Lavdowsky) or fused with (Nuel) the body of the lower cell. The tops of the upper cells (Corti's *absteigende*, or *Stäbchenzellen*, Lavdowsky) occupy the rings; the tops of the processes of the lower cell occupy the phalanges of the *membrana reticularis*. The lower part of the united cells appears as their common body, and contains the lower nucleus. The nerve-fibre unites with the cell at the side near the lower nucleus. The twin cells end below by a single basal process. The above account is mainly from Lavdowsky. Nuel agrees with him in the main, but the latter's paper I know only from the abstract in Hoffmann's and Schwalbe's *Jahresbericht*.

Connected with the third row, or outer hair-cells, are various structures, which are probably to be grouped under the general head of intercellular formations. Of these the most important are the "*Stützfasern*" (supporting fibres) and the *membrana reticularis*. The latter is generally regarded as the exposed edges of the intercellular substance, the rings and phalanges being the spaces where the free end of the hair-cells are exposed. The "*Stützfasern*" form a network underneath the tunnel, and also a finer network between the outer hair-cells. They were dimly recognized by Böttcher, clearly seen by Nuel, and elaborately described by Lavdowsky.

The fourth row of cells, Fig. 427, 6, undergoes no striking differentiation; it decreases in height from the hair-cells outward, so that the row merges gradually into the low cells of the *zona pectinata*. Klein states that in the guinea-pig the supporting cells do not form, as is usually the case, a simple continuation of the last row of the outer hair-cells, but ride upon the sides of the hair-cells.

Underneath the organ of Corti is developed the *membrana basilaris*. A large space is developed in the mesenchyma underneath the organ; this space is the *scala tympani*, and is apparently a lymph-chamber. Between the *scala tympani* and the organ of Corti, there remains a sheet of connective tissue, which contains the *vas spirale*. Fig. 427, *v.sp.*, and is the anlage of the *membrana basilaris*. The cells next the epithelium of the *scala media* flatten out, their nuclei

elongate and take radial positions, Fig. 427, *m.bas*, thus marking out a subepithelial layer from the loose connective tissue below; the looser tissue gradually disappears; the denser subepithelial layer becomes the permanent membrana, in which we can distinguish three layers: a thin homogeneous basement membrane next Corti's organ, a homogeneous nucleated layer, and a lowest fibrillar layer. The spiral vessel underlies the rods of Corti; the basilar membrane as described is developed only beyond the vessel; that is, underneath the outer hair-cells. Embryologically speaking, the so-called inner zone (*habenula tecta*) is not a part of the true basilar membrane (B. Baginsky, 86.1, 31-34).

According to the preceding summary, the cochlea is a tubular extension of the lower side of the primitive ectodermal otocyst; upon one side of this tube are two ridges; a larger one, which forms a thick cuticula, the *membrana tectoria*, and a smaller one which, through complicated differentiations, becomes the organ of Corti. The nerves grow to the hair-cells.

5. Sacculus and Utriculus.—The separation of the *sacculus* has been studied principally by Böttcher. There is first developed a constricted tube, the *canalis reuniens*, Fig. 428, *b*, between the base

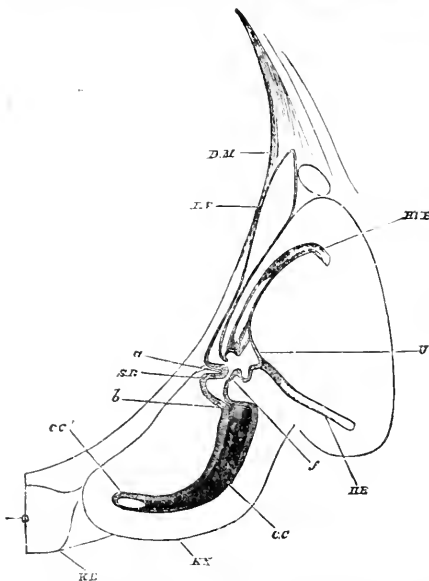


FIG. 428.—Section through the Internal Ear of a Sheep Embryo, 28 mm. (After Böttcher). *D.M.*, Dura mater; *R.V.*, recessus vestibuli; *H.B.V.*, posterior vertical canal; *U.*, utriculus; *H.B.*, horizontal canal; *a.f.*, the constriction between sacculus, *S.R.*, and utriculus; *b*, canalis reuniens; *cc.*, cochlea; *K.K.* and *K.B.*, cartilage; *ch.*, chorda dorsalis.

of the cochlea and the central otocystic cavity. Afterward appears a ring-shaped constriction, *a.f.*, around the main cavity (primitive vestibule, Kölliker), by which it is divided, in most mammals, into two cavities connected by a narrow canal, into which opens the *recessus labyrinthi* (*ductus endolymphaticus* of Hasse); hence the recessus appears to have two legs, derived from the canal; one leg leading into the upper secondary cavity, the adult *utricle*, Fig. 423, 428, and the other into the lower cavity, the adult *sacculus rotundus*, Fig. 425, 428. These relations, as well as the other essential dispositions of the parts of the labyrinth, are sometimes all recognizable in a single fortunate section, as in Fig. 428, or better in a model, Fig. 425, reconstructed from sections. In man, however, the relations are somewhat different in that the ductus opens directly into the sacculus (Fig. 429, *de*). The developmental process resulting in this disposition has not yet been followed out.

The *maculae acusticae* of the sacculus and utriculus arise as circumscribed areas where, as before stated, the epithelium remains

thick, and is differentiated into auditory cells of elongated forms, with hairs on the free ends.

Of the *otoliths* the development is unknown. Kölliker merely says, they "appear as quite small punctiform bodies, and remain a long time in that form, until they finally increase in size and gradually assume a crystalline form" ("Entwicklungsgeschichte," 1879, p. 735).

The development of the definite form of the inner ear is, as we learn from the investigations of Retzius, nearly complete by the end

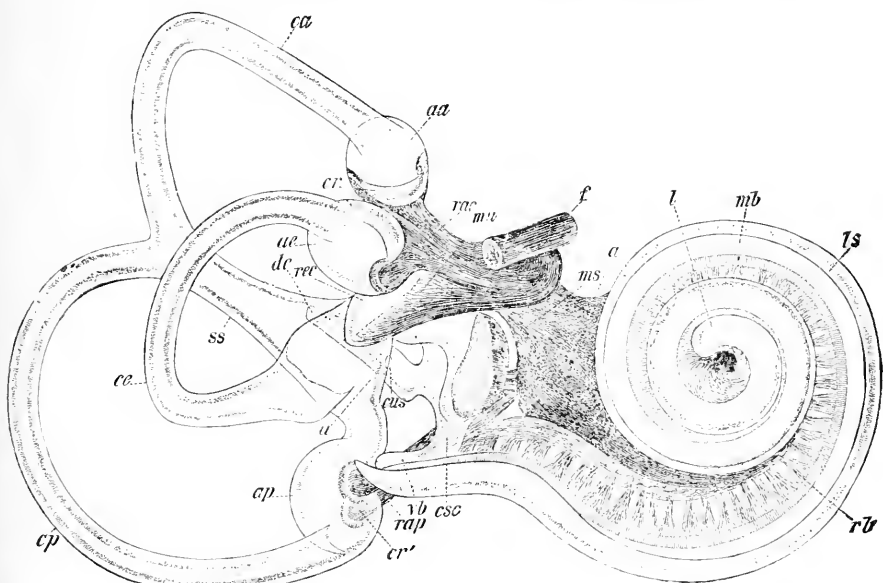


FIG. 429.—Isolated Right Membranous Labyrinth of Human Embryo of six Months seen from in front and outside. Magnified about eight diameters. *ca*, Anterior semicircular canal; *ce*, external semicircular canal; *cp*, posterior semicircular canal; *aa*, anterior; *ae*, exterior; *ap*, posterior, ampullæ; *cr*, crista ampullæ; *rac*, ranulus ampullæ communis; *ma*, macula utriculi; *f*, nervus facialis; *ms*, macula acustica sacculi; *l*, lagena cochlearis; *mb*, membrana basilaris; *ls*, ligamentum spirale; *rb*, ranulus basilaris of the cochlear nerve; *csc*, canalis sacculo-cochlearis or reuniens Henseni; *rb*, Vorhofsbindsack of Retzius; *rap*, nerve of the posterior ampullæ; *cr'*, crista acustica of the same; *ss*, sinus utriculi superior; *de*, ductus endolymphaticus, with its internal opening, *cus*; *rec*, recessus utriculi. After Retzius.

of the sixth month of foetal life, as shown by the accompanying Fig. 429, which represents the isolated right labyrinth of a six months' human embryo, seen from in front and the outside. In the figure the most conspicuous parts are the semicircular canals, the cochlea, and the nerves stained dark by the osmic acid with which the preparation had been treated. The cochlea is a long spiral, commencing with a central blind end, *l*, and making two and one-half turns, and continuing off tangentially toward the posterior ampulla, *ap*, to end in a small blind pouch, *vb*, the *Vorhofsbindsack* of Retzius. At the base of the pouch springs a small canal, *csc*, canalis sacculo-cochlearis (*canalis reuniens Henseni*), which affords direct communication with the sacculus. In the cochlea (as shown in the figure) we can distinguish the *ligamentum spirale*, *ls*, the *membrana basi-*

laris, *mb*, and the branches, *rb*, of the cochlear nerve. The three semicircular canals—anterior, *ca*; external, *ce*; and posterior, *cp*—together with their respective ampullæ, *aa*, *ae*, *ap*, are easily identified. The anterior and posterior canals have a common stem, *ss*, which leads into the wide *utriculus*, *u*; from the utriculus a second canal leads into the posterior ampullæ, *ap*; finally from the upper portion of the utriculus arises a wide cœcal evagination, *rec*, the *recessus utriculi*, the development of which has not been yet followed out, so far as I am aware. The *canalis reuniens*, *csc*, leads into the *sacculus rotundus*, which has on one side a large *macula acustica*, *ms*, and on the other communicates with the *ductus endolymphaticus*, *de*, of which only the commencement is shown in the figure; in reality it extends clear through the *pars petrosa*, and terminates in the *dura mater* with a blind enlargement. It is noteworthy that the ductus opens into the *sacculus rotundus*, and not, as in many mammals, into the canal between the *sacculus* and *utriculus*. The last-mentioned canal may be seen in part between the points lettered *mu* and *ms* in the figure. From this description it is evident that the *labyrinth is merely an otocyst of extremely complex form, and is still a closed epithelial sac, continuous through all its parts*. The acoustic nerve reaches the neighborhood of the labyrinth in company with the *n. facialis*, which, of course, passes on beyond. The acoustic nerve divides, first, into two branches: one, the posterior, *rac* and *mu*, and the other, anterior, *a*, which supplies the cochlea and also gives off a few small branches to the *macula acustica sacculi*, *ms*, and a more considerable branch, *rap*, to the posterior ampullæ.

The labyrinth has only six sensory areas; two—namely, the *macula neglecta* and the *papilla acustica lagenæ*—being wanting, though present in amphibia, reptiles, and birds. The six present in man are: 1, 2, 3, in the three ampullæ; 4, in the *recessus utriculi*; 5, in the *sacculus*; 6, in the *scala media cochleæ* (the organ of Corti).

The auditory Passages are developed from the first gill-cleft of the embryo. It will be remembered, see p. 264, that the clefts are not open, as in lower vertebrates, but closed by a thin membrane. This membrane is the rudiment of the tympanal membrane; the portion of the gill-cleft within it becomes the Eustachian tube and the cavity of the drum, which are accordingly lined throughout life by an epithelium derived from the entoderm; the inner division of the first gill-cleft has been named the *tubo-tympanal canal*. The portion of the gill-cleft outside the membrane is lined by ectoderm and becomes the *meatus auditorius externus*. That, contrary to the assumption of older writers, the tympanum and external meatus never communicate, even in early stages, was first discovered by D. Hunt, 79.1. Some recent writers, *e. g.* Urbantschitsch, 73.1, and N. Kastschenko, 87.1, 9, have maintained that the auditory passages are not derived from the first gill-cleft, but they appear to me to offer no justification of this singular view, which has been, in fact, set aside by F. P. Mall, 88.1.

In the chick (according to Mall, *l. c.*) during the third day of incubation an ectodermal involution is formed from the dorsal part of the first external branchial groove. This involution lies in direct

apposition with the dorsal part of the first internal branchial pocket, and blends with the facial nerve. During the fifth day of incubation the connection between the facial nerve and the ectoderm is severed, and a new outgrowth (*canalis tubo-tympanicus*), from the outer part of the first internal branchial pocket, takes its place. This new outgrowth first extends outward, upward, and forward, but through the erection of the head its direction is changed to outward, upward, and backward. It forms the tympanic cavity. In mammals the development of the tympanic cavity is essentially the same; it arises as a blind dilatation of the end of the ectodermal portion of the first gill-cleft. The dilatation at first forms only a thin, flattened cavity, which for some time, at least in the human embryo, is only potentially present, because the opposite epithelial walls grow together and obliterate the actual lumen. In the human embryo at three months the tympanic cavity is still very small, Fig. 430, *Ty*, and immediately over-

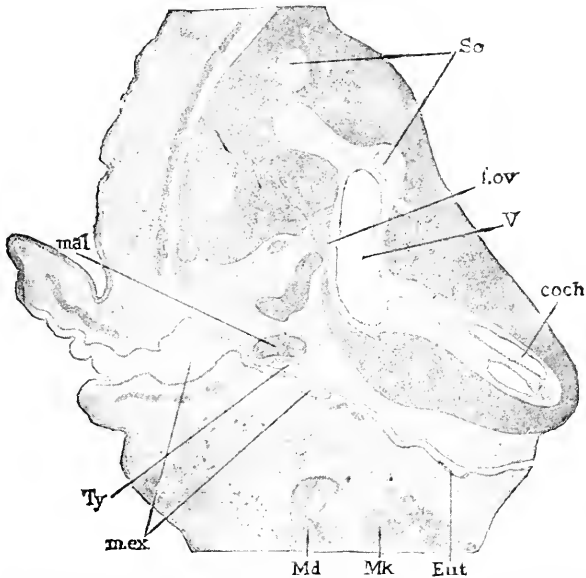


FIG. 430.—Section through the Region of the Ear of a Human Embryo of three Months (Minot Coll. No. 41). *Sc*, Semicircular canals; *f.ov*, position of the foramen ovale; *V*, primitive vestibule; *coch*, cochlea; *Eut*, eustachian tube; *Mk*, Meckel's cartilage; *Md*, mandible; *m.ex.*, meatus externus; *Ty*, tympanum; *mal*, malleus.

lies the inner end of the solid plug of epithelium, *m.ex.*, representing the meatus externus; immediately above the tympanum lies the malleus, *mal*, or upper end of the cartilage of Meckel. The same figure shows the auditory labyrinth lying in the cartilaginous periotic capsule, the precursor of the os petrosum; between the cochlea, *coch*, and the semicircular canals, *Sc*, lies the primitive vestibule, *V*, the wall of which comes close to the outer surface of the periotic capsule, at a point, *f.ov*, where the fenestra ovalis is to be developed; close to this point arises the anlage of the stapes; it will be observed in the figure that there is a considerable space around the ear bones between the fenestra ovalis, *f.ov*, on the one hand,

and the auditory passages, *m.ex*, *Ty*, on the other; this space is filled with embryonic connective tissue. After birth the connective tissue atrophies, while in the same measure the tympanal cavity expands around the bones of the ear (malleus, incus, and stapes), so that these ossicula apparently lie within the tympanal cavity; but they are, of course, covered by the tympanal epithelium or eutoderm, and are, therefore, morphologically *outside the cavity*, just as the intestine is outside the peritoneal cavity. As mentioned above, the inner end of the meatus externus, *m.ex*, lies immediately against the tympanal cavity, *Ty*; the two passages are separated by a plate composed of two layers of epithelium; this plate is the closing membrane of the gill-clefts, and also the anlage of the tympanal membrane; mesenchyma is found between the two epithelial layers in the adult, but when it penetrates, I do not know. The enlargement of the membrane depends chiefly upon the expansion of the tympanum around the malleus, in part also, doubtless, upon the actual growth of the membrane; it is said to measure at three months, 2.0×1.25 mm.; at five, 7.0×5.5 mm.; at nine, 9.75×8.5 mm. (compare Kölliker, "Entwicklungsgesch.," 2te Aufl., 751).

The inner end of the tubo-tympanal canal is transformed into the *tuba Eustachii*. It becomes small in diameter, and has a small opening into the pharynx just behind the root of the soft palate, Fig. 323; it widens out gradually into the tympanum. Its lumen is obliterated for a time, presumably, simply by conrescence of the epithelial walls. The cartilage of the *tuba* appears during the fourth month, as a plate of hyaline cartilage on the medial side of the upper end of the tube (Kölliker).

The *meatus auditorius externus* is at first shallow, but gradually deepens, becoming a long horizontal tube; the diameter of this tube very early diminishes, and it soon loses its lumen, Fig. 430, by the conrescence of the epithelium; the occlusion continues till after birth. The wax-glands appear during the fifth month, and are developed, according to Kölliker, after the type of the sweat-glands. A special bone arises, as the so-called *annulus tympanicus*, around the margin of the tympanum, and subsequently extends itself outward around the meatus; the ring, however, is incomplete on the lower anterior side, and so remains for several years after birth.

The *fenestra rotundus* and the *fenestra ovalis* are spots where the tissue between the labyrinth and the tympanum is so much reduced that only a thin membrane is left over each spot.

The Bones of the Ear are the malleus, incus, and stapes. The development of the first two is described p. 444.

The *stapes* (compare also p. 446) develops from the connective tissue near the fenestra ovalis. Staderini's careful observations, 91.1, show that in very early stages the external jugular vein runs past the tympanum; immediately below it lies the facial nerve, between which and the tympanum is situated a small branch (arteria stapedia) of the carotid artery; the mesenchyma around this artery becomes condensed (embryos of pig, of 15 mm.) and the condensed tissue is the anlage of the stapes, and subsequently ossifies, according to H. Rathke, from three centres. The artery atrophies in man, leaving the perforated bone, but persists in many other

mammals. Staderini seems to me to settle the debate as to the origin of the stapes, and to show that it is to be regarded as an ossification of the fenestra ovalis, not as a modification either in whole or in part of the visceral skeleton (mandibular or hyoid cartilages). This view is confirmed by F. Villy, 90.1, 178, who states that in the frog the stapes is formed independently of the branchial cartilages, "as a chondrification in the capsular membrane closing the fenestra ovalis, at a period when the remainder of the capsule is well developed, and not long before the tadpole begins to assume the frog's form."

The External Ear.—W. His has traced out very fully the history of the form of the external ear ("Anat. Mensch. Embryonen," Heft III., 211-221). Before the end of the first gill-cleft a series of

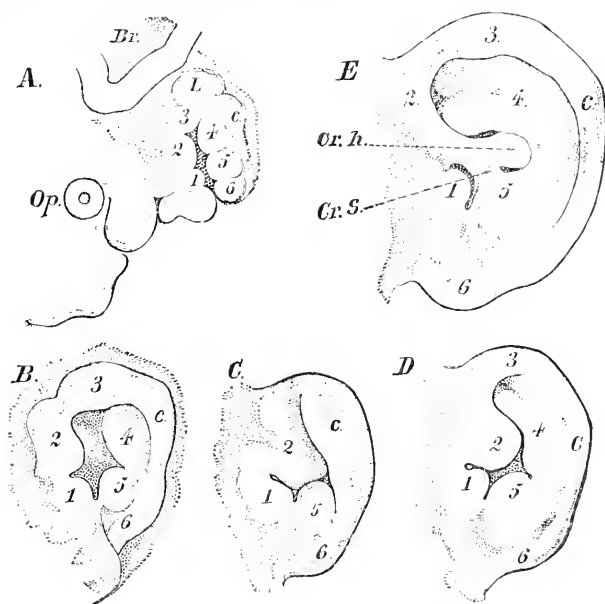


FIG. 431.—Development of the Human External Ear. A, Embryo of one month; B, six weeks; C, eight weeks; D, ten weeks; E, fourteen weeks. The six primitive tubercles are numbered 1 to 6; the primitive ridge is marked *c*; 1 is the tragus; 4, the anthelix; 5, the antitragus; 6, tania lobularis; 2, 3, and *c* form the helix.

six tubercles, Fig. 431, A; two in front, on the hind edge of the first visceral (or the mandibular) arch; one above the cleft, and three behind it. Similar tubercles have been observed by G. Schwalbe, 91.1, in the embryos of birds and reptiles. A little later a vertical furrow appears down the middle of the hyoid arch in such a way as to mark off a little ridge, Fig. 431, A, *c*, which joins on to tubercle, 3, and descends behind tubercles 4 and 5. The second stage is reached by the growth of all the parts; the fusion of tubercles 2 and 3 and the growth of the ridge down behind tubercle 5 to become continuous with 6. After these changes, it is not difficult to identify the parts, Fig. 431, B. 1 is the *tragicum*; 2 and 3, together with the arching

ridge, represent the *helix*; 4 is the *anthelix*; 5, the *anti-tragicum*; 6, the *tenia lobularis*. The deep pit bounded by 1, 2, 3, 4, and 5 is the *fossa angularis*. During the latter part of the second month the ear changes its proportions somewhat, becoming more slender: tubercle 2 projects farther backward toward the helix, making the separation between it and the *tragicum* more marked, and also rendering the *fossa angularis* more irregular.

The third stage begins with the third month. The upper and posterior part of the concha arises from the surface of the head and gradually, but rapidly, bends over forward, so as to completely cover the anthelix, B, 4, and the upper portion of the fossa angularis, Fig. 431, c. It is during this stage that in mammals the assumption of the pointed form of the ear commences. For a discussion of the development, significance, and frequency of the pointed form of the ear in man, see G. Schwalbe's admirable papers. 89.1, 91.2. The antiversion lasts only a short period, probably not much over a fortnight. The ear now unfolds and shows the anterior tubercle still more projecting than before, Fig. 431, D, and the upper part of the fossa angularis very much reduced.

The fourth stage commences with the fourth month. The tuberculum anterior encroaches still more upon the fossa angularis, and reduces the lower part of it also to a fissure, hence the tuberculum, 2, itself almost touches the anthelix, 4, and the anti-tragicum, 5. There now appears a ridge which grows out from the second tubercle and unites it with the anthelix, Fig. 431, C, *Cr.h.*, and divides the upper part of the fossa from the lower, which latter becomes the opening of the meatus. Shortly after the first ridge a second appears, which unites the second tubercle with the anti-tragicum, Fig. 431, E, *Cr.s.* Finally the sixth tubercle becomes pendent and appears distinctly as the *tenia lobularis*. These changes are completed by the end of the fifth month. The further development is very gradual and is partly post-natal. Of the two ridges, the first formed is permanent, and is the *crus* or *spina helicis*, while the second (*crus supra-tragicum*, His) becomes nearly obliterated; the subdivision of the tragicum, already indicated in Fig. 431, E, 1, becomes more marked; the concha enlarges, and its cavity grows more evident. By these and other subsidiary changes, the adult ear is developed. The differences in the ears of adults are mainly the product of secondary modifications.

CHAPTER XXIX.

THE ENTODERMAL CANAL.

THE first stages of the entodermal canal are described in Chapters IV. and V., its earliest differentiation as the archenteron in Chapter XII. We have now to take up the differentiation of the various entodermal organs after the formation of the gill-clefts.

For convenience I prefix a list of all the organs or parts derived from the entodermal canal. They are:

- | | |
|--------------------------------|-----------------------|
| 1. Gill-clefts. | 10. Duodenum. |
| 2. Pharynx and tonsils. | 11. Yolk-sac. |
| 3. Thyroid gland. | 12. Small intestines. |
| 4. Thymus gland. | 13. Cæcum. |
| 5. Larynx, trachea, and lungs. | 14. Vermix. |
| 6. Œsophagus. | 15. Colon. |
| 7. Stomach. | 16. Rectum. |
| 8. Liver. | 17. Allantois. |
| 9. Pancreas. | 18. Schwanzdarm. |

Of these there have been already described—1, the gill-clefts; 11, the yolk-sac; 17, the allantois, and, 18, the Schwanzdarm.

In this chapter is presented, *first*, the history of the alimentary tract; *second*, the history of the respiratory organs (*i. e.*, of the above list, 5, larynx, trachea, and lungs).

I. THE ALIMENTARY TRACT.

Pharynx or Branchial Region.—That part of the archenteron in which the gill-clefts are situated becomes the pharynx of the adult. The entodermal pouches of the gill-clefts undergo profound modifications. The pouch of the first or hyo-mandibular cleft becomes the tubo-tympanal canal, compare p. 738. The pouch of the second cleft becomes broad and shallow, and gives rise to the tonsils, p. 745. The remaining pouches, so far as I know, have no recognizable traces on the surface of the adult pharynx, though their epithelial walls are concerned in the development of the thyroid and thymus glands.

The pharyngeal cavity early becomes continuous with the mouth cavity by the rupture of the oral plate, p. 262.

The change of shape in the pharynx has never been traced, nor have we any definite knowledge of the histological development of its walls. In the adult it resembles the œsophagus histologically.

Its posterior limit is marked by the opening of the trachea. It is, therefore, a relatively small tract in the adult, although in the embryo, when the gill-clefts arise, it constitutes nearly half the

archenteron. So too, among vertebrates, as we ascend the series, we find that the relative importance of the pharynx diminishes.

From the floor of the pharynx are developed the tongue and the epiglottis; the tongue is treated, p. 592, in connection with the mouth-cavity; the epiglottis is treated, p. 778, in connection with the larynx.

Cervical Sinus (*Sinus præ-cervicalis* of His).—Although the cervical sinus is an ectodermal structure, yet its formation is due to modifications of the gill-arches, and therefore its history may be presented conveniently in connection with that of the pharynx. E. Dursy, **69.1**, 112, gives the earliest accurate description of the cervical sinus known to me. He observed that in a cow's embryo of 11 mm. the third and fourth branchial arches are much smaller than the others and constitute a triangular area depressed below the level of the surrounding external surface; the apex of the triangle points toward the ventral side. The corresponding stage in man is found in embryos of 9-10 mm., compare Fig. 219, *cs*. By the growth of the caudal margin of the second branchial arch the depressed area becomes further invaginated; Dursy compared the second arch to the operculum (*Keimendeckel*) of fishes—a comparison originally suggested by H. Rathke in 1825, **25.1**. His ("Anat. Menschlicher Embryonen," III. 28,) also, **86.3**, has traced the invagination of the third and fourth gill-arches in the human embryo, resulting in the

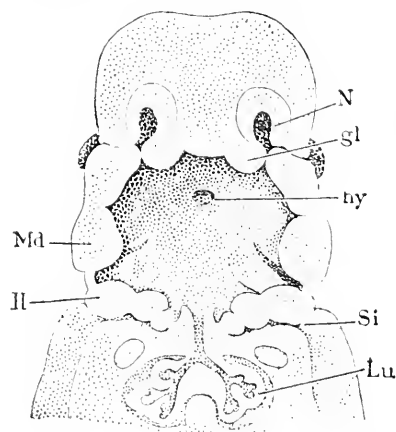


FIG. 432.—Reconstruction of the Pharyngeal Region of a Human Embryo of 11.5 mm. (His' *Rg*). *N*, Nasal pit; *gl*, processus globularis; *hy*, hypophysis; *Si*, sinus cervicalis; *Lu*, lung; *Md*, mandible; *II*, second branchial arch. After W. His. $\times 10$ diams.

formation of a deep fissure on each side of the neck somewhat toward the ventral surface, Fig. 432; owing to its position toward the ventral side His named the fissure *præ-cervical* sinus; Rabl mistook the prefix to mean headward of the neck, and accordingly made an acrimonious attack, **86.1**, upon His for saying that the sinus was not connected with the neck. Rabl's blunder was corrected by His, **86.3**, 428. His has shown that the fourth arch is turned in first, and that the third arch is turned in a little later; the sinus is so narrow that the arches come in contact with the opposite wall; the ectoderm of the arches concretes with that of the caudal side of the sinus, the opening of which is thus obliterated. The sinus is now

an epithelial cord connected with the epidermis on the one hand, and on the other with two spaces lined with ectoderm: one space corresponds to the ectodermal furrow of the second gill-cleft, the other to the ectodermal furrow of the third gill-cleft. All trace of the second furrow is soon obliterated (compare Fig. 434), but the remnant of the third furrow persists longer and lies in close proximity to the anlage of the thymus, Fig. 434. His, "Anat. menschl.

Embryonen," III., 104, regarded the buried remnant of the third ectodermal branchial furrow as the anlage of the thymus. In 1886, he still adhered to this opinion in an article, 86.3, which gives the fullest history of the sinus we have yet, but after the entodermal origin of the thymus had been demonstrated in various types, His reworked the question, and in a brief paper, 89.2, withdrew his earlier opinion.

So far as known, the cervical sinus entirely disappears, but its abnormal persistence may account for certain cysts occurring pathologically in the neck.

Tonsils.—The tonsils are developed from the second gill-cleft. In an embryo of four or five months, the shallow pouch which represents this cleft is found bounded in front by the arcus palatoglossus, which is a survival of part of the second branchial arch, and is partly covered by the uvula, which is continued on to the wall of the pharynx as a fold, the *plica triangularis* of His ("Anat. menschlicher Embryonen," Heft III., 82), which bounds the pouch on the dorsal side. The pouch is lined by the mucous membrane (entoderm plus mesenchyma) of the pharynx.

The histogenesis of the tonsils has been made the subject of a long memoir by E. Retterer, 88.1, who maintains that the epithelium commingles with the connective tissue, forming a special angiothelial tissue of double origin. P. Stöhr, 91.1, and Gulland (Lab. Rept. R. Coll. Phys. Edinburgh, III., 1891) have shown that Retterer's view is erroneous. According to Stöhr, the tonsil has, at three months, a stratified epithelium resting on mesenchyma without leucocytes. At four months the tonsillar fissures begin to branch, and the epithelium presents buds, some of which are the solid anlagen of glands, while others are the commencements of branches of the tonsils. The formation of solid tonsillar buds continues not only through the embryonic period, but also for a year after birth. The solid buds gradually become hollow by a change in the central cells, which assume a corneous appearance and gradually contract into a mass in the centre of the bud, Fig. 433, *c*. Meanwhile, the cavity of the tonsil extends into the upper part of the bud, until it communicates with the space containing the degenerated mass, which is then expelled. The epithelium is at all periods separated from the mesoderm by a distinct endothelial basement membrane, Fig. 433, *b.m.*, nevertheless it is penetrated by leucocytes during the fourth month, Fig. 433, *l.l.* Up to the time of birth the number of the immigrant cells in the epithelium gradually increases; indeed they may become so numerous that the epithelium and basement membrane are scarcely recognizable. In the mesenchyma there are connective-tissue fibrillæ at three months, and at

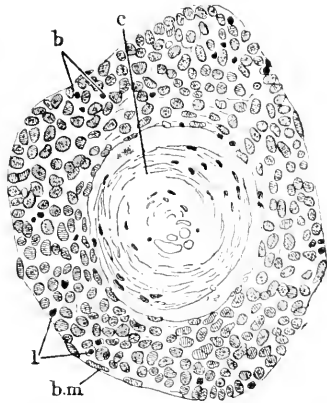


FIG. 433.—From a Section of a Tonsil of a Human Embryo of five Months. *c*, Corneous central mass; *b.m.*, basement membrane; *l.l.*, leucocytes. After P. Stöhr.

that stage there are also leucocytes scattered about, but the infiltration is diffuse. As the number of leucocytes increases, they show an increasing tendency to form groups—the anlagen of follicles—but it is not until after birth that the follicles become well defined with distinct germinating centres. The leucocytes are probably derived from the blood by migration to the walls of the blood-vessels *in loco*.

The **Thymus** is developed from the entoderm of the third gill-cleft, as a thickening, which remains after the cleft aborts. That the thymus is of exclusively entodermal origin in all birds and mammals is extremely probable, though not quite certain. Froriep, 91.2, 64, asserts that in sharks the thickening is identical with that which forms the epibranchial organ, a view that interprets the thymus as ectodermal. The form of the third gill-cleft in young embryos is described p. 264. In a human embryo from the begin-

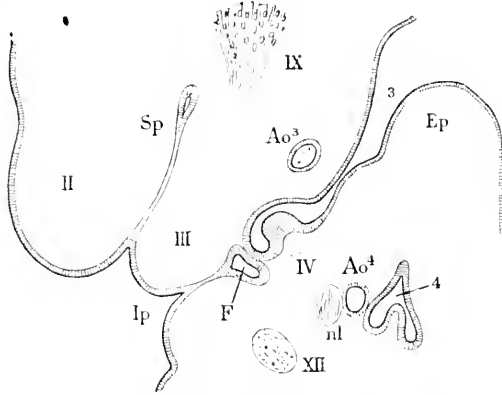


FIG. 434.—Section through the Third Gill-Cleft of a Human Embryo from the beginning of the third Week. II, III, IV, Second, third and fourth branchial arch; *Sp*, remnant of ectodermal groove between the second and third arches; IX, ganglion of the glosso-pharyngeus; 3, third entodermal pouch; *Ao*³, third, *Ao*⁴, fourth aortic arch; *Ep*, epiglottis; 4, fourth entodermal pouch; *nl*, nervus laryngeus superior; XII, hypoglossus; *Ip*, Isthm' infundibulum præcervicale; *F*, Fundus of cervical sinus. After W. His.

ning of the fifth week, His, 89.2, found the entodermal pouch of the third gill-cleft open, Fig. 434, 3; the entoderm in the distal part of the cleft is somewhat thickened, and is in immediate contact with the ectoderm of the cervical sinus. In a pig embryo of 11 mm. Born, 83.1, 288, finds the lower part of the entodermal pouch still open, but in the dorsal apex the epithelium has grown and obliterated the cavity. In a pig embryo of 13 mm. Born, p. 29, finds the dorsal and distal end of the third pouch enlarged, and the rest transformed into a very narrow canal by which the end is connected with the pharynx proper. In a cow embryo of 12 mm., Froriep, 85.1, 23, found a very similar condition, but the lumen of the canal was beginning to disappear. In the rabbit at thirteen days, Piersol, 88.1, 175, and Fig. 24, finds the distal dorsal dilatation of the pouch very marked; its walls are greatly thickened, but the central cavity still persists; the canal to the pharynx has become a solid epithelial cord. The connection of the pouch with the pharynx is soon lost, and the third entodermal gill-pouch may be then designated as the independent anlage of the thymus. This anlage is an elongated sac

with thickened epithelial walls; it occupies an oblique dorso-ventral line; its dorsal end is especially enlarged and corresponds to the future head of the thymus. Born, p. 297, found the connection of the thymus with the pharynx severed in a pig embryo of 20 mm. F. P. Mall, **87.1**, 16-28, has followed the development of the thymus in the chick, and found it essentially identical with that in mammals; the thickening of the entodermal walls begins the fourth day; the fifth day the thymus separates from the pharynx and becomes an elongated body, situated at about the same level as, and nearly parallel with, the pharynx and overlying the third and fourth aortic arches. The manner in which the thymus changes its form and position is clear from the reconstructions in Fig. 436, *thm*, and therefore requires no special description.

The lumen of the anlage, though long persistent, is gradually obliterated until it completely disappears (pig of 35 mm.); in a pig embryo of 25 mm. the ventral end of the thymus is developing lateral buds, and in an embryo of 35 mm. the whole organ is budding (Born, **83.1**, 306). A similar condition is found in the rabbit at sixteen days, in man about the twelfth week (Kölliker, "Grundriss," 2te Aufl., 370, 371).

Histogenesis.—Kölliker ("Entwicklungsgesch.," 2te Aufl., 878) records for the rabbit, that between the twentieth and twenty-third days the cells of the thymus become smaller and their outlines disappear, so that the organ appears to be an accumulation of small round nuclei. At about the same period blood-vessels and connective tissue grow into the epithelial anlage. After the penetration of the vessels the differentiation of the cortex and medulla is recognizable; in carmine preparations the cortex is the darker part. According to Stieda, **81.1**, the concentric bodies of the adult thymus are derived from the epithelium (entoderm).

The remarkable changes in the thymus after birth are outlined in all the principal "Anatomies." For details see especially Afanassiew, **77.1**.

Historical Note.—L. Stieda, **81.1**, discovered in 1881 that the thymus gland arises in intimate connection with a gill-cleft. Kölliker in 1884 recorded ("Grundriss," 2te Aufl., 369) that the primitive anlage of the gland was an epithelial mass. G. Born in an essay of great excellence, **83.1**, demonstrated that the gland is developed from the entodermal lining of the third gill-cleft. Born's result has been confirmed by C. Rabl, **86.1**, Fischeles, **85.1**, De Meuron, **86.1**, F. P. Mall, **87.1**, **88.2**, Froriep, **85.1**, 47, **91.2**, 64, and Prenant, **91.2**. His, **85.3**, "Anat. menschl. Embryonen," III., at first maintained that the thymus arose from the ectoderm of the cervical sinus, but having made further observations finally reached the same conclusion as Born, and showed, **89.2**, that in man the thymus is derived from the third entodermal pouch. Kastschenko, **87.1**, believed that the thymus was partly ectodermal, partly entodermal, an opinion which is incompatible with our present knowledge.

Thyroid Gland.—The thyroid gland is developed from three anlagen, one median and two lateral, which unite and undergo a common differentiation. We take up: 1, the median anlage; 2, the lateral anlagen; 3, their union; 4, their differentiation; 5, homologies.

1. *The Median Anlage.*—This is an evagination of the floor of the pharynx between the bases of the first and second branchial arches; it lies in the median line behind the tuberculum impar, p. 592, and the furcula, or the two parts of the tongue. In the human embryo, as we learn from His ("Anat. menschl. Embryonen." II., 64-72, 97-102), the evagination is a small pouch beginning to expand sideways in an embryo of 5 mm.; in an embryo of 10 mm. (cf. Fig. 335, *m.th*) the lateral expansion has increased very much and there is a distinct, though narrow, median duct, the opening of which upon the surface of the tongue corresponds to the *foramen cœcum*; the duct itself is known as the *ductus thyreoglossus*. The anlage now consists of a bilateral epithelial vesicle, connected by a slender, hollow pedicle with the surface of the tongue. The duct persists up to

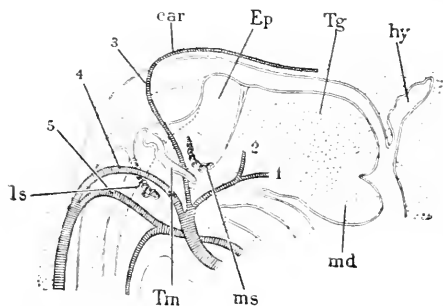


FIG. 435.—Reconstruction of the Pharyngeal Region of a Human Embryo of 9.1 mm. (His' Ru). 1, 2, 3, 4, 5. Aortic arches; *car*, carotid; *Ep*, epiglottis; *Tg*, tongue; *hy*, hypopharynx; *md*, lower jaw; *ms*, median anlage of thyroid; *Tm*, thymus; *ls*, lateral anlage of thyroid. After W. His. $\times 30$ diams.

the eighth week, gradually elongating as the thyroid and the tongue separate. The duct usually obliterates completely or partially, but it sometimes persists more or less intact throughout life. The abortion of the duct begins usually during the fifth week, and when the anlage of the hyoid bone reaches the median line, it is situated directly in the path of the duct, a topographical relation of pathological importance (W. His, 91.1). The abortion begins with the closure of the lumen of the duct; the solid cord gradually diminishes in size and becomes fragmented as resorption progresses, but the upper portion near the surface of the tongue retains its thickness for a time at least. Kanthack, in an article of slight value, 91.1, has denied without justification the existence of the thyroid duct. The vesicular portion of the median anlage expands quite rapidly, Fig. 435, *ms*, and lies nearly at the level of the third aortic arch, 3, or internal carotid, and, indeed, is from the beginning in close proximity to the larynx. In embryos of 9-10 mm. it is a narrow, long transverse body, the lateral ends of which curve dorsalward, and which, with the duct, form a figure somewhat like an inverted T.

The development in other mammals, so far as known, is closely similar to that in man. Thus in the rabbit, Piersol, 88.1, 182, found the anlage to appear the end of the ninth day (embryo of 3.3 mm.); the epithelium of the thyroid evagination at once thickens and the anlage becomes solid the tenth day: the twelfth day the abortion of the duct begins; and *after* the separation, not before, as in man, the lateral outgrowth of the anlage begins. In the pig, G. Born, 83.1; in the chick, Seessel, 78.1, and F. Mall, 87.1; in Amphibia, A. Götte, 75.1; in Petromyzon, W. Müller, 71.3, 73.1, and A. Dohrn, 86.1, 87.2, have studied the median anlage of the thyroid, which may now be said to be a structure common to, and therefore

the upper portion near the surface of the tongue retains its thickness for a time at least. Kanthack, in an article of slight value, 91.1, has denied without justification the existence of the thyroid duct. The vesicular portion of the median anlage expands quite rapidly, Fig. 435, *ms*, and lies nearly at the level of the third aortic arch, 3, or internal carotid, and, indeed, is from the beginning in close proximity to the larynx. In embryos of 9-10 mm. it is a narrow, long transverse body, the lateral ends of which curve dorsalward, and which, with the duct, form a figure somewhat like an inverted T.

characteristic of all vertebrates. The references just given might easily be multiplied.

G. Born, **83.1**, 301, found that in the pig the median anlage commences its histological differentiation and is penetrated by blood-vessels before it is joined by the lateral anlages. In man the differentiation is much less advanced when the union occurs.

2. *The lateral anlages* are derived from the epithelium (entoderm) of the fourth gill-clefts. The fourth entodermal pouch develops a ventral prolongation (human embryo of 10 mm., Fig. 435, *ls*). His ("Anat. menschl. Embryonen," III., 97) draws a distinction between the diverticulum and the pouch, but upon what grounds is not clear to me. In an embryo of 12.5 mm. (Nackenlänge) His, *l.c.*, 98, found the diverticulum a closed vesicle entirely separated from the pharynx; the vesicle curved forward and was just beginning to form a few round, hollow buds, and may now be designated as the lateral thyroid anlage. The median anlage at this stage is situated further toward the mouth and the ventral side. In an embryo of 13.8 mm. (Nackenlänge) the lateral anlages have moved nearer the median, and take such a position that they prolong the median anlage forward and upward on each side.

In a pig embryo of 13 mm. Prenant, **91.2**, 211, observed the ventral diverticulum of the fourth pouch still connected with the

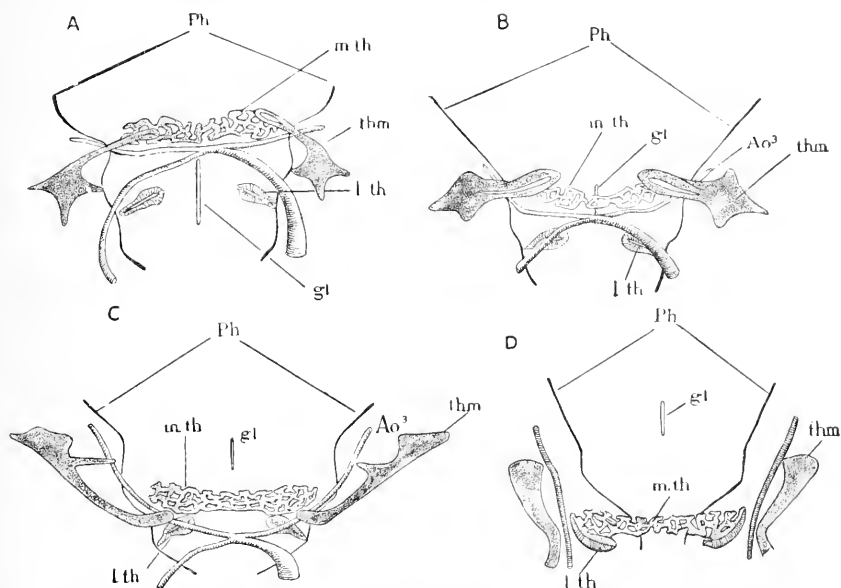


FIG. 436.—Reconstructions to show the development of the Thyroid Gland in the Pig. A, Embryo of 15 mm.; B, of 16 mm.; C, of 20 mm.; D, of 22.5 mm. *Ph*, Outline of pharynx; *m.th*, median thyroid; *thm*, thymus; *l.th*, lateral thyroid; *gl*, glottis; *Ao³*, third aortic arch. After G. Born. \times about 20 diams

pharynx, and records a similar condition for a bat embryo of 6 mm. and a sheep embryo of 14 mm. Piersol, **88.1**, 182, found the corresponding stage in a rabbit embryo of the eleventh day, and states that the anlage remains "for a relatively long time" connected with

the pharynx by an epithelial cord. Born does not state clearly when the lateral anlages separate in the pig from the pharyngeal epithelium, but apparently the separation occurs in embryos of about 15 mm., compare Born, **83.1**, 299.

3. *Union of the Three Anlages.*—This was discovered by Born, **83.1**, 299. It takes place in the pig when the embryo is from 20 to 22 mm. long; the median anlage is at this time a network of epithelial cords and considerably larger than the lateral anlages, which have gradually changed their position, Fig. 436, A, B, C, D, until they have come to lie against the lateral ends of the median part, C; with these ends the lateral parts then unite and soon acquire the same reticulate structure as the median portion, and there remains no evidence of the triple origin of the gland.

In man the union takes place probably during the seventh week—the exact time has not been recorded. The lateral anlages are relatively larger, and the median anlage less differentiated before the union in man than in the pig. As to the process of union in other mammals I find no precise data.

4. *Differentiation.*—In a pig embryo of 15 mm. (Born, **38.1**, 301) the median thyroid is a transverse band of epithelium, around which the mesenchyma is beginning to form a capsule. The epithelial band is beset with buds, which grow in such a way that the band soon becomes a network of epithelial cords, Fig. 436; the cords are solid with a superficial layer of distinct high cylinder cells with elongated nuclei, and surrounding a granular nucleated mass without distinct cell boundaries. At the same stage the lateral thyroid is merely an epithelial vesicle, at the ventral end of which the walls are thickened. After the fusion of the three parts one can still recognize (pig embryos of 26 mm.) the lateral portions, because, though now similar in structure to the middle portion, the epithelial cords are thicker and the meshes between them smaller than in the middle part. In an embryo of 37 mm. (Born, *l.c.*, 305) the gland has become an oval body inclosed in a smooth capsule of connective tissue.

His ("Anat. menschl. Embryonen," III., 102) records that in a human embryo of the eighth week the formation of the hollow acini had begun; the acini were lined by epithelial cells with each an outer granular zone containing the nucleus, and an inner zone of clearer appearance. The outer zone stains more deeply than the inner. Wölfler, **71.1**, has claimed that the hollow epithelial acini are formed by the degeneration of the central tissue of the solid cords, and in this conclusion he is supported by Lustig, **91.1**, but whereas Wölfler maintained that the differentiation begins in the centre of the organ and progresses toward the periphery, Lustig asserts that the differentiation goes on throughout, so that mature and immature acini may be found in every part at once. Fig. 437 represents a section of the human foetal thyroid at about four months. It will be noticed that many of the acini are still solid.

At two months the gland in man consists of two lobes connected by a narrow isthmus (Müller, **71.3**, 447). Müller, *l.c.*, also gives some details of the growth of the acini up to the period of puberty, as well as good observations on the foetal gland in various vertebrates.

5. *Homologies*.—The mammalian thyroid gland is shown by its development to be a double organ. The median part is alone homologous with the so-called thyroid gland of other vertebrates, while

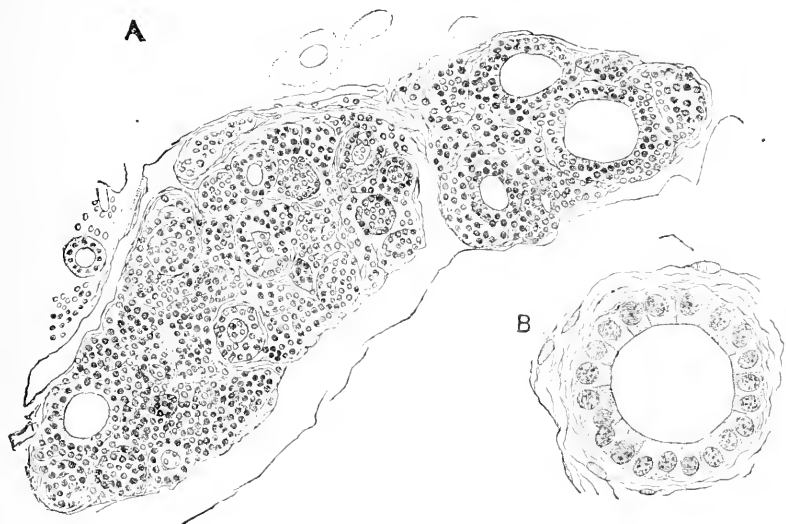


FIG. 437.—A Section of the Thyroid Gland of a Human Embryo of about four Months. B, a single acinus more highly magnified.

its later portions are presumably homologous with supra-pericardial bodies; see Piersol, **88.1**, 183, also Van Bemmelen, **86.1**, **89.2**, F. Maurer, **85.1**, **87.1**, etc.

Historical Note.—That the thyroid gland arose from the pharynx, and commenced as a thickening of the entoderm, was discovered by Remak, **50.1**, 81—82. This discovery was confirmed by Goette's observations on the chick, **67.1**, and on Bombinator, **75.1**, 667. W. Müller's investigations, **71.3**, **73.1**, added considerably to our knowledge of the median anlage in various classes, and led him to homologize the thyroid evagination with the hypobrachial groove or endostyle of tunicates and Amphioxus. This homology has found an earnest defender in Anton Dohrn, **86.1**. Seesel gave, **77.1**, a more accurate description of the anlage in the chick, and it was also studied in man by His ("Anat. menschl. Embryonen," I., 56), and in the rabbit by Kölliker ("Entwickelungsgesch.," 2te Aufl., 871). In 1881 L. Stieda, **81.1**, discovered the lateral anlages, and traced them to a connection with one of the gill-clefts; the same discovery was made the same year, but independently, by Wölfler, **81.1**, who gives an extensive review of the previous literature. Stieda and Wölfler overlooked the median portion. Born's thorough investigation, **83.1**, finally cleared away the uncertainty by tracing out with rare precision the exact rôle of each part of the triple anlage. Born's results have since been abundantly confirmed by His, "Anat. Embryonen," III, **91.1**, Von Kölliker ("Grundriss," 2te Aufl., 369), Froriep, **85.1**, De Meuron, **86.1**, Piersol, **88.1**, F. P. Mall, **87.1**, **88.2**, and A. Prenant, **91.2**, 204—220.

The œsophagus is developed from the short piece of the vorderdarm, p. 261, between the pharynx and the stomach, Fig. 441, *oe*. During the fourth week it begins to lengthen out, and by the end of

the fifth week has become a cylindrical tube of considerable length, Fig. 444, *C*. As regards its further history we have little exact information. I have observed that during the fourth to sixth month it has usually four well-marked ridges formed by its mucous membrane, and that below the larynx these ridges are so arranged as to give the cavity of the œsophagus, as seen in cross sections, the outline of a Greek cross, which

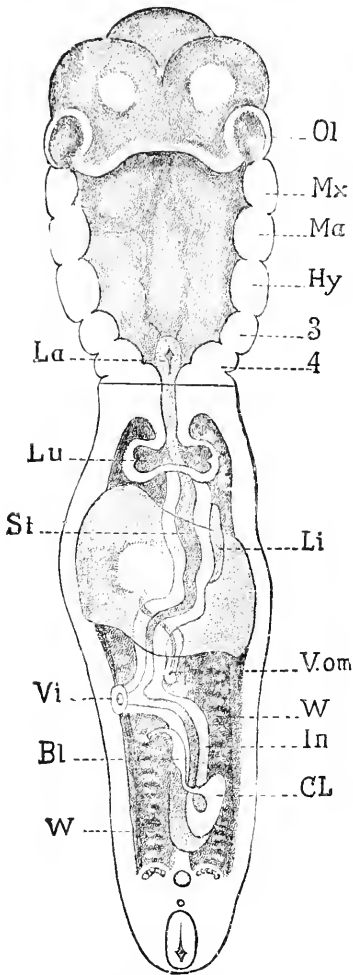


FIG. 438.—Reconstruction of His' Embryo B; the Head is drawn as if erected. *Ol*, Nasal pit; *Mx*, maxillary process; *Mα*, mandibular arch; *Hy*, hyoid arch; 3, 4, branchial arches; *Li*, liver; *V.om*, omphalo-mesaraic vein; *W*, Wolffian body; *In*, intestine; *CL*, cloaca; *Bl*, allantois; *Vi*, vitelline stalk; *St*, stomach; *Lu*, lung; *La*, larynx. After W. His.

cylindrical form, and bear a crown of cilia. The presence of cilia in the human embryo of eighteen to thirty-two weeks was discovered by E. Neumann, 76.1.

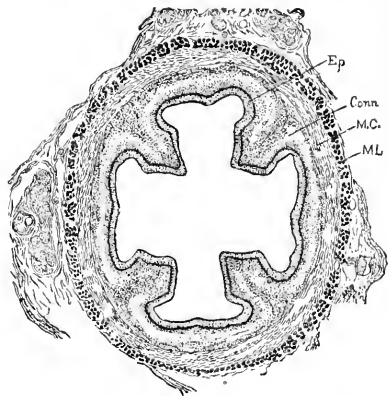


FIG. 439.—Transverse Section of the Œsophagus of a Human Embryo of four Months (Minot Coll. No. 35). *Ep*, epithelium; *conn*, connective tissue of mucosa; *M.C.*, circular muscular coat; *ML*, longitudinal muscular coat.

was observed by Kölliker ("Entwickelungsges.," 2te Aufl., 853). At four months the inner circular muscular coat, Fig. 439, *M.C.*, and the outer longitudinal muscular coat, *ML*, are clearly differentiated.

The epithelium* of the œsophagus at four months, Fig. 440, consists of numerous layers of clear cells, but at certain points some of the cells at the free surface have a granular protoplasmatic appearance, a somewhat

*Demon, 85.1. has also studied the foetal œsophagus, but at the time of writing I have been unable to consult his dissertation.

Balfour ("Works," III., 61) records that in shark embryos the cavity of the œsophagus is entirely obliterated about the time the fourth gill-cleft is formed, and so remains for a long period; the ob-

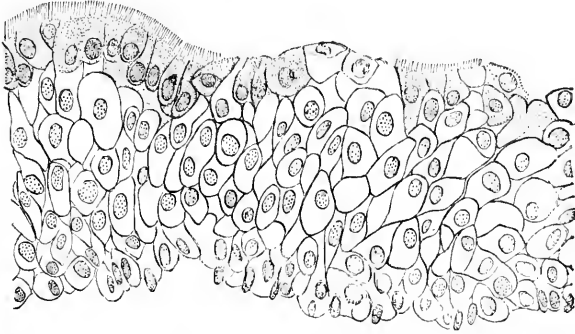


FIG. 440.—Highly magnified View of a small portion of the Epithelium of Fig. 439.

literation is effected by the growth of the entodermal epithelium. That the entodermal canal is for a time in teleost embryos a solid cord has been already stated, and accordingly we find in them the œsophagus without a lumen during certain stages, *cf.* McIntosh and Prince, 90.1, 771. De Meuron, 86.2, states that the obliteration can be observed in anura, just after the larva hatches; in lizards, and the chick embryo of five and one-half days; in lizards the obliteration is incomplete. W. Opitz, 87.1, states that part of the lumen is closed in the human embryo, and concludes from that fact that the amniotic fluid cannot be swallowed by the foetus.

Stomach.—The first trace of the stomach appears in a human embryo of five or six days as a slight dilatation of the entodermal canal, Fig. 441, *st*, between the œsophagus, *oe*, and the liver, *f*; the stomach at this stage is in the median plane and overlies the septum transversum. The dilatation continues to increase during the whole fetal period. The stomach very early migrates into the abdominal cavity below the liver, Fig. 444, A, B, C, there being a corresponding elongation of the œsophagus. In conse-

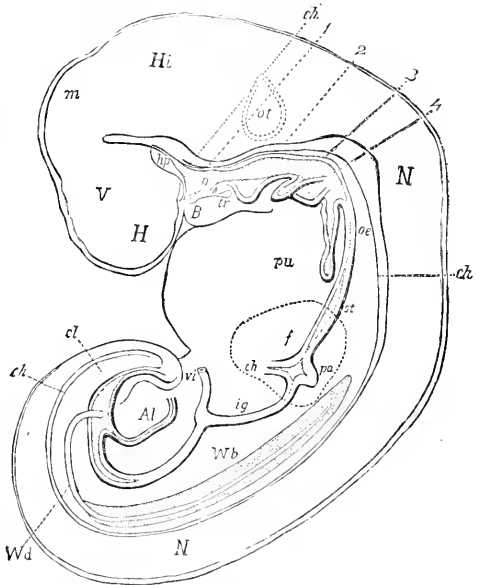


FIG. 441.—Reconstruction of Fol's Embryo. 17. Fore-brain: *H.* hemisphere; *hp.* hypophysis; *B.* mandible; *tr.* median thyroid; *m.* mid-brain; *Hb.* hind-brain; *ch.* notochord; 1, 2, 3, 4, gill-pouches; *N, N.* neuron; *oe.* œsophagus; *pu.* lung; *st.* stomach; *f.* liver; *pa.* pancreas; *ig.* small intestine; *Wb.* Wolffian body; *Wd.* Wolffian duct; *vi.* vitelline duct; *Al.* allantois; *cl.* cloaca. After Fol.

quence of this migration the stomach acquires a mesentery, which on its dorsal side is known as the mesogastrium, on the ventral side as the lesser omentum; the mesogastrium is the anlage of the greater omentum or epiploon. During its migration the stomach also becomes asymmetrical in shape and position, Fig. 444, C; in that figure, which is taken from a five weeks' embryo, the adult form of the stomach is clearly indicated; the figure also shows that the greater curvature belongs to the dorsal, the lesser curvature to the ventral side of the stomach. Finally during its migration the stomach also revolves around its own axis so that its left surface is turned forward and its right surface backward, see Fig. 445, *st.* and moreover the cephalic end of the stomach is on the left side, the caudal or pyloric end on the right side. In the change of position of the stomach we find the explanation of the origin of the omentum by the folding of the mesogastrium, and also of the connection of the ventral mesentery or lesser omentum with the lesser curvature or primitive median ventral line of the stomach on the one hand, and the liver on the other.

The revolution of the stomach around its own axis explains the asymmetrical position of the vagus in the adult, for the embryonic left side innervated by the left vagus becomes the "anterior" surface, according to the descriptive anatomy of the adult.

HISTOGENESIS.—Our knowledge of the development of the gastric glands rests chiefly on the admirable memoir of Toldt, **80.1**, who also reviews the scanty results of his predecessors. The entoderm of the stomach consists in young embryos (cat 30–130 mm.) of a cylinder epithelium, which gradually increases in thickness until the formation of the *peptic glands* begins (cat embryos of 60–70 mm., human embryos tenth week). Groups of cells arrange themselves in miniature glands, which are contained entirely within the thickness of the epithelium; that is, they do not project into the

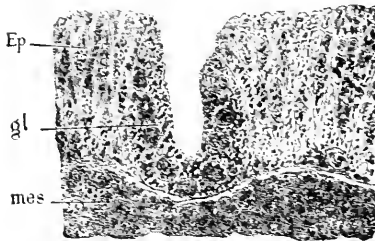


FIG. 442.—Epithelium of the Greater Curvature of the Stomach of an Embryo Cat of 5 mm. *Ep*, epithelium; *gl*, anlage of peptic gland. After C. Toldt.

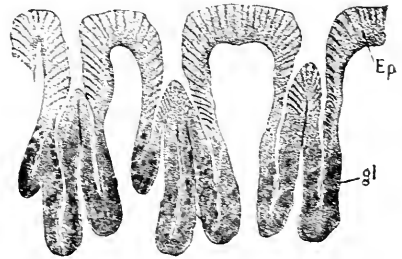

FIG. 443.—Peptic Glands from the greater Curvature of Stomach of a Human Embryo from the end of the eighth lunar month. *Ep*, epithelium; *gl*, branching gland. After C. Toldt.

mesoderm: each gland, Fig. 443, *gl*, when fully marked out, consists of a small central cavity and a wall of finely granular cuboidal cells, and is separated from the neighboring glands by the unaltered high cylinder-cells. This stage is described for a rabbit embryo of 42 mm. by E. Salvioli, **90.1**, 73. The glands grow down into the mesoderm (cat embryos of 85 mm.), and one can soon distinguish an upper portion or duct lined by high cylinder-cells and a lower gland-

ular portion with a cuboidal epithelium, Fig. 443. The gland proper forms terminal and later lateral buds also, so that each duct acquires several branches, Fig. 443. The formation of new gland anlagen ceases when the budding begins, but the glands continue to multiply, owing to the division of the ducts. At seven months the foetal stomach has about seven glands to each duct, and this proportion is kept until birth; but after birth, owing to the continued division of the ducts, the proportion is diminished; thus Toldt found at ten years an average of six glands for each duct; at fifteen years five glands; in the adult only three. The *peptic cells* (*parietal* or *delomorphous cells*, *Belegzellen*) arise by differentiation of single gland-cells; the differentiation begins by the accumulation of coarse granules (zymogen?), at first in the outer part, later through the whole cell; these glandular cells first become recognizable about the time the branching of the glands commences (in man toward the end of the fourth month). The number of peptic cells increases both by division of the cells and the metamorphosis of the original cells. As the peptic cells are differentiated they take up their position on the outside of the gland. After the sixth month pepton may be obtained from the stomach. H. Sewall, 78.1, asserted that the peptic cells immigrated from the mesoderm, an error which, as Toldt has shown, was due to incomplete observation.

The *mucous glands* (Toldt, 80.1, 119) appear about the same time (cat embryo of 50 mm.) as the peptic, as evaginations of the epithelium, which are lined throughout by cylinder—not by cuboidal—cells. Later the glands become branched. Kölliker ("Entwicklungsgesch.," 2te Aufl., 854) observed that the gastric glands measure during the fifth month from 0.13–0.22 mm.; during the sixth 0.42–0.71 mm.

The spaces between the gland-openings become somewhat prominent during the third month, and these prominences have been described as villi by Kölliker and others, but there are no sufficient grounds for maintaining that there are any true gastric villi at any period. The pseudo-villous appearance is most marked toward the pylorus, and persists at least through the fifth month. A little later than the villi there appear also on the inner surface of the stomach longitudinal ridges which vary in number from 12 to 15.

During the fourth month the inner circular muscle layer and the outer longitudinal layer become well marked (Kölliker, "Entwicklungsgesch.," 2te Aufl., 853).

Intestine.—The intestine includes the whole of the entodermal canal from the stomach to the anus. Four entodermal organs are appended to it, the liver, pancreas, yolk-sac, and allantois or bladder. When first formed it is a short, straight, median tube, to the ventral side of which are appended the yolk-sac and allantoic diverticulum, compare Chap. XII. The intestinal canal very early begins to elongate, and continues to do so throughout foetal life; while elongating it also increases gradually in diameter. I know no measures of the growth of the intestine. A consequence of its growth is that it has to form coils, which finally produce important anatomical changes. The posterior portion of the intestine increases more than the rest in diameter and becomes the large intestine (colon and rec-

tum). From the anterior end of the colon grows out the cœcum, and from the cœcum the appendix vermiformis.

GENERAL GROWTH.—The elongation and twisting of the intestine in the embryo is indicated by Fig. 444. It has been carefully worked

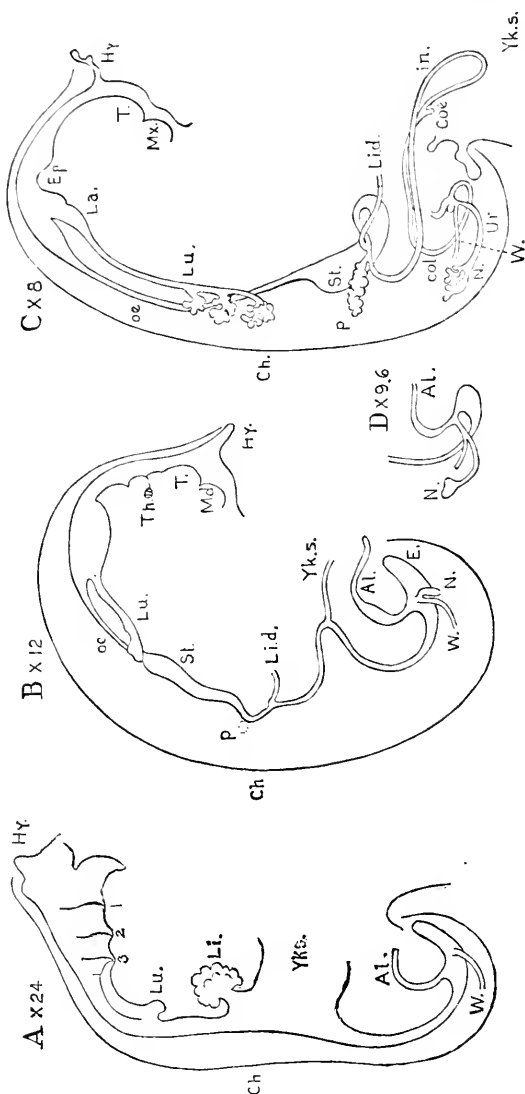


FIG. 444.—Digestive Tracts of four Human Embryos. A, Embryo of 12.5 mm. *Hy*, Hypopharynx cephalic; 1, 2, 3, gill-slits; *L.a.*, lungs; *M.d.*, maxilla inferior; *T.*, tongue; *Th*, thyroid gland; *Ep*, epiglottis; *Lu.*, barynx; *oe*, oesophagus; *St.*, stomach; *L.i.*, liver; *L.i.d.*, liver-duct; *Yks.*, yolk-sac; *Al.*, allantois; *E.*, epididym. or extension of the clonae; *in.*, small intestine; *Coæ*, cœcum; *col.*, colon; *N.*, kidney; *Uir.*, ureter; *W.*, Wolffian duct; *ch*, notochord. After His.

by W. His ("Anat. menschl. Embryonen," III., 12-25). In an embryo of 4.2 mm. the stomach is barely indicated, A; the neck of the yolk-sac, *Yks.*, is very wide; nearly the whole space between the yolk-stalk and the stomach is occupied by the hepatic anlage, *li.* In an embryo of 7 mm., Fig. 444, B, the stomach has elongated and

begun to descend into the abdominal cavity; the yolk-stalk is considerably smaller, *Yks*; between it and the stomach the entodermal canal has lengthened; near the stomach are appended the pancreas, *P*, and the liver, *Li.d*; the intestinal canal below the yolk-sac has also lengthened out, so that the intestine as a whole describes a long loop toward the ventral side, to be there attached to the yolk-sac, see also Fig. 17; as the stomach is situated entirely on the left side, it follows that the loop is asymmetrical, the upper limb of the loop lying more to the right, while the lower limb lies more to the left. The asymmetry is more evident in later stages, Fig. 444, C. The upper limb, together with part of the lower limb, forms the small intestine; the division between large and small intestine does not coincide with the insertion of the yolk-stalk. The cephalic limit of the large intestine is first given in embryos of about 1.2 mm. by a small diverticulum, Fig. 445, B, *Coe*, the anlage of the cœcum, compare also Fig. 444, C, *Coe*; the whole of the canal on the caudal side of the cœcum increases in diameter and forms the large intestine, Fig. 445, B, *col*. The small intestine now lengthens rapidly for a long period, and forms coils below the level of the cœcum,

Fig. 445, B; at the same time the large intestine, *col*, also lengthens, but more slowly, and its cœcal end is carried over to the left side toward the cardiac end of the stomach, with the result that the small intestine has to cross ventrad of the large intestine from right to left. The crossing of the two intestines introduces considerable complexity into the arrangement of the mesentery, as explained in the next section. At the stage we have now reached, Fig. 445, the stomach, *st*, is relatively large, and has essentially its adult form, but it still lies almost wholly on the left side; its pyloric end is to the right of the median line; from the pylorus springs the duodenum or beginning of the small intestine; it runs toward the median line nearly parallel with the greater curvature of the stomach; the liver duct, *Li*, and pancreas, *Pan*, are both connected with the upper end of the duodenum; the pancreas lies, as stated, p. 767, in a transverse position between the duodenum and the stomach. The small intestine makes several coils and terminates on the right side of the body by joining the colon; in Fig. 445, B, however, the end of the colon lies on the left, but this is unusual and was, perhaps, a case of partial reversus situs viscerum.

As the *large intestine* grows, its cœcal end descends toward the pelvis on the right side, and it may then be subdivided into the four

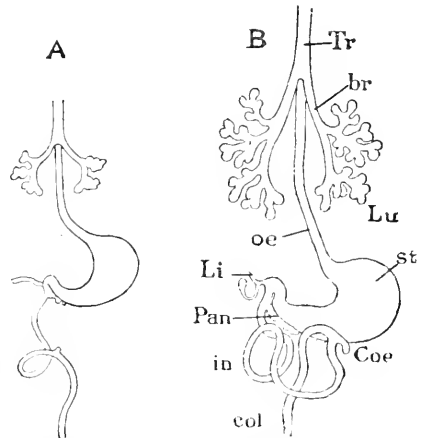


FIG. 445.—Two Front Views of the Entodermal Canal; A. Embryo Sch. 1 of His; B. His' embryo, Sch. 2. *Tr*, Trachea; *br*, truncus; *Lu*, lung; *St*, stomach; *Coe*, cœcum; *col*, colon; *in*, small intestine; *Pan*, pancreas; *Li*, liver; *oe*, oesophagus. After W. His. $\times 8$ diams.

parts recognized in descriptive anatomy, to wit: 1, 2, 3, the ascending, transverse, and descending colons; and 4, the rectum.

CŒCUM AND APPENDIX VERMIFORMIS.—The cœcum arises as an outgrowth of the ileal end of the large intestine; it appears in human embryos of 10-12 mm. The appendix appears as a blind outgrowth, Fig. 446, 1', of the cœcum. At six months, Fig. 446, it is long and slender, with a narrow free mesentery and is relatively much better developed than in the adult, and also is less sharply marked off from the cœcum proper.

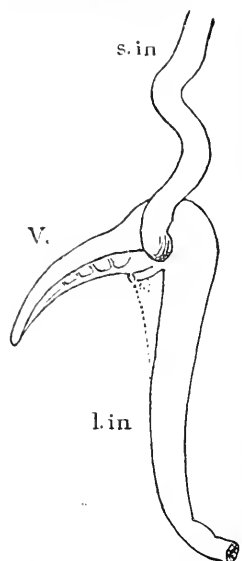


FIG. 446.—Part of the Intestine of a Human Embryo of about six Months (Minot Coll., No. 65). *s.in.*, Small intestine; 1', vermiform appendix, with its free mesentery and arising from the small cœcum; *l.in.*, large intestine. Natural size.

INTESTINAL HERNIA.—By this term we may designate the normal temporary extrusion of the intestinal canal into the umbilical cord. So far as I can now recall this extrusion has been observed only in man. In human embryos of 10 mm. the part of the intestine attached to the yolk-stalk begins to enter the umbilical cord, and thereafter the length of the intestine, which leaves the body cavity proper and lodges in the cœlum of the yolk-stalk, increases until, perhaps, the tenth week. Thereafter it is gradually withdrawn into the abdomen. The cause of this temporary *umbilical hernia* is believed to be the strain produced by the yolk-sac; attention is directed to it in the descriptions and figures of embryos in Chapter XVIII.

HISTOGENESIS.—The intestinal canal consists at the end of the first month of an inner layer of entoderm and an outer layer of mesoderm; the former becomes the epithelium of the villi and glands, the latter gives rise to the connective tissue of the villi, mucosa, submucosa, etc., and also to the two muscular layers and to the peritoneal covering. The epithelium is a high cylinder epithelium like that throughout the undifferentiated entodermal canal. The mesoderm is a thick layer of mesenchyma covered externally by the cuboidal epithelium (mesothelium), which lines the cœlum, except that the anal end of the intestine (future rectum) has no mesothelium because it lies beyond the cœlum.

At two months I find the villi and glands of the small intestine beginning their development, Fig. 447, and all the layers of the mesoderm sufficiently differentiated to be recognized. The stratification of the intestinal mesoderm can be recognized in a cat embryo of 25 mm. according to Patzelt, **83.1**, 146. The villi, 17, are short, thick, and few in number, but additional villi are developing between those already present; the entoderm has altered its primitive character very slightly; the epithelial glands are to grow out between the bases of the villi. The villi also appear throughout the large intestine, but are obliterated (Kölliker "Grundriss," 2te Aufl., 360) there by the upward growth of the glands, while in the small intestine the villi enlarge and persist throughout life. C. von Langer, **87.1**, 54-56, studied the mesodermal cores of the villi and found

them well developed in the large intestine during the fourth month, partially aborted at birth, and completely aborted one month after birth. The mesothelium, *msth*, has begun to thin out to convert itself into the peritoneal epithelium, but the connective-tissue layer of the peritoneum is not yet recognizable. The two muscular layers, *lm*, *cm*, are marked out by the elongation of the mesenchymal cells to form smooth muscle-fibres. The submucosa, *conn*, consists of dense undifferentiated mesenchyma; its thickness about equals that of the entoderm, *Ent*, or that of the two muscular layers, *lm*, *cm*, taken together.

The entoderm often contains leucocytes. it gradually loses its embryonic character.

After the second month it becomes a beautiful cylinder epithelium with basally placed nuclei, which all lie nearly at one level, in marked contrast to their earlier distribution. The villi themselves are more or less cylindrical in form with the free ends rounded. In the sections, which I have examined, the entodermal villi are only partially filled with mesoderm—a peculiarity which I am inclined to regard as normal, not as artificial. The *glands* begin to arise early in the third

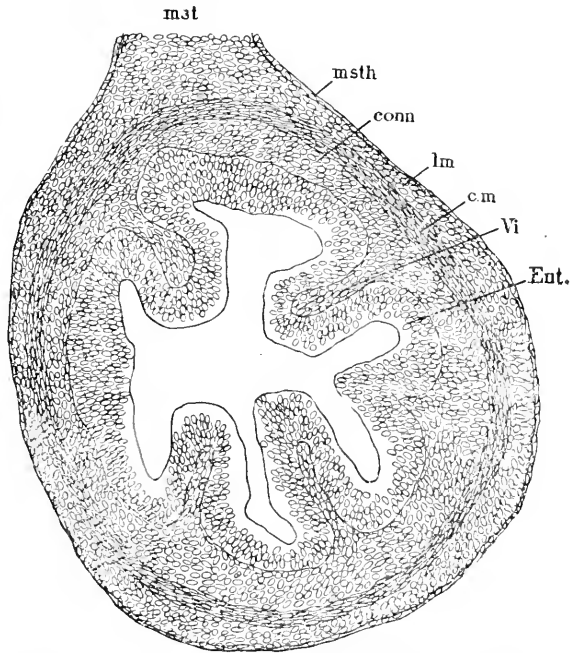


FIG. 447.—Section of the Small Intestine of a Human Embryo of sixty-three to sixty-eight Days (Minot Coll., No. 138.) *mst*, Mesentery; *msth*, mesothelium; *conn*, connective tissue of submucosa; *lm*, longitudinal muscles; *cm*, circular muscles; *Vi*, villus; *Ent*, epithelial entoderm. $\times 144$ diams.

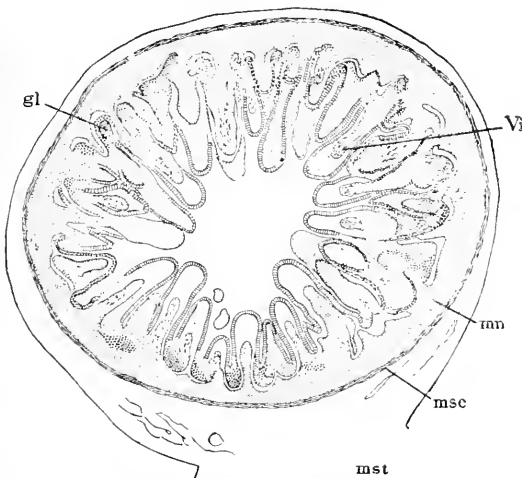


FIG. 448.—Section of the Small Intestine of a Human Embryo of three Months (Minot Coll. No. 41). *gl*, Gland; *Vi*, villus; *mu*, mucosa; *msc*, muscularis; *mst*, mesenterial insertion.

month (in the rabbit, when the embryo is about 45 mm., Barth, **68.1**, 131). They are hollow outgrowths of the entoderm (Barth, *l.c.*; Patzelt, **83.1**), extending into the mesoderm; for a considerable period they remain short as compared with the villi, see Fig. 448. The development of the *glands of the small intestine* has been imperfectly studied; Barth, **68.1**, 133, states that the glands of Brunner may be recognized by their branching in rabbit embryos of 70 mm. The *glands of the large intestine* have been studied by Patzelt, **83.1**, principally in the pig and rabbit embryos, which he found more favorable than human embryos; the entoderm in cat embryos of 33 mm. contains small groups of short granular cells, with oval nuclei with nucleoli; these groups are gland anlagen, and are easily recognized by their pale nuclei; the anlagen are separated from one another by lines of cells with longer nuclei, which stain more darkly with hæmatoxylin; but in embryos of 50 mm. and older all the nuclei stain nearly alike. The villi of the large intestine are temporary; they have been shown by C. von Langer, **87.1**, 54-56, to be united by ridges running between their bases; the ridges subdivide the surface into little areas, and in each area lie several glands; in the human fœtus the ridges are still present at term, but disappear in the course of the first month after birth. The gland anlagen grow slowly—in the cat at birth they are only 0.23 mm. Both the anlagen and the young glands multiply by division, which begins at the lower end of the gland and spreads to its mouth. Patzelt found in a section of the large intestine of cat embryos of

33 mm.,	6-8 glands.	95 mm.,	45-50 glands.
50 "	14-17 "	101 "	54-57 "
60 "	16-19 "	114 "	67-70 "
68 "	21-23 "	140 "	110-120 "
82 "	40-42 "		

The first beaker-cells of the large intestine appear on the villi (cat embryos of 60 mm.), they rapidly increase in number, so that in the cat most of the entoderm consists of beaker-cells both over the villi and in the glands.

GROWTH OF THE INTESTINAL ENTODERM.—The gland anlagen and later the fundi of the glands are the centres of growth for the intestinal epithelium, as first suggested by Pfitzner's observation that the karyokinetic figures occur chiefly in the glands, not generally over the epithelium (*Arch. f. mikrosk. Anat.*, XX., 137), but the definite recognition of the fact is due to Patzelt, **83.1**, 165. The multiplication of cells in the glands of the intestine and stomach is confined in the adult to the fundi of the glands. That the bottom of each gland is a separate centre of growth was, I think, first suggested by W. Flemming, **85.2**, and has since been fully demonstrated by the researches of Bizzozero and Vasale, **85.1**, Heidenhain, **88.1**, 26-28, Bizzozero, **88.1**, **89.2**, and E. Salvioli, **90.1**. I consider that the notion of discrete centres of growth in epithelia, with its corollary of translation of the cells from their place of origin, is an important advance in our conceptions. It is probable that other glands also grow in the embryo as in the adult, but no direct observations on this point have yet been made.

The Liver.—The early development of the liver has been described p. 268, and its situation in the septum transversum explained. O. Hertwig ("Lehrb. d. Entwicklungsgesch.," 3te Aufl.) describes the liver as being primitively lodged in the ventral mesentery—an error of statement for which I cannot account.

The liver of all vertebrates consists of two parts: 1, a branching system of epithelial gall-ducts, and 2, a network of hepatic cylinders. The two parts are morphologically distinct. The gall-ducts are surrounded by connective tissue, and, as is well known, are accompanied by the branches of the portal vein and hepatic artery. The hepatic cylinders are separated from one another only by endothelial blood-vessels. The essential primitive features of the hepatic cylinders are illustrated by Fig. 449; every cylinder, *hp*, is an epithelial tube with a small central lumen and covered by an endothelium, which is easily recognized by its flattened, darkly stained nuclei; the endothelium is the wall of a blood-vessel or channel, *bl*. The hepatic cylinders by branching and uniting form a network, all the meshes of which are entirely occupied by blood-vessels. In sharks, Fig. 449, each cylinder comprises in its cross section usually eight to ten cells, and is almost completely bathed in blood. In amphibia the cylinders are smaller; they comprise only four to five cells in cross section, and their lumen is very small, and the blood-channels between them are relatively diminished. In mammals

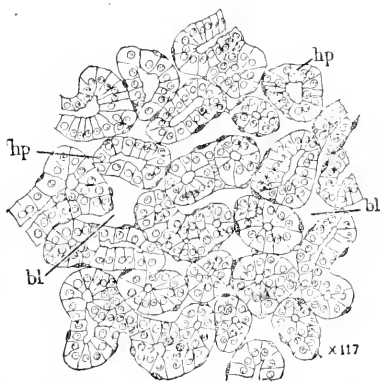


FIG. 449.—Portion of a Section of the Liver of an *Acanthias* Embryo of 29 mm. *hp*, Hepatic cylinders; *bl*, blood-channels. $\times 117$ diams.

each hepatic cylinder comprises merely two epithelial cells; the lumen is reduced to a minute canal (the gall capillary); the cylinders anastomose with one another very frequently and at very short intervals; and finally the blood-vessels between the cylinders become smaller for the most part than the cylinders. In mammals we have further the hepatic cylinders gathered into radiating groups; the groups are the lobules of descriptive anatomy. In most text-books the mammalian hepatic cylinders are referred to as "radiating rows of liver cells." If the fundamental notions just recapitulated are kept in mind the following paragraphs can be better understood.

The liver commences, as stated p. 268, as a diverticulum of the entodermal canal extending into the septum transversum. This single median diverticulum may be designated as the Amphioxus stage, since a similar diverticulum in the cyclostome is regarded, probably correctly, as the homologue of the primitive hepatic anlage of true vertebrates. The single diverticulum develops to a considerable size in shark and amphibian embryos, but in amniota it forms two branches almost immediately (chick fifty-five to sixty hours, rabbit eleventh day), so that it is usual to describe the amniote liver as arising from two diverticula. The evaginations are, of course,

lined by entoderm; they are situated immediately behind the heart, and embrace between them the two vitelline veins forming the roots of the ductus venosus. In the chick the right pouch is from the first longer, but of smaller diameter than the left (Foster and Balfour, "Elements," 2d ed., 179). In the rabbit, according to Kölliker ("Grundriss," 2te Aufl., 372), the left pouch appears the tenth, the right the eleventh day. In the human embryo of 3 mm. His, **81.1**, found the hepatic diverticulum single.

In the primitive form of vertebrate development (Petromyzon and amphibians) the hepatic diverticulum extends into a mass of entodermal yolk-cells, so that it has from the start several layers of entodermal cells around its cavity. The cells form a mass which, as described by W. T. Shore, **91.1**, 179-183, separate off (in the frog, at least) from the rest of the yolk, the cells themselves multiplying and changing into liver-cells. They constitute a thick, solid wall around the hepatic diverticulum; channels appear in the solid walls, and these channels acquire endothelial linings, and blood enters them; the yolk-cells between the blood spaces gradually develop into hepatic cylinders. These changes can be favorably studied in a frog's tadpole six or seven days after hatching.

In amniota there is an early separation of the liver anlage and yolk-sac, and the former has thin walls when it arises. W. T. Shore, **91.1**, 184, states that in the chick the walls of the diverticulum begin to thicken almost immediately by the proliferation of the cells, and in the thickened mass channels appear, "there take place irruptions, as it were, of capillary blood-vessels from the vitelline vein into the solid mass of proliferated hypoblast (*i.e.*, entoderm), breaking it up into more or less branched rods of cells (second half of the third day)." In most text-books the hepatic entoderm is described as sending out solid buds between which the blood-vessels arise, but it is doubtful whether such a description is accurate. I strongly incline to accept Shore's view that the solid anlage is broken up by the formation of blood-vessels in it. If Shore is right we can understand why the hepatic cylinders form a network. So far as known the hepatic cylinders are at first solid and do not acquire their lumen until later. In the later stages of incubation the liver has the color of the yolk. In a chicken just hatched the liver-cells contain oil drops.

In mammals the development of the liver is similar to that in the chick. The walls of the primitive diverticulum thicken, become permeated by blood-vessels, and so divide into hepatic cylinders, Fig. 450. The cylinders are at first solid and quite irregular in shape and size, Fig. 450, *hp*, and the blood-channels, *bl*, are very large. The differentiation of the cylinders in the human embryo has been studied by Toldt and Zuckerkandl, **76.1**. They found the cylinders to have a lumen in a four weeks' embryo; from this age till the end of fetal life the cylinders contain two forms of cells: 1, large polyhedral cells, resembling those of the adult organ; 2, smaller round cells, the nuclei of which stain darkly; the two forms are mingled irregularly; the smaller cells entirely disappear after birth and are presumably only a young stage of the liver-cell. It is not until some time after birth that the cylinders assume the adult mammalian

type; they become longer and slenderer, not, however, by a change in the size of the liver-cells, but by a rearrangement of the cells, such that the number of cells in a cross section of a cylinder is gradually reduced to two; the cylinders after this change are zig-zag, but soon straighten out. The metamorphosis takes place irregularly, so that several stages can be seen under the microscope in one field of view. As regards the development of gall-duets, we have no definite

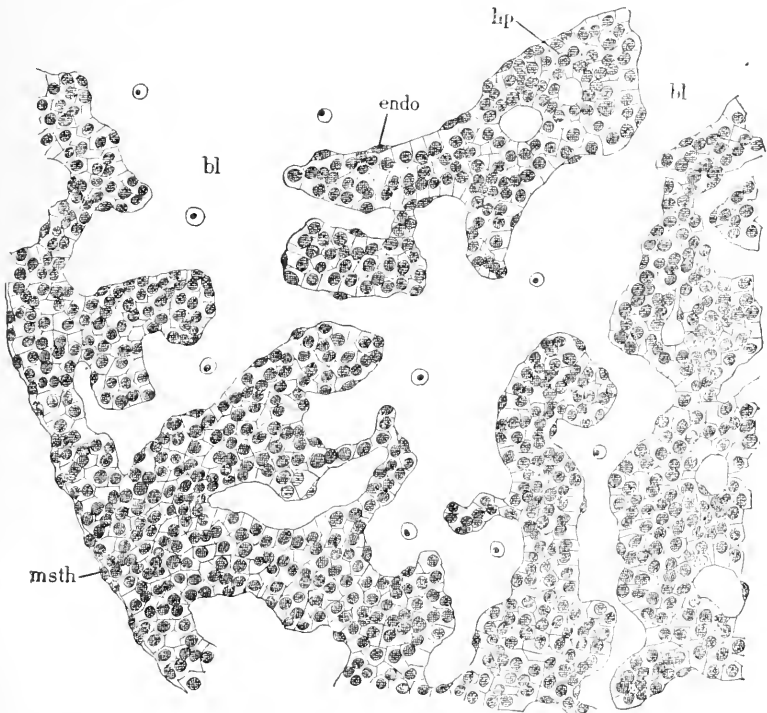


FIG. 450.—Section through the Liver of a Rabbit Embryo of thirteen Days. *hp*, Hepatic cylinder; *endo*, vascular endothelium; *bl*, blood-channels; *msth*, mesothelium. $\times 225$ diams.

knowledge. We may surmise that they arise as evaginations of the primitive diverticulum and are always distinct from the hepatic cylinders.

LOBULES.—Toldt and Zuckerkandl, 76.1, have investigated the changes in the blood-vessels in the human liver. In a four weeks' embryo the vessels are all large, compare Fig. 450, but by the eighth or ninth week the main efferent and afferent stems are recognizable. For the history of the metamorphosis of the large veins passing through the liver see p. 545. During the third or fourth month, the vascular territories of the portal and hepatic veins become distinguishable, for the branches of the two veins distribute themselves so as always to be separated. There now appear, scattered through the liver, islands of tissue with abundant fine ramifications of the hepatic vein; each island is the anlage of a group of lobules, and is surrounded by portions of the liver containing the branches of the portal

vein. The portal system cuts into the island, so as to divide it gradually, while it expands, into lobules, and these primary lobules are similarly subdivided until the permanent lobules are established. The lobules enlarge after the production of new lobules has ceased.

GROWTH.—The liver enlarges very rapidly, compare Figs. 179, 222, 444, and 451, and consequently has to project from the septum transversum into the abdominal cavity more and more. It forms two lobes, one each side and connected across the median line; between the two lobes, Fig. 451, *r.li* and *l.Li*, is situated the

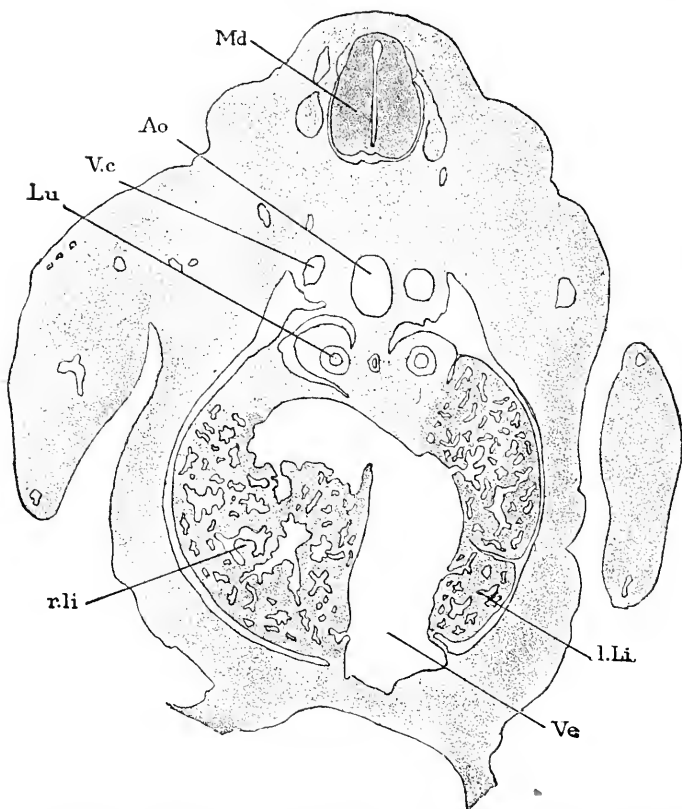


FIG. 451.—Section of a Rabbit Embryo of thirteen Days through the Region of the Fore Limbs and Liver. *Md*, Spinal cord; *Ao*, aorta; *V.c*, cardinal vein; *Lu*, lung; *r.li*, right liver; *Ve*, great vein of liver; *l.Li*, left liver.

great vein, *Ve*, of the liver; as that vein is constituted partly by the umbilical vein, it is attached to the ventral body-wall of the embryo. In a rabbit of thirteen days both lobes are well developed and project beyond the level of the umbilical vein, but in the median line the liver is entirely on the cephalic side of the vein. In longitudinal median sections this shows very clearly, as does also the fact that the liver is an appendix of the septum transversum. While the liver is expanding the stomach migrates into the abdominal cavity; after that migration we find the stomach connected by

a thin membrane, or ventral mesentery, with the median dorsal line of the liver; the membrane extends forward to the septum transversum and joins it; the membrane is the anlage of the *omentum minus*; concerning its development we possess no accurate information beyond the fact that it arises after the first differentiation of the liver and stomach, and *is a new structure* produced as the stomach and liver descend into the abdominal cavity. Similarly we find on the ventral side of the liver there is developed a mesenterial membrane by which the liver is bound to the median ventral line of the somatopleure; this membrane is the anlage of the *suspensory ligament*; posteriorly it extends at least to the umbilical vein, anteriorly to the septum transversum, with which it is continuous. The liver now has the following attachments: 1, by the omentum minus to the lesser curvature of the stomach; 2, by the suspensory ligament to the median line of the body and the inferior surface of the ventral part of the septum transversum (or future diaphragm); 3, to the dorsal part of the septum transversum. The connection with the septum transversum is both primitive and permanent, so that in the adult the liver may be described as an appendage to the diaphragm. But whereas in early embryonic stages the attachment of the liver occupies nearly the entire septum, in later stages the septum develops over a considerable expanse, so that the attachment becomes relatively smaller, Fig. 455, and is confined to the dorsal region of the septum or diaphragm. The area of attachment finally becomes round, with two lateral prolongations; the round part is the *coronary ligament*, while the prolongations are the *lateral ligaments* of descriptive anatomy.

As the liver grows in the septum it is, of course, covered by mesothelium, and as it enlarges and becomes a more independent projection it retains its mesothelial envelope, Fig. 450, *msth.* Later a layer of mesenchyma is developed between the liver-cells and the mesothelium, and the two mesodermic layers together constitute the *peritoneum*. As to the histogenesis of the hepatic peritoneum we have no accurate information. From the mode of development of the liver it is evident that *first* the mesothelium, and *later* the peritoneum, covering the liver must be directly continued on to the ligaments of the liver, the diaphragm, and the lesser omentum.

For illustrations of the growth and position of the human foetal liver see Figs. 153, 170, 259, 284, 303, 305, 319. During the second month it becomes of relatively enormous size; so that during the third month it extends far into the hypogastric region and fills out the greater part of the abdominal cavity. After the fifth month the intestines and other viscera overtake the liver, but at birth the liver makes two thirty-sixths of the total weight, as against one thirty-sixth in the adult. Immediately after birth the liver diminishes in size (Kölliker, "Entwickelungsges." 2te Aufl., 889). The right lobe of the liver is probably always larger than the left; after birth its predominance increases.

Another important factor of the development of the liver is the atrophy of the hepatic cylinders in certain parts, as discovered by Toldt and Zuckerkandl, 76.1. They have observed this atrophy near the lateral and suspensory ligaments, next the gall-bladder and

in the neighborhood of the umbilical vein. When the atrophy begins the liver-cells become finely granular, opaque, and lose their outline; the protoplasm breaks down and disappears; the nuclei persist a little longer. Changes occur also in the gall-ducts of the atrophying regions.

FUNCTIONS.—I cannot do more than allude to the manifold and important functions of the foetal liver. For its sanguinifactive rôle, see Chapter X. For a general discussion of its physiology, see W. Preyer, "Specielle Physiologie des Embryo." For speculations upon the relation of its functions to its mode of development, see W. T. Shore, 91.1, who also makes suggestive remarks as to the evolution of the liver. In regard to the glycogenic function of the liver in the embryo, see especially Claude Bernard (C. R. Acad. Sci. Paris, XLVIII., 77-86).

The gall-bladder arises in the chick during the fifth day as an evagination of the right primary diverticulum. Kölliker observed it in the human embryo during the second month, and saw folds on its inner surface during the fifth month.

Pancreas.—In amphibia, there are three pancreatic evaginations; one dorsal, and two symmetrically placed on the ventral side close to the ductus choledochus; the triple anlagen were first discovered by A. Goette, 75.1, in *Bombinator*, and have since been studied in *Triton*, *Siredon*, *Rana*, and *Bufo*, by E. Göppert, 91.1, 113-118.

In the chick the pancreas, as described by Foster and Balfour ("Elements," 2d ed., 181), arises during the fourth day, in the form of an almost solid outgrowth from the dorsal side of the intestine, nearly opposite, but slightly behind the hepatic outgrowths. Its blind end becomes somewhat enlarged, and from it numerous diverticula grow out into the passive splanchnic mesoblast. As the ductules grow longer and become branched, vascular processes grow in between them, and the whole forms a compact glandular body in the mesentery on the dorsal side of the alimentary tract. The primitive outgrowth elongates and assumes the character of a duct. On the sixth day a new similar outgrowth from the duodenum takes place between the primary diverticulum and the stomach. This, which ultimately coalesces with its predecessor, gives rise to the second duct, and forms a considerable part of the adult pancreas. A third duct is formed at a much later period.

In mammals only the single pancreatic evagination was known until recently. Its development in man is thus described by O. Hertwig ("Entwickelungsgesch.," 3te Aufl., 280): The dorsal anlage appears a little later than the hepatic diverticulum; it has been observed by W. His in embryos of 8 mm. as a small diverticulum, Fig. 444, B, *P*, which grows into the dorsal mesentery, sending out meanwhile hollow, branching buds, Fig. 444, C, *P*, and thus becoming by the sixth week an elongated gland, which extends so as to lie in the mesogastrium or future omentum, and, therefore, between the greater curvature of the stomach and the vertebral column. The pancreas, therefore, changes its position as the omentum develops; thus at six weeks it lies parallel with the longitudinal axis of the body; thereafter it revolves so that its anterior end moves to the left, as the

omentum develops, until the gland occupies its permanent transverse position, and the so-called head of the gland lies in the bend of the duodenum, while the so-called tail is near the spleen and the left kidney. The duct of the pancreas is at first in front of the bile duct, but during foetal life it shifts and first approaches and then joins the ductus choledochus.

Stoss in a preliminary notice, 91.1, states that in mammals he has found the dorsal and double ventral pancreatic anlagen (sheep embryos of 4 mm. about seventeen to eighteen days). The two anlagen unite (sheep of 15 mm.); the duct of the ventral anlage is the *ductus Wirsiugianus*, of the dorsal anlage the *ductus Santorini*. In sheep and man the ventral duct is preserved; in the horse and dog both ducts; in cattle and the pig probably the dorsal duct only. In sheep the lumen of the dorsal duct is obliterated in embryos of 70 mm., and in embryos of 90 mm. only the ventral duct can be found.

As regards the relations of the pancreas to the peritoneum: the entodermal portion of the pancreas being situated in the mesogastrium, it is, of course, covered on both sides by peritoneum and may be said to be attached to the wall of the abdomen by a mesentery of its own, although the pancreatic mesentery is only a part of the mesogastrium (C. Toldt, 89.1). The pancreatic mesentery aborts during the fifth month, and the pancreas, losing its movability, becomes directly attached to the dorsal abdominal wall.

The histogenesis of the pancreas is still to be investigated. In a human embryo of four months, Fig. 452, the alveoli show clearly

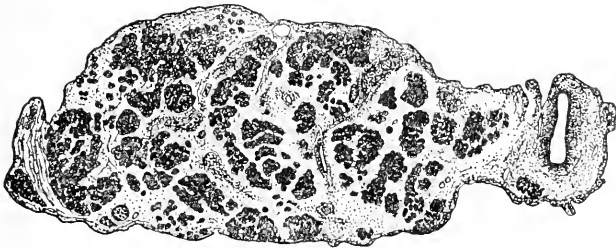


FIG. 452.—Section of the Pancreas of a Human Embryo of four Months (Minot Coll., No. 35). The dark masses are groups of alveoli.

and lie in groups—drawn dark in the figure—which are widely separated from one another by young connective tissue. The ducts are lined by a cuboidal epithelium; the cells of the alveoli are small, containing very little protoplasm, but each having a well-developed spherical granular nucleus.

Mesentery and Omentum.—To understand the development of the mesentery it is necessary to recall the fact that the ventral portion of the coelom, or, in other words, the splanchnocoel, is constituted by a pair of cavities (pleuro-peritoneal spaces), which are separated from one another throughout the body by a median partition or mesentery, Fig. 453, A, *mes*: in this partition is lodged the entodermal canal, *ent*; the partition consists of mesenchyma and is, of course, covered on both sides by mesothelium, *mslh*. The con-

nection of the mesentery with the somatopleure along the median ventral line is lost for the most part very early, but the stomach is

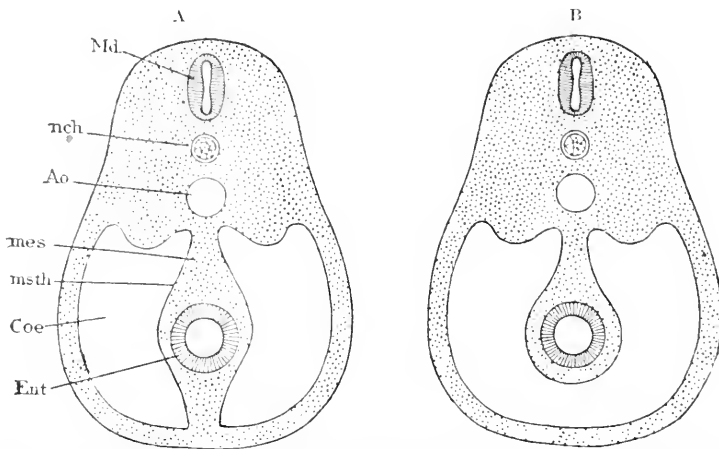


FIG. 453.—Two Diagrams to illustrate Morphological Relations of the Vertebrate Mesentery; A, earlier. B, later condition. *md*, Medullary tube; *nch*, notochord; *ao*, aorta; *mes*, mesentery; *msth*, mesothelium; *coe*, coelom; *ent*, entoderm.

always connected by a ventral mesentery (omentum minus) with the ventral body wall. The partial disappearance of the ventral mesentery establishes the condition indicated by Fig. 453, B; the entodermal tube, together with the mesoderm around it, constitutes the alimentary canal, which is suspended by a dorsal permanent mesentery from the median line; the coelom, *coe*, of one side communicates below the intestine with the coelom of the opposite side. In other words, by the disappearance of the ventral mesentery the paired splanchnocoeloms have fused, and there is henceforth a single abdominal cavity.

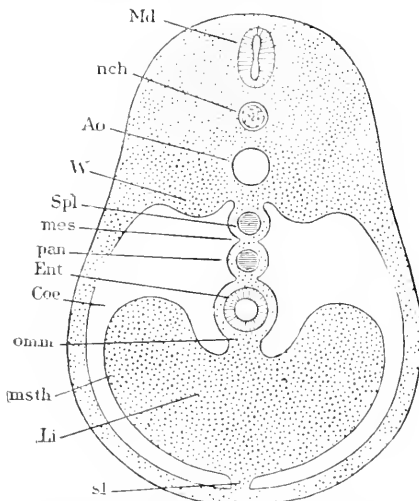


FIG. 454.—Diagram to illustrate the Relations of the Mesentery. *Md*, Spinal cord; *nch*, notochord; *ao*, aorta; *w*, Wolffian ridge; *spl*, spleen; *mes*, mesogastrium; *pan*, pancreas; *ent*, entoderm; *coe*, coelom; *om.m*, omentum minus; *msth*, mesothelium; *li*, liver; *sl*, suspensory ligament.

and is never aborted either on the ventral or dorsal side. Four organs are lodged in this partition, Fig. 454, the spleen, *Spl*, pancreas,

pan, stomach, *Ent*, and liver, *Li*. Each of these organs produces a thickening of the partition, and therefore causes the mesothelium on both surfaces to bulge laterally. Later, when a special connective-tissue layer is developed under the mesothelium, we have the peritoneum produced, and this peritoneum covers the partition and the four organs contained in the partition. The part of the partition in which the spleen and pancreas are lodged, and by which the stomach, *Ent*, is connected with the median dorsal line, is the future greater omentum, *mes*; the portion between the stomach and liver is the future omentum minus, *om.m*, while the portion joining the liver, *Li*, to the ventral somatopleure is the future suspensory ligament, *sl*, of descriptive anatomy.

Besides these names there are also employed *mesogastrium* for the embryonic greater omentum, and *mesocolon* for the portion of the mesentery connected with the large intestine.

The condition just described is reached by the human embryo during the fourth week. Concerning the mode of disappearance of

the ventral mesentery I can recall no exact observations, nor do I know of any satisfactory descriptions of the early stages of the partition in which the stomach, etc., are lodged. We are, therefore, forced to content ourselves for the present with the preceding diagrammatic explanation. The diagram, Fig. 455, will serve to render both the preceding account and the subsequent changes clearer. The diagram is fairly correct, except in representing the stomach in the median line, for as soon as the stomach descends it takes an asymmetrical position, p. 754. It will be evident upon glancing at the diagram that the mesogastrium, *msg*, mesentery, *mst*, and mesocolon, *msc*, are merely different regions of the same membrane, and that the spleen, *spl*, pancreas, *pan*, stomach, *st*, and liver, *Li*, are located in one complete mesenterial partition, so that in the region of the stomach and the liver, in order to get from the left splanchnocœle to the right splanchnocœle, we must pass around the liver on the caudal side; the septum transversum, *st*, prevents our passing across on the cephalic side.

The further changes in the relations of the mesentery depend chiefly on two factors: first, the elongation and coiling of the stomach and intestines; second, the formation of secondary adhesions of certain parts of the mesentery with other parts and with the abdominal wall.

The development of the stomach and intestine has been described

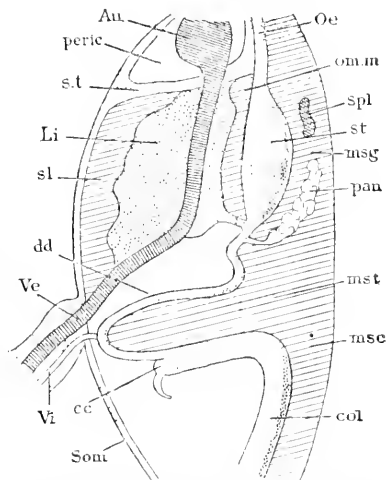


FIG. 455.—Diagram of the Human Mesentery in its Primitive Relations. *Au*, Auricle; *peric*, pericardium; *s.t*, septum transversum; *Li*, liver; *sl*, suspensory ligament; *dd*, duodenum; *Ve*, vein; *Vi*, vitelline stalk; *cc*, cæcum; *som*, somatopleure; *Oe*, oesophagus; *om.m*, omentum minus; *spl*, spleen; *st*, stomach; *msg*, mesogastrium; *pan*, pancreas; *mst*, mesentery; *msc*, mesocolon; *col*, colon.

pp. 753, 755. The result of the primary twisting upon the mesentery is illustrated by Fig. 456. Owing to the deflection of the stomach to the left, and of its revolution around its axis, by which its median dorsal line or greater curvature becomes lateral, the mesogastrium, *msg*, is folded so as to form a pouch that projects toward the left side; the pouch is the anlage of the great omentum, *Om*; it opens toward the right side, its opening being the foramen of Wins-

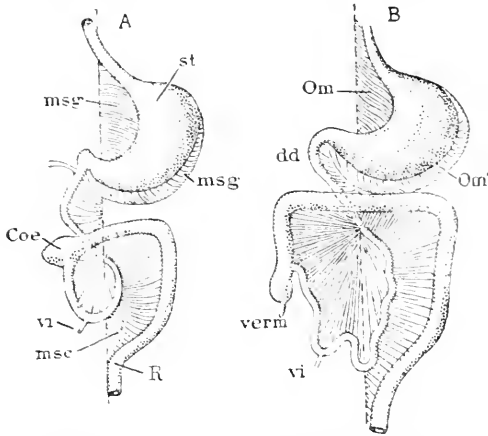


FIG. 456.—Diagrams to illustrate the History of the Human Mesentery; A, earlier. B, later condition. *msg*, *msg'* Mesogastrium or omentum; *st*, stomach; *Coe*, coecum; *v*, vitelline duct; *msc*, mesocolon; *R*, rectum; *Om*, *Om'*, omentum or mesogastrium; *dd*, duodenum; *verm*, vermiform appendix. After O. Hertwig.

low; the inner surface of the pouch is formed by the right surface of the mesogastrium, the outer by the left. The cavity of the pouch may be termed the *omental cavity* (*Netzbeutel*); F. P. Mall, 91.2. terms it the gastric diverticulum; in descriptive anatomy it is known as the *lesser peritoneal space*. From the lesser curvature of the stomach extends the ventral mesentery or lesser omentum; an inspection of the diagram, Fig. 456, will show that it extends the pouch of the omentum toward the right. A section of a human embryo in which the omental cavity is just beginning to form is figured by F. Mall, 91.3, 474. The duodenum is situated near the dorsal side of the body cavity and has, even in the young embryo, only a short mesentery; as development progresses the duodenum, after making its pyloric bend, comes to lie in a nearly transverse direction close to the dorsal abdominal wall; its mesentery obliterates, and thereafter the duodenum forms merely a slight projection covered by mesothelium (and later by peritoneum), compare Fig. 457, A. Finally, owing to the intestines forming a great loop to the right, the large intestine crosses the body on the ventral side of the duodenum; the mesentery meanwhile remains attached along the median dorsal line, but its ventral border elongates with the intestine; and further, the manner in which the loop is developed brings the right surface of the mesentery to face ventralward (or "forward," according to human descriptive anatomy) and the left surface to face dorsalward.

The additional changes are indicated by the two diagrams after O. Hertwig, Fig. 457, A, B. The star (*) is placed in the omental cavity. In A the liver, *l*, is attached to the dorsal part of the diaphragm, *zf*; the stomach, *mg*, occupies a transverse position, and is, therefore, seen in cross sections; along what was primitively its median ventral line is attached the lesser omentum, *kn*, by which the stomach is connected with the liver. Along the greater curvature, *gc*, of the stomach is inserted the mesogastrium, *gn*¹, *gn*², or,

as we may now call it, the greater omentum; it has grown so much that it forms a fold, which is beginning to hang over the transverse colon, *ct*; the fold is destined to grow still further, as indicated by the dotted line, *gn³*; the pancreas, *p*, lies in the omentum close to the dorsal wall of the abdomen. The duodenum, *du*, is already closely united with the dorsal wall. The transverse mesocolon, *msc*, springs from the wall of the abdomen between the pancreas, *p*, and duodenum, *du*; the reason for this apparent anomaly will be understood by referring to Fig. 456. Below the duodenum, *du*, springs the mesentery, *mes*, of the small intestine, *dd*. In B the omental fold has extended, *gn³*, far down in front; the mesocolon, *msc*, has united

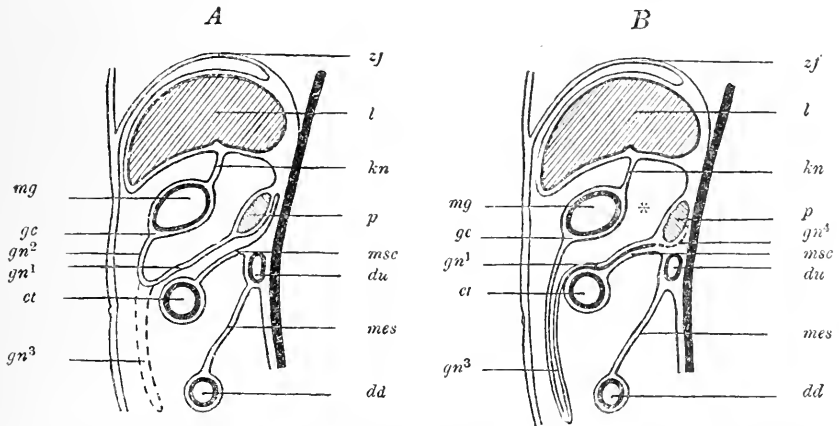


FIG. 457.—Two Diagrams to illustrate the History of the Mesentery. A, earlier, B, later stages. The diagrams represent median vertical sections. The black line on the right of each diagram represents the aorta. For explanation of lettering see text.

with the part of the omental fold nearest it, and there results a single membrane of double origin, by which the colon is suspended; it is this membrane which is known in the descriptive anatomy of the adult as the mesocolon; the adult mesocolon, therefore, includes the true mesocolon and part of the mesogastrium. As a further result of the secondary adhesion, we note that the omentum, *gn³*, appears to spring from the transverse colon, *ct*. Both the pancreas, *p*, and duodenum, *du*, now occupy their permanent (or so-called retro-peritoneal) positions.

Admirable descriptions of the condition of the mesentery at successive stages in the human embryo are given by C. Toldt in his classic memoir, **79.1**, and farther valuable observations on the adhesions are recorded by Toldt in his second article, **89.1**.

HISTOGENESIS.—From its mode of formation it is evident that the mesentery is primitively a sheet of mesenchyma covered on both sides by mesothelium. The differentiation of this simple membrane has been carefully traced by C. Toldt, **79.1**, 42-50. At four weeks the mesenchymal cells are very much crowded—there being but little basal substance—and they have but little protoplasm; some of them are beginning to assume the spindle shape; the mesothelium varies somewhat, being here a cuboidal, there a cylinder epithelium. At six

weeks more of the mesenchymal cells are spindle-shaped, and the mesothelial cells are beginning to flatten out; they are thinner and wider and their nuclei protrude. At eight weeks the mesothelium has essentially the endothelial type, which it retains throughout life. At eight weeks the mesenchymal cells next the mesothelium on each side commence to form a special recognizable layer, which is perfectly distinct by the end of the third month; this layer is four to six cells thick and contains no vessels; together with the overlying mesothelium it constitutes the peritoneal membrane of descriptive anatomy. Between the two peritoneal membranes lies the looser mesenchyma, corresponding to the *membrana propria mesenterii* of Toldt, and in which are distributed the blood-vessels and nerves, and later (fifth month) the lymphatic glands and fat-cells. The mesentery thus comprises five layers, all of which can be well seen in embryos of the fourth month. The development of the connective-tissue fibrils in the omentum has been previously described, p. 400. The fat-cells do not attain their typical development until the end of the eighth month, though their differentiation begins during the fifth, when the anlagen of the lymph-glands also appear.

The mesodermic layer of the peritoneum is always very thin, but Toldt, **79.1**, 46, distinguishes in it toward the end of foetal life three sub-layers, viz.: 1, next the mesothelium with fine elastic net-work; 2, middle sub-layers with coarser elastic network; 3, sub-serous layer of looser texture uniting the peritoneum to the *membrana propria*.

MESHES OF THE OMENTUM.—After birth the omentum becomes pierced with numerous holes. A few months after birth (C. Toldt, **79.1**, 49) there can be seen numerous scattered spots where the membrane is thinner and contains fewer connective-tissue fibrils than elsewhere; these spots lie more or less remote from the blood-vessels. At these spots the holes are formed and are at first always very small. The formation of the omental perforations may be followed in children of from a few weeks to four years old. If the omentum of a child a few months old is stained with nitrate of silver there will appear, between the mesothelial cells, spots colored by the silver; then other spots similarly colored, but larger and light in the centre; and finally still larger ones in which the light centre has become a hole, Toldt, *l.c.*, Fig., 17. Toldt regards the holes as the result of the distention of the membrane, and the silver marks just described as indicating the pulling apart of the endothelial cells; the blood-vessels and fat-cells around them serve to maintain the thickness of the membrane between the holes. Ranvier, **74.1**, sought to attribute the origin of the holes to leucocytes forcing their way between the omental tissues, but Toldt has shown that this explanation does not hold good.

HISTORICAL NOTE.—The foundations of our knowledge of the embryonic mesentery were laid by J. F. Meckel, **17.1**, and Johannes Müller, **30.1**. But little was added until the investigations of C. Toldt, whose two memoirs, **79.2**, **79.1**, constitute the classic authority on the subject. Lockwood's article, **84.1**, did not add much, and contains important errors, as pointed out by Toldt, **89.1**.

II. THE RESPIRATORY TRACT.

The respiratory organs arise as a single evagination of the entodermal canal on the ventral side of the caudal end of the pharynx.. The evagination branches, each branch develops into a lung; the main stem becomes the trachea, and the opening of the stem into the pharynx forms the larynx. Accordingly we take up: 1, the pulmonary anlage; 2, the lungs; 3, the trachea; 4, the larynx and epiglottis.

Pulmonary Anlage.—The first trace of the outgrowth of the entodermal canal to form the lungs is an increase of the vertical diameter of the canal in the œsophageal region. This increase results from the development of what may be called the *pulmonary groove*, which is a furrow lined with entoderm, and begins just behind the fourth gill-cleft and extends to the stomach, Fig. 458. The groove is shallow toward the pharynx and deepens toward the stomach, ending abruptly as a rounded projection. The entoderm lining the pulmonary groove is thicker than that lining the œsophagus above it (W. His, 87.3, 90). This stage may be seen in a human embryo of 3.2 mm., or in chick of sixty to seventy-two hours. The pulmonary groove is narrower than the œsophageal division from which it springs, hence in a cross section of this stage the entodermal canal has in the region of the œsophagus the outline of an inverted pear. The groove now deepens and its gastric end grows out farther, Fig. 458, *Lu*, and the œsophagus between the end of the groove and the stomach begins to lengthen. Presently the blind, free, lower end of the groove widens out, and, as it grows, forks; each fork is the anlage of a lung, and has the form, Fig. 438, of a short rounded pouch situated laterally. In front views the two pouches are easily found; in a side view one hides the other. The median portion, by which the pouches are connected with the pulmonary groove, is the anlage of the trachea. As is well shown in Fig. 444, A, B, C, the œsophagus, lungs, and trachea all grow rapidly; the branching of the lungs begins in embryos of seven millimetres, B. In embryos of seven millimetres the fundamental parts are all marked out, except that the dilatation of the upper end of the trachea follows later (embryos of 13 mm. Fig. 444, C, *Lo*). The elongated opening of the pulmonary groove is the future glottis, and in front of it is the anlage of the epiglottis, Fig. 444, C, *Ep*; the median cylindrical tube, Fig. 445, *Tr*, is the trachea, and its two branches are the lungs.

The situation and topographical relations of the pulmonary anlage are very important, because they explain numerous anatomical facts.

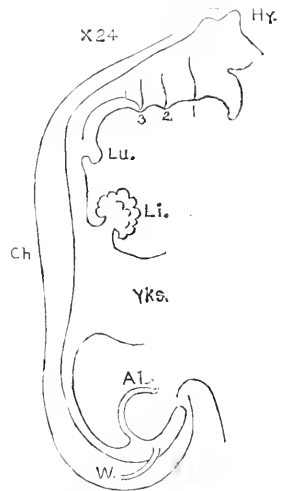


FIG. 458.—Outline of the Entodermal Canal of His' Embryo Lr. *Hy*, Hypophysis; *Ch*, notochord; *Lu*, anlage of lung; *Li*, liver; *Yks*, yolk-sac; *AL*, duct of allantois; *W*, Wolffian duct. After W. His.

At first the anlage directly overlies the heart and the septum transversum, including the liver, as illustrated by Fig. 259. It will be remembered, see p. 480, that the cœlom extends above the septum transversum on either side of the œsophagus, making during early stages a free communication between the abdominal and pericardial cavities. In transverse sections one sees at once that the lungs project into the cœlomatic passage (or future pleural cavity) above the liver and septum transversum. The manner in which the pleural cavities are finally shut off is described p. 482. It is essential to note that the lungs arise on the dorsal side of the heart and liver. The lungs (and pleural cavities) only gradually expand forward on the right and left of the heart.

In the above description heed is given only to the epithelial or entodermal portion of the pulmonary anlage. The epithelium is, however, surrounded by mesoderm, which makes a thick layer. In sections the rudimentary lung is readily seen to consist of a ring of epithelium composed of high cylinder cells; the epithelium is inclosed by a thick layer of mesenchyma, and so far as the lung projects into the cœlom it is, of course, covered by mesothelium. The mesothelium of the adult is known in descriptive anatomy as the epithelium of the pleural membrane.

Lungs.—The lungs arise, as described in the previous section, as two nearly symmetrical diverticula of the pulmonary anlage and immediately above the auricle of the heart (human embryo of 4 mm.). The diverticula lengthen out and grow dorsalward on either side of the œsophagus close to the cephalic end of the stomach, Fig. 444, B, and there form branches, C, all of which at first extend dorsalward. These branches of the entodermal diverticulum are inclosed in a thick covering of mesoderm; the two layers thus associated constitute the embryonic lung. The organ as a whole projects into the cœlom above the septum transversum; its cœlomatic surface is, of course, covered by mesothelium.

The branching entodermal tube forms the so-called bronchial tree, the entoderm itself persisting as the lining epithelium of the bronchi, bronchioles, infundibula, and air-cells. The development of the branches during early stages has been traced by W. His, 87.3, in the human embryo, and less thoroughly by A. Robinson, 91.1, in rats and mice. The following account refers to man. The right diverticulum is somewhat larger than the left and extends further back—peculiarities which are, perhaps, connected with the changes accompanying the asymmetrical development of the heart. At six weeks the asymmetry of the lungs is more marked, for the right diverticulum is much longer and has three primary branches budding forth, while the left lung has only two; each of these primary branches corresponds to a lobe of the adult lung, hence the right lung has three lobes, the left lung two. Morphologically, however, the upper and anterior branches of the right lung (and therefore the lobes they produce) are equivalent to the single upper branch of the left lung. Each branch elongates and branches, and the branches branch, and so on, Fig. 459; every branch is short and has a rounded and somewhat enlarged end; as new branches are added those previously formed become stems and increase in diameter. The

branching occurs in a highly characteristic manner, for the stem always forks, but the forks develop unequally, one (terminal bud) growing more rapidly and becoming practically the continuation of the main stem, while the other (lateral bud) appears as a lateral branch. Speaking in general, it may be said that the ventral fork serves as the stem, *cf.* Fig. 444, C, *L''*. In consequence of this method of growth the adult lung consists of main stems with lateral branches, as we learned through the able investigations of Aeby ("Der Bronchialbaum," etc., Leipzig, 1880). But it is erroneous to

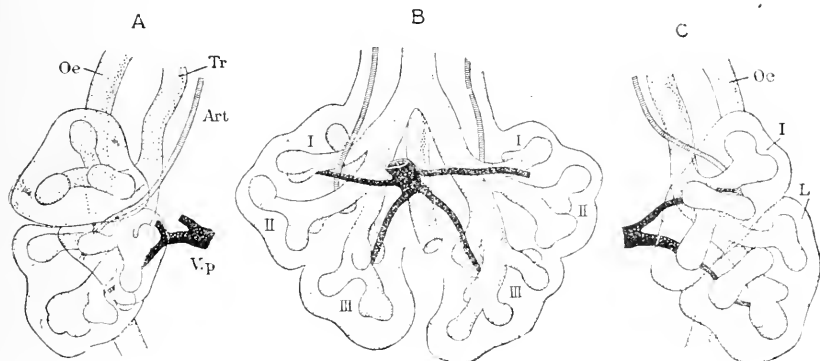


FIG. 459.—Three Views of the Lungs of a Human Embryo of 10.5 mm. (His' Embryo N). A. Seen from the right side; B, seen from in front; C, seen from the left side; the figures are reconstructions from sections. Oe, Esophagus; Tr, trachea; Art, pulmonary artery; Vp, pulmonary vein; I, II, III, primary branches of the bronchus; L', upper; L'', lower lobe of the lung. After W. His. $\times 30$ diams.

suppose, as did Aeby, that the system of growth is strictly monopodial, it being in reality a modified dichotomous system. The branches all arise by terminal forking, never as outgrowths from the side of a stem. In cross sections the lung has a triangular outline; one apex is the point of attachment and contains the main bronchus; the three sides we may designate as dorsal, lateral, and ventral; the branches of the bronchial tubes arrange themselves so that we can distinguish those toward the ventral from those toward the dorsal side, while the terminations of the tubes in the embryo lie, for the most part, toward the lateral side of the lung. Later the lungs revolve forward, and the ventral surface becomes medial or cardiac; the lateral side corresponds to the costal surface. Fig. 459 shows the bronchial ramifications of an embryo of 10.5 mm.; they have been described in detail by His, *l.c.*, 98. The same primary branches appear in both lungs, and they occupy essentially symmetrical relations as regards the veins; examined in detail, however, the two lungs are not perfectly symmetrical. The arteries, on the other hand, are entirely asymmetrical; the right artery, *A, Art*, passes in front of, but the left artery passes behind, the first branch; this relation persists throughout life, and led Aeby to designate the first right bronchus as *eparterial* and all the other bronchi *hypparterial*; Aeby—and His seems to accept his view—inferred that the right lung contained a bronchus not represented in the left lung. I think, however, that this view is untenable and that the right and left *first*

branches, I., are homologous; the difference between the two sides is due to the precocious development on the right side, and to secondary modifications of the arteries; the relation of the veins to the bronchi confirms the interpretation here advanced. His' account of the development appears to me to flatly contradict Aeby's conclusion. The peculiar course of the right pulmonary artery is probably due to the abortion of the fifth aortic arch on the right side, and the consequent transfer of the origin of the artery to the left side; if this suggestion is correct there should be in reptiles no eparterial bronchus.

The further ramifications of the bronchi begin as short, rounded buds forking off at the end of the branches, as may be easily seen in sections through the fœtal lung, Fig. 462; hence the primary branches are permanent, and by their enlargement give rise to the main bronchi. Fig. 460 represents four views of the lungs of an embryo

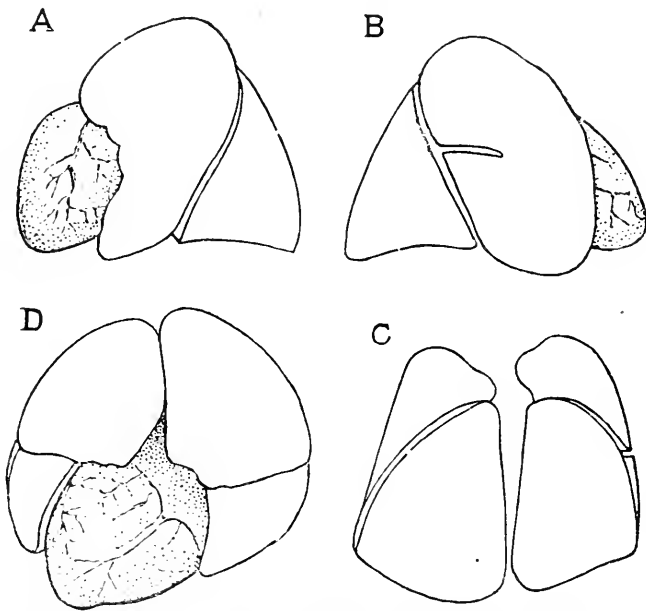


FIG. 460.—Lungs of a Human Embryo of five Months (Minot Coll., No. 71). A, From left side; B, from right side; C, from behind; D, from below.

of five months, and is intended to show the homology of the two primary lobes on each side; the upper (and anterior) lobe of the right side, B, being partially subdivided.

HISTOGENESIS.—The entodermal bronchial tubes are at first widely separated from one another; the space between them is filled with mesenchyma. The tubes themselves have at first a high cylinder epithelium, Fig. 461, with oval granular nuclei, and have only a small lumen, but by their growth the mesoderm is condensed around them, forming a special envelope, Fig. 461, which ultimately enters into the composition of the bronchial wall. The smooth muscle-fibres

were observed in the bronchial wall in sheep embryos of 120 mm. by L. Stieda, 78.1, 111. As development progresses the ramifications of the bronchial tubes arise more rapidly than the growth of the mesenchyma, so that the amount of connective tissue between the branches gradually diminishes, Fig. 462, until at birth only thin partitions are left between the adjacent air-spaces. The epithelium remains in its embryonic stage (*i.e.*, a high-cylinder epithelium) in the bronchi; in the bronchioles it becomes a cuboidal epithelium, in the infundibula (*Alveolargänge*) and alveoli a very thin layer (pavement epithelium, endothelium). This differentiation I find is established as the buds are formed; thus the first buds are lined by cylinder epithelium and form bronchi; later buds are lined with cuboidal epithelium, Fig. 462, *Alv*, and form bronchioles;

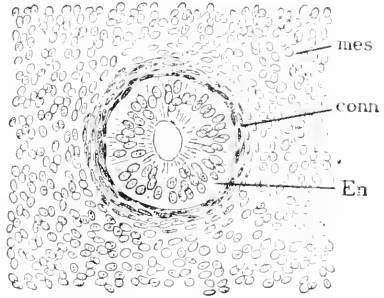


FIG. 461.—Cross Section of the Bronchial Tube of a Human Embryo of sixty-three to sixty-eight Days (Minot Coll., No. 138).

toward the close of fetal life the buds appear, which are converted into the infundibula and alveoli, and these are lined with flattened epithelium, as discovered in sheep embryos of 250 mm. by L. Stieda, 77.1, 113. The common assumption that the flat alveolar epithelium is not present until the lungs are stretched by the first breath is erroneous.

Trachea.—Except upon the early development of the trachea as part of the pulmonary anlage (p. 463) I have found no observations. In sections of the trachea of a four months' embryo, Fig. 463, the epithelium is a high cylinder epithelium as in early stages and also in the adult, since the entoderm of the trachea and bronchi preserves the embryonic type throughout life; the epithelium is ciliated; glands are present and lined with mucous cells.



FIG. 462.—Section through the Lung of a Human Embryo of the fourth Month (Minot Coll., No. 6). *Br*, Bronchiole; *C*, connective tissue; *Alv*, terminal bud.

and bronchi preserves the embryonic type throughout life; the epithelium is ciliated; glands are present and lined with mucous cells.

A six months' specimen (Minot Coll., No. 8) shows the glands well advanced, as are also the tracheal cartilages.

Larynx.—The larynx is essentially the portion of the trachea opening into the œsophagus. It is best regarded as the metamorphosed pulmonary groove; the groove early becomes marked off from the œsophagus or pharynx by two ridges, one on each side; the ridges approach one another in front and devaricate posteriorly; they are the anlagen of the vocal chords.

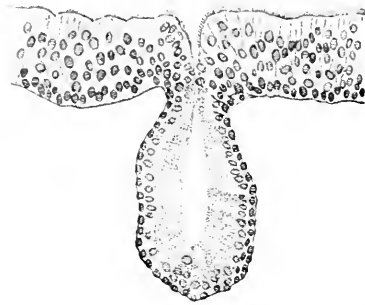


FIG. 463.—Epithelium and Gland of the Trachea of a four Months' Embryo (Minot Coll., No. 35. \times about 270 diams. (The nuclei in the gland should be of the same size as those in the epithelium.))

Kölliker found the anlagen of the arytenoid cartilages the sixth week, but chondrification does not take place in the larynx until the eighth or ninth week. The annular and arytenoid cartilages are disproportionately large in early stages, while the thyroid cartilages develop more tardily. For a certain period the larynx of the fœtus is completely closed by the concrecence

of its lining epithelium, a fact which was first recorded by Roth, 80.1, and since by Kölliker and Putelli, 88.1; Strazza, 88.1, has published some observations on the development of the laryngeal muscles.

EPIGLOTTIS.—In a human embryo of 4.25 mm. His has found ("Anat. menschlicher Embryonen," III., 66) that the elongated opening of the larynx lies just behind the fourth branchial arch and is bounded by two slight ridges which meet in front, but fade out behind. He has also found that the ridges are the anlagen of the median epiglottis and of the lateral ary-epiglottic folds. In an embryo of 10 mm., Fig. 335, the epiglottis, *Epg*, is well developed. As to the further growth and the histogenesis of the organ little is known, though a few details are given by Ganghofner, 80.1.

HARVARD MEDICAL SCHOOL, BOSTON,
March 11th, 1892.

REFERENCES.

THE following list embraces only the articles actually referred to in the course of the work. The full bibliography of over three thousand titles is published by the Boston Society of Natural History, and contains the full title of each paper or book, together with the pages and number of plates. In the bibliography the titles are classified by subjects. In the list below, the arrangement is alphabetical, and the titles are replaced by a word or two indicating the subject. As regards the reference numbers: the two digits before the period indicate the year of publication, "18" being understood before them; the digit after the period is arbitrary, for it is merely the accession number for that author and year in my private catalogue. For example—"KÖLLIKER, A. VON, 46.2," means that the paper in question was published in 1846, and was the second paper of Kölliker's published in that year to be entered in my card catalogue. An exception is made in the case of my own papers, the numbers for which follow another and arbitrary system, and do not indicate the year. To save space, the following special abbreviations are used; the remaining abbreviations are the usual ones and therefore do not require explanation:

ABBREVIATIONS.

- A. A.—Anatomischer Anzeiger.
A. f. m. A.—Archiv für mikroskopische Anatomie.
Berlin Sb.—Sitzungsberichte der k. Akademie der Wissenschaften, Berlin.
C. R.—Comptes Rendus de l'Académie des Sciences de Paris.
His' Arch.—Archiv für Anatomie und Physiologie, Abtheilung für Anatomie.
M. A.—Archiv für Anatomie und Physiologie (Müller's).
Phil. Trans.—Philosophical Transactions of the Royal Society of London.
Q. J.—Quarterly Journal of Microscopical Science.
Wien. Sb.—Sitzungsberichte der k. k. Akademie der Wissenschaften, Vienna.
Z. Z.—Zeitschrift für wissenschaftliche Zoologie.

☞ The author requests that any errors found in the list of references be communicated to him.

Aeby, Ch. 58.1. Bone. *Zeitschr. f. rat. Med.* 3te Reihe. iv. 1-77. **85.1.** Pigment of Skin. *Cbl. f. med. Wiss.* xxiii. 273-275. **Ackeren, F. van. 89.1.** Sexual organs. *Zeitschr. f. wiss. Zool.* xlviii. 1-46. **Afanassiew, B. 77.1.** Thyreas. *Arch. f. mikrosk. Anat.* xiv. 343-390. **Agassiz, Alexander, and Whitman, C. O. 84.1.** Teleosts. *Proc. Amer. Acad.* xx. 23-75. **Ahlborn, Fr. 84.1.** Pineal gland. *Z. Z.* xl. 331-337. **Ahlfeld, Fr. 78.1.** Human ovum. *Arch. f. Gyn.* xiii. 241-248. **Altmann, R. 85.1.** Nerves. *His' Arch.* 1885. 344-348. **Aly, W. 84.1.** Blood. Hofmann-Schwalbe, *Jahresber.* 1884. p. 58. **Angelucci, A. 81.1.** Uvea. *A. f. m. A.* xix. 152-182. **Antonelli, A. 90.1.** Nerves. *Arch. Ital. Biol.* xiv. 132-135. **Arnold, Julius, 71.1.** Capillaries. *Virchow's Arch.* liii. 70-92. **84.1.** Blood corpuscles. *Virchow's Arch.* xcvi. 107-130. **Aubert, 56.1.** Heart. *Z. Z.* vii. 345-364. **Ayers, Howard. 89.1.** Carotids. *Bull. Mus. Comp. Zool.* xvii. 191-223. **90.1.** Cephalogenesis. *Journ. Morph.* iv. 221-245. **91.2.** Membrana tectoria. *Anat. Anz.* vi. 219-220.

- Babuchin, 65.1. *Retina*. Würzburg naturwiss. Zeit. v. 127-143. Baer, C. E. von. 27.1. *De ovi mammalium*. Lipsiæ, 1827. pp. 40. 28.2. *Entwicklungsgeschichte*. i. Theil. 35.1. *Entwicklungsgesch. der Fische*. Leipzig. 37.1. *Entwicklungsgeschichte*. ii. Theil. 88.1. *Entwicklungsgeschichte*. Schluss. Baginsky, Benno. 86.1. *Ear*. A. f. m. A. xxviii. 14-37. Balbiani, G. 79.1. *Leçons sur la Génération*. 8vo. pp. vi. 279. Paris. Balfour, F. M. 73.1. *Blood-vessels, chick*. Q. J. xiii. 280-290. 78.2. *Ovary*. Q. J. xviii. 383-438. 78.3. *Monograph on Development of Elasmobranchs*. 8vo. pp. 295. London. 79.1. *Development of Lacertilia*. Q. J. xix. 421-430. 81.1. *Fins*. Proc. Zool. Soc. London, 1881. 656-671. 81.3. *Suprarenals*. Biol. Cbl. i. 136-138. 83.1. *Peripatus*. Q. J. xxiii. 213-259. Balfour, F. M., and Parker, W. N. 82.1. *Lepidosteus*. Phil. Trans. 1882. pt. ii. 359-442. Balfour, F. M. and Sedgwick, Adam. 78.1. *Head-kidney*. Proc. R.S. London. xxvii. 443-446. 79.1. *Head-kidney*. Q. J. 1879. 1-20. Bambeke, Charles van. 68.1. *Pelobates*. Mém. couron. Acad. Belg. xxxiv. pp. 66. 70.1. *Amphibian egg*. Bull. Acad. Belg. 2me sér. xxx. 58-71. 76.2. *Amphibian ova*. Bull. Acad. R. Belg. 2me sér. lxi. 97-135. 80.2. *Germ-layers in Urodela*. Bull. Acad. R. Belg. 2me sér. l. 83-91. Barnes, William. 84.1. *Spinal cord*. Proc. Amer. Acad. xix. 97-110. Barth. 68.1. *Intestine*. Wien. Sb. lviii. 129-136. Barry, Martin. 38.1. *Researches*. First Series. Phil. Trans. 1838. 301-341. 39.1. *Researches*. Second Series. Phil. Trans. 1839. 307-380. 40.1. *Researches*. Third Series. Phil. Trans. 1840. 529-612. Baur, G. 86.1. *Vertebral column*. Biol. Cbl. vi. 332-342 Bardeleben, K. 79.1. *Episternum*. Sitzb. Jena. Nat-wiss. Ges. 146. Bayerl, B. 84.1. *Blood*. A. f. m. A. xxiii. 30-44. Beard, J. 85.1. *Branchial sense organs*. Q. J. xxvi. 95-156. 87.2. *Ciliary ganglion*. Anat. Anz. ii. 565-575. 88.2. *Parietal eye*. Q. J. xxix. 55-73. 88.3. *Peripheral nerves*. Q. J. xxix. 153-227. Béclard, 20.1. *Skeleton*. Meckel's Archiv. vi. 405-446. Beigel, 78.1. *Human ovum*. Archiv f. Gynaek. xiii. 437-439. Beigel und Löwe. 77.1. *Human ovum*. Arch. f. Gynaek. xii. 421-432. Bellonci, G. 84.1. *Blastopore*. Amphibians. R. Accad. Lincei. sér. 3e. xix. 45 pp. 85.1. *Polar globules*. Mem. Roy. Acad. Bologna. ser. 4. vi. 363-368. Bellonci, G. et Stafani, A. 89.1. *Cerebellum*. Archiv Ital. Biol. xi. 21-25. Below, E. 88.1. *Ganglion cells at birth*. Arch. Anat. Physiol. Abth. 187-188. Beltzow, A. 83.1. *Tendons*. A. f. m. A. xxii. 714-738. Bemmelen, J. F. van. 86.1. *Gill-clefts*. Mitth. zool. Stat. Neapol. vi. 165-184. 89.1. *Lingual muscles*. A. A. iv. 240-255. 89.2. *Thymus and thyroid*. Tijdschrift d. Nederland. Vereenig. ii. d. 2. afl. 3. Verslagen xxxvii-xxxix. 90.1. *Heredity*. Biol. Centralbl. x. 641-652; 686-694. Benda, C. 89.1. *Testes*. Verb. Anat. Ges. Berlin. iii. 125-130. Beneden, E. van. 70.1. *Composition of ovum*. Bruxelles Mém. Cour. xxxiv. 285 pp. 75.1. *Fecondation*. Bruxelles Bull. Acad. Sci. Belgique. xl. 686-736. 76.1. *Maturation of mammalian ovum*. Journ. Zool. v. 10-56. 80.1. *Germ layers, rabbit*. Arch. de biol. i. 136-224. 80.2. *Ovary, mammals*. Arch. de biol. i. 475-550. 83.1. *Maturation of Ascaris ovum*. Arch. biol. iv. 265-640. 88.3. *Germ-layers, mammals*. A. A. iii. 709-714. Beneden, E. van, and Julin, Charles. 80.1. *Impregnation, Cheiroptera*. Arch. biol. i. 551-571. 84.1. *Fœtal appendages*. Arch. biol. v. 369-434. Beneden, E. van, et Neyt, A. 87.1. *Fecondation, Ascaris megaloccephala*. Bull. Acad. Roy. Belgique. xiv. 215-295. Béraneck, E. 84.1. *Nerves*. Recueil zool. Suisse. i. 519-603. 87.1. *Parietal eye*. Jena Zeitschr. Nat. xxi. 374-410. Bernard, C. 59.1. *Placenta*. C. R. lviii. 77-86. Benckiser, A. 84.1. *Corpus luteum*. Arch. f. Gynaek. xxiii. 350-366. Bernays, A. 76.1. *Atrio-ventricular valves*. Morph. Jahrb. ii. 478-518. 78.1. *Knee-joint*. Morph. Jahrb. iv. 403-446. Bernheimer, S. 89.1. *Chiasma*. Archiv. f. Augenh. Wiesbaden. xx. 133-179. Biehinger, J. 88.1. *Inversion of germ-layers*. His' Archiv. 1888. 279-286. 91.1. *Inversion of germ-layers*. Biol. Centralbl. x. 403-414. Bischoff, Th. L. W. 42.1. *Entwicklung Kaninchen*. 4to. Braunschweig. pp. x. + 154. 42.3. *Embryology*. Leipzig. 8vo. pp. 575. 45.1. *Entwicklung des Hundes*. Braunschweig. 4to. pp. 134. 52.1. *Entwicklung der Meerschweinchen*. Giessen. 4to. pp. 56. 54.1. *Entwicklung des Rehes*. Giessen. 4to. pp. 36. 68.1. *Cerebral convolutions*. Abhandl. d. K. v. Akad. Wiss. x. ii. Abth. 391-497. 70.1. *Entwicklung des Meerschweinchens*. Abh. bayr. Akad., Cl. ii. x. 115-166. Bizzozero, G. 88.1. *Gastric glands*. A. A. iii. 781-784. 89.2. *Intestinal glands*. Atti. d. R. Accad. d. Sci. Torino. xxiv. 702. Bizzozero, J. 84.1. *Blood corpuscles*. Virchow's Archiv. xev. 26-45; Arch. Ital. Biol. iv. 329-345. Bizzozero, J. und Torre, A. 84.1. *Blood corpuscles*. Virchow's Arch. xev. 1-25; Arch. Ital. Biol. iv.

- 309-329. **Bizzozero, J. und Vasale, G. 85.1.** Intestinal glands. *Centralbl. Med. Wiss.* xxiii. 49-51. **Blaschko, A. 87.1.** Epidermis. *Archiv. f. m. A.* xxx. 495-528. **Blaue, J. 84.1.** Olfactory epithelium. *Hist. Arch.* 1884. 231-309. **Bloch, L. 89.1.** Placenta. *Beiträge z. path. Anat. z. a. Pathol.* iv. 559-592. **Blochmann, F. 87.1.** Polar globules. *Morph. Jahrb.* xii. 544-574. **88.1.** Polar globules. *Morph. Jahrb.* xiii. 654-663. **Blumenau, L. 91.1.** Corpus callosum. *A. f. m. A.* xxxvii. 1-15. **Boas, J. E. V. 84.1.** Nails. *Morph. Jahrb.* ix. 389-399. **87.1.** Aortic arches. *Morph. Jahrb.* xiii. 115-118. **Böhm, A. A. 88.1.** Impregnation, Petromyzon. *A. f. m. A.* xxxvii. 613-670. **Böttcher, A. 69.1.** Ear. *Nov. Act. L. C. Acad.* xxxv. *Abh.* v. 1-203. **Boll, F. 73.1.** Histogenesis of nervous system. *Arch. Psychiatrie u. Nervenkr.* iv. 1-138. **Bonnet, R. 84.1.** Embryology, ruminants. *Hist. Archiv.* 1884. 170-230. **87.1.** Wolffian duct. *München, med. Woch.* xxxiv. 579-581. **88.1.** Allantois. *A. A.* iii. 105-126. **89.1.** Embryology of ruminants, *cont.* *Hist. Archiv.* 1-106. **Born, G. 73.1.** Muscles. *Svo.* pp. 65. Berlin. **76.1.** Nasal cavities. *Morph. Jahrb.* ii. 577-646. **79.1.** Lachrymal duct. *Morph. Jahrb.* v. 62-140; 401-429. **83.1.** Thymus and thyroid. *A. f. m. A.* xxii. 271-318. **83.3.** Lachrymal duct, *cont.* *Morph. Jahrb.* viii. 188-232. **84.3.** Influence of gravity. *Bresl. ärztl. Zeitschr.* vi. 185-189. **89.1.** Heart, rabbit. *A. f. m. A.* xxxiii. 284-378. **Bornhaupt, Th. 67.1.** Urogenital. *4to.* pp. 48. Riga. **Bowen, J. T. 89.1.** Epitrichium. *A. A.* iv. 412-450. **Boveri, Th. 88.1.** Cells. *Jena. Zeits. f. Naturw.* xxii. 685-882. **90.1.** Polar globules. *Jena. Zeits. f. Naturw.* xxiv. 314-401. **Bramann, F. 84.1.** Descensus testiculorum. *Hist. Arch.* 1884. 310-340. **Braun, M. 77.4.** Urogenital system, reptiles. *Arb. zool. zoot. Inst. Würzburg.* iv. 113-228. **82.1.** Supra-renals. *Arb. zool. zoot. Inst. Würzburg.* v. 1-30. **82.3.** Development of perroquet. *Arb. zool. zoot. Inst. Würzburg.* v. 161-204; 205-341. **Bremer, L. 83.1.** Muscles. *A. f. m. A.* xxii. 318-356. **Brock, J. 76.1.** Mandible. *Z. Z.* xxvii. 287-318. **78.1.** Sexual organs, Teleosts. *Morph. Jahrb.* iv. 505-572. **Brook, G. 87.1.** Wolffian duct. *Proc. Roy. Soc. Edinburgh.* xiv. 368-370. **Bruch, 53.1.** Clavicle. *Z. Z.* iv. 371-376. **Brunn, A. v. 87.1.** Teeth. *A. f. m. A.* xxix. 367-383. **Budge, A. 87.1.** Lymphatics. *Hist. Arch.* 1887. 59-88. **Bumm, 90.1.** Placenta. *Arch. f. Gynaek.* xxxvii. 1-15. **Bütschli, O. 76.1.** Egg-cell. *Abhandl. Senkenb. naturf. Ges.* x. 213-452. **83.3.** Phylogeny of blood vessels. *Morph. Jahrb.* viii. 474-482. **84.1.** Polar globules. *Biol. Centralbl.* iv. 5-12. **Bütschli, O. und Schewiakoff, W. 91.1.** Muscles. *Biol. Centralbl.* xi. 33-39.
- Cadiat, O. 84.2.** Uterus. *Robin's Journ. Anat.* 1880. 409-431. **Cajal, S. Ramon y 90.1.** Ramification of nerve fibres. *A. A.* v. 85-95; 111-119. **Calberla, E. 76.1.** Muscles. *A. f. m. A.* xi. 442-458. **78.1.** Impregnation, Petromyzon. *Z. Z.* xxx. 437-487. **Caldwell, W. H. 87.1.** Monotremes. *Proc. Roy. Soc. London.* xlii. 177-180. **Callender, G. W. 70.1.** Bones of face. *Phil. Trans.* elix. 163-172. **Carius, F. 88.1.** Notochord. *Svo.* pp. 33. Marburg. **Carnoy, J. B. 86.1.** Polar globules. *La Cellule.* ii. 1-76. **87.1.** Polar globules. *La Cellule.* iii. 229-324. **Chiarugi, G. 88.1.** Human embryo 2.6 mm. *Atti. soc. tosc. sci. nat. Pisa.* x. 66-94. **89.2.** Nerves. *Atti. soc. tosc. sci. nat. Pisa.* x. 149-245. **90.1.** Nerves. *Arch. Ital. Biol.* xiii. 309-341; 423-443. **91.1.** Nerves. *Monit. zool. Ital.* ii. 47-60. **Chievitz, J. H. 81.1.** Lymph glands. *Hist. Archiv.* 1881. 347-370. **85.1.** Salivaries. *Hist. Archiv.* 1885. 401-436. **Clarke, S. F. 80.1.** Amblystoma. *Martin's Studies. Biol. Lab.* i. 105-125. **Cope, E. D. 74.1.** Teeth. *4to.* pp. 21. Philadelphia. **86.4.** Intercentrum. *Trans. American Phil. Soc.* xvi. 243-253. **Corning, H. F. 88.1.** Substantia gelatinosa. *A. f. m. A.* xxxi. 594-613. **Coste, Jean, J. M. C. V. 47.1.** Développement des corps organisés. *4to.* I. 1847. II. 1859. Paris. **Creighton, Ch. 77.1.** Mammary. *Journ. Anat. and Phys.* xi. 1-32. **78.1.** Placenta, Guinea pig. *J. Anat. and Phys.* vii. 534-590. **79.1.** Placenta, Guinea pig. *Journ. Anat. and Phys.* xiii. 173-182. **Cunningham, D. J. 90.1.** Fissure of Rolando. *Journ. Anat. and Physiol.* xxv. 1-23. **91.1.** Sylvian fissure. *Journ. Anat. and Physiol.* xxv. 286-291. **91.2.** Cerebral fissures. *Journ. Anat. and Physiol.* xxv. 338-348. **Cunningham, J. T. 91.2.** Conger eel. *Journ. Marine Biol. Assoc. U. K.* II. 16-42. **Curtis, F. 89.2.** Nail. *Journ. de l'Anat. et Physiol.* xxv. 125-186. **Czerny, A. 89.1.** Organ of Giraldès. *A. f. m. A.* xxxiii. 445-461.
- Dalton, J. C. 78.1.** Corpus luteum. *Am. Gyn. Soc.* **Dastre, A. 76.1.** Allantois and chorion. *Ann. Sci. Nat. sér. 6.* iii. pp. 118. **66.1.** Duality of

- heart. C. R. lxxiii. 603-606. **Davidoff, M. v.** 79.1. Fins. *Morph. Jahr.* v. 450-520. **84.1.** Red blood cells. *Zool. Anz.* vii. 453-456. **90.1.** Distalpia. *Mitt. Zool. Stat. Neapel.* ix. 533-650. **Deiters, O.** 61.1. Muscles. *Archiv. f. Anat. u. Physiol.* 1861. 393-424. **Demon, F.** 83.1. Intestine. 8vo. pp. 126. Lille. **Denys, J.** 87.1. Marrow of bone, birds. *La Cellule.* iv. 199-240. **Dewitz, J.** 85.1. Impregnation. *Pflüger's Arch. f. d. Ges. Physiol.* xxxvii. 219-23. **86.1.** Movements of spermatozoa. *Archiv. f. d. Ges. Physiol.* xxxviii. 358-385. **Dexter, Samuel.** 91.1. Somites. A. A. vi. 284-289. **Disse, J.** 78.1. Mesoderm. A. f. m. A. xv. 67-94. **79.1.** Blood. A. f. m. A. xvi. 545-592. **Dobrynin, P. v.** 71.1. Allantois. *Wiener akad. Sitzb.* 1871. 185-192. **Döderlein, A.** 90.1. Amniotic fluid. *Arch. f. Gynäk.* xxxvii. 141-173. **Dohrn, A.** 75.2. Ursprung der Wirbelthiere. 8vo. pp. 87. Leipzig. **82.1.** Mouth and hypophysis, teleosts. *Mitth. zool. Stat. Naples.* iii. 252-279. **83.1.** Hypophysis, Petromyzon. *Mitth. zool. Stat. Naples.* iv. 172-189. **84.1.** Gill-clefts and limbs of selachians. *Mitth. zool. Stat. Naples.* v. 102-195. **86.1.** Gill-clefts and thyroid. *Mitth. zool. Stat. Naples.* vi. 1-92. **86.2.** Fins, and eye. *Mitt. zool. Stat. Naples.* vi. 399-480. **87.2.** Thyroid. *Mitt. zool. Stat. Naples.* vii. 301-337. **88.1.** Nerves. *Mitt. zool. Stat. Naples.* viii. 441-461. **90.1.** Head, origin. A. A. v. 53-64 : 78-85. **90.2.** Segments of head. *Mitt. zool. Stat. Naples.* ix. 330-434. **91.1.** Nerves. *Mitt. zool. Stat. Naples.* x. 1-40. **91.2.** Nerve fibres. *Mitt. zool. Stat. Naples.* x. 255-341. **Dohrn, H.** 75.1. Hymen. *Schrift. Ges. Nat. wiss. Marburg.* x. Suppl. pp. 8. **78.1.** Umbilical cord. *Arch. f. Gynäk.* xliii. 234-240. **Durham, H. E.** 86.1. Neuroenteric canal. *Q. J.* xxvi. 509-510. **Dursy, E.** 65.1. Wolffian body. *Zeitschr. f. ration. med.* iii. Reihe. xxiii. 257-263. **69.1.** Entwickelungsgeschichte des Kopfes. 8vo. pp. 232. Tübingen. **Duval, M.** 78.1. Primitive streak. *Ann. Sci. Nat. sér. 6.* vii. pp. 48. **84.1.** Blastoderm, birds. *Ann. Sci. Nat. Zool. sér. 6.* xviii. 1-208. **84.2.** Foetal appendages, birds. *Journ. Anat. et Physiol.* xx. 201-241. **87.1.** Placenta, Guinea pigs. C. R. *biol. Paris.* iv. ser. 8. 148-150. **87.2.** Placenta, rabbit. C. R. *biol. Paris.* iv. ser. 8. 425-427. **88.1.** Placenta, rodents. C. R. *soc. biol. Paris.* v. ser. 8. 675-676. **88.2.** Discoid placentas. C. R. *soc. biol. Paris.* v. ser. 8. 729-732. **89.1.** Placenta, rodents. *Journ. l'Anat. et Physiol.* xxv. 309-342; 573-627. **90.1.** Placenta, rodents. *Journ. l'Anat. et Physiol.* xxvi. 1-48; 273-344. **90.2.** Inversion of germ-layers. *Journ. l'Anat. et Physiol.* xxvi. 521-601. **90.3.** Uterus. C. R. *hebd. soc. de biol. Paris.* 1890. 697-698.
- Eberth, C. J.** 84.1. Impregnation, Echinoids. *Fortschr. d. Med.* ii. 469-472. **Eberth, C. J. and Aly, W.** 85.1. Blood corpuscles. *Fortschr. d. Med.* iii. 1-7. **Ebner, V. v.** 90.1. Teeth. *Handb. d. Zahnheilkunde.* 1890. 209-262. **Ecker, A.** 80.1. Human embryos. *Hist. Arch.* 1880. 403-406. **83.1.** Die Hirnwindungen des Menschen. 8vo. pp. 58. Braunschweig. **Egli, Th.** 76.1. Sexual organs. 8vo. pp. 62. Zürich. **Ehlers, E.** 85.1. Nebendarm. *Nach. Ges. wiss. Georg. Anz. Univ. Göttingen.* 1885. 390-404. **Eichhorst, F.** 75.1. Spinal cord. *Virchow's Arch.* lxxiv. 425-475. **Eimer, G. H. Th.** 92.1. Muscle. *Zeitschr. f. wiss. zool.* liii. Suppl. 1892. 67-111. **Elischer, J.** 76.1. Uterine muscle. *Arch. f. Gynäk.* ix. 10-21. **Emery, C.** 83.1. Kidney. *Arch. Ital. Biol.* iv. 80-92. **90.1.** Hand and foot. A. A. V. 283-294. **Engelmann, Th. W.** 73.1. Muscle. *Pflüger's Arch.* vii. 33-71. **Engelmann, Geo. J.** 75.1. Uterus. *Amer. Journ. Obstetrics.* viii. 30-87. **Ercolani, G. B.** 68.1. Utricu- lar glands. *Mem. Accad. sci. est. Bologna.* vii. ser. 2. 133-207. **77.1.** Placenta. *Mem. Accad. sci. est. Bologna.* vii. ser. 3. 271-346. **Ewetzky, Th.** 88.1. Lachrymal duct. *Arch. f. Ophthal.* Leipzig. xxiv. 23-35.
- Falchi, F.** 87.2. Optic nerve and retina. *Arch. Ital. Biol.* ix. 382-399. **Farre, A.** 58.1. Uterus. *Todd's Cyclopæd. Anat.* v. Suppl. 545-725. **Fehling, H.** 79.1. Amniotic fluid. *Arch. f. Gynäk.* xiv. 221-244. **Felix, W.** 89.1. Muscles. *Z. Z.* xlviii. 224-259. **Field, H. H.** 91.1. Pronephros. *Bull. Mus. Comp. Zool.* xxi. 201-340. **Fischelis, Ph.** 85.1. Thyroid and thymus. A. f. m. A. xxv. 405-440. **Flechsigg, P.** 76.1. Die Leitungsbahnen im Gehirn und Rückenmark. 8vo. pp. 382. Leipzig. **Fleischer, R.** 78.1. Jacobson's organ. *Sitzb. phys-med. Soc. Erlangen.* 1878. 8-19. **Flemming, W.** 71.1. Fat-cell. A. f. m. A. vii. 32-80. **71.2.** Fat-cell. A. f. m. A. vii. 327-371. **75.1.** De- velopment of Najadae. *Wien. Sb.* lxxi. 81-212. **78.2.** Smooth muscle. *Z. Z.* xxx. Suppl. 466-473. **79.1.** Fat. *Hist. Arch.* 401-454. **82.2.** Cells. A. f. m. A. xx. 1-86. **85.2.** Regeneration. A. f. m. A. xxiv. 50-91. **86.1.** Wolffian duct. *Hist. Arch.* 1886. 236-248. **88.1.** Glands. *Hist. Arch.* 1888. 287-303.

- 90.1. Capillaries. A. f. m. A. xxxv. 275-286. **Flourens, 36.1.** Placental vessels. Ann. Sci. Nat. Zool. v. ser. 2. 65-68. **Flower, W. H. 67.1.** Teeth. Phil. Trans. clvii. 631-641. **Förster, A. 58.1.** Meconium. Wien. med. Woch. viii. 569. **Fol. H. 78.1.** Hénoignée. Mem. soc. phys. et hist. nat. Genève. xxvi. 89-394. **85.1.** Tail. C. R. c. 1469-1472. **Foulis, J. 76.1.** Ovary. Q. J. xvi. 190-221. **Francotte, P. 87.1.** Epiphysis. Bull. l'Acad. roy. Belgique. xiv. ser. 3. 810-840. **88.1.** Epiphysis. Arch. de biol. viii. 757-321. **Franqué, O. von. 90.1.** Muscle. Verhandl. Phys.-med. Ges. Würzburg. xxiv. 19-48. **Fraser, A. 82.1.** Ear bones. Phil. Trans. clxxiii. 901-925. **83.1.** Inversion of germ-layers. Proc. Roy. Soc. London. xxxiv. 430-437. **Frenzel, J. 86.5.** Idioplasma. A. f. m. A. xxvii. 73-128. **Freud, S. 78.1.** Spinal ganglia. Wien. Sb. lxxviii., Abth. 3, 81-167. **Friedländer, C. 70.1.** Untersuchungen über den Uterus. Svo. pp. 57. Leipzig. **76.1.** Uterus post partum. Arch. f. Gynäk. ix. 22-28. **Frommann, K. 86.3.** Ei. Eulenburg's Real-encyclopädie d. ges. Heilk. 2te. Aufl. v. 591-659. **89.1.** Cell. Jena. zeit. Naturw. xliii. 389-412. **Froriep, A. 82.1.** Notochord. Beiträge z. Anat. u. Embryol. Festgabe. F. G. J. Henle. 1882. 26-40. Taf. iii. **83.1.** Vertebral column. His' Arch. 1883. 177-234. **85.1.** Sense organs. His' Arch. 1885. 1-55. **86.1.** Vertebral column. His' Arch. 1886. 69-150. **87.1.** Chordatumpani. A. A. ii. 486-493. **91.1.** Optic nerve. A. A. vi. 155-161. **91.2.** Nerves. Verhandl. Anat. Ges. v. (München.) 55-65. **Fuchs, S. 84.1.** Histogenesis cerebrum. Wien. Sb. lxxxviii. 157-184. **Fürbringer, M. 78.1.** Excretory organs. Morph. Jahrb. iv. 1-111. **Funcke, E. 80.1.** Blood corpuscles, chick. Centralbl. f. d. med. Wiss. 754-756.
- Ganghofner, F. 80.1.** Epiglottis. Z. f. Heilkunde, i. 187-206. **Gardiner, E. G. 84.1.** Epitrichium. Svo. pp. 50. Leipzig. **Gaskell, W. H. 90.1.** Origin of vertebrates. Q. J. xxxi. 379-444. **Gasser, E. 74.1.** Allantois. Abh. Senck. Naturf. Ges. ix. 293-368. **77.1.** Primitive streak. Sitzb. Ges. Beförd. g. Naturw. Marburg. 1877. 100-103. **77.3.** Heart, birds. A. f. m. A. xiv. 459-470. **79.1.** Primitive streak. Schrift. Ges. Beförd. g. Naturw. Marburg. ii. 1-98. **80.1.** Cloaca. His' Arch. 1880. 297-319. **82.2.** Blastoderm, birds. His' Arch. 1882. 359-398. **82.3.** Alytes. Sitzb. Marburg. Ges. Nat. 1882. 73-97. **Gaule, J. 90.1.** Fat. Arch. f. Anat. u. Physiol., Physiol. Abth. 1890. 551-553. **Gegenbaur, C. 71.1.** Nerves of Hexanchus. Jena. Zeit. Nat.-Wiss. vi. 497-559. **72.1.** Das Kopfskelet der Selachier. 4to. pp. 316. Leipzig. **73.1.** Milk glands. Jena Zeit. vii. 204-217. **75.1.** Teats. Morph. Jahrb. i. 266-281. **76.1.** Limbs. Morph. Jahrb. ii. 396-420. **85.1.** Nails. Morph. Jahrb. x. 465-479. **86.1.** Mammarorgane der Monotremen. 4to. pp. 39. Leipzig. **88.1.** Metamerism of head. Morph. Jahrb. xliii. 1-114. **Geigel, R. 83.1.** Sexual organs. Würzburg. Verh. xvii. 129-148. **Giacomini, C. 88.1.** Neurenteric canal. Giorn. d. R. Accad. d. Med. 209-232. Arch. Ital. Biol. x. 273-294. **Giacomini, E. 90.1.** Salivaries. Monit. Zool. Ital. 158-163; 176-188; 195-211. **Gibson, G. A. 91.1.** Heart. Verhandl. x. intern. med. Kong. Berlin. ii. Abth. i. Anat. 144. **Gierke, H. 85.1.** Neuroglia. A. f. m. A. xxv. 441-554. **86.1.** A. f. m. A. xxvi. 129-228. **Giraldés, J. A. 61.1.** Organ of Giraldés. Brown-Séquard Journ. Anat. et Physiol. Paris. iv. 1-8. **Godet, R. 77.1.** Placenta, rabbit. Svo. pp. 48. Neuveville. **Goepfert, E. 91.1.** Pancreas, amphibians. Morph. Jahrb. xvii. 100-122. **Goette, A. 67.1.** Intestine, chick. Svo. pp. 82. Tübingen. **73.1.** Trout egg. A. f. m. A. ix. 679-708. **68.1.** Hairs. A. f. m. A. iv. 273-322. **74.1.** Germ-layers, chick. A. f. m. A. x. 145-199. **75.1.** Entwicklungsgeschichte der Unke. Svo. pp. 964. Leipzig. **77.1.** Skeleton. A. f. m. A. xiv. 592-620. **90.1.** Entwicklungsgeschichte des Flussneunauges. 4to. pp. 95. Leipzig. **Golgi, C. 89.1.** Kidney. Rend. d. R. Accad. Lincei. v. 334-342. **90.3.** Spinal cord. A. A. v. 372-396; 423-435. **Golubew, A. 69.1.** Capillaries. A. f. m. A. v. 49-89. **Gottschau, M. 83.1.** Supra-renal. His' Arch. 1883. 412-458. **Gusserow, A. 78.1.** Stoffaustausch. Arch. f. Gynäk. xliii. 56-72.
- Haddon, A. C. 85.1.** Blastodermic vesicle. Proc. Roy. Dublin Soc. iv. 536-547. **Haeckel, E. 74.2.** Gastrea theory. Jena. Zeit. f. Naturw. viii. 1-55. **75.1.** Gastrula. Jena. Zeit. g. Naturw. ix. 402-508. **Hagen-Torn O. 82.1.** Synovia. A. f. m. A. xxi. 591-663. **Haidlen, R. 85.1.** Amniotic fluid. Arch. f. Gynäk. xxv. 40-50. **Hamburger, O. 90.1.** Kidney. Arch. f. Anat. Entw. 1890. Suppl. 15-51. **Harz, W. 83.1.** Ovary. A. f. m. A. xxii. 374-407. **Hasse, C. 73.1.** Atlas. Anat. Stud. i. 542-568. **79.1.**

- Cartilage. Zool. Anz. ii. 325-329; 351-355; 371-374. **Hatschek, B.** 87.1. Sexual propagation. Prager med. Woch. xii. 385-388. **88.1.** Germ-layers. Amphioxus. A. A. iii. 662-667. **89.1.** Limbs. Verh. Anat. Ges. Berlin. iii. 82-90. **Heape, W.** 83.1. Mole. Q. J. xxiii. 412-452. **86.1.** Mole. Q. J. xxvi. 157-174. **86.2.** Mole, Stages E-J. Q. J. xxvii. 123-163. **A. Sedgwick, Studies.** iii. 105-145. **Heinricus, G.** 89.1. Placenta, dog. A. f. m. A. xxxiii. 419-410. **Held, H.** 92.1. Nerve-fibres in brain. His' Arch. 1892. 31-39. **Henke, W. u. Rehyer, C.** 74.1. Joints. Wien. Sitz. lxx. iii. Abth. 217-273. **Henneguy, F.** 88.1. Trout. Journ. d. Anat. xxiv. 413-502; 525-617. **Hennig, C.** 73.1. Human ova. Arch. f. Gyn. v. 169-173. **Hensen, V. von.** 76.1. Rabbit. Zeit. Anat. Entwicklungsges. i. 213-353; 423. 77.1. Brain, embryo. His' Arch. 1877. 1-8. **81.1.** Physiol. d. Zeugung. Svo. pp. 301. Leipzig. **Hepburn, D.** 89.1. Joints. Journ. of Anat. and Phys. xxiii. 507-522. **Hermann, F.** 85.1. Taste. A. f. m. A. xxiv. 216-229. **89.2.** Testis. A. f. m. A. xxxiv. 429-437. **Ferms, E.** 84.1. Ganglion cells. Sitzb. math.-phys. München. Acad. 1884. 333-354. **Hertwig, O.** 74.1. Teeth, selachians. Jena. Zeit. vii. 331-404. **74.2.** Teeth, amphibia. A. f. m. A. xi. Suppl. 1-208. **75.1.** Impregnation, i. Morph. Jahrb. i. 347-434. **76.1.** Dermal skeleton. Morph. Jahrb. ii. 328-395. **77.1.** Impregnation, ii. Morph. Jahrb. iii. 271-279. **77.2.** Impregnation, iii. Morph. Jahrb. iii. 1-86. **78.1.** Impregnation, iv. Morph. Jahrb. iv. 156-175; 179-213. **79.1.** Dermal skeleton. Morph. Jahrb. v. 1-19. **82.1.** Mesoderm. Jena. Zeit. Naturw. xv. 286-340. **83.1.** Mesoderm, cont. Jena. Zeit. Naturw. xvi. 247-328. **84.2.** Isotropism. Jena. Zeit. Naturw. xviii. 276-318. **88.1.** Lehrbuch der Entwicklungsgeschichte. Jena. 1888. pp. vii. 507. **90.1.** Genoblasts, Nematods. A. f. m. A. xxxvi. 1-137. **Hertwig, C. u. R.** 81.1. Celom theory. Jena. Zeit. Naturw. xv. 1-150. **85.1.** Hybrids. Jena. Zeit. Naturw. xix. 121-165. **Hicks, J. B.** 72.1. Placenta. Journ. Anat. and Phys. vi. 405-410. **Hill, C.** 91.1. Epiphysis. Journ. of Morph. v. 503-510. **Hiltner, L.** 85.1. Optic nerve. Biol. Centralbl. v. 38-40. **His, W.** 65.1. Die Häute und Höhlen des Körpers. Basel. pp. 34. 1865. **65.2.** Ovary. A. f. m. A. i. 151-202. **68.1.** Untersuchungen über die erste Anlage des Wirbelthierleibes. 4to. pp. 237. Leipzig. **74.1.** Unsere Körperform. Svo. pp. 224. Leipzig. 1874. **76.1.** Teleosts. Z. f. Anat. u. Entwickl. i. 1-39. **76.2.** Germinal wall. Zeit. f. Anat. u. Entwickl. i. 274-287. **77.1.** Selachians. Zeit. f. Anat. u. Entwickl. ii. 108-124. **77.2.** Chick. His' Arch. 1877. 112-187. **80.1.** Anatomie menschlicher Embryonen. Svo. mit Atlas Fol. Heft i., ii. Leipzig. **81.1.** Zur Embryologie der Säugethiere. His' Arch. 1881. 303-329. **82.1.** Parablast. His' Arch. 1882. 62-108. **86.1.** Retromandibularbucht. A. A. i. 22-25. **86.2.** Spinal cord. Abh. K. Sächs. Ges. Wiss. xiii. 479-513. **86.3.** Cervical sinus. His' Arch. 1886. 421-427; 428-435. **87.3.** Lungs. His' Arch. 89-106. **88.1.** Nervenbahnen. His' Arch. 1887. 368-378. **88.2.** Cephalic nerves. His' Arch. 1888. 379-453. **88.3.** Brain. Abhandl. math.-phys. Cl. K. Sächs. Ges. Wiss. xiv. 341-392. **89.1.** Neuroblasts. His' Arch. 1889. 249-300. **89.2.** Thymus. His' Arch. 1889. 155-158. **89.4.** Olfactory ganglion. Verh. Anat. Ges. Berlin. iii. 63-66. **90.1.** Nervous tissue. His' Arch. Suppl. 1890. 95-117. **90.2.** Medulla oblongata. Abhandl. d. K. S. Ges. d. Wiss. xxix. pp. 74. **91.1.** Tractus thyroglossus. His' Arch. 1891. 26-32. **91.2.** Conerescence. Verh. Anat. Ges. München. v. 70-83. **His, W., Jr.,** 89.1. Facial and acoustic nerves. His' Arch. Suppl. 1-29. **Hochstetter, F.** 87.2. Vena cava. A. A. ii. 517-520. **88.1.** Venous system. Morph. Jahrb. xiii. 575-585. **88.3.** Vena cava inferior. A. A. iii. 867-872. **90.1.** Vertebral artery. Morph. Jahrb. xvi. 572-586. **90.2.** Arteries of limbs. Morph. Jahrb. xvi. 300-318. **90.3.** Subclavian arteries. Morph. Jahrb. xvi. 484-493. **91.1.** Veins of limbs. Morph. Jahrb. xvii. 1-43. **91.2.** Choanae. Verhandl. Anat. Ges. München. v. 145-151. **Hoffmann, C. K.** 79.1. Comp. Anat. Vertebrates. Nederl. Arch. Zool. v. 19-114. **80.1.** Nederl. Arch. f. Zool. v. 19-112. **84.3.** Reptiles. Z. Z. xl. 214-246. **85.1.** Reptiles. Morph. Jahrb. xi. 176-219. **92.1.** Heart. A. A. vii. 270-273. **Holl, M.** 90.1. Maturation of the ovum. Wien. Sb. xcix. Abth. 3. 311-370. **Hoggan, G. and Hoggan, F. E.** 79.1. Fat-cells. Journ. R. micros. Soc. London. ii. 353-380. **Hollard, H.** 63.1. Placenta, rodents. Ann. d. Sci. Nat. ser. 4. xix. 223-232. **Houssay, F.** 90.1. Axolotl. Arch. zool. Ex. et Gen. viii. 143-244. **Howell, W. H.** 88.1. Blood. New York Med. Record. xxxiv. 337-338. **90.1.** Blood. Journ. of Morph. iv. 57-116. **Howes, G. B.** 87.1.

- Fins. Proc. Zool. Soc. London. 3-26. **Hubrecht, A. A. W. 87.1.** Relation of nemertea to vertebrates. Q. J. xxvii. 605-644. **89.1.** Placentation, hedgehog. Q. J. xxx. 283-404. **Huss. 73.1.** Milk-glands. Jena. Zeit. vii. 176-203. **Huxley, T. H. 58.1.** Theory of the skull. Proc. Roy. Soc. London. ix. 381-433. **69.1.** Ear bones. Proc. Zool. Soc. 1869. 391-407. **75.1.** Classification. Q. J. xv. 52-56. **Hyrtl, J. 70.1.** Die Blutgefäße der menschlichen Nachgeburt. Wien. 4to. pp. 152. 1870.
- Janosik, J. 83.1.** Supra-renals. A. f. m. A. xxii. 738-746. **85.1.** Urogenital system. Wien. Sb. xci. Abth. 3. 97-192. **87.1.** Human embryos. A. f. m. A. xxx. 559-595. **Jassinsky, P. 67.1.** Placenta. Virchow's Arch. xl. 341-352. **Jeffries, J. A. 83.1.** Proc. Boston. Soc. Nat. Hist. xxii. 203-241. **Johnson, Alice. 83.1.** Pelvic girdle. Q. J. xxiii. 399-411. **84.1.** Blastopore. Proc. Roy. Soc. London. xxxvii. 65-66. **Jones, T. W. 37.1.** Ova. Phil. Trans. 1837. 339-345. **Julin, Ch. 87.3.** Lateral nerve. Bull. Acad. Roy. Belgique. ser. 3. xiii. 300-309. **Jungbluth. 69.1.** Amniotic fluid. Bonn. 1869. **Jürgensen, H. F. E. 89.1.** Sexual organs, teleosts. Arb. zool. zoot. Inst. Würzburg. ix. 89-219. **Junglöw, H. 89.1.** Heart, lacerta. A. A. iv. 288.
- Kaestner, S. 90.1.** Muscles. His' Arch. Suppl. 1890. 1-14. **Kanthack, A. 91.1.** Thyroid duct. Journ. of Anat. and Physiol. xxv. 155-165. **Kastschenko, N. 85.1.** Chorion. His' Arch. 1885. 451-480. **87.1.** Gill-clefts. A. f. m. A. xxx. 1-26. **88.1.** Selachians. A. A. iii. 445-467. **88.2.** Yolk-nuclei. A. A. iii. 253-257. **Kazzander, J. 91.1.** Muscle of jaw. A. A. vi. 224-227. **Keibel, F. 86.1.** Vitreous humor. His' Archiv. 1886. 358-369. **87.1.** Blastopore. A. A. ii. 769-773. **88.2.** Tail, etc. His' Arch. 407-430. **89.1.** Optic nerve. Deutsche med. Woch. xv. 116. **89.2.** Placenta. A. A. iv. 537-539. **90.1.** Human ovum. His' Arch. 1890. 250-267. **91.1.** Bladder. A. A. vi. 186-192; Verhandl. x. inter. med. Kongress. Berlin. ii. Abth. i. Anat. 136-137. **91.4.** Human embryo. His' Arch. 1891. 352-355. **Kenner, J. v. 91.1.** Evolution of Arthropods. 4to. pp. 27. Dorpat: Sitzb. Dorpat. Nat. Ges. 1891. 441-444. **Kessler, L. 77.1.** Entwicklung des Auges der Wirbelthiere. 4to. pp. 112. Leipzig. **Kerbert, C. 77.1.** Skin. A. f. m. A. xiii. 205-262. **Killian, 91.1.** Metamerism of head. Verhandl. Anat. Ges. v. München. 85-107. **Klaatsch, H. 84.1.** Tits. Morph. Jahrb. ix. 233-324. **Klebs, 63.1.** Ovary. Virchow's Archiv. xxviii. 301-336. **Kleinenberg, N. 72.1.** Hydra. 4to. pp. 90. Leipzig. **Kobelt, G. L. 47.1.** Paradiymis. 8vo. pp. 52. Heidelberg. 1847. **Kodis, Th. 89.1.** Epidermis. Arch. Anat. u. Physiol. Physiol. Abth. 1889. 1-40. **Kölliker, A. 46.2.** Tissue of batrachians. Ann. Sci. nat. vi. ser. 3. 91-108. **50.2.** Primordial cranium. Z. Z. ii. 281-294. **57.1.** Histology of muscle, etc. Z. Z. ix. 138-142. **62.1.** Nerves. Z. Z. ii. 149-164. **77.2.** Jacobson's organ. Festschr. z. Jubiläum F. v. Rineckers. 1-11. **79.2.** Entwicklungsgeschichte der Menschen und der höheren Thiere. pp. 1031. zweite Auflage. Leipzig. 1879. **82.1.** Histologische Mittheilungen. Sitzb. Würzburg. phys.-med. Ges. 1882. 66-72. **83.1.** Notochord. Sitzb. Würzburg. phys.-med. Ges. 1883. 2-9. **84.2.** Parablatt. Sitzb. phys.-med. Ges. Würzburg. 1884. 14-18. **84.4.** Germ-layers. Z. Z. xl. 179-213; 356-357. **85.1.** Heredity. Z. Z. xlii. 1-46. **85.2.** Batrachian larvae. Z. Z. xliii. 1-40. **85.3.** Akroblast. Z. Z. xli. 155-158. **87.2.** Pigment. Sitzb. Würzburg. phys.-med. Ges. 1887. **87.3.** Pigment. Z. Z. xlv. 713-720. **88.2.** Nails. Z. Z. xlvii. 129-153. **89.1.** Attraction sphere. A. A. iv. 147-155. **90.2.** Spinal cord. Z. Z. li. 1-54. **90.5.** Olfactory nerve. Sitzb. Würzburg. phys.-med. Ges. 1890. 127-133. **Koller, C. 79.1.** Germ-layers, chick. Wien. Sb. lxxx. 3. Abth. 316-329. **82.1.** Germ layers. A. f. m. A. xx. 174-211. **Kollmann, J. 79.1.** Human ova. His' Arch. 1879. 275-311. **82.2.** Cœlum and nephridium. Festschr. f. d. 300jähr. Besteh. d. Julius Maximil. Univ. z. Würzburg. 1882. 1-57. **84.1.** Mesoblasts. Biol. Centralbl. iii. 737-747. **84.3.** Randwulst. His' Arch. 1884. 341-434; 461-465. **85.1.** Vertebrates. His' Arch. 1885. 279-306. **85.2.** Vertebrates. Z. Z. xli. 517-524. **89.1.** Form of embryo. His' Arch. 105-138. **91.1.** Rump segments. His' Arch. 1891. 39-88. **Kolster, R. 87.1.** Cartilage. A. f. m. A. xxix. 533-538. **Kowalewski, M. von. 86.1.** Teleosts. Z. Z. xliii. 434-480. **86.2.** Gastrulation, teleosts. Sitzb. phys.-med. Soc. Erlangen. 1886. 31-36. **Krause, R. 90.1.** Semicircular canals. A. f. m. A. xxxv. 287-304. **Krause, W. 76.1.** Allantois, man. M. A. 1875. 215; 1876. 204-207. **80.1.** Human

- embryo. Zool. Anz. iii. 283-284. 81.1. Human allantois. Zool. Anz. iv. 185. 81.2. Allantois, human. Z. Z. xxxvi. 175-179. Kraushaar, R. 85.1. Hypophysis and Epiphysis. Z. Z. xli. 79-98. Krukenberg, G. 84.1. Amniotic fluid. Arch. f. Gynäk. xxii. 1-46. Kuborn, P. 90.1. Blood. A. A. v. 277-282. Kükenthal, W. 91.1. Teeth, opossum. A. A. vi. 658-666. Kundrat, H. u. Engelmann, G. J. 73.1. Uterus. Stricker's Med. Jahrb. 1873. 135-177. Kupffer, C. 65.1. Urogenital system. A. f. m. A. i. 233-248. 66.1. Urogenital system, *cont.* A. f. m. A. ii. 473-489. 68.1. Teleosts. A. f. m. A. iv. 209-272. 82.1. Impregnation. Sitzb. Münch. Acad. xii. 608-618. 82.2. Gastrulation. His' Arch. 1882. 1-28; 139-154. 82.3. Arvicola. Sitzb. math.-phys. Kl. Akad. München. 1882. 621-637. 84.1. Gastrulation, *cont.* His' Arch. 1884. 1-40. 86.1. Neuromeres. Sitzb. math.-phys. Kl. Akad. München. 469-476. 90.1. Petromyzon. A. f. m. A. xxxv. 469-558. 91.1. Cephalic nerves. Verh. Anat. Ges. München. v. 22-54. Kupffer, C. u. Benecke, B. 78.2. Reptiles. Svo. pp. 11. Königsberg. Kuskow, N. 87.1. Elastic tissue. A. f. m. A. xxx. 32-38.
- Lachi, P. 84.1. Granulosa. Arch. Ital. Biol. vi. 62-67. 90.1. Neuroglia. Atti. d. Soc. Tosc. Nat. xi. 267-310. Laguesse, E. 90.1. Spleen, sharks. Journ. de l'Anat. et Physiol. xxvi. 345-406; 425-495. Lahousse, E. 88.1. Cerebellum. Arch. de Biol. viii. 43-110. Langer, C. 52.1. Milk-glands. Denkschr. Wien. Akad. iii. 25-38. 87.1. Ileo-cæcal valve. Denkschr. Math. Naturw. Cl. K. Akad. Wiss. liv. 3-10. Langhans, Th. 77.1. Placenta. His' Arch. 1877. 188-267. 82.1. Chorion. Beiträge z. Anat. u. Embryol. als Festgabe. F. G. J. Henle. 1882. 69-79. Lankester, E. R. 73.1. Gastrula theory. Ann. Mag. N. H. xi. ser. 4. 321-338. 77.1. Notes on Embryology and Classification. Q. J. xvii. 399-454. Lataste, F. 89.1. Dentition. Journ. l'Anat. et Physiol. xxv. 200-222. Leboucq, H. 80.1. Notochord. Arch. de Biol. i. 718-736. Legal, E. 81.1. Lachrymal duct. Svo. pp. 32. Breslau. 1881. 83.1. Lachrymal duct. Morph. Jahrb. viii. 353-372. Lenhossék, M. von. 89.1. Nerve-fibres. A. f. m. A. xxxiii. 71-125. 91.1. Ganglia. His' Arch. 1891. 1-25. 91.2. Neuroglia. Verhand. d. Anat. Ges. v. 193-221. 91.3. Nerve-fibres. Verhandl. d. x. intern. medic. Kong. Berlin. ii. Abth. Anat. 115-124. Leopold, G. 74.1. Lymph-vessels of uterus. Arch. f. Gyn. vi. 1-54. 77.1. Decidua. Arch. f. Gyn. xi. 110-144; 443-500; xii. 169-210. 83.1. Ovulation. Arch. f. Gynäk. xxi. 347-408. Levison, F. 76.1. Amniotic fluid. Virchow-Hirsch. Jahrb. ii. 650; Arch. f. Gynäk. ix. 517-519. Leydig, Fr. von. 90.1. Parietal eye. Biol. Centralbl. x. 278-285. Lieberkühn, N. 79.1. Germ-layers. Funzf. Jahrb.-Dr.-J. Herrn Hermann Nasse, Marburg. 4to. pp. 26. 1879. 82.1. Notochord. His' Arch. 1882. 396-438. 84.1. Notochord, *cont.* His' Arch. 1884. 435-452. 88.1. Embryochemische Untersuchungen. Arch. Physiol. xliiii. 71-151. Lilienfeld, L. 92.1. Blood. His' Arch. 1892. 115-154. Lindgren, H. 77.1. Zona pellucida. His' Arch. 1877. 334-380. Lindes, G. 65.1. Heart. 4to. pp. 59. Dorpat. 1865. List, J. H. 89.1. Pigment. A. A. iv. 596-599. Lockwood, C. B. 84.1. Omentum. Journ. of Anat. Physiol. xviii. 257-264. 88.1. Diaphragm. Phil. Trans. clxxix. 365-384. Löwe, L. 78.1. Retina. A. f. m. A. xv. 596-630. 79.1. Fætal membranes. Arch. f. Gyn. xiv. 190-196. 80.1. Nervous system. Schenk's Mitth. embry. Inst. ii. 1-9. 80.2. Beiträge zur Anatomie und zur Entwicklungsgeschichte des Nervensystems. Fol. pp. 126. Berlin. 1880. 83.1. Beiträge zur Anatomie und zur Entwicklungsgeschichte des Nervensystems. Fol. pp. 50. Leipzig. 1883. Löwenthal, W. 85.1. Menstruation. Arch. Gyn. xxiv. 168-261; Cbl. Gyn. 1885. 306-312. Löwit, M. 87.1. Erythroblasts. Wien. Sb. xcv. Abth. 3. 129-178. Lustig, A. 84.1. Organs of taste. Wien. Sitzb. lxxxix. Abth. 3. 91.1. Thyroid. Arch. Ital. Biol. xv. 291-295. Lwoff, B. 89.1. Fibrille. Wien. Sitzb. xxviii. 184-210.
- McClure, C. F. W. 90.1. Neuromeres. Journ. Morph. iv. 35-56. McIntosh, W. C. and Prince, E. E. 90.1. Teleosts. Trans. Roy. Soc. Edinburgh. xxxv. 665-946. McKay, W. J. 89.1. Pineal eye. Rep. Austral. Ass. Adv. Sc. Sidney. i. 332-334. McMurrich, J. P. 91.1. Hexactiniae. Journ. Morph. iv. 303-330. Magini, G. 88.1. Neuroglia. Arch. Ital. Biol. ix. 59-60. Malassez, L. 82.1. Blood corpuscles. Arch. d. Physiol. norm. et pathol. 2 sér. ix. 1-47. Mall, F. P. 87.1. Branchial arches. His' Arch. 1887. 1-34. 88.1. Middle ear. Studies fr. Biol. Labr. J. Hopkins Univ. iv. 185-192. 88.2. Gill-clefts, dog. Studies fr. Biol. Labr. Johns Hopkins

- Univ. iv. 193-216. 88.3. Elastic tissue. A. A. iii. 397-401. 91.1. Reticulate tissue. Abhandl. math-phys. cl. K. Sächs. Ges. Wiss. xvii. 5-41. 91.2. Omental cavity. Journ. Morph. v. 165-179. 91.3. Human embryo. Journ. Morph. v. 459-480. Marchand, F. 91.1. Corpus callosum. A. f. m. A. xxxvii. 298-334. Margo, Th. 59.1. Muscles. Wien. Sb. xxxvi. 219-240. Mark, E. L. 81.1. Maturation, etc. Limax. Bull. M. C. Zool. vi. 173-625. 90.1. Lepidosteus. Bull. Mus. Comp. Zool. xix. 1-127. Marshall, A. M. 78.1. Cranial nerves. Q. J. xviii. 10-40. 79.1. Olfactory organ. Q. J. xix. 300-340. 81.2. Head-cavities. Q. J. xxi. 72-97. Marshall, A. M. and Bles. Ed. J. 90.1. Kidney, frog. Studies fr. Biol. Labor. Owens. Coll. ii. 133-158. Marshall, A. M. and Spencer, W. B. 81.1. Q. J. xxi. 469-499. Marshall, C. F. 87.1. Muscles. Q. J. xxviii. 75-107. 90.1. Muscle. Q. J. xxxi. 65-82. Studies Physiol. Lab. Owen's Coll. i. 207-224. Martin, E. 88.1. Wolffian body. His' Arch. 109-123. Martin, Paul. 90.1. Neuroblasts. A. A. v. 530-532. 90.3. Nerves. Oesterreich. Monats. f. Thierheilk. Wien. xiv. 337-385. Masquelin, H. 78.1. Mandible. Bull. l'Acad. roy. Belgique. xlv. 2 sér. 371-376. Masquelin, H. et Swaen, A. 80.1. Placenta, rabbit. Arch. biol. i. 25-44. Masius, Jean. 89.1. Placenta, rabbit. Arch. de biol. ix. 83-118. 89.2. Heart, chick. Arch. de biol. ix. 403-417. Maurer, F. 85.1. Thyroid and thymus. Morph. Jahrb. xi. 129-175. 87.1. Thyroid, etc., Amphibians. Morph. Jb. xiii. 296-384. 90.1. Spleen. Morph. Jahrb. xvi. 203-208. Mauthner, J. 73.1. Placenta. Wien. Sitzb. lxvii. 118-124. Mayer, P. 87.1. Heart, Selachians. Mitth. Zool. Station z. Neapel. vii. 338-370. Mayer, S. 86.1. Sarcoplasts. A. A. i. 231-235. Meckel, J. F. 17.1. Intestine. Meckel's Archiv. iii. 1-84. Melland, B. 85.1. Muscle. Q. J. xxv. 371-390. A. M. Marshall's Studies. Biol. Lab. Owen's Coll. i. 225-241. Meola, F. 84.1. Fetal membranes. Riv. internaz. d. med. e. chir. i. 505-552: 582-609. Merk, L. 85.1. Nervous system. Wien. Sb. xxii. Biol. Cb. v. 729-730. 87.1. Nervous system. Denkschr. math. naturw. cl. k. Acad. Wiss. Wien. liii. 1-42. Meuron, P. de. 86.1. Thymus, etc. Recueil Zool. Suisse. iii. 86.2. (Esophagus. C. R. 1886. Mihalkowicz, V. v. 74.1. Hypophysis. Centrbl. f. med. Wiss. xii. 307-308. 75.1. Hypophysis. A. f. m. A. xi. 389-441. 77.1. Entwicklungsgeschichte des Gehirns. 4to. pp. 195. Leipzig. 85.1. Urogenital system. Krause Inter. Monatschr. Anat. Histol. ii. 41-62: 64-106: 284-339: 346-385: 387-433: 435-485. Miklucho-Maclay, N. 70.1. Neurology. 4to. pp. 74. Leipzig. 1870. Minot, Charles-Sedgwick. 17. Proc. Boston Soc. Nat. Hist. xix. 165-171. 22. Growth. Proc. Boston Soc. N. H. xx. 190-201. 23. Differentiation. Proc. Boston Soc. N. H. xx. 202-209. 35. Proc. Amer. Assoc. Adv. Sci. xxx. 240-242. 47. Genoblasts. Biol. Centrbl. ii. 365-367. 70. Formative force. Science. vi. 4-6. 83. Skin. Amer. Nat. 575-578. 85. Heredity. Science. viii. 125-130. 98. Uterus and Embryo. Journ. Morph. ii. 341-462. 116. Placenta, rabbit. Biol. Centrbl. x. 114-122. 122. Blood corpuscles. A. A. v. 601-604. 125. Growing old. Proc. Amer. Assoc. Adv. Sci. xxix. 271-289. Mitsukuri, K. 82.1. Suprarenals. Q. J. xxii. 17-29. 88.1. Wolffian duct. Zool. Anz. xi. 111. 90.1. Fetal membranes of Chelonia. Journ. College Sci. Imp. Univ. Japan. iv. 1-53. A. A. v. 510-519. Mivart, St. George. 79.1. Fins. Trans. Zool. Soc. London. x. 439-484. Möricke, 82.1. Uterus. Zeitschr. f. Geburtsk. Gyn. vii. 84-137. Mogilowa, A. Reinstein, 91.1. Chorion. Virchow's Archiv. cxxiv. 522-545. Mollier, S. 90.1. Head-kidney. His' Arch. 209-235. Mondino, C. 88.1. Blood plates. Arch. Ital. Biol. xii. 297-304. Rend. d. R. Acad. d. Lincei. iv. 378-382. Moquin-Tandon, A. 76.1. Amphibia. Ann. d. Sci. Nat. iii. 1-50. Morgan, T. H. 90.2. Blastopore. Studies Labor. Johns Hopkins Univ. Baltimore. iv. 355-377. Morpurgo, B. 85.1. Artery. Wien. Sitzb. xc. 231-252. Mosso, A. 88.2. Leucocytes. Arch. Ital. Biol. x. 48-68. Müller, E. 88.1. Muscles of vessels. His' Arch. 124-145. Müller, H. 58.2. Bone. Zeits. wiss. Zool. ix. 147-233. Müller, J. 30.1. Bildungsgeschichte der Genitalien. Düsseldorf. 1830. 30.2. Human embryos. Meckel's Arch. 1830. 411-434. 71.2. Ber. Kön. Sächs. Wiss. 1871. 125-134. Müller, W. 71.1. Notochord. Jena. Zeit. vi. 327-353. 71.2. Notochord. Jena. Zeit. f. Med. u. Naturw. vi. 327-495. 71.3. Thyroid. Jena. Zeit. vi. 428-453. 71.4. Thyroid. Jena. Zeit. vi. 354-425. 73.1. Endostyle of Tunicates. Jena. Zeit. f. Naturw. vii. 327-332. 74.1. Phylogeny of eye. Beitr. Anat. Physiol. als Festgabe Carl. Ludwig zum 15 Oct. 1874. Gewidmet von seinen Schuelern.

- Nagel, W. 88.1. Human ovum. A. f. m. A. xxxvi. 342-423. Sitzb. k. preuss. Akad. Wiss. 1887, 759-763. 89.3. Urogenital, human. A. f. m. A. xxiv. 269-384. 91.2. Uterus and vagina. A. f. m. A. xxxvii. 620-654. Nakagawa, I. 90.1. Cerebral cortex. Journ. Morph. iv. 1-10. Neumann, E. 74.1. Blood. Arch. d. Heilk. xv. 441-476. 76.1. Oesophagus. A. f. m. A. xii. 570-574. Nicolaides, R. 91.1. Blood. Arch. f. Anat. u. Physiol., Physiol. Abth. 373-379. Niessing, G. 88.1. Spermatogenesis. Verh. d. phys.-med. Ges. z. Würzburg, xxii. 35-63. Nitabuch, R. 87.1. Placenta. 8vo. pp. 39. Bern. 1887. Noorden, W. von. 87.1. Skull. His' Arch. 241-257. Nussbaum, M. 80.1. A. f. m. A. xviii. 1-121. 84.2. Heredity. A. f. m. A. xxiii. 155-213. 86.1. Künstliche Theilung der Infusorien. A. f. m. A. xxvi. 485-538.
- Obrastzow. 81.1. Blood. Virchow's Arch. lxxxiv. 358-414. Oellacher, J. 72.1. Germulative vesicle. A. f. m. A. viii. 1-27. 72.3. Teleost. Z. Z. xxii. 373-421. Onodi, A. D. 86.1. Sympathetic. A. f. m. A. xxvi. 61-81. Orth, J. 78.1. Placenta. Zeit. f. Geburtsh. Gyn. ii. 9-23. Osborn, H. F. 86.1. Corpus callosum, I. Morph. Jahrb. xii. 223-251. 87.1. Corpus callosum, II. Morph. Jahrb. xii. 530-543. 88.2. Teeth. Am. Nat. xxii. 1068-1079. Opitz, W. 87.1. Amniotic fluid. Centralbl. f. Gynäk. Leipzig, xi. 734-735. Oppel, A. 90.1. Head segments. A. f. m. A. xxxvi. 603-627. Orr, H. 87.1. Lizards. Journ. Morph. i. 311-364. Ostroumoff, A. 88.1. Lizards. Zool. Anz. xi. 620-622. Overlach, M. 85.1. A. f. m. A. xxv. 191-235. Owsjannikow, Ph. 88.1. Pineal eye. Mém. l'Acad. Sci. St. Petersburg, sér. 7, xxxvi. pp. 26.
- Paneth, J. 85.1. Muscles. Wien. Sitzb. xcii. 236-269. 87.1. Sarcoplasts. A. A. ii. 136-138. Parker, W. K. 68.1. Monograph on the shoulder girdle. Folio. Roy. Soc. London, pp. xi. 237. 86.1. Skull. Pt. ii. Edentata. Phil. Trans. clxxvi. 1-119. 86.2. Skull. Part iii. Insectivora. Phil. Trans. clxxvi. 121-275. Parker, W. K. and Bettamy, G. T. 77.1. Morph. of the skull. 12mo, pp. viii. 368. London. Paterson, A. M. 87.1. Muscle-plate. Q. J. xxviii. 109-129. Stud. fr. Biol. Labor. Owen's Coll. ii. 103-122 (1890). 91.1. Sympathetic. Phil. Trans. clxxxi. 159-186. 91.2. Position of limbs. Studies in Anat. Owen's Coll. i. 31-47. Patzelt, V. 83.1. Intestine. Wien. Sitzb. lxxxvi. 145-172. Peremeschko. 67.1. Spleen. Wien. Sitzb. iv. 539-542. 67.2. Spleen. Wien. Sitzb. lvi. 31-38. 79.1. Blood. Centralbl. med. Wiss. 1879, 673-675. Perenyi, von. 87.1. Wolffian duct. Zool. Anz. x. 66. Pflüger, E. 65.1. Ueber die Bedeutung und Ursache der Menstruation, 1865. 83.6. Influence of Gravity. Pflüger's Arch. xxxi. 311-318; xxxii. 1-80. Phisalix. 88.1. Human embryo. Arch. zool. expériment. sér. 2, vi. 279-320; 321-351. Piersol, G. A. 88.1. Gill-clefts. Zeitsch. f. wiss. Zool. Leipzig. xlvii. 155-189. 90.2. Pigment of skin. Univ. Med. Mag. Pennsylvania. ii. 571-579. Platner, G. 86.1. Impregnation, Arion. A. f. m. A. xxvii. 32-72. 86.2. Nebenkern. A. f. m. A. xxvi. 343-369. 89.1. Polar globules. Biol. Centralbl. viii. 718-720. 89.2. Cell division. A. f. m. A. xxxiii. 125-152. Platt, Julia B. 89.1. Segmentation of embryo. Bull. M. C. Z. xvii. 171-190. 91.1. Head. A. A. vi. 251-265. 91.2. Head. Journ. Morph. v. 79-112. Poljakoff, P. 88.1. Fat. A. f. m. A. xxxii. 123-186. Pouchet. 80.1. Blood. Q. J. xx. 331-350. Prenant, A. 88.1. Spermatozoa. La cellule. iv. 135-177. 89.1. Semen. Intern. Monatschr. f. Anat. vi. 1-30. 90.1. Genital gland. C. R. Soc. biol. sér. 9, ii. 192-195. 91.2. Intestine. Journ. l'Anat. et Physiol. xxvii. 197-233. Prevost et Lebert. 44.1. Blood. Ann. Sci. Natur. sér. 3, i. 193-229. 44.3. Blood. Ann. Sci. Natur. ii. sér. 3, 222-247. Prince, E. E. 90.1. Fins. 4to, pp. 24. Glasgow. Pritchard, Urban. 79.1. Organ of Corti. Journ. of Anat. Physiol. xiii. 99-103. Prochownick, L. 77.1. Amniotic fluid. Arch. f. Gynäk. xi. 304-345. Purkinje, J. E. 30.1. Symbolæ ad ovi historiam. 4to, pp. 24. Leipzig, 1830. Putelli, F. 88.1. Larvnx. Med. Jahr. Wien. lxxxiv. 323-328. Mitth. Embryol. Institut. k. k. Univ. Wien. 74-79.
- Rabl, C. 76.1. Malermuschel. Jena Zeit. x. 310-393. 84.1. Cell-division. Morph. Jahrb. x. 214-330. 86.1. Neck. Prager med. Woch. xi. No. 52. 87.1. Facial nerve. A. A. ii. 219-227. 89.1. Cell-division. Anat. Anz. iv. 21-30. 89.2. Theorie des Mesoderms. Morph. Jb. xv. 113-250. Rabl, H. 91.1. Supra-renals. A. f. m. A. xxxviii. 492-523. Rabl-Rückhard, H. 63.1. Cartilage. Arch. f. Anat. Physiol. 1863. 41-65. 80.1. Notochord,

- hypophysis, etc. *Morph. Jahrb.* vi. 535-570. **82.1.** Brain. *His' Arch.* 1882. 111-158. **Ranvier, L. 74.1.** Tendons. *Arch. de Physiol.* vi. 181-202. **74.2.** Blood-vessels. *Arch. de Physiol.* vi. 429-450. **Rathke, H. 20.1.** Beiträge zur Geschichte der Thierwelt. Neuste Schrift. (Ges. Danzig. i. Hft. 1. pp. 136; 1824. pp. 210; 1825. pp. 146; 1827. pp. 129. **25.1.** Gill-clefts. *Isis.* xviii. 1100-1101. **32.1.** Genital ducts. *Meckel's Arch.* xvi. 379-389. **32.2.** Abhandlungen zur Entwicklungsgeschichte der Menschen, etc. 4to. pp. 114. Leipzig. 1832. **38.1.** Hypophysis. *Müller's Arch.* 1838. 482-485. **38.2.** Skeleton. *Müller's Arch.* 1838. 361-372. **39.1.** Coluber. 4to. pp. iv. 232. Königsberg. **57.1.** Aortic arches, Saurians. *Denkschr. K. Akad. Wien.* xiii. 51-135. **61.1.** Entwicklungsgeschichte der Wirbelthiere. 8vo. pp. viii. 201. Leipzig. **Ratner, G. 91.1.** Intestine. 8vo. pp. 34. Dorpat. **Rauber, A. 75.2.** Rabbit. Sitzb. Leipzig. nat.forsch. Ges. 103. **76.2.** Urmund des Hühnechens. *Morph. Jahrb.* ii. 550-576. **77.1.** Neurula der Wirbelthiere. 8vo. pp. 85. Leipzig. **83.2.** Blastopore. *Zool. Anz.* vi. 143-147; 163-167. **83.1.** Spinal cord. *Batrachians.* A. f. m. A. xxvi. 622-644. **Ravn, E. 89.2.** Diaphragm. *His' Arch.* 123-154. **89.3.** Diaphragm. *His' Arch. Suppl.* 1889. 270-280. **Reichel, P. 83.1.** Oral glands. *Morph. Jahrb.* viii. 1-71. **Reichert, K. B. 37.1.** Gill arches. *Müller's Arch.* 1837. 120-222. **40.1.** Das Entwicklungsleben im Wirbelthierreiche. 4to. pp. 261. Berlin. 1840. **43.1.** Beiträge zur Kenntniss des Zustandes der heutigen Entwicklungsgeschichte. pp. 137. 1843. Berlin. **62.1.** Guinea pig. *Abhandl. K. Akad. Wiss.* Berlin. 97-216. **Rein, G. 82.1.** Milk-glands, i. A. f. m. A. xx. 431-501. **82.2.** Milk-glands, ii. A. f. m. A. xxi. 678-694. **83.1.** Impregnation, mammals. A. f. m. A. xxii. 233-270. **Remak, R. 50.1.** Untersuchungen über die Entwicklung der Wirbelthiere. pp. 194. Berlin. 1850-55. **Remy, Ch. 80.1.** Human embryo. *Robin Journ. Anat.* 1880. 556-565. **Renaut, J. 87.2.** Cartilage. C. R. civ. 1452-1455. **Renson, G. 83.1.** Head-kidney. A. f. m. A. xxii. 599-608. **Retterer, E. 88.1.** Tonsil. *Journ. de l'Anat.* xxiv. 1-80; 274-360. **90.1.** Anus. *Journ. de l'Anat.* xxvi. 126-151; 153-216. **90.2.** Anus. C. R. Soc. Biol. Paris. sér. 9. ii. 51-54. **Retzius, G. 80.1.** Nerve cells. *His' Arch., Anat. Abth.* 369-402. **81.2.** Muscle. *Biol. Unters.* i. 1-26. **Riedel, B. 74.1.** Kidney. *Unters. Anat. Inst. Rostock.* 1874. 38-72. **Rindfleisch, E. 80.1.** Blood. A. f. m. A. xvii. 1-11; 21-42. **Ritter, W. E. 91.1.** Parietal eye. *Bull. Mus. Comp. Zool.* xx. 209-228. **Robin, Ch. 54.1.** Chorion. *Mém. Soc. Biol.* 2d sér. i. 63-75. **64.1.** Atlas. *Journ. de l'Anat. et Physiol.* Paris. i. 274-299. **Robinson, A. 91.1.** Spinal cord. *Stud. Anat. f. Anat. Depart. Owen's Coll.* i. 67-102. **Robinson, A., and Assheton, R. 91.1.** Rana. Q. J. xxxii. 451-504. **Röse, C. 88.1.** Heart. 4to. pp. 19. Heidelberg. **91.2.** Teeth. A. f. m. A. xxxviii. 447-491. **Rohr, K. 89.1.** Placenta. *Virchow's Arch.* cxv. 505-534. **Romiti, G. 86.1.** Notochord. *Arch. Ital. Biol.* vii. 226-231. **Rosenberg, A. 73.1.** Limbs. Z. Z. xxiii. 116-166. **Rosenberg, E. 75.1.** Vertebra. *Morph.* i. 82-197. **Rosenmüller, J. C. 02.1.** Ovary. 4to. pp. 20. Lipsia. **Roth, W. 80.1.** Epiglottis. *Mitth. Embry. Inst. Univ. Wien.* i. 145-162. **Rouget, 58.1.** Genital. *Journ. de la Physiol.* i. 320-343; 479-496; 735-750. **Rouget, C. 75.1.** Nerves. *Arch. Phys. sér. 2.* ii. 801-853. **Roux, W. 81.1.** Der Kampf der Theile im Organismus. 8vo. Leipzig. **87.1.** Embryonic axes. A. f. m. A. xxix. 157-213. **Rückert, J. 85.1.** Germ-layers, Selachians. 8vo. pp. 58. München. **87.1.** Mesoderm, Torpedo. A. A. ii. 97-112; 154-176. **88.1.** Excretory organs. *His' Arch.* 1888. 205-278. **92.3.** Polyspermie. A. A. vii. 320-333. **Rüdinger, N. 88.2.** Ear. Sitzb. Akad. Wiss. München. xviii. 493-502. **Ruge, C. 86.1.** Fetal membranes. In *Schröder.* 1886. 113-151. **Ruge, G. 80.1.** Sternum. *Morph. Jahrb.* vi. 362-414. **Rusconi, 36.1.** Teleosts. *Ann. Sci. Nat. Zool.* sér. 2. v. 300-312. **Ryder, J. A. 81.2.** Belone. *Bull. U. S. Fish. Comm.* i. 283-335. **83.1.** Nucleus. *Science.* i. 273-277. **84.1.** Teleosts. *Ann. Rep. Comm. Fish and Fisheries for 1882.* **85.5.** Archistome. *Amer. Nat.* xix. 1115-1121. **85.9.** Conerescence. *Amer. Nat.* xix. 614-615. **86.3.** Amnion. *Amer. Nat.* xx. 179-185. **87.1.** Am. Nat. xxi. 298-302. **87.6.** Origin of placenta. *Amer. Nat.* xxi. 780-784.

Sabatier, A. 80.1. Pelvic and shoulder girdles. 4to. pp. 457. Montpellier. **Sagemehl, M. 82.1.** Spinal nerves. 4to. pp. 47. 1882. Dorpat. **Salensky, W. 80.1.** Ear-bones. *Morph. Jahrb.* vi. 415-431. **81.1.** Accipenser. *Arch. Biol.* ii. 233-341. **Salviola, I. 90.1.** Gastric glands. *Arch. Ital. Biol.*

- xiv. 71-80. **Sarasin, C. F. 83. 1.** Maturation of ovum, Reptiles. Arb. Zool. Inst. Würzburg, vi. 159-216. **Schäfer, E. A. 74.1.** Blood corpuscles. Proc. Roy. Soc. London, xxii. 243-245. **78.1.** Blastodermic vesicle. Proc. Roy. Soc. London, xxiv. 399-403. **Schanz, F. 87.1.** Blastopore. Jena Zeit. Nat. xxi. 411-422. **Scherer, J. 49.1.** Amniotic fluid. Zeit. f. wiss. Zool. i. 88-92. **Schimkevitch, W. 85.1.** Heart. Zool. Anz. viii. 37-40; 384-386. **Schmidt, F. 62.1.** Brain. Z. Z. xi. 43-61. **70.1.** Heart. Nordiske Med. Ark. Stockholm, ii. 1-47. **Schmiegelow, E. 82.1.** Testis. Arch. f. Anat. Physiol. Physiol. Abth. 1882, 157-168. **Schöbel, J. 85.1.** Fat tissue. A. f. m. A. xxiv. 92-97. **Schott, J. A. G. 36.1.** Nerves in umbilical cord. 4to, pp. 122, Frankfurt a. M. **Schrön, O. 63.1.** Ovary. Z. Z. xii. 409-426. **Schultze, B. S. 61.1.** Das Nabelbläschen ein constantes Gebilde in der Nachgeburt, 1861, Leipzig. **87.1.** Insertion of umbilical cord. Arch. f. Gyn. xxx. 47-56. **Schultze, M. 56.1.** Petromyzon. Natur. Verh. Ges. Wiss. Harlem, xii. 1-49. **61.1.** Muscle. Arch. f. Anat. u. Physiol. 1861, 1-27. **66.1.** Retina. A. f. m. A. ii. 175-286. **Schultze, O. 87.1.** Maturation of amphibian ovum. Z. Z. xlv. 177-226. **87.2.** Axes of embryo. Biol. Centralbl. vii. 577-588. **88.1.** Germ-layers. Rana. Z. Z. xlvii. 325-352. **Schulze, F. E. 62.1.** Muscle. M. A. 1862., 385-392. **Schwabe, G. 79.1.** Human embryo. Zeit. f. Gebk. u. Gyn. iv. 196. **Schwalbe, G. 89.1.** External ear. A. A. iv. 176-189. **91.1.** External ear. A. A. vi. 43-53. **91.2.** External ear. Intern. Beit. wiss. Medicin, Berlin, 1891, 93-144. **Schwarz, D. 89.1.** Tail. Z. Z. xlvi. 191-224. **Schwegel, 58.1.** Limbs. Wien. Sb. xxx. 337-388. **Schweigger-Seidel, F. 66.1.** Præputium, Eyelids. Virchow's Arch. xxxvii. 219-232. **Scott, W. B. 83.2.** Hypophysis. Science, ii. 184-186. **87.1.** Petromyzon. Journ. Morph. i. 233-310. **Scott, W. B. and Osborn, H. F. 79.1.** Newt. Q. J. xix. 449-475. **Sedgwick, A. 80.1.** Kidney. Q. J. xx. 146-166. **80.2.** Glomus of head kidney. Q. J. xx. 372-374. **81.1.** Head-kidney, xxi. 432-468. **83.1.** Function of medullary canal. Proc. Phil. Soc. Cambridge, iv. 325-328. **85.2.** Peripatus, part 1. Q. J. xxv. 449-468. **86.1.** Peripatus, part 2. Q. J. xxvi. 175-212. **Seessel, A. 78.1.** Vorderdarm. His' Arch. 1878, 449-467. **Seiler, D. Burkhard, W. 32.1.** Placenta. Fol. Dresden, 1832, pp. 38. **Selenka, E. 82.1.** Germ-layers, Mouse. Biol. Centralbl. ii., 550. **83.1.** Studien über Entwicklungsgeschichte. Heft i. Wiesbaden, Kreidel, pp. 32. 1883. **84.1.** Studien über Entwicklungsgeschichte. Heft iii. Wiesbaden, Kreidel, pp. 99. **86.1.** Studien über Entwicklungsgeschichte. Heft iv. Wiesbaden, 1886, pp. 101-132. **87.1.** Studien über Entwicklungsgeschichte. Heft iv. 2 Hälfte, 4to, pp. 123-172. **88.1.** Gaumentasche. Biol. Centralbl. vii. 679-683. **90.1.** Paraphysis. Biol. Centralbl. x. 323-326. **Semon, R. 91.1.** Urogenital system. Jena Zeit. Naturw. xxvi. 89-203. **Semper, C. 75.2.** Urogenital system. Plagiostomes. Arb. Zool. Inst. Würzburg, ii. 195-509. **76.3.** Strobilation and segmentation. Semper's Arb. Zool. Zoot. Inst. Würzburg, iii. 115-404. **Sernoff, D. 74.1.** Testis. Centralbl. med. Wiss. xii. 481-483. **Sertoli, E. 66.1.** Lymph-glands. Sitzb. Wien. Akad. liv. 149-162. **Sewall, H. 78.1.** Gastric epithelium. Journ. of Physiol. i. 321-334. **Shipley, A. E. 83.1.** Petromyzon. Q. J. xxvii. 325-370. **Shore, T. W. 91.1.** Liver. Journal of Anat. Physiol. xxv. 166-197. **Shore, T. W. and Pickering, J. W. 82.1.** Proamnion. Journ. Anat. xxiv. 1-22. **de Sinéty, 76.1.** Uterus. Ann. Gynéc. vi. 217-220. **Solger, B. 85.1.** Celom. Morph. Jahrb. x. 494-528. **Spee, F. 84.1.** Wolffian duct. His' Arch. 1884, 89-102. **89.1.** Human embryo. His' Arch. 159-176. **Spencer, W. B. 86.1.** Pineal gland. Q. J. xxvii. 165-238. **Spengel, J. W. 76.3.** Amphibian urogenital system. Arb. Zool. Zoot. Inst. Würzburg, iii. 1-114. **Spöndli, H. 46.1.** Ueber den Primordialschädel. 8vo. pp. 38. Zurich, 1846. **Spronck, C. H. 87.1.** Cartilage. A. A. ii. 259-269. **Staderini, R. 91.1.** Annulus stapedialis. Monit. Zool. Ital. ii. 147-160. **Stassano, 83.1.** Spermatozoa. Z. A. vi. 393-395. **Stieda, L. 78.1.** Lungs. Z. Z. xxx. Suppl. 106-122. **81.1.** Thymus, etc. 4to, pp. 38. Leipzig, 1881. **Stöhr, P. 91.1.** Tonsils. Festschr. f. Fei. fünfzigjähr.-Doc.-Jub. d. H. Prof. Dr. W. v. Nägeli u. Geheimmr. Prof. Dr. A. von Kölliker, pp. 17. **Stoss, 91.1.** Pancreas. A. A. vi. 666-669. **Strahl, H. 80.1.** Neurenteric canal. Marburg. Sitzb. 1880. 37-41. **80.2.** Allantois. Marburg. Sitzb. 1880, 47-49. **80.3.** Neurenteric canal. Marburg. 1880, 54-55. **83.1.** Reptiles. His' Arch. 1883, 1-43. **86.1.** Wolffian bodies. Sitzb. Ges. Beförd. Natur. Marburg. 43-46. **86.2.** Cloaca, rabbit. His' Arch. 1886, 156-168. **87.1.** Yolk-sac, reptiles. Z. Z. xlv. 283-307. **89.1.** Placenta. His' Arch. 1889.

- 213-230. **89.4.** Placenta. His' Arch. Suppl. 1889. 197-212. **90.1.** Placenta, dog. His' Arch. 1890. 185-203. **Strahl, H.** and **Martin, E.** **88.1.** Parietal eye. His' Arch. 1888. 146-163. **Strasser, H.** **79.1.** Cartilage, limbs. *Morph. Jahrb.* v. 240-315. **Strazza, G.** **88.1.** Laryngeal muscles. *Mediz. Jahrb. Wien.* iii. 105-116. **Strelzoff, Z. Z.** **73.1.** Bone. Unter. aus dem pathol. Institut. Zürich, 1-94. **Swaen, A.** **87.1.** Torpedo. *Arch. de Biol.* vii. 537-585.
- Tafari, A.** **86.1.** Placenta. *Arch. d'Anat. Pathol. Pellizari.* iv. 53-216. **89.1.** Fecundation. *Arch. Ital. Biol.* xi. 112-117. **Tait, L.** **76.1.** Umbilical cord. *Proc. Roy. Soc. London.* 1876. 417-440. **Thacker, J. K.** **77.1.** Fins. *Trans. Conn. Acad.* iii. 281-310. **Thayssen, A.** **73.1.** Kidney. *Centralbl. f. d. med. Wiss.* xi. 593-594. **Thiersch, 52.1.** Urogenital. *Illustrirte med. Zeitung.* i. **Thompson, Allen.** **39.1.** Human embryos. *Edinburgh Med. Surg. Journ.* lii. 119-136. **Thompson, W. D'Arcy,** **86.1.** Limbs. *Journ. Anat. Phys.* xx. 532-535. **Tiedemann, Fr.** **16.1.** Bildungsgeschichte des Gehirns. Nürnberg. 1816. **Toldt, C.** **74.1.** Kidney. *Wien. Sb.* lxi. 3 Abth. 123-150. **79.1.** Embryos, age. *Prag. med. Woch.* iv. 121. **79.2.** Mesentery. *Denkschr. Akad. Wiss. Wien.* xli. 2 Abth. 1-56. **80.1.** Glands, stomach. *Wien. Sitzb.* lxxxii. 3 Abth. 57-128. **89.1.** Mesentery. *Denkschr. Math. Naturw. Kl. Akad. Wien.* lvi. 1-46. **Toldt, C.** and **Zuckermandl, E.** **76.1.** Liver. *Wien. Sitzb.* lxxxii. 3 Abth. 241-295. **Tonge, M.** **70.1.** Semilunar valves. *Phil. Trans.* elix. 387-411. **Tourneux, F.** **87.2.** Male vagina. *C. R. Soc. Biol. Paris.* sér. 8. iv. 807-812. **88.1.** Cloaca, etc. *Journ. l'Anat.* xxiv. 503-517. **88.3.** Organ of Rosenmüller, Robin's *Journ. Anat.* xxiv. 169-192. **89.1.** Genital tubercle. *Journ. de l'Anat.* xxv. 229-263. **90.3.** Rectum. *C. R. Soc. Biol. Paris.* sér. 9. ii. 207-211. **Tourneux, F. et Hermann G.** **87.3.** Medullary vestiges. *Journ. de Anat. Physiol.* xxiii. 498-529. **Tourneux, F. et Legay, Ch.** **84.1.** Uterus and vagina. *Robin's Journ. Anat.* 1884. 330-386. **Trinchese, S.** **86.1.** Muscle-plates. *Arch. Ital. de Biol.* vii. 376-379. **Tuckerman, F.** **89.1.** Taste-bulbs. *Journ. Anat. and Physiol.* xxiii. 559-582. **89.2.** Taste-bulbs. *Journ. Anat. and Physiol.* xxiv. 130-131. **Turner, Wm.** **73.1.** Placenta, man. *Journ. of Anat. Physiol.* vi. 2 sér. 120-133. **76.1.** Lectures on the Comparative Anatomy of the Placenta. Svo. pp. 124. Edinburgh. **76.3.** Placenta, lemurs. *Phil. Trans. Roy. Soc. London.* clxvi. 569-587. **77.1.** Placenta, evolution. *Journ. of Anat. Physiol.* xi. 33-53. **77.2.** Placenta, lemurs. *Journ. Anat. and Phys.* xii. 147-153. **79.1.** Placenta, apes. *Phil. Trans.* clxix. 523-562. **88.1.** Placenta, lemurs. *Proc. Roy. Soc. London.* xlv. 277-282. **90.2.** Cerebral Convulsions. *Journ. of Anat. and Physiol.* xxv. 105-152. *Verhandl. d. x. Inter. medic. Kongress. Berlin.* ii. Abth. Anat. 8-46. **Türstig, J.** **86.1.** Aorta, chick. pp. 21. Dorpat. 1886.
- Underhill, 75.1.** Menstruating uterus. *Edinburgh Med. Journ.* xxi. 132-133. **Unna, P.** **76.1.** Epidermis. *A. f. m. A.* xii. 665-741. **Urbantschitsch, v.** **73.1.** Tympanum. *Wien. Sitzb.* lxxvii. 19-30. **Uskoff, N.** **82.1.** Karyokinesis. *A. f. m. A.* xxi. 291-295. **Uskow, N.** **83.1.** Diaphragm. *A. f. m. A.* xxii. 143-219. **87.1.** Blood. *Mém. l'Acad. Impér. Sci. St. Petersburg.* xxxv. sér. 7. pp. 48.
- Vignal, W.** **83.1.** Nerve fibres. *Arch. de Physiol.* 513-535. **83.2.** Nerve fibres, growth. *Arch. de Physiol.* xv. 536-548. **84.1.** Medulla, mammals. *Arch. de Physiol.* xvi. 177-237: 364-426. **88.1.** Histogenesis, brain. *Arch. de Physiol.* xx. 228-254: 311-336. **Villy, F.** **90.1.** Ear, frog. *Q. J.* xxx. 523-550. *Stud. fr. Biol. Labor. Owen's Coll.* ii. 159-184. **Virchow, H.** **75.1.** Yolk-sac. Svo. pp. 29. Berlin. **85.1.** Zona pellucida. *A. f. m. A.* xxiv. 113-116. **91.1.** Yolk-sac, chick. *Intern. Beitr. Wiss. Medicin.* i. *Festchr. R. Virchow.* **92.1.** Yolk-sac, vertebrates. *Zeit. Zool. Suppl.* 166-206. **Virchow, R.** **57.1.** Untersuchungen über die Entwicklung des Schädelgrundes. *Fol. pp.* 128. Berlin. **Viti, A.** **86.1.** Amnion. *Svo. Siena.* pp. 59. 1886. **Vrolik, A. J.** **73.1.** Skull, teleosts. *Nederl. Arch. Zool.* i. 319-318.
- Wagner, R.** **35.1.** Germinative vesicle. *Müller's Arch.* 1835. 373-377. **Waldeyer, W.** **65.1.** Human embryo. *Stud. Physiol. Inst. Breslau.* 55-70. **69.1.** Germ-layers, chick. *Z. rat. Med.* xxiv. 159-178. **70.1.** Eierstock und Ei. Svo. pp. 174. Leipzig. **72.1.** Teeth. *Stricker's His-*

- tology. 321-341. **76.1.** Central canal. Arch. f. Path. Anat. lxxviii. 20-26. **83.1.** Archiblast und Parablast. A. f. m. A. xxii. 1-77. **87.1.** Placental circulation. Berlin. Sb. vi. 83-93. **90.1.** Placenta, man and apes. A. f. m. A. xxxv. 1-51. **Walker, A. 87.1.** Abdominal pregnancy. Virchow's Arch. cxvii. 72-79. **Warren, J. C. 77.1.** Skin. Boston Med. and Surg. J. April 19, 1877. **Weismann, A. 61.1.** Muscles. Zeit. f. rat. Med. iii. 12 Reihe. x. 263-284. **83.1.** Ueber die Vererbung. 8vo. pp. 59. Jena. **85.1.** Die Continuität des Keimplasmas. 8vo. pp. 122. 1885. Jena. **Weismann, A. und Ischikawa. 87.2.** Polar globules. Bericht. Nat. Ges. Freiburg. iii. 1-44. **88.2.** Partial impregnation. Bericht. Nat. Ges. Freiburg. iv. 55-58. **88.4.** Polar globules, number. Zool. Jahrb. Abth. Anat. iii. 575-610. **Welcker, 64.1.** Haut von Bradypus. Halle. 1864. **Weldon, W. F. R. 83.1.** Lacerta. Q. J. xxiii. 134-144. **85.1.** Supra-renals. Q. J. xxv. 137-150. **Wenckebach, K. F. 85.1.** Blood, Perca. Journ. of Anat. and Physiol. xix. 231-236. **Whitman, C. O. 78.2.** Clepsine. Q. J. xviii. 215-315. **83.1.** Blastoderm. Q. J. xxiii. 375-397. **87.3.** Oökinesis. Journ. Morph. i. 227-252. **88.1.** Formative energy. Journ. Morph. ii. 27-49. **Wiedersheim, R. 86.1.** Parietal eye. A. A. i. 148-149. **90.3.** Urogenital system, reptiles. A. A. v. 337-344. A. f. m. A. xxxvi. 410-468. **Wieger, G. 85.1.** Descensus ovariorum. His' Arch. 1885. 349-360. **Wiener, M. 81.1.** Amniotic fluid. Arch. f. Gynäk. xvii. 24-44. **Wijhe, J. W. van. 82.1.** Mesodermic head segments. Verh. K. Akad. Wetens. Amsterdam. xxii. 3te Art. pp. 50. **84.1.** Neuroporus. Zool. Anz. vii. 683-687. **86.1.** Wolffian duct. Zool. Anz. ix. 633-635. **89.1.** Excretory organs, selachians. A. f. m. A. xxxiii. 461-516. **Will, L. 89.1.** Platydactylus. Berlin. Sb. lii. 1121-1128. **90.1.** Gecko. Biol. Centralb. x. 592-600. **Williams, John. 75.1.** Uterus. Obstet. Journ. Gt. Brit. and Ireland. ii. 681-696: 753-767. **75.2.** Uterus. Obstet. Journ. Gt. Brit. and Ireland. iii. 496-504. **Wilson, H. V. 91.1.** Sea-Bass. Bull. U. S. Fish. Comm. ix. (1889.) 209-277. **Winogradow. 72.1.** Amnion. Virchow's Arch. liv. 78-81. **Winkler, F. N. 72.1.** Placenta. Arch. f. Gynäk. iv. 238-265. **Wisozky, N. 77.1.** Blood. A. f. m. A. xiii. 479-496. **Wölfler, A. 81.1.** Ueber die Entwicklung und den Bau der Schilddrüse. 4to. pp. 59. Berlin. **Wyder, A. Th. 78.1.** Uterus. Arch. f. Gyn. xiii. 1-55.
- Zacharias, O. 87.1.** Impregnation, ascaris. A. f. m. A. xxx. 111-182. **Zander, R. 84.1.** Nails. His' Arch. 1884. 103-143. **86.1.** Nails. His' Arch. 1886. 273-306. **88.1.** Cornification. His' Arch. 1888. 51-96. **Ziegenspeck, K. 83.1.** Fœtal circulation. Preyer. Specielle Physiol. d. Embryo. 596-607. **Ziegler, H. E. 87.1.** Blood, teleosts. A. f. m. A. xxx. 596-665. **88.1.** Mesenchyma. A. f. m. A. xxxii. 378-400. **89.1.** Blood, vertebrates. Berichte Nat. Ges. Freiburg, iv. 171-182. **Zimmermann, K. W. 89.1.** Aorta. A. A. iv. 720. **90.1.** Pigment-cells. A. f. m. A. xxxvi. 404-410. **91.1.** Metamerism. head. Verhandl. Anat. Ges. v. München, 107-113. **Zumstein, J. J. 87.1.** Mesoderm. 8vo. pp. 56. Bern. 1887. **Zweifel, 75.1.** Meconium. Arch. f. Gynäk. vii. 474-490.

INDEX.

- ABDOMINAL and pleural cavities,
separation of the, 484
- Abducens nerve, 644
- Achromatic threads, 95
- Achsenstrang*, 134
- Aeroblast, 154
- After-birth, the, 364
- Afterdarm*, 260
- Afterhaut* in sauropsida, 190
- Ahlfeld's ovum, 289
- Aire germinative*, 271
- vasculaire*, differentiation of the,
272
- Ala vespertilionis, origin of, 244
- Alecithal ova, 61
- Alimentary tract, 743
- Allantoic fluid, 355
- Allantois, the, 353
- conversion of, into the bladder,
514
- histology of, 353
- in mammals, 354
- in man, 354
- origin of, 257
- union of, with the chorion, 376
- Allantoishöcker*, 259
- Allantois-stalk, 354
- partial closure of, in embryo of
twenty-seven days, 387
- see also *Bauchstiel* and umbilical
cord
- Allantoismulst*, 259
- Alveolargänge*, 777
- Ameloblasts, 586
- Ammonsfurche*, 692, 696
- Amnion, the, 333
- and chorion, union of, 337
- definition of, 333
- differentiation of, 334
- evolution of, 344
- histology of, 333
- origin of, 281
- Amnion, progressive history of, 35
- retrogressive history of, 28
- Amnionstrang*, 284
- Amniotic cord, 284
- fluid, 337
- Amphiaster of the ovum, 63, 95
- Amphibia, condescence in, 120
- development of the primitive seg-
ments in, 195
- medullary groove of, 177
- mesoderm of, 145
- primitive axis in, 129
- Amphioxus, differentiation of the
mesoderm of, 209
- Anal canal, 189
- membrane, 260
- plate, 190
- Annulus tympanicus, 740
- Anus of Rusconi, 124, 129
- primitive, 259
- Aorta, division of the, 531
- dorsal, and its branches, 539
- pulmonary, 538
- Aortic arches, 534
- evolution of the, 538
- in branchiate vertebrates, 537
- Aortic valves, 534
- Aortic wall, development of the, 537
- Appendix vermiformis, 758
- Aqueductus endolymphaticus, 729
- Sylvii, 678
- Aqueous humor, 724
- Archenteric cavity, 254
- extension of the, 271
- Archenteron, 115
- comparison of mammalian and
amphibian, 269
- definitive, 127
- early development of the, 254
- separation of the, from the yolk-
sac, 255
- Arches, aortic, 534

- Arches, branchial, 265, 267
 branchial, muscles of the, 477
 gill, 265, 267
 mandibular, 578
 visceral, 265, 267
- Archamphiaser of the ovum, 63
- Archiblast, 120, 153
- Archipterygium, 450
- Archistome, 113
- Artes branchiaux*, 265, 267
- Area embryonalis, 271
 generativa, 271
 gland, 564
 interposita, 525
 opaca, 134, 254, 271
 pellucida, 254, 271
 pellucida of a hen's egg, 131
 placentalis, 374
 vasculosa, 197, 274
 vasculosa, differentiation of the, 272
 vitellina, 272
- Arm, skeleton of the, 456
- Arsenoblasts, 78
- Arterial system, transformation of the, 534
- Arteries, intersegmental, 540
- Atrioventricular valves, 533
- Attraction, sphere of, 94
- Auditory passages, 738
- Auricles, division of the, 528
 formation of the, 521
- Auricular canal, division of the, 529
- Aussenfalte*, *vordere*, 132
- Axial cord, 134
- Axis, development of the, 430
 primitive, 118
- BARs. hyoid, 445
 mandibular, 441
 thyro-hyoid, 447
- Bartholini's glands, development of, 516
- Basal ganglia, 694
 layer of the epidermis, 550
 substance, mesenchymal, 166
- Basement membranes, 421
- Basilarleiste*, 712
- Bauchganglienketten*, 570
- Bauchstiel*, 33, 354, 356
 partial closure of, in embryo of twenty-seven days, 387
- Beelhaare*, 561
- Beigel's ova, 289, 308
- Belegknochen*, 461
- Belegzellen*, 755
- Bildungsgewebszellen*, transformation of leucocytes into, 208
- Birds, concrescence in, 124
 primitive axis and streak of, 131
- Bladder, development of the, 514
- Blastocyst, see Blastodermic vesicle
- Blastodermic rim, 117
- Blastodermic vesicle, 105
 homologies of, 107
 homologies of the mammalian, 141
 mammalian, 135
 with one complete layer, 135
 with primitive streak, 139
 with primitive streak and head process, 140
 with two layers, 137
- Blastophore, 80
- Blastopore, 127
 secondary, 190
 yolk, 124
- Blastoporic canal, 128
- Blastula, 111
 stage of segmentation, 97
- Blatt, animales*, of Von Baer, 167
vegetatives, of Von Baer, 167
- Blood, one-celled, 223
 origin of the, 211
 plastid, 224
 two-celled, 223
- Blood-cells, red, 215, 218
- Blood-corpuseles, morphology of the, 223
- Blood-germ, the, 212
- Blood-islands, 213
- Blood-plates, origin of the, 223
- Blood-vessels, growth of, into the embryo, 214
 origin of the, 211
 primitive, 218
 transformations of the, 534
- Blutkeim*, 212
- Bodenplatte*, 606
- Body-cavity, 197
- Bogenfurche*, 692, 696
- Bone, growth of, 410
 origin of, 407
 origin of the marrow of, 420
- Bones, dermal, 422, 461
 frontal, development of, 463

- Bones, interparietal, development of, 463 .
 jugal, development of, 464
 lachrymal, development of, 463
 malar, development of, 464
 maxillary, development of, 464
 nasal, development of, 463
 of the human skull, homologies of the, 465
 palatine, development of, 463
 parietal, development of, 463
 præ-maxillary, development of, 464
 pterygoid, development of, 464
 splenial, or splint, 461
 squamosal, development of, 463
 tympanal, development of, 464
 typical dermal, in amniota, 462
- Botallischer Gang*, 539
Bouchon cloacal, 516
Bourrelet entodermo-vitellin, 193
- Brain, anlage of the, 178
 definition of the, 593
 development of the, 593
 fore-, 178, 595, 610
 hind-, 178, 595, 598
 mid-, 178, 595, 598, 610, 677
- Branchial arches, 265, 267
 arches, muscles of the, 477
 clefts, 263
 nerves, 636
 region, 743
 sense-organs, 706
 skeleton, 443
- Branchiate vertebrates, aortic arches in, 537
- Braun's cords, 513
 third canal, 190
- Breus' ovum, 288
- Broad ligament, development of the, 499
- Bronchi, hyparterial, 775
 Bronchial tree, 774
 Bronchus, eparterial, 775
 Bruch's embryo, 308
Brücken Kern, zackiger, 671
Brückenkrümmung, 599
 in embryo of thirty-one days, 389
- Bündel, ovals*, 661
 Bundle, oval, 661
 Burdach, cords of, 661
 Bursa Fabricii, 260
 parietalis, 482
- Bursal cavities, development of, 421
- CADUCA, see Decidua
 Calcar avis, 693
 Canal, anal, 189
 blastoporic, 128
 Braun's third, 190
 central, of the spinal cord, 659
 entodermal, 743
 hyaloid, 723
 medullary, 178
 neural, 179
 neurenteric, 188
 notochordal, 126
 notochordal, differentiation of the, 182
 of Schlemm, 724
 true neurenteric, 188
 tubo-tympanal, 738
- Canalis cranio-pharyngeus, 574
 hyaloideus, 713
 reuniens Henseni, 737
- Canals, Fontana's, 726
 Gärtner's, 503
 semicircular, 730, 738
- Cap, cephalic, 282
 Capsule of the lens, 716, 723
 Capsules, periotic, 438
 supra-renal, 485
- Capuchon caudale*, 283
céphalique, 282
- Carotids, internal, development of the, 538
- Carpus, ossification of the, 457
- Cartilage, appearance of the matrix* of, 404
 degeneration of ossifying, 406
 elastic, 406
 ensiform, 434
 fibro-, 406
 growth of, 405
 mature hyaline, 405
 Meckel's, 445
 origin of, 403
 Reichert's, 445
 xyphoid, 434
 young hyaline, 404
- Cauda equina, 658
 Caudicantia, 687
Cavité somatique, 197
 Cavities, bursal, development of, 421
 colomatic, in the head, 199
 mesenchymal, 420

- Cavities, pleural, expansion, of the, 483
 separation of the pleural and abdominal, 484
 separation of the pleural and pericardial, 482
 synovial, development of, 421
- Cavity, amniotic, 284
 archenteric, 254
 archenteric, extension of the, 271
 mandibular, 200
 of the primitive segment, 202
 omental, 770
 oral, development of, 567
 pleuro-peritoneal, 197
 pre-mandibular, 200
 primitive body, 150
 segmentation, 97
 sub-germinal, 115
 yolk, 115
- Cells, Corti's, 734
 daughter, 44
 decidua, 12
 Deiter's, 734
 dome, 550
 dumb-bell, of the ovum, 56
 ectodermal, 97 *et seq.*
 egg-, 48
 enamel, 586
 entodermal, 97 *et seq.*, 254
 epidermic, 548
 fat-, development of, 417
 germinating, 611
 lutein, 67
 mother, 44
 nerve, development of, 624
 nerve, origin of, 611
 of the Graafian follicle, 53
 of the seminiferous tubules, 42
 of the vitelline epithelium, 347
 ovic, 48
 parent, 43
 peptic, 755
 pigment, origin of, 419
 plasma, possibly regressive stages
 of fat-cells, 419
 primitive mesodermic, 149
 red blood- 215, 218
 Sertoli's, 42
 sexual, 249
 special sense-, 709
 vasoformative, 218
 young neuroglia, 611
- Cement, dental, 589
- Centrolecithal ova, 61
- Centrosoma, 94
- Cephalic cap, 282
 ganglia, 603
 nerves, general morphology of, 633
- Cerebellum, 672
 histogenesis of the, 674
- Cerebral convolutions, 695
 flexures, 600
 hemispheres, 690
 nerves, morphology of the, 633
 vesicles, 178, 593
- Cerebrum, peduncles of the, 678
- Cervical nerves, 629
 sinus, 744
- Chamber, anterior, 723
- Cheek-plate, 568
- Cheiropterygium, 450
- Chiarugi's embryo, 304
- Chiasm, optic, 688, 718
- Chondrocranium, 434
 atrophy of parts of the, 441
 ultimate history of the, 438
- Chorda dorsalis, 181
- Chorda funiculae, 362
- Chorion and amnion, union of, 337
 blood-vessels of the, 331
 evolution of the, 331
 frondosum, 318
 general description of the, 317
 histology of the, 322
 leve, 318
 primitive, 281
 progressive history of the, 35
 retrogressive history of the, 28
 the human, 317
 true, 286
 union of the allantois with, 376
- Chorionic fluid, 318
 vesicle, 317
 villi, 318
- Choroid, 713, 722
 plexus, 681
 processes, 722
- Chromatin, the essential factor in
 the function of heredity, 90
- Cicatricula, 99
- Ciliary ganglion, 640, 642
 muscle, 725
- Circulatory system, origin of the, 211
- Clavicle, development of the, 454

- Cleavage, see Segmentation
 Clefts, branchial or gill, 263
 Clitoris, origin of the, 518
 Cloaca, 259
Cloison mésodermique, 482
 Cochlea, 731
 Cœcum, 758
 Cœlenteron, 113
 Cœlom, 144
 extension of the, 271
 extra-embryonic, extension of the, 280
 formation of the, 150
 of the head, 199
 primitive divisions of the, 192
 theory of the mesoderm, 155
 unsegmented, 197
 ventral, 197
 Commissure, ganglionic, 603
 Commissures, cerebral, 684
 Conarium, 688
 Concrecence, 115
 in birds, 124
 in bony fishes, 117
 in elasmobranchs, 118
 in mammals, 124
 in marsipobranchs, ganoids, and amphibians, 120
 in sauropsida, 122
 law of, 115
 significance of, 125
 summary of, 125
 Conjunctiva, 726
 Connective-tissue fibrils, origin of, 599
 Continuity, germinal, 87
 Convolutions, cerebral, 695
 Cord, amniotic, 284
 genital, 501
 genital, formation of the, 491
 spinal, 607, see Spinal cord
 sympathetic, 630
 umbilical, 356, see Umbilical cord
 Cords, Braunn's, 513
 medullary, development of, 249
 of Burdach, 661
 vocal, 778
 Corium, 553
 Cornea, 724
 Cornu Ammonis, 692
 Corona radiata of the discus proligerus, 53, 59
 Corpora albicantia, 687
 Corpora quadrigemina, 678
Corps innominé, 501
 Corpus albicans, 68
 callosum, 683
 cavernosum, 518
 hemorrhagicum, 66
 luteum of menstruation, 67
 luteum of pregnancy, 68
 spongiosum, 518
 striatum, 691
 Corpuscles, Malpighian, 509
 red blood-, origin of, 221
 white blood-, origin of, 221
 Corti, organ of, 733
 Corti's cells, 734
 Coste's embryo, 300
 Cotyledons of the placenta, 366
Couronne polaire, 95
 Cowper's glands, development of, 516
 Cranial nerves, morphology of the, 633
 Cranium, development of the, 434
 ossification of the, 439
 Crescent, anterior, of the area pellucida, 132
 Crest, neural, 601
 Crura cerebri, 695
 Cumulus proligerus of the Graafian follicle, 52
 Cutis, development of the, 553
 Cuvier, duct of, 275, 542
Cylinderfurche, 607, 662

Darmfaserblatt of the mesoderm, 152
Darmforte, vordere, 261
 Decidua, changes in the, at parturition, 21
 graviditatis, 6, 26
 menstrualis, 4, 26
 reflexa, 8
 reflexa, fate of the, 19
 serotina, 8
 serotina at the end of seven months, 17
 subchorialis, as described by Kölliker and others, 18
 vera, 8
Deckknochen, 461
Decklamelle, graue moleculäre, 675
 Deck-plate of the fore-brain, 681
Deckplatte of His, 606
Deckschicht, 106, 108, 135, 139
 modification of, in rodents, 141

- Deiter's cells, 734
 Dental follicle, origin of the, 584
 papilla, 587
 processes, 588
 ridge, 578
 shelf, 583
 Dentine, 588
 Dentition, double, of mammals, 589
 Dermal bones, 461
 Dermal teeth of sharks, 581
 Dermis, development of the, 553
 Descemet, membrane of, 725
 Deutoplasm of the ovum, 49
 Development, human, general outline of, 28
 Diadern, 111
 Diaphragm, development of the, 485
 rudiment of the, 269
 Differentiation, 160
 histological, 164
 Dilatations, 161
 Diphyodont, definition of term, 582
 Disc, germinal, 99
 Discus proligerus, 99
 of the Graafian follicle, 52
 Diverticula, 161
 Dome cells, 550
 Dorsal flexure, the, 313
Dotterbildung, Herd der, 53
Dotterhaut, 58
Dotternabel, 124
Dottersackepithel, cells of the, 347
Drüsen, zusammengesetzte, 163
Drüsenfeld, 564
 Duct, lachrymal, 580
 milk, 565
 Müllerian, 230, 244, 253, 503
 of Santorini, 767
 of Wirsung, 767
 pronephric, 230, 234, 253
 segmental, 230, 234, 253
 Wolffian, 230, 234, 253, 502
 Ductus arteriosus, 539
 Botalli, 539
 Cuvieri, 275, 542
 Cuvieri, changes in the, 544
 thyreoglossus, 748
 EAR, bones of the, 740
 development of the, 727
 external, 741
 Ecker's ovum, 307
 Ectental line, 97
 Ectoderm and entoderm, differentiation of, 110
 differentiation of the, 323
 formation of the, 97 *et seq.*
 Ectodermal organs of the human body, 160
 Egg, see Embryo, Fœtus, and Ovum
 Ehrenritter's ganglion, 649
Einzeldrüsen, 163
 Elasmobranchs, conerescence in, 118
 mesoderm of, 144
 primitive axis in, 130
 Elastic tissue, origin of, 401
 Embryo, 170
 amniote, 278
 attachment of the, 374
 cross-section of a typical, 279
 determination of the age of, 384
 form of the, 277
 growth of the, 381
 human, progressive history of the, 35
 human, retrogressive history of the, 28
 measuring the length of, 384
 mesoblastic, 128
 primitive type of vertebrate, 277
 secondary type of vertebrate, 277
 transition from the, to the fœtus, 391
 see also Fœtus, Ova, and Ovum
 Embryos, classification of known human, by stages, 286
 of known ages, characteristics of, 384
 for those of His and others, see under Ova
 Enamel, deposit of, 587
 organ, development of, 584, 585
Enddarm, the, 260
Endocardkissen of the auricular canal, 530
Endothelherz, 226
Endothelkissen of the auricular canal, 530
Endstück of a spermatozoon, 41
 Ensiform cartilage, 434
 Enterocœle, 169
 Enteron, 113
 Entoderm and ectoderm, differentiation of, 110
 cells of the, 254
 formation of the, 97 *et seq.*

- Entoderm, intestinal, growth of the, 760
 separation of notochordal band from, 182
- Entodermal canal, 743
 organs of the human body, 160
- Euvellope moléculaire grise*, 675
- Envelopes, fetal, progressive history of the, 35
 fetal, retrogressive history of the, 28
- Ependyma, 599
- Ependyma, 616
- Eperou périaéal*, 517
- Epibranchialis nerve, 651
- Epicæle, 169
- Epidermal system, 548
- Epidermis, formation of the, 548
- Epididymis, development of the, 500
- Epiglottis, 778
- Epiphysis cerebri, 688
- Episternum, 454
- Epistropheus, formation of the, 430
- Epithelium, differentiation of, 165
 germinal, 247
- Epitrichium, 550, 552
- Eponychium, 555
- Epoöphoron, development of the, 500
- Ersatzhaare*, 561
- Eustachian tube, 740
- Eye, anterior mesenchyma of the, 723
 development of the, 710
 evolution of the vertebrate, 727
 parietal or pineal, 688
- Eyelashes, 726
- Eyelid, 726
 third, 727
- FABRICIUS, bursa of, 260
- Face, development of the, 567
- Facial apparatus, position of the, 467
- Fallopian tube, 504
 origin of the, 245
- Falte, vena cava*, 483
- Falx cerebri, 691
- Fat-cells, development of, 417
- Femur, ossification of the, 459
- Fenestra ovalis, 740
 rotunda, 740
- Fentes branchiales*, 263
- Feuille angioplastique*, 212
- Feuillet vasculaire*, 341
- Fibres, ganglionic, 619
 medullary, 616
 muscle, multiplication of, 474
 nerve, origin of, 616
 osteogenetic, 409
 segmental or skeletal muscle, 470
 smooth-muscle, origin of, 417
- Fibrillæ, muscular, 473
- Fibrils, connective-tissue, origin of, 399
- Fibrin, canalisirtes*, 323
- Fibula, ossification of the, 459
- Filament epiaxial*, 132
- Fissura calcarina, 697
 parieto-occipitalis, 697
- Fissure, calloso-marginal, 697
 choroid, 712
 of Rolando, 698
 splenic, 697
 triradiate, 700
- Fissures, cerebral, 695
 accessory, 702
 evolution of, 702
 of the frontal lobe, 700
 of the island of Reil, 701
 of the occipital lobe, 701
 of the parietal lobe, 701
 of the temporal lobe, 701
 transitory, 702
- Fleischschicht* of Von Baer, 167
- Flexure, dorsal, 313
- Flexures, cerebral, 600
- Floor of the third ventricle, 687
- Flügelleiste* of the medulla, 666
- Flügelplatte*, 607
- Flügelwulst* of the medulla, 667
- Fluid, allantoic, 355
 amniotic, 337
 chorionic, 318
- Fœtal appendages, 314
 appendages, origin of the, 280
- Fœtus, the, 379
 growth of, 381
 nutrition of, 373
 progressive history of, 35
 retrogressive history of, 28
 transition from the embryo to, 391
 see also under Embryo, Ova, and Ovum
- Follicle, dental, origin of the, 584
 Graafian, development of the, 51
- Follicles, primary, growth of the, 50

- Fontana's canals, 726
 Fontanelles, the, 465
 Foramen caecum, 592, 748
 of Monro, 597, 680, 693
 of Winslow, 770
 ovale, 529
 Fore-brain, 178, 595, 610
 median portion of the, 679
 Fore-gut, origin of the, 261
 Formative yolk, 99
 Fornix, 684
 Fossa of Sylvius, 695
 Fourth ventricle and its roof, 676
 Fovea cardiaca, 261
 Fretum Halleri, 523, 525
 Froriep's ganglion, 656
 law, 469
Fruchtschneiere, 562
Fruchtwasser, 337
 Funiculus amnii, 284, 285
 restiformis, 667
 Funnel, Müllerian, 245
Furchung of ova, 93
 Furrow, dorsal, 173
Fusszellen, origin of, 494
- GANGLIA, basal, 694
 cephalic, 603
 sensory, origin of, 601
 sympathetic, 631
Ganglienteiste, 602
 Ganglion, acustico-faciale, 644
 ciliary, 640, 642
 cochleare, 645
 Ehrenritter's, 649
 Froriep's, 656
 Gasserian, 642
 geniculi, 645
 glosso-pharyngeal, 648
 hypoglossal, 656
 impar, 632
 intracranial, 645
 jugulare, 652
 mesocephalic, 640
 nodosum, 652
 olfactory, 637
 petrosun, 649
 spiral, 647
 thalamic, 640
 trigeminal, 641
 trochlear, 641
 vagus, 651
 vestibulare, 645
- Ganglionic commissure, 603
 fibres, 619
 nerve cells, 626
 sense-organs, 706
 Ganoids, concrescence in, 120
 development of the primitive
 segments in, 195
 primitive axis in, 129
 Gall-bladder, 766
Gallertgewebe, 329
Gallertschicht, 329
 Gärtner's canals, 503
 Gasserian ganglion, 642
 Gastrula theory, 112
Ganumentasche of Selenka, 183
Gefässhof, 197
 differentiation of the, 272
Gefässschicht, 167, 212
 Gegenbauer's theory of the skull,
 469
Gehirnbläschen, 595
Gekröse, 244
 Genital cord, 501
 cord, formation of the, 491
 fold, 247
 mesenchyma, production of the,
 248
 products, the, 37
 ridge, 230, 244, 251
 tubercle, 516
 Genitalia, external, development of
 the, 516
Genitalstrang, 501
 Genoblasts, history of the, 39
 Germ-band theory of the mesoderm,
 156
 Germ-layers, the, 91, 159
 differentiation of, 160
 inversion of, in rodents, 141
 law of the unequal growth of, 162
 organs of the human body de-
 rived from the several, 160
 rôle of, 159
 Germinal area, 271
 continuity, 87
 disc, 99
 epithelium, 48, 247
 spot of the ovum, 57
 vesicle of the ovum, 57
 wall, 133, 271
Geschlechtszellen, 249
Gesichtskopfbeuge, 600
 Gill-arches, 265, 267

- Gill-clefts, 263
 Gingivæ, 578
 Girdle, pelvic, 455
 shoulder, 453
 Gland, pineal, 680, 688
 prostatic, 515
 thyroid, 747
 Glands, 161
 Bartholini's, 516
 classification of, 163
 Cowper's, 516
 intestinal, 739
 lacrimal, 727
 lymph-, development of, 414
 mammary, 564
 Montgomery's, 565
 mucous, of the stomach, 755
 of the skin, 563
 salivary, 590
 sebaceous, development of, 562
 sexual, development of, 492
 sweat, 563
Globules de maturation parfaite, 81
 du début, 80
 polaires, 64, 65
 précoces, 80
 tardifs, 80
 Globules, groups of, eliminated from
 the ovules, 80
 polar, of the ovum, 64
 Glosso-pharyngeal nerve, 648
 Goette's theory of the mesoderm, 156
 Graafian follicle, development of the,
 51
 ovulatory metamorphosis of
 the, 66
Grünzplatte, 671
 Gray matter, 616
 of the medulla oblongata, 670
 of the spinal cord, 663
Grenzvene of the placenta, 373
 Groove, dorsal, 134
 medullary, 134, 173
 primitive, 140
 primitive, stage when it is at its
 maximum, 134
 pulmonary, 773
 Growth, law of unequal, 162
Grundplatte, 607
Grundsubstanz, 166
 Gubernaculum, 248, 496
 Gums, formation of the, 578
 Gut, post-anal, 260
 Gyri of the brain, 695
 Gyrus arcuatus, 696
 choroideus anterior et posterior,
 677
 dentatus, 696
 fornicatus, 698
 subcallosus, 703
 uncinatus, 696
 HABENULA tecta, 736
Hahnentritt of the ovum, 99
 Hairs, development of, 557
 embryonic, 561
 loss and renewal of, 561
Hakenkrümmung, 600
Hautzellen of the ovum, 56
Harsack of Von Baer, 296
 Hatschek's germ-band theory of the
 mesoderm, 156
Hauptstück of a spermatozoon, 40,
 41
Hautfaserblatt of the mesoderm, 152
Hautschicht of Von Baer, 167
 Head, œlom of the, 199
 evolution of the, 704
 Head-kidney, 231
 Head-process, 128, 134, 140
 Heart, amniote mode of development
 of the, 225
 division into right and left, 528
 endothelium of the, 228
 muscles of the, 478
 non-muscular areas of the, 527
 origin of the, 224
 primitive mode of development
 of the, 224
 transformations of the, 521
 valves of the, 532
 walls of the, 525
 Hecker's ovum, 308
 Hemispheres, cerebral, 690
 Hensen's knot, 124, 138
Herd der Dotterbildung, 53
 Heredity, 85
 the essential factor in the func-
 tion of, 90
 Hernia, intestinal, 758
Hexenmilch, 565
 Hillocks on the inner surface of the
 pregnant uterus, 13
 Hind-brain, 178, 595, 598
Hinterdarm, 260
Hinterhirn, 178, 595, 598

- Hinterseitenstrang* of the spinal cord, 662
- Hippocampus major, 692
minor, 692, 693
- Hirnanhang*, 571
- Hirnblasen*, 178
- Hirnsichel*, 691
- His, zones of, 696, 661
zones of, in the adult, 666
zones of, in the fore-brain, 686, 687
- His' embryos, 291, 293, 294, 297, 298, 304
- Historical references to—
concrecence, 117
epiphysis cerebri, 689
ganglionic fibres, 620
hypoglossal ganglion, 657
hypophysis cerebri, 575
kidney, 514
mammary glands, 566
mesentery, 772
neuromeres, 606
origin of the decidual cells, 12
ossification, 412
ovulation, 69
peripheral nerve-fibres, 622
placenta, 373
spermatozoa, 47
theories of the mesoderm, 153
theories of the skull, 468
theory of the germ-layers, 166
thymus gland, 747
thyroid gland, 751
Wolffian bodies, 243
- Holoblastie ova, 55, 99, 111
- Horustreif*, 695
- Horzellen, ab- und aufsteigende*, 734
- Hülle, seröse*, 286
- Humerus, ossification of the, 456
- Humor, aqueous, 724
vitreous, 723
- Hyaloid canal, 723
- Hydatid of Morgagni, 503
- Hymen, biperforate, cause of, 505, 507
development of, 507
- Hyoid bars, 445
- Hypochordal brace of the vertebra, 425
- Hypoglossal nerve, 655
- Hypophysis cerebri, 571
- IDIOPLASMA, 88
- Impregnation, 69
- Incus, 445
- Infundibulum, 687
- Innenschicht* of the medullary wall, 616
- Inseln* on the inner surface of the pregnant uterus, 13
- Insertio fureata of the umbilical cord, 361
velamentosa of the umbilical cord, 361
- Intercellular network, origin of, 401
substance, disappearance of, 413
substance, hypertrophy of, 413
- Intersegmental arteries, 540
- Intervertebral ligament, 426
- Intervillous space, 317
- Intestine, 755
- Invaginations of the germ-layers, 161
- Iris, 725
primitive, 714
- Island of Reil, 696
fissures of, 701
- JACOBSON'S organ, 577
- Janosik's embryo, 300
- Joints, embryological classification of, 461
of the limbs, development of the, 460
- Jones' (Wharton) ovum, 289
- KARYOKINESIS of the ovum, 94
- Karyosomen*, 76
- Küsesfirniss*, 562
- Keibel's ovum, 291
- Keilstränge, Burdach'sche*, 661
- Keimcylinder* of Selenka, 141
- Keimepithel*, 48, 247
- Keimhof*, 271
- Keimplasma*, 87
- Keimscheibe*, 99
- Keimstreif*, 158
- Keimwall*, 133
- Keimzellen des Markes*, 611
- Kernplatte*, 63, 95
- Kernsaft*, 62
- Kernspindel*, 63
- Kidney, development of the, 507
head-, 231
primitive, 231, 235
shape of the, 513
the human, 513
- Kiemenbögen*, 265, 267

- Kiemenspalten*, 263
 Knot, Hensen's, 124, 138
Kolbenhaare, 561
 Kolk's (Schroeder van der) embryo, 303
 Kollmann's ova, 289, 295
Kopfbau, 600
Kopffortsatz, 128, 134, 140
Kopfkappe, 282
Kopfkrümmung, cordere, 600

 LABIA majora, origin of the, 520
 minora, origin of the, 518
 Labyrinth, 737
 Lachrymal duct, formation of, 580
 gland, 727
 Lamina spiralis, 732
 terminalis, 597, 679, 682
Laugsbündel, hinteres, 671
 Lanugo, 561
 Larynx, 778
 Lateral nerve, 654
 Layer, outer nuclear, of the cerebellum, 675
Lederhaut, 553
 Leg, skeleton of the, 458
Leibeshöhle, 197
 Lens, optic, 714
 capsule of the, 716, 723
 vascular tunic of the, 716
 Lenticular zone of the optic cup, 722
 Leucocytes, origin of, 221
 Ligament, broad, development of the, 499
 Ligaments, development of, 421
 of the liver, 765
 Ligamentum epididymis, origin of, 244
 pectinatum, 726
 spirale, 737
 Ligula, 677
 Limbs, joints of the, 460
 origin of vertebrate, 448
 position of the, 452
 Limbus Viuesenii, 529
 Lip-groove, 609
Lippenfurche, 609
 Lips, formation of the, 578
 Liquor amnii, 337
 folliculi, 51
 Liver, development of the, 761
 functions of the, 766
 origin of the, 268

 Liver, relation of, to the septum transversum, 269
 veins of, changes in the, 545
 Lobes, cerebral, 692
 olfactory, 703
 Lobules of the liver, 763
 Lobus inferior medialis, 484
 Lungs, 774
 Lutein cells, 67
 Lymphatic vessels, origin of, 413
 Lymph-glands, development of, 414

 MACULA ampullæ posterioris, 647
 sacculi, 647
 Maculae acusticae, 736
 Mallens, 445
 Malpighian corpuscles, 509
 corpuscles, differentiation of the, 238
 layer of the epidermis, 550
 Mammals, allantois in, 354
 blastodermic vesicle in, 135
 conerescence in, 124
 mesoderm of, 148
 yolk-sac of, 349
 Mammary glands, 564
 evolution of the, 565
 literature of, 566
 Man, allantois in, 354
 yolk-sac of, 349
 Mandible, development of the, 464
 Mandibular arch, 578
 bars, 444
 museles, 478
 Mantle layer of the hemispheres, 691, 694
 of the medullary wall, 616
 of the spinal cord, growth of, 661
 Manubrium, 434
 Margo's theory of the multiplication of muscle fibres, 474
Markcylinder, cordere, 607
Markkügelchen, 687
Markprisma, hinteres, 607
Marksegel, hinteres, 673, 677
Markstränge, 249
 origin of the follicular cells from the, 50
 Marrow, origin of, 420
 Marsipobranchs, conerescence in, 120
 development of the primitive segments in, 195

- Marsipobranchs, primitive axis in, 129
 Mass, relations of surface to, 161
Mastzellen, possibly regressive stages of fat-cells, 419
 Matrix, mesenchymal, 166
 Maxillary process, 578
 of the first branchial arch, 268
 Meatus auditorius externus, 738, 740
 Meckel's cartilage, 445
 Mediastinum, 483
 Medulla oblongata, 599, 665
 development of, 607
 dorsal zone of His, 666
 gray matter, 670
 neuroblasts of the dorsal zone, 668
 ventral zone of His, 668
 zones of His in the adult, 666
 Medullary canal, 178
 canal, evolution of the, 179
 cords, development of the, 249
 fibres, 616
 groove, 173
 nerve-cells, 624
 plate, 173
 sheaths, 620
 tube, widening of the, 595
 wall, layers of the, 616
 Membrana adamantina, 586
 basilaris, 735
 capsularis lentis, 717
 capsulo-pupillaris, 717
 eboris, 587
 fauces, 262
 granulosa of the Graafian follicle, 52
 limitans interna, 612, 613
 nietitans, 727
 olfactoria, 710
 pleuro-pericardiaca, 482
 præformativa, 588
 propria mesenterii, 772
 propria of the Graafian follicle, 52
 pupillaris, 717
 serosa, 286
 tectoria, 732
 Membrane of Descemet, 725
 Membrane-bones, 461
 Membranes, basement, 421
 development of, 421
 lining, of the splanchnocœle, 485
 Menstruation, changes in the mucosa corporis during, 4
 Meridional cleavage, 98
Meriten, 75
 Meroblastic embryo, 128
 ova, 55, 99, 111
Merocyten, 352
Merocytenkerne, 352
 Mesamœboids, 112, 166
 Mesencephalon, 178, 595, 598, 610, 677
 Mesenchyma, 112, 144
 anterior, of the eye, 723
 condensation of, in the formation of cartilage, 403
 differentiation of, 165
 embryonic, 398
 genital, production of the, 248
 intercellular, differentiation of, 399
 organs of the human body derived from the, 160
 origin of the, 153, 207
 tissues resulting from the differentiation of the, 397
 Mesenchymal cavities, 420
 matrix, differentiation of, 399
 portion of the kidney, 508
 tissues, 397
 tissues, classification of, 397
 Mesentery, 483, 767
 Mesoblast, 157
 Mesocardium, 228, 483
 laterale, 481
 Mesocephalic ganglion, 640
 Mesocolon, 769
 Mesoderm, 112, 144
 cœlon theory of the, 155
 differentiation of the, 327
 division of, into somatic and splanchnic layers, 271
 expansion of the, 150
 gastral and peristomial, of Rabl, 145, 147, 156
 germ-band theory of the, 156
 Goette's theory of the, 156
 Hatschek's germ-band theory of the, 156
 of amphibia, 145
 of elasmobranchs, 144
 of mammals, 148
 of sauropsida, 147
 of teleosts, 145
 origin of the, 144
 parablast theory of the, 153

- Mesoderm, peristomial and gastral of
 Rabl, 145, 147, 156
 primitive cells of the, 149
 Rabl's theory of the, 155
 somatic, 152
 splanchnic, 152
 theories of the, 153
 vertebrate type of origin of, 148
- Mesodermal organs of the human
 body, 160
- Mesogastrum, 769
- Mesomeres, 193
- Mesonephros, 231, 235
- Mesorehium, 497
 origin of, 244
- Mesothelial muscles, 470
- Mesothelium, 144
 histogenesis of the, 152
 organs of the human body de-
 rived from the, 160
 origin of ova from, 48
- Mesovarium, origin of, 244
- Metacarpal bones, ossification of the,
 458
- Metagastrula stage of segmentation,
 104
- Metameres, 193
- Metatarsal bones, ossification of the,
 460
- Metencephalon, 178, 595, 598
- Micropyle of the ovum, 59
- Microporus in the head of some sper-
 matozoa, 41
- Microsoma of the segmentation nu-
 cleus, 93
- Microsomen*, 76
- Mid-brain, 178, 595, 598, 610, 677
- Mid-gut, 113
- Milchlinie*, 564
- Milk at birth, 565
- Milk-glands, 564
- Minot's ova, 296
- Mittelhirn*, 178, 595, 598
- Mittelplatte*, 201
- Mittelstück* of a spermatozoon, 40,
 21
- Monro, foramen of, 597, 680, 693
 sulcus of, 680
- Montgomery's glands, 565
- Morgagni, hydatid of, 503
- Mouth cavity, development of the,
 567
 evolution of the vertebrate, 569
- Mucosa cervicis uteri, 24
- Mucosa corporis uteri, 3
 changes in the blood-vessels of
 the, during pregnancy, 11
 changes in the glands of the, dur-
 ing pregnancy, 10
 during menstruation, 4
 during pregnancy, 6
 in the virgin, 3
 post-partum regeneration of the,
 21
- Mucous tissue, 358, 361, 403
- Müllerian duct, 230, 244, 253, 503
 funnel, 245
- Müller's embryo, 308
- Mundrachenhaut*, 262
- Mundrachenraum*, 568
- Muscle-fibre, segmental or skeletal,
 470
 smooth, origin of, 417
- Muscle-plates, 475
- Muscles, mandibular, 478
 mesothelial, 470
 myotomic, 477
 of the branchial arches, 477
 of the heart, 478
 union of nerves and, 624
- Muscularis uteri, 1
- Muskelknospen*, 475
- Muskelspindel*, 475
- Mutterkuchen*, 364
- Mutterzellen*, 44
- Myelencephalon, 599
- Myeloplaxes, 410
- Myocole of Hatschek, 209
- Myotome, 201
- Myotomic muscles, 477
- Nachhirn*, 599
- Nackengrube*, gradual obliteration
 of, in the embryo of forty days,
 391
 in embryo of thirty-one days,
 388
- Nackenhöcker*, 600
- Nackenkrümmung*, 600
 in embryo of thirty-one days, 389
 in embryos of twenty-three days
 and above, 385
- Nackenlänge*, a measure of the em-
 bryo, 384
- Nagelfeld*, 556
- Nagelplatte*, 556

- Nagelzellen* of the ovum, 56
Nährplasma, 88
Nährzellen of Nagel, 51
 Nail-plate, 556
 Nails, development of the, 554
Narbe of the ovum, 99
 Nasal pits, 575
 process, 576
Nebendarm in invertebrates, 187
Neben Kern of Platner, homology of, 46
 sphere of attraction not improbably identical with, 94
Nebenolive, 671
 Neck-bend, 600
 in embryo of thirty-one days, 389
 in embryos of twenty-three days and above, 385
 Nephridia, 230
 Nephridial ridge, 230, 251
 Nephrotome, 201
 Nerve, abducens, 644
 acoustic, 644
 cochlear, 647
 epibranchialis, 651
 facial, 644
 glosso-pharyngeal, 648
 hypoglossal, 655
 lateral, 654
 oculo-motor, 639
 olfactory, 637
 ophthalmicus profundus, 642
 optic, 638, 717
 pathetic, 640
 post-trematic branch of the glosso-pharyngeal, 650
 post-trematic branches of the vagus, 654
 præ-trematic branch of the glosso-pharyngeal, 650
 præ-trematic branches of the vagus, 654
 spinal accessory, 654
 thalamic, 640
 trigeminal, 641
 trochlear, 640
 vagus, 650
 Nerve-cells, development of, 624
 ganglionic, 626
 medullary, 624
 origin of, 611
 Nerve-fibres, origin of, 616
Nervenleiste, 602
 Nerves, branchial, 636
 cervical, 629
 cranial, 633
 growth of, 622
 origin of, 622
 spinal, 627
 sympathetic, 630
 union of muscles and, 624
 Nervous layer of the epidermis, 549
 system, development of the, 593
 system, sympathetic, 630
Netzbeutel, 770
Neugliederung des Axenskelets, hypothesis of, 423
 Neural canal, 179
 crest or ridge, 601
Neuralleiste, 601
 Neurenteric canal, 188
 canal, significance of the, 191
 Neuroblasts, 611, 613
 of the dorsal zone of the medulla, 668
 Neuroglia, origin of the, 612
 specialization of the, 614
 Neuroglia-layer, outer, 616, 671
 Neuromeres, 604
 relations of the cranial nerves to, 636
 Neuron, axis of the, 600
 Neuroporus, 177
Nickhaut, 727
 Nose, development of the, 575
 external, development of, 578
 Notochord, 181
 disappearance of the, 187
 histogenesis of the, 186
 morphology of the, 187
 of teleosts, 184
 origin of, from the notochordal canal, 182
 relations of, to other parts, 185
 separation of, from the entoderm, 182
 shape of the, 185
 Notochordal canal, 126
 and yolk cavity, fusion of, 127
 Nuclear substance, the essential factor in the function of heredity, 90
 Nucleus, segmentation-, 93
 the organ of hereditary transmission, 90

- Nutrition of the foetus, 373
 Nymphæ, development of the, 518
- Oberkieferfortsatz*, 268, 578
 Obex, 677
 Oculo-motor nerve, 639
 Odontoblasts, 587
 Œsophagus, 752
 Oil-globules of the yolk, 54
Oken'sche Körper, 243
 Olfactory lobes, 703
 membrane, 710
 nerve, 637
 pit, distinctness of, after the
 twenty-fifth day, 387
 plates, 575
 Ovary body, 671
 Omentum, 767
 meshes of the, 772
 minus, 765
 sac of the, 483
 Oöspore, 78
 Operculum, 696
 Opossum, yolk-sac of the, 351
 Optic chiasma, 688, 718
 cup, secondary, 713
 evaginations, 594
 nerve, 638, 717
 recessus, 688
 thalami, 686
 vesicles, 710
 Oral plate, 262
 Organs of special sense, 706
 Ossification, 407
 metaplastic, 408
 neoplastic, 410
 Osteoblasts, 409
 Osteoclasts, 410
 Ostium primum, 529
 secundum, 529
 Oöcyst, origin of the, 728
 Otoliths, 737
 Ova, 48
 alecithal, 61
 centrolecithal, 61
 holoblastic, 55, 99, 111
 known human, eight stages of,
 308
 known human, of the second and
 third weeks, 286
 Abhfeld's, 289
 Allen Thomson's, 293, 294, 307
 Biege's, 289, 308
 Ova, known human, of the second
 and third weeks, Breus', 288
 Bruch's, 308
 Chiarugi's, 304
 Coste's, 300
 Ecker's, 307
 Hecker's, 308
 His', 291, 293, 294, 297, 298, 304
 Janosik's, 300
 Keibel's, 291
 Kollmann's, 289, 295
 Minot's, 296
 Müller's, 308
 Reichert's, 287
 Remy's, 303
 Schröder van der Kolk's, 303
 Schwabe's, 290
 Spree's, 291, 295
 Von Baer's, 296, 307
 Wagner's, 308
 Wharton Jones', 289
 mesoblastic, 55, 99, 111
 primitive, 48
 primitive, appearance of the, 250
 telecithal, 61
 see also under Embryo and
 Fœtus.
 Ovary, development of the, 495
 Oviduct, 230, 244, 253
 Ovoblast, appearance of the, 250
Ocomeriten, 75
 Ovulation, 66
 physiology of, 68
 Ovum, 48
 amphiasier of the, 63
 animal pole of the, 60
 archiamphiasier of the, 63
 attachment of the, 374
 definition of, 48
 entrance of the spermatozoon
 into the, 70
 envelopes of the, 57
 full-grown, before maturation, 55
 growth of the, 49, 50
 human, of three weeks, 32
 karyokinesis of the, 94
 maturation of the, 61
 nuclear spindle, 63
 nucleus and nucleolus of, 57
 polar globules of the, 61
 polarity of the, 60
 primordial, 49
 segmentation of the, 93

- Ovum, vegetative pole of the, 61
see also under Embryo and Fœtus.
- PALATE, formation of the, 579
- Pallium of the hemispheres, 691, 694
- Pancreas, 766
- Pangenesiſ, 85
- Papilla, dental, 587
- Parablast, 120, 153
- Parablast theory of the mesoderm, 153
- Parablastic nuclei of the yolk, 348, 352
- Parachordals, 430
- Paradidymis, 501
- Paraphysis cerebri, 690
- Parietalhöhle*, 151, 197
- Paroöphoron, 501
- Parovarium, 500
- Parturition, causes of, 27
changes in the decidua at, 21
- Pathetic nerve, 640
- Peduncles of the cerebrum, 678
- Pelvic girdle, 455
- Penis, development of the, 517
- Peptic cells, 755
- Pericardial and pleural cavities, separation of, 482
- Perionix, 555
- Periotic capsules, 438
- Perivitelline space of the ovum, 56
- Pflüger'sche Schläuche*, 48, 496
- Phalanges, ossification of the, 458, 460
- Pharynx, 743
origin of the, 263
- Pigment-cells, origin of, 419
- Pigment layer of the retina, 721
- Pigment-Strasse*, in certain amphibian ova, 74
- Pineal gland, 680, 688
- Pits, nasal, 575
- Pituitary body, 571
- Placenta, the, 364
allantoic, 376
at different periods of pregnancy, 30
at full term, 364
chorionic, 376
cotyledons of, 366
evolution of, 376
fetal circulation of, 369
lobes of, 366
maternal circulation of, 372
- Placenta, theory of, 374, 378
two types of, 376
- Placoid scales, 582
- Planula, 112
- Plastids, red, origin of, 221
- Plate, anal, 190
buccal, 262
medullary, 173
nail-, 556
oral, 262
sole-, 556
sub-germinal, 102
vertebral, 193
- Plates, blood-, origin of, 223
muscle, 475
olfactory, 575
- Pleural and abdominal cavities, separation of the, 484
and pericardial cavities, separation of, 482
cavities, expansion of the, 483
- Plexus, choroid, 681
- Plica choroidea, 610
semilunaris, 727
- Polar crown, formation of the, 95
globules of the ovum, 64
- Polyphyodont, definition of term, 582
- Pons Varolii, 672
- Poreuten*, 154
- Post-trematic branch of the glosso-pharyngeus, 650
of the vagus, 354
- Præ-cartilage, 404
- Præcervical sinus, 744
- Præ-trematic branch of the glosso-pharyngeus, 650
of the vagus, 654
- Pregnancy, changes in the mucosa corporis during, 6
decidua reflexa at various periods of, 19
decidua serotina at the seventh month, 17
uterus at the fifth week of, 31
uterus at the first month of, 13
uterus at the third month of, 30
uterus at the eighth month of, 28
- Primitive anus, 259
- Primitive axis, 118
axis in marsipobranchs, ganoids, and amphibians, 129
cartilaginous skull, 434

- Primitive chorion, 281
 groove, 140
 groove, stage when it is at its maximum, 134
 ova, appearance of the, 250
 segment, cavity of the, 202
 segments, 157
 segments, division of the, 201
 segments of the œolom, 192
 streak in birds, 131
 streak in elasmobranchs, 130
 streak in mammals, 139
 streak, origin of, 128
 vertebral bow, 425
- Primordialeier*, appearance of the, 250
- Primordialniere* of Jacobson, 243
- Proamnion, 150, 341
 importance of, in mammals, 284
- Process, dental, 588
 maxillary, 578
 nasal, 576
- Processes, choroid, 722
- Processus globularis, 576
 infundibuli, 687
 vaginalis, 496
- Prochondrium, 404
- Proctodæum, 259
- Projections of the germ-layers, 161
- Proliferation islands, 320, 326
- Proliferationsinseln*, 320, 326
- Pronephric duct, 230, 234, 253
- Pronephros, 231
- Pronucleus, female, 65
 fusion of the male and female, 74
 male, 71
- Prosencephalon, 178, 595, 610
- Prostatic gland, development of, 515
- Protoplasm of the ovum, 49
- Protovertebra, 192, 201, 423
- Pseudocœle, 684
- Pulmonary anlage, 773
 aorta and arteries, 538
 groove, 773
 veins, formation of, 547
- Pupil of the eye, 713
- Parkinje'sches Bläschen*, 57
- RABBIT, yolk-sac of the, 351
- Rabl's theory of the mesoderm, 155
- Rachenhaut*, 262
- Radius, ossification of the, 457
- Randbogen*, 696
- Randfurche*, 607
 of the spinal cord, 662
- Randkeim*, 154
- Randschleier*, 613, 614, 616, 671
- Randvene* of the hand or foot, 545
- Randwulst*, 117
- Randzone*, *weisse*, 672
- Rathke's pocket, 571
- Rautenlippe*, 608
- Recessus labyrinthi, 736
 laterales of the fourth ventricle, 676
 occipitalis, 693
 opticus, 680, 688
 parietalis dorsalis, 481
 superior sacci omenti, 484
 utriculi, 738
 vestibuli, 729
- Reichert's cartilages, 445
- Reichert's ovum, 287
- Reil, island of, 696
 island of, fissures of, 701
- Remy's embryo, 303
- Repli périnéal*, 517
- Repose, period of, after fusion of the pronuclei, 94
- Respiratory tract, 773
- Rete Halleri, 501
- Rêtes d'Henle*, 551
- Retina, 719
 central artery of the, 712
- Retinacula of the Graafian follicle, 52
- Ribs, development of the, 432
- Richtungskörperchen*, 65
- Richtungsspindel*, *zweites*, 64
- Ridge, dental, 578
 genital, 230, 244, 251
 nephridial, 230, 251
 neural, 601
 Wolffian, 230, 251
- Ridges, epidermal, 551
 optic, 688
- Riechgrube*, distinctness of, after the twenty-fifth day, 387
- Riechlappen*, 703
- Riegel*, 677
- Riemchen*, 677
- Rodents, inversion of the germ-layers in, 141
- Roland, gelatinous substance of, 662
- Rolando, fissure of, 698
- Roof of the fourth ventricle, 676
- Rosenmüller, organ of, 500

Rückenfurche, 173
Rückenkrümmung, 313
Rückenplatte of Remak, 470
Rückenrinne, 134
 Ruseoni, anus of, 121, 129

SACculus, 736
Saccus omentis, 484
 Salivary glands, development of, 590
Sauveufäden, 40
Samenstammzellen, 43
 origin of, 494
Sammelröhrchen from the Malpighian corpuscles, 239
 Santorini, ducts of, 767
Sarcoplasten, 474
 Sauropsida, conescence in, 122
 development of the primitive segments in, 195
 mesoderm of, 147
 the allantois in, 353
 yolk-sac of, 347
Scala tympani, 735
Schallstück, 662
Scheitelkrümmung, 600
Scheitelplatte, 570
 Schizocœle, 169
Schleimblatt of Pander, 167
Schleimscheide in rats and mice, 484
 Schlemm, canal of, 724
Schlundspalten, 263
Schlussplatte of Winekler, 325
Schmelzzellen, 586
Schulterzungenstrang, 658
Schwanzdarm, 260
Schwanzkappe, 283
Schwerchfell, development of the, 485
 Schwabe's ovum, 290
 Selera, 713, 722
 Sclerotome, 202, 205, 423
 Scrotum, origin of the, 520
 Sebaceous glands, development of, 562
 Seessel's pocket, 268
 Segmental sense-organs, 706
Segmentalbläschen of Braun, 237
Segmentalorgane, 232
Segmentalstränge, 249
 Segmentation cavity, 97
 Segmentation of the ovum, 93
 modified, of placental mammals, 103
 planes of division during, 109

Segmentation, primitive type of, 96
 vertebrate type of, 97
 Segmentation planes, relation of, to the embryonic axis, 110
 Segments, cephalic, 199
 mandibular, 200
 pre-oral, 200
 primitive, 157
 primitive, cavity of the, 202
 primitive, division of the, 201
Schüttelcentrum, mediane, 687
Schstreif, 688
Seitenfortsätze of the vertebra, 431
Seilenteiler, 712
 Sella turcica, 436
 Semiferous tubules, 42
 Sense-cells, special, 709
 Sensory ganglia, origin of the, 601
 Sense organs, 706
 evolution of the ganglionic, 709
 Septum inferius, 530
 intermedium, 530
 lucidum, 684
 pellucidum, 684
 primum or superius, 524, 528
 secundum, 529
 spurium, 525, 533
 superius of the auricles, 524, 528
 transversum, development of the, 480
 transversum, relation of the liver to the, 269
 Sertoli's column, 39, 42
 column, origin of, 494
 Sex, changes in the uro-genital system characteristic of, 491
 nature of, 84
 theory of, 77
 Sexual cells, 249
 cords, 249
 elements, 39
 elements, the bringing together of the, 69
 glands, development of the, 492
 glands, differentiation of the, 251
 Sexuality, nature of, 77
 object of, 83
 origin of, 82
Sexualstränge, 249
 Sharks, dermal teeth of, 581
 Sheaths, medullary, 620
 Sheep, yolk-sac of, 350
 Shoulder-girdle, 453

- Sinus, cervical, 657, 744
 cervical, deepening of, in embryo of twenty-seven days, 387
 lacteus, 565
 præcervicalis, 744
 præcervicalis, deepening of, in embryo of twenty-seven days, 387
 reuniens, 527
 rhomboidalis, 176
 terminalis, 213, 272
 urogenital, 515
 venosus, 275, 525
- Skeleton, the, 422
 appendicular, 448
 axial, 424
 branchial, 443
 dermal, 461
 development of, 422
 of the arm, 456
 of the leg, 458
 of the limbs, 448
 relative importance of, as compared with the other systems, 422
 stages of, 422
- Skin, the, 548
 glands of, 563
- Skull, development of the, 434
 Froriep's law concerning, 469
 Gegenbauer's theory of the, 469
 homologies of the bones of the human, 465
 morphology of the, 465
 ossification of the, 439
 primary, 466
 relations of primary and secondary, 466
 secondary, 467
 theories of the, 468
 Vicq d'Azyr's theory of the, 468
- Smegma embryonum, 562
Sohlenhorn of the claw, 556
 Sole-plate of the claw, 556
 Somatic mesoderm, 152
 Somatopleure, 152
 extra-embryonic, 281
- Somites, mesoblastic, 157, 193
 relation of the limbs to the, 451
- Spaces, interglobular, in the adult tooth, 588
Sponge of the vertebra, 425
 Spatium interseptale, 525
- Spermatoblasts, 43
 Spermatoeytes (daughter-cells), 44
 origin of, 494
 Spermatogenesis, 42
Spermatomeriten, 75
 Spermatozoa, 39
 development of, 39
 historical note, 47
 human, 42
 mammalian, 40
 of amphibia, 40
 of birds, 40
 of fish, 40
 of the rat, 41
 of reptiles, 40
 vertebrate, 40
- Spermatozoon, entrance of, into the ovum, 70
 parts of, 39
- Spermiduct, 503
- Sphere of attraction, 94
- Spheres, segmentation, 105
- Spinal accessory nerve, 654
- Spinal cord, 658
 blood-vessels of the, 664
 central canal of, 659
 development of the, 607
 dorsal zone of His, 661
 general growth of, 658
 gray matter, 663
 growth of the mantle layer, 661
 ventral zones of His, 662
 white matter, 663
- Spinal nerves, 627
- Spindle, nuclear, of the ovum, 63
- Spini vestibuli, 525
- Splanchnic mesoderm, 152
- Splanchnoceles, 197, 480
 lining membranes of the, 485
- Splanchnopleure, 152
- Spleen, development of the, 415
- Splenic bones, 461
- Splint bones, 461
- Spongioblasts, 611, 612
- Spree's embryos, 291, 295
Spundzellen of the ovum, 56
- S-shaped tubules of the Wolffian body, 237, 241
- Stammzellen*, 43
Stammzone, 193
- Stapes, 740
- Sternum, development of the, 434
- Stigma of the Graafian follicle, 52

- Stirnfortsatz*, 576
Stirnorgan, 690
Stirneulst, 569
 Stratum corneum of the epidermis, 550
 lucidum of the epidermis, 550
 proligerum, 99
 Streak, primitive, origin of, 128
Streifenhügelstiel, 695
 Stria cornea, 695
 Stomach, 753
 Stomodæum, 126
 Sub-germinal cavity, 115
 plate, 102
Substantia gelatinosa Rolandi, 662
Sulcus centralis insulae, 702
 corporis callosi, 692
 habenulae, 687
 hippocampi, 696
 of Monro, 680
 olfactorius, 700
 pineal, 687
 rectus, 700
 spiralis, 732
 Supra-renal capsules, 485
 Surface, relations of mass to, 161
 Sweat glands, 563
 Sylvius, aqueduct of, 678
 fossa of, 695
 Sympathetic nervous system, 630
 Synovial cavities, development of, 421

Tache embryonnaire, 136
Taches laiteuses, 218
 Tail, origin of the, 260
 Tail-fold, 283
 Tail-gut, 260
 Tarsus, ossification of the, 460
 Taste, organs of, 710
 Tear gland, 727
 Teeth, age of development of the parts of, 589
 dermal, of sharks, 581
 development of the, 581
Tela choroidea, 681
 Teleosts, mesoderm of, 145
 notochord of, 184
 Telolecithal ova, 61
 Tendons, development of, 421
 Testis, descent of the, 496
 development of the, 492
Thalamencephalon, 596, 679
Thalami, optic, 686
 Thalamie nerve, 640
Theca folliculi, 51
 Thelyblast, 78
 Third ventricle, floor of the, 687
 Thomson's (Allen) embryos, 293, 294, 307
Thrinendritse, 727
Thrinennasengung, 580
 Threads, achromatic, 95
 Thymus, 746
 Thyro-hyoid bars, 447
 Thyroid gland, 747
 Tibia, ossification of the, 459
 Tissues, genesis of the, 164
 mesenchymal, 397
Tonia, 609
 fossæ rhomboidalis, 677
 semicircularis, 695
 Tongue, development of the, 592
 Tonsils, 745
 Tooth-germs, amniote, 583
Totalfurchen, 692
 Touch, organs of, lack of knowledge concerning, 710
Trabeculae cranii, 434
 significance of the, 468
 Trachea, 777
Tractus intermedius, 668
 solitarius, 667
 Trigeminal nerve, 641
 Trochlear nerve, 640
 Tube, Eustachian, 740
 Fallopian, 504
 Fallopian, origin of, 245
Tubenfalte of Braun, 245
Tubuleiste of Mihalkovics, 245
Tuber cinereum, 687
 Tubercle, genital, 516
 Tubercles, mammillary, 687
Tuberculum impar, 306, 592
 Tubules, segmental, 230, 235
 renal, 509
 seminiferous, 42
 Wolffian, 235
 Wolffian, multiplication of the, 239
Tunica fibrosa of the Graafian follicle, 52
 propria of the Graafian follicle, 52
 vasculosa lentis, 716
 vasculosa of the primary follicle, 51
 'Tween-brain, 596

- ULNA, ossification of the, 457
- Umbilical arteries, 541
- Umbilical cord, 356
 at birth, 360
 at different periods of pregnancy, 30
 development of the, 357
 twisting of the, 361
- Umbilical hernia, 758
- Unterhautzellgewebe*, 553
- Urachus, 515
- Urdarm*, 113
- Ureter*, appearance of the, 250
 in the embryo, 82
 origin of, 48
- Ureter, development of the, 514
- Urethra, origin of, 517
- Urkeimzellen*, 82
- Urmund*, 113
- Urnere*, 231, 235
- Urnierenbläschen*, 237, 240
- Urnierblastem*, 239
- Urogenital apparatus, homologies of,
 in the two sexes, 492
- Urogenital organs, special histories
 of the, 492
- Urogenital sinus, 515
- Urogenital system, evolution of the,
 251
 fundamental parts of the, 230
 general history of the, 490
 indifferent stage, 490
 origin of the, 230
- Ursegmente*, 157, 193
- Urwirbel*, 192, 423
- Urwirbelkern*, 196
- Urwirbelplatte* of Remak, 196
- Uterus, attachment of embryo in, 374
 blood-vessels of the, 24
 decidua graviditatis, 6, 26
 decidua menstrualis, 4, 26
 decidual cells, 12
 degeneration of tissues of, 375
 development of, 504, 506
 eight months pregnant, 28
 five weeks pregnant, 31
 histology of the, 1
 lymphatics of the, 25
 masculinus, 503
 mucosa cervicis, 24
 mucosa corporis, 3
 muscularis, 1
 one month pregnant, 13
- Uterus, post-partum regeneration of
 the mucosa, 21
 size of the, 1
 special physiology of the, 25
 three months pregnant, 30
 weight of the, 1
- Utriculus, 736
- Uvea, 722
- Uvula, development of the, 580
- VAGINA, development of, 504; 506
- Vagus nerve, 650
- Valves of the heart, 532
 aortic, 534
 atrioventricular, 533
 semilunar 534
- Valvula Eustachii, 525, 532
 Thebesii, 525, 532
 vestibuli sinistra, 525
- Varoliam bend, 599, 601
- Vascular area, 274
 growth of, 276
- Vascular layer, 212
- Vascular system, origin of the, 229
- Vasoformative cells, 218
- Veins, hepatic, changes in the,
 545
 of the hand and foot, changes in
 the, 545
 omphalo-mesaraic, 215, 275
 primitive, 541
 primitive, metamorphoses of the,
 544
 pulmonary, 547
- Velum medullare posticum, 673, 677
- Vena Arantii, 546
 cava, inferior, early history of
 the, 543
 porte, origin of the, 546
 the, 213
- Venous system, transformations in
 the, 541
- Ventriele, primitive cardiac, 525
 fourth, and its roof, 676
 third, floor of the, 687
- Ventricles, cardiac, division of the,
 530
- Verbindungstück* of a spermatozoon,
 41
- Vermiform appendix, 758
- Vernix caseosa, 562
 caseosa found in the meconium,
 338

- Verschlussplatte* closing the gill-cleft, 267
- Vertebra, typical development of a, 424
- Vertebrae, caudal, 431
coccygeal, 431
evolution of, 429
occipital, 429
ossification of the, 428
sacral, 431
- Vertebral column, 424
plate, 193
- Vertebrate type of origin of the mesoderm, 148
- Verwachsungsbrücke*, 482
- Vesicle, blastodermic, 105, see Blastodermic vesicle.
chorionic, 317
chorionic, fluid contents of the, 331
cylindrical, 141
- Vesicles, 162
amnio-cardial, 198
cerebral, 178, 593
optic, 710
primary cerebral, 595
- Vesicula germinativa of the ovum, 57
prostatica, 504
seminalis, 503
- Vesiculae cerebrales, 595
- Vessels, blood, see Blood-vessels.
lymphatic, development of, 413
- Vestibule anale*, 516
- Vicq d'Azyr's theory of the skull, 468
- Villi, chorionic, 318
chorionic, outgrowth of, 375
placental, vessels of the, 371
- Virgin, uterine mucosa in the, 3
- Visceral arches, 265, 267
Visceralbögen, 265, 267
Visceralspalten, 263
- Vitelline membrane, 58
veins, 542
- Vitreous humor, 723
- Vocal chords, 778
- Vomer, development of the, 463
- Von Baer's ova, 296, 307
- Vorderdarm*, 126
origin of the, 261
- Vorderhirn*, 178, 596
- Vorhofsblindsack*, 737
- Vorknorpel*, 404
- Vorniereugang*, 234
- V-shaped grains, 95
- WAGNERIAN spot of the ovum, 57
- Wagner's embryo, 308
- Wagner'scher Fleck*, 57
- Wangenplatte*, 568
- Weismann's theory of the multiplication of muscle fibres, 475
- Wharton's jelly, 358, 361, 403
- White matter, 616
of the spinal cord, 663
- Willis, accessory nerve of, 654
- Winslow, foramen of, 483, 770
- Wirbelbogen*, 425
- Wirbelplatte*, 193
- Wirbelsaite*, 181
- Wirsung, duct of, 767
- Wolffian body, 231, 235
historical note, 243
resorption of, 243
structure of the mature, 240
- Wolffian duct, 230, 234, 253, 502
- Wolffian ridge, 230, 251
- Wolffian tubules, multiplication of the, 239
- XYPHOID cartilage, 434
- YOLK, changes in, during the passage of the spermatozoon through the ovic envelopes, 73
development of the, 49
formative, 99
parablastic nuclei of, 348, 352
- Yolk-blastopore, 124
- Yolk-cavity, 115.
and notochordal canal, fusion of, 127
- Yolk-grains, first appearance of the, 53
- Yolk-nucleus, 54
- Yolk-sac, 346
general morphology of the, 346
of mammals, 349
of man, 349
of sauropsida, 347
of sheep, 350
of the opossum, 351
of the rabbit, 351
separation of the archenteron from the, 255

- Zahnleiste*, 583
Zahnsack, origin of the, 584
Zapfern of the mucosa, 23
Zellen, leucocytoide, 420
Zellknoten, 326
Zellschicht of Langhans, 323
Zellstreif, 675
Zirbel, 688
Zirbeldrüse, 688
Zinn, zonule of, 723
Zona pectinata, 735
 pellucida, 51, 53, 58
 radiata, 51, 53, 58
- Zone*, lenticular, of the optic cup, 722
 parietal, of the mesoderm, 193
 segmental, of the mesoderm, 193
 segmenting, 101
Zones of His, 606, 661, 662, 686, 687
 in the adult, 666, 668
Zonule of Zinn, 723
Zwerchfellband der Urniere, 245
Zwillingszellen of the ovum, 56
Zwischenganglion, 648
Zwischenhirn, 596, 679
Zwischenrinne, 603
Zwischenstrang, 601

